



HEALTH SCIENCES STANDARD

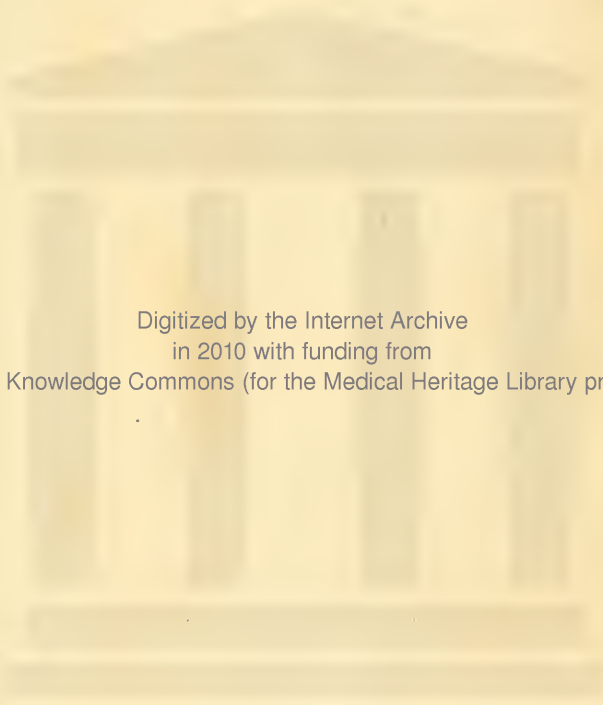
HX64171051

QM23 .G79 1913a Anatomy, descriptive

RECAP

Columbia University
in the City of New York
College of Physicians and Surgeons
Library





Digitized by the Internet Archive
in 2010 with funding from
Open Knowledge Commons (for the Medical Heritage Library project)

ANATOMY

DESCRIPTIVE AND APPLIED

BY

HENRY GRAY, F.R.S.

FELLOW OF THE ROYAL COLLEGE OF SURGEONS; LECTURER ON ANATOMY AT ST. GEORGE'S
HOSPITAL MEDICAL SCHOOL, LONDON

A NEW AMERICAN EDITION

THOROUGHLY REVISED AND RE-EDITED

WITH THE ORDINARY TERMINOLOGY

FOLLOWED BY THE

BÂSLE ANATOMICAL NOMENCLATURE IN LATIN

BY

EDWARD ANTHONY SPITZKA, M.D.

DIRECTOR OF THE DANIEL BAUGH INSTITUTE OF ANATOMY AND PROFESSOR OF GENERAL ANATOMY IN THE
JEFFERSON MEDICAL COLLEGE, PHILADELPHIA

Illustrated with 1225 Engravings



LEA & FEBIGER

PHILADELPHIA AND NEW YORK

Copyright Office
Library of Congress

245

211

1913

Entered according to the Act of Congress, in the year 1913, by

LEA & FEBIGER

in the Office of the Librarian of Congress. All rights reserved.

THE FIRST EDITION OF THIS WORK
WAS DEDICATED TO
SIR BENJAMIN COLLINS BRODIE, BART., F.R.S., D.C.L.
IN ADMIRATION OF
HIS GREAT TALENTS
AND IN REMEMBRANCE OF
MANY ACTS OF KINDNESS SHOWN TO THE ORIGINAL
AUTHOR OF THE BOOK
FROM AN
EARLY PERIOD OF HIS PROFESSIONAL CAREER

PREFACE.

As a thoroughly practical treatise on the subject for the medical student, *Gray's Anatomy*, both in the original and its many succeeding editions, has long been held in the highest esteem. In this as in previous revisions the Editor has endeavored to adhere to the plan as much as possible, supplying such facts and views as the advances in the science of anatomy rendered it necessary to incorporate. Descriptions of undue length have been curtailed, and any difficult passages in the text have been clarified; so that the essentials are here embodied into a fairly complete account of the structures of the human body and their development. It has also been the Editor's aim to achieve the utmost degree of uniformity in the mode of treatment throughout the work.

Under the heading of *Applied Anatomy* many important medical and surgical considerations are discussed. In the use of descriptive terms, concerning which widely different opinions prevail, the Editor has sought to take a middle course, employing such designations as seem sanctioned by their usage in current medical literature. The *Bâsle Nomina Anatomica* Nomenclature, in italics, has been added in parentheses, except where the two nomenclatures are identical, and the terms are listed in the General Index. Here, also, they have been italicized, and thus distinguished they afford a working glossary of the *BNA* system. Other synonyms are printed in Roman type.

Illustrations have been added from original drawings and preparations, and some from standard works, wherever it seemed that any important point could be made more clear.

The Editor is greatly indebted to his assistants, Dr. Howard Dehoney, Demonstrator of Anatomy, and Dr. Henry E. Radasch, Assistant Professor of Histology and Embryology in the Jefferson Medical College, for valuable aid in the preparation of this revision. The Editor also wishes to thank Mr. William A. Hassett, of Lea & Febiger, for indexing the book, for seeing it through the press, and for the valuable aid he has ungrudgingly given.

E. A. S.

PHILADELPHIA, 1913.

PUBLISHERS' NOTE.

Books, like men, have characters that can be analyzed to a certain point, but beyond or below lies a quality, subtle as life, and incapable of analysis or imitation, which is called personality. The greater the author, and the more intense his mental action in creating his book, the more it partakes of this element. This principle, so clear as to be almost axiomatic, is illustrated to the fullest extent in the work in hand. Henry Gray combined two faculties, either one sufficient to make his name famous. He was a great anatomist and a great teacher. He possessed a thorough knowledge of anatomy and an equal insight into the best methods of imparting it to other minds. His text was unequalled in clearness, and he united with it a series of incomparable illustrations. He devised the method of engraving the names of the parts directly upon them, thereby exhibiting at a glance not only their nomenclature, but also their position, extent, and relations. His work, still unique in this respect, was also the first to employ colors. Summing all, it is hardly to be wondered at that students and teachers alike find their labors reduced and the permanence of knowledge increased by the use of such a book.

On its original appearance, half a century ago, it immediately took the leading place, and it has not only maintained its position in its own subject, but has also become the best-known work in all medical literature in the English language. It is incomparably the greatest text-book in medicine, measured by the numbers of students who have used it, and it is unique also in being the one work which is certain to be carried from college to afford guidance in the basic questions underlying practice.

The consequent demand is evidenced in the number of editions, which collectively represent the labors of many of the leading anatomists since the early death of its talented author. In this new revision every line has been carefully considered, any possible obscurity has been clarified, the latest accessions to anatomical knowledge have been introduced, and much has been rewritten. Care has been exercised to make the text a homogeneous, sequential, and complete presentation of the subject, sufficing for every need of the student, physician, or surgeon.

As ample directions are given for dissecting, this volume will serve every requirement of the student throughout his course. The new nomenclature and that still in common use have been introduced in a manner rendering the work universal in the prime essential of terminology. The Table of Contents is so arranged as to give a complete conspectus of anatomy, a feature of obvious value. The whole book is thoroughly organized in its headings and the sequence of subjects, so that the student receives his knowledge of the parts in their anatomical dependence.

As a teaching instrument the new *Gray's Anatomy* embodies all that careful thought and unstinted expenditure can combine in book form.

OSTEOLOGY.

(ix)

THE UPPER EXTREMITY.

<i>The Shoulder Girdle.</i>	
The Clavicle.....	169
Surface Form of the Clavicle.....	171
Applied Anatomy of the Clavicle.....	172
The Scapula or Shoulder Blade.....	172
Surface Form of the Scapula.....	177
Applied Anatomy of the Scapula.....	178
<i>The Arm.</i>	
The Humerus or Arm Bone.....	178
Surface Form of the Humerus.....	184
Applied Anatomy of the Humerus.....	184
<i>The Forearm.</i>	
The Ulna or Elbow Bone.....	185
Surface Form of the Ulna.....	190
The Radius.....	190
Surface Form of the Radius.....	192
Applied Anatomy of the Radius and Ulna.....	192
<i>The Hand.</i>	
The Carpus.....	195
Bones of the Upper Row.....	196
The Scaphoid or Navicular Bone.....	196
The Semilunar Bone.....	197
The Cuneiform Bone.....	197
The Pisiform Bone.....	198
Bones of the Lower Row.....	198
The Trapezium.....	198
The Trapezoid.....	199
The Os Magnum.....	199
The Unciform.....	200
The Metacarpus.....	201
Peculiar Characters of the Metacarpal Bones.....	202
The Phalanges of the Hand.....	204
Surface Form of the Bones of the Hand.....	205
Applied Anatomy of the Bones of the Hand.....	205
Development of the Bones of the Hand.....	206

THE LOWER EXTREMITY.

The Os Innominatum.....	207
The Ilium.....	207
The Ischium.....	210
The Pubis.....	212
The Cotyloid Cavity or Acetabulum.....	213
The Obturator or Thyroid Foramen.....	213
The Pelvis.....	215
Position of the Pelvis.....	217
Axes of the Pelvis.....	218
Differences between the Male and Female Pelvis.....	218
Surface Form of the Pelvis.....	219
Applied Anatomy of the Pelvis.....	220
<i>The Thigh.</i>	
The Femur or Thigh Bone.....	221
Surface Form of the Femur.....	228
Applied Anatomy of the Femur.....	229
<i>The Leg.</i>	
The Patella or Knee Cap.....	230
Surface Form of the Patella.....	231
Applied Anatomy of the Patella.....	231
The Tibia or Shin Bone.....	231
Surface Form of the Tibia.....	236
The Fibula or Calf Bone.....	236
Surface Form of the Fibula.....	238
Applied Anatomy of the Bones of the Leg.....	239
<i>The Foot.</i>	
The Tarsus.....	239
The Calcaneus.....	239
The Astragalus or Ankle Bone.....	244
The Cuboid.....	245
The Scaphoid or Navicular Bone.....	246
The Cuneiform or Wedge Bones.....	247
The Metatarsal Bones.....	249
Peculiar Characters of the Metatarsal Bones.....	250
The Phalanges of the Foot.....	252
Development of the Foot.....	254
Construction of the Foot as a Whole.....	254
Surface Form of the Foot.....	255
Applied Anatomy of the Foot.....	256
Sesamoid Bones.....	257

THE ARTICULATIONS OR JOINTS.

Structures Composing the Joints.....	259
Bone.....	259
Cartilage.....	259
Ligaments.....	261
Synovial Membrane.....	261
Forms of Articulation:	
Synarthrosis (Immovable Articulation).....	263
Amphiarthrosis (Mixed Articulation).....	264
Diarthrosis (Movable Articulation).....	264
Kinds of Movement Admitted in Joints.....	266
Ligamentous Action of Muscles.....	267
<i>ARTICULATIONS OF THE TRUNK.</i>	
Articulations of the Vertebral Column.....	268
The Ligaments of the Vertebral Bodies or Centra.....	268
The Ligaments Connecting the Laminae.....	271
The Ligaments Connecting the Articular Processes.....	271
The Ligaments Connecting the Spinous Processes.....	272
The Ligaments Connecting the Transverse Processes.....	272
Articulations of the Atlas with Axis.....	273
<i>Articulations of the Vertebral Column with Cranium.</i>	
Articulation of Atlas with Occipital Bone.....	275
Articulation of Axis with Occipital Bone.....	277
Applied Anatomy of Articulations of the Vertebral Column.....	278
The Temporomandibular Articulation.....	279
Surface Form.....	281
Applied Anatomy.....	281
Articulations of the Ribs with the Vertebral or the Costovertebral Articulations.....	282
The Costocentral Articulations.....	282
The Costotransverse Articulations.....	284
The Costosternal Articulations.....	286
Articulations of the Cartilages of the Ribs with Each Other.....	288
Articulations of the Ribs with their Cartilages.....	288
Articulations of the Sternum.....	288
Articulation of the Vertebral Column with the Pelvis.....	289
Articulations of the Pelvis.....	290
Articulation of the Sacrum and Ilium.....	290
Ligaments Passing between the Sacrum and Ischium.....	291
Articulation of the Sacrum and Coccyx.....	292
Articulation of the Pubic Bones.....	294
<i>ARTICULATIONS OF THE UPPER EXTREMITY.</i>	
Sternoclavicular Articulation.....	295
Surface Form.....	297
Applied Anatomy.....	297
Acromioclavicular Articulation or Scapulo-clavicular Articulation.....	297
Surface Form.....	299
Applied Anatomy.....	299

Proper Ligaments of the Scapula.....	299	The Hip-joint—	
The Shoulder-joint.....	301	Applied Anatomy.....	329
Surface Form.....	304	The Knee-joint.....	331
Applied Anatomy.....	304	Surface Form.....	338
The Elbow-joint.....	306	Applied Anatomy.....	338
Surface Form.....	309	Tibiofibular Articulation.....	340
Applied Anatomy.....	309	Superior Tibiofibular Articulation.....	340
Radio-ulnar Articulation.....	310	Middle Tibiofibular Ligament or Inter-	
Superior Articulation.....	310	osseous Membrane.....	341
Surface Form.....	311	Inferior Tibiofibular Articulation.....	341
Applied Anatomy.....	311	The Tibiotarsal Articulation or Ankle-joint	342
Middle Radio-ulnar Ligaments.....	311	Surface Form of Ankle-joint.....	346
Inferior Articulation.....	312	Applied Anatomy of Ankle-joint.....	346
Surface Form.....	314	Articulations of the Tarsus.....	347
The Radiocarpal or Wrist-joint.....	314	Articulation of the Calcaneus and	
Surface Form.....	315	Astragalus.....	347
Applied Anatomy.....	315	Articulation of the Calcaneus with the	
Articulations of the Carpus.....	315	Cuboid.....	347
Articulations of the First Row of Carpal		The Ligaments Connecting the Cal-	
Bones.....	315	caneus and Scaphoid.....	348
Articulations of the Second Row of		Applied Anatomy.....	349
Carpal Bones.....	316	Articulation of the Astragalus with	
Articulations of the Two Rows of		the Scaphoid Bone.....	349
Carpal Bones with Each Other.....	316	The Articulation of the Scaphoid with	
Carpometacarpal Articulations.....	317	the Cuneiform Bones.....	349
Articulation of the Metacarpal Bone		The Articulation of the Scaphoid with	
of the Thumb with the Trapezium.....	317	the Cuboid.....	350
Articulations of the Metacarpal Bones		The Articulations of the Cuneiform	
of the Four Inner Fingers with the		Bones with Each Other or the Inter-	
Carpus.....	318	cuneiform Articulations.....	350
Articulations of the Metacarpal Bones		The Articulation of the External	
with Each Other.....	319	Cuneiform Bone with the Cuboid	
Metacarpophalangeal Articulations.....	320	Applied Anatomy.....	351
Surface Form.....	321	Tarsometatarsal Articulations.....	351
Articulations of the Phalanges.....	321	Articulations of the Metatarsal Bones	
		with Each Other.....	352
		Metatarsophalangeal Articulations.....	353
		Articulations of the Phalanges.....	354
		Surface Form.....	354
		Applied Anatomy.....	354

ARTICULATIONS OF THE LOWER EXTREMITY.

THE MUSCLES AND FASCIÆ.

General Description of Muscles.....	355	The Maxillary Region.....	373
Form and Attachment of Muscles.....	357	Levator Labii Superioris.....	373
Applied Anatomy of Muscles.....	359	Levator Anguli Oris.....	373
General Description of Tendons.....	360	Zygomaticus Major.....	373
General Description of Aponeurosis.....	360	Zygomaticus Minor.....	373
General Description of Fasciæ.....	360	The Mandibular Region.....	374
Development of Skeletal Musculature.....	361	Levator Menti.....	374
		Depressor Labii Inferioris or Quad-	
		ratus Menti.....	374
		Depressor Anguli Oris.....	374
		The Buccal Region.....	374
		Orbicularis Oris.....	374
		Buccinator.....	375
		Risorius.....	377
		The Temporomandibular Region.....	377
		Masseteric Fasciæ.....	377
		Masseter Muscle.....	377
		Temporal Fasciæ.....	378
		Temporal Muscle.....	378
		The Pterygomandibular Region.....	379
		External Pterygoid Muscle.....	379
		Internal Pterygoid Muscle.....	380
		Surface Form of Muscles of Head and Face.....	381
		MUSCLES AND FASCIÆ OF THE NECK.	
		Subdivisions into Groups.....	381
		The Superficial Cervical Region.....	381
		Superficial Cervical Fasciæ.....	381
		Platysma.....	381
		Deep Cervical Fasciæ.....	382
		Applied Anatomy.....	384
		Sternomastoid.....	385
		Triangles of the Neck.....	386
		Applied Anatomy.....	386
		The Infrahyoid Region.....	386
		Sternohyoid.....	386
		Sternothyroid.....	387
		Thyrohyoid.....	387
		Omohyoid.....	388

MUSCLES AND FASCIÆ OF THE NECK.

Subdivisions into Groups.....	381
The Superficial Cervical Region.....	381
Superficial Cervical Fasciæ.....	381
Platysma.....	381
Deep Cervical Fasciæ.....	382
Applied Anatomy.....	384
Sternomastoid.....	385
Triangles of the Neck.....	386
Applied Anatomy.....	386
The Infrahyoid Region.....	386
Sternohyoid.....	386
Sternothyroid.....	387
Thyrohyoid.....	387
Omohyoid.....	388

The Suprahyoid Region.....	388
Digastric.....	388
Stylohyoid.....	389
Mylohyoid.....	389
Geniohyoid.....	390
The Lingual Region.....	391
Geniohyoglossus.....	391
Hyoglossus.....	391
Chondroglossus.....	392
Styloglossus.....	392
The Muscle Substance of the Tongue..	393
Applied Anatomy.....	394
The Pharyngeal Region.....	394
Inferior Constrictor.....	394
Middle Constrictor.....	395
Superior Constrictor.....	395
Stylopharyngeus.....	396
The Palatal Region.....	397
Levator Palati.....	397
Tensor Palati.....	397
Palatal Aponeurosis.....	397
Azygos Uvulae.....	398
Palatoglossus.....	398
Palatopharyngeus.....	398
Salpingopharyngeus.....	399
Applied Anatomy.....	399
The Anterior Vertebral Region.....	400
Rectus Capitis Anticus Major.....	400
Rectus Capitis Anticus Minor.....	400
Rectus Capitis Lateralis.....	400
Longus Colli.....	401
The Lateral Vertebral Region.....	401
Scalenus Anticus.....	401
Scalenus Medius.....	401
Scalenus Posticus.....	402
Surface Form of Muscles of Neck.....	402
MUSCLES AND FASCLE OF THE TRUNK.	
Subdivision into Groups.....	403
<i>Muscles of the Back.</i>	
Subdivision into Groups.....	403
The First Layer.....	404
Superficial Fascia.....	404
Deep Fascia.....	404
Trapezius.....	404
Ligamentum Nuchae.....	406
Latissimus Dorsi.....	406
The Second Layer.....	407
Levator Anguli Scapulae.....	407
Rhomboideus Minor.....	407
Rhomboideus Major.....	407
The Third Layer.....	408
Serratus Posticus Superior.....	408
Serratus Posticus Inferior.....	408
Vertebral Aponeurosis.....	408
Splenius Capitis.....	409
Splenius Colli.....	409
The Fourth Layer.....	410
Erector Spinae.....	410
Iliocostalis.....	410
Musculus Accessorius.....	410
Cervicalis Ascendens.....	412
Longissimus Dorsi.....	412
Transversalis Cervicis.....	412
Trachelomastoid.....	412
Spinalis Dorsi.....	412
Spinalis Colli.....	412
Complexus.....	412
The Fifth Layer.....	413
Semispinalis Dorsi.....	413
Semispinalis Colli.....	413
Multifidus Spinae.....	413
Rotatores Spinae.....	413
Supraspinales.....	414
Interspinales.....	414
Extensor Coccygis.....	414
Intertransversales.....	414
Rectus Capitis Posticus Major.....	414
Rectus Capitis Posticus Minor.....	414
Obliquus Inferior.....	415
Obliquus Superior.....	415
Suboccipital Triangle.....	415
Applied Anatomy.....	416

Muscles and Fascia of the Thorax.

Intercostal Fascia.....	417
Intercostal Muscles.....	417
External Intercostals.....	417
Internal Intercostals.....	417
Infracostales.....	417
Triangularis Sterni.....	417
Levatores Costarum.....	417
Diaphragm.....	418

Muscles of the Abdomen.

Antero-lateral Muscles of the Abdomen...	423
Superficial Fascia.....	424
Deep Fascia.....	424
External or Descending Oblique.....	424
Aponeurosis of the External Oblique.....	425
External Abdominal Ring.....	426
Applied Anatomy.....	427
Poupart's Ligament.....	427
Gimbernat's Ligament.....	428
Triangular Fascia.....	428
Ligament of Cooper.....	428
Internal or Ascending Oblique.....	428
Cremaster Muscle.....	430
Transversalis.....	432
Rectus Abdominis.....	433
Pyramidalis.....	435
Linea Alba.....	435
Linea Semilunares.....	436
Fascia Transversalis.....	436
Internal or Deep Abdominal Ring.....	437
Inguinal or Spermatic Canal.....	437
Surface Form.....	439
Posterior Muscles of the Abdomen.....	439
The Fascia Covering the Quadratus Lumborum.....	439
Quadratus Lumborum.....	439

Muscles and Fascia of the Pelvic Outlet

The Central Tendinous Point of the Perineum.....	442
The Muscles of the Perineum in the Male.....	442
Superficial Transverse Perineal.....	442
Accelerator Urinae.....	443
Erector Penis.....	444
The Muscles of the Perineum in the Female.....	445
Superficial Transverse Perineal.....	445
Sphincter Vaginae.....	445
Erector Clitoridis.....	446
The Triangular Ligament in the Male and in the Female.....	446
Compressor or Constrictor Urethrae.....	448
The Pelvic Fascia.....	448
Levator Ani.....	450
Coccygeus.....	453
Muscles of the Ischiorectal Region.....	453
Corrugator Cutis Ani.....	453
External Sphincter Ani.....	453
Internal Sphincter Ani.....	454
Ischiorectal Fossa.....	454

MUSCLES AND FASCLE OF THE UPPER EXTREMITY.

Subdivision into Groups.....	455
Dissection of Pectoral Region and Axilla...	455

Muscles and Fascia of the Thoracic Region.

The Anterior Thoracic Region.....	455
Superficial Fascia.....	455
Deep Fascia.....	456
Pectoralis Major.....	456
Costocoracoid Membrane or the Clavicular Fascia.....	459
Pectoralis Minor.....	460
Subclavius.....	460
The Lateral Thoracic Region.....	461
Serratus Magnus.....	461
Applied Anatomy.....	461

<i>Muscles and Fasciæ of the Shoulder and Arm.</i>		Surface Form of Muscles of the Upper Ex-	
The Aeromial Region.....	462	tremity.....	495
Deltoid.....	462	Applied Anatomy of Muscles of the Upper	
Applied Anatomy.....	463	Extremity.....	497
The Anterior Scapular Region.....	463	MUSCLES AND FASCIE OF THE LOWER EXTREMITY.	
Subscapularis.....	464	Subdivision into Groups.....	501
The Posterior Scapular Region.....	464	<i>Muscles and Fasciæ of the Iliac Region.</i>	
Supraspinatus.....	464	Iliac Fascia.....	502
Infraspinatus.....	465	Psoas Magnus.....	504
Teres Minor.....	466	Psoas Parvus.....	504
Teres Major.....	466	Iliacus.....	504
<i>Muscles and Fasciæ of the Arm.</i>		Applied Anatomy.....	505
The Anterior Humeral Region.....	467	<i>Muscles and Fasciæ of the Thigh.</i>	
Deep Fascia.....	467	The Anterior Femoral Region.....	505
Coracobrachialis.....	468	Superficial Fascia.....	506
Biceps or Biceps Flexor Cubiti.....	469	Deep Fascia or Fascia Lata.....	506
Brachialis Anticus.....	469	Applied Anatomy.....	508
The Posterior Humeral Region.....	470	Tensor Fasciæ Femoris.....	508
Triceps or Triceps Extensor Cubiti.....	470	Sartorius.....	508
Subanconeus.....	471	Quadriceps Extensor.....	509
<i>Muscles and Fasciæ of the Forearm.</i>		Rectus Femoris.....	510
Deep Fascia.....	471	Vastus Externus.....	510
The Anterior Radioulnar Region.....	472	Vastus Internus.....	510
Superficial Layer.....	472	Crureus.....	511
Pronator Teres.....	472	Suberureus.....	512
Applied Anatomy.....	473	Applied Anatomy.....	512
Flexor Carpi Radialis.....	473	The Internal Femoral Region.....	512
Palmaris Longus.....	474	Graeilis.....	512
Flexor Carpi Ulnaris.....	474	Pectineus.....	513
Flexor Sublimis Digitorum.....	475	Adductor Longus.....	513
Deep Layer.....	476	Adductor Brevis.....	514
Flexor Profundus Digitorum.....	476	Adductor Magnus.....	514
Flexor Longus Pollicis.....	476	Hunter's Canal.....	515
Pronator Quadratus.....	478	Applied Anatomy.....	515
Applied Anatomy.....	478	<i>The Muscles and Fasciæ of the Hip.</i>	
The Radial Region.....	479	The Gluteal Region.....	515
Brachioradialis.....	479	Gluteus Maximus.....	515
Extensor Carpi Radialis Longior.....	479	Gluteus Medius.....	516
Extensor Carpi Radialis Brevior.....	479	Gluteus Minimus.....	517
The Posterior Radioulnar Region.....	480	Pyriformis.....	517
Superficial Layer.....	480	Obturator Membrane.....	517
Extensor Communis Digitorum.....	480	Obturator Internus.....	518
Extensor Minimi Digiti.....	481	Gemelli.....	520
Extensor Carpi Ulnaris.....	482	Quadratus Femoris.....	520
Anconæus.....	482	Obturator Externus.....	521
Supinator (Brevis).....	482	The Posterior Femoral Region.....	522
Extensor Ossis Metacarpi Pollicis.....	482	Biceps Femoris.....	522
Extensor Brevis Pollicis.....	483	Semitendinous.....	524
Extensor Longus Pollicis.....	484	Semimembranous.....	524
Extensor Indicis.....	484	Applied Anatomy.....	525
Applied Anatomy.....	485	<i>Muscles and Fasciæ of the Leg.</i>	
<i>Muscles and Fasciæ of the Hand.</i>		The Anterior Tibiofibular Region.....	525
Anterior Annular Ligament.....	486	Deep Fascia of the Leg.....	525
The Synovial Membranes of the Flexor		Tibialis Anticus.....	526
Tendons at Wrist.....	486	Extensor Proprius Hallucis.....	527
Applied Anatomy.....	487	Extensor Longus Digitorum.....	527
Bursa about the Hand and Wrist.....	487	Peroneus Tertius.....	527
Posterior Annular Ligament.....	487	The Posterior Tibiofibular Region.....	528
Superficial Transverse Ligament of Fingers.....	489	Superficial Layer.....	528
The Radial Region.....	489	Gastrocnemius.....	528
Abductor Pollicis.....	489	Soleus.....	529
Opponens Pollicis.....	490	Tendo Achillis.....	530
Flexor Brevis Pollicis.....	490	Plantaris.....	530
Adductor Obliquus Pollicis.....	490	Deep Layer.....	531
Adductor Transversus Pollicis.....	492	Deep Transverse Fascia.....	531
The Ulnar Region.....	492	Popliteus.....	531
Palmaris Brevis.....	492	Flexor Longus Hallucis.....	532
Abductor Minimi Digiti.....	492	Flexor Longus Digitorum.....	533
Flexor Brevis Minimi Digiti.....	493	Tibialis Posticus.....	533
Opponens Minimi Digiti.....	493	The Fibular Region.....	534
The Middle Palmar Region.....	493	Peroneus Longus.....	534
Lumbriales.....	493	Peroneus Brevis.....	535
Interossei.....	493	Applied Anatomy.....	535
Dorsal Interossei.....	494		
First Dorsal Interossei Muscle or			
Abductor Indicis.....	494		
Palmar Interossei.....	494		

Muscles and Fasciæ of the Foot.

Anterior Annular Ligament.....	536
Internal Annular Ligament.....	536
External Annular Ligament.....	537
The Dorsal Region.....	537
Fascia of the Dorsal Region.....	537
Extensor Brevis Digitorum.....	537
The Plantar Region.....	537
Plantar Fascia.....	537
The First Layer.....	538
Abductor Hallucis.....	538
Flexor Brevis Digitorum.....	538
Fibrous Sheaths of Flexor Tendons.....	539
Abductor Minimi Digiti.....	539

The Plantar Region—	
The Second Layer.....	539
Flexor Accessorius.....	539
Lumbricales.....	540
The Third Layer.....	541
Flexor Brevis Hallucis.....	541
Adductor Obliquus Hallucis.....	541
Adductor Transversus Hallucis.....	541
Flexor Brevis Minimi Digiti.....	541
The Fourth Layer.....	541
Interossei Muscles.....	541
Surface Form of Muscles of the Lower	
Extremity.....	543
Applied Anatomy of Muscles of the Lower	
Extremity.....	544

THE VASCULAR SYSTEMS.

THE HEART AND BLOODVESSELS.

The Circulation of the Blood.....	547
-----------------------------------	-----

The Pericardium.

Structure of the Pericardium.....	548
Vestigial Fold of the Pericardium.....	550
Applied Anatomy of the Pericardium.....	550

The Heart.

Position of the Heart.....	551
Component Parts of the Heart.....	553
The Cavities of the Heart.....	553
Right Auricle.....	554
Right Ventricle.....	557
Left Auricle.....	559

The Cavities of the Heart—	
Left Ventricle.....	560
Capacity of the Cavities of the Heart.....	561
Size and Weight of the Heart.....	562
Structure of the Heart.....	562
Endocardium.....	562
Myocardium.....	562
Fibres of Auricles.....	562
Fibres of Ventricles.....	563
The Cardiac Cycle and the Action of the	
Valves.....	565
Surface Form of the Heart.....	567
Applied Anatomy of the Heart.....	568
Peculiarities of the Vascular System in the	
Fetus.....	568
Fetal Circulation.....	570
Changes in the Vascular System at Birth..	571

THE ARTERIES.

The Distribution of the Arteries.....	572
Anastomosis of the Arteries.....	572
Histology of Arteries and Capillaries.....	573
Bloodvessels of the Bloodvessel Wall.....	573
Lymphatics of the Arteries.....	574
Nerves of the Arteries.....	574
Arterial Sheath.....	574
Applied Anatomy of the Arteries.....	574

THE PULMONARY ARTERY.

Right Branch of the Pulmonary Artery....	575
Left Branch of the Pulmonary Artery.....	575
Applied Anatomy of the Pulmonary Artery	575

THE AORTA.

The Ascending Aorta.

Relations of the Ascending Aorta.....	576
Branches of the Ascending Aorta.....	578
The Coronary Arteries.....	578
Applied Anatomy of the Coronary	
Arteries.....	578

The Arch of the Aorta.

Relations of the Arch of the Aorta.....	579
Peculiarities of the Arch of the Aorta.....	580
Applied Anatomy of the Arch of the Aorta..	580
Branches of the Arch of the Aorta.....	581
The Innominate Artery.....	582
Relations.....	582
Branches.....	582
Thyroidea Ima.....	582
Applied Anatomy.....	582
Peculiarities.....	583

THE ARTERIES OF THE HEAD AND NECK.

The Common Carotid Artery.

Relations of the Common Carotid Artery..	583
Peculiarities of the Common Carotid Artery	586
Surface Marking of the Common Carotid	
Artery.....	586
Applied Anatomy of the Common Carotid	
Artery.....	586

The External Carotid Artery.....	588
Relations.....	588
Surface Marking.....	588
Applied Anatomy.....	588
Branches.....	589
Superior Thyroid Artery.....	589
Applied Anatomy.....	590
Lingual Artery.....	590
Applied Anatomy.....	591
Facial Artery.....	592
Applied Anatomy.....	595
Occipital Artery.....	595
Posterior Auricular Artery.....	596
Ascending Pharyngeal Artery.....	597
Applied Anatomy.....	597
Superficial Temporal Artery.....	597
Applied Anatomy.....	598
Internal Maxillary Artery.....	598
Applied Anatomy.....	600
The Triangles of the Neck.....	602
Anterior Triangle of the Neck.....	603
Posterior Triangle of the Neck.....	605
The Internal Carotid Artery.....	606
Cervical Portion.....	607
Petrous Portion.....	607
Cavernous Portion.....	608
Cerebral Portion.....	608
Peculiarities.....	608
Applied Anatomy.....	608
Branches.....	609
Tympanic.....	609
Vidian.....	609
Arteriae Receptaculi.....	609
Anterior Meningeal.....	609
Ophthalmic.....	610
Anterior Cerebral.....	614
Middle Cerebral.....	616
Posterior Communicating Artery..	617
Choroid Artery.....	617

The Arteries of the Brain.

The Central Ganglionic System.....	618
The Cortical Arterial System.....	619
The Vertebral Artery.....	619
Applied Anatomy.....	620

THE ARTERIES OF THE UPPER EXTREMITY.

<i>The Subclavian Artery.</i>	
First Part of the Right Subclavian Artery . . .	623
First Part of the Left Subclavian Artery . . .	625
Second and Third Parts of the Subclavian Artery . . .	625
Peculiarities of the Subclavian Artery . . .	626
Surface Marking of the Subclavian Artery . . .	626
Applied Anatomy of the Subclavian Artery . . .	627
Branches . . .	628
Vertebral Artery . . .	628
Thyroid Axis . . .	628
Peculiarities . . .	630
Internal Mammary Artery . . .	631
Superior Intercostal Artery . . .	633
<i>The Axilla.</i>	
Boundaries of the Axilla . . .	633
Contents of the Axilla . . .	634
Applied Anatomy . . .	634
The Axillary Artery . . .	635
Surface Marking . . .	637
Applied Anatomy . . .	637
Branches . . .	638
Superior Thoracic . . .	638
Aeromiothoracic . . .	638
Long Thoracic or External Mammary . . .	638
Alar Thoracic . . .	639
Subscapular . . .	639
Circumflex Arteries . . .	639
<i>The Brachial Artery.</i>	
Relations of the Brachial Artery . . .	640
Anatomy of the Bend of the Elbow . . .	641
Peculiarities of the Brachial Artery . . .	641
Surface Marking of the Brachial Artery . . .	641
Applied Anatomy of the Brachial Artery . . .	641
Branches of the Brachial Artery . . .	642
Superior Profunda Artery . . .	642
Nutrient Artery . . .	643
Inferior Profunda Artery . . .	643
Anastomotica Magna . . .	643
Muscular Branches . . .	644
The Anastomosis Around the Elbow-joint . . .	644
The Radial Artery . . .	644
The Deep Palmar Arch . . .	645
Surface Marking . . .	646
Applied Anatomy . . .	646
Branches . . .	646
Radial Recurrent . . .	646
Muscular Branches . . .	646
Anterior Radial Carpal . . .	647
Superficialis Volæ . . .	647
Posterior Radial Carpal . . .	647
Dorsalis Pollicis . . .	647
Dorsalis Indicis . . .	647
Princeps Pollicis . . .	647
Radialis Indicis . . .	647
Perforating Arteries . . .	648
Palmar Interosseous . . .	648
Palmar Recurrent Branches . . .	648
The Ulnar Artery . . .	648
Surface Marking . . .	649
Applied Anatomy . . .	649
Branches . . .	650
Anterior Ulnar Recurrent . . .	650
Posterior Ulnar Recurrent . . .	650
Interosseous Artery . . .	650
Muscular Branches . . .	651
Anterior Ulnar Carpal . . .	651
Posterior Ulnar Carpal . . .	651
Profunda Branch . . .	651
Superficial Palmar Arch . . .	652
Surface Marking . . .	652
Applied Anatomy . . .	652
THE ARTERIES OF THE TRUNK.	
<i>The Descending Aorta.</i>	
The Thoracic Aorta . . .	653
Applied Anatomy . . .	654
Branches . . .	654

The Thoracic Aorta—Branches—

Bronchial Arteries . . .	654
Esophageal Arteries . . .	654
Pericardial Arteries . . .	654
Mediastinal Branches . . .	654
Intercostal Arteries . . .	655
Applied Anatomy . . .	657
The Abdominal Aorta . . .	657
Surface Marking . . .	657
Applied Anatomy . . .	658
Branches . . .	658
Inferior Phrenic Arteries . . .	658
The Cœliac Axis or Artery . . .	659
Applied Anatomy . . .	662
The Suprarenal Artery . . .	662
The Lumbar Arteries . . .	662
The Superior Mesenteric Artery . . .	663
The Renal Arteries . . .	665
The Spermatic Arteries . . .	665
The Ovarian Arteries . . .	665
The Inferior Mesenteric Artery . . .	666
<i>The Common Iliac Arteries.</i>	
Relations of the Common Iliac Arteries . . .	668
Branches of the Common Iliac Arteries . . .	668
Peculiarities of the Common Iliac Arteries . . .	668
Surface Marking . . .	669
Applied Anatomy of the Common Iliac Arteries . . .	669
The Internal Iliac Artery . . .	669
Applied Anatomy . . .	671
Branches . . .	671
Superior Vesical . . .	671
Middle Vesical . . .	672
Inferior Vesical . . .	672
Middle Hemorrhoidal . . .	672
Uterine Artery . . .	672
Vaginal Artery . . .	672
Applied Anatomy . . .	673
Obturator Artery . . .	673
Internal Pudic Artery . . .	674
Sciatic Artery . . .	677
Iliolumbar Artery . . .	678
Lateral Sacral Arteries . . .	678
Gluteal Artery . . .	678
Surface Marking . . .	679
Applied Anatomy . . .	679
The External Iliac Artery . . .	679
Surface Marking . . .	680
Applied Anatomy . . .	680
Branches . . .	680
Deep Epigastric Artery . . .	680
Applied Anatomy . . .	681
Deep Circumflex Iliac Artery . . .	682
THE ARTERIES OF THE LOWER EXTREMITY.	
<i>The Femoral Artery.</i>	
The Femoral or Crural Sheath . . .	683
The Femoral or Crural Canal . . .	684
Scarpa's Triangle . . .	685
Hunter's Canal or the Adductor Canal . . .	685
Relations of the Femoral Artery . . .	686
Peculiarities of the Femoral Artery . . .	687
Surface Marking of the Femoral Artery . . .	687
Applied Anatomy of the Femoral Artery . . .	687
Branches of the Femoral Artery . . .	688
Superficial Epigastric . . .	689
Superficial Circumflex Iliac . . .	689
Superficial External Pudic or the Superior Superficial External Pudic . . .	689
Deep External Pudic . . .	689
Muscular Branches . . .	689
Deep Femoral or the Profunda Femoris . . .	689
<i>The Popliteal Artery.</i>	
The Popliteal Space . . .	691
Boundaries . . .	692
Contents . . .	692
Position of Contained Parts . . .	692
Peculiarities . . .	693
Surface Marking . . .	693
Applied Anatomy . . .	693
Branches . . .	694

The Popliteal Space—Branches—		The Dorsalis Pedis Artery—Branches—	
Superior Muscular Branches.....	694	Cutaneous Branches.....	699
Inferior Muscular or Sural		Tarsal Artery.....	699
Branches.....	694	Metatarsal Artery.....	699
Cutaneous Branches.....	694	Communicating Artery.....	700
Superior Articular Arteries.....	694	The Posterior Tibial Artery.....	700
Azygos Articular Artery.....	695	Surface Marking.....	701
Inferior Articular Arteries.....	695	Applied Anatomy.....	701
Circumpatellar Anastomosis.....	696	Branches.....	701
The Anterior Tibial Artery.....	696	Peroneal Artery.....	701
Surface Marking.....	697	Cutaneous Branches.....	702
Applied Anatomy.....	697	Nutrient Artery.....	702
Branches.....	697	Muscular Branches.....	703
Posterior Recurrent Tibial.....	698	Communicating Branch.....	703
Superior Fibular.....	698	Malleolar or Internal Malleolar.....	703
Anterior Recurrent Tibial.....	698	Internal Calcaneal.....	703
Muscular Branches.....	698	Internal Plantar Artery.....	703
The Dorsalis Pedis Artery.....	698	External Plantar Artery.....	703
Surface Marking.....	699	Surface Marking.....	704
Applied Anatomy.....	699	Applied Anatomy.....	704
Branches.....	699		

THE VEINS.

Subdivisions of the Veins.....	705	The Sinuses of the Dura. Ophthalmic Veins	
Histology of the Veins.....	706	and Emissary Veins—	
Superficial or Cutaneous Veins.....	707	Inferior Petrosal Sinus.....	726
Deep Veins.....	707	Transverse or Basilar Sinus.....	727
Sinuses.....	707	Emissary Veins.....	727
		Applied Anatomy.....	727
THE PULMONARY VEINS.		<i>The Veins of the Upper Extremity and Thorax.</i>	
Applied Anatomy of the Pulmonary Veins..	708	The Superficial Veins of the Upper Ex-	
		tremitry.....	728
THE SYSTEMIC VEINS.		Superficial Veins of the Hand and	
<i>The Cardiac Veins.</i>		Fingers.....	728
The Coronary Sinus.....	708	Anterior Ulnar Vein.....	729
		Posterior Ulnar Vein.....	729
<i>The Veins of the Head and Neck.</i>		Common Ulnar Vein.....	729
Veins of the Exterior of the Head and Face	710	Radial Vein.....	730
Frontal Vein.....	710	Median Vein.....	730
Supraorbital Vein.....	710	Basilic Vein.....	730
Angular Vein.....	710	Cephalic Vein.....	730
Facial Vein.....	710	The Deep Veins of the Upper Extremity...	731
Common Facial Vein.....	710	Interosseous Veins.....	731
Applied Anatomy.....	711	Deep Palmar Veins.....	731
Superficial Temporal Vein.....	712	Brachial Veins.....	731
Pterygoid Plexus.....	712	Axillary Vein.....	731
Internal Maxillary Vein.....	712	Applied Anatomy.....	732
Temporomaxillary Vein.....	712	Subclavian Vein.....	732
Posterior Auricular Vein.....	712	Innominate or Brachiocephalic Veins...	733
Occipital Vein.....	713	Internal Mammary Veins.....	734
The Veins of the Neck.....	713	Vertebral Vein.....	734
External Jugular Vein.....	713	Inferior Thyroid Veins.....	734
Posterior External Jugular Vein.....	713	Superior Intercostal Veins.....	735
Anterior Jugular Vein.....	713	Superior Vena Cava.....	735
Internal Jugular Vein.....	714	Azygos Veins.....	736
Applied Anatomy.....	717	Applied Anatomy.....	737
Vertebral Vein.....	717	Bronchial Veins.....	737
The Veins of the Diploë.....	718	The Vertebral Veins.....	737
Meningeal or Dural Veins.....	719	Extravertebral Veins.....	737
The Cerebral Veins.....	719	Intravertebral Veins.....	738
Superficial Cerebral Veins.....	719	Veins of the Bodies of the Vertebrae...	738
Deep Cerebral Veins or Veins of Galen	720	Veins of the Spinal Cord.....	739
Superficial Cerebellar Veins.....	720		
Deep Cerebellar Veins.....	720	<i>Veins of the Lower Extremity, Abdomen, and Pelvis.</i>	
Veins of the Pons.....	720	Superficial Veins of the Lower Extremity...	739
Veins of the Medulla Oblongata.....	721	Superficial Veins of the Foot.....	739
The Sinuses of the Dura. Ophthalmic Veins	721	Internal or Long Saphenous Vein.....	740
and Emissary Veins.....	721	External or Short Saphenous Vein.....	741
Superior Sagittal Sinus.....	721	Applied Anatomy.....	741
Inferior Sagittal Sinus.....	722	Deep Veins of the Lower Extremity.....	741
Straight or Tentorial Sinus.....	722	Deep Veins of the Foot.....	741
Lateral Sinuses.....	722	Posterior Tibial Veins.....	742
Occipital Sinus.....	723	Anterior Tibial Veins.....	742
Cavernous Sinus.....	724	Popliteal Vein.....	742
Applied Anatomy.....	724	Femoral Vein.....	742
Sphenoparietal Sinuses.....	725	External Iliac Vein.....	742
Circular Sinus.....	726	Deep Epigastric Vein.....	742
Superior Petrosal Sinus.....	726	Deep Circumflex Iliac Vein.....	742

Deep Veins of the Lower Extremity—

Pubic Vein.....	743
Internal Iliac Vein.....	743
Hæmorrhoidal Plexus.....	745
Vesicoprostatic Plexus.....	745
Vesical Plexus.....	745
Applied Anatomy.....	745
Dorsal Veins of the Penis.....	746
Vaginal Plexuses and Veins.....	747
Uterine Plexuses.....	747
Common Iliac Veins.....	747
Inferior Vena Cava.....	748
Applied Anatomy.....	748
Lumbar Veins.....	749
Spermatic Veins.....	750
Applied Anatomy.....	750
Ovarian Veins.....	751

Deep Veins of the Lower Extremity—

Renal Veins.....	751
Suprarenal Veins.....	751
Inferior Phrenic Veins.....	751
Hepatic Veins.....	751

THE PORTAL SYSTEM OF VEINS.

The Portal Vein.....	751
The Splenic Vein.....	752
The Superior Mesenteric Vein.....	753
The Cystic Vein.....	754
Paraumbilical Veins.....	754
Anastomosis between Portal and Systemic Veins.....	754
Applied Anatomy.....	754
Development of the Blood-vascular System.....	755

THE LYMPHATIC SYSTEM.

Subdivisions into Superficial and Deep Sets.....	767
Lymph Nodes or Lymphatic Glands.....	768
Hemolymph Nodes.....	768
Structure of Lymphatics.....	769
Origin of Lymphatics.....	769
Termination of Lymphatics.....	769
Development of Lymphatic Vessels.....	769
Applied Anatomy.....	770

THE THORACIC DUCT.

Structure of the Thoracic Duct.....	773
The Right Lymphatic Duct.....	773
Applied Anatomy.....	774

LYMPHATICS OF THE HEAD, FACE, AND NECK.

The Lymphatic Nodes of the Head and Face.....	774
Occipital Nodes.....	774
Posterior Auricular or Mastoid Nodes.....	774
Parotid Lymph Nodes.....	774
Internal Maxillary Nodes.....	776
Lingual Nodes.....	776
Retropharyngeal Nodes.....	776
Lymphatic Vessels of the Scalp.....	776
Lymphatic Vessels of the Pinna and External Auditory Meatus.....	777
Lymphatic Vessels of the Face.....	777
Lymphatic Vessels of the Nasal Fosse.....	777
Lymphatic Vessels of the Mouth.....	777
Lymphatic Vessels of the Tongue.....	777
Lymph Nodes of the Neck.....	777
Superficial Cervical Nodes.....	777
Submaxillary Nodes.....	778
Submental or Suprahyoid Nodes.....	779
Retropharyngeal Nodes.....	779
Deep Cervical Nodes.....	779
Lymphatic Vessels of the Skin and Muscles of the Neck.....	780
Applied Anatomy.....	780

THE LYMPHATICS OF THE UPPER EXTREMITY.

The Lymph Nodes of the Upper Extremity.....	781
Superficial Lymph Nodes.....	781
Deep Lymph Nodes or the Axillary Nodes.....	782
Lymphatic Vessels of the Upper Extremity.....	783
Superficial Lymphatic Vessels.....	783
Deep Lymphatic Vessels.....	784
Applied Anatomy.....	784

THE LYMPHATICS OF THE LOWER EXTREMITY.

The Lymph Nodes of the Lower Extremity.....	784
Anterior Tibial Node.....	784
Popliteal Nodes.....	784
Inguinal Nodes.....	785
Superficial Inguinal Nodes.....	785
Deep Inguinal Nodes.....	786
Applied Anatomy.....	786
The Lymphatic Vessels of the Lower Extremity.....	786
Superficial Vessels.....	786
Deep Vessels.....	787

THE LYMPHATICS OF THE PELVIS AND ABDOMEN.

The Parietal Nodes.....	787
External Iliac Nodes.....	787
Internal Iliac or Hypogastric Nodes.....	787
Common Iliac Nodes.....	788
Lumbar Nodes.....	788
Lateral Aortic Nodes.....	788
Lymphatic Vessels of the Abdomen and Pelvis.....	789
Superficial Vessels.....	789
Deep Vessels.....	790
Lymphatic Vessels of the Perineum and External Genitals.....	790
The Visceral Nodes.....	790
The Superior Mesenteric Nodes.....	790
Mesenteric Nodes.....	790
Applied Anatomy.....	791
Ileocolic Nodes.....	791
Mesocolic Nodes.....	791
Inferior Mesenteric Nodes.....	791
Lymphatic Vessels of the Abdomen and Pelvic Viscera.....	792
Lymphatic Vessels of the Stomach.....	792
Applied Anatomy.....	793
Lymphatic Vessels of the Duodenum.....	793
Lymphatic Vessels of the Small Intestine.....	793
Lymphatic Vessels of the Large Intestine.....	794
Lymphatic Vessels of the Anus and Rectum.....	794
Lymphatic Vessels of the Liver.....	794
Lymphatic Vessels of the Gall-bladder.....	795
Lymphatic Vessels of the Pancreas.....	796
Lymphatic Vessels of the Spleen.....	796
Lymphatic Vessels of the Suprarenal Glands.....	796
Lymphatic Vessels of the Urinary Organs.....	796
Lymphatic Vessels of the Kidney.....	796
Lymphatic Vessels of the Ureter.....	796
Lymphatic Vessels of the Bladder.....	796
Lymphatic Vessels of the Prostate.....	796
Lymphatic Vessels of the Urethra.....	796
Lymphatic Vessels of the Reproductive Organs.....	796
Lymphatic Vessels of the Testes.....	796
Lymphatic Vessels of the Vas Deferens.....	797
Lymphatic Vessels of the Ovary.....	797
Lymphatic Vessels of the Fallopian Tube.....	797
Lymphatic Vessels of the Uterus.....	797
Lymphatic Vessels of the Vagina.....	797

THE LYMPHATICS OF THE THORAX.

The Parietal Lymph Nodes.....	798
Internal Mammary Nodes.....	798
Intercostal Nodes.....	798
Diaphragmatic Nodes.....	798

Superficial Lymphatic Vessels of the Thoracic Wall.....	798	The Visceral Lymph Nodes—	
Lymphatic Vessels of the Mammary Gland.....	798	Tracheobronchial Nodes.....	800
Deep Lymphatics of the Thoracic Wall.....	799	Applied Anatomy.....	802
Lymphatic Vessels of the Diaphragm.....	799	Lymphatic Vessels of the Thoracic Viscera.....	802
Applied Anatomy.....	800	Lymphatic Vessels of the Heart.....	802
The Visceral Lymph Nodes.....	800	Lymphatic Vessels of the Lungs.....	802
Anterior Mediastinal Nodes.....	800	Lymphatic Vessels of the Pleura.....	802
Posterior Mediastinal Nodes.....	800	Lymphatic Vessels of the Thymus Gland.....	802
		Lymphatic Vessels of the Oesophagus.....	802

THE NERVE SYSTEM.

THE SPINAL CORD AND BRAIN, WITH THEIR MENINGES.		Parts Derived from the Hindbrain—	
Fundamental Facts Regarding the Development of the Nerve System.....	804	The Pons.....	864
Development of Nerve Tissue.....	806	Fourth Ventricle of the Brain.....	864
Structure of the Nerve System.....	807	Internal Structure of the Medulla Oblongata.....	867
The Neurone.....	807	Internal Structure of the Pons and Pars Dorsalis Pontis.....	874
The Dendrites.....	809	Central Connections of the Cranial Nerves to the Hindbrain.....	877
The Axone.....	810	The Cerebellum.....	884
The Collaterals.....	811	Internal Structure of Cerebellum.....	888
Nerve Cell Nidi or Nuclei.....	812	The Cerebellar Peduncles.....	889
"Nerve Fibres" and Nerves.		Weight of the Cerebellum.....	893
Origin and Termination of Nerves.....	814	The Midbrain.....	893
The Supporting Tissue Elements of the Nerve System.....	818	External Morphology.....	894
The Neuroglia.....	818	Corpora Quadrigemina.....	894
Chemical Composition of Nerves.....	819	Superior Brachium.....	895
THE CENTRAL NERVE SYSTEM.		Internal Geniculate Body.....	895
Preliminary Considerations.....	819	Crura Cerebri.....	895
The Spinal Cord.		Taenia Pontis.....	895
External Morphology of the Spinal Cord.....	822	Tractus Peduncularis Transversus.....	895
The Enlargements of the Spinal Cord.....	823	Internal Structure of Midbrain.....	896
Fissures and Grooves of the Spinal Cord.....	825	The Aqueduct and Central Aqueduct Gray.....	897
Columns of the Spinal Cord.....	826	Substantia Nigra or Intercalatum.....	897
Development of the Spinal Cord.....	827	Corpora Quadrigemina.....	897
Internal Structure of the Spinal Cord.....	829	Tegmentum.....	897
Gray Substance of the Cord.....	829	Red Nucleus or Rubrum.....	898
White Substance of the Cord.....	833	Fountain Decussation.....	900
Tracts of the Spinal Cord.....	834	Crusta or Pes.....	900
Ground Bundle of the Dorsal Column.....	837	Summary of the Gray Masses in the Midbrain.....	900
Ground Bundle of the Lateral Column.....	839	Deep Origin of Cranial Nerves Arising in the Midbrain.....	900
Ground Bundle of the Ventral Column.....	840	Parts Derived from the Forebrain.....	902
Myelination of the Axones of the Cord.....	840	External Morphology.....	902
Applied Anatomy of the Spinal Cord.....	842	The Thalamus.....	902
The Membranes of the Cord.		The Pineal Body.....	906
The Spinal Dura.....	843	Third Ventricle.....	907
The Arachnoid.....	844	External Morphology of the Optic Portion of the Hypothalamus.....	908
The Pia of the Cord.....	845	Tuber Cinereum.....	908
Applied Anatomy of the Membranes of the Cord.....	846	Pituitary Body or Hypophysis.....	909
The Brain or Encephalon.		Lamina Terminalis or Terma.....	909
General Appearance and Topography of the Brain.....	847	Optic Tract and its Central Connections.....	909
Dimensions of the Brain.....	849	Optic Chiasm.....	910
Weight of the Brain.....	849	The Cerebral Hemispheres.....	912
The Development of the Brain and the Usual Classifications of its Subdivisions.....	850	External Morphology.....	912
Brief Consideration of the Phases of Development of the Brain Tube.....	852	Configuration of Each Cerebral Hemisphere.....	914
Forebrain.....	852	Cerebral Fissures and Gyres.....	915
Midbrain.....	855	Cerebral Lobes and Fissures.....	916
Hindbrain.....	855	The Interlobar Fissures.....	916
Flexures of the Brain Tube.....	855	Frontal Lobe.....	919
Dorsal and Ventral Laminae or Longitudinal Zones of the Brain.....	855	Parietal Lobe.....	922
Descriptive Anatomy of the Adult Human Brain.		Occipital Lobe.....	924
Parts Derived from the Hindbrain (Rhombencephalon).....	861	Temporal Lobe.....	924
The Medulla Oblongata.....	861	The Island of Reil.....	925
		The Rhinencephalon or Olfactory Lobe.....	926
		Internal Configuration of the Cerebral Hemispheres.....	931
		The Cortex.....	932
		The Corpus Callosum.....	933
		The Lateral Ventricles.....	936
		The Choroid Fissure or Rima.....	940
		The Choroid Plexus of the Lateral Ventricles and Velum Interpositum.....	940

The Cerebral Hemispheres—Internal Configuration of—

The Hippocampus and Fornix.....	942
The Septum Lucidum.....	945
The Anterior Commissure.....	946
Gray Masses in the Cerebral Hemisphere.....	946

Intimate Structure of the Cerebral Cortex and its Special Types in Different Regions.....

Summary of the Cerebral Fibre System.....	951
The Olfactory Pathways.....	958

Cortical Localization of Function.

Motor Area.....	959
Sensory Area.....	960
Language Area.....	960
Association Areas.....	961
Craniocerebral Typography.....	962

The Meninges or Meningeal Membranes of the Brain.

The Dura of the Brain.....	964
Processes of the Dura.....	966
The Arachnoid of the Brain.....	968
Subarachnoid Space.....	969
The Arachnoid Villi or Pacchionian Bodies.....	970
The Pia of the Brain.....	971
Velum Interpositum or the Tela Chorioidea Superior.....	971

THE CRANIAL NERVES.

The First or Olfactory Nerves.

Applied Anatomy.....	974
----------------------	-----

The Second or Optic Nerve.

Optic Chiasm.....	974
Applied Anatomy.....	975

The Third or Oculomotor Nerve.

Applied Anatomy.....	977
----------------------	-----

The Fourth or Trochlear Nerve.

Applied Anatomy.....	978
----------------------	-----

The Fifth, Trigeminal, or Trifacial Nerve.

Gasserian or Semilunar Ganglion.....	978
Ophthalmic Nerve.....	979
The Superior Maxillary Nerve.....	982
The Inferior Maxillary or Mandibular Nerve.....	987
Surface Marking.....	990
Applied Anatomy.....	991

The Sixth or Abducent Nerve.

Applied Anatomy.....	994
----------------------	-----

The Seventh or Facial Nerve.

Applied Anatomy.....	999
----------------------	-----

The Eighth or Acoustic Nerve.

The Cochlear Nerve.....	1000
The Vestibular Nerve.....	1000
Applied Anatomy.....	1001

The Ninth or Glossopharyngeal Nerve.

The Superior or Jugular Ganglion.....	1002
The Inferior or Petrous Ganglion.....	1002
The Gustatory Path.....	1003
Applied Anatomy.....	1003

The Tenth, Vagus, or Pneumogastric Nerve.

The Ganglion of the Root or the Jugular Ganglion.....	1005
The Ganglion of the Trunk or the Inferior Ganglion.....	1005
Applied Anatomy.....	1008

The Eleventh or Spinal Accessory Nerve.

The Bulbar or Vagal Accessory Part.....	1009
The Spinal Portion.....	1009
Applied Anatomy.....	1009

The Twelfth or Hypoglossal Nerve.

Applied Anatomy.....	1012
----------------------	------

THE SPINAL NERVES.

The Anterior or Ventral Root.....	1013
The Posterior or Dorsal Root.....	1013
Spinal Ganglia.....	1013
Points of Emergence of Spinal Nerves.....	1014
Divisions of Spinal Nerves.....	1014

The Cervical Plexus.

The Superficial Branches of the Cervical Plexus.....	1020
The Deep Branches of the Cervical Plexus, Internal Series.....	1023
Applied Anatomy.....	1025
The Deep Branches of the Cervical Plexus, External Series.....	1025
Applied Anatomy.....	1026

The Brachial Plexus.

Applied Anatomy.....	1039
The Anterior or Ventral Divisions of Thoracic Nerves.....	1040
Applied Anatomy.....	1043

The Lumbosacral Plexus.

The Anterior or Ventral Divisions of the Lumbar Nerves.....	1044
The Lumbar Plexus.....	1044
The Anterior or Ventral Divisions of the Sacral and Coccygeal Nerves.....	1051

The Sacral Plexus.

Relations.....	1053
----------------	------

The Pudendal Plexus.

Applied Anatomy.....	1062
----------------------	------

THE SYMPATHETIC NERVE SYSTEM.

Structure of the Sympathetic System.....	1063
------------------------------------------	------

The Gangliated Cord.

Cervicocephalic Portion of the Gangliated Cord.....	1066
The Superior Cervical Ganglion.....	1066
The Middle Cervical Ganglion.....	1069
The Inferior Cervical Ganglion.....	1069
Applied Anatomy.....	1069
Thoracic Portion of the Gangliated Cord.....	1070
Lumbar Portion of the Gangliated Cord.....	1071
Pelvic Portion of the Gangliated Cord.....	1072

The Great Plexuses of the Sympathetic System.

The Cardiac Plexus.....	1072
The Cœliac or Solar Plexus.....	1073
The Hypogastric Plexus.....	1077
The Pelvic Plexuses.....	1077

THE ORGANS OF SPECIAL SENSE.

THE NOSE.

The Outer Nose.

Structure..... 1079

The Nasal Passæ.

The Anterior Nares..... 1081
 The Posterior Nares..... 1081
 The Outer Wall..... 1082
 The Inner Wall..... 1083
 The Mucous Membrane..... 1083
 Applied Anatomy of the Nose..... 1085

THE EYE.

The Capsule of Ténon..... 1086

The Tunics of the Eye.

The Sclera and Cornea..... 1089
 The Sclera..... 1090
 The Cornea..... 1090
 The Choroid, Ciliary Body, and Iris..... 1092
 The Choroid..... 1093
 The Ciliary Body..... 1094
 The Iris..... 1096
 Membrana Pupillaris..... 1100
 The Retina or Tunica Interna..... 1100

The Refracting Media.

The Aqueous Humor..... 1105
 The Vitreous Body..... 1105
 The Crystalline Lens..... 1106
 Applied Anatomy of the Eye..... 1109

The Appendages of the Eye.

The Eyebrows..... 1112
 The Eyelids..... 1112
 The Eyelashes..... 1113
 The Meibomian or Tarsal Glands..... 1114
 The Conjunctiva..... 1114
 The Lacrimal Apparatus..... 1115
 The Lacrimal Gland..... 1115
 The Lacrimal Canals..... 1116
 The Lacrimal Sac..... 1116

The Lacrimal Apparatus—

The Nasal Duct..... 1117
 Surface Form..... 1117
 Applied Anatomy..... 1118

THE EAR.

The External Ear.

The Pinna or Auricula..... 1119
 The Auditory Canal or Meatus..... 1122
 Applied Anatomy..... 1124

The Middle Ear, Drum or Tympanum.

The Tympanic Cavity..... 1125
 The Membrana Tympani..... 1128
 The Ossicles of the Tympanum..... 1131
 The Malleus..... 1131
 The Incus..... 1132
 The Stapes..... 1133
 Applied Anatomy..... 1135

The Internal Ear or Labyrinth.

The Osseous Labyrinth..... 1136
 The Vestibule..... 1136
 The Bony Semicircular Canals..... 1137
 The Modiolus..... 1138
 The Membranous Labyrinth..... 1140
 The Utricle..... 1140
 The Saccule..... 1141
 The Membranous Semicircular Canals..... 1142
 Structure..... 1142

THE ORGANS OF TASTE..... 1148

THE SKIN.

The Cuticle, Scarf Skin, or Epidermis..... 1151
 The Corium, Cutis Vera, Derma, or True Skin..... 1153

The Appendages of the Skin.

The Nails..... 1156
 The Hairs..... 1159
 The Sebaceous Glands..... 1161
 The Sudoriferous or Sweat Glands..... 1161

THE ORGANS OF VOICE AND RESPIRATION.

THE LARYNX.

The Cartilages of the Larynx..... 1163
 The Ligaments of the Larynx..... 1167
 Interior of the Larynx..... 1169
 Muscles of the Larynx..... 1172

THE TRACHEA AND BRONCHI.

The Right Bronchus..... 1176
 The Left Bronchus..... 1177
 Surface Form..... 1179
 Applied Anatomy..... 1180

THE PLEURÆ.

The Mediastinum or Interpleural Space.

The Superior Mediastinum..... 1186

The Anterior Mediastinum..... 1186
 The Middle Mediastinum..... 1186
 The Posterior Mediastinum..... 1187
 Applied Anatomy..... 1188

THE LUNGS.

The Apex of the Lung..... 1188
 The Base of the Lung..... 1188
 Surfaces of the Lung..... 1189
 Borders of the Lung..... 1190
 Fissures and Lobes of the Lung..... 1190
 The Root of the Lung..... 1193
 Divisions of the Bronchi..... 1194
 Surface Form..... 1196
 Applied Anatomy..... 1197

THE ORGANS OF DIGESTION.

THE MOUTH, ORAL OR BUCCAL CAVITY.

The Lips..... 1200
 The Vestibule of the Mouth..... 1200
 The Mucous Membrane..... 1200
 The Cheeks..... 1200
 The Buccal Glands..... 1200
 The Gums..... 1200

The Cavity of the Mouth Proper..... 1201
 Floor of the Mouth..... 1201
 The Palate..... 1202
 The Teeth..... 1204
 Temporary, Deciduous, or Milk Teeth..... 1205
 Permanent Teeth..... 1206
 Chemical Composition of the Teeth..... 1210
 Development of the Teeth..... 1212

The Tongue.

The Body of the Tongue.....	1217
The Base or Root of the Tongue.....	1217
The Apex or Tip of the Tongue.....	1217
The Dorsum of the Tongue.....	1217
The Margin of the Tongue.....	1217
The Under or Inferior Surface of the Tongue.....	1217
Development of the Tongue.....	1221
Applied Anatomy.....	1222

The Salivary Glands.

The Parotid Gland.....	1223
The Submaxillary Gland.....	1225
The Sublingual Gland.....	1226
Development of the Salivary Glands.....	1227
Surface Form.....	1227
Applied Anatomy.....	1229

THE PHARYNX.

The Nasal Part or Nasopharynx.....	1229
The Oral Part.....	1230
The Tonsils.....	1230
Development.....	1232
Applied Anatomy.....	1233
The Laryngeal Part.....	1233
Development of the Pharynx.....	1234
Applied Anatomy of the Pharynx.....	1235

THE ŒSOPHAGUS.

Applied Anatomy.....	1239
----------------------	------

THE ABDOMEN.

Boundaries of the Abdomen.....	1241
Regions of the Abdomen.....	1242

The Peritoneum.

Development of the Peritoneum and Alimentary Tract.....	1245
Retroperitoneal Fossæ.....	1265
Applied Anatomy.....	1268

The Stomach.

Openings of the Stomach.....	1271
Curvatures of the Stomach.....	1271
Surfaces of the Stomach.....	1271
Component Parts of the Stomach.....	1272

Interior of the Stomach.....	1273
Movement and Innervation of the Stomach.....	1279
Surface Form.....	1280
Applied Anatomy.....	1280

The Small Intestine.

The Duodenum.....	1282
Interior of the Duodenum.....	1286
Applied Anatomy.....	1287
The Jejunum and Ileum.....	1287
Meckel's Diverticulum.....	1288
Structure of the Villi.....	1291
Applied Anatomy of the Small Intestine.....	1295

The Large Intestine.

The Cecum.....	1296
The Vermiform Appendix.....	1298
The Ileocecal Valve.....	1301
Applied Anatomy.....	1302
The Colon.....	1303
Applied Anatomy.....	1306
The Rectum.....	1306
The Anal Canal.....	1309
The Anal Orifice or Anus.....	1309
Movements and Innervations of the Intestines.....	1312
Surface Form of the Intestines.....	1313
Applied Anatomy of the Intestines.....	1314

The Liver.

Surfaces of the Liver.....	1320
Fissures of the Liver.....	1322
Lobes of the Liver.....	1323
Ligaments of the Liver.....	1324
Support and Movability of the Liver.....	1325
Abnormalities of the Liver.....	1326
The Excretory Apparatus of the Liver.....	1331
The Hepatic Duct.....	1332
The Gall-bladder.....	1332
The Cystic Duct.....	1333
The Common Bile Duct.....	1333
Surface Relations of the Liver.....	1334
Applied Anatomy of the Liver.....	1335

The Pancreas.

Pancreatic Juice.....	1341
Surface Form of the Pancreas.....	1341
Applied Anatomy of the Pancreas.....	1341

THE URINOGENITAL ORGANS.

THE URINARY ORGANS.

The Kidneys.

Relations of the Kidneys.....	1343
Anterior Surface of Right Kidney.....	1343
Anterior Surface of Left Kidney.....	1343
Posterior Surface of the Kidney.....	1345
Borders of the Kidney.....	1347
Extremities of the Kidney.....	1348
Fixation of the Kidney.....	1348
Minute Anatomy of the Kidney.....	1350
Variations and Abnormalities of the Kidney.....	1354
Surface Form of the Kidney.....	1354
Applied Anatomy of the Kidney.....	1355

The Ureters.

Applied Anatomy of the Ureters.....	1358
-------------------------------------	------

The Urinary Bladder.

Surfaces of the Bladder.....	1359
The Fundus or Base.....	1361
The Summit or Apex.....	1361
The Urachus or Middle Umbilical Ligament.....	1361
The Ligaments of the Bladder.....	1361
The Interior of the Bladder.....	1364
Surface Form of the Bladder.....	1365
Applied Anatomy of the Bladder.....	1366

The Male Urethra.

The Prostatic Portion.....	1366
The Membranous Portion.....	1367

The Penile or Spongy Portion.....	1368
Applied Anatomy.....	1369

The Female Urethra..... 1370

THE MALE REPRODUCTIVE ORGANS.

The Testicles.

The Scrotum.....	1372
The Intercolumnar or External Spermatic Fascia.....	1374
The Cremasteric Fascia.....	1374
The Infundibuliform Fascia.....	1374
The Tunica Vaginalis.....	1374
The Inguinal or Spermatic Canal.....	1375
The Spermatic Cord.....	1375
The Testes.....	1377
The Epididymis.....	1378
The Tunics of the Testicle.....	1379
The Semen.....	1381
Applied Anatomy of the Testicle.....	1382

The Vas Deferens.

Organ of Giralde's.....	1384
-------------------------	------

The Seminal Vesicles.

Applied Anatomy of the Seminal Vesicles.....	1385
----------------------------------------------	------

The Ejaculatory Ducts..... 1386

<i>The Penis.</i>		Abnormalities of the Uterus.....	1408
The Root of the Penis.....	1388	Changes at a Menstrual Period.....	1408
The Body of the Penis.....	1388	Changes Induced by Pregnancy.....	1409
Applied Anatomy of the Penis.....	1390	Applied Anatomy of the Uterus.....	1411
<i>The Prostate Gland.</i>		<i>The Vagina.</i>	
Applied Anatomy of the Prostate Gland...	1395	Relations of the Vagina.....	1414
<i>Cowper's Glands</i>		1397	<i>The External Organs.</i>
THE FEMALE REPRODUCTIVE ORGANS.		The Mons Veneris.....	1415
<i>The Ovaries.</i>		The Labia Majora.....	1415
The Ovary at Different Ages.....	1399	The Labia Minora or Nymphae.....	1416
Applied Anatomy of the Ovaries.....	1401	The Vestibule of the Vagina.....	1416
<i>The Fallopian Tube or Oviduct.</i>		The Clitoris.....	1418
Applied Anatomy of the Fallopian Tube...	1402	The Vaginal Bulb.....	1420
<i>The Uterus or Womb.</i>		The Glands of Bartholin.....	1420
The Fundus of the Uterus.....	1404	Development of the Urinary and Generative Organs.....	1420
The Body of the Uterus.....	1404	<i>The Mammary Gland.</i>	
The Neck or Cervix Uteri.....	1405	The Nipple.....	1428
Folds and Ligaments of the Uterus.....	1406	Variations in Mammae.....	1429
The Uterus at Different Ages.....	1408	Applied Anatomy.....	1432
		The Male Breast.....	1433
		Applied Anatomy.....	1433

THE DUCTLESS GLANDS.

THE THYROID GLAND OR BODY.		Surface Form of the Spleen.....	1446
Accessory Thyroids.....	1436	Applied Anatomy.....	1447
Applied Anatomy.....	1438	THE SUPRARENAL GLAND OR ADRENAL CAPSULE.	
<i>The Parathyroid Gland.</i>		Accessory Suprarenal Glands.....	1448
Embryology.....	1440	THE CAROTID GLANDS OR CAROTID BODIES.	
Applied Anatomy.....	1440	Applied Anatomy.....	1450
THE THYMUS GLAND.		THE COCCYGEAL GLAND OR BODY, OR LUSCHKA'S GLAND.	
Applied Anatomy.....	1442	Structure of the Coccygeal Gland.....	1450
THE SPLEEN.		THE PARASYMPATHETIC BODIES...	
Relations of the Spleen.....	1444	1450	

DESCRIPTIVE AND APPLIED ANATOMY.

INTRODUCTION.

ANATOMY (*ἀνά*, apart, and *τέμνω*, I cut) is the name given to that division of natural science which deals with the structure or organization of living things. Human anatomy is that division of general anatomy which applies to the structure of man, bearing in mind the fact that man is distinguished as a separate genus among primate mammals, an order of vertebrates.

Man, as a vertebrate, possesses an internal skeleton with a median longitudinal axis, which is divided transversely into segments called vertebræ. This vertebral axis (spinal column) in the habitually erect position of the human body is supported by the pelvic limbs, and is surmounted by the skull. The pelvic limbs serve the purposes of progression, while the pectoral limbs are adapted as organs of prehension; a distinction common to nearly all primates is the possession of an opposable first digit or thumb. The possession of milk glands, rudimentary in the male, but well developed and important in the female, relegates the human species to the class of mammals.

The present work is an account of the various parts and organs of the human body, being descriptive of their characteristics as revealed by dissection, and, with a view toward practical application, certain parts or regions of the body are examined in their entirety. These two methods of studying anatomy are conventionally termed *descriptive anatomy* and *applied* or *topographic anatomy*. *Embryology* deals with the origin and development of the body and its organs. *Histology* deals with the minute structure of the tissues and organs as revealed by the microscope. In the present work only brief accounts of the embryology and histology of the organs are interpolated in their proper places; the minute details must be sought for in special works upon these subjects.

The systematic consideration of the parts of the human body requires a foreword as to the descriptive terms, nomenclature, and classification employed in anatomy.

The descriptive terms are names indicative of position and direction. Despite the structural homologies discernible among vertebrates in general, there are wide differences regarding the natural attitude or position habitually assumed, so that whatever is situated "in front" in the erect man is "below" in the quadrupedal animal. The use of terms like anterior, posterior, superior, inferior, in front of, beneath, has given rise to great ambiguity and confusion whenever applied at one and the same time to homologous parts in man and other vertebrates.

It is essential that the names used in designating structural parts shall be so definite that each of the terms shall have but one signification. The study of anatomy has been made unnecessarily difficult by a multiplicity of synonyms and compound names, when single words would answer all requirements. Furthermore, many of the terms even now in general use are not equally applicable to lower animals and man, a condition which constitutes a great hindrance to anatomic progress. Various reforms have been proposed, chief of which has been that of a commission of the German Anatomic Society, which, in 1895, formulated a list of terms, the *Bâsle Nomina Anatomica* (BNA), which is unfortunately

replete with serious imperfections and inconsistencies. Thus while one of the branches of the radial nerve is called the *N. cutaneus brachii posterior*, the nominal suffix of two other branches of the same nerve is *dorsalis*. It cannot be said that the BNA has as yet completely displaced some of the designations in common use to that degree which its enthusiastic advocates would wish. The ambiguous, confusing, and vague terms will gradually fall into disuse as time shows their inutility and better expressions achieve universal adoption.

For descriptive purposes the human body is supposed to be in the erect position, the arms hanging by the sides and the palms of the hands directed forward. The body, as a whole, as with most vertebrates, consists of two general divisions, *axial* and *appendicular*; the former is the body proper (*soma*), the latter comprises the limbs (*membra*). The middle plane of the body is called the *meson*, from the Greek *το μέσον*, the middle; while *mesal* and *mesad* (*ad* being the Latin equivalent of the English -ward) are adjectival and adverbial inflections. The mesal plane is also the dorsoventral plane which passes approximately through the sagittal suture of the skull, and hence any plane parallel to it is termed a *sagittal plane*. A vertical plane at right angles to the mesal plane passes, roughly speaking, through the central part of the coronal suture or through a line parallel to it; such a plane is therefore called a *coronal plane* or *frontal plane*. A plane at right angles to both the mesal and coronal planes is termed a *transverse plane*. The terms *anterior* and *posterior* have been employed to indicate the relation of parts to the front or back of the body, and the terms *superior* and *inferior* to signify the relative levels of different structures; but the growing use of data derived from comparative anatomy and embryology in the elucidation of the human structure makes it desirable that terms should be employed which may without ambiguity indicate relative position in both man and animals. Thus, *ventral* and *dorsal*, *cephalic* and *caudal* (together with their adverbial derivatives ending in *-ad*), are preferable and are thus sometimes used in this edition. *Lateral* and *laterad* are general terms pertaining to the sides of the body, while *dextral* and *sinistral* are specific terms for right and left respectively. The terms *central* (*centrad*) and *peripheral* (*peripherad*) are in general use, though specially applicable to the bloodvessels and the nerve system. The common terms "inner" and "outer," "deep" and "superficial," "beneath," "under," and so on, are too frequently ambiguous. The use of the words *ental* and *ectal*, derived respectively from *ἐντός* (inward) and *ἐξτός* (outward), and their inflections *ental* and *ectal* often serve to avoid such ambiguity. Wherever a series of organs embraces several similar parts, bearing like names, the general terms are combined with distinctive prefixes, as, for instance, *supraspinatus* and *infraspinatus*. The terms *proximal* and *distal* refer to the attached and free ends of the limbs and their parts, being preferable to the less precise and sometimes confusing designations of upper and lower. The other aspects (borders or sides) of each limb are variously designated by the terms *ulnar*, *radial*, *anconal*, and *thenar*; *tibial*, *fibular*, *patellar*, and *popliteal*. It is often convenient to speak of the *flexor* and *extensor aspects* of the limb divisions and their bones. The designation of parts in the limbs by anterior and posterior is still largely employed, though the demands of consistency and logic will probably compel the adoption of substitutes more in accord with the nomenclature of comparative anatomy. The classification which is used in the present work is as follows:

Osteology, or description of the bones.

Syndesmology, or description of the joints and ligaments.

Myology, or description of the muscles and fasciæ.

Angiology, or description of the heart and the bloodvessels and lymph vessels.

Neurology, or description of the nerve system and organs of special sense.

Splanchnology, or description of the viscera, comprising the organs of respiration and phonation, digestion, reproduction, excretion, and internal secretion.

OSTEOLOGY.

GENERAL ANATOMY OF THE SKELETON.

THE general framework of the body is built up mainly of a series of bones, supplemented, however, in certain regions by pieces of cartilage; the bony part of the framework constitutes the *skeleton*.

In comparative anatomy the term skeleton has a wider application, as in some of the lower animals hard, protective, and supporting structures are more extensively distributed, being developed in association with the integumentary system. In such animals the skeleton may be described as consisting of an internal or deep skeleton, the *endoskeleton*, and an external or superficial, the *exoskeleton*. In the human subject the exoskeleton is extremely rudimentary, its only important representatives being the teeth and nails. The term skeleton is, therefore, confined to the endoskeleton, and this is divisible into an *axial* part, which includes that of the head and trunk, and an *appendicular* part, which comprises that of the limbs.

In the skeleton of the adult there are 206 distinct bones, as follows:

Axial Skeleton	{	Vertebral column	26	
		Skull	22	
		Hyoid bone	1	
		Ribs and sternum	25	
			—	74
Appendicular Skeleton	{	Upper limbs	64	
		Lower limbs	62	
			—	126
Auditory ossicles				6
Total				206

The patellæ are included in this enumeration, but the smaller sesamoid bones are not reckoned.

Bones are divisible, according to their shape, into four classes—*long*, *short*, *flat*, and *irregular*.

Long Bones.—The long bones are found in the limbs, where they form a system of levers, which sustain the weight of the trunk and confer the power of locomotion and prehension. A long bone consists of a shaft and two extremities. The **shaft**, or **diaphysis**, is a hollow cylinder, the central cavity being termed the **medullary canal**; the wall consists of dense, compact tissue of considerable thickness in the middle part of the shaft, but becoming thinner toward the extremities; the cancellous tissue is scanty. The **extremities**, or **epiphyses**, are generally expanded, for the purposes of articulation and to afford broad surfaces for muscle attachment. They are usually developed from separate centres of ossification termed **epiphyses**, and consist of cancellous tissue surrounded by a thin layer of compact bone. The long bones are not straight, but curved, the curve generally taking place in two planes, thus affording greater strength to the bone. The

bones belonging to this class are the *clavicle*, *humerus*, *radius*, *ulna*, *femur*, *tibia*, *fibula*, *metacarpal* and *metatarsal* bones, and the *phalanges*.

Short Bones.—Where a part of the skeleton is intended for strength and compactness, and its motion is at the same time slight and limited, it is divided into a number of small bones united by ligaments, and the separate bones are short and compressed, such as the bones of the *carpus* and *tarsus*. These consist of cancellous tissue covered by a thin crust of compact substance. The *patellæ* also, together with the other sesamoid bones, are by some regarded as short bones.

Flat Bones.—Where the principal requirement is either extensive protection or the provision of broad surfaces for the attachment of muscles, we find the osseous structure expanded into broad, flat plates, as is seen in the bones of the skull and the *scapulæ*. Flat bones are composed of two thin layers of compact tissue enclosing between them a variable quantity of cancellous tissue. In the cranial bones these layers of compact tissue are familiarly known as the *tables of the skull*; the outer table is thick and tough; the inner table is thinner, denser, and more brittle, and hence is termed the *vitreous table*. The intervening cancellous tissue is called the *diploë*. The flat bones are: the *occipital*, *parietal*, *frontal*, *nasal*, *lacrima*, *vomer*, *scapula*, *os innominatum*, *sternum*, *ribs*, and, according to some, the *patella*.

Irregular Bones.—The irregular or mixed bones are such as, from their peculiar form, cannot be grouped under either of the preceding heads. Their structure is similar to that of other bones, consisting of a layer of compact tissue externally and of spongy, cancellous tissue within. The irregular bones are: the *vertebræ*, *sacrum*, *coccyx*, *temporal*, *sphenoid*, *ethmoid*, *malar*, *maxilla*, *mandible*, *palate*, *turbinated*, and *hyoid*.

Surfaces of Bones.—If the surface of any bone is examined, certain eminences and depressions are seen, to which descriptive anatomists have given the following names.

These eminences and depressions are of two kinds: *articular* and *nonarticular*. Well-

marked examples of *articular eminences* are found in the heads of the *humerus* and *femur*, and of *articular depressions* in the *glenoid cavity* of the *scapula* and the *acetabulum*. *Nonarticular eminences* are designated according to their form. Thus a broad, rough, uneven elevation is called a *tuberosity*; a small, rough prominence, a *tubercle*; a sharp, slender, pointed eminence, a *spine*; a narrow, rough elevation, running some way along the surface, a *ridge*, *line*, or *crest*.

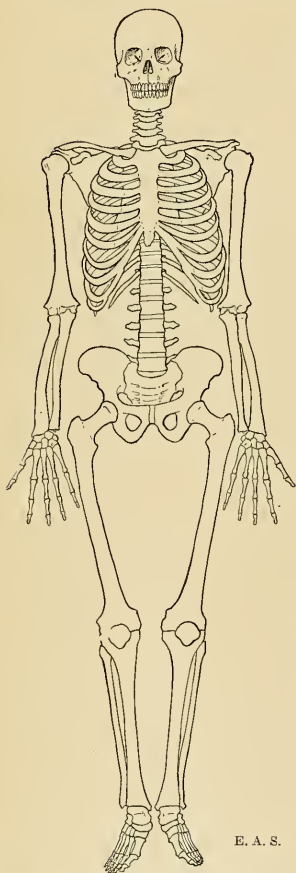


FIG. 1.—General view of the human skeleton.

The nonarticular depressions are also of very variable form, and are described as *fossæ*, *grooves*, *furrows*, *fissures*, *notches*, *sulci*, etc. These nonarticular eminences and depressions serve to increase the extent of surface for the attachment of ligaments and muscles, and are usually well marked in proportion to the muscularity of the subject; the grooves, fissures, and notches often transmit vessels and nerves.

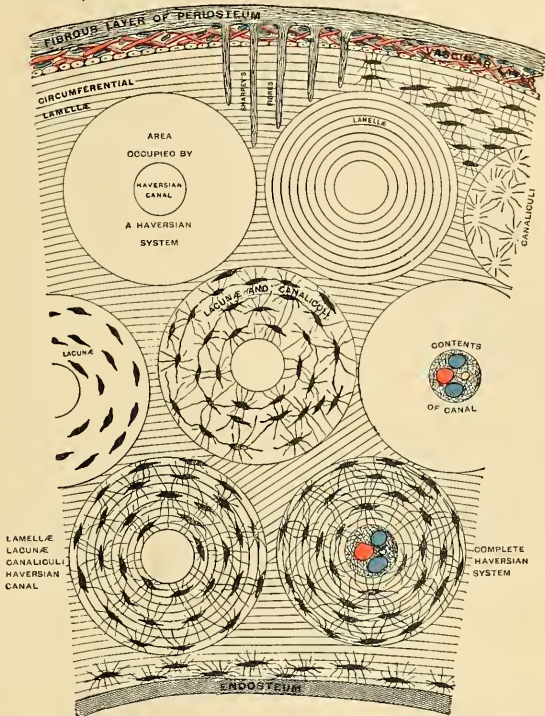


FIG. 2.—Diagram of the structure of compact bone. A small part of a transverse section of the shaft of a long bone is shown. At the uppermost part is the periosteum covering the outside of the bone; at the lowermost part is the endosteum lining the marrow cavity. Between these is the compact tissue, consisting largely of a series of Haversian systems, each being circular in outline and perforated by a central canal. In the first one is shown only the area occupied by a system; in the second is seen the concentric arrangement of the lamellæ; and in the others, respectively, canaliculi; lacunæ; lacunæ and canaliculi; the contents of the canal, artery, vein, lymphatic and areolar tissue; lamellæ, lacunæ, and canaliculi; and, finally, all of the structures composing a complete system. Between the systems are circumferential and intermediate lamellæ, only a few of which are represented as lodging lacunæ, though it is to be understood that the lacunæ are in all parts. The periosteum is seen to be made up of a fibrous layer and a vascular layer, and to have upon its attached surface a stratum of cells. From the fibrous layer project inward the rivet-like fibres of Sharpey. (F. H. Gerrish.)

A prominent process projecting from the surface of a bone which it has never been separate from or movable upon is termed an **apophysis** (from ἀπόφυσις, an excrescence); but if such process is developed as a separate piece from the rest of the bone, to which it is afterward joined, it is termed an **epiphysis** (from ἐπιφυσις, an accretion). The main part of the bone, or shaft, which is formed from the primary centre of ossification, is termed the **diaphysis**, and is separated, during growth, from the epiphysis by a layer of cartilage, at which growth in length of the bone takes place. Some bones are hollow and contain sinuses,

which are spaces for air. **Canals**, or **foramina**, are channels or openings in bone through which nerves or vessels pass.

Structure of Bone.—Bone is a highly specialized form of connective tissue. In reality, it is white fibrous tissue, calcified and structurally modified until it becomes osseous tissue. Bone is not simply a crude mass resulting from the calcification of cartilage or fibrous tissue; it is a distinct tissue, of a definite structure, the constituent parts of which are arranged symmetrically.

There are two varieties of bone: **dense or compact bone** (*substantia compacta*), and **cancellous, loose, or spongy bone** (*substantia spongiosa*).

Compact bone is dense, and is always found upon the exterior of the bony tissue. Even this apparently compact tissue is porous; it differs from cancellous bone in its greater density and in the arrangement of its osseous substance into lamellæ. It forms practically the entire shafts of the long bones and constitutes the outer portion of their extremities and of the short, flat, and irregular bones. With the exception of enamel and dentin it represents the hardest substance of the body, is tough and elastic, and much force is required to break it. Compact bone consists of an outer membrane, the **periosteum**, internal to which is seen the **osseous tissue**.

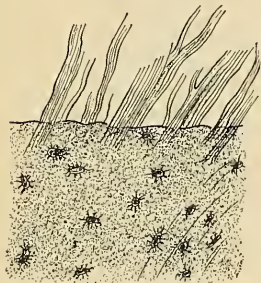


FIG. 3.—Fibres of Sharpey from the parietal bone (adult man) isolated by dissociation. (After Kölliker.)

Sharpey's fibres (Fig. 3), which penetrate the bone at right angles to its surface, and carry bloodvessels. They do not directly enter the Haversian systems, but only the circumferential and intermediate lamellæ—parts that are formed by periosteal action. Prolongations from some of these vessels reach the Haversian canals, and even the bone marrow. In the extremities of

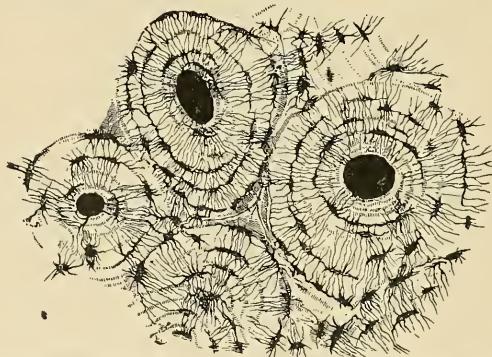

FIG. 4.—Transverse section of compact tissue of bone. Magnified about 150 diameters. (Sharpey.)

a long bone, vessels from the periosteum penetrate the layer of compact bone and reach the cancellous tissue. In the newborn and in the young the periosteum is composed of three layers: an **outer or fibrous layer**, containing some bloodvessels, and composed of bundles of white fibrous tissue; a **middle or fibroelastic layer**, containing some bloodvessels, fibrous tissue, and much elastic tissue; and an **inner or osteogenetic layer**, which is very vascular and contains numerous cells, which are converted into osteoblasts or bone-forming cells.

Transverse Section of Compact Bone (Fig. 4).—The osseous tissue consists of cells, osteoblasts, and intercellular substance arranged in lamellæ. In the osseous tissue are found **Haversian systems**, **lacunæ**, **canaliculi**, and **osteoblasts**. In the middle of long bones is a space, the **medullary** or **marrow cavity**, containing the marrow.

There are four varieties of lamellæ: (1) The **periosteal**, **peripheral**, **circumferential**, or **external**; (2) the **Haversian**, or **concentric**; (3) the **interstitial**, **ground**, or **intermediate**; and (4) the **perimedullary**, or **internal**. The periosteal lamellæ are sometimes called **primary**, as they are the first to appear, and are formed by the direct transformation of the inner layer of the periosteum into bone. In the shaft of a long bone there are several layers of periosteal lamellæ, but no one layer is extensive enough to surround the bone completely. Lacunæ and canaliculi are present.

In the outer surface of the layer of periosteal lamellæ depressions exist that are known as **Howship's foveolæ**, or **lacunæ**. These depressions are made by large cells, called **osteoclasts**, which destroy bone. There are no Haversian canals in this outer layer, but there are some large channels, **Volkmann's canals**, that convey bloodvessels into the bone and run at right angles to the periosteal surface. Many small arteries from the periosteum enter the periphery both of the shaft and of the epiphyses.

The **Haversian** or **concentric lamellæ** are circular layers arranged around a central space, or canal, known as the **Haversian canal**. There is no fixed number of these layers, there being usually from five to ten. The layers of each system are parallel to one another,

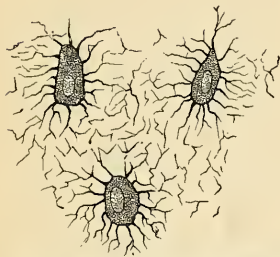

FIG. 5.—Nucleated bone cells (osteoblasts) and their processes, contained in the bone lacunæ and their canaliculi respectively. From a section through the vertebra of an adult mouse. (Klein and Noble Smith.)

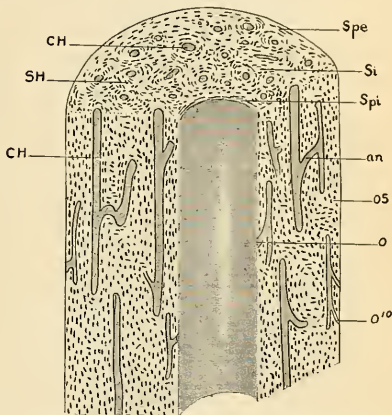


FIG. 6.—Combined transverse and longitudinal section of compact bone. CH, Longitudinal Haversian canal and anastomosing canals. o, Communicating with medullary cavity. Si, Intermediate systems. Spe, Circumferential lamellæ. Spi, Perimedullary lamellæ. os, Osteoblasts. (Poirier and Charpy.)

but the layers of different systems cross at various angles. Between these layers are small, irregular spaces called **lacunæ**; and extending radially out from the lacunæ and piercing the various lamellæ are delicate canals known as **canaliculi**, which connect the lacunæ. The lacuna nearest to the Haversian canal communicates with it by means of canaliculi; and canaliculi also communicate with other Haversian systems. The Haversian canal contains bloodvessels—an artery or a vein, or both—and a nerve. The vessel in the canal is covered with endothelial cells, and the canal itself is lined with them. The space thus formed is a lymph channel, and into these channels the canaliculi empty. Beneath the periosteum and at the periphery of the medullary cavity there are lymph spaces that are in direct communication with the canaliculi of the Haversian systems. In each lacuna is a bone cell—a corpuscle that almost fills the space, and sends arms, or processes, out into the canaliculi (Fig. 5). This bone cell is an **osteoblast**.

The **interstitial** or **intermediate lamellæ** occupy the spaces between the Haversian systems. They represent the remains of peripheral lamellæ. They are usually short and very irregular, but possess lacunæ and canaliculi, which are arranged as in the Haversian systems.

The **perimedullary lamellæ** are irregular and few in number. They surround the marrow cavity, and in areas may be interrupted. Lacunæ, canaliculi, and osteoblasts are present.

Lining the marrow cavity surface of the bone is a membrane, the **endosteum**, that resembles the periosteum in structure, but is not quite so prominent.

The **osteoblasts** are irregular, flattened, stellate masses of protoplasm, possessing a number of processes. The protoplasm is granular, and each cell contains a large and distinct nucleus.

Osteoblasts are met with in the deeper layer of the periosteum, in the endosteum, and in the lacunæ.

Longitudinal Section of Compact Bone (Figs. 6 and 8).—We do not see concentric rings, as in a transverse section, but rows of lacunæ parallel to the course of the Haversian canals—and these canals appear like half tubes instead of circular spaces. The tubes are seen to branch and communicate, so that each separate Haversian canal runs only a short distance. In other respects the structure closely resembles that of a transverse section.

Cancellous bone is found in the interior of flat and irregular bones and forming the bulk of the extremities of the long bones. It consists of anastomosing spicules of bone forming a meshwork for the red marrow. The spicules have a fibrillar structure, and contain lacunæ and canaliculi, but no Haversian systems.

In the epiphyses the spicules are placed, as a rule, at right angles to the planes of the articular surface (the lines of greatest pressure); these are bound together by other spicules that correspond in direction to the planes of the articulation (the lines of greatest tension). Those spicules nearer the marrow cavity are usually heavier and stronger (Fig. 181).

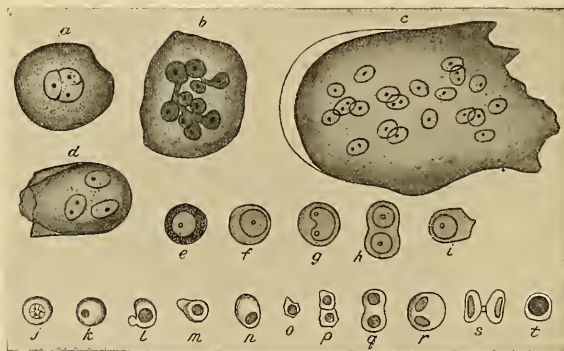


FIG. 7.—Cells of red marrow of the guinea-pig. *a-d*, Myeloplasmæ. *e-t*, Marrow cells proper. *j-l*, Erythroblasts, some in process of division. (Schäfer.)

Marrow.—There are three varieties: **red**, **yellow**, and **mucoid**.

Red marrow (*medulla ossium rubra*) is found in the diplotæ of the cranial bones, in the cancellous tissue of the vertebrae, ribs, and sternum, and in the extremities of the long bones. Red marrow contains much less fat and is less solid than yellow marrow. It consists of a delicate network of retiform connective tissue, supporting a dense capillary plexus; some fat; and numerous cellular elements. Surrounding the marrow is the *endosteum*. The cellular elements of red marrow (Figs. 7 and 12) comprise four main groups: (1) **Marrow cells**, or **myelocytes**, which are granular protoplasmic masses, capable of ameboid movements, and containing large nuclei. They are not found in normal blood, but are abundant in leukemia. (2) Small nucleated, reddish cells called **erythroblasts** are found; they resemble the nucleated red cells of the blood of the embryo; eventually by the loss of their nuclei they become normal red blood corpuscles. (3) Nonnucleated red blood corpuscles; and (4) giant cells, containing one or more nuclei—the **osteoclasts**—complete the cellular elements. In addition there are a large number of **leukocytes**, or white blood cells, *i. e.*, *polynuclear cells*, *eosinophiles*, and *basophiles*.

Yellow marrow is found in the shafts of long bones of adults, and differs from the preceding in the presence of a great quantity of fat and a corresponding decrease in the number of cellular elements.

Gelatinous or mucoid marrow is formed by the absorption of the fat and the cellular elements of yellow marrow, and by the serous infiltration of the intercellular substance. It is produced by starvation, old age, and certain pathological conditions. Neither yellow nor mucoid marrow are blood-cell forming in function.

Bloodvessels of Bone.—Small arteries derived from the periosteum enter Volkmann's canals and pass to the Haversian canals and ultimately to the marrow. The cancellous tissue is supplied by fewer but larger vessels, which are derived from the periosteum, and which often penetrate the covering of the compact bone and ramify in the cavities of the spongy tissue.

The marrow is supplied by a large artery (sometimes more than one) called the **nutrient artery**. It enters the bone by the nutrient foramen, which is usually near the centre of the shaft, runs in an oblique canal through the compact substance, giving off branches to this

structure, and entering the medullary cavity, sends branches toward the extremities, thus forming capillary plexuses in the marrow. These branches communicate with branches from the periosteal vessels. The walls of the vessels are very thin; the venous blood enters the spaces of the red marrow, and the current becomes extremely slow. Small veins collect the venous blood and emerge from the bone.

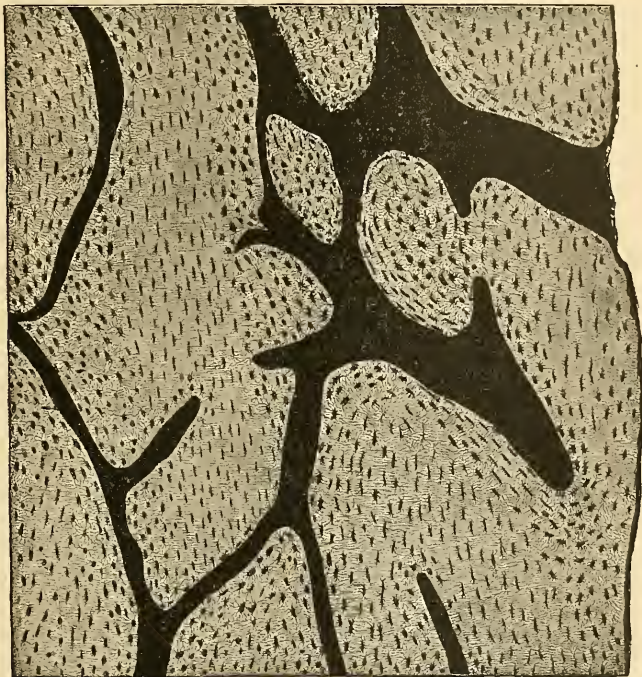


FIG. 8.—From a ground longitudinal section through the diaphysis of the human ulna. All canals are filled with pigment, which is here black. Haversian canals are cut longitudinally. $\times 90$. (Szymonowicz.)

Veins emerge from the long bones in three places: (1) One or two large veins accompany the nutrient artery. (2) Numerous veins emerge at the articular extremities. (3) Many small veins arise in and emerge from compact substance. The latter two classes do not accompany arteries. The veins in the marrow and in the bone are devoid of valves; but immediately after emerging from the bone they have numerous valves. In the flat cranial bones the veins are numerous and large.

The **lymphatics** are chiefly periosteal; but some have been demonstrated as entering the bone, along with the vessels, and running in the Haversian canals.

Nerves, medullated (*myelinic*) and nonmedullated (*amyelinic*), are found in bone. They are distributed freely to the periosteum, and some of the fibres terminate in this structure as Pacinian corpuscles. Nerves accompany the nutrient arteries into the interior of the bone, and also reach the marrow from the periosteum by way of Volkmann's canals and the Haversian canals. They certainly supply the arterial coats and possibly ramify about the osteoblasts. Nerves are most numerous in the articular extremities of the long bones, in the vertebrae, and the large flat bones.

Chemical Composition of Bone.—Bone consists of about 36 per cent. of *animal (organic)* and about 64 per cent. of *earthy (inorganic)* substance intimately combined.

The *animal* part may be obtained by immersing the bone for a considerable time in dilute mineral acid, after which process the bone comes out exactly the same shape as before, but perfectly flexible, so that a long bone (one of the ribs, for example) can easily be tied into a knot. If now a transverse section is made, the same general arrangement of the Haversian canals

lamellae, lacunae, and canaliculi is seen, though not so plainly as in the ordinary section. The animal basis is largely composed of **ossein**, or **fat collagen**. When boiled with water, especially under pressure, fat collagen is almost entirely resolved into gelatin.

The *earthy* part may be obtained by calcination, in which process the animal matter is completely burned out. The bone will still retain its original form, but it will be white and brittle, will have lost about one-third of its original weight, and will crumble upon the slightest pressure. The earthy matter confers on bone its hardness and rigidity, and the animal matter its tenacity. The mineral matter consists chiefly of calcium phosphate, forming about two-thirds of the weight of bone.

Ossification and Growth of Bone.—For the early development of the skeleton the reader is referred to text-books on embryology. Embryonic connective-tissue cells of the meso-

blast develop membrane. Membrane may become bone directly or cartilage may be deposited, which cartilage by the process of ossification is changed into bone. The tissue which is eventually to become bone contains cellular elements which evolve into **osteoblasts**, or bone-forming cells. Osteoblasts exist in the connective tissues which become bone by intramembranous ossification, and in the deeper layers of the tissue called perichondrium which invests cartilage and which becomes the osteogenetic layer of the periosteum. In view of the fact that in the fetal skeleton some bones are preceded by membrane (parietal bones, frontal bone, upper part of tabular portion of occipital bone, most of the bones of the face), and others are preceded by rods of cartilage (the long bones), two kinds of ossification are described—viz., the **intramembranous** and the **intracartilaginous**.

Intramembranous Ossification.—In the case of bones which are developed in membrane no cartilaginous mould precedes the appearance of the bone tissue. The membrane, which occupies the place of the future bone, consists of white, fibrous connective tissue, and ultimately forms the periosteum. At this stage it is seen to be composed of fibres and granular cells in a matrix.

The outer portion is more fibrous, while internally the cells or osteoblasts predominate; the whole tissue is quite vascular. At the outset of the process of bone formation a little network of bony spicules is first noticed radiating from the point or centre of ossification. When these rays of

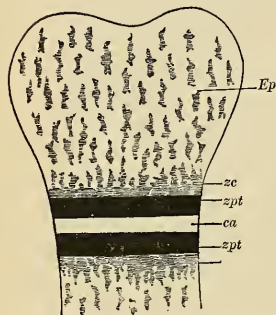


FIG. 9.—Schematic diagram, showing epiphysis and diaphysis and line of ossification. *Ep*, Epiphysis of endochondral bone. *zpt*, Zone of proliferation. *zc*, Zone of calcification. *ca*, Cartilage. (Poirier and Charpy.)

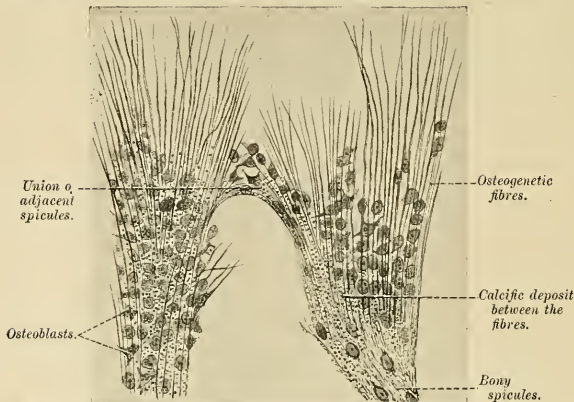


FIG. 10.—Part of the growing edge of the developing parietal bone of a fetal cat. (After J. Lawrence.)

growing bone are examined with a microscope they are found to consist at their growing point of a network of fine, clear fibres and granular corpuscles, with an intervening ground substance (Fig. 10). The fibres are termed **osteogenetic fibres**, and are made up of fine fibrils differing

little from those of white fibrous tissue. Like them, they are probably deposited in the matrix through the influence of the cells—in this case the osteoblasts. The osteogenetic fibres soon assume a dark and granular appearance from the deposition of calcareous granules in the fibres and in the intervening matrix, and as they calcify they are found to enclose some of the granular

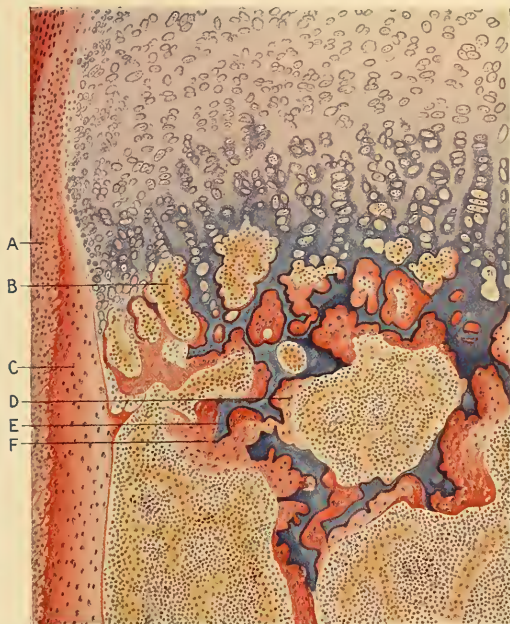


FIG. 11.—Longitudinal section through the second phalanx of the finger of a seven months' human embryo. Stained in hematoxylin and eosin. $\times 104$. A. Periosteum. B. Primary areola. C. Periosteal bone. D. Secondary areola and marrow. E. Calcareous material. F. Endochondral bone. (Szymonowicz.)

corpuscles, or osteoblasts. By the fusion of the calcareous granules the bony tissue again assumes a more transparent appearance, but the fibres are no longer so distinctly seen. The involved osteoblasts form the corpuscles of the future bone, the spaces in which they are enclosed constituting the lacunæ. As the osteogenetic fibres grow out to the periphery they continue to ossify and give rise to fresh bone spicules. Thus, a network of bone is formed, the meshes of

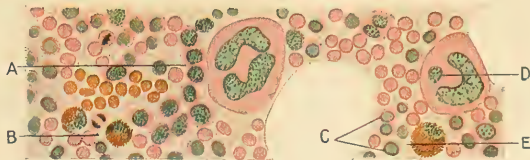


FIG. 12.—Section through the red bone marrow of a rabbit. Biondi's stain. $\times 640$. A. Myelocytes. B. Eosinophiles. C. Nucleated red blood corpuscles. D. Giant cells. E. Myelocyte. (Szymonowicz.)

which contain the bloodvessels and a delicate connective tissue crowded with osteoblasts. The bony trabeculæ thicken by the addition of fresh layers of bone formed by the osteoblasts on their surface, and the meshes are correspondingly encroached upon. Subsequently successive layers of bony tissue are deposited under the periosteum and around the larger vascular channels,

which become the Haversian canals, so that the bone increases much in thickness. The process spreads laterally to the region of the future suture, and here between the various bones a layer of fibrous tissue, the **cambium layer**, is maintained until the full size of the bone is reached. The cambium layer then ossifies and the bone ceases to grow at its edges.

Intracartilaginous Ossification.—Just before ossification begins the bone is entirely cartilaginous, and in the long bone, which may be taken as an example, the process commences in the centre and proceeds toward the extremities, which for some time remain cartilaginous. Subsequently a similar process commences in one or more places in those extremities and gradually ossifies them. The extremities do not, however, become joined to the shaft by bony tissue until growth has ceased, but are attached to it by a layer of cartilaginous tissue termed the **epiphyseal cartilage**.

The first step (*proliferation*) in the ossification of the cartilage is that the cartilage cells, at the point where ossification is commencing and which is termed a **centre of ossification**, multiply, enlarge, and arrange themselves in rows (Fig. 11). The matrix in which they are embedded

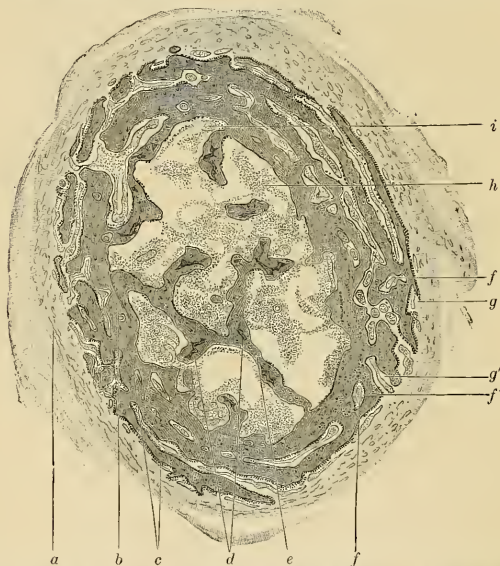

FIG. 13.—Cross-section of a developing bone of a human fetus of four months. *a*. Periosteum. *b*. Boundary between endochondral and periosteal bone. *c*. Perichondral bone. *d*. Remains of area of calcification. *e*. Endochondral bone. *f*, *f'*. Bloodvessels. *g*, *g'*. Developing Haversian spaces. *h*. Marrow. *i*. Bloodvessel. (Radasch, after Stöhr's Histology.)

increases in quantity, so that the cells become further separated from each other. A deposit of calcareous material (*calcification*) now takes place in this matrix, between the rows of cells, so that they become separated from each other by longitudinal columns of calcified matrix. These columns are connected to one another by transverse bars of calcareous substance, and present a granular and opaque appearance. In the calcareous areas the cartilage cells reproduce so rapidly that a number of cells are seen in each large lacuna, or space, which is called a **primary areola**. This process is succeeded by destruction of some of the columns between the smaller spaces, forming thus a fewer number of larger spaces, the **secondary areolæ**. Some of the cells within the areolæ disappear, others become osteoblasts, which apply themselves to the columns and secrete a thin veneer of osseous tissue upon the calcareous matter; still others of these cells become osteoclasts.

At the same time that this process is going on in the centre of the solid bar of cartilage of which the fetal bone consists, certain changes are taking place on its surface. This is covered by a very vascular membrane, the **perichondrium**, entirely similar to the embryonic connective tissue already described as constituting the basis of membrane bone, on the inner or cartilage

surface of which the cells become **osteoblasts**, or bone-forming cells. By the agency of these cells a thin layer of bony tissue is being formed between the outer membrane, now the **periosteum**, and the cartilage by the *intramembranous* mode of ossification just described; this constitutes the first periosteal lamella. These two processes go on simultaneously. The second stage (*vascularization*) consists in the prolongation into the cartilage of processes of the deeper or osteogenetic layer of the periosteum, these processes consisting of bloodvessels and cells—**osteoblasts**, or **bone formers**, and **osteoclasts**, or **bone destroyers**. The latter are similar to the giant cells (myeloplakes) found in marrow, and they excavate passages through the new-formed bony layer by absorption, and pass through it into the areolæ. Wherever these processes come in contact with the calcified walls of the primary areolæ they absorb it, and thus cause a fusion of the original cavities and assist in the formation of larger spaces, which are termed the **secondary areolæ** (Sharpey), or **medullary spaces**. These secondary spaces become filled with embryonic marrow, consisting of osteoblasts, vessels, a few leukocytes, and a few myelocytes.

The first periosteal lamella is rapidly followed by the formation of others of the same nature, the osteoblasts secreting the lamellæ remaining between the successive layers with their processes passing from one to the other. The spaces occupied by these cells are the **lacunæ** and the small channels occupied by the processes are the **canaliculi**. A periosteal lamella is not smooth and regular and does not extend completely around the developing bone, but meets others that aid in completing the circle. The irregularities are due to projecting processes of bone that

meet others and enclose small, irregular, longitudinal canals, which contain vessels and primitive marrow, and are the **primitive Haversian canals**. These are also seen at the junctions of the lamellæ (Fig. 13). The osteoclasts of the primitive marrow apply themselves to the walls of the canals and absorb the osseous tissue until a comparatively large and regular canal is formed, and within this canal the osteoblasts secrete successive concentric layers of bone until a small central canal alone remains which contains a little marrow and the vessels. This canal is the true **Haversian canal**. The concentric lamellæ are the Haversian lamellæ, between which the osteoblasts remain in their **lacunæ** and radiating **canaliculi**. The remains of the periosteal lamellæ between the Haversian systems constitute the **interstitial lamellæ** (Fig. 6). Within the centre

of the rod of developing bone the osteoclasts meanwhile destroy the trabeculæ of calcified material covered by osseous tissue, and thus is formed one common cavity—the *beginning of the medullary cavity*. The marrow then forms one common mass in the centre of the bone, and the surrounding fibrous tissue becomes a second periosteum, or **endosteum**, which surrounds the marrow and secretes incomplete lamellæ, thus bounding the marrow cavity as the **perimedullary lamellæ**. All of the above osseous tissue is merely temporary in the growth of the bone thickness. As can now be readily seen, the long bones increase evenly in thickness by the periosteal method, while increase in length is due entirely to the intracartilaginous method.

Such are the changes which may be observed at one particular point, the centre of ossification. While they have been going on here a similar process has been set up in the surrounding parts and has been gradually proceeding toward the ends of the shaft, so that in the ossifying bone all the changes described above may be seen in different parts, from the true bone in the centre of the shaft to the hyaline cartilage at the extremities. The bone thus formed differs from the bone of the adult in being more spongy and less regularly lamellated.

As more and more bone is removed by this process of absorption from the interior of the bone to form the medullary canal, so more and more bone is deposited on the exterior by the periosteum, until at length the bone has attained the shape and size which it is destined to retain during adult life. As the ossification of the cartilaginous shaft extends toward the articular ends it carries with it, as it were, a layer of cartilage, or the cartilage grows as it ossifies, and thus the bone is increased in length. During this period of growth the articular end, or *epiphysis*, remains for some time entirely cartilaginous; then a bony centre appears in it, and it undergoes the same process of intracartilaginous ossification; the cancellous bone of the extremities of the processes of the bones is never completely removed to form a single marrow cavity, but the

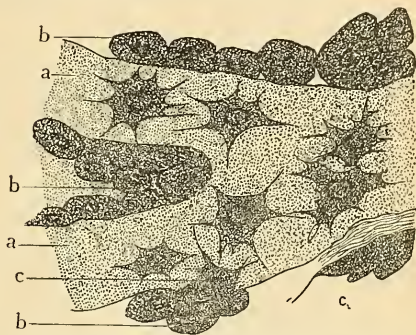


FIG. 14.—Osteoblasts from the parietal bone of a human embryo thirteen weeks old. *a*, Bony septa with the cells of the lacunæ. *b*, Layers of osteoblasts. *c*, The latter in transition to bone corpuscles. (After Gegenbaur.)

spaces become somewhat enlarged as the bones grow. The epiphyses remain separated from the shaft by a narrow cartilaginous (*cambium*) layer for a definite time (Fig. 9). This layer ultimately ossifies, the distinction between shaft and epiphysis is obliterated, and the bone assumes its completed form and shape. The same remarks also apply to the processes of bone which are separately ossified, such as the trochanters of the femur. The bones, having been formed, continue to grow until the body has acquired its full stature.

The number of ossific centres varies in different bones. In most of the short bones ossification commences at a single point in the centre, and proceeds toward the circumference. In the long bones there is a central point of ossification for the shaft or diaphysis; and one or more for each extremity, the epiphysis. That for the shaft is the first to appear. The union of the epiphyses with the shaft takes place in the reverse order to that in which their ossification began, with the exception of the fibula, and appears to be regulated by the direction of the nutrient artery of the bone. Thus, the nutrient arteries of the bones of the arm and forearm are directed toward the elbow, and the epiphyses of the bones forming this joint become united to the shaft before those at the shoulder and wrist. In the lower limb, on the other hand, the nutrient arteries pass in a direction from the knee; that is, upward in the femur, downward in the tibia and fibula; and in them it is observed that the upper epiphysis of the femur and the lower epiphysis of the tibia and fibula become first united to the shaft.

Where there is only one epiphysis, the nutrient artery is directed toward that end of the bone where there is no additional centre, as toward the acromial end of the clavicle, toward the distal end of the metacarpal bone of the thumb and great toe, and toward the proximal end of the other metacarpal and metatarsal bones.

Besides these epiphyses for the articular ends, there are others for projecting parts or processes, which are formed separately from the bulk of the bone. For an account of these the reader is referred to the description of the individual bones in the sequel.

A knowledge of the exact periods when the epiphyses become joined to the shaft is often of great importance in medicolegal inquiries. It also aids the surgeon in the diagnosis of many of the injuries to which the joints are liable; for it not infrequently happens that on the application of severe force to a joint the epiphysis becomes separated from the shaft, and such an injury may be mistaken for a fracture or dislocation.

Applied Anatomy.—It has been stated above that the bones increase first *in length* by ossification continuing to extend in the epiphyseal cartilage, which goes on growing in advance of the ossifying process; and secondly *in circumference* by deposition of new bone from the deeper layer of the periosteum. A thorough realization of these facts is essential to the student, when he comes to consider the various pathological changes which affect bone. Anything which interferes with the growth at the epiphysal line will lead to a diminution in the length which the bone should attain in adult life, and similarly anything which interferes with the growth from the deeper layer of the periosteum will result in a disproportion in the thickness of the bone. Thus, separation of the epiphyses, septic or tuberculous disease about the epiphyseal line, and excisions involving the epiphysal line, will result in varying amounts of shortening of the bone, as compared with that of the opposite side; whereas separation or imperfect nutrition of the periosteum results in defective growth in circumference.

It is thus obvious that a careful study of osseous development is of the very greatest utility in the proper understanding of bone disease; and, moreover, that an accurate knowledge of the blood supply of a long bone has many important bearings. The outer portion of the compact tissue being supplied by periosteal vessels, which reach the bone through muscle attachments, it follows that where the muscles or muscle attachments are well developed, and therefore amply supplied with blood, the periosteum will also be well nourished and the bones proportionately well developed in girth; this is well seen in strong, muscular men with well-marked ridges on the bones. Conversely, if the muscle development be poor, the bones are correspondingly thin and light, and if from any cause a limb has been paralyzed from early childhood, all of the bones of that extremity are remarkable for their extreme thinness—that is to say, the periosteal blood supply has been insufficient to nourish that membrane, and consequently very little new osseous tissue has been added to the bones from the outside.

The best example of this condition is seen in connection with the disease known as *infantile paralysis*, where a limb becomes paralyzed at a very early period of childhood, where the muscles become flaccid and atonic, and where the blood supply is in consequence very greatly diminished. In such cases, although the limb does continue to grow in length from the epiphyseal lines, its length is considerably less than on the normal side, as a result of the imperfect nutrition; but the most striking feature about all the long bones of the limb is their remarkable tenuity, little or no addition having been made to their diameters.

In cases where the periosteum has been separated from the compact tissue by extensive injury or inflammatory exudation, necrosis or death of the underlying portion of bone takes place, due to interference with the blood supply, and the dead portion or *sequestrum* has to be subsequently separated and cast off.

Cases, however, occur in which the inflammatory process affects the whole or a great portion

of the diaphysis of a long bone, and here extensive necrosis of the affected portion takes place, and the condition goes by the name of *acute infective periostitis*. Where this occurs the shaft of the bone dies very rapidly, especially if the singly nutrient artery be thrombosed at the same time. The pus which has formed beneath the periosteum is set free by timely excision, or burrows to the surface; the periosteum then falls back on the necrosed diaphysis and rapidly forms a layer of new periosteal bone, surrounding the sequestrum. This layer is called the *involucrum* and the openings in it through which the pus escapes the *clavæ*. When the inflammatory process affects mainly the medullary canal, the condition is spoken of as *osteomyelitis*, and the two conditions very frequently co-exist, and then go by the name of *acute infective necrosis of bone* or *acute diaphysitis*. When the medullary cavity is filled with pus, septic thrombosis of the veins in the Haversian canals takes place, and there is a very great danger of septic emboli being separated and carried into the general circulation, thus setting up a fatal *pyemia*. In fact, pyemia is more frequently due to septic bone conditions than to any other cause.

In the preantiseptic days pyemia frequently resulted from amputations, when the medullary canal of a long bone was opened by the saw cut. Osteomyelitis ensued, and if the patient survived, a tubular sequestrum of the divided shaft subsequently separated.

A proper understanding of the epiphyses is of the utmost possible importance to the student, and greatly simplifies many of the problems in the pathology of bone disease.

Speaking generally, the long bones have at either end an epiphysis from the cartilage of which growth occurs, and hence the shaft of the bone increases in length at both ends. In every case, however, one epiphysis is the more active, and also continues in its activity for a longer time. This *actively growing epiphysis* is always the one from which the nutrient foramen in the diaphysis is directed, and it unites to the shaft at a later date. It follows, therefore, that the increase in length of a long bone is largely dependent on the epiphysis, and hence anything which interferes with the growth from this epiphyseal line at any time prior to the union of the epiphysis with the shaft must result in a cessation of growth in length of that bone. Thus, when dealing with disease in the neighborhood of this actively growing epiphysis very great care should be taken not to excise or destroy its line of union with the shaft. These epiphyses are particularly prone to become the seat of tuberculous disease, which especially tends to attack the soft, highly vascular cancellous tissue.

Again, the actively growing epiphyseal line is the portion of a long bone which is in the vast majority of cases affected by tumor growth in bone, whether it be innocent or malignant, the former (viz., osteoma) usually appearing about puberty, and the latter (viz., sarcoma) usually toward the end of the active period of epiphyseal growth.

Epiphyseal growth, moreover, has to be considered by the surgeon when he is about to amputate in a child. If the amputation is being performed through a bone, the actively growing epiphysis of which is at the upper end, and which will continue to grow for many years (*i. e.*, humerus and tibia), it will be necessary to make allowance for this and to cut the flaps long; as otherwise, owing to continued growth, the sawed end of the bone will ultimately project through the stump, and a condition known as "*conical stump*" will result. This requires removal of a further portion of the bone.

An inflammatory condition termed *acute epiphysitis* also occurs, although it is not so frequent as the acute infective conditions of the diaphysis, owing to the freer blood supply of the epiphysis; in late years it has been shown that acute epiphysitis in children is very frequently the result of a pneumococcal infection, and it may pass on to complete separation of the epiphysis. In this connection it is worthy of note that some of the epiphyseal lines lie entirely within the capsules of their corresponding joints, in other cases entirely without the capsules; and it must follow that in the former case epiphyseal disease, acute or chronic, becomes, *ipso facto*, practically synonymous with disease of that joint. The best examples of intracapsular epiphyses are those of the head of the femur and the head of the humerus, and the vast majority of all cases of tuberculous disease of the hip starts as a tuberculous epiphysitis about the intracapsular epiphyseal line of the femur; again, cases of acute septic arthritis of the shoulder- or hip-joint generally have their origins in these intracapsular epiphyseal lines, and often result in separation of the affected epiphysis. The other class, or extracapsular epiphysitis, when diseased, do not tend to involve the neighboring joint so readily; and it should be the surgeon's duty to keep the disease from involving the joint. For example, the trochanteric epiphysis of the femur is extracapsular as regards the hip-joint, and the epiphyseal line of the head of the tibia is well below the level of the knee-joint, and should a chronic tuberculous abscess form in the latter situation, it should be attacked from the outside before it has time to spread up and involve the cartilage of the head of the tibia. It is, therefore, of great surgical interest to note in every case the relations which the various epiphyseal lines bear to their respective joint capsules.

SPECIAL ANATOMY OF THE SKELETON.

THE VERTEBRAL OR SPINAL COLUMN, OR THE SPINE
(COLUMNA VERTEBRALIS).

The **vertebral column** is a flexuous and flexible column formed of a series of bones called **vertebræ**.

The **vertebræ** are thirty-three in number, and have received the names **cervical**, **thoracic**, **lumbar**, **sacral**, and **coccygeal**, according to the position which they occupy; seven are found in the cervical region, twelve in the thoracic, five in the lumbar, five in the sacral, and four in the coccygeal.

This number is sometimes increased by an additional vertebra in one region, or the number may be diminished in one region, the deficiency being supplied by an additional vertebra in another. These observations do not apply to the cervical portion of the vertebral column, as the number of bones forming it is rarely increased or diminished.

The **vertebræ** in the upper three regions of the spine remain separate throughout life, and are known as **true** or **movable** **vertebræ**; but those found in the sacral and coccygeal regions are firmly united in the adult, so as to form two bones—five entering into the formation of the upper bone or **sacrum**, and four into the terminal bone of the spine or **coccyx**. The fused **vertebræ** are known as **false** or **immovable** **vertebræ**.

With the exception of the first and second cervical, the true or movable **vertebræ** present certain common characteristics which are best studied by examining one from the middle of the thoracic region.

GENERAL CHARACTERS OF A VERTEBRA.

A **typic vertebra** consists of two essential parts—an anterior solid segment, the **body**, and a posterior segment, the **arch** (*arcus vertebrae*), or the **neural arch**. The arch is formed of two **pedicles** and two **laminae**, supporting seven processes—viz., four **articular**, two **transverse**, and one **spinous**.

The bodies of the **vertebræ** are placed one upon the other, forming a strong pillar for the support of the skull and trunk; the arches forming a hollow cylinder behind the bodies for the protection of the spinal cord. The different **vertebræ** are connected by means of the articular processes and the intervertebral fibrocartilages; while the transverse and spinous processes serve as levers for the attachment of muscles which move the different parts of the vertebral column. Lastly, between each pair of **vertebræ** apertures (*foramina intervertebralia*) exist through which the spinal nerves pass.

The **Body** (*corpus vertebrae*) is the largest part of a vertebra. Its *upper* and *lower surfaces* are flattened and rough for the attachment of the intervertebral fibrocartilages, and each presents a rim around its circumference. In *front* it is convex from side to side, concave from above downward. *Behind* it is flat from above downward and slightly concave from side to side. Its anterior surface is perforated by a few small apertures, for the passage of nutrient vessels; while on the posterior surface is a single large, irregular aperture, or occasionally more than one, for the exit of veins, the **venae basis vertebrae**, from the body of the vertebra.

Pedicles (*radix arcus vertebrae*).—The pedicles are two short, thick pieces of bone, which project backward, one on each side, from the upper part of the

body of the vertebra, at the line of junction of its posterior and lateral surfaces and form the root of the vertebral arch. The concavities above and below the pedicles are the **superior** and **inferior intervertebral notches** (*incisura vertebralis superior et inferior*); they are four in number, two on each side, the **inferior ones** being generally the deeper. When the vertebræ are articulated the notches of each contiguous pair of bones form the **intervertebral foramina** (*foramina intervertebralia*), which communicate with the vertebral canal and transmit the spinal nerves and bloodvessels.

Laminæ.—The laminæ are two broad plates of bone which complete the neural arch by fusing together in the middle line behind. They enclose a foramen, the **spinal or vertebral foramen** (*foramen vertebrale*), which serves for the protection of the spinal cord. When the vertebræ are joined they form, with their ligaments, the **vertebral canal** (*canalis vertebralis*). The laminæ are connected to the body by means of the pedicles. Their upper and lower borders are rough, for the attachment of the *ligamenta subflava*.

Processes. Spinous Process (*processus spinosus*).—The spinous process is a rather long, three-sided mass of bone which projects backward from the junction of the two laminæ and may terminate in a tubercle, and serves for the attachment of muscles and ligaments.

Articular Processes.—The articular processes (*zygapophyses*), four in number, two on each side, spring from the junction of the pedicles with the laminæ. Each **superior process** (*processus articularis superior*) projects upward, its **articular surface** (*facies articularis superior*) being directed more or less backward; each **inferior process** (*processus articularis inferior*) projects downward, its **articular surface** (*facies articularis inferior*) looking more or less forward.¹

Transverse Processes (*processus transversi*).—The transverse processes, two in number, project one at each side from the point where the lamina joins the pedicle, between the superior and inferior articular processes. They serve for the attachment of muscles and ligaments.

The Cervical Vertebrae (Vertebrae Cervicales) (Fig. 15).

The cervical vertebrae are smaller than those in any other region of the spine, and may be readily distinguished by the foramen in the transverse process, which does not exist in the transverse process of either a thoracic or lumbar vertebra.

Body.—The body is small, comparatively dense, and broader from side to side than from before backward. The *anterior* and *posterior surfaces* are flattened and of equal depth; the former is placed on a lower level than the latter, and its inferior border is prolonged downward, so as to overlap the upper and fore part of the vertebra below. Its *upper surface* is concave transversely, and presents a projecting lip on each side; its *lower surface* is convex from side to side, concave from before backward, and presents laterally a shallow concavity which receives the corresponding projecting lip of the adjacent vertebra.

Pedicles.—The pedicles are directed outward and backward, and are attached to the body midway between the upper and lower borders; so that the superior intervertebral notch is as deep as the inferior, but it is, at the same time, narrower.

Laminæ.—The laminæ are narrow, long, thinner above than below, and overlap each other, enclosing the vertebral foramen, which is very large, and of a triangular form.

Processes. Spinous Process.—The spinous process is short, and bifid at the extremity, to afford greater extent of surface for the attachment of muscles, the

¹ It may, perhaps, be as well to remind the reader that the direction of a surface is determined by that of a line drawn at right angles to it.

two divisions being often of unequal size. They increase in length from the fourth to the seventh vertebra.

Articular Processes.—The articular processes are flat, oblique, and of an oval form; the superior are directed backward and upward, the inferior forward and downward.

Transverse Processes.—The transverse processes are short, directed downward, outward, and forward, bifid at their extremity, and marked by a groove along the upper surface, which runs downward and outward from the superior intervertebral notch and serves for the transmission of one of the cervical nerves. They are situated in front of the articular processes and on the outer side of the pedicles. The transverse processes are pierced at their bases by a foramen, for the transmission of the vertebral artery, vein, and a plexus of sympathetic nerves. This foramen is known as the **transverse foramen**, the **costotransverse foramen**, and the **vertebral foramen** (*foramen transversarium*). Each process is formed by two roots—the anterior root, sometimes called the **costal process**, arising from the side of the body, and the homologue of the rib in the thoracic region of the column; the posterior root springs from the junction of the pedicle with the lamina, and corresponds to the transverse process in the thoracic region.

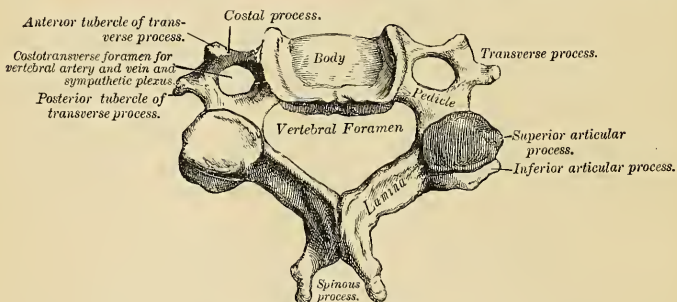


FIG. 15.—Cervical vertebra.

It is by the junction of the two that the foramen for the vertebral vessels is formed. The extremity of each of these roots form the anterior and posterior tubercles of the transverse processes.

The peculiar vertebrae in the cervical regions are the *first*, or **atlas**; the *second*, or **axis**; and the *seventh*, or **vertebra prominens**. The great modifications in the form of the atlas and axis are designed to admit of the nodding and rotatory movements of the head.

Atlas.—The atlas (Fig. 16) is so named because it supports the globe of the head. The chief peculiarities of this bone are that it has neither body nor spinous process. The body is detached from the rest of the bone, and forms the odontoid process of the second vertebra; while the parts corresponding to the pedicles join in front to form the anterior arch. The atlas is ring-like, and consists of an anterior arch, a posterior arch, and two lateral masses. The **anterior arch** (*arcus anterior*) forms about one-fifth of the ring; its anterior surface is convex, and presents about its centre a **tubercle** (*tuberculum anterius*), for the attachment of the *Longus colli* muscle; posteriorly it is concave, and marked by a smooth, oval facet (*fovea dentis*), covered with cartilage, for articulation with the odontoid process of the axis. The upper and lower borders give attachment to the anterior occipito-atlantal and the anterior atlanto-axial ligaments, which connect it with

the occipital bone above and the axis below. The **posterior arch** (*arcus posterior*) forms about two-fifths of the circumference of the bone; it terminates behind in a tubercle (*tuberculum posterius*), which is the rudiment of a spinous process, and gives origin to the *Rectus capitis posterior minor*. The diminutive size of this process prevents any interference in the movements between the atlas and the cranium. The posterior part of the arch presents above and behind a rounded edge for the attachment of the posterior occipitoatlantal ligament, while in front, immediately behind each superior articular process, is a groove (*sulcus arteriæ vertebralis*) (Fig. 16), sometimes converted into a foramen by a delicate bony spiculum, which arches backward from the posterior extremity of the superior articular process. These grooves represent the superior intervertebral notches, and are peculiar in that they are situated behind the articular processes, instead of in front of them, as in the other vertebræ. They serve for the transmission of the vertebral artery, which, ascending through the foramen in the transverse process, winds around the lateral mass in a backward and inward direction. They also transmit the suboccipital (first spinal) nerve. On the under surface of the posterior arch, in the same situation, are two other grooves, placed behind the lateral masses, and representing the inferior intervertebral notches of other vertebræ. They are much less marked than the superior. The lower border

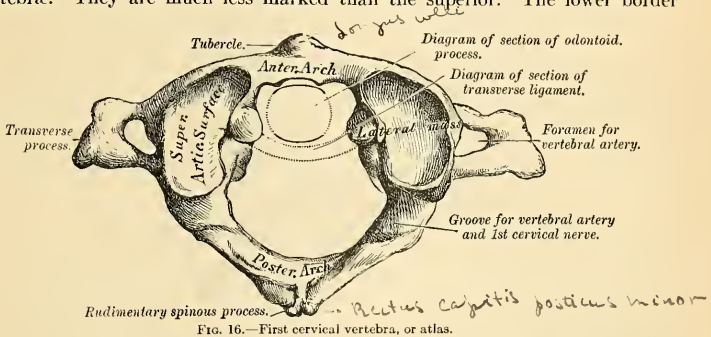


FIG. 16.—First cervical vertebra, or atlas.

also gives attachment to the posterior atlanto-axial ligament, which connects it with the axis. The **lateral masses** (*massæ laterales*) are the most bulky and solid parts of the atlas, in order to support the weight of the head; they present two articulating surfaces above and two below. Each represents one-fifth of the ring. The **superior articular surface** (*fovea articularis superior*) of each is of large size, oval, concave, and approaches its companion in front, but diverges from it behind; it is directed upward, inward, and a little backward, forming a kind of cup for the corresponding condyle of the occipital bone. The two processes are admirably adapted to the nodding movements of the head. Not infrequently they are partially subdivided by a more or less deep indentation, which encroaches upon each lateral margin. Each **inferior articular process** (*facies articularis inferior*) is circular in form, flattened or slightly concave, and directed downward and inward, articulating with the axis. The inferior processes permit the rotatory movements. Just below the inner margin of each superior articular surface is a small tubercle, for the attachment of the transverse ligament, which, stretching across the ring of the atlas, divides it into two unequal parts or arches; the anterior or smaller segment receiving the odontoid process of the axis, the posterior allowing the transmission of the spinal cord and its membranes. This part of the vertebral canal is of considerable size, to afford space for the spinal cord; and hence lateral

displacement of the atlas may occur without compression of this structure. The **transverse processes** are of large size, project directly outward and downward from the lateral masses, and serve for the attachment of special muscles which assist in rotating the head. They are long, not bifid, and perforated at their bases by a canal for the vertebral artery, which is directed from below, upward, and backward.

Axis.—The axis (*epistropheus*) (Fig. 17) is the pivot upon which the first vertebra, carrying the head, rotates. The most distinctive character of this bone is the strong, prominent process, tooth-like in form, which rises perpendicularly from the upper surface of the body. The **body** is deeper in front than behind, and prolonged downward anteriorly so as to overlap the upper and fore part of the next vertebra. It presents in front a median longitudinal ridge, separating two lateral depressions, for the attachment of the Longus colli muscles of either side. The **odontoid process** presents two articulating surfaces covered with cartilage; one in front, of an oval form, for articulation with the atlas (*facies articularis anterior*); another behind (*facies articularis posterior*), for the transverse

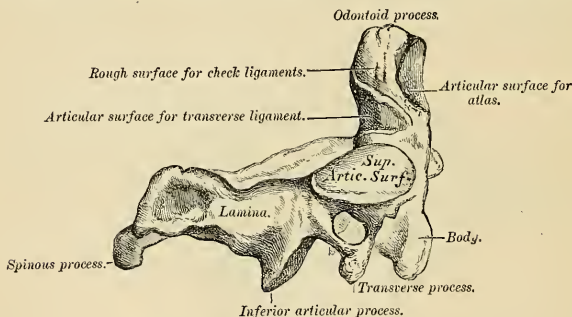


FIG. 17.—Second cervical vertebra, or axis.

ligament—the latter frequently encroaching on the sides of the process. The **apex** is pointed, and gives attachment to the middle odontoid ligament. Below the apex the process is somewhat enlarged, and presents on either side a rough impression for the attachment of the lateral fasciculi of the odontoid or check ligaments, which connect it to the occipital bone; the **base** of the process, where it is attached to the body, is constricted, so as to prevent displacement from the transverse ligament, which binds it in this situation to the anterior arch of the atlas. The **pedicles** are broad and strong, especially their anterior extremities, which coalesce with the sides of the body and the root of the odontoid process. The **laminae** are thick and strong, and the spinal foramen large, but smaller than that of the atlas. The **transverse processes** are very small, not bifid, and each is perforated by the foramen for the vertebral artery, which is directed obliquely upward and outward. The **superior articular surfaces** (*facies articulares superiores*) are circular, slightly convex, directed upward and outward, and are peculiar in being supported on the body, pedicles, and transverse processes. The **inferior articular surfaces** (*facies articulares inferiores*) have the same direction as those of the other cervical vertebrae. The **superior intervertebral notches** are very shallow, and lie behind the articular processes; the inferior in front of them, as in the other cervical vertebrae. The **spinous process** is of large size, very strong, deeply channelled on its under surface, and presents a bifid, tubercular extremity for the attachment of muscles which serve to rotate the head upon the spine.

Seventh Cervical (Fig. 18).—The most distinctive character of this vertebra is the existence of a very long and prominent spinous process, hence the name, *vertebra prominens*. This process is thick, nearly horizontal in direction, not bifurcated, and gives attachment to the lower end of the ligamentum nuchæ. The transverse process is usually of large size, its posterior tubercles are large and prominent, while the anterior are small and faintly marked; its upper surface has usually a shallow groove, and it seldom presents more than a trace of bifurcation at its extremity. The foramen in the transverse process is sometimes as large as in the other cervical vertebrae, but is usually smaller on one or both sides, and is sometimes absent. Usually the vertebral artery and vein pass in front of the transverse process, but occasionally it is traversed on both sides by these vessels, or the left one alone may give passage to them. Occasionally the anterior root of the transverse process exists as a separate bone, and attains a large size. It is then called a **cervical rib**.

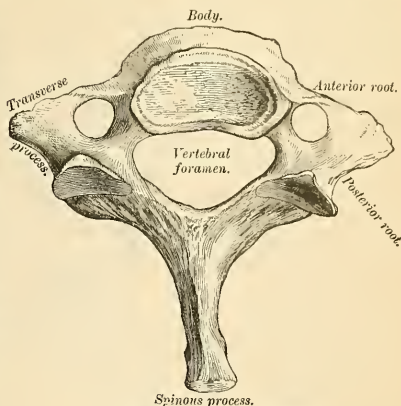


FIG. 18.—Seventh cervical vertebra.

The Thoracic Vertebrae (Vertebrae Thoracales).

The **thoracic vertebrae** are intermediate in size between those in the cervical and those in the lumbar region, and increase in size from above downward, the upper vertebrae in this segment of the column being much smaller than those in the lower part. A thoracic vertebra may be at once recognized by the presence on each side of the body of one or more facets or half-facets for the heads of the ribs.

Bodies.—The bodies of the thoracic vertebrae resemble those in the cervical and lumbar regions at the respective ends of this portion of the vertebral column, but in the middle of the thoracic region their form is very characteristic, being heart-shaped, and as broad in the antero-posterior as in the lateral direction. They are thicker behind than in front, flat above and below, convex and prominent in front, deeply concave behind, slightly constricted in front and at the sides, and marked on each side, near the root of the pedicle, by two demi-facets, one above, the other below (*fovea costalis superior et inferior*). These are covered by cartilage in the recent state, and, when articulated with the adjoining vertebrae, form, with the intervening fibrocartilage, oval surfaces for the reception of the heads of the corresponding ribs.

Pedicles.—The pedicles are directed backward, and the inferior intervertebral notches are of large size, and deeper than in any other region of the spine.

Laminae.—The laminae are broad, thick, and imbricated—that is to say, overlapping one another like tiles on a roof. The vertebral foramen is small, and of a circular form.

Processes.—**Spinous Processes.**—Each spinous process is long, triangular on transverse section, directed obliquely downward, and terminates in a tubercular

extremity. They overlap one another from the fifth to the eighth vertebra, but are less oblique in direction above and below.

Articular Processes.—The articular processes are flat, nearly vertical in direction, and project from the upper and lower part of the pedicles; the superior being directed backward and slightly outward and upward, the inferior forward and a little inward and downward.

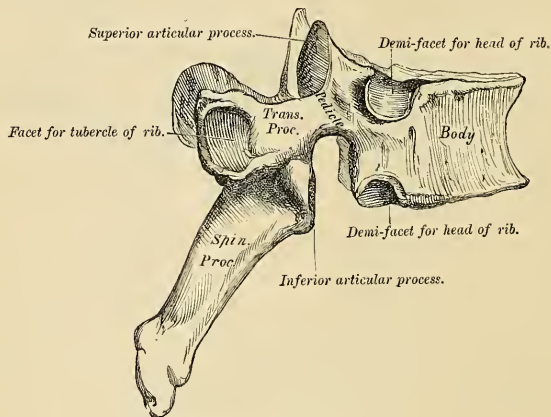


FIG. 19.—A thoracic vertebra.

Transverse Processes.—The transverse processes arise from the same parts of the arch as the posterior roots of the transverse processes in the neck, and are situated behind the articular processes and pedicles; they are thick, strong, and of great length, directed obliquely backward and outward, presenting a clubbed extremity, and having on its anterior part near its tip a small concave surface, for articulation with the tubercle of a rib (*fovea costalis transversalis*). Besides the articular facet for the rib, three indistinct tubercles may be seen arising from the transverse processes—one at the upper border, one at the lower border, and one externally. In man they are of comparatively small size, and serve only for the attachment of muscles. But in some animals they attain considerable magnitude, either for the purpose of more closely connecting the segments of this portion of the vertebral column or for muscular and ligamentous attachment.

The peculiar thoracic vertebræ are the *first, ninth, tenth, eleventh, and twelfth* (Fig. 20).

First Thoracic Vertebra.—The first thoracic vertebra presents, on each side of the body, a single entire articular facet for the head of the first rib and a demi-facet for the upper half of the second. The body is like that of a cervical vertebra, being broad transversely, its upper surface is concave, and lipped on each side. The articular surfaces are oblique, and the spinous process thick, long, and almost horizontal.

Ninth Thoracic Vertebra.—The ninth thoracic vertebra has no demi-facet below. In some subjects, however, the ninth has two demi-facets on each side; when this occurs the tenth has only a demi-facet at the upper part.

Tenth Thoracic Vertebra.—The tenth thoracic vertebra has (except in the case just mentioned) an entire articular facet on each side, above, which is partly

placed on the outer surface of the pedicle. It has no demi-facet below. Sometimes it has no facet on its transverse process.

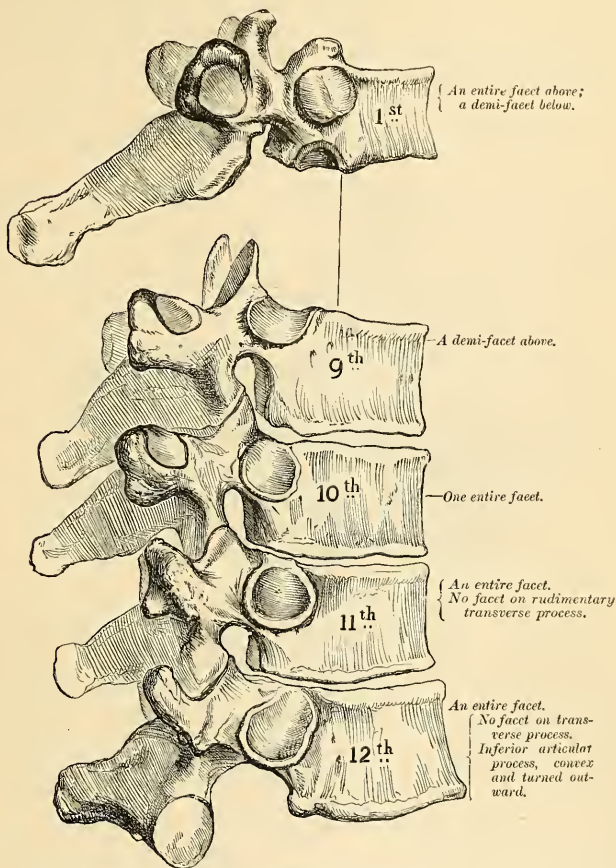


FIG. 20.—Peculiar thoracic vertebræ.

Eleventh Thoracic Vertebra.—The body of this vertebra approaches in its form and size that of the lumbar vertebræ. The articular facets for the heads of the ribs, one on each side, are of large size, and placed chiefly on the pedicles, which are thicker and stronger in this and the next vertebra than in any other part of the thoracic region. The spinous process is short, and nearly horizontal in direction. The transverse processes are very short, tubercular at their extremities, and have no articular facets for the tubercles of the ribs.

Twelfth Thoracic Vertebra.—The twelfth thoracic vertebra has the same general characters as the eleventh, but may be distinguished from it by the in-

ferior articular processes being convex and turned outward, like those of the lumbar vertebræ; and by the fact that this vertebra resembles the lumbar vertebræ in the general form of the body, laminae, and spinous process; and by the transverse processes being shorter, and marked by three elevations, the superior, inferior, and external tubercles, which correspond to the mammillary, accessory, and transverse processes of the lumbar vertebræ. There is no facet on its transverse process for the twelfth rib.

The Lumbar Vertebræ (*Vertebrae Lumbales*) (Fig. 21).

The lumbar vertebræ are the largest segments of the vertebral column, and can at once be distinguished by the absence of the foramen in the transverse process, the characteristic point of the cervical vertebræ, and by the absence of any articulating facet on the side of the body, the distinguishing mark of the thoracic vertebræ.

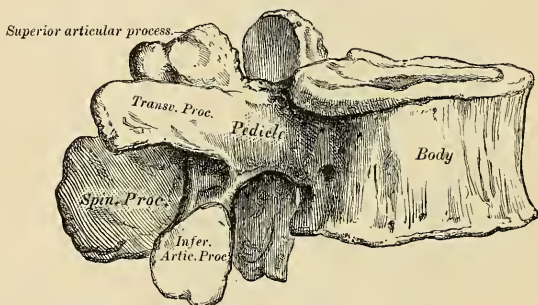


FIG. 21.—Lumbar vertebra.

Body.—The body is large, and has a greater diameter from side to side than from before backward, slightly thicker in front than behind, flattened or slightly concave above and below, concave behind, and deeply constricted in front and at the sides, presenting prominent margins, which afford a broad surface for the support of the superincumbent weight.

Pedicles.—The pedicles are very strong, directed backward from the upper part of the bodies; consequently, the inferior intervertebral notches are of considerable depth.

Laminae.—The laminae are broad, short, and strong, and the vertebral foramen triangular, larger than in the thoracic, smaller than in the cervical, region.

Processes. Spinous Processes.—The spinous processes are thick and broad, somewhat quadrilateral, horizontal in direction, thicker below than above, and terminating in a rough, uneven border.

Articular Processes.—The superior articular processes are concave, and look backward and inward; the inferior are convex, and look forward and outward; the former are separated by a much wider interval than the latter, embracing the lower articulating processes of the vertebra above.

Transverse Processes.—The transverse processes are long, slender, directed transversely outward in the upper three lumbar vertebræ, slanting a little upward in the lower two. They are situated in front of the articular processes, instead of behind them, as in the thoracic vertebræ, and are homologous with the ribs. Of the three tubercles noticed in connection with the transverse processes of the

twelfth thoracic vertebra, the superior one on each side becomes connected in this region with the back part of the superior articular process, and has received the name of **mamillary process** (*processus mamillaris*); the inferior is represented by a small process pointing downward, situated at the back part of the base of the transverse process, and called the **accessory process** (*processus accessorius*); these are the true transverse processes, which are rudimentary in this region of the spine. The external one, the so-called **transverse process**, is the homologue of the rib, and constitutes the **costal process** (*processus costarius*) (Fig. 22). Although in man the costal processes are comparatively small, in some animals they attain considerable size, and serve to lock the vertebræ more closely together.

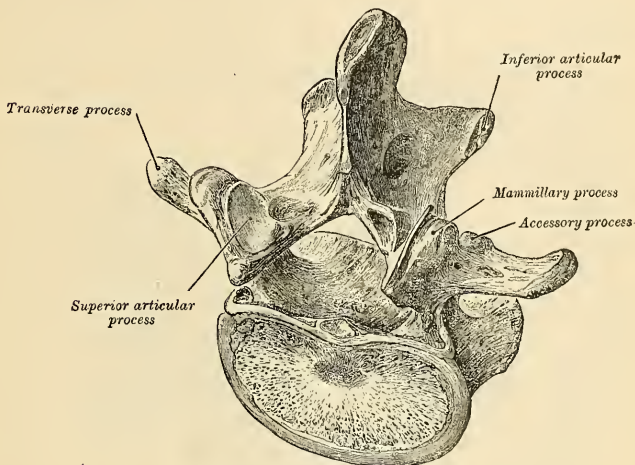


FIG. 22.—Lumbar vertebra, viewed obliquely.

Fifth Lumbar Vertebra.—The fifth lumbar vertebra is characterized by having the body much thicker in front than behind, which accords with the prominence of the sacrovertebral articulation; by the smaller size of its spinous process; by the wide interval between the inferior articulating processes; and by the greater size and thickness of its transverse processes, which spring from the body as well as from the pedicles.

Attachment of Muscles.—To the **Atlas** are attached *nine* pairs: the Longus colli, Rectus capitis anticus minor, Rectus lateralis, Obliquus capitis superior and inferior, Splenius colli, Levator anguli scapulae, First Intertransverse, and Rectus capitis posticus minor.

To the **Axis** are attached *eleven* pairs: the Longus colli, Levator anguli scapulae, Splenius colli, Scapulus medius, Transversalis colli, Intertransversales, Obliquus capitis inferior, Rectus capitis posticus major, Semispinalis colli, Multifidus spinae, Interspinales.

To the remaining vertebræ, generally, are attached thirty-five pairs and a single muscle: anteriorly, the Rectus capitis anticus major, Longus colli, Scalenus anticus, medius, and posticus, Psoas magnus and parvus, Quadratus lumborum, Diaphragm, Obliquus abdominis internus, and Transversalis abdominis; posteriorly, the Trapezius, Latissimus dorsi, Levator anguli scapulae, Rhomboideus major and minor, Serratus posticus superior and inferior, Splenius, Erector spinae, Iliocostalis, Longissimus dorsi, Spinalis dorsi, Cervicalis ascendens, Transversalis colli, Trachelomastoid, Complexus, Biventer cervicis, Semispinalis dorsi and colli, Multifidus spinae, Rotatores spinae, Interspinales, Supraspinales, Intertransversales, Levatores costarum.

The Sacral and Coccygeal Vertebrae.

The **sacral** and **coccygeal vertebrae** consist, at an early period of life, of nine separate pieces, which are united in the adult so as to form two bones, five entering into the formation of the sacrum, four into that of the coccyx. Occasionally, the coccyx consists of five bones.¹

Sacrum (*os sacrum*).—The sacrum is a large, triangular bone (Fig. 23), situated at the lower part of the vertebral column, and at the upper and back part of the pelvic cavity, where it is inserted like a wedge between the two innominate bones; its upper part or base articulating with the last lumbar vertebra,

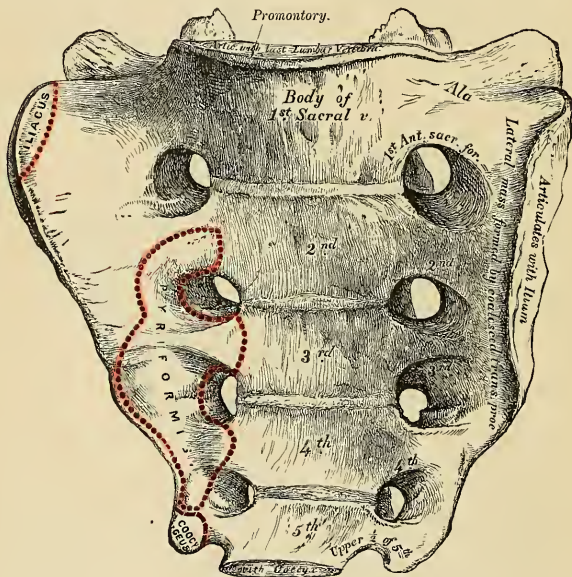


FIG. 23.—Sacrum, anterior surface.

its apex with the coccyx. It is composed of five segments of bone. The sacrum is curved upon itself, and placed very obliquely, its upper extremity projecting forward, and forming, with the last lumbar vertebra, a very prominent angle, called the **promontory** (*promontorium*), or **sacrovertebral angle**; while its central part is directed backward, so as to give increased capacity to the pelvic cavity. It presents for examination an anterior and posterior surface, two lateral surfaces, a base, an apex, and a central canal.

Surfaces. **Anterior or Pelvic Surface** (*facies pelvina*).—The anterior surface is concave from above downward, and slightly so from side to side. In the middle are seen four **transverse ridges** (*lineae transversae*), indicating the original division of the bone into five separate pieces. The portions of bone intervening

¹ Sir George Humpbry describes this as the usual composition of the coccyx. "On the Skeleton," p. 456.

between the ridges correspond to the bodies of the vertebræ. The body of the first segment is of large size, and in form resembles that of a lumbar vertebra; the succeeding ones diminish in size from above downward, are flattened from before backward, and curved so as to accommodate themselves to the form of the sacrum, being concave in front, convex behind. At each end of the ridges above mentioned are seen the **anterior sacral foramina** (*foramina sacralia anteriora*), analogous to the intervertebral foramina, four in number on each side, somewhat circular in form, diminishing in size from above downward, and directed outward and forward; they transmit the anterior branches of the sacral nerves and the lateral sacral arteries. External to these foramina is the **lateral mass** (*pars lateralis*), consisting at an early period of life of separate segments; these become blended, in the adult, with the bodies, with each other, and with the posterior transverse processes. Each lateral mass is traversed by four broad, shallow grooves, which lodge the anterior divisions of the sacral nerves as they pass outward, the grooves being separated by prominent ridges of bone, which give attachment to the slips of the Piriformis muscle.

If a vertical section is made through the centre of the sacrum (Fig. 24), the bodies are seen to be united at their circumference by bone, a wide interval being left centrally, which, in the recent state, is filled by intervertebral substance. In some bones this union is more complete between the lower segments than between the upper ones.

Posterior or Dorsal Surface (*facies dorsalis*).—The posterior surface (Fig. 25) is convex and much narrower than the anterior. In the middle line are three or four tubercles, which represent the rudimentary spinous processes of the sacral vertebræ. Of these tubercles, the first is usually prominent, and perfectly distinct from the rest; the second and third are either separate or united into a

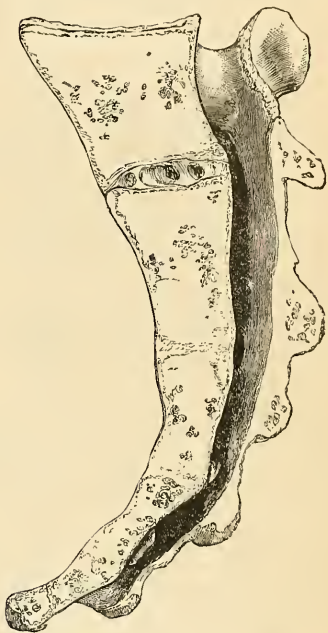

FIG. 24.—Vertical section of the sacrum.

tubercular ridge (*crista sacralis media*), which diminishes in size from above downward; the fourth usually, and the fifth always, remaining undeveloped; being undeveloped, in this situation the lower end of the sacral canal is exposed. The gap is called the **hiatus sacralis**. External to the spinous processes on each side are the laminae, broad and well marked in the first three pieces; sometimes the fourth, and generally the fifth. External to the laminae is a linear series of indistinct tubercles representing the articular processes (*cristae sacrales articulares*); the upper pair are large, well developed, and correspond in shape and direction to the superior articulating processes of a lumbar vertebra; the second and third are small; the fourth and fifth (usually blended together) are situated on each side of the exposed part of the sacral canal and form downward projecting processes, the **sacral cornua**, and are connected to the cornua of the coccyx.

External to the articular processes are the four posterior sacral foramina (*foramina sacralia posteriora*); they are smaller in size and less regular in form than the anterior, and transmit the posterior branches of the sacral nerves. On the outer side of the posterior sacral foramina is a series of tubercles, the rudimentary transverse processes of the sacral vertebrae (*cristae sacrales laterales*). The first pair of transverse tubercles are large, very distinct, and correspond with each superior angle of the bone; they, together with the second pair, which are of small size, give attachment to the horizontal part of the posterior sacroiliac ligament; the third gives attachment to the oblique fasciculi of the posterior sacroiliac ligaments; and the fourth and fifth to the great sacrospinous ligaments. The interspace between the spinous and transverse processes on the back of the sacrum presents a wide, shallow concavity, called the **sacral**

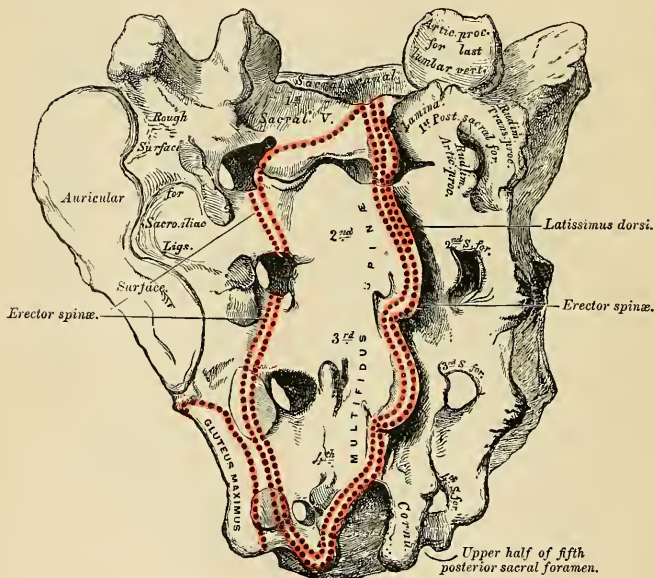


FIG. 25.—Sacrum, dorsolateral view.

groove; it is continuous above with the vertebral groove, and lodges the origin of the Multifidus spinæ.

Lateral Surface.—The lateral surface, broad above, becomes narrowed into a thin edge below. Its upper half presents in front a broad, ear-shaped surface for articulation with the ilium. This is called the **auricular surface** (*facies auricularis*), and in the fresh state is coated with fibrocartilage. It is bounded posteriorly by deep and uneven impressions, for the attachment of the posterior sacroiliac ligaments. The chief prominence is called the **tuberosity** (*tuberositas sacralis*). The lower half is thin and sharp, and terminates in a projection called the **inferior lateral angle**; below this angle is a notch, which is converted into a foramen by articulation with the transverse process of the upper piece of the coccyx, and

transmits the anterior division of the fifth sacral nerve. This lower, sharp border gives attachment to the greater and lesser sacrosciatic ligaments, and to some fibres of the Gluteus maximus posteriorly, and to the Coccygeus in front.

Base (*basis oss. sacri*).—The base of the sacrum, which is broad and expanded, is directed upward and forward. In the middle is seen a large oval articular surface, which is connected with the under surface of the body of the last lumbar vertebra by a fibrocartilaginous disk. It is bounded behind by the large, triangular orifice of the sacral canal. The orifice is formed behind by the laminae and spinous process of the first sacral vertebra: the superior articular processes project from it on each side; they are oval, concave, directed backward and inward, like the superior articular processes of a lumbar vertebra; and in front of each articular process is an intervertebral notch, which forms the lower part of the foramen between the last lumbar and first sacral vertebra. Lastly, on each side of the large oval articular plate is a broad and flat triangular surface of bone, which extends outward, supports the Psoas magnus muscle and lumbosacral cord, and is continuous on each side with the iliac fossa. This is called the **ala of the sacrum** (*ala sacralis*), and gives attachment to a few of the fibres of the Iliacus muscle. The posterior part of the ala represents the transverse process of the first sacral segment.

Apex (*apex oss. sacri*).—The apex, directed downward and slightly forward, presents a small, oval, concave surface for articulation with the coccyx.

The **Sacral Canal** (*canalis sacralis*) runs throughout the greater part of the bone; it is large and triangular in form above, small and flattened, from before backward, below. In this situation its posterior wall is incomplete, from the non-development of the laminae and spinous processes (*hiatus sacralis*). It lodges the sacral nerves, and is perforated by the anterior and posterior sacral foramina, through which these pass out. It constitutes the sacral continuation of the vertebral canal (Fig. 24).

Differences in the Sacrum of the Male and Female.—The sacrum in the female is shorter and wider than in the male; the lower half forms a greater angle with the upper, the upper half of the bone being nearly straight, the lower half presenting the greatest amount of curvature. The bone is also directed more obliquely backward, which increases the size of the pelvic cavity; but the sacrovertebral angle projects less. In the male the curvature is more evenly distributed over the whole length of the bone, and is altogether greater than in the female.

Variations.—This bone, in some cases, consists of six pieces; occasionally the number is reduced to four. Sometimes the bodies of the first and second segments are not joined or the laminae and spinous processes have not coalesced. Occasionally the upper pair of transverse tubercles are not joined to the rest of the bone on one or both sides; and, lastly, the sacral canal may be open for nearly the lower half of the bone, in consequence of the imperfect development of the laminae and spinous processes. The sacrum, also, varies considerably with respect to its degree of curvature.

Articulations.—With *four* bones: the last lumbar vertebra, coccyx, and the two innominate bones.

Attachment of Muscles.—To *eight* pairs: in front, the Pyriformis and Coccygeus, and a portion of the Iliacus to the base of the bone; behind, the Gluteus maximus, Latissimus dorsi, Multifidus spinæ, and Erector spinæ, and sometimes the Extensor coccygis.

Coccyx (*os coccygis*).—The coccyx (Fig. 26) is usually formed of four small segments of bone, the most rudimentary parts of the vertebral column (**vertebrae coccygeae**). In each of the first three segments may be traced a rudimentary body, articular and transverse processes; the last piece (sometimes the third) is a mere nodule of bone, without distinct processes. All the segments are destitute of pedicles, laminae, and spinous processes, and consequently of intervertebral foramina and vertebral canal. The first segment is the largest; it resembles the lowermost sacral vertebra, and often exists as a separate piece; the last three,

diminishing in size from above downward, are usually blended to form a single bone. The gradual diminution in the size of the pieces gives this bone a triangular form, the base of the triangle joining the apex of the sacrum. It presents for examination an anterior and posterior surface, two borders, a base, and an apex.

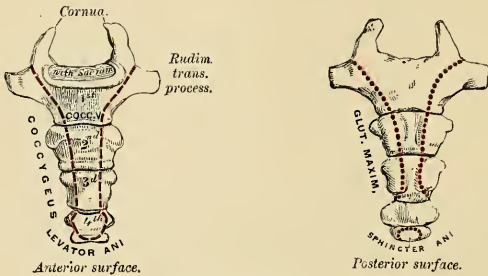


FIG. 26.—Coccyx.

Surfaces. Anterior Surface.—The anterior surface is slightly concave and marked with three transverse grooves, indicating the points of junction of the different pieces. It has attached to it the anterior sacrococcygeal ligament and Levator ani muscle, and supports the lower end of the rectum.

Posterior Surface.—The posterior surface is convex, marked by transverse grooves similar to those on the anterior surface; and presents on each side a lineal row of tubercles, the rudimentary articular processes of the coccygeal vertebræ. Of these, the superior pair are large, and are called the **cornua of the coccyx** (*cornua coccygea*); they project upward, and articulate with the cornua of the sacrum, the junction between these two bones completing the fifth posterior sacral foramen for the transmission of the posterior division of the fifth sacral nerve.

Borders.—The lateral borders are thin, and present a series of small eminences, which represent the transverse processes of the coccygeal vertebræ. Of these, the first on each side is the largest, flattened from before backward, and often ascends to join the lower part of the thin lateral edge of the sacrum, thus completing the fifth anterior sacral foramen for the transmission of the anterior division of the fifth sacral nerve; the others diminish in size from above downward, and are often wanting. The borders of the coccyx are narrow, and give attachment on each side to the sacrosciatic ligaments, to the Coccygeus muscles in front of the ligaments, and to the Gluteus maximus behind them.

Base.—The base presents an oval surface for articulation with the sacrum.

Apex.—The apex is rounded, and has attached to it the tendon of the external Sphincter muscle. It is occasionally bifid, and sometimes deflected to one or the other side.

Articulation.—With the sacrum.

Attachment of Muscles.—To four pairs and one single muscle: on either side, the Coccygeus; behind, the Gluteus maximus and Extensor coccygis, when present; at the apex, the Sphincter ani; and in front, the Levator ani.

Structure of the Vertebræ.—The body is composed of light, spongy, cancellous tissue, having a thin coating of compact tissue on its external surface perforated by numerous orifices of various sizes for the passage of vessels; its interior is traversed by one or two large canals (for the transmission of veins), which converge toward a single large, irregular aperture or several small apertures at the posterior part of the body of each bone. The arch and processes pro-

jecting from it have, on the contrary, an exceedingly thick covering of compact tissue (Fig. 27).

The **sacrum** and **coccyx** consist mainly of spongy bone covered by a thin layer of compact bone.

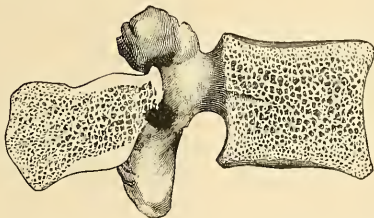


FIG. 27.—Bony structure of a lumbar vertebra. (Poirier and Charpy.)

Development.—Each vertebra is formed of *four* primary centres of ossification (Fig. 28), one for each lamina and its processes, and two for the body.¹ Ossification commences in the laminae about the sixth week of fetal life, in the situation where the transverse processes afterward project, the ossific granules spreading backward to the spine, forward into the pedicles, and onward into the transverse and articular processes. Ossification in the body commences in the middle of the cartilage about the eighth week by two closely approximated centres, which speedily coalesce to form one central ossific point. According to some authors, ossification commences in the laminae only in the upper vertebræ—*i. e.*, in the cervical and upper thoracic. The first ossific points in the lower vertebræ are those which are to form the body, the osseous centres for the laminae appearing at a subsequent period. At birth these three pieces are entirely separate. During the first year the laminae become united behind, the union taking place first in the lumbar vertebræ and then extending upward through the thoracic and lower cervical vertebræ. About the third year the body is joined to the arch on each side in such a manner that the body is formed from the three original centres of ossification, the amount contributed by the pedicles increasing in extent from below upward. Thus, the bodies of the sacral vertebræ are formed almost entirely from the central nuclei; the bodies of the lumbar are formed laterally and behind by the pedicles; in the thoracic region the pedicles advance as far forward as the articular depressions for the head of the ribs, forming these cavities of reception; and in the neck the lateral portions of the bodies are formed entirely by the advance of the pedicles. The line along which union takes place between the body and the neural arch is named **neurocentral suture**. Before puberty no other changes occur, excepting a gradual increase in the growth of these primary centres; the upper and under surfaces of the bodies and the ends of the transverse and spinous processes being tipped with cartilage, in which ossific granules are not as yet deposited. At sixteen years (Fig. 30) three secondary centres appear, one for the tip of each transverse process, and one for the extremity of the spinous process. In some of the lumbar vertebræ, especially the first, second, and third, a second ossifying centre appears at the base of the spinous process. At twenty-one years (Fig. 29) a thin, circular, epiphyseal plate of bone is formed in the layer of cartilage situated on the upper and under surfaces of the body, the former being the thicker of the two. These represent two additional secondary centres of ossification. All these become joined, and the bone is completely formed between the twenty-fifth and thirtieth year of life.

Exceptions to this mode of development occur in the first, second, and seventh cervical, and in the vertebræ of the lumbar region.

Atlas (Fig. 31).—The number of centres of ossification of the atlas is quite variable. It may be developed from *two, three, four, or five* centres. The most frequent method is from three centres. Two of these are destined for the two lateral or neural masses, the ossification of which commences about the seventh week near the articular processes, and extends backward; these portions of bone are separated from one another behind, at birth, by a narrow interval filled in with cartilage. Between the third and fourth years they unite either directly or through the medium of a separate centre developed in the cartilage in the median line. The anterior

¹ By many observers it is asserted that the bodies of the vertebra are developed from a single centre which speedily becomes bilobed, so as to give the appearance of two nuclei; but that there are two centres, at all events sometimes, is evidenced by the facts that the two halves of the body of the vertebra may remain distinct throughout life, and be separated by a fissure through which a protrusion of the spinal membrane may take place, constituting an *anterior spina bifida*.

arch, at birth, is altogether cartilaginous, and in this a separate nucleus appears about the end of the first year after birth, and, extending laterally, joins the neural processes in front of the pedicles. Sometimes there are two centres developed in the cartilage, one on either side of the median line, which join to form a single mass.

And occasionally there is no separate centre, but the anterior arch is formed by the gradual extension forward and ultimate junction of the two neural processes.

Axis.—The axis (Fig. 32) is developed by seven centres, five primary and two secondary. The body and arch of this bone are formed in the same manner as the corresponding parts in the other vertebrae: one centre (or two, which speedily coalesce) for the lower part of the body, and one for each lamina. The centres for the laminae appear about the seventh or eighth week, that for the body about the fourth month. The odontoid process consists originally of an extension upward of the cartilaginous mass in which the lower part of the body is formed. At about the sixth month of fetal life two centres make their appearance in the base of this process; they are placed laterally, and join before birth to form a conical bilobed mass deeply cleft above; the interval between the cleft and the summit of the process is formed by a wedge-shaped piece of cartilage, the base of the process being separated from the body by a cartilaginous interval, which gradually becomes ossified at its circumference, but remains cartilaginous in its centre until advanced age. Finally, the apex of the odontoid process has a separate (secondary) centre, which appears in the second year and joins about the twelfth year. In addition to these there is a secondary centre for a thin epiphyseal plate on the under surface of the body of the bone.

Seventh Cervical.—The anterior or costal part of the transverse process of the seventh cervical is developed from a separate osseous centre at about the sixth month of fetal life, and joins the body and posterior division of the transverse process between the fifth and sixth years. In rare instances this process continues as a separate piece, and, becoming lengthened outward, constitutes what is known as a *cervical rib*. This separate ossific centre for the costal process has also been found in the fourth, fifth, and sixth cervical vertebrae.

Lumbar Vertebrae.—The lumbar vertebrae (Fig. 33) have two additional centres (besides those peculiar to the vertebrae generally) for the mammillary tubercles, which project from the back part of the superior articular processes. The transverse process of the first lumbar is sometimes developed as a separate piece, which may remain per-

By 4 primary centres.

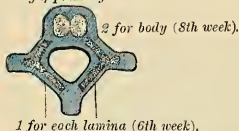

FIG. 28.—Development of a vertebra.

By 2 additional plates.

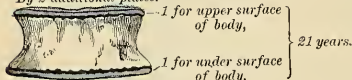
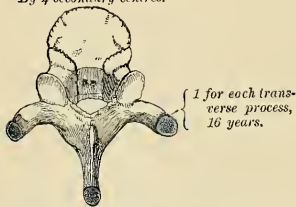


FIG. 29

By 4 secondary centres.



2 (sometimes 1) for spinous process (16 years).

FIG. 30

By 3 centres.

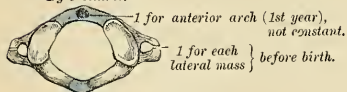


FIG. 31.—Atlas.

By 7 centres.

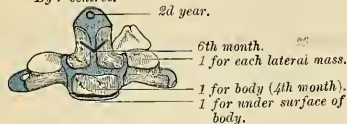
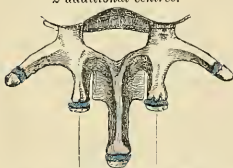

FIG. 32.—Axis.

2 additional centres.



for tubercles on superior articular process.

FIG. 33.—Lumbar vertebra.

manently unconnected with the remaining portion of the bone, thus forming a *lumbar rib*—a peculiarity.

The **sacrum**, formed by the union of five vertebræ, has *thirty-five* centres of ossification.

The **bodies** of the sacral vertebræ have each three ossific centres—one for the central part, and one for the epiphyseal plates on its upper and under surface. Occasionally the primary centres for the bodies of the first and second piece of the sacrum are double. The **arch** of each sacral vertebra is developed from two centres, one for each lamina. These unite with each other behind, and subsequently join the body.

The **lateral masses** have six additional centres, two for each of the first three vertebræ. These centres, representing costal elements, make their appearance above and to the outer side of the anterior sacral foramina (Fig. 34), and are developed into separate segments (Fig. 35); they are subsequently blended with each other, and with the bodies and transverse processes to form the lateral mass.

Lastly, each **lateral surface** of the sacrum is developed from two epiphyseal plates (Fig. 36)—one for the auricular surface, and one for the remaining part of the thin lateral edge of the bone.

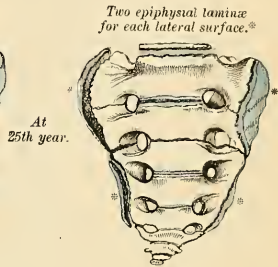
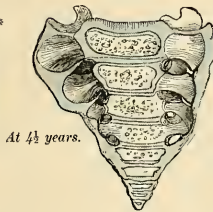
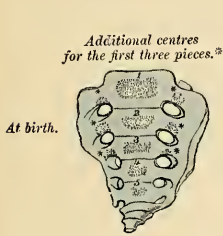

FIG. 34.—Development of the sacrum.

FIG. 35

FIG. 36

Period of Development.—At about the eighth or ninth week of fetal life ossification of the central part of the bodies of the first three vertebræ commences, and between the fifth and eighth months in the last two. Between the sixth and eighth months ossification of the laminae takes place; and at about the same period the centres for the lateral masses for the first three sacral vertebræ make their appearance. The period at which the arch becomes completed by the junction of the laminae with the bodies in front and with each other behind varies in different segments. The junction between the laminae and the bodies takes place first in the lower vertebræ as early as the second year, but is not effected in the uppermost until the fifth or sixth year. About the sixteenth year the epiphyses for the upper and under surfaces of the bodies are formed, and between the eighteenth and twentieth years those for each lateral surface of the sacrum make their appearance. The bodies of the sacral vertebræ are, during early life, separated from each other by intervertebral disks. At about the eighteenth year the two lowest segments become joined by ossification extending through the disk. This process gradually extends upward until all the segments become united, and the bone is completely formed from the twenty-fifth to the thirtieth year of life.

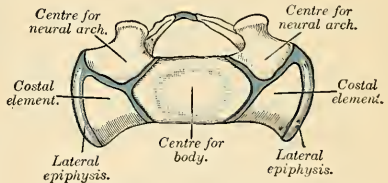


FIG. 37.—Base of sacrum at an early stage.

The **coccyx** is developed from *four* centres, one for each piece. Occasionally one of the first three pieces of this bone is developed from two centres, placed side by side. The ossific nuclei make their appearance in the following order: In the first segment, between the first and fourth years; in the second piece, at from five to ten years; in the third, from ten to fifteen years; in the fourth from fourteen to twenty years. As age advances these various segments become united with each other from below upward, the union between the first and second segments being frequently delayed until after the age of twenty-five or thirty. At a late period of life, especially in females, the coccyx often becomes ankylosed to the end of the sacrum.

The Vertebral Column as a Whole.

The vertebral column (*columna vertebralis*), formed by the interarticulation of the vertebræ, is situated in the median line, in the posterior part of the trunk; its average length is about two feet two or three inches (65 to 67.5 cm.), measuring along the curved anterior surface of the column. Of this length, the cervical part measures about five, the thoracic about eleven, the lumbar about seven inches, and the sacrum and coccyx the remainder. The female column is about one inch less than that of the male.

Viewed laterally (Fig. 38), the spinal column presents several curves which correspond to the different regions of the column, and are called cervical, thoracic, lumbar, and pelvic. The **cervical curve** commences at the apex of the odontoid process, and terminates at the middle of the second thoracic vertebra; it is convex in front, and is the least marked of all the curves. The **thoracic curve**, which is concave forward, commences at the middle of the second, and terminates at the middle of the twelfth thoracic vertebra. Its most prominent point behind corresponds to the spine of the seventh thoracic vertebra. The **lumbar curve** commences at the middle of the last thoracic vertebra, and terminates at the sacrovertebral angle. It is convex anteriorly; the convexity of the lower three vertebræ being much greater than that of the upper two. The **pelvic curve** commences at the sacrovertebral articulation and terminates at the point of the coccyx. It is concave anteriorly. The thoracic and pelvic curves are the primary curves, and begin to be formed at an early period of fetal life, and are due to the shape of the bodies of the vertebræ. The cervical and lumbar curves are compensatory or secondary, and are developed after birth in order to maintain the erect position. They are due mainly to the shape of the intervertebral disks. Not uncommonly the thoracic portion of the vertebral column—even in healthy persons—deviates toward the right. This is due to the position of the heart and of the arch of the aorta.

The movable part of the vertebral column presents for examination an anterior, a posterior, and two lateral surfaces; a base, a summit, and the vertebral canal.

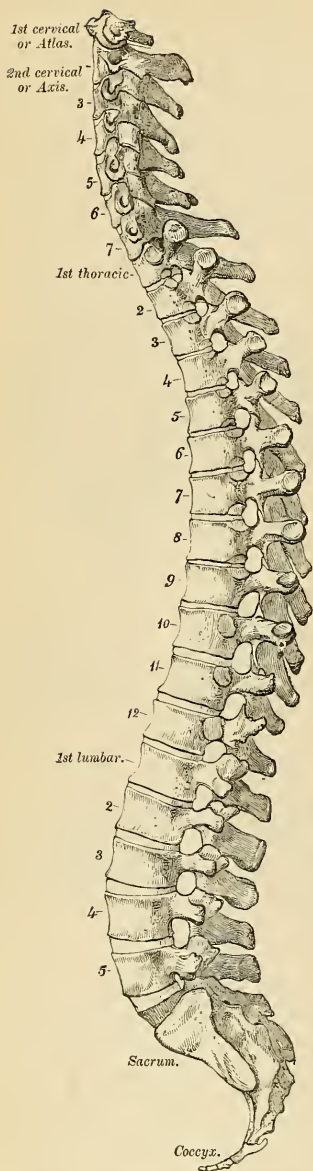


FIG. 38.—Lateral view of the vertebral column.

Surfaces.—The **anterior** or **ventral surface** presents the bodies of the vertebrae separated in the recent state by the intervertebral disks. The bodies are broad in the cervical region, narrow in the upper part of the thoracic, and broadest in the lumbar region. The whole of this surface is convex transversely, concave from above downward in the thoracic region, and convex in the same direction in the cervical and lumbar regions.

The **posterior** or **dorsal surface** presents in the median line the spinous processes. These are short, horizontal, with bifid extremities, in the cervical region. In the thoracic region they are directed obliquely above, assume almost a vertical direction in the middle, and are horizontal below, as are also the spines of the lumbar vertebrae. They are separated by considerable intervals in the loins, by narrower intervals in the neck, and are closely approximated in the middle of the thoracic region. On either side of the spinous processes, extending the whole length of the column, is the **vertebral groove** formed by the laminae in the cervical and lumbar regions, where it is shallow, and by the laminae and transverse processes in the thoracic region, where it is deep and broad. In the recent state these grooves lodge the deep muscles of the back. External to each vertebral groove are the articular processes, and still more externally are the transverse processes. In the thoracic region the latter processes stand backward, on a plane considerably posterior to that of like processes in the cervical and lumbar regions. In the cervical region the transverse processes are placed in front of the articular processes, and on the outer side of the pedicles, between the intervertebral foramina. In the thoracic region they are posterior to the pedicles, intervertebral foramina, and articular processes. In the lumbar region they are placed in front of the articular processes, but behind the intervertebral foramina.

The **lateral surfaces** are separated from the dorsal surface by the articular processes in the cervical and lumbar regions, and by the transverse processes in the thoracic region. These surfaces present in front the sides of the bodies of the vertebrae, marked in the thoracic region by the facets for articulation with the heads of the ribs. More posteriorly are the intervertebral foramina, formed by the juxtaposition of the intervertebral notches, oval in shape, smallest in the cervical and upper part of the thoracic regions, and gradually increasing in size to the last lumbar vertebra. They are situated between the transverse processes in the neck, and in front of them in the back and loins, and transmit the spinal nerves.

Base.—The base of that portion of the vertebral column formed by the twenty-four movable vertebrae is formed by the under surface of the body of the fifth lumbar vertebra; and the summit by the upper surface of the atlas.

Vertebral Canal.—The vertebral canal follows the different curves of the vertebral column; it is largest in those regions in which the vertebral column enjoys the greatest freedom of movement, as in the neck and loins, where it is wide and triangular; and is narrow and cylindrical in the back, where motion is more limited.

Surface Form.—The only parts of the vertebral column which lie closely under the skin, and so directly influence surface form, are the apices of the spinous processes. These are always distinguishable at the bottom of a median furrow, which, more or less evident, runs down the mesal line of the back from the external occipital protuberance above to the middle of the sacrum below. Occasionally one of these processes deviates a little from the median line—a fact to be remembered in practice, as irregularities of this kind are attendant also on fracture or displacements of the vertebral column. In the cervical region the furrow is between the Trapezius muscles; in the back and loins it is between the Erector spinae muscles. In the neck the furrow is broad, and terminates in a conspicuous projection, which is caused by the spinous process of the seventh cervical vertebra (*vertebra prominens*). Above this the spinous process of the sixth cervical vertebra may sometimes be seen projecting; the other cervical spines are sunken, and are not visible, though the spine of the axis can be felt, and generally also the spines of the third, fourth, and fifth cervical vertebrae. In the thoracic region the furrow is shallow, and during stooping disappears, and then the spinous processes become more or less visible. The markings produced by these spines are small and close together. In the lumbar region the furrow is deep, and the situation of the lumbar spines is frequently indicated by little pits, or depressions,

especially if the muscles in the loins are well developed and the process incurved. They are much larger and farther apart than in the thoracic region. In the sacral region the furrow is shallower, presenting a flattened area which terminates below at the most prominent part of the posterior surface of the sacrum, formed by the spinous processes of the third sacral vertebra. At the bottom of the furrow may be felt the irregular posterior surface of the bone. Below this, in the deep groove leading to the anus, the coccyx may be felt. The only other portions of the vertebral column which can be felt from the surface are the transverse processes of three of the cervical vertebrae, viz., the first, the sixth, and the seventh. The transverse process of the atlas can be felt as a rounded nodule of bone just below and in front of the apex of the mastoid process, along the anterior border of the Sternomastoid. The transverse process of the sixth cervical vertebra is of surgical importance. If deep pressure be made in the neck in the course of the carotid artery, opposite the cricoid cartilage, the prominent anterior tubercle of the transverse process of the sixth cervical vertebra can be felt. This has been named **Chassaignac's tubercle**, and against it the carotid artery may be most conveniently compressed by the finger. The transverse process of the seventh cervical vertebra can also often be felt. Occasionally the anterior root, or costal process, is large and separate, forming a cervical rib.

Applied Anatomy.—It is frequently necessary to locate certain vertebrae. Several of them can be easily found and identified. The seventh cervical spine is conspicuously prominent, and when the skin over it has been marked with a blue pencil the spine of the sixth cervical above and of the first thoracic below may be located. The spine of the third thoracic vertebra is on a level with the root of the spine of the scapula. The spine of the fourth lumbar vertebra is on a level with the highest point of the iliac crest. When one or two vertebrae have been definitely recognized the other ones can be found by counting the spines from a fixed point or from fixed points. Over the fifth lumbar spine there is no prominence, but a depression. The third sacral spine is on a level with the posterior superior spines of the ilium. The level at which the spinal cord terminates should be known to the surgeon if he proposes to tap the spinal theca (*lumbar puncture*) for diagnostic or therapeutic purposes or for spinal anesthesia. In an adult the cord terminates at the lower border of the first lumbar vertebra, and the theca terminates opposite the body of the third sacral vertebra. In a young child the cord terminates opposite the body of the third lumbar vertebra, and the theca ends at about the same level as in an adult. Hence, in either a child or an adult, a puncture below the level of the fourth lumbar vertebra will inflict no injury upon the cord. In children the puncture is made just beneath the spinous process, and in adults about one-half an inch to either side of the spinous process, although the needle should be made to enter the dura in the median line. In either case the needle is directed upward and forward. As previously pointed out, the surgical anatomy of an infant's spine is not identical with the surgical anatomy of an adult's spine. The umbilicus of an infant is opposite the body of the fourth lumbar vertebra; in an adult it is opposite the spinous process of the third lumbar vertebra. In an infant the base of the sternum is on a level with the top of the seventh cervical spine, and in an adult of the second thoracic spine (A. H. Tubby). The vertebral column may be the seat of tuberculosis, which may destroy the bodies of the vertebrae; in such cases a deflection of the column may be directed either forward or backward. This deflection is produced by the great weight of the trunk on the diseased bone. If the deflection is directed forward, it is called *lordosis*; if backward, *kyphosis*. *Scoliosis* (lateral deviation of the vertebral column) is usually due to a faulty attitude of children while standing or while sitting at school desks.

Occasionally the coalescence of the laminae is not completed, and consequently a cleft is left in the arches of the vertebrae, through which a protrusion of the spinal membranes (dura mater and arachnoid), and sometimes of the spinal cord itself, takes place, constituting a malformation known as *spina bifida* or *hydrorhachitis*. This condition is most common in the lumbosacral region; but it may occur in the thoracic or cervical region, or the arches throughout the whole length of the canal may remain unapproximated. In some rare cases, in consequence of the noncoalescence of the two primary centres from which the body is formed, a similar condition may occur in front of the canal, the bodies of the vertebrae being found cleft and the tumor projecting into the thorax, abdomen, or pelvis, between the lateral halves of the bodies affected.

The construction of the spinal column of a number of pieces, securely connected together and enjoying only a slight degree of movement between any two individuals pieces, though permitting of a very considerable range of movement, as a whole, allows a sufficient degree of mobility without any material diminution of strength. The main joints of which the spine is composed, together with the very varied movements to which it is subjected, render it liable to *sprains*, which may complicate other injuries or may exist alone; but so closely are the individual vertebrae articulated that these sprains are seldom severe, and an amount of violence sufficiently great to produce tearing of the ligaments would tend to cause a dislocation or fracture. The further safety of the column and its less liability to injury is provided for by its disposition in curves instead of in one straight line. For it is an elastic column, and must first bend before it breaks; under these circumstances, being made up of three curves, it represents three columns, and greater force is required to produce bending of a short column than of a longer one that is equal to it in breadth and material. Again, the safety of the column is provided for by the interposition of the intervertebral disks between the bodies of the vertebrae, which act as admirable

buffers in counteracting the effects of violent jars or shocks. *Fracture dislocation* of the vertebral column may be caused by direct or indirect violence, or by a combination of the two, as when a person falling from a height strikes against some prominence and is doubled over it. The fractures from indirect violence are the more common, and here the bodies of the vertebræ are compressed, while the arches are torn asunder; while in fractures from direct violence the arches are compressed and the bodies of the vertebræ separated from each other. It will therefore be seen that in both classes of injury the spinal cord is the part least likely to be injured, and may escape damage even when there has been considerable lesion of the bony framework. For, as Mr. Jacobson states, "being lodged in the centre of the column, it occupies neutral ground in respect to forces which might cause fracture. For it is a law in mechanics that when a beam, as of timber, is exposed to breakage and the force does not exceed the limits of the strength of the material, one division resists compression, another laceration of the particles, while the third, between the two, is in a negative condition."¹ Applying this principle to the vertebral column, it will be seen that, whether the fracture dislocation be produced by direct violence or by indirect force, one segment, either the anterior or posterior, will be exposed to compression, the other to laceration, and the intermediate part, where the cord is situated, will be in a neutral state. When a fracture dislocation is produced by indirect violence the displacement is almost always the same, the upper segment being driven forward on the lower, so that the cord is compressed between the body of the vertebra below and the arch of the vertebra above.

The parts of the vertebral column most liable to be injured are (1) the thoracolumbar region, for this part is near the middle of the column, and there is therefore a greater amount of leverage, and, moreover, the portion above is comparatively fixed, and the vertebræ which form it, though much smaller, have nevertheless to bear almost as great a weight as those below; (2) the cervico-thoracic region, because here the flexible cervical portion of the vertebral column joins the more fixed thoracic region; and (3) the atlantoaxial region, because it enjoys an extensive range of movement, and, being near the skull, is influenced by violence applied to the head. In fracture dislocation, spinous processes and portions of the laminae may be removed (*laminectomy*) in order to free the spinal cord from pressure, and to permit the surgeon to explore, to arrest hemorrhage, to remove bone fragments, or to apply sutures. Laminectomy is also resorted to in some cases of *paraplegia* due to *Pott's disease* of the spine.

THE SKULL.

The **Skull**, or superior expansion of the vertebral column, has been described as if composed of four vertebræ, the elementary parts of which are specially modified in form and size, and almost immovably connected, for the reception of the brain and special organs of the senses. These vertebræ are the occipital, parietal, frontal, and nasal. Descriptive anatomists, however, divide the skull into two parts, the **Cranium** and the **Face**. The **Cranium** is composed of *eight* bones, viz., the *occipital*, two *parietals*, *frontal*, two *temporals*, *sphenoid*, and *ethmoid*. The **Face** is composed of *fourteen* bones, viz., the two *nasals*, two *maxillæ*, two *lacrimals*, two *malars*, two *palates*, two *turbinates*, *vomer*, and *mandible*. The *ossiculi auditus*, the *teeth*, and *Wormian bones* are not included in this enumeration.

Skull, 22 bones	{	Cranium, 8 bones .	{	Occipital.
				Two parietals.
	{	Face, 14 bones . .	{	Frontal.
				Two temporals.
				Sphenoid.
				Ethmoid.
				Two nasals.
				Two maxillæ.
				Two lacrimals.
				Two malars.
				Two palates.
				Two turbinates.
				Vomer.
				Mandible.

The **Hyoid Bone**, situated at the root of the tongue and attached to the base of the skull by ligaments, has also to be considered in this section.

¹ Holmes' System of Surgery, 1883, vol. i, p. 529.

THE CEREBRAL CRANIUM (CRANIUM CEREBRALE)

The Occipital Bone (*Os Occipitale*).

The **occipital bone** is situated at the back part and base of the cranium, is curved on itself, and is trapezoidal in shape. The bone presents for examination two surfaces, four borders, and four angles.

Surfaces.—The **external surface** is convex. Midway between the summit of the bone and the posterior margin of the foramen magnum—a large oval opening for transmission of the spinal cord—is a prominent tubercle, the **external occipital protuberance** (*protuberantia occipitalis externa*), and, descending from it

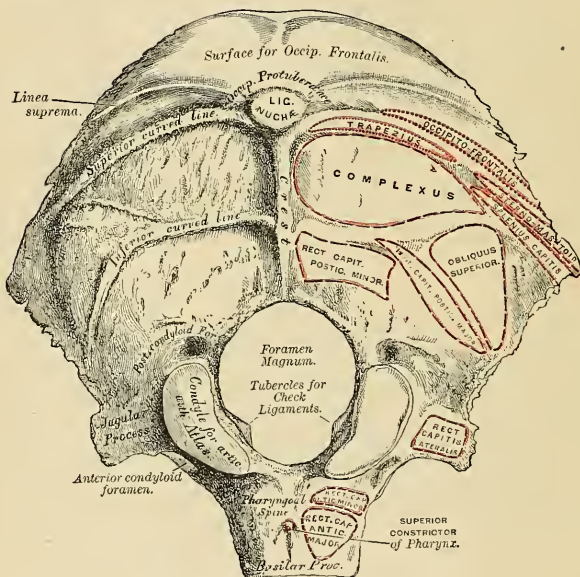


FIG. 39.—Occipital bone. Outer surface.

as far as the foramen, a vertical ridge, the **external occipital crest** (*crista occipitalis externa*). This protuberance and crest give attachment to the ligamentum nuchae and Trapezius, and vary in prominence in different skulls. Passing outward from the occipital protuberance is a semicircular ridge on each side, the **superior curved line** (*linea nuchae superior*). Above this line there is often a second less distinctly marked ridge, called the **highest curved line** (*linea nuchae suprema*); to it the epicranial aponeurosis is attached. The bone between these two lines is smoother and denser than the rest of the surface. Running parallel with these from the middle of the crest is another semicircular ridge, on each side, the **inferior curved line** (*linea nuchae inferior*). The surface of the bone above the linea suprema is rough and porous, and in the recent state is covered by the Occipitofrontalis muscle. The superior and inferior curved lines, together with the surfaces of bone between and below them, serve for the attachment of several muscles.

The superior curved line gives attachment internally to the Trapezius, externally to the muscular origin of the Occipitofrontalis, and to the Sternomastoid to the extent shown in Fig. 39; the depressions between the curved lines to the Complexus internally, the Splenius capitis and Obliquus capitis superior externally. The inferior curved line and the depressions below it afford insertion to the Rectus capitis posticus, major and minor.

The **foramen magnum** (*foramen occipitale magnum*) is a large, oval aperture, its long diameter extending from before backward. It transmits the lower portion of the medulla oblongata and its membranes, the spinal part of the spinal accessory nerves, the vertebral arteries, the anterior and posterior spinal arteries, and the occipitoaxial ligaments. Its back part is wide for the transmission of the medulla oblongata, and the corresponding margin rough for the attachment of the dura enclosing it; the fore part is narrower, being encroached upon by the condyles; it has projecting toward it, from below, the odontoid process, and its margins are smooth and bevelled internally to support the medulla oblongata. On each side of the foramen magnum are the condyles for articulation with the atlas. Each **condyle** (*condylus occipitalis*) is convex, oval, or reniform in shape, and directed downward and outward. The condyles converge in front, and encroach slightly upon the anterior segment of the foramen. On the inner border of each condyle is a rough tubercle for the attachment of the ligaments (*check*) which connect this bone with the odontoid process of the axis; while external to them is a rough tubercular prominence, the **transverse** or **jugular process** (*processus jugularis*), channelled in front by a deep notch (*incisura jugularis*), which forms part of the **jugular foramen** (*foramen lacerum posterius*). The under surface of this process presents an eminence (*processus intrajugularis*), which represents the paramastoid process of some mammals. The eminence is occasionally large, and extends as low as the transverse process of the atlas. This surface affords attachment to the Rectus capitis lateralis muscle and to the lateral occipitoatlantal ligament; its upper or cerebral surface presents a deep groove, which lodges part of the lateral sinus, while its external surface is marked by a quadrilateral rough facet, covered with cartilage in the fresh state, and articulating with a similar surface on the petrous portion of the temporal bone. On the outer side of each condyle, near its fore part, is a foramen, the **anterior condylar foramen** (*canalis hypoglossi*); it is directed downward, outward, and forward, and transmits the hypoglossal nerve, and occasionally a meningeal branch of the ascending pharyngeal artery. This foramen is sometimes double. Behind each condyle is a fossa¹ (*fossa condyloidea*), sometimes perforated at the bottom by a foramen, the **posterior condylar foramen** (*canalis condyloideus*), for the transmission of a vein to the lateral sinus. The **basilar process** (*pars basilaris*) is a strong quadrilateral plate of bone, which is wider behind than in front, and is situated in front of the foramen magnum. Its under surface is rough, presents in the median line a tubercular ridge, the **pharyngeal spine** (*tuberculum pharyngeum*), for the attachment of the tendinous raphé and Superior constrictor of the pharynx, and on each side of it rough depressions for the attachment of the Rectus capitis anticus, major and minor.

The **internal surface** (Fig. 40) is deeply concave. The posterior part is divided by a **crucial ridge** into four fossæ. The two superior fossæ receive the occipital lobes of the cerebrum, and present slight eminences and depressions corresponding to their convolutions. The two inferior, which receive the hemispheres of the cerebellum, are larger than the former, and comparatively smooth; both are marked by slight grooves for the lodgement of arteries. At the point of meeting of the four

¹ This fossa presents many variations in size. It is usually shallow, and the foramen small; occasionally wanting on one or both sides. Sometimes both fossa and foramen are large, but confined to one side only; more rarely, the fossa and foramen are very large on both sides.

occipital protuberance. More anteriorly is the foramen magnum, and on each side of it, but nearer its anterior than its posterior part, the internal openings of the anterior condylar foramen. On the superior aspect of the lateral portion of the bone the **jugular tubercle** (*tuberculum jugulare*) is seen. This corresponds to the portion of bone which roofs in the anterior condylar foramen. The internal openings of the posterior condylar foramina are a little external and posterior to the openings of the anterior condylar foramina, protected by a small arch of bone. At this part of the internal surface there is a very deep groove in which the posterior condylar foramen, when it exists, has its termination. This groove is continuous, in the complete skull, with the transverse groove on the posterior part of the bone, and lodges the end of the lateral sinus. In front of the foramen magnum is the basilar process, presenting a shallow depression, the **basilar groove** (*clivus*), which slopes from behind, upward and forward, and supports the medulla oblongata and part of the pons (Varolii), and on each side of the basilar process is a narrow channel, which, when united with a similar channel on the petrous portion of the temporal bone, forms a groove (*sulcus petrosus inferior*), which lodges the inferior petrosal sinus.

Borders.—The **superior border** (*margo lambdoideus*) extends on each side from the superior to the lateral angle, is deeply serrated for articulation with the parietal bone, and forms, by this union, the **lambdoid suture**.

The **inferior border** extends from the lateral to the inferior angle; its upper half (*margo mastoideus*) is rough, and articulates with the mastoid portion of the temporal, forming the **masto-occipital suture**; the inferior half articulates with the petrous portion of the temporal, forming the **petro-occipital suture**; these two portions are separated from each other by the jugular process. In front of this process is a deep notch, which with a similar one on the petrous portion of the temporal forms the jugular foramen (*foramen lacerum posterius*). This notch is occasionally subdivided into two parts by a small process of bone (*processus intrajugularis*), and it generally presents an aperture at its upper part, the internal opening of the posterior condylar foramen.

Angles.—The **superior angle** is received into the interval between the posterior superior angles of the two parietal bones; it corresponds with that part of the skull in the fetus which is called the posterior fontanelle.

The **inferior angle** is represented by the square-shaped surface of the basilar process. At an early period of life a layer of cartilage separates this part of the bone from the sphenoid, but in the adult the union between them is osseous.

The **lateral angles** correspond to the outer ends of the transverse grooves, and are received into the interval between the posterior inferior angles of the parietal and the mastoid portion of the temporal.

Structure.—The occipital bone consists of two compact laminae, called the **outer** and **inner tables**, having between them the diploic tissue; this bone is especially thick at the ridges, protuberances, condyles, and anterior part of the basilar process; while at the bottom of the fossæ, especially the inferior, it is thin, semitransparent, and destitute of diploë.

Development (Fig. 41).—At birth the bone consists of four distinct parts—a **tabular or squamous portion**, which lies behind the foramen magnum; two **condylic parts**, which form the sides of the foramen; and a **basilar part**, which lies in front of the foramen. The tabular portion is usually developed from *four* centres, though the number may vary from one to eight; two centres appear near the median line of the bone

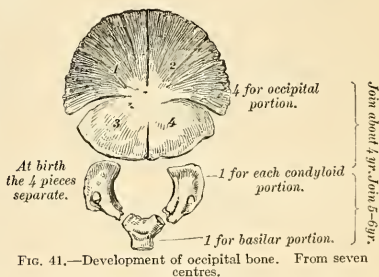


FIG. 41.—Development of occipital bone. From seven centres.

during the second month, and two more a little lateral to the preceding during the third month. These parts tend to unite, but complete union does not occur until about the fourth month after birth. That part of the tabular portion above the highest curved line is developed by the *intramembranous method*, and may exist in the adult as a separate element, the **interparietal bone**, or **os incae**, because of its frequent occurrence in Peruvian skulls. The remainder of the tabular portion and the basilar and two condyloid parts are developed from cartilage. Usually two centres appear in the basilar portion during the sixth fetal week, and by rapid coalescence give the appearance of a single centre. Each condylic portion develops from a single centre that appears at about the end of the eighth fetal week. At about the fourth year the tabular and the two condyloid pieces unite, and about the sixth year the bone consists of a single piece. Between the eighteenth and twenty-fifth years the occipital and sphenoid become united, forming a single bone.

Articulations.—With *six* bones—two parietal, two temporal, sphenoid, and atlas.

Attachment of Muscles.—To *twelve* pairs—to the superior curved line are attached the Occipitofrontalis, Trapezius, and Sternomastoid. To the space between the curved lines, the Complexus,¹ Splenius capitis, and Obliquus capitis superior; to the inferior curved line, and the space between it and the foramen magnum, the Rectus capitis posticus, major and minor; to the transverse process, the Rectus capitis lateralis; and to the basilar process, the Rectus capitis anticus, major and minor, and Superior constrictor of the pharynx.

The Parietal Bone (Os Parietale).

The **parietal bones** are paired bones, and form, by their union, the sides and roof of the cranium proper. Each bone is of an irregular quadrilateral form, and presents for examination two surfaces, four borders, and four angles.

Surfaces.—The **external surface** (*facies parietalis*) (Fig. 42) is convex, smooth, and marked about its centre by an eminence called the **parietal eminence** (*tuber parietale*), which indicates the point where ossification commenced. Crossing the middle of the bone in an antero-posterior direction are two well-marked curved ridges, the **upper and lower temporal ridges** (*linea temporalis superior et inferior*); the former gives attachment to the temporal fascia, while the latter indicates the upper limit of the origin of the Temporal muscle. These lines form the **temporal crest**. Above these ridges the surface of the bone is covered by the aponeurosis of the Occipitofrontalis; below them the bone forms part of the temporal fossa, and affords attachment to the temporal muscle. At the back part of the superior border, close to the sagittal suture, which separates the two parietal bones, is a small foramen (*foramen parietale*), which transmits the emissary vein of Santorini to the scalp from the superior sagittal sinus. It sometimes also transmits a small branch of the occipital artery. Its existence is not constant, and its size varies considerably.

The **internal or cerebral surface** (*facies cerebralis*) (Fig. 43) is concave, presents depressions for the lodgement of the convolutions of the cerebrum, and numerous furrows for the branches of the middle meningeal artery; the latter runs upward and backward from the anterior inferior angle and from the central and posterior part of the lower border of the bone. Sometimes a distinct canal exists for the artery, but it never remains a canal for a long distance. Along the upper margin of the bone is part of a shallow groove, which, when joined to the opposite parietal, forms a channel for the **superior sagittal sinus**. The elevated edges of the groove afford attachment to the falx cerebri. Near the groove are seen several depressions, **Pacchionian depressions** (*foveolae granulares* [*Pacchioni*]). They are most frequently found in the skulls of old persons, and lodge the arachnoid villi (**Pacchionian bodies**). The internal opening of the parietal foramen is also seen when that aperture exists. On the inner surface of the posterior inferior portion of the bone is a portion of the groove for the lodgement of the lateral sinus.

¹ To these the Biventer cervicis should be added, if it is regarded as a separate muscle.

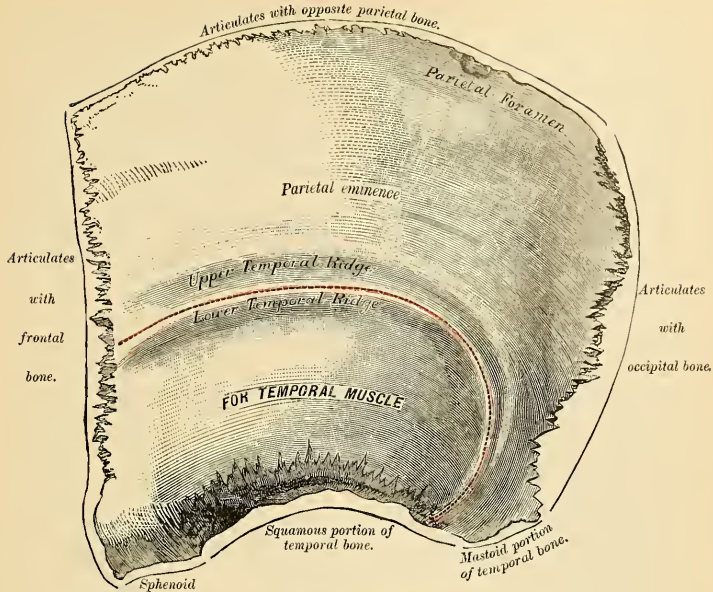


FIG. 42.—Left parietal bone. External surface.

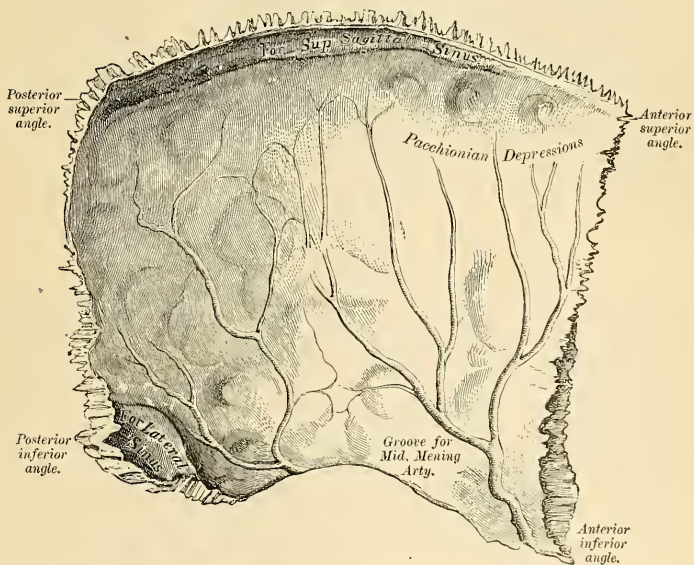


FIG. 43.—Left parietal bone. Internal surface.

Borders.—The **superior border** (*margo sagittalis*), the longest and thickest, is dentated to articulate with its fellow of the opposite side, forming the **sagittal suture**.

The **inferior border** (*margo squamosus*) is divided into three parts; of these, the anterior is thin and pointed, bevelled at the expense of the outer surface, and overlapped by the tip of the greater wing of the sphenoid; the middle portion is arched, bevelled at the expense of the outer surface, and overlapped by the squamous portion of the temporal; the posterior portion is thick and serrated for articulation with the mastoid portion of the temporal.

The **anterior border** (*margo frontalis*), deeply serrated, is bevelled at the expense of the outer surface above and of the inner below; it articulates with the frontal bone, forming the **coronal suture**.

The **posterior border** (*margo occipitalis*), deeply denticulated, articulates with the occipital, forming the **lambdoid suture**.

Angles.—The **anterior superior angle** (*angulus frontalis*), thin and pointed, corresponds with that portion of the skull which in the fetus is membranous, and is called the **anterior fontanelle** (*bregma*).

The **anterior inferior angle** (*angulus sphenoidalis*) is thin and lengthened, being received in the interval between the greater wing of the sphenoid and the frontal. Its inner surface is marked by a deep groove, sometimes a canal, for the anterior branch of the middle meningeal artery. At the anterior inferior angle the parietal and frontal bones and the greater wing of the sphenoid bone meet. This spot is called the **pterion**.

The **posterior superior angle** (*angulus occipitalis*) corresponds with the junction of the sagittal and lambdoid sutures. In the fetus this part of the skull is membranous, and is called the **posterior fontanelle** (*lambda*).

The **posterior inferior angle** (*angulus mastoideus*) articulates with the mastoid portion of the temporal bone, and generally presents on its inner surface a broad, shallow groove for the lodgement of part of the lateral sinus.

Development.—The parietal bone is formed in membrane, being developed from one centre, which corresponds with the parietal eminence, and makes its first appearance about the seventh or eighth week of fetal life. Ossification gradually extends from the centre to the circumference of the bone; the angles are consequently the parts last formed, and it is in their situation that the fontanelles exist previous to the completion of the growth of the bone. Occasionally the parietal bone is divided into two parts, upper and lower, by an antero-posterior suture.

Articulations.—With *five* bones—the opposite parietal, the occipital, frontal, temporal, and sphenoid.

Attachment of Muscles.—*One* only, the Temporal.

The Frontal Bone (Os Frontale).

The **frontal bone** consists of two portions—a **vertical** or **frontal** portion, situated at the anterior part of the cranium proper, forming the forehead; and a **horizontal** or **orbital** portion, which enters into the formation of the roof of the orbits and nasal fossæ.

Vertical Portion. Surfaces.—**External Surface** (*facies frontalis*) (Fig. 44).—In the median line, traversing the bone from the upper to the lower part, is occasionally seen a slightly elevated ridge, and in young subjects a suture (*frontal* or *metopic suture*) which represents the line of union of the two lateral halves of which the bone consists at an early period of life; in the adult this suture is usually obliterated and the bone forms one piece. On either side of this ridge, a little below the centre of the bone, is a rounded prominence, the **frontal eminence** (*tuber frontale*). These eminences vary in size in different individuals, and are occasionally unsymmetrical

in the same subject. The whole surface of the bone above this part is smooth, and covered by the aponeurosis of the Occipitofrontalis muscle. Below the frontal eminence and separated from it by a slight groove is the **superciliary ridge** (*arcus superciliaris*), broad internally, where it is continuous with the nasal eminence, but less distinct as it arches outward. These ridges are caused by the projection outward of the frontal air sinuses,¹ and give attachment to the Orbicularis palpebrarum and Corrugator supercilii. Between the two superciliary ridges is a smooth, flat surface, the **glabella**. Beneath the superciliary ridge is the **supraorbital arch** (*margo supraorbitalis*), a curved and prominent margin, which forms the upper boundary of the orbit and separates the vertical from the horizontal portion of the bone. The outer part of the arch is sharp and prominent, affording to the eye, in that situation, considerable protection from injury;

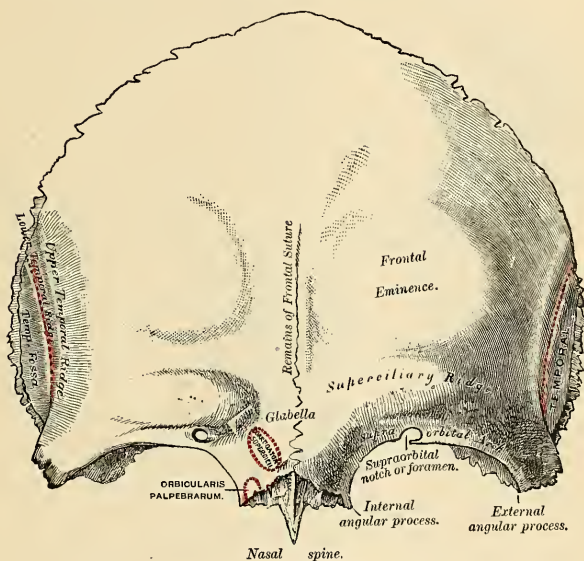


FIG. 44.—Frontal bone. Outer surface.

the inner part is less prominent. At the junction of the internal and middle third of this arch is a notch, sometimes converted into a foramen, and called the **supraorbital notch** (*incisura supraorbitalis*). It transmits the supraorbital artery, vein, and nerve. A small aperture is seen in the upper part of the notch, which transmits a vein from the diploë to join the supraorbital vein. To the median side of the supraorbital notch there is often a notch (*incisura frontalis*) for the passage of the frontal artery and nerve. The supraorbital arch terminates externally in the **external angular process** and internally in the **internal angular**

¹ Some confusion is occasioned to students commencing the study of anatomy by the name "sinuses" having been given to two perfectly different kinds of spaces connected with the skull. It may be as well, therefore, to state here, at the outset, that the "sinuses" in the interior of the cranium which produce the grooves on the inner surface of the bones are venous channels along which the blood runs in its passage back from the brain, while the "sinuses" external to the cranial cavity (the frontal sphenoidal, ethmoidal, and maxillary) are hollow spaces in the bones themselves which communicate with the nostrils, and contain air.

process. The external angular process is strong, prominent, and articulates with the malar bone; running upward and backward from it are two well-marked lines, which, starting together from the external angular process as the **temporal crest**, soon diverge from each other and run in a curved direction across the bone. These are the **upper and lower temporal ridges**; the upper gives attachment to the temporal fascia, the lower to the Temporal muscle. Beneath them is a slight concavity that forms the anterior part of the temporal fossa and gives origin to the Temporal muscle. The internal angular process is less marked than the external, articulates with the lacrimal bones, and gives attachment to the Orbicularis palpebrarum.

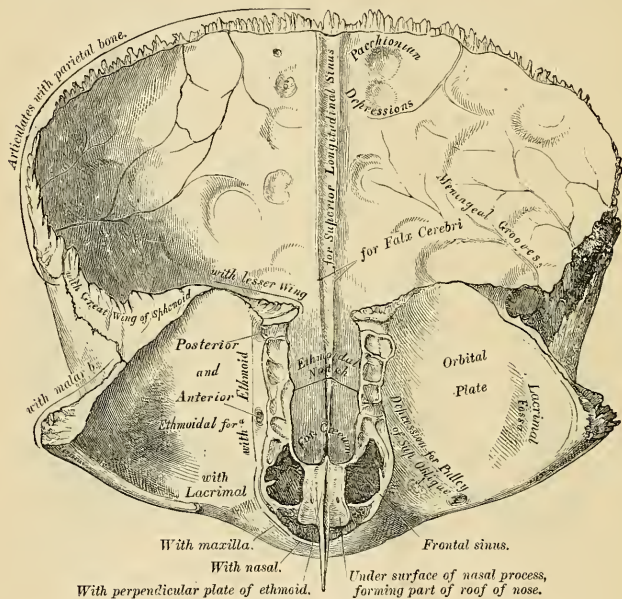


FIG. 45.—Frontal bone. Inner surface.

Internal Surface (*cerebral surface, facies cerebralis*) (Fig. 45).—Along the median line is a vertical groove, the **sulcus sagittalis**, the edges of which unite below to form a ridge, the **frontal crest** (*crista frontalis*); the groove lodges the superior sagittal sinus, while its margins afford attachment to the falx cerebri. The crest terminates below at a small notch which is converted into a foramen by articulation with the ethmoid. It is called the **foramen cecum**, and varies in size in different subjects; it is sometimes partially or completely impervious, lodges a process of the falx, and when open transmits a vein from the mucous membrane of the nose to the superior sagittal sinus. On either side of the groove the bone is deeply concave, presenting depressions for the convolutions of the brain, and numerous small furrows for the ramifications of the anterior branches of the middle meningeal arteries. Several small, irregular fossae are seen also on either side of the groove, for the reception of the arachnoid villi.

The border of the vertical portion is thick, deeply serrated, bevelled at the

expense of the internal table above, where it rests upon the parietal bones, and at the expense of the external table at each side, where it receives the lateral pressure of those bones; this border is continued below into a triangular rough surface which articulates with the greater wing of the sphenoid.

Horizontal or Orbital Portion.—This portion of the bone consists of two thin plates, the **orbital plates**, which form the vault of the orbit, separated from one another by a median gap, the **ethmoidal notch**.

Surfaces. Orbital Surface.—The surface of each orbital plate (*facies orbitalis*) consists of a smooth, concave, triangular lamina of bone, marked at its front and external part (immediately beneath the external angular process) by a shallow depression, the **lacrimal fossa** (*fossa glandulae lacrimalis*), occupied by the lacrimal gland; and at its anterior and internal part by a depression (sometimes a small tubercle), the **trochlear fossa** (*fovea trochlearis*), for the attachment of the cartilaginous pulley of the Superior oblique muscle of the eye. These plates are united in front by a roughened uneven surface called the nasal process, which articulates in front with the nasal bones, laterally with the nasal process of each maxilla. From the middle of the nasal process a thin lamina of bone (the *nasal spine*) projects downward and forward; on either side of this is a shallow groove, which enters into the formation of the nasal fossa. The nasal spine articulates in front with the nasal bones and behind with the perpendicular plate of the ethmoid, and by so doing assists in forming the septum of the nose. The **ethmoidal notch** (*incisura ethmoidalis*) separates the two orbital plates; it is quadrilateral, and occupied, when the bones are united, by the cribriform plate of the ethmoid. The margins of this notch present several half cells, which, when united with corresponding half cells on the upper surface of the ethmoid, complete the **ethmoidal cells**; two grooves are also seen crossing these edges obliquely; they are converted into canals by articulation with the ethmoid, and are called the **anterior** and **posterior ethmoidal canals** (*foramen ethmoidale anterius* and *foramen ethmoidale posterius*); they open on the inner wall of the orbit. The anterior one transmits the nasal nerve and anterior ethmoidal vessels; the posterior one, the posterior ethmoidal vessels. In front of the ethmoidal notch, on each side of the nasal process, is the opening of the **frontal air sinus** (*sinus frontalis*). These are two irregular cavities, which extend upward and outward, a variable distance, between the two tables of the skull, and are separated from each other by a thin bony septum (*septum sinuum frontaliū*), which is often displaced to one side. Within the sinuses imperfect trabeculae of bone often exist. The sinuses are beneath and give rise to the prominences above the supraorbital arches called the **superciliary ridges** (*arcus superciliares*). The frontal air sinuses are absent at birth, become apparent about the seventh year of life, and from this period until the age of twenty gradually increase in size. Sometimes, however, the sinuses remain very small or never develop at all—or one side may be large and the other small—or one may exist on one side and be absent on the other. The right sinus is usually the larger. These cavities are larger in men than in women. The floor of each sinus is very thin and is over the orbit and the upper border of the lateral mass of the ethmoid. The thinnest portion of the floor is at the upper and inner angle of the orbit. The frontal sinuses are lined by mucous membrane, and each sinus communicates with the middle meatus of the nose by the infundibulum. In some cases the sinuses communicate with each other by means of an aperture in the septum and occasionally join the sinus in the crista galli of the ethmoid.

The **internal surface** (*cerebral surface, facies cerebralis*) of the horizontal portion presents the convex upper surfaces of the orbital plates, separated from each other in the median line by the ethmoidal notch, and marked by eminences and depressions for the convolutions of the frontal lobes of the cerebrum.

The border of the horizontal portion is thin, serrated, and articulates with the lesser wing of the sphenoid.

Structure.—The frontal portion and external angular processes consist of diploic tissue surrounded by compact bone. In the frontal sinus region the cancellous tissue is wanting. The horizontal portion is thin, translucent, and composed entirely of compact tissue.

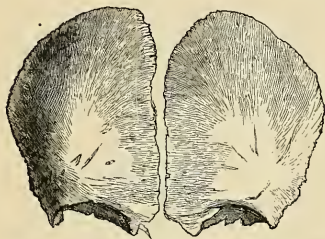


FIG. 46.—Frontal bone at birth. Developed from two lateral halves.

along the median line, by a suture (metopic) which runs from the vertex to the root of the nose. This suture usually becomes obliterated within a few years after birth, but it occasionally remains throughout life.

Articulations.—With twelve bones—two parietal, the sphenoid, the ethmoid, two nasal, two maxillæ, two lacrimal, and two malar.

Attachment of Muscles.—To three pairs—the Corrugator supercili, Orbicularis palpebrarum, and Temporal, on each side.

Development (Fig. 46).—The frontal bone is formed in membrane, being developed from two primary centres, one for each lateral half, which make their appearance about the seventh or eighth week, above the orbital arches. From this point ossification extends, in a radiating manner, upward into the forehead and backward over the orbit. The nasal spine is developed from two secondary centres, while additional centres appear in the regions of the internal and external angular processes. Sometimes a centre appears on either side at the lower end of the coronal suture. This latter centre sometimes remains ununited, and is known as the **pterion ossicle**, or it may join with the parietal, sphenoid, or temporal bone. At birth the bone consists of two pieces, which afterward become united,

The Temporal Bone (Os Temporale).

The **temporal bone** consists of three parts—(a) the squamous, (b) the petromastoid, and (c) the tympanic portions—which, though separate in early life, become united in the adult. The three parts meet and form a part of the outer wall and a part of the base of the skull and the external auditory meatus.

The Squamous Portion (*pars squamosa temporalis*).—The squamous portion, the anterior and upper part of the bone, is scale-like in form, and is thin and translucent (Fig. 47). Its **external surface** is smooth, convex, and grooved at its back part for the deep temporal arteries; it affords attachment to the Temporal muscle and forms part of the temporal fossa. At its back part may be seen a curved ridge (part of the *temporal ridge*), which serves for the attachment of the temporal fascia, limits the origin of the Temporal muscle, and marks the boundary between the squamous and mastoid portions of the bone. Projecting from the lower part of the squamous portion is a long, arched process of bone, the **zygoma**, or **zygomatic process**. This process is at first directed outward, its two surfaces looking upward and downward; it then appears as if twisted upon itself, and runs forward, its surfaces now looking inward and outward. The superior border of the process is long, thin, and sharp, and serves for the attachment of the temporal fascia. The inferior, short, thick, and arched, has attached to it some fibres of the Masseter muscle. Its outer surface is convex and subcutaneous; its inner is concave, and also affords attachment to the Masseter. The extremity, broad and deeply serrated, articulates with the malar bone. The zygomatic process is connected to the temporal bone by three divisions, called its **roots**—an anterior, middle, and posterior. The *anterior*, which is short, but broad and strong, is directed inward, to terminate in a rounded eminence,

the *eminentia articularis*. This eminence forms the front boundary of the glenoid fossa, and in the recent state is covered with cartilage. The *middle root* (*postglenoid process*) forms the posterior boundary of the *mandibular* portion of the glenoid fossa; while the *posterior root*, which is strongly marked, runs from the upper border of the zygoma, in an arched direction, upward and backward, forming the posterior part of the temporal ridge (*supramastoid crest*). At the junction of the anterior root with the zygoma is a projection, called the **tubercle**, for the attachment of the external lateral ligament of the mandible; and between

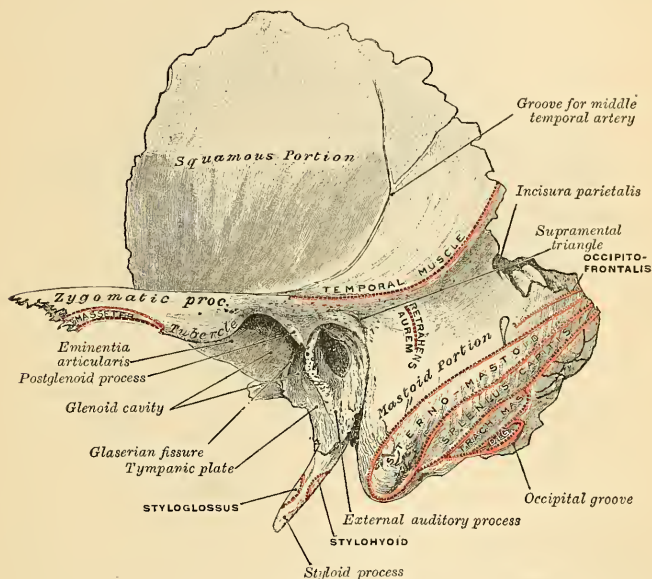


FIG. 47.—Left temporal bone. Lateral surface.

the anterior and middle roots is an oval depression, forming part (mandibular) of the glenoid fossa, for the reception of the condyle of the mandible. Between the posterior wall of the external auditory meatus and the posterior root of the zygoma is the area called the **suprameatal triangle** (Macewen), often marked by a spinous process (spine of Henle).

The **internal surface** of the squamous portion (Fig. 48) is concave, presents numerous eminences and depressions for the convolutions of the cerebrum, and two well-marked grooves for the branches of the middle meningeal artery.

Borders.—The **superior border** is thin, bevelled at the expense of the internal surface, so as to overlap the lower border of the parietal bone, forming the squamous suture. The **anterior inferior border** is thick, serrated, and bevelled, alternately at the expense of the inner and outer surfaces, for articulation with the greater wing of the sphenoid.

The Petromastoid Portion (*partes petrosa et mastoidea*).—The petromastoid portion consists of (a) a mastoid portion, the thick conical posterior part behind

the external auditory meatus, and (b) a pyramidal portion named the petrous portion, which contains the internal ear and forms part of the floor of the cranial cavity.

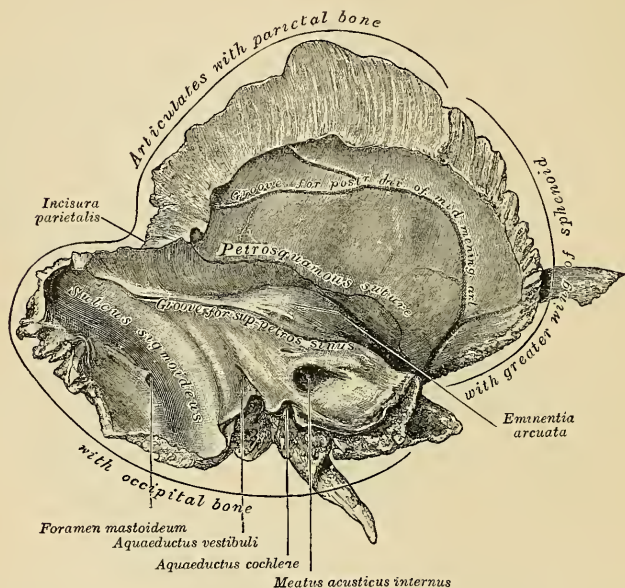


FIG. 48.—Left temporal bone. Inner surface.

The Mastoid Portion (*pars mastoidea*).—The mastoid portion is situated at the posterior part of the bone (Figs. 47 and 49).

Surfaces. Outer Surface.—The outer surface of the mastoid is rough, and gives attachment to the Occipitofrontalis and Retrahens aurem muscles. It is perforated by numerous foramina; one of these, of large size, situated at the posterior border of the bone, is termed the **mastoid foramen** (*foramen mastoideum*); it transmits a vein from the lateral sinus and a small artery from the occipital to supply the dura. The position and size of this foramen are very variable. It is not always present; sometimes it is situated in the occipital bone or in the suture between the temporal and the occipital. The mastoid portion is continued below into a conical projection, the **mastoid process** (*processus mastoideus*), the size and form of which vary somewhat. This process serves for the attachment of the Sternomastoid, Splenius capitis, and the Trachelomastoid. On the inner side of the mastoid process is a deep groove, the **digastric fossa** (*incisura mastoidea*), for the attachment of the Digastric muscle; and, running parallel with it, but more internal, the **occipital groove** (*sulcus a. occipitalis*), which lodges the occipital artery (*fossa mastoidea*).

Internal Surface.—The internal surface of the mastoid portion presents a deep, curved groove, the **sigmoid fossa**, which lodges part of the lateral sinus; and into

it may be seen opening the mastoid foramen, which transmits an emissary vein from the lateral sinus to the posterior auricular or occipital vein and a small artery, the mastoid branch of the occipital artery. A section of the mastoid process (Figs. 49 and 50) shows it to contain a number of cellular spaces, communicating with one another, called the **mastoid cells** (*cellulae mastoideae*), which exhibit the greatest possible variety as to their size and number. At the upper and front part of the bone these cells are large and irregular, and contain air. They diminish in size toward the lower part of the bone; those situated at the apex of the mastoid process are quite small, representing spaces of cancellous bone, and usually containing marrow. Occasionally they are entirely absent, and

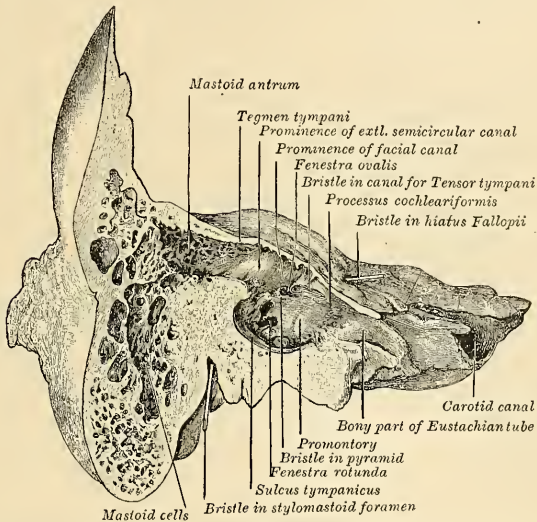


FIG. 49.—Section through the petrous and mastoid portions of the temporal bone, showing the communication of the cavity of the tympanum with the mastoid antrum.

the mastoid is solid throughout. In addition to these pneumatic cells may be seen a large, irregular cavity, the **mastoid antrum** (Figs. 49 and 50), situated at the upper and front part of the section. This must be distinguished from the mastoid cells, though it communicates with them. The mastoid cells are not developed until after puberty, but the mastoid antrum is almost as large at birth as it is in the adult bone. The antrum and cells are filled with air, and are lined with a prolongation of the mucous membrane of the tympanum, which extends into them through an opening, by which they communicate with the cavity of the tympanum.

In consequence of the communication which exists between the tympanum and mastoid cells, inflammation of the lining membrane of the former cavity may easily travel backward to that of the antrum, leading to caries and necrosis of their walls and the risk of transference of the inflammation to the lateral sinus or encephalon.

The Petrous Portion (*pars petrosa* [*pyramis*]) (Fig. 48).—The **petrous portion** is a pyramidal process of bone wedged in at the base of the skull between the

sphenoid and occipital bones. Its direction from without is inward, forward, and a little downward. It presents for examination an **apex**, **four surfaces**, and **four borders**, and contains in its interior the essential parts of the organ of hearing.

Apex (*apex pyramidis*).—The apex of the petrous portion, rough and uneven, is received into the angular interval between the posterior border of the greater wing of the sphenoid and the basilar process of the occipital; it presents the anterior or internal orifice of the carotid canal (foramen caroticum internum), and forms the posterior and external boundary of the foramen lacerum medium.

Surfaces.—The **superior surface** of the petrous portion (Fig. 48) forms the posterior part of the middle fossa of the skull; it looks upward and forward. This surface is continuous with the squamous portion, to which it is united by

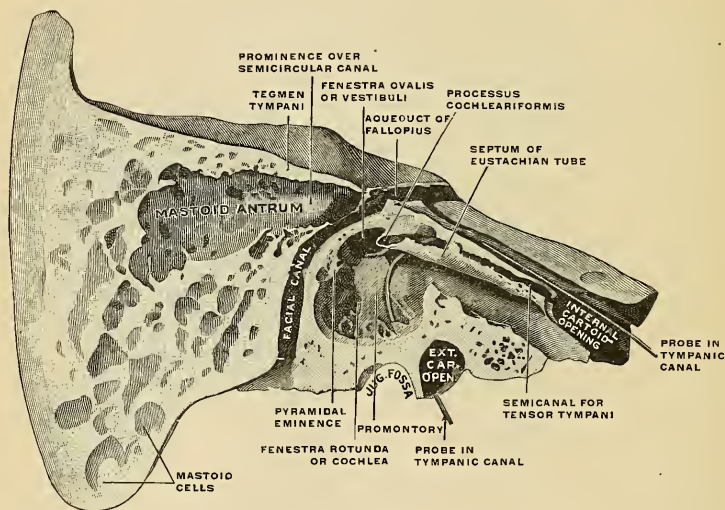


FIG. 50.—Right temporal bone cut open to show the anterior surface of the petrous portion. $\times 2$. (Spalteholz.)

a suture, the **petrosquamous suture**, the remains of which are distinct even at a late period of life.

The superior surface presents five points for examination: (1) An **eminence** (*eminentia arcuata*) near the centre, which indicates the situation of the superior semicircular canal. (2) In front and a little to the outer side of this eminence a depression indicating the position of the tympanum; here the layer of bone which separates the tympanum from the cranial cavity is extremely thin, and is known as the **tegmen tympani**. The thin inferior extremity of this plate drops downward and presents itself at the inner extremity of the Glaserian fissure, there making the fissure double; the anterior slit is called the **canal of Huguier**, and it transmits the chorda tympani nerve. (3) A shallow groove, sometimes double, leading outward and backward to an oblique opening, the **hiatus Fallopii** (*hiatus canalis facialis*), for the passage of the greater petrosal nerve and the petrosal branch of the middle meningeal artery. (4) A smaller opening (*apertura superior canaliculi tympanici*), occasionally seen external to the latter, for the passage of the smaller petrosal nerve. (5) A shallow depression, the **trigeminal depression** (*impressio*

trigeminum), for the reception of the Gasserian ganglion, is placed at the inner extremity of this surface.

The **anterior or tympanic surface** (Fig. 50) is mostly hidden by the tympanic portion of the bone, and is best studied either in very young skulls or in bones which have been cut behind the tympanic membrane. This surface forms the postero-internal wall of the tympanum and presents an oval foramen (*fenestra vestibuli*), into which the base of the stapes is fitted. Just above and external to the fenestra ovalis is the *mastoid antrum*, leading from the tympanum to the mastoid cells. The antrum is roofed by the tegmen tympani. Below and internal to the fenestra ovalis is a rounded eminence, the **promontory**, formed by the first turn of the cochlea. Below the promontory is situated the *fenestra rotunda*, which is closed in the recent state by a membrane.

Internal to the fenestra ovalis is the orifice of the canal which transmits the Tensor tympani; below this is the Eustachian canal for the passage of air from the pharynx to the tympanum. The two canals are separated by the **processus cochleariformis**. On this surface, just above, then external to the oval foramen, between it and the antrum, is the facial canal (*canalis facialis*). This canal is traversed by the facial nerve on its way to the stylomastoid foramen. The portion of the anterior surface not covered by the tympanic plate is occupied by the termination of the carotid canal (foramen caroticum internum), the wall of which is deficient in front.

The **posterior surface** forms the front part of the posterior fossa of the skull, and is continuous with the inner surface of the mastoid portion of the bone. It presents three points for examination: (1) About its centre a large orifice, the **meatus auditorius internus** (*meatus acusticus internus*), through which pass the facial, auditory and intermediate nerves, and the auditory artery. The size of this meatus varies considerably; its margins are smooth and rounded, and it leads into a short canal, about one-third inch in length, which runs directly outward and is closed by a vertical plate, the **lamina cribrosa**, which is divided by a horizontal crest, the **falciform crest** (*crista transversa*), into two unequal portions (Fig. 51). Each portion is subdivided by a small vertical crest into two parts, named, respectively, anterior and posterior. The lower portion presents three sets of foramina: one group just below the posterior part of the crest, the **area cribrosa media**, consisting of a number of small openings for the nerves of the sacculæ; below and posterior to this, the **foramen singulare**, or opening for the nerve of the posterior semicircular canal; in front and below the first, the **tractus spiralis foraminosus**, consisting of a number of small, spirally arranged openings which terminate in the **canalis centralis cochleæ** and transmit the nerve of the cochlea; the upper portion, that above the crista, presents behind a series of small openings, the **area cribrosa superior**, for the passage of filaments of the utricle and superior and external semicircular canal, and, in front, one large opening, the commencement of the **aquaeductus Fallopii** (*canalis facialis*), for the passage of the facial nerve. (2) External and below the meatus

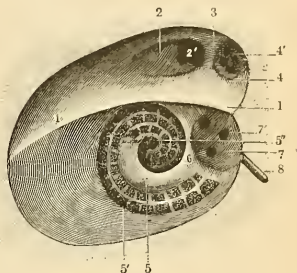


FIG. 51.—Diagrammatic view of the fundus of the internal auditory meatus: 1, Falciform crest. 2, Anterior superior cribriform area. 2', Internal opening of the aqueductus Fallopii. 3, Vertical crest which separates the anterior and posterior superior cribriform areas. 4, Posterior superior cribriform area, with (4') openings for nerve filaments. 5, Anterior inferior cribriform area. 5', Spirally arranged, sieve-like openings for the nerves to the cochlea. 6, Crest which separates the anterior and posterior inferior cribriform areas. 7, Posterior inferior cribriform area. 7', Orifices for the branches of the nerve to the sacculæ. 8, Foramen singulare of Morgagni, with the anterior portion of the canal which gives passage to the nerve to the posterior semicircular canal. (Testut.)

auditorius is a small slit (*apertura externa aquaeductus vestibuli*), almost hidden by a thin plate of bone, leading to a canal, the **aquaeductus vestibuli**, which transmits the **ductus endolymphaticus**, together with a small artery and vein. (3) In the interval between these two openings, but above them, is an angular depression (*fossa subarcuata*), which lodges a process of the dura, and transmits a small vein into the cancellous tissue of the bone. In the child this depression is represented by a large fossa, the **floccular fossa**, which extends backward as a blind tunnel under the superior semicircular canal.

The **inferior or basilar surface** (Fig. 52) is rough and irregular, and forms part of the base of the skull. Passing from the apex to the base, this surface presents the following points for examination: (1) A rough surface, quadrilateral in form, which serves partly for the attachment of the Levator palati and Tensor tympani

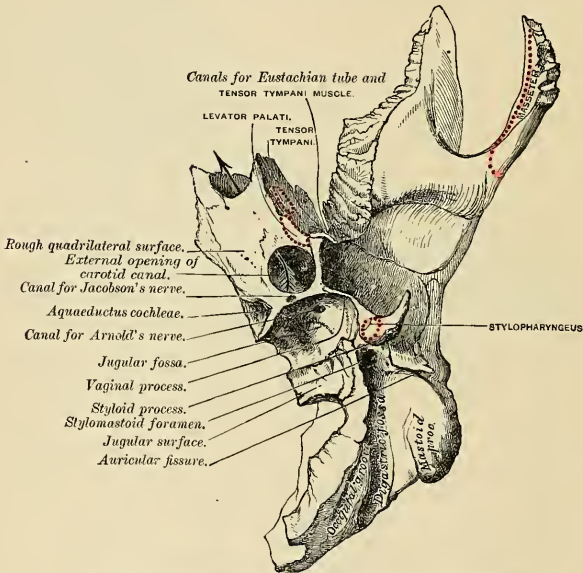


FIG. 52.—Petrus portion of the left temporal bone. Inferior surface.

muscles. (2) The large circular aperture of the carotid canal, the **external carotid opening** (foramen caroticum externum); the canal ascends at first vertically, and then, making a bend, runs horizontally forward and inward; it transmits the internal carotid artery and the carotid sympathetic plexus. Within the carotid canal are several openings (*canaliculi caroticotympanici*), which transmit tympanic branches of the internal carotid artery and of the carotid sympathetic plexus. (3) The opening of the **aquaeductus cochleae** (*apertura externa canaliculi cochleae*), a small, triangular opening, lying on the inner side of the latter, close to the posterior border of the petrous portion; it transmits a vein from the cochlea, which joins the internal jugular. (4) External to these openings a deep depression, the **jugular fossa** (*fossa jugularis*), which varies in depth and size in different skulls; it lodges the lateral sinus, and, with a similar depression on the margin of the jugular process of the occipital bone, forms the foramen lacerum posterius or

jugular foramen. (5) A foramen which is the opening of a small canal (*canaliculus tympanicus*) for the passage of Jacobson's nerve (the tympanic branch of the glossopharyngeal); this foramen is seen in front of the bony ridge dividing the carotid canal from the jugular fossa. (6) A small foramen on the wall of the jugular fossa, for the passage of the auricular branch of the vagus (*Arnold's*) nerve. (7) Behind the jugular fossa a smooth, square-shaped facet, the **jugular surface**; it is covered with cartilage in the recent state, and articulates with the jugular process of the occipital bone. (8) The **stylomastoid foramen** (*foramen stylomastoideum*), a rather large orifice, placed between the styloid and mastoid processes; it is the termination of the facial canal, and transmits the facial nerve and stylomastoid artery.

Borders.—The **posterosuperior border** (*angulus superior pyramidis*), the longest, is grooved for the superior petrosal sinus, and has attached to it the tentorium cerebelli; at its inner extremity is a semilunar notch, upon which the fifth nerve lies.

The **postero-inferior border** is intermediate in length between the posterosuperior and antero-inferior. Its inner half is marked by a groove, which, when completed by its articulation with the occipital, forms the channel for the inferior petrosal sinus. Its outer half presents a deep excavation, the **jugular fossa** (*fossa jugularis*), which, with a similar notch on the occipital, forms the foramen lacerum posterius. A projecting eminence of bone occasionally stands out from the centre of the notch, and divides the foramen into two parts.

The **anterosuperior border** is divided into two parts—an outer, joined to the squamous portion by a suture, the remains of which are distinct; an inner, free, articulating with the spinous process of the sphenoid. At the angle of junction of the petrous and squamous portions is seen the opening of the *canalis musculotubarius*.

The **antero-inferior border** is also divided into two parts—the outer portion is hidden from view by the tympanic plate. The inner part is free and forms the inferior lip of the carotid canal and gives attachment to the Tensor tympani and Levator palati muscles.

The Tympanic Portion (*pars tympanica*).—The tympanic portion is placed in front of the anterior surface of the petrous portion; its most internal part is narrow and forms the anterior wall of the Eustachian canal. Externally it broadens out and has an antero-inferior and a posterosuperior surface, an anterosuperior, an antero-inferior, and an external border. The **antero-inferior surface** looks forward and downward and forms the posterior part of the glenoid fossa. The **posterosuperior surface** forms the anterior wall of the external auditory canal. From this surface there continues on to the anterior part of the mastoid portion a U-shaped process, with its concavity upward; this process shares in forming the inferior and posterior wall of the external auditory canal. Between the upturned part of the U-shaped process and the mastoid is a foramen (*fissura tympanomastoidea*) transmitting the tympanic (auricular nerve of Arnold) branch of the vagus. In the concavity of this U-shaped process is a furrow (*sulcus tympanicus*), in which is placed the tympanic membrane (*membrana tympani*), like a mirror in its frame. The **anterosuperior border** fuses with the middle zygomatic root. Internally, this border is continuous with the upper border of the narrow part of the bone, and is separated from the squamous portion of the bone by the Glaserian fissure and a small part of the tegmen tympani. The **antero-inferior border** is thin internally; externally it divides into two laminae and ensheaths the root of the styloid process—hence the name **vaginal process** given to this border. The **external border** is free and rough, and has attached to it the cartilaginous part of the ear.

The **glenoid fossa** (*fossa mandibularis*) is a considerable hollow formed in front

by the squamous part of the temporal, and behind by the tympanic bone. The part of the fossa formed by the squamous portion is covered with cartilage and articulates with the condyle of the mandible. The posterior part of the fossa lodges part of the parotid gland, and is formed by the antero-inferior surface of the tympanic portion. The fossa is crossed by an oblique fissure, the **petrotympanic fissure** (*Glaserian fissure*), which leads into the tympanum, lodges the *processus gracilis* of the malleus, and transmits the tympanic branch of the internal maxillary artery. This fissure is closed externally; at its inner extremity it is separated from the squamous portion by the downgrowth of a process of bone from the *tegmen tympani* (*processus inferior tegmini tympani*) of the petrous portion between the squamous and tympanic plates, making the fissure at its internal extremity a double one. The anterior limb is known as the **canal of Huguier** (*canaliculus chordae tympani*), and transmits the chorda tympani nerve.

The **external auditory meatus** is bounded in front, below, and behind by the tympanic portion. The roof and the upper part of the posterior wall are formed by the squamous portion. The canal is about three-quarters of an inch (18 mm.) in length, and is directed inward and forward. In vertical section it is of oval outline, the long axis of the oval being vertical in the outer segment and oblique in the inner segment.

The **styloid process** is a sharp spine of varying length. It projects downward and forward from the vaginal process of the tympanic part, and gives origin to the stylohyoid and stylomandibular ligaments, and to the Styloglossus, Stylopharyngeus, and Stylohyoid muscles.

Structure.—The squamous portion is like that of the other cranial bones; the mastoid portion, cellular; and the petrous portion, dense and hard.

Development (Fig. 53).—The temporal bone is developed from *ten* centres, exclusive of those for the internal ear and the ossicles—viz., one for the squamous portion, including the zygoma,

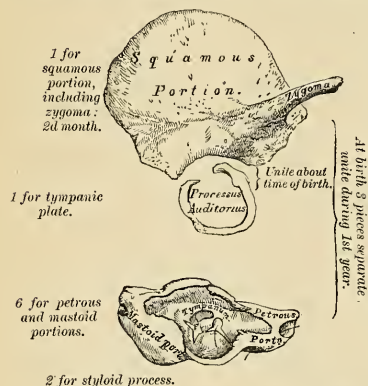


FIG. 53.—Development of the temporal bone. From ten centres.

This portion he has named the **pro-otic**. The second portion—the **opisthotic**—consists of the rest of the petrous, and is thus made up: the floor of the tympanum and vestibule surrounds the carotid canal and the outer and lower portions of the cochlea and spread inward below the internal auditory meatus. The third portion—the **pteriotic**—roofs the antrum and tympanic cavity. The fourth portion—the **epiotic**—includes the remainder of the mastoid. The petromastoid is ossified in cartilage. (4) The **styloid process** is also ossified in cartilage from two centres—one for the base, which appears before birth, and is termed the **tympanohyal**; the other, comprising

the rest of the process, is named the **stylohyal**, and does not appear until after birth. Shortly before birth the tympanic plate unites with the squamous. The petrous and mastoid unite at puberty, and in some skulls never becomes united. The subsequent changes in this bone are, that the tympanic plate extends outward and backward, so as to form the **meatus auditorius**. (1) The extension of the tympanic plate, however, does not take place at an equal rate all around the circumference of the ring, but occurs most rapidly on its anterior and posterior portions, and these outgrowths meet and blend, and thus, for a time, there exists in the floor of the meatus a foramen, the **foramen of Huschke**; this foramen, usually closed by the fifth year, may persist throughout life. (2) The glenoid cavity is at first extremely shallow, and looks outward as well as downward; it becomes deeper and is ultimately directed downward. Its change in direction is accounted for as follows: the part of the squamous temporal which supports it lies at first *below* the level of the zygoma. As, however, the base of the skull increases in width, this lower part of the squama is directed horizontally inward to contribute to the middle fossa of the skull, and its surfaces therefore come to look upward and downward. (3) The mastoid portion is at first quite flat, and the stylo-mastoid foramen and rudimentary styloid process lie immediately behind the tympanic ring. With the development of the air cells the outer part of the mastoid portion grows downward and forward to form the mastoid process, and the styloid process and stylo-mastoid foramen now come to lie on the under surface. The descent of the foramen is necessarily accompanied by a corresponding lengthening of the aqueduct of Fallopius.

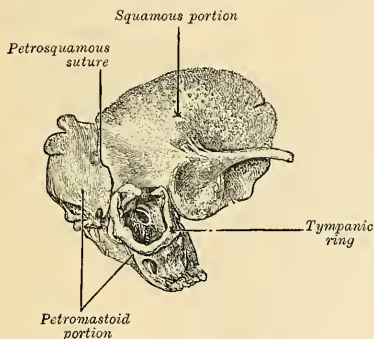


FIG. 54.—Temporal bone at birth. Outer aspect.

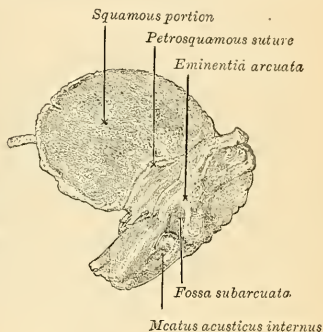


FIG. 55.—Temporal bone at birth. Inner aspect.

(4) The downward and forward growth of the mastoid process also pushes forward the tympanic plate, so that the portion of it which formed the original floor of the meatus and containing the foramen of Huschke is ultimately found in the anterior wall. (5) With the gradual increase in size of the petrous portion the floccular fossa or tunnel under the superior semicircular canal becomes filled up and almost obliterated.

Articulations.—With *five* bones—occipital, parietal, sphenoid, mandible, and malar.

Attachment of Muscles.—To *fifteen*—to the squamous portion, the Temporal; to the zygoma, the Masseter; to the mastoid portion, the Occipitofrontalis, Sternomastoid, Splenius capitis, Trachelomastoid, Digastric, and Posterior auricular; to the styloid process, the Stylopharyngeus, Stylohyoid, and Styloglossus; and to the petrous portion, the Levator palati, Tensor tympani, Tensor palati, and Stapedius.

The Sphenoid Bone (Os Sphenoidale).

The **sphenoid bone** is situated at the anterior part of the base of the skull, articulating with all the other cerebral cranial bones, which it binds firmly and solidly together. In its form it somewhat resembles a bat with its wings extended; and is divided into a **central portion** or **body**, two **greater** and two **lesser wings**

extending outward on each side of the body, and two processes—the **pterygoid processes**—which project from the lower part of this body.

The Body (corpus).—The body is of large size and hollowed out in its interior so as to form a mere shell of bone. It presents for examination *four surfaces*—a superior, an inferior, an anterior, and a posterior.

Surfaces.—The **superior surface** (Fig. 56) presents in front a prominent spine, the **ethmoidal spine**, for articulation with the cribriform plate of the ethmoid; behind this is a smooth surface having in the median line a slight longitudinal eminence, with a depression on each side for the lodgment of the olfactory lobes. This surface is bounded behind by a ridge, which forms the anterior border of a narrow, transverse groove, the **optic groove** (*sulcus chiasmatis*); behind the ridge lies the optic chiasm; the groove is continuous on each side with the **optic foramen** (*foramen opticum*), for the passage of the optic nerve and ophthalmic artery. Behind the optic groove is a small eminence, olive-like in shape, the

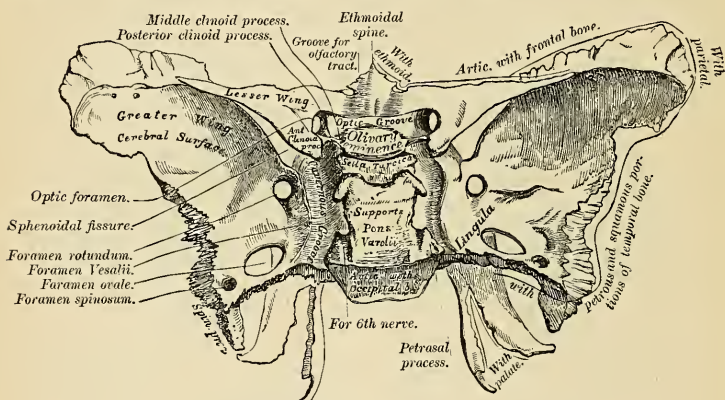


FIG. 56.—Sphenoid bone. Superior surface.

olivary eminence (*tuberculum sellae*); and still more posteriorly a deep depression, the **sella turcica** (*fossa hypophyseos*), which lodges the circular sinus and the hypophysis. This fossa is perforated by numerous foramina, for the transmission of nutrient vessels into the substance of the bone. It is bounded in front by the **olivary eminence**, and also by two small processes, one on either side, called the **middle clinoid processes** (*processus clinoides medii*), which are sometimes connected by a spiculum of bone to the anterior clinoid processes. It is bounded behind by a square-shaped plate of bone, the **dorsum sellae**, terminating at each superior angle in a tubercle, the **posterior clinoid process** (*processus clinoides posterior*). The size and form of these processes vary considerably in different individuals. They deepen the sella turcica, and serve for the attachment of prolongations from the tentorium cerebelli. The sides of the dorsum sellae are notched for the passage of the abducent nerves, and below present a sharp process, the **petrosal process**, which is joined to the apex of the petrous portion of the temporal bone, forming the inner boundary of the middle lacerated foramen. Behind this plate the bone presents a shallow depression, which slopes obliquely backward, and is continuous with the basilar groove of the occipital bone; it is called the **clivus**, and supports the upper part of the pons. On either side of the body is

(*rostrum sphenoidalis*), which is continuous with the sphenoidal crest on the anterior surface, and is received into a deep fissure between the *alæ* of the vomer. On each side may be seen a projecting lamina of bone, the **vaginal process** (*processus vaginalis*), which runs horizontally inward from near the base of the pterygoid process and articulates with the edges of the vomer. Close to the root of the pterygoid process is a groove (*sulcus pterygopalatinus*), formed into a complete canal when articulated with the sphenoidal process of the palate bone; it is called the **pterygopalatine canal**, and transmits the pterygopalatine vessels and a pharyngeal branch of the sphenopalatine ganglion.

The Greater or Temporal Wings (*alæ magna*).—The greater wings are two strong processes of bone which arise from the sides of the body, and are curved in a direction upward, outward, and backward, each being prolonged behind into a sharp-pointed extremity, the **alar**, or **sphenoidal spine** (*spina angularis*). Each wing presents three surfaces and a circumference.

Surfaces.—The **superior surface** (*facies cerebialis*) (Fig. 56) forms part of the middle fossa of the skull; it is deeply concave, and presents eminences and depressions for the convolutions of the cerebrum. At its anterior and internal part is seen a circular aperture, the **foramen rotundum**, for the transmission of the second division of the trigeminal nerve. Behind and external to this is a large oval foramen, the **foramen ovale**, for the transmission of the third division of the trigeminal nerve, the small meningeal artery, and sometimes the small petrosal nerve. At the inner side of the foramen ovale a small aperture may occasionally be seen opposite the root of the pterygoid process; it is the **foramen Vesalii**, transmitting a small vein. In the posterior angle, near to the spine of the sphenoid, is a short canal, sometimes double, the **foramen spinosum**, which transmits the middle meningeal artery and the meningeal branch of the superior maxillary nerve. Just to the inner side of the foramen spinosum a minute foramen (canaliculus innominatum) is occasionally found, for the passage of the small petrosal nerve.

The **external surface** (Fig. 57) is convex and divided by a transverse ridge, the **pterygoid ridge** (*crista infratemporalis*), into two portions. The superior or larger, convex from above downward, concave from before backward, enters into the formation of the **temporal fossa**, and gives attachment to part of the Temporal muscle. The inferior portion, smaller in size and concave, enters into the formation of the **zygomatic fossa**, and affords attachment to the External pterygoid muscle. It presents, at its posterior part, a sharp-pointed eminence of bone, the **spine**, to which are connected the internal lateral ligament of the mandible and the Tensor palati muscle. At its inner and anterior extremity is a triangular spine of bone, which serves to increase the extent of origin of the External pterygoid muscle.

The **anterior surface** is divided into two parts, the orbital surface above and the sphenomaxillary below. The **orbital surface** is quadrilateral in form; it looks inward and forward, and assists in forming the outer wall of the orbit. It is bounded above by a serrated edge for articulation with the frontal bone. Internally this edge is sharp and free and forms the lower boundary of the sphenoidal fissure. At about the centre of the free part of this border a little tubercle projects, giving origin to one head of the External rectus muscle of the eyeball. At its outer part is a notch for the transmission of a recurrent branch of the lacrimal artery. The **outer border** is serrated for articulation with the malar bone. The **lower border** is rounded and enters into the formation of the sphenomaxillary fissure. This border separates the orbital surface above from the sphenomaxillary portion below. This latter portion is situated just above the pterygoid process and helps to form the posterior wall of the sphenomaxillary

fossa in the articulated skull and exhibits the anterior extremity of the foramen rotundum.

Circumference (Fig. 56).—Commencing from behind, that portion of the circumference of the body of the sphenoid to the spine is serrated and articulates by its outer half with the inner part of the antero-superior border of the petrous portion of the temporal bone, while the inner half forms the anterior boundary of the middle lacerated foramen, and presents the posterior aperture of the **Vidian canal** (*canalis pterygoideus*), for the passage of the Vidian nerve and artery. In front of the spine, the circumference of the greater wing presents a serrated edge, bevelled at the expense of the inner table below and of the external above, which articulates with the squamous portion of the temporal bone. At the tip of the greater wing a triangular portion is seen, bevelled at the expense of the internal surface, for articulation with the anterior inferior angle of the parietal bone. Internal to this is a triangular, serrated surface, for articulation with the frontal

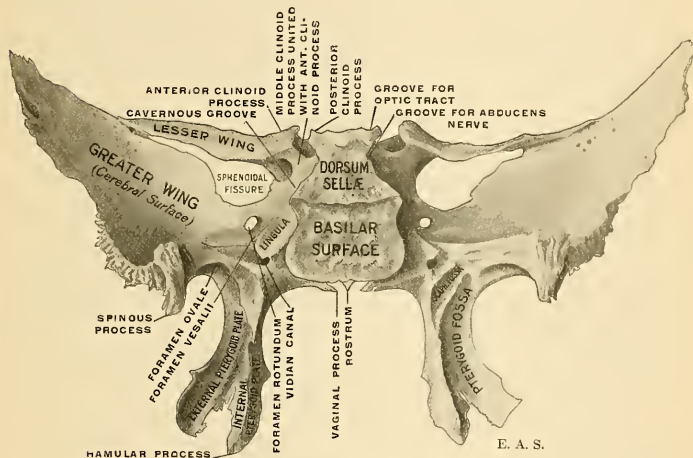


FIG. 58.—Sphenoid bone. Posterior view.

bone; this surface is continuous internally with the sharp inner edge of the orbital plate, which assists in the formation of the sphenoidal fissure, and externally with the serrated margin for articulation with the malar bone.

The Lesser or Orbital Wings (*alae parvae*).—The lesser wings are two thin triangular plates of bone which arise, one on each side, from the upper part of the lateral surface of the body of the sphenoid, and, projecting transversely outward, terminate in a sharp point (Fig. 56). The **superior surface** of each forms part of the anterior fossa of the skull, is smooth, flat, broader internally than externally, and supports part of the frontal lobe of the cerebrum. The **inferior surface** forms the back part of the roof of the orbit and the upper boundary of the sphenoidal fissure, or **foramen lacerum anterius**. This fissure is of a triangular form, and leads from the cavity of the cranium into the orbit. It transmits the third, the fourth, the three branches of the ophthalmic division of the trigeminal, the abducent nerve, some filaments from the cavernous plexus of the sympathetic, the orbital branch of the middle meningeal artery, a recurrent branch from the lacrimal artery to the dura and the ophthalmic vein. The **anterior border** of the lesser

wing is serrated for articulation with the frontal bone; the **posterior border**, smooth and rounded, is received into the sylvian fissure of the cerebrum. The inner extremity of this border forms the **anterior clinoid process** (*processus clinoideus anterior*). The lesser wing is connected to the side of the body by two roots, the upper thin and flat, the lower thicker, obliquely directed, and presenting on its outer side, near its junction with the body, a small tubercle, for the attachment of the common tendon of origin of three of the Extrinsic muscles of the eye. Between the two roots is the **optic foramen**, for the transmission of the optic nerve and ophthalmic artery.

The Pterygoid Processes (*processus pterygoidei*).—The pterygoid processes, one on each side, descend perpendicularly from the place where the body and greater wing unite (Fig. 59). Each process consists of an external and an internal plate, which are joined together by their anterior borders above, but are separated below, leaving an angular cleft, the **pterygoid notch**, in which the pterygoid tuberosity of the palate bone is received. The two plates diverge from each other from their line of connection in front, so as to form in conjunction with the tuberosity of the palate bone a V-shaped fossa, the **pterygoid fossa**. The **external pterygoid plate** (*lamina lateralis processus pterygoidei*) is broad and

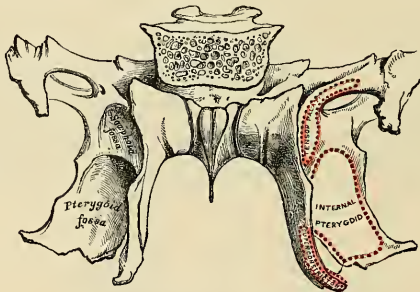


FIG. 59.—Sphenoid bone. Posterior surface.

thin, turned a little outward, and, by its outer surface, forms part of the inner wall of the zygomatic fossa, giving attachment to the External pterygoid; its inner surface forms part of the pterygoid fossa, and gives attachment to the Internal pterygoid. The **posterior border** of this plate frequently has one or more rough projections, to one of which is attached the pterygospinous ligament, when this is present. The **internal pterygoid plate** (*lamina medialis processus pterygoidei*) is much narrower and longer, curving outward, at its extremity, into a hook-like process of bone, the **hamular process** (*hamulus pterygoideus*), around which turns the tendon of the Tensor palati muscle. The outer surface of this plate forms part of the pterygoid fossa, the inner surface forming the outer boundary of the posterior aperture of the nares. The posterior border of this plate gives attachment to the pharyngeal aponeurosis throughout its entire length. The Superior constrictor muscle of the pharynx arises from its lower half. Projecting backward from the middle of this border is a spine (*processus tubarius*), which supports the pharyngeal end of the Eustachian tube. Above this the border divides into two lips; the space between is the **scaphoid fossa** (*fossa scaphoidea*). In this fossa arises the Tensor palati muscle. The **anterior margin** articulates with the posterior border of the perpendicular plate of the palate bone.

Superiorly, the internal pterygoid plate has a thin lamina of bone, the **vaginal**

process (*processus vaginalis*), which runs inward on the under surface of the body of the sphenoid nearly to the rostrum. In the groove between the two in the articulated skull are seen the *alæ* of the vomer. On the under surface of the vaginal process is a groove (*sulcus pterygopalatinus*), which in the articulated skull is converted into the pterygopalatal canal by union with the sphenoidal process of the palate bone. At the junction of the vaginal process and the inner plate is the **pterygoid tubercle**, just above which is the posterior opening of the Vidian canal. The anterior surface of the pterygoid process is quite broad at its base, and forms the chief part of the posterior wall of the sphenomaxillary fossa.

The Sphenoidal Turbinated Processes (*conchae sphenoidales*).—The sphenoidal turbinated processes are two thin curved plates of bone, which exist as separate pieces until puberty, and occasionally are not joined to the sphenoid in the adult. They are situated at the anterior part of the body of the sphenoid, an aperture (*apertura sinus sphenoidalis*) of variable size being left in the anterior wall of each, through which the sphenoidal sinuses open into the nasal fossæ. They are irregular in form and taper to a point behind, being broader and thinner in front. Their upper surface, which looks toward the cavity of the sinus, is concave; their under surface convex. Each bone articulates in front with the ethmoid, externally with the palate; its pointed posterior extremity is placed above the vomer, and is received between the root of the pterygoid process on the outer side and the rostrum of the sphenoid on the inner.¹

Development.—Up to about the eighth month of fetal life the sphenoid bone consists of two distinct parts—a **posterior** or **postsphenoid** part, which comprises the sella turcica, the greater wings, and the pterygoid processes; and an **anterior** or **presphenoid** part, to which the anterior part of the body and lesser wings belong. It is developed from *fourteen* centres—eight for the postsphenoid division and six for the presphenoid. All parts except the internal pterygoid plates have an intracartilaginous origin.

Postsphenoid Division.—The first nuclei to appear are those for the greater wings (*alisphenoids*). They make their appearance between the foramen rotundum and foramen ovale about the eighth week, and from them the external pterygoid plates are also formed. Soon after, the nuclei for the posterior part of the body appear, one on either side of the sella turcica, and become blended together about the middle of fetal life. About the ninth or tenth week the centre for the internal pterygoid plate appears, followed by the centre for the hamular process; the centre for the lingula appears during the fourth month, and soon joins the rest of the body. The internal and external pterygoid plates become joined at about the sixth month.

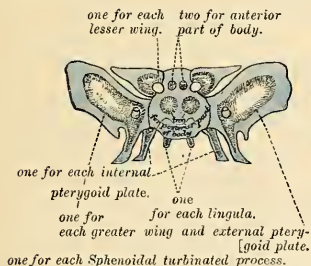


FIG. 60.—Plan of development of the sphenoid. From fourteen centres.

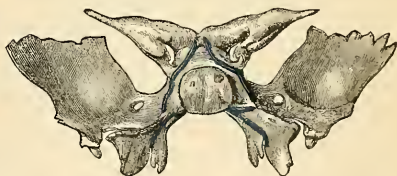

FIG. 61.—Sphenoid bone at birth. Posterior aspect.

Presphenoid Division.—The first nuclei to appear are those for the lesser wings (*orbitosphenoids*). They make their appearance about the ninth week, at the outer borders of the optic

¹ A small portion of the sphenoidal turbinated process sometimes enters into the formation of the inner wall of the orbit, between the os planum of the ethmoid in front, the orbital plate of the palate below, and the frontal above.—Cleveland, Roy. Soc. Trans., 1862.

foramina. A second pair of nuclei appears on the inner side of the foramina shortly after, and, becoming united, form the front part of the body of the bone. The remaining two centres for the sphenoidal turbinated processes make their appearance about the fifth month. At birth they consist of small triangular laminae, and it is not until the third year that they become hollowed out and cone-shaped. About the fourth year they become fused with the lateral masses of the ethmoid, and between the ninth and twelfth years they unite with the sphenoid bone.

The presphenoid is united to the body of the postsphenoid about the eighth month, so that at birth the bone consists of three pieces—viz., the body in the centre, and on each side the great wings with the pterygoid processes. The lesser wings become joined to the body at about the time of birth. During the first year after birth the greater wings and body are united. From the ninth to the twelfth year the turbinated processes are partially united to the sphenoid, their junction being complete by the twentieth year. Lastly, the sphenoid joins the occipital from the eighteenth to the twenty-fifth year.

Articulations.—The sphenoid articulates with *all* the bones of the cerebral cranium, and *five* of the face—the two malar, the two palate, and vomer; the exact extent of articulation with each bone is shown in the accompanying figures.¹

Attachment of Muscles.—To *eleven* pairs—the Temporal, External pterygoid, Internal pterygoid, Superior constrictor, Tensor palati, Levator palpebrae, Superior oblique, Superior rectus, Internal rectus, Inferior rectus, External rectus.

The Ethmoid Bone (Os Ethmoidale).

The **ethmoid** is an exceedingly light, spongy bone, of a cubical form, situated at the anterior part of the base of the cranium proper, between the two orbits at the root of the nose, and contributing to the formation of each of these cavities. It consists of four parts—a **horizontal plate**, which forms part of the base of the cranium proper; a **perpendicular plate**, which forms part of the septum of the nose; and two **lateral masses**, containing a number of spaces.

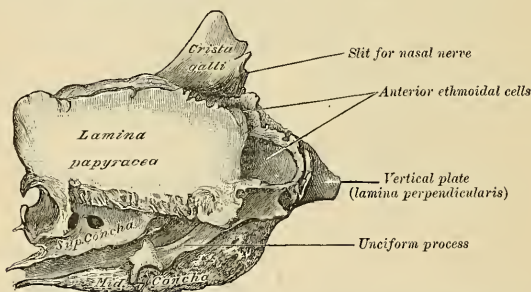


FIG. 62.—Ethmoid bone. Outer surface of right lateral mass. (Enlarged.)

The **Horizontal Lamina**, or **Cribriform Plate** (*lamina cribrosa*) (Fig. 62), forms part of the anterior fossa of the base of the skull, and is received into the ethmoid notch of the frontal bone between the two orbital plates. Projecting upward from the middle line of this plate is a thick, smooth, triangular process of bone, the **crista galli**. Its *base* joins the cribriform plate. Its *posterior border*, long, thin, and slightly curved, serves for the attachment of the falx cerebri. Its *anterior border*, short and thick, articulates with the frontal bone, and presents two small projecting **alæ** (*processus alares*), which are received into corresponding depressions in the frontal, completing the **foramen cecum** behind. Its sides are smooth and sometimes bulging, in which case it is found to enclose a small sinus. On each side of the crista galli the cribriform plate is narrow and deeply grooved, to support the bulb of the olfactory tract, and is perforated by foramina for the passage of the olfactory nerves. These foramina are arranged in three rows: The innermost, which are the largest and least numerous, are lost in grooves on the

¹ It also sometimes articulates with the tuberosity of the maxilla.

upper part of the septum; the foramina of the outer row are continued on to the surface of the superior turbinated process. The foramina of the middle row are the smallest; they perforate the bone and transmit nerves to the roof of the nose. At the front part of the cribriform plate, on each side of the crista galli, is a small fissure, which transmits the nasal branch of the ophthalmic nerve; and at its posterior part a triangular notch, which receives the ethmoidal spine of the sphenoid.

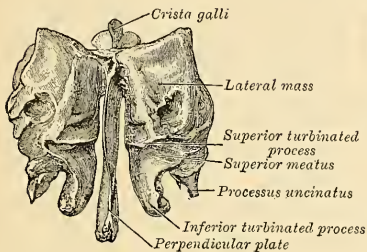


FIG. 63.—Ethmoid bone from behind.

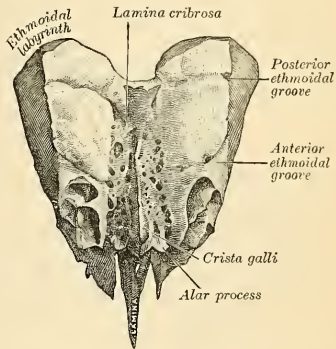


FIG. 64.—Ethmoid bone from above. (Spalteholz.)

The **Vertical Plate** (*lamina perpendicularis*) (Fig. 65) is a thin, flattened, lamella of bone, which descends from the under surface of the cribriform plate, and assists in forming the septum of the nose. It is much thinner in the middle than at the circumference, and is generally deflected a little to one side. Its **anterior border** articulates with the nasal spine of the frontal bone and crest of the nasal bones. Its **posterior border**, divided into two parts, articulates by its upper half with the sphenoidal crest of the sphenoid, by its lower half with the vomer. The **inferior border** serves for the attachment of the triangular cartilage of the nose. On each side of the perpendicular plate numerous grooves are seen, leading from the foramina on the cribriform plate; they lodge filaments of the olfactory nerves.

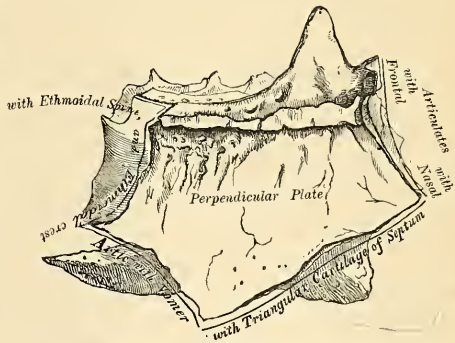


FIG. 65.—Perpendicular plate of ethmoid (enlarged), shown by removing the right lateral mass.

The **Lateral Mass**, or **Labyrinth** (*labyrinthus ethmoidalis*), of the ethmoid consists of a number of thin-walled cellular cavities, the **ethmoidal cells** (*cellulae ethmoidales*), interposed between two vertical plates of bone, the outer one of which forms part of the orbit, and the inner one part of the outer wall of the nasal fossa

of the corresponding side. There are two lateral masses, one on each side. The ethmoidal cells are not present at birth, but appear during the fifth year. In the disarticulated bone many of these cells appear to be broken; but when the bones are articulated they are closed in at every part, except where they open into the nasal fossæ. The **upper surface** of each lateral mass presents a number of apparently half-broken cellular spaces; these are closed in, when articulated, by the edges of the ethmoidal notch of the frontal bone. Crossing this surface are two grooves on each side, converted into canals by articulation with the frontal; they are the **anterior and posterior ethmoidal canals** (*canalis ethmoidale antierius et posterius*), and open on the inner wall of the orbit. The anterior transmits the nasal nerve and the anterior ethmoidal vessels; the posterior transmits the posterior ethmoidal vessels. The **posterior surface** also presents large irregular cellular cavities, which are closed in by articulation with the sphenoidal turbinated processes and the orbital process of the palate. The cells at

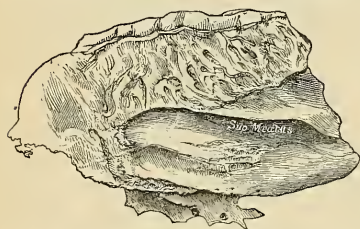


Fig. 66.—Ethmoid bone. Inner surface of right lateral mass. (Enlarged.)

the anterior surface are completed by the lacrimal bone and nasal process of the maxilla, and those below also by the maxilla. The **outer surface** of each lateral mass consists chiefly of a thin, smooth, oblong plate of bone, called the **os planum** (*lamina papyracea*); it forms part of the inner wall of the orbit, and articulates, *above*, with the orbital plate of the frontal; *below*, with the maxilla; *in front*, with the lacrimal; and *behind*, with the sphenoid and orbital process of the palate. In

front of the os planum are found the **anterior ethmoidal cells**, which are completed by the lacrimal bone and the nasal process of the maxilla.

From the inferior part of each lateral mass, immediately beneath the os planum, there projects downward and backward an irregular hook-like lamina of bone, called the **unciform process** (*processus uncinatus*); it serves to close in the upper part of the orifice of the antrum (Fig. 71), and articulates with the ethmoidal process of the turbinated bone. It is often broken in disarticulating the bones.

The **inner surface** of each lateral mass forms part of the outer wall of the nasal fossa of the corresponding side. It is formed of a thin lamella of bone, which descends from the under surface of the cribriform plate, and terminates below in a free, convoluted margin, the **middle turbinated process** (*concha nasalis media*). The whole of this surface is rough and marked above by numerous grooves, which run nearly vertically downward from the cribriform plate; they lodge branches of the olfactory nerve, which are distributed on the mucous membrane covering the bone. The back part of this surface is subdivided by a narrow oblique fissure, the **superior meatus of the nose**, bounded above by a thin, curved plate of bone, the **superior turbinated process** (*concha nasalis superior*). By means of an orifice at the upper part of this fissure the posterior ethmoidal cells open into the superior meatus. Below, and in front of the superior meatus, is seen the convex surface of the middle turbinated process. It extends along the whole length of the inner surface of each lateral mass. The middle of its lower margin is free and thick. The anterior portion articulates with the superior turbinated crest of the nasal process of the maxilla, and the posterior portion articulates with the superior turbinated crest of the maxilla and palate bone. Its concavity, directed outward, assists in forming the middle meatus. It is by a large orifice at the upper and

front part of the middle meatus that the anterior ethmoidal cells, and through them the frontal sinuses, communicate with the nose by means of a funnel-shaped canal, the *infundibulum* (*infundibulum ethmoidale*) (Fig. 62). The cellular cavities of each lateral mass, thus walled in by the os planum in the outer side and by the other bones already mentioned, are divided by a thin transverse bony partition into two sets, which do not communicate with each other; they are termed the **anterior** and **posterior ethmoidal sinuses**. The former, more numerous, communicate with the frontal sinuses above and the middle meatus; below by means of the infundibulum; the posterior, less numerous, open into the superior meatus and communicate (occasionally) with the sphenoidal sinuses. In some cases the ethmoidal sinuses communicate with the maxillary sinus. In some cases the os planum never develops, and the ethmoidal sinuses are separated from the orbit merely by membrane.

Development.—The ethmoid is developed in cartilage from *three* centres—one for the perpendicular lamella, and one for each lateral mass. The lateral masses are first developed, ossific granules making their appearance in the os planum between the fourth and fifth months of fetal life, and extending into the turbinated processes. At birth the bone consists of the two lateral masses, which are small and poorly developed. During the first year after birth the perpendicular plate and crista galli begin to ossify, from a single centre, and become joined to the lateral masses about the beginning of the second year. The cribriform plate is ossified partly from the perpendicular plate and partly from the lateral masses. The formation of the ethmoidal cells, which completes the bone, does not commence until the end of the fourth year.

Articulations.—With *thirteen* bones—the sphenoid, the frontal, and eleven of the face, the two nasal, two palate, two maxillæ, two lacrimal, two turbinated, and the vomer. *No muscles* are attached to this bone.

THE BONES OF THE FACE (OSSA FACIEI).

The **facial bones** are fourteen in number—viz., the

Two nasal.	Two palate.
Two maxillæ.	Two turbinated.
Two lacrimal.	Vomer.
Two malar.	Mandible.

The Nasal Bones (Ossa Nasalia).

The **nasal bones** are two small oblong bones, varying in size and form in different individuals; they are placed side by side at the middle and upper part of the face, forming by their junction “the bridge” of the nose (Fig. 67). Each bone presents for examination two surfaces and four borders.

Surfaces.—The **outer surface** is concave from above downward, convex from side to side; it is covered by the *Pyramidalis* and *Compressor nasi* muscles. It is marked by numerous small arterial furrows, and perforated about its centre by a foramen (*foramen nasale*), sometimes double, for the transmission of a small vein.

The **inner surface** is concave from side to side, convex from above downward, in which direction it is traversed by a longitudinal groove (sometimes a canal), for the passage of a branch of the nasal nerve.

Borders.—The **superior border** is narrow, thick, and serrated, for articulation with the nasal notch of the frontal bone.

The **inferior border** is broad, thin, sharp, inclined obliquely downward, outward, and backward, and serves for the attachment of the lateral cartilage of the nose. This border presents, about its middle, a notch, through which passes

the branch of the nasal nerve above referred to, and is prolonged at its inner extremity into a sharp spine, which, when articulated with the opposite bone, forms the **nasal angle**.

The **external border** is serrated, bevelled at the expense of the internal surface above and of the external below, to articulate with the nasal process of the maxilla.

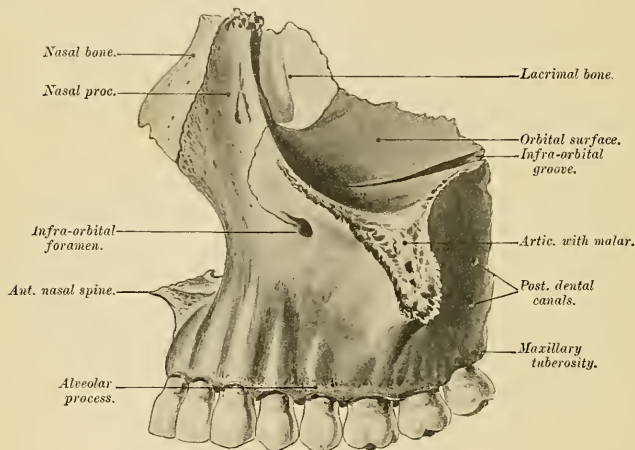


FIG. 67.—Nasal and lacrimal bones *in situ*.

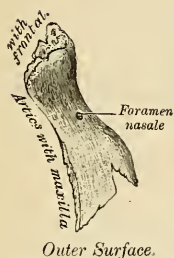


FIG. 68.—Right nasal bone.

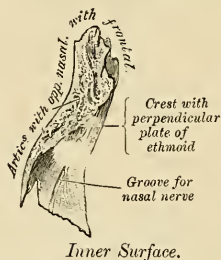


FIG. 69.—Left nasal bone.

The **internal border**, thicker above than below, articulates with its fellow of the opposite side, and is prolonged behind into a vertical crest, which forms part of the septum of the nose; this crest articulates from above downward with the nasal spine of the frontal, the perpendicular plate of the ethmoid, and the triangular septal cartilage of the nose.

Development.—Of intramembranous origin and from *one* centre for each bone, which appears about the eighth week.

Articulations.—With *four* bones—two of the cerebral cranium, the frontal and ethmoid, and two of the face, the opposite nasal and the maxilla.

The nasal bone has *no* muscles attached to it.

The Maxillæ (Upper Jaw).

The **maxillæ** are the largest bones of the face, excepting the mandible, and form, by their union, the whole of the upper jaw. Each maxilla assists in the formation of the walls of three cavities, the roof of the mouth, the floor and outer wall of the nasal fossæ, and the floor of the orbit, and also enters into the

they are termed the **posterior dental canals** (*foramina alveolaria*), and transmit the posterior dental vessels and nerves. At the lower part of this surface is a rounded eminence, the **maxillary tuberosity** (*tuber maxillare*), especially prominent after the growth of the wisdom tooth, rough on its inner side for articulation with the tuberosity of the palate bone, and sometimes with the external pterygoid plate. It gives attachment to a few fibres of origin of the Internal pterygoid muscle. Immediately above this is a smooth surface, which forms the anterior boundary of the sphenomaxillary fossa; it presents a groove which, running obliquely downward, is converted into a canal by articulation with the palate bone, forming the **posterior palatine or palatomaxillary canal** for the descending palatine artery and great palatine nerve. The posterior border forms the anterior boundary of the pterygomaxillary fissure.

The **superior or orbital surface** (*facies orbitalis*) is thin, smooth, triangular, and forms part of the floor of the orbit. It is bounded internally by an irregular margin, which in front presents a notch, the **lacrimal notch** (*incisura lacrimalis*), which receives the lacrimal bone; in the middle it articulates with the os planum of the ethmoid, and behind with the orbital process of the palate bone; bounded externally by a smooth, rounded edge which enters into the formation of the sphenomaxillary fissure, and which sometimes articulates at its anterior extremity with the orbital plate of the sphenoid; bounded in front by part of the circumference of the orbit, which is continuous on the inner side with the nasal, on the outer side with the malar process. Along the middle line of the orbital surface is a deep groove, the **infraorbital groove** (*sulcus infraorbitalis*), for the passage of the infraorbital vessels and nerve. The groove commences at the middle of the outer border of this surface, and, passing forward, terminates in a canal, which subdivides into two branches. One of the canals, the **infraorbital canal**, opens just below the margin of the orbit; the other, which is smaller, runs downward in the substance of the anterior wall of the antrum; it is called the **anterior dental canal**, and transmits the anterior dental vessels and nerve to the front teeth of the maxilla. From the back part of the infraorbital canal a second small canal is sometimes given off, which runs downward in the outer wall of the antrum, and conveys the middle dental nerve to the bicuspid teeth. Occasionally this canal is a branch of the anterior dental canal.

At the inner and fore part of the orbital surface, just external to the lacrimal groove for the nasal duct, is a depression which gives origin to the Inferior oblique muscle of the eye.

The **internal surface** (Fig. 71) is unequally divided into two parts by a horizontal projection of bone, the **palatal process** (*processus palatinus*); the portion above the palatal process is known as the **nasal surface** (*facies nasalis*). It forms part of the outer wall of the nasal fossa. Below the palatal process is the cavity of the mouth. The superior division of the nasal surface presents a large, irregular opening (*hiatus maxillaris*), leading into the maxillary sinus. At the upper border of this aperture are numerous broken cellular cavities, which in the articulated skull are closed by the ethmoid and lacrimal bones. Below the aperture is a smooth concavity which forms part of the inferior meatus of the nasal fossa, and behind it is a rough surface which articulates with the perpendicular plate of the palate bone, traversed by a groove which, commencing near the middle of the posterior border, runs obliquely downward and forward, and forms, when completed by its articulation with the palate bone, the **posterior palatine or palatomaxillary canal**. In front of the opening of the antrum is a deep groove, converted into a canal (*canalis nasolacrimalis*) by the lacrimal and turbinated bones. The groove is called the **lacrimal groove** (*sulcus lacrimalis*), and lodges the nasal duct. More anteriorly is a well-marked rough ridge, the **inferior turbinated crest** (*crista conchalis*), for articulation with the turbinated bone. The shallow con-

cavity above this ridge forms part of the middle meatus of the nose, while that below it forms part of the inferior meatus. The portion of this surface below the palatal process is concave, rough, and uneven, and perforated by numerous small foramina for the passage of nutrient vessels. It enters into the formation of the roof of the mouth.

The antrum of **Higmore** (*sinus maxillaris*) is a pyramidal cavity hollowed out of the body of the maxilla. It varies much in size. It is in most cases a large cavity, but in some is very small. The apex of the antrum, directed outward, is formed by the malar process; its base by the outer wall of the nose. Its walls are everywhere exceedingly thin, and correspond to the orbital, facial, and zygomatic surfaces of the body of the bone. The floor is formed by the alveolar process of the maxilla. The roof corresponds to the orbital plate. Its inner wall, or base, presents, in the disarticulated bone, a large, irregular aperture (*hiatus maxillaris*), which communicates with the nasal fossa. The margins of this aperture are thin and ragged, and the aperture itself in the articulated skull is much con-

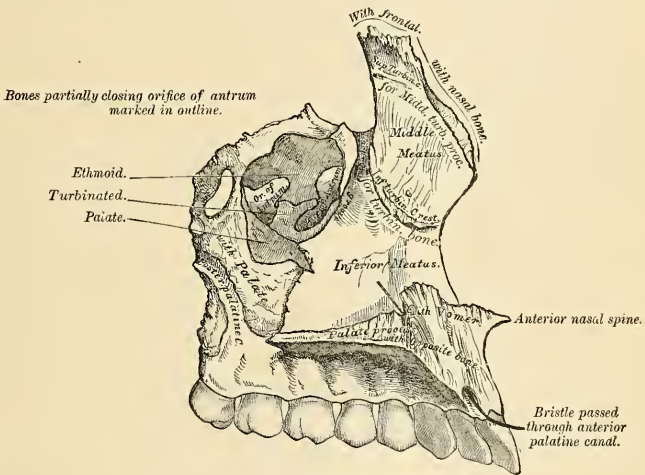


FIG. 71.—Left maxilla. Internal surface.

tracted by its articulation with the ethmoid above, the turbinated bone below, and the palate bone behind.¹ In the articulated skull this cavity communicates with the middle meatus of the nasal cavity, generally by two small apertures left between the above-mentioned bones. In the recent state usually only one small opening exists, near the upper part of the cavity, sufficiently large to admit the end of a probe, the other being closed by the lining membrane of the sinus.

Crossing the cavity of the antrum are often seen several projecting laminae of bone, similar to those seen in the sinuses of the cranium; on its posterior wall are the posterior dental canals, transmitting the posterior dental vessels and nerves to the teeth. Projecting into the floor are several conical processes, corresponding

¹ In some cases, at any rate, the lacrimal bone encroaches slightly on the anterior superior portion of the opening, and assists in forming the inner wall of the antrum.

to the roots of the first and second molar teeth; in some cases the floor is perforated by the teeth in this situation; projecting into the antrum from the roof is a ridge corresponding to the infraorbital canal.

The Processes.—The **malar process** (*processus zygomaticus*) is a rough, triangular eminence, situated at the angle of separation of the facial from the zygomatic surface. In front it is concave, forming part of the facial surface; behind it is also concave, and forms part of the zygomatic fossa; above it is rough and serrated for articulation with the malar bone; while below a prominent ridge marks the division between the facial and zygomatic surfaces. A small part of the Masseter muscle arises from this process.

The **nasal process** (*processus frontalis*) is a strong, triangular plate of bone, which projects upward, inward, and backward by the side of the nose, forming part of its lateral boundary. Its *external surface* is concave, smooth, perforated by numerous foramina, and gives attachment to the Levator labii superioris alaeque nasi, the Orbicularis palpebrarum, and the Tendo oculi. Its *internal surface* forms part of the outer wall of the nasal fossa; at its upper part it presents a rough, uneven surface, which articulates with the ethmoid bone, closing in the anterior ethmoidal cells; below this is a transverse ridge, the **superior turbinated crest** (*crista ethmoidalis*), for articulation with the middle turbinated process of the ethmoid; below the crest is a shallow, smooth concavity which forms part of the middle meatus; below this again is the inferior turbinated crest (already described), where the process joins the body of the bone. Its *upper border* articulates with the nasal notch of the frontal bone. The *anterior border* of the nasal process is thin, directed obliquely downward and forward, and presents a serrated edge for articulation with the nasal bone; its *posterior border* is thick, and hollowed into a groove, the **lacrimal groove**, for the nasal duct; of the two margins of this groove, the inner one articulates with the lacrimal bone, the outer one forms part of the circumference of the orbit. Just where the latter joins the orbital surface is a small tubercle, the **lacrimal tubercle**, which articulates with the hamular process of the lacrimal bone. The lacrimal groove in the articulated skull is converted into a canal (*canalis lacrimalis*) by the lacrimal bone and lacrimal process of the turbinated bone; it is directed downward, and a little backward and outward, is about the diameter of a goose-quill, slightly narrower in the middle than at either extremity, and terminates below in the inferior meatus. It lodges the nasal duct.

The **alveolar process** (*processus alveolaris*) is the thickest and most spongy part of the bone, broader behind than in front, and excavated into deep cavities for the reception of the teeth (*alveoli dentales*). These cavities are eight in number, and vary in size and depth according to the teeth they contain. That for the canine tooth is the deepest; those for the molars are the widest, and subdivided into minor cavities by septa; those for the incisors are single, but deep and narrow. The Buccinator muscle arises from the outer surface of this process as far forward as the first molar tooth. After the loss of the prominent teeth at any time, but especially in old age, this process, like that of the mandible, is absorbed.

The **palatal process** (*processus palatinus*), thick and strong, projects horizontally inward from the inner surface of the body. It is much thicker in front than behind, and forms a considerable part of the floor of the nostril and the roof of the mouth. Its *inferior surface* (Fig. 72) is concave, rough and uneven, contains numerous little cavities for the glands of the mucous membrane, and forms part of the roof of the mouth. This surface is perforated by numerous foramina for the passage of the nutrient vessels, channelled at the back part of its alveolar border by a longitudinal groove, sometimes a canal, for the transmission of the posterior palatine vessels, and the great posterior palatine nerve from Meckel's ganglion, and presents little depressions for the lodgement of the palatine glands. When the two maxillæ are articulated, a large fossa may be seen in the middle

line, immediately behind the incisor teeth. This is the **anterior palatine fossa**. On examining the bottom of this fossa four canals are seen: two branch off laterally to the right and left nasal fossæ, and two—one in front and one behind—lie in the middle line. The former pair of these openings are named the **incisor foramina**, or **foramina of Stenson**; they are the openings of the forking **incisor canal**, through which pass the anterior or terminal branches of the descending or posterior palatine arteries, which ascend from the mouth to the nasal fossæ, and they contain the remains of Jacobson's organ. The canals in the middle line are termed the **foramina of Scarpa**, and transmit the nasopalatine nerves, the left passing through the anterior, and the right through the posterior, canal. Occasionally in adults' skulls, often in children's skulls, on the palatal surface of the process a delicate linear suture may sometimes be seen extending from the anterior palatine fossa to the interval between the lateral incisor and the canine tooth. This marks out the **premaxillary bones** (*os incisivum*) on each side, and includes the whole thickness of the alveolus, the corresponding part of the floor of the nose, and the anterior nasal spine, and contains the sockets of the incisor teeth; in some animals it exists as a separate bone. The *upper surface* of the palatal process is concave from side to side, smooth, and forms part of the floor of the nose. It presents the upper orifices of the foramina of Stenson and Scarpa, the former being on each side of the middle line, the latter being situated in the intermaxillary suture, and therefore not visible unless the two bones are placed in apposition. The *outer border* of the palatal process is incorporated with the rest of the bone. The *inner border* is thicker in front than behind, and is raised above into a ridge, the **nasal crest** (*crista nasalis*), which, with the corresponding ridge in the opposite bone, forms a groove for the reception of the vomer. In front this crest rises to a considerable height, and this portion is named the **incisor crest**. The *anterior margin* is bounded by the thin, concave border of the opening of the nose, prolonged forward internally into a sharp process, forming, with a similar process of the opposite bone, the **anterior nasal spine** (*spina nasalis anterior*). The *posterior border* is serrated for articulation with the horizontal plate of the palate bone.

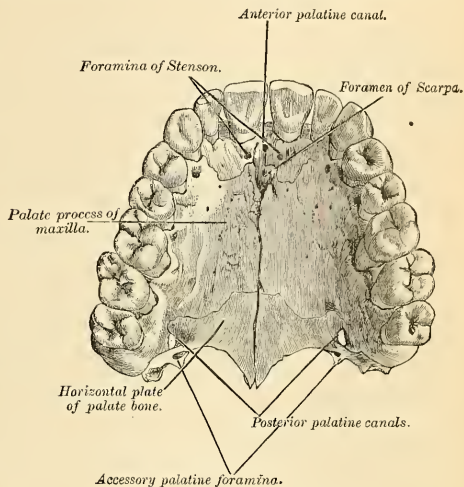


FIG. 72.—The palate and alveolar arch.

Development.—This bone commences to ossify at a very early period, and ossification proceeds in it with great rapidity, so that it is difficult to ascertain with certainty its precise number of centres. It appears, however, probable that it is ossified from *six* centres, which develop in membrane: (1) One, the *orbitonasal*, which forms that portion of the body of the bone which lies internal to the infraorbital canal, including the floor of the orbit, the outer wall of the nasal fossa, and the nasal process. (2) A *malar*, which gives origin to that

portion of the bone which lies external to the infraorbital canal and the malar process. (3) A *palatal*, from which is developed the palatal process posterior to Stenson's canal and the adjoining part of the nasal wall. 4. A *premaxillary*, for the front part of the alveolus, which carries the incisor teeth and corresponds to the premaxillary bone of the lower animals. (5) A *nasal*, that gives rise to the nasal process and the portion above the canine tooth. (6) An *infravomerine*, that lies beneath the vomer and between the palatal and premaxillary centres. The premaxillary centre is in close association with the development of the perpendicular plate of the ethmoid and the vomer. According to Albrecht it develops from two centres of ossification, each having an

incisive tooth. The one possessing the mesal segment he calls the *endognathion*. The lateral segment he calls the *mesognathion*, while to the maxilla he gives the name *exognathion*. These segments are separated by five sutures. The failure of union of any of these segments will lead to the various forms of cleft palate. These centres appear about the eighth week, and by the tenth week have become fused together so that the bone consists of two portions, one the maxilla proper, and the other the premaxillary portion. The suture between these two portions on the palate persists until middle life, but is not to be seen on the facial surface. This is believed by Callender to be due to the fact that the front wall of the sockets of the incisive teeth is not formed by the premaxillary bone, but by an outgrowth from the facial part of the maxilla. The antrum appears as a shallow groove on the inner surface of the bone at an earlier period than any of the other nasal sinuses, its development commencing about the fourth month of fetal life, and reaches its full size after the second dentition. The sockets for the teeth are formed by the growing downward of two plates from the dental groove, which subsequently becomes divided by partitions jutting across from the one to the other. If the two palatal processes fail to unite partially or completely, a partial or complete cleft palate results.

Articulations.—With *nine* bones, two of the cerebral cranium, the frontal and ethmoid, and seven of the face—viz., the nasal, malar, lacrimal, turbinated, palate, vomer, and its fellow of the opposite side. Sometimes it articulates with the orbital plate of the sphenoid, and sometimes with its external pterygoid plate.

Attachment of Muscles.—To *twelve*—the Orbicularis palpebrarum, Obliquus oculi inferior, Levator labii superioris alaeque nasi, Levator labii superioris, Levator anguli oris, Compressor naris, Depressor alae nasi, Dilatator naris posterior, Masseter, Buccinator, Internal pterygoid, and Orbicularis oris.

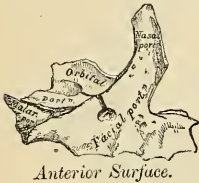
Applied Anatomy.—It is from the extreme thinness of the walls of the antrum that we are enabled to explain how a tumor growing from the antrum encroaches upon the adjacent parts, pushing up the floor of the orbit and displacing the eyeball, projecting inward into the nose, protruding forward on to the cheek, and making its way backward into the zygomatic fossa and downward into the mouth.

CHANGES PRODUCED IN THE UPPER JAW BY AGE.

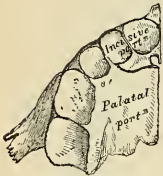At birth and during infancy the diameter of the bone is greater in an antero-posterior than in a vertical direction. Its nasal process is long, its orbital surface large, and its tuberosity well marked. In the adult the vertical diameter is the greater, owing to the development of the alveolar process and the increase in size of the antrum. In old age the bone approaches again in character to the infantile condition; its height is diminished, and after the loss of the teeth the alveolar process is absorbed, and the lower part of the bone contracted and diminished in thickness.

The Lacrimal Bone (Os Lacrimale).

The **lacrimal** (*lacrima*, a tear) is the smallest and most fragile bone of the face. There are two lacrimal bones. They are situated at the front part of the inner wall of the orbit (Fig. 67), and resemble somewhat in form, thinness, and size a finger nail; hence, they are termed the *ossa unguis*. Each bone presents for examination two surfaces and four borders.



Anterior Surface.



Inferior Surface.

FIG. 73.—Development of the maxillæ. At birth.

Surfaces.—The **external or orbital surface** (Fig. 74) is divided by a vertical ridge, the **lacrimal crest** (*crista lacrimalis posterior*), into two parts. The portion of bone in front of this ridge presents a smooth, concave, longitudinal groove (*sulcus lacrimalis*), the free margin of which unites with the nasal process of the maxilla, completing the **lacrimal canal**. The upper part of this groove (*fossa sacci lacrimalis*) lodges the lacrimal sac; the lower part lodges the nasal duct. The portion of bone behind the ridge is smooth, slightly concave, and forms part of the inner wall of the orbit. The ridge, with a part of the orbital surface immediately behind it, affords origin to the Tensor tarsi muscle; it terminates below in a small hook-like projection, the **hamular process** (*hamulus lacrimalis*), which articulates with the lacrimal tubercle of the maxilla and completes the upper orifice of the lacrimal canal. It sometimes exists as a separate piece, which is then called the **lesser lacrimal bone**.

The **internal or nasal surface** presents a depressed furrow, corresponding to the ridge on its outer surface. The surface of bone in front of this forms part of the middle meatus, and that behind it articulates with the ethmoid bone, closing in the anterior ethmoidal cells.

Borders.—Of the four borders, the **anterior** is the longest, and articulates with the nasal process of the maxilla. The **posterior**, thin and uneven, articulates with the os planum of the ethmoid. The **superior**, the shortest and thickest, articulates with the internal angular process of the frontal bone. The **inferior** is divided by the lower edge of the vertical crest into two parts; the posterior part articulates with the orbital plate of the maxilla; the anterior portion is prolonged downward into a pointed process, which articulates with the lacrimal process of the turbinated bone and assists in the formation of the lacrimal canal.

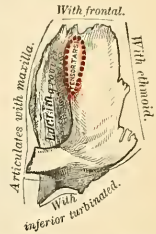


FIG. 74.—Left lacrimal bone. External surface. (Slightly enlarged.)

Development.—From a *single* centre, which makes its appearance in membrane at about the eighth or ninth week.

Articulations.—With *four* bones—two of the cerebral cranium, the frontal and ethmoid, and two of the face, the maxilla and the turbinated.

Attachment of Muscles.—To *one* muscle, the Tensor tarsi.

The Malar Bone (Os Zygomaticum).

The **malar bone** is a quadrangular bone, situated at the upper and outer part of the face. It forms the prominence of the cheek, part of the outer wall and floor of the orbit, and part of the temporal and zygomatic fossæ (Fig. 75). Each bone presents for examination an external and an internal surface; three processes, the frontal, orbital, and zygomatic processes; and four borders.

Surfaces.—The **external surface** (*facies malaris*) (Fig. 76) is smooth, convex, perforated near its centre by a small aperture, the **malar foramen**, for the passage of nerves and vessels from the orbit. The malar surface is covered by the Orbicularis palpebrarum muscle, and affords attachment to the Zygomaticus major and minor muscles.

The **internal surface** (*facies temporalis*) (Fig. 77), directed backward and inward, is concave, presenting anteriorly a rough, triangular surface, for articulation with the maxilla; and behind, a smooth concave surface, which above forms the anterior boundary of the temporal fossa, and below, where it is wider, forms part of the zygomatic fossa. This surface presents, a little above its centre, the aperture of

a malar canal (*foramen zygomaticotemporale*), and affords attachment at its lower part to a portion of the Masseter muscle.

Processes.—The frontal process (*processus frontosphenoidalis*) is thick and serrated, and articulates with the external angular process of the frontal bone. To its orbital margin is attached the external tarsal ligament.

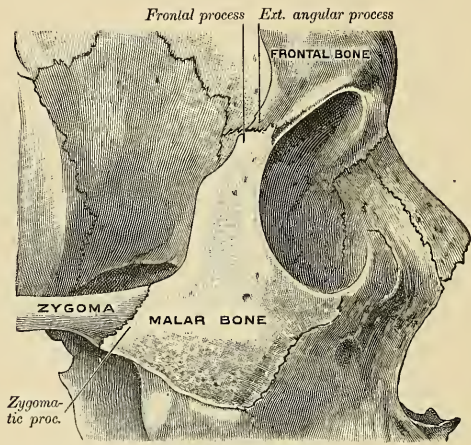


FIG. 75.—Right malar bone in situ.

The orbital process is a thick and strong plate, which projects backward from the orbital margin of the bone. Its *supero-internal surface* (*facies orbitalis*), smooth and concave, forms, by its junction with the orbital surface of the maxilla and with the greater wing of the sphenoid, part of the floor and outer wall of the orbit. Its *temporal surface*, smooth and concave, forms part of the zygomatic and temporal

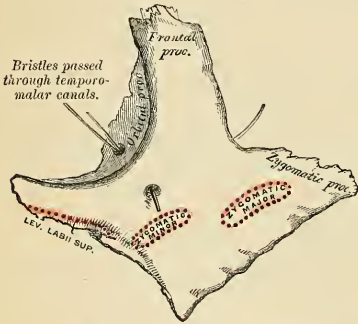


FIG. 76.—Left malar bone. Outer surface.

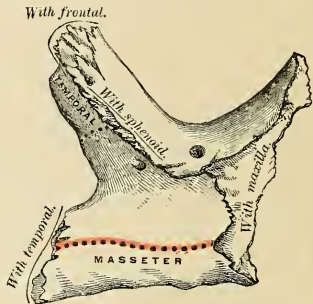


FIG. 77.—Left malar bone. Inner surface.

fossæ. Its *anterior margin* is smooth and rounded, forming part of the circumference of the orbit. Its *superior margin*, rough and directed horizontally, articulates with the frontal bone behind the external angular process. Its *posterior*

margin is rough and serrated for articulation with the sphenoid; *internally* it is also serrated for articulation with the orbital surface of the maxilla. At the angle of junction of the sphenoidal and maxillary portions a short, rounded, non-articular margin is generally seen; this forms the anterior boundary of the sphenomaxillary fissure; occasionally no such nonarticular margin exists, the fissure being completed by the direct junction of the maxilla and sphenoid bones or by the interposition of a small Wormian bone in the angular interval between them. On the *supero-internal surface* of the orbital process is seen the orifice of one of the temporomalar canals. This canal may be bifurcated, or there may be two canals from the beginning; one of these usually opens on the temporal surface, the other (occasionally two) on the facial surface; they transmit filaments of the orbital branch of the superior maxillary nerve.

The **zygomatic process** (*processus temporalis*), long, narrow, and serrated, articulates with the zygomatic process of the temporal bone.

Borders.—The **antero-superior** (*orbital border*) is smooth, arched, and forms a considerable part of the circumference of the orbit. The **antero-inferior** (*maxillary border*) is rough, and bevelled at the expense of its inner table, to articulate with the maxilla, affording attachment by its margin to the Levator labii superioris, just at its point of junction with the maxilla. The **postero-superior** (*temporal border*) curved like an italic letter *f*, is continuous above, with the commencement of the temporal ridge; below, with the upper border of the zygomatic arch; it affords attachment to the temporal fascia. The **postero-inferior** (*masseteric border*) is continuous with the lower border of the zygomatic arch, affording attachment by its rough edge to the Masseter muscle.

Development.—The malar bone ossifies generally from *three* centres, which appear about the eighth week—one for the zygomatic and two for the orbital portion—and which fuse about the fifth month of fetal life. The bone is sometimes, after birth, seen to be divided by a horizontal suture into an upper and larger and a lower and smaller division. In some primates the malar bone consists of two parts, an orbital and a malar.

Articulations.—With *four* bones—three of the cranium, frontal, sphenoid, and temporal; and one of the face, the maxilla.

Attachment of Muscles.—To *four*—the Levator labii superioris proprius, Zygomaticus major and minor, and Masseter.

The Palate Bone (Os Palatinum).

The **palatal bones**¹ are situated at the back part of the nasal fossæ; they are wedged in between the maxilla and the pterygoid processes of the sphenoid (Fig. 78). Each bone assists in the formation of three cavities—the floor and outer wall of the nose, the roof of the mouth, and the floor of the orbit—and enters into the formation of two fossæ, the **sphenomaxillary** and **pterygoid fossæ**; and one fissure, the **sphenomaxillary fissure**. In form the palate bone somewhat resembles the letter L, and may be divided into an inferior or horizontal plate and a superior or vertical plate.

The **Horizontal Plate** (*pars horizontalis*) (Figs. 79 and 80) is of a quadrilateral form, and presents two surfaces and four borders.

Surfaces.—The **superior or nasal surface** (*facies nasalis*), concave from side to side, forms the back part of the floor of the nasal cavity.

The **inferior or palatine surface** (*facies palatina*), slightly concave and rough, forms the back part of the hard palate. At its posterior part may be seen a transverse ridge, more or less marked, for the attachment of part of the aponeurosis of the

¹ The word *palate* is frequently used as an adjective. *Palatal* is the correct form (from *palatum*, the palate), but usage sanctions *palatine* in certain compounds, despite the fact that palatine is derived from *palatium*, a palace. This is another example of what is charitably called a "late Latin" form, akin to *halluz* and *hallucis*. —[Editor.]

Tensor palati muscle. At the outer extremity of this ridge is a deep groove, the **pterygopalatine groove** (*sulcus pterygopalatinus*), converted into a canal by its articulation with the tuberosity of the maxilla, and forming the lower end of the **posterior palatine canal** (*canalis pterygopalatinus*). Near this groove the orifices of one or two small canals, **accessory posterior palatine canals** (*canales palatini*), may be seen for the passage of the middle and posterior palatine nerves from the sphenopalatine (Meckel's) ganglion. Through the posterior palatine canal emerge the descending palatine artery and the great posterior palatine nerve.

Borders.—The **anterior** is serrated, bevelled at the expense of its inferior surface, and articulates with the palatal process of the maxilla. The **posterior** is concave, free, and serves for the attachment of the soft palate. Its inner extremity is sharp and pointed, and when united with the opposite bone forms a

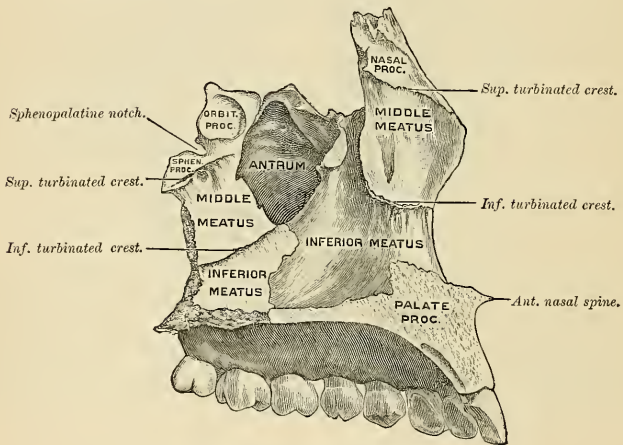


FIG. 75.—Internal surface of left maxilla and palate.

projecting process, the **palatine spine** (*spina nasalis posterior*), for the attachment of the Azygos uvulae muscle. The **external** is united with the lower part of the perpendicular plate almost at right angles. The **internal**, the thickest, is serrated for articulation with its fellow of the opposite side; its superior edge is raised into a ridge, which, united with the opposite bone, forms a **crest** (*crista nasalis*), into which the vomer is received.

The **Vertical or Perpendicular Plate** (*pars perpendicularis*) (Figs. 79 and 80) forms the back part of the outer wall of the nasal fossa, is thin, of an oblong form, and directed upward and a little inward. It presents two surfaces, an external and an internal, and three borders.

Surfaces.—The **internal, medial, or nasal surface** (*facies nasalis*) presents at its lower part a broad, shallow depression, which forms part of the **inferior meatus** of the nose. Immediately above this is a well-marked ridge, the **inferior turbinate crest** (*crista conchalis*), for articulation with the turbinated bone; above this a second broad, shallow depression, which forms part of the **middle meatus**, surmounted above by a horizontal ridge less prominent than the inferior, the **superior turbinate crest** (*crista ethmoidalis*), for articulation with the middle turbinated

process. Above the superior turbinated crest is a narrow, horizontal groove, which forms part of the **superior meatus**.

The **external or lateral surface** (*facies maxillaris*) is rough and irregular throughout the greater part of its extent, for articulation with the inner surface of the maxilla, its upper and back part being smooth where it enters into the formation of the sphenomaxillary fossa; it is also smooth in front, where it covers the orifice of the antrum. Toward the back part of this surface is a deep groove, the **pterygopalatine groove**, converted into a canal, the **posterior palatine canal**, by its articulation with the maxilla. It transmits the posterior or descending palatine vessels and the great or anterior palatine nerve from Meckel's ganglion.

Borders. — The **anterior border** (Fig. 79) is thin, irregular, and presents opposite the inferior turbinated crest a pointed, projecting lamina, the **maxillary process** (*processus maxillaris*), which is directed forward, and closes in the lower and back part of the opening of the antrum.

The **posterior border** (Fig. 80) presents a deep groove, the edges of which are serrated for articulation with the pterygoid process of the sphenoid. At the lower part of this border is seen a pyramidal process of bone, the **tuberosity of the palate** (*processus pyramidalis*), which is received into the angular interval between

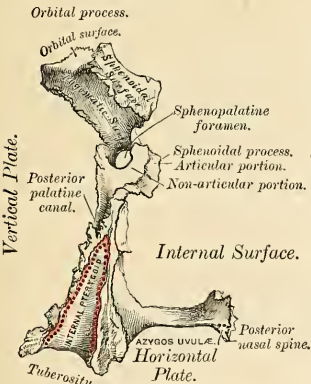


FIG. 80.—Left palate bone. Posterior view. (Enlarged.)

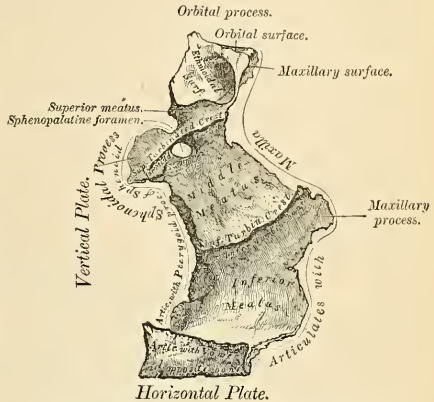


FIG. 79.—Left palate bone. Internal view. (Enlarged.)

the two pterygoid plates of the sphenoid at their inferior extremity. This process presents at its back part a median groove and two lateral surfaces. The groove is smooth, and forms part of the pterygoid fossa, affording attachment to the Internal pterygoid muscle; while the lateral surfaces are rough and uneven, for articulation with the anterior border of each pterygoid plate. A few fibres of the Superior constrictor of the pharynx arise from the tuberosity of the palate bone. The base of this process, continuous with the horizontal portion of the bone, presents the apertures of the accessory posterior palatine canals, through which pass the two smaller descending branches of Meckel's ganglion; while its outer surface is rough for articulation with the inner surface of the body of the maxilla.

The **superior border** of the vertical plate presents two well-marked processes separated by an intervening notch. The anterior, or larger, is called the orbital process; the posterior, the sphenoidal process.

Processes.—The **orbital process** (*processus orbitalis*), directed upward and outward, is placed on a higher level than the sphenoidal. It presents five surfaces, which enclose a hollow cellular cavity, and is connected with the perpendicular plate by a narrow, constricted neck. Of these five surfaces, three are articular, two nonarticular or free surfaces. The three articular are the *anterior* or *maxillary surface*, which is directed forward, outward, and downward, is of an oblong form, and rough for articulation with the maxilla. The *posterior* or *sphenoidal surface* is directed backward, upward, and inward. It ordinarily presents a small, open cell, the **orbital sinus**, which communicates with the sphenoidal cells, and the margins of which are serrated for articulation with the vertical part of the sphenoidal turbinated process. The *internal* or *ethmoidal surface* is directed inward, upward, and forward, and articulates with the lateral mass of the ethmoid bone. In some cases the cellular cavity opens on the internal surface of the bone; it then communicates with the posterior ethmoidal cells. More rarely it opens on both surfaces, and then communicates with both the posterior ethmoidal and the sphenoidal cells. The nonarticular or free surfaces are the *superior* or *orbital surface*, directed upward and outward, of triangular form, concave, smooth, and forming the back part of the floor of the orbit; and the *external* or *zygomatic surface*, directed outward, backward, and downward, of an oblong form, smooth, lying in the sphenomaxillary fossa, and looking into the zygomatic fossa. The latter surface is separated from the orbital by a smooth, rounded border, which enters into the formation of the sphenomaxillary fissure.

The **sphenoidal process** (*processus sphenoidalis*) of the palate bone is a thin, compressed plate, much smaller than the orbital, and directed upward and inward. It presents three surfaces and two borders. The *superior surface*, the smallest of the three, articulates with the under surface of the sphenoidal turbinated process; it presents a groove, which contributes to the formation of the pterygopalatine canal. The *internal surface* is concave, and forms part of the outer wall of the nasal fossa. The *external surface* is divided into an articular and a nonarticular portion; the former is rough, for articulation with the inner surface of the internal pterygoid plate of the sphenoid; the latter is smooth, and forms part of the sphenomaxillary fossa. The *anterior border* forms the posterior boundary of the sphenopalatine notch. The *posterior border*, serrated at the expense of the outer table, articulates with the inner surface of the internal pterygoid plate.

The orbital and sphenoidal processes are separated from each other by a deep notch, the **sphenopalatine notch** (*incisura sphenopalatina*), which is converted into a foramen, the **sphenopalatine foramen** (*foramen sphenopalatinum*), by articulation with the under surface of the body of the sphenoid bone. Sometimes the two processes are united above, and form between them a complete foramen (Figs. 79 and 80), or the notch is crossed by one or more spiculæ of bone, so as to form two or more foramina. In the articulated skull this foramen is seen to pass from the sphenomaxillary fossa into the back part of the superior meatus. It transmits the sphenopalatine vessels and the superior nasal and nasopalatine nerves.

Development.—From a *single* centre, which makes its appearance in membrane about the second month at the angle of junction of the two plates of the bone. From this point ossification spreads inward to the horizontal plate, downward into the tuberosity, and upward into the vertical plate. In the fetus the horizontal plate is much larger than the vertical, and even after it is fully ossified the whole bone is remarkable for its shortness.

Articulations.—With *six* bones—the sphenoid, ethmoid, maxilla, turbinated, vomer, and opposite palate.

Attachment of Muscles.—To *four*—the Tensor palati, Azygos uvulae, Internal pterygoid, and Superior constrictor of the pharynx.

The Turbinated Bone (Concha Nasalis Inferior).

The **turbinated bones** are situated one on each side of the outer wall of each nasal fossa. Each consists of a layer of thin, spongy bone, curled upon itself like a scroll—hence its name “turbinated”—and extends horizontally along the outer wall of the nasal fossa, immediately below the orifice of the antrum (Fig. 81). Each bone presents two surfaces, two borders, and two extremities.

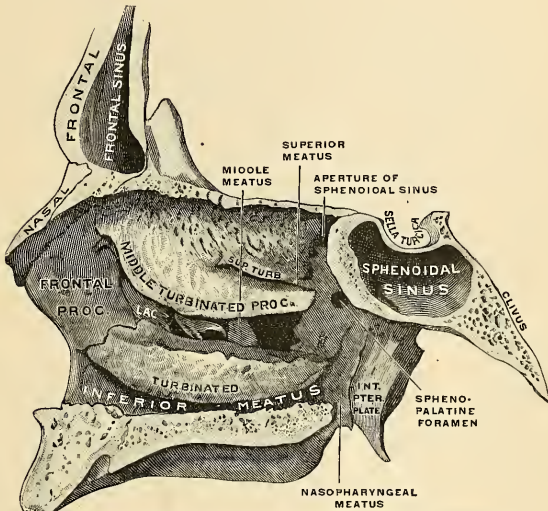


FIG. 81.—Nasal cavity, right lateral wall, from the left. (Spalteholz.)

Surfaces.—The **internal surface** (Fig. 82) is convex, perforated by numerous apertures, and traversed by longitudinal grooves and canals for the lodgement of arteries and veins. In the recent state it is covered by the lining membrane of the nose. The **external surface** is concave (Fig. 83), and forms part of the inferior meatus.

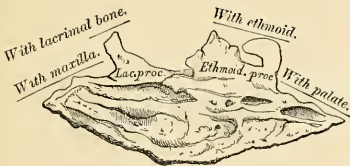


FIG. 82.—Right turbinate bone. Internal surface.

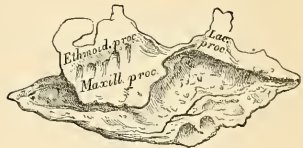

FIG. 83.—Right turbinate bone. External surface.

Borders.—Its **upper border** is thin, irregular, and connected to various bones along the outer wall of the nose. It may be divided into three portions; of these, the anterior articulates with the inferior turbinate crest of the maxilla; the posterior with the inferior turbinate crest of the palate bone; the middle portion of the

superior border presents three well-marked processes, which vary much in their size and form. Of these, the anterior and smallest is situated at the junction of the anterior fourth with the posterior three-fourths of the bone; it is small and pointed, and is called the **lacrimal process** (*processus lacrimalis*); it articulates by its apex with the anterior inferior angle of the lacrimal bone, and by its margins with the groove on the back of the nasal process of the maxilla, and thus assists in forming the canal for the nasal duct. At the junction of the two middle fourths of the bone, but encroaching on its posterior fourth, a broad, thin plate, the **ethmoidal process** (*processus ethmoidalis*), ascends to join the unciform process of the ethmoid; from the lower border of this process a thin lamina of bone curves downward and outward, hooking over the lower edge of the orifice of the antrum, which it narrows below; it is called the **maxillary process** (*processus maxillaris*), and fixes the bone firmly to the outer wall of the nasal fossa. The **inferior border** is free and thick, more especially in the middle of the bone. Both **extremities** are more or less narrow and pointed, the posterior being the more tapering. If the bone is held so that its outer concave surface is directed backward (*i. e.*, toward the holder), and its superior border, from which the lacrimal and ethmoidal processes project, upward, the lacrimal process will be directed to the side to which the bone belongs.¹

Development.—From a *single* centre, which makes its appearance about the middle of fetal life in the outer wall of the cartilaginous nasal septum.

Articulations.—With *four* bones—one of the cerebral cranium, the ethmoid, and three of the face, the maxilla, lacrimal, and palate.

No muscles are attached to this bone.

The Vomer.

The **vomer** is a single bone, situated vertically at the back part of the nasal fossæ, forming part of the septum of the nose (Fig 84). It is thin, somewhat like a ploughshare in form; but varies in different individuals, being frequently bent to one or the other side; it presents for examination two surfaces and four borders.

Surfaces.—The **lateral surfaces** are smooth, marked by small furrows for the lodgement of bloodvessels, and by a groove on each side, sometimes a canal, the **nasopalatine groove**, or **canal**, which runs obliquely downward and forward to the intermaxillary suture; it transmits the nasopalatine nerve.

Borders.—The **superior border**, the thickest, presents a deep groove, bounded on each side by a horizontal projecting leaf of bone; these leaves are the **alæ** (*alæ vomeris*). The groove formed by the alæ receives the rostrum of the sphenoid, while the alæ are overlapped and retained by the vaginal processes, which project on the under surface of the body of the sphenoid at the base of the pterygoid processes. At the front of the groove a fissure is left for the transmission of bloodvessels to the substance of the bone. The **inferior border**, the longest, is broad and uneven in front, where it articulates with the crests of the two maxillæ; thin and sharp behind, where it joins with the palate bones. The upper half of the **anterior border** usually consists of two laminae of bone, in the groove between which is received the perpendicular plate of the ethmoid; the lower half, also separated into two lamellæ, receives between them the lower margin of the septal cartilage of the nose. The **posterior border** is free, concave, and separates the nasal fossæ behind. It is thick and bifid above, thin below.

The surfaces of the vomer are covered by mucous membrane, which is intimately connected with the periosteum, with the intervention of very little, if any, submucous connective tissue.

¹If the lacrimal process is broken off, as is often the case, the side to which the bone belongs may be known by recollecting that the maxillary process is nearer the back than the front of the bone.

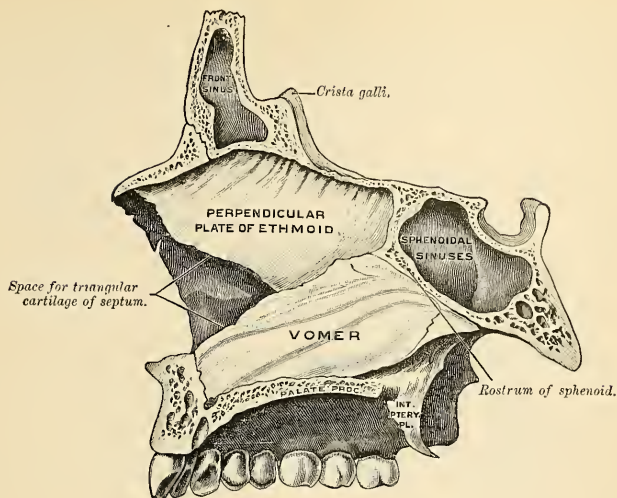


FIG. 84.—Vomer in situ.

Development.—The vomer at an early period consists of two laminae, separated by a very considerable interval, and enclosing between them a plate of cartilage, the **vomerine cartilage**, which is prolonged forward to form the remainder of the septum. Ossification commences, about the eighth week, in the membrane at the postero-inferior part of this cartilage from *two* centres, one on each side of the middle line, which extend to form the two laminae. The intervening cartilaginous plate is absorbed. They begin to coalesce at the lower part, but their union is not complete until after puberty.

Articulations.—With *six* bones—two of the cerebral cranium, the sphenoid and ethmoid, and four of the face, the maxillae and the two palate bones; and with the cartilage of the septum. The vomer has *no* muscles attached to it.

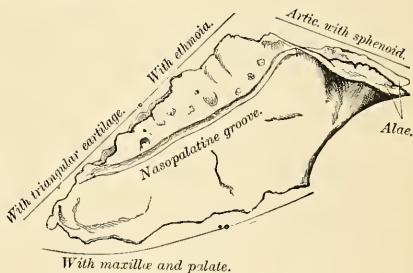


FIG. 85.—The vomer.

The Mandible, or Lower Jaw (Mandibula).

The **mandible**, the largest and strongest bone of the face, serves for the reception of the lower teeth. It consists of a curved, horizontal portion, the **body**, and two perpendicular portions, the **rami**, which join the back part of the body nearly at right angles.

The Body (*corpus mandibulae*) (Fig. 86).—The body is convex in its general outline, and curved somewhat like a horseshoe. It presents for examination two surfaces and two borders.

Surfaces.—The **external surface** is convex from side to side, concave from above downward. In the median line is a vertical ridge, the **symphysis**, which extends

from the upper to the lower border of the bone, and indicates the point of junction of the two pieces of which the bone is composed at an early period of life. The lower part of the ridge terminates in a prominent triangular eminence, the **mental process** (*protuberantia mentalis*). This eminence is rounded below, and often

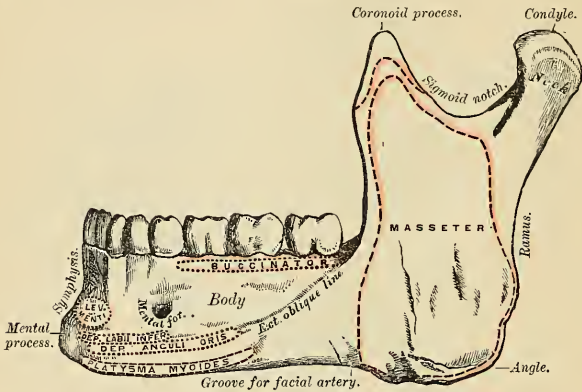


FIG. 86.—The mandible. Outer surface. Side view.

presents a median depression separating two processes, the **mental tubercles** (*tubercula mentalia*). It forms the chin, a feature peculiar to the human skull. On either side of the symphysis, just below the cavities for the incisor teeth, is a depression, the **incisor fossa**, for the attachment of the Levator menti; more externally is

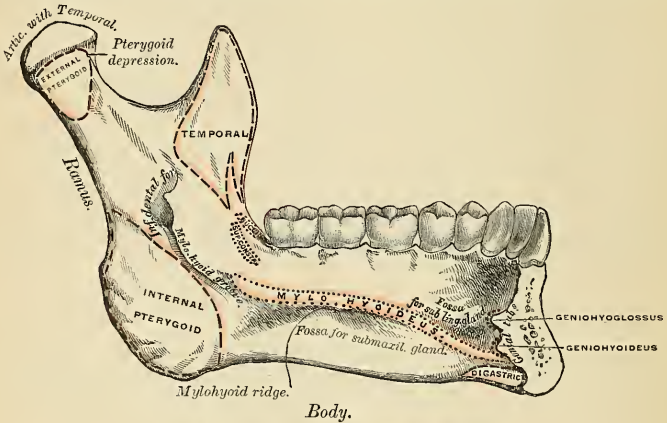


FIG. 87.—The mandible. Inner surface. Side view.

attached a portion of the Orbicularis oris, and still more externally, a foramen, the **mental foramen** (*foramen mentale*), for the passage of the mental vessels and nerve. This foramen is placed just below the interval between the two bicuspid teeth. Running outward from the base of the mental process on each side is a

ridge, the **external oblique line** (*linea obliqua*). The ridge is at first nearly horizontal, but afterward inclines upward and backward, and is continuous with the anterior border of the ramus; it affords attachment to the Depressor labii inferioris and Depressor anguli oris; below it the Platysma is attached.

The **internal surface** (Fig. 87) is concave from side to side, convex from above downward. In the middle line is an indistinct linear depression, corresponding to the symphysis externally; on either side of this depression, just below its centre, are two prominent tubercles, one above and one below, the **genial tubercles** (*spinæ mentales*), which afford attachment, the upper pair to the Geniohyoglossi, the lower pair to the Geniohyoidei, muscles. Sometimes the tubercles on each side are blended into one; at others they all unite into an irregular eminence; or, again, nothing but an irregularity may be seen on the surface of the bone at this part. On either side of the genial tubercles is an oval depression, the **sublingual fossa** (*fovea sublingualis*), for the lodgement of the sublingual gland; and beneath the fossa a rough depression, the **digastric fossa** (*fossa digastrica*), on each side, which gives attachment to the anterior belly of the Digastric muscle.

At the back part of the sublingual fossa the **internal oblique line**, or **mylohyoid ridge** (*linea mylohyoidea*), commences; it is at first faintly marked, but becomes more distinct as it passes upward and outward, and is especially prominent opposite the last two molar teeth; it affords attachment throughout its whole extent to the Mylohyoid muscle; the Superior constrictor of the pharynx with the pterygomandibular ligament being attached above its posterior extremity, near the alveolar margin. The portion of the bone above this ridge is smooth and covered by the mucous membrane of the mouth; the portion below presents an oblong depression, the **submaxillary fossa** (*fovea submaxillaris*), wider behind than in front, for the lodgment of the submaxillary gland. The external and internal oblique lines divide the body of the bone into a superior or alveolar and an inferior or basilar portion.

Borders.—The superior or alveolar portion of the body (*pars alveolaris*) has above a narrow border which is wider and the margins of which are thicker behind than in front. It is hollowed into numerous cavities (*alveoli dentales*), for the reception of the teeth; these cavities are sixteen in number, and vary in depth and size according to the teeth which they contain. To the outer side of the alveolar border the Buccinator muscle is attached as far forward as the first molar tooth. The inferior or basilar portion (*basis mandibulae*) is rounded, longer than the superior and thicker in front than behind; it presents a shallow groove, just where the body joins the ramus, over which the facial artery turns.

The Perpendicular Portions or Rami (*rami mandibulae*).—The perpendicular portions or rami are of a quadrilateral form. Each presents for examination two surfaces, four borders, and two processes.

Surfaces.—The **external surface** is flat, marked with ridges, and gives attachment throughout nearly the whole of its extent to the Masseter muscle.

The **internal surface** presents about its centre an **oblique foramen** (*foramen mandibulare*), the beginning of the **inferior dental canal**, which transmits the inferior dental vessels and nerve. The margin of this opening is irregular; it presents in front a prominent ridge, surmounted by a sharp spine, the **lingula** (*lingula mandibulae*), which gives attachment to the internal lateral ligament of the mandible, and at its lower and back part a notch leading to a groove, the **mylohyoidean groove** (*sulcus mylohyoideus*), which runs obliquely downward to the back part of the submaxillary fossa, and lodges the mylohyoid vessels and nerve. Behind the groove is a rough surface, for the insertion of the Internal pterygoid muscle. The **inferior dental canal** (*canalis mandibulae*) runs obliquely downward and forward in the substance of the ramus, and then horizontally forward in the body; it is here placed under the alveoli, with which it communicates by small

openings. On arriving at the incisor teeth, it turns back to communicate with the mental foramen, giving off two small canals, which run forward, to be lost in the cancellous tissue of the bone beneath the incisor teeth. This canal, in the posterior two-thirds of the bone, is situated nearer the internal surface of the jaw; and in the anterior third, nearer its external surface. Its walls are composed of compact tissue at either extremity, and of cancellous in the centre. It contains the inferior dental vessels and nerve, from which branches are distributed to the teeth through small apertures at the bases of the alveoli.

Borders.—The **lower border** of the ramus is thick, straight, and continuous with the body of the bone. At its junction with the posterior border is the **angle of the jaw** (*angulus mandibulae*). The angle is either inverted or everted, and marked by rough, oblique ridges on each side, for the attachment of the Masseter externally and the Internal pterygoid internally; the stylomaxillary ligament is attached to the angle between these muscles. The **anterior border** is thin above, thicker below, and continuous with the external oblique line. The **posterior border** is thick, smooth, rounded, and covered by the parotid gland. The **upper border** of the ramus is thin, and presents two processes, separated by a deep concavity, the **sigmoid notch**. Of these processes, the anterior is the **coronoid**, the posterior, the **condyloid**.

The **coronoid process** (*processus coronoidcus*) is a thin, flat, triangular eminence, which varies in shape and size. Its anterior border is convex, and is continuous below with the anterior border of the ramus; its posterior border is concave, and forms the anterior boundary of the sigmoid notch. Its *external surface* is smooth, and affords attachment to the Temporal and Masseter muscles. Its *internal surface* gives insertion to the Temporal muscle, and presents a ridge which begins near the apex of the process and runs downward and forward to the inner side of the last molar tooth. Between this ridge and the anterior border is a grooved triangular area, the upper part of which gives attachment to the Temporal, the lower part to some fibres of the Buccinator.

The **condyloid process** (*processus condyloideus*), shorter but thicker than the coronoid, consists of two portions, the **condyle** (*capitulum mandibulae*), and the constricted portion which supports the condyle, the **neck** (*collum mandibulae*). The condyle is of an oblong form, its long axis being transverse, and set obliquely on the neck in such a manner that its outer end is a little more forward and a little higher than its inner. It is convex from before backward and from side to side, the articular surface extending farther on the posterior than on the anterior aspect. At its outer extremity is a small tubercle for the attachment of the external lateral ligament of the temporomandibular joint. The neck of the condyle is flattened from before backward, and strengthened by ridges which descend from the fore part and sides of the condyle. Its lateral margins are narrow, the external one giving attachment to part of the external lateral ligament. Its posterior surface is convex; its anterior is hollowed out on its inner side by a depression, the **pterygoid depression** (*fovea pterygoidea*), for the attachment of the External pterygoid muscle.

The **sigmoid notch** (*incisura mandibulae*), separating the two processes, is a deep semilunar depression, crossed by the masseteric vessels and nerve.

Development.—The mandible is ossified in the fibrous membrane covering the outer surfaces of Meckel's cartilages. These cartilages, one on either side, form the cartilaginous bar of the mandibular arch, being joined at the symphysis by mesodermal tissue. The proximal end of each cartilage is connected with the periotic capsule, and here serves to form the malleus and incus. The next succeeding portion as far as the lingula is replaced by fibrous tissue to form the sphenomandibular ligament. Between the lingula and the canine tooth the cartilage disappears, while the portion near the symphysis becomes ossified and incorporated with the incisor division of the mandible. This ossific centre appears in about the sixth week of fetal life—*i. e.*, earlier than in any other bone except the clavicle; ossification is practically complete by the tenth

week. Accessory nuclei develop to form the condyle and the coronoid process, in the front part of both alveolar walls and along the front of the lower border of the bone.

These accessory nuclei possess no separate ossific centres, but ossification extends into them from the adjacent membrane bone and they undergo absorption. The inner alveolar border, usually described as arising from a separate ossific centre (*splénial centre*), is formed in the human mandible by an ingrowth from the main mass of the bone. At birth the bone consists of two halves, united by a fibrous symphysis, in which ossification takes place during the first year.

Articulation.—With the glenoid fosse of the two temporal bones.

Attachment of Muscles.—To *fifteen pairs*—to its external surface, commencing at the symphysis, and proceeding backward: Levator menti, Depressor labii inferioris, Depressor anguli oris, Platysma, Buccinator, Masseter; a portion of the Orbicularis oris is also attached to this surface. To its internal surface, commencing at the same point: Geniohyoglossus, Geniohyoid, Mylohyoid, Digastric, Superior constrictor, Temporal, Internal pterygoid, External pterygoid.

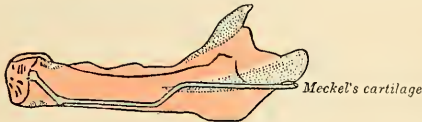

FIG. 88.—Scheme showing ossification of the mandible, inner side (Low). The membrane bone is colored red. The greater part of Meckel's cartilage is colored blue. The upturned, stippled portion near the symphysis represents the part of Meckel's cartilage, which is surrounded and invaded by the membrane bone. The accessory nuclei of cartilage in the condyle, coronoid process, alveolar border, and body are indicated by stippled areas.

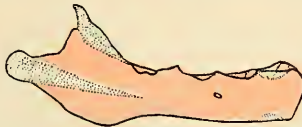

FIG. 89.—Scheme showing ossification of mandible from the outer side (Low). Membrane bone colored red. Accessory nuclei of cartilage stippled.

CHANGES PRODUCED IN THE MANDIBLE BY AGE.

The changes which the mandible undergoes after birth relate (1) to the alterations effected in the body of the bone by the first and second dentitions, the loss of the teeth in the aged, and the subsequent absorption of the alveoli; (2) to the size and situation of the dental canal; and (3) to the angle at which the ramus joins with the body.

At birth (Fig. 90) the bone consists of lateral halves, united by fibrous tissue. The body is a mere shell of bone, containing the sockets of the two incisor, the canine, and the two temporary molar teeth, imperfectly partitioned from one another. The dental canal is of large size, and runs near the lower border of the bone, the mental foramen opening beneath the socket of the first molar. The angle is obtuse (175 degrees), and the condyloid portion nearly in the same horizontal line with the body; the neck of the condyle is short, and bent backward. The coronoid process is of comparatively large size, and situated at right angles with the rest of the bone.

SIDE VIEW OF THE MANDIBLE AT DIFFERENT PERIODS OF LIFE.

After birth (Fig. 91) the two segments of the bone become joined at the symphysis, from below upward, in the first year; but a trace of separation may be visible in the beginning of the second year near the alveolar margin. The body becomes elongated in its whole length, but more especially behind the mental foramen, to provide space for the three additional teeth developed in this part. The depth of the body becomes greater, owing to increased growth of the alveolar part, to afford room for the fangs of the teeth, and by thickening of the submental portion, which enables the jaw to withstand the powerful action of the masticatory muscles; but the alveolar portion is the deeper of the two, and, consequently, the chief part of the body lies above the oblique line. The dental canal after the second dentition is situated just above the level of the mylohyoid ridge, and the mental foramen occupies the position usual to it in the adult. The angle becomes less obtuse, owing to the separation of the jaws by the teeth. (About the fourth year it is 140 degrees.)

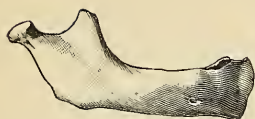


FIG. 90.—Mandible in newborn.

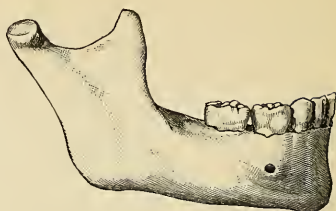


FIG. 91.—In child six to seven years of age.

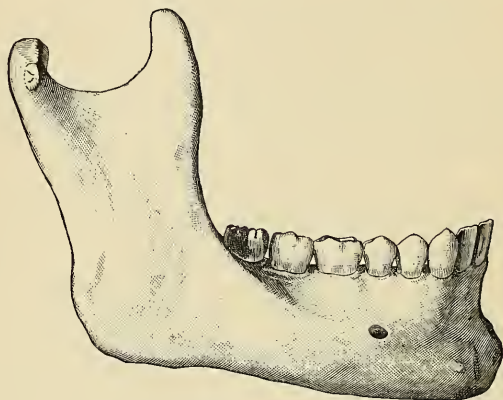


FIG. 92.—In the adult.

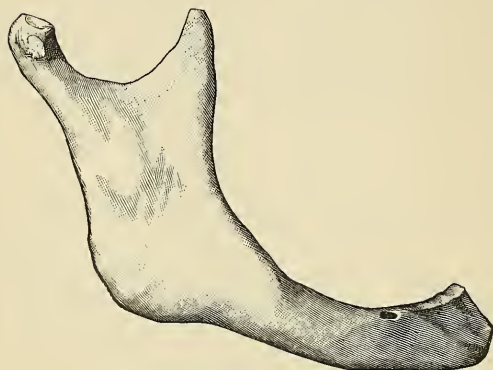

FIG. 93.—In old age. (Spalteholz.)

In the adult (Fig. 92) the alveolar and basilar portions of the body are usually of equal depth. The mental foramen opens midway between the upper and lower border of the bone, and the dental canal runs nearly parallel with the mylohyoid line. The ramus is almost vertical in direction, and joins the body nearly at right angles.

In old age (Fig. 93) the bone becomes greatly reduced in size; for with the loss of the teeth the alveolar process is absorbed, and the basilar part of the bone alone remains, consequently, the chief part of the bone is *below* the oblique line. The dental canal, with the mental foramen opening from it, is close to the alveolar border. The rami are oblique in direction, the angle obtuse, and the neck of the condyle more or less bent backward.

The Sutures.

The bones of the cerebral cranium and face are connected to each other by means of **sutures**. That is, the articulating surfaces or edges of the bones are more or less **roughened** or uneven, and are closely adapted to each other, a small amount of intervening fibrous tissue, the **sutural ligament**, fastening them together. The cranial sutures may be divided into three sets: (1) Those at the vertex of the skull. (2) Those at the side of the skull. (3) Those at the base.

The sutures at the vertex of the skull are four—the **metopic**, the **sagittal**, the **coronal**, and the **lambdoid**.

The **metopic** or **frontal suture** (*sutura frontalis*) (Fig. 44) is usually noted in adults as a trivial fissure, just above the glabella. At birth the two halves of the frontal bone are separated by the suture. This suture is, as a rule, almost completely or completely closed during the fifth or sixth year, but occasionally it persists throughout life.

The **interparietal** or **sagittal suture** (*sutura sagittalis*) is formed by the junction of the two parietal bones, and extends from the middle of the frontal bone backward to the superior angle of the occipital. This suture is sometimes perforated, near its posterior extremity, by the parietal foramen; and in front, where it joins the coronal suture, a space is occasionally left which encloses a large Wormian bone.

The **frontoparietal** or **coronal suture** (*sutura coronalis*) (Fig. 99) extends transversely across the vertex of the skull, and connects the frontal with the parietal bones. It commences at the extremity of the greater wing of the sphenoid on one side, and terminates at the same point on the opposite side. The dentations of the suture are more marked at the sides than at the summit, and are so constructed that the frontal rests on the parietal above, while laterally the frontal supports the parietal.

The **occipitoparietal** or **lambdoid suture** (*sutura lambdoidea*) (Fig. 99), so called from its resemblance to the Greek letter Λ , connects the occipital with the parietal bones. It commences on each side at the mastoid portion of the temporal bone, and inclines upward to the end of the sagittal suture. The dentations of this suture are very deep and distinct, and are often interrupted by several small Wormian bones.

The **lateral sutures** (Fig. 99) extend from the external angular process of the frontal bone to the lower end of the lambdoid suture behind. The **anterior portion** is formed between the lateral part of the frontal bone above and the malar and greater wing of the sphenoid below, forming the **frontomalar suture** (*sutura zygomaticofrontalis*) and **frontosphenoidal suture** (*sutura sphenofrontalis*). These sutures can also be seen in the orbit, and form part of the so-called **transverse facial suture**. The **posterior portion** is formed between the parietal bone above and the greater wing of the sphenoid, the squamous and mastoid portions of the temporal bone below, forming the **sphenoparietal**, **squamoparietal**, and **mastoparietal sutures**.

The **sphenoparietal** (*sutura sphenoparietalis*) is very short; it is formed by the tip of the greater wing of the sphenoid, which overlaps the anterior inferior angle of the parietal bone.

The **squamoparietal** (*sutura squamosa*) is arched, and is formed by the squamous portion of the temporal bone overlapping the middle division of the lower border of the parietal.

The **mastoparietal** (*sutura parietomastoidea*), a short suture, deeply dentated, is formed by the posterior inferior angle of the parietal and the superior border of the mastoid portion of the temporal.

The sutures at the base of the skull (Fig. 98) are the basilar in the centre, and on each side the petro-occipital, the masto-occipital, the petrosphenoidal, and the squamosphenoidal.

The **basilar suture** (*fissura sphenoccipitalis*) is formed by the junction of the basilar surface of the occipital bone with the posterior surface of the body of the sphenoid. At an early period of life a thin plate of cartilage exists between these bones, but in the adult they become fused into one (*synchondrosis sphenoccipitalis*). Between the outer extremity of the basilar suture and the termination of the lambdoid an irregular suture exists, which is subdivided into two portions. The inner portion, formed by the union of the petrous part of the temporal with the occipital bone, is termed the **petro-occipital fissure** (*fissura petrooccipitalis*). The outer portion, formed by the junction of the mastoid part of the temporal with the occipital, is called the **masto-occipital suture** (*sutura occipitomastoidea*). Between the bones forming the petro-occipital suture a thin plate of cartilage exists; in the masto-occipital is occasionally found the opening of the mastoid foramen. Between the outer extremity of the basilar suture and the sphenoparietal an irregular suture may be seen, formed by the union of the sphenoid with the temporal bone. The inner and smaller portion of this suture is termed the **petrosphenoidal fissure** (*fissura sphenopetrosa*); it is formed between the petrous portion of the temporal and the greater wing of the sphenoid; the outer portion, of greater length and arched, is formed between the squamous portion of the temporal and the greater wing of the sphenoid; it is called the **squamosphenoidal suture** (*sutura sphenosquamosa*).

The bones of the cerebral cranium are connected with those of the face, and the facial bones with each other, by numerous sutures, which, though distinctly marked, have received no special names. The only remaining suture deserving especial consideration is the **transverse suture**. This extends across the upper part of the face, and is formed by the junction of the frontal with the facial bones; it extends from the external angular process of one side to the same point on the opposite side, and connects the frontal with the malar, the sphenoid, the ethmoid, the lacrimal, the maxillæ, and the nasal bones on each side (*sutura zygomatico-frontalis*; the orbital portion of the *sutura sphenofrontalis*, *sutura frontoethmoidalis*, *sutura frontolacrimalis*, *sutura frontomaxillaris*, *sutura nasofrontalis*).

The sutures remain separate for a considerable period after the complete formation of the skull. It is probable that they serve the purpose of permitting the growth of the bones at their margins, while their peculiar formation, together with the interposition of the sutural ligament between the bones forming them, prevents the dispersion of blows or jars received upon the skull. Humphry remarks, "that, as a general rule, the sutures are first obliterated at the parts in which the ossification of the skull was last completed—viz., in the neighborhood of the fontanelles; and the cranial bones seem in this respect to observe a similar law to that which regulates the union of the epiphyses to the shafts of the long bones." The same author remarks that the time of their disappearance is extremely variable; they are sometimes found well marked in skulls edentulous with age, while in others which have only just reached maturity they can hardly

be traced. The obliteration of the sutures takes place sooner on the inner than on the outer surface of the skull. The sagittal and coronal sutures are, as a rule, the first to become ossified—the process starting near the posterior extremity of the former and the lower ends of the latter.

THE SKULL AS A WHOLE.

The **skull**, formed by the union of the several cranial and facial bones already described, when considered as a whole is divisible into five regions—a superior region or **vertex**, an inferior region or **base**, two **lateral regions**, and an anterior region, the **face**.

The Vertex of the Skull.—The **superior region**, or **vertex**, presents two surfaces, an external and an internal.

Surfaces.—The **external surface** (*norma verticalis*) is bounded, in *front*, by the glabella and superciliary ridges; *behind*, by the occipital protuberance and superior curved lines of the occipital bone; *laterally*, by an imaginary line extending from the outer end of the superior curved line, along the temporal ridge, to the external angular process of the frontal bone. This surface includes the greater part of the vertical portion of the frontal, the greater part of the parietal, and the superior third of the occipital bone; it is smooth, convex, of an elongated oval form, crossed transversely by the coronal suture, and from before backward by the sagittal, which terminates behind in the lambdoid. The point of junction of the coronal and sagittal sutures is named the **bregma**. The point of junction of the sagittal and lambdoid sutures is called the **lambda**, and is about $2\frac{3}{4}$ inches (7 cm.) above the external occipital protuberance. From before backward may be seen the frontal eminences and remains of the suture connecting the two lateral halves of the frontal bone; on each side of the sagittal suture are the parietal foramen and parietal eminence, and still more posteriorly the convex surface of the occipital bone. In the neighborhood of the parietal foramen the skull is often flattened, and the name of **obelion** is sometimes given to that point of the sagittal suture which lies exactly opposite to the parietal foramen.

The **internal** or **cerebral surface** is concave, presents depressions for the convolutions of the cerebrum, and numerous furrows for the lodgement of branches of the meningeal arteries. Along the middle line of this surface is a longitudinal groove, narrow in front, where it commences at the frontal crest, but broader behind, where it lodges the superior longitudinal sinus, and by its margin affords attachment to the falx cerebri. On either side of it are several depressions for the arachnoid villi, and at its back part the internal openings of the parietal foramina. This surface is crossed, in front, by the coronal suture; from before backward by the sagittal; behind, by the lambdoid.

The Base of the Skull (the Skull being without the Mandible).—The inferior region, or base of the skull, presents two surfaces—an internal or cerebral, and an external or basilar.

Surfaces.—The **internal** or **cerebral surface** (Fig. 94) presents three fossæ, called the anterior, middle, and posterior fossæ of the cranium.

The **anterior fossa** (*fossa cranii anterior*) (Fig. 94) is formed by the orbital plates of the frontal, the cribriform plate of the ethmoid, the anterior third of the superior surface of the body, and the upper surface of the lesser wings of the sphenoid bone, and is situated at a higher level than the other fossæ. It is the most elevated of the three fossæ, convex externally where it corresponds to the roof of the orbit, concave in the median line in the situation of the cribriform plate of the ethmoid. It is traversed on either side by three sutures, the ethmoidfrontal, ethmosphenoidal, and frontosphenoidal, and lodges the frontal lobes of the cerebrum. It presents,

in the median line, from before backward, the commencement of the groove for the superior sagittal sinus and the frontal crest for the attachment of the falx cerebri;

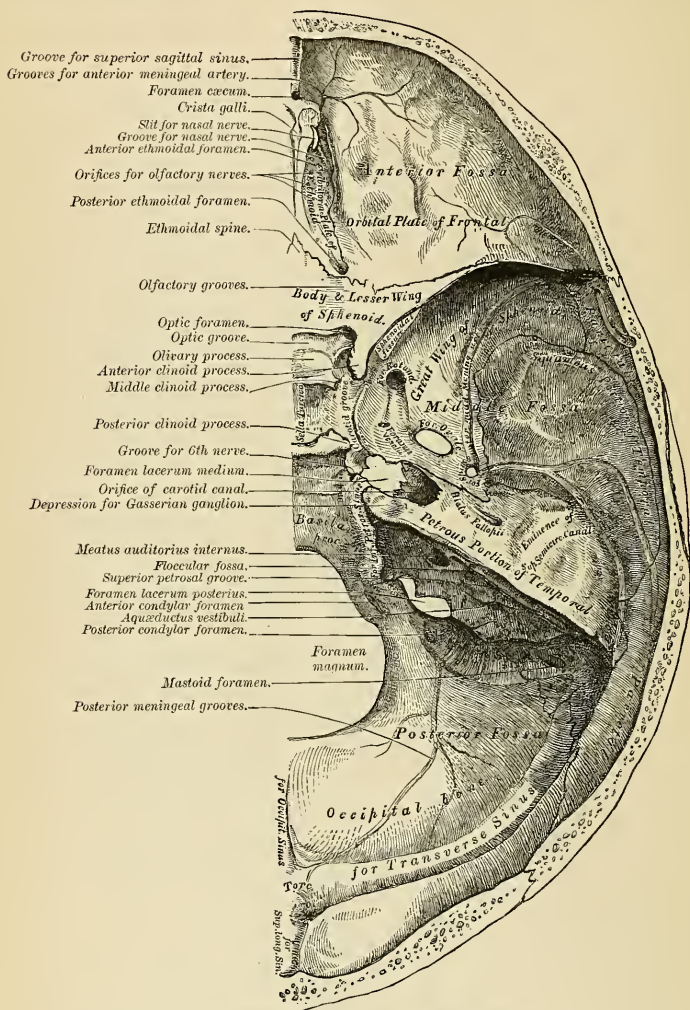


FIG. 94.—Base of the skull. Inner or cerebral surface.

the foramen cecum, an aperture formed between the frontal bone and the crista galli of the ethmoid, which, if pervious, transmits a small vein from the nose to the sagittal sinus; behind the foramen cecum, the crista galli, the posterior mar-

gin of which affords attachment to the falx cerebri; on either side of the crista galli, the **cribriform plate**, which supports the olfactory bulb, and presents three rows of foramina for the transmission of its nerve filaments, and in front a slit-like opening (*nasal slit*) for the nasal branch of the ophthalmic division of the trigeminal nerve. On the outer side of each olfactory groove are the internal openings of the anterior and posterior ethmoidal foramina, the former situated about the middle of the outer margin of the olfactory groove. The anterior ethmoidal foramen transmits the anterior ethmoidal vessels and the nasal nerve, which latter runs in a depression along the surface of the ethmoid to the slit-like opening above mentioned; while the posterior ethmoidal foramen opens at the back part of this margin under cover of the projecting lamina of the sphenoid, and transmits the posterior ethmoidal vessels. Farther back in the middle line is the **ethmoidal spine**, bounded behind by a slight elevation, separating two shallow longi-

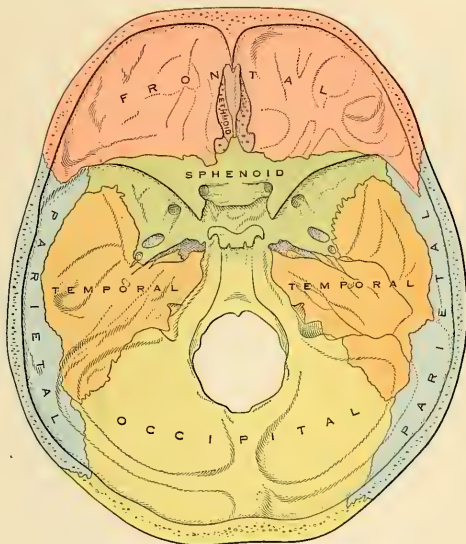


FIG. 95.—Base of the skull. Interior view.

tudinal grooves which support the olfactory lobes. Behind this is a transverse sharp ridge, running outward on either side to the anterior margin of the optic foramen, and separating the anterior from the middle fossa of the base of the skull. The anterior fossa presents, laterally, depressions for the convolutions of the cerebrum and grooves for the lodgement of the anterior meningeal arteries.

The **middle fossa** (*fossa cranii media*) (Fig. 94), deeper than the preceding, is narrow in the middle line, but becomes wider at the side of the skull. It is bounded in *front* by the posterior margin of the lesser wings of the sphenoid, the anterior clinoid processes, and the ridge forming the anterior margin of the optic groove; *behind*, by the superior border and anterior surface of the petrous portions of the temporal and the dorsum sellæ; *externally*, by the squamous portions of the temporal and the anterior inferior angle of the parietal bones and greater wings of the sphenoid. On each side it is traversed by four sutures, the squamoparietal, sphenoparietal,

squamosphenoidal, and petrosphenoidal. In the middle line, from before backward, is the **optic groove**, which supports the optic commissure; the groove terminates on each side in the **optic foramen**, for the passage of the optic nerve and ophthalmic artery; behind the optic groove is the **olivary process** and laterally the **anterior clinoid processes**, to which are attached processes of the tentorium cerebelli. Farther back is the **sella turcica**, a deep depression which lodges the hypophysis and circular sinus, bounded in front by a small eminence on either side, the **middle clinoid process**, and behind by a broad, square plate of bone, the **dorsum sellae**, surmounted at each superior angle by a tubercle, the **posterior clinoid process**; beneath the latter process is a notch, for the abducent nerve. On each side of the sella turcica is the **carotid groove**; it is broad, shallow, and curved somewhat like the italic letter *f*; it commences behind at the foramen lacerum medium, and

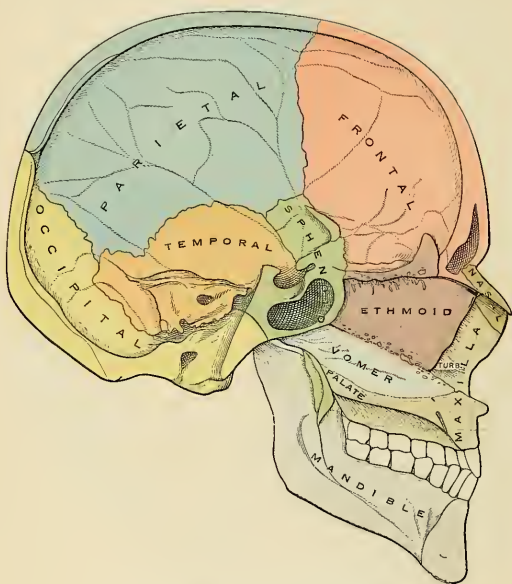


FIG. 96.—Median sagittal section of the skull.

terminates on the inner side of the anterior clinoid process, and presents along its outer margin a ridge of bone, the **lingula**. This groove lodges the cavernous sinus, the internal carotid artery, and the nerves which enter the orbit. The sides of the middle fossa are of considerable depth; they present depressions for the convolutions of the cerebrum and grooves for the branches of the middle meningeal artery; the latter commence on the outer side of the foramen spinosum, and consist of two large branches, an anterior and a posterior; the former passing upward and forward to the anterior inferior angle of the parietal bone, the latter passing upward and backward. The following foramina may also be seen on either side from before backward. Most anteriorly is seen the **sphenoidal fissure** (*foramen lacerum anterius*), formed above by the lesser wing of the sphenoid; below, by the greater wing; internally, by the body of the sphenoid; and some-

times completed externally by the orbital plate of the frontal bone. It transmits the third, the fourth, the three branches of the ophthalmic division of the trigeminal, the abducent nerve, some filaments from the cavernous plexus of the sympathetics, the orbital branch of the middle meningeal artery, a recurrent branch from the lacrimal artery to the dura, and the ophthalmic vein. Behind the inner extremity of the sphenoidal fissure is the **foramen rotundum**, for the passage of the second division of the trigeminal nerve; still more posteriorly is seen a small orifice, the **foramen Vesalii**, an opening situated between the foramen rotundum and the foramen ovale, a little internal to both; it varies in size in different individuals, and is often absent; when present it transmits a small vein and opens below into the outer side of the scaphoid fossa. Behind and external to the latter opening is the **foramen ovale**, which transmits the third division of the trigeminal nerve, the small meningeal artery, and sometimes the small petrosal nerve. On the outer side of the foramen ovale is the **foramen spinosum**, for the passage of the middle meningeal artery; occasionally a small foramen (*canaliculus innominatus*) for the transmission of the small superficial petrosal nerve is seen internal to the foramen spinosum. On the inner side of the foramen ovale is the **foramen lacerum medium** (*foramen lacerum*); the lower part of this aperture is filled in the recent state with cartilage which is pierced by the Vidian nerve and a meningeal branch from the ascending pharyngeal artery. On the anterior surface of the petrous portion of the temporal bone is seen, from without inward, the eminence caused by the projection of the superior semicircular canal; in front of and a little outside this is a depression, the **tegmen tympani**, corresponding to the roof of the tympanum; the groove leading to the hiatus Fallopii, for the transmission of the greater petrosal nerve and the petrosal branch of the middle meningeal artery; beneath it, a smaller groove, for the passage of the lesser petrosal nerve; and, near the apex of the bone, the depression for the Gasserian ganglion; and the internal orifice of the carotid canal, for the passage of the internal carotid artery and carotid plexus of nerves.

The **posterior fossa** (*fossa cranii posterior*), deeply concave, is the largest of the three, and situated on a lower level than either of the preceding. It is formed by the posterior third of the superior surface of the body of the sphenoid, by the occipital, the posterior surface of the petrous and the mastoid portions of the temporal, and the posterior inferior angle of the parietal bones; it is crossed on either side by four sutures, the petro-occipital, the masto-occipital, the mastoparietal, and the basilar; and lodges the cerebellum, pons, and medulla oblongata. It is separated from the middle fossa in the median line by the dorsum sellæ, and on each side by the superior border of the petrous portion of the temporal bone. This border serves for the attachment of the tentorium cerebelli, is grooved for the superior petrosal sinus, and at its inner extremity presents a notch, in which rests the trigeminal nerve. The circumference of the fossa is bounded posteriorly by the grooves for the lateral (transverse) sinuses. In the centre of this fossa is the **foramen magnum**, bounded on either side by a rough tubercle, which gives attachment to the odontoid or cheek ligaments; and a little above these are seen the internal openings of the **anterior condylar foramina**, through which pass the hypoglossal nerve and meningeal branches from the ascending pharyngeal arteries. In front of the foramen magnum is a grooved surface, formed by the basilar process of the occipital bone and by the posterior third of the superior surface of the body of the sphenoid, which supports the medulla oblongata and pons; and articulates on each side with the petrous portion of the temporal bone, forming the **petro-occipital suture**, the anterior half of which is grooved for the inferior petrosal sinus, the posterior half being encroached upon by the **foramen lacerum posterius** (*foramen jugulare*). This foramen presents three compartments—through the anterior passes the inferior petrosal sinus; through the posterior, the lateral sinus and some meningeal

branches from the occipital and ascending pharyngeal arteries; and through the middle, the glossopharyngeal, vagus, and spinal accessory nerves. Above the jugular foramen is the **internal auditory meatus**, for the facial and auditory nerves and auditory artery; behind and external to this is the slit-like opening leading into the **aquaeductus vestibuli**, which lodges the ductus endolymphaticus; while between the two latter, and near the superior border of the petrous portion, is a small, triangular depression, the remains of the **floccular fossa**, which lodges a process of the dura and occasionally transmits a small vein from the substance of the bone. Behind the foramen magnum are the **inferior occipital fossæ**, which lodge the hemispheres of the cerebellum, separated from each other by the **internal occipital crest**, which serves for the attachment of the falx cerebelli and lodges the occipital sinus. The posterior fossæ are limited above by the deep transverse grooves for the lodgment of the lateral sinuses, which diverge forward on each side from a depression in the mesal plate, the **torcular**. These channels, in their passage outward, groove the occipital bone, the posterior inferior angles of the parietals, the mastoid portions of the temporals, and the jugular processes of the occipital, and terminate at the back part of the jugular foramen. Where the lateral sinus grooves the mastoid portion of the temporal bone (sigmoid fossa) the orifice of the **mastoid foramen** may be seen. Just previous to the termination of the groove the **posterior condylar foramen** opens into it. Neither foramen is constant.

The **basilar surface** (*norma basalis*) (Fig. 97) of the skull is extremely irregular. It is bounded in front by the incisor teeth in the maxillæ; behind by theinion and the superior curved lines of the occipital bone; and laterally by the alveolar arch, the lower border of the malar bones, the zygoma, and an imaginary line extending from the zygoma to the mastoid process and extremity of the superior curved line of the occiput. It is formed by the palatal processes of the maxillæ and palate bones, the vomer, the pterygoid processes, under surface of the greater wings, spinous processes and part of the body of the sphenoid, the under surface of the squamous, mastoid, and petrous portions of the temporals, and the under surface of the occipital bone. The anterior part of the base of the skull is raised above the level of the rest of this surface (when the skull is turned over for the purpose of examination), is surrounded by the alveolar process, which is thicker behind than in front, and excavated by sixteen depressions for the lodgment of the teeth of the maxillæ, the cavities varying in depth and size according to the teeth they contain. Immediately behind the incisor teeth is the **anterior palatine fossa**. At the bottom of this fossa may usually be seen four apertures, two placed laterally, the **foramina of Stenson**, which open above, one in the floor of each nostril, and transmit the anterior branch of the posterior palatine vessels, and two in the median line in the intermaxillary suture, the **foramina of Scarpa**, one in front of the other, the anterior transmitting the left, and the posterior (the larger) the right, nasopalatine nerve. These two lateral canals are sometimes wanting, or they may join to form a single one, or one of them may open into one of the lateral canals above referred to. The palatine vault is concave, uneven, perforated by numerous foramina, marked by depressions for the palatine glands, and crossed by a crucial suture, formed by the junction of the four bones of which it is composed. At the front part of this surface a delicate linear suture may frequently be seen, passing outward and forward from the anterior palatine fossa to the interval between the lateral incisor and canine teeth, and marking off the **premaxillary portion** of the bone. At each posterior angle of the hard palate is the **posterior palatine foramen**, for the transmission of the posterior palatine vessels and great descending palatine nerve; and running forward and inward from it a groove, for the same vessels and nerve. Behind the posterior palatine foramen is the **tuberosity of the palate bone**, perforated by one or more **accessory posterior palatine canals**, giving passage to the

middle and posterior palatine nerves from the sphenopalatine (Meckel's) ganglion, and marked by the commencement of a ridge which runs transversely inward,

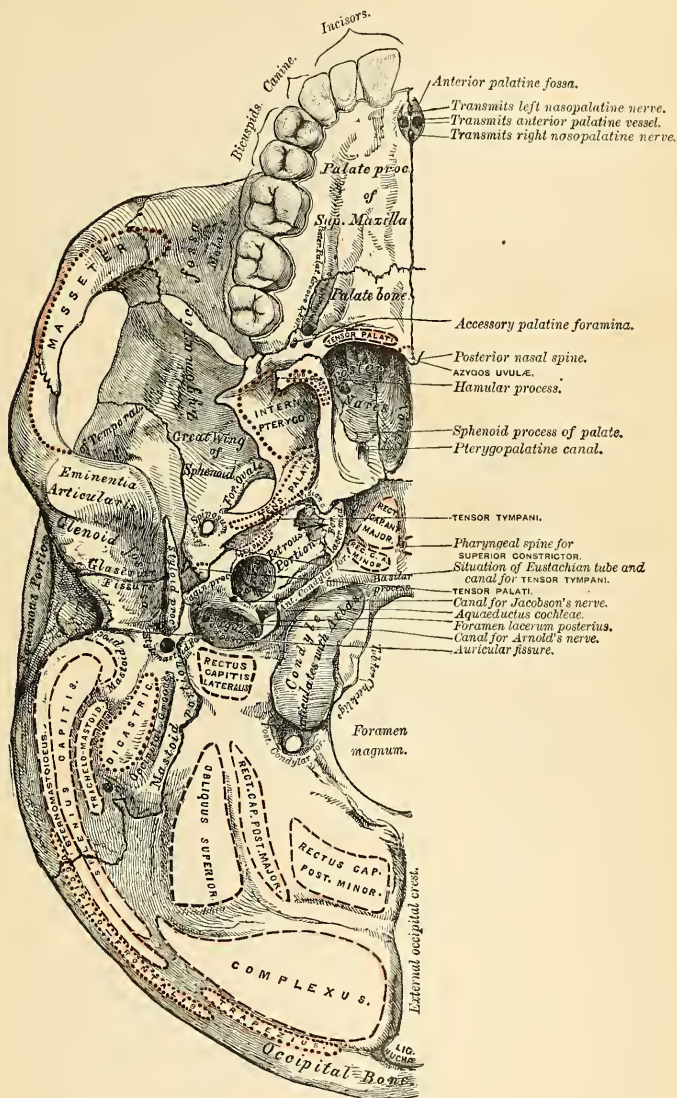


FIG. 97.—Base of the skull. External surface.

and serves for the attachment of the tendinous expansion of the Tensor palati muscle. Projecting backward from the centre of the posterior border of the hard palate is the **posterior nasal spine**, for the attachment of the Azygos uvulae muscle. Behind and above the hard palate is the posterior aperture of the nasal fossæ (choanæ), divided into two parts by the **vomer**, bounded above by the body of the sphenoid, below by the horizontal plate of the palate bone, and laterally by the internal pterygoid plate of the sphenoid. Each aperture measures about an inch in the vertical and about half an inch in the transverse direction. At the base of the vomer may be seen the expanded alæ of this bone, receiving between them the **rostrum of the sphenoid**. Near the lateral margins of the vomer, at the root of the pterygoid processes, are the **pterygopalatine canals**, which transmit the pterygopalatine vessels and the pharyngeal nerve from the sphenopalatine (Meckel's) ganglion. The pterygoid process, which bounds the posterior nares on each side, presents near its base the **pterygoid** or **Vidian canal**, for the Vidian nerve and artery. Each process consists of two plates, which bifurcate at the extremity to receive the tuberosity of the palate bone, and are separated behind by the pterygoid fossa, which lodges the Internal pterygoid muscle. The internal

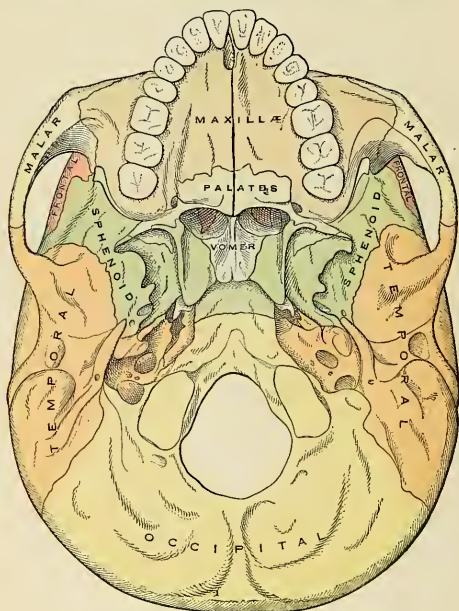


FIG. 98.—Base of the skull. External surface.

plate is long and narrow, presenting on the border of its base the **scaphoid fossa**, for the origin of the Tensor palati muscle, and at its extremity the **hamular process**, around which the tendon of this muscle turns. The external pterygoid plate is broad, forms the inner boundary of the **zygomatic fossa**, and affords attachment by its outer surface to the External pterygoid muscle.

Behind the nasal fossæ in the middle line is the basilar surface of the occipital

bone, presenting in its centre the **pharyngeal spine**, for the attachment of the Superior constrictor muscle of the pharynx, with depressions on each side for the insertion of the Rectus capitis anticus major and minor. At the base of the external pterygoid plate is the **foramen ovale**, for the transmission of the third division of the trigeminal nerve, the small meningeal artery, and sometimes the small petrosal nerve; behind this, the **foramen spinosum**, which transmits the middle meningeal artery, and the prominent spinous process of the sphenoid, which gives attachment to the internal lateral ligament of the mandible and the Tensor palati muscle. External to the spinous process is the **glenoid fossa**, divided into two parts by the Glaserian fissure (page 88), the anterior portion concave, smooth, bounded in front by the **eminentia articularis**, and serving for the articulation of the condyle of the mandible; the posterior portion rough, bounded behind by the **tympanic plate**, and serving for the reception of part of the parotid gland. Emerging from between the laminae of the vaginal process of the tympanic plate is the **styloid process**, and at the base of this process is the **stylo-mastoid foramen**, for the exit of the facial nerve and entrance of the stylo-mastoid artery. External to the stylo-mastoid foramen is the **auricular fissure**, for the exit of the auricular branch of the vagus, bounded behind by the mastoid process. Upon the inner side of the mastoid process is a deep groove, the **digastric fossa**; and a little more internally the **occipital groove**, for the occipital artery. At the base of the internal pterygoid plate is a large and somewhat triangular aperture, the **foramen lacerum medium**, bounded in *front* by the greater wing of the sphenoid, *behind* by the apex of the petrous portion of the temporal bone, and *internally* by the body of the sphenoid and basilar process of the occipital bone; it presents in front the posterior orifice of the Vidian canal; behind, the aperture of the carotid canal. The basilar surface of this opening is filled in the recent state by fibrocartilaginous substance, which is pierced by the Vidian nerve and a meningeal branch of the ascending pharyngeal artery; across its upper or cerebral aspect passes the internal carotid artery. External to this aperture the **petrosphenoidal suture** is observed, at the outer termination of which is seen the orifice of the canal for the Eustachian tube and that for the Tensor tympani muscle. Behind this suture is seen the under surface of the petrous portion of the temporal bone, presenting from within outward, the quadrilateral, rough surface, part of which affords attachment to the Levator palati and Tensor tympani muscles; posterior to this surface is the orifice of the **carotid canal** and the orifice of the **aquaeductus cochleae**, the former transmitting the internal carotid artery and the ascending branches of the superior cervical ganglion of the sympathetic, the latter serving for the passage of a small artery to and a small vein from the cochlea. Behind the carotid canal is a large aperture, the **jugular foramen**, formed in *front* by the petrous portion of the temporal, and *behind* by the occipital; it is generally larger on the right than on the left side, and is divided into three compartments by processes of dura. The anterior is for the passage of the inferior petrosal sinus; the posterior, for the lateral sinus and some meningeal branches from the occipital and ascending pharyngeal arteries; the central one, for the glossopharyngeal, vagus, and spinal accessory nerves. On the ridge of the bone dividing the carotid canal from the jugular foramen is the small foramen for the transmission of Jacobson's nerve (tympanic branch of the glossopharyngeal); and on the wall of the jugular foramen, near the root of the styloid process, is the small aperture for the transmission of the auricular branch of the vagus nerve (Arnold's nerve). Behind the basilar surface of the occipital bone is the **foramen magnum**, bounded on each side by the condyles, rough internally for the attachment of the check ligaments, and presenting externally a rough surface, the **jugular process**, which serves for the attachment of the Rectus capitis lateralis muscle and the lateral occipito-atlantal ligament. The middle of the posterior margin of the foramen magnum is called the **basion**. The mid-point of the posterior margin is called the

opisthion. On either side of each condyle anteriorly is the **anterior condylar fossa**, continued as the **anterior condylar foramen**, for the passage of the hypoglossal nerve and often a meningeal branch of the ascending pharyngeal artery. Behind each condyle is the **posterior condylar fossa**, continued as the **posterior condylar foramen**, for the transmission of a vein to the lateral sinus. Behind the foramen magnum is the **external occipital crest**, terminating above at the **external occipital protuberance**, while on each side are seen the **superior and inferior curved lines**; these, as well as the surfaces of bone between them, are rough for the attachment of the muscles, which are enumerated on pages 70 and 71.

The Lateral Region of the Skull.—The *norma lateralis* is of a somewhat triangular form, the base of the triangle being formed by a line extending from the external angular process of the frontal bone along the temporal ridge backward to the outer extremity of the superior curved line of the occiput; and the sides by two lines, the one drawn downward and backward from the external angular process of the frontal bone to the angle of the mandible, the other from the angle of the mandible upward and backward to the outer extremity of the superior curved line. This region is divisible into three portions—temporal fossa, mastoid portion, and zygomatic or infratemporal fossa.

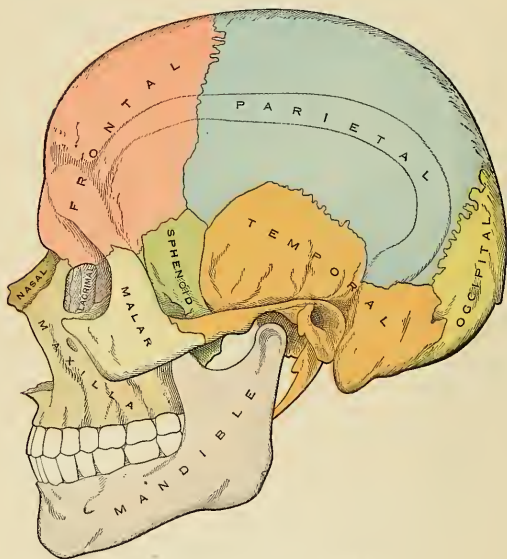


FIG. 99.—Lateral aspect of the skull.

The Temporal Fossa (*fossa temporalis*).—The temporal fossa is bounded above and behind by the temporal ridges, which extend from the external angular process of the frontal upward and backward across the frontal and parietal bones, curving downward behind to terminate in the posterior root of the zygomatic process. In *front* it is bounded by the frontal, malar, and greater wing of the sphenoid; *externally* by the zygomatic arch formed conjointly by the malar and temporal bones; *below*, it is separated from the zygomatic fossa by the **pterygoid ridge**, seen on the outer

surface of the greater wing of the sphenoid. This fossa is formed by five bones, part of the frontal, greater wing of the sphenoid, parietal, squamous portion of the temporal and malar bones, and is traversed by six sutures, part of the frontomalar, sphenomalar, coronal, sphenoparietal, squamoparietal, and squamosphenoidal. The point where the coronal suture crosses the superior temporal ridge is named the **stephanion**; and the region where the four bones, the parietal, the frontal, the squamous portion of the temporal, and the greater wing of the sphenoid, meet, at the anterior inferior angle of the parietal bone, is named the **pterion**. This point is about on a level with the external angular process of the frontal bone and about one and a half inches (3.75 cm.) behind it. This fossa is deeply concave in front, convex behind, traversed by grooves which lodge branches of the deep temporal arteries, and filled by the Temporal muscle.

The Mastoid Portion.—The mastoid portion of the side of the skull is bounded in front by the anterior root of the zygoma; above, by a line which runs from the posterior root of the zygoma to the end of the mastoparietal suture; behind and below by the masto-occipital suture. It is formed by the mastoid and part of the squamous and petrous portions of the temporal bone; its surface is convex and rough for the attachment of muscles, and presents, from behind forward, the **mastoid foramen**, the **mastoid process**, the **external auditory meatus** surrounded by

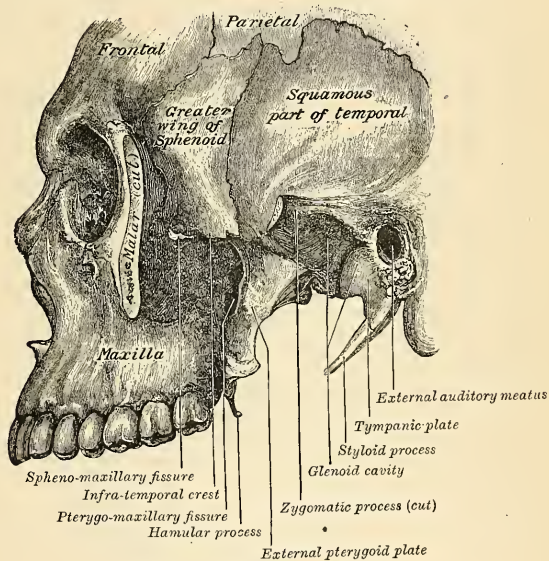


FIG. 100.—Left zygomatic fossa.

the **tympanic plate**, and, most anteriorly, the **temporomandibular articulation**. The point where the posterior inferior angle of the parietal meets the occipital and mastoid portion of the temporal is named the **asterion**.

The Zygomatic Fossa (*fossa infratemporalis*).—The zygomatic fossa is an irregularly shaped cavity, situated below and on the inner side of the zygoma; bounded in front by the zygomatic surface of the maxilla and the ridge which descends from its

malar process; *behind*, by the posterior border of the external pterygoid plate and the eminentia articularis; *above*, by the pterygoid ridge on the outer surface of the greater wing of the sphenoid and the under part of the squamous portion of the temporal; *below*, by the alveolar border of the maxilla; *internally*, by the external pterygoid plate; and *externally*, by the zygomatic arch and ramus of the mandible (Fig. 100). It contains the lower part of the Temporal, the External and Internal pterygoid muscles, the internal maxillary artery and vein, and inferior maxillary nerve and their branches. In its roof are seen the foramen ovale and the foramen spinosum; on its anterior wall open the posterior dental canals. At its upper and inner part may be observed the **sphenomaxillary** and **pterygomaxillary** fissures.

The **sphenomaxillary fissure** (*fissura orbitalis inferior*), horizontal in direction, opens into the outer and back part of the orbit. It is formed *above* by the lower border of the orbital surface of the greater wing of the sphenoid; *below*, by the external border of the orbital surface of the maxilla and a small part of the palate bone; *externally*, by a small part of the malar bone;¹ *internally*, it joins at right angles with the pterygomaxillary fissure. This fissure permits the orbit to communicate with three fossæ—the **temporal**, **zygomatic**, and **sphenomaxillary** fossæ; it transmits the superior maxillary nerve and its orbital branch, the infraorbital vessels, and ascending branches from the sphenopalatine or Meckel's ganglion.

The **pterygomaxillary fissure** is vertical, and descends at right angles from the inner extremity of the preceding; it is a V-shaped interval formed by the divergence of the maxilla from the pterygoid process of the sphenoid. It serves to connect the sphenomaxillary fossa with the zygomatic fossa, and transmits the internal maxillary artery.

The Sphenomaxillary Fossa (*fossa pterygopalatina*).—The sphenomaxillary fossa is a small, triangular space situated at the angle of junction of the sphenomaxillary and pterygomaxillary fissures, and placed beneath the apex of the orbit. It is formed *above* by the under surface of the body of the sphenoid and by the orbital process of the palate bone; *in front*, by the maxilla; *behind*, by the anterior surface of the base of the pterygoid process and lower part of the anterior surface of the greater wing of the sphenoid; *internally*, by the vertical plate of the palate. This fossa has three fissures terminating in it—the **sphenoidal**, **sphenomaxillary**, and **pterygomaxillary**; it communicates with the orbit by the sphenomaxillary fissure; with the nasal fossæ by the sphenopalatine foramen, and with the zygomatic fossa by the pterygomaxillary fissure. It also communicates with the cavity of the cranium, and has opening into it five foramina. Of these, there are three on the posterior wall—the **foramen rotundum** above; below and internal to this, the **Vidian canal**; and still more inferiorly and internally, the **pterygopalatine canal**. On the inner wall is the **sphenopalatine foramen**, by which the sphenomaxillary communicates with the nasal fossa; and below is the superior orifice of the **posterior palatine canal**, besides occasionally the orifices of the accessory posterior palatine canals. The fossa contains the superior maxillary nerve and Meckel's ganglion, and the termination of the internal maxillary artery.

The Anterior Region of the Skull (*norma frontalis*).—The **norma frontalis** forms the face, is of an oval form, presents an irregular surface, and is excavated for the reception of two of the organs of sense, the eyes and the nose. It is bounded *above* by the glabella and margins of the orbit; *below*, by the prominence of the chin; on *each side* by the malar bone and interior margin of the ramus of the mandible. In the median line are seen from above downward the **glabella**, and diverging from it are the **superciliary ridges**, which indicate the situation of the frontal sinuses and support the eyebrow. Below the glabella is the frontonasal suture, the mid-point of which is termed the **nasion**, and below this is the arch of the nose,

¹ Occasionally the maxilla and the sphenoid articulate with each other at the anterior extremity of this fissure; the malar is then excluded from entering into its formation.

formed by the nasal bones, and the nasal processes of the maxillæ. The nasal arch is convex from side to side, concave from above downward, presenting in the median line the **internasal suture** (*sutura internasalis*), formed between the nasal bones, laterally, on either side, the **nasomaxillary suture** (*sutura nasomaxillaris*), formed between the nasal bone and the nasal process of the maxilla. Below the nose is seen the opening of the **apertura pyriformis**, which is heart-shaped, with the narrow end upward, and presents laterally the thin, sharp margins serving for the attachment of the lateral cartilages of the nose, and in the middle line below a prominent process, the **anterior nasal spine**, bounded by two deep notches. Below this is the **intermaxillary suture** (*sutura intermaxillaris*), and on each side of it the **incisive fossa**. Beneath this fossa are the alveolar processes of the maxilla and mandible, containing the incisor teeth, and at the lower part of the median line the symphysis of the chin, the **mental process**, with its two mental tubercles, separated by a median groove, and the **incisive fossa** of the mandible.

On each side, proceeding from above downward, is the **supraorbital ridge**, terminating externally in the **external angular process** at its junction with the malar, and internally in the **internal angular process**; toward the inner third of this ridge is the **supraorbital notch or foramen**, for the passage of the supraorbital vessels

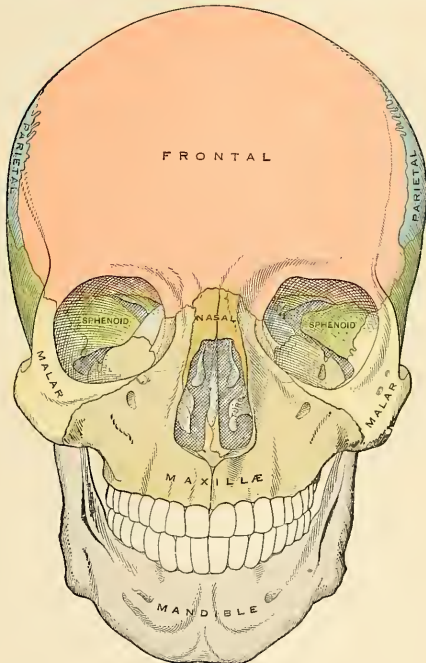


FIG. 101.—Anterior aspect of the skull.

and nerve. Beneath the supraorbital ridge is the opening of the **orbit**, bounded externally by the orbital ridge of the malar bone; below, by the orbital ridge formed by the malar and maxilla; internally, by the nasal process of the maxilla

and the internal angular process of the frontal bone. On the outer side of the orbit is the quadrilateral outer surface of the malar bone, perforated by one or two small **malar foramina**. Below the inferior margin of the orbit is the **infra-orbital foramen**, the termination of the **infraorbital canal**, and beneath this the **canine fossa**, which gives attachment to the *Levator anguli oris*; still lower are the **alveolar processes**, containing the teeth of the upper and lower jaws. Beneath the alveolar arch of the mandible is the **mental foramen**, for the passage of the mental

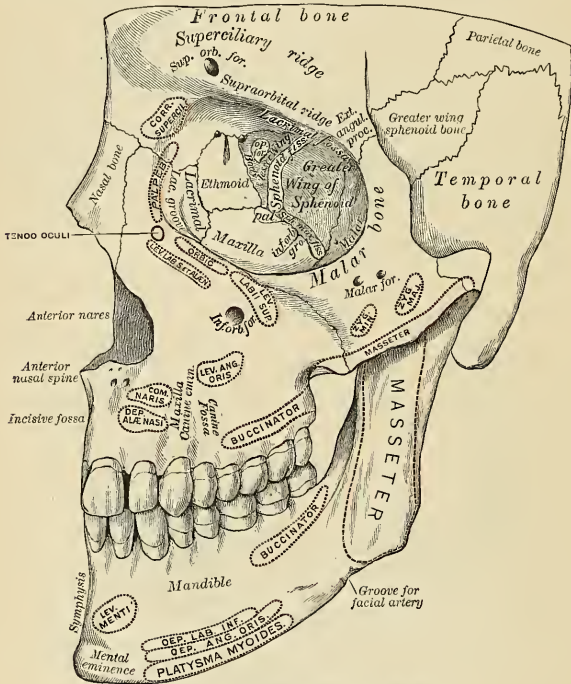


FIG. 102.—Anterolateral region of the skull.

vessels and nerve, the **external oblique line**, and at the lower border of the bone, at the point of junction of the body with the ramus, a shallow groove for the passage of the facial artery.

The Orbits.—The orbits (Fig. 102) are two quadrilateral pyramidal cavities, situated at the upper and anterior part of the face, their bases being directed forward and outward, and their apices backward and inward, so that the axes of the two, if continued backward, would meet over the body of the sphenoid bone. Each orbit (*orbita*) is formed of *seven* bones—the frontal, sphenoid, ethmoid, maxilla, malar, lacrimal, and palate; but three of these, the frontal, ethmoid, and sphenoid, enter into the formation of *both* orbits, so that the two cavities are formed of *eleven* bones only. Each cavity presents for examination a **roof**, a **floor**, an **inner** and an **outer wall**, four **angles**, a **base**, and an **apex**.

The **roof** (*paries superior*) is concave, directed downward and slightly forward, and formed in *front* by the orbital plate of the frontal; *behind*, by the lesser wing of the sphenoid. This surface presents internally the depression for the cartilaginous pulley of the Superior oblique muscle; externally, the depression for the lacrimal gland; and posteriorly, the suture connecting the frontal and lesser wing of the sphenoid.

The **floor** (*paries inferior*) is directed upward and outward, and is of less extent than the roof; it is formed chiefly by the orbital surface of the maxilla; in *front*, to a small extent, by the orbital process of the malar, and *behind*, by the superior surface of the orbital process of the palate. This surface presents at its anterior and internal part, just external to the lacrimal groove, a depression for the attachment of the Inferior oblique muscle; externally, the suture between the malar and the maxilla; near its middle, the **infraorbital groove**; and posteriorly, the suture between the maxilla and palate bone.

The **inner or medial wall** (*paries medialis*) is flattened, nearly vertical, and formed from before backward by the nasal process of the maxilla, the lacrimal, os planum of the ethmoid, and a small part of the body of the sphenoid. This surface presents the **lacrimal groove** and **crests of the lacrimal bone**, and the sutures connecting the lacrimal with the maxilla, the ethmoid with the lacrimal in front, and the ethmoid with the sphenoid behind.

The **outer or lateral wall** (*paries lateralis*) is directed forward and inward, and is formed in *front* by the orbital process of the malar bone; *behind*, by the orbital surface of the greater wing of the sphenoid. On it are seen the orifices of one or two malar canals, and the suture connecting the sphenoid and malar bones.

Of the **angles**, the **superior external** is formed by the junction of the upper and outer walls; it presents from before backward, the suture connecting the frontal with the malar in front and with the greater wing of the sphenoid behind; quite posteriorly is the foramen lacerum anterius, or sphenoidal fissure, which transmits the third, the fourth, the three branches of the ophthalmic division of the trigeminal, the abducent nerve, some filaments from the cavernous plexus of the sympathetics, the orbital branch of the middle meningeal artery, a recurrent branch from the lacrimal artery to the dura, and the ophthalmic vein. The **superior internal** is formed by the junction of the upper and inner wall, and presents the suture connecting the frontal bone with the lacrimal in front and with the ethmoid behind. The point of junction of the anterior border of the lacrimal with the frontal has been named the **dacryon**. This angle presents two foramina, the **anterior** and **posterior ethmoidal foramina**, the former transmitting the anterior ethmoidal vessels and nasal nerve, the latter the posterior ethmoidal vessels. The **inferior external**, formed by the junction of the outer wall and floor, presents the **sphenomaxillary fissure**, which transmits the superior maxillary nerve and its orbital branches, the infraorbital vessels, and the ascending branches from the sphenopalatine or Meckel's ganglion. The **inferior internal** is formed by the union of the lacrimal bone and the os planum of the ethmoid with the maxilla and palate bone.

The **circumference** or **base** of the orbit, quadrilateral in form, is bounded *above* (*margo supraorbitalis*) by the supraorbital ridge; *below* (*margo infraorbitalis*), by the anterior border of the orbital plate of the malar and maxilla; *externally*, by the external angular process of the frontal and malar bones; *internally*, by the internal angular process of the frontal and the nasal process of the maxilla. The circumference is marked by three sutures, the frontomaxillary internally, the frontomalar externally, and the malomaxillary below; it contributes to the formation of the lacrimal groove, and presents, above, the supraorbital notch (or foramen), for the passage of the supraorbital vessels and nerve.

The **apex** is situated at the back of the orbit and corresponds to the **optic foramen**,¹ a short circular canal which transmits the optic nerve and ophthalmic artery. It will thus be seen that there are *nine* openings communicating with each orbit—viz., the optic foramen, sphenoidal fissure, sphenomaxillary fissure, supraorbital foramen, infraorbital canal, anterior and posterior ethmoidal foramina, malar foramina, and the canal for the nasal duct.

The Nasal Cavity.—The nasal cavities (*cavum nasi*), or **nasal fossæ** (Figs. 81 and 103), are two large, irregular cavities situated on either side of the middle line of the face, extending from the base of the cranium to the roof of the mouth, and separated from each other by a thin vertical septum, the **septum of the nose**, formed by the perpendicular plate of the ethmoid and by the vomer. Each cavity communicates by a large aperture, the **anterior nasal aperture** (*apertura pyriformis*),² with the front of the face, and by the two **posterior nares** (*choanæ*)

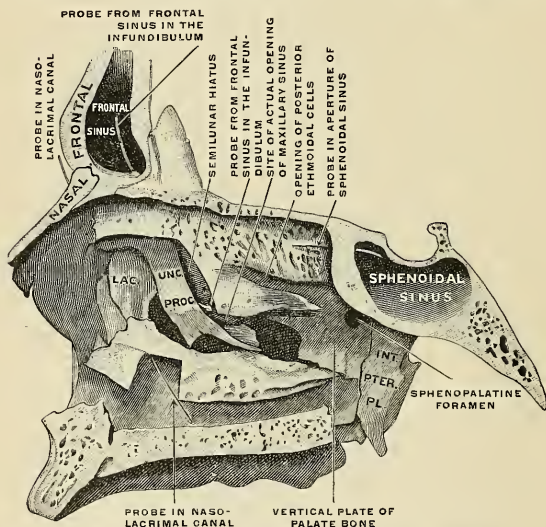


FIG. 103.—Nasal cavity, right lateral wall, from the left. (Spalteholz.)

with the nasopharynx behind. These fossæ are much narrower above than below, and in the middle than at the anterior or posterior openings; their depth, which is considerable, is much greater in the middle than at either extremity. The nasal fossæ are surrounded by four other fossæ—above is the **cranial fossa**; laterally, the **orbital fossæ**; and below, the **cavity of the mouth**. Each nasal fossa communicates with four sinuses—the frontal above, the sphenoidal behind, and the maxillary and ethmoidal on the outer wall. Each fossa also communicates with four cavities—with the orbit by the **lacrimal groove**, with the mouth by the **anterior palatine canal**, with the cranium by the **olfactory foramina**, and with the sphenomaxillary fossa by the **sphenopalatine foramen**; and they occasionally

¹Quain, Testut, and others give the apex of the orbit as corresponding with the inner end of the sphenoidal fissure. It seems better, however, to adopt the statement in the text, since the muscles of the eyeball take origin around the optic foramen, and diverge from it to the globe of the eye.

²In the skull freed of soft parts the anterior nasal cavities open in front by the *apertura pyriformis*. In the skull with the soft parts in place they open by the anterior nares.

communicate with each other by an aperture in the septum. The bones entering into their formation are *fourteen* in number—three of the cerebral cranium, the frontal sphenoid, and ethmoid, and all the bones of the face, excepting the malar and mandible. Each cavity is bounded by a roof, a floor, an inner and an outer wall.

The **upper wall, or roof**, is long, narrow, and horizontal in its centre, but slopes downward at its anterior and posterior extremities; it is formed in *front* by the nasal bones and nasal spine of the frontal, which are directed downward and forward; in the *middle*, by the cribriform plate of the ethmoid, which is horizontal; and *behind*, by the anterior and under surface of the body of the sphenoid and sphenoidal turbinated process, the ala of the vomer and the sphenoidal process of the palate bone, which are directed downward and backward. This surface presents, from before backward, the internal aspect of the nasal bones; on their outer side, the suture formed between the nasal bone and the nasal process of the maxilla; on their inner side, the elevated crest which receives the nasal spine of the frontal and the perpendicular plate of the ethmoid, and articulates with its fellow of the opposite side; while the surface of the bones is perforated by a few small vascular apertures, and presents the longitudinal groove for the nasal nerve; farther back is the **transverse suture**, connecting the frontal with the nasal in front, and the ethmoid behind, the **olfactory foramina** and **nasal slit** on the under surface of the cribriform plate, and the suture between it and the sphenoid behind; quite posteriorly are seen the **sphenoidal turbinated process**, the orifice of the **sphenoidal sinus**, and the articulation of the **ala of the vomer** with the under surface of the body of the sphenoid.

The **floor** (Fig. 103) is flattened from before backward, concave from side to side, and wider in the middle than at either extremity. It is formed in *front* by the palatal process of the maxilla; *behind*, by the horizontal plate of the palate bone. This surface presents, from before backward, the **anterior nasal spine**; behind this, the upper orifices of the **anterior palatine canal**; the elevated crest which articulates with the vomer; and behind, the suture between the palate and maxilla, and the **posterior nasal spine**.

The **inner or medial wall, or septum** (septum nasi osseum) (Fig. 105), is a thin vertical partition which separates the nasal fossæ from each other. It is formed, in *front*, by the crest of the nasal bones and nasal spine of the frontal; in the *middle*, by the perpendicular plate of the ethmoid and ethmoidal crest of the sphenoid; *behind*, by the vomer and rostrum of the sphenoid; *below*, by the crests of the maxillæ and palate bones. It presents, in *front*, a large, triangular notch, which receives the septal cartilage of the nose; and *behind*, the grooved edge of the vomer. Its surface is marked by numerous canals for vessels and nerves, and the groove for the nasopalatine nerve, and is traversed by sutures connecting the bones of which it is formed.

The **outer or lateral wall** (Figs. 81 and 103) is formed, in *front*, by the nasal process of the maxilla and lacrimal bones; in the *middle*, by the ethmoid and inner surface of the body of the maxilla and turbinated bone; *behind*, by the vertical plate of the palate bone; and the internal pterygoid plate of the sphenoid. Upon this outer wall are two marked projections of bone (Fig. 81). One is known as the **turbinated bone** and the other as the **middle turbinated process**. The **superior turbinated process** appears as a less distinct bony projection. This surface presents three irregular longitudinal passages, termed the superior, middle, and inferior meatuses of the nose (Fig. 104). The **superior meatus**, the smallest of the three, is situated at the upper and back part of each nasal fossa, occupying the posterior third of the outer wall. It is situated between the superior and middle turbinated processes, and has opening into it two foramina, the **sphenopalatine foramen** at the back of its outer wall, and the **posterior ethmoidal cells** at the front

part of the outer wall. The sphenoidal sinus opens into a recess (*recessus sphenothmoidalis*), which is situated above and behind the superior turbinated process. The middle meatus is situated external to the middle turbinated process, between

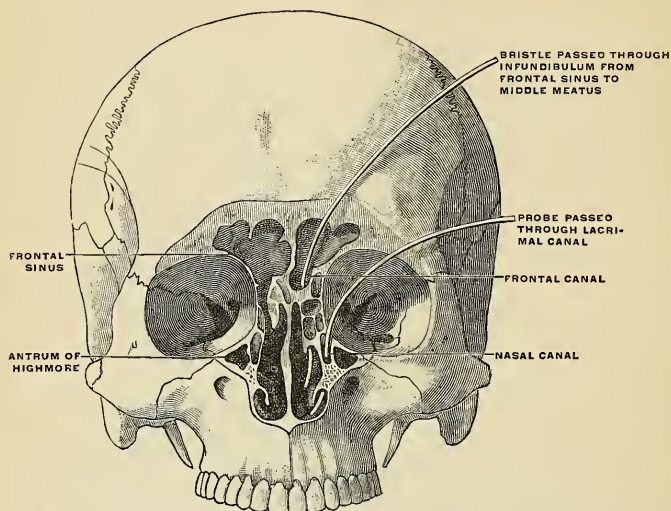


FIG. 104.—Coronal section through the frontal sinus and nasal fossa. (Poirier and Charpy.)

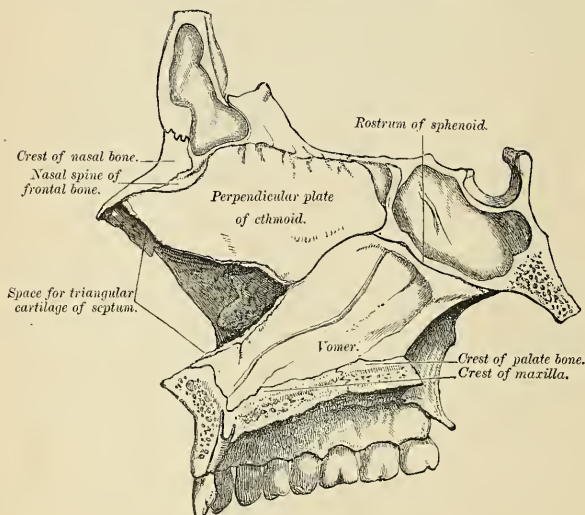


FIG. 105.—Inner wall of nasal fosse, or septum of nose.

it and the turbinated bone, and extends from the anterior end of the turbinated to the sphenopalatine foramen of the outer wall of the nasal fossa. Anteriorly it terminates in a depression, the **atrium of the nasal meatus** (*atrium meatus medii*). The middle meatus presents in front the orifice of the **infundibulum**, by which the middle meatus communicates with the anterior ethmoidal cells, and through these with the frontal sinuses. The posterior ethmoidal cells also open into this meatus, while at the centre of the outer wall is the **orifice of the maxillary antrum** which varies somewhat as to its exact position in different skulls. The **inferior meatus**, the largest of the three, is the space between the turbinated bone and the floor of the nasal fossa. It extends along the entire length of the outer wall of the nose, is broader in front than behind, and presents anteriorly the lower orifice of the canal for the nasal duct.

Development of the Skull.—Up to a certain stage the development of the skull corresponds with that of the vertebral column; but it is modified later in association with the expansion of the brain vesicles, the formation of the organs of smell, sight, and hearing, and the development of the mouth and pharynx.

The notochord extends as far forward in the base of the future skull as the anterior end of the mid-brain, and becomes partly surrounded by mesoderm (Fig. 106). The posterior part of this mesodermal investment corresponds with the future basiocciput, and shows a subdivision into four segments, which are separated by the roots of the hypoglossal nerve. The mesoderm then extends over the brain vesicles, and thus the entire brain is enclosed by a mesodermal investment, which is termed the *membranous primordial cranium*. From the inner layer of this the bones of the skull and the membranes of the brain are developed; from the outer layer the muscles, blood-vessels, true skin, and subcutaneous tissues of the scalp. In the shark and dog-fish this membranous cranium undergoes complete chondrification, and forms the cartilaginous skull, or *chondrocranium*, of these animals. In mammals, on the other hand, the process of chondrification is limited to the base of the skull—the roof and sides being covered in by membrane. Thus, the bones of the base of the skull are preceded by cartilage, those of the roof and sides by membrane. The posterior part of the base of the skull is developed around the notochord, and exhibits a segmented condition analogous to that of the vertebral column, while the anterior part arises in front of the notochord and shows no regular segmentation. The base of the skull may therefore be divided into (a) a *chordal* or *vertebral*, and (b) a *prechordal* or *prevertebral* portion.

In the lower vertebrates two pairs of cartilages are developed, viz., a pair of parachordal cartilages, one on either side of the notochord; and a pair of prechordal cartilages, the *trabeculae cranii*, in front of the notochord (Figs. 107 and 108). The *parachordal cartilages* (Fig. 108) unite to form a cartilaginous plate, from which the cartilaginous part of the occipital bone and the basi-sphenoid are developed. On the lateral aspect of the parachordal cartilages the *otic* or *auditory vesicles* are situated, and the mesoderm enclosing them is soon converted into cartilage, forming the *cartilaginous ear capsules*. These cartilaginous ear capsules, which are of an oval shape, fuse with the lateral aspects of the basilar plate, and from them arise the petromastoid portions of the temporal bones. The *trabeculae cranii* (Fig. 107) are two curved bars of cartilage which embrace the pituitary body; their posterior ends soon unite with the basilar plate, while their anterior ends join to form the *ethmoidal plate*, which extends forward between the forebrain and the olfactory pits. Later, the trabeculae meet and fuse below the pituitary body, forming the floor of the pituitary fossa, and so cutting off the anterior lobe of the pituitary body from the stomatodaeum. The mesal part of the ethmoidal plate forms the bony and cartilaginous parts of the nasal septum. From the lateral margins of the trabeculae cranii three processes grow out on either side. The anterior forms the lateral mass of the ethmoid and the alar cartilages of the nose; the middle gives rise to the lesser wing of the sphenoid, while from the posterior the greater wing and external pterygoid plate of the sphenoid are developed (Figs. 109 and 110). The bones

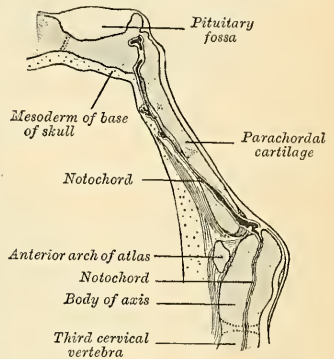
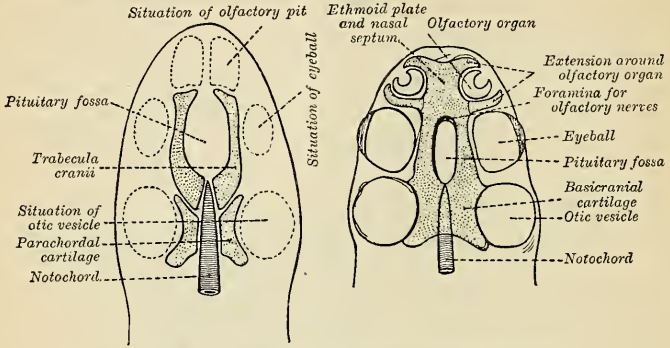


FIG. 106.—Sagittal section of cephalic end of notochord. (Furness).

of the vault are of membranous formation, and are termed *dermal* or *covering bones*. They are partly developed from the mesoderm of the primordial cranium, and partly from that which lies outside the entoderm of the foregut. They comprise the upper part of the tabular portion of the occipital (interparietal), the squamous temporals and tympanic plates, the parietals,



FIGS. 107 and 108.—Diagrams of the cartilaginous cranium. (Wiedersheim.)

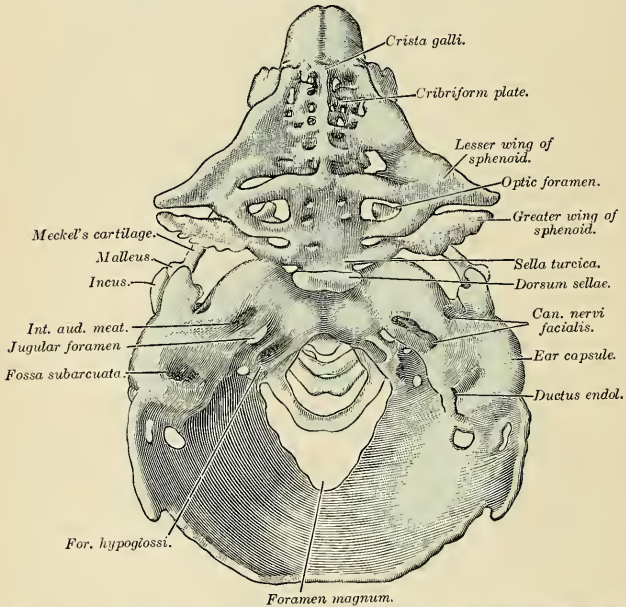


FIG. 109.—Model of the chondrocranium of a human embryo, 8 cm. The membrane bones are not represented. (From Hertwig's *Handbuch der Entwicklungslehre*.)

the frontal, the vomer, the internal pterygoid plates, and the bones of the face. Some of them remain distinct throughout life (*e. g.*, parietal and frontal), while others join with the bones of the chondrocranium (*e. g.*, interparietal, squamous temporals, and internal pterygoid plates).

Recent observations have shown that, in mammals, the basicranial cartilage, both in the

chordal and prechordal regions of the base of the skull, is developed as a single plate, which extends from behind forward. In man, however, its posterior part shows an indication of its being developed from two chondrifying centres which fuse rapidly in front and below. The relation of this cartilaginous plate to the notochord differs in different animals. In the rat embryo it lies ventrad of the notochord (Robinson); in the sheep, pig, calf, and ferret the cranial part of the notochord is enclosed within it; in man, the anterior and posterior thirds of the cartilage surround the notochord, but its middle third lies on the dorsal aspect of the notochord, which in this region is placed between the cartilage and the wall of the pharynx.

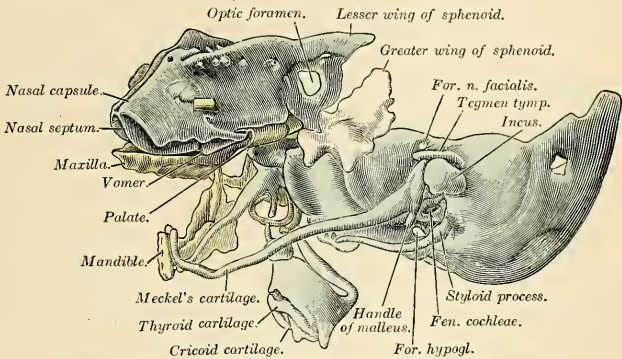


FIG. 110.—The same model as shown in Fig. 109 from the left side. Certain of the membrane bones of the right side are represented in yellow.

Differences in the Skull Due to Age.—At birth the skull as a whole is large in proportion to the other parts of the skeleton, but its facial portion is small, and equals only about one-eighth of the bulk of the cranium as compared with one-half in the adult. The frontal and parietal eminences are prominent, and the greatest width of the skull is at the level of the latter; on the other hand, the glabella, superciliary ridges, and mastoid processes are not developed. Ossification of the skull bones is not completed, and many of them—*e. g.*, the occipital, temporals, sphenoid, frontal, and mandible—consist of more than one piece. Unossified

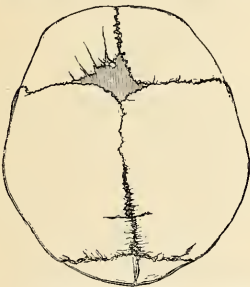


FIG. 111.—Skull at birth, showing the anterior and posterior fontanelles.

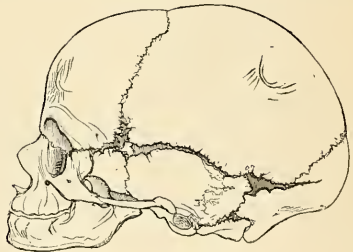


FIG. 112.—The lateral fontanelles.

membranous intervals, termed *fontanelles*, are seen at the angles of the parietal bones; these fontanelles are six in number; two, an anterior and a posterior, are situated in the middle line, and four, two on each side, an antero-lateral and a postero-lateral, are placed on either side.

The anterior or bregmatic fontanelle (Fig. 111) is the largest, and is situated at the junction of the sagittal, coronal, and interfrontal sutures; it is lozenge-shaped, and measures about an inch and a half in its antero-posterior and an inch in its transverse diameter. The posterior

fontanelle is triangular in form and is situated at the junction of the sagittal and lambdoid sutures. The lateral *fontanelles* (Fig. 112) are small, irregular in shape, and correspond respectively with the antero-inferior and postero-inferior angles of the parietal bones. An additional fontanelle is sometimes seen in the sagittal suture at the region of the obelion. The fontanelles are usually closed by the growth and extension of the bones which surround them, but sometimes they are the sites of separate ossific centres which develop into Wormian bones. The posterior and lateral fontanelles are obliterated within a month or two after birth, but the anterior is not completely closed until the first half of the second year; sometimes it remains open beyond the second year, a condition which is usually seen in rickets, and is due to malnutrition. A knowledge of the shape and position of the fontanelles is of service to the accoucheur in enabling him to determine which part of the fetal head is presenting during parturition.

The small size of the face at birth is mainly accounted for by the rudimentary condition of the jaws, the noneruption of the teeth, and the small size of the maxillary air sinuses and nasal cavities. At birth the nasal cavities lie almost entirely between the orbits, and the lower border of the anterior nasal aperture is only a little below the level of the orbital floor. With the eruption of the milk teeth there is an enlargement of the face and jaws, and these changes are still more marked after the second dentition.

The skull grows rapidly from birth to the seventh year, by which time the foramen magnum and petrous parts of the temporals have reached their full size and the orbital cavities are only a little smaller than those of the adult. Growth is slow from the seventh year until the approach of puberty, when a second period of activity takes place; this consists of an increase in all directions, but it is especially marked in the frontal and facial regions, where it is associated with the development of the air sinuses.

Obliteration of the Sutures.—Obliteration of the sutures of the vault takes place as age advances, usually beginning during the fourth decade of life and first becoming manifest on the inner surface, appearing externally about ten years later; the posterior part of the sagittal suture is usually the first to become obliterated, next the coronal, and then the lambdoid. The most striking feature of an old skull is the marked diminution in the size of the jaws consequent on the loss of the teeth and the absorption of the alveolar processes, thus reducing the facial height and altering the mandibular angles.

Differences in the Skull Due to Sex.—Until the age of puberty little difference exists between the male and the female skull. The skull of an adult female is, as a rule, lighter and smaller. While the cranial capacity of white males averages 1560 c.c., that of females is nearly 200 c.c. less. The female skull has thinner walls, its ridges for muscle attachment are less strongly marked, the superciliary ridges, glabella, and mastoid processes are less prominent, and the corresponding air sinuses are smaller. The upper margin of the orbit is sharper, the frontal and parietal eminences are more prominent, and the vault is somewhat flattened as compared with the male skull. The contour of the face is more rounded, the facial bones are smoother, and the jaws and teeth are smaller.

No single structural characteristic, however, serves to determine the sex, and the features enumerated above can guide in the examination only when they are sufficiently pronounced to justify a probable diagnosis.¹

Supernumerary, Wormian,² Sutural, or Epactal Bones (*Ossa Triquetra*).

In addition to the constant centres of ossification of the skull, additional ones are occasionally found in the course of the sutures. These form irregular, isolated bones, interposed between the cranial bones, and have been termed **Wormian bones**, or *ossa triquetra*. They are most frequently found in the course of the lambdoid suture, but occasionally also occupy the situation of the fontanelles, especially the posterior and, more rarely, the anterior. Frequently one is found between the anterior inferior angle of the parietal bone and the greater wing of the sphenoid, the **epipteric bone**, or the **pterion ossicle** (Fig. 113). They have a great tendency to be symmetrical on the two sides of the skull, and they vary much in size, being in some cases not larger than a pin's head, and confined to the outer table; in other cases so large that one pair of these bones may form the whole of the occipital bone above the superior curved lines.

Craniology.

Skulls vary in shape and size, and the term *craniology* is applied to the comparative study of these variations. By means of exact measurements and their correlation, skulls may be classified in various ways.

¹ See P. J. Möbius: Ueber die Verschiedenheit männlicher und weiblicher Schädel. Archiv für Anthropologie, 1907, N. F., vol. vi.

² Wormian, a physician of Copenhagen, is said to have given the first detailed description of these bones.

I. According to capacity, measured by means of shot, mustard seed, etc.

1. *Microcephalic*, with a capacity of less than 1350 c.c. (e. g., Australians, Andamanese).
2. *Mesocephalic*, with a capacity of from 1350 to 1450 c.c. (e. g., Negroes, Chinese).
3. *Megacephalic*, with a capacity of over 1450 c.c. (e. g., Europeans, Japanese, and Eskimos).

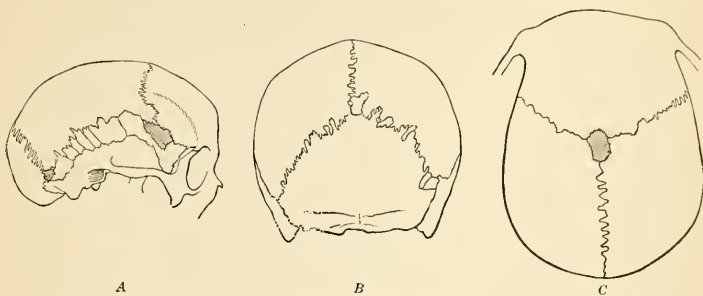


FIG. 113.—Wormian bones.

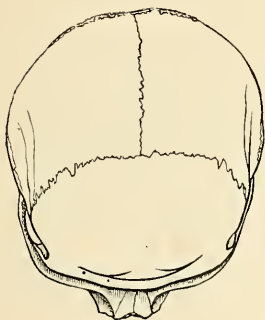


FIG. 114.—Brachycephalic cranium. (Poirier and Charpy.)

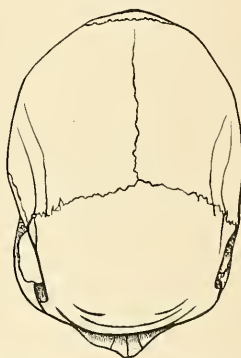


FIG. 115.—Dolichocephalic cranium (Poirier and Charpy.)

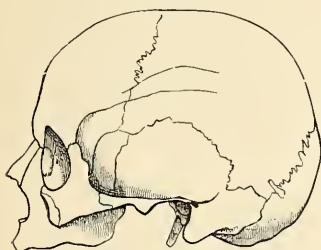


FIG. 116.—Brachycephalic cranium, (Poirier and Charpy.)

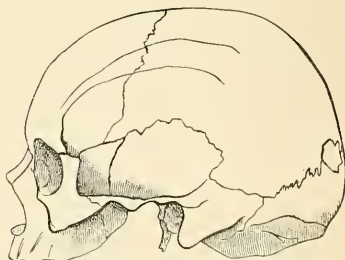


FIG. 117.—Dolichocephalic cranium. (Poirier and Charpy.)

II.—To facilitate regional description and to compare the normæ of one skull with those of another, the skull is placed in such a way that a plane passing through the inferior margin of the orbit and the superior margin of the external auditory meatus shall be horizontal (the horizontal line of the Frankfort agreement). Various linear and arc measurements are made between definite and easily localized points on the surface of the skull, and, although previously mentioned, are here tabulated for convenience of reference. They are divided into two groups: (1) those in the mesal plane, and (2) those on either side of it.

The Points in the Mesal Plane are:

Mental Point.—The most prominent point of the chin.

Alveolar Point, or Prosthion.—The central point of the anterior margin of the upper alveolar arch.

Subnasal Point.—The middle of the lower border of the anterior nasal aperture, at the base of the nasal spine.

Nasion.—The central point of the frontonasal suture.

Glabella.—The point in the middle line at the level of the superciliary ridges.

Ophryon.—The point in the middle line at the level where the temporal lines most nearly approach each other.

Bregma.—The meeting point of the coronal and sagittal sutures.

Obelion.—A point in the sagittal suture on a level with the parietal foramina.

Lambda.—The point of junction of the sagittal and lambdoid sutures.

Occipital Point.—The point in the middle line of the occipital bone farthest from the glabella.

Inion.—The external occipital protuberance.

Opisthion.—The mid-point of the posterior margin of the foramen magnum.

Basion.—The mid-point of the anterior margin of the foramen magnum.

The Points on Either Side of the Mesal Plane are:

Gonion.—The outer margin of the angle of the mandible.

Dacryon.—The point of union of the antero-superior angle of the lacrimal with the frontal bone and the frontal process of the maxilla.

Stephanion.—The point where the temporal line intersects the coronal suture.

Pterion.—The point where the greater wing of the sphenoid joins the antero-inferior angle of the parietal.

Auricular Point.—The centre of the orifice of the external auditory meatus.

Asterion.—The point of meeting of the lambdoid, masto-occipital, and mastoparietal sutures.

The *horizontal circumference* of the cranium is measured in a plane passing through the glabella (Turner) or the ophryon (Flower) in front, and the occipital point behind; it averages about twenty inches (50 cm.) in the female and twenty-one inches (52.5 cm.) in the male.

The *occipitofrontal* or *longitudinal arc* is measured from the nasion over the middle line of the vertex to the opisthion; while the *basinasal length* is the distance between the basion and the nasion. These two measurements, plus the antero-posterior diameter of the foramen magnum, represent the *vertical circumference* of the cranium.

The *length* is measured from the glabella to the occipital point, while the *breadth*, or greatest transverse diameter, is usually found near the external auditory meatus. The proportion of breadth to length $\frac{(\text{breadth} \times 100)}{\text{length}}$ is termed the *cephalic index*, or *index of breadth*.

The *height* is usually measured from the basion to the bregma, and the proportion of height to length $\frac{(\text{height} \times 100)}{\text{length}}$ constitutes the *vertical* or *height index*.

In studying the face the principal points to be noticed are the proportion of its length and breadth, the shape of the orbits and of the anterior nasal aperture, and the degree of projection of the jaws.

The *length of the face* may be measured from the ophryon or nasion to the chin, or, if the mandible be wanting, to the alveolar point; while its *width* is represented by the distance between the zygomatic arches. By comparing the length with the width of the face, skulls may be divided into two groups—*dolichofacial*, or *leptoprosopæ* (long-faced), and *brachyfacial*, or *chemoprosopæ* (short-faced).

The *orbital index* signifies the proportion which the orbital height bears to the orbital width, thus:

$$\frac{\text{orbital height} \times 100}{\text{orbital width}}$$

The *nasal index* expresses the proportion which the width of the anterior nasal aperture bears to the height of the nose, the latter being measured from the nasion to the lower margin of the nasal aperture, thus:

$$\frac{\text{nasal width} \times 100}{\text{nasal height}}$$

The degree of projection of the jaws is determined by the *gnathic* or *alveolar index*, which represents the proportion between the basialveolar and basinasal lengths, thus:

$$\frac{\text{basialveolar length} \times 100}{\text{basinasal length}}$$

The following table, modified from that given by Duckworth, illustrates how these different indices may be utilized in the classification of skulls.

Index.	Classification.	Nomenclature.	Examples.
1. Cephalic . . .	Below 75 Between 75 and 80 Above 80	Dolichocephalic Mesaticephalic Brachycephalic	Kaffirs and Native Australians Europeans and Chinese Mongolians and Andamans
2. Orbital . . .	Below 84 Between 84 and 89 Above 89	Microseme Mesoseme Megaseme	Tasmanians and Native Australians Europeans Chinese and Polynesians
3. Nasal . . .	Below 48 Between 48 and 53 Above 53	Leptorhine Mesorhine Platyrrhine	Europeans Chinese and Japanese Negroes and Native Australians
4. Gnathic . . .	Below 98 Between 98 and 103 Above 103	Orthognathous Mesognathous Prognathous	Europeans Chinese and Japanese Native Australians

Surface Form.—The various bony prominences or landmarks which can be easily felt and recognized in the head and face, and which afford the means of mapping out the important structures comprised in this region, are as follows:

1. Supraorbital arch.
2. Internal angular process.
3. External angular process.
4. Zygomatic arch.
5. Mastoid process.
6. External occipital protuberance.
7. Superior curved line of occipital bone.
8. Parietal eminences.
9. Temporal ridge.
10. Frontal eminences.
11. Superciliary ridges.
12. Nasal bones.
13. Lower margin of orbit.
14. Mandible.

(1) The **supraorbital arches** are to be felt throughout their entire extent, covered by the eyebrows. They form the upper boundary of the circumference or base of the orbits, and separate the face from the forehead. They are strong and arched, and terminate internally on each side of the root of the nose in the internal angular process, which articulates with the lacrimal bone. Externally they terminate in the external angular process, which articulates with the malar bone. This arched ridge is sharper and more defined in its outer than in its inner half, and forms an overhanging process which protects and shields the lacrimal gland. It thus protects the eye in its most exposed situation and in the direction from which blows are most likely to descend. The supraorbital arch varies in prominence in different individuals. It is more marked in the male than in the female, and in some races of mankind than others. In the less civilized races, as the forehead recedes backward, the supraorbital arch becomes more prominent, and approaches more to the characters of the monkey tribe, in which the supraorbital arches are very largely developed, and acquire additional prominence from the oblique direction of the frontal bone. (2) The **internal angular process** is scarcely to be felt. Its position is indicated by the angle formed by the supraorbital arch with the nasal process of the maxilla and the lacrimal bone at the inner side of the orbit. Between the internal angular processes of the two sides is a broad surface which assists in forming the root of the nose, and immediately above this a broad, smooth, somewhat triangular surface, the **glabella**, situated between the superciliary ridges. (3) The **external angular process** is much more strongly marked than the internal, and is plainly to be felt. It is formed by the junction or confluence of the supraorbital and temporal ridges, and, articulating with the malar bone, it serves to a very considerable extent to support the bones of the face. In carnivorous animals the external angular process does not articulate with the malar, and therefore this lateral support to the bones of the face is not present. (4) The **zygomatic arch** is plainly to be felt throughout its entire length, being situated almost immediately under the skin. It is formed by the malar bone and the zygomatic process of the temporal bone. At its anterior extremity, where it is formed by the malar bone, it is broad and forms the prominence

of the cheek; the posterior part is narrower, and terminates just in front and a little above the tragus of the external ear. The lower border is more plainly to be felt than the upper, in consequence of the dense temporal fascia being attached to the latter, which somewhat obscures its outline. Its shape differs very much in individuals and in different races of mankind. In the skulls of savages—as, for instance, in the skull of the negro of the Guinea Coast—the malar bones project forward and not outward, and the zygoma at its posterior extremity extends farther outward before it is twisted on itself to be prolonged forward. This makes the zygomatic arch stand out in bold relief, and affords greater space for the Temporal muscle. In skulls which have a more pyramidal shape, as in the Eskimos or Greenlanders, the malar bones do not project forward and downward under the eyes, as in the preceding form, but take a direction outward, forming with the zygoma a large, rounded sweep or segment of a circle. Thus it happens that if two lines are drawn from the zygomatic arches, touching the temporal ridges, they meet above the top of the head, instead of being parallel, or nearly so, as in the European skull, in which the zygomatic arches are not nearly so prominent. This gives to the face a more or less oval type. (5) Behind the ear is the **mastoid portion of the temporal bone**, plainly to be felt, and terminating below in a nipple-shaped process. Its anterior border can be traced immediately behind the concha, and its apex is on about a level with the lobule of the ear. It is rudimentary in infancy, but gradually develops in childhood, and is more marked in the negro than in the European. (6) The **external occipital protuberance (inion)** is always plainly to be felt just at the level where the skin of the neck joins that of the head. At this point the skull is thick for the purposes of safety, while radiating from it are numerous curved arches or buttresses of bone which give to this portion of the skull further security. (7) Running outward on either side from the external occipital protuberance is an arched ridge of bone, which can be more or less plainly perceived. This is the **superior curved line of the occipital bone**, and gives attachment to some of the muscles which keep the head erect on the vertebral column; accordingly, we find it more developed in the negro tribes, in whom the jaws are much more massive, and therefore require stronger muscles to prevent their extra weight carrying the head forward. Below this line the surface of bone at the back of the head is obscured by the overlying muscles. Above it the vault of the cranium is thinly covered with soft structures, so that the form of this part of the head is almost exactly that of the upper portion of the occipital, the parietal, and the frontal bones themselves; and in bald persons, even the lines of junction of the bones, especially the junction of the occipital and parietal at the lambdoid suture, may be defined as a slight depression caused by the thickening of the borders of the bones in this situation. (8) In the line of the greatest transverse diameter of the head, on each side of the middle line, are generally to be found the **parietal eminences**, one on each side of the middle line, though sometimes these eminences are not situated at the point of the greatest transverse diameter, which is at some other prominent part of the parietal region. They denote the point where ossification of the parietal bone began. They are much more prominent and well marked in early life, in consequence of the sharper curve of the bone at this period, so that it describes the segment of a smaller circle. Later in life, as the bone grows, the curve spreads out and forms the segment of a larger circle, so that the eminence becomes less distinguishable. In consequence of this sharp curve of the bone in early life, the whole of the vault of the skull has a squarer shape than it has in later life, and this appearance may persist in those suffering from rachitis. The eminence is more apparent in the negro's skull than in that of the European. This is due to greater flattening of the temporal fossa in the former skull to accommodate the larger Temporal muscle which exists in these races. The parietal eminence is particularly exposed to injury from blows or falls on the head, but fracture is to a certain extent prevented by the shape of the bone, which forms an arch, so that the force of the blow is diffused over the bone in every direction. (9) At the side of the head may be felt the **temporal ridge**. Commencing at the external angular process, it may be felt as a curved ridge, passing upward and then curving backward, on the frontal bone, separating the forehead from the temporal fossa. It may then be traced passing backward in a curved direction, over the parietal bone, and, though less marked, still generally to be recognized. Finally, the ridge curves downward, and terminates in the posterior root of the zygoma, which separates the squamous from the subcutaneous mastoid portion of the temporal bone. (10) The **frontal eminences** vary a good deal in different individuals, being considerably more prominent in some than in others, and they are often not symmetrical on the two sides of the body, the one being much more pronounced than the other. This is often especially noticeable in the skull of the young child or infant, and becomes less marked as age advances. The prominence of the frontal eminences depends more upon the general shape of the whole bone than upon the size of the protuberances themselves. As the skull is more highly developed in consequence of increased intellectual capacity, so the frontal bone becomes more upright and the frontal eminences stand out in bolder relief. Thus they may be considered as affording, to a certain extent, an indication of the development of the hemispheres of the cerebrum beneath, and of the mental powers of the individual. They are not so much exposed to injury as the parietal eminences. In falls forward the upper extremities are involuntarily thrown out, and break the force of the fall, and thus shield the frontal bone from injury. (11) Below the frontal eminences on the fore-

head are the **superciliary ridges**, which denote the position of the frontal sinuses, and vary according to the size of the sinuses in different individuals, being, as a rule, small in the female, absent in children, and sometimes unusually prominent in the male, when the frontal sinuses are largely developed. They commence on either side of the glabella, and at first present a rounded form, which gradually fades away at their outer ends. (12) The **nasal bones** form the prominence of the nose. They vary much in size and shape, and to them are due the variations in contour of this organ and much of the character of the face. Thus, in the Mongolian or Ethiopian they are flat, broad, and thick at their base, giving to these races the flattened nose by which they are characterized, and differing very decidedly from the Caucasian, in whom the nose, owing to the shape of the nasal bones, is narrow, elevated at the bridge, and elongated downward. Below, the nasal bones are thin and connected with the cartilages of the nose, and the angle or arch formed by their union serves to throw out the bridge of the nose, and is much more marked in some individuals than others. (13) The **lower margin of the orbit**, formed by the maxilla and the malar bone, is plainly to be felt throughout its entire length. It is continuous internally with the nasal process of the maxilla, which forms the inner boundary of the orbit. At the point of junction of the lower margin of the orbit with the nasal process is to be felt a little tubercle of bone, which can be plainly perceived by running the finger along the bone in this situation. This tubercle serves as a guide to the position of the lacrimal sac, which is situated above and behind it. (14) The outline of the **mandible** may be felt throughout its entire length. Just in front of the tragus of the external ear, and below the zygomatic arch, the condyle can be made out. When the mouth is opened this prominence of bone can be perceived advancing out of the glenoid fossa on to the eminentia articularis, and receding again when the mouth is closed. From the condyle the posterior border of the ramus can be felt extending down to the angle. A line drawn from the condyle to the angle would indicate the exact position of this border. From the angle to the symphysis of the chin the lower, rounded border of the body of the bone may be plainly felt. At the point of junction of the two halves of the bone is a well-marked triangular eminence, the **mental process**, which forms the prominence of the chin.

Applied Anatomy.—The thickness of the skull varies greatly in different regions of the same skull and in different individuals. The average thickness of the skullcap is about one-fifth of an inch (5 mm.). The thickest portions are the occipital protuberance, the inferior portion of the frontal bone, and the mastoid process. The thinnest portions are the occipital fossæ, the squamous portion of the temporal bone, and over certain sinuses and arteries. An arrest in the ossifying process may give rise to deficiencies or gaps, or to fissures, which are of importance in a medicolegal point of view, as they are liable to be mistaken for fractures. The fissures generally extend from the margin toward the centre of the bone, but gaps may be found in the middle as well as at the edges. In course of time they may become covered with a thin lamina of bone.

Occasionally a protrusion of the brain or its membranes may take place through one of these gaps in an imperfectly developed skull. When the protrusion consists of membranes only, and is filled with cerebrospinal fluid, it is called a **meningocele**; when the protrusion consists of brain as well as membranes, it is termed an **encephalocele**; and when the protruded brain is a prolongation from one of the ventricles, and is distended by a collection of fluid from an accumulation in the ventricle, it is termed a **hydrencephalocele**. This latter condition is sometimes found at the root of the nose, where a protrusion of the anterior horn of the lateral ventricle takes place through a deficiency of the frontonasal suture. These malformations are usually found in the middle line, and most frequently at the back of the head, the protrusion taking place through the fissures which separate the four centres of ossification from which the tabular portion of the occipital bone is originally developed (see page 73). They most frequently occur through the upper part of the vertical fissure, which is the last to ossify, but not uncommonly through the lower part, when the foramen magnum may be incomplete. More rarely these protrusions have been met with in other situations than those above mentioned, both through normal fissures, as the sagittal, lambdoid, and other sutures, and also through abnormal gaps and deficiencies at the sides, and even at the base of the skull. Force may be responsible in a young person for *separating a suture*. This accident, seldom met with even in the young, is only occasionally encountered in older persons.

Fractures of the skull may be divided into those of the *vault* and those of the *base*. Fractures of the vault are usually produced by direct violence. This portion of the skull varies in thickness and strength in different individuals, but, as a rule, is sufficiently strong to resist a very considerable amount of violence without being fractured. This is due to several causes—the rounded shape of the head and its construction of a number of secondary elastic arches, each made up of a single bone; the fact that it consists of a number of bones, united at all events in early life by a sutural ligament, which acts as a sort of buffer and interrupts the continuity of any violence applied to the skull; the presence of arches or ridges, both on the inside and outside of the skull, which materially strengthen it; and the mobility of the head upon the vertebral column, which further enables it to withstand violence. The elasticity of the bones of the head is especially marked in the skull of the child, and this fact, together with the wide separation of

the individual bones from each other, and the interposition between them of other and softer structures render fracture of the bones of the head a very uncommon event in infants and quite young children; as age advances and the bones become joined, fracture is more common, though still less liable to occur than in the adult. Fractures of the vault may, and generally do, involve the *whole thickness* of the bone; but sometimes one table may be fractured without any corresponding injury to the other. Thus, the *outer table* of the skull may be splintered and driven into the diploë, or in the frontal or mastoid regions into the frontal or mastoid cells, without any injury to the internal table. And on the other hand, the *internal table* has been fractured, and portions of it depressed and driven inward, without any fracture of the outer table. As a rule, in fractures of the skull the inner table is more splintered and comminuted than the outer, and this is due to several causes. It is thinner and more brittle; the force of the violence as it passes inward becomes broken up, and is more diffused by the time it reaches the inner table; the bone, being in the form of an arch, bends as a whole and spreads out, and thus presses the particles together on the convex surface of the arch—*i. e.*, the outer table—and forces them asunder on the concave surface or inner table; and lastly, there is nothing firm under the inner table to support it and oppose the force. *Fractures of the vault* may be *simple fissures* or *starred* and *comminuted fractures*, and these may be *depressed* or *elevated*. These latter cases of fracture with elevation of the fractured portion are uncommon, and can only be produced by direct wound. In comminuted fracture a portion of the skull is broken into several pieces, the lines of fracture radiating from a centre where the chief impact of the blow was felt; if depressed, a fissure circumscribes the radiating line, enclosing a portion of skull. If this area is circular, it is termed a **pond fracture**, and would in all probability have been caused by a round instrument, as a blackjack or hammer; if elliptical in shape, it is termed a **gutter fracture**, and would owe its shape to the instrument which had produced it, as a poker. A fracture may take place along the line of an ossified or partly ossified suture. When a surgeon explores the vault of the skull through a wound he must not mistake a Wormian bone for a fragment produced by a fracture. A Wormian bone which may lead to mistake is encountered at the anterior inferior angle of the parietal bone.

Fractures of the base are most frequently produced by the extension of a fissure from the vault, as in falls on the head, where the fissure starts from the part of the vault which first struck the ground. Sometimes, however, they are caused by direct violence, when foreign bodies have been forced through the thin roof of the orbit, through the cribriform plate of the ethmoid from being thrust up the nose, or through the roof of the pharynx. Other cases of fracture of the base occur from indirect violence, as in fracture of the occipital bone from impaction of the spinal column against its condyles in falls on the buttocks, knees, or feet, or in cases where the glenoid cavity has been fractured by the violent impact of the condyle of the mandible against it from blows on the chin.

The most common place for fracture of the base to occur is through the middle fossa, and here the fissure usually takes a fairly definite course. Starting from the point struck, which is generally somewhere in the neighborhood of the parietal eminence, it runs downward through the parietal bone and the squamous portion of the temporal bone and across the petrous portion of this bone, frequently traversing and implicating the internal auditory meatus, to the middle lacerated foramen. From this it may pass across the body of the sphenoid, through the pituitary fossa to the middle lacerated foramen of the other side, and may indeed travel round the whole cranium, so as completely to separate the anterior from the posterior part. The course of the fracture should be borne in mind, as it explains the symptoms to which fracture in this region may give rise; thus, if the fissure pass across the internal auditory meatus, injury to the facial and auditory nerves may result, with consequent facial paralysis and deafness; or the tubular prolongation of the arachnoid around these nerves in the meatus may be torn, and thus permit of the escape of the cerebrospinal fluid should there be a communication between the internal ear and the tympanum and the membrana tympani be ruptured, as is frequently the case; again, if the fissure passes across the pituitary fossa and the mucopariosteum covering the under surface of the body of the sphenoid is torn, blood will find its way into the pharynx and be swallowed, and after a time vomiting of blood will result. Fractures of the anterior fossa, involving the bones forming the roof of the orbit and nasal fossa, are generally the results of blows on the forehead; but fracture of the cribriform plate of the ethmoid may be a complication of fracture of the nasal bone. When the fracture implicates the roof of the orbit, the blood finds its way into this cavity, and, travelling forward, appears as a subconjunctival ecchymosis. Subconjunctival ecchymosis can also be caused by fracture of the malar bone. If the roof of the nasal fossa be fractured, the blood escapes from the nose. In rare cases there may be also escape of cerebrospinal fluid from the nose where the dura and arachnoid have been torn. In fractures of the posterior fossa extravasation of blood takes place beneath the deep fascia, and discoloration of the skin is soon observed in the course of the posterior auricular artery, the discoloration first appearing in the skin over the tip of the mastoid process of the temporal bone (**Battle's sign**). Some of the blood which was extravasated beneath the deep fascia approaches the surface through the openings in the deep fascia for the passage of vessels and nerves.

The bones of the skull are frequently the seat of nodes, and not uncommonly **necrosis** results from this cause, also from injury. Necrosis may involve the entire thickness of the skull, but is usually confined to the external table. Necrosis of the internal table alone is rarely met with. The bones of the skull are also sometimes the seat of *sarcomatous tumors*.

The skull in *rachitis* is peculiar—the forehead is high, square, and projecting, and the antero-posterior diameter of the skull is long in relation to the transverse diameter. The bones of the face are small and ill-developed, and this gives the appearance of a larger head than actually exists. The bones of the head are often thick, especially in the neighborhood of the sutures, and the anterior fontanelle is late in closing, sometimes remaining unclosed until the fourth year. The condition of **craniotabes** has by some been also believed to be the result of rachitis, by others is believed to be due to inherited syphilis. In all probability it is due to both. In these cases the bone undergoes atrophic changes in patches, so that it becomes greatly thinned in places, generally where there is pressure, as from the pillow or nurse's arm. It is, therefore, usually met with in the parietal bone and vertical plate of the occipital bone.

In *congenital syphilis* deposits of porous bone are often found at the angles of the parietal bones and two halves of the frontal bone which bound the anterior fontanelle. These deposits are separated by the coronal and sagittal sutures, and give to the skull the appearance of a hot cross bun. They are known as *Parrot's nodes*, and such a skull has received the name of **natiform**,

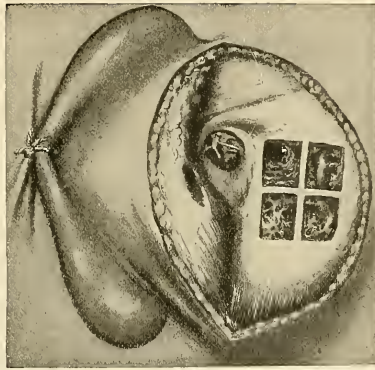


FIG. 118.—Division of the mastoid process into four equal parts. An opening in the upper anterior quadrant reaches the mastoid antrum; into the upper posterior quadrant reaches the lateral sinus; the lower anterior quadrant into mastoid cells; a superficial opening into the lower posterior quadrant reaches mastoid cells; a deep opening reaches the descending limb of the lateral sinus. (A. E. Schmitt.)

from its fancied resemblance to the buttocks. The cells of the mastoid are sometimes the seat of suppuration as the result of infection extending backward from the tympanic cavity. In such cases the antrum of the mastoid must be opened in order that the pus escape. This is done by applying the gouge between the posterior wall of the external auditory meatus and the posterior root of the zygoma. This space is called the *suprameatal triangle of Macewen*.

In connection with the bones of the face a common malformation is **cleft palate**, owing to the nonunion of the palatal processes of the maxillary or preoral arch. This cleft may involve the whole or only a portion of the hard palate, and usually involves the soft palate also. The cleft is in the middle line, except it involves the alveolus in front, when it follows the suture between the main portion of the bone and the premaxillary bone. Sometimes the cleft runs on either side of the premaxillary bone, so that this bone is quite isolated from the maxillary bones and hangs from the end of the vomer. In such a case the premaxillary bone usually contains the germs of the central incisors only. In some cases there is no premaxillary bone and the great gap in the lip is in the median line. Cleft palate (page 106) is usually associated with harelip, which, when single, is almost always on one side, corresponding to the position of the suture between the lateral incisor and canine tooth. Some few cases of median harelip have been described. In double **harelip** there is a cleft on each side of the middle line.

The outlines and the height of the arch of the palate vary greatly in different persons. A narrow palate with a high arch is common in idiots and certain degenerates.

The bones of the face are sometimes fractured as the result of direct violence. The two

most commonly broken are the nasal bone and the mandible, and of these, the latter is by far the most frequently fractured of all the bones of the face. Fracture of the *nasal* bone is for the most part transverse, and takes place about half an inch from the free margin. The broken portion may be displaced backward or more generally to one side by the force which produced the lesion, as there are no muscles here which can cause displacement. The *malar* bone is probably never broken alone; that is to say, unconnected with a fracture of the other bones of the face. The *zygomatic arch* is occasionally fractured, and when this occurs from direct violence, as is usually the case, the fragments may be displaced inward. This lesion is often attended with great difficulty or even inability to open and shut the mouth, and this has been stated to be due to the depressed fragments perforating the temporal muscle, but would appear rather to be caused by the injury done to the bony origin of the Masseter muscle. *Fractures of the maxilla* may vary much in degree, from the chipping off of a portion of the alveolar arch, to an extensive comminution of the whole bone from severe violence, as the kick of a horse. The most common situation for a *fracture of the mandible* is in the neighborhood of the canine tooth, as at this spot the jaw is weakened by the deep socket for the fang of this tooth; it is next most frequently fractured at the angle; then at the symphysis, and finally the neck of the condyle or the coronoid process may be broken. Occasionally a double fracture may occur, one in either half of the bone. The fractures are usually compound, from laceration of the mucous membrane covering the gums. The displacement is mainly the result of the same violence as produced the injury, but may be further increased by the action of the muscles passing from the neighborhood of the symphysis to the hyoid bone.

The maxilla and mandible are both of them frequently the seat of *nerosis*, though the disease affects the latter much more frequently than the former. It may be the result of periostitis, from tooth irritation, injury, or the action of some specific poison, as syphilis, or from salivation by mercury; it not infrequently occurs in children after attacks of the exanthematous fevers, and a special form occurs from the action of the fumes of phosphorus in persons engaged in the manufacture of matches.

Tumors attack the jaw bones not infrequently, and these may be either innocent or malignant; in the upper jaw cysts may occur in the antrum, constituting the so-called dropsy of the antrum; or, again, cysts may form in either jaw in connection with the teeth—either cysts connected with the roots of fully developed teeth, the “dental cyst,” or cysts connected with imperfectly developed teeth, the “dentigerous cyst.” Solid innocent tumors include the fibroma, the chondroma, and the osteoma. Of malignant tumors there are the endotheliomata, the sarcomata, and the epitheliomata. The sarcomata are of various kinds, the spindle-celled, the round-celled, which are of a very malignant character, and the myeloid sarcomata, principally affecting the alveolar margin of the bone. Of the epitheliomata we find the squamous variety spreading to the bone from the palate or gum, and the cylindrical epithelioma originating in the antrum or nasal fosse.

Both mandible and maxilla occasionally require **excision** for tumors and in some other conditions. The maxilla is removed by an incision from the inner canthus of the eye, along the side of the nose, around the ala, and down the middle line of the upper lip. A second incision is carried outward from the inner canthus of the line along the lower margin of the orbit as far as the prominence of the malar bone. The flap thus formed is reflected outward and the surface of the bone exposed, and the central incisor of the diseased side is removed. The connections of the bone to the other bones of the face are then divided with a narrow saw and bone-cutting forceps. They are (1) the junction with the malar bone, passing into the sphenomaxillary fissure; (2) the nasal process; a small portion of its upper extremity, connected with the nasal bone in front, the lacrimal bone behind, and the frontal bone above, being left; (3) the connection with the bone on the opposite side and the palate in the roof of the mouth. The bone is now firmly grasped with lion-jaw forceps, and by means of a rocking movement upward and downward the remaining attachments of the orbital plate with the ethmoid and the back of the bone with the palate, broken through. The soft palate is first separated from the hard with a scalpel, and is not removed. Occasionally in removing the maxilla it will be found that the orbital plate can be spared, and this should always be done if possible. A horizontal saw-cut is to be made just below the infraorbital foramen and the bone cut through with a chisel and mallet. Lockwood has pointed out that in removing the maxilla the surgeon must be careful in dividing the nasal process of the maxilla to preserve the internal orbital or palpebral ligament (*Tendo oculi*), because this ligament arises from the palpebral fascia, and if it is interfered with the eye will inevitably drop downward. Removal of one-half of the mandible is sometimes required. If possible, the section of the bone should be made to one side of the symphysis, so as to save the genial tubercles and the origin of the Geniohyoglossus muscle, as otherwise the tongue tends to fall backward and may produce suffocation. Having extracted the central or preferably the lateral incisor tooth, a vertical incision is made down to the bone, commencing at the free margin of the lip, and carried to the lower border of the bone; it is then carried along its lower border to the angle and up the posterior margin of the ramus to a level with the lobule of the ear. The flap

thus formed is raised by separating all the structures attached to the outer surface of the bone. The jaw is now sawed through at the point where the tooth has been extracted, and the knife passed along the inner side of the mandible, separating the structures attached to this surface. The mandible is then grasped by the surgeon and strongly depressed, so as to bring down the coronoid process and enable the operator to sever the tendon of the Temporal muscle. The mandible can be now further depressed, care being taken to not evert it nor rotate it outward, which would endanger the internal maxillary artery, and the External pterygoid muscle is torn through or divided. The capsular ligament is now opened in front and the lateral ligaments divided, and the mandible removed with a few final touches of the knife.

The antrum of Highmore occasionally requires tapping for suppuration. This may be done through the socket of a tooth, preferably the first molar, the fangs of which are most intimately connected with the antrum, or through the facial aspect of the bone above the alveolar process. This latter method does not perhaps afford such efficient drainage, but there is less chance of food finding its way into the cavity. The operation may be performed by incising the mucous membrane above the second molar tooth, and driving a trocar or any sharp-pointed instrument into the cavity.

THE HYOID OR LINGUAL BONE (OS HYOIDEUM).

The **hyoid bone** (Fig. 119) is a bony arch, shaped like a horseshoe, and consisting of five segments—a body, two greater cornua, and two lesser cornua. It is suspended from the tips of the styloid processes of the temporal bones by ligamentous bands, the stylohyoid ligaments.

The **Body**, or **basihyal** (*corpus ossei hyoidei*), forms the central part of the bone, and is of a quadrilateral form.

Surfaces.—Its **anterior surface** (Fig. 119), convex, directed forward and upward, is divided into two parts by a vertical ridge which descends along the median

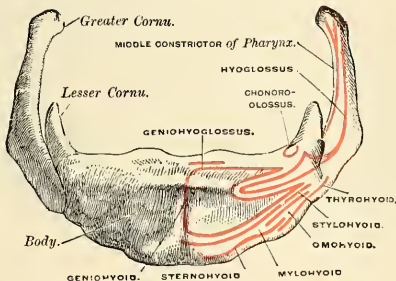


FIG. 119.—Hyoid bone. Anterior surface. (Enlarged.)

line and is crossed at right angles by a horizontal ridge, so that this surface is divided into four spaces or depressions. At the point of meeting of these two lines is a prominent elevation, the **tubercle**. The anterior surface gives attachment to the Geniohyoid in the greater part of its extent; *above*, to the Geniohyoglossus; *below*, to the Mylohyoid, Stylohyoid, and the aponeurosis of the Digastric (suprahyoid aponeurosis); and between these to part of the Hyoglossus. The **posterior surface** is smooth, concave, directed backward and downward, and separated from the epiglottis by the thyrohyoid membrane and by a quantity of loose areolar tissue. The **lateral surfaces** are joined to the greater cornua. In early life they are connected with the cornua by cartilaginous surfaces, and held together by ligaments, and occasionally a synovial membrane is found between them.

Borders.—The **superior border** is rounded, and gives attachment to the thyrohyoid membrane, part of the Geniohyoglossi and Chondroglossi muscles. The **inferior border** gives attachment, in *front*, to the Sternohyoid; *behind*, to the Omohyoid and to the part of the Thyrohyoid at its junction with the great cornua. It also gives attachment to the Levator glandulae thyroideae when this muscle is present.

The **Greater Cornua** (*cornua majora*), or **thyrohyals**, project backward from the lateral surfaces of the body; they are flattened from above downward, diminish in size from before backward, and terminate posteriorly in a tubercle for the attachment of the lateral thyrohyoid ligament. The outer surface gives attachment to the Hyoglossus, their upper border to the Middle constrictor of the pharynx, their lower border to part of the Thyrohyoid muscle.

The **Lesser Cornua** (*cornua minora*), or **ceratohyals**, are two small, conical-shaped eminences attached by their bases to the angles of junction between the body and greater cornua, and giving attachment by their apices to the stylohyoid ligaments.¹ The smaller cornua are connected to the body of the bone by a distinct diarthrodial joint, which usually persists throughout life, but occasionally becomes ankylosed.

Development.—From *six* centres—two (sometimes one) for the body, and one for each cornu. Ossification commences in the body about the eighth month, and in the greater cornua toward the end of fetal life. Ossification of the lesser cornua commences in the first or second year after birth.

Attachment of Muscles.—Sternohyoid, Thyrohyoid, Omohyoid, aponeurosis of the Digastric, Stylohyoid, Mylohyoid, Geniohyoid, Geniohyoglossus, Chondroglossus, Hyoglossus, Middle constrictor of the pharynx, and occasionally a few fibres of the Inferior lingualis. It also gives attachment to the thyrohyoidean membrane and the stylohyoid, thyrohyoid, and hyoepiglottic ligaments.

Surface Form.—The hyoid bone can be felt in the receding angle below the chin, and the finger can be carried along the whole length of the bone to the greater cornu, which is situated just below the angle of the mandible. This process of bone is best perceived by making pressure on one cornu, and so pushing the bone over to the opposite side, when the cornu of this side will be distinctly felt immediately beneath the skin. This process of bone is an important landmark in ligation of the lingual artery.

Applied Anatomy.—The hyoid bone is occasionally *fractured*, generally from direct violence, as in the act of garroting or throttling. It is frequently found broken in those who have been hanged. The greater cornu is the part of the bone most frequently broken, but sometimes the fracture takes place through the body of the bone. In consequence of the muscles of the tongue having important connections with this bone, there is great pain upon any attempt being made to move the tongue, as in speaking or swallowing.

THE THORAX.

The **thorax**, or **chest**, is an osseocartilaginous cage, the cavity of which (*cavum thoracis*) contains and protects the principal organs of respiration and circulation. It is conical in shape, being narrow above and broad below, flattened from before backward, and longer behind than in front. It is somewhat reniform on transverse section.

Boundaries.—The **posterior surface** is formed by the twelve thoracic vertebræ and the posterior part of the ribs. It is concave from above downward, and presents on each side of the middle line a deep groove, the **vertebral groove**, in consequence of the direction backward and outward which the ribs take from their vertebral extremities to their angles. The **anterior surface** is flattened or slightly convex, and inclined forward from above downward. It is formed by the sternum

¹ These ligaments in many animals are distinct bones, and in man are occasionally ossified to a certain extent.

and costal cartilages. The **lateral surfaces** are convex; they are formed by the ribs, separated from each other by spaces. Each space is called an **intercostal space** (*spatium intercostale*). These are eleven in number, and are occupied by the intercostal muscles.

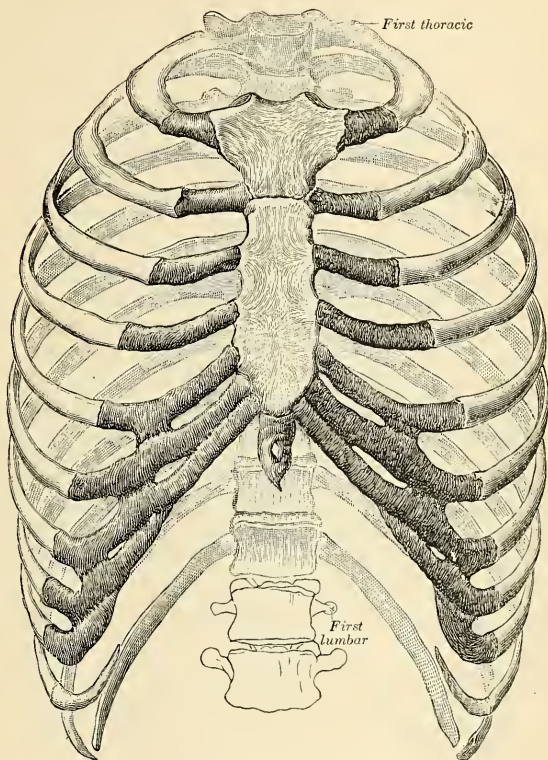


FIG. 120.—The thorax. Ventral view.

The **superior or upper aperture** of the thorax, the **inlet** (*apertura thoracis superior*), is reniform in shape, being broader from side to side than from before backward. It is formed by the first thoracic vertebra behind, the upper margin of the sternum in front, and the first rib on each side. It slopes downward and forward, so that the anterior boundary is on a lower level than the posterior. The antero-posterior diameter is about two inches (5 cm.), and the transverse about four (10 cm.). The parts which pass through the upper opening of the thorax are, from before backward in or near the middle line, the Sternohyoid and Sternothyroid muscles, the remains of the thymus gland, the trachea, œsophagus, thoracic duct, the inferior thyroid veins, and the Longus colli muscle of each side; at the sides, the innominate artery, the left common carotid, and

left subclavian arteries, the internal mammary and superior intercostal arteries, the right and left innominate veins, the vagus, cardiac, phrenic, and sympathetic nerves, the anterior branch of the first thoracic nerve, and the recurrent laryngeal nerve of the left side. The apex of each lung, covered by the pleura, also projects through this aperture, a little above the margin of the first rib.

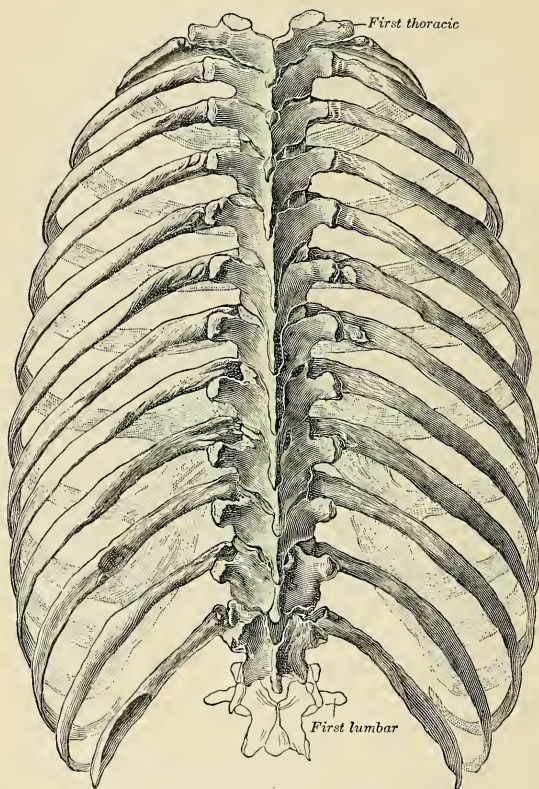


FIG. 121.—The thorax. Dorsal view. (Spaltcholz.)

The inferior or lower opening (*apertura thoracis inferior*) is formed by the twelfth thoracic vertebra behind, by the twelfth ribs at the sides, and in front by the eleventh, tenth, ninth, eighth, and seventh costal cartilages, which ascend on either side and form an angle, the *subcostal angle* (*angulus infrasternalis*), from the apex of which the ensiform cartilage projects. It is wider transversely than from before backward. It slopes obliquely downward and backward, so that the cavity of the thorax is much deeper behind than in front. The Diaphragm closes in the opening forming the floor of the thorax.

The Cavity of the Thorax (*cavum thoracis*).—The capacity of the cavity of the thorax does not correspond with its apparent size externally, because (1) the space enclosed by the lower ribs is occupied by some of the abdominal viscera; and (2) the cavity extends above the first rib into the neck. The size of the cavity of the thorax is constantly varying during life, with the movements of the ribs and Diaphragm, and with the degree of distention of the abdominal viscera. From the collapsed state of the lungs, as seen when the thorax is opened, in the dead body, it would appear as if the viscera only partly filled the cavity of the thorax, but during life there is no vacant space, that which is seen after death being filled up during life by the expanded lungs.

In the female the thorax differs as follows from the male: (1) Its general capacity is less. (2) The sternum is shorter. (3) The upper margin of the sternum is on a level with the lower part of the body of the third thoracic vertebra, whereas in the male it is on a level with the lower part of the body of the second thoracic vertebra. (4) The upper ribs are more movable, and so allow a greater enlargement of the upper part of the thorax than in the male.

The Sternum, or Breast Bone.

The **sternum**, or **breast bone** (Figs. 122 and 123), is a flat, narrow bone, situated in the median line of the front of the chest, and consisting, in the adult, of three portions. It has been likened to an ancient sword; the upper piece, representing the handle, is termed the **manubrium sterni** (presternum); the middle and largest piece, which represents the chief part of the blade, is termed the **gladiolus** (*corpus sterni* or mesosternum); and the inferior piece, which is likened to the point of the sword, is termed the **ensiform appendix** (*processus xiphoideus* or metasternum). In its natural position its inclination is oblique from above downward and forward. It is slightly convex in front, concave behind, broad above, becoming narrowed at the point where the first and second pieces are connected, after which it again widens a little, and is pointed at its extremity. Its average length in the adult is about seven inches (17.5 cm.), being rather longer in the male than in the female. At the junction of the manubrium and gladiolus is a distinct angle (*angulus Ludovici*), the gladiolus looking forward, the manubrium also looking forward, but to a less degree. This angle is on a level with the second rib, and is produced by retraction of the upper portion of the thorax.

First Piece.—The **manubrium sterni** is of a somewhat triangular form, broad and thick above, narrow below at its junction with the middle piece.

Surfaces.—Its **anterior surface**, convex from side to side, concave from above downward, is smooth, and affords attachment on each side to the Pectoralis major and sternal origin of the Sternomastoid muscle. In well-marked bones the ridges limiting the attachment of these muscles are very distinct. Its **posterior surface**, concave and smooth, affords attachment on each side of the Sternohyoid and Sternothyroid muscles.

Borders.—The **superior border**, the thickest, presents at its centre the **presterneal notch** (*incisura jugularis*), and on each side an oval articular surface, the **clavicular facet** (*incisura clavicularis*), directed upward, backward, and outward, for articulation with the sternal end of the clavicle. The **inferior border** presents an oval, rough surface, covered in the recent state with a thin layer of cartilage, for articulation with the second portion of the bone (*synchondrosis sternalis*). The junction of the manubrium with the gladiolus is marked by a transverse ridge, which corresponds to the attachment on each side of the cartilage of the second rib. The **lateral borders** are marked above by a depression (*incisura costalis I*) for the first costal cartilage, and below by a small facet, which, with a

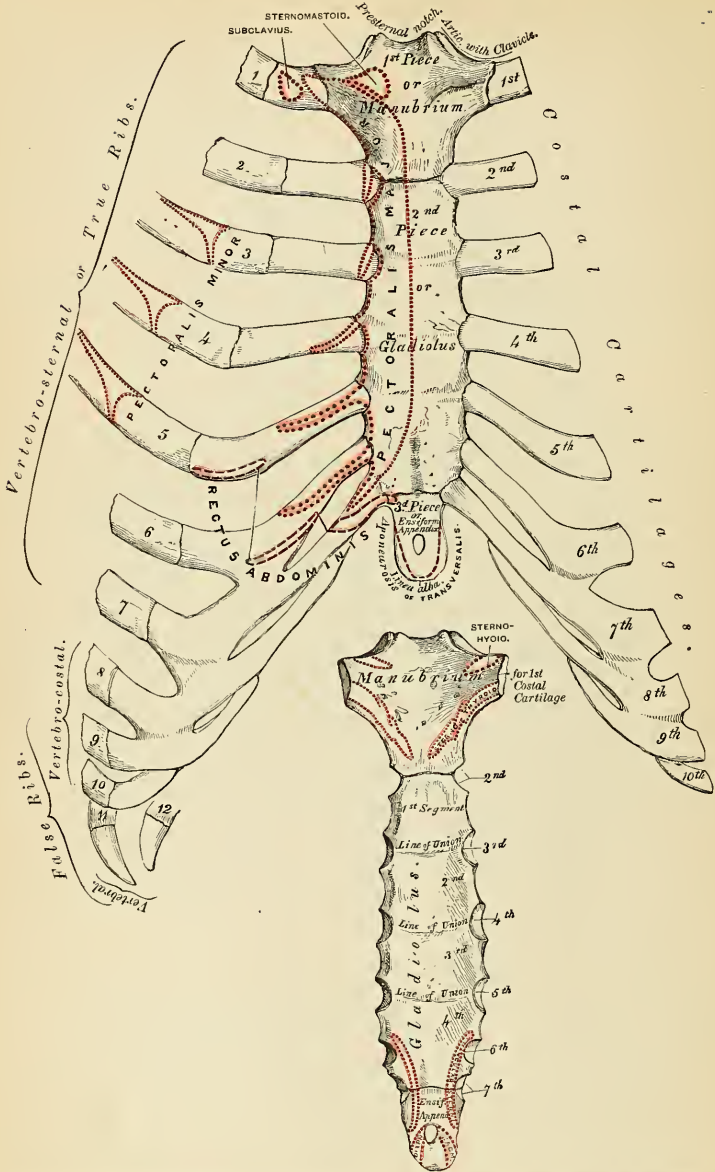


FIG. 122.—Anterior (ventral) surface of sternum and costal cartilages.

FIG. 123.—Posterior (dorsal) surface of sternum.

similar facet on the upper angle of the middle portion of the bone, forms a notch (*incisura costalis II*) for the reception of the costal cartilage of the second rib. These articular surfaces are separated by a narrow, curved edge, which slopes from above downward and inward.

Second Piece.—The *gladiolus*, considerably longer, narrower, and thinner than the first piece, is broader below than above.

Surfaces.—Its *anterior surface* (*planum sternale*) is nearly flat, directed upward and forward, and marked by three transverse lines which cross the bone opposite the third, fourth, and fifth articular depressions. These lines are produced by the union of the four separate pieces of which this part of the bone consists at an early period of life. At the junction of the third and fourth pieces is occasionally seen an orifice, the *sternal foramen*; it varies in size and form in different individuals and pierces the bone from before backward. This surface affords attachment on each side to the sternal origin of the *Pectoralis major*. The *posterior surface*, slightly concave, is also marked by three transverse lines, but they are less distinct than those in front; this surface affords attachment below, on each side, to the *Triangularis sterni* muscle, and occasionally presents the posterior opening of the sternal foramen.

Borders.—The *superior border* presents an oval surface for articulation with the manubrium. The *inferior border* is narrow, and articulates with the ensiform appendix. Each *lateral border* presents, at each superior angle, a small facet, which, with a similar facet on the manubrium, forms a cavity for the cartilage of the second rib; the four succeeding angular depressions receive the cartilages of the third, fourth, fifth, and sixth ribs; while each inferior angle presents a small facet, which, with a corresponding one on the ensiform appendix, forms a notch for the cartilage of the seventh rib. They are separated by a series of curved interarticular intervals, which diminish in length from above downward, and correspond to the intercostal spaces. Most of the cartilages belonging to the true ribs, as will be seen from the foregoing description, articulate with the sternum at the line of junction of two of its primitive component segments. This is well seen in many of the lower animals, where the separate parts of the bone remain ununited longer than in man. In this respect a striking analogy exists between the mode of connection of the ribs with the vertebral column and the connection of the costal cartilages with the sternum.

Third Piece.—The *ensiform* or *xiphoid appendix* is the smallest of the three; it is thin and elongated in form, cartilaginous in structure in youth, but more or less ossified at the upper part in the adult.

Surfaces.—Its *anterior surface* affords attachment to the *chondroxiphoid ligament*; its *posterior surface*, to some of the fibres of the *Diaphragm* and *Triangularis sterni* muscles; its *lateral borders*, to the aponeurosis of the *abdominal muscles*. Above it articulates with the lower end of the *gladiolus*, and at each superior angle presents a facet (*incisura costalis VII*), for the lower half of the cartilage of the seventh rib; below, by its pointed extremity, it gives attachment to the *linea alba*. This portion of the sternum varies much in appearance, being sometimes pointed, broad, and thin, sometimes bifid or perforated by a circular opening, occasionally curved or deflected considerably to one or the other side.

Structure.—The bone is composed of delicate cancellous structure, covered by a thin layer of compact tissue, which is thickest in the manubrium between the articular facets for the clavicles.

Development.—The cartilaginous sternum originally consists of two bars, situated one on either side of the mesal plane and connected with the rib cartilages of its own side. It is usual for the eighth cartilage to lose its attachment to the sternum and become attached to the seventh cartilage. The sternal end of the ninth cartilage divides longitudinally, the mesal part remains

attached to the sternum and becomes the ensiform process. The remaining part acquires attachment to the eighth cartilage. These two bars fuse with each other along the middle line, and the bone, including the ensiform appendix, is usually developed from *six* centres, one for the first piece or manubrium, four for the second piece or gladiolus, and one for the ensiform appendix. Up to the middle of fetal life the sternum is entirely cartilaginous, and when ossification takes place the ossific granules are deposited in the middle of the intervals between the articular depressions for the costal cartilages, in the following order (Fig. 125): In the manubrium and first piece of the gladiolus, during the sixth month; in the second and third pieces of the gladiolus between the seventh and ninth months; the fourth piece of the gladiolus ossifies toward the latter part of the first year; the ensiform process ossifies between the fifth and eighteenth years. The centres appear in the upper part of each segment and proceed gradually downward. To these may be added the occasional existence, as described by Breschet, of two episternal centres, which make their appearance one on each side of the presternal notch. They are probably vestiges of the episternal bone of the monotremata and lizards. It occasionally happens that some of the segments are formed from more than

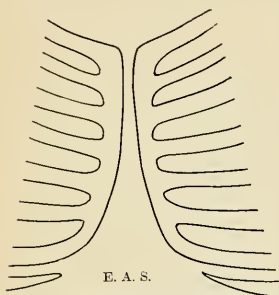


FIG. 124.—Showing ventral ends of the upper seven (cartilaginous) ribs fused to form a pair of longitudinal sternal bars.

one centre, the number and position of which vary (Fig. 127). Thus, the first piece may have two, three, or even six centres. When two are present, they are generally situated one above the other, the upper one being the larger;¹ the second piece has seldom more than one; the

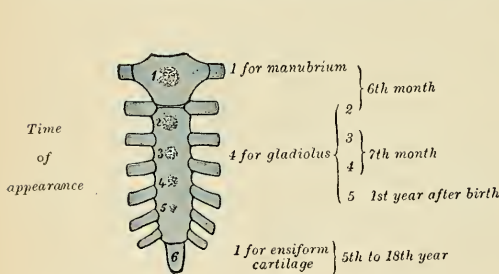


FIG. 125.—Development of the sternum from six centres. Time of appearance.

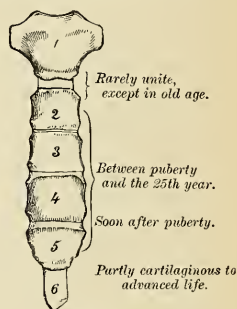


FIG. 126.—Time of union of sternum.

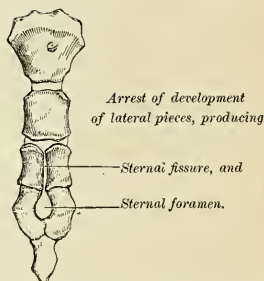
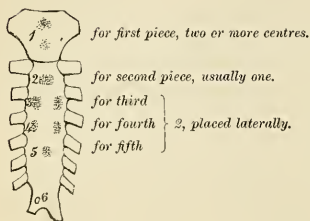


FIG. 127.—Peculiarities in number of centres of sternum. FIG. 128.—Peculiarities in mode of union of sternum.

¹ Sir George Humphry states that this is "probably the more complete condition."

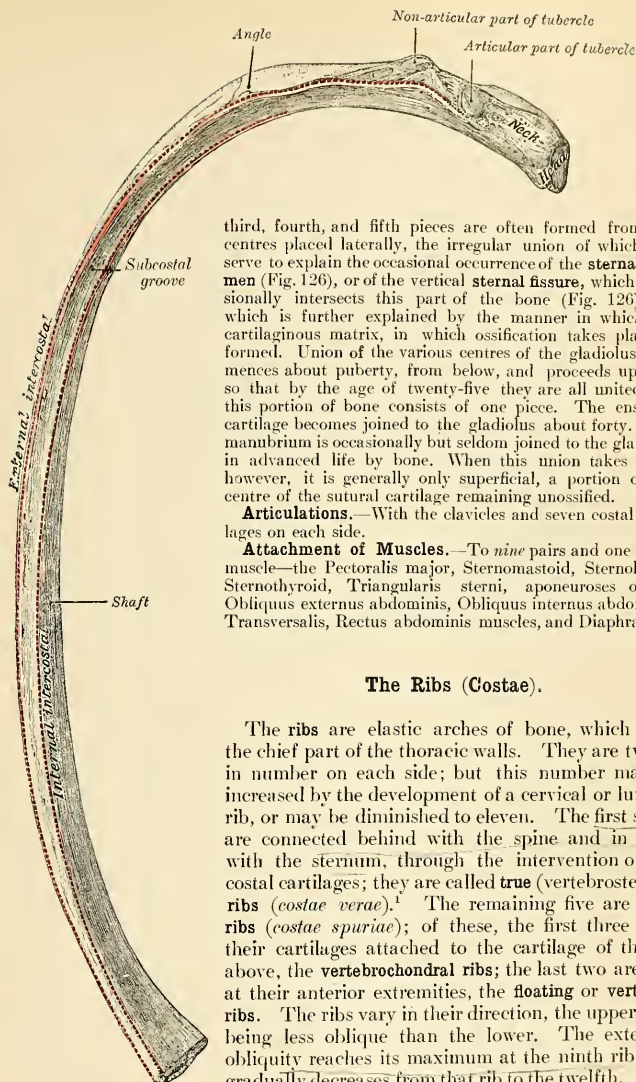


FIG. 129.—A central rib of the left side. Inferior aspect.

third, fourth, and fifth pieces are often formed from two centres placed laterally, the irregular union of which will serve to explain the occasional occurrence of the **sternal foramen** (Fig. 126), or of the vertical **sternal fissure**, which occasionally intersects this part of the bone (Fig. 126), and which is further explained by the manner in which the cartilaginous matrix, in which ossification takes place, is formed. Union of the various centres of the gladiolus commences about puberty, from below, and proceeds upward, so that by the age of twenty-five they are all united, and this portion of bone consists of one piece. The ensiform cartilage becomes joined to the gladiolus about forty. The manubrium is occasionally but seldom joined to the gladiolus in advanced life by bone. When this union takes place, however, it is generally only superficial, a portion of the centre of the sutural cartilage remaining unossified.

Articulations.—With the clavicles and seven costal cartilages on each side.

Attachment of Muscles.—To *nine* pairs and one single muscle—the Pectoralis major, Sternomastoid, Sternohyoid, Sternothyroid, Triangularis sterni, aponeuroses of the Obliquus externus abdominis, Obliquus internus abdominis, Transversalis, Rectus abdominis muscles, and Diaphragm.

The Ribs (Costae).

The **ribs** are elastic arches of bone, which form the chief part of the thoracic walls. They are twelve in number on each side; but this number may be increased by the development of a cervical or lumbar rib, or may be diminished to eleven. The first seven are connected behind with the spine and in front with the sternum, through the intervention of the costal cartilages; they are called **true** (vertebrosternal) ribs (*costae verae*).¹ The remaining five are **false** ribs (*costae spuriae*); of these, the first three have their cartilages attached to the cartilage of the rib above, the **vertebrochondral** ribs; the last two are free at their anterior extremities, the **floating** or **vertebral** ribs. The ribs vary in their direction, the upper ones being less oblique than the lower. The extent of obliquity reaches its maximum at the ninth rib, and gradually decreases from that rib to the twelfth. The ribs are situated one below the other in such a manner that spaces are left between them. Each

¹ Sometimes the eighth rib cartilage articulates with the sternum; this condition occurs more frequently on the right than on the left side.

space is called an **intercostal space** (*spatium intercostale*). The length of these spaces corresponds to the length of the ribs and their cartilages; their breadth is greater in front than behind, and between the upper than between the lower ribs. The ribs increase in length from the first to the seventh, when they again diminish to the twelfth. In breadth they decrease from above downward; in the upper ten the greatest breadth is at the sternal extremity.

Common Characters of the Ribs.—A rib from the middle of the series should be taken in order to study the common characters of the ribs (Figs. 129 and 130). Each rib presents two extremities, a **posterior or vertebral**, an **anterior or sternal**, and an intervening portion—the **body or shaft**.

Posterior Extremity.—The **posterior or vertebral extremity** presents for examination a head, neck, and tuberosity.

The **head** (*capitulum costae*) (Fig. 130) is marked by a kidney-shaped articular surface, divided by a horizontal ridge (*crista capituli*) into two facets for

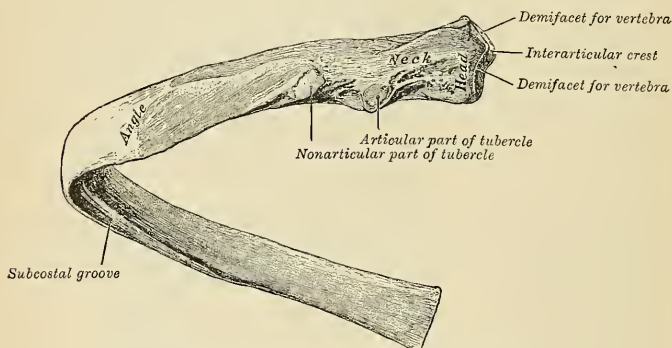


FIG. 130.—A central rib of the left side, viewed from behind.

articulation with the costal cavity formed by the junction of the bodies of two contiguous thoracic vertebræ; the upper facet is small, the inferior one of larger size; the ridge separating them serves for the attachment of the interarticular ligament.

The **neck** (*collum costae*) is that flattened portion of the rib which extends outward from the head; it is about an inch long, and is placed in front of the transverse process of the lower of the two vertebræ with which the head articulates. Its *anterior surface* is flat and smooth, its *posterior surface* is rough for the attachment of the middle costotransverse ligament, and is perforated by numerous foramina, the direction of which is less constant than those found on the inner surface of the shaft. Of its two borders, the *superior border* presents a rough crest (*crista colli costae*) for the attachment of the anterior costotransverse ligament; its *inferior border* is rounded. On the posterior surface of the neck, just where it joins the shaft, and nearer the lower than the upper border, is an eminence—the **tuberosity, or tubercle**.

The **tuberosity** (*tuberculum costae*) consists of an articular and a nonarticular portion. The **articular portion** (*facies articularis tuberculi costae*), the more internal and inferior of the two, presents a small, oval surface or articulation with the extremity of the transverse process of the lower of the two vertebræ to which the head is connected. The **nonarticular portion** is a rough elevation, which

affords attachment to the posterior costotransverse ligament. The tubercle is much more prominent in the upper than in the lower ribs.

Anterior Extremity.—The **anterior** or **sternal extremity** is flattened, and presents a porous, oval, concave depression, into which the costal cartilage is received.

The **shaft** (*corpus costae*) is thin and flat, so as to present two surfaces, an external and an internal, and two borders, a superior and an inferior.

The **external surface** is convex, smooth, and marked at its back part, a little in front of the tuberosity, by a prominent line, directed obliquely from above downward and outward; this gives attachment to a tendon of the *Iliocostalis* muscle or of one of its accessory portions, and is called the **angle** (*angulus costae*). At this point the rib is bent in two directions. If the rib is laid upon its lower border, it will be seen that the portion of the shaft in front of the angle rests upon this border, while the portion of the shaft behind the angle is bent inward and at the same time tilted upward. The interval between the angle and the tuberosity increases gradually from the second to the tenth rib. The portion of bone between these two parts is rounded, rough, and irregular, and serves for the attachment of the *Longissimus dorsi* muscle. The portion of bone between the tubercle and sternal extremity is also slightly twisted upon its own axis, the external surface looking downward behind the angle, a little upward in front of it. This surface presents toward its sternal extremity an oblique line, the **anterior angle**.

The **internal surface** is concave, smooth, directed a little upward behind the angle, a little downward in front of it. This surface is marked by a ridge which commences at the lower extremity of the head; it is strongly marked as far as the inner side of the angle, and gradually becomes lost at the junction of the anterior with the middle third of the bone. The interval between it and the inferior border presents a groove, **subcostal groove** (*sulcus costae*), for the intercostal vessels and nerve. At the back part of the bone this groove belongs to the inferior border, but just in front of the angle, where it is deepest and broadest, it corresponds to the internal surface. The superior edge of the groove is rounded; it serves for the attachment of the Internal intercostal muscle. The inferior edge corresponds to the lower margin of the rib and gives attachment to the External intercostal muscle. Within the groove are seen the orifices of numerous small foramina which traverse the wall of the shaft obliquely from before backward.

The **superior border**, thick and rounded, is marked by an external and an internal lip, more distinct behind than in front; they serve for the attachment of the External and Internal intercostal muscles.

The **inferior border**, thin and sharp, has attached to it the External intercostal muscle.

Peculiar Ribs.—The ribs which require especial consideration are five in number, viz., the **first**, **second**, **tenth**, **eleventh**, and **twelfth**.

First Rib.—The first rib (Fig. 131) is the shortest and the most curved of all the ribs; it is broad and flat, its surfaces looking upward and downward, and its borders inward and outward. The **head** is of small size, rounded, and presents only a single articular facet for articulation with the body of the first thoracic vertebra. The **neck** is narrow and rounded. The **tuberosity**, thick and prominent, rests on the outer border. There is *no angle*, but in this situation the rib is slightly bent, with the convexity of the bend upward, so that the head of the bone is directed downward. The **upper surface** of the shaft is marked by two shallow depressions, separated by a small rough surface (*tuberculum scalen*i) for the attachment of the *Scalenus anticus* muscle—the shallow groove in front of it transmitting the subclavian vein, the deeper groove behind it (*sulcus subclaviae*) the subclavian artery. Between the groove for the subclavian artery and the tuberosity is a rough surface, for the attachment of the *Scalenus medius* muscle. The **under surface** is smooth, and destitute of the groove observed on the other

ribs. The **outer border** is convex, thick, and rounded, and at its posterior part gives attachment to the first serration of the Serratus magnus; the **inner** is concave, thin, and sharp, and marked about its centre by the commencement of

FIG. 131

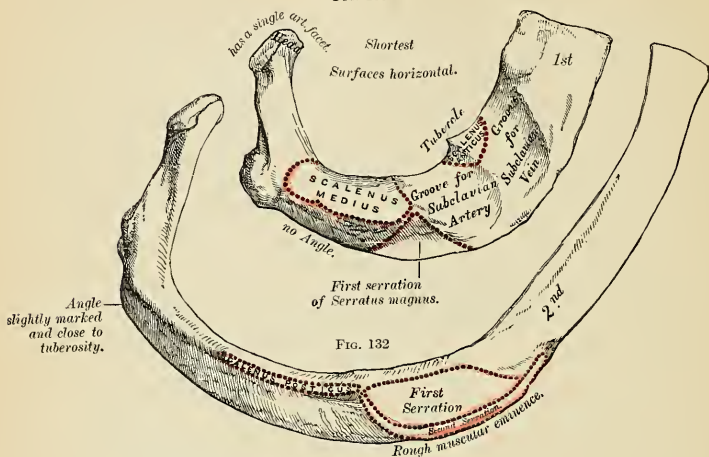


FIG. 133

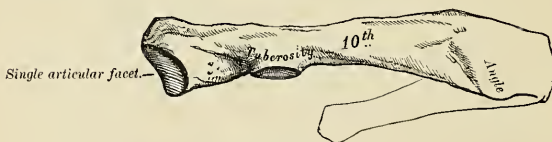

FIG. 134

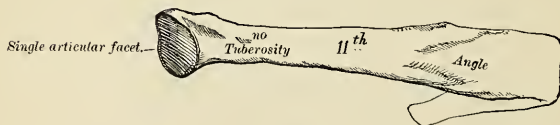
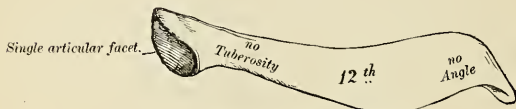


FIG. 135



FIGS. 131 to 135.—Peculiar ribs.

the rough surface for the Scalenus anticus. The **anterior extremity** is larger and thicker than any of the other ribs.

Second Rib.—The second rib (Fig. 132) is much longer than the first, but bears a very considerable resemblance to it in the direction of its curvature. The non-

articular portion of the tuberosity is occasionally only slightly marked. The angle is slight and situated close to the tuberosity, and the shaft is not twisted, so that both ends touch any plane surface upon which it may be laid; but there is a similar though slighter bend, with its convexity upward, to that found in the first rib. The shaft is not horizontal, like that of the first rib, its **outer surface**, which is convex, looking upward and a little outward. It presents, near the middle, a rough eminence (*tuberositas costae II*), for the attachment of part of the first and all of the second digitations of the Serratus magnus; behind and above which is attached the Scalenus posticus. The **inner surface**, smooth and concave, is directed downward and a little inward; it presents a short groove toward its posterior part.

Tenth Rib.—The tenth rib (Fig 133) has only a single articular facet on its head.

Eleventh and Twelfth Ribs.—The eleventh and twelfth ribs (Figs. 134 and 135) have each a single articular facet on the head, which is of rather large size; they have *no neck or tuberosity*, and are pointed at the extremity. The eleventh has a slight angle and a shallow groove on the lower border. The twelfth has neither, and is much shorter than the eleventh, and the head has a slight inclination downward. Sometimes the twelfth rib is even shorter than the first.

Structure.—The ribs consist of cancellous tissue enclosed in a thin layer of compact bone.

Development.—Each rib, with the exception of the last two, is developed from *three* centres, *one* for the shaft near the angle, *one* for the head, and *one* for the tubercle. The last two ribs have only two centres, that for the tubercle being wanting. Ossification commences in the shaft of the ribs between the ninth and eleventh weeks before its appearance in the vertebræ. The epiphysis of the head, which is of slightly angular shape, and that for the tubercle, of a lenticular form, make their appearance between the sixteenth and twentieth years, and are not united to the rest of the bone until about the twenty-fifth year.

Attachment of Muscles.—To *nineteen*—the Intercostales externi et interni, Scalenus anticus, Scalenus medius, Scalenus posticus, Pectoralis minor, Serratus magnus, Obliquus externus abdominis, Quadratus lumborum, Diaphragm, Latissimus dorsi, Serratus posticus superior, Serratus posticus inferior, Iliocostalis, Musculus accessorius ad iliocostalem, Longissimus dorsi, Cervicalis ascendens, Levatores costarum, and Infracostales.

The Costal Cartilages.

The **costal cartilage** (*cartilago costalis*) (Fig. 122) is white, hyaline cartilage. The cartilages serve to prolong the ribs forward to the front of the thorax, and they contribute very materially to the elasticity of its walls. The first seven are connected with the sternum, the next three with the lower border of the cartilage of the preceding rib. The cartilages of the last two ribs have pointed extremities, which terminate in free ends in the walls of the abdomen. Like the ribs, the costal cartilages vary in their length, breadth, and direction. They increase in length from the first to the seventh, then gradually diminish to the last. They diminish in breadth, as well as the intervals between them, from the first to the last. They are broad at their attachment to the ribs, and taper toward their sternal extremities, excepting the first two, which are of the same breadth throughout, and the sixth, seventh, and eighth, which are enlarged where their margins are in contact. In direction they also vary; the first descends a little, the second is horizontal, the third ascends slightly, while all the rest follow the course of the ribs for a short extent, and then ascend to the sternum or preceding cartilage. Each costal cartilage presents two surfaces, two borders, and two extremities.

Surfaces.—The **anterior surface** is convex, and looks forward and upward; that of the first gives attachment to the costoclavicular ligament and the Subclavius muscle; that of the second, third, fourth, fifth, and sixth, at their sternal ends, to the Pectoralis major.¹ The others are covered by, and give partial attachment to, some of the great flat muscles of the abdomen. The **posterior surface** is con-

¹ The first and seventh also, occasionally, give origin to the same muscle.

cave, and directed backward and downward, the first giving attachment to the Sternothyroid, the third to the sixth inclusive to the Triangularis sterni, and the six or seven inferior ones to the Transversalis muscle and the Diaphragm.

Borders.—Of the two borders, the **superior border** is concave, the **inferior** convex; they afford attachment to the Internal intercostal muscles, the upper border of the sixth giving attachment to the Pectoralis major muscle. The contiguous borders of the sixth, seventh, and eighth, and sometimes the ninth and tenth, costal cartilages present small, smooth, oblong-shaped facets at the points where they articulate.

Extremities.—Of the two extremities, the **outer extremity** is continuous with the osseous tissue of the rib to which it belongs. The **inner extremity** of the first is continuous with the sternum; the six succeeding ones have rounded extremities, which are received into shallow concavities on the lateral margins of the sternum. The inner extremities of the eighth, ninth, and tenth costal cartilages are pointed, and are connected with the cartilage above. Those of the eleventh and twelfth are free and pointed.

The costal cartilages are most elastic in youth, those of the false ribs being more so than the true. In old age they become of a deep yellow color, and are prone to calcify.

Attachment of Muscles.—To *nine*—the Subclavius, Sternothyroid, Pectoralis major, Internal oblique, Transversalis, Rectus abdominis, Diaphragm, Triangularis sterni, and Internal intercostals.

Surface Form.—The bones of the thorax are to a very considerable extent covered by muscles, so that in the strongly developed muscular subject they are for the most part concealed. In the emaciated subject, on the other hand, the ribs, especially in the lower and lateral region, stand out as prominent ridges with the sunken, intercostal spaces between them.

In the median line, in front, the superficial surface of the sternum is to be felt throughout its entire length, at the bottom of a deep median furrow (the **sternal furrow**) situated between the two great pectoral muscles. These muscles overlap the anterior surface somewhat, so that the whole of the sternum in its entire width is not subcutaneous; and this overlapping is greater opposite the centre of the bone than above and below, so that the furrow is wider at its upper and lower parts, but narrower in the middle. The centre of the upper border of the sternum is visible, constituting the **presternal notch**, but the lateral parts of this border are obscured by the tendinous origins of the Sternomastoid muscles, which present themselves as oblique tendinous cords, which narrow and deepen the notch. Lower down on the subcutaneous surface, a well-defined transverse ridge, the **angulus Ludovici**, is always to be felt. This denotes the line of junction of the manubrium and the body of the bone, and is a useful guide to the second costal cartilage, and thus to the identity of any given rib. The second rib being found through its costal cartilage, it is easy to count downward and find any other. From the middle of the sternum the furrow spreads out, and, exposing more of the surface of the body of the bone, terminates below in a sudden depression, the **infrasternal depression**, or **pit of the stomach** (*scrobiculus cordis*), which corresponds to the ensiform cartilage. This depression lies between the cartilages of the seventh ribs, and in it the ensiform cartilage may be felt. The sternum in its vertical diameter presents a general convexity forward, the most prominent point of which is at the joint between the manubrium and gladiolus.

On each side of the sternum the costal cartilages and ribs on the front of the thorax are partially obscured by the great pectoral muscles, through which, however, they are to be felt as ridges, with yielding intervals between them, corresponding to the intercostal spaces. Of these spaces, the one between the second and third ribs is the widest, the next two somewhat narrower, and the remainder, with the exception of the last two, comparatively narrow.

The lower border of the Pectoralis major muscle corresponds to the sixth rib, and below this, on the front of the thorax, the broad, flat outline of the ribs as they begin to ascend, and the more rounded outline of the costal cartilages, are often visible. The lower boundary of the front of the thorax, the **abdominothoracic arch**, which is most plainly seen by arching the body backward, is formed by the ensiform cartilage and the cartilages of the seventh, eighth, ninth, and tenth ribs, and the extremities of the eleventh and twelfth ribs or their cartilages.

On each side of the thorax, from the axilla downward, the flattened external surfaces of the ribs may be defined in the form of oblique ridges, separated by depressions corresponding to the intercostal spaces. They are, however, covered by muscles, which obscure their outline to a certain extent in the strongly developed. Nevertheless, the ribs, with the exception of the first, can generally be followed over the front and sides of the thorax without difficulty. The first rib, being almost completely covered by the clavicle and scapula, can only be distinguished in a

small portion of its extent. At the back the angles of the ribs form a slightly marked oblique line on each side of and some distance from the vertebral spines. This line diverges somewhat as it descends, and external to it is a broad, convex surface caused by the projection of the ribs beyond their angles. Over this surface, except where covered by the scapula, the individual ribs can be distinguished.

Applied Anatomy.—*Malformations of the sternum* present nothing of surgical importance beyond the fact that abscesses of the mediastinum may sometimes escape through the sternal foramen. *Fractures of the sternum* are by no means common, due, no doubt, to the elasticity of the ribs and their cartilages, which support it like so many springs. When broken it is frequently associated with fracture of the vertebral column, and may be caused by forcibly bending the body either backward or forward until the chin becomes impacted against the top of the sternum. It may also be fractured by direct violence or by muscular action. The fracture usually occurs in the upper half of the body of the bone. *Dislocation of the gladiolus* from the manubrium also takes place, and is sometimes described as a fracture.

The bone, cancellous in structure and being subcutaneous, is frequently the seat of *gummatous tumors*, and not uncommonly is affected with *caries*. Occasionally the bone, and especially its ensiform appendix, becomes altered in shape and driven inward, in workmen, by the pressure of tools against the chest.

The ribs are frequently broken, though from their connections and shape they are able to withstand great force, yielding under the injury and recovering themselves like a spring. The middle of the series are the ones most liable to fracture. The first, and to a less extent the second, being protected by the clavicle, are rarely fractured; and the eleventh and twelfth, on account of their loose and floating condition, enjoy a like immunity. The fracture generally occurs from indirect violence, from forcible compression of the thoracic wall, and the bone then gives way at its weakest part—i. e., just in front of the angle. But the ribs may also be broken by direct violence, when the bone gives way and is driven inward at the point struck, or they may be broken by muscular action. It seems probable, however, that in the latter case the bone has undergone some atrophic changes. Fracture of the ribs is frequently complicated by some injury to the viscera contained within the thorax or upper part of the abdominal cavity, and this is most likely to occur in fractures from direct violence. Occasionally supernumerary ribs exist. They may come from the lumbar vertebrae or from the cervical vertebrae. A **cervical rib** is due to excessive development of the costal element of the seventh cervical vertebra. In nearly two-thirds of the reported cases the condition is bilateral. It rarely produces symptoms until after the twentieth year. The symptoms are a superficial pulsation of the subclavian artery, a prominence which can be felt, and evidences of pressure in the brachial plexus (Carl Beck). Beck divides the different types of the condition as follows: (a) Slight degree: The cervical rib reaches beyond the transverse process. (b) More advanced: The cervical rib reaches beyond the transverse process, either with a free end or touching the first rib. (c) Almost complete: The connection between the cartilage of the first rib is formed either by means of a distinct band or by the end of its long body. (d) Complete: It has become a true rib and possesses a true cartilage which unites with the cartilage of the first rib.¹ A very rare condition is a rib from the sixth cervical vertebra. The diagnosis is confirmed by the x-rays. The treatment of cervical rib is excision.

Fracture of the costal cartilages may also take place, though it is a comparatively rare injury.

The thorax is frequently found to be altered in shape in certain diseases. The shape of the thorax in those suffering from rhachitis is produced chiefly by atmospheric pressure. The balance between the air on the inside of the thorax and the air on the outside during some stage of respiration is not equal, the preponderance being in favor of the air outside; and this, acting on the softened ribs, causes them to be forced in at the junction of the cartilages with the bones, which is the weakest part. In consequence of this the sternum projects forward with a deep depression on either side caused by the sinking in of the softened ribs. The depression is less on the left side, on account of the ribs being supported by the heart. The condition is known as *pigeon-breast*. The lower ribs, however, are not involved in this deformity, as they are prevented from falling in by the presence of the stomach, liver, and spleen. And when the liver and spleen are enlarged, as they sometimes are in rhachitis, the lower ribs may be pushed outward; this causes a transverse constriction just above the costal arch. The anterior extremities of the ribs are usually enlarged in rhachitis, giving rise to what has been termed the *rhachitic rosary*. The *phthisical chest* is often long and narrow, flattened from before backward, and with great obliquity of the ribs and projection of the scapulae. In *pulmonary emphysema* the thorax is enlarged in all its diameters, and presents on section an almost circular outline. It has received the name of the *barrel-shaped chest*. In severe cases of *lateral curvature of the spine* the thorax becomes much distorted. In consequence of the rotation of the bodies of the vertebrae which takes place in this disease the ribs opposite the convexity of the thoracic curve become extremely convex behind, being thrown out and bulging, and at the same time flattened

¹ Jour. Amer. Med. Assoc., June 17, 1905.

in front, so that the two bends of the same rib are almost parallel. Coincident with this, the ribs on the opposite side, on the concavity of the curve, are sunken and depressed behind and bulging and convex in front. In addition to this the ribs become occasionally welded together by bony material.

The ribs are frequently the seat of *caries* leading to abscesses and sinuses, which may burrow to a considerable extent over the wall of the thorax. The only special anatomical point in connection with abscesses and sinuses is that care must be taken in dealing with them that the intercostal space is not punctured and the pleural cavity opened or the intercostal vessels wounded, as the necrosed portion of bone is generally situated on the internal surface of the rib.

In cases of *empyema* the thorax requires opening to evacuate the pus. There is considerable difference of opinion as to the best position to do this. Probably the best place for intercostal drainage is between the fifth and sixth ribs, in or a little in front of the mid-axillary line. This is the last part of the cavity to be closed by the expansion of the lung; it is not thickly covered by soft parts; the space between the two ribs is sufficiently great to allow of the introduction of a fair-sized drainage tube, and when the patient is confined to bed he does not lie upon the drainage tube as he does when the opening is posterior. Better than intercostal drainage in the vast majority of cases is rib resection and drainage. A portion of the fifth or sixth rib should be removed in the mid-axillary line. In *chronic empyema* the lung becomes shrunken and adherent, and simple drainage will not bring about a cure. It is necessary in such cases to do an operation that will permit of collapse of the chest wall. *Estlander's operation* consists in resecting a portion of every rib which overlies the cavity of the empyema. *Schede's operation* consists in removing ribs from the second rib down over the empyema cavity. The ribs are removed from cartilages to angles, and intercostal muscles and the parietal layer of the pleura are also taken away. Fowler and de Lorme not only practise extensive rib resection and remove the parietal layer of the pleura, but also remove pulmonary pleura (*total pleurectomy* or *pulmonary decortication*).

THE EXTREMITIES.

The **extremities**, or **limbs**, are those long, jointed appendages of the body which are connected to the trunk by one end and free in the rest of their extent. They are *four* in number: an **upper** or **thoracic pair**, connected with the thorax through the intervention of the shoulder and subservient mainly to prehension; and a **lower** or **pelvic pair**, connected with the pelvis, intended for support and locomotion. Both pairs of limbs are constructed after one common type, so that they present numerous analogies, while at the same time certain differences are observed between the upper and lower pair, dependent on the peculiar offices they have to perform.

The bones by which the upper and lower limbs are attached to the trunk are named, respectively, the **shoulder** and **pelvic girdles**, and they are constructed on the same general type, though presenting certain modifications relating to the different uses to which the upper and lower limbs are respectively applied. The **shoulder girdle** is formed by the scapulæ and clavicles, and is imperfect in front and behind. In front, however, the girdle is completed by the upper end of the sternum, with which the inner extremities of the clavicle articulate. Behind, the girdle is widely imperfect and the scapula is connected to the trunk by muscles only. The **pelvic girdle** is formed by the innominate bones, and is completed in front through the symphysis pubis, at which the two innominate bones articulate with each other. It is imperfect behind, but the intervening gap is filled in by the upper part of the sacrum. The pelvic girdle, therefore, presents, with the sacrum, a complete ring, massive and comparatively rigid, in marked contrast to the lightness and mobility of the shoulder girdle.

THE UPPER EXTREMITY.

The bones of the upper extremity consist of the clavicle and scapula (*pectoral girdle*), the humerus (*arm*), the radius and ulna (*forearm*), the carpal bones (*wrist*), the metacarpal bones (*palm*), and the phalanges (*digits*).

THE SHOULDER GIRDLE.

The shoulder girdle consists of the **clavicle** and the **scapula**.

The Clavicle, or Collar Bone (*Clavicula*).

The **clavicle** forms the anterior portion of the shoulder girdle. It is a long bone, curved somewhat like the italic letter *f*, and placed nearly horizontally at the upper and anterior part of the thorax, immediately over the first rib. It articulates by its inner extremity with the upper border of the sternum, and by its outer extremity with the acromion process of the scapula, serving to sustain the upper extremity in the various positions which it assumes, while at the same time it allows of great latitude of motion in the arm.¹ It presents a double curvature when looked at in front, the convexity being forward at the sternal end and the concavity at the scapular end. Its outer third is flattened from above downward, and extends, in the natural position of the bone, from a point opposite the coracoid process to the acromion. Its inner two-thirds are of a prismatic form, and extend from the sternum to a point opposite the coracoid process of the scapula.

Outer or Flattened Portion.—The outer third is flattened from above downward, so as to present two surfaces, an upper and a lower; and two borders, an anterior and a posterior.

Surfaces.—The **upper surface** is flat, rough, marked by impressions for the attachment of the Deltoid in front and the Trapezius behind; between these two impressions a small portion of the bone is subcutaneous. The **under surface** is flattened. At its posterior border, a little external to the point where the prismatic joins with the flattened portion, is a rough eminence, the **conoid tubercle** (*tuberositas coracoidea*); this, in the natural position of the bone, surmounts the coracoid process of the scapula and gives attachment to the conoid ligament. From this tubercle an oblique line, occasionally a depression, passes forward and outward to near the outer end of the anterior border; it is called the **oblique line** or **trapezoid ridge**, and affords attachment to the trapezoid ligament.

Borders.—The **anterior border** is concave, thin, and rough, and gives attachment to the Deltoid; it occasionally presents, at its inner end, at the commencement of the deltoid impression, a tubercle, the **deltoid tubercle**. The **posterior border** is convex, rough, broader than the anterior, and gives attachment to the Trapezius.

Inner or Prismatic Portion.—The prismatic portion forms the *inner two-thirds* of the bone. It is curved so as to be convex in front, concave behind, and is marked by three borders, separating three surfaces.

Borders.—The **anterior border** is continuous with the anterior margin of the flat portion, and separates the anterior surface from the inferior; at the inner half of the clavicle it forms the lower boundary of an elliptical space for the attachment of the clavicular portion of the Pectoralis major, and approaches the posterior border of the bone; it coincides with the anterior margin of the subclavian groove. The **superior border** is continuous with the posterior margin of the flat portion, and separates the anterior from the posterior surface. At its commencement it is smooth and rounded, becomes rough toward the inner third for the attachment of the Sternomastoid muscle, and terminates at the upper angle of the sternal extremity. The **posterior or subclavian border** separates the posterior

¹ The clavicle acts especially as a fulcrum to enable the muscles to give lateral motion to the arm. It is accordingly absent in those animals in which the fore limbs are used only for progression, but is present for the most part in those animals in which the anterior extremities are clawed and used for prehension, though in some of them—as, for instance, in a large number of the carnivora—it is merely a rudimentary bone suspended among the muscles, and not articulating with the scapula or sternum.

from the inferior surface, and extends from the conoid tubercle to the rhomboid impression. It forms the posterior boundary of the groove for the Subclavius muscle, and gives attachment to a layer of cervical fascia covering the Omohyoid muscle.

Surfaces.—The **anterior surface** is included between the superior and anterior borders. It is directed forward and a little upward at the sternal end, outward and still more upward at the acromial extremity, where it becomes continuous with the upper surface of the flat portion. Externally, it is smooth, convex, nearly subcutaneous, being covered only by the Platysma; but, corresponding to the inner half of the bone, it is divided by a more or less prominent line into two parts—a lower portion, elliptical in form, rough, and slightly convex, for the attachment of the Pectoralis major; and an upper part, which is rough, for the attachment of the Sternomastoid. Between the two muscular impressions

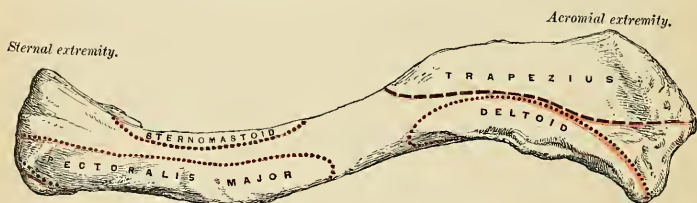

FIG. 136.—Left clavicle. Superior surface.

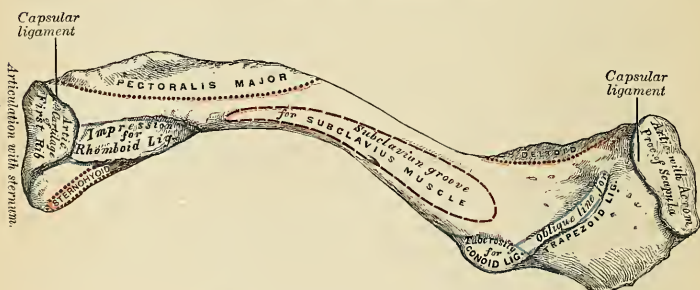


FIG. 137.—Left clavicle. Inferior surface.

is a small subcutaneous interval. The **posterior or cervical surface** is smooth, flat, and looks backward toward the root of the neck. It is limited, *above*, by the superior border; *below*, by the posterior border; *internally*, by the margin of the sternal extremity; *externally*, it is continuous with the posterior border of the flat portion. It is concave from within outward, and is in relation, by its lower part, with the suprascapular vessels. This surface, at about the junction of the inner and outer curves, is also in close relation with the brachial plexus and subclavian vessels. It gives attachment, near the sternal extremity, to part of the Sternohyoid muscle; and presents, at or near the middle, a nutrient foramen. It opens into a nutrient canal, which is directed obliquely outward and transmits the chief nutrient artery of the bone. Sometimes there are two foramina on the posterior surface, or one on the posterior and one on the inferior surface. The **inferior or subclavian surface** is bounded, in *front*, by the anterior border; *behind*,

by the posterior border. It is narrow internally, but gradually increases in width externally, and is continuous with the under surface of the flat portion. Commencing at the sternal extremity may be seen a small facet, the *costal facet*, for articulation with the cartilage of the first rib. This is continuous with the articular surface at the sternal end of the bone. External to this is a broad, rough surface, the *rhomboid impression* (*tuberositas costalis*), rather more than an inch in length, for the attachment of the costoclavicular (rhomboid) ligament. The remaining part of this surface is occupied by a longitudinal groove, the *subclavian groove*, broad and smooth externally, narrow and more uneven internally; it gives attachment to the Subclavius muscle, and by its margins to the costocoracoid membrane, which splits to enclose the muscle. Not infrequently this groove is subdivided into two parts by a longitudinal line, which gives attachment to the intermuscular septum of the Subclavius muscle.

Internal or Sternal Extremity (*extremitas sternalis*).—The internal or sternal extremity of the clavicle is triangular in form, directed inward and a little downward and forward; and presents an *articular facet* (*facies articularis sternalis*), concave from before backward, convex from above downward, which articulates with the sternum through the intervention of an intra-articular fibrocartilage; the circumference of the articular surface is rough, for the attachment of numerous ligaments. The *posterior border* of this surface is prolonged backward, so as to increase the size of the articular facet; the *upper border* gives attachment to the intra-articular fibrocartilage, and the *lower border* is continuous with the costal facet on the inner end of the inferior surface, which articulates with the cartilage of the first rib.

Outer or Acromial Extremity (*extremitas acromialis*).—The outer or acromial extremity, directed outward and forward, presents a small, flattened, oval facet, *acromial surface* (*facies articularis acromialis*), which looks obliquely downward, and which articulates with the acromion process of the scapula. The circumference of the articular facet is rough, especially above, for the attachment of the acromioclavicular ligaments.

Peculiarities of the Bone in the Sexes and in Individuals.—In the female the clavicle is generally shorter, thinner, less curved, and smoother than in the male; in the female it is placed almost, if not quite, horizontal, while in the male it inclines slightly downward and inward. In those persons who perform considerable manual labor, which brings into constant action the muscles connected with this bone, it becomes thicker and more curved, its ridges for muscle attachment become prominently marked. The right clavicle is generally longer, thicker, and rougher than the left.

Structure.—The shaft, as well as the extremities, consists of cancellous tissue, invested by a compact layer much thicker in the middle than at either end. It has no true medullary cavity.

Development.—From *two* centres, one for the shaft and outer extremity and one for the sternal extremity. The primary centre for the shaft appears very early, before that of any other bone, at about the fifth or sixth week of fetal life. The secondary centre for the sternal end makes its appearance about the fifteenth to the twentieth year, and unites with the rest of the bone about the twenty-fifth year.

Articulations.—With the sternum, scapula, by intra-articular fibrocartilaginous disks, and with the cartilage of the first rib.

Attachment of Muscles.—To *six*—the Sternomastoid, Trapezius, Pectoralis major, Deltoid, Subclavius, and Sternohyoid.

Surface Form.—The clavicle can be felt throughout its entire length, even in persons who are very fat. Commencing at the inner end, the enlarged sternal extremity, where the bone projects above the upper margin of the sternum, can be felt, forming with the sternum and the rounded tendon of the Sternomastoid a V-shaped notch, the *presternal notch*. Passing outward, the shaft of the bone can be felt immediately under the skin, with its convexity forward in the inner two-thirds, the surface partially obscured above and below by the attachments of the Sternomastoid and Pectoralis major muscles. In the outer third it forms a gentle curve backward, and terminates at the outer end in a somewhat enlarged extremity which articulates with the acromial process of the scapula. The direction of the clavicle is almost, if not quite, horizontal when the arm is lying quietly by the side, though in well-developed subjects it may

incline a little upward at its outer end. Its direction is, however, very changeable, altering with the varying movements of the shoulder-joint.

Applied Anatomy.—The clavicle is the most frequently *fractured* of any single bone in the body. This is due to the fact that it is much exposed to violence, and is the only bony connection between the upper limb and the trunk. The bone, moreover, is slender, and is very superficial. The bone may be broken by direct or indirect violence or by muscular action. The most common cause is, however, from indirect violence, and the bone then gives way at the junction of the fixed outer one-third with the movable inner two-thirds of the bone. This is the weakest and most slender part of the bone. The fracture is generally oblique, and the displacement of the outer fragments is inward, away from the surface of the body; hence, compound fracture of the clavicle is of rare occurrence. The inner fragment, as a rule, is little displaced. Beneath the bone the main vessels of the upper limb and the great nerve cords of the brachial plexus lie on the first rib, and are liable to be wounded in fracture, especially in fracture from direct violence, when the force of the blow drives the broken ends inward. Fortunately, the Subclavius muscle is interposed between these structures and the clavicle, and this often protects them from injury.

The clavicle is not uncommonly the seat of *sarcomatous tumors*, rendering the operation of excision of the entire bone necessary. This operation is best performed by exposing the bone freely, disarticulating at the acromial end, and turning it inward. The removal of the outer part is comparatively easy, but resection of the inner part is fraught with difficulty, the main danger being the risk of wounding the great veins which are in relation with its under surface.

The Scapula, or Shoulder Blade.

The **scapula** forms the back part of the shoulder girdle. It is a large flat bone, triangular in shape, situated at the posterior aspect and side of the thorax, between the second and seventh or sometimes the eighth rib, its internal border or base being about an inch from and nearly but not quite parallel with the spinous processes of the vertebræ, so that it is rather closer to them above than below. It presents for examination two surfaces, three borders, and three angles.

Surfaces.—The **anterior** or **ventral surface** (*facies costalis*) (Fig. 138) presents a broad concavity, the **subscapular fossa** (*fossa subscapularis*). It is marked, in the inner two-thirds, by several **oblique ridges** (*lineæ musculares*), which pass outward and upward; the outer third is smooth. The oblique ridges give origin to the tendinous intersections, and the surfaces between them to the fleshy fibres, of the Subscapularis muscle. The outer third of the fossa is smooth, is covered by, but does not afford attachment to, the fibres of this muscle. This surface is separated from the internal border by a smooth, triangular margin at the superior and inferior angles, and in the interval between these by a narrow edge which is often deficient. This marginal surface affords attachment throughout its entire extent to the Serratus magnus muscle. The subscapular fossa presents a transverse depression at its upper part, where the bone appears to be bent on itself, forming a considerable angle, called the **subscapular angle**, thus giving greater strength to the body of the bone from its arched form, while the summit of the arch serves to support the spine and acromion process. It is in this situation that the fossa is deepest, so that the thickest part of the Subscapularis muscle lies in a line perpendicular to the plane of the glenoid cavity, and must consequently operate most effectively on the head of the humerus, which is contained in that cavity.

The **posterior** or **dorsal surface** (*facies dorsalis*) (Fig. 139) is arched from above downward, alternately concave and convex from side to side. It is subdivided unequally into two parts by the **spine**; the portion above the spine is called the **supraspinous fossa**, and that below it the **infraspinous fossa**.

The **supraspinous fossa** (*fossa supraspinata*), the smaller of the two, is concave, smooth, and broader at the vertebral than at the humeral extremity. It affords attachment by its inner two-thirds to the Supraspinatus muscle.

The **infraspinous fossa** (*fossa infraspinata*) is much larger than the preceding;

toward its vertebral margin a shallow concavity is seen at its upper part; its centre presents a prominent convexity, while toward the axillary border is a deep groove which runs from the upper toward the lower part. The inner two-thirds of this surface affords origin to the *Infraspinatus* muscle; the outer third is only covered by it, without giving attachment to its fibres. This surface is separated from the axillary border by an elevated ridge, which runs from the lower margin of the glenoid

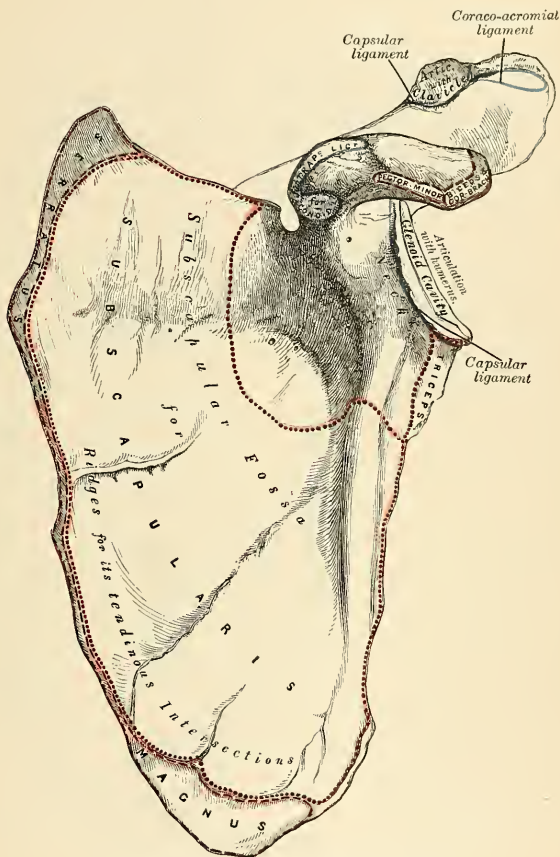


FIG. 138.—Left scapula. Anterior surface or venter.

cavity downward and backward to the internal border, about an inch above the inferior angle. The ridge serves for the attachment of a strong aponeurosis which separates the *Infraspinatus* from the two *Teres* muscles. The surface of bone between this line and the axillary border is narrow in the upper two-thirds of its extent, and traversed near its centre by a groove for the passage of the dorsalis scapulae vessels; it affords origin to the *Teres minor* muscle. Its lower third

above downward, its apex corresponding to the vertebral border, its base (which is directed outward) to the neck of the scapula. It presents two surfaces and three borders. Its *superior surface* is concave, assists in forming the supraspinous fossa, and affords attachment to part of the Supraspinatus muscle. Its *inferior surface* forms part of the infraspinous fossa, gives origin to part of the Infraspinatus muscle, and presents near its centre the orifice of a nutrient canal. Of the three borders, the *anterior* is attached to the dorsum of the bone; the *posterior*, or *crest* of the spine, is broad, and presents two lips and an intervening rough interval. To the *superior lip* is attached the Trapezius to the extent shown in Fig. 139. A rough tubercle is generally seen occupying that portion of the spine which receives the insertion of the middle and inferior fibres of this muscle. From the *inferior lip*, throughout its whole length, arises the Deltoid. The interval between the lips is also partly covered by the tendinous fibres of these muscles. The *external border*, or *base*, the shortest of the three, is slightly concave, its edge thick and round, continuous above with the under surface of the acromion process, below with the neck of the scapula. The narrow portion of bone external to this border, and separating it from the glenoid cavity, is called the **great scapular notch**, and serves to connect the supra- and infraspinous fossæ.

The **acromion process** (*acromion*) is a large and somewhat triangular or oblong process, flattened from behind forward, directed at first a little outward, and then curving forward and upward, so as to overhang the glenoid cavity. Its *upper surface*, directed upward, backward, and outward, is convex, rough, and gives origin to some fibres of the Deltoid, and in the rest of its extent it is subcutaneous. Its *under surface* is smooth and concave. Its *outer border* is thick and irregular, and presents three or four tubercles for the tendinous origins of the Deltoid muscle. Its *inner margin*, shorter than the outer, is concave, gives attachment to a portion of the Trapezius muscle, and presents about its centre a small oval surface for articulation with the acromial end of the clavicle. Its *apex*, which corresponds to the point of meeting of these two borders in front, is thin, and has attached to it the coracoacromial ligament.

Margins, or Borders of the Scapula.—The *superior border* (*margo superior*) is the shortest and thinnest of the three borders; it is concave and extends from the internal angle to the coracoid process. At its outer part is a deep, semicircular notch, the **suprascapular notch** (*ineisura scapulae*), formed partly by the base of the coracoid process. The notch is converted into a foramen by the suprascapular ligament, and serves for the passage of the suprascapular nerve. Sometimes this foramen is entirely surrounded by bone. The adjacent margin of the superior border affords attachment to the Omohyoid muscle.

The **external or axillary border** (*margo axillaris*) is the thickest of the three. It commences above at the lower margin of the glenoid cavity, and inclines obliquely downward and backward to the inferior angle. Immediately below the glenoid cavity is a rough impression, the **infraglenoid tubercle** (*tuberositas infraglenoidalis*), about an inch in length, which affords origin to the long head of the Triceps muscle; in front of this is a longitudinal groove, which extends as far as the lower third of the external border and affords origin to part of the Subscapularis muscle. The inferior third of this border, which is thin and sharp, serves for the origin of a few fibres of the Teres major behind and the Subscapularis in front.

The **internal or vertebral border** (*margo vertebralis*) is the longest of the three, and extends from the internal to the inferior angle of the bone. It is arched, is intermediate in thickness between the superior and the external borders, and the portion of it above the spine is bent considerably outward, so as to form an obtuse angle with the lower part. The internal border presents an anterior lip, a posterior lip, and an intermediate space. The *anterior lip* affords attachment to the Serratus magnus; the *posterior lip*, an origin to the Supraspinatus above the spine, the

Infraspinatus below; to the interval between the two lips, the Levator anguli scapulae is inserted; above the triangular surface at the commencement of the spine, the Rhomboideus minor to the edge of that surface; the Rhomboideus major is attached by means of a fibrous arch connected above to the lower part of the triangular surface at the base of the spine, and below to the lower part of the posterior border.

Angles.—The **internal angle** (*angulus medialis*), formed by the junction of the superior and internal borders, is thin, smooth, rounded, somewhat inclined outward, and gives attachment to a few fibres of the Levator anguli scapulae muscle.

The **inferior angle** (*angulus inferior*), thick and rough, is formed by the union of the vertebral and axillary borders, its posterior surface affording origin to the Teres major and frequently to a few fibres of the Latissimus dorsi.

The **external angle** (*angulus lateralis*) is the thickest part of the bone, and forms what is called the **head** of the scapula. The head presents a shallow, pyriform, articular surface, the **glenoid surface** (*caritas glenoidalis*), the longest diameter of which is from above downward, and its direction outward and forward. It is broader below than above. Just above it is a rough surface, the **supraglenoid tubercle** (*tuberositas supraglenoidalis*), from which arises the long tendon of the Biceps muscle. The glenoid cavity is covered with cartilage in the recent state; and its margins are slightly raised and give attachment to a fibrocartilaginous structure, the **glenoid ligament**, by which its cavity is deepened. The **neck** of the scapula (*collum scapulae*) is the slightly depressed surface which surrounds the head; it is more distinct on the posterior than on the anterior surface, and below than above. In the latter situation it has arising from it a thick prominence, the **coracoid process**.

The **coracoid process** (*processus coracoideus*) is a thick, curved process of bone which arises by a broad base from the upper part of the neck of the scapula; it is directed at first upward and inward, then, becoming smaller, it changes its direction and passes forward and outward. The ascending portion, flattened from before backward, presents in front a smooth, concave surface over which passes the Subscapularis muscle. The horizontal portion is flattened from above downward, its upper surface is convex and irregular; its under surface is smooth; its inner border is rough, and gives attachment to the Pectoralis minor; its outer border is also rough for the coracoacromial ligament, while the apex is embraced by the conjoined tendon of origin of the short head of the Biceps and of the Coracobrachialis and gives attachment to the costocoracoid ligament. At the inner side of the root of the coracoid process is a rough impression for the attachment of the conoid ligament; and running from it obliquely forward and outward on the upper surface of the horizontal portion, an elevated ridge for the attachment of the trapezoid ligament.

Structure.—In the head, processes, and all the thickened parts of the bone the scapula is composed of cancellous tissue covered by compact bone, while in the rest of its extent it is composed of a thin layer of dense, compact tissue. The central part of the supraspinous fossa and the upper part of the infraspinous fossa, but especially the former, are usually so thin as to be semitransparent; occasionally the bone is found wanting in this situation, and the adjacent muscles come into contact.

Development (Fig. 140).—From *seven* or more centres—one for the body, two for the coracoid process, two for the acromion, one for the vertebral border, and one for the inferior angle. Ossification of the body of the scapula commences about the second month of fetal life by the formation of an irregular quadrilateral plate of bone immediately behind the glenoid cavity. This plate extends itself so as to form the chief part of the bone, the spine growing up from its posterior surface about the third month. At birth a large part of the scapula is osseous, but the glenoid cavity, coracoid and acromion processes, the posterior border, and inferior angle are cartilaginous. From the fifteenth to the eighteenth month after birth

ossification takes place in the middle of the coracoid process, which usually becomes joined with the rest of the bone at the time when the other centres make their appearance. Between the fourteenth and twentieth years ossification of the remaining centres takes place in quick succession, and in the following order: *first*, in the root of the coracoid process, in the form of a broad scale; *second*, near the base of the acromion process; *third*, in the inferior angle and contiguous part of the posterior border; *fourth*, near the extremity of the acromion; *fifth*, in the posterior border. The acromion process, besides being formed of two separate nuclei, has its base formed by an extension into it of the centre of ossification which belongs to the spine, the extent of which varies in different cases. The two separate nuclei unite and then join with the extension from the spine. These various epiphyses become joined to the bone between the ages of twenty-two and twenty-five years. Sometimes failure of union between the acromion process and spine occurs, the junction being effected by fibrous tissue or by an imperfect articulation; in some cases of supposed fracture of the acromion with ligamentous union it is probable that the detached segment was never united to the rest of the bone. The upper third of the glenoid cavity is usually ossified from a separate centre (*sub-coracoid*) which makes its appearance between the tenth and eleventh years. Very often, in addition, an epiphysis appears for the lower part of the glenoid cavity.

Articulations.—With the humerus and clavicle.

Attachment of Muscles.—To *seventeen*—to the anterior surface, the Subscapularis; posterior surface, Supraspinatus, Infraspinatus; spine, Trapezius, Deltoid; superior border, Omohyoid; vertebral border, Serratus magnus, Levator anguli scapulae, Rhomboidens, minor and major; axillary border, Triceps, Teres minor, Teres major; apex of glenoid cavity, long head of the Biceps; coracoid process, short head of the Biceps, Coracobrachialis, Pectoralis minor; and to the inferior angle occasionally a few fibres of the Latissimus dorsi.

Surface Form.—The only parts of the scapula which are truly subcutaneous are the spine and acromion process, but, in addition to these, the coracoid process, the internal or vertebral border and inferior angle, and, to a less extent, the axillary border, may be defined. The acromion process and spine of the scapula are easily felt throughout their entire length, forming, with the clavicle, the arch of the shoulder. The acromion can be ascertained to be connected to the clavicle at the acromioclavicular joint by running the finger along it, its position being often indicated by an irregularity or bony outgrowth from the clavicle close to the joint. The acromion can be felt forming the point of the shoulder, and from this can be traced backward to join the spine of the scapula. The place of junction is usually denoted by a prominence, which is sometimes called the **acromial angle**. From here the spine of the scapula can be felt as a prominent ridge of bone, marked on the surface as an oblique depression, which becomes less and less distinct, and terminates a little external to the spinous processes of the vertebrae. Its termination is usually indicated by a slight dimple in the skin on a level with the interval between the third and fourth thoracic spines. Below this point the vertebral border of the scapula may be traced, running downward and outward, and thus diverging from the vertebral spines, to the inferior angle of the bone, which can be recognized, although covered by the Latissimus dorsi muscle. From this angle the axillary border can usually be traced through this thick muscular covering, forming, with the muscles, the posterior fold of the axilla. The coracoid

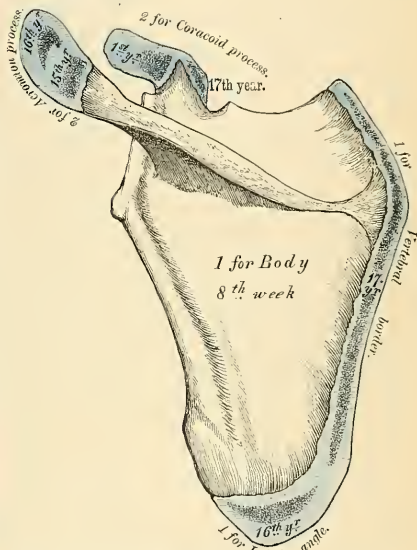


FIG. 140.—Plan of the development of the scapula. From seven centres. The epiphyses (except one for the coracoid process) appear from fifteen to seventeen years, and unite between twenty-two and twenty-five years of age.

process may be felt about an inch below the junction of the middle and outer thirds of the clavicle. Here it is covered by the anterior border of the Deltoid and lies a little to the outer side of a slight depression which corresponds to the interval between the Pectoralis major and Deltoid muscles. When the arms are hanging by the side, the upper angle of the scapula corresponds to the upper border of the second rib or the interval between the first and second thoracic spines, the inferior angle to the upper border of the eighth rib or the interval between the seventh and eighth thoracic spines.

Applied Anatomy.—*Fractures* of the body of the scapula are rare, owing to the mobility of the bone, the thick layer of muscles by which it is encased on both surfaces, and the elasticity of the ribs on which it rests. Fracture of the neck of the bone is also uncommon. The most frequent course of a line of fracture of the neck is from the suprascapular notch to the infraglenoid tubercle (*surgical neck*), and it derives its principal interest from its simulation to a subglenoid dislocation of the humerus. The diagnosis can be made by noting the alteration in the position of the coracoid process. A fracture of the neck external to, and not including, the coracoid process (*anatomical neck*) is said to occur, but it is exceedingly doubtful whether such an accident ever takes place. The acromion process is more frequently broken than any other part of the bone, and there is sometimes, in young subjects, a separation of the epiphysis. It is believed that many of the cases of supposed fracture of the acromion, with fibrous union, which have been found on postmortem examination are really cases of imperfectly united epiphysis. Sir Astley Cooper believed that most fractures of this bone are united by fibrous tissue, and the cause of this mode of union is the difficulty that arises in keeping the fractured ends in constant apposition. The coracoid process is occasionally broken off, either by direct violence or perhaps, rarely, by muscular action.

Tumors of various kinds grow from the scapula. Of the innocent form of tumors, probably the osteomata are the most common. When an osteoma grows from the anterior surface of the scapula, as it sometimes does, it is of the compact variety, such as usually grows from membrane-formed bones, as the bones of the skull. This would appear to afford evidence that this portion of the bone is formed from membrane, and not, like the rest of the bone, from cartilage. Sarcomatous tumors sometimes grow from the scapula, and may necessitate removal of the bone, with or without amputation of the upper limb. Removal of the upper limb with the scapula and the outer two-thirds of the clavicle is known as the *interscapulothoracic amputation*. The scapula may be partially resected or completely excised. There are several methods of complete excision. The bone may be excised by a T-shaped incision, and, the flaps being reflected, the removal is commenced from the vertebral border, so that the subscapular vessels which lie along the axillary border are among the last structures divided, and can be at once secured.

THE ARM.

The **arm** is that portion of the upper extremity which is situated between the shoulder and the elbow. Its skeleton consists of a single bone, the **humerus**.

The Humerus, or Arm Bone (Figs. 141, 142).

The **humerus** is the longest and largest bone of the upper extremity; it presents for examination a shaft and two extremities.

Upper or Proximal Extremity.—The upper extremity presents a large, rounded head, joined to the shaft by a constricted portion, called the neck, and two other eminences, the greater and lesser tuberosities.

The Head (*caput humeri*).—The head, nearly hemispherical in form,¹ is directed upward, inward, and slightly backward, and articulates with the glenoid surface of the scapula; its surface is smooth and coated with cartilage in the recent state. The circumference of its articular surface is slightly constricted, and is termed the **anatomical neck**, in contradistinction to the constriction which exists below the tuberosities. The latter is called the **surgical neck** (*collum chirurgicum*), as it is often the seat of fracture.

The **anatomical neck** (*collum anatomicum*) is obliquely directed, forming an

¹ Though the head is nearly hemispherical in form, its margin, as Sir G. Humphry has shown, is by no means a true circle. Its greatest measurement is from the top of the bicipital groove in a direction downward, inward, and backward. Hence, it follows that the greatest elevation of the arm can be obtained by rolling the articular surface in this direction—that is to say, obliquely upward, outward, and forward.

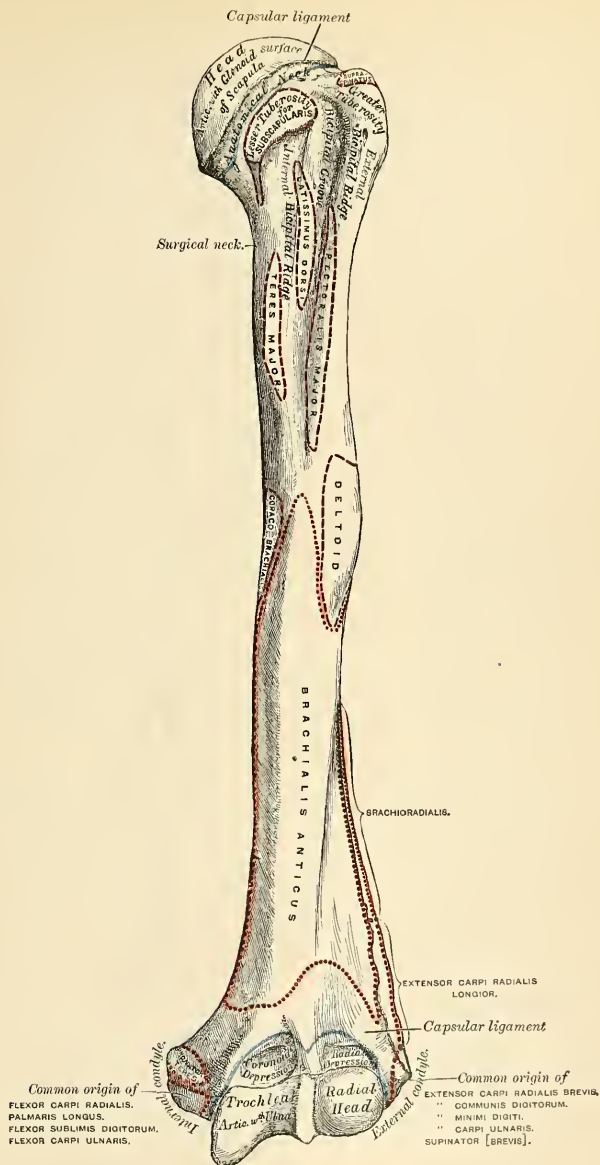


FIG. 141.—Left humerus. Anterior view.

obtuse angle with the shaft. It is more distinctly marked in the lower half of its circumference than in the upper half, where it presents a narrow groove, separating the head from the tuberosities. Its circumference affords attachment to the capsular ligament and is perforated by numerous vascular foramina.

The Greater Tuberosity (*tuberculum majus*).—The greater tuberosity is situated on the outer side of the head and lesser tuberosity. Its upper surface is rounded and marked by three flat facets, separated by two slight ridges; the highest facet gives attachment to the tendon of the Supraspinatus; the middle one, to the Infraspinatus; the inferior facet and the shaft of the bone below it, to the Teres minor. The outer surface of the greater tuberosity is convex, rough, and continuous with the outer side of the shaft.

The Lesser Tuberosity (*tuberculum minus*).—The lesser tuberosity is more prominent, although smaller than the greater; it is situated in front of the head, and is directed inward and forward. Its summit presents a prominent facet for the insertion of the tendon of the Subscapularis muscle. The tuberosities are separated from each other by a deep groove, the **bicipital groove** (*sulcus intertubercularis*). This groove lodges the long tendon of the Biceps muscle, accompanied by a branch of the anterior circumflex artery. It commences above between the two tuberosities, passes obliquely downward and a little inward, and terminates at the junction of the upper with the middle third of the bone. It is deep and narrow at the commencement, and becomes shallow and a little broader as it descends. In the recent state it is covered with a thin layer of cartilage, lined by a prolongation of the synovial membrane of the shoulder-joint, and receives the tendon of insertion of the Latissimus dorsi muscle.

The Shaft (*corpus humeri*).—The shaft of the humerus is almost cylindrical in the upper half of its extent, prismatic and flattened below, and presents three borders and three surfaces for examination.

The **anterior border** runs from the front of the greater tuberosity above to the coronoid depression below, separating the internal from the external surface. Its upper part is very prominent and rough, forms the *outer lip* of the bicipital groove, and serves for the attachment of the tendon of the Pectoralis major. About its centre it forms the anterior boundary of the rough **deltoid impression**; below, it is smooth and rounded, affording attachment to the Brachialis anticus muscle.

The **external border** (*margo lateralis*) runs from the back part of the greater tuberosity to the external condyle, and separates the external from the posterior surface. It is rounded and indistinctly marked in its upper half, serving for the attachment of the lower part of the insertion of the Teres minor muscle, and below this of the external head of the Triceps muscle; its centre is traversed by a broad, but shallow, oblique depression, the **musculospiral groove** (*sulcus nervi radialis*); its lower part is marked by a prominent, rough margin, a little curved from behind forward, the **external supracondylar ridge**, which presents an anterior lip for the attachment of the Brachioradialis above and Extensor carpi radialis longior below, a posterior lip for the Triceps, and an intermediate space for the attachment of the external intermuscular septum.

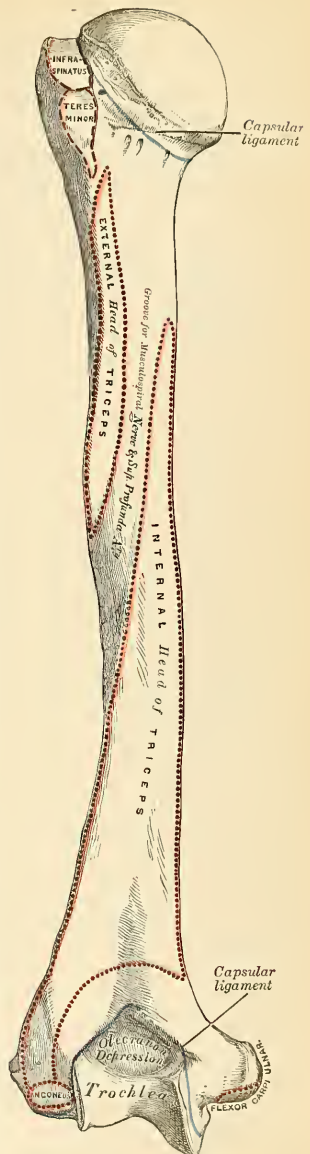
The **internal border** (*margo medialis*) extends from the lesser tuberosity to the internal condyle. Its upper third is marked by a prominent ridge, forming the *internal lip* of the bicipital groove, and gives attachment to the tendon of the Teres major. About its centre is an impression for the attachment of the Coracobrachialis, and just below this is seen the entrance of the **nutrient canal**, directed downward. Sometimes there is a second canal situated at the commencement of the musculospiral groove, for a nutrient artery derived from the superior profunda branch of the brachial artery. The inferior third of this border is raised into a slight ridge, the **internal supracondylar ridge**, which becomes very prominent

below; it presents an anterior lip for the attachment of the Brachialis anticus muscle, a posterior lip for the internal head of the Triceps muscle, and an intermediate space for the attachment of the internal intermuscular septum.

The **external surface** (*facies anterior lateralis*) is directed outward above, where it is smooth, rounded, and covered by the Deltoid muscle; forward and outward below, where it is slightly concave from above downward, and gives origin to part of the Brachialis anticus muscle. About the middle of this surface is seen a rough, triangular impression for the insertion of the Deltoid muscle, **deltoid impression** (*tuberositas deltoidea*), and below this the musculospiral groove, directed obliquely from behind forward and downward, and transmitting the musculospiral nerve and superior profunda artery.

The **internal surface** (*facies anterior medialis*), less extensive than the external, is directed inward above, forward and inward below; at its upper part it is narrow and forms the floor of the bicipital groove; to it is attached the Latissimus dorsi. The middle part of this surface is slightly roughened for the attachment of some of the fibres of the tendon of insertion of the Coracobrachialis; its lower part is smooth, concave from above downward, and gives attachment to the Brachialis anticus muscle.¹ A little below the middle of the shaft is the nutrient foramen. This leads into a nutrient canal, which is directed toward the elbow-joint.

The **posterior surface** (*facies posterior*) (Fig. 142) appears somewhat twisted, so that its upper part is directed a little inward, its lower part backward and a little outward. Nearly the whole of this surface is covered by the external and internal heads of the



¹ A small hook-shaped process of bone, the *supracondylar process*, varying from $\frac{1}{10}$ to $\frac{3}{4}$ of an inch in length, is not infrequently found projecting from the inner surface of the shaft of the humerus two inches above the internal condyle. It is curved downward, forward, and inward, and its pointed extremity is connected to the internal border, just above the inner condyle, by a ligament or fibrous band, which gives origin to a portion of the Pronator teres; through the arch completed by this fibrous band the median nerve and brachial artery pass when these structures deviate from their usual course. Sometimes the nerve alone is transmitted through it, or the nerve may be accompanied by the ulnar artery in cases of high division of the brachial. A well-marked groove is usually found behind the process in which the nerve and artery are lodged. This space is analogous to the supracondylar foramen in many animals, and probably serves in them to protect the nerve and artery from compression during the contraction of the muscles in this region.

FIG. 142.—Left humerus. Posterior surface.

Triceps, the former of which is attached to its upper and outer part, the latter to its inner and back part, the two being separated by the musculospiral groove.

The **Lower or Distal Extremity** is flattened from before backward, and curved slightly forward; it terminates below in a broad, articular surface which is divided into two parts by a slight ridge. Projecting on either side are the external and internal condyles. By some anatomists the external condyle is called the external epicondyle and the internal condyle is called the internal epicondyle. The **articular surface** extends a little lower than the condyles, and is curved slightly forward, so as to occupy the more anterior part of the bone; its greatest breadth is in the transverse diameter, and it is obliquely directed, so that its inner extremity occupies a lower level than the outer. The outer portion of the articular surface presents a smooth, rounded eminence, which has received the name of the **capitellum**, or **radial head** of the humerus (*capitulum humeri*); it articulates with the cup-shaped depression on the head of the radius, and is limited to the front and lower part of the bone, not extending as far back as the other portion of the articular surface. On the inner side of this eminence is a shallow groove, in which is received the inner margin of the head of the radius. Above the front part of the capitellum is a slight depression, the **radial fossa** (*fossa radialis*), which receives the anterior border of the head of the radius when the forearm is flexed. The inner portion of the articular surface, the **trochlea** (*trochlea humeri*), presents a deep depression between two well-marked borders. This surface is convex from before backward, concave from side to side, and occupies the anterior, lower, and posterior parts of the bone. The **external border**, less prominent than the internal, corresponds to the interval between the radius and the ulna. The **internal border** is thicker, more prominent, and consequently of greater length, than the external. The grooved portion of the articular surface fits accurately within the greater sigmoid cavity of the ulna; it is broader and deeper on the posterior than on the anterior aspect of the bone, and is inclined obliquely from behind forward and from without inward. Above the front part of the trochlear surface is seen a smaller depression, the **coronoid fossa** (*fossa coronoidea*), which receives the coronoid process of the ulna during flexion of the forearm. Above the back part of the trochlear surface is a deep, triangular depression, the **olecranon fossa** (*fossa olecrani*), in which is received the summit of the olecranon process in extension of the forearm. These fossæ are separated from one another by a thin, transparent lamina of bone, which is sometimes perforated by a foramen, the **supratrochlear foramen**; their upper margins afford attachment to the anterior and posterior ligaments of the elbow-joint, and they are lined, in the recent state, by the synovial membrane of this articulation. The articular surfaces, in the recent state, are covered with a thin layer of hyaline cartilage. The **external condyle** (*epicondylus lateralis*) is a small, tubercular eminence, less prominent than the internal, curved a little forward, and giving attachment to the external lateral ligament of the elbow-joint, and to a tendon common to the origin of some of the Extensor and Supinator muscles. The **internal condyle** (*epitrochlea* or *epicondylus medialis*), larger and more prominent, is directed a little backward; it gives attachment to the internal lateral ligament, to the Pronator teres, and to a tendon common to the origin of some of the Flexor muscles of the forearm. The ulnar nerve runs in a groove, the **ulnar groove** (*sulcus nervi ulnaris*), at the back of the internal condyle, or between it and the olecranon process. These condyles are directly continuous above with the external and internal supracondylar ridges.

Structure.—The extremities consist of cancellous tissue, covered with a thin compact layer; the shaft is composed of a cylinder of compact tissue, thicker at the centre than at the extremities, and hollowed out by a large medullary canal, which extends along its whole length. In the head of the humerus the plates of the cancellous tissue are arranged in curves (Fig. 143), known as **pressure curves**. Most of the bone plates are at right angles to the plane of the

articular surface (the lines of greatest pressure), and they are bound together by other bone fibres, which usually correspond to the plane of the articulation (the lines of greatest tension). This arch-like arrangement strengthens the head of the bone, and it is further strengthened by the binding fibres.

Development.—From *eight* centres (Fig. 144), one for each of the following parts: The shaft, head, each tuberosity, the radial head, the trochlear portion of the articular surface, and each condyle. The nucleus for the shaft appears near the centre of the bone in the eighth week, and soon extends toward the extremities. At birth the humerus is ossified nearly in its whole length, the extremities remaining cartilaginous. During the first year, sometimes even before birth, ossification commences in the head of the bone, and during the third year the centre for the greater tuberosity makes its appearance, that for the lesser being small and not appearing until the fifth year. By the sixth year the centres for the head and tuberosities have increased in size and become joined, so as to form a single large epiphysis.

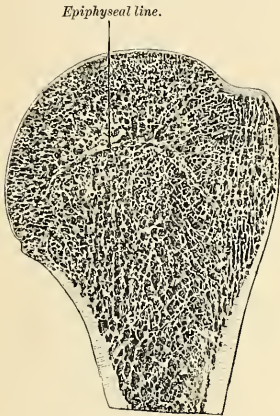


FIG. 143.—Longitudinal section of head of left humerus.

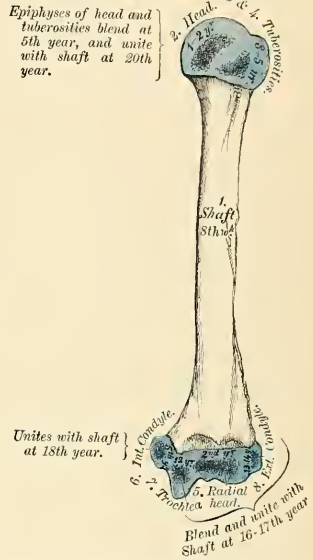


FIG. 144.—Plan of the development of the humerus from eight centres.

The lower end of the humerus is developed in the following manner: At the end of the second year ossification commences in the capitellum, and from this point extends inward, so as to form the chief part of the articular end of the bone, the centre for the inner part of the trochlea not appearing until about the age of twelve. Ossification commences in the internal condyle about the fifth year, and in the external one not until about the thirteenth or fourteenth year. About the sixteenth or seventeenth year the outer condyle and both portions of the articulating surface (which have already joined) unite with the shaft; at the eighteenth year the inner condyle becomes joined; while the upper epiphysis, although the first formed, is not united until about the twentieth year.

Articulations.—With the glenoid cavity of the scapula and with the ulna and radius.

Attachment of Muscles.—To *twenty-four*—to the greater tuberosity, the Supraspinatus, Infraspinatus, and Teres minor; to the lesser tuberosity, the Subscapularis; to the external bicipital ridge, the Pectoralis major; to the internal bicipital ridge, the Teres major; to the bicipital groove, the Latissimus dorsi; to the shaft, the Deltoid, Coracobrachialis, Brachialis anticus, external and internal heads of the Triceps; to the internal condyle, the Pronator teres, and common tendon of the Flexor carpi radialis, Palmaris longus, Flexor sublimis digitorum, and Flexor carpi ulnaris; to the external, supracondylar ridge, the Brachioradialis and Extensor carpi radi-

alis longior; to the external condyle, the common tendon of the Extensor carpi radialis brevior, Extensor communis digitorum, Extensor minimi digiti, Extensor carpi ulnaris, and Supinator [breviss]; to the back of the external condyle, the Anconeus.

Surface Form.—The humerus is almost entirely clothed by the muscles which surround it, and the only parts of this bone which are strictly subcutaneous are small portions of the internal and external condyles. In addition to these, the tuberosities and a part of the head of the bone can be felt under the skin and muscles by which they are covered. Of these, the greater tuberosity forms the most prominent bony point of the shoulder, extending beyond the acromion process and covered by the Deltoid muscle. It influences materially the surface form of the shoulder. It is best felt while the arm is lying loosely by the side; if the arm be raised, it recedes from under the finger. The lesser tuberosity, directed forward and inward, is to be felt to the inner side of the greater tuberosity, just below the acromioclavicular joint. Between the two tuberosities lies the bicipital groove. This can be defined by placing the finger and making firm pressure just internal to the greater tuberosity; then, by rotating the humerus, the groove will be felt to pass under the finger as the bone is rotated. With the arm abducted from the side, by pressing deeply in the axilla the lower part of the head of the bone is to be felt. On each side of the elbow-joint, and just above it, the internal and external condyles of the bone may be felt. Of these, the internal is the more prominent, but the ridge passing upward from it, the internal supracondylar ridge, is much less marked than the external, and, as a rule, is not to be felt. Occasionally, however, we find along this border the hook-shaped process mentioned in the foot-note on page 181. The external condyle is most plainly to be seen during semiflexion of the forearm, and its position is indicated by a depression between the attachment of the adjacent muscles. From it is to be felt a strong bony ridge running up the outer border of the shaft of the bone. This is the external supracondylar ridge; it is concave forward, and corresponds with the curved direction of the lower extremity of the humerus.

Applied Anatomy.—There are several points of surgical interest connected with the humerus. First, as regards its development. The upper end, though the first to ossify, is the last to join the shaft, and the length of the bone is mainly due to growth from this upper epiphysis. Hence, in cases of *amputation of the arm* in young subjects the humerus continues to grow considerably, and the end of the bone, which immediately after the operation was covered with a thick cushion of soft tissue, begins to project, thinning the soft parts and rendering the *stump conical*. This may necessitate another operation, which consists in the removal of a couple of inches or so of the bone, and even after this operation a recurrence of the conical stump may take place.

There are several points of surgical interest in connection with *fractures*. First, as regards their causation, the bone may be broken by direct or indirect violence like the other long bones, but, in addition to this, it is probably more frequently fractured by muscular action than any other of this class of bone in the body. It is usually the shaft, just below the insertion of the Deltoid, which is thus broken. Fractures of the upper end may take place through the anatomical neck, through the surgical neck, or separation of the greater tuberosity may occur. Fracture of the anatomical neck is a very rare accident; in fact, it is doubted by some whether it ever occurs. These fractures are usually considered to be *intracapsular*, but they are probably partly within and partly without the capsule, as the lower part of the capsule is inserted some little distance below the anatomical neck, while the upper part is attached to it. They may be *impacted* or *nonimpacted*. In most cases there is little or no displacement on account of the capsule, in whole or in part, remaining attached to the lower fragment. Separation of the *upper epiphysis* of the humerus sometimes occurs in the young subject, and is marked by a characteristic deformity by which the lesion may be at once recognized. This consists in the presence of an abrupt projection at the front of the joint a short distance below the coracoid process, caused by the upper end of the lower fragment. In fractures of the *shaft of the humerus* the lesion may take place at any point, but appears to be more common in the lower than in the upper part of the bone. The points of interest in connection with these fractures are: (1) That the musculospiral nerve may be injured as it lies in the groove on the bone, or may become involved in the callus which is subsequently thrown out; and (2) the frequency of nonunion. This is believed to be more common in the humerus than in any other bone, and various causes have been assigned for it. It would seem most probably to be due to the difficulty that there is in fixing the shoulder-joint and the upper fragment, and possibly the elbow-joint and lower fragment also. Other causes which have been assigned for the nonunion are: (1) That in attempting passive motion of the elbow-joint to overcome any rigidity which may exist, the movement does not take place at the articulation, but at the seat of fracture; or that the patient, in consequence of the rigidity of the elbow, in attempting to flex or extend the forearm moves the fragment and not the joint. (2) The presence of small portions of muscle tissue between the broken ends. (3) Want of support to the elbow, so that the weight of the arm tends to drag the lower fragment away from the upper. An important distinction to make in fractures of the *lower end of the humerus* is between those that involve the elbow-joint and those which do not; the former are always serious, as they may lead to stiffness of the joint and impairment of the

utility of the limb. They include the T-shaped fracture and oblique fractures which involve the articular surface. The fractures which do not involve the joint are the transverse above the condyles and the so-called epitrochlear fracture, in which the tip of the internal condyle is broken off, generally by direct violence.

Under the head of *separation of the lower epiphysis* two separate injuries have been described: (1) Where the whole of the four ossific centres which form the lower extremity of the bone are separated from the shaft; and (2) where the articular portion is alone separated, the two condyles remaining attached to the shaft of the bone. The *epiphyseal line* between the shaft and lower end runs across the bone just above the tips of the condyles, a point to be borne in mind in performing the operation of excision. Shortening may follow *epiphysitis*.

Tumors originating from the humerus are of frequent occurrence. A not uncommon place for a *chondroma* to grow from is the shaft of the bone somewhere in the neighborhood of the insertion of the deltoid. *Sarcomata* frequently grow from this bone.

THE FOREARM.

The **forearm** is that portion of the upper extremity which is situated between the elbow and the wrist. Its skeleton is composed of two bones, the **ulna** and **radius**.

The Ulna, or Elbow Bone (Figs. 145, 147).

The **ulna** is a long bone, prismatic in form, placed at the inner side of the forearm, parallel with the radius. It is the larger and longer of the two bones. Its upper extremity, of great thickness and strength, forms a large part of the articulation of the elbow-joint; it diminishes in size from above downward, its lower extremity being very small, and excluded from the wrist-joint by the interposition of an intra-articular fibrocartilage. It is divisible into a shaft and two extremities.

The **Upper or Proximal Extremity**, the strongest part of the bone, presents for examination two large, curved processes, the olecranon process and the coronoid process; and two concave, articular cavities, the greater and lesser sigmoid cavities.

The **olecranon process** (*olecranon*) is a large, thick, curved eminence situated at the upper and back part of the ulna. It is curved forward at the summit so as to present a prominent tip which is received into the olecranon fossa of the humerus in extension of the forearm, its base being contracted where it joins the shaft. This is the narrowest part of the upper end of the ulna. The *posterior surface* of the olecranon, directed backward, is triangular, smooth, subcutaneous, and covered by a bursa. Its *upper surface* is of a quadrilateral form, marked behind by a rough impression for the attachment of the Triceps muscle; and in front, near the margin, by a slight transverse groove for the attachment of part of the posterior ligament of the elbow-joint. Its *anterior surface* is smooth, concave, covered with cartilage in the recent state, and forms the upper and back part of the greater sigmoid cavity. The *lateral borders* present a continuation of the same groove that was seen on the margin of the superior surface; they serve for the attachment of ligaments—viz., the back part of the internal lateral ligament internally, the posterior ligament externally. To the *inner border* is also attached a part of the Flexor carpi ulnaris, while to the *outer border* is attached the Anconeus muscle.

The **coronoid process** (*processus coronoideus*) is a triangular eminence of bone which projects horizontally forward from the upper and front part of the ulna. Its *base* is continuous with the shaft, and of considerable strength; so much so that fracture of it is an accident of rare occurrence. Its *apex* is pointed, slightly curved upward, and is received into the coronoid depression of the humerus in

flexion of the forearm. Its *upper surface* is smooth, concave, and forms the lower part of the greater sigmoid cavity. The *under surface* is concave; and marked by an impression internally for the insertion of the Brachialis anticus. At the junction of this surface with the shaft is a rough eminence, the **tubercle of the ulna** (*tuberositas ulnae*), for the attachment of the oblique ligament of the middle radio-ulnar articulation. Its outer surface presents a narrow, oblong, articular depression, the **lesser sigmoid cavity**. The *inner surface*, by its prominent free margin, serves for the attachment of part of the internal lateral ligament. At the front part of this surface is a small, rounded eminence for the attachment of one head of the Flexor sublimis digitorum; behind the eminence, a depression for part of the origin of the Flexor profundus digitorum; and, descending from the eminence, a ridge which gives attachment to one head of the Pronator teres. Generally, the Flexor longus pollicis has an origin from the lower part of the coronoid process by a rounded bundle of muscle fibres.

The **greater sigmoid cavity** (*incisura semilunaris*) is a semilunar depression of large size, formed by the olecranon and coronoid processes, and serving for articulation with the trochlear surface of the humerus. About the middle of either lateral border of this cavity is a notch which contracts it somewhat, and serves to indicate the junction of the two processes of which it is formed. The cavity is concave from above downward, and divided into two lateral parts by a smooth, elevated ridge which runs from the summit of the olecranon to the tip of the coronoid process. Of these two portions, the internal is the larger, and is slightly concave transversely; the external portion is convex above, slightly concave below. The articular surface, in the recent state, is covered with a thin layer of hyaline cartilage.

The **lesser sigmoid cavity** (*incisura radialis*) is a narrow, oblong, articular depression, placed on the outer side of the coronoid process, and receives the lateral articular surface of the head of the radius. It is concave from before backward, and its extremities, which are prominent, serve for the attachment of the orbicular ligament. In the recent state it is covered with a thin layer of hyaline cartilage.

The **Shaft** (*corpus ulnae*), at its upper part, is prismatic in form, and curved from behind forward and from without inward, so as to be convex behind and externally; its central part is quite straight; its lower part rounded, smooth, and bent a little outward; it tapers gradually from above downward, and presents for examination three borders and three surfaces.

The **anterior or palmar border** (*margo volaris*) commences above at the prominent inner angle of the coronoid process, and terminates below in front of the styloid process. It is well marked above, smooth and rounded in the middle of its extent; and affords origin to the Flexor profundus digitorum; its lower fourth, marked off from the rest of the border by the commencement of an oblique ridge on the anterior surface, serves for the origin of the Pronator quadratus. It separates the anterior from the internal surface.

The **posterior or dorsal border** (*margo dorsalis*) commences above at the apex of the triangular subcutaneous surface at the back part of the olecranon, and

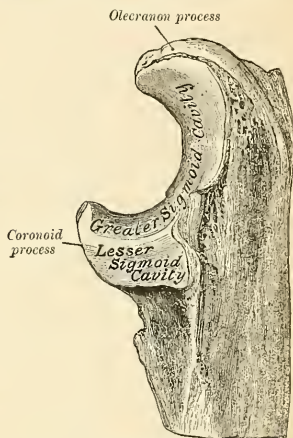


FIG. 146.—Upper extremity of left ulna. Outer aspect.

terminates below at the back part of the styloid process; it is well marked in the upper three-fourths, and gives origin to the aponeurosis common to the Flexor carpi ulnaris, the Extensor carpi ulnaris, and the Flexor profundus digitorum muscles; its lower fourth is smooth and rounded. This border separates the internal from the posterior surface.

The **external or interosseous border** (*erista interossea*) commences above by the union of two lines, which converge one from each extremity of the lesser sigmoid cavity, enclosing between them a triangular space for the origin of part of the Supinator [brevis], and terminates below at the middle of the lower extremity. Its two middle fourths are very prominent; its lower fourth is smooth and rounded. This border gives attachment to the interosseous membrane, and separates the anterior from the posterior surface.

The **anterior or palmar surface** (*facies volaris*) lies between the anterior and external borders, is much broader above than below, is concave in the upper three-fourths of its extent, and affords origin to the Flexor profundus digitorum; its lower fourth, also concave, is covered by the Pronator quadratus. The lower fourth is separated from the remaining portion of the bone by a prominent ridge (*pronator ridge*) directed obliquely from above downward and inward; this ridge marks the extent of attachment of the Pronator quadratus. At the junction of the upper with the middle third of the bone is the **nutrient foramen**. It opens into the **nutrient canal**, which is directed obliquely inward and upward (proximally).

The **posterior or extensor surface** (*facies dorsalis*) is bounded externally by the interosseous border, internally by the posterior border, and is directed backward and outward; it is broad and concave above, somewhat narrower and convex in the middle of its course, narrow, smooth, and rounded below. It presents, above, an oblique ridge, which runs from the posterior extremity of the lesser sigmoid cavity, downward to the posterior border; the triangular surface above this ridge receives the insertion of the Anconeus muscle, while the upper part of the ridge itself affords origin to the Supinator. The surface of bone below this is subdivided by a longitudinal ridge into two parts; the internal part is smooth, and covered by the Extensor carpi ulnaris; the external portion, wider and rougher, gives origin from above downward to part of the Supinator, the Extensor ossis metacarpi pollicis, the Extensor longus pollicis, and the Extensor indicis muscles.

The **internal surface** (*facies medialis*) is broad and concave above, narrow and convex below. It gives origin by its upper three-fourths to the Flexor profundus digitorum muscle; its lower fourth is subcutaneous. The anterior and the inner surfaces constitute the **flexor surface**.

The **Distal or Lower Extremity** is of small size, and excluded from the articulation of the wrist-joint. It presents for examination two eminences, the outer and larger of which is a rounded, articular eminence, termed the **head** (*capitulum ulnae*), the inner, narrower and more projecting, is a nonarticular eminence, the **styloid process** (*processus styloideus*). The head presents an articular facet, part of which, of an oval form, is directed downward, and plays on the upper surface of the triangular fibrocartilage which separates it from the wrist-joint; the remaining portion, directed outward, is narrow, convex, and received into the sigmoid cavity of the radius. The **styloid process** projects from the inner and back part of the bone, and descends a little lower than the head, terminating in a rounded summit, which affords attachment to the internal lateral ligament of the wrist. The head is separated from the styloid process by a depression for the attachment of the triangular intra-articular fibrocartilage; and behind, by a shallow groove for the passage of the tendon of the Extensor carpi ulnaris.

Structure.—Similar to that of the other long bones.

Development.—From *three* centres—one for the shaft, one for the inferior extremity, and one for the olecranon (Fig. 148). Ossification commences near the middle of the shaft about the eighth week, and soon extends through the greater part of the bone. At birth the ends are cartilaginous. About the fourth year a separate osseous nucleus appears in the middle of the head, which soon extends into the styloid process. About the tenth year ossific material appears in the olecranon near its extremity, the chief part of this process being formed from an extension of the shaft of the bone into it. At about the sixteenth year the upper epiphysis becomes joined to the shaft, and at about the twentieth year the lower one.

Articulations.—With the humerus and radius.

Attachment of Muscles.—To *sixteen*: To the olecranon, the Triceps, Anconeus, and one to the coronoid process, the Brachialis anticus, Pronator teres, Flexor sublimis digitorum, and Flexor profundus digitorum; generally also the Flexor longus pollicis. To the shaft, the Flexor profundus digitorum, Pronator quadratus, Flexor carpi ulnaris, Extensor carpi ulnaris, Anconeus, Supinator [brevis], Extensor ossis metacarpi pollicis, Extensor longus pollicis, and Extensor indicis.

Surface Form.—The most prominent part of the ulna on the surface of the body is the olecranon process, which can always be felt at the back of the elbow-joint. When the forearm is flexed, the upper quadrilateral surface can be felt, directed backward; during extension it recedes into the olecranon fossa, and the contracting fibres of the triceps prevent its being perceived. At the back of the olecranon is the smooth, triangular, subcutaneous surface, which below is continuous with the posterior border of the shaft of the bone, and felt in every position of the forearm. During extension the upper border of the olecranon is slightly above the level of the internal condyle, and the process itself is nearer to this condyle than the outer one. Running down the back of the forearm, from the apex of the triangular surface which forms the posterior surface of the olecranon, is a prominent ridge of bone, the posterior border of the ulna. This may be felt throughout the entire length of the shaft of the bone, from the olecranon above to the styloid process below. As it passes down the forearm it pursues a sinuous course and inclines to the inner side, so that, though it is situated in the middle of the back of the limb above, it is on the inner side of the wrist at its termination. It becomes rounded off in its lower third, and may be traced below to the small, subcutaneous surface of the styloid process. Internal to this border the lower fourth of the inner surface may be felt. The styloid process may be

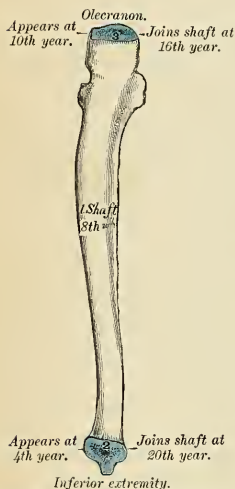


FIG. 148.—Plan of the development of the ulna. From three centres.

felt as a prominent tubercle of bone, continuous above with the posterior subcutaneous border of the ulna, and terminating below in a blunt apex, which lies a little internal and behind, but on a level with, the wrist-joint. The styloid process is best felt when the hand is in the same line as the bones of the forearm, and in a position midway between supination and pronation. If the forearm is pronated while the finger is placed on the process, it will be felt to recede, and another prominence of bone will appear just behind and above it. This is the head of the ulna, which articulates with the lower end of the radius and the triangular intra-articular fibrocartilage, and now projects between the tendons of the Extensor carpi ulnaris and the Extensor minimi digiti muscles.

The Radius.

The **radius** is situated on the outer side of the forearm, lying side by side with the ulna, which exceeds it in length and size (Fig. 145). Its upper end is small, and forms only a small part of the elbow-joint; but its lower end is large, and forms the chief part of the wrist. It is one of the long bones, prismatic in form, slightly curved longitudinally, and, like other long bones, has a shaft and two extremities.

The **Proximal** or **Upper Extremity** presents a head, neck, and tuberosity.

The **head** (*capitulum radii*) is of a cylindrical form, depressed on its upper surface into a shallow cup (*fovea capituli radii*), which articulates with the capitulum or radial head of the humerus. In the recent state it is covered with a layer

of hyaline cartilage which is thinnest at its centre. Around the circumference of the head is a smooth, articular surface (*circumferentia articularis*), broad internally, where it articulates with the lesser sigmoid cavity of the ulna; narrow in the rest of its circumference, where it rotates within the orbicular ligament. It is coated with hyaline cartilage in the recent state. The head is supported on a round, smooth, and constricted portion of bone, called the **neck** (*collum radii*), which presents, behind, a slight ridge, for the attachment of part of the Supinator [brevis]. Beneath the neck, at the inner and front aspect of the bone, is a rough eminence, the **bicipital tuberosity** (*tuberositas radii*). Its surface is divided into two parts by a vertical line—a posterior, rough portion, for the insertion of the tendon of the Biceps muscle; and an anterior, smooth portion, on which a bursa is interposed between the tendon and the bone.

The **Shaft** (*corpus radii*) is prismoid in form, narrower above than below, and slightly curved, so as to be convex outward. It presents three surfaces, separated by three borders.

The **anterior border** (*margo volaris*) extends from the lower part of the tuberosity above to the anterior part of the base of the styloid process below. It separates the anterior from the external surface. Its upper third is very prominent; and from its oblique direction, downward and outward, has received the name of the **oblique line of the radius**. It gives insertion externally at the Supinator [brevis] internally, it limits the origin of the Flexor longus pollicis, and between these, arising from it, is the radial origin of the Flexor sublimis digitorum. The middle third of the anterior border is indistinct and rounded. Its lower fourth is sharp, prominent, affords attachment to the Pronator quadratus and to the posterior annular ligament of the wrist, and terminates in a small tubercle at the base of the styloid process, into which is inserted the tendon of the Brachioradialis.

The **posterior border** (*margo dorsalis*) commences above at the back part of the neck of the radius, and terminates below at the posterior part of the base of the styloid process; it separates the posterior from the external surface. It is indistinct above and below, but well marked in the middle third of the bone.

The **internal border** (*crista interossea*) commences above at the back part of the tuberosity, where it is rounded and indistinct, becomes sharp and prominent as it descends, and at its lower part divides into two ridges, which descend to the anterior and posterior margins of the sigmoid cavity. This border separates the anterior from the posterior surface, and has the interosseous membrane attached to it throughout the greater part of its extent.

The **anterior or flexor surface** (*facies volaris*) is concave for its upper three-fourths, and gives origin to the Flexor longus pollicis muscle; it is broad and flat for its lower fourth, and gives attachment to the Pronator quadratus. A prominent ridge limits the attachment of the Pronator quadratus below, and between this and the inferior border is a triangular rough surface for the attachment of the anterior ligament of the wrist-joint. At the junction of the upper and middle third of this surface is the **nutrient foramen**, the opening of the **nutrient canal**, which is directed obliquely upward (proximally).

The **posterior or extensor surface** (*facies dorsalis*) is rounded, convex, and smooth in the upper third of its extent, and covered by the Supinator [brevis] muscle. Its middle third is broad, slightly concave, and gives origin to the Extensor ossis metacarpi pollicis above, the Extensor brevis pollicis below. Its lower third is broad, convex, and covered by the tendons of the muscles, which subsequently run in the grooves on the lower end of the bone.

The **external surface** (*facies lateralis*) is rounded and convex throughout its entire extent. Its upper third gives attachment to the Supinator [brevis] muscle. About its centre is seen a rough ridge, for the insertion of the Pronator teres muscle. Its lower part is narrow, and covered by the tendons of the Extensor ossis metacarpi pollicis and Extensor brevis pollicis muscles.

The **Lower Extremity** is large, of quadrilateral form, and provided with two articular surfaces—one at the extremity, for articulation with the carpus, and one at the inner side of the bone, for articulation with the ulna. The **carpal articular surface** (*facies articularis carpea*) is of triangular form, concave, smooth, and divided by a slight antero-posterior ridge into two parts. Of these, the external is of a triangular form, and articulates with the scaphoid bone; the inner is quadrilateral and articulates with the semilunar bone. The articular surface for the head of the ulna is called the **sigmoid cavity of the radius** (*incisura ulnaris*); it is narrow, concave, smooth, and articulates with the head of the ulna. The circumference of this end of the bone presents three surfaces—an anterior, external, and posterior. The *anterior surface*, rough and irregular, affords attachment to the anterior ligament of the wrist-joint. The *external surface* is prolonged obliquely downward into a strong conical projection, the **styloid process** (*processus styloideus*), which gives attachment by its base to the tendon of the Brachioradialis, and by its apex to the external lateral ligament of the wrist-joint. The outer surface of this process is marked by a flat groove, which runs obliquely downward and forward, and gives passage to the tendons of the Extensor ossis metacarpi pollicis and the Extensor brevis pollicis. The *posterior surface* is convex, affords attachment to the posterior ligament of the wrist, and is marked by three grooves. Proceeding from without inward, the first groove is broad but shallow, and subdivided into two by a slightly elevated ridge; the outer of these two transmits the tendon of the Extensor carpi radialis longior, the inner the tendon of the Extensor carpi radialis brevior. The second, which is near the centre of the bone, is a deep but narrow groove, bounded on its outer side by a sharply defined ridge; it is directed obliquely from above, downward and outward, and transmits the tendon of the Extensor longus pollicis. The third, lying most internally, is a broad groove, for the passage of the tendons of the Extensor indicis and Extensor communis digitorum.

Structure.—Similar to that of the other long bones.

Development (Fig. 149).—From *three* centres, *one* for the shaft and *one* for each extremity. That for the shaft makes its appearance near the centre of the bone, about the eighth week of fetal life. About the end of the second year ossification commences in the lower epiphysis, and about the fifth year in the upper end. At the age of seventeen or eighteen the upper epiphysis becomes joined to the shaft, the lower epiphysis becoming united about the twentieth year. Sometimes an additional centre appears about the fourteenth year in the bicipital tuberosity.

Articulation.—With *four* bones—the humerus, ulna, scaphoid, and semilunar.

Attachment of Muscles.—To *nine*: To the tuberosity, the Biceps; to the oblique ridge, the Supinator [brevis], Flexor sublimis digitorum, and Flexor longus pollicis; to the shaft (its anterior surface), the Flexor longus pollicis and Pronator quadratus; (its posterior surface), the Extensor ossis metacarpi pollicis and Extensor brevis pollicis; (its outer surface), the Pronator teres; and to the styloid process, the Brachioradialis.

Surface Form.—Just below and a little in front of the posterior surface of the external condyle a part of the head of the radius may be felt, covered by the orbicular and external lateral ligaments. There is in this situation a little dimple in the skin, which is most visible when the arm is extended, and which marks the position of the head of the bone. If the finger is placed on this dimple and the forearm pronated and supinated, the head of the bone will be distinctly perceived rotating in the lesser sigmoid cavity. The upper half of the shaft of the radius cannot be felt, as it is surrounded by the fleshy muscles arising from the external condyle. The lower half of the shaft can be readily examined, although covered by tendons and muscles and not strictly subcutaneous. If traced downward, the shaft will be felt to terminate in a lozenge-shaped, convex surface on the outer side of the base of the styloid process. This is the only subcutaneous part of the bone, and from its lower extremity the apex of the styloid process will be felt bending inward toward the wrist. About the middle of the posterior aspect of the lower extremity of the bone is a well-marked ridge, best perceived when the hand is slightly flexed on the wrist. It forms the outer boundary of the oblique groove on the posterior surface of the bone, through which the tendon of the Extensor longus pollicis runs, and serves to keep that tendon in place.

Applied Anatomy of the Radius and Ulna.—The two bones of the forearm are more often broken together than is either the radius or ulna separately. It is, therefore, convenient to consider *fractures* of both bones in the first instance, and subsequently to mention the principal fractures

which take place in each bone individually. These fractures may be produced by either direct or indirect violence, though more commonly by direct violence. When indirect force is applied to the forearm the radius generally alone gives way, though both bones may suffer. The fracture from indirect force generally takes place somewhere about the middle of the bones; fracture from direct violence may occur at any part, more often, however, in the lower half of the bone. The fracture is usually transverse, but may be more or less oblique. A point of interest in connection with these fractures is the tendency that there is for the two bones to unite across the interosseous membrane; the limb should therefore be put up in a position midway between supination and pronation, which is not only the most comfortable position, but also separates the bones most widely from each other, and therefore diminishes the risk of the bones becoming united across the interosseous membrane. The splints, anterior and posterior, which are applied in these cases should be rather wider than the limb, so as to prevent any lateral pressure on the bones. In these cases there is a greater liability to gangrene from the pressure of the splints than in other parts of the body. This is no doubt due principally to two causes: (1) The flexion of the forearm compressing to a certain extent the brachial artery and retarding the flow of blood to the limb; and (2) the superficial position of the two main arteries of the forearm in a part of their course, and their liability to be compressed by the splints. The special fractures of the ulna are: (1) Fracture of the olecranon. This may be caused by direct violence, falls on the elbow with the forearm flexed, or by muscular action by the sudden contraction of the triceps. The most common place for the fracture to occur is at the constricted portion where the olecranon joins the shaft of the bone, and the fracture may be either transverse or oblique; but any part may be broken, even a thin shell may be torn off. Fractures from direct violence are occasionally comminuted. The displacement is sometimes very slight, owing to the fibrous structures around the process not being torn. (2) Fracture of the coronoid process sometimes occurs as a complication of dislocation backward of the bones of the forearm, but it is doubtful if it ever occurs as an uncomplicated injury. (3) Fractures of the shaft of the ulna may occur at any part, but usually takes place at the middle of the bone or a little below it. They are usually the result of direct violence. (4) The styloid process may be knocked off by direct violence. Fractures of the radius consist of: (1) Fracture of the head of the bone; this generally occurs in conjunction with some other lesion, but may occur as an uncomplicated injury. (2) Fracture of the neck may also take place, but is generally complicated with other injury. (3) Fractures of the shaft of the radius are very common, and may take place at any part of the bone. They may take place from either direct or indirect violence. In fractures of the upper third of the shaft of the bone, that is to say, above the insertion of the Pronator teres, the displacement is very great. The upper fragment is strongly supinated by the Biceps and Supinator, and flexed by the Biceps, while the lower fragment is pronated and drawn toward the ulna by the two pronators. If such a fracture is put up in the ordinary position, midway between supination and pronation, the fracture will unite with the upper fragment in a position of supination, and the lower one in the mid-position, and thus considerable impairment of the movements of the hand will result. The limb should be put up with the forearm supinated. (4) The most important fracture of the radius is that of the lower end (*Colles' fracture*). The fracture is transverse, and generally takes place about an inch from the lower extremity. It is caused by falls on the palm of the hand, and is an injury of advanced life, occurring more frequently in the female than the male. In consequence of the manner in which the fracture is caused, the upper fragment becomes driven into the lower, and impaction is the result; or else the lower fragment becomes split up into two or more pieces, so that no fixation occurs. Separation of the lower epiphysis of the radius may take place in the young. This injury and Colles' fracture may be distinguished from other injuries in this neighborhood—especially dislocation, with which it is liable to be confounded—by observing the relative positions of the styloid processes of the ulna and radius. In the natural condition of parts, with the arm hanging by the side, the styloid process of the radius is on a lower level than that of the ulna; that is to say, nearer the ground. After fracture or separation of the epiphysis this process is on the same or a higher level than that of the ulna, whereas it would be unaltered in position in dislocation.

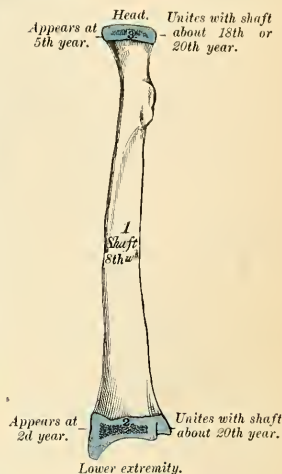


FIG. 149.—Plan of the development of the radius. From three centres.

The Carpus (Ossa Carpi) (Figs. 150, 151).

The bones of the *carpus*, *eight* in number, are arranged in two rows. Those of the upper row, enumerated from the radial to the ulnar side, are the *scaphoid*,

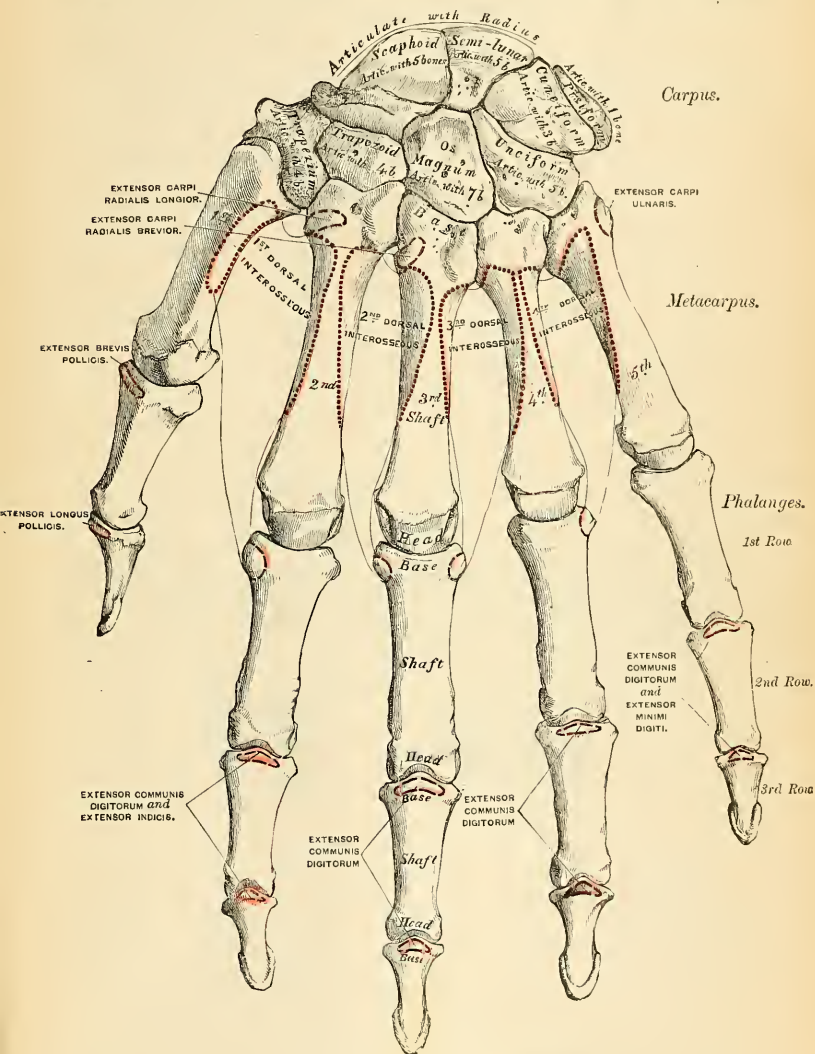


FIG. 151.—Bones of the left hand. Dorsal surface.

semilunar, cuneiform, and pisiform; those of the lower row, enumerated in the same order, are the trapezium, trapezoid, os magnum, and unciform.

Common Characters of the Carpal Bones.—Each bone (excepting the pisiform) presents six surfaces. Of these the *anterior*, *palmar*, or *volar*, and the *posterior* or *dorsal* are rough for ligamentous attachment, the dorsal surface being the broader, except in the scaphoid and semilunar. The *superior* or *proximal* and *inferior* or *distal* are articular, the superior generally convex, the inferior concave; and the *internal* and *external* are also articular when in contact with contiguous bones, otherwise rough and tubercular. The structure of all is similar, consisting of cancellous tissue enclosed in a layer of compact bone.

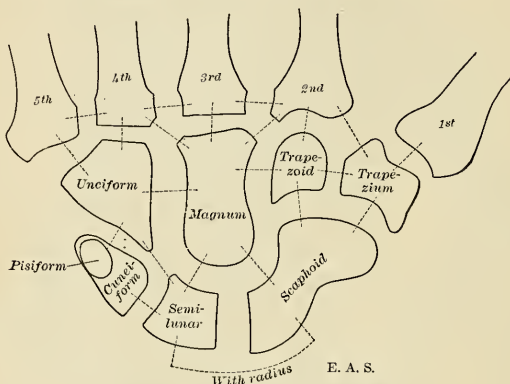


FIG. 152.—Diagram to show articulations.

Bones of the Upper Row.—The scaphoid or navicular bone (*os naviculare manus*) (Fig. 153) is the largest bone of the first row. It is situated at the upper and outer part of the carpus, its long axis being from above downward, outward, and forward.

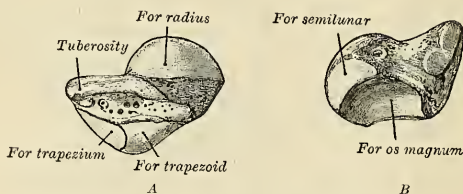


FIG. 153.—The left scaphoid. A, seen from behind; B, seen from in front.

Surfaces.—The *superior surface* is convex, smooth, of triangular shape, and articulates with the lower end of the radius. The *inferior surface*, directed downward, outward, and backward, is smooth, convex, also triangular, and divided by a slight ridge into two parts, the external of which articulates with the trapezium, the inner with the trapezoid. The *posterior* or *dorsal surface* presents a narrow, rough groove which runs the entire length of the bone and serves for the attachment of ligaments. The *anterior* or *palmar surface* is concave above, and elevated at its lower and outer part into a prominent rounded *tuberosity* (*tuberculum ossis navicularis*), which projects forward from the front of the carpus and gives attach-

ment to the anterior annular ligament of the wrist and sometimes a few fibres of the Abductor pollicis. The **external surface** is rough and narrow, and gives attachment to the external lateral ligament of the wrist. The **internal surface** presents two articular facets; of these, the superior or smaller one is flattened, of semilunar form, and articulates with the semilunar; the inferior or larger is concave, forming, with the semilunar bone, a concavity for the head of the os magnum.

To ascertain to which side the bone belongs, hold the convex radial articular surface upward, and the dorsal surface backward; the prominent tubercle will be directed to the side to which the bone belongs.

Articulations.—With *five* bones—the radius above, trapezium and trapezoid below, os magnum and semilunar internally.

Attachment of Muscles.—Occasionally a few fibres of the Abductor pollicis.

The **semilunar** bone (Fig. 154) may be distinguished by its deep concavity and crescentic outline. It is situated in the centre of the upper row of the carpus, between the scaphoid and cuneiform.

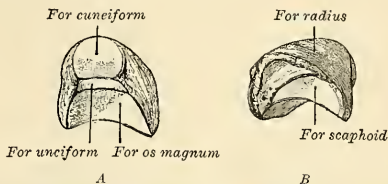


FIG. 154.—The left semilunar. A, anterior and internal surfaces; B, external surface.

Surfaces.—The **superior surface**, convex, smooth, and bounded by four edges, articulates with the radius. The **inferior surface** is deeply concave, and of greater extent from before backward than transversely; it articulates with the head of the os magnum and by a long, narrow facet (separated by a ridge from the general surface) with the unciform bone. The **anterior or palmar** and **posterior or dorsal surfaces** are rough, for the attachment of ligaments, the former being the broader and of a somewhat rounded form. The **external surface** presents a narrow, flattened, semilunar facet for articulation with the scaphoid. The **internal surface** is marked by a smooth, quadrilateral facet, for articulation with the cuneiform.

To ascertain to which hand this bone belongs, hold it with the dorsal surface upward, and the convex articular surface backward; the quadrilateral articular facet will then point to the side to which the bone belongs.

Articulations.—With *five* bones—the radius above, os magnum and unciform below, scaphoid externally, and cuneiform internally.

The **cuneiform** (*os triquetrum*) (Fig. 155) may be distinguished by its pyramidal shape, and by its having an oval, isolated facet for articulation with the pisiform bone. It is situated at the upper and inner side of the carpus.

Surfaces.—The **superior surface** presents an internal, rough, nonarticular portion, and an external or articular portion, which is convex, smooth, and articulates with the triangular intra-articular fibrocartilage of the wrist. The **inferior surface**, directed outward, is concave, sinuously curved, and smooth for articulation with the unciform. The **posterior or dorsal surface** is

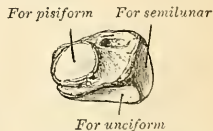


FIG. 155.—The left cuneiform, showing palmar and lateral surfaces.

rough, for the attachment of ligaments. The **anterior** or **palmar surface** presents, at its inner side, an oval facet, for articulation with the pisiform, and is rough externally, for ligamentous attachment. The **external surface**, the base of the pyramid, is marked by a flat, quadrilateral, smooth facet, for articulation with the semilunar. The **internal surface**, the summit of the pyramid, is pointed and roughened, for the attachment of the internal lateral ligament of the wrist.

To ascertain to which hand this bone belongs, hold it so that the base is directed backward, and the articular facet for the pisiform bone upward; the concave articular facet will point to the side to which the bone belongs.

Articulations.—With *three* bones—the semilunar externally, the pisiform in front, the unciform below; and with the triangular, interarticular fibrocartilage which separates it from the lower end of the ulna.

The **pisiform** (*os pisiforme*) (Fig. 156) may be known by its small size and by its presenting a single articular facet. It is situated on a plane anterior to the other bones of the carpus; it is spheroidal in form, with its long diameter directed vertically.

For cuneiform



FIG. 156.—The left pisiform, showing posterior and lateral surfaces.

Surfaces.—Its **posterior surface** is a smooth, oval facet, for articulation with the cuneiform. This facet approaches the superior, but not the inferior border of the bone. The **anterior** or **palmar surface** is rounded and rough, and gives attachment to the anterior annular ligament and to the Flexor carpi ulnaris and origin to the Abductor minimi digiti. The **outer** and **inner surfaces** are also rough, the former being concave, the latter usually convex.

To ascertain to which hand this bone belongs, hold the bone with its posterior or articular facet downward and the nonarticular portion of the same surface backward; the inner concave surface will point to the side to which it belongs.

Articulations.—With *one* bone, the cuneiform.

Attachment of Muscles.—To *two*—the Flexor carpi ulnaris and Abductor minimi digiti; and to the anterior annular ligament.

Bones of the Lower Row.—The **trapezium** (*os multangulum majus*) (Fig. 157) is of very irregular form. It may be distinguished by a deep groove, for the tendon of the Flexor carpi radialis muscle. It is situated at the external and inferior part of the carpus between the scaphoid and first metacarpal bone.

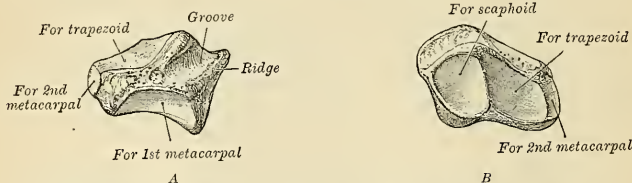


FIG. 157.—The left trapezium. A, as seen from in front; B, from above and mesal side.

Surfaces.—The **superior surface**, concave and smooth, is directed upward and inward, and articulates with the scaphoid. The **inferior surface**, directed downward and inward, is oval, concave from side to side, convex from before backward, so as to form a saddle-shaped surface, for articulation with the base of the first metacarpal bone. The **anterior** or **palmar surface** is narrow and rough. At its upper part is a deep groove running from above obliquely downward and inward; it transmits the tendon of the Flexor carpi radialis, and is bounded externally

by a prominent ridge, the **oblique ridge of the trapezium** (*tuberculum ossis multanguli majoris*). This surface gives origin to the Abductor pollicis, Opponens pollicis, sometimes to a portion of the superficial head of the Flexor brevis pollicis muscles, and the anterior annular ligament. The **posterior or dorsal surface** is rough. The **external surface** is also broad and rough, for the attachment of ligaments. The **internal surface** presents two articular facets; the upper one, large and concave, articulates with the trapezoid; the lower one, small and oval, with the base of the second metacarpal bone.

To ascertain to which hand this bone belongs, hold it with the grooved palmar surface upward, and the external broad, nonarticular surface backward; the saddle-shaped surface will then be directed to the side to which the bone belongs.

Articulations.—With *four* bones—the scaphoid above, the trapezoid and second metacarpal bones internally, the first metacarpal below.

Attachment of Muscles.—Abductor pollicis, Opponens pollicis, and sometimes the superficial head of the Flexor brevis pollicis.

The **trapezoid** (*os multangulum minus*) (Fig. 158) is the smallest bone in the second row. It may be known by its wedge-shaped form, the broad end of the wedge forming the dorsal, the narrow end the palmar, surface, and by its having four articular surfaces touching each other and separated by sharp edges.

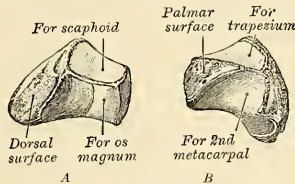


FIG. 158.—The left trapezoid. A, as seen from above, inner side and behind; B, from in front, below and outer side.

Surfaces.—The **superior surface**, quadrilateral in form, smooth, and slightly concave, articulates with the scaphoid. The **inferior surface** articulates with the upper end of the second metacarpal bone; it is convex from side to side, concave from before backward, and subdivided by an elevated ridge into two unequal lateral facets. The **posterior or dorsal** and **anterior or palmar surfaces** are rough, for the attachment of ligaments, the former being the larger of the two. The **external surface**, convex and smooth, articulates with the trapezium. The **internal surface** is concave and smooth in front, for articulation with the os magnum; rough behind, for the attachment of an interosseous ligament.

To ascertain to which hand this bone belongs, let the broad dorsal surface be held upward, and the inferior concavo-convex surface forward; the internal concave surface will then point to the side to which the bone belongs.

Articulations.—With *four* bones—the scaphoid above, second metacarpal bone below, trapezium externally, os magnum internally.

The **os magnum** (*os capitatum*) (Fig. 159) is the largest bone of the carpus, and occupies the centre of the wrist. It presents, above, a rounded portion or **head**, which is received into the concavity formed by the scaphoid and semilunar bones; a constricted portion or **neck**; and, below, the **body**.

Surfaces.—The **superior surface** is rounded, smooth, and articulates with the semilunar. The **inferior surface** is divided by two ridges into three facets for articulation with the second, third, and fourth metacarpal bones, that for the third (the middle facet) being the largest of the three. The **posterior or dorsal surface** is broad and rough; the **anterior or palmar**, narrow, rounded, and also rough, for the

attachment of ligaments, and it gives origin to a part of the Adductor obliquus pollicis. The **external surface** articulates with the trapezoid by a small facet at its anterior inferior angle, behind which is a rough depression for the attachment of an interosseous ligament. Above this is a deep and rough groove, which forms part of the neck and serves for the attachment of ligaments, bounded superiorly by a smooth, convex surface for articulation with the scaphoid. The

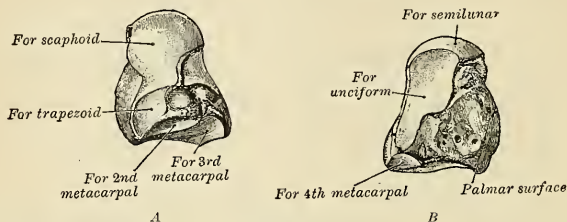


FIG. 159.—The left os magnum. A, outer side seen from below; B, internal posterior surface.

internal surface articulates with the unciform by a smooth, concave, oblong facet which occupies its posterior and superior parts, and is rough in front, for the attachment of an interosseous ligament.

To ascertain to which hand this bone belongs, the rounded head should be held upward, and the broad dorsal surface forward; the internal concave articular surface will point to the side to which the bone belongs.

Articulations.—With *seven* bones—the scaphoid and semilunar above; the second, third, and fourth metacarpal below; the trapezoid on the radial side; and the unciform on the ulnar side.

Attachment of Muscles.—Part of the Adductor obliquus pollicis.

The **unciform** (*os hamatum*) (Fig. 160) may be readily distinguished by its wedge-shaped form and the hook-like process that projects from its palmar surface. It is situated at the inner and lower angle of the carpus, with its **base** downward, resting on the two inner metacarpal bones, and its **apex** directed upward and outward.

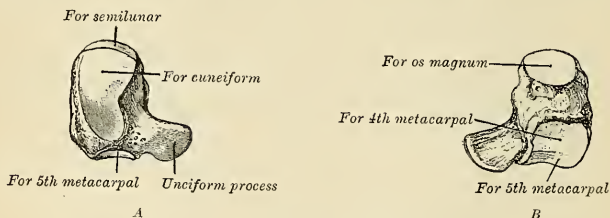


FIG. 160.—The left unciform. A, internal surface; B, outer and distal surfaces.

Surfaces.—The **superior surface**, the apex of the wedge, is narrow, convex, smooth, and articulates with the semilunar. The **inferior surface** articulates with the fourth and fifth metacarpal bones, the concave surface for each being separated by a ridge which runs from before backward. The **posterior or dorsal surface** is triangular and rough, for ligamentous attachment. The **anterior or palmar surface** presents, at its lower and inner side, a curved, hook-like process of bone, the **unciform process** (*hamulus ossis hamati*), directed from the palmar surface forward and outward. It gives attachment by its apex to the annular liga-

ment and insertion to some of the fibres of the Flexor carpi ulnaris; by its inner surface it gives origin to the Flexor brevis minimi digiti and the Opponens minimi digiti; and is grooved on its outer side, for the passage of the Flexor tendons into the palm of the hand. This is one of the four eminences on the front of the carpus to which the anterior annular ligament is attached, the others being the pisiform internally, the oblique ridge of the trapezium and the tuberosity of the scaphoid externally. The **internal surface** articulates with the cuneiform by an oblong facet cut obliquely from above, downward and inward. The **external surface** articulates with the os magnum by its upper and posterior part, the remaining portion being rough, for the attachment of ligaments.

To ascertain to which hand it belongs, hold the apex of the bone upward, and the broad dorsal surface backward; the concavity of the process will be on the side to which the bone belongs.

Articulations.—With *five* bones—the semilunar above, the fourth and fifth metacarpal below, the cuneiform internally, the os magnum externally.

Attachment of Muscles.—To *three*—the Flexor brevis minimi digiti, the Opponens minimi digiti, the Flexor carpi ulnaris.

The Metacarpus (Ossa Metacarpalia) (Figs. 150, 151).

The **metacarpal bones** are *five* in number, and they are numbered from 1 to 5 inclusive, the first being the metacarpal bone of the thumb, the fifth the metacarpal bone of the little finger. They are long, cylindrical bones, presenting for examination a shaft and two extremities.

Common Characters of the Metacarpal Bones.—The **shaft** (*corpus*) is prismoid in form, and curved longitudinally, so as to be convex in the longitudinal direction behind, concave in front. It presents three surfaces—two lateral and one posterior. The two lateral surfaces constitute the **palmar** or **volar aspect**. The **lateral surfaces** are concave, for the origin of the Interossei muscles, and separated from one another by a prominent anterior ridge. The **posterior** or **dorsal surface** presents in its distal half a smooth, triangular, flattened area which is covered, in the recent state, by the tendons of the Extensor muscles. This triangular surface is bounded by two lines, which commence in small tubercles situated on the dorsal aspect on either side of the digital extremity, and, running backward, converge to meet some distance behind the centre of the bone and form a ridge which runs along the rest of the dorsal surface to the carpal extremity. This ridge separates two lateral, sloping surfaces for the origin of the Dorsal interossei muscles.¹ To the tubercles on the digital extremities are attached the lateral ligaments of the metacarpophalangeal joints. On the palmar surface of each metacarpal bone is a **nutrient foramen**, which opens into a **nutrient canal**. In the first metacarpal the direction of this foramen is toward the phalanges (distad). In each of the other metacarpals it is from the phalanges (proximad).

The **carpal** or **proximal extremity** (*basis*) is of a cuboidal form, and broader behind than in front; it articulates above with the carpus, and on each side with the adjoining metacarpal bones; its **dorsal** and **palmar surfaces** are rough, for the attachment of tendons and ligaments.

The **distal extremity** (*capitulum*) presents an oblong surface, markedly convex from before backward, less so from side to side, and flattened laterally; it articulates with the proximal phalanx; it is broader and extends farther forward on the palmar than on the dorsal aspect. It is longer in the antero-posterior than in the transverse diameter. On either side of the head is a tubercle for the attach-

¹ By these sloping surfaces the metacarpal bones of the hand may be at once differentiated from the metatarsal bones of the foot.

ment of the lateral ligament of the metacarpophalangeal joint. The **posterior surface**, broad and flat, supports the Extensor tendons; the **anterior surface** is grooved in the middle line for the passage of the Flexor tendons, and marked on each side by an articular eminence continuous with the terminal articular surface.

The **metacarpal spaces** (*spatia interossea metacarpi*) are the intervals between the metacarpal bones. They are occupied by the Interossei muscles. The broadest space is between the metacarpal bones of the thumb and index finger.

Peculiar Characters of the Metacarpal Bones.

—The **metacarpal bone of the thumb** (*os metacarpale I*) (Fig. 161) is shorter and wider than the rest, diverges to a greater degree from the carpus, and its palmar surface is directed inward toward the palm. The **shaft** is flattened and broad on its dorsal aspect, and does not present the ridge which is found on the other metacarpal bones; it is concave from above downward, on its palmar surface. The **carpal extremity**, or **base**, presents a concavo-convex surface, for articulation with the trapezium; it has no lateral facets, but presents

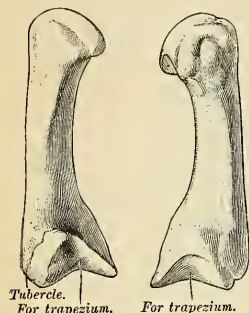


FIG. 161.—The first metacarpal. (Left.)

externally a tubercle for the insertion of the Extensor ossis metacarpi pollicis. The **distal extremity** is less convex than that of the other metacarpal bones, broader from side to side than from before backward. It presents on its palmar aspect two distinct articular eminences for the two sesamoid bones in the tendons of the Flexor brevis pollicis, the outer one being the larger of the two.

The side to which this bone belongs may be known by holding it in the position it occupies in the hand, with the carpal extremity upward and the dorsal surface backward; the tubercle for the Extensor ossis metacarpi pollicis will point to the side to which it belongs.

Attachment of Muscles.—To *four*—the Opponens pollicis, the Extensor ossis metacarpi pollicis, the Flexor brevis pollicis, and the First dorsal interosseous.

The **metacarpal bone of the index finger** (*os metacarpale II*) (Fig. 162) is the longest and its base the largest of the other four. Its **carpal extremity** is prolonged upward and inward, forming a prominent ridge. The dorsal and palmar surfaces of this extremity are rough, for the attachment of tendons and ligaments. It presents four articular facets—three on the upper aspect of the base; the middle one of the three is the largest, concave from side to side, convex from before backward, for articulation with the trapezoid; the external one is a small, flat, oval facet, for articulation with the trapezium; the internal one on the summit of the ridge is long and narrow, for articulation with the os magnum. The fourth facet is on the inner or the ulnar side of the extremity of the bone, and is for articulation with the third metacarpal bone.

The side to which this bone belongs is indicated by the absence of the lateral facet on the outer (radial) side of its base, so that if the bone is placed with the base toward the student and the palmar surface upward, the side on which there is no lateral facet will be that to which it belongs.

Attachment of Muscles.—To *six*—Flexor carpi radialis, Extensor carpi radialis longior, the deep portion of the Flexor brevis pollicis, First and Second dorsal interosseous, and First palmar interosseous.

The **metacarpal bone of the middle finger** (*os metacarpale III*) (Fig. 163) is a little smaller than the preceding; it presents a pyramidal eminence, the **styloid**

process (*processus styloideus*), on the radial side of its base (dorsal aspect), which extends upward behind the os magnum; immediately below this, on the dorsal aspect, is a rough surface for the attachment of the Extensor carpi radialis brevis. The carpal, articular facet is concave behind, flat in front, and articulates with the os magnum. On the radial side is a smooth, concave facet, for articulation with the second metacarpal bone, and on the ulnar side two small, oval facets, for articulation with the fourth metacarpal.

The side to which this bone belongs is easily recognized by the styloid process on the radial side of its base. With the palmar surface uppermost and the base toward the student, this process points toward the side to which the bone belongs.

Attachment of Muscles.—To six—Extensor carpi radialis brevis, Flexor carpi radialis, Adductor transversus pollicis, Adductor obliquus pollicis, and Second and Third dorsal interosseous.

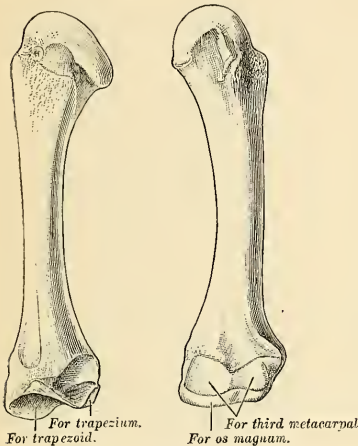


FIG. 162.—The second metacarpal. (Left.)

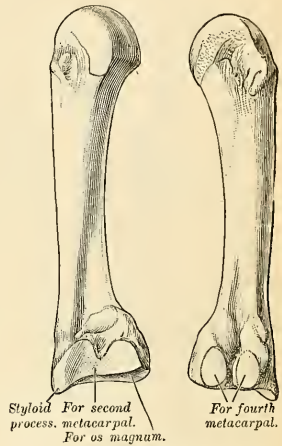


FIG. 163.—The third metacarpal. (Left.)

The metacarpal bone of the ring finger (*os metacarpale IV*) (Fig. 164) is shorter and smaller than the preceding, and its base small and quadrilateral; the carpal surface of the base presenting two facets, a large one internally, for articulation with the unciform, and a small one externally, for the os magnum. On the radial side are two oval facets, for articulation with the third metacarpal bone; and on the ulnar side a single concave facet, for the fifth metacarpal.

If this bone is placed with the base toward the student and the palmar surface upward, the radial side of the base, which has two facets for articulation with the third metacarpal bone, will be on the side to which it belongs. If, as sometimes happens in badly marked bones, one of these facets is indistinguishable, the side may be known by selecting the surface on which the larger articular facet is present. This facet is for the fifth metacarpal bone, and would therefore be situated on the ulnar side—that is, the one to which the bone does *not* belong.

Attachment of Muscles.—To three—the Third and Fourth dorsal and Second palmar interosseous.

The metacarpal bone of the little finger (*os metacarpale I*) (Fig. 165) presents on its base one facet, which is concavo-convex, and which articulates with the unciform bone, and one lateral, articular facet, which articulates with the fourth metacarpal bone. On its ulnar side is a prominent tubercle, for the insertion of

the tendon of the Extensor carpi ulnaris. The dorsal surface of the shaft is marked by an oblique ridge which extends from near the ulnar side of the upper extremity to the radial side of the lower. The outer division of this surface serves for the attachment of the Fourth dorsal interosseous muscle; the inner division is smooth and covered by the Extensor tendons of the little finger.

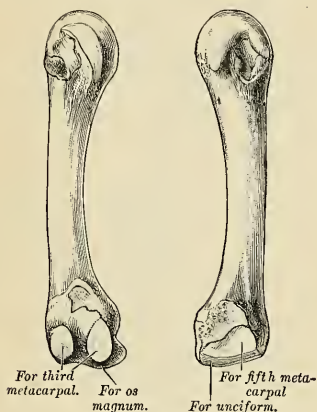


FIG. 164.—The fourth metacarpal. (Left.)

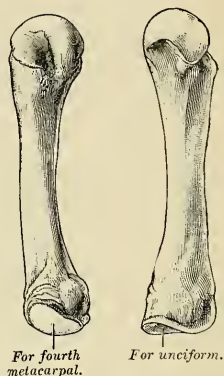


FIG. 165.—The fifth metacarpal. (Left.)

If this bone is placed with its base toward the student and its palmar surface upward, the side of the head which has a lateral facet will be that to which the bone belongs.

Attachment of Muscles.—To *five*—the Extensor carpi ulnaris, Flexor carpi ulnaris, Opponens minimi digiti, Fourth dorsal, and Third palmar interossei.

Articulations.—Besides the phalangeal articulations, the first metacarpal bone articulates with the trapezium; the second with the trapezium, trapezoid, os magnum, and third metacarpal bones; the third with the os magnum and second and fourth metacarpal bones; the fourth with the os magnum, unciform, and third and fifth metacarpal bones; and the fifth with the unciform and fourth metacarpal.

The *first* has no lateral facets on its carpal extremity; the *second* has no lateral facet on its radial side, but one on its ulnar side; the *third* has one on its radial and two on its ulnar side; the *fourth* has two on its radial and one on its ulnar side; and the *fifth* has only one on its radial side.

The Phalanges of the Hand (Phalanges Digitorum Manus).

The **phalanges** (*phalanges digitorum manus*) are *fourteen* in number, three for each finger, and two for the thumb. In numbering them the proximal bone is designated as the first phalanx (*phalanx I*). They are long bones, and present for examination a shaft and two extremities. The **shaft** (*corpus phalangis*) tapers from above downward, is convex posteriorly, concave in front from above downward, flat from side to side, and marked laterally by rough ridges, which give attachment to the fibrous sheaths of the Flexor tendons. A nutrient foramen on the palmar surface leads into a **nutrient canal** which runs toward the periphery (*distad*). The **metacarpal extremity**, or **base** (*basis phalangis*), of each phalanx in the first row presents an oval, concave, articular surface, broader from side to side than from before backward; and the same extremity in the other two rows, a double concavity, separated by a longitudinal median ridge, extending from before backward. The **distal extremity** of the first phalanx of the thumb

and of the first and second phalanx of each of the fingers is smaller than the base, and terminates in two small, lateral condyles, separated by a slight groove (*trochlea phalangis*); the articular surface being prolonged farther forward on the palmar than on the dorsal surface, especially in the first row.

The **ungual phalanges** (*distal*) are convex on their dorsal, flat on their palmar, surfaces; they are recognized by their small size and by a roughened, elevated surface of a horseshoe form on the palmar aspect of their ungual extremity (*tuberositas unguicularis*), which serves to support the sensitive pulp of the finger.

Articulations.—The first row, with the metacarpal bones and the second row of phalanges; the second row, with the first and third; the third, with the second row.

Attachment of Muscles.—To the base of the first phalanx of the thumb, *five* muscles—the Extensor brevis pollicis, Flexor brevis pollicis, Abductor pollicis, Adductores transversus and Obliquus pollicis. To the second phalanx, *two*—the Flexor longus pollicis and the Extensor longus pollicis. To the base of the first phalanx of the index finger, the First dorsal and the First palmar interosseous; to that of the middle finger, the Second and Third dorsal interosseous; to that of the ring finger, the Fourth dorsal and the Second palmar interossei; and to that of the little finger, the Third palmar interosseous, the Flexor brevis minimi digiti, and Abductor minimi digiti. To the second phalanges, the Flexor sublimis digitorum, Extensor communis digitorum, and, in addition, the Extensor indicis to the index finger, the Extensor minimi digiti to the little finger. To the third phalanges, the Flexor profundus digitorum and Extensor communis digitorum.

Surface Form of Carpal and Metacarpal Bones and of the Phalanges.—On the front of the wrist are two subcutaneous eminences, one on the radial side, the larger and flatter, due to the tuberosity of the scaphoid and the ridge on the trapezium; the other, on the ulnar side, caused by the pisiform bone. The tubercle of the scaphoid may be felt just below and in front of the apex of the styloid process of the radius. It is best perceived by extending the hand on the forearm. Immediately below may be felt another prominence, better marked than the tubercle; this is the ridge on the trapezium which gives attachment to some of the short muscles of the thumb. On the inner side of the front of the wrist the pisiform bone may be felt, forming a small but prominent projection in this situation. It is some distance below the styloid process of the ulna, and may be said to be just below the level of the styloid process of the radius. The rest of the front of the carpus is covered by tendons and the annular ligament, and entirely concealed, with the exception of the hooked process of the unciform, which can only be made out with difficulty. The back of the carpus is convex and covered by the Extensor tendons, so that none of the posterior surfaces of the bones are to be felt, with the exception of the cuneiform on the inner side. Below the carpus the dorsal surfaces of the metacarpal bones, except the fifth, are covered by tendons, and are scarcely visible except in very thin hands. The dorsal surface of the fifth is, however, subcutaneous throughout almost its whole length, and may be plainly perceived and felt. In addition to this, slightly external to the middle line of the hand, is a prominence, frequently well marked, but occasionally indistinct, formed by the base of the metacarpal of the middle finger. The heads of the metacarpal bones may be plainly felt and seen, rounded in contour and standing out in bold relief under the skin, when the fist is clenched. It should be borne in mind that when the fingers are flexed on the hand, the articular surfaces of the first phalanges glide off the heads of the metacarpal bones on to their anterior surfaces, so that the head of these bones form the prominence of the knuckles and receive the force of any blow which may be given. The head of the third metacarpal bone is the most prominent, and receives the greater part of the shock of the blow. This bone articulates with the os magnum, so that the concussion is carried through this bone to the scaphoid and semilunar, with which the head of the os magnum articulates, and by these bones is transferred to the radius, along which it may be carried to the capitellum of the humerus. The enlarged extremities of the phalanges may be plainly felt; they form the joints of the fingers. When the digits are bent the proximal phalanges of the joints form prominences, which in the joint between the first and second phalanges is slightly hollowed, in accordance with the grooved shape of their articular surfaces, while at the last row the prominence is flattened and square-shaped. In the palm of the hand the four inner metacarpal bones are covered by muscles, tendons, and the palmar fascia, and no part of them but their heads is to be distinguished. With regard to the thumb, on the dorsal aspect the base of the metacarpal bone forms a prominence below the styloid process of the radius; the shaft is to be felt, covered by tendons, terminating at its head in a flattened prominence, in front of which can be felt the sesamoid bones.

Applied Anatomy.—The carpal bones are not very liable to *fracture*, except from extreme violence, when the parts may be so comminuted as to necessitate amputation. Occasionally they are the seat of *tuberculous* disease. The metacarpal bones and the phalanges are not infrequently broken by direct violence. The first metacarpal bone is the one most commonly frac-

tured; then the second, the fourth, and the fifth, the third being the one least frequently broken. There are two diseases of the metacarpal bones and phalanges which require special mention on account of the frequency of their occurrence. One is *tuberculous dactylitis*, consisting in a deposit of tuberculous material in the medullary canal, expanding the bone, with subsequent caseation and resulting necrosis. The other is *chondroma*, which is perhaps more frequently found in connection with the metacarpal bones and phalanges than with any other bones. When chondromatous growth takes place there are usually multiple tumors, and they may spring either from the medullary canal or from the periosteum.

Development of the Bones of the Hand.—The **carpal bones** are each developed from a *single* centre. At birth they are all cartilaginous. Ossification proceeds in the following order (Fig. 166): In the *os magnum* and *unciform* an ossific point appears during the first year, the former preceding the latter; in the *cuneiform*, at the third year; in the *trapezium* and *semilunar*, at the fifth year, the latter preceding the former; in the *scaphoid*, in the sixth to the eighth year; in the *trapezoid*, during the eighth year; and in the *pisiform*, about the twelfth year.

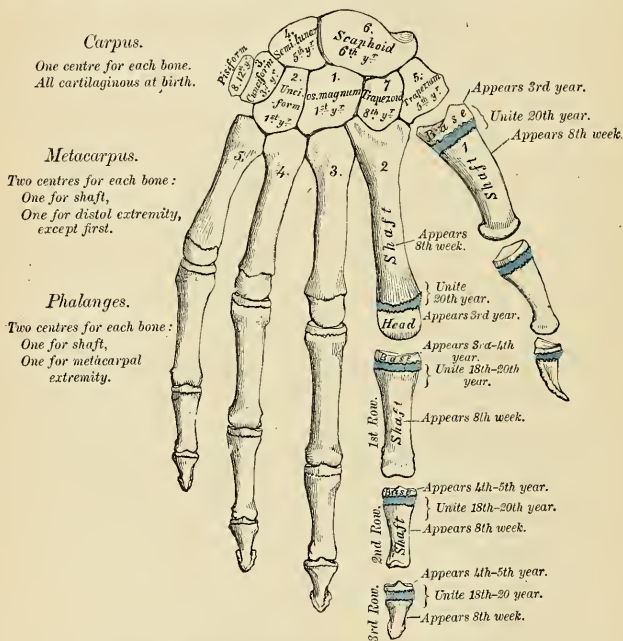


FIG. 166.—Plan of the development of the bones of the hand.

Occasionally an additional bone, the *os centrale*, is found in the carpus, lying between the scaphoid, trapezoid, and *os magnum*. During the second month of fetal life it is represented by a small cartilaginous nodule, which, however, fuses with the cartilaginous scaphoid about the third month. Sometimes the styloid process of the third metacarpal is detached and forms an additional ossicle.

The **metacarpal bones** are each developed from *two* centres, *one* for the shaft and *one* for the distal extremity for the four inner metacarpal bones; *one* for the shaft and *one* for the base for the metacarpal bone of the thumb, which in this respect resembles the phalanges.¹ Ossification commences in the centre of the shaft about the eighth or ninth week, the centre for the first metacarpal bone being the last to appear; ossification gradually proceeds to either end of

¹ Allan Thomson has demonstrated the fact that the first metacarpal bone is often developed from three centres; that is to say, there is separate nucleus for the distal end, forming a distinct epiphysis, visible at the age of seven or eight years. He also states that there are traces of a proximal epiphysis in the second metacarpal bone.—*Journal of Anatomy and Physiology*, 1869.

the bone: about the third year the distal extremities of the four inner metacarpal bones and the base of the first metacarpal begin to ossify, and they unite with the shaft about the twentieth year.

The **phalanges** are each developed from *two* centres, *one* for the shaft and *one* for the base. Ossification commences in the shaft, in all three rows, at about the eighth week, and gradually involves the whole bone excepting the upper extremity. Ossification of the base commences in the first row between the third and fourth years, and a year later in those of the second and third rows. The two centres become united, in each row, between the eighteenth and twentieth years.

In the ungual phalanges the centre for the shaft appears at the distal extremity of the phalanx, instead of at the middle of the shaft, as is the case with the other phalanges. The ungual phalanges are the first bones of the hands to begin to ossify.

THE LOWER EXTREMITY.

The **lower extremity** consists of the following bones: *Ossa innominata* (with the sacrum and coccyx forming the *pelvis*), the femur (*thigh*), the tibia and fibula (the *leg*), the tarsus, the metatarsus and phalanges (the *foot*).

THE OS INNOMINATUM, CALLED ALSO OS COXAE, HIP BONE (Figs. 167, 168).

The **os innominatum** is a large, irregularly shaped, flat bone, constricted in the centre and expanded above and below. With its fellow of the opposite side it forms the sides and anterior wall of the pelvic cavity. In young subjects it consists of three separate parts, which meet and form the large, cup-like cavity, the **acetabulum**, situated near the middle of the outer surface of the bone; and, although in the adult these have become united, it is usual to describe the bone as divisible into three portions—the **ilium**, the **ischium**, and the **pubis**.

The **ilium** is the superior, broad, and expanded portion which runs upward from the acetabulum and forms the prominence of the hip.

The **ischium** is the inferior and strongest portion of the bone; it proceeds downward from the acetabulum, expands into a large tuberosity, and then, curving forward, helps to bound, with the descending ramus of the os pubis, a large aperture, the **obturator foramen**.

The **os pubis** is that portion which extends inward and downward from the acetabulum to articulate in the middle line with the bone of the opposite side; it forms the front of the pelvis and supports the external organs of generation.

The **Ilium** (*os ilium*) presents for examination two surfaces, an external and an internal, a crest, and two borders, an anterior and a posterior.

The **external surface** (Fig. 167) is divided into two parts—an upper or gluteal and a lower or acetabular. The upper portion—known as the **dorsum ilii**—is directed backward and outward behind, and downward and outward in front. It is smooth, convex in *front*, deeply concave *behind*; bounded *above* by the crest, *below* by the upper border of the acetabulum; in *front* and *behind* by the anterior and posterior borders. This surface is crossed in an arched direction by three semicircular lines—the superior, middle, and inferior curved lines. The **superior curved line** (*linea glutea posterior*), the shortest of the three, commences at the crest, about two inches in front of its posterior extremity; it is at first distinctly marked, but as it passes downward and backward to the upper part of the great sacrosciatic notch, where it terminates, it becomes less marked, and is often altogether lost. Behind this line is a narrow semilunar surface, the upper part of which is rough and affords origin to part of the *Gluteus maximus*; the lower part is smooth and has no muscle fibres attached to it. The **middle curved line** (*linea glutea anterior*), the longest of the three, commences at the crest, about an inch behind its anterior extremity, and, taking a curved direction downward and backward, terminates at the upper part of the great sacrosciatic notch. The

space between the superior and middle curved lines and the crest is concave, and affords origin to the Gluteus medius muscle. Near the central part of this line may often be observed the orifice of a nutrient foramen. The inferior curved

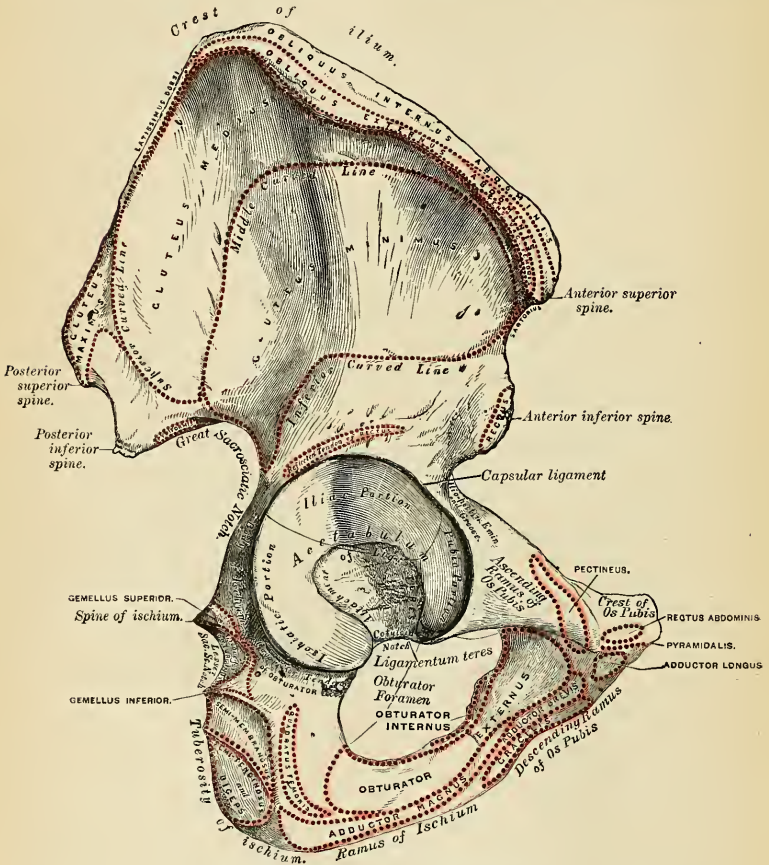


FIG. 167.—Right os innominatum. External surface.

line (*linea glutea inferior*), the least distinct of the three, commences in front at the notch on the anterior border, and, taking a curved direction backward and downward, terminates at the middle of the great sacrospinous notch. The surface of bone included between the middle and inferior curved lines is concave from above downward, convex from before backward, and affords origin to the Gluteus minimus muscle. Beneath the inferior curved line, and corresponding to the upper part of the acetabulum, is a roughened surface (sometimes a depression), from which arises the reflected tendon of the Rectus femoris muscle.

The lower or acetabular part of the external surface enters into the formation

of the **acetabulum**, of which it forms rather less than two-fifths. It is separated from the gluteal portion by a prominent rim, which forms part of the margin of the acetabular cavity.

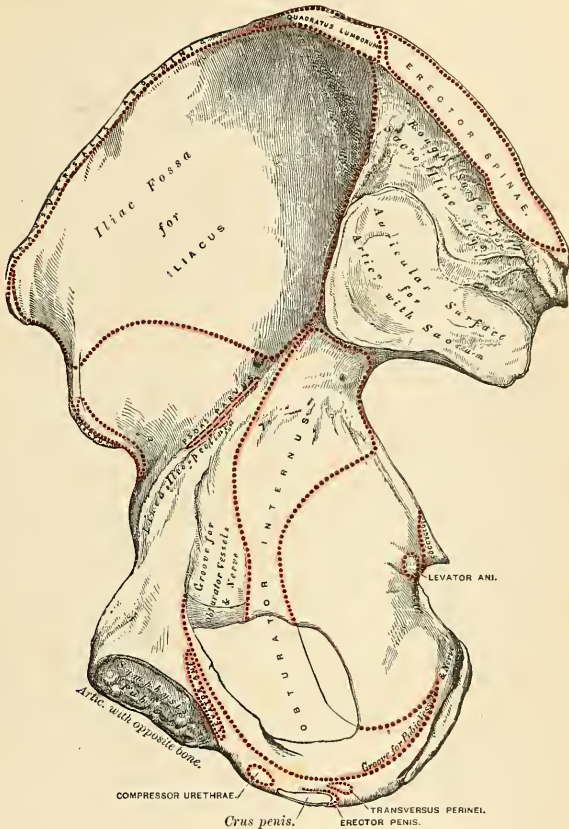


FIG. 168.—Right os innominatum. Internal surface.

The **internal surface** (Fig. 168) is bounded *above* by the crest; *below* it is continuous with the pelvic surface of the os pubis and ischium, a faint line only indicating the place of union; and *before* and *behind* it is bounded by the anterior and posterior borders. It presents a large, smooth, concave surface, called the **iliac fossa** (*fossa iliaca*), which lodges the Iliacus muscle, and presents at its lower part the orifice of a nutrient canal, and below this a smooth, rounded border, the **iliopectineal line** (*linea arcuata*), which separates the iliac fossa from that portion of the internal surface which enters into the formation of the true pelvis, and which gives origin to part of the Obturator internus muscle. Behind the iliac fossa is a rough surface divided into two portions, an anterior and a posterior

The **anterior** or **auricular portion** (*facies auricularis*), so called from its resemblance in shape to the ear, is coated with cartilage in the recent state, and articulates with a surface of similar shape on the side of the sacrum. The **posterior portion** (*tuberositas iliaca*) is rough, for the attachment of the posterior sacroiliac ligaments and for a part of the origin of the Erector and Multifidus spinae.

The **crest of the ilium** (*crista iliaca*) is convex in its general outline and sinuously curved, being concave inward in front, concave outward behind. It is longer in the female than in the male, very thick behind, and thinner at the centre than at the extremities. It terminates at either end in a prominent eminence, the **anterior superior** and **posterior superior spinous process** (*spina iliaca anterior superior et spina iliaca posterior superior*). The surface of the crest is broad, and divided into an **external lip** (*labium externum*), an **internal lip** (*labium internum*), and an **intermediate space** (*linea intermedia*). About two inches behind the anterior superior spinous process there is a prominent **tubercle** on the outer lip. To the external lip is attached the Tensor fasciae femoris, Obliquus externus abdominis, and Latissimus dorsi, and along its whole length, the fascia lata; to the space between the lips, the Internal oblique; to the internal lip, the Transversalis, Quadratus lumborum, and Erector spinae, the Iliacus, and the iliac fascia.

The **anterior border** of the ilium is concave. It presents two projections, separated by a notch. Of these, the uppermost, situated at the junction of the crest and anterior border, is called the **anterior superior spinous process of the ilium**, the outer border of which gives attachment to the fascia lata and the origin of the Tensor fasciae femoris; its inner border, to the Iliacus; while its extremity affords attachment to Poupart's ligament and the origin of the Sartorius. Beneath this eminence is a notch which gives origin to the Sartorius muscle, and across which passes the external cutaneous nerve. Below the notch is the **anterior inferior spinous process** (*spina iliaca anterior inferior*), which terminates in the upper lip of the acetabulum; it gives origin to the straight tendon of the Rectus femoris muscle and the iliofemoral ligament. On the inner side of the anterior inferior spinous process is a broad, shallow groove, over which passes the Iliopsoas muscle. This groove is bounded internally by an eminence, the **iliopectineal eminence** (*eminentia iliopectinea*), which marks the point of union of the ilium and os pubis.

The **posterior border** of the ilium, shorter than the anterior, also presents two projections separated by a notch, the **posterior superior spinous process** (*spina iliaca posterior superior*) and the **posterior inferior spinous process** (*spina iliaca posterior inferior*). The former corresponds with that portion of the inner surface of the ilium which serves for the attachment of the oblique portion of the sacroiliac ligaments and the Multifidus spinae muscle; the latter, to the auricular portion which articulates with the sacrum. Below the posterior inferior spinous process the posterior border forms the upper part of a deep notch, the **great sacrosciatic notch**.

The **Ischium** (*os ischi*) forms the lower and back part of the os innominatum. It is divisible into a thick and solid portion—the body; a large, rough eminence, on which the trunk rests in sitting—the tuberosity; and a thin part which passes inward and slightly upward—the ramus.

The **body** (*corpus ossis ischi*), somewhat triangular in form, presents three surfaces, antero-external, internal, and postero-external; and three borders, external, internal, and posterior. The **antero-external surface** corresponds to that portion of the acetabulum formed by the ischium; it is smooth and concave, and forms a little more than two-fifths of the acetabular cavity; its outer margin is bounded by a prominent rim or lip, the external border, to which the cotyloid fibrocartilage is attached. Below the acetabulum, between it and the tuberosity, is a deep groove, along which the tendon of the Obturator externus muscle runs

as it passes outward to be inserted into the trochanteric fossa of the femur. The **internal surface** is smooth, concave, and enters into the formation of the lateral boundary of the true pelvic cavity. This surface is perforated by two or three large, vascular foramina, and affords origin to part of the Obturator internus muscle. The **postero-external surface** is quadrilateral in form, broad and smooth. Below, where it joins the tuberosity, it presents a groove, the **obturator groove** (*sulcus obturatorius*), continuous with that on the antero-external surface; in this groove is received the posterior fleshy part of the Obturator externus muscle when the thigh is flexed. The lower edge of this groove is formed by the tuberosity of the ischium, and affords origin to the Gemellus inferior muscle. The postero-external surface is limited, externally, by the margin of the acetabulum; behind, by the posterior border; it supports the Piriformis, the two Gemelli, and the Obturator internus muscles in their passage to the great trochanter. The **external border** separates the postero-external from the antero-external surface. The **internal border** is thin, and forms the outer circumference of the obturator foramen. The **posterior border** of the body of the ischium is continuous with the posterior border of the ilium; it presents, a little below the centre, a thin and pointed triangular eminence, the **spine of the ischium** (*spina ischiadica*), more or less elongated in different subjects; its external surface gives origin to the Gemellus superior, its internal surface to the Coccygeus and Levator ani; while to the pointed extremity is connected the lesser sacrosciatic ligament. Above the spine is a notch of large size, the **great sacrosciatic notch**, converted into a foramen, the **great sacrosciatic foramen** (*foramen ischiadicum majus*), by the lesser and greater sacrosciatic ligaments; it transmits the Piriformis muscle, the gluteal vessels, and superior and inferior gluteal nerves; the sciatic vessels, the greater and lesser sciatic nerves, the internal pudic vessels and nerve, and the nerves to the Obturator internus and Quadratus femoris. Of these, the gluteal vessels and superior gluteal nerve pass out above the Piriformis muscle, the other structures, below it. Below the spine is a smaller notch, the **lesser sacrosciatic notch** (*incisura ischiadica minor*); it is smooth, coated in the recent state with cartilage. It is converted into a foramen, the **lesser sacrosciatic foramen** (*foramen ischiadicum minus*), by the sacrosciatic ligaments, and transmits the tendon of the Obturator internus, the nerve which supplies that muscle, and the internal pudic vessels and nerve.

The **tuberosity of the ischium** (*tuber ischiadicum*) is the portion of bone between the body and the ramus. The tuberosity presents for examination three surfaces—external, internal, and posterior. The **external surface** is quadrilateral in shape and rough, for the attachment of muscles. It is bounded *above* by the groove for the tendon of the Obturator externus; in *front* it is limited by the posterior margin of the obturator foramen, and *below* it is continuous with the ramus of the bone; *behind*, it is bounded by a prominent margin which separates it from the posterior surface. In front of this margin the surface gives origin to the Quadratus femoris, and anterior to this some of the fibres of origin of the Obturator externus. The lower part of the surface gives origin to part of the Adductor magnus. The **internal surface** forms part of the bony wall of the true pelvis. In *front* it is limited by the posterior margin of the obturator foramen; *behind*, it is bounded by a sharp ridge, for the attachment of a falciform prolongation of the great sacrosciatic ligament; it sometimes presents a groove on the inner side of this ridge for the lodgement of the internal pudic vessels and nerve; and, more anteriorly, has attached the Transversus perinaei and Erector penis vel clitoridis muscles. The **posterior surface** is divided into two portions—a lower rough, somewhat triangular part, and an upper smooth, quadrilateral portion. The lower portion is subdivided by a prominent vertical ridge, passing from base to apex, into two parts; the outer one gives origin to the Adductor magnus;

the inner, to the great sacrosciatic ligament. The upper portion is subdivided into two facets by an oblique ridge which runs downward and outward; from the upper and outer facet arises the Semimembranosus; from the lower and inner, the Biceps and Semitendinosus.

The **ramus** (*ramus inferior ossis ischi*) is the thin, flattened part of the ischium which ascends from the tuberosity upward and inward, and joins the descending ramus of the os pubis, their point of junction being indicated in the adult by a rough line. The outer surface of the ramus is rough, for the origin of the Obturator externus muscle, and also some fibres of the Adductor magnus; its inner surface forms part of the anterior wall of the pelvis. Its inner border is thick, rough, slightly everted, forms part of the outlet of the pelvis, and presents two ridges and an intervening space. The ridges are continuous with similar ones on the descending ramus of the os pubis; to the outer one is attached the deep layer of the superficial perineal fascia, and to the inner, the superficial layer of the triangular ligament of the perineum. If these two ridges are traced backward, they will be found to join with each other just behind the point of origin of the Transversus perinei muscle; here the two layers of fascia are continuous behind the posterior border of the muscle. To the intervening space, just in front of the point of junction of the ridges, is attached the Transversus perinei muscle, and in front of this arises a portion of the crus penis vel clitoridis and the Erector penis vel clitoridis muscle. Its outer border is thin and sharp, and forms part of the inner margin of the obturator foramen.

The **Pubis** (*os pubis*) forms the anterior part of the os innominatum, and, with the bone of the opposite side, forms the front boundary of the true pelvic cavity. It is divisible into a body, a superior or ascending and an inferior or descending ramus.

The **body** (*corpus ossis pubis*) is the broad portion of bone formed at the junction of the two rami. It is somewhat quadrilateral in shape, and presents for examination two surfaces and three borders. The **anterior surface** is rough, directed downward and outward, and serves for the attachment of various muscles. From the upper and inner angle, immediately below the upper border, arises the Adductor longus; lower down, from without inward, arise the Obturator externus, the Adductor brevis, and the upper part of the Gracilis. The **posterior surface**, convex from above downward, concave from side to side, is smooth, and forms part of the anterior wall of the pelvis. It gives origin to the Levator ani, Obturator internus, a few muscle fibres prolonged from the bladder, and the puboprostatic ligaments. At the outer part of the **upper border** is a prominent tubercle, which projects forward and is called the **spine** (*tuberculum pubicum*); to it is attached Poupart's ligament. Passing upward and outward from this is a prominent ridge, forming part of the **iliopectineal line** (*linea arcuata*). It marks the brim of the true pelvis; to it are attached a portion of the conjoined tendon of the Internal oblique and Transversalis muscles, Gimbernat's ligament, and the triangular fascia. Internal to the spine the upper border is called the **crest**, which extends from this process to the inner extremity of the bone. It affords attachment to the conjoined tendon of the Internal Oblique and Transversalis, and to the Rectus abdominis and Pyramidalis muscles. The point of junction of the crest with the inner border of the bone is called the **angle**; to it, as well as to the symphysis, is attached the internal pillar of the external abdominal ring. The **internal border** is articular; it is oval, covered by eight or nine transverse ridges, which serve for the attachment of a thin layer of cartilage. This surface is united to its fellow of the opposite side in the whole pelvis. The joint is called the symphysis pubis. The **outer border** presents a sharp margin, which forms part of the circumference of the obturator foramen and affords attachment to the obturator membrane.

The **ascending ramus** (*ramus superior ossis pubis*) extends from the body to

the point of junction of the os pubis with the ilium, and forms the upper part of the circumference of the obturator foramen. It presents for examination a superior, inferior, and posterior surface, and an outer extremity. The **superior surface** presents a continuation of the iliopectineal line, already mentioned as commencing at the pubic spine. In front of this ridge the surface of bone is triangular in form, wider externally than internally, smooth, and is covered by the Pectineus muscle. The surface is bounded externally by a rough eminence, the **iliopectineal eminence** (*eminentia iliopectinea*), which serves to indicate the point of junction of the ilium and os pubis, and gives attachment to the Psoas parvus, when this muscle is present. The triangular surface is bounded below by a prominent ridge, the **obturator crest** (*crista obturatoria*), which extends from the cotyloid notch to the spine of the os pubis. The **inferior surface** forms the upper boundary of the obturator foramen, and presents externally a broad and deep oblique groove, the **obturator groove** (*sulcus obturatorius*), for the passage of the obturator vessels and nerve; and internally a sharp margin which forms part of the circumference of the obturator foramen, and to which the obturator membrane is attached. The **posterior surface** forms part of the anterior boundary of the true pelvis. It is smooth, convex from above downward, and affords origin to some fibres of the Obturator internus. The **outer extremity**, the thickest part of the ramus, forms one-fifth of the cavity of the acetabulum.

The **descending ramus** (*ramus inferior ossis pubis*) is thin and flattened. It passes outward and downward, becoming narrower as it descends, and joins with the ramus of the ischium. Its **anterior surface** is rough, for the origin of muscles—the Gracilis along its inner border; a portion of the Obturator externus where the ramus enters into the formation of the obturator foramen; and between these two muscles the Adductores brevis and magnus from within outward. The **posterior surface** is smooth, and gives origin to the Obturator internus, and, close to the inner margin, to the Compressor urethrae. The **inner border** is thick, rough, and everted, especially in females. It presents two ridges, separated by an intervening space. The ridges extend downward, and are continuous with similar ridges on the ascending ramus of the ischium; to the external one is attached the deep layer of the superficial perineal fascia, and to the internal one the superficial layer of the triangular ligament of the perineum. The **outer border** is thin and sharp, forms part of the circumference of the obturator foramen, and gives attachment to the obturator membrane.

The **Cotyloid Cavity, or Acetabulum**, is a deep, cup-shaped, hemispherical depression, directed downward, outward, and forward; formed *internally* by the os pubis, *above* by the ilium, *behind, externally*, and *below* by the ischium, a little less than two-fifths being formed by the ilium, a little more than two-fifths by the ischium, and the remaining fifth by the pubic bone. It is bounded by a prominent uneven rim, which is thick and strong above, and serves for the attachment of the cotyloid ligament, which contracts its orifice and deepens the surface for articulation. It presents below and internally a deep notch, the **cotyloid notch** (*incisura acetabuli*), which is continuous with a circular depression, the **fossa of the acetabulum** (*fossa acetabuli*), at the bottom of the cavity; this depression is perforated by numerous apertures, lodges a mass of fat, and its margins, as well as those of the notch, serve for the attachment of the ligamentum teres. The fossa acetabuli is partly surrounded by a concave rim of bone (*facies lunata*). The cotyloid notch is converted, in the natural state, into a foramen by a dense ligamentous band, the *transverse ligament*, which passes across it. Through this foramen the nutrient vessels and nerves of the joint pass.

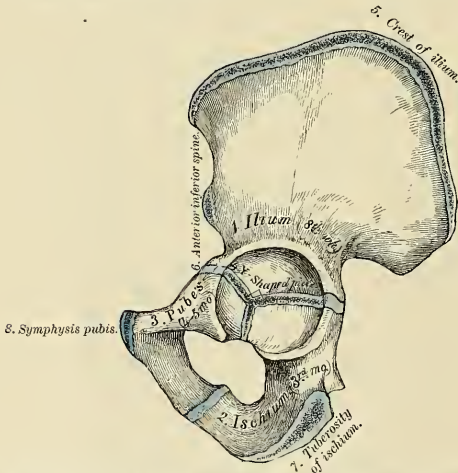
The **Obturator, or Thyroid Foramen** (*foramen obturatum*), is a large aperture situated between the ischium and os pubis. In the male it is large, of an oval form, its longest diameter being obliquely from before backward; in the female

it is smaller and more triangular. It is bounded by a thin, uneven margin, to which a strong membrane is attached, and presents, anteriorly, a deep groove, the **obturator groove** (*sulcus obturatorius*), which runs from the pelvis obliquely inward and downward. This groove is converted into a foramen by a ligamentous band, a specialized part of the obturator membrane, attached to two tubercles, one (*tuberculum obturatorium posterius*) on the internal border of the ischium, just in front of the cotyloid notch, the other (*tuberculum obturatorium anterius*) on the inferior margin of the posterior surface of the ascending ramus of the pubis, and transmits the obturator vessels and nerve.

Structure.—This bone consists of much cancellous tissue, especially where it is thick, enclosed between two layers of dense, compact tissue. In the thinner parts of the bone, as at the bottom of the acetabulum and centre of the iliac fossa, it is usually semitransparent, and composed entirely of compact tissue.

Development (Fig. 169).—From *eight* centres—three primary, *one* for the ilium, *one* for the ischium, and *one* for the os pubis; and *five* secondary, *one* for the crest of the ilium, *one* for the anterior inferior spinous process (said to occur more frequently in the male than in the female), *one* for the tuberosity of the ischium, *one* for the symphysis pubis (more frequent in the female than the male), and *one* or more for the Y-shaped piece at the bottom of the acetabulum. These

From eight centres { Three primary (Ilium, Ischium, and Os Pubis).
Five secondary.



The three primary centres unite through a Y-shaped piece about puberty. Epiphyses appear about puberty, and unite about the twenty-fifth year.

FIG. 169.—Plan of the development of the os innominatum.

various centres appear in the following order: First, in the ilium, at the lower part of the bone, immediately above the sciatic notch, at about the eighth or ninth week; secondly, in the body of the ischium, at about the third month of fetal life; thirdly, in the body of the os pubis, between the fourth and fifth months. At birth the three primary centres are quite separate, the crest, the bottom of the acetabulum, the ischial tuberosity, and the rami of the ischium and pubes being still cartilaginous. At about the seventh or eighth year the rami of the os pubis and ischium are almost completely united by bone. About the twelfth year the three divisions of the bone have extended their growth into the bottom of the acetabulum, being separated from each other by a Y-shaped portion of cartilage, which now presents traces of ossification, often by two or more centres. One of these, the *os acetabuli*, appears about the age of twelve, between the ilium and os pubis, and fuses with them about the age of eighteen. It forms the pubic part of the acetabulum. The ilium and ischium then become joined, and lastly the os pubis to the ischium, through the

intervention of this Y-shaped portion. At about the age of puberty ossification, takes place in each of the remaining portions, and they become joined to the rest of the bone between the twentieth and twenty-fifth years. Separate centres are frequently found for the pubic and ischial spines.

Articulations.—With its fellow of the opposite side, the sacrum, and femur.

Attachment of Muscles.—To the ilium, *sixteen*. To the outer lip of the crest, the Tensor vaginae femoris, Obliquus externus abdominis, and Latissimus dorsi; to the internal lip, the Iliacus, Transversalis, Quadratus lumborum, and Erector spinae; to the interspace between the lips, the Obliquus internus. To the outer surface of the ilium, the Gluteus maximus, Gluteus medius, Gluteus minimus, reflected tendon of the Rectus femoris; to the upper part of the great sacrosciatic notch, a portion of the Piriformis; to the internal surface, the Iliacus; to that portion of the internal surface below the iliopectineal line, the Obturator internus to the internal surface of the posterior superior spine, and the Multifidus spinae; to the anterior border, the Sartorius and straight tendon of the Rectus femoris. To the ischium, *thirteen*. To the outer surface of the ramus, the Obturator externus and Adductor magnus; to the internal surface, the Obturator internus and Erector penis. To the spine, the Gemellus superior, Levator ani, and Coccygeus. To the tuberosity, the Biceps, Semitendinosus, Semimembranosus, Quadratus femoris, Adductor magnus, Gemellus inferior, Transversus perinei, Erector penis. To the pubis, *sixteen*: Obliquus externus, Obliquus internus, Transversalis, Rectus abdominis, Pyramidalis, Psoas parvus, Pectineus, Adductor magnus, Adductor longus, Adductor brevis, Gracilis, Obturator externus and internus, Levator ani, Compressor urethrae, and occasionally a few fibres of the Accelerator urinae.

THE PELVIS (Figs. 170, 171).

The **pelvis** is stronger and more massively constructed than either the cranial or thoracic cavity; it is a bony ring, interposed between the lower end of the vertebral column, which it supports, and the lower extremities, upon which it rests. It is composed of four bones—the two **ossa innominata**, which bound it on either side and in front, and the **sacrum** and **coccyx**, which complete it behind. The pelvis is divided by an oblique plane passing through the prominence of the sacrum, the iliopectineal line, and the upper margin of the symphysis pubis into the **false** and **true pelvis**.

The **False Pelvis** (*pelvis major*) is the expanded portion of the pelvic cavity which is situated above this plane. It is bounded on each side by the ossa ilii; in front it is incomplete, presenting a wide interval between the spinous processes of the ilia on either side, which is filled up in the recent state by the parietes of the abdomen; behind, in the middle line, is a deep notch. This broad, shallow cavity is fitted to support the intestines and to transmit part of their weight to the anterior wall of the abdomen, and is, in fact, really a portion of the abdominal cavity. The term false pelvis is incorrect, and this space ought more properly to be regarded as part of the hypogastric and iliac regions of the abdomen.

The **True Pelvis** (*pelvis minor*) is that part of the pelvic cavity which is situated below the iliopectineal line. It is smaller than the false pelvis, but its walls are more perfect. For convenience of description it is divided into a **superior circumference**, or **inlet**, an **inferior circumference**, or **outlet**, and a **cavity**.

The **superior circumference**, or **inlet** (*apertura pelvis superior*), forms the **brim** of the **pelvis**, the included space being called the **inlet**. It is formed by the iliopectineal line, completed in front by the crests of the pubic bones, and behind by the anterior margin of the base of the sacrum and sacrovertebral angle. The inlet of the pelvis is somewhat heart-shaped, obtusely pointed in front, diverging on either side, and encroached upon behind by the projection forward of the promontory of the sacrum. It has three principal diameters—antero-posterior (sacropubic), transverse, and oblique. The **antero-posterior** or **conjugate diameter** (*conjugata*) extends from the sacrovertebral angle to the symphysis pubis. Its average measurement is four inches in the male and four and three-fifths inches in the female. The **transverse diameter** (*diameter transversa*) extends across the greatest width of the inlet, from the middle of the brim on one side to the

same point on the opposite; its average measurement is five inches in the male, five and one-fourth inches in the female. The **oblique diameter** (*diameter obliqua*) extends from the margin of the pelvis, corresponding to the iliopectineal eminence

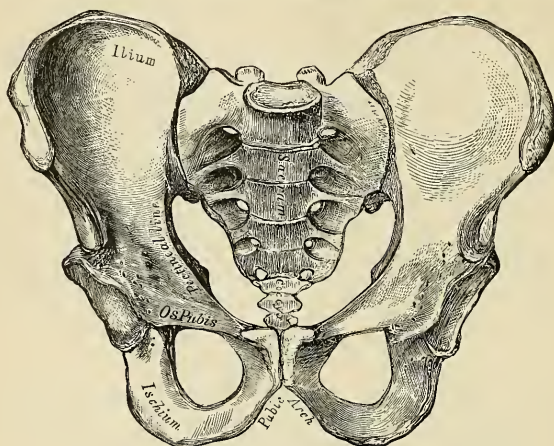


FIG. 170.—Male pelvis (adult).

on one side, to the sacroiliac articulation on the opposite side; its average measurement is four and one-fourth inches in the male and five in the female.

The **cavity** of the true pelvis is bounded in *front* by the symphysis pubis; *behind*, by the concavity of the sacrum and coccyx, which, curving forward above and

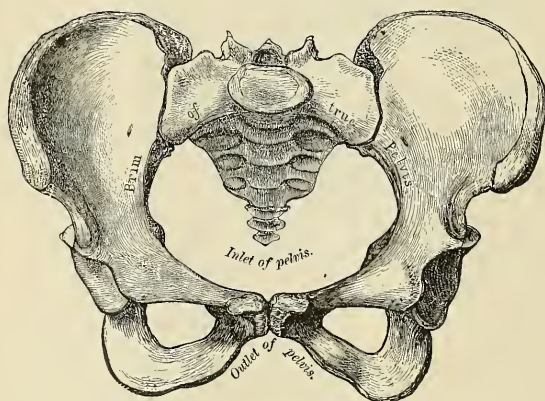


FIG. 171.—Female pelvis (adult).

below, contracts the inlet and outlet of the canal; and *laterally* it is bounded by a broad, smooth, quadrangular surface of bone, corresponding to the inner surface of the body of the ischium and that part of the ilium which is below the ilio-

pectineal line. The cavity is shallow in front, measuring at the symphysis an inch and a half in depth, three inches and a half in the middle, and four inches and a half posteriorly. From this description it will be seen that the cavity of the pelvis is a short, curved canal, considerably deeper on its posterior than on its anterior wall. This cavity contains, in the recent subject, the rectum, bladder, and some of the organs of generation. The rectum is placed at the back of the pelvis, and corresponds to the curve of the sacrococcygeal segment of the vertebral column; the bladder in front, behind the symphysis pubis. In the female the uterus and vagina occupy the interval between these viscera.

The **lower circumference** is very irregular; the space enclosed by it is called the **outlet** (*apertura pelvis inferior*). It is bounded by three prominent eminences—one posterior, formed by the point of the coccyx; and one on each side, the tuberosities of the ischia. These eminences are separated by three notches; one in front, the **pubic arch** (*arcus pubis*), formed by the convergence of the rami of the ischia and pubic bones on each side. The other notches, one on each side, are formed by the sacrum and coccyx behind, the ischium in front, and the ilium above; they are called the **sacrosciatic notches**; in the natural state they are converted into foramina by the lesser and greater sacrosciatic ligaments. In the recent state, when the ligaments are *in situ*, the outlet of the pelvis is lozenge-shaped, bounded in front by the subpubic ligament and the rami of the os pubis and ischium; on each side by the tuberosities of the ischia; and behind by the great sacrosciatic ligaments and the tip of the coccyx.

The diameters of the outlet of the pelvis are two, antero-posterior and transverse. The **antero-posterior diameter** extends from the tip of the coccyx to the lower part of the symphysis pubis; its average measurement is three and three-quarter inches in the male and four and one-half inches in the female. The antero-posterior diameter varies with the length of the coccyx, and is capable of increase or diminution on account of the mobility of that bone. During labor the coccyx may be bent back so that the conjugate is increased one inch, or even one and one-fourth inches. The **transverse diameter** extends from the posterior part of one ischiatic tuberosity to the same point on the opposite side; the average measurement is three and one-half inches in the male and four and three-fourths in the female.¹

Position of the Pelvis.—In the erect posture the pelvis is placed obliquely with regard to the trunk of the body; the bony ring, which forms the brim of the true pelvis, is placed so as to form an angle of about 60 to 65 degrees with the ground on which we stand (*inclinatio pelvis*). The pelvic surface of the symphysis pubis looks upward and backward, the concavity of the sacrum and coccyx downward and forward, the base of the sacrum in well-formed female bodies being nearly four inches above the upper border of the symphysis pubis, and the apex of the coccyx a little more than half an inch above its lower border. In consequence of the obliquity of the pelvis the line of gravity of the head, which passes through the middle of the odontoid process of the axis and through the points of junction of the curves of the vertebral column to the sacrovertebral angle, descends toward the front of the cavity, so that it bisects a line drawn transversely through the middle of the heads of the thigh bones. And thus the centre of gravity of the head is placed immediately over the heads of the thigh bones on which the trunk is supported.

¹ The measurements of the pelvis given above are, I believe, fairly accurate, but different measurements are given by various authors, no doubt due in a great measure to differences in the physique and stature of the population from whom the measurements have been taken. The accompanying table has been formulated to show the measurements of the pelvis which are adopted by many obstetricians.—[EDITOR.]

DIAMETERS OF THE TRUE PELVIS IN WOMAN.

	Antero-posterior.	Oblique.	Transverse.
Of inlet . . .	4½ inches (118 mm.)	5 inches (127 mm.)	5¼ inches (135 mm.)
Of outlet . . .	4½ inches (115 mm.)		4¾ inches (120 mm.)

Axes of the Pelvis (Fig. 172).—The plane of the inlet of the true pelvis will be represented by a line drawn from the base of the sacrum to the upper margin of the symphysis pubis. A line carried at right angles with this at its middle would correspond at one extremity with the umbilicus, and at the other with the middle of the coccyx; the **axis of the inlet** is therefore directed downward and backward. The **axis of the outlet**, prolonged upward, would touch the base of

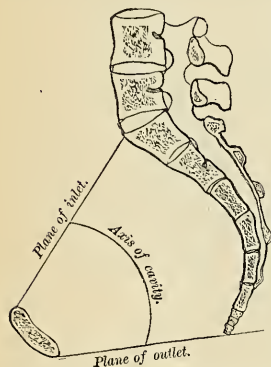


FIG. 172.—Vertical section of the pelvis, with lines indicating the axis of the pelvis.

the sacrum, and is therefore directed downward and forward. The **axis of the cavity** is curved like the cavity itself; this curve corresponds to the concavity of the sacrum and coccyx, the extremities being indicated by the central points of the inlet and outlet. A knowledge of the direction of these axes serves to explain the course of the fetus in the passage through the pelvis during parturition.

Differences between the Male and Female Pelvis.—The female pelvis, looked at as a whole, is distinguished from the male by the bones being more delicate, by its width being greater and its depth smaller. The whole pelvis is less massive, and its bones are lighter and more slender, and its muscular impressions are slightly marked. The iliac fossæ are shallow, and the anterior iliac spines widely separated; hence the greater prominence of the hips. The **inlet** in the female is larger than in the male; it is more nearly circular, and the sacrovertebral angle projects less forward. The **cavity** is shallower and wider; the sacrum is shorter, wider, and less curved; the obturator foramina are triangular, and smaller in size than in the male. The **outlet** is larger and the coccyx more movable. The

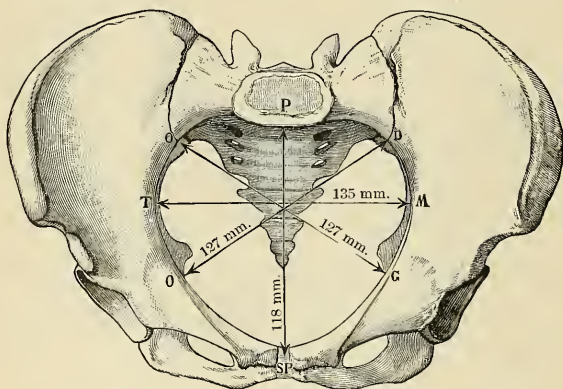


FIG. 173.—Diameters of the pelvic inlet in the female.

spines of the ischia project less inward. The tuberosities of the ischia and the acetabula are wider apart. The **pubic arch** is wider and more rounded than in the male, where it is an angle rather than an arch. In consequence of this the

width of the fore part of the pelvic outlet is much increased and the passage of the fetal head facilitated.

The size of the pelvis varies not only in the two sexes, but also in different members of the same sex. This does not appear to be influenced in any way by the height of the individual. Women of short stature, as a rule, have broad pelves. Occasionally the pelvis is equally contracted in all its dimensions, so much so that all its diameters measure an inch less than the average, and this even in women of average height and otherwise well formed. The principal divergences, however, are found at the inlet, and affect the relation of the antero-posterior to the transverse diameter. Thus we may have a pelvis the inlet of which is elliptical either in a transverse or antero-posterior direction; the transverse diameter in the former and the antero-posterior in the latter greatly exceeding the other diameters. Again, the inlet of the pelvis in some instances is seen to be almost circular. The same differences are found in various races. European women are said to have the most roomy pelves. That of the negress is smaller, circular in shape, and with a narrow pubic arch. The Hottentots and Bushwomen possess the smallest pelves.

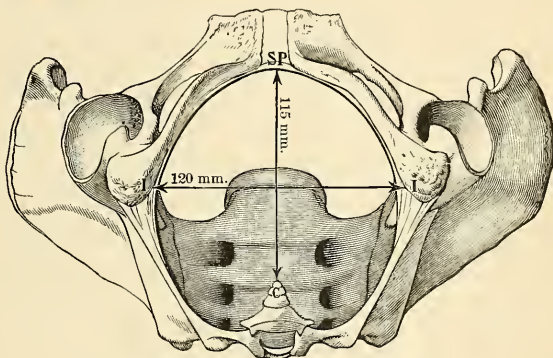


FIG. 174.—Diameters of the pelvic outlet in the female.

In the *fetus* and for several years after birth the pelvis is small in proportion to that of the adult. The cavity is deep and the projection of the sacrovertebral angle less marked. The generally accepted opinion that the female pelvis does not acquire its sexual characters until after puberty has been shown by recent observations¹ to be erroneous, the characteristic differences between the male and female pelvis being distinctly indicated as early as the fourth month of fetal life. At birth these differences are distinct (Romiti), the female pelvis possessing less straight ilia, a broader subpubic arch, and less height than the male.

Surface Form.—The pelvic bones are so thickly covered with muscles that it is only at certain points that they approach the surface and can be felt through the skin. In front, the anterior superior spinous process is easily recognized; a portion of it is subcutaneous, and in thin subjects may be seen to stand out as a prominence at the outer extremity of the fold of the groin. In fat subjects its position is marked by an oblique depression among the surrounding fat, at the bottom of which the bony process may be felt. Proceeding upward and outward from this process, the crest of the ilium may be traced throughout its whole length, sinuously curved. It is represented, in muscular subjects, on the surface, by a groove or furrow, the *iliac furrow*, caused by the projection of fleshy fibres of the External oblique muscles of the abdomen; the

¹ Fehling, *Zeitschr. für Geburt. u. Gynäk.*, Band ix and x; and Arthur Thomson, *Journal of Anatomy and Physiology*, vol. xxxiii.

iliac furrow lies slightly below the level of the crest. It terminates behind in the posterior superior spinous process, the position of which is indicated by a slight depression on a level with the spinous process of the second sacral vertebra. Between the two posterior superior spinous processes, but at a lower level, is to be felt the spinous process of the third sacral vertebra (see page 68). Another part of the bony pelvis easily accessible to touch is the tuberosity of the ischium, situated beneath the gluteal fold, and, when the hip is flexed, it is easily felt, as it is then to a great extent uncovered by muscle. Finally, the spine of the os pubis can always be readily felt, and constitutes an important surgical guide, especially in connection with the subject of hernia. It is nearly in the same horizontal line with the upper edge of the great trochanter. In thin subjects it is very apparent, but in the obese it is obscured by the pubic fat. It can, however, be detected by everting the thigh and following up the tendon of origin of the Adductor longus muscle.

Applied Anatomy.—There is arrest of development in the bones of the pelvis in cases of *extroversion of the bladder*; the anterior part of the pelvic girdle being deficient, the bodies of the pubic bones imperfectly developed, and the symphysis absent. The pubic bones are separated to the extent of from two to four inches, the superior rami shortened and directed forward, and the obturator foramen diminished in size, narrowed, and turned outward. The iliac bones are straightened out more than normal. The sacrum is very peculiar. The lateral curve, instead of being concave, is flattened out or even convex, with the iliosacral facets turned more outward than normal, while the vertical curve is straightened.¹

Fractures of the pelvis are divided into fractures of the false pelvis and of the true pelvis. Fractures of the false pelvis vary in extent: a small portion of the iliac crest may be broken or one of the spinous processes may be torn off, and this may be the result of muscular action; or the bone may be extensively comminuted. This latter accident is the result of some crushing violence, and may be complicated with fracture of the true pelvis. These cases may be accompanied by injury to the intestine as it lies in the hollow of the bone, or to the iliac vessels as they course along the margin of the true pelvis. Fractures of the true pelvis generally occur through the ascending ramus of the os pubis and the ramus of the ischium, as this is the weakest part of the bony ring, and may be caused either by crushing violence applied in an antero-posterior direction, when the fracture occurs from direct force, or by compression laterally, when the acetabula are pressed together, and the bone gives way in the same place from indirect violence. Occasionally the injury may be double, a break occurring on both sides of the body. In fracture of the true pelvis the contained viscera are liable to be damaged; the small intestines, the urethra, the bladder, the rectum, the vagina, and even the uterus, in the female, have all been lacerated by a displaced fragment. Fractures of the acetabulum are occasionally met with; either a portion of the rim may be broken off, or a fracture may take place through the bottom of the cavity, and the head of the femur may be driven inward and project into the pelvic cavity. Separation of the Y-shaped cartilage at the bottom of the acetabulum may also occur in the young subject, dispersing the bone into its three anatomical portions.

The *sacrum* is seldom broken. The cause is direct violence—*i. e.*, blows, kicks, or falls on the part. The lesion may be complicated with injury to the nerves of the sacral plexus, leading to paralysis and loss of sensation in the lower extremity or to incontinence of feces from paralysis of the Sphincter ani.

Fracture of the coccyx is a very rare injury, but does occasionally take place. Some supposed dislocations of this bone have been fractures and so have some of the cases diagnosed as coccygodynia. A fracture of the coccyx is due to direct force.

The pelvic bones often undergo important deformity in *rachitis*, the effect of which in the adult woman may interfere seriously with childbearing. The deformity is due mainly to the weight of the spine and trunk, which presses on the sacrovertebral angle and greatly increases it, so that the antero-posterior diameter of the pelvis is diminished. But, in addition to this, the weight of the viscera on the venter ilii causes the ilia to expand and the tuberosities of the ischia to incurve. In *osteomalacia* also great deformity may occur. The weight of the trunk causes an increase in the sacrovertebral angle and a lessening of the antero-posterior diameter of the inlet, and at the same time the pressure of the acetabula on the heads of the thigh bones causes these cavities, with the adjacent bone, to be pushed upward and backward, so that the oblique diameters of the pelvis are also diminished, and the cavity of the pelvis assumes a tri-radiate shape, with the symphysis pubis pushed forward.

THE THIGH.

The **thigh** is that portion of the lower extremity which is situated between the pelvis and the knee. It consists in the skeleton of a single bone, the **femur**.

¹ Wood, Heath's Dictionary of Practical Surgery, i, 426.

The Femur, or Thigh Bone

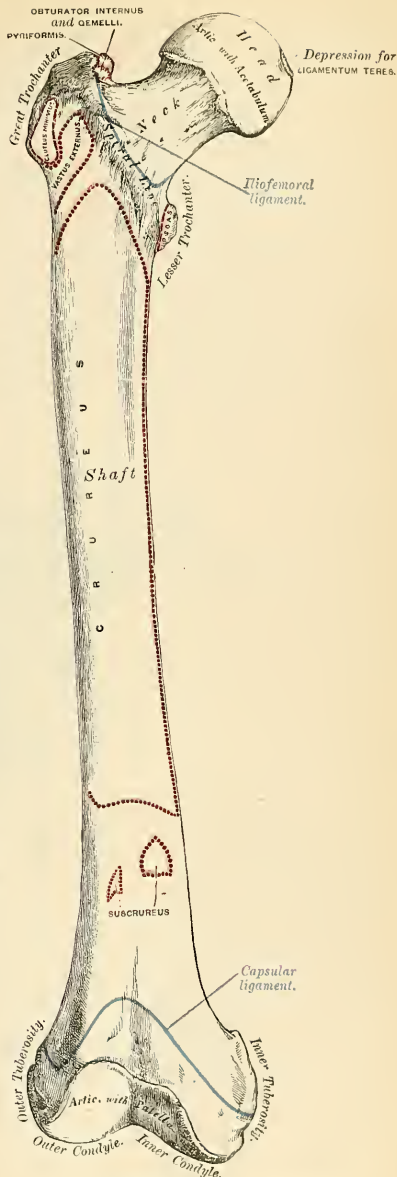
(Figs. 175, 177).

The **femur** (*femur*) is the longest,¹ largest, and strongest bone in the skeleton, and almost perfectly cylindrical throughout the greater part of its extent. In the erect posture it is not vertical, being separated from its fellow above by a considerable interval, which corresponds to the entire breadth of the pelvis, but inclining gradually downward and inward, so as to approach its fellow toward its lower part, for the purpose of bringing the knee-joint near the line of gravity of the body. The degree of this inclination varies in different persons, and is greater in the female than the male, on account of the greater breadth of the pelvis. The femur, like other long bones, is divisible into a shaft and two extremities.

The **Upper or Proximal Extremity** presents for examination a head, a neck, and a greater and a lesser trochanter.

The **head** (*caput femoris*), which is globular and forms rather more than a hemisphere, is directed upward, inward, and a little forward, the greater part of its convexity being above and in front. Its surface is smooth, coated with hyaline cartilage in the recent state, except at a little behind and below its centre, where there is an **ovoid depression** (*fovea capitis femoris*), for the attachment for the ligamentum teres.

The **neck** (*collum femoris*) is a flattened pyramidal process of bone which connects the head with the shaft. It varies in length and obliquity at various periods in life and under different circumstances. The angle is widest in infancy, and becomes lessened during growth, so that at puberty it forms a gentle curve from the



¹ In a man six feet high it measures eighteen inches—one-fourth of the whole body stature.

FIG. 175.—Right femur. Anterior surface.

axis of the shaft. In the adult it forms an angle of about 125 degrees with the shaft, but varies in inverse proportion to the development of the pelvis and the stature. In consequence of the prominence of the hips and widening of the pelvis in the female, the neck of the thigh bone forms more nearly a right angle with the shaft than it does in the male. The neck is flattened from before backward, contracted in the middle, and broader at its outer extremity, where it is connected with the shaft, than at its summit, where it is continuous with the head. The vertical diameter of the outer half is increased by the thickening of the lower edge, which slopes downward to join the shaft at the lesser trochanter; as a result of this the outer half of the neck is flattened from before backward, and its vertical diameter measures one-third more than the antero-posterior. The inner half is smaller and of a more circular shape. The *anterior surface* of the neck is perforated by numerous vascular foramina. The *posterior surface* is smooth, and is broader and more concave than the anterior; it gives attachment to the posterior part of the capsular ligament of the hip-joint, about half an inch above the posterior intertrochanteric line. The *superior border* is short and thick, and terminates externally at the great trochanter; its surface is perforated by large foramina. The *inferior border*, long and narrow, curves a little backward, to terminate at the lesser trochanter.

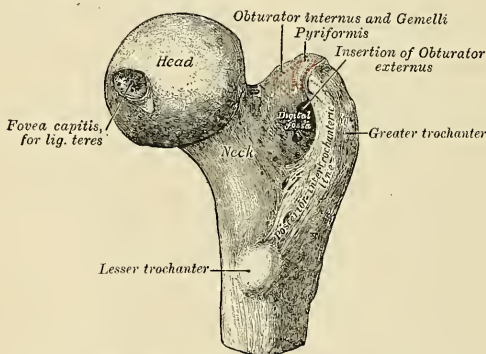


FIG. 176.—Upper extremity of the femur viewed from behind and above.

The **trochanters** are prominent processes of bone which afford leverage to the muscles which rotate the thigh on its axis. They are two in number, the greater and the lesser.

The **greater trochanter** (*trochanter major*) is a large, irregular, quadrilateral eminence, situated at the outer side of the neck, at its junction with the upper part of the shaft. It is directed a little outward and backward, and in the adult is about three-quarters of an inch lower than the head. It presents for examination two surfaces and four borders. The *external surface*, quadrilateral in form, is broad, rough, convex, and marked by a prominent diagonal impression, which extends from the posterior superior to the anterior inferior angle, and serves for the attachment of the tendon of the Gluteus medius. Above the impression is a triangular surface, sometimes rough for part of the tendon of the same muscle, sometimes smooth for the interposition of a bursa between that tendon and the bone. Below and behind the diagonal line is a smooth, triangular surface, over which the tendon of the Gluteus maximus muscle plays, a bursa being interposed. The *internal surface* is of much less extent than the external, and presents

at its base a deep depression, the **digital or trochanteric fossa** (*fossa trochanterica*), for the attachment of the tendon of the Obturator externus muscle; above and in front of this an impression for the attachment of the Obturator internus and Gemelli. The *superior border* is free; it is thick and irregular, and marked near the centre by an impression, which extends onto the internal surface, for the attachment of the Pyliformis. The *inferior border* corresponds to the point of junction of the base of the trochanter with the outer surface of the shaft; it is marked by a rough, prominent, slightly curved ridge, which gives origin to the upper part of the Vastus externus muscle. The *anterior border* is prominent, somewhat irregular, as well as the surface of bone immediately below it; it affords attachment at its outer part to the Gluteus minimus. The *posterior border* is very prominent, and appears as a free, rounded edge, which forms the back part of the digital fossa.

The **lesser trochanter** (*trochanter minor*) is a conical eminence which varies in size in different subjects; it projects from the lower and back parts of the base of the neck. Its base is triangular, and connected with the adjacent parts of the bone by three well-marked borders; two of these are above — the *internal border*, continuous with the lower border of the neck, the *external border*, with the posterior intertrochanteric line — while the *inferior border* is continuous with the middle division of the linea aspera. Its summit, which is directed inward and backward, is rough and gives insertion to the tendon of the Iliopsoas. The Iliacus is also inserted into the shaft below the lesser trochanter between the Vastus internus in front and the Pectineus behind.

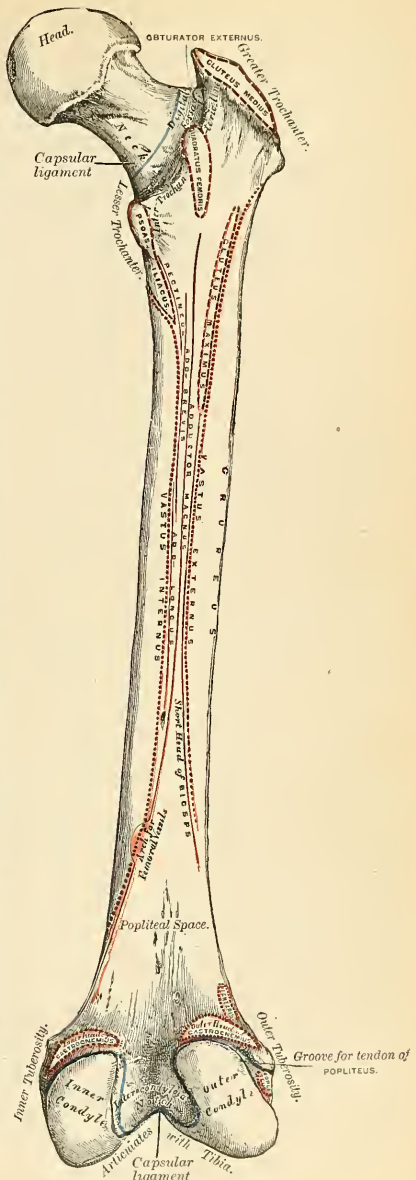


FIG. 177.—Right femur. Posterior surface.

A well-marked prominence of variable size, which projects from the upper and front part of the neck at its junction with the great trochanter, is called the **tubercle of the femur**; it is the point of meeting of five muscles—the Gluteus minimus externally, the Vastus externus below, and the tendon of the Obturator internus and Gemelli internally. Running obliquely downward and inward from the tubercle is the **spiral line of the femur**, or **anterior intertrochanteric line** (*linea intertrochanterica*); it winds around the inner side of the shaft, below the lesser trochanter, and terminates about two inches below this eminence in the *linea aspera*. Its upper half is rough, and affords attachment to the iliofemoral ligament of the hip-joint; its lower half is less prominent, and gives origin to the upper part of the Vastus internus. Running obliquely downward and inward from the summit of the great trochanter on the posterior surface of the neck is a very prominent,

well-marked ridge, the **posterior intertrochanteric line** (*crista intertrochanterica*). Its upper half forms the posterior border of the great trochanter, and its lower half runs downward and inward to the upper and back part of the lesser trochanter. A slight ridge sometimes commences about the middle of the posterior intertrochanteric line, and passes vertically downward for about two inches along the back part of the shaft; it is called the **linea quadrati**, and gives attachment to the Quadratus femoris and a few fibres of the Adductor magnus muscles.¹

The Shaft (*corpus femoris*).—The shaft, almost cylindrical in form, is a little broader above than in the centre, and somewhat flattened below, from before backward. It is slightly arched, so as to be convex in front and concave behind, where it is strengthened by a prominent longitudinal ridge, the **linea aspera**. It presents for examination three borders, separating three surfaces. Of the three borders, one, the *linea aspera*, is posterior; the other two are placed laterally.

The **linea aspera** (Fig. 178) is a prominent longitudinal ridge or crest, on the middle third of the bone, presenting an **external lip** (*labium laterale*), an **internal lip** (*labium mediale*), and a rough **intermediate space**. Above, this crest is prolonged by three ridges. The most **external ridge** is very rough, and is continued almost

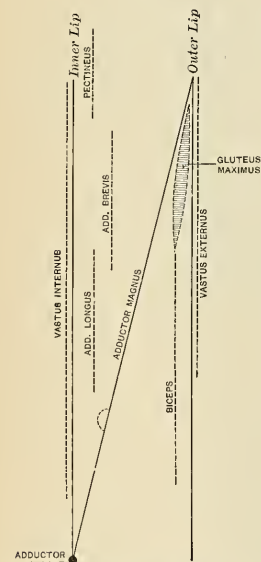


FIG. 178.—Diagram of linea aspera of the right femur. (After Birmingham.)

vertically upward to the base of the great trochanter. It is sometimes termed the **gluteal ridge** (*tuberositas glutea*), and gives attachment to part of the Gluteus maximus muscle; its upper part is sometimes elongated into a roughened crest, on which is a more or less well-marked, rounded tubercle, a **rudimental third trochanter** (*trochanter tertius*). The **middle ridge** (*linea pectinea*), the least distinct, is continued to the base of the lesser trochanter, and the **internal ridge** is lost above in the spiral line of the femur. Below, the *linea aspera* is prolonged by two ridges, which pass to the condyles and enclose between them a triangular space, the **popliteal surface** (*planum popliteum*), upon which rests the popliteal artery. Of these two ridges, the **outer** one is the more prominent, and descends to the summit of the outer condyle. The **inner** one is less marked, especially at

¹ Generally there is merely a slight thickening about the centre of the intertrochanteric line, marking the point of attachment of the Quadratus femoris. This is termed by some anatomists the *tubercle of the Quadratus*.

its upper part, where it is crossed by the femoral artery. It terminates, below, at the summit of the internal condyle, in a small tubercle, the **adductor tubercle**, which affords attachment to the tendon of the Adductor magnus. To the inner lip of the linea aspera and its inner prolongation above and below arises the Vastus internus, and to the outer lip and its outer prolongation above arises the Vastus externus. The Adductor magnus is attached to the linea aspera, to its outer prolongation above and its inner prolongation below. Between the Vastus externus and the Adductor magnus are attached two muscles—viz., the Gluteus maximus above, and the short head of the Biceps femoris below. Between the Adductor magnus and the Vastus internus four muscles are attached—the Iliacus and Pectineus above, the Adductor brevis and Adductor longus below (Fig. 178). A little below the centre of the linea aspera is the **nutrient foramen**, the orifice of the **nutrient canal**, which is directed obliquely upward (proximally).

The **two lateral borders** of the femur are only slightly marked, the outer one extending from the anterior inferior angle of the great trochanter to the anterior extremity of the external condyle; the inner one from the spiral line at a point opposite the lesser trochanter, to the anterior extremity of the internal condyle. The internal border marks the limit of origin of the Crureus muscle internally.

The **anterior surface** includes that portion of the shaft which is situated between the two lateral borders. It is smooth, convex, broader above and below than in the centre, slightly twisted, so that its upper part is directed forward and a little outward, its lower part forward and a little inward. From the upper three-fourths of this surface the Crureus takes origin; the lower fourth is separated from the muscle by the intervention of the synovial membrane of the knee-joint and a bursa, and affords origin to the Subcrureus to a small extent.

The **external surface** includes the portion of bone between the external border and the outer lip of the linea aspera; it is continuous above with the outer surface of the great trochanter, below with the outer surface of the external condyle; from its upper three fourths arises the outer portion of the Crureus muscle.

The **internal surface** includes the portion of bone between the internal border and the inner lip of the linea aspera; it is continuous above with the lower border of the neck, below with the inner side of the internal condyle; it is covered by the Vastus internus muscle.

Lower or Distal Extremity.—The lower extremity, larger than the upper, is of a cuboidal form, flattened from before backward, and divided into two large eminences, the **condyles**, by an interval which presents a smooth depression in front called the **trochlea** (*facies patellaris*), and a notch of considerable size behind—the **intercondyloid notch** (*fossa intercondyloidea*). The **external condyle** (*condylus lateralis*) is the more prominent anteriorly, and is the broader both in the antero-posterior and transverse diameters. The **internal condyle** (*condylus medialis*) is the longer, and more prominent inferiorly. This difference in the length of the two condyles is only observed when the bone is perpendicular and depends upon the obliquity of the thigh bones, in consequence of their separation above at the articulation with the pelvis. If the femur is held obliquely, the surfaces of the two condyles will be seen to be nearly horizontal. The two condyles are directly continuous in front, and form a smooth, trochlear surface, the **trochlea**. The trochlea and the inferior surface of the condyles constitute the articular surface of the lower end of the femur, and are covered by hyaline cartilage in the recent state. The trochlea articulates with the patella. It presents a median groove, which extends downward and backward to the intercondyloid notch; and two lateral convexities, of which the external is the broader, more prominent, and prolonged farther upward upon the front of the outer condyle. The external border of this articular surface is also more prominent, and ascends higher than the internal one. The inferior surfaces of the condyles are convex from side to side

and from before backward, and articulate with the corresponding surfaces of the tibia. They are marked off from the trochlea by two irregular grooves. The outer groove runs obliquely outward and forward from the anterior extremity of the intercondyloid notch to the outer side of the external condyle. The inner is less well marked and placed farther forward than the one on the external condyle; it extends obliquely inward and backward. In the grooves the semilunar cartilages fit when the knee is extended. The opposed surfaces of the condyles form the lateral walls of the intercondyloid notch.

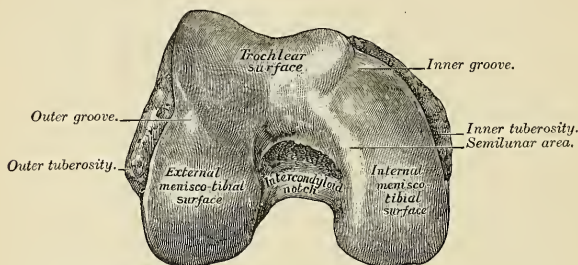


FIG. 179.—Lower extremity of right femur viewed from below.

The **outer surface** of the external condyle presents, a little behind its centre, an eminence, the **outer tuberosity** (*epicondylus lateralis*); it is less prominent than the inner tuberosity, and gives attachment to the external lateral ligaments of the knee. Immediately beneath it is the **popliteal groove**, which commences at a depression a little behind the centre of the lower border of this surface; the front part of this depression gives origin to the Popliteus muscle, the tendon of which is lodged in the groove during flexion of the knee. The groove is smooth, covered with hyaline cartilage in the recent state, and runs upward and backward to the posterior extremity of the condyle. The posterior extremity is convex and smooth; just above and to the outer side of the articular surface is a depression for the tendon of the outer head of the Gastrocnemius, above which is the origin of the Plantaris.

The **inner surface** of the inner condyle presents a convex eminence, the **inner tuberosity** (*epicondylus medialis*), rough, for the attachment of the internal lateral ligament. Just above the articular surface of this condyle, behind, is a depression for the tendon of origin of the inner head of the Gastrocnemius.

The intercondyloid notch is bounded laterally by the opposed surfaces of the condyles, and lodges the crucial ligaments of the knee-joints. The inner wall of the notch at its front part has attached to it the posterior crucial ligament. The external wall at its upper and back part affords attachment to the anterior crucial ligament. Above, it is separated from the popliteal surface by a ridge—the *linea intercondyloidea*.

Structure.—The shaft of the femur is a cylinder of compact tissue, hollowed by a large medullary canal. The cylinder is of great thickness and density in the middle third of the shaft, where the bone is narrowest and the medullary canal well formed; but above and below this the cavity gradually becomes smaller, owing to a separation of the layers of the bone into cancelli, which project into the medullary canal and finally obliterate it, so that the upper and lower ends of the shaft, and the articular extremities more especially, consist of cancellated tissue invested by a thin, compact layer.

The arrangement of the cancelli in the ends of the femur is remarkable. In the upper end they are arranged in two sets. One, starting from the top of the head, the upper surface of the neck,

and the great trochanter, converge to the inner circumference of the shaft (Figs. 180 and 181); these are placed in the direction of greatest pressure, and serve to support the vertical weight of the body. The second set are planes of lamellæ intersecting the former nearly at right angles, and are situated in the line of the greatest tension—that is to say, along the lines in which the muscles and ligaments exert their traction. In the head of the bone these planes are arranged in a curved form, in order to strengthen the bone when exposed to pressure in all directions. In the midst of the cancellous tissue of the neck is a vertical plane of compact bone, the **femoral spur** (*calcar femorale*), which commences at the point where the neck joins the shaft just external to the lesser trochanter, and extends in the direction of the digital fossa (Fig. 182). This materially strengthens this portion of the bone. Another point in connection with the structure of the neck of the femur requires mention, especially on account of its influence on the production of fracture in this situation. It will be noticed that a considerable portion of the great trochanter lies behind the level of the posterior surface of the neck; and if a section be made through the trochanter at this level, it will be seen that the posterior wall of the neck is prolonged into the trochanter. This prolongation is termed by Bigelow the **true neck**,¹ and forms a thin, dense plate of bone, which passes beneath the posterior intertrochanteric ridge toward the outer surface of the bone. In the lower end the cancelli spring on all sides from the inner surface of the

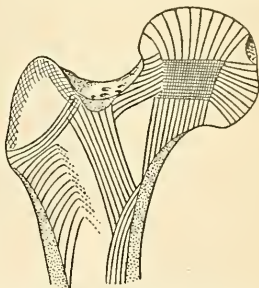


FIG. 180.—Scheme showing disposition of principal cancellous lamellæ in upper extremity of femur.

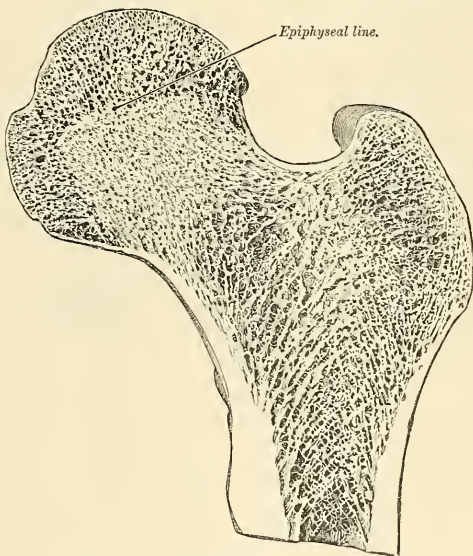


FIG. 181.—Longitudinal section of head and neck of femur.

cylinder, and descend in a perpendicular direction to the articular surface, the cancelli being strongest and having a more accurately perpendicular course above the condyles. In addition

¹Bigelow, on the Hip, p. 121.

to this, however, horizontal planes of cancellous tissue are to be seen, so that the spongy tissue in this situation presents an appearance of being mapped out into a series of rectangular areas.

Articulations.—With *three* bones—the os innominatum, tibia, and patella.

Development (Fig. 183).—The femur is developed from *five* centres—one for the shaft, one for each extremity, and one for each trochanter. Of all the long bones, except the clavicle, it is the first to show traces of ossification; this commences in the shaft, at about the seventh week of fetal life, the centres of ossification in the epiphyses appearing in the following order: First, in the lower end of the bone, at the ninth month of fetal life¹ (from this the condyles and tuberosities are formed); in the head at the end of the first year after birth; in the great trochanter, during the fourth year; and in the lesser trochanter, between the thirteenth and fourteenth years. The order in which the epiphyses are joined to the shaft is the reverse of that of their appearance; their junction does not commence until after puberty, the lesser trochanter being first joined, then the great, then the head, and lastly the inferior extremity (the first in which ossification commenced), which is not united until the twentieth year. Because of this late union, the lower extremity of the femur has been called the “growing end” of the bone, and early arrest of ossification here results in more or less marked diminution of stature.

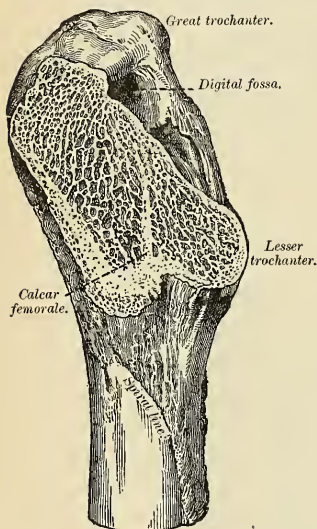


FIG. 182.—Calcar femorale.

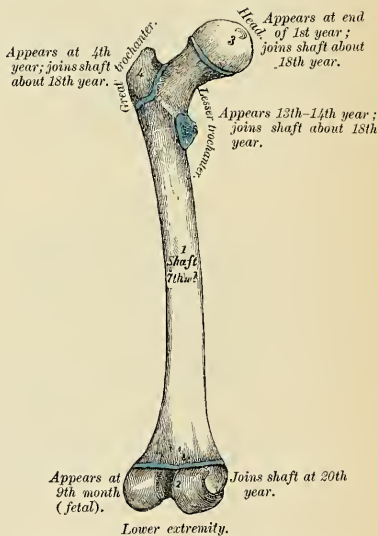


FIG. 183.—Plan of the development of the femur. From five centres.

Attachment of Muscles.—To *twenty-three*. To the great trochanter: the Gluteus medius, Gluteus minimus, Piriformis, Obturator internus, Obturator externus, Gemellus superior, and Gemellus inferior. To the lesser trochanter: the Psoas magnus and the Iliacus below it. To the shaft: the Quadratus femoris, Vastus externus, Gluteus maximus, short head of the Biceps femoris, Vastus internus, Adductor magnus, Pectineus, Adductor brevis, Adductor longus, Crureus, and Suberureus. To the condyles: the Gastrocnemius, Plantaris, and Popliteus.

Surface Form.—The femur is covered with muscles, so that in fairly muscular subjects the shaft is not to be detected through its fleshy covering, and the only parts accessible to the touch are the outer surface of the great trochanter and the lower expanded end of the bone. The external surface of the great trochanter may be felt, especially in certain positions of the limb. Its position is generally indicated by a depression, owing to the thickness of the Gluteus medius and

¹ This is said to be the only epiphysis in which ossification begins before birth; though, according to some observers, the centre for the upper epiphysis of the tibia also appears before birth.

minimus, which project above it. When, however, the thigh is flexed, and especially if crossed over the opposite one, the trochanter produces a blunt eminence on the surface. The upper border is about on a line with the spine of the os pubis, and its exact level is indicated by a line drawn from the anterior superior spinous process of the ilium, over the outer side of the hip, to the most prominent point of the tuberosity of the ischium. This is known as **Nélaton's line**. The outer and inner condyles of the lower extremity may easily be felt. The outer one is more subcutaneous than the inner one, and readily felt. The tuberosity on it is comparatively little developed, but can be more or less easily recognized. The inner condyle is more thickly covered, and this gives a general convex outline to this part, especially when the knee is flexed. The tuberosity on it is easily felt, and at the upper part of the condyle the sharp tubercle for the insertion of the tendon of the Adductor magnus can be recognized without difficulty. Occasionally, exostoses develop in the tendon of insertion of the Adductor magnus; these are the "*rider's bones*" of cavalry soldiers and horsemen (pp. 360, 515). When the knee is flexed, and the patella situated in the interval between the condyles and the upper end of the tibia, a part of the trochlear surface of the femur can be made out above the patella.

Applied Anatomy.—There are one or two points about the ossification of the femur bearing on practice to which allusion must be made. It has been stated above that the lower end of the femur is the only epiphysis in which ossification has commenced at the time of birth. The presence of the ossific centre in newly born children found dead is, therefore, a proof that the child has arrived at the full period of uterogestation. However, according to Hartman, at term this centre is absent in 12 per cent. of cases. The position of the *epiphyseal line* should be carefully noted. It is on a level with the adductor tubercle, and the epiphysis does not, therefore, form the whole of the cartilage-clad portion of the lower end of the bone. It is essential to bear this point in mind in performing *excision of the knee*, since growth in length of the femur takes place chiefly from the lower epiphysis, and any interference with the epiphyseal cartilage in a young child would involve such ultimate shortening of the limb, from want of growth, as to render it almost useless. Separation of the *lower epiphysis* may take place up to the age of twenty, at which time it becomes completely joined to the shaft of the bone; but, as a matter of fact, few cases occur after the age of sixteen or seventeen. The epiphysis of the head of the femur is of interest principally on account of its being the seat of origin of a large number of cases of *tuberculous disease of the hip-joint*. The disease commences in the majority of cases in the highly vascular and growing tissue in the neighborhood of the epiphysis, and from here extends into the joint. In the condition known as *coxa vara* the head of the femur falls to a lower level than normal. The angle between the neck and shaft is greatly diminished and may become a right angle, or the head may actually descend to a lower level than that of the trochanter. The neck is also bent with a convexity forward; *coxa vara* is due to rachitis.

Fractures of the femur are divided, like those of the other long bones, into fractures of the upper end, of the shaft, and of the lower end. The fractures of the upper end may be classified into (1) fracture of the neck; (2) fracture at the junction of the neck with the great trochanter; (3) fracture of the great trochanter; and (4) separation of the epiphysis, either of the head or the great trochanter. The first of these, *fracture of the neck*, is usually termed *intracapsular fracture*, but this is scarcely a correct designation, as, owing to the attachment of the capsular ligament, the fracture may be partly within and partly without the capsule, when the fracture occurs at the lower part of the neck. It generally occurs in old people, principally women, and usually from a very slight degree of indirect violence. Probably the main cause of the fracture taking place in old people is in consequence of the degenerative changes which the bone has undergone. Merkel believes that it is mainly due to the absorption of the calcar femorale. These fractures are occasionally impacted. As a rule, they unite by fibrous tissue, and frequently no union takes place, and the surfaces of the fracture become smooth and eburnated. The lack of reparative power in intracapsular fracture is due to lack of apposition of the fragments and diminution in the amount of blood sent to the smaller fragment. The head of the bone receives blood from the neck through the reflected portions of the capsule and through the ligamentum teres. A fracture cuts off the supply by the neck and by the reflected portions of the capsule.

Fractures at the junction of the neck with the great trochanter are usually termed *extracapsular*, but this designation is also incorrect, as the fracture is partly within the capsule, owing to its attachment in front to the anterior intertrochanteric line, which is situated below the line of fracture. These fractures are produced by direct violence to the great trochanter, as from a blow or fall laterally on the hip. From the manner in which the accident is caused, the neck of the bone is driven into the trochanter, where it may remain impacted or the trochanter may split up into two or more fragments, and thus no fixation takes place.

Fractures of the great trochanter may be either "oblique fracture through the trochanter major, without implicating the neck of the bone" (Astley Cooper), or separation of the great trochanter. Most of the recorded cases of this latter injury occurred in young persons, and were probably cases of separation of the epiphysis of the great trochanter. Separation of the epiphysis of the head of the femur has been said to occur, but has probably never been verified by postmortem examination.

Fracture of the shaft may occur at any part, but the most usual situation is at or near the centre of the bone. They may be caused by direct or indirect violence or by muscular action. Fractures of the upper third of the shaft are almost always the result of indirect violence, while those of the lower third are the result, for the most part, of direct violence. In the middle third fractures occur from both forms of injury in about equal proportions. Fractures of the shaft are generally oblique, but they may be transverse, longitudinal, or spiral. The transverse fracture occurs most frequently in children. The fractures of the lower end of the femur include transverse fracture above the condyles, the most common; and this may be complicated by a vertical fracture between the condyles, constituting the *T-shaped fracture*. In these cases the popliteal artery is in danger of being wounded. Oblique fracture, separating either the internal or external condyle, and a longitudinal incomplete fracture between the condyles, may also take place.

The femur and also the bones of the leg are frequently the seat of *acute osteomyelitis* in young children. This is no doubt due to their greater exposure to injury, which is often the exciting cause of this disease. *Tumors* not infrequently are found growing from the femur, the most common forms being sarcoma, which may grow either from the periosteum or from the medullary tissue within the interior of the bone; and *exostosis*, which is commonly found originating in the neighborhood of the epiphyseal cartilage of the lower end.

Genu varum is a form of *bow-leg* in which the tibia and femur are curved outward, the knees being widely separated. Both extremities are usually affected. In early life the disease is due to rachitis. In elderly people it may be due to arthritis deformans. *Genu valgum* (*knock-knee*) is a condition in which the knees are close together, the feet are wide apart, and the internal lateral ligament of the knee-joint is stretched. It is due to excessive growth of the inner condyle of the femur, the shaft of the femur curving inward. It may be due to rachitis, attitude of an occupation, or flat-foot, and one or both knees may be affected.

THE LEG.

The skeleton of the leg consists of three bones—the **patella**, a large sesamoid bone, placed in front of the knee; the **tibia**; and the **fibula**.

The Patella, or Kneecap (Fig. 184).

The **patella** is a flat, triangular bone, situated at the anterior part of the knee-joint. It is usually regarded as a sesamoid bone, developed in the tendon of the Quadriceps extensor. It serves to protect the front of the joint, and increases the leverage of the Quadriceps extensor by making it act at a greater angle. It presents an anterior and a posterior surface, three borders, and an apex.

It presents an anterior and a posterior surface, three borders, and an apex.

Surfaces.—The anterior surface is convex, perforated by small apertures, for the passage of nutrient vessels, and marked by numerous rough, longitudinal striæ. This surface is covered, in the recent state, by an

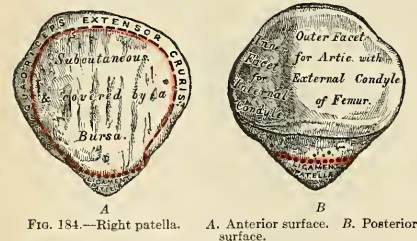


FIG. 184.—Right patella.

A. Anterior surface. B. Posterior surface.

expansion from the tendon of the Quadriceps extensor, which is continuous below with the superficial fibres of the ligamentum patellæ. It is separated from the integument by a bursa.

The **posterior surface** presents a smooth, oval-shaped, articular surface (*facies articularis*), covered with hyaline cartilage in the recent state, and divided into two facets by a vertical ridge, which descends from the superior border toward the inferior angle of the bone. The ridge corresponds to the groove on the trochlear

surface of the femur, and the two facets to the articular surfaces of the two condyles; the outer facet, for articulation with the outer condyle, being broader and deeper. This character serves to indicate the side to which the bone belongs. Below the articular surface is a rough, convex, nonarticular depression, the lower half of which gives attachment to the ligamentum patellae, the upper half being separated from the head of the tibia by adipose tissue.

Borders.—The **superior border** (*basis patellae*) is thick, and sloped from behind, downward and forward; it gives attachment to that portion of the Quadriceps extensor which is derived from the Rectus femoris and Crureus muscles.

The **lateral borders** are thinner, converging below. They give attachment to that portion of the Quadriceps extensor derived from the external and internal Vasti muscles.

The **apex** (*apex patellae*) is pointed, and gives attachment to the ligamentum patellae.

Structure.—This bone resembles a sesamoid bone (1) in being developed in a tendon; (2) in its centre of ossification presenting a knotty or tuberculated outline; (3) in its structure being composed mainly of dense cancellous tissue. It consists of a nearly uniform, dense cancellous tissue covered by a thin compact lamina. The cancelli immediately beneath the anterior surface are arranged parallel with it. In the rest of the bone they radiate from the posterior articular surface toward the other parts of the bone.

Development.—From a *single* centre, which makes its appearance in the second or third, but may not appear until the sixth year. More rarely, the bone is developed by two centres, placed side by side. Ossification is completed about the age of puberty.

Articulations.—With the two condyles of the femur.

Attachment of Muscles.—To *four*—the Rectus, Crureus, Vastus internus, and Vastus externus. These muscles, joined at their insertion, constitute the Quadriceps extensor cruris.

Surface Form.—The external surface of the patella can be seen and felt in front of the knee. In the extended position of the limb the internal border is a little more prominent than the outer, and if the Quadriceps extensor is relaxed the bone can be moved from side to side and appears to be loosely fixed. If the joint is flexed, the patella recedes into the hollow between the condyles of the femur and the upper end of the tibia, and becomes firmly fixed against the femur.

Applied Anatomy.—The main surgical interest about the patella is in connection with *fractures*, which are of common occurrence. They may be produced by muscular action; that is to say, by violent contraction of the Quadriceps extensor while the limb is in a position of semi-flexion, so that the bone is snapped across the condyles; or by direct violence, such as falls on the knee. Most fractures are due to muscular action; in fact, the patella is more often broken by muscular action than is any other bone. In fractures by muscular action the line of fracture is transverse. In fractures by direct force the line of fracture may be oblique, longitudinal, stellate, or the bone variously comminuted. The principal interest in these cases attaches to their treatment. Owing to the wide separation of the fragments, and the difficulty there is in maintaining them in apposition, union takes place by fibrous tissue, and this may subsequently stretch, producing wide separation of the fragments and permanent lameness. Various plans, including opening the joint and suturing the fragments, have been advocated for overcoming this difficulty. In many cases a portion of fascia or capsule gets between the fragments. In such a condition operation is necessary.

In the larger number of cases of fracture of the patella the knee-joint is involved, the cartilage which covers its posterior surface being torn, the synovial membrane lacerated, the lateral fibrous expansions ruptured, and the patellar bursa torn open. In cases of fracture from direct violence, however, this need not necessarily happen, the lesion may involve only the superficial part of the bone; and, as Morris has pointed out, it is an anatomical possibility, in complete fracture, if the lesion involve only the lower and nonarticular part of the bone, for it to take place without injury to the synovial membrane.

The Tibia, or Shin Bone (Figs. 185, 186).

The **tibia** is situated at the front and inner side of the leg, and, excepting the femur, is the longest and largest bone in the skeleton. It is prismoid in form, expanded above, where it enters into the knee-joint, more slightly enlarged below.

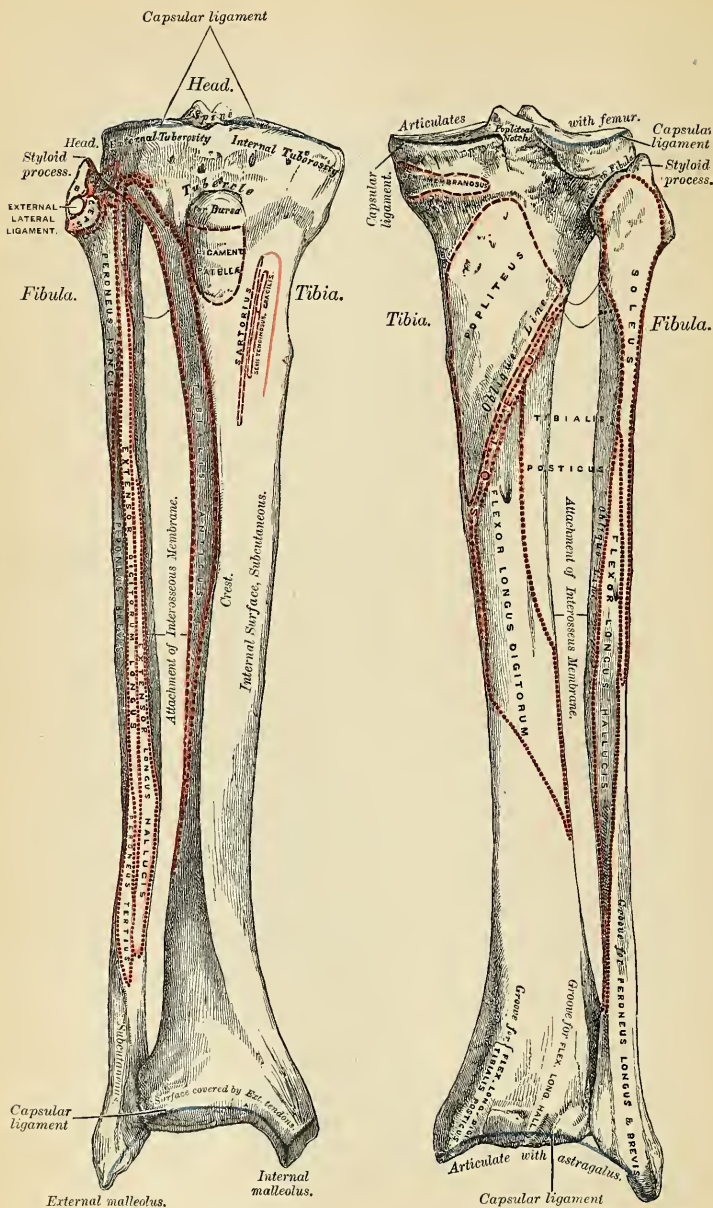


FIG. 185.—Bones of the right leg. Anterior surface. FIG. 186.—Bones of the right leg. Posterior surface.

In the male its direction is vertical and parallel with the bone of the opposite side; but in the female it has a slightly oblique direction downward and outward, to compensate for the oblique direction of the femur inward. It presents for examination a **shaft** and two **extremities**.

The Proximal or Upper Extremity.—The upper extremity, or **head**, is large, and expanded on each side into two lateral eminences, the **internal** and **external tuberosities** (*condylus medialis* and *condylus lateralis*). *Superiorly*, each tuberosity presents a smooth, concave surface (*facies articularis superior*), which articulates with a condyle of the femur. The *internal articular surface* is oval in shape and concave from side to side; the *external* one is circular, concave from side to side, but slightly convex from before backward, especially at its posterior part, where it is prolonged on to the posterior surface for a short distance; the central portions of these surfaces articulate with the condyles, while the peripheral portions are overlaid by the semilunar cartilages of the knee. Between the two articular surfaces, and nearer the posterior than the anterior aspect of the bone, is an eminence, the **spine of the tibia** (*eminentia intercondyloidea*); surmounted by a prominent **tubercle** on each side (the *tuberculum intercondyloideum mediale* and the *tuberculum intercondyloideum laterale*), on to the lateral aspect of which

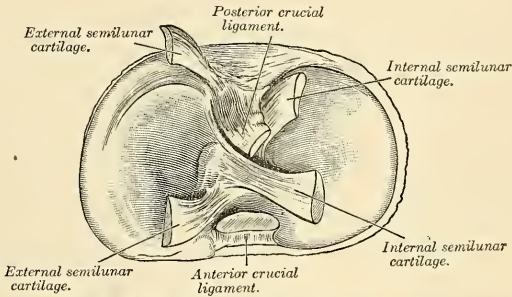


FIG. 187.—Upper surfaces of right tibia, showing attachment of crucial ligaments and semilunar cartilages. The cartilages have been partly cut away.

the facets just described are prolonged; in front and behind the spinous process is a rough depression (*fossa intercondyloidea anterior* and the *fossa intercondyloidea posterior*) for the attachment of the anterior and posterior crucial ligaments and the semilunar fibrocartilages (Fig. 187).

The anterior surfaces of the tuberosities are continuous with one another, forming a single large surface, which is somewhat flattened; it is triangular, broad above, and perforated by large vascular foramina; narrow below, where it terminates in a prominent oblong elevation of large size, the **tubercle of the tibia** (*tuberositas tibiae*); the lower half of this tubercle is rough, for the attachment of the ligamentum patellae; the upper half presents a smooth facet supporting, in the recent state, a *bursa* which separates the ligament from the bone. *Posteriorly* the tuberosities are separated from each other by a shallow depression, the **popliteal notch** (*incisura poplitea*), which gives attachment to part of the posterior crucial ligament and part of the posterior ligament of the knee-joint. The *inner tuberosity* presents posteriorly a deep transverse groove, for the insertion of one of the fasciculi of the tendon of the Semimembranosus (Fig. 266). Its lateral surface is convex, rough, and prominent, and gives attachment to the internal lateral ligament. The *outer tuberosity* presents posteriorly a flat articular facet (*facies articularis fibularis*), nearly circular in form, directed downward, backward,

and outward, for articulation with the fibula. Its lateral surface is convex and rough, more prominent in front than the internal, and presents a prominent rough eminence, situated on a level with the upper border of the tubercle of the tibia at the junction of its anterior and outer surfaces, for the attachment of the **iliotibial band**. Just below this the *Extensor longus digitorum* arises, and a slip from the *Biceps femoris cruris* is attached.

Shaft of the Tibia (*corpus tibiae*).—The shaft of the tibia is of a triangular prismoid form, broad above, gradually decreasing in size to its most slender part, the commencement of its lower fourth; it then enlarges again toward its lower extremity. It presents for examination three borders and three surfaces.

The **anterior border**, the most prominent, is called the **crest of the tibia** (*crista anterior*); it commences above at the tubercle, and terminates below at the anterior margin of the inner malleolus. This border is very prominent in the upper two-thirds of its extent, smooth and rounded below. It presents a very sinuous course, being usually curved outward above and inward below; it gives attachment to the deep fascia of the leg.

The **internal border** (*margo medialis*) is smooth and rounded above and below, but more prominent in the centre; it commences at the back part of the inner tuberosity, and terminates at the posterior border of the internal malleolus; its upper part gives attachment to the internal lateral ligament of the knee to the extent of about two inches, and to some fibres of the *Popliteus* muscle, and its middle third to some fibres of origin of the *Soleus* and *Flexor longus digitorum* muscles.

The **external border** (*crista interossea*), or **interosseous ridge**, is thin and prominent, especially its central part, and gives attachment to the interosseous membrane; it commences above in front of the fibular articular facet, and bifurcates below, to form the boundaries of a triangular rough surface, for the attachment of the interosseous ligament connecting the tibia and fibula.

The **internal surface** (*facies medialis*) is smooth, convex, and broader above than below; its upper third, directed forward and inward, is covered by the aponeurosis derived from the tendon of the *Sartorius*, and by the tendons of the *Gracilis* and *Semitendinosus*, all of which are inserted nearly as far forward as the anterior border; in the rest of its extent it is subcutaneous.

The **external surface** (*facies lateralis*) is narrower than the internal; its upper two-thirds presents a shallow groove for the origin of the *Tibialis anticus* muscle; its lower third is smooth, convex, curves gradually forward to the anterior aspect of the bone, and is covered from within outward by the tendons of the following muscles: *Tibialis anticus*, *Extensor proprius hallucis*, *Extensor longus digitorum*.

The **posterior surface** (*facies posterior*) (Fig. 186) presents, at its upper part, a prominent ridge, the **oblique line of the tibia** (*linea poplitea*), which extends from the back part of the articular facet for the fibula obliquely downward, to the internal border, at the junction of its upper and middle thirds. It marks the lower limit for the insertion of the *Popliteus* muscle, and serves for the attachment of the popliteal fascia and part of the *Soleus*, *Flexor longus digitorum*, and *Tibialis posticus* muscles; the triangular concave surface, above and to the inner side of this line, gives attachment to the *Popliteus* muscle. The middle third of the posterior surface is divided by a vertical ridge into two lateral halves; the ridge is well marked at its commencement at the oblique line, but becomes gradually indistinct below; the inner and broader half gives origin to the *Flexor longus digitorum*, the outer and narrower to part of the *Tibialis posticus*. The remaining part of the bone presents a smooth surface covered by the *Tibialis posticus*, *Flexor longus digitorum*, and *Flexor longus hallucis* muscles. Immediately below the oblique line is the **nutrient foramen**, which is large and directed obliquely downward. It is the opening of the nutrient canal, which is directed toward the ankle.

The Distal or Lower Extremity.—The lower extremity, much smaller than the upper, presents five surfaces; it is prolonged downward, on its inner side, to a strong process, the **internal malleolus** (*malleolus medialis*).

The **inferior surface** (*facies articularis inferior*) of the bone is quadrilateral, and smooth for articulation with the astragalus. This surface is concave from before backward, and broader in front than behind. It is traversed from before backward by a slight elevation, separating two lateral depressions. It is narrow internally, where the articular surface becomes continuous with that on the inner malleolus.

The **anterior surface** of the lower extremity is smooth and rounded above, and covered by the tendons of the Extensor muscles of the toes; its lower margin presents a rough transverse depression, for the attachment of the anterior ligament of the ankle-joint.

The **posterior surface** presents a superficial groove directed obliquely downward and inward, continuous with a similar groove on the posterior surface of the astragalus, and serving for the passage of the tendon of the Flexor longus hallucis.

The **external surface** presents a triangular rough depression for the attachment of the interior interosseous ligament, connecting it with the fibula; the lower part of this depression, the *incisura fibularis*, is smooth, covered with cartilage in the recent state, and articulates with the fibula. This surface is bounded by two prominent borders, continuous above with the interosseous ridge; they afford attachment to the anterior inferior and posterior inferior tibiofibular ligaments.

The **internal surface** of the lower extremity is prolonged downward to form a strong pyramidal process, flattened from without inward—the **internal malleolus** (*malleolus medialis*). The *inner surface* of this process is convex and subcutaneous; its *outer surface* is smooth and slightly concave, and articulates with the astragalus; its *anterior border* is rough, for the attachment of the anterior fibres of the internal lateral or deltoid ligament; its *posterior border* presents a broad and deep groove (*sulcus malleolaris*), directed obliquely downward and inward, which is occasionally double; this groove transmits the tendons of the Tibialis posticus and Flexor longus digitorum muscles. The *apex* of the internal malleolus is marked by a rough depression behind, for the attachment of the internal lateral ligaments of the ankle-joint.

Structure.—Like that of the other long bones. At the junction of the middle and lower third, where the bone is smallest, the wall of the shaft is thicker than in other parts, in order to compensate for the smallness of the calibre of the bone.

Development.—From *three* centres (Fig. 188), one for the shaft and one for each extremity. Ossification commences in the centre of the shaft about the seventh week, and gradually extends toward either extremity. The centre for the upper epiphysis appears before or shortly after birth; it is flattened in form, and has a thin, tongue-shaped process in front which forms the tubercle. That for the lower epiphysis appears in the second year. The lower epiphysis joins the shaft at about the eighteenth, and the upper one about the twentieth year. Two additional centres occasionally exist—one for the tongue-shaped process of the upper epiphysis, which forms the tubercle, and one for the inner malleolus.

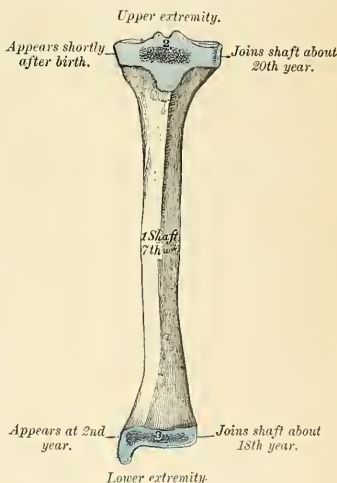


FIG. 188.—Plan of the development of the tibia. From three centres.

Articulations.—With *three* bones—the femur, fibula, and astragalus.

Attachment of Muscles.—To *twelve*: To the inner tuberosity, the Semimembranosus; to the outer tuberosity, the Tibialis anticus and Extensor longus digitorum and Biceps femoris, to the shaft, its internal surface, the Sartorius, Gracilis, and Semitendinosus; to its external surface, the Tibialis anticus; to its posterior surface, the Popliteus, Soleus, Flexor longus digitorum, and Tibialis posticus; to the tubercle, the ligamentum patellae, by which the Quadriceps extensor muscle is inserted into the tibia. In addition to these muscles, the Tensor fasciae femoris is inserted indirectly into the tibia, through the iliotibial band, and the Peroneus longus occasionally derives a few fibres of origin from the outer tuberosity.

Surface Form.—A considerable portion of the tibia is subcutaneous and easily felt. At the upper extremity the tuberosities are to be recognized just below the knee. The internal one is broad and smooth, and merges into the subcutaneous surface of the shaft below. The external one is narrower and more prominent, and on it, about midway between the apex of the patella and the head of the fibula, may be felt a prominent **tubercle** for the insertion of the iliotibial band. In front of the upper end of the bone, between the tuberosities, is the tubercle of the tibia, forming an oval eminence which is continuous below with the anterior border or crest of the bone. This border can be felt, forming the prominence of the shin, in the upper two-thirds of its extent as a sharp and sinuous ridge, curved outward above and inward below. In the lower third of the leg the border disappears, and the bone is concealed by the tendons of the muscles on the front of the leg. Internal to the anterior border is to be felt the broad internal surface of the tibia, slightly encroached upon by the muscles in front and behind. It commences above at the wide expanded inner tuberosity, and terminates below at the internal malleolus. The internal malleolus is a broad prominence situated on a higher level and somewhat farther forward than the external malleolus. It overhangs the inner border of the arch of the foot. Its anterior border is nearly straight; its posterior border presents a sharp edge which forms the inner margin of the groove for the tendon of the Tibialis posticus muscle.

The Fibula, or Calf Bone (Figs. 185, 186).

The **fibula** is situated at the outer side of the leg. It is the smaller of the two bones, and, in proportion to its length, the most slender of all the long bones; it is placed on the outer side of the tibia, with which it is connected above and below. Its upper extremity is small, placed toward the back of the head of the tibia and below the level of the knee-joint, and excluded from its formation; the lower extremity inclines a little forward, so as to be on a plane anterior to that of the upper end, projects below the tibia, and forms the outer ankle. It presents for examination a shaft and two extremities.

The Proximal or Upper Extremity.—The upper extremity, or head (*capitulum fibulae*), is of an irregular quadrate form, presenting above a flattened articular facet, directed upward, forward, and inward, for articulation with a corresponding facet on the external tuberosity of the tibia. On the outer side is a thick and rough prominence, continued behind into a pointed eminence, the **styloid process of the fibula** (*apex capituli fibulae*), which projects upward from the posterior part of the head. The *prominence* gives attachment to the tendon of the Biceps femoris muscle and to the long external lateral ligament of the knee, the ligament dividing the tendon into two parts. The *apex* of the styloid process gives attachment to the short external lateral ligament. The remaining part of the circumference of the head is rough, for the attachment of muscles and ligaments. It presents in front a tubercle for the origin of the upper and anterior part of the Peroneus longus, and the adjacent surface gives attachment to the anterior superior tibiofibular ligament; and behind, another tubercle for the attachment of the posterior superior tibiofibular ligament and the upper fibres of origin of the Soleus muscle.

The Shaft (*corpus fibulae*).¹—The shaft presents four borders—the antero-external, the antero-internal, the postero-external, and the postero-internal; and four surfaces—anterior, posterior, internal, and external.

¹ Authorities differ as to the best description of the borders and surfaces of the shaft of the fibula. The editor has followed the scheme in general use at the present time. A more appropriate plan might be afforded by the consideration of three surfaces: extensor, peroneal, and flexor, the last being subdivided by the oblique ridge.—Editor.

The **antero-external border** (*crista anterior*) commences above in front of the head, runs vertically downward to a little below the middle of the bone, and then, curving somewhat outward, bifurcates so as to embrace the triangular subcutaneous surface immediately above the outer surface of the external malleolus. This border gives attachment to an intermuscular septum, which separates the Extensor muscles on the anterior surface of the leg from the Peroneus longus and brevis muscles on the outer surface.

The **antero-internal border** (*crista interossea*), or **interosseous ridge**, is situated close to the inner side of the preceding, and runs nearly parallel with it in the upper third of its extent, but diverges from it so as to include a broader space in the lower two-thirds. It commences above, just beneath the head of the bone (sometimes it is quite indistinct for about an inch below the head), and terminates below at the apex of a rough triangular surface immediately above the articular facet of the external malleolus. It serves for the attachment of the interosseous membrane, which separates the Extensor muscles in front from the Flexor muscles behind.

The **postero-external border** (*crista lateralis*) is prominent; it commences above at the base of the styloid process, and terminates below in the posterior border of the outer malleolus. It is directed outward, above, backward in the middle of its course, backward and a little inward below, and gives attachment to an aponeurosis which separates the Peronei muscles on the outer surface of the shaft from the Flexor muscles on its posterior surface.

The **postero-internal border** (*crista medialis*) sometimes called the **oblique line**, commences above at the inner side of the head, and terminates by becoming continuous with the interosseous ridge at the lower fourth of the bone. It is well marked and prominent at the upper and middle parts of the bone. It gives attachment to an aponeurosis which separates the Tibialis posticus from the Soleus above and the Flexor longus hallucis below.

The **anterior surface** (*facies anterior*) is the interval between the antero-external and antero-internal borders. It is extremely narrow and flat in the upper third of its extent, broader and grooved longitudinally in its lower third; it serves for the origin of three muscles, the Extensor longus digitorum, Peroneus tertius, and Extensor proprius hallucis.

The **external surface** (*facies lateralis*) is the space between the antero-external and postero-external borders. It is much broader than the preceding, and often deeply grooved, is directed outward in the upper two-thirds of its course, backward in the lower third, where it is continuous with the posterior border of the external malleolus. This surface is completely occupied by the Peroneus longus and brevis muscles.

The **internal surface** (*facies medialis*) is the interval included between the antero-internal and the postero-internal borders. It is directed inward, and is grooved for the origin of the Tibialis posticus muscle.

The **posterior surface** (*facies posterior*) is the space included between the postero-external and the postero-internal borders; it is continuous below with the rough triangular surface above the articular facet of the outer malleolus; it is directed backward above, backward and inward at its middle, directly inward below. Its upper third is rough, for the origin of the Soleus muscle; its lower part presents a triangular rough surface, connected to the tibia by a strong interosseous ligament, and between these two points the entire surface is covered by the fibres of origin of the Flexor longus hallucis muscle. At about the middle of this surface is the **nutrient foramen**. It opens into the **nutrient canal**, which is directed downward.

The Distal or Lower Extremity.—The lower extremity, or **external malleolus** (*malleolus lateralis*), is of a pyramidal form, somewhat flattened from without inward, and is longer, and descends lower than the internal malleolus. Its **external surface** is convex, subcutaneous, and continuous with the triangular (also sub-

cutaneous) surface on the outer side of the shaft. The *internal surface* presents in front a smooth triangular facet (*facies articularis malleoli*), broader above than below, and convex from above downward, which articulates with a corresponding surface on the outer side of the astragalus. Behind and beneath the articular surface is a rough depression which gives attachment to the posterior fasciculus of the external lateral ligament of the ankle. The *anterior border* is thick and rough, and marked below by a depression for the attachment of the anterior fasciculus of the external lateral ligament. The *posterior border* is broad and marked by a shallow groove (*sulcus malleolaris*), for the passage of the tendons of the Peroneus longus and brevis muscles. The *apex* is rounded, and gives attachment to the middle fasciculus of the external lateral ligament.

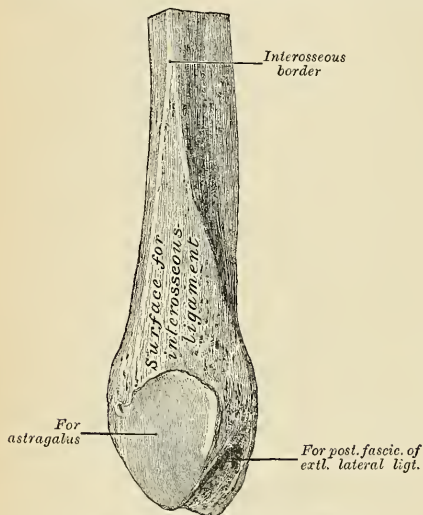


FIG. 189.—Lower extremity of right fibula. Internal aspect.

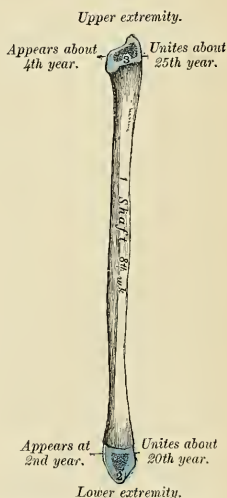


FIG. 190.—Plan of the development of the fibula. From three centres.

In order to distinguish the side to which the bone belongs, hold it with the lower extremity downward and the broad groove for the Peronei tendons backward—*i. e.*, toward the holder; the triangular subcutaneous surface will then be directed to the side to which the bone belongs.

Development.—From *three centres* (Fig. 190)—one for the shaft and one for each extremity. Ossification commences in the shaft about the eighth week of fetal life, a little later than in the tibia, and extends gradually toward the extremities. At birth both ends are cartilaginous. Ossification commences in the lower end in the second year, and in the upper one about the fourth year. The lower epiphysis, the first in which ossification commences, becomes united to the shaft about the twentieth year; the upper epiphysis joins about the twenty-fifth year. Ossification appearing first in the lower epiphysis is contrary to the rule which prevails with regard to the commencement of ossification in epiphyses—*viz.*, that epiphysis toward which the nutrient artery is directed commences to ossify last; but it follows the rule which prevails with regard to the union of epiphyses, by uniting first.

Articulations.—With *two bones*: the tibia and astragalus.

Attachment of Muscles.—To *nine*: To the head, the Biceps femoris, Soleus, and Peroneus longus; to the shaft, its anterior surface, the Extensor longus digitorum, Peroneus tertius, and Extensor proprius hallucis; to the internal surface, the Tibialis posticus; to the posterior surface, the Soleus and Flexor longus hallucis, to the external surface, the Peroneus longus and brevis.

Surface Form.—The only parts of the fibula which may be felt are the head and the lower part of the external surface of the shaft and the external malleolus. The head may be seen

and felt behind and to the outer side of the outer tuberosity of the tibia. It presents a small, prominent triangular eminence slightly above the level of the tubercle of the tibia. The external malleolus presents a narrow elongated prominence, situated on a plane posterior to the internal malleolus and reaching to a lower level. From it may be traced the lower third or half of the external surface of the shaft of the bone in the interval between the *Peroneus tertius* in front and the other two *Peronei* tendons behind.

Applied Anatomy.—In *fractures of the bones of the leg* both bones are usually fractured, but either bone may be broken separately, the fibula more frequently than the tibia. Fracture of both bones may be caused either by direct or indirect violence. When it occurs from indirect force the fracture in the tibia is usually at the junction of the middle and lower third of the bone. Many causes conduce to render this the weakest part of the bone. The fracture of the fibula is usually at rather a higher level. These fractures present great variety, both as regards their direction and condition. They may be oblique, transverse, longitudinal, or spiral. When oblique, they are usually the result of indirect violence, and the direction of the fracture is from behind, downward, forward, and inward in many cases, but may be downward and outward or downward and backward. When transverse, the fracture is often at the upper part of the bone, and is the result of direct violence. The spiral fracture usually commences as a vertical fissure, involving the ankle-joint, and is associated with fracture of the fibula higher up. It is the result of torsion, from twisting of the body while the foot is fixed.

Fractures of the tibia alone are almost always the result of direct violence, except where the malleolus is broken off by twists of the foot. Fractures of the fibula alone may arise from indirect or direct force, those of the lower end being usually the result of the former, and those higher up being caused by a direct blow on the part.

The tibia and fibula, like the femur, are frequently the seat of *acute osteomyelitis*. *Tuberculous abscess* is more frequently met with in the cancellous tissue of the head and lower end of the tibia than in any other bone of the body. The abscess is of small size, very chronic, and probably the result of tuberculous osteitis in the highly vascular growing tissue at the end of the shaft near the epiphyseal cartilage in the young subject. Such an abscess in bone is called *Brodie's abscess*.

The tibia is the bone which is most frequently and most extensively distorted in *rhachitis*. It gives way at the junction of the middle and lower third, its weakest part, and presents a curve forward and outward. *Bow-leg* is due to outward curvature of the femur, tibia, and fibula, the bend being about the junction of the shafts and lower extremities.

THE FOOT (Figs. 191, 192).

The skeleton of the foot consists of three divisions—the **tarsus**, **metatarsus**, and **phalanges**.

The Tarsus (*ossa tarsi*).—The bones of the tarsus are *seven* in number—viz., the **calcaneus**, or **os calcis**, **astragalus**, **cuboid**, **scaphoid**, **internal**, **middle**, and **external cuneiform**.

The Calcaneus (*os calcis*) (Fig. 194).—The heel bone is the largest and strongest of the tarsal bones. It is irregularly cuboidal in form, having its long axis directed forward and outward. It is situated at the lower and back part of the foot, serving to transmit the weight of the body to the ground, and forming a strong lever for the muscles of the calf. It presents for examination six surfaces—superior, inferior, external, internal, anterior, and posterior.

The **superior surface** is formed, behind, by the upper aspect of that part of the *os calcis* which projects backward to form the heel. It varies in length in different individuals; is convex from side to side, concave from before backward, and corresponds above to a mass of adipose substance placed in front of the tendo Achillis. In the middle of the superior surface are two (sometimes three) articular facets, separated by a broad shallow groove (*sulcus calcanei*), which is directed obliquely forward and outward, and is rough for the attachment of the interosseous ligament connecting the astragalus and *os calcis*. When the calcaneus is in contact with the astragalus this groove is converted into a canal (*sinus tarsi*). Of the articular surfaces, the **posterior articular surface** (*facies articularis posterior*) is the larger, and is situated on the body of the bone; it is of an oblong form, wider behind than in

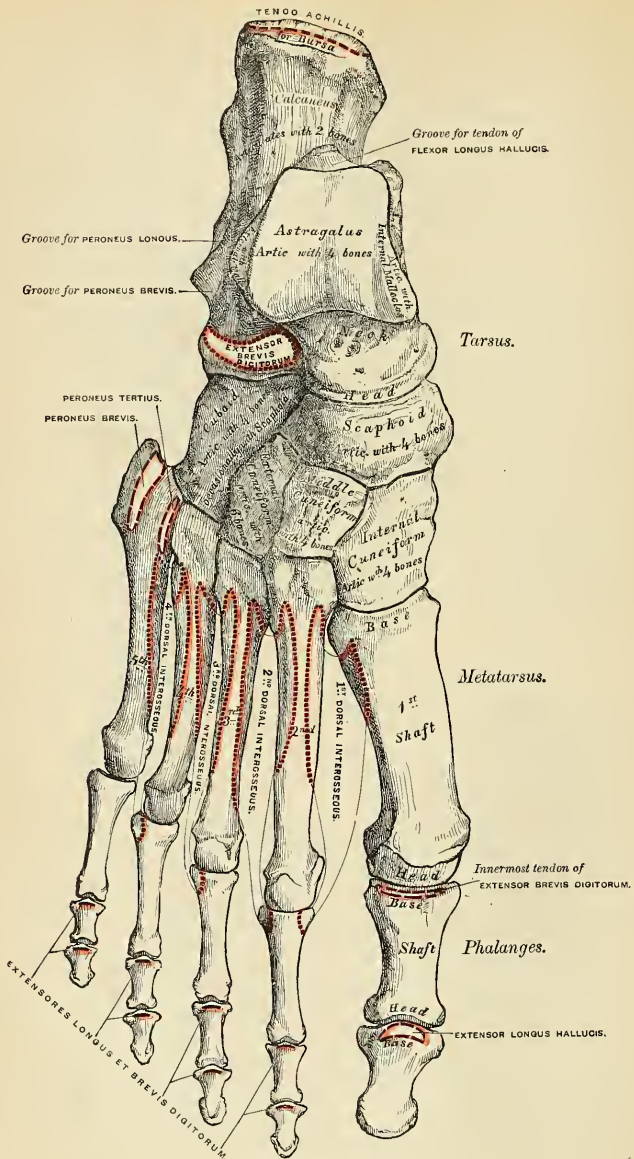


FIG. 191.—Bones of the right foot. Dorsal surface.

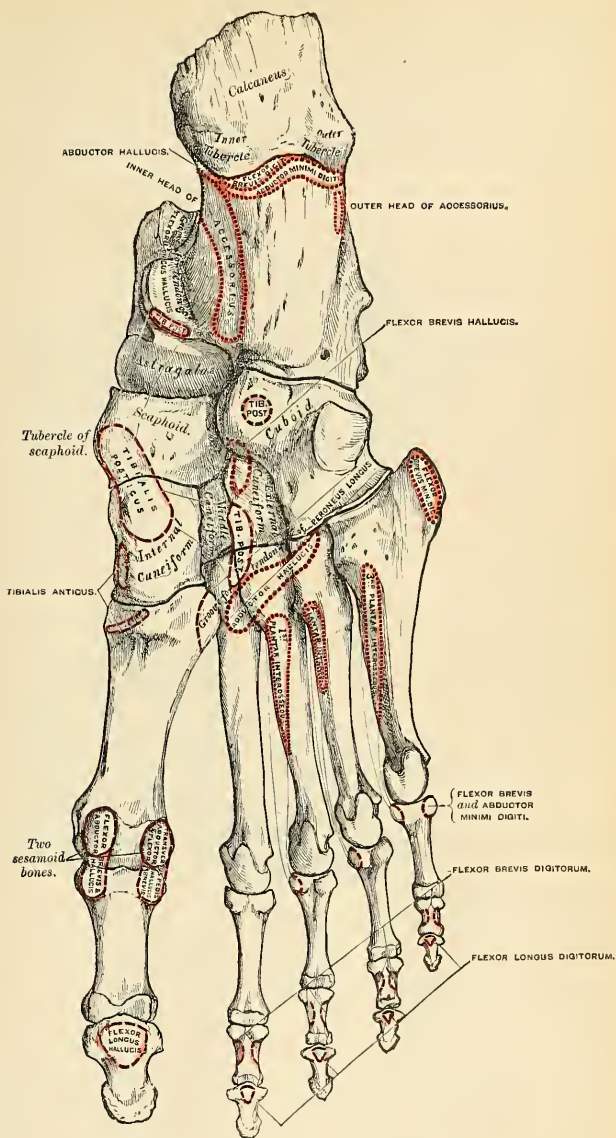
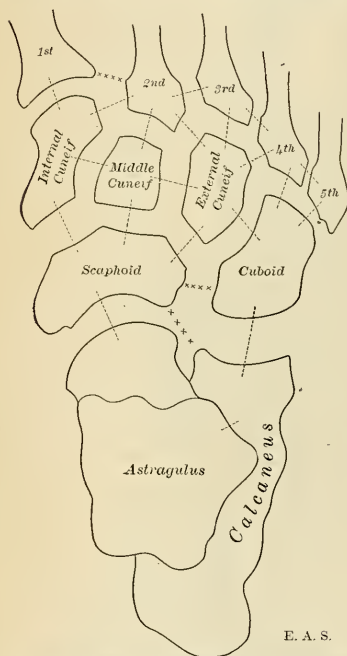


FIG. 192.—Bones of the right foot. Plantar surface.

front, and convex; it articulates with the posterior articular area of the astragalus. The **anterior articular surface** is usually divided into two facets, the anterior of which (*facies articularis anterior*) supports the head of the astragalus. The more posteriorly situated facet (*facies articularis calcanea media*) articulates with the middle facet on the under surface of the astragalus. The anterior articular surface is supported on a projecting process of bone, called the **lesser process of the calcaneus** (*sustentaculum tali*); it is oblong, concave longitudinally, and sometimes subdivided into two parts, which differ in size and shape. More anteriorly is

seen the upper surface of the **greater process of the calcaneus**, marked by a rough depression for the attachment of numerous ligaments, and a tubercle for the origin of the Extensor brevis digitorum muscle.

The **inferior surface** is narrow, rough, uneven, wider behind than in front, and convex from side to side; it is bounded posteriorly by two tubercles separated by a rough depression; the **external tubercle** (*processus lateralis tuberis calcanei*), small, prominent, and rounded, gives origin to part of the Abductor minimi digiti; the **internal tubercle** (*processus medialis tuberis calcanei*), broader and larger, for the support of the heel, gives origin, by its prominent inner margin, to the Abductor hallucis, and in front to the Flexor brevis digitorum muscle and plantar fascia; the depression between the tubercles gives origin to the Abductor minimi digiti. The rough surface in front of the tubercles gives attachment to the long plantar ligament and origin to the outer head of the Flexor accessorius muscle; while to a prominent tubercle nearer the anterior part of this surface, as well as to a transverse groove in front of it, is attached the short plantar ligament.



E. A. S.

FIG. 193.—Schematic representation of the articulations of the tarsus. Occasional articulations shown by *xxxx*.

The **external surface** is broad, flat, and almost subcutaneous; it presents near its centre a tubercle, for the attachment of the middle fasciculus of the external lateral ligament. At its upper and anterior part this surface gives attachment to the external calcaneo-astragaloid ligament; and in front of the tubercle it presents a narrow surface marked by two oblique grooves; separated by an elevated ridge which varies much in size in different bones, it is named the **peroneal spine** (*processus trochlearis*), and gives attachment to a fibrous process from the external annular ligament. The **superior groove** transmits the tendon of the Peroneus brevis; the **inferior groove** the tendon of the Peroneus longus.

The **internal surface** is deeply concave; it is directed obliquely downward and forward, and serves for the transmission of the plantar vessels and nerves into the sole of the foot; it affords origin to part of the Flexor accessorius muscle. At its upper and fore part it presents an eminence of bone, the **sustentaculum tali**,

which projects horizontally inward, and to it a slip of the tendon of the *Tibialis posticus* is attached. This process is concave above, and supports the anterior articular surface of the astragalus; below, it is grooved for the tendon of the *Flexor longus hallucis*. Its free margin is rough, for the attachment of part of the internal lateral ligament of the ankle-joint.

The **anterior surface** (*facies articularis cuboidea*), of a somewhat triangular form, articulates with the cuboid. It is concave from above downward and outward, and convex in the opposite direction. Its *inner border* gives attachment to the inferior calcaneoscapoid ligament.

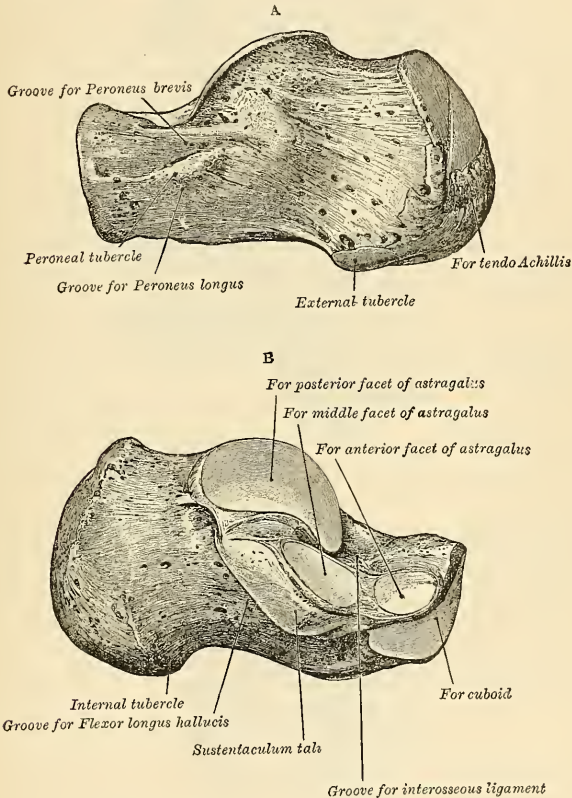


FIG. 194.—The left calcaneus. A. Postero-external view. B. Antero-internal view.

The **posterior surface** is rough, prominent, convex, and wider below than above. The posterior extremity is the projection of the heel. It is called the **tuberosity** (*tuber calcanei*). Its lower part is rough, for the attachment of the tendo Achillis and the tendon of the *Plantaris* muscle; its upper part is smooth, and is covered by a bursa which separates the tendons from the bone.

Articulations.—With *two* bones—the astragalus and cuboid.

Attachment of Muscles.—To *eight*, part of the Tibialis posticus, the tendo Achillis, Plantaris, Abductor hallucis, Abductor minimi digiti, Flexor brevis digitorum, Flexor accessorius, and Extensor brevis digitorum.

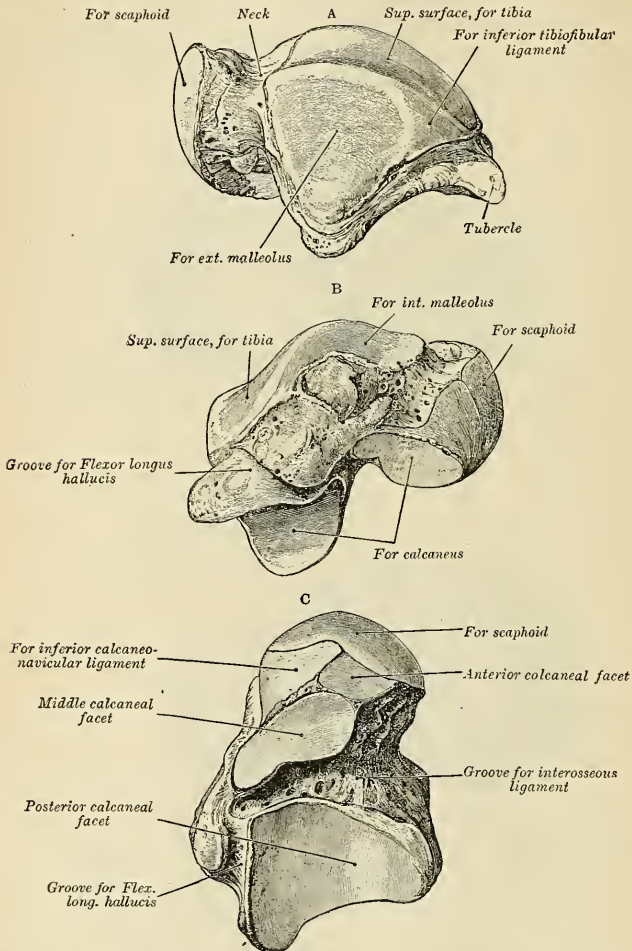


FIG. 195.—The left astragalus. A. Supero-external view. B. Infero-internal view. C. Inferior view.

The Astragalus, or Ankle Bone (*talus*) (Fig. 195).—The astragalus is the second largest of the tarsal bones. It occupies the middle and upper part of the tarsus, supporting the tibia above, articulating with the malleoli on either side, resting below upon the calcaneus, and joined in front to the scaphoid. This bone may

be easily recognized by its large rounded head, by the broad articular facet on its upper convex surface, and by the two articular facets separated by a deep groove on its under concave surface. It presents six surfaces for examination.

The **superior surface** presents, behind, a broad smooth **trochlear surface** (*trochlea tali*) for articulation with the tibia. The trochlea is broader in front than behind, convex from before backward, slightly concave from side to side; in front of it is the upper surface of the neck of the astragalus, rough for the attachment of ligaments.

The **inferior surface** presents two articular areas separated by a deep groove (*sulcus tali*). The groove runs obliquely forward and outward, becoming gradually broader and deeper in front; it corresponds with a similar groove upon the upper surface of the calcaneus, and forms, when articulated with that bone, a canal, filled up in the recent state by the calcaneo-astragaloid ligament. Of the two articular areas, the posterior (*facies articularis calcanea posterior*) is the larger, of an oblong form, and deeply concave from side to side; it rests on the posterior articular surface of the os calcis; the **anterior articular area** is shorter and narrower, of an elongated oval form, convex longitudinally, and most often subdivided into two facets by an elevated ridge; of these, the *posterior* (*facies articularis calcanea media*) articulates with the hinder portion of the anterior articular surfaces of the calcaneus; the *anterior* (*facies articularis calcanea anterior*) rests upon the anterior portion of the anterior articular surface of the calcaneus just mentioned.

The **internal surface** presents at its upper part a pear-shaped articular facet (*facies malleolaris medialis*) for the inner malleolus, continuous above with the trochlear surface; below the articular surface is a rough depression, for the attachment of the deep portion of the internal lateral ligament.

The **external surface** presents a large triangular facet (*facies malleolaris lateralis*), concave from above downward for articulation with the external malleolus; it is continuous above with the trochlear surface; and in front of it is a rough depression for the attachment of the anterior fasciculus of the external lateral ligament of the ankle-joint.

The **anterior surface** (*facies articularis navicularis*) forms the head of the astragalus, is convex and rounded, smooth, of an oval form, and directed obliquely inward and downward; it articulates with the scaphoid. On its under and inner surface is a small facet, continuous in front with the articular surface of the head, and behind with the anterior articular area for the calcaneus. This rests on the inferior calcaneoscaphoid ligament, being separated from it by the synovial membrane. The head is attached to the rest of the bone by a constricted portion, the **neck of the astragalus** (*collum tali*).

The **posterior surface** is traversed by a groove (*sulcus m. flexoris hallucis longi*), which runs obliquely downward and inward, and transmits the tendon of the Flexor longus hallucis, external to which is the prominent **external tubercle** (*processus posterior tali*), to which the posterior fasciculus of the external lateral ligament is attached. This tubercle is sometimes separated from the rest of the astragalus, and is then known as the **os trigonum**.

To ascertain to which foot the bone belongs, hold it with the broad articular surface upward, and the rounded head forward; the lateral triangular articular surface for the external malleolus will then point to the side to which the bone belongs.

Articulations.—With four bones—tibia, fibula, calcaneus, and scaphoid.

The Cuboid (*os cuboideum*) (Fig. 196).—The cuboid is placed on the outer side of the foot, in front of the calcaneus, and behind the fourth and fifth metatarsal bones. It is of a pyramidal shape, its base being directed inward, its apex outward. It may be distinguished from the other tarsal bones by the existence

of a deep groove on its under surface, for the tendon of the *Peroneus longus* muscle. It presents for examination six surfaces, three articular and three nonarticular.

The **nonarticular surfaces** are the dorsal, plantar, and external. The **dorsal surface**, directed upward and outward, is rough, for the attachment of numerous ligaments. The **plantar surface** presents in front a deep groove, the **peroneal groove** (*sulcus m. peronei longi*), which runs obliquely from without, forward and inward; it lodges the tendon of the *Peroneus longus*, and is bounded behind by a prominent ridge, to which is attached the long calcaneocuboid ligament. The ridge terminates externally in an eminence (*tuberositas ossis cuboidei*), the surface of which presents a convex facet, for articulation with the sesamoid bone of the tendon contained in the groove. The surface of bone behind the groove is rough, for the attachment of the short plantar ligament, a few fibres of origin of the *Flexor brevis hallucis*, and a fasciculus from the tendon of the *Tibialis posticus*. The **external surface**, the smallest and narrowest of the three, presents a deep notch formed by the commencement of the peroneal groove.

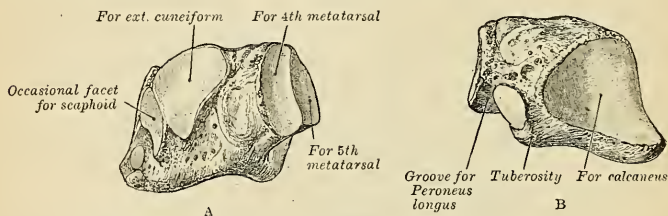


FIG. 196.—The left cuboid. A. Antero-internal view. B. Postero-external view.

The **articular surfaces** are the posterior, anterior, and internal. The **posterior surface** is smooth, triangular, and concavo-convex, for articulation with the anterior surface of the calcaneus. The **anterior surface**, of smaller size, but also irregularly triangular, is divided by a vertical ridge into two facets: the inner one, quadrilateral in form, articulates with the fourth metatarsal bone; the outer one, larger and more triangular, articulates with the fifth metatarsal. The **internal surface** is broad, rough, irregularly quadrilateral, presenting at its middle and upper part a smooth oval facet, for articulation with the external cuneiform bone; and behind this (occasionally) a smaller facet, for articulation with the scaphoid; it is rough in the rest of its extent, for the attachment of strong interosseous ligaments.

To ascertain to which foot the bone belongs, hold it so that its under surface, marked by the peroneal groove, looks downward, and the large concavo-convex articular surface backward toward the holder: the narrow nonarticular surface, marked by the commencement of the peroneal groove, will point to the side to which the bone belongs.

Articulations.—With *four* bones—the calcaneus, external cuneiform, and the fourth and fifth metatarsal bones; occasionally with the scaphoid.

Attachment of Muscles.—Part of the *Flexor brevis hallucis* and a slip from the tendon of the *Tibialis posticus*.

Scaphoid or Navicular Bone (*os naviculare pedis*) (Fig. 197).—The scaphoid is situated at the inner side of the tarsus, between the astragalus behind and the three cuneiform bones in front. It may be distinguished by its form, being concave behind, convex and subdivided into three facets in front.

The **anterior surface**, of an oblong form, is convex from side to side, and subdivided by two ridges into three facets, for articulation with the three cuneiform bones. The **posterior surface** is oval, concave, broader externally than internally,

and articulates with the rounded head of the astragalus. The **dorsal surface** is convex from side to side, and rough for the attachment of ligaments. The **plantar** is irregular, and also rough for the attachment of ligaments. The **internal surface** presents a rounded tubercular eminence, the **tuberosity** (*tuberositas ossis navicularis*), the lower part of which projects, and gives attachment to part of the tendon of the *Tibialis posticus*. The **external surface** is rough and irregular, for the attachment of ligamentous fibres, and occasionally presents a small facet for articulation with the cuboid bone.

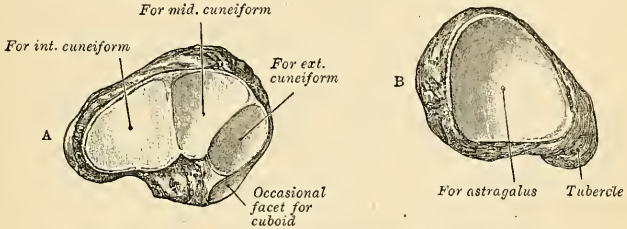


FIG. 197.—The left scaphoid. A. Antero-external view. B. Postero-internal view.

To ascertain to which foot the bone belongs, hold it with the concave articular surface backward, and the convex dorsal surface upward; the external surface—i. e., the surface opposite the tubercle—will point to the side to which the bone belongs.

Articulations.—With four bones—astragalus and three cuneiform; occasionally also with the cuboid.

Attachment of Muscles.—Part of the *Tibialis posticus*.

Cuneiform or Wedge Bones.—The cuneiform bones have received their name from their wedge-like shape. They form, with the cuboid, the distal row of the tarsus, being placed between the scaphoid behind, the three innermost metatarsal bones in front, and the cuboid externally. They are called the **first**, **second**, and **third**, counting from the inner to the outer side of the foot, and, from their position, **internal**, **middle**, and **external**.

Internal or First Cuneiform (*os cuneiforme primum*) (Fig. 198).—The internal cuneiform is the largest of the three. It is situated at the inner side of the foot, between the scaphoid behind and the base of the first metatarsal in front. It may be distinguished from the other

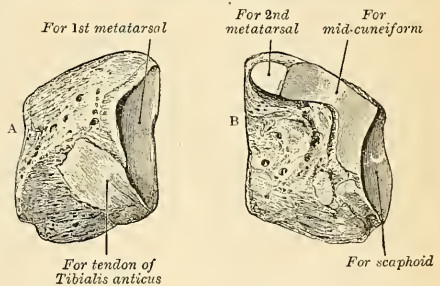


FIG. 198.—The left internal cuneiform. A. Antero-external view. B. Postero-external view.

two by its large size, and by its not presenting such a distinct wedge-like form. Without the others it may be known by the large, kidney-shaped anterior articulating surface and by the prominence on the inferior or plantar surface for the attachment of the *Tibialis posticus*. It presents for examination six surfaces.

The **internal surface** is subcutaneous, and forms part of the inner border of the foot; it is broad, quadrilateral, and presents at its anterior inferior angle a smooth oval facet, into which the tendon of the *Tibialis anticus* is partially inserted; in the rest of its extent it is rough, for the attachment of ligaments. The **external**

surface is concave, presenting, along its superior and posterior borders, a narrow, reversed, L-shaped surface, for articulation with the middle cuneiform behind and second metatarsal bone in front; in the rest of its extent it is rough, for the attachment of ligaments, and part of the tendon of the Peroneus longus. The **anterior surface**, kidney-shaped, much larger than the posterior, articulates with the metatarsal bone of the great toe. The **posterior surface** is triangular, concave, and articulates with the innermost and largest of the three facets on the anterior surface of the scaphoid. The **plantar surface** is rough, and presents a prominent tuberosity at its back part for the attachment of part of the tendon of the Tibialis posticus. It also gives attachment in front to part of the tendon of the Tibialis anticus. The **dorsal surface** is the narrow-pointed end of the wedge, which is directed upward and outward; it is rough for the attachment of ligaments.

To ascertain to which side the bone belongs, hold it so that its dorsal narrow edge looks upward, and the long, kidney-shaped, articular surface forward; the external surface, marked by its vertical and horizontal articular facets, will point to the side to which it belongs.

Articulations.—With *four* bones: scaphoid, middle cuneiform, first and second metatarsal bones.

Attachment of Muscles.—To *three*—the Tibialis anticus and posticus, and Peroneus longus.

Middle or Second Cuneiform (*os cuneiforme secundum*) (Fig. 199).—The middle cuneiform, the smallest of the three, is of very regular wedge-like form, the broad extremity being placed upward, the narrow end downward. It is situated between

the other two bones of the same name, and articulates with the scaphoid behind and the second metatarsal in front. It is smaller than the external cuneiform bone, from which it may be further distinguished by the L-shaped articular facet, which runs around the upper and back part of its inner surface.

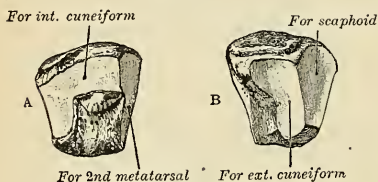


FIG. 199.—The left middle cuneiform. A. Antero-internal view. B. Postero-external view.

posterior, articulates with the base of the second metatarsal bone. The **posterior surface**, also triangular, articulates with the scaphoid. The **internal surface** presents an L-shaped articular facet, running along the superior and posterior borders, for articulation with the internal cuneiform, and is rough in the rest of its extent, for the attachment of ligaments. The **external surface** presents posteriorly a smooth facet for articulation with the external cuneiform bone. The **dorsal surface** forms the base of the wedge; it is quadrilateral, broader behind than in front, and rough for the attachment of ligaments. The **plantar surface**, pointed and tubercular, is also rough for ligamentous attachment and for the insertion of a slip from the tendon of the Tibialis posticus.

To ascertain to which foot the bone belongs, hold its superior or dorsal surface upward, the broadest edge being toward the holder; the smooth facet (limited to the posterior border) will then point to the side to which it belongs.

Articulations.—With *four* bones—scaphoid, internal and external cuneiform, and second metatarsal bone.

Attachment of Muscles.—A slip from the tendon of the Tibialis posticus is attached to this bone.

External or Third Cuneiform (*os cuneiforme tertium*) (Fig. 200).—The external cuneiform, intermediate in size between the two preceding, is of a very regular wedge-like form, the broad extremity being placed upward, the narrow end down-

ward. It occupies the centre of the front row of the tarsus, between the middle cuneiform internally, the cuboid externally, the scaphoid behind, and the third metatarsal in front. It is distinguished from the internal cuneiform bone by its more regular wedge-like shape and by the absence of the kidney-shaped articular surface; from the middle cuneiform, by the absence of the L-shaped facet, and by the two articular facets which are present on both its inner and outer surfaces. It has six surfaces for examination.

The **anterior surface**, triangular in form, articulates with the third metatarsal bone. The **posterior surface** articulates with the most external facet of the scaphoid, and is rough below for the attachment of ligamentous fibres. The **internal surface** presents two articular facets, separated by a rough depression; the anterior one, sometimes divided into two, articulates with the outer side of the base of the second metatarsal bone; the posterior one skirts the posterior border and articulates with the middle cuneiform; the rough depression between the two gives attachment to an interosseous ligament. The **external surface** also presents two articular facets, separated by a rough nonarticular surface; the anterior facet, situated at the superior angle of the bone, is small, and articulates with the inner side of the base of the fourth metatarsal; the posterior and larger one articulates with the cuboid; the rough, nonarticular surface serves for the attachment of

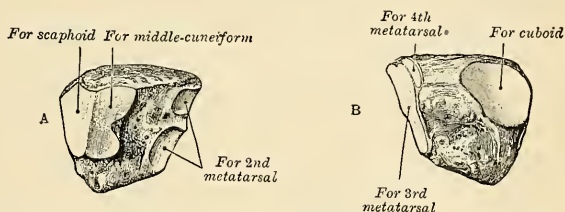


FIG. 200.—The left external cuneiform. A. Postero-internal view. B. Antero-external view.

an interosseous ligament. The three facets for articulation with the three metatarsal bones are continuous with one another, and covered by a prolongation of the same cartilage; the facets for articulation with the middle cuneiform and scaphoid are also continuous, but that for articulation with the cuboid is usually separate. The **dorsal surface** is of an oblong square form, its posterior external angle being prolonged backward. The **plantar surface** is an obtuse rounded margin, and serves for the attachment of ligaments and a part of the tendon of the Tibialis posticus, and for part of the fibres of origin of the Flexor brevis hallucis.

To ascertain to which side the bone belongs, hold it with the broad dorsal surface upward, the prolonged edge backward; the separate articular facet for the cuboid will point to the proper side.

Articulations.—With *six* bones—the scaphoid, middle cuneiform, cuboid, and second, third, and fourth metatarsal bones.

Attachment of Muscles.—To *two*—part of the Tibialis posticus, and Flexor brevis hallucis.

The number of tarsal bones may be reduced owing to congenital ankylosis which may occur between the os calcis and cuboid, the os calcis and scaphoid, the os calcis and astragalus, or the astragalus and scaphoid.

The Metatarsal Bones (*ossa metatarsalia*).—The **metatarsal bones** are five in number, and are numbered one to five, in accordance with their position from within outward; they are long bones, and present for examination a shaft and two extremities.

Common Characters.—The shaft (*corpus*) is prismoid in form, tapers gradually from the tarsal to the phalangeal extremity, and is slightly curved longitudinally, so as to be concave below, slightly convex above. On the plantar surface of the

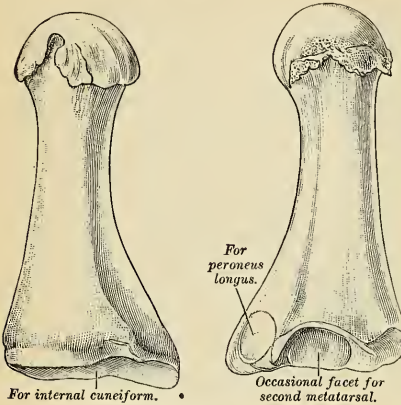


FIG. 201.—The first metatarsal. (Left.)

under surface is grooved in the middle line for the passage of the Flexor tendon, and marked on each side by an articular eminence continuous with the terminal articular surface.

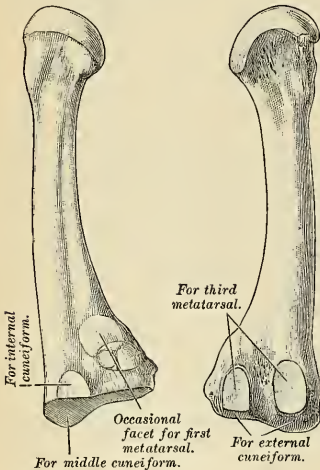


FIG. 202.—The second metatarsal. (Left.)

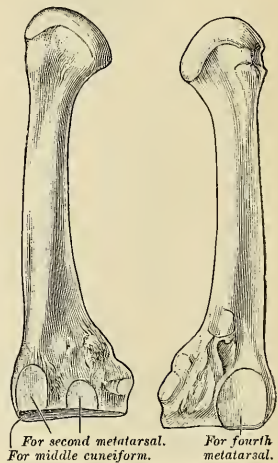


FIG. 203.—The third metatarsal. (Left.)

Peculiar Characters.—The metatarsal bone of the great toe (*os metatarsale I*) (Fig. 201) is remarkable for its great thickness, but is the shortest of all the metatarsal bones. The shaft is strong and of well-marked prismoid form. The

shaft of each bone is a nutrient foramen corresponding to the nutrient foramen in each metacarpal bone. The proximal extremity, or base (*basis*), is wedge-shaped, articulating by its terminal surface with the tarsal bones, and by its lateral surfaces with the contiguous metatarsal bones, its dorsal and plantar surfaces being rough for the attachment of ligaments. The distal extremity, or head (*capitulum*), presents a terminal rounded articular surface, oblong from above downward, and extending farther backward below than above. Its sides are flattened and present a depression, surmounted by a tubercle, for ligamentous attachment. Its

proximal extremity presents, as a rule, no lateral articular facet, but occasionally on the outer side there is an oval facet by which it articulates with the second metatarsal bones. Its proximal articular surface is of large size and kidney shaped; it corresponds to the distal extremity of the internal cuneiform; its circumference is grooved, for the tarsometatarsal ligaments, and internally gives attachment to part of the tendon of the *Tibialis anticus* muscle; its inferior angle presents a rough oval prominence, the **tuberosity** (*tuberositas ossis metatarsalis I*), for the insertion of the tendon of the *Peroneus longus*. The head is of large size; on its plantar surface are two grooved facets, over which glide sesamoid bones; the facets are separated by a smooth elevated ridge.

This bone is known by the single kidney-shaped articular surface on its base, the deeply grooved appearance of the plantar surface of its head, and its great thickness relatively to its length. When it is placed in its natural position, the concave border of the kidney-shaped articular surface on its base points to the side to which the bone belongs.

Attachment of Muscles.—To *three*—part of the *Tibialis anticus*, the *Peroneus longus*, and the First dorsal interosseous.

The **second metatarsal** (*os metatarsale II*) (Fig. 202) is the longest and largest of the remaining metatarsal bones, being prolonged backward into the recess formed between the three cuneiform bones. Its *tarsal extremity* is broad above, narrow and rough below. It presents four articular surfaces—one behind, of a triangular form, for articulation with the middle cuneiform; one at the upper part of its internal lateral surface, for articulation with the internal cuneiform; and two on its external lateral surface—an upper and a lower, separated by a rough nonarticular interval. Each of these articular surfaces is divided by a vertical ridge into two facets, thus making four facets; the two anterior of these articulate with the third metatarsal; the two posterior (sometimes continuous) with the external cuneiform. In addition to these articular surfaces there is occasionally a fifth when this bone articulates with the first metatarsal bone. It is oval in shape, and is situated on the inner side of the shaft near the base.

The facets on the tarsal extremity of the second metatarsal bone serve at once to distinguish it from the rest, and to indicate the foot to which it belongs; there being one facet at the upper angle of the internal surface, and two facets, each subdivided into two parts, on the external surface, pointing to the side to which the bone belongs. The fact that the two posterior subdivisions of these external facets sometimes run into one should not be forgotten.

Attachment of Muscles.—To *four*—the *Adductor obliquus hallucis*, First and Second dorsal interossei, and a slip from the tendon of the *Tibialis posticus*; occasionally also a slip from the *Peroneus longus*.

The **third metatarsal** (*os metatarsale III*) (Fig. 203) articulates proximally, by means of a triangular smooth surface, with the external cuneiform; on its inner side, by two facets, with the second metatarsal; and on its outer side, by a single facet, with the fourth metatarsal. The latter facet is of circular form and situated at the upper angle of the base.

The third metatarsal is known by possessing at its tarsal end two undivided facets on the inner side, and a single facet on the outer. This distinguishes it from the second metatarsal, in which the two facets, found on one side of its tarsal end, are each subdivided into two. The single facet (when the bone is put in its natural position) is on the side to which the bone belongs.

Attachment of Muscles.—To *five*—*Adductor obliquus hallucis*, Second and Third dorsal and First plantar interossei, and a slip from the tendon of the *Tibialis posticus*.

The **fourth metatarsal** (*os metatarsale IV*) (Fig. 204) is smaller in size than the preceding; its *tarsal extremity* presents a terminal quadrilateral surface, for articulation with the cuboid; a smooth facet on the inner side, divided by a ridge into an anterior portion for articulation with the third metatarsal, and a posterior

portion for articulation with the external cuneiform; on the outer side a single facet, for articulation with the fifth metatarsal.

The fourth metatarsal is known by its having a single facet on either side of the tarsal extremity, that on the inner side being divided into two parts. If this subdivision be not recognizable, the fact that its tarsal end is bent somewhat outward will indicate the side to which it belongs.

Attachment of Muscles.—To *five*—Adductor obliquus hallucis, Third and Fourth dorsal, and Second plantar interossei, and a slip from the tendon of the Tibialis posticus.

The **fifth metatarsal bone**, or the **metatarsal bone of the little toe** (*os metatarsale V*) (Fig. 205), is recognized by the **tubercle** (*tuberositas ossis metatarsalis V*) on the outer side of its base. It articulates behind, by a triangular surface cut obliquely from without inward, with the cuboid, and internally with the fourth metatarsal.

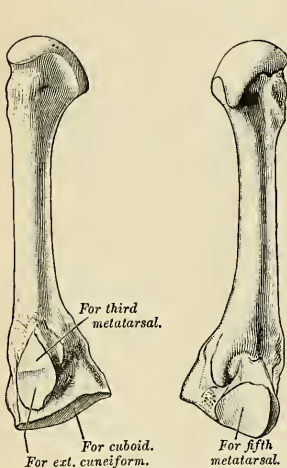


FIG. 204.—The fourth metatarsal. (Left.)

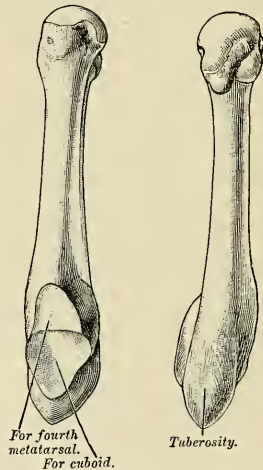


FIG. 205.—The fifth metatarsal. (Left.)

The projection on the outer side of this bone at its tarsal end at once distinguishes it from the others, and points to the side to which it belongs.

Attachment of Muscles.—To *six*—the Peroneus brevis, Peroneus tertius, Flexor brevis minimi digiti, Adductor transversus hallucis, Fourth dorsal, and Third plantar interossei.

Articulations.—Each bone articulates with the tarsal bones by one extremity (proximal), and by the other (distal) extremity with the first row of phalanges. The number of tarsal bones with which each metatarsal articulates is one for the first, three for the second, one for the third, two for the fourth, and one for the fifth.

The Phalanges of the Foot (*Phalanges Digitorum Pedis*).

The **phalanges** of the foot, both in number and general arrangement, resemble those in the hand; there being two in the great toe and three in each of the other toes. The nutritive foramina correspond to those in the phalanges of the hand.

The **first or proximal phalanx** (*phalanx prima*) resembles closely the corresponding bone of the hand. The **shaft** also is compressed from side to side, convex above, concave below. The **proximal extremity** is concave; and the **distal extremity** presents a trochlear surface, for articulation with the second phalanx.

The **second phalanx** (*phalanx secunda*) is remarkably small and short, but rather broader than the first phalanx.

The **ungual or distal phalanx** (*phalanx tertia*) in form resembles the bone of the corresponding finger, but is smaller, flattened from above downward, presenting a broad base for articulation with the second phalanx, and an expanded extremity for the support of the nail and end of the toe.

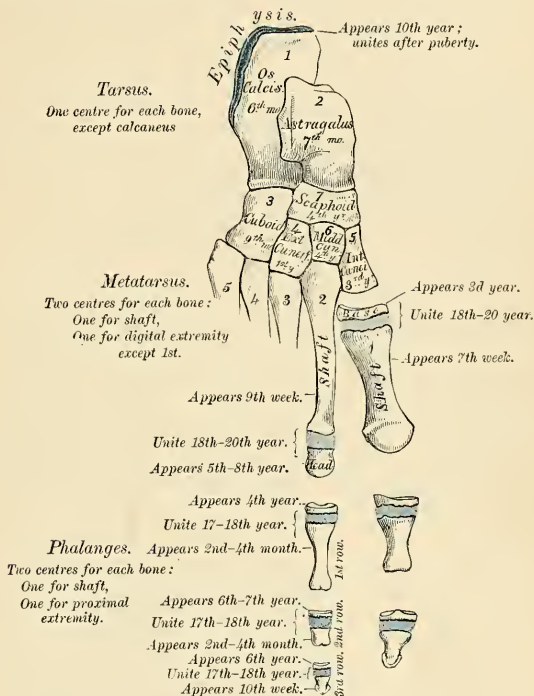


FIG. 206.—Plan of the development of the foot.

Articulation.—The first row, with the metatarsal bones behind and second phalanges in front; the second row of the four outer toes, with the first and third phalanges; of the great toe, with the first phalanx; the third row of the four outer toes, with the second phalanges.

Attachment of Muscles.—To the first phalanges: Great toe, *five* muscles—innermost tendon of Extensor brevis digitorum, Abductor hallucis, Adductor obliquus hallucis, Flexor brevis hallucis, Adductor transversus hallucis. Second toe, *three* muscles—First and Second dorsal interosseous and First lumbrical. Third toe, *three* muscles—Third dorsal and First plantar interosseous and Second lumbrical. Fourth toe, *three* muscles—Fourth dorsal and Second plantar interosseous and Third lumbrical. Fifth toe, *four* muscles—Flexor brevis minimi digiti, Abductor minimi digiti, and Third plantar interosseous, and Fourth lumbrical. Second phalanges: Great toe—Extensor longus hallucis, Flexor longus hallucis. Other toes—Flexor brevis digitorum, one slip of the common tendon of the Extensor longus and brevis digitorum.¹ Third phalanges: Two slips from the common tendon of the Extensor longus and Extensor brevis digitorum, and the Flexor longus digitorum.

¹ Except the second phalanx of the fifth toe, which receives no slip from the Extensor brevis digitorum.

Development of the Foot (Fig. 206).

The **tarsal bones** are each developed from a *single* centre, excepting the calcaneus, which has an epiphysis for its posterior extremity. The centres make their appearance in the following order: calcaneus, at the sixth month of fetal life; astragalus, about the seventh month; cuboid, at the ninth month; external cuneiform, during the first year; internal cuneiform, in the third year; middle cuneiform and scaphoid, in the fourth year. The epiphysis for the posterior tuberosity of the calcaneus appears at the tenth year, and unites with the rest of the bone soon after puberty. When this part remains as a separate bone, it is called the *os trigonum*.

The **metatarsal bones** are each developed from *two* centres—one for the shaft and *one* for the digital extremity in the four outer metatarsal; *one* for the shaft and *one* for the base in the metatarsal bone of the great toe.¹ Ossification commences in the centre of the shaft about the ninth week, and extends toward either extremity. The centre in the proximal end of the first metatarsal bone appears about the third year, the centre in the distal end of the other bones between the fifth and eighth years; they unite with the shaft between the eighteenth and twentieth years.

The **phalanges** are developed from *two* centres for each bone—one for the shaft and *one* for the proximal extremity. The centre for the shaft appears about the tenth week, that for the epiphysis between the fourth and tenth years; they join the shaft about the eighteenth year.

Construction of the Foot as a Whole (Figs. 207, 208).

The **foot** is constructed on the same principles as the hand, but modified to form a firm basis of support for the rest of the body when in the erect position. It is more solidly constructed, and its component parts are less movable on each other than in the hand. This is especially the case with the great toe, which has to assist in supporting the body, and is therefore constructed with greater solidity; it lies parallel with the other toes, and has a very limited degree of mobility, whereas the thumb, which is occupied in numerous and varied movements, is constructed in such a manner as to permit of great mobility. Its metacarpal bone is directed away from the others, so as to form an acute angle with the second, and it enjoys a considerable range of motion at its articulation with the carpus. The foot is placed at right angles to the leg—a position which is almost peculiar to man, and has relation to the erect position which he maintains. In order to allow of its supporting the weight of the whole body in this position with the least expenditure of material, it is constructed in the form of an arch. This **antero-posterior** or **longitudinal arch** is made up of two unequal limbs. The hinder one, which is made up of the calcaneus and the posterior part of the astragalus, is about half the length of the anterior limb, and measures about three inches. The anterior limb consists of the rest of the tarsal and the metatarsal bones, and measures about seven inches. It may be said to consist of two parts, an inner segment made up of the head of the astragalus, the scaphoid, the three cuneiform, and the three inner metatarsal bones; and an outer segment composed of the calcaneus, the cuboid, and the two outer metatarsal bones. The summit of the arch is at the superior articular surface of the astragalus; and its two extremities—that is to say, the two piers on which the arch rests in standing—are the internal tubercle on the under surface of the calcaneus posteriorly, and the heads of the metatarsal bones anteriorly. The weakest part of the arch is the joint between the astragalus and scaphoid; and here it is more liable to yield in those who are overweighted, and in those in whom the ligaments which complete and preserve the arch are relaxed. This weak point in the arch is braced on its concave surface by the inferior calcaneoscaphoid ligament, which is more elastic than most other ligaments, and thus allows the arch to yield from jars or shocks applied to the anterior portion of the foot and quickly restores it to its pristine

¹ As was noted in the first metacarpal bone, so in the first metatarsal, there is often to be observed a tendency to the formation of a second epiphysis in the distal extremity.

condition. This ligament is supported internally by blending with the deltoid ligament, and inferiorly by the tendon of the *Tibialis posticus* muscle, which is spread out into a fan-shaped insertion, and prevents undue tension of the ligament or such an amount of stretching as would permanently elongate it.

In addition to this longitudinal arch the foot presents a **transverse arch**, at the anterior part of the tarsus and hinder part of the metatarsus. This, however, can scarcely be described as a true arch, but presents more the character of a half-dome. The inner border of the central portion of the longitudinal arch is elevated

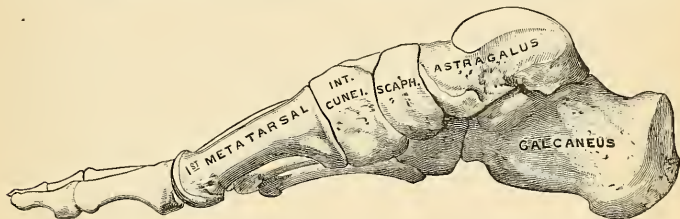


FIG. 207.—Skeleton of the foot, internal border. (Poirier and Charpy.)

from the ground, and from this point the bones arch over to the outer border, which is in contact with the ground, and, assisted by the longitudinal arch, produce a sort of rounded niche on the inner side of the foot, which gives the appearance of a transverse as well as a longitudinal arch.

The line of the foot, from the point of the heel to the toes, is not quite straight, but is directed a little outward, so that the inner border is a little convex and the outer border concave. This disposition of the bones becomes more marked when the longitudinal arch of the foot is lost, as in the condition known under the name of "flat-foot."

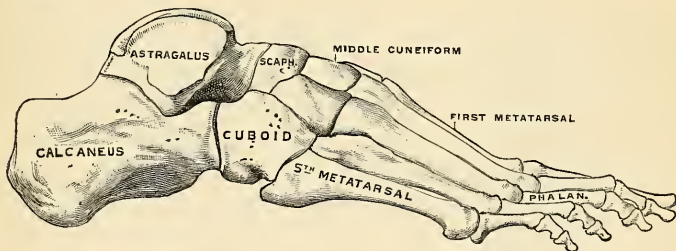


FIG. 208.—Skeleton of the foot, external border. (Poirier and Charpy.)

Surface Form.—On the dorsum of the foot the individual bones are not to be distinguished with the exception of the head of the astragalus, which forms a rounded projection in front of the ankle-joint when the foot is forcibly extended. The whole surface forms a smooth convex outline, the summit of which is the ridge formed by the head of the astragalus, the scaphoid, the middle cuneiform, and the second metatarsal bones; from this it gradually inclines outward and more rapidly inward. On the inner side of the foot, the internal tubercle of the calcaneus and the ridge separating the inner from the posterior surface of the bone may be felt most posteriorly. In front of this, and below the internal malleolus, may be felt the projection of the sustentaculum tali. Passing forward is the well-marked tuberosity of the scaphoid bone, situated about an inch or an inch and a quarter in front of the internal malleolus. Further toward the front, the ridge formed by the base of the first metatarsal bone can be obscurely felt, and from this the shaft of the bone can be traced to the expanded head articulating with the base

of the first phalanx of the great toe. Immediately beneath the base of this phalanx, the internal sesamoid bone is to be felt. Lastly, the expanded ends of the bones forming the last joint of the great toe are to be felt. On the outer side of the foot the most posterior bony point is the external tubercle of the calcaneus, with the ridge separating the posterior from the outer surface of the bone. In front of this the greater part of the external surface of the calcaneus is subcutaneous; on it, below and in front of the external malleolus, may be felt the peroneal spine when this is present. Farther forward, the base of the fifth metatarsal bone forms a prominent and well-defined landmark, and in front of this the shaft of the bone, with its expanded head, and the base of the first phalanx may be defined. The sole of the foot is almost entirely covered by soft parts, so that but few bony parts are to be made out, and these somewhat obscurely. The hinder part of the under surface of the calcaneus and the heads of the metatarsal bones, with the exception of the first, which is concealed by the sesamoid bones, may be recognized.

Applied Anatomy.—Considering the injuries to which the foot is subjected, it is surprising how seldom the tarsal bones are fractured. This is no doubt due to the fact that the tarsus is composed of a number of bones, articulated by a considerable extent of surface and joined together by very strong ligaments, which serve to mitigate the intensity of violence applied to this part of the body. When fracture does occur, these bones, being composed for the most part of a soft cancellous structure, covered only by a thin shell of compact tissue, are often extensively comminuted, especially as most of the fractures are produced by direct violence. As the bones have only a very scanty amount of soft parts over them, fractures are very often compound, and amputation is frequently necessary.

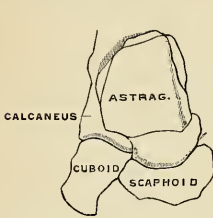


FIG. 209.—Line of Chopart's amputation.
(Poirier.)

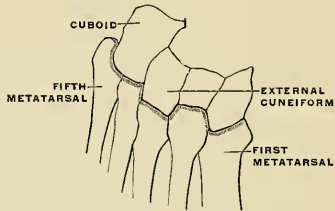


FIG. 210.—Line of Lisfranc's amputation.
(Poirier.)

When fracture occurs in the *anterior group of tarsal bones*, it is almost invariably the result of direct violence, but fractures of the posterior group, that is, of the *calcaneus* and *astragalus*, are most frequently produced by falls from a height on to the feet; though *fracture of the calcaneus* may be caused by direct violence or by muscular action. The posterior part of the bone, that is, the part behind the articular surfaces, is almost always the seat of the fracture, though some few cases of *fracture of the sustentaculum tali* and of vertical fracture between the two articulating facets have been recorded. The neck of the astragalus, being the weakest part of the bone, is most frequently fractured, though fractures may occur in any part and almost in any direction, either associated or not with fracture of other bones.

In cases of *club-foot*, especially in congenital cases, the bones of the tarsus become altered in shape and size, and displaced from their proper positions. This is especially the case in *congenital equinovarus*, in which the astragalus, particularly about the head, becomes twisted and atrophied, and a similar condition may be present in the other bones, more especially the scaphoid. The tarsal bones are peculiarly liable to become the seat of *tuberculous caries*, and this condition may arise after comparatively trivial injuries. There are several reasons to account for this. They are composed of a delicate cancellated structure, surrounded by intricate synovial membranes. They are situated at the farthest point from the central organ of the circulation and exposed to vicissitudes of temperature; and, moreover, on their dorsal surface are thinly clad with soft parts which have but a scanty blood-supply. And finally, after slight injuries, they are not maintained in a condition of rest to the same extent as structures suffering from similar injuries in some other parts of the body. *Caries* of the calcaneus or astragalus may remain limited to the one bone for a long period, but when one of the other bones is affected, the remainder frequently become involved, in consequence of the disease spreading through the large and complicated synovial membrane which is more or less common to these bones.

Amputation of the whole or a part of the foot is frequently required either for injury or disease. The principal amputations are as follows: (1) *Syme's amputation* at the ankle-joint by a heel-flap, with the removal of the malleoli and a thin slice from the lower end of the tibia. (2) *Pirogoff's amputation*: removal of the whole of the tarsal bones, except the posterior part of the

calcaneus. A thin slice is sawed from the tibia and fibula, including the two malleoli. The sawed surface of the calcaneus is then turned up and united to the similar surface of the tibia. (3) *Subastragaloid amputation*: removal of the foot below the astragalus through the joint between it and the calcaneus.

The bones of the tarsus occasionally require removal individually. This is especially the case with the astragalus and calcaneus for disease limited to the one bone, or again the astragalus may require *excision* in cases of subastragaloid dislocation. In cases of inveterate *talipes* the head of the astragalus and greater process of the calcaneus is often removed, sometimes the scaphoid is also taken out. Finally, Mikulicz and Watson have devised operations for the removal of more extensive portions of the tarsus. *Mikulicz's operation* consists in the removal of the calcaneus and astragalus, along with the articular surfaces of the tibia and fibula, and also of the scaphoid and cuboid. The remaining portion of the tarsus is then brought into contact with the sawed surfaces of the tibia and fibula, and fixed there. The result is a position of the shortened foot resembling *talipes equinus*. *Watson's operation* is adapted to those cases where the disease is confined to the anterior tarsal bones. By two lateral incisions he saws through the bases of the metatarsal bones in front and opens up the joints between the scaphoid and astragalus, and the cuboid and calcaneus, and removes the intervening bones.

Fractures of the metatarsal bones and phalanges are nearly always due to direct violence, and in many cases the injury is the result of severe crushing accidents, necessitating amputation. The metatarsal bones, and especially the metatarsal bone of the great toe are frequently diseased, either in tuberculous subjects or in *perforating ulcer* of the foot.

Sesamoid Bones (Ossa Sesamoidea) (Figs. 211, 212).

These are small rounded masses, cartilaginous in early life, osseous in the adult, which are developed in those tendons which exert a great amount of pressure upon

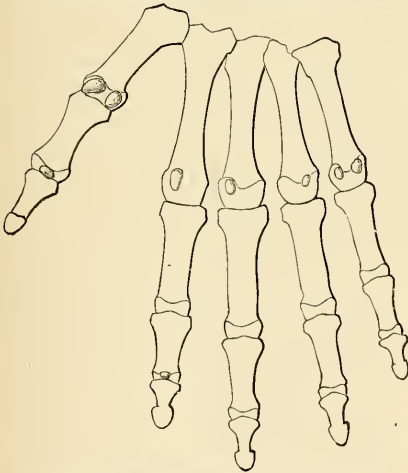


FIG. 211 —Sesamoid bones of the hand. (Poirier and Charpy.)

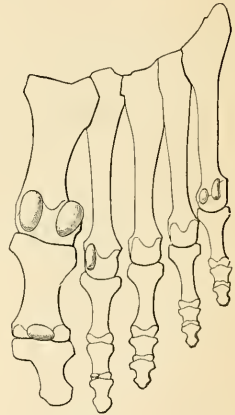


FIG. 212.—Sesamoid bones of the foot. (Poirier and Charpy.)

the parts over which they glide. It is said that they are more commonly found in the male than in the female, and in persons of an active muscular habit than in those who are weak and debilitated. They are invested throughout their whole surface by the fibrous tissue of the tendon in which they are found, excepting upon that side which lies in contact with the part over which they play, where they present a free articular facet. They may be divided into two kinds—those

which glide over the articular surfaces of the joints, and those which play over the cartilaginous facets found on the surfaces of certain bones.

The sesamoid bones of the joints in the upper extremity are two on the palmar surface of the metacarpophalangeal joint in the thumb, developed in the tendons of the *Flexor brevis pollicis*; one on the palmar surface of the interphalangeal joint of the thumb; occasionally one or two opposite the metacarpophalangeal articulations of the fore and little fingers; and, still more rarely, one opposite the same joints of the third and fourth fingers. In the lower extremity, the patella, which is developed in the tendon of the *Quadriceps extensor*; two small sesamoid bones, found in the tendons of the *Flexor brevis hallucis*, opposite the metatarsophalangeal joint of the great toe; one sometimes over the interphalangeal joint of the great toe; and occasionally one in the metatarsophalangeal joint of the second toe, the little toe, and, still more rarely, the third and fourth toes.

Those found in the tendons which glide over certain bones occupy the following situations: One sometimes found in the tendon of the *Biceps brachii*, opposite the tuberosity of the radius; one in the tendon of the *Peroneus longus*, where it glides through the groove in the cuboid bone; one appears late in life in the tendon of the *Tibialis anticus*, opposite the smooth facet of the internal cuneiform bone; one is found in the tendon of the *Tibialis posticus*, opposite the inner side of the head of the astragalus; one in the outer head of the *Gastrocnemius*, behind the outer condyle of the femur; and one in the conjoined tendon of the *Psoas* and *Iliacus*, where it glides over the *os pubis*. Sesamoid bones are found occasionally in the tendon of the *Gluteus maximus*, as it passes over the great trochanter, and in the tendons which wind around the inner and outer malleoli.

THE ARTICULATIONS, OR JOINTS.

THE various bones of which the skeleton consists are connected at different parts of their surfaces, and such connections are designated by the name of **joints**, or **articulations**. Certain joints are *immovable*, as all those between the cranial bones excepting the temporomandibular joint. In an immovable joint the adjacent margins of the bones are applied in close contact, a thin layer of fibrous membrane, the **sutural ligament**, or, as at the base of the skull, in certain situations, a thin layer of cartilage, being interposed. Where slight movement is required, combined with great strength, the osseous surfaces are united by tough and elastic **fibrocartilages**, as in the joints between the vertebral bodies and in the interpubic articulation; but in the *movable* joints the bones forming the articulation are generally expanded for greater convenience of mutual connection, covered by hyaline **cartilage**, held together by strong bands or *capsules* of fibrous tissue called **ligaments**, and partially lined by a membrane, the **synovial membrane**, which transudes a fluid to lubricate the various parts of which the joint is formed; so that the structures which enter into the formation of a joint are bone, hyaline cartilage, fibrocartilage, ligament, and synovial membrane.

Bone.—Bone constitutes the fundamental element of all the joints. In the long bones the extremities are the parts which form the articulations; they are generally somewhat enlarged, and consist of spongy, cancellous tissue, with a thin coating of compact substance. The layer of compact bone which forms the articular surface, and to which the cartilage is attached, is called the **articular lamella**. It is of a white color, extremely dense, and varies in thickness. Its structure differs from ordinary bone tissue in this respect, that it contains no Haversian canals, and its lacunæ are much larger than in ordinary bone and have no canaliculi. The vessels of the cancellous tissue, as they approach the articular lamella, turn back in loops, and do not perforate it; this layer is consequently more dense and firmer than ordinary bone, and is evidently designed to form a firm and unyielding support for the articular cartilage. In the flat bones the articulations usually take place at the edges, and, in the short bones, at various parts of their surface.

Cartilage.—There are three varieties of cartilage—*A*, hyaline; *B*, fibrocartilage; and *C*, yellow elastic cartilage; of these, but two, hyaline and fibrocartilage are utilized in the structure of a joint.

In general, cartilage consists of a genetic investing membrane, the **perichondrium**, surrounding the cartilage **substance proper**. The latter consists of the **cellular elements**, or **chondroblasts**, and the **intercellular substance**, or **matrix**.

The **perichondrium** is composed chiefly of white fibrous connective tissue with a few added yellow elastic fibres and cellular elements. The *outer* part contains few cells, and is called the **fibrous layer**. The *inner* part, or **genetic layer**, contains the bloodvessels, and is rich in flattened, elongated, or spindle-shaped cells, the **chondroblasts**.

The **chondroblasts** vary in shape; those immediately beneath the perichondrium are flat and elongated, while those farther in become larger and oval in form. Each cell contains a prominent nucleus embedded in a clear protoplasm that may contain one or more vacuoles. Each cell is sharply outlined, and lies in a space called the **lacuna**, but two or more cells may be seen to occupy the same lacuna. The matrix immediately surrounding the lacuna is somewhat differentiated from the remaining matrix, and is called the **capsule** of the lacuna.

The **matrix** varies in the different varieties of cartilage. In hyaline cartilage it is bluish or pearly in appearance, and under low magnification is apparently homogeneous; in the fibrocartilage the matrix consists mainly of white fibrous tissue arranged in bundles of varying size with islands of hyaline matrix and cartilage cells at intervals; the matrix of elastic cartilage is mainly yellow elastic tissue with islands of hyaline matrix and cartilage cells.

A. Hyaline cartilage is surrounded by its perichondrium, internal to which is found the apparently homogeneous or slightly granular matrix. If the latter be examined by polarized light or be first treated with potassium hydrate, the fundamental fibrillæ are discernible. The fibrils form a meshwork that contains the hyaline substance and cells.

In joints the hyaline cartilage is found as a thin layer covering the articular surfaces of the bones concerned, and is here called **articular cartilage**. In this form the peripheral cells are parallel to the surface; deeper in toward the bone the cells become arranged in rows at right angles to the surface. The latter condition may account for the vertical splitting of articular cartilage that occurs in certain diseases.

Hyaline cartilage is also found in the **costal, tracheal, bronchial, and most of the laryngeal cartilages**. It tends to calcify and even ossify in old age, and upon boiling yields a substance called **chondrin**.

The hyaline cartilage that covers the joint surfaces of the bones, by its elasticity enables it to break the force of any concussion, while its smoothness affords ease and freedom of movement. It varies in thickness according to the shape of the articular surface on which it lies; where this is convex the cartilage is thickest at the centre, where the greatest pressure is received; the reverse is the case on the concave articular surfaces.

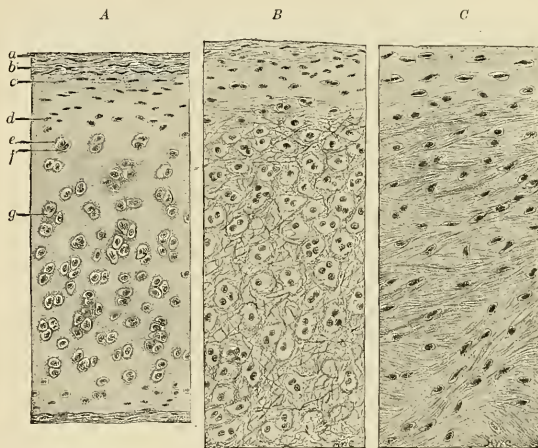


FIG. 213.—Sections of cartilage. A. Hyaline cartilage. a. Fibrous layer of perichondrium. b. Genetic layer of perichondrium. c. Youngest chondroblasts. d. Older chondroblasts. e. Capsule. f. cells. g. Lacuna. B. Elastic cartilage. C. White fibrocartilage. (Radasch.)

B. Fibrocartilage is surrounded by a perichondrium; its **matrix** differs from that of the hyaline variety in consisting chiefly of white fibrous tissue arranged in bundles with little islands of hyaline substance and cells scattered here and there. It is found in the intra-articular cartilages, deepening joint cavities, and in the intervertebral disks. It is arranged in three groups—(1) intra-articular, (2) connecting, and (3) circumferential.

1. The **articular fibrocartilages, or articular disks (menisci articulares)**, are flattened, fibrocartilaginous plates, of a round, oval, triangular, or sickle-like form, interposed between the articular cartilages of certain joints. They are free on both surfaces, thinner toward their centre than at their circumference, and held in position by the attachment of their margins and extremities to the surrounding ligaments. The synovial membrane of the joint is prolonged over them a short distance from their attached margins. They are found in the temporomandibular, sternoclavicular, acromioclavicular, wrist- and knee-joints. These cartilages are

usually found in those joints which are most exposed to violent concussion and subject to frequent movements. Their use is to maintain the apposition of the opposed surfaces in their various motions; to increase the depth of the articular surfaces and give ease to the gliding movement; to moderate the effects of great pressure and deaden the intensity of the shocks to which the parts may be subjected. Humphry has pointed out that these intra-articular fibrocartilages serve an important purpose in increasing the variety of movements in a joint. Thus, in the knee-joint there are two kinds of motion—viz., angular movement and rotation—although it is a hinge-joint, in which, as a rule, only one variety of motion is permitted; the former movement takes place between the condyles of the femur and the articular cartilages, the latter between the cartilages and the head of the tibia. So, also, in the temporomandibular joint, the upward and downward movement of opening and shutting the mouth takes place between the fibrocartilage and the mandible, the grinding movement between the glenoid cavity and the fibrocartilage, the latter moving with the mandible.

Intra-articular cartilages may divide the joint into two distinct cavities, as in the temporomandibular articulation. The periphery of an articular cartilage is attached particularly to the capsule, and may also be attached to the nonarticular portion of the bone. The semilunar cartilages of the knee resemble tendon more than they do cartilage. The fibres are arranged in dense, more or less parallel bundles, separated by small, scattered hyaline cells, and the disks are attached to the bone by thin layers of hyaline cartilage.

2. The **connecting fibrocartilages** are interposed between the bony surfaces of those joints which admit of only slight mobility, as between the bodies of the vertebræ and between the pubic bones. They form disks which adhere closely to both of the opposed surfaces, and are composed of concentric rings of fibrous tissue, with cartilaginous laminae interposed, the former tissue predominating toward the circumference, the latter toward the centre.

3. The **circumferential fibrocartilages** consist of a rim of fibrocartilage, which surrounds the margin of some of the articular cavities, as the cotyloid cavity of the hip and the glenoid cavity of the shoulder; they serve to deepen the articular surface, and to protect its edges.

Elastic cartilage, although not utilized in joints, may be considered here. It is surrounded by a perichondrium, and its matrix differs from the preceding varieties in being composed chiefly of yellow elastic tissue. It is found in the pinna of the ear, Eustachian tube, epiglottis, and small cartilages of the larynx. It does not ossify or calcify.

Cartilage, in the adult, is an avascular tissue, and although vessels at times are seen in the costal cartilages, they do not nourish it, as no branches are given off. Nerves are likewise absent.

Ligaments consist of bands of various forms, serving to connect the articular extremities of bones, and are composed mainly of coarse bundles of very dense, white, fibrous tissue placed parallel with, or closely interlaced with, one another, and presenting a white, shining, silvery aspect. A ligament is pliant and flexible, so as to allow of the most perfect freedom of movement, but it is strong, tough, and inextensible, so as not readily to yield under the most severely applied force; it is consequently well adapted to serve as the connecting medium between the bones. Some ligaments consist entirely of **yellow elastic tissue**, as the ligamenta subflava, which connect together the adjacent arches of the vertebræ in man, and the ligamentum nuchæ in the lower animals are composed of yellow elastic tissue. In these cases it will be observed that the elasticity of the ligament is intended to act as a substitute for muscular power.

Synovial membrane is a thin, delicate, serous membrane, arranged in its simplest form like a short, wide tube, attached by its open ends to the margins of the articular cartilages and covering the inner surfaces of the various ligaments which connect the articulating surfaces, so that, along with cartilages, it completely encloses the joint-cavity. Its transudate is thick, viscid, and glairy, like the white of an egg, hence it is termed **synovia**. It is composed of a single layer of endothelial cells resting upon a thin layer of fibroelastic (subendothelial) tissue. The synovial membranes found in the body admit of subdivision into three kinds—articular, bursal, and vaginal.

Articular synovial membrane is found in every freely movable joint. It lines the capsule of the joint and is reflected upon the nonarticular intracapsular portion of the bones which enter into the formation of the joint. In the fetus this membrane is said, by Toynebee, to

be continued over the surface of the cartilages; but in the adult it merely encroaches for a short distance upon the margins of the cartilages, to which it is firmly attached; it then invests the inner surface of the capsular or other ligaments enclosing the joint, and is reflected over the surface of any tendons passing through its cavity, as the tendons of the Popliteus in the knee and the tendon of the Biceps in the shoulder. In some of the joints the synovial membrane is thrown into folds, which pass across the cavity. They are called **synovial ligaments**, and are especially distinct in the knee. These folds, when large, frequently contain considerable quantities of fat, which acts as a cushion between the two articular surfaces and serves a valuable purpose in filling up gaps. In some joints there are flattened folds, subdivided at their margins into fringe-like processes (**synovial villi**), the vessels of which have a convoluted arrangement. These latter generally project from the synovial membrane near the margin of the cartilage and lie flat upon its surface. They consist of fibroelastic tissue covered with endothelium, and contain fat-cells in variable quantities, and, more rarely, isolated cartilage-cells. Under certain diseased conditions similar processes are found covering the entire surface of the synovial membrane, forming a mass of pedunculated fibrofatty growths which project into the joint. Similar structures are also found in some of the bursal and vaginal synovial membranes.

The **bursal synovial membranes** are sacs interposed between surfaces which move upon each other, producing friction, as in the gliding of a tendon or of the integument over projecting bony surfaces. There are two groups of synovial bursæ designated according to situation: (1) **Subcutaneous synovial bursæ** (*bursae mucosae subcutaneae*) (Fig. 214) are those situated between the integument and a prominent process of bone. Subcutaneous bursæ are found between the integument and the front of the patella, over the olecranon, the malleoli, and other prominent parts. (2) **Subtendinous synovial bursæ** (*bursae mucosae subtendineae*) (Fig. 214) are those situated between tendons or muscles and the bony or cartilaginous surfaces over which the tendons or muscles glide. For example, a bursa is placed between the Glutei muscles and the surface

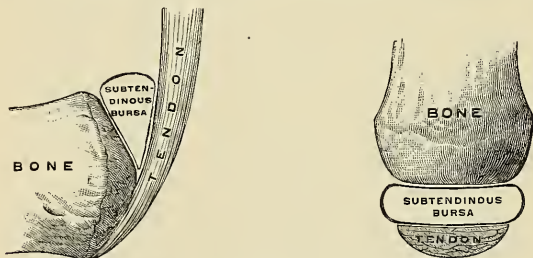


FIG. 214.—Scheme of a serous bursa. (Poirier and Charpy.)

of the great trochanter. Subtendinous bursæ are found often about joints and not unusually communicate directly with the cavity of the joint by means of an opening in the joint capsule, the synovial membrane of the joint being continuous with the synovial membrane of the bursa. For instance, the bursa between the tendon of the Psoas and Iliacus muscles and the capsular ligament of the hip communicates with the hip-joint; and the bursa between the under surface of the Subscapularis muscle and the neck of the scapula communicates with the shoulder-joint. Bursæ consist of a thin wall of connective tissue, lined by endothelial cells, and contain a viscid fluid.

The **vaginal synovial membrane** (Figs. 257 and 365), which is the **synovial sheath** or the **thecal synovial bursa** (*vagina mucosa tendinis*), serves to facilitate the gliding of a tendon in the osseofibrous canal through which it passes. The membrane is here arranged in the form of a sheath, one layer of which adheres to the wall of the canal, and the other is reflected upon the surface of the contained tendon, the space between the two surfaces of the membrane containing synovia. These sheaths are chiefly found surrounding the tendons of the Flexor and Extensor muscles of the fingers and toes as they pass through the osseofibrous canals in the hand or foot. A vaginal sheath covers the long head of the Biceps brachii muscle from its origin to the surgical neck of the humerus (Fig. 247).

Subjacent to the synovial membrane of certain joints are found pads of adipose tissue, the **synovial pads**. These serve to fill up large spaces, and by adapting themselves to changes of position maintain the form of the joint during movement.

The articulations are divided into three classes—**synarthrosis**, or immovable; **amphiarthrosis**, or mixed; and **diarthrosis**, or movable joints.

Synarthrosis (Immovable Articulation).—Synarthrosis includes all those articulations in which the surfaces of the bones are in almost direct contact, being fastened together by an intervening mass of connective tissue, and in which there

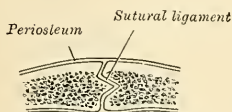


FIG. 215.—Section across the sagittal suture.

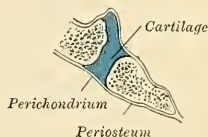

FIG. 216.—Section through the occipitospheonoid synchondrosis of an infant.

is no joint cavity and no appreciable motion. Examples of synarthrosis are the joints between the bones of the cranium and of the face, excepting those of the mandible. The varieties of synarthrosis are four in number—*sutura*, *schindylesis*, *gomphosis*, and *synchondrosis*.

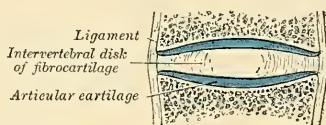


FIG. 217.—Diagrammatic section of a symphysis.

The **sutura** is that form of articulation met with only in the skull, where the contiguous margins of flat bones are apparently but not really in immediate contact, a thin layer of fibrous tissue, **sutural membrane**, being interposed. This membrane is continuous externally with the pericranium and internally with the

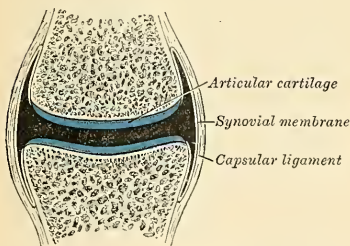


FIG. 218.—Diagrammatic section of a diarthrodial joint.

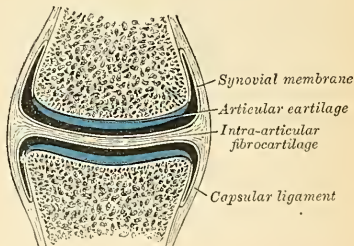


FIG. 219.—Diagrammatic section of a diarthrodial joint, with an intra-articular fibrocartilage.

dura. In some of the sutures the sutural membrane gradually disappears as age advances and the two bones form an osseous fusion. Where the articulating surfaces are connected by a series of processes and indentations interlocked,

it is termed a **true suture**, or *sutura vera*, of which there are three varieties—*sutura dentata*, *serrata*, and *limbosa*. The *sutura dentata* is so called from the tooth-like form of the projecting articular processes, as in the suture between the parietal bones. In the *sutura serrata* the edges of the two bones forming the articulation are serrated like the teeth of a fine saw, as between the two portions of the frontal bone. In the *sutura limbosa* besides the dentated processes, there is a certain degree of bevelling of the articular surfaces, so that the bones overlap each other, as in the suture between the parietal and frontal bones. When the articulation is formed by roughened surfaces placed in apposition with one another, it is termed the **false suture**, of which there are two kinds—the *sutura squamosa*, formed by the overlapping of two contiguous bones by broad bevelled margins, as in the squamoparietal (squamous) suture; and the *sutura harmonia*, where there is simple apposition of two contiguous, rough, bony surfaces, as in the articulation between the two maxillæ or of the horizontal plates of the palate bones.

Schindylesis is that form of articulation in which a thin plate of bone is received into a cleft or fissure formed by the separation of two laminæ in another bone, as in the articulation of the rostrum of the sphenoid and perpendicular plate of the ethmoid with the vomer, or in the reception of the latter in the median fissure between the maxillæ and palate bones.

A **gomphosis** is an articulation formed by the insertion of a conical process into a socket, as a nail is driven into a board; this is not illustrated by any articulation between bones, properly so called, but is seen in the articulation of the teeth with the alveoli of the maxillæ and mandible.

A **synchondrosis** is a joint in which the connecting medium is hyaline cartilage. This is a temporary form of joint, because the hyaline cartilage becomes converted into bone before adult life. Such joints are found between the epiphyses and shafts of long bones, between the occipital and the sphenoid at, and for some years after birth.

Amphiarthrosis (Mixed Articulation).—In this form of articulation the contiguous osseous surfaces are either connected by broad flattened disks of fibro-cartilage which adhere to the end of each bone, as in the articulation between the bodies of the vertebræ, or else the articular surfaces are covered with fibro-cartilage, partially lined by synovial membrane, and connected by external ligaments, as in the pubic symphysis, both of these joints being capable of limited motion.

The articulation between the bodies of the vertebræ resemble the synarthrodial joints in the continuity of their surfaces and the absence of a synovial sac; the symphysis pubis resembles the diarthrodial articulation.

Diarthrosis (Movable Articulation).—This form of articulation includes the greater number of the joints in the body, mobility being their distinguishing character. They are formed by the approximation of two contiguous bony surfaces covered with cartilage, connected by ligaments and lined with synovial membrane. The varieties of joints in this class have been determined by the kind of motion permitted in each. There are two varieties in which the movement is uniaxial; that is to say, all movements take place around one axis. In one form, the **ginglymus**, or **hinge-joint**, this axis is, practically speaking, transverse; in the other, the **trochoid**, or **pivot-joint**, it is longitudinal. There are two varieties where the movement is **biaxial** or around two horizontal axes at right angles to each other or at any intervening axis between the two. These are the **condyloid joint** and the **saddle-joint**. There is one form of joint where the movement is **polyaxial**, the **enarthrosis**, or **ball-and-socket joint**. And finally there are the **arthrodia**, or **gliding joints**. In a diarthrosis there is always a joint cavity lined with synovial membrane—the articular surfaces of the bones are covered with hyaline cartilage, and the bones are held in contact by ligaments.

The **ginglymus**, or **hinge-joint**, is that form of joint in which the articular surfaces are moulded to each other in such a manner as to permit motion only in one plane, forward and backward; the extent of motion at the same time being considerable. The direction which the distal bone takes in this motion is never in the same plane as that of the axis of the proximal bone, and there is always a certain amount of alteration from the straight line during flexion. The articular surfaces are connected together by strong lateral ligaments, which form their chief bond of union. The most perfect forms of ginglymus are the interphalangeal joints.

A **trochoid**, or **pivot-joint** or **rotary joint**, is one in which the movement is limited to rotation; the joint is formed by a pivot-like process turning within a ring, or the ring on the pivot, the ring being formed partly of bone, partly of ligament. In the superior radioulnar articulation the ring is formed partly by the lesser sigmoid cavity of the ulna and in the rest of its extent by the orbicular ligament; here the head of the radius rotates within the ring. In the articulation of the odontoid process of the axis with the atlas the ring is formed in front by the anterior arch of the atlas; behind, by the transverse ligament; here the ring rotates around the odontoid process.

Condylod or **biaxial articulation** is that form of joint in which an ovoid articular head, or condyle, is received into an elliptical cavity in such a manner as to permit of flexion and extension, adduction and abduction and circumduction, but no axial rotation. The articular surfaces are connected together by anterior, posterior, and lateral ligaments. An example of this form of joint is found in the wrist.

Articulation by reciprocal reception, or **saddle-joint**, is that variety in which the articular surfaces are concavo-convex; that is to say, they are inversely convex in one direction and concave in the other. The movements are the same as in the preceding form; that is to say, there is flexion, extension, adduction, abduction, and circumduction, but no axial rotation. The articular surfaces are connected by a capsular ligament. The best example of this form of joint is the carpometacarpal joint of the thumb.

An **enarthrosis**, or **ball-and-socket joint**, is that form of joint in which the distal bone is capable of motion around an indefinite number of axes which have one common centre. It is formed by the reception of a globular head into a deep cup-like cavity, the parts being kept in apposition by a capsular ligament strengthened by accessory ligamentous bands. Examples of this form of articulation are found in the hip- and shoulder-joints.

Arthrodia.—Arthrodia is that form of joint which admits of a gliding movement; it is formed by the approximation of plane surfaces or of one slightly concave to one slightly convex, the amount of motion between them being limited by the ligaments, or osseous processes, surrounding the articulation; as in the articular processes of the vertebræ, the carpal joints, except that of the os magnum with the scaphoid and semilunar bones.

Below, in tabular form, are the names, distinctive characters, and examples of the different kinds of articulations:

<i>Synarthrosis</i> , or Im- movable Joint. Sur- faces separated by fibrous membrane or by a line of cartilage, without any interven- ing synovial cavity, and immovably con- nected with each other.	{	<i>Sutura</i> . Artic- ulation by processes and indentations interlocked.	{	<i>Dentata</i> , having tooth- like processes. As in interparietal suture.
				<i>Serrata</i> , having serrated edges like the teeth of a saw. As in interfrontal suture.
	{	<i>Sutura vera</i> (true) articulate by indent- ed borders.	{	<i>Limbose</i> , having bevelled margins and dentated pro- cesses. As in frontoparietal su- ture.
				<i>Squamosa</i> , formed by thin bevelled margins, over- lapping each other. As in squamoparietal suture.
<i>Amphiarthrosis</i> , Mixed Articulation.	{	<i>Sutura notha</i> (false), articulate by rough surfaces.	{	<i>Harmonia</i> , formed by the apposition of contigu- ous rough surfaces. As in intermaxillary su- ture.
	{	<i>Schindylcsis</i> .—Articulation formed by the reception of a thin plate of one bone into a fissure of another.	{	
	{	<i>Gomphosis</i> .—Articulation formed by the insertion of a conical process into a socket—the teeth.	{	
	{	<i>Synchondrosis</i> —(1) Surfaces connected by fibrocartilage and not separated by synovial membrane. Has limited motion. As in joints between bodies of vertebræ.	{	
	{	(2) Surfaces covered by fibrocartilage, lined by partial synovial membrane. As in pubic symphysis.	{	
	{	<i>Ginglymus</i> .—Hinge-joint; motion limited to two directions, for- ward and backward. Articular surfaces fitted together so as to permit of movement in one plane. As in the interphalangeal joints.	{	
	{	<i>Trochoid, or Pivot-joint</i> .—Articulation by a pivot process turning within a ring or ring around a pivot. As in superior radioulnar articu- lation and atlanto-axial joint.	{	
<i>Diarthrosis</i> , Movable Joint.	{	<i>Condyloid</i> .—Ovoid head received into elliptical cavity. Movements in every direction except axial rotation. As the wrist-joint.	{	
	{	<i>Reciprocal Reception</i> (saddle-joint).—Articular surfaces inversely con- vex in one direction and concave in the other. Movement in every direction except axial rotation. As in the carpometacarpal joint of the thumb.	{	
	{	<i>Enarthrosis</i> .—Ball-and-socket joint; capable of motion in all directions. Articulations by a globular head received into a cup-like cavity. As in hip- and shoulder-joints.	{	
	{	<i>Arthrodia</i> .—Gliding joint; articulations by plane surfaces, which glide upon each other. As in carpal and tarsal articulations.	{	

The Kinds of Movement Admitted in Joints.

The movements admissible in the joints may be divided into four kinds—gliding, angular movement, circumduction, and rotation. These movements are often, however, more or less combined in the various joints, so as to produce an infinite variety, and it is seldom that we find only one kind of motion in any particular joint.

Gliding movement is the most simple kind of motion that can take place in a joint, one surface gliding or moving over another without any angular or rotatory movement. It is common to all movable joints, but in some, as in the articulations of the carpus and tarsus, it is the only motion permitted. This movement is not confined to plane surfaces, but may exist between any two contiguous

surfaces, of whatever form, limited by the ligaments which enclose the articulation. Gliding over a wide range, as is seen in the sliding of the patella over the condyles of the femur, is called **coaptation**.

Angular movement occurs only between the long bones, and by it the angle between the two bones is increased or diminished. It may take place in four directions—forward and backward, constituting **flexion** or **bending** and **extension** or **straightening**, or inward toward and outward from the medial line of the body, constituting **adduction** and **abduction**. Abduction of a limb is movement away from the medial line of the body. Adduction of a limb is movement toward the medial line of the body. In the fingers and toes the significance of the terms are different; abduction means movement of the fingers away from the middle finger or of the toe away from the second toe; adduction means movement of fingers toward the middle finger or of the toes toward the second toe. The strictly ginglymoid or hinge-joints admit of flexion and extension only. Abduction and adduction, combined with flexion and extension, are met with in the more movable joints; as in the hip-, shoulder-, and metacarpal-joint of the thumb, and partially in the wrist. When two anterior surfaces are brought nearer together, as by bending the elbow or wrist, we speak of the movement as **anterior** or **ventral flexion**. Ventral flexion of the wrist is also called **volar** or **palmar flexion**. If two posterior surfaces are brought nearer together, as by bending the knee or extending the wrist, we speak of the movement as **posterior** or **dorsal flexion**.

At the wrist-joint the bending of the ulnar margin of the hand toward the ulnar side of the forearm is **ulnar flexion**; the bending of the radial margin of the hand toward the radial side of the forearm is **radial flexion**.

Circumduction is that limited degree of motion which takes place between the head of the bone and its articular cavity, while the extremity and sides of the limb are made to circumscribe a conical space, the base of which corresponds with the inferior extremity of the limb, the apex with the articular cavity; this kind of motion is best seen in the shoulder- and hip-joints.

Rotation is the movement of a bone upon an axis, which is the axis of the pivot on which the bone turns, as in the articulation between the atlas and axis, when the odontoid process serves as a pivot around which the atlas turns; or else is the axis of a pivot-like process which turns within a ring, as in the rotation of the radius upon the humerus.

Ligamentous Action of Muscles.—The movements of the different joints of a limb are combined by means of the long muscles which pass over more than one joint, and which, when relaxed and stretched to their greatest extent, act as elastic ligaments in restraining certain movements of one joint, except when combined with corresponding movements of the other, these latter movements being usually in the opposite direction. Thus, the shortness of the Hamstring muscles prevents complete flexion of the hip, unless the knee-joint is also flexed, so as to bring their attachments nearer together. The uses of this arrangement are threefold: (1) It coördinates the kinds of movement which are the most habitual and necessary, and enables them to be performed with the least expenditure of power. "Thus, in the usual gesture of the arms, whether in grasping or rejecting, the shoulder and the elbow are flexed simultaneously, and simultaneously extended," in consequence of the passage of the Biceps and Triceps brachii over both joints. (2) It enables the short muscles which pass over only one joint to act upon more than one. "Thus, if the Rectus femoris remain tonically of such length that, when stretched over the extended hip, it compels extension of the knee, then the Gluteus maximus becomes not only an extensor of the hip, but an extensor of the knee as well." (3) It provides the joints with ligaments which, while they are of very great power in resisting movements to an extent incompatible with the mechanism of the joint, at the same time spontaneously yield when necessary. "Taxed beyond its strength, a ligament will be ruptured, whereas a contracted muscle is easily relaxed; also, if neighboring joints be united by ligaments, the amount of flexion or extension of each must remain in constant proportion to that of the other; while, if the union be by muscles, the separation of the points of attachment of those muscles may vary considerably in different varieties of movement, the muscles adapting themselves tonically to the length required."¹ Dr. W. W. Keen points out how important it is "that the surgeon should remember this ligamentous action of

¹ Dr. Cleland, in *Journal of Anatomy and Physiology*, 1866, No. 1, p. 85.

muscles in making passive motion—for instance, at the wrist after Colles' fracture. If the fingers be extended, the wrist can be flexed to a right angle. If, however, they be first flexed, as in 'making a fist,' flexion at the wrist is strictly limited to from 40 to 50 degrees in different persons, and is very painful beyond that point. Hence, passive motion here should be made with the fingers extended. In the leg, when flexing the hip, the knee should be flexed." Dr. Keen further points out that "a beautiful illustration of this is seen in the perching of birds, whose toes are forced to clasp the perch by just such a passive ligamentous action so soon as they stoop. Hence, they can go to sleep and not fall off the perch."

The articulations may be arranged into those of the trunk, those of the upper extremity, and those of the lower extremity.

ARTICULATIONS OF THE TRUNK.

These may be divided into the following groups, viz.:

- | | |
|--------------------------------------------|--------------------------------------------------------------------------|
| I. Of the Vertebral Column. | VII. Of the Cartilages of the Ribs with the Sternum and with Each Other. |
| II. Of the Atlas with the Axis. | VIII. Of the Sternum. |
| III. Of the Atlas with the Occipital Bone. | IX. Of the Vertebral Column with the Pelvis. |
| IV. Of the Axis with the Occipital Bone. | X. Of the Pelvis. |
| V. Of the Mandible. | |
| VI. Of the Ribs with the Vertebrae. | |

I. Articulations of the Vertebral Column.

The different segments of the vertebral column are connected by **spinal ligaments** (*ligamenta columnae vertebralis*), which may be divided into five sets: (1) Those connecting the **bodies** of the vertebrae. (2) Those connecting the **laminæ**. (3) Those connecting the **articular processes**. (4) Those connecting the **spinous processes**. (5) Those of the **transverse processes** (the last four kinds being known as *interneural*).

The articulations of the bodies of the vertebrae with each other form a series of amphiarthrodial joints; those between the articular processes form a series of arthrodial joints.

1. LIGAMENTS OF THE VERTEBRAL BODIES OR CENTRA (INTERCENTRAL LIGAMENTS).

- Anterior Common Ligament.
- Posterior Common Ligament.
- Intervertebral Substance.

The **anterior common ligament** (*ligamentum longitudinale anterius*) (Figs. 222, 225, and 228) is a broad and strong band of longitudinal fibres which extends along the anterior (*ventral*) surface of the bodies of the vertebrae from the axis to the sacrum. It is broader below than above, thicker in the thoracic than in the cervical or lumbar regions, and somewhat thicker opposite the front of the body of each vertebra than opposite the intervertebral substance. It is attached, above, to the body of the axis by a pointed process, where it is continuous with the anterior atlanto-axial ligament, is connected with the tendon of insertion of the Longus colli muscle, and extends down as far as the upper bone of the sacrum. It consists of dense longitudinal fibres, which are intimately adherent to the intervertebral substance and the prominent margins of the vertebrae, but less

closely to the middle of the bodies. In the latter situation the fibres are exceedingly thick, and serve to fill up the concavities on their front surface and to make the anterior surface of the vertebral column more even. This ligament is composed of several layers of fibres, which vary in length, but are closely interlaced with each other. The most superficial or longest fibres extend between four or five vertebrae. A second subjacent set extends between two or three vertebrae, while a third set, the shortest and deepest, extends from one vertebra to the next. At the side of the bodies the ligament consists of a few short fibres, which pass from one vertebra to the next, separated from the median portion by large oval apertures for the passage of vessels.

The **posterior common ligament** (*ligamentum longitudinale posterius*) (Figs. 227 and 228) is situated within the vertebral canal, and extends along the posterior (dorsal) surface of the bodies of the vertebrae from the body of the axis above, where

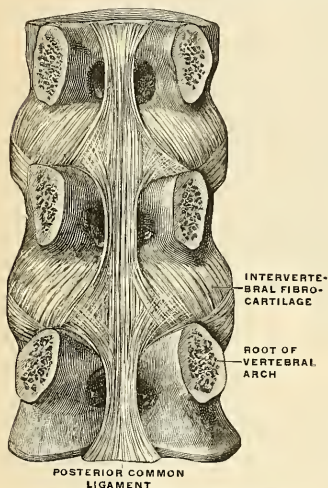


Fig. 220.—Vertebral bodies with ligaments, from behind. (Spalteholz.)

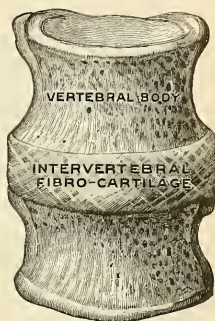


Fig. 221.—Intervertebral disk, with the adjacent vertebral bodies, from in front. (Spalteholz.)

it is continuous with the posterior occipito-axial ligament, to the sacrum below. It is broader above than below, and thicker in the thoracic than in the cervical or lumbar regions. In the situation of the intervertebral substance and contiguous margins of the vertebrae, where the ligament is more intimately adherent, it is broad, and presents a series of dentations with intervening concave margins; but it is narrow and thick over the centre of the bodies, from which it is separated by the *venæ basis vertebrae*. This ligament is composed of smooth, shining, longitudinal fibres, denser and more compact than those of the anterior ligament, and formed of a superficial layer occupying the interval between three or four vertebrae, and of a deeper layer which extends between one vertebra and the next adjacent to it. It is separated from the dura of the spinal cord by loose connective tissue.

The **Intervertebral Fibrocartilages** (*fibrocartilagines intervertebrales*) (Figs. 221 and 222).—Each fibrocartilaginous disk is of lenticular form and of composite structure. The disks are interposed between the adjacent surfaces of the bodies of the vertebrae from the axis to the sacrum, and form the chief bonds of connection between those bones. In young children intervertebral substance exists in the coccyx. These disks vary in shape, size, and thickness in different parts of the vertebral column. In shape they accurately correspond with the surfaces of the bodies between which they are placed, being oval in the cervical and lumbar regions, and circular in the thoracic. Their size is greatest in the lumbar region.

In thickness they vary not only in the different regions of the vertebral column, but in different parts of the same disk; thus, they are thicker in front than behind in the cervical and lumbar regions, while they are uniformly thick in the thoracic region. The intervertebral disks form about one-fourth of the vertebral column, exclusive of the first two vertebræ; they are not equally distributed, however, between the various bones; the thoracic portion of the vertebral column having, in proportion to its length, a much smaller quantity than in the cervical and lumbar

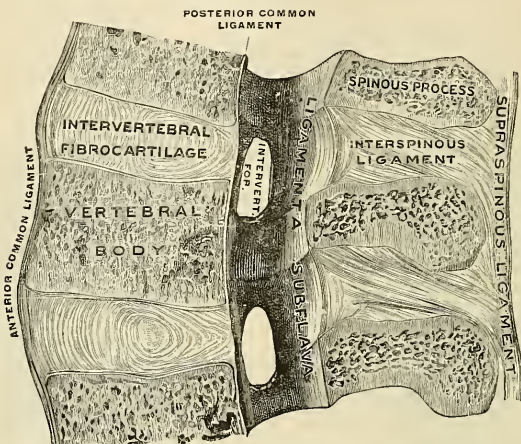


FIG. 222.—Median section of a piece of the lumbar vertebral column, right half of section viewed from the left. (Spalteholz.)

regions, which necessarily gives to the latter parts greater pliancy and freedom of movement. The intervertebral disks are adherent, by their surfaces, to a thin layer of hyaline cartilage which covers the upper and under surfaces of the bodies of the vertebræ, and in which, in early life, the epiphyseal plates develop, and by their circumference are closely connected in front to the anterior, and behind to the posterior common ligament; while in the thoracic region they are connected laterally, by means of the interarticular ligament, to the heads of those ribs which articulate with two vertebræ; they, consequently, form part of the articular cavities in which the heads of these bones are received.

Structure of the Intervertebral Substance.—The outer portion of the intervertebral substance is composed of many layers of fibrous connective tissue. This enveloping portion is called the **annulus fibrosus**. The central portion of the disk is composed of soft, pulpy, highly elastic fibrocartilage, containing some bands of connective tissue. It is called the **nucleus pulposus**, is of a yellowish color, and rises up considerably above the surrounding level when the disk is divided horizontally. This pulpy substance, which is especially well developed in the lumbar region, is the remains of the notochord, and, according to Luschka, contains a small synovial cavity in its centre. The outer layers of the disk are arranged concentrically one within the other, the outermost consisting of ordinary fibrous tissue, but the others and more numerous consisting of white fibrocartilage. These plates are not quite vertical in their direction, those near the circumference being curved outward and closely approximated; while those nearest the centre curve in the opposite direction, and are somewhat more widely separated. The fibres of which each plate is composed are directed, for the most part, obliquely from above downward, the fibres of adjacent plates passing in opposite directions and varying in every layer; so that the fibres of one layer are directed across those of another, like the limbs of the letter X. This laminar arrangement belongs to about the outer half of each disk. The pulpy substance presents no concentric arrangement, and consists of a fine fibrous matrix, containing angular cells, united to form a reticular

structure. J. Bland Sutton¹ calls attention to the fact that in the human fetus a transverse ligamentous band crosses the dorsal aspect of the intervertebral disk and is continuous with the interosseous ligaments of the heads of the ribs; and also that a fetal ligamentous band exists in the ventral surface of the intervertebral disk which, after development, becomes the middle fasciculus of the stellate ligament. These bands are named by Sutton the **posterior conjugal ligaments** and the **anterior conjugal ligaments**.

Interneural articulations include the ligaments of the laminæ; articular processes, spinous processes, and transverse processes.

2. LIGAMENTS CONNECTING THE LAMINÆ.

Ligamenta Subflava.

The **ligamenta subflava** (*ligamenta intercruralia*) (Figs. 222 and 223) are interposed between the laminæ of the vertebræ, from the axis to the sacrum. They are most distinct when seen from the interior of the vertebral canal; when viewed from the outer surface they appear short, being overlapped by the laminæ. Each ligamentum subflavum consists of two lateral portions, which commence on each side at the root of either articular process, and pass backward to the point where the laminæ converge to form the spinous process, where their margins are in contact and to a certain extent united; slight intervals being left for the passage of small vessels. These ligaments consist of yellow elastic tissue, the fibres of which, almost perpendicular in direction, are attached to the anterior surface of the laminæ above, some distance from its inferior margin, and to the posterior surface, as well as to the margin of the lamina below. In the cervical region they are thin in texture, but very broad and long; they become thicker in the thoracic region, and in the lumbar acquire very considerable thickness. Their highly elastic property serves to preserve the upright posture and to assist in resuming it after the spine has been flexed. These ligaments do not exist between the occiput and atlas or between the atlas and axis.

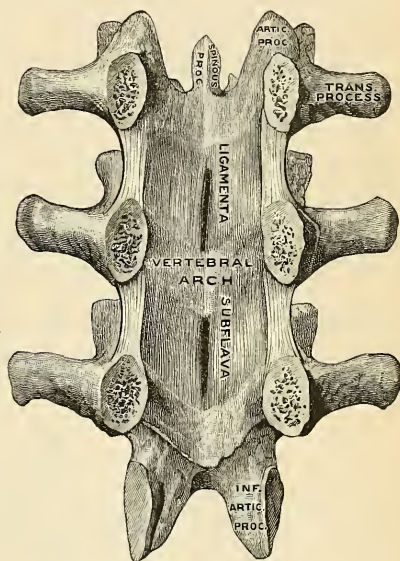


FIG. 223.—Vertebral arches with ligamenta flava. (Spalteholz.)

3. LIGAMENTS CONNECTING THE ARTICULAR PROCESSES.

Capsular Ligaments.

The **capsular ligaments** (*capsulae articulares*) (Fig. 225) are thin and loose ligamentous sacs, attached to the contiguous margins of the articulating processes

¹ Ligaments: Their Nature and Morphology, 1887.

of each vertebra through the greater part of their circumference, and completed internally by the ligamenta subflava. They are longer and looser in the cervical than in the thoracic or lumbar regions. The capsular ligaments are lined on their inner surface with synovial membrane.

4. LIGAMENTS CONNECTING THE SPINOUS PROCESSES.

Supraspinous Ligament.

Ligamentum Nuchae.

Interspinous Ligaments.

The **supraspinous ligament** (*ligamentum supraspinale* (Fig. 222) is a strong fibrous cord, which connects the apices of the spinous processes from the seventh cervical to the spinous processes of the sacrum. It is thicker and broader in the lumbar than in the thoracic region, and intimately blended, in both situations, with the neighboring aponeurosis. The most superficial fibres of this ligament connect three or four vertebrae; those deeper-seated pass between two or three vertebrae; while the deepest connect the contiguous extremities of neighboring vertebrae. It is continued upward to the external occipital protuberance as the ligamentum nuchae.

The **ligamentum nuchae** is a fibrous membrane which, in the neck, represents the supraspinous ligaments of the lower vertebrae. It extends from the external occipital protuberance and crest to the spinous process of the seventh cervical vertebra. From its anterior border a fibrous lamina is given off, which is attached to the posterior tubercle of the atlas, and to the spinous processes of all the cervical vertebrae, so as to form a septum between the muscles on either side of the neck. In man it is merely a rudiment of an important elastic band which, in some of the lower animals, serves to sustain the weight of the head.

The **interspinous ligaments** (*ligamenta interspinalia*) (Fig. 222), thin and membranous, are interposed between the spinous processes. Each ligament extends from the root to the summit of each spinous process and connects their adjacent margins. They meet the ligamenta subflava in front and the supraspinous ligament behind. They are narrow and elongated in the thoracic region; broader, quadrilateral in form, and thicker in the lumbar region; and only slightly developed in the neck.

5. LIGAMENTS CONNECTING THE TRANSVERSE PROCESSES.

Intertransverse Ligaments.

The **intertransverse ligaments** (*ligamenta intertransversaria*) (Fig. 235) consist of bundles of fibres interposed between the transverse processes. In the cervical region they consist of a few irregular, scattered fibres; in the thoracic, they are rounded cords intimately connected with the deep muscles of the back; in the lumbar region they are thin and membranous.

Movements of the Vertebral Column.—The movements permitted in the vertebra column are *flexion, extension, lateral movement, circumduction, and rotation.*

In **flexion** (*forward flexion*), or movement of the vertebral column forward, the anterior common ligament is relaxed, and the intervertebral substances are compressed in front, while the posterior common ligament, the ligamenta subflava, and the inter- and supraspinous ligaments are stretched, as well as the posterior fibres of the intervertebral disks. The interspaces between the laminae are widened, and the inferior articular processes of the vertebrae above glide upward upon the articular processes of the vertebrae below. Flexion is the most extensive of all the movements of the vertebral column.

In **extension** (*backward flexion*), or movement of the vertebral column backward, an exactly opposite disposition of the parts take place. This movement is not extensive, being limited by the anterior common ligament and by the approximation of the spinous processes.

Flexion and extension are greatest in the lower part of the lumbar region between the third and fourth and fourth and fifth lumbar vertebrae; above the third they are much diminished, and reach their minimum in the middle and upper part of the back. They increase again in the neck, the capability of motion backward from the upright position being in this region greater than that of the motion forward, whereas in the lumbar region the reverse is the case.

In **lateral flexion**, the sides of the intervertebral disks are compressed, the extent of motion being limited by the resistance offered by the surrounding ligaments and by the approximation of the transverse processes. This movement may take place in any part of the vertebral column, but has the greatest range in the neck and loins.

Circumduction is limited, and is produced merely by a succession of the preceding movements.

Rotation is produced by the twisting of the intervertebral substances; this, although only slight between any two vertebrae, produces a considerable extent of movement when it takes place in the whole length of the vertebral column, the front of the upper part of the column being turned to one or the other side. This movement takes place only to a slight extent in the neck, but is more pronounced in the upper part of the thoracic region, and is altogether absent in the lumbar region. It is thus seen that the *cervical region* enjoys the greatest extent of each variety of movement, flexion and extension, especially, being very extensive. In the *thoracic region* the three movements of flexion, extension, and circumduction are permitted only to a slight extent, while rotation is very extensive in the upper part and ceases below. In the lumbar region there is extensive flexion, extension, and lateral movement, but no rotation.

The movements permitted are mainly due to the shape and position of the articulating processes. In the loins the inferior articulating processes are turned outward and are embraced by the superior; this renders rotation in this region of the vertebral column impossible, while there is nothing to prevent a sliding upward and downward of the surfaces on each other, so as to allow of flexion and extension. In the thoracic region, on the other hand, the articulating processes, by their direction and mutual adaptation, especially at the upper part of the series, permit of rotation, but prevent extension and flexion, while in the cervical region the greater obliquity and lateral slant of the articular processes allow not only flexion and extension, but also rotation.

The principal muscles which produce *flexion* are the Sternomastoid, Rectus capitis anticus major, and Longus colli; the Scaleni; the abdominal muscles and the Psoas magnus. *Extension* is produced by the fourth layer of the muscles of the back, assisted in the neck by the Splenius, Semispinales dorsi et colli, and the Multifidus spinae. *Lateral motion* is produced by the fourth layer of the muscles of the back, by the Splenius and the Scaleni, the Quadratus lumborum and Psoas magnus, the muscles of one side only acting; and *rotation* by the action of the following muscles of one side only—viz., the Sternomastoid, the Rectus capitis anticus major, the Scaleni, the Multifidus spinae, the Complexus, and the abdominal muscles.

II. Articulation of the Atlas with the Axis (Articulatio Atlantoepistrophica).

The articulation of the atlas with the axis is of a complicated nature, comprising no fewer than four distinct joints. There is a pivot articulation between the odontoid process of the axis and the ring formed between the anterior arch of

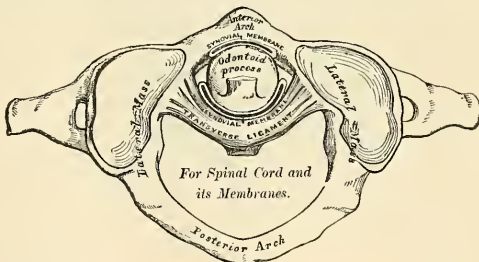


FIG. 224.—Articulation between odontoid process and atlas.

the atlas and the transverse ligament (Fig. 224). Here there are two joints—one in front between the posterior surface of the anterior arch of the atlas and the front

of the odontoid process (atlanto-odontoid joint); the other between the anterior surface of the transverse ligament and the back of the process (syndesmo-odontoid joint). Between the articular processes of the two bones there is a double arthroidal or gliding joint. The ligaments which connect these bones are the

Anterior Atlanto-axial.
Posterior Atlanto-axial.

Transverse.
Two Capsular.

The **anterior atlanto-axial ligament** (Figs. 225 and 228) is a strong, membranous layer, attached, *above*, to the lower border of the anterior arch of the atlas; *below*, to the base of the odontoid process and to the front of the body of the axis. It is strengthened in the middle line by a rounded cord, which is attached, *above*, to the tubercle on the anterior arch of the atlas, and *below* to the body of the axis, being a continuation upward of the anterior common ligament of the vertebral column. The ligament is in relation, in front, with the *Recti antici majores*.

The **posterior atlanto-axial ligament** (Figs. 225 and 228) is a broad and thin membranous layer, attached, *above*, to the lower border of the posterior arch of the atlas; *below*, to the upper edge of the laminae of the axis. This ligament supplies the place of the ligamenta subflava, and is in relation, behind, with the *Inferior oblique* muscles.

The **transverse ligament of the atlas**¹ (*ligamentum transversum atlantis*) (Figs. 227 and 228) is a thick, strong band, which arches across the ring of the atlas, and serves to retain the odontoid process in firm connection with its anterior

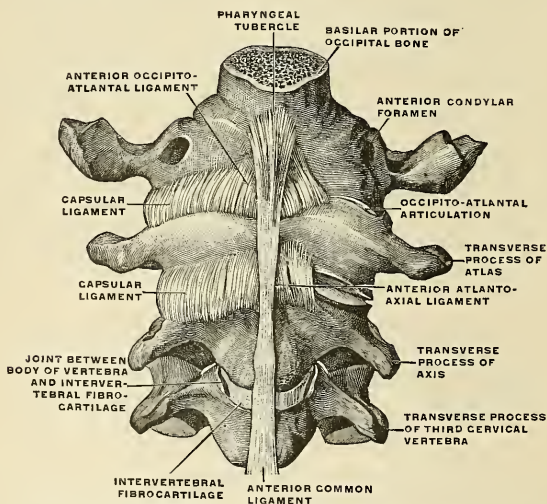


FIG. 225.—Occipital bone and first three cervical vertebrae with ligaments, from in front. (Spalteholz.)

arch. This ligament is flattened from before backward, broader and thicker in

¹ It has been found necessary to describe the transverse ligament with those of the atlas and axis; but the student must remember that it is really a portion of the mechanism by which the movements of the head on the vertebral column are regulated; so that the connections between the atlas and axis ought always to be studied together with those between the latter bones and the skull.

the middle than at either extremity, and firmly attached on each side to a small tubercle on the inner surface of the lateral mass of the atlas. As it crosses the odontoid process, a small fasciculus is derived from its upper, and another from its lower border; the former passing upward, to be inserted into the anterior surface of the foramen magnum of the occipital bone; the latter, downward, to be attached to the posterior surface of the body of the axis; hence, the whole ligament has received the name of **cruciform ligament** (*ligamentum cruciatum atlantis*). A synovial surface is interposed between the odontoid process and the transverse ligament, and one is placed between the anterior surface of the odontoid process and the anterior arch of the atlas. The transverse ligament divides the vertebral foramen of the atlas into two unequal compartments; of these, the posterior and larger serves for the transmission of the cord and its membranes and the spinal accessory nerves; the anterior and smaller contains the odontoid process. Since the space between the anterior arch of the atlas and the transverse ligament is smaller at the lower part than the upper (because the transverse ligament embraces tightly the narrow neck of the odontoid process), this process is retained in firm connection with the atlas after all the other ligaments have been divided.

The **capsular ligaments** (*capsulae articulares*) (Figs. 226 and 227) are two thin and loose capsules, connecting the lateral masses of the atlas with the superior articular surfaces of the axis, the fibres being strengthened at the posterior and inner part of each articulation by an **accessory ligament**, which is attached below to the body of the axis near the base of the odontoid process.

Synovial Membranes (Fig. 224).—There are *four* synovial membranes in this articulation—one lining the inner surface of each of the capsular ligaments; one between the anterior surface of the odontoid process and the anterior arch of the atlas; and one between the posterior surface of the odontoid process and the transverse ligament. The latter often communicates with those between the condyles of the occipital bone and the articular surfaces of the atlas.

Movements.—This joint allows the rotation of the atlas (and, with it, of the cranium) upon the axis, the extent of rotation being limited by the odontoid ligaments.

The principal muscles by which this action is produced are the Sternomastoid and Complexus of one side, acting with the Rectus capitis anticus major, Splenius, Trachelomastoid, Rectus capitis posticus major, and Inferior oblique of the other side.

ARTICULATIONS OF THE VERTEBRAL COLUMN WITH THE CRANIUM.

The ligaments connecting the vertebral column with the cranium may be divided into two sets—those connecting the occipital bone with the atlas, and those connecting the occipital bone with the axis.

III. Articulation of the Atlas with the Occipital Bone (Articulatio Atlanto-occipitalis).

This articulation is a double condyloid joint. Its ligaments are the

Anterior Occipito-atlantal.	Posterior Occipito-atlantal.
Two Capsular.	

The **anterior occipito-atlantal ligament** (*membrana atlantooccipitalis anterior*) (Figs. 225 and 228) is a broad membranous layer, composed of densely woven fibres, which passes between the anterior margin of the foramen magnum above, and the whole length of the upper border of the anterior arch of the atlas below. Laterally, it is continuous with the capsular ligaments. In the middle line in

front it is strengthened by a strong, narrow, rounded cord, which is attached, above, to the basilar process of the occiput, and, below, to the tubercle on the anterior arch of the atlas, and which is a continuation of the anterior common ligament. This ligament is in relation, in *front*, with the Recti antici minores; *behind*, with the odontoid ligaments.

The **posterior occipito-atlantal ligament** (*membrana atlanto-occipitalis posterior*, posterior occipito-atloid ligament) (Figs. 226 and 228) is a very broad but thin membranous lamina intimately blended with the dura. It is connected, *above*, to the posterior margin of the foramen magnum; *below*, to the upper border of the posterior arch of the atlas. This ligament is incomplete at each side, and forms, with the groove in the upper surface of the posterior arch, an opening for the vertebral artery and suboccipital nerve. The fibrous band which arches over the artery and nerve sometimes becomes ossified. The ligaments are in relation, *behind*, with the Recti postici minores and Obliqui superiores; in *front*, with the dura of the vertebral canal, to which they are intimately adherent.

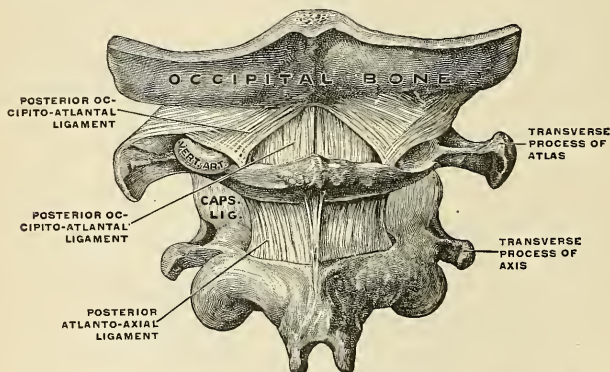


FIG. 226.—Occipital bone, first and second cervical vertebrae with ligaments from behind. (Spalteholz.)

The **capsular ligaments** (*capsulae articulares*) (Fig. 227) surround the condyles of the occipital bone, and connect them with the articular processes of the atlas; they consist of thin and loose capsules, which enclose the synovial membranes of the articulations.

Synovial Membranes.—There are *two* synovial membranes in this articulation, one lining the inner surface of each of the capsular ligaments. These occasionally communicate with that between the posterior surface of the odontoid process and the transverse ligament.

Movements.—The movements permitted in this joint are flexion and extension, which give rise to the ordinary forward and backward nodding of the head. Slight lateral motion to one or the other side may also take place. When either of these actions is carried beyond a slight extent, the whole of the cervical portion of the spine assists in its production. *Flexion* is mainly produced by the action of the Rectus capitis anticus major et minor and the Sternomastoid muscles; *extension* by the Rectus capitis posticus major et minor, the Obliquus superior, the Complexus, Splenius, and upper fibres of the Trapezius. The Recti laterales are concerned in the lateral movement, assisted by the Trapezius, Splenius, Complexus, and the Sternomastoid of the same side, all acting together. According to Cruveilhier, there is a slight amount of rotation in this joint.

IV. Articulation of the Axis with the Occipital Bone.

The ligaments of this articulation are the

Occipito-axial.

Three Odontoid.

To expose these ligaments the vertebral canal should be laid open by removing the posterior arch of the atlas, the laminae and spinous process of the axis, and the portion of the occipital bone behind the foramen magnum, as seen in Fig. 227.

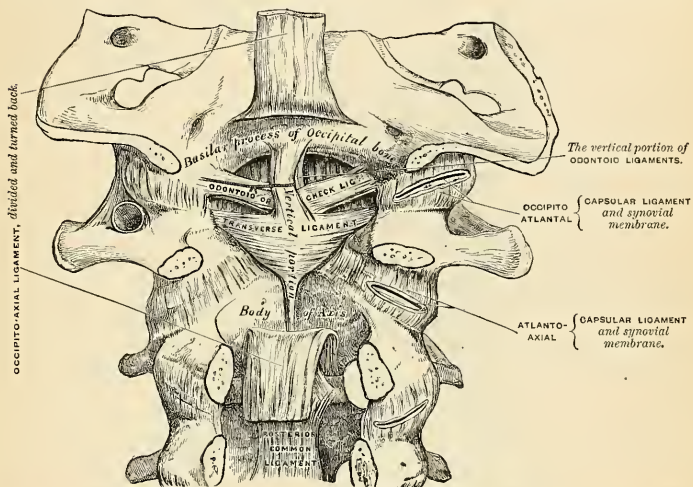


FIG. 227.—Occipito-axial and atlanto-axial ligaments. Posterior view, obtained by removing the arches of the vertebrae and the posterior part of the skull.

The **posterior occipito-axial ligament** (*membrana tectoria*) (Figs. 227 and 228) is situated within the vertebral canal. It is a broad, strong band, which covers the odontoid process and its ligaments, and appears to be a prolongation upward of, or a membrane due to fusion with, the posterior common ligament of the spine. It is attached, below, to the posterior surface of the body of the axis, and, becoming expanded as it ascends, is inserted into the basilar groove of the occipital bone, in front of the foramen magnum, where it becomes blended with the dura of the skull.

Relations.—By its *anterior surface* with the transverse ligament; by its *posterior surface* with the posterior common ligament.

The **lateral odontoid ligaments** (*ligamenta alaria*) (Figs. 227 and 228) are strong, rounded, fibrous cords, which arise one on either side of the upper part of the odontoid process, and, passing obliquely upward and outward, are inserted into the rough depressions on the inner side of the condyles of the occipital bone. In the triangular interval left between these ligaments another strong fibrous

cord, the **middle odontoid ligament** (*ligamentum apicis dentis*), may be seen, which passes almost perpendicularly from the apex of the odontoid process to the anterior margin of the foramen magnum, being intimately blended with the deep portion of the anterior occipito-atlantal ligament and upper fasciculus of the transverse ligament of the atlas.

Movements.—The odontoid ligaments serve to limit the extent to which rotation of the cranium may be carried; hence, they have received the name of *check ligaments*.

In addition to these ligaments, which connect the atlas and axis to the skull, the ligamentum nuchæ must be regarded as one of the ligaments by which the vertebral column is connected with the cranium. It is described on page 272.

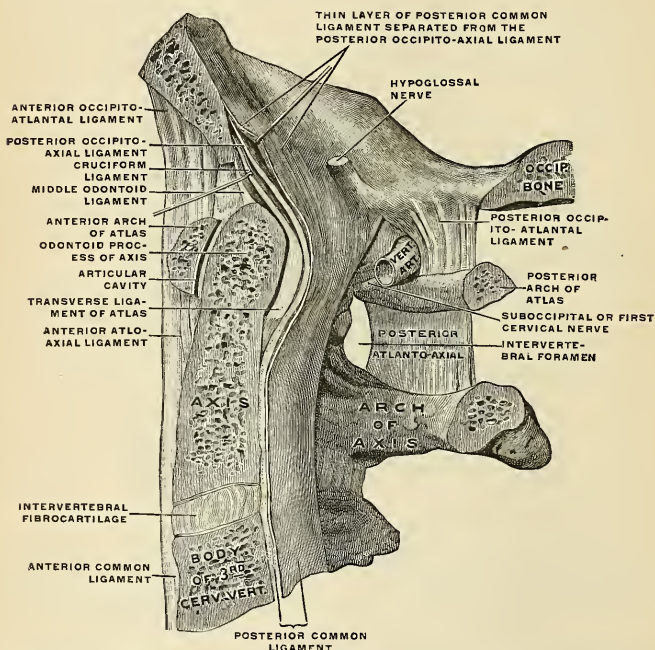


FIG. 228.—Median sagittal section through the occipital bone and first three cervical vertebrae with ligaments. (Spalteholz).

Applied Anatomy.—The ligaments which unite the component parts of the vertebrae together are so strong, and these bones are so interlocked by the arrangement of their articulating processes, that *dislocation* is very uncommon, and, indeed, unless accompanied by *fracture*, seldom occurs, except in the upper part of the neck. Dislocation of the occiput from the atlas has only been recorded in one or two cases; but dislocation of the atlas from the axis, with rupture of the transverse ligament, is much more common; it is the mode in which death is produced in some cases of execution by hanging. In the lower part of the neck—that is, below the third cervical vertebra—dislocation unattended by fracture occasionally takes place.

V. Temporomandibular Articulation (*Articulatio Mandibularis*).

This is a **ginglymo-arthro**dial joint; the parts entering into its formation on each side are, *above*, the anterior part of the glenoid cavity of the temporal bone and the eminentia articularis; and, *below*, the condyle of the mandible. The ligaments are the following:

External Lateral.

Internal Lateral.

Stylomandibular.

Capsular.

Articular Disk

The **external lateral ligament** (*ligamentum temporomandibulare*) (Fig. 229) is a short, thin, and narrow fasciculus, attached, *above*, to the outer surface of the zygoma and to the tubercle on its lower border; *below*, to the outer border of the neck and to the tubercle at the outer extremity of the condyle of the mandible. It is broader above than below; its fibres are placed parallel to one another,

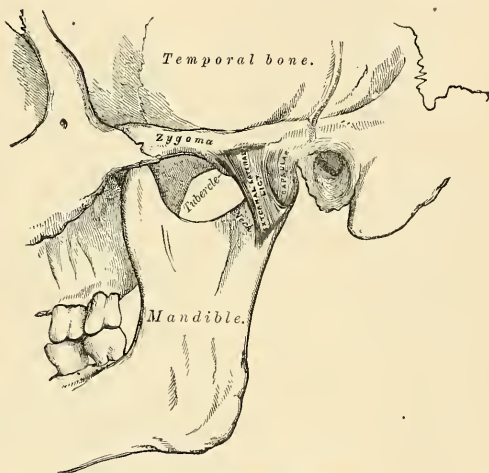


FIG. 229.—Temporomandibular articulation.

and directed obliquely downward and backward. Externally, it is covered by the parotid gland and by the integument. Internally it is in relation with the capsular ligament, of which it is an accessory band, and from which it is not separable.

The **internal lateral ligament** (*ligamentum sphenomandibulare*) (Fig. 230) is a flat, thin band which is attached above to the spine of the sphenoid bone, and, becoming broader as it descends, is inserted into the margin of the dental foramen and the portion of bone, the lingula, which overhangs the foramen in front. This ligament is not a true articular ligament, but is an accessory band, contributed to the capsule by the deep cervical fascia. Its outer surface is in relation, above, with the External pterygoid muscle; lower down it is separated from the neck of the condyle by the internal maxillary artery; and still more inferiorly, the inferior dental vessels and nerve separate it from the ramus of the mandible. The inner surface is in relation with the Internal pterygoid.

The **stylomandibular ligament** (*ligamentum stylomandibulare*) (Fig. 230) is a specialized band of the cervical fascia, which extends from near the apex of the styloid process of the temporal bone to the angle and posterior border of the ramus of the mandible, between the Masseter and Internal pterygoid muscles. This ligament separates the parotid from the submaxillary gland, and has

attached to its inner side part of the fibres of origin of the Styloglossus muscle. Although usually classed among the ligaments of the mandible, it can be considered only as an accessory to the articulation.

The **capsular ligament** (*capsula articularis*) (Figs. 229 and 230) forms a thin and loose capsule, passing from the circumference of the glenoid cavity and the articular surface immediately in front to the upper margin of the articular disk, and from the lower margin of the articular disk to the neck of the condyle of the mandible. It consists of very thin fibres, and is complete. It forms two joint cavities, distinct from each other, and separated by the articular disk. So thin is

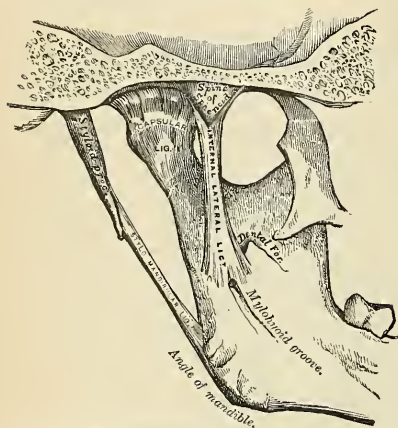


FIG. 230.—Temporomandibular articulation. Internal view.

it that it is hardly to be considered as a distinct ligament; it is thickest at the back part, and thinnest on the inner side of the articulation.¹

The **articular meniscus** (*discus articularis*) (Fig. 231) is a thin plate of an oval form, placed horizontally between the condyle of the mandible and the glenoid cavity. Its upper surface is concavo-convex from before backward, and a little convex transversely, to accommodate itself to the form of the glenoid cavity. Its under surface, where it is in contact with the condyle, is concave. Its circumference is connected to the capsular ligament, and in front to the tendon of the External pterygoid muscle. It is thicker at its circumference, especially behind, than at its centre. The fibres of which it is composed have a concentric arrangement, more apparent at the circumference than at the centre. Its surfaces are smooth. It divides the joint into two cavities, each of which is furnished with a separate synovial membrane reflected from the capsular ligament.

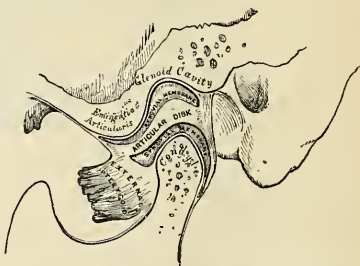


FIG. 231.—Vertical section of the temporomandibular articulation.

Synovial Membranes (Fig. 231).—The synovial membranes, *two* in number, are placed, one above, and the other below, the articular disk. The *upper* one, the larger and looser of the two, is continued from the margin of the cartilage covering the glenoid cavity and eminentia

¹ Sir G. Humphry describes the internal portion of the capsular ligament separately as the short internal lateral ligament; and it certainly seems as deserving of a separate description as is the external lateral ligament.

articularis on to the upper surface of the articular disk. The *lower one* passes from the under surface of the articular disk to the neck of the condyle of the mandible, being prolonged downward a little farther behind than in front. The articular disk is sometimes perforated in its centre; the two synovial sacs then communicate with each other.

The *nerves* of this joint are derived from the auriculotemporal and masseteric branches of the inferior maxillary. The *arteries* are derived from the temporal branch of the external carotid.

Movements.—The movements possible in this articulation are very extensive. Thus, the mandible may be depressed or elevated, or it may be carried forward or backward. It must be borne in mind that there are two distinct joints in this articulation—that is to say, one between the condyle of the mandible and the articular disk, and another between the disk and the glenoid fossa; when the mandible is depressed, as in opening the mouth, the movements which take place in these two joints are not the same. In the lower compartment, that between the condyle and the articular disk, the movement is of a ginglymoid or hinge-like character, the condyle rotating on a transverse axis on the articular disk; while in the upper compartment the movement is of a gliding character, the articular disk, together with the condyle, gliding forward on to the eminentia articularis. These two movements take place simultaneously—the condyle and articular disk move forward on the eminence, and at the same time the condyle revolves on the articular disk. In the opposite movement of shutting the mouth the reverse action takes place; the articular disk glides back, carrying the condyle with it, and this at the same time revolves back to its former position. When the mandible is carried horizontally forward, as in protruding the lower incisors in front of the upper, the movement takes place principally in the upper compartment of the joint—the articular disk, carrying with it the condyle, glides forward on the glenoid fossa. This is because this movement is mainly effected by the External pterygoid muscles, which are inserted into both condyle and articular disk. The grinding or chewing movement is produced by the alternate movement of one condyle, with its disk, forward and backward, while the other condyle moves simultaneously in the opposite direction; at the same time the condyle undergoes a vertical rotation on its own axis on the disk in the lower compartment. One condyle advances and rotates, the other condyle recedes and rotates, in alternate succession.

The mandible is *depressed* by its own weight, assisted by the Platysma, the Digastric, the Mylohyoid, and the Geniohyoid muscles. It is *elevated* by the anterior part of the Temporal, Masseter, and Internal pterygoid muscles. It is drawn *forward* by the simultaneous action of the External pterygoid and the superficial fibres of the Masseter; and it is drawn *backward* by the deep fibres of the Masseter and the posterior fibres of the Temporal muscles. The grinding movement is caused by the alternate action of the two External pterygoids.

Surface Form.—The temporomandibular articulation is quite superficial, situated below the base of the zygoma, in front of the tragus and external auditory meatus, and behind the posterior border of the upper part of the Masseter muscle. Its exact position can be at once ascertained by feeling for the condyle of the mandible, the working of which can be distinctly felt in the movements of the mandible in opening and shutting the mouth. When the mouth is opened wide, the condyle advances out of the glenoid fossa on to the eminentia articularis, and a depression is felt in the situation of the joint.

Applied Anatomy.—Genuine *dislocation* of the mandible is almost always forward. Croker, King, and Theim, however, have reported posterior displacement. Dislocation is caused by violence or muscular action. When the mouth is open, the condyle is situated on the eminentia articularis, and any sudden violence, or even a sudden muscular spasm, as during a convulsive yawn, may displace the condyle forward into the zygomatic fossa. The displacement may be unilateral or bilateral, according as one or both of the condyles is displaced. The latter of the two is the more common. The articular disk adheres to the condyle until it passes over the eminentia articularis, but at this point remains behind.

Sir Astley Cooper described a condition which he termed "*subluxation*." It occurs principally in delicate women, and is believed by some to be due to the relaxation of the ligaments, permitting too free movement of the bone. Others believe it is due to displacement of the articular disk. Still others attribute the symptoms to gouty or rheumatic changes in the joint. In close relation to the condyle of the mandible is the external auditory meatus and the tympanum; any force, therefore, applied to the bone is liable to be attended with damage to these parts, or inflammation in the joint may extend to the ear, or, on the other hand, inflammation of the middle ear may involve the articulation and cause its destruction, thus leading to ankylosis of the joint. In children, arthritis of this joint may follow the exanthemata, and in adults it occurs as the result of some constitutional conditions, as rheumatism or gout. The temporomandibular joint is also occasionally the seat of *osteoarthritis*, leading to great suffering during efforts of mastication. A peculiar affection sometimes attacks the neck and condyle of the mandible, consisting in *hypertrophy* and elongation of these parts and consequent protrusion of the chin to the opposite side.

surface. The *superior* fibres pass upward to be connected with the body of the vertebra above; the *inferior* one descends to the body of the vertebra below; and the *middle* one, the smallest and least distinct, passes horizontally inward, to be attached to the intervertebral substance.

On the first rib, which articulates with a single vertebra, this ligament does not present a distinct division into three fasciculi; its fibres, however, radiate, and are attached to the body of the last cervical vertebra, as well as to the body of the vertebra with which the rib articulates. In the tenth, eleventh, and twelfth ribs also, which likewise articulate with a single vertebra, the division does not exist; but the fibres of the ligament in each case radiate and are connected with the vertebra above, as well as that with which the ribs articulate.

Relations.—In *front*, with the thoracic ganglia of the sympathetic, the pleura, and, on the right side, with the vena azygos major; *behind*, with the interarticular ligament and synovial membranes.

The **capsular ligament** (*capsula articularis*) is a thin and loose ligamentous bag, which surrounds the joint between the head of the rib and the articular cavity formed by the intervertebral disk and the adjacent vertebra. It is very thin, firmly connected with the anterior ligament, and most distinct at the upper and lower parts of the articulation. Behind, some of its fibres pass through the intervertebral foramen to the back of the intervertebral disk. This is the homologue of the *ligamentum conjugale* of some mammals, which unites the heads of opposite ribs across the back of the intervertebral disk.

The **intra-articular ligament** (*ligamentum capituli costae interarticulare*) (Figs. 233 and 234) is situated in the interior of the joint. It consists of a short band of fibres, flattened from above downward, attached by one extremity to the sharp crest which separates the two articular facets on the head of the rib, and by the other to the intervertebral disk. It divides the joint into two cavities, which have no communication with each other. For the first, tenth, eleventh, and twelfth ribs the intra-articular ligament does not exist; consequently there is but one synovial membrane.

Synovial Membranes (Figs. 233 and 234).—There are *two* synovial membranes in each of the articulations in which there is an intra-articular ligament, one on each side of this structure.

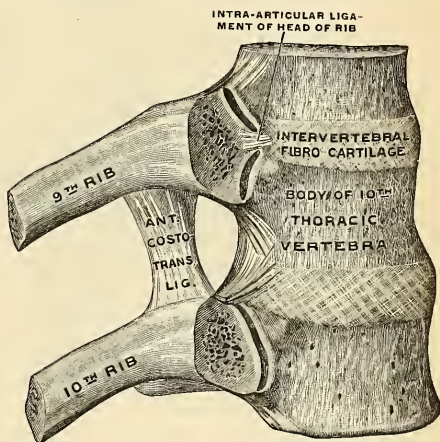


FIG. 233.—Ribs and corresponding vertebral bodies with their ligaments, viewed from the right. (Spalteholz.)

2. COSTOTRANSVERSE ARTICULATIONS (ARTICULATIONES COSTOTRANSVERSARIAE) (Fig. 234).

The articular portion of the tubercle of the rib and adjacent transverse process form an arthrodial joint.

For the *eleventh* and *twelfth ribs* this articulation is wanting.

The ligaments connecting these parts are the

Anterior or Superior Costotransverse.
Middle Costotransverse (Interosseous).

Posterior Costotransverse.
Capsular.

The **anterior or superior ligament** (*ligamentum costotransversarium anterius*) (Figs. 234 and 235) consists of two sets of fibres; the one (**anterior**) is attached below to the sharp crest on the upper border of the neck of each rib, and passes

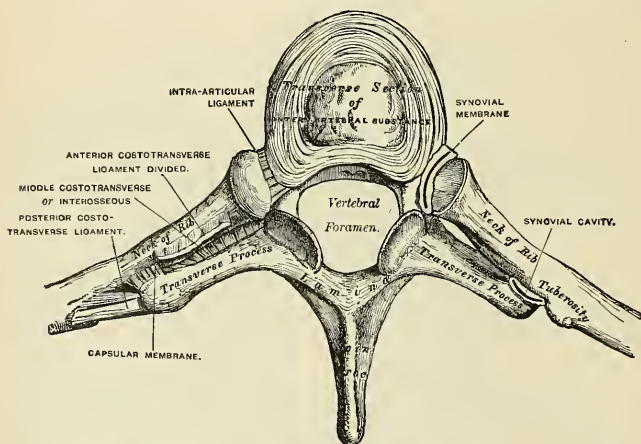


FIG. 234.—Costotransverse articulation. Seen from above.

obliquely upward and outward to the lower border of the transverse process immediately above; the other (**posterior**) is attached below to the neck of the rib, and passes upward and inward to the base of the transverse process and outer border of the lower articular process of the vertebra above.

The *first rib* has no anterior costotransverse ligament. For the *twelfth rib* the ligament is absent or is a mere vestige.

Relations.—This ligament is in relation, in *front*, with the intercostal vessels and nerves; *behind*, with the Longissimus dorsi muscle. Its *internal border* is thickened and free, and bounds an aperture through which pass the posterior branches of the intercostal vessels and nerves. Its *external border* is continuous with a thin aponeurosis which covers the External intercostal muscle.

The **middle costotransverse** or **interosseous ligament** (*ligamentum collicostae*) (Fig. 234) consists of short but strong fibres which pass between the rough surface on the posterior part of the neck of each rib and the anterior surface of the adjacent transverse process. In order to fully expose this ligament, a horizontal

section should be made across the transverse process and corresponding part of the rib; or the rib may be forcibly separated from the transverse process and the fibres of the ligament put on the stretch.

For the *eleventh* and *twelfth ribs* this ligament is quite rudimentary or wanting.

The **posterior costotransverse ligament** (*ligamentum costotransversarium posterius*) (Fig. 234) is a short but thick and strong fasciculus which passes obliquely from the summit of the transverse process to the rough nonarticular portion of the tubercle of the rib.

This ligament is shorter and more oblique in the upper than in the lower ribs. Those corresponding to the superior ribs ascend, while those of the inferior ribs descend slightly.

For the *eleventh* and *twelfth ribs* this ligament is wanting.

The **capsular ligament** (*capsula articularis*) is a thin, membranous sac attached to the circumference of the articular surfaces, and enclosing a synovial membrane.

For the *eleventh* and *twelfth ribs* this ligament is absent.

Movements.—The heads of the ribs are so closely connected to the bodies of the vertebræ by the stellate and intra-articular ligaments, and the necks and tubercles of the ribs to the transverse processes, that only a slight gliding movement of the articular surfaces on each other can take place in these articulations. The result of this gliding movement with respect to the six upper ribs consists in an elevation of the front and middle portion of the rib with a consequent enlargement of the antero-posterior diameter of the thorax, the hinder part being prevented from performing any upward movement by its close connection with the vertebral column. In this gliding movement the rib rotates on an axis corresponding to a line drawn through the two articulations, **costocentral** and **costotransverse**, which the rib forms with the vertebral column. None of the ribs lie in a truly horizontal plane; they are all directed more or less obliquely, so that their anterior extremities lie at a lower level than their posterior; this obliquity increases from the first to the seventh, and then again decreases. If we examine any one rib—say that in which there is the greatest obliquity—we shall see that it is obvious that as its sternal extremity is carried upward it must also be thrown forward; so that the rib may be regarded as a radius moving on the vertebral joint as a centre, and causing the sternal attachment to describe an arc of a circle in the vertical plane of the body. Since all the ribs are oblique and connected in front to the sternum by the flexible costal cartilages, they must have a tendency to thrust the sternum forward, and so increase the antero-posterior diameter of the thorax. With respect to the seventh, eighth, ninth, and tenth ribs, each one, besides rotating in a similar manner to the upper six, also rotates on an axis corresponding with a line drawn from the head of the rib to the sternum. By this movement an elevation of the middle portion of the rib takes place, and consequently an increase in the transverse diameter of the thorax. For the ribs not only slide downward and forward from their vertebral attachment, but they are also oblique in relation to their transverse plane—that is to say, their middle is at a lower level than

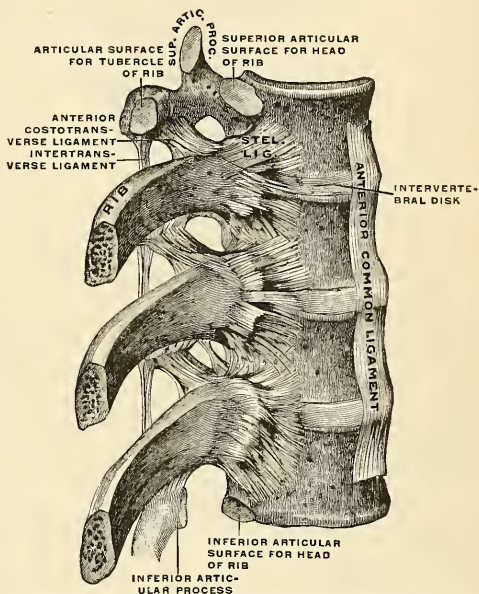


FIG. 235.—Ribs and corresponding vertebræ with ligaments, viewed from the right. (Spalteholz.)

either their vertebral or sternal extremities. It results from this that when the ribs are raised, the central portion is thrust outward, somewhat after the fashion in which the handle of a bucket is thrust away from the side when raised to a horizontal position, and the lateral diameter of the thorax is increased (see Fig. 236). The mobility of the different ribs varies greatly. The first rib is more fixed than the others, on account of the weight of the upper extremity and the strain of the ribs beneath; but on the freshly dissected thorax it moves as freely as the others. From the same causes the movement of the second rib is also not very extensive. In the other ribs this mobility increases successively down to the last two, which are very movable. The ribs are generally more movable in the female than in the male.

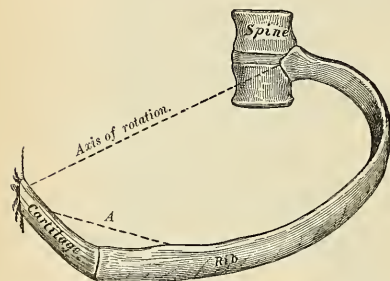
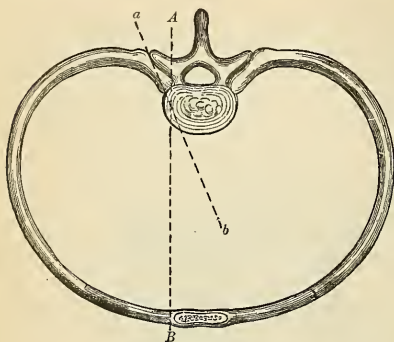


FIG. 236.—Diagrams showing the axis of rotation of the ribs in the movements of respiration. The one axis of rotation corresponds with the line drawn through the two articulations which the rib forms with the vertebral column (*a, b*), and the other with a line drawn from the head of the rib to the sternum (*A, B*). (From Kirke's *Handbook of Physiology*.)

VII. Costosternal Articulations (*Articulationes Sternocostales*) (Fig. 237).

The articulations of the cartilages of the true ribs with the sternum are arthrodial joints, with the exception of the first, in which the cartilage is almost always directly united with the sternum, and which must therefore be regarded as a synarthrodial articulation. The ligaments connecting them are the

Anterior Chondrosternal.

Capsular.

Posterior Chondrosternal.

Intra-articular Chondrosternal.

Chondroxiphoid.

The **anterior chondrosternal ligament** (*ligamentum sternocostale radiatum*) (Fig. 237) is a broad and thin membranous band that radiates from the front of the inner extremity of the cartilages of the true ribs to the anterior surface of the sternum. It is composed of fasciculi which pass in different directions. The *superior fasciculi* ascend obliquely, the *inferior fasciculi* pass obliquely downward, and the *middle fasciculi* pass horizontally. The superficial fibres of this ligament are the longest; they intermingle with the fibres of the ligaments above and below them, with those of the opposite side, and with the tendinous fibres of origin of the Pectoralis major, forming a thick fibrous membrane which covers the surface of the sternum (*membrana sterni*). This is more distinct at the lower than at the upper part.

The **capsular ligament** (*capsula articularis*) surrounds the joint formed between the cartilage of a true rib and the sternum. It is very thin, intimately blended with the anterior and posterior ligaments, and strengthened at the upper and lower part of the articulation by a few fibres which pass from the cartilage to the side of the sternum. These ligaments protect the synovial membranes.

The **posterior chondrosternal** or **sternocostal ligament** (*ligamentum sternocostale radiatum*), less thick and distinct than the anterior, is composed of fibres

which radiate from the posterior surface of the sternal end of the cartilages of the true ribs to the posterior surface of the sternum, becoming blended with the periosteum.

The **intra-articular chondrosternal ligament** (*ligamentum sternocostale inter-articulare*) (Fig. 237) is found between the second costal cartilage and the sternum. The cartilage of the second rib is connected with the sternum by means of an

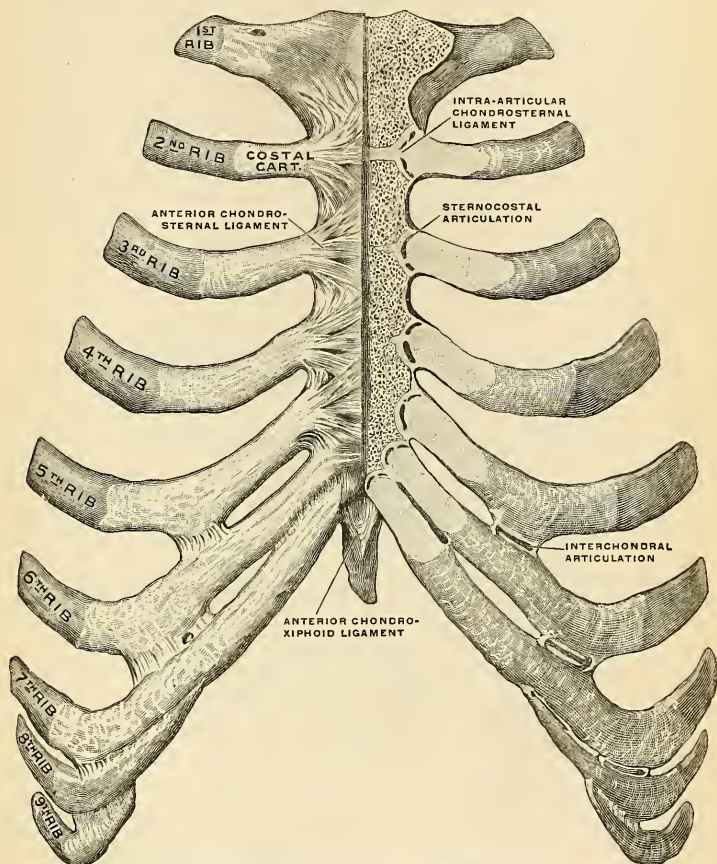


FIG. 237.—Sternum and ribs with ligaments, from in front. In the right half of the figure the most anterior layer has been removed and the joint cavities have been opened; the parts are separated somewhat from one another on the left side. (Spalteholz.)

intra-articular ligament attached by one extremity to the cartilage of the second rib, and by the other extremity to the cartilage which unites the first and second pieces of the sternum. This articulation is provided with *two* synovial membranes. The cartilage of the third rib is also occasionally connected with the sternum by means of an intra-articular ligament which is attached by one extremity to the cartilage of the third rib, and by the other extremity to the sternum. This

articulation may be provided with *two* synovial membranes. In the other joints intra-articular ligaments may exist, but they rarely completely divide the joint into two cavities.

The **anterior chondroxiphoid ligament** (*ligamentum costoxiphoideum anterius*) (Fig. 237) is a band of ligamentous fibres which connects the anterior surface of the seventh costal cartilage, and occasionally also that of the sixth, to the anterior surface of the ensiform cartilage. It varies in length and breadth in different subjects. A similar band of fibres on the posterior surface, though less thick and distinct, may be demonstrated. It is spoken of as the **posterior chondroxiphoid ligament**.

Synovial Membranes (Fig. 237).—There is *no* synovial membrane between the first costal cartilage and the sternum, as this cartilage is directly continuous with the manubrium. There are *two* synovial membranes, both in the articulation of the second and third costal cartilages to the sternum. There is generally *one* synovial membrane in each of the joints between the fourth, fifth, sixth, and seventh costal cartilages to the sternum; but it is sometimes absent in the sixth and seventh chondrosternal joints. Thus, there are usually *eight* synovial cavities on each side in the articulations between the costal cartilages of the true ribs and the sternum. After middle life the articular surfaces lose their polish, become roughened, and the synovial membranes appear to be wanting. In old age the articulations do not exist, the cartilages of most of the ribs becoming continuous with the sternum.

Movements.—The movements which are permitted in the chondrosternal articulations are limited to *elevation and depression*, and these only to a slight extent.

Articulations of the Cartilages of the Ribs with Each Other (*articulationes interchondrales*) (Fig. 237).—The contiguous borders of the sixth, seventh, and eighth, and sometimes the ninth and tenth, costal cartilages articulate with each other by small, smooth, oblong-shaped facets. Each articulation is enclosed in a thin **capsular ligament** lined by **synovial membrane**, and strengthened externally and internally by ligamentous fibres, **external and internal interchondral ligaments** (*ligamenta intercostalia externa et interna*), which pass from one cartilage to the other. Sometimes the fifth costal cartilage, more rarely that of the ninth, articulates, by its lower border, with the adjoining cartilage by a small oval facet; more frequently they are connected by a few ligamentous fibres. Occasionally the articular surfaces above mentioned are wanting.

Articulations of the Ribs with their Cartilages (Fig. 237).—The outer extremity of each costal cartilage is received into a depression in the sternal ends of the ribs, and the two are held together by the periosteum. There is no real joint. Occasionally a synovial membrane exists between the first rib and the corresponding cartilage.

VIII. Articulations of the Sternum (Fig. 237)

The first piece of the sternum is united to the second either by an amphiarthrodial joint—a single piece of true fibrocartilage uniting the segments—or by a diarthrodial joint, in which each bone is clothed with a distinct lamina of hyaline cartilage, adherent on one side, free and lined with synovial membrane on the other. In the latter case the cartilage covering the gladiolus is continued without interruption on to the cartilages of the second ribs. The two segments are further connected by an

Anterior Intersternal Ligament.

Posterior Intersternal Ligament.

The **anterior intersternal ligament** consists of a layer of fibres, having a longitudinal direction; it blends with the fibres of the anterior chondrosternal ligaments on both sides, and with the tendinous fibres of origin of the Pectoralis

major muscle. This ligament is rough, irregular, and much thicker below than above.

The **posterior intersternal ligament** is disposed in a somewhat similar manner on the posterior surface of the articulation.

IX. Articulation of the Vertebral Column with the Pelvis.

The ligaments connecting the last lumbar vertebra with the sacrum are similar to those which connect the segments of the vertebral column with each other—viz.: (1) The continuation downward of the anterior and posterior common ligaments. (2) The intervertebral substance connecting the flattened oval surfaces of the two bones and forming an amphiarthrodial joint. (3) Ligamenta subflava, connecting the arch of the last lumbar vertebra with the posterior border of the sacral canal. (4) Capsular ligaments connecting the articulating processes and forming a double arthrodia. (5) Inter- and supraspinous ligaments.

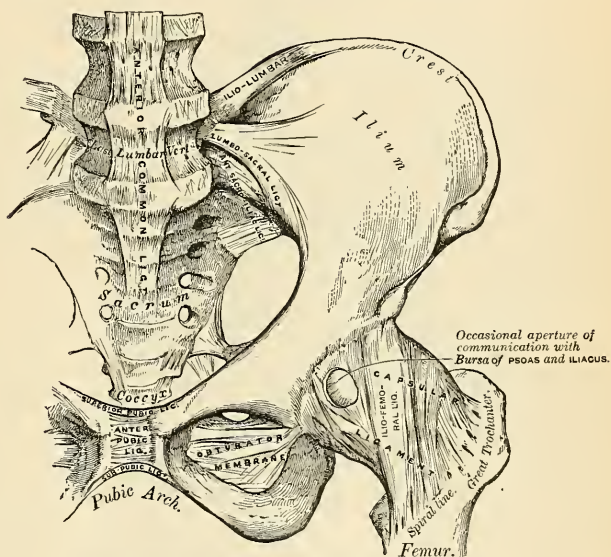


FIG. 238.—Articulations of the pelvis and hip. Anterior view.

The two proper ligaments connecting the pelvis with the vertebral column are the lumbosacral and iliolumbar.

The **lumbosacral ligament** (Fig. 238) is a short, thick, triangular fasciculus, which is connected above to the lower and front part of the transverse process of the last lumbar vertebra; it passes obliquely outward and is attached below to the lateral surface of the base of the sacrum. It is closely blended with the anterior sacroiliac and the iliolumbar ligaments, and is to be regarded as a portion of the iliolumbar ligament. This ligament is in relation, in *front*, with the Psoas muscle. The internal border of the lumbosacral ligament margins the foramen of the last lumbar nerve.

The **iliolumbar ligament** (*ligamentum iliolumbale*) (Fig. 238) passes horizontally outward from the apex of the transverse process of the last lumbar vertebra to the crest of the ilium immediately in front of the sacroiliac articulation. It is of a triangular form, thick and narrow internally, broad and thinner externally. It is in relation, *in front*, with the Psoas muscle; *behind*, with the muscles occupying the vertebral groove; *above*, with the Quadratus lumborum. It blends in places with the lumbosacral ligament, and its crescentic inner margin marks the limit of the foramen for the fourth lumbar nerve. These ligaments are thick prolongations from the anterior layer of the lumbar fascia.

X. Articulations of the Pelvis.

The ligaments connecting the bones of the pelvis with each other may be divided into four groups: (1) Those connecting the **sacrum** and **ilium**. (2) Those passing between the **sacrum** and **ischium**. (3) Those connecting the **sacrum** and **coccyx**. (4) Those between the two **pubic bones**.

1. ARTICULATION OF THE SACRUM AND ILIUM (ARTICULATIO SACROILIACA).

The **sacroiliac articulation** is an amphiarthrodial joint, formed between the lateral surfaces of the sacrum and ilium. The anterior or auricular portion of each articular surface is covered with a thin plate of hyaline cartilage, thicker on the sacrum than on the ilium. These are in close contact with each other, and to a certain extent united together by irregular patches of softer fibro-cartilage, and at their upper and posterior part by fine fibres of interosseous fibrous tissue. Throughout a considerable part of their extent, especially in advanced life, they are not connected together, but are separated by a space containing a synovial-like fluid, and hence the joint presents the characters of a diarthrosis.

The ligaments connecting these surfaces are the

Anterior Sacroiliac.

Posterior Sacroiliac.

The **anterior sacroiliac ligament** (*ligamenta sacroiliaca anteriora*) (Fig. 238) consists of numerous thin bands which connect the anterior surfaces of the sacrum and ilium.

The **posterior sacroiliac ligament** (*ligamentum sacroiliacum posterius*) (Fig. 239) is a strong ligament, situated in a deep depression between the sacrum and ilium behind, and forming the chief bond of connection between those bones. It consists of numerous strong fasciculi which pass between the bones in various directions. The *upper part* of the ligament, the **short sacroiliac** (*ligamentum sacroiliacum posterius breve*) is nearly horizontal in direction and passes from the first and second transverse tubercles on the posterior surface of the sacrum to the rough, uneven surface at the posterior part of the inner surface of the ilium. The *lower part* (*ligamentum sacroiliacum posterius longum*), oblique in direction, is attached by one extremity to the third transverse tubercle on the posterior surface of the sacrum, and by the other to the posterior superior spine of the ilium; it is sometimes called the **oblique sacroiliac ligament**.

Surface Form.—The position of the sacroiliac joint is indicated by the posterior superior spine of the ilium. This process is immediately behind the centre of the articulation.

2. LIGAMENTS PASSING BETWEEN THE SACRUM AND ISCHIUM (Fig. 239).

The Great Sacrosciatic (Posterior).

The Small Sacrosciatic (Anterior).

The **great or posterior sacrosciatic ligament** (*ligamentum sacrotuberosum*) (Figs. 239 and 240) is situated at the lower and back part of the pelvis. It is flat, and triangular in form; narrower in the middle than at the extremities; attached by its broad base to the posterior inferior spine of the ilium, to the fourth and fifth transverse tubercles of the sacrum, and to the lower part of the lateral margin of that bone and the coccyx. Passing obliquely downward, outward, and for-

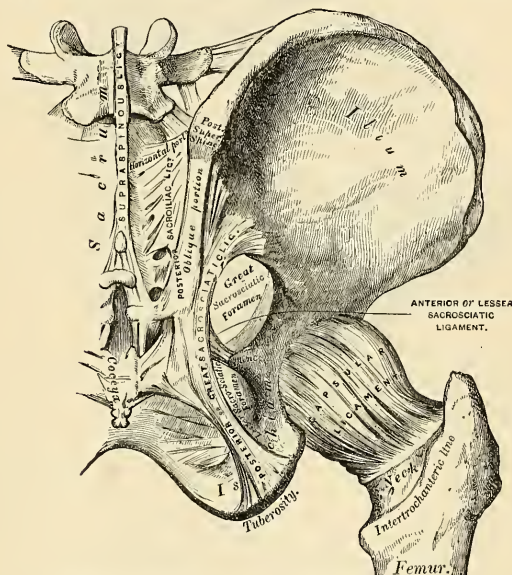


FIG. 239.—Articulations of pelvis and hip. Posterior view.

ward, it becomes narrow and thick, and at its insertion into the inner margin of the tuberosity of the ischium it increases in breadth, and is prolonged forward along the inner margin of the ramus, forming what is known as the *falciform process* of the great sacrosiatic ligament (*processus falciformis*). The free concave edge of this prolongation has attached to it the obturator fascia, with which it forms a kind of groove, protecting the internal pudic vessels and nerve. One of its surfaces is turned toward the perineum, the other toward the Obturator internus muscle.

Relations.—The *superficial surface* of this ligament gives origin, by its whole extent, to fibres of the Gluteus maximus muscle. Its *deep surface* is united to the lesser sacrosiatic ligament. Its *external border* forms, above, the posterior boundary of the great sacrosiatic foramen, and, below, the posterior boundary of the lesser sacrosiatic foramen. Its *lower border* forms part of the boundary of the perineum. It is pierced by the coccygeal branch of the sciatic artery and the coccygeal nerve.

The **small or anterior sacrosciatic ligament** (*ligamentum sacrospinosum*) (Figs. 239 and 240), much shorter and smaller than the preceding, is thin, triangular in form, attached by its apex to the spine of the ischium, and internally, by its broad base, to the lateral margin of the sacrum and coccyx, anterior to the attachment of the great sacrosciatic ligament, with which its fibres are intermingled.

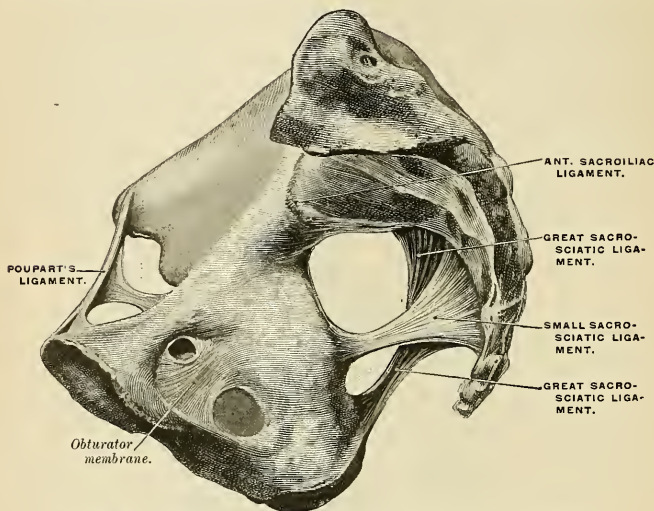


FIG. 240.—Side view of pelvis, showing the greater and lesser sacrosciatic ligaments.

Relations.—Its *deep surface* is in relation with the Coëcygeus muscle; its *superficial surface* is covered by the great sacrosciatic ligament and crossed by the internal pudic vessels and nerve. Its *superior border* forms the lower boundary of the great sacrosciatic foramen; its *inferior border*, part of the lesser sacrosciatic foramen.

These two ligaments convert the sacrosciatic notches into foramina. The **superior or great sacrosciatic foramen** (*foramen ischiadicum majus*) (Figs. 239 and 240) is bounded, in *front* and *above*, by the posterior border of the os innominatum; *behind*, by the great sacrosciatic ligament; and *below*, by the lesser sacrosciatic ligament. It is partially filled in the recent state by the Piriformis muscle, which passes through it. Above this muscle the gluteal vessels and superior gluteal nerve emerge from the pelvis, and, below it, the sciatic vessels and nerves, the internal pudic vessels and nerve, the inferior gluteal nerve, and the nerves to the Obturator internus and Quadratus femoris. The **inferior or lesser sacrosciatic foramen** (*foramen ischiadicum minus*) (Figs. 239 and 240) is bounded, in *front*, by the tuber ischii; *above*, by the spine and lesser sacrosciatic ligament; *behind*, by the greater sacrosciatic ligament. It transmits the tendon of the Obturator internus muscle, its nerve, and the internal pudic vessels and nerve.

3. ARTICULATION OF THE SACRUM AND COCCYX (SYMPHYSIS SACROCOCCYGEA).

This articulation is an amphiarthrodial joint, formed between the oval surface at the apex of the sacrum and the base of the coccyx. It is analogous to the joints between the bodies of the vertebræ. The ligaments are the

Anterior Sacrococcygeal.
Posterior Sacrococcygeal.

Lateral Sacrococcygeal.
Interposed Fibrocartilage.

The **anterior sacrococcygeal ligament** (*ligamentum sacrococcygeum anterius*) consists of a few irregular fibres which descend from the anterior surface of the sacrum to the front of the coccyx, becoming blended with the periosteum. It is a continuation of the anterior common ligament.

The **posterior sacrococcygeal ligament** (*ligamentum sacrococcygeum posterius*) (Fig. 241) is divided into two portions, the deep and the superficial. The **deep portion** (*ligamentum sacrococcygeum posterius profundum*), which is a continuation of the posterior common ligament, is a flat band of a pearly tint, which arises from the margin of the lower orifice of the sacral canal, and descends to be inserted into the posterior surface of the coccyx. This ligament completes the lower and back part of the sacral canal. Its superficial fibres are much longer than the more deeply seated. This ligament is in relation, behind, with the *Gluteus maximus*. The **superficial portion** (*ligamentum sacrococcygeum posterius superficiale*) is composed of longitudinal fibrous bands which extend from the lower portion of the middle sacral ridge to the posterior surface of the coccyx and closes partly the sacral hiatus, and of fibrous bands which extend from the sacral cornua to the coccygeal cornua. A portion of this ligament corresponds to the *ligamenta subflava* and the balance to the capsular ligament.

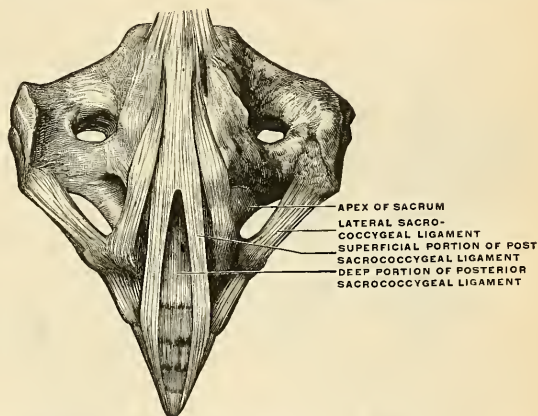


FIG. 241.—Ligaments between the sacrum and the coccyx. (Spalteholz.)

A **lateral sacrococcygeal** or **intertransverse ligament** (Fig. 241) connects the transverse process of the coccyx to the lower lateral angle of the sacrum on each side.

A **fibrocartilage** or **articular disk** is interposed between the contiguous surfaces of the sacrum and coccyx; it differs from that interposed between the bodies of the vertebrae in being thinner, and its central part firmer in texture. It is somewhat thicker in front and behind than at the sides. Occasionally, a synovial membrane is found and the coccyx is freely movable. This is especially the case during pregnancy.

The different **segments of the coccyx** are connected by an extension downward of the anterior and posterior sacrococcygeal ligaments, a thin annular articular disk being interposed between each of the bones. In the adult male all the pieces become ossified, but in the female this does not commonly occur until a later period of life. The separate segments of the coccyx are first united, and at a more advanced age the joint between the sacrum and coccyx is obliterated.

Movements.—The movements which take place between the sacrum and coccyx, and between the different pieces of the latter bone, are *forward* and *backward*, and are very limited. Their extent increases during pregnancy.

4. ARTICULATION OF THE PUBIC BONES (SYMPHYSIS OSSIUM PUBIS) (Figs. 238, 242).

The articulation between the pubic bones is an amphiarthrodial joint, formed by the apposition of the two oval articular surfaces of the pubic bones. The ligaments of this articulation are the

Anterior Pubic.	Superior Pubic.
Posterior Pubic.	Inferior Pubic.
Interpubic Disk.	

The **anterior pubic ligament** (Fig. 238) consists of several superimposed layers which pass across the front of the articulation. The superficial fibres pass obliquely from one bone to the other, decussating and forming an interlacement with the fibres of the aponeurosis of the External oblique and the tendon of the Rectus abdominalis muscles. The deep fibres pass transversely across the symphysis, and are blended with the interpubic disk.

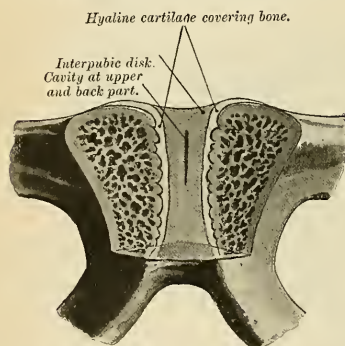


FIG. 242.—Vertical section of the symphysis pubis.
Made near its posterior surface.

The **posterior pubic ligament** consists of a few thin, scattered fibres which unite the two pubic bones posteriorly.

The **superior pubic ligament** (*ligamentum pubicum superius*) (Fig. 238) is a band of fibres which connects the two pubic bones superiorly.

The **inferior pubic** or **subpubic ligament** (*ligamentum arcuatum pubis*) (Fig. 238) is a thick, triangular arch of ligamentous fibres, connecting the

two pubic bones below and forming the upper boundary of the pubic arch. Above, it is blended with the articular disk; laterally it is united with the descending rami of the pubis. Its fibres are closely connected and have an arched direction. Its lower margin is separated from the triangular ligament of the perineum by a gap, through which runs the dorsal vein of the penis.

The **interpubic disk** (*lamina fibrocartilaginea interpubica*) (Fig. 242) consists of a disk of fibrocartilage connecting the surfaces of the pubic bones in front. Each of the two surfaces is covered by a thin layer of hyaline cartilage which is firmly connected to the bone by a series of nipple-like processes which accurately fit within corresponding depressions on the osseous surfaces. These apposed cartilaginous surfaces are connected by an intermediate stratum of fibrous tissue and fibrocartilage which varies in thickness in different subjects. It often contains a cavity (*cavum articulare*) in its centre, probably formed by the softening and absorption of the fibrocartilage, since it rarely appears before the tenth year of life, and is not lined by synovial membrane. It is larger in the female than in the male. It is most frequently limited to the upper and back

part of the joint, but it occasionally reaches to the front, and may extend the entire length of the cartilage. This cavity may sometimes be demonstrated by making a vertical section of the symphysis pubis near its posterior surface (Fig. 242).

The **obturator ligament** is more properly regarded as analogous to the muscular fasciæ, with which it will be described.

ARTICULATIONS OF THE UPPER EXTREMITY.

The articulations of the upper extremity may be arranged in the following groups:

- | | |
|-------------------------------------|------------------------------------------|
| I. Sternoclavicular Articulation. | VII. Wrist-joint. |
| II. Acromioclavicular Articulation. | VIII. Articulations of the Carpal Bones. |
| III. Ligaments of the Scapula. | IX. Carpometacarpal Articulations. |
| IV. Shoulder-joint. | X. Metacarpophalangeal Articulations. |
| V. Elbow-joint. | XI. Articulations of the Phalanges. |
| VI. Radioulnar Articulations. | |

I. Sternoclavicular Articulation (*Articulatio Sternoclavicularis*) (Fig. 243).

The **sternoclavicular** is an arthrodial joint. The parts entering into its formation are the sternal end of the clavicle, the upper and lateral part of the first piece of the sternum, and the cartilage of the first rib. The articular surface of the

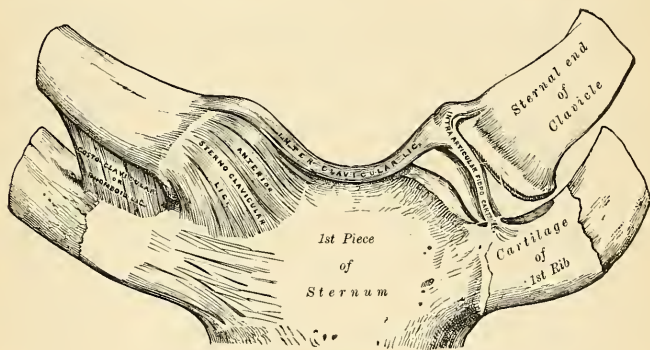


FIG. 243.—Sternoclavicular articulation. Anterior view.

sternum is covered with hyaline cartilage. The articular surface of the clavicle is much larger than that of the sternum, and invested with a layer of hyaline cartilage¹ which is considerably thicker than that on the latter bone. The ligaments of this joint are the

Capsular.
Anterior Sternoclavicular.
Posterior Sternoclavicular.

Interclavicular.
Costoclavicular.
Articular Disk.

¹ According to Bruch, the sternal end of the clavicle is covered by a tissue which is rather fibrous than cartilaginous in structure.

The **capsular ligament** (*capsula articularis*) completely surrounds the articulation, consisting of fibres of varying degrees of thickness and strength. Those in front and behind are of considerable thickness, and form the anterior and posterior sternoclavicular ligaments; but those above and below, especially in the latter situation, are thin and scanty.

The **anterior sternoclavicular ligament** (*ligamentum sternoclaviculare*) (Fig. 243) is a part of the capsule. It is a broad band of fibres which covers the anterior surface of the articulation, being attached, *above*, to the upper and front part of the inner extremity of the clavicle, and, passing obliquely downward and inward, is attached, *below*, to the upper and front part of the first piece of the sternum. This ligament is covered, in *front*, by the sternal portion of the Sternomastoid and the integument; *behind*, it is in relation with the articular disk and the two synovial membranes.

The **posterior sternoclavicular ligament**, also a part of the capsule, is a band of fibres which covers the posterior surface of the articulation, being attached, *above*, to the upper and back part of the inner extremity of the clavicle, and, passing obliquely downward and inward, is attached, *below*, to the upper and back part of the first piece of the sternum. It is in relation, in *front*, with the articular disk and synovial membranes; *behind*, with the Sternohyoid and Sternothyroid muscles.

The **interclavicular ligament** (*ligamentum interclaviculare*) (Fig. 243) is a flattened band which varies considerably in form and size in different individuals; it passes in a curved direction from the upper part of the inner extremity of one clavicle to the other, and is also attached to the upper margin of the sternum. It is in relation, in *front*, with the integument; *behind*, with the Sternothyroid muscles.

The **costoclavicular or rhomboid ligament** (*ligamentum costoclaviculare*) (Fig. 243) is short, flat, and strong; it is of a rhomboid form, attached, *below*, to the upper and inner part of the cartilage of the first rib; it ascends obliquely backward and outward, and is attached, *above*, to the rhomboid depression on the under surface of the clavicle. It is in relation, in *front*, with the tendon of origin of the Subclavius; *behind*, with the subclavian vein.

The **articular disk** (*discus articularis*) (Fig. 243) is a flat and nearly circular meniscus, interposed between the articulating surfaces of the sternum and clavicle. It is attached, *above*, to the upper and posterior border of the articular surface of the clavicle; *below*, to the cartilage of the first rib, at its junction with the sternum; and by its circumference, to the anterior and posterior sternoclavicular and the interclavicular ligaments. It is thicker at the circumference, especially its upper and back part, than at its centre or below. It divides the joint into two cavities, each of which is furnished with a separate synovial membrane.

Synovial Membrane.—Of the *two* synovial membranes found in this articulation, one is reflected from the sternal end of the clavicle over the adjacent surface of the articular disk and cartilage of the first rib; the other is placed between the articular surface of the sternum and adjacent surface of the articular disk; the latter is the larger of the two.

Movements.—This articulation is the centre of the movements of the shoulder, and admits of a limited amount of motion in nearly every direction—upward, downward, backward, forward—as well as circumduction. When these movements take place in the joint, the clavicle in its motion carries the scapula with it, this bone gliding on the outer surface of the thorax. This joint therefore forms the centre from which all movements of the supporting arch of the shoulder originate, and is the only point of articulation of this part of the skeleton with the trunk. “The movements attendant on elevation and depression of the shoulder take place between the clavicle and the articular disk, the bone rotating upon the ligament on an axis drawn from before backward through its own articular facet. When the shoulder is moved forward and backward, the clavicle, with the articular disk, rolls to and fro on the articular surface of the sternum, revolving, with a gliding movement, around an axis drawn nearly vertically through the sternum. In the circumduction of the shoulder, which is compounded of these two movements, the clavicle revolves

upon the articular disk, and the latter, with the clavicle, rolls upon the sternum."¹ Elevation of the clavicle is principally limited by the costoclavicular ligament; depression by the interclavicular. The muscles which *raise* the clavicle, as in shrugging the shoulder, are the upper fibres of the Trapezius, the Levator anguli scapulae, the clavicular head of the Sternomastoid, assisted to a certain extent by the two Rhomboids, which pull the vertebral border of the scapula backward and upward, and so raise the clavicle. The *depression* of the clavicle is principally effected by gravity, assisted by the Subclavius, Pectoralis minor, and lower fibres of the Trapezius. It is drawn *backward* by the Rhomboids and the middle and lower fibres of the Trapezius; and *forward* by the Serratus magnus and Pectoralis minor.

Surface Form.—The position of the sternoclavicular joint may be easily ascertained by feeling the enlarged sternal end of the collar-bone just external to the long, cord-like, sternal origin of the Sternomastoid muscle. If this muscle is relaxed by bending the head forward, a depression just internal to the end of the clavicle, and between it and the sternum, can be felt, indicating the exact position of the joint, which is subcutaneous. When the arm hangs by the side, the cavity of the joint is V-shaped. If the arm is raised, the bones become more closely approximated, and the cavity becomes a mere slit.

Applied Anatomy.—The strength of this joint mainly depends upon its ligaments, and it is because of the ligaments and because the force of a blow is generally transmitted along the long axis of the clavicle, that dislocation so rarely occurs, and that the bone is generally broken rather than displaced. When *dislocation* does occur, the course which the displaced bone takes depends more upon the direction in which the violence was applied than upon the anatomical construction of the joint; it may be either forward, backward, or upward. A complete upward dislocation is also inward. A complete forward or backward dislocation is also inward and downward. The chief point worthy of note, as regards the construction of the joint, in regard to dislocations, is the fact that, owing to the shape of the articular surfaces being so little adapted to each other, and that the strength of the joint mainly depends upon the ligaments, the displacement when reduced is very liable to recur, and hence it is extremely difficult to keep the end of the bone in its proper place, and it may be necessary to incise the soft parts and wire the bone in place.

II. Acromioclavicular or Scapuloclavicular Articulation (Articulatio Acromioclavicularis) (Fig. 244).

The **acromioclavicular** is an arthrodial joint formed between the outer extremity of the clavicle and the inner margin of the acromion process of the scapula. The ligaments which surround the joint form a capsule. The ligaments of this articulation are the

Superior Acromioclavicular.	Coracoclavicular {	Trapezoid and Conoid.
Inferior Acromioclavicular.		
Articular Disk.		

The **superior acromioclavicular ligament** (*ligamentum acromioclaviculare*) (Figs 244 and 245) is a portion of the joint capsule. It is a quadrilateral band which covers the superior part of the articulation, extending between the upper part of the outer end of the clavicle and the adjoining part of the upper surface of the acromion. It is composed of parallel fibres which interlace with the aponeurosis of the Trapezius and Deltoid muscles; *below*, it is in contact with the articular disk (when it exists) and the synovial membranes.

The **inferior acromioclavicular ligament**, somewhat thinner than the preceding, and, like it, a portion of the capsule, covers the under part of the articulation and is attached to the adjoining surfaces of the two bones. It is in relation, *above*, with the synovial membranes, and in rare cases with the articular disk; *below*, with the tendon of the Supraspinatus. These two ligaments are continuous with each other in front and behind, and form a complete capsule around the joint.

¹ Humphry, On the Human Skeleton, p. 402.

The **articular disk** (*discus articularis*) is frequently absent in this articulation. When the meniscus exists it is generally incomplete and only partially separates the articular surfaces, and occupies the upper part of the articulation. More rarely it completely separates the joint into two cavities.

The Synovial Membrane.—There is usually only *one* synovial membrane in this articulation, but when a complete articular disk exists there are two synovial membranes.

The **coracoclavicular ligament** (*ligamentum coracoclaviculare*) (Figs. 244 and 245) serves to connect the clavicle with the coracoid process of the scapula. It does not properly belong to this articulation, but as it forms a most efficient means in retaining the clavicle in contact with the acromial process, it is usually described with it. It consists of two fasciculi, called the trapezoid and conoid ligaments.

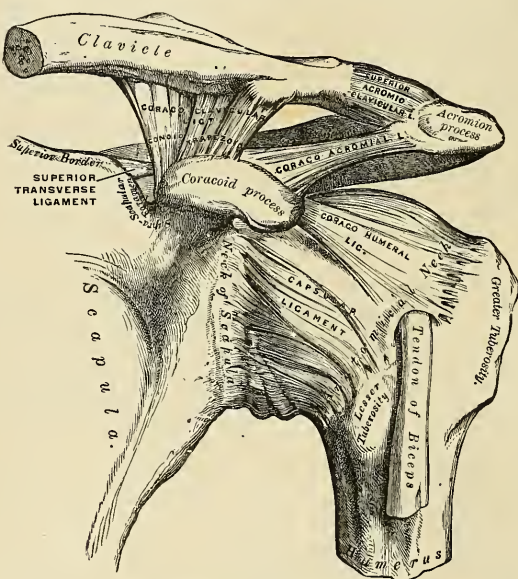


FIG. 244.—The left shoulder-joint, scapuloclavicular articulations, and proper ligaments of the scapula.

The **trapezoid ligament** (*ligamentum trapezoidcum*), the anterior and external fasciculus, is broad, thin, and quadrilateral; it is placed obliquely between the coracoid process and the clavicle. It is attached, *below*, to the upper surface of the coracoid process; *above*, to the oblique line on the under surface of the clavicle. Its *anterior border* is free; its *posterior border* is joined with the conoid ligament, the two forming by their junction a projecting angle.

The **conoid ligament** (*ligamentum conoideum*), the posterior and internal fasciculus, is a dense band of fibres, conical in form, the base being directed upward, the summit downward. It is attached, *below*, by its apex to a rough impression at the base of the coracoid process, internal to the trapezoid ligament; *above*, by its expanded base, to the conoid tubercle on the under surface of the clavicle, and to a line proceeding internally from it for half an inch. These ligaments are

in relation, in *front*, with the Subclavius and Deltoid; *behind*, with the Trapezius. They serve to limit rotation of the scapula, the trapezoid limiting rotation forward, and the conoid backward.

Movements.—The movements of this articulation are of two kinds: (1) A gliding motion of the articular end of the clavicle on the acromion. (2) Rotation of the scapula forward and backward upon the clavicle, the extent of this rotation being limited by the two portions of the coraco-clavicular ligament.

The acromioclavicular joint has important functions in the movements of the upper extremity. It has been well pointed out by Sir George Humphry that if there had been no joint between the clavicle and scapula the circular movement of the scapula on the ribs (as in throwing both shoulders backward or forward) would have been attended with a greater alteration in the direction of the shoulder than is consistent with the free use of the arm in such position, and it would have been impossible to give a blow straight forward with the full force of the arm; that is to say, with the combined force of the scapula, arm, and forearm. "This joint," as he happily says, "is so adjusted as to enable either bone to turn in a hinge-like manner upon a vertical axis drawn through the other, and it permits the surfaces of the scapula, like the baskets in a roundabout swing, to look the same way in every position, or nearly so." Again, when the whole arch formed by the clavicle and scapula rises and falls (in elevation or depression of the shoulders), the joint between these two bones enables the scapula still to maintain its lower part in contact with the ribs.

Surface Form.—The position of the acromioclavicular joint can generally be ascertained by the slightly enlarged extremity of the outer end of the clavicle, which causes it to project above the level of the acromion process of the scapula. Sometimes this enlargement is so considerable as to form a rounded eminence, which is easily to be felt. The joint lies in the plane of a vertical line passing up the middle of the front of the arm.

Applied Anatomy.—Owing to the slanting shape of the articular surfaces of this joint, the commonest *dislocation* is the passing of the acromion process of the scapula under the outer end of the clavicle; but dislocations in the opposite direction have been described. The first form of dislocation is produced by violent force applied to the scapula so as to drive the shoulder forward. The displacement in acromioclavicular dislocation is often incomplete, on account of the strong coracoclavicular ligaments which remain un torn. The same difficulty exists, as in the sternoclavicular dislocation, in maintaining the ends of the bone in apposition after reduction, and it may become necessary to wire them in place after incision of the soft parts.

III. Proper Ligaments of the Scapula (Figs. 244, 245).

The proper ligaments of the scapula pass between portions of that bone, but are not parts of an articulation. They are the

Coracoacromial.

Superior Transverse.

Inferior Transverse.

The **coracoacromial ligament** (*ligamentum coracoacromiale*) is a strong triangular band, extending between the coracoid and acromial processes. It is attached, by its apex, to the summit of the acromion just in front of the articular surface for the clavicle, and by its broad base to the whole length of the outer border of the coracoid process. Its posterior fibres are directed inward, its anterior fibres forward and inward. This ligament completes the vault formed by the coracoid and acromion processes for the protection of the head of the humerus. It is in relation, *above*, with the clavicle and under surface of the Deltoid muscle; *below*, with the tendon of the Supraspinatus muscle, a bursa being interposed. Its *outer border* is continuous with a dense lamina that passes beneath the Deltoid upon the tendons of the Supra- and Infraspinatus muscles. This ligament is sometimes described as consisting of two marginal bands and a thinner intervening portion, the two bands being attached, respectively, to the apex and base of the coracoid process, and joining together at their attachment into the acromion process. When the Pectoralis minor is inserted, as sometimes is the case, into

the capsule of the shoulder-joint instead of into the coracoid process, it passes between these two bands, and the intervening portion is then deficient.

The **superior transverse** or **suprascapular ligament** (*ligamentum transversum scapulae superius*) (Figs. 245 and 246) converts the suprascapular notch into a

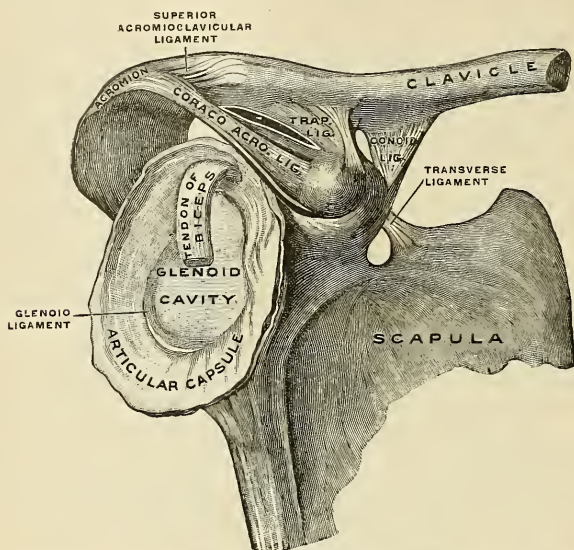


FIG. 245.—Right clavicle and scapula with ligament, from without and somewhat from in front. (Spalteholz.)

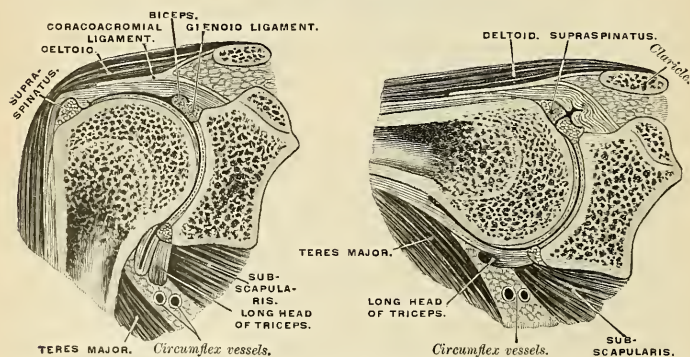


FIG. 246.—Vertical sections through the shoulder-joint, the arm being vertical and horizontal. (After Henle.)

foramen. It is a thin and flat fasciculus, narrower at the middle than at the extremities, attached by one end to the base of the coracoid process, and by the other to the inner extremity of the scapular notch. The suprascapular nerve passes through the foramen; the suprascapular vessels pass over the ligament.

An additional ligament, the **inferior transverse** or **spinoglenoid ligament** (*ligamentum transversum scapulae inferius*), is sometimes found on the scapula, stretching from the outer border of the spine to the margin of the glenoid cavity. When present, it forms an arch under which the suprascapular vessels and nerve pass as they enter the infraspinous fossa.

Movements.—The scapula is capable of being moved upward and downward, forward and backward, or, by a combination of these movements, circumducted on the wall of the thorax. The muscles which *raise* the scapula are the upper fibres of the Trapezius, the Levator anguli scapulae, and the two Rhomboids; those which *depress* it are the lower fibres of the Trapezius, the Pectoralis minor, and, through the clavicle, the Subclavius. The scapula is drawn *backward* by the Rhomboids and the middle and lower fibres of the Trapezius, and *forward* by the Serratus magnus and Pectoralis minor, assisted, when the arm is fixed, by the Pectoralis major. The mobility of the scapula is very considerable, and greatly assists the movements of the arm at the shoulder-joint. Thus, in raising the arm from the side the Deltoid and Supraspinatus can only lift it to a right angle with the trunk, the further elevation of the limb being effected by the Trapezius and Serratus magnus moving the scapula on the wall of the thorax. This mobility is of special importance in ankylosis of the shoulder-joint, the movement of this bone compensating to a very great extent for the immobility of the joint.

IV. Shoulder-Joint (Articulatio Humeri) (Figs. 245, 246).

The **shoulder-joint** is an enarthrodial or ball-and-socket joint. The bones entering into its formation are the large globular head of the humerus, which is received into the shallow glenoid cavity of the scapula—an arrangement which permits of very considerable movement, while the joint itself is protected against displacement by the tendons which surround it and by atmospheric pressure. The ligaments do not maintain the joint surfaces in apposition, because when they alone remain the humerus can be separated to a considerable extent from the glenoid cavity; their use, therefore, is to limit the amount of movement. *Above*, the joint is protected by an arched vault, formed by the under surfaces of the coracoid and acromion processes, and the coracoacromial ligament. The articular surfaces are covered by a layer of hyaline cartilage; that on the head of the humerus is thicker at the centre than at the circumference, the reverse being the case in the glenoid cavity. The ligaments of the shoulder are the

Capsular.

Coracohumeral.

Transverse Humeral.

Glenoid.¹

The **capsular ligament** (*capsula articularis*) (Figs. 245 and 247) completely encircles the articulation, being attached, *above*, to the circumference of the glenoid cavity beyond the glenoid ligament, *below*, to the anatomical neck of the humerus, approaching nearer to the articular cartilage above than in the rest of its extent. It is thicker above and below than elsewhere, and is remarkably loose and lax, and much larger and longer than is necessary to keep the bones in contact, allowing them to be separated from each other more than an inch—an evident provision for that extreme freedom of movement which is peculiar to this articulation. Its superficial surface is strengthened, *above*, by the Supraspinatus; *below*, by the long head of the Triceps; *behind*, by the tendons of the Infraspinatus and Teres minor; and in *front*, by the tendon of the Subscapularis. The capsular ligament usually presents three openings: One anteriorly, below the coracoid process, establishes a communication between the synovial membrane of the joint and a bursa beneath the tendon of the Subscapularis muscle.

¹ The long tendon of origin of the Biceps brachii muscle also acts as one of the ligaments of this joint. See the observations on p. 267 on the function of the muscles passing over more than one joint.

The second, which is not constant, is at the posterior part, where a communication sometimes exists between the joint and a bursal sac belonging to the Infraspinatus muscle. The third is seen between the two tuberosities, for the passage of the long tendon of the Biceps brachii muscle. It transmits a sac-like prolongation of the synovial membrane, which ends as a blind pouch opposite the surgical neck of the bone.

The **coracohumeral ligament** (*ligamentum coracohumerale*) (Fig. 244) is a broad band which strengthens the upper part of the capsular ligament. It arises from the outer border of the coracoid process, and passes obliquely downward and outward to the front of the great tuberosity of the humerus, being blended with the tendon of the Supraspinatus muscle. This ligament is intimately united to the capsular ligament throughout the greater part of its extent.

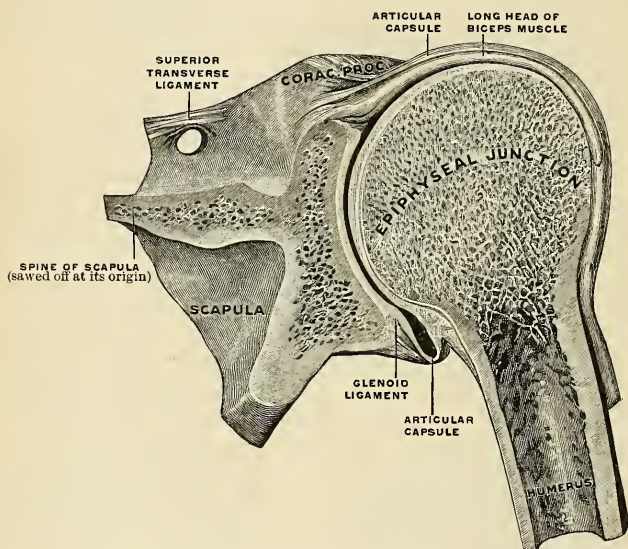


FIG. 247.—Right shoulder-joint, frontal section, from behind. (Spalteholz.)

Supplemental Bands of the Capsular Ligament.—In addition to the coracohumeral ligament, the capsular ligament is strengthened by supplemental bands in the interior of the joint, and can be best studied by opening the capsule from behind and removing the head of the humerus. One of these bands (**Flood's ligament**) passes from the anterior edge of the glenoid cavity to the lower part of the lesser tuberosity of the humerus. It is supposed to correspond with the ligamentum teres of the hip-joint. A second of these bands (**Schlemm's ligament**), is situated at the lower part of the joint, and passes from the under edge of the glenoid cavity to the under part of the neck of the humerus. A third, called the **glenohumeral ligament**, is situated at the upper part of the joint. It is attached, *above*, to the apex of the glenoid cavity, close to the root of the coracoid process, and, passing downward along the inner edge of the tendon of the Biceps brachii, is attached, *below*, above the lesser tuberosity of the humerus, where it forms the inner boundary

of the upper part of the bicipital groove. It is a thin, ribbon-like band, occasionally quite free from the capsule.

The **transverse humeral ligament** is a prolongation of the capsular ligament. It is a broad band of fibrous tissue passing from the lesser to the greater tuberosity of the humerus, and always limited to that portion of the bone which lies above the epiphyseal line. It converts the bicipital groove into an osseoponeurotic canal, and is the homologue of the strong process of bone which connects the summits of the two tuberosities in the musk ox.

The **glenoid ligament** (*labrum glenoidale*) (Figs. 245 and 247) is a fibrocartilaginous rim, attached around the margin of the glenoid cavity. It is triangular on section, the thickest portion being fixed to the circumference of the cavity, the free edge being thin and sharp. It is continuous above with the long tendon of the Biceps muscle, which bifurcates at the upper part of the cavity into two fasciculi, and becomes continuous with the fibrous tissue of the glenoid ligament. This ligament deepens the cavity for articulation, and protects the edges of the bone.

Synovial Membrane (Fig. 247).—The synovial membrane is reflected from the margin of the glenoid cavity over the fibrocartilaginous rim surrounding it; it is then reflected over the internal surface of the capsular ligament, covers the lower part and sides of the anatomical neck of the humerus as far as the cartilage covering the head of the bone. The long tendon of the Biceps brachii, which passes through the capsular ligament, is enclosed in a tubular sheath of synovial membrane (*vagina mucosa intertubercularis*), which is reflected upon it at the point where it perforates the capsule, and is continued around it as far as the level of the surgical neck of the humerus. The tendon of the Biceps is thus enabled to traverse the articulation, but it is not contained in the interior of the synovial cavity.

Bursæ.—A large bursa, the **subscapular bursa**, exists between the joint capsule and the tendon of the Subscapularis muscle. This sac communicates with the shoulder-joint by means of an opening at the inner side of the capsular ligament. Occasionally another and smaller bursa, the **infraspinatus bursa**, exists beneath the tendon of the Infraspinatus. It communicates with the shoulder-joint by means of an opening in the outer surface of the capsule. The **subdeltoid** or **subacromial bursa** is placed between the under surface of the Deltoid muscle and the outer surface of the capsule. It does not communicate with the joint. The **subcutaneous acromial bursa** is between the surface and the summit of the acromion process. There is a bursa beneath the Coracobrachialis muscle, one beneath the Teres major, and one beneath the tendinous portion of the Latissimus dorsi. There is also a bursa between the tendon of insertion of the Pectoralis major muscle and the long head of the Biceps.

The **muscles** in relation with the joint are, *above*, the Supraspinatus; *below*, the long head of the Triceps; *in front*, the Subscapularis; *behind*, the Infraspinatus and Teres minor; *within*, the long tendon of the Biceps. The Deltoid is placed most externally, and covers the articulation on its outer side, as well as in front and behind.

The **arteries** supplying the joint are articular branches of the anterior and posterior circumflex, and the suprascapular.

The **nerves** are derived from the circumflex and suprascapular.

Movements.—The shoulder-joint is capable of movement in every direction, forward, backward, abduction, adduction, circumduction, and rotation. The humerus is drawn *forward* by the Pectoralis major, anterior fibres of the Deltoid, Coracobrachialis, and by the Biceps when the forearm is flexed; *backward*, by the Latissimus dorsi, Teres major, posterior fibres of the Deltoid, and by the Triceps when the forearm is extended; it is *abducted* (elevated) by the Deltoid and Supraspinatus; it is *adducted* (depressed) by the Subscapularis, Pectoralis major, Latissimus dorsi, and Teres major; it is *rotated outward* by the Infraspinatus and Teres minor; and it is *rotated inward* by the Subscapularis, Latissimus dorsi, Teres major, and Pectoralis major.

The most striking peculiarities in this joint are: (1) The large size of the head of the humerus in comparison with the depth of the glenoid cavity, even when supplemented by the glenoid ligament. (2) The looseness of the capsule of the joint. (3) The intimate connection of the capsule with the muscles attached to the head of the humerus. (4) The peculiar relation of the Biceps tendon to the joint.

It is in consequence of the relative size of the two articular surfaces that the joint enjoys such free movement in every possible direction. When these movements of the arm are arrested in the shoulder-joint by the contact of the bony surfaces and by the tension of the corresponding fibres of the capsule, together with that of the muscles acting as accessory ligaments, they can be carried considerably farther by the movements of the scapula, involving, of course, motion at

the acromio- and sternoclavicular joints. These joints are therefore to be regarded as accessory structures to the shoulder-joint.¹ The extent of these movements of the scapula is very considerable, especially in extreme elevation of the arm, which movement is best accomplished when the arm is thrown somewhat forward and outward, because the margin of the head of the humerus is by no means a true circle; its greatest diameter is from the bicipital groove downward, inward, and backward, and the greatest elevation of the arm can be obtained by rolling its articular surface in the direction of this measurement. The great width of the central portion of the humeral head also allows of very free horizontal movement when the arm is raised to a right angle, in which movement the arch formed by the acromion, the coracoid process, and the coracoacromial ligament constitutes a sort of supplemental articular cavity for the head of the bone.

The looseness of the capsule is so great that the arm will fall about an inch from the scapula when the muscles are dissected from the capsular ligament and an opening made in it to remove the atmospheric pressure. The movements of the joint, therefore, are not regulated by the capsule so much as by the surrounding muscles and by the pressure of the atmosphere—an arrangement which “renders the movements of the joint much more easy than they would otherwise have been, and permits a swinging, pendulum-like vibration of the limb when the muscles are at rest” (Humphry). The fact, also, that in all ordinary positions of the joint the capsule is not put on the stretch enables the arm to move freely in all directions. Extreme movements are checked by the tension of appropriate portions of the capsule, as well as by the interlocking of the bones. Thus it is said that “abduction is checked by the contact of the great tuberosity with the upper edge of the glenoid cavity, adduction by the tension of the coraco-humeral ligament” (Beaunis et Bouchard). Cleland² maintains that the limitations of movement at the shoulder-joint are due to the structure of the joint itself, the glenoid ligament fitting, in different positions of the elevated arm, into the anatomical neck of the humerus.

Cathcart³ has pointed out that in abducting the arm and raising it above the head, the scapula rotates throughout the whole movement with the exception of a short space at the beginning and at the end; that the humerus moves on the scapula not only from the hanging to the horizontal position, but also in passing upward as it approaches the vertical above; that the clavicle moves not only during the second half of the movement but in the first as well, though to a less extent—*i. e.*, the scapula and clavicle are concerned in the first stage as well as in the second; and that the humerus is partly involved in the second as well as chiefly in the first.

The intimate union of the tendons of the four short muscles with the capsule converts these muscles into elastic and spontaneously acting ligaments of the joint, and it is regarded as being also intended to prevent the folds into which all portions of the capsule would alternately fall in the varying positions of the joint from being driven between the bones by the pressure of the atmosphere.

The peculiar relations of the Biceps tendon to the shoulder-joint appear to subserve various purposes. In the first place, by its connection with both the shoulder and elbow the muscle harmonizes the action of the two joints, and acts as an elastic ligament in all positions, in the manner previously adverted to.⁴ Next, it strengthens the upper part of the articular cavity, and prevents the head of the humerus from being pressed up against the acromion process, when the Deltoid contracts, instead of forming the centre of motion in the glenoid cavity. By its passage along the bicipital groove it assists in rendering the head of the humerus steady in the various movements of the arm. When the arm is raised from the side it assists the Supra- and Infra-spinatus in rotating the head of the humerus in the glenoid cavity. It also holds the head of the bone firmly in contact with the glenoid cavity, and prevents its slipping over its lower edge, or being displaced by the action of the Latissimus dorsi and Pectoralis major, as in climbing and many other movements.

Surface Form.—The direction and position of the shoulder-joint may be indicated by a line drawn from the middle of the coracoacromial ligament, in a curved direction, with its convexity inward, to the innermost part of that portion of the head of the humerus which can be felt in the axilla when the arm is forcibly abducted from the side. When the arm hangs by the side, not more than one-third of the head of the bone is in contact with the glenoid cavity, and three-quarters of its circumference is in front of a vertical line drawn from the anterior border of the acromion process.

Applied Anatomy.—Owing to the construction of the shoulder-joint and the freedom of movement which it enjoys, as well as in consequence of its exposed situation, it is more frequently *dislocated* than any other joint in the body. Dislocations of the shoulder contribute about forty per cent. of the cases in tables of dislocations. *Dislocation* occurs when the arm is thrown into extreme abduction, and when, therefore, the head of the humerus presses against the lower and front part of the capsule, which is the thinnest and least supported part of the liga-

¹ See p. 299.

² *Ibid.*, vol. xviii.

³ *Journal of Anatomy and Physiology*, 1884, vol. xviii.

⁴ See p. 267.

ment. The rent in the capsule almost invariably takes place in this situation, between the tendon of the Subscapularis and the Triceps, and through it the head of the bone escapes, so that the dislocation in most instances is primarily *subglenoid*. The head of the bone does not usually remain in this situation, but generally assumes some other position, which varies according to the direction and amount of force producing the dislocation and the relative strength of the muscles in front and behind the joint. In consequence of the muscles at the back being weaker than those in front, and especially on account of the long head of the Triceps preventing the bone passing backward, dislocation forward is much more common than backward. The most frequent position which the head of the humerus ultimately assumes is on the front of the neck of the scapula, beneath the coracoid process, and hence named *subcoracoid* dislocation. Occasionally, in consequence, probably, of a greater amount of force being brought to bear on the limb, the head is driven farther inward, and rests on the upper part of the front of the thorax, beneath the clavicle (*subclavicular*). If the head of the bone passes under the Subscapularis muscle and also under the Teres major or the lower border of the Pectoralis major, the arm remains abducted, or even with the elbow raised above the head (*luxotio erecta*). Sometimes the humerus remains in the position in which it was primarily displaced, resting on the axillary border of the scapula (*subglenoid*), and rarely it passes backward and remains in the infraspinous fossa beneath the spine (*subspinous*). If *dislocation* frequently recurs the condition may be amended in some cases by exposing the capsule and putting tucks in it by means of sutures.

An old unreduced dislocation is sometimes treated by incising the soft parts and returning the head of the humerus into the glenoid cavity. In other cases the head of the humerus is excised. *Dislocation* of the long tendon of the *Biceps muscle* from the bicipital groove is a rare accident. When it occurs the arm is rigid in abduction, but the head of the humerus is found to be in the glenoid cavity. It is reduced by flexion of the elbow and rotation of the arm. *Rupture* of the long tendon of the Biceps is more common than dislocation of the tendon. After this injury the belly of the muscle is relaxed and is nearer than normal to the elbow; flexion of the forearm is much weakened, and is weaker in supination than it is in pronation. The head of the humerus passes forward and inward, and the condition is often mistaken for dislocation of the bone.

If we desire to *aspirate* the shoulder-joint, place the arm against the side, flex the forearm at a right angle to the arm, carry the forearm across the front of the thorax, and enter the trocar below the acromion (De Vos).

The shoulder-joint is sometimes the seat of all those *inflammatory affections*, both acute and chronic, which attack joints, though perhaps it suffers less frequently than some other joints of equal size and importance. *Acute synovitis* may result from injury, rheumatism, or pyemia, or may follow secondarily on the so-called acute epiphysitis of infants. It is attended with effusion into the joint, and when this occurs the capsule is evenly distended and the contour of the joint rounded. Special projections may occur at the site of the openings in the capsular ligament. Thus, a swelling may appear just in front of the joint, internal to the lesser tuberosity, from effusion into the bursa beneath the Subscapularis muscle; or, again, a swelling which is sometimes bilobed may be seen in the interval between the Deltoid and Pectoralis major muscles, from effusion into the diverticulum, which runs down the bicipital groove with the tendon of the Biceps. The effusion into the synovial membrane can be best ascertained by examination from the axilla, where a soft, elastic, fluctuating swelling can usually be felt. The *bursa* beneath the *Deltoid* is sometimes ruptured by violence, and sometimes inflames, suppurates, or becomes tuberculous.

Tuberculous arthritis not infrequently attacks the shoulder-joint, and may lead to total destruction of the articulation, when ankylosis may result or long-protracted suppuration may necessitate excision. This joint is also one of those which is most liable to be the seat of *osteoarthritis*, and may also be affected in gout and rheumatism; or in locomotor ataxia, when it occasionally becomes the seat of *Charcot's disease*.

Excision of the shoulder-joint may be required in cases of arthritis (especially the tuberculous form) which have gone on to destruction of the articulation; in *compound dislocations* and *fractures*, particularly those arising from gunshot injuries, in which there has been extensive injury to the head of the bone; in some cases of old *unreduced dislocation*, where there is much pain; and possibly in some few cases of growth connected with the upper end of the bone. The operation is best performed by making an incision from the middle of the coracoclavicular ligament down the arm for about three inches; this will expose the bicipital groove and the tendon of the Biceps, which may be either divided or hooked out of the way, according as to whether it is implicated in the disease or not. The capsule is then freely opened, and the muscles attached to the greater and lesser tuberosities of the humerus divided. The head of the bone can then be thrust out of the wound and sawed off, or divided with a narrow saw *in situ* and subsequently removed. The section should be made, if possible, just below the articular surface, so as to leave the bone as long as possible. The glenoid cavity must then be examined, and gouged if carious.

V. Elbow-joint (*Articulatio Cubiti*) (Figs. 248, 249).

The elbow is a ginglymus or hinge-joint. The bones entering into its formation are the trochlea of the humerus, which is received into the greater sigmoid cavity of the ulna, and admits of the movements peculiar to such a joint—viz., flexion and extension; while the capitellum or radial head of the humerus articulates with the cup-shaped depression on the head of the radius; the circumference of the head of the radius articulates with the lesser sigmoid cavity of the ulna, allowing of the movement of rotation of the radius on the ulna, the chief action of the superior radioulnar articulation. The articular surfaces are covered by a thin layer of hyaline cartilage, and connected by a capsular

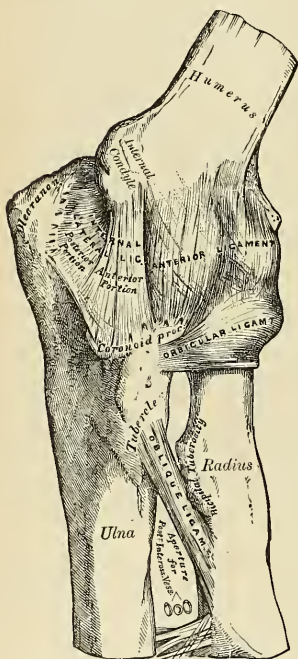


FIG. 248.—Left elbow-joint, showing anterior and internal ligaments.

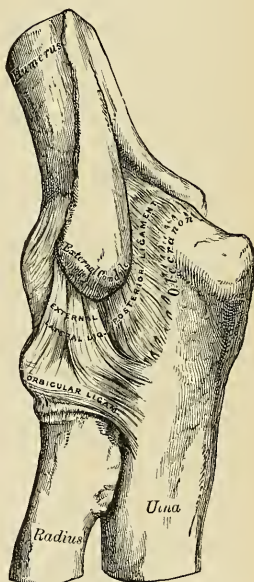


FIG. 249.—Left elbow-joint, showing posterior and external ligaments.

ligament (*capsula articularis*) (Fig. 250) of unequal thickness, being especially thickened on its two sides and, to a less extent, in front and behind. These thickened portions are usually described as distinct ligaments under the following names:

Anterior.
Posterior.

Internal Lateral.
External Lateral.

The **orbicular ligament** of the upper radio-ulnar articulation must also be reckoned among the ligaments of the elbow (see p. 310).

The **anterior ligament** (Fig. 248) is a broad and thin fibrous layer which covers the anterior surface of the joint. It is attached, *above*, to the front of the internal condyle and to the front of the humerus immediately above the coronoid and radial fossæ; *below*, to the anterior surface of the coronoid process of the ulna and to the orbicular ligament, being continuous on each side with the lateral ligaments. Its superficial fibres pass obliquely from the inner condyle of the humerus outward to the orbicular ligament. The middle fibres, vertical in direction, pass from the upper part of the coronoid depression and become partly blended with the preceding, but are mainly inserted into the anterior surface of the coronoid process. The deep or transverse set intersects these at right angles. This ligament is in relation, in front, with the Brachialis anticus muscle, except at its outermost part.

The **posterior ligament** (Fig. 249) is a thin and loose membranous fold, attached, *above*, to the lower end of the humerus, above and at the sides of the olecranon fossa; *below*, to the groove on the upper and outer surfaces of the olecranon. The superficial or transverse fibres pass between the adjacent margins of the olecranon fossa. The deeper portion consists of vertical fibres, some of which, thin and weak, pass from the upper part of the olecranon fossa to the margin of the olecranon; others, thicker and stronger, pass from the back of the capitellum of the humerus to the posterior border of the lesser sigmoid cavity of the ulna. This ligament is in relation, behind, with the tendon of the Triceps muscle and the Anconeus muscle.

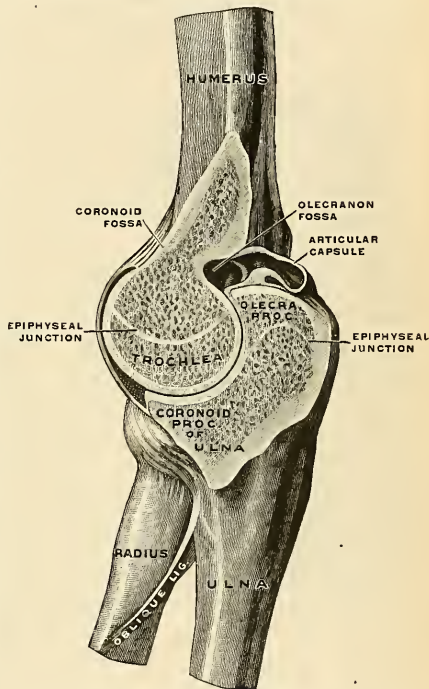


FIG. 250.—Right elbow-joint, cut through at right angles to the axis of the trochlea humeri, from the ulnar side. (Spalteholz.)

The **internal lateral ligament** (*ligamentum collaterale ulnare*) (Fig. 248) is a thick triangular band consisting of two portions, an anterior and posterior, united by a thinner intermediate portion. The **anterior portion**, directed obliquely forward, is attached, *above*, by its apex, to the front part of the internal condyle of the humerus; and, *below*, by its broad base, to the inner margin of the coronoid process. The **posterior portion**, also of triangular form, is attached, *above*, by its apex, to the lower and back part of the internal condyle; *below*, to the inner margin of the olecranon. Between these two bands a few intermediate fibres descend from the internal condyle to blend with a transverse band of ligamentous

tissue which bridges across the notch between the olecranon and coronoid processes. This ligament is in relation, internally, with the Triceps and Flexor carpi ulnaris muscles and the ulnar nerve, and gives origin to part of the Flexor sublinis digitorum muscle.

The **external lateral ligament** (*ligamentum collaterale radiale*) (Fig. 249) is a short and narrow fibrous band less distinct than the internal, attached, *above*, to a depression below the external condyle of the humerus; *below*, to the orbicular ligament, some of its most posterior fibres passing over that ligament, to be inserted into the outer margin of the ulna. This ligament is intimately blended with the tendon of origin of the Supinator [brevis] muscle.

Synovial Membrane (Fig. 250).—The synovial membrane is very extensive. It covers the margin of the articular surface of the humerus, and lines the coronoid and olecranon fossæ on that bone; from these points it is reflected over the anterior, posterior, and lateral ligaments,

and forms a pouch (*recessus sacciformis*) between the lesser sigmoid cavity, the internal surface of the orbicular ligament, and the circumference of the head of the radius. Projecting into the cavity is a crescentic fold of synovial membrane, between the radius and ulna, suggesting the division of the joint into two—one the humeroradial, the other the humeroulnar.

Between the capsular ligament and the synovial membrane are three masses of fat—one, the largest, above the olecranon fossa, which is pressed into the fossa by the Triceps during flexion; a second, over the coronoid fossa; and a third, over the radial fossa. The two last-named pads are pressed into their respective fossæ during extension.

The **muscles** (Fig. 251) in relation with the joint are, in *front*, the Brachialis anticus; *behind*, the Triceps and Anconeus; *externally*, the Supinator [brevis] and the common tendon of origin of the Extensor muscles; *internally*, the common tendon of origin of the Flexor muscles, and the Flexor carpi ulnaris, with the ulnar nerve.

The **arteries** supplying the joint are derived from the anastomosis between the superior profunda, inferior profunda, and anastomotica magna, branches of the brachial, with the anterior, posterior, and interosseous recurrent branches of the ulnar and the recurrent branch of the radial. These vessels form a complete chain of anastomoses around the joint.

The **nerves** are derived from the ulnar as it passes between the internal condyle and the olecranon; a filament from the musculocutaneous, and two filaments from the median.

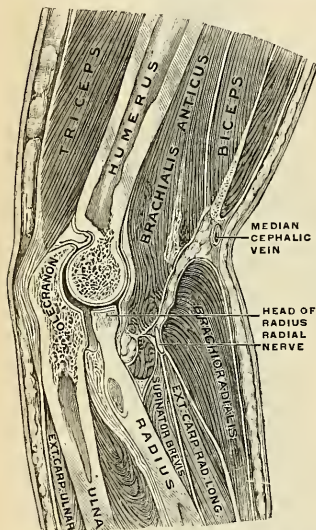


FIG. 251.—Sagittal section of the right elbow-joint, taken somewhat obliquely and seen from the radial aspect. (After Braune.)

Bursæ.—The **olecranon bursa** (*bursa subcutanea olecrani*) is placed between the olecranon process and the cutaneous surface. A bursa exists between the tendon of the Biceps brachii and the tubercle of the radius (*bursa bicipitoradialis*); another between the Triceps tendon and the olecranon process (*bursa subtendinea olecrani*); a third between the cutaneous surface and the external condyle (*bursa subcutanea epicondylus humeri lateralis*); a fourth between the cutaneous surface and the internal condyle (*bursa subcutanea epicondylus humeri medialis*); and a fifth internal to the Triceps tendon at its insertion on the olecranon (*bursa intratendinea olecrani*).

Movements.—The elbow-joint comprises three different portions—viz., the joint between the ulna and humerus, that between the head of the radius and the humerus, and the superior radioulunar articulation, described below. All these articular surfaces are invested by a common synovial membrane, and the movements of the whole joint should be studied together. The combination of the movements of flexion and extension of the forearm with those of pronation and supination of the hand, which is insured by the two being performed at the same joint, is essential to the accuracy of the various minute movements of the hand.

The portion of the joint between the ulna and humerus is a simple hinge-joint, and allows

of movements of flexion and extension only. Owing to the obliquity of the trochlear surface of the humerus, this movement does not take place in a straight line. When the forearm is extended and supinated the axis of the arm is not in the same line as the axis of the forearm, but the axis of the arm forms an angle with the axis of the forearm, and the hand, with the forearm, is directed outward. During flexion, on the other hand, the forearm and the hand tend to approach the middle line of the body, and thus enable the hand to be easily carried to the face. The shape of the articular surface of the humerus, with its prominences and depressions accurately adapted to the opposing surface of the olecranon, prevents any lateral movement. *Flexion* is produced by the action of the Biceps and Brachialis anticus, assisted by the muscles arising from the internal condyle of the humerus and by the Brachioradialis; *extension*, by the Triceps and Anconeus, assisted by the Extensors of the wrist and by the Extensor communis digitorum and Extensor minimi digiti.

The joint between the head of the radius and the capitellum or radial head of the humerus is an arthrodial joint. The bony surfaces would of themselves constitute an enarthrosis, and allow of the movement in all directions were it not for the orbicular ligament by which the head of the radius is bound down firmly to the lesser sigmoid cavity of the ulna, an arrangement which prevents any lateral separation of the two bones. It is to the same ligament that the head of the radius owes its security from dislocation, which would otherwise constantly occur as a consequence of the shallowness of the cup-like surface on the head of the radius. In fact, but for this ligament the tendon of the Biceps would be liable to pull the head of the radius out of joint.¹ In complete extension the head of the radius glides so far back on the outer condyle that its edge is plainly felt at the back of the articulation. Flexion and extension of the elbow-joint are limited by the tension of the structures on the front and back of the joint, the limitation of flexion being also aided by the soft structures of the arm and forearm coming in contact.

In combination with any position of flexion or extension the head of the radius can be rotated in the upper radioulnar joint, carrying the hand with it. The hand is directly articulated to the lower surface of the radius only, and the concave or sigmoid surface on the lower end of the radius travels around the lower end of the ulna. The latter bone is excluded from the wrist-joint (as will be seen in the sequel) by the articular disk. Thus, rotation of the head of the radius around an axis which passes through the centre of the radial head of the humerus imparts circular movement to the hand through a very considerable arc.

Surface Form.—If the forearm be slightly flexed on the arm, a curved crease or fold with its convexity downward may be seen running across the front of the elbow, extending from one condyle to the other. The centre of this fold is some slight distance above the line of the joint. The position of the radiohumeral portion of the joint can be at once ascertained by feeling for a slight groove or depression between the head of the radius and the capitellum of the humerus at the back of the articulation.

Applied Anatomy.—From the great breadth of the joint, and the manner in which the articular surfaces are interlocked, and also on account of the strong lateral ligaments and the support which the joint derives from the mass of muscles attached to each condyle of the humerus, *lateral displacement* of the bones is very uncommon, whereas *antero-posterior dislocation*, on account of the shortness of the antero-posterior diameter, the weakness of the anterior and posterior ligaments, and the want of support of muscles, much more frequently takes place, dislocation backward taking place when the forearm is in a position of extension, and forward when in a position of flexion. For, in the former position, that of extension, the coronoid process is not interlocked into the coronoid fossa, and loses its grip to a certain extent, whereas the olecranon process is in the olecranon fossa, and entirely prevents displacement forward. On the other hand, during flexion, the coronoid process is in the coronoid fossa, and prevents dislocation backward, while the olecranon loses its grip and is not so efficient, as during extension, in preventing a forward displacement. When lateral dislocation does take place, it is generally incomplete.

Dislocation of the elbow-joint is of common occurrence in children, far more common than dislocation of any other articulation. In lesions of this joint there is often very great difficulty in ascertaining the exact nature of the injury. *Sprain* of the elbow is a very common injury in childhood. Injury to the radiohumeral joint is frequently produced by lifting a child by the hand, as in swinging it over a gutter. The Supinator [brevis], which under normal circumstances would retain the head of the radius against the capitellum of the humerus, is unable to do so, the radiohumeral articulation receives the force and the orbicular ligament undergoes upward displacement, is caught between the head of the radius and the capitellum, and jams the joint. This injury is often called *subluxation of the head of the radius*.

The elbow-joint is occasionally the seat of *acute synovitis*. The synovial membrane then becomes distended with fluid, the bulging showing itself principally around the olecranon process; that is to say, on its inner and outer sides and above, in consequence of the laxness of the

¹ Humphry, op. cit., p. 419.

posterior ligament. Occasionally, a well-marked, triangular projection may be seen on the outer side of the olecranon, from bulging of the synovial membrane beneath the Anconeus muscle. Again, there is often some swelling just above the head of the radius, in the line of the radio-humeral joint. There is generally not much swelling at the front of the joint, though sometimes deep-seated fulness beneath the Brachialis anticus may be noted. When suppuration occurs the abscess usually points at one or other border of the Triceps muscle; occasionally the pus discharges itself in front, near the insertion of the Brachialis anticus muscle. *Chronic synovitis*, usually of tuberculous origin, is of common occurrence in the elbow-joint; under these circumstances the forearm tends to assume the position of semiflexion, which is that of greatest ease and relaxation of ligaments. It should be borne in mind that should ankylosis occur in this or the extended position, the limb will not be nearly so useful as if it becomes ankylosed in a position of rather less than a right angle. *Loose cartilages* are sometimes met with in the elbow-joint, not so commonly, however, as in the knee; nor do they, as a rule, give rise to such urgent symptoms. They rarely require operative interference. The elbow-joint is also sometimes affected with *osteoarthritis*, but this affection is less common in this articulation than in some other of the larger joints. *Bursitis* about the elbow, generally known as *miners' elbow*, is not uncommon.

Excision of the elbow is principally required for one of three conditions—viz., tuberculous arthritis, injury and its results, and ankylosis in a position which greatly impairs the usefulness of the limb; but may be necessary for some other rarer conditions, such as disorganizing arthritis after pyæmia, unreduced dislocation, and osteoarthritis. The results of the operation are, as a rule, more favorable than those of excision of any other joint, and it is one, therefore, that the surgeon should never hesitate to perform, especially in the first three of the conditions mentioned above. The operation is best performed by a single vertical incision down the back of the joint, a transverse incision, over the outer condyle, being added if the parts are much thickened and fixed. A straight incision is made about four inches long, the mid-point of which is on a level with and a little to the inner side of the tip of the olecranon. This incision is made down to the bone, through the substance of the Triceps muscle. The operator with the point of his knife, and guarding the soft parts with his thumb-nail, separates them from the bone. In doing this there are two structures which he should carefully avoid—the ulnar nerve, which lies parallel to his incision, but a little internal, as it courses down between the internal condyle and the olecranon process, and the prolongation of the Triceps into the deep fascia of the forearm over the Anconeus muscle. Having cleared the bones and divided the lateral and posterior ligaments, the forearm is strongly flexed and the ends of the bone turned out and sawed off. The section of the humerus should be through the base of the condyles, that of the ulna and radius should be just below the level of the lesser sigmoid cavity of the ulna and the neck of the radius. In this operation the object is to obtain such fibrous union as shall allow free motion of the bones of the forearm: and, therefore, passive motion must be commenced early, that is to say, about the tenth day.

VI. Radioulnar Articulation (*Articulatio Radioulnaris*).

The articulation of the radius with the ulna is effected by ligaments which connect both extremities as well as the shafts of these bones. It may, consequently, be subdivided into three articulations: (1) The **superior radioulnar**, which is a portion of the elbow-joint; (2) the **middle radioulnar**; and (3) the **inferior radioulnar** articulations.

1. SUPERIOR ARTICULATION (*Articulatio Radioulnaris Proximalis*).

This articulation is a trochoid or pivot-joint. The bones entering into its formation are the inner side of the circumference of the head of the radius rotating within the lesser sigmoid cavity of the ulna. Its only ligament is the annular or orbicular.

The **orbicular** or **annular ligament** (*ligamentum annulare radii*) (Figs. 248, 249, and 252) is a strong, flat band of ligamentous fibres which surrounds the head of the radius and retains it in firm connection with the lesser sigmoid cavity of the ulna. It forms about four-fifths of an osseofibrous ring, attached by each end to the extremities of the lesser sigmoid cavity, and is smaller at the lower part of its

circumference than above, by which means the head of the radius is more securely held in its position. Its *outer surface* is strengthened by the external lateral ligament of the elbow, and affords origin to part of the Supinator [brevis] muscle. Its *inner surface* is smooth, and lined with synovial membrane. The synovial membrane is continuous with that which lines the elbow-joint.

Movements.—The movement which takes place in this articulation is limited to rotation of the head of the radius within the orbicular ligament, and upon the lesser sigmoid cavity of the ulna; the axis of rotation passes through the centre of the capitellum of the humerus. Rotation forward is called *pronation*; rotation backward, *supination*. Supination is performed by the Biceps and Supinator [brevis], assisted to a slight extent by the Extensor muscles of the thumb and, in certain positions, by the Brachioradialis. Pronation is effected by the Pronator teres and Pronator quadratus, assisted, in some positions, by the Brachioradialis.

Surface Form.—The position of the superior radioulnar joint is marked on the surface of the body by the little dimple on the back of the elbow, which indicates the position of the head of the radius.

Applied Anatomy.—Dislocation of the head of the radius alone is not an uncommon accident, and occurs most frequently in young persons from falls on the hand when the forearm is extended and supinated, the head of the bone being displaced forward. It is attended by rupture of the orbicular ligament. Occasionally a peculiar injury, which is supposed to be a *subluxation*, occurs in young children in lifting them from the ground by the hand or forearm. It is believed that the head of the radius is displaced downward or the orbicular ligament upward, and the upper border of the ligament becomes folded over the head of the radius, between it and the capitellum of the humerus.

2. MIDDLE RADIOULNAR LIGAMENTS.

The interval between the shafts of the radius and ulna is occupied by two ligaments.

Oblique.
Interosseous.

The **oblique ligament** (*chorda obliqua*) (Figs. 248 and 252) is a small, flattened fibrous band which extends obliquely downward and outward from the tubercle of the ulna at the base of the coronoid process to the radius a little below the bicipital tuberosity. Its fibres run in the opposite direction to those of the

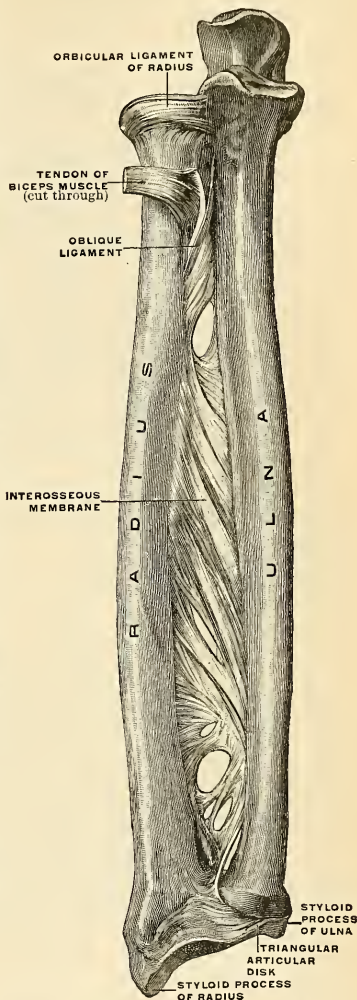


FIG. 252.—Bones of the right forearm, with their ligaments; volar aspect. (Spalteholz.)

interosseous ligament, and it appears to be placed as a substitute for it in the upper part of the interosseous interval. This ligament is sometimes wanting.

The **interosseous membrane** (*membrana interossea antebrachii*) (Fig. 252) is a broad and thin plane of fibrous tissue descending obliquely downward and inward, from the interosseous ridge on the radius to that on the ulna. It is deficient above, commencing about an inch beneath the tubercle of the radius; is broader in the middle than at either extremity; and presents an oval aperture just above its lower margin for the passage of the anterior interosseous vessels to the back of the forearm. This ligament serves to connect the bones and to increase the extent of surface for the attachment of the deep muscles. Between its upper border and the oblique ligament an interval exists through which the posterior interosseous vessels pass to the dorsum of the forearm. Two or three fibrous bands are occasionally found on the dorsal surface of this membrane which descend obliquely from the ulna toward the radius, and which have consequently a direction contrary to that of the other fibres. It is in relation, *in front*, by its upper three-fourths with the Flexor longus pollicis on the outer side, and with the Flexor profundus digitorum on the inner, lying upon the interval between which are the anterior interosseous vessels and nerve; by its lower fourth, with the Pronator quadratus; *behind*, with the Supinator [brevis], Extensor ossis metacarpi pollicis, Extensor brevis pollicis, Extensor longus pollicis, Extensor indicis; and, near the wrist, with the anterior interosseous artery and posterior interosseous nerve.

3. INFERIOR ARTICULATION (ARTICULATIO RADIOULNARIS DISTALIS).

This is a **pivot-joint**, formed by the sigmoid cavity at the inner side of the lower end of the radius receiving the head of the ulna. The articular surfaces are covered by a thin layer of hyaline cartilage, and connected by a capsule, portions of which are usually described as distinct ligaments. The ligaments of the articulation are:

Anterior Radioulnar.	Posterior Radioulnar.
Triangular Articular Disk.	

The **anterior radioulnar ligament** (Fig. 253) is a narrow band of fibres extending from the anterior margin of the sigmoid cavity of the radius to the anterior surface of the head of the ulna.

The **posterior radioulnar ligament** (Fig. 254) extends between similar points on the posterior surface of the articulation.

The **triangular articular disk** (*discus articularis*) (Figs. 252 and 256) is triangular in shape, and is placed transversely beneath the head of the ulna, binding the lower end of this bone and the radius firmly together. Its periphery is thicker than its centre, which is thin and occasionally perforated. It is attached by its apex to a depression which separates the styloid process of the ulna from the head of that bone; and by its base, which is thin, to the prominent edge of the radius, which separates the sigmoid cavity from the carpal articulating surface. Its margins are united to the ligaments of the wrist-joint. Its *upper surface*, smooth and concave, articulates with the head of the ulna, forming an arthrodial joint; its *under surface*, also concave and smooth, forms part of the wrist-joint and articulates with the cuneiform and inner part of the semilunar bone. Both surfaces are covered by a synovial membrane—the upper surface by one peculiar to the radioulnar articulation; the under surface, by the synovial membrane of the wrist.

Synovial Membrane.—The synovial membrane (Fig. 256) of this articulation has been called, from its extreme looseness, the *membrana sacciformis*. It projects horizontally inward between the head of the ulna and the articular disk, and upward between the radius and the ulna, forming a very loose cul-de-sac (*recessus sacciformis*). The quantity of synovia which it contains is usually considerable. The inferior radioulnar joint does not communicate with the wrist-joint.

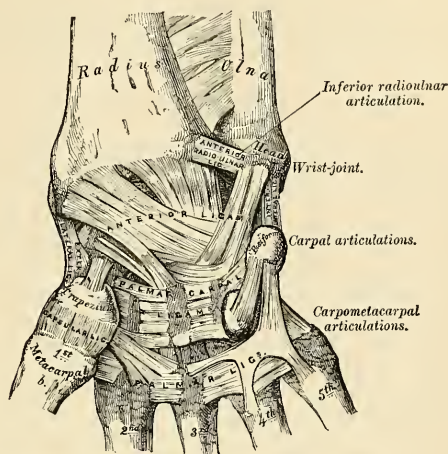


FIG. 253.—Ligaments of wrist and hand. Anterior view.

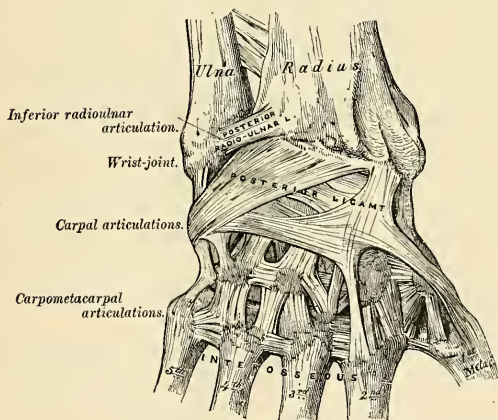


FIG. 254.—Ligaments of wrist and hand. Posterior view.

Movements.—These consist of a movement of rotation through about 160 degrees of the lower end of the radius around an axis which corresponds to the centre of the head of the ulna. When the radius rotates forward, *pronation* of the forearm and hand is the result; and when backward, *supination*. It will thus be seen that in pronation and supination of the forearm and hand the radius describes a segment of a cone, the axis of which extends from the centre of the head

of the radius to the middle of the head of the ulna. In this movement, however, the ulna is not quite stationary, but rotates a little in the opposite direction. So that it also describes the segment of a cone, though of smaller size than that described by the radius. The movement which causes this alteration in the position of the head of the ulna takes place principally at the shoulder-joint by the rotation of the humerus, but possibly also to a slight extent at the elbow-joint.¹

Surface Form.—The position of the inferior radio-ulnar joint may be ascertained by feeling for a slight groove at the back of the wrist, between the prominent head of the ulna and the lower end of the radius, when the forearm is in a state of almost complete pronation.

VII. Radiocarpal or Wrist-joint (*Articulatio Radiocarpea*) (Figs. 253, 254).

The **wrist** is a condyloid articulation. The parts entering into its formation are the lower end of the radius and under surface of the articular disk, which form together the receiving cavity, and the scaphoid, semilunar, and the cuneiform bones, which form the condyle. The articular surface of the radius and the under surface of the articular disk are the receiving cavity, forming together a transversely elliptical concave surface. The articular surfaces of the scaphoid, semilunar, and cuneiform bones form together a smooth, convex surface, the condyle, which is received into the concavity above mentioned. All the bony surfaces of the articulation are covered by hyaline cartilage, and are connected by a capsule, which is divided into the following ligaments:

External Lateral.
Internal Lateral.

Anterior.
Posterior.

The **external lateral ligament** (*ligamentum collaterale carpi radiale*) (Fig. 253) extends from the summit of the styloid process of the radius to the outer side of the scaphoid, some of its fibres being prolonged to the trapezium and annular ligament.

The **internal lateral ligament** (*ligamentum collaterale carpi ulnare*) (Fig. 253) is a rounded cord, attached, *above*, to the extremity of the styloid process of the ulna, and dividing, *below*, into two fasciculi, which are attached, one to the inner side of the cuneiform bone, the other to the pisiform bone and annular ligament.

The **anterior or volar ligament** (*ligamentum radiocarpeum volare*) (Fig. 253) is a broad, membranous band, attached, *above*, to the anterior margin of the lower end of the radius, to its styloid process, and to the ulna; its fibres pass downward and inward to be *inserted* into the palmar surface of the scaphoid, semilunar, and cuneiform bones. Some of the fibres are continued to the os magnum. In addition to this broad membrane there is a distinct rounded fasciculus, superficial to the rest, which passes from the base of the styloid process of the ulna to the semilunar and cuneiform bones. This ligament is perforated by numerous apertures for the passage of vessels, and is in relation, in *front*, with the tendons of the Flexor profundus digitorum and of the Flexor longus pollicis.

The **posterior or dorsal ligament** (*ligamentum radiocarpeum dorsale*) (Fig. 254), thinner and weaker than the anterior, is attached, *above*, to the posterior border of the lower end of the radius; its fibres pass obliquely downward and inward, to be attached to the dorsal surface of the scaphoid, semilunar, and cuneiform bones, and are continuous with those of the dorsal carpal ligaments. This ligament is in relation, *behind*, with the Extensor tendons of the fingers.

Synovial Membrane.—The synovial membrane (Fig. 255) lines the inner surface of the ligaments above described, extending from the lower end of the radius and articular disk above

¹ See Hultkrantz, *Das Ellenbogen Gelenk und seine Mechanik*, Jena, 1897.

to the articular surfaces of the carpal bones below. It is loose and lax, and presents numerous folds, especially behind.

The **arteries** supplying the joint are the anterior and posterior carpal branches of the radial and ulnar, the anterior and posterior interosseous, and some ascending branches from the deep palmar arch.

The **nerves** are derived from the ulnar and posterior interosseous.

Movements.—The movements permitted in this joint are *volar flexion*, *dorsi-flexion*, *abduction*, *adduction*, and *circumduction*. Its actions will be further studied with those of the carpus, with which they are combined.

Surface Form.—The line of the radiocarpal joint is on a level with the apex of the styloid process of the ulna.

Applied Anatomy.—The wrist-joint is rarely *dislocated*, its strength depending mainly upon the numerous strong tendons which surround the articulation. Its security is further provided for by the number of small bones of which the carpus is made up, and which are united by very strong ligaments. The slight movement which takes place between the several bones serves to break the jars that result from falls or blows on the hand. Dislocation backward, which is the more common dislocation, simulates to a considerable extent Colles' fracture of the radius, and is apt to be mistaken for it. The diagnosis can be easily made out by observing the relative position of the styloid processes of the radius and ulna. In the natural condition the styloid process of the radius is on a lower level—*i. e.*, nearer the ground—when the arm hangs by the side, than that of the ulna, and the same would be the case in dislocation. In Colles' fracture, on the other hand, the styloid process of the radius is on the same or even a higher level than that of the ulna.

The wrist-joint is occasionally the seat of *acute synovitis*, the result of traumatism or consequent upon rheumatic or pyemic conditions. When the synovial sac is distended with fluid, the swelling is greatest on the dorsal aspect of the wrist, and shows a general fulness, with some bulging between the tendons. The inflammation is prone to extend to the intercarpal joints and to attack also the sheaths of the tendons in the neighborhood. *Chronic inflammation* of the wrist is generally tuberculous, and often leads to similar disease in the synovial sheaths of adjacent tendons and of the intercarpal joints. The disease, therefore, when progressive, frequently leads to necrosis of the carpal bones, and the result is often unsatisfactory.

VIII. Articulations of the Carpus (*Articulatio Intercarpea*) (Figs. 253, 254).

These articulations may be subdivided into three sets:

1. The Articulations of the First Row of Carpal Bones.
2. The Articulations of the Second Row of Carpal Bones.
3. The Articulations of the Two Rows with each other.

1. ARTICULATIONS OF THE FIRST ROW OF CARPAL BONES

These are arthrodial joints. The ligaments connecting the scaphoid, semilunar, and cuneiform bones are:

Dorsal.

Palmar.

Two Interosseous.

The **dorsal ligaments** (*ligamenta intercarpea dorsalia*) are placed transversely behind the bones of the first row; they connect the scaphoid and semilunar and the semilunar and cuneiform.

The **palmar** or **volar ligaments** (*ligamenta intercarpea volaria*) connect the scaphoid and semilunar and the semilunar and cuneiform bones; they are weaker than the dorsal, and placed very deeply below the anterior ligament of the wrist.

The **interosseous ligaments** (*ligamenta intercarpea interossea*) (Fig. 255) are two narrow bundles of fibrous tissue connecting the semilunar bone on one side with the scaphoid, and on the other with the cuneiform. They are on a level with the superior surfaces of these bones, and close the upper part of the spaces

between them. Their upper surfaces are smooth, and form with the bones the convex articular surfaces of the wrist-joint.

The ligaments connecting the pisiform bone are:

Capsular.

Two Palmar Ligaments.

The **capsular ligament** is a thin membrane which connects the pisiform bone to the cuneiform. It is lined by a separate synovial membrane.

The **two palmar ligaments** are two strong fibrous bands which connect the pisiform to the unciform (*ligamentum pisohamatum*), and to the base of the fifth metacarpal bone (*ligamentum pisometacarpeum*).

2. ARTICULATIONS OF THE SECOND ROW OF CARPAL BONES.

These are also arthrodial joints. The articular surfaces are covered with hyaline cartilage, and connected by the following ligaments:

Dorsal.

Palmar.

Three Interosseous.

The **dorsal ligaments** (*ligamenta intercarpea dorsalia*) extend transversely from one bone to another on the dorsal surface, connecting the trapezium with the trapezoid, the trapezoid with the os magnum, and the os magnum with the unciform.

The **palmar ligaments** (*ligamenta intercarpea volaria*) have a similar arrangement on the palmar surface.

The **three interosseous ligaments** (*ligamenta intercarpea interossea*) (Fig. 255), much thicker than those of the first row, are placed one between the os magnum and the unciform, a second between the os magnum and the trapezoid, and a third between the trapezium and trapezoid. The first of these is much the strongest, and the third is sometimes wanting.

3. ARTICULATIONS OF THE TWO ROWS OF CARPAL BONES WITH EACH OTHER (Figs. 253, 254).

The joint between the scaphoid, semilunar, and cuneiform, and the second row of the carpus, or the **midcarpal joint**, is made up of three distinct portions; in the centre the head of the os magnum and the superior surface of the unciform articulate with the deep, cup-shaped cavity formed by the scaphoid and semilunar bones, and constitute a sort of **ball-and-socket joint**. On the outer side the trapezium and trapezoid articulate with the scaphoid, and on the inner side the unciform articulates with the cuneiform, forming **gliding joints**.

Sometimes a small ligament joins the navicular to the neck of the os magnum and is representative of the os centrale (p. 206) (Sutton).

The ligaments are:

Anterior.

External Lateral.

Posterior.

Internal Lateral.

The **anterior or palmar ligaments** (*ligamenta intercarpea volaria*) consist of short fibres, which pass, for the most part, from the palmar surface of the bones of the first row to the front of the os magnum.

The **posterior or dorsal ligaments** (*ligamenta intercarpea dorsalis*) consist of short, irregular bundles of fibres passing between the bones of the first and second row on the dorsal surface of the carpus.

The **lateral ligaments** are very short; they are placed, one on the radial, the other on the ulnar side of the carpus; the *former*, the stronger and more distinct, connecting the scaphoid and trapezium, the *latter* the cuneiform and unciform; they are continuous with the lateral ligaments of the wrist-joint. In addition to these ligaments, a slender interosseous band sometimes connects the os magnum and the scaphoid.

Synovial Membrane (Fig. 255).—The synovial membrane of the carpus is very extensive; it passes from under the surface of the scaphoid, semilunar, and cuneiform bones to the upper surface of the bones of the second row, sending upward two prolongations—between the scaphoid and semilunar and the semilunar and cuneiform; sending downward three prolongations between the four bones of the second row, which are further continued onward into the carpometacarpal joints of the four inner metacarpal bones, and also for a short distance between the metacarpal bones. There is a separate synovial membrane between the pisiform and the cuneiform bones.

Movements.—The articulation of the hand and wrist, considered as a whole, is divided into three parts: (1) The radius and the articular disk, (2) the *meniscus*,¹ formed by the scaphoid, semilunar, and cuneiform, the pisiform bone having no essential part in the movements of the hand; (3) the hand proper, the metacarpal bones with the four carpal bones on which they are supported—viz., the trapezium, trapezoid, os magnum, and unciform. These three elements form two joints: (1) The superior, **wrist-joint proper**, between the meniscus and bones of the forearm; (2) the inferior, **transverse or midcarpal joint**, between the hand and meniscus.

1. The articulation between the forearm and carpus is a **true condyloid articulation**, and therefore all movements but rotation are permitted. Flexion and extension are the most extensive, and of these a greater amount of extension than flexion is permitted on account of the articulating surfaces extending farther on the dorsal than on the palmar aspect of the carpal bones. In this movement the carpal bones rotate on a transverse axis drawn between the tips of the styloid processes of the radius and ulna. A certain amount of adduction (or ulnar flexion) and abduction (or radial flexion) is also permitted. Of these movements, the former is considerably greater in extent than the latter. In these movements the carpus revolves upon an antero-posterior axis drawn through the centre of the wrist. Finally, *circumduction* is permitted by the consecutive movements of adduction, extension, abduction, and flexion, with intermediate movements between them. There is no rotation, but this is provided for by the supination and pronation of the radius on the ulna. The movement of *volar flexion* is performed by the Flexor carpi radialis, the Flexor carpi ulnaris, and by the Palmaris longus; *dorsi-flexion*, by the Extensor carpi radialis longior et brevior and the Extensor carpi ulnaris; *adduction* (ulnar flexion), by the Flexor carpi ulnaris and the Extensor carpi ulnaris; and *abduction* (radial flexion), by the Extensors of the thumb and the Extensores carpi radialis longior et brevior and the Flexor carpi radialis.

2. The chief movements permitted in the transverse or midcarpal joint are flexion, extension, and a slight amount of rotation. In *flexion* and *extension*, which are the movements most freely enjoyed, the trapezium and trapezoid on the radial side and the unciform on the ulnar side glide forward and backward on the scaphoid and cuneiform respectively, while the head of the os magnum and the superior surface of the unciform rotate in the cup-shaped cavity of the scaphoid and semilunar. Flexion at this joint is of greater range than extension. A very trifling amount of *rotation* is also permitted, the head of the os magnum rotating around a vertical axis drawn through its own centre, while at the same time a slight gliding movement takes place in the lateral portions of the joint.

IX. Carpometacarpal Articulations (*Articulationes Carpometacarpeae*) (Fig. 254).

1. ARTICULATION OF THE METACARPAL BONE OF THE THUMB WITH THE TRAPEZIUM (*ARTICULATIO CARPOMETACARPEA POLLICIS*).

This is a joint of reciprocal reception, and enjoys great freedom of movement, on account of the configuration of its articular surfaces, which are saddle-shaped,

¹ Called meniscus because the bones composing it serve the essential purposes of an articular disk.

so that, on section, each bone appears to be received into a cavity in the other, according to the direction in which they are cut. The joint is surrounded by a capsular ligament.

The **capsular ligament** is thick and fibrous, but loose, and passes from the circumference of the upper extremity of the metacarpal bones to the rough edge bounding the articular surface of the trapezium; it is thickest externally and behind, and lined with a separate synovial membrane.

Movements.—In the articulation of the metacarpal bone of the thumb with the trapezium, the movements permitted are *flexion*, *extension*, *adduction*, *abduction*, and *circumduction*. When the joint is flexed the metacarpal bone is brought in front of the palm and the thumb is gradually turned to the fingers. It is by this peculiar movement that the tip of the thumb is opposed to the other digits; for by slightly flexing the fingers the palmar surface of the thumb can be brought in contact with their palmar surfaces.

2. ARTICULATIONS OF THE METACARPAL BONES OF THE FOUR INNER FINGERS WITH THE CARPUS (ARTICULATIONES CARPOMETACARPEAE).

The joints formed between the carpus and four inner metacarpal bones are arthrodial joints. The ligaments are:

Dorsal.	Palmar.
Interosseous.	

The **dorsal ligaments** (*ligamenta carpometacarpea dorsalis*), the strongest and most distinct, connect the carpal and metacarpal bones on their dorsal surface. The second metacarpal bone receives two fasciculi—one from the trapezium, the other from the trapezoid; the third metacarpal receives two—one from the trapezoid and one from the os magnum; the fourth, two—one from the os magnum and one from the unciform; the fifth receives a single fasciculus from the unciform bone, which is continuous with a similar ligament on the palmar surface, thus forming an incomplete capsule.

The **palmar ligaments** (*ligamenta carpometacarpea volaria*) have a somewhat similar arrangement on the palmar surface, with the exception of the third metacarpal, which has three ligaments—an *external one* from the trapezium, situated above the sheath of the tendon of the Flexor carpi radialis; a *middle one*, from the os magnum; and an *internal one*, from the unciform.

The **interosseous ligaments** consist of short, thick fibres, which are limited to one part of the carpometacarpal articulation; they connect the contiguous inferior angles of the os magnum and unciform with the adjacent surfaces of the third and fourth metacarpal bones.

Synovial Membrane.—The synovial membrane is a continuation of that between the two rows of carpal bones. Occasionally, the articulation of the unciform with the fourth and fifth metacarpal bones has a separate synovial membrane.

The synovial membranes of the wrist and carpus (Fig. 255) are thus seen to be five in number. The *first*, the **membrana sacciformis** of the inferior radioulnar articulation, passes from the lower end of the ulna to the sigmoid cavity of the radius, and lines the upper surface of the articular disk. The *second* passes from the lower end of the radius and articular disk above to the bones of the first row below. The *third*, the most extensive, passes between the contiguous margins of the two rows of carpal bones—between the bones of the second row to the carpal extremities of the four inner metacarpal bones. The *fourth* passes from the margin of the trapezium to the metacarpal bone of the thumb. The *fifth* passes between the adjacent margins of the cuneiform and pisiform bones.

Movements.—The movement permitted in the carpometacarpal articulations of the four inner fingers is limited to a slight gliding of the articular surfaces upon each other, the extent of which varies in the different joints. Thus, the articulation of the metacarpal bone of the little finger is most movable, then that of the ring finger. The metacarpal bones of the index and middle fingers are almost immovable.

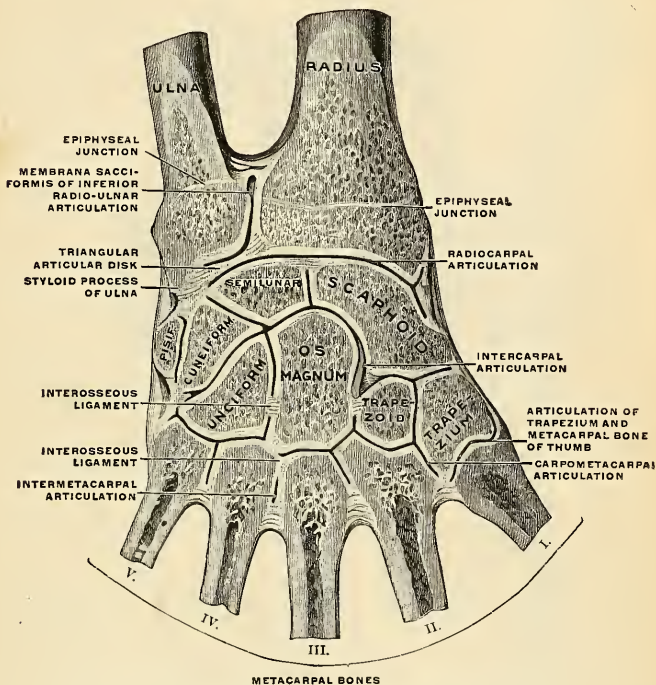


FIG. 255.—Joints of the right hand, from the back of the hand. (Spalteholz.)

3. ARTICULATIONS OF THE METACARPAL BONES WITH EACH OTHER (ARTICULATIONES INTERMETACARPEAE (Figs. 254, 255).

The carpal extremities of the four inner metacarpal bones articulate with one another at each side by small surfaces covered with cartilages, and connected by dorsal, palmar, and interosseous ligaments.

The **dorsal ligaments** (*ligamenta basium oss. metacarp. dorsalia*) and **palmar ligaments** (*ligamenta basium oss. metacarp. volaria*) pass transversely from one bone to another on the dorsal and palmar surfaces.

The **interosseous ligaments** (*ligamenta basium oss. metacarp. interossea*) pass between their contiguous surfaces, just beneath their lateral articular facets.

Synovial Membrane (Fig. 255).—The synovial membrane between the lateral facets is a reflection from that between the two rows of carpal bones.

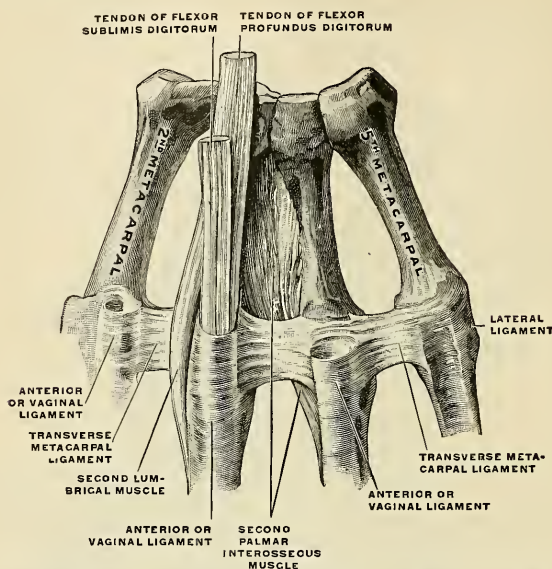


FIG. 256.—Metacarpal bones and first phalanges of the second to the fifth finger of the right hand, with ligaments, from the volar surface. (Spalteholz.)

The **transverse metacarpal ligament** (*ligamentum capitulorum oss. metacarpalium transversum*) (Fig. 256) is a narrow, fibrous band which passes transversely across the anterior surfaces of the digital extremities of the four inner metacarpal bones, connecting them. It is blended anteriorly with the palmar ligaments of the metacarpophalangeal articulations. To its posterior border is connected the fascia which covers the Interossei muscles. Its anterior surface is concave where the Flexor tendons pass over it. Behind it the tendons of the Interossei muscles pass to their insertion.

X. Metacarpophalangeal Articulations (*Articulationes Metacarpophalangeae*) (Figs. 256, 257).

These articulations are of the condyloid variety, formed by the reception of the rounded head of the metacarpal bone into a shallow cavity in the extremity of the first phalanx. The expansion of the Extensor communis digitorum tendon acts as a dorsal ligament. There is a capsular ligament which at certain points has strengthening ligaments. The ligaments are:

Anterior.

Two Lateral.

The **palmar or vaginal ligament** (*ligamentum vaginale*, glenoid ligament of Cruveilhier) is a thick, dense, fibrous structure, placed on the palmar surface of the joint in the interval between the lateral ligaments, to which it is connected; it is loosely united to the metacarpal bone, but very firmly to the base of the first phalanx. Its palmar surface is intimately blended with the transverse metacarpal ligament, and presents a groove for the passage of the Flexor tendons, the sheath surrounding which is connected to each side of the groove. By its deep surface it forms part of the articular surface for the head of the metacarpal bone, and is lined by a synovial membrane.

The **lateral ligaments** (*ligamenta collateralia*) are strong, rounded cords placed one on each side of the joint, each being attached by one extremity to the posterior tubercle on the side of the head of the metacarpal bone, and by the other to the contiguous extremity of the phalanx.

Movements.—The movements which occur in these joints are *flexion*, *extension*, *adduction*, *abduction*, and *circumduction*; the lateral movements are very extensive.

Surface Form.—The prominences of the knuckles do not correspond to the position of the joints either of the metacarpophalangeal or interphalangeal articulations. These prominences are invariably formed by the distal ends of the proximal bone of each joint, and the line indicating the position of the joint must be sought considerably in front of the middle of the knuckle.

XI. Articulations of the Phalanges (*Articulationes Digitorum Manus*) (Fig. 257)

These are ginglymus joints. Each joint has a capsule, and certain accentuated portions are regarded as definite ligaments. These ligaments are:

Anterior or Palmar.

Two Lateral (*ligamenta collateralia*).

The arrangement of these ligaments is similar to those in the metacarpophalangeal articulations; the Extensor tendon supplies the place of a dorsal ligament.

Movements.—The only movements permitted in the phalangeal joints are *flexion* and *extension*; these movements are more extensive between the first and second phalanges than between the second and third. The movement of flexion is very considerable, but extension is limited by the anterior and lateral ligaments.

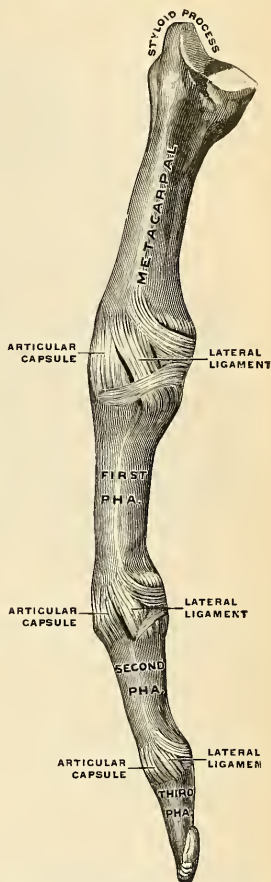


FIG. 257.—Metacarpal bones and first phalanges of the third finger of the right hand, with ligaments, from the radial side. (Spalteholz.)

ARTICULATIONS OF THE LOWER EXTREMITY.

The articulations of the lower extremity comprise the following groups:

- | | |
|---------------------------------------------------------|----------------------------------------------|
| I. The Hip-joint. | VI. The Tarsometatarsal Articulations. |
| II. The Knee-joint. | VII. Articulations of the Metatarsal |
| III. The Articulations between the
Tibia and Fibula. | Bones with each other. |
| IV. The Ankle-joint. | VIII. The Metatarsophalangeal Articulations. |
| V. The Articulations of the Tarsus. | IX. The Articulations of the Phalanges. |

I. The Hip-joint (*Articulatio Coxae*) (Figs. 258, 259).

This articulation is an enarthrodial or ball-and-socket joint, formed by the reception of the head of the femur into the cup-shaped cavity of the acetabulum. The articulating surfaces are covered by hyaline cartilage, that on the head of the femur being thicker at the centre than at the circumference, and covering the entire surface with the exception of a depression just below its centre for the attachment of the ligamentum teres; that covering the acetabulum is much thinner at the centre than at the circumference. This cartilage forms an incomplete ring of a horseshoe shape, being deficient below, where there is a circular depression, which in the recent state is occupied by a mass of fat covered by synovial membrane. The ligaments of the joints are the

Capsular.
Iliofemoral.

Teres.
Cotyloid.

Transverse.

The **capsular ligament** (*capsula articularis*) (Figs. 258 and 259) is a strong, dense, ligamentous capsule, embracing the margin of the acetabulum above and surrounding the neck of the femur below. Its *upper circumference* is attached to the acetabulum a short distance *above* and *behind* the cotyloid ligament, but in *front* it is attached to the outer margin of the ligament, and opposite to the notch, where the margin of this cavity is deficient, it is connected to the transverse ligament, and by a few fibres to the edge of the obturator foramen. Its *lower circumference* surrounds the neck of the femur, being attached, in *front*, to the spiral or anterior intertrochanteric line; *above*, to the base of the neck; *behind*, to the neck of the bone, about half an inch above the posterior intertrochanteric line. From this insertion the fibres are reflected upward over the neck of the femur, forming a sort of tubular sheath, the **cervical reflection**, which blends with the periosteum and can be traced as far as the cartilage which covers the head of the femur. On the surface of the neck of the femur some of these reflected fibres are raised into longitudinal folds, termed **retinacula**. It is much thicker at the upper and fore part of the joint, where the greatest amount of resistance is required, than below and internally, where it is thin, loose, and longer than in any other part. It consists of two sets of fibres, circular and longitudinal. The circular fibres, **zona orbicularis** (Fig. 261), are most abundant at the lower and back part of the capsule, and form a sling or collar around the neck of the femur. Anteriorly they blend with the deep surface of the iliofemoral ligament, and through this medium reach the anterior inferior spine of the ilium. The longitudinal fibres are greatest in amount at the upper and front part of the capsule, where

they form distinct bands or accessory ligaments, of which the most important is the **iliofemoral**. Other accessory bands are known as the **pubofemoral** (*ligamentum pubocapsulare*), passing from the outer portion of the horizontal pubic ramus, the iliopectineal eminence, the obturator crest and the obturator mem-

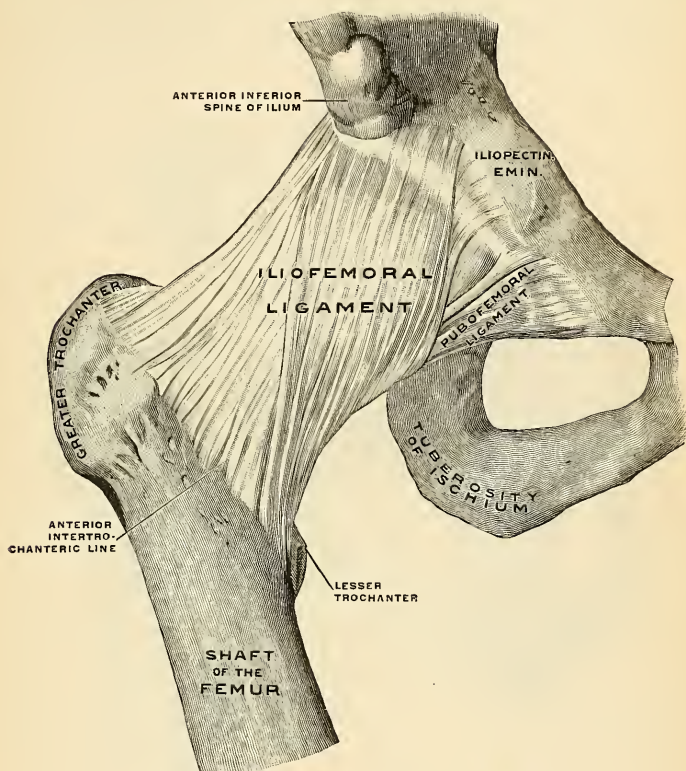


FIG. 258.—Right hip-joint, from in front. (Spalteholz.)

brane, to the front of the capsule; and the **ischiocapsular ligament** or **ligament of Bertin** (*ligamentum ischiocapsulare*), which passes from the ischium, just below the acetabulum, to blend with the circular fibres at the lower part of the joint. The *external surface* is rough, covered by numerous muscles, and separated in front from the Psoas and Iliacus muscles by a synovial bursa, which not infrequently communicates, by a circular aperture, with the cavity of the joint. It differs from the capsular ligament of the shoulder in being much less loose and lax, and in not being perforated for the passage of a tendon.

The **iliofemoral** (*ligamentum iliofemorale*) (Figs. 261 and 262) is an accessory band of fibres extending obliquely across the front of the joint; it is intimately connected with the capsular ligament, and serves to strengthen it in this situa-

tion. It is attached, *above*, to the lower part of the anterior inferior spine of the ilium and the adjacent rim of the acetabulum; and, diverging below, forms two bands, of which one passes downward to be inserted into the lower part of the anterior intertrochanteric line; the other passes downward and outward to be inserted into the upper part of the same line and the adjacent part of the neck of the femur. Between the two bands is a thinner part of the capsule. Sometimes there is no division, but the ligament spreads out into a flat, triangular

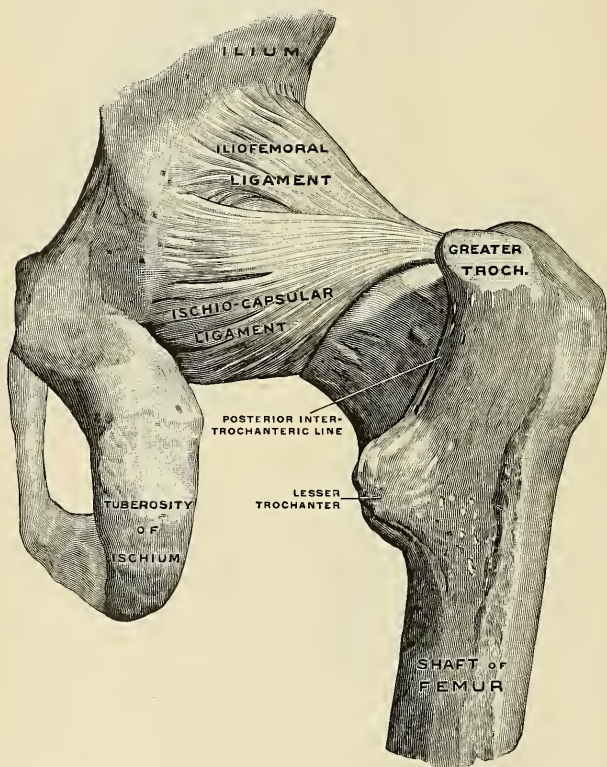


FIG. 259.—Right hip-joint, from behind. (The joint capsule, except for the strengthening ligaments, has been removed). (Spalteholz.)

band, which is attached below into the whole length of the anterior intertrochanteric line. This ligament is frequently called the **Y-shaped ligament of Bigelow**; and the outer or upper of the two bands is sometimes described as a separate ligament, under the name of the **iliotrochanteric ligament**.

The **ligamentum teres** (*ligamentum teres femoris*) (Figs. 261 and 262) is a triangular band implanted by its apex into the depression a little behind and below

the centre of the head of the femur, and by its broad base into the margins of the cotyloid notch, where it blends with the transverse ligament. It is formed of white fibrous connective tissue, surrounded by a tubular sheath of synovial membrane. Sometimes only the synovial fold exists. Very rarely it is absent. The ligament is made tense when the hip is semiflexed, and the limb adducted and rotated outward; it is, on the other hand, relaxed when the limb is abducted. It has, however, but little influence as a ligament, and though it may to a certain extent limit movement, it would appear to be merely a "vestigial and practically useless ligament."¹

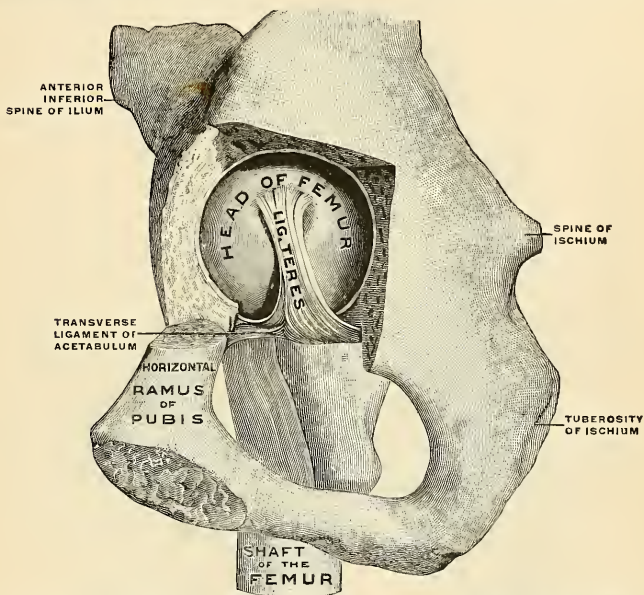


FIG. 260.—Right hip-joint from the mesal side. (The bottom of the acetabulum has been chiselled away sufficiently to make the head of the femur visible.) (Spalteholz.)

The **cotyloid ligament** (*labrum glenoidale* (Fig. 263) is a fibrocartilaginous rim attached to the margin of the acetabulum, the cavity of which it deepens; at the same time it protects the edges of the bone and fills up the inequalities on its surface. It bridges over the notch as the **transverse ligament of the acetabulum**, and thus forms a complete circle, which closely surrounds the head of the femur, and assists in holding it in its place. It is prismoid on section, its base being attached to the margin of the acetabulum and its opposite edge being free and sharp. Its two surfaces are invested by synovial membrane, the external one being in contact with the capsular ligament, the internal one being inclined inward, so as to narrow the acetabulum and embrace the cartilaginous surface of the head of the femur. It is much thicker above and behind than below and in front, and consists of close, compact fibres, which arise from different points of the

¹ J. Bland Sutton, *Ligaments: Their Nature and Morphology*, 1887.

circumference of the acetabulum and interlace with each other at very acute angles.

The **transverse ligament of the acetabulum** (*ligamentum transversum acetabuli*) (Figs. 260 and 263) is in reality a portion of the cotyloid ligament, though differing from it in having no cartilage cells among its fibres. It consists of strong, flattened fibres, which cross the notch at the lower part of the acetabulum and convert it into a foramen. Thus an interval is left beneath the ligament for the passage of nutrient vessels to the joint.

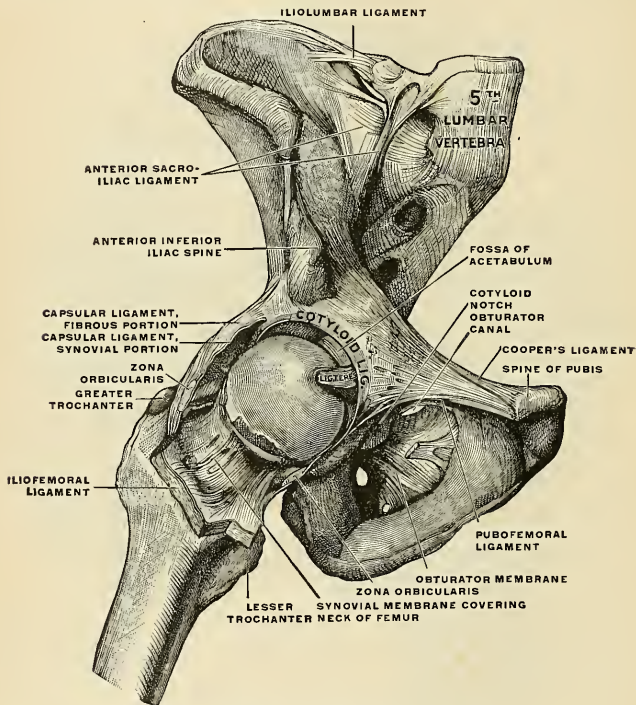


FIG. 261.—The right hip-joint, seen from before. (Toldt.)

The **synovial membrane** (Figs. 261 and 262) is very extensive. Commencing at the margin of the cartilaginous surface of the head of the femur, it covers all that portion of the neck which is contained within the joint; from the neck it is reflected on the internal surface of the capsular ligament; it covers both surfaces of the cotyloid ligament and the mass of fat contained in the depression at the bottom of the acetabulum, and it is prolonged as far as the head of the femur in the form of a tubular sheath around the ligamentum teres. It sometimes communicates through an aperture in the capsular ligament between the inner band of the Y-shaped ligament and the pubofemoral ligament with a bursa situated on the under surface of the Iliopsoas muscle.

The **muscles** in relation with the joint (Fig. 263) are, in *front*, the Psoas and Iliacus, separated from the capsular ligament by a synovial bursa; *above*, the reflected head of the Rectus femoris and Gluteus minimus, the latter being closely adherent to the capsule; *internally*, the

Obturator externus and Pectineus; *behind*, the Piriformis, Gemellus superior, Obturator internus, Gemellus inferior, Obturator externus, and Quadratus femoris.

The **arteries** supplying the joint are derived from the obturator, sciatic, internal circumflex, and gluteal.

The **nerves** are articular branches from the sacral plexus, great sciatic, obturator, accessory obturator, and a filament from the branch of the femoral (anterior crural) supplying the Rectus femoris.

Bursæ.—Numerous bursæ exist in the neighborhood of the hip-joint. Some anatomists have counted twenty-one (Synnestredt). The chief ones are: (1) The **iliopectineal bursa** (*bursa iliopectinea*) (Fig. 264), between the Iliopsoas tendon and the capsule of the joint. This bursa often communicates with the hip-joint. (2) The **subtendinous iliac bursa** (*bursa iliaca subtendinea*), between the tendon of the Psoas and Iliacus and the lesser trochanter. (3) The **ischio-**

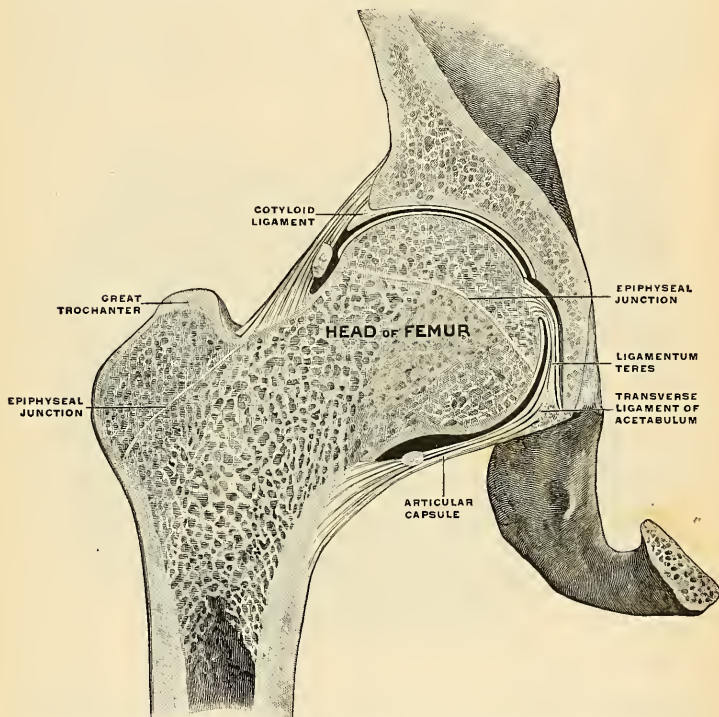


FIG. 262.—Right hip-joint. Frontal section. Posterior half, viewed from in front. The joint surfaces have been somewhat pulled apart. (Spalteholz.)

gluteal bursa (*bursa ischiadica m. glutæi maximi*), between the Gluteus maximus muscle and the tuberosity of the ischium (not constant). (4) The **bursa of the greater trochanter** (*bursa trochanterica m. glutæi maximi*), between the greater trochanter and the Gluteus maximus muscle near the muscular insertion. (5) Two or three **gluteofemoral bursæ** (*bursæ glutæofemorales*) below. (6) The **obturator bursa** (*bursa m. obturatorii interni*), between the margin of the great sacrosciatic notch and the tendon of the Obturator internus muscle. (7) The **subcutaneous trochanteric bursa** (*bursa trochanterica subcutanea*), between the cutaneous surface and the great

trochanter. Besides these there is a bursa between the greater trochanter and the anterior part of the Gluteus medius; between the greater trochanter and the posterior part of the Gluteus medius; between the greater trochanter and the Gluteus minimus; beneath the Piriformis muscle; between the lesser trochanter and the Quadratus femoris muscle; and there are bursæ beneath the Biceps femoris muscle.

Movements.—The movements of the hip are very extensive, and consist of *flexion, extension, adduction, abduction, circumduction, and rotation.*

The hip-joint presents a very striking contrast to the shoulder-joint in the much more complete mechanical arrangements for its security and for the limitation of its movements. In the shoulder, as we have seen, the head of the humerus is not adapted at all in size to the glenoid cavity, and is hardly restrained in any of its ordinary movements by the capsular ligament. In the hip-joint, on the contrary, the head of the femur is closely fitted to the acetabulum for a distance extending over nearly half a sphere, and at the margin of the bony cup it is still more closely embraced by the cotyloid ligament, so that the head of the femur is held in its place by that ligament even when the fibres of the capsule have been quite divided (Humphry). The anterior portion of the capsule, described as the iliofemoral ligament, is the strongest of all the ligaments in the body, and is put on the stretch by any attempt to extend the femur beyond a straight line with the trunk. That is to say, this ligament is the chief agent in maintaining the erect position without muscular fatigue; for a vertical line passing through the

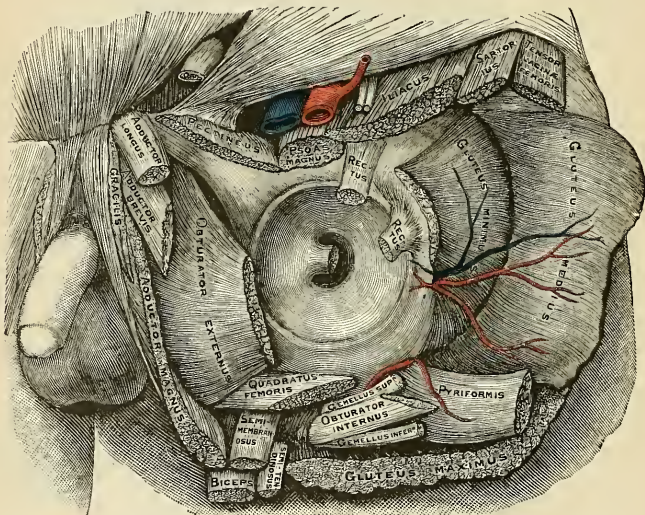


FIG. 263.—Relation of muscles to the capsule of the hip-joint. (From a drawing by Mr. F. A. Barton.)

centre of gravity of the trunk falls behind the centres of rotation in the hip-joint, and therefore the pelvis tends to fall backward, but is prevented by the tension of the iliofemoral and capsular ligaments. The security of the joint may be also provided for by the two bones being directly united through the ligamentum teres; but it is doubtful whether this so-called ligament can have much influence upon the mechanism of the joint. *Flexion* of the hip-joint is arrested by the soft parts of the thigh and abdomen being brought into contact when the leg is flexed on the thigh; and by the action of the Hamstring muscles when the leg is extended.¹ *Extension* is arrested by the tension of the iliofemoral ligament and the front of the capsule; *adduction*, by the thighs coming into contact; *adduction with flexion*, by the outer band of the iliofemoral ligament, and the outer part of the capsular ligament; *abduction*, by the inner band of the ilio-

¹ The hip-joint cannot be completely flexed, in most persons, without at the same time flexing the knee, on account of the shortness of the Hamstring muscles.—Cleland, Jour. of Anat. and Physiol., No. 1, Old Series, p. 87.

femoral ligament and the pubofemoral band; *rotation outward*, by the outer band of the iliofemoral ligament; and *rotation inward*, by the ischiocapsular ligament and the hinder part of the capsule. The muscles which *flex* the femur on the pelvis are the Psoas, Iliacus, Rectus femoris, Sartorius, Pectineus, Adductor longus and brevis, and the anterior fibres of the Gluteus medius and minimus. *Extension* is mainly performed by the Gluteus maximus, assisted by the Hamstring muscles. The thigh is *adducted* by the Adductores magnus, longus, and brevis, the Pectineus, the Gracilis, and the lower part of the Gluteus maximus, and *abducted* by the Gluteus medius and minimus and the upper part of the Gluteus maximus. The muscles which *rotate* the thigh *inward* are the anterior fibres of the Gluteus medius, the Gluteus minimus, and the Tensor fasciæ femoris; while those which rotate it *outward* are the posterior fibres of the Gluteus medius, the Piriformis, Obturator externus and internus, Gemellus superior and inferior, Quadratus femoris, Iliacus, Gluteus maximus, the three Adductors, the Pectineus, and the Sartorius.

Surface Form.—A line drawn from the anterior superior spinous process of the ilium to the most prominent part of the tuberosity of the ischium (*Nélaton's line*) runs through the centre of the acetabulum, and would, therefore, indicate the level of the hip-joint; or, in other words, the upper border of the great trochanter, which lies on *Nélaton's line*, is on a level with the centre of the hip-joint.

Applied Anatomy.—*Inflammation of bursa* about the hip-joint gives rise to confusing symptoms, and is not uncommonly mistaken for hip-joint disease.

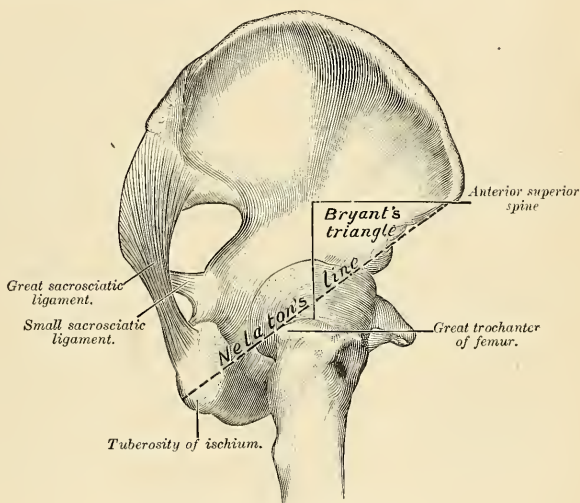


FIG. 264.—*Nélaton's line* and *Bryant's triangle*.

In *dislocation of the hip* "the head of the thigh bone may rest at any point around its socket" (Bryant); but whatever position the head ultimately assumes, the primary displacement is generally downward and inward, the capsule giving way at its weakest—that is, its lower and inner—part. The situation that the head of the bone subsequently assumes is determined by the degree of flexion or extension, and of outward or inward rotation of the thigh at the moment of luxation, influenced, no doubt, by the iliofemoral ligament, which is not easily ruptured. When, for instance, the head is forced backward, this ligament forms a fixed axis, around which the head of the bone rotates, and the head is thus driven on to the dorsum of the ilium. The iliofemoral ligament also influences the position of the thigh in the various dislocations: in the dislocations backward it is tense, and produces inversion of the limb; in the dislocation on to the pubes it is relaxed, and therefore allows the External rotators to evert the thigh; while in the thyrod dislocation it is tense and produces flexion.

The iliofemoral ligament is rarely torn in dislocations of the hip, and this fact is taken advantage of by the surgeon in reducing these dislocations by manipulation. It is made to act as a fulcrum to a lever of which the long arm is the shaft of the femur, and the short arm the neck of the bone.

The hip-joint is rarely the seat of *acute synovitis* from injury, on account of its deep position and its thick covering of soft parts. *Acute inflammation* may, and does, frequently occur as the result of constitutional conditions, as rheumatism, pyemia, etc. When, in these cases, effusion takes place, and the joint becomes distended with fluid, the swelling is not very easy to detect on account of the thickness of the capsule and the depth of the articulation. It is principally to be found on the front of the joint, just internal to the iliofemoral ligament; or behind, at the lower and back part. In these two places the capsule is thinner than elsewhere. Disease of the hip-joint is much more frequently of a chronic character and is usually, of *tuberculous* origin. It begins either in the bones or in the synovial membrane, more frequently in the former, and probably, in most cases, in the growing, highly vascular tissue in the neighborhood of the epiphyseal cartilage. In this respect it differs very materially from the tuberculous arthritis of the knee, where the disease often commences in the synovial membrane.

In *chronic hip disease* the affected limb assumes an altered position, the cause of which it is important to understand. In the early stage of a typical case the limb is flexed, abducted, and rotated outward. In this position all the ligaments of the joint are relaxed—the front of the capsule by flexion; the outer band of the iliofemoral ligament by abduction; and the inner band of this ligament and the back of the capsule by rotation outward. It is, therefore, the position of the greatest ease. The condition is not quite obvious at first upon examining a patient. If the patient is laid in the supine position, the affected limb will be found to be extended and parallel with the other. But it will be found that the pelvis is tilted downward on the diseased side and the limb apparently longer than its fellow, and that the lumbar portion of the vertebral column is arched forward (*lordosis*). If now the thigh is abducted and flexed, the tilting downward and the arching forward of the pelvis disappears. The condition is thus explained. A limb which is flexed and abducted is obviously useless for progression, and, to overcome the difficulty, the patient depresses the affected side of his pelvis in order to produce parallelism of his limbs, and at the same time rotates his pelvis on its transverse horizontal axis, so as to direct the limb downward instead of forward. In the latter stages of the disease the limb becomes flexed, adducted, and inverted. The position probably depends upon the muscular action, at all events as regards the adduction. The Adductor muscles are supplied by the obturator nerve, which also largely supplies the joint. These muscles are therefore thrown into reflex action by the irritation of the peripheral terminations of this nerve in the inflamed articulation. *Osteoarthritis* is not uncommon in the hip-joint, and it is said to be more common in the male than in the female, in whom the knee-joint is more frequently affected. It is a disease of middle age or more advanced period of life.

Congenital dislocation is more commonly met with in the hip-joint than in any other articulation. The displacement usually takes place on to the dorsum ilii. It gives rise to extreme lordosis, and a waddling gait is noticed as soon as the child commences to walk.

Excision of the hip may be required for disease or for injury, especially for gunshot wound. It may be performed either by an anterior or an external incision. The former one entails less interference with important structures, especially muscles, than the posterior one, but permits of less efficient drainage. In the operation in front the surgeon makes an incision three or four inches in length, starting immediately below and external to the anterior superior spinous process of the ilium, downward and inward between the Sartorius and Tensor fasciæ femoris, to the neck of the bone, dividing the capsule at its upper part. A narrow-bladed saw now divides the neck of the femur, and the head of the bone is extracted with sequestrum forceps. All diseased tissue is carefully removed with a sharp spoon or scissors, and the cavity thoroughly flushed with a hot aseptic fluid.

The external method consists in making an incision three or four inches long, commencing midway between the top of the great trochanter and the anterior superior spine, and ending over the shaft, just below the trochanter. The muscles are detached from the great trochanter, and the capsule opened freely. The head and neck are freed from the soft parts and the bone sawed through just below the top of the trochanter with a narrow saw. The head of the bone is then levered out of the acetabulum. In both operations, if the acetabulum is eroded, it must be freely gouged.

II. The Knee-joint (Articulatio Genu).

The **knee-joint** was formerly described as a ginglymus or hinge-joint, but is really of a much more complicated character. It must be regarded as consisting of *three* articulations in one—one between each condyle of the femur and the corresponding tuberosity of the tibia, which are condyloid joints, and one between the patella and the femur, which is partly arthroidal, but not completely so, since the articular surfaces are not mutually adapted to each other, so that the movement is not a simple gliding one. This view of the construction of the knee-joint receives confirmation from the study of the articulation in some of the lower mammals, where three synovial membranes are sometimes found, corresponding to these three subdivisions, either entirely distinct or only connected by small communications. This view is further rendered probable by the existence of the two crucial ligaments within the joint, which must be regarded as the external and internal lateral ligaments of the inner and outer joints respectively. The existence of the ligamentum mucosum would further indicate a tendency to separation of the synovial cavity into two minor sacs, one corresponding to each joint.

The bones entering into the formation of the knee-joint are the condyles of the femur *above*, the head of the tibia *below*, and the patella in *front*. The bones are connected by ligaments, some of which are placed on the exterior of the joint, while others occupy its interior.

External Ligaments.

Capsular.
Anterior, or Ligamentum Patellae.
Posterior.
Internal Lateral.
Two External Lateral.

Interior Ligaments.

Anterior, or External Crucial.
Posterior, or Internal Crucial.
Two Semilunar Fibrocartilages.
Transverse.
Coronary.

The **capsular ligament** (*capsula articularis*) (Fig. 265) consists of an exceedingly thin, but strong, fibrous membrane, which is strengthened in almost its entire extent by heavy bands which are inseparably connected with it. In *front* it blends with and forms part of the lateral patellar ligaments and fills in the interval between the anterior and lateral ligaments of the joints, with which latter structures it is closely connected. It is deficient *above* the joint and beneath the tendon of the Quadriceps extensor. *Behind*, it is formed chiefly of vertical fibres, which arise above from the condyles and intercondyloid notch of the femur, and is connected *below* with the back part of the head of the tibia, being closely united with the origins of the Gastrocnemius, Plantaris, and Popliteus muscles. It passes in front of, but is inseparably connected with, the posterior ligament.

The **anterior ligament, or ligamentum patellae** (Figs. 265, 269, and 270), is the central portion of the common tendon of the Extensor muscles of the thigh, which is continued from the patella to the tubercle of the tibia, supplying the place of an anterior ligament. It is a strong, flat, ligamentous band about three inches in length, attached, *above*, to the apex of the patella and to the rough depression on its posterior surface; *below*, to the lower part of the tubercle of the tibia, its superficial fibres being continuous over the front of the patella with those of the tendon of the Quadriceps extensor. The lateral portions of the tendon of the Extensor muscles in conjunction with the fascia lata pass down on either side of the patella, and are attached to the tibia on either side of the tubercle; these are termed **lateral patellar ligaments** (*retinaculum patellae mediale et laterale*), and merge into the capsule. The posterior surface of the ligamentum patellae is separated,

above, from the synovial membrane by a fold of fat; below, it is separated from the head of the tibia by a synovial bursa.

The **posterior ligament** (*ligamentum popliteum obliquum*) (Fig. 266) is a broad, flat, fibrous band, formed of fasciculi separated from one another by apertures for the passage of vessels and nerves. It is attached, *above*, to the upper margin of the intercondyloid notch of the femur, and, *below*, to the posterior margin of the head of the tibia. Superficial to the main part of the ligament and forming a portion of it is a strong fasciculus derived from the tendon of the Semimembranosus; it passes from the back part of the inner tuberosity of the tibia obliquely upward and outward to the back part of the outer condyle of the femur and blends with the posterior ligament. This expansion from the tendon of the Semimem-

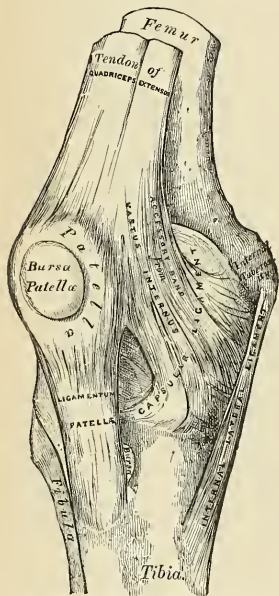


FIG. 265.—Right knee-joint. Anterior view.

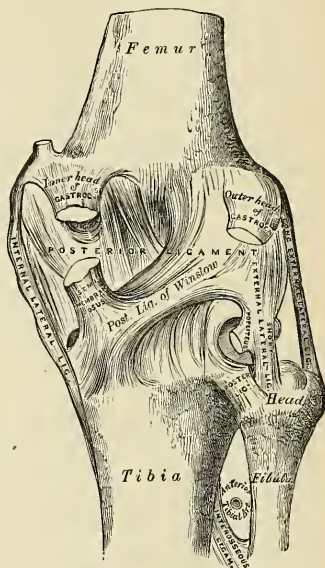


FIG. 266.—Right knee-joint. Posterior view.

branosus muscle is called the **posterior ligament of Winslow**. The posterior ligament forms part of the floor of the popliteal space, and the popliteal artery rests upon it.

The **internal lateral ligament** (*ligamentum collaterale tibiale*) (Figs. 265 and 266) is a broad, flat, membranous band, thicker behind than in front, and situated nearer to the back than the front of the joint. It is attached, *above*, to the inner tuberosity of the femur; *below*, to the inner tuberosity and inner surface of the shaft of the tibia to the extent of about two inches. It is crossed, at its lower part, by the tendons of the Sartorius, Gracilis, and Semitendinosus muscles, a synovial bursa being interposed. Its *deep surface* covers the anterior portion of the tendon of the Semimembranosus, with which it is connected by a few fibres, and the inferior internal articular vessels and nerve; it is intimately adherent to the internal semilunar fibrocartilage.

The **external lateral** or **long external lateral ligament** (*ligamentum collaterale fibulare*) (Figs. 266 and 270) is a strong, rounded, fibrous cord situated nearer to the back than the front of the joint. It is attached, *above*, to the back part of the outer tuberosity of the femur; *below*, to the outer part of the head of the fibula. Its *outer surface* is covered by the tendon of the Biceps femoris, which divides at its insertion into two parts, separated by the ligament. The ligament has, passing beneath it, the tendon of the Popliteus muscle and the inferior external articular vessels and nerve.

The **short external lateral ligament** (*ligamentum laterale externum breve seu posticum*) (Fig. 266) is not a constant structure. It is an accessory bundle of fibres placed behind and parallel with the preceding, attached, *above*, to the lower and back part of the outer tuberosity of the femur; *below*, to the summit of the styloid process of the fibula. This ligament is intimately connected with the capsular ligament, and has, passing beneath it, the tendon of the Popliteus muscle and the inferior external articular vessels and nerve.

The **crucial ligaments** (*ligamenta cruciata genu*) (Figs. 267 and 268) are two interosseous ligaments of considerable strength situated in the interior of the joint, nearer its posterior than its anterior part. They are called crucial because they cross each other somewhat like the lines of the letter X; and have received the names anterior crucial and posterior crucial, from the position of their attachment to the tibia.

The **anterior or external crucial ligament** (*ligamentum cruciatum anterius*) (Fig. 267) is attached to the depression in front of the spine of the tibia, being blended with the anterior extremity of the external semilunar fibrocartilage, and, passing obliquely upward, backward, and outward, is inserted into the inner and back part of the outer condyle of the femur.

The **posterior or internal crucial ligament** (*ligamentum cruciatum posterius*) is stronger, but shorter and less oblique in its direction than the anterior. It is attached to the back part of the depression behind the spine of the tibia, to the popliteal notch, and to the posterior extremity of the external semilunar fibrocartilage; and passes upward, forward, and inward, to

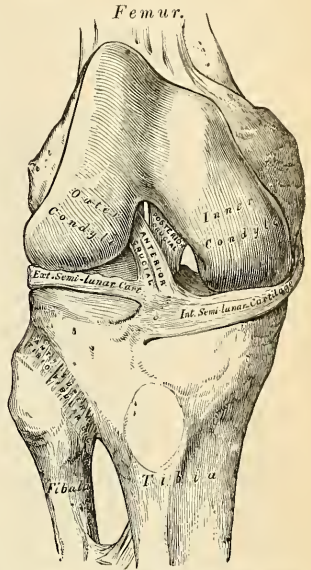


FIG. 267.—Right knee-joint. Showing interior ligaments.

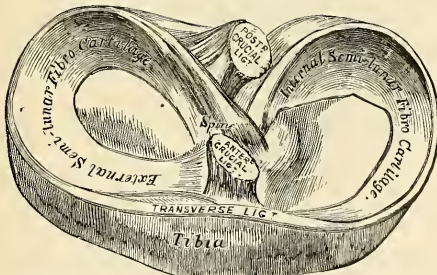


FIG. 268.—Head of tibia, with semilunar cartilages, etc. Seen from above. Right side.

be inserted into the outer and fore part of the inner condyle of the femur. It is in relation, in *front*, with the anterior crucial ligament; *behind*, with the capsular ligament.

The **semilunar fibrocartilages** (*menisci*) (Figs. 267 and 268) are two crescentic lamellæ which serve to deepen the surface of the head of the tibia, for articulation with the condyles of the femur. The *circumference* of each cartilage is thick, convex, and attached to the inside of the capsule of the knee; the *inner border*

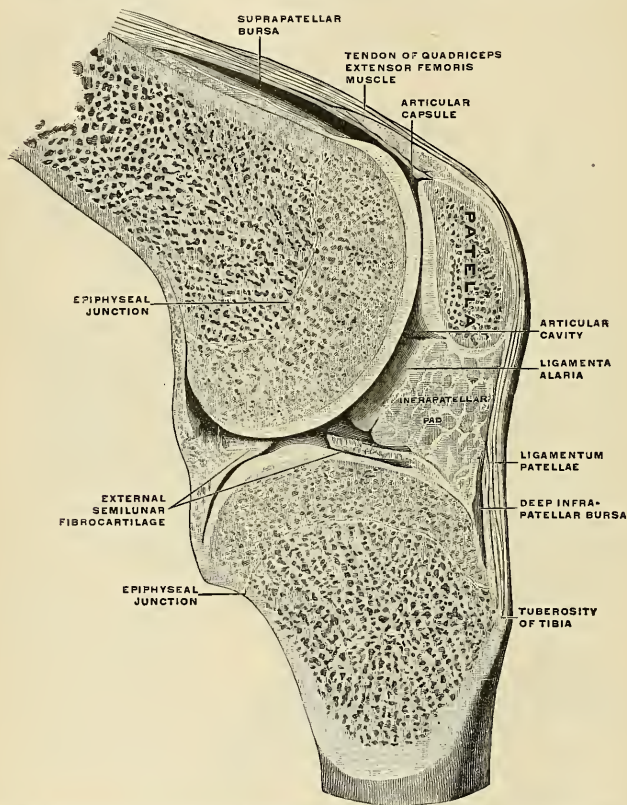


FIG. 269.—Right knee-joint. Sagittal section through the external condyle of the femur. Mesal half of section, from the lateral side. The knee is slightly flexed; the joint surfaces have been pulled a little apart. (Spatteholz.)

is thin, concave, and free. Their *upper surfaces* are concave, and in relation with the condyles of the femur; their *lower surfaces* are flat, and rest upon the head of the tibia. Each cartilage covers nearly the outer two-thirds of the corresponding articular surface of the tibia, leaving the inner third uncovered; both surfaces are smooth and invested by synovial membrane.

The **internal semilunar fibrocartilage** (*meniscus medialis*) is nearly semicircular in form, a little elongated from before backward, and broader behind than

in front; its *anterior extremity*, thin and pointed, is attached to a depression on the anterior margin of the head of the tibia, in front of the anterior crucial ligament; its *posterior extremity* is attached to the depression behind the spine, between the attachments of the external cartilage and the posterior crucial ligaments.

The **external semilunar fibrocartilage** (*meniscus lateralis*) forms nearly an entire circle, covering a larger portion of the articular surface than the internal one.

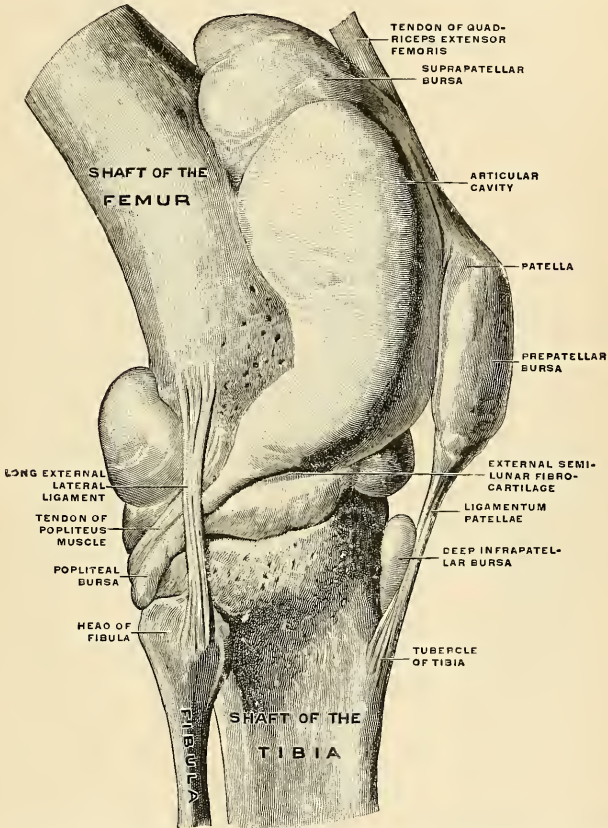


FIG. 270.—Right knee-joint, from the lateral surface. The joint cavity and several bursæ have been injected with a stiffening medium and then dissected out. (Spalteholz.)

It is grooved on its outer side for the tendon of the Popliteus muscle. Its extremities, at their insertion, are interposed between the two extremities of the internal cartilage; the *anterior extremity* is attached in front of the spine of the tibia to the outer side of, and behind, the anterior crucial ligament, with which it blends; the *posterior extremity* is attached behind the spine of the tibia, in front of the posterior extremity of the internal cartilage. Just before its insertion

posteriorly it gives off a strong fasciculus, the **ligament of Wrisberg**, which passes obliquely upward and outward, to be inserted into the inner condyle of the femur, close to the attachment of the posterior crucial ligament. Occasionally a small fasciculus is given off which passes forward to be inserted into the back part of the anterior crucial ligament. The external cartilage gives off from its anterior convex margin a fasciculus which forms the transverse ligament.

The **transverse ligament** (*ligamentum transversum genu*) (Fig. 268) is a band of fibres which passes transversely from the anterior convex margin of the external cartilage to the anterior convex margin of the internal cartilage; its thickness varies considerably in different subjects, and it is sometimes absent altogether.

The **coronary ligaments** are merely portions of the capsular ligament, which connect the circumference of each of the semilunar fibrocartilages with the margin of the head of the tibia.

Synovial Membrane (Figs. 269 and 270).—The synovial membrane encloses the **articular cavity** (*cavum articulare*) of the knee-joint. It is the largest and most extensive synovial membrane in the body. Commencing above the upper border of the patella, it forms, on the lower part of the front of the shaft of the femur, a short *cul-de-sac* beneath the Quadriceps extensor tendon of the thigh; this communicates, by an orifice of variable size, with a synovial bursa interposed between the tendon and the front of the femur (*bursa suprapatellaris*). On each side of the patella the synovial membrane extends beneath the aponeurosis of the Vasti muscles, and more especially beneath that of the Vastus internus. Below the patella it is separated from the anterior ligament by the anterior part of the capsule and a considerable quantity of adipose tissue, known as the **infrapatellar pad** (Fig. 269). In this situation the synovial membrane sends off a triangular prolongation, containing a few ligamentous fibres, which extends from the anterior part of the joint below the patella to the front of the intercondyloid notch. This fold has been termed the **ligamentum mucosum** (*plica synovialis patellaris*). It also sends off two fringe-like folds, called the **ligamenta alaria** (*plicae alares*) (Fig. 269), which extend from the sides of the ligamentum mucosum, upward and laterally between the patella and femur. On either side of the joint it passes downward from the femur, lining the capsule to its point of attachment to the semilunar cartilages; it may then be traced over the upper surfaces of these cartilages to their free borders, and from thence along their under surfaces to the tibia. At the back part of the external one it forms a *cul-de-sac* between the groove on its surface and the tendon of the Popliteus; it surrounds the crucial ligaments and lines the inner surface of the ligaments which enclose the joint. The pouch of synovial membrane between the Quadriceps extensor tendon and the front of the femur is supported, during the movements of the knee, by a small muscle, the Subcrureus, which is inserted into the upper part of the capsular ligament.

The folds of synovial membrane and the fatty processes contained in them act, as it seems, mainly as a padding to fill up interspaces and obviate concussions. Sometimes the bursa beneath the Quadriceps extensor is completely shut off from the rest of the synovial cavity, thus forming a closed sac between the Quadriceps and the lower part of the front of the femur; sometimes it communicates with the synovial cavity by a minute aperture; usually the two cavities are incompletely separated by a synovial fold.

Bursæ.—The bursæ about the knee-joint are the following: In front there are *four* bursæ; one is interposed between the patella and the skin. It is known as the **prepatellar bursa** (*bursa præpatellaris subcutanea*); another, of small size, between the upper part of the tuberosity of the tibia and the ligamentum patellæ is called the **deep infrapatellar bursa** (*bursa infrapatellaris profunda*); and a third between the lower part of the tuberosity of the tibia and the skin, the **subcutaneous tibial bursa** (*bursa subcutanea tuberositatis tibiæ*). A fourth bursa exists in front, the **suprapatellar bursa** (*bursa suprapatellaris*). It lies between the anterior surface of the lower end of the femur and the posterior surface of the Quadriceps femoris. Spalteholz says that the suprapatellar bursa is closely connected with the Quadriceps tendon and is usually incompletely shut off from the cavity of the joint.¹ Occasionally there is a bursa between the expansion of the fascia lata and the Quadriceps and the patella (*bursa præpatellaris subfascialis*), and sometimes one between the tendon of the Quadriceps and the anterior surface of the patella (*bursa præpatellaris subtendinea*). On the outer side there are *four* bursæ: (1) One (which sometimes communicates with the joint) beneath the outer head of the Gastrocnemius; (2) one above the external lateral ligament between it and the tendon of the Biceps femoris; (3) one beneath the

¹ Spalteholz's Hand Atlas of Human Anatomy. Translated by Lewellys F. Barker.

external lateral ligament between it and the tendon of the Popliteus (this is sometimes only an expansion from the next bursa); (4) one beneath the tendon of the Popliteus (*bursa musculi poplitei*) between it and the condyle of the femur, which is almost always an extension from the synovial membrane of the joint. On the inner side there are *five* bursæ: (1) One beneath the inner head of the Gastrocnemius, which sends a prolongation between the tendons of the Gastrocnemius and Semimembranosus; this bursa often communicates with the joint; (2) one above the internal lateral ligament between it and the tendons of the Sartorius, Gracilis, and Semitendinosus; (3) one beneath the internal lateral ligament between it and the tendon of the Semimembranosus; this is sometimes only an expansion from the next bursa; (4) one beneath the tendon of the Semimembranosus, between it and the head of the tibia; (5) sometimes there is a bursa between the tendons of the Semimembranosus and of the Semitendinosus.

Structures around the Joint.—In *front* and *at the sides*, the Quadriceps extensor; on the *outer side*, the tendons of the Biceps femoris and the Popliteus and the external popliteal nerve; on the *inner side*, the Sartorius, Gracilis, Semitendinosus, and Semimembranosus; *behind*, an expansion from the tendon of the Semimembranosus, the popliteal vessels, and the internal popliteal nerve, the Popliteus, the Plantaris, and the inner and outer heads of the Gastrocnemius, some lymph nodes, and fat.

The *arteries* supplying the joint are derived from the anastomotica magna branch of the femoral, articular branches of the popliteal, anterior and posterior recurrent branches of the anterior-tibial, and a descending branch from the external circumflex of the profunda.

The *nerves* are derived from the obturator, femoral, and external and internal popliteal.

Movements.—The knee-joint permits of movements of *flexion* and *extension*, and, in certain positions, of *slight rotation* inward and outward. The movement of flexion and extension does not, however, take place in a simple, finger-like manner, as in other joints, but is a complicated movement, consisting of a certain amount of gliding and rotation; so that the same part of one articular surface is not always applied to the same part of the other articular surface, and the axis of motion is not a fixed one. If the joint is examined while in a condition of extreme flexion, the posterior part of the articular surfaces of the tibia will be found to be in contact with the posterior rounded extremities of the condyles of the femur; and if a simple hinge-like movement were to take place, the axis, around which the revolving movement of the tibia occurs, would be in the back part of the condyle. If the leg is now brought forward into a position of semiflexion, the upper surface of the tibia will be seen to glide over the condyles of the femur, so that the middle part of the articular facets are in contact, and the axis of rotation must therefore have shifted forward to nearer the centre of the condyles. If the leg is now brought into the extended position, a still further gliding takes place and a further shifting forward of the axis of rotation. This is not, however, a simple movement, but is accompanied by a certain amount of rotation outward around a vertical axis drawn through the centre of the head of the tibia. This rotation is due to the greater length of the internal condyle, and to the fact that the anterior portion of its articular surface is inclined obliquely outward. In consequence of this it will be seen that toward the close of the movement of extension—that is to say, just before complete extension is effected—the tibia glides obliquely upward and outward over this oblique surface on the inner condyle, and the leg is therefore necessarily rotated outward. In flexion of the joint the converse of these movements takes place; the tibia glides backward around the end of the femur, and at the commencement of the movement the tibia is directed downward and inward along the oblique curve of the inner condyle, thus causing an inward rotation to the leg.

During flexion and extension the patella moves on the lower end of the femur, but this movement is not a simple gliding one; for if the articular surface of this bone is examined, it will be found to present on each side of the central vertical ridge two less marked transverse ridges, which divide the surface, except a small portion along the inner border, which is cut off by a slight vertical ridge into six facets (Fig. 271), and therefore does not present a uniform curved surface as would be the case if a simple gliding movement took place. These six facets—three on each side of the median vertical ridge—correspond to and denote the parts of the bone, respectively, in contact with the condyles of the femur during flexion, semiflexion, and extension. In flexion only the upper facets on the patella are in contact with the trochlea of the femur; the lower two-thirds of the bone rests upon the infrapatellar pad which occupies the space between the femur and tibia. In the semiflexed position of the joint the middle facets on the patella rest upon the most prominent portion of the trochlea, and thus afford greater leverage to the Quadriceps by increasing its distance from the centre of motion. In complete extension the patella is drawn up, so that only the lower facets are in contact with the trochlea. The narrow strip

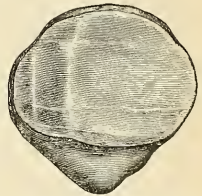

FIG. 271.—View of the posterior surface of the right patella, showing diagrammatically the areas of contact with the femur in different positions of the knee.

along the inner border is in contact with the outer aspect of the internal condyle when the leg is fully flexed at the knee-joint. As in the elbow, so it is in the knee—the axis of rotation in flexion and extension is not precisely at right angles to the axis of the bone, but during flexion there is a certain amount of alteration of plane; so that, whereas in flexion the femur and tibia are in the same plane, in extension the one bone forms an angle of about 10 degrees with the other. There is, however, this difference between the two extremities: that in the upper, during extension, the humeri are parallel and the bones of the forearm diverge; in the lower, the femora converge below and the tibiæ are parallel.

In addition to the slight rotation during flexion and extension, the tibia enjoys an independent rotation on the condyles of the femur in certain positions of the joint. This movement takes place between the articular menisci and the tibia, whereas the movement of flexion and extension takes place between the articular menisci and the femur. So that the knee may be said to consist of two joints, separated by the menisci—an upper, **meniscofemoral**, in which flexion and extension take place; and a lower, **meniscotibial**, allowing of a certain amount of rotation. This latter movement can only take place in the semiflexed position of the limb, when all the ligaments are relaxed.

During *flexion* the ligamentum patellæ is put upon the stretch, as is also the posterior crucial ligament in extreme flexion. The other ligaments are all relaxed by flexion of the joint, though the relaxation of the anterior crucial ligament is very trifling. During life flexion is checked by the contact of the leg with the thigh. In the act of extending the leg upon the thigh the ligamentum patellæ is tightened by the Quadriceps extensor; but when the leg is fully extended, as in the erect posture, the ligament becomes relaxed, so as to allow free lateral movement to the patella, which then rests on the front of the lower end of the femur. The other ligaments, with the exception of the posterior crucial, which is partly relaxed, are all on the stretch. When the limb has been brought into a straight line, extension is checked mainly by the tension of all the ligaments except the posterior crucial and the ligamentum patellæ. The movements of *rotation* of which the knee is capable are permitted in the semiflexed condition by the partial relaxation of both crucial ligaments, as well as of the lateral ligaments. Rotation inward appears to be limited by the tension of the anterior crucial ligament, and by the interlocking of the two ligaments; but rotation outward does not appear to be checked by either crucial ligament, since they uncross during the execution of this movement, but it is checked by the lateral ligaments, especially the internal. The main function of the crucial ligaments is to act as a direct bond of union between the tibia and femur, preventing the former bone from being carried too far backward or forward. Thus, the anterior crucial ligament prevents the tibia being carried too far forward by the Extensor tendons, and the posterior crucial checks too great movement backward by the Flexors. They also assist the lateral ligaments in resisting any lateral bending of the joint. The semilunar cartilages are intended, evidently, to adapt to a certain extent the surface of the tibia to the shape of the femur, in order to fill intervals which would otherwise occur in the changing of joint position and to interrupt jars which otherwise would be so frequently transmitted up the limb through jumping or falling on the feet. These cartilages also contribute to the varieties of motion—flexion, extension, and rotation—as explained above. The patella is a great defence to the knee-joint from any injury inflicted in front, and it distributes upon a large and tolerably even surface during kneeling the pressure which would otherwise fall upon the prominent ridges of the condyles; it also affords leverage to the Quadriceps extensor muscle when it acts upon the tibia; and Mr. Ward has pointed out¹ how this leverage varies in the various positions of the joint, so that the action of the muscles produces velocity at the expense of force in the commencement of extension, and, on the contrary, at the close of extension tends to diminish velocity, and therefore the shock to the ligaments at the moment tension of the structures takes place.

Extension of the leg on the thigh is performed by the Quadriceps extensor; *flexion* by the Hamstring muscles, assisted by the Gracilis and Sartorius, and, indirectly, by the Gastrocnemius, Popliteus, and Plantaris; *rotation outward*, by the Biceps femoris; and *rotation inward* by the Popliteus, Semitendinosus, and, to a slight extent, the Semimembranosus, the Sartorius, and the Gracilis.

Surface Form.—The interval between the two bones entering into the formation of the knee-joint can always easily be felt. If the limb is extended, it is situated on a slightly higher level than the apex of the patella; but if the limb is slightly flexed, a knife carried horizontally backward immediately below the apex of the patella would pass directly into the joint. When the knee-joint is distended with fluid, the outline of the synovial membrane at the front of the knee may be fairly well mapped out.

Applied Anatomy.—The *bursæ* about the knee are frequently the seat of inflammation. Enlargement of the *prepatellar bursa* constitutes *housemaid's knee*. The bursa beneath the

¹ Human Osteology, p. 405.

Semimembranosus may enlarge greatly. It communicates with the knee-joint and can frequently be made to disappear by pressure when the knee is flexed. Treves points out that enlargement of the bursa between the Biceps tendon and the external lateral ligament causes great pain because the peroneal nerve crosses the sac.¹

From a consideration of the construction of the knee-joint it would at first sight appear to be one of the least secure of any of the joints in the body. It is formed between the two longest bones, and therefore the amount of leverage which can be brought to bear upon it is very considerable; the articular surfaces are but ill adapted to each other, and the range and variety of motion which it enjoys is great. All these circumstances tend to render the articulation very insecure; but, nevertheless, on account of the very powerful ligaments which bind the bones together, the joint is one of the strongest in the body, and *dislocation from traumatism* is of very rare occurrence. When, on the other hand, the ligaments have been softened or destroyed by disease, *partial displacement* is very liable to occur, and is frequently brought about by the mere action of the muscles displacing the articular surfaces from each other. The tibia may be dislocated in any direction from the femur—forward, backward, inward, or outward; or a combination of two of these dislocations may occur—that is, the tibia may be dislocated forward and laterally, or backward and laterally, and any of these dislocations may be complete or incomplete. As a rule, however, the antero-posterior dislocations are complete, the lateral ones incomplete.

One or other of the *semilunar cartilages* may become displaced and nipped between the femur and tibia. The accident is produced by a twist of the leg when the knee is flexed, and is accompanied by a sudden pain and fixation of the knee in a flexed position. The cartilage may be displaced either inward or outward; that is to say, either inward toward the tibial spine, so that the cartilage becomes lodged in the intercondyloid notch; or outward, so that the cartilage projects beyond the margin of the articular surface. *Acute synovitis*, the result of traumatism or exposure to cold, is very common in the knee, on account of its superficial position. When distended with fluid, the swelling shows itself above and at the sides of the patella, reaching about an inch or more above the trochlear surface of the femur, and extending a little higher under the Vastus internus than the Vastus externus. Occasionally the swelling may extend two inches or more. At the sides of the patella the swelling extends lower at the inner side than it does on the outer side. The lower level of the synovial membrane is just above the level of the upper part of the head of the fibula. In the middle line it covers the upper third of the ligamentum patellae, being separated from it, however, by the capsule and a pad of fat. *Chronic synovitis* principally shows itself in the form of pulpy degeneration of the synovial membrane, the result of *tuberculous arthritis*. The reasons why tuberculous disease of the knee so often commences in the synovial membrane appear to be the complex and extensive nature of this sac; the extensive vascular supply to it; and the fact that injuries are generally diffused and applied to the front of the joint rather than to the ends of the bone. *Syphilis* not infrequently attacks the knee-joint. In the hereditary form of the disease the attack is usually symmetrical—both joints are involved. They become filled with synovial effusion and cure is very difficult. In acquired syphilis gummatous infiltration of the synovial membrane may take place. The knee is one of the joints most commonly affected with *osteoarthritis*, and is said to be more frequently the seat of this disease in women than in men. The occurrence of the so-called *loose cartilage* is almost confined to the knee, though loose cartilages are occasionally met with in the elbow, and, rarely, in some other joints. Many of them occur in cases of *osteoarthritis*, in which calcareous or cartilaginous material is formed in one of the synovial fringes and constitutes the foreign body, and may or may not become detached, in the former case only meriting the usual term, "loose" cartilage. In other cases they have their origin in the exudation of inflammatory lymph, and possibly, in some rare instances, a portion of the articular cartilage or one of the semilunar cartilages becomes detached and constitutes the foreign body.

Genu valgum, or *knock-knee*, is a common deformity of childhood, in which, owing to changes in and about the joint, the angle between the outer border of the tibia and femur is diminished, so that as the patient stands the two internal condyles of the femora are in contact, but the two internal malleoli of the tibiae are more or less widely separated from each other. When, however, the knees are flexed to a right angle, the two legs are practically parallel with each other. At the commencement of the disease there is a yielding of the internal lateral ligament and other fibrous structures on the inner side of the joint; as a result of this there is a constant undue pressure of the outer tuberosity of the tibia against the outer condyle of the femur. This extra pressure causes arrest of growth, and, possibly, wasting of the outer condyle, and a consequent tendency for the tibia to become separated from the internal condyle. To prevent this the internal condyle becomes depressed; probably, as was first pointed out by Mikulicz, by an increased growth of the lower end of the diaphysis on its inner side, so that the line of the epiphysis becomes oblique instead of transverse to the axis of the bone, with a direction down-

ward and inward. It is often said that the deformity is produced by undue length of the inner condyle, but in reality the condyle grows as the deformity progresses.

Excision of the knee-joint is most frequently required for tuberculous disease of this articulation, but is also practised in cases of disorganization of the knee after rheumatic fever, pyemia, etc., in osteoarthritis, and in ankylosis. It is also occasionally called for in cases of injury, gun-shot or otherwise. The operation is best performed either by a horseshoe incision, starting from one condyle, descending as low as the tubercle of the tibia, where it crosses the leg, and is then

carried upward to the other condyle; or by a transverse incision across the patella. In this latter incision the patella is either removed or sawed across, and the halves subsequently sutured together. The bones having been cleared, and in those cases where the operation is performed for tuberculous disease all pulpy tissue having been carefully removed, the section of the femur is first made. This should never include, in children, more than, at the most, two-thirds of the articular surface, otherwise the epiphyseal cartilage will be involved, with disastrous results as regards the growth of the limb. Afterward a thin slice should be removed from the upper end of the tibia, not more than half an inch. If any diseased tissue still appears to be left in the bones, it should be removed with the gouge rather than by making a further section of the bones.

III. The Tibiofibular Articulation (Articulatio Tibiofibularis).

The articulations between the tibia and fibula are effected by ligaments which connect both extremities, as well as the shafts of the bones. It may, consequently, be subdivided into three articulations: (1) The **superior tibiofibular articulation**. (2) The **middle tibiofibular ligament** or **interosseous membrane**. (3) The **inferior tibiofibular articulation**.

1. THE SUPERIOR TIBIOFIBULAR ARTICULATION (ARTICULATIO TIBIOFIBULARIS).

This articulation is an arthrodial joint. The contiguous surfaces of the bones present two flat, oval facets covered with cartilage, and are interconnected by the following ligaments:

Capsular.

Anterior Superior Tibiofibular.

Posterior Superior Tibiofibular.

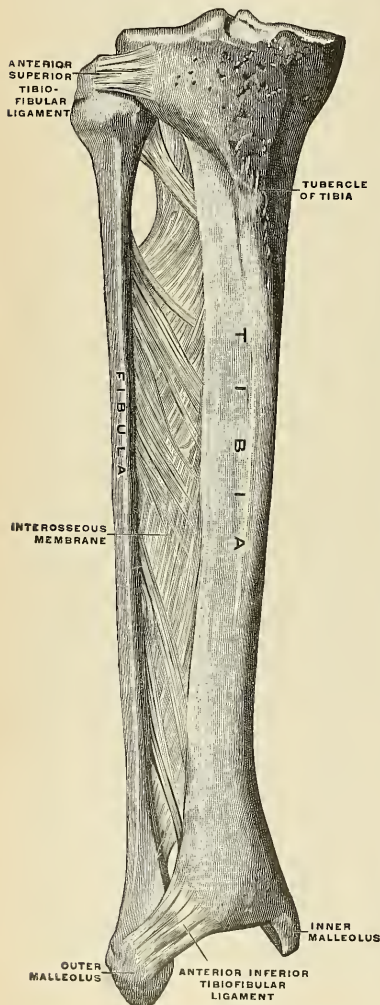


FIG. 272.—Ligaments of the right leg, from in front. (Spalteholz.)

The **capsular ligament** (*capsula articularis*) consists of a membranous bag which surrounds the articulation, being attached around the margins of the articular facets on the tibia and fibula, and is much thicker in front than behind.

The **anterior superior ligament** (Fig. 272) consists of two or three broad and flat bands which pass obliquely upward and inward from the front of the head of the fibula to the front of the outer tuberosity of the tibia.

The **posterior superior ligament** (Fig. 265) is a single thick and broad band which passes upward and inward from the back part of the head of the fibula to the back part of the outer tuberosity of the tibia. It is covered by the tendon of the Popliteus muscle.

Synovial Membrane.—A synovial membrane lines this articulation, which at its upper and back part is occasionally continuous with that of the knee-joint.

2. THE MIDDLE TIBIOFIBULAR LIGAMENT OR INTEROSSEOUS MEMBRANE (MEMBRANA INTEROSSEA CRURIS) (Fig. 272).

An **interosseous membrane** extends between the contiguous margins of the tibia and fibula and separates the muscles on the front from those on the back of the leg. It consists of a thin, aponeurotic lamina composed of oblique fibres which for the most part pass downward and outward between the interosseous ridges on the two bones; some few fibres, however, pass in the opposite direction, downward and inward. It is broader above than below. Its upper margin does not quite reach the superior tibiofibular joint, but presents a free concave border, above which is a large, oval aperture for the passage of the anterior tibial vessels forward to the anterior aspect of the leg. At its lower part is an opening for the passage of the anterior peroneal vessels. It is continuous below with the inferior interosseous ligament, and is perforated in numerous places for the passage of small vessels. It is in relation, in *front*, with the Tibialis anticus, Extensor longus digitorum, Extensor proprius hallucis, Peroneus tertius, and the anterior tibial vessels and nerve; *behind*, with the Tibialis posticus and Flexor longus hallucis.

3. THE INFERIOR TIBIOFIBULAR ARTICULATION (SYNDESMOSIS TIBIOFIBULARIS) (Figs. 274, 275).

This articulation is formed by the rough, convex surface of the inner side of the lower end of the fibula, connected with a concave rough surface on the outer side of the tibia. Below, to the extent of about one-sixth of an inch, these surfaces are smooth, and covered with cartilage, which is continuous with that of the ankle-joint. The ligaments of this joint are:

Anterior Inferior Tibiofibular.
Posterior Inferior Tibiofibular.

Transverse or Inferior.
Inferior Interosseous.

The **anterior inferior ligament** (*ligamentum malleoli lateralis anterioris*) (Figs. 272 and 276) is a flat, triangular band of fibres, broader below than above, which extends obliquely downward and outward, between the adjacent margins of the tibia and fibula, on the front aspect of the articulation. It is in relation, in *front*, with the Peroneus tertius, the aponeurosis of the leg, and the integument, *behind*, with the inferior interosseous ligament; and lies in contact with the cartilage covering the astragalus.

The **anterior tibiotalar ligament** (*ligamentum talotibiale anterius*) is a broad, thin, membranous layer, attached, *above*, to the anterior margin of the lower extremity of the tibia; *below*, to the margin of the astragalus, in front of its articular surface. It is in relation, in *front*, with the Extensor tendons of the toes, with the tendons of the Tibialis anticus and Peroneus tertius, and the anterior tibial vessels and nerve; *behind*, it lies in contact with the synovial membrane.

The **posterior tibiotalar ligament** (*ligamentum talotibiale posterius*) is very thin, and consists principally of transverse fibres. It is attached, *above*, to the margin of the articular surface of the tibia, blending with the inferior transverse tibiofibular ligament; *below*, to the astragalus, behind its trochlear surface, *externally*, where it blends with the inferior transverse tibiofibular ligament, it is thickest.

The **internal lateral or deltoid ligament** (*ligamentum deltoideum*) (Figs. 274 and 275) consists of a superficial and a deep set of fibres; the **superficial set** consti-

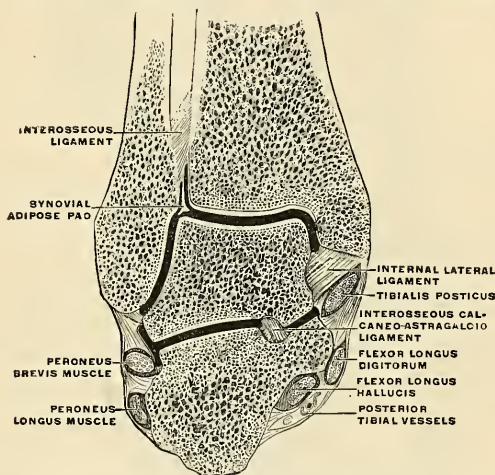


FIG. 274.—Coronal section through the ankle-joint and the calcaneo-astragaloid articulation. (Poirier and Charpy.)

tute a strong, flat, triangular band, which is attached, *above*, to the apex and to the anterior and posterior borders of the inner malleolus. The most *anterior* fibres pass forward to be inserted into the scaphoid bone (*lig. calcaneotibiale*) and the inferior calcaneoscaphoid ligament (*lig. tibionaviculare*), the *middle* descend almost perpendicularly to be inserted into the sustentaculum tali of the calcaneus (*lig. calcaneotibiale*); and the *posterior* fibres pass backward and outward to be attached to the inner side of the astragalus (*lig. talotibiale posterius*). The **deep set** is attached, *above*, to the notch of the inner malleolus, and, *below*, to the inner side of the astragalus. This ligament is covered by the tendons of the Tibialis posticus and Flexor longus digitorum muscles.

The **external lateral ligament** (Figs. 275 and 276) consist of three distinctly specialized fasciculi of the capsule, taking different directions and separated by distinct intervals; for which reason it is divided by some anatomists into three distinct ligaments, and so described.¹

¹ Humphry, On the Skeleton, p. 559.

The **anterior fasciculus** (*ligamentum talofibulare anterius*); the shortest of the three, passes from the anterior margin of the external malleolus forward and inward to the astragalus, in front of its external articular facet.

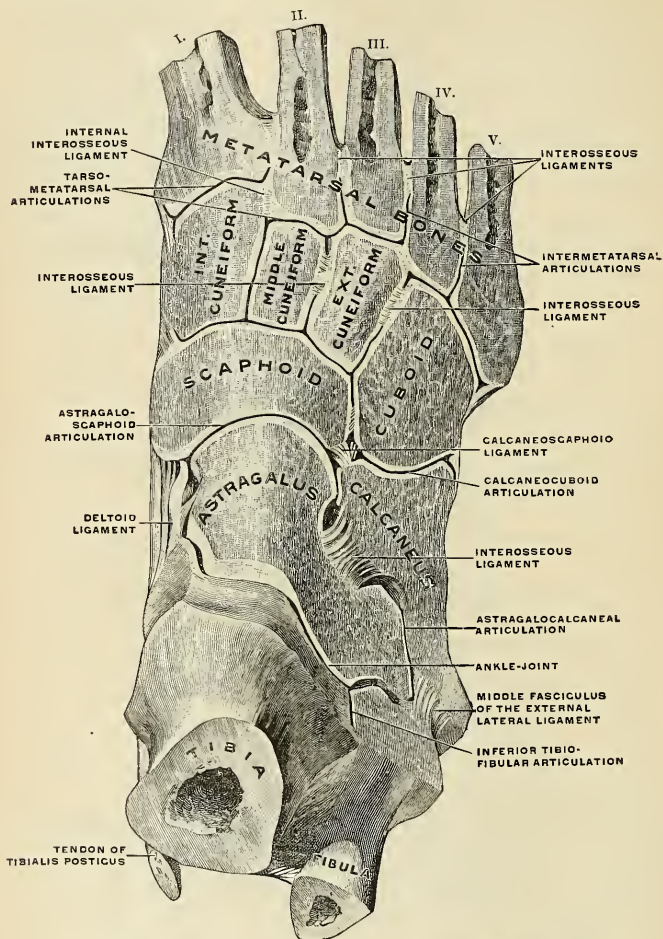


FIG. 275.—Joints of the right foot, from the back of the foot. (Spalteholz.)

The **posterior fasciculus** (*ligamentum talofibulare posterius*), the most deeply seated, passes inward from the depression at the inner and back part of the external malleolus to the prominent external tubercle on the posterior surface of the astragalus. Its fibres are almost horizontal in direction.

The **middle fasciculus** (*ligamentum calcaneofibulare*) (Figs. 275 and 276), the longest of the three, is a narrow, rounded cord passing from the apex of the

external malleolus downward and slightly backward to the peroneal spine on the outer surface of the calcaneus. It is covered by the tendons of the Peroneus longus and brevis.

Synovial Membrane.—The synovial membrane (Fig. 272) invests the inner surface of the ligaments, and sends a duplicature upward between the lower extremities of the tibia and fibula for a short distance.

Relations.—The tendons, vessels, and nerves in connection with the joint are, in *front*, from within outward, the Tibialis anticus, Extensor proprius hallucis, anterior tibial vessels and nerve, Extensor longus digitorum, and Peroneus tertius; *behind*, from within outward, the Tibialis posticus, Flexor longus digitorum, posterior tibial vessels and nerve, Flexor longus hallucis; and in the groove behind the external malleolus, the tendons of the Peroneus longus and brevis.

The **arteries** supplying the joint are derived from the malleolar branches of the anterior tibial and the peroneal.

The **nerves** are derived from the anterior and posterior tibial.

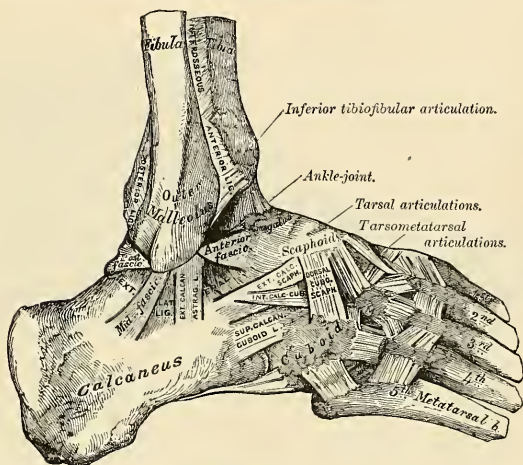


FIG. 276.—Ankle-joint: tarsal and tarsometatarsal articulations. External view. Right side.

Movements.—The movements of the joint are those of *flexion* and *extension*. *Flexion* consists in the approximation of the dorsum of the foot to the front of the leg, while in *extension* the heel is drawn up and the toes pointed downward. The malleoli tightly embrace the astragalus in all positions of the joint, so that any slight degree of lateral movement which may exist is simply due to stretching of the inferior tibiofibular ligaments and slight bending of the shaft of the fibula. Of the ligaments, the internal is of very great strength—so much so that it usually resists a force which fractures the process of bone to which it is attached. Its middle portion, together with the middle fasciculus of the external lateral ligament, binds the bones of the leg firmly to the foot and resists displacement in every direction. Its anterior and posterior fibres limit extension and flexion of the foot, respectively, and the anterior fibres also limit abduction. The posterior portion of the external lateral ligament assists the middle portion in resisting the displacement of the foot backward, and deepens the cavity for the reception of the astragalus. The anterior fasciculus is a security against the displacement of the foot forward, and limits extension of the joint. The movements of *inversion* and *eversion* of the foot, together with the minute changes in form by which it is applied to the ground or takes hold of an object in climbing, etc., are mainly effected in the tarsal joints, the one which enjoys the greatest amount of motion being that between the astragalus and calcaneus behind and the scaphoid and cuboid in front. This is often called the **transverse** or **mediotarsal joint**, and it can, with the subordinate joints of the tarsus, replace the ankle-joint in a great measure when the latter has become ankylosed.

Extension of the tarsal bones upon the tibia and fibula is produced by the *Gastrocnemius*, *Soleus*, *Plantaris*, *Tibialis posticus*, *Peroneus longus* and *brevis*, *Flexor longus digitorum*, and *Flexor longus hallucis*; *flexion*, by the *Tibialis anticus*, *Peroneus tertius*, *Extensor longus digitorum*, and *Extensor proprius hallucis*¹ (Fig. 268); *inversion*, in the extended position, is produced by the *Tibialis anticus* and *posticus*; and *eversion* by the *Peronei*.

Surface Form.—The line of the ankle-joint may be indicated by a transverse line drawn across the front of the lower part of the leg, about half an inch above the level of the tip of the internal malleolus.

Applied Anatomy.—*Displacement* of the trochlear surface of the astragalus from the tibio-fibular mortise is not of common occurrence, as the ankle-joint is a very strong and powerful articulation, and great force is required to produce dislocation. Nevertheless, dislocation does occasionally occur, both in antero-posterior and a lateral direction. In the latter, which is the most common, fracture is a necessary accompaniment of the injury. The dislocation in these cases is somewhat peculiar, and is not a displacement in a horizontally lateral direction, such as usually occurs in lateral dislocations of ginglymoid joints, but the astragalus undergoes a partial rotation around an antero-posterior axis drawn through its own centre, so that the superior surface, instead of being directed upward, is inclined more or less inward or outward according to the variety of the displacement.

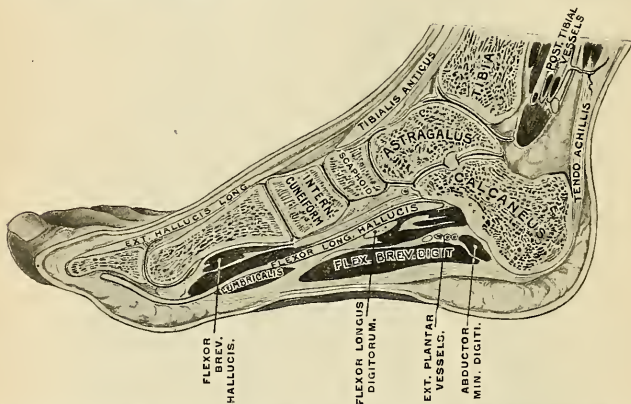


FIG. 277.—Section of the right foot near its inner border, dividing the tibia, astragalus, calcaneus, scaphoid, internal cuneiform, and first metatarsal bone, and the first phalanx of the great toe. (After Braune.)

The ankle-joint is more frequently sprained than any other joint in the body, and this may lead to *acute synovitis*. In these cases, when the synovial sac is distended with fluid, the bulging appears principally in the front of the joint, beneath the anterior tendons, and on either side, between the *Tibialis anticus* and the internal lateral ligament on the inner side, and between the *Peroneus tertius* and the external lateral ligament on the outer side. In addition to this, bulging frequently occurs posteriorly, and a fluctuating swelling may be detected on either side of the *tendo Achillis*.

Chronic synovitis may result from frequent sprains, and when once this joint has been sprained it is more liable to a recurrence of the injury than it was before; chronic synovitis may be tuberculous in its origin, the disease usually commencing in the astragalus and extending to the joint, though it may commence as a synovitis, the result probably of some slight strain in a tuberculous subject.

Excision of the ankle-joint is not often performed for two reasons. In the first place, disease of the articulation, for which this operation is indicated, is frequently associated with disease of the tarsal bones, which prevents its performance; and, secondly, the foot after excision is frequently of very little use; far less, in fact, than after a *Syme's amputation*, which is often, therefore, a preferable operation in these cases.

¹ The student must bear in mind that the *Extensor longus digitorum* and *Extensor proprius hallucis* are *extensors* of the toes, but *flexors* of the ankle, and that the *Flexor longus digitorum* and *Flexor longus hallucis* are *flexors* of the toes, but *extensors* of the ankle.

V. The Articulations of the Tarsus (Articulationes Intertarseae) (Figs. 275, 276).

1. THE ARTICULATION OF THE CALCANEUS AND ASTRAGALUS (ARTICULATIO TALOCALCANEAE) (Fig. 275).

The articulations between the calcaneus and astragalus are two in number— anterior and posterior. They are arthrodial joints. The bones are connected by a **capsule** (*capsula articularis*), which is at certain points accentuated into definite ligaments. There are five ligaments in this articulation:

External Calcaneo-astragaloid.	Anterior Calcaneo-astragaloid.
Internal Calcaneo-astragaloid.	Posterior Calcaneo-astragaloid.
Interosseous.	

The **external calcaneo-astragaloid ligament** (*ligamentum talocalcaneum laterale*) (Fig. 276) is a short, strong, fasciculus passing from the outer surface of the astragalus, immediately beneath its external malleolar facet, to the outer surface of the calcaneus. It is placed in front of the middle fasciculus of the external lateral ligament of the ankle-joint, with the fibres of which it is parallel.

The **internal calcaneo-astragaloid ligament** (*ligamentum talocalcaneum mediale*) is a band of fibres connecting the internal tubercle of the back of the astragalus with the back of the sustentaculum tali. Its fibres blend with those of the inferior calcaneoscaphoid ligament.

The **anterior calcaneo-astragaloid ligament** (*ligamentum talocalcaneum anterius*) passes from the front and outer surface of the neck of the astragalus to the superior surface of the calcaneus.

The **posterior calcaneo-astragaloid ligament** (*ligamentum talocalcaneum posterius*) connects the external tubercle of the astragalus with the upper and inner part of the calcaneus; it is a short band, the fibres of which radiate from their narrow attachment to the astragalus.

The **interosseus ligament** (*ligamentum talocalcaneum interosseum*) (Fig. 279) forms the chief bond of union between the bones. It consists of numerous vertical and oblique fibres attached by one extremity to the groove between the articulating facets on the under surface of the astragalus; by the other to a corresponding depression on the upper surface of the calcaneus. It is very thick and strong, being at least an inch in breadth from side to side, and serves to unite the calcaneus and astragalus solidly together.

Synovial Membrane.—The synovial membranes (Fig. 279) are two in number, one for the posterior calcaneo-astragaloid articulation, a second for the anterior calcaneo-astragaloid joint. The latter synovial membrane is continued forward between the contiguous surfaces of the astragalus and scaphoid bones.

Movements.—The movements permitted between the astragalus and calcaneus are limited to a *gliding* of the one bone on the other in a direction from before backward, and from side to side.

2. THE ARTICULATION OF THE CALCANEUS WITH THE CUBOID (ARTICULATIO CALCANEOCUBOIDEA) (Fig. 275).

In this joint the articular capsule (*capsula articularis*) is strengthened at certain points by definite ligaments.

The ligaments connecting the calcaneus with the cuboid are four in number:

Superior Calcaneocuboid.	Two Plantar {	Long Calcaneocuboid.
The Internal Calcaneocuboid.		Short Calcaneocuboid.

The **superior calcaneocuboid ligament** (*ligamentum calcaneocuboideum dorsale*) (Fig. 276) is a broad portion of the capsule which passes between the contiguous surfaces of the calcaneus and cuboid on the dorsal surface of the joint.

The **internal calcaneocuboid** or the **interosseous ligament** (*pars calcaneocuboidea ligamenti bifurcati*) is a short but thick and strong band of fibres arising from the calcaneus, in the deep hollow which intervenes between it and the astragalus, and closely blended, at its origin, with the superior calcaneoscaphoid ligament. These two ligaments are often regarded as a single bifurcated ligament (*ligamentum bifurcatum*). The internal calcaneocuboid ligament is inserted into the inner side of the cuboid bone. This ligament forms one of the chief bonds of union between the first and second rows of the tarsus.

The **long calcaneocuboid** or **long plantar** or **superficial long plantar ligament** (*ligamentum plantare longum*) (Fig. 278), the more superficial of the two plantar ligaments, is the longest of all the ligaments of the tarsus; it is attached to the under surface of the calcaneus, from near the tuberosities, as far forward as the anterior tubercle; its fibres pass forward to be attached to the ridge on the under surface of the cuboid bone, the more superficial fibres being continued onward to the bases of the second, third, and fourth metatarsal bones. This ligament crosses the groove on the under surface of the cuboid bone, converting it into a canal for the passage of the tendon of the Peroneus longus.

The **short calcaneocuboid** or **short plantar ligament** (*ligamentum calcaneocuboideum plantare*) (Fig. 278) lies nearer the bones than the preceding, from which it is separated by a little areolar tissue. It is exceedingly broad, about an inch in length, and extends from the tubercle and the depression in front of it, on the fore part of the under surface of the calcaneus, to the inferior surface of the cuboid bone behind the peroneal groove.

Synovial Membrane (Fig. 279).—The synovial membrane in this joint is distinct. It lines the inner surface of the ligaments.

Movements.—The movements permitted between the calcaneus and cuboid are limited to a slight *gliding* upon each other.

3. THE LIGAMENTS CONNECTING THE CALCANEUS AND SCAPHOID.

Though these two bones do not, as a rule, directly articulate, they are connected by two ligaments:

Superior or External Calcaneoscaphoid.

Inferior or Internal Calcaneoscaphoid.

The **superior** or **external calcaneoscaphoid ligament** (*pars calcaneonavicularis ligamenti bifurcati*) arises, as already mentioned, with the internal calcaneocuboid in the deep hollow between the astragalus and calcaneus, constituting a part of the *ligamentum bifurcatum*; it passes forward from the upper surface of the anterior extremity of the calcaneus to the outer side of the scaphoid bone. These two ligaments resemble the letter Y, being blended together behind, but separated in front.

The **inferior** or **internal calcaneoscaphoid ligament** (*ligamentum calcaneonaviculare plantare*) (Fig. 278) is by far the larger and stronger of the two ligaments between these bones; it is a broad and thick band of fibres, which passes forward and inward from the anterior margin of the sustentaculum tali of the calcaneus to the under surface of the scaphoid bone. This ligament not only serves to connect the calcaneus and scaphoid, but supports the head of the astragalus, forming part of the articular cavity in which it is received. The *upper surface*

presents a fibrocartilaginous facet, lined with the synovial membrane continued from the anterior calcaneo-astragaloid articulation, upon which a portion of the head of the astragalus rests. Its *under surface* is in contact with the tendon of the Tibialis posticus muscle, its *inner border* is blended with the fore part of the deltoid ligament, thus completing the socket for the head of the astragalus.

Applied Anatomy.—The *inferior calcaneoscaphoid ligament*, by supporting the head of the astragalus, is principally concerned in maintaining the arch of the foot, and when it yields the head of the astragalus is pressed downward, inward, and forward by the weight of the body, and the foot become flattened, expanded, and turned outward, constituting the condition known as *flat-foot*. This ligament contains a considerable amount of elastic tissue, so as to give elasticity to the arch and spring to the foot; hence, it is sometimes called the “spring” ligament. It is supported, on its under surface, by the tendon of the Tibialis posticus, which spreads out at its insertion into a number of fasciculi which are attached to most of the tarsal and metatarsal bones; this prevents undue stretching of the ligament, and is a protection against the occurrence of flat-foot.

4. THE ARTICULATION OF THE ASTRÁGALUS WITH THE SCAPHOID BONE (ARTICULATIO TALONAVICULARIS) (Fig. 275).

This is an arthrodial joint, the rounded head of the astragalus being received into the concavity formed by the posterior surface of the scaphoid, the anterior articulating surface of the calcaneus; and the upper surface of the inferior calcaneoscaphoid ligament, which fills up the triangular interval between these bones. The only ligament of this joint is the **superior astragaloscaphoid** (Fig. 273). It is a broad band, which passes obliquely forward from the neck of the astragalus to the superior surface of the scaphoid bone. It is thin, and weak in texture, and covered by the Extensor tendons. The inferior calcaneoscaphoid ligament supplies the place of an inferior astragaloscaphoid ligament.

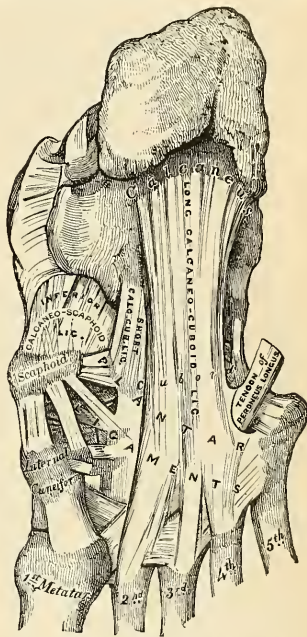


FIG. 278.—Ligaments of the plantar surface of the foot.

Synovial Membrane (Fig. 279).—The synovial membrane which lines the joint is continued forward from the anterior calcaneo-astragaloid articulation.

Movements.—This articulation permits of considerable mobility, but its feebleness is such as to allow occasionally of dislocation of the other bones of the tarsus from the astragalus.

The **transverse tarsal** or **midtarsal joint** (*articulatio tarsi transversa* [Chopart]) (Figs. 275 and 280) is formed by the articulation of the os calcis with the cuboid, and by the articulation of the astragalus with the scaphoid. The movement which takes place in this joint is more extensive than that in the other tarsal joints, and consists of a sort of rotation by means of which the sole of the foot may be slightly flexed and extended or carried inward (*inverted*) and outward (*everted*).

5. THE ARTICULATION OF THE SCAPHOID WITH THE CUNEIFORM BONES (ARTICULATIO CUNEONAVICULARIS) (Fig. 275).

The scaphoid is connected to the three cuneiform bones by

Dorsal and Plantar Ligaments.

The **dorsal ligaments** (*ligamenta navicularicuneiformia dorsalia*) (Figs. 273 and 275) are small, longitudinal bands of fibrous tissue arranged as three bundles, one to each of the cuneiform bones. That bundle of fibres which connects the scaphoid with the internal cuneiform is continued around the inner side of the articulation to be continuous with the plantar ligament which connects these two bones.

The **plantar ligaments** (*ligamenta navicularicuneiformia plantaria*) (Fig. 278) have a similar arrangement to those on the dorsum. They are strengthened by processes given off from the tendon of the Tibialis posticus.

Synovial Membrane (Fig. 279).—The synovial membrane of these joints is part of the great tarsal synovial membrane.

Movements.—The movements permitted between the scaphoid and cuneiform bones are limited to a slight *gliding* upon each other.

6. THE ARTICULATION OF THE SCAPHOID WITH THE CUBOID (ARTICULATIO CUBOIDEONAVICULARIS).

The scaphoid bone is connected with the cuboid by

Dorsal, Plantar, and Interosseous Ligaments.

The **dorsal ligament** (*ligamentum cuboideonaviculare dorsale*) (Fig. 276) consists of a band of fibrous tissue which passes obliquely forward and outward from the scaphoid to the cuboid bone.

The **plantar ligament** (*ligamentum cuboideonaviculare plantare*) consists of a band of fibrous tissue which passes nearly transversely between these two bones.

The **interosseous ligament** (Figs. 275 and 279) consists of strong transverse fibres which pass between the rough nonarticular portions of the lateral surfaces of these two bones.

Synovial Membrane (Fig. 279).—The synovial membrane of this joint is part of the great tarsal synovial membrane.

Movements.—The movements permitted between the scaphoid and cuboid bones are limited to a slight *gliding* upon each other.

7. THE ARTICULATIONS OF THE CUNEIFORM BONES WITH EACH OTHER OR THE INTERCUNEIFORM ARTICULATIONS (Fig. 275).

These bones are connected by

Dorsal, Plantar, and Interosseous Ligaments.

The **dorsal ligaments** (*ligamenta intercuneiformia dorsalia*) consist of two bands of fibrous tissue which pass transversely, one connecting the internal with the middle cuneiform, and the other connecting the middle with the external cuneiform.

The **plantar ligaments** (*ligamenta intercuneiformia plantaria*) have a similar arrangement to those on the dorsum. They are strengthened by the processes given off from the tendon of the Tibialis posticus.

The **interosseous ligaments** (*ligamenta intercuneiformia interossea*) consist of strong transverse fibres which pass between the rough nonarticular portions of the lateral surfaces of the first and second and the second and third cuneiform bones. The outer portion of the third cuneiform is attached to the cuboid by the *ligamentum cuneocuboideum interosseum* (page 351).

Synovial Membrane (Fig. 279).—The synovial membrane of these joints is part of the great tarsal synovial membrane.

Movements.—The movements permitted between the cuneiform bones are limited to a slight *gliding* upon each other.

8. THE ARTICULATION OF THE EXTERNAL CUNEIFORM BONE WITH THE CUBOID (Fig. 275).

These bones are connected by

Dorsal, Plantar, and Interosseous Ligaments.

The **dorsal ligament** (*ligamentum cuneocuboideum dorsale*) (Fig. 276) consists of a band of fibrous tissue which passes transversely between these two bones.

The **plantar ligament** (*ligamentum cuneocuboideum plantare*) has a similar arrangement. It is strengthened by a process given off from the tendon of the *Tibialis posticus*.

The **interosseous ligament** (*ligamentum cuneocuboideum interosseum*) (Fig. 275) consists of strong transverse fibres which pass between the rough non-articular portions of the lateral surfaces of the adjacent sides of these two bones.

Synovial Membrane (Fig. 279).—The synovial membrane of this joint is part of the great tarsal synovial membrane.

Movements.—The movements permitted between the external cuneiform and cuboid are limited to a slight *gliding* upon each other.

Nerve Supply.—All the joints of the tarsus are supplied by the anterior tibial nerve.

Applied Anatomy.—In spite of the great strength of the ligaments which hold the tarsal bones together, *dislocation* at some of the tarsal joints occasionally occurs; these bones, on account of their spongy character, are, as the result of direct violence, more frequently broken than dislocated. When dislocation does occur, it is most commonly in connection with the astragalus; for not only may this bone be dislocated from the tibia and fibula at the ankle-joint, but the other bones may be dislocated from it, the trochlear surface of the bone remaining *in situ* in the tibiofibular mortise. This constitutes what is known as the *subastragaloid dislocation*. Or, again, the astragalus may be dislocated from all its connections—from the tibia and fibula above, the os calcis below, and the scaphoid in front—and may even undergo a rotation, either on a vertical or horizontal axis. In the former case the long axis of the bone becoming directed across the joint, so that the head faces the articular surface on one or other malleolus; or, in the latter, the lateral surfaces becoming directed upward and downward, so that the trochlear surface faces to one or the other side. Finally, dislocation may occur at the mediotarsal joint, the anterior tarsal bones being luxated from the astragalus and calcaneum. The other tarsal bones are also, occasionally, though rarely, dislocated from their connections.

Pes planus or *flat-foot* is a condition in which there is abduction, eversion, and loss of both the longitudinal and the transverse arch. The head of the astragalus passes downward and inward; the anterior portion of the foot is turned outward and the inner side of the foot is lengthened and broadened. Deformity is increased when standing. In severe cases the patient walks on the inner side of the foot. The condition is due to weakness of the *Tibialis posticus* muscle, with a consequent yielding of the tarsal ligaments. Abduction is permitted by yielding of the internal lateral and calcaneo-astragaloid ligaments. Yielding of the inferior calcaneo-scaphoid ligament permits the head of the astragalus to pass downward and forward, and the entire arch falls.

VI. The Tarsometatarsal Articulations (*Articulationes Tarsometatarsae*) (Figs. 275, 276).

These are arthrodial joints. The bones entering into their formation are four tarsal bones—viz., the internal, middle, and external cuneiform and the cuboid—which articulate with the metatarsal bones of the five toes. The metatarsal bone of the great toe articulates with the internal cuneiform; that of the second is deeply wedged in between the internal and external cuneiform, rests against the middle cuneiform, and is the most strongly articulated of all the metatarsal

bones; the third metatarsal articulates with the extremity of the external cuneiform; the fourth, with the cuboid and external cuneiform; and the fifth, with the cuboid. The articular surfaces are covered by hyaline cartilage, lined with synovial membrane, and interconnected by **capsules** and by the following ligaments:

Dorsal.

Plantar.

Interosseous.

The **dorsal ligaments** (*ligamenta tarsometatarsea dorsalia*) consist of strong, flat, fibrous bands, which connect the tarsal with the metatarsal bones. The first metatarsal is connected to the internal cuneiform by a single broad, thin, fibrous band; the second has three dorsal ligaments, one from each cuneiform bone; the third has one from the external cuneiform; the fourth has two, one from the external cuneiform and one from the cuboid; and the fifth, one from the cuboid.

The **plantar ligaments** (*ligamenta tarsometatarsea plantaria*) consist of longitudinal and oblique fibrous bands connecting the tarsal and metatarsal bones, but disposed with less regularity than on the dorsal surface. Those for the first and second metatarsal are the most strongly marked; the second and third metatarsal receive strong fibrous bands which pass obliquely across from the internal cuneiform; the plantar ligaments of the fourth and fifth metatarsal consist of a few scanty fibres derived from the cuboid.

The **interosseous ligaments** (*ligamenta cuneometatarsea interossea*) are three in number—internal, middle, and external. The **internal** one is the strongest of the three, and passes from the outer extremity of the internal cuneiform to the adjacent angle of the second metatarsal. The **middle** one, less strong than the preceding, connects the external cuneiform with the adjacent angle of the second metatarsal. The **external** interosseous ligament connects the outer angle of the external cuneiform with the adjacent side of the third metatarsal.

Synovial Membrane (Fig. 279).—The synovial membrane between the internal cuneiform bone and the first metatarsal bone is a distinct sac. The synovial membrane between the middle and external cuneiform behind, and the second and third metatarsal bones in front, is part of the great tarsal synovial membrane. Two prolongations are sent forward from it—one between the adjacent sides of the second and third metatarsal bones, and one between the third and fourth metatarsal bones. The synovial membrane between the cuboid and the fourth and fifth metatarsal bones is a distinct sac. From it a prolongation is sent forward between the fourth and fifth metatarsal bones.

Movements.—The movements permitted between the tarsal and metatarsal bones are limited to a slight *gliding* upon each other.

VII. The Articulations of the Metatarsal Bones with Each Other (Articulationes Intermetatarsee) (Figs. 275, 276).

The base of the first metatarsal bone is not connected with the second metatarsal bone by any ligaments; in this respect it resembles the thumb.

The bases of the four outer metatarsal bones are connected by dorsal, plantar, and interosseous ligaments.

The **dorsal ligaments** (*ligamenta basium* [oss. metatars.] *dorsalia*) consist of bands of fibrous tissue which pass transversely between the adjacent metatarsal bones.

The **plantar ligaments** (*ligamenta basium* [oss. metatars.] *plantaria*) have a similar arrangement to those on the dorsum.

The **interosseous ligaments** (*ligamenta basium* [oss. metatars.] *interossea*) consist of strong transverse fibres which pass between the rough nonarticular portions of the lateral surfaces.

Synovial Membrane.—The synovial membrane between the second and third and the third and fourth metatarsal bones is part of the great tarsal synovial membrane. The synovial membrane between the fourth and fifth metatarsal bones is a prolongation of the synovial membrane of the cubometatarsal joint (Fig. 279).

Movements.—The movement permitted in the tarsal ends of the metatarsal bones is limited to a slight *gliding* of the articular surfaces upon one another.

The Synovial Membranes in the Tarsal and Metatarsal Joints.—The synovial membranes (Fig. 279) found in the articulations of the tarsus and metatarsus are *six* in number—one for the posterior calcaneo-astragaloid articulation; a *second* for the anterior calcaneo-astragaloid and astragaloscaphoid articulations; a *third* for the calcaneocuboid articulation; and a *fourth* for the articulations of the scaphoid with the three cuneiform, the three cuneiform with each other, the external cuneiform with the cuboid, and the middle and external cuneiform with the bases of the second and third metatarsal bones, and the lateral surfaces of the second, third, and fourth metatarsal bones with each other. The *fifth* synovial membrane is found in the articulation of the internal cuneiform with the metatarsal bone of the great toe; and there is a *sixth* for the articulation of the cuboid with the fourth and fifth metatarsal bones. A small synovial membrane is sometimes found between the contiguous surfaces of the scaphoid and cuboid bones.

Nerve Supply.—The nerves supplying the tarsometatarsal joints are derived from the anterior tibial.

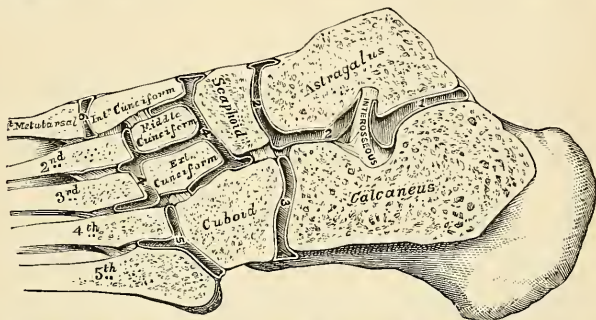


FIG. 279.—Oblique section of the articulations of tarsus and metatarsus. Showing the six synovial membranes.

The **digital extremities** of all the metatarsal bones are connected by the **transverse metatarsal ligament**.

The **transverse metatarsal ligament** is a narrow fibrous band which passes transversely across the anterior extremities of all the metatarsal bones, connecting them. It is blended *anteriorly* with the plantar (*glenoid*) ligament of each metatarsophalangeal articulation. To its *posterior border* is connected the fascia covering the Interossei muscles. Its *inferior surface* is concave where the Flexor tendons pass over it. *Above* it the tendons of the Interossei muscles pass to their insertion. It differs from the transverse metacarpal ligament in that it connects the metatarsal bone of the great toe with the rest of the metatarsal bones.

VIII. The Metatarsophalangeal Articulations (*Articulationes Metatarsophalangeae*).

The metatarsophalangeal articulations are of the condyloid variety, formed by the reception of the rounded heads of the metatarsal bones into shallow cavities in the extremities of the first phalanges. Each joint has a capsule and certain other ligaments. These ligaments are:

Plantar.

Two Lateral.

The **plantar ligaments** (*ligamenta accessoria plantaria*) are thick, dense, fibrous structures. Each is placed on the plantar surface of the joint in the interval between the lateral ligaments, to which it is connected. The plantar ligaments are loosely united to the metatarsal bones, but very firmly to the bases of the first phalanges. The plantar surface of each is intimately blended with the transverse metatarsal ligament, and, except in the great toe, presents a groove for the passage of the Flexor tendons, the sheath surrounding which is connected to each side of the groove. The plantar ligament of the great toe contains two large sesamoid bones. By their deep surface they form part of the articular surface for the head of the metatarsal bone, and are lined with synovial membrane.

The **lateral ligaments** (*ligamenta collateralia*) are strong, rounded cords, placed one on each side of the joint, each being attached, by one extremity, to the posterior tubercle on the side of the head of the metatarsal bone; and, by the other, to the contiguous extremity of the phalanx.

The place of a **dorsal ligament** is supplied by the Extensor tendon over the back of the joint.

Movements.—The movements permitted in the metatarsophalangeal articulations are *flexion*, *extension*, *abduction*, and *adduction*.

IX. The Articulations of the Phalanges (*Articulationes Digitorum Pedis*).

The articulations of the phalanges are ginglymoid joints. Besides the capsular the ligaments are:

Plantar.

Two Lateral (*ligamenta collateralia*).

The arrangement of these ligaments is similar to those in the metatarsophalangeal articulations; the Extensor tendon supplies the place of a dorsal ligament.

Movements.—The only movements permitted in the phalangeal joints are *flexion* and *extension*; these movements are more extensive between the first and second phalanges than between the second and third. The movement of flexion is very considerable, but extension is limited by the plantar and lateral ligaments.

Surface Form.—The principal joints which it is necessary to distinguish, with regard to the surgery of the foot, are the *intertarsal* and the *tarsometatarsal*. The joint between the astragalus and the scaphoid is best found by means of the *tubercle of the scaphoid*, for the line of the joint is immediately behind this process. If the foot is grasped and forcibly extended, a rounded prominence, the *head of the astragalus*, will appear on the inner side of the dorsum in front of the ankle-joint, and if a knife is carried downward, just in front of this prominence and behind the line of the scaphoid tubercle, it will enter the astragaloscaphoid joint. The calcaneocuboid joint is situated midway between the external malleolus and the prominent end of the fifth metatarsal bone. The plane of the joint is in the same line as that of the astragaloscaphoid. The position of the joint between the fifth metatarsal bone and the cuboid is easily found by the projection of the fifth metatarsal bone, which is the guide to it. The direction of the line of the joint is very oblique, so that, if continued onward, it would pass through the head of the first metatarsal bone. The joint between the fourth metatarsal bone and the cuboid and external cuneiform is the direct continuation inward of the previous joint, but its plane is less oblique; it would be represented by a line drawn from the outer side of the articulation to the middle of the first metatarsal bone. The plane of the joint between the third metatarsal bone and the external cuneiform is almost transverse. It would be represented by a line drawn from the outer side of the joint to the base of the first metatarsal bone. The tarsometatarsal articulation of the great toe corresponds to a groove which can be felt by making firm pressure on the inner side of the foot one inch in front of the tubercle on the scaphoid bone; and the joint between the second metatarsal bone and the middle cuneiform is to be found on the dorsum of the foot, half an inch behind the level of the tarsometatarsal joint of the great toe. The line of the joints between the metatarsal bones and the first phalanges is about an inch behind the webs of the corresponding toes.

Applied Anatomy.—This is considered on p. 256.

THE MUSCLES AND FASCIÆ.¹

MYOLOGY is the branch of anatomy which treats of the muscles. The muscles are formed of bundles of reddish fibres, endowed notably with the property of contractility in the direction of the long axes of the muscle cells. Contractions of muscle fibres induce motion. The two principal kinds of muscle tissue found in the body are the more highly differentiated, or **voluntary**, and the less highly differentiated, or **involuntary**. The former of these, from the characteristic appearances which its fibres exhibit under the microscope, is known as **striated**, or **striped muscle**. As most striped muscles are capable of being put into action and controlled by the will, they are generally called "voluntary" muscles. The fibres of involuntary muscle do not present any cross-striped appearance, and are not under the control of the will; such muscles are known as **unstriated**, **unstriped** or **vegetative**. The muscle fibres of the heart differ in certain particulars from both these groups, and they are therefore separately described as **cardiac muscle fibres**.

Thus, it will be seen that there are *three* varieties of muscle tissue: (1) Transversely striated fibres, which are for the most part voluntary and under the control of the will. This variety of muscle is also called **skeletal**. (2) Transversely striated muscle fibres, which are not under the control of the will—*i. e.*, the **cardiac muscles**. The cardiac muscle occupies a mid-position in the scale between the cells of involuntary and the striated fibres of voluntary muscle. (3) **Plain or unstriped muscle fibres**, which are involuntary, and are controlled by a different part of the nerve system from that which controls the activity of the voluntary muscles. Such are the muscular walls of the stomach and intestine, of the uterus and bladder, of the bloodvessels, of certain canals and ducts, etc. The statement that striated muscle is *always* voluntary, and that nonstriated muscle is *always* involuntary, cannot be accepted as invariably and inevitably true. There are animals in which some voluntary muscle is free from distinct striation, while the Diaphragm, made up of striated muscle fibres, is not wholly under the control of the will.

Although the voluntary striated muscle tissue alone is concerned in the skeletal musculature, all three varieties of muscle tissue will be described here. The skeletal muscles act upon the bones, and thus produce movement. The primitive contractile elements of a muscle are the **fibres**. Fibres are gathered into groups known as **primary bundles** or **fasciculi**, and the fasciculi are aggregated into masses called **secondary bundles**. In coarse muscles the fasciculi are of considerable size; in fine muscles they are of trivial size. Fasciculi may be long or short, and the length does not depend on the length of the muscle.

Structure of Striated Muscle.—Each muscle is surrounded by a sheath of fibrous tissue called the **epimysium**; this sends in **septa** which surround the secondary bundles; these in turn send in the **perimysium** which surrounds each muscle fasciculus. The fibres of each

¹ The Muscles and Fasciæ are described conjointly, in order that the student may consider the arrangement of the latter in his dissection of the former. It is rare for the student of anatomy in this country to dissect the fasciæ separately; and it is for this reason, as well as from the close connection that exists between the muscles and their investing sheaths, that they are considered together. Some general observations are first made on the histology and anatomy of the muscles and fasciæ, the special description being given in connection with the different regions.

fasciculus are separated by a delicate meshwork of fibroelastic tissue, the **endomysium**, which supports the small vessels and nerves.

Structure of the Muscle Fibre.—A muscle fibre is a long cylindrical cell varying from less than one to five inches (2.5 to 12.5 cm.) in length. It is surrounded by a delicate sheath called the **sarcolemma**, within which lie the **nuclei** and **muscle substance**. The muscle substance consists of two elements—the **fibrillæ**, or contractile portion of the fibre, and the **sarcoplasm**, or undifferentiated portion. The fibrillæ are arranged parallel to one another and are separated by the sarcoplasm; and as the former respond well to the protoplasmic stains, and the latter practically not at all, the alternation of such stained and unstained stripes produces the

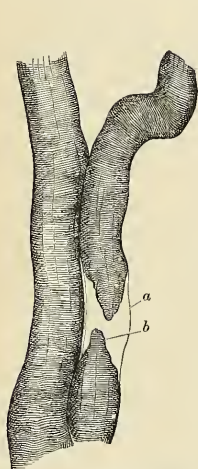


FIG. 280.—Two human muscle fibres. $\times 350$. In the one the bundle of fibrillæ (b) is torn, and the sarcolemma (a) is seen as an empty tube.

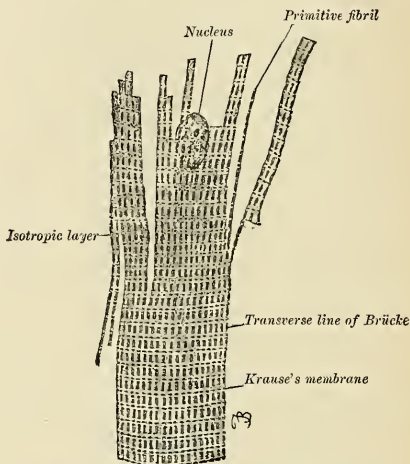


FIG. 281.—A bit of a cross-striated muscle of a frog, showing the nucleus and the ease of its division both transversely and longitudinally. $\times 650$. (Szymonowicz and MacCallum.)

longitudinal striations so typical of the appearance of a longitudinal section of muscle under the microscope. In a cross-section the fibrillæ are arranged more or less in groups called **Cohnheim's fields**.

The fibrillæ, or **sarcostyle**, are not unbroken threads, but all are interrupted at intervals into short segments called **sarcous elements**. As a result of this segmentation a fibre exhibits alternating transverse dark and light bands (cross-striations). If a muscle fibre be examined under high magnification, a light line is seen traversing each dark band (anisotropic); this is the **membrane of Hensen**. The light band (isotropic) is traversed by a dark line, **Dobie's line**, or the **membrane of Krause**, that divides the band into two parts, the **lateral disks**. A **sarcomere** is that part of a fibril between two membranes of Krause, and consists of a sarcous element and a lateral disk at each end of the sarcous element.

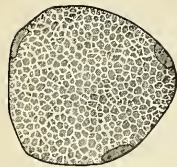


FIG. 282.—Section of a muscle fibre, showing areas of Cohnheim. Three nuclei are seen lying close to the sarcolemma. (Schäfer.)

between myoplasm and the white fibres. The *white* fibres are poor in sarcoplasm and predominate in human muscles. The Trapezius muscle contains both red and white fibres.

The **arteries** of voluntary muscles are numerous. They pierce the epimysium, pass along the septa from the epimysium, and divide into small branches, which enter between the

fasciculi. These small branches pass into capillaries which run parallel to the fibres. At intervals dilatable connections (*ampullae*) are established between the capillaries, and it is into these that during contractions of the muscle the blood passes to relieve the tension in the longitudinal capillaries.

Veins accompany the arteries, and even the smaller ones possess valves (*Spaltelholz*).

The **nerve endings** in voluntary muscle comprise both motor and sensor varieties. A motor nerve pierces the epimysium and breaks up into numerous branches to form an interfascicular plexus in the perimysium. From this plexus nerve fibrils arise, and usually one nerve fibril passes to each muscle fibre. The nerve fibril pierces the sarcolemma, the neurilemma, and myelinic sheath disappearing before the nerve fibril reaches the muscle fibre, and probably being lost by fusing with the sarcolemma. The naked axone beneath the sarcolemma of a fibre continues to the surface of the muscle fibre and undergoes arborization to form an *end organ*. Around the end organ is a quantity of granular sarcoplasm, which, with the nerve and organ, constitutes a **sole plate**. A sensor nerve takes origin from a **muscle spindle**, which consists of a bundle of encapsulated muscle fibres about sensor nerve twigs.

Involuntary striated or cardiac muscle is found in the heart and is not under the control of the will. Each fibre is a short cylinder varying from $100\ \mu$ to $200\ \mu$ in length and of about $25\ \mu$ to $40\ \mu$ in diameter. The striations are both longitudinal and transverse, but the latter are usually not distinct. Each fibre is surrounded by a delicate membrane. The cells give off narrow processes of branches which connect with each other, thus forming "a reticulum of muscle fibres. The meshes of this reticulum are occupied by areolar tissue in which the vascular and nerve supply of the tissue is situated."

Usually a single, large, oval nucleus occupies the centre of the cell and is surrounded by an area of clear and undifferentiated protoplasm in which fibrillae do not exist. Pigment granules are seen in this undifferentiated protoplasm.

Purkinje fibres are peculiar muscle fibres found in the heart, and will be described with that organ.

The **nerves** are both sympathetic and cerebrospinal.

Involuntary non-striated or smooth muscle is not under the control of the will. It is found in the alimentary tract from the middle third of the oesophagus down, in gland ducts, trachea, bronchi, bronchial tubes, in the urinogenital system, bloodvessels and lymph vessels, etc. It is found arranged in layers that encircle the organs longitudinally, transversely, and sometimes in an interlaced manner.

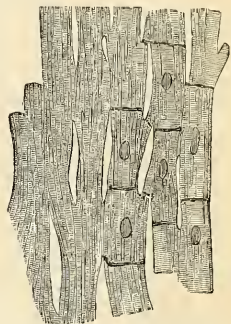


FIG. 283.—Anastomosing muscle fibres of the heart, seen in a longitudinal section. On the right the limits of the separate cells with their nuclei are exhibited somewhat diagrammatically.



FIG. 284.—Longitudinal section in the smooth muscle of a dog's large intestine, to show especially intercellular bridges. $\times 530$. (Szymonowicz and MacCallum.)

Each fibre is short and spindle-shaped, varying from $25\ \mu$ to $200\ \mu$ in length and from $5\ \mu$ to $7\ \mu$ in diameter. In the gravid uterus they are much larger in both dimensions. Occasionally, longitudinal striations are seen, and then the fibrillae so formed are coarse and peripherally located. Each fibre contains a single slender nucleus which is centrally located. **Branched fibres** are occasionally seen in the aorta and in the bladder.

The **bloodvessels** form a meshwork between the fibres.

The **nerves** are from the sympathetic system, though Kuntz has recently shown that in some organs, at least, the nerves are originally derived from the vagus.

Form and Attachment of Muscles.—The muscles are connected with the bones, cartilages, ligaments, and skin, either directly or through the intervention of

fibrous structures called **tendons** or **aponeuroses**. Where a muscle is attached to bone or cartilage, the fibres terminate in blunt extremities upon the periosteum or perichondrium, and do not come into direct relation with the osseous or cartilaginous tissue. Where muscles are connected with the skin, they either lie as a flattened layer beneath it, or are connected with its areolar tissue by larger or smaller bundles of fibres, as in the muscles of the face. The origin of a muscle is its **head** (*caput*), while the intermediate portion is called the **belly**, or **venter**.

The muscles vary extremely in their **form**. In the limbs they are of considerable length, especially the more superficial ones, the deep ones being generally broad; they surround the bones and form an important protection to the various joints. In the trunk they are broad, flattened, and expanded, forming the parietes of the cavities which they enclose; hence the reason of the terms *long*, *broad*, *short*, etc., used in the description of a muscle.

There is a considerable variation in the arrangement of the fibres of certain muscles with reference to the tendons to which they are attached. In some, the fibres are parallel and run directly from their origin to their insertion; these are **quadrilateral muscles**, such as the Thyrohyoid. A modification of these is found in the **fusiform muscles** in which the muscle tapers at each end; in their action,

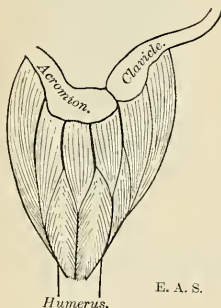


FIG. 285.—Diagram of the Deltoid, an example of a multipennate muscle.

however, they resemble the quadrilateral muscles. Secondly, in other muscles the fibres are convergent; arising by a broad origin, they converge to a narrow or pointed insertion. This arrangement of fibres is found in the **triangular muscles**—e. g., the Temporal. In some muscles, which otherwise would belong to the quadrilateral or triangular type, the origin and insertion are not in the same plane, but the plane of the line of origin intersects that of their insertion; such is the case in the Pectineus muscle. Thirdly, in some muscles the fibres are oblique and converge, like the plumes of a pen, to one side of a tendon, which runs the entire length of the muscle. Such a muscle is **penniform** (*m. unipennatus*), as the Peronei. A modification of these muscles is found in those cases where oblique fibres converge to both sides of a central tendon which runs down the

middle of the muscle; these are called **bipenniform** (*m. bipennatus*), and an example is afforded in the Rectus femoris. **Multipennate** muscles are those in which the muscle fibres alternate with a series of tendinous bands, as in the Deltoid. **Biventral** muscles occur, such as the Digastric, while the Rectus abdominis shows subdivision into four or more sections by intervening *inscriptiones tendineae*. Certain muscles do not act in a direct manner, for they or their tendons pass around a bony projection or through a septal pulley (trochlea). Finally, we have muscles in which the fibres are arranged in curved bundles in one or more planes, as in an **orbicular muscle** and in that variety of orbicular muscle called a **sphincter muscle**. The arrangement of the muscle fibres is of considerable importance in respect to their relative strength and range of movement. Those muscles in which the fibres are long and few in number have great range, but diminished strength; where, on the other hand, the fibres are short and more numerous, there is great power, but lessened range.

Muscles differ much in **size**; the Gastrocnemius forms the chief bulk of the back of the leg; the Sartorius is very long; the Stapedius, a small muscle of the internal ear, weighs about a grain, and its fibres are not more than 4 mm. in length.

The names applied to the various muscles have been derived (1) from their *situation*, as the Tibialis, Radialis, Ulnaris, Peroneus; (2) from their *direction*, as the Rectus abdominis, Obliquus capitis, Transversalis; (3) from their *uses*, as Flexors, Extensors, Abductors, Levators, Compressors, etc.; (4) from their *shape*, as the Deltoid, Trapezius, Rhomboideus, Digastric; (5) from the *number of their divisions*, as the Biceps, the Triceps; (6) from their *points of attachment*, as the Sternomastoid, Sternohyoid, Sternothyroid.

In the description of a muscle the term **origin** is meant to imply its more fixed or central attachment, and the term **insertion**, the movable point to which the force of the muscle is directed; but the origin is absolutely fixed in only a very small number of muscles, such as those of the face, which are attached by one extremity to the bone and by the movable integument; the greater number of muscles can be made to act from either extremity.

In the **dissection** of the muscles, the student should pay especial attention to the exact *origin*, *insertion*, and *actions* of each, and its more important *relations* with surrounding parts. While accurate knowledge of the points of attachment of the muscles is of great importance in the determination of their actions, it is not to be regarded as conclusive. The action of a muscle deduced from its attachments, or even by pulling on it in the dead subject is not necessarily its action in the living. By pulling, for example, on the Brachioradialis in the cadaver the hand may be slightly supinated¹ when in the prone position and slightly pronated when in the supine position, but there is no evidence that these actions are performed by the muscle during life. It is impossible for an individual to throw into action any one muscle; in other words, movements, not muscles, are represented in the central nerve system. To carry out a movement a definite combination of muscles is called into play, and the individual has no power either to leave out a muscle from this combination, or to add one to it. One muscle (or more) of the combination is the chief moving force: when this muscle passes over more than one joint other muscles (**synergic muscles**) come into play to inhibit the movements not required; a third set of muscles (**fixation muscles**) fix the limb—*i. e.*, in the case of the limb movements—and also prevent disturbances of the equilibrium of the body generally. As an example, the movement of the closing of the fist may be considered: (1) The prime movers are the Flexores digitorum, Flexor longus pollicis, and the small muscles of the thumb; (2) the synergic muscles are the Extensores carpi, which prevent flexion of the wrist; while (3) the fixation muscles are the Biceps and Triceps, which steady the elbow and shoulder. A further point which must be borne in mind in considering the actions of muscles is that in certain positions a movement can be effected by gravity, and in such a case the muscles acting are the antagonists of those which might be supposed to be in action. Thus, in flexing the trunk when no resistance is interposed the Erectores spinæ contract to regulate the action of gravity, and the Recti abdominis are relaxed.²

Applied Anatomy.—By a consideration of the action of the muscles the surgeon is able to explain the causes of displacement in various forms of fracture, and the causes which produce distortion in various deformities, and, consequently, to adopt appropriate treatment in each case. The relations, also, of some of the muscles, especially those in immediate apposition with the larger bloodvessels, and the surface-markings they produce, should be carefully remembered, as they form useful guides in the application of ligatures to those vessels.

Degeneration of muscle tissue is important clinically, and is met with in two main conditions. In one, the degeneration is myopathic, or primary in the muscles themselves; in the other it is neuropathic, or secondary to some lesion of the nerve system—a hemorrhage into the brain,

¹ Hence the old name *Supinator longus*, now supplanted by Brachioradialis.

² Consult in this connection the Croonian Lectures (1903) on "Muscular Movements and Their Representation in the Central Nervous System," by Charles E. Beevor, M.D.

for example, or injury or inflammation of some part of the spinal cord or peripheral nerves. In either case more or less paralysis and atrophy of the affected muscles result. When the degeneration begins primarily in the muscles, however, it often happens that though the muscle fibres waste away, their place is taken by fibrous and fatty tissue to such an extent that the affected muscles increase in volume, and actually appear to hypertrophy.

Ossification of muscle tissue as a result of repeated strain or injury is not infrequent. It is oftenest found about the tendon of the Adductor longus and Vastus internus in horsemen, or in the Pectoralis major and Deltoid of soldiers. It may take the form of exostoses firmly fixed to the bone—e. g., “*rider's bones*” on the femur (pages 229 and 515)—or of layers or spicules of bone lying in the muscles of their fasciæ and tendons. Busse states that these bony deposits are preceded by a hemorrhagic myositis due to injury, the effused blood organizing and being finally converted into bone. In the rarer disease, progressive *myositis ossificans*, there is an unexplained tendency for practically any of the voluntary muscles to become converted into solid and brittle bony masses which are completely rigid.

Tendons are white, glistening, fibrous cords, varying in length and thickness, sometimes round, sometimes flattened, of considerable strength, and devoid of elasticity. They consist almost entirely of dense, white fibrous tissue, the fibrils of which run in an undulating parallel course and are firmly united together. They are very sparingly supplied with bloodvessels, the smaller tendons presenting not a trace of them in their interior. Nerves supplying tendons have special modifications of their terminals, termed *neurotendinous spindles* or organs of Golgi (p. 817).

Aponeuroses are flattened or ribbon-shaped tendons, of a pearly-white color, iridescent, glistening, and similar in structure to the tendons; the thicker ones are only sparingly supplied with bloodvessels.

The tendons and aponeuroses are connected, on the one hand, with the muscles, and, on the other hand, with movable structures, as the bones, cartilages, ligaments, fibrous membranes (for instance, the sclera). Where the muscle fibres are in a direct line with those of the tendon or aponeurosis, the two are directly continuous, the muscle fibre being distinguishable from that of the tendon only by its striation and increase of muscle nuclei. But where the muscle fibres join the tendon or aponeurosis at an oblique angle the former terminate, according to Kölliker, in rounded extremities, which are received into corresponding depressions on the surface of the latter, the connective tissue between the fibres being continuous with that of the tendon. The latter mode of attachment occurs in all the penniform and bipenniform muscles, and in those muscles the tendons of which commence in a membranous form, as the Gastrocnemius and Soleus.

The **fasciæ** are fibroareolar or aponeurotic laminae of variable thickness and strength, found in all regions of the body, investing the softer and more delicate organs. The fasciæ have been subdivided, from the situation in which they are found, into two groups, **superficial** and **deep**.

The **superficial fascia** (*panniculus adiposus*) is found immediately beneath the integument over almost the entire surface of the body. It connects the skin with the deep or aponeurotic fascia, and consists of fibroareolar tissue, containing in its meshes pellicles of fat, in varying quantity. The superficial fascia varies in thickness in different parts of the body: in the groin it is so thick as to be capable of being subdivided into several laminae. Beneath the fatty layer of the superficial fascia, which is immediately subcutaneous, there is generally another layer of the same structure, comparatively devoid of adipose tissue, in which the trunks of the subcutaneous vessels and nerves are found, as the superficial epigastric vessels in the abdominal region, the radial and ulnar veins in the forearm, the saphenous veins in the leg and thigh, and the superficial lymph nodes. Certain cutaneous muscles also are situated in the superficial fascia, as the Platysma in the neck, and the Orbicularis palpebrarum around the eyelids. This fascia is most distinct at the lower part of the abdomen, the scrotum, perineum, and extremities; it is very thin in those regions where mus-

cle fibres are inserted into the integument, as on the side of the neck, the face, and around the margin of the anus. It is very dense in the scalp, in the mammae, the palms of the hands and soles of the feet, forming a fibrofatty layer which binds the integument firmly to the subjacent structure.

The superficial fascia connects the skin to the subjacent parts, facilitates the movement of the skin, serves as a soft medium for the passage of vessels and nerves to the integument, and retains the warmth of the body, since the fat contained in its areolæ is a poor conductor of heat.

The **deep** or **aponeurotic** fascia is a dense, inelastic, unyielding fibrous membrane, forming sheaths for the muscles and affording them broad surfaces for attachment. It consists of shining tendinous fibres, placed parallel to one another, and connected by other fibres disposed in a rectilinear manner. It is usually exposed on the removal of the superficial fascia, forming a strong investment, which not only binds down collectively the muscles in each region, but gives a separate sheath to each, as well as to the vessels and nerves. The fasciæ are thick in unprotected situations, as on the outer side of a limb, and thinner on the inner side. The deep fasciæ assist the muscles in their action by the degree of tension and pressure they make upon their surface; and in certain situations this is increased and regulated by muscular action; as, for instance, by the Tensor fasciæ femoris and Gluteus maximus in the thigh, by the Biceps in the upper and lower extremities, and Palmaris longus in the hand. In the limbs the fasciæ not only invest the entire limb, but give off septa which separate the various muscles, and are deeply attached to the periosteum; these prolongations of fasciæ are usually spoken of as *intermuscular septa*.

Development of the Skeletal Musculature.—The voluntary muscles are developed from the myotomes of the mesodermal somites. Portions of the myotomes retain their position along the body axis in segmental order, such as the short muscles of the vertebral column. Others migrate into the body wall, where again they may retain their segmental relation (intercostal muscles), or may fuse with adjacent segments to form flat muscles such as those in the abdominal wall. In the *limbs*, portions of myotomes wander into the limb buds and there undergo fusions and alterations in form to produce the limb muscles, thus losing their segmental character, but retaining the appropriate segmental nerve supplies. Some of the limb muscles expand and migrate secondarily toward the dorsimesal line (*e. g.*, Trapezius, Latissimus) or toward the ventromesal line (*e. g.*, Pectoralis major). Again, muscles may migrate cephalad (*e. g.*, the facial muscles derived from the hyoid arch) or caudad (*e. g.*, Serratus magnus). In all cases the muscles carry with them the segmental nerves of the myotomes from which they were derived; the most striking example is the Diaphragm which is derived from the third, fourth, and fifth cervical myotomes, and is supplied by the phrenic nerves, which spring from the third, fourth, and fifth cervical nerves. Some of the derivatives of the myotomes degenerate and are converted into aponeuroses (*e. g.*, epicranial aponeurosis) or into ligaments (*e. g.*, great sacroscopic ligament and external lateral ligament of the knee).

Various disturbances of development characterize what are known as **variable** or **anomalous muscles**. Such muscles may be wanting, or excessively developed in the way of accessory portions or with atypic attachments. The resemblance which such muscles in the human subject bear to certain muscles in lower animals has been regarded by some anatomists as an expression of atavistic reversion.¹

The **muscles** and **fasciæ** may be arranged according to the general division of the body, into those of the **cranium, face, and neck**; those of the **trunk**; those of the **upper extremity** or **pectoral limb**; and those of the **lower extremity** or **pelvic limb**.

¹ See, however, Huntington, American Journal of Anatomy, 1902-03, vol. ii, p. 157.

MUSCLES AND FASCIÆ OF THE CRANIUM AND FACE.

The muscles of the cranium and face consist of ten groups, arranged according to the region in which they are situated:

- | | |
|----------------------|-------------------------------|
| 1. Cranial Region. | 6. Maxillary Region. |
| 2. Auricular Region. | 7. Mandibular Region. |
| 3. Palpebral Region. | 8. Buccal Region. |
| 4. Orbital Region. | 9. Temporomandibular Region. |
| 5. Nasal Region. | 10. Pterygomandibular Region. |

The muscles contained in each of these groups are the following:

- | | |
|---------------------------------------------------------------------------------------------------------------------------------------------------------------------------------------------------------------------------|------------------------------------------------------------------------------------------------------------------------------|
| 1. <i>Cranial Region.</i>
Occipitofrontalis. | 6. <i>Maxillary Region.</i>
Levator labii superioris.
Levator anguli oris.
Zygomaticus major.
Zygomaticus minor. |
| 2. <i>Auricular Region.</i>
Attrahens aurem.
Attollens aurem.
Retrahens aurem. | 7. <i>Mandibular Region.</i>
Levator menti.
Depressor labii inferioris.
Depressor anguli oris. |
| 3. <i>Palpebral Region.</i>
Orbicularis palpebrarum.
Corrugator supercilii.
Tensor tarsi. | 8. <i>Buccal Region.</i>
Buccinator.
Risorius.
Orbicularis oris. |
| 4. <i>Orbital Region.</i>
Levator palpebrae.
Rectus superior.
Rectus inferior.
Rectus internus.
Rectus externus.
Obliquus oculi superior.
Obliquus oculi inferior. | 9. <i>Temporomandibular Region.</i>
Masseter.
Temporal. |
| 5. <i>Nasal Region.</i>
Pyramidalis nasi.
Levator labii superioris alaeque nasi.
Dilatator naris posterior.
Dilatator naris anterior.
Compressor nasi.
Compressor narium minor.
Depressor alae nasi. | 10. <i>Pterygomandibular Region.</i>
Pterygoideus externus.
Pterygoideus internus. |

1. The Cranial Region.

Occipitofrontalis.

Dissection (Fig. 286).—The head being shaved, and a block placed beneath the back of the neck, make a vertical incision through the skin, commencing at the root of the nose in front,

and terminating behind at the occipital protuberance; make a second incision in a horizontal direction along the forehead and around the side of the head, from the anterior to the posterior extremity of the preceding. Raise the skin in front, from the subjacent muscle, from below upward; this must be done with extreme care, removing the integument from the outer surface of the vessels and the nerves which lie immediately beneath the skin.

The Skin of the Scalp.—This is thicker than in any other part of the body. It is intimately adherent to the superficial fascia, which attaches it firmly to the underlying aponeurosis and muscle. Movements of the muscle move the skin. The hair follicles are very closely set together, and extend throughout the whole thickness of the skin. It also contains a number of sebaceous glands.

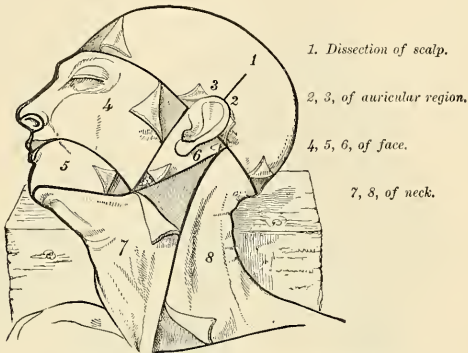


FIG. 286.—Dissection of the head, face, and neck.

The **superficial fascia** in the cranial region is a firm, dense, fibrofatty layer, intimately adherent to the integument, and to the Occipitofrontalis and its tendinous aponeurosis; it is continuous, behind, with the superficial fascia at the back part of the neck; and, laterally, is continued over the temporal fascia. It contains between its layers the superficial vessels and nerves and much fat.

The **Occipitofrontalis** (*m. epicranius*) (Fig. 287) is a broad musculofibrous layer, which covers the whole of one side of the vertex of the skull, from the occiput to the eyebrow. It consists of two muscle slips, separated by an intervening tendinous aponeurosis. The occipital portion (*m. occipitalis*) is thin, quadrilateral in form, and about an inch and a half in length; it *arises* from the outer two-thirds of the superior curved line of the occipital bone, and from the mastoid portion of the temporal bone. Its fibres of origin are tendinous, but they are soon succeeded by muscle fibres, and ascend in a parallel direction to *terminate* in a tendinous aponeurosis. The frontal portion (*m. frontalis*) is thin, of a quadrilateral form, and intimately adherent to the superficial fascia. It is broader, its fibres are longer, and their structures paler than the occipital portion. It has no bony attachments. Its medial fibres are continuous with those of the *Pyramidalis nasi*. Its middle fibres become blended with the *Corrugator supercilii* and *Orbicularis palpebrarum*; and the outer fibres are also blended with the latter muscle over the external angular process. From these attachments the fibres are directed upward, and join the aponeurosis in front of the coronal suture. The inner margins of the frontal portions of the two muscles are joined together for some distance above the root of the nose; but between the occipital portions there is a considerable, though variable, interval, which is occupied by the aponeurosis.

The **epicranial aponeurosis** (*galea aponeurotica*) covers the upper part of the vertex of the skull, being continuous across the middle line with the aponeurosis of the

opposite muscle. *Behind*, it is attached, in the interval between the occipital origins, to the occipital protuberance and highest curved lines of the occipital bone; *in front*, it forms a short and narrow prolongation between the frontal portions; and on each side it gives origin to the Attollens and Attrahens aurem muscles. This aponeurosis is closely connected to the integument by the firm, dense, fibrofatty layer which forms the superficial fascia; it is connected with the peri-

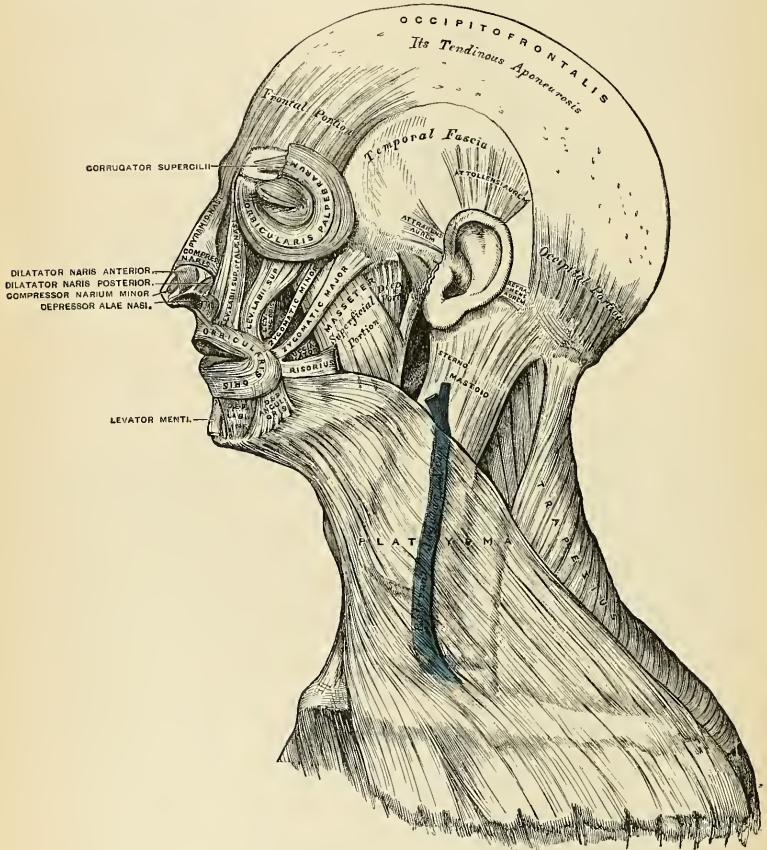


FIG. 287.—Muscles of the head, face, and neck.

cranium (cranial periosteum) by loose cellular tissue, which allows of a considerable degree of movement of the integument. It is continuous with the temporal fascia below the temporal ridge, and it is in reality the representative of the deep fascia.

Nerves.—The frontal portion of the Occipitofrontalis is supplied by the temporal branches of the facial nerve; its occipital portion by the posterior auricular branch of the facial.

Actions.—The frontal portion of the muscle raises the eyebrows and the skin over the root of the nose, and at the same time draws the scalp forward, throwing the integument of the forehead into transverse wrinkles. The posterior portion draws the scalp backward. By bringing alternately into action the frontal and occipital portions the entire scalp may be moved forward and backward. In the ordinary action of the muscles, the eyebrows are elevated, and at the same time the aponeurosis is fixed by the posterior portion, thus giving to the face the expression of surprise; if the action is more exaggerated, the eyebrows are still further raised, and the skin of the forehead thrown into transverse wrinkles, as in the expression of fright or horror.

Applied Anatomy.—The skull is covered by the *scalp* (Fig. 288). This consists, from without inward, of *five* layers: (1) Skin; (2) subcutaneous fat; (3) the Occipitofrontalis muscle and aponeurosis; (4) a layer of connective tissue beneath the Occipitofrontalis aponeurosis (subaponeurotic tissue); (5) the pericranium. The subcutaneous tissue is composed of bands of fibrous tissue enclosing spaces filled with fat. The fibrous character of this tissue greatly limits discoloration and swelling when inflammation occurs. The edges of a wound which does not involve the aponeurosis or muscle do not retract, hence the wound does not gape. The bloodvessels run practically in the skin, and as they lie in very dense tissue and are adherent to it, wounds bleed profusely, the arteries being unable freely to contract and retract. It is very difficult or impossible to pick up with forceps a vessel in the skin of the scalp, and bleeding must be arrested by suture ligatures or by the stitches which close the wound. Sebaceous glands in the skin of the scalp may develop into *sebaceous cysts* (wens). If a wound involves the muscle or aponeurosis, it gapes widely, the greatest amount of gaping being observed in transverse wounds. The subaponeu-

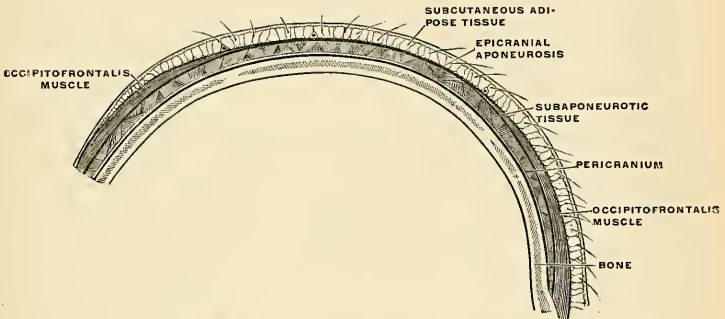


FIG. 288.—The scalp. Sagittal section. (Schematic.) (Poirier and Charpy.)

rotic tissue space between the aponeurosis and the pericranium is called by Treves *the dangerous area of the scalp*. It contains a layer of connective tissue, and suppuration in this tissue spreads widely. An *abscess* in the dangerous area should be opened above the superior curved line of the occipital bone, above the eyebrow or above the zygoma. In a wound or contusion superficial to the aponeurosis but little blood can be effused in the tissue because its fibrous structure prevents it, and abscesses do not tend to spread widely. Between the aponeurosis and the pericranium a great amount of blood can be effused. An effusion of blood beneath the pericranium is called a *cephalhematoma*. Such a condition may occur from pressure during birth. An extravasation beneath the pericranium is limited to the surface of one bone. The pericranium is tightly attached to the sutures, but adheres lightly to the surface of the bone, and abscess beneath the pericranium is restricted to the surface of one bone.

2. The Auricular Region (Fig. 287).

Attrahens aurem.

Attollens aurem.

Retrahens aurem.

These three small muscles are placed immediately beneath the skin, around the external ear. In man, in whom the external ear is almost immovable, they are

rudimentary. They are the homologues of large and important muscles in some of the mammalia.

Dissection.—This requires considerable care, and should be performed in the following manner: To expose the *Attollens aurem*, draw the pinna, or broad part of the ear, downward, when a tense band will be felt beneath the skin, passing from the side of the head to the upper part of the concha; by dividing the skin over this band in a direction from below upward, and then reflecting it on each side, the muscle is exposed. To bring into view the *Attrahens aurem*, draw the helix backward by means of a hook, when the muscle will be made tense, and may be exposed in a similar manner to the preceding. To expose the *Retrahens aurem*, draw the pinna forward, when the muscle, being made tense, may be felt beneath the skin at its insertion into the back part of the concha, and may be exposed in the same manner as the other muscles.

The **Attrahens aurem** (*m. auricularis anterior*), the smallest of the three, is thin, fan-shaped, and its fibres pale and indistinct; they *arise* from the lateral edge of the aponeurosis of the Occipitofrontalis, and converge to be *inserted* into a projection of the front of the helix.

The **Attollens aurem** (*m. auricularis superior*), the largest of the three, is thin and fan-shaped; its fibres *arise* from the aponeurosis of the Occipitofrontalis and converge to be *inserted* by a thin, flattened tendon into the upper part of the cranial surface of the pinna.

The **Retrahens aurem** (*m. auricularis posterior*) consists of two or three fleshy fasciculi, which *arise* from the mastoid portion of the temporal bone by short aponeurotic fibres. They are *inserted* into the lower part of the cranial surface of the concha.

Nerves.—The *Attrahens* and *Attollens aurem* are supplied by the temporal branch of the facial; the *Retrahens aurem* is supplied by the posterior auricular branch of the same nerve.

Actions.—In man, these muscles possess very little action: the *Attrahens aurem* draws the pinna forward and upward; the *Attollens aurem* slightly raises it; and the *Retrahens aurem* draws it backward.

3. The Palpebral Region (Fig. 287).

Orbicularis palpebrarum.
Corrugator supercilii.

Levator palpebrae.
Tensor tarsi.

Dissection (Fig. 286).—In order to expose the muscles of the face, continue the longitudinal incision made in the dissection of the Occipitofrontalis down the median line of the face to the tip of the nose, and from this point onward to the upper lip; and carry another incision along the margin of the lip to the angle of the mouth, and transversely across the face to the angle of the mandible. Then make an incision in front of the external ear, from the angle of the mandible upward; to join the transverse incision made in exposing the Occipitofrontalis. These incisions include a square-shaped flap, which should be removed in the direction marked in the figure, with care, as the muscles at some points are intimately adherent to the integument.

The **Orbicularis palpebrarum** (*m. orbicularis oculi*) is a sphincter muscle, which surrounds the circumference of the orbit and eyelids. It *arises* from the internal angular process of the frontal bone, from the frontal process of the maxilla in front of the lacrimal groove for the nasal duct, and from the anterior surface and borders of a short tendon, the *tendo oculi*, or *internal tarsal ligament*, placed at the inner angle of the orbit. From this origin the fibres are directed outward, forming a broad, thin, and flat layer, which covers the eyelids, surrounds the circumference of the orbit, and spreads out over the temple and downward on the cheek. The *internal* or *palpebral portion* (*pars palpebralis*) of the Orbicularis is thin and pale; it *arises* from the bifurcation of the *tendo oculi*, and forms a series of concentric curves, which are on the outer side of the eyelids *inserted* into the *external tarsal ligament*. The *external* or *orbital portion* (*pars orbitalis*) is thicker and of a reddish color; its fibres are well developed, and form complete

ellipses. The upper fibres of this portion blend with the Occipitofrontalis and Corrugator supercilii.

Relations.—By its *superficial surface*, with the integument. By its *deep surface, above*, with the Occipitofrontalis and Corrugator supercilii, with which it is intimately blended, and with the supraorbital vessels and nerve; *below*, it covers the lacrimal sac, and the origin of the Levator labii superioris alaeque nasi, the Levator labii superioris, and the Zygomaticus minor muscles. *Internally*, it is occasionally blended with the Pyramidalis nasi. *Externally*, it lies on the temporal fascia. On the eyelids it is separated from the conjunctiva by the Levator palpebrae, the tarsal ligaments, the tarsal plates, and the Meibomian glands.

The **tendo oculi** or **internal tarsal ligament** (*ligamentum palpebrale mediale*) is a short tendon, about one-sixth of an inch in length and half as much in breadth, attached to the frontal process of the maxilla in front of the lacrimal groove. Crossing the lacrimal sac, it divides into two parts, each division being attached to the inner extremity of the corresponding tarsal plate. As the tendon crosses the lacrimal sac, a strong aponeurotic lamina is given off from the posterior surface, which expands over the sac, and is attached to the ridge on the lacrimal bone. This is the **reflected aponeurosis** of the tendo oculi.

The **external tarsal ligament** (*raphé palpebralis lateralis*) is a much weaker structure than the tendo oculi. It is attached to the margin of the frontal process of the malar bone, and passes inward to the outer commissure of the eyelid, where it divides into two slips, which are attached to the margins of the two tarsal plates.

USE OF TENDO OCULI.—Besides giving attachment to part of the Orbicularis palpebrarum and to the tarsal plates, it serves to suck the tears into the lacrimal sac, by its attachment to the sac. Thus, each time the eyelids are closed, the tendo oculi becomes tightened, through the action of the Orbicularis, and draws the wall of the lacrimal sac outward and forward, so that the tears are sucked along the lacrimal canals into it.

The **Corrugator supercilii** (Figs. 287 and 289) is a small, narrow, pyramidal muscle, placed at the inner extremity of the eyebrow, beneath the Occipitofrontalis and Orbicularis palpebrarum muscles. It *arises* from the inner extremity of the superciliary ridge, from whence its fibres pass upward and outward between the palpebral and orbital portions of the Orbicularis palpebrarum, and are *inserted* into the deep surface of the skin, opposite the middle of the orbital arch.

Relations.—By its *superficial surface* with the Occipitofrontalis and Orbicularis palpebrarum muscles; by its *deep surface*, with the frontal bone and supratrochlear nerve.

The **Tensor tarsi** or **Horner's muscle** (*pars lacrimalis m. orbicularis oculi*) (Fig. 289) is a small thin muscle about a quarter of an inch in breadth and half an inch in length, situated at the inner side of the orbit, behind the tendo oculi and lacrimal sac. It *arises* from the crest and adjacent part of the orbital surface of the lacrimal bone, and, passing across the lacrimal sac, divides into two slips, which cover the lacrimal canals and are *inserted* into the tarsal plates internal to the puncta lacrimalia. Its fibres appear to be continuous with those of the palpebral portion of the Orbicularis palpebrarum; it is occasionally very indistinct.

Nerves.—The Orbicularis palpebrarum, Corrugator supercilii, and Tensor tarsi are supplied by the facial nerve.

Actions.—The Orbicularis palpebrarum is the sphincter muscle of the eyelids. The palpebral portion acts involuntarily, closing the lids gently, as in sleep, or in blinking; the orbicular portion is subject to the will. When the entire muscle is brought into action, the skin of the forehead, temple, and cheek is drawn inward toward the inner angle of the orbit, and the eyelids are firmly closed as in photophobia. When the skin of the forehead, temple, and cheek is thus drawn inward by the action of the muscle it is thrown into folds, especially radiating from the

outer angle of the eyelids, which give rise in old age to the so-called "crow's feet." The Levator palpebrae is the direct antagonist of this muscle; it raises the upper eyelid and exposes the globe of the eye. The Corrugator supercilii draws the eyebrow downward and inward, producing the vertical wrinkles of the forehead. It is the "frowning" muscle, and may be regarded as the principal agent in the expression of suffering. The Tensor tarsi draws the eyelids inward and compresses the eyelids and the extremities of the lacrimal canals against the surface of the globe of the eye; thus placing the canals in the most favorable situation for receiving the tears. It serves, also, to compress the lacrimal sac.

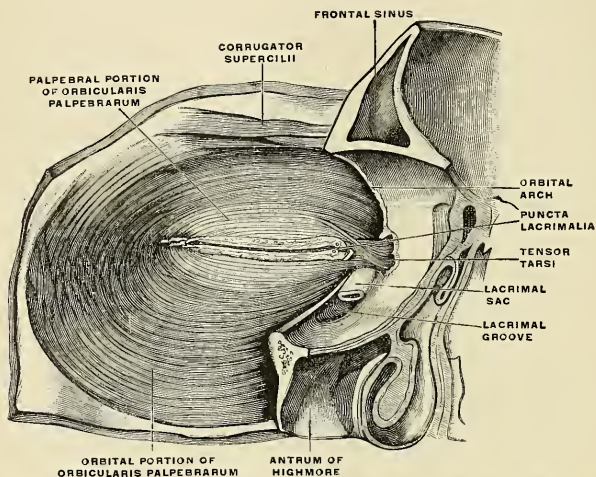


FIG. 289.—The three portions of the Orbicularis palpebrarum muscle, and the relation of this muscle to the Corrugator supercilii muscle, seen from behind. (Left side.) (Toldt.)

4. The Orbital Region (Fig. 291).

Levator palpebrae superioris.

Rectus superior.

Rectus inferior.

Rectus internus.

Rectus externus.

Obliquus oculi superior.

Obliquus oculi inferior.

Dissection.—To open the cavity of the orbit, remove the skullcap and brain; then saw through the frontal bone at the inner extremity of the supraorbital ridge, and externally at its junction with the malar. Break in pieces the thin roof of the orbit by a few slight blows of the hammer, and take it away; drive forward the superciliary portion of the frontal bone by a smart stroke, but do not remove it, as that would destroy the pulley of the Obliquus superior. When the fragments are cleared away, the periosteum of the orbit will be exposed; this being removed, together with the fat which fills the cavity of the orbit, the several muscles of this region can be examined. The dissection will be facilitated by distending the globe of the eye. In order to effect this, puncture the optic nerve near the eyeball with a curved needle, and push the needle onward into the globe; insert the point of a blowpipe through this aperture, and force a little air into the cavity of the eyeball; then apply a ligature around the nerve so as to prevent the air escaping. The globe being now drawn forward, the muscles will be put upon the stretch.

Orbital Septum.—Subjacent to the Orbicularis palpebrarum a dense fascial sheet supports the tarsal plates and serves as a septum (*septum orbitale*), which is attached to the orbital margin. It is perforated by the small vessels and

nerves which supply the integument of the eyelids. The tarsal ligaments previously described are reënforcing bands of this fascial septum.

The **Levator palpebrae superioris** is thin, flat, and triangular in shape. It arises from the under surface of the lesser wing of the sphenoid, above and in front of the optic foramen, from which it is separated by the origin of the Superior

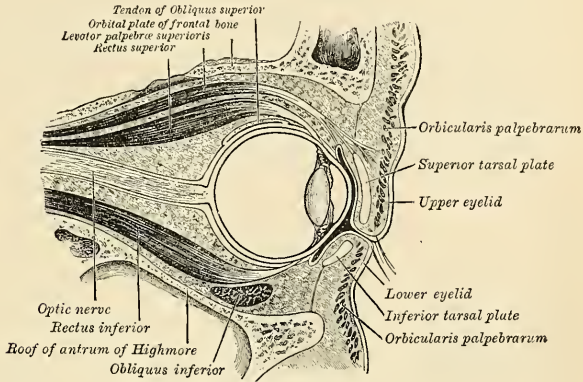


FIG. 290.—Sagittal section of left orbital cavity.

rectus (Fig. 292). At its origin it is narrow and tendinous, but soon becomes broad and fleshy, and terminates anteriorly in a wide aponeurosis, which splits into three lamellæ. The *superficial lamella blends* with the superior palpebral ligament, and is prolonged forward above the superior tarsal plate to the palpebral part of the Orbicularis palpebrarum and to the deep surface of the skin of the

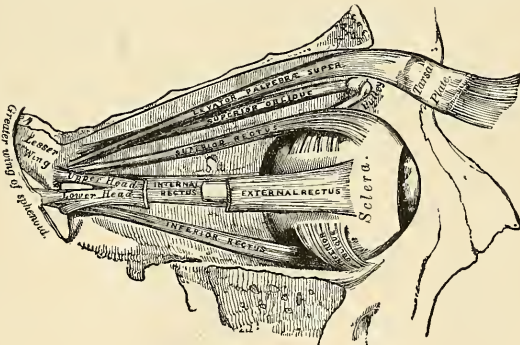


FIG. 291.—Muscles of the right orbit.

upper eyelid. The *middle lamella*, largely made up of unstriated muscle fibres (*superior tarsal muscle*), is inserted into the upper margin of the superior tarsal plate, while the *deepest lamella blends* with an expansion from the sheath of the Superior rectus muscle and with it is attached to the superior fornix of the conjunctiva (Fig. 290).

Relations.—By its *orbital surface*, with the frontal nerve and supraorbital artery, the periosteum of the orbit and lacrimal gland; and, in the lid, with the inner surface of the tarsal ligament; by its *ocular surface*, with the Superior rectus, and, in the lid, with the conjunctiva. A small branch of the oculomotor nerve enters its under surface.

The four Recti (Fig. 292) arise from a fibrous ring (*annulus tendineus communis*) [Zinn] which surrounds the upper, inner, and lower margins of the optic foramen and encircles the optic nerve. Two specialized parts of this ring may be made out: (1) A lower, **ligament of Zinn**, which gives *origin* to the Inferior rectus, part of the Internal rectus, and the lower head of the External rectus; and (2) an upper, the **tendon of Lockwood**, which gives *origin* to the Superior rectus, the rest of the Internal rectus, and the upper head of the External rectus.

Each of the four Recti passes forward in the position implied by its name, to be *inserted* by a tendinous expansion into the sclera, about a quarter of an inch from the margin of the cornea.

Between the two heads of the External rectus is a narrow interval, through which pass the two divisions of the oculomotor nerve, the nasal branch of the ophthalmic division of the trigeminal nerve, the abducent nerve, and the ophthalmic vein. Of the four Recti, the Internal rectus is the broadest, the External the longest, and the Superior the thinnest and narrowest. Beyond the insertion of the Inferior rectus a thin layer of non-striated muscle fibres (*inferior tarsal muscle*) continues into the lower eyelid to be inserted into the inferior tarsal plate.

The **Superior oblique** (*m. obliquus oculi superior*) is a fusiform muscle placed at the upper and inner side of the orbit, internal to the Levator palpebrae. It arises a little above the inner margin of the optic foramen (Fig. 292), and, passing forward to the inner angle of the orbit, terminates in a rounded tendon, which plays in a fibrocartilaginous ring or pulley, the **trochlea**, attached to the trochlear fossa near the internal angular process of the frontal bone. The contiguous surfaces of the tendon and ring are covered with a delicate synovial membrane and are enclosed in a thin fibrous investment. The tendon is reflected backward, outward, and downward beneath the Superior rectus to the outer part of the globe of the eye, and is *inserted* into the sclera, behind the equator of the eyeball, the insertion of the muscle lying between the Superior and External recti.

Relations.—By its *orbital surface*, with the periosteum covering the roof of the orbit and the trochlear nerve; the tendon, where it lies on the globe of the eye, is covered by the Superior rectus; by its *ocular surface*, with the nasal nerve, ethmoidal arteries, and the upper border of the Internal rectus.

The **Inferior oblique** (*m. obliquus oculi inferior*) is a thin, narrow muscle placed near the anterior margin of the orbit. It arises from a depression on the orbital plate of the maxilla, external to the lacrimal groove (Fig. 291). Passing outward, backward, and upward between the Inferior rectus and the floor of the orbit, and then between the eyeball and the External rectus, it is *inserted* into the outer part of the sclera between the Inferior and External recti, near to, but somewhat behind, the tendon of insertion of the Superior oblique.

Relations.—By its *ocular surface*, with the globe of the eye and with the Inferior rectus; by its *orbital surface*, with the periosteum covering the floor of the orbit, and with the External rectus. Its borders look forward and backward; the posterior one receives a branch of the oculomotor nerve.

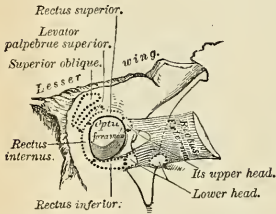


FIG. 292.—The relative position and attachment of the muscles of the left eyeball.

The **orbital muscle**, or **Müller's muscle** (*musculus orbitale*), which spans the sphenomaxillary fissure and infraorbital groove, is composed of nonstriated fibres, and is a rudimentary structure continuous with the periosteum of the orbit.¹

Nerves.—The Levator palpebrae, Inferior oblique, and all the Recti excepting the External are supplied by the oculomotor nerve; the Superior oblique, by the trochlear; the External rectus, by the abducent.

Actions.—The Levator palpebrae *raises* the upper eyelid, and is the direct antagonist of the Orbicularis palpebrarum. The four Recti muscles are attached in such a manner to the globe of the eye that, acting singly, they will turn its corneal surface either upward, downward, inward, or outward, as expressed by their names. The movement produced by the Superior or Inferior rectus is not quite a simple one, for, inasmuch as they pass obliquely outward and forward to the eyeball, the elevation or depression of the cornea must be accompanied by a certain deviation inward, with a slight amount of rotation. These latter movements are corrected by the Oblique muscles, the Inferior oblique correcting the deviation inward of the Superior rectus, and the Superior oblique that of the Inferior rectus. The contraction of the External and Internal recti, on the other hand, produces a purely horizontal movement. If any two contiguous Recti of one eye act together, they carry the globe of the eye in the diagonal of these directions—viz., upward and inward, upward and outward, downward and inward, or downward and outward. The movement of circumduction, as in looking around a room, is performed by the alternate action of the four Recti. The Oblique muscles rotate the eyeball on its *antero-posterior axis*, this kind of movement being required for the correct viewing of an object when the head is moved laterally, as from shoulder to shoulder, in order that the picture may fall in all respects on the same part of the retina of either eye. Sometimes the corresponding Recti and sometimes the opposite ones of the two eyes act together; for instance, the two Superior and Inferior recti carry both eyeballs upward and downward, respectively. In looking toward the right, the right External and left Internal recti act together, the reverse being the case in looking toward the left. In turning both eyes toward the middle line, as in directing our vision toward an object less than twenty feet distant, the two Internal recti act together.

Fasciæ of the Orbit.—The connective tissue of the orbit is in various places condensed into thin membranous layers, which may be conveniently described as (1) the orbital fascia; (2) the sheaths of the muscles; and (3) the fascia of the eyeball.

1. **The Orbital Fascia.**—This forms the periosteum of the orbit. It is loosely connected to the bones, from which it can be readily separated. *Behind*, it is connected with the dura by processes which pass through the optic foramen and sphenoidal fissure, and with the sheath of the optic nerve. *In front* it is connected with the periosteum at the margin of the orbit, and sends off a process which assists in forming the palpebral fascia or orbital septum. From its internal surface two processes are given off—one to enclose the lacrimal gland, the other to hold the pulley of the Superior oblique muscle in position.

2. **The Sheaths of the Muscles.**—The sheaths of the muscles give off expansions to the margins of the orbit which limit the action of the muscles.

3. **The Fascia of the Eyeball.**—*Ténon's capsule*—surrounds the posterior two-thirds of the eyeball; it will be described with the anatomy of the eyeball.

Applied Anatomy.—The position and exact point of insertion of the tendons of the Internal and External recti muscles into the globe should be carefully examined from the front of the eyeball, as the surgeon is often required to divide the one or the other muscle for the cure of *strabismus* (squint). In convergent strabismus, which is the more common form of the disease, the eye is turned inward, requiring the division of the Internal rectus. In the divergent form which is more rare, the eye is turned outward, the External rectus being especially implicated. The deformity produced in either case is to be remedied by division of one or the other muscle. The operation is thus performed: The lids are to be well separated; the eyeball being rotated outward or inward, the conjunctiva should be raised by a pair of forceps and divided immediately beneath the lower border of the tendon of the muscle to be divided, a little behind its insertion into the sclera; the submucous areolar tissue is then divided, and into the small aperture thus made a blunt hook is passed upward between the muscle and the globe, and the tendon of the muscle and conjunctiva covering it divided by a pair of blunt-pointed scissors. Or the tendon may be divided by a subconjunctival incision, one blade of the scissors being passed upward between the tendon and the conjunctiva, and the other between the tendon and the sclera. Inflammation of the synovial membrane lining the trochlea of the Superior oblique may lead to the formation of a *cyst* of considerable size.

¹ See F. Groyer, in the Vienna Sitzungsberichte der Kaiserlichen Akademie der Wissenschaften, 1903, Band cxlii.

In performing *enucleation of the eyeball* the conjunctiva is clipped with scissors near the cornea and the capsule of Ténon is divided with it. One Rectus muscle after another is caught up on a blunt hook and divided. The scissors are now pushed well in along the outer orbital wall and the optic nerve is divided. Finally, the Oblique muscles, the ciliary vessels and nerves, and fragments of tissue helping to retain the globe are cut and the eyeball is enucleated.

An *orbital abscess* is evacuated by making an incision close to the border of the orbit, above or below the eyeball.

Exophthalmos, or abnormal protrusion of the eyeball, is believed to be due to hypersecretion of the thyroid (as in goitre), which, through the cervicocephalic division of the sympathetic, stimulates the nonstriated tarsal muscles to sustained contraction. These muscles are arranged like a cuff, and may be regarded as having their origin in the orbital septum and their insertion at the equator of the eyeball. In their action they are antagonists of the Recti, and of the Levator palpebræ superioris, and open wide the palpebral fissure and draw the eyeball forward. (Consult J. Landström, Ueber Morbus Basedowii, Thesis, Stockholm, 1907.)

5. The Nasal Region (Fig. 287).

Pyramidalis nasi.

Levator labii superioris alaeque nasi.

Dilatator naris posterior.

Dilatator naris anterior.

Compressor nasi.

Compressor narium minor.

Depressor alae nasi.

The **Pyramidalis nasi** (*m. procerus*) is a small pyramidal slip placed over the nasal bone. Its *origin* is by tendinous fibres from the fascia covering the lower part of the nasal bone and upper part of the cartilage, where it blends with the Compressor nasi, and it is *inserted* into the skin over the lower part of the forehead between the two eyebrows, its fibres decussating with those of the Occipitofrontalis (see page 364).

The **Levator labii superioris alaeque nasi** is a thin triangular muscle placed by the side of the nose, and extending between the inner margin of the orbit and upper lip. It *arises* by a pointed extremity from the upper part of the nasal process of the maxilla, and, passing obliquely downward and outward, divides into two slips, one of which is *inserted* into the cartilage of the ala of the nose; the other is prolonged into the upper lip, becoming attached to the under surface of the skin and blended with the Orbicularis oris and Levator labii superioris proprius.

The **Dilatator naris posterior** is a small muscle which is placed partly beneath the elevator of the nose and lip. It *arises* from the margin of the nasal notch of the maxilla and from the sesamoid cartilages, and is *inserted* into the skin near the margin of the nostril.

The **Dilatator naris anterior** is a thin, delicate fasciculus passing from the cartilage of the ala of the nose to the integument near its margin. This muscle is situated in front of the preceding.

The **Compressor naris** (*m. nasalis*) is a small, thin, triangular muscle *arising* by its apex from the maxilla, above and a little external to the incisive fossa; its fibres proceed upward and inward, expanding into a thin aponeurosis which is attached to the fibrocartilage of the nose and is continuous on the bridge of the nose with that of the muscle of the opposite side and with the aponeurosis of the Pyramidalis nasi.

The **Compressor narium minor** is a small muscle attached by one end to the alar cartilage, and by the other to the integument at the end of the nose.

The **Depressor alae nasi** (*m. depressor septi*) is a short radiated muscle *arising* from the incisive fossa of the maxilla; its fibres ascend to be *inserted* into the septum and back part of the ala of the nose. This muscle lies between the mucous membrane and muscular structure of the lip.

Nerves.—All of the muscles of this group are supplied by the facial nerve.

Actions.—The *Pyramidalis nasi* draws down the inner angle of the eyebrows and produces transverse wrinkles over the bridge of the nose. The *Levator labii superioris alaeque nasi* draws upward the upper lip and ala of the nose; its most important action is upon the nose, which it dilates to a considerable extent. The action of this muscle produces a marked influence over the countenance, and it is the principal agent in the expression of contempt and disdain. The two *Dilatatores nasi* enlarge the aperture of the nose. Their action in ordinary breathing is to resist the tendency of the nostrils to close from atmospheric pressure, but in difficult breathing they may be noticed to be in violent action, as well as in some emotions, as anger. The *Depressor alae nasi* is a direct antagonist of the other muscles of the nose, drawing the ala of the nose downward, and thereby constricting the aperture of the nares. The *Compressor naris* depresses the cartilaginous part of the nose and compresses the ala together.

6. The Maxillary Region (Fig. 287).

Levator labii superioris.

Zygomaticus major.

Levator anguli oris.

Zygomaticus minor.

In the BNA term *musculus quadratus labii superioris* three muscles are included. The *caput angulare* is called in this book the *Levator labii superioris alaeque nasi*. The *caput infraorbitale* is called the *Levator labii superioris*. The *caput zygomaticum* is called the *Zygomaticus minor*.¹

The **Levator labii superioris** is a thin muscle of a quadrilateral form. It arises from the lower margin of the orbit immediately above the infraorbital foramen, some of its fibres being attached to the maxilla, others to the malar bone; its fibres converge to be inserted into the muscular substance of the upper lip.

The **Levator anguli oris** (*m. caninus*) arises from the canine fossa immediately below the infraorbital foramen; its fibres incline downward and a little outward, to be inserted into the deep surface of the skin and into the subcutaneous tissue near the angle of the mouth and intermingles with the fibres of the *Zygomaticus major*, the *Depressor anguli oris*, and the *Orbicularis oris*.

The **Zygomaticus major** (*m. zygomaticus*) is a slender fasciculus which arises from the malar bone, in front of the zygomatic suture, and, descending obliquely downward and inward, is inserted into the deep surface of the skin and subcutaneous tissue at the outer portion of the upper lip and into the angle of the mouth, where it blends with the fibres of the *Levator anguli oris*, the *Orbicularis oris*, and the *Depressor anguli oris*.

The **Zygomaticus minor**, which is often absent, arises from the malar bone immediately behind the maxillary suture, and, passing downward and inward, is inserted internal to the angle of the mouth and is continuous with the *Orbicularis oris* at the outer margin of the *Levator labii superioris*. It lies in front of the *Zygomaticus major*.

Nerves.—This group of muscles is supplied by the facial nerve.

Actions.—The *Levator labii superioris* is the proper elevator of the upper lip, carrying it at the same time a little forward. It assists in forming the *nasolabial ridge* which passes from the side of the nose to the upper lip and gives to the face an expression of sadness. The *Levator anguli oris* raises the angle of the mouth and draws it inward, and assists the *Levator labii superioris* in producing the nasolabial ridge. The *Zygomaticus major* draws the angle of the mouth backward and upward, as in laughing; while the *Zygomaticus minor*, being inserted into the outer part of the upper lip and not into the angle of the mouth, draws it backward, upward, and outward, and thus gives to the face an expression of sadness.

¹ That this grouping is quite artificial and morphologically unwarranted has been shown by McMurrich *American Journal of Anatomy*, vol. iii, Proceedings, p. iii.

7. The Mandibular Region (Fig. 287).

Levator menti.

Depressor labii inferioris.

Depressor anguli oris.

Dissection.—The muscles in this region may be dissected by making a vertical incision through the integument from the margin of the lower lip to the chin; a second incision should then be carried along the margin of the mandible as far as the angle, and the integument carefully removed in the direction shown in Fig. 286.

The **Levator menti** (*m. mentalis*) is a small conical fasciculus placed on the side of the frenum of the lower lip. It *arises* from the mandibular incisive fossa, external to the symphysis of the mandible; its fibres descend to be *inserted* into the integument of the chin.

The **Depressor labii inferioris**, or **Quadratus menti** (*m. quadratus labii inferioris*) (Fig. 294), is a small quadrilateral muscle. It *arises* from the external oblique line of the mandible, between the symphysis and mental foramen, and passes obliquely upward and inward, to be *inserted* into the integument of the lower lip, its fibres blending with the Orbicularis oris and with those of its fellow of the opposite side. It is continuous with the fibres of the Platysma at its origin. This muscle contains much fat intermingled with its fibres.

The **Depressor anguli oris** (*m. triangularis*) (Fig. 287) is triangular in shape, *arising*, by its broad base, from the external oblique line of the mandible, from whence its fibres pass upward, to be *inserted*, by a narrow fasciculus, into the angle of the mouth. It is continuous with the Platysma at its origin and with the Orbicularis oris and Risorius at its insertion, and some of its fibres are directly continuous with those of the Levator anguli oris.¹

Nerves.—This group of muscles is supplied by the facial nerve.

Actions.—The Levator menti raises the lower lip and protrudes it forward, and at the same time wrinkles the integument of the chin, expressing doubt or disdain. The Depressor labii inferioris draws the lower lip directly downward and a little outward, as in the expression of irony. The Depressor anguli oris depresses the angle of the mouth, being the antagonist to the Levator anguli oris and Zygomaticus major; acting with the Levator anguli oris, it will draw the angle of the mouth directly inward.

8. The Buccal Region.

Orbicularis oris.

Buccinator.

Risorius.

Dissection.—The dissection of these muscles may be considerably facilitated by filling the cavity of the mouth with tow, so as to distend the cheeks and lips; the mouth should then be closed by a few stitches and the integument carefully removed from the surface.

The **Orbicularis oris** (Figs. 287 and 293) is not a simple sphincter muscle, like the Orbicularis palpebrarum, but consists of numerous strata of muscle fibres, having different directions, which surround the orifice of the mouth. These fibres are partially derived from the other facial muscles which are inserted into the lips, and are partly fibres proper to the lips themselves. Of the *former*, a considerable number are derived from the Buccinator and form the deeper stratum of the Orbicularis. Some of the Buccinator fibres—namely, those near the middle of the muscle—decussate at the angle of the mouth, those arising from the maxilla passing to the lower lip, and those from the mandible to the

¹ Muscle fibres connecting the two muscles below the chin are occasionally met with; they constitute the *Musculus transversus menti* of His and Waldeyer.

upper lip. Other fibres of the muscle, situated at its upper and lower part, pass across the lips from side to side without decussation. Superficial to this stratum is a *second*, formed by the Levator and Depressor anguli oris, which cross each other at the angle of the mouth, those from the Depressor passing to the upper lip, and those from the Levator to the lower lip, along which they run to be inserted into the skin near the median line. In addition to these there are fibres from the other muscles inserted into the lips—the Levator labii superioris, the Levator labii superioris alaeque nasi, the Zygomatici, and the Depressor labii inferioris; these intermingle with the transverse fibres above described, and have principally an oblique direction. The proper fibres of the lips are oblique, and pass from the under surface of the skin to the mucous membrane through the thickness of the lip. In addition to these are fibres by which the muscle is connected directly with the maxilla and mandible and with the septum of the nose. In the upper lip these consist of two bands, an *inner* and an *outer*, on each side of the nasal plane; the *outer* band (*m. incisivus superior*) arises from the alveolar border of the maxilla, opposite the lateral incisor tooth, and, arching outward on each side, is continuous

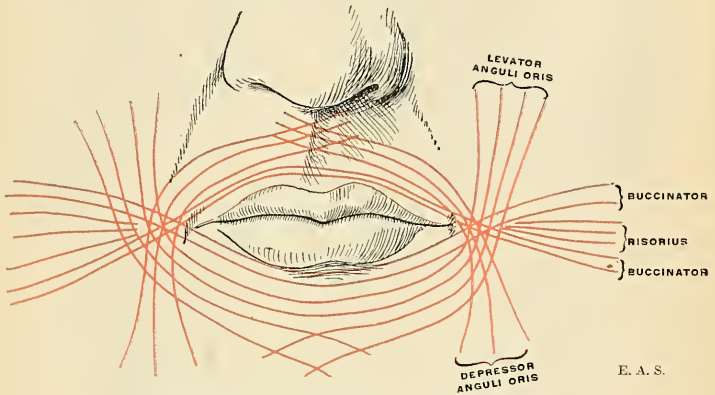


FIG. 293.—Plan of the fibres constituting the Orbicularis oris muscle.

at the angle of the mouth with the other muscles inserted into this part. The *inner* band (*m. nasolabialis*) connects the upper lip to the septum of the nose. The interval between the two inner bands corresponds with the depression called the *philtrum* seen on the surface of the skin beneath the septum of the nose. The additional fibres for the lower lip (*m. incisivus inferior*) arise from the mandible, externally to the Levator menti, and arch outward to the angles of the mouth to join the Buccinator and the other muscles attached to this part.

The **Buccinator** (Fig. 294) is a broad, thin muscle, quadrilateral in form, which occupies the interval between the jaws at the side of the face. It *arises* from the outer surface of the alveolar processes of the maxilla and mandible, corresponding to the three molar teeth, and, behind, from the anterior border of the pterygomandibular ligament, which separates it from the Superior constrictor of the pharynx. The fibres converge toward the angle of the mouth, where the central fibres intersect each other, those from below being continuous with the upper segment of the Orbicularis oris, and those from above with the inferior segment; the highest and lowest fibres continue forward uninterruptedly into the corresponding segment of the lip, without decussation.

Relations.—By its *superficial surface*, behind, with a large mass of fat, the **sucking pad** (*corpus adiposum buccae*), which separates it from the ramus of the mandible, the Masseter, and a small portion of the Temporal muscle. The sucking pad is much more developed, relatively, in children than in adults. It assists sucking by aiding the cheek to resist atmospheric pressure. The Buccinator muscle is in relation, anteriorly, with the Zygomatici, Risorius, Levator anguli

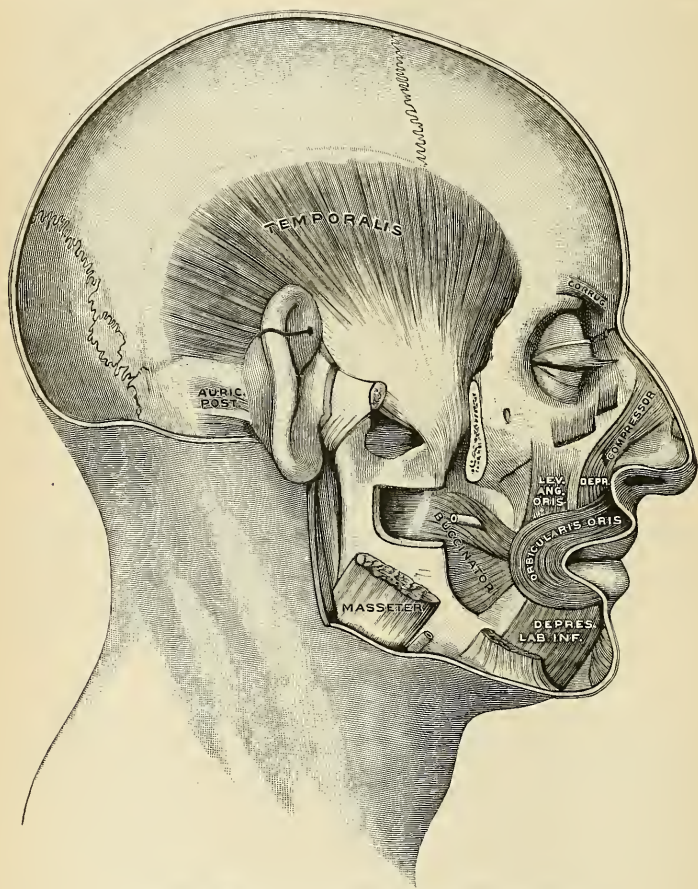


FIG. 294.—Temporal and deep muscles about the mouth. (Testut.)

oris, Depressor anguli oris, and the parotid duct, which pierces it opposite the second molar tooth of the maxilla; the facial artery and vein cross it from below upward; it is also crossed by the branches of the facial and buccal nerves. By its *deep surface* it is in relation with the buccal glands and mucous membrane of the mouth.

The **pterygomandibular ligament** (*raphe pterygomandibularis*) is a tendinous thickening of the buccopharyngeal fascia, attached by one extremity to the apex of the internal pterygoid plate, and by the other to the posterior extremity (lingula)

of the internal oblique line of the mandible. Its *deep surface* corresponds to the cavity of the mouth, and is lined with mucous membrane. Its *superficial surface* is separated from the ramus of the mandible by a quantity of adipose tissue. Its *posterior border* gives attachment to the Superior constrictor of the pharynx; its *anterior border*, to the fibres of the Buccinator.

The **buccopharyngeal fascia** (*fascia buccopharyngea*) is a thin fascia covering the superficial surface of the Buccinator muscle. It is gradually lost in front of the angle of the mouth. Posteriorly, it is continued over the superficial surface of the Constrictor muscles. Its thickened cord-like portion is the stylomandibular ligament.

The **Risorius** (*m. risorius*) (Fig. 287) consists of a narrow bundle of fibres which *arises* in the fascia over the Masseter muscle, and, passing horizontally forward, is *inserted* with the Depressor anguli oris into the subcutaneous and muscular tissue at the angle of the mouth. It is placed superficial to the Platysma, and is broadest at its outer extremity. This muscle varies much in its size and form.

Nerves.—The muscles in this group are all supplied by the facial nerve.

Actions.—The Orbicularis oris in its ordinary action produces the direct closure of the lips; by its deep fibres, assisted by the oblique ones, it closely applies the lips to the alveolar arch. The superficial part, consisting principally of the decussating fibres, brings the lips together and also protrudes them forward. The Buccinators contract and compress the cheeks, so that, during the process of mastication, the food is kept under the immediate pressure of the teeth. When the cheeks have been previously distended with air, the Buccinator muscles expel it from between the lips, as in blowing a trumpet. Hence the name (*buccina*, a trumpet). The Risorius retracts the angles of the mouth, and produces the unpleasant expression which is sometimes seen in tetanus, and is known as *risus sardonicus*, the sardonic laugh.

9. The Temporomandibular Region.

Masseter.

Temporal.

The **masseteric fascia** (*fascia parotideomasseterica*) covers the Masseter muscle. It is firmly connected with this muscle and is derived from the deep cervical fascia. *Above*, this fascia is attached to the lower border of the zygoma, and *behind*, it invests the parotid gland, constituting the **parotid fascia**.

The **Masseter muscle** (*m. masseter*) (Fig. 287) is a short, thick muscle, somewhat quadrilateral in form, consisting of two portions, the superficial and the deep. The **superficial portion**, the larger, *arises* by a thick, tendinous aponeurosis from the malar process of the maxilla, and from the anterior two-thirds of the lower border of the zygomatic arch; its fibres pass downward and backward, to be *inserted* into the angle and lower half of the outer surface of the ramus of the mandible. The **deep portion** is much smaller and more muscular in texture; it *arises* from the posterior third of the lower border and the whole of the deep surface of the zygomatic arch; its fibres pass downward and forward, to be *inserted* into the upper half of the ramus and outer surface of the coronoid process of the mandible. The deep portion of the muscle is partly concealed, in front by the superficial portion; behind, it is covered by the parotid gland. The fibres of the two portions are continuous at their insertion.

Relations.—By its *superficial surface*, with the Zygomatici, the parotid gland (the *socia parotidis*), the parotid duct, the branches of the facial nerve and the transverse facial vessels, which cross it; the masseteric fascia; the Risorius, Platysma, and the integument. By its *deep surface* it is in relation with the Temporal muscle at its insertion, the ramus of the mandible, the Buccinator and the long buccal nerve, from which it is separated by a mass of fat (sucking pad). The masseteric nerve and artery enter in on its deep surface. Its *posterior margin* is overlapped by the parotid gland. Its *anterior margin*, which projects over the Buccinator muscle, is crossed below by the facial vein.

The **temporal fascia** (*fascia temporalis*) covers the Temporal muscle. It is a strong, fibrous investment, covered, on its superficial surface, by the *Attrahens* and *Attollens* aurem muscles, the aponeurosis of the *Occipitofrontalis*, and by part of the *Orbicularis palpebrarum*. The temporal vessels and the auriculo-temporal nerve cross it from below upward. *Above*, it is a single layer, attached to the entire extent of the upper temporal ridge; but *below*, where it is attached to the zygoma, it consists of two layers, one of which is inserted into the outer, and the other into the inner, border of the zygomatic arch. A small quantity of fat, the orbital branch of the temporal artery, and a filament from the orbital, or temporomalar, branch of the superior maxillary nerve are contained between these two layers. It affords attachment by its deep surface to the superficial fibres of the Temporal muscle.

Dissection.—In order to expose the Temporal muscle, remove the temporal fascia, which may be effected by separating it at its attachment along the upper border of the zygoma and dissecting it upward from the surface of the muscle. The zygomatic arch should then be divided in front at its junction with the malar bone, and behind near the external auditory meatus, and drawn downward with the *Masseter*, which should be detached from its insertion into the ramus and angle of the mandible. The whole extent of the Temporal muscle is then exposed

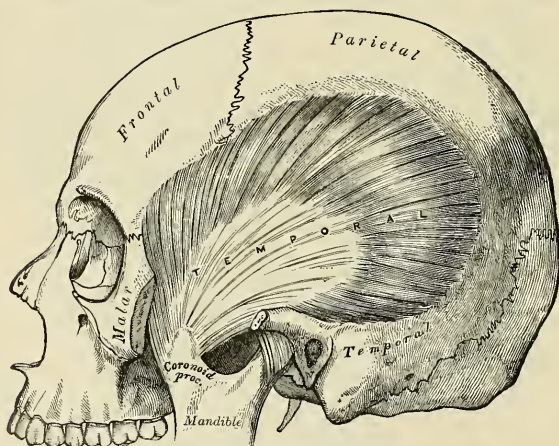


FIG. 295.—The Temporal muscle, the zygoma and Masseter having been removed.

The **Temporal muscle** (*m. temporalis*) (Figs. 294 and 295) is a broad, radiating muscle situated at the side of the head and occupying the entire extent of the temporal fossa. It *arises* from the whole of the temporal fossa except that portion of it which is formed by the malar bone. Its attachment extends from the external angular process of the frontal in front to the mastoid portion of the temporal behind, and from the curved line on the frontal and parietal bones above to the pterygoid ridge on the greater wing of the sphenoid below. It is also attached to the inner surface of the temporal fascia. Its fibres converge as they descend, and terminate in a flat tendon, which is *inserted* into the inner and outer surfaces, apex, and anterior border of the coronoid process and the anterior border of the ramus of the mandible, nearly as far forward as the last molar tooth.

Relations.—By its *superficial surface*, with the integument, the *Attrahens* and *Attollens* aurem muscles, the temporal vessels and nerves, the aponeurosis of the *Occipitofrontalis*, the temporal

fascia, the zygoma, and Masseter; by its *deep surface*, with the temporal fossa, the External pterygoid and part of the Buccinator muscles, the internal maxillary artery and its deep temporal branches, and the deep temporal nerves. *Behind* the tendon are the masseteric vessels and nerve, and in front of it the buccal vessels and nerve. Its *anterior border* is separated from the malar bone by a mass of fat.

Nerves.—Both the Masseter and Temporal muscles are supplied by branches of the inferior maxillary division of the trigeminal nerve.

10. The Pterygomandibular Region (Figs. 296, 297).

External pterygoid.

Internal pterygoid.

Dissection.—The Temporal muscle having been examined, saw through the base of the coronoid process and draw it upward, together with the Temporal muscle, which should be detached from the surface of the temporal fossa. Divide the ramus of the mandible just below the condyle, and also, by a transverse incision extending across the middle, just above the dental foramen; remove the fragment, and the Pterygoid muscles will be exposed.

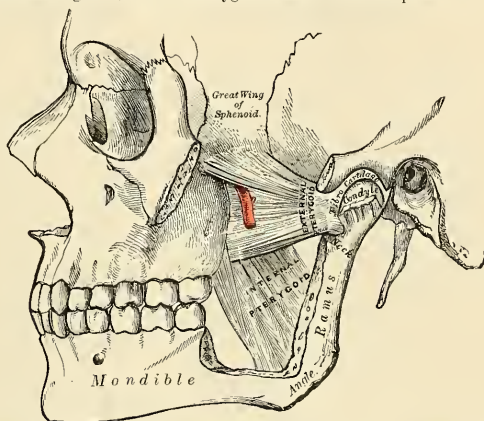


FIG. 296.—The Pterygoid muscles, the zygomatic arch, and a portion of the ramus of the mandible having been removed.

The **External pterygoid muscle** (*m. pterygoideus externus*) is a short, thick muscle, somewhat conical in form, which extends almost horizontally between the zygomatic fossa and the condyle of the mandible. It *arises* by two heads, separated by a slight interval; the **upper head** *arises* from the inferior surface of the greater wing of the sphenoid and from the pterygoid ridge which separates the zygomatic from the temporal fossa; the **lower head** *arises* from the outer surface of the external pterygoid plate. Its fibres pass horizontally backward and outward, to be *inserted* into a depression in front of the neck of the condyle of the mandible and into the front of the articular disk of the temporomandibular articulation.

Relations.—By its *superficial surface*, with the ramus of the mandible, the internal maxillary artery, which crosses it,¹ the tendon of the Temporal muscle, and the Masseter; by its *deep surface* it rests against the upper part of the Internal pterygoid muscle, the internal lateral ligament, the middle meningeal artery, and inferior maxillary nerve; by its *upper border* it is in relation with the temporal and masseteric branches of the inferior maxillary nerve; by its *lower border* it is in relation with the inferior dental and lingual nerves. Through the interval between the two portions of the muscle, the buccal nerve emerges and the internal maxillary artery passes, when the trunk of this vessel lies on the muscle (Fig. 292).

¹ This is the usual relation, but in many cases the artery will be found below the muscle.

The **Internal pterygoid muscle** (*m. pterygoideus internus*) is a thick, quadrilateral muscle, and resembles the Masseter in form. It *arises* from the pterygoid fossa, being attached to the inner surface of the external pterygoid plate and to the grooved surface of the tuberosity of the palate bone, and by a second slip from the outer surface of the tuberosities of the palate and maxilla: its fibres pass downward, outward, and backward, to be *inserted*, by a strong, tendinous lamina, into the lower and back part of the inner side of the ramus and angle of the mandible as high as the dental foramen.

Relations.—By its *superficial surface*, with the ramus of the mandible, from which it is separated, at its upper part, by the External pterygoid muscle, the internal lateral ligament, the internal maxillary artery, the dental vessels and nerves, and the lingual nerve, and a process of the parotid gland. By its *deep surface*, with the Tensor palati, being separated from the Superior constrictor of the pharynx by a cellular interval.

Nerves.—These muscles are supplied by branches of the mandibular division of the trigeminal nerve.

Actions.—The Temporal, Masseter, and Internal pterygoid *raise* the mandible against the maxillæ with great force. The External pterygoids assist in opening the mouth, but their main action is to *draw forward* the condyles and articular disks so that the mandible is protruded and the inferior incisors are projected in front of the upper; in this action they are assisted by the Internal pterygoids. The mandible is *retracted* by the posterior fibres of the Temporal. If the Internal and External pterygoids of one side act, the corresponding side of the mandible is *drawn forward*, while the opposite condyle remains comparatively fixed, and *lateral movement*, such as occurs during the trituration of the food, takes place.

Surface Form.—The outline of the muscles of the head and face cannot be traced on the surface of the body, except in the case of two of the masticatory muscles. Those of the head are thin, so that the outline of the bone is perceptible beneath them. Those in the face are small, covered by soft skin, and often by a considerable layer of fat, so that their outline is concealed, but they serve to round off and smooth prominent borders and to fill up what would be otherwise unsightly angular depressions. Thus, the Orbicularis palpebrarum rounds off the prominent margin of the orbit, and the Pyramidalis nasi fills in the sharp depression beneath the glabella, and thus softens and tones down the abrupt depression which is seen on the unclothed bone. In like manner, the labial muscles, converging to the lips and assisted by the superimposed fat, fill in the sunken hollow of the lower part of the face. Although the muscles of the face are usually described as arising from the bones and inserted into the nose, lips, and corners of the mouth, they have fibres inserted into the skin of the face along their whole extent, so that almost every point of the skin of the face has its muscular fibre to move it; hence it is that when in action the facial muscles produce alterations in the skin-surface, giving rise to the formation of various folds or wrinkles, or otherwise altering the relative position of the parts, so as to produce the varied expressions with which the face is endowed; hence these muscles are termed the *muscles of expression*.¹ The only two muscles in this region which greatly influence surface form are the Masseter and the Temporal. The Masseter is a quadrilateral muscle, which imparts fulness to the hinder part of the cheek. When the muscle is firmly contracted, as when the teeth are clenched, its outline is plainly visible; the anterior border forms a prominent vertical ridge, behind which is a considerable fulness, especially marked at the lower part of the muscle; this fulness is entirely lost when the mouth is opened and the muscle no longer in a state of contraction. The Temporal muscle is fan-shaped, and fills the temporal fossa, substituting for it a somewhat convex form, the anterior part of which, on account of the absence of hair over the temple, is more marked than the posterior, and stands out in strong relief when the muscle is in a state of contraction.

MUSCLES AND FASCIAE OF THE NECK.

The muscles of the neck may be arranged into groups corresponding with the region in which they are situated.

These groups are nine in number:

1. Superficial Cervical Region.
2. Infrahyoid Region.
3. Suprahyoid Region.
4. Lingual Region.
5. Pharyngeal Region.
6. Palatal Region.
7. Anterior Vertebral Region.
8. Lateral Vertebral Region.
9. Muscles of the Larynx.

¹ Consult Darwin, *The Expression of the Emotions in Man and Animals*, and several articles in the *Journal of Anatomy and Physiology*, vols. xiii, xv, and xxxi.

The muscles contained in each of these groups are the following:

1. *Superficial Region.*

Platysma.
Sternomastoid.

5. *Muscles of the Pharynx.*

Inferior constrictor.
Middle constrictor.
Superior constrictor.
Stylopharyngeus.
Palatopharyngeus.
Salpingopharyngeus.

2. *Infrahyoid Region.*

Sternohyoid.
Sternothyroid.
Thyrohyoid.
Omohyoid.

6. *Muscles of the Soft Palate.*

Levator palati.
Tensor palati.
Azygos uvulae.
Palatoglossus.
Palatopharyngeus.
Salpingopharyngeus.

3. *Suprahyoid Region.*

Digastric.
Stylohyoid.
Mylohyoid.
Geniohyoid.

7. *Muscles of the Anterior Vertebral Region.*

Rectus capitis anticus major.
Rectus capitis anticus minor.
Rectus capitis lateralis.
Longus colli.

4. *Lingual Region.*

Extrinsic.	{	Geniohyoglossus.
		Hyoglossus.
		Chondroglossus.
		Styloglossus.
		Palatoglossus.
Intrinsic.	{	Superior lingual.
		Inferior lingual.
		Transverse lingual.
		Vertical lingual.

8. *Muscles of the Lateral Vertebral Region.*

Scalenus anticus.
Scalenus medius.
Scalenus posticus.

9. *Muscles of the Larynx (Intrinsic).*

Included in the description of the Larynx (page 1172.)

1. The Superficial Cervical Region.

Platysma.

Sternomastoid.

Dissection.—A block having been placed at the back of the neck, and the face turned to the side opposite that to be dissected, so as to place the parts upon the stretch, make two transverse incisions, one from the chin, along the margin of the mandible, to the mastoid process, and the other along the upper border of the clavicle. Connect these by an oblique incision made in the course of the Sternomastoid muscle, from the mastoid process to the sternum; the two flaps of integument having been removed in the direction shown in Fig. 286, the superficial fascia will be exposed.

The **superficial cervical fascia** is a thin, aponeurotic lamina which is hardly demonstrable as a separate membrane. It invests the Platysma.

The **Platysma** (*platysma*) (Fig. 287) is a broad, thin plane of muscle fibres situated on the side of the neck. It *arises* by thin, fibrous bands from the fascia covering the upper part of the Pectoral and Deltoid muscles; its fibres pass

over the clavicle and proceed obliquely upward and inward along the side of the neck. The anterior fibres interlace, below and behind the symphysis menti, with the fibres of the muscle of the opposite side; the posterior fibres pass over the mandible, some of them are attached to the bone below the external oblique line, others pass on to be *inserted* into the skin and subcutaneous tissue of the lower part of the face, and many of these fibres blend with the muscles about the angle and lower part of the mouth. Sometimes fibres can be traced to the Zygomatic muscles or to the margin of the Orbicularis oris. Beneath the Platysma the external jugular vein may be seen descending in a line from the angle of the mandible to the middle of the clavicle.

Relations.—By its *superficial surface*, with the integument, to which it is united more closely below than above; by its *deep surface*, with the Pectoralis major and Deltoid, and with the clavicle. In the *neck*, with the external and anterior jugular veins, the deep cervical fascia, the superficial branches of the cervical plexus, the Sternomastoid, Sternohyoid, Omohyoid, and Digastric muscles. Behind the Sternomastoid muscle the Platysma covers in the posterior triangle of the neck; on the *face* it is in relation with the parotid gland, the facial artery and vein, and the Masseter and Buccinator muscles.

Nerves.—The lower division of the facial nerve supplies this muscle.

Action.—The Platysma produces a slight wrinkling of the surface of the skin of the neck in an oblique direction, when the entire muscle is brought into action. Its anterior portion, the thickest part of the muscle, depresses the mandible; it also serves to draw down the lower lip and the angle of the mouth on each side, thus being one of the chief agents in the expression of melancholy. In the pressure upon the bloodvessels of the neck induced by strong inspiratory effort, this muscle draws away the skin and fascia, and by so doing greatly diminishes the pressure on the veins.

The **deep cervical fascia** (*fascia colli*) (Fig. 297) lies under cover of the Platysma muscle and constitutes a complete investment for the neck. It also forms a sheath for the carotid vessels, and, in addition, is prolonged deeply in the shape of certain processes or lamellæ, which come into close relation with the structures situated in front of the vertebral column.

The investing portion of the fascia is attached, *behind*, to the ligamentum nuchæ and to the spine of the seventh cervical vertebra. It forms a thin investment for the Trapezius muscle, at the anterior border of which it is continued forward as a loose areolar layer, which covers the posterior triangle of the neck; thence it passes to the posterior border of the Sternomastoid, where it begins to assume the appearance of a fascial membrane. Along the hinder edge of the Sternomastoid the membrane divides to enclose this muscle, at the anterior edge of which it once more forms a single lamella, which roofs in the anterior triangle of the neck, and, reaching forward to the middle line, is continuous with the corresponding part from the opposite side of the neck. In the middle line of the neck it is attached to the symphysis menti and to the body of the hyoid bone.

Above, the fascia is attached to the superior curved line of the occiput, to the mastoid process of the temporal, and to the whole length of the body of the mandible. Opposite the angle of the mandible the fascia is very strong, and binds the anterior edge of the Sternomastoid firmly to that bone. Between the mandible and the mastoid process it ensheaths the parotid gland—the layer which covers the gland extending upward (*parotid fascia*) to be fixed to the zygomatic arch. The parotid fascia is prolonged forward to cover the Masseter muscle, the *masseteric fascia*. From the layer which passes under the parotid a strong band, the **stylomandibular ligament**, reaches from the styloid process to the angle of the mandible. Three other bands may be defined—the **internal lateral ligament** of the temporomandibular articulation (p. 279), the **pterygomandibular**, and the **pterygospinous ligaments**. The pterygospinous ligament stretches across from the upper half of the posterior free border of the external pterygoid plate to the spinous process of the sphenoid. It occasionally ossifies, producing an adventi-

tious **pterygospinous foramen**, which transmits the branches of the mandibular division of the trigeminal nerve to the muscles of mastication.

Below, the cervical fascia is attached to the acromion process, the clavicle, and to the manubrium sterni. Some little distance above the last-named point, however, it splits into two layers, **superficial** and **deep**. The former is attached to the anterior border of the manubrium, the latter to its posterior border and to the interclavicular ligament. Between these two layers is a slit-like interval, the **suprasternal space** (*spatium suprasternale*). It contains a small quantity of

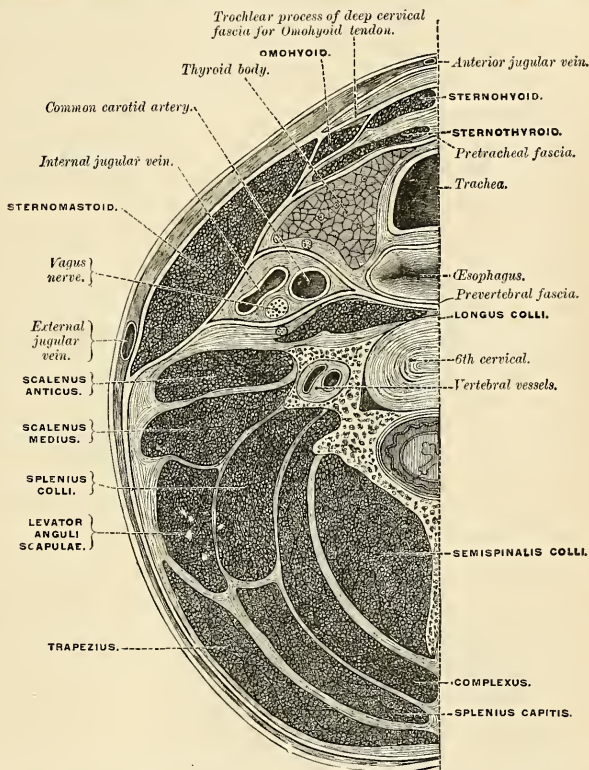


FIG. 297.—Section of the neck at about the level of the sixth cervical vertebra. Showing the arrangement of the deep cervical fascia.

areolar tissue, sometimes a lymph node, the lower portions of the anterior jugular veins and their transverse connecting branch, and also the sternal heads of the Sternomastoid muscles.

The fascia which covers the deep aspect of the Sternomastoid gives off certain important processes, viz.: (1) A trochlear process to envelop the tendon of the Omohyoid, and bind it down to the sternum and first costal cartilage. (2) A strong sheath, the **carotid sheath**, for the large vessels of the neck, enclosed within which are the carotid artery, internal jugular vein, the vagus, and descendens hypoglossi nerves.

(3) The **prevertebral fascia** (*fascia praevertebralis*), which extends inward behind the carotid vessels, where it assists in forming their sheath, and passes in front of the prevertebral muscles. It thus forms the posterior limit of a fibrous compartment which contains the larynx and trachea, the thyroid gland, and the pharynx and œsophagus. The prevertebral fascia is fixed above to the base of the skull, while below it is continued into the thorax in front of the Longus colli muscles. Parallel to the carotid vessels and along their inner aspect it gives off a thin lamina, the buccopharyngeal fascia, which closely invests the Constrictor muscles of the pharynx, and is continued forward from the Superior constrictor on to the Buccinator. The prevertebral fascia is attached to the prevertebral layer by loose connective tissue only, and thus an easily distended space, the **retropharyngeal space**, is found between them. This space is limited above by the base of the skull, while below it extends behind the œsophagus into the thorax, where it is continued into the posterior mediastinum. This fascia is also prolonged downward and outward behind the carotid vessels and in front of the Scalenî muscles, and forms a sheath for the brachial plexus of nerves and for the subclavian vessels in the posterior triangle of the neck, and, continuing under the clavicle as the axillary sheath, it becomes attached to the deep surface of the costocoracoid membrane. Immediately above the clavicle an areolar space exists between the investing layer and the sheath of the subclavian vessels, and in it are found the lower part of the external jugular vein, the descending clavicula nerves, the suprascapular and transversalis colli vessels, and the posterior belly of the Omohyoid muscle. This space extends downward behind the clavicle, and is limited below by the fusion of the costocoracoid membrane with the anterior wall of the axillary sheath.

(4) The **pretracheal fascia**, which extends inward in front of the carotid vessels, and assists in forming the carotid sheath. It is further continued behind the Depressor muscles of the hyoid bone, and, after enveloping the thyroid body, is prolonged in front of the trachea to meet the corresponding layer of the opposite side. Above, it is fixed to the hyoid bone, while below it is carried downward in front of the trachea and large vessels at the root of the neck, and ultimately blends with the fibrous pericardium. This layer is fused on either side with the prevertebral layer, with which it completes the compartment containing the larynx and trachea, the thyroid gland, the pharynx, and œsophagus.

Applied Anatomy.—The deep cervical fascia is of considerable importance from a surgical point of view. As will be seen from the foregoing description, it may be divided into three layers: (1) A superficial layer; (2) a layer passing in front of the trachea, and forming with the superficial layer a sheath for the Depressors of the hyoid bone; (3) a prevertebral layer passing in front of the bodies of the cervical vertebrae, and forming with the second layer a space in which are contained the trachea, œsophagus, etc. The superficial layer forms a complete investment for the neck. It is attached behind to the ligamentum nuchae and the spine of the seventh cervical vertebra; above, it is attached to the external occipital protuberance, to the superior curved line of the occiput, to the mastoid process, to the zygoma and the mandible; below, it is attached to the manubrium sterni, the clavicle, the acromion process, and the spine of the scapula; in front it blends with the fascia of the opposite side. This layer opposes the extension of *abscesses* or new growths toward the surface, and pus forming beneath it has a tendency to extend laterally. If pus is in the posterior triangle, it might extend backward under the Trapezius, forward under the Sternomastoid, or downward under the clavicle for some distance, until stopped by the junction of the cervical fascia to the costocoracoid membrane. If the pus is contained in the anterior triangle, it might find its way into the anterior mediastinum, being situated in front of the layer of fascia which passes down into the thorax to become continuous with the pericardium; but owing to the lesser density and thickness of the fascia in this situation it more frequently finds its way through it and points above the sternum. The second layer of fascia is connected above with the hyoid bone. It passes down beneath the Depressors and in front of the thyroid body and trachea to become continuous with the fibrous layer of the pericardium. Laterally it invests the great vessels of the neck and is connected with the superficial layer beneath the Sternomastoid. Pus forming beneath this layer would in all probability find its way into the posterior mediastinum. The third layer (the prevertebral fascia) is connected above to the base of the skull. Pus forming beneath this layer, in cases, for instance, of caries of the bodies

of the cervical vertebræ, might extend toward the posterior and lateral part of the neck and point in this situation, or might perforate this layer of fascia and the pharyngeal fascia and point into the pharynx (*retropharyngeal abscess*).

In cases of *cut throat* the cervical fascia is of considerable importance. When the wound involves only the superficial layer the injury is usually trivial, the only special danger being injury to the external jugular vein, and the only special complication being diffuse cellulitis. But where the second of the two layers has been opened up, and where important structures may have been injured, serious results may ensue.

The **Sternomastoid** (*m. sternocleidomastoideus*) (Fig. 298) is a large, thick muscle, which passes obliquely across the side of the neck, being enclosed between two layers of the deep cervical fascia. It is thick and narrow at its central part, but is broader and thinner at each extremity. It *arises*, by two heads, from the sternum and clavicle. The **sternal portion** is a rounded fasciculus, tendinous in front, fleshy behind, which *arises* from the upper and anterior part of the first piece of the sternum, and is directed upward, outward, and backward. The **clavicular portion** *arises* from the inner third of the superior border and anterior surface of the clavicle, being composed of fleshy and aponeurotic fibres; it is directed almost vertically upward. These two portions are separated from each

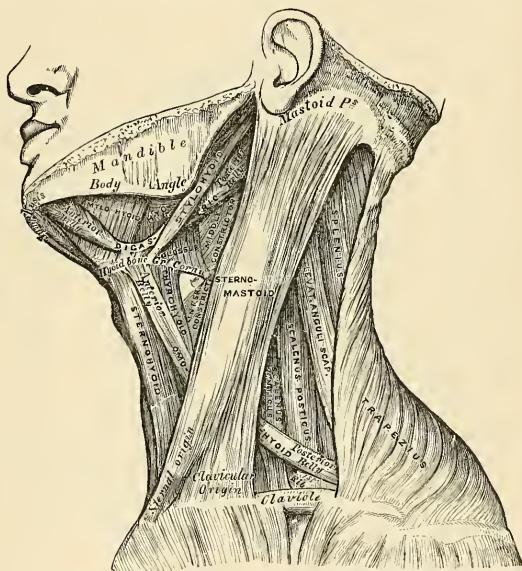


FIG. 298.—Muscles of the neck and boundaries of the triangles.

other, at their origin, by a triangular cellular interval, but become gradually blended, below the middle of the neck, into a thick, rounded muscle, which is *inserted*, by a strong tendon, into the outer surface of the mastoid process of the temporal bone, from its apex to its superior border, and by a thin aponeurosis into the outer half of the superior curved line of the occipital bone. The Sternomastoid varies much in its extent of attachment to the clavicle; in one case the clavicular may be as narrow as the sternal portion; in another, the former, may be

as much as three inches in breadth. When the clavicular origin is broad, it is occasionally subdivided into numerous slips separated by narrow intervals. More rarely, the corresponding margins of the Sternomastoid and Trapezius have been found in contact.

Triangles of the Neck.—The Sternomastoid muscle divides the quadrilateral area of the side of the neck into two triangles, an anterior and a posterior. The boundaries of the **anterior triangle** are, in *front*, the median line of the neck; *above*, the lower border of the body of the mandible, and an imaginary line drawn from the angle of the mandible to the mastoid process; *behind*, the anterior border of the Sternomastoid muscle. The *apex* of the triangle is at the upper border of the sternum. The boundaries of the **posterior triangle** are, in *front*, the posterior border of the Sternomastoid; *below*, the middle third of the clavicle; *behind*, the anterior margin of the Trapezius.¹ The *apex* corresponds with the meeting of the Sternomastoid and Trapezius on the occipital bone.

Relations.—By its *superficial surface*, with the integument and Platysma, from which it is separated by the external jugular vein, some of the superficial branches of the cervical plexus, and the superficial layer of the deep cervical fascia. By its *deep surface* it is in relation with the Sternoclavicular articulation; a process of the deep cervical fascia; the Sternohyoid, Sternothyroid, Omohyoid, posterior belly of the Digastric, Levator anguli scapulae, Splenius and Scaleri muscles; common carotid artery, internal jugular vein, commencement of the internal and external carotid arteries, the occipital, subclavian, transversalis colli, and suprascapular arteries and veins; the phrenic, vagus, hypoglossal, descendens and communicans hypoglossi nerves; the spinal accessory nerve, which pierces its upper third; the cervical plexus, parts of the thyroid and parotid glands, and deep lymph nodes.

Nerves.—The Sternomastoid is supplied by the spinal accessory nerve and deep branches of the cervical plexus.

Actions.—When only one Sternomastoid muscle acts, it draws the head toward the shoulder of the same side, assisted by the Splenius and the Obliquus capitis inferior of the opposite side. At the same time it rotates the head so as to carry the face toward the opposite side. When the two muscles act together they flex the head upon the neck. If the head is fixed, the two muscles assist in elevating the thorax in forced inspiration.

Applied Anatomy.—The applied anatomy of the Sternomastoid muscle is of importance chiefly in connection with the deformity known as *wry-neck* (*torticollis*). Wry-neck may be either acquired, congenital, or spasmodic. The *acquired* may be caused by acute glandular enlargement, cellulitis of the neck, myositis of the Sternomastoid, or cervical caries. The *congenital* variety is due to injury of the Sternomastoid during birth, which probably causes a subsequent chronic fibrous myositis (Mikulicz). This is best remedied by making an open horizontal incision over the origin of the muscle and exposing it. A director is then passed underneath and the muscle clearly divided, making sure that any tense bands of fascia are thoroughly divided. *Spasmodic torticollis* is a condition of adult life. It is marked by clonic or tonic spasm, first of the Sternomastoid, then of many of the other neck muscles. It is thought to be a disease of the central nerve system.

2. The Infrahyoid Region (Figs. 298, 299).

DEPRESSORS OF THE HYOID BONE AND LARYNX.

Sternohyoid.
Sternothyroid.

Thyrohyoid.
Omohyoid.

Dissection.—The muscles in this region may be exposed by removing the deep fascia from the front of the neck. In order to see the entire extent of the Omohyoid it is necessary to divide the Sternomastoid at its centre, and turn its ends aside, and to detach the Trapezius from the clavicle and scapula. This, however, should not be done until the Trapezius has been dissected.

The **Sternohyoid** (*m. sternohyoideus*) is a thin, narrow, ribbon-like muscle, which *arises* from the inner extremity of the clavicle, the posterior sternoclavicular ligament, and the upper and posterior part of the first piece of the sternum; passing upward and inward, it is *inserted*, by short, tendinous fibres, into the lower border of the body of the hyoid bone. This muscle is separated, below, from

¹ The anatomy of these triangles will be more exactly described with that of the vessels of the neck.

its fellow by a considerable interval; but the two muscles come into contact with each other in the middle of their course, and from this upward lie side by side. It sometimes presents, immediately above its origin, a transverse tendinous intersection, like those in the Rectus abdominis. As a rule, two bursæ (*bursæ sternohyoidii*) lie between the cricothyroid membrane and the Sternohyoid muscle.

Relations.—By its *superficial surface*, below, with the sternum, the sternal end of the clavicle, and the Sternomastoid; and *above*, with the Platysma and deep cervical fascia; by its *deep surface*, with the Sternothyroid, Cricothyroid, and Thyrohyoid muscles, the thyroid gland, the superior thyroid vessels, the thyroid cartilage, the cricothyroid and thyrohyoid membranes.

The **Sternothyroid** (*m. sternothyroideus*) is situated beneath the preceding muscle, but is shorter and wider than it. It *arises* from the posterior surface of the first piece of the sternum, below the origin of the Sternohyoid, and from the edge of the cartilage of the first rib, occasionally of the second rib also, and is *inserted* into the oblique line on the side of the ala of the thyroid cartilage. This muscle is in close contact with its fellow at the lower part of the neck, and is occa-

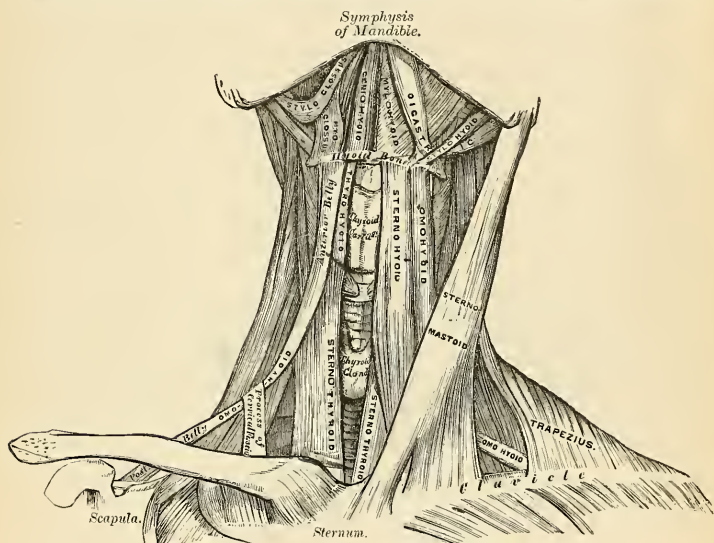


FIG. 299.—Muscles of the neck. Anterior view.

sionally traversed by a transverse or oblique tendinous intersection, like those in the Rectus abdominis.

Relations.—By its *superficial surface*, with the Sternohyoid, Omohyoid, and Sternomastoid; by its *deep surface*, from below upward, with the trachea, innominate veins, common carotid (and on the right side the innominate artery), the thyroid gland and its vessels, and the lower part of the larynx and pharynx. The inferior thyroid vein lies along its *inner border*, a relation which it is important to remember in the operation of tracheotomy. On the left side the deep surface of the muscle is in relation to the œsophagus.

The **Thyrohyoid** (*m. thyrohyoideus*) is a small, quadrilateral muscle appearing like a continuation of the Sternothyroid. It *arises* from the oblique line on

the side of the thyroid cartilage, and passes vertically upward to be *inserted* into the lower border of the body and greater cornu of the hyoid bone.

Relations.—By its *superficial surface*, with the Sternohyoid and Omohyoid muscles; by its *deep surface*, with the thyroid cartilage, the thyrohyoid membrane, and the superior laryngeal vessels and nerve.

The **Omohyoid** (*m. omohyoideus*) passes across the side of the neck, from the scapula to the hyoid bone. It consists of two fleshy bellies, united by a central tendon. It *arises* from the upper border of the scapula, and occasionally from the transverse ligament which crosses the suprascapular notch, its extent of attachment to the scapula varying from one-sixth of an inch to an inch. From this origin the **posterior belly** (*venter inferior*) forms a flat, narrow fasciculus, which inclines forward and slightly upward across the lower part of the neck, behind the Sternomastoid muscle, where it becomes tendinous; it then changes its direction, forming an obtuse angle, and terminates in the **anterior belly** (*venter superior*), which passes almost vertically upward, close to the outer border of the Sternohyoid, to be *inserted* into the lower border of the body of the hyoid bone, just external to the insertion of the Sternohyoid. The central tendon of this muscle, which varies much in length and form, is held in position by a process of the deep cervical fascia, which includes it in a sheath. This process is prolonged down, to be attached to the clavicle and first rib. It is by this means that the angular form of the muscle is maintained.

The posterior belly of the Omohyoid divides the posterior triangle of the neck into an upper or **occipital**, and a lower or **subclavian triangle**, while its anterior belly divides the anterior triangle of the neck into an upper or **carotid**, and a lower or **muscular triangle**.

Relations.—By its *superficial surface*, with the Trapezius, the Sternomastoid, deep cervical fascia, Platysma, and integument; by its *deep surface*, with the Scaleri muscles, phrenic nerve, lower cervical nerves which go to form the brachial plexus, the suprascapular vessels and nerve, sheath of the common carotid artery and internal jugular vein, the Sternothyroid and Thyrohyoid muscles.

Nerves.—The Depressors of the hyoid bone are supplied by branches from the *ansa cervicalis* formed by the first three cervical nerves.

Actions.—These muscles depress the larynx and hyoid bone, after they have been drawn up with the pharynx in the act of deglutition. The Omohyoid muscles not only depress the hyoid bone, but carry it backward and to one side. This bone is concerned especially in prolonged inspiratory efforts; for by rendering the lower part of the cervical fascia tense it lessens the inward suction of the soft parts, which would otherwise compress the great vessels and the apices of the lungs. This action is synergistic with that of the Platysma. The Thyrohyoid may act as an elevator of the thyroid cartilage when the hyoid bone ascends, drawing upward the thyroid cartilage, behind this bone. The Sternothyroid acts as a depressor of the thyroid cartilage.

3. The Suprahyoid Region (Figs. 298, 299).

ELEVATORS OF THE HYOID BONE—DEPRESSORS OF THE MANDIBLE.

Digastric.
Stylohyoid.

Mylohyoid.
Geniohyoid.

Dissection.—To dissect these muscles a block should be placed beneath the back of the neck, and the head drawn backward and retained in that position. On the removal of the deep fascia the muscles are at once exposed.

The **Digastric** (*m. digastricus*) consists of two fleshy bellies united by an intermediate, rounded tendon. It is a small muscle, situated below the side of the body of the mandible, and extending, in a curved form, from the side of the head to the symphysis of the mandible. The **posterior belly** (*venter posterior*), longer than the anterior, *arises* from the digastric groove on the inner side of the mastoid process of the temporal bone, and passes downward, forward, and inward.

The **anterior belly** (*venter anterior*) arises from a depression on the inner side of the lower border of the mandible, close to the symphysis, and passes downward and backward. The two bellies terminate in the central tendon which perforates the Stylohyoid, and is held in connection with the side of the body and the greater cornu of the hyoid bone by a fibrous loop, lined with a synovial membrane. A broad aponeurotic layer is given off from the tendon of the Digastric on each side, which is attached to the body and greater cornu of the hyoid bone; this is termed the **suprahyoid aponeurosis**. It forms a strong layer of fascia between the anterior portions of the two muscles, and a firm investment for the other muscles of the suprahyoid region which lie deeper.

Relations.—By its *superficial surface*, with the mastoid process, the Platysma, Sternomastoid, part of the Splenius, Trachelomastoid, and Stylohyoid muscles, and the parotid gland. By its *deep surface*, the anterior belly lies on the Mylohyoid; the posterior belly on the Styloglossus, Stylopharyngeus, and Hyoglossus muscles, the external carotid artery and its occipital, lingual, facial, and ascending pharyngeal branches, the internal carotid artery, internal jugular vein, and hypoglossal nerve.

The **Stylohyoid** (*m. stylohyoideus*) is a small, slender muscle, lying in front of and above the posterior belly of the Digastric. It arises from the back and outer surface of the styloid process of the temporal bone, near the base; and, passing downward and forward, is inserted into the body of the hyoid bone, just at its junction with the greater cornu, and immediately above the Omohyoid. This muscle is perforated, near its insertion, by the tendon of the Digastric.

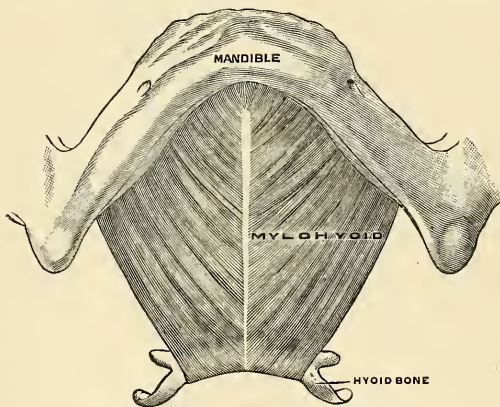


FIG. 300.—Mylohyoid muscle. (Poirier and Charpy.)

Relations.—By its *superficial surface*, above, with the parotid gland and deep cervical fascia; below, this muscle is superficial, being situated immediately beneath the deep cervical fascia. By its *deep surface*, with the posterior belly of the Digastric, the external carotid artery, with its lingual and facial branches, the Hyoglossus muscle, and the hypoglossal nerve.

The **Stylohyoid Ligament** (*ligamentum stylohyoideus*).—In connection with the Stylohyoid muscle may be described a ligamentous band, the **stylohyoid ligament**. It is a fibrous cord, often containing a little cartilage in its centre, which continues the styloid process down to the hyoid bone, being attached to the tip of the former and to the lesser cornu of the latter. It is often more or less ossified, and in many animals forms a distinct bone, the *epihyal*.

The **Mylohyoid** (*m. mylohyoideus*) (Fig. 300) is a flat, triangular muscle,

situated immediately beneath the anterior belly of the Digastric, and forming, with its fellow of the opposite side, a muscular floor for the cavity of the mouth. It *arises* from the whole length of the mylohyoid ridge of the mandible, extending from the symphysis in front to the last molar tooth behind. The posterior fibres pass inward and slightly downward, to be *inserted* into the body of the hyoid bone. The middle and anterior fibres are *inserted* into a median fibrous raphé, extending from the symphysis of the mandible to the hyoid bone, where they join at an angle with the fibres of the opposite muscle. The median raphé is sometimes wanting; the muscle fibres of the two sides are then directly continuous with one another.

Relations.—By its *superficial surface*, with the Platysma, the anterior belly of the Digastric, the suprahyoid aponeurosis, the submaxillary gland, submental vessels, and mylohyoid vessels and nerve; by its *deep surface*, with the Geniohyoid, part of the Hyoglossus and Styloglossus muscles, the hypoglossal and lingual nerves, the submaxillary ganglion, the sublingual gland, the deep portion of the submaxillary gland and duct; the sublingual and ranine vessels, and the buccal mucous membrane.

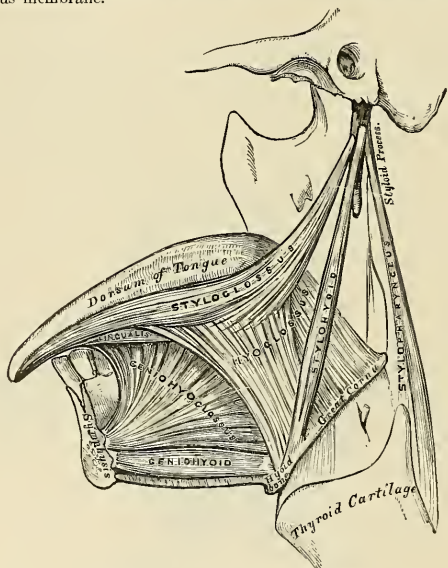


FIG. 301.—Muscles of the tongue. Left side.¹

Dissection.—The Mylohyoid should now be removed, in order to expose the muscles which lie beneath; this is effected by reflecting it from its attachments to the hyoid bone and mandible, and separating it by a vertical incision from its fellow of the opposite side.

The **Geniohyoid** (*m. geniohyoideus*) (Fig. 301) is a narrow, slender muscle, situated immediately beneath² the inner border of the Mylohyoid. It *arises* from the inferior genial tubercle on the inner side of the symphysis of the mandible, and passes downward and backward, to be *inserted* into the anterior surface of the body of the hyoid bone. This muscle lies in close contact with its fellow of the opposite side, and increases slightly in breadth as it descends.

¹The muscles and ligaments attached to the styloid process have been termed the "bouquet of Riolanus."

²This refers to the depth of the muscles from the skin in the order of dissection. In the erect position of the body the Geniohyoid is above the Mylohyoid.

Relations.—It is covered by the Mylohyoid and lies along the lower border of the Geniohyoglossus.

Nerves.—The anterior belly of the Digastric is supplied by the mylohyoid branch of the inferior dental; its posterior belly, by the facial; the Stylohyoid is supplied by the facial; the Mylohyoid, by the mylohyoid branch of the inferior dental; the Geniohyoid, by a branch from the ansa cervicalis which accompanies the hypoglossal in a common sheath.

Actions.—This group of muscles performs two very important actions. They raise the hyoid bone, and with it the base of the tongue, during the act of deglutition; or, when the hyoid bone is fixed by its Depressors and those of the larynx, they depress the mandible. During the first act of deglutition, when the mass is being driven from the mouth into the pharynx, the hyoid bone, and with it the tongue, is carried upward and forward by the anterior belly of the Digastric, the Mylohyoid, and Geniohyoid muscles. In the second act, when the mass is passing through the pharynx, the direct elevation of the hyoid bone takes place by the combined action of all the muscles; and after the food has passed, the hyoid bone is carried upward and backward by the posterior belly of the Digastric and Stylohyoid muscles, which assist in preventing the return of the bolus into the mouth.

4. The Lingual Region (Figs. 301, 302).

Geniohyoglossus.

Hyoglossus.

Styloglossus.

Palatoglossus.¹

Chondroglossus.

Dissection.—After completing the dissection of the preceding muscles, saw through the mandible just external to the symphysis. Then draw the tongue forward, and attach it, by a stitch, to the nose; when its muscles, which are thus put on a stretch, may be examined.

The **Geniohyoglossus** (*m. genioglossus*) has received its name from its triple attachment to the mandible, hyoid bone, and tongue. It is a flat, triangular muscle, placed vertically on either side of the middle line, its apex corresponding with its point of attachment to the mandible, its base with its insertion into the tongue and hyoid bone. It *arises* by a short tendon from the superior genial tubercle on the inner side of the symphysis of the mandible, immediately above the Geniohyoid; from this point the muscle spreads out in a fan-like form, a few of the inferior fibres passing downward, to be *attached* by a thin aponeurosis into the upper part of the body of the hyoid bone, a few fibres passing between the Hyoglossus and Chondroglossus to blend with the Constrictor muscles of the pharynx; the middle fibres passing backward, and the superior ones upward and forward, to enter the whole length of the under surface of the tongue, from the base to the apex. The two muscles lie on either side of the median plane; behind they are quite distinct from each other, and are separated at their insertion into the under surface of the tongue by a tendinous raphé, which extends through the middle of the organ. In front the two muscles are more or less blended; distinct fasciculi are to be seen passing off from one muscle, crossing the middle line, and intersecting with bundles of fibres derived from the muscle on the other side.

Relations.—By its *deep surface* this muscle is in contact with its fellow of the opposite side; by its *superficial surface*, with the Inferior lingualis, the Hyoglossus, the lingual artery and hypoglossal nerve, the lingual nerve, and sublingual gland; by its *upper border*, with the mucous membrane of the floor of the mouth (*frenum lingue*); by its *lower border* with the Geniohyoid.

The **Hyoglossus** (*m. hyoglossus*) is a thin, flat, quadrilateral muscle which *arises* from the side of the body and whole length of the greater cornu of the hyoid bone, and passes almost vertically upward to enter the side of the tongue,

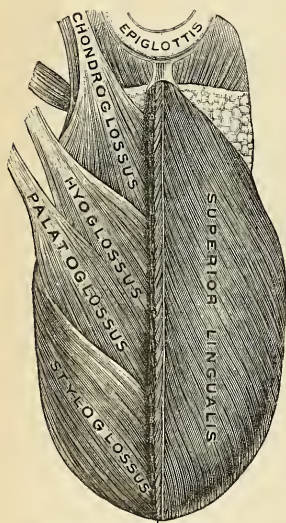
¹ The Palatoglossus, or *constrictor isthmi faucium*, although one of the muscles of the tongue which serves to draw the base of that organ upward during the act of deglutition, is more nearly associated, both in situation and function, with the soft palate. It will consequently be described with the group of Palatal muscles.

between the Styloglossus and Lingualis. The fibres of this muscle which arise from the body are directed upward and backward, overlapping those arising from the greater cornu, which are directed upward and forward.

Relations.—By its *superficial surface*, with the Digastric, the Stylohyoid, Styloglossus, and Mylohyoid muscles, the submaxillary ganglion, the lingual and hypoglossal nerves, the submaxillary duct, the ranine vein, the sublingual gland, and the deep portion of the submaxillary gland. By its *deep surface*, with the Stylohyoid ligament, the Geniohyoglossus, Lingualis, and Middle constrictor, the lingual vessels, and the glossopharyngeal nerve.

The **Chondroglossus** (*m. chondroglossus*) is a distinct muscular slip, though it is sometimes described as a part of the Hyoglossus, from which, however, it is separated by the fibres of the Geniohyoglossus, which pass to the side of the pharynx. It is about three-quarters to an inch in length; it *arises* from the inner side and base of the lesser cornu and contiguous portion of the body of the hyoid bone, and passes directly upward to blend with the Intrinsic muscle fibres of the tongue, between the Hyoglossus and Geniohyoglossus.

The **Styloglossus** (*m. styloglossus*), the shortest and smallest of the three styloid muscles, *arises* from the anterior and outer side of the styloid process, near the apex, and from the stylomandibular ligament, to which its fibres, in most cases, are attached by a thin aponeurosis. Passing downward and forward between the internal and external carotid arteries, and becoming nearly horizontal in its direction, this muscle divides upon the side of the tongue into two portions—one longitudinal, which enters the



CUT EDGE OF SUPERIOR LINGUALIS.

FIG. 302.—Muscles on the dorsum of the tongue.

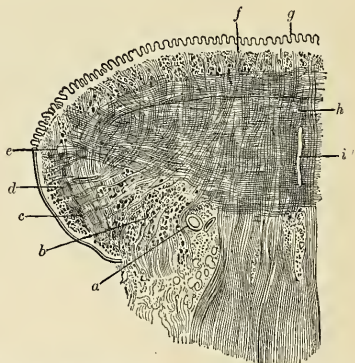


FIG. 303.—Coronal section of tongue. Showing intrinsic muscles. *a.* Lingual artery. *b.* Inferior lingualis, cut through. *c.* Fibres of Hyoglossus. *d.* Oblique fibres of Styloglossus. *e.* Insertion of Transverse lingualis. *f.* Superior lingualis. *g.* Papilla of tongue. *h.* Vertical fibres of Geniohyoglossus intersecting Transverse lingualis. *i.* Septum. (Altered from Krause.)

side of the tongue near its dorsal surface and blends with the fibres of the Lingualis in front of the Hyoglossus; the other oblique, which overlaps the Hyoglossus muscle and decussates with its fibres.

Relations.—By its *superficial surface*, from above downward, with the parotid gland, the Internal pterygoid muscle, the lingual nerve, and the mucous membrane of the mouth; by its *deep surface*, with the tonsil, the Superior constrictor, and the Hyoglossus muscle.

Nerves.—The muscles of this group are supplied by the hypoglossal nerve.

The Muscle Substance of the Tongue (Figs. 302 and 303).—The muscle fibres of the tongue run in various directions. These fibres are divided into two sets—Extrinsic and Intrinsic. The **Extrinsic muscles** of the tongue are those which have their origin *external to*, and only their terminal fibres contained *within*, the substance of the organ. They are: the Styloglossus, the Hyoglossus, the Palatoglossus, the Geniohyoglossus, and part of the Superior constrictor of the pharynx (Pharyngoglossus). The **Intrinsic muscles** are those which are contained entirely *within* the tongue, and which form the greater part of its muscular structure.

The tongue consists of symmetrical halves separated from each other in the middle line by a **fibrous septum** (*septum lingue*). Each half is composed of muscle fibres arranged in various directions, containing much interposed fat, and supplied by vessels and nerves. Immediately beneath the mucous membrane is a *submucous fibrous layer*, into which the muscle fibres which terminate in this stratum of the tongue are inserted. Upon removing this, with the mucous membrane, the *first stratum* of muscle fibres is exposed. This belongs to the group of Intrinsic muscles, and has been named the **Superior lingualis** (*m. longitudinalis superior*). It consists of a thin layer of oblique and longitudinal fibres which arise from the submucous fibrous layer, close to the epiglottis, and from the fibrous septum, and which pass forward and outward to the edges of the tongue. Between its fibres pass some vertical fibres derived from the Geniohyoglossus and from the vertical Intrinsic muscle, which will be described later on.

Beneath this layer is the *second stratum* of muscle fibres, derived principally from the Extrinsic muscles. In front this stratum is formed by the fibres derived from the Styloglossus, which run along the side of the tongue and which in turn send out two sets of fibres. The *first* of these two latter sets of fibres extends over the dorsum and runs obliquely forward and inward to the middle line. The *second* set of fibres goes on to the under surface of the sides of the anterior part of the tongue, and runs between the fibres of the Hyoglossus muscle forward and inward to the middle line. Behind this layer of fibres, derived from the Styloglossus, are fibres derived from the Hyoglossus, assisted by some few fibres of the Palatoglossus. The Hyoglossus, entering the side of the under surface of the tongue, between the Styloglossus and Inferior lingualis, passes around its margin and spreads out into a layer on the dorsum, which occupies the middle third of the organ, and runs almost transversely inward to the septum. It is reinforced by some fibres from the Palatoglossus; other fibres of this muscle pass more deeply and intermingle with the next layer. The posterior part of the second layer of the muscle fibres of the tongue is derived from those fibres of the Hyoglossus which arise from the lesser cornu of the hyoid bone, and are here described as a separate muscle—the **Chondroglossus**. The fibres of this muscle are arranged in a fan-shaped manner, and spread out over the posterior third of the tongue.

Beneath this layer is the *third layer*, the great mass of Intrinsic muscles of the tongue, which is intersected at right angles by the terminal fibres of one of the Extrinsic muscles—the Geniohyoglossus. This portion of the tongue is paler in color and softer in texture than that already described, and is sometimes designated the medullary portion in contradistinction to the firmer superficial part, which is termed the cortical portion. The medullary portion consists largely of transverse fibres, the Transverse lingualis, and of vertical fibres, the Vertical lingualis. The **Transverse lingualis** (*m. transversus lingue*) forms the largest portion of the third layer of muscle fibres of the tongue. The fibres arise from the median septum, and pass outward to be inserted into the submucous fibrous layer at the sides of the tongue. Intermingled with these transverse intrinsic fibres are transverse extrinsic fibres derived from the Palatoglossus and the Superior constrictor of the pharynx. These transverse extrinsic fibres, however, run in the opposite direction, passing inward toward the septum. Intersecting the transverse fibres are a large number of vertical fibres derived partly from the Geniohyoglossus and partly from intrinsic fibres, the Vertical lingualis. The fibres derived from the Geniohyoglossus enter the under surface of the tongue on each side of the median septum from base to apex. They ascend in a radiating manner to the dorsum, being inserted into the submucous fibrous layer covering the tongue on each side of the middle line. The **Vertical lingualis** (*m. verticalis lingue*) is found only at the borders of the forepart of the tongue, external to the fibres of the Geniohyoglossus. Its fibres extend from the upper to the under surface of the organ, and decussate with the fibres of the other muscles, and especially with those of the Transverse lingualis.

The *fourth layer* of muscle fibres of the tongue consists partly of extrinsic fibres derived from the Styloglossus, and partly of intrinsic fibres, the Inferior lingualis. At the sides of the under surface of the organ are some fibres derived from the Styloglossus, which, as it runs forward at the side of the tongue, gives off fibres which, passing forward and inward between the fibres of the Hyoglossus, form an inferior oblique stratum which joins in front with the anterior fibres of the Inferior lingualis. The **Inferior lingualis** (*m. longitudinalis inferior*) is a longitudinal band, situated on the under surface of the tongue, and extending from the base to the apex of the organ. Behind, some of its fibres are connected with the body of the hyoid bone. It lies between the Hyoglossus and the Geniohyoglossus, and in front of the Hyoglossus it enters into relation with the Styloglossus, with the fibres of which it blends. It is in relation by its under surface with the ranine artery.

Applied Anatomy.—The fibrous septum which exists between the two halves of the tongue is almost complete, so that the anastomosis between the two lingual arteries is not very free, a fact often illustrated by injecting one-half of the tongue with colored gelatin, while the other half is left uninjected or may be injected with gelatine of a different color.

This is a point of considerable importance in connection with removal of one-half of the tongue for cancer, an operation which is now frequently resorted to when the disease is strictly confined to one side of the anterior portion of the tongue. If the mucous membrane is divided longitudinally exactly in the middle line, the tongue can be split into halves along the median raphe without any appreciable hemorrhage, and the diseased half can then be removed.

Actions.—The movements of the tongue, although numerous and complicated, may be understood by carefully considering the direction of the fibres of its muscles. The Geniohyoglossi muscles, by means of their posterior fibres, draw the base of the tongue forward, so as to protrude the apex from the mouth. The anterior fibres draw the tongue back into the mouth. The whole length of these two muscles, acting along the middle line of the tongue, draw it downward, so as to make it concave from side to side, forming a channel along which fluids may pass toward the pharynx, as in sucking. The Hyoglossi muscles depress the tongue and draw down its sides, so as to render it convex from side to side. The Styloglossi muscles draw the tongue upward and backward. The Palatoglossi muscles draw the base of the tongue upward. With regard to the Intrinsic muscles, both the Superior and Inferior lingualis tend to shorten the tongue, but the former, in addition, turn the tip and sides upward so as to render the dorsum concave, while the latter pull the tip downward and cause the dorsum to become convex. The Transverse lingualis narrows and elongates the tongue, and the Vertical lingualis flattens and broadens it. The complex arrangement of the muscle fibres of the tongue, and the various directions in which they run, give to this organ the power of assuming the various forms necessary for the enunciation of the different consonantal sounds.

5. The Pharyngeal Region (Figs. 304, 305).

Inferior constrictor.

Middle constrictor.

Palatopharyngeus.

Salpingopharyngeus.

Superior constrictor.

Stylopharyngeus.

} (See next section.)

Dissection (Fig. 304).—In order to examine the muscles of the pharynx, cut through the trachea and œsophagus just above the sternum, and draw them upward by dividing the loose areolar tissue connecting the pharynx with the front of the vertebral column. The parts being drawn well forward, apply the edge of the saw immediately behind the styloid processes, and saw the base of the skull through from below upward. The pharynx and mouth should then be stuffed with tow, in order to distend its cavity and render the muscles tense and easier of dissection.

The **Inferior constrictor** (*m. constrictor pharyngis inferior*), the most superficial and thickest of the three Constrictors, arises from the side of the cricoid cartilages, in the interval between the Cricothyroid muscle in front and the articular facet for the thyroid cartilage behind; from the oblique line on the side of the ala of the thyroid cartilage, the cartilaginous surface behind it, nearly as far as its posterior border, and from the inferior cornu. From these origins the fibres spread backward and inward, to be inserted into the fibrous raphe in the posterior median line of the pharynx. The inferior fibres are horizontal, and continuous with the fibres of the œsophagus; the rest ascend, increasing in obliquity, and overlap the Middle constrictor.

Relations.—The Inferior Constrictor is covered by a thin membrane which surrounds the entire pharynx, the **buccopharyngeal fascia** (*fascia buccopharyngea*). Behind, this fascia is in relation with the vertebral column and the prevertebral fascia and muscles; laterally, with the thyroid gland, the common carotid artery, and the Sternothyroid muscle; by its deep surface, with the Middle constrictor, the Stylopharyngeus, Palatopharyngeus, the fibrous coat and mucous membrane of the pharynx. The internal laryngeal nerve and the laryngeal branch of the superior thyroid artery pass near the upper border, and the recurrent laryngeal nerve and the laryngeal branch of the inferior thyroid artery, beneath the lower border of this muscle, previous to their entering the larynx.

The **Middle constrictor** (*m. constrictor pharyngis medius*) is a flattened, fan-shaped muscle, smaller than the preceding. It arises from the whole length of the upper border of the greater cornu of the hyoid bone, from the lesser cornu, and from the stylohyoid ligament. The fibres diverge from their origin, the lower ones descending beneath the Inferior constrictor, the middle fibres passing transversely, and the upper fibres ascending and overlapping the Superior constrictor. The muscle is inserted into the posterior median fibrous raphé, blending in the middle line with its fellow of the opposite side.

Relations.—Between this muscle and the Superior constrictor are the glossopharyngeal nerve, the Stylopharyngeus muscle and the stylohyoid ligament; and between it and the Inferior constrictor is the superior laryngeal nerve. *Behind*, the Middle constrictor lies on the vertebral column, the Longus colli, and the Rectus capitis anticus major. *On each side* it is in relation with the carotid vessels, the pharyngeal plexus, and some lymph nodes. Near its origin it is covered by the Hyoglossus, the lingual vessels being placed between the two muscles. It lies upon the Superior constrictor, the Stylopharyngeus, the Palatopharyngeus, the fibrous coat, and the mucous membrane of the pharynx.

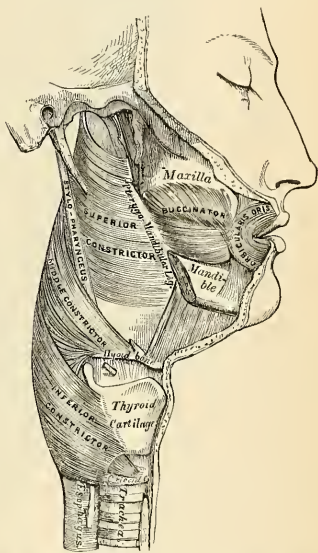


FIG. 304.—Muscles of the pharynx. External view.

The **Superior constrictor** (*m. constrictor pharyngis superior*) is a quadrilateral muscle, thinner and paler than the other Constrictors, and situated at the upper part of the pharynx. It arises from the lower half of the posterior margin of the internal pterygoid plate and its hamular process, from the contiguous portion of the palate bone and the reflected tendon of the Tensor palati muscle, from the pterygomandibular ligament, from the alveolar process above the posterior extremity of the mylohyoid ridge, and by a few fibres from the side of the tongue. From these points the fibres curve backward, to be inserted into the median raphé, being also prolonged by means of a fibrous aponeurosis to the pharyngeal spine on the basilar process of the occipital bone.¹ The superior fibres arch beneath the Levator palati and the Eustachian tube. The interval between the upper border of the muscle and the basilar process is deficient in muscle fibres and is closed by a portion of the **pharyngeal aponeurosis**. This interval is known as the **sinus of Morgagni** (Fig. 305).

Relations.—By its *superficial surface* the Superior constrictor is in relation with the prevertebral fascia and muscles, the vertebral column, the internal carotid and ascending pharyngeal arteries, the internal jugular vein and pharyngeal venous plexus, the glossopharyngeal, vagus, spinal accessory, hypoglossal, lingual, and sympathetic nerves, the Middle constrictor and Internal pterygoid muscles, the styloid process, the stylohyoid ligament, and the Stylopharyngeus. By its *deep surface*, it is in relation with the Palatopharyngeus, the tonsil, the fibrous coat, and the mucous membrane of the pharynx.

¹ Accessory bundles of origin sometimes arise from the margins of the middle lacerated foramen and descend to blend with the main muscle mass.

The **Stylopharyngeus** (*m. stylopharyngeus*) is a long, slender muscle, cylindrical above, broad and thin below. It arises from the inner side of the base of the styloid process of the temporal bone, passes downward along the side of the pharynx between the Superior and Middle constrictors, and spreads out beneath the mucous membrane, where some of its fibres are lost in the Constrictor muscles; and others, joining with the Palatopharyngeus, are inserted into the posterior border of the thyroid cartilage. The glossopharyngeal nerve runs on the outer side of this muscle, and crosses over it in passing forward to the tongue.

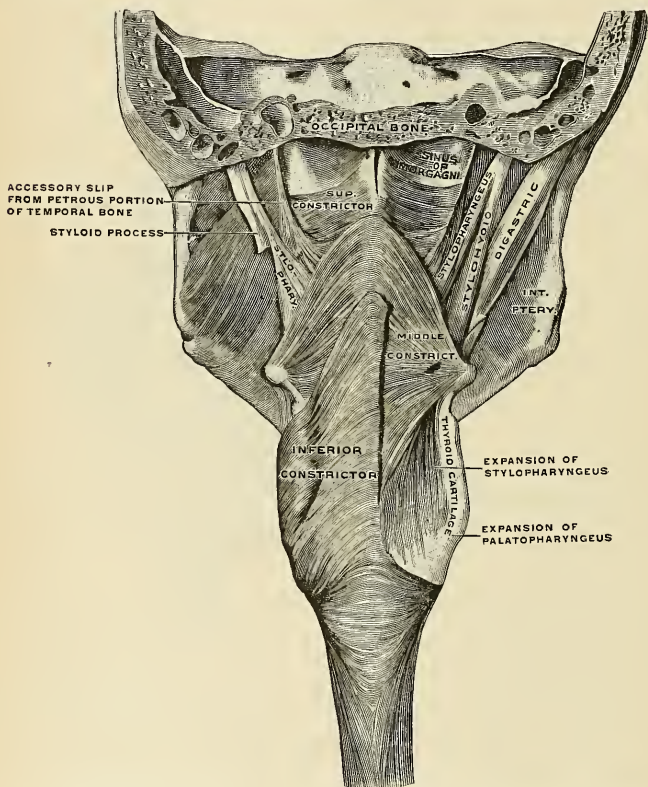


FIG. 305.—The muscles of the pharynx. On the right side most of the Inferior constrictor has been removed, on the left side the Digastric and Stylohyoid have been removed. (Spalteholz.)

Relations.—By its *superficial surface*, with the Styloglossus muscle, the parotid gland, the external carotid artery, and the Middle constrictor; by its *deep surface*, with the internal carotid, the internal jugular vein, the Superior constrictor, Palatopharyngeus, and pharyngeal mucous membrane.

Nerves.—The Constrictors are supplied by branches from the pharyngeal plexus formed by the vagus, glossopharyngeal, and sympathetic nerves. The Inferior constrictor also receives an additional branch from the external laryngeal nerve and one from the recurrent laryngeal. The Stylopharyngeus is supplied by a branch from the glossopharyngeal nerve.

Actions.—When deglutition is about to be performed, the pharynx is drawn upward and dilated in different directions, to receive the bolus propelled into it from the mouth. The Stylo-pharyngei, which are much farther removed from one another at their origin than at their insertion, draw the sides of the pharynx upward and outward, and so increase its transverse diameter; its breadth in the antero-posterior direction is increased by the larynx and tongue being carried forward in their ascent. As soon as the bolus is received in the pharynx, the Elevator muscles relax, the bag descends, and the Constrictors contract upon the bolus, and convey it gradually downward into the oesophagus. Besides its action in deglutition, the pharynx also exerts an important influence in the modulation of the voice, especially in the production of the higher tones.

6. The Palatal Region (Fig. 306).

Levator palati.
Tensor palati.
Azygos uvulae.

Palatoglossus.
Palatopharyngeus.
Salpingopharyngeus.

Dissection (Fig. 306).—Lay open the pharynx from behind by a vertical incision extending from its upper to its lower part, and partially divide the occipital attachment by a transverse incision on each side of the vertical one; the posterior surface of the soft palate is then exposed. Having fixed the uvula so as to make it tense, the mucous membrane and glands should be carefully removed from the posterior surface of the soft palate, and the muscles of this part are at once exposed.

The **Levator palati** (*m. levator veli palatini*) is a long, thick, rounded muscle, placed on the outer side of the posterior nares. It *arises* from the under surface of the apex of the petrous portion of the temporal bone, and from the lower margin of the cartilaginous portion of the Eustachian tube; after passing into the pharynx, above the upper concave margin of the Superior constrictor, it passes obliquely downward and inward, its fibres spreading out into the soft palate as far as the middle line, where they blend with those of the opposite side.

Relations.—By its *superficial surface*, this muscle is in relation with the Tensor palati, the Superior constrictor, and the Eustachian tube; by its *deep surface*, with the mucous membrane of the pharynx; *posteriorly*, with the posterior fasciculus of the Palatopharyngeus, the Azygos uvulae, and the mucous membrane of the soft palate.

The **Tensor palati** (*m. tensor veli palatini*) is a broad, thin, ribbon-like muscle, placed on the outer side of the Levator palati, and consisting of a vertical and a horizontal portion. The **vertical portion** *arises* by a flat lamella from the scaphoid fossa at the base of the internal pterygoid plate; from the spine of the sphenoid and from the outer side of the cartilaginous portion of the Eustachian tube; it descends vertically between the internal pterygoid plate and the inner surface of the Internal pterygoid muscle, and terminates in a tendon, which winds around the hamular process, being retained in this situation by some of the fibres of origin of the Internal pterygoid muscle. Between the hamular process and the tendon is a small bursa (*bursa m. tensoris veli palati*). The **tendon** or **horizontal portion** then passes horizontally inward, and is *inserted* into a broad aponeurosis, the **palatal aponeurosis**, and into the transverse ridge on the horizontal portion of the palate bone.

Relations.—By its *superficial surface*, this muscle is in relation with the Internal pterygoid; by its *deep surface*, with the Levator palati, from which it is separated by the Eustachian tube and Superior constrictor, and with the internal pterygoid plate. In the soft palate its tendon and the palatal aponeurosis are anterior to those of the Levator palati, being covered by the Palatoglossus and the mucous membrane.

Palatal Aponeurosis.—Attached to the posterior border of the hard palate is a thin, firm, fibrous lamella which supports the muscles and gives strength to the

soft palate. It is thicker above than below, where it becomes very thin and difficult to define. Laterally, it is continuous with the pharyngeal aponeurosis.

The **Azygos uvulae** (*m. uvulae*) is not a single muscle, as would be inferred from its name, but a pair of narrow cylindrical fleshy fasciculi placed on either side of the median line of the soft palate. Each muscle *arises* from the posterior nasal spine of the palate bone and from the contiguous tendinous aponeurosis of the soft palate, and descends to be *inserted* into the uvula.

Relations.—*Anteriorly*, with the tendinous expansion of the Levatores palati; *posteriorly*, with the posterior fasciculus of the Palatopharyngeus and the mucous membrane.

The next two muscles are exposed by removing the mucous membrane from the pillars of the fauces throughout nearly their whole extent.

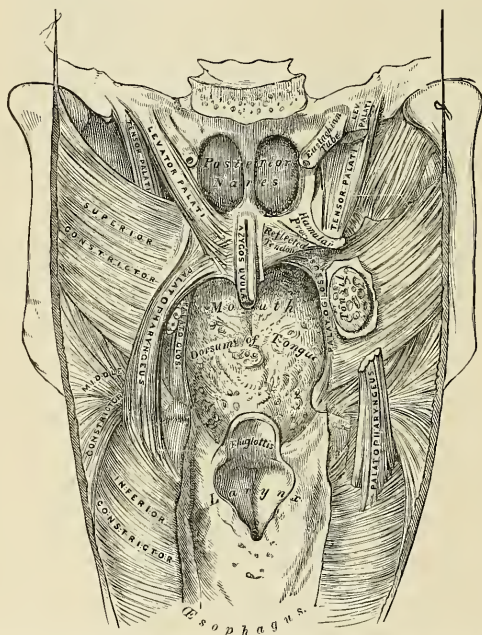


FIG. 306.—Muscles of the soft palate, the pharynx being laid open from behind and mucous membrane removed.

The **Palatoglossus** (*m. glossopalatinus*) is a small fleshy fasciculus, narrower in the middle than at either extremity, forming, with the mucous membrane covering its surface, the anterior pillar of the soft palate. It *arises* from the anterior surface of the soft palate on each side of the uvula, and, passing downward, forward, and outward in front of the tonsil, is *inserted* into the side of the tongue, some of its fibres spreading over the dorsum, and others passing deeply into the substance of the organ to intermingle with the Transverse lingualis. In the soft palate the fibres of this muscle are continuous with those of the muscle of the opposite side.

The **Palatopharyngeus** (*m. pharyngopalatinus*) is a long, fleshy fasciculus, narrower in the middle than at either extremity, forming, with the mucous,

membrane covering its surface, the posterior pillar of the soft palate. It is separated from the Palatoglossus by an angular interval, in which the tonsil is lodged. It *arises* from the soft palate by an expanded fasciculus, which is divided into two parts by the Levator palati and Azygos uvulae. The **posterior fasciculus** lies in contact with the mucous membrane, and also joins with the corresponding muscle in the middle line; the **anterior fasciculus**, the thicker, lies in the soft palate between the Levator and Tensor, and joins in the middle line the corresponding part of the opposite muscle. Passing outward and downward behind the tonsil, the Palatopharyngeus joins the Stylopharyngeus, and is *inserted* with that muscle into the posterior border of the thyroid cartilage, some of its fibres being lost on the side of the pharynx, and others passing across the middle line posteriorly to decussate with the muscle of the opposite side.

Relations.—In the soft palate its *posterior surface* is covered by mucous membrane, from which it is separated by a layer of palatal glands. By its *anterior surface* it is in relation with the Tensor palati. Where it forms the posterior pillar of the fauces it is covered by mucous membrane, excepting on its outer surface. In the *pharynx* it lies between the mucous membrane and the Constrictor muscles.

The **Salpingopharyngeus** (*m. salpingopharyngeus*) *arises* from the inferior part of the Eustachian tube near its orifice; it passes downward and blends with the posterior fasciculus of the Palatopharyngeus.

In a dissection of the soft palate from its posterior or nasal surface to its anterior or oral surface, the muscles would be exposed in the following order—viz., the posterior fasciculus of the Palatopharyngeus, covered over by the mucous membrane reflected from the floor of the nasal fossæ; the Azygos uvulae; the Levator palati; the anterior fasciculus of the Palatopharyngeus; the aponeurosis of the Tensor palati, and the Palatoglossus, covered over by a reflection from the oral mucous membrane.

Nerves.—The Tensor palati is supplied by a branch from the otic ganglion; the remaining muscles of this group are in all probability supplied by the internal branch of the spinal accessory, the fibres of which are distributed along with certain branches of the vagus through the pharyngeal plexus.¹

Actions.—During the *first stage* of deglutition the bolus of food is driven back into the fauces by the pressure of the tongue against the hard palate; the base of the tongue is, at the same time, retracted, and the larynx is raised with the pharynx, and carried forward under it. During the *second stage* the entrance to the larynx is closed, not, as was formerly supposed, by the folding backward of the epiglottis over it, but, as Anderson Stuart has shown, by the drawing forward of the arytenoid cartilages toward the cushion of the epiglottis—a movement produced by the contraction of the outer portion of the Thyroarytenoid, the Arytenoid, and Aryteno-epiglottidean muscles.

The bolus of food after leaving the tongue passes on to the posterior or laryngeal surface of the epiglottis, and glides along this for a certain distance;² then the Palatoglossi muscles, the constrictors of the fauces, contract behind the food; the soft palate is slightly raised by the Levatores palati, and made tense by the Tensores palati; and the Palatopharyngei, by their contraction, pull the pharynx upward over the bolus of food, and at the same time come nearly together, the uvula filling up the slight interval between them. By these means the food is prevented from passing into the upper part of the larynx or the posterior nares; at the same time the latter muscles form an inclined plane, directed obliquely downward and backward, along the under surface of which the bolus descends into the lower part of the pharynx. Each Salpingopharyngeus raises the upper and lateral part of the pharynx—*i. e.*, that part which is above the point where the Stylopharyngeus is attached to the pharynx.

Applied Anatomy.—After operation for cleft palate the Tensor palati and Levator palati retard union by causing undue tension along the line of suture. In order to overcome this it is necessary to divide these muscles, and this is done by making longitudinal incisions on either side, parallel to the cleft and just internal to the hamular process, in such a position as to avoid the posterior palatine artery.

¹ Journal of Anatomy and Physiology, vol. xxiii, p. 523.

² We now know that normal deglutition can be carried out when the epiglottis is so small that it cannot cover the opening into the larynx, or when it has been removed surgically. In such cases the sphincter muscles which surround the laryngeal aperture contract during swallowing and prevent the entrance of foreign bodies into the larynx.

7. The Anterior Vertebral Region (Fig. 307).

Rectus capitis anticus major.
Rectus capitis anticus minor.

Rectus capitis lateralis.
Longus colli.

The **Rectus capitis anticus major** (*m. longus capitis*), broad and thick above and narrow below, appears like a continuation upward of the *Scalenus anticus*. It *arises* by four tendinous slips from the anterior tubercles of the transverse processes of the third, fourth, fifth, and sixth cervical vertebræ, and ascends, converging toward its fellow of the opposite side, to be *inserted* into the basilar process of the occipital bone.

Relations.—By its *anterior surface*, this muscle is in relation with the pharynx, the inferior cervical sympathetic ganglion and nerve, and the sheath enclosing the internal and common carotid artery, internal jugular vein, and vagus nerve; by its *posterior surface*, with the *Longus colli*, the *Rectus capitis anticus minor*, and the upper cervical vertebræ.

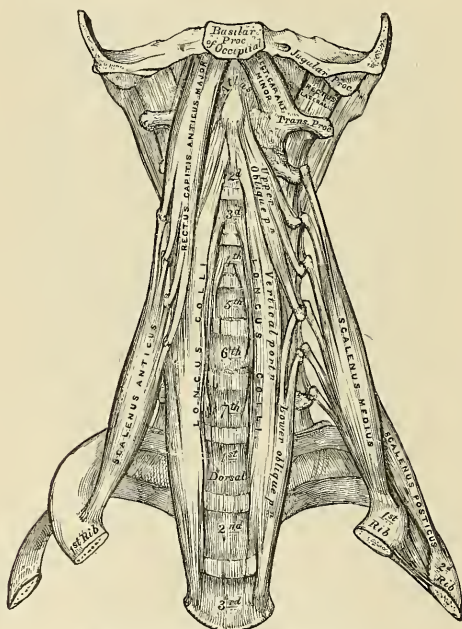


FIG. 307.—The prevertebral muscles (ventral view).

The **Rectus capitis anticus minor** (*m. rectus capitis anterior*) is a short, flat muscle, situated immediately behind the upper part of the preceding. It *arises* from the anterior surface of the lateral mass of the atlas and from the root of its transverse process, and, passing obliquely upward and inward, is *inserted* into the basilar process immediately behind the rectus capitis anticus major.

The **Rectus capitis lateralis** (*m. rectus capitis lateralis*) is a short, flat muscle, which *arises* from the upper surface of the transverse process of the atlas and is

inserted into the under surface of the jugular process of the occipital bone. This muscle lies behind the internal jugular vein, and in front of the upper portion of the vertebral artery.

The **Longus colli** (*m. longus colli*) is a long, flat muscle, situated on the anterior surface of the vertebral column, between the atlas and the third thoracic vertebra. It is broad in the middle, narrow and pointed at each extremity, and consists of three portions—a superior oblique, an inferior oblique, and a vertical portion. The **superior oblique portion** *arises* from the anterior tubercles of the transverse processes of the third, fourth, and fifth cervical vertebrae, and, ascending obliquely inward, is *inserted* by a narrow tendon into the tubercle on the anterior arch of the atlas. The **inferior oblique portion**, the smallest part of the muscle, *arises* from the front of the bodies of the first two or three thoracic vertebrae, and, ascending obliquely outward, is *inserted* into the anterior tubercles of the transverse processes of the fifth and sixth cervical vertebrae. The **vertical portion** lies directly on the front of the vertebral column; it *arises*, below, from the front of the bodies of the upper three thoracic and lower three cervical vertebrae, and is *inserted* above into the front of the bodies of the second, third, and fourth cervical vertebrae.

Relations.—By its *superficial surface*, with the prevertebral fascia, the pharynx, œsophagus, sympathetic nerve, the sheath of the great vessels of the neck, the inferior thyroid artery, and the recurrent laryngeal nerve; by its *deep surface*, with the cervical and thoracic portions of the vertebral column. Its *inner border* is separated from the opposite muscle by a considerable interval below, but they approach each other above.

Nerves.—The Rectus capitis anticus minor and the Rectus lateralis are supplied from the loop between the first and second cervical nerves; the Rectus capitis anticus major, by branches from the second, third, and fourth cervical; the Longus colli, by branches from the second to the seventh cervical nerves.

Actions.—The Rectus anticus major and minor are the direct antagonists of the muscles at the back of the neck, serving to restore the head to its natural position after it has been drawn backward. These muscles also serve to flex the head, and, from their obliquity, rotate it, so as to turn the face to one or the other side. The Longus colli flexes and slightly rotates the cervical portion of the vertebral column.

8. The Lateral Vertebral Region (Figs. 307, 308).

Scalenus anticus.

Scalenus medius.

Scalenus posticus.

The **Scalenus anticus** (*m. scalenus anterior*) is a conical-shaped muscle, situated deeply at the side of the neck, behind the Sternomastoid. It *arises* from the anterior tubercles of the transverse processes of the third, fourth, fifth, and sixth cervical vertebrae, and, descending almost vertically, is *inserted* by a narrow, flat tendon into the scalene tubercle on the inner border and upper surface of the first rib. The lower part of this muscle separates the subclavian artery and vein, the latter being in front, and the former, with the brachial plexus, behind.

Relations.—By its *superficial surface*, this muscle is in relation with the clavicle, the Subclavius, Sternomastoid, and Omohyoid muscles, the transversalis colli, and the suprascapular arteries, the subclavian vein, and the phrenic nerve; by its *deep surface*, with the Scalenus medius, pleura, subclavian artery, and brachial plexus of nerves. It is separated from the Longus colli, on the inner side, by the vertebral artery. On the anterior tubercles of the transverse processes of the cervical vertebrae, between the attachments of the Scalenus anticus and Longus colli lies the ascending cervical branch of the inferior thyroid artery.

The **Scalenus medius** (*m. scalenus medius*), the largest and longest of the three Scaleni, *arises* from the posterior tubercles of the transverse processes of the lower six cervical vertebrae, and, descending along the side of the vertebral column,

is *inserted* by a broad attachment into the upper surface of the first rib, behind the groove for the subclavian artery, as far back as the tubercle. It is separated from the *Scalenus anticus* by the subclavian artery below and by the cervical nerves above. The posterior thoracic, or nerve of Bell, is formed in the substance of the *Scalenus medius* and emerges from it. The nerve to the Rhomboids also pierces it.

Relations.—By its *superficial surface*, with the *Sternomastoid*; it is crossed by the clavicle, the *Omohyoid* muscle, subclavian artery, and cervical nerves. To its *outer side* is the *Levator anguli scapulae* and the *Scalenus posticus* muscle.

The ***Scalenus posticus*** (*m. scalenus posterior*), the smallest of the three *Scaleni*, arises, by two or three separate tendons, from the posterior tubercles of the transverse processes of the lower two or three cervical vertebræ, and, diminishing as it descends, is *inserted* by a thin tendon into the outer surface of the second rib, behind the attachment of the *Serratus magnus*. This is the most deeply placed of the three *Scaleni*, and is occasionally blended with the *Scalenus medius*.

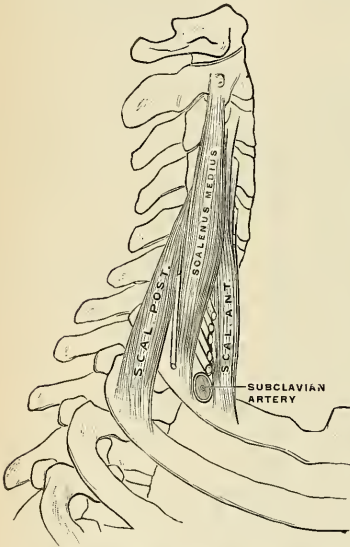


FIG. 308.—Scaleni muscles. (Poirier and Charpy.)

Nerves.—The *Scalenus anticus* receives branches from the fourth to the seventh cervical; the *Scalenus medius* from the third to the eighth cervical; and the *Scalenus posticus*, from the fourth to the eighth cervical nerves.

Actions.—The *Scaleni* muscles, when they take their fixed point from above, elevate the first and second ribs, and are, therefore, inspiratory muscles. When they take their fixed point from below, they bend the vertebral column to one or the other side. If the muscles of both sides act, lateral movement is prevented, but the vertebral column is slightly flexed. The *Rectus lateralis*, acting on one side, bends the head laterally.

Surface Form.—The muscles in the neck, with the exception of the *Platysma*, are invested by the deep cervical fascia, which softens down their form, and is of considerable importance in connection with deep cervical abscesses and tumors, modifying the direction of the growth of tumors and of the enlargement of abscesses, and causing them to extend laterally instead

of toward the surface. The *Platysma* does not influence surface form except when in action, when it produces wrinkling of the skin of the neck, which is thrown into oblique ridges parallel with the fasciculi of the muscle. Sometimes this contraction takes place suddenly and repeatedly as a sort of spasmodic twitching, the result of a nervous habit. The *Sternomastoid* is the most important muscle of the neck as regards its surface form. If the muscle is put into action by drawing the chin downward and to the opposite shoulder, its surface form will be plainly outlined. The sternal origin will stand out as a sharply defined ridge, while the clavicular origin will present a flatter and not so prominent outline. The fleshy middle portion will appear as an oblique roll or elevation, with a thick, rounded anterior border gradually becoming less marked above. On the opposite side—*i. e.*, on the side to which the head is turned—the outline is lost, its place being occupied by an oblique groove in the integument. When the muscle is at rest its anterior border is still visible, forming an oblique rounded ridge, terminating below in a sharp outline of the sternal head. The posterior border of the muscle does not show above the clavicular head. The anterior border is defined by drawing a line from the tip of the mastoid process to the sternoclavicular joint. It is an important surface-marking in the operation

of ligation of the common carotid artery and in some other operations. Between the sternal and clavicular heads is a slight depression, most marked when the muscle is in action. This is bounded below by the prominent sternal extremity of the clavicle. Between the sternal origins of the two muscles is a V-shaped space, the *suprasternal notch*, more pronounced below, and becoming toned down above, where the Sternohyoid and Sternotheroid muscles, lying upon the trachea, become more prominent. Above the hyoid bone, in the middle line, the anterior belly of the *Digastric* to a certain extent influences surface form. It corresponds to a line drawn from the symphysis of the mandible to the side of the body of the hyoid bone, and renders convex this part of the hyomental region. In the posterior triangle of the neck, the posterior belly of the *Omo-hyoid*, when in action, forms a conspicuous object, especially in thin necks, presenting a cord-like form running across this region, almost parallel with, and a little above, the clavicle.

MUSCLES AND FASCIÆ OF THE TRUNK.

The muscles of the Trunk may be arranged in four groups, corresponding with the region in which they are situated.

- I. The Back.
- II. The Thorax.

- III. The Abdomen.
- IV. The Perineum.

I. MUSCLES OF THE BACK.

The muscles of the back are very numerous, and may be subdivided into five layers:

FIRST LAYER.

Trapezius.
Latissimus dorsi.

Longissimus dorsi.
Spinalis dorsi.

Cervical Region.

SECOND LAYER.

Levator anguli scapulae.
Rhomboides minor.
Rhomboides major.

Cervicalis ascendens.
Transversalis cervicis.
Trachelomastoid.
Complexus.
Biventer cervicis.
Spinalis colli.

THIRD LAYER.

Serratus posticus superior.
Serratus posticus inferior.
Splenius capitis.
Splenius colli.

FIFTH LAYER.

Semispinalis dorsi.
Semispinalis colli.
Multifidus spinæ.
Rotatores spinæ.
Supraspinales.
Interspinales.
Extensor coccygis.
Intertransversalis.
Rectus capitis posticus major.
Rectus capitis posticus minor.
Obliquus capitis inferior.
Obliquus capitis superior.

FOURTH LAYER.

Sacral and Lumbar Regions.

Erector spinæ

Dorsal Region.

Iliocostalis.
Musculus accessorius ad iliocostalem

The First Layer (Fig. 310).

Trapezius.

Latissimus dorsi.

Dissection (Fig. 309).—Place the body in a prone position, with the arms extended over the sides of the table, and the thorax and abdomen supported by several blocks, so as to render the muscles tense. Then make an incision along the middle line of the back from the occipital protuberance to the coccyx. Make a transverse incision from the upper end of this to the mastoid process, and a third incision from its lower end, along the crest of the ilium to about its middle. This large intervening space should, for convenience of dissection, be subdivided by a fourth incision, extending obliquely from the spinous process of the last thoracic vertebra, upward and outward, to the acromion process. This incision corresponds with the lower border of the Trapezius muscle. The flaps of integument are then to be removed in the direction shown in the figure.

The **superficial fascia** is exposed upon removing the skin from the back. It forms a layer of considerable thickness and strength, in which a quantity of granular pinkish fat is contained. It is continuous with the superficial fascia in other parts of the body.

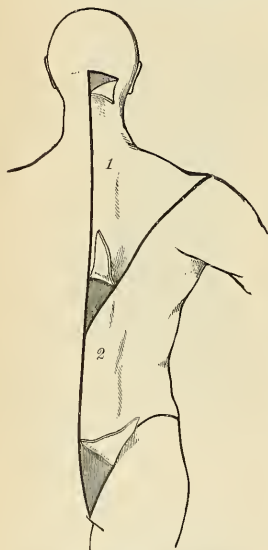


FIG. 309.—Dissection of the muscles of the back.

The **deep fascia** is a dense fibrous layer attached to the occipital bone, the spines of the vertebrae, the crest of the ilium, and the spine of the scapula. It covers over the superficial muscles, forming sheaths for them, and in the neck forms the posterior part of the deep cervical fascia; in the thorax it is continuous with the deep fascia of the axilla and thorax, and in the abdomen with that covering the abdominal muscles. In the back of the thoracic region the deep fascia is called the **vertebral aponeurosis**. It covers the Erector spinae muscles, and is the dorsal layer of the lumbar fascia.

The **Trapezius** (*m. trapezius*) is a broad, flat, triangular muscle, placed immediately beneath the skin and fascia, and covering the upper and back part of the neck and shoulders. It *arises* from the external occipital protuberance and the inner third of the superior curved line of the occipital bone; from the ligamentum nuchae, the spinous process of the seventh cervical, and the spinous processes of all the thoracic vertebrae; and from the corresponding portion of the supraspinous ligament. From this origin the superior fibres proceed downward and outward, the inferior ones upward and outward, the middle fibres horizontally, and are *inserted*, the superior ones into the outer third of the posterior border of the clavicle and into the adjacent part of its upper surface. The middle fibres pass into the inner margin of the acromion process, and into the superior lip of the posterior border or crest of the spine of the scapula; the inferior fibres converge near the scapula, and terminate in a triangular aponeurosis, which glides over a smooth surface at the inner extremity of the spine, to be *inserted* into a tubercle at the outer part of this smooth surface. The Trapezius is fleshy in the greater part of its extent, but tendinous at its origin and insertion. At its occipital origin

it is connected to the bone by a thin fibrous lamina, firmly adherent to the skin, and wanting the lustrous, shining appearance of aponeuroses. At its origin from the spines of the vertebrae it is connected to the bones by means of a broad semi-elliptical aponeurosis, which occupies the space between the sixth cervical and the third thoracic vertebrae, and forms, with the aponeurosis of the opposite muscle, a tendinous ellipse. The rest of the muscle arises by numerous short tendinous fibres. If the Trapezius is dissected on both sides, the two muscles resemble a trapezium or diamond-shaped quadrangle; two angles corresponding to the shoulders; a third to the occipital protuberance; and the fourth to the spinous process of the last thoracic vertebra. The clavicular insertion of this muscle varies as to the extent of its attachment; it sometimes advances as far as the middle of the clavicle, and may even become blended with the posterior edge of the Sternomastoid or may overlap it. This should be borne in mind in the operation for tying the third part of the subclavian artery.

Relations.—By its *superficial surface*, the Trapezius is in relation with the integument; by its *deep surface*, in the neck, with the Complexus, Splenius, Levator anguli scapulae, and Rhomboideus minor; in the back, with the Rhomboideus major, Supraspinatus, Infraspinatus, and vertebral aponeurosis (which separates it from the prolongations of the Erector spinae), and the Latissimus dorsi. The spinal accessory nerve and the superficial cervical artery and branches from the third and fourth cervical nerves pass beneath the anterior border of this muscle. The anterior margin of its cervical portion forms the posterior boundary of the posterior triangle of the neck, the other boundaries being the Sternomastoid in front and the clavicle below.

The **Ligamentum nuchae** (Fig. 310) is a fibrous membrane, which, in the neck, represents the supraspinous and interspinous ligaments of the lower vertebrae. It extends from the external occipital protuberance to the spinous process of the seventh cervical vertebra. From its anterior border a fibrous lamina (*fascia nuchae*) is given off, which is attached to the external occipital crest, the posterior tubercle of the atlas, and the spinous process of each of the cervical vertebrae, so as to form a septum between the muscles on each side of the neck. In man it is merely the rudiment of an important elastic ligament, which, in some of the lower animals, serves to sustain the weight of the head.

The **Latissimus dorsi** (*m. latissimus dorsi*) is a broad, flat muscle, which covers the lumbar and the lower half of the thoracic regions, and is gradually contracted into a narrow fasciculus at its insertion into the humerus. It *arises* by tendinous fibres from the spinous processes of the six inferior thoracic vertebrae and from the dorsal layer of the lumbar fascia (see page 410), by which it is attached to the spines of the lumbar and sacral vertebrae and to the supraspinous ligament. It also *arises* from the external lip of the crest of the ilium, behind the insertion of the External oblique muscle, and by fleshy digitations from the three or four lower ribs, which are interposed between similar processes of the External oblique (Fig. 317, page 425). From this extensive origin the fibres pass in different directions, the upper ones horizontally, the middle obliquely upward, and the lower vertically upward, so as to converge and form a thick fasciculus, which crosses the inferior angle of the scapula, and which usually receives a few fibres of origin from it. The muscle curves around the lower border of the Teres major, and is twisted upon itself so that the superior fibres become at first posterior and then inferior, and the vertical fibres at first anterior and then superior. It terminates in a short quadrilateral tendon, about three inches in length, which, passing in front of the tendon of the Teres major, is *inserted* into the bottom of the bicipital groove of the humerus, its insertion extending higher on the humerus than that of the tendon of the Pectoralis major. The lower border of the tendon of this muscle is united with that of the Teres major, the surfaces of the two being separated near their insertions by a bursa; another bursa is sometimes interposed

between the muscle and the inferior angle of the scapula. This muscle at its insertion gives off an expansion to the deep fascia of the arm.

A fleshy slip, the **axillary arch**, varying from 3 to 4 inches in length, and from $\frac{1}{4}$ to $\frac{3}{4}$ of an inch in breadth, occasionally arises from the upper edge of the Latissimus dorsi about the middle of the posterior fold of the axilla, and crosses the axilla in front of the axillary vessels and nerves, to join the under surface of the tendon of the Pectoralis major, the Coracobrachialis, or the fascia over the Biceps. The position of this abnormal slip is a point of interest in its relation to the axillary artery, as it crosses the vessel just above the spot usually selected for the application of a ligature, and may mislead the surgeon during the operation. It may be easily recognized by the transverse direction of its fibres. Dr. Struther found it, in 8 out of 105 subjects, occurring seven times on both sides. In most subjects there is a fibrous axillary arch, in only a few is the arch composed of muscle tissue.

There is usually a fibrous slip which passes from the lower border of the tendon of the Latissimus dorsi, near its insertion, to the long head of the Triceps. This is occasionally fleshy, and is the representative of the *Dorso-epitrochlearis* muscle of apes.

Relations.—The *superficial surface* of the Latissimus dorsi is subcutaneous, excepting at its upper part, where it is covered by the Trapezius, and at its insertion, where its tendon is crossed by the axillary vessels and the brachial plexus of nerves. By its *deep surface* it is in relation with the lumbar fascia, the Serratus posticus inferior, the lower External intercostal muscles and ribs, the inferior angle of the scapula, Rhomboideus major, Infraspinatus, and Teres major muscles. Its outer margin is separated below from the External oblique by a small triangular interval, the **triangle of Petit** (*trigonum lumbale* [Petiti]); and another triangular interval exists between its upper border and the margin of the Trapezius in which the Rhomboideus major muscle is exposed.

Nerves.—The Trapezius is supplied by the spinal accessory, and by branches from the anterior divisions of the third and fourth cervical nerves; the Latissimus dorsi by the sixth, seventh and eighth cervical nerves through the middle or long subscapular nerve.

The Second Layer (Fig. 310).

Levator anguli scapulae.

Rhomboideus minor.

Rhomboideus major.

Dissection.—The Trapezius must be removed, in order to expose the next layer; to effect this, detach the muscle from its attachment to the clavicle and spine of the scapula, and turn it back toward the vertebral column.

The **Levator anguli scapulae** (*m. levator scapulae*) is situated at the back part and side of the neck. It *arises* by tendinous slips from the transverse process of the atlas, and from the posterior tubercles of the transverse processes of the second, third, and fourth cervical vertebræ; these, becoming fleshy, are united so as to form a flat muscle, which, passing downward and backward, is *inserted* into the posterior border of the scapula, between the superior angle and the triangular smooth surface at the root of the spine.

The **Rhomboideus minor** (*m. rhomboideus minor*) *arises* from the ligamentum nuchæ and spinous processes of the seventh cervical and first thoracic vertebræ. Passing downward and outward, it is *inserted* into the margin of the triangular smooth surface at the root of the spine of the scapula. This small muscle is usually separated from the Rhomboideus major by a slight cellular interval.

The **Rhomboideus major** (*m. rhomboideus major*) is situated immediately below the preceding, the adjacent margins of the two being occasionally united. It *arises* by tendinous fibres from the spinous processes of the four or five upper thoracic vertebræ and the supraspinous ligament, and is inserted into a narrow tendinous arch attached above to the lower part of the triangular surface at the root of the spine; below, to the inferior angle, the arch being connected to the border of the scapula by a thin membrane. When the arch extends, as it occasionally does, a short distance, the muscle fibres are *inserted* into the scapula itself.

Nerves.—The Rhomboid muscles are supplied by branches from the anterior division of the fifth cervical nerve; the Levator anguli scapulae, by the anterior divisions of the third and fourth cervical nerves, and frequently by a branch from the nerve to the Rhomboids.

Actions.—The movements effected by the preceding muscles are numerous, as may be conceived from their extensive attachment. The whole of the Trapezius when in action retracts the scapula and braces back the shoulder; if the head is fixed, the upper part of the Trapezius will elevate the point of the shoulder, as in supporting weights; when the lower fibres are brought into action, they assist in depressing the bone. The middle and lower fibres of the muscle rotate the scapula, causing elevation of the acromion process. If the shoulders are fixed, both Trapezii, acting together, will draw the head directly backward; or if only one acts the head is drawn to the corresponding side. The Latissimus dorsi, when it acts upon the humerus, depresses it, draws it backward, adducts, and at the same time rotates it inward. It is the muscle which is principally employed in giving a downward blow, as in felling a tree or in sabre practice. If the arm is fixed, the muscle may act in various ways upon the trunk; thus, it may raise the lower ribs and assist in forcible inspiration; or, if both arms are fixed, the two muscles may assist the Abdominal and great Pectoral muscles in suspending and drawing the whole trunk forward, as in climbing or walking on crutches. The Levator anguli scapulae raises the superior angle of the scapula, and by so doing depresses the point of the shoulder. It assists the Trapezius in bearing weights and in shrugging the shoulders. If the shoulder be fixed, the Levator anguli scapulae inclines the neck to the corresponding side and rotates it in the same direction. The Rhomboid muscles carry the inferior angle backward and upward, thus producing a slight rotation of the scapula upon the side of the thorax, the Rhomboideus major acting especially on the lower angle of the scapula through the tendinous arch by which it is inserted. The Rhomboid muscles, acting together with the middle and inferior fibres of the Trapezius, will draw the scapula directly backward toward the vertebral column.

The Third Layer.

Serratus posticus superior.

Serratus posticus inferior.

Splenius { Splenius capitis.
 { Splenius colli.

Dissection.—To bring into view the third layer of muscles, remove the whole of the second, together with the Latissimus dorsi, by cutting through the Levator anguli scapulae and Rhomboid muscles near their origin, and reflecting them downward, and by dividing the Latissimus dorsi in the middle by a vertical incision carried from its upper to its lower part, and reflecting the two halves of the muscle.

The **Serratus posticus superior** (*m. serratus posterior superior*) is a thin, flat quadrilateral muscle situated at the upper and back part of the thorax. It arises by a thin and broad aponeurosis from the ligamentum nuchae, and from the spinous processes of the last cervical and two or three upper thoracic vertebrae and from the supraspinous ligament. Inclining downward and outward, it becomes muscular, and is inserted, by four fleshy digitations, into the upper borders of the second, third, fourth, and fifth ribs, a little beyond their angles.

The **Serratus posticus inferior** (*m. serratus posterior inferior*) (Fig. 310) is situated at the junction of the thoracic and lumbar regions; it is of an irregularly quadrilateral form, broader than the preceding, and separated from it by a considerable interval. It arises by a thin aponeurosis from the spinous processes of the last two thoracic and two or three upper lumbar vertebrae, and from the supraspinous ligaments. Passing obliquely upward and outward, it becomes fleshy, and divides into four flat digitations, which are inserted into the lower borders of the four lower ribs, a little beyond their angles. The thin aponeurosis of origin is intimately blended with the lumbar fascia.

The **vertebral aponeurosis** is a thin, fibrous lamina, extending along the whole length of the back part of the thoracic region, serving to bind down the long Extensor muscles of the back which support the vertebral column and head, and separate them from those muscles which connect the vertebral column to the upper

extremity. It consists of longitudinal and transverse fibres blended together, forming a thin lamella, which is attached, in the median line, to the spinous processes of the thoracic vertebræ; externally, to the angles of the ribs; and is continuous with the intercostal fascia. It is continuous below with the aponeurosis of the Serratus posticus inferior and a portion of the lumbar fascia, which gives origin to the Latissimus dorsi; above, it passes beneath the Serratus posticus superior and the Splenius, and blends with the deep fascia of the neck.

The **lumbar fascia or aponeurosis** (Figs. 310 and 325), which may be regarded as the posterior aponeurosis of the Transversalis abdominis muscle, consists of three laminae, which are attached as follows: The **dorsal layer**, to the spines of the lumbar and sacral vertebræ and their supraspinous ligaments; the **middle layer**, to the tips of the transverse processes of the lumbar vertebræ and their intertransverse ligaments; the **ventral layer**, to the roots of the lumbar transverse processes. The dorsal layer is continued above as the vertebral aponeurosis, while inferiorly it is fixed to the outer lip of the iliac crest. With this layer are blended the aponeurotic origin of the Serratus posticus inferior and part of that of the Latissimus dorsi. The middle layer is attached above to the last rib, and below to the iliac crest; the ventral layer is fixed below to the iliolumbar ligament and iliac crest; while above it is thickened to form the external arcuate ligament of the Diaphragm, and stretches from the tip of the last rib to the transverse process of the first or second lumbar vertebra. These three layers, together with the vertebral column, enclose two spaces, the posterior of which is occupied by the Erector spinae muscle, and the anterior by the Quadratus lumborum.

Now detach the Serratus posticus superior from its origin, and turn it outward, when the Splenius muscle will be brought into view.

The **Splenius muscle mass** (Fig. 310) is situated at the back of the neck and upper part of the thoracic region. At its origin it is a single muscle, which soon after its origin becomes broad, and divides into two portions, which have separate insertions. It *arises*, by tendinous fibres, from the lower half of the ligamentum nuchae, from the spinous processes of the last cervical and of the six upper thoracic vertebræ, and from the supraspinous ligament. From this origin the fleshy fibres proceed obliquely upward and outward, forming a broad, flat muscle sheet, which divides as it ascends into two portions, the **Splenius capitis** and **Splenius colli**.

The **Splenius capitis** (*m. splenius capitis*) is *inserted* into the mastoid process of the temporal bone, and into the rough surface on the occipital bone, just beneath the superior curved line.

The **Splenius colli** (*m. splenius cervicis*) is *inserted*, by tendinous fasciculi, into the posterior tubercles of the transverse processes of the two or three upper cervical vertebræ.

The Splenius muscles are separated from their fellows of the opposite side by a triangular interval, in which is seen the Complexus.

Nerves.—The Splenius capitis and colli muscles are supplied from the external branches of the posterior primary divisions of the middle and lower cervical nerves; the Serratus posticus superior is supplied by the external branches of the upper three or four intercostal nerves; the Serratus posticus inferior by branches of the ninth, tenth, and eleventh intercostal nerves.

Actions.—The Serrati are respiratory muscles. The Serratus posticus superior elevates the ribs; it is therefore an inspiratory muscle; while the Serratus inferior draws the lower ribs downward and backward, and thus elongates the thorax. It also fixes the lower ribs, thus aiding the downward action of the Diaphragm and resisting the tendency which it has to draw the lower ribs upward and forward. It must therefore be regarded as a muscle of inspiration. This muscle is also probably a tensor of the vertebral aponeurosis. The Splenii muscles of the two sides, acting together, draw the head directly backward, assisting the Trapezius and Complexus; acting separately, they draw the head to one or the other side, and slightly rotate it, turning the face to the same side. They also assist in supporting the head in the erect position.

The Fourth Layer (Fig. 311).

I. Erector spinae.

a. Outer Column.

Iliocostalis.

Musculus accessorius.

Cervicalis ascendens.

b. Middle Column

Longissimus dorsi.

Transversalis cervicis.

Trachelomastoid.

c. Inner Column.

Spinalis dorsi.

Spinalis colli.

II. Complexus.

Dissection.—To expose the muscles of the fourth layer, remove entirely the Serrati and the vertebral and lumbar fasciæ. Then detach the Splenius by separating its attachment to the spinous processes and reflecting it outward.

The **Erector spinae** (*m. sacrospinalis*) and its prolongations in the thoracic and cervical regions fill up the vertebral groove on each side of the vertebral column. It is covered in the lumbar region by the lumbar fascia; in the thoracic region, by the Serrati muscles and the vertebral aponeurosis; and in the cervical region, by a layer of cervical fascia continued beneath the Trapezius and the Splenius. This large muscular and tendinous mass varies in size and structure at different parts of the vertebral column. In the sacral region the Erector spinae is narrow and pointed, and its origin is chiefly tendinous in structure. In the lumbar region the muscle becomes enlarged, and forms a large, fleshy mass. In the thoracic region it subdivides into two parts, which gradually diminish in size as they ascend to be inserted into the vertebræ and ribs.

The Erector spinae arises from the anterior surface of a very broad and thick tendon, the *erector spinae aponeurosis*, which is attached, *internally*, to the spines of the sacrum, to the spinous processes of the lumbar and the eleventh and twelfth thoracic vertebræ, and to the supraspinous ligament; *externally*, to the back part of the inner lip of the crest of the ilium, and to the series of eminences on the posterior part of the sacrum, which represents the transverse processes, where it blends with the great sacrosciatic and posterior sacroiliac ligaments. Some of its fibres are continuous with the fibres of origin of the Gluteus maximus. The muscle fibres form a single large fleshy mass, bounded in front by the transverse processes of the lumbar vertebræ and by the middle lamella of the lumbar fascia. Opposite the last rib it divides into three parts: (1) The **Iliocostalis**; (2) the **Longissimus dorsi**; and (3) the **Spinalis dorsi**.

1. The **Iliocostalis** (*m. iliocostalis lumborum*), the external portion of the Erector spinae, is *inserted*, generally, by six or seven flattened tendons into the inferior borders of the angles of the six or seven lower ribs. The number of the tendons of this muscle is, however, quite variable, and therefore the number of ribs into which it is inserted varies. Internally this muscle is reinforced by a series of muscle slips which arise from the angles of the ribs; by means of these the Iliocostalis is continued upward to the upper ribs and to the cervical portion of the vertebral column. These accessory portions form two additional muscles, the **Musculus accessorius** and the **Cervicalis ascendens**.

The **Musculus accessorius** (*m. iliocostalis dorsi*) arises, by separate flattened tendons, from the upper borders of the angles of the six lower ribs; these become muscular, and are finally *inserted*, by separate tendons, into the upper borders of the angles of the six upper ribs and into the back of the transverse processes of the seventh cervical vertebra.

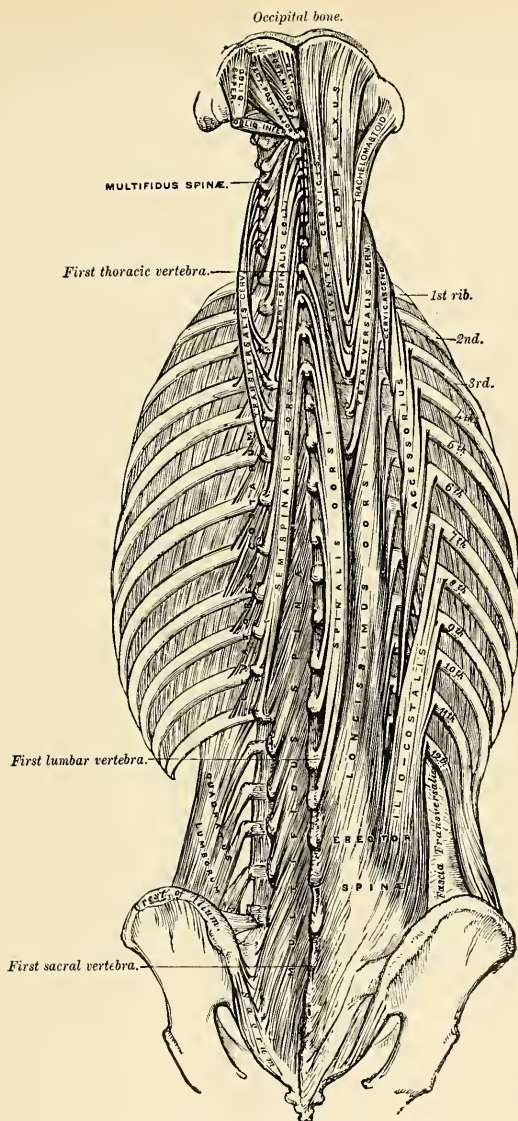


FIG. 311.—Muscles of the back, Deep layers.

The **Cervicalis ascendens** (*m. iliocostalis cervicis*) is the continuation of the Accessorius upward into the neck; it is situated on the inner side of the tendons of the Accessorius, *arising* from the angles of the four or five upper ribs, and is *inserted* by a series of slender tendons into the posterior tubercles of the transverse processes of the fourth, fifth, and sixth cervical vertebræ.

2. The **Longissimus dorsi** is the middle and largest portion of the Erector spinae. In the lumbar region, where it is as yet blended with the Iliocostalis, some of the fibres are attached to the whole length of the posterior surface of the transverse processes and the accessory processes of the lumbar vertebræ, and to the middle layer of the lumbar fascia. In the thoracic region the Longissimus dorsi is *inserted*, by long, thin tendons, into the tips of the transverse processes of all the thoracic vertebræ, and into from seven to eleven of the lower ribs between their tubercles and angles. This muscle is continued upward to the cranium and cervical portion of the vertebral column by means of two additional muscles, the **Transversalis cervicis** and **Trachelomastoid**.

The **Transversalis cervicis** (*m. longissimus cervicis*), placed on the inner side of the Longissimus dorsi, *arises* by long, thin tendons from the summits of the transverse processes of the six upper thoracic vertebræ, and is *inserted* by similar tendons into the posterior tubercles of the transverse processes of the cervical vertebræ, from the second to the sixth inclusive.

The **Trachelomastoid** (*m. longissimus capitis*) lies on the inner side of the preceding, between it and the Complexus muscle. It *arises*, by tendons, from the transverse processes of the five or six upper thoracic vertebræ, and the articular processes of the three or four lower cervical vertebræ. The fibres form a small muscle, which ascends to be *inserted* into the posterior margin of the mastoid process, beneath the Splenius and Sternomastoid muscles. This small muscle is almost always crossed by a tendinous intersection near its insertion into the mastoid process.¹

3. The **Spinalis dorsi** is situated at the inner side of the Longissimus dorsi, with which it is intimately blended. It *arises*, by three or four tendons, from the spinous processes of the first two lumbar and the last two thoracic vertebræ; these, uniting, form a small muscle, which is *inserted*, by separate tendons, into the spinous processes of the thoracic vertebræ, the number varying from four to eight. It is intimately united with the Semispinalis dorsi, which lies beneath it.

The **Spinalis colli** (*m. spinalis cervicis*) is a small muscle, connecting the spinous processes of the cervical vertebræ, and analogous to the Spinalis dorsi in the thoracic region. It varies considerably in its size and in the extent of its attachment to the vertebræ, not only in different bodies, but on the two sides of the same body. It usually *arises* by fleshy or tendinous slips, varying from two to four in number, from the spinous processes of the fifth, sixth, and seventh cervical vertebræ, and occasionally from the first and second thoracic, and is *inserted* into the spinous process of the axis, and occasionally into the spinous processes of the two vertebræ below it. This muscle was found absent in five cases out of twenty-four.

The **Complexus** (*m. semispinalis capitis*) is a broad thick muscle, situated at the upper and back part of the neck, beneath the Splenius, and internal to the Transversalis cervicis and Trachelomastoid. It *arises*, by a series of tendons, from the tips of the transverse processes of the upper six or seven thoracic and the last cervical vertebræ, and from the articular processes of the three cervical vertebræ above this. The tendons, uniting, form a broad muscle, which passes obliquely upward and inward, and is *inserted* into the innermost depression between the two curved lines of the occipital bone. At about its middle it is traversed

¹ These two muscles (Transversalis cervicis and Trachelomastoid) are sometimes described as one having a common origin, but dividing above at their insertion. The Trachelomastoid is then termed the *Transversalis capitis*.

by a transverse tendinous intersection. The inner portion of this muscle is usually separate and is called the **biventer cervicis**, from the intervention of a tendon between its two fleshy bellies.

The Fifth Layer (Fig. 311).

Semispinalis dorsi.	Extensor coccygis.
Semispinalis colli.	Intertransversales.
Multifidus spinæ.	Rectus capitis posticus major.
Rotatores spinæ.	Rectus capitis posticus minor.
Supraspinales.	Obliquus inferior.
Interspinales.	Obliquus superior.

Dissection.—Remove the muscles of the preceding layer by dividing and turning aside the Complexus; then detach the Spinalis and Longissimus dorsi from their attachments, divide the Erector spinæ at its connection below to the sacral lumbar vertebræ and turn it outward. The muscles filling up the interval between the spinous and transverse processes are then exposed.

The **Semispinalis dorsi** (*m. semispinalis dorsi*) consists of thin, narrow, fleshy fasciculi interposed between tendons of considerable length. It *arises* by a series of small tendons from the transverse processes of the lower thoracic vertebræ, from the tenth or eleventh to the fifth or sixth; and is *inserted*, by five or six tendons, into the spinous processes of the upper four thoracic and lower two cervical vertebræ.

The **Semispinalis colli** (*m. semispinalis cervicis*), thicker than the preceding, *arises* by a series of tendinous and fleshy fibres from the transverse processes of the upper five or six thoracic vertebræ, and is *inserted* into the spinous processes of four cervical vertebræ, from the axis to the fifth cervical. The fasciculus connected with the axis is the largest, and is chiefly muscular in structure.

Superficial to this muscle and the preceding are the profunda cervicis artery, the princeps cervicis artery, and the internal branches of the posterior divisions of the first, second, and third cervical nerves; their *deep surfaces* lie upon the Multifidus spinæ.

The **Multifidus spinæ** (*m. multifidus*) consists of a number of fleshy and tendinous fasciculi which fill up the groove on either side of the spinous processes of the vertebræ, from the sacrum to the axis. In the sacral region these fasciculi *arise* from the back of the sacrum, as low as the fourth sacral foramen, and from the aponeurosis of origin of the Erector spinæ; from the inner surface of the posterior superior spine of the ilium and posterior sacro-iliac ligaments; in the lumbar regions from the mammillary processes; in the thoracic region, from the transverse processes; and in the cervical region, from the articular processes of the three or four lower vertebræ. Each fasciculus, passing obliquely upward and inward, is *inserted* into the whole length of the spinous process of one of the vertebræ above. These fasciculi vary in length; the most superficial, the longest, pass from one vertebra to the third or fourth above; those next in order pass from one vertebra to the second or third above; while the deepest connect two contiguous vertebræ.

Its *superficial surface* is covered by the Semispinalis dorsi, and the Semispinalis colli, and its *deep surface*, lies upon the laminae and spinous processes of the vertebræ.

The **Rotatores spinæ** (*mm. rotatores*) are found only in the thoracic region of the spine, beneath the Multifidus spinæ; they are eleven in number on each side. Each muscle is small and somewhat quadrilateral in form; and *arises* from the

upper and back part of the transverse process, and is *inserted* into the lower border and outer surface of the lamina of the vertebra above, the fibres extending as far inward as the root of the spinous process. The first is found between the first and second thoracic; the last, between the eleventh and twelfth. Sometimes the number of these muscles is diminished by the absence of one or more from the upper or lower end.

The **Supraspinales** (*mm. supraspinales*) consist of a series of fleshy bands which lie on the spinous processes in the cervical region of the vertebral column.

The **Interspinales** (*mm. interspinales*) are short muscular fasciculi, placed in pairs between the spinous processes of the contiguous vertebrae, one on each side of the interspinous ligament. In the *cervical region* they are most distinct, and consist of *six* pairs, the first being situated between the axis and the third vertebra, and the last between the last cervical and the first thoracic vertebra. They are small narrow bundles, attached, above and below, to the apices of the spinous processes. In the *thoracic region* they are found between the first and second vertebrae, and occasionally between the second and third; and below, between the eleventh and twelfth. In the *lumbar region* there are *four* pairs of these muscles in the intervals between the five lumbar vertebrae. There is also occasionally one in the interspinous space between the last thoracic and first lumbar, and between the fifth lumbar and the sacrum.

The **Extensor coccygis** is a slender muscular fasciculus, occasionally present, which extends over the lower part of the posterior surface of the sacrum and coccyx. It *arises* by tendinous fibres from the last bone of the sacrum or first piece of the coccyx, and passes downward to be *inserted* into the lower part of the coccyx. It is a rudiment of the Extensor muscle of the caudal vertebrae of the lower animals.

The **Intertransversales** (*mm. intertransversarii*) are small muscles placed between the transverse processes of the vertebrae. In the *cervical region* they are most developed, consisting of rounded muscular and tendinous fasciculi, which are placed in pairs, passing between the anterior and the posterior tubercles of the transverse processes of two contiguous vertebrae, separated from one another by the anterior division of the cervical nerve, which lies in the groove between them. In this region there are *seven* pairs of these muscles, the first pair being between the atlas and axis, and the last pair between the seventh cervical and first thoracic vertebrae. In the *thoracic region* they are least developed, consisting chiefly of rounded tendinous cords in the intertransverse spaces of the upper thoracic vertebrae; but between the transverse processes of the lower three thoracic vertebrae, and between the transverse processes of the last thoracic and the first lumbar, they are muscular in structure. In the *lumbar region* they are arranged in pairs, on either side of the vertebral column, one set occupying the entire interspace between the transverse processes of the lumbar vertebrae, the **intertransversales laterales**; the other set, **intertransversales mediales**, passing from the accessory process of one vertebra to the mammillary process of the next below.

The **Rectus capitis posticus major** (*m. rectus capitis posterior major*) *arises* by a pointed tendinous origin from the spinous process of the axis, and, becoming broader as it ascends, is *inserted* into the inferior curved line of the occipital bone and the surface of bone immediately below it. As the muscles of the two sides pass upward and outward, they leave between them a triangular space, in which are seen the *Recti capitis postici minores* muscles. The *superficial surface* is crossed by the Complexus; its *deep surface* lies on the posterior occipito-atlantal ligament.

The **Rectus capitis posticus minor** (*m. rectus capitis posterior minor*), the smallest of the four muscles in this region, is of a triangular shape; it *arises* by a narrow pointed tendon from the tubercle on the posterior arch of the atlas, and, becoming broader as it ascends, is *inserted* into the rough surface beneath the inferior

curved line, nearly as far as the foramen magnum, and nearer to the middle line than the preceding.

The **Obliquus inferior** (*m. obliquus capitis inferior*), the larger of the two Oblique muscles, *arises* from the apex of the spinous process of the axis, and passes outward and slightly upward, to be *inserted* into the lower and back part of the transverse process of the atlas.

The **Obliquus superior** (*m. obliquus capitis superior*), narrow below, wide and expanded above, *arises* by tendinous fibres from the upper surface of the transverse process of the atlas; it joins with the insertion of the preceding, and, passing obliquely upward and inward, is *inserted* into the occipital bone, between the two curved lines, external to the Complexus.

The **Suboccipital triangle** is the triangular interval between the two oblique muscles and the Rectus capitis posterior major. This triangle is bounded, *above* and *internally*, by the Rectus capitis posterior major; *above* and *externally*, by the Obliquus superior; *below* and *externally*, by the Obliquus inferior. It is covered in by a layer of dense fibrofatty tissue, situated beneath the Complexus muscle. The *floor* is formed by the posterior occipito-atlantal ligament and the posterior arch of the atlas. It contains the vertebral artery, as it runs in a deep groove on the upper surface of the posterior arch of the atlas, and the posterior division of the suboccipital nerve.

Nerves.—The fourth and fifth layers of the muscles of the back are supplied by the posterior primary divisions of the spinal nerves.

Actions.—When both the Spinales dorsi contract, they extend the thoracic region of the vertebral column; when only one muscle contracts, it helps to bend the thoracic portion of the vertebral column to one side. The Erector spinae, comprising the Iliocostalis and the Longissimus dorsi with their accessory muscles, serves, as its name implies, to maintain the vertebral column in the erect posture; it also serves to bend the trunk backward when it is required to counterbalance the influence of any weight at the front of the body, as, for instance, when a heavy weight is suspended from the neck, or when there is any great abdominal distention, as in pregnancy or dropsy; the peculiar gait under such circumstances depends upon the vertebral column being drawn backward by the counterbalancing action of the Erector spinae muscles. The muscles which form the continuation of the Erector spinae upward steady the head and neck, and fix them in the upright position. If the Iliocostalis and Longissimus dorsi of one side act, they serve to draw down the thorax and vertebral column to the corresponding side. The Cervicales ascendens, taking their fixed points from the cervical vertebrae, elevate those ribs to which they are attached; taking their fixed points from the ribs, both muscles help to extend the neck; while one muscle bends the neck to its own side. The Transversales cervicis, when both muscles act, taking their fixed point from below, bend the neck backward. The Trachelomastoid, when both muscles act, taking their fixed point from below, bend the head backward; while if only one muscle acts, the face is turned to the side on which the muscle is acting, and then the head is bent to the shoulder. The two Recti muscles draw the head backward. The Rectus capitis posterior major, owing to its obliquity, rotates the cranium, with the atlas, around the odontoid process, turning the face to the same side. The Multifidus spinae acts successively upon the different parts of the vertebral column; thus, the sacrum furnishes a fixed point from which the fasciculi of this muscle act upon the lumbar region; these then become the fixed points for the fasciculi moving the thoracic region, and so on throughout the entire length of the vertebral column; it is by the successive contraction and relaxation of the separate fasciculi of this and other muscles that the spine preserves the erect posture without the fatigue that would necessarily have been produced had this position been maintained by the action of a single muscle. The Multifidus spinae, besides preserving the erect position of the vertebral column, serves to rotate it, so that the front of the trunk is turned to the side opposite to that from which the muscle acts, this muscle being assisted in its action by the Obliquus externus abdominis. The Complexi draw the head directly backward; if one muscle acts, it draws the head to one side, and rotates it so that the face is turned to the opposite side. The Superior oblique draws the head backward, and, from the obliquity in the direction of its fibres, will slightly rotate the cranium, turning the face to the opposite side. The Inferior oblique rotates the atlas, and with it the cranium, around the odontoid process, turning the face to the same side. The Semispinales, when the muscles of the two sides act together, help to extend the vertebral column; when the muscles of one side only act, they rotate the thoracic and cervical parts of the vertebral column, turning the body to the opposite side. The Supraspinales and Interspinales by approximating the spinous processes help to extend the vertebral column. The Intertransversales approximate the transverse processes, and help

to bend the vertebral column to one side. The *Rotatores spinæ* assist the *Multifidus spinæ* to rotate the vertebral column, so that the front of the trunk is turned to the side opposite to that from which the muscle acts.

Surface Forms.—The surface forms produced by the muscles of the back are numerous and difficult to analyze unless they are considered in systematic order. The most superficial layer, consisting of large strata of muscle tissue, influences to a certain extent the surface form, and at the same time reveals the forms of the layers beneath. The *Trapezius* at the upper part of the back, and in the neck, covers over and softens down the outline of the underlying muscles. Its anterior border forms the posterior boundary of the posterior triangle of the neck. It forms a slight undulating ridge which passes downward and forward from the occiput to the junction of the middle and outer third of the clavicle. The tendinous ellipse formed by a part of the origin of the two muscles at the back of the neck is always to be seen as an oval depression, more marked when the muscle is in action. A slight dimple on the skin opposite the interval between the spinous processes of the third and fourth thoracic vertebræ marks the triangular aponeurosis by which the inferior fibres are inserted into the root of the spine of the scapula. From this point the inferior border of the muscle may be traced as an undulating ridge to the spinous process of the twelfth thoracic vertebra. In like manner the *Latissimus dorsi* softens down and modulates the underlying structures at the lower part of the back and lower part of the side of the thorax. In this way it modulates the outline of the *Erector spinæ*; of the *Serratus posticus inferior*, which is sometimes to be discerned through it. The anterior border of the muscle is the only part which gives a distinct surface form. This border may be traced, when the muscle is in action, as a rounded edge, starting from the crest of the ilium, and passing obliquely forward and upward to the posterior border of the axilla, where it combines with the *Teres major* in forming a thick rounded fold, the posterior boundary of the axillary space. The muscles in the second layer influence to a very considerable extent the surface form of the back of the neck and upper part of the trunk. The *Levator anguli scapulae* reveals itself as a prominent divergent line, running downward and outward, from the transverse processes of the upper cervical vertebræ to the angle of the scapula, covered over and toned down by the overlying *Trapezius*. The *Rhomboidei* produce, when in action, a vertical eminence between the vertebral border of the scapula and the vertebral furrow, varying in intensity according to the condition of contraction or relaxation of the *Trapezius* muscle, by which they are for the most part covered. The lowermost part of the *Rhomboideus major* is not covered by the *Trapezius*, and forms on the surface an oblique ridge running upward and inward from the inferior angle of the scapula. Of the muscles of the third layer of the back, the *Serratus posticus superior* does not in any way influence surface form. The *Serratus posticus inferior*, when in strong action, may occasionally be revealed as an elevation beneath the *Latissimus dorsi*. The *Splenii* by their divergence serve to broaden out the upper part of the back of the neck and produce a local fulness in this situation, but do not otherwise influence surface form. Beneath all these muscles those of the fourth layer—the *Erector spinæ* and its continuations—influence the surface form in a decided manner. In the loins, the *Erector spinæ*, bound down by the lumbar fascia, forms a rounded vertical eminence, which determines the depth of the vertebral furrow, and which below tapers to a point on the posterior surface of the sacrum and becomes lost there. In the back it forms a flattened plane which gradually becomes lost. In the neck the only part of this group of muscles which influences surface form is the *Trachelomastoid*, which produces a short convergent line across the upper part of the posterior triangle of the neck, appearing from under cover of the posterior border of the *Sternomastoid* and being lost below beneath the *Trapezius*.

Applied Anatomy.—In cases of tuberculous caries of the vertebral bodies, and in other diseases affecting the vertebral column, rigidity of the spinal muscles is one of the earliest and most constant symptoms. A child with commencing vertebral disease always maintains the affected portion of the column in a state of absolute rigidity, to prevent the inflamed structures from being moved against each other; this is one of the best examples of nature's method of producing rest of the affected part.

II. MUSCLES AND FASCIÆ OF THE THORAX.

The muscles belonging exclusively to this region are few in number. They are the

Intercostales externi.
Intercostales interni.
Infracostales.

Triangularis sterni.
Levatores costarum.
Diaphragm.

Intercostal Fascia.—A thin but firm layer of fascia covers the outer surface of the External intercostal and the inner surface of the Internal intercostal muscles; and a third layer, more delicate, is interposed between the two planes of muscle fibres. These are the **intercostal fasciæ**, *external*, *middle*, and *internal*; they are best marked in those situations where the muscle fibres are deficient, as between the External intercostal muscles and sternum, in front, and between the Internal intercostals and vertebral column, behind.

The **Intercostal muscles** (Figs. 319 and 347) are two thin planes of muscle and tendon fibres, placed one over the other. They fill up the intercostal spaces, and are directed obliquely between the margins of the adjacent ribs. They have received the name **external** and **internal** from the position they bear to each other. Between them in the grooved under surface of the rib run the intercostal vessels and nerve. The tendon fibres are longer and more numerous than the muscle fibres; hence the walls of the intercostal spaces possess very considerable strength, to which the crossing of the muscle fibres materially contributes.

The **External intercostals** (*mm. intercostales externi*) are *eleven* in number on each side. They extend from the tubercles of the ribs, *behind*, to the commencement of the cartilages of the ribs, in *front*, where they terminate in a thin membrane, the *anterior intercostal membrane*, which is continued forward to the sternum. They *arise* from the lower border of the rib above, and are *inserted* into the upper border of the rib below. In the two lowest spaces they extend to the ends of the cartilages, and in the upper two or three spaces they do not quite extend to the ends of the ribs. Their fibres are directed obliquely downward and forward, in a similar direction with those of the External oblique muscle of the abdomen. They are thicker than the Internal intercostals.

The **Internal intercostals** (*mm. intercostales interni*) are also *eleven* in number on each side. They commence anteriorly at the sternum in the interspaces between the cartilage of the true ribs, and from the anterior extremities of the cartilages of the false ribs, and extend backward as far as the angles of the ribs, whence they are continued to the vertebral column by a thin aponeurosis, the *posterior intercostal membrane*. They *arise* from the ridge on the inner surface of the rib above, as well as from the corresponding costal cartilage, and are *inserted* into the upper border of the rib below. Their fibres are directed obliquely downward and backward, passing in the opposite direction to the fibres of the External intercostal muscle.

The **Infracostales** (*mm. subcostales*) consist of muscular and aponeurotic fasciculi, which vary in number and length; they are placed on the inner surface of the ribs, where the Internal intercostal muscles cease; they *arise* from the inner surface of one rib, and are *inserted* into the inner surface of the first, second, or third rib below. Their direction, like the Internal intercostals, is usually oblique. They are most frequently found between the lower ribs.

The **Triangularis sterni** (*m. transversus thoracis*) (Fig. 312) is a thin plane consisting of muscle and tendon fibres, and is situated upon the inner wall of the front of the thorax. It *arises* from the lower third of the posterior surface of the sternum, from the posterior surface of the ensiform cartilage, and from the sternal ends of the costal cartilages of the three or four lower true ribs. Its fibres diverge upward and outward, to be *inserted* by digitations into the lower borders and inner surfaces of the costal cartilages of the second, third, fourth, fifth, and sixth ribs. The lowest fibres of this muscle are horizontal in their direction, and are continuous with those of the Transversalis; those which succeed are oblique, while the superior fibres are almost vertical. This muscle varies much in its attachment, not only in different bodies, but on opposite sides of the same body. The internal mammary artery runs between this muscle and the costal cartilages.

The **Levatores costarum** (*mm. levatores costarum*) (Fig. 311), *twelve* in number on each side, are small tendinous and fleshy bundles which *arise* from the extrem-

ities of the transverse processes of the seventh cervical and the eleven upper thoracic vertebra. They pass obliquely downward and outward and are *inserted* into the upper border, between the tubercle and the angle of the rib, immediately below its vertebra of origin. In some instances the muscle divides into two fasciculi, one of which is inserted as above described; the other fasciculus passes down to the second rib below its origin.

Nerves.—The muscles of this group are supplied by the intercostal nerves.

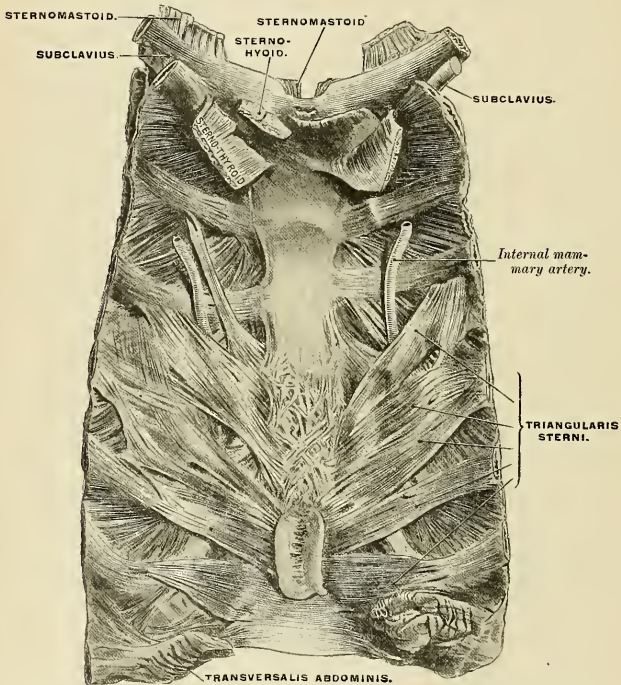


FIG. 312.—Posterior surface of sternum and costal cartilages, showing Triangularis sterni muscle. (From a preparation in the Museum of the Royal College of Surgeons of England.)

The **Diaphragm** (*diaphragma*) (Figs. 313 and 314) is a thin, musculo-fibrous septum placed at the junction of the upper with the middle third of the trunk; it separates the thoracic from the abdominal cavity, its convex upper surface forming the floor of the former, and its concave under surface the roof of the latter. Its peripheral part consists of muscle fibres which *arise* from the internal circumference of the thoracic outlet, as well as from certain lumbar vertebræ, and pass upward and inward to converge to a central tendon. *Anteriorly*, the Diaphragm *arises* from the dorsal surface of the ensiform cartilage by two fleshy strips (*pars sternalis*); on either side, from the inner surfaces of the six lower costal cartilages (seventh to twelfth) (*pars costalis*), interdigitating with slips of origin of the Transversalis abdominis. *Behind*, it takes *origin* from certain

lumbar vertebræ by two **crura**; and from aponeurotic arches named the **arcuate ligaments** (*pars lumbalis*).

The **crura** are situated on the bodies of the lumbar vertebræ, on each side of the aorta. The crura, at their origin, are tendinous in structure; the *right* crus, larger and longer than the left, *arises* from the anterior surface of the bodies and articular disks of the four upper lumbar vertebræ; the *left* crus *arises* from the three upper lumbar vertebræ; both blend with the anterior common ligament of the vertebral column.

The tendinous portion of each crus passes forward and inward to meet the corresponding portion of the opposite side, thus forming the tendinous arch known as the **middle arcuate ligament**. From this arch diverging muscle fibres *arise*, the outermost portion of which is directed upward and outward to the central tendon; the innermost portion decussate in front of the aorta, diverge in order to surround the œsophagus, and likewise end in the central tendon. The fibres derived from the right crus are the more numerous and pass in front of those derived from the left.

Each crus, in its tendinous portion, is perforated by the great and lesser splanchnic nerves and sometimes the ascending lumbar radicle of the azygos veins.

The **internal arcuate ligament** (*arcus lumbocostalis medialis*) is a tendinous arch in the fascia covering the upper part of the Psoas magnus muscle, on each side of the vertebral column. This tendinous arch is connected mesad to the body of the first (or second) lumbar vertebræ, laterad to the front of the tip of the transverse process of the first (or second) lumbar vertebræ.

The **external arcuate ligament** (*arcus lumbocostalis lateralis*) is the thickened upper margin of the anterior lamella of the lumbar fascia; it arches across the upper part of the Quadratus lumborum from the front of the transverse process of the first (or second) lumbar vertebra to the apex and lower margin of the twelfth rib.

The fibres of the Diaphragm derived from these sources vary in length; those arising from the ensiform cartilage are short and occasionally aponeurotic, continuous with the posterior layer of the Rectus abdominis sheath. Those arising from the arcuate ligaments, and more especially those from the cartilages of the ribs at the side of the thorax, are longer, describe well-marked curves as they ascend, and finally converge to be *inserted* into the margin of the central tendon.

The **central tendon of the Diaphragm** (*centrum tendineum*) (Fig. 314) is a thin but strong tendinous aponeurosis, situated at the centre of the vault formed by the muscle, immediately below the pericardium, with which it is partly blended. It is shaped somewhat like a trefoil leaf, consisting of three divisions, or leaflets, separated from one another by slight indentations. The right leaflet is the largest; the middle one, directed toward the ensiform cartilage, the next in size; and the left, the smallest. In structure, the tendon is composed of several planes of fibres which intersect one another at various angles, and unite into straight or curved bundles—an arrangement which affords it additional strength.

The **openings** in the Diaphragm are three large and several smaller apertures. The former are the aortic, the œsophageal, and the opening for the inferior vena cava.

The **aortic opening** (*hiatus aorticus*) is the lowest and the most posterior of the three large apertures connected with this muscle, being at the level of the first lumbar vertebra. It is situated slightly to the left of the middle line, immediately in front of the bodies of the vertebræ; and is, therefore, *behind* the Diaphragm, not in it. It is an osseaponeurotic aperture, formed by a tendinous arch (middle arcuate ligament) thrown across the front of the bodies of the vertebræ, from the crus on one side to that on the other, and it transmits the aorta, the vena azygos

major, and the thoracic duct. Sometimes the vena azygos major is transmitted upward through the right crus. Occasionally some tendinous fibres are pro-

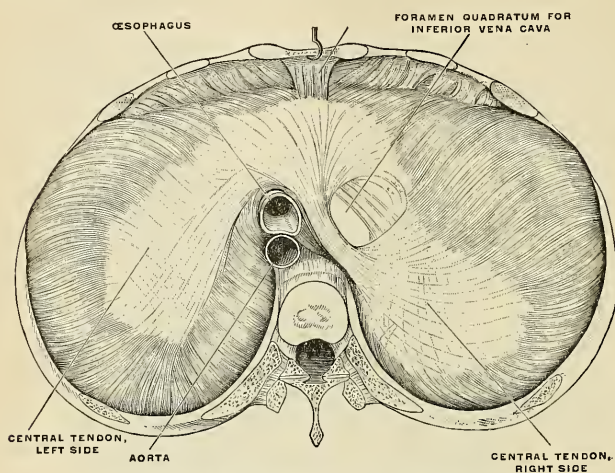


FIG. 313.—The Diaphragm, seen from above. (Poirier and Charpy.)

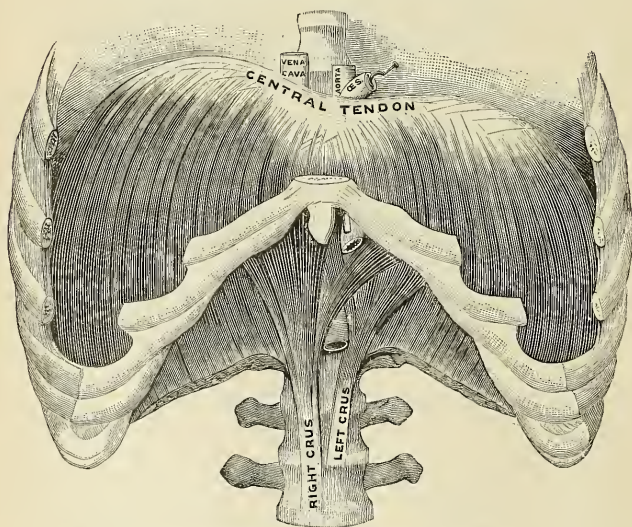


FIG. 314.—The Diaphragm, viewed from in front. (Testut.)

longed across the bodies of the vertebræ from the inner part of the lower end of the crura, pass behind the aorta, and thus convert the opening into a fibrous ring

The **œsophageal opening** (*hiatus œsophageus*) is situated at the level of the tenth thoracic vertebra; it is elliptical in form, oblique in direction, muscular in structure, and is formed by the decussating fibres of the two crura. It is placed above, and at the same time anterior, and a little to the left of the aortic opening. It transmits the œsophagus and vagus nerves and some small œsophageal arteries. The anterior margin of this aperture is occasionally tendinous, being formed by the margin of the central tendon. The posterior and lateral margins are thick and the gullet is in contact with them for about half an inch. The right margin of the œsophageal opening is particularly prominent and lies in the *œsophageal groove* on the posterior surface of the left lobe of the liver.

The **opening for the inferior vena cava** (*foramen venae cavae*) is the highest opening, being about on the level of the disk between the eighth and ninth thoracic vertebrae; it is quadrilateral in form, tendinous in structure, and is placed at the junction of the right and middle leaflets of the central tendon, its margins being adherent to the wall of the inferior vena cava.

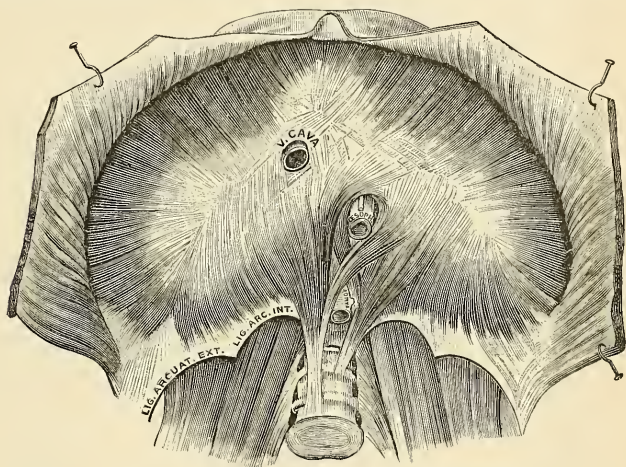


FIG. 315.—The Diaphragm, viewed from below. (Testut.)

The **right crus** transmits the greater and lesser splanchnic nerves of the right side; the **left crus** transmits the greater and lesser splanchnic nerves of the left side, and the vena azygos minor (inferior). The gangliated cords of the sympathetic usually enter the abdominal cavity by passing behind the internal arcuate ligaments.

Serous Membranes.—The serous membranes in relation with the Diaphragm are four in number, three covering its upper or thoracic surface, and one its abdominal surface. The three serous membranes on its upper surface are the two pleurae on either side and the pericardium, which covers the middle portion of the tendinous centre. The greater portion of the under surface of the Diaphragm is covered by the peritoneum.

Nerves.—The Diaphragm is supplied by the right and left phrenic nerves, derived from the anterior primary divisions of the third, fourth, and fifth cervical nerves. The nerve filaments which pass to the Diaphragm from the lower four intercostal nerves are sensor in function and supply only the peritoneum.

Actions.—Each External intercostal muscle elevates the rib below. Owing to the oblique axis of the costovertebral articulation, the curved obliquity of the ribs themselves, and the

angular arrangement of the lower costal cartilages, the sternum is lifted upward and forward, the ribs upward and slightly outward, and the diameters of the thorax are thus increased.

The action of the Internal intercostals is in dispute. Haller long ago taught that they act together with the External intercostals as inspiratory muscles. Investigators have since endeavored to show that they act as expiratory muscles.¹ Others believe that the Intercostal muscles contract simultaneously and serve merely as strong septal supports which prevent the intercostal spaces from being pushed out or drawn in during respiration. Masoin and Du Bois Reymond,² in experiments on animals, proved that the intercartilaginous portions of the Internal intercostals contracted synchronously with the Diaphragm.

The Diaphragm is the principal muscle of inspiration, and presents the form of a dome concave toward the abdomen. The central part of the dome is tendinous, and the pericardium is attached to its upper surface; the circumference is muscular. During inspiration the lowest ribs are fixed, and from these and the crura the muscle fibres contract and draw downward and forward the central tendon with the attached pericardium. In this movement the curvature of the Diaphragm is scarcely altered, the dome moving downward nearly parallel to its original position and pushing before it the abdominal viscera. The descent of the abdominal viscera is permitted by the elasticity of the abdominal wall, but the limit of this is soon reached. The central tendon applied to the abdominal viscera then becomes a fixed point for the action of the Diaphragm, the effect of which is to elevate the lower ribs and through them to push forward the sternum and the upper ribs. The right cupola of the Diaphragm, lying on the liver, has a greater resistance to overcome than the left, which lies over the stomach, but to compensate for this the right crus and the fibres of the right side generally are stronger than those of the left.

In all expulsive acts the Diaphragm is called into action to give additional power to each expulsive effort. Thus, before sneezing, coughing, laughing, crying, or vomiting, and previous to the expulsion of urine or feces, or of the fœtus from the uterus, a deep inspiration takes place. The height of the Diaphragm is constantly varying during respiration; it also varies with the degree of distention of the stomach and intestines and with the size of the liver. After a forced expiration the right cupola is on a level in front with the fourth costal cartilage, at the side with the fifth, sixth, and seventh ribs, and behind with the eighth rib; the left cupola is a little lower than the right. Halls Dally states that the absolute range of movement between deep inspiration and deep expiration averages in the male and female 30 mm. on the right side and 28 mm. on the left; in quiet respiration the average movement is 12.5 mm. on the right side and 12 mm. on the left.³

Skiagraphy shows that the height of the Diaphragm in the thorax varies considerably with the position of the body. It stands highest when the body is horizontal and the patient on his back, and in this position it performs the largest respiratory excursions with normal breathing. When the body is erect the dome of the Diaphragm falls, and its respiratory movements become less. The dome falls still lower when the sitting posture is assumed, and in this position its respiratory excursions are least in extent. These facts may, perhaps, explain why it is that patients suffering from severe dyspnea are most comfortable and least short of breath when they sit up. When the body is horizontal and the patient on his side, the two halves of the Diaphragm do not behave alike. The uppermost half sinks to a level lower even than when the patient sits, and moves little with respiration; the lower half rises higher in the thorax than it does when the patient is supine, and its respiratory excursions are much increased. In unilateral disease of the pleura or lungs analogous interference with the position or movement of the Diaphragm can generally be observed skiagraphically.

It appears that the position of the Diaphragm in the thorax depends upon three main factors, viz.: (1) The elastic retraction of the lung tissue, tending to pull it upward; (2) the pressure exerted on its under surface by the viscera; this naturally tends to be a negative pressure, or a downward suction, when the patient sits or stands, and a positive or an upward pressure when he lies; (3) the intra-abdominal tension due to the abdominal muscles. These are in a state of contraction in the standing position and not in the sitting position; hence, the Diaphragm when the patient stands is pushed up higher than when he sits.

The Levatores costarum being inserted near the fulcrum of the ribs can exert but little action on them; they act as rotators and lateral flexors of the vertebral column.

The Triangularis sterni draws down the costal cartilages, and is therefore a muscle of expiration.

Mechanism of Respiration.—The respiratory movements must be examined during (a) quiet respiration, and during (b) forced respiration.

¹ Consult articles by Cleland in the *Journal of Anatomy and Physiology*, May, 1867, p. 209; Baumler, *Observations on the Action of the Intercostal Muscles*, Erlangen, 1860 (Ref. in New Syd. Soc.'s Year-Book for 1861, p. 69); Keen, *Trans. Coll. of Phys., Phila.*, Third series, vol. i, 1875, p. 97; Flusser, *Ueber die Wirkung der Musculi Intercostales*, *Anat. Anz.*, April 16, 1908; Boecker, *Anat. Anz.*, June 27, 1908.

² *Zur Lehre von der Function der Musculi intercostales interni*, *Archiv für Physiologie*, 1896, p. 85.

³ Inquiry into the Physiological Mechanism of Respiration, *Journal of Anatomy and Physiology*, vol. xliii, 1908.

Quiet Respiration.—The first and second pairs of ribs are fixed by the Scaleni and by the resistance of the cervical structures; the last pair, and through it the eleventh pair, are fixed by the Quadratus lumborum muscles. The other ribs are elevated, so that the first two intercostal spaces are diminished while the other spaces are increased in width. It has already been shown (p. 285) that elevation of the third, fourth, fifth, and sixth ribs leads to an increase in the antero-posterior and transverse diameters of the thorax; the vertical diameter is increased by the descent of the diaphragmatic dome so that the lungs are expanded in all directions except backward and upward. Elevation of the eighth, ninth, and tenth ribs is accompanied by an outward and backward movement, leading to an increase in the transverse diameter of the upper part of the abdomen; the elasticity of the anterior abdominal wall allows a slight increase in the antero-posterior diameter of this part, and in this way the decrease in the vertical diameter of the abdomen is compensated and space provided for its displaced viscera. Expiration is effected by the elastic recoil of the abdominal walls and by the action of the abdominal muscles, which push back the viscera displaced downward by the Diaphragm.

Forced Respiration.—All the movements of quiet respiration are here carried out, but to a greater extent. In inspiration the shoulders and the vertebra borders of the scapulae are fixed and the limb muscles, Trapezius, Serratus magnus, Pectorals, and Latissimus dorsi, are called into play. The Scaleni are in stronger action, and the Sternomastoids also assist, when the head is fixed, by drawing up the sternum and by fixing the clavicles. The first rib is therefore no longer stationary, but, with the sternum, is raised; with it all the other ribs except the last are raised to a higher level. In conjunction with the increased descent of the Diaphragm this provides for a considerable augmentation of all the thoracic diameters. The anterior abdominal muscles come into action so that the umbilicus is drawn upward and backward, and this allows the Diaphragm to exert a more powerful influence on the lower ribs; the transverse diameter of the upper part of the abdomen is greatly increased and the subcostal angle is opened out. The deeper muscles of the back, *e. g.*, the Serrati postici superiores and the Erectores spinae, are also brought into action; the thoracic curve of the vertebral column is partially straightened, and the whole column, above the lower lumbar vertebrae, is drawn backward. This increases the antero-posterior diameters of the thorax and of the upper part of the abdomen and widens the intercostal spaces. Forced expiration is effected by the recoil of the abdominal walls, by the contraction of the antero-lateral muscles of the abdominal wall, and of the Serrati postici inferiores and Triangularis sterni.

Halls Dally (*op. cit.*) gives the following figures as representing the average changes which occur during deepest possible respiration. The manubrium moves 30 mm. in an upward, and 14 mm. in a forward direction; the width of the subcostal angle, at a level of 30 mm. below the articulation of the manubrium with the gladiolus, is increased by 26 mm.; the umbilicus is retracted and drawn upward for a distance of 13 mm.

Artificial Respiration.—By the “prone pressure” method of Prof. E. A. Schäfer advantage is taken of the contour of the diaphragm and of the elastic recoil of the thoracic wall in providing for a tidal air exchange in the lungs.

III. MUSCLES OF THE ABDOMEN.

The muscles of the abdomen may be divided into two groups: (1) The antero-lateral muscles of the abdomen. (2) The posterior muscles of the abdomen.

1. The Antero-lateral Muscles of the Abdomen.

The muscles of this group are the

External oblique.
Internal oblique.

Transversalis.
Rectus.

Pyramidalis.

Dissection (Fig. 316).—To dissect the abdominal muscles, make a vertical incision from the ensiform cartilage to the symphysis pubis; a second incision from the umbilicus obliquely upward and outward to the outer surface of the thorax, as high as the lower border of the fifth or sixth rib; and a third, commencing midway between the umbilicus and pubes, transversely outward to the anterior superior iliac spine, and along the crest of the ilium as far as its posterior third.

Then reflect the three flaps included between these incisions from within outward, in the line of direction of the muscle fibres. If necessary, the abdominal muscles may be made tense by inflating the peritoneal cavity through the umbilicus.

The **superficial fascia** of the abdomen consists, over the greater part of the abdominal wall, of a single layer of fascia, which contains a variable amount of fat; but as this layer approaches the groin it is easily divisible into two layers, between which are found the superficial vessels and nerves and the superficial inguinal lymph nodes. The **superficial layer of the superficial fascia** (*fascia of Camper*) is thick, areolar in texture, and contains in its meshes adipose tissue, the quantity of which varies in different subjects. Below, it passes over Poupart's ligament, and is continuous with the outer layer of the superficial fascia of the thigh. In the male this fascia is continued over the penis and outer surface of

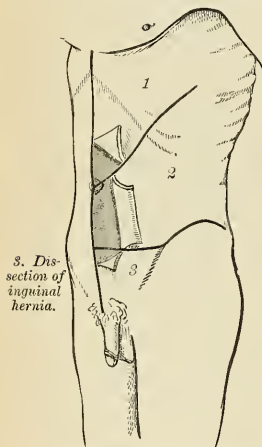


FIG. 316.—Dissection of abdomen.

the cord to the scrotum, where it helps to form the **dartos**. As it passes to the scrotum it changes its character, becoming thin, destitute of adipose tissue, and of a pale reddish color, and in the scrotum it acquires some nonstriated muscle fibres. From the scrotum it may be traced backward to be continuous with the superficial fascia of the perineum. In the female this fascia is continued into the labia majora. The **deep layer of the superficial fascia** (*fascia of Scarpa*) is thinner and more membranous in character than the superficial layer, and contains a considerable quantity of yellow elastic fibres. In the middle line it is intimately adherent to the linea alba and to the symphysis pubis, and is prolonged, in the male, on to the dorsum of the penis, forming the **suspensory ligament of the penis**; above, it joins the superficial layer and is continuous with the superficial fascia over the rest of the trunk; below, it blends with the fascia lata of the thigh a little below Poupart's ligament; and below and internally it is continued over the penis and spermatic cord to the scrotum, where it helps to

form the **dartos**. From the scrotum it may be traced backward to be continuous with the deep layer of the superficial fascia of the perineum (*fascia of Colles*). In the female it is continued into the labia majora.

The **deep fascia** invests the External oblique muscle, but is so thin over the aponeurosis of the muscle as to be scarcely recognizable.

The **External or Descending oblique muscle** (*m. obliquus externus abdominis*) (Fig. 317) is situated on the side and fore part of the abdomen; being the largest and the most superficial of the three flat muscles in this region. It is broad, thin, and irregularly quadrilateral, its muscular portion occupying the side, its aponeurosis the anterior wall, of the abdomen. It *arises*, by eight fleshy digitations, from the external surface and lower borders of the eight inferior ribs; these digitations are arranged in an oblique line running downward and backward; the upper ones being attached close to the cartilages of the corresponding ribs; the lowest, to the apex of the cartilage of the last rib; the intermediate ones, to the ribs at some distance from their cartilages. The five superior serrations increase in size from above downward, and are received between corresponding processes of the Serratus magnus; the three lower ones diminish in size from above downward, receiving between them corresponding processes from the Latis-simus dorsi. From these attachments, the fleshy fibres proceed in various directions. Those from the lowest ribs pass nearly vertically downward, to be *inserted*

into the anterior half of the outer lip of the crest of the ilium; the middle and upper fibres, directed downward and forward, terminate in an aponeurosis, opposite a line drawn from the prominence of the ninth costal cartilage to the anterior superior spine of the ilium.

The **aponeurosis of the External oblique** is a thin, but strong membranous aponeurosis, the fibres of which are directed obliquely downward and inward. It is joined with that of the opposite muscle along the median line and covers the whole of the front of the abdomen; *above*, it is covered by and gives origin to the lower border of the Pectoralis major; *below*, some of its fibres are *inserted* into the symphy-

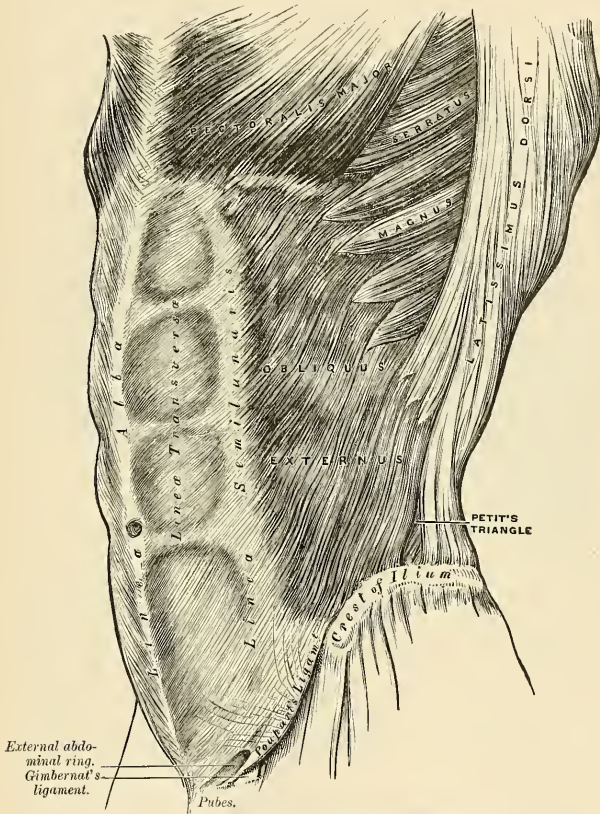


FIG. 317.—The External oblique muscle.

sis pubis, while others pass deeply through the middle line to be attached to the crest and iliopectineal line of the opposite side; these latter fibres are termed the **triangular fascia**. But the great majority of the fibres below are closely aggregated, and extend obliquely across from the anterior superior spine of the ilium to the spine of the os pubis and the iliopectineal line. In the *median line* it inter-

laces with the aponeurosis of the opposite muscle, forming the **linea alba**, which extends from the ensiform cartilage to the symphysis pubis.

That portion of the aponeurosis which extends between the anterior superior spine of the ilium and the spine of the os pubis is a broad band, folded inward, and continuous below with the fascia lata; it is called **Poupart's ligament**. The inner half inch of this ligament is reflected and attached to the subjacent pectineal line. This reflected part is called **Gimbernath's ligament**.

In the aponeurosis of the External oblique, immediately above the crest of the os pubis, is a triangular space, the **external abdominal ring**, formed by a thinning of the fibres of the aponeurosis in this situation.

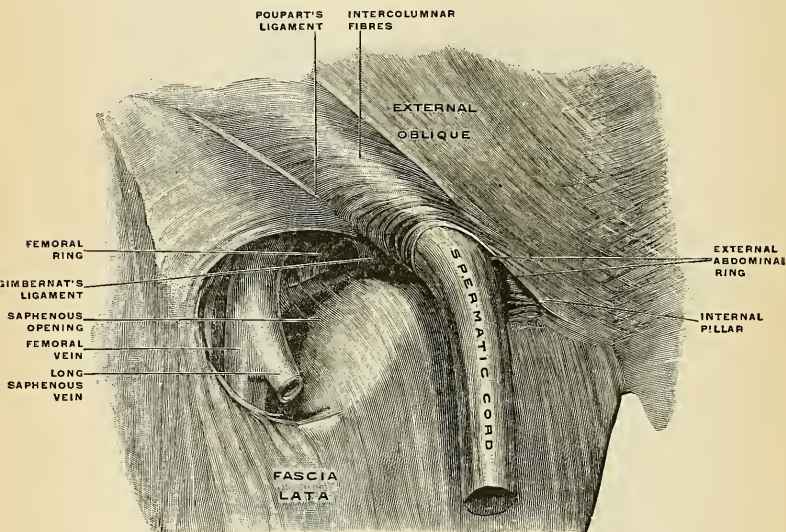


FIG. 318.—Right external abdominal ring and saphenous opening in the male. (Spalteholz.)

Relations.—By its *superficial surface*, the External oblique muscle is in relation with the superficial fascia, superficial epigastric and circumflex iliac vessels, and some cutaneous nerves; by its *deep surface*, with the Internal oblique, the lower part of the eight inferior ribs, and Intercostal muscles, the Cremaster, the spermatic cord in the male, and round ligament in the female. Its *posterior border*, extending from the last rib to the crest of the ilium, is fleshy throughout and free; it is occasionally overlapped by the Latissimus dorsi, though generally a triangular interval exists between the two muscles near the crest of the ilium, in which is seen a portion of the Internal oblique. This triangle, **Petit's triangle** (*trigonum lumbale*) is therefore bounded in *front* by the External oblique, *behind* by the Latissimus dorsi, *below* by the crest of the ilium, and its floor is formed by the Internal oblique muscle (Fig. 317).

The following parts of the aponeurosis of the External oblique muscle require to be further described:

- | | |
|-----------------------------------|----------------------------------|
| External Abdominal Ring. | Intercolumnar Fibres and Fascia. |
| Poupart's Ligament. | Gimbernath's Ligament. |
| Triangular Fascia of the Abdomen. | |

The **External Abdominal Ring** (*annulus inguinalis subcutaneus*) (Figs. 318 and 321).—Just above and to the outer side of the crest of the os pubis an interval

known as the **external abdominal ring** is seen in the aponeurosis of the External oblique muscle. The interval is oblique in direction, corresponding with the course of the fibres of the aponeurosis, is somewhat triangular in form, and usually measures about an inch (2.5 cm.) from base to apex and about half an inch (1.25 cm.) transversely. It gives passage to the spermatic cord in the male and to the round ligament in the female. It is bounded *below* by the crest of the os pubis; *above*, by a series of curved fibres, the *external spermatic* or the *intercolumnar fibres* which pass across the upper angle of the ring, thus increasing its strength; and on *each side*, by the margins of the opening in the aponeurosis, which are called the *columns* or *pillars of the ring*.

The **external pillar** (*crus inferius*) is inferior from the obliquity of its direction. It is stronger than the internal pillar; it is formed by that portion of Poupart's ligament which is inserted into the spine of the os pubis; it is curved so as to form a kind of groove, upon which the spermatic cord rests.

The **internal pillar** (*crus superius*), a broad, thin, flat band, is formed by the fibres of the aponeurosis which are inserted into the crest and the symphysis pubis.

The **intercolumnar fibres** (*fibræ intercrurales*) (Fig. 318) are a series of curved tendinous fibres, which arch across the lower part of the aponeurosis of the External oblique. They have received their name from stretching across between the two pillars of the external ring, describing a curve with the concavity downward. They are much thicker and stronger at the outer margin of the external ring, where they are connected to the outer third of Poupart's ligament, than internally, where they are inserted into the linea alba. They are more strongly developed in the male than in the female. The intercolumnar fibres increase the strength of the lower part of the aponeurosis, and prevent the divergence of the pillars from each other.

These intercolumnar fibres as they pass across the external abdominal ring are themselves connected together by delicate fibrous tissue, thus forming a fascia, the **intercolumnar fascia** or the **external spermatic fascia**, which, as it is attached to the pillars of the ring, covers it in. This intercolumnar fascia is continued down as a tubular prolongation around the outer surface of the cord and testis or of the round ligament, and encloses them in a distinct sheath.

Applied Anatomy.—The sac of an inguinal hernia, in passing through the external abdominal ring, receives an investment from the intercolumnar fascia. If the finger is introduced a short distance into the external abdominal ring and the limb is then extended and rotated outward, the aponeurosis of the External oblique, together with the iliac portion of the fascia lata, will be felt to become tense, and the external ring much contracted; if the limb is, on the contrary, flexed upon the pelvis and rotated inward, this aponeurosis will become lax and the external abdominal ring sufficiently enlarged to admit the finger with comparative ease; hence the patient should always be put in the latter position when the taxis is applied for the reduction of an inguinal hernia in order that the abdominal walls may be relaxed as much as possible.

Poupart's Ligament (*ligamentum inguinale*).—Poupart's ligament is the lower border of the aponeurosis of the External oblique muscle, and extends from the anterior superior spine of the ilium to the pubic spine. From this latter point it is reflected to the iliopectineal line for about half an inch, thus forming **Gimbernat's ligament**. Its general direction is curved downward toward the thigh, where it is continuous with the fascia lata. Its outer half is rounded and oblique in direction and gives partial origin to the Internal oblique and Transversalis muscles. Its inner half gradually widens at its attachment to the os pubis, is more horizontal in direction, and lies beneath the spermatic cord. Nearly the whole of the space included between the femoral arch and the innominate bone is filled in by the parts which descend from the abdomen into the thigh (Fig. 326). These are referred to again on a subsequent page.

Gimbernat's ligament (*ligamentum lacunare*) (Figs. 318 and 326) is that part of Poupart's ligament which is reflected to the iliopectineal line. It is about half an inch in length, more prominent in the male than in the female, almost horizontal in direction in the erect posture, and of a triangular form with the base directed outward. Its *base*, or outer margin, is concave, thin, and sharp, and lies in contact with the crural sheath, forming the inner boundary of the **femoral or crural ring** (*annulus femoralis*). Its *apex* corresponds to the spine of the os pubis. Its *deep margin* is attached to the iliopectineal line, and is continuous with the pubic portion of the fascia lata. Its *superficial margin* is continuous with Poupart's ligament. Its *surfaces* are directed upward and downward.

Triangular Fascia (*ligamentum inguinale reflexum*).—The triangular fascia of the abdomen is a triangular layer of tendinous fibres, which comes from the aponeurosis of the opposite External oblique, and is attached by its *apex* to the iliopectineal line, where it is continuous with Gimbernat's ligament. It lies beneath the spermatic cord, behind the inner pillar of the external abdominal ring, and in front of the conjoined tendon.

Ligament of Cooper (Fig. 328).—This is a strong ligamentous band, which was first described by Sir Astley Cooper. It extends upward and backward from the base of Gimbernat's ligament along the iliopectineal line, to which it is attached. It is strengthened by the fascia transversalis, by the iliopectineal aponeurosis, and by a lateral expansion from the lower attachment of the linea alba (*adnunculum lineae albae*).

Dissection.—Detach the External oblique by dividing it across, just in front of its attachment to the ribs, as far as its posterior border, and separate it below from the crest of the ilium as far as the anterior superior spine; then separate the muscle carefully from the Internal oblique, which lies beneath, and turn it toward the opposite side.

The **Internal or Ascending oblique muscle** (*m. obliquus internus abdominis*) (Fig. 319), thinner and smaller than the preceding, beneath which it lies, is of an irregularly quadrilateral form, and is situated at the side and fore part of the abdomen. It *arises*, by fleshy fibres, from the outer half of Poupart's ligament, to the groove on the upper surface of which it is attached; from the anterior two-thirds of the middle lip of the crest of the ilium, and from the posterior lamella of the lumbar fascia (Fig. 325). From this origin the fibres diverge; those from Poupart's ligament, few in number and paler in color than the rest, arch downward and inward across the spermatic cord in the male and across the round ligament in the female, and, becoming tendinous, are *inserted*, conjointly with those of the Transversalis, into the crest of the os pubis and iliopectineal line, to the extent of half an inch or more, forming what is known as the conjoined tendon of the Internal oblique and Transversalis. The fibres from the anterior third of the iliac origin are horizontal in their direction, and, becoming tendinous along the lower fourth of the linea semilunaris, pass in front of the Rectus muscle to be *inserted* into the linea alba; those which arise from the middle third of the origin from the crest of the ilium pass obliquely upward and inward, and terminate in an aponeurosis which divides at the outer border of the Rectus muscle into two lamellæ (Fig. 326), and are continued forward, in front and behind this muscle, to be *inserted* into the linea alba. The posterior lamella is also connected to the cartilages of the seventh, eighth, and ninth ribs; the fibres arising most posteriorly pass almost vertically upward, to be *inserted* into the lower borders of the cartilages of the three lower ribs, and are continuous with the Internal intercostal muscles. The lower fibres of this muscle are continuous with the Cremaster.

The **aponeurosis of the Internal oblique** is continued forward to the middle of the abdomen, where it joins with the aponeurosis of the opposite muscle at the linea alba, and extends from the costal arch to the os pubis. At the outer margin of the Rectus muscle this aponeurosis, for the upper three-fourths of its extent,

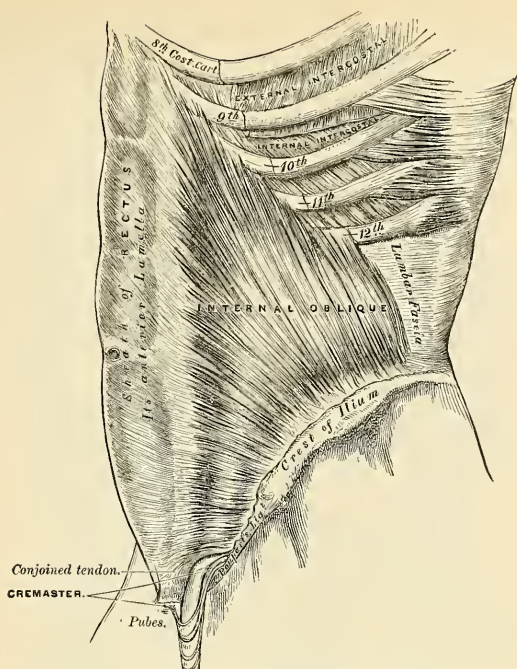


FIG. 319.—The Internal oblique muscle.

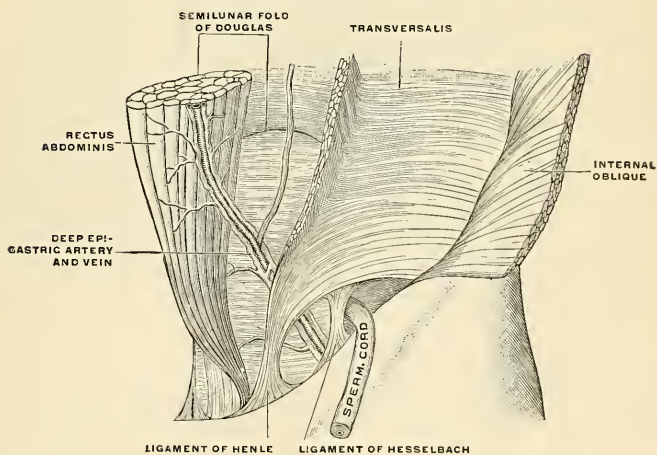


FIG. 320.—The deep epigastric artery and veins, ligament of Henle and ligament of Hesselbach, seen from in front. (Modified from Braune.)

divides into two lamellæ, which pass, one in front and the other behind the muscle, enclosing it in a kind of sheath, and reuniting on its inner border at the linea alba; the anterior layer is blended with the aponeurosis of the External oblique muscle; the posterior layer with that of the Transversalis. Along the lower fourth the aponeurosis passes altogether in front of the Rectus without any separation. Where the aponeurosis ceases to split, and passes altogether in front of the Rectus muscle, a deficiency is left in the sheath of the Rectus behind; this is marked above by a sharp lunated margin which has its concavity downward, and is known as the **semilunar fold of Douglas** (*linea semicircularis*) (Fig. 323).

Relations.—By its *superficial surface* the Internal oblique is in relation with the External oblique, Latissimus dorsi, spermatic cord, and external ring; by its *deep surface*, with the Transversalis muscle, the lower intercostal vessels and nerves, the iliohypogastric and the ilioinguinal nerves. Near Poupart's ligament it lies on the fascia transversalis, internal ring, and spermatic cord. Its lower border forms the upper boundary of the inguinal canal.

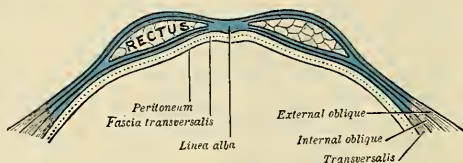


FIG. 321.—Diagram of sheath of Rectus.

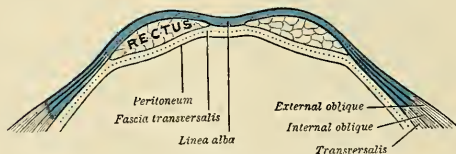


FIG. 322.—Diagram of a transverse section through the anterior abdominal wall, below the semilunar fold of Douglas.

The **Cremaster muscle** (*m. cremaster*) (Fig. 319) is a thin layer of muscle, composed of a number of fasciculi which *arise* from the inner part of Poupart's ligament, where its fibres are continuous with those of the Internal oblique and also occasionally with the Transversalis. It passes along the outer side of the spermatic cord, descends with it through the external abdominal ring upon the front and sides of the cord, and forms a series of loops which differ in thickness and length in different subjects. Those at the upper part of the cord are exceedingly short, but they become in succession longer and longer, the longest reaching down as low as the testicle, where a few are *inserted* into the tunica vaginalis. These loops are united by areolar tissue, and form a thin covering, the **cremasteric fascia**, over the cord and testis. The fibres of this muscle ascend along the inner side of the cord, and are *inserted* by a small pointed tendon into the crest of the os pubis and in front of the sheath of the Rectus muscle.

It will be observed that the origin and insertion of the Cremaster is precisely similar to that of the lower fibres of the Internal oblique. This fact affords an easy explanation of the manner in which the testicle and cord are invested by this muscle. At an early period of fetal life the testis is placed at the lower and back part of the abdominal cavity, but during its descent toward the scrotum, which takes place before birth, it passes beneath the arched fibres of the Internal oblique. As the testis and cord go to their destination in the scrotum they pass beneath this

muscle and carry with them and retain fibres from its lower part. It occasionally happens that the loops of the Cremaster surround the cord, some lying behind as well as in front. It is probable that under these circumstances the testis, in its descent, passed through instead of beneath the fibres of the Internal oblique.

In the descent of an inguinal hernia, which takes the same course as the spermatic cord, the Cremaster muscle forms one of its coverings. This muscle becomes largely developed in cases of hydrocele and large old scrotal hernia. The Cremaster muscle is found only in the

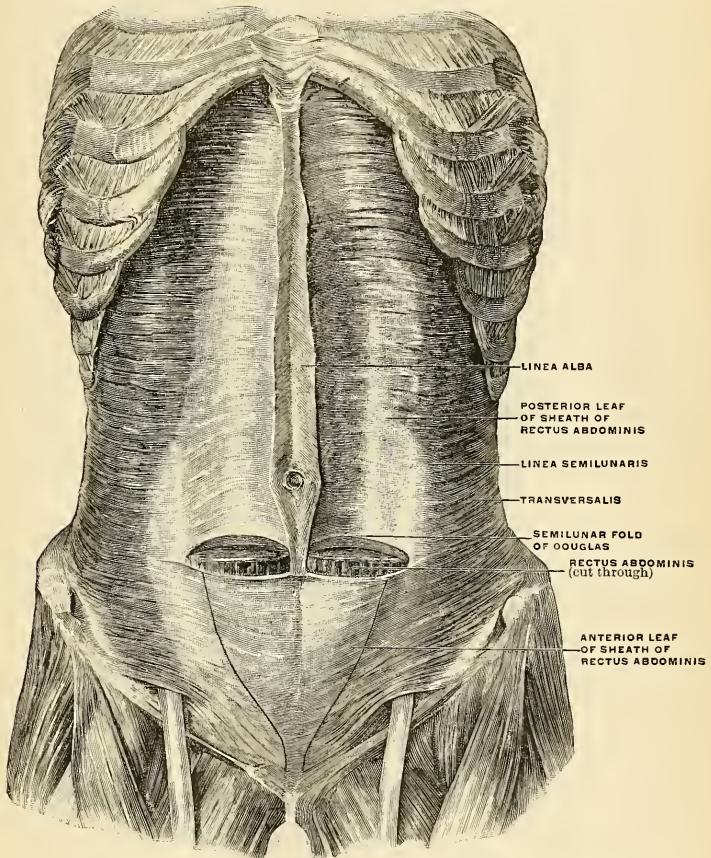


FIG. 323.—The muscles of the abdomen, showing the semilunar fold of Douglas. Viewed from in front. (Spalteholz.)

male, but almost constantly in the female a few muscle fibres may be seen on the surface of the round ligament which correspond to this muscle, and in cases of inguinal hernia in the female a considerable amount of muscle tissue may be found covering the sac.

Relations.—By its *superficial surface*, with the External oblique, Latissimus dorsi, spermatic cord, and external ring; by its *deep surface*, with the Transversalis muscle, the lower intercostal

vessels and nerves, the iliohypogastric and the ilioinguinal nerves. Near Poupart's ligament the Cremaster lies on the fascia transversalis, internal ring, and spermatic cord. Its lower border forms the upper boundary of the spermatic canal.

Dissection.—Detach the Internal oblique in order to expose the Transversalis beneath. This may be effected by dividing the muscle, *above*, at its attachment to the ribs; *below*, at its connection with Poupart's ligament and the crest of the ilium; and *behind*, by a vertical incision extending from the last rib to the crest of the ilium. The muscle should previously be made

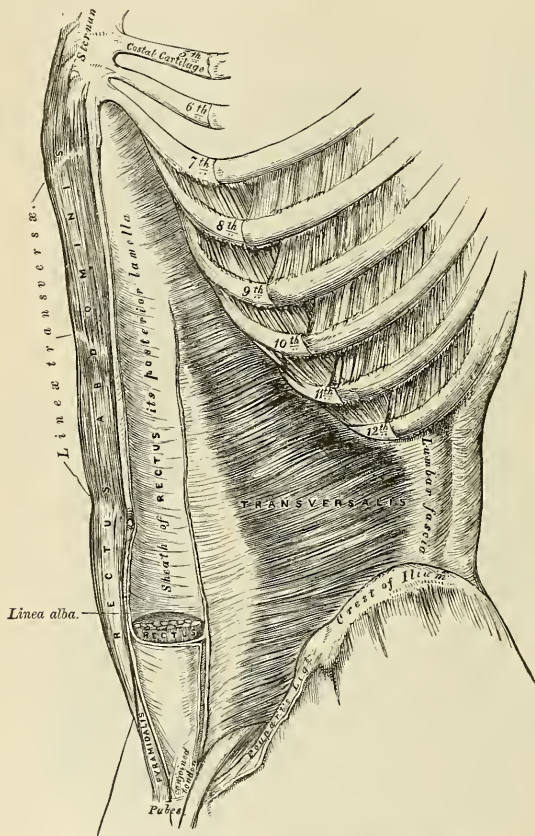


FIG. 324.—The Transversalis, Rectus, and Pyramidalis muscles.

tense by drawing upon it with the fingers of the left hand, and if its division be carefully effected, the cellular interval between it and the Transversalis, as well as the direction of the fibres of the latter muscle, will afford a clear guide to their separation; along the crest of the ilium the circumflex iliac vessels are interposed between them, and form an important guide in separating them. The muscle should then be thrown inward toward the linea alba.

The **Transversalis muscle** (*m. transversus abdominis*) (Fig. 324), so called from the direction of its fibres, is the deepest flat muscle of the abdominal wall,

being placed immediately beneath the Internal oblique. It *arises* by fleshy fibres from the outer third of Poupart's ligament; from the inner lip of the crest of the ilium for its anterior three-fourths; from the inner surface of the cartilages of the six lower ribs, interdigitating with the Diaphragm; and from the lumbar fascia (Fig. 325), which may be regarded as the posterior aponeurosis of the muscle. The muscle terminates in front in a broad aponeurosis, the lower fibres of which curve downward and inward, and are *inserted*, together with those of the Internal oblique, on the crest of the os pubis and iliopectineal line, thus forming what is known as the conjoined tendon of the Internal oblique and Transversalis muscles. Throughout the rest of its extent the aponeurosis passes horizontally inward, and is *inserted* into the linea alba, its upper three-fourths passing behind the Rectus abdominis muscle, blending with the posterior lamella of the Internal oblique; its lower fourth passing in front of the Rectus.

The **conjoined tendon** of the Internal oblique and Transversalis is chiefly formed by the lower part of the tendon of the Transversalis, and is *inserted* into the crest of the os pubis and iliopectineal line, immediately behind the external abdominal ring, thus serving to protect what would otherwise be a weak point in the abdominal wall. The conjoined tendon is sometimes divided into an outer and an inner portion—the former termed the **ligament of Hesselbach** (*ligamentum inierfoveolare*); the latter, the **ligament of Henle** (Fig. 320).

Relations.—By its *superficial surface*, with the Internal oblique, the lower intercostal nerves, and the inner surface of the cartilages of the lower ribs; by its *deep surface*, with the fascia transversalis, which separates it from the peritoneum. Its lower border forms the upper boundary of the inguinal canal.

Dissection.—To expose the Rectus abdominis muscle, open its sheath by a vertical incision extending from the costal arch to the os pubis, and then reflect the two portions from the surface of the muscle, which is easily done, excepting at the lineae transversae, where so close an adhesion exists that the greatest care is requisite in separating them. Now raise the outer edge of the muscle, in order to examine the posterior layer of the sheath. By dividing the muscle in the centre, and turning its lower part downward, the point where the posterior wall of the sheath terminates in a thin curved margin will be seen.

The **Rectus abdominis** (*m. rectus abdominis*) (Figs. 323 and 324) is a long flat muscle, which extends along the whole length of the front of the abdomen, being separated from its fellow of the opposite side by the linea alba. It is much broader, but thinner, above than below, and *arises* by two tendons; the external or larger is attached to the crest of the os pubis, the internal, smaller portion interlaces with its fellow of the opposite side, and is connected with the ligaments covering the front of the symphysis pubis. The fibres ascend, and the muscle is *inserted* by three portions of unequal size into the cartilages of the fifth, sixth, and seventh ribs. The longest portion attached principally to the cartilage of the fifth rib, usually has some fibres of insertion into the anterior extremity of the rib itself. Some fibres are occasionally connected with the costoxiphoid ligaments and side of the ensiform cartilage.

The Rectus muscle is traversed by tendinous intersections, three in number, which have received the name of **lineae transversae** (*inscriptiones tendineae*). One of these is usually situated opposite the umbilicus, and two above that point; of the latter, one corresponds to the extremity of the ensiform cartilage, and the other to the interval between the ensiform cartilage and the umbilicus. These intersections pass transversely or obliquely across the muscle in a zigzag course; they rarely extend completely through its substance, sometimes they pass only half-way across it, and are intimately adherent in front to the sheath in which the muscle is enclosed. Sometimes one or two additional lines may be seen, one usually below the umbilicus; the position of the other, when it exists, is variable. These additional lines are for the most part incomplete.

The Rectus is enclosed in a sheath, the **rectus sheath** (*vagina m. recti abdominis*) (Figs. 325 and 326), formed by the aponeurosis of the Oblique and Transversalis

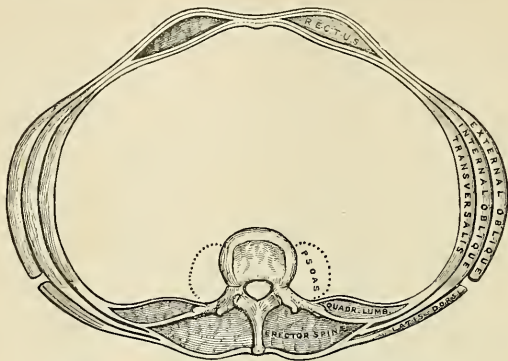


FIG. 325.—A transverse section of the abdomen in the lumbar region.

muscles, which are arranged in the following manner. When the aponeurosis of the Internal oblique arrives at the outer margin of the Rectus it divides into two

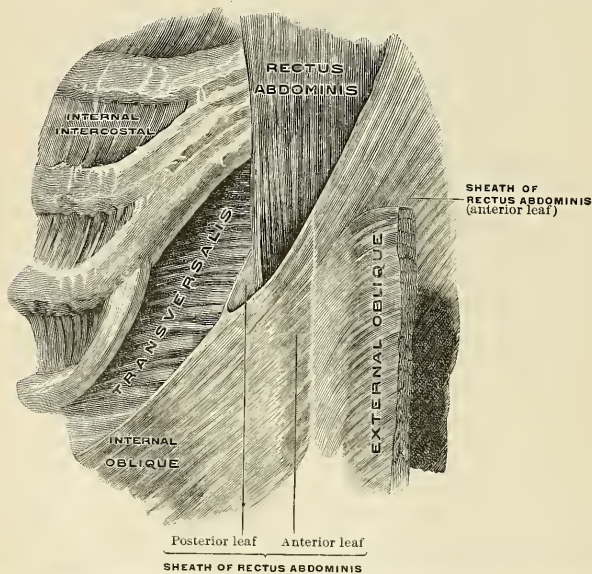


FIG. 326.—Transition of the tendon of the right internal oblique into the sheath of the rectus. (Spalteholz.)

lamellæ, one of which passes in *front* of the Rectus, blending with the aponeurosis of the External oblique; the other, *behind* it, blending with the aponeurosis of the

Transversalis; and these, joining again at its inner border, are inserted into the linea alba. This arrangement of the aponeuroses exists along the upper three-fourths of the muscle; at the commencement of the lower fourth, the posterior wall of the sheath terminates in a thin curved margin, the **semilunar fold of Douglas** (*linea semicircularis*) (Fig. 323), the concavity of which looks downward toward the pubes; the aponeuroses of all three muscles pass in front of the Rectus without any separation. A very thin aponeurotic layer does pass behind the lower one-fourth of the muscle, but it is trivial as compared with the thickness of the layer behind the upper three-fourths of the muscle. This sudden thinning causes the semilunar fold of Douglas. The extremities of the fold of Douglas descend as pillars to the os pubis. The inner pillar is attached to the symphysis pubis; the outer pillar passes downward as a distinct band on the inner side of the internal abdominal ring to join with the outer fibres of the conjoined tendon, and assist in forming the ligament of Hesselbach (Fig. 320). There its fibres divide into two sets, internal and external; the internal fibres are attached to the ascending ramus of the os pubis; the external fibres pass to the psoas fascia, to the deep surface of Poupart's ligament, and to the tendon of the Transversalis on the outer side of the ring. The Rectus muscle, in the situation where its sheath is deficient, is separated from the peritoneum by the transversalis fascia. Since the tendon of the Internal oblique and the Transversalis only reach as high as the costal margin, it follows that above this level the sheath of the Rectus is also deficient behind, the muscle resting directly on the cartilages of the ribs, being covered merely by the aponeurotic tendon of the External oblique. The convex outer border of the Rectus muscle corresponds to the linea semilunaris.

The **Pyramidalis** (*m. pyramidalis*) is a small muscle, triangular in shape, placed at the lower part of the abdomen, in front of the Rectus, and is contained in the same sheath. It *arises* by tendinous fibres from the front of the os pubis and the anterior pubic ligament; the fleshy portion of the muscle passes upward, diminishing in size as it ascends, and terminates by a pointed extremity, which is *inserted* into the linea alba, midway between the umbilicus and the os pubis. This muscle is sometimes found wanting on one or both sides; the lower end of the Rectus then becomes proportionately increased in size. Occasionally it has been found double on one side, or the muscles of the two sides are of unequal size. Its length varies slightly.

Besides the Rectus and Pyramidalis muscles, the sheath of the Rectus contains the superior and deep epigastric arteries, the terminations of the lumbar arteries and of the lower intercostal arteries and nerves.

Nerves.—The abdominal muscles are supplied by the lower intercostal nerves. The Transversalis and Internal oblique also receive filaments from the hypogastric branch of the iliohypogastric and sometimes from the ilioinguinal. The Cremaster is supplied by the genital branch of the genitofemoral. The Pyramidalis is supplied by the twelfth thoracic nerve.

The **linea alba** (Figs. 324 and 325) is a tendinous raphé seen along the middle line of the abdomen, extending from the ensiform cartilage to the superior pubic ligament, to which it is attached. It is placed between the inner borders of the Recti muscles, and is formed by the blending of the aponeuroses of the Obliqui and Transversales muscles. It is narrow below, corresponding to the narrow interval existing between the Recti, but broader above, as these muscles diverge from one another in their ascent; it becomes of considerable breadth when there is great distention of the abdomen from pregnancy or from ascites. It presents numerous apertures for the passage of vessels and nerves; the largest of these is the **umbilicus** (Fig. 327). The umbilicus is a fibrous ring formed by the fibres of the aponeurosis of the linea alba; in the fetus it transmits the umbilical vein, the two hypogastric arteries, the allantoic duct, and the vitello-intestinal duct; but in the adult the aperture is filled with scar tissue and is obliterated; the resulting cicatrix is stronger than the neighboring parts; hence umbilical hernia occurs in the adult *near* the umbilicus, while in the fetus it occurs *at* the umbilicus. The remains of the fetal structures are cord-like in character; and they diverge from the umbilicus within the abdomen.

The remains of the umbilical vein constitute the round ligament of the liver, and this cord passes upward (Fig. 327). The remains of the hypogastric arteries pass downward (Fig. 327). The remains of the allantois become the urachus, which passes to the summit of the bladder (Fig. 327). The depression of the umbilicus is created by the urachus.

The **lineae semilunares** (Figs 317 and 323) are two curved tendinous lines placed one on each side of the linea alba. Each corresponds with the outer border of the Rectus muscle, and

each extends from the cartilage of the ninth rib to the pubic spine, and is formed by the aponeurosis of the Internal oblique at its point of division to enclose the Rectus, where it is reinforced in front by the External oblique and behind by the Transversalis.

Actions.—The abdominal muscles perform a three-fold action:

When the pelvis and thorax are fixed, they compress the abdominal viscera, by constricting the cavity of the abdomen, in which action they are materially assisted by the descent of the Diaphragm. By these means assistance is given in expelling the fetus from the uterus, the feces from the rectum, the urine from the bladder, and the contents of the stomach in vomiting.

If the pelvis and vertebral column be fixed, these muscles compress the lower part of the thorax, materially assisting expiration. If the pelvis alone is fixed, the thorax is bent directly forward when the muscles of both sides act, or to either side when those of the two sides act alternately, rotation of the trunk at the same time taking place to the opposite side.

If the thorax be fixed, these muscles, acting together, draw the pelvis upward, as in climbing, or, acting singly, they draw the pelvis upward, and bend the vertebral column to one side or the other. The Recti muscles, when acting from below, depress the thorax, and consequently flex the vertebral column; when acting from above, they flex the pelvis upon the vertebral column. The Pyramidales are tensors of the linea alba.

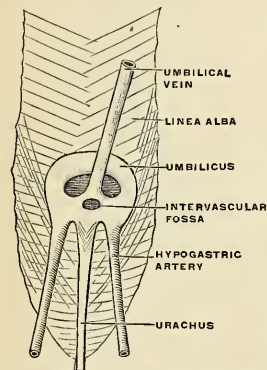


FIG. 327.—The umbilicus of the fetus seen from within the abdomen. (Poirier and Charpy.)

acting from below, depress the thorax, and consequently flex the vertebral column; when acting from above, they flex the pelvis upon the vertebral column. The Pyramidales are tensors of the linea alba.

The **fascia transversalis** (*fascia transversalis*) is a thin aponeurotic membrane which lies between the deep surface of the Transversalis muscle and the extra-peritoneal fat. It forms part of the general layer of fascia which lines the interior of the abdominal and pelvic cavities, and is directly continuous with the iliac and pelvic fasciae. In the inguinal region the transversalis fascia is thick and dense in structure, and joined by fibres from the aponeurosis of the Transversalis muscle, but it becomes thin and cellular as it ascends to the Diaphragm, and blends with the fascia covering this muscle. In *front*, it unites across the middle line with the fascia on the opposite side of the body, and *behind* it becomes lost in the fat which covers the posterior surfaces of the kidneys. *Below*, it has the following attachments: Posteriorly, it is connected to the whole length of the crest of the ilium, between the attachments of the Transversalis and Iliacus muscles; between the anterior superior spine of the ilium and the femoral vessels it is connected to the posterior margin of Poupart's ligament, and is there continuous with the iliac fascia. Internal to the femoral vessels it is thin and attached to the pubis and to the iliopectineal line, behind the conjoined tendon, with which it is united; and, corresponding to the point where the femoral vessels pass into the thigh, this fascia descends in front of them, and forms the anterior wall of the femoral sheath. Beneath Poupart's ligament the transversalis fascia is strengthened by a band of fibrous tissue, which is only loosely connected to Poupart's ligament, and is specialized as the **deep femoral arch**. The spermatic cord in the male and the round ligament in the female pass through this fascia; the point where they pass through is called the **internal abdominal ring**. This opening is not visible externally, owing to a prolongation of the transversalis fascia on these structures, which forms the **infundibuliform fascia**.

The **internal or deep abdominal ring** (*annulus inguinalis abdominis*) (Figs. 320 and 328) is situated in the transversalis fascia, midway between the anterior superior spine of the ilium and the symphysis pubis, and about half an inch above Poupart's ligament. It is of an oval form, the extremities of the oval directed upward and downward, varies in size in different subjects, and is much larger in the male than in the female. The internal ring is bounded, *above* and *externally*, by the arched fibres of the Transversalis; *below* and *internally*, by the deep epigastric vessels. It transmits the spermatic cord in the male and the round ligament in the female. From its circumference a thin funnel-shaped membrane, the **infundibuliform or internal spermatic fascia**, is continued around the cord and testis, enclosing them in a distinct covering.

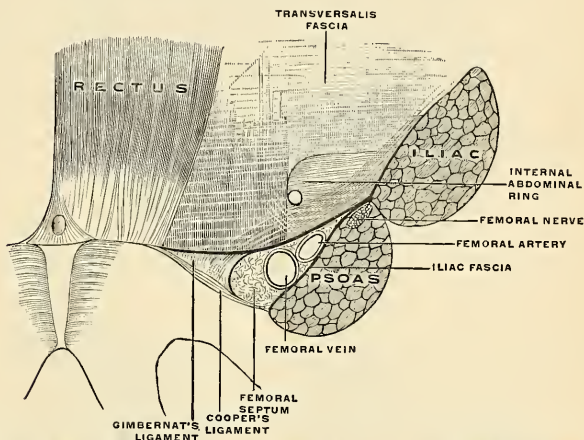


FIG. 328.—The relation of the femoral and internal abdominal rings, seen from within the abdomen after removal of the peritoneum. (Poirier and Charpy.)

When the sac of an oblique inguinal hernia passes through the internal or deep abdominal ring, the infundibuliform process of the transversalis fascia forms one of its coverings.

The Inguinal or Spermatic Canal (*canalis inguinalis*) (Figs. 329 and 330).—The inguinal or spermatic canal contains the **spermatic cord** (*funiculus spermaticus*) in the male and the **round ligament** (*ligamentum teres uteri*) in the female. It is an oblique canal about an inch and a half in length, directed downward and inward, and placed parallel to and a little above Poupart's ligament. It commences above at the internal or deep abdominal ring, which is the point where the cord enters the spermatic canal, and terminates below at the external ring. It is bounded in *front* by the aponeurosis of the External oblique throughout its whole length, and by the Internal oblique for its outer third; *behind*, from within outward, by the triangular fascia (when this is present), the conjoined tendon, and the transversalis fascia; *below*, by Gimbernat's ligament, and by the union of the fascia transversalis with Poupart's ligament. The deep epigastric artery passes upward and inward behind the canal lying close to the inner side of the internal abdominal ring (Fig. 320). The interval between this artery and the outer edge of the Rectus abdominis is named **Hesselbach's triangle**, the base of which is formed by Poupart's ligament.

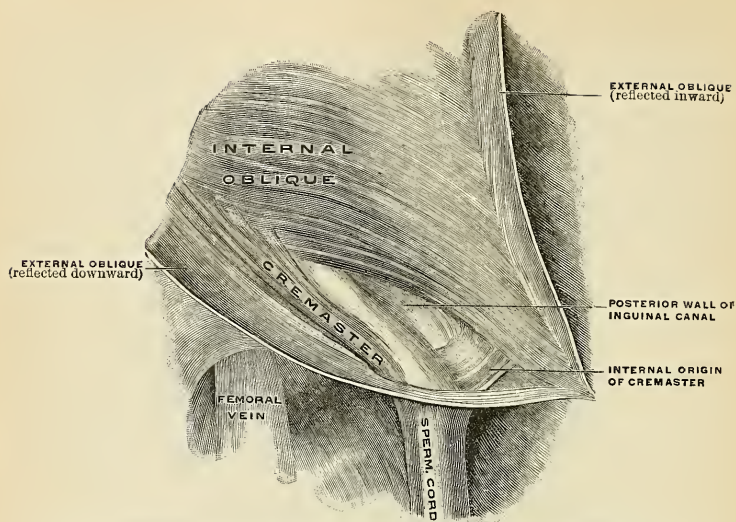


FIG. 329.—The right inguinal canal in the male, second layer, viewed from in front. (The first layer is shown in Fig. 318.) (Spalteholz.)

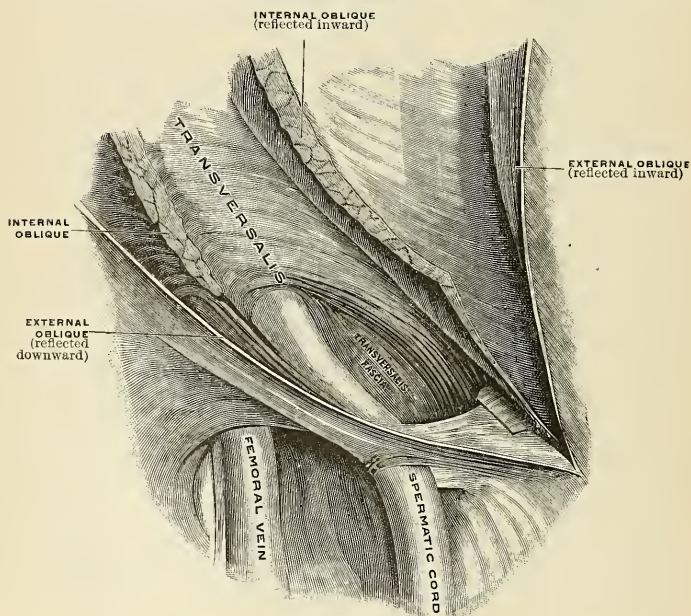


FIG. 330.—The right inguinal canal in the male, third layer, viewed from in front. (Spalteholz.)

That form of protrusion in which the intestine follows the course of the spermatic cord along the spermatic canal is called oblique inguinal hernia.

Surface Form.—The only two muscles of this group which have any considerable influence on surface form are the External oblique and the Rectus muscles of the abdomen. With regard to the External oblique, the upper digitations of its origin from the ribs are well marked, and are intermingled with the serrations of the Serratus magnus; the lower digitations are not visible, as they are covered by the thick border of the Latissimus dorsi. The attachment of the External oblique to the crest of the ilium, in conjunction with the Internal oblique, forms a thick oblique roll, which determines the *iliac furrow*. Sometimes on the front of the lateral region of the abdomen an undulating outline marks the spot where the muscle fibres terminate and the aponeurosis commences. The outer border of the Rectus is defined by the *linea semilunaris*, which may be exactly located by putting the muscle into action. It corresponds with a curved line, with its convexity outward, drawn from the end of the cartilage of the ninth rib to the spine of the os pubis, so that the centre of the line, at or near the umbilicus, is three inches from the median line. The inner border of the Rectus corresponds to the *linea alba*, marked on the surface of the body by a groove, the **abdominal furrow**, which extends from the infrasternal fossa to, or to a little below, the umbilicus, where it gradually becomes lost. The surface of the Rectus presents three transverse furrows, the *lineae transversae*. The upper two of these, one opposite or a little below the tip of the ensiform cartilage, and another, midway between this point and the umbilicus, are usually well marked; the third, opposite the umbilicus, is not so distinct. The umbilicus, situated in the linea alba, varies very much in position as regards its level. It is always situated above a zone drawn around the body opposite the highest point of the crest of the ilium, generally being from three-quarters of an inch to an inch above this line. It usually corresponds, therefore, to the articular disk between the third and fourth lumbar vertebrae.

2. The Posterior Muscles of the Abdomen.

Psoas magnus.
Psoas parvus.

Iliacus.
Quadratus lumborum.

The Psoas magnus, the Psoas parvus, and the Iliacus muscles, with the fascia covering them, will be described with the Muscles of the Lower Extremity.

The Fascia Covering the Quadratus Lumborum (Fig. 325).—This is the most anterior of the three layers of the lumbar fascia. It is a thin layer of fascia, which, passing over the anterior surface of the Quadratus lumborum, is attached, *internally*, to the bases of the transverse processes of the lumbar vertebrae; *below*, to the iliolumbar ligament; and *above*, to the apex and lower border of the last rib.

The portion of this fascia which extends from the transverse process of the first lumbar vertebra to the apex and lower border of the last rib constitutes the **ligamentum arcuatum externum of the Diaphragm**.

The Quadratus lumborum (*m. quadratus lumborum*) (Fig. 311) is situated in the lumbar region. It is irregularly quadrilateral in shape, and broader below than above. It *arises* by aponeurotic fibres from the iliolumbar ligament and the adjacent portion of the crest of the ilium for about two inches, and is *inserted* into the lower border of the last rib for about half its length, and by four small tendons, into the apices of the transverse processes of the four upper lumbar vertebrae. Occasionally a second portion of this muscle is found situated in front of the preceding. This *arises* from the upper borders of the transverse processes of three or four of the lower lumbar vertebrae, and is *inserted* into the lower margin of the last rib. The Quadratus lumborum is contained in a sheath formed by the anterior and middle lamellae of the lumbar fasciae.

Relations.—Its *deep surface* (or rather the fascia which covers its anterior surface) is in relation with the colon, the kidney, the Psoas muscle, and the Diaphragm. Between the fascia and the muscle are the last thoracic, iliohypogastric, and ilioinguinal nerves. Its *superficial surface* is in relation with the middle lamella of the lumbar fascia, which separates it from the

Erector spinae. The Quadratus lumborum extends, however, beyond the outer border of the Erector spinae.

Nerve-supply.—The anterior branches of the last thoracic and the first lumbar nerves; sometimes also a branch from the second lumbar nerve.

Actions.—The Quadratus lumborum draws down the last rib. It acts as a muscle of inspiration by helping to fix the origin of the Diaphragm. If the thorax and vertebral column are fixed, it may act upon the pelvis, raising it toward its own side when only one muscle is put in action; and when both muscles act together, either from below or above, they flex the trunk.

IV. MUSCLES AND FASCIÆ OF THE PELVIC OUTLET.

The **muscles and fasciæ** of the pelvic outlet are those structures which form the floor of the pelvis. **Perineum** is a term used to designate that segment of the structure lying dorsal to the pubic arch and subpubic ligament and ventral to a line drawn transversely, in front of the anus, between the anterior part of the tuberosity of the ischium of each side. The **ischiorectal space** is the name given to the segment dorsal to the line above mentioned and ventral to the tip of the coccyx. This space is bounded laterally by the Gluteus maximus muscle.

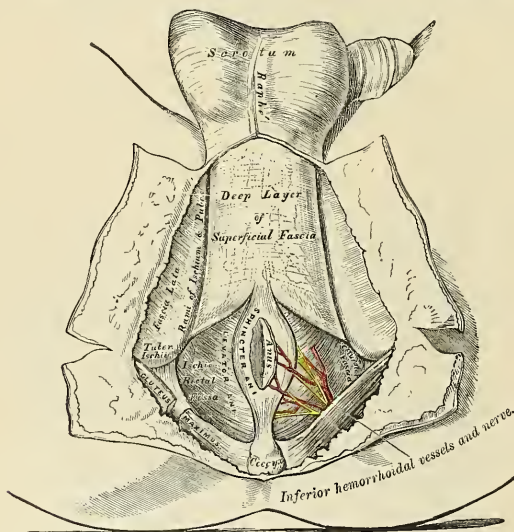


FIG. 331.—The perineum. The integument and superficial layer of superficial fascia reflected.

The **fascia** of the pelvic outlet is most easily understood if it is considered in the order of its dissection. Considered thus, it resolves itself into three strata—the superficial fascia, the triangular ligament, and the pelvic fascia. The *superficial fascia* is made up, as in other regions of the body, of a *superficial* and a *deep* layer. The fascia over the ischio-rectal region is arranged in fatty layers, which fill the ischio-rectal fossa on each side of the rectum and anus. In the region of the perineum the fascia requires fuller consideration; here it is definitely arranged into two layers—*superficial* and *deep*. The **superficial layer** is thick, loose, areolar in texture, and, except toward the scrotum, contains in its meshes

some adipose tissue, the amount of which varies in different subjects. In *front* this layer is continuous with the dartos of the scrotum, in the mid-line of which it dips deeply to form the scrotal septum. In the female this structure enters

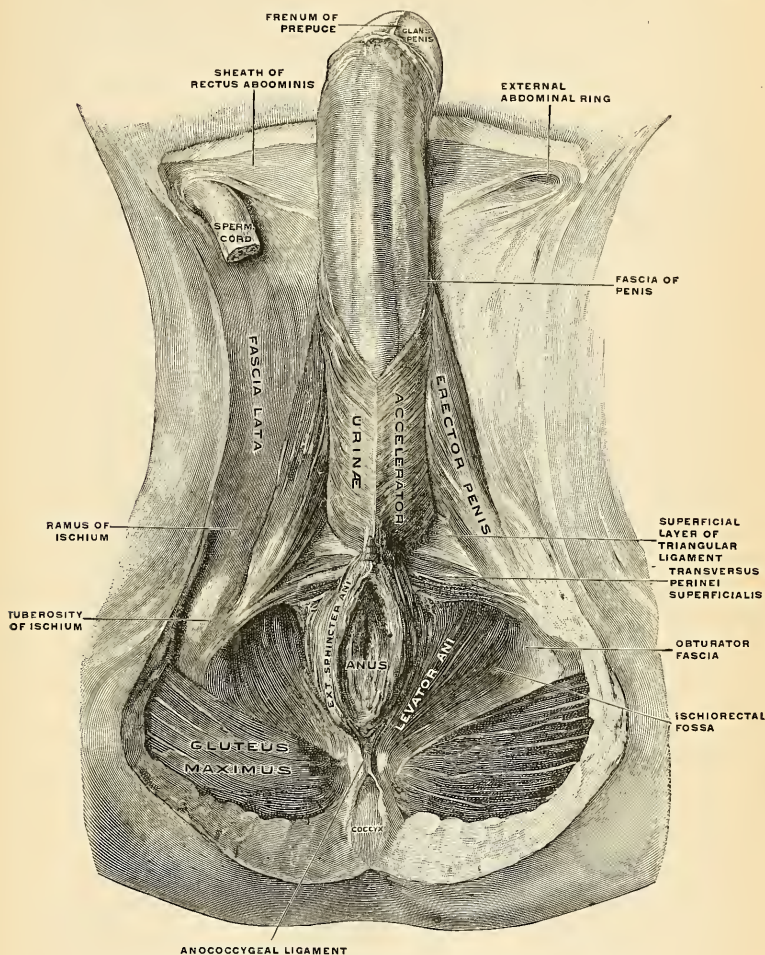


FIG. 332.—The muscles of the male perineum, viewed from below. (Spalteholz.)

into the formation of the mons veneris and the labia majora. The superficial layer is continuous on either side with the fatty fascia on the inner side of the thighs. The *deep layer of the superficial fascia*, or the *fascia of Colles* (Fig. 331), is thin, aponeurotic in structure, and of considerable strength. It serves to bind

down the muscle of the root of the penis. It is continuous with the dartos of the scrotum, with the fascia of the penis, and with Scarpa's fascia on the anterior surface of the abdomen; on *either side* it is firmly attached to the outer lip of the ischiopubic ramus. *Posteriorly* (dorsally) the deep layer curves around the superficial transverse perineal muscle to blend with the base of the triangular ligament. The *deep* (cephalic) surface of this fascia covers the superficial muscles and the superficial bloodvessels and nerves of the perineum (Fig. 333). From its deep surface a septum which is incomplete in front is given off and divides the adjacent space in two.

The Central Tendinous Point of the Perineum.—This is a fibrous point in the middle line of the pelvic outlet, between the urethra and the rectum, and about half an inch in front of the anus. At this point four muscles converge and are attached—viz., the External sphincter ani, the Accelerator urinae, and the two Superficial transverse perineal; so that by the contraction of these muscles, which extend in opposite directions, it serves as a fixed point of support (Fig. 333).

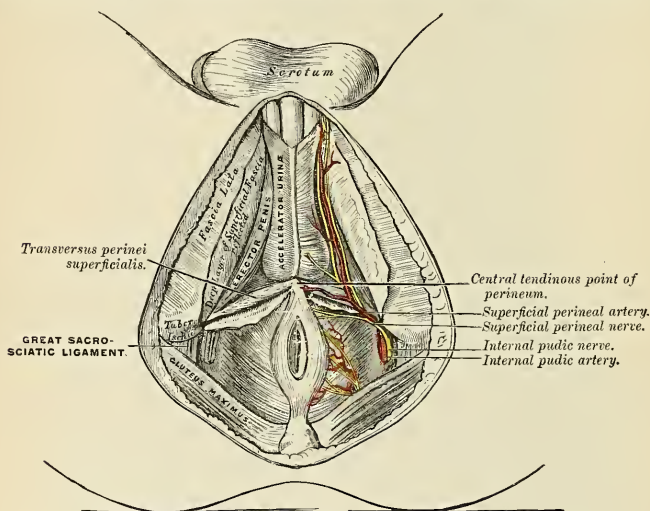


FIG. 333.—The superficial muscles and vessels of the perineum.

The Muscles of the Perineum in the Male (Figs. 332, 333).

Superficial transverse perineal.
Accelerator urinae.

Erector penis.
Compressor urethrae.

The **Superficial transverse perineal muscle** (*m. transversus perinei superficialis*) is a narrow muscular slip, which passes more or less transversely across the pelvic outlet. It *arises* by a small tendon from the inner and fore part of the tuberosity of the ischium, and, passing inward, is *inserted* into the central tendinous point of the perineum, joining in this situation with the muscle of the opposite side, the External sphincter ani behind, and the Accelerator urinae in front. The base of the triangular ligament lies under cover of this muscle.

Nerve-supply.—The perineal branch of the internal pudic.

Actions.—By their contraction they serve to fix the central tendinous point of the perineum.

The **Accelerator urinae** (*m. bulbocavernosus*) is placed in the middle line of the perineum, immediately in front of the anus. It consists of two symmetrical

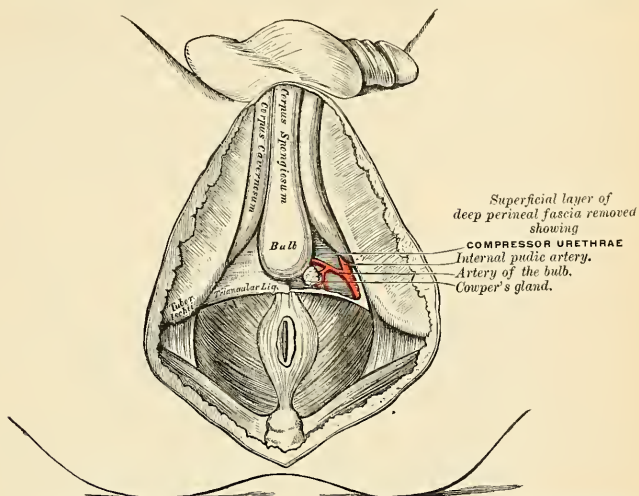


FIG. 334.—Triangular ligament or deep perineal fascia. On the left side the anterior layer has been removed.

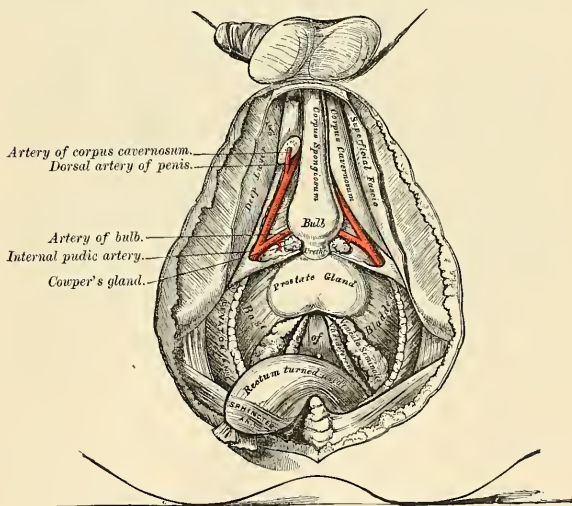


FIG. 335.—A view of the position of the viscera at the outlet of the pelvis.

halves, united along the median line by a tendinous raphé. It arises from the central tendon of the perineum, and from the median raphé in front. From this

point its fibres diverge symmetrically; the most posterior form a thin layer, which is lost on the superficial surface of the triangular ligament; the middle fibres encircle the bulb and adjacent parts of the corpus spongiosum, and join with the fibres of the opposite side, on the upper part of the corpus spongiosum, in a strong aponeurosis. The anterior fibres, the longest and most distinct, spread out over the sides of the corpus cavernosum, and are *inserted* partly into that body, anterior to the Erector penis (occasionally extending to the os pubis), and partly terminate in a tendinous expansion, which covers the dorsal vessels of the penis. The latter fibres are best seen by dividing the muscle longitudinally, and dissecting it outward from the surface of the urethra. Many fibres of the External sphincter ani and of the Superficial transverse perineal muscles pass into this muscle.

This muscle is sometimes so developed that it may be arranged under four distinct layers. In such subjects the posterior and greatest part of the muscle is composed of two layers. The deeper invests the bulb of the corpus spongiosum in a cap-like manner. It is called the **Compressor hemisphaerium bulbi**.

The superficial portion, called the **Compressor bulbi**, arises in the central tendon of the perineum, where it blends with the Superficial transversus perinei and the External sphincter ani muscles, and from the greater portion of the median tendinous raphe. The muscle spreads out to cover the bulb and adjacent portion of the corpus spongiosum, and meets its fellow of the opposite side in the strong aponeurosis on the upper part of the corpus spongiosum. The hindmost fibers are attached to the inferior surface of the subjacent triangular ligament.

The **Constrictor radices penis** consists of the most anterior fibers of the Accelerator urinae. They take origin from the portion of the median raphé not occupied by the Compressor bulbi, and spread outward, forward, and upward over the Corpus cavernosum, anterior to the insertion of the *Erector penis*, and are inserted partly into the Corpus cavernosum; other fibers terminate in a tendinous expansion which encircle the root of the penis, and, therefore, cover the dorsal vessels of this organ.

The **Ischiobulbosus** lies superficial to the Compressor bulbi; it arises from the tuberosity of the ischium and passes upward and forward to be inserted into that part of the median raphé which has to do with the bulb.

Action.—This muscle serves to empty the canal of the urethra, after the bladder has expelled its contents; during the greater part of the act of micturition its fibres are relaxed, and it only comes into action at the end of the process. The middle fibres are supposed, by Krause, to assist in the erection of the corpus spongiosum, by compressing the erectile tissue of the bulb. The anterior fibres, on each side, according to Tyrrel, also contribute to the erection of the penis, as they are inserted into, and are continuous with, the fascia of the penis, and thus compress the dorsal vein during the contraction of the muscle.

The **Erector penis** (*m. ischiocavernosus*) covers part of the crus penis. It is an elongated muscle, broader in the middle than at either extremity, and situated on either side of the lateral boundary of the perineum. It *arises* by tendinous and fleshy fibres from the inner surface of the tuberosity of the ischium and the great sacro-sciatic ligament behind the crus penis, and from the adjacent portion of the ramus of the ischium and pubis. From these points fleshy fibres succeed, which end in an aponeurosis which is *inserted* into the sides and under surface of the crus penis. Occasionally some of the fibres of this muscle that arise from the pubic ramus pass to the dorsum of the penis. To these fibres is given the name **Pubocavernosus** or **Levator penis**.

Nerve-supply.—The perineal branch of the internal pudic.

Actions.—This muscle compresses the crus penis and retards the return of the blood through the veins, and thus serves to maintain the organ erect.

Between the muscles just examined a triangular space exists, bounded internally by the Accelerator urinae, externally by the Erector penis, and behind by the Transversus perinei superficialis. The floor of this space is formed by the triangular ligament of the perineum (deep perineal fascia), and running in it from behind forward (toward the pubis) are the superficial perineal vessels and nerves, the long pudendal nerve, and the transverse perineal artery, which courses along the posterior boundary of the space on the Superficial transverse perineal muscle.

The Muscles of the Perineum in the Female.

Superficial transverse perineal.
Sphincter vaginae.

Erector clitoridis.
Compressor urethrae.

The **Superficial transverse perineal** (*m. transversus perinei superficialis*) in the female is a narrow slip which passes more or less transversely across the back part of the perineal space. It *arises* by a small tendon from the inner and fore part of the tuberosity of the ischium, and, passing inward, is *inserted* into the central point of the perineum, joining in this situation with the muscle of the opposite side, the External sphincter ani behind, and the Sphincter vaginae in front.

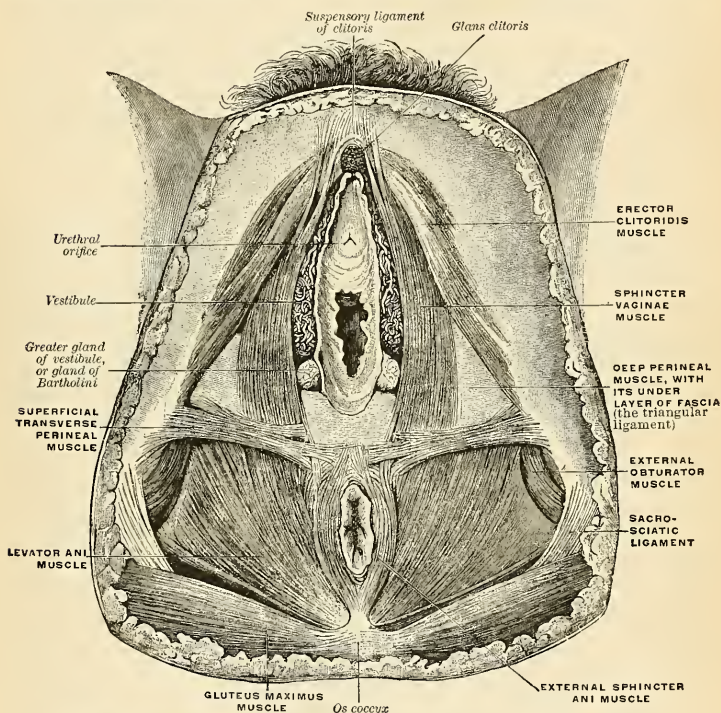


FIG. 336.—The female perineum after removal of the skin and superficial fascia. (Bardeleben.)

Nerve-supply.—The perineal branch of the internal pudic.

Actions.—By their contraction these muscles serve to fix the central tendinous point of the perineum.

The **Sphincter vaginae** (*m. bulbocavernosus*) surrounds the orifice of the vagina; it is homologous with the Accelerator urinae in the male. It *arises* posteriorly from the central tendinous point of the perineum, where it blends with the External sphincter ani. Its fibres pass forward on each side of the vagina, where it covers

the vaginal bulb, to be *inserted* into the corpora cavernosa of the clitoris; a fasciculus crosses over the body of the organ and compresses the dorsal vein.

Nerve-supply.—The perineal branch of the internal pudic.

Actions.—It diminishes the orifice of the vagina. The anterior fibres contribute to the erection of the clitoris, as they are inserted into and are continuous with the fascia of the clitoris and compress the dorsal vein during the contraction of the muscle.

The **Erector clitoridis** (*m. ischiocavernosus*) resembles the Erector penis in the male, but is smaller. It covers the unattached part of the crus clitoridis. It is an elongated muscle, broader at the middle than at either extremity, and situated on either side of the lateral boundary of the perineum. It *arises* by tendinous and fleshy fibres from the inner surface of the tuberosity of the ischium, behind the crus clitoridis from the surface of the crus, and from the adjacent portion of the ramus of the ischium. From these points fleshy fibres succeed, ending in an aponeurosis, which is *inserted* into the sides and under surface of the crus clitoridis.

Nerve-supply.—The perineal branch of the internal pudic.

Actions.—It compresses the crus clitoris and retards the return of blood through the veins, and thus serves to maintain the organ erect.

The Triangular Ligament in the Male and in the Female.

The **triangular ligament** or the **deep perineal fascia** (*diaphragma urogenitale*) (Figs. 336, 337, 338) is stretched almost horizontally across the pubic arch, so as to close in the front part of the outlet of the pelvis. It consists of two dense membranous laminae, which are united along their dorsal borders, but are separated ventrally by intervening structures. The **superficial layer** (*fascia diaphragmatis urogenitalis inferior*) is triangular in shape and about an inch and a half in depth. Its apex is directed forward, and is separated from the subpubic ligament by an oval opening for the transmission of the dorsal vein of the penis. A strengthening band, the **transverse pelvic ligament** (*ligamentum transversum pelvis*), passes from one pubic bone to the other below the vein. The lateral margins of the inferior layer of the triangular ligament are attached on each side to the rami of the ischium and os pubis, above the crura penis. The base is directed toward the rectum, and connected to the central tendinous point of the perineum. It is continuous with the deep layer of the superficial fascia behind the Superficial transverse perineal muscles (Fig. 337), and with a thin fascia which covers the cutaneous surface of the Levator ani muscle, the **anal or ischiorectal fascia** (Fig. 341).

This layer of the triangular ligament is perforated, about an inch below the symphysis pubis, by the urethra, the aperture for which is circular in form; by the arteries to the bulb and by the ducts of Cowper's glands close to the urethral aperture; by the arteries to the corpora cavernosa—one on each side, close to the pubic arch and about half-way along the attached margin of the ligament; and by the dorsal arteries and nerves of the penis near the apex of the ligament. Its base is also perforated by the superficial perineal vessels and nerves, while between its apex and the subpubic ligament passes the dorsal vein of the penis.

When this superficial layer of the triangular ligament is detached, the following structures will be seen between it and the deeper layer: The membranous portion of the urethra and the Compressor urethrae muscle; Cowper's glands and their ducts; the pudic vessels and dorsal nerve of the penis; the artery and nerve of the bulb, and a plexus of veins (Fig. 334).

The triangular ligament in the *female* (Fig. 336) is not so strong as in the male. It is divided in the middle line by the aperture of the vagina, with the external coat of which it becomes blended; between the vaginal orifice and the pubis it is

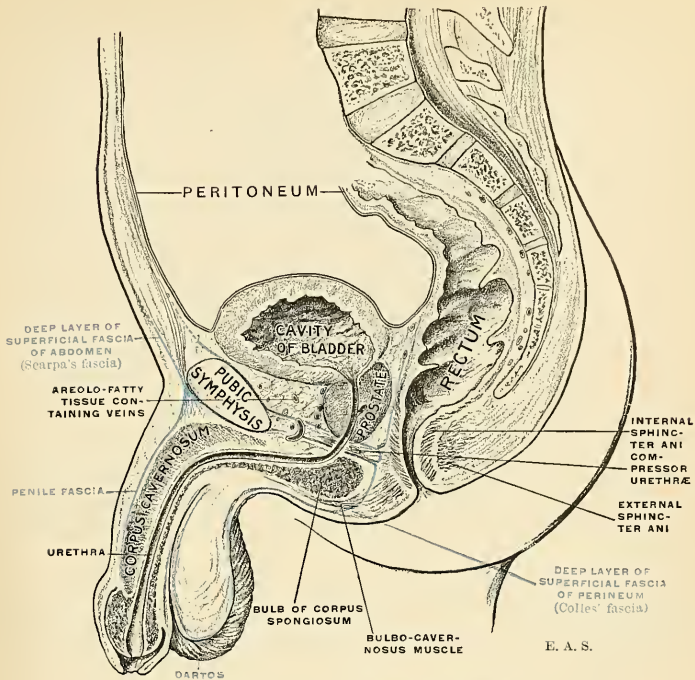


FIG. 337.—The triangular ligament of the perineum.

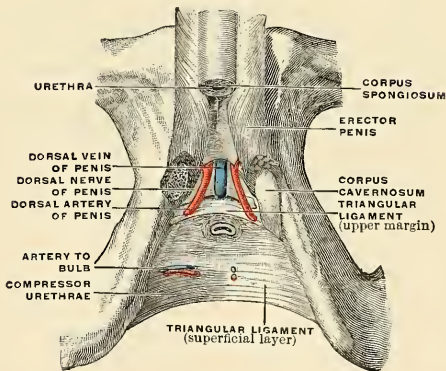


FIG. 338.—The superficial layer of the triangular ligament. The Compressor urethrae muscle lies behind the superficial layer of the triangular ligament and is shown in the figure for convenience. (Poirier and Charpy.)

perforated by the urethra. Its base is continuous, as in the male, with the deep layer of the superficial fascia surrounding the Transversus perinei muscles. Like the triangular ligament in the male, it consists of two layers, between which are to be found the following structures: The dorsal vein and nerves of the clitoris, a portion of the urethra and the Compressor urethrae muscle, the glands of Bartholin and their ducts, the pudic vessels, the arteries of the vestibular bulbs, and a plexus of veins. The deep layer of the triangular ligament is a part of the pelvic fascia, and is described on page 449.

The **Compressor** or **Constrictor urethrae** (*m. sphincter urethrae membranacea*) in the *male* surrounds the whole length of the membranous portion of the urethra, and is contained between the two layers of the triangular ligament. It *arises*, by aponeurotic fibres, from the junction of the rami of the os pubis and ischium, to the extent of half or three-quarters of an inch—the point where the crura penis join the transverse ligament of the perineum and the layers of the triangular ligament; each segment of the muscle passes inward, and divides into two fasciculi, which *surround* the membranous urethra and *unite*, at the upper and lower surfaces of this tube, with the muscle of the opposite side by means of a tendinous raphé. This muscle is frequently discovered in two portions, an **anterior** and a **posterior**, separated by a distinct interval. In such cases the posterior fibres are called the **transversus perinei profundus**, and the anterior fibres are called the **sphincter urethrae membranaceae**. The Compressor urethrae in the *female* arises as in the male; passing mesally, likewise, it divides into two fasciculi; these latter, however, have not the same intimate functional relationship to the urethra as has the muscle of the male. One fasciculus passes ventrad of the urethra to blend with its opposite fellow; the posterior fascicle inserts itself into the lateral vaginal wall.

Nerve-supply.—The perineal branch of the internal pudic.

Actions.—The muscles of both sides act together as a sphincter, compressing the membranous portion of the urethra. During the transmission of fluid they, like the Acceleratores urinae, are relaxed, and come into action only at the end of the process, to eject the last drops of the fluid.

The Pelvic Fascia.

The **pelvic fascia** binds strongly together the pelvic structures, supports the bloodvessels, nerves, and lymphatics, and strengthens the floor of the cavity. *Above*, it is loosely connected to the back part of the iliopectineal line, and is continuous here with the iliac fascia. *Posteriorly*, over the sacrum, it is very thin and lies ventrad to the Piriformis muscle and to the sacral plexus of nerves. This part is often called the **fascia of the Piriformis**, and extends outward along the muscle into the gluteal region. At its sacral attachments around the margins of the sacral foramina it comes into intimate association with and ensheathes the nerves as they emerge from these foramina. Anterior to its iliopectineal attachment the pelvic fascia sinks in its attachment below the brim of the pelvis. It arches below the obturator vessels and nerves, completing the obturator canal, and at the front of the pelvis the line of attachment is depressed on the posterior surface of the os pubis, so that at the symphysis it lies just above the inferior border of this bone. From this line of attachment the posterior part is prolonged outward on the Obturator internus into the gluteal region. The middle portion descends on the visceral surface of the Obturator internus to become attached to the falciform process of the great sacrosciatic ligament. Because of this relation with the Obturator internus this part is called the **Obturator fascia** (Fig. 340). The part attached to the body of the pubis descends to be attached to the ischiopubic ramus, and here becomes blended with the base of the triangular ligament (Fig. 341). From the ischiopubic ramus it is continued

onward behind the Compressor urethrae muscle across the pubic arch, to be continuous with the fascia of the opposite side. Here it takes a special name, the

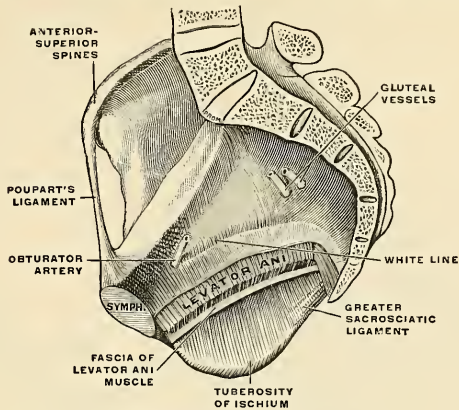


FIG. 339.—Pelvic fascia (semidiagrammatic).

deep layer of the triangular ligament (*fascia diaphragmatis urogenitalis superior*) (Figs. 337 and 341). This part of the fascia is perforated by the urethra; a por-

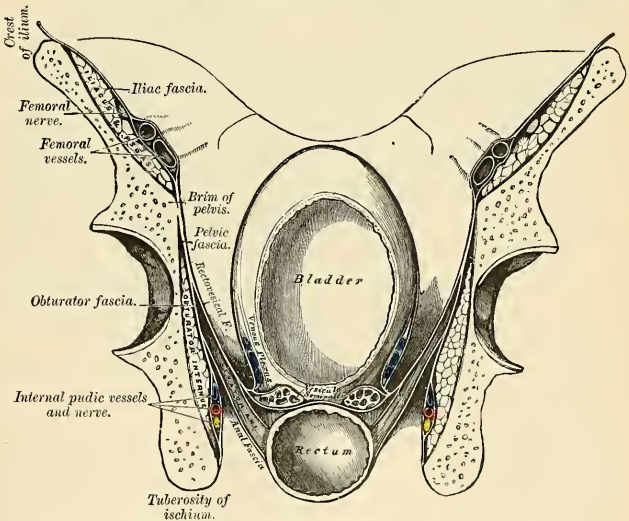


FIG. 340.—A transverse section of the pelvis, showing the pelvic fascia from behind.

tion of it turns backward around the anterior extremity of the Levator ani muscle to join the visceral layer next to be considered.

At the level of a line extending from the back part of the symphysis pubis to the spine of the ischium is a thick, whitish band termed the **white line** (*arcus*

tendineus) (Fig. 339). Above this line the fascia lies in contact with the peritoneum and belongs to the pelvic cavity. Below this line the obturator fascia has to do with the ischiorectal space. The pudic vessels and nerves cross this area enclosed in a special sheath (**Alcock's canal**). At the white line the obturator fascia gives off a special layer to the pelvic viscera, Rectovesical fascia (*fascia endopelvina*); where these two layers diverge partly arises the Levator ani (Figs. 339 and 340). The Rectovesical fascia lies superior (cephalad) to the Levator ani (Fig. 340). Traced forward it is seen to be attached to the posterior surface of the body of the pubis three-fourths of an inch higher than the pelvic fascia. Traced internally it approaches the bladder and rectum; here it splits into several layers. The upper layer invests the bladder and constitutes the *lateral true ligament* of the bladder; another prolongation invests the seminal vesicle, passes between the bladder and rectum, being continuous with the same fascia on the

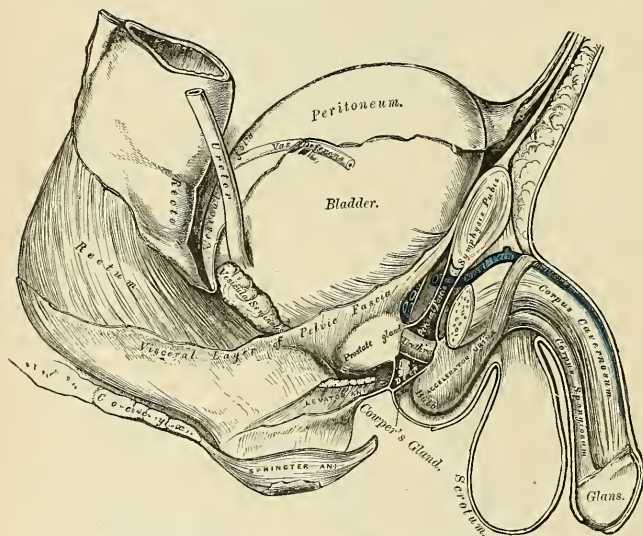


FIG. 341.—Side view of the pelvic viscera of the male subject, showing the pelvic and perineal fasciae.

opposite side; a third investment is also prolonged downward on the rectum within the insertion of the Levator ani muscle. In front of the bladder the fascia closely ensheathes the prostate gland and prostate plexus of veins, forming the capsule of the prostate. That portion of the fascia which is attached to the body of the pubis passes backward as a narrow cord-like band to the upper part of the prostate and upper part of the neck of the bladder; this is the **anterior true ligament** of the bladder, or **puboprostatic ligament** (Figs. 340, 341).

The **Anal fascia** is a thin, aponeurotic fascia which clothes the under surface of the Levator ani muscle. It arises from the obturator fascia just below the origin of the Levator ani, and extends inward and downward and separates this muscle from the ischiorectal fossa. (See page 454.)

The **Levator ani** (Fig. 343) is a broad, thin muscle, situated on the side of the pelvis. It is attached to the inner surface of the side of the true pelvis, and descends to unite with its fellow of the opposite side. Together these structures

form the greater part of the floor of the pelvic cavity. They support the viscera in this cavity and surround the various structures which pass through it. This muscle *arises*, in *front*, from the posterior surface of the body of the pubis on the outer side of the symphysis; *behind*, from the inner surface of the spine of the ischium; and *between* these two points, from the obturator fascia. *Posteriorly*, this fascial origin corresponds, more or less closely, with the white line (page 449),

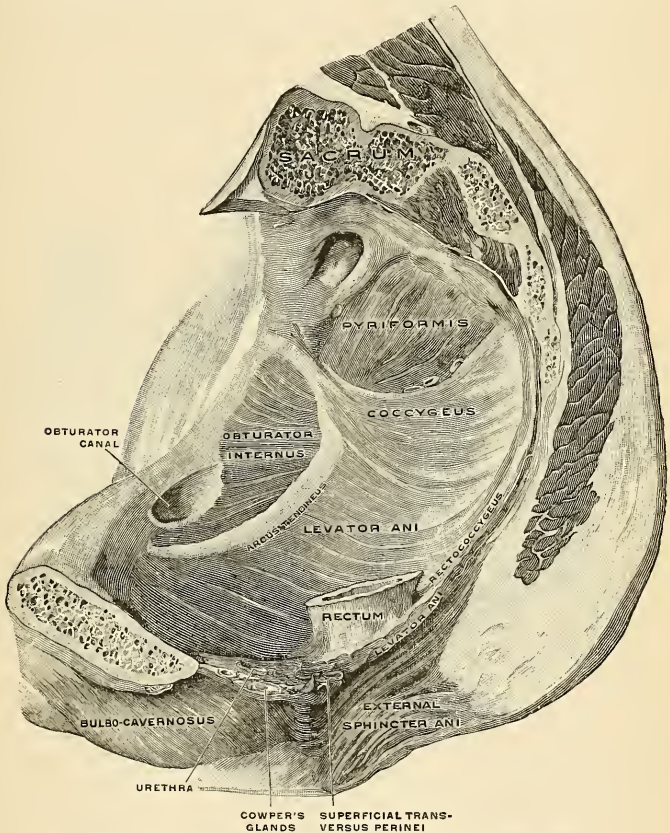


FIG. 342.—The right Levator ani in the male, viewed from the left. (Spalteholz.)

but in front the muscle arises from the fascia at a varying distance above the white line, in some cases reaching nearly as high as the canal for the obturator vessels and nerve. The fibres pass downward to the middle line of the floor of the pelvis; the most posterior are *inserted* into the sides of the last two segments of the coccyx; those placed more anteriorly unite with the muscle of the opposite side, in a median fibrous raphé (*anococcygeal raphé*), which extends between the coccyx and the margin of the anus. The middle fibres are *inserted* into the side of the rectum,

blending with the fibres of the Sphincter muscles; lastly, the anterior fibres descend upon the side of the prostate gland to unite beneath it with the muscle of the opposite side, joining with the fibres of the External sphincter and Transversus perinei muscles at the central tendinous point of the perineum.

The anterior portion is occasionally separated from the rest of the muscle by connective tissue. From this circumstance, as well as from its peculiar relation with the prostate gland, descending by its side, and surrounding it as in a sling, it has been described by Santorini and others as a distinct muscle, under the name of *Levator prostatae*. In the female the anterior fibres of the Levator ani descend upon the side of the vagina.

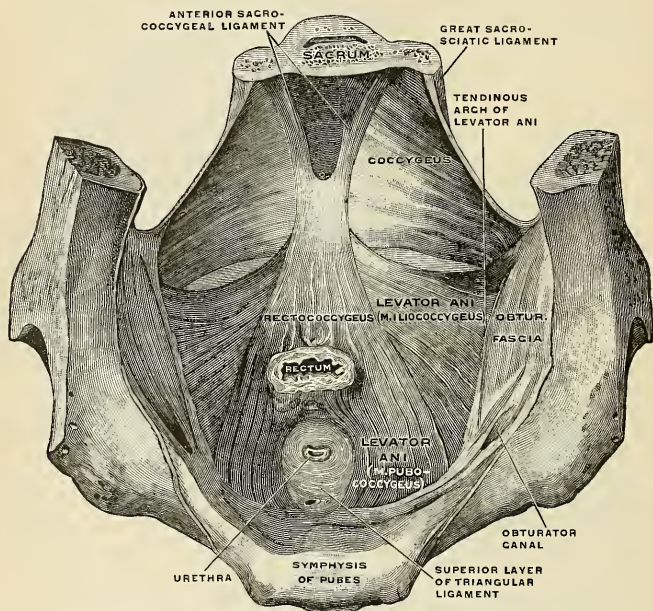


FIG. 343.—The levator ani of the male, viewed from above. (Spalteholz.)

Relations.—By its *deep, upper, or pelvic surface* the Levator ani is in relation with the rectovesical fascia, which separates it from the bladder, prostate, rectum, and peritoneum. By its *superficial, lower, or perineal surface* it forms the inner boundary of the ischioanal fossa, and is covered by a thin layer of fascia, the *anal fascia*, given off from the obturator fascia. Its *posterior border* is free and separated from the Coccygeus muscle by a cellular interspace. Its *anterior border* is separated from the muscle of the opposite side by a triangular space, through which the urethra, and in the female the vagina, pass from the pelvis.

The Levator ani may be divided into iliococcygeal and pubococcygeal parts. (Fig. 343.)

The *Iliococcygeus* arises from the ischial spine and from the posterior part of the pelvic fascia, and is attached to the coccyx and anococcygeal raphe; it is usually thin, and may fail entirely, or be largely replaced by fibrous tissue. An accessory slip at its posterior part is sometimes named the *Iliosacralis*. The *Pubococcygeus* arises from the back of the pubis and from the anterior part of the pelvic fascia, and "is directed backward almost horizontally along the side of the anal canal toward the coccyx and sacrum, to which it finds attachment. Between the termination of the vertebral column and the anus the two pubococcygeal muscles come together and form a thick, fibromuscular layer lying on the raphe formed by the iliococcygei" (Thompson). The greater part of this muscle is *inserted* into the coccyx and into the last one or two pieces of the sacrum. This insertion into the vertebral column is, however, not admitted by all observers. The fibres which form a sling for the rectum are named the *Puborectalis* or *Sphincter recti*.

They arise from the lower part of the symphysis pubis, and from the upper layer of the triangular ligament. They meet with the corresponding fibres of the opposite side around the lower part of the rectum, and form for it a strong sling.

Nerve-supply.—The Levator ani is supplied by a branch from the fourth sacral nerve and by a branch which is sometimes derived from the perineal, sometimes from the inferior hemorrhoidal division of the pudic nerve.

The **Coccygeus** (*m. coccygeus*) (Fig. 343) is situated behind and parallel with the preceding. It is a triangular plane of muscular and tendinous fibres, arising by its apex from the spine of the ischium and lesser sacrosciatic ligament, and inserted by its base into the margin of the coccyx and into the side of the lower piece of the sacrum. It assists the Levator ani and Piriformis in closing in the back part of the outlet of the pelvis.

Nerve-supply.—The Coccygeus is supplied by a branch from the fourth and fifth sacral nerves.

Actions.—The Levatores ani constrict the lower end of the rectum and vagina. They elevate and invert the lower end of the rectum after it has been protruded and everted during the expulsion of the feces. The Coccygei muscles pull forward and support the coccyx, after it has been pressed backward during defecation or parturition. The Levatores ani and Coccygei together form a muscular diaphragm which supports the pelvic viscera.

Muscles of the Ischiorectal Region.

Corrugator cutis ani.	Internal sphincter ani.
External sphincter ani.	Levator ani (described on page 450).
Coccygeus (described above).	

The Corrugator Cutis Ani.—Around the anus is a thin stratum of involuntary muscle fibre which radiates from the orifice. *Internally*, the fibres fade into the submucous tissue, while *externally* they blend with the true skin. By its contraction it raises the skin into ridges around the margin of the anus.

The **External sphincter ani** (*m. sphincter ani externus*) (Figs. 332, 333, 336, and 342) is a thin, flat plane of muscle fibre, elliptical in shape and intimately adherent to the integument surrounding the margin of the anus. It measures about three or four inches in length from its anterior to its posterior extremity, being about an inch in breadth opposite the anus. It consists of two strata, superficial and deep. The *superficial*, constituting the main portion of the muscle, arises from a narrow tendinous band, the *anococcygeal raphe*, which stretches from the tip of the coccyx to the posterior margin of the anus; it forms two flattened planes of muscle tissue, which encircle the anus and meet in front of be inserted into the central tendinous point of the perineum, joining with the Transversus perinei, the Levator ani, and the Accelerator urinae. The *deeper portion* forms a complete sphincter to the anal canal. Its fibres surround the canal, closely applied to the Internal sphincter, and in front blend with the other muscles at the central point of the perineum. In a considerable proportion of cases the fibres decussate in front of the anus, and are continuous with the Transversus perinei. Posteriorly, they are not attached to the coccyx, the fibres of opposite sides being continuous behind the anal canal. The upper edge of the muscle is ill-defined, since fibres are given off from it to join the Levator ani.

Nerve-supply.—A branch from the fourth sacral and twigs from the inferior hemorrhoidal branch of the internal pudic supply the muscle.

Actions.—The action of this muscle is peculiar: (1) It is, like other muscles, always in a state of tonic contraction, and having no antagonistic muscle it keeps the anal canal and orifice closed. (2) It can be put into a condition of greater contraction under the influence of the will, so as more firmly to occlude the anal aperture in expiratory efforts, unconnected with defecation. (3) Taking its fixed point at the coccyx, it helps to fix the central point of the perineum, so that the Accelerator urinae may act from this fixed point.

The **Internal sphincter ani** (*m. sphincter ani internus*) is a ring of muscle which surrounds the anal canal for about an inch; its inferior border being contiguous with, but quite separate from, the External sphincter. This muscle is about a sixth of an inch in thickness, and is formed by an aggregation of the involuntary circular fibres of the intestine. It surrounds the canal for about an inch, its lower border being about a quarter of an inch from the external orifice. It is paler in color and less coarse in texture than the External sphincter.

Actions.—Its action is entirely involuntary. It helps the External sphincter to occlude the anal aperture.

The **Ischiorectal fossa** (*fossa ischiorectalis*) (Figs. 332 and 342) is situated between the end of the rectum and the ischial tuberosity. It is triangular in shape; its **base**, directed to the surface of the body, is formed by the integument of the ischiorectal region; its **apex**, directed upward, corresponds to the point of division of the obturator fascia and the thin membrane given off from it, which covers the outer surface of the Levator ani (anal fascia). Its dimensions are about an inch in breadth at the base and about two inches in depth, being deeper behind than in front. It is bounded, *internally*, by the Sphincter ani, Levator ani, and the Coccygeus muscles; *externally*, by the tuberosity of the ischium and the obturator fascia, which covers the inner surface of the Obturator internus muscle; in *front*, it is limited by the line of junction of the deep layer of the superficial fascia with the base of the triangular ligament; and *behind*, by the margin of the Gluteus maximus muscle and the great sacrosciatic ligament. This space is filled with a large mass of adipose tissue, which explains the frequency with which abscesses in the neighborhood of the rectum burrow to a considerable depth.

The fascia covering the inferior surface of the pelvic diaphragm is known as the **anal fascia** (*fascia inferior diaphragmatis pelvis*). It is attached above to the obturator fascia along the line of origin of the Levator ani, while below it is continuous with the deep layer of the triangular ligament and with the fascia on the Internal sphincter ani. The layer covering the upper surface of the pelvic diaphragm (*pars diaphragmatica fasciae pelvis*) follows, *above*, the line of origin of the Levator ani, and is therefore somewhat variable. In *front* it is attached to the back of the symphysis pubis about three-quarters of an inch above its lower border. It can then be traced outward across the back of the body of the pubis for a distance of about half an inch, where it joins the obturator fascia. It is attached to this fascia along a line which pursues a somewhat irregular course to the spine of the ischium. The irregularity of this line is due to the fact that the origin of the Levator ani, which in lower forms is from the pelvic brim, is in man lower down, on the obturator fascia. Tendinous fibres of origin of the muscle are therefore often found extending up toward, and in some cases reaching, the pelvic brim, and on these the fascia is carried.

MUSCLES AND FASCIAE OF THE UPPER EXTREMITY.

The muscles of the upper extremity are divisible into groups, corresponding with the different regions of the limb.

I. OF THE THORACIC REGION.

1. Anterior Thoracic Region.

Pectoralis major. Pectoralis minor.
Subclavius.

2. Lateral Thoracic Region.

Serratus magnus.

II. OF THE SHOULDER AND ARM.

3. Acromial Region.

Deltoid.

4. Anterior Scapular Region.

Subscapularis.

5. *Posterior Scapular Region.*

Supraspinatus.	Teres minor.
Infraspinatus.	Teres major.

6. *Anterior Humeral Region.*

Coracobrachialis.	Biceps.
Brachialis anticus.	

7. *Posterior Humeral Region.*

Triceps.	Subanconeus.
----------	--------------

III. OF THE FOREARM.

8. *Anterior Radioulnar Region.*

Deep	Superficial	Layer.	{	Pronator teres.
				Flexor carpi radialis.
Deep	Superficial	Layer.	{	Palmaris longus.
				Flexor carpi ulnaris.
				Flexor sublimis digitorum.
				Flexor profundus digitorum.
				Flexor longus pollicis.
				Pronator quadratus.

9. *Radial Region.*

Brachioradialis.
Extensor carpi radialis longior.
Extensor carpi radialis brevior.

10. *Posterior Radioulnar Region.*

Superficial	Layer.	{	Extensor communis digitorum.
			Extensor minimi digiti.
Deep	Layer.	{	Extensor carpi ulnaris.
			Anconeus.
			Supinator [brevis].
			Extensor ossis metacarpi pollicis.
			Extensor brevis pollicis.
			Extensor longus pollicis.
Deep	Layer.	{	Extensor indicis.

IV. OF THE HAND.

11. *Radial Region.*

Abductor pollicis.
Opponens pollicis.
Flexor brevis pollicis.
Adductor obliquus pollicis.
Adductor transversus pollicis.

12. *Ulnar Region.*

Palmaris brevis.
Abductor minimi digiti.
Flexor brevis minimi digiti.
Opponens minimi digiti.

13. *Middle Palmar Region.*

Lumbricales.
Interossei palmares.
Interossei dorsales.

Dissection of Pectoral Region and Axilla (Fig. 344).—The arm being drawn away from the side nearly at right angles with the trunk and rotated outward, make a vertical incision through the integument in the median line of the thorax, from the upper to the lower part of the sternum; a second incision along the lower border of the Pectoral muscle, from the ensiform cartilage to the inner side of the axilla; a third, from the sternum along the clavicle, as far as its centre; and a fourth, from the middle of the clavicle obliquely downward, along the interspace between the Pectoral and Deltoid muscles, as low as the fold of the axilla. The flap of integument is then to be dissected off in the direction indicated in the figure, but not entirely removed, as it should be replaced on completing the dissection. If a transverse incision is now made from the lower end of the sternum to the side of the thorax, as far as the posterior fold of the axilla, and the integument reflected outward, the axillary space will be more completely exposed.

I. THE MUSCLES AND FASCIÆ OF THE THORACIC REGION.

1. *The Anterior Thoracic Region.*

Pectoralis major	Pectoralis minor.
[Sternalis.]	Subclavius.

The **superficial fascia** of the thoracic region is a loose cellulofibrous layer enclosing masses of fat in its spaces. It is continuous with the superficial fascia of the neck and upper extremity above, and with that of the abdomen below. Oppo-

site the mamma it divides into two layers, one of which passes in front, the other behind that gland; and from both of these layers numerous septa pass into its substance, supporting its various lobes; from the anterior layer fibrous processes pass forward to the integument and nipple. These processes were called by Sir A. Cooper the **suspensory ligaments**, from the support they afford to the gland in this situation.

The **deep thoracic fascia** is a thin aponeurotic lamina, covering the surface of the great Pectoral muscle, and sending numerous prolongations between its fasciculi; it is attached, *in the mid-line*, to the front of the sternum, and *above* to the clavicle; *externally* and below it becomes continuous with the fascia over the shoulder, axilla, and thorax. It is very thin over the upper part of the muscle, thicker in the interval between the Pectoralis major and Latissimus dorsi, where

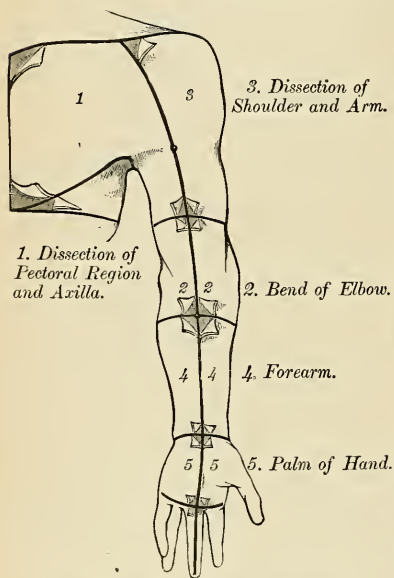


FIG. 344.—Dissection of the upper extremity.

it closes in the axillary space, and is known as the **axillary fascia** (*fascia axillaris*). It passes behind into the fascia of the Latissimus dorsi and Teres major, in front into the fascia of the Deltoid and outward into the fascia of the arm. The fascia of the Latissimus dorsi divides at the outer margin of the muscle into two layers, one of which passes in front and the other behind it; these proceed as far as the spinous processes of the thoracic vertebræ, to which they are attached. As the axillary fascia leaves the lower edge of the Pectoralis major to pass across the floor of the axilla it sends a layer upward under cover to the muscle, the **deep pectoral fascia**; this lamina splits to envelop the Pectoralis minor, at the upper edge of which it becomes continuous with the **costocoracoid membrane** (*clavipectoral fascia*). The hollow of the axilla, seen when the arm is abducted, is mainly produced by the traction of this fascia on the axillary floor, the **axillary fascia**

hence it is sometimes named the **suspensory ligament of the axilla**. The axillary fascia is not a distinct and complete rigid floor of the axillary space. Like all other fasciæ, it follows muscular planes, and splits to encompass vessels, nerves, and muscles. In it are numerous perforations. At the lower part of the thoracic region the deep thoracic fascia is well developed, and is continuous with the fibrous sheath of the Recti abdominis.

The **Pectoralis major** (*m. pectoralis major*) (Fig. 345) is a broad, thick, triangular muscle, situated at the upper and fore part of the thorax, in front of the axilla. It *arises* from the anterior surface of the sternal half of the clavicle; from half the breadth of the anterior surface of the sternum, as low down as the attachment of the cartilage of the sixth or seventh rib; this portion of its origin consists of aponeurotic fibres, which intersect with those of the opposite muscle; it also *arises* from the cartilages of all true ribs, with the exception, frequently, of the first

or the seventh, or both; and from the aponeurosis of the External oblique muscle of the abdomen. The fibres from this extensive origin converge toward its insertion, giving to the muscle a radiated appearance. Those fibres which arise from the clavicle pass obliquely outward and downward and are usually separated from the rest by a cellular interval; those from the lower part of the sternum, and the cartilages of the lower true ribs, pass upward and outward, while the middle fibres pass horizontally. They all terminate in a flat tendon, about two inches

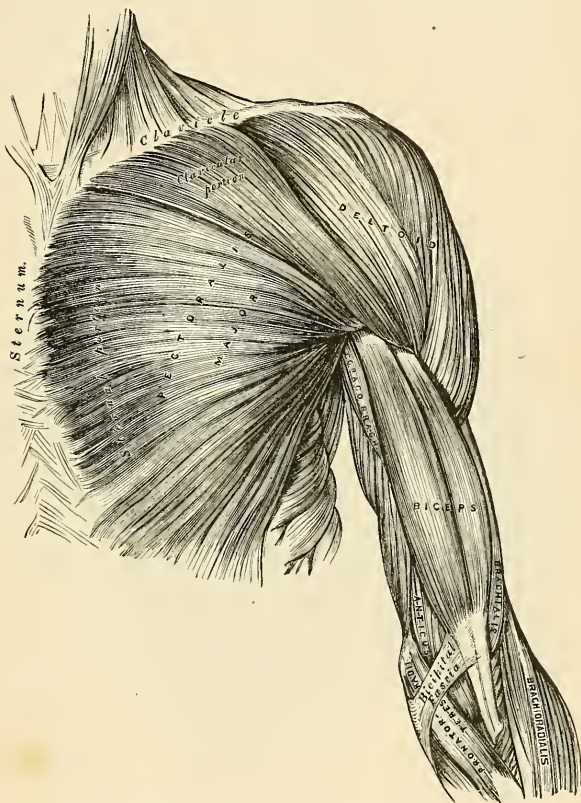


FIG. 345.—Muscles of the thorax and front of the arm. Superficial view.

broad, which is *inserted* into the outer bicipital ridge of the humerus. This tendon consists of two laminæ, placed one in front of the other, and usually blended together below. The *superficial*, the thicker, receives the clavicular and upper half of the sternal portion of the muscle; and its fibres are inserted in the same order as that in which they arise; that is to say, the outermost fibres of origin from the clavicle are inserted at the uppermost part of the tendon; the upper fibres

of origin from the sternum pass down to the lowermost part of this superficial lamina of the tendon and extend as low as the tendon of the Deltoid and join with it. The *deep* lamina of the tendon receives the attachment of the lower half of the sternal portion and the deeper part of the muscle from the costal cartilages. These deep fibres, and particularly those from the lower costal cartilages ascend, the higher turning backward successively behind the superficial and upper ones, so that the tendon appears to be twisted. The deep lamina reaches higher on the humerus than the superficial one, and from it an expansion is given off which covers the bicipital groove and blends with the capsule of the shoulder-joint. From the deepest fibres of this lamina at its insertion an expansion is given off which lines the bicipital groove of the humerus, while from the lower border of the tendon a third expansion passes downward to the fascia of the arm. Between the posterior surface of the tendon of the Great pectoral and the anterior surface of the long head of the Biceps there is usually a bursa (bursa m. pectoralis majoris).

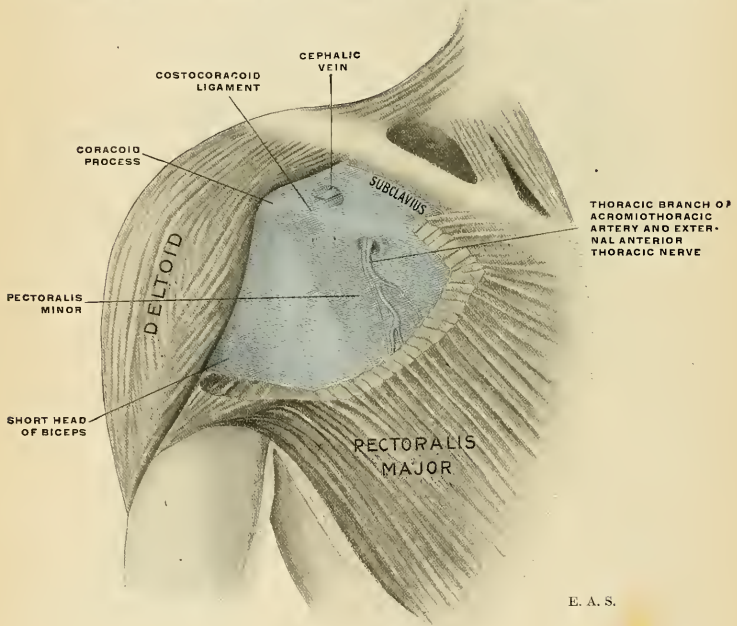


FIG. 346.—Costocoracoid membrane.

Relations.—By its *superficial surface*, with the integument, the superficial fascia, the Platysma, some of the branches of the descending cervical nerves, the mammary gland, and the deep fascia; by its *deep surface*: its *thoracic portion*, with the sternum, the ribs and costal cartilages, the costocoracoid membrane, the Subclavius, Pectoralis minor, Serratus magnus, and the Intercostals; its *axillary portion* forms the anterior wall of the axillary space, and covers the axillary vessels and nerves, the Biceps brachii and Coracobrachialis muscles. Its *upper border* lies parallel with the Deltoid, from which it is separated by a slight interspace in which lie the cephalic vein and humeral branch of the acromial thoracic artery. Its *lower border* forms the anterior margin of the axilla, being at first separated from the Latissimus dorsi by a considerable interval; but both muscles gradually converge toward the outer part of the space.

A **Sternalis** muscle is occasionally found in the pectoral region; it may be confined to one side, or may be bilateral. It is sometimes represented by delicate scattered fibres overlying a normal Pectoralis major, or by a well-developed muscle associated with a defective Pectoralis major. It is often attached to the sternal end of the Sternomastoid; below, it becomes lost in the presternal fascia or in the aponeurosis of the External oblique. This variant is regarded as a displaced and rotated segment of the Pectoralis major; it is supplied by branches from the anterior thoracic nerve.

Dissection.—Detach the Pectoralis major by dividing the muscle along its attachment to the clavicle, and by making a vertical incision through its substance a little external to its line of attachment to the sternum and costal cartilages. The muscle should then be reflected outward, and its tendon carefully examined. The Pectoralis minor is now exposed, and immediately above it, in the interval between its upper border and the clavicle, a strong fascia, the costo-coracoid membrane.

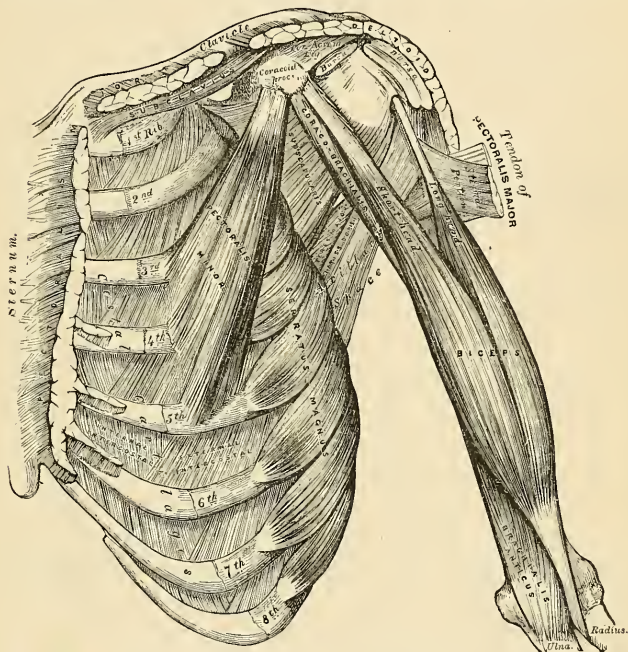


FIG. 347.—Muscles of the thorax and front of the arm, showing some of the boundaries of the axilla.

The **Costocoracoid Membrane**, or the **Clavipectoral Fascia** (*fascia coracoclavicularis*) (Fig. 346), is a strong fascia, situated under cover of the clavicular portion of the Pectoralis major muscle. It occupies the interval between the Pectoralis minor and Subclavius muscle, and protects the axillary vessels and nerves. Traced upward, it splits to enclose the Subclavius muscle, and its two layers are attached to the clavicle, one in front of and the other behind the muscle; the deep layer fuses with the deep cervical fascia and with the sheath of the axillary vessels. *Medially*, it blends with the fascia, covering the first two intercostal spaces, and is attached also to the first rib internal to the origin of the Subclavius muscle. *Laterally*, it is very thick and dense, and is attached to the coracoid

process. The portion extending from its attachment to the first rib to the coracoid process is often whiter and denser than the rest; this is sometimes called the **costocoracoid ligament**. *Below*, it is thin, and at the upper border of the Pectoralis minor it splits into two layers to invest this muscle; from the lower border of the Pectoralis minor it is continued downward to join the axillary fascia, and outward to join the fascia over the short head of the Biceps. The costocoracoid membrane is pierced by the cephalic vein, the acromiothoracic artery and vein, superior thoracic artery, and anterior thoracic nerve.

The **Pectoralis minor** (*m. pectoralis minor*) (Fig. 347) is a thin, flat, triangular muscle, situated at the upper part of the thorax, beneath the Pectoralis major. It *arises* by three tendinous digitations from the upper margin and outer surface of the third, fourth, and fifth ribs, near their cartilages, and from the aponeurosis covering the Intercostal muscles; the fibres pass upward and outward, and converge to form a flat tendon, which is *inserted* into the inner border and upper surface of the coracoid process of the scapula.

Relations.—By its *superficial surface*, with the Pectoralis major and the thoracic branches of the acromiothoracic artery. By its *deep surface*, with the ribs, Intercostal muscles, Serratus magnus, the axillary space, and the axillary vessels and brachial plexus of nerves. Its upper border is separated from the clavicle by a narrow triangular interval, occupied by the costocoracoid membrane, behind which are the axillary vessels and nerves. The long thoracic artery runs parallel to the lower border of this muscle and the anterior thoracic nerve pierces it.

The costocoracoid membrane should now be removed, and the Subclavius muscle will be exposed.

The **Subclavius** (*m. subclavius*) is a small triangular muscle, placed in the interval between the clavicle and the first rib. It *arises* in front of the rhomboid ligament by a short, thick tendon from the first rib and its cartilage at their junction; the fleshy fibres proceed obliquely upward and outward, to be *inserted* into the groove on the under surface of the clavicle. An extension from the aponeurosis of this muscle lies upon the subclavian vein.

Relations.—Its *deep surface* is separated from the first rib by the subclavian vessels and brachial plexus of nerves. Its *superficial surface* is separated from the Pectoralis major by the costocoracoid membrane, which, with the clavicle, forms an osseofibrous sheath in which the muscle is enclosed.

If the costal attachment of the Pectoralis minor be divided across, and the muscle reflected outward, the axillary vessels and nerves are brought fully into view, and should be examined.

Nerves.—The Pectoral muscles are supplied by the external and internal anterior thoracic nerves; the Pectoralis major through these nerves receives filaments from all the spinal nerves entering into the formation of the brachial plexus; the Pectoralis minor receives its fibres from the eighth cervical and first thoracic nerves through the internal anterior thoracic nerve. The Subclavius is supplied by a filament derived from the fifth and sixth cervical nerves.

Actions.—If the arm has been raised by the Deltoid, the Pectoralis major will, conjointly with the Latissimus dorsi and Teres major, depress it to the side of the thorax. If acting alone, it adducts and draws forward the arm, bringing it across the front of the thorax, and at the same time rotating it inward. The Pectoralis minor depresses the point of the shoulder, drawing the scapula downward and inward to the thorax, and throwing the inferior angle backward. The Subclavius depresses the shoulder, drawing the clavicle downward and forward. When the arms are fixed, all three muscles act upon the ribs, drawing them upward and expanding the thorax, and thus becoming very important agents in forced inspiration. During an attack of asthma patients always assume an attitude which fixes the shoulders, so that all these muscles may be brought into action to assist in increasing the capacity of the thorax.

2. The Lateral Thoracic Region.

Serratus magnus.

The **Serratus magnus** (*m. serratus anterior*) (Fig. 347) is a thin, irregularly quadrilateral muscle, situated between the ribs and the scapula at the upper and lateral part of the thorax. It *arises* by fleshy digitations or slips from the outer surfaces and upper borders of the upper eight or nine ribs, and from the aponeuroses covering the intervening intercostal muscles. Each digitation (except the first) *arises* from the corresponding rib; the first digitation arises from the first and second ribs and from the fascia covering the first intercostal space. From this extensive attachment the fibres pass backward, closely applied to the thoracic wall, and reach the vertebral border of the scapula, and are inserted into its ventral aspect in the following manner. The first digitation, arising from the first and second ribs, is *inserted* into a triangular area on the ventral aspect of the superior angle. The next two digitations (from the second and third ribs) spread out to form a thin triangular sheet, the base of which is directed backward and is *inserted* into nearly the whole length of the ventral aspect of the vertebral border. The lower five or six digitations converge to form a fan-shaped mass, the apex of which is *inserted*, by muscular and tendinous fibres, into a triangular impression on the ventral aspect of the inferior angle. The lower four slips interdigitate at their origin with the upper five slips of the External oblique muscle of the abdomen.

Relations.—This muscle is partly covered, in *front*, by the Pectoral muscles; *behind*, by the Subscapularis. The axillary vessels and nerves lie upon its upper part, while its *deep surface* rests upon the ribs and intercostal muscles.

Nerves.—The Serratus magnus is supplied by the posterior thoracic nerve, which is derived from the fifth, sixth, and seventh cervical nerves.

Actions.—The Serratus magnus, as a whole, carries the scapula forward, and at the same time raises the vertebral border of the bone. It is therefore concerned in the action of pushing. Its lower and stronger fibres move forward the lower angle and assist the Trapezius in rotating the bone around an axis through its centre, and thus assist this muscle in raising the acromion and supporting weights upon the shoulder. It also assists the Deltoid in raising the arm, inasmuch as during the action of this latter muscle it fixes the scapula and so steadies the glenoid cavity in which the head of the humerus rotates. After the Deltoid has raised the arm to a right angle with the trunk, the Serratus magnus and the Trapezius, by rotating the scapula, raise the arm into an almost vertical position. It is possible that when the shoulders are fixed the lower fibres of the Serratus magnus may assist in raising and everting the ribs; but it is not the important inspiratory muscle which it was formerly believed to be.

Applied Anatomy.—When the muscle is paralyzed, the vertebral border, and especially the lower angle of the scapula, leaves the ribs and stands out prominently on the surface, giving a peculiar “winged” appearance to the back. The patient is unable to raise the arm, and an attempt to do so is followed by a further projection of the lower angle of the scapula from the back of the thorax.

Dissection.—After completing the dissection of the axilla, if the muscles of the back have been dissected, the upper extremity should be separated from the trunk. Saw through the clavicle at its centre, and then cut through the muscles which connect the scapula and arm with the trunk—viz., the Pectoralis minor in front, Serratus magnus at the side, and the Levator anguli scapulae, the Rhomboids, Trapezius, and Latissimus dorsi behind. These muscles should be cleaned and traced to their respective insertions. Then make an incision through the integument, commencing at the outer third of the clavicle, and extending along the margin of that bone, the acromion process, and spine of the scapula; the integument should be dissected from above downward and outward, when the fascia covering the Deltoid will be exposed (Fig. 344, No. 3).

II. MUSCLES AND FASCIÆ OF THE SHOULDER AND ARM.

The **superficial fascia** of the upper extremity is a thin cellulofibrous layer, containing the superficial veins and lymphatics, and the cutaneous nerves. It is

most distinct in front of the elbow, and contains very large superficial veins and nerves; in the hand it is hardly demonstrable, the integument being closely adherent to the deep fascia by dense fibrous bands. Small subcutaneous bursæ are found in this fascia over the acromion, the olecranon, and the knuckles.

The **deep fascia** of the upper extremity comprises the aponeurosis of the shoulder, arm, and forearm, the anterior and posterior annular ligaments of the carpus, and the palmar fascia. These will be considered in the description of the muscles of the several regions.

3. The Acromial Region.

Deltoid.

The **deep fascia** covering the Deltoid invests this muscle and sends down numerous prolongations between its fasciculi. In *front*, it is continuous with the fascia covering the great Pectoral muscle; *behind*, with that covering the Infraspinatus; *above*, it is attached to the clavicle, the acromion, and spine of the scapula; *below*, it is continuous with the deep fascia of the arm.

The **Deltoid** (*m. deltoideus*) (Fig. 345) is a large, thick, triangular muscle, which gives the rounded outline to the shoulder, and has received its name from its resemblance to the Greek letter Δ (*delta*) inverted. It covers the shoulder-joint in front, behind, and on its outer side. It *arises* from the outer third of the anterior border and upper surface of the clavicle; from the outer margin and upper surface of the acromion process, and from the lower lip of the posterior border of the spine of the scapula, as far back as the triangular surface at its mesal end. From this extensive origin the fibres converge toward their insertion, the middle passing vertically, the anterior obliquely backward, the posterior obliquely forward, they unite to form a thick tendon, which is *inserted* into a rough triangular prominence on the middle of the outer side of the shaft of the humerus. At its insertion the muscle gives off an expansion to the deep fascia of the arm. This muscle is remarkably coarse in texture, and the arrangement of its muscle fibres is somewhat peculiar; the central portion of the muscle—that is to say, the part arising from the acromion process—consists of fibres having an oblique direction, which arise in a bipenniform manner from the sides of tendinous intersections, generally four in number, which are attached above to the acromion process and pass downward parallel to one another in the substance of the muscle. The oblique muscle fibres thus formed are inserted into similar tendinous intersections, generally three in number, which pass upward from the insertion of the muscle into the humerus and alternate with the descending septa. The portions of the muscle which arise from the clavicle and spine of the scapula are not arranged in this manner, but pass from their origin above, to be inserted into the margins of the inferior tendon.

Relations.—By its *superficial surface*, the Deltoid is in relation with the integument, the superficial and deep fasciæ, Platysma, and supra-acromial nerves. Its *deep surface* is separated from the capsule of the shoulder-joint by a large sacculated synovial bursa, the **subdeltoid bursa** (*bursa subdeltoidea*). This bursa often communicates with the **subacromial bursa** (*bursa subacromialis*), which is between the acromial process and the coraco-acromial ligament above and the capsule of the shoulder-joint and the Supraspinatus muscle below. The deep surface of the Deltoid covers the coracoid process, coraco-acromial ligament, Pectoralis minor, Coracobrachialis, both heads of the Biceps, the tendon of the Pectoralis major, the insertions of the Supraspinatus, Infraspinatus, and Teres minor, the scapular and external heads of the Triceps, the circumflex vessels and nerve, and the humerus. Its *anterior border* is separated at its upper part from the Pectoralis major by a cellular interspace, which lodges the cephalic vein and humeral branch of the acromiothoracic artery; lower down the two muscles are in close contact. Its *posterior border* rests on the Infraspinatus and Triceps muscles.

Nerves.—The Deltoid is supplied by the fifth and sixth cervical through the circumflex nerve.

Actions.—The Deltoid raises the arm directly from the side, so as to bring it to a right angle with the trunk, but this act cannot be performed without the aid of the Serratus magnus, which muscle steadies the lower angle of the scapula. Its anterior fibres, assisted by the Pectoralis major, draw the arm forward; and its posterior fibres, aided by the Teres major and Latissimus dorsi, draw it backward.

Applied Anatomy.—The Deltoid is very liable to atrophy, and when in this condition dislocation of the shoulder-joint is simulated, as there is flattening of the shoulder and apparent prominence of the acromion process; upon examination, however, it will be found that the relative position of the greater tuberosity of the humerus to the acromion and coracoid process is unchanged. Atrophy of the Deltoid may be due to disuse or loss of trophic influence, either from injury to the circumflex nerve (as in "*crutch-palsy*") or from spinal cord lesions, as in *infantile paralysis*. In the operation performed for the obliteration of the subdeltoid bursa, the incision through the Deltoid should be as far anterior as possible, in order to avoid severing the nerves which enter the muscle from behind.

4. The Anterior Scapular Region.

Subscapularis.

Dissection.—Divide the Deltoid across, near its upper part, by an incision carried along the margin of the clavicle, the acromion process and spine of the scapula, and reflect it downward, when the structures under cover of it will be seen.

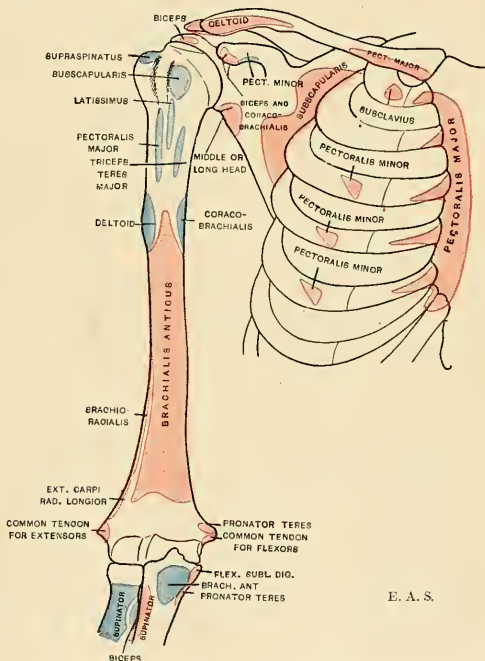


FIG. 348.—Diagram showing attachment of muscles of the shoulder and arm. Anterior aspect. Origins, red; insertions, blue.

The *subscapular fascia* (*fascia subscapularis*) is a thin membrane attached to the entire circumference of the subscapular fossa, and affording attachment by its inner surface to some of the fibres of the Subscapularis muscle.

The **Subscapularis** (*m. subscapularis*) (Fig. 347) is a large triangular muscle which fills up the subscapular fossa, *arising* from its internal two-thirds, with the exception of a narrow margin along the internal border, and the surfaces at the superior and inferior angles which afford attachment to the Serratus magnus; it also arises from the lower two-thirds of the groove on the axillary border of the bone. Some fibres arise from the tendinous laminae, which intersect the muscle, and are attached to ridges on the bone; and others form an aponeurosis, which separates the muscles from the Teres major and the long head of the Triceps. The fibres pass outward, and, gradually converging, terminate in a tendon, which is *inserted* into the lesser tuberosity of the humerus and into the neck of the humerus just behind this tuberosity and into the capsular ligament of the shoulder-joint. The tendon of the muscle is in close contact with the anterior part of the capsular ligament of the shoulder-joint, and glides over a large bursa (*bursa m. subscapularis*), which separates it from the base of the coracoid process. This bursa communicates with the cavity of the joint by an aperture in the capsular ligament.

Relations.—Its *deep surface* forms a considerable part of the posterior wall of the axilla, and is in relation with the Serratus magnus, Coracobrachialis, and Biceps, the axillary vessels and brachial plexus of nerves, and the subscapular vessels and nerves. By its *superficial surface*, with the scapula and the capsular ligament of the shoulder-joint. Its *lower border* is contiguous to the Teres major and Latissimus dorsi.

Nerves.—It is supplied by the fifth and sixth cervical nerves through the upper and lower subscapular nerves.

Actions.—The Subscapularis rotates the head of the humerus inward; when the arm is raised, it draws the humerus forward and downward. It is a powerful defence to the front of the shoulder-joint, preventing displacement of the head of the bone.

5. The Posterior Scapular Region (Figs. 349, 350).

Supraspinatus.

Teres minor.

Infraspinatus.

Teres major.

Dissection.—To expose these muscles, and to examine their insertion into the humerus, detach the Deltoid and Trapezius from their attachment to the spine of the scapula and acromion process. Remove the clavicle by dividing the ligaments connecting it with the coracoid process, and separate it at its articulation with the scapula; divide the acromion process near its root with a saw. The fragments being removed, the tendons of the posterior Scapular muscles will be fully exposed. A block should be placed beneath the shoulder-joint, so as to make the muscles tense.

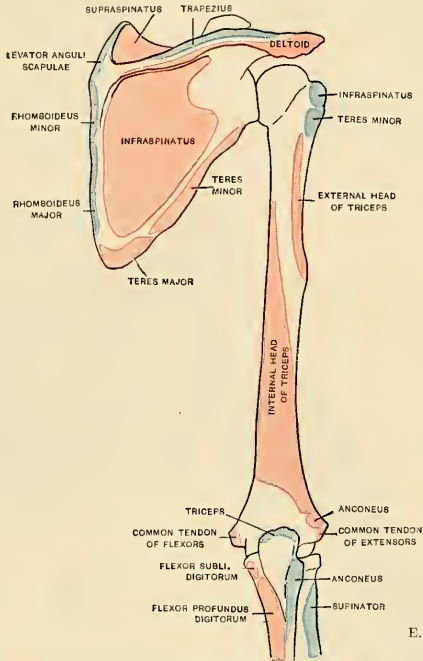
The **supraspinatus fascia** (*fascia supraspinata*) is a thick and dense membranous layer, which completes the osseofibrous case in which the Supraspinatus muscle is contained; it affords attachment, by its deep surface, to some of the fibres of the muscle. It is thick internally, but thinner externally under the coraco-acromial ligament.

The **Supraspinatus muscle** (*m. supraspinatus*) occupies the whole of the supraspinous fossa, *arising* from its internal two-thirds and from the strong fascia which covers the surface of the muscle. The muscle fibres converge to a tendon which passes across the upper part of the capsular ligament of the shoulder-joint, to which it is intimately adherent, and is *inserted* into the highest of the three facets on the greater tuberosity of the humerus.

Relations.—By its *superficial surface*, with the Trapezius, the clavicle, the acromion, the coraco-acromial ligament, and the Deltoid; by its *deep surface*, with the scapula, the suprascapular vessels and nerve, and upper part of the shoulder-joint.

The **infraspinatus fascia** (*fascia infraspinata*) is a dense fibrous membrane, covering in the Infraspinatus muscle and attached to the circumference of the

infraspinous fossa; it affords attachment, by its inner surface, to some fibres of that muscle. At the point where the Infraspinatus commences to be covered by the Deltoid, this fascia divides into two layers; one layer passes over the Deltoid muscle, helping to form the deltoid fascia already described; the other passes beneath the Deltoid to the capsule of the shoulder-joint.



E. A. S.

FIG. 349.—Diagram showing attachment of muscles of shoulder and arm. Posterior aspect. Origins, red; insertions, blue.

The **Infraspinatus** (*m. infraspinatus*) is a thick, triangular muscle, which occupies the chief part of the infraspinous fossa, *arising* by fleshy fibres from its internal two-thirds, and by tendinous fibres from the ridges on its surfaces; it also arises from a strong fascia which covers it externally, and separates it from the Teres major and minor. The fibres converge to a tendon which glides over the external border of the spine of the scapula, and, passing across the posterior part of the capsular ligament of the shoulder-joint, is *inserted* into the middle impression on the greater tuberosity of the humerus. The tendon of this muscle is sometimes separated from the capsule of the shoulder-joint by a synovial bursa (*bursa m. infraspinati*), which may communicate with the joint-cavity.

Relations.—By its *superficial surface*, with the Deltoid, the Trapezius, Latissimus dorsi, and the integument; by its *deep surface*, with the scapula, from which it is separated by the supra-scapular and dorsalis scapulae vessels, and with the capsular ligament of the shoulder-joint. Its *lower border* is in contact with the Teres minor, occasionally united with it, and with the Teres major.

The **Teres minor** (*m. teres minor*) is a narrow, elongated muscle, which *arises* from the dorsal surface of the axillary border of the scapula for the upper two-thirds of its extent, and from the two aponeurotic laminae, one of which separates this muscle from the Infraspinatus, the other from the Teres major; its fibres pass obliquely upward and outward, and terminate in a tendon which is *inserted* into the lowest of the three facets on the greater tuberosity of the humerus, and by fleshy fibres, into the humerus immediately below it. The tendon of this muscle passes across the posterior part of the capsular ligament of the shoulder-joint.

Relations.—By its *superficial surface*, with the Deltoid and the integument; by its *deep surface*, with the scapula and dorsal branch of the subscapular artery, the long head of the Triceps, and the shoulder-joint; by its *upper border*, with the Infraspinatus; by its *lower border*, with the Teres major, from which it is separated anteriorly by the long head of the Triceps.

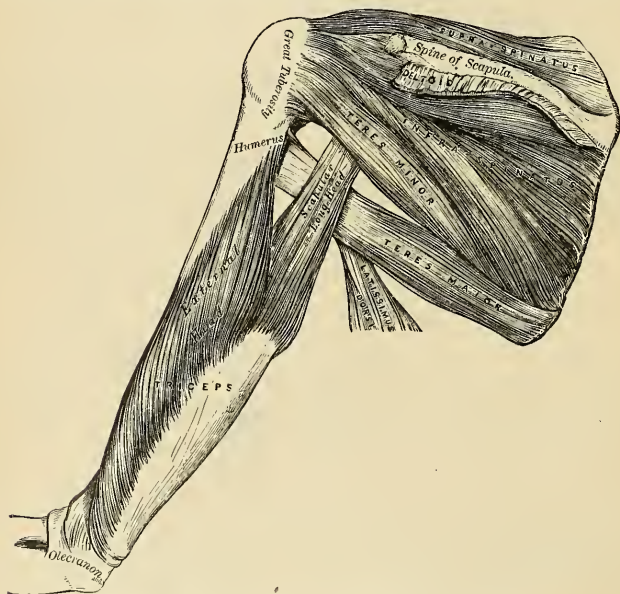


FIG. 350.—Muscles on the dorsum of the Scapula and the Triceps.

The **Teres major** (*m. teres major*) is a thick but somewhat flattened muscle, which *arises* from the oval surface on the dorsal aspect of the inferior angle of the scapula, and from the fibrous septa interposed between it and the Teres minor and Infraspinatus; the fibres are directed upward and outward, and terminate in a flat tendon, about two inches in length, which is *inserted* into the inner bicipital ridge of the humerus. The tendon of this muscle, at its insertion into the humerus, lies behind that of the Latissimus dorsi, from which it is separated by a synovial bursa, the two tendons being, however, united along their lower borders for a short distance. A bursa (*bursa m. teretis majoris*) is found between the tendon of the Teres major and the bone.

Relations.—By its *superficial surface*, with the Latissimus dorsi below, and the long head of the Triceps above. By its *deep surface*, with the Subscapularis, Latissimus dorsi, Coracobrachialis, short head of the Biceps brachii, the axillary vessels, and brachial plexus of nerves. Its *upper border* is at first in relation with the Teres minor, from which it is afterward separated by the long head of the Triceps. Its *lower border* forms, in conjunction with the Latissimus dorsi, part of the posterior boundary of the axilla. The Latissimus dorsi at first covers the origin of the Teres major, then wraps itself obliquely around its lower border, so that its tendon ultimately comes to lie in front of that of the Teres major.

Nerves.—The Supra- and Infraspinatus muscles are supplied by the fifth and sixth cervical nerves through the suprascapular nerve; the Teres minor, by the fifth cervical, through the circumflex; and the Teres major, by the fifth and sixth cervical, through the lower subscapular.

Actions.—The Supraspinatus assists the Deltoid in raising the arm from the side, and fixes the head of the humerus in the glenoid cavity. The Infraspinatus and Teres minor rotate the head of the humerus outward; when the arm is raised, they assist in retaining it in that position and carrying it backward. One of the most important uses of these three muscles is the great protection they afford to the shoulder-joint, the Supraspinatus supporting it above, and preventing displacement of the head of the humerus upward, while the Infraspinatus and Teres minor protect it behind, and prevent dislocation backward. The Teres major assists the Latissimus dorsi in drawing the humerus downward and backward, when previously raised, and in rotating it inward; when the arm is fixed, it may assist the Pectoral and Latissimus dorsi muscles in drawing the trunk forward.

THE MUSCLES AND FASCIÆ OF THE ARM.

6. The Anterior Humeral Region (Fig. 347).

Coracobrachialis.

Biceps.

Brachialis anticus.

Dissection.—The arm being placed on the table, with the front surface uppermost, make a vertical incision through the integument along the middle line, from the clavicle to about two inches below the elbow-joint, where it should be joined by a transverse incision, extending from the inner to the outer side of the forearm; the two flaps being reflected on either side, the fascia should be examined (Fig. 344).

The *deep fascia (fascia brachii)* of the arm is continuous with that covering the Deltoid and the great Pectoral muscles, by means of which it is attached, above, to the clavicle, acromion, and spine of the scapula, and it is also continuous with the axillary fascia. It forms a thin, loose, membranous sheath investing the muscles of the arm, sending down septa between them, and is composed of fibres disposed in a circular or spiral direction, and connected by vertical and oblique fibres. It differs in thickness at different parts, being thin over the Biceps brachii, but thicker where it covers the Triceps, and over the condyles of the humerus; it is strengthened by fibrous aponeuroses, derived from the Pectoralis major and Latissimus dorsi, on the inner side, and from the Deltoid externally. On either side it gives off a strong *intermuscular septum*, which is attached to the supracondylar ridge and to the condyle of the humerus. These septa serve to separate the muscles of the anterior from those of the posterior brachial region. The *external intermuscular septum* extends from the lower part of the external bicipital ridge, along the external supracondylar ridge, to the outer condyle; it is blended with the tendon of the Deltoid, gives attachment to the Triceps behind, to the Brachialis anticus, Brachioradialis, and Extensor carpi radialis longior in front. It is perforated by the musculospiral nerve and the anterior terminal branch of the superior profunda artery. The *internal intermuscular septum*, thicker than the preceding, extends from the lower part of the internal lip of the bicipital groove below the Teres major, along the internal supracondylar ridge to the inner condyle, it is blended with the tendon of the Coracobrachialis, and affords attachment to the Triceps behind, and the Brachialis anticus in front. It is perforated by the ulnar nerve and the inferior profunda and anastomotica magna arteries. At

the elbow the deep fascia is attached to all the prominent points around the joint—viz., the condyles of the humerus and the olecranon process of the ulna—and is continuous with the deep fascia of the forearm. Just below the middle of the arm, on its inner side, in front of the intermuscular septum, is an oval opening in the deep fascia which transmits the basilic vein and some lymphatic vessels.

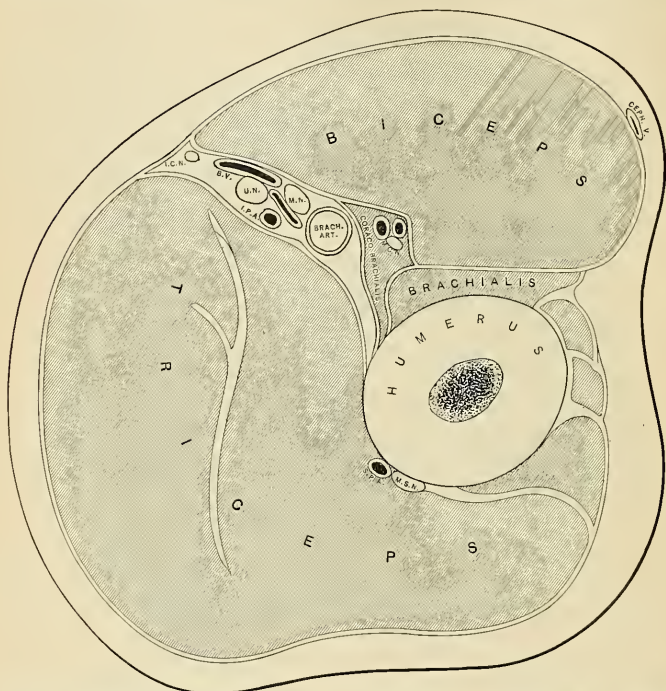


FIG. 351.—Horizontal section at middle of right arm—upper surface of lower segment. B. V., basilic vein. CEPH. V., cephalic vein. I. C. N., internal cutaneous nerve. I. P. A., inferior profunda artery. M. C. N., musculocutaneous nerve. M. N., median nerve. M. S. N., musculospiral nerve. S. P. A., superior profunda artery. U. N., ulnar nerve. (After Braune.)

The **Coracobrachialis** (*m. coracobrachialis*), the smallest of the three muscles in this region, is situated at the upper and inner part of the arm. It *arises* by fleshy fibres from the apex of the coracoid process, in common with the short head of the Biceps, and from the intermuscular septum between the two muscles; the fibres pass downward, backward, and a little outward, to be *inserted* by means of a flat tendon into an impression at the middle of the inner surface and internal border of the shaft of the humerus between the origins of the Triceps and Brachialis anticus. It is perforated by the musculocutaneous nerve. The inner border of the muscle forms a guide to the position of the terminal portion of the axillary and upper part of the brachial arteries.

Relations.—By its *superficial surface*, with the Pectoralis major above, and at its insertion with the brachial vessels and median nerve which cross it; by its *deep surface*, with the tendons of the Subscapularis, Latissimus dorsi, and Teres major, the inner head of the Triceps, the

humerus, and the anterior circumflex vessels; by its *inner border*, with the brachial artery, and the median and musculocutaneous nerves; by its *outer border*, with the short head of the Biceps and Brachialis anticus.

The **Biceps**, or the **Biceps flexor cubiti** (*m. biceps brachii*), is a long fusiform muscle, occupying the whole of the anterior surface of the arm, and divided above into two portions or heads, from which circumstance it has received its name. The **short head** (*caput breve*) *arises* by a thick flattened tendon from the apex of the coracoid process, in common with the Coracobrachialis. The **long head** (*caput longum*) *arises* from the upper margin of the glenoid cavity, and is continuous with the glenoid ligament. This tendon arches over the head of the humerus, being enclosed in a special sheath of the synovial membrane of the shoulder-joint; it then passes through an opening in the capsular ligament at its attachment to the humerus, and descends in the bicipital groove, in which it is retained by a fibrous prolongation from the tendon of the Pectoralis major. Each tendon is succeeded by an elongated muscle belly, and the two bellies, although closely applied to each other, can readily be separated until within about three inches of the elbow-joint. Here they end in a flattened tendon, which is *inserted* into the back part of the tuberosity of the radius, a synovial bursa, being interposed between the tendon and the front of the tuberosity; another bursa is often interposed between the ulna and the tendon. As the tendon of the muscle approaches the radius it becomes twisted upon itself, so that its anterior surface becomes external and is applied to the tuberosity of the radius at its insertion; opposite the bend of the elbow the tendon gives off, from its inner side, a broad aponeurosis, the **bicipital fascia** (*lacertus fibrosus*), which passes obliquely downward and inward across the brachial artery, and is continuous with the deep fascia covering the origins of the superficial Flexor muscles of the forearm (Fig. 340).¹

Relations.—Its *superficial surface* is overlapped above by the Pectoralis major and Deltoid; in the rest of its extent it is covered by the superficial and deep fasciæ and the integument. Its *deep surface* rests above on the shoulder-joint and upper part of the humerus; below it rests on the Brachialis anticus, with the musculocutaneous nerve intervening between the two, and on the Supinator [brevis]. Its *inner border* is in relation with the Coracobrachialis, and overlaps the brachial vessels and median nerve; its *outer border*, with the Deltoid and Brachioradialis.

The **Brachialis anticus** (*m. brachialis*) is a broad muscle, which covers the elbow-joint and the lower half of the front of the humerus. It is somewhat compressed from before backward, and is broader in the middle than at either extremity. It *arises* from the lower half of the outer and inner surfaces of the shaft of the humerus, and commences above at the insertion of the Deltoid, which it embraces by two angular processes. Its origin extends below, to within an inch of the margin of the articular surface, and is limited on each side by the external and internal borders of the shaft of the humerus. It also arises from the intermuscular septa on each side, but more extensively from the inner, from which it is separated below by the Brachioradialis and Extensor carpi radialis longior. Its fibres converge to a thick tendon, which is *inserted* into a rough depression on the anterior surface of the coronoid process of the ulna, being received into an interval between two fleshy slips of the Flexor profundus digitorum.

Relations.—By its *superficial surface*, with the Biceps, the brachial vessels, musculocutaneous and median nerves; by its *deep surface*, with the humerus and front of the elbow-joint; by its *inner border*, with the Triceps, ulnar nerve, and Pronator teres, from which it is separated by the intermuscular septum; by its *outer border*, with the musculospiral nerve, radial recurrent artery, the Brachioradialis, and Extensor carpi radialis longior.

¹ A third head to the Biceps is occasionally found (Theile says as often as once in eight or nine subjects), arising at the upper and inner part of the Brachialis anticus, with the fibres of which it is continuous, and inserted into the bicipital fascia and inner side of the tendon of the Biceps. In most cases this additional slip passes behind the brachial artery in its course down the arm. Occasionally the third head consists of two slips which pass down, one in front of, the other behind, the artery, concealing the vessel in the lower half of the arm.

Nerves.—The muscles of this group are supplied by the musculocutaneous nerve. The Brachialis anticus usually receives an additional filament from the musculospiral. The Coracobrachialis receives its supply primarily from the seventh cervical, the Biceps and Brachialis anticus from the fifth and sixth cervical nerves.

Actions.—The Coracobrachialis draws the humerus forward and inward, and at the same time assists in elevating it toward the scapula. The Biceps is a flexor of the forearm; it is also a powerful supinator, and serves to render tense the deep fascia of the forearm by means of the broad aponeurosis given off from its tendon. The Brachialis anticus is a flexor of the forearm, and forms an important defence to the elbow-joint. When the forearm is fixed, the Biceps and Brachialis anticus flex the arm upon the forearm, as is seen in efforts at climbing.

7. The Posterior Humeral Region.

Triceps.

Subanconeus.

The **Triceps**, or the **Triceps extensor cubiti** (*m. triceps brachii*) (Fig. 352) is situated on the back of the arm, extending the entire length of the posterior surface of the humerus. It is of large size, and is divided above into three parts; hence its name. These three portions have been named: (1) the middle, scapular, or long head; (2) the external or long humeral head; and (3) the internal or short humeral head.

The **middle or scapular head** (*caput longum*) arises by a flattened tendon from a rough triangular depression on the scapula, immediately below the glenoid cavity, being blended at its upper part with the capsular ligament; the muscle fibres pass downward between the two other portions of the muscle, and join with them in the common tendon of insertion.

The **external head** (*caput laterale*) arises from the posterior surface of the shaft of the humerus, between the insertion of the Teres minor and the upper part of the musculospiral groove; from the external border of the humerus and the external intermuscular septum; the fibres from this origin converge toward the common tendon of insertion.

The **internal head** (*caput mediale*) arises from the posterior surface of the shaft of the humerus, below the groove for the musculospiral nerve; commencing above, narrow and pointed, below the insertion of the Teres major, and extending to within an inch of the trochlear surface; it also arises from the internal border of the humerus, and from the back of the whole length of the internal and lower part of the external intermuscular septum. Certain fibres of this portion of the muscle are directed downward to the olecranon, while others converge to the tendon of insertion.

The **tendon of the triceps** commences about the middle of the back part of the muscle; it consists of two aponeurotic laminae, one of which is subcutaneous and covers the posterior surface of the muscle for the lower half of its extent; the other is more deeply seated in the substance of the muscle; after receiving the attachment of the muscle fibres, they join above the elbow, and are *inserted*, for the most part, into the back part of the upper surface of the olecranon process; a band of fibres is, however, continued downward, on the outer side, over the Anconeus, to blend with the deep fascia of the forearm.

Relations.—By its *superficial surface*, the Triceps is in relation with the Deltoid above; in the rest of its extent it is subcutaneous; by its *deep surface*, with the humerus, musculospiral nerve, superior profunda vessels, and back part of the elbow-joint. Its *middle or long head* is in relation, behind, with the Deltoid and Teres minor; in front, with the Subscapularis, Latissimus dorsi, and Teres major.

The long head of the Triceps descends between the Teres minor and Teres major, dividing the triangular space between these two muscles and the humerus into two smaller spaces, one triangular, the other quadrangular (Fig. 350). The **triangular space** contains the dorsalis

scapulae vessels; it is bounded by the Teres minor above, the Teres major below, and the scapular head of the Triceps externally; the **quadrangular space** transmits the posterior circumflex vessels and the circumflex nerve; it is bounded by the Teres minor above, the Teres major below, the scapular head of the Triceps internally, and the humerus externally.

The **Subanconeus** is a name given to a few fibres from the under surface of the lower part of the Triceps muscle, which are *inserted* into the posterior ligament of the elbow-joint. By some authors it is regarded as the homotype of the Subcrureus in the lower limb, but it is not a separate muscle.

Nerves.—The Triceps is supplied by the seventh and eighth cervical nerves through the musculospiral nerve.

Actions.—The Triceps is the great Extensor muscle of the forearm, serving, when the forearm is flexed, to extend the elbow-joint. It is the direct antagonist of the Biceps and Brachialis anticus. When the arm is extended the long head of the muscles may assist the Teres major and Latissimus dorsi in drawing the humerus backward and in adducting it to the thorax. The long head of the Triceps protects the under part of the shoulder-joint, and prevents displacement of the head of the humerus downward and backward. The Subanconeus draws up the synovial membrane of the elbow-joint out of the way of the advancing olecranon process during extension of the forearm.

Applied Anatomy.—The existence of the band of fibres from the Triceps to the fascia of the forearm is of importance in excision of the elbow, and should always be carefully preserved from injury by the operator, as by means of these fibres the patient is enabled to extend the forearm, a movement which would otherwise mainly be accomplished by gravity—that is to say, allowing the forearm to drop from its own weight.

III. MUSCLES AND FASCIÆ OF THE FOREARM.

Dissection.—To dissect the forearm, place the limb in the position indicated in Fig. 344, make a vertical incision along the middle line from the elbow to the wrist, and a transverse incision at the extremity of this; the superficial structures being removed, the deep fascia of the forearm is exposed.

The **deep fascia** of the forearm (*fascia antibrachii*),¹ continuous above with that enclosing the arm, is a dense, highly glistening aponeurotic investment, which forms a general sheath enclosing the muscles in this region; it is attached, *behind*, to the olecranon and posterior border of the ulna, and gives off from its inner surface numerous *intermuscular septa*, which enclose each muscle separately. *Below*, it is continuous in front with the *anterior annular ligament*, and forms a sheath for the tendon of the Palmaris longus muscle, which passes over the annular ligament to be inserted into the palmar fascia. *Behind*, near the wrist-joint, it becomes much thickened by the addition of many transverse fibres, and forms the posterior annular ligament. It consists of circular and oblique fibres, connected by numerous vertical fibres. It is much thicker on the dorsal than on the palmar surface, and at the lower than at the upper part of the forearm, and is strengthened above by tendinous fibres derived from the Brachialis anticus and Biceps in front, and from the Triceps behind. Its deep surface gives origin to muscle fibres, especially at the upper part of the inner and outer sides of the forearm, and forms the boundaries of a series of conical-shaped cavities, in which the muscles are contained. Besides the vertical septa separating each muscle, transverse septa are given off on the anterior and posterior surfaces of the forearm, separating the deep from the superficial layer of muscles. Numerous apertures exist in the fascia for the passage of vessels and nerves; one of these, of large size, situated at the front of the elbow, serves for the passage of a communicating branch between the superficial and deep veins. This fascia is also perforated on its anterior surface, near the wrist, by the ulnar artery and nerve.

¹ The correct spelling is *antebrachium*, not *antibrachium*, as is given in the list of the B.N.A.—[EDITOR.]

The muscles of the forearm may be subdivided into groups corresponding to the region they occupy. One group occupies the inner and anterior aspect of the forearm, and comprises the Flexor and Pronator muscles. Another group occupies its outer side, and a third its posterior aspect. The two latter groups include all the Extensor and Supinator muscles.

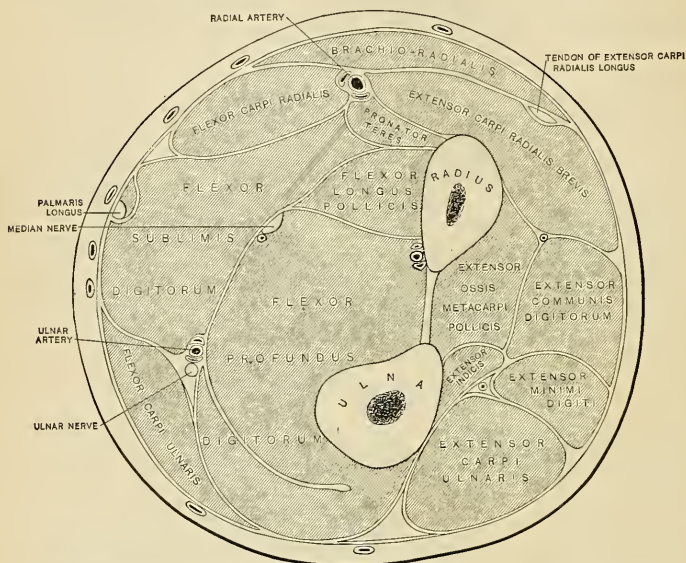


FIG. 352.—Transverse section through the middle of the right forearm, in the position of semipronation. (After Braune.)

8. The Anterior Radioulnar Region.

The muscles in this region are divided for convenience of description into two groups or layers, **superficial** and **deep**.

The Superficial Layer.

Pronator teres.

Flexor carpi radialis.

Flexor sublimis digitorum.

Palmaris longus.

Flexor carpi ulnaris.

These muscles take partial origin from the internal condyle of the humerus by a common tendon.

The **Pronator teres** (*m. pronator teres*) has two heads. One (*caput humerale*), the larger and more superficial, arises from the humerus, immediately above the internal condyle, from the tendon common to the origin of the other muscles; and from the fascia of the forearm and the intermuscular septum between it and the Flexor carpi radialis. The deep head (*caput ulnare*) is a thin fasciculus

which *arises* from the inner side of the coronoid process of the ulna, joining the preceding at an acute angle. The median nerve enters the forearm between the two heads of the muscle and is separated from the ulnar artery by the deep head. The muscle passes obliquely across the forearm from the inner to the outer side, and terminates in a flat tendon, which turns over the outer margin of the radius, and is *inserted* into a rough impression at the middle of the outer surface of the shaft of that bone.

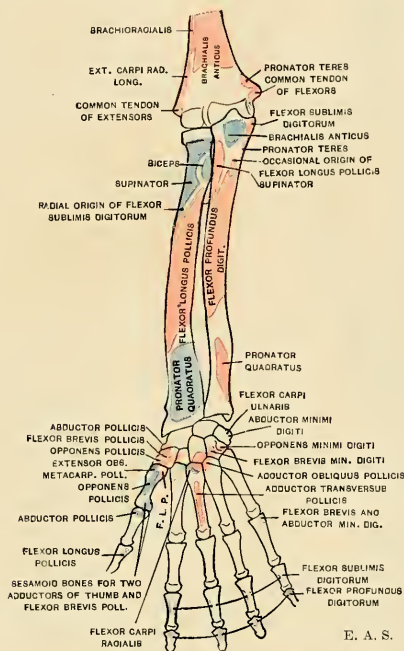


FIG. 353.—Diagram showing attachments of the muscles of the forearm and hand. Anterior aspect. Origins, red; insertions, blue. The origins and insertions of the Palmar interosseous muscles are omitted. (See Fig. 150.)

Relations.—By its *superficial surface*, throughout the greater part of its extent, with the deep fascia; at its insertion the muscle is crossed by the radial vessels and nerve, and is covered by the Brachioradialis; by its *deep surface*, with the Brachialis anticus, Flexor sublimis digitorum, the median nerve, and ulnar artery, the small or deep head being interposed between the two latter structures. Its *outer border* forms the inner boundary of a triangular space (*antecubital space*) (page 641), in which are placed the brachial artery, median nerve, and the tendon of the Biceps muscle. Its *inner border* is in contact with the Flexor carpi radialis.

Applied Anatomy.—This muscle, when suddenly brought into very active use, as in the game of lawn tennis, is liable to be strained, producing slight swelling and tenderness, and pain on putting the muscle into action. This is known as *lawn-tennis arm*.

The **Flexor carpi radialis** (*m. flexor carpi radialis*) lies on the inner side of the preceding muscle. It *arises* from the internal condyle by the common tendon, from the fascia of the forearm, and from the intermuscular septa between it and the Pronator teres, on the outside, the Palmaris longus internally, and the Flexor sublimis digitorum beneath. Slender and aponeurotic in structure at

its commencement, it increases in size, and terminates in a tendon which forms rather more than the lower half of its length. This tendon passes through a canal on the outer side of the annular ligament, runs through a groove in the os trapezium (which is converted into a canal by a fibrous sheath, and is lined with a synovial membrane), and is inserted into the base of the metacarpal bone of the index finger, and by a slip into the base of the metacarpal bone of the middle finger.

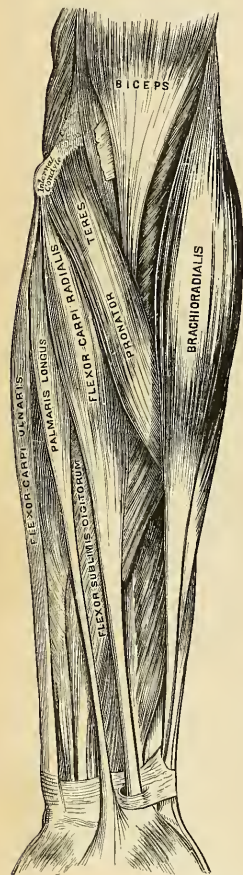


FIG. 354.—Front of the left forearm.
Superficial muscles.

Relations.—By its *superficial surface*, with the deep fascia and the integument; by its *deep surface*, with the Flexor sublimis digitorum, Flexor longus pollicis, and wrist-joint; by its *outer border*, with the Pronator teres and the radial vessels; by its *inner border*, with the Palmaris longus above and the median nerve below.

The **Palmaris longus** (*m. palmaris longus*) (Fig. 354) is a slender, fusiform muscle, lying on the inner side of the preceding. It arises from the inner condyle of the humerus by the common tendon, from the deep fascia, and the intermuscular septa between it and the adjacent muscles. It terminates in a slender flattened tendon, which passes over the upper part of the annular ligament, to end in the central part of the palmar fascia and lower part of the annular ligament, frequently sending a tendinous slip to the short muscles of the thumb. This muscle is often absent, and is subject to very considerable variations; it may be tendinous above and muscular below; or it may be muscular in the centre, with a tendon above and below; or it may present two muscle bundles with a central tendon; or, finally, it may consist simply of a mere tendinous band.

Relations.—By its *superficial surface*, with the deep fascia. By its *deep surface*, with the Flexor sublimis digitorum. *Internally*, with the Flexor carpi ulnaris. *Externally*, with the Flexor carpi radialis. The median nerve lies close to the tendon, just above the wrist, on its inner and posterior side.

The **Flexor carpi ulnaris** (*m. flexor carpi ulnaris*) (Fig. 354) lies along the ulnar side of the forearm. It arises by two heads, connected by a tendinous arch, beneath which pass the ulnar nerve and posterior ulnar recurrent artery. One head (*caput humerale*) arises from the inner condyle of the humerus, by the common tendon; the other (*caput ulnare*), from the inner margin of the olecranon

and from the upper two-thirds of the posterior border of the ulna, by an aponeurosis, common to it and the Extensor carpi ulnaris and Flexor profundus digitorum; and from the intermuscular septum between it and the Flexor sublimis digitorum. The fibres terminate in a tendon which occupies the anterior part of the lower half of the muscle, and is inserted into the pisiform bone, and is prolonged from this to the unciform and fifth metacarpal bones by the pisco-

unciform and pisometacarpal ligaments; it is also attached by a few fibres to the annular ligament.

Relations.—By its *superficial surface*, with the deep fascia, with which it is intimately connected for a considerable extent; by its *deep surface*, with the Flexor sublimis digitorum, the Flexor profundus digitorum, the Pronator quadratus, and the ulnar vessels and nerve; by its *outer or radial border*, with the Palmaris longus above and the ulnar vessels and nerve below.

The **Flexor sublimis digitorum** (*m. flexor digitorum sublimis*) (Fig. 354) is placed beneath the preceding muscles, which therefore must be removed in order to bring its attachment into view. It is the largest of the muscles of the superficial layer, and *arises* by three heads. One head (*caput humerale*) *arises* from the internal condyle of the humerus by the common tendon, from the internal lateral ligament of the elbow-joint, and from the intermuscular septum common to it and the preceding muscles. The second head (*caput ulnare*) *arises* from the inner side of the coronoid process of the ulna, above the ulnar origin of the Pronator teres (Fig. 145, p. 186). The third head (*caput radiale*) *arises* from the oblique line of the radius, extending from the tuberosity to the insertion of the Pronator teres. The fibres pass vertically downward, forming a broad and thick muscle, which speedily divides into two planes of muscle fibres, superficial and deep; the superficial plane divides into two parts which end in tendons for the middle and ring fingers; the deep plane also divides into two parts, which end in tendons for the index and little fingers, but previously to having done so it gives off a muscular slip, which joins that part of the superficial plane which is intended for the ring finger. As the four tendons thus formed pass beneath the annular ligament into the palm of the hand, they are arranged in pairs, the superficial pair corresponding to the middle and ring fingers, the deep pair to the index and little fingers. The tendons diverge from one another as they pass onward. Opposite the bases of the first phalanges each tendon divides into two slips (*chiasma tendinum*) to permit the passage of the corresponding tendon of the Flexor profundus digitorum; the two portions of the tendon then unite and form a grooved channel for the reception of the accompanying deep Flexor tendon. Finally, they subdivide a second time, to be *inserted* into the sides of the second phalanges about their middle. The insertion in the index finger is shown in Fig. 361. After leaving the palm the tendons of the superficial Flexor, accompanied by the deep Flexor tendons, lie in osseoponeurotic canals (Fig. 356). Each canal or *theca* extends from the metacarpophalangeal articulation to the proximal end of the distal phalanx (Fig. 256). It is formed by strong fibrous bands, which arch across the tendons, and are attached on each side to the margins of the phalanges. Opposite the middle of the proximal and second phalanges the sheath is very strong, and the fibres pass transversely; but opposite the joints it is much thinner, and the fibres pass obliquely. It is very thin over the metacarpophalangeal articulation, and is absent over the distal phalanx. Each sheath is lined by a synovial membrane, which is reflected on the contained tendons.

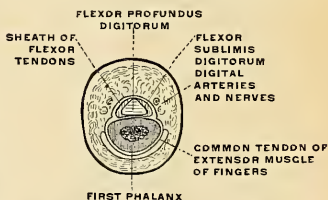


FIG. 355.—Section passing through the middle third of the first phalanx of the middle finger (frozen section). The tendon of the Flexor sublimis digitorum is divided into two small bands, which spread laterally and engage themselves between the osseous plane and the Flexor profundus digitorum. (Poirier and Charpy.)

Relations.—In the forearm, by its *superficial surface*, with the deep fascia and all the preceding superficial muscles; by its *deep surface*, with the Flexor profundus digitorum, Flexor

longus pollicis, the ulnar vessels and nerve, and the median nerve. In the hand its tendons are in relation, *superficially*, with the palmar fascia, superficial palmar arch, and the branches of the median nerve; *deeply*, with the tendons of the deep Flexor and the Lumbricales.

The Deep Layer (Fig. 356).

Flexor profundus digitorum.

Flexor longus pollicis.

Pronator quadratus.

Dissection.—Divide each of the superficial muscles at its centre, and turn either end aside; the deep layer of muscles, together with the median nerve and ulnar vessels, will then be exposed.

The **Flexor profundus digitorum** (*m. flexor digitorum profundus*) (Fig. 356) is situated on the ulnar side of the forearm, immediately beneath the superficial Flexors. It *arises* from the upper three-fourths of the anterior and inner surfaces of the shaft of the ulna, embracing the insertion of the Brachialis anticus above, and extending, below, to within a short distance of the Pronator quadratus. It also arises from a depression on the inner side of the coronoid process; by an aponeurosis from the upper three-fourths of the posterior border of the ulna, in common with the Flexor and Extensor carpi ulnaris; and from the ulnar half of the interosseous membrane. The fibres form a fleshy belly of considerable size, which divides into four tendons; these pass under the annular ligament beneath the tendons of the Flexor sublimis digitorum. Opposite the first phalanges the tendons pass through the openings in the tendons of the Flexor sublimis digitorum, and are finally *inserted* into the bases of the last phalanges. The portion of the muscle for the index finger (Fig. 360) is usually distinct throughout, but the tendons for the three inner fingers are connected by cellular tissue and tendinous slips as far as the palm of the hand. The tendons of this muscle and those of the Flexor sublimis digitorum, while contained in the osseaponeurotic canals of the fingers, are invested in a synovial sheath, and are connected to each other and to the phalanges by slender tendinous filaments, called **vincula accessoria tendinum** (*vincula tendineae*). Of these there are two sets: (a) The *ligamenta brevia*—two in each finger—are composed of triangular bands of fibres which connect respectively (1) the tendon of the Flexor sublimis digitorum to the front of the first interphalangeal joint, and (2) the head of the first phalanx and the tendon of the Flexor profundus digitorum to the front of the second interphalangeal joint and to the head of the second phalanx. (b) The *ligamenta longa* connect the under surfaces of the Flexor sublimis digitorum to the proximal end of the palmar surface of the first phalanx, and the under surface of the Flexor profundus digitorum to those of the subjacent Flexor sublimis digitorum after the tendons of the former have passed through the latter (Fig. 361).

Four small muscles, the Lumbricales, are connected with the tendons of the Flexor profundus in the palm. They will be described with the muscles in that region.

Relations.—By its *superficial surface*, in the forearm, with the Flexor sublimis digitorum, the Flexor carpi ulnaris, the ulnar vessels, and nerve, and the median nerve; and in the hand, with the tendons of the superficial Flexor; by its *deep surface*, in the forearm, with the ulna, the interosseous membrane, the Pronator quadratus; and in the hand, with the Interossei, Adductor pollicis, and deep palmar arch; by its *ulnar border*, with the Flexor carpi ulnaris; by its *radial border*, with the Flexor longus pollicis, the anterior interosseous vessels and nerve being interposed.

The **Flexor longus pollicis** (*m. flexor pollicis longus*) (Fig. 356) is situated on the radial side of the forearm, lying on the same plane as the preceding. It *arises* from the grooved anterior surface of the shaft of the radius, commencing above,

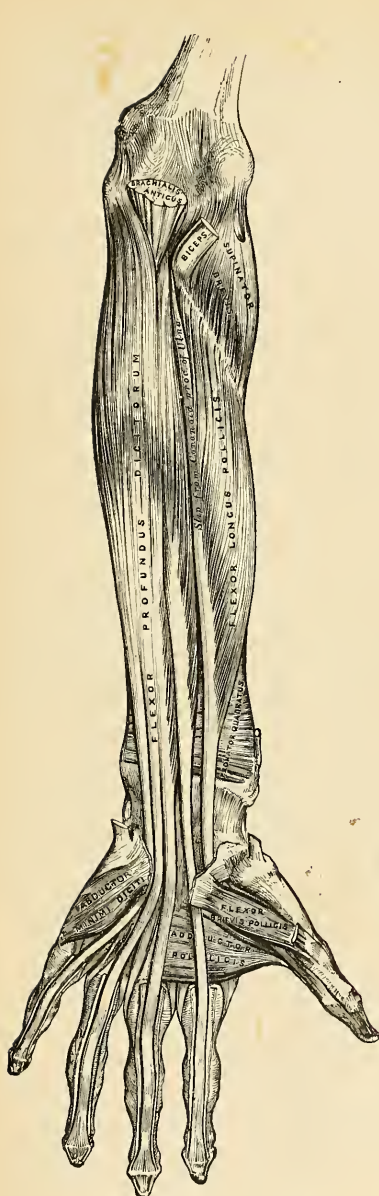


FIG. 356.—Front of the left forearm.
Deep muscles.

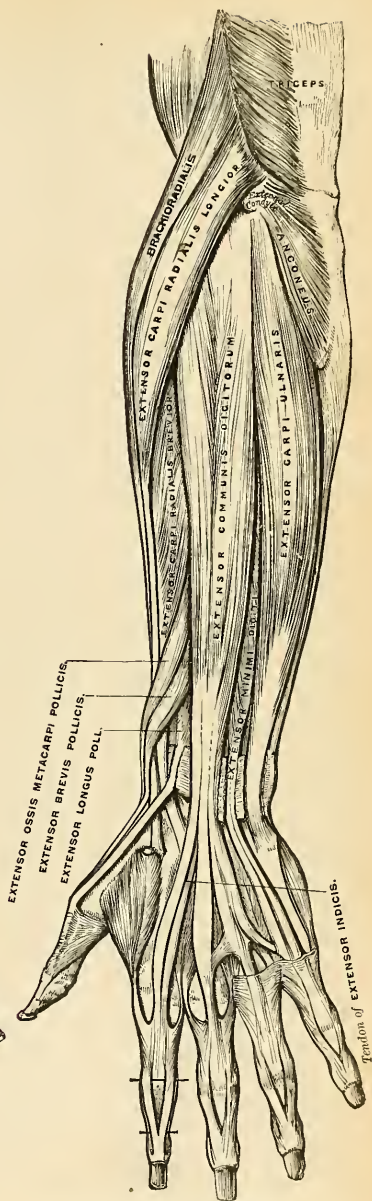


FIG. 357.—Posterior surface of the left forearm.
Superficial muscles.

immediately below the tuberosity and oblique line, and extending below to within a short distance of the Pronator quadratus. It also arises from the adjacent part of the interosseous membrane and generally by a fleshy slip from the inner border of the coronoid process or from the internal condyle of the humerus. The fibres pass downward, and terminate in a flattened tendon which passes beneath the annular ligament, is then lodged in the interspace between the superficial head of the Flexor brevis pollicis and the Adductor obliquus pollicis, and, entering an osseoponeurotic canal similar to those for the other Flexor tendons, is *inserted* into the base of the last phalanx of the thumb.

Relations.—By its *superficial surface*, with the Flexor sublimis digitorum, Flexor carpi radialis, Brachioradialis, and radial vessels; by its *deep surface*, with the radius, interosseous membrane, and Pronator quadratus; by its *ulnar border*, with the Flexor profundus digitorum, from which it is separated by the anterior interosseous vessels and nerve.

The **Pronator quadratus** (*m. pronator quadratus*) (Figs. 356 and 365) is a small, flat, quadrilateral muscle, extending transversely across the front of the radius and ulna, above their carpal extremities. It *arises* from the oblique ridge on the lower part of the anterior surface of the shaft of the ulna; from the lower fourth of the anterior surface and the anterior border of the ulna; and from a strong aponeurosis which covers the inner third of the muscle. The fibres pass outward and slightly downward, to be *inserted* into the lower fourth of the anterior surface and anterior border of the shaft of the radius.

Relations.—By its *superficial surface*, with the Flexor profundus digitorum, the Flexor longus pollicis, Flexor carpi radialis, and the radial vessels; by its *deep surface*, with the radius, ulna, and interosseous membrane.

Nerves.—All the muscles of the superficial layer are supplied by the median nerve, excepting the Flexor carpi ulnaris, which is supplied by the ulnar nerve. The Pronator teres and the Flexor carpi radialis derive their supply primarily from the sixth and seventh cervicals; the Palmaris longus from the eighth cervical; the Flexor sublimis digitorum from the seventh and eighth cervical and first thoracic, and the Flexor carpi ulnaris from the eighth cervical and first thoracic nerves. Of the deep layer, the Flexor profundus digitorum is supplied by the seventh and eighth cervicals and first thoracic through the ulnar and anterior interosseous branch of the median. The remaining two muscles, the Flexor longus pollicis and Pronator quadratus, are also supplied by the eighth cervical and first thoracic through the anterior interosseous branch of the median.

Actions.—These muscles act upon the forearm, the wrist, and hand. The Pronator teres helps to rotate the radius upon the ulna, rendering the hand prone; when the radius is fixed it assists the other muscles in flexing the forearm. The Flexor carpi radialis is one of the Flexors of the wrist; when acting alone it flexes the wrist, inclining it to the radial side. It can also assist in pronating the forearm and hand, and, by continuing its action, in bending the elbow. The Flexor carpi ulnaris is one of the flexors of the wrist; when acting alone it flexes the wrist, inclining it to the ulnar side (adducting the wrist), and, by continuing to contract, it bends the elbow. The Palmaris longus is a tensor of the palmar fascia. It also assists in flexing the wrist and elbow. The Flexor sublimis digitorum flexes first the middle and then the proximal phalanges. It assists in flexing the wrist and elbow. The Flexor profundus digitorum is one of the Flexors of the phalanges. After the Flexor sublimis has bent the second phalanx, the Flexor profundus flexes the terminal one, but it cannot do so until after the contraction of the superficial muscle. It also assists in flexing the wrist. The Flexor longus pollicis is the flexor of the distal phalanx of the thumb. When the thumb is fixed it also assists in flexing the wrist. The Pronator quadratus helps to rotate the radius upon the ulna, rendering the hand prone.

Applied Anatomy.—When a finger is amputated so that the fibrous sheath of the Flexor tendons is divided in a region in which it is firm and dense, the tendon contracts but the theca does not, and the rigid theca constitutes a permeable passage to the palm. If the parts should be infected the theca will draw pus toward the palm. Hence, it is best to close the theca by sutures. "Over the terminal phalanx, and over the joint between the middle and terminal phalanges, there is no fibrous sheath. In front of the metacarpophalangeal joint it is scarcely evident. Over the first and second (proximal and middle) phalanges, and in front of the joint between these bones, the fibrous sheath is well marked, and appears as a rigid tube when cut across. As the sheath crosses the metacarpophalangeal and first interphalangeal joints it is adherent

to the glenoid (anterior metacarpophalangeal) ligament, and is easily closed by two fine catgut sutures passed vertically—*i. e.*, from the dorsal to the palmar wall. Opposite the shafts of the first and second phalanges, however, there is much difficulty in effecting closure, since the sheath is united to the periosteum, and that membrane is very thin. In these situations the periosteum should be stripped up a little from the palmar aspect of the bone, and the orifice of the tube secured by two fine sutures passed either vertically or transversely, as may appear the more convenient. This stripping off of periosteum should be effected before the bone is divided."¹

9. The Radial Region (Figs. 354, 357).

Brachioradialis [Supinator longus]. Extensor carpi radialis longior.
Extensor carpi radialis brevior.

Dissection.—Divide the integument in the same manner as in the dissection of the anterior brachial region, and, after having examined the cutaneous vessels and nerves and deep fascia, remove all those structures. The muscles will then be exposed. The removal of the fascia will be considerably facilitated by detaching it from below upward. Great care should be taken to avoid cutting across the tendons of the muscles of the thumb, which cross obliquely the larger tendons running down the back of the radius.

The **Brachioradialis** (*m. brachioradialis*, formerly **Supinator longus**) (Fig. 354) is the most superficial muscle on the radial side of the forearm; it is fleshy for the upper two-thirds of its extent, and becomes tendinous below. It *arises* from the upper two-thirds of the external supracondylar ridge of the humerus, and from the external intermuscular septum, being limited above by the musculospiral groove. The fibres terminate above the middle of the forearm in a flat tendon, which is *inserted* into the outer side of the base of the styloid process of the radius.

Relations.—By its *superficial surface*, with the integument and fascia for the greater part of its extent; near its insertion it is crossed by the Extensor ossis metacarpi pollicis and the Extensor brevis pollicis; by its *deep surface*, with the humerus, the Extensor carpi radialis longior and brevior, the insertion of the Pronator teres, and the Supinator [brevis]; by its *inner border*, above the elbow, with the Brachialis anticus, the musculospiral nerve, and the radial recurrent artery; and in the forearm with the radial vessels and nerve.

The **Extensor carpi radialis longior** (*m. extensor carpi radialis longus*) (Fig. 357) is placed partly beneath the preceding muscle. It *arises* from the lower third of the external supracondylar ridge of the humerus, and from the external intermuscular septum by a few fibres from the common tendon of origin of the Extensor muscles of the forearm. The fibres terminate at the upper third of the forearm in a flat tendon, which runs along the outer border of the radius, beneath the Extensor tendons of the thumb; it then passes through a groove common to it and the Extensor carpi radialis breviar, immediately behind the styloid process, and is *inserted* into the base of the metacarpal bone of the index finger, on its radial side.

Relations.—By its *superficial surface*, with the Brachioradialis and fascia of the forearm; its *outer side* is crossed obliquely by the Extensor tendons of the thumb; by its *deep surface*, with the elbow-joint, the Extensor carpi radialis brevis, and back part of the wrist.

The **Extensor carpi radialis brevis** (*m. extensor carpi radialis brevis*) (Fig. 357) is shorter, as its name implies, and thicker than the preceding muscle, beneath which it is placed. It *arises* from the external condyle of the humerus by a tendon common to it and the three following muscles; from the external lateral ligament of the elbow-joint, from a strong aponeurosis which covers its surface, and from

the intermuscular septa between it and the adjacent muscles. The fibres terminate about the middle of the forearm in a flat tendon which is closely connected with that of the preceding muscle, and accompanies it to the wrist, lying in the same groove on the posterior surface of the radius; it passes beneath the Extensor tendons of the thumb, then beneath the annular ligament, and, diverging somewhat from its fellow, is *inserted* into the base of the metacarpal bone of the middle finger, on its radial side. There is often a bursa between a portion of the base of the bone and the tendon.

The tendons of the two preceding muscles pass through the same compartment of the annular ligament, and are lubricated by a single synovial membrane, but are separated from each other by a small vertical ridge of bone as they lie in the groove at the back of the radius.

Relations.—By its *superficial surface*, with the Extensor carpi radialis longior, and with the Extensor muscles of the thumb which cross it; by its *deep surface*, with the Supinator [brevis], tendon of the Pronator teres, radius, and wrist-joint; by its *ulnar border*, with the Extensor communis digitorum.

10. The Posterior Radioulnar Region (Fig. 357).

The muscles in this region are divided for purposes of description into two groups or layers, **superficial** and **deep**.

The Superficial Layer.

Extensor communis digitorum.
Extensor minimi digiti.

Extensor carpi ulnaris.
Anconeus.

The **Extensor communis digitorum** (*m. extensor digitorum communis*) is situated at the back part of the forearm. It *arises* from the external condyle of the humerus by the common tendon, from the deep fascia, and the intermuscular septa between it and the adjacent muscles. It divides below into four tendons which pass, together with that of the Extensor indicis, through a separate compartment of the annular ligament, lubricated by a synovial membrane. The tendons then diverge, pass across the back of the hand, and are *inserted* into the second and third phalanges of the fingers in the following manner: The *outermost* tendon, accompanied by the Extensor indicis, goes to the index finger (Figs. 357 and 360); the *second* tendon is sometimes connected to the first by a thin transverse band, and receives a slip from the third tendon (Fig. 357); it goes to the middle finger; the *third* tendon gives off the slip to the second (Fig. 357), and receives a very considerable part of the fourth tendon; the *fourth*, or *innermost* tendon, divides into two parts; one goes to join the third tendon, the other, reinforced by the Extensor minimi digiti, goes to the little finger. Each tendon opposite the metacarpophalangeal articulation becomes narrow and thickened, and gives off a thin fasciculus upon each side of the joint, which blends with the lateral ligaments and serves as the posterior ligament; after having passed the joint it spreads out into a broad aponeurosis, which covers the whole of the dorsal surface of the first phalanx, being reinforced, in this situation, by the tendons of the Interossei and Lumbricales. Opposite the first phalangeal joint this aponeurosis divides into three slips, a middle and two lateral; the former is *inserted* into the base of the second phalanx, and the two lateral, which are continued onward along the sides of the second phalanx, unite by their contiguous margins, and are *inserted* into the dorsal surface of the last phalanx. As the tendons cross the phalangeal joints they furnish them with posterior ligaments. The accessory

slips or **lateral vincula** which join the tendon of the ring finger to the tendon of the little finger and to the tendon of the middle finger are constant. If the middle and little fingers are held flexed the lateral vincula greatly limit the range of extension possible in the ring finger.

Relations.—By its *superficial surface*, with the fascia of the forearm and hand, the posterior annular ligament, and integument; by its *deep surface*, with the Supinator [brevis], the Extensor muscles of the thumb and index finger, the posterior interosseous vessels and nerve, the wrist-joint, carpus, metacarpus, and phalanges; by its *radial border*, with the Extensor carpi radialis brevis; by its *ulnar border*, with the Extensor minimi digiti and Extensor carpi ulnaris.

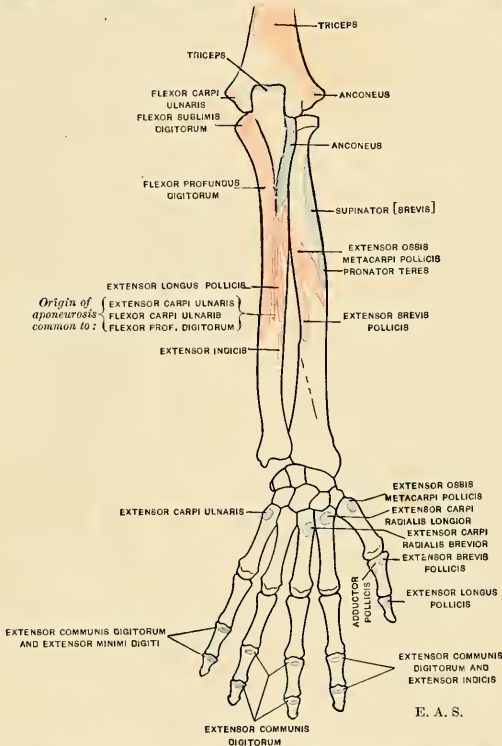


FIG. 358.—Diagram showing attachments of muscles of forearm and hand. Posterior aspect. Origins, red; insertions, blue. The origins and insertions of the Dorsal interossei muscles are omitted. (See Fig. 151.)

The **Extensor minimi digiti** (*m. extensor digiti quinti proprius*) is a slender muscle placed on the inner side of the Extensor communis, with which it is generally connected. It *arises* from the common Extensor tendon by a thin, tendinous slip, and from the intermuscular septa between it and the adjacent muscles. Its tendon runs through a separate compartment in the annular ligament behind the inferior radioulnar joint, then divides into two as it crosses the hand, the outermost division being joined by the slip from the innermost tendon of the common Extensor. The two slips thus formed spread into a broad aponeurosis, which, after receiving a slip from the Abductor minimi digiti, is *inserted* into the second and third phalanges of the little finger. The tendon is situated on the ulnar side of, and is somewhat more superficial than, the common Extensor.

The **Extensor carpi ulnaris** is the most superficial muscle on the ulnar side of the forearm. It *arises* from the external condyle of the humerus by the common Extensor tendon; by an aponeurosis from the posterior border of the ulna in common with the Flexor carpi ulnaris and the Flexor profundus digitorum; and from the deep fascia of the forearm. This muscle terminates in a tendon which runs through a groove behind the styloid process of the ulna, passes through a separate compartment in the annular ligament, and is *inserted* into the prominent tubercle on the ulnar side of the base of the metacarpal bone of the little finger.

The **Anconeus** (*m. anconaeus*) is a small triangular muscle placed behind and below the elbow-joint, and appears to be a continuation of the external portion of the Triceps. It *arises* by a separate tendon from the back part of the outer condyle of the humerus, and is *inserted* into the side of the olecranon and upper fourth of the posterior surface of the shaft of the ulna; its fibres diverge from their origin, the upper ones being directed transversely, the lower obliquely inward.

The Deep Layer (Fig. 362).

Supinator [brevis].	Extensor brevis pollicis.
Extensor ossis metacarpi pollicis.	Extensor longus pollicis.
Extensor indicis.	

The **Supinator** [brevis] (*m. supinator*) (Figs. 359 and 360) is a broad muscle, of hollow cylindrical form, curved around the upper third of the radius. It consists of two distinct planes of muscle fibres, between which lies the posterior interosseous nerve (Fig. 359). The two planes *arise* in common—the superficial one by tendinous, and the deeper by muscle fibres from the external condyle of the humerus, from the external lateral ligament of the elbow-joint and the orbicular ligament of the radius; from the ridge on the ulna, which runs obliquely downward from the posterior extremity of the lesser sigmoid cavity; from the triangular depression in front of the cavity; and from a tendinous expansion which covers the surface of the muscle. The superficial fibres surround the upper part of the radius, and are *inserted* into the outer edge of the bicipital tuberosity and into the oblique line of the radius, as low down as the insertion of the Pronator teres. The upper fibres of the deeper plane form a sling-like fasciculus, which encircles the neck of the radius above the tuberosity and is attached to the back part of its inner surface; the greater part of this portion of the muscle is *inserted* into the posterior and external surface of the shaft, midway between the oblique line and the head of the bone. Between the insertion of the two planes the posterior interosseous nerve lies on the shaft of the bone (Fig. 359).

Relations.—By its *superficial surface*, with the superficial Extensors and the Brachioradialis muscles, and the radial vessels and nerve; by its *deep surface*, with the elbow-joint, the interosseous membrane, and the radius.

The **Extensor ossis metacarpi pollicis** (*m. abductor pollicis longus*) is the most external and the largest of the deep Extensor muscles; it lies immediately below the Supinator [brevis], with which it is sometimes united. It *arises* from the outer part of the posterior surface of the shaft of the ulna below the insertion of the Anconeus, from the interosseous membrane, and from the middle third of the posterior surface of the shaft of the radius. Passing obliquely downward and outward, it terminates in a tendon which runs through a groove on the outer side of the styloid process of the radius, accompanied by the tendon of the Extensor brevis pollicis, and is *inserted* into the base of the metacarpal bone of the thumb.

It occasionally gives off two slips near its insertion—one to the trapezium, and the other to blend with the origin of the Abductor pollicis.

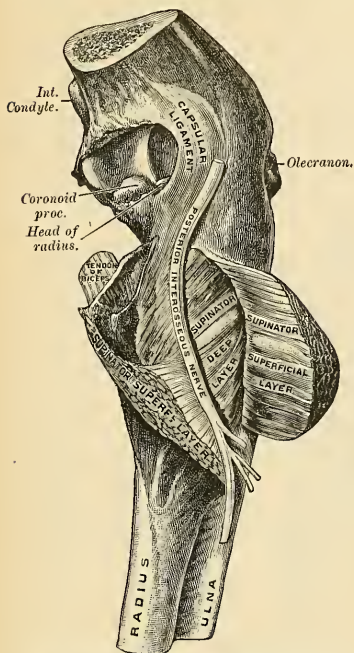


FIG. 359.—Supinator [brevis]. (From a preparation in the Museum of the Royal College of Surgeons of England.)

Relations.—By its *superficial surface*, with the Extensor communis digitorum, Extensor minimi digiti, and fascia of the forearm, and with the branches of the posterior interosseous artery and nerve which cross it; by its *deep surface*, with the ulna, the interosseous membrane, the radius, the tendons of the Extensor carpi radialis longior and brevior, which it crosses obliquely, and at the outer side of the wrist, with the radial vessels; by its *upper border*, with the Supinator [brevis]; by its *lower border*, with the Extensor brevis pollicis.

The **Extensor brevis pollicis** (*m. extensor pollicis brevis*), the smallest muscle of this group, lies on the inner side of the preceding. It arises from the posterior surface of the shaft of the radius, below the Extensor ossis metacarpi pollicis, and from the interosseous membrane. Its direction is similar to that of the Extensor ossis metacarpi

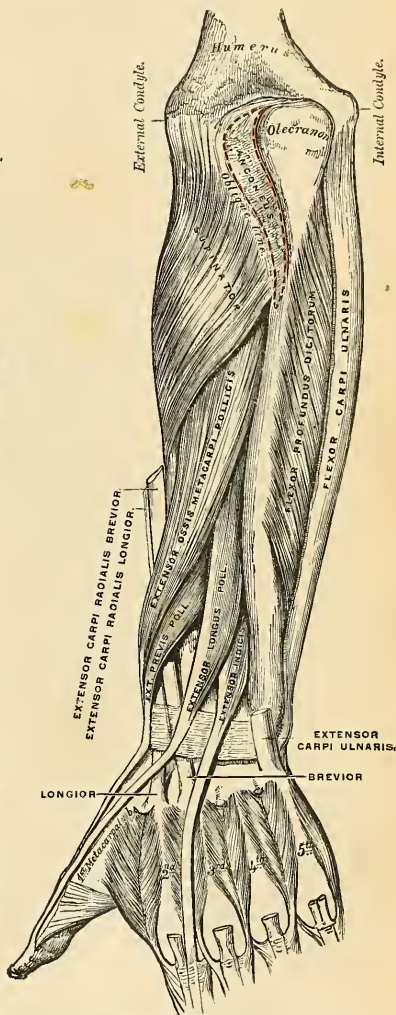


FIG. 360.—Posterior surface of the left forearm. Deep muscles.

pollicis, its tendon passing through the same groove on the outer side of the styloid process, to be *inserted* into the base of the first phalanx of the thumb.

Relations.—The same as those of the Extensor ossis metacarpi pollicis.

The **Extensor longus pollicis** (*m. extensor pollicis longus*) is much larger than the preceding muscle, the origin of which it partly covers in. It *arises* from the outer part of the posterior surface of the shaft of the ulna, below the origin of the Extensor ossis metacarpi pollicis, and from the interosseous membrane. It terminates in a tendon which passes through a separate compartment

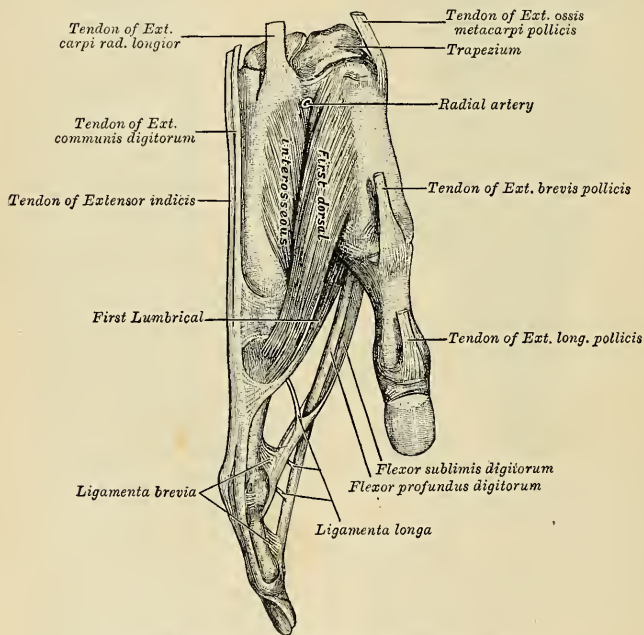


FIG. 361.—The tendons attached to the right index finger.

in the annular ligament, lying in a narrow, oblique groove at the back part of the lower end of the radius. It then crosses obliquely the tendons of the Extensor carpi radialis longior and breviar, being separated from the other Extensor tendons of the thumb, by a triangular interval, in which the radial artery is found, and is finally *inserted* into the base of the last phalanx of the thumb.

Relations.—By its *superficial surface*, with the same parts as the Extensor ossis metacarpi pollicis; by its *deep surface*, with the ulna, interosseous membrane, the posterior interosseous nerve, radius, the wrist, the radial vessels, and metacarpal bone of the thumb.

The **Extensor indicis** (*m. extensor indicis proprius*) (Figs. 357 and 360) is a narrow, elongated muscle placed on the inner side of, and parallel with, the

preceding. It *arises* from the posterior surface of the shaft of the ulna, below the origin of the Extensor longus pollicis and from the interosseous membrane. Its tendon passes with the Extensor communis digitorum through the same canal in the annular ligament, and subsequently joins the tendon of the Extensor communis which belongs to the index finger, opposite the lower end of the corresponding metacarpal bone, lying to the ulnar side of the tendon from the common Extensor.

Nerves.—The Brachioradialis is supplied by the fifth and sixth, the Extensor carpi radialis longior by the sixth and seventh, and the Anconeus by the seventh and eighth cervical nerves, all through the musculospiral nerve; the remaining muscles of the radial and posterior brachial region are supplied through the posterior interosseous nerve, the Supinator [brevis] being supplied by the sixth cervical, the Extensor carpi radialis brevis by the sixth and seventh cervicals, and all the other muscles by the seventh cervical.

Actions.—The muscles of the radial and posterior brachial regions, which comprise all the Extensor and Supinator muscles, act upon the forearm, wrist, and hand; they are the direct antagonists of the Pronator and Flexor muscles. The Anconeus assists the Triceps in extending the forearm. The chief action of the Brachioradialis is that of a Flexor of the elbow-joint, but in addition to this it may act both as a Supinator or a Pronator; that is to say, if the forearm is forcibly pronated it will act as a Supinator, and bring the bones into a position midway between supination and pronation; and, *vice versa*, if the arm is forcibly supinated, it will act as a pronator, and bring the bones into the same position, midway between supination and pronation. The action of the muscle is therefore to throw the forearm and hand into the position they naturally occupy when placed across the chest. The Supinator [brevis] is a true supinator; that is to say, when the radius has been carried across the ulna in pronation and the back of the hand is directed forward, this muscle carries the radius back again to its normal position on the outer side of the ulna, and the palm of the hand is again directed forward. The Extensor carpi radialis longior extends the wrist and abducts the hand. It may also assist in bending the elbow-joint; at all events, it serves to fix or steady this articulation. The Extensor carpi radialis brevis assists the Extensor carpi radialis longior in extending the wrist, and may also act slightly as an abductor of the hand. The Extensor carpi ulnaris helps to extend the hand, but when acting alone inclines it toward the ulnar side; by its continued action it extends the elbow-joint. The Extensor communis digitorum extends the phalanges, then the wrist, and finally the elbow. It acts principally on the proximal phalanges, the middle and terminal phalanges being extended by the Interossei and Lumbricales. It has also a tendency to separate the fingers as it extends them. The Extensor minimi digiti extends similarly the little finger, and by its continued action it assists in extending the wrist. It is owing to this muscle that the little finger can be extended or pointed while the others are flexed. The chief action of the Extensor ossis metacarpi pollicis is to carry the thumb outward and backward from the palm of the hand, and hence it has been called the **Abductor pollicis longus**. By its continued action it helps to extend and abduct the wrist. The Extensor brevis pollicis extends the proximal phalanx of the thumb. By its continued action it helps to extend and abduct the wrist. The Extensor longus pollicis extends the terminal phalanx of the thumb. By its continued action it helps to extend and abduct the wrist. The Extensor indicis extends the index finger, and by its continued action assists in extending the wrist. It is owing to this muscle that the index finger can be extended or pointed while the others are flexed.

Applied Anatomy.—The tendons of the Extensor muscles of the thumb are liable to become strained and their sheaths inflamed after excessive exercise, producing a sausage-shaped swelling along the course of the tendon, and giving a peculiar creaking sensation to the finger when the muscle acts; it is known as *tenosynovitis*. In piano-players the slips which join the tendons of the Extensor communis digitorum may limit freedom of motion in individual fingers. Their complete extension, without operative interference, can only be brought about by long-continued exertion in practice, when elongation of certain accessory, but restricting, tendons is made by nutritive growth. If there is much limitation, division of the hindering slips is advisable.¹ Paralysis of the Extensor muscles of the hand is common in lead poisoning, and causes the well-known "*wrist drop*." Curiously enough, the Brachioradialis and Extensor ossei metacarpi pollicis muscles escape. The paralysis is due to a neuritis of the musculospiral nerve.

¹ Prof. William S. Forbes, in the Philadelphia Medical Journal, January 15, 1898.

IV. MUSCLES AND FASCIÆ OF THE HAND.

The muscles of the hand are subdivided into three groups: (1) Those of the thumb, which occupy the radial side and produce the **thenar eminence**. (2) Those of the little finger, which occupy the ulnar side and give rise to the **hypothenar eminence**. (3) Those in the middle of the palm and within the interosseous spaces.

Dissection (Fig. 344).—Make a transverse incision across the front of the wrist, and a second across the heads of the metacarpal bones; connect the two by a vertical incision in the middle line, and continue it through the centre of the middle finger. The anterior and posterior annular ligaments and the palmar fascia should then be dissected.

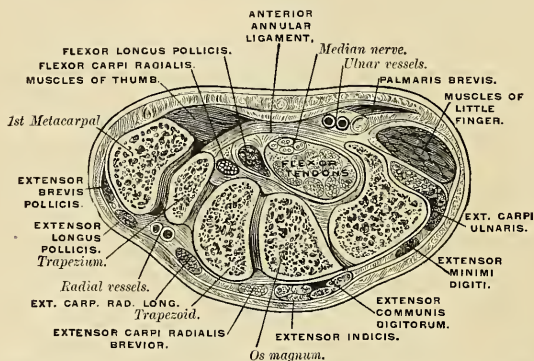


FIG. 362.—Transverse section through the carpus, showing the relative positions of the tendons, vessels, and nerves. (Henle.)

The **Anterior Annular Ligament** (*ligamentum carpi transversum*) (Fig. 362) is a strong, fibrous band which arches over the carpus, converting the deep groove on the front of the carpal bones into a canal, beneath which pass the Flexor tendons of the fingers. It is attached, internally, to the pisiform bone and the hook of the ulniform bone, and externally to the tuberosity of the scaphoid and to the inner part of the anterior surface and the ridge of the trapezium. It is continuous, *above*, with the deep fascia of the forearm, of which it may be regarded as a thickened portion, and, *below*, with the palmar fascia. It is crossed by the ulnar vessels and nerve and the cutaneous branches of the median and ulnar nerves. At its outer extremity is the tendon of the Flexor carpi radialis, which lies in the groove on the trapezium between the attachments of the annular ligaments to the bone. It has inserted into its anterior surface a part of the tendon of the Palmaris longus and part of the tendon of the Flexor carpi ulnaris, and has arising from it, below, the small muscles of the thumb and little finger. Beneath it pass the tendons of the Flexores sublimis and Profundus digitorum, the tendon of the Flexor longus pollicis, and the median nerve.

The Synovial Membranes of the Flexor Tendons at the Wrist.—There are two vaginal synovial membranes which enclose all the tendons as they pass beneath this ligament—one for the Flexores sublimis and Profundus digitorum, the other for the Flexor longus pollicis. They extend up into the forearm for about an inch above the annular ligament, and downward about half-way along the metacarpal bone, where they terminate in a blind diverticulum around each pair

of tendons, with the exception of those of the thumb and little finger; in each of these two digits the diverticulum is continued on, and communicates with the synovial sheath of the tendons in the fingers. In the other three fingers the synovial sheath of the tendons begins as a blind pouch without communication with the large synovial sac (Fig. 363).

Applied Anatomy.—This arrangement of the synovial sheaths explains the fact that thecal abscess in the thumb or little finger is liable to be followed by abscesses of the forearm, from extension of the inflammation along the continuous synovial sheaths. Tuberculous inflammation is liable to occur in this situation, constituting *compound palmar ganglion*; it presents an hour-glass outline, with a swelling in front of the wrist and in the palm of the hand, and a constriction corresponding to the annular ligament between the two. The fluid can be forced from the one swelling to the other under the ligament.

Bursæ about the Hand and Wrist.—

Bursæ usually exist between the distal extremities of the metacarpal bones (*bursæ intermetacarpophalangeæ*), and a subcutaneous bursa often exists over the dorsal surface of the head of the fifth metacarpal bone. Subcutaneous digital dorsal bursæ occur “almost constantly in the first finger-joints (between the first and second phalanx), occasionally in the second joint of the second and fourth fingers”¹ (*bursæ subcutaneæ digitorum dorsales*). A bursa exists between the tendon of the Extensor carpi radialis brevis and the base of the third metacarpal bone; another between the Flexor carpi ulnaris and the pisiform bone; another between the Flexor carpi radialis and the base of the second metacarpal bone.

The **Posterior Annular Ligament** (*ligamentum carpi dorsale*) is a strong fibrous band extending obliquely downward and inward across the back of the wrist, and consisting of the deep fascia of the back of the forearm, strengthened by the addition of some transverse fibres. It binds down the Extensor tendons in their passage to the fingers, being attached, *internally*, to the styloid process of the ulna, the cuneiform and pisiform bones; *externally*, to the margin of the radius; and, in its passage across the wrist, to the ridges on the posterior surface of the radius. It presents six compartments for the passage of tendons, each of which is lined with a separate synovial membrane (Fig. 364). These are, from without inward: (1) On the outer side of the styloid process, for the tendons of the Extensor ossis metacarpi and Extensor brevis pollicis. (2) Behind the styloid process, for the tendons of the Extensor carpi radialis longior and

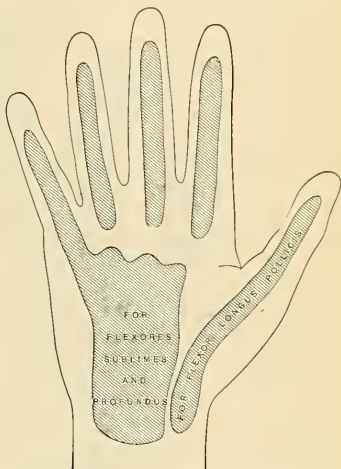


Fig. 363.—Diagram showing the arrangement of the synovial sheaths of the palm and fingers.

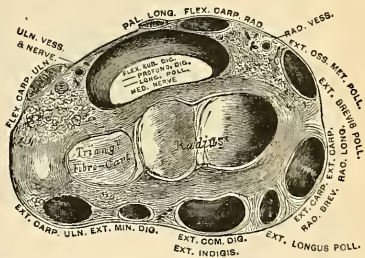


Fig. 364.—Transverse section through the wrist, showing the annular ligaments and the canals for the passage of the tendons.

brevior. (3) About the middle of the posterior surface of the radius, for the tendon of the Extensor longus pollicis. (4) To the inner side of the latter, for the tendons of the Extensor communis digitorum and Extensor indicis. (5) Opposite the interval between the radius and ulna, for the Extensor minimi digiti. (6) Grooving the back of the ulna, for the tendon of the Extensor carpi ulnaris. The synovial membranes lining these sheaths are usually very extensive, reaching from above the annular ligament down upon the tendons for a variable distance on the back of the hand.

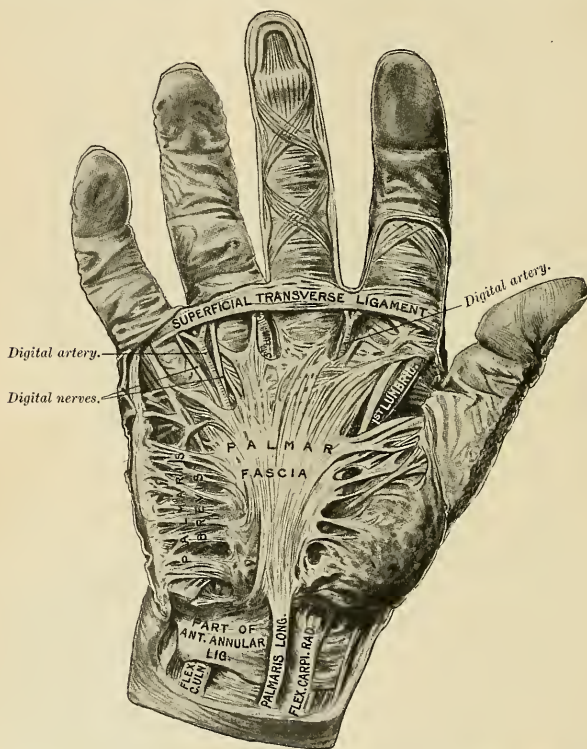


FIG. 365.—Palmar fascia. (From a preparation in the Museum of the Royal College of Surgeons of England.)

The **deep palmar fascia** (*aponeurosis palmaris*) (Fig. 365) forms a common sheath which invests the muscles of the hand. It consists of a **central** and **two lateral** portions.

The **central portion** occupies the middle of the palm, is triangular in shape, of great strength and thickness, and binds down the tendons and protects the vessels and nerves in this situation. It is narrow *above*, where it is attached to the lower margin of the annular ligament, and receives the expanded tendon of the Palmaris longus muscle. *Below*, it is broad and expanded, and divides into four slips for the four fingers. Each slip gives off superficial fibres, which are inserted

into the skin of the palm and finger, those to the palm joining the skin at the furrow corresponding to the metacarpophalangeal articulation, and those to the fingers passing into the skin at the transverse fold at the base of the fingers. The deeper part of each slip subdivides into two processes, which are inserted into the lateral margins of the anterior ligament of the metacarpophalangeal joint. From the sides of these processes portions are sent backward (dorsal) to be attached to the borders of the lateral surfaces of the metacarpal bones at their distal extremities. By this arrangement short channels are formed on the front of the lower ends of the metacarpal bones, through which the Flexor tendons pass.¹ The intervals left in the fascia between the four fibrous slips transmit the digital vessels and nerves and the tendons of the Lumbricales. At the points of division of the palmar fascia into the slips above mentioned numerous strong, transverse fibres bind the separate processes together. The palmar fascia is intimately adherent to the integument by dense, fibroareolar tissue, forming the superficial palmar fascia, and gives origin by its inner margin to the *Palmaris brevis*; it covers the superficial palmar arch, the tendons of the Flexor muscles, and the branches of the median and ulnar nerves, and on each side it gives off a vertical septum, which is continuous with the interosseous aponeurosis and separates the two lateral from the middle palmar group of muscles.

The lateral portions of the palmar fascia are thin, fibrous layers, which cover, on the radial side, the muscles of the ball of the thumb, and, on the ulnar side, the muscles of the little finger; they are continuous with the dorsal fascia, and in the palm with the central portion of the palmar fascia.

The **Superficial Transverse Ligament of the Fingers** is a thin band of transverse fibres (*fasciculi transversi*); it stretches across the roots of the four fingers, and is closely attached to the skin of the clefts, and internally to the fifth metacarpal bone, forming a sort of rudimentary web. Beneath it the digital vessels and nerves pass onward to their destination.

Applied Anatomy.—The palmar fascia is liable to undergo contraction, producing a very inconvenient deformity known as *Dupuytren's contraction*. The ring and little fingers are most frequently implicated, but the middle, the index, and the thumb may be involved. The proximal phalanx is flexed and cannot be straightened, and the two distal phalanges become similarly flexed as the disease advances.

11. The Radial Region (Figs. 366, 367).

Abductor pollicis.

Opponens pollicis.

Flexor brevis pollicis.

Adductor obliquus pollicis.

Adductor transversus pollicis.

The **Abductor pollicis** (*m. abductor pollicis brevis*) (Fig. 357) is a thin, flat muscle, placed immediately beneath the integument. It arises from the anterior annular ligament, the tuberosity of the scaphoid, and the ridge of the trapezium, frequently by two distinct slips; and, passing outward and downward, is inserted by a thin, flat tendon into the radial side of the base of the first phalanx of the thumb, sending a slip to join the tendon of the Extensor longus pollicis.

Relations.—By its *superficial surface*, with the palmar fascia and superficialis volæ artery, which frequently perforates it. By its *deep surface*, with the Opponens pollicis. Its *inner border* is separated from the Flexor brevis pollicis by a narrow cellular interval.

¹ Dr. Keen describes a fifth slip as frequently found passing to the thumb.

The **Opponens pollicis** (*m. opponens pollicis*) (Figs. 366 and 367) is placed beneath and partially to the outer side of the preceding. It *arises* from the ridge on the trapezium and from the anterior annular ligament, passes downward and outward, and is *inserted* into the whole length of the metacarpal bone of the thumb on its radial side.

Relations.—By its *superficial surface*, with the Abductor and Flexor brevis pollicis. By its *deep surface*, with the first metacarpal bone. By its *inner border*, with the Adductor obliquus pollicis.

The **Flexor brevis pollicis** (*m. flexor pollicis brevis*) (Fig. 367) consists of two portions, superficial and deep. The **superficial portion** *arises* from the outer two-thirds of the lower border of the anterior annular ligaments and sometimes from

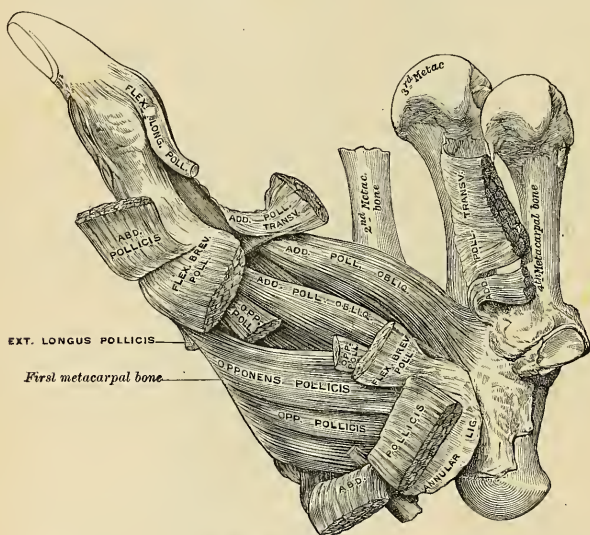


FIG. 366.—Muscles of the thumb.

the ridge of the trapezium, and passes along the outer side of the tendon of the Flexor longus pollicis; and, becoming tendinous, has a sesamoid bone developed in its tendon, and is *inserted* into the outer side of the base of the first phalanx of the thumb. The **deeper portion** of the muscle is very small, and arises from the ulnar side of the first metacarpal bone beneath the Adductor obliquus pollicis, and is *inserted* into the inner side of the base of the first phalanx with this muscle.

Relations.—By its *superficial surface*, with the palmar fascia. Its *deep surface* is separated from the Adductor obliquus pollicis by the tendon of the Flexor longus pollicis. By its *external (radial) surface*, with the Abductor pollicis.

The **Adductor obliquus pollicis** (*m. adductor pollicis*) (Figs. 366 and 367) *arises* by several slips from the os magnum, the bases of the second and third

metacarpal bones, the anterior carpal ligaments, and the sheath of the tendon of the Flexor carpi radialis. From this origin the greater number of fibres pass obliquely downward and converge to a tendon, which, uniting, with the tendons of the deeper portion of the Flexor brevis pollicis and the Adductor transversus,

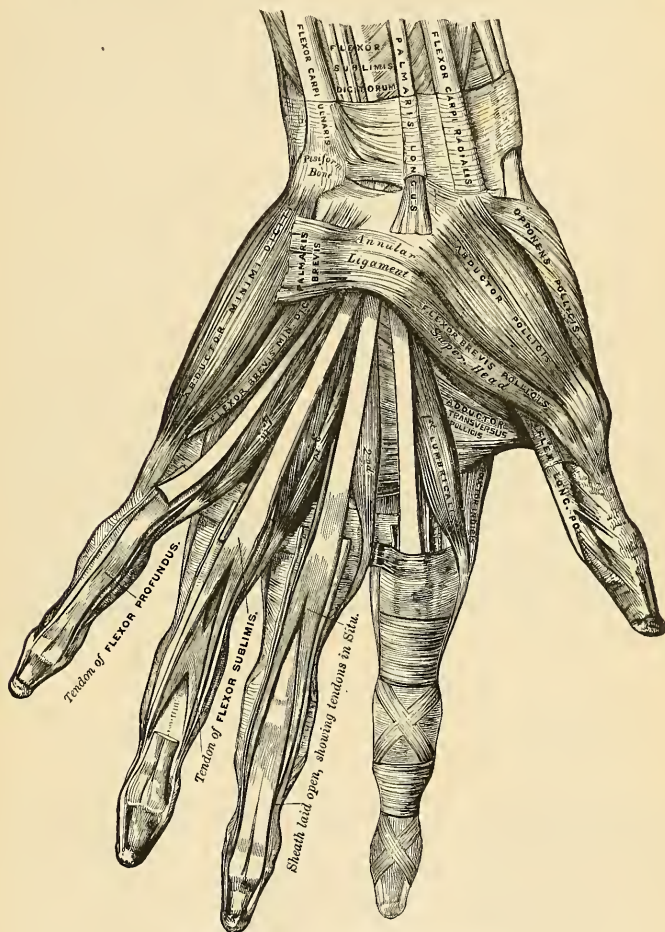


FIG. 367.—Muscles of the left hand. Palmar surface.

is *inserted* into the inner side of the base of the first phalanx of the thumb, a sesamoid bone being developed in the tendon of insertion. A considerable fasciculus, however, passes more obliquely outward beneath the tendon of the long Flexor to join the superficial portion of the short Flexor and the Abductor pollicis.¹

¹ This muscle is described by some as the deep portion of the Flexor brevis pollicis.

Relations.—By its *superficial surface*, with the Flexor longus pollicis and the superficial head of the Flexor brevis pollicis. Its *deep surface* is in relation with the deep palmar arch, which passes between the two Adductors.

The **Adductor transversus pollicis** (*m. adductor transversus pollicis*) (Figs. 366 and 367) is the most deeply seated of this group of muscles. It is of a triangular form, *arising*, by its broad base, from the lower two-thirds of the metacarpal bone of the middle finger on its palmar surface; the fibres, proceeding outward, converge to be *inserted*, with the deeper part of the Flexor brevis pollicis, and the Adductor obliquus pollicis, into the ulnar side of the base of the first phalanx of the thumb. From the common tendon of insertion a slip is prolonged to the Extensor longus pollicis.

Relations.—By its *superficial surface*, with the tendons of the Flexor profundus and the Lumbricales. Its *deep surface* covers the first two interosseous spaces, from which it is separated by a strong aponeurosis.

Three of these muscles of the thumb, the Abductor, the Adductor transversus, and the Flexor brevis pollicis, at their insertions give off fibrous expansions which join the tendon of the Extensor longus pollicis. This permits of flexion of the proximal phalanx and extension of the terminal phalanx at the same time.

Nerves.—The Abductor, Opponens, and superficial head of the Flexor brevis pollicis are supplied by the sixth cervical through the median nerve; the deep head of the Flexor brevis, and the Adductors, by the eighth cervical through the ulnar nerve.

Actions.—The actions of the muscles of the thumb are almost sufficiently indicated by their names. This segment of the hand is provided with three Extensors—an Extensor of the metacarpal bone, an Extensor of the first, and an Extensor of the second phalanx; these occupy the dorsal surface of the forearm and hand. There are also three Flexors on the palmar surface—a Flexor of the metacarpal bone, a Flexor of the proximal, and a Flexor of the terminal phalanx; there is also an Abductor and two Adductors. The Abductor pollicis moves the metacarpal bone of the thumb outward; that is, away from the index finger. The Opponens pollicis flexes the first metacarpal bone—that is, draws it inward over the palm—so as to turn the ball of the thumb toward the fingers, thus producing the movement of opposition. The Flexor brevis pollicis flexes and adducts the proximal phalanx of the thumb. The Adductores pollicis move the metacarpal bone of the thumb inward; that is, toward the index finger. These muscles give to the thumb its extensive range of motion. It will be noticed, however, that in consequence of the position of the first metacarpal bone, these movements differ from the corresponding movements of the metacarpal bones of the other fingers. Thus extension of the thumb more nearly corresponds to the motion of abduction in the other fingers, and flexion to adduction.

12. The Ulnar Region (Fig. 367).

Palmaris brevis.

Abductor minimi digiti.

Flexor brevis minimi digiti.

Opponens minimi digiti.

The **Palmaris brevis** (*m. palmaris brevis*) is a thin quadrilateral muscle placed beneath the integument on the ulnar side of the hand. It *arises* by tendinous fasciculi from the anterior annular ligament and palmar fascia; the fleshy fibres pass inward, to be *inserted* into the skin on the inner border of the palm of the hand.

The **Abductor minimi digiti** (*m. abductor digiti quinti*) is situated on the ulnar border of the palm of the hand. It *arises* from the pisiform bone and from the tendon of the Flexor carpi ulnaris, and terminates in a flat tendon, which divides into two slips; one is *inserted* into the ulnar side of the base of the first phalanx of the little finger. The other slip is *inserted* into the ulnar border of the aponeurosis of the Extensor minimi digiti.

Relations.—By its *superficial surface*, with the inner portion of the palmar fascia and the Palmaris brevis; by its *deep surface*, with the Opponens minimi digiti; by its *outer border*, with the Flexor brevis minimi digiti.

The **Flexor brevis minimi digiti** (*m. flexor digiti quinti brevis*) lies on the same plane as the preceding muscle, on its radial side. It *arises* from the convex aspect of the hook of the unciform bone and anterior surface of the annular ligament, and is *inserted* into the inner side of the base of the first phalanx of the little finger. It is separated from the Abductor at its origin by the deep branches of the ulnar artery and nerve. This muscle is sometimes wanting; the Abductor is then, usually, of large size.

Relations.—By its *superficial surface*, with the internal portion of the palmar fascia and the Palmaris brevis; by its *deep surface*, with the Opponens. The deep branch of the ulnar artery and the corresponding branch of the ulnar nerve pass between the Abductor and Flexor brevis minimi digiti muscles.

The **Opponens minimi digiti** (*m. opponens digiti quinti*) (Fig. 356) is of a triangular form, and placed immediately beneath the preceding muscles. It *arises* from the convexity of the hook of the unciform bone and the contiguous portion of the anterior annular ligament; its fibres pass downward and inward, to be *inserted* into the whole length of the metacarpal bone of the little finger, along its ulnar margin.

Relations.—By its *superficial surface*, with the Flexor brevis and Abductor minimi digiti; by its *deep surface*, with the Interossei muscles in the fourth metacarpal space, the metacarpal bone, and the Flexor tendons of the little finger.

Nerves.—All the muscles of this group are supplied by the eighth cervical nerve through the ulnar nerve.

Actions.—The Abductor minimi digiti abducts the little finger from the middle line of the hand. It corresponds to a dorsal interosseous muscle. It also assists in flexing the proximal phalanx and extending the second and third phalanges. The Flexor brevis minimi digiti abducts the little finger from the middle line of the hand. It also assists in flexing the proximal phalanx. The Opponens minimi digiti draws forward the fifth metacarpal bone, so as to deepen the hollow of the palm. The Palmaris brevis corrugates the skin on the inner side of the palm of the hand and probably serves to protect the ulnar nerve and artery from damage by the pressure of grasping a hard object.

13. The Middle Palmar Region.

Lumbricales.

Interossei dorsales.

Interossei palmares.

The **Lumbricales** (*mm. lumbricales*) (Fig. 367) are four small fleshy fasciculi, accessories to the deep Flexor muscle. They *arise* from the tendons of the Flexor profundus digitorum; the *first* and *second*, from the radial side and palmar surface of the tendons of the index and middle fingers, respectively; the *third*, from the contiguous sides of the tendons of the middle and ring fingers; and the *fourth*, from the contiguous sides of the tendons of the ring and little fingers. They pass to the radial side of the corresponding fingers and opposite the metacarpophalangeal articulation each tendon is *inserted* into the tendinous expansion of the Extensor communis digitorum, covering the dorsal aspect of each finger.

The **Interossei muscles** (*mm. interossei*) (Figs. 368 and 369) are so named from occupying the intervals between the metacarpal bones, and are divided into two sets, dorsal and palmar.

The **Dorsal interossei** (*mm. interossei dorsales*) are four in number, larger than the palmar, and occupy the intervals between the metacarpal bones. They are bipenniform muscles, *arising* by two heads from the adjacent sides of the metacarpal bones, but more extensively from the metacarpal bone of the finger into which the muscle is inserted. They are *inserted* into the bases of the first phalanges and into the aponeurosis of the common Extensor tendon. Between the double origin of each of these muscles is a narrow triangular interval, through the first of which passes the radial artery; through each of the other three passes a perforating branch from the deep palmar arch.

The **First dorsal interosseous muscle**, or **Abductor indicis**, is larger than the others. It is flat, triangular in form, and *arises* by two heads, separated by a fibrous arch, for the passage of the radial artery from the dorsum to the palm of the hand. The **outer head** *arises* from the upper half of the ulnar border of the first metacarpal bone; the **inner head**, from almost the entire length of the radial border of the second metacarpal bone; the tendon is *inserted* into the radial side of the index finger. The **Second** and **Third dorsal interossei** are *inserted* into the middle finger, the former into its radial, the latter into its ulnar side. The **Fourth** is *inserted* into the ulnar side of the ring finger.

The **Palmar interossei** (*mm. interossei volares*), three in number, are smaller than the Dorsal, and placed upon the palmar surface of the metacarpal bones, rather than between them. Each muscle *arises* from the entire length of the metacarpal bone of one finger, and is *inserted* into the side of the base of the first

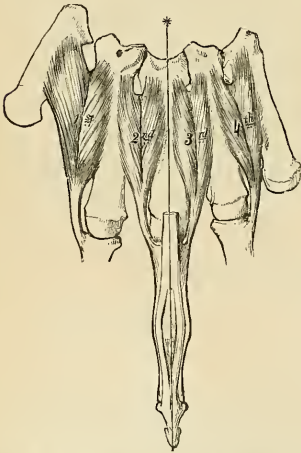


FIG. 368.—The Dorsal interossei of left hand. The line marked by an * is that from which abduction is made.

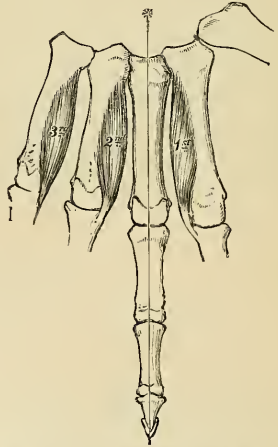


FIG. 369.—The Palmar interossei of left hand. The line marked by an * is that to which adduction is made.

phalanx and aponeurotic expansion of the common Extensor tendon of the same finger. The **First** *arises* from the ulnar side of the second metacarpal bone, and is *inserted* into the same side of the first phalanx of the index finger. The **Second** *arises* from the radial side of the fourth metacarpal bone, and is *inserted* into the same side of the ring finger. The **Third** *arises* from the radial side of the fifth metacarpal bone, and is *inserted* into the same side of the little finger. From

this account it may be seen that each finger is provided with two Interosseous muscles, with the exception of the little finger, in which the Abductor muscle takes the place of one of the pair.

Nerves.—The two outer Lumbricales are supplied by the sixth cervical nerve, through the third and fourth digital branches of the median nerve; the two inner Lumbricales and all the Interossei are supplied by the eighth cervical nerve, through the deep palmar branch of the ulnar nerve. The third Lumbrical frequently receives a twig from the median.

Actions.—The Palmar interossei muscles adduct the finger to an imaginary line drawn longitudinally through the centre of the middle finger; and the Dorsal interossei abduct the fingers from that line. In addition to this, the Interossei, in conjunction with the Lumbricales, flex the first phalanges at the metacarpophalangeal joints, and extend the second and third phalanges in consequence of their insertion into the expansion of the Extensor tendons. The Extensor communis digitorum is believed to act almost entirely on the first phalanges.

SURFACE FORM OF THE UPPER EXTREMITY.

The **Pectoralis major muscle** largely influences surface form and conceals a considerable part of the thoracic wall in front. Its sternal origin presents a festooned border which bounds and determines the width of the sternal furrow. Its clavicular origin is somewhat depressed and flattened, and between the two portions of the muscle is often an oblique depression which differentiates the one from the other. The outer margin of the muscle is generally well marked above, and bounds the *infraclavicular fossa* (Fossa of Mohrenheim), a triangular interval which separates the Pectoralis major from the Deltoid. It gradually becomes less marked as it approaches the tendons of insertion, and becomes more closely blended with the Deltoid muscle. The lower border of the Pectoralis major forms the rounded *anterior axillary fold*, and corresponds with the direction of the fifth rib. The **Pectoralis minor muscle** influences surface form. When the arm is raised its lowest slip of origin produces a local fullness just below the border of the anterior fold of the axilla, and so serves to break the sharp line of the lower border of the Pectoralis major muscle, which is produced when the arm is in this position. The origin of the **Serratus magnus muscle** produces a very characteristic surface marking. When the arm is raised from the side in a well-developed subject, the five or six lower serrations are plainly discernible, forming a zigzag line, caused by the series of digitations, which diminish in size from above downward, and have their apices arranged in the form of a curve. When the arm is lying by the side, the first serration to appear, at the lower margin of the Pectoralis major, is the one attached to the fifth rib. The **Deltoid muscle**, with the prominence of the upper extremity of the humerus, produces the rounded outline of the shoulder. It is rounder and fuller in front than behind, where it presents a somewhat flattened form. Its anterior border, above, presents a rounded, slightly curved eminence, which bounds externally the *infraclavicular fossa*; below, it is closely united with the Pectoralis major. Its posterior border is thin, flattened, and scarcely marked above; below, it is thicker and more prominent. When the muscle is in action, the middle portion becomes irregular, presenting alternate longitudinal elevations and depressions, the elevations corresponding to the fleshy portions, the depressions to the tendinous intersections of the muscle. The insertion of the Deltoid is marked by a depression on the outer side of the middle of the arm. Of the scapular muscles, the only one which materially influences surface form is the **Teres major**, which assists the Latissimus dorsi in forming the thick, rounded fold of the *posterior boundary of the axilla*. When the arm is raised, the **Coracobrachialis** reveals itself as a long, narrow elevation which emerges from under cover of the anterior fold of the axilla and runs downward, internal to the shaft of the humerus. When the arm is hanging by the side, its front and inner part presents the prominence of the **Biceps**, bounded on either side by an intermuscular depression. This muscle determines the contour of the front of the arm, and extends from the anterior margin of the axilla to the bend of the elbow. Its upper tendons are concealed by the Pectoralis major and the Deltoid, and its lower tendon sinks into the space at the bend of the elbow. When the muscle is in a state of complete contraction—that is to say, when the forearm has been flexed and supinated—it presents a rounded convex form, bulged out laterally, and its length is diminished. On each side of the Biceps, at the lower part of the arm, the **Brachialis anticus** is discernible. On the outer side it forms a narrow eminence which extends some distance up the arm along the border of the Biceps. On the inner side it shows itself only as a little fullness just above the elbow. On the back of the arm the long head of the **Triceps** may be seen as a longitudinal eminence emerging from under cover of the Deltoid, and gradually merging into the longitudinal flattened plane of the tendon of the muscle on the lower part of the back of the arm. The tendon of insertion of the

muscle extends about half-way up the back of the arm, where it forms an elongated flattened plane when the muscle is in action. Under similar conditions the surface forms produced by the three heads of the muscle are well seen.

On the anterior aspect of the elbow are to be seen two muscular elevations, one on each side, separated above and converging below so as to form a triangular space. Of these, the inner elevation, consisting of the Flexors and Pronators, forms the prominence along the inner side and front of the forearm. It is a fusiform mass, pointed above at the internal condyle and gradually tapering off below. The **Pronator teres**, the innermost muscle of the group, forms the boundary of the triangular space at the bend of the elbow. It is shorter, less prominent, and more oblique than the outer boundary. The most prominent part of the eminence is produced by the **Flexor carpi radialis**, the muscle next in order on the inner side of the preceding one. It forms a rounded prominence above, and can be traced downward to its tendon, which can be felt lying on the front of the wrist, nearer to the radial than to the ulnar border, and to the inner side of the radial artery. The **Palmaris longus** presents no surface marking above, but below is the most prominent tendon on the front of the wrist, standing out, when the muscle is in action, as a sharp, tense cord beneath the skin. The **Flexor sublimis digitorum** does not directly influence surface form. The position of its four tendons on the front of the lower part of the forearm is indicated by an elongated depression between the tendons of the **Palmaris longus** and the **Flexor carpi ulnaris**. The **Flexor carpi ulnaris** occupies a small part of the posterior surface of the forearm, and is separated from the Extensor and Supinator group, which occupies the greater part of this surface, by the ulnar furrow, produced by the subcutaneous posterior border of the ulna. Its tendon can be perceived along the ulnar border of the front of the forearm, and is most marked when the hand is flexed and adducted. The deep muscles of the front of the forearm have no direct influence on surface form. The external group of muscles of the forearm, consisting of the Extensors and Supinators, occupy the outer and a considerable portion of the posterior surface of this region. It has a fusiform outline, which is altogether on a higher level than the Pronator teres and Flexors. Its apex emerges from between the Triceps and Brachialis anticus muscles some distance above the elbow-joint, and acquires its greatest breadth opposite the external condyle, and thence gradually shades off into a flattened surface. About the middle of the forearm it divides into two longitudinal eminences which diverge from each other, leaving a triangular interval between them. The outer of these two groups of muscles consists of the Brachioradialis and the Extensores carpi radialis longior et brevior, which form a longitudinal eminence descending from the external condylar ridge in the direction of the styloid process of the radius. The other and more posterior group consists of the Extensor communis digitorum, the Extensor minimi digiti, and the Extensor carpi ulnaris. It commences above as a tapering form at the external condyle of the humerus, and is separated behind at its upper part from the Anconeus by a well-marked furrow, and below, from the Pronator-flexor mass, by the ulnar furrow. In the triangular interval left between these two groups the Extensors of the thumb and index finger are seen. The only two muscles of this region which require special mention as independently influencing surface form are the Brachioradialis and the Anconeus. The inner border of the **Brachioradialis** forms the outer boundary of the triangular space at the bend of the elbow. It commences as a rounded border above the condyle, and is longer, less oblique, and more prominent than the inner boundary. Lower down, the muscle forms a full fleshy mass on the outer side of the upper part of the forearm, and below tapers into a tendon, which may be traced down to the styloid process of the radius. The **Anconeus** presents a well-marked and characteristic surface form in the shape of a triangular, slightly elevated surface, immediately external to the subcutaneous posterior surface of the olecranon, and differentiated from the common Extensor group by a well-marked oblique longitudinal depression. The upper angle of the triangle corresponds to the external condyle, and is marked by a depression or dimple in this situation. In the interval caused by the divergence from each other of the two groups of muscles into which the Extensor and Supinator group is divided at the lower part of the forearm an oblique elongated eminence is seen, caused by the emergence of two of the Extensors of the thumb from their deep origin at the back of the forearm. This eminence, full above and becoming flattened out and partially subdivided below, runs downward and outward over the back and outer surface of the radius to the outer side of the wrist-joint, where it forms a ridge, especially marked when the thumb is extended, which passes onward to the posterior aspect of the thumb. The tendons of most of the Extensor muscles are to be seen and felt at the level of the wrist-joint. Most externally are the tendons of the Extensor ossis metacarpi pollicis and the Extensor brevis pollicis, forming a vertical ridge over the outer side of the joint from the styloid process of the radius to the thumb. Internal to this is the oblique ridge produced by the tendon of the Extensor longus pollicis, very noticeable when the muscle is in action. The Extensor carpi radialis longior is scarcely to be felt, but the Extensor carpi radialis brevior can be distinctly perceived as a vertical ridge emerging from under the inner border of the tendon of the Extensor longus pollicis, when the hand is forcibly extended at the wrist. Internal to this, again, can be felt

the tendons of the Extensor indicis, Extensor communis digitorum, and Extensor minimi digiti; the latter tendon being separated from those of the common Extensor by a slight furrow.

The muscles of the hand are principally concerned, so far as regards surface form, in producing the **thenar** and **hypothelar eminences**, and individually are not to be distinguished, on the surface, from each other. The **Adductor transversus pollicis** is, however, an exception to this; its anterior border gives rise to a ridge across the web of skin connecting the thumb to the rest of the hand. The **thenar eminence** is much larger and rounder than the **hypothelar**, which presents a longer and narrower eminence along the ulnar side of the hand. When the **Palmaris brevis** is in action it produces a wrinkling of the skin over the hypothelar eminence, and a deep dimple on the ulnar border of the hand. The anterior extremities of the **Lumbrical muscles** help to produce the soft eminences just behind the clefts of the fingers, separated from each other by depressions corresponding to the Flexor tendons in their sheaths. Between the thenar and hypothelar eminences, at the wrist-joint, is a slight groove or depression, widening out as it approaches the fingers; beneath this we have the strong central part of the palmar fascia. On the back of the hand the **Dorsal interossei** produce elongated markings between the metacarpal bones. When the thumb is adducted the **First dorsal interosseous** forms a prominent fusiform bulging; the other Interossei are not so marked.

The skin over the inner side and front of the forearm is thin, smooth, and sensitive; it contains few hairs and many sweat glands. Over the outer side and back of the arm and forearm it is thicker, denser, and less sensitive, and contains more hairs and fewer sweat glands. Over the olecranon the cuticle is thick and rough; the skin is loosely connected to the underlying tissues and becomes transversely wrinkled when the forearm is extended. At the front of the wrist the skin presents three transverse furrows, which correspond from above downward to the position of the styloid process of the ulna, the wrist-joint, and the midcarpal joint, respectively. The skin of the palm of the hand differs considerably from that of the forearm. At the wrist it suddenly becomes hard and dense, and covered by a thick layer of cuticle. The skin in the thenar region presents these characteristics less than elsewhere. In spite of this hardness and density, the skin of the palm is exceedingly sensitive and very vascular. It is destitute of hair, and no sebaceous follicles have been found in this region. It is tied down by fibrous bands along the lines of flexion of the digits, producing certain furrows of a permanent character. One of these, starting from about the tubercle of the scaphoid, curves around the thenar eminence, and ends on the radial border of the hand, a little above the metacarpophalangeal joint of the index finger. It corresponds to the outer border of the central portion of the palmar fascia, and is produced by the movements of the thumb at the carpometacarpal joint. A second line begins at the end of the first and extends obliquely across the palm upward and inward, to the ulnar margin about the middle of the fifth metacarpal bone. A third commences at the ulnar border of the hand about an inch below the termination of the second and extends outward across the palm over the heads of the third, fourth, and fifth metacarpal bones. These last two lines are caused by the flexion of the fingers at the metacarpophalangeal joints. Over the fingers the skin again becomes thinner, especially at the flexures of the joints, and over the terminal phalanges it is thrown into numerous ridges in consequence of the arrangement of the papillæ in it. These ridges form, in different individuals, distinctive and permanent patterns, which may be used for purposes of identification. (See page 1150.) The **superficial fascia** in the palm is made up of dense fibrofatty tissue. This tissue binds down the skin so firmly to the deep palmar fascia that very little movement is permitted between the two.

APPLIED ANATOMY OF THE UPPER EXTREMITY.

The student, having completed the dissection of the muscles of the upper extremity, should consider the effects likely to be produced by the action of the various muscles in fracture of the bones.

In considering the action of the various muscles upon fractures of the upper extremity, the most common forms of injury have been selected both for illustration and description.

Fracture of the *middle of the clavicle* (Fig. 370) is always attended with considerable displacement; the inner end of the outer fragment is displaced inward and backward, while the outer end of the same fragment is rotated forward. The whole outer fragment is somewhat depressed. The deformity is described by saying that the shoulder goes downward, forward, and inward.

The displacement is produced as follows: *inward*, by the muscles passing from the thorax to the outer fragment of the clavicle, to the scapula, and to the humerus—viz., the Subclavius and the Pectoralis minor, and, to a less extent, the Pectoralis major and the Latissimus dorsi; *backward*, in consequence of the rotation of the outer fragment. The Serratus magnus causes the

scapula to rotate on the thoracic wall; this carries the acromion and outer end of the outer fragment of the clavicle forward and causes the piece of bone to rotate around a vertical axis through its centre, and so carries the inner end of the outer portion backward. The depression of the whole outer fragment is produced by the weight of the arm and by the contraction of the Deltoid. The outer end of the inner fragment appears to be elevated, the skin being drawn tensely over it; this is owing to the depression of the outer fragment, as the inner fragment is usually kept fixed by the costoclavicular ligament and by the antagonism between the Sternomastoid and Pectoralis major muscles. But it may be raised by an unusually strong Sternomastoid, or by the inner end of the outer fragment getting below and behind it. The causes of displacement having been ascertained, it is easy to apply the appropriate treatment. The outer fragment is to be drawn outward, and, together with the scapula, raised upward to a level with the inner fragment, and retained in that position. This deformity is corrected by carrying the shoulder upward, outward, and backward.

In fracture of the *acromial end of the clavicle*, between the conoid and trapezoid ligaments only slight displacement occurs, as these ligaments, from their oblique insertion, serve to hold both portions of the bone in apposition. Fracture, also, of the *sternal end*, internal to the costoclavicular ligament, is attended with only slight displacement, this ligament serving to retain the fragments in close apposition.

Fracture of the *acromion process* usually arises from violence applied to the upper and outer part of the shoulder; it is generally known by the rotundity of the shoulder being lost, from the Deltoid drawing the fractured portion downward and forward; and the displacement may easily be discovered by tracing the margin of the clavicle outward, when the fragment will be found resting on the front and upper part of the head of the humerus. In order to relax the anterior and outer fibres of the Deltoid (the opposing muscle), the arm should be drawn forward across the thorax and the elbow well raised, so that the head of the bone may press the acromion process upward and retain it in its position.

Fracture of the *coracoid process* is an extremely rare accident, and is usually caused by a sharp blow on the point of the shoulder. Displacement is here produced by the combined actions of the Pectoralis minor, the short head of the Biceps, and the Coracobrachialis, the former muscle drawing the fragment inward, and the latter muscles directly downward, the amount of displacement being limited by the connection of this process to the acromion by means

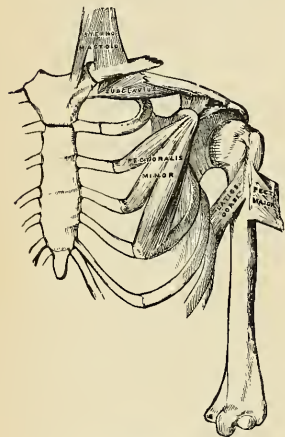


FIG. 370.—Fracture of the middle of the clavicle.

of the coraco-acromial ligament. In many cases there appears to have been little or no displacement, from the fact that the coracoclavicular ligament has remained intact, and has kept the separated fragment from displacement. In order to relax these muscles and replace the fragments in close apposition, the forearm should be flexed so as to relax the Biceps, and the arm drawn forward and inward across the chest, so as to relax the Coracobrachialis; the humerus should then be pushed upward against the coraco-acromial ligament, and the arm retained in that position.

Fracture of the *surgical neck of the humerus* (Fig. 371) is very common, is attended with considerable displacement, and its appearances correspond somewhat with those of dislocation of the head of the humerus into the axilla. The upper fragment is slightly elevated under the coraco-acromial ligament by the muscles attached to the greater and lesser tuberosities; the lower fragment is drawn inward by the Pectoralis major, Latissimus dorsi, and Teres major; and the humerus is thrown obliquely outward from the side by the Deltoid, and occasionally elevated so as to cause the upper end of the lower fragment to project beneath and in front of the coracoid process. The deformity is reduced by fixing the shoulder, and drawing the arm outward and downward. To counteract the opposing muscles, and to keep the fragments in position, a conical-shaped pad should be placed with the apex in the axilla; while the forearm is flexed to an angle of 90 degrees the shoulder is padded with cotton, a shoulder-cap of plaster of Paris is applied to cover the shoulder, a portion of the thorax and back, and the arm down to the external condyle (Scudder). The arm, with the elbow slightly forward, is bandaged to the side. In some cases a splint is placed between the axillary pad and the inner side of the arm.

In fracture of the *shaft of the humerus* below the insertion of the Pectoralis major, Latissimus dorsi, and Teres major, and above the insertion of the Deltoid, there is also considerable deformity, the upper fragment being drawn inward by the first-mentioned muscles, and the lower fragment upward and outward by the Deltoid, producing shortening of the limb and a considerable prominence at the seat of fracture, from the fractured ends of the bone riding over one another, especially if the fracture takes place in an oblique direction. The fragments may be brought into apposition by extension from the elbow, and are retained in that position by adopting the same means as in the preceding injury, or by the use of an internal angular splint with three short humeral splints.

In fractures of the *shaft of the humerus* immediately below the insertion of the Deltoid, the amount of deformity depends greatly upon the direction of the fracture. If it occurs in a transverse direction, only slight displacement takes place, the upper fragment being drawn a little forward; but in oblique fracture the combined actions of the Biceps and Brachialis anticus muscles in front and the Triceps behind draw upward the lower fragment, causing it to glide over the upper fragment, either backward or forward, according to the direction of the fracture. Simple extension reduces the deformity, and the application of an internal angular splint and three short humeral splints will retain the fragments in apposition. Care should be taken not to raise the elbow, but the forearm and hand may be supported in a sling.

Fracture of the *humerus* (Fig. 372) *above the condyle* deserves very attentive consideration, as the general appearances correspond somewhat with those produced by separation of the epiphysis of the humerus, and with those of dislocation of the radius and ulna backward. If the direction of the fracture is oblique from above, downward and forward, the lower fragment

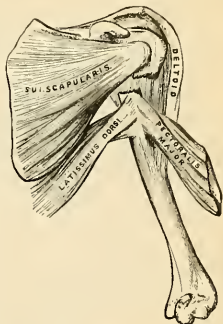


FIG. 371.—Fracture of the surgical neck of the humerus.

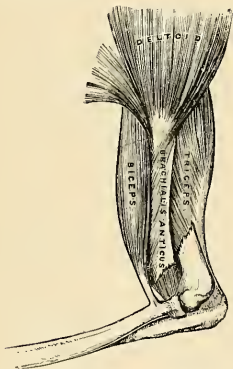


FIG. 372.—Fracture of the humerus above the condyle.

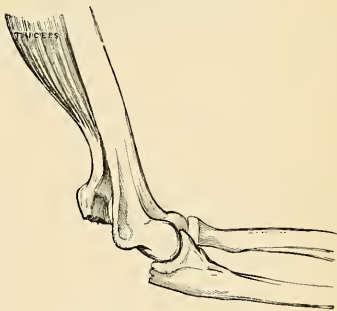


FIG. 373.—Fracture of the olecranon.

is drawn upward by the Brachialis anticus and Biceps in front and the Triceps behind; and at the same time is drawn backward behind the upper fragment by the Triceps. This injury may be differentiated from dislocation by the increased mobility in fracture, the existence of crepitus, and the fact of the deformity being remedied by extension, on the discontinuance of which it is reproduced. The age of the patient is of importance in distinguishing this form of injury from separation of the epiphysis. If fracture occurs in the opposite direction to that shown in Fig. 362, the lower fragment is drawn upward and forward, causing a considerable prominence in front, and the upper fragment projects backward beneath the tendon of the Triceps muscle.

Fracture of the *olecranon process* (Fig. 373) is a frequent accident. The detached fragment is displaced upward, by the action of the Triceps muscle, from half an inch to two inches; the prominence of the elbow is consequently lost, and a deep hollow is felt at the back part of the joint, which is much increased on flexing the limb. The patient at the same time loses, more or less, the power of extending the forearm. The treatment consists in relaxing the Triceps by extending the limb, and retaining it in the extended position by means of a long straight splint applied to the front of the arm; the fragments are thus brought into close apposition, and may be further approximated by drawing down the upper fragment. The fragments may be wired together and thus prevent the formation of a ligamentous union, as is generally the case when wiring is not employed; passive motion must be instituted at the end of the third week to prevent ankylosis.

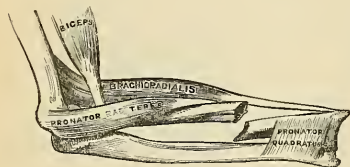


FIG. 374.—Fracture of the shaft of the radius.

caused by direct violence. Its diagnosis is somewhat obscure, on account of the slight deformity visible, the injured part being surrounded by a large number of muscles; but the movements of pronation and supination are entirely lost. The upper fragment is drawn outward by the Supinator [brevis], the extent of displacement being limited by the attachment of the orbicular ligament. The lower fragment is drawn forward and slightly upward by the Biceps, and inward by the Pronator teres, its displacement forward and upward being counteracted in some degree by the Supinator. The treatment essentially consists in relaxing the Biceps, Supinator, and Pronator teres muscles by flexing the forearm, and placing it in a position midway between pronation and supination, extension having been previously made so as to bring the parts in apposition.

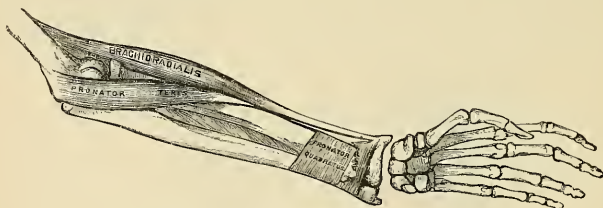


FIG. 375.—Fracture of the lower end of the radius.

In fracture of the *radius* below the insertion of the Biceps, but above the insertion of the Pronator teres, the upper fragment is strongly supinated by the Biceps and Supinator, and at the same time drawn forward and flexed by the Biceps; the lower fragment is pronated and drawn inward toward the ulna by the Pronators. Thus, there is extreme displacement with very little deformity. In treating such a fracture the arm must be put up in a position of supination, otherwise union will take place with great impairment of the movements of the hand. In fractures of the radius below the insertion of the Pronator teres (Fig. 374), the upper fragment is drawn upward by the Biceps and inward by the Pronator teres, holding a position midway between pronation and supination, and a degree of fulness in the upper half of the forearm is thus produced; the lower fragment is drawn downward and inward toward the ulna by the Pronator quadratus, and thrown into a state of pronation by the same muscle; at the same time, the Brachioradialis, by elevating the styloid process, into which it is inserted, will serve to depress the upper end of the lower fragment still more toward the ulna. In order to relax the opposing muscles the forearm should be bent, and the limb placed in a position midway between pronation and supination; the fracture is then easily reduced by extension from the wrist and elbow; well-padded splints should be applied on both sides of the forearm from the elbow to the wrist; the hand, being allowed to fall, will, by its own weight, counteract the action of the Pronator quadratus and of the Brachioradialis, and elevate the lower fragment to the level of the upper one.

In fracture of the *shaft of the ulna* the upper fragment retains its usual position, but the lower fragment is drawn outward toward the radius by the Pronator quadratus, producing a well-

marked depression at the seat of fracture and some fulness on the dorsal and palmar surfaces of the forearm. The fracture is easily reduced by extension from the wrist and forearm. The forearm should be flexed, and placed in a position midway between pronation and supination, and well-padded splints applied from the elbow to the ends of the fingers.

In fracture of the *shafts of the radius and ulna together* the lower fragments are drawn upward, sometimes forward, sometimes backward, according to the direction of the fracture, by the combined actions of the Flexor and Extensor muscles, producing a degree of fulness on the dorsal or palmar surface of the forearm; at the same time the two fragments are drawn into contact by the Pronator quadratus, the radius being in a state of pronation; the upper fragment of the radius is drawn upward and inward by the Biceps and Pronator teres to a higher level than the ulna; the upper portion of the ulna is slightly elevated by the Brachialis anticus. The fracture may be reduced by extension from the wrist and elbow, and the forearm should be placed in the same position as in fracture of the ulna.

In fracture of the *lower end of the radius (Colles' fracture)* (Fig. 375) the displacement which is produced is very considerable, and bears some resemblance to dislocation of the carpus backward and upward, from which it should be carefully distinguished. The lower fragment is displaced backward and upward, but this displacement is probably due to the force of the blow driving the portion of the bone into this position and not to any muscular influence. The upper fragment projects forward, often lacerating the substance of the Pronator quadratus, and is drawn by this muscle into close contact with the lower end of the ulna, causing a projection on the anterior surface of the forearm, immediately above the carpus, from the Flexor tendons being thrust forward. This fracture may be distinguished from dislocation by the deformity being removed on making sufficient extension, when crepitus may be occasionally detected; at the same time, on extension being discontinued, the parts immediately resume their deformed appearance. The age of the patient will also assist in determining whether the injury is fracture or separation of the epiphysis. Reduction is effected by hyperextension, longitudinal traction, and forced flexion.¹ The posterior straight splint with suitable pads is the best dressing.

MUSCLES AND FASCIÆ OF THE LOWER EXTREMITY.

The muscles of the lower extremity are subdivided into groups corresponding with the different regions of the limb.

I. ILIAC REGION.

Psoas magnus.
Psoas parvus.
Iliacus.

2. Internal Femoral Region.

Gracilis.
Pectineus.
Adductor longus.
Adductor brevis.
Adductor magnus.

II. THIGH.

1. Anterior Femoral Region.

	Tensor fasciæ femoris.
	Sartorius.
Quadriceps extensor.	Rectus femoris.
	Vastus externus.
	Vastus internus.
	Crureus.
	Subcrureus.

III. HIP.

3. Gluteal Region.

Gluteus maximus.
Gluteus medius.
Gluteus minimus.
Pyriformis.
Obturator internus.
Gemellus superior.
Gemellus inferior.
Quadratus femoris.
Obturator externus.

¹ R. J. Levis.

4. *Posterior Femoral Region.*

“Hamstring” muscles. { Biceps femoris.
Semitendinosus.
Semimembranosus.

IV. LEG.

5. *Anterior Tibiofibular Region.*

Tibialis anticus.
Extensor proprius hallucis.
Extensor longus digitorum.
Peroneus tertius.

6. *Posterior Tibiofibular Region.**Superficial Layer.*

Gastrocnemius.
Soleus.
Plantaris.

Deep Layer.

Popliteus.
Flexor longus hallucis.
Flexor longus digitorum.
Tibialis posticus.

7. *Fibular Region.*

Peroneus longus.
Peroneus brevis.

V. FOOT.

8. *Dorsal Region.*

Extensor brevis digitorum.

9. *Plantar Region.**First Layer.*

Abductor hallucis.
Flexor brevis digitorum.
Abductor minimi digiti.

Second Layer.

Flexor accessorius.
Lumbricales.

Third Layer.

Flexor brevis hallucis.
Adductor obliquus hallucis.
Flexor brevis minimi digiti.
Adductor transversus hallucis.

Fourth Layer.

Interossei.

I. MUSCLES AND FASCIÆ OF THE ILIAC REGION.

Psoas magnus.

Psoas parvus.

Iliacus.

Dissection.—No detailed description is required for the dissection of these muscles. On the removal of the viscera from the abdomen they are exposed, covered by the peritoneum and a thin layer of fascia, the iliac fascia.

The *iliac fascia* (*fascia iliaca*) is the aponeurotic layer which lines the back part of the abdominal cavity, and covers the Psoas and Iliacus muscles throughout their whole extent. It is thin above, and becomes gradually thicker below as it approaches the femoral arch.

The *portion covering the Psoas* is thickened, *above*, to form the *ligamentum arcuatum internum*; *internally* it is attached, by a series of arched processes, to the intervertebral substances, to the prominent margins of the bodies of the vertebræ, and to the upper part of the sacrum, the intervals so left, opposite the constricted portions of the bodies, transmitting the lumbar arteries and veins and the filaments of the sympathetic cord. *Externally*, above the crest of the ilium, this portion of the iliac fascia is continuous with the anterior lamella of the lumbar fascia covering the front of the Quadratus lumborum, but below the crest of the ilium it is continuous with the fascia covering the Iliacus.

The **portion investing the Iliacus** is connected externally to the whole length of the inner border of the crest of the ilium, and internally to the brim of the true pelvis, where it is continuous with the periosteum; at the iliopectineal eminence it receives the tendon of insertion of the *Psoas parvus*, when that muscle exists. External to the external iliac vessels, this fascia is intimately connected to the posterior margin of Poupart's ligament, and is continuous with the fascia transversalis. Immediately to the outer side of the external iliac vessels, as they pass beneath Poupart's ligament, the fascia iliaca is prolonged backward and inward from Poupart's ligament as a band, the **iliopectineal ligament** (Fig. 376), and is attached to the iliopectineal eminence. The ligament divides the space

between Poupart's ligament and the horizontal ramus of the pubis into two parts, the inner of which (*lacuna vasorum*) transmits the femoral vessels, and the femoral branch of the genitofemoral nerve is bounded internally by the base of Gimbernat's ligament and contains the femoral ring. The outer part (*lacuna musculorum*) transmits the Iliopsoas and the femoral nerve and the external cutaneous nerve (Fig. 376). Internal to the vessels the iliac fascia is attached to the iliopectineal line behind the conjoined tendon, where it is again continuous with the transversalis fascia; and, corresponding to the point where the femoral vessels pass into the thigh, this fascia descends behind them, forming the posterior wall of the femoral sheath. This portion of the iliac fascia which passes behind the femoral vessels is also attached to the iliopectineal line beyond the limits of the attachment of the conjoined tendon; at this part it

is continuous with the pubic portion of the fascia lata of the thigh. The external iliac vessels lie in front of the iliac fascia, but all the branches of the lumbar plexus lie behind it; it is separated from the peritoneum by a quantity of loose areolar tissue. The **femoral sheath** (*fascia cruris*) is formed by the transversalis fascia in front of the vessels and the iliac fascia behind them. In the thigh the fasciæ join to the inner side of the femoral vein, a space, the **femoral canal** (*canalis femoralis*) (Fig. 376), intervening between the vein and their junction.

Between the femoral vein and the edge of Gimbernat's ligament is the **femoral or crural ring** (*annulus femoralis*) (Fig. 376). It is the upper opening of the femoral canal, just mentioned, and leads into the cavity of the abdomen. It is bounded in front by Poupart's ligament; behind by the horizontal ramus of the pubes covered by the Pectineus muscle; internally by the base of Gimbernat's ligament; externally by the fibrous septum lying in the inner side of the femoral vein. The

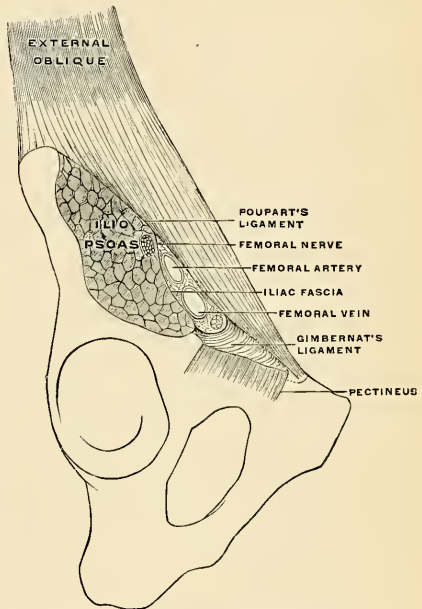


FIG. 376.—Poupart's ligament and the relation of the parts passing beneath it. (Poirier and Charpy.)

femoral ring is closed by the septum crurale of Cloquet (*septum femorale* [*Cloqueti*]), which is a process of transversalis fascia (Fig. 378). The femoral canal is the interval between the femoral vein and the inner wall of the femoral sheath. This canal extends from the femoral ring to the saphenous opening.

The **Psoas magnus** (*m. psoas major*) (Fig. 379) is a long fusiform muscle placed on the side of the lumbar region of the vertebral column and the margin of the pelvis. It *arises* from the front of the bases and lower borders of the transverse processes of the lumbar vertebræ by five fleshy slips; also from the sides of the bodies and the corresponding intervertebral substances of the last thoracic and all the lumbar vertebræ. The muscle is connected to the bodies of the vertebræ by five slips; each slip is attached to the upper and lower margins of two vertebræ, and to the intervertebral substance between them, the slips themselves being connected by the tendinous arches which extend across the constricted part of the bodies, and beneath which pass the lumbar arteries and veins and filaments of the sympathetic cord. These tendinous arches also give origin to muscle fibres, and protect the bloodvessels and nerves from pressure during the action of the muscle. The first slip is attached to the contiguous margins of the last thoracic and first lumbar vertebræ; the last to the contiguous margins of the fourth and fifth lumbar vertebræ, and to the intervertebral substance. From these points the muscle descends across the brim of the pelvis, and, diminishing gradually in size, passes beneath Poupart's ligament, and terminates in a tendon which, after receiving nearly the whole of the fibres of the Iliacus, is *inserted* into the lesser trochanter of the femur.

Relations.—In the lumbar region, by its *anterior surface*, which is placed behind the peritoneum, the Psoas magnus is in relation with the fascia which covers it, with the ligamentum arcuatum internum, the kidney, Psoas parvus, renal vessels, ureter, spermatic vessels, genito-femoral nerve, and the colon. In many cases the vermiform appendix rests upon the right Psoas muscle (page 505). By its *posterior surface*, with the transverse processes of the lumbar vertebræ and the Quadratus lumborum muscle, from which it is separated by the anterior lamella of the lumbar fascia. The lumbar plexus is situated in the posterior part of the substance of the muscle. By its *inner side* the muscle is in relation with the bodies of the lumbar vertebræ, the lumbar arteries, the ganglia of the sympathetic cord, and their branches of communication with the spinal nerves; the lumbar nodes; the inferior vena cava on the right and the aorta on the left side, and along the brim of the pelvis with the external iliac artery. In the *thigh* it is in relation, *superficially*, with the fascia lata; *deeply*, with the capsular ligament of the hip, from which it is separated by a synovial bursa (*bursa iliopectinea*), which frequently communicates with the cavity of the joint through an opening of variable size; between the tendon and part of the lesser trochanter is the *bursa iliaca subtendinea*; by its *inner border*, with the Pectineus and internal circumflex artery, and also with the femoral artery, which slightly overlaps it; by its *outer border*, with the femoral nerve and Iliacus muscle.

The **Psoas parvus** (*m. psoas minor*) (Fig. 379) is a long, slender muscle placed in front of the Psoas magnus. It *arises* from the sides of the bodies of the last thoracic and first lumbar vertebræ and from the intervertebral substance between them. It forms a small, flat, fleshy bundle, which terminates in a long flat tendon *inserted* into the iliopectineal eminence, and, by its outer border, into the iliac fascia. This muscle is most often absent, and is sometimes double.

The **Iliacus** (*m. iliacus*) (Fig. 379) is a flat, triangular muscle which fills up the whole of the iliac fossa. It *arises* from the upper two-thirds of this fossa and from the inner margin of the crest of the ilium; *behind*, from the iliolumbar ligament and base of the sacrum; in *front*, from the anterior superior and anterior inferior spinous processes of the ilium, from the notch between them. The fibres converge to be *inserted* into the outer side of the tendon of the Psoas, some of them being prolonged and attached to the shaft of the femur for about an inch below and in front of the lesser trochanter.¹ The most external fibres are inserted into the capsule of the hip-joint.

¹ The Psoas and Iliacus are often regarded as a single muscle—the Iliopsoas—having two heads of origin and a single insertion.

Relations.—Within the *abdomen*, by its *anterior surface*, with the iliac fossa, which separates the muscle from the peritoneum, and with the external cutaneous nerve; on the right side, with the cecum; on the left side, with the pelvic colon; by its *posterior surface*, with the iliac fossa; by its *inner border*, with the Psoas magnus and femoral nerve. In the *thigh*, it is in relation, by its *superficial surface*, with the fascia lata, the Rectus and Sartorius muscles, and the profunda femoris artery; by its *deep surface*, with the capsule of the hip-joint, a synovial bursa common to it and the Psoas magnus being interposed.

Nerves.—The Psoas magnus is supplied by the anterior branches of the second and third lumbar nerves; the Psoas parvus, when it exists, is supplied by the anterior branch of the first lumbar nerve; and the Iliacus, by the anterior branches of the second and third lumbar nerves through the femoral.

Actions.—The Psoas and Iliacus muscles, acting from above, flex the thigh upon the pelvis. Acting from below, the femur being fixed, the muscles of both sides bend the lumbar portion of the vertebral column and pelvis forward. They also serve to maintain the erect position, by supporting the vertebral column and pelvis upon the femur, and assist in raising the trunk when the body is in the recumbent posture.

The Psoas parvus is a tensor of the iliac fascia. It assists in flexing the lumbar portion of the vertebral column laterally, the pelvis being its fixed point.

Applied Anatomy.—There is no definite septum between the portions of the iliac fascia covering the Psoas and Iliacus, respectively, and the fascia is only connected to the subjacent muscles by a quantity of loose connective tissue. When an *abscess* forms beneath this fascia, as it is very liable to do, the pus is contained in an osseofibrous cavity, which is closed on all sides within the abdomen, and is open only at its lower part, where the fascia is prolonged over the muscle into the thigh.

Abscess within the sheath of the Psoas muscle (*Psoas abscess*) is generally due to tuberculous caries of the bodies of the lower thoracic or of the lumbar vertebrae. When the disease is in the thoracic region, the pus courses down the posterior mediastinum, in front of the bodies of the vertebrae, and, passing beneath the ligamentum arcuatum internum, enters the sheath of the Psoas muscle, down which it passes as far as the pelvic brim; it then gets beneath the iliac portion of the fascia and fills up the iliac fossa. In consequence of the attachment of the fascia to the pelvic brim, it rarely finds its way into the pelvis, but passes by a narrow opening under Poupart's ligament into the thigh, to the outer side of the femoral vessels. It thus follows that a Psoas abscess may be described as consisting of four parts: (1) A somewhat narrow channel at its upper part, in the Psoas sheath; (2) a dilated sac in the iliac fossa; (3) a constricted neck under Poupart's ligament; and (4) a dilated sac in the upper part of the thigh. When the lumbar vertebrae are the seat of the disease, the pus finds its way directly into the substance of the muscle. If a Psoas abscess forms, the muscle fibres are destroyed, and the nerve cords contained in the abscess are isolated and exposed in its interior; the femoral vessels which lie in front of the fascia remain intact, and the peritoneum seldom becomes implicated. All Psoas abscesses do not, however, pursue this course; the pus may leave the muscle above the crest of the ilium, and, tracking backward, may point in the loin (*lumbar abscess*); or it may point above Poupart's ligament in the inguinal region; or it may follow the course of the iliac vessels into the pelvis, and, passing through the great sacrosciatic notch, discharge itself on the back of the thigh; it may open into the bladder or find its way into the perineum, or it may pass down the thigh to the popliteal space or even lower. *Strain* of the Psoas muscle is not unusual, and induces pain which may be mistaken for appendicitis. The *bursa* beneath the tendon of the Psoas and Iliacus and the hip-joint or that between the tendon and the lesser trochanter may greatly enlarge and produce pain and disablement. Byron Robinson¹ pointed out that trauma of the Psoas muscle may be an important factor in the etiology of appendicitis, as it may induce periappendicular adhesions which interfere with the circulation of blood and feces. Robinson says, in the previously quoted article, that in 46 per cent. of men and in 20 per cent. of women the appendix rests on the Psoas muscle.

II. MUSCLES AND FASCIAE OF THE THIGH.

1. The Anterior Femoral Region.

Tensor fasciae femoris.	Quadriceps extensor.	Rectus femoris.
Sartorius.		Vastus externus.
		Vastus internus.
		Crureus.
Suberureus.		

Dissection.—To expose the muscles and fasciae in this region, make an incision along Poupart's ligament, from the anterior superior spine of the ilium to the spine of the os pubis;

¹Annals of Surgery, April, 1901.

a vertical incision from the centre of this, along the middle of the thigh to below the knee-joint; and a transverse incision from the inner to the outer side of the leg, at the lower end of the vertical incision. The flaps of integument having been removed, the superficial and deep fasciæ should be examined. The more advanced student should commence the study of this region by an examination of the anatomy of femoral hernia and Scarpa's triangle, the incisions for the dissection of which are marked out in Fig. 377.

Superficial Fascia.—The superficial fascia forms a continuous layer over the whole of the thigh. It consists of areolar tissue, containing in its meshes much fat, and is capable of being separated into two or more layers, between which are

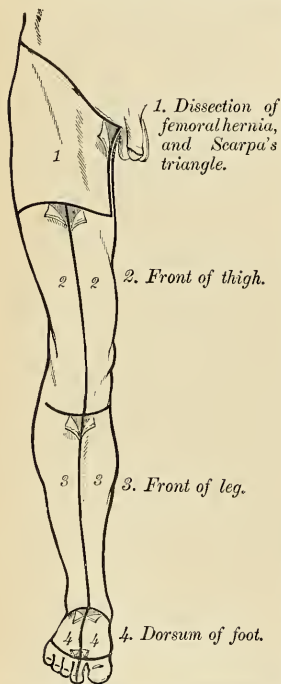


FIG. 377.—Dissection of lower extremity. Front view.

found the superficial vessels and nerves. It varies in thickness in different parts of the limb; in the groin it is thick, and the two layers are separated from one another by the superficial inguinal lymph nodes, the internal saphenous vein, and several smaller vessels. One of these two layers, the superficial, is continuous above with the superficial fascia of the abdomen. Internally it is continuous with the superficial fascia of the perineum. The deep layer of the superficial fascia is a very thin fibrous layer, best marked on the inner side of the long saphenous vein and below Poupart's ligament. It is placed beneath the subcutaneous vessels and nerves and upon the surface of the fascia lata. It is intimately adherent to the fascia lata a little below Poupart's ligament. It covers the saphenous opening (Fig. 378) in the fascia lata, being closely united to the margins of the opening, and is connected to the sheath of the femoral vessels. The portion of the fascia covering this aperture is perforated by the internal saphenous vein and by numerous bloodvessels and lymphatic vessels; hence, it has been termed the **cribriform fascia** (*fascia cribrosa*). The cribriform fascia adheres closely both to the superficial fascia and to the fascia lata, so that it is described by some anatomists as part of the fascia lata, but is usually considered (as in this work) as belonging to the superficial fascia. It is not until the cribriform fascia has been cleared away that the saphenous opening is seen, so that this opening does not in ordinary cases exist naturally, but is the

result of dissection. A large subcutaneous bursa (*bursa praepatellaris subcutanea*) is found in the superficial fascia over the patella, and another (*bursa trochanterica subcutanea*) in the superficial fascia over the great trochanter.

The Deep Fascia, or Fascia Lata (Fig. 378).—The deep fascia of the thigh is exposed on the removal of the superficial fascia, and is named, from its great extent, the **fascia lata**; it forms a uniform investment for the whole of this region of the limb, but varies in thickness in different parts; thus, it is thicker in the upper and outer part of the thigh, where it receives a fibrous expansion from the Gluteus maximus muscle, and where the Tensor fasciæ femoris is inserted between its layers; it is very thin behind, and at the upper and inner part where it covers the Adductor muscles, and again becomes stronger around the knee, receiving

fibrous expansions from the tendons of the Biceps femoris externally, from the Sartorius internally, and from the Quadriceps extensor in front. The fascia lata is attached *above*, and *behind*, to the back of the sacrum and coccyx; *externally*, to the crest of the ilium; in *front*, to Poupart's ligament and to the body of the os pubis; and *internally*, to the descending ramus of the os pubis, to the ramus and tuberosity of the ischium, and to the lower border of the great sacrospinous ligament. From its attachment to the crest of the ilium it passes down over the Gluteus medius muscle to the upper border of the Gluteus maximus, where it splits into two layers, one passing superficial to and the other beneath this muscle. At the lower border of the muscle the two layers reunite. Externally the fascia lata receives the greater part of the tendon of insertion of the Gluteus maximus, and becomes proportionately thickened. The portion of the fascia lata arising from the front part of the crest of the ilium, corresponding to the origin of the Tensor

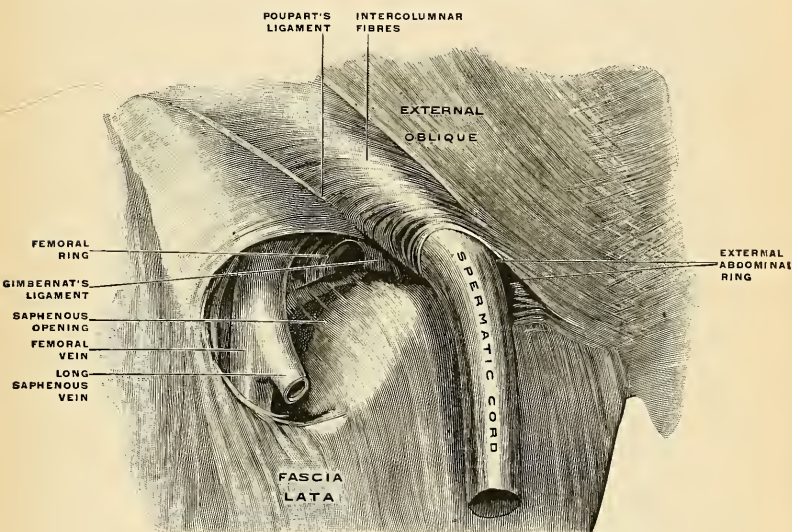


FIG. 37S.—Right external abdominal ring and saphenous opening in the male. (Spalteholz.)

fasciae femoris, passes down the outer side of the thigh as two layers, one superficial to and the other beneath this muscle. These layers at the lower end of the muscle become blended into a thick and strong band, having first received the insertion of the muscle. This band is continued downward, under the name of the *iliotibial band* (*tractus iliotibialis* [Maissiat]), to be inserted into the external tuberosity of the tibia. Below, the fascia lata is attached to all the prominent points around the knee-joint—viz., the condyles of the femur, tuberosities of the tibia, and head of the fibula. On each side of the patella it is strengthened by transverse fibres given off from the lower part of the Vasti muscles, which are attached to and support this bone. Of these, the outer fibres are the stronger, and are continuous with the iliotibial band. From the deep surface of the fascia lata are given off two strong *intermuscular septa*, which are attached to the whole length of the linea aspera and its prolongations above and below; the **external**

intermuscular septum (*septum intermusculare laterale*) is the stronger. It extends from the insertion of the Gluteus maximus to the outer condyle, separates the Vastus externus in front from the short head of the Biceps femoris behind, and gives partial origin to these muscles; the **internal intermuscular septum** (*septum intermusculare mediale*), the thinner of the two, separates the Vastus internus from the Adductor and Pectineus muscles. Besides these there are numerous smaller septa, separating the individual muscles and enclosing each in a distinct sheath. At the upper and inner part of the thigh, a little below Poupart's ligament, a large, oval-shaped aperture is observed; it transmits the internal saphenous vein and other smaller vessels, and is termed the **saphenous opening** (*fossa ovalis*) (Fig. 378). This opening is covered by a portion of the deep layer of the superficial fascia, the **cribriform fascia**. In order more correctly to consider the mode of formation of this aperture, the fascia lata in this part of the thigh is described as consisting of two portions—an iliac portion and a pubic portion.

The **iliac portion** is all that part of the fascia lata on the outer side of the saphenous opening. It is attached, *externally*, to the crest of the ilium and its anterior superior spine, to the whole length of Poupart's ligament as far internally as the spine of the os pubis, and to the iliopectineal line in conjunction with Gimbernat's ligament. From the spine of the os pubis it is reflected downward and outward, forming an arched margin, the **falciform process** or the **falciform margin of Burns** (*margo falciformis*). This margin overlies and is adherent to the superficial layer of the sheath of the femoral vessels; to its edge is attached the cribriform fascia; and, *below*, it is continuous with the pubic portion of the fascia lata. The **femoral ligament**, or the **ligament of Hey**, is the point at which the falciform process joins the base of Gimbernat's ligament.

The **pubic portion** is situated at the inner side of the saphenous opening; at the lower margin of this aperture it is continuous with the iliac portion. Traced upward, the pubic portion covers the surface of the Pectineus, Adductor longus, and Gracilis muscles, and, passing behind the sheath of the femoral vessels, to which it is closely united, is continuous with the sheath of the Psoas and Iliacus muscles, and is attached above to the iliopectineal line, where it becomes continuous with the iliac fascia. From this description it may be observed that the iliac portion of the fascia lata passes superficial to the femoral vessels, and the pubic portion behind them, so that an apparent aperture exists between the two, through which the internal saphenous joins the femoral vein.

Applied Anatomy.—The *iliotibial band* at a point between the crest of the ilium and the great trochanter is so tense that it is impossible to sink the fingers deeply in this region. Dr. Allis points out that in fracture of the neck of the femur the great trochanter mounts toward the iliac crest, the iliotibial band relaxes, and the fingers can be sunk deeply into the space between the great trochanter and the iliac crest. Shortening is thus indicated. This is known as *Allis' sign*. A *Psoas abscess* usually points at the termination of the Psoas muscle, but the tuberculous pus may be directed down the thigh beneath the fascia lata, and it may reach the popliteal space or may go even lower.

The **Tensor fasciæ femoris** (*m. tensor fasciæ latae*) (Fig. 379) *arises* from the anterior part of the outer lip of the crest of the ilium, from the outer surface of the anterior superior spine, and part of the outer border of the notch below it, between the Gluteus medius and Sartorius, and from the surface of the fascia covering the Gluteus medius. It is *inserted* between two layers of the fascia lata, about one-fourth down the outer side of the thigh. From the point of insertion the fascia is continued downward to the external tuberosity of the tibia as a thickened band, the **iliotibial band**.

The **Sartorius** (*m. sartorius*) (Fig. 379), the longest muscle in the body, is flat, narrow, and ribbon-like; it *arises* by tendinous fibres from the anterior superior

spine of the ilium and the upper half of the notch below it, passes obliquely across the upper and anterior part of the thigh, from the outer to the inner side of the limb, then descends vertically, as far as the inner side of the knee, passing behind the inner condyle of the femur, and terminates in a tendon which, curving obliquely forward, expands into a broad aponeurosis, to be *inserted* in front of the Gracilis and Semitendinosus, into the upper part of the inner surface of the shaft of the tibia, nearly as far forward as the crest. The upper part of the tendon is curved backward over the upper edge of the tendon of the Gracilis in order to be *inserted* behind it (Fig. 185). An offset is derived from the upper margin of the aponeurosis, which blends with the fibrous capsule of the knee-joint, and another, given off from its lower border, blends with the fascia on the inner side of the leg.

Relations.—By its *superficial surface*, with the fascia lata; by its *deep surface*, with the Rectus femoris, Iliacus, Vastus internus, femoral nerve, sheath of the femoral vessels, Adductor longus, Gracilis, Semitendinosus, long saphenous nerve, and internal lateral ligament of the knee-joint. Frequently there is a *bursa* (*bursa m. sartorii propria*) between the tendon of the Sartorius and the tendons of the Gracilis and Semimembranosus.

The relations of this muscle to the femoral artery should be carefully examined, as it constitutes the chief guide in tying the vessel. In the upper third of the thigh it forms the outer side of a triangular space, **Scarpa's triangle** (*trigonum femorale*), the inner side of which is formed by the inner border of the Adductor longus, and the base, which is turned upward, by Poupart's ligament; the femoral artery passes perpendicularly through the middle of this space from its base to its apex. In the middle third of the thigh the femoral artery lies first along the inner border, and then behind the Sartorius.

The **Quadriceps extensor** (*m. quadriceps femoris*) (Fig. 381) includes the four remaining muscles on the front of the thigh. It is the great Extensor muscle of the leg, forming a large fleshy mass which covers the front and sides of the femur, being united below into a single tendon; attached to the patella, and above subdivided into separate portions, which have received distinct names. Of these, one occupying the middle of the thigh, connected above with the ilium, is called the **Rectus femoris**, from its straight course. The other divisions lie in immediate connection with the shaft of the femur, which they cover from the trochanters to the condyles. The

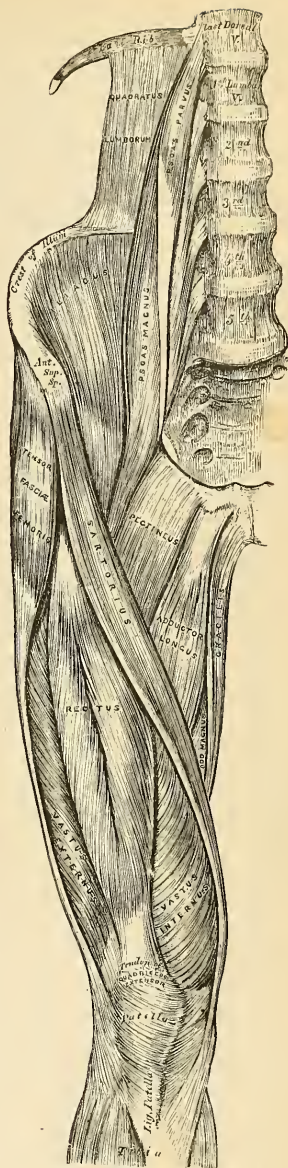


FIG. 379. —Muscles of the iliac and anterior femoral region.

portion on the outer side of the femur is termed the **Vastus externus**; that covering the inner side, the **Vastus internus**; and that covering the front of the femur, the **Crureus**.

The **Rectus femoris** (*m. rectus femoris*) is situated in the middle of the anterior region of the thigh; it is fusiform in shape, and its superficial fibres are arranged in a bipenniform manner, the deep fibres running straight down to the deep aponeurosis. It *arises* by two tendons—one, the anterior or straight, from the anterior inferior spine of the ilium; the other, the posterior or reflected tendon, from a groove above the brim of the acetabulum; the two unite at an acute angle and spread into an aponeurosis, which is prolonged downward on the anterior surface of the muscle and from which the muscle fibres arise.¹ The muscle terminates in a broad and thick aponeurosis, which occupies the lower two-thirds of its posterior surface, and, gradually becoming narrowed into a flattened tendon, is *inserted* into the patella in common with the Vasti and Crureus. Between the tendon of origin and the acetabulum there is often a **bursa** (*bursa m. recti femoris*).

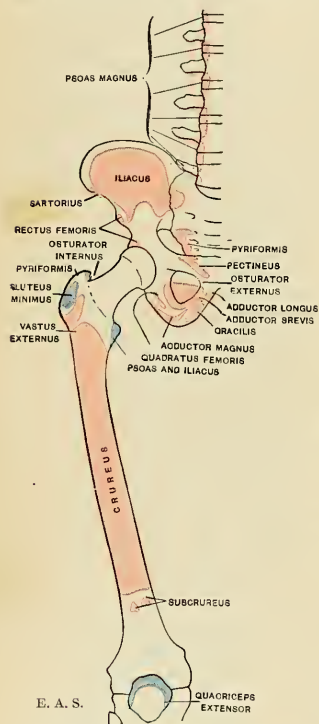


FIG. 380.—Diagram showing the attachments of the muscles of the thigh. Anterior aspect. Origins, red; insertions, blue.

to the capsule of the knee-joint. Some of the fibres run down by the side of the patella to the condyle of the tibia, and are called the **retinaculum patellae laterale**.

The **Vastus internus** and **Crureus** appear to be inseparably united, but when the **Rectus femoris** has been reflected, a narrow interval will be observed extending upward from the inner border of the patella between the two muscles. Here they can be separated, and the separation should be continued upward as far

The **Vastus externus** (*m. vastus lateralis*) is the largest division of the Quadriceps extensor. It *arises* by a broad aponeurosis, which is attached to the upper half of the anterior intertrochanteric line, to the anterior and inferior borders of the root of the great trochanter, to the outer lip of the gluteal ridge, and to the upper half of the outer lip of the linea aspera; this aponeurosis covers the upper three-fourths of the muscle, and from its inner surface many fibres take origin. A few additional fibres arise from the tendon of the Gluteus maximus, and from the external intermuscular septum between the Vastus externus and short head of the Biceps. The fibres form a large fleshy mass, which is attached to a strong aponeurosis, placed on the under surface of the muscle at its lower part; this becomes narrowed and thickened into a flat tendon, which is *inserted* into the outer border of the patella, blending with the Quadriceps extensor tendon, and giving an expansion

¹ Mr. W. R. Williams, in an interesting paper in the Journ. of Anat. and Phys., vol. xiii, p. 204, points out that the reflected tendon is the real origin of the muscle, and is alone present in early fetal life. The direct tendon is merely an accessory band of condensed fascia. The paper will well repay perusal, though in some particulars the description in the text is more generally accurate.

as the lower part of the anterior intertrochanteric line, where, however, the two muscles are frequently continuous.

The **Vastus internus** (*m. vastus medialis*) arises from the lower half of the anterior intertrochanteric line, the inner lip of the linea aspera, the upper part of the internal supracondylar line, the tendon of the Adductor magnus, and

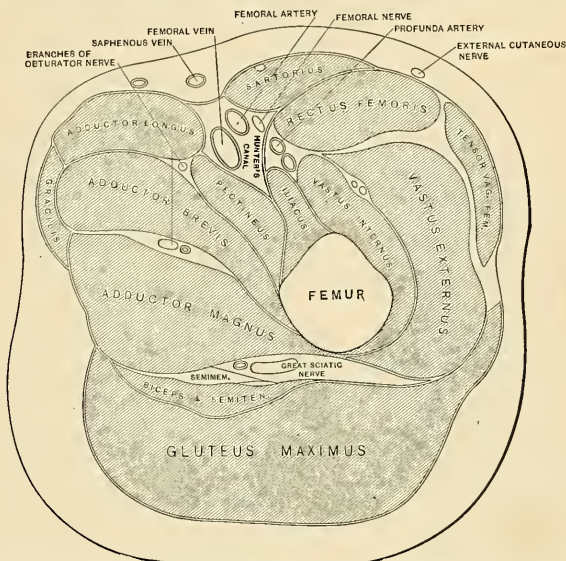


FIG. 381.—Transverse section of the thigh below the lesser trochanter. The femoral artery, vein, and nerve are seen in Hunter's canal. (After Braune.)

the internal intermuscular septum. Its fibres are directed downward and forward, and are chiefly attached to an aponeurosis which lies on the deep surface of the muscle and is *inserted* into the inner border of the patella and the Quadriceps extensor tendon, an expansion being sent to the capsule of the knee-joint. Some of the fibres run down by the side of the patella to the condyle of the tibia and are called the *retinaculum patellae mediale*.

The **Crureus** (*m. vastus intermedius*) arises from the front and outer aspect of the shaft of the femur in its upper two-thirds and from the lower part of the external intermuscular septum. Its fibres end in a superficial aponeurosis, which forms the deep part of the Quadriceps extensor tendon.

Relations.—The *inner edge* of the Crureus is in contact with the anterior edge of the Vastus internus, but when separated from each other, as directed above, the latter muscle is seen merely to overlap the inner aspect of the femoral shaft without taking any fibres of origin from it. The Vastus internus is partly covered by the Rectus femoris and Sartorius, but where these separate near the knee it becomes superficial, and produces a well-marked prominence above the inner aspect of the knee. In the middle third of the thigh it forms the *outer wall* of **Hunter's canal** (*canalis adductorius* [*Hunteri*]) (Fig. 381), which contains the femoral vessels and the long saphenous nerve; the *roof* of the canal is formed by a strong fascia which extends from the Vastus internus to the Adductores longus and magnus. The Crureus is almost completely hidden by the Rectus femoris and Vastus externus. The *deep surface* of the two muscles is in relation with the femur and Subcrureus muscles. A synovial **bursa** (*bursa suprapatellaris*) is situated between the femur and the portion of the Quadriceps extensor tendon above the patella; in the adult it communicates with the synovial cavity of the knee-joint.

The **tendons** of the different portions of the Quadriceps extensor unite at the lower part of the thigh, so as to form a single strong tendon, which is *inserted* into the upper part of the patella; some few fibres pass over it to blend with the ligamentum patellae. Strictly speaking, the patella may be regarded as a sesamoid bone, developed in the tendon of the Quadriceps; and the ligamentum patellae, which is continued from the lower part of the patella to the tuberosity of the tibia, as the proper tendon of insertion of the muscle. A synovial bursa, the **deep patellar bursa** (*bursa infrapatellaris profunda*), is interposed between the tendon and the upper part of the tubercle of the tibia; and another, the **prepatellar bursa** (*bursa praepatellaris subcutanea*), is placed over the patella itself. This latter bursa often becomes enlarged, constituting "house-maid's knee."

The **Subcrureus** (*m. articularis genu*) is a small muscle, usually distinct from the Crureus, but occasionally blended with it, which *arises* from the anterior surface of the lower part of the shaft of the femur, and is *inserted* into the upper part of the *cul-de-sac* of the capsular ligament, which projects upward beneath the Quadriceps for a variable distance. It sometimes consists of several separate muscle bundles.

Nerves.—The Tensor fasciæ femoris is supplied by the fourth and fifth lumbar and first sacral nerves through the superior gluteal nerve; the other muscles of this region, by the second, third, and fourth lumbar nerves, through branches of the femoral.

Actions.—The Tensor fasciæ femoris is a tensor of the fascia lata; continuing its action, the oblique direction of its fibres enables it to abduct and to rotate the thigh inward. In the erect posture, acting from below, it will serve to steady the pelvis upon the head of the femur, and by means of the iliotibial band it steadies the condyles of the femur on the articular surfaces of the tibia, and assists the Gluteus maximus in supporting the knee in the extended position. The Sartorius flexes the leg upon the thigh, and, continuing to act, flexes the thigh upon the pelvis; it next rotates the thigh outward. When the knee is bent the Sartorius assists the Semitendinosus, Semimembranosus, and Popliteus in rotating the tibia inward. Taking its fixed point from the leg, it flexes the pelvis upon the thigh, and, if one muscle acts, assists in rotating the pelvis. The Quadriceps extensor extends the leg upon the thigh. The Rectus muscle assists the Psoas and Iliacus in supporting the pelvis and trunk upon the femur. It also assists in flexing the thigh on the pelvis, or if the thigh is fixed it will flex the pelvis. The Vastus internus draws the patella inward as well as upward.

Applied Anatomy.—A few fibres of the Rectus femoris muscle are liable to be ruptured from severe strain. This accident is especially liable to occur during the games of football and baseball. The patient experiences a sudden pain in the part, as if he had been struck, and the Rectus muscle stands out and is felt to be tense and rigid. The accident is often followed by considerable swelling from inflammatory effusion. Occasionally the Quadriceps extensor may be torn away from its insertion into the patella, or the tendon of the Quadriceps may be ruptured about an inch above the bone. This accident is caused in the same manner that fracture of the patella by muscular action is produced—viz., by a violent muscular effort to prevent falling while the knee is in a position of semiflexion. A distinct gap can be felt above the patella, and, owing to the retraction of the muscle fibres, union may fail to take place. Sudden and powerful contraction of the Quadriceps extensor femoris is the usual cause of transverse fracture of the patella.

2. The Internal Femoral Region.

Gracilis.

Pectineus.

Adductor longus.

Adductor brevis.

Adductor magnus.

Dissection.—These muscles are at once exposed by removing the fascia from the fore part and inner side of the thigh. The limb should be abducted, so as to render the muscles tense and easier of dissection.

The **Gracilis** (*m. gracilis*) (Figs. 379 and 384) is the most superficial muscle on the inner side of the thigh. It is *thin* and flattened, broad above, narrowing and tapering below. It *arises* by a thin aponeurosis from the posterior half of the margin of the symphysis and the anterior half of the pubic arch. The fibres pass vertically downward, and terminate in a rounded tendon which passes behind the internal condyle of the femur, and, curving around the inner tuberosity of the tibia,

becomes flattened, and is *inserted* into the upper part of the inner surface of the shaft of the tibia, below the tuberosity. A few of the fibres of the lower part of the tendon are prolonged into the deep fascia of the leg. The tendon of this muscle is situated immediately above that of the Semitendinosus, and its upper edge is overlapped by the tendon of the Sartorius, with which it is in part blended. As it passes across the internal lateral ligament of the knee-joint it is separated from it by a **synovial bursa** (*bursa anserina*) common to it and the Semitendinosus muscle.

Relations.—By its *superficial surface*, with the fascia lata and the Sartorius below; the internal saphenous vein crosses it obliquely near its lower part, lying superficial to the fascia lata; the internal saphenous nerve emerges between its tendon and that of the Sartorius; by its *deep surface*, with the Adductor brevis and the Adductor magnus and the internal lateral ligament of the knee-joint.

The **Pectineus** (*m. pectineus*) (Fig. 379) is a flat, quadrangular muscle, situated at the anterior part of the upper and inner aspect of the thigh. It *arises* from the iliopectineal line, and to a slight extent from the surface of the bone in front of it between the pectineal eminence and spine of the os pubis, and from the fascia covering the anterior surface of the muscle; the fibres pass downward, backward, and outward, to be *inserted* into a rough line leading from the lesser trochanter to the linea aspera.

Relations.—By its *superficial surface*, with the pubic portion of the fascia lata, which separates it from the femoral vessels and internal saphenous vein; by its *deep surface*, with the capsular ligament of the hip-joint, the Adductor brevis and Obturator externus muscles, the obturator vessels and nerve being interposed; by its *outer border*, with the Psoas, a cellular interval separating them, through which pass the internal circumflex vessels; by its *inner border*, with the margin of the Adductor longus. There is usually a **bursa** (*bursa m. pectinei*) between the Pectineus and the tendon of the Psoas and Iliacus.

The **Adductor longus** (*m. adductor longus*) (Figs. 379 and 382), the most superficial of the three Adductors, is a flat triangular muscle lying on the same plane as the Pectineus. It *arises*, by a flat narrow tendon, from the front of the os pubis, at the angle of junction of the crest with the inner border; and soon expands into a broad fleshy belly, which, passing downward, backward, and outward, is *inserted*, by an aponeurosis, into the linea aspera,

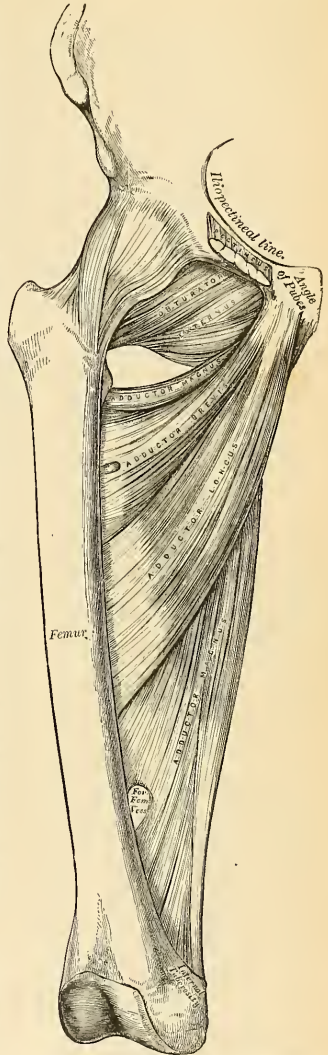


FIG. 382.—Deep muscles of the internal femoral region.

between the Vastus internus and the Adductor magnus, with both of which it is usually blended.

Relations.—By its *superficial surface*, with the fascia lata, the Sartorius, and, near its insertion, with the femoral artery and vein; by its *deep surface*, with the Adductores brevis and magnus, the anterior branches of the obturator nerve, and with the profunda artery and vein near its insertion; by its *outer border*, with the Pectineus; by its *inner border*, with the Gracilis.

The Pectineus and Adductor longus should now be divided near their origin, and turned downward, when the Adductor brevis and Obturator externus will be exposed.

The **Adductor brevis** (*m. adductor brevis*) (Fig. 382) is situated immediately behind the two preceding muscles. It is somewhat triangular in form, and *arises* by a narrow origin from the outer surface of the body and descending ramus of the os pubis, between the Gracilis and Obturator externus. Its fibres passing backward, outward, and downward, are *inserted*, by an aponeurosis, into the lower part of the line leading from the lesser trochanter to the linea aspera, and the upper part of the same line, immediately behind the Pectineus and upper part of the Adductor longus.

Relations.—By its *superficial surface*, with the Pectineus, Adductor longus, profunda femoris artery, and anterior branches of the obturator nerve; by its *deep surface*, with the Adductor magnus and posterior branch of the obturator nerve; by its *outer border*, with the internal circumflex artery, the Obturator externus, and conjoined tendon of the Psoas and Iliacus; by its *inner border*, with the Gracilis and Adductor magnus. This muscle is pierced, near its insertion, by the second or by the first and second perforating branches of the profunda femoris artery.

The Adductor brevis should now be cut away near its origin, and turned outward, when the entire extent of the Adductor magnus will be exposed.

The **Adductor magnus** (*m. adductor magnus*) (Fig. 382) is a large, triangular muscle forming a septum between the muscles on the inner and those on the back of the thigh. It *arises* from a small part of the descending ramus of the os pubis, from the ramus of the ischium, and from the outer margin of the inferior part of the tuberosity of the ischium. Those fibres which arise from the ramus of the os pubis are very short, horizontal in direction, and are *inserted* into the rough line leading from the great trochanter to the linea aspera, internal to the Gluteus maximus. They are considered by some a distinct muscle and called the **Adductor minimus**. The fibres taking origin from the ramus of the ischium are directed downward and outward with different degrees of obliquity, to be *inserted*, by means of a broad aponeurosis, into the linea aspera and the upper part of its internal prolongation below. The **internal portion** of the muscle, consisting principally of those fibres which *arise* from the tuberosity of the ischium, forms a thick fleshy mass consisting of coarse bundles which descend almost vertically, and terminate about the lower third of the thigh in a rounded tendon, which is *inserted* into the Adductor tubercle on the inner condyle of the femur, and is connected by a fibrous expansion to the line leading upward from the tubercle to the linea aspera. Between the two portions of the muscle an interval is left, tendinous in front and fleshy behind, for the passage of the femoral vessels from Hunter's canal into the popliteal space. The **external portion** of the muscle at its attachment to the femur presents three or four osseoponeurotic openings, formed by tendinous arches attached to the bone, from which muscle fibres arise. The three superior of these apertures are for the three perforating arteries, and the fourth, when it exists, is for the terminal branch of the profunda.

Relations.—By its *superficial surface*, with the Pectineus, Adductor brevis, Adductor longus, and the femoral and profunda vessels and obturator nerve; by its *deep surface*, with the great sciatic nerve, the Gluteus maximus, Biceps femoris, Semitendinosus, and Semimembranosus. By its *superior or shortest border* it lies parallel to the Quadratus femoris, the internal circumflex

artery passing between them; by its *internal* or *longer border*, with the Gracilis, Sartorius, and fascia lata; by its *external* or *attached border* it is inserted into the femur behind the Adductor brevis and Adductor longus, which separate it from the Vastus internus, and in front of the Gluteus maximus and short head of the Biceps femoris, which separate it from the Vastus externus.

Nerves.—The three Adductor muscles and the Gracilis are supplied by the third and fourth lumbar nerves through the obturator nerve; the Adductor magnus receiving an additional branch from the sacral plexus through the great sciatic. The Pectineus is supplied by the second, third, and fourth lumbar nerves through the femoral, and by the accessory obturator, from the third lumbar, when it exists. Occasionally it receives a branch from the obturator nerve.¹

Actions.—The Pectineus and three Adductors adduct the thigh powerfully; they are especially used in horseback riding, the flanks of the horse being grasped between the knees by the actions of these muscles. In consequence of the obliquity of their insertion into the linea aspera they rotate the thigh outward, assisting the external Rotators, and when the limb has been abducted they draw it inward, carrying the thigh across that of the opposite side. The Pectineus and Adductor brevis and longus assist the Psoas and Iliacus in flexing the thigh upon the pelvis. In progression, also, all these muscles assist in drawing forward the hinder limb. The Gracilis assists the Sartorius in flexing the leg; it is also an adductor of the thigh. If the lower extremities are fixed, these muscles may take their fixed point from below and act upon the pelvis, serving to maintain the body in an erect posture, or, if their action is continued, to flex the pelvis forward upon the femur.

Hunter's Canal (*canalis adductorius* [*Hunteri*]) extends from the apex of Scarpa's triangle to the opening in the Adductor magnus muscle. The *antero-internal boundary* or *roof* of Hunter's canal is the Sartorius and the aponeurotic expansion from the Adductors to the Vastus internus. It is bounded *externally* by the Vastus internus. The Adductor longus and magnus constitute its *floor* or the *postero-internal boundary*. The canal contains the femoral artery, femoral vein, the long saphenous nerve, and the nerve to the Vastus internus.

Applied Anatomy.—The Adductor longus is liable to be severely *strained* in those who ride much on horseback, or its tendons to be *ruptured* by suddenly gripping the saddle. Occasionally, especially in cowboys and cavalry soldiers, the tendon of insertion of the Adductor magnus may become ossified, constituting the *rider's bone* (pp. 229, 360).

III. MUSCLES AND FASCÆ OF THE HIP.

3. The Gluteal Region (Figs. 384, 385).

Gluteus maximus.	Obturator internus.
Gluteus medius.	Gemellus superior.
Gluteus minimus.	Gemellus inferior.
Pyriformis.	Quadratus femoris.
Obturator externus.	

Dissection (Fig. 383).—The subject should be turned on its face, a block placed beneath the pelvis to make the buttocks tense, and the limbs allowed to hang over the end of the table, with the foot inverted and the thigh abducted. Make an incision through the integument along the crest of the ilium to the middle of the sacrum, and thence downward to the tip of the coccyx, and carry a second incision from that point obliquely downward and outward to the outer side of the thigh, four inches below the great trochanter. The portion of integument included between these incisions is to be removed in the direction shown in the figure.

The **Gluteus maximus** (*m. gluteus maximus*) (Fig. 384), the most superficial muscle in the gluteal region, is a very broad and thick, fleshy mass of a quadrilateral shape, which forms the prominence of the buttock. Its large size is one of the most characteristic points in the muscular system of man, connected as it is with the power he has of maintaining the trunk in the erect posture. In structure the muscle is remarkably coarse, being made up of muscle fasciculi lying parallel

¹ Professor Paterson describes the Pectineus as consisting of two incompletely separated strata, of which the outer or dorsal stratum, which is constant, is supplied by the femoral nerve, or in its absence by the accessory obturator, with which it is intimately related; while the inner or ventral stratum, when present, is supplied by the obturator nerve.—*Journ. of Anat. and Phys.*, vol. xxvi, p. 43.

to one another, and collected into large bundles, separated by deep cellular intervals. It *arises* from the superior curved line of the ilium, and the portion of bone, including the crest, immediately above and behind it; from the posterior surface of the lower part of the sacrum, the side of the coccyx, the aponeurosis of the Erector spinae muscle, the great sacrosciatic ligament, and the fascia covering the Gluteus medius. The fibres are directed obliquely downward and outward; those forming the upper and large portion of the muscle, together with the superficial fibres of the lower portion, terminate in a thick tendinous lamina, which passes across the great trochanter and is *inserted* into the fascia lata covering the outer side of the thigh; the deeper fibres of the lower portion of the muscles are *inserted* into the rough line leading from the great trochanter to the linea aspera between the Vastus externus and Adductor magnus.

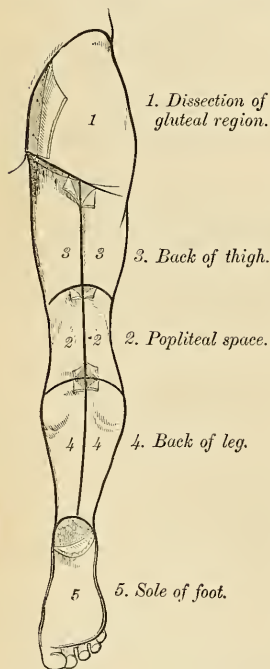


FIG. 353.—Dissection of lower extremity. Posterior view.

rotator muscles beneath. The upper portion of the muscle is to be altogether detached, and the lower portion turned outward; the loose areolar tissue filling up the interspace between the trochanter major and tuberosity of the ischium being removed, the parts already enumerated as exposed by the removal of this muscle will be seen.

The **Gluteus medius** (*m. gluteus medius*) (Fig. 384) is a broad, thick, radiating muscle, situated on the outer surface of the pelvis. Its posterior third is covered by the Gluteus maximus; its anterior two-thirds by the fascia lata, which separates it from the integument. It *arises* from the outer surface of the ilium, between the superior and middle curved lines, and from the outer lip of that portion of the crest which is between them; it also *arises* from the dense fascia, the **gluteal aponeurosis**, covering its outer surface. The fibres converge to a strong flattened

Relations.—By its *superficial surface*, with a thin fascia, which separates it from the subcutaneous tissue; by its *deep surface*, from above downward, with the ilium, sacrum, coccyx, and great sacrosciatic ligament, part of the Gluteus medius, Piriformis, Gemelli, Obturator internus, Quadratus femoris, the tuberosity of the ischium, great trochanter, the origin of the Biceps femoris, Semitendinosus, Semimembranosus, and Adductor magnus muscles. The superficial part of the gluteal artery reaches the deep surface of the muscle by passing between the Piriformis and the Gluteus medius; the sciatic and internal pudic vessels and nerves and muscular branches from the sacral plexus issue from the pelvis below the Piriformis. The first perforating artery and the terminal branches of the internal circumflex artery are also found under cover of the muscle. Its *upper border* is thin, and connected with the Gluteus medius by the fascia lata. Its *lower border* is free and prominent.

Several **synovial bursæ** are found in relation with this muscle. One of these (*bursa trochanterica m. glutei maximi*), of large size, and generally multilocular, separates it from the great trochanter. A second (*bursa ischiadica m. glutei maximi*), often wanting, is situated on the tuberosity of the ischium. A third bursa is found between the tendon of this muscle and the Vastus externus. Two or three small bursæ (*bursae glutacofemorales*) are placed between the tendon of the muscle and that of the Vastus externus.

Dissection.—Divide the Gluteus maximus near its origin by a vertical incision carried from its upper to its lower border; a cellular interval will be exposed, separating it from the Gluteus medius and External

tendon which is *inserted* into the oblique line which traverses the outer surface of the great trochanter.

Relations.—By its *superficial surface*, with the Gluteus maximus behind, the Tensor fasciae femoris and deep fascia in front; by its *deep surface*, with the Gluteus minimus and the gluteal vessels and superior gluteal nerve. Its *anterior border* is blended with the Gluteus minimus. Its *posterior border* lies parallel to the Pyriformis, the gluteal vessels intervening.

A **synovial bursa** (*bursa trochanterica m. glutaci medii anterior*) separates the tendon of the muscle from the summit of the great trochanter. There is frequently a bursa (*bursa trochanterica m. glutaci medii posterior*) between the tendons of the Gluteus medius and Pyriformis.

This muscle should now be divided near its insertion and turned upward, when the Gluteus minimus will be exposed.

The **Gluteus minimus** (*m. gluteus minimus*) (Fig. 384), the smallest of the three Glutei, is placed immediately beneath the preceding. It is fan-shaped, arising from the outer surface of the ilium, between the middle and inferior curved lines, and behind, from the margin of the great sciatic notch; the fibres converge to the deep surface of a radiated aponeurosis, which, terminating in a tendon, is *inserted* into an impression on the anterior border of the great trochanter.

Relations.—By its *superficial surface*, with the Gluteus medius and the gluteal vessels and superior gluteal nerve; by its *deep surface*, with the ilium, the reflected tendon of the Rectus femoris, and the capsular ligament of the hip-joint. Its *anterior margin* is blended with the Gluteus medius; its *posterior margin* is in contact and sometimes joined with the tendon of the Pyriformis. There is a synovial bursa (*bursa trochanterica m. glutaci minimi*) between the tendon of the Gluteus minimus and the great trochanter.

The **Pyriformis** (*m. piriformis*) (Figs. 384 and 385) is a flat muscle, pyramidal in shape, lying almost parallel with the posterior margin of the Gluteus medius. It is situated partly within the pelvis at its posterior part and partly at the back of the hip-joint. It arises from the front of the sacrum by three fleshy digitations attached to the portions of bone between the first, second, third, and fourth anterior sacral foramina, and also from the grooves leading from the foramina; a few fibres also arise from the margin of the great sacrosciatic foramen and from the anterior surface of the great sacrosciatic ligament. The muscle passes out of the pelvis through the great sacrosciatic foramen, the upper part of which it fills, and is *inserted* by a rounded tendon into the inner side of the upper border of the great trochanter, behind, but often partly blended with, the tendon of the Obturator internus and Gemelli muscles.

Relations.—By its *deep surface*, within the pelvis, with the rectum (especially on the left side), the sacral plexus of nerves, and the branches of the internal iliac vessels; *external to the pelvis*, with the posterior surface of the ischium and the capsular ligament of the hip-joint; by its *superficial surface*, within the pelvis, with the sacrum, and *external to it*, with the Gluteus maximus; by its *upper border*, with the Gluteus medius, from which it is separated by the gluteal vessels and superior gluteal nerve; by its *lower border*, with the Gemellus superior and Coccygeus, the sciatic vessels and nerves, the internal pudic vessels and nerve, and muscular branches from the sacral plexus, passing from the pelvis in the interval between the two muscles.

The **Obturator Membrane** (*membrana obturatoria*) (Fig. 240) is a thin layer of interlacing fibres which closes almost completely the obturator foramen. It is attached, externally, to the margin of the foramen; internally, to the posterior surface of the ischiopubic ramus, below and internal to the margin of the foramen. It presents at its upper and outer parts a small canal, **obturator canal** (*canalis obturatorius*) for the passage of the obturator vessels and nerve. Both obturator muscles are connected with this membrane.

There is usually a **bursa** (*bursa m. piriformis*) between the tendon of the Pyriformis and the ilium.

Dissection.—The next muscle, as well as the origin of the Pyriformis, can only be seen when the pelvis is divided and the viscera removed.

In order to display the peculiar appearances presented by the tendon of this muscle, it must be divided near its insertion and reflected inward.

Relations.—*Within the pelvis* this muscle is in relation, by its *deep surface*, with the obturator membrane and inner surface of the anterior wall of the pelvis; by its *superficial surface*, with the pelvic and obturator fascia, which separate it from the Levator ani; and it is crossed by the internal pudic vessels and nerve. This surface forms the outer boundary of the ischio-

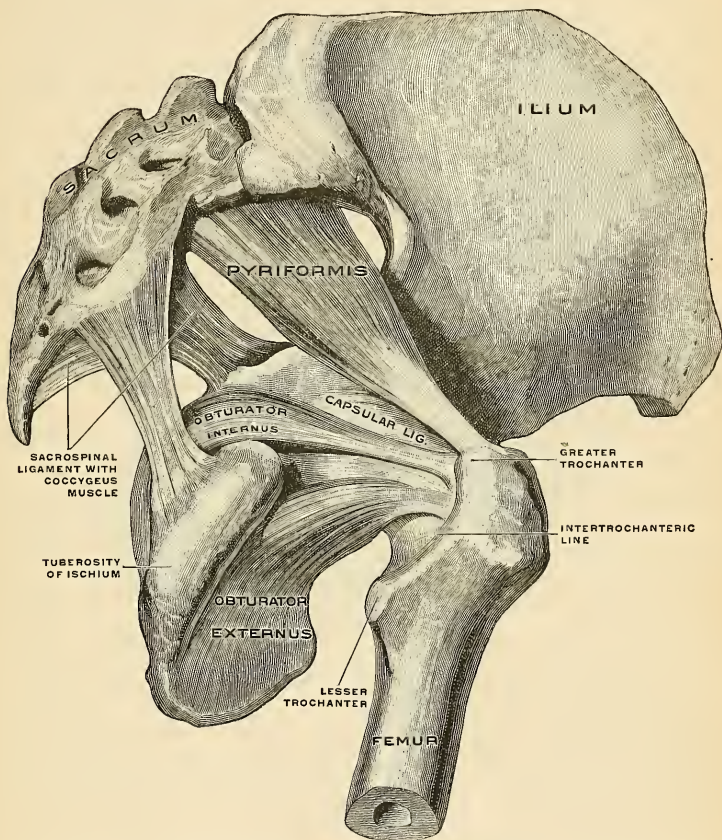


FIG. 385.—Muscles of the true pelvis on the right side, viewed from without and below. The quadratus having been removed, the gemelli are also not shown. (Spalteholz.)

rectal fossa. *External to the pelvis* it is covered by the Gluteus maximus, is crossed by the great sciatic nerve, and rests on the back part of the hip-joint. As the tendon of the Obturator internus emerges from the lesser sacrosclatic foramen it is overlapped by the two Gemelli, while nearer its insertion the Gemelli pass in front of it and form a groove in which the tendon lies. A synovial **bursa**, narrow and elongated in form, is usually found between the tendon of this muscle and the capsular ligament of the hip; it occasionally communicates with the bursa between the tendon and the tuberosity of the ischium, the two forming a single sac.

The **Gemelli** (Fig. 375) are two small muscular fasciculi, accessories to the tendon of the Obturator internus, which is received into a groove between them. They are called **superior** and **inferior**.

The **Gemellus superior** (*m. gemellus superior*), the smaller of the two, arises from the outer surface of the spine of the ischium, and, passing horizontally outward, becomes blended with the upper part of the tendon of the Obturator internus, and is inserted with it into the inner surface of the great trochanter. This muscle is sometimes wanting.

Relations.—By its *superficial surface*, with the Gluteus maximus and the sciatic vessels and nerves; by its *deep surface*, with the capsule of the hip-joint; by its *upper border*, with the lower margin of the Psoformis; by its *lower border*, with the tendon of the Obturator internus.

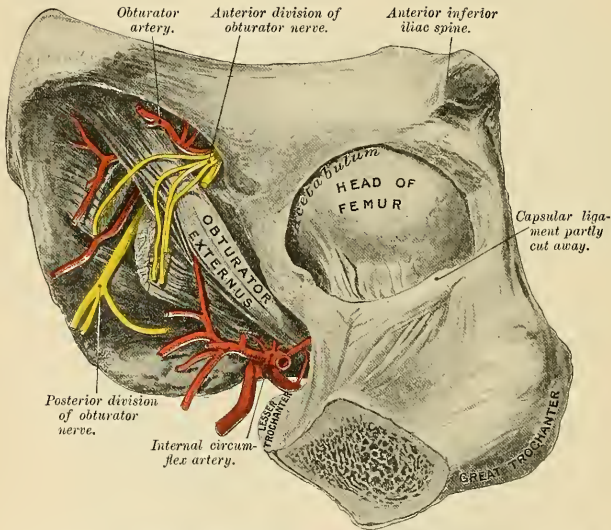


FIG. 386.—Obturator externus muscle. (From a preparation in the Museum of the Royal College of Surgeons of England.)

The **Gemellus inferior** (*m. gemellus inferior*) arises from the upper part of the tuberosity of the ischium, where it forms the lower edge of the groove for the Obturator internus tendon, and, passing horizontally outward, is blended with the lower part of the tendon of the Obturator internus, and is inserted with it into the inner surface of the great trochanter.

Relations.—By its *superficial surface*, with the Gluteus maximus and the sciatic vessels and nerves; by its *deep surface*, with the capsular ligament of the hip-joint; by its *upper border*, with the tendon of the Obturator internus; by its *lower border*, with the tendon of the Obturator externus and Quadratus femoris.

The **Quadratus femoris** (*m. quadratus femoris*) (Fig. 384) is a short, flat muscle, quadrilateral in shape, situated between the Gemellus inferior and the upper margin of the Adductor magnus. It arises from the upper part of the external lip of the tuberosity of the ischium, and, proceeding horizontally outward, is

inserted into the upper part of the linea quadrata; that is, the line which crosses the posterior intertrochanteric line.

Relations.—By its *superficial surface*, with the Gluteus maximus and the sciatic vessels and nerves; by its *deep surface*, with the tendon of the Obturator externus and trochanter minor and with the capsule of the hip-joint; by its *upper border*, with the Gemellus inferior. Its *lower border* is separated from the Adductor magnus by the terminal branches of the internal circumflex vessels. A synovial *bursa* is often found between the under surface of this muscle and the lesser trochanter, which it covers.

Dissection.—In order to expose the next muscle (the Obturator externus) it is necessary to remove the Psoas, Iliacus, Pectineus, and Adductores brevis and longus muscles from the front and inner side of the thigh, and the Gluteus maximus and Quadratus femoris from the back part. Its dissection should, consequently, be postponed until the muscles of the anterior and internal femoral regions have been explained.

The **Obturator externus** (*m. obturator externus*) (Figs. 385 and 386) is a flat, triangular muscle, which covers the outer surface of the anterior wall of the pelvis. It *arises* from the margin of bone immediately around the inner side of the obturator foramen—viz., from the body and ramus of the os pubis and the ramus of the ischium; it also *arises* from the inner two-thirds of the outer surface of the obturator membrane, and from the tendinous arch which completes the canal for the passage of the obturator vessels and nerves. The fibres from the pubic arch extend on to the inner surface of the bone, from which they obtain a narrow origin between the margin of the foramen and the attachment of the membrane. The fibres converging pass backward, outward, and upward, and terminate in a tendon which runs across the back part of the hip-joint, and is *inserted* into the digital fossa of the femur.

Relations.—In *front*, with the Psoas, Iliacus, Pectineus, Adductor magnus, and Adductor brevis; and more externally, with the neck of the femur and capsule of the hip-joint. The external and internal terminal branches of the obturator artery and accompanying veins lie between this muscle and the obturator membrane; the superficial part of the obturator nerve lies above the muscle, and the deep branch perforates it; by its *deep surface*, with the obturator membrane and Quadratus femoris at its insertion.

Nerves.—The Gluteus maximus is supplied by the fifth lumbar and first and second sacral nerves through the inferior gluteal nerve from the sacral plexus; the Gluteus medius and minimus, by the fourth and fifth lumbar and first sacral nerves, through the superior gluteal; the Piriformis is supplied by the first and second sacral nerves; the Gemellus inferior and Quadratus femoris by the last lumbar and first sacral nerve; the Gemellus superior and Obturator internus by the fifth lumbar and first and second sacral nerves, and the Obturator externus by the second, third, and fourth lumbar nerves through the obturator nerve.

Actions.—The Gluteus maximus, when it takes its fixed point from the pelvis, extends the femur and brings the bent thigh into a line with the body. Taking its fixed point from below, it acts upon the pelvis, supporting it and the whole trunk upon the head of the femur, which is especially obvious in standing on one leg. Its most powerful actions are to hold the head of the femur in close approximation to the acetabulum in walking and to cause the body to regain the erect position after stooping by drawing the pelvis backward, being assisted in this action by the Biceps, Semitendinosus, and Semimembranosus. The Gluteus maximus is a tensor of the fascia lata, and by its connection with the iliotibial band it steadies the femur on the articular surface of the tibia during standing, when the Extensor muscles are relaxed. The lower part of the muscle also acts as an Adductor and External rotator of the limb. The Gluteus medius and minimus abduct the thigh when the limb is extended, and are principally called into action in supporting the body on one limb, in conjunction with the Tensor fasciae femoris. Their anterior fibres, by drawing the great trochanter forward, rotate the thigh inward, in which action they are also assisted by the Tensor fasciae femoris. The remaining muscles are powerful Rotators of the thigh outward. In the sitting posture, when the thigh is flexed upon the pelvis, their action as Rotators cease, and they become Abductors, with the exception of the Obturator externus, which still rotates the femur outward. When the femur is fixed, the Piriformis and Obturator muscles serve to draw the pelvis forward if it has been inclined backward, and assist in steadying it upon the head of the femur.

4. The Posterior Femoral Region.

(Hamstring Muscles.)

Biceps femoris.

Semitendinosus.

Semimembranosus.

Dissection (Fig. 383).—Make a vertical incision along the middle of the back of the thigh, from the lower fold of the buttock to about three inches below the back of the knee-joint, and there connect it with a transverse incision, carried from the inner to the outer side of the leg. Make a third incision transversely at the junction of the middle with the lower third of the thigh. The integument having been removed from the back of the knee, and the boundaries of the popliteal space having been examined, the removal of the integument from the remaining part of the thigh should be continued, when the fascia and muscles of this region will be exposed.

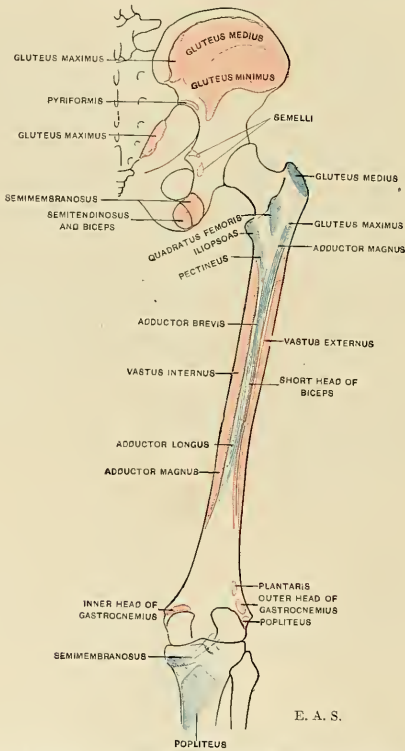


FIG. 387.—Diagram showing the attachments of the muscles of the thigh. Posterior aspect. Origins, red; insertions, blue.

The **Biceps femoris** (*m. biceps femoris*) is a large muscle, of considerable length, situated on the posterior and outer aspect of the thigh (Figs. 384 and 388). It arises by two heads. One, the **long head** (*caput longum*), arises from the lower and inner impression on the back part of the tuberosity of the ischium, by a tendon

common to it and the Semitendinosus, and from the lower part of the great sacro-sciatic ligament. The **femoral** or **short head** (*caput breve*) arises from the outer lip of the linea aspera, between the Adductor magnus and Vastus externus, extending up almost as high as the insertion of the Gluteus maximus; from the outer prolongation of the linea aspera to within two inches of the outer condyle, and from the external intermuscular septum. The fibres of the long head form a fusi-

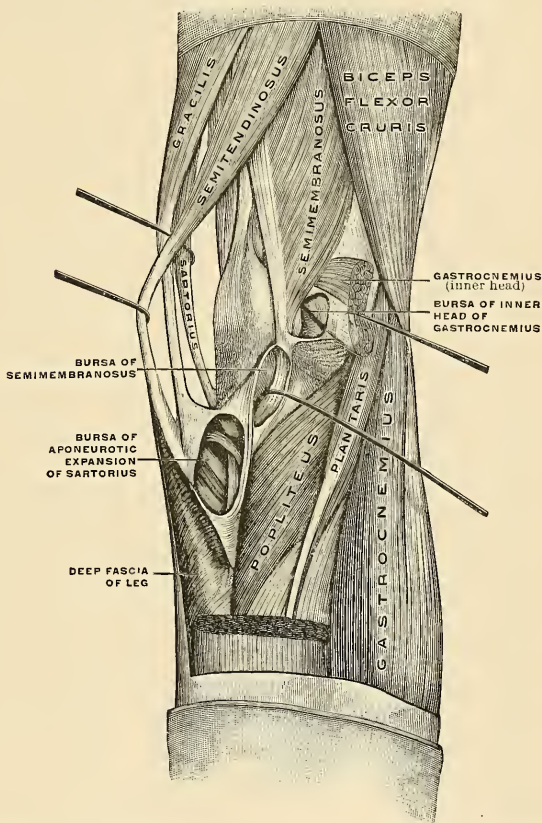


FIG. 388.—Region of the knee, seen obliquely from behind and within. Right limb. (Toldt.)

form belly, which, passing obliquely downward and a little outward, terminates in an aponeurosis which covers the posterior surface of the muscle, and receives the fibres of the short head; this aponeurosis becomes gradually contracted into a tendon, which is *inserted* into the outer side of the head of the fibula, and by a small slip into the lateral surface of the external tuberosity of the tibia. At its insertion the tendon divides into two portions, which embrace the long external lateral ligament of the knee-joint. From the posterior border of the tendon a

thin expansion is given off to the fascia of the leg. The tendon of this muscle forms the **outer Hamstring**.

Relations.—By its *superficial surface*, with the Gluteus maximus and the small sciatic nerve, the fascia lata, and integument. By its *deep surface*, with the Semimembranosus, Adductor magnus, and Vastus externus, the great sciatic nerve, and, near its insertion, with the external head of the Gastrocnemius, the Plantaris, the superior external articular artery, and the external popliteal nerve. A bursa (*bursa m. bicipitis femoris inferior*) is found between the long tendon of origin of this muscle and the Semitendinosus and Semimembranosus. Sometimes there is a bursa (*bursa bicipitogastrocnemialis*) between the tendon of the insertion of the Biceps and the origin of the Gastrocnemius, and there is a bursa (*bursa m. bicipitis femoris inferior*) between the tendon of the Biceps and the external lateral ligament.

The **Semitendinosus** (*m. semitendinosus*) (Figs. 384 and 388), remarkable for the great length of its tendon, is situated at the posterior and inner aspect of the thigh. It *arises* from the lower and inner impression on the tuberosity of the ischium by a tendon common to it and the long head of the Biceps femoris; it also *arises* from an aponeurosis which connects the adjacent surfaces of the two muscles to the extent of about three inches after their origin. The Semitendinosus is a fusiform muscle, which, passing downward and inward, terminates a little below the middle of the thigh in a long round tendon which lies along the inner side of the popliteal space, then curves around the inner tuberosity of the tibia, and is *inserted* into the upper part of the inner surface of the shaft of that bone nearly as far forward as its anterior border. At its insertion it gives off from its lower border a prolongation to the deep fascia of the leg. This tendon lies behind the tendon of the Sartorius, and below that of the Gracilis, to which it is united. A tendinous intersection is usually observed about the middle of the muscles. The **bursa anserina** lies between the tendon of the Semitendinosus and the tibia.

The **Semimembranosus** (*m. semimembranosus*) (Figs. 384 and 388), so called from its membranous tendon of origin, is situated at the back part and inner side of the thigh. It *arises* by a thick tendon from the upper and outer impression on the back part of the tuberosity of the ischium, above and to the outer side of the Biceps femoris and Semitendinosus, and is *inserted* into the groove on the inner and back part of the inner tuberosity of the tibia, beneath the internal lateral ligament. The tendon of the muscle at its origin expands into an aponeurosis which covers the upper part of its anterior surface; from this aponeurosis muscle fibres arise, and converge to another aponeurosis, which covers the lower part of its posterior surface and contracts into the tendon of insertion. The tendon of the muscle at its insertion gives off certain fibrous expansions; one of these, of considerable size, passes upward and outward, to be *inserted* into the back part of the outer condyle of the femur, forming part of the posterior ligament of the knee-joint; a second is continued downward to the fascia which covers the Popliteus muscle. The tendon also sends a few fibres to join the internal lateral ligament of the joint.

The tendons of the two preceding muscles, with that of the Gracilis, form the **inner Hamstrings**.

Nerves.—The muscles of this region are supplied by the fourth and fifth lumbar and the first, second, and third sacral nerves through the great sciatic nerve.

Actions.—The Hamstring muscles flex the leg upon the thigh. When the knee is semiflexed, the Biceps, in consequence of its oblique direction downward and outward, rotates the leg slightly outward; and the Semitendinosus, and to a slight extent the Semimembranosus, rotate the leg inward, assisting the Popliteus. Taking their fixed point from below, these muscles, especially the Semimembranosus, serve to support the pelvis upon the head of the femur and to draw the trunk directly backward, as in raising it from the stooping position or in feats of strength, when the body is thrown backward in the form of an arch. When the leg is extended on the thigh, they limit the amount of flexion of the trunk on the lower limbs.

Applied Anatomy.—The Hamstring tendons are occasionally *ruptured*. In disease of the knee-joint the Hamstrings may *contract*, flexing the knee, drawing the tibia backward, and sometimes causing incomplete dislocation. The tendons of these muscles occasionally require *subcutaneous division* in some forms of *spurious ankylosis* of the knee-joint dependent upon permanent contraction and rigidity of the Flexor muscles, or from stiffening of the ligamentous other tissues surrounding the joint, the result of disease. Division of a tendon is effected by putting the tendon upon the stretch, and inserting a narrow sharp-pointed knife between it and the skin; the cutting edge being then turned toward the tendon, it should be divided, taking great care that the wound in the skin is not at the same time enlarged. The relation of the external popliteal nerve to the tendon of the Biceps must always be borne in mind in dividing this tendon; in fact, a complete exposure of the tendon is much to be preferred.

IV. MUSCLES AND FASCIÆ OF THE LEG.

These may be divided into three groups: those on the **anterior**, those on the **posterior**, and those on the **outer side of the leg**.

5. The Anterior Tibiofibular Region (Fig. 390).

Tibialis anticus.

Extensor proprius hallucis.¹

Extensor longus digitorum.

Peroneus tertius.

Dissection (Fig. 377).—The knee should be bent, a block placed beneath it, and the foot kept in an extended position; then make an incision through the integument in the middle line of the leg to the ankle, and continue it along the dorsum of the foot to the toes. Make a second incision transversely across the ankle, and a third in the same direction across the bases of the toes; remove the flaps of integument included between these incisions in order to examine the deep fascia of the leg.

The **deep fascia of the leg** (*fascia cruris*) forms a complete investment to the muscles, but is not continuous over the subcutaneous surfaces of the bones. It is continuous *above* with the fascia lata, receiving an expansion from the tendon of the Biceps femoris, on the outer side, and from the tendons of the Sartorius Gracilis, and Semitendinosus on the inner side; in *front*, it blends with the periosteum covering the subcutaneous surface of the tibia, and with that covering the head and external malleolus of the fibula; *below*, it is continuous with the annular ligaments of the ankle. It is thick and dense in the upper and anterior part of the leg, and gives attachment, by its deep surface, to the Tibialis anticus and Extensor longus digitorum muscles, but is thinner behind, where it covers the Gastrocnemius and Soleus muscles. Over the popliteal space it is much strengthened by transverse fibres which stretch across from the inner to the outer Hamstring muscles, and it is here perforated by the external saphenous vein. Its deep surface gives off, on the outer side of the leg, two strong intermuscular septa which enclose the Peronei muscles, and separate them from the muscles of the anterior and posterior tibial regions. It also gives off several smaller and more slender processes which enclose the individual muscles in each region; at the same time a broad transverse, intermuscular septum, called the **deep transverse fascia of the leg**, intervenes between the superficial and deep muscles in the posterior tibiofibular region.

¹There is no such word as "Hallux, -cis." It is the result of some ignorant blunder, copied until it has become established by usage; it has been thought better, therefore, to retain it. According to Lewis and Short, the word is ALLEX, masculinæ; genitive, ALLICIS, the great toe, and the correct rendering would be Extensor proprius allicis. It is a rare word, and is sometimes spelt, but not so correctly, "Hallex." It is used by Plautus, in the "Poenulus," V. v. 31, of a little man, as we might say, "a hop-o'-my-thumb." "Tunc hic amator audes esse, *allex viri*" (To think of you daring to make up to her, you hop-o'-my-thumb!). The word "alex," sometimes spelt "allex," a fish sauce, is probably a different word altogether. It is used by Horace and Pliny.

Remove the fascia by dividing it in the same direction as the integument, excepting opposite the ankle, where it should be left entire. Commence the removal of the fascia from below, opposite the tendons, and detach it in the line of direction of the muscle fibres.

The **Tibialis anticus** (*m. tibialis anterior*) is situated on the outer side of the tibia; it is thick and fleshy at its upper part, tendinous below. It *arises* from the outer tuberosity and upper two-thirds of the external surface of the shaft of the tibia; from the adjoining part of the interosseous membrane; from the deep surface

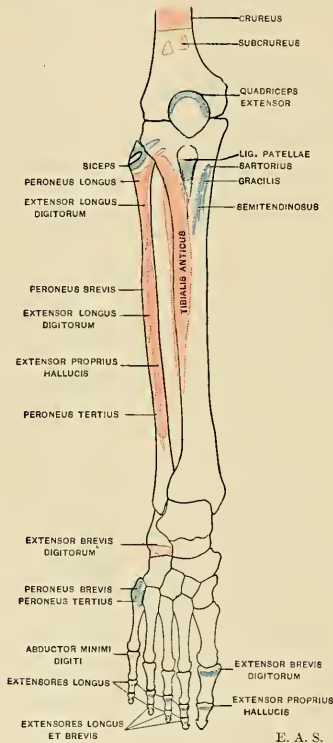


FIG. 389.—Diagram showing the attachments of the muscles of the leg. Anterior aspect. Origins, red; insertions, blue.

of the fascia; and from the intermuscular septum between it and the Extensor longus digitorum; the fibres pass vertically downward, and terminate in a tendon which is apparent on the anterior surface of the muscle at the lower third of the leg. After passing through the innermost compartment of the anterior annular ligament, it is *inserted* into the inner and under surface of the internal cuneiform bone and base of the metatarsal bone of the great toe. There is usually a *bursa* (*bursa subtendinea m. tibialis anterioris*) between the tendon of the Tibialis anticus and the internal cuneiform bone. At the upper part of the leg this muscle overlaps the anterior tibial vessels and nerve.

The **Extensor proprius hallucis** (*m. extensor hallucis longus*) is a thin, elongated, and flattened muscle situated between the Tibialis anticus and Extensor longus digitorum. It *arises* from the anterior surface of the fibula for about the middle two-fourths of its extent, its origin being internal to that of the Extensor longus digitorum; it also *arises* from the interosseous membrane to a similar extent. The fibres pass downward, and terminate in a tendon which occupies the anterior border of the muscle, passes through a distinct compartment in the lower portion of the annular ligament, crosses the anterior tibial vessels near the bend of the ankle, and is *inserted* into the base of the last phalanx of the great toe. Opposite the metatarsophalangeal articulation the tendon gives off a thin prolongation on each side, which covers the surface of the joint. It usually sends an expansion from the inner side of the tendon, to be inserted into the base of the first phalanx.

The **Extensor longus digitorum** (*m. extensor digitorum longus*) is an elongated, flattened, penniform muscle situated the most externally of all the muscles on the fore part of the leg. It *arises* from the outer tuberosity of the tibia; from the upper three-fourths of the anterior surface of the shaft of the fibula; from the interosseous membrane; from the deep surface of the fascia; and from the intermuscular septa between it and the Tibialis anticus on the inner and the Peronei on the outer side. The tendon enters a canal in the annular ligament with the Peroneus tertius, and divides into four slips, which run across the dorsum of the foot and are *inserted* into the second and third phalanges of the four lesser toes. The mode in which the tendons are inserted is the following: Each of the three inner tendons opposite the metatarsophalangeal articulation is joined, on its outer side, by a tendon from the Extensor brevis digitorum. The outer tendon does not receive such a tendinous slip. They all receive a fibrous expansion from the Interossei and Lumbricales, and then spread out into a broad aponeurosis, which covers the dorsal surface of the first phalanx; this aponeurosis, at the articulation of the first with the second phalanx, divides into three slips—a middle one, which is inserted into the base of the second phalanx, and two lateral slips, which, after uniting on the dorsal surface of the second phalanx, are continued onward, to be inserted into the base of the third.

The **Peroneus tertius** (*m. peroneus tertius*) is a part of the Extensor longus digitorum, and might be described as its fifth tendon. The fibres belonging to this tendon *arise* from the lower fourth of the anterior surface of the fibula, from the lower part of the interosseous membrane, and from an internus-

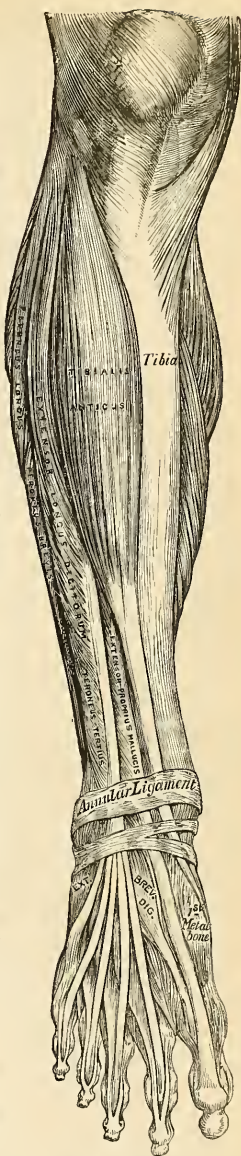

FIG. 390.—Muscles of the front of the leg.

cular septum between it and the Peroneus brevis. The tendon, after passing through the same canal in the annular ligament as the Extensor longus digitorum, is inserted into the dorsal surface of the base of the metatarsal bone of the little toe. This muscle is sometimes wanting.

Nerves.—These muscles are supplied by the fourth and fifth lumbar and first sacral nerves through the anterior tibial nerve.

Actions.—The Tibialis anticus and Peroneus tertius are the direct Flexors of the foot at the ankle-joint; the former muscle, when acting in conjunction with the Tibialis posticus, raises the inner border of the foot (*i. e.*, inverts the foot); and the latter, acting with the Peroneus brevis and longus, draws the outer border of the foot upward, and the sole outward (*i. e.*, everts the foot). The Extensor longus digitorum and Extensor proprius hallucis extend the phalanges of the toes, and, continuing their action, flex the foot upon the leg. Taking their fixed point from below, in the erect posture, all these muscles serve to fix the bones of the leg in the perpendicular position, and give increased strength to the ankle-joint.

6. The Posterior Tibiofibular Region (Figs. 388, 394).

Dissection (Fig. 383).—Make a vertical incision along the middle line of the back of the leg, from the lower part of the popliteal space to the heel, connecting it below by a transverse incision extending between the two malleoli; the flaps of integument being removed, the fascia and muscles should be examined.

The muscles in this region of the leg are subdivided into two layers—**superficial** and **deep**. The superficial layer constitutes a powerful muscular mass, forming the calf of the leg. Their large size is one of the most characteristic features of the muscular apparatus in man, and bears a direct connection with his ordinary attitude and mode of progression.

The Superficial Layer.

Gastrocnemius.

Soleus.

Plantaris.

The **Gastrocnemius** (*m. gastrocnemius*) is the most superficial muscle, and forms the greater part of the calf. It arises by two heads, which are connected to the condyles of the femur by two strong flat tendons. The inner and larger head (*caput mediale*) arises from a depression at the upper and back part of the inner condyle and from the adjacent part of the femur. The outer head (*caput laterale*) arises from an impression on the outer side of the external condyle and from the posterior surface of the femur immediately above the condyle. Both heads, also, arise by a few tendinous and fleshy fibres from the ridges which are continued upward from the condyles to the linea aspera. Each tendon spreads out into an aponeurosis, which covers the posterior surface of that portion of the muscle to which it belongs; the muscle fibres of the inner head form a thicker mass and extend lower than those of the outer. From the anterior surface of these tendinous expansions muscle fibres are given off. The fibres in the median line, which correspond to the accessory portions of the muscle derived from the bifurcations of the linea aspera, unite at an angle upon a median tendinous raphé below; the remaining fibres converge to an aponeurosis which covers the anterior surface of the muscle, and this, gradually contracting, unites with the tendon of the Soleus, and forms with it the *tendo Achillis*.

Relations.—By its *superficial surface*, with the fascia of the leg, which separates it from the external saphenous vein and nerve; by its *deep surface*, with the posterior ligament of the knee-joint, the Popliteus, Soleus, Plantaris, popliteal vessels, and internal popliteal nerve. The tendon of the inner head corresponds with the back part of the inner condyle, from which it is

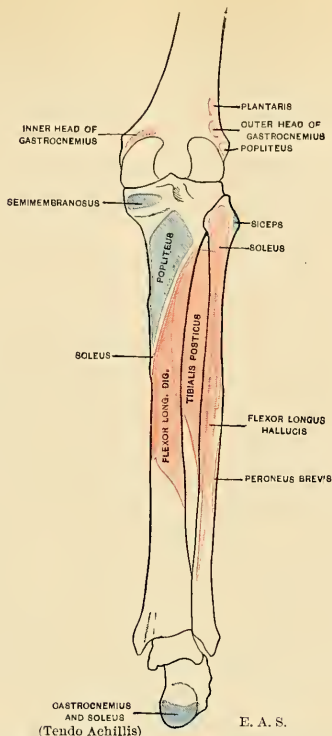


FIG. 391.—Diagram showing the attachments of muscles of leg. Posterior aspect. Origins, red; insertions, blue. The attachments of muscles of bones of foot are given in detail in Figs. 191 and 192.

separated by a synovial bursa, which, in some cases, communicates with the cavity of the knee-joint. The tendon of the outer head contains a sesamoid fibrocartilage (rarely osseous), where it plays over the corresponding outer condyle; and one is occasionally found in the tendon of the inner head.

The Gastrocnemius should be divided across, just below its origin, and turned downward, in order to expose the next two muscles.

The **Soleus** (*m. soleus*) is a broad flat muscle situated immediately beneath the Gastrocnemius. It has received its name from its resemblance in shape to a sole-fish. It *arises* by tendinous fibres from the back part of the head of the fibula and from the upper third of the posterior surface of its shaft; from the oblique line of the tibia and from the middle third of its internal border; some fibres also arise from a tendinous arch placed between the tibial and fibular origins of the muscle, beneath which the popliteal vessels and internal popliteal nerve pass. The fibres pass backward to an aponeurosis which covers the posterior surface of the muscle, and this,

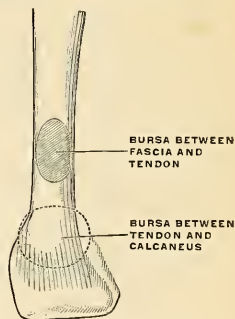


FIG. 392.—Bursae of the tendo Achillis. (Poirier and Charpy.)

The fibres pass backward to an aponeurosis which covers the posterior surface of the muscle, and this,

gradually becoming thicker and narrower, joins with the tendon of the Gastrocnemius, and forms with it the tendo Achillis.

Relations.—By its *superficial surface*, with the Gastrocnemius and Plantaris; by its *deep surface*, with the Flexor longus digitorum, Flexor longus hallucis, Tibialis posticus, and posterior tibial vessels and nerve, from which it is separated by the transverse intermuscular septum or deep transverse fascia of the leg.

The **Tendo Achillis** (*tendo calcaneus*), the common tendon of the Gastrocnemius and Soleus,¹ is the thickest and strongest tendon in the body. It is about six inches in length, and *commences* about the middle of the leg, but receives fleshy fibres on its anterior surface nearly to its lower end. Gradually becoming contracted below, it is *inserted* into the lower part of the posterior surface of the

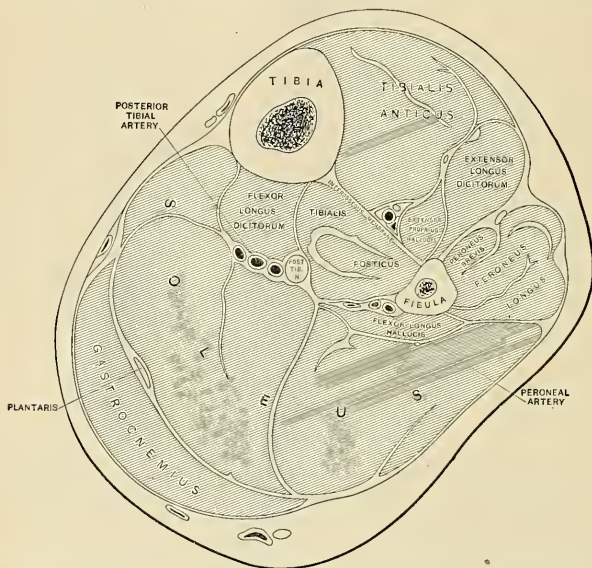


FIG. 393.—Transverse section at the middle of the leg. In front of the interosseous membrane are the anterior tibial vessels and nerve; in front of the Soleus, the posterior tibial vessels and nerve; and close to the fibula, the peroneal vessels. (After Braune.)

calcaneus, a synovial bursa (*bursa tendinis calcanei* [*Achillis*]) (Fig. 392) being interposed between the tendon and the upper part of this surface. The tendon spreads out somewhat at its lower end, so that its narrowest part is usually about an inch and a half above its insertion. The tendon is covered by the fascia and the integument, a bursa (*bursa subcutanea calcanea*) (Fig. 392) being often interposed between the tendon and the fascia. The tendon is separated from the deep muscles and vessels by a considerable interval filled up with areolar and adipose tissues. Along its outer side, but superficial to it, is the external saphenous vein.

The **Plantaris** (*m. plantaris*) is an extremely diminutive muscle placed between the Gastrocnemius and Soleus, and remarkable for its long and delicate tendon.

¹ These two muscles with a common tendon are by some anatomists classed together as one muscle, the *Triceps surae*, the two heads of origin of the Gastrocnemius and the Soleus constituting the three heads of the Triceps, and the tendo Achillis the single tendon of insertion.

It *arises* from the lower part of the outer prolongation of the linea aspera and from the posterior ligament of the knee-joint. It forms a small fusiform belly, about three or four inches in length, terminating in a long slender tendon which crosses obliquely between the two muscles of the calf, and, running along the inner border of the tendo Achillis, is *inserted* with it into the posterior part of the calcaneus. This muscle is occasionally double, and is sometimes wanting. Occasionally its tendon is lost in the internal annular ligament or in the fascia of the leg.

Nerves.—The Gastrocnemius is supplied by the first and second sacral nerves, and the Plantaris by the fourth and fifth lumbar and first sacral nerves through the internal popliteal. The Soleus is supplied by the fifth lumbar and first and second sacral nerves through the internal popliteal and posterior tibial.

Actions.—The muscles of the calf are the chief Extensors of the foot at the ankle-joint. They possess considerable power, and are constantly called into use in standing, walking, dancing, and leaping; hence, the large size they usually present. In walking, these muscles draw powerfully upon the calcaneus, raising the heel, and with it the entire body, from the ground; the body being thus supported on the raised foot, the opposite limb can be carried forward. In standing, the Soleus, taking its fixed point from below, steadies the leg upon the foot, and prevents the body from falling forward, to which there is a constant tendency from the superincumbent weight. The Gastrocnemius, acting from below, serves to flex the femur upon the tibia, assisted by the Popliteus. The Plantaris is the rudiment of a large muscle which exists in some of the lower animals and is continued over the os calcis to be inserted into the plantar fascia. In man it is an accessory to the Gastrocnemius, extending the ankle if the foot is free, or bending the knee if the foot is fixed. Possibly, acting from below, by its attachment to the posterior ligament of the knee-joint, it may pull that ligament backward during flexion, and so protect it from being compressed between the two articular surfaces.

The Deep Layer (Fig. 395).

Popliteus.

Flexor longus hallucis.

Flexor longus digitorum.

Tibialis posticus.

Dissection.—Detach the Soleus from its attachment to the fibula and tibia, and turn it downward, when the deep layer of muscles is exposed, covered by the deep transverse fascia of the leg.

The **deep transverse fascia** of the leg is a transversely placed, intermuscular septum, between the superficial and deep muscles in the posterior tibiofibular region. On either side it is connected to the margins of the tibia and fibula. Above, where it covers the Popliteus, it is thick and dense, and receives an expansion from the tendon of the Semimembranosus; it is thinner in the middle of the leg, but below, where it covers the tendons passing behind the malleoli, it is thickened and continuous with the internal annular ligament.

This fascia should now be removed, commencing from below opposite the tendons, and detaching it from the muscles in the direction of their fibres.

The **Popliteus** (*m. popliteus*) (Fig. 388) is a thin, flat, triangular muscle, which forms part of the floor of the popliteal space. It *arises* by a strong tendon, about an inch in length, from a deep depression on the outer side of the external condyle of the femur, and from the posterior ligament of the knee-joint. The muscle is *inserted* into the inner two-thirds of the triangular surface above the oblique line on the posterior surface of the shaft of the tibia, and into the tendinous expansion covering the surface of the muscle. The tendon of the muscle is covered by that of the Biceps femoris and by the external lateral ligament of the knee-joint; it grooves the posterior border of the external semilunar fibrocartilage, and is invested by the synovial membrane of the knee-joint.

Relations.—By its *superficial surface*, with the fascia covering it, which separates it from the Gastrocnemius, Plantaris, popliteal vessels, and internal popliteal nerve; by its *deep surface*, with the knee-joint and back of the tibia.

The **Flexor longus hallucis** (*m. flexor hallucis longus*) is situated on the fibular side of the leg, and is the most superficial and largest of the three next muscles.

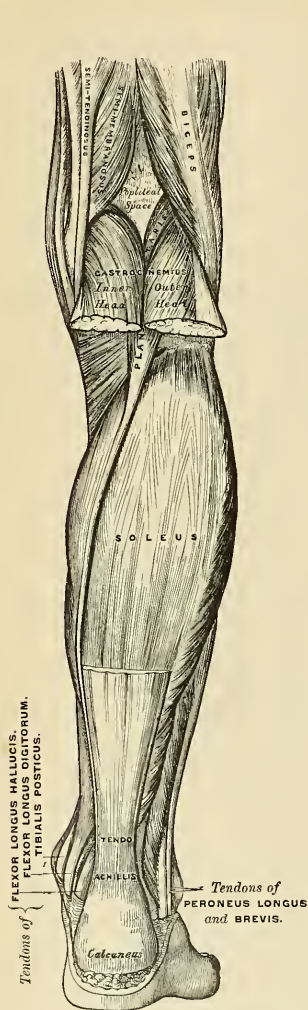


FIG. 394.—Muscles of the back of the right leg. Superficial layer.

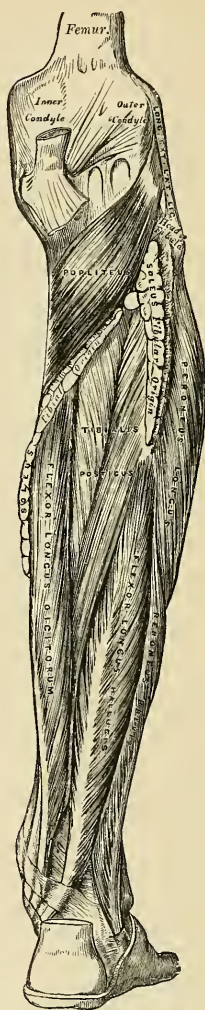


FIG. 395.—Muscles of the back of the right leg. Deep layer.

It arises from the lower two-thirds of the posterior surface of the shaft of the fibula, with the exception of an inch at its lowest part; from the lower part of the interosseous membrane; from an intermuscular septum between it and the

Peronei, externally; and from the fascia covering the Tibialis posticus internally. The fibres pass obliquely downward and backward, and terminate in a tendon which occupies nearly the whole length of the posterior surface of the muscle. This tendon occupies a groove on the posterior surface of the lower end of the tibia; it then lies in a second groove on the posterior surface of the astragalus, and finally in a third groove, beneath the sustentaculum tali of the calcaneus, and passes into the sole of the foot, where it runs forward between the two heads of the Flexor brevis hallucis, and is *inserted* into the base of the last phalanx of the great toe (Fig. 397). The grooves in the astragalus and calcaneus, which contain the tendon of the muscle, are converted by tendinous fibres into distinct canals lined by synovial membrane; and as the tendon crosses the sole of the foot, it is connected to the Common Flexor by a tendinous slip.

Relations.—By its *superficial surface*, with the Soleus and tendo Achillis, from which it is separated by the deep transverse fascia; by its *deep surface*, with the fibula, Tibialis posticus, the peroneal vessels, the lower part of the interosseous membrane, and the ankle-joint; by its *outer border*, with the Peronei; by its *inner border*, with the Tibialis posticus and posterior tibial vessels and nerve. In the sole of the foot it lies above the Abductor hallucis and Flexor longus digitorum.

The **Flexor longus digitorum** (*m. flexor digitorum longus*) is situated on the tibial side of the leg. At its origin it is thin and pointed, but gradually increases in size as it descends. It *arises* from the posterior surface of the shaft of the tibia, immediately below the oblique line to within three inches of its extremity, internal to the tibial origin of the Tibialis posticus; some fibres also arise from the fascia covering the Tibialis posticus. The fibres terminate in a tendon which runs nearly the whole length of the superficial surface of the muscle. This tendon passes behind the internal malleolus in a groove, common to it and the Tibialis posticus, but separated from the latter by a fibrous septum, each tendon being contained in a special sheath lined by a separate synovial membrane. It then passes obliquely forward and outward, superficial to the internal lateral ligament, into the sole of the foot (Fig. 397), where, crossing superficially to the tendon of the Flexor longus hallucis,¹ to which it is connected by a strong tendinous slip, it becomes expanded, is joined by the Flexor accessorius, and finally divides into four tendons, which are *inserted* into the bases of the last phalanges of the four lesser toes, each tendon passing through a fissure in the tendon of the Flexor brevis digitorum opposite the base of the first phalanges (Fig. 396).

Relations.—*In the leg*, by its *superficial surface*, with the posterior tibial vessels and nerve, and the deep transverse fascia, which separates it from the Soleus muscle; by its *deep surface*, with the Tibia and Tibialis posticus. *In the foot* it is covered by the Abductor hallucis and Flexor brevis digitorum, and crosses superficial to the Flexor longus hallucis.

The **Tibialis posticus** (*m. tibialis posterior*) lies between the two preceding muscles, and is the most deeply seated of all the muscles in the leg. It commences above by two pointed processes, separated by an angular interval, through which the anterior tibial vessels pass forward to the front of the leg. It *arises* from the whole of the posterior surface of the interosseous membrane, excepting its lowest part, from the outer portion of the posterior surface of the shaft of the tibia, between the commencement of the oblique line above, and the junction of the middle and lower third of the shaft below; and from the upper two-thirds of the internal surface of the fibula; some fibres also arise from the deep transverse fascia and from the intermuscular septa, separating it from the adjacent muscles on each side. This muscle, in the lower fourth of the leg, passes in front of the Flexor longus digitorum, and terminates in a tendon which passes through a groove behind the inner malleolus with the tendon of that muscle, but enclosed in a separ-

¹That is, in the order of dissection of the sole of the foot.

ate sheath; it then passes through another sheath, over the internal lateral ligament into the foot, and then beneath the inferior calcaneoscapoid ligament. Beyond this sheath the tendon passes between the sustentaculum tali and the tubercle of the scaphoid to the plantar aspect and divides into two main slips. The *stronger medial slip is inserted* into the tubercle of the scaphoid and into the internal cuneiform and sends an expansion to the plantar surface of the sustentaculum tali. The *weaker lateral slip* divides into lesser slips, which are *inserted* into the middle and external cuneiform, the cuboid and the base of the second, third, and fourth metatarsal bones. The stronger tendon as it passes over the scaphoid contains a sesamoid bone. A bursa is often situated between the tendon and the scaphoid.

Relations.—By its *superficial surface*, with the Soleus, from which it is separated by the deep transverse fascia, the Flexor longus digitorum, the posterior tibial vessels and nerve, and the peroneal vessels; by its *deep surface*, with the interosseous ligament, the tibia, fibula, and ankle-joint.

Nerves.—The Popliteus is supplied by the fourth and fifth lumbar and first sacral nerves, through the internal popliteal; the Flexor longus digitorum and Tibialis posticus by the fifth lumbar and first and second sacral; and the Flexor longus hallucis by the fifth lumbar and first and second sacral nerves through the posterior tibial.

Actions.—The Popliteus assists in flexing the leg upon the thigh; when the leg is flexed, it will rotate the tibia inward. It is especially called into action at the commencement of the act of bending the knee, inasmuch as it produces a slight inward rotation of the tibia, which is essential in the early stages of this movement. The Tibialis posticus is a direct Extensor of the foot at the ankle-joint; acting in conjunction with the Tibialis anticus, it turns the sole of the foot inward (*i. e.*, inverts the foot), antagonizing the Peronei, which turn it outward (evert it). In the sole of the foot the tendon of the Tibialis posticus lies directly below the inferior calcaneoscapoid ligament, and is therefore an important factor in maintaining the arch of the foot. The Flexor longus digitorum and Flexor longus hallucis are the direct Flexors of the phalanges, and, continuing their action, extend the foot upon the leg; they assist the Gastrocnemius and Soleus in extending the foot, as in the act of walking or in standing on tiptoe. In consequence of the oblique direction of the tendon of the long Flexor, the toes would be drawn inward were it not for the Flexor accessorius muscle, which is inserted into the outer side of its tendon and draws it to the middle line of the foot during its action. Taking their fixed point from the foot, these muscles serve to maintain the upright posture by steadying the tibia and fibula perpendicularly upon the ankle-joint. They also serve to raise these bones from the oblique position they assume in the stooping posture.

7. The Fibular Region (Fig. 381).

Peroneus longus.

Peroneus brevis.

Dissection.—The muscles are readily exposed by removing the fascia covering their surface, from below upward, in the line of direction of their fibres.

The **Peroneus longus** (*m. peronæus longus*) is situated at the upper part of the outer side of the leg, and is the more superficial of the two muscles. It *arises* from the head and upper two-thirds of the outer surface of the shaft of the fibula, from the deep surface of the fascia, and from the intermuscular septa between it and the muscles on the front, and those on the back of the leg, occasionally also by a few fibres from the outer tuberosity of the tibia. Between its attachment to the head and to the shaft of the fibula there is a small interval of bone from which no muscle fibres arise; through this gap the external popliteal nerve passes beneath the muscle. The muscle terminates in a long tendon, which passes behind the outer malleolus, in a groove common to it and the tendon of the Peroneus brevis, behind which it lies, the groove being converted into a canal by a fibrous band, and the tendons being invested by a common synovial membrane; it is then reflected obliquely forward across the outer side of the calcaneus, below its peroneal tubercle, being contained in a separate fibrous sheath, lined by a prolongation of the synovial membrane which lines the groove behind the malleolus. Having reached the outer side of the cuboid bone, it runs in a groove on the under

surface of that bone, which is converted into a canal by the long calcaneocuboid ligament, and is lined by a synovial membrane; the tendon then crosses the sole of the foot obliquely, and is *inserted* into the outer side of the base of the metatarsal bone of the great toe and the internal cuneiform bone (Figs. 397 and 398). Occasionally it sends a slip to the base of the second metatarsal bone. The tendon changes its direction at two points—first, behind the external malleolus; secondly, on the outer side of the cuboid bone; in both of these situations the tendon is thickened, and in the latter a sesamoid fibrocartilage, or sometimes a bone, is usually developed in its substance.

Relations.—By its *superficial surface*, with the fascia and integument; by its *deep surface*, with the fibula, external popliteal nerve, the Peroneus brevis, calcaneus, and cuboid bone; by its *anterior border*, with an intermuscular septum, which intervenes between it and the Extensor longus digitorum; by its *posterior border*, with an intermuscular septum, which separates it from the Soleus above and the Flexor longus hallucis below.

The **Peroneus brevis** (*m. peronaeus brevis*) lies beneath the Peroneus longus, and is shorter and smaller than it. It *arises* from the lower two-thirds of the external surface of the shaft of the fibula, internal to the Peroneus longus, and from the intermuscular septa separating it from the adjacent muscles on the front and back part of the leg. The fibres pass vertically downward, and terminate in a tendon which runs in front of that of the preceding muscle through the same groove, behind the external malleolus, being contained in the same fibrous sheath and lubricated by the same synovial membrane. It then passes through a separate sheath on the outer side of the calcaneus, above that for the tendon of the Peroneus longus, the two tendons being here separated by the peroneal tubercle, and is finally *inserted* into the tuberosity at the base of the metatarsal bone of the little toe, on its outer side.

Relations.—By its *superficial surface*, with the Peroneus longus and the fascia of the leg and foot; by its *deep surface*, with the fibula and outer side of the os calcis.

Nerves.—The Peroneus longus and brevis are supplied by the fourth and fifth lumbar and first sacral nerves through the musculocutaneous branch of the external popliteal nerve.

Actions.—The Peroneus longus and brevis extend the foot upon the leg, in conjunction with the Tibialis posticus, antagonizing the Tibialis anticus and Peroneus tertius, which are Flexors of the foot. The Peroneus longus also everts the sole of the foot; hence, the extreme eversion occasionally observed in fracture of the lower end of the fibula, where that bone offers no resistance to the action of this muscle. From the oblique direction of the Peroneus longus tendon across the sole of the foot it is an important agent in the maintenance of the transverse arch of the foot. Taking their fixed point below, the Peronei serve to steady the leg upon the foot. This is especially the case when standing upon one leg, when the tendency of the superincumbent weight is to throw the leg inward; the Peroneus longus overcomes this tendency by drawing on the outer side of the leg, and thus maintains the perpendicular direction of the limb.

Applied Anatomy.—The student should now consider the position of the tendons of the various muscles of the leg, their relation with the ankle-joint and surrounding bloodvessels, and especially their action upon the foot, as their rigidity and contraction give rise to one or other of the kinds of deformity known as club-foot. The most simple and common deformity, and one that is rarely, if ever, congenital, is the *talipes equinus*, the heel being raised by rigidity and contraction of the Gastrocnemius muscle, and the patient walking upon the ball of the foot. In the *talipes varus* the foot is forcibly adducted and the inner side of the sole raised, sometimes to a right angle with the ground, by the action of the Tibialis anticus and posticus. In the *talipes valgus* the outer edge of the foot is raised by the Peronei muscles, and the patient walks on the inner ankle. In the *talipes calcaneus* the toes are raised by the Extensor muscles, the heel is depressed, and the patient walks upon it. Other varieties of deformity are met with, as the *talipes equinovarus*, *equinovalgus*, and *calcaneovalgus*, whose names sufficiently indicate their nature. Of these, the *talipes equinovarus* is the most common congenital form; the heel is raised by the tendo Achillis, the inner border of the foot drawn upward by the Tibialis anticus, the anterior two-thirds twisted inward by the Tibialis posticus, and the arch increased by the contraction of the plantar fascia, so that the patient walks on the middle of the outer border of the foot. Each of these deformities may sometimes be successfully relieved by division of the opposing tendons and fascia; by this means the foot regains its proper position,

and the tendons subsequently heal. The operation is easily performed by putting the contracted tendon upon the stretch, and dividing it by means of a narrow, sharp-pointed knife inserted beneath it. *Pes cavus*, or hollow foot, is accentuation of the longitudinal arch. *Pes planus*, or flat-foot, has been discussed on page 349.

Rupture of a few of the fibres of the Gastrocnemius may take place. *Rupture of the Plantaris tendon* not uncommonly occurs, especially in men somewhat advanced in life, from some sudden exertion, and frequently occurs during the game of lawn tennis, and is hence known as *lawn-tennis leg*. The accident is accompanied by a sudden pain, and produces a sensation as if the individual had been struck a violent blow on the part. The tendo Achillis is also sometimes ruptured. It is stated that John Hunter ruptured his tendo Achillis while dancing at the age of forty. The bursa interposed between the posterior surface of the os calcis and the tendo Achillis, just above the point of insertion of the tendon, may become inflamed, producing a disabling pain (*achillodynia*, or *Albert's disease*).

V. MUSCLES AND FASCIA OF THE FOOT.

The fibrous bands, or thickened portions of the fascia of the leg, which bind down the tendons in front of and behind the ankle in their passage to the foot, are termed the annular ligaments, and are three in number—**anterior**, **internal**, and **external**.

The **Anterior Annular Ligament** (Fig. 390) consists of a **superior** or **transverse portion** (*ligamentum transversum cruris*), which binds down the Extensor tendons as they descend on the front of the tibia and fibula; and an **inferior** or **Y-shaped portion** (*ligamentum cruciatum cruris*), which retains them in connection with the tarsus, the two portions being connected by a thin intervening layer of fascia. The transverse portion is attached externally to the lower end of the fibula and internally to the tibia; above it is continuous with the fascia of the leg; it contains only one synovial sheath, for the tendon of the Tibialis anticus; the other tendons and the anterior tibial vessels and nerve passing beneath it, but without any distinct synovial sheath. The Y-shaped portion is placed in front of the ankle-joint, the stem of the Y, the **fundiform ligament of Retzius**, being attached externally to the upper surface of the calcaneus, in front of the depression for the interosseous ligament; it is directed inward, as a double layer, one lamina passing in front, and the other behind, the tendons of the Peroneus tertius and Extensor longus digitorum. At the inner border of the latter tendon these two layers join, forming a sheath in which the tendons are enclosed, surrounded by a synovial membrane. From the inner extremity of this sheath the two limbs of the Y diverge; one passes upward and inward, to be attached to the internal malleolus, passing over the Extensor proprius hallucis and the vessels and nerves, but enclosing the Tibialis anticus and its synovial sheath by a splitting of its fibres. The other limb extends downward and inward to be attached to the inner border of the plantar fascia, and passes over the tendons of the Extensor proprius hallucis and Tibialis anticus and also the vessels and nerves. These two tendons are contained in separate synovial sheaths situated beneath the ligament.

The **Internal Annular Ligament** (*ligamentum laciniatum*) is a strong fibrous band which extends from the inner malleolus above to the internal margin of the calcaneus below, converting a series of grooves in this situation into canals for the passage of the tendons of the Flexor muscles and vessels into the sole of the foot. It is continuous by its upper border with the deep fascia of the leg, and by its lower border with the plantar fascia and the fibres of origin of the Abductor hallucis muscle. The four canals which the ligament completes transmit, counting from before backward, *first*, the tendon of the Tibialis posticus; *second*, the tendon of the Flexor longus digitorum; *third*, the posterior tibial vessels and nerve, which run through a broad space beneath the ligament; *lastly*, in a canal formed partly by the astragalus, the tendon of the Flexor longus hallucis. The canals for the tendons are lined by a separate synovial membrane.

The **External Annular Ligament** is divided into two portions—a **superior portion** (*retinaculum mm. peronaeorum superius*), which extends from the extremity of the outer malleolus to the outer surface of the calcaneus; it binds down the tendons of the Peroneus longus and brevis muscles in their passage behind the external malleolus. The two tendons are enclosed in one synovial sac. An **inferior portion** (*retinaculum mm. peronaeorum inferius*), which bridges the Peronei on the side of the calcaneus and is attached to the bone above and below them.

8. The Dorsal Region (Fig. 390).

Extensor brevis digitorum.

Fascia (*fascia dorsalis pedis*).—The fascia on the dorsum of the foot is a thin membranous layer continuous above with the anterior margin of the annular ligament; it becomes gradually lost opposite the heads of the metatarsal bones, and on each side blends with the lateral portions of the plantar fascia; it forms a sheath for the tendons placed on the dorsum of the foot. On the removal of this fascia the muscle and tendons of the dorsal region of the foot are exposed.

The **Extensor brevis digitorum** (*m. extensor digitorum brevis*) (Fig. 390) is a broad thin muscle which *arises* from the fore part of the upper and outer surfaces of the calcaneus, in front of the groove for the Peroneus brevis, from the external calcaneo-astragaloid ligament, and from the common limb of the Y-shaped portion of the anterior annular ligament. It passes obliquely across the dorsum of the foot, and terminates in four tendons. The innermost, which is the largest, is *inserted* into the dorsal surface of the base of the first phalanx of the great toe, crossing the dorsalis pedis artery; the other three, into the outer sides of the long Extensor tendons of the second, third, and fourth toes.

Nerves.—It is supplied by the anterior tibial nerve.

Actions.—The Extensor brevis digitorum is an accessory to the long Extensor, extending the phalanges of the four inner toes, but acting only on the first phalanx of the great toe. The obliquity of its direction counteracts the oblique movement given to the toes by the long Extensor, so that, both muscles acting together, the toes are evenly extended.

9. The Plantar Region (Figs. 396, 397).

The **plantar fascia** (*aponeurosis plantaris*), the densest of all the fibrous membranes, is of great strength, and consists of pearly white glistening fibres, disposed, for the most part, longitudinally; it is divided into a central and two lateral portions.

The **central portion**, the thickest, is narrow behind and *attached* to the inner tubercle of the calcaneus, posterior to the origin of the Flexor brevis digitorum, and, becoming broader and thinner in front, divides near the heads of the metatarsal bones into five processes, one for each of the toes. Each of these processes divides opposite the metatarsophalangeal articulation into two strata, superficial and deep. The superficial stratum is *inserted* into the skin of the transverse sulcus which divides the toes from the sole. The deeper stratum divides into two slips which embrace the sides of the Flexor tendons of the toes, and blend with the sheaths of the tendons, and laterally with the transverse metatarsal ligament, thus forming a series of arches through which the tendons of the short and long Flexors pass to the toes. The intervals left between the five processes allow the digital vessels and nerves and the tendons of the Lumbricales muscles to become superficial. At the point of division of the fascia into processes and slips numerous transverse fibres are superadded, which serve to increase the strength of the fascia

at this part by binding the processes together and connecting them with the integument. The central portion of the plantar fascia is continuous with the lateral portions at each side, and from its deep surface sends upward two strong vertical intermuscular septa, which separate the middle from the external and internal groups of plantar muscles; from these, again, thinner transverse septa are derived, which separate the various layers of muscles in this region. The deep surface of this fascia gives attachment behind to the Flexor brevis digitorum muscle.

The **lateral portions** of the plantar fascia are thinner than the central division, and cover the sides of the foot. The **outer portion** covers the under surface of the Abductor minimi digiti; it is thick behind, thin in front, and extends from the calcaneus to the base of the fifth metatarsal bone, to the outer side of which it is attached; it is continuous internally with the central portion of the plantar fascia, and externally with the dorsal fascia. The **inner portion** is very thin, and covers the Abductor hallucis muscle; it is attached to the internal annular ligament, and is continuous around the side of the foot with the dorsal fascia, and externally with the middle portion of the plantar fascia.

The muscles in the plantar region of the foot may be divided into three groups, in a similar manner to those in the hand: (1) Those of the internal plantar region are connected with the great toe, and correspond with those of the thumb; (2) those of the external plantar region are connected with the little toe, and correspond with those of the little finger; and (3) those of the middle plantar region are connected with the tendons intervening between the two former groups. But in order to facilitate the dissection of these muscles it will be found more convenient to divide them into four layers, as they present themselves, in the order in which they are successively exposed.

The First Layer.

Abductor hallucis.

Flexor brevis digitorum.

Abductor minimi digiti.

Dissection.—Remove the fascia on the inner and outer sides of the foot, commencing in front over the tendons and proceeding backward. The central portion should be divided transversely in the middle of the foot, and the two flaps dissected forward and backward.

The **Abductor hallucis** (*m. abductor hallucis*) lies along the inner border of the foot and covers the first parts of the plantar vessels and nerves. It *arises* from the inner tubercle on the under surface of the calcaneus (Fig. 396); from the internal annular ligament; from the plantar fascia; and from the intermuscular septum between it and the Flexor brevis digitorum. The fibres terminate in a tendon which is *inserted*, together with the innermost tendon of the Flexor brevis hallucis, into the inner side of the first phalanx of the great toe.

The **Flexor brevis digitorum** (*m. flexor digitorum brevis*) lies in the middle of the sole of the foot, immediately beneath¹ the plantar fascia, with which it is firmly united. Its deep surface is separated from the external plantar vessels and nerves by a thin layer of fascia. It *arises* by a narrow tendinous process, from the inner tubercle of the calcaneus (Fig. 396), from the central part of the plantar fascia, and from the intermuscular septa between it and the adjacent muscles. It passes forward, and divides into four tendons, one for each of the four outer toes. Opposite the bases of the first phalanges each tendon divides into two slips, to allow of the passage of the corresponding tendon of the Flexor longus digitorum; the two portions of the tendon then unite and form a grooved channel for the reception of the accompanying long Flexor tendon. Finally,

¹That is, in order of dissection of the sole of the foot.

they divide a second time, to be *inserted* into the middle of the sides of the second phalanges. The mode of division of the tendons of the Flexor brevis digitorum and their insertion into the phalanges is analogous to the division and insertion of the Flexor sublimis digitorum in the hand.

Fibrous Sheaths of the Flexor Tendons.—These are not so well marked as in the fingers. The Flexor tendons of the toes as they run along the phalanges are retained against the bones by a fibrous sheath, forming osseoponeurotic canals. These sheaths are formed by strong fibrous bands which arch across the tendons and are attached on each side to the margins of the phalanges. Opposite the middle of the proximal and second phalanges the sheath is very strong, and the fibres pass transversely, but opposite the joints it is much thinner, and the fibres pass obliquely. Each sheath is lined by a synovial membrane which is reflected upon the contained tendon.

The **Abductor minimi digiti** (*m. abductor digiti quinti*) lies along the outer border of the foot, and is in relation by its inner margin with the external plantar vessels and nerves. It *arises*, by a very broad origin, from the outer tubercle of the calcaneus, from the under surface of the calcaneus between the two tubercles, from the fore part of the inner tubercle (Fig. 396), from the plantar fascia and the intermuscular septum, between it and the Flexor brevis digitorum. Its tendon, after gliding over a smooth facet on the under surface of the base of the fifth metatarsal bone, is *inserted* with the short Flexor of the little toe into the outer side of the base of the first phalanx of this toe.

Dissection.—The muscles of the superficial layer should be divided at their origin by inserting the knife beneath each, and cutting obliquely backward, so as to detach them from the bone; they should then be drawn forward, in order to expose the second layer, but not cut away at their insertion. The two layers are separated by a thin membrane, the *deep plantar fascia*, on the removal of which is seen the tendon of the Flexor longus digitorum, the Flexor accessorius, the tendon of the Flexor longus hallucis, and the Lumbricales. The long Flexor tendons diverge from each other at an acute angle; the Flexor longus hallucis runs along the inner side of the foot, on a plane superior to that of the Flexor longus digitorum, the direction of the latter being obliquely outward.

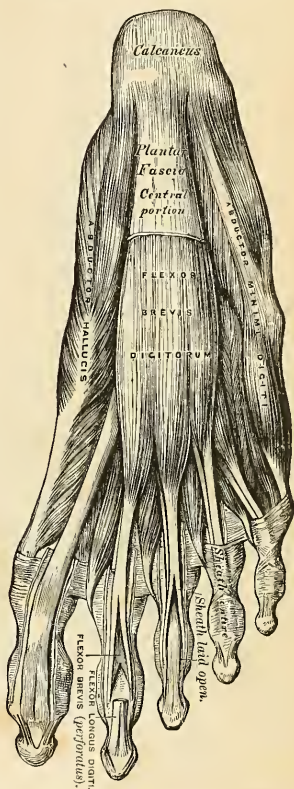


FIG. 396.—Muscles of the sole of the foot.
First layer.

The Second Layer.

Flexor accessorius.

Lumbricales.

The **Flexor accessorius** (*m. quadratus plantae*) is separated from the muscles of the first layer by the external plantar vessels and nerves. It *arises* by two heads, which are separated from each other by the long plantar ligament; the *inner* or *larger* head, which is muscular, *arises* from the inner concave surface of the cal-

caneus below the groove which lodges the tendon of the Flexor longus digitorum; the **outer head**, flat and tendinous, *arises* from the outer surface of the calcaneus, in front of its lesser tubercle (Fig. 397), and from the long plantar ligament; the two portions join at an acute angle, and are *inserted* into the outer margin and upper and under surfaces of the tendon of the Flexor longus digitorum, forming a kind of groove in which the tendon is lodged.¹

The **Lumbricales** (*m. lumbricales*) are four small muscles accessory to the tendons of the Flexor longus digitorum; they *arise* from the tendons of the long

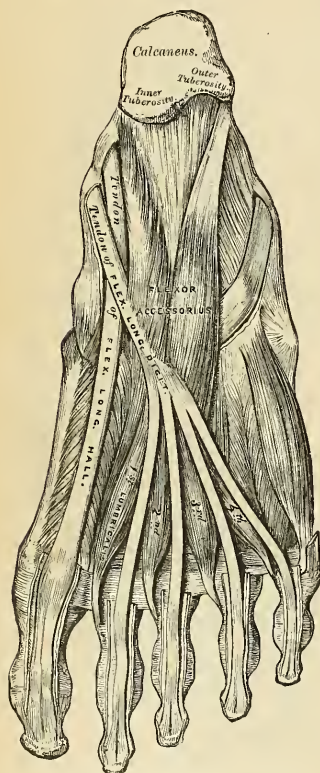


FIG. 397.—Muscles of the sole of the right foot.
Second layer.

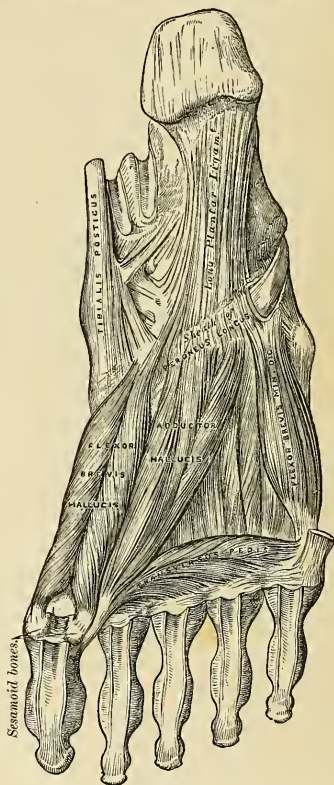

FIG. 398.—Muscles of the sole of the right foot.
Third layer.

Flexor, as far back as their angle of division, each arising from two tendons, except the internal one. Each muscle terminates in a tendon, which passes forward on the inner side of the four lesser toes and is *inserted* into the expansion of the long Extensor tendon on the dorsum of the first phalanx of the corresponding toe.

Dissection.—The Flexor tendons should be divided at the back part of the foot, and the Flexor accessorius at its origin, and drawn forward, in order to expose the third layer.

¹ According to Turner, the fibres of the Flexor accessorius end in aponeurotic bands, which contribute slips to the second, third, and fourth digits.

The Third Layer.

Flexor brevis hallucis.

Flexor brevis minimi digiti.

Adductor obliquus hallucis.

Adductor transversus hallucis.

The **Flexor brevis hallucis** (*m. flexor hallucis brevis*) arises, by a pointed tendinous process, from the inner part of the under surface of the cuboid bone, from the contiguous portion of the external cuneiform, and from the prolongation of the tendon of the Tibialis posticus, which is attached to that bone. The muscle divides in front into two portions which are *inserted* into the inner and outer sides of the base of the first phalanx of the great toe, a sesamoid bone being developed in each tendon at its insertion. The **inner portion** of this muscle is blended with the Abductor hallucis previous to its insertion, the **outer portion** with the Adductor obliquus hallucis, and the tendon of the Flexor longus hallucis lies in a groove between them.

The **Adductor obliquus hallucis** (*caput obliquum m. adductoris hallucis*) is a large, thick, fleshy mass passing obliquely across the foot and occupying the hollow space between the four inner metatarsal bones. It *arises* from the tarsal extremities of the second, third, and fourth metatarsal bones, and from the sheath of the tendon of the Peroneus longus, and is *inserted*, together with the outer portion of the Flexor brevis hallucis, into the outer side of the base of the first phalanx of the great toe.

The small muscles of the great toe, the Abductor, Flexor brevis, Adductor obliquus, and Adductor transversus, like the similar muscles of the thumb, give off fibrous expansions, at their insertions, to blend with the long Extensor tendon.

The **Adductor transversus hallucis** (*caput transversum m. adductoris hallucis*) is a narrow, flat, muscular fasciculus, stretched transversely across the heads of the metatarsal bones, between them and the Flexor tendons. It *arises* from the inferior metatarsophalangeal ligaments of the three outer toes, sometimes only from the third and fourth and from the transverse ligament of the metatarsus; and is inserted into the outer side of the first phalanx of the great toe, its fibres being blended with the tendon of insertion of the Adductor obliquus hallucis.

The **Flexor brevis minimi digiti** (*m. flexor digiti quinti brevis*) lies on the metatarsal bone of the little toe, and much resembles one of the Interossei. It *arises* from the base of the metatarsal bone of the little toe, and from the sheath of the Peroneus longus; its tendon is *inserted* into the base of the first phalanx of the little toe on its outer side. Occasionally some of the deeper fibres of the muscle are inserted into the outer part of the distal half of the fifth metatarsal bone; these are described by some as a distinct muscle, the **Opponens minimi digiti**.

The Fourth Layer.

The Interossei.

The **Interossei muscles** (*mm. interossei*) in the foot are similar to those in the hand, with this exception, that they are grouped around the middle line of the *second* digit, instead of the middle line of the *third* digit, as in the hand. They are *seven* in number, and consist of two groups, Dorsal and Plantar.

The **Dorsal Interossei** (*m. interossei dorsales*), *four* in number, are situated between the metatarsal bones. They are bipenniform muscles, *arising* by two heads from the adjacent sides of the metatarsal bones, between which they are placed; their tendons are *inserted* into the bases of the first phalanges, and into the aponeurosis of the corresponding slip of the common Extensor tendon. In the angular interval left between the heads of each muscle at its posterior extremity the perforating arteries pass to the dorsum of the foot, except in the First interosseous muscle, where the interval allows the passage of the communicating branch of the

dorsalis pedis artery. The First dorsal interosseous muscle is *inserted* into the inner side of the second toe; the other three are *inserted* into the outer sides of the second, third, and fourth toes.

The **Plantar Interossei** (*m. interossei plantares*), three in number, lie beneath, rather than between, the metatarsal bones. They are single muscles, and each arises from but one metatarsal bone. They *arise* from the base and inner sides of the shaft of the third, fourth, and fifth metatarsal bones, and are *inserted* into the inner sides of the bases of the first phalanges of the same toes, and into the aponeurosis of the corresponding slip of the common Extensor tendon.

Nerves.—The Flexor brevis digitorum, the Flexor brevis and Abductor hallucis, and the innermost Lumbrical are supplied by the medial plantar nerve. All the other muscles in the sole of the foot by the lateral plantar. The First dorsal interosseous muscle frequently receives an extra filament from the internal branch of the anterior tibial nerve on the dorsum of the foot, and the Second dorsal interosseous a twig from the external branch of the same nerve.

Actions.—All the muscles of the foot act upon the toes, and for purposes of description as regard their action may be grouped as Abductors, Adductors, Flexors, or Extensors. The *Abductors* are the Dorsal interossei, the Abductor hallucis, and the Abductor minimi digiti. The Dorsal interossei are Abductors from an imaginary line passing through the axis of the second toe, so that the first muscle draws the second toe inward, toward the great toe; the second muscle draws the

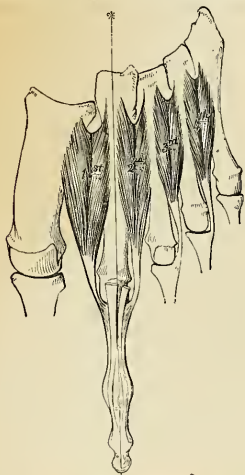


FIG. 399.—The Dorsal interossei. Left foot. The line marked by an * is that from which abduction is performed.

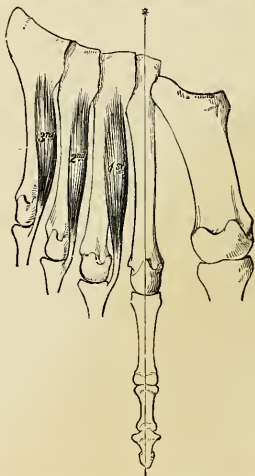


FIG. 400.—The Plantar interossei. Left foot. The line marked by an * is that to which adduction is made.

same toe outward; the third draws the third toe, and the fourth draws the fourth toe, in the same direction. Like the Interossei in the hand, they also help to flex the proximal phalanges and to extend the two terminal phalanges. The Abductor hallucis abducts the great toe from the others, and also flexes the proximal phalanx of this toe. And in the same way the action of the Abductor minimi digiti is twofold—as an Abductor of this toe from the others, and also as a Flexor of the proximal phalanx. The *Adductors* are the Plantar interossei, the Adductor obliquus hallucis, and the Adductor transversus hallucis. The Plantar interosseous muscles adduct the third, fourth, and fifth toes toward the imaginary line passing through the second toe, and by means of their insertion into the aponeurosis of the Extensor tendon they, with the Dorsal interossei, flex the proximal phalanges and extend the two terminal phalanges. The Adductor obliquus hallucis is chiefly concerned in adducting the great toe toward the second one, but also assists in flexing this toe. The Adductor transversus hallucis approximates all the toes, and thus increases the curve of the transverse arch of the metatarsus. The *Flexors* are the Flexor brevis digitorum, the Flexor accessorius, the Flexor brevis hallucis, the Flexor brevis minimi digiti, and the Lumbricales. The Flexor brevis digitorum flexes the second phalanges upon the first, and, con-

tinuing its action, may flex the first phalanges also and bring the toes together. The Flexor accessorius assists the long Flexor of the toes, and converts the oblique pull of the tendons of that muscle into a direct backward pull upon the toes. The Flexor brevis hallucis flexes and slightly adducts the first phalanx of the great toe. The Flexor brevis minimi digiti flexes the little toe and draws its metatarsal bone downward and inward. The Lumbricales, like the corresponding muscles in the hand, assist in flexing the proximal phalanx, and by their insertion into the long Extensor tendon aid in straightening the two terminal phalanges. The only muscle in the *Extensor* group is the Extensor brevis digitorum. It extends the first phalanx of the great toe, and assists the long Extensor in extending the next three toes, and at the same time gives to the toes an outward direction when they are extended.

SURFACE FORM OF THE LOWER EXTREMITY.

Of the muscles of the thigh, those of the iliac region have no influence on surface form, while those of the anterior femoral region, being to a great extent superficial, largely contribute to the surface form of this part of the body. The **Tensor fasciæ femoris** produces a broad elevation immediately below the anterior portion of the crest of the ilium and behind the anterior superior spinous process. From its lower border a longitudinal groove, corresponding to the ilio-tibial band, may be seen running down the outer side of the thigh to the outer side of the knee-joint. The **Sartorius** muscle, when it is brought into action by flexing the leg on the thigh and the thigh on the pelvis, and rotating the thigh outward, presents a well-marked surface form. At its upper part, where it constitutes the outer boundary of Scarpa's triangle, it forms a prominent oblique ridge, which becomes changed into a flattened plane below, and this gradually merges in a general fulness on the inner side of the knee-joint. When the Sartorius is not in action, a depression exists between the **Quadriceps extensor** and the Adductor muscles, running obliquely downward and inward from the apex of Scarpa's triangle to the inner side of the knee, which depression corresponds to this muscle. In the depressed angle formed by the divergence of the Sartorius and Tensor fasciæ femoris muscles, just below the anterior superior spinous process of the ilium, the **Rectus femoris** muscle appears, and, below this, determines to a great extent the convex form of the front of the thigh. In a well-developed subject the borders of the muscle, when in action, are clearly to be defined. The **Vastus externus** forms a long flattened plane on the outer side of the thigh, traversed by the longitudinal groove formed by the iliotibial band. The **Vastus internus**, on the inner side of the lower half of the thigh, gives rise to a considerable prominence, which increases toward the knee and terminates somewhat abruptly in this situation with a full, curved outline. The **Crureus** and **Subcrureus** are completely hidden, and do not directly influence surface form. The Adductor muscles, constituting the internal femoral group, are not to be individually distinguished from each other, with the exception of the upper tendon of the Adductor longus and the lower tendon of the Adductor magnus. The upper tendon of the **Adductor longus**, when the muscle is in action, stands out as a prominent ridge, which runs obliquely downward and outward from the neighborhood of the pubic spine, and forms the inner boundary of a flattened triangular space on the upper part of the front of the thigh, known as Scarpa's triangle. The lower tendon of the **Adductor magnus** can be distinctly felt as a short ridge extending down to the Adductor tubercle on the internal condyle, between the Sartorius and Vastus internus. The Adductor group of muscles fills in the triangular space at the upper part of the thigh, formed between the oblique femur and the pelvic wall, and to them is due the contour of the inner border of the thigh, the **Gracilis** largely contributing to the smoothness of the outline. These muscles are not marked off on the surface from those of the posterior femoral region by any intermuscular marking, but on the outer side of the thigh these latter muscles are defined from the Vastus externus by a distinct marking, corresponding to the external intermuscular septum. The **Gluteus maximus** and a part of the **Gluteus medius** are the only muscles of the buttock which influence surface form. The other part of the Gluteus medius, the Gluteus minimus, and the external Rotators are completely hidden. The Gluteus maximus forms the full rounded outline of the buttock; it is more prominent behind, compressed in front, and terminates at its tendinous insertion in a depression immediately behind the great trochanter. Its lower border does not correspond to the gluteal fold, but is much more oblique, being marked by a line drawn from the side of the coccyx to the junction of the upper with the lower two-thirds of the thigh on the outer side. From beneath the lower margin of this muscle the *Hamstring muscles* appear, at first narrow and not well marked, but as they descend becoming more prominent and widened out, and eventually dividing into two well-marked ridges, which constitute the upper boundaries of the popliteal space, and are formed by the tendons of the inner and outer Hamstring muscles, respectively. In the upper part of the thigh these muscles are not to be individually distinguished from each other, but lower down the separation between the Semitendinosus and Semimembranosus is denoted by a slight intermuscular marking. The external hamstring tendon, formed by the **Biceps** is seen as a thick cord running down to the head of the fibula. The inner Hamstring tendons comprise the Semitendinosus, the Semimembranosus, and the Gracilis. The **Semitendinosus** is the most internal of these, and can be felt, in certain positions of the

limb, as a sharp cord; the **Seminembranosus** is thick, and the **Gracilis** is situated a little farther forward than the other two. All the muscles on the front of the leg appear to a certain extent somewhere on the surface, but the form of this region is mainly dependent upon the **Tibialis anticus** and the **Extensor longus digitorum**. The **Tibialis anticus** is well marked, and presents a fusiform enlargement at the outer side of the tibia, and projects beyond the crest of the shin bone. From the muscular mass its tendons may be traced downward, standing out boldly, when the muscle is in action, on the front of the tibia and ankle-joint, and coursing down to its insertion along the inner border of the foot. A well-marked groove separates this muscle externally from the **Extensor longus digitorum**, which fills up the rest of the space between the upper part of the shaft of the tibia and fibula. It does not present so bold an outline as the **Tibialis anticus**, and its tendon below, diverging from the tendon of the **Tibialis anticus**, forms with the latter a sort of plane, in which may be seen the tendon of the **Extensor proprius hallucis**. A groove on the outer side of the **Extensor longus digitorum**, seen most plainly when the muscle is in action, separates the tendon from a slight eminence corresponding to the **Peroneus tertius**. The fleshy fibres of the **Peroneus longus** are strongly marked at the upper part of the outer side of the leg, especially when the muscle is in action. It forms a bold swelling, separated by furrows from the **Extensor longus digitorum** in front and the **Soleus** behind. Below, the fleshy fibres terminate abruptly in a tendon which overlaps the more flattened form of the **Peroneus brevis**. At the external malleolus the tendon of the **Peroneus brevis** is more marked than that of the **Peroneus longus**. On the dorsum of the foot the tendons of the **Extensor** muscles, emerging from beneath the anterior annular ligament, spread out and can be distinguished in the following order: The most internal and largest is the **Tibialis anticus**, then the **Extensor proprius hallucis**; next comes the **Extensor longus digitorum**, dividing into four tendons to the four outer toes; and lastly, most externally, is the **Peroneus tertius**. The flattened form of the dorsum of the foot is relieved by the rounded outline of the fleshy belly of the **Extensor brevis digitorum**, which forms a soft fulness on the outer side of the tarsus in front of the external malleolus, and by the **Dorsal interossei**, which bulge between the metatarsal bones. At the back of the knee is the popliteal space, bounded above by the tendons of the **Hamstring** muscle; below, by the two heads of the **Gastrocnemius**. Below this space is the prominent fleshy mass of the calf of the leg, produced by the **Gastrocnemius** and **Soleus**. When these muscles are in action, as in standing on tiptoe, the borders of the **Gastrocnemius** are well defined, presenting two curved lines, which converge to the tendon of insertion. Of these borders, the inner is more prominent than the outer. The fleshy mass of the calf terminates somewhat abruptly below in the tendo **Achillis**, which stands out prominently on the lower part of the back of the leg. It presents a somewhat tapering form in the upper three-fourths of its extent, but widens out slightly below. When the muscles of the calf are in action, the lateral portions of the **Soleus** may be seen, forming curved eminences, of which the outer is the longer, on either side of the **Gastrocnemius**. Behind the inner border of the lower part of the shaft of the tibia a well-marked ridge, produced by the tendon of the **Tibialis posticus**, is visible when this muscle is in a state of contraction. On the sole of the foot the superficial layer of muscles influences surface form; the **Abductor minimi digiti** most markedly. This muscle forms a narrow rounded elevation along the outer border of the foot, while the **Abductor hallucis** does the same, though to a less extent, on the inner side. The **Flexor brevis digitorum**, bound down by the plantar fascia, is not very apparent; it produces a flattened form, covered by the thickened skin of the sole, which is here thrown into numerous wrinkles.

APPLIED ANATOMY OF THE LOWER EXTREMITY.

The student should now consider the effects produced by the action of the various muscles in fractures of the bones of the lower extremity. The more common forms of fractures are selected for illustration and description.

In *fracture of the neck of the femur internal to the capsular ligament* (Fig. 401) the characteristic marks are slight shortening of the limb and eversion of the foot, neither of which symptoms occurs, however, in certain cases until some time after the injury. The eversion is caused by the weight of the limb rotating it outward. The shortening is produced by the action of the **Glutei**, and by the **Rectus femoris** in front and the **Biceps**, **Semitendinosus**, and **Seminembranosus** behind.

In *fracture of the femur just below the trochanters* (Fig. 402) the upper fragment, the portion chiefly displaced, is tilted forward almost at right angles with the pelvis by the combined action of the **Psoas** and **Iliacus**, and, at the same time, everted and drawn outward by the external **Rotator** and **Glutei** muscles, causing a marked prominence at the upper and outer side of the thigh, and much pain from the bruising and laceration of the muscles. The limb is shortened, in consequence of the lower fragment being drawn upward by the **Rectus** in front, and the **Biceps**, **Seminembranosus**, and **Semitendinosus** behind, and is at the same time everted. This fracture may be reduced by direct relaxation of all the opposing muscles, to effect which the limb should be put up in such a manner that the thigh is flexed on the pelvis and the leg on the thigh.

Oblique fracture of the femur immediately above the condyles (Fig. 403) is a formidable injury, and attended with considerable displacement. On examination of the limb the lower frag-

ment may be felt deep in the popliteal space, being drawn backward by the Gastrocnemius and Plantaris muscles, and upward by the Hamstring and Rectus femoris muscles. The pointed

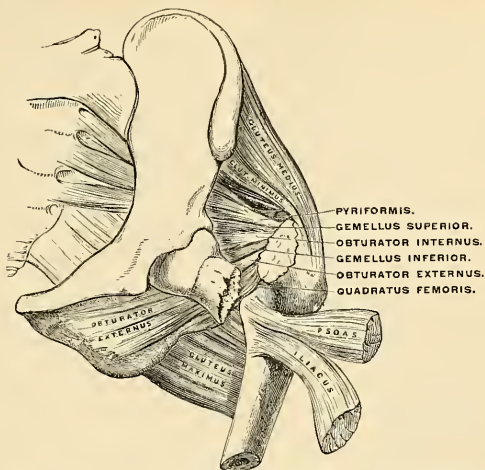


FIG. 401.—Fracture of the neck of the femur within the capsular ligament.

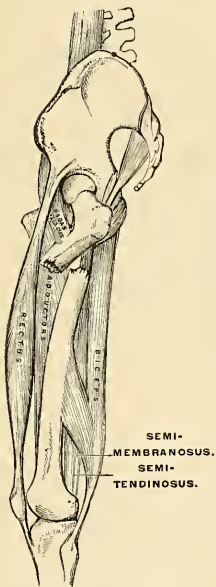

FIG. 402.—Fracture of the femur below the trochanters.

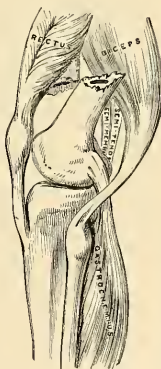


FIG. 403.—Fracture of the femur above the condyles.

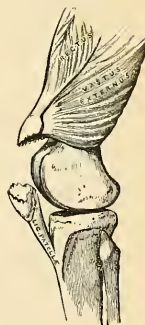

FIG. 404.—Fracture of the patella.

end of the upper fragments is drawn inward by the Pectineus and Adductor muscles, and tilted forward by the Psoas and Iliacus, piercing the Rectus muscle and occasionally the integument. The greatest care is requisite in keeping the pointed extremity of the upper fragment in proper position; otherwise, after union of the fracture, the power of extension of the limb is partially destroyed from the Rectus femoris muscle being held down by the fractured end of the bone, and from the patella, when elevated, being drawn upward against the projecting fragment.

In *fracture of the patella* (Fig. 404) the fragments are separated by the effusion which takes place into the joint, and by the action of the Quadriceps extensor; the extent of separation of the two fragments depending upon the degree of laceration of the ligamentous structures around the bone.

The *tibia is fractured* most commonly by indirect force at the junction of the middle third with the lower third of the shaft. Compound fractures are more common in the leg than in any other region of the body because the tibia is such a superficial bone and is so much exposed to injury. Most fractures from indirect force are oblique.

In *oblique fracture of the shaft of the tibia* (Fig. 405), if the fracture has taken place obliquely from above, downward and forward, the fragments override each other, the lower fragments being drawn backward and upward by the powerful action of the muscles of the calf; the pointed extremity of the upper fragment projects forward immediately beneath the integument, often protruding through it and rendering the fracture a compound one. If the direction of the fracture is the reverse of that shown in the figure, the pointed extremity of the lower fragment projects forward, riding upon the lower end of the upper one. By bending the knee, which relaxes the opposing muscles, and making extension from the ankle and counterextension at the knee, the fragments may be brought into apposition.

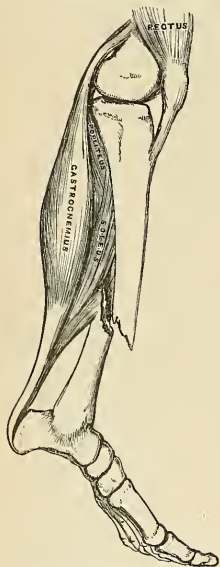


FIG. 405.—Oblique fracture of the shaft of the tibia.

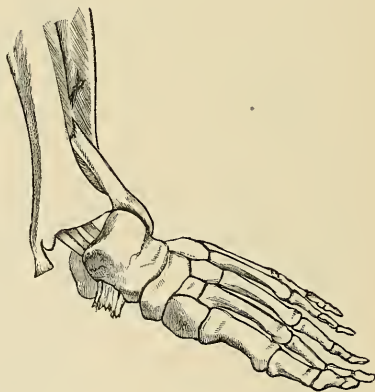


FIG. 406.—Fracture of the fibula, with dislocation of the foot outward—"Pott's fracture."

Fracture of the fibula with dislocation of the foot outward (Fig. 406), commonly known as *Pott's fracture*, is one of the most frequent injuries of the ankle-joint. The fibula is fractured about three inches above the ankle; in addition to this the internal malleolus is broken off, or the deltoid ligament torn through, and the end of the tibia displaced from the corresponding surface of the astragalus. The foot is markedly everted, and the sharp edge of the upper end of the fractured malleolus presses strongly against the skin; at the same time, the heel is drawn up by the muscles of the calf. This injury can generally be reduced by flexing the leg at right angles with the thigh, which relaxes all the opposing muscles, and by making extension from the ankle and counterextension at the knee.

THE VASCULAR SYSTEMS.

THE vascular systems comprise the heart and bloodvessels (*blood-vascular system*) for the circulation of the blood, and the lymphatics and lacteals (*lymph-vascular system*), which collect the lymph from the tissues and the chyle from the digestive tract and conveying them to the great veins.

THE HEART AND BLOODVESSELS.

The heart is the central organ of the blood-vascular system, and consists of a hollow mass of muscle tissue; by its contraction the blood is forced to all parts of the body through a complicated series of tubes, termed **arteries**. The arteries undergo enormous ramification in their course throughout the body, and end in very minute vessels, called **arterioles**, which, in their turn, open into a close-meshed network of microscopic vessels, termed **capillaries**. After the blood has passed through the capillaries it enters into minute vessels called **venules** and from them it is collected into a series of larger vessels, called **veins**, by which it is again returned to the heart. The passage of the blood through the heart and bloodvessels constitutes what is termed the **circulation of the blood**, of which the following is an outline: The human heart is divided by a septum into right and left halves, and each half is further separated into two cavities, termed the **auricle** and the **ventricle**. The heart, therefore, consists of *four* chambers, *two*, the right auricle and right ventricle, forming the right half, and *two*, the left auricle and left ventricle, forming the left half. The right half of the heart contains venous or deoxygenated blood; the left, arterial or oxygenated blood. From the cavity of the left ventricle the aerated blood passes into a large artery, the **aorta**, through the numerous branches of which it is distributed to all parts of the body. In its passage through the capillaries of the body the blood carries to the tissues the materials necessary for their growth and nourishment, and at the same time receives from the tissues the waste products resulting from their metabolism. In doing so it becomes changed from arterial into venous

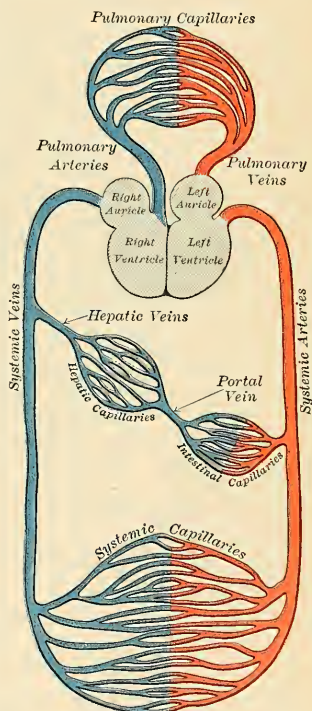


FIG. 407.—Diagram showing the course of the circulation of the blood. This diagram does not show that the liver also receives blood through the hepatic artery.

blood, which is collected by the veins and through them returned to the right auricle of the heart. From this cavity the deoxygenated blood passes into the right ventricle, from which it is conveyed through the **pulmonary arteries** to the lungs. In the capillaries of the lungs it again becomes oxygenated, and is then carried to the left auricle by the **pulmonary veins**. From this cavity it passes into that of the left ventricle, from which the cycle once more begins.

The course of the blood from the left ventricle through the body generally to the right side of the heart constitutes the greater or **systemic circulation**, while its passage from the right ventricle through the lungs to the left side of the heart is termed the lesser or **pulmonary circulation**.

It is necessary, however, to state that the blood which circulates through the spleen, pancreas, stomach, small intestine, and the greater part of the large intestine is not returned directly from these organs to the heart, but is collected into a large vein, termed the **portal vein**, by which it is carried to the liver. In the liver this vein divides, after the manner of an artery, and ultimately ends in capillary vessels, from which the rootlets of a series of veins, called the **hepatic veins**, arise, these carry the blood into the inferior vena cava (postcava), whence it is conveyed to the right auricle. From this it will be seen that the blood contained in the portal vein passes through two sets of capillary vessels—(1) those in the spleen, pancreas, stomach, etc., and (2) those in the liver.

Speaking generally, the arteries may be said to contain pure and the veins impure blood. This is true of the systemic, but not of the pulmonary vessels, since it has been seen that the impure blood is conveyed from the heart to the lungs by the pulmonary arteries, and the pure blood returned from the lungs to the heart by the pulmonary veins. Arteries, therefore, must be defined as vessels which convey blood *from* the heart, and veins as vessels which return blood *to* the heart.

The heart and lungs are contained within the cavity of the thorax, the walls of which afford them protection (Fig. 421). The heart lies between the two lungs, and is there enclosed within a serofibrous bag, the **pericardium**, while each lung is invested by a serous membrane, the **pleura**. The skeleton and cavity of the thorax were described on page 154.

THE PERICARDIUM.

The **pericardium** (Fig. 408) is a conical serofibrous sac in which the heart and the commencement of the great vessels are contained. It is placed in the middle mediastinum and lies on and is somewhat attached to the Diaphragm. It consists of two layers, an external fibrous, the **fibrous pericardium**, and an internal serous, the **serous pericardium**.

The **fibrous pericardium** is a strong, dense connective tissue layer and forms the outer wall of the pericardial sac. Of conical shape, its base is applied to the muscular substance and central tendon of the diaphragm; to the latter a small portion is inseparably blended, the base is pierced by the inferior vena cava, the apex is directed upward and posteriorly, and is closed by fusion with the external coat of the great vessels and is continuous with the pretracheal layer of the deep cervical fascia.

In *front*, it is separated from the anterior wall of the thorax, in the greater part of its extent, by the lungs and pleuræ; but a small area, somewhat variable in size, and usually corresponding with the left half of the lower portion of the gladiolus of the sternum and the inner extremities of the cartilages of the fourth and fifth ribs of the left side, comes into direct relationship with the thoracic wall. The sac is attached to the posterior surface of the sternum by two fibrous bands, the superior and inferior sternopericardial ligaments (*lig. sternopericardica*) (Fig. 408);

the upper passing to the manubrium, and the lower to the ensiform cartilage. *Behind*, it rests upon the bronchi, the œsophagus, and the descending aorta. *Laterally*, it is covered by the pleuræ, and is in relation to the inner surface of the lungs; the phrenic nerve with its accompanying vessels descends between the pericardium and pleura on either side (Fig. 409).

The vessels receiving fibrous prolongation from this membrane are the aorta, the superior vena cava, the right and left pulmonary arteries, the four pulmonary veins, and the impervious ductus arteriosus. The inferior vena cava enters the pericardium through the central tendon of the Diaphragm, and consequently it receives no covering from the fibrous layer.

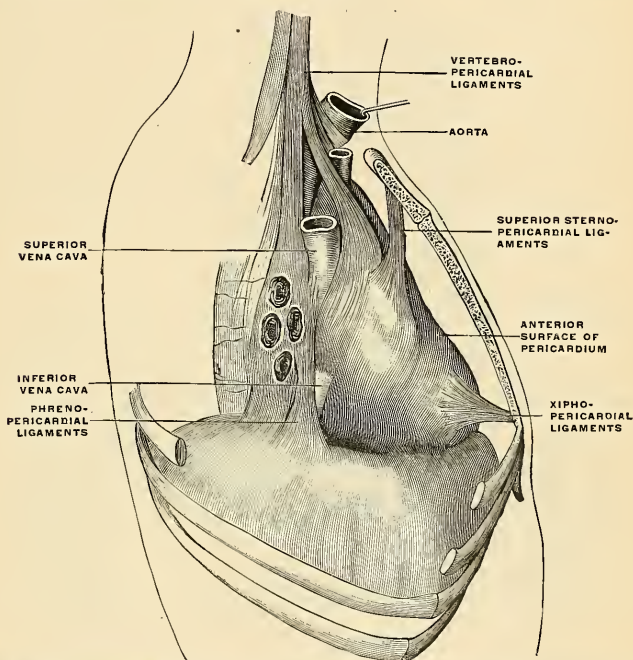


FIG. 408.—Ligaments of the pericardium. (Modified from Teutleben.) Right lateral view, showing the right vertebropericardial ligaments, the right phrenopericardial, and the superior and inferior sternopericardial ligaments. (Poirier and Charpy.)

The **Serous pericardium** is a closed sac which lines the fibrous pericardium and is invaginated by the heart; it therefore consists of a *visceral* and a *parietal* portion. The **visceral portion** or **epicardium** covers the heart and the great vessels, and from the latter is continuous with the parietal layer which lines the fibrous pericardium. The serous pericardium encloses the aorta and pulmonary artery in a single tube, but it only partially covers the superior and inferior vena cava and the four pulmonary veins. From these vessels the serous pericardium is reflected to the parietal layer and presents the shape of an inverted Ω (Fig. 409). The *cul-de-sac* enclosed between the limbs of the Ω is known as the **oblique sinus**, while the passage between the venous and arterial mesocardia—i. e., between the aorta and pulmonary artery

in front and the auricles behind—is termed the **transverse sinus** (*sinus transversus pericardii*). The serous pericardium is smooth and glistening, and transudes a serous fluid, which serves to facilitate the movements of the heart.

The Vestigial Fold of the Pericardium.—Between the left pulmonary artery and subjacent pulmonary vein and behind the left extremity of the transverse sinus is a triangular fold of the serous pericardium; it is known as the **vestigial fold of Marshall** (*ligamentum v. cavae sinistrae*). It is formed by the duplicature of the serous layer over the remnant of the lower part of the **fetal left superior vena cava** (*v. cava sinistra*), or the **duct of Cuvier**, which becomes impervious after birth, and remains as a fibrous band stretching from the left superior intercostal vein

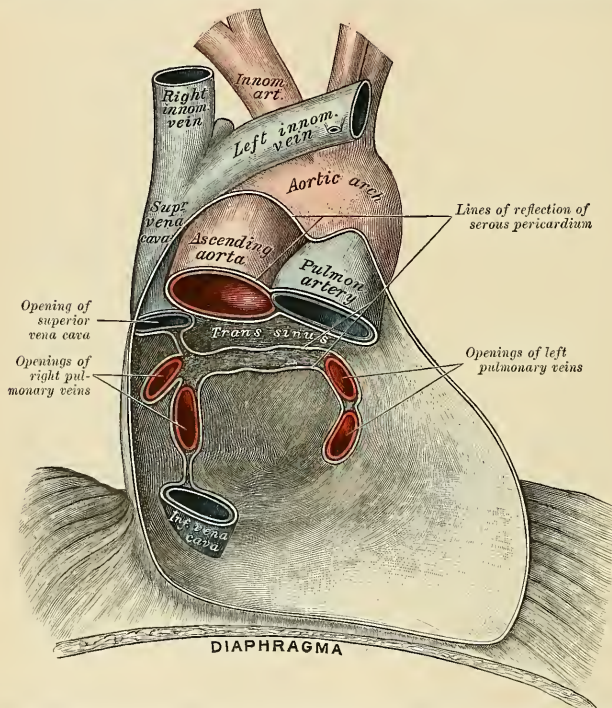


FIG. 409.—Posterior wall of the pericardial sac, showing the lines of reflection of the serous pericardium from the great vessels.

to the left auricle, where it is continuous with a small vein, the **oblique vein of Marshall** (*v. obliqua atrii sinistri* [*Marshalli*]), which opens into the coronary sinus.

The arteries of the pericardium are derived from the internal mammary and its musculophrenic branch, and from the descending thoracic aorta.

The nerves of the pericardium are derived from the vagi, the phrenics, and the sympathetics.

Applied Anatomy.—The effusion of fluid into the pericardial sac often occurs in acute rheumatism or pneumonia, or in patients with chronic vascular and renal disease, embarrassing the heart's action and giving rise to signs of cardiac distress, such as pallor, a rapid and feeble pulse, dyspnea, and restlessness. On examination, the apical cardiac impulse is absent, or replaced by a more extensive indefinite and wavering pulsation; it may appear to be in the second, third, or fourth left space, and is then not an apex impulse, as Potain has stated, but due to the impact of some portion of the heart wall nearer its base. In children the precordial intercostal spaces may bulge outward. The most striking sign, however, is the great increase in all directions of the precordial dullness on percussion. This becomes pear-shaped, the stalk

of the pear reaching up to about the left sternoclavicular articulation; the dulness also extends some distance to the right of the sternum, particularly in the fifth interspace (Roth). The fluid collects mainly on either side of the heart, and below it, especially on the left side, where the Diaphragm can yield more readily to pressure than it can on the right.

Paracentesis of the pericardium is often required to relieve the urgent cardiac or respiratory distress in these cases, and should be performed without hesitation and before the patient is *in extremis*. It may also be required when the pericardium is filled with blood or pus, and as it is advisable to perform this operation without transfixing the pleura, the puncture should be made either in the fifth or sixth intercostal space on the left side and close to the sternum, so as to avoid wounding the internal mammary artery, which descends about half an inch from the sternal margin; or the needle may be entered at the left costoensiform angle and made to pass upward and backward behind the lower end of the body of the sternum into the pericardial sac. It must be remembered that even in the largest pericardial effusions, the heart itself lies almost in contact with the anterior wall of the thorax, and great care must be exercised to avoid piercing this organ.

Pericardiotomy is required when the effusion is of a purulent nature. In this operation a portion of the fifth or sixth costal cartilage is excised. An incision is made along the left border of the sternum from the upper border of the fourth cartilage to the seventh. Transverse incisions an inch long are then made outward from either extremity of this, and the rectangular flap thus formed reflected outward. The fifth costal cartilage is now separated from the sternum by means of a gouge, great care being taken not to let the instrument slip and penetrate too deeply. The cartilage is then seized with lion forceps and raised, the tissues beneath it being peeled off, so as to avoid wounding the internal mammary artery or the pleura. The *Triangularis sterni* is now scratched through with a director or the nail of the index finger close to the sternum, and the pericardium felt for and opened, the finger guarding the pleura and left internal mammary artery.

THE HEART (COR).

The heart is a hollow muscular organ of a somewhat conical form, placed between the lungs, and occupying the cavity of the pericardium.

Position (Fig. 410).—The heart is placed obliquely in the thorax; the broad attached end or base (*basis cordis*) is directed backward and corresponds with the thoracic vertebræ, from the fifth to the eighth inclusive, the apex (*apex cordis*) is directed downward, forward, and to the left, and corresponds to the space between the cartilages of the fifth and sixth ribs, about three and a quarter inches from the middle line of the sternum. The heart projects farther into the left than into the right half of the cavity of the chest, extending from the median line over three inches in the former direction, and only one and one-half in the latter; about one-third of the heart lies to the right and two-thirds to the left of the mesial plane.

The base of the heart is formed by the auricles and forms the whole of the posterior surface. It is separated from the fifth, sixth, seventh, and eighth thoracic vertebræ by the œsophagus, aorta, and thoracic duct. Somewhat quadrilateral in form, it is in relation above with the bifurcation of the pulmonary artery, and is bounded below by the posterior part of the auriculoventricular sulcus, containing the coronary sinus. On the right it is limited by the sulcus terminalis (page 554) of the right auricle. This corresponds to a ridge in the interior of the auricle, called the *crista terminalis*. The entrance of the two left pulmonary veins into the left auricle forms the left limit of the base. The four pulmonary veins, two on either side, open into the left auricle, while the superior vena cava opens into the upper and the inferior vena cava into the lower part of the right auricle.

The apex is directed downward, forward, and to the left, and is overlapped by the left lung and pleura; it lies behind the fifth left intercostal space, three and a quarter inches (8 cm.) from the midsternal line, or about an inch and a half (4 cm.) below and three-quarters of an inch (2 cm.) to the inner side of the left nipple in the male. The apex is wholly made up of the left ventricle.

The antero-superior surface (*facies sternoeostalis*) (Fig. 412) is directed forward, upward, and to the left. Its lower part is convex, formed chiefly by the right

ventricle, together with a small part of the left ventricle. It lies behind the middle portion of the sternum and the costal cartilages of the third, fourth, fifth, and sixth ribs of both sides, but, on account of the heart's inclination to the left, only a small part of it lies behind the cartilages of the right ribs (Fig. 412).

The **postero-inferior surface** (*facies diaphragmatica*) (Fig. 412), which looks downward and slightly backward, is formed by the ventricles, chiefly the left, and rests upon the central tendon and a small part of the left muscular portion of the Diaphragm. It is separated from the base by the posterior part of the auriculo-

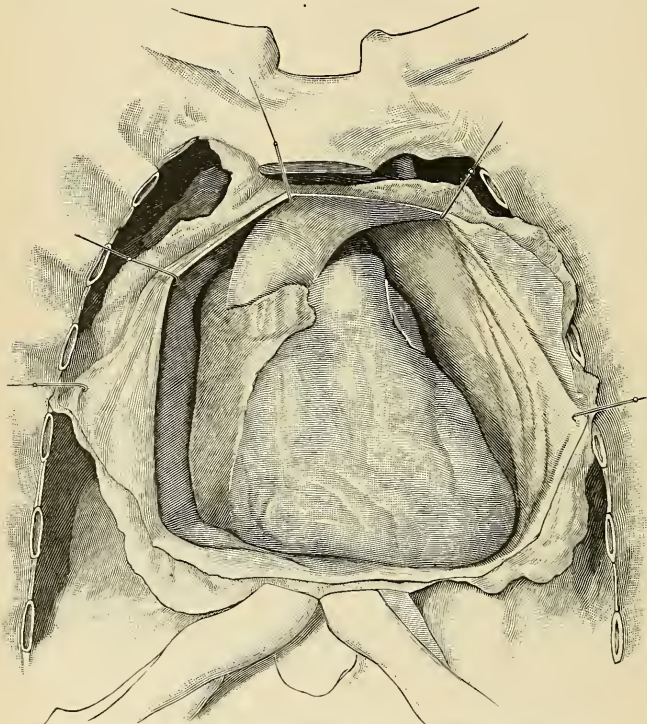


FIG. 410.—Position of the heart. The pericardium laid open. Adult male. (Poirier and Charpy.)

ventricular furrow, and is traversed obliquely by the posterior interventricular groove. This surface is flattened or slightly convex.

The **right margin** of the heart is long, and is formed by the right auricle above and the right ventricle below. The auricular portion is almost vertical, and is situated behind the third, fourth, and fifth right costal cartilages about 3 cm. from the middle line. The ventricular portion, thin and sharp, is named the *margo acutus*; it is nearly horizontal, and extends from the sternal end of the sixth right costal cartilage behind the lower end of the gladiolus to the apex of the heart.

The **left margin**, or *margo obtusus*, is short, thick, and rounded; it is formed mainly by the left ventricle, but to a slight extent, above, by the left auricle. It extends from a point in the second left intercostal space, about 4.5 cm. from

the mesal (middle) line, obliquely downward, with a convexity to the left, to the apex of the heart.

Component Parts.—The heart cavity is subdivided by a muscular septum into two lateral halves, which are named, respectively, the **right** or **pulmonary heart** and the **left** or **systemic heart**; and a transverse constriction subdivides each half of the organ into two cavities, the posterior cavity on each side being called the **auricle**; the anterior, the **ventricle**. The heart, therefore, consists of *four* chambers—viz., the right and left auricles, and right and left ventricles. The course of the blood through the heart cavities and bloodvessels has already been described (page 547).

The division of the heart into four cavities is indicated upon its surface by grooves. The groove separating the auricles from the ventricles is called the

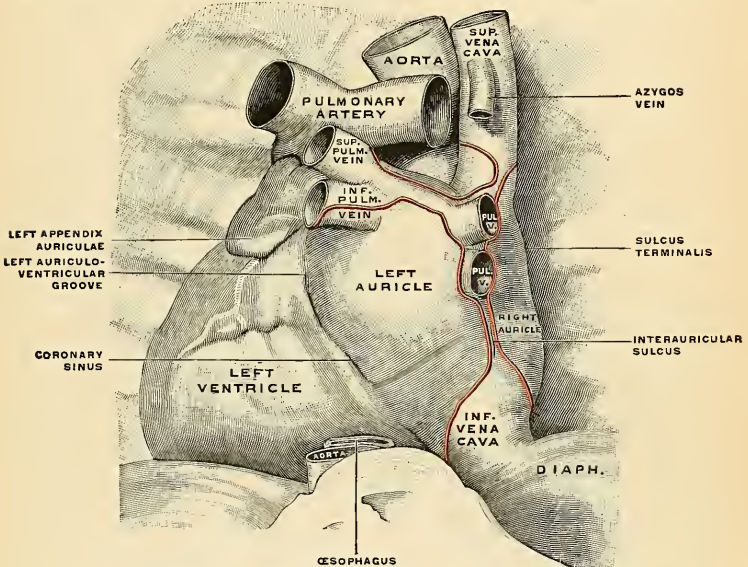


FIG. 411.—Base of the heart in place. The attachments of the pericardium are outlined in red. (Poirier and Charpy.)

auriculoventricular groove (*sulcus coronarius*). It contains the trunks of the nutrient vessels of the heart, but is obliterated in front, where it is crossed by the root of the pulmonary artery.

The **interauricular groove**, separating the two auricles, is scarcely marked on the postero-inferior aspect; while superiorly it is hidden by the pulmonary artery and aorta. The ventricles are separated by two furrows, the **interventricular grooves** (*sulci longitudinales*), one of which (*sulcus longitudinalis anterior*) is situated on the antero-superior surface close to the left margin of the heart, the other (*sulcus longitudinalis posterior*) on the postero-inferior surface near the right margin; these grooves extend from the base of the ventricular portion to a point a little to the right of the apex of the heart.

The Cavities of the Heart.—Each of the cavities of the heart is lined by the endocardium, a thin, smooth membrane which gives the glistening appearance to their internal surfaces and by reduplications forming the valves (mitral and

tricuspid) guarding the orifices of communication and the semilunar valves of the aorta and pulmonary artery.

The **Right Auricle**¹ (*atrium dextrum*) is the larger of the two auricles, although its walls are somewhat thinner than those of the left, measuring about 2 mm. It consists of two parts, a principal cavity, the **sinus venosus**, situated posteriorly, and an antero-superior, smaller portion, the **auricular appendix**.

The **sinus venosus** (*sinus venarum*) is the large quadrangular cavity, placed between the two venæ cavæ. Its walls, which are extremely thin, are connected in front and to the left with the right ventricle, and mesally with the left auricle, but are free in the rest of their extent.

The **right auricular appendix** (*auricula dextra*), so called from its fancied resemblance to a dog's ear, is a small conical muscular pouch, the margins of which

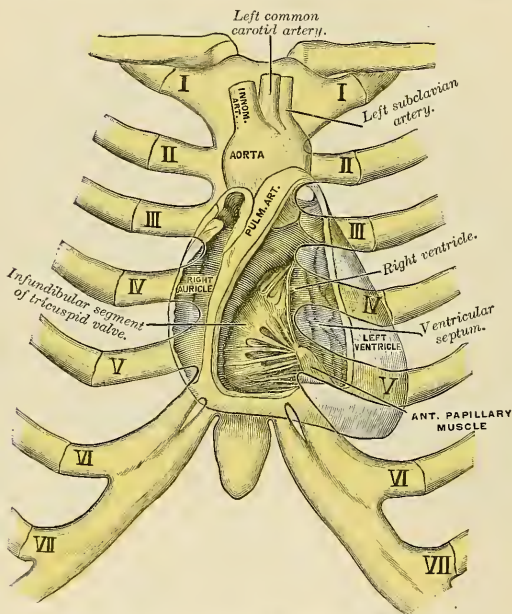


FIG. 412.—Showing relations of opened heart to front of thorax.

present a dentated edge. It projects from the sinus forward and toward the left side, overlapping the root of the aorta.

The separation of the appendix from the sinus venosus is indicated externally by a groove, the **sulcus terminalis** (His), which extends from the front of the superior vena cava to the front of the inferior vena cava, and represents the line of union of the sinus venosus of the embryo with the primitive auricle. In the cavity of the auricle the separation is marked by a vertical, smooth, muscular ridge on the anterior wall, the **crista terminalis** (His) (Fig. 414). Behind the crista the internal surface of the auricle is smooth, while in front of it the muscle fibres of the wall are raised into parallel ridges resembling the teeth of a comb, and hence named the **musculi pectinati**.

¹ In the new nomenclature the auricle is called the atrium, and the auricular appendix is called the auricle.

To examine the interior of the right auricle, an incision should be made along its right border from the entrance of the superior vena cava to that of the inferior vena cava. A second cut is to be made from the centre of the first incision to the tip of the auricular appendix, and the flap raised.

The interior of the right auricle (Fig. 413) presents the following parts for examination:

Openings	{	Superior vena cava.	Valves	{	Eustachian.
		Inferior vena cava.			Coronary.
		Coronary sinus.			
		Foramina Thebesii.			
		Auriculoventricular.			
		Anterior cardiac veins.			
		Fossa ovalis.			
		Annulus ovalis.			
		Tuberculum Loweri.			
		Musculi pectinati.			
		Crista terminalis.			

The **superior vena cava** (precava) returns the blood from the upper half of the body, and opens into the upper and back part of the auricle, the direction of its orifice being downward and forward. Its opening has no valves.

The **inferior vena cava** (post-cava), larger than the superior vena cava, returns the blood from the lower half of the body, and opens into the lowest part of the auricle near the septum, the direction of its orifice being upward and inward, and guarded by a rudimentary valve, the **Eustachian valve**. The blood which enters the auricle through the superior vena cava is directed downward and forward, *i. e.*, toward the auriculoventricular orifice, while that entering it through the inferior vena cava is directed upward and backward toward the auricular septum. This is the normal direction of the two currents in fetal life.

The **coronary sinus** (*sinus coronarius*) opens into the auricle, between the inferior vena cava and the auriculoventricular opening. It returns the blood from the substance of the heart, and is protected by an incomplete semicircular fold of the lining membrane of the auricle, the **coronary valve**, or **valve of Thebesius**.

The **foramina Thebesii** (*foramina venarum minimarum*) are depressions in the walls of the auricle; the majority of these are *culs-de-sac*, but about one-third are the orifices of minute veins (*venae minimae cordis*), which return the blood directly from the muscle substance of the heart.

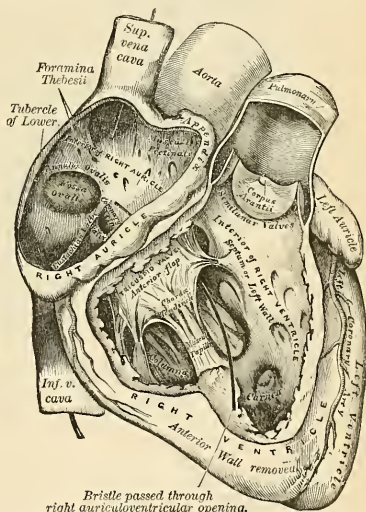


FIG. 413.—The right auricle and ventricle laid open, the anterior walls of both being removed.

The anterior cardiac veins open into the lower fore part of the right auricle.

The right auriculoventricular opening, or the *tricuspid orifice* (*ostium venosum dextrum*), is the large oval aperture of communication between the right auricle and the ventricle; it will be described with the right ventricle.

The *Eustachian valve* (*valvula venae cavae inferioris* [*Eustachii*]) is situated in front of the orifice of the inferior vena cava. It is semilunar in form, its convex margin being attached to the anterior margin of the inferior caval orifice; its concave margin, which is free, terminates in two cornua, of which the left is continuous with the anterior edge of the annulus ovalis, while the right is lost on the wall of

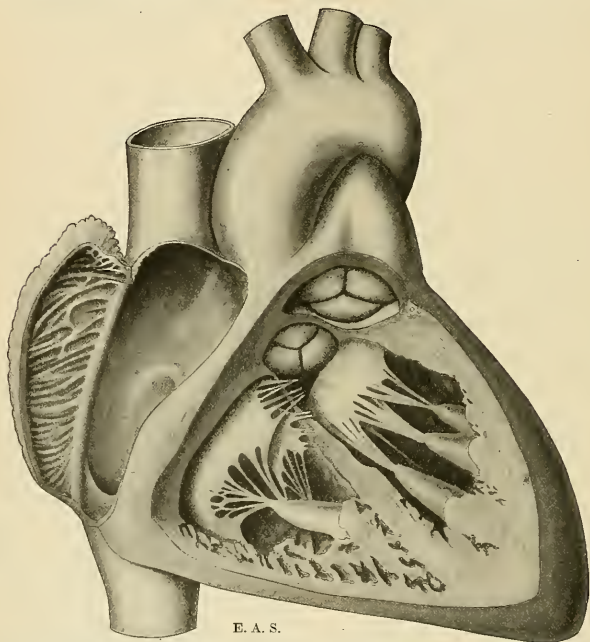


FIG. 414.—Heart opened to show the interior of the right auricle and of the two ventricles, from in front. The wall of the right auricle is turned back to show the muscoli pectinati and the crista terminalis. The ventricular walls and the ventricular septum have been cut. The aortic valve is made more prominently visible in the drawing than it really is in nature.

auricle, containing a few muscle fibres. *In the fetus* this valve is of large size, and tends to direct the blood from the inferior vena cava, through the foramen ovale, into the left auricle. *In the adult* it is occasionally large, and may assist in preventing the reflux of blood into the inferior vena cava; more commonly it is small, and its free margin presents a cribriform or filamentous appearance; occasionally it is altogether wanting.

The coronary valve or valve of Thebesius (*valvulae sinus coronarii* [*Thebesii*]) is a semicircular fold of the lining membrane of the auricle, protecting the orifice of the coronary sinus. It prevents the regurgitation of blood into the sinus during the contraction of the auricle. This valve is occasionally double.

The **fossa ovalis** is an oval depression corresponding to the situation of the **foramen ovale** in the fetus. It is situated at the lower part of the interauricular septum, above and to the left of the orifice of the inferior vena cava. In fetal life an opening, the **foramen ovale**, exists at this point between the two auricles; almost immediately after birth the valve-like edge is pressed down by the increased pressure in the left auricle, and by the tenth day it passes to the annulus and closes the opening.

The **annulus ovalis** (*limbus fossae ovalis* [Vieussenii]) is the prominent oval margin of the fossa ovalis. It is most distinct *above* and at the sides; *below*, it is deficient. A small, slit-like, valvular opening is occasionally found, at the upper anterior margin of the fossa ovalis, which leads upward beneath the annulus into the left auricle; it is the remains of the fetal aperture between the two auricles.

The **tubercle of Lower** (*tuberculum intervenosum* [Loweri]) is a small projection on the interauricular septum between the fossa ovalis and the opening of the superior vena cava. It is most distinct in the hearts of quadrupeds; in man it is scarcely visible. It was supposed by Lower to direct the blood from the superior vena cava toward the auriculoventricular opening.

The *internal surface* of the right auricle is smooth, except in the appendix and adjacent part of the anterior wall of the sinus venosus, where the muscular wall is thrown into parallel ridges resembling the teeth of a comb, and hence named the **musculi pectinati**. These end behind in a vertical smooth ridge, the **crista terminalis** (Fig. 414).

The **Right Ventricle** (*ventriculus dexter*) is pyramidal in form, and extends from the right auricle to near the apex of the heart. Its *antero-superior surface* is rounded and convex, and forms the larger part of the front of the heart. Its *under surface* is flattened, rests upon the Diaphragm, and forms a small part of the postero-inferior surface of the heart. Its *posterior wall* is formed by the septum between the two ventricles, the **interventricular septum** (*septum ventriculorum*), which bulges into the right ventricle, so that a transverse section of the cavity presents a semilunar outline. The basal and inner angle of the ventricle is prolonged into a conical pouch, the **infundibulum** (*conus arteriosus*), from which the pulmonary artery arises. The balance of the ventricle, the **body**, is the portion into which the auriculoventricular orifice opens. The **conus arteriosus** is marked off from the body of the ventricle by a muscular projection (*crista supraventricularis*). The walls of the right ventricle are thinner than those of the left, the proportion between them being as 1 to 3. The wall is thickest at the base, and gradually becomes thinner toward the apex.

To examine the interior of the right ventricle, its anterior wall should be turned downward and to the right in the form of a triangular flap. This is accomplished by making two incisions: (1) From the pulmonary artery to the apex of the ventricle parallel to, but a little, to the right of, the anterior interventricular furrow; (2) another, starting from the upper extremity, of the first and carried onward parallel to, but a little below, the auriculoventricular furrow, care being taken not to injure the auriculoventricular valve.

The interior of the right ventricle presents for examination:

Openings	{	Auriculoventricular.
		Opening of the pulmonary artery.
		Foramina Thebesii.
Valves	{	Tricuspid.
		Semilunar.

Columnae carneae.

Chordae tendineae.

The **right auriculoventricular opening**, or the **tricuspid orifice** (*ostium venosum ventriculi dextri*), is the large oval aperture of communication between the auricle and ventricle. It is situated at the base of the ventricle, near the right border of

the heart. The plane of this opening is nearly vertical. It is oval and about 3.75 cm. (1.5 inches) in diameter from side to side, surrounded by a fibrous ring (*annulus fibrosus*) and covered by the lining membrane of the heart; it is considerably larger than the corresponding aperture on the left side, being sufficient to admit the ends of four fingers. The circumference of the orifice is about 12 cm. (4.8 inches) in the male, and 10.5 cm. (4.2 inches) in the female. It is guarded by the tricuspid valve.

The opening of the pulmonary artery (*ostium arteriosum pulmonis*) is circular in form, and is situated at the summit of the conus arteriosus, close to the ventricular septum. It is placed above and to the left of the auriculoventricular opening, and is guarded by the pulmonary valve.

Foramina Thebesii are scattered over the interior of the right ventricle.

The **tricuspid valve** (*valvula tricuspidalis*) consists of three **segments** or **cusps** (*cuspides*) of a triangular or trapezoidal shape, each formed by a duplicature of the lining membrane of the heart, strengthened by intervening layers of fibrous tissue. The largest and most movable segment is placed toward the left side of the auriculoventricular opening, and is interposed between that opening and the infundibulum; hence it is called the **left or infundibular cusp** (*cusps medialis*). Another segment is in relation with the right part of the front of the ventricle, the **right or marginal cusp** (*cusps anterior*), and a third with its posterior wall, the **posterior or septal cusp** (*cusps posterior*). The central part of each segment is thick and strong; the lateral margins are thin and translucent. These segments are connected by their bases to the oval fibrous ring surrounding the auriculoventricular orifice (*annulus fibrosus dexter*), and by their sides with one another, so as to form a continuous annular membrane, which is attached around the margin of the auriculoventricular opening; their serrated free margins and ventricular surfaces afford attachment to a number of delicate tendinous cords, the **chordae tendineae**. The chordae tendineae are connected with the adjacent margins of the principal segments of the valve, and are further attached to each segment in the following manner: (1) Three or four reach the attached margin of each segment, where they are continuous with the auriculoventricular tendinous ring. (2) Others, four to six in number, are attached to the central thickened part of each segment. (3) The most numerous and finest are connected with the marginal portion of each segment.

The **columnae carneae** (*trabeculae carneae*) are the rounded muscle columns which project from nearly the whole of the inner surface of the ventricle, excepting near the opening of the pulmonary artery, where the wall is smooth. They may be classified, according to their mode of connection with the ventricle, into three sets. The *first* set merely forms prominent **ridges** on the inner surfaces of the ventricle, being attached by their entire length on one side, as well as by their extremities. The *second* set are attached by their two extremities, but are free in the rest of their extent, forming **arches**; while a *third set* (*musculi papillares*) are continuous by their bases with the wall of the ventricle, while their apices give origin to the **chordae tendineae**, the **papillary muscles**. There are usually *two* papillary muscles or groups of muscles, the **anterior** and the **posterior**; of these, the anterior is the larger, its chordae tendineae are connected with the right and left segments of the tricuspid valve. The posterior sometimes consists of two or three muscle columns; its chordae tendineae are connected with the posterior and the right segments of the tricuspid valve. In addition to these, some few chordae spring directly from the ventricular septum, or from small eminences on it, and pass to the left and posterior segments. A fleshy band, well marked in the sheep and some other animals, is frequently seen passing from the base of the anterior papillary muscle to the interventricular septum. From its attachments it may assist in preventing overdistention of the ventricle, and so has been named the **moderator band**.

The **pulmonary valve** (Fig. 414) consists of three semilunar segments (*valvulae semilunares a. pulmonalis*), two of which are **anterior** and one of which is **posterior**, formed by duplicatures of the lining membrane of the ventricle, strengthened by fibrous tissue. They are attached, by their outer convex margins, to the wall of the artery, at its junction with the ventricle, their inner borders being free, and directed upward in the lumen of the vessel. The free and attached margins of each are strengthened by a bundle of tendinous fibres, and the former presents, at its middle, a small projecting thickened nodule, consisting of bundles of interlacing connective-tissue fibres with branched connective-tissue cells and some few elastic fibres. Such a nodule is called the **corpus Arantii** (*nodulus valvulae semilunaris [Arantii]*). From this nodule tendinous fibres radiate through the valve to its attached margin, but are absent from two narrow crescentic portions, the **lunulae** (*lunulae valvularum semilunarium*), placed one on either side of the nodule immediately adjoining the free margin.

The basal end of the pulmonary artery presents three dilatations opposite to the valve. These are the **pulmonary sinuses of Valsalva**. Similar sinuses exist between the semilunar valves and the commencement of the aorta; they are larger than the pulmonary sinuses.

In order to examine the interior of the left auricle, make an incision on the posterior surface of the auricle from the pulmonary veins on one side to those on the other, the incision being carried a little way into the vessels. Make another incision from the middle of the horizontal one to the auricular appendix.

The **Left Auricle** (*atrium sinistrum*) is rather smaller than the right, but its walls are thicker, measuring about 3 mm.; it consists, like the right, of two parts, a **principal cavity** and an **auricular appendix**.

The **principal cavity** is cuboidal in form, and concealed in front by the pulmonary artery and aorta; in *front* and to the *right*, it is separated from the right auricle by the **interauricular septum** (*septum atriorum*); *behind*, it receives on either side two pulmonary veins.

The **left auricular appendix** (*auricula sinistra*) is somewhat constricted at its junction with the principal cavity; it is longer, narrower, and more curved than that of the right side, and its margins are more deeply indented. It is directed forward and toward the right and overlaps the root of the pulmonary artery.

The interior of the left auricle presents the following parts for examination:

The openings of the four pulmonary veins.

Auriculoventricular opening.

Musculi pectinati.

Foramina Thebesii.

The **pulmonary veins**, four in number, open into the upper part of the posterior surface of the left auricle—two on either side of its middle line. They are not provided with valves. The two left veins frequently terminate by a common opening.

The **left auriculoventricular opening**, or **mitral orifice** (*ostium venosum ventriculi sinistri*), is the aperture of communication between the left auricle and the left ventricle. It is rather smaller than the corresponding opening on the right side.

The **musculi pectinati**, fewer and smaller than in the right auricle, are confined to the inner surface of the auricular appendix.

On the interauricular septum may be seen a lunated impression bounded below by a crescentic ridge the concavity of which is turned upward. The depression is just above the fossa ovalis of the right auricle. The inner surface of the left auricle also shows **foramina Thebesii** and **venae minimae cordis**.

To examine the interior of the left ventricle, make an incision a little to the left of the anterior interventricular groove from the base to the apex of the heart, and carry it up from thence, a little to the left of the posterior interventricular groove, nearly as far as the auriculoventricular groove.

The **Left Ventricle** (*ventriculus sinister*) is longer and more conical in shape than the right ventricle, and on transverse section its cavity presents an oval or nearly circular outline. It forms a small part of the anterior surface of the heart and a considerable part of its postero-inferior surface. It also forms the apex of the heart by its projection beyond the right ventricle. Its walls are much thicker than those of the right side, the proportion being as 3 to 1.

Its interior (Fig. 415) presents the following parts for examination:

Openings { Auriculoventricular.
Aortic.
Foramina Thebesii.
Chordae tendineae.

Valves { Mitral or Bicuspid.
Semilunar.
Columnae carneae.

The **left auriculoventricular opening**, or the **mitral orifice** (*ostium venosum ventriculi sinistri*), is placed below and to the left of the aortic orifice. It is a little smaller than the corresponding aperture of the opposite side, admitting only two

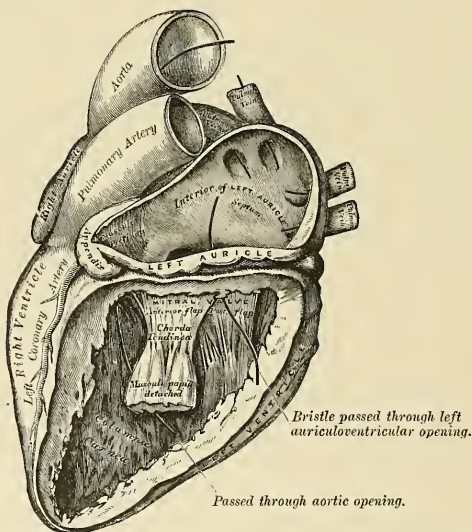


FIG. 415.—The left auricle and ventricle laid open, the posterior walls of both being removed.

fingers; but, like it, is broader in the transverse than in the antero-posterior diameter. Its right, posterior, and left sides are surrounded by a dense horseshoe-shaped, fibrous ring (*annulus fibrosus sinister*). The orifice is guarded by the mitral or bicuspid valve.

The **aortic opening** (*ostium arteriosum*) is a circular aperture, in front and to the right side of the auriculoventricular opening, from which it is separated by the aortic cusp of the mitral valve. Its orifice is guarded by the **aortic valve**, which

consists of three semilunar segments. The portion of the ventricle immediately below the aortic orifice is often termed the **aortic vestibule**, and possesses fibrous instead of muscular walls.

The inner walls of the left ventricle are dotted with **foramina Thebesii**.

The **mitral** or **bicuspid valve** (*valvula bicuspidalis*) is attached to the circumference of the auriculoventricular orifice in the same way that the tricuspid valve is on the opposite side. It consists of two triangular cusps, formed by duplicatures of the lining membrane, strengthened by fibrous tissue, and containing a few muscle fibres. The cusps are of unequal size, and are larger, thicker, and stronger than those of the tricuspid valve. The larger segment, the **anterior** or **aortic cusp** (*cusps anterior*), is placed in front and to the right between the auriculoventricular and aortic orifices; the smaller, the **posterior** or **marginal cusp** (*cusps posterior*), is placed to the left and behind the opening. Two smaller cusps are usually found at the angles of junction of the larger. The cusps of the mitral valve are furnished with chordae tendineae, which are attached in a manner similar to those on the right side; they are, however, thicker, stronger, and less numerous.

The **aortic valve** consists of three semilunar segments (*valvulae semilunares aortae*), which surround the orifice of the aorta; two are posterior (right and left) and one anterior. They are similar in structure and in their mode of attachment to those of the pulmonary valve, but are larger, thicker, and stronger; the **lunulae** are more distinct and the **corpora Arantii** thicker and more prominent. Opposite the segments the wall of the aorta presents slight dilations, the **sinuses of Valsalva**, which are larger than those at the origin of the pulmonary artery.

The **columnae carneae** are of three kinds, like those upon the right side; but they are more numerous, and present a dense interlacement, especially at the apex, and upon the posterior wall. The **musculi papillares** are *two* in number, one being connected to the anterior, the other to the posterior wall; they are of large size, and terminate by free rounded extremities, from which the **chordae tendineae** arise. The chordae tendineae from each papillary muscle are connected to both cusps of the mitral valve.

The **interventricular septum** (*septum ventriculorum*) is directed obliquely backward and to the right, and is curved with the convexity toward the right ventricle; its margins correspond with the interventricular grooves. The greater portion of it is thick and fleshy (*septum musculare ventriculorum*), but its upper and posterior part, which separates the aortic vestibule from the lower part of the right auricle and upper part of the right ventricle is thin and fibrous, and is termed the **undefended** or **membranous part of the interventricular septum** (*septum membranaceum ventriculorum*). It is derived from the lower part of the aortic septum of the fetus, and an abnormal communication may exist at this part, owing to defective development of this septum.

Capacity of the Cavities of the Heart.—Each of the cavities of the heart is capable of holding about 100 c.c., but this is subject to considerable variation among different individuals.

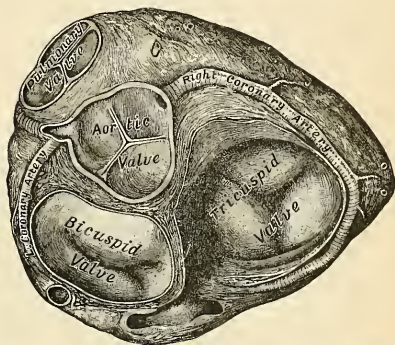


FIG. 416.—Base of ventricles exposed by removal of the auricles.

Size and Weight of the Heart.—The normal heart, in the adult, measures five inches in length, three inches and a half in breadth at the broadest part, and two inches and a half in thickness. The prevalent weight, in the male, varies from ten to twelve ounces (average, eleven ounces); in the female, from eight to ten; its proportions to the body being as 1 to 160 in males; 1 to 150 in females. The heart continues to increase in weight and in size up to an advanced period of life; this increase is more marked in men than in women.

Structure of the Heart.—The heart is a hollow muscular organ, and its walls are divisible into three coats—the **endocardium**, **myocardium**, and **epicardium**, or **visceral layer of the pericardium** (page 549).

The **endocardium** is a thin, smooth, serous membrane which lines and gives the glistening appearance to the internal surface of the heart; it assists in forming the valves by reduplications and is continuous with the endothelial coat of the bloodvessels which pass to and emerge from the heart. It is composed of endothelial cells resting upon a fibro-elastic membrane which contains some unstriated muscle cells. The endocardium is more opaque on the left than on the right side of the heart, thicker in the auricles than in the ventricles, and thickest in the left auricle. It is thin on the *musculi pectinati* and on the *columnae carneae*, but thicker on the smooth parts of the auricular and ventricular walls and on the tips of the *musculi papillares*.

The **fibrous rings** (*annuli fibrosi*) surround the auriculoventricular and arterial orifices; they are stronger upon the left than on the right side of the heart, and are composed of dense white fibrous connective tissue. The auriculoventricular rings serve for the attachment of the muscle fibres of the auricles and ventricles, and also for the mitral and tricuspid valves; the ring on the left side is closely connected by its right margin with the aortic arterial ring. Between these and the right auriculoventricular ring is a mass of fibrous tissue (*trigonum fibrosum*), and in some of the larger animals, as the ox and elephant, a nodule of bone, the *os cordis*.

The fibrous rings surrounding the arterial orifices serve for the attachment of the great vessels and semilunar valves. Each ring receives, at its ventricular margin, the attachment of the muscle fibres of the ventricles; its opposite margin presents three deep semicircular notches, within which the middle coat of the artery (which presents three convex semicircular segments)

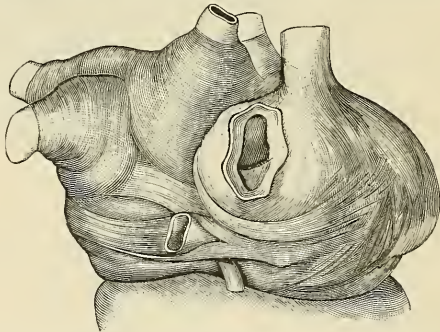


FIG. 417.—The arrangement of the muscles of the auricles. (Poirier and Charpy.)

is firmly fixed, the attachment of the artery to its fibrous ring being strengthened by the thin fibrous coat and serous membrane externally and by the endocardium within. It is opposite the margins of these semicircular notches, in the arterial rings, that the endocardium by its reduplication, strengthened by white fibrous tissue, forms the semilunar valves, the fibrous structure of the ring being continued into each of the segments of the valve. The middle coat of the artery in this situation is thin, and the sides of the vessels are dilated to form the sinuses of Valsalva.

The **myocardium** of the heart consists of bands and layers of muscle tissue which present an exceedingly intricate interlacement. It consists of (a) the fibres of the auricles, (b) the fibres of the ventricles, and (c) the auriculoventricular bundle of His.

Fibres of the Auricles (Fig. 417).—These are disposed in two layers—a superficial layer common to both cavities, and a deep layer proper to each. The **superficial fibres** are more distinct on the anterior surface of the auricles, across the bases of which they run in a transverse

direction, forming a thin but incomplete layer. Some of these fibres pass into the septum atriorum. The **internal or deep fibres** proper to each auricle consist of two sets, looped and annular fibres. The **looped fibres** pass upward over each auricle, being attached by two extremities to the corresponding auriculoventricular rings in front and behind. The **annular fibres** surround the auricular appendices, and form annular bands around the terminations of the veins and around the fossa ovalis.

The **fibres of the ventricles** are arranged in a complex manner, and various accounts have been given of their course and connections. The following description is based on the work of McCallum.¹ They consist of superficial and deep layers, all of which, with the exception of two, are inserted into the papillary muscles of the ventricles. The **superficial layers** consist of the following: (a) Fibres which spring from the tendon of the conus arteriosus and sweep downward and toward the left across the anterior interventricular furrow and around the apex of the heart, where they pass upward and inward to terminate in the papillary muscles of the left ventricle. Those which spring from the upper half of the tendon of the conus arteriosus pass to the anterior papillary muscle, those from the lower half to the posterior papillary muscle and the papillary muscles of the septum. (b) Fibres which arise from the right auriculoventricular ring and run diagonally across the back of the right ventricle and around its right border on to its anterior surface, where they dip beneath the fibres just described, and, crossing the interventricular groove, wind around the apex of the heart and terminate in the posterior papillary muscle of the left ventricle. (c) Fibres which spring from the left auriculoventricular ring, and, crossing the posterior interventricular furrow, pass successively into the right ventricle and end in its papillary muscles. The **deep layers** are three in number; they arise in the papillary muscles of one ventricle and, curving in an S-shaped manner, turn in at the interventricular furrow and end in the papillary muscles of the other ventricle. The layer which is most superficial in the right ventricle lies next the lumen of the left, and *vice versa*. Those of the first layer almost encircle the right ventricle, and, crossing in the septum to the left, unite with the superficial fibres from the right auriculoventricular ring to form the posterior papillary muscle. Those of the second layer have a less extensive course in the wall of the right ventricle, and a correspondingly greater course in the left, where they join with the superficial fibres from the anterior half of the tendon of the conus arteriosus

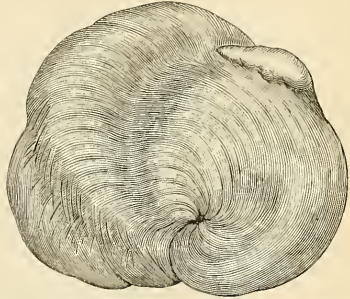


FIG. 418.—The muscular arrangement of the apex of the heart. (Poirier and Charpy.)

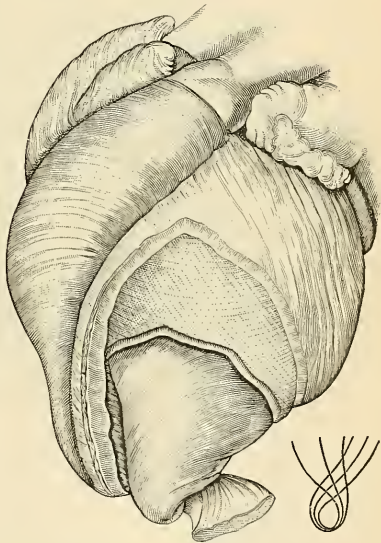


FIG. 419.—The arrangement of the muscle of the ventricle. (Poirier and Charpy.)

¹ Johns Hopkins Hospital Reports, vol. ix.

to form the papillary muscles of the septum. Those of the third layer pass almost entirely around the left ventricle and unite with the superficial fibres from the lower half of the tendon of the conus arteriosus to form the anterior papillary muscle. Besides the layers just described there are two bands which do not end in papillary muscles. One springs from the right auriculoventricular ring and crosses in the auriculoventricular septum; it then encircles the deep layers of the left ventricle and ends in the left auriculoventricular ring. The second band is apparently confined to the left ventricle; it is attached to the left auriculoventricular ring, and encircles the portion of the ventricles adjacent to the aortic orifice.

The **auriculoventricular bundle of His** (*fasciculus atrioventricularis*) (Fig. 420) is the only direct muscle connection known to exist between the auricles and ventricles. It *arises* near the opening of the coronary sinus, where it is connected with the annular and septal fibres of the right auricle. These fibres converge, form a **node** (*node of Tawara*), and continue

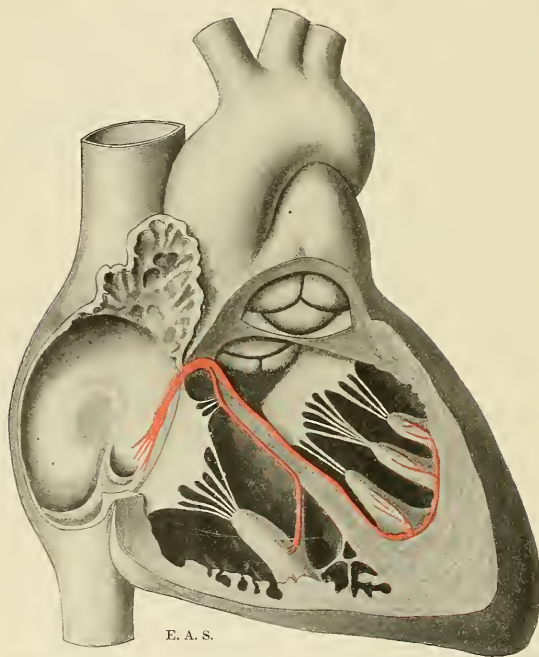


FIG. 420.—Schematic representation of the auriculoventricular bundle of His. The bundle, represented in red, originates near the orifice of the coronary sinus, undergoes slight enlargement to form a node, passes forward in the interventricular septum, and divides into two limbs. The ultimate distribution cannot be completely shown in this diagram.

as a compact bundle which passes forward in the lower part of the *pars membranacea septi* to the upper limit of the muscle portion of the ventricular septum, and divides into right and left fasciculi. These run down to the right and left ventricles, one on either side of the interventricular septum, the left limb being just covered by endocardium, while the right limb, for a part of its course, is more deeply placed in the muscle layer. Each limb is enclosed in a layer of connective tissue, which isolates it from the musculature of the interventricular septum, but in the lower parts of the ventricles each fasciculus separates into numerous strands which enter the papillary muscles and spread over the entire internal surface of the ventricular muscle and form histological connections with the true cardiac muscle fibres. The right limb is the smaller of the two and usually reaches the anterior papillary muscle by passing along the moderator band when this is present. The undivided portion of the auriculoventricular bundle consists of narrow, somewhat fusiform fibres, but its two divisions and their terminal

strands are composed of Purkinje fibres. The bundle is not always easily recognized in the human heart, but is readily demonstrated in the heart of the sheep or calf.

A constant **bursa** or lubricating mechanism is in relation with the main bundle, according to Curran,¹ and a special artery, arising from the right coronary, enters the bundle at its beginning and follows it in direction.

The **Purkinje fibres** are very much larger in size than the cardiac cells, and differ from them in several ways. In longitudinal section they are quadrilateral in shape, being about twice as long as they are broad. The central portion of each fibre contains one or more nuclei and is made up of granular protoplasm, with no indication of striations, while the peripheral portion is clear and has distinct transverse striations. The fibres are intimately connected with each other, possess no definite sarcolemma, and do not branch.

The **epicardium**, or **visceral layer of the pericardium**, is a serous membrane analogous in structure to the endocardium, but contains no smooth muscle tissue. It is thin, smooth, glistening, and transparent, and is reflected over the roots of the great vessels to the inner surface of the pericardial sac, forming there the **parietal layer of the pericardium**.

Applied Anatomy.—Clinical and experimental evidence go to prove that the auriculoventricular bundle conveys the impulse to systolic contraction from the auricular septum to the ventricles, and much attention has recently been paid to it, because it appears to become attacked by various disease processes and to lose much of its conducting power in many cases of *Stokes-Adams disease* (heart block). This condition is characterized by a slow pulse, a tendency to syncopal or epileptiform seizures, and the fact that while the cardiac auricles beat at a normal rate, the ventricles contract much less frequently. The existence of a bursa in relation with the bundle suggests the possibility of a bursitis, in view of which these cardiac symptoms may be the result of acute rheumatism or other febrile diseases.

Vessels and Nerves.—The arteries supplying the heart are the right and left coronary from the aorta.

The **veins** terminate in the right auricle, and will be described with the general venous system.

The **lymphatics** end in the thoracic and right lymphatic ducts.

The **nerves** are derived from the **superficial** and **deep cardiac plexuses**, and from these plexuses obtain fibres of the vagus, spinal accessory, and sympathetic. The superficial cardiac plexus lies under the arch of the aorta. The deep cardiac plexus is in front of the tracheal bifurcation. The nerves from the plexuses are freely distributed both on the surface and in the substance of the heart, the separate filaments being furnished with small ganglia. A special system of ganglion cells and nerve fibres has been found² in the auriculoventricular bundle.

The Cardiac Cycle and the Action of the Valves.³—By the contractions and pumping action of the heart the blood is forced through the arteries, capillaries and veins of the systemic and pulmonic vascular systems. Normally, these contractions are rhythmic in character and occur at the rate of about seventy per minute. Each period of activity is followed by a period of rest, and during these two periods certain events take place in the various parts of the heart in regular sequential order. The period included between the occurrence of any one of these events and the recurrence of the same event constitutes a **cardiac cycle**, or **cardiac revolution**.

The cardiac cycle may be conveniently divided into three phases, which succeed one another, as follows: (1) A short, practically simultaneous contraction of both auricles, termed the *auricular systole*, followed, after a slight pause, by (2) a simultaneous, but more prolonged, contraction of both ventricles, named the *ventricular systole*, and (3) a period of rest during which the whole heart is relaxed, *i. e.*, in a state of *diastole*. The contraction process begins at the venous openings or in an area in the right auricle between the venae cavae, whence it spreads, in the form of a wave, over the auricles and then to and over the ventricles. The quick contraction of the auricles forces the blood contained in these chambers, through the auriculoventricular openings into the relaxed ventricles, which become fully distended. The contraction of the ventricles follows almost immediately. There ensues a rapid compression of the contained mass of blood and a relatively high pressure is thus developed which occasions the forcible closure of the auriculoventricular valves. These are prevented from being everted into the auricular cavities by their attachment to the papillary muscles through the intermeditation of the chordae tendineae. The diminution in size of the ventricular

¹The Anatomical Record, December, 1909, vol. iii, No. 12.

²J. Gordon Wilson, Proceedings of the Royal Society, B., 1909, vol. lxxxi.

³Revised by Dr. G. Bachmann.

cavities might be followed by a slackening of these tendinous cords were it not for the compensating effect of the active shortening of the papillary muscles which takes place shortly after the onset of the contraction of the general ventricular musculature. The pressure in the ventricles soon rises above that in the pulmonary artery and aorta. At that moment the valves at the orifices of these vessels are forced open and the blood is driven, by a sustained contraction, from the right ventricle into the pulmonary artery and from the left ventricle into the aorta. As soon as the ventricular systole ceases and the pressure in the pulmonary artery and aorta exceeds that in the ventricles the pulmonary and aortic valves close, thus preventing a regurgitation of the blood into the ventricles. While the ventricles are contracting blood is flowing from the veins into the auricles, where it accumulates and distends them. As the ventricles relax, the pressure of the blood in the auricles opens the auriculoventricular valves and blood now flows passively from the veins into the auricles and from these into the ventricles. The rapid accumulation of the blood in the ventricles leads to a floating up of the auriculoventricular valves which are shortly afterward pushed aside during the next succeeding auricular contraction.

It will be observed that each set of chambers contracts and relaxes alternately. However, the time occupied by the auricular contraction is short, while that occupied by the relaxation is long in comparison with the time occupied by the similar events in the ventricles. From the beginning of the ventricular diastole until the beginning of the next auricular systole the entire heart is at rest—the so-called *common pause* of the heart's chambers. The average duration of a cardiac cycle is about $\frac{8}{10}$ of a second, which may be divided, approximately, among its different phases as follows:

Auricular systole, $\frac{1}{10}$.

Ventricular systole, $\frac{3}{10}$.

Auricular diastole, $\frac{7}{10}$.

Ventricular diastole, $\frac{5}{10}$.

Common pause $\frac{4}{10}$.

As mentioned before, the contraction process, which begins at the mouths of the great veins, spreads with great rapidity over the auricles, and then to and over the ventricles. A slight delay is experienced by the contraction wave in passing from the auricles to the ventricles. This is due in all probability to the circumstance that the contraction wave must be conducted along a narrow bridge of muscle tissue which is more or less embryonic in character. This bridge of muscle tissue connecting the auricles with the ventricles, morphologically and physiologically, is the auriculoventricular bundle of His (page 564). In accordance with this view, the origin and conduction of the contraction process is a property of the muscle tissue, and the theory which embodies this view is known as the *myogenic theory* of the heart beat. Inasmuch as nerve cells and their axones are found in many parts of the heart, the auriculoventricular bundle included, it is thought by some that the origin and conduction of the stimulus giving rise to the contraction process is a property of the nerve tissue. The theory embodying this view is known as the *neurogenic theory* of the heart beat. It must be said, however, that many facts tend to demonstrate that the myogenic theory is the correct one. Whatever be the tissue in which the heart beat originates, the cause of the contraction must be sought in the heart itself; for the mammalian heart can be made to beat for a relatively long time when completely isolated from the body of the animal.

The cardiac muscle, therefore, does not depend for its contractions on the discharge of nerve impulses by the central nerve system, although the latter, through the extracardiac nerves, exercises a regulative influence on the heart's action, increasing or decreasing the rate or force of the heart beats in accordance with the physiological needs of the body.

Surface Form.—In order to show the extent of the heart in relation to the front of the thorax, draw a line from a point in the second left intercostal space, 4.5 cm. (nearly two inches) from the median line to the upper border of the third right costal cartilage, 3 cm. (one inch and a quarter) from the median line. This represents the base line or upper limit of the organ. Take a point in the fifth left intercostal space 8 cm. from the median line (about three and a quarter inches); this represents the apex of the heart. Draw a line from this apex point, with a slight convexity downward, to the junction of the seventh right costal cartilage to the sternum 2.5 cm. from the median line. This represents the lower limit of the heart. Join the right extremity of the first line—that is, the base line—with the right extremity of this line—that is, to the seventh right chondrosternal joint—with a slight curve outward, so that it projects about 3.5 cm. (one inch and a half) from the mid-line of the sternum. Lastly, join the left extremity of the base line and the apex point by a line curved slightly to the left.

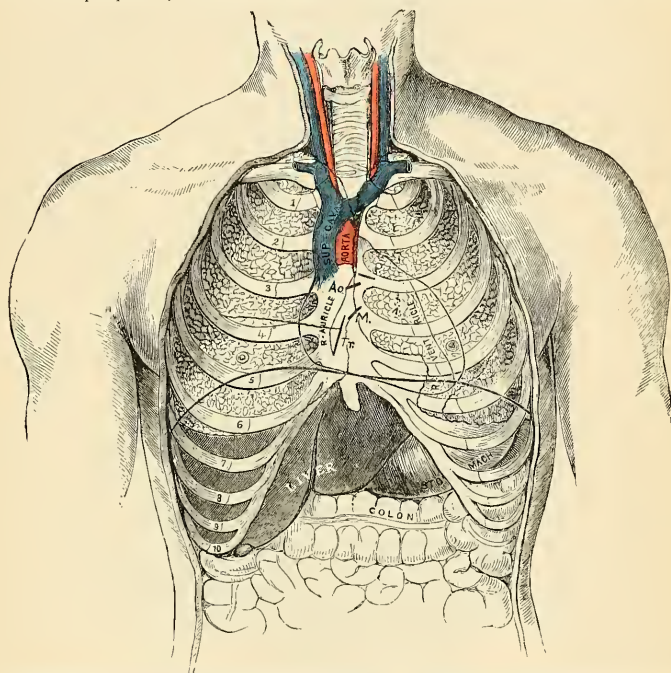


FIG. 421.—Front view of the thorax, showing relation of the heart, lungs, etc., to the ribs and sternum. *P.* Pulmonary orifice. *Ao.* Aortic orifice. *M.* Left auriculoventricular orifice. *Tr.* Right auriculoventricular orifice.

A portion of the area of the heart thus mapped out is uncovered by lung, and therefore gives a dull note on percussion; the remainder, being overlapped by the lung, gives a more or less resonant note. The former is known as the *area of complete cardiac dullness*. The area of complete cardiac dullness is included between a line drawn from the centre of the sternum, on a level with the fourth costal cartilage, to the apex of the heart, and a line drawn from the same point down the lower third of the midline of the sternum. Below, this area merges into the dullness which corresponds to the liver.

Topography of the various orifices is as follows—viz., the *pulmonary orifice* is situated in the upper angle formed by the articulation of the third left costal cartilage with the sternum; the *aortic orifice* is a little below and internal to this, behind the left border of the sternum, close to the articulation of the third left costal cartilage to this bone. The *left auriculoventricular opening* is behind the sternum, rather to the left of the median line, and opposite the fourth costal cartilages. The *right auriculoventricular opening* is a little lower, opposite the fourth interspace and in the middle line of the body (Fig. 421).

Applied Anatomy.—*Wounds* of the heart are often immediately fatal, but not necessarily so. They may be nonpenetrating, when death may occur from hemorrhage, if one of the coronary vessels has been wounded, or subsequently from pericarditis; or, on the other hand, the patient may recover. Even a penetrating wound is not necessarily fatal, if the wound is a small one. An attempt should be made to save the patient by means of a surgical operation. A trap-door flap comprising the whole thickness of the thoracic wall should be made. The hinges of the trap-door are the rib cartilages. The pericardium is exposed and freely opened, clots are removed, the wound in the heart is sought for, and when discovered is sutured. In a penetrating wound the sutures include the whole thickness of the heart, except the endocardium. Interrupted sutures should be used, and each one had better be tied during diastole. A number of successful operations of this character have been performed.

Peculiarities in the Vascular System of the Fetus (Fig. 423).

The chief peculiarities in the heart of the fetus are the direct communication between the two auricles through the foramen ovale, and the large size of the Eustachian valve. There are also several minor peculiarities. Thus, the position of the heart is vertical until the fourth month, when it commences to assume an oblique direction. Its size is also very considerable as compared with the body, the proportion at the second month being 1 to 50; at birth it is as 1 to 120; while in the adult the average is about 1 to 160. At an early period of fetal life the auricular portion of the heart is larger than the ventricular, the right auricle being more capacious than the left; but toward birth the ventricular portion becomes the larger. The thickness of both ventricles is at first about equal, but toward birth the left becomes much the thicker of the two.

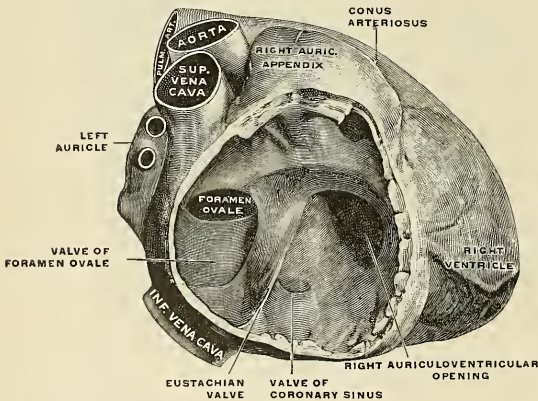


FIG. 422.—The right auricle of a fetal heart (eighth month). Enlarged. (Spalteholz.)

The **foramen ovale** (Fig. 422) is situated at the lower and back part of the interauricular septum, forming a communication between the auricles. It remains as a free oval opening until the middle period of fetal life. About this period a fold grows up from the posterior wall of the auricle to the left of the foramen ovale, and advances over the opening so as to form a sort of valve, which allows the blood to pass only from the right to the left auricle, but not in the opposite direction.

The **Eustachian valve** (Fig. 422) projects upward in front of the opening of the inferior vena cava, and tends to direct the blood from this vessel through the foramen ovale into the left auricle.

The peculiarities in the arterial system of the fetus are the communication between the pulmonary artery and the descending aorta by means of the **ductus arteriosus**, and the continuation of the internal iliac arteries as the **umbilical arteries** to the placenta.

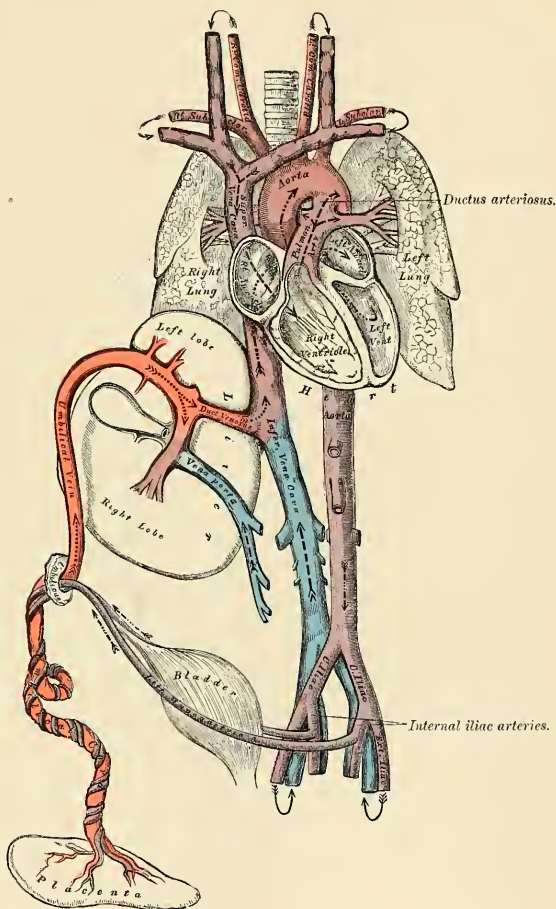


FIG. 423.—Plan of the fetal circulation. In this plan the figured arrows represent the kind of blood, as well as the direction which it takes in the vessels. Thus, arterial blood is figured >>.....>>; venous blood, >>----->>; mixed (arterial and venous) blood, >>.....>>.

The **ductus arteriosus** (Fig. 423) is a short tube, about 10 mm. (half an inch) in length at birth, and 2 mm. (one-twelfth of an inch) in diameter. In the early condition it forms the continuation of the pulmonary artery, and opens into the descending aorta just below the origin of the left subclavian artery, and so con-

ducts the greater part of the blood from the right ventricle into this vessel. When the branches of the pulmonary artery have become relatively larger to the ductus arteriosus, the latter is chiefly connected to the left pulmonary artery; and the fibrous cord (*ligamentum arteriosum*), which is all that remains of the ductus arteriosus in later life, will be found to be attached to the root of that vessel. Occasionally a small lumen persists in the ligamentum arteriosum.

The **umbilical** or **hypogastric arteries** are continued from the internal iliacs, along the sides of the bladder to its apex; they pass out of the abdomen at the umbilicus and are carried in the umbilical cord to the placenta. They convey the blood which has circulated in the system of the fetus to the placenta.

The peculiarities in the venous system of the fetus are the communications established between the placenta and the liver and portal vein, through the umbilical vein; and between the umbilical vein and the inferior vena cava through the ductus venosus.

Fetal Circulation (Fig. 423).—The blood destined for the nutrition of the fetus is returned from the placenta to the fetus by the umbilical vein. This vein enters the abdomen at the umbilicus, and passes upward along the free margin of the suspensory ligament of the liver to the under surface of that organ, where it gives off two or three branches to the left lobe, one of which is of large size, and others to the quadrate and Spigelian lobes. At the transverse fissure it divides into two branches; of these, the larger is joined by the portal vein and enters the right lobe; the smaller branch continues outward, under the name of the ductus venosus, and joins the left hepatic vein at the point of junction of that vessel with the inferior vena cava. The blood, therefore, which traverses the umbilical vein reaches the inferior vena cava in three different ways; the greater quantity circulates through the liver with the portal venous blood before entering the inferior vena cava by the hepatic veins; some enters the liver directly, and is also returned to the inferior vena cava by the hepatic veins; the smaller quantity passes directly into the inferior vena cava by the junction of the ductus venosus with the left hepatic vein.

In the inferior vena cava (postcava) the blood carried by the ductus venosus and hepatic veins becomes mixed with that returning from the lower extremities and wall of the abdomen. It enters the right auricle, and, guided by the Eustachian valve, passes through the foramen ovale into the left auricle, where it becomes mixed with a small quantity of blood returned from the lungs by the pulmonary veins. From the left auricle it passes into the left ventricle, and from the left ventricle into the aorta, by means of which it is distributed almost entirely to the head and upper extremities, a small quantity being probably carried into the descending aorta. From the head and upper extremities the blood is returned by the tributaries of the superior vena cava to the right auricle, where it becomes mixed with a small portion of the blood from the inferior vena cava. From the right auricle it descends over the Eustachian valve into the right ventricle, and from the right ventricle passes into the pulmonary artery. The lungs of the fetus being inactive, only a small quantity of the blood of the pulmonary artery is distributed to them by the right and left pulmonary arteries, and is returned by the pulmonary veins to the left auricle; the greater part passes through the ductus arteriosus into the commencement of the descending aorta, where it becomes mixed with the blood transmitted by the left ventricle into the aorta. Through this vessel it descends to supply the lower extremities and viscera of the abdomen and pelvis, the chief portion being, however, conveyed by the umbilical arteries to the placenta.

From the preceding account of the circulation of the blood in the fetus it will be seen—

1. That the placenta serves the purposes of nutrition, respiration, and excretion,

receiving the impure blood from the fetus, and returning it charged with additional nutritive material.

2. That nearly the whole of the blood of the umbilical vein traverses the liver before entering the inferior vena cava; hence the large size of this organ, especially at an early period of fetal life.

3. That the right auricle is the point of meeting of a double current, the blood in the inferior vena cava being guided by the Eustachian valve into the left auricle, while that in the superior vena cava descends into the right ventricle. At an early period of the fetal life it is somewhat probable that the two streams are distinct, for the inferior vena cava opens almost directly into the left auricle, and the Eustachian valve would tend to exclude the current along the vein from entering the right ventricle. At a later period, as the separation between the two auricles becomes more distinct, it seems more probable that mixture of the two streams must take place.

4. The pure blood carried from the placenta to the fetus by the umbilical vein, mixed with the blood from the portal vein and the inferior vena cava, passes almost directly to the arch of the aorta, and is distributed by the branches of that vessel to the head and upper extremities; hence the large size and advanced development of those parts at birth.

5. The blood contained in the descending aorta, largely derived from that which has already circulated through the head and upper limbs, together with a small quantity from the left ventricle, is distributed to the lower extremities; hence the small size and less advanced development of these parts at birth.

Changes in the Vascular System at Birth.—At birth, when respiration is established, an increased amount of blood from the pulmonary artery passes through the lungs, which now perform their office as respiratory organs, and at the same time the placental circulation is cut off. Soon after birth the foramen ovale is closed by the valvular edge being pressed against the annulus ovalis, the pressure being due to respiration, which increases the pressure in the left auricle. The structures fuse, and closure is usually complete by about the tenth day after birth. The valvular fold above mentioned becomes adherent to the margins of the foramen for the greater part of its circumference, but above a slit-like opening is left between the two auricles which sometimes remains persistent.

The *ductus arteriosus* begins to contract immediately after respiration is established, usually becomes completely closed from the fourth to the tenth day, and ultimately degenerates into an impervious cord (*lig. arteriosum*) which serves to connect the left pulmonary artery to the arch of the aorta.

Of the *umbilical* or *hypogastric arteries*, the portion continued on to the bladder from the trunk of the corresponding internal iliac remains pervious as the superior vesical artery, and the part extending from the side of the bladder to the umbilicus becomes impervious between the second and fifth days after birth, and projects as a fibrous cord toward the abdominal cavity, carrying on it a fold of peritoneum.

The *umbilical vein* and the *ductus venosus* become impervious between the second and fifth days after birth, and ultimately dwindle to fibrous cords, the former becoming the *round ligament* of the liver, the latter the *ligamentum venosum* of the liver.

THE ARTERIES.

THE arteries are cylindrical tubular vessels which serve to convey blood from both ventricles of the heart to every part of the body. These vessels were named arteries (*ἀήρ*, air; *τηρεῖν*, to contain) from the belief entertained by the ancients that they contained air. Galen is believed to have been the first to show that during life they contain blood.

The *distribution* of the systemic arteries is like a highly ramified tree, the common trunk of which, formed by the aorta, commences at the left ventricle of the heart, the smallest ramifications corresponding to the periphery of the body and the contained organs. The arteries are found in nearly every part of the body, with the exception of the hairs, nails, epidermis, cartilages, and cornea; and the larger trunks usually occupy the most protected situations, running, in a limb, along the flexor side, where they are less exposed to injury.

There is considerable variation in the *mode of division* of the arteries; occasionally a short trunk subdivides into several branches at the same point, as we observe

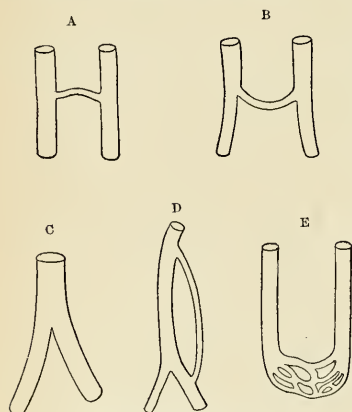


FIG. 424.—Diagram showing the anastomosis of arteries. (Poirier and Charpy.)

in the celiac and thyroid axes; or the vessel may give off several branches in succession, and still continue as the main trunk, as is seen in the arteries of the limbs; but the usual division is dichotomous; as, for instance, the aorta dividing into the two common iliacs, and the common carotid into the external and internal carotids.

A branch of an artery is smaller than the trunk from which it arises; but if an artery divides into two branches, the combined cross-section area of the two vessels is, in nearly every instance, somewhat greater than that of the trunk; and the combined cross-section area of all the arterial branches greatly exceeds that of the aorta; so that the arteries collectively may be regarded as a cone, the apex of which corresponds to the aorta, the base to the capillary system.

The arteries, in their distribution, communicate with one another, forming what are called **anastomoses** or **inosculations** (Fig. 424); and these communications are very free between the large as well as between the smaller branches. An anastomosis between trunks of equal size is found where great activity of the circulation is requisite, as at the base of the brain; here the two vertebral arteries unite to form the basilar, and the two internal carotid arteries are connected by a short communicating trunk; it is also found in the abdomen, the intestinal arteries having very ample anastomoses between their larger branches. In the limbs the anastomoses are most numerous and of largest size around the joints, the branches of an artery above anastomosing with branches from the vessels below; these anastomoses are of considerable interest to the surgeon, as it is by their enlargement that a

collateral circulation is established after the application of a ligature to an artery. The smaller branches of arteries anastomose more frequently than the larger, and between the smallest twigs these inosculations become so numerous as to constitute a close network that pervades nearly every tissue of the body. A **terminal artery** is one which forms no anastomoses. Such vessels are believed to exist in the brain, spleen, kidneys, lungs, mesentery, and papillary layer of the skin.

Throughout the body generally the larger arterial branches usually pursue a straight course, but in certain situations they are tortuous; thus, the facial arteries in their course over the face, and the arteries of the lips, are extremely tortuous in their course, to accommodate themselves to the movements of the parts. The uterine arteries are also tortuous, to accommodate themselves to the increase of size which the organ undergoes during pregnancy.

The arteries are dense in structure, of considerable strength, highly elastic, and, when divided, they usually preserve, although empty, their cylindrical form.

Histology of Arteries and Capillaries.—An artery consists of an endothelial tube covered by certain accessory coats.

The coats of an artery are: (1) **internal coat**, or *tunica intima*; (2) a **middle coat**, or *tunica media*; and (3) an **external coat**, or *tunica adventitia* (Fig. 409).

1. The **inner coat** (*tunica intima*) consists of endothelial cells resting upon some **subendothelial fibroelastic tissue**. Limiting the intima is a wavy band of yellow elastic tissue called the **internal elastic lamina**. In small arteries the endothelial cells rest upon the elastic lamina. In large arteries (aorta, pulmonary a.) the elastic tissue forms the **fenestrated membrane of Henle**.

2. The **middle coat** (*tunica media*) consists of muscle, elastic tissue, and white fibrous tissue. In medium-sized arteries the smooth muscle tissue is circularly arranged, with only a small quantity of elastic tissue here and there. In small arteries the elastic tissue is absent; in the large arteries the elastic tissue predominates; in some vessels (retinal, first part of aorta, and pulmonary artery) the elastic tissue may entirely replace the muscle tissue. Occasionally longitudinally arranged muscle tissue is seen in the media. In medium-sized arteries the media is bounded by a layer of elastic tissue called the **external elastic lamina**.

3. The **external coat** (*tunica adventitia*) is called the fibrous coat. It contains fibroelastic tissues, and in some arteries fibres of nonstriated muscle longitudinally arranged. It contains the nutrient vessels, nerves, and lymphatics of the arteries. As the arteries diminish in size the coats likewise become thinner. The endothelial cells rest upon the internal elastic lamina; the media becomes reduced to a few layers of muscle fibres, and the adventitia is represented by some bundles of fibroelastic tissue. This represents the **precapillary arteriole**, and it gradually becomes the capillary.

Capillaries are small endothelial tubes connecting arterial and venous systems. They vary from $\frac{1}{5000}$ to $\frac{1}{2000}$ of an inch (5μ to 13μ) in diameter, and about $\frac{1}{50}$ of an inch (500μ) in length. The endothelial cells are thin, flat, and irregular in outline; the darkly staining nucleus usually causes a bulging of the cell, as it is thicker than the protoplasmic portion of the cells. These cells are held together by a small amount of cement substance, and are considered by many to have the property of *phagocytosis*. These cells are also said to be contractile. Small openings called *stomata* are frequently noted between these cells, but they are considered artifacts. Capillaries anastomose and form vast networks. **Ampullæ, sinusoids, retia mirabilia, sinuses, and anastomoses** are forms of capillaries seen in certain organs and tissues.

Bloodvessels of the Bloodvessel Wall.—Many small bloodvessels, the *vasa vasorum*, enter the adventitia; from these vessels branches are sent into the media, but not the intima. The latter is nourished by the blood that flows over it. They may arise from the vessels to which they are distributed or take origin from an adjacent vessel. The blood is returned from the walls of the vessels by small veins.

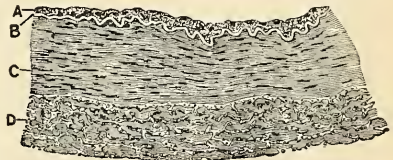


FIG. 425.—Transverse section of part of the wall of the posterior tibial artery. $\times 75$. A. Endothelial and subendothelial layers of inner coat. B. Elastic layer (fenestrated membrane) of inner coat, appearing as a bright line in section. C. Muscle layer (middle coat). D. Outer coat, consisting of connective-tissue bundles. In the interstices of the bundles are some connective-tissue nuclei, and, especially near the muscular coat, a number of elastic fibres cut across. (Schäfer.)

Lymphatics.—Distinct lymphatic vessels may exist in the adventitia, but are represented by *lymph spaces* in the other coats. Lymph capillaries often surround small bloodvessels, or a small bloodvessel may lie in a **perivascular lymph space**.

Nerves.—Arteries are supplied with nerves, myelinic and amyelinic. A network of nerve fibres may surround a vessel, and usually capillaries are so surrounded. In the arteries a network of nerves exists in the media. These nerves supply the muscle fibres, and are called *vasomotor nerves*. According to Stöhr, nerve endings are found in the endothelium of the capillaries, giving them the power of contractility.

The **Arterial Sheath** (*vagina vasis*) surrounds the artery. It is composed of connective tissue, and is attached to the vessel at numerous points by fibrous tissue.

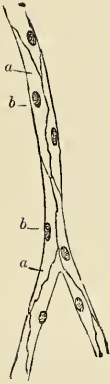


FIG. 426.—Capillaries from the mesentery of a guinea-pig after treatment with a solution of nitrate of silver. *a*, Cells. *b*, Their nuclei.

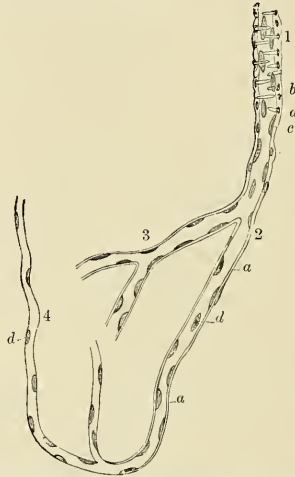


FIG. 427.—Finest vessels on the arterial side. From the human brain. Magnified 300 times. 1, Small artery. 2, Transition vessel. 3, Coarse capillaries. 4, Finer capillaries. *a*, Structureless membrane still with some nuclei, representative of the tunica adventitia. *b*, Nuclei of the muscle fibre cells. *c*, Nuclei within the small artery; perhaps appertaining to an endothelium. *d*, Nuclei in the transition vessels.

Applied Anatomy.—Arteries are liable to a degenerative process known as atheroma or arteriosclerosis. It is essentially a senile change, although it may begin at any age and is predisposed by renal disease, gout, diabetes mellitus, and many other morbid states, and results in the replacement of the arterial elastic tissue by fibrous tissue. The process results in the rise of the arterial blood-pressure with a corresponding hypertrophy of the heart. The weakening of the vessel wall, with reduction of the calibre, renders such affected arteries liable to rupture.

THE PULMONARY ARTERY (A. PULMONALIS) (Figs. 429, 433).

The **pulmonary artery** conveys the venous blood from the heart to the lungs. It is a short, wide vessel, about two inches (5 cm.) in length and one and one-fifth inches (30 mm.) in diameter, *arising* from the left side of the base (*conus arteriosus*) of the right ventricle, in front of the aorta. At its origin are three dilatations, the **sinuses of Valsalva**, described on page 559. It extends obliquely upward and backward, passing at first in front of and then to the left of the ascending aorta, as far as the under surface of the arch, where it divides, about on a level with the intervertebral disk between the fifth and sixth thoracic vertebrae, into right and left branches of nearly equal size.

Relations.—The whole of the vessel is contained, together with the ascending aorta, in the pericardium. It is enclosed with the aorta in a single tube of the serous pericardium, which is continued upward upon them from the base of the heart and connects them together. The

fibrous layer of the pericardium becomes gradually lost upon the external coats of its two branches. *In front*, the pulmonary artery is separated from the anterior extremity of the second left intercostal space by the pleura and left lung, in addition to the pericardium; it rests at first upon the ascending aorta, and higher up lies in front of the left auricle on a plane posterior to the ascending aorta. On *either side* of its origin is the appendix of the corresponding auricle and a coronary artery, the left coronary artery passing, in the first part of its course, behind the vessel. The superficial cardiac plexus lies above its bifurcation, between it and the arch of the aorta.

The **right branch of the pulmonary artery** (*ramus dexter a. pulmonalis*), longer and larger than the left, runs horizontally outward to the root of the right lung, where it divides into two branches, of which the lower and larger supplies the middle and lower lobes; the upper and smaller is distributed to the upper lobe. It has *in front* of it the ascending aorta, the superior vena cava, and the right phrenic nerve. It has *behind* it the right bronchus. *Above* it is the arch of the aorta. *Below* it is the right auricle.

The **left branch of the pulmonary artery** (*ramus sinister a. pulmonalis*), shorter and somewhat smaller than the right, passes horizontally to the root of the left lung, where it divides into two branches for the two lobes. *In front* of it and below it are the pulmonary veins of the left side. *Behind* are the descending aorta and the left bronchus. *Above* it are the arch of the aorta, the left recurrent laryngeal nerve, and the ligamentum arteriosum. The left bronchus in a portion of its course lies below as well as behind.

The root of the left pulmonary artery is connected to the under surface of the arch of the aorta by a short fibrous cord, the **ligamentum arteriosum**; this is the remains of a vessel peculiar to fetal life, the **ductus arteriosus**.

The terminal branches of the pulmonary artery will be described with the anatomy of the lung.

Applied Anatomy.—Stenosis of the pulmonary artery, either with, or, more rarely, without defective formation of the interventricular septum, is one of the commonest congenital defects of the heart. It may be due either to fetal endocarditis or to maldevelopment of the bullus cordis. As in most forms of congenital heart disease, the child is cyanosed (*morbus coeruleus*), especially when excited or on exertion, and rarely lives to adolescence, commonly dying of heart failure in infancy, or of pulmonary tuberculosis or intercurrent disease in childhood. The chief signs of the condition are the loud, harsh systolic cardiac murmur best heard over the second left costal cartilage, cyanosis, clubbing of the finger tips, and the presence of an excess of red corpuscles in the blood.

Embolism of the pulmonary artery by a clot of blood coming from the right side of the heart in patients with heart disease, or from a thrombosed vein in cases, for example, of influenza, enteric fever, puerperal sepsis, or fractured limbs, is a common cause of sudden or rapid death. The patient may cry out with sudden excruciating pain in the precordia when the detached embolus lodges, and after a brief period of intense dyspnea, pallor, and anguish, die.

A few cases of surgical interference in embolism of the pulmonary artery are on record. Several were in a measure successful, death being usually due to septic complications, such as pleurisy and pericarditis. (Cf. Kreuzer, *Centralblatt für Chirurgie*, No. 21, 1909.)

THE AORTA (Figs. 428, 429).

The **aorta**, or **arteria magna**, is the main trunk of a series of vessels which convey the oxygenated blood to the tissues of the body for their nutrition. It commences at the upper part of the left ventricle, where it is about one and one-eighth inches (28 mm.) in diameter, and, after ascending for a short distance, arches backward and to the left side, over the root of the left lung, then descends within the thorax on the left side of the vertebral column, passes through the aortic opening in the Diaphragm, and, entering the abdominal cavity, terminates, considerably diminished in size, about seven-tenths of an inch (17.5 mm.) in diameter, opposite the lower border of the fourth lumbar vertebra, where it divides into the right and left common iliac arteries. Hence, it is divided into the **ascending aorta**, the **arch of the aorta**, and the **descending aorta**, which last is again divided into the **thoracic aorta** and the **abdominal aorta**, from the position of these parts.

THE ASCENDING AORTA (AORTA ASCENDENS).

The ascending aorta is about two inches (5 to 6 cm.) in length. It commences at the base of the left ventricle, on a level with the lower border of the third costal cartilage, behind the left half of the sternum; it passes obliquely upward, forward, and to the right, as high as the upper border of the second right costal cartilage,

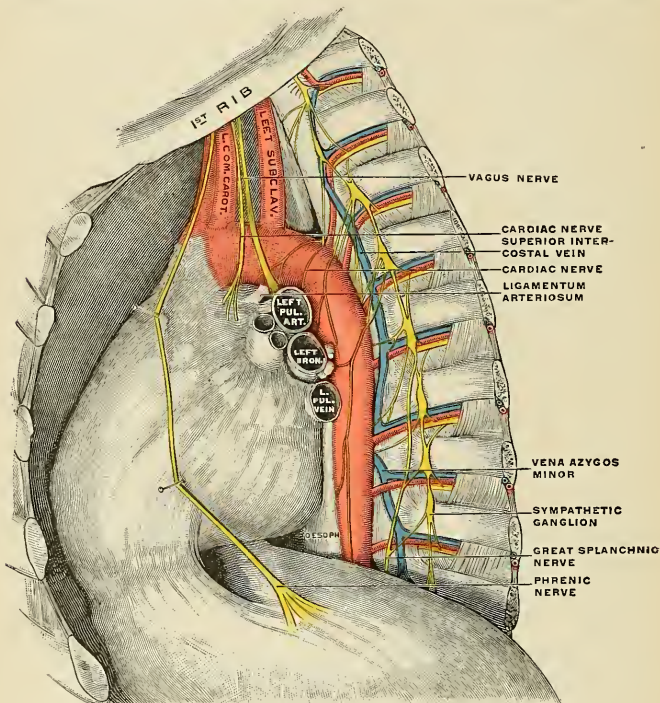


FIG. 428.—The thoracic aorta and its relations. (Poirier and Charpy.)

describing a slight curve in its course, and being situated, when distended, about a quarter of an inch behind the posterior surface of the sternum. At its origin it presents, opposite the segments of the aortic valve, three small dilatations called the **sinuses of Valsalva**, described on page 561. At the union of the ascending with the transverse part of the aorta the caliber of the vessel is increased, owing to a dilatation of its right wall. This dilatation is termed the **great sinus of the aorta** (*bulbous aortae*). A section of the aorta through this part is somewhat oval in outline. The ascending aorta is contained within the pericardium, and, together with the pulmonary artery, is invested in a tube of serous membrane, continued on to them from the surface of the heart.

Relations.—The ascending aorta is largely covered (*ventrad*) at its commencement by the trunk of the pulmonary artery and the right auricular appendix, and, higher up, is separated from the sternum by the pericardium, the right pleura, and anterior margin of the right lung,

some loose areolar tissue, and the remains of the thymus gland; *behind*, it rests upon the right pulmonary artery, left auricle, and the right bronchus. On the *right side* it is in relation with the superior vena cava and right auricle; on the *left side*, with the pulmonary artery.

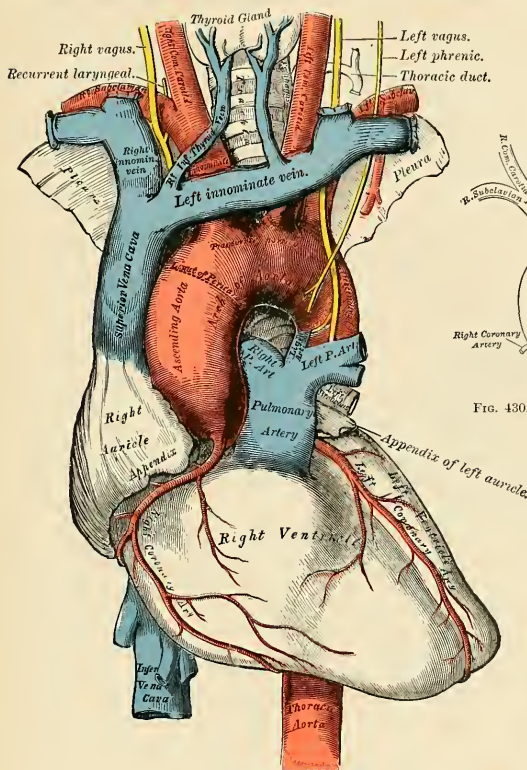


FIG. 429.—The arch of the aorta and its branches.

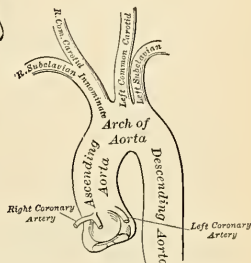


FIG. 430.—Plan of the branches.


PLAN OF THE RELATIONS OF THE ASCENDING AORTA.

In front.

Pulmonary artery.
Right auricular appendix.
Pericardium.
Right pleura and lung.
Remains of the thymus gland.

Right side.

Superior vena cava.
Right auricle.



Left side.

Pulmonary artery.

Behind.

Right pulmonary artery.
Left auricle.
Right bronchus.

Branches.—The only branches of the ascending aorta are the **coronary arteries** which supply the heart. They are two in number, right and left, arising near the commencement of the aorta immediately above the attached margin of the semilunar valves.

The Coronary Arteries (Fig. 429).—The **right coronary artery** (*a. coronaria [cordis] dextra*), about the size of a crow's quill, *arises* from the anterior sinus of Valsalva. It passes forward between the pulmonary artery and the right auricular appendix, then runs obliquely to the right side, in the groove between the right auricle and ventricle, and, curving around the right border of the heart, runs to the left along its postero-inferior surface as far as the postero-inferior interventricular groove, where it divides into two branches, one of which, the **transverse**, continues onward in the groove between the left auricle and ventricle, and anastomoses with the left coronary; the other, the **descending** (*ramus descendens posterior a. coronariae [cordis] dextrae*), courses along the postero-inferior interventricular furrow, supplying lateral branches to both ventricles and to the septum, and anastomosing at the apex of the heart with the descending branches of the left coronary.

This vessel sends a large branch, the **marginal**, along the thin margin of the right ventricle, to the apex, which in its course gives off numerous small branches to the sternal and diaphragmatic surfaces of the right ventricle. It

also gives off a branch, the **infundibular**, which ramifies over the front part of the conus arteriosus of the right ventricle. A small branch of the right coronary is said to supply the auriculoventricular bundle of His (see page 564).

The **left coronary artery** (*a. coronaria [cordis] sinistra*), larger than the former, *arises* from the left posterior sinus of Valsalva; it passes forward between the pulmonary artery and the left auricular appendix, and divides into two branches. Of these, one, the **transverse**, passes transversely outward in the left auriculoventricular groove, and winds around the left border of the heart to its diaphragmatic surface, where it anastomoses with the transverse branch of the right coronary; the other, the **descending** (*ramus descendens anterior a. coronariae [cordis] sinistrae*), passes along the antero-superior interventricular groove to the apex of the heart, where it anastomoses with the descending branches of the right coronary. The left coronary supplies the left auricle and its appendix, gives branches to both ventricles, and numerous twigs to the pulmonary artery and commencement of the aorta.

Peculiarities.—These vessels occasionally arise by a common trunk, or their number may be increased to three, the additional branch being of small size. More rarely there are two additional branches.

Applied Anatomy.—The sudden blocking of a coronary artery by an embolus, or its more gradual obstruction by arterial disease or thrombosis, are common causes of sudden death in persons past middle age. If the obstruction to the passage of blood is incomplete, true Angina pectoris may occur. In this condition the patient is suddenly seized with a spasm of agonizing pain in the precordial region and down the left arm, together with an indescribable sense of anguish. He may die in such an attack, or succumb a few hours or days later from heart failure, or he may survive a number of attacks.

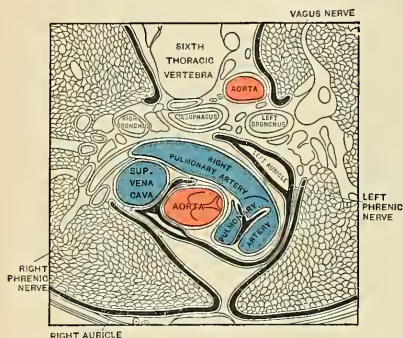


FIG. 431.—Horizontal section through the sixth thoracic vertebra—upper surface of the lower segment—showing the ascending portion of the aortic arch, the thoracic aorta, and related structures.

THE ARCH OF THE AORTA (ARCUS AORTAE).

The arch, or transverse aorta, commences at the level of the upper border of the second chondrosterneal articulation of the right side, and passes at first upward, backward, and to the left in front of the trachea; it is then directed backward on the left side of the trachea, and finally passes downward on the left side of the body of the fourth thoracic vertebra, at the lower border of which it becomes continuous with

the descending aorta. It thus forms two curvatures, one with its convexity upward, the other with its convexity forward and to the left. Its upper border is usually about an inch below the upper margin of the sternum.

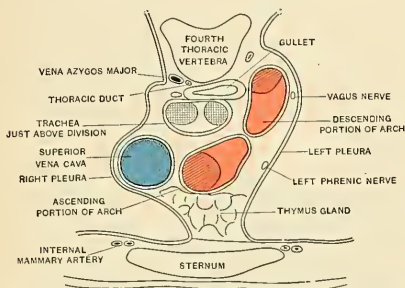


FIG. 435.—Horizontal section through the fourth thoracic vertebra—upper surface of the lower segment. The cut is made at the lower part of the transverse portion of the aortic arch.

phrenic, the inferior cervical cardiac branch of the left vagus, the superior cardiac branch of the left sympathetic, and the trunk of the left vagus. As the left vagus crosses the arch it gives off its recurrent laryngeal branch, which hooks around below the vessel and then passes upward on its right side. The left superior intercostal vein runs obliquely upward and forward, on the left side of the arch between the phrenic and vagus nerves. On the right are the deep cardiac plexus, the left recurrent laryngeal nerve, the œsophagus, and thoracic duct; the trachea lies behind and to the right of the vessel. Above are the innominate, left common carotid, and left subclavian arteries, which arise from the convexity of the arch and are crossed close to their origins by the left innominate vein. Below are the bifurcation of the pulmonary artery, the left bronchus, the ligamentum arteriosum, the superficial cardiac plexus, and the left recurrent laryngeal nerve. As already stated, the ligamentum arteriosum connects the commencement of the left pulmonary artery to the aortic arch.

Relations.—The arch of the aorta is covered *in front* by the pleuræ and anterior margins of the lungs, and by the remains of the thymus gland. As the vessel runs backward its *left* side is in contact with the left lung and pleura. Passing downward on the left side of this part of the arch are four nerves; in order from before backward these are the left

PLAN OF THE RELATIONS OF THE ARCH OF THE AORTA.

Above.

Left innominate vein.
Innominate artery.
Left carotid.
Left subclavian.

In Front.

Pleuræ and lungs.
Remains of thymus gland.
Left vagus nerve.
Left phrenic nerve.
Superficial cardiac nerves.
Left superior intercostal vein.

*Behind.*

Trachea.
Deep cardiac plexus.
œsophagus.
Thoracic duct.
Left recurrent nerve.

Below.

Bifurcation of pulmonary artery.
Ligamentum arteriosum.
Superficial cardiac plexus.
Left recurrent nerve.
Left bronchus.

Between the origin of the left subclavian artery and the attachment of the ligamentum arteriosum the lumen of the fetal aorta is considerably narrowed, forming what is termed the **aortic isthmus** (*isthmus aortae*), while immediately beyond the ligamentum arteriosum the vessel presents a fusiform dilatation which His has named the **aortic spindle** (*aortenspindel*)—the point of junction of the two parts being marked in the concavity of the arch by an indentation or angle. These conditions persist, to some extent, in the adult, where His found that the average diameter of the spindle exceeded that of the isthmus by 3 mm. (about one-eighth of an inch).

Peculiarities.—The height to which the aorta rises in the thorax is usually about an inch below the upper border of the sternum; but it may ascend nearly to the top of that bone. Occasionally it is found an inch and a half, more rarely two or even three inches, below this point.

In Direction.—Sometimes in man, as is normal in birds, the aorta arches over the root of the right instead of the left lung, and passes down on the right side of the vertebral column; such an arrangement is usually found to be associated with transposition of other viscera. Less frequently, the aorta, after arching over the root of the right lung, is directed to its usual position on the left side of the vertebral column, this peculiarity not being accompanied by any transposition of the viscera.

In Conformation.—The aorta occasionally divides, as in some quadrupeds, into an ascending and descending trunk, the former of which is directed vertically upward, and subdivides into three branches, to supply the head and upper extremities. Sometimes the aorta subdivides soon after its origin into two branches, which soon reunite.

In one of these cases the œsophagus and trachea were found to pass through the interval left by the division of the aorta; this is the normal condition of the vessel in the reptilia.

Applied Anatomy.—Of all the vessels of the arterial system, the aorta, and more especially its arch, is most frequently the seat of disease; hence it is important to consider some of the consequences that may ensue from aneurism of this part. Aortic aneurisms usually occur along a spiral line, the so-called "surf-line of the aorta," which begins at the anterior sinus of Valsalva and is lost in the dorsomesal wall of the descending aorta, as shown in Fig. 433.

It will be remembered that the ascending aorta is contained in the pericardium, just behind the sternum, being crossed at its commencement by the pulmonary artery and right auricular appendix, and having the right pulmonary artery behind, the superior vena cava on the right side, and the pulmonary artery and left auricle on the left side.

Aneurism of the ascending aorta, in the situation of the sinuses of Valsalva, in the great majority of cases, affects the anterior sinus; this is mainly owing to the fact that the regurgitation of blood upon the sinuses seems to take place chiefly on the anterior aspect of the vessel. As the aneurismal sac enlarges it may compress any or all of the structures in immediate proximity to it, but chiefly project toward the

right anterior side, and, consequently, interferes mainly with those structures which have a corresponding relation with the vessel. In the majority of cases it bursts into the cavity of the pericardium, the patient suddenly drops dead, and, upon a postmortem examination, the pericardial sac is found full of blood; or it may compress the right auricle, or the pulmonary artery and adjoining part of the right ventricle, and open into one or the other of these parts, or may press upon or even rupture into the superior vena cava.

Aneurism of the ascending aorta, originating above the sinuses, most frequently implicates the right anterior wall of the vessel, where, as has been explained, there exists a normal dilatation, the great sinus of the aorta; this is probably mainly owing to the blood being impelled against this part. The direction of the aneurism is also chiefly toward the right of the median line. It attains a large size and projects forward, it may cause absorption of the sternum and the cartilages of the ribs, usually on the right side, and appears as a pulsating tumor on the front of the thorax, just below the manubrium; or it may burst into the pericardium, or may compress or open into the right lung, the trachea, bronchi, or œsophagus.

Regarding the *arch of the aorta*, the student is reminded that the vessel lies on the trachea, the œsophagus, and thoracic duct; that the left recurrent laryngeal nerve winds around it; and that from its upper part are given off three large trunks, which supply the head, neck, and upper

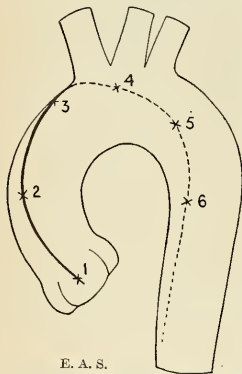


FIG. 433.—The "surf-line of the aorta," showing the commoner points of origin of aneurisms.

extremities. An aneurismal tumor, taking origin from the posterior part of the vessel, may press upon the trachea, impede the breathing, or produce cough, hemoptysis, or stridulous breathing, or it may ultimately burst into that tube, producing fatal hemorrhage. Again, its pressure on the laryngeal nerves may give rise to symptoms which so accurately resemble those of laryngitis that the operation of tracheotomy has in some cases been resorted to, from the supposition that disease existed in the larynx; or it may press upon the thoracic duct and destroy life by inanition; or it may involve the œsophagus, producing dysphagia; or may burst into the œsophagus, when fatal hemorrhage will occur. Again, the innominate artery, or the subclavian, or left carotid, may be so obstructed by clots as to produce a weakness, or even a disappearance, of the pulse in one or the other wrist or in the left temporal artery; or the tumor may present itself at or above the manubrium, generally either in the median line or to the right of the sternum, and may simulate an aneurism of one of the arteries of the neck.

Branches (Figs. 429 and 430).—The branches given off from the arch of the aorta are three in number—the innominate, the left common carotid, and the left subclavian arteries.

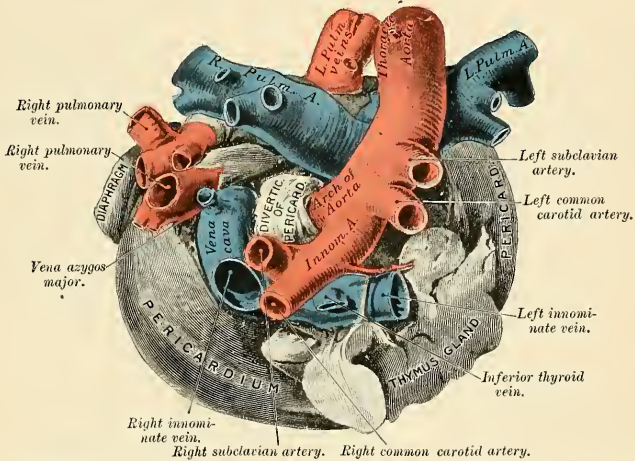


FIG. 434.—Relation of great vessels at base of a fetal heart, seen from above (enlarged). (From a preparation in the Museum of the Royal College of Surgeons of England.)

Peculiarities. Position of the Branches.—The branches, instead of arising from the highest part of the arch (their usual position), may be moved more to the right, arising from the commencement of the transverse or upper part of the ascending portion; or the distance from one another at their origin may be increased or diminished, the most frequent change in this respect being the approximation of the left carotid toward the innominate artery.

The number of the primary branches may be reduced to a single vessel, or more commonly two, the left carotid arising from the innominate artery, or (more rarely) the carotid and subclavian arteries of the left side arising from the innominate artery. But the number may be increased to four, from the right carotid and subclavian arteries arising directly from the aorta, the innominate being absent. In most of these latter cases the right subclavian has been found to arise from the left end of the arch; in other cases it was the second or third branch given off instead of the first. Another common form in which there are four primary branches is that in which the left vertebral artery arises from the arch of the aorta between the left carotid and subclavian arteries. Lastly, the number of trunks from the arch may be increased to five or six; in these instances, the external and internal carotids arise separately from the arch, the common carotid being absent on one or both sides. In some cases six branches have been found, and this condition is associated with the origin of both vertebral arteries from the arch.

Number Usual, Arrangement Different.—When the aorta arches over to the right side, the three branches have an arrangement the reverse of that which is usual. the innominate sup-

plying the left side, and the carotid and subclavian (which arise separately) the right side. In other cases, where the aorta takes its usual course, the two carotids may be joined in a common trunk, and the subclavians arise separately from the arch, the right subclavian generally arising from the left end of the arch.

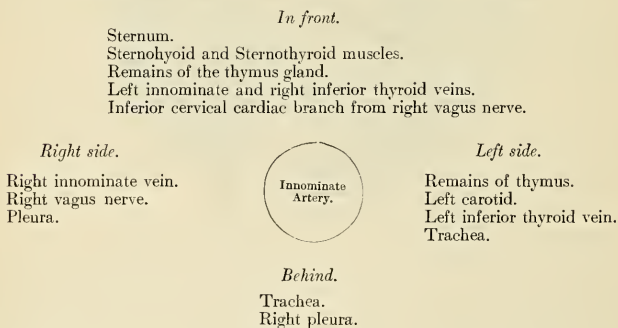
In some instances other arteries are found to arise from the arch of the aorta. Of these the most common are the bronchial, one or both, and the thyroidea ima; also the internal mammary and the inferior thyroid have been seen to arise from this part of the vessel.

The Innominate Artery (A. Anonyma) (Figs. 429 and 430).

The **innominate** or **brachiocephalic** artery is the largest branch given off from the arch of the aorta. It *arises*, on a level with the upper border of the second right costal cartilage, from the commencement of the arch of the aorta in front of the left carotid, and, ascending obliquely to the upper border of the right sternoclavicular articulation, divides into the right common carotid and right subclavian arteries. This vessel varies from an inch and a half to two inches in length.

Relations.—*In front*, it is separated from the first piece of the sternum by the Sternohyoid and Sternothyroid muscles, the remains of the thymus gland, the left innominate and right inferior thyroid veins which cross its root, and sometimes the inferior cervical cardiac branch of the right vagus. *Behind*, it lies upon the trachea, which it crosses obliquely, and continuing upward it lies in the right pleura. On the *right side* is the right innominate vein, right vagus nerve, and the pleura; and on the *left side*, the remains of the thymus gland, the origin of the left carotid artery, the left inferior thyroid vein, and the trachea.

PLAN OF THE RELATIONS OF THE INNOMINATE ARTERY.



Branches.—The innominate usually gives off no branches, but occasionally a small branch, the **thyroidea ima**, is given off from this vessel. It also sometimes gives off a **thymic** or **bronchial** branch.

The **thyroidea ima** (*a. thyroidea ima*), which is occasionally present, ascends in front of the trachea to the lower part of the thyroid body, which it supplies. It varies greatly in size, and appears to compensate for the deficiency or absence of one of the other thyroid vessels. It occasionally is found to arise from the right common carotid or from the aorta, the subclavian, or internal mammary vessels.

Applied Anatomy.—Ligation of the innominate artery is an extremely grave operation. This was first done by Mott. The “operation of choice” seems to be that done by Burrell. “An incision is made at the anterior edge of the right Sternomastoid muscle, extending from the level of the cricoid cartilage to two inches below the upper border of the sternum. From this point another incision, extending outward four inches in length to the junction (right) of the outer

and middle thirds of the clavicle. The skin flap with the fascia and Platysma muscle is turned back. The Sternomastoid is severed close to its insertion into clavicle and sternum. The Sternothyroid, Sternohyoid, and Omohyoid are also divided." The sternoclavicular joint and the right side of the manubrium are honeycombed by means of a surgical engine or trephine. A flat retractor is slid underneath the joint while the trephining is done to protect the underlying parts. The block of bone is now removed. The right and left innominate veins going down to form the superior vena cava, with the vagus and right recurrent laryngeal nerves resting on the innominate artery, are all plainly to be seen. The sheath of the innominate artery is now opened and a ligature is applied. Burrell states that the exposure which is given by the removal of a part of the sternum is extremely satisfactory, and he fails to understand how a ligature can be applied to the innominate artery with any safety without a clear view of the anatomical structures involved.

Peculiarities in Point of Division.—When the bifurcation of the innominate artery varies from the point above mentioned it sometimes ascends a considerable distance above the sternal end of the clavicle; less frequently it divides below it. In the former class of cases its length may exceed two inches, and in the latter be reduced to an inch or less. These are points of considerable interest for the surgeon to remember in connection with the operation of tying this vessel.

Position.—When the aorta arches over to the right side, the innominate is directed to the left side of the neck instead of the right.

Collateral Circulation.—Allan Burns demonstrated, on the dead subject, the possibility of the establishment of the collateral circulation after ligation of the innominate artery, by tying and dividing that artery, after which, he says, "Even coarse injection, impelled into the aorta, passes freely by the anastomosing branches into the arteries of the right arm, filling them and all the vessels of the head completely."¹ The branches by which this circulation would be carried on are very numerous; thus, all the communications across the middle line between the branches of the carotid arteries of opposite sides would be available for the supply of blood to the right side of the head and neck; while anastomosis between the superior intercostal of the subclavian and the first aortic intercostal (see page 654 on the collateral circulation after obliteration of the thoracic aorta) would bring the blood, by a free and direct course, into the right subclavian; the numerous connections, also, between the intercostal arteries and the branches of the axillary and internal mammary arteries would, doubtless, assist in the supply of blood to the right arm, while the deep epigastric, from the external iliac, would, by means of its anastomosis with the internal mammary, compensate for any deficiency in the vascularity of the wall of the thorax.

ARTERIES OF THE HEAD AND NECK.

The chief artery which supplies the head and neck on each side is the **common carotid**; it ascends in the neck and divides into two branches: (1) The external carotid, supplying the superficial parts of the head and face and the greater part of the neck; (2) the internal carotid, supplying to a great extent the parts within the cranial cavity.

THE COMMON CAROTID ARTERY (*A. CAROTIS COMMUNIS*) (Figs. 428, 429).

The **common carotid arteries** differ in length and in their mode of origin. The **right common carotid** (*a. carotis communis dextra*) begins at the bifurcation of the innominate artery, behind the right sternoclavicular articulation, and is confined to the neck. The **left common carotid** (*a. carotis communis sinistra*) arises from the highest part of the arch of the aorta to the left of and on a plane posterior to the innominate artery, and therefore consists of a thoracic and a cervical portion.

The **thoracic portion of the left common carotid artery** ascends from the arch of the aorta through the superior mediastinum to the level of the left sternoclavicular joint, where it continues as the cervical portion.

Relations.—*In front*, it is separated from the first piece of the sternum by the Sternohyoid and Sternothyroid muscles, the anterior portions of the left pleura and lung, the left innominate vein, and the remains of the thymus gland; *behind*, it lies on the trachea, cesophagus, thoracic

¹ Surgical Anatomy of the Head and Neck, p. 62.

duct, and the left recurrent laryngeal nerve. To its *right side*, it is in relation with the innominate artery, inferior thyroid veins, and remains of the thymus gland. To its *left side*, with the left vagus nerve, left pleura, and left lung. The left subclavian artery is posterior and slightly external to it.

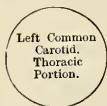PLAN OF THE RELATIONS OF THE LEFT COMMON CAROTID. THORACIC PORTION.

In front.

Sternum.
Sternohyoid and Sternothyroid muscles.
Left innominate vein.
Remains of the thymus gland.

Internally.

Innominate artery.
Inferior thyroid veins.
Remains of the thymus gland.



Externally.

Left vagus nerve.
Left pleura and lung.
Left subclavian artery.

Behind.

Trachea.
Œsophagus.
Thoracic duct.
Left recurrent laryngeal nerve.

The **cervical portions** of the two common carotids resemble each other so closely that one description will apply to both. Each vessel passes obliquely upward from behind the sternoclavicular articulation to a level with the upper border of the thyroid cartilage, opposite the fourth cervical vertebra, where it divides into the **external** and **internal carotid arteries**.

At the lower part of the neck the two common carotid arteries are separated from each other by a small interval, which contains the trachea; but at the upper part, the thyroid body, the larynx, and pharynx project forward between the two vessels, and give the appearance of their being placed farther back in this situation. The common carotid artery is contained in a sheath derived from the deep cervical fascia, which also encloses the internal jugular vein and vagus nerve, the vein lying on the outer side of the artery, and the nerve between the artery and vein, on a plane posterior to both. On opening the sheath these three structures are seen to be separated from one another, each being enclosed in a separate fibrous investment.

Relations.—At the lower part of the neck the common carotid artery is very deeply seated, being *covered* by the integument, superficial fascia, Platysma, and deep cervical fascia, the Sternomastoid, Sternohyoid, and Sternothyroid muscles, and by the Omohyoid, opposite the cricoid cartilage; but in the upper part of its course, near its termination, it is more superficial, being covered merely by the integument, the superficial fascia, Platysma, deep cervical fascia, and inner margin of the Sternomastoid, and, when the latter is drawn backward, it is seen to be contained in a triangular space, bounded behind by the Sternomastoid, above by the posterior belly of the Digastric, and below by the anterior belly of the Omohyoid. This part of the artery is crossed obliquely, from within outward, by the sternomastoid artery; it is crossed also by the superior and middle thyroid veins, which terminate in the internal jugular; and, descending on its sheath in front, is seen the descendens hypoglossi nerve, this filament being joined by one or two branches from the cervical nerves, which cross the vessel from without inward. Sometimes the descendens hypoglossi is contained within the sheath. The middle thyroid vein crosses the artery about its middle, and the anterior jugular vein below; the latter, however, is separated from the artery by the Sternohyoid and Sternothyroid muscles. *Behind*, the artery is separated from the transverse processes of the vertebræ by the Longus colli and

Rectus capitis anticus major muscles, the sympathetic cord being interposed between it and the muscles. The recurrent laryngeal nerve and inferior thyroid artery cross behind the vessel at its lower part. *Internally*, it is in relation with the trachea and thyroid gland, the latter overlapping it, the inferior thyroid artery and recurrent laryngeal nerve being interposed; higher up, with the larynx and pharynx. On its *outer side* are placed the internal jugular vein and vagus nerve. At the lower part of the neck the internal jugular vein on the right side diverges

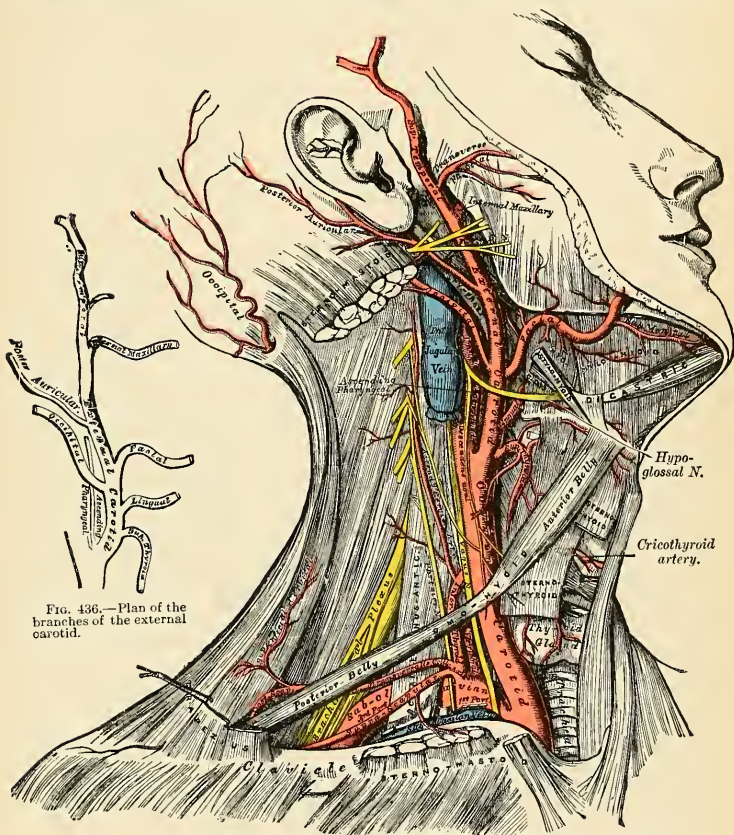


FIG. 436.—Plan of the branches of the external carotid.

FIG. 435.—Applied anatomy of the arteries of the neck, showing the carotid and subclavian arteries.¹

from the artery, but on the left side it approaches it, and often overlaps its lower part. This is an important fact to bear in mind during the performance of any operation on the lower part of the left common carotid artery. In this region the relation which the right and left recurrent laryngeal nerves bear to the arteries is not identical. The left recurrent laryngeal nerve lies behind the thoracic portion of the left common carotid artery and internal to the cervical portion of the vessel. The right nerve passes obliquely upward and inward behind the right common carotid to reach its inner side.

¹ The hypoglossal nerve is not rightly placed in this drawing. It forms the upper side of a triangle, the two lower sides of which are the two bellies of the Digastric. The lingual artery would then run under the Hyoglossus muscle, below the hypoglossal nerve. (See FIG. 437.)

PLAN OF THE RELATIONS OF THE COMMON CAROTID ARTERY.

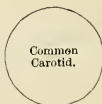In front.

Integument and superficial fascia.
 Deep cervical fascia.
 Platysma.
 Sternomastoid.
 Sternohyoid.
 Sternothyroid.

Omoxyoid.
 Descendens and communicans hypoglossi nerves.
 Sternomastoid artery.
 Superior and middle thyroid veins.
 Anterior jugular vein.

Externally.

Internal jugular vein.
 Vagus nerve.

*Internally.*

Trachea.
 Thyroid gland.
 Recurrent laryngeal nerve.
 Inferior thyroid artery.
 Larynx.
 Pharynx.

Behind.

Longus colli.
 Rectus capitis anticus major.

Sympathetic cord.
 Inferior thyroid artery.

Recurrent laryngeal nerve.

On the posterior aspect of the angle of bifurcation of the common carotid is a reddish-brown oval body known as the **carotid gland**. (See Ductless Glands.)

Peculiarities as to Origin.—The *right common carotid* may arise above or below the upper border of the sternoclavicular articulation. This variation occurs in one out of about eight cases and a half, and the origin is more frequently below than above; or the artery may arise as a separate branch from the arch of the aorta or in conjunction with the left carotid. The *left common carotid* varies more frequently in its origin than the right. In the majority of abnormal cases it arises with the innominate artery, or, if the innominate artery is absent, the two carotids arise usually by a single trunk. It rarely joins with the left subclavian, except in cases of transposition of the arch.

Peculiarities as to Point of Division.—In the majority of abnormal cases this occurs higher than usual, the artery dividing into two branches opposite the hyoid bone, or even higher; more rarely it occurs below, opposite the middle of the larynx or the lower border of the cricoid cartilage; and one case is related by Morgagni where the common carotid, only an inch and a half in length, divided at the root of the neck. Very rarely the common carotid ascends in the neck without any subdivision, the internal carotid being wanting; and in a few cases the common carotid has been found to be absent, the external and internal carotids arising directly from the arch of the aorta. This peculiarity existed on both sides in some instances, on one side in others.

Occasional Branches.—Each common carotid usually gives off no branch previous to its bifurcation; but it occasionally gives origin to the superior thyroid or its laryngeal branch, the ascending pharyngeal, the inferior thyroid, or, more rarely, the vertebral artery.

Surface Marking.—The course of each common carotid artery is indicated by a line drawn from the sternal end of the clavicle below, to a point midway between the angle of the mandible and the mastoid process above. That portion of the line below the level of the upper border of the thyroid cartilage would represent the course of the vessel.

Applied Anatomy.—The operation of tying the common carotid artery may be necessary in a case of wound of that vessel or its branches, in aneurism, or in a case of pulsating tumor of the orbit or skull. If the wound involves the trunk of the common carotid, it will be necessary to tie the artery through the wound above and below the wounded part. If the wound is too small to admit of safe and rapid work it must be enlarged. In cases of aneurism, or where one of the branches of the common carotid is wounded in an inaccessible situation, it may be judged necessary to tie the trunk. In such cases the whole of the artery is accessible, and any part may be tied except close to either end. When the case is such as to allow of a choice being made, the lower part of the carotid should never be selected as the spot upon which to place a ligature, for not only is the artery in this situation placed very deeply in the neck, but it is covered by three layers of muscles, and, on the left side, in the great majority of cases, the internal jugular vein passes obliquely in front of it. Neither should the upper end be selected, for here the superior thyroid vein and its tributaries would give rise to very considerable difficulty in the application of a ligature. The point most favorable for the operation is that part of the vessel which is at the level of the cricoid cartilage. It occasionally happens that the carotid artery bifurcates

below its usual position; if the artery be exposed at its point of bifurcation, both divisions of the vessel should be tied near their origin, in preference to tying the trunk of the artery near its termination; and if, in consequence of the entire absence of the common carotid or from its early division, two arteries, the external and internal carotids, are met with, the ligature should be placed on that vessel which is found on compression to be connected with the diseased area.

Ligation of the Carotid at the Level of the Cricoid Cartilage (*Ligation in the Triangle of Election*).¹—The triangle of election is bounded *posteriorly* by the anterior edge of the Sternomastoid; is bounded *above* by the posterior belly of the Digastric; is bounded *below* by the anterior belly of the Omohyoid. In this operation the direction of the vessel and the inner margin of the Sternomastoid are the chief guides to its performance. The patient should be placed on his back with the head thrown back and turned slightly to the opposite side; an incision is to be made, three inches long, in the direction of the anterior border of the Sternomastoid, so that the centre corresponds to the level of the cricoid cartilage; after dividing the integument, superficial fascia, and Platysma, the deep fascia must be cut through on a director, so as to avoid wounding numerous small veins that are usually found beneath. The head may now be brought forward so as to relax the parts somewhat, and the margins of the wound are held asunder by retractors. The descendens hypoglossi nerve may now be exposed, and must be avoided, and, the sheath of the vessel having been raised by forceps, is to be opened to a small extent over the artery at its inner side. The internal jugular vein may present itself alternately distended and relaxed; this should be compressed both above and below, and drawn outward, in order to facilitate the operation. The aneurism needle is passed from the outside, care being taken to keep the needle in close contact with the artery, and thus avoid the risk of injuring the internal jugular vein or including the vagus nerve. Before the ligature is tied it should be ascertained that nothing but the artery is included in it.

Ligation of the Common Carotid at the Lower Part of the Neck (*Ligation in the Triangle of Necessity*).¹—The triangle of necessity is bounded *above* by the anterior belly of the Omohyoid; is bounded *behind* by the anterior margin of the Sternomastoid; is bounded *in front* by the mid-line of the neck. This operation is sometimes required in cases of aneurism of the upper part of the carotid, especially if the sac is of large size. It is best performed by dividing the sternal origin of the Sternomastoid muscle, but may be done in some cases, if the aneurism is not of very large size, by an incision along the anterior border of the Sternomastoid, extending down to the sternoclavicular articulation, and by then retracting the muscle. The easiest and best plan, however, is to make an incision two or three inches long down the lower part of the anterior border of the Sternomastoid muscle to the sternoclavicular joint, and a second incision, starting from the termination of the first, along the upper border of the clavicle for about two inches. This incision is made through the superficial and deep fascia, and the sternal origin of the muscle is exposed. This is to be divided on a director, and turned up, with the superficial structures, as a triangular flap. Some loose connective tissue is to be divided or torn through, and the outer border of the Sternohyoid muscle exposed. In doing this care must be taken not to wound the anterior jugular vein, which crosses the muscle to reach the external jugular or subclavian vein. The Sternohyoid, and with it the Sternothyroid, are to be drawn inward by means of a retractor, and the sheath of the vessel is exposed. This must be opened with great care on its inner or tracheal side, so as to avoid the internal jugular vein. This is especially necessary on the left side, where the artery is commonly overlapped by the vein. On the right side there is usually an interval between the artery and the vein, and not the same risk of wounding the latter.

The common carotid artery, being a long vessel without any branches, is particularly suitable for the performance of Brasdor's operation for the cure of an aneurism of the lower part of the vessel. Brasdor's procedure consists in ligating the artery on the distal side of the aneurism, and in the case of the common carotid there are no branches given off from the vessel between the aneurism and the site of the ligature; hence, the flow of blood through the sac of the aneurism is diminished, and cure takes place in the usual way, by the deposit of laminated fibrin.

Collateral Circulation.—After ligation of the common carotid the collateral circulation can be perfectly established by the free communication which exists between the carotid arteries of opposite sides, both without and within the cranium, and by enlargement of the branches of the subclavian artery on the side corresponding to that on which the vessel has been tied—the chief communication outside the skull taking place between the superior thyroid from the external carotid and the inferior thyroid from the subclavian, the profunda cervicis from the subclavian and the superior intercostal with the arteria princeps cervicis of the occipital; the vertebral taking the place of the internal carotid within the cranium.

¹ For description of the triangles of the neck, see page 602.

The External Carotid Artery (*A. Carotis Externa*) (Figs. 434, 435).

The **external carotid artery** commences opposite the upper border of the thyroid cartilage, and, taking a slightly curved course, passes upward and forward, and then inclines backward to the space between the neck of the condyle of the mandible and the external meatus, where it divides into the superficial temporal and internal maxillary arteries. It rapidly diminishes in size in its course up the neck, owing to the number and large size of the branches given off from it. In the child it is somewhat smaller than the internal carotid, but in the adult the two vessels are of nearly equal size. At its origin this artery is more superficial and placed nearer the middle line than the internal carotid, and is contained in the triangular space bounded by the Sternomastoid behind, the anterior belly of the Omohyoid below, and the posterior belly of the Digastric and the Stylohyoid above (*i. e.*, the superior carotid triangle).

Relations.—It is *covered* by the skin, superficial fascia, Platysma, deep fascia, and anterior margin of the Sternomastoid, and is crossed by the hypoglossal nerve, and by the lingual and facial veins; it is afterward crossed by the Digastric and Stylohyoid muscles, and higher up passes deeply into the substance of the parotid gland, where it lies beneath the facial nerve and the junction of the temporal and internal maxillary veins. *Internally* is the hyoid bone, wall of the pharynx, the superior laryngeal nerve, and the ramus of the mandible, from which it is separated by a portion of the parotid gland. *Externally*, in the lower part of its course, is the internal carotid artery. *Behind* it, near its origin, is the superior laryngeal nerve; and higher up, it is separated from the internal carotid by the Styloglossus and Stylopharyngeus muscles, the glossopharyngeal nerve, and part of the parotid gland.

PLAN OF THE RELATIONS OF THE EXTERNAL CAROTID.

In front.

Skin, superficial fascia.
Platysma and deep fascia.
Anterior border of Sternomastoid.
Hypoglossal nerve.
Lingual and facial veins.
Digastric and Stylohyoid muscles.
Parotid gland with facial nerve and temporomaxillary vein in its substance.

Internally.

Hyoid bone.
Pharynx.
Superior laryngeal nerve.
Parotid gland.
Ramus of mandible.



Externally.

Internal carotid artery
(lower part).

Behind.

Superior laryngeal nerve.
Styloglossus.
Stylopharyngeus.
Glossopharyngeal nerve.
Parotid gland.

Surface Marking.—The position of the external carotid artery may be marked out with sufficient accuracy by a line drawn from the front of the meatus of the external ear to the side of the cricoid cartilage, slightly arching the median line.

Applied Anatomy.—The application of a ligature to the external carotid may be required in case of wounds of this vessel, or of its branches when these cannot be tied, and in some cases of pulsating tumor of the scalp or face. The operation has not received the attention which it

deserves, owing to the fear which surgeons have entertained of secondary hemorrhage, on account of the number of branches given off from the vessel. This fear, however, has been shown by Mr. Cripps not to be well founded.¹ Ligation is often very useful as a means of preventing excessive hemorrhage in operations about the face, jaws, and mouth. It is sometimes employed with the hope of lessening the growth of tumors by cutting off the blood supply, but ligation is useless for this purpose. Ligation of one external carotid artery arrests the circulation for only a brief period, and within a very few days the circulation is practically freely reëstablished. This result is seen to be inevitable when we recall the numerous branches of the external carotid, their free anastomoses, and the fact that a very great number of extremely minute vessels in the middle line join the external carotid system of one side to that of the other side. Robert H. M. Dawbarn points out that ligation of both external carotids produces only temporary anemia, for "inside of a week or ten days thereafter the pulse can again be felt in the temporals and facials upon both sides."² Dawbarn points out that even after excision of the external carotids, with separate ligation of each of the eight branches, blood can still reach the nose, tongue, etc., from outside systems by twenty-nine distinct routes. Whereas ligation of even both carotids will not prevent the growth of a malignant tumor, excision of each external carotid, with separate control of its eight branches, will sometimes prove of great value in retarding the progress of a growth. It "starves" the growth and may cause it to shrink (Dawbarn's operation). To tie the external carotid near its origin, below the point where it is crossed by the Digastric, an incision about three inches in length should be made along the margin of the Sternomastoid, from the angle of the mandible to the upper border of the thyroid cartilage. The ligature should be applied between the lingual and superior thyroid branches. To tie the vessel above the Digastric, between it and the parotid gland, an incision should be made, from the lobe of the ear to the greater cornu of the hyoid bone, dividing successively the skin, Platysma, and fascia. By drawing the Sternomastoid outward, the posterior belly of the Digastric and Stylohyoid muscles downward, and separating them from the parotid gland, the vessel will be exposed, and a ligature may be applied to it. The circulation is at once reëstablished by the free communication between most of the large branches of the artery (facial, lingual, superior thyroid, occipital) and the corresponding arteries of the opposite side and by the anastomosis of its branches with those of the internal carotid, and of the occipital with the branches of the subclavian, etc.

Branches.—The external carotid artery gives off eight branches, which, for convenience of description, may be divided into four sets. (See Fig. 436, Plan of the Branches.)

<i>Anterior.</i>	<i>Posterior.</i>	<i>Ascending.</i>	<i>Terminal.</i>
Superior Thyroid.	Occipital.	Ascending Phar-	Superficial Temporal.
Lingual.	Posterior Auric-	yngeal.	Internal Maxillary.
Facial.	ular.		

The student is here reminded that many variations are met with in the number, origin, and course of these branches in different subjects; but the above arrangement is that which is found in the great majority of cases.

1. The **superior thyroid artery** (*a. thyroidea superior*) (Figs. 435 and 436) arises from the external carotid artery, just below the greater cornu of the hyoid bone, and terminates in the thyroid gland.

Relations.—From its origin under the anterior border of the Sternomastoid it runs upward and forward for a short distance in the superior carotid triangle, where it is covered by the integument, fascia, and Platysma; it then arches downward and forward beneath the Omohyoid, Sternohyoid, and Sternothyroid muscles. To the inner side are the Inferior constrictor of the pharynx and the external branch of the laryngeal nerve. It distributes numerous branches to the upper part of the gland, anastomosing with its fellow of the opposite side and with the inferior thyroid arteries. The terminal branches supplying the gland are generally two in number; one, the largest, the **anterior branch** (*ramus anterior*), descends at the anterior border of the lateral lobe of the gland, reaches the upper border of the isthmus, and then passes in the substance of the isthmus to the middle line of the neck, where it anastomoses with the corresponding artery of the opposite side; the **posterior branch** (*ramus posterior*) descends along

¹ Med.-Chir. Trans., lxi, 229.

² The Treatment of Certain Malignant Growths.

the posterior border of the lateral lobe of the gland, the anterior and posterior branches anastomose with each other and with branches of the inferior thyroid, and both of them send branches to the thyroid gland (*rami glandulares*). Besides the arteries distributed to the muscles by which it is covered and to the substance of the gland.

Branches.—The branches of the superior thyroid are the following:

Infrahyoid.
Sternomastoid.

Superior Laryngeal.
Cricothyroid.

The **infrahyoid branch** (*ramus hyoideus*) is small, and runs along the lower border of the hyoid bone beneath the Thyrohyoid muscle; after supplying the muscles connected to that bone, it forms an arch, by anastomosing with the vessel of the opposite side.

The **sternomastoid branch** (*ramus sternocleidomastoideus*) runs downward and outward across the sheath of the common carotid artery, and supplies the Sternomastoid and neighboring muscles and integument. There is frequently a separate branch from the external carotid distributed to the Sternomastoid muscle.

The **superior laryngeal** (*a. laryngea superior*), larger than either of the preceding, accompanies the internal branch of the superior laryngeal nerve, beneath the Thyrohyoid muscle; it pierces the thyrohyoid membrane, and supplies the muscles, mucous membrane, and glands of the larynx, anastomosing with the branch from the opposite side.

The **cricothyroid** (*ramus cricothyreoideus*) is a small branch which runs transversely across the cricothyroid membrane, and communicates with the artery of the opposite side.

Applied Anatomy.— The superior thyroid, or one of its branches, is often divided in cases of cut throat, giving rise to considerable hemorrhage. In such cases the artery should be secured, the wound being enlarged for that purpose, if necessary. The operation may be easily performed, the position of the artery being very superficial, and the only structures of importance covering it being a few small veins. The superior and inferior thyroid arteries of the involved side are ligated before extirpating a goitrous lobe of the thyroid gland.

The position of the superficial descending branch is of importance in connection with the operation of ligation of the common carotid artery. It crosses and lies on the sheath of this vessel, and may be wounded in opening the sheath. The position of the cricothyroid branch should be remembered, as it may prove the source of troublesome hemorrhage during the operation of laryngotomy. In performing the operation of *quick laryngotomy* the cricothyroid membrane should be incised transversely in order to avoid this vessel.

2. The **lingual artery** (*a. lingualis*) (Figs. 435 and 436) arises from the external carotid between the superior thyroid and facial; it first runs obliquely upward and inward to the great cornu of the hyoid bone; it then curves downward and forward, forming a loop which is crossed by the hypoglossal nerve, and passing

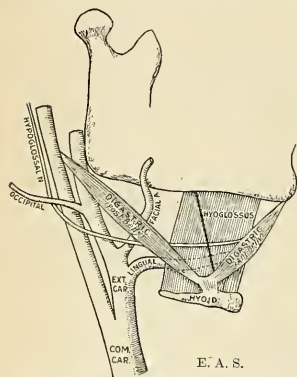


FIG. 437.—Showing the relation of the lingual artery and hypoglossal nerve. *Lesser's triangle* is bounded above by the nerve, below by the posterior belly of the Digastric, and in front by the posterior border of the Mylohyoid, indicated by a solid line. The floor of the triangle is occupied by the Hyoglossus.

ing beneath the Digastric and Stylohyoid muscles, it runs horizontally forward, beneath the Hyoglossus, and finally, ascending almost perpendicularly to the tongue, turns forward on its under surface as far as the tip, under the name of the **ranine artery**.

Relations.—Its *first*, or *oblique*, *portion* is superficial, being contained in the same triangular space as the superior thyroid artery, resting upon the Middle constrictor of the pharynx, and covered by the Platysma and fascia of the neck. Its *second*, or *curved*, *portion* also lies upon the Middle constrictor, being covered at first by the tendon of the Digastric and the Stylohyoid muscle, and afterward by the Hyoglossus, the latter muscle separating it from the hypoglossal nerve. Its *third*, or *horizontal*, *portion* lies between the Hyoglossus and Geniohyoglossus muscles. The *fourth*, or *terminal*, *part*, under the name of the **ranine**, runs along the under surface of the tongue to its tip; it is very superficial, being covered only by the mucous membrane, and rests on the Lingualis on the outer side of the Geniohyoglossus. The hypoglossal nerve crosses the lingual artery, and then becomes separated from it, in the second part of its course, by the Hyoglossus muscle.

Branches.—The branches of the lingual artery are the

Suprahyoid.
Dorsalis Linguae.

Sublingual.
Ranine.

The **suprahyoid branch** (*ramus hyoideus*) runs along the upper border of the hyoid bone, supplying the muscles attached to it and anastomosing with its fellow of the opposite side.

The **dorsalis linguae** (*ramus dorsalis linguae*) (Fig. 496) *arises* from the lingual artery beneath the Hyoglossus muscle; it ascends to the back of the dorsum of the tongue, and supplies the mucous membrane, the tonsil, soft palate, and epiglottis, anastomosing with its fellow from the opposite side. This artery is frequently represented by two or three small branches.

The **sublingual** (*a. sublingualis*), which may be described as a branch of bifurcation of the lingual artery, *arises* at the anterior margin of the Hyoglossus muscle, and runs forward between the Geniohyoglossus and the sublingual gland. It supplies the substance of the gland, giving branches to the Mylohyoid and neighboring muscles, the mucous membrane of the mouth and gums. One branch runs behind the alveolar process of the mandible in the substance of the gum to anastomose with a similar artery from the other side.

The **ranine**, or **deep lingual** (*a. profunda linguae*), may be regarded as the other branch of bifurcation. It is usually described as the continuation of the lingual artery; it runs along the under surface of the tongue, resting on the Inferior lingualis, and covered by the mucous membrane of the mouth; it lies on the outer side of the Geniohyoglossus, accompanied by the lingual nerve. On arriving at the tip of the tongue it is said to anastomose with the artery of the opposite side, but this is denied by Hyrtl. In the mouth these vessels are placed one on either side of the frenum.

Applied Anatomy.—The lingual artery may be divided near its origin in cases of *cut throat*, a complication that not infrequently happens in this class of wounds; or *severe hemorrhage* which cannot be restrained by ordinary means may ensue from a wound or deep ulcer of the tongue. In the former case the primary wound may be enlarged if necessary, and the bleeding vessels secured. In the latter case it has been suggested that the lingual artery should be tied near its origin. Ligation of the lingual artery is also occasionally practised, as a palliative measure, in cases of *cancer of the tongue*, in order to check the progress of the disease by starving the growth and it is often tied as a preliminary measure to *removal of the tongue*. The operation is a somewhat difficult one, on account of the depth of the artery, the number of important structures by which it is surrounded, the loose and yielding nature of the parts upon which it is supported, and its occasional irregularity of origin. An incision is to be made in a curved direction from a point one finger's breadth external to the symphysis of the mandible downward to the cornu of the hyoid bone, and then upward to near the angle of the mandible. Care must be taken not to carry this incision too far backward, for fear of endangering the facial vein. In the first incision the skin, superficial fascia, and Platysma will be divided, and the deep fascia exposed. The deep fascia is then to be incised, and the submaxillary gland exposed and pulled upward by retractors. A triangular space is now exposed, *Lesser's triangle* (Fig. 437), bounded internally by the posterior border of the Mylohyoid muscle; below and externally, by the tendon of the Digastric; and above, by the hypoglossal nerve. The floor of the space is formed by the

Hyoglossus muscle, beneath which the artery lies. The fibres of this muscle are now to be cut through horizontally and the vessel exposed, care being taken, while near the vessel, not to open the pharynx.

Troublesome hemorrhage may occur in the *division of the frenum* in children if the ranine arteries, which lie on each side of it, are wounded. The student should remember that the operation is always to be performed with a pair of blunt-pointed scissors, and the mucous membrane only is to be divided by a very superficial cut, which cannot endanger any vessel. The scissors, also, should be directed toward the floor of the mouth. Any further liberation of the tongue which may be necessary can be effected by tearing.

3. The **facial artery** (*a. maxillaris externa*) (Figs. 435 and 438) arises a little above the lingual, and passes obliquely upward, beneath the Digastric and Stylohyoid muscles, and frequently beneath the hypoglossal nerve; it now runs forward

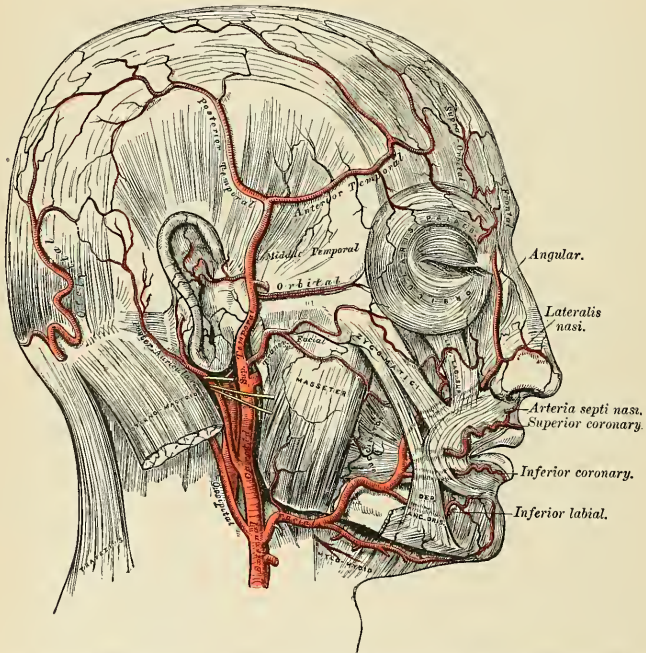


FIG. 438.—The arteries of the face and scalp. The muscle tissue of the lips must be supposed to have been cut away, in order to show the course of the coronary arteries.

under cover of the body of the mandible, lodged in a groove on the posterior surface of the submaxillary gland; this may be called the **cervical part** of the artery. It then curves upward over the body of the mandible at the anterior inferior angle of the Masseter muscle; passes forward and upward across the cheek to the angle of the mouth, then upward along the side of the nose, and terminates at the inner canthus of the eye, under the name of the **angular artery**. The facial artery, both in the neck and on the face, is remarkably tortuous; in the former situation its tortuosity enables it to accommodate itself to the movements of the pharynx in deglutition, and in the latter to the movements of the mandible and the lips and cheeks.

Relations.—In the neck its origin is superficial, being covered by the integument, Platysma, and fascia; it then passes beneath the Digastric and Stylohyoid muscles and part of the submaxillary gland. It lies upon the Middle constrictor of the pharynx, and is separated from the Styloglossus and Hyoglossus muscles by a portion of the submaxillary gland. On the face, where it passes over the body of the mandible, it is comparatively superficial, lying immediately beneath the Platysma. In this situation its pulsation may be distinctly felt, and compression of the vessel against the bone can be effectually made. In its course over the face it is covered by the integument, the fat of the cheek, and, near the angle of the mouth, by the Platysma, Risorius, and Zygomatic muscles. It rests on the Buccinator, the Levator anguli oris, and the Levator labii superioris (sometimes piercing or else passing under this last muscle). The facial vein lies to the outer side of the artery, and takes a more direct course across the face, where it is separated from the artery by a considerable interval. In the neck it lies superficial to the artery. The branches of the facial nerve cross the artery, and branches of the infra-orbital nerve lie beneath it.

Branches.—The branches of this vessel may be divided into two sets—those given off below the mandible (*cervical*), and those on the face (*facial*).

Cervical Branches.

Ascending Palatine.
Tonsillar.
Submaxillary.
Submental.

Facial Branches.

Inferior labial.
Inferior labial coronary.
Superior labial coronary.
Lateral nasal.
Angular.
Muscular.

The **ascending palatine** (*a. palatine ascendens*) passes up between the Styloglossus and Stylopharyngeus to the outer side of the pharynx, along which it is continued between the Superior constrictor and the Internal pterygoid to near the base of the skull. It divides, near the Levator palati, into two branches; one follows the course of the Levator palati, and, winding over the upper border of the Superior constrictor, supplies the soft palate and the palatal glands, anastomosing with its fellow of the opposite side and with the posterior palatine branch of the internal maxillary artery; the other pierces the Superior constrictor and supplies the tonsil and Eustachian tube, anastomosing with the tonsillar and ascending pharyngeal arteries.

The **tonsillar branch** (*ramus tonsillaris*) passes up between the Internal pterygoid and Styloglossus, and then ascends along the side of the pharynx, perforating the Superior constrictor, to ramify in the substance of the tonsil and root of the tongue.

The **submaxillary** or **glandular branches** (*rami glandulares*) consist of three or four large vessels, which supply the submaxillary gland, some being prolonged to the neighboring muscles, lymph nodes, and integument.

The **submental** (*a. submentalis*) (Fig. 435), the largest of the cervical branches, is given off from the facial artery just as that vessel emerges from the submaxillary gland; it runs forward upon the Mylohyoid muscle, just below the body of the mandible and beneath the Digastric; after supplying the surrounding muscles, and anastomosing with the sublingual artery by branches which perforate the Mylohyoid muscle, it arrives at the symphysis of the mandible, where it turns over the border of the mandible and divides into a superficial and a deep branch; the former passes between the integument and Depressor labii inferioris, supplies both, and anastomoses with the inferior labial. The deep branch passes between the latter muscle and the bone, supplies the lip, and anastomoses with the inferior labial and mental arteries.

The **inferior labial** (*a. labialis inferior*) (Fig. 438) passes beneath the Depressor anguli oris, to supply the muscles and integument of the chin and lower lip, anastomosing with the inferior labial coronary and submental branches of the facial, and with the mental branch of the inferior dental artery.

The **inferior labial coronary** (Figs. 438 and 439) is derived from the facial artery, near the angle of the mouth; it passes upward and inward beneath the Depressor anguli oris, and, penetrating the Orbicularis oris muscle, runs in a tortuous course along the edge of the lower lip between this muscle and the mucous membrane, anastomoses with the artery of the opposite side. This artery supplies the labial glands, the mucous membrane, and muscles of the lower lip, and anastomoses with the inferior labial from the facial and the mental branch of the inferior dental artery.

The **superior labial coronary** (*a. labialis superior*) (Figs. 438 and 439) is larger and more tortuous in its course than the preceding. It follows the same course along the edge of the upper lip, lying between the mucous membrane and the Orbicularis oris, and anastomoses with the artery of the opposite side. It supplies the tissues of the upper lip, and gives off in its course two or three vessels which ascend to the nose. One, named the **inferior artery of the septum**, ramifies on the septum of the nostrils as far as the point of the nose; another, the **artery of the ala**, supplies the ala of the nose.

The **lateralis nasi** is derived from the facial, as that vessel is ascending along the side of the nose; it supplies the ala and dorsum of the nose, anastomosing with its fellow, the nasal branch of the ophthalmic, the inferior artery of the septum, the artery of the ala, and the infraorbital.

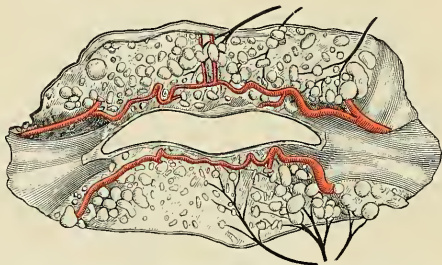


FIG. 439.—The labial coronary arteries, the glands of the lips, and the nerves of the right side seen from the posterior surface after removal of the mucous membrane. (Poirier and Charpy.)

The **angular artery** (*a. angularis*) is the termination of the trunk of the facial; it ascends to the inner angle of the orbit, embedded in the fibres of the Levator labii superioris alaeque nasi, and accompanied by a large vein, the **angular vein**; it distributes some branches on the cheek which anastomose with the infraorbital. After supplying the lacrimal sac and Orbicularis palpebrarum muscle, the angular artery terminates by anastomosing with the nasal branch of the ophthalmic artery.

The **muscular branches** are distributed to the Internal pterygoid and Stylohyoid in the neck, and to the Masseter and Buccinator on the face.

The anastomoses of the facial artery are very numerous, not only with the vessel of the opposite side, but, in the neck, with the sublingual branch of the lingual; with the ascending pharyngeal; and with the posterior palatine, a branch of the internal maxillary, by its ascending palatine and tonsillar branches; on the face, with the mental branch of the inferior dental as it emerges from the mental foramen, with the transverse facial, a branch of the temporal; with the infraorbital, a branch of the internal maxillary, and with the nasal branch of the ophthalmic.

Peculiarities.—The facial artery not infrequently arises by a common trunk with the lingual. This vessel is also subject to some variations in its size and in the extent to which it supplies the face. It occasionally terminates as the submental, and not infrequently supplies the face

only as high as the angle of the mouth or nose. The deficiency is then supplied by enlargement of one of the neighboring arteries.

Applied Anatomy.—The passage of the facial artery over the body of the mandible would appear to afford a favorable position for the application of pressure in case of hemorrhage from the lips, the result either of an accidental wound or during an operation; but its application is useless, except for a very short time, on account of the free communication of this vessel with its fellow and with numerous branches from different sources. In a *wound involving the lip* it is better to seize the part between the fingers, and evert it, when the bleeding vessel may be at once secured with pressure forceps. In order to *prevent hemorrhage* in cases of removal of diseased growths from the part, the lip should be compressed on each side between the fingers and thumb or by a pair of specially devised clamp forceps, while the surgeon excises the diseased part. In order to stop hemorrhage where the lip has been divided in an operation, it is necessary, in uniting the edges of the wound, to pass the sutures through the cut edges from the skin almost as deep as the mucous surface; by these means not only are the cut surfaces more neatly and securely adapted to each other, but the possibility of hemorrhage is prevented by including in the suture the divided artery. If the suture is, on the contrary, passed through merely the cutaneous portion of the wound, hemorrhage occurs into the cavity of the mouth. Lastly, the relation of the angular artery to the lacrimal sac should be observed, and it will be seen that, as the vessel passes up along the inner margin of the orbit, it ascends on the nasal side. In operating for *fistula lacrimalis* the sac should always be opened on its outer side, in order that this vessel may be avoided.

4. The **occipital artery** (*a. occipitalis*) (Figs. 435 and 440) *arises* from the posterior part of the external carotid, opposite the facial, near the lower margin of the Digastric muscle.

Relations.—At its origin it is covered by the posterior belly of the Digastric muscle and the Stylohyoid muscle, and the hypoglossal nerve winds around it from behind forward; higher up, it passes across the internal carotid artery, the internal jugular vein, and the vagus and spinal accessory nerves; it then ascends to the interval between the transverse process of the atlas and the mastoid process of the temporal bone, and passes horizontally backward in the occipital groove on the mastoid portion of the temporal, being covered by the Sternomastoid, Splenius, Trachelomastoid, and Digastric muscles, and resting upon the Rectus lateralis, the Superior oblique, and Complexus muscles; it then changes its course and passes vertically upward, pierces the fascia which connects the cranial attachment of the Trapezius with the Sternomastoid, and ascends in a tortuous course over the occiput, as high as the vertex, where it divides into numerous branches. It is accompanied in the latter part of its course by the great occipital nerve, and occasionally by a cutaneous filament from the suboccipital nerve.

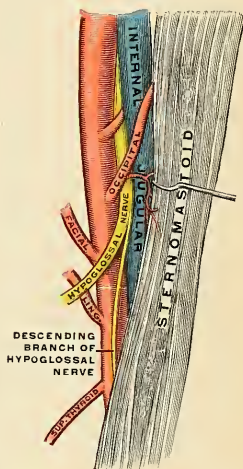


FIG. 440.—The loop of the hypoglossal nerve and the branches of the external carotid artery.

Branches.—The branches given off from this vessel are:

Muscular.	Meningeal or dural.
Sternomastoid.	Mastoid.
Auricular.	Arteria princeps cervicis.
Cranial branches.	

The **muscular branches** (*rami musculares*) supply the Digastric, Stylohyoid, Splenius, and Trachelomastoid muscles.

The **sternomastoid** (*a. sternocleidomastoidea*) is a large and constant branch, generally arising from the artery close to its commencement, but sometimes springing directly from the external carotid. It first passes downward and backward over the hypoglossal nerve, and enters the substance of the muscle in company with the spinal accessory nerve.

The **auricular branch** (*ramus auricularis*) supplies the back part of the concha. It frequently gives off a branch, which enters the skull through the mastoid foramen and supplies the dura, the diploë, and the mastoid cells.

The **meningeal or dural branch** (*ramus meningeus*) ascends with the internal jugular vein, and enters the skull through the foramen lacerum posterius, or through the anterior condylar foramen, to supply the dura in the posterior fossa.

The **mastoid branch** (*ramus mastoideus*) is a small vessel, by no means constant. It passes into the skull through the mastoid foramen and is distributed upon the dura of the posterior fossa.

The **arteria princeps cervicis** (*ramus descendens*), the largest branch of the occipital, descends along the back part of the neck and divides into a superficial and a deep branch. The superficial branch runs beneath the Splenius, giving off branches which perforate that muscle to supply the Trapezius, and then anastomose with the superficial cervical artery, a branch of the transversalis colli; the deep branch passes beneath the Complexus between it and the Semispinalis colli, and anastomoses with branches from the vertebral and with the deep cervical artery, a branch of either the superior intercostal or the subclavian. The anastomosis between these vessels helps to establish the collateral circulation after ligation of the carotid or subclavian artery.

The **cranial branches** (*rami occipitales*) of the occipital artery are distributed upon the occiput; they are very tortuous, and lie between the integument and Occipitofrontalis, anastomosing with the artery of the opposite side, the posterior auricular and temporal arteries. They supply the back part of the Occipitofrontalis muscle, the integument, and pericranium.

5. The **posterior auricular artery** (*a. auricularis posterior*) (Figs. 436 and 438) is a small vessel which *arises* from the external carotid, above the Digastric and Stylohyoid muscles, opposite the apex of the styloid process. It ascends, under cover of the parotid gland, on the styloid process of the temporal bone, to the groove between the cartilage of the ear and the mastoid process, immediately above which it divides into its two terminal branches, the **auricular** and **mastoid**. Just before arriving at the mastoid process, this artery is crossed by the facial nerve, and has beneath it the spinal accessory nerve.

Branches.—Besides several small branches to the Digastric, Stylohyoid, and Sternomastoid muscles and to the parotid gland, this vessel gives off three branches:

Stylomastoid.

Auricular.

Mastoid.

The **stylomastoid branch** (*a. stylomastoidca*) enters the stylomastoid foramen, and supplies the tympanum, mastoid cells, and semicircular canals. In the young subject a branch from this vessel forms, with the tympanic branch from the internal maxillary, a vascular circle, which surrounds the tympanic membrane, and from which delicate vessels ramify on that membrane. It anastomoses with the petrosal branch of the middle meningeal artery by a twig, which enters the hiatus Fallopii.

The **auricular branch** (*ramus auricularis*), one of the terminal branches, ascends behind the ear, beneath the Retrahens aurem muscle, and is distributed to the back part of the cartilage of the ear, upon which it ramifies minutely, some branches curving around the margin of the fibrocartilage, others perforating it, to supply its anterior surface. It anastomoses with the posterior branch and also with the anterior auricular branches of the superficial temporal.

The **mastoid branch** (*ramus mastoideus*) passes backward, over the Sternomastoid muscle, to the scalp above and behind the ear. It supplies the posterior belly of the Occipitofrontalis muscles and the scalp in this situation. It anastomoses with the occipital artery.

6. The **ascending pharyngeal artery** (*a. pharyngea ascendens*) (Figs. 435 and 436), the smallest branch of the external carotid, is a long, slender vessel, deeply seated in the neck, beneath the other branches of the external carotid and the Stylopharyngeus muscle. It *arises* from the back part of the external carotid, near the commencement of that vessel, and ascends vertically between the internal carotid and the side of the pharynx, to the under surface of the base of the skull, lying on the Rectus capitis anticus major muscle.

Branches.—Its branches may be subdivided as follows:

Prevertebral.
Pharyngeal.

Meningeal or dural.

Palatine.
Tympanic.

The **prevertebral branches** are numerous small vessels which supply the Recti capitis antici and Longus colli muscles, the sympathetic, hypoglossal, and vagus nerves, and the lymph nodes. They anastomose with the ascending cervical artery, a branch of the inferior thyroid.

The **pharyngeal branches** (*rami pharyngei*) are three or four in number. Two of these descend to supply the Middle and Inferior constrictors and the Stylopharyngeus, ramifying in the substance of the muscles and in the submucous tissue of the mucous membrane lining them.

The **palatine branch** varies in size, and may take the place of the ascending palatine branch of the facial artery, when that vessel is small. It passes inward upon the Superior constrictor, and sends ramifications to the soft palate and tonsil, and supplies a branch to the Eustachian tube.

The **tympanic branch** (*a. tympanica inferior*) is a small artery which passes through a minute foramen in the petrous portion of the temporal bone, in company with the tympanic branch of the glossopharyngeal nerve to supply the inner wall of the tympanum and anastomose with the other tympanic arteries.

The **meningeal or dural branches** consist of several small vessels, which pass through foramina in the base of the skull, to supply the dura. One, the **posterior meningeal or postdural** (*a. meningea posterior*), enters the cranium through the foramen lacerum posterius; a second passes through the foramen lacerum medium; and occasionally a third through the anterior condylar foramen.

Applied Anatomy.—The ascending pharyngeal artery has been wounded from the throat, as in the case in which the stem of a tobacco-pipe was driven into the vessel, causing fatal hemorrhage. After removal of the tonsil there is sometimes severe bleeding. This is almost never due to wounding of the internal carotid artery, as the latter vessel, if normally placed, is too far away to be damaged. The bleeding comes from the branches of the ascending pharyngeal, tonsillar, or ascending palatine arteries.

7. The **superficial temporal artery** (*a. temporalis superficialis*) (Figs. 435 and 438), the smaller of the two terminal branches of the external carotid, appears, from its direction, to be the continuation of that vessel. It commences in the substance of the parotid gland, behind the neck of the mandible, and crosses over the posterior root of the zygoma, passes beneath the Attrahens aurem muscle, lying on the temporal fascia, and divides, about two inches above the zygomatic arch, into two branches, an **anterior** and a **posterior**. This vessel is accompanied by the auriculo-temporal nerve.

Relations.—The superficial temporary artery, as it crosses the zygoma, is covered by the Attrahens aurem muscle, and by a dense fascia given off from the parotid gland; it is crossed by the temporofacial division of the facial nerve and one or two veins, and is accompanied by the auriculotemporal nerve, which lies behind it.

Besides some twigs to the parotid gland, the articulation of the mandible, and the Masseter muscle, its branches are:

Transverse facial.	Anterior auricular.
Middle temporal.	Anterior temporal.
Orbital.	Posterior temporal.

The **transverse facial branch** (*a. transversa faciei*) is given off from the temporal before that vessel quits the parotid gland; running forward through its substance, it passes transversely across the face, between the parotid duct and the lower border of the zygoma, and divides on the side of the face into numerous branches, which supply the parotid gland, the Masseter muscle, and the integument, anastomosing with the facial, masseteric, and infraorbital arteries. This vessel rests on the Masseter, and is accompanied by one or two branches of the facial nerve. It is sometimes a branch of the external carotid.

The **middle temporal artery** (*a. temporalis media*) arises immediately above the zygomatic arch, and, perforating the temporal fascia, gives branches to the Temporal muscle, anastomosing with the deep temporal branches of the internal maxillary. It occasionally gives off an **orbital branch**, which runs along the upper border of the zygoma, between the two layers of the temporal fascia, to the outer angle of the orbit. This branch, which may arise directly from the superficial temporal artery, supplies the Orbicularis palpebrarum, and anastomoses with the lacrimal and palpebral branches of the ophthalmic artery.

The **orbital artery** (*a. zygomaticoorbitalis*) comes off from the temporal just above the zygoma and is distributed to the upper orbital margin.

The **anterior auricular branches** (*rami auriculares anteriores*) are distributed to the anterior portion of the pinna, the lobule, and part of the external meatus, anastomosing with branches of the posterior auricular.

The **anterior temporal** runs tortuously upward and forward, to the forehead, supplying the muscles, integument, and pericranium in this region, and anastomoses with the supraorbital and frontal arteries. The terminal portion of the anterior branch is called the **frontal artery** (*ramus frontalis*).

The **posterior temporal**, larger than the anterior, curves upward and backward along the side of the head, lying superficial to the temporal fascia, and inosculates with its fellow of the opposite side, and with the posterior auricular and occipital arteries. The terminal portion of the posterior branch is named the **parietal artery** (*ramus parietalis*).

Applied Anatomy.—The temporal artery, as it crosses the zygoma, lies immediately beneath the skin, and its pulsations may be readily felt during the administration of an anesthetic, or under circumstances where the radial pulse is not available; or it may be easily compressed against the bone in order to check bleeding from the temporal region of the scalp. When a flap is raised from this part of the head, as in the operation of trephining, the incision should be shaped like a horseshoe, with its convexity upward, so that the flap shall contain the temporal artery which insures a sufficient supply of blood. The same principle is applied, as far as possible, in making incisions to raise flaps in other parts of the scalp.

8. The **internal maxillary artery** (*a. maxillaris interna*) (Figs. 441 and 442), the larger of the two terminal branches of the external carotid, *arises* behind the neck of the mandible, and is at first embedded in the substance of the parotid gland; it passes inward between the ramus of the mandible and the internal lateral ligament, and then upon the outer surface of the External pterygoid muscle to the sphenomaxillary fossa to supply the deep structures of the face. For convenience of description it is divided into three portions—a **maxillary**, a **pterygoid**, and a **sphenomaxillary**.

The **first or maxillary portion** passes horizontally forward and inward, between the ramus of the mandible and the internal lateral ligament, where it lies parallel

to and a little below the auriculotemporal nerve; it crosses the inferior dental nerve, and lies along the lower border of the External pterygoid muscle.

The **second or pterygoid portion** runs obliquely forward and upward under cover of the ramus of the mandible, on the outer (very frequently on the inner) surface of the External pterygoid muscle; it then passes between the two heads of origin of this muscle and enters the sphenomaxillary fossa.

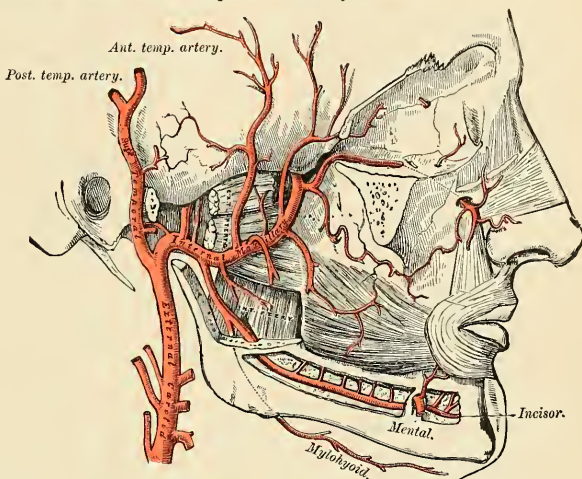


FIG. 441.—The internal maxillary artery and its branches.

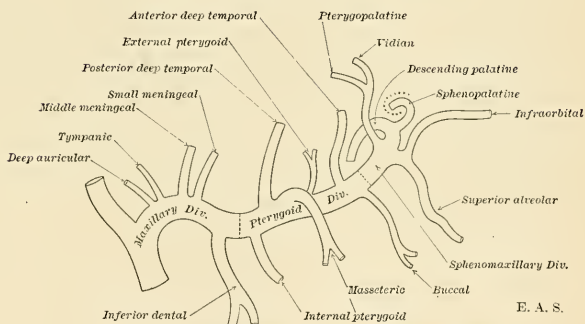


FIG. 442.—Plan of the branches of the internal maxillary artery.

The **third or sphenomaxillary portion** lies in relation with Meckel's ganglion.

The branches of this vessel may be divided into three groups, corresponding with its three divisions.

Branches of the maxillary portion (Fig. 442):

Anterior tympanic.

Deep auricular.

Middle meningeal or Medidural.

Small meningeal or Parvidural.

Inferior dental.

The **anterior tympanic branch** (*a. tympanica anterior*) passes upward behind the articulation of the mandible, enters the tympanum through the Glaserian fissure, and ramifies upon the membrana tympani, forming a vascular circle around the membrane with the stylomastoid artery, and anastomosing with the Vidian and the tympanic branch from the internal carotid.

The **deep auricular branch** (*a. auricularis profunda*) often arises in common with the preceding. It ascends in the substance of the parotid gland, behind the temporomaxillary articulation, pierces the cartilaginous or bony wall of the external auditory meatus, and supplies its cuticular lining and the outer surface of the tympanic membrane. It gives a branch to the temporomandibular joint.

The **middle meningeal or medidural branch** (*a. meningea media*) is the largest of the branches which supply the dura. It ascends between the internal lateral ligament and the neck of the mandible, and passes vertically upward between the two roots of the auriculotemporal nerve to the foramen spinosum of the sphenoid bone, through which it enters the cranium; it then runs upward and forward in a groove on the greater wing of the sphenoid bone and divides into two branches, anterior and posterior. The **anterior branch**, the larger, crosses the greater wing of the sphenoid, and reaches the groove, or canal, in the antero-inferior angle of the parietal bone, and then divides into two branches which spread out between the dura and internal surface of the cranium, some passing upward as far as the vertex, and others backward to the occipital region. The **posterior branch** crosses the squamous portion of the temporal, and on the inner surface of the parietal bone divides into branches which supply the posterior part of the dura and cranium. The branches of this vessel are distributed partly to the dura, but chiefly to the bones; they anastomose with the arteries of the opposite side, and with the anterior and posterior meningeal arteries.

The middle meningeal on entering the cranium gives off the following collateral branches: (1) Numerous small vessels to the Gasserian ganglion, and to the dura in this situation. (2) A branch, the **petrosal branch** (*ramus petrosus superficialis*), which enters the hiatus Fallopii, supplies the facial nerve, and anastomoses with the stylomastoid branch of the posterior auricular artery. (3) A minute **superior tympanic branch** (*a. tympanica superior*), which runs in the canal for the Tensor tympani muscle, and supplies this muscle and the lining membrane of the canal. (4) **Orbital branches**, which pass through the sphenoidal fissure, or through separate canals in the greater wing of the sphenoid to anastomose with the lacrimal or other branches of the ophthalmic artery. (5) **Temporal or anastomotic branches**, which pass through the foramina in the greater wing of the sphenoid bone and anastomose in the temporal fossa with the deep temporal arteries.

Applied Anatomy.—The middle meningeal is an artery of considerable surgical importance, as it may be injured in *fractures of the temporal region* of the skull. The vessel may be ruptured by traumatism, even though the skull escape fracture. *Rupture of the middle meningeal artery* will be followed by considerable hemorrhage between the bone and dura, which may cause compression of the brain and require the operation of trephining for its relief. This artery crosses the anterior inferior angle of the parietal bone at a point $1\frac{1}{2}$ inches (3.75 cm.) behind the external angular process of the frontal bone, and $1\frac{3}{4}$ inches (4.5 cm.) above the zygoma. From this point the anterior branch passes upward and slightly backward to the sagittal suture, lying about $\frac{1}{2}$ inch (12 mm.) to $\frac{3}{4}$ inch (18 mm.) behind the coronal suture. The posterior branch passes upward and backward over the squamous portion of the temporal bone. In order to expose the artery as it lies in the groove in the parietal bone, a semilunar incision, with its convexity upward, should be made, commencing an inch behind the external angular process, and carried backward for two inches. The structures cut through are: (1) Skin; (2) superficial fascia, with branches of the superficial temporal vessels and nerves; (3) the fascia continued down from the aponeurosis of the Occipitofrontalis; (4) the two layers of the temporal fascia; (5) the Temporal muscle; (6) the deep temporal vessels; (7) the pericranium. The bone is trephined, the clot removed, and the vessel secured by ligatures, suture ligatures, or gauze packing.

The **small meningeal or parvidural branch** (*ramus meningeus accessorius*) is sometimes derived from the preceding. It enters the skull through the foramen ovale, and supplies the Gasserian ganglion and dura.

The **inferior dental branch** (*a. alveolaris inferior*) descends with the inferior dental nerve to the foramen on the inner side of the ramus of the mandible. It runs along the *dental canal* in the substance of the bone, accompanied by the nerve, and opposite the first bicuspid tooth divides into two branches, the incisor and mental; the **incisor branch** is continued forward beneath the incisor teeth as far as the symphysis, where it anastomoses with the artery of the opposite side; the **mental branch** (*a. mentalis*) escapes with the nerve at the mental foramen, supplies the structures composing the chin, and anastomoses with the submental, inferior labial, and inferior coronary arteries. Near its origin the inferior dental artery gives off a **lingual branch**, which descends with the lingual nerve and supplies the mucous membrane of the mouth. As the inferior dental artery enters the foramen it gives off a **mylohyoid branch** (*ramus mylohyoideus*), which runs in the mylohyoid groove, and ramifies on the under surface of the Mylohyoid muscle. The inferior dental artery and its incisor branches during their course through the substance of the bone give off a few twigs which are lost in the cancellous tissue, and a series of branches which correspond in number to the roots of the teeth; these enter the minute apertures at the extremities of the fangs and supply the pulp of the teeth.

Branches of the pterygoid portion (Fig. 442):

Deep temporal.
Pterygoid.

Masseteric.
Buccal.

These branches are distributed, as their names imply, to the muscles in the maxillary region.

The **deep temporal branches**, two in number, **anterior** (*a. temporalis profunda anterior*) and **posterior** (*a. temporalis profunda posterior*), each occupy that part of the temporal fossa indicated by its name. Ascending between the Temporal muscle and pericranium, they supply the muscle and anastomose with the middle temporal artery. The anterior branch communicates with the lacrimal artery by means of small branches which perforate the malar bone and greater wing of the sphenoid.

The **pterygoid branches** (*rami pterygoidei*), irregular in their number and origin, supply the Pterygoid muscles.

The **masseteric** (*a. masseterica*) is a small branch which passes outward, above the sigmoid notch of the mandible, to the deep surface of the Masseter muscle. It supplies that muscle, and anastomoses with the masseteric branches of the facial and with the transverse facial artery.

The **buccal** (*a. buccinatoria*) is a small branch which runs obliquely forward between the Internal pterygoid and the ramus of the mandible, to the outer surface of the Buccinator, to which it is distributed, anastomosing with branches of the facial artery.

Branches of the sphenomaxillary portion (Fig. 442):

Alveolar or Posterior dental.
Infraorbital.
Descending palatine.

Vidian.
Pterygopalatine.
Naso- or sphenopalatine.

The **alveolar or posterior dental branch** (*a. alveolaris superior posterior*) is given off from the internal maxillary in conjunction with the infraorbital, and just as the trunk of the vessel is passing into the sphenomaxillary fossa. Descending upon the tuberosity of the maxilla, it divides into numerous branches, some of which enter the posterior dental canals, to supply the upper molar and bicuspid teeth and the lining of the antrum, while others are continued forward on the alveolar process to supply the gums.

The **infraorbital** (*a. infraorbitalis*) appears, from its direction, to be the continuation of the trunk of the internal maxillary, but often it *arises* from that vessel in conjunction with the preceding branch. It runs along the infraorbital canal with the superior maxillary nerve, and emerges upon the face at the infraorbital foramen, beneath the Levator labii superioris muscle. While in the canal, it gives off (*a*) branches which ascend into the orbit, and assist in supplying the Inferior rectus and Inferior oblique muscles and the lacrimal gland, and (*b*) the **anterior dental branches** (*aa. alveolares superiores anteriores*), which descend through the anterior dental canals in the bone to supply the mucous membrane of the antrum and the front teeth of the maxilla. On the face, some branches pass upward to the inner angle of the orbit and the lacrimal sac, anastomosing with the angular branch of the facial artery; others run inward toward the nose, anastomosing with the nasal branch of the ophthalmic; and others descend beneath the Levator labii superioris muscle, and anastomose with the transverse facial and buccal arteries.

The four remaining branches arise from that portion of the internal maxillary which is contained in the sphenomaxillary fossa.

The **descending palatine** (*a. palatina descendens*) descends through the posterior palatine canal with the anterior palatine branch of the sphenopalatine (Meckel's) ganglion, and, emerging from the posterior palatine foramen, runs forward in a groove on the inner side of the alveolar border of the hard palate to the anterior palatine canal, where the terminal branch of the artery passes upward through the incisive canal (foramen of Stenson) to anastomose with the nasopalatine artery. Branches are distributed to the gums, the mucous membrane of the hard palate, and the palatine glands. In the palatine canal it gives off branches which descend in the accessory palatine canals to supply the soft palate and tonsil, anastomosing with the ascending palatine artery.

Applied Anatomy.—The position of the descending palatine artery on the hard palate should be borne in mind in performing an operation for the closure of a cleft in the hard palate, as the vessel is in danger of being wounded, and may give rise to formidable hemorrhage. In case it should be wounded it may be necessary to plug the posterior palatine canal in order to arrest the bleeding.

The **Vidian branch** (*a. canalis pterygoidei*) passes backward along the Vidian canal with the Vidian nerve. It is distributed to the upper part of the pharynx and Eustachian tube, sending a small branch into the tympanum, which anastomoses with the other tympanic arteries.

The **pterygopalatine**, a very small branch, runs backward through the pterygopalatine canal with the pharyngeal nerve, and is distributed to the upper part of the pharynx and Eustachian tube.

The **naso- or sphenopalatine** (*a. sphenopalatina*) passes through the sphenopalatine foramen into the cavity of the nose, at the back part of the superior meatus, and divides into several branches. One, the **nasopalatine**, or **artery of the septum**, courses obliquely downward and forward along the septum nasi, supplies the mucous membrane, and anastomoses in front with the terminal branch of the descending palatine; the other branches, two or three in number, are distributed to the lateral wall of the nose, the antrum, and to the ethmoidal and sphenoidal cells.

THE TRIANGLES OF THE NECK (Fig. 443).

The student having considered the relative anatomy of the large arteries of the neck and their branches, and the relations they bear to the veins and nerves, should now examine these structures collectively, as they present themselves in certain

regions of the neck, in each of which important operations are constantly being performed.

The side of the neck presents a somewhat quadrilateral outline, limited, *above*, by the lower border of the body of the mandible, and an imaginary line extending from the angle of the mandible to the mastoid process; *below*, by the prominent upper border of the clavicle; in *front*, by the median line of the neck; *behind*, by the anterior margin of the Trapezius muscle. This space is subdivided into two large triangles by the Sternomastoid muscle, which passes obliquely across the neck, from the sternum and clavicle below to the mastoid process above. The triangular space in front of this muscle is called the **anterior triangle**; and that behind it, the **posterior triangle**.

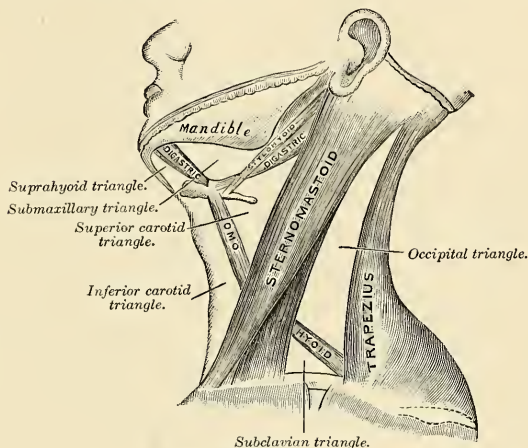


FIG. 443.—The triangles of the neck.

The **anterior triangle** is bounded, in *front*, by a line extending from the symphysis menti to the sternum; *behind*, by the anterior margin of the Sternomastoid; its *base*, directed upward, is formed by the lower border of the body of the mandible and a line extending from the angle of the mandible to the mastoid process; its *apex* is below, at the sternum. This space is subdivided into four smaller triangles by the Digastric muscle above and the anterior belly of the Omohyoid below. These smaller triangles are named from below upward, the **inferior carotid**, the **submaxillary**, and the **suprahyoid triangles**.

The **inferior carotid triangle**, or the **triangle of necessity**, is bounded, in *front*, by the median line of the neck; *behind*, by the anterior margin of the Sternomastoid; *above*, by the anterior belly of the Omohyoid; and is covered by the integument, superficial fascia, Platysma, and deep fascia, ramifying between which are some of the descending branches of the superficial cervical plexus. Beneath these superficial structures are the Sternohyoid and Sternothyroid muscles, which, together with the anterior margin of the Sternomastoid, conceal the lower part of the common carotid artery.¹ The floor of this triangle is formed by the Longus

¹ Therefore, the common carotid artery and internal jugular vein are not, strictly speaking, contained in this triangle, since they are covered by the Sternomastoid muscle; that is to say, lie behind the anterior border of that muscle, which forms the posterior border of the triangle. But, as they lie very close to the structures which are really contained in the triangle, and whose position it is essential to remember in operating on this part of the artery, it has seemed expedient to study the relations of all these parts together.

colli muscle below and by the Scalenus anticus muscle above, between which muscles the vertebral artery and vein will be found passing into the foramen of the transverse process of the sixth cervical vertebra. A small portion of the origin of the Rectus capitis anticus major may also be seen on the floor of the space.

The common carotid artery is enclosed within its sheath, together with the internal jugular vein and vagus nerve; the vein lying on the outer side of the artery on the right side of the neck, but overlapping it below on the left side; the nerve lying between the artery and vein, on a plane posterior to both. In front of the sheath are a few filaments descending from the loop of communication between the descendens and communicans hypoglossi; behind the sheath are seen the inferior thyroid artery, the recurrent laryngeal nerve, and the sympathetic cord; and on its inner side, the trachea, the thyroid gland—much more prominent in the female than in the male—and the lower part of the larynx. By cutting into the upper part of this space and slightly displacing the Sternomastoid muscle the common carotid artery may be tied below the Omohyoid muscle.

The **superior carotid triangle**, or the **triangle of election**, is bounded, *behind*, by the Sternomastoid; *below*, by the anterior belly of the Omohyoid; and *above*, by the posterior belly of the Digastric muscle. It is covered by the integument, superficial fascia, Platysma, and deep fascia, ramifying between which are branches of the facial and superficial cervical nerves. Its floor is formed by parts of the Thyrohyoid and Hyoglossus muscles, and the Inferior and Middle constrictor muscles of the pharynx. This space, when dissected, is seen to contain the upper part of the common carotid artery, which bifurcates opposite the upper border of the thyroid cartilage into the external and internal carotid. These vessels are occasionally somewhat concealed from view by the anterior margin of the Sternomastoid muscle, which overlaps them. The external and internal carotid lie side by side, the external being the more anterior of the two. The following branches of the external carotid are also met with in this space, the superior thyroid running forward and downward, the lingual directly forward, the facial forward and upward, the occipital backward, and the ascending pharyngeal directly upward on the inner side of the internal carotid. The veins met with are the internal jugular, which lies on the outer side of the common and internal carotid arteries, and veins corresponding to the above-mentioned branches of the external carotid—viz., the superior thyroid, the lingual, facial, ascending pharyngeal, and sometimes the occipital, all of which accompany their corresponding arteries and terminate in the internal jugular. The nerves in this space are the following: In front of the sheath of the common carotid is the descendens hypoglossi. The hypoglossal nerve crosses both the internal and external carotids above, curving around the occipital artery at its origin. Within the sheath, between the artery and vein, and behind both, is the vagus nerve; behind the sheath, the sympathetic cord. On the outer side of the vessels the spinal accessory nerve runs for a short distance before it pierces the Sternomastoid muscle; and on the inner side of the external carotid, just below the hyoid bone, may be seen the internal branch of the superior laryngeal nerve; and, still more inferiorly, the external branch of the same nerve. The upper part of the larynx and lower part of the pharynx are also found in the front part of this space.

The **submaxillary triangle** corresponds to the part of the neck immediately beneath the body of the mandible. It is bounded, *above*, by the lower border of the body of the mandible and a line drawn from its angle to the mastoid process; *below*, by the posterior belly of the Digastric muscle and the Stylohyoid muscle; in *front*, by the anterior belly of the Digastric. It is covered by the integument, superficial fascia, Platysma, and deep fascia, ramifying between which are branches of the facial and ascending filaments of the superficial cervical nerves. Its floor is formed by the Mylohyoid and Hyoglossus muscles. This space contains, in front, the

submaxillary gland, superficial to which is the facial vein, while embedded in it are the facial artery, and its glandular branches; beneath this gland, on the surface of the Mylohyoid muscle, are the submental artery and the mylohyoid artery and nerve. The posterior part of this triangle is separated from the anterior part by the stylomaxillary ligament; it contains the external carotid artery, ascending deeply in the substance of the parotid gland; this vessel here lies in front of, and superficial to, the internal carotid, being crossed by the facial nerve, and gives off in its course the posterior auricular, temporal, and internal maxillary branches; more deeply are the internal carotid artery, the internal jugular vein, and the vagus nerve, separated from the external carotid by the Styloglossus and Stylopharyngeus muscles and the glossopharyngeal nerve.¹

The **suprahyoid triangle** is limited *behind* by the anterior belly of the Digastric, *in front* by the middle line of the neck between the symphysis menti and the hyoid bone, *below* by the body of the hyoid bone; its floor is formed by the Mylohyoid. It contains one or two lymph nodes and some small veins; the latter unite to form the anterior jugular vein.

The **posterior triangle** is bounded, *in front*, by the Sternomastoid muscle; *behind*, by the anterior margin of the Trapezius; its *base* corresponds to the middle third of the clavicle; its *apex*, to the occiput. The space is crossed, about an inch above the clavicle, by the posterior belly of the Omohyoid, which divides it unequally into two, an **upper or occipital** and a **lower or subclavian triangle**.

The **occipital triangle**, the larger division of the posterior triangle, is bounded, *in front*, by the Sternomastoid; *behind*, by the Trapezius; *below*, by the Omohyoid. Its floor is formed from above downward by the Splenius, Levator anguli scapulae, and the Middle and Posterior scaleni muscles. It is covered by the integument, the Platysma below, the superficial and deep fasciæ; the spinal accessory nerve is directed obliquely across the space from the Sternomastoid, which it pierces, to the under surface of the Trapezius; below, the descending branches of the cervical plexus and the transversalis colli artery and vein cross the space. A chain of lymph nodes is also found running along the posterior border of the Sternomastoid, from the mastoid process to the root of the neck.

The **subclavian triangle**, the smaller of the two posterior triangles, is bounded, *above*, by the posterior belly of the Omohyoid; *below*, by the clavicle, its *base*, directed forward, being formed by the Sternomastoid. The size of the subclavian triangle varies according to the extent of attachment of the clavicular portion of the Sternomastoid and Trapezius muscles, and also according to the height at which the Omohyoid crosses the neck above the clavicle. Its height also varies much according to the position of the arm, being much diminished by raising the limb, on account of the ascent of the clavicle, and increased by drawing the arm downward, when that bone is depressed. This space is covered by the integument, the Platysma, the superficial and deep fasciæ, and crossed by the descending branches of the cervical plexus. Just above the level of the clavicle the third portion of the subclavian artery curves outward and downward from the outer margin of the Scalenus anticus, across the first rib, to the axilla. Sometimes this vessel rises as high as an inch and a half above the clavicle, or to any point intermediate between this and its usual level. Occasionally it passes in front of the Scalenus anticus or pierces the fibres of that muscle. The subclavian vein lies behind the clavicle, and is usually not seen in this space; but it occasionally rises as high up as the artery, and has even been seen to pass with that vessel behind the Scalenus anticus. The brachial plexus of nerves lies above the artery, and in close contact with it. Passing transversely behind the clavicle are the supra-

¹ The remark made about the carotid triangle applies also to this one. The structures enumerated as contained in its posterior part lie, strictly speaking, beneath the muscles which form the posterior boundary of the triangle; but as it is very important to bear in mind their close relation to the parotid gland, all these parts are spoken of together.

scapular vessels, and traversing its upper angle in the same direction, the transversalis colli artery and vein. The external jugular vein runs vertically downward behind the posterior border of the Sternomastoid muscle, to terminate in the subclavian vein; it receives the transverse cervical and suprascapular veins, which occasionally form a plexus in front of the artery, and a small vein which crosses the clavicle from the cephalic. The small nerve to the Subclavius muscle also crosses this triangle about its middle. A lymph node is also found in the space. Its floor is formed by the first rib with the first digitation of the Serratus magnus.

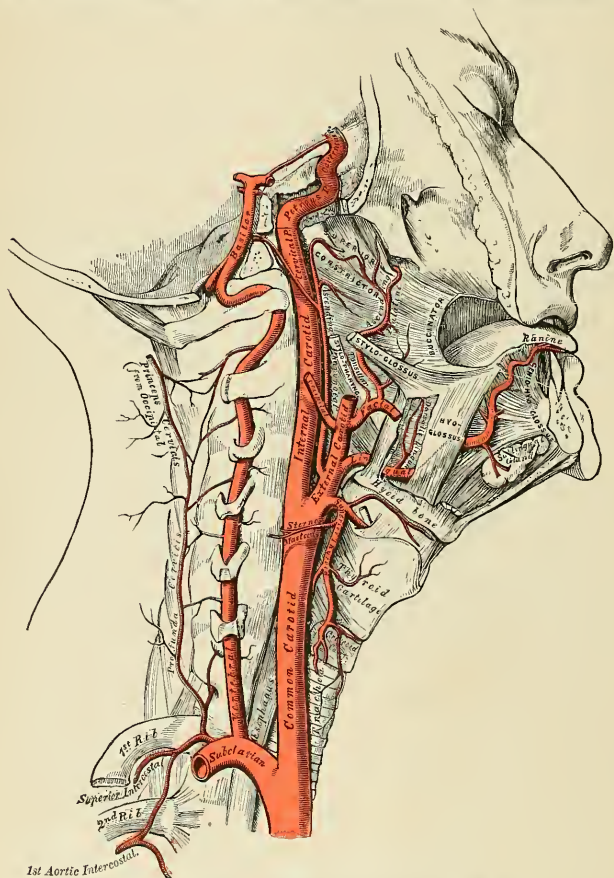


FIG. 444.—The internal carotid and vertebral arteries. Right side.

The Internal Carotid Artery (*A. Carotis Interna*).

The internal carotid artery supplies the anterior part of the brain, the eye and its appendages, and sends branches to the forehead and nose. Its size in the

adult is equal to that of the external carotid, though in the child it is larger than that vessel. It is remarkable for the number of curvatures that it presents in different parts of its course. It occasionally has one or two flexures near the base of the skull, while in its passage through the carotid canal and along the side of the body of the sphenoid bone it describes a double curve which resembles somewhat the letter S.

In considering the course and relations of this vessel it may be conveniently divided into four portions—the **cervical**, **petrous**, **cavernous**, and **cerebral portions**.

Cervical Portion.—This portion of the internal carotid commences at the bifurcation of the common carotid, opposite the upper border of the thyroid cartilage, and runs perpendicularly upward, in front of the transverse processes of the upper three cervical vertebræ, to the carotid canal in the petrous portion of the temporal bone. It is comparatively superficial at its commencement, where it is contained in the superior carotid triangle, and lies behind and to the outer side of the external carotid, overlapped by the Sternomastoid and covered by the deep fascia, Platysma, and integument; it then passes beneath the parotid gland, being crossed by the hypoglossal nerve, the Digastric and Stylohyoid muscles, and the occipital and posterior auricular arteries. Higher up, it is separated from the external carotid by the Styloglossus and Stylopharyngeus muscles, the tip of the styloid process and the stylohyoid ligament, the glossopharyngeal nerve, and pharyngeal branch of the vagus.

Relations.—It is in relation, *behind*, with the Rectus capitis anticus major, the superior cervical ganglion of the sympathetic, and superior laryngeal nerve; *externally*, with the internal jugular vein and vagus nerve, the nerve lying on a plane posterior to the artery; *internally*, with the pharynx, tonsil, the superior laryngeal nerve, and ascending pharyngeal artery. At the base of the skull the glossopharyngeal, vagus, spinal accessory, and hypoglossal nerves lie between the artery and the internal jugular vein.

PLAN OF THE RELATIONS OF THE INTERNAL CAROTID ARTERY IN THE NECK.

In front.

Skin, superficial and deep fascia.
Platysma.
Sternomastoid.
Occipital and posterior auricular arteries.
Hypoglossal nerve.
Parotid gland.
Styloglossus and Stylopharyngeus muscles.
Glossopharyngeal nerve.
Pharyngeal branch of the vagus.

Externally.

Internal jugular vein.
Vagus nerve.



Internally.

Pharynx.
Superior laryngeal nerve.
Ascending pharyngeal artery.
Tonsil.

Behind.

Rectus capitis anticus major.
Sympathetic.
Superior laryngeal nerve.

Petrous Portion.—When the internal carotid artery enters the canal in the petrous portion of the temporal bone, it first ascends a short distance, then curves forward and inward, and again ascends as it leaves the canal to enter the cavity of

the skull between the lingula and petrosal process. In this canal the artery lies at first below and in front of the cochlea and tympanum; behind and internal to the canals for the Eustachian tube and Tensor tympani; from the tympanum it is separated by a thin, bony lamella. Farther forward it is separated from the Gasserian ganglion by a thin plate of bone, which forms the floor of the fossa for the ganglion and the roof of the horizontal portion of the canal. Frequently this bony plate is more or less deficient, and then the ganglion is separated from the artery by a fibrous membrane. The artery is separated from the bony wall of the carotid canal by a prolongation of the dura, and is surrounded by a number of small veins and by filaments of the carotid plexus, derived from the ascending branch of the superior cervical ganglion of the sympathetic.

Cavernous Portion.—The internal carotid artery in this part of its course is situated between the layers of the dura forming the cavernous sinus, but is covered by the lining membrane of the sinus. It at first ascends to the posterior clinoid process, then passes forward by the side of the body of the sphenoid bone, and again curves upward on the inner side of the anterior clinoid process, and perforates the dura forming the roof of the sinus. In this part of its course it is surrounded by filaments of the sympathetic nerve, and has in relation with it externally the abducent nerve.

Cerebral Portion.—Having perforated the dura, on the inner side of the anterior clinoid process, the internal carotid passes between the optic and oculomotor nerves to the anterior perforated substance at the inner extremity of the sylvian fissure, where it gives off its terminal or cerebral branches. This portion of the artery has the optic nerve on its inner side, and the oculomotor nerve externally.

Peculiarities.—The length of the internal carotid varies according to the length of the neck, and also according to the point of bifurcation of the common carotid. Its origin sometimes takes place from the arch of the aorta; in such rare instances this vessel has been found to be placed nearer the middle line of the neck than the external carotid, as far upward as the larynx, when the latter vessel crossed the internal carotid. The course of the vessel, instead of being straight, may be very tortuous. A few instances are recorded in which this vessel was altogether absent; in one of these the common carotid passed up the neck, and gave off the usual branches of the external carotid, the cranial portion of the internal carotid being replaced by two branches of the internal maxillary, which entered the skull through the foramen rotundum and the foramen ovale and joined to form a single vessel.

Applied Anatomy.—The cervical part of the internal carotid is very rarely wounded. Mr. Cripps, in an interesting paper in the *Medico-Chirurgical Transactions*, compares the rareness of a wound of the internal carotid with one of the external carotid or its branches. It is, however, sometimes injured by a *stab or gunshot wound in the neck*, or even occasionally by a *stab from within the mouth*, as when a person receives a thrust from the end of a parasol or falls down with a tobacco-pipe in his mouth. It used to be believed that the internal carotid was occasionally wounded in the removal of the tonsil. Such an accident cannot happen if the artery is normally placed. The severe and sometimes fatal hemorrhage which has followed this operation in a few instances probably had as its source enlarged branches of the ascending pharyngeal, tonsillar, or ascending palatine arteries. Recently, however, Dr. Gwilym G. Davis, of Philadelphia, demonstrated a specimen in which the internal carotid could have been wounded by incision of the tonsil. The indications for ligation are *wounds*, when the vessel should be exposed by a careful dissection and tied above and below the bleeding point; and *aneurism*, which if non-traumatic may be treated by ligation of the common carotid, but if traumatic in origin by exposing the sac and tying the vessel above and below. The incision for ligation of the cervical portion of the internal carotid should be made along the anterior border of the Sternomastoid, from the angle of the mandible to the upper border of the thyroid cartilage. The superficial structures being divided and the Sternomastoid defined and drawn outward, the cellular tissue must be carefully separated and the posterior belly of the Digastric muscle and the hypoglossal nerve sought for as guides to the vessel. When the artery is found the external carotid should be drawn inward and the Digastric muscles upward, and the aneurism needle passed from without inward.

Obstruction of the internal carotid by *embolism or thrombosis* may give rise to symptoms of cerebral anemia and softening if the collateral circulation is ill-developed. The patient suffers from giddiness, with failure of mental powers, and convulsions, coma, or hemiplegia on the opposite side of the body, may be observed.

The **branches** given off from the internal carotid artery are:

From the <i>Petrous Portion</i>	{ Tympanic (internal or deep). Vidian.
From the <i>Cavernous Portion</i>	{ Arteriae Receptaculi. Anterior Meningeal. Ophthalmic.
From the <i>Cerebral Portion</i>	{ Anterior Cerebral. Middle Cerebral. Posterior Communicating. Anterior Choroid or Prechoroid.

The cervical portion of the internal carotid gives off no branches.

1. The **tympanic** (*ramus caroticotympanicus*) is a small branch from the petrous portion, which enters the cavity of the tympanum through a minute foramen in the carotid canal, and anastomoses with the tympanic branch of the internal maxillary, and with the stylomastoid artery.

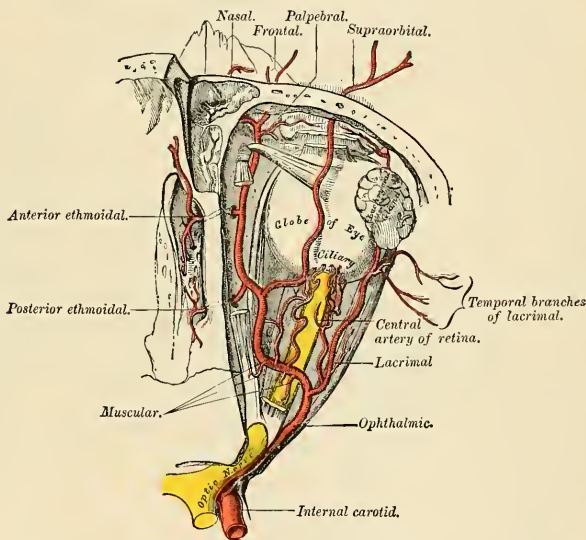


FIG. 445.—The ophthalmic artery and its branches, the roof of the orbit having been removed.

2. The **Vidian** is a small, inconstant branch which passes through the Vidian canal and anastomoses with the Vidian branch of the internal maxillary artery.

3. The **arteriae receptaculi** are numerous small vessels, derived from the internal carotid in the cavernous sinus; they supply the hypophysis (pituitary body), the Gasserian ganglion, and the walls of the cavernous and inferior petrosal sinuses. Some of these branches anastomose with branches of the middle meningeal.

4. The **anterior meningeal** (*a. meningea anterior*) is a small branch which passes over the lesser wing of the sphenoid to supply the dura of the anterior

fossa; it anastomoses with the dural branch from the posterior ethmoidal artery.

5. The **ophthalmic artery** (*a. ophthalmica*) arises from the internal carotid, just as that vessel is emerging from the cavernous sinus, on the inner side of the anterior clinoid process, and enters the orbit through the optic foramen, below and on the outer side of the optic nerve. It then passes over the nerve to the inner wall of the orbit and thence horizontally forward, beneath the lower border of the Superior oblique muscle, to a point behind the internal angular process of the frontal bone, where it divides into two terminal branches, the **frontal** and **nasal branches**. As the artery crosses the optic nerve it is accompanied by the nasal nerve, and is separated from the frontal nerve by the Rectus superior and Levator palpebrae superioris muscles.

Branches.—The branches of this vessel may be divided into an **orbital group**, which are distributed to the orbit and surrounding parts, and an **ocular group**, which supply the muscles and globe of the eye:

<i>Orbital Group.</i>	<i>Ocular Group.</i>
Lacrimal.	Short ciliary.
Supraorbital.	Long ciliary.
Posterior ethmoidal.	Anterior ciliary.
Anterior ethmoidal.	Central artery of the retina.
Internal palpebral.	Muscular.
Frontal.	
Nasal.	

The **lacrimal** (*a. lacrimalis*) is one of the largest branches derived from the ophthalmic, arising close to the optic foramen; not infrequently it is given off from the ophthalmic artery before it enters the orbit. It accompanies the lacrimal nerve along the upper border of the External rectus muscle, and is distributed to the lacrimal gland. Its terminal branches, escaping from the gland, are distributed to the eyelids and conjunctiva; of those supplying the eyelids, two are of considerable size and are named the **external palpebral** (*aa. palpebrales laterales*); they run inward in the upper and lower lids respectively, and anastomose with the *internal palpebral arteries*, forming an arterial circle in this situation. The lacrimal artery gives off one or two **malar branches**, one of which passes through a foramen in the malar bone, to reach the temporal fossa, and anastomoses with the deep temporal arteries; the other appears on the cheek through the malar foramen, and anastomoses with the transverse facial. A **recurrent** branch passes backward through the sphenoidal fissure to the dura, and anastomoses with a branch of the middle meningeal artery.

Peculiarities.—The lacrimal artery is sometimes derived from one of the anterior branches of the middle meningeal artery.

The **supraorbital artery** (*a. supraorbitalis*) arises from the ophthalmic as that vessel is crossing over the optic nerve. Ascending so as to arise above all the muscles of the orbit, it passes forward, with the supraorbital nerve, between the periosteum and Levator palpebrae muscle; and, passing through the supraorbital foramen, divides into a superficial and deep branch, which supply the integument, the muscles, and the pericranium of the forehead, anastomosing with the frontal, the anterior branch of the temporal, and the supraorbital artery of the opposite side. This artery in the orbit supplies the Superior rectus and the Levator palpebrae muscles, and sends a branch inward, across the pulley of the Superior oblique muscle, to supply the parts at the inner canthus. At the supraorbital foramen it frequently transmits a branch to the diploë.

The ethmoidal branches are two in number—posterior (*a. ethmoidalis posterior*), and anterior (*a. ethmoidalis anterior*). The posterior ethmoidal artery, which is the smaller, passes through the posterior ethmoidal foramen, supplies the posterior ethmoidal cells, and, entering the cranium, gives off a meningeal or dural branch,

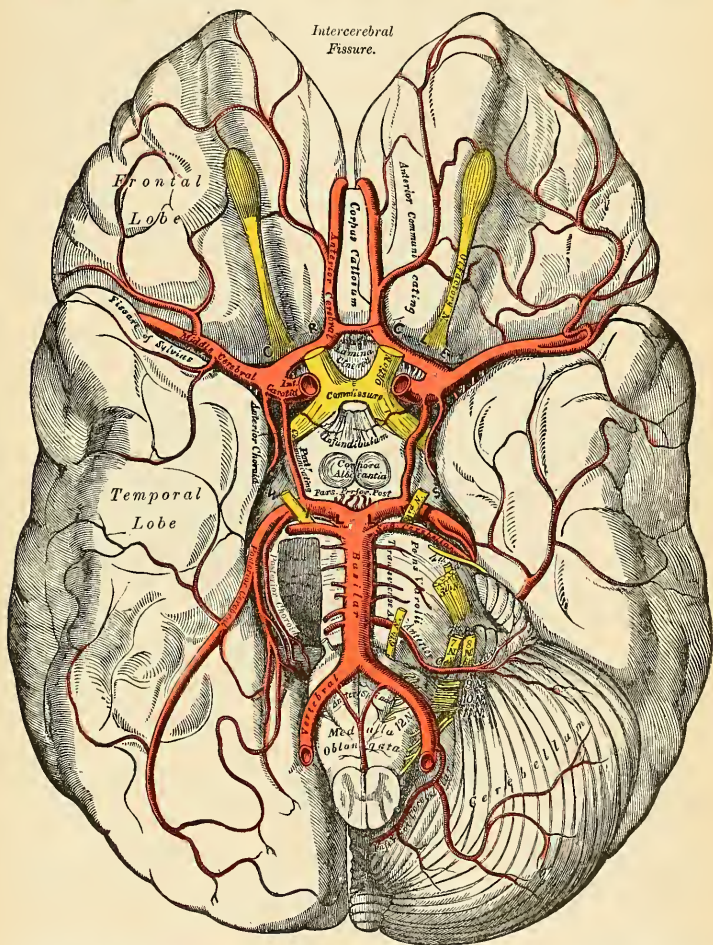


FIG. 446.—The arteries of the base of the brain. The right half of the cerebellum and pons have been removed. N. B.—It will be noticed that the two anterior cerebral arteries have been drawn at a considerable distance from each other; this makes the anterior communicating artery appear very much longer than it really is.

which supplies the adjacent dura; and nasal branches which descend into the nose through apertures in the cribriform plate, anastomosing with branches of the sphenopalatine. The anterior ethmoidal artery accompanies the nasal nerve through the anterior ethmoidal foramen, supplies the anterior ethmoidal cells and frontal

sinuses, and, entering the cranium, gives off a dural branch which supplies the adjacent dura; and nasal branches, which descend into the nose, through the slit by the side of the crista galli, and, running along the groove on the under surface of the nasal bone, supply the skin of the nose.

The **internal palpebral arteries** (*aa. palpebrales mediales*), two in number, **superior** and **inferior**, arise from the ophthalmic, opposite the pulley of the Superior oblique muscle; they leave the orbit to encircle the eyelids near their free margin, forming a **superior tarsal arch** (*arcus tarseus superior*) and an **inferior tarsal arch** (*arcus tarseus inferior*), which lie between the Orbicularis muscle and the tarsal plates. The superior palpebral anastomoses, at the outer angle of the orbit, with the orbital branch of the temporal artery, and with the upper of the two external palpebral branches from the lacrimal artery; the inferior palpebral anastomoses,

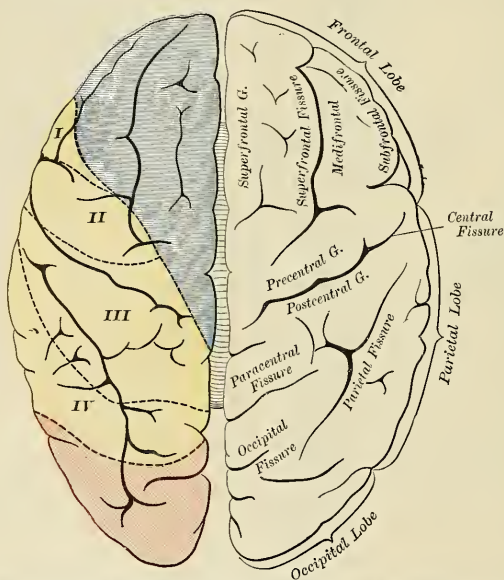


FIG. 447.—Vascular area of the upper surface of the cerebrum. I. The part supplied by the external and inferior frontal artery. II. The part supplied by the ascending frontal. III. The part supplied by the ascending parietal. IV. The part supplied by the sphenoparietal artery. (After Duret.)

at the outer angle of the orbit, with the lower of the two external palpebral branches from the lacrimal and with the transverse facial artery, and at the inner side of the lid with a branch from the angular artery. From this last anastomosis a branch passes to the nasal duct, ramifying in its mucous membrane, as far as the inferior meatus.

The **frontal artery** (*a. frontalis*), one of the terminal branches of the ophthalmic, leaves the orbit at its inner angle with the supratrochlear nerve, and, ascending on the forehead, supplies the integument, muscles, and pericranium, anastomosing with the supraorbital artery and with the frontal artery of the opposite side.

The **nasal artery** (*a. dorsalis nasi*), the other terminal branch of the ophthalmic, emerges from the orbit above the tendo oculi, and, after giving a branch to the upper part of the lacrimal sac, divides into two branches, one of which crosses

the root of the nose, the **transverse nasal**, and anastomoses with the angular artery; the other, the **dorsalis nasi**, runs along the dorsum of the nose, supplies its outer surface, and anastomoses with the artery of the opposite side and with the lateral nasal branch of the facial.

The **ciliary arteries** (*a. ciliares*) are divisible into three groups—the **short, long, and anterior**. The **short ciliary arteries** (*aa. ciliares posteriores breves*), from six to twelve in number, *arise* from the ophthalmic or some of its branches; they surround the optic nerve as they pass forward to the posterior part of the eyeball, pierce the sclera around the entrance of the nerve, and supply the choroid coat and ciliary processes. The **long ciliary arteries** (*aa. ciliares posteriores longae*), two in number, pierce the posterior part of the sclera at some little distance from the optic nerve, and run forward, along each side of the eyeball, between the sclera and choroid, to the ciliary muscle, where they divide into two branches; these form an arterial circle, the **circulus major**, around the circumference of the iris, from which numerous radiating branches pass forward, in its substance, to its pupillary aperture, where they form a second arterial circle, the **circulus minor**.

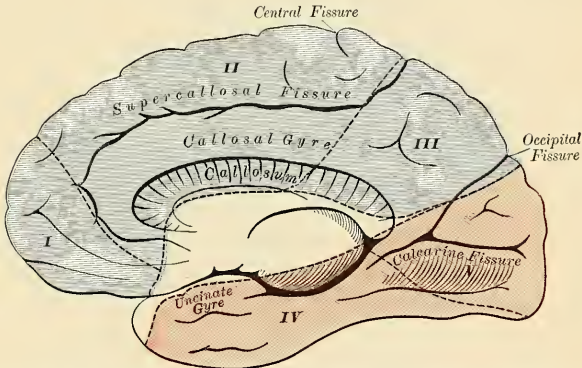


FIG. 448.—Vascular area of the internal surface of the cerebrum. I. The part supplied by the anterior internal frontal. II. The part supplied by the middle internal frontal. III. The part supplied by the posterior internal frontal. IV. The part supplied by the posterior temporal. V. The part supplied by the occipital, both terminal branches of the posterior cerebral. (After Duret.)

The **anterior ciliary arteries** (*aa. ciliares anteriores*) are derived from the muscular branches (see below); they pass to the front of the eyeball in company with the tendons of the Recti muscles, form a vascular zone beneath the conjunctiva, and then pierce the sclera a short distance from the cornea and terminate in the **circulus major** of the iris.

The **central artery of the retina** (*arteria centralis retinae*) is the first and one of the smallest branches of the ophthalmic artery. It runs for a short distance within the dural sheath of the optic nerve, but about half an inch behind the eyeball it pierces the optic nerve obliquely, and runs forward in the centre of its substance, and enters the globe of the eye through the porus opticus. Its mode of distribution will be described in the section on the anatomy of the eye.

The **muscular branches** (*rami musculares*), two in number, **superior** and **inferior**, frequently spring from a common trunk. The **superior**, the smaller, often wanting, supplies the Levator palpebrae, Superior rectus, and Superior oblique. The **inferior**, more constant in its existence, passes forward between the optic nerve and the Inferior rectus muscle, and is distributed to the External, Internal, and Inferior recti, and Inferior oblique. This vessel gives off most of the anterior ciliary

arteries. Additional muscular branches are given off from the lacrimal and supra-orbital arteries or from the ophthalmic itself.

(For the *Circulus* or Circle of Willis, the posterior cerebral artery, and the bloodvessels of the cerebellum, see page 617.)

The **anterior cerebral** (*a. cerebri anterior*) arises from the internal carotid at the inner extremity of the sylvian fissure. It passes forward and inward across the anterior perforated substance, above the optic nerve, to the commencement of the intercerebral fissure. Here it comes into close relationship with the anterior cerebral artery of the opposite side, and the two vessels are connected by a short anastomosing trunk, about two lines, $\frac{1}{6}$ inch (4 mm.) in length, the **anterior communicating artery**. From this point the two vessels run side by side in the intercerebral fissure, curve around the genu of the corpus callosum, and, turning backward, continue along its upper surface to its posterior part, where they terminate by anastomosing with the posterior cerebral arteries.

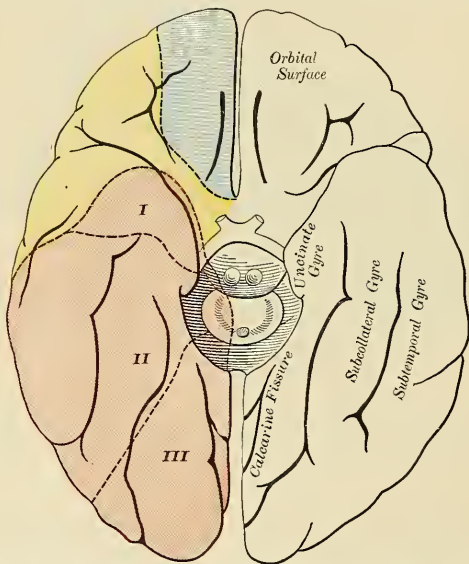


FIG. 449.—Vascular area of the inferior surface of the cerebrum. I. The part supplied by the anterior temporal from the posterior cerebral artery. II. The part supplied by the posterior temporal from the posterior cerebral artery. III. The part supplied by the occipital from the posterior cerebral artery. (After Duret.)

Branches.—In their course the anterior cerebral arteries give off the following branches:

Antero-median ganglionic.
Inferior internal frontal.

Anterior internal frontal.
Middle internal frontal.

Posterior internal frontal.

The **antero-median ganglionic** are a group of small arteries which arise at the commencement of the anterior cerebral artery; they pierce the anterior perforated

substance and lamina terminalis, and supply the rostrum of the corpus callosum, the septum lucidum, and the head of the caudate nucleus.

The **inferior internal frontal branches**, two or three in number, are distributed to the orbital surface of the frontal lobe, where they supply the olfactory lobe, gyrus rectus, and internal orbital (mesorbital) convolution.

The **anterior internal frontal** supply a part of the mesal surface of the prefrontal region, and send branches over the edge of the hemisphere to the superfrontal and medifrontal gyre and upper part of the precentral gyre.

The **middle internal frontal** supplies the corpus callosum, the callosal gyre, the

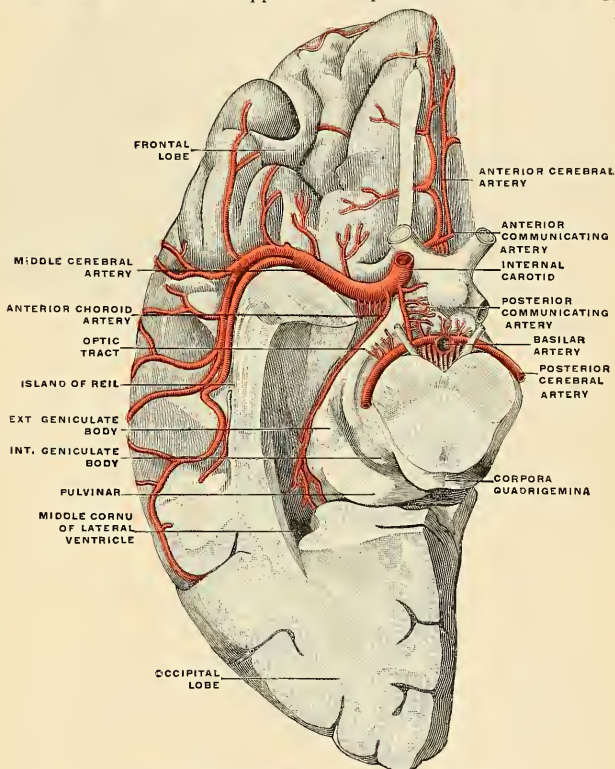


FIG. 450.—The anterior cerebral and choroid arteries. (Spalteholz.)

mesal surface of the superfrontal convolution, and the dorsal part of the precentral gyre.

The **posterior internal frontal** supplies the precuneus and adjacent outer surface of the hemisphere.

The **anterior communicating artery** (*a. communicans anterior*, *a. praecommunicans*) is a short branch, about 4 mm. in length, but of moderate size, connecting the two anterior cerebral arteries across the intercerebral fissure. Sometimes this vessel is wanting, the two arteries joining to form a single trunk, which afterward divides. Or the vessel may be wholly or partially divided into two;

frequently it is longer and smaller than usual. It gives off some of the antero-median ganglionic group of vessels, which are, however, principally derived from the anterior cerebral.

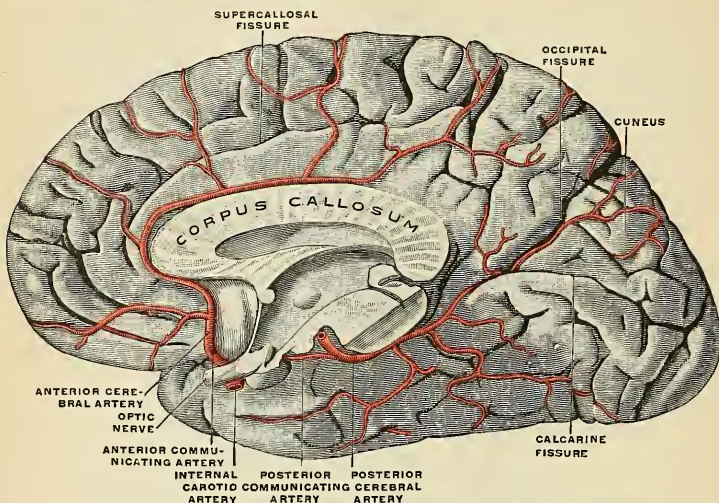


FIG. 451.—The arteries of the medial surface of the right cerebral hemisphere. (Spalteholz.)

The **middle cerebral artery** (*a. cerebri media*) (Fig. 452), the largest branch of the internal carotid, passes obliquely outward along the sylvian fissure, and divides on the surface of the insula into its terminal branches.

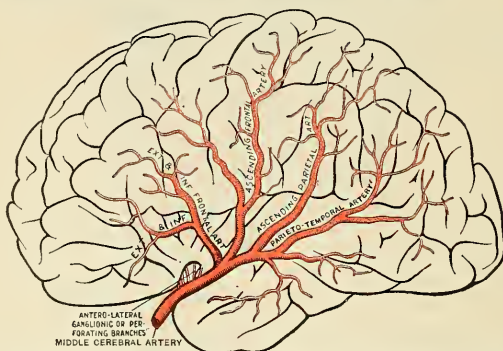

FIG. 452.—The distribution of the middle cerebral artery. The trunk of the middle cerebral artery lies in the depths of the sylvian cleft. (After Charcot.)

Branches.—The branches of the middle cerebral artery are:

Antero-lateral ganglionic.
Inferior external frontal.
Ascending frontal.

Ascending parietal.
Parietotemporal.
Temporal.

The **antero-lateral ganglionic branches**, a group of small arteries which *arise* at the commencement of the middle cerebral artery, are arranged in two sets; one, the **internal striate**, passes upward through the inner segment of the lenticular nucleus, and supplies it, the caudate nucleus, and the internal capsule; the other, the **external striate**, ascends through the outer segment of the lenticular nucleus, and supplies the caudate nucleus and the thalamus. One artery of this group (also called **lenticulostriate artery**) is of larger size than the rest, and is of special importance, as being the artery in the brain most frequently ruptured; it has been termed by Charcot the **artery of cerebral hemorrhage**. It passes up between the lenticular nucleus and the external capsule, and ultimately ends in the caudate nucleus.

The **inferior external frontal** supplies the subfrontal convolution (**Broca's convolution**) and the outer part of the orbital surface of the frontal lobe.

The **ascending frontal** supplies the precentral gyre.

The **ascending parietal** is distributed to the postcentral convolution and the lower part of the superior parietal convolution.

The **parietotemporal** supplies the supramarginal and angular gyres, the supertemporal, and part of the mediotemporal gyre.

The **temporal** branches, two or three in number, are distributed to the outer surface of the temporal lobe.

The **posterior communicating artery** (*a. communicans posterior*) runs backward from the internal carotid, and anastomoses with the posterior cerebral, a branch of the basilar. This artery varies considerably in size, being sometimes small, and occasionally so large that the posterior cerebral may be considered as arising from the internal carotid rather than from the basilar. It is frequently larger on one side than on the other. From the posterior half of this vessel are given off a number of small branches, the **postero-median ganglionic branches**, which, with similar vessels from the posterior cerebral, pierce the posterior perforated substance and supply the internal surfaces of the thalami and the walls of the third ventricle.

The **choroid artery** (*a. chorioidea*) is a small but constant branch which *arises* from the back part of the internal carotid, near the posterior communicating artery. Passing backward and outward between the temporal lobe and the crus, it enters the descending horn of the lateral ventricle through the choroidal fissure and ends in the choroid plexus. It is distributed to the hippocampus, fimbria, velum interpositum, and choroid plexus.

THE ARTERIES OF THE BRAIN.

Investigations show that the mode of distribution of the vessels of the brain has an important bearing upon a considerable number of the anatomical lesions of which this part of the nerve system may be the seat; it is therefore important to consider a little more in detail the manner in which the cerebral vessels are distributed.

The cerebral arteries are derived from the internal carotid and the vertebral, which at the base of the brain form a remarkable anastomosis known as the **circle of Willis** (*circulus arteriosus*) (Fig. 453). It is formed in front by the anterior cerebral arteries, branches of the internal carotid, which are connected by the anterior communicating; behind by the two posterior cerebrals, branches of the basilar, which are connected on each side to the internal carotid by the posterior communicating (Fig. 446). The parts of the brain included within this arterial circle are the lamina terminalis, the chiasm or commissure of the optic nerves, the tuber cinereum, the corpora albicantia, and the posterior perforated substance. This arrangement of the vessels of the circle is not invariable; according to Windle, it

is maintained in little more than half the recorded cases. In the other cases there are different variations.

The three trunks which together supply each cerebral hemisphere *arise* from the circle of Willis. From its anterior part proceed the two anterior cerebrals, from its antero-lateral part the middle cerebrals, and from its posterior part the posterior cerebrals. Each of these principal arteries gives origin to two very different systems of secondary vessels. One of these systems has been named the **central ganglionic system**, and the vessels belonging to it supply the central ganglia of the brain; the other has been named the **cortical arterial system**, and its vessels ramify in the pia and supply the cortex and subjacent medullary substance. These two systems, although they have a common origin, do not communicate at any point of their peripheral distribution, and are entirely independent of each other, *representing terminal arteries*. Though some of the arteries of the cortical system approach, at their terminations, the regions supplied by the central ganglionic system, no communication between the two sets of vessels takes place, and there is between the parts supplied by the two systems a borderland of diminished nutritive activity. In the brains of old people softening is especially apt to occur in this ill-nourished territory.

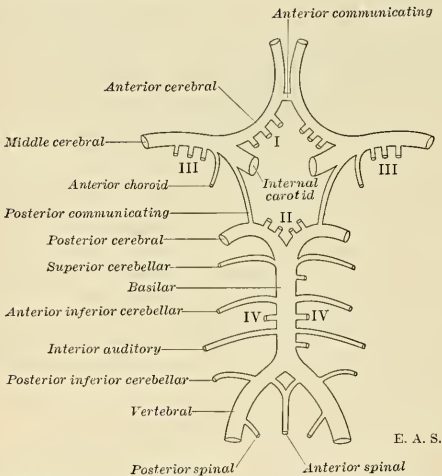


FIG. 453.—Diagram of the arteries at the base of the brain, including the circle of Willis. I. Antero-median group of ganglionic branches. II. Postero-median group. III. Right and left antero-lateral group. IV. Right and left postero-lateral group.

The Central Ganglionic System.—All the vessels belonging to this system are given off from the circle of Willis or from the vessels immediately after their origin from it, so that if a circle is drawn at a distance of about an inch from the circle of Willis, it will include the origin of all the arteries belonging to this system (Fig. 453). The vessels of this system form four principal groups: (I) The **antero-median group**, derived from the anterior cerebrals and anterior communicating; (II) the **postero-median group**, from the posterior cerebrals and posterior communicating; (III) the right and left **antero-lateral group**, from the middle cerebrals; and (IV) the right and left **postero-lateral group**, from the posterior cerebrals, after they have wound around the crura. The vessels belonging to this system are larger than those of the cortical system, and are what Cohnheim has termed **terminal arteries**—that is to say, vessels which from their origin to their termination neither

supply nor receive any anastomotic branches, so that by one of the small vessels only a limited area of the central ganglia can be injected; and the injection cannot be driven beyond the area of the part supplied by the particular vessel which is the subject of the experiment.

The Cortical Arterial System.—The vessels forming this system are the terminal branches of the anterior, middle, and posterior cerebral arteries, described above. These vessels divide and ramify in the substance of the pia, and give off nutrient arteries which penetrate the cortex perpendicularly. These nutrient vessels are divisible into two classes—the long and short. The **long**—or, as they are sometimes called, the **medullary**—arteries pass through the gray substance to penetrate the centrum ovale to the depth of about an inch and a half, without intercommunicating otherwise than by very fine capillaries, and thus constitute so many

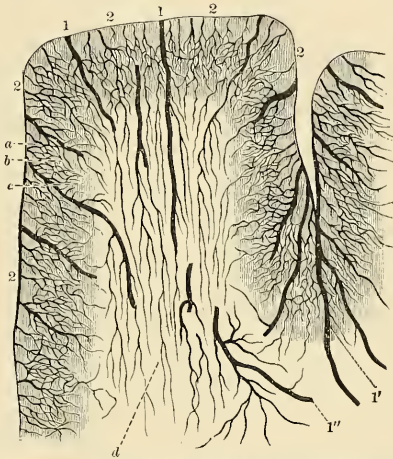


FIG. 454.—Distribution of the cortical arteries. 1. Medullary arteries. 1'. Group of medullary arteries in the sulcus between two adjacent convolutions. 2, 2. Cortical arteries. a. Capillary network with fairly wide meshes, situated beneath the pia. b. Network with more compact, polygonal meshes, situated in the cortex. c. Transitional network, with wider meshes. d. Capillary network in the white substance. (After Chareot.)

independent small systems. The **short vessels** are confined to the cortex, where they form with the long vessels a compact network in the middle zone of the gray substance, the outer and inner zones being sparingly supplied with blood (Fig. 454). The vessels of the cortical arterial system are not so strictly terminal as those of the central ganglionic system, but they approach this type very closely, so that injection of one area from the vessel of another area, though it may be possible, is frequently very difficult, and is only effected through vessels of small caliber. As a result of this, obstruction of one of the main branches or its divisions may have the effect of producing softening in a very limited area of the cortex.

The Vertebral Artery (A. Vertebralis).

The **vertebral artery** (*a. vertebralis*) (Figs. 444 and 455) is generally the first and largest branch of the subclavian; in rare instances it springs independently from the arch of the aorta. It *arises* from the upper and back part of the first portion of the vessel, and, passing upward, enters the foramen in the transverse process of

the sixth cervical vertebra,¹ and ascends through the foramina in the transverse processes of all the vertebræ above this. Above the upper border of the axis it inclines outward and upward to the foramen in the transverse process of the atlas, through which it passes; it then winds backward behind its articular process, runs in a deep groove on the upper surface of the posterior arch of this bone (Fig. 16), and, passing beneath the posterior occipito-atlantal ligament (Figs. 224 and 227), pierces the dura and arachnoid, and enters the skull through the foramen magnum. It then passes forward and upward, inclining from the lateral aspect to the front of the medulla oblongata. It unites in the middle line with the vessel of the opposite side at the lower border of the pons to form the **basilar artery** (Fig. 426).

Relations.—At its origin it is situated behind the internal jugular and vertebral veins, and is crossed by the inferior thyroid artery; it lies between the Longus colli and Scalenus anticus muscles, having the thoracic duct in front of it on the left side. It rests on the transverse process of the seventh cervical vertebra and the sympathetic cord. Within the foramina formed by the transverse processes of the vertebræ it is accompanied by a plexus of nerves from the inferior cervical ganglion of the sympathetic, and is surrounded by a dense plexus of veins which unite to form the vertebral vein at the lower part of the neck. It is situated in front of the cervical nerves, as they issue from the intervertebral foramina. While winding around the articular process of the atlas, it is contained in the **suboccipital triangle**—a triangular space formed by the Rectus capitis posterior major, the Obliquus capitis superior and the Obliquus capitis inferior muscles. The suboccipital nerve here lies between the artery and the posterior arch of the atlas. Within the skull, as the artery winds around the oblongata, it is placed between the hypoglossal nerve and the anterior root of the suboccipital nerve, beneath the first digitation of the ligamentum denticulatum, and finally ascends between the basilar process of the occipital bone and the anterior surface of the medulla oblongata.

Applied Anatomy.—The vertebral artery has been tied in several instances. (1) For wounds or traumatic aneurism; (2) after ligation of the innominate, either immediately to prevent hemorrhage, or later on to arrest bleeding where it has occurred at the seat of ligation. The *operation of ligation of the vertebral* is performed by making an incision along the posterior border of the Sternomastoid muscle, just above the clavicle. The muscle is pulled to the inner side, and the anterior tubercle of the transverse process of the sixth cervical vertebra is sought for. A deep layer of fascia being now divided, the interval between the Scalenus anticus and the Longus colli muscles just below their attachment to the tubercle is defined, and the artery and vein are found in the interspace. The vein is to be drawn to the outer side, and the aneurism needle is passed from without inward. Drs. Ramskill and Bright have pointed out that severe pain at the back of the head may be symptomatic of disease of the vertebral artery just before it enters the skull. This is explained by the close connection of the artery with the suboccipital nerve in the groove on the posterior arch of the atlas. Disease of the same artery has been also said to affect speech, from pressure on the hypoglossal nerve where it is in relation with the vessel, leading to paralysis of the muscles of the tongue.

Branches.—These may be divided into two sets—those given off in the neck and those within the cranium.

Cervical Branches.

Spinal rami, or Lateral spinal.
Muscular.

Cranial Branches.

Posterior meningeal.
Anterior spinal, or Ventral spinal.
Posterior spinal, or Dorsal spinal.
Posterior inferior cerebellar.
Bulbar.

The **spinal branches** (*rami spinales*) enter the vertebral canal through the intervertebral foramina and divide into two branches. Of these, one passes along the roots of the nerves to supply the spinal cord and its membranes, anastomosing with the other arteries of the spinal cord; the other divides into an ascending and

¹ The vertebral artery sometimes enters the foramen in the transverse process of the fifth vertebra. Dr. Smyth, who tied this artery in the living subject, found it, in one of his dissections, passing into the foramen in the seventh vertebra.

a descending branch, which unite with similar branches from the artery above and below, so that two lateral anastomotic chains are formed on the posterior surface of the vertebræ near the attachment of the pedicles. From these anastomotic chains branches are given off to supply the periosteum and the bodies of the vertebræ, and to communicate with similar branches from the opposite side; from these communicating branches small branches are given off which join similar branches above and below, so that a central anastomotic chain is formed on the posterior surface of the bodies of the vertebræ.

Muscular branches are given off to the deep muscles of the neck, where the vertebral artery curves around the articular process of the atlas. They anastomose with the occipital and with the ascending and deep cervical arteries.

The **posterior meningeal** (*ramus meningeus*) is a small branch given off from the vertebral opposite the foramen magnum. It ramifies between the bone and dura in the cerebellar fossæ, and supplies the falx cerebelli. It is frequently represented by two small branches.

The **anterior or ventral spinal** (*a. spinalis anterior*) is a small branch which rises near the termination of the vertebral, and, descending ventrad of the medulla oblongata, unites with its fellow on the opposite side at about the level of the foramen magnum. One of these vessels is usually larger than the other, but occasionally they are about equal in size. The single trunk thus formed descends on the front of the spinal cord, and is reinforced by a succession of small branches which enter the vertebral canal through the intervertebral foramina; these branches are derived from the vertebral artery and the ascending cervical branch of the inferior thyroid artery in the neck; from the intercostal in the thoracic region; and from the lumbar, ilio-lumbar, and lateral sacral arteries in the lower part of the vertebral column. They unite, by means of ascending and descending branches, to form a single terminal artery, which extends as far as the lower part of the spinal cord. This vessel is placed in the pia along the anterior median fissure; it supplies that membrane and the substance of the cord, and sends off branches at its lower part to be distributed to the cauda equina, and ends on the central fibrous prolongation of the cord.

The **posterior or dorsal spinal** (*a. spinalis posterior*) arises from the vertebral at the side of the medulla oblongata; passing backward to the dorsal aspect of the spinal cord, it descends on each side, lying behind the dorsal roots of the spinal nerves, and is reinforced by a succession of small branches which enter the vertebral canal through the intervertebral foramina, and by which it is continued to the lower part of the cord and to the cauda equina. Branches from the posterior spinal arteries form a free anastomosis around the dorsal roots of the spinal nerves, and communicate, by means of very tortuous transverse branches, with the vessel of the opposite side. Close to its origin each gives off an ascending branch, which terminates at the side of the fourth ventricle.

Applied Anatomy.—Bleeding into the spinal membranes or into the substance of the spinal cord itself is not common, but may occur from injuries received at birth when labor is unduly prolonged or instruments are used. It is also met with in chronic insanity, and in tetanus and strychnine poisoning.

The **posterior inferior cerebellar artery** (*a. cerebelli inferior posterior*) (Fig. 446), the largest branch of the vertebral, winds backward around the upper part of the medulla oblongata, passing between the origin of the vagus and spinal accessory nerves, over the restiform body to the under surface of the cerebellum, where it divides into two branches—an **internal**, which is continued backward to the notch between the two hemispheres of the cerebellum; and an **external**, which supplies the under surface of the cerebellum as far as its outer

border, where it anastomoses with the anterior inferior cerebellar and the superior cerebellar branches of the basilar artery. Branches from this artery supply the choroid plexus of the fourth ventricle.

The **bulbar arteries** comprise several minute vessels which spring from the vertebral and its branches and are distributed to the medulla oblongata.

The **basilar artery** (*a. basilaris*) (Fig. 446), so named from its position at the base of the skull, is a single trunk formed by the junction of the two vertebral arteries; it extends from the posterior to the anterior border of the pons, lying in the median pontile groove, under cover of the arachnoid. It ends by dividing into the two **posterior cerebral arteries**.

Branches.—Its branches on either side are the following:

Transverse.	Anterior inferior cerebellar.
Internal auditory.	Superior cerebellar.
	Posterior cerebral.

The **transverse** or **pontile branches** (*rami ad pontem*) are a number of small vessels which come off at right angles on either side of the basilar artery and supply the pons and adjacent parts of the brain.

The **internal auditory** (*a. auditiva interna*), a long slender branch, *arises* from near the middle of the artery; it accompanies the corresponding auditory nerve into the internal auditory meatus and is distributed to the internal ear.

The **anterior inferior cerebellar artery** (*a. cerebelli inferior anterior*) passes backward to be distributed to the anterior part of the under surface of the cerebellum, anastomosing with the posterior inferior cerebellar branch of the vertebral.

The **superior cerebellar artery** (*a. cerebelli superior*) *arises* near the termination of the basilar. It passes outward, immediately behind the oculomotor nerve, which separates it from the posterior cerebral artery, winds around the crus, close to the trochlear nerve, and, arriving at the upper surface of the cerebellum, divides into branches which ramify in the pia and, reaching the circumference of the cerebellum, anastomose with the branches of the inferior cerebellar artery. Several branches are given to the epiphysis, the superior medullary velum, and the velum interpositum.

The **posterior cerebral artery** (*a. cerebri posterior*) (Figs. 446 and 453) is larger than the preceding, from which it is separated near its origin by the oculomotor nerve. Passing outward, parallel to the superior cerebellar artery, and receiving the posterior communicating from the internal carotid, it winds around the crus, and passes to the under surface of the temporal lobe of the cerebrum, and divides up into branches for the supply of the temporal and occipital lobes.

The **branches** of the posterior cerebral artery are:

Ganglionic	{	Postero-median ganglionic.	Cortical	{	Anterior temporal.
		Posterior choroid.			Posterior temporal.
		Postero-lateral ganglionic.			Occipital.

Ganglionic.—The **postero-median ganglionic branches** (Fig. 453) are a group of small arteries which *arise* at the commencement of the posterior cerebral artery; these, with similar branches from the posterior communicating, pierce the posterior perforated substance, and supply the internal surfaces of the thalamus and the walls of the third ventricle. The **posterior choroid** enters the interior of the brain beneath the splenium of the corpus callosum, and supplies the velum interpositum and the choroid plexus. The **postero-lateral ganglionic branches** are a group of small arteries which *arise* from the posterior cerebral artery, after it has turned around the crus; they supply a considerable portion of the thalamus.

Cortical.—The cortical branches are the **anterior temporal branches**, to the basal surface of the anterior portion of the temporal lobe; the **posterior temporal branches**, to the external surface of the occipital lobe and the subtemporal convolution; and the **occipital branches**, to the mesal and lateral surfaces of the occipital lobe.

ARTERIES OF THE UPPER EXTREMITY.

The artery which supplies the upper extremity continues as a single trunk from its commencement down to the elbow, but different portions of it have received different names according to the region through which it passes. That part of the vessel which extends from its origin to the outer border of the first rib is termed the **subclavian artery**; beyond this point to the lower border of the axilla it is termed the **axillary artery**; and from the lower margin of the axillary space to the bend of the elbow it is termed the **brachial artery**; here the single trunk terminates by dividing into two branches, the **radial** and **ulnar**.

THE SUBCLAVIAN ARTERY (A. SUBCLAVIA) (Fig. 456).

On the right side the **subclavian artery** *arises* from the innominate artery opposite the right sternoclavicular articulation; on the left side it *arises* from the arch of the aorta. The two vessels, therefore, in the first part of their course, differ in length, direction, and relation with neighboring structures.

In order to facilitate the description of these vessels, more especially from a surgical point of view, each subclavian artery has been divided into three parts.

The *first portion*, on the *right side*, passes upward and outward from the origin of the vessel to the inner border of the *Scalenus anticus*. On the *left side* it ascends nearly vertically, to gain the inner border of that muscle. The *second part* passes outward, behind the *Scalenus anticus*; and the *third part* passes from the outer margin of that muscle, beneath the clavicle, to the outer border of the first rib, where it becomes the *axillary artery*. The first portion of these two vessels differs so much in its course and in its relations with neighboring parts that it will be described separately. The second and third parts are alike on the two sides.

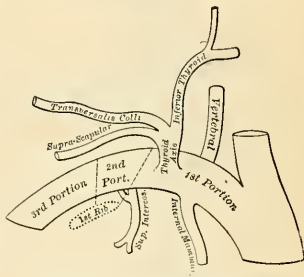


FIG. 455.—Plan of the branches of the right subclavian artery.

First Part of the Right Subclavian Artery (Fig. 456).—The *first part* of the **right subclavian artery** *arises* from the innominate artery, opposite the upper part of the right sternoclavicular articulation, and passes upward and outward to the inner margin of the *Scalenus anticus* muscle (Fig. 456). It ascends a little above the clavicle, the extent to which it does so varying in different cases.

Relations.—It is covered, *in front*, by the integument, superficial fascia, *Platysma*, deep fascia, the clavicular origin of the *Sternomastoid*, the *Sternohyoid*, and the *Sternothyroid* muscles, and another layer of deep fascia. It is crossed by the internal jugular and vertebral veins, and by the *vagus* nerve and the cardiac branches of the *vagus* and sympathetic nerves. A loop of the sympathetic nerve itself also crosses the artery, forming a ring (*ansa subclavia*) around the vessel. The anterior jugular vein passes outward in front of the artery, but is not in contact with it, being separated from it by the *Sternohyoid* and *Sternothyroid* muscles. *Below* and *behind* the artery is the *pleura*; *behind* is the gangliated cord of the sympathetic, the *Longus colli* muscle and the first thoracic vertebra. The right recurrent laryngeal nerve winds around the lower and back part of the vessel.

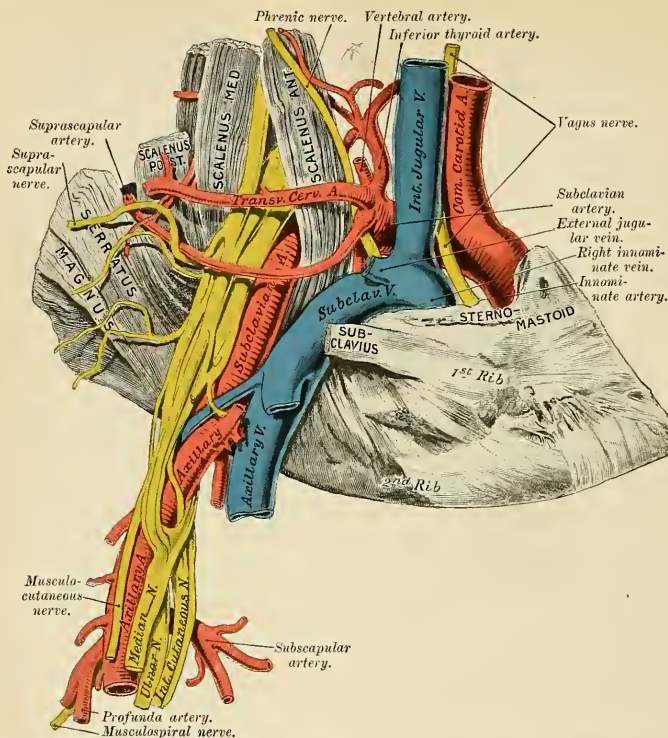


Fig. 456.—The subclavian artery, showing its relations. (From a preparation in the Museum of the Royal College of Surgeons of England.)

PLAN OF THE RELATIONS OF FIRST PORTION OF THE RIGHT SUBCLAVIAN ARTERY.

In front.

Skin, superficial fascia.
 Platysma, deep fascia.
 Clavicular origin of Sternomastoid.
 Sternohyoid and Sternothyroid.
 Anterior jugular, internal jugular, and vertebral veins.
 Vagus and cardiac nerves.
 Loop from the sympathetic.

Right
 Subclavian
 Artery.
 First Portion.

Beneath.

Pleura.
 Recurrent laryngeal nerve.

Behind.

Recurrent laryngeal nerve.
 Sympathetic.
 Pleura and apex of lung.
 Longus colli.
 First thoracic vertebra.

First Part of the Left Subclavian Artery (Figs. 428 and 429).—The first part of the left subclavian artery arises from the arch of the aorta, behind the left common carotid, and at the level of the fourth thoracic vertebra; it ascends nearly vertically to the root of the neck and then arches outward to the inner margin of the Scalenus anticus muscle.

Relations.—It is in relation, *in front*, with the vagus, cardiac, and phrenic nerves, which lie parallel with it, the left carotid artery, left internal jugular and vertebral veins, and the commencement of the left innominate vein, and is covered by the Sternothyroid, Sternohyoid, and Sternomastoid muscles. A loop of the sympathetic encircles the artery, forming the *ansa subclavia*. *Behind*, it is in relation with the œsophagus, thoracic duct, inferior cervical ganglion of the sympathetic, and Longus colli muscle; higher up, however, the œsophagus and thoracic duct lie to its right side; the latter ultimately arching over the vessel to join the angle of union between the subclavian and internal jugular veins. To its *inner side* are the œsophagus, trachea, thoracic duct, and left recurrent laryngeal nerve; to its *outer side*, the left pleura and lung.

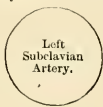PLAN OF THE RELATIONS OF FIRST PORTION OF THE LEFT SUBCLAVIAN ARTERY.

In front.

Vagus, cardiac, and phrenic nerves.
Left carotid artery.
Thoracic duct.
Left internal jugular, vertebral, and innominate veins.
Sternothyroid, Sternohyoid, and Sternomastoid muscles.

Inner side.

Trachea.
œsophagus.
Thoracic duct.
Left recurrent laryngeal nerve.



Outer side.

Pleura and left lung.

Behind.

œsophagus and thoracic duct.
Inferior cervical ganglion of sympathetic.
Longus colli.

Second and Third Parts of the Subclavian Artery (Figs. 432 and 456).—The second portion of the subclavian artery lies behind the Scalenus anticus muscle; it is very short, and forms the highest part of the arch described by that vessel.

Relations.—It is covered, *in front*, by the skin, superficial fascia, Platysma, deep cervical fascia, the Sternomastoid and the Scalenus anticus muscles. On the right side the phrenic nerve is separated from the second part of the artery by the Scalenus anticus muscle, while on the left side the nerve crosses the first part of the artery immediately to the inner edge of the muscle. *Behind*, it is in relation with the pleura and the Scalenus medius muscle. *Above*, is the brachial plexus of nerves; *below*, the pleura. The subclavian vein lies below and in front of the artery, separated from it by the Scalenus anticus muscle.

PLAN OF THE RELATIONS OF SECOND PORTION OF SUBCLAVIAN ARTERY.

In front.

Skin and superficial fascia.
Platysma and deep cervical fascia.
Sternomastoid.
Phrenic nerve.
Scalenus anticus.
Subclavian vein.

Above.

Brachial plexus.



Below.

Pleura.

Behind.

Pleura and Middle Scalenus.

The **third portion of the subclavian artery** passes downward and outward from the outer margin of the *Scalenus anticus* muscle to the outer border of the first rib, where it becomes the axillary artery. This portion of the vessel is the most superficial, and is contained in the subclavian triangle (see page 606).

Relations.—It is covered, *in front*, by the skin, the superficial fascia, the *Platysma*, the descending claviclar branches of the cervical plexus, and the deep cervical fascia; by the clavicle, the *Subclavius* muscle, the suprascapular artery and vein, and the transverse cervical vein; the nerve to the *Subclavius* muscle passes vertically downward in front of the artery. The external jugular vein crosses the artery at its inner side, and receives the suprascapular and transverse cervical veins, which frequently form a plexus in front of it. The subclavian vein is below and in front of the artery, lying close behind the clavicle. *Behind*, it lies on the *Middle Scalenus* muscle and the lowest cord of the brachial plexus, formed by the union of the last cervical and first thoracic nerves. *Above* and to its outer side are the upper trunks of the brachial plexus and the *Omothyoid* muscle. *Below*, it rests on the upper surface of the first rib, or on the cervical rib if one be present.

PLAN OF THE RELATIONS OF THIRD PORTION OF SUBCLAVIAN ARTERY.

In front.

Skin and superficial fascia.

Platysma and deep cervical fascia.

Descending branches of cervical plexus. Nerve to *Subclavius* muscle.

Subclavius muscle, suprascapular artery, and vein.

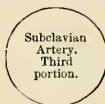The external jugular and transverse cervical veins.

The clavicle.

Above.

Brachial plexus.

Omothyoid.



Below.

First rib.

Behind.

Scalenus medius.

Lower cord of brachial plexus.

Peculiarities.—The subclavian arteries vary in their origin, their course, and the height to which they rise in the neck.

The origin of the right subclavian from the innominate takes place, in some cases, above the sternoclavicular articulation, and occasionally, but less frequently, in the cavity of the thorax, below that point. Or the artery may arise as a separate trunk from the arch of the aorta. In such cases it may be either the first, second, third, or even the last branch derived from that vessel; in the majority of cases it is the first or last, rarely the second or third. When it is the first branch, it occupies the ordinary position of the innominate artery; when the second or third, it gains its usual position by passing behind the right carotid; and when the last branch, it arises from the left extremity of the arch, at its upper or back part, and passes obliquely toward the right side, usually behind the trachea, œsophagus, and right carotid, sometimes between the œsophagus and trachea to the upper border of the first rib, whence it follows its ordinary course. Its manner of development is such that the inferior laryngeal nerve is not looped under the vessel, but passes in a nearly straight course on its way to the larynx. In very rare instances this vessel arises from the thoracic aorta, as low down as the fourth thoracic vertebra. Occasionally it perforates the *Scalenus anticus* muscle; more rarely it passes in front of that muscle. Sometimes the subclavian vein passes with the artery behind the *Scalenus anticus* muscle. The artery may ascend as high as an inch and a half above the clavicle or any intermediate point between this and the upper border of the bone, the right subclavian usually ascending higher than the left.

The left subclavian is occasionally joined at its origin with the left common carotid.

Surface Marking.—The course of the subclavian artery in the neck may be mapped out by describing a curve, with its convexity upward at the base of the posterior triangle. The inner

end of this curve corresponds to the sternoclavicular joint, the outer end of the centre of the lower border of the clavicle. The curve is to be drawn with such an amount of convexity that its mid-point reaches half an inch above the upper border of the clavicle. The left subclavian artery is more deeply placed than the right in the first part of its course, and, as a rule, does not reach quite as high a level in the neck. It should be borne in mind that the posterior border of the Sternomastoid muscle corresponds to the outer border of the Scalenus anticus muscle, so that the third portion of the artery, that part most accessible for operation, lies immediately external to the posterior border of the Sternomastoid muscle.

Applied Anatomy.—The relations of the subclavian arteries of the two sides having been examined, the student should direct his attention to a consideration of the best position in which compression of the vessel may be effected, or in what situation a ligature may be best applied in cases of aneurism or wound.

Compression of the subclavian artery is required in cases of operation about the shoulder, in the axilla, or at the upper part of the arm; and the student will observe that there is only one situation in which it can be effectually applied—viz., where the artery passes across the upper surface of the first rib. In order to compress the vessel in this situation, the shoulder should be depressed, and the surgeon, grasping the side of the neck, should press with his thumb in the angle formed by the posterior border of the Sternomastoid with the upper border of the clavicle, downward, backward, and inward against the rib; if from any cause the shoulder cannot be sufficiently depressed, pressure may be made from before backward, so as to compress the artery against the Scalenus medius muscle and the transverse process of the seventh cervical vertebra. In appropriate cases a preliminary incision may be made through the cervical fascia, and the finger may be pressed down directly upon the artery.

Ligation of the subclavian artery may be required in cases of wounds or of aneurism in the axilla, or in cases of aneurism on the cardiac side of the point of ligation; and the third part of the artery is that which is most favorable for an operation, on account of its being comparatively superficial and most remote from the origin of the large branches. In those cases where the clavicle is not displaced, this operation may be performed with comparative facility; but where the clavicle is pushed up by a large aneurismal tumor in the axilla the artery is placed at a great depth from the surface, which materially increases the difficulty of the operation. Under these circumstances it becomes a matter of importance to consider the height to which this vessel reaches above the bone. In ordinary cases its arch is about half an inch above the clavicle, occasionally it is as high as an inch and a half, and sometimes so low as to be on a level with the upper border of the clavicle. If the clavicle is displaced, these variations will necessarily make the operation more or less difficult, according as the vessel is more or less accessible.

The procedure in the operation of tying the *third portion* of the subclavian artery is as follows: The patient being placed on a table in the supine position, with the head drawn over to the opposite side and the shoulder depressed as much as possible, the integument should be drawn downward over the clavicle, and an incision made through it, upon that bone, from the anterior border of the Trapezius to the posterior border of the Sternomastoid, to which may be added a short vertical incision meeting the inner end of the preceding. The object in drawing the skin downward is to avoid any risk of wounding the external jugular vein, for as it perforates the deep fascia above the clavicle, it cannot be drawn downward with the skin. The soft parts should now be allowed to glide up, and the cervical fascia should be divided upon a director, and if the interval between the Trapezius and Sternomastoid muscles be insufficient for the performance of the operation, a portion of one or both may be divided. The external jugular vein will now be seen toward the inner side of the wound; this and the suprascapular and transverse cervical veins, which terminate in it, should be held aside. If the external jugular vein is at all in the way and exposed to injury, it should be tied in two places and divided. The suprascapular artery should be avoided, and the Omohyoid muscle held aside if necessary. In the space beneath this muscle careful search must be made for the vessel; a layer of deep fascia and some connective tissue having been divided carefully, the outer margin of the Scalenus anticus muscle must be felt for, and, the finger being guided by it to the first rib, the pulsation of the subclavian artery will be felt as it passes over the rib. The sheath of the vessels having been opened, the aneurism needle may then be passed around the artery from above downward and inward, so as to avoid including any of the branches of the brachial plexus. If the clavicle is so raised by the tumor that the application of the ligature cannot be effected in this situation, the artery may be tied above the first rib, or even behind the Scalenus anticus muscle; the difficulties of the operation in such a case will be materially increased, on account of the greater depth of the artery and the alteration in position of the surrounding parts.

The *second part* of the subclavian artery, from being that portion which rises highest in the neck, has been considered favorable for the application of the ligature when it is difficult to tie the artery in the third part of its course. There are, however, many objections to the operation in this situation. It is necessary to divide the Scalenus anticus muscle, upon which lies the phrenic nerve, and at the inner side of which is situated the internal jugular vein; and a

wound of either of these structures might lead to the most dangerous consequences. Again, the artery is in contact, below, with the pleura, which must also be avoided; and, lastly, the proximity of so many of its large branches arising internal to this point must be a still further objection to the operation. In cases, however, where the sac of an axillary aneurism encroaches on the neck, it may be necessary to divide the outer half or two-thirds of the *Scalenus anticus* muscle, so as to place the ligature on the vessel at a greater distance from the sac. The operation is performed exactly in the same way as a ligation of the third portion, until the *Scalenus anticus* is exposed, when it is to be divided on a director (never to a greater extent than its outer two-thirds), and it immediately retracts. The operation is therefore merely an extension of ligation of the third portion of the vessel.

In those cases of aneurism of the axillary or subclavian artery in which the aneurism encroaches upon the outer portion of the *Scalenus* muscle to such an extent that a ligature cannot be applied in that situation, it may be deemed advisable, as a last resource, to tie the first portion of the subclavian artery. On the left side this operation has been regarded as almost impracticable; the great depth of the artery from its surface, its intimate relation with the pleura, and its close proximity to the thoracic duct and to so many important veins and nerves, presents a series of difficulties which it is very difficult to overcome. Nevertheless, it has been successfully done several times. The main objection to the operation in this situation is the smallness of the interval which usually exists between the commencement of the vessel and the origin of the nearest branch. The operation may be performed in the following manner: The patient being placed on the table in the supine position with the neck extended, an incision should be made along the upper border of the inner part of the clavicle, and a second along the inner border of the *Sternomastoid*, meeting the former at an angle. The attachment of both heads of the *Sternomastoid* must be divided on a director and turned outward; a few small arteries and veins, and occasionally the anterior jugular vein, must be avoided, or, if necessary, ligated in two places and divided, and the *Sternohyoid* and *Sternothyroid* muscles are to be divided in the same manner as the preceding muscle. After tearing through the deep fascia, the internal jugular vein will be seen crossing the subclavian artery; this should be pressed aside and the artery secured by passing the needle from below upward, by which the pleura is more effectually avoided. The exact position of the *vagus*, the recurrent laryngeal, the phrenic and sympathetic nerves should be remembered, and the ligature should be applied near the origin of the vertebral, in order to afford as much room as possible for the formation of a coagulum between the ligature and the origin of the vessel. It should be remembered that the right subclavian artery is occasionally deeply placed in the first part of its course when it arises from the left side of the aortic arch, and passes in such cases behind the œsophagus or between it and the trachea.

Branches.—The branches given off from the subclavian artery are:

Vertebral.

Internal mammary.

Superior intercostal.

Thyroid axis { Inferior thyroid.
Suprascapular.
Transverse cervical.

On the left side all four branches generally *arise* from the first portion of the vessel, but on the right side the superior intercostal usually arises from the second portion of the vessel. On both sides of the body the first three branches arise close together at the inner margin of the *Scalenus anticus*; in the majority of cases a free interval of from half an inch to an inch exists between the commencement of the artery and the origin of the nearest branch. The vertebral artery arises from the upper and posterior part of the subclavian artery, the internal mammary from the lower part of the artery; the thyroid axis from in front and the superior intercostal from behind.

The **vertebral artery**, the first branch of the subclavian, is distributed entirely to the head and neck, chiefly supplying the posterior portion of the brain. It has been described on pages 619 to 623.

The **thyroid axis** (*truncus thyrocervicalis*) (Figs. 435 and 458) is a short thick trunk which *arises* from the fore part of the first portion of the subclavian artery,

close to the inner border of the *Scalenus anticus* muscle, and divides, almost immediately after its origin, into three branches—the **inferior thyroid**, **suprascapular**, and **transverse cervical**.

The **inferior thyroid artery** (*a. thyreoidea inferior*) (Fig. 435) passes upward, in front of the vertebral artery and *Longus colli* muscle; then turns inward behind the sheath of the common carotid artery and internal jugular vein, and also behind the sympathetic cord, the middle cervical ganglion resting upon the vessel, and, reaching the lower border of the lateral lobe of the thyroid gland, it divides into two branches, which supply the postero-inferior parts of the gland, and anastomose with the superior thyroid and with the corresponding artery of the opposite side. The recurrent laryngeal nerve passes upward, generally behind, but occasionally in front of, the artery. Its **branches** are:

Inferior laryngeal.
Tracheal.

Œsophageal.
Ascending cervical.

Muscular.

The **inferior laryngeal branch** (*a. laryngea inferior*) ascends upon the trachea to the back part of the larynx, in company with the recurrent laryngeal nerve, and supplies the muscles and mucous membrane of this part, anastomosing with the inferior laryngeal branch from the opposite side and with the laryngeal branch from the superior thyroid artery.

The **tracheal branches** (*rami tracheales*) are distributed upon the trachea, anastomosing below with the bronchial arteries.

The **œsophageal branches** (*rami œsophagei*) are distributed to the œsophagus, and anastomose with the œsophageal branches of the aorta.

The **ascending cervical** (*a. cervicalis ascendens*) is a small branch which arises from the inferior thyroid just where that vessel is passing behind the common carotid artery, and runs up on the anterior tubercles of the transverse processes of the cervical vertebræ in the interval between the *Scalenus anticus* and *Rectus capitis anticus major* muscles. It gives branches to the muscles of the neck, which anastomose with branches of the vertebral, and sends one or two branches into the vertebral canal through the intervertebral foramina to be distributed to the spinal cord and its membranes, and to the bodies of the vertebræ in the same manner as the lateral spinal branches from the vertebral. It anastomoses with the ascending pharyngeal and occipital arteries.

The **muscular branches** supply the Depressors of the hyoid bone, the *Longus colli*, the *Scalenus anticus*, and the Inferior constrictor of the pharynx. One of the muscular branches passes between the transverse processes of the fourth and fifth cervical vertebræ and reaches the deep muscles of the neck. It is called the **ramus profundus**.

The **suprascapular artery** (*a. transversa scapulae*) (Figs. 435 and 457) passes at first downward and outward across the *Scalenus anticus* and phrenic nerve, being covered by the *Sternomastoid*; it then crosses the subclavian artery and the cords of the brachial plexus, and runs outward, behind and parallel with the clavicle and *Subclavius* muscle, and beneath the posterior belly of the *Omohyoid*, to the superior border of the scapula, where it passes over the transverse ligament of the scapula, which separates it from the suprascapular nerve, and reaches the supraspinous fossa. In this situation it lies close to the bone, and ramifies between it and the *Supraspinatus* muscle, to which it supplies branches. It then passes downward behind the neck of the scapula, to reach the infraspinous fossa, where it anastomoses with the *dorsalis scapulae* branch of the subscapular artery and branches of the posterior scapular arteries. Besides distributing branches to the *Sternomastoid*, *Subclavius*, and neighboring muscles, it gives off a **supra-**

sternal branch, which crosses over the sternal end of the clavicle to the skin of the upper part of the thorax; and a **supra-acromial branch** (*ramus acromialis*), which piercing the Trapezius muscle, supplies the skin over the acromion, anastomosing with a branch of the acromiothoracic artery. A small **subscapular branch** is given off as the artery passes over the transverse ligament of the scapula; it descends into the subscapular fossa, ramifies beneath the Subscapular muscle, and anastomoses with the posterior and subscapular arteries. The suprascapular artery also sends branches to the acromioclavicular and shoulder-joints, and a nutrient artery to the clavicle.

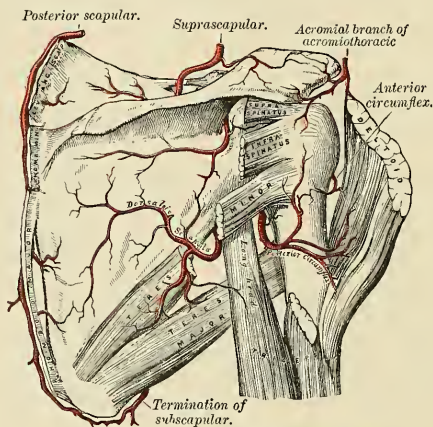


FIG. 457.—The scapular and circumflex arteries.

The **transverse cervical artery** (*a. transversa colli*) (Fig. 435), larger than the suprascapular, passes transversely outward, across the upper part of the subclavian triangle, to the anterior margin of the Trapezius muscle, beneath which it divides into two branches, the **superficial cervical** and the **posterior scapular**. In its passage across the neck it crosses in front of the phrenic nerve, Scaleni muscles, and the brachial plexus, between the divisions of which it sometimes passes, and is covered by the Platysma, Sternomastoid, Omohyoid, and Trapezius muscles.

The **superficial cervical** (*ramus ascendens*) ascends beneath the anterior margin of the Trapezius, distributing branches to it and to the neighboring muscles and lymph nodes in the neck, and anastomosing with the superficial branch of the *arteria princeps cervicis*.

The **posterior scapular** (*ramus descendens*) (Fig. 435) passes beneath the Levator anguli scapulae muscle to the superior angle of the scapula, and then descends along the posterior border of that bone as far as the inferior angle. In its course it is covered by the Rhomboid muscles, supplying them and the Latissimus dorsi and Trapezius, and anastomosing with the suprascapular and subscapular arteries. and with the posterior branches of some of the intercostal arteries.

Peculiarities.—The superficial cervical frequently arises as a separate branch from the thyroid axis; and the posterior scapular, from the third, more rarely from the second, part of the subclavian.

The **internal mammary artery** (*a. mamma interna*) (Fig. 458) arises from the under surface of the first portion of the subclavian artery, opposite the thyroid

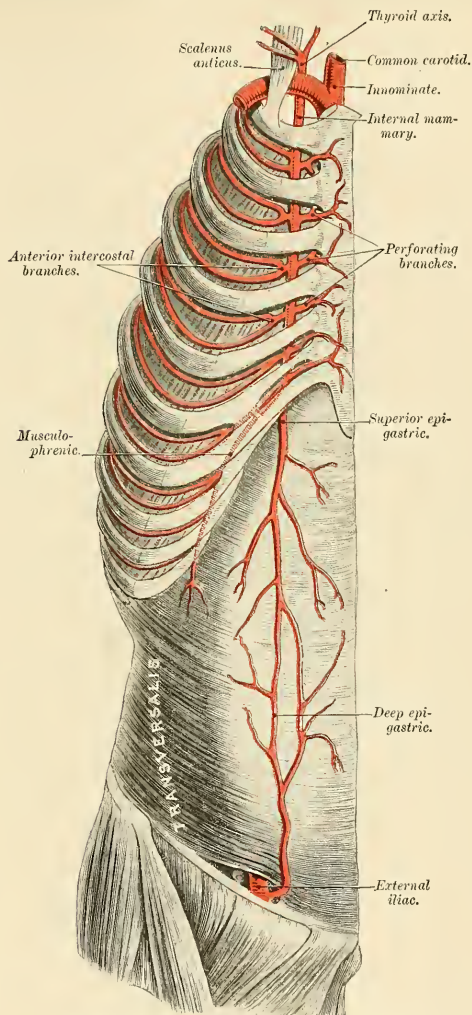


FIG. 458.—The internal mammary artery and its branches.

axis. It descends behind the cartilages of the upper six ribs at a distance of about half an inch from the margin of the sternum; and at the level of the sixth intercostal space divides into the **musculo-phrenic** and **superior epigastric** arteries.

Relations.—At its origin it is covered by the internal jugular and subclavian veins, and as it enters the thorax is crossed from without inward by the phrenic nerve, and then passes forward close to the outer side of the innominate vein. In the upper part of the thorax it lies behind the costal cartilages and Internal intercostal muscles, and is crossed by the terminations of the upper six intercostal nerves. Behind it lies upon the pleura, as far as the third costal cartilage; below this level upon the Triangularis sterni muscle. It is accompanied by two *venae comites*; these unite into a single vein, which passes to the inner side of the artery and ends in the corresponding innominate vein.

Branches.—The branches of the internal mammary are:

*Comes nervi phrenici.	Anterior intercostal.
Mediastinal.	Perforating.
Pericardiac.	Musculophrenic.
Sternal.	Superior epigastric.

The **comes nervi phrenici** (*a. pericardiophrenica*) is a long slender branch which accompanies the phrenic nerve, between the pleura and pericardium, to the Diaphragm to which it is distributed; it anastomoses with the other phrenic branches from the internal mammary and with phrenic branches of the abdominal aorta.

The **mediastinal branches** (*aa. mediastinales anteriores*) are small vessels which are distributed to the areolar tissue and lymph nodes in the anterior mediastinum and to the remains of the thymus gland.

The **pericardiac branches** supply the upper part of the anterior surface of the pericardium, the lower part receiving branches from the musculophrenic artery.

The **sternal branches** (*rami sternales*) are distributed to the Triangularis sterni and to the posterior surface of the sternum.

The mediastinal, pericardiac, and sternal branches, together with some twigs from the comes nervi phrenici, anastomose with branches from the intercostal and bronchial arteries, and form a minute plexus beneath the pleura, which has been named by Turner the **subpleural mediastinal plexus**.

The **anterior intercostal arteries** (*rami intercostales*) supply the five or six upper intercostal spaces. The branch corresponding to each space soon divides into two, or the two branches may come off separately from the parent trunk. The small vessels pass outward in the intercostal spaces, one, the larger, lying near the lower margin of the rib above, and the other, the smaller, near the upper margin of the rib below, and anastomose with the intercostal arteries from the aorta. They are at first situated between the pleura and the Internal intercostal muscles, and then between the Internal and External intercostal muscles. They supply the Intercostal muscles, and, by branches which perforate the External intercostal muscle, reach the Pectoral muscles and the mammary gland.

The **perforating arteries** (*rami perforantes*) correspond to the five or six upper intercostal spaces. They arise from the internal mammary, pass forward through the intercostal spaces, and, curving outward, supply the Pectoralis major and the integument. Those which correspond to the second, third, and fourth spaces are distributed to the mammary gland. In females, during lactation, these branches are of large size.

The **musculophrenic artery** (*a. musculophrenica*) is directed obliquely downward and outward, behind the cartilages of the false ribs, perforating the Diaphragm at the eighth or ninth rib, and terminating, considerably reduced in size, opposite the last intercostal space. It gives off anterior intercostal arteries to each of the intercostal spaces across which it passes; these diminish in size as the spaces decrease in length, and are distributed in a manner precisely similar to

the anterior intercostals from the internal mammary. The musculophrenic also gives branches to the lower part of the pericardium, and others which run backward to the Diaphragm and downward to the Abdominal muscles.

The **superior epigastric** (*a. epigastrica superior*) continues in the original direction of the internal mammary; it descends through the cellular interval between the costal and sternal attachments of the Diaphragm, and enters the sheath of the Rectus abdominis muscle, at first lying behind the muscle, and then perforating it and supplying it, and anastomosing with the deep epigastric artery from the external iliac. Some branches perforate the sheath of the Rectus and supply the muscles of the abdomen and the integument, and a small branch, which passes inward upon the side of the ensiform appendix, anastomoses in front of that cartilage with the superior epigastric artery of the opposite side. It also gives some twigs to the Diaphragm, while from the artery of the right side small branches extend into the falciform ligament of the liver and anastomose with the hepatic artery.

The **superior intercostal** (*truncus costocervicalis*) (Figs. 444 and 464) arises from the upper and back part of the subclavian artery, behind the Scalenus anticus muscle on the right side and to the inner side of that muscle on the left side. Passing backward, it gives off the **deep cervical branch**, and then descends behind the pleura in front of the necks of the first two ribs, and anastomoses with the first aortic intercostal. As it crosses the neck of the first rib it lies to the inner side of the anterior division of the first thoracic nerve and to the outer side of the first thoracic ganglion of the sympathetic cord.

In the first intercostal space it gives off a branch which is distributed in a manner similar to the distribution of the aortic intercostals. The branch for the second intercostal space usually joins with one from the highest aortic intercostal. Each intercostal gives off a branch to the posterior spinal muscles, and a small branch which passes through the corresponding intervertebral foramen to the spinal cord and its membranes.

The **deep cervical branch** (*a. cervicalis profunda*) arises, in most cases, from the superior intercostal, and is analogous to the posterior branch of an aortic intercostal artery; occasionally it arises as a separate branch from the subclavian artery. Passing backward, above the eighth cervical nerve and between the transverse process of the seventh cervical vertebra and the first rib, it runs up the back part of the neck, between the Complexus and Semispinalis colli muscles, as high as the axis vertebra, supplying these and adjacent muscles, and anastomosing with the deep branch of the arteria princeps cervicis of the occipital, and with branches which pass outward from the vertebral. It gives off a special branch which enters the vertebral canal through the intervertebral foramen between the seventh cervical and first thoracic vertebræ.

THE AXILLA.

The **axilla** or **armpit** is a pyramidal space, situated between the upper and lateral part of the thorax and the inner side of the arm.

Boundaries.—Its *apex*, which is directed upward toward the root of the neck, corresponds to the interval between the first rib, the upper edge of the scapula, and the clavicle, through which the axillary vessels, the brachial plexus of nerves, and the long thoracic nerve pass. This interval is the **cervico-axillary passage**. The *base*, directed downward, is formed by the integument and a thick layer of fascia, the **axillary fascia** (*fascia axillaris*) (Fig. 346), extending between the lower border of the Pectoralis major in front and the lower border of the Latissimus

dorsi behind (page 406). The axilla is broad internally at the thorax, but narrow and pointed externally at the arm. The *anterior* wall is formed by the Pectoralis major and minor muscles, the former covering the whole of the anterior wall of the axilla, the latter covering only its central part, the costocoracoid membrane, the clavicle, and the Subclavius muscle. The *posterior boundary*, which extends somewhat lower than the anterior, is formed by the Subscapularis above, the Teres major and Latissimus dorsi below. On the *inner side* are the first four ribs with their corresponding Intercostal muscles, and part of the Serratus magnus. On the *outer side*, where the anterior and posterior boundaries converge, the space is narrow, and bounded by the humerus, the Coracobrachialis and Biceps muscles.

Contents.—It contains the axillary vessels, and the brachial plexus of nerves, with their branches, some branches of the intercostal nerves, and a large number of lymph nodes, all connected by a quantity of fat and loose areolar tissue.

Position of the Contents.—The axillary artery and vein, with the brachial plexus of nerves, extend obliquely along the outer boundary of the axilla, from its apex to its base, and are placed much nearer the anterior than the posterior wall, the vein lying to the inner or thoracic side of the artery and partially concealing it. At the fore part of the axilla, in contact with the Pectoral muscles, and along the anterior margin are the thoracic branches of the axillary artery, and along the lower margin of the Pectoralis minor the long thoracic artery extends to the side of the thorax. At the back part, in contact with the lower margin of the Subscapularis muscle, are the subscapular vessels and nerves; winding around the outer border of this muscle is the dorsalis scapulae artery and veins; and, close to the neck of the humerus, the posterior circumflex vessels and the circumflex nerve are seen curving backward to the shoulder.

Along the inner or thoracic side no vessel of any importance exists, the upper part of the space being crossed merely by a few small branches from the superior thoracic artery. There are some important nerves, however, in this situation—viz., the long thoracic nerve, descending on the surface of the Serratus magnus, to which it is distributed; and perforating the upper and anterior part of this wall, the intercostohumeral nerve or nerves, passing across the axilla to the inner side of the arm.

The cavity of the axilla is filled by a quantity of loose areolar tissue and a large number of small arteries and veins, all of which are, however, of inconsiderable size, and numerous lymph nodes, the position and arrangement of which are described on a subsequent page.

Applied Anatomy.—The axilla is a space of considerable surgical importance. It transmits the large vessels and nerves to the upper extremity, and these may be the seat of injury or disease; it contains numerous lymph nodes which may require removal when diseased; in it is a quantity of loose connective and adipose tissue which may be readily infiltrated with blood or pus. The axilla may be the seat of rapidly growing tumors. Moreover, it is covered at its base by thin skin, largely supplied with sebaceous and sweat glands, which is frequently the seat of small cutaneous *abscesses* and *boils*, and of eruptions due to irritation.

In *suppuration* in the axilla the arrangement of the fasciæ plays a very important part in the direction which the pus takes. As described on p. 456, the costocoracoid membrane, after covering in the space between the clavicle and the upper border of the Pectoralis minor, splits to enclose this muscle, and, reblending at its lower border, becomes incorporated with the axillary fascia at the anterior fold of the axilla. Suppuration may take place either superficial to or beneath this layer of fascia; that is, either between the Pectorals or beneath the Pectoralis minor; in the former case the pus would point either at the anterior border of the axillary fold or in the groove between the Deltoid and the Pectoralis major; in the latter instance, the pus would have a tendency to surround the vessels and nerves and ascend into the neck, that being the direction in which there is least resistance. Its progress toward the skin is prevented by the axillary fascia; its progress backward, by the Serratus magnus; forward, by the costocoracoid fascia; inward, by the wall of the thorax; and outward, by the upper limb. The pus in these cases,

after extending into the neck, has been known to spread through the superior opening of the thorax into the mediastinum.

In opening an *axillary abscess* the knife should be entered in the floor of the axilla, midway between the anterior and posterior margins and near the thoracic side of the space. It is well to use a director and dressing forceps after an incision has been made through the skin and fascia in the manner directed by the late Mr. Hilton.

The relations of the vessels and nerves in the several parts of the axilla are important, for it is the universal plan to remove the nodes from the axilla in operating for *cancer of the breast*.

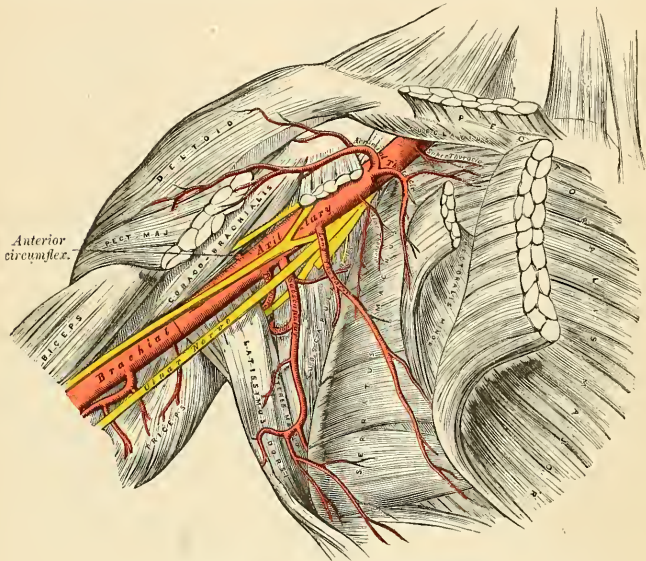


FIG. 459.—The axillary artery and its branches.

The Axillary Artery (*A. Axillaris*) (Fig. 459).

The **axillary artery**, the continuation of the subclavian, commences at the outer border of the first rib, and terminates at the lower border of the tendon of the *Teres major* muscle, where it takes the name of *brachial*. Its direction varies with the position of the limb; when the arm lies by the side of the thorax, the vessel forms a gentle curve, the convexity being upward and outward; when the arm is directed at right angles with the trunk, the vessel is nearly straight; and when the arm is elevated still higher, the arteries describe a curve the concavity of which is directed upward. At its commencement the artery is very deeply situated, but near its termination it is superficial, being covered only by the skin and fascia. The description of the relations of this vessel is facilitated by its division into three portions, the *first* portion being above, the *second* portion behind, and the *third* below the *Pectoralis minor*.

Relations.—The *first* portion of the axillary artery is in relation, *in front*, with the clavicular portion of the *Pectoralis major*, the costocoracoid membrane, the external anterior thoracic nerve, and the acromiothoracic and cephalic veins; *behind*, with the first intercostal space, the corre-

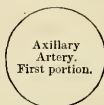sponding Intercostal muscle, the first and second digitations of the Serratus magnus, and the Long thoracic nerve; on its *outer side*, with the brachial plexus, from which it is separated by a little areolar tissue; on its *inner* or thoracic side, with the axillary vein, which overlaps the artery. It is enclosed, together with the axillary vein and the brachial plexus, in a fibrous sheath—the **axillary sheath**—continuous above with the cervical fascia.

RELATIONS OF THE FIRST PORTION OF THE AXILLARY ARTERY.

In front.

Pectoralis major.
Costocoracoid membrane.
External anterior thoracic nerve.
Acromiothoracic and cephalic veins.

Outer side.
Brachial plexus.



Inner side.
Axillary vein.

Behind.

First Intercostal space and Intercostal muscle.
First and Second digitations of Serratus magnus.
Long thoracic and internal anterior thoracic nerves.

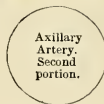The **second portion** is covered, *in front*, by the Pectoralis major and minor muscles; *behind* it is the posterior cord of the brachial plexus and some areolar tissue which intervenes between it and the Subscapularis; on the *inner side* is the axillary vein, separated from the artery by the inner cord of the brachial plexus and the internal anterior thoracic nerve; on the *outer side* is the outer cord of the brachial plexus. The brachial plexus of nerves thus surrounds the artery on three sides, and separates it from direct contact with the vein and adjacent muscles.

RELATIONS OF THE SECOND PORTION OF THE AXILLARY ARTERY.

In front.

Pectoralis major and minor.

Outer side.
Outer cord of brachial plexus.



Inner side.
Axillary vein.
Inner cord of brachial plexus.
Internal anterior thoracic nerve.

Behind.

Subscapularis.
Posterior cord of brachial plexus.

The **third portion** of the axillary artery extends from the lower border of the Pectoralis minor to the lower border of the tendon of the Teres major. It is in relation, *in front*, with the lower part of the Pectoralis major above, being covered only by the integument and fascia below; *behind*, with the lower part of the Subscapularis and the tendons of the Latissimus dorsi and Teres major; on its *outer side*, with the Coracobrachialis; on its *inner* or thoracic side, with the axillary vein. The nerves of the brachial plexus bear the following relation to the artery in this part of its course; on the *outer side* is the median nerve and the musculocutaneous for a short distance; on the *inner side*, the ulnar nerve (between the vein and artery) and the lesser internal cutaneous nerve (to the inner side of the vein); *in front* are the inner head of the median and the internal cutaneous nerve, and *behind*, the musculospiral and circumflex, the latter extending only as far as the lower border of the Subscapularis muscle.

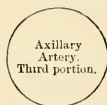RELATIONS OF THE THIRD PORTION OF THE AXILLARY ARTERY.

In front.

Integument and fascia.
Pectoralis major.
Inner head of median nerve.
Internal cutaneous nerve.

Outer side.

Coracobrachialis.
Median nerve.
Musculocutaneous nerve.

*Inner side.*

Ulnar nerve.
Axillary vein.
Lesser internal cutaneous nerve.

Behind.

Subscapularis.
Tendons of Latissimus dorsi and Teres major.
Musculospiral and circumflex nerves.

Peculiarities.—The axillary artery, in about one case out of every ten, gives off a large branch, which forms either one of the arteries of the forearm or a large muscular trunk. In the first set of cases this artery is most frequently the radial (1 in 33), sometimes the ulnar (1 in 72) and, very rarely, the interosseous (1 in 506). In the second set of cases the trunk has been found to give origin to the subscapular, circumflex, and profunda arteries of the arm. Sometimes only one of the circumflex, or one of the profunda arteries, arises from the trunk. In these cases the brachial plexus surrounded the trunk of the branches and not the main vessel.

Surface Marking.—The course of the axillary artery may be marked out by raising the arm to a right angle with the body and drawing a line from the middle of the clavicle to the point where the tendon of the Pectoralis major crosses the prominence caused by the Coracobrachialis as it emerges from under cover of the anterior fold of the axilla. The third portion of the artery can be felt pulsating beneath the skin and fascia, at the junction of the anterior with the middle third of the space between the anterior and posterior folds of the axilla, close to the inner border of the Coracobrachialis muscle.

Applied Anatomy.—*Compression* of the vessel may be required in the removal of tumors or in amputation of the upper part of the arm; and the only situation in which this can be effectually made is in the lower part of its course; by pressing on it in this situation from within outward against the humerus the circulation may be effectually arrested.

With the exception of the popliteal, the axillary artery is perhaps more frequently lacerated than any other artery in the body by violent movements of the extremity, especially in those cases where its coats are diseased. It has occasionally been *ruptured* in attempts to reduce old dislocations of the shoulder-joint. This accident is most likely to occur during the preliminary breaking down of adhesions, in consequence of the artery having become fixed to the capsule of the joint. *Aneurism of the axillary artery* is of frequent occurrence, a large percentage of the cases being traumatic in their origin, due to the violence to which the vessel is exposed in the varied, extensive, and often violent movements of the limb.

The application of a ligature to the axillary artery may be required in cases of aneurism of the upper part of the brachial or as a distal operation for aneurism of the subclavian; and there are only two situations in which the vessel can be secured—viz., in the first and in the third parts of its course; for the axillary artery at its central part is so deeply seated, and, at the same time, so closely surrounded with large nerve trunks, that the application of a ligature to it in that situation would be almost impracticable.

In the *third part* of its course the operation is most simple, and may be performed in the following manner: The patient being placed on a bed and the arm separated from the side, with the hand supinated, an incision about two inches in length is made through the integument forming the floor of the axilla, the cut being a little nearer to the anterior than the posterior fold of the axilla. After carefully dissecting through the areolar tissue and fascia, the median nerve and axillary vein are exposed; the former having been displaced to the outer and the latter to the inner side of the arm, the elbow being at the same time bent, so as to relax the structures and facilitate their separation, the ligature may be passed around the artery from the ulnar to the radial side.

This portion of the artery is occasionally crossed by a muscular slip, the *axillary arch*, derived from the Latissimus dorsi, which may mislead the surgeon during an operation. The occasional existence of this muscle fasciculus was spoken of in the description of the muscles. It may easily be recognized by the transverse direction of its fibres.

The *first portion* of the axillary artery may be tied in cases of aneurism encroaching so far upward that a ligature cannot be applied in the lower part of its course. Notwithstanding that this operation has been performed in some few cases, and with success, its performance is attended with much difficulty and danger. The student will remark that in this situation it would be necessary to divide a thick muscle, and, after incising the costocoracoid membrane, the artery would be exposed at the bottom of a more or less deep space, with the cephalic and axillary veins in such relation with it as must render the application of a ligature to this part of the vessel particularly hazardous. Under such circumstances it is an easier, and at the same time more advisable, operation to tie the subclavian artery in the third part of its course.

The vessel in the first part of its course can best be secured through a curved incision the convexity of which is downward. This incision passes from a point half an inch external to the sternoclavicular joint to a point half an inch internal to the coracoid process. The limb is to be well abducted and the head inclined to the opposite side, and this incision is carried through the superficial structures, care being taken to avoid the cephalic vein at the outer angle of the incision. The clavicular origin of the Pectoralis major is then divided in the whole extent of the wound. The arm is now to be brought to the side, and the upper edge of the Pectoralis minor defined and drawn downward. The costocoracoid membrane is to be carefully divided close to the coracoid process, and the axillary sheath exposed; this is to be opened with especial care, on account of the vein overlapping the artery. The needle should be passed from below, so as to avoid wounding the vein.

In a case of wound of the vessel the general practice of cutting down upon and tying it above and below the wounded point should be adopted in all cases.

Branches.—The branches of the axillary artery are:

From first part	{ Superior thoracic. Acromiothoracic.	From second part	{ Long thoracic. Alar thoracic.
	From third part		{ Subscapular. Posterior circumflex. Anterior circumflex.

The **superior thoracic** (*a. thoracalis suprema*) is a small artery which arises from the axillary separately or by a common trunk with the acromiothoracic. Running forward and inward along the upper border of the Pectoralis minor, it passes between it and the Pectoralis major to the side of the thorax. It supplies these muscles and the parietes of the thorax, anastomosing with the internal mammary and intercostal arteries.

The **acromiothoracic** (*a. thoracoacromialis*) is a short trunk which arises from the fore part of the axillary artery, its origin being generally overlapped by the upper edge of the Pectoralis minor. Projecting forward to the upper border of the Pectoralis minor, it divides into four sets of branches—**thoracic, acromial, descending, and clavicular.**

The **thoracic branches** (*rami pectorales*), two or three in number, are distributed to the Serratus magnus and Pectoral muscles, anastomosing with the intercostal branches of the internal mammary.

The **acromial branch** (*ramus acromialis*) is directed outward toward the acromion, supplying the Deltoid muscle, and anastomosing, on the surface of the acromion, with the suprascapular and posterior circumflex arteries.

The **descending or humeral branch** (*ramus deltoideus*) runs in the space between the Pectoralis major and Deltoid, in the same groove as the cephalic vein, and supplies both muscles.

The **clavicular branch** (*ramus clavicularis*), which is very small, runs upward to the Subclavius muscle.

The **long thoracic** or the **external mammary** (*a. thoracalis lateralis*) passes downward and inward along the lower border of the Pectoralis minor to the side of the thorax, supplying the Serratus magnus, the Pectoral muscles, and mammary gland, and sending branches across the axilla to the axillary nodes and Subscapularis; it anastomoses with the internal mammary and intercostal arteries.

The **alar thoracic** is a small branch which supplies the nodes and areolar tissue of the axilla. Its place is frequently supplied by branches from some of the other thoracic arteries.

The **subscapular** (*a. subscularis*), the largest branch of the axillary artery, *arises* opposite the lower border of the Subscapularis muscle, and passes downward and backward along its lower margin to the inferior angle of the scapula, where it anastomoses with the long thoracic and intercostal arteries and with the posterior scapular branch of the transverse cervical, and terminates by supplying branches to the muscles in the neighborhood. About an inch and a half from its origin it gives off a large branch, the **dorsalis scapulae**.

The **dorsalis scapulae** (*a. circumflexa scapulae*) is generally larger than the continuation of the subscapular. It curves around the axillary border of the scapula, leaving the axilla through the space between the Teres minor above, the Teres major below, and the long head of the Triceps externally (Fig. 457), and enters the infraspinous fossa by passing under cover of the Teres minor, where it anastomoses with the posterior scapular and suprascapular arteries. In its course it gives off two branches: one (**infrascapular**) enters the subscapular fossa beneath the Subscapularis, which it supplies, anastomosing with the posterior scapular and suprascapular arteries; the other is continued along the axillary border of the scapula, between the Teres major and minor, and, at the dorsal surface of the inferior angle of the bone, anastomoses with the posterior scapular. In addition to these, small branches are distributed to the back part of the Deltoid muscle and the long head of the Triceps, anastomosing with an ascending branch of the superior profunda of the brachial.

The **circumflex arteries** wind around the surgical neck of the humerus. The **posterior circumflex** (*a. circumflexa humeri posterior*) (Fig. 457), the larger of the two, *arises* from the back part of the axillary opposite the lower border of the Subscapularis muscle, and, passing backward with the circumflex veins and nerve through the quadrangular space bounded by the Teres major and minor, the scapular head of the Triceps and the humerus, winds around the neck of that bone and is distributed to the Deltoid muscle and shoulder-joint, anastomosing with the anterior circumflex and acromial thoracic arteries, and with the superior profunda branch of the brachial artery. The **anterior circumflex** (*a. circumflexa humeri anterior*) (Figs. 457 and 459), considerably smaller than the preceding, *arises* nearly

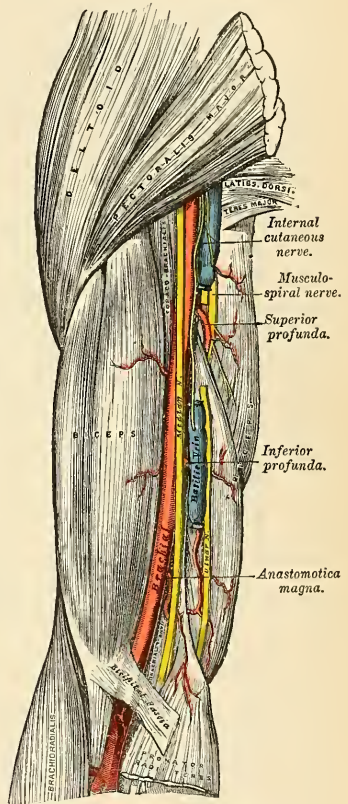


FIG. 460.—The brachial artery.

opposite that vessel from the outer side of the axillary artery. It passes horizontally outward beneath the Coracobrachialis and short head of the Biceps lying upon the fore part of the neck of the humerus, and, on reaching the bicipital groove, gives off an ascending branch which passes upward along the groove to supply the head of the bone and the shoulder-joint. The trunk of the vessel is then continued outward beneath the Deltoid, which it supplies, and anastomoses with the posterior circumflex artery.

The Brachial Artery (A. Brachialis) (Fig. 460).

The **brachial artery** (*a. brachialis*) commences at the lower margin of the tendon of the Teres major, and, passing down the inner and anterior aspect of the arm, terminates about half an inch below the bend of the elbow, where it divides into the **radial and ulnar arteries**. At first the brachial artery lies internal to the humerus, but as it passes down the arm it gradually gets in front of the bone, and at the bend of the elbow it lies midway between the two condyles.

Relations.—This artery is superficial throughout its entire extent, being covered, *in front*, by the integument, the superficial and deep fasciæ; the bicipital fascia separates it opposite the elbow from the median basilic vein; the median nerve crosses it at its middle; *behind*, it is separated from the long head of the Triceps by the musculospiral nerve and superior profunda artery. It then lies upon the inner head of the Triceps, next upon the insertion of the Coracobrachialis, and lastly on the Brachialis anticus. By its *outer side*, it is in relation with the commencement of the median nerve and the Coracobrachialis and Biceps muscles, the two muscles overlapping the artery to a considerable extent. By its *inner side*, its upper half is in relation with the internal cutaneous and ulnar nerves, its lower half with the median nerve. The basilic vein lies on the inner side of the artery, but is separated from it in the lower part of the arm by the deep fascia. The brachial artery is accompanied by two venæ comites, which lie in close contact with the artery, being connected at intervals by short transverse communicating branches.

PLAN OF THE RELATIONS OF THE BRACHIAL ARTERY.

In front.

Integument and fasciæ.
Bicipital fascia, median basilic vein.
Median nerve (in middle portion).
Overlapped by Coracobrachialis and Biceps.

Outer side.

Median nerve (above).
Coracobrachialis.
Biceps.



Inner side.

Internal cutaneous and ulnar nerves.
Median nerve (below).
Basilic vein

Behind.

Triceps (long and inner heads).
Musculospiral nerve.
Superior profunda artery.
Coracobrachialis.
Brachialis anticus.

THE ANATOMY OF THE BEND OF THE ELBOW (ANTECUBITAL FOSSA).

At the bend of the elbow the brachial artery sinks deeply into a triangular interval, the **antecubital fossa**, the *base* of which is directed upward, and may be represented by a line connecting the two condyles of the humerus; the *sides* are bounded, *externally*, by the inner edge of the Brachioradialis; *internally*, by the outer margin of the Pronator teres; its *floor* is formed by the Brachialis anticus and Supinator [brevis]. This space contains the brachial artery with its accompanying veins, the radial and ulnar arteries, the median and musculospiral nerves, and the tendon of the Biceps. The brachial artery occupies the middle line of this space, and divides opposite the neck of the radius into the radial and ulnar arteries; it is covered, *in front*, by the integument, the superficial fascia, and the median basilic vein, the vein being separated from direct contact with the artery by the bicipital fascia. *Behind*, it lies on the Brachialis anticus, which separates it from the elbow-joint. The median nerve lies on the inner side of the artery, close to it above, but separated from it below by the coronoid origin of the Pronator teres. The tendon of the Biceps lies to the outer side of the space, and the musculospiral nerve still more externally, situated upon the Supinator [brevis] and partly concealed by the Brachioradialis.

Peculiarities of the Brachial Artery as Regards its Course.—The brachial artery, accompanied by the median nerve, may leave the inner border of the Biceps and descend toward the inner condyle of the humerus, where it usually curves around a prominence of bone, the supracondylar process. From this process, in most subjects, a fibrous arch is thrown over the artery. The vessel then inclines outward, beneath or through the substance of the Pronator teres muscle, to the bend of the elbow. The variation bears considerable homology to the normal condition of the artery in some of the carnivora; it has been referred to in the description of the humerus (page 181).

As Regards its Division.—Occasionally, the artery is divided for a short distance at its upper part into two trunks which are united above and below. A similar peculiarity occurs in the main vessel of the lower limb.

The vessels concerned in the high division of the brachial artery are three—viz., radial, ulnar, and interosseous. Most frequently the radial is given off high up, the other limb of the bifurcation consisting of the ulnar and interosseous. In some instances the ulnar arises from the brachial above the ordinary level, and the radial and interosseous form the other limb of the division; and occasionally the interosseous arises high up.

Sometimes long slender vessels, **vasa aberrantia**, connect the brachial or axillary arteries with one of the arteries of the forearm or a branch from them. These vessels usually join the radial.

Varieties in Muscular Relations.¹—The brachial artery is occasionally concealed in some part of its course by muscular or tendinous slips derived from the Coracobrachialis, Biceps, Brachialis anticus, and Pronator teres muscles.

Surface Marking.—The direction of the brachial artery is marked by a line drawn along the inner edge of the Biceps from the junction of the anterior and middle thirds of the axillary outlet to the middle of the front of the elbow-joint.

Applied Anatomy.—Compression of the brachial artery is required in cases of amputation and some other operations in the arm and forearm; and it will be observed that it may be effected in almost any part of the course of the artery. If pressure is made in the upper part of the limb, it should be directed from within outward, and if in the lower part, from before backward, as the artery lies on the inner side of the humerus above and in front of the humerus below. The most favorable situation is about the middle of the arm, where it lies on the tendon of the Coracobrachialis on the inner flat side of the humerus.

The application of a ligature to the brachial artery may be required in case of wound of the vessel and in some cases of wound of the palmar arch. It is also sometimes necessary in cases of aneurism of the brachial, the radial, ulnar, or interosseous arteries. The artery may be secured in any part of its course. The chief guides in determining its position are the surface markings produced by the inner margin of the Coracobrachialis and Biceps, the known

¹ See Struther's Anatomical and Physiological Observations.

course of the vessel, and its pulsation, which should be carefully felt for before any operation is performed, as the vessel occasionally deviates from its usual position in the arm. In whatever situation the operation is performed, great care is necessary, on account of the extreme thinness of the parts covering the artery and the intimate connection which the vessel has throughout its whole course with important nerves and veins. Sometimes a thin layer of muscle fibre is met with concealing the artery; if such is the case, it must be cut across in order to expose the vessel.

In the upper third of the arm the artery may be exposed in the following manner: The patient being placed supine upon a table, the affected limb should be raised from the side and the hand supinated. An incision about two inches in length should be made on the inner side of the Coracobrachialis muscle, and the subjacent fascia cautiously divided, so as to avoid wounding the internal cutaneous nerve or basilic vein, which sometimes runs on the surface of the artery as high as the axillary. The fascia having been divided, it should be remembered that the ulnar and internal cutaneous nerves lie on the inner side of the artery, the median on the outer side, the latter nerve being occasionally superficial to the artery in this situation, and that the venae comites are also in relation with the vessel, one on either side. These being carefully separated, the aneurism needle should be passed around the artery from the inner to the outer side.

In the case of a high division, the two arteries are usually placed side by side; and if they are exposed in an operation, the surgeon should endeavor to ascertain, by alternately pressing on each vessel, which of the two communicates with the wound or aneurism, when a ligature may be applied accordingly; or if pulsation or hemorrhage ceases only when both vessels are compressed, both vessels may be tied, as it may be concluded that the two communicate above the seat of disease or are reunited.

It should also be remembered that two arteries may be present in the arm in a case of high division, and that one of these may be found along the inner intermuscular septum, in a line toward the inner condyle of the humerus, or in the usual position of the brachial, but deeply placed beneath the common trunk; a knowledge of these facts will suggest the precautions necessary in every case, and indicate the measures to be adopted when anomalies are met with.

In the middle of the arm the brachial artery may be exposed by making an incision along the inner margin of the Biceps muscle. The forearm being bent so as to relax the muscle, it should be drawn slightly aside, and, the fascia being carefully divided, the median nerve will be exposed lying upon the artery (sometimes beneath); this being drawn inward and the muscle outward, the artery should be separated from its accompanying veins and secured. In this situation the inferior profunda may be mistaken for the main trunk, especially if enlarged, from the collateral circulation having become established; this may be avoided by directing the incision externally toward the Biceps, rather than inward or backward toward the Triceps.

The lower part of the brachial artery is of interest from a surgical point of view, on account of the relation which it bears to the veins most commonly opened in **venesection**. Of these vessels, the *median basilic* is the largest and most prominent, and, consequently, the one usually selected for the operation. It should be remembered that this vein runs parallel with the brachial artery, from which it is separated by the bicipital fascia, and that care should be taken in opening the vein not to carry the incision too deeply, so as to endanger the artery.

Collateral Circulation.—After the application of a ligature to the brachial artery in the upper third of the arm, the circulation is carried on by branches from the circumflex and subscapular arteries, anastomosing with ascending branches from the superior profunda. If the brachial is tied *below* the origin of the profunda arteries, the circulation is maintained by the branches of the profundæ, anastomosing with the recurrent radial, ulnar, and interosseous arteries.

Branches.—The branches of the brachial artery are:

Superior profunda.
Nutrient.

Inferior profunda.
Anastomotica magna.

Muscular.

The **superior profunda artery** (*a. profunda brachii*) arises from the inner and back part of the brachial, just below the lower border of the *Teres major*, and passes backward to the interval between the outer and inner heads of the *Triceps* muscle; accompanied by the musculospiral nerve it winds around the back part of the shaft of the humerus in the spiral groove, between the outer head of the *Triceps* and the bone, to the outer side of the humerus, where it reaches the external intermuscular septum and divides into two terminal branches. One of these pierces the external intermuscular septum, and descends, in company with the musculo-

spiral nerve, to the space between the Brachialis anticus and Brachioradialis, where it anastomoses with the recurrent branch of the radial artery; while the other, much the larger of the two, descends along the back of the external intermuscular septum to the back of the elbow-joint, where it anastomoses with the posterior interosseous recurrent, and across the back of the humerus with the posterior ulnar recurrent, the anastomotica magna, and inferior profunda (Fig. 464). The superior profunda supplies the Triceps muscle and gives off a nutrient artery which enters the bone at the upper end of the musculospiral groove. Near its commencement it sends off a branch which passes upward between the external and long heads of the Triceps muscle to anastomose with the posterior circumflex artery, and, while in the groove, a small branch which accompanies a branch of the musculospiral nerve through the substance of the Triceps muscle and ends in the Anconeus below the outer condyle of the humerus.

The **nutrient artery** (*a. nutritia humeri*) of the shaft of the humerus arises from the brachial, about the middle of the arm. Passing downward it enters the nutrient canal of that bone near the insertion of the Coracobrachialis muscle.

The **inferior profunda** (*a. collateralis ulnaris superior*), of small size, arises from the brachial, a little below the middle of the arm; piercing the internal intermuscular septum, it descends on the surface of the inner head of the Triceps muscle to the space between the inner condyle and olecranon, accompanied by the ulnar nerve, and terminates by anastomosing with the posterior ulnar recurrent and anastomotica magna. It sometimes supplies a branch to the front of the internal condyle, which anastomoses with the anterior ulnar recurrent.

The **anastomotica magna** (*a. collateralis ulnaris inferior*) arises from the brachial about two inches above the elbow-joint. It passes transversely inward upon the Brachialis anticus, and, piercing the internal intermuscular septum, winds

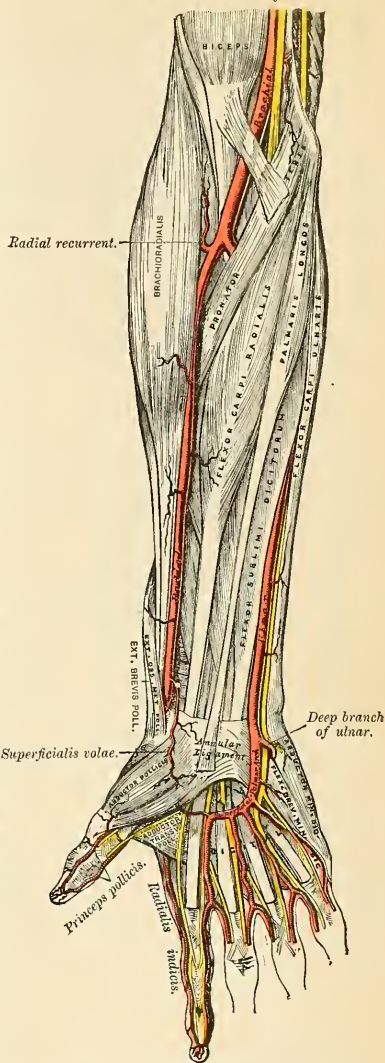


FIG. 461.—The radial and ulnar arteries.

around the back of the humerus between the Triceps and the bone, forming an arch above the olecranon fossa by its junction with the posterior articular branch of the superior profunda. As this vessel lies on the Brachialis anticus, branches ascend to join the inferior profunda, and others descend in front of the inner condyle to anastomose with the anterior ulnar recurrent. Behind the internal condyle an offset is given off which anastomoses with the inferior profunda and posterior ulnar recurrent arteries and supplies the Triceps.

The **muscular** (*rami musculares*) are three or four large branches, which are distributed to the muscles in the course of the artery. They supply the Coracobrachialis, Biceps, and Brachialis anticus muscles.

The Anastomosis around the Elbow-joint (Fig. 462).—The vessels engaged in this anastomosis may be conveniently divided into those situated *in front* and

behind the internal and external condyles. The branches anastomosing *in front* of the internal condyle are the anastomotica magna, the anterior ulnar recurrent, and the anterior terminal branch of the inferior profunda. Those *behind* the internal condyle are the anastomotica magna, the posterior ulnar recurrent, and the posterior terminal branch of the inferior profunda. The branches anastomosing *in front* of the external condyle are the radial recurrent and the anterior terminal branch of the superior profunda. Those *behind* the external condyle (perhaps more properly described as being situated between the external condyle and the olecranon) are the anastomotica magna, the interosseous recurrent, and the posterior terminal branch of the superior profunda. There is also a large arch of anastomosis above the olecranon, formed by the interosseous recurrent, joining with the anastomotica magna and posterior ulnar recurrent.

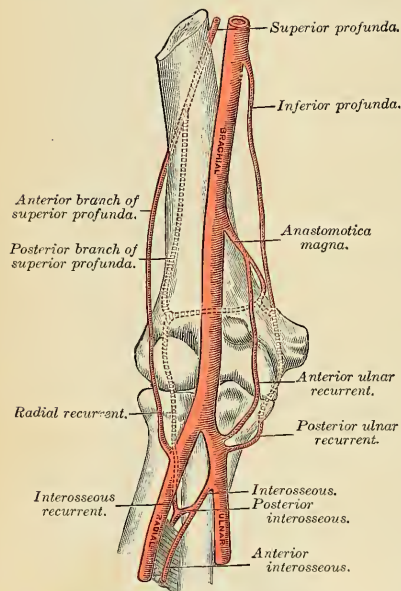


Fig. 462.—Diagram of the anastomosis around the right elbow-joint.

magna is the vessel most engaged, the only part of the anastomosis in which it is not employed being that *in front* of the external condyle.

The Radial Artery (A. Radialis) (Figs. 461, 463).

The radial artery appears, from its direction, to be the continuation of the brachial, but in size it is smaller than the ulnar. It commences at the bifurcation of the brachial, just below the bend of the elbow, and passes along the radial side of the forearm to the wrist; it then winds backward, around the outer side of the carpus, beneath the Extensor tendons of the thumb, to the upper end of the

space between the metacarpal bones of the thumb and index finger, and finally passes forward, between the two heads of the First dorsal interosseous muscle, into the palm of the hand, where it crosses the metacarpal bones to the ulnar border of the hand, to form the **deep palmar arch**. At its termination it anastomoses with the profunda branch of the ulnar artery. The relations of this vessel may thus be conveniently divided into three parts—viz., in the forearm, at the back of the wrist, and in the hand.

Relations.—In the forearm this vessel extends from opposite the neck of the radius to the fore part of the styloid process, being placed to the inner side of the shaft of the bone above and in front of it below. It is overlapped in the upper part of its course by the fleshy belly of the Brachioradialis muscle; throughout the rest of its course it is superficial, being covered by the integument, the superficial and deep fasciæ. In its course downward it lies upon the tendon of the Biceps, the Supinator [brevis], the Pronator teres, the radial origin of the Flexor sublimis digitorum, the Flexor longus pollicis, the Pronator quadratus, and the lower extremity of the radius. In the upper third of its course it lies between the Brachioradialis and the Pronator teres; in the lower two-thirds, between the tendons of the Brachioradialis and the Flexor carpi radialis. The radial nerve lies close to the outer side of the artery in the middle third of its course, and some filaments of the musculocutaneous nerve, after piercing the deep fascia, run along the lower part of the artery as it winds around the wrist. The vessel is accompanied by venæ comites throughout its whole course.

PLAN OF THE RELATIONS OF THE RADIAL ARTERY IN THE FOREARM.

In front.

Skin, superficial and deep fasciæ.
Brachioradialis.

Inner side.

Pronator teres.
Flexor carpi radialis.



Outer side.

Brachioradialis.
Radial nerve (middle third).

Behind.

Tendon of Biceps.
Supinator [brevis].
Pronator teres.
Flexor sublimis digitorum.
Flexor longus pollicis.
Pronator quadratus.
Radius.

At the wrist, as it winds around the outer side of the carpus from the styloid process to the first interosseous space, it lies upon the external lateral ligament, and then upon the scaphoid bone and trapezium, being covered by the Extensor tendons of the thumb, subcutaneous veins, some filaments of the radial nerve, and the integument. It is accompanied by two veins and a filament of the musculocutaneous nerve.

In the hand it passes from the upper end of the first interosseous space, between the heads of the Abductor indicis or First dorsal interosseous muscle, transversely across the palm, to the base of the metacarpal bone of the little finger, where it anastomoses with the communicating branch from the ulnar artery, forming the **deep palmar arch**.

The **deep palmar arch** (*arcus volaris profundus*) (Fig. 463) lies upon the carpal extremities of the metacarpal bones and the Interossei muscles, being covered by the Adductor obliquus pollicis, the Flexor tendons of the fingers, the Lumbricales, the Opponens, and Flexor brevis minimi digiti. Alongside of it, but running in the opposite direction—that is to say, from within outward—is

the deep branch of the ulnar nerve. The branches of the deep palmar arch are the palmar interosseous, perforating and palmar recurrent vessels (page 648).

Peculiarities.—The origin of the radial artery, according to Quain, is, in nearly one case in eight, higher than usual; more frequently arising from the axillary or upper part of the brachial than from the lower part of this vessel. The variations in the position of this vessel in the arm and at the bend of the elbow have been already mentioned. In the forearm it deviates less frequently from its position than the ulnar. It has been found lying over the fascia instead of beneath it. It has also been observed superficial to the Brachioradialis, instead of under its inner border; and in turning around the wrist it has been seen lying over, instead of beneath, the Extensor tendons of the thumb.

Surface Marking.—The position of the radial artery in the forearm is represented by a line drawn from the outer border of the tendon of the Biceps in the centre of the hollow in front of the elbow-joint with a straight course to the inner side of the forepart of the styloid process of the radius.

Applied Anatomy.—The radial artery is much exposed to injury in its lower third, and is frequently wounded. The injury is often followed by a *traumatic aneurism*, for which the operation of extirpation or laying open the sac after securing the vessel above and below is required.

The operation of *tying the radial artery* is required in cases of wounds either of its trunk or of some of its branches, or for aneurism; and it will be observed that the vessel may be exposed in any part of its course through the forearm without the division of any muscle fibres. The operation in the middle or inferior third of the forearm is easily performed, but in the upper third, near the elbow, it is attended with some difficulty, from the greater depth of the vessel and from its being overlapped by the Brachioradialis muscle.

To tie the artery in the upper third an incision three inches in length should be made through the integument, in a line drawn from the centre of the bend of the elbow to the front of the styloid process of the radius, avoiding the branches of the median vein; the fascia of the arm being divided and the Brachioradialis drawn a little outward, the artery will be exposed. The venae comites should be carefully separated from the vessel, and the ligature passed from the radial to the ulnar side.

In the middle third of the forearm the artery may be exposed by making an incision of similar length on the inner margin of the Brachioradialis. In this situation the radial nerve lies in close relation with the outer side of the artery, and should, as well as the veins, be carefully avoided.

In the lower third the artery is easily secured by dividing the integument and fascia in the interval between the tendons of the Brachioradialis and Flexor carpi radialis muscles.

Branches (Figs. 461 and 463).—The branches of the radial artery may be divided into three groups, corresponding with the three regions in which the vessel is situated.

<i>In the Forearm</i>	{	Radial recurrent.	<i>At the Wrist</i>	{	Posterior radial carpal.
		Muscular.			First dorsal interosseous.
		Anterior radial carpal.			Dorsales pollicis.
		Superficialis volae.			Dorsalis indicis.
<i>In the Hand</i>	{	Princeps pollicis.			
		Radialis indicis.			
		Perforating.			
		Palmar interosseous.			
		Palmar recurrent.			

The **radial recurrent** (*a. recurrens radialis*) (Fig. 463) is given off immediately below the elbow. It ascends between the branches of the musculospiral nerve lying on the Supinator [brevis], and then between the Brachioradialis and Brachialis anticus, supplying these muscles and the elbow-joint, and anastomosing with the anterior terminal branch of the superior profunda.

The **muscular branches** (*rami musculares*) are distributed to the muscles on the radial side of the forearm.

The **anterior radial carpal** (*ramus carpeus volaris*) (Fig. 463) is a small vessel which *arises* from the radial artery near the lower border of the Pronator quadratus, and, running inward in front of the radius, anastomoses with the anterior carpal branch of the ulnar artery. In this way an arterial anastomosis, the **anterior carpal arch** (*rete carpi volare*) is formed in front of the wrist; it is joined by branches from the anterior interosseous above, and by recurrent branches from the deep palmar arch below, and gives off branches which descend to supply the articulations of the wrist and carpus.

The **superficialis volae** (*ramus volaris superficialis*) (Fig. 463) *arises* from the radial artery, just where this vessel is about to wind around the wrist. Running forward, it passes between, occasionally over, the muscles of the thumb, which it supplies, and sometimes anastomoses with the palmar portion of the ulnar artery, completing the superficial palmar arch. This vessel varies considerably in size; usually it is very small, and terminates in the muscles of the thumb; sometimes it is as large as the continuation of the radial.

The **posterior radial carpal** (*ramus carpeus dorsalis*) (Fig. 464) is a small vessel which *arises* from the radial artery beneath the Extensor tendons of the thumb; crossing the carpus transversely to the inner border of the hand, it anastomoses with the posterior carpal branch of the ulnar, forming the **posterior carpal arch** (*rete carpi dorsale*), which is joined by the termination of the anterior interosseous artery. From this arch are given off descending branches, the **dorsal interosseous arteries** (*aa. metacarpeae dorsales*) for the second, third, and fourth interosseous spaces, which run forward on the Second, Third, and Fourth dorsal interossei muscles, and divide into **dorsal digital branches** (*aa. digitales dorsales*), which supply the adjacent sides of the index, middle, ring, and little fingers, respectively, communicating with the digital arteries of the superficial palmar arch. The dorsal interosseous arteries anastomose with the perforating branches from the deep palmar arch.

The **first dorsal interosseous** *arises* beneath the Extensor tendons of the thumb, sometimes with the posterior radial carpal; running forward on the Second dorsal interosseous muscle, it divides into two dorsal digital branches, which supply the adjoining sides of the index and middle fingers; it forms anastomoses similar to those of the two other dorsal interosseous arteries.

The **dorsales pollicis** (Fig. 464) are two vessels which run along the sides of the dorsal aspect of the thumb. They usually *arise* separately, but occasionally by a common trunk, near the base of the first metacarpal bone.

The **dorsalis indicis** (Fig. 464), also a small branch, runs along the radial side of the back of the index finger, sending a few branches to the Abductor indicis.

The **princeps pollicis** (*a. princeps pollicis*) (Fig. 463) *arises* from the radial just as it turns inward to the deep part of the hand; it descends between the Abductor indicis and Adductor obliquus pollicis, then between the Adductor transversus pollicis and Adductor obliquus pollicis, along the ulnar side of the metacarpal bone of the thumb, to the base of the first phalanx, where it lies beneath the tendon of the Flexor longus pollicis and divides into two branches. These make their appearance between the inner and outer insertions of the Adductor obliquus pollicis, and run along the sides of the palmar aspect of the thumb, forming on the palmar surface of the last phalanx an arch, from which branches are distributed to the integument and subcutaneous tissue of the thumb.

The **radialis indicis** (*a. volaris indicis radialis*) (Fig. 463) *arises* close to the preceding, descends between the First dorsal interosseous and Adductor transversus pollicis, and runs along the radial side of the index finger to its extremity, where it anastomoses with the collateral digital artery from the superficial palmar arch. At the lower border of the Adductor transversus pollicis this vessel anastomoses with the princeps pollicis, and gives a communicating branch to the superficial palmar arch.

The **perforating arteries** (*rami perforantes*) (Fig. 463), three in number, pass backward from the deep palmar arch through the second, third, and fourth interosseous spaces and between the heads of the corresponding Interossei, to anastomose with the dorsal interosseous arteries.

The **palmar interosseous** (*aa. metacarpeae volares*) (Fig. 463), three or four in number, arise from the convexity of the deep palmar arch; they run downward upon the Interossei muscles, and anastomose at the clefts of the fingers with the digital branches of the superficial arch.

The **palmar recurrent branches** arise from the concavity of the deep palmar arch. They ascend in front of the wrist, supplying the carpal articulations and anastomosing with the anterior carpal arch.

The Ulnar Artery (*A. Ulnaris*) (Figs. 461, 463).

The ulnar artery, the larger of the two terminal branches of the brachial, commences a little below the bend of the elbow, and passes obliquely across the inner side of the forearm to a point about midway between the elbow and the wrist. It then runs along the ulnar border to the wrist, crosses the annular ligament on the radial side of the pisiform bone, and immediately beyond this bone divides into two branches which enter into the formation of the superficial and deep palmar arches.

Relations.—In the Forearm.—In

its *upper half* it is deeply seated, being covered by all the superficial Flexor muscles, excepting the Flexor carpi ulnaris; the median nerve is in relation with the inner side of the artery for about an inch and then crosses the vessel, being separated from it by the deep head of the Pronator teres; it lies upon the Brachialis anticus and Flexor profundus digitorum muscles. In the *lower half* of the forearm it lies upon the Flexor profundus, being covered by the integument, the superficial and deep fasciae, and is placed between the Flexor carpi ulnaris and Flexor sublimis digitorum muscles. It is accompanied by two venae comites; the ulnar nerve lies on its inner side for the lower two-thirds of its extent, and a small branch from the nerve descends on the lower part of the vessel to the palm of the hand.

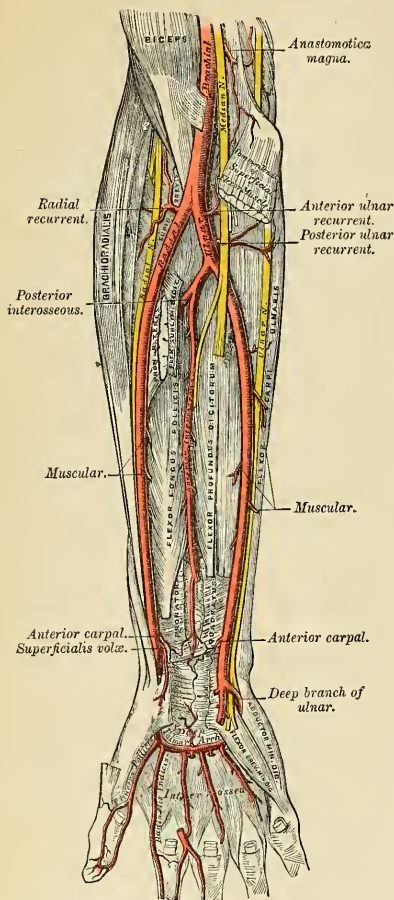


FIG. 463.—Ulnar and radial arteries. Deep view.

PLAN OF RELATIONS OF THE ULNAR ARTERY IN THE FOREARM.

In front.

Upper Half { Superficial layer of Flexor muscles.
 { Median nerve.

Lower Half—Superficial and deep fasciæ.

Inner side.

Flexor carpi ulnaris.
 Ulnar nerve (lower two-thirds).

*Outer side.*

Flexor sublimis digitorum.

Behind.

Brachialis anticus.
 Flexor profundus digitorum.

At the wrist (Fig. 461) the ulnar artery is covered by the integument and fascia, and lies upon the anterior annular ligament. On its inner side is the pisiform bone, and somewhat behind the artery, the ulnar nerve. The nerve and artery are crossed by a band of fibres, which extends from the pisiform bone to the anterior annular ligament.

Peculiarities.—The ulnar artery has been found to vary in its origin nearly in the proportion of one in thirteen cases, in one case arising lower than usual, about two or three inches below the elbow, and in all other cases much higher, the brachial being a more frequent source of origin than the axillary.

Variations in the position of this vessel are more frequent than in the radial. When its origin is normal, the course of the vessel is rarely changed. When it arises high up it is almost invariably superficial to the Flexor muscles in the forearm, lying commonly beneath the fascia, more rarely between the fascia and integument. In a few cases its position was subcutaneous in the upper part of the forearm, subaponeurotic in the lower part.

Surface Marking.—On account of the curved direction of the ulnar artery the line on the surface of the body which indicates its course is somewhat complicated. *First*, draw a line from the front of the internal condyle of the humerus to the radial side of the pisiform bone; the lower two-thirds of this line represents the course of the middle and lower third of the ulnar artery. *Secondly*, draw a line from the centre of the antecubital fossa to the junction of the upper and middle third of the first line; this represents the course of the upper third of the artery.

Applied Anatomy.—The application of a ligature to this vessel is required in cases of wound of the artery or of its branches, or in consequence of aneurism. In the upper half of the forearm the artery is deeply seated beneath the Superficial Flexor muscles, and the application of a ligature in this situation is attended with some difficulty. An incision is to be made in the course of a line drawn from the front of the internal condyle of the humerus to the outer side of the pisiform bone, so that the centre of the incision is three fingers' breadth below the internal condyle. The skin and superficial fascia having been divided and the deep fascia exposed, the white line which separates the Flexor carpi ulnaris from the other Flexor muscles is to be sought for, and the fascia incised in this line. The Flexor carpi ulnaris is now to be carefully separated from the other muscles, when the ulnar nerve will be exposed, and must be drawn aside.

Some little distance below the nerve the artery will be found accompanied by its venæ comites, and it may be ligated by passing the needle from within outward. In the middle and lower third of the forearm this vessel may be easily secured by making an incision on the radial side of the tendon of the Flexor carpi ulnaris; the deep fascia being divided, and the Flexor carpi ulnaris and its companion muscle, the Flexor sublimis, being separated from each other, the vessel will be exposed, accompanied by its venæ comites, the ulnar nerve lying on its inner side.

The veins being separated from the artery, the ligature should be passed from the ulnar to the radial side, taking care to avoid the ulnar nerve.

Branches (Figs. 463 and 464).—The branches of the ulnar artery may be arranged in the following groups:

Forearm	{	Anterior ulnar recurrent.
		Posterior ulnar recurrent.
	{	Interosseous { Anterior interosseous. Posterior interosseous.
	{	Muscular.
Wrist	{	Anterior ulnar carpal.
		Posterior ulnar carpal.
Hand	{	Profunda.
		Superficial palmar arch.

The **anterior ulnar recurrent** (*a. recurrentes ulnaris anterior*) (Fig. 463) *arises* immediately below the elbow-joint, passes upward and inward between the Brachialis anticus and Pronator teres, supplies twigs to those muscles, and, in front of the inner condyle, anastomoses with the anastomotica magna and inferior profunda.

The **posterior ulnar recurrent** (*a. recurrentes ulnaris posterior*) (Figs. 463 and 464) is much larger, and *arises* somewhat lower than the preceding. It passes backward and inward, beneath the Flexor sublimis, and ascends behind the inner condyle of the humerus. In the interval between this process and the olecranon it lies beneath the Flexor carpi ulnaris, and ascending between the heads of that muscle, in relation with the ulnar nerve; it supplies the neighboring muscles and joint, and anastomoses with the inferior profunda, anastomotica magna, and interosseous recurrent arteries.

The **interosseous artery** (*a. interossea communis*) (Fig. 463) is a short trunk about half an inch in length, and of considerable size, which *arises* immediately below the tuberosity of the radius, and, passing backward to the upper border of the interosseous membrane, divides into two branches, the **anterior** and **posterior interosseous**.

The **anterior interosseous** (*a. interossea volaris*) (Fig. 463) passes down the forearm on the anterior surface of the interosseous membrane, to which it is connected by a thin aponeurotic arch. It is accompanied by the interosseous branch of the median nerve, and overlapped by the contiguous margins of the Flexor profundus digitorum and Flexor longus pollicis muscles, giving off in this situation *muscular* branches and the *nutrient* arteries of the radius and ulna. At the upper border of the Pronator quadratus a branch, **anterior communicating artery**, descends beneath the muscle to anastomose in front of the carpus with the anterior carpal arch. The continuation of the artery passes behind the Pronator quadratus, and, piercing the interosseous membrane, reaches the back of the forearm, and anastomoses with the posterior interosseous artery (Fig. 464). It then descends to the back of the wrist to join the posterior carpal arch. The anterior interosseous gives off a long, slender branch, the **comes nervi mediana artery** (*a. mediana*), which accompanies the median nerve and gives branches to its substance. This artery is sometimes much enlarged, and accompanies the nerve into the palm of the hand.

The **posterior interosseous artery** (*a. interossea dorsales*) (Figs. 463 and 464) passes backward through the interval between the oblique ligament and the upper border of the interosseous membrane. It appears between the contiguous borders of the Supinator [brevis] and the Extensor ossis metacarpi pollicis, and runs down the back part of the forearm, between the superficial and deep layer of muscles, to both of which it distributes branches (Fig. 464). Where it lies upon the Extensor ossis metacarpi pollicis and the Extensor brevis pollicis, it is accompanied by the posterior interosseous nerve. At the lower part of the forearm it anastomoses with the termination of the anterior interosseous artery and with the posterior carpal arch. Then, continuing its course over the head of the ulna,

it joins the posterior carpal branch of the ulnar artery. This artery gives off, near its origin, the **interosseous recurrent branch**.

The **interosseous recurrent artery** (*a. interossea recurrens*) (Fig. 464) is a large vessel which ascends to the interval between the external condyle and olecranon, on or through the fibres of the Supinator [brevis], but beneath the Anconeus, anastomosing with a branch from the superior profunda, and with the posterior ulnar recurrent and anastomotica magna.

The **muscular branches** (*rami musculares*) are distributed to the muscles along the ulnar side of the forearm.

The **anterior ulnar carpal** (*ramus carpeus volaris*) (Fig. 463) is a small vessel which crosses the front of the carpus beneath the tendons of the Flexor profundus and inosculates with a corresponding branch of the radial artery.

The **posterior ulnar carpal** (*ramus carpeus dorsalis*) (Fig. 464) arises immediately above the pisiform bone, and winds backward beneath the tendon of the Flexor carpi ulnaris; it passes across the dorsal surface of the carpus beneath the Extensor tendons to anastomose with a corresponding branch of the radial artery and complete the **posterior carpal arch** (*rete carpi dorsale*) (Fig. 464). Immediately after its origin it gives off a small branch, which runs along the ulnar side of the fifth metacarpal bone, and supplies the ulnar side of the dorsal surface of the little finger.

The **profunda branch** (*ramus volaris profundus*) (Fig. 463) passes deeply inward between the Abductor minimi digiti and Flexor brevis minimi digiti, near their origins; it anastomoses with the termination of the radial artery, completing the deep palmar arch.

The continuation of the trunk of the ulnar artery in the hand forms the greater part of the superficial palmar arch.

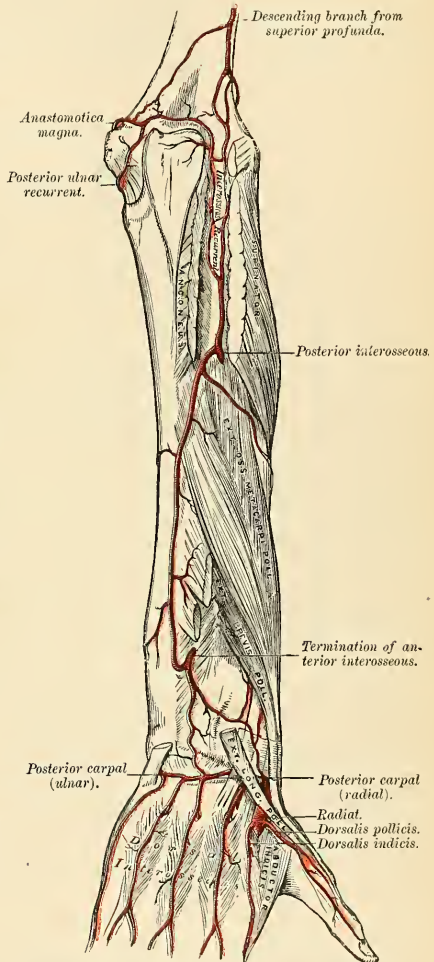


FIG. 464.—Arteries of the back of the forearm and hand.

The **superficial palmar arch** (*arcus volaris superficialis*) (Fig. 461) is formed by the ulnar artery in the hand, and is usually completed on the outer side by a branch from the *radialis indicis*, but sometimes by the *superficialis volae* or the *princeps pollicis* of the radial artery. The arch passes across the palm, describing a curve, with its convexity downward.

Relations.—The superficial palmar arch is covered by the skin, the *Palmaris brevis*, and the palmar fascia. It lies upon the annular ligament, the *Flexor brevis* and *Opponens minimi digiti*, the tendons of the *Flexor sublimis digitorum*, the *Lumbrical* muscles, and the divisions of the median and ulnar nerves.

PLAN OF THE RELATIONS OF THE SUPERFICIAL PALMAR ARCH.

In front.

Skin.
Palmaris brevis.
 Palmar fascia.



Behind.

Annular ligament.
Flexor brevis minimi digiti.
Opponens minimi digiti.
 Tendons of *Flexor sublimis digitorum*.
Lumbrical muscles.
 Branches of median and ulnar nerves.

Branches.—The branches of the Superficial palmar arch are:

Four Digital Arteries.

Four digital arteries (*aa. digitales volares communes*) (Fig. 461) are given off from the convexity of this arch. The innermost accompanies the inner digital branch of the ulnar nerve, and runs along the ulnar side of the little finger; it is joined by a twig from the deep palmar arch or from the innermost palmar interosseous artery. The three outer run downward in front of the three inner interosseous spaces, superficial to the corresponding nerves and *Lumbrical* muscles. A little above the interdigital clefts they are joined by the palmar interosseous arteries, and by the inferior perforating branches of the dorsal interosseous arteries. Each then divides into **collateral digital arteries** (*aa. digitales volares propriae*) for the supply of the contiguous sides of the index, middle, ring, and little fingers. These collateral branches lie behind the corresponding digital nerves; they anastomose freely in the subcutaneous tissue of the finger tip and by smaller branches near the interphalangeal joints. Each supplies a couple of dorsal branches which anastomose with the dorsal digital arteries, and supply the soft parts on the back of the second and third phalanges, including the matrix of the finger nail.

Surface Marking.—The superficial palmar arch is represented by a curved line, starting from the outer side of the pisiform bone and carried downward as far as the middle third of the palm, and then curved outward on a level with the upper (proximal) end of the cleft between the thumb and index finger. The deep palmar arch is situated about half an inch nearer to the carpus.

Applied Anatomy.—Wounds of the palmar arches are of special interest, and are always difficult to deal with. When the superficial arch is wounded it is generally possible, by enlarging the wound if necessary, to secure the vessel and tie it; or in cases where it is found impossible to

encircle the vessel with a ligature, a pair of hemostatic forceps may be applied and left on for twenty-four or forty-eight hours. Wounds of the deep arch are not so easily dealt with. It may be possible to secure the vessel by ligature or by forcipressure forceps, which may be left on; or, failing in this, the wound may be carefully plugged with gauze and an outside dressing carefully bandaged on. The plug should be allowed to remain untouched for three or four days. In wounds of the deep palmar arch a ligature may be applied to the bleeding points from the dorsum of the hand by resection of the upper part of the third metacarpal bone. It is useless in these cases to ligate one of the arteries of the forearm alone, and, indeed, simultaneous ligation of both radial and ulnar arteries above the wrist is often unsuccessful, on account of the anastomosis carried on by the carpal arches. Therefore, if unable to ligate the divided ends of the arch, upon the failure of pressure to arrest hemorrhage, it is expedient to apply a ligature to the brachial artery.

ARTERIES OF THE TRUNK.

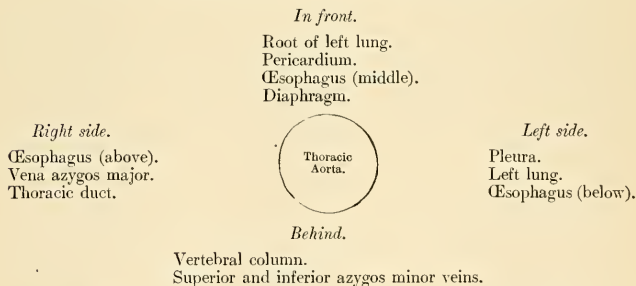
THE DESCENDING AORTA (Figs. 465, 466).

The **descending aorta** is divided into two portions, the **thoracic** and **abdominal**, in correspondence with the two great cavities of the trunk in which it is situated.

The Thoracic Aorta (*aorta thoracalis*) (Fig. 465).—The thoracic aorta is contained in the back part of the posterior mediastinum and commences at the lower border of the fourth thoracic vertebra, on the left side, and terminates at the aortic opening in the Diaphragm, in front of the lower border of the last thoracic vertebra. At its commencement it is situated on the left side of the vertebral column; it approaches the median line as it descends, and at its termination lies directly in front of the vertebral column. The direction of this vessel being influenced by the vertebral column, upon which it rests, it describes a curve which is concave forward in the thoracic region. As the branches given off from it are small, the diminution in the size of the vessel is inconsiderable.

Relations.—It is in relation, *in front*, from above downward, with the root of the left lung, the pericardium, the œsophagus, and the Diaphragm; *behind*, with the vertebral column and the azygos minor veins; on the *right side*, with the vena azygos major and thoracic duct; on the *left side*, with the left pleura and lung. The œsophagus, with its accompanying nerves, lies on the right side of the aorta *above*; but at the lower part of the thorax it passes in front of the aorta, and close to the Diaphragm is situated to its left side.

PLAN OF THE RELATIONS OF THE THORACIC AORTA.



Peculiarities.—The aorta is occasionally found to be obliterated at a particular spot—viz., at the junction of the arch with the thoracic aorta just below the ligamentum arteriosum. Whether this is the result of disease or of congenital malformation is immaterial to our present purpose; it affords an interesting opportunity of observing the resources of the collateral circulation.

The course of the anastomosing vessels, by which the blood is brought from the upper to the lower part of the artery, will be found well described in an account of two cases in the *Pathological Transactions*, vols. viii and x. In the former (p. 162) Mr. Sydney Jones thus sums up the detailed description of the anastomosing vessels: "The principal communications by which the circulation was carried on were: *First*, the internal mammary, anastomosing with the intercostal arteries, with the phrenic of the abdominal aorta by means of the musculophrenic and comes nervi phrenici, and largely with the deep epigastric. *Secondly*, the superior intercostal, anastomosing anteriorly by means of a large branch with the first aortic intercostal, and posteriorly with the posterior branch of the same artery. *Thirdly*, the inferior thyroid, by means of a branch about the size of an ordinary radial, formed a communication with the first aortic intercostal. *Fourthly*, the transverse cervical, by means of very large communications with the posterior branches of the intercostals. *Fifthly*, the branches (of the subclavian and axillary) going to the side of the thorax were large, and anastomosed freely with the lateral branches of the intercostals." In the second case also (vol. x, p. 97) Mr. Wood describes the anastomoses in a somewhat similar manner, adding the remark that "the blood which was brought into the aorta through the anastomoses of the intercostal arteries appeared to be expended principally in supplying the abdomen and pelvis, while the supply to the lower extremities had passed through the internal mammary and epigastrics."

Applied Anatomy.—The student should now consider the effects likely to be produced by *aneurism of the thoracic aorta*, a disease of common occurrence. When we consider the great depth of the vessel from the surface and the number of important structures which surround it on every side, it may easily be conceived what a variety of obscure symptoms may arise from disease of this part of the arterial system, and how they may be liable to be mistaken for those of other affections. Aneurism of the thoracic aorta most usually extends backward along the left side of the vertebral column, producing absorption of the bodies of the vertebræ, with curvature of the spine; while the irritation or pressure on the spinal cord will give rise to pain, either in the thorax, back, or loins, with radiating pain in the left upper intercostal spaces, from pressure on the intercostal nerves; at the same time the tumor may project backward on each side of the vertebral column, beneath the integument, as a pulsating swelling, simulating abscess connected with diseased bone, or it may displace the œsophagus and compress the lung on one or the other side. If the tumor extend forward, it may press upon and displace the heart, giving rise to palpitation and other symptoms of disease of that organ; or it may displace, or even compress, the œsophagus, causing pain and difficulty of swallowing, as in stricture of that tube; and ultimately even open into it by ulceration, producing fatal hemorrhage. If the disease extends to the right side, it may press upon the thoracic duct; or it may burst into the pleural cavity or into the trachea or lung; and, lastly, it may open into the posterior mediastinum. The diagnosis of thoracic aneurism is facilitated by the use of the x-rays.

Branches of the Thoracic Aorta.—

Visceral	{	Bronchial.	Parietal	{	Intercostal.
	{	Œsophageal.		{	Subcostal.
	{	Pericardial.		{	Superior phrenic.
	{	Mediastinal.			

The **bronchial arteries** (*aa. bronchiales*) are the nutrient vessels of the lungs, and vary in number, size, and origin. There is, as a rule, only one *right bronchial artery*, which *arises* from the first aortic intercostal, or from the left bronchial. The *left bronchial arteries*, usually two in number, *arise* from the thoracic aorta, one a little lower than the other. Each vessel runs along the back part of the corresponding bronchus, dividing and subdividing along the bronchial tubes, supplying them, the cellular tissue of the lungs, the bronchial nodes, and the œsophagus.

The **œsophageal arteries** (*aa. œsophageæ*), usually four or five in number, *arise* from the front of the aorta, and pass obliquely downward to the œsophagus, forming a chain of anastomoses along that tube, anastomosing with the œsophageal branches of the inferior thyroid arteries above, and with ascending branches from the phrenic and gastric arteries below.

The **pericardial** (*rami pericardiaci*) are a few small vessels, irregular in their origin, distributed to the pericardium.

The **mediastinal branches** (*rami mediastinales*) are numerous small vessels which supply the nodes and loose areolar tissue in the posterior mediastinum.

The **intercostal arteries** (*aa. intercostales*) (Fig. 465) arise from the back of the aorta. The aortic intercostals are usually nine in number on each side, the two superior intercostal spaces being supplied by the superior intercostal, a branch of the subclavian. The **right** aortic intercostals are longer than the left, on account of the position of the aorta on the left side of the vertebral column; they pass across the bodies of the vertebrae, behind the oesophagus, thoracic duct, and the vena azygos major, and are covered by the *right lung and pleura*. The **left** aortic intercostals run backward on the sides of the vertebrae and are covered by the *left lung and pleura*; the two upper are crossed by the left superior intercostal vein, the lower vessels by the azygos minor veins. Opposite the heads of the ribs the sympathetic cord passes downward in front of them, and the splanchnic nerves also descend in front of the lower arteries. Each artery crosses the corresponding intercostal space obliquely toward the angle of the upper rib and thence is continued forward in the subcostal groove. It is placed at first between the pleura and the posterior intercostal membrane, then pierces this membrane and lies between it and the External intercostal muscle as far as the rib angle; from this onward it runs between the External and Internal intercostal muscles and anastomoses with the anterior intercostal branches of the internal mammary or musculophrenic. Each intercostal artery is accompanied by a vein and nerve, the former being above, and the latter below, except in the upper intercostal spaces, where the nerve is at first above the artery. The first aortic intercostal anastomoses with the superior intercostal branch of the subclavian, and the last two intercostals continue anteriorly from the intercostal spaces into the abdominal wall, anastomosing with the superior epigastric, subcostal and lumbar arteries.

Branches.—Each intercostal artery gives off numerous muscular and cutaneous branches.

Posterior or dorsal.
Muscular.

Collateral intercostal.
Lateral cutaneous.

The **posterior or dorsal branch** (*ramus posterior*) runs with the posterior division of a spinal nerve and passes backward through a small opening which is bounded *above* and *below* by the necks of the ribs and adjacent transverse processes, *internally* by the vertebral body, and *externally* by the anterior costotransverse ligament. It gives off a **spinal branch**, which enters the vertebral canal through the intervertebral foramen, is distributed to the spinal cord and its membranes,

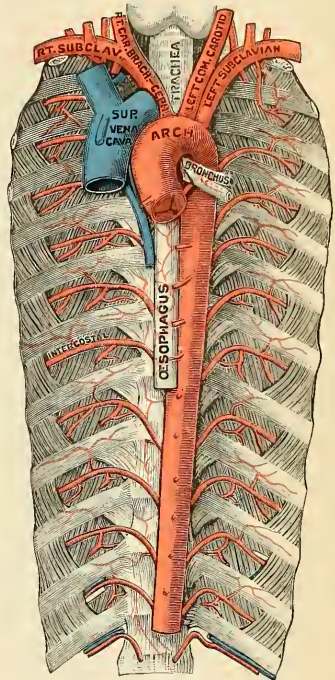


FIG. 465.—Thoracic aorta. (Testut.)

and to the bodies of the vertebræ in the same manner as the lateral spinal branches from the vertebral.

The **collateral intercostal branch** comes off from the intercostal artery near the angle of the rib, and descends to the upper border of the rib below, along which it courses to anastomose with the anterior intercostal branch of the internal mammary.

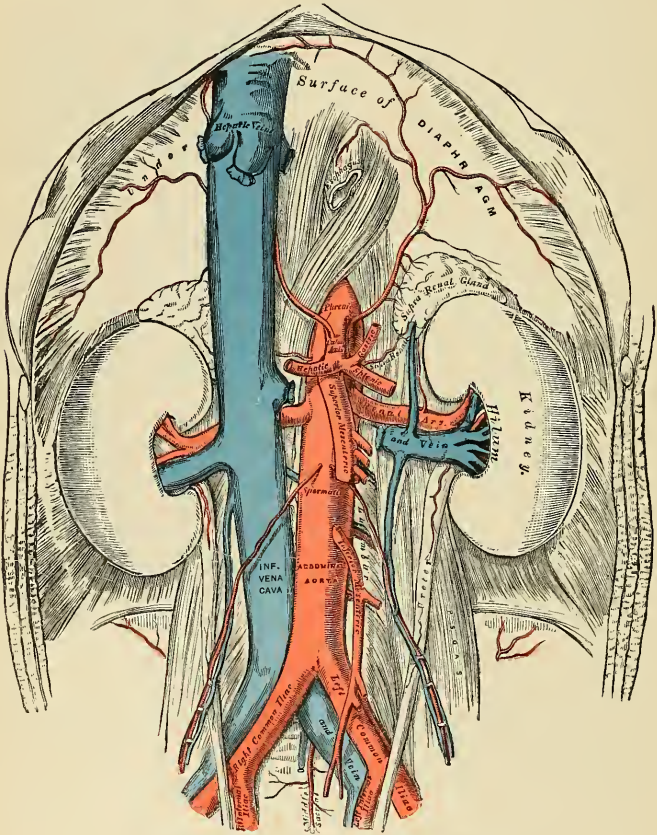


FIG. 466.—The abdominal aorta and its branches.

Muscular branches (*rami musculares*) are given to the Intercostal and Pectoral muscles and to the Serratus magnus; they anastomose with the superior and long thoracic branches of the axillary artery.

The **lateral cutaneous branches** (*rami cutanei laterales*) accompany the lateral cutaneous branches of the intercostal nerves, and divide into anterior and posterior branches.

Mammary branches are given off by the intercostal arteries in the third, fourth, and fifth spaces. They supply the mammary gland, and increase considerably in size during the period of lactation.

Applied Anatomy.—The position of the intercostal vessels should be borne in mind in performing the operation of *paracentesis thoracis*. The puncture should never be made nearer the middle line posteriorly than the angle of the rib, as the artery crosses the space internal to this point. In the lateral portion of the thorax, where the puncture is usually made, the artery lies at the upper part of the intercostal space, and therefore the puncture should be made just above the upper border of the rib forming the lower boundary of the space.

The Abdominal Aorta (*aorta abdominalis*) (Fig. 466).—The abdominal aorta commences at the aortic opening of the Diaphragm, in front of the lower border of the body of the last thoracic vertebra, and, descending a little to the left side of the vertebral column, terminates on the body of the fourth lumbar vertebra, usually a little to the left of the middle line,¹ by dividing into the two common iliac arteries. It diminishes rapidly in size, in consequence of the many large branches which it gives off. As it lies upon the bodies of the vertebræ, the curve which it describes is convex forward, the greatest convexity corresponding to the third lumbar vertebra, which is a little above and to the left side of the umbilicus.

Relations.—It is covered, *in front*, by the lesser omentum and stomach, behind which are the branches of the celiac axis and the solar plexus; below these, by the splenic vein, the pancreas, the left renal vein, the transverse portion of the duodenum, the mesentery, and aortic plexus. *Behind*, it is separated from the lumbar vertebræ and intervening disks by the anterior common ligament and left lumbar veins. On the *right side* it is in relation with the inferior vena cava (the right crus of the Diaphragm being interposed above), the vena azygos major, thoracic duct, and right semilunar ganglion; on the *left side*, with the gangliated cord of the sympathetic and left semilunar ganglion the fourth part of the duodenum and some coils of the small intestine.

PLAN OF THE RELATIONS OF THE ABDOMINAL AORTA.

In front.

Lesser omentum and stomach.
Branches of the celiac axis and solar plexus.
Splenic vein.
Pancreas.
Left renal vein.
Transverse duodenum.
Mesentery.
Aortic plexus.

Right side.

Right crus of Diaphragm.
Inferior vena cava.
Vena azygos major.
Thoracic duct.
Right semilunar ganglion.

Left side.

Gangliated cord.
Left semilunar ganglion.



Behind.

Left lumbar veins.
Vertebral column.

Surface Marking.—In order to map out the abdominal aorta on the surface of the abdomen, a line must be drawn from the middle line of the body, on a level with the costal extremity of the seventh costal cartilage, downward and slightly to the left, so that it just skirts the umbilicus, to a zone drawn around the body opposite the highest point of the crest of the ilium. This point

¹ Lord Lister, having accurately examined 30 bodies in order to ascertain the exact point of termination of this vessel, found it "either absolutely, or almost absolutely, mesal in 15, while in 13 it deviated more or less to the left, and in 2 was slightly to the right" (System of Surgery, edited by T. Holmes, 2d ed., vol. v, p. 652).

is generally half an inch below and to the left of the umbilicus, but as the position of this structure varies with the obesity of the individual, it is not a reliable landmark as to the situation of the bifurcation of the aorta.

Applied Anatomy.—*Aneurisms of the abdominal aorta* near the coeliac axis communicate in nearly equal proportion with the anterior and posterior parts of the artery.

When an aneurismal sac is connected with the back part of the abdominal aorta, it usually produces absorption of the bodies of the vertebræ, and forms a pulsating tumor that presents itself in the left hypochondriac or epigastric regions, and is accompanied by symptoms of disturbance in the alimentary canal. Pain is invariably present, and is usually of two kinds—a fixed and constant pain in the back, caused by the tumor pressing on or displacing the branches of the solar plexus and splanchnic nerves; and a sharp lancinating pain, radiating along those branches of the lumbar nerves which are pressed on by the tumor; hence the pain in the loins, the testes, the hypogastrium, and in the lower limb (usually of the left side). This form of aneurism usually bursts into the peritoneal cavity or behind the peritoneum in the left hypochondriac region; or it may form a large aneurismal sac, extending down as low as Poupart's ligament; hemorrhage in these cases being generally very extensive, but slowly produced, and not rapidly fatal.

When an aneurismal sac is connected with the front of the aorta near the coeliac axis it forms a pulsating tumor in the left hypochondriac or epigastric region, usually attended with symptoms of disturbance of the alimentary canal, as nausea, dyspepsia, or constipation, and is accompanied by pain, which is constant, but nearly always fixed in the loins, epigastrium, or some part of the abdomen; the radiating pain being rare, as the lumbar nerves are seldom implicated. This form of aneurism may burst into the peritoneal cavity or behind the peritoneum, between the layers of the mesentery, or, more rarely, into the duodenum; it seldom extends backward so as to affect the vertebral column.

The abdominal aorta has been tied several times, and although none of the patients permanently recovered, still, as Prof. Keen's lived forty-eight days, the possibility of the reëstablishment of the circulation is proved. In the lower animals this artery has been often successfully tied. The chief difficulty consists in isolating the artery in consequence of its great depth; and the embarrassment resulting from the proximity of the aneurismal tumor, and the great probability of disease in the vessel itself, add to the dangers and difficulties of this formidable operation.

The collateral circulation would be carried on by the anastomosis between the internal mammary and the deep epigastric; by the free communication between the superior and inferior mesenterics if the ligature were placed above the latter vessel: or by the anastomosis between the inferior mesenteric and the internal pudic when (as is more common) the point of ligation is below the origin of the inferior mesenteric; and possibly by the anastomoses of the lumbar arteries with the branches of the internal iliac.

Branches.—The branches of the abdominal aorta comprise visceral, parietal, and terminal arteries. The branches *in order of origin* are as follows:

1. Right and left inferior phrenics (*p.*).
 2. Coeliac axis $\left\{ \begin{array}{l} \text{Gastric} \\ \text{Hepatic} \\ \text{Splanic} \end{array} \right\} (v.)$.
 3. Right and left suprarenals (*v.*).
 4. Right and left first lumbar (*p.*).
 5. Superior mesenteric (*v.*).
 6. Right and left renal (*v.*).
 7. Right and left spermatics or ovarian (*v.*).
 8. Right and left second lumbar (*p.*).
 9. Inferior mesenteric (*v.*).
 10. Right and left third lumbar (*p.*).
 11. Right and left fourth lumbar (*p.*).
 12. Right and left common iliac (*t.*).
 13. Middle sacral (*p.*).
- (*p.*), *Parietal*; (*v.*), *visceral*; (*t.*), *terminal*.

The **inferior phrenic arteries** (*aa. phrenicæ inferiores*) (Fig. 466) are two small vessels which present much variety in their origin. They may *arise* separately

from the front of the aorta, immediately above the coeliac axis, or by a common trunk, which may spring either from the aorta or from the coeliac axis. Sometimes one is derived from the aorta, and the other from one of the renal arteries. In only one out of thirty-six cases examined did these arteries arise as two separate vessels from the aorta. They diverge from one another across the crura of the Diaphragm, and then pass obliquely upward and outward upon the under surface of the Diaphragm. The **left phrenic** passes behind the œsophagus and runs forward on the left side of the œsophageal opening. The **right phrenic** passes behind the inferior vena cava, and ascends along the right side of the aperture for transmitting that vein. Near the back part of the central tendon each vessel divides into two branches. The **internal branch** runs forward to the front of the thorax, supplying the Diaphragm, and anastomosing with its fellow of the opposite side, and with the musculophrenic and comes nervi phrenici branches of the internal mammary. The **external branch** passes toward the side of the thorax and anastomoses with the intercostal arteries and with the musculophrenic. The internal branch of the right phrenic gives off a few vessels to the inferior vena cava, and the left one some branches to the œsophagus. Each vessel also sends **glandular**

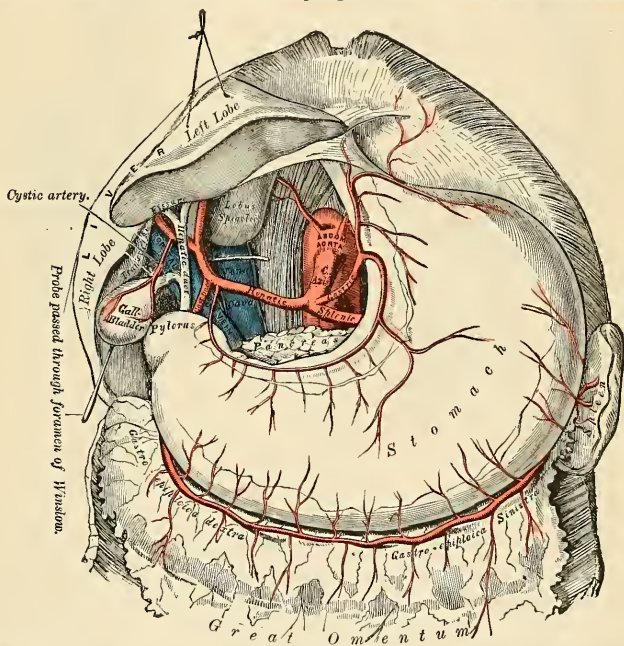


FIG. 467.—The coeliac axis and its branches, the liver having been raised and the lesser omentum removed.

branches (*rami suprarenales superior*) to the suprarenal glands of its own side. The spleen and the liver also receive a few branches from the left and right vessels respectively.

The **coeliac axis, or artery** (*a. coeliaca*) (Figs. 467 and 468), is a short, thick trunk, about half an inch in length, which *arises* from the aorta, close to the margin of the opening in the Diaphragm, behind the posterior parietal perito-

neum, above the pancreas, and below the twelfth thoracic vertebra, and, passing nearly horizontally forward (in the erect posture), divides into three large branches, the **gastric**, **hepatic**, and **splenic**, occasionally giving off one of the phrenic arteries.

Relations.—It is covered by the lesser omentum. On the *right side* it is in relation with the right semilunar ganglion; on the *left side*, with the left semilunar ganglion and cardiac end of the stomach. *Below*, it rests upon the upper border of the pancreas.

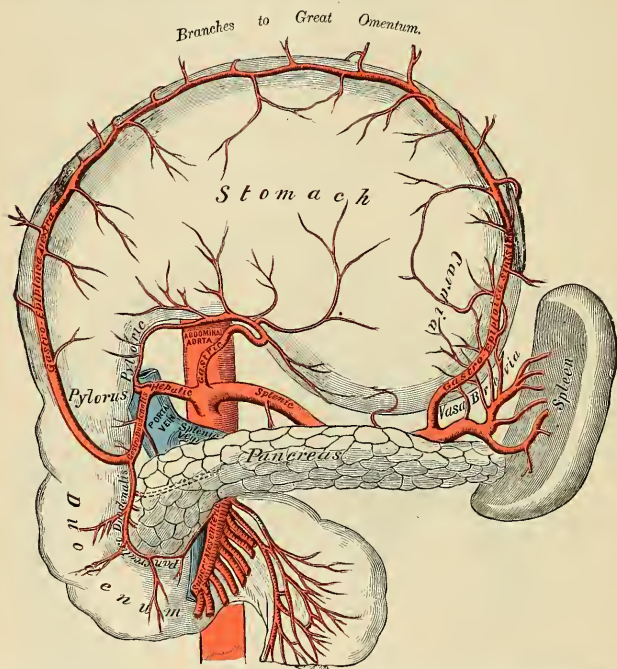


FIG. 468.—The celiac axis and its branches, the stomach having been raised and the transverse mesocolon removed (semi-diagrammatic).

The **gastric or coronary artery** (*a. gastrica sinistra*) (Figs. 467 and 468), the smallest of the three branches of the celiac axis, passes upward and to the left side, behind the peritoneum of the lesser peritoneal cavity. It continues this course until it nearly reaches the lesser curvature of the stomach just below the cardia. It then turns to the front and curves forward, distributing branches to the œsophagus which anastomose with the aortic œsophageal arteries; others supply the cardiac end of the stomach, anastomosing with branches of the splenic artery; it then passes from left to right, along and upon the lesser curvature of the stomach and beneath the peritoneum to the pylorus, lying in its course between the layers of the lesser omentum, and sometimes dividing into two vessels, which run along each side of the lesser curvature. One vascular arch gives branches to the antero-superior wall of the stomach and the other to the postero-inferior wall; at its termination it anastomoses with the pyloric branches of the hepatic. The

œsophageal branches (*rami œsophagei*) anastomose with the œsophageal branches from the thoracic aorta and the inferior phrenic. Occasionally the gastric artery gives off an hepatic branch of variable size, which is usually distributed to the left lobe of the liver.

The **hepatic artery** (*a. hepatica*) (Figs. 467 and 468) in the adult is intermediate in size between the gastric and splenic; in the fetus it is the largest of the three branches of the cœliac axis. It runs forward and to the right, to be distributed to the upper margin of the pyloric end of the stomach; in its course it forms the lower boundary of the foramen of Winslow. It then passes upward between the layers of the lesser omentum, and in front of the foramen of Winslow, to the transverse fissure of the liver, where it divides into two branches, right and left, which supply the corresponding lobes of that organ, accompanying the ramifications of the portal vein and hepatic duct. The hepatic artery, in its course along the right border of the lesser omentum, is in relation with the common bile duct and portal vein, the duct lying to the right of the artery and the portal vein behind.

Its **branches** (Figs. 467 and 468) are:

Pyloric.

Gastroduodenal { Right gastroepiploic.
Superior pancreaticoduodenal.

Cystic.

The **pyloric** (*a. gastrica dextra*) arises from the hepatic, above the pylorus, descends between the layers of the lesser omentum to the pyloric end of the stomach, and passes from right to left along its lesser curvature, supplying it with branches and anastomosing with the terminal branches of the gastric artery.

The **gastroduodenal** (*a. gastroduodenalis*) (Fig. 468) is a short but large branch, which descends near the pylorus, behind the first portion of the duodenum, and divides at the lower border of this viscus into two branches, the **right gastroepiploic** (*a. gastroepiploica dextra*) and the **superior pancreaticoduodenal**. Previous to its division, it gives off two or three small **inferior pyloric branches**, to the pyloric end of the stomach and pancreas.

The **right gastroepiploic** runs from right to left along the greater curvature of the stomach, between the layers of the great omentum, anastomosing about the middle of the greater curvature of the stomach with the left gastro-epiploic from the splenic artery. This vessel gives off numerous branches, some of which ascend to supply both surfaces of the stomach, while others descend to supply the great omentum (*rami epiploici*).

The **superior pancreaticoduodenal** (*a. pancreaticoduodenalis superior*) descends between the contiguous margins of the duodenum and pancreas. It supplies the head of the pancreas by means of the *rami pancreatica*, and the duodenum by means of the *rami duodenalis*, and anastomoses with the inferior pancreaticoduodenal branch of the superior mesenteric artery and with the pancreatic branches of the splenic.

The **cystic artery** (*a. cystica*) (Fig. 467), usually a branch of the right hepatic, passes downward and forward along the cystic duct to the gall-bladder and divides into two branches, one of which ramifies on its free surface beneath the peritoneum, the other between the gall-bladder and the substance of the liver.

The **splenic artery** (*a. lienalis*) (Figs. 467 and 468), in the adult, is the largest of the three branches of the cœliac axis, and is remarkable for the extreme tortuosity of its course. It passes horizontally to the left side, behind the peritoneum and along the upper border of the pancreas, accompanied by the splenic vein, which lies below it; it crosses in front of the upper part of the left kidney, and on arriving near the spleen divides into branches, some of which enter the hilum of that organ between the two layers of the lienorenal ligament to be distributed to its

structure; some branches, given off along its course, are distributed to the pancreas, while others pass to the greater curvature of the stomach between the two layers of the gastrosplenic omentum. Its branches are:

Pancreatic.

Vasa brevia.

Left gastroepiploic.

The **pancreatic branches** (*rami pancreatici*) are numerous small branches derived from the splenic as it runs behind the upper border of the pancreas, supplying its middle and left parts. One of these, larger than the rest, is sometimes given off from the splenic near the left extremity of the pancreas; it runs from left to right near the posterior surface of the gland, following the course of the pancreatic duct, and is called the **pancreatica magna**. These vessels anastomose with the pancreatic branches of the pancreaticoduodenal arteries, derived from the hepatic on the one hand and the superior mesenteric on the other.

The **vasa brevia** (*aa. gastricae breves*) consist of from five to seven small branches, which *arise* either from the end of the splenic artery or from its terminal branches. They pass from left to right, between the layers of the gastrosplenic omentum, are distributed to the greater curvature of the stomach, anastomosing with branches of the gastric and left gastroepiploic arteries.

The **left gastroepiploic** (*a. gastroepiploica sinistra*), the largest branch of the splenic, runs from left to right along but distinctly below the greater curvature of the stomach, between the layers of the great omentum, and anastomoses with the right gastroepiploic. In its course it distributes several ascending branches to both surfaces of the stomach; others descend to supply the greater omentum.

Applied Anatomy.—The operation of *pylorectomy* can be made an almost bloodless procedure by tying the gastric, the pyloric, and the right and left gastroepiploic arteries. "The gastric is doubly tied about one inch below the cardiac orifice at a point where it joins the lesser curvature and is divided between the ligatures. The pyloric is doubly tied and divided. The fingers are passed beneath the pylorus, raising the gastrocolic omentum from the transverse mesocolon, and in this way safe ligation behind the pylorus of the right gastro-epiploic artery, or in most cases its parent vessel, the gastroduodenal, is secured. The left gastro-epiploic is now tied at an appropriate point, and the necessary amount of gastrocolic omentum doubly tied and cut."¹ Embolism of branches of the splenic artery is not uncommon in heart disease, the embolus coming from the left side of the heart. It is characterized by the occurrence of a sudden sharp pain or "stitch" in the splenic region, with subsequent local enlargement of the spleen from the formation of an infarct in its substance.

The **suprarenal artery** (*a. suprarenalis media*) (Fig. 466), or **capsular artery**, *arises*, one from each side of the aorta, opposite the superior mesenteric artery. It is a small vessel which passes obliquely upward and outward, over the corresponding crus of the Diaphragm, to the under surface of the suprarenal gland, to which it is distributed, anastomosing with capsular branches from the phrenic and renal arteries. In the adult these arteries are of small size; in the fetus they are as large as the renal arteries.

The **lumbar arteries** (*aa. lumbales*) are in series with the intercostals. They are usually four in number on either side, and *arise* from the back part of the aorta opposite the bodies of the upper four lumbar vertebræ. A fifth pair, small in size, is occasionally present; it *arises* from the middle sacral artery. They run outward and backward on the bodies of the lumbar vertebræ, behind the sympathetic cord, to the intervals between the adjacent transverse processes, and are then continued into the abdominal wall. The arteries of the right side pass behind the inferior vena cava, and the upper two on each side run behind the corresponding crus of the Diaphragm. The arteries of both sides pass beneath the tendinous arches which give origin to the Psoas magnus, and are then continued behind this

¹William J. Mayo, *Annals of Surgery*, March, 1904.

muscle and the lumbar plexus. They now cross the *Quadratus lumborum*, the upper three arteries running behind, the last usually in front of the muscle. At the outer border of the *Quadratus lumborum* they pierce the posterior aponeurosis of the *Transversalis abdominis* and are carried forward between this muscle and the *Internal oblique*. They anastomose with the lower intercostals, the subcostal, the *iliolumbar*, the deep circumflex iliac, and the deep epigastric arteries.

Branches.—In the interval between the adjacent transverse processes each lumbar artery gives off a **dorsal branch** (*ramus dorsalis*), which is continued backward between the transverse processes and is distributed to the muscles and skin of the back. It gives off a **spinal branch** (*ramus spinalis*) which enters the vertebral canal and is distributed in a similar manner to the lateral spinal branches of the vertebral (page 620). **Muscular branches** are supplied from each lumbar artery and from its dorsal branch to the neighboring muscles.

The **superior mesenteric artery** (*a. mesenterica superior*) (Figs. 466 and 470) is a vessel of large size which supplies the whole length of the small intestine, except the first part of the duodenum; it also supplies the cecum and the ascending and transverse parts of the colon. It *arises* from the front of the aorta about half an inch below the *cœliac axis*, and is covered at its origin by the splenic vein and the neck of the pancreas. It passes downward and forward in front of the lower part of the head of the pancreas—*processus uncinatus*—and the third portion of the duodenum, and descends between the layers of the mesentery to the right iliac fossa, where, considerably diminished in size, it anastomoses with one of its own branches—viz., the ileocolic. In its course it forms an arch, the convexity of which is directed forward and downward to the left side, the concavity backward and upward to the right. It is accompanied by the superior mesenteric vein, and is surrounded by the superior mesenteric plexus of nerves.

Dissection.—In order to expose the superior mesenteric artery raise the great omentum and transverse colon, draw down the small intestines, and cut through the peritoneum where the transverse mesocolon and mesentery join; the artery will then be exposed just as it issues from over the unciform process of the head of the pancreas.

Branches.—Its branches are:

Inferior pancreaticoduodenal.

Vasa intestini tenuis.

Middle colic.

Ileocolic.

Right colic.

The **inferior pancreaticoduodenal** (*a. pancreaticoduodenalis inferior*) is given off from the superior mesenteric, or from its first intestinal branch behind the pancreas. It courses to the right between the head of the pancreas and duodenum, and then ascends to anastomose with the superior pancreaticoduodenal artery. It distributes branches to the head of the pancreas and to the second and third portions of the duodenum.

The **vasa intestini tenuis** (*aa. intestinales*) *arise* from the convex side of the superior mesenteric artery. They are usually from twelve to fifteen in number, and are distributed to the jejunum (*aa. jejunales*) and ileum (*aa. ileae*). They run parallel with one another between the layers of the mesentery, each vessel dividing into two branches, which unite with similar branches on each side, forming a series of arches the convexities of which are directed toward the intestine. From this first set of arches branches arise, which again unite with similar branches from either side, and thus a second series of arches is formed; and from these latter, a third and a fourth, or even a fifth, series of arches is constituted, diminishing in size the nearer they approach the intestine. From the terminal arches numerous small straight vessels arise which encircle the intestine, upon which they are distributed, ramifying between its coats. Throughout their

course small branches are given off to the nodes and other structures between the layers of the mesentery. (See the description of the vascular loops in the section upon the Intestines.)

The **ileocolic artery** (*a. ileocolica*) is the lowest branch given off from the concavity of the superior mesenteric artery. It descends between the layers of the mesentery to the right iliac fossa, where it divides into two branches. Of these, the *inferior division* anastomoses with the termination of the superior mesenteric artery, forming with it an arch, from the convexity of which branches proceed to supply the termination of the ileum, the cecum, the vermiform appendix, and the ileocecal valve. The *superior division* anastomoses with the right colic and supplies the commencement of the colon.

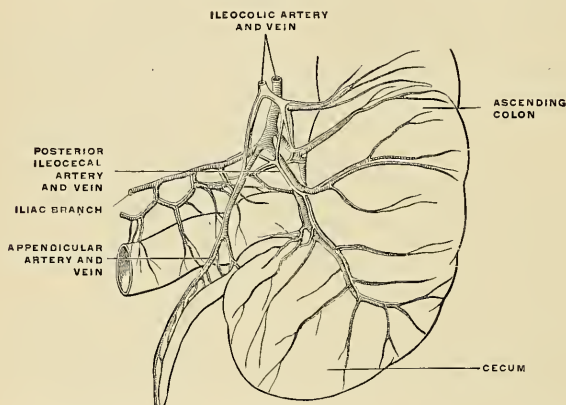


FIG. 469.—Arteries and veins of the cecum and vermiform appendix seen from behind. (Poirier and Charpy)

The descending branch of the ileocolic runs toward the upper border of the ileocecal junction and gives off the following branches:

(a) **Colic**, which passes upward on the ascending colon; (b) **anterior and posterior cecal** (or *ileocecal*), which are distributed to the front and back of the cecum; (c) **appendicular** (*a. appendicularis*), which passes downward behind the terminal part of the ileum and runs in the mesoappendix close to its free margin for the supply of the appendix; and (d) **ileal**, which runs upward and to the left on the terminal part of the ileum and anastomoses with the termination of the superior mesenteric (Fig. 469).

The **right colic artery** (*a. colica dextra*) arises from about the middle of the concavity of the superior mesenteric artery; it passes to the right behind the peritoneum to the middle of the ascending colon, and divides into two branches—a **descending branch**, which anastomoses with the ileocolic, and an **ascending branch**, which anastomoses with the middle colic. These branches form arches, from the convexity of which vessels are distributed to the ascending colon.

The **middle colic artery** (*a. colica media*) arises from the upper part of the concavity of the superior mesenteric, and, passing downward and forward between the layers of the transverse mesocolon, divides into two branches, the one on the right side anastomosing with the right colic; that on the left side, with the left colic, a branch of the inferior mesenteric. From the arches formed by their anastomosis branches are distributed to the transverse colon. The branches of this vessel lie between the two layers of the transverse mesocolon.

The **renal arteries** (*aa. renales*) (Fig. 466) are two large trunks which *arise* from the sides of the aorta immediately below the superior mesenteric artery. Each is directed outward across the corresponding crus of the Diaphragm, so as to form nearly a right angle with the aorta. The right is longer than the left, on account of the position of the aorta; it passes behind the inferior vena cava. The left is somewhat higher than the right. Before reaching the hilum of the kidney, each artery usually divides into four branches. Two of these vessels enter the anterior portion and two the posterior portion of the kidney. The anterior branches supply three-fourths of the kidney, the posterior supply one-fourth. Each vessel gives off a small branch to the suprarenal gland (*a. suprarenalis inferior*) and branches to the ureter, **ureteral branches**, and to the surrounding cellular tissue and muscles, **perirenal branches**. The two circulations are distinct and do not anastomose even at the periphery. Between these two sets of vessels is a nearly bloodless zone, the **exsanguinated renal zone of Hyrtl**, which does not correspond to the lateral border, but is one-half inch dorsal to the external border of the kidney. The ventral or anterior segment is much the larger. In very rare instances the bloodless zone corresponds to the lateral border (Kümmel).

Applied Anatomy.—An incision of the middle third of the kidney exactly at the junction of the two segments does not divide large vessels. As the incision approaches either pole there is danger of cutting a large branch (Schede). Frequently there is a second renal artery, which is given off from the abdominal aorta either above or below the renal artery proper, the former being the more common position. Instead of entering the kidney at the hilum, one or more **accessory renal arteries** often pierce the upper or the lower part of the gland.

The **spermatic arteries** (*aa. spermaticae internae*) (Fig. 466) are distributed to the testes. They are two slender vessels of considerable length, which *arise* from the front of the aorta a little below the renal arteries. Each artery passes obliquely outward and downward behind the peritoneum, resting on the Psoas muscle, the right spermatic lying in front of the inferior vena cava, the left behind the sigmoid flexure of the colon. It then crosses obliquely over the ureter (to which it sends a few branches) and the lower part of the external iliac artery to reach the internal abdominal ring, through which it passes, and accompanies the other constituents of the spermatic cord along the inguinal canal to the scrotum, where it becomes tortuous and divides into several branches. Two or three of these accompany the vas deferens, anastomosing with the artery of the vas deferens, and are distributed to the epididymis; others pierce the back part of the tunica albuginea and supply the substance of the testis. The spermatic artery in the inguinal canal gives off cremasteric branches to supply the Cremaster muscle. In the canal and scrotum the artery lies behind the pampiniform plexus and in front of the vas deferens.

The **ovarian arteries** (*aa. ovaricae*) (Fig. 473) in the female correspond to the spermatic arteries in the male. They supply the ovaries, and are shorter than the spermatic. The origin and course of the first part of each artery are the same as the spermatic in the male, but on arriving at the margin of the pelvis the ovarian artery passes inward, between the two layers of the broad ligament of the uterus, to be distributed to the ovary. Small branches go to the Fallopian tube, the ureter, and the broad ligament; and one passes on to the side of the uterus and anastomoses with the uterine artery. Other offsets are continued along the round ligament through the inguinal canal, to the integument of the labium and groin.

At an early period of fetal life, when the testes or ovaries lie at the side of the vertebral column below the kidneys, the spermatic or ovarian arteries are short; but as these organs descend from the abdomen into the scrotum or pelvis, the arteries gradually become lengthened.

The **inferior mesenteric artery** (*a. mesenterica inferior*) (Figs. 466 and 471) supplies the descending colon, the sigmoid flexure of the colon, and the greater part of the rectum. It is smaller than the superior mesenteric, and *arises* from the front and toward the left side of the aorta, between one and two inches above the division of that vessel into the common iliacs. It passes downward to the left iliac fossa, and then descends between the layers of the mesorectum, into the pelvis, under the name of the **superior hemorrhoidal artery**. It lies at first in close relation with the left side of the aorta, and then passes as the superior hemorrhoidal in front of the left common iliac artery.

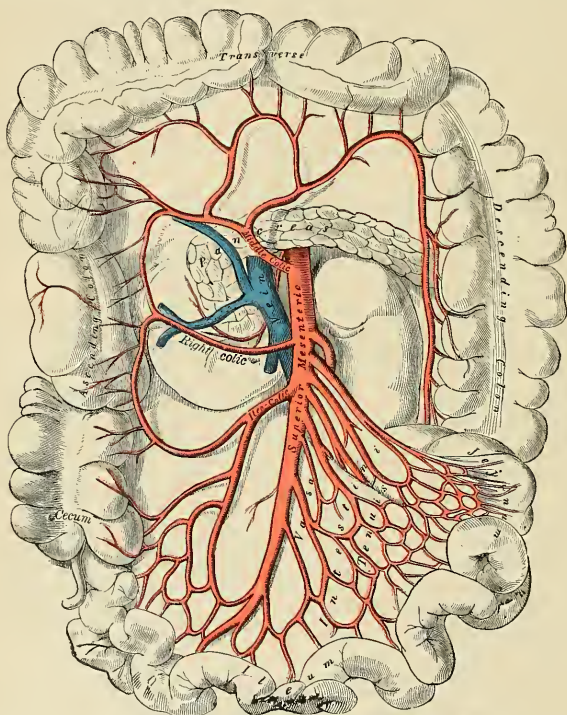


FIG. 470.—The superior mesenteric artery and its branches.

Dissection.—In order to expose the inferior mesenteric artery draw the small intestines and mesentery over to the right side of the abdomen, raise the transverse colon toward the thorax, and divide the peritoneum covering the front of the aorta.

Branches.—Its branches are:

Left colic.

Superior hemorrhoidal.

Sigmoid.

The **left colic artery** (*a. colica sinistra*) passes behind the peritoneum, in front of the left kidney, to reach the descending colon; it divides into an ascending

branch which anastomoses with the middle colic, and a descending branch which anastomoses with the upper sigmoid artery. From the arches formed by these anastomoses, branches are distributed to the descending colon.

The **sigmoid arteries** (*aa. sigmoideae*) run obliquely downward and outward behind the peritoneum across the Psoas muscle to the sigmoid flexure of the colon. They divide into branches which supply the lower part of the descending colon and the sigmoid flexure, anastomosing above with the left colic, and below with the superior hemorrhoidal artery.

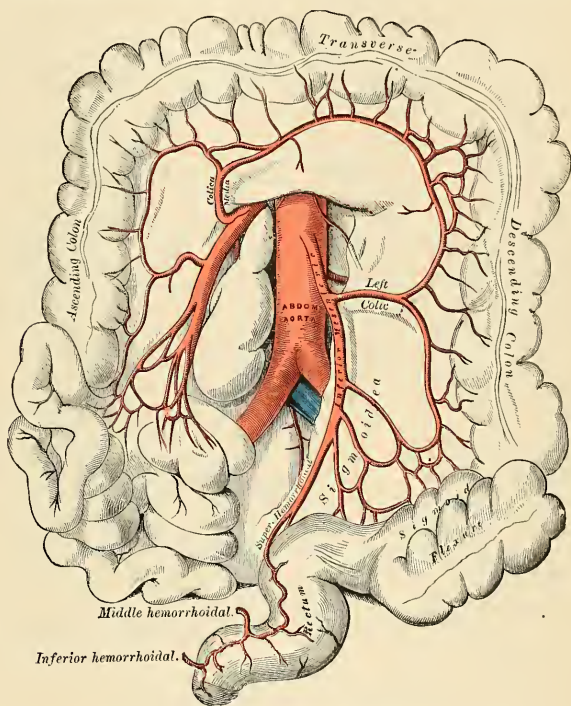


FIG. 471.—The inferior mesenteric and its branches.

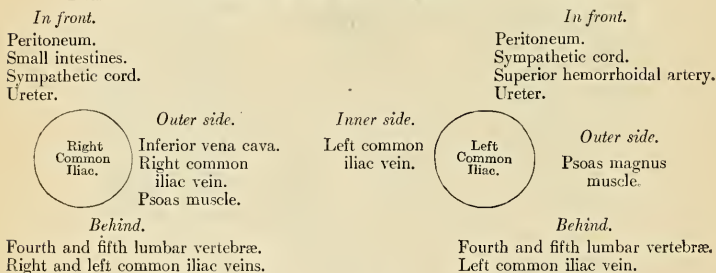
The **superior hemorrhoidal artery** (*a. hemorrhoidalis superior*) (Figs. 471 and 472), the terminal portion of the inferior mesenteric, descends into the pelvis between the layers of the mesorectum, crossing, in its course, the left ureter and left common iliac vessels. Opposite the middle of the sacrum it divides into two branches, which descend one on either side of the rectum, and about five inches from the anus break up into several small branches, which pierce the muscular coat of the bowel and run downward, as straight vessels, placed at regular intervals from each other in the wall of the intestine between its muscular and mucous coat, to the level of the Internal sphincter; here they form a series of loops around the lower end of the rectum, and communicate with the middle hemorrhoidal arteries, which are branches of the internal iliac, and with the inferior hemorrhoidal branches of the internal pudic.

THE COMMON ILIAC ARTERIES (AA. ILIACAE COMMUNES) (Figs. 466, 472).

The **abdominal aorta** divides on the left side of the body of the fourth lumbar vertebra into the two **common iliac arteries**. Each is about two inches in length. They diverge from the termination of the aorta, pass downward and outward to the margin of the pelvis, and divide, opposite the intervertebral disk, between the last lumbar vertebra and the sacrum, into two branches, the **internal** and **external iliac arteries**, the *latter* supplying the lower extremity; the *former*, the viscera and parietes of the pelvis.

The **right common iliac** is somewhat longer than the left, and passes more obliquely across the body of the last lumbar vertebra. In *front* of it are the peritoneum, the small intestines, branches of the sympathetic cord, and, at its point of division, the ureter. *Behind*, it is separated from the bodies of the fourth and fifth lumbar vertebrae, and the intervening intervertebral disk, by the two common iliac veins. On its *outer side*, it is in relation above with the inferior vena cava and the right common iliac vein; and *below*, with the Psoas magnus muscle. On its *inner side*, above, is the left common iliac vein.

The **left common iliac** is in relation, *in front*, with the peritoneum, small intestines, branches of the sympathetic cord, and the superior hemorrhoidal artery; and is crossed at its point of bifurcation by the ureter. It rests on the bodies of the fourth and fifth lumbar vertebrae, with the intervening disk. The left common iliac vein lies partly on the *inner side*, and partly behind the corresponding artery; on its *outer side*, the artery is in relation with the Psoas magnus muscle.

PLAN OF THE RELATIONS OF THE COMMON ILIAC ARTERIES.

Branches.—The common iliac arteries give off small branches to the peritoneum, Psoas magnus, ureters, and the surrounding areolar tissue, and occasionally give origin to the iliolumbar or to the accessory renal arteries.

Peculiarities.—The *point of origin* varies according to the bifurcation of the aorta. In three-fourths of a large number of cases the aorta bifurcated either upon the fourth lumbar vertebra or upon the intervertebral disk between it and the fifth, the bifurcation being, in one case out of nine below, and in one out of eleven above, this point. In ten out of every thirteen cases the vessel bifurcated within half an inch above or below the level of the crest of the ilium, more frequently below than above.

The *point of division* is subject to great variety. In two-thirds of a large number of cases it was between the last lumbar vertebra and the upper border of the sacrum, being above that point in one case out of eight and below it in one case out of six. The left common iliac artery divides lower down more frequently than the right.

The *relative lengths*, also, of the two common iliac arteries vary. The right common iliac was the longer in sixty-three cases, the left in fifty-two, while they were both equal in fifty-three. The length of the arteries varied in five-sevenths of the cases examined from an inch and a half

to three inches; in about half of the remaining cases the artery was longer and in the other half shorter, the minimum length being less than half an inch, the maximum four and a half inches. In two instances the right common iliac has been found wanting, the external and internal iliacs arising directly from the aorta.

Surface Marking.—Draw a line between the highest points of the iliac crests; this is usually half an inch below the umbilicus; in this line take a point half an inch to the left of the middle line. From this draw two lines to points midway between the anterior superior spines of the ilium and the symphysis pubis. These two diverging lines will represent the course of the common and external iliac arteries. Draw a second line corresponding to the level of the anterior superior spines of the ilium; the portion of the diverging lines between these two levels will represent the course of the common iliac artery; the portion below the lower zone, that of the external iliac artery.

Applied Anatomy.—The application of a ligature to the common iliac artery may be required on account of aneurism or hemorrhage implicating the external or internal iliacs. The abdomen is opened by an incision in either the semilunar line or the linea alba; the intestines are drawn to one side and the peritoneum covering the artery divided. The sheath is then opened, and the needle passed from within outward. On the right side great care must be exercised in passing the needle, since both the common iliac veins lie behind the artery. After the vessel has been tied the incision in the peritoneum over the artery should be sutured. In amputation of the hip-joint the common iliac can be compressed most certainly and safely by opening the abdomen and compressing the vessel by means of the fingers against the Psoas muscle (McBurney's method).

Collateral Circulation.—The principal agents in carrying on the collateral circulation after the application of a ligature to the common iliac are the anastomoses of the hemorrhoidal branches of the internal iliac with the superior hemorrhoidal from the inferior mesenteric; the anastomoses of the uterine and ovarian arteries and of the vesical arteries of opposite sides; of the lateral sacral with the middle sacral artery; of the epigastric with the internal mammary inferior intercostal, and lumbar arteries; of the circumflex iliac with the lumbar arteries; of the ilio-lumbar with the last lumbar artery; of the obturator artery, by means of its pubic branch, with the vessel of the opposite side and with the deep epigastric.

From the back part of the aorta, just at its bifurcation, *arises* the **middle sacral artery** (*a. sacralis media*) (Fig. 472). It is a small vessel, and descends upon the last lumbar vertebra, along the middle line of the front of the sacrum, to the upper part of the coccyx, where it anastomoses with the lateral sacral arteries, and terminates in the coccygeal body. From it minute branches arise which run through the mesorectum to supply the posterior surface of the rectum. Other branches are given off on each side, which anastomose with the lateral sacral arteries, and send branches into the anterior sacral foramina. It is crossed by the left common iliac vein, and is accompanied by a pair of venae comites; these unite to form a single vessel which opens into the left common iliac vein.

This artery and its lateral branches probably represent fused segmental arteries (see page 763).

The Internal Iliac Artery (Figs. 466, 472).

The **internal iliac** or **hypogastric artery** (*a. hypogastrica*) supplies the walls and viscera of the pelvis, the buttock, the generative organs, and inner side of the thigh. It is a short thick vessel, smaller in the adult than the external iliac, and about an inch and a half in length. It *arises* at the bifurcation of the common iliac, opposite the lumbosacral articulation, and, passing downward to the upper margin of the great sacrosciatic foramen, divides into two large trunks, an **anterior** and a **posterior**. From its anterior division a partially impervious cord, a part of the **fetal hypogastric artery**, extends forward to the bladder.

Relations.—*In front*, with the ureter, which is between the artery and the peritoneum. *Behind*, with the internal iliac vein, the lumbosacral cord, and Piriformis muscle. On its *outer side*, near its origin with the external iliac vein, which lies between it and the Psoas magnus muscle; lower down, with the obturator nerve.

PLAN OF THE RELATIONS OF THE INTERNAL ILIAC ARTERY.

In front.
Peritoneum.
Ureter.

Outer side.
Psoas magnus.



Behind.
Internal iliac vein.
Lumbosacral cord.
Pyriformis muscle.

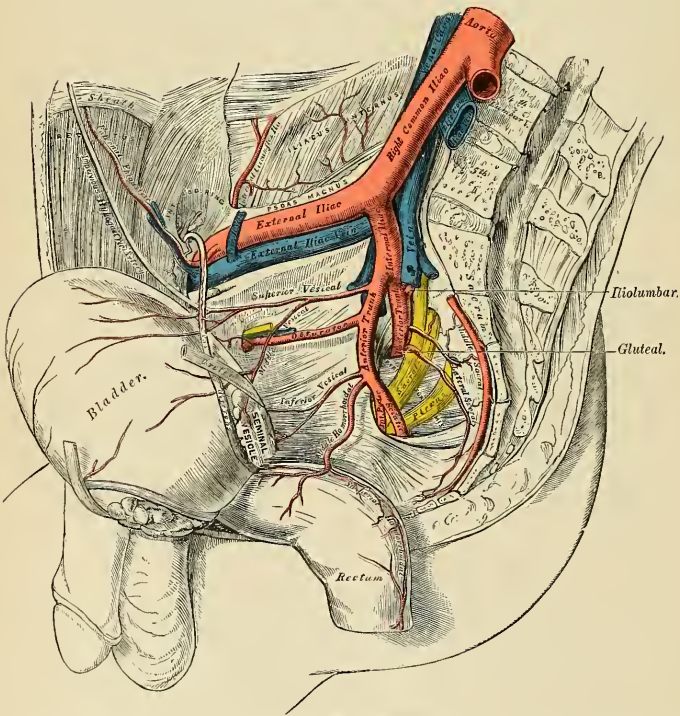


FIG. 472.—Arteries of the pelvis.

In the fetus the hypogastric artery is twice as large as the external iliac, and appears to be the continuation of the common iliac. Instead of dipping into the pelvis, it passes forward to the bladder, and ascends along the sides of that viscus to its summit, to which it gives branches; it then passes upward along the back part of the anterior wall of the abdomen to the umbilicus, converging toward its fellow of the opposite side. Having passed through the umbilical opening,

the two arteries, now termed **umbilical**, enter the umbilical cord, where they are coiled around the umbilical vein and ultimately ramify in the placenta.

At birth, when the placental circulation ceases, the portion of the hypogastric artery which extends from the summit of the bladder to the umbilicus, contracts, and ultimately dwindles to a solid fibrous cord, the **impervious hypogastric artery** (*lig. umbilicale laterale*), but the lower portion, extending from its origin (in what is now the internal iliac artery) for about an inch and a half to the wall of the bladder, and thence to the summit of that organ, is not totally impervious, though it becomes considerably reduced in size, and serves to convey blood to the bladder under the name of the **superior vesical artery**.

Peculiarities as Regards Length.—In two-thirds of a large number of cases the length of the internal iliac varied between an inch and an inch and a half; in the remaining third it was more frequently longer than shorter, the maximum length being three inches, the minimum half an inch.

The lengths of the common and internal iliac arteries bear an inverse proportion to each other, the internal iliac artery being long when the common iliac is short, and *vice versa*.

As Regards its Place of Division.—The place of division of the internal iliac varies between the upper margin of the sacrum and the upper border of the sacrosciatic foramen.

The arteries of the two sides in a series of cases often differed in length, but neither seemed constantly to exceed the other.

Applied Anatomy.—The application of a ligature to the internal iliac artery may be required in cases of aneurism or hemorrhage affecting one of its branches. The best method of tying the internal iliac artery is by an abdominal section in the median line and reaching the vessel through the peritoneal cavity. This plan has been advocated by Dennis, of New York, on the following grounds: (1) It in no way increases the danger of the operation; (2) it prevents a series of accidents which have occurred during ligature of the artery by the older methods; (3) it enables the surgeon to ascertain the exact extent of disease in the main arterial trunk, and select his spot for the application of the ligature; and (4) it occupies much less time.

Collateral Circulation.—The circulation after ligature of the internal iliac artery¹ is carried on by the anastomoses of the uterine and ovarian arteries; of the opposite vesical arteries; of the hemorrhoidal branches of the internal iliac with those from the inferior mesenteric; of the obturator artery, by means of its pubic branch, with the vessel of the opposite side and with the epigastric and internal circumflex; of the circumflex and perforating branches of the profunda femoris with the sciatic; of the gluteal with the posterior branches of the sacral arteries; of the iliolumbar with the last lumbar; of the lateral sacral with the middle sacral; and of the circumflex iliac with the iliolumbar and gluteal.

Branches (Fig. 472).—The branches of the internal iliac are:

From the Anterior Trunk.

Superior vesical.
Middle vesical.
Inferior vesical.
Middle hemorrhoidal.
Obturator.
Internal pudic.
Sciatic.
Uterine }
Vaginal } *In the female.*

From the Posterior Trunk.

Iliolumbar.
Lateral sacral.
Gluteal.

The **superior vesical** (*a. vesicalis superior*) (Fig. 472) represents the pervious portion of the fetal hypogastric artery. It extends to the side of the bladder, distributing numerous branches to the apex and body of the organ. From one of these a slender vessel is derived which accompanies the vas deferens in its course to the testis, where it anastomoses with the spermatic artery. This is the **artery of the vas deferens**. Other branches supply the ureter.

¹For a description of a case in which Owen made a dissection ten years after ligature of the internal iliac artery, see *Medico-Chirurgical Transactions*, vol. xvi.

The **middle vesical** (*a. vesicalis medialis*) (Fig. 472), usually a branch of the superior, is distributed to the base of the bladder and under surface of the seminal vesicles.

The **inferior vesical** (*a. vesicalis inferior*) (Fig. 472) frequently *arises* in common with the middle hemorrhoidal, and is distributed to the base of the bladder, the prostate gland, and seminal vesicles. The branches distributed to the prostate communicate with the corresponding vessel of the opposite side.

The **middle hemorrhoidal artery** (*a. haemorrhoidalis media*) (Fig. 472) usually *arises* together with the preceding vessel. It is distributed to the rectum, anastomosing with the superior and inferior hemorrhoidal arteries. It gives branches to the seminal vesicle and prostate gland.

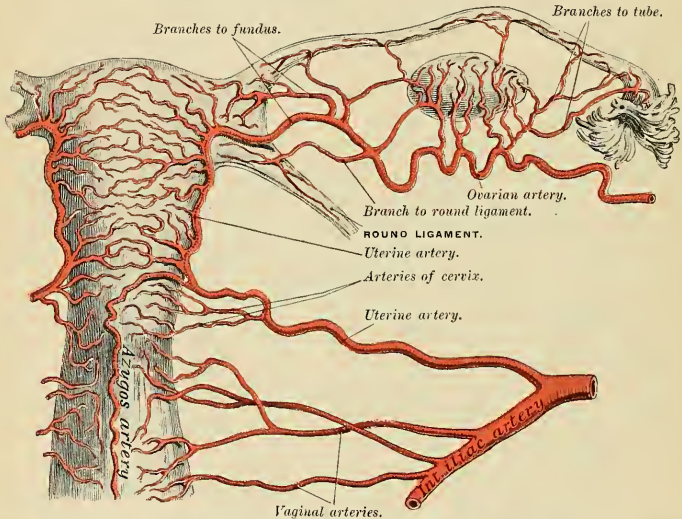


FIG. 473.—The arteries of the internal organs of generation of the female, seen from behind. (After Hyrtl.)

The **uterine artery** (*a. uterina*) (Fig. 473) *arises* from the anterior division of the internal iliac and runs inward on the Levator ani to the neck of the uterus. About three-quarters of an inch from the cervix it crosses the front of the ureter, to which it supplies a small branch. Ascending in a tortuous course on the side of the uterus, between the layers of the broad ligament, it distributes branches to its substance and to the round ligament and the Fallopian tube (*ramus tubarius*), anastomosing near its termination with the ovarian artery. It gives a branch to the ovary (*ramus ovarii*), which anastomoses with a branch from the ovarian branches to the cervix of the uterus, **cervicouterine**, and a branch which descends on the vagina, the **cervicovaginal**, and, joining with branches from the vaginal arteries, form a median longitudinal vessel both in front and behind; these descend on the anterior and posterior surfaces of the vagina, and are named the **azygos arteries of the vagina**.

The **vaginal artery** (*a. vaginalis*) usually corresponds to the inferior vesical in the male; it descends upon the vagina, supplying its mucous membrane, and sends branches to the bulb of the vestibule, the neck of the bladder, and the contiguous

part of the rectum. It assists in forming the *azygos arteries* of the vagina, which are anterior and posterior vessels, running longitudinally, and due to anastomoses of the branches of the vaginal from each side and the cervicovaginal artery. The vaginal artery is frequently represented by two or three branches.

Luschka, Hyrtl, Waldeyer, Robinson, and others, instead of describing the ovarian and uterine arteries as two distinct vessels, regard them as constituting the chief parts of one vessel, the *arteria uterina ovarica*. What has been called "the circle of Robinson" is composed of a spiral segment (the *arteria uterina ovarica*), with a portion of the abdominal aorta, common iliaes, and internal iliaes.

Robinson¹ has made a careful study of this vascular circle; he shows that it is of great importance in certain surgical procedures, and that its remarkable "capacity for extension" saves it from damage when the uterus is enormously distended by pregnancy, or when it is "drawn through the pudendum with traction forceps for palpation, inspection, or repair."

The author just quoted says further that the utero-ovarian artery has three origins, because it develops from the Wolffian body: The **ovarian segment** arises from the abdominal aorta. The **uterine segment** arises from the anterior branch of the internal iliac artery. The **artery of the round ligament** arises from the deep epigastric. The *arteria uterina ovarica* secures nutrition to the uterus by bringing blood from three sources. It is spiral throughout its entire course, in certain parts is convoluted or looped, and it is accompanied by the pampiniform plexus of veins.

The three origins of this vessel are freely united by anastomoses, and *rami laterales* are given off, which unite the bilateral vessels in the median line. Robinson describes three bifurcations of the utero-ovarian artery. The **distal bifurcation**, which is "about midway between the uterus and the pelvic wall," forms an acute angle with the main vessel. This bifurcation indicates the point of division of the external from the internal genitals. The cervicovaginal artery supplies the external genitals. The **proximal bifurcation** marks the situation of the ovary. The artery bifurcates at an acute angle into two branches to supply the ovary and Fallopian tube. The **middle bifurcation** consists of (1) the division of the uterine segment at the angle formed by the uterus and oviduct ("forming the *ramus oviductus* and *ramus ovarii*"), and (2) "the bifurcation of the *ramus oviductus* forming the *ramus oviductus* and the *ramus ligamenti teretis*, or the segment of the round ligament."²

Applied Anatomy.—As pointed out by Robinson, the source of bleeding after vaginal hysterectomy is usually the torn and unclamped cervicovaginal artery.

As previously mentioned, the spiral and convoluted course of the utero-ovarian artery allows the uterus, ovary, and tube to be drawn into the vagina without injury to the vessels. Robinson points out that in vaginal hysterectomy the genital circle is not divided and only the *rami laterales* which go to the uterus are cut, the ovaries retaining a normal blood supply and continuing to functionate.

The **obturator artery** (*a. obturatoria*) (Fig. 472) passes forward and downward on the lateral wall of the pelvis, to the upper part of the obturator foramen, and, escaping from the pelvic cavity through a short canal, formed by a groove on the under surface of the ascending ramus of the os pubis and the arched border of the obturator membrane, it divides into an **internal** and **external branch**. In the pelvic cavity this vessel is in relation, *externally*, with the obturator fascia; *internally*, with the ureter, vas deferens, and peritoneum; while a little below it is the obturator nerve.

Branches.—*Within the pelvis*, the obturator artery gives off an **iliac branch** (*ramus iliacus*) to the iliac fossa, which supplies the bone and the Iliacus muscle, and anastomoses with the iliolumbar artery; a **vesical branch** (*ramus vesicalis*), which runs backward to supply the bladder; and a **pubic branch** (*ramus pubicus*), which is given off from the vessel just before it leaves the pelvic cavity. The pubic branch ascends upon the back of the pubis, communicating with offshoots from the deep epigastric artery and with the corresponding vessel of the opposite side; it is sometimes placed on the inner side of the femoral ring.

Outside the pelvis, the obturator artery divides into an internal and an external branch, they are deeply situated between the Obturator externus and the pelvis.

¹ F. Byron Robinson. The Utero-ovarian Artery, or the Genital Vascular Circle, 1903.

² Ibid.

The **internal branch** (*ramus anterior*) curves backward along the inner margin of the obturator foramen, lying between it and the Obturator externus muscle; it distributes branches to the Obturator externus, Pectineus, Adductors and Gracilis, and anastomoses with the external branch, and with the internal circumflex artery.

The **external branch** (*ramus posterior*) curves backward around the outer margin of the obturator foramen, also lying between the obturator foramen and the Obturator externus muscle, to the space between the Gemellus inferior and Quadratus femoris, where it divides into two branches. One, the smaller, courses inward around the lower margin of the foramen and anastomoses with the internal branch and with the internal circumflex; the other inclines outward in the groove below the acetabulum (*a. acetabulis*), and supplies the muscles attached to the tuberosity of the ischium and anastomoses with the sciatic artery. It sends through the cotyloid notch a branch to the hip-joint, which ramifies on the ligamentum teres as far as the head of the femur.

Peculiarities (Figs. 474 and 475).—The obturator artery sometimes arises from the main stem or from the posterior trunk of the internal iliac, from the deep epigastric (28 per cent.), or it may arise from the external iliac (1.2 per cent.).



FIGS. 474 and 475.—Variations in origin and course of the obturator artery.

When the obturator artery arises at the front of the pelvis from the deep epigastric, it descends almost vertically to the upper part of the obturator foramen. The artery in this course usually lies in contact with the external iliac vein and on the outer side of the femoral ring (Fig. 474); in such cases it would not be endangered in the operation for femoral hernia. Occasionally, however, it curves inward along the free margin of Gimbernat's ligament (Fig. 475), and under such circumstances would almost completely encircle the neck of the hernial sac, and would be in great danger of being wounded if an operation were performed for strangulation.

The **internal pudic artery** (*a. pudenda interna*) (Figs. 476 and 477) is the smaller of the two terminal branches of the anterior trunk of the internal iliac, and supplies the external organs of generation. Though the course of the artery is the same in the two sexes, the vessel is much smaller in the female than in the male, and the distribution of its branches somewhat different. The description of its arrangement in the male will first be given, and subsequently the differences which it presents in the female will be mentioned.

The **internal pudic artery in the male** passes downward and outward to the lower border of the great sacrosciatic foramen, and emerges from the pelvis between the Piriformis and Coccygeus muscles; it then crosses the spine of the ischium and enters the pelvis through the lesser sacrosciatic foramen. The artery now crosses the Obturator internus muscle along the outer wall of the ischio-rectal fossa, being situated about an inch and a half above the lower margin of the ischial tuberosity. It gradually approaches the margin of the ramus of the ischium, passes forward between the two layers of the triangular ligament of the perineum; it then runs forward along the inner margin of the ramus of the pubis and about half an inch behind the subpubic ligament it pierces the superficial layer of the triangular ligament and divides into its two terminal branches, the dorsal artery of the penis and the artery of the corpus cavernosum.

Relations.—Within the pelvis, at its beginning, it lies in front of the Piriformis muscle and sacral plexus of nerves, and the sciatic artery, and on the outer side of the rectum (on the left side). As it crosses the spine of the ischium it is covered by the Gluteus maximus and overlapped by the great sacrosciatic ligament. Here the pudic nerve lies to the inner side and the nerve to the Obturator internus to the outer side of the vessel. On entering the pelvis it lies on the outer side of the ischiorectal fossa, upon the surface of the Obturator internus muscle, contained in a fibrous canal (**Alcock's canal**), formed by the splitting of the obturator fascia. It is accompanied by the pudic veins and the pudic nerve.

Peculiarities.—The internal pudic is sometimes smaller than usual, or fails to give off one or two of its usual branches; in such cases the deficiency is supplied by branches derived from an additional vessel, the **accessory pudic**, which generally arises from the internal pudic artery before its exit from the great sacrosciatic foramen. It passes forward along the lower part of the bladder and across the side of the prostate gland to the root of the penis, where it perforates the triangular ligament and gives off the branches usually derived from the pudic artery. The deficiency most frequently met with is that in which the internal pudic ends as the artery of the bulb, the artery of the corpus cavernosum and dorsal artery of the penis being derived from the accessory pudic. Or the pudic may terminate as the superficial perineal, the artery of the bulb being derived, with the other two branches, from the accessory vessel. Occasionally the accessory pudic artery is derived from one of the other branches of the internal iliac, most frequently the inferior vesical or the obturator.

Branches.—The branches of the internal pudic artery are:

Muscular.	Artery of the bulb.
Inferior hemorrhoidal.	Urethral artery.
Superficial perineal.	Artery of the corpus cavernosum.
Transverse perineal.	Dorsal artery of the penis.

The **muscular branches** consist of two sets—one given off in the pelvis, the other as the vessel crosses the ischial spine. The former are several small offshoots which supply the Levator ani, the Obturator internus, the Piriformis, and the Coccygeus muscles. The branches given off outside the pelvis are distributed to the adjacent part of the Gluteus maximus and External rotator muscles. They anastomose with branches of the sciatic artery.

The **inferior hemorrhoidal artery** (*a. haemorrhoidalis inferior*) arises from the internal pudic as it passes above the tuberosity of the ischium. Crossing the ischiorectal fossa it is distributed by two or three terminal branches to the muscles and integument of the anal region. Instead of one inferior hemorrhoidal artery two or three small vessels may arise from the internal pudic.

The **superficial perineal artery** (*a. perinei*) (Fig. 476) supplies the scrotum and the muscles and integument of the perineum. It arises from the internal pudic in front of the preceding branches, and turns upward, crossing either over or under the Transversus perinei superficialis muscle, and runs forward, parallel to the pubic arch, in the interspace between the Accelerator urinae (*m. bulbocavernosus*) and Erector penis (*m. ischiocavernosus*) muscles, both of which it supplies, and is finally distributed to the skin and dartos of the scrotum. In its passage through the perineum it lies beneath the superficial perineal fascia.

The **transverse perineal artery** is a small branch which arises either from the internal pudic or from the superficial perineal artery as it crosses the Transversus perinei muscle. It runs transversely inward along the cutaneous surface of the Transversus perinei superficialis muscle and anastomoses with the like vessel of the opposite side, and with the superficial perineal and inferior hemorrhoidal arteries. It supplies the Transversus perinei and the structures between the anus and bulb of the urethra.

The **artery of the bulb** (*a. bulbi urethrae*) is a short vessel of large caliber which arises from the internal pudic between the two layers of the triangular ligament; it passes nearly transversely inward, through the fibres of the Compressor urethrae muscle, pierces the superficial layer of the triangular ligament, and gives off

branches which ramify in the bulb of the urethra. It is then continued forward in the corpus spongiosum to the glans penis. It gives off a small branch to Cowper's gland.

The **urethral artery** (*a. urethralis*) is a small vessel which passes to the corpus spongiosum at the angle of the converging crura of the penis. It reaches the glans penis and anastomoses with the artery of the corpus cavernosum and the dorsal artery of the penis. This vessel is quite often absent.

The **artery of the corpus cavernosum** (*a. profunda penis*), one of the terminal branches of the internal pudic, arises just after that vessel has perforated the superficial triangular ligament, and, quickly entering the crus penis obliquely, runs forward in the centre of the corpus cavernosum, to which its branches are distributed.

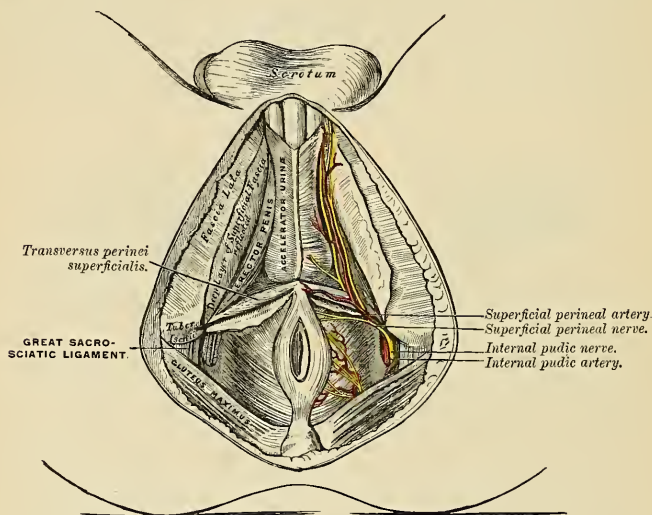


FIG. 476.—The superficial muscles and vessels of the perineum.

The **dorsal artery of the penis** (*a. dorsalis penis*) ascends between the crus and pubic symphysis, and passes between the two layers of the suspensory ligament of the penis, and runs forward on the dorsum of the penis to the glans, where it divides into two branches which supply the glans and prepuce. On the dorsum of the penis it lies immediately beneath the integument, between the dorsal nerve and the deep dorsal vein, the former being on its outer side. It supplies the integument and fibrous sheath of the corpus cavernosum, sending branches through the sheath to anastomose with the preceding vessel.

The **internal pudic artery in the female** is smaller than in the male. Its origin and course are similar, and there is considerable analogy in the distribution of its branches. The superficial perineal artery supplies the labia pudendi; the artery of the bulb supplies the bulbi vestibuli and the erectile tissue of the vagina; the artery of the corpus cavernosum (*a. profunda clitoridis*) supplies the cavernous body of the clitoris; and the dorsal artery of the clitoris (*a. dorsalis clitoridis*) supplies the dorsum of that organ, and terminates in the glans and in the membranous fold corresponding to the prepuce of the male.

The **sciatic artery** (*a. glutea inferior*) (Fig. 477), the larger of the two terminal branches of the anterior trunk of the internal iliac, is distributed chiefly on the buttock and back of the thigh. It passes down to the lower part of the great sacrosciatic foramen behind the internal pudic artery, resting on the sacral plexus of nerves and Piriformis muscle, and escapes from the pelvis through this foramen between the Piriformis and Coccygeus. It then descends in the interval between the trochanter major and tuberosity of the ischium, accompanied by the sciatic nerves, and covered by the Gluteus maximus, and is continued down the back of the thigh supplying the skin, and anastomosing with branches of the perforating arteries.

Within the pelvis it distributes branches to the Piriformis, Coccygeus, and Levator ani muscles; some hemorrhoidal branches, which supply the rectum, and occasionally take the place of the middle hemorrhoidal artery; and vesical branches to the base and neck of the bladder, seminal vesicles, and prostate gland. Outside the pelvis it gives off the following branches:

- Muscular.
- Coccygeal.
- Comes nervi ischiadici.
- Anastomotic.
- Articular.
- Cutaneous.

The **muscular branches** supply the Gluteus maximus, anastomosing with the gluteal artery in the substance of the muscle; the External rotators, anastomosing with the internal pudic artery; and the muscles attached to the tuberosity of the ischium, anastomosing with the external branch of the obturator and the internal circumflex arteries.

The **coccygeal branch** runs inward, pierces the great sacrosciatic ligament, and supplies the Gluteus maximus, the integument, and other structures on the back of the coccyx.

The **comes nervi ischiadici** (*a. comitans n. ischiadici*) is a long, slender vessel which accompanies the great sciatic nerve for a short distance; it then penetrates it and runs in its substance to the lower part of the thigh.

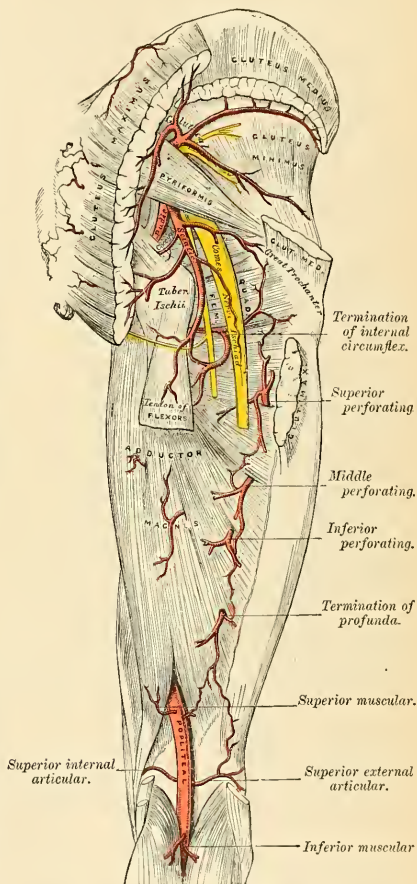


FIG. 477.—The arteries of the gluteal and posterior femoral regions.

The **anastomotic artery** is directed downward across the External rotators and assists in forming the so-called **crucial anastomosis** by anastomosing with the superior perforating and the internal and external circumflex arteries.

The **articular branch**, generally derived from the anastomotic, is distributed to the capsule of the hip-joint.

The **cutaneous branches** are distributed to the skin of the buttock and back of the thigh.

The **iliolumbar artery** (*a. iliolumbalis*), given off from the posterior trunk of the internal iliac, turns upward and outward between the obturator nerve and lumbosacral cord, to the inner margin of the Psoas muscle, behind which it divides into a **lumbar** and an **iliac branch**.

The **lumbar branch** (*ramus lumbalis*) supplies the Psoas and Quadratus lumborum muscles, anastomosing with the last lumbar artery, and sends a small **spinal branch** (*ramus spinalis*) through the intervertebral foramen, between the last lumbar vertebra and the sacrum, into the vertebral canal, to supply the cauda equina.

The **iliac branch** (*ramus iliacus*) descends to supply the Iliacus muscle; some offshoots, running between the muscle and the bone, anastomose with the iliac branch of the obturator; one of these enters an oblique canal to supply the diploë, while others run along the crest of the ilium, distributing branches to the Gluteal and Abdominal muscles, and anastomose in their course with the gluteal circumflex iliac, and external circumflex arteries.

The **lateral sacral arteries** (*a. sacralis lateralis*) (Fig. 472) are usually two in number—**superior** and **inferior**.

The **superior**, which is of large size, passes inward, and, after anastomosing with branches from the middle sacral, enters the first or second anterior sacral foramen, supplies branches to the contents of the sacral canal, and, escaping by the corresponding posterior sacral foramen, is distributed to the skin and muscles on the dorsum of the sacrum, anastomosing with the gluteal.

The **inferior** passes obliquely across the front of the Piriformis muscle and sacral nerves to the inner side of the anterior sacral foramina, descends on the front of the sacrum, and anastomoses over the coccyx with the middle sacral and opposite lateral sacral artery. In its course it gives off branches which enter the anterior sacral foramina (*rami spinales*); these, after supplying the contents of the sacral canal, escape by the posterior sacral foramina, and are distributed to the muscles and skin on the dorsal surface of the sacrum, anastomosing with the gluteal.

The **gluteal artery** (*a. glutæa superior*) (Fig. 477) is the largest branch of the internal iliac, and appears to be the continuation of the posterior division of that vessel. It is a short, thick trunk which runs backward between the lumbosacral cord and the first sacral nerve, and, passing out of the pelvis above the upper border of the Piriformis muscle, immediately divides into a **superficial** and a **deep branch**. Within the pelvis it gives off a few muscular branches to the Iliacus, Piriformis, and Obturator internus, and, just previous to emerging from that cavity, a nutrient artery which enters the ilium.

The **superficial branch** enters the deep surface of the Gluteus maximus, and divides into numerous branches, some of which supply the muscle, while others perforate its tendinous origin, and supply the integument covering the posterior surface of the sacrum, anastomosing with the posterior branches of the sacral arteries.

The **deep branch** lies under the Gluteus medius and almost immediately subdivides into two. Of these, the **superior division** (*ramus superior*), continuing the original course of the vessel, passes along the upper border of the Gluteus minimus to the anterior superior spine of the ilium, anastomosing with the circumflex iliac and ascending branches of the external circumflex artery. The **inferior division** (*ramus inferior*) crosses the Gluteus minimus obliquely to the trochanter

major, distributing branches to the Gluteus muscles, and anastomoses with the external circumflex artery. Some branches pierce the Gluteus minimus to supply the hip-joint.

Surface Marking.—The position of the three main branches of the internal iliac, the sciatic, internal pudic, and gluteal, which may occasionally be the object of surgical interference, is indicated on the surface in the following way: A line is to be drawn from the posterior superior iliac spine to the posterior superior angle of the great trochanter, with the limb slightly flexed and rotated inward; the point of emergence of the gluteal artery from the upper part of the sciatic notch will correspond with the junction of the upper with the middle third of this line. A second line is to be drawn from the same point to the outer part of the tuberosity of the ischium; the junction of the lower with the middle third marks the point of emergence of the sciatic and pudic arteries from the great sciatic notch.

Applied Anatomy.—Any of these three vessels may require ligating for a wound or for aneurism, which is generally traumatic. The gluteal artery is ligated by turning the patient two-thirds over on his face and making an incision from the posterior superior spine of the ilium to the upper and posterior angle of the great trochanter. This must expose the Gluteus maximus muscle, and its fibres are to be separated through the whole thickness of the muscle and pulled apart with retractors. The contiguous margins of the Gluteus medius and Piriformis are now to be separated from each other, and the artery will be exposed emerging from the sciatic notch. In ligation of the sciatic artery, the incision should be made parallel with that for ligation of the gluteal, but one inch and a half lower down. After the fibres of the Gluteus maximus have been separated, the vessel is to be sought for at the lower border of the Piriformis; the great sciatic nerve, which lies just above it, forms the chief guide to the artery. The internal pudic can be reached through the incision used to reach the sciatic.

The External Iliac Artery (A. Iliaca Externa) (Fig. 472).

The **external iliac artery** is larger in the adult than is the internal iliac. It passes obliquely downward and outward along the inner border of the Psoas muscle, from the bifurcation of the common iliac to a point beneath Poupart's ligament, midway between the anterior superior spine of the ilium and the symphysis pubis, where it enters the thigh and becomes the femoral artery.

Relations.—*In front*, the artery is in relation with the peritoneum, subperitoneal areolar tissue, the termination of the ileum on the right side, and the sigmoid flexure on the left, and a thin layer of fascia derived from the iliac fascia, which surrounds the artery and vein. At its origin it is crossed by the ovarian artery in the female, and occasionally by the ureter. The spermatic vessels descend for some distance upon it near its termination, and it is crossed in this situation by the genital branch of the genitofemoral nerve and the deep circumflex iliac vein; the vas deferens in the male, and the round ligament in the female, curve down along its inner side. *Behind*, it is in relation with the inner border of the Psoas muscle, from which it is separated by the iliac fascia. At the upper part of its course, the external iliac vein lies partly behind it, but lower down lies entirely to its inner side. *Externally*, it rests against the Psoas muscle, from which it is separated by the iliac fascia. Numerous lymphatic vessels and nodes are found lying on the front and inner side of the vessel.

PLAN OF THE RELATIONS OF THE EXTERNAL ILIAC ARTERY.

In front.

Near Poupart's Ligament. { Peritoneum, intestines, and fascia.
Lymphatic vessels and nodes.
Spermatic vessels.
Genitofemoral nerve (genital branch).
Deep circumflex iliac vein.

Outer side.

Psoas magnus.
Iliac fascia.



Inner side.

External iliac vein and vas deferens
near Poupart's ligament.

Behind.

External iliac vein.
Psoas magnus.

Surface Marking.—The surface line indicating the course of the external iliac artery has been already given (see page 669).

Applied Anatomy.—The application of a *ligature* to the external iliac may be required in cases of aneurism of the femoral artery or for a wound of the artery. This vessel may be secured in any part of its course, excepting near its upper end, which is to be avoided on account of the proximity of the internal iliac, and near its lower end, which should also be avoided, on account of the proximity of the deep epigastric and circumflex iliac vessels. The patient having been placed in the supine position, an incision should be made, commencing below at a point about three-quarters of an inch above Poupart's ligament, and a little external to its middle, and running upward and outward, parallel to Poupart's ligament, to a point one inch internal and one inch above the anterior superior spine of the ilium. When the artery is deeply seated more room will be required, and may be obtained by curving the incision from the point last named inward toward the umbilicus for a short distance. The Abdominal muscles and transversalis fascia having been cautiously divided, the peritoneum should be separated from the iliac fossa and raised toward the pelvis; and on introducing the finger to the bottom of the wound, the artery may be felt pulsating along the inner border of the Psoas muscle. The external iliac vein is generally found on the inner side of the artery, and must be cautiously separated from it by the finger nail or handle of the knife, and the aneurism needle should be introduced on the inner side, between the artery and the vein.

Ligation of the external iliac artery is also performed by a transperitoneal method. An incision four inches in length is made in the semilunar line, commencing about an inch below the umbilicus and carried through the abdominal wall into the peritoneal cavity. The intestines are then pushed upward and held out of the way by a broad abdominal retractor, and an incision is made through the peritoneum at the brim of the pelvis in the course of the artery, and the vessel is secured in any part of its course which may seem desirable to the operator. The advantages of this operation appear to be that if it is found necessary the common iliac artery can be ligated instead of the external iliac without extension or modification of the incision; and secondly, that the vessel can be ligated without in any way interfering with the coverings of the sac of an aneurism. Possibly a disadvantage may exist in the greater risk of hernia after this method.

Collateral Circulation.—The principal anastomoses in carrying on the collateral circulation, after the application of a ligature to the external iliac, are the ilio-lumbar with the circumflex iliac; the gluteal with the external circumflex; the obturator with the internal circumflex; the sciatic with the superior perforating and circumflex branches of the profunda artery; and the internal pudic with the external pudic. When the obturator arises from the epigastric it is supplied with blood by branches, either from the internal iliac, the lateral sacral, or the internal pudic. The epigastric receives its supply from the internal mammary and inferior intercostal arteries, and from the internal iliac by the anastomoses of its branches with the obturator.¹

Branches.—Besides several small branches to the Psoas muscle and the neighboring lymph nodes, the external iliac gives off two branches of considerable size—the **deep epigastric** and **deep circumflex iliac arteries**.

The **deep epigastric artery** (*a. epigastrica inferior*) (Fig. 472) arises from the external iliac above Poupart's ligament. It curves forward below the peritoneum, and then ascends obliquely along the inner margin of the internal abdominal ring, lying between the transversalis fascia and peritoneum; continuing its course upward, it pierces the transversalis fascia, and passing over the semilunar fold of Douglas, ascends between the Rectus and the posterior lamella of its aponeurotic sheath. It finally divides into numerous branches which anastomose, above the umbilicus, with the superior epigastric branch of the internal mammary and with the lower intercostal arteries (Fig. 458). As the deep epigastric artery passes obliquely upward and inward from its origin it lies along the lower and inner margin of the internal abdominal ring and behind the commencement of the spermatic cord. This part of the vessel is crossed by the vas deferens in the male and the round ligament of the uterus in the female.

Branches.—The branches of this vessel are: The **cremasteric** (*a. spermatica externa in the male, a. ligamenti teretis uteri in the female*), which accompanies the spermatic cord, and supplies the Cremaster muscle and other coverings of the

¹ Sir Astley Cooper describes the dissection of a limb eighteen years after successful ligation of the external iliac artery in Vol. 1 of Guy's Hospital Reports.

spermatic cord, anastomosing with the spermatic artery in the male, and which accompanies the round ligament in the female; a **pubic branch** (*ramus pubicus*), which runs along Poupart's ligament, and then descends behind the os pubis to the inner side of the femoral ring, and anastomoses with offshoots from the obturator artery; **muscular branches**, some of which are distributed to the Abdominal muscles and peritoneum, anastomosing with the lumbar and circumflex iliac arteries; **cutaneous branches**, which perforate the tendon of the External oblique, and supply the integument, anastomosing with branches of the superficial epigastric.

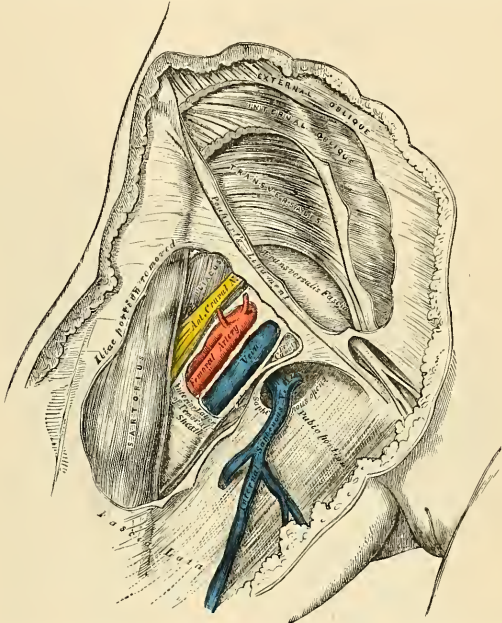


FIG. 478.—Femoral sheath laid open to show its three compartments. Iliac portion of fascia lata removed.

Peculiarities.—The origin of the deep epigastric may take place from any part of the external iliac between Poupart's ligament and two inches and a half above it, or it may arise below this ligament, from the common femoral or from the deep femoral. It frequently arises from the external iliac by a common trunk with the obturator. Sometimes the epigastric arises from the obturator, the latter vessel being furnished by the internal iliac, or the epigastric may be formed by two branches, one derived from the external iliac, the other from the internal iliac.

Applied Anatomy.—The deep epigastric artery follows a line drawn from the middle of Poupart's ligament toward the umbilicus; but shortly after this line crosses the linea semilunaris the direction changes, and the course of the vessel is directly upward in the line of junction of the inner third with the outer two-thirds of the Rectus muscle. It has important surgical relations, in addition to the fact that it is one of the principal means, through its anastomosis with the internal mammary, in establishing the collateral circulation after ligation of either the common or external iliac arteries. It lies close to the internal abdominal ring, and is therefore *internal* to an oblique inguinal hernia, but *external* to a direct inguinal hernia, as the hernia emerges from the abdomen. It forms the outer boundary of Hesselbach's triangle. It is in close relationship with the spermatic cord, which lies in front of it in the inguinal canal, separated only by the transversalis fascia. The vas deferens curves round its outer side.

The **deep circumflex iliac artery** (*a. circumflexa ilium profunda*) (Fig. 471) arises from the outer side of the external iliac nearly opposite the epigastric artery. It ascends obliquely outward behind Poupart's ligament, contained in a fibrous sheath formed by the junction of the transversalis and iliac fasciæ, to the anterior superior spinous process of the ilium. It then runs along the inner surface of the crest of the ilium to about its middle, where it pierces the Transversalis, and runs backward between that muscle and the Internal oblique, to anastomose with the iliolumbar and gluteal arteries. Opposite the anterior superior spine of the ilium it gives off a large branch which ascends between the Internal oblique and Transversalis muscles, supplying them, and anastomosing with the lumbar and epigastric arteries. It also gives off cutaneous branches.

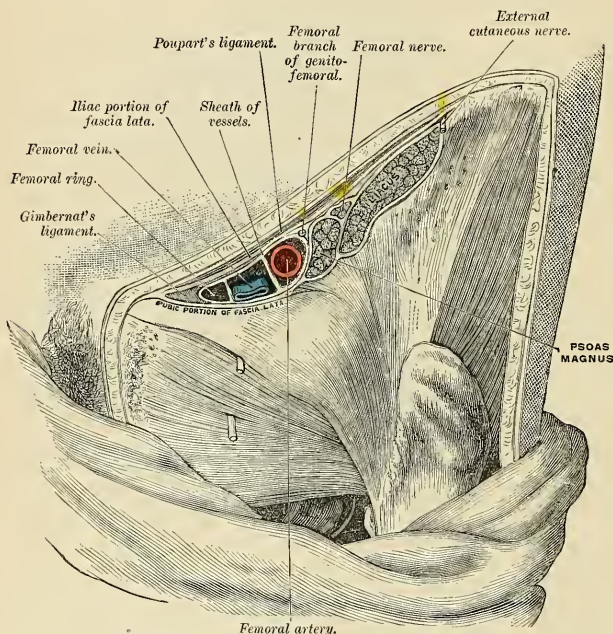


FIG. 479.—Structures which pass beneath the crural arch.

ARTERIES OF THE LOWER EXTREMITY

The artery which supplies the greater part of the lower extremity is the direct continuation of the external iliac. It continues as a single trunk from Poupart's ligament to the lower border of the Popliteus muscle, and here divides into two branches, the anterior and posterior tibial. For convenience of description, the upper part of the main trunk is named **femoral**, the lower part, **popliteal**.

THE FEMORAL ARTERY (A. FEMORALIS) (Figs. 481 and 482).

The **femoral artery** commences immediately behind Poupart's ligament, midway between the anterior superior spine of the ilium and the symphysis pubis, and, passing down the fore part and inner side of the thigh, terminates at the opening in the Adductor magnus, at the junction of the middle with the lower third of the thigh, where it becomes the popliteal artery. The vessel, at the upper part of the thigh, lies in front of the hip-joint, on a line with the innermost part of the head of the femur; in the lower part of its course it is in close relation with the inner side of the shaft of the bone, and between these two parts the vessel is some distance from the bone. The first inch and a half of the vessel is enclosed, together with the femoral vein, in a fibrous sheath—the **femoral sheath**. In the upper third of the thigh it is contained in a triangular space called **Scarpa's triangle**, and in this space it gives off its largest branch, the **deep femoral**. In the middle third of the thigh it is contained in an aponeurotic canal called **Hunter's canal**. That portion of the femoral artery which extends from Poupart's ligament to the origin of the deep femoral is sometimes called the **common femoral**; its continuation is the **superficial femoral**.

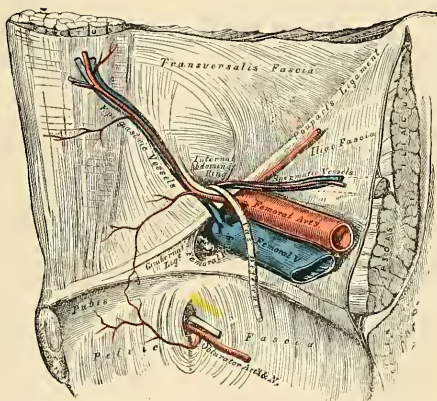


FIG. 480.—The relations of the femoral and internal abdominal rings, seen from within the abdomen. Right side.

The **femoral or crural sheath** (Fig. 479) is a continuation downward of the fasciæ that line the abdomen, the **transversalis fascia** passing down in front of the femoral vessels, and the **iliac fascia** descending behind them; these fasciæ are directly continuous on the iliac side of the femoral artery, but a small space exists between the femoral vein and the point where they are continuous on the pubic side of that vessel, which constitutes the **femoral or crural canal** (Fig. 479). The femoral sheath is closely adherent to the contained vessels about an inch below the saphenous opening, being blended with the sheath of the vessels, but opposite Poupart's ligament it is much larger than is required to contain them; hence the funnel-shaped form which it presents. The outer border of the sheath is perforated by the femoral nerve. Its inner border is pierced by the internal saphenous vein and numerous lymphatic vessels. In front it is covered by the iliac portion of the fascia lata; and behind it is the pubic portion of the same fascia.

The anterior wall of the sheath is a thickened band of fascia continuous above Poupart's ligament with the transversalis fascia, called the **deep crural arch**. From it stretch two septa, one between the femoral artery and the vein, the other lying just internal to the vein, and cutting off a small space between the vein and the inner wall of the sheath. The septa are stretched between the anterior and posterior walls of the sheath, so that each vessel is enclosed in a separate compartment. The interval left between the vein and the inner wall of the sheath is not

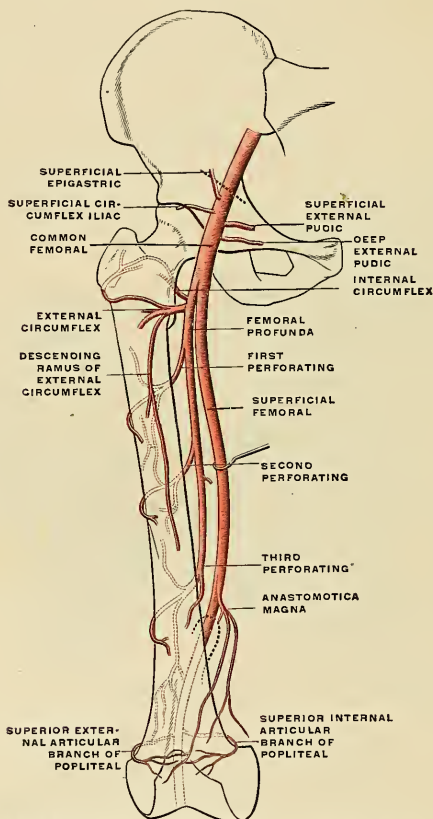


FIG. 451.—Scheme of the femoral artery. (Poirier and Charpy.)

filled up by any structure, excepting a little loose areolar tissue, a few lymphatic vessels, and occasionally by a small lymph node; this is the **femoral or crural canal** through which the intestine descends in femoral hernia.

The **femoral or crural canal** (*canalis femoralis*) (Figs. 479 and 480) is the narrow interval between the femoral vein and the inner wall of the femoral sheath. It exists as a distinct canal only when the sheath has been separated from the vein by dissection or by the pressure of a hernia or tumor. Its length is from a quarter

to half an inch, and it extends from the femoral ring to the upper part of the saphenous opening.

This canal has two orifices—an upper one, the **femoral or crural ring**, closed by the septum crurale; and a lower one, the **saphenous opening**, closed by the cribriform fascia.

The **femoral or crural ring** (*annulus femoralis*) (Figs. 462 and 463) is the upper opening of the femoral canal, and leads into the cavity of the abdomen. It is of an oval form; its long diameter, directed transversely, measures about half an inch, and it is larger in the female than in the male, which is one of the reasons of the greater frequency of femoral hernia in the former sex.

Scarpa's triangle (*trigonum femorale*) corresponds to the depression seen immediately below the fold of the groin. It is a triangular space, the *apex* of which is directed downward, and the sides formed *externally* by the Sartorius, *internally* by the inner margin of the Adductor longus, and *above* by Poupart's ligament. The floor of the space is formed from without inward by the Iliacus, Psoas, Pectineus (in some cases a small part of the Adductor brevis), and the Adductor longus muscles; and it is divided into two nearly equal parts by the femoral vessels, which extend from the middle of its base to its apex, the artery giving off in this situation its superficial and profunda branches, the vein receiving the deep femoral and internal saphenous. On the outer side of the femoral artery is the femoral nerve dividing into its branches. In the outer corner of the space is the external cutaneous nerve. Within the sheath of the artery, and lying upon the outer side of the vessel, is the femoral branch of the genitofemoral nerve. At the base of the triangle the vein is to the inner side of the artery; at the apex of the triangle it is passing behind the artery. Besides the vessels and nerves, this space contains some fat and lymphatics.

Hunter's canal, or the **adductor canal** (*canalis adductorius* [*Hunteri*]) (Fig. 381), is the aponeurotic space in the middle third of the thigh, extending from

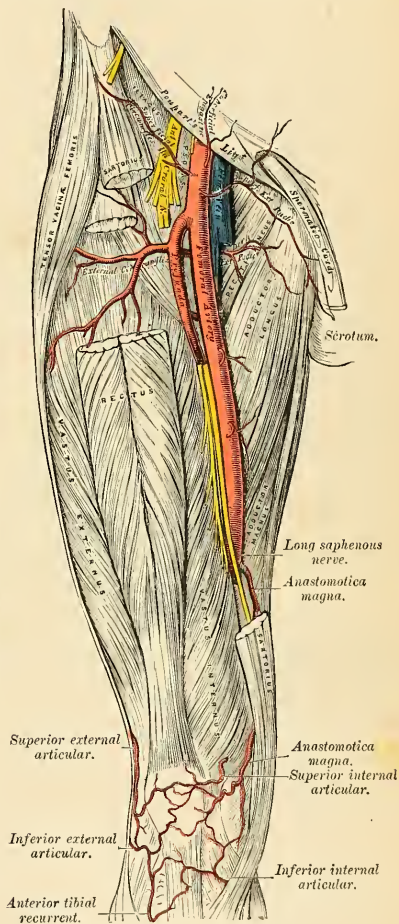


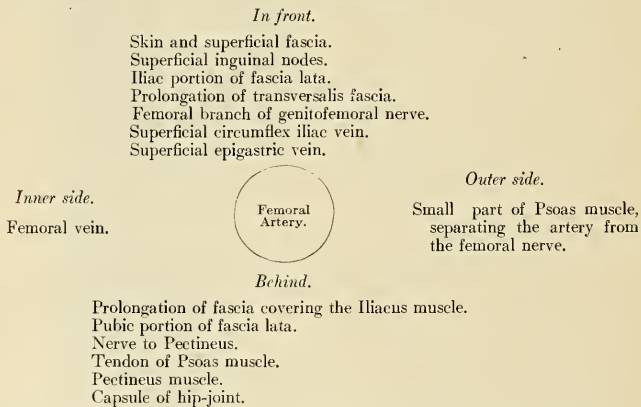
FIG. 482.—The femoral artery.

the apex of Scarpa's triangle to the femoral opening in the Adductor magnus muscle. It is bounded, *externally*, by the Vastus internus; *internally*, by the Adductores longus and magnus muscles; and is *covered* in by a strong aponeurosis which extends transversely from the Vastus internus across the femoral vessels to the Adductor longus and magnus; lying on which aponeurosis is the Sartorius muscle. It contains the femoral artery and vein enclosed in their own sheath of areolar tissue, the vein being behind and on the outer side of the artery, and the internal or long saphenous nerve lying at first on the outer side and then in front of the vessels.

Relations.—The relations of the artery differ along its course. In *Scarpa's triangle* the femoral artery is very superficial, being covered by the skin and superficial fascia, superficial inguinal lymph nodes, the iliac portion of the fascia lata, and the anterior part of the femoral sheath. The femoral branch of the genitofemoral nerve courses for a short distance within the outer compartment of the femoral sheath and lies at first in front and then on the outer side of the artery. Near the apex of Scarpa's triangle the internal cutaneous nerve crosses the artery from without inward.

Behind the artery are the posterior part of the femoral sheath, the pubic portion of the fascia lata, the inner part of the tendon of the Psoas, the Pectineus and Adductor longus. The artery is separated from the capsule of the hip-joint by the tendon of the Psoas, from the Pectineus by the femoral vein and profunda vessels, and from the Adductor longus by the femoral vein. The nerve to the Pectineus passes inward behind the artery. On the *outer* side of the artery, but separated from it by some fibres of the Psoas, is the femoral nerve. The femoral vein is on the inner side of the upper part of the artery, but is behind the vessel in the lower part of Scarpa's triangle.

PLAN OF THE RELATIONS OF THE FEMORAL ARTERY IN SCARPA'S TRIANGLE.

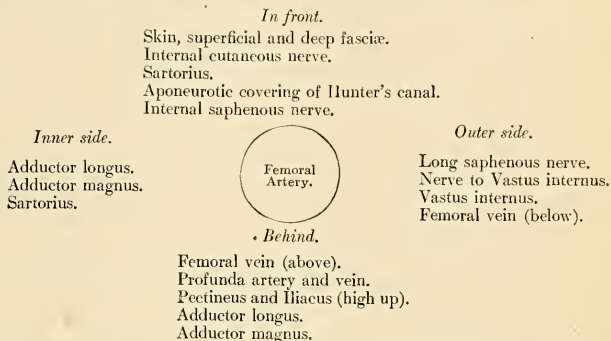


In *Hunter's canal* the femoral artery is more deeply situated, being *covered* by the integument, the superficial and deep fasciæ, the Sartorius and the fibrous roof of the canal; it is *crossed* from without inward by the long saphenous nerve. *Behind* the artery are the Adductores longus et magnus; in *front* and to its outer side is the Vastus internus. The femoral vein lies behind the upper part, and on the outer side of the lower part of the artery. As the artery passes out of Scarpa's

triangle into Hunter's canal, the Iliacus and Pectineus muscles lie behind it for a short distance (Fig. 482).

That portion of the femoral artery which extends from Poupart's ligament to the origin of the profunda is sometimes named the **common femoral**.

PLAN OF THE RELATIONS OF THE FEMORAL ARTERY IN HUNTER'S CANAL.



Peculiarities, Double Femoral Reunited.—Several cases are recorded in which the femoral artery divided into two trunks below the origin of the profunda, and became reunited near the opening of the Adductor magnus so as to form a single popliteal artery. One of them occurred in a patient operated upon for popliteal aneurism.

Change of Position.—A few cases have been recorded in which the femoral artery was situated at the back of the thigh, the vessel being continuous above with the internal iliac, escaping from the pelvis through the great sacrosciatic foramen, and accompanying the great sciatic nerve to the popliteal space, where its division occurred in the usual manner. The external iliac in these cases was small, and terminated in the profunda.

Position of the Vein.—The femoral vein is occasionally placed along the inner side of the artery, throughout the entire extent of Scarpa's triangle, or it may be divided so that a large vein is placed on each side of the artery for a greater or less extent.

Surface Marking.—The upper two-thirds of a line drawn from a point midway between the anterior superior spine of the ilium and the symphysis pubis to the adductor tubercle on the inner condyle of the femur, with the thigh abducted and rotated outward, will indicate the course of the femoral artery.

Applied Anatomy.—*Compression* of the femoral artery, which is constantly requisite in amputations and other operations on the lower limbs, and also for the cure of popliteal aneurisms, is most effectually made immediately below Poupart's ligament. In this situation the artery is very superficial, and is merely separated from the ascending ramus of the os pubis by the Psoas muscle; so that the surgeon, by means of his thumb or a compressor, may effectually control the circulation through it. This vessel may also be compressed in the middle third of the thigh by placing a compress over the artery, beneath the tourniquet, and directing the pressure from within outward, so as to compress the vessel against the inner side of the shaft of the femur.

The **application of a ligature** to the femoral artery may be required in the cases of wound or aneurism of the arteries of the leg, of the popliteal or femoral;¹ and the vessel may be exposed and tied in any part of its course. The great depth of this vessel at its lower part, its close connection with important structures, and the density of its sheath render the operation in this situation one of much greater difficulty than the application of a ligature at its upper part, where it is more superficial.

Ligation of the common femoral artery is usually considered unsafe, on account of the connection of large branches with it—viz., the deep epigastric and the deep circumflex iliac arising just above Poupart's ligament; on account of the number of small branches which arise from it in its short course; and on account of the uncertainty of the origin of the profunda femoris, which, if it arise high up, would be too close to the ligature for the formation of a firm coagulum. The profunda sometimes arises higher than the point above mentioned, and rarely

¹ Ligation of the femoral artery has been also recommended and performed for elephantiasis of the leg and acute inflammation of the knee-joint (Maunder, Clin. Soc. Trans., vol. ii, p. 37).

between two or three inches (in one case four) below Poupart's ligament. It would appear, then, that the most favorable situation for the application of a ligature to the femoral is on the superficial femoral at the apex of Scarpa's triangle. In order to expose the artery in this situation, an incision between three and four inches long should be made in the course of the vessel, the patient lying in the recumbent position, with the limb slightly flexed and abducted, and rotated outward. A large vein is frequently met with, passing in the course of the artery to join the internal saphenous vein; this must be avoided, and the fascia lata having been cautiously divided and the Sartorius exposed, that muscle must be drawn outward in order to expose fully the sheath of the vessels. The finger being introduced into the wound and the pulsation of the artery felt, the sheath should be opened on the outer side of the vessel to a sufficient extent to allow of the introduction of the ligature, but no farther; otherwise the nutrition of the coats of the vessel may be interfered with, or muscular branches which arise from the vessel at irregular intervals may be divided. In this part of the operation the long saphenous nerve and the nerve to the Vastus internus, which is in close relation with the sheath, should be avoided. The aneurism needle must be carefully introduced and kept close to the artery, to avoid the femoral vein, which lies behind the vessel in this part of its course.

To expose the artery in Hunter's canal, an incision should be made between three and four inches in length, a finger's breadth internal to the line of the artery, in the middle of the thigh—*i. e.*, midway between the groin and the knee. The integument is first divided. The fascia lata having been divided, and the outer border of the Sartorius muscle exposed, it should be drawn inward, when the strong fascia which is stretched across from the Adductors to the Vastus internus will be exposed, and must be freely divided; the sheath of the vessels is now seen, and must be opened, and the artery secured by passing the aneurism needle between the vein and artery in the direction from without inward. The femoral vein in this situation lies on the outer side of the artery and the long saphenous nerve on the anterior and outer side of the artery.

It has been seen that the femoral artery occasionally divides into two trunks below the origin of the profunda. If in the operation for tying the femoral two vessels are met with, the surgeon should alternately compress each, in order to ascertain which vessel is connected with the aneurismal tumor or with the bleeding from the wound, and that one only should be tied which controls the pulsation or hemorrhage. If, however, it is necessary to compress both vessels before the circulation in the tumor is controlled, both should be tied, as it would be probable that they became reunited, as in the instances referred to above.

In wounds of the femoral artery the question of the mode of treatment is of considerable importance. If the wound in the superficial structures is a large one, the injured vessel must be exposed and tied; but if the wound is a punctured one and the bleeding has ceased, the question will arise whether to cut down upon the artery or to trust to pressure. Mr. Cripps advises that if the wound is in the "upper part of the thigh—that is to say, in a position where the femoral artery is comparatively superficial—the surgeon may enlarge the opening with a good prospect of finding the wounded vessel without an extensive or prolonged operation. If the wound be in the lower half of the thigh, owing to the greater depth of the artery and the possibility of its being the popliteal that is wounded, the search is rendered a far more severe and hazardous operation, and it should not be undertaken until a thorough trial of pressure has proved ineffectual."

Great care and attention are necessary for the successful application of pressure. The limb should be carefully bandaged from the foot upward to the wound, which is not covered, and then onward to the groin. The wound is then dusted with iodoform or boracic powder and a conical pad applied over the wound. Rollers the thickness of the index finger are then placed along the course of the vessel above and below the wound, and the whole carefully bandaged to a back splint with a foot piece.

Collateral Circulation.—After ligation of the femoral artery, the main channels for carrying on the circulation are the anastomoses between (1) the gluteal and sciatic branches of the internal iliac with the internal and external circumflex and superior perforating branches of the profunda femoris; (2) the obturator branch of the internal iliac with the internal circumflex of the profunda; (3) the internal pudic of the internal iliac with the superficial and deep external pudic of the common femoral; (4) the deep circumflex iliac of the external iliac with the external circumflex of the profunda and the superficial circumflex iliac of the femoral; and (5) the sciatic and comes nervi ischiadici of the internal iliac with the perforating branches of the profunda.

Branches (Figs. 481 and 482).—The branches of the femoral artery are:

Superficial epigastric.
Superficial circumflex iliac.
Superficial external pudic.
Deep external pudic.

	Muscular.
	External circumflex.
Profunda femoris	Internal circumflex.
	Three perforating.

Anastomotica magna.

The **superficial epigastric** (*a. epigastrica superficialis*) arises from the femoral about half an inch below Poupart's ligament, and, passing through the saphenous opening in the fascia lata, ascends on the abdomen in the superficial fascia covering the External oblique muscle, nearly as high as the umbilicus. It distributes branches to the superficial inguinal nodes, the superficial fascia, and the integument, anastomosing with branches of the deep epigastric.

The **superficial circumflex iliac** (*a. circumflexa ilium superficialis*), the smallest of the cutaneous branches, arises close to the preceding, and, piercing the fascia lata, runs outward, parallel with Poupart's ligament, as far as the crest of the ilium, dividing into branches which supply the integument of the groin, the superficial fascia, and the superficial inguinal lymph nodes, anastomosing with the deep circumflex iliac and with the gluteal and external circumflex arteries.

The **superficial external pudic** (*a. pudenda externa superficialis*) arises from the inner side of the femoral artery, close to the preceding vessels, and, after passing through the saphenous opening, courses inward, across the spermatic cord or round ligament, to be distributed to the integument on the lower part of the abdomen, the penis and scrotum in the male, and the labium majus in the female, anastomosing with branches of the internal pudic.

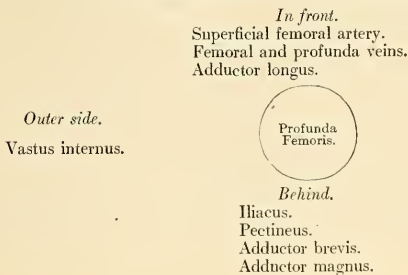
The **deep external pudic** (*a. pudenda externa profunda*), more deeply seated than the preceding, passes inward across the Pectineus and Adductor longus muscles, covered by the fascia lata, which it pierces at the inner border of the thigh, its branches being distributed, in the male, to the integument of the scrotum and perineum; and in the female to the labium majus, anastomosing with branches of the superficial perineal artery.

Muscular branches (*rami musculares*) are supplied by the femoral to the Sartorius, Vastus internus, and Adductors.

The **deep femoral**, or the **profunda femoris** (*a. profunda femoris*) (Fig. 481 and 482), is a large vessel arising from the outer and back part of the femoral artery, from one to two inches below Poupart's ligament. It at first lies on the outer side of the superficial femoral, and then passes behind it and the femoral vein to the inner side of the femur, and, passing downward beneath the Adductor longus, terminates at the lower third of the thigh in a small branch which pierces the Adductor magnus (and from this circumstance is sometimes called the **fourth perforating artery**), and is distributed to the Flexor muscles on the back of the thigh, anastomosing with branches of the popliteal and inferior perforating arteries. The deep femoral supplies all the tissues on the back and outer side of the thigh not supplied by the sciatic and gluteal arteries.

Relations.—*Behind*, it lies first upon the Iliacus, and then on the Pectineus, Adductor brevis, and Adductor magnus muscles. *In front*, it is separated from the superficial femoral artery, above by the femoral and profunda veins, and below by the Adductor longus. On its *outer side* the origin of the Vastus internus separates it from the femur.

PLAN OF THE RELATIONS OF THE PROFUNDA ARTERY.



Peculiarities of Origin of the Profunda.—This vessel occasionally arises from the inner side, and, more rarely, from the back of the common trunk; but the more important peculiarity, from a surgical point of view, is that which relates to the height at which the vessel arises from the femoral. In three-fourths of a large number of cases it arose between one to two inches below Poupart's ligament; in a few cases the distance was less than an inch; more rarely, opposite the ligament; and in one case, above Poupart's ligament, from the external iliac. Occasionally, the distance between the origin of the vessel and Poupart's ligament exceeds two inches, and in one case it was found to be as much as four inches.

Branches.—The profunda gives off the following-named branches:

External circumflex.	Four perforating.
Internal circumflex.	Muscular.

The **external circumflex artery** (*a. circumflexa femoris lateralis*) supplies the muscles on the front of the thigh. It *arises* from the outer side of the profunda, passes horizontally outward, between the divisions of the femoral nerve and behind the Sartorius and Rectus muscles, and divides into three sets of branches—**ascending, transverse, and descending.**

The **ascending branch** (*ramus ascendens*) passes upward, beneath the Tensor fasciæ femoris muscle, to the outer side of the hip, anastomosing with the terminal branches of the gluteal and deep circumflex iliac arteries. It sends out muscular branches.

The **descending branch** (*ramus descendens*) passes downward, behind the Rectus, upon the Vasti muscles, to which its branches are distributed, one or two passing beneath the Vastus externus as far as the knee, anastomosing with the superior articular branches of the popliteal artery. These are accompanied by the branch of the femoral nerve to the Vastus externus.

The **transverse branch**, the smallest, passes outward over the Crureus, pierces the Vastus externus, and winds around the femur to its back part, just below the great trochanter, anastomosing at the back of the thigh with the internal circumflex, sciatic, and superior perforating arteries.

The **internal circumflex artery** (*a. circumflexa femoris medialis*), smaller than the external, *arises* from the inner and back part of the profunda, and winds around the inner side of the femur, between the Pectineus and Psoas muscles. On reaching the upper border of the Adductor brevis it gives off two **muscular branches**, one of which passes inward to be distributed to the Adductor muscles, the Gracilis, and Obturator externus, anastomosing with the obturator artery; the other descends, and passes beneath the Adductor brevis, to supply it and the great Adductor; while the continuation of the vessel passes backward and divides into an ascending and a transverse branch (Fig. 386). The **ascending branch** (*ramus profundus*) passes obliquely upward upon the tendon of the Obturator externus and under cover of the Quadratus femoris toward the digital fossa, where it anastomoses with twigs from the gluteal and sciatic arteries. The **transverse branch** (*ramus superficialis*), larger than the ascending, appears between the Quadratus femoris and upper border of the Adductor magnus, anastomosing with the sciatic, external circumflex, and superior perforating arteries, the **crucial anastomosis**. Opposite the hip-joint the artery gives off an **articular vessel** (*ramus acetabuli*), which enters the joint beneath the transverse ligament; and, after supplying the adipose tissue, passes along the round ligament to the head of the bone.

The **perforating arteries** (Figs. 481 and 482), usually three in number, are so called from their perforating the tendon of the Adductor magnus muscle to reach the back of the thigh. They pass backward close to the linea aspera of the femur, under cover of small tendinous arches in the Adductor magnus. The **first** is given off above the Adductor brevis, the **second** in front of that muscle, and the **third** immediately below it

The **first perforating artery** (*a. perforans prima*) passes backward between the Pectineus and Adductor brevis (sometimes perforates the latter); it then pierces the Adductor magnus close to the linea aspera. It gives off branches which supply the Adductor brevis, the Adductor magnus, the Biceps, the Gluteus maximus muscles, and anastomoses with the sciatic, internal and external circumflex, and second perforating arteries.

The **second perforating artery** (*a. perforans secunda*), larger than the first, pierces the tendons of the Adductor brevis and Adductor magnus muscles, and divides into ascending and descending branches, which supply the Flexor muscles of the thigh, anastomosing with the first and third perforating arteries. The second artery frequently arises in common with the first. The **nutrient artery of the femur** (*a. nutritia femoris*) is usually given off from this branch.

The **third perforating artery** (*a. perforans tertia*) is given off below the Adductor brevis; it pierces the Adductor magnus, and divides into branches which supply the Flexor muscles of the thigh; anastomosing above with the higher perforating arteries, and below with the terminal branches of the profunda and the muscular branches of the popliteal.

A **fourth perforating artery** is represented by the termination of the profunda femoris artery.

Numerous **muscular branches** arise from the profunda; some of these end in the Adductor muscles, others pierce the Adductor magnus, give branches to the Hamstring muscles, and anastomose with the internal circumflex artery and with the upper muscular branches of the popliteal.

The **anastomotica magna** (*a. genu suprema*) (Figs. 481 and 482) arises from the femoral artery just before it passes through the tendinous opening in the Adductor magnus muscle, and immediately divides into a **superficial** and **deep** branch.

The **superficial branch** (*ramus saphenus*) pierces the aponeurotic covering of Hunter's canal, and accompanies the long saphenous nerve to the inner side of the thigh. It passes between the Sartorius and Gracilis muscles, and, piercing the fascia lata, is distributed to the integument of the upper and inner part of the leg, anastomosing with the inferior internal articular artery.

The **deep branch** (*ramus muscularticularis*) descends in the substance of the Vastus internus, lying in front of the tendon of the Adductor magnus, to the inner side of the knee, where it anastomoses with the superior internal articular artery and the anterior recurrent branch of the anterior tibial. A branch from this vessel crosses outward above the articular surface of the femur, forming an anastomotic arch with the superior external articular artery, and supplies branches to the knee-joint.

THE POPLITEAL ARTERY (A. POPLITEA) (Figs. 477 and 481).

The popliteal artery commences at the termination of the femoral at the opening in the Adductor magnus, and, passing obliquely downward and outward behind the knee-joint to the lower border of the Popliteus muscle, divides into the **anterior** and **posterior tibial arteries**. A portion of the artery lies in the popliteal space; but above and below, to a considerable extent, it is covered by the muscles which form the boundaries of the space, and is therefore beyond the confines of the space.

The Popliteal Space (Fig. 483).

Dissection.—A vertical incision about eight inches in length should be made along the back part of the knee-joint, connected above and below by a transverse incision from the inner to the outer side of the limb. The flaps of integument included between these incisions should be reflected in the direction shown in Fig. 383, p. 518.

Boundaries.—The **popliteal space** is a lozenge-shaped space, widest at the back part of the knee-joint, and deepest above the articular end of the femur. It is bounded *externally, above the joint*, by the Biceps, and *below the joint* by the Plantaris and external head of the Gastrocnemius. *Internally, above the joint*, by the Semimembranosus, Semitendinosus, Gracilis, and Sartorius; *below the joint*, by the inner head of the Gastrocnemius.

Above, it is limited by the apposition of the inner and outer Hamstring muscles; *below*, by the junction of the two heads of the Gastrocnemius. The floor is formed by the lower part of the posterior surface of the shaft of the femur, the posterior ligament of the knee-joint, the upper end of the tibia, and the fascia covering the Popliteus muscle, and the space is covered in by the fascia lata.

Contents.—It contains the popliteal vessels and their branches, together with the termination of the external saphenous vein, the internal and external popliteal nerves and some of their branches, the lower extremity of the small sciatic nerve, the articular branch from the obturator nerve, a few small lymph nodes, and a considerable quantity of loose adipose tissue.

Position of Contained Parts.—The internal popliteal nerve descends in the middle line of the space lying superficial and crossing the artery from without inward. The external popliteal nerve descends on the outer side of the upper part of the space, lying close to the tendon of the Biceps muscle. More deeply at the bottom of the space are the popliteal vessels, the vein lying superficial to the artery, to which it is closely united by dense areolar tissue; it is a thick-walled vessel, and lies at first to the outer side of the artery, and then crosses it to gain the inner side below; sometimes the vein is double, the artery lying between the two venae comites, which are usually connected by short transverse branches. More deeply and, at its upper part, close to the surface of the bone is the popliteal artery, and passing off from it at right angles are its articular branches. The articular branch from the obturator nerve descends upon the popliteal artery to supply the knee, and occasionally there is found deep in the space an articular filament from the great sciatic nerve.

The popliteal lymph nodes, four or five in number, are found surrounding the artery; one usually lies superficial to the vessel;

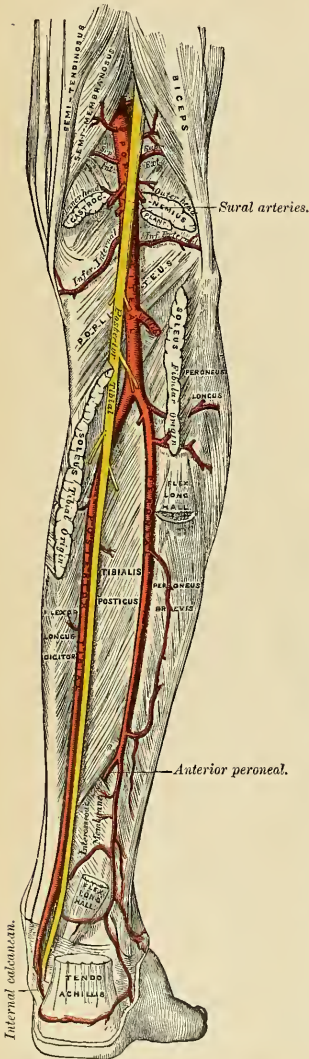



FIG. 483.—The popliteal, posterior tibial, and peroneal arteries. The external popliteal (or peroneal) nerve has been removed. (See Fig. 776.)

another is situated between it and the bone, and the rest are placed on either side of it.

The **popliteal artery**, in its course downward from the aperture in the Adductor magnus to the lower border of the Popliteus muscle, rests first on the inner surface of the femur, and is then separated by a little fat from the hollowed popliteal surface of the bone; in the middle of its course it rests on the posterior ligament of the knee-joint, and below on the fascia covering the Popliteus muscle. *Superficially*, it is covered above by the Semimembranosus; in the middle of its course, by a quantity of fat, which separates it from the deep fascia and integument; and below it is overlapped by the Gastrocnemius, Plantaris, and Soleus muscles, the popliteal vein, and the internal popliteal nerve. The popliteal vein, which is intimately attached to the artery, lies superficial and external to it above; it then crosses it and lies to its inner side. The internal popliteal nerve is still more superficial and external above, but below the joint it crosses the artery and lies on its inner side. *Laterally*, the artery is bounded by the muscles which are situated on either side of the popliteal space.

PLAN OF THE RELATIONS OF THE POPLITEAL ARTERY.



Peculiarities in Point of Division.—Occasionally the popliteal artery divides prematurely into its terminal branches; this unusual division occurs most frequently opposite the knee-joint. The anterior tibial under these circumstances may pass in front of the Popliteus muscle.

Unusual Branches.—The artery sometimes divides into the anterior tibial and peroneal, the posterior tibial being wanting or very small. Occasionally the popliteal is found to divide into three branches, the anterior and posterior tibial and peroneal.

Surface Marking.—The course of the upper part of the popliteal artery is indicated by a line drawn from the outer border of the Semimembranosus muscle at the junction of the middle and lower third of the thigh obliquely downward to the middle of the popliteal space, exactly behind the knee-joint. From this point it passes vertically downward to the level of a line drawn through the lower part of the tubercle of the tibia.

Applied Anatomy.—The popliteal artery is not infrequently the seat of injury. It may be torn by direct violence, as by the passage of a cart-wheel over the knee or by hyperextension of the knee; and in the dead body, at all events, the middle and internal coats may be ruptured by extreme flexion. It may also be lacerated by fracture of the lower part of the shaft of the femur or by antero-posterior dislocation of the knee-joint. It has been torn in breaking down adhesions in cases of fibrous ankylosis of the knee, and is in danger of being wounded, and, in fact, has been wounded, in performing Macewen's operation for osteotomy of the lower end of the femur for genu valgum. In addition, Spencer records a case in which the popliteal artery was wounded from in front by a stab just below the knee, the knife passing through the interosseous space.

The popliteal artery is more frequently the seat of aneurism than is any other artery in the body, with the exception of the thoracic aorta. This is due, no doubt, in a great measure, to the amount of movement to which it is subjected, and to the fact that it is supported by loose and lax tissue only, and not by muscles, as is the case with most arteries.

Ligation of the popliteal artery is required in cases of wound of that vessel, but for aneurism of the posterior tibial it is preferable to tie the superficial femoral. The popliteal may be tied in the upper or lower part of its course; but in the middle of its course the operation is attended with considerable difficulty, from the great depth of the artery and from the extreme degree of tension of the lateral boundaries of the space.

In order to expose the vessel in the upper part of its course, the patient should be placed in the supine position, with the knee flexed and the thigh rotated outward, so that it rests on its outer surface; an incision three inches in length, beginning at the junction of the middle and lower third of the thigh, is to be made parallel to and immediately behind the tendon of the Adductor magnus, and the skin, superficial and deep fascia divided. The tendon of the muscle is thus exposed, and is to be drawn forward and the Hamstring tendons backward. A quantity of fatty tissue will now be exposed, in which the artery will be felt pulsating. This is to be separated with the point of a director until the artery is exposed. The vein and nerve will not be seen, as they lie to the outer side of the artery. The sheath is to be opened and the aneurism needle passed from before backward, keeping its point close to the artery for fear of injuring the vein. The only structure to avoid is the long saphenous vein in the superficial incision. The upper part of the popliteal artery may also be tied by an incision on the back of the limb, along the outer margin of the Semimembranosus, but the operation is a more difficult one, as the internal popliteal nerve and the popliteal vein are first exposed, and great care has to be exercised in separating them from the artery.

To expose the vessel in the lower part of its course, where the artery lies between the two heads of the Gastrocnemius, the patient should be placed in the prone position with the limb extended. An incision should then be made through the integument in the middle line, commencing opposite the bend of the knee-joint, care being taken to avoid the external saphenous vein and nerve. After dividing the deep fascia and separating some dense cellular membrane, the artery, vein, and nerve will be exposed, descending between the two heads of the Gastrocnemius. Some muscular branches of the popliteal should be avoided if possible, or, if divided, tied immediately. The leg being now flexed, in order the more effectually to separate the two heads of the Gastrocnemius, the nerve should be drawn inward and the vein outward, and the aneurism needle passed between the artery and vein from without inward.

Branches.—The branches of the popliteal artery are:

Muscular	{ Superior.	Superior external articular.
	{ Inferior or sural.	Azygos articular.
Cutaneous.		Inferior internal articular.
Superior internal articular.		Inferior external articular.

The **superior muscular branches**, two or three in number, *arise* from the upper part of the popliteal artery, and are distributed to the lower part of the Adductor magnus and Flexor muscles of the thigh, anastomosing with the fourth perforating branch of the profunda.

The **inferior muscular** or **sural** (*aa. surales*) are two large branches which are distributed to the two heads of the Gastrocnemius and to the Plantaris muscle. They *arise* from the popliteal artery opposite the knee-joint.

The **cutaneous branches** *arise* separately from the popliteal artery or from some of its branches; they descend between the two heads of the Gastrocnemius muscle, and, piercing the deep fascia, are distributed to the integument of the calf. One branch usually accompanies the short, or external, saphenous vein, the **superficial sural artery**.

The **superior articular arteries**, two in number, *arise* one on each side of the popliteal, and wind around the femur immediately above its condyles to the front of the knee-joint. The **internal branch** (*a. genu superior medialis*) winds inward beneath the Hamstring muscles, to which it supplies branches, above the inner head of the Gastrocnemius, and, passing beneath the tendon of the Adductor magnus, divides into two branches, one of which supplies the Vastus internus,

anastomosing with the anastomotica magna and inferior internal articular; the other ramifies close to the surface of the femur, supplying it and the knee-joint, and anastomosing with the superior external articular artery. This branch is frequently of small size, a condition which is associated with an increase in the size of the anastomotica magna. The **external branch** (*a. genu superior lateralis*) passes above the outer condyle, beneath the tendon of the Biceps, and divides into a superficial and deep branch; the superficial branch supplies the Vastus externus, and anastomoses with the descending branch of the external circumflex and the inferior external articular arteries; the deep branch supplies the lower part of the femur and knee-joint, and forms an anastomotic arch across the bone with the anastomotica magna and the inferior internal articular arteries.

The **azygos articular** (*a. genu media*) is a small branch arising from the popliteal artery opposite the bend of the knee-joint. It pierces the posterior ligament, and supplies the ligaments and synovial membrane in the interior of the articulation.

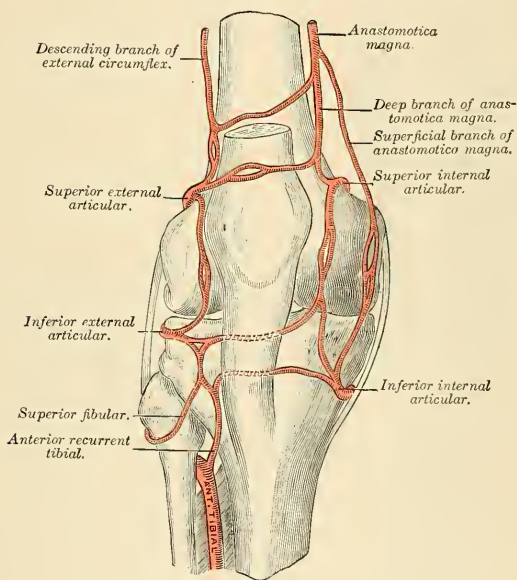
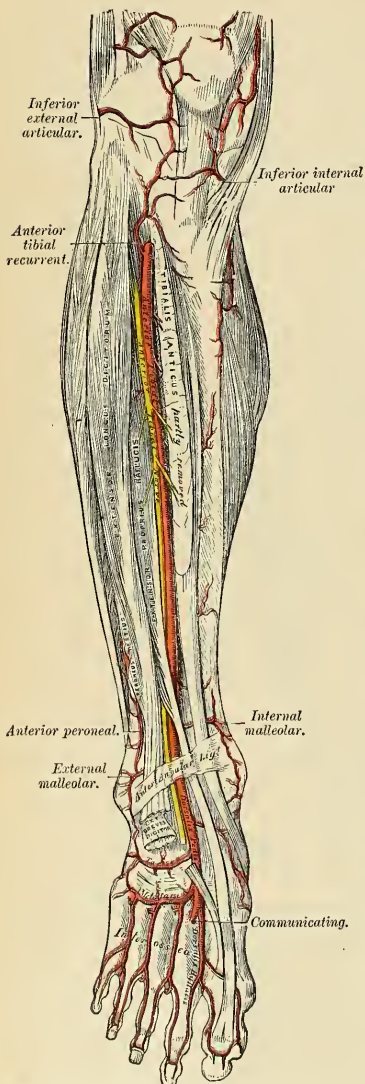


FIG. 484.—Circumpatellar anastomosis.

The **inferior articular arteries**, two in number, arise from the popliteal beneath the Gastrocnemius, and wind around the head of the tibia below the joint. The **internal branch** (*a. genu inferior medialis*) first descends along the upper margin of the Popliteus muscle, to which it gives branches; it then passes below the inner tuberosity, beneath the internal lateral ligament, at the anterior border of which it ascends to the front and inner side of the joint, to supply the head of the tibia and the articulation of the knee, anastomosing with the inferior external articular and superior internal articular arteries. The **external branch** (*a. genu inferior lateralis*) passes outward above the head of the fibula, to the front of the knee-joint, passing in its course beneath the outer head of the Gastrocnemius, the

external lateral ligament, and the tendon of the Biceps muscle, and divides into branches which anastomose with the inferior internal articular artery, the superior external articular artery, and the anterior recurrent branch of the anterior tibial.



Circumpatellar Anastomosis. — Around and above the patella, and on the contiguous ends of the femur and tibia, is a large network of vessels, forming a superficial and a deep plexus. The superficial plexus is situated between the fascia and skin around about the patella; the deep plexus, which forms a close network of vessels, lies on the surface of the lower end of the femur and upper end of the tibia around their articular surfaces, and sends numerous offshoots into the interior of the joint. The arteries from which this plexus is formed are the two internal and two external articular branches of the popliteal, the anastomotica magna, the terminal branch of the profunda, the descending branch from the external circumflex, and the anterior recurrent branch of the anterior tibial.

The Anterior Tibial Artery (A. Tibialis Anterior) (Fig. 485).

The anterior tibial artery commences at the bifurcation of the popliteal at the lower border of the Popliteus muscle, passes forward between the two heads of the Tibialis posticus, and through the large oval aperture above the upper border of the interosseous membrane to the deep part of the front of the leg; it here lies close to the inner side of the neck of the fibula; it then descends on the anterior surface of the interosseous membrane, gradually approaching the tibia; and at the lower part of the leg lies on this bone, and then on the anterior ligament of the ankle to the bend of the ankle-joint, where it lies more superficially, and becomes the dorsalis pedis.

Relations.—In the upper two-thirds of its extent it rests upon the interosseous membrane, to which it is connected by delicate fibrous arches thrown across it; in the lower third, upon the front of the tibia and

FIG. 485.—Applied anatomy of the anterior tibial and dorsalis pedis arteries.

the anterior ligament of the ankle-joint. In the upper third of its course it lies between the Tibialis anticus and Extensor longus digitorum; in the middle third, between the Tibialis anticus and Extensor proprius hallucis. At the bend of the ankle it is crossed by the tendon of the Extensor proprius hallucis, and lies between it and the innermost tendon of the Extensor longus digitorum. It is covered, in the upper two-thirds of its course, by the muscles which lie on either side of it and by the deep fascia; in the lower third, by the integument anterior annular ligament and fascia.

The anterior tibial artery is accompanied by two veins, *venae comites*, which lie one on each side of the artery; the anterior tibial nerve, coursing around the outer side of the neck of the fibula, comes into relation with the outer side of the artery shortly after it has passed through the opening in the interosseous membrane; about the middle of the leg it is placed superficial to it; at the lower part of the artery the nerve is generally again on the outer side.

PLAN OF THE RELATIONS OF THE ANTERIOR TIBIAL ARTERY.

In front.

Integument, superficial and deep fasciae.
Anterior tibial nerve.
Tibialis anticus (overlaps it in the upper part of the leg).
Extensor longus digitorum } (overlap it slightly).
Extensor proprius hallucis }
Anterior annular ligament.

Inner side.

Tibialis anticus.
Extensor proprius hallucis
(crosses it at its lower
part).



Outer side.

Anterior tibial nerve.
Extensor longus digitorum.
Extensor proprius hallucis.

Behind.

Interosseous membrane.
Tibia.
Anterior ligament of ankle-joint.

Peculiarities in Size.—This vessel may be very small, may be deficient to a greater or less extent, or may be entirely wanting, its place being supplied by perforating branches from the posterior tibial or by the anterior division of the peroneal artery.

Course.—The artery occasionally deviates in its course toward the fibular side of the leg, regaining its usual position beneath the annular ligament at the front of the ankle. In two instances the vessel has been found to approach the surface in the middle of the leg, being covered merely by the integument and fascia below that point.

Surface Marking.—Draw a line from the inner side of the head of the fibula to midway between the two malleoli. In this line take a point one inch and a quarter below the head of the fibula, and the portion of the line below this point will mark the course of the artery.

Applied Anatomy.—The anterior tibial artery may be tied in the upper or lower part of the leg. In the upper part the operation is attended with great difficulty, on account of the depth of the vessel from the surface. An incision, about four inches in length, should be made through the integument, midway between the tubercle of the tibia and the outer margin of the fibula, and the deep fascia exposed. The wound must now be carefully dried, its edges retracted, and the white line separating the Tibialis anticus from the Extensor longus digitorum sought for. When this has been clearly defined, the deep fascia is to be divided in this line, and the Tibialis anticus separated from the adjacent muscles with the handle of the scalpel or a director until the interosseous membrane is reached. The foot is to be flexed in order to relax the muscles, and upon drawing them apart the artery will be found lying on the interosseous membrane with the nerve on its outer side or on top of the artery. The nerve should be drawn outward, and the *venae comites* separated from the artery and the needle passed around it.

To tie the vessel in the lower third of the leg above the ankle-joint an incision about three inches in length should be made through the integument between the tendons of the Tibialis anticus and Extensor proprius hallucis muscles, the deep fascia being divided to the same extent. The tendon on either side should be held aside, when the vessel will be seen lying upon the tibia, with the nerve on the outer side and one of the *venae comites* on either side.

Branches.—The branches of the anterior tibial artery are:

Posterior recurrent tibial.
Superior fibular.
Anterior recurrent tibial.

Muscular.
Internal malleolar.
External malleolar.

The **posterior recurrent tibial** (*a. recurrens tibialis posterior*) is not a constant branch, and is given off from the anterior tibial before that vessel passes through the interosseous space. It ascends beneath the Popliteus muscle, which it supplies, and anastomoses with the lower articular branches of the popliteal artery, giving an offshoot to the superior tibiofibular joint.

The **superior fibular** is sometimes given off from the anterior tibial, sometimes from the posterior tibial. It passes outward, around the neck of the fibula, through the Soleus, which it supplies, and ends in the substance of the Peroneus longus.

The **anterior recurrent tibial** (*a. recurrens tibialis anterior*) arises from the anterior tibial as soon as that vessel has passed through the interosseous space; it ascends in the Tibialis anticus muscle, and ramifies on the front and sides of the knee-joint, anastomosing with the articular branches of the popliteal, with the anastomotica magna, and the external articular branches of the popliteal assisting in the formation of the circumpatellar plexus.

The **muscular branches** are numerous; they are distributed to the muscles which lie on each side of the vessel, some **cutaneous branches** piercing the deep fascia to supply the integument, others passing through the interosseous membrane, and anastomosing with branches of the posterior tibial and peroneal arteries.

The **internal malleolar branch** (*a. malleolaris anterior medialis*) arises about two inches above the articulation, and passes beneath the tendons of the Extensor proprius hallucis and Tibialis anticus to the inner ankle, upon which it ramifies, anastomosing with branches of the posterior tibial and internal plantar arteries and with the internal calcanean from the posterior tibial.

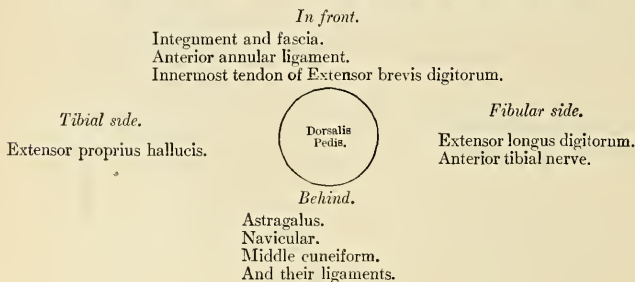
The **external malleolar branch** (*a. malleolaris anterior lateralis*) passes beneath the tendons of the Extensor longus digitorum and Peroneus tertius, and supplies the outer ankle, anastomosing with the anterior peroneal artery and with ascending branches from the tarsal branch of the dorsalis pedis.

The Dorsalis Pedis Artery (A. Dorsalis Pedis) (Figs. 485, 486).

The **dorsalis pedis**, the continuation of the anterior tibial, passes forward from the ankle along the tibial side of the foot to the back part of the first intermetatarsal space, where it divides into two branches, the **dorsalis hallucis** and **communicating**.

Relations.—This vessel, in its course forward, rests upon the astragalus, navicular, and middle cuneiform bones and the ligaments connecting them, being covered by the integument and fascia, anterior annular ligament, and crossed near its termination by the innermost tendon of the Extensor brevis digitorum. On its *tibial side* is the tendon of the Extensor proprius hallucis; on its *fibular side*, the innermost tendon of the Extensor longus digitorum, and the termination of the anterior tibial nerve. The nerve is, however, quite as often upon the tibial side of the artery. The artery is accompanied by two veins.

PLAN OF THE RELATIONS OF THE DORSALIS PEDIS ARTERY.



Peculiarities in Size.—The dorsal artery of the foot may be larger than usual, to compensate for a deficient plantar artery; or it may be deficient in its terminal branches to the toes, which are then derived from the internal plantar; or its place may be supplied altogether by a large anterior peroneal artery.

Position.—This artery frequently curves outward, lying external to the line between the middle of the ankle and the back part of the first interosseous space.

Surface Marking.—The dorsalis pedis artery is indicated on the surface of the dorsum of the foot by a line drawn from the centre of the space between the two malleoli to the back of the first intermetatarsal space.

Applied Anatomy.—This artery may be tied, by making an incision through the integument between two and three inches in length, on the fibular side of the tendon of the Extensor proprius hallucis, in the interval between it and the inner border of the short Extensor muscle. The incision should not extend farther forward than the back part of the first intermetatarsal space, as the artery divides in that situation. The deep fascia being divided to the same extent, the artery will be exposed, the nerve lying upon its outer side.

Branches.—The branches of the dorsalis pedis are:

Cutaneous.

Tarsal.

Metatarsal — Interosseous.

Dorsalis hallucis.

Communicating.

Cutaneous branches go to the skin of the dorsum and inner surface of the foot.

The **tarsal artery** (*a. tarsea lateralis*) arises from the dorsalis pedis, as that vessel crosses the navicular bone; it passes in an arched direction outward, lying upon the tarsal bones, and covered by the Extensor brevis digitorum; it supplies that muscle and the articulations of the tarsus, and anastomoses with branches from the metatarsal, external malleolar, peroneal, and external plantar arteries.

The **metatarsal** (*a. arcuata*) arises a little anterior to the preceding; it passes outward to the outer part of the foot, over the bases of the metatarsal bones, beneath the tendons of the short Extensor, its direction being influenced by its point of origin; and it anastomoses with the tarsal and external plantar arteries. This vessel gives off three branches, the **dorsal interosseous arteries** (*aa. metatarsae dorsales*), which pass forward upon the three outer Dorsal interossei muscles, and, in the clefts between the toes, divide into two dorsal collateral branches for the adjoining toes (*aa. digitales dorsales*). At the back part of each interosseous space these vessels receive the posterior perforating branches from the plantar arch, and at the fore part of each interosseous space they are joined by

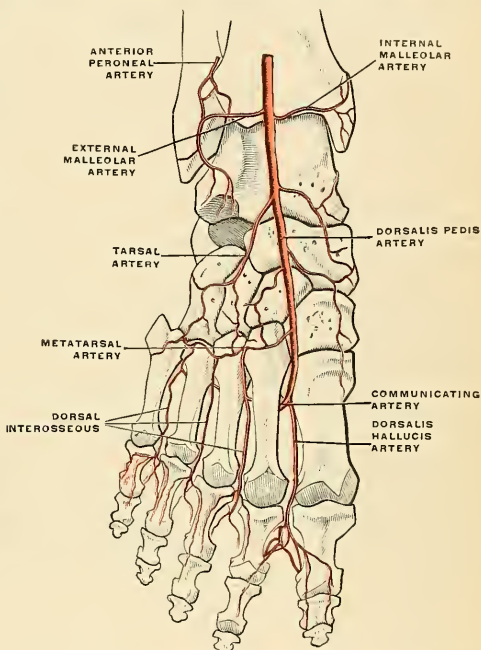


FIG. 486.—Diagram of the arteries of the dorsal surface of the foot. (Poirier and Charpy.)

the anterior perforating branches from the digital arteries. The outermost interosseous artery gives off a branch which supplies the outer side of the little toe.

The **dorsalis hallucis**, or the **first dorsal interosseous** (*a. dorsalis hallucis*), is one of the terminal branches of the dorsalis pedis. It runs forward along the outer border of the first metatarsal bone, and at the cleft between the first and second toes divides into two branches, one of which passes inward, beneath the tendon of the Extensor proprius hallucis, and is distributed to the inner border of the great toe; the outer branch bifurcates, to supply the adjoining sides of the great and second toes.

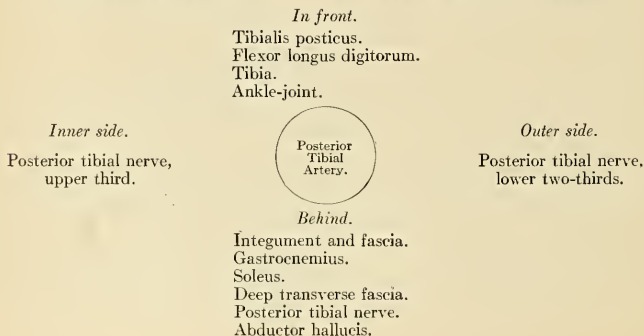
The **communicating artery** (*ramus plantaris profundus*), the other terminal branch of the dorsalis pedis, dips down into the sole of the foot, between the two heads of the First dorsal interosseous muscle, and anastomoses with the termination of the external plantar artery, to complete the plantar arch. It here gives off its plantar digital branch, which is named the **arteria magna hallucis**, or the **princeps hallucis**. This artery passes forward along the first interosseous space, and, after sending a branch along the inner side of the great toe, bifurcates for the supply of the adjacent sides of the great and second toes.

The Posterior Tibial Artery (A. Tibialis Posterior) (Fig. 483).

The **posterior tibial** is an artery of large size, which extends obliquely downward from the lower border of the Popliteus muscle, along the tibial side of the leg, to the fossa between the inner malleolus and the heel, where it divides beneath the origin of the Abductor hallucis, on a level with a line drawn from the point of the internal malleolus to the centre of the convexity of the heel, into the **internal** and **external plantar arteries**. At its origin it lies opposite the interval between the tibia and fibula; as it descends, it approaches the inner side of the leg, lying behind the tibia, and, in the lower part of its course, is situated midway between the inner malleolus and the tuberosity of the os calcis.

Relations.—The posterior tibial artery lies successively upon the Tibialis posticus, the Flexor longus digitorum, the tibia, and the back part of the ankle-joint. It is covered by the deep transverse fascia, which separates it above from the Gastrocnemius and Soleus muscles; at its termination it is covered by the Abductor hallucis muscle. In the lower third, where it is more superficial, it is covered only by the integument and fascia, and runs parallel with the inner border of the tendo Achillis. It is accompanied by two veins and by the posterior tibial nerve, which lies at first to the inner side of the artery, but soon crosses it, and is, in the greater part of its course, on its outer side.

PLAN OF THE RELATIONS OF THE POSTERIOR TIBIAL ARTERY.



Behind the inner malleolus the tendons and bloodvessels are arranged, under cover of the internal annular ligament, in the following order, from within outward: First, the tendons of the Tibialis posticus and Flexor longus digitorum, lying in the same groove, behind the inner malleolus, the former being the more internal. External to these is the posterior tibial artery, having a vein on either side, and, still more externally, the posterior tibial nerve. About half an inch nearer the heel is the tendon of the Flexor longus hallucis.

Peculiarities in Size.—The posterior tibial is not infrequently smaller than usual, or absent, its place being supplied by a large peroneal artery which passes inward at the lower end of the tibia, and either joins the small tibial artery or continues alone to the sole of the foot.

Surface Marking.—The course of the posterior tibial artery is indicated by a line drawn from a point one inch below the centre of the popliteal space to midway between the tip of the internal malleolus and the centre of the convexity of the heel.

Applied Anatomy.—The application of a ligature to the posterior tibial may be required in cases of wound of the sole of the foot attended with great hemorrhage, when the vessel should be tied at the inner ankle. In cases of wound of the posterior tibial it will be necessary to enlarge the opening so as to expose the vessel at the wounded point, excepting where the vessel is injured by a punctured wound from the front of the leg. In cases of aneurism from wound of the artery low down, the vessel should be tied in the middle of the leg. But in aneurism of the posterior tibial high up it would be better to tie the femoral artery.

To tie the posterior tibial artery at the ankle, a semilunar incision, convex backward, should be made through the integument, about two inches and a half in length, midway between the heel and the inner ankle or a little nearer the latter. The subcutaneous cellular tissue having been divided, a strong and dense fascia, the internal annular ligament, is exposed. This ligament is continuous above with the deep fascia of the leg, covers the vessels and nerves, and is intimately adherent to the sheaths of the tendons. This having been cautiously divided upon a director, the sheath of the vessels is exposed, and, being opened, the artery is seen with one of the venae comites on each side. The aneurism needle should be passed around the vessel from the heel toward the ankle, in order to avoid the posterior tibial nerve, care being taken at the same time not to include the venae comites.

The vessel may also be tied in the lower third of the leg by making an incision, about three inches in length, parallel with the inner margin of the tendo Achillis. The internal saphenous vein being carefully avoided, the two layers of fascia must be divided upon a director, when the artery is exposed along the outer margin of the Flexor longus digitorum, with one of its venae comites on either side and the nerve lying external to it.

To tie the posterior tibial in the middle of the leg is a very difficult operation, on account of the great depth of the vessel from the surface. The patient being placed in the recumbent position, the injured limb should rest on its outer side, the knee being partially bent and the foot extended, so as to relax the muscles of the calf. An incision about four inches in length should then be made through the integument a finger's breadth behind the inner margin of the tibia, taking care to avoid the internal saphenous vein. The deep fascia having been divided, the margin of the Gastrocnemius is exposed, and must be drawn aside, and the tibial attachment of the Soleus divided, a director being previously passed beneath it. The artery may now be felt pulsating beneath the deep fascia about an inch from the margin of the tibia. The fascia having been divided, and the limb placed in such a position as to relax the muscles of the calf as much as possible, the veins should be separated from the artery, and the aneurism needle passed around the vessel from without inward, so as to avoid wounding the posterior tibial nerve.

Branches.—The branches of the posterior tibial artery are:

Peroneal.
Nutrient.
Muscular.

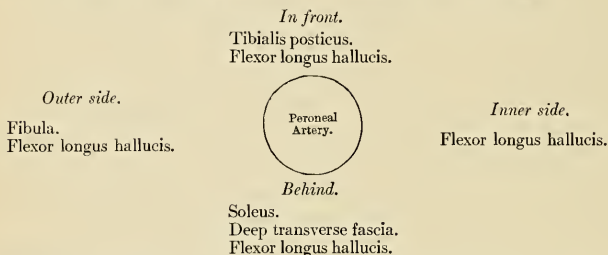
Cutaneous.
Communicating.
Internal calcaneal.

Malleolar cutaneous.

The **peroneal artery** (*a. peronaea*) (Fig. 483) lies, deeply seated, along the back part of the fibular side of the leg. It arises from the posterior tibial about an inch below the lower border of the Popliteus muscle, passes obliquely outward to the fibula, and then descends along the inner border of that bone, contained in a fibrous canal between the Tibialis posticus and the Flexor longus hallucis, or in the substance of the latter muscle to the lower third of the leg, where it gives off the **anterior peroneal**. It then passes across the articulation between the tibia and fibula to the outer side of the os calcis, where it gives off its terminal branches, the **external calcaneal**.

Relations.—This vessel rests at first upon the *Tibialis posticus*, and then, for the greater part of its course, in a fibrous canal between the origins of the *Flexor longus hallucis* and *Tibialis posticus*, covered or surrounded by the fibres of the *Flexor longus hallucis*. It is *covered*, in the *upper part* of its course, by the *Soleus* and deep transverse fascia; *below*, by the *Flexor longus hallucis*.

PLAN OF THE RELATIONS OF THE PERONEAL ARTERY.



Peculiarities in Origin.—The peroneal artery may arise three inches below the Popliteus, or from the posterior tibial high up, or even from the popliteal.

Its size is more frequently increased than diminished; and then it either reinforces the posterior tibial by its junction with it, or altogether takes the place of the posterior tibial in the lower part of the leg and foot, the latter vessel only existing as a short muscular branch. In those rare cases where the peroneal artery is smaller than usual a branch from the posterior tibial supplies its place, and a branch from the anterior tibial compensates for the diminished anterior peroneal artery. In one case the peroneal artery has been found entirely wanting.

The anterior peroneal is sometimes enlarged, and takes the place of the dorsal artery of the foot.

Branches.—The branches of the peroneal are:

Muscular.	Communicating.
Nutrient.	Posterior peroneal.
Anterior peroneal.	External calcaneal.

Muscular Branches.—The peroneal artery in its course gives off branches to the *Soleus*, *Tibialis posticus*, *Flexor longus hallucis*, and *Peronei* muscles.

The **nutrient artery** (*a. nutricia fibulae*) supplies the fibula.

The **anterior peroneal** (*ramus perforans*) (Fig. 486) pierces the interosseous membrane, about two inches above the outer malleolus, to reach the fore part of the leg, and, passing down beneath the *Peroneus tertius* to the outer ankle, ramifies on the front and outer side of the tarsus, anastomosing with the external malleolar and tarsal arteries.

The **communicating** (*ramus communicans*) is given off from the peroneal about an inch from its lower end, and, passing inward, joins the communicating branch of the posterior tibial.

The **posterior peroneal** passes down behind the outer ankle to the back of the external malleolus, to terminate in branches which ramify on the outer surface and back of the os calcis.

The **external calcaneal** (*ramus calcaneus lateralis*) are the terminal branches of the peroneal artery; they pass to the outer side of the heel, and communicate with the external malleolar, and, on the back of the heel, with the internal calcaneal arteries.

Cutaneous branches come from the posterior tibial and supply the skin of the inner side and back of the leg.

The **nutrient artery** of the tibia (*a. nutricia tibiae*) arises from the posterior tibial near its origin, and, after supplying a few muscular branches, enters the

nutrient canal of that bone, which it traverses obliquely from above downward. This is the largest nutrient artery of bone in the body.

The **muscular branches** of the posterior tibial are distributed to the Soleus and deep muscles along the back of the leg.

The **communicating branch** (*ramus communicans*), to join a similar branch of the peroneal, runs transversely across the back of the tibia, about two inches above its lower end, passing beneath the Flexor longus hallucis.

The **malleolar** or **internal malleolar** (*a. malleolaris posterior medialis*) lies upon the tibia, sends branches over the inner ankle, and anastomoses with the inner malleolar branch of the anterior tibial.

The **internal calcaneal** (*rami calcanei mediales*) are several large arteries which arise from the posterior tibial just before its division; they are distributed to the fat and integument behind the tendo Achillis and about the heel, and to the muscles on the inner side of the sole, anastomosing with the peroneal and internal malleolar, and, on the back of the heel, with the external calcaneal arteries.

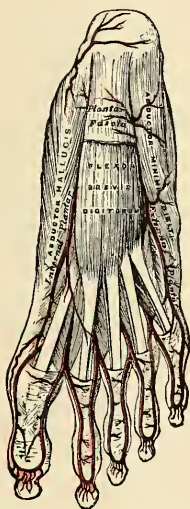


FIG. 487.—The plantar arteries. Superficial view.

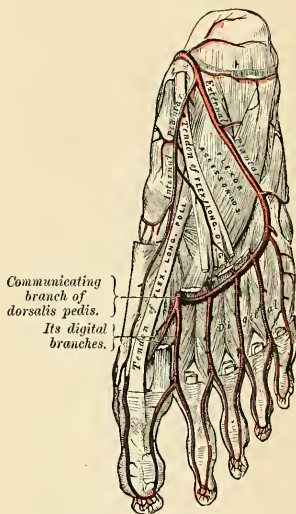


FIG. 488.—The plantar arteries. Deep view.

The **internal plantar artery** (*a. plantaris medialis*) (Figs. 487 and 488), much smaller than the external, passes forward along the inner side of the foot. It is at first situated above¹ the Abductor hallucis, and then between it and the Flexor brevis digitorum, both of which it supplies. At the base of the first metatarsal bone, where it has become much diminished in size, it passes along the inner border of the great toe, anastomosing with its digital branch. Small superficial digital branches (*ramus superficialis*) accompany the digital branches of the medial plantar nerve and join the plantar digital arteries of the three inner spaces. In addition, this vessel gives off numerous cutaneous branches.

The **external plantar artery** (*a. plantaris lateralis*) (Figs. 487 and 488), much larger than the internal, passes obliquely outward and forward to the base of the

¹ This refers to the erect position of the body. In the ordinary position for dissection the artery is deeper than the muscle.

fifth metatarsal bone. It then turns obliquely inward to the interval between the bases of the first and second metatarsal bones, where it anastomoses with the communicating branch from the *dorsalis pedis* artery, thus completing the **plantar arch** (*arcus plantaris*) (Fig. 488). As this artery passes outward, it is first placed between the *os calcis* and *Abductor hallucis*, and then between the *Flexor brevis digitorum* and *Flexor accessorius*, and as it passes forward to the base of the little toe it lies more superficially between the *Flexor brevis digitorum* and *Abductor minimi digiti*, covered by the deep fascia and integument. The remaining portion of the vessel is deeply situated; it extends from the base of the metatarsal bone of the little toe to the back part of the first interosseous space, and forms the plantar arch; it is convex forward, lies below or on the plantar aspect of the tarsal ends of the second, third, and fourth metatarsal bones and the corresponding Interosseous muscles and upon the *Adductor obliquus hallucis*.

Surface Marking.—The course of the internal plantar artery is represented by a line drawn from the mid-point between the tip of the internal malleolus and the centre of the convexity of the heel to the middle of the under surface of the great toe; the external plantar by a line from the same point to within a finger's breadth of the tuberosity of the fifth metatarsal bone. The plantar arch is indicated by a line drawn from this point—*i. e.*, a finger's breadth internal to the tuberosity of the fifth metatarsal bone transversely across the foot to the back of the first interosseous space.

Applied Anatomy.—Wounds of the plantar arch are always serious, on account of the depth of the vessel and the important structures which must be interfered with in an attempt to ligate it. They must be treated on similar lines to those of wounds of the palmar arches (see page 654). Delorme has shown that the plantar arch may be ligated from the dorsum of the foot in almost any part of its course by removing a portion of one of the three middle metatarsal bones.

Branches.—The plantar arch, besides distributing numerous branches to the muscles, integument, and fasciæ in the sole, gives off the following branches:

Posterior perforating.

Digital.

The **posterior perforating** (*rami perforantes posteriores*) are three small branches which ascend through the back part of the three outer interosseous spaces, between the heads of the *Dorsal interossei* muscles, and anastomose with the interosseous branches from the metatarsal artery.

The **digital branches** (*aa. metatarsæ plantares*) are four in number, and supply the three outer toes and half the second toe. It will be remembered that the *arteria princeps hallucis* is the plantar digital branch of the communicating rami in the first interosseous space and supplies the adjacent sides of the great and second toes. The *first digital branch* of the plantar arch passes outward from the outer side of the plantar arch, and is distributed to the outer side of the little toe, passing in its course beneath the *Abductor* and short *Flexor* muscles. The *second, third, and fourth* run forward along the interosseous spaces, and on arriving at the clefts between the toes each divides into **collateral digital branches** (*aa. digitales plantares*), which supply the adjacent sides of the three outer toes and the outer side of the second. At the bifurcation of the toes each digital artery sends upward, through the fore part of the corresponding interosseous space, a small branch which anastomoses with the interosseous branches of the metatarsal artery. These are the **anterior perforating branches** (*rami perforantes anteriores*).

From the description given it will be seen that both sides of the three outer toes and the outer side of the second toe are supplied by branches from the plantar arch; both sides of the great toe and the inner side of the second are supplied by the communicating branch of the *dorsalis pedis* (*princeps hallucis*).

THE VEINS.

THE **Veins** convey the blood from the capillaries of the different parts of the body toward the heart. They consist of two distinct sets of vessels, the **pulmonary** and **systemic veins**, and an appendage to the systemic, the **portal system**.

The **Pulmonary Veins** are concerned in the circulation of the blood through the lungs. Unlike other vessels of this kind, they contain arterial blood, which they return from the lungs to the left auricle of the heart.



FIG. 489.—Valves of a vein. In the lower part of the figure are seen the parietal valves; the upper part shows the mouth of a vein guarded by a valve. (Poirier and Charpy.)

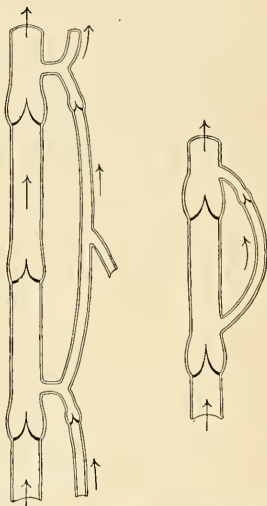


FIG. 490.—Collateral anastomosis of veins. The arrows indicate the direction of the flow of blood (schematic). (Poirier and Charpy.)

The **Systemic Veins** are concerned in the general circulation; they return the venous blood from the body generally to the right auricle of the heart.

The **Portal Vein** and its radicles constitute the portal system. The portal system is in reality an appendage to the systemic venous system, and is confined to the abdominal cavity, returning the venous blood from the viscera of the digestive system, and carrying it to the liver by a single trunk of large size, the **portal vein**. This vessel ramifies in the substance of the liver and breaks up into a minute network of capillaries. These capillaries then re-collect to form the **hepatic veins**, by which the blood is conveyed to the inferior vena cava.

The veins, like the arteries, are found in nearly every tissue of the body. They commence by minute plexuses which receive the blood from the capillaries. The

branches which have their commencement in these plexuses unite into trunks, and these, in their passage toward the heart, constantly increase in size as they receive tributaries or join other veins. The veins are larger and altogether more numerous than the arteries; hence the capacity of the venous system is much greater than that of the arterial, the pulmonary veins excepted, which only slightly exceed in capacity the pulmonary arteries. From the combined area of the smaller venous tributaries being greater than the main trunks, it results that the venous system represents a cone, the summit of which corresponds to the heart, its base to the periphery of the body. In form the veins are cylindrical, like the arteries, their walls collapsing when empty, and the uniformity of their surface being interrupted at intervals by slight dilatations, which indicate the existence of valves in their interior (Fig. 489). They usually retain, however, about the same calibre as long as they receive no tributaries, but not so uniformly as do the arteries.

The veins communicate very freely with one another (Fig. 491), especially in certain regions of the body, and this communication exists between the larger trunks as well as between the smaller tributaries. Thus, in the cavity of the cranium and between the veins of the neck, where obstruction would be attended with imminent danger to the cerebral venous system, we find that the sinuses and larger veins have large

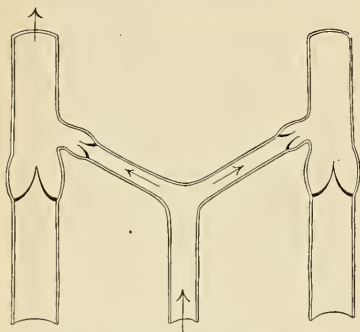


FIG. 491.—The venous circle of Braune (schematic). The arrows indicate the direction of the blood current. (Poirier and Charpy.)

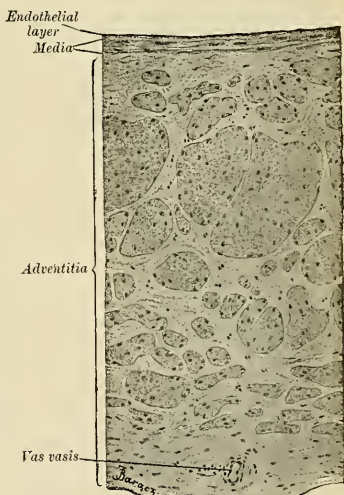


FIG. 492.—Part of a cross-section of the vena cava inferior of a dog. (Szymonowicz.)

and very frequent anastomoses (Fig. 490). The same free communication exists throughout the whole extent of the vertebral canal, and between the veins composing the various venous plexuses in the abdomen and pelvis, as the spermatic, uterine, vesical, and prostatic plexuses.

Veins have thinner walls than arteries, the difference in thickness being due to the small amount of elastic and muscular tissues which the veins contain. The superficial veins usually have thicker coats than the deep veins, and the veins of the lower limb are thicker than those of the upper.

Histology of the Veins.—As previously stated, capillaries enter into **venules** or **post-capillary veins**. The venules empty into larger veins. Vein walls are much thinner than arterial walls. The coats are: **tunica intima**, **tunica media**, and **tunica adventitia**. A vein has a much thinner **media** and much less elastic tissue than an artery, and a very strongly

developed **adventitia**. The **intima** is a connective-tissue layer containing a small number of elastic fibers and lined with endothelium. The internal elastic lamina is usually poorly developed. The valves are duplications of the intima. The **media** consists chiefly of white fibrous tissue containing some circular muscle fibres and some fine elastic fibres. In some veins the media is thoroughly well developed (veins of the lower extremities), in others it is practically absent (veins of the retina, of the pia, of bone, the superior vena cava). The **adventitia** is dense and strong, and is composed of fibro-elastic tissue and non-striated muscle fibres longitudinally placed. Fig. 492 shows a transverse section of part of the wall of a vein. The large veins and the veins of medium size possess vasa vasorum in the adventitia and to some extent in the media. The walls of veins contain vasomotor nerves. Lymph capillaries often surround the smaller bloodvessels and sometimes by spaces lined with endothelium and which are in communication with the lymphatic system; these spaces are called **perivascular lymph spaces**.

The systemic veins are subdivided into three sets—**superficial, deep, and sinuses**.

The **Superficial or Cutaneous Veins** are found between the layers of the superficial fascia, immediately beneath the integument; they return the blood from these structures, and communicate with the deep veins by perforating the deep fascia.

The **Deep Veins** accompany the arteries, and are usually enclosed in the same sheath with those vessels. With the smaller arteries—as the radial, ulnar, brachial, tibial, and peroneal—they exist generally in pairs, one lying on each side of the vessel, and are called **venae comites**. The larger arteries—as the axillary, subclavian, popliteal, and femoral—have usually only one accompanying vein. In certain organs of the body, however, the deep veins do not accompany the arteries; for instance, the veins in the skull and vertebral canal, the hepatic veins in the liver, and the larger veins returning blood from the osseous tissue.

Sinuses are venous channels which, in their structure and mode of distribution, differ altogether from the veins. They are found only in the interior of the skull, and consist of channels formed by a separation of the two layers of the dura, their outer coat consisting of fibrous tissue, their inner of an endothelial layer continuous with the lining membrane of the veins.

THE PULMONARY VEINS (V. PULMONALES) (Fig. 493).

The **pulmonary veins** return the arterialized blood from the lungs to the left auricle of the heart. They are four in number, two for each lung, and are destitute of valves. They commence in a capillary network upon the walls of the air-cells, where they are continuous with the capillary ramifications of the pulmonary artery, and uniting, form one vessel for each lobule. These vessels, uniting successively form a single trunk for each lobe, three for the right and two for the left lung. Each venous trunk is about 1.5 cm. in length and of about the same calibre. The vein from the middle lobe of the right lung generally unites with that from the upper lobe. Thus, two trunks are formed on each side, which open separately into the left auricle. Occasionally the three veins on the right side remain separate. Not infrequently the two left pulmonary veins terminate by a common opening.

Within the lung, the tributaries of the pulmonary artery are *in front*, the veins *behind*, and the bronchi *between* the two.

At the root of the lung, the upper pulmonary vein lies in front of and a little below the pulmonary artery; the lower is situated below the other structures in the lung root, and on a plane posterior to the upper vein; behind the pulmonary artery is the bronchus.

Within the pericardium, their anterior surfaces are invested by the serous layer of this membrane. The right pulmonary veins pass behind the right auricle and ascending aorta and superior vena cava; the left pass in front of the thoracic aorta.

Applied Anatomy.—*Thrombosis* of larger or smaller tributaries of the pulmonary veins is common in inflamed areas of the lung; or as a consequence of pressure from tumors, but it does not give rise to any special symptoms.

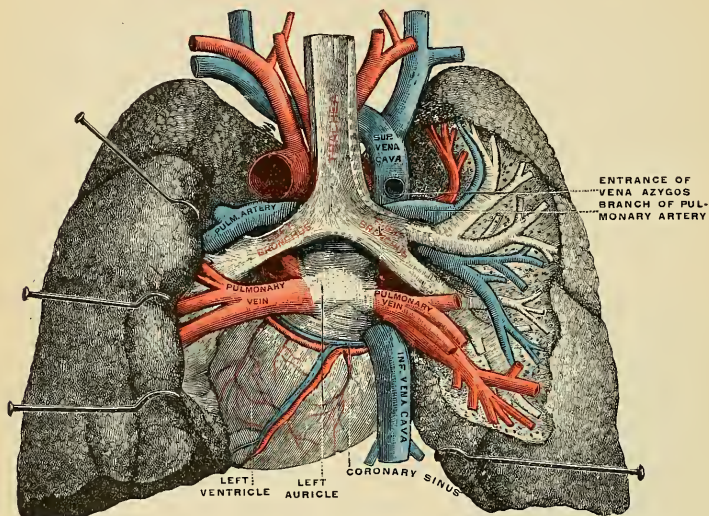


FIG. 493.—Pulmonary veins, seen in a dorsal view of the heart and lungs. The left lung is pulled to the left, and the right lung has been partly cut away to show the ramifications of the air tubes and bloodvessels. (Testut.)

THE SYSTEMIC VEINS.

The **systemic veins** may be arranged into three groups: (1) The **cardiac veins**, which open directly into the right auricle of the heart. (2) Those of the **head and neck, upper extremity, and thorax**, which terminate in the superior vena cava. (3) Those of the **lower extremity, abdomen, and pelvis**, which terminate in the inferior vena cava.

THE CARDIAC VEINS.

The **coronary sinus** (*sinus coronarius*) is a wide venous channel about an inch in length which receives the majority of the veins draining the blood from the substance of the heart. It is situated in the posterior part of the auriculo-ventricular groove, and is partly covered by muscle fibres from the left auricle. It terminates in the right auricle between the opening of the inferior vena cava and the auriculoventricular aperture, its orifice being guarded by a semilunar valve, the **coronary valve**, or **valve of Thebesius**.

Tributaries.—

Great cardiac or left coronary.
Small cardiac or right coronary.

Middle or posterior cardiac.
Posterior vein of the left ventricle.
Oblique vein of Marshall.

1. The **great cardiac** or **left coronary vein** (*v. cordis magna*) begins at the apex of the heart and ascends along the anterior interventricular groove to the base of the ventricles. It then curves to the left in the auriculoventricular groove to the back of the heart, and opens into the left extremity of the coronary sinus. It receives tributaries from the left auricle, and from both ventricles; one of these, the **left marginal vein**, is of considerable size, and ascends along the left margin of the heart.

2. The **small cardiac** or **right coronary vein** (*v. cordis parva*) runs in the groove between the right auricle and ventricle, and opens into the right extremity of the coronary sinus. It receives blood from the back of the right auricle and ventricle; its largest tributary, the **right marginal vein**, ascends along the right margin of the heart and joins it in the auriculoventricular groove.

3. The **middle, or posterior, cardiac vein** (*v. cordis media*) commences at the apex of the heart, ascends in the posterior interventricular groove, and ends in the coronary sinus near its right extremity.

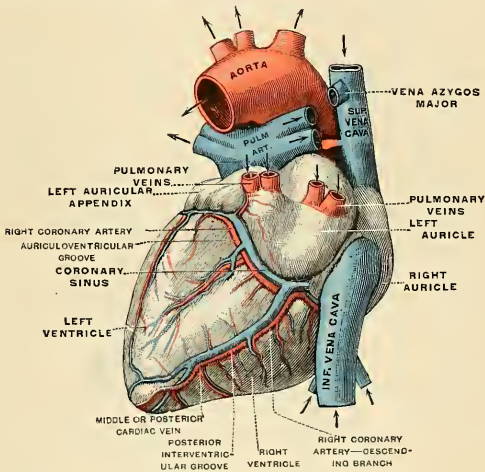


FIG. 494.—Cardiac veins, dorsal view. (Testut.)

4. The **posterior vein of the left ventricle** (*v. posterior ventriculi sinistri*) ascends on the back of the left ventricle to the coronary sinus, but may end in the great cardiac vein.

5. The **oblique vein of Marshall** (*v. obliqua atrii sinistri*) is a small vessel which descends obliquely on the back of the left auricle and ends in the coronary sinus near its right extremity; it is continuous above with the *vestigial fold of Marshall*, and the two structures form the remnant of the left Cuvierian duct.

The following cardiac veins do not terminate in the coronary sinus: (1) The **anterior cardiac veins** (*vv. cordis anteriores*), comprising three or four small vessels which collect blood from the front of the right ventricle and open into the right auricle. The right marginal vein frequently opens into the right auricle, and is therefore sometimes regarded as belonging to this group. (2) The **veins of Thebesius** (*vv. cordis minimae*), consisting of a number of minute veins which arise in the muscular wall of the heart; the majority open into the auricles, but a few empty their blood into the ventricles.

VEINS OF THE HEAD AND NECK.

The veins of the head and neck may be subdivided into three groups: (1) The veins of the exterior of the head and face. (2) The veins of the neck. (3) The veins of the diploë and the interior of the cranium.

Veins of the Exterior of the Head and Face (Fig. 495).

The veins of the exterior of the head and face are:

Frontal.	Superficial temporal.
Supraorbital.	Internal maxillary.
Angular.	Temporomaxillary.
Facial.	Posterior auricular.
Occipital.	

The **frontal vein** (*v. frontalis*) commences on the anterior part of the skull in a venous plexus which communicates with the anterior tributaries of the superficial temporal vein. The veins converge to form a single trunk, which runs downward near the middle line of the forehead parallel with the vein of the opposite side. The two veins are joined, at the root of the nose, by a transverse branch called the **nasal arch** (*v. nasofrontalis*), which receives some small veins from the dorsum of the nose. Occasionally the frontal veins join to form a single trunk, which bifurcates at the root of the nose into the two angular veins. At the root of the nose the veins diverge and join the supraorbital vein, at the inner angle of the orbit, to form the angular vein.

The **supraorbital vein** (*v. supraorbitalis*) commences on the forehead, communicating with the anterior temporal vein, and runs downward and inward, superficial to the Occipitofrontalis muscle, receiving tributaries from the neighboring structures, and from the frontal vein of the diploë, and joins the frontal vein at the inner angle of the orbit to form the angular vein. Previous to its junction with the frontal vein, it sends through the supraorbital notch into the orbit a branch which communicates with the ophthalmic vein. As this vessel passes through the notch, it receives a diploic vein from the diploë of the frontal bone, through a foramen at the bottom of the notch.

The **angular vein** (*v. angularis*), formed by the junction of the frontal and supraorbital veins, runs obliquely downward and outward on the side of the root of the nose to the level of the lower margin of the orbit, where it becomes the facial vein. It receives the veins of the ala nasi on its inner side and the superior palpebral veins on its outer side; it, moreover, communicates with the ophthalmic vein, thus establishing an important anastomosis between the facial vein and the cavernous sinus.

The **facial vein** (*v. facialis anterior*) commences at the side of the root of the nose, being a direct continuation of the angular vein. It lies behind and follows a less tortuous course than the facial artery. It passes obliquely downward and outward, beneath the Zygomaticus major and minor muscles, descends along the anterior border of the Masseter, crosses over the body of the mandible with the facial artery to beneath the angle, and unites with the anterior division of the temporomaxillary vein to form the common facial vein.

The **common facial vein** (*v. facialis communis*) is formed by the union of the facial and the anterior division of the temporomaxillary vein, just beneath the angle of the mandible. The vein is covered by the Platysma, runs downward and backward beneath the Sternomastoid muscle, crosses the external carotid artery,

and empties into the internal jugular vein at the level of the hyoid line. It receives a large communicating branch at the anterior border of the Sternomastoid muscle, which comes from the anterior jugular vein in the suprasternal fossa.

Tributaries of Facial Veins.—The facial vein receives, near the angle of the mouth, communicating tributaries of considerable size, the deep facial (or anterior internal maxillary vein), from the pterygoid plexus. It is also joined by the inferior palpebral, the superior and inferior labial veins, the buccal veins from the cheek,

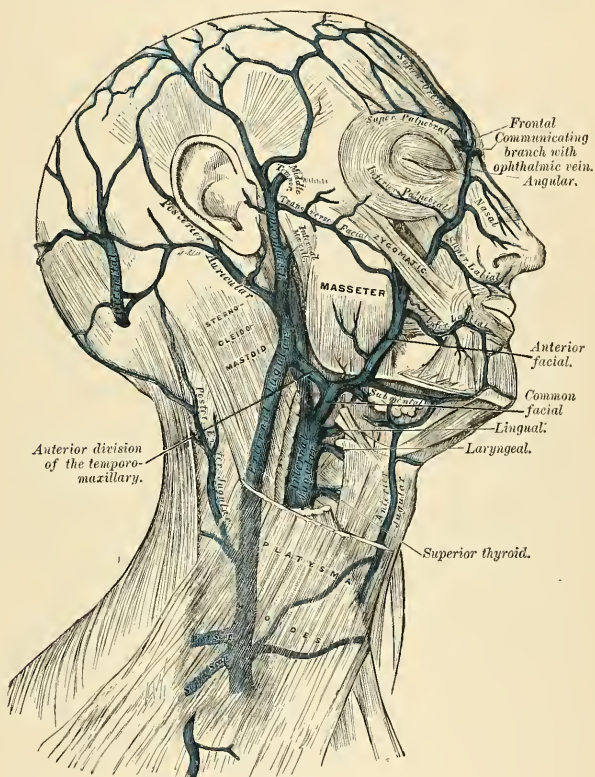


FIG. 495.—Veins of the head and neck.

and the masseteric veins. The common facial vein receives the submental; the inferior palatine, which returns the blood from the plexus around the tonsil and soft palate; the submaxillary vein, which commences in the submaxillary gland; and, generally, the ranine vein.

Applied Anatomy.—There are some points about the facial vein which render it of great importance in surgery. It is not so flaccid as are most superficial veins, and, in consequence of this, remains more patent when divided. It has, moreover, no valves. It communicates freely with the intracranial channels, not only at its commencement by its tributaries, the angular and supraorbital veins, communicating with the ophthalmic vein, a tributary of the cavernous

sinus, but also by its deep tributaries, which communicate through the pterygoid plexus with the cavernous sinus by tributaries which pass through the foramen ovale and foramen lacerum medium. These facts have an important bearing upon the surgery of some diseases of the face, for on account of its patency the facial vein favors septic absorption, and therefore any phlegmonous inflammation of the face following a poisoned wound is liable to set up thrombosis in the facial vein, and detached portions of the clot may give rise to purulent foci in other parts of the body. On account of its communications with the cerebral sinuses these thrombi are apt to extend upward into them and so induce a fatal issue.

The **superficial temporal vein** (*vv. temporales superficiales*) commences by a minute plexus on the side and vertex of the skull, which communicates with the frontal and supraorbital veins in front, the corresponding vein of the opposite side, and the posterior auricular and occipital veins behind. From this network anterior and posterior branches are formed which unite above the zygoma, forming the trunk of the vein. The trunk is joined in this situation by a large vein, the **middle temporal** (*v. temporalis media*), which receives blood from the substance of the Temporal muscle and pierces the fascia at the upper border of the zygoma. The junction of the superficial temporal and the middle temporal vein forms the **common temporal vein** which descends between the external auditory meatus and the condyle of the mandible, enters the substance of the parotid gland, and unites with the internal maxillary vein to form the **temporomaxillary vein**.

Tributaries.—The common temporal vein receives in its course some parotid veins, an articular branch from the articulation of the mandible, anterior auricular veins from the external ear, and a vein of large size, the **transverse facial** (*v. transversa faciei*), from the side of the face. The middle temporal vein, previous to its junction with the temporal vein, receives a branch, the **orbital vein** (*v. orbitalis*), which is formed by some external palpebral branches, and passes backward between the layers of the temporal fascia.

The **pterygoid plexus** (*plexus pterygoideus*) is of considerable size, and is situated between the Temporal and External pterygoid, and partly between the two Pterygoid muscles. It receives tributaries corresponding with the branches of the internal maxillary artery. Thus, it receives the middle meningeal veins, the deep temporal, the pterygoid, masseteric, buccal, alveolar, some palatine veins, the inferior dental, and a branch which communicates with the ophthalmic vein through the sphenomaxillary fissure. This plexus communicates very freely with the facial vein and with the cavernous sinus by branches through the foramen Vesalii, foramen ovale, and foramen lacerum medium, at the base of the skull.

The **internal maxillary vein** (*v. maxillaris interna*) is a short trunk which accompanies the first part of the internal maxillary artery. It is formed by a confluence of the veins of the pterygoid plexus, and passes backward between the internal lateral ligament and the neck of the mandible, and unites with the superficial temporal vein to form the temporomaxillary vein.

The **temporomaxillary vein** (*v. facialis posterior*), formed by the union of the superficial temporal and internal maxillary veins, descends in the substance of the parotid gland, superficial to the external carotid artery, but beneath the facial nerve between the ramus of the mandible and the Sternomastoid muscle. It divides into two vessels, an *anterior*, sometimes called the **deep facial vein**, which passes inward to join the facial vein, and a *posterior*, which is joined by the posterior auricular vein and becomes the external jugular.

The **posterior auricular vein** (*v. auricularis posterior*) commences upon the side of the head by a plexus which communicates with the tributaries of the temporal and occipital veins. It descends behind the external ear, and joins the posterior division of the temporomaxillary vein, forming the external jugular. It receives the stylomastoid vein and some tributaries from the back part of the external ear.

The **occipital vein** (*v. occipitalis*) commences in a plexus at the back part of the vertex of the skull. From the plexus the vein follows the course of the occipital artery, passing deeply beneath the muscles of the back part of the neck, and terminating in the suboccipital triangle by becoming continuous with the posterior vertebral vein (*v. cervicalis profunda*). Sometimes it is more superficial, and in this case is a tributary of the external jugular vein. As it passes across the mastoid portion of the temporal bone, it receives the mastoid vein, which thus establishes a communication with the lateral sinus.

The Veins of the Neck (Fig. 495).

The veins of the neck, which return the blood from the head and face, are:

External jugular.	Anterior jugular.
Posterior external jugular.	Internal jugular.
Vertebral.	

The **external jugular vein** (*v. jugularis externa*) receives the greater part of the blood from the exterior of the cranium and deep parts of the face, and is formed by the junction of the posterior division of the temporomaxillary and the posterior auricular veins. It commences in the substance of the parotid gland, on a level with the angle of the mandible, and runs perpendicularly down the neck in the direction of a line drawn from the angle of the mandible to the middle of the clavicle. In its course it crosses the Sternomastoid muscle, and runs parallel with its posterior border as far as its attachment to the clavicle, where it perforates the deep fascia, and terminates in the subclavian vein, on the outer side of, or in front of, the Scalenus anticus muscle. It is separated from the Sternomastoid by the investing layer of the deep cervical fascia, and is covered by the Platysma, the superficial fascia, and the integument. This vein crosses about its middle the superficial cervical nerve, and throughout the upper half of its course is accompanied by the great auricular nerve. The external jugular vein varies in size, bearing an inverse proportion to that of the other veins of the neck; it is occasionally double. It is provided with two pairs of valves, the lower pair being placed at its entrance into the subclavian vein, the upper pair in most cases about an inch and a half above the clavicle. The portion of vein between the two sets of valves is often dilated, and is termed the **sinus**. These valves do not prevent the regurgitation of the blood or the passage of injection masses from below upward.

Tributaries.—This vein receives the occipital occasionally, the posterior external jugular, and, near its termination, the suprascapular, transverse cervical, and anterior jugular veins; in the substance of the parotid gland a large branch of communication from the internal jugular joins it.

The **posterior external jugular vein** (*v. jugularis posterior*) commences in the occipital region, and returns the blood from the integument and superficial muscles in the upper and back part of the neck, lying between the Splenius and Trapezius muscles. It runs down the back part of the neck, and opens into the external jugular just below the middle of its course.

The **anterior jugular vein** (*v. jugularis anterior*) commences near the hyoid bone from the convergence of the inferior labial coronary, the submental and the mental veins, and communicating branches. It passes down between the median line and the anterior border of the Sternomastoid, and at the lower part of the neck passes beneath that muscle to open into the termination of the external jugular, or, in some instances, into the subclavian vein (Fig. 514). It varies considerably in size, bearing almost always an inverse proportion to the external

jugular. Most frequently there are two anterior jugulars, a right and left, but occasionally only one. Its tributaries are some laryngeal veins, and occasionally a small thyroid vein. Just above the sternum the two anterior jugular veins communicate by a transverse trunk, which receives tributaries from the inferior thyroid veins; each also communicates with the internal jugular. There are no valves in this vein.

The **internal jugular vein** (*v. jugularis interna*) collects the blood from the interior of the cranium, from the superficial parts of the face, and from the neck. It is directly continuous with the lateral sinus, and *commences* in the posterior compartment of the jugular foramen, at the base of the skull (Fig. 507). At its origin it is somewhat dilated, and this dilatation is called the **sinus** or **bulb of the internal jugular vein** (*bulbus v. jugularis superior*). The vein runs down the side of the neck in a vertical direction, lying at first on the outer side of the internal carotid artery, and then on the outer side of the common carotid artery, and at

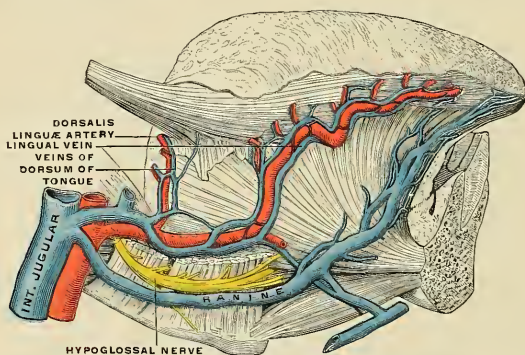


FIG. 496.—Veins of the tongue. (Testut, modified from Hirschfeld.)

NOTE.—The hypoglossal nerve has been displaced downward in this preparation. The correct relations of the nerve and the lingual artery are shown in Fig. 437.

the root of the neck unites with the subclavian vein to form the innominate vein. Just before its termination it is again distinctly dilated (*bulbus v. jugularis inferior*). The internal jugular vein, at its *commencement*, lies upon the Rectus capitis lateralis, and behind the internal carotid artery and the nerves passing through the jugular foramen; lower down, the vein and artery lie upon the same plane, the glossopharyngeal and hypoglossal nerves passing forward between them; the vagus descends between and behind them in the same sheath, and the spinal accessory passes obliquely outward, behind or in front of the vein. At the root of the neck the vein of the right side is placed at a little distance from the artery; on the left side it usually lies over the artery at its lower part. The right internal jugular vein crosses the first part of the subclavian artery. The internal jugular vein is of considerable size, but varies in different individuals, the left one being usually the smaller. It is provided with a pair of valves, which are placed about an inch above its termination.

Tributaries.—This vein receives in its course the inferior petrosal sinus, the common facial, lingual, pharyngeal, superior, and middle thyroid veins, and sometimes the occipital. A tributary from the cochlea opens into the bulb of the internal jugular vein. A venous plexus from the lateral sinus (*plexus venosus caroticus internus*) surrounds the internal carotid artery in the carotid canal and

empties into the internal jugular vein. At its point of junction with the common facial vein it becomes increased in size. (See Facial Veins, p. 710.)

The **inferior petrosal sinus** leaves the skull through the anterior compartment of the jugular foramen, and joins the vein near its commencement. Sometimes the inferior petrosal sinus is not a direct tributary of the internal jugular vein, the blood being conveyed to it by a venous plexus in the hypoglossal canal.

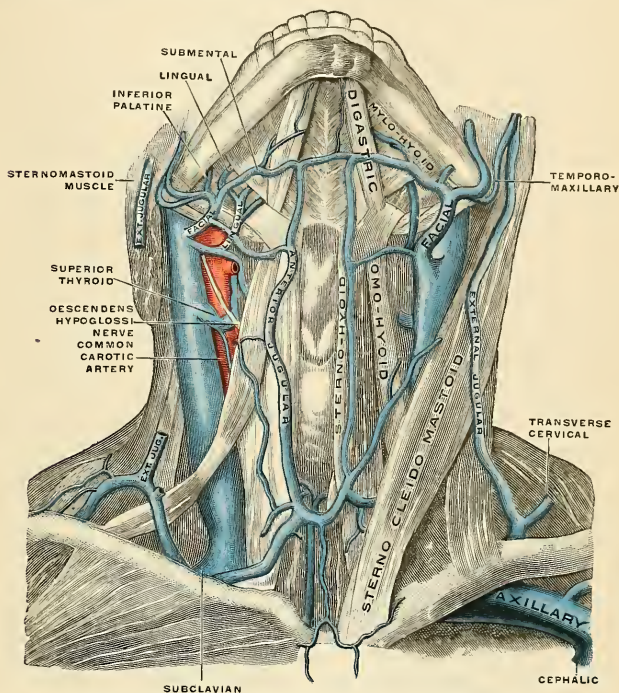


FIG. 497.—The veins of the neck, viewed from in front. (Spalteholz.)

The **lingual veins** (*vv. linguales*) (Fig. 496) commence on the dorsum, sides, and under surface of the tongue, and, passing backward along the course of the lingual artery and its branches, terminate in the internal jugular. The **ranine vein**, a tributary of considerable size commencing below the tip of the tongue, may join the lingual; generally, however, it passes backward on the Hyoglossus muscle in company with the hypoglossal nerve, and joins the facial. The lingual veins receive the sublingual and the dorsal lingual veins.

The **pharyngeal veins** (*vv. pharyngeae*) commence in the **pharyngeal plexus** on the wall of the pharynx, and, after receiving meningeal tributaries, the dural or meningeal veins, the Vidian veins, and the sphenopalatine veins, terminate in the internal jugular. They occasionally open into the facial, lingual, or superior thyroid vein.

The **superior thyroid vein** (*v. thyroidea superioris*) (Fig. 497) commences in the substance and on the surface of the thyroid gland by tributaries corresponding

with the branches of the superior thyroid artery, and terminates in the upper part of the internal jugular vein. It receives the superior laryngeal and crico-thyroid veins.

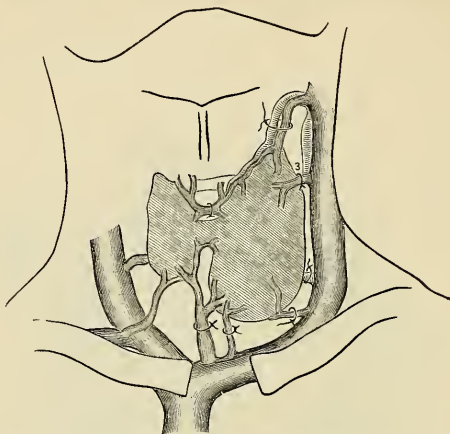


FIG. 498.—Diagram showing common arrangement of thyroid veins. (Kocher.)

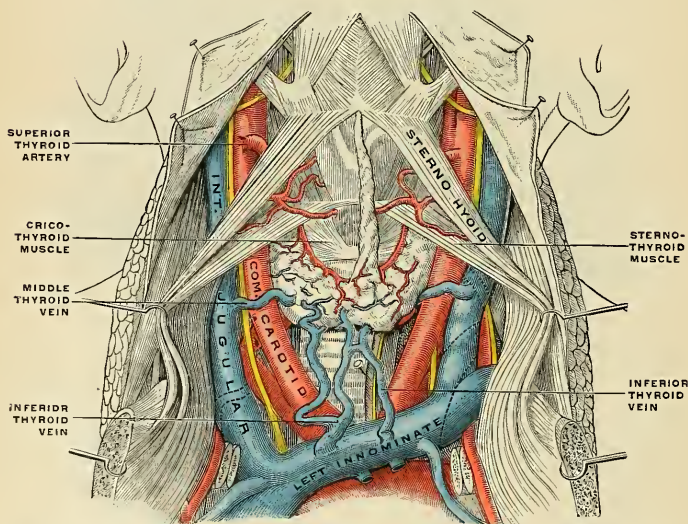


FIG. 499.—The fascia and middle thyroid veins. The veins here designated the inferior thyroid are called by Kocher the *thyroidea ima*. (Poirier and Charpy.)

The **middle thyroid vein** (Fig. 483) collects the blood from the lower part of the lateral lobe of the thyroid gland, and after being joined by some veins from the larynx and trachea, terminates in the lower part of the internal jugular vein. Often

in place of the middle thyroid vein there are two veins, the **superior** and **inferior accessory thyroid**. These veins pass into the internal jugular.

The **facial** and **occipital veins** have been described on pages 710 and 713.

Applied Anatomy.—The internal jugular vein occasionally requires ligation in cases of *septic thrombosis of the lateral sinus* from suppuration of the middle ear. This is done in order to prevent septic emboli being carried into the general circulation. This operation has been performed in a number of cases, with satisfactory results. The cases are generally those of chronic disease of the middle ear, with discharge of pus which perhaps has existed for many years. The patient is seized with acute septic inflammation, spreading to the mastoid cells, and, consequent on this, septic thrombosis of the lateral sinus extending to the internal jugular vein. Such cases are always extremely grave, for there is danger that a portion of the septic clot will be detached and cause septic embolism in the thoracic viscera. If thrombophlebitis of the sinus is suspected the mastoid should be opened and cleansed and the sinus should be at once exposed and explored. If the sinus is found to be thrombosed the surgeon should at once proceed to ligate the internal jugular vein, by an incision along the anterior border of the sternomastoid, the centre of which is on a level with the greater cornu of the hyoid bone. The vein should be ligated in two places or opened between. After the vessel has been secured and divided the lateral sinus is to be thoroughly cleared out, and, by removing the ligature from the upper end of the divided vein, all septic clots may be removed by syringing from the sinus through the vein. If hemorrhage occurs from the distal end of the sinus, it can be arrested by careful plugging with gauze.

The internal jugular vein is also surgically important, because it is surrounded by a large number of the deep chain of cervical lymph nodes; and when these are enlarged in tuberculous or malignant disease, they are liable to become adherent to the vessel, rendering their removal difficult and often dangerous. The proper course to pursue in these cases is to ligate the vessel above and below the glandular mass, and resect the included portion together with the nodes.

Cardiac pulsation is often demonstrable in the internal jugular vein at the root of the neck. There are no valves in the innominate veins or superior vena cava; in consequence, the systole of the right auricle causes a wave to pass up these vessels, and when the conditions are favorable this wave appears as a somewhat feeble flicker over the internal jugular vein at the root of the neck, quite distinct from, and just preceding, the more forcible impulse transmitted from the underlying common carotid artery and due to the ventricular systole.¹ This auricular systolic venous impulse is much increased in conditions in which the right auricle is abnormally distended with blood or is hypertrophied, as is often the case in disease of the auriculoventricular valves. In Stokes-Adams' disease (p. 565) it is this pulsation which gives evidence of the fact that the auricles are beating faster—often two or three times faster—than the ventricles.

The **vertebral vein** (*v. vertebralis*) (Fig. 500) is formed in the suboccipital triangle, from numerous small tributaries which spring from the intraspinal venous plexuses (*plexus venosi vertebrales*) and issue from the vertebral canal above the posterior arch of the atlas. They unite with small veins from the deep muscles at the upper and back part of the neck, and form a vessel which passes outward and enters the foramen in the transverse process of the atlas, and descends, forming a dense plexus around the vertebral artery, in the canal formed by the foramina in the transverse processes of the cervical vertebræ. This plexus unites at the lower part of the neck into a single trunk, which emerges from the foramen in the transverse process of the sixth cervical vertebra, and terminates at the root of the neck in the back part of the innominate vein near its origin, its mouth being guarded by a pair of valves. On the right side, it crosses the first part of the subclavian artery.

Tributaries.—In its course the vertebral vein communicates with a vein transmitted from the lateral sinus of the skull through the posterior condylar foramen. It anastomoses with the occipital vein and receives muscular veins from the muscles in the prevertebral region; intraspinal veins, from the back part of the cervical portion of the vertebral column; meningorachidian veins, from the interior of the vertebral canal; the anterior and posterior vertebral veins; and close to its termination it is sometimes joined by the first intercostal vein.

The **ascending cervical** or **anterior vertebral vein** *commences* in a plexus around the transverse processes of the upper cervical vertebræ, descends in company with the

¹ The Interpretation of the Venous Pulse, by G. Bachmann, Amer. Jour. Med. Sci., November, 1908.

ascending cervical artery between the *Scalenus anticus* and *Rectus capitis anticus* major muscles, and opens into the vertebral vein just before its termination.

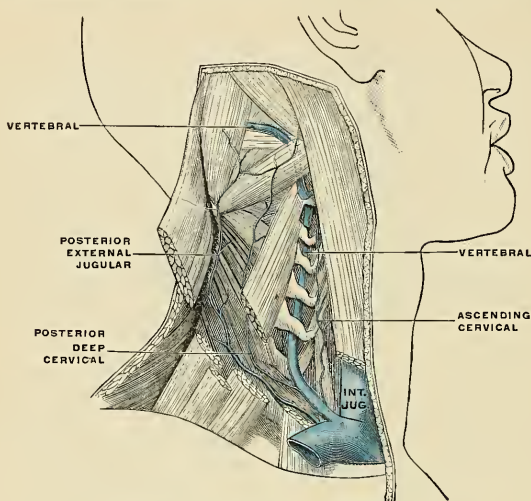


FIG. 500.—The vertebral vein. (Poirier and Charpy.)

The posterior vertebral or posterior deep cervical vein (*v. cervicalis profunda*) (Fig. 500) accompanies the deep cervical artery, lying between the *Complexus* and *Semispinalis colli*. It commences in the suboccipital region by communicating branches from the occipital vein and tributaries from the deep muscles at the back of the neck. It receives tributaries from the plexuses around the spinous processes of the cervical vertebrae; and terminates in the lower end of the vertebral vein.

The Veins of the Diploë (*Venae Diploicae*) (Fig. 501).

The diploic spaces of the cranial bones in the adult contain a number of tortuous canals, the **diploic canals** (*canales diploici* [*Brescheti*]), which are bounded by a more or less complete layer of compact osseous tissue. The veins they contain are large and capacious, their walls being thin, and formed only of endothelium resting upon a layer of elastic tissue; they present at irregular intervals pouch-like dilatations, or *culs-de-sac*, which serve as reservoirs for the blood.

In adult life, so long as the cranial bones are distinct and separable, these veins are confined to the particular bones; but in old age, when the sutures are united, they communicate with one another and increase in size. They communicate, in the interior of the cranium, with the veins and the sinuses of the dura, and on the exterior of the skull with the veins of the pericranium. They consist of (1) the **frontal diploic vein** (*v. diploica frontalis*), which opens into the supra-orbital vein by an aperture in the supraorbital notch; (2) the **anterior temporal diploic vein** (*v. diploica temporalis anterior*), which is confined chiefly to the frontal bone, and opens into one of the deep temporal veins through an aperture in the greater wing of the sphenoid; (3) the **posterior temporal vein** (*v. diploica*

temporalis posterior), which is situated in the parietal bone, and terminates in the lateral sinus through an aperture at the postero-inferior angle of the parietal bone or through the mastoid foramen; and (4) the **occipital diploic vein** (*v. diploica occipitalis*), the largest of the four, which is confined to the occipital bone, and opens into the lateral sinus or the torcular Herophili.

The **emissary veins** are considered on page 727.

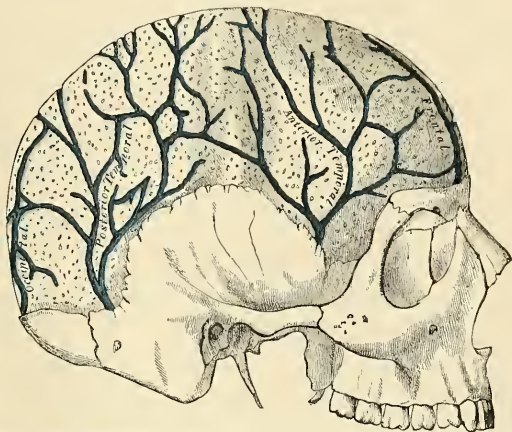

FIG. 501.—Veins of the diploë as displayed by the removal of the outer table of the skull.

The **meningeal or dural veins** (*vv. meningeae*) chiefly correspond with the middle meningeal artery and its branches, as its two *venae comites*. The veins accompany the middle meningeal artery, are united to the sphenoparietal sinus, pass through the foramen spinosum, and join the pterygoid plexus. The other dural veins correspond somewhat to the anterior and posterior meningeal distribution and empty into the neighboring sinuses.

The Cerebral Veins (*Venae Cerebri*).

The **cerebral veins** possess no valves, and their walls, owing to the absence of muscle tissue, are extremely thin. They pierce the arachnoid membrane and the inner or meningeal layer of the dura and open into the cranial venous sinuses. They may be divided into two sets, cerebral and cerebellar.

The cerebral veins consist of (a) the **superficial veins**, which are placed on the surface of the brain, and (b) the **deep veins**, which lie in its interior.

The **superficial cerebral veins** ramify upon the surface of the brain, being lodged in the fissures between the convolutions, a few running across the convolutions. They receive tributaries from the substance of the brain and terminate in the sinuses. They are divisible into two sets, superior and inferior.

The **superior cerebral veins** (*vv. cerebri superiores*), eight to twelve in number on each side, return the blood from the convolutions on the superior surface of the hemisphere; they pass forward and inward toward the intercerebral fissure, where they receive the veins from the mesal surface of the hemisphere; near their terminations they become invested with tubular sheaths of the arachnoid, and open into the longitudinal sinus in the opposite direction to the course of the current of the blood in the sinus.

The **inferior cerebral veins** (*vv. cerebri inferiores*) ramify on the lower part of the outer and on the under surfaces of the cerebral hemisphere. Some, collecting tributaries from the under surface of the frontal lobes of the brain, terminate in the cavernous sinus. One vein of large size, the **middle cerebral or superficial sylvian vein** (*v. cerebri media*), commences on the under surface of the temporal lobe, and, running along the sylvian fissure, opens into the cavernous sinus. Another large vein, the **great anastomotic vein of Trolard**, connects the superior sagittal sinus with the cavernous sinus by becoming continuous above with one of the superior cerebral veins and below by joining the middle cerebral vein. A third, the **posterior anastomotic vein** connects the middle cerebral vein with the lateral sinus by coursing over the temporal lobe. A fourth, the **basilar vein** (*v. basis* [*Rosenthalii*]), is formed at the anterior perforated spot by the union of (a) a small **anterior cerebral vein**, which accompanies the anterior cerebral artery (b) the **deep sylvian vein**, which receives tributaries from the island of Reil (or insula) and neighboring convolutions, and runs in the lower part of the sylvian fissure; and (c) the **inferior striate veins**, which leave the corpus striatum through the anterior perforated substance. The basilar vein passes backward around the crus cerebri, and ends in the vein of Galen; it receives tributaries from the interpeduncular space, the descending horn of the lateral ventricle, the uncinate gyre, and the midbrain. Small inferior cerebral veins from the under surface of the frontal lobe end in the cavernous sinus; others from the temporal lobe terminate in the superior petrosal and lateral sinuses.

The **deep cerebral veins, or veins of Galen** (*vv. cerebri internae*) (Fig. 725), are two in number. Each is formed by the union of two veins, the **vena corporis striati**, and the **choroid vein**, on either side. They run backward, parallel with each other, between the layers of the velum interpositum, and beneath the splenium, and in the region of the pineal body unite to form a short trunk, the **vena magna Galeni** (*v. cerebri magna*), which passes out of the brain at the great transverse fissure, and ends in the anterior extremity of the straight sinus. The two velar veins receive tributaries from the callosal region, from a portion of the occipital lobe, and just before their union each vein receives the corresponding basilar vein. Each vena magna Galeni also receives the superior cerebellar veins.

The **vena corporis striati** on each side commences in the groove between the corpus striatum and thalamus, receives numerous veins from both of these parts, and unites, behind the anterior pillars of the fornix, with the choroid vein to form one of the deep cerebral veins.

The **choroid vein** (*v. choroidea*) originates in the extreme end of the middle horn of the lateral ventricle and runs along the whole length of the outer border of the choroid plexus, receiving veins from the hippocampus, the fornix, and corpus callosum, and unites, at the anterior extremity of the choroid plexus, with the vein of the corpus striatum to form the deep cerebral veins of that side.

The **superficial cerebellar veins** (Fig. 723) occupy the surface of the cerebellum, and are disposed in two sets, **superior** and **inferior**.

The **superior superficial cerebellar veins** (*vv. cerebelli superiores*) pass partly forward and inward, across the superior vermis (*prevermis*), to terminate in lateral branches which pass partly to the tentorial sinus and partly outward to the lateral and superpetrosal sinuses.

The **subcerebellar or inferior superficial cerebellar veins** (*vv. cerebelli inferiores*), of large size, terminate in the lateral, subpetrosal, and occipital sinuses.

The **deep cerebellar veins** bring blood from the interior of the cerebellum to the superficial veins.

Veins of the Pons.—Veins come from the interior of the pons, the **deep veins**, and empty into a plexus of **superficial veins**. From this superficial venous plexus a **superior vein** passes to the basilar vein, and an **inferior vein** either into a cerebellar vein or into the superpetrosal sinus.

Veins of the Medulla Oblongata.—Veins pass from the interior of the medulla oblongata and end in a plexus on the surface. From this plexus comes an **anterior median vein**, which is a prolongation of a like vein of the spinal cord—a **posterior median vein** corresponding to a like vein of the cord—and small branches which pass with the roots of the glossopharyngeal, vagus, spinal accessory, and hypoglossal nerves, and empty into the occipital and the subpetrosal sinuses.

The perivascular lymph spaces are especially found in connection with the vessels of the brain. These vessels are enclosed in a sheath, which acts as a lymphatic channel, through which the lymph is carried to the subarachnoid and subdural spaces, from which it is returned into the general circulation.

The Sinuses of the Dura (*Sinus Durae Matris*) (Figs. 502, 503). Ophthalmic Veins and Emissary Veins.

The **sinuses of the dura** are venous channels which drain the blood from the brain; they are situated between the two layers of the dura and are lined by endothelium continuous with that which lines the veins. They are sixteen in number, of which six are single and situated in the mesal plane; the other ten are paired, five being placed on either side of the mesal plane. They are divided into two sets: (1) Those situated at the upper and back part of the skull; (2) those at the base of the skull. The former are:

Superior sagittal sinus.
Inferior sagittal sinus.

Tentorial or straight sinus.
Lateral sinuses.

Occipital sinus.

The **superior sagittal sinus** (*sinus sagittalis superior*) (Figs. 502 and 503) occupies the attached margin of the falx cerebri. Commencing at the foramen cecum, through which it usually communicates by a small branch with the veins of the nasal fossæ, it runs from before backward, grooving the inner surface of the frontal, the adjacent margins of the two parietals, and the superior division of the crucial ridge of the occipital; near the internal occipital protuberance it usually deviates toward the right, and is continued as the corresponding lateral sinus. The sinus is triangular on transverse section, is narrow in front, and gradually increases in size as it passes backward. Its inner surface presents the internal openings of the superior cerebral veins, which run, for the most part, from behind forward, and open chiefly at the back part of the sinus, their orifices being concealed by valve-like folds; numerous fibrous bands, *chordæ Willisii* (Fig. 504), are also seen extending transversely across the inferior angle of the sinus; and some small, white, projecting bodies, the *glandulae Pacchioni* (*granulationes arachnoidales*). This sinus communicates by numerous small apertures with spaces in the dura known as *lacunae laterales*, or *parasinoidal spaces* (Fig. 504). The arachnoid villi project into these spaces. The superior sagittal sinus receives the superior cerebral veins, numerous veins from the diploë and dura, the outlets of the parasinoidal spaces, and, at the posterior extremity of the sagittal suture, veins from the pericranium, which pass through the parietal foramina. Sometimes the sagittal sinus receives a twig from the nose which passes through the foramen cecum.

The **inferior sagittal sinus** (*sinus sagittalis inferior*, s. *falcialis*) (Fig. 503) is contained in the posterior half or two-thirds of the free margin of the falx cerebri. It is of a cylindric form, increases in size as it passes backward, and terminates in the straight sinus. It receives several veins from the falx cerebri, and occasionally a few from the mesal surface of the hemispheres.

The **straight** or **tentorial sinus** (*sinus rectus*, s. *tentorii*) (Figs. 502 and 503) is situated at the line of junction of the falx cerebri with the tentorium cerebelli. It is triangular on section, increases in size as it proceeds backward, and runs obliquely downward and backward from the termination of the inferior sagittal

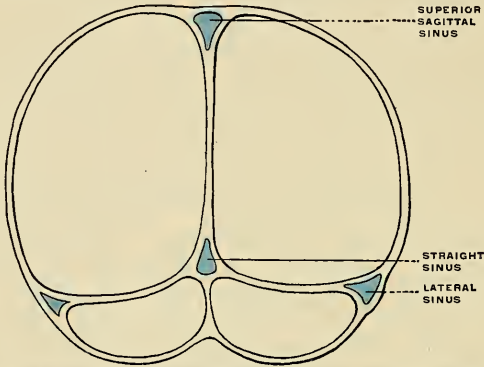


FIG. 502.—Coronal section of the skull to show the situations and shapes of the chief sinuses. (Poirier and Charpy.)

sinus to the lateral sinus of the opposite side to that into which the sagittal sinus is prolonged. Its terminal part communicates by a cross-branch with the torcular Herophili (confluence of the sinuses). Besides the inferior sagittal sinus, it receives the vena magna Galeni and the superior cerebellar veins. A few transverse bands cross its lumen.

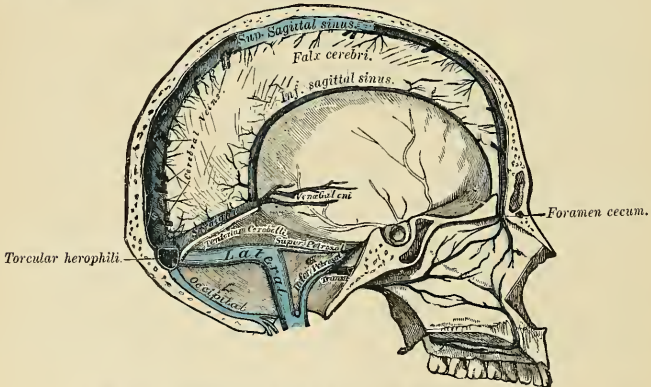


FIG. 503.—Sagittal section of the skull, showing the sinuses of the dura.

The **lateral sinuses** (Figs. 502 and 503) are of large size and *commence* at the internal occipital protuberance; one, generally the right, being the direct continuation of the superior sagittal sinus, the other of the straight sinus. Each lateral sinus (*sinus transversus*) passes outward and forward, describing a slight curve with its convexity upward, to the base of the petrous portion of the temporal

bone, and is situated, in this part of its course, in the attached margin of the tentorium cerebelli; it then leaves the tentorium, curves downward and inward to reach the jugular foramen, where it terminates in the internal jugular vein. In its course it rests upon the inner surface of the occipital, the postero-inferior angle of the parietal, the mastoid portion of the temporal bone, and on the occipital again, at the jugular process, just before its termination. The portion of the sinus which occupies the groove on the mastoid portion of the temporal bone is known as the **sigmoid sinus**. The lateral sinuses are frequently of unequal size, that formed by the sagittal sinus being the larger, and they increase in size as they proceed from behind forward. The horizontal portion is triangular on section, the curved portion semicylindric. Their inner surface is smooth, and not crossed by the fibrous bands found in the other sinuses. The lateral sinuses receive the blood from the superior petrosal sinuses at the base of the petrous portion of

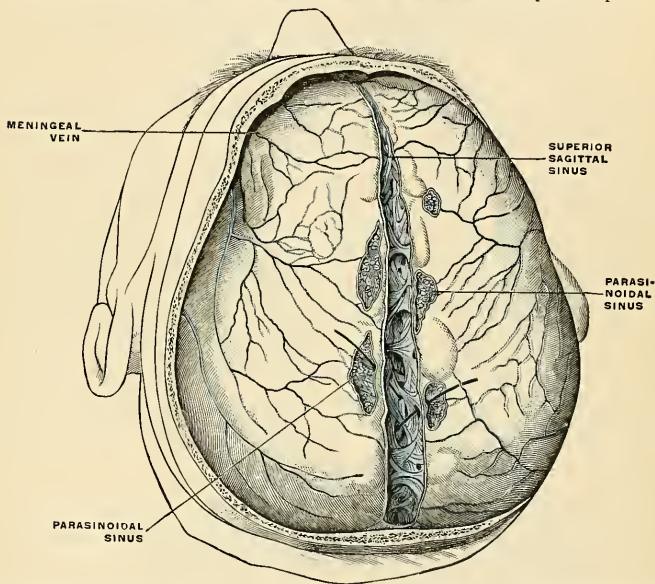


FIG 504.—Sagittal sinus seen from above after removal of the skullcap. The chordae Willisii are clearly visible. The parasinoidal sinuses are also well shown. Probes passing from the latter to the longitudinal sinus show that they communicate. (Poirier and Charpy.)

the temporal bone, and they unite with the inferior petrosal sinus, just external to the jugular foramen, to form the internal jugular vein (Fig. 508). They communicate with the veins of the pericranium by means of the mastoid and posterior condylar veins, and they receive some of the inferior cerebral and inferior cerebellar veins, some veins from the diploë, and often veins from the internal ear (*vv. auditivæ internæ*), which come out of the internal auditory meatus. The **petrosquamous sinus**, when present, runs backward along the junction of the petrous and squamous portions of the temporal bone, and opens into the lateral sinus.

The **occipital sinus** (*sinus occipitalis*) (Fig. 503) is the smallest of the cranial sinuses. It is generally single, but occasionally there are two. It is situated in

the attached margin of the falx cerebelli. It commences by several small veins around the margin of the foramen magnum, one of which joins the termination of the lateral sinus; it communicates with the posterior spinal veins and terminates in the torcular Herophili.

The **torcular Herophili**, or **confluence of the sinuses** (*confluens sinuum*), is the term applied to the dilated extremity of the superior sagittal sinus. It is of irregular form, and is lodged on one side (generally the right) of the internal occipital protuberance. From it the lateral sinus of the side to which it is deflected is derived. It also receives the blood from the occipital sinus, and is connected across the middle line with the commencement of the lateral sinus of the opposite side.

The sinuses at the base of the skull are:

Two cavernous sinuses.	Two superior petrosal sinuses.
Two sphenoparietal sinuses.	Two inferior petrosal sinuses.
Circular sinus.	Transverse sinus.

The **cavernous sinuses** (Figs. 507 and 508) are so named because they present a reticulated structure, due to their being traversed by numerous interlacing filaments (Fig. 505). They are of irregular form, larger behind than in front, and are placed one on each side of the sella turcica, extending from the sphenoidal fissure to the apex of the petrous portion of the temporal bone. Each cavernous sinus (*sinus cavernosus*) receives anteriorly the superior ophthalmic vein through the sphenoidal fissure, and opens behind into the petrosal sinuses. On the inner wall of each sinus is the internal carotid artery, accompanied by filaments of the carotid plexus and by the abducent nerve; and on its outer wall, the oculomotor, trochlear, ophthalmic, and superior maxillary divisions of the trigeminal nerve (Fig. 505). These parts are separated from the blood flowing along the sinus by the lining membrane, which is continuous with the inner coat of the veins. Each cavernous sinus receives some of the cerebral veins, and also the sphenoparietal sinus. It communicates with the lateral sinus by means of the superior petrosal sinus; with the internal jugular vein through the inferior petrosal sinus and through a plexus of veins on the internal carotid artery; with the pterygoid plexus through the foramen ovale, and with the angular vein through the ophthalmic vein. The two sinuses also communicate with each other by means of the circular sinus.

Applied Anatomy.—An arteriovenous communication may be established between the cavernous sinus and the internal carotid artery, as it lies in it, giving rise to a *pulsating tumor* in the orbit. Such a communication may be the result of injury, such as a bullet wound, a stab, or a blow or fall sufficiently severe to cause a fracture of the base of the skull in this situation, or it may occur from the rupture of an aneurism or a diseased condition of the internal carotid artery. The disease begins with sudden noise and pain in the head, followed by exophthalmos, swelling and congestion of the lids and conjunctivæ. A pulsating tumor develops at the margin of the orbit, with thrill and the characteristic bruit; accompanying these symptoms there may be impairment of the sight, paralysis of the iris and orbital muscles, and pain of varying intensity. In some cases the opposite orbit becomes affected by the passage of the arterial blood into the opposite sinus by means of the circular sinus. Or the arterial blood may find its way through the emissary veins into the pterygoid plexus, and thence into the veins of the face. Pulsating tumors of the orbit may also be due to traumatic aneurism of one of the orbital arteries, and symptoms resembling those of pulsating tumor may be produced by pressure on the ophthalmic vein, as it enters the sinus, by an aneurism of the internal carotid artery. Ligation of the internal or the common carotid artery has been performed in these cases with some degree of success.

Of recent years more attention has been paid to thrombosis of the cavernous sinus than formerly, and it is now well established that caries in the upper parts of the nasal fossæ and supuration in certain of the accessory sinuses of the nose, are frequently responsible for septic thrombosis of the cavernous sinuses, in exactly the same way as lateral sinus thrombosis is due to septic disease in the mastoid process. Many deaths from meningitis, hitherto unaccounted for, are in reality due to the spread of an infection from an ethmoidal or sphenoidal air cell to the cavernous sinus, and thence to the meninges. It is obvious, therefore, that no case of chronic nasal supuration should be left untreated.

The **sphenoparietal sinuses** may be regarded, together with the ophthalmic veins, as the commencement of the corresponding cavernous sinuses. Each of these sinuses (*sinus sphenoparietalis*) is lodged in the dura on the under surface of the lesser wing of the sphenoid bone. It takes origin from one of the middle meningeal

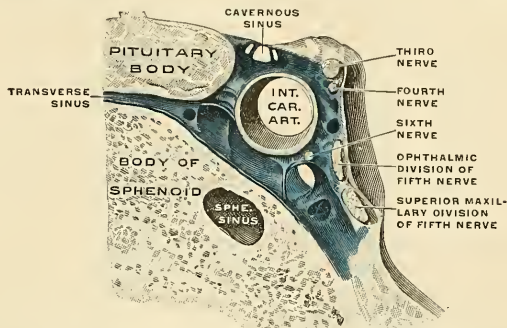


FIG. 505.—Frontal section through the right cavernous sinus, enlarged. (Spalteholz.)

veins, usually receives blood from the diploë of the skull, passes inward, and ends in the anterior part of the cavernous sinus.

The **ophthalmic veins** are two in number, superior and inferior.

The **superior ophthalmic vein** (*v. ophthalmica superior*) (Fig. 506) begins as the **nasofrontal vein** (*v. nasofrontalis*), which communicates with the angular vein at the inner angle of the orbit. It joins the angular vein with the cavernous sinus;

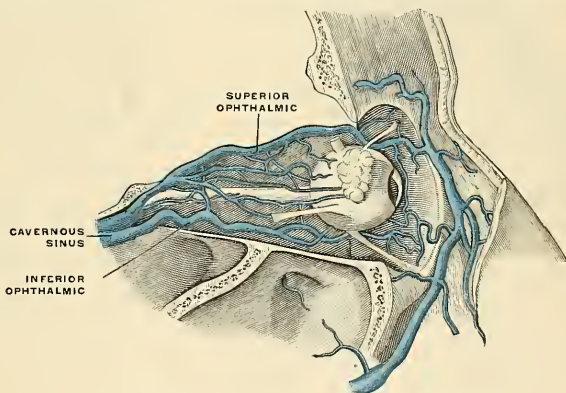


FIG. 506.—Veins of the orbit. (Poirier and Charpy.)

it pursues the same course as the ophthalmic artery, and receives tributaries corresponding to the branches derived from that vessel. Forming a short single trunk, it passes through the inner extremity of the sphenoidal fissure, and terminates in the cavernous sinus. It anastomoses with the inferior ophthalmic vein and receives lacrimal, anterior and posterior ethmoidal, and muscular branches, and veins of the eyelids and of the eyeball (*vv. vorticossae*).

The **inferior ophthalmic vein** (*v. ophthalmica inferior*) (Fig. 506) arises in the veins of the eyelids and lacrimal sac, receives the veins from the floor of the orbit, and either passes out of the orbit through the sphenoidal fissure to join the pterygoid plexus of veins, or else, passing backward through the sphenoidal fissure, it enters the cavernous sinus, either by a separate opening, or, more frequently, in common with the superior ophthalmic vein. It receives muscular tributaries and veins of the eyeball, and anastomoses with the superior ophthalmic and deep facial vein.

The **circular sinus** (*sinus circularis*) (Figs. 505 and 507) is formed by two transverse vessels, the **anterior and posterior intracavernous sinuses** (*sinus intercavernosus anterior* and *sinus intercavernosus posterior*), which connect the two cavernous sinuses; one passes in front of and the other behind the pituitary body, and thus they form with the cavernous sinuses a venous circle around that body. The anterior one is usually the larger of the two, and one or other is occasionally absent.

The **superior petrosal sinus** (*sinus petrosus superior*) (Figs. 503 and 507) is situated along the superior border of the petrous portion of the temporal bone, in the front part of the attached margin of the tentorium cerebelli. It is small and narrow, and connects the cavernous and lateral sinuses at each side. It receives some cerebellar and inferior cerebral veins, and veins from the tympanic cavity.

The **inferior petrosal sinus** (*sinus petrosus inferior*) (Fig. 503) is situated in the groove formed by the junction of the posterior border of the petrous portion of the temporal with the basilar process of the occipital bone. It commences in front at the termination of the cavernous sinus, and, passing through the anterior compartment of the jugular foramen, ends

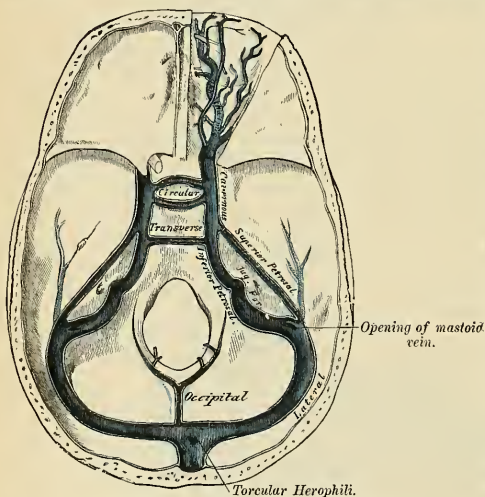


FIG. 507.—The sinuses at the base of the skull.

in the commencement of the internal jugular vein. The inferior petrosal sinus receives a vein from the internal ear (*vv. auditavae internae*) and also veins from the medulla oblongata, pons, and under surface of the cerebellum.

The exact relation of the parts to one another in the foramen is as follows: The inferior petrosal sinus is in front, with the meningeal branch of the ascending pharyngeal artery, and is directed obliquely downward and backward; the lateral sinus is situated at the back part of the foramen with a meningeal branch of the occipital artery, and between the two are the glossopharyngeal, vagus, and spinal accessory nerves. These three sets of structures are divided from each other by two processes of fibrous tissue. The junction of the inferior petrosal sinus with the internal jugular vein takes place superficial to the nerves, so that these latter lie a little internal to the venous channels in the foramen.

The **transverse or basilar sinus** (*plexus basilaris*) (Fig. 507) consists of several interlacing veins between the layers of the dura over the basilar process of the occipital bone, which serve to connect the two inferior petrosal sinuses. They communicate with the anterior spinal veins.

The **emissary veins** (*emissaria*) are vessels which pass through apertures in the cranial wall and establish communications between the sinuses inside the skull and the diploic veins in the diploë, and the veins external to the skull. Some of these are always present, others only occasionally so. They vary much in size in different individuals. The principal emissary veins are the following: (1) A vein (*emissarium mastoideum*) almost always present, runs through the mastoid foramen and connects the lateral sinus with the posterior auricular or with the occipital vein. (2) A vein (*emissarium parietale*) which passes through the parietal foramen and connects the superior sagittal sinus with the veins of the scalp. (3) A plexus of minute veins (*rete canalis hypoglossi*), which pass through the anterior condylar (hypoglossal) foramen and connect the occipital sinus with the vertebral vein and deep veins of the neck. (4) An inconstant vein (*emissarium condyloideum*) which passes through the posterior condylar foramen and connects the lateral sinus with the deep veins of the neck. (5) A plexus of veins (*rete foraminis ovalis*) connects the cavernous sinus with the pterygoid and pharyngeal plexuses through the foramen ovale. (6) Two or three small veins run through the foramen lacerum medium and connect the cavernous sinus with the pterygoid and pharyngeal plexuses. (7) There is sometimes a small vein connecting the same parts and passing through the inconstant foramen of Vesalius opposite the root of the pterygoid process of the sphenoid bone. (8) A plexus of veins (*plexus venosus caroticus internus*) traverses the carotid canal and connects the cavernous sinus with the internal jugular vein. (9) A small vein (*emissarium occipitale*) usually connects the occipital vein with the lateral sinus or the torcular Herophili and the occipital diploic vein. (10) A vein is usually transmitted through the foramen cecum and connects the superior sagittal sinus with the veins of the mucous membrane of the nose.

Applied Anatomy.—These emissary veins are of great importance in surgery. In addition to them there are, however, other communications between the intra- and extracranial channels, as, for instance, the communication of the angular and supraorbital veins with the ophthalmic vein at the inner angle of the orbit, and the communication of the veins of the scalp with the diploic veins. Through these communications inflammatory processes commencing on the outside of the skull may travel inward, leading to osteophlebitis of the diploë and inflammation of the membranes of the brain. This is one of the principal dangers of scalp wounds and other injuries of the scalp.

By means of these emissary veins blood may be abstracted almost directly from the intracranial vessels. For instance, leeches applied behind the ear abstract blood almost directly from the lateral sinus by means of the vein passing through the mastoid foramen. Again, epistaxis in children will frequently relieve severe headache, the blood which flows from the nose being derived from the superior sagittal sinus by means of the vein which passes through the foramen cecum.

VEINS OF THE UPPER EXTREMITY AND THORAX.

The **veins of the upper extremity** are divided into two sets, **superficial** and **deep**.

The **Superficial Veins** are placed immediately beneath the integument between the layers of the superficial fascia.

The **Deep Veins** accompany the arteries, and constitute the *venae comites* of those vessels.

Both sets of vessels are provided with valves, which are more numerous in the deep than in the superficial veins.

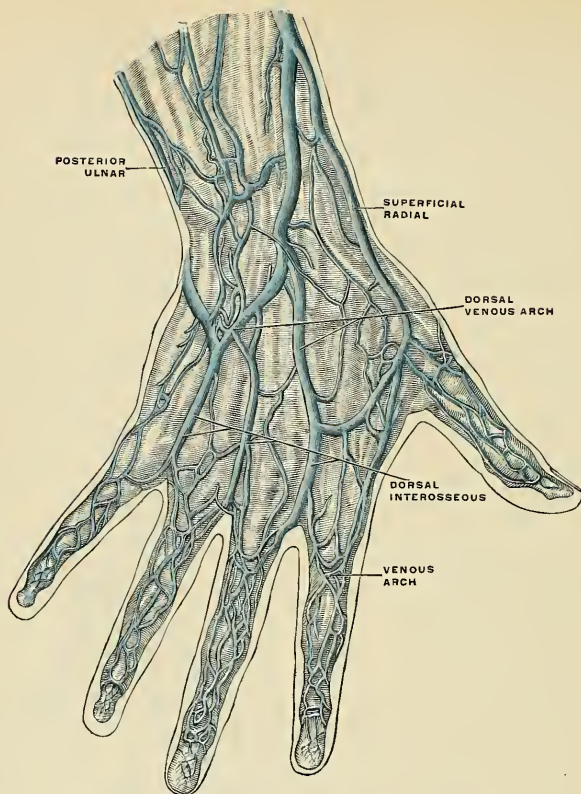


FIG. 508.—The veins on the dorsum of the hand. (Bourgery.)

The Superficial Veins of the Upper Extremity (Fig. 509).

The superficial veins of the upper extremity are:

Superficial veins of the hand.
 Anterior ulnar.
 Posterior ulnar.
 Common ulnar.
 Radial.

Median.
 Median cephalic
 Median basilic.
 Basilic.
 Cephalic.

The **superficial veins of the hand and fingers** (Figs. 508 and 509) are principally situated on the dorsal surface. These dorsal veins *begin* in each finger as a venous plexus, in which are distinct veins running in a longitudinal direction and called **dorsal digital veins** (*vv. digitales dorsales propriae*). The dorsal digital veins terminate over the first phalanges in the **venous arches of the fingers** (*arcus*

venosi digitales). From these arches take origin the four dorsal interosseous or the **interdigital veins** (*vv. metacarpeae dorsales*). These veins form the **dorsal venous plexus of the hand** (*rete venosum dorsale manus*). This plexus lies in a line with the lower ends of the shafts of the metacarpal bones. It receives the dorsal interosseous veins, the radial digital vein of the index finger, and numerous superficial veins from the back of the hand. It gives origin to the superficial radial vein and the posterior ulnar vein. The superficial veins of the palmar surface are of less size and number than the dorsal veins. They arise from each of the phalanges by a plexus (*vv. digitales volares propriae*). Vessels at the borders of the fingers take most of the blood to the dorsal veins. There are also veins in the finger webs (*vv. intercapitulares*), which convey the blood from the palm to the dorsum. A superficial plexus, the **palmar plexus**, lies upon the palmar fascia, the fascia of the thenar eminence, and the fascia of the hypothenar eminence.

The **anterior ulnar vein** (Fig. 509) commences on the anterior surface of the ulnar side of the hand and wrist, and ascends along the anterior surface of the ulnar side of the forearm to the bend of the elbow, where it joins with the posterior ulnar vein to form the common ulnar. Occasionally it opens separately into the median basilic vein. It communicates with tributaries of the median vein in front and with the posterior ulnar behind.

The **posterior ulnar vein** (Fig. 508) commences on the posterior surface of the ulnar side of the wrist. It runs on the posterior surface of the ulnar side of the forearm, and just below the elbow unites with the anterior ulnar vein to form the common ulnar, or else joins the median basilic and helps to form the basilic. It communicates with the deep veins of the palm by a vein which emerges from beneath the Abductor minimi digiti muscle.

The **common ulnar vein** (Fig. 509) is a short trunk which is not constant. When it exists it is formed by the

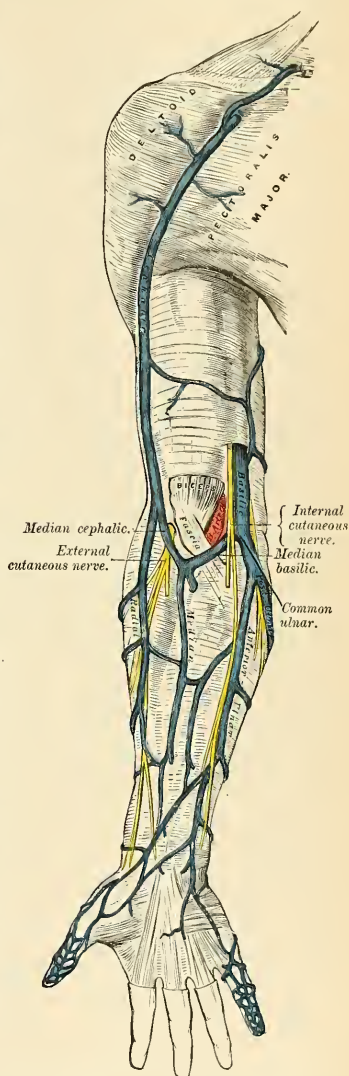


FIG. 509.—The superficial veins of the flexor aspect of the upper extremity.

junction of the two preceding veins, and, passing upward and outward, joins the median basilic to form the basilic vein. When it does not exist the anterior and posterior ulnar veins open separately into the median basilic vein.

The **radial vein** (*v. radialis*) (Figs. 509 and 510) *commences* upon the dorsal surface of the wrist, and communicates with the deep veins of the palm by a branch which passes through the first interosseous space. The radial vein soon forms a large vessel, which ascends along the radial side of the forearm and receives numerous veins from both its surfaces. At the bend of the elbow it unites with the median cephalic to form the cephalic vein.

The **median vein** (*v. mediana cubiti*) (Fig. 509) ascends on the front of the forearm, and communicates with the anterior ulnar and radial veins. At the bend of the elbow it receives a branch of communication from the deep veins, the **deep median vein**, and divides into two trunks, the **median cephalic** and **median basilic**, which diverge from each other as they ascend.

The **median cephalic** (*v. mediana cephalica*) (Fig. 509), usually the smaller of the two, passes outward in the groove between the Brachioradialis and Biceps muscles, and joins with the radial to form the cephalic vein. The branches of the external cutaneous nerve pass beneath this vessel.

The **median basilic vein** (*v. mediana basilica*) (Fig. 509) passes obliquely inward, in the groove between the Biceps and Pronator teres muscles, and joins the common ulnar to form the basilic. This vein passes in front of the brachial artery, from which it is separated by a fibrous expansion, the **bicipital fascia**, which is given off from the tendon of the Biceps to the fascia covering the Flexor muscles of the forearm. Filaments of the internal cutaneous nerve pass in front as well as behind this vessel.

Venesection is usually performed at the bend of the elbow, and as a matter of practice the largest vein in this situation is commonly selected. This is usually the median basilic, and there are anatomical advantages and disadvantages in selecting this vein. The advantages are, that, in addition to its being the largest, and therefore yielding a greater supply of blood, it is the least movable and can be easily steadied on the bicipital fascia on which it rests. The disadvantages are, that it is in close relationship with the brachial artery, separated only by the bicipital fascia; and formerly, when venesection was frequently practised, arteriovenous aneurism was no uncommon result of this practice. Another disadvantage is, that the median basilic is crossed by some of the branches of the internal cutaneous nerve, and these may be divided in the operation, giving rise to "traumatic neuralgia of extreme intensity" (Tillaux).

Intravenous infusion of normal saline solution is very frequently required for all conditions of severe shock and after profuse hemorrhages. The patient's arm is surrounded by a tight bandage so as to impede the venous return, and a small incision is made over the largest vein visible in front of the elbow; a double ligature is now passed around the vein, and the lower one is tied; the vein is then opened and a cannula connected with a funnel by tubing and filled with warm saline solution is inserted. The bandage is next removed from the arm, and two, three, or more pints of fluid are allowed to flow into the vein; when a sufficient quantity has gone in, the upper ligature around the vein is tied and a stitch put in the skin wound.

The **basilic vein** (*v. basilica*) (Figs. 509 and 511) is of considerable size and is formed by the coalescence of the common ulnar vein with the median basilic. It passes upward along the inner side of the Biceps muscle and pierces the deep fascia a little below the middle of the arm. The opening in the fascia is known as the **semilunar hiatus**. The vein ascends in the course of the brachial artery to the lower border of the tendons of the Latissimus dorsi and Teres major muscles, and is continued onward as the axillary vein.

The **cephalic vein** (*v. cephalica*) (Fig. 509) is formed by the union of the median cephalic and the radial veins. It courses along the outer border of the Biceps muscle, lying in the same groove with the upper external cutaneous branch of the musculospiral nerve, to the upper third of the arm; it then passes in the interval between the Pectoralis major and Deltoid muscles, lying in the same groove

with the descending or humeral branch of the acromiothoracic artery. It pierces the costocoracoid membrane, and, crossing the axillary artery, terminates in the axillary vein just below the clavicle. This vein is occasionally connected with the external jugular or subclavian by a branch which passes from it upward in front of the clavicle.

The **accessory cephalic vein** (*v. cephalica accessoria*) arises either from a small tributary plexus on the back of the forearm or from the ulnar side of the dorsal venous arch; it joins the cephalic above the elbow. In some cases the accessory cephalic springs from the cephalic above the wrist and joins it again higher up. A large oblique branch frequently connects the basilic and cephalic veins on the back of the forearm.¹

The Deep Veins of the Upper Extremity.

The **deep veins of the upper extremity** (Fig. 510) follow the course of the arteries, forming their **venae comites**, or **companion veins**. Usually there is one vein lying on each side of the corresponding artery, and they are connected at intervals by short transverse branches.

Two **digital veins** accompany each artery along the sides of the fingers; these, uniting at their base, pass along the interosseous spaces in the palm, and terminate in the two venae comites which accompany the superficial palmar arch. Branches from these vessels on the radial side of the hand accompany the superficialis volae, and on the ulnar side terminate in the deep ulnar veins (Fig. 510). The deep ulnar veins, as they pass in front of the wrist, communicate with the interosseous and superficial veins, and at the elbow unite with the deep radial veins to form the venae comites of the brachial artery. The venae comites of the brachial communicate by numerous transverse branches, which cross over or under the artery.

The **interosseous veins** (Fig. 510) accompany the anterior and posterior interosseous arteries. The anterior interosseous veins *commence* in front of the wrist, where they communicate with the deep radial and ulnar veins; at the upper part of the forearm they receive the posterior interosseous veins, and terminate in the venae comites of the ulnar artery.

The **deep palmar veins** accompany the deep palmar arch, being formed by tributaries which accompany the ramifications of that vessel. At the wrist they receive a dorsal and a palmar tributary from the thumb. The deep palmar veins communicate with the deep ulnar veins at the inner side of the hand, and on the outer side terminate in the **deep radial veins** (Fig. 510), which are the venae comites of the radial artery. Accompanying the radial artery the deep radial veins terminate in the venae comites of the brachial artery.

The **brachial veins** (*vv. brachiales*) (Fig. 510) are placed one on each side of the brachial artery; receiving tributaries corresponding with the branches given off from that vessel; at the lower margin of the Subscapularis muscle they join the axillary vein.

These deep veins have numerous anastomoses, not only with each other, but also with the superficial veins. One of the brachial veins empties into the axillary, the other, usually the smaller, generally unites with the basilic.

The **axillary vein** (*v. axillaris*) (Fig. 511) is of large size, and is the continuation upward of the basilic vein. It *commences* at the lower border of the tendon of the Teres major muscle, increases in size as it ascends, by receiving tributaries corre-

¹ Concerning the variations in the arrangement and course of the veins of the upper extremity, consult the article by W. Krause in Henle's *Handbuch der Anatomie*.

sponding with the branches of the axillary artery, and terminates immediately beneath the clavicle at the outer border of the first rib, where it becomes the subclavian vein. This vessel is covered in front by the Pectoral muscles and costocoracoid membrane, and lies on the thoracic side of the axillary artery, which it partially overlaps. Near the lower margin of the Subscapularis it receives the venae comites of the brachial artery, and, near its termination, the cephalic vein. This vein is provided with a pair of valves opposite the lower border of the Subscapularis muscle; valves are also found at the termination of the cephalic and subscapular veins.

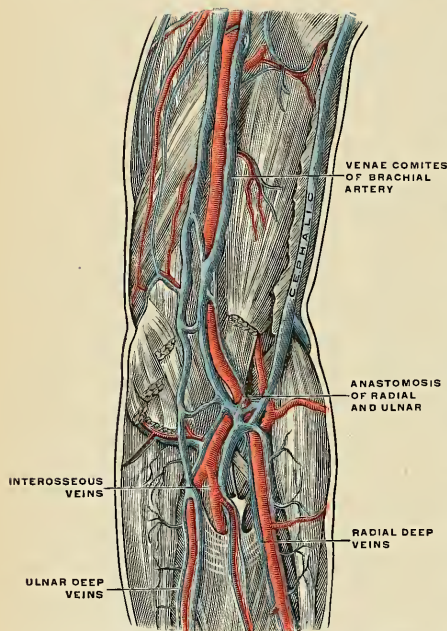


FIG. 510.—The deep veins of the upper extremity. (Bourguery.)

Being more superficial, larger, and slightly overlapping the axillary artery, it is more liable to be wounded in the operation of extirpation of the axillary nodes, especially as these nodes, when diseased, are liable to become adherent to the vessel. When wounded there is always danger of air being drawn into its interior, in which case death is usually the result. This is due not only to the fact that it is near the thorax, and therefore liable to be influenced by the respiratory movements, but also because it is adherent by its anterior surface to the costocoracoid membrane, and therefore if wounded is likely to remain patulous and favor the chance of air being sucked in. This adhesion of the vein to the fascia prevents its collapsing, and therefore favors the furious bleeding which takes place in these cases.

To avoid wounding the axillary vein in the extirpation of nodes from the axilla no undue force should be used in isolating the nodes. If the vein is found to be so embedded in the malignant deposit that the latter cannot be removed without taking away a part of the vein, this must be done, the vessel having been first ligated above and below the diseased area.

The **subclavian vein** (*v. subclavia*) (Figs. 512 and 513), the continuation of the axillary, extends from the outer border of the first rib to the inner end of the clavicle, where it unites with the internal jugular to form the innominate vein. It is in relation, in *front*, with the clavicle and the Subclavius muscle; *behind* and *above*, with the subclavian artery, from which it is separated internally by the Scalenus anticus muscle and phrenic nerve. *Below*, it rests in a depression on the first rib and upon the pleura. *Above*, it is covered by the cervical fascia and integument.

Other tributaries of the axillary vein are:

The **long thoracic vein** (*v. thoracalis lateralis*) (Fig. 511), which receives the **thoracico-epigastric vein** (*v. thoracoepigastrica*), and which comes from the superficial epigastric or from the femoral vein; and the **costoaxillary veins** (*vv. costoaxillares*) (Fig. 511), which come from the first six intercostal spaces and convey the blood from the intercostal veins to the axillary.

Applied Anatomy.—There are several points of surgical interest in connection with the axillary vein.

An expansion of the aponeurosis of the Subclavius muscle lies upon the vein (Fig. 512).

The subclavian vein occasionally rises in the neck to a level with the third part of the subclavian artery, and in two instances has been seen passing with this vessel behind the Scalenus anticus. It is usually provided with a pair of valves about an inch from its termination.

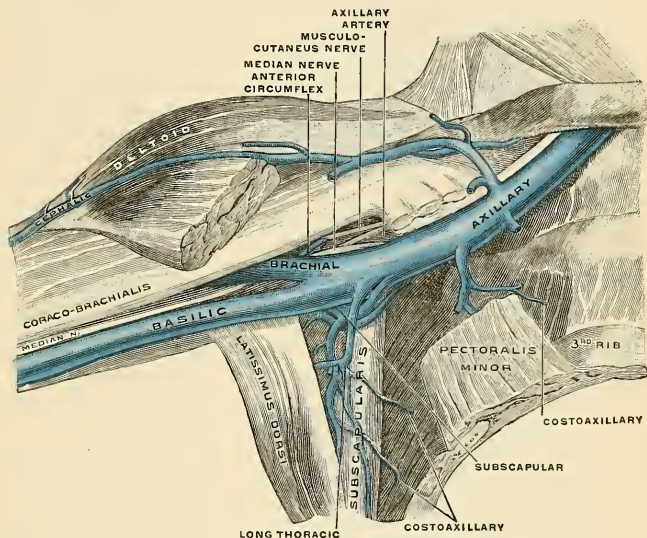


FIG. 511.—The veins of the right axilla, viewed from in front. (Spalteholz.)

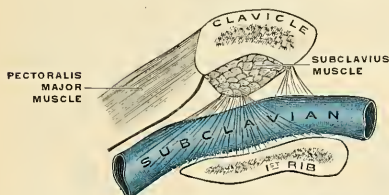


FIG. 512.—The aponeurotic expansion of the Subclavius muscle over the subclavian vein. (Poirier and Charpy.)

Tributaries.—It receives the external jugular vein, sometimes the anterior jugular vein, and occasionally a small branch from the cephalic. At the angle of junction with the internal jugular the left subclavian vein receives the thoracic duct (Fig. 513), while the right subclavian vein receives the right lymphatic duct.

The **innominate** or **brachio-cephalic veins** (*vv. anonymae*) (Fig. 514) are two large trunks, placed one on either side of the root of the neck, and formed by the union of the internal jugular and subclavian veins of the corresponding side.

The **right innominate vein** (*v. anonyma dextra*) is a short vessel, an inch in length, which commences at the inner end of the clavicle, and, passing almost vertically downward, joins with the left innominate vein just below the cartilage of the first rib, close to the right border of the sternum, to form the superior vena cava. It lies superficial and external to the innominate artery; on its right side is the phrenic nerve, and the pleura is here interposed between it and the apex of the lung. This vein, at the angle of junction of the internal jugular with the

subclavian, receives the right vertebral vein, and, lower down, the right internal mammary, right inferior thyroid, and sometimes the right thyroidea ima and the right superior intercostal veins.

The **left innominate vein** (*v. anonyma sinistra*), about two and a half inches in length, and larger than the right, passes from left to right across the upper and front part of the thorax, at the same time inclining downward, and unites with the right innominate vein to form the superior vena cava. It is in relation, in *front*, with the first piece of the sternum, from which it is separated by the Sternohyoid and Sternothyroid muscles, the thymus gland or its remains, and some loose areolar tissue. *Behind* it are the three large arteries arising from the arch of the aorta, together with the vagus and phrenic nerves. This vessel is joined by the left vertebral, left internal mammary, left inferior thyroid, left thyroidea ima, and the left superior intercostal veins, and occasionally some thymic and pericardiac veins. There are no valves in the innominate veins.

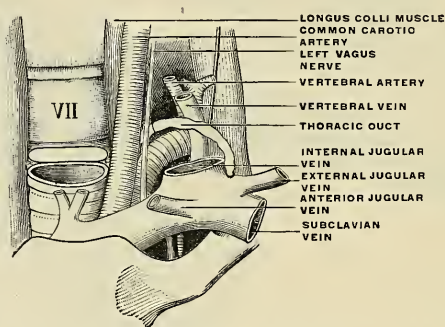


FIG. 513.—The bend of the thoracic duct at its termination in the subclavian vein. (Poirier and Charpy.)

Peculiarities.—Sometimes the innominate veins open *separately* into the right auricle; in such cases the right vein takes the ordinary course of the superior vena cava; but the left vein—the *left superior vena cava*, as it is termed—after communicating by a small branch with the right one, passes in front of the root of the left lung, and, turning to the back of the heart, receives the cardiac veins, and terminates in the back of the right auricle. This occasional condition in the adult is due to the persistence of the early fetal condition, and is the normal state of things in birds and some mammalia.

The **internal mammary veins** (*vv. mammae internae*), two to each internal mammary artery, follow the course of that vessel, and receive tributaries corresponding to the branches of the artery. The two veins unite into a single trunk which terminates in the corresponding innominate vein. It receives the twelve anterior intercostal veins from the upper six intercostal spaces of the corresponding side—six anterior perforating veins (*rami perforantes*)—veins from the surface of the sternum (*rami sternales*)—muscular veins, and vessels from the mediastinum and pleura. The internal mammary veins anastomose below with the *venae comites* of the musculophrenic and superior epigastric arteries. The **superior phrenic vein** (*i. e.*, the vein accompanying the *arteria comes nervi phrenici*) usually opens into the internal mammary vein.

The **vertebral vein** (see p. 717).

The **inferior thyroid veins** (*vv. thyroideae inferiores*) (Fig. 499), two, frequently three or four, in number, arise in the **venous plexus on the thyroid body** (*plexus thyroideus impar*), communicating with the middle and superior thyroid veins. They form a plexus in front of the trachea, behind the Sternothyroid muscles.

From this plexus a left vein descends and joins the left innominate trunk, and a right vein passes obliquely downward and outward across the innominate artery to open into the right innominate vein, just at its junction with the superior vena cava. The **thyreoidea ima vein** (*v. thyreoidea ima*) passes downward in front of the trachea and terminates in the left innominate vein. These veins receive tributaries from the **tracheal veins** (*vv. tracheales*), from the **oesophageal veins** (*vv. oesophageae*), from the **inferior laryngeal veins** (*v. laryngea inferior*).

The **superior intercostal veins** (right and left) drain the blood from two or three of the intercostal spaces below the first. The **right superior intercostal vein** (*v. intercostalis suprema dextra*) passes downward and inward and opens into the vena azygos major; the **left superior intercostal vein** (*v. intercostalis suprema sinister*) runs across the arch of the aorta and opens into the left innominate vein. It usually receives the left bronchial and left superior phrenic vein, and communicates below with the vena azygos minor superior. The vein from the first intercostal space opens directly into the corresponding vertebral or innominate vein.

The **superior vena cava** (*v. cava superior*; precava) (Fig. 514) receives the blood which is conveyed to the heart from the whole of the upper half of the body. It is a short trunk, varying from two inches and a half to three inches in length, formed by the junction of the two innominate veins. It commences at the level of the

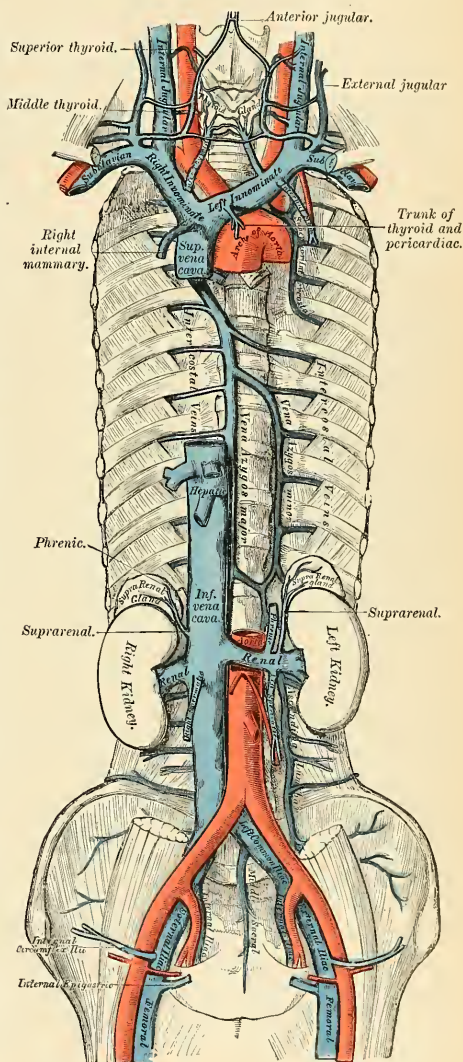


FIG. 514.—The venae cavae and azygos veins, with their formative tributaries.

lower border of the cartilage of the first rib close to the sternum on the right side, and, descending vertically, enters the pericardium about an inch and a half above the heart, and terminates in the upper part of the right auricle opposite the upper border of the third right costal cartilage. In its course it describes a slight curve, the convexity of which is to the right side.

Relations.—*In front*, with the pericardium and process of cervical fascia which is continuous with it; these separate it from the thymus gland, the sternum, and the second and third right costal cartilages; *behind*, with the root of the right lung. On its *right side*, it is in relation with the phrenic nerve and right pleura; on its *left side*, with the commencement of the innominate artery and ascending part of the aorta, the latter somewhat overlapping it. The portion contained within the pericardium is covered in front and laterally by the serous layer of that membrane. It receives the vena azygos major just before it enters the pericardium, and several small veins from the pericardium and parts in the mediastinum. The superior vena cava has no valves.

The **azygos veins** are three in number; they collect the blood from the majority of the intercostal spaces, and connect the superior and inferior venæ cavæ.

The **vena azygos major** (*v. azygos*) (Fig. 514) *commences* opposite the first or second lumbar vertebra by a branch from the right lumbar veins, called the **right ascending lumbar vein** (*v. lumbalis ascendens*); sometimes by a branch from the right renal vein or from the inferior vena cava. It enters the thorax through the aortic opening in the Diaphragm, and passes along the right side of the vertebral column to the fourth thoracic vertebra, where it arches forward over the root of the right lung, and terminates in the superior vena cava just before that vessel enters the pericardium. While passing through the aortic opening of the Diaphragm it lies with the thoracic duct on the right side of the aorta; and in the thorax it lies upon the intercostal arteries on the right side of the aorta and thoracic duct, and is partly covered by pleura.

Tributaries.—It receives the lower ten posterior intercostal veins of the right side, the upper two or three of these opening, first of all, into the **right superior intercostal vein**. On the left side the first posterior intercostal vein follows the same course as the right and empties into the vertebral or innominate vein. The second, third, and fourth posterior intercostal veins unite and form the **left superior intercostal vein**. This vein then passes forward across the arch of the aorta and unites with the left innominate vein. The fifth, sixth, and seventh posterior intercostals of the left side contribute to the vena azygos minor superior. The rest of the posterior intercostal veins of the left side terminate in the vena azygos minor inferior. It receives the azygos minor veins, several cesophageal mediastinal and pericardial veins; near its termination, the right bronchial vein. A few imperfect valves are found in this vein; but its tributaries are provided with complete valves.

The **intercostal veins** (*vv. intercostalis*) are divided into anterior and posterior intercostals.

The **anterior intercostal veins** are tributaries of the internal mammary or the musculophrenic veins (p. 734).

The **posterior intercostal veins** (Fig. 514) number eleven on each side, there being one vein in each intercostal space. Each vein lies in the groove at the lower margin of the rib above the corresponding intercostal artery. On the right side the first posterior intercostal vein crosses the neck of the first rib anteriorly and opens into the vertebral vein or the innominate vein. The posterior intercostals of the right side, from the fifth to the eleventh inclusive, open individually into the vena azygos major. The second, third, and fourth intercostals of this side unite to form a common trunk, the right superior intercostal vein, which then joins the vena azygos major.

The **vena azygos minor inferior** (*v. hemiazygos*) (Fig. 514) *commences* in the lumbar region by a branch from one of the lumbar veins, **ascending lumbar** (*v.*

lumbalis ascendens), or from the left renal. It enters the thorax through the left crus of the Diaphragm, and, ascending on the left side of the vertebral column as high as the eighth or ninth thoracic vertebra, passes across the vertebral column, behind the aorta, œsophagus, and thoracic duct, to terminate in the major azygos vein. It receives the four or five lower intercostal veins of the left side, and some œsophageal and mediastinal veins.

The **vena azygos minor superior** (*v. hemiazygos accessoria*) varies inversely in size with the left superior intercostal. It receives veins from the intercostal spaces between the left superior intercostal vein and highest tributary of the vena azygos minor inferior. They are usually three or four in number, usually the fifth, sixth, and seventh left posterior intercostal veins. They join to form a trunk which ends in the major azygos vein or in the vena azygos minor inferior. When this vein is small or altogether wanting, the left superior intercostal vein will extend as low as the fifth or sixth intercostal space. It sometimes receives the left bronchial vein.

Applied Anatomy.—In obstruction of the inferior vena cava, the azygos veins are one of the principal means by which the venous circulation is carried on, connecting as they do the superior and inferior venae cavae, and communicating with the common iliac veins by the ascending lumbar veins and with many of the tributaries of the inferior vena cava.

Thrombosis of the superior vena cava is oftenest due to pressure exerted on the vessel by an aneurism or a tumor; it may also occur by propagation of clotting from a tributary peripheral vein. If occlusion of the vessel take place slowly, a collateral venous circulation may be established; the patient will have some œdema with dilatation and congestion of the veins about the head and neck, and may also suffer from attacks of dyspnea and recurrent pleural effusion. In most cases, however, the blockage of the superior vena cava takes place rapidly, and is rapidly fatal.

The **bronchial veins** (*vv. bronchiales anteriores et posteriores*) return the blood from the larger bronchi and from the structures at the roots of the lungs; that of the right side opens into the vena azygos major, near its termination; that of the left side opens into the left superior intercostal vein or the vena azygos minor superior. A considerable quantity of the blood which is carried to the lungs through the bronchial arteries is returned to the left side of the heart by the pulmonary veins.

The Vertebral Veins.

The vertebral veins may be arranged into four groups—viz.:

1. The extravertebral veins.
2. The intravertebral veins.
3. The veins of the bodies of the vertebræ.
4. The veins of the spinal cord.

1. The **extravertebral veins** (*plexus venosi vertebrales externi*) commence by small branches which receive their blood from the integument of the back of the vertebral column and from the muscles in the vertebral grooves. They form two plexuses, an **anterior plexus** (*plexus venosi vertebrales anteriores*), upon the vertebral bodies, and a **posterior plexus** (*plexus venosi vertebrales posteriores*), which surrounds the spinous processes, the laminae, and the transverse and articular processes of all the vertebræ. At the bases of the transverse processes they communicate, by means of ascending and descending branches, with the veins surrounding the contiguous vertebræ, and they join with the veins in the vertebral canal by branches which perforate the ligamenta subflava. Other branches pass obliquely forward, between the transverse processes, and communicate with the intravertebral veins through the intervertebral foramina (*vv. intervertebrales*). The extravertebral veins terminate by joining the vertebral veins in the neck, the intercostal veins in the thorax, and the lumbar and lateral sacral veins in the loins and pelvis.

2. The **intravertebral veins** (*plexus venosi vertebrales interni*) are situated between the spinal dura and the vertebræ. They consist of two longitudinal plexuses, one of which runs along the posterior surface of the bodies of the vertebræ, **anterior longitudinal vertebral veins**. The other plexus, **posterior longitudinal vertebral veins**, is placed on the inner or anterior surface of the laminae of the vertebræ.

The **anterior longitudinal vertebral veins** (*sinus vertebrales longitudinales*) consist of two large, tortuous veins which extend along the whole length of the vertebral column, from the foramen magnum, where they communicate with each other by a venous ring around that opening and with the basilar and occipital sinuses through the foramen, to the base of the coccyx, being placed one on each side of the posterior surface of the bodies of the vertebræ along the margin of the posterior common ligament. These veins communicate opposite each vertebræ by transverse trunks which pass beneath the ligament. Each transverse trunk receives the large **vena basis vertebrae** (*v. basivertebralis*) from the interior of the body of the vertebra. The anterior longitudinal vertebral veins are least developed in the cervical and sacral regions. They are not of uniform size throughout,

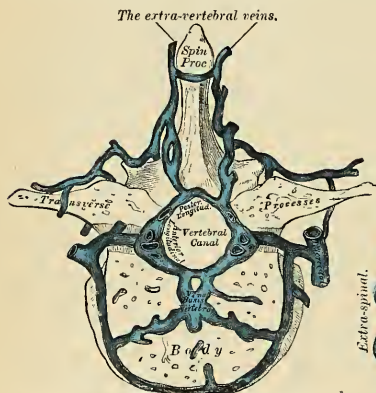


FIG. 515.—Transverse section of a thoracic vertebra, showing the vertebral veins.

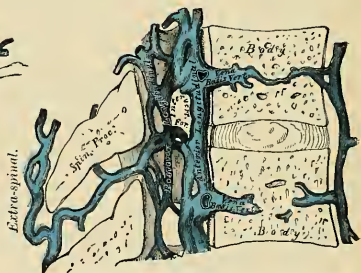


FIG. 516.—Vertical section of two thoracic vertebrae showing the vertebral veins.

being alternately enlarged and constricted. At the intervertebral foramina they communicate with the extravertebral veins, and with the vertebral veins in the neck, with the intercostal veins in the thoracic region, and with the lumbar and sacral veins in the corresponding regions.

The **posterior longitudinal vertebral veins**, smaller than the anterior, are situated one on either side, between the inner surface of the laminae and the theca vertebralis. They communicate (like the anterior) opposite each vertebra by transverse trunks, and with the anterior longitudinal veins by lateral transverse branches which pass from behind forward. The posterior longitudinal veins, by branches which perforate the ligamenta subflava, join with the extravertebral veins. From them branches are given off which pass through the intervertebral foramina and join the vertebral, intercostal, lumbar, and sacral veins.

The **intervertebral veins** (*vv. intervertebrales*) accompany the spinal nerves in the intervertebral foramina, receive veins from the spinal cord, and join the intra- and extravertebral veins.

3. The **veins of the bodies of the vertebræ** (*vv. basivertebrales*) emerge from the foramen on the posterior surface of each vertebra and join the transverse

trunk connecting the anterior longitudinal vertebral veins. They are contained in large, tortuous channels in the substance of the bones, similar in every respect to those found in the diploë of the cranial bones. These canals lie parallel to the upper and lower surfaces of the bones. They commence by small openings on the front and sides of the bodies of the vertebræ, through which communicating branches from the veins external to the bone pass into its substance, and converge to the principal canal, which is sometimes double toward its posterior part. They open into the corresponding transverse branch uniting the anterior longitudinal veins. They become greatly enlarged in advanced age.

4. The **veins of the spinal cord** (*vv. spiniales*) emerge from the cord substance and form a minute, tortuous, venous plexus which covers the entire surface of the cord, being situated between the pia and arachnoid. In this plexus there are (1) two median longitudinal veins, one in front of the ventral fissure, and the other behind the dorsal groove of the cord; and (2) four lateral longitudinal veins which run behind the nerve roots. These vessels are largest in the lumbar region. Near the base of the skull they unite, and form two or three small trunks, which communicate with the vertebral veins, and terminate in the inferior cerebellar veins or in the inferior petrosal sinuses. Each of the spinal nerves is accompanied by a radicular efferent vessel as far as the intervertebral foramina, where it joins the other veins from the vertebral canal.

There are no valves in the vertebral veins.

VEINS OF THE LOWER EXTREMITY, ABDOMEN, AND PELVIS

(Figs. 517, 518).

The **veins of the lower extremity** are subdivided, like those of the upper, into two sets, **superficial** and **deep**; the superficial veins are situated beneath the integument, between the two layers of superficial fascia, the deep veins accompanying the arteries, and forming the *venae comites* of those vessels. Both sets of veins are provided with valves, which are more numerous in the deep than in the superficial set. These valves are also more numerous in the lower than in the upper limb.

The Superficial Veins of the Lower Extremity.

The Superficial Veins of the Foot.—In the sole of the foot there is a **subcutaneous venous plexus** (*rete venosum plantare cutaneum*), from which some branches go to the deep veins, but most of the branches pass around the margins to the dorsum of the foot. There is a transverse venous arch at the root of the toes which receives plantar vessels from the toes and sends branches between the toes (*vv. intercapitulares*) to the venous arch of the dorsum. On the dorsum of each toe the veins gather into two vessels, known as the **dorsal digital veins** (*vv. digitales pedis dorsalis*). The dorsal digital veins from the opposed margins of two toes unite to form a dorsal interdigital vein. There are four **dorsal interdigital veins** (*vv. digitales communes pedis*), and they pass into the venous arch of the dorsum. The dorsal digital vein, from the inner surface of the great toe, passes directly into the internal saphenous vein, and the dorsal digital vein, from the outer surface of the little toe, passes directly into the external saphenous vein.

The **venous arch of the dorsum** of the foot (*arcus venosus dorsalis pedis*) is situated in the superficial structures over the anterior extremities of the metatarsal bones. It has its convexity directed forward, and receives digital tributaries from the upper surface of the toes; at its concavity it is joined by numerous small veins which form a **plexus** on the dorsum of the foot (*rete venosum dorsale pedis cutaneum*). The arch terminates internally in the long saphenous, externally in the short saphenous vein.

The chief superficial veins of the lower extremity are the **internal or long saphenous** and the **external or short saphenous**.

The **internal or long saphenous vein** (*v. saphena magna*) (Figs. 517 and 520) commences at the inner side of the arch on the dorsum of the foot; it ascends in

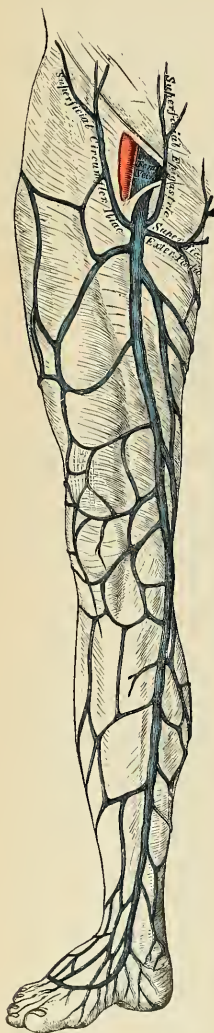

FIG. 517.—The internal or long saphenous vein and its tributaries.

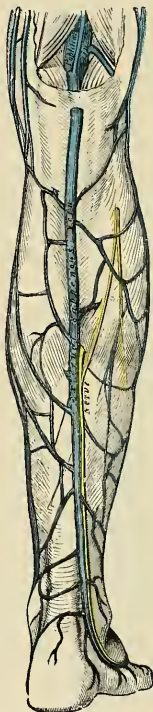

FIG. 518.—External or short saphenous vein.

front of the inner malleolus and along the inner side of the leg, behind the inner margin of the tibia, accompanied by the internal saphenous nerve. At the knee it passes backward behind the inner condyle of the femur, ascends along the inside of the thigh, and, passing through the saphenous opening in the fascia lata, terminates in the femoral vein about an inch and a half below Poupart's ligament. This vein receives in its course cutaneous tributaries from the leg and thigh, and at the saphenous opening receives the superficial epigastric, superficial circumflex iliac, and external pudic veins. The veins from the inner and back part of the thigh frequently unite to form a large vessel, which enters the main trunk near the saphenous opening; and sometimes those on the outer

side of the thigh join to form another large vessel; so that occasionally three large veins are seen converging from different parts of the thigh toward the saphenous opening. The internal saphenous vein communicates in the foot with the internal plantar vein; in the leg, with the posterior tibial veins by branches which perforate the tibial origin of the Soleus muscle, and also with the anterior tibial veins; at the knee, with the articular veins; in the thigh, with the femoral vein by one or more branches. The valves in this vein vary from two to six in number; they are more numerous in the thigh than in the leg.

The **external or short saphenous vein** (*v. saphena parva*) (Fig. 518) commences at the outer side of the arch on the dorsum of the foot; it ascends behind the outer malleolus, and along the outer border of the tendo Achillis, across which it passes at an acute angle to reach the middle line of the posterior aspect of the leg. Passing directly upward, it perforates the deep fascia in the lower part of the popliteal space, and terminates in the popliteal vein, between the heads of the Gastrocnemius muscle. It receives numerous large tributaries from the back part of the leg, and communicates with the deep veins on the dorsum of the foot and behind the outer malleolus. Before it perforates the deep fascia it gives off a communicating branch, which passes upward and inward to join the internal saphenous vein. This vein contains from nine to twelve valves, one of which is always found near its termination in the popliteal vein. The external saphenous nerve lies close beside this vein.

Applied Anatomy.—A *varicose* condition of the saphenous veins is more frequently met with than in the other veins of the body, except perhaps the spermatic and hemorrhoidal veins. The course of the internal saphenous is in front of the tip of the inner malleolus, over the subcutaneous surface of the lower end of the tibia, and then along the internal border of this bone to the back part of the internal condyle of the femur, whence it follows the course of the Sartorius muscle, and is represented on the surface by a line drawn from the posterior border of the Sartorius on a level with the internal condyle to the saphenous opening. The external saphenous lies behind the external malleolus, and from this follows the middle line of the calf to just below the ham. It is not generally so apparent beneath the skin as the internal saphenous. Both these veins in the leg are accompanied by nerves, the internal saphenous being joined by its companion nerve just below the level of the knee-joint. No doubt much of the pain of varicose veins in the leg is due to this fact.

Operations for the relief of varicose veins are frequently required, portions of the veins being removed after having been ligated above and below. It is important to note whether the main varicose area drains into the internal or the external saphenous vein—the former condition being much the more common—and to control the venous return by removing a small portion of the main trunk just before it opens into the deep vein by passing through the deep fascia; thus in most cases a piece should be removed from the internal saphenous just before it passes through the saphenous opening, and in addition the affected veins should be excised just above and just below the level of the knee-joint. In other cases the external saphenous will have to be dealt with immediately below the point where it pierces the fascial roof of the popliteal space.

The Deep Veins of the Lower Extremity.

The **deep veins of the lower extremity** accompany the arteries and their branches and are called the **venae comites** of those vessels. The venae comites in the lower extremity pass into one trunk, the **popliteal vein**, whereas in the upper extremity the venae comites continue with the artery to the axilla.

The Deep Veins of the Foot.—The plantar digital veins (*vv. digitales plantares*) form the **plantar metatarsal veins** (*vv. metatarsae plantares*), which communicate with the veins of the dorsum of the foot by perforating veins and also communicate with the deep venous arch of the sole of the foot (*arcus venosus plantaris*). The plantar arch gives off **lateral or external plantar veins**, which unite with **median or internal plantar veins** to form the posterior tibial veins. On the dorsum of the foot the deep veins begin as the **dorsal metatarsal veins** (*vv. metatarsae dorsales pedis*), which form the venae comites of the dorsalis pedis artery.

The **posterior tibial veins** (*vv. tibiales posteriores*) accompany the posterior tibial artery and are joined by the peroneal veins.

The **anterior tibial veins** (*vv. tibialis anteriores*) are formed by a continuation upward of the *venae comites* of the *dorsalis pedis* artery. They pass between the tibia and fibula, through the large oval aperture above the interosseous membrane, and form, by their junction with the posterior tibial, the popliteal vein.

The valves in the deep veins are very numerous.

The **popliteal vein** (*v. poplitea*) (Fig. 519) is formed by the junction of the anterior and posterior tibial veins; it ascends through the popliteal space to the aperture in the Adductor magnus tendon, where it becomes the femoral vein. In the lower part of its course it is placed internal to the artery; between the heads of the Gastrocnemius it is superficial to that vessel; but above the knee-joint it is close to the outer side of the artery. It receives the **sural veins** from the Gastrocnemius muscle, the articular veins, and the external saphenous veins. The valves in this vein are usually four in number.

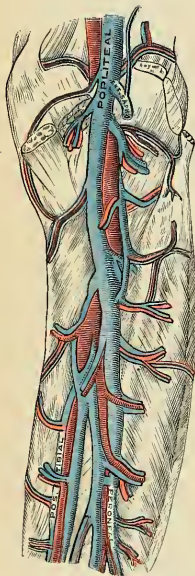


FIG. 519.—The popliteal vein.
(Poirier and Charpy.)

The **femoral vein** (*v. femoralis*) (Figs. 520 and 521) accompanies the femoral artery through the upper two-thirds of the thigh. In the lower part of its course it lies external to the artery; higher up it is behind it; and at Poupart's ligament it lies to its inner side and on the same plane. It receives numerous muscular tributaries, and about an inch and a half below Poupart's ligament it is joined by the deep femoral; near its termination it is joined by the internal saphenous vein. The valves in the femoral vein are four or five in number.

The **deep femoral vein** (*v. profunda femoris*) receives tributaries corresponding to the perforating branches of the profunda artery, and through these establishes communications with the popliteal vein below and the sciatic vein above. It also receives the internal and external circumflex veins.

The **external iliac vein** (*v. iliaca externa*) (Figs. 521 and 523) *commences* at the termination of the femoral, beneath the crural arch, and, passing upward along the brim of the pelvis, terminates opposite the sacroiliac joint by uniting with the internal iliac to form the common iliac vein. On the right side it lies at first along the inner side of the external iliac artery, but as it passes upward gradually inclines behind it. On the left side it lies altogether on the inner side of the artery. It receives, immediately above Poupart's ligament, the deep epigastric and deep circumflex iliac veins and a small pubic vein, corresponding to the pubic branch of the obturator artery. It frequently contains one and sometimes two valves.

Tributaries.—The external iliac vein receives the deep epigastric, deep circumflex iliac, and pubic veins.

The **deep epigastric vein** (*v. epigastrica inferior*) (Fig. 521) is formed by the union of the *venae comites* of the deep epigastric artery, which communicates above with the superior epigastric vein; it joins the external iliac about half an inch above Poupart's ligament.

The **deep circumflex iliac vein** (*v. circumflexa ilium profunda*) (Fig. 521) is formed by the union of the *venae comites* of the deep circumflex iliac artery,

and joins the external iliac vein about three-quarters of an inch above Poupart's ligament.

The **pubic vein** communicates with the obturator vein in the obturator foramen, and ascends on the back of the pubis to terminate in the external iliac vein.

The **internal iliac vein** (*v. hypogastrica*) commences near the upper part of the great sacrosciatic foramen, passes upward behind and slightly to the inner side of the internal iliac artery, and at the brim of the pelvis joins with the external iliac to form the common iliac.

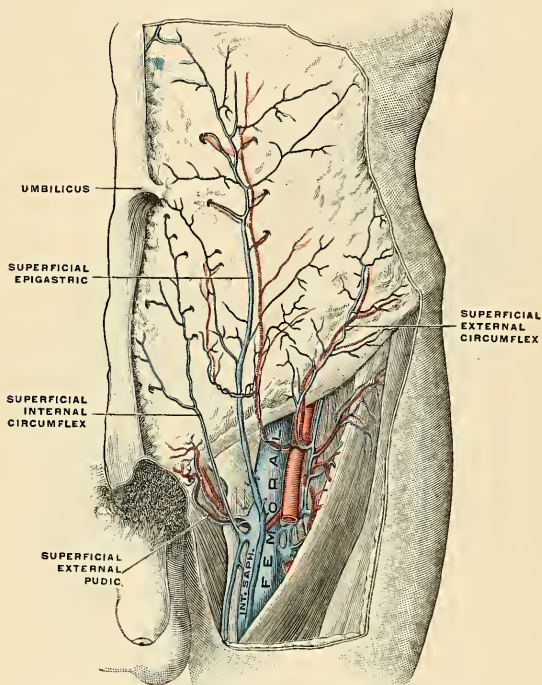


FIG. 520.—The femoral vein and its tributaries. (Poirier and Charpy.)

Tributaries.—With the exception of the fetal umbilical vein, which passes upward and backward from the umbilicus to the liver, and the ilio-lumbar vein which usually joins the common iliac vein, the tributaries of the internal iliac vein correspond with the branches of the internal iliac artery. It receives (*a*) the gluteal, sciatic, internal pudic, and obturator veins, which have their origins outside the pelvis; (*b*) the lateral sacral veins, which lie in front of the sacrum; and (*c*) the middle hemorrhoidal, vesical, uterine, and vaginal veins, which originate in venous plexuses connected with the pelvic viscera.

1. The **gluteal veins** (*vv. glutaecae superiores*) or *venae comites* of the gluteal artery, receive tributaries from the buttock corresponding with the branches of

the artery; they enter the pelvis through the great sacrosciatic foramen, above the Piriformis, and frequently unite before ending in the internal iliac vein.

2. The **sciatic veins** (*vv. glutaee inferiores*), or *venae comites* of the sciatic artery, begin on the upper part of the back of the thigh, where they anastomose with the internal circumflex and first perforating veins. They enter the pelvis through the lower part of the sacrosciatic foramen and join to form a single stem which opens into the lower part of the internal iliac vein.

3. The **internal pudic veins** are the *venae comites* of the internal pudic artery. They *commence* in the veins which issue from the corpus cavernosum, accompany the internal pudic artery, and unite to form a single vessel, which ends in the internal iliac vein. They receive the veins from the bulb of the urethra, the superficial perineal, and the inferior hemorrhoidal veins (*vv. hemorrhoidales inferiores*). The deep dorsal vein of the penis communicates with the internal pudic veins, but ends mainly in the vesicoprostatic venous plexus.

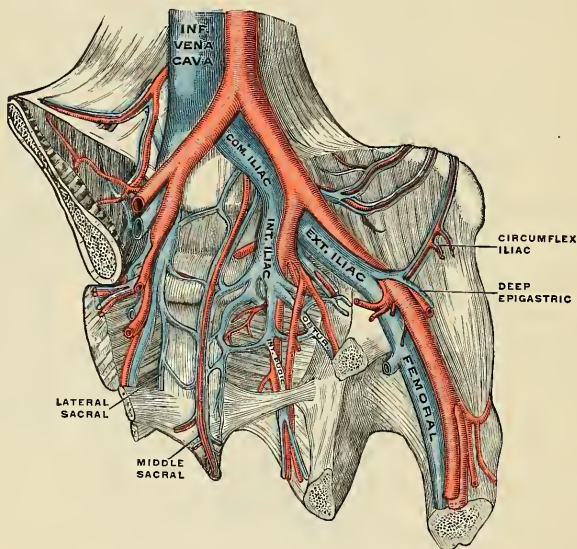


FIG. 521.—The iliac veins. (Poirier and Charpy.)

4. The **obturator vein** (*v. obturatoria*) begins in the upper portion of the adductor region of the thigh and enters the pelvis through the anterior part of the obturator foramen. It runs backward and upward on the lateral wall of the pelvis below the obturator artery, and then passes between the ureter and the internal iliac artery, to end in the internal iliac vein.

5. The **lateral sacral veins** (*vv. sacrales laterales*) accompany the lateral sacral arteries on the anterior surface of the sacrum and terminate in the internal iliac vein.

6. The **middle hemorrhoidal vein** (*v. hemorrhoidalis media*) takes origin in the hemorrhoidal plexus and receives tributaries from the bladder, prostate gland, and seminal vesicle; it runs outward on the pelvic surface of the Levator ani to end in the internal iliac vein.

The **hemorrhoidal plexus** surrounds the rectum, and communicates in front with the vesicoprostatic plexus in the male, and the uterovaginal plexus in the female. It consists of two parts, an *internal* in the submucosa, and an *external* outside the muscular coat. Below, the internal plexus presents a series of dilated pouches which are arranged in a circle around the tube immediately above the anal orifice and are connected by transverse branches.

The lower part of the external plexus is drained by the inferior hemorrhoidal veins into the internal pudic; its middle part by the middle hemorrhoidal vein, which joins the internal iliac; and its upper part by the superior hemorrhoidal vein, which forms the commencement of the inferior mesenteric vein, a tributary of the portal vein. A free communication between the portal and systemic venous systems is established through the hemorrhoidal plexus.

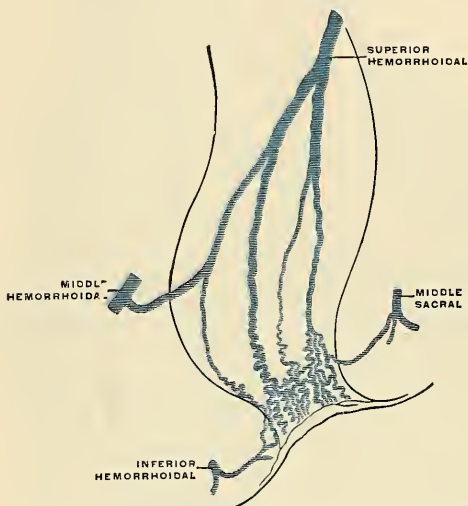


FIG. 522.—Scheme of the anastomosis of the veins of the rectum. (Poirier and Charpy.)

The **vesicoprostatic plexus** surrounds the prostate gland and the neck of the bladder, and lies partly in the fascial sheath of the prostate and partly between the sheath and the capsule of the gland. In front it receives the deep dorsal vein of the penis; behind, it communicates with the hemorrhoidal and vesical plexuses, and derives tributaries from the vasa deferentia and seminal vesicles. It is drained into the internal iliac veins by one or more vessels on either side. The corresponding plexus in the female is named the **vesicovaginal**.

The **vesical plexus** lies on the muscular coat of the bladder, and is best marked toward the base and sides of this viscus; it drains into the vesicoprostatic plexus.

Applied Anatomy.—The veins of the hemorrhoidal plexus are liable to become dilated and varicose, and form piles. This is due to several anatomical reasons: the vessels are contained in very loose, lax connective tissue, so that they get less support from surrounding structures than most other veins, and are less capable of resisting increased blood pressure; the condition is favored by gravitation, being influenced by the erect posture, either sitting or standing, and by the fact that the superior hemorrhoidal and portal veins have no valves; the veins pass

through muscle tissue and are liable to be compressed by its contraction, especially during the act of defecation; they are affected by every form of portal obstruction.

The prostatic plexus of veins is liable to become congested in many inflammatory conditions in the neighborhood, such as acute gonorrheal prostatitis. It is owing to the free communication which exists between this and the middle hemorrhoidal plexus that great relief can be given by free saline purgation.

Hemorrhage may be very profuse from the prostatic plexus after operations on that gland, but can usually be checked by hot fluid irrigation. Septic thrombosis sometimes occurs after operations, and infected emboli may find their way into the general circulation.

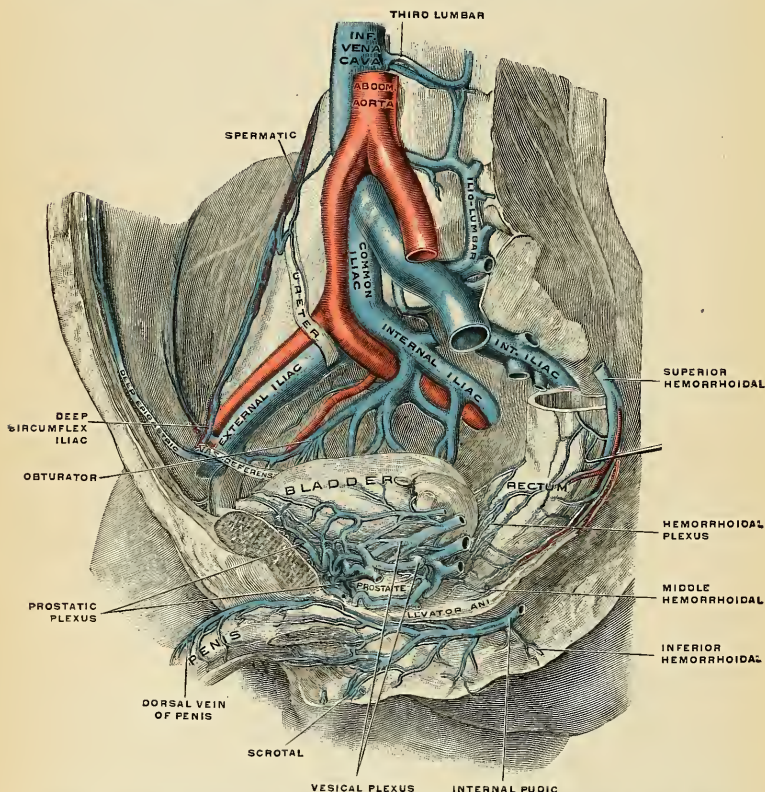


FIG. 523.—The veins of the male pelvis, right half, viewed from the left. The Psoas muscle has been removed and the rectum drawn down somewhat to the side. (Spalteholz.)

The **dorsal veins of the penis** are two in number, a superficial and a deep. The *superficial* vein drains the prepuce and skin of the penis, and, running backward in the subcutaneous tissue, inclines to the right or left, and opens into the corresponding superficial external pudic vein, a tributary of the internal or long saphenous vein. The *deep* vein receives the blood from the glans penis and corpora cavernosa; it courses backward in the middle line between the dorsal arteries, beneath the deep fascia, and near the root of the penis passes between

the two parts of the suspensory ligament and then through an aperture between the subpubic ligament and the apex of the triangular ligament, and divides into two branches, which enter the vesicoprostatic plexus. The dorsal vein of the clitoris corresponds in woman to the dorsal vein of the penis in man, and empties into the inferior vesical plexus.

The Vaginal Plexuses and Veins (Fig. 525).—The vaginal plexuses are placed at the sides of the vagina, being especially developed at the orifice of the canal. They receive vessels from the vaginal walls. The plexuses communicate with the uterine plexus above, with the bulbar veins below, with the inferior vesical plexus in front, and with the hemorrhoidal plexus behind, and are drained by the **vaginal veins**, one on either side, into the internal iliac veins.

The **uterine plexuses** (Fig. 525) are situated along the sides and superior angles of the uterus, between the two layers of the broad ligament, and communicate with the ovarian and vaginal plexuses. They are drained by the **uterine veins**

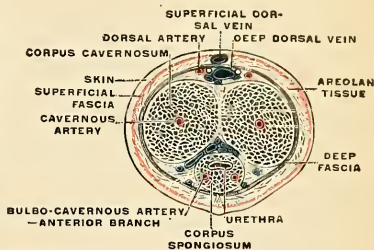


FIG. 524.—The penis in transverse section, showing the blood-vessels. (Testut.)

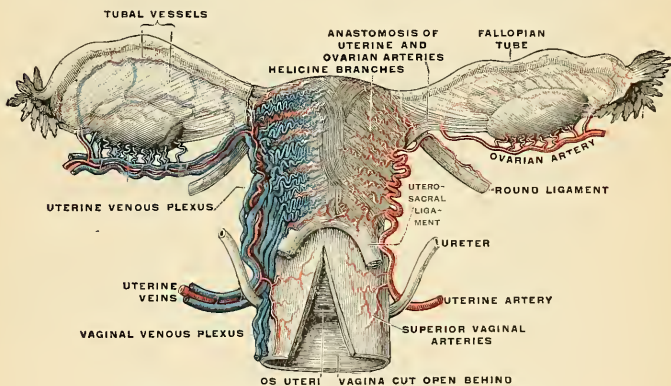


FIG. 525.—Vessels of the uterus and its appendages, rear view. (Testut.)

(*vv. uterinae*) (Fig. 525) which arise from the lower part of the plexus. There are usually two veins on each side, and they are not provided with valves. These veins for the first portion of their course are placed in the base and inner portion of the broad ligament; they then pass back with the uterine artery and terminate in the internal iliac vein.

During pregnancy the uterine veins become greatly enlarged.

The **common iliac veins** (Figs. 521 and 523) are formed by the union of the external and internal iliac veins in front of the sacroiliac articulation; passing obliquely upward toward the right side, each vein terminates upon the intervertebral substance between the fourth and fifth lumbar vertebræ, where the veins of

the two sides unite at an acute angle to form the inferior vena cava. The **right common iliac** (*v. iliaca communis dextra*) is shorter than the left, nearly vertical in its direction, and ascends behind and then to the outer side of its corresponding artery. The **left common iliac** (*v. iliaca communis sinistra*), longer than the right, and more oblique in its course, is at first situated on the inner side of the corresponding artery, and then behind the right common iliac. Each common iliac receives the iliolumbar, and sometimes the lateral sacral veins. The left receives, in addition, the middle sacral vein. No valves are found in these veins.

The **middle sacral veins** (Figs. 521 and 522) accompany the corresponding artery along the front of the sacrum, and join to form a single vein (*v. sacralis media*), which terminates in the left common iliac vein; occasionally in the angle of junction of the two iliac veins. The middle sacral veins communicate with the inferior hemorrhoidal.

The **iliolumbar veins** (*vv. iliolumbales*) receive branches from the iliac fossæ, spinal muscles, and vertebral canal. One vein on each side runs with the artery, passes posterior to the Psoas muscle, and joins the common iliac vein.

Peculiarities.—The left common iliac vein, instead of joining with the right in its usual position, occasionally ascends on the left side of the aorta as high as the kidney, where, after receiving the left renal vein, it crosses over the aorta, and then joins with the right vein to form a short inferior vena cava. In these cases the two common iliacs are connected by a small communicating branch at the spot where they are usually united.

The **inferior vena cava** (*v. cava inferior*; postcava) (Figs. 514 and 521) returns to the heart the blood from nearly all the parts below the Diaphragm. It is formed by the junction of the two common iliac veins on the right side of the intervertebral substance between the fourth and fifth lumbar vertebræ. It passes upward along the front of the vertebral column on the right side of the aorta, and, having reached the liver, is contained in a groove on its posterior surface. It then passes through the Diaphragm between the mesal and right portions of the central tendon; it subsequently inclines forward and inward for about an inch, and, piercing the fibrous pericardium, passes behind the serous pericardium to open into the lower and back part of the right auricle. In front of its auricular orifice is a semilunar valve, the Eustachian valve; this is rudimentary in the adult, but is of large size and exercises an important function in the fetus.

Relations.—*In front*, from below upward, with the mesentery, right spermatic artery, transverse portion of the duodenum, the pancreas, portal vein, and the posterior surface of the liver, which, in most cases, partly and occasionally completely surrounds it; *behind*, with the vertebral column, the right crus of the Diaphragm, the right renal and lumbar arteries, the right semilunar ganglion, and the inner part of the right suprarenal gland; on the *right side*, with the right kidney and ureter; on the *left side*, with the aorta. The thoracic portion is short and covered anterolaterally by the serous layer of the pericardium.

Peculiarities.—*In Position.*—This vessel is sometimes placed on the left side of the aorta, as high as the left renal veins, after receiving which it crosses over to its usual position on the right side; or it may be placed altogether on the left side of the aorta, as far upward as its termination in the heart; in such cases the abdominal and thoracic viscera, together with the great vessels, are all transposed. The vessel may be double, due to the bilateral persistence of the cardinal veins.

Point of Termination.—Occasionally the inferior vena cava joins the vena azygos major, which is then of large size. In such cases the superior vena cava receives the whole of the blood from the body before transmitting it to the right auricle, except the blood from the hepatic veins, which passes directly into the right auricle.

Applied Anatomy.—Thrombosis of the inferior vena cava is due to much the same causes as that of the superior (see page 737). It usually causes edema of the legs and back, without ascites; if the renal veins are involved, blood and albumin will often appear in the urine. An extensive collateral venous circulation is soon established by enlargement either of the superficial or of the deep veins, or of both. In the first case the epigastric, the circumflex iliac, the

long thoracic, the internal mammary, the intercostals, the external pudic, and the lumbovertebral anastomotic veins of Braune effect the communication with the superior cava; in the second, the deep anastomosis is made by the azygos major and minor and the lumbar veins.

Tributaries.—It receives in its course the following veins:

Lumbar.	Suprarenal.
Right spermatic, or ovarian.	Inferior phrenic.
Renal.	Hepatic.

The **lumbar veins** (*vv. lumbales*), four in number on each side, collect the blood by dorsal tributaries from the muscles and integument of the loins and by abdominal tributaries from the walls of the abdomen, where they communicate with the epigastric veins. At the vertebral column they receive veins from the spinal plexuses, and then pass forward, around the sides of the bodies of the

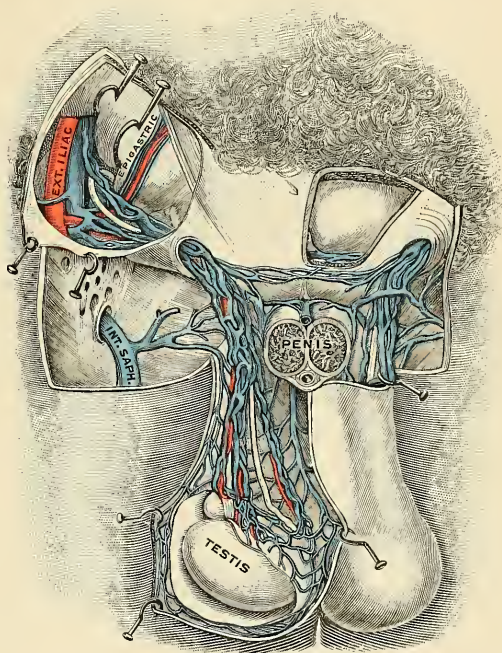


Fig. 526.—Spermatic veins. (Testut.)

vertebræ beneath the Psoas magnus muscle, and terminate at the back part of the inferior vena cava. The left lumbar veins are longer than the right, and pass behind the aorta. The lumbar veins of either side are connected by a longitudinal vein which passes in front of the transverse processes of the lumbar vertebræ, and is called the **ascending lumbar vein** (*v. lumbalis ascendens*) (Fig. 514). It forms the most frequent origin of the corresponding azygos vein, and

serves to connect the common iliac, ilio-lumbar, lumbar, and azygos veins of the corresponding side of the body.

The **spermatic veins** (*vv. spermaticae*) (Fig. 526) emerge from the back of the testis, and receive tributaries from the epididymis; they unite and form a convoluted plexus called the **spermatic plexus** (*plexus pampiniformis*), which constitutes the greater mass of the cord; the vessels composing this plexus are very numerous, and ascend along the cord in front of the vas deferens; below the external abdominal ring they unite to form three or four veins, which pass along the inguinal canal, and, entering the abdomen through the internal abdominal ring, coalesce to form two veins, which ascend on the Psoas muscle behind the peritoneum, lying one on either side of the spermatic artery. These unite to form a single vein, which opens on the *right* side into the inferior vena cava at an acute angle; on the *left* side into the *left* renal vein at a right angle (Fig. 527). The spermatic

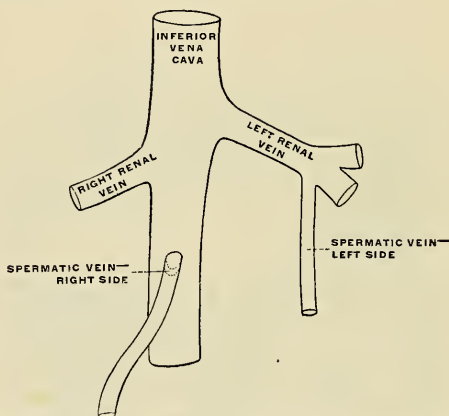


Fig. 527.—Terminations of the right and left spermatic veins. (Poirier and Charpy.)

veins are provided with valves, particularly at the termination. The left spermatic vein passes behind the sigmoid flexure of the colon.

• **Applied Anatomy.**—The spermatic veins are very frequently *varicose*, constituting the disease known as *varicocele*. Though it is quite possible that the originating cause of this affection may be a congenital abnormality either in the size or number of the veins of the spermatic plexus, still it must be admitted that there are many anatomical reasons why these veins should become varicose—viz., the imperfect support afforded to them by the loose tissue of the scrotum; their great length; their vertical course; their dependent position; their plexiform arrangement in the scrotum, with their termination in one small vein in the abdomen; their few and imperfect valves; and the fact that they may be subjected to pressure in their passage through the abdominal wall. The left veins more often become varicose than the right veins, probably, as Brinton suggests, because the right spermatic vein practically always has a valve and opens into the inferior vena cava at an acute angle, whereas the left spermatic vein is not unusually destitute of a valve at its opening and passes into the left renal vein at a right angle.

The operation for the removal of a varicocele consists in making a small incision just over the external abdominal ring and passing an aneurism needle around the mass of veins, taking care that the vas deferens is not included. The veins are isolated from the vas and ligated above and below, as high and as low as possible, and the intermediate portion cut away; the divided ends are fixed together with a suture, and the skin wound closed.

The **ovarian veins** (*vv. ovaricae*) (Fig. 525) correspond with the spermatic in the male; they form a plexus in the broad ligament near the ovary and about the Fallopian tube, and communicate with the uterine plexus. They terminate in the same way as the spermatic veins in the male. Valves are occasionally found in these veins. Like the uterine veins, these vessels become greatly enlarged during pregnancy.

The **renal veins** (*vv. renales*) (Fig. 515) are of large size, and are placed in front of the renal arteries. The left is longer than the right, and passes in front of the aorta, just below the origin of the superior mesenteric artery. It receives the left spermatic, the left inferior phrenic, and, generally, the left suprarenal veins. It opens into the inferior vena cava a little higher than the right.

The **suprarenal veins** (*vv. suprarenales*) (Fig. 514) are two in number; that on the right side terminates in the inferior vena cava; that on the left side, in the left renal or in the left phrenic vein.

The **inferior phrenic veins** (*vv. phrenicae inferiores*) follow the course of the phrenic arteries; the right ends in the inferior vena cava, the left in the left renal vein.

The **hepatic veins** (*vv. hepaticae*) commence in the substance of the liver, in the capillary terminations of the portal vein and hepatic artery, **intra-lobular veins**; these tributaries, gradually uniting into **sublobular veins**, usually form three large hepatic veins, which converge toward the posterior surface of the liver and open into the inferior vena cava, where that vessel is situated in the groove at the back part of this organ. Of these three veins, one from the right and another from the left lobe open obliquely into the inferior vena cava, that from the middle of the organ and lobulus Spigelii having a straight course. The hepatic veins run singly, and are in direct contact with the hepatic tissue. They are destitute of valves.

THE PORTAL SYSTEM OF VEINS (Fig. 528).

The **portal system** includes all the veins which drain the blood from the abdominal part of the alimentary canal (with the exception of the lower part of the rectum) and from the spleen, pancreas, and gall-bladder. From these viscera the blood is conveyed to the liver by the *portal vein*. In the substance of the liver the portal vein ramifies like an artery and terminates in the *portal capillaries* (*sinusoids*), from which the blood is conveyed to the inferior vena cava by the hepatic veins. From this it will be seen that the blood of the portal system passes through two sets of capillary vessels—viz., (*a*) the capillaries of the alimentary canal, spleen, pancreas, and gall-bladder; and (*b*) the portal capillaries in the substance of the liver. The portal vein and its tributaries are destitute of valves.

The **portal vein** (*vena portae*) is about three inches in length, and is formed at the level of the second lumbar vertebra by the junction of the superior mesenteric and splenic veins, the union of these veins taking place in front of the inferior vena cava and behind the neck of the pancreas. It passes upward behind the first part of the duodenum and then ascends near the right border of the lesser omentum to the right extremity of the transverse fissure of the liver, where it divides into right and left branches, which accompany the corresponding branches of the hepatic artery into the substance of the liver. In the lesser omentum it is placed behind and between the common bile duct and the hepatic artery, the former lying to the right of the latter. It is surrounded by the hepatic plexus of nerves, and is accompanied by numerous lymphatic vessels and some lymph nodes. The *right branch* of the portal vein enters the right lobe of the liver, but before doing so generally receives the cystic vein. The *left branch*, longer but of smaller caliber than the right, crosses the longitudinal fissure, gives branches

to the caudate and Spigelian lobes, and then enters the left lobe of the liver. As it crosses the longitudinal fissure it is joined in front by a fibrous cord, the *ligamentum teres* of the liver or impervious *umbilical vein*, and is united to the inferior vena cava by a second fibrous cord, the *ligamentum venosum* or impervious ductus venosus.

The tributaries of the portal vein are:

Splenic.
Superior mesenteric.
Gastric.

Pyloric.
Cystic.
Parumbilical.

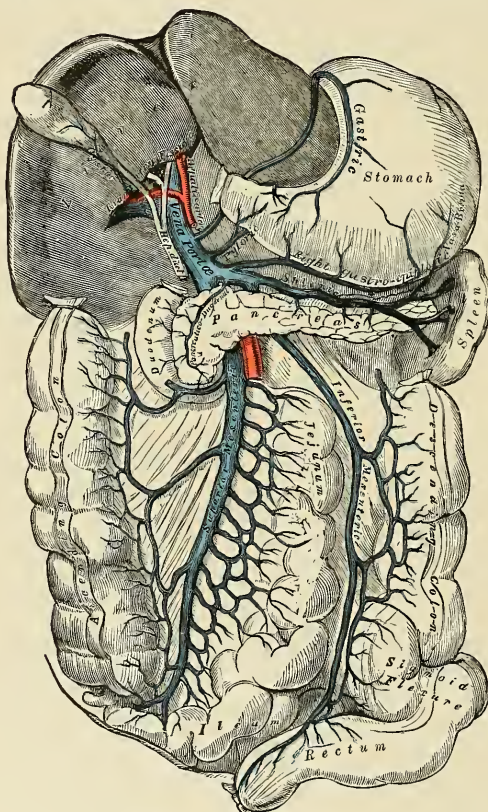


FIG. 528.—Portal vein and its tributaries.

NOTE.—In this diagram the right gastroepiploic vein opens into the splenic vein; generally it empties into the superior mesenteric, close to its termination.

The **splenic vein** (*v. lienalis*) (Fig. 528) *commences* by five or six large branches which return the blood from the substance of the spleen. These, uniting, form a

single vessel, which passes from left to right, grooving the upper and back part of the pancreas below the artery, and terminates at its greater end by uniting at a right angle with the superior mesenteric to form the portal vein. The splenic vein is of large size, and not tortuous like the artery.

Tributaries.—The splenic vein receives the *vasa brevia* from the left extremity of the stomach, the left gastroepiploic vein, the pancreatic veins, and the inferior mesenteric vein.

(a) The **short gastric veins** (*vv. gastricae breves*), some four or five in number, drain the fundus and left part of the greater curvature of the stomach, and pass between the two layers of the gastrosplenic omentum to terminate in the splenic vein or in one of its large tributaries.

(b) The **left gastroepiploic vein** (*v. gastroepiploica sinistra*) receives tributaries from the anterior and posterior surfaces of the stomach and from the great omentum; it runs from right to left along the greater curvature of the stomach and ends in the commencement of the splenic vein.

(c) The **pancreatic veins** (*vv. pancreaticae*) consist of several small vessels which drain the body and tail of the pancreas, and open into the trunk of the splenic vein.

(d) The **inferior mesenteric vein** (*v. mesenterica inferior*) returns blood from the rectum, and the pelvic, iliac, and descending parts of the colon. It begins in the rectum as the *superior hemorrhoidal vein* (*v. haemorrhoidalis superior*), which has its origin in the hemorrhoidal plexus, and through this plexus communicates with the middle and inferior hemorrhoidal veins. The superior hemorrhoidal vein leaves the pelvis and crosses the iliac vessels in company with the superior hemorrhoidal artery, and is continued upward as the inferior mesenteric vein. This vein lies to the left of the inferior mesenteric artery, and ascends behind the peritoneum and in front of the left Psoas; it then passes behind the body of the pancreas and opens into the splenic vein; sometimes it terminates in the angle of union of the splenic and superior mesenteric veins.

Tributaries.—The inferior mesenteric vein receives the *sigmoid veins* (*vv. sigmoideae*) from the sigmoid flexure and the *left colic vein* (*v. colica sinistra*) from the descending colon and splenic flexure.

The **superior mesenteric vein** (*v. mesenterica superior*) returns the blood from the small intestine, and from the cecum and ascending and transverse portions of the colon. It begins in the right iliac fossa by the union of the veins which drain the terminal part of the ileum, the cecum, and vermiform appendix, and ascends between the two layers of the mesentery on the right side of the superior mesenteric artery. In its upward course it passes in front of the right ureter, the inferior vena cava, the third part of the duodenum, and the uncinate process of the head of the pancreas. Behind the neck of the pancreas it unites with the splenic vein to form the portal vein.

Tributaries.—Besides the tributaries which correspond with the branches of the superior mesenteric artery—viz., the **veins of the small intestine** (*vv. intestinales*), the **ileocolic** (*v. ileocolica*), the **right colic** (*vv. colica dextrae*), and the **middle colic** (*v. colica media*)—the superior mesenteric vein is joined by the right gastroepiploic and pancreaticoduodenal veins.

The **right gastroepiploic vein** (*v. gastroepiploica dextra*) receives tributaries from the great omentum and from the lower parts of the anterior and posterior surfaces of the stomach; it runs from left to right along the greater curvature of the stomach between the two layers of the great omentum.

The **pancreaticoduodenal veins** (*vv. pancreaticoduodenales*) accompany their corresponding arteries; the lower of the two frequently joins the right gastroepiploic vein.

The **gastric vein** (*v. coronaria ventriculi*) derives tributaries from both surfaces

of the stomach; it runs from right to left along the lesser curvature of the stomach, between the two layers of the gastrohepatic omentum, to the œsophageal end of the stomach, where it receives some œsophageal veins. It then turns backward and passes from left to right behind the lesser sac of the peritoneum and ends in the portal vein.

The **pyloric vein** is of small size, and runs from left to right along the pyloric portion of the lesser curvature of the stomach, between the two layers of the gastrohepatic omentum, to terminate in the portal vein.

The **cystic vein** (*v. cystica*) (Fig. 528) drains the blood from the gall-bladder, and, ascending along the cystic duct, usually terminates in the right branch of the portal vein.

Parumbilical Veins (*vv. parumbilicales*).—In the course of the ligamentum teres of the liver and of the urachus small veins (*parumbilical*) are found, which establish an anastomosis between the veins of the anterior abdominal wall and the portal and iliac veins. The best marked of these small veins is one which commences at the umbilicus and runs backward and upward in, or on the surface of, the ligamentum teres between the layers of the falciform ligament to terminate in the left branch of the portal vein.

Anastomoses between the Portal and Systemic Veins.—Some tributaries of the portal vein communicate with certain neighboring systemic veins. The more important communications are between (*a*) the gastric veins and the œsophageal veins which empty into the vena azygos minor; (*b*) the parumbilical veins, which anastomose with the deep epigastric and internal mammary veins; (*c*) the superior and middle hemorrhoidal veins, the latter opening into the internal iliacs.

Applied Anatomy.—Obstruction to the portal vein may produce *ascites*, and this may arise from many causes, as (1) the pressure of a tumor on the portal vein, such as cancer or hydatid cyst, in the liver, enlarged lymph nodes in the lesser omentum, or cancer of the head of the pancreas; (2) from cirrhosis of the liver, when the radicles of the portal vein are pressed upon by the contracting fibrous tissue in the portal canals; (3) from valvular disease of the heart, and back pressure on the hepatic veins, and so on the whole of the circulation through the liver. In this condition the prognosis as regards life and freedom from ascites may be much improved by the establishment of a good collateral venous circulation to relieve the portal obstruction in the liver. This is effected by communications between (*a*) the gastric veins, and the œsophageal veins emptying themselves into the vena azygos minor inferior, which often project as a varicose bunch into the stomach; (*b*) the veins of the colon and duodenum, and the left renal vein; (*c*) the accessory portal system of Sappey, branches of which pass in the round and falciform ligaments (particularly the latter), to unite with the epigastric and internal mammary veins, and through the diaphragmatic veins with the azygos; a single large vein shown to be a parumbilical vein, may pass from the hilus of the liver by the round ligament to the umbilicus, producing there a bunch of prominent varicose veins known as the *Caput Medusae*; (*d*) the veins of Retzius, which connect the intestinal veins with the inferior vena cava and its retroperitoneal branches; (*e*) the inferior mesenteric veins, and the hemorrhoidal veins that open into the internal iliacs; (*f*) very rarely the ductus venosus remains patent, affording a direct connection between the portal vein and the inferior vena cava.

An operation for the relief of portal obstruction on these lines has been advocated by Rutherford Morison and by Talma. It consists in curetting the opposed surfaces of the liver and diaphragm and stitching them together, so as to secure vascular inflammatory adhesions between the two. The great omentum may with advantage be interposed between them, so as to increase the amount of the adhesions, and the spleen has been similarly scraped and sutured to or into the abdominal wall. The operation should not be deferred until the patient is moribund.

Thrombosis of the portal vein, or *pylithrombosis*, is a very serious event, and is oftenest due to pathological processes causing compression of the vessel or injury to its wall, such as tumors or inflammation about the pylorus, head of the pancreas, or appendix, or to gallstones or cirrhosis of the liver. If the thrombus is infected with bacteria, as is often the case when it is due to appendicitis, septic or suppurative *pylphlebitis* results; this condition is known also as *portal pyemia*. Fragments of the infected clot break off and are carried away to lodge in the smaller veins in the liver, with the development of multiple abscesses in its substance and a rapidly fatal result. When the thrombus is sterile, the chief signs produced are enlargement of the spleen, recurrent ascites, and the establishment of a collateral venous circulation, the case clinically resembling one of atrophic cirrhosis of the liver.

DEVELOPMENT OF THE BLOOD-VASCULAR SYSTEM.

There are three distinct stages in the development of the circulatory system, each in accordance with the manner in which nourishment is provided for at different periods of the existence of the individual. In the first stage there is the *vitelline circulation*, during which nutriment is extracted from the *vitellus* or contents of the yolk sac. In the second stage there is the *placental circulation*, during which nutriment is obtained by means of the placenta from the blood of the mother. In the third stage, commencing after birth, there is the *complete circulation of the adult*, during which nutrition is provided for by the organs of the individual.¹

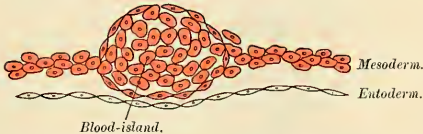

FIG. 529.—Section through vascular area to show commencing development of bloodvessel. (Semidiagrammatic.)

Bloodvessels first make their appearance in the mesodermal wall of the yolk sac, *i. e.*, outside the body of the embryo. Here the cells become arranged into solid strands or cords which join to form a close-meshed network. The peripheral cells of these strands become flattened and joined to each other by their edges to form the walls of the primitive bloodvessels. Fluid collects within the strands and converts them into tubes, and the more centrally situated cells of the cell cords are thus pushed to the sides of the vessels and appear as masses of loosely arranged cells which project toward the lumen of the tube. These masses are termed *blood islands* (Fig. 529); their cells acquire coloring matter (hemoglobin), and are then detached to form the blood-corpuscles or erythroblasts (Fig. 530).² Later, red cells are formed in organs where the circulation

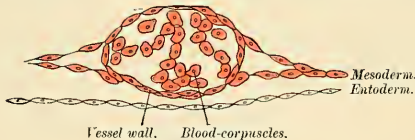


FIG. 530.—Later stage.

is sluggish, as liver, spleen, and bone-marrow. At birth this function is lost by the liver and spleen. The earliest blood corpuscles are all nucleated; they are also capable of subdivision and of executing ameboid movements, and in these respects resemble colorless blood corpuscles. Soon, however, true colorless blood corpuscles make their appearance, and, according to Beard,³ are first derived from the rudiments of the thymus.

Coincidentally with the development of the bloodvessels in the vascular area, the first rudiment of the **heart** appears as a pair of tubular vessels which are developed in the splanchnopleure of the pericardial area in the precephalic part of the embryonic area. These are named the *primitive aortæ*, and a direct continuity is soon established between them and the vessels of the vascular area. Each receives precardially a vein—the vitelline vein—from the yolk sac, and is prolonged backward on the lateral aspect of the notochord under the name of the dorsal aorta. The dorsal aortæ end at first on the yolk sac; but with the development of the allantois, they are continued onward through the body stalk as the umbilical arteries to the villi of the chorion frondosum.

By the forward growth and flexure of the head the pericardial area and the precardial portions of the primitive aortæ are folded caudad on the ventral aspect of the fore-gut, and the original

¹ That the umbilical circulation precedes the vitelline in the human embryo seems to be shown by Eternod's and Dandy's independent observations. Consult the latter's article, *A Human Embryo with Seven Pairs of Somites*, *American Journal of Anatomy*, January, 1910.

² According to Dandy (*loc. cit.*) there is at first no apparent connection between this blood-forming area and the vascular system of the very young human embryo, and that the presence of blood corpuscles in the latter is probably explained by endothelial proliferation from the capillaries in the chorionic membrane.

³ *Anatomischer Anzeiger*, December, 1900.

relation of the layers of the pericardial area is reversed. Each primitive aorta now consists of a ventral and a dorsal part connected cephalad by an arched vessel traversing the first or mandibular branchial arch. In each succeeding branchial arch a similar vessel develops, so that in all *six pairs* of aortic arches are formed, of which the fifth atrophies early.

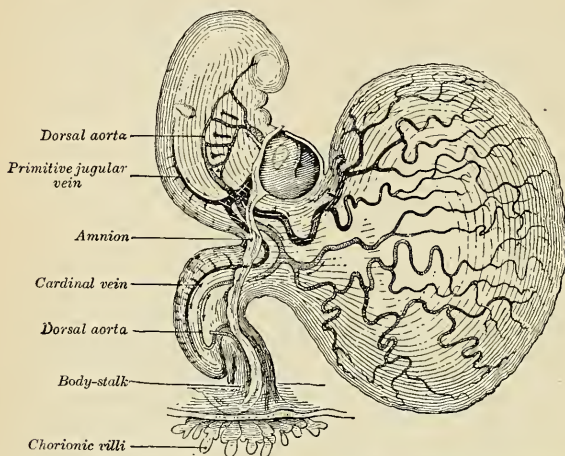


FIG. 531.—Human embryo of about fourteen days old with yolk sac. (After His, from Kollmann's *Entwicklungsgeschichte*.)

In the pericardial region the two primitive aortae grow together and fuse to form the *single-chambered* primitive heart tube (Fig. 532), the caudal end of which receives the two vitelline veins, while from its cephalic end the two ventral aortae emerge. By the rhythmic contraction of the tubular heart the blood is forced through the aorte and bloodvessels of the vascular area,

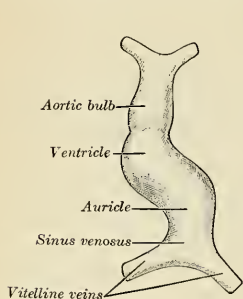


FIG. 532.—Diagram to illustrate the simple tubular condition of the heart. (Drawn from Ecker-Ziegler model.)

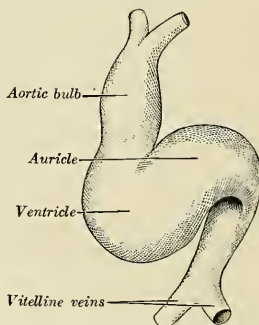


FIG. 533.—Heart further advanced than in Fig 532. (Drawn from Ecker-Ziegler model.)

from which it is returned to the heart by the vitelline veins; by this vitelline circulation the nutriment is absorbed from the vitellus.

Umbilical or Placental Circulation.—With the atrophy of the yolk sac the vitelline circulation diminishes and ultimately ceases, while an increasing amount of blood is carried through

the umbilical arteries to the villi of the chorion. Subsequently, as the nonplacental chorionic villi atrophy, their vessels disappear, and then the umbilical arteries convey the whole of the blood to the placenta, whence it is returned to the heart by the umbilical veins. In this manner the placental circulation is established, and by means of it nutritive materials are absorbed from, and waste products given up to, the maternal blood.

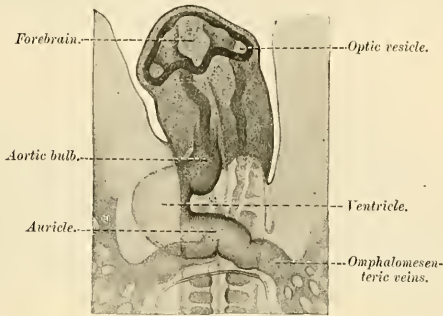


FIG. 534.—Head of chick embryo of about thirty-eight hours' incubation, viewed from the ventral surface. $\times 26$. (From Duval's Atlas d'Embryologie.)

The umbilical veins, like the vitelline, become interrupted by the liver, and the blood returned by them passes through this organ before reaching the heart. Ultimately the right umbilical vein largely disappears, being represented in the adult by a small vein of the belly wall.

During the occurrence of these changes great alterations take place in the primitive heart and bloodvessels, and now require description.

Further Development of the Heart.—The simple tubular heart, already described, becomes elongated and bent on itself so as to form an S-shaped loop, the cephalic part bending to the right and the caudal part to the left. The intermediate portion arches transversely from right to left, and then turns sharply forward into the cephalic part of the loop. Slight con-

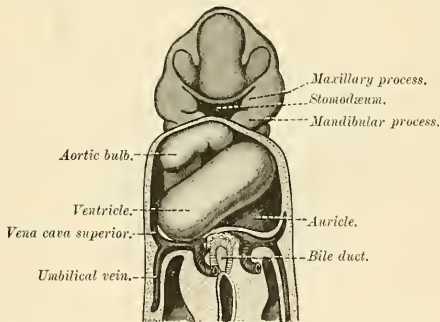


FIG. 535.—Heart of human embryo of about fifteen days. (Reconstruction by His.)

strictions make their appearance in the tube and divide it from behind forward into four parts, viz.: (1) The *sinus venosus*; (2) the *primitive auricle*; (3) the *primitive ventricle*; (4) the *aortic bulb*, which consists of two portions, a proximal muscular portion known as the *bulbus cordis*, and a distal portion, the *primitive aortic stem* (Figs. 532 to 534). The constriction between the auricle and ventricle constitutes the *auricular canal*, and indicates the site of the future auriculo-ventricular valves.

The *sinus venosus* is at first situated in the septum transversum behind the common auricle, and is formed by the union of the vitelline veins. The veins or ducts of Cuvier from the body of

the embryo and the umbilical veins from the placenta subsequently open into it (Fig. 545). The sinus is at first placed transversely, and opens by a median aperture into the common auricle.

Soon, however, it assumes an oblique position, and becomes crescentic in form; its right half or horn increases more rapidly than the left, while the opening into the auricle now communicates with the right portion of the auricular cavity. The right horn ultimately becomes incorporated with and forms a part of the right auricle, the line of union between it and the auricle proper being indicated in the interior of the adult auricle by a vertical crest (*crista terminalis* of His). The left horn, which ultimately receives only the left duct of Cuvier, persists as the

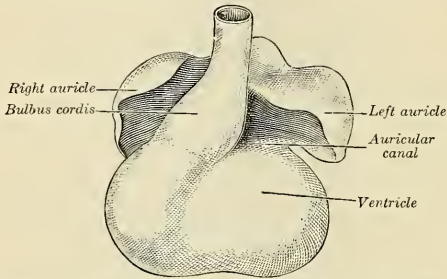


FIG. 536.—Heart showing expansion of auricles. (Drawn from Ecker-Ziegler model.)

coronary sinus (Fig. 494). The vitelline and umbilical veins are soon replaced by a single vessel, the inferior vena cava, and the three veins (inferior vena cava and right and left Cuvierian ducts) open into the dorsal aspect of the auricle by a common slit-like aperture (Fig. 542). The upper part of this aperture represents the opening of the adult superior vena cava, the lower that of the inferior vena cava, and the intermediate part the orifice of the coronary sinus. The slit-like aperture lies obliquely, and is guarded by two valves, the **right and left venous valves**, which unite with each other above the opening and are continuous with a fold named the **septum spurium**. The left venous valve practically disappears, while the right is subsequently divided to form the Eustachian and Thebesian valves. At the lower extremity

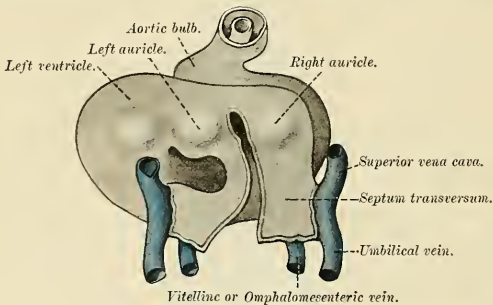


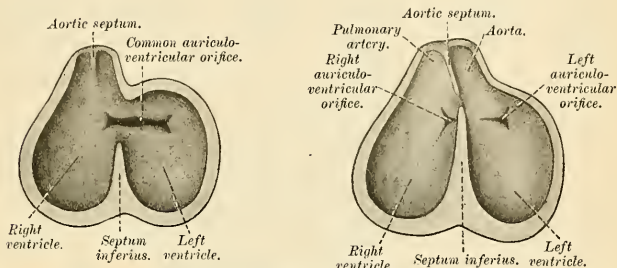
FIG. 537.—Heart of human embryo, 4.2 mm. long, seen from behind. (His.)

of the slit is a triangular thickening, the *spina vestibuli* of His, which partly closes the aperture between the two auricles, and, according to His, takes a part in the formation of both the inter-auricular and interventricular septa.

The auricular canal is at first a short straight tube connecting the auricular with the ventricular portion of the heart, but its growth is relatively slow, and it becomes overlapped by the auricles and ventricles so that its position on the surface of the heart is indicated only by an annular constriction (Fig. 536). Its lumen is reduced to a transverse slit, and two thickenings appear, one on its dorsal and another on its ventral wall. These thickenings, or *endocardial cushions* (Fig. 542), as they are termed, project into the canal, and, meeting in the middle line,

unite to form the *septum intermedium* which divides the canal into two channels, the future right and left auriculoventricular orifices.

The primitive auricular cavity becomes subdivided into right and left auricles by an incomplete septum, the *septum primum* (Fig. 542), which grows downward into the auricular cavity. For a time the two auricles communicate with each other by an opening, the *ostium primum* of Born, below the free margin of the septum. This opening is, however, closed by the union of the septum primum with the septum intermedium, and the communication between the auricles is reestablished through an opening which is developed in the upper part of the septum primum;



FIGS. 538 and 539.—Diagrams to show the development of the septum of the aortic bulb and of the ventricles. (Born.)

this opening is known as the **foramen ovale** (*ostium secundum* of Born), and persists until shortly after birth. A second septum, the **septum secundum**, semilunar in shape, grows downward from the upper wall of the auricle to the right of the primary septum and foramen ovale, forming the ventral and lower boundary of the latter. This fold becomes continuous with the Eustachian valve and forms the adult annulus ovalis. Shortly after birth it fuses with the primary septum, and by this means the foramen ovale is closed, but sometimes the fusion is incomplete and the upper part of the foramen remains patent.

The primitive ventricle becomes divided by a septum, the **septum inferius** or **interventricular septum** (Figs. 538, 539, 542), which grows upward from the lower part of the ventricle, its position

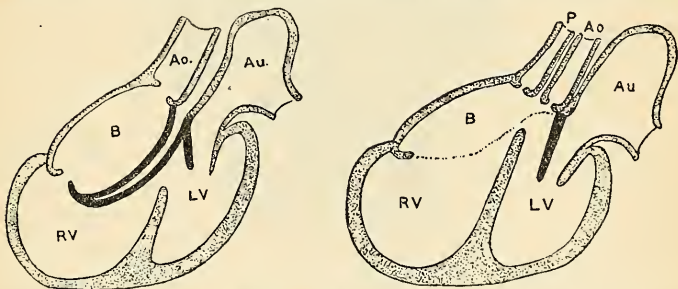


FIG. 540.—Diagrams to illustrate the transformation of the bulbus cordis. Ao. Primitive aortic stem. Au. Auricle. B. Bulbus cordis. RV. Right ventricle. LV. Left ventricle. P. Pulmonary artery. (Keith.)

being indicated on the surface of the heart by a furrow. Its dorsal part grows more rapidly than its ventral portion, and fuses with the dorsal part of the septum intermedium. For a time an interventricular foramen exists above its ventral portion, but this foramen is ultimately closed by the fusion of the *aortic septum* with the interventricular septum.

As already stated, the *aortic bulb* consists of a proximal muscular portion, the *bulbus cordis*, and a distal portion, the *primitive aortic stem*. When the heart assumes its S-shaped form the bulbus cordis lies ventral to or in front of the primitive ventricle. The adjacent walls of the bulbus cordis and ventricle approximate, fuse, and finally disappear, and the bulbus cordis now communicates freely with the right ventricle, while the junction of the bulbus with the primitive

aortic stem is brought directly ventral to and applied to the auricular canal. By the upgrowth of the interventricular septum the bulbus cordis is in great measure separated from the left ventricle, but remains an integral part of the right ventricle, of which it forms the *infundibulum*.

The *primitive aortic stem* is divided by the **aortic septum** (Fig. 541). This makes its appearance as two lateral ridge-like thickenings which project into the lumen of the tube from just above the level of the sixth arch vessels; these increase in size, and ultimately meet and fuse to form the septum, and thus the primitive aortic stem is divided into the pulmonary artery and

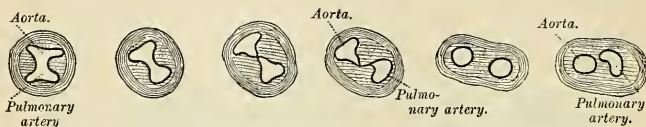


FIG. 541.—Transverse sections through the aortic bulb to show the growth of the aortic septum. The lowest section is on the left, the highest on the right of the figure. (After His.)

the aorta. The aortic septum takes a spiral course toward the proximal end of the stem, so that the two vessels lie side by side above, but near the heart the pulmonary artery is in front of the aorta (Fig. 414). The septum grows down into the ventricle as an oblique partition, which ultimately blends with the interventricular septum in such a way as to bring the bulbous cordis into communication with the pulmonary artery, and through the latter with the sixth pair of aortic arches; while the left ventricle is brought into continuity with the aorta which communicates with the remaining aortic arches.

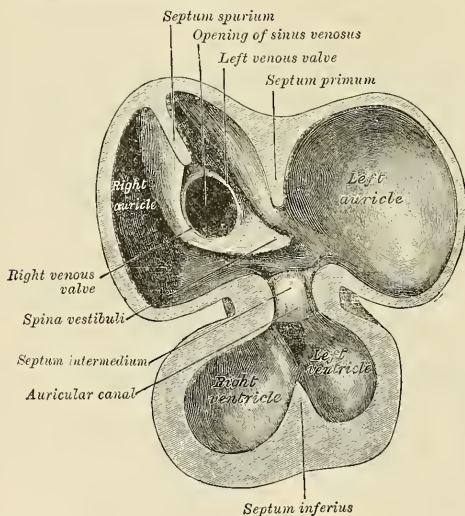


FIG. 542.—Interior of dorsal half of heart from a human embryo 10 mm. long. (His.)

The Valves of the Heart.—The auriculoventricular valves are developed in relation to the auricular canal. By the upward expansion of the bases of the ventricles the canal becomes invaginated into the ventricular cavities. The invaginated margin forms the rudiments of the lateral cusps of the auriculoventricular valves; the mesal or septal cusps of the valves are developed as downward prolongations of the septum intermedium. The aortic and pulmonary valves are formed from four endocardial thickenings—an anterior, a posterior, and two lateral—which appear at the proximal end of the primitive aortic stem. As the aortic septum grows downward it divides each of the lateral thickenings into two, thus giving rise to six thickenings—the rudiments of the semilunar valves—three at the aortic and three at the pulmonary orifice.

Further Development of the Arteries.—It has been seen (p. 756) that each primitive aorta consists of a ventral and a dorsal stem, which are continuous through the first aortic arch. The dorsal aortæ at first run backward separately on either side of the notochord, but about the third week they fuse from about the level of the fourth thoracic to that of the fourth lumbar segment to form a single trunk, the descending aorta. The first aortic arches pass through the mandibular arches, and caudad of them five additional pairs are developed within the branchial arches; so that, in all, six pairs of aortic arches are formed (Fig. 544). The first and second arches pass between the ventral and dorsal aortæ, while the others arise at first by a common trunk from the aortic bulb, but terminate separately in the dorsal aortæ. As the neck elongates, the ventral aortæ are lengthened, and the third and fourth arches arise directly from these vessels.

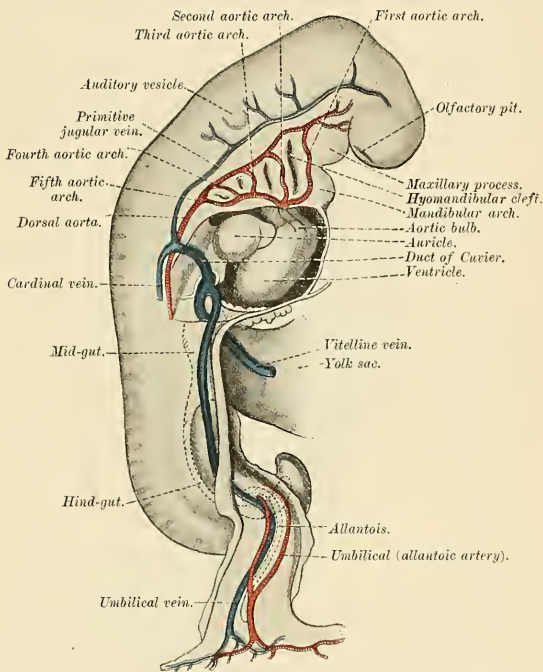


FIG. 543.—Profile view of a human embryo estimated at twenty or twenty-one days old. (After His.)

In fishes these arches persist and give off branches to the gills, in which the blood is oxygenated. In mammals some of them remain as permanent structures, while others disappear or become impervious (Fig. 544).

The Ventral Aortæ.—These persist on both sides. The right forms (a) the innominate artery, (b) the right common and external carotid arteries. The left gives rise to (a) the short portion of the aortic arch, which reaches from the origin of the innominate artery to that of the left common carotid artery; (b) the left common and external carotid trunks.

The Aortic Arches.—The first and second disappear; the third (*carotid arch*) constitutes the commencement of the internal carotid artery. The fourth right arch forms the right subclavian as far as the origin of its internal mammary branch; while the fourth left arch constitutes the arch of the aorta between the origin of the left carotid artery and the termination of the ductus arteriosus. The fifth arch disappears on both sides. The sixth right arch disappears;

the sixth left arch gives off the pulmonary arteries and forms the ductus arteriosus; this duct remains pervious throughout fetal life, but becomes impervious a few days after birth.¹

The Dorsal Aortæ.—Cephalad of the third aortic arches the dorsal aortæ persist and form the headward continuation of the internal carotid arteries. Caudad of the third arch the right dorsal aorta disappears as far as the point where the two dorsal aortæ fuse to form the descending aorta. The part of the left dorsal aorta which intervenes between the third and fourth arches disappears, while the remainder persists to form the descending part of the arch of the aorta. A constriction, the *aortic isthmus*, is sometimes seen in the aorta between the origin of the left subclavian and the attachment of the ligamentum arteriosum. Below this isthmus the aorta expands slightly to form the **aortic spindle**.

Sometimes the right subclavian artery arises from the aortic arch beyond the origin of the left subclavian and passes upward and to the right behind the trachea and œsophagus. This condition may be explained by the persistence of the right dorsal aorta and the obliteration of the fourth right arch.

In birds the fourth right arch forms the arch of the aorta; in reptiles the fourth arch on both sides persists and gives rise to the double aortic arch in these animals.

The heart originally lies on the ventral aspect of the pharynx, immediately caudad of the stomatodeum. With the elongation of the neck and development of the lungs it recedes within the thorax, and, as a consequence, the anterior ventral aortæ are drawn out and the original position of the fourth and fifth arches is greatly modified. Thus, on the right side the fourth recedes to

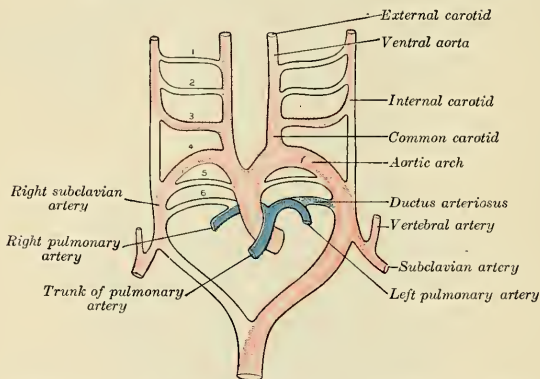


FIG. 544.—Scheme of the aortic arches and their derivatives. (Modified from Kollmann.)

the root of the neck, while on the left side it is withdrawn within the thorax. The recurrent laryngeal nerves originally pass to their distribution under the sixth pair of arches, and are therefore pulled backward with the descent of these structures, so that in the adult the left hooks around the ligamentum arteriosum; owing to the disappearance of the fifth and the sixth right arches the right nerve hooks around that immediately above them, *i. e.*, the commencement of the subclavian artery. A series of segmental arteries arises from the primitive dorsal aortæ, those in the neck alternating with the cervical segments of the vertebral column. The seventh segmental artery, which lies between the sixth and seventh cervical segments, is of special interest, since it forms the lower part of the vertebral artery and, when the forelimb bud appears, sends a branch to it (*i. e.*, the subclavian artery); the upper part of the vertebral artery is formed by an inter-segmental anastomosis between the higher segmental arteries. From the seventh segmental arteries the entire left subclavian and the greater part of the right subclavian are formed.

The subclavian artery is prolonged into the limb under the names of the axillary and brachial arteries, and these together constitute the arterial stem for the upper arm. The direct continuation of this stem into the forearm forms the anterior interosseous artery; while the radial and ulnar vessels, which ultimately exceed this artery in size, are in reality lateral branches of the main stem.

The formation of the primary caudal branches has already been referred to (p. 755), and the fusion of the dorsal aortæ to form the greater part of the systemic aorta has been pointed out

¹ His found that in the young embryo the right and left sixth arches each give off a branch to the lungs, but that later both pulmonary arteries take origin from the left arch.

(page 761). The middle sacral artery of the adult was formerly regarded as the direct continuation of the adult aorta, but Young and Robinson¹ maintain that it is a secondary branch, probably representing fused segmental arteries. The caudal continuations of the aortæ in the adult are the common iliac, internal iliac, and the partially impervious hypogastric arteries.

The *hypogastric arteries* are continued into the umbilical cord as the umbilical arteries. After birth they become impervious cords from the umbilicus as far as the origin of the superior vesical arteries.

The primary arterial stem for the lower limb is formed by the sciatic artery, which accompanies the great sciatic nerve along the posterior aspect of the thigh to the back of the knee, where it is continued as the peroneal artery. The femoral artery arises later as a branch of the common iliac, and, passing down the front and inner side of the thigh to the bend of the knee, joins the sciatic artery. The femoral quickly enlarges, and coincidently with this the part of the sciatic immediately above the knee undergoes atrophy. The anterior and posterior tibial arteries are branches of the main arterial stem.

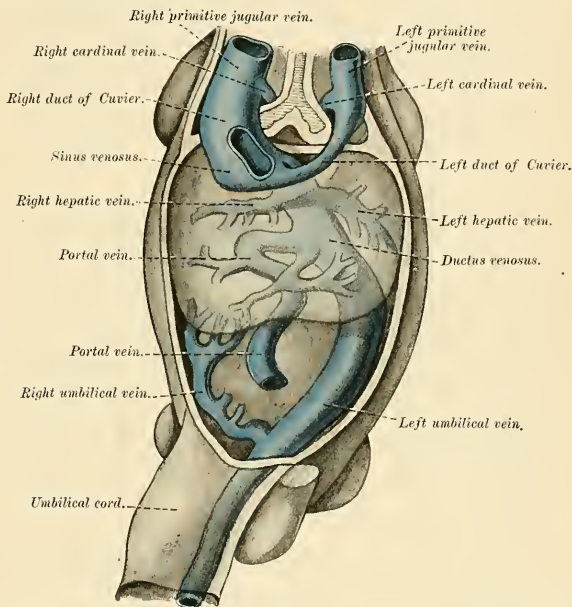


FIG. 545.—Human embryo with heart and anterior body wall removed to show the sinus venosus and its tributaries. (After His, from Kollmann's *Entwicklungsgeschichte*.)

Further Development of the Veins.—The formation of the great veins of the embryo may be best considered by dividing them into two groups, visceral and parietal.

The *visceral veins* are the two vitelline or omphalomesenteric veins bringing the blood from the yolk sac, and the two umbilical or allantoic veins returning the blood from the placenta; these four veins open close together into the sinus venosus (Fig. 547).

The *vitelline veins* run cephalad at first in front, and subsequently on either side of the intestinal canal. They unite on the ventral aspect of the canal, and beyond this are connected to one another by two cross branches, the first on the dorsal, the second on the ventral aspect of the duodenal portion of the intestine, which is thus encircled by two venous rings (Fig. 546). The portions of the veins above the upper ring become invaded by the developing liver and broken up by it into a plexus of small capillary-like vessels termed *sinusoids* (Minot). The branches conveying the blood to this plexus are named the *venae advehentes*, and become the branches of the

¹ Journal of Anatomy and Physiology, vol. xxxii.

portal vein; while the vessels draining the plexus into the sinus venosus are termed the *venae revehentes*, and form the future hepatic veins (Figs. 545 and 546). Ultimately the left *vena revehens* no longer communicates directly with the sinus venosus, but opens into the right *vena revehens*. The lower part of the *portal vein* is formed from the fused vitelline veins which receive the veins from the alimentary canal; its upper part is derived from the venous rings by the persistence of the left half of the lower and the right half of the upper ring, so that the vessel forms a spiral turn round the duodenum (Fig. 546).

The two *umbilical veins* fuse early to form a single trunk in the body stalk, but remain separate within the embryo and pass forward to the sinus venosus in the side walls of the body. Like the vitelline veins, their direct connection with the sinus venosus becomes interrupted by the invasion of the liver, and thus at this stage the whole of the blood from the yolk sac and placenta passes through the substance of the liver before it reaches the heart. The right umbilical vein becomes disconnected from the sinus venosus, shrivels, and forms a small vein of belly wall; the left, on the other hand, becomes enlarged and opens into the upper venous ring of the vitelline veins. Finally, a direct channel is established between this ring and the heart; this channel is called the **ductus venosus**, and, enlarging rapidly, forms a wide channel through which most of the blood, returned from the placenta, is carried directly to the heart without being obliged to pass through the liver. The left umbilical vein and ductus venosus become impervious after birth, and form, respectively, the *ligamentum teres* and *ligamentum venosum* of the liver (Fig. 1071).

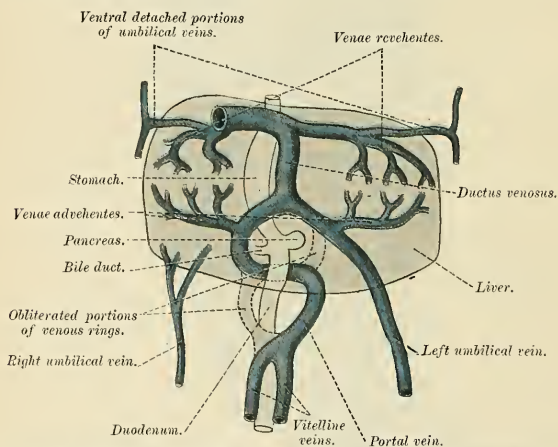


FIG. 546.—The liver, and the veins in connection with it, of a human embryo, twenty-four or twenty-five days old, as seen from the visceral surface. (After His.) (Copied from Milnes Marshall's *Embryology*.)

The Parietal Veins.—The first indication of a parietal system consists in the appearance of two short transverse veins (the **ducts of Cuvier**), which open, one on either side, into the sinus venosus. Each of these ducts receives an ascending and descending vein. The ascending veins return the blood from the parietes of the trunk and from the mesonephroi, and are called **postcardinal veins**. The descending veins return the blood from the head and upper limbs, and are called the **precordial** or **primitive jugular veins** (Fig. 547). The blood from the lower limbs is collected by the right and left iliac veins, which, in the earlier stages of development, open into the corresponding right and left postcardinals (Fig. 548); later on, a transverse channel (the *left common iliac vein*) is developed between the caudal parts of the two postcardinal veins (Fig. 549), and through this the blood is carried to the right postcardinal vein. The portion of the left postcardinal vein below the level of the left renal vein atrophies and disappears up to the point of entrance of the left spermatic vein; above this level the left postcardinal persists as the superior and inferior azygos minor veins. The right postcardinal vein, which now receives the blood from both lower limbs, forms a large venous trunk along the posterior abdominal wall. Above the level of the renal veins the right postcardinal vein persists as the *vena azygos major*, and receives the right intercostal veins, while the azygos minor veins are brought into communication with it by the development of transverse anastomotic channels in front of the vertebral column (Fig. 514).

Inferior Vena Cava.—The development of the inferior vena cava is associated with the formation of two pairs of veins, the *subcardinal* and *supracardinal veins* (Figs. 548 and 549), and with the *ductus venosus*. The **subcardinal veins** lie parallel to, and ventrad of, the postcardinal veins and originate as longitudinal anastomosing channels which communicate with the post-

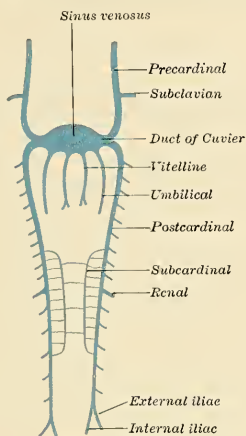


FIG. 547.—Scheme of arrangement of parietal veins.

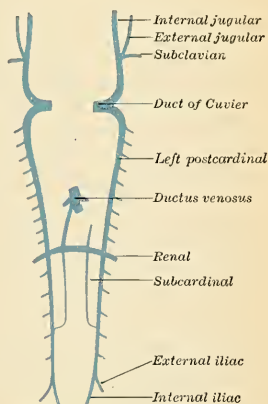


FIG. 548.—Scheme showing early stages of development of the inferior vena cava.

cardinals above and below and also with each other by a series of transverse channels. Of the transverse channels, only one persists to join each renal vein. The left subcardinal vein practically disappears, while the right subcardinal enlarges and joins the ductus venosus cephalad and the right postcardinal caudad. At this stage the blood draining the lower extremities passes along a right-sided channel which courses ventrad of the ureter.

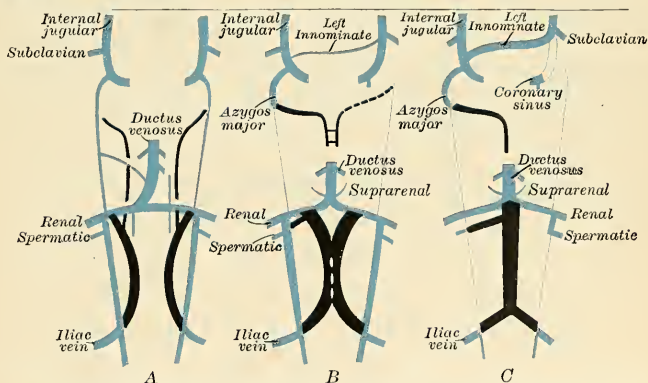


FIG. 549.—Diagram illustrating the development of the inferior vena cava in the cat. The cardinal and subcardinal veins and ductus venosus are blue and the supracardinal black. (Adapted from McClure and Huntington.)

The **supracardinal veins** develop as bilaterally symmetrical channels dorsomesad of the postcardinals, by longitudinal anastomoses between parietal postcardinal tributaries (Huntington and McClure). Each vein extends from where the posterior limb veins open into the post

cardinals to the junction of the primitive renal vein with the transverse subcardinal segment, and is situated *dorsad* of the corresponding ureter. The two supracardinals fuse almost wholly into a single channel and largely replace the postrenal segment of the primitive postcardinal system. To review, it is seen that the inferior vena cava is a composite vessel made up of the following parts, enumerated in order from the heart: (1) The part of the ductus venosus between the hepatic veins and the heart; (2) the cephalic part (renal level) of the right subcardinal; (3) the fused supracardinals, the caudal portions only remaining separate to drain the right and left iliaes (Fig. 549).

In consequence of the atrophy of the Wolffian bodies the postcardinal veins diminish in size; the precardinal veins, on the other hand, become enlarged, owing to the rapid development of the head and brain. They are further augmented by receiving the veins (*subclavian*) from the upper extremities, and so come to form the chief veins of the Cuvierian ducts; these ducts gradually assume an almost vertical position in consequence of the descent of the heart into the thorax. The right and left Cuvierian ducts are originally of the same diameter, and are frequently termed the *right* and *left superior venae cavae*. By the development of a transverse channel (the *left brachiocephalic vein*) between the two precardinal veins, the blood is carried across from the left to the right precardinal (Fig. 547). The portion of the right primitive jugular vein between the left brachiocephalic and the vena azygos major forms the upper part of the superior vena cava of the adult; the lower part of this vessel (*i. e.*, below the entrance of the vena azygos major) is formed by the right Cuvierian duct. Below the origin of the transverse channel the left primitive jugular vein and left Cuvierian duct atrophy, the former constituting the upper part of the left superior intercostal vein, while the latter is represented by the *vestigial fold* and *oblique vein of Marshall*. Both right and left superior venae cavae are present in some animals, and are occasionally found in the adult human being. The oblique vein of Marshall passes downward across the back of the left auricle to open into the coronary sinus, which, as already indicated, represents the persistent left horn of the sinus venosus.

The primitive jugular or precardinal veins are situated on the ventral surface of the brain, on the mesal side of the cranial nerve roots. A considerable portion of each of these veins disappears and is replaced by a vein which is developed on the lateral aspect of the cranial nerves from the fifth to the twelfth, inclusive. This new vein (*vena capitis lateralis*) leaves the skull in company with the facial nerve. The blood from the hind-brain is collected into a vein (*the future lateral sinus*) which passes through the foramen jugulare on the lateral aspect of the vagus nerve; here the two vessels join to form the internal jugular vein. On the dorsal aspect of the ear capsule an anastomotic channel is opened up between the vena capitis lateralis and the lateral sinus; and, coincident with this, the portion of the former vein which extends from the fifth to the tenth cranial nerve becomes obliterated, and thus the whole of the blood from the brain is ultimately drained away by the lateral sinuses. The primitive jugular vein is therefore represented in the adult by the internal jugular, and not by the external jugular, as is usually stated.¹ The external jugular vein is a vessel of later formation, which at first drains the region behind the ear (posterior auricular) and enters the primitive jugular as a lateral tributary. A group of veins from the face and lingual region converge to form a common vein, the linguofacial,² which also terminates in the primitive jugular. Later, cross communications develop between the external jugular and the linguofacial, with the result that the posterior group of facial veins are transferred to the external jugular.

The development of the lymphatics will be described at the beginning of the section on the lymph-vascular system.

¹ Consult *Die Entwicklung des Blutgefäß-systems*, by Höchstetter, in Hertwig's *Entwicklungslehre*; and also an article by Mall in the *American Journal of Anatomy*, December, 1904, vol. iv.

² Heuer, *American Journal of Anatomy*, February, 1909, vol. ix, No. 1.

THE LYMPHATIC SYSTEM.

THE lymphatic system¹ includes the lymphatic vessels and lymph nodes or lymphatic glands. The lymphatic vessels of the small intestine receive the special designation of *lacteals* or *chyliferous vessels*; they differ in no respect from the lymphatic vessels, except that during digestion they contain a milk-white fluid, the *chyle*.

It is now generally held that the lymphatic system is a closed system peripherally, and that the tissue spaces are not in direct communication with lymphatics, although Mall has shown that granules injected into the portal vein are returned by both lymphatics and veins. Elsewhere, apparently, the absorption of the lymph is carried on by transudation through the endothelial lining of the lymph vessels and not by permanent openings (the so-called *stomata*) between the endothelial cells.

The *tissue spaces* (*lymph spaces*) are found in practically all tissues and organs, and may be classified as *pericellular* or *intercellular*, *perivascular* and *perineural spaces*, which are not lined by endothelium. The lymph exudes into these spaces out of the blood capillaries and transudes into the lymphatic capillaries wherever such exist. Spaces like the subdural and subarachnoid, and the serous cavities of the body (pleural, pericardial, peritoneal, synovial bursae) are lined by endothelium, through which the lymph transudes by osmosis, while the lymphocytes may actually traverse the membrane. The ventricles of the brain and the central canal of the spinal cord, lined by the ependyma, contain a similar fluid derived from the plasma of the blood in the choroid plexuses, and they communicate with the subarachnoid space through the foramen of Magendie and those of Key and Retzius.

Lymph is a transparent, colorless or slightly yellow fluid of a specific gravity of 1.015, more dilute than the blood plasma from which it is derived, containing only about 5 per cent. of proteins and 1 per cent. of salts and extractives. It contains formed elements of the lymphocyte class, and is slightly coagulable.

Chyle is the intestinal lymph which is of a milky appearance during digestion on account of the emulsified fats absorbed by the lacteals.

The **lymphatic vessels** are arranged into a superficial and a deep set. On the surface of the body the **superficial lymphatic vessels** are placed immediately beneath the integument, accompanying the superficial veins; they join the deep lymphatics in certain situations by perforating the deep fascia. In the interior of the body the lymphatics lie in the submucous areolar tissue throughout the whole length of the gastropulmonary and genitourinary tracts, and in the subserous tissue of the thoracic and abdominal cavities. In the cranial cavity the perivascular sheaths are lymph spaces. A plexiform network of minute, closed, capillary lymphatics may be found interspersed among the proper elements and bloodvessels of the several tissues, the vessels composing which, as well as the meshes between them, are much larger than those of the capillary bloodvessel plexus. From these networks small collecting vessels emerge, pass to a neighboring node, and divide

¹ In the revision of the section on the lymphatic system, the editor has consulted the work by Poirier and Cancó, translated by Cecil H. Leaf, 1904; the articles by Sabin, Lewis, and Heuer in the *American Journal of Anatomy*, February 1, 1909; and the articles by Huntington, McClure, and others (symposium) in the *Anatomical Record*, May, 1908. Consult also G. S. Huntington and C. F. W. McClure, on the *Anatomy and Development of the Jugular Lymph Sacs in the Domestic Cat (Felis domestica)*, *American Journal of Anatomy*, April, 1910, vol. x, No. 2, and several articles by various authors in the *Anatomical Record*, vol. vi, No. 6, June 20, 1912.

into a capillary network in the node. Numerous small vessels emerge from the node, which unite into one lymphatic vessel, which joins a larger lymphatic trunk, which empties into a tributary of the superior vena cava. The **deep lymphatics**, fewer in number and larger than the superficial, accompany the deep bloodvessels. Their mode of origin is probably similar to that of the superficial vessels. The lymphatics of any part or organ exceed the veins in number and in capacity, but in size they are much smaller. Their anastomoses also, especially those of the large trunks, are more frequent, and are effected by vessels equal in calibre to those which they connect, the continuous trunks retaining the same diameter throughout.

The **lymph nodes**, or **lymphatic glands** (*lymphoglandulae*), are small, solid, gland-like bodies situated in the course of the lymphatic and lacteal vessels. They vary from microscopic dimensions to the size of an olive, and their color, on section, is of a pinkish-gray tint, excepting the bronchial nodes, which in the adult are mottled with black, the hepatic nodes, which are yellow, and the splenic nodes, which are brown. Each node has a layer or capsule of cellular tissue investing it, from which prolongations dip into its substance, forming partitions. The lymphatic and lacteal vessels traverse these nodes in their passage to the lymphatic ducts. Before entering a node a lymphatic or lacteal vessel divides into several small branches, which are named **afferent vessels** (*vasa afferentia*). As they enter, the external coat becomes continuous with the capsule of the node, and the vessels becoming much thinned, and consisting only of their internal or endothelial coat, pass into the node, and branch out upon and in the tissue of the capsule, these branches opening into the **lymph sinuses** of the node. There is an extensive sinus beneath the capsule; from this **subcapsular sinus** numerous channels run inward to a **central sinus**. From both sinuses fine branches proceed to form a plexus, the vessels of which unite to form a single **efferent vessel** (*vas efferens*), which, on emerging from the node, is again invested with an external coat from the gland capsule. The lymph nodes are

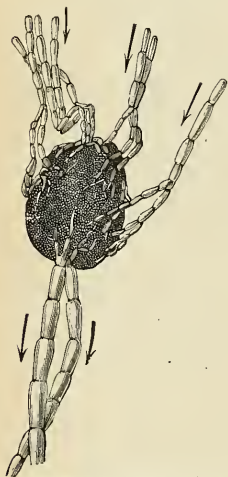


FIG. 550.—A lymph node with its afferent and efferent vessels. (Testut.)

and also have a cytogenic function. In the nodes are masses of newly formed lymphocytes which attack any bacteria in the lymph or chyle.

Like the lymphatics, the lymph nodes are arranged in **superficial** and **deep** sets; they are usually embedded in fat and are distinctly movable. Occasionally a node exists alone, but, as a rule, from eight to twelve, or even more, are assembled in communities or chains, and are usually arranged around bloodvessels. The nodes have a plentiful blood supply, and contain not only vasomotor nerves, but definite nerve plexuses. Besides the nodes, the body contains numerous lymphoid areas, which, in structure and function, are allied to lymph nodes (tonsils, Peyer's patches, etc.).

Hemolymph nodes exist in various regions, but are most common in the abdomen in front of the vertebræ. They are like ordinary lymph nodes in form and also in size, but differ from them in being deep red instead of light pink. Their function is to destroy red blood cells and to form lymphocytes, phagocytes, and eosinophiles. Hemolymph nodes develop like the ordinary lymphatic nodes except that the sinuses are blood channels.

Structure of Lymphatics.—The lymphatic vessels, including in this term the lacteal vessels, which are identical in structure with them, are composed of three coats. The **internal** is an endothelial and elastic coat. It is thin, transparent, slightly elastic, and ruptures more easily than the other coats. It is composed of a layer of elongated endothelial cells with serrated margins, by which the adjacent cells are dovetailed into one another. These are supported on a fibro-elastic membrane. The **middle** coat is composed of smooth muscle and fine elastic fibres, disposed in a transverse direction. The **external** coat consists of connective tissue, intermixed with smooth muscle fibres, longitudinally or obliquely disposed. It forms a protective covering to the other coats, and serves to connect the vessel with the neighboring structures. The above description applies only to the larger lymphatics; in the smaller vessels there is no muscular or elastic coat, and the wall consists only of a connective-tissue coat, lined by endothelium. The thoracic duct has a more complex structure than the other lymphatics; it presents a distinct subendothelial layer of branched cells, similar to that found in the arteries, and in the middle coat is a layer of connective tissues with its fibres arranged longitudinally. The lymphatics are supplied by nutrient vessels, which are distributed to their outer and middle coats; and here also have been traced many amyelinic nerve fibres in the form of several fine plexuses of fibrils.

The lymphatics are very generally provided with valves, which assist materially in effecting the flow of the lymph. These valves are formed of thin layers of fibrous tissue, covered on both surfaces by endothelium, which presents the same arrangement upon the two surfaces as was described in connection with the valves of veins. In form they are semilunar; they are attached by their convex edges to the sides of the vessel, the concave edges being free and directed along the course of the contained current. Usually two such valves, of equal size, are found opposite each other; but occasionally exceptions occur, especially at or near the anastomoses of lymphatic vessels. Thus, one valve may be of very rudimentary size and the other increased in proportion.

The valves in the lymphatic vessels are placed at much shorter intervals than in the veins. They are most numerous near the lymphatic nodes, and are found more frequently in the lymphatics of the neck and upper extremity than in those of the lower extremity. The wall of a lymphatic immediately above the point of attachment of each segment of a valve is expanded into a pouch or sinus, which gives to these vessels, when distended, the knotted or beaded appearance which they present. Valves are wanting in the vessels composing the plexiform network in which the lymphatics usually originate on the surface of the body.

Lymphatic vessels have been found in nearly every tissue and organ of the body which contains bloodvessels; nonvascular structures, such as cartilage, the nails, cuticle, and hair, have none. Lymphatic vessels have not been demonstrated in the brain, spinal cord, eyeball, and internal ear; the pathway of the lymph is apparently along the intercellular and perivascular tissue spaces.

Origin of Lymphatics.—The finest lymphatic vessels (lymphatic capillaries) form a plexiform network in the tissues and organs, and their walls consist of a single layer of endothelial plates, with more or less sinuous margins; the vessels of the lymphatic system, therefore, form a series of closed tubes similar to those of the blood-vascular system. The lymphatic vessels, for the most part, accompany the arteries or veins throughout the body; sometimes a minute artery may be seen to be ensheathed for a certain distance by a lymphatic capillary vessel, which is often many times wider than a blood capillary. These are known as perivascular lymphatics.

Terminations of Lymphatics.—The lymphatics, including the lacteals, discharge their contents into the veins at two points, namely, at the angles of junction of the subclavian and internal jugular veins—on the left side by means of the thoracic duct, and on the right side by the right lymphatic duct.

Development of the Lymphatic Vessels.—The lymphatic system begins as a series of sacs at the points of junction of certain of the embryonic veins. These lymph spaces are developed from their first inception as independent perivenous mesenchymal intercellular clefts. The cells lining these spaces develop into a lymphatic intimal endothelium.¹

In the human embryo the lymph sacs from which the lymphatic vessels are derived are six in number—two paired, the jugular and the caudal lymph sacs; and two unpaired, the retro-peritoneal and the cisterna chyli. In lower mammals an additional pair, subclavian, is present, but in the human embryo these are merely extensions of the jugular sacs.

¹ Cf. Huntington, *Anatomical Record*, vol. iv, No. 11, November, 1910

The position of the sacs is as follows: (1) *jugular sac*, at the junction of the subclavian vein with the primitive jugular; (2) *caudal sac*, at the junction of the iliac vein with the postcardinal; (3) *retroperitoneal*, in the position of the cross-branch between the renal veins; (4) *cisterna chyli*, at the site of the cross-branch between the two iliac veins (Fig. 551). From the lymph sacs the lymphatic vessels bud out along fixed lines corresponding more or less closely to the course of the embryonic bloodvessels. Both in the body wall and in the wall of the intestine the deeper plexuses are the first to be developed; by continued growth of these the vessels in the superficial layers are gradually formed. By the confluence of peri-azygos lymphatic segments the thoracic duct is formed; this gains connection with the venous system at the site of the jugular lymph sac. At its connection with the cisterna chyli it is at first double, but the right vessel soon joins with the left.

All the lymph sacs except the cisterna chyli are, at a later stage, divided up by slender connective-tissue bridges and transformed into groups of lymph nodes. The lower portion of the cisterna chyli is similarly converted, but its upper portion remains as the receptaculum chyli.

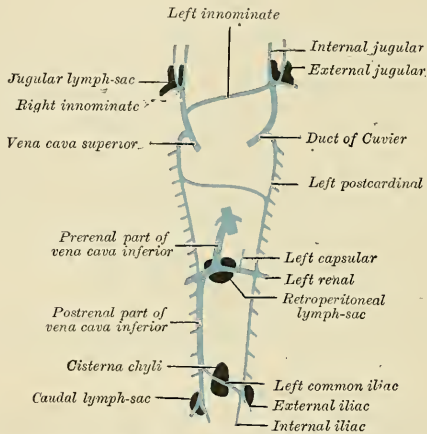


FIG. 551.—Scheme showing relative positions of primary lymphatic sacs based on the description given by Florence Sabin.

Applied Anatomy.—The lymphatic channels and nodes draining any infected area of the body are very liable to become infected, and do so with the production of acute or chronic *lymphangitis* and *lymphadenitis*. In acute cases the paths of the superficial lymphatics are often marked out on the skin by the appearance over them of the four cardinal signs of inflammation—pain, redness, heat, and swelling—while the nodes swell and may suppurate. Chronic inflammation leads to growth and fibrosis of the lymphatics and the connective tissue around them; obstruction to the passage of the lymph results, as the fibrous tissue contracts and causes stenosis or obliteration of the lymphatic channels, and hard edema of the involved skin and subcutaneous tissue follows (*pachydermia lymphangiectatica*). Chronic lymphangitis, together with the blocking of numerous lymphatic vessels by the escaped ova of the minute parasitic worm *Microfilaria nocturna*, is the cause of elephantiasis, a condition common in the tropics and subtropics, and characterized by enormous enlargement and thickening of the integument of some part of the body, most frequently the leg. Tubercular and syphilitic enlargements of the lymphatics and nodes are both very commonly met with. Primary tumors of the lymphatics are lymphangioma and endothelioma; the so-called “congenital cystic hygroma” of the neck, arm, trunk, or thigh is a cystic lymphangioma. Primary tumors of the lymph nodes may be benign (lymphadenoma, myxoma, chondroma) or malignant (lymphosarcoma); cancer is an extremely common secondary affection.

In an operation for cancer it is not sufficient to cut wide of the growth and remove it; it is imperatively necessary to remove the lymph nodes which receive lymph from the diseased

area, and also, when possible, the lymphatic vessels between the cancer and the nodes. Nodes are diseased very early in cancer, long before they are palpably enlarged, and are usually infected by emboli of cancer cells. The rule is in any cancer, however recent, to regard the associated nodes as diseased, whether enlarged or not, and to remove them thoroughly, if possible, in one piece, with the intervening lymph vessels and the area of primary malignant growth.

THE THORACIC DUCT.

The **thoracic duct** (*ductus thoracicus*) (Fig. 552) conveys the great mass of lymph and chyle into the blood. It is the common trunk of all the lymphatic vessels of the body, excepting those of the right side of the head and neck, the right upper extremity, the right lung, right side of the heart, and part of the convex surface of the liver. In the adult it varies in length from 15 to 18 inches (38–45 cm.), and extends from the second lumbar vertebra to the root of the neck. It commences in the abdomen at a triangular or fusiform dilatation, the *receptaculum chyli*, which is situated upon the front of the bodies of the first and of the second lumbar vertebrae, to the right side and behind the aorta, overlapped by the right crus of the Diaphragm. It enters the thorax through the aortic opening in the Diaphragm, lying to the right of the aorta, and is then placed in the posterior mediastinum between the aorta and vena azygos major. Here it lies in front of the vertebral column, from which it is separated by the right intercostal arteries, and by the azygos minor veins as they cross the middle line to open into the vena azygos major. Opposite the fifth thoracic vertebra it inclines toward the left side, enters the superior mediastinum, and ascends behind the arch of the aorta on the left side of the œsophagus, and behind the first portion of the left subclavian artery, to the upper opening of the thorax. Opposite the seventh cervical vertebra it turns outward in front of the vertebral artery and vein, behind the left common carotid artery and vagus nerve, and then curves downward over the subclavian artery and in front of the Scalenus anticus muscle and the phrenic nerve, so as to form an arch; it terminates in the angle of junction of the left

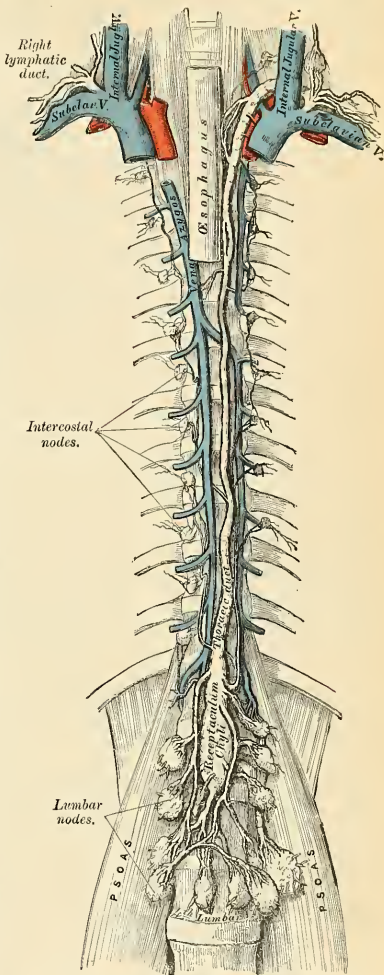


FIG. 552.—The thoracic and right lymphatic ducts.

subclavian artery and in front of the *Scalenus anticus* muscle and the phrenic nerve, so as to form an arch; it terminates in the angle of junction of the left subclavian vein with the left internal jugular vein. It usually opens at the apex of the angle in the superior and outer surface, but may open on the posterior surface. Sometimes it terminates by two or more branches. Figs. 552 and 554 show the termination of the thoracic duct. The thoracic duct, at its commencement, is about 2 to 3 mm. in diameter, diminishes considerably in its caliber in the middle of the thorax, and is again dilated just before its termination, the **ampulla**. It is generally flexuous in its course, the older the person the greater the flexuosity, and it is constricted at intervals so as to present a varicose appearance. The thoracic duct not infrequently divides in the middle of its course into two branches of unequal size, which soon reunite, or divides into several branches, which form a plexiform interlacement. It occasionally divides, at its upper part, into two vessels, of which the one on the left side terminates in the usual manner, while that on the right opens into the right subclavian vein, in connection with the right lymphatic duct. The thoracic duct has several valves throughout its whole course, but they are more numerous in the upper than in the lower part, and the lower valves are not competent; at its termination it is provided with a pair of competent valves, the free borders of which are turned toward the vein, so as to prevent the passage of venous blood into the duct.

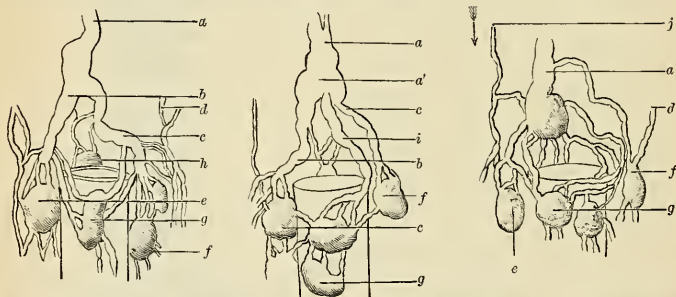


FIG. 553.—Modes of origin of the thoracic duct: *a*, Thoracic duct. *a'*, Receptaculum chyli. *b, c*, Efferent trunks from lateral aortic nodes. *d*, An efferent passing through the left crus of the diaphragm. *e, f*, Lateral aortic nodes. *g*, Preaortic node. *h*, Retroaortic node. *i*, Common intestinal trunk. *j*, Descending tributary from intercostal lymphatics. (Poirier and Charpy.)

The **receptaculum chyli** (*cisterna chyli*) (Figs. 552 and 553) receives the two lumbar lymphatic trunks, right and left, and the intestinal lymphatic trunk. The **lumbar lymphatic trunks** (*trunci lumbales*) are formed by the union of the efferent vessels from the lateral aortic lymph nodes. They receive the lymph from the lower limbs, from the walls and viscera of the pelvis, from the kidneys and suprarenal bodies, and the deep lymphatics of the greater part of the abdominal wall. The **intestinal lymphatic trunk** (*truncus intestinalis*) receives the lymph from the stomach and small intestine, from the pancreas and spleen, and from the lower and front part of the liver.

Tributaries.—Opening into the commencement of the thoracic duct, on either side, is a descending trunk from the posterior intercostal nodes of the lower six or seven intercostal spaces. In the thorax the duct is joined, on either side, by a trunk which drains the upper lumbar nodes and pierces the crus of the Diaphragm. It also receives the efferents from the posterior mediastinal nodes and from the posterior intercostal nodes of the upper six left spaces. In the neck it is joined by the *left jugular*, *left subclavian*, and *internal mammary* trunks, and sometimes by the *left bronchomediastinal* trunk; the last named, however, usually opens independently into the junction of the left subclavian and internal jugular veins.

Structure.—The thoracic duct is composed of three coats, which differ in some respects from those of the lymphatic vessels. The **internal coat** consists of a single layer of flattened endothelial cells; of a subendothelial layer, similar to that found in the arteries; and an elastic fibrous layer, the fibres of which run in a longitudinal direction. Each endothelial cell is shaped like a lance-head and has serrated borders. The **middle coat** consists of a longitudinal layer

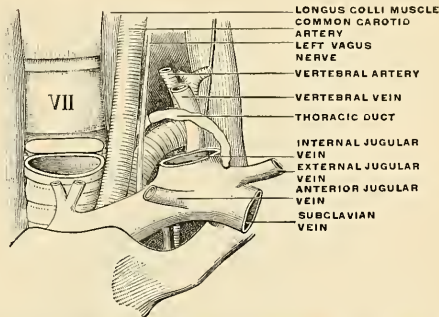


FIG. 554.—The bend of the thoracic duct at its termination in the subclavian vein. (Poirier and Charpy.)

of white connective tissue with elastic fibres, external to which are several laminae of muscle tissue, the fibres of which are for the most part disposed transversely, but some are oblique or longitudinal. The muscle fibres are intermixed with elastic fibres. The **external coat** is composed of areolar tissue, with elastic fibres and isolated fasciculi of nonstriated muscle fibres.

The Right Lymphatic Duct (Ductus Lymphaticus Dexter) (Figs. 552, 555).

The **right lymphatic duct**, about half an inch in length, courses along the inner border of the *Scalenus anticus* at the root of the neck and terminates in the right

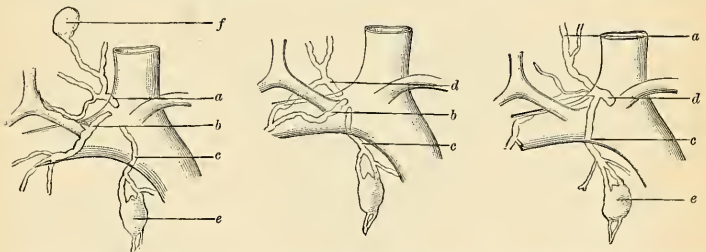


FIG. 555.—Terminal collecting trunks of the right side: *a*, Jugular trunk *b*, Subclavian trunk, *c*, Bronchomediastinal trunk, *d*, Right lymphatic trunk, *e*, Node of the internal mammary chain, *f*, Node of the deep cervical chain. (Poirier and Charpy.)

subclavian vein at its angle of junction with the right internal jugular vein. The orifice of the right lymphatic duct is guarded by two semilunar valves, which prevent the passage of venous blood into the duct.

Tributaries.—It receives the lymph from the right side of the head and neck through the *right jugular trunk*; from the right upper extremity through the *right subclavian trunk*; from the right side of the thorax, the right lung, and right side of the heart, and from part of the convex surface of the liver, through the *right bronchomediastinal trunk*. These three collecting trunks frequently open separately in the angle of union of the two veins.

Applied Anatomy.—Blockage of the thoracic duct by mature specimens of the minute parasitic worm *Microfilaria nocturna* gives rise to stasis of the chyle, and to its passage in various abnormal directions on its course past the obstruction. The neighboring abdominal, renal, and pelvic lymphatics become enlarged, varicose, and tortuous, and chyle may make its way into the urine (*chyluria*), the tunica vaginalis (*chyloccele*), the abdominal cavity (*chylous ascites*), or the pleural cavity (*chylous pleural effusion*), in consequence of rupture of some of these distended lymphatic vessels.

The thoracic duct may be secondarily infected in intestinal or pulmonary tuberculosis, and may contain either miliary tubercles, caseating tuberculous masses, or even tuberculous ulcers. It is often the seat of secondary carcinomatous deposits in cases of cancer of some abdominal viscus, becoming infiltrated throughout until it becomes a stiff moniliform rod as thick as a pencil, with multiple stenoses and dilatations of its lumen; in such cases the left supraclavicular nodes often become infected and enlarged, while the lungs remain entirely free from secondary growths.

LYMPHATICS OF THE HEAD, FACE, AND NECK.

Intracranial lymphatics have not been demonstrated. It is probable, but not yet conclusively demonstrated, that the perivascular spaces around the cerebral arteries are the beginning of a cerebral lymph system, and that these perivascular lymph channels pass out of the cranium with the arteries and the internal jugular veins and terminate in the superior deep cervical nodes. It is also probable that lymph spaces surround the dural bloodvessels and terminate in the superior deep cervical and the internal maxillary nodes. The lymphatics of the nasal fossæ can be injected from the subdural and subarachnoid spaces.

The **extracranial lymphatics** are divided into **superficial** and **deep**, and the two systems freely communicate. All of these vessels run into nodes about the head and neck. The superficial lymphatics take origin in the subcutaneous tissue and superficial muscles. The deep vessels arise in the orbit, mouth, nose, pharynx, œsophagus, tongue, larynx, and the muscular, ligamentous, and osseous structures.

The Lymph Nodes of the Head and Face.

The lymphatic nodes of the head and face are as follows:

1. The Occipital.
2. The Posterior Auricular.
3. The Parotid and Subparotid.
4. The Facial.
5. The Internal Maxillary.
6. The Lingual.
7. The Retropharyngeal.

The **occipital nodes** (*lymphoglandulae occipitales*) (Fig. 556), one to three in number, are situated upon the occipital insertion of the Complexus muscle, at the lateral border of the Trapezius, and beneath the deep fascia. Their afferents drain the occipital region of the scalp, while their efferents pass to the upper deep cervical nodes.

The **posterior auricular** or **mastoid nodes** (*lymphoglandulae auriculares posteriores*) (Fig. 556), usually two in number, are situated upon the mastoid insertion of the Sternomastoid muscle. Their afferents drain the posterior part of the temporoparietal region, the upper part of the internal surface of the pinna, and the posterior surface of the external auditory canal; their efferents pass to the upper deep cervical nodes.

The **parotid lymph nodes** (*lymphoglandulae parotideae*) (Figs. 556 and 557) are divided into three groups, superficial, deep, and the subparotid.

The **superficial parotid or preauricular lymph nodes** (*lymphoglandulae auriculares anteriores*) are situated between the parotid fascia and the parotid salivary gland.

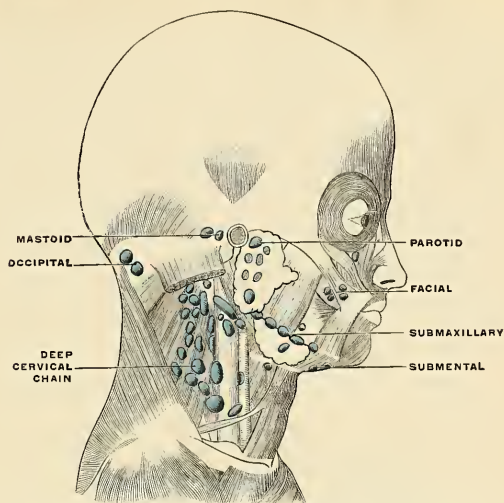


FIG. 556.—General arrangement of the lymph nodes of the head and neck. (Poirier and Charpy.)

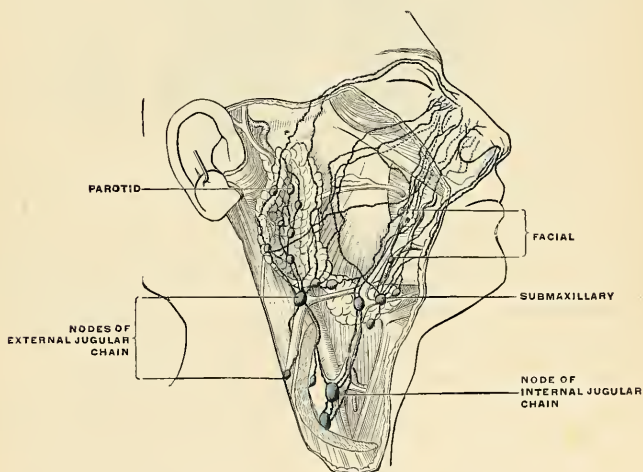


FIG. 557.—The lymphatics of the neck. (Küttner.)

The **deep parotid lymph nodes**, from fifteen to twenty in number, are embedded in the substance of the parotid gland. The afferents of the superficial and deep

parotid nodes drain the eyelids, eyebrows, the root of the nose, upper portion of the cheek, frontotemporal portion of the scalp, from the outer surface of the pinna, from the external auditory canal, and from the tympanum. Their efferents pass to the upper deep cervical nodes.

The **subparotid nodes** lie beneath the parotid gland, on the lateral wall of the pharynx, and they are close to the internal carotid artery and the internal jugular vein. Their afferents drain the posterior part of the nasal fossa, nasopharynx, and Eustachian tube; their efferents pass to the upper deep cervical nodes.

The **facial nodes** comprise three groups in the course of the afferents of the submaxillary nodes. (1) A **maxillary**, over the infraorbital region; (2) a **buccal**, upon the outer surface of the Buccinator where that muscle is pierced by the parotid duct; (3) a **mandibular** group, upon the outer surface of the mandible, at the anterior margin of the Masseter muscle, beneath the Platysma and in contact with the facial vessels. Their afferent vessels drain the eyelids, the conjunctiva, integument, and mucous membrane of the nose and cheek. Their efferents pass to both submaxillary and upper deep cervical nodes.

The **internal maxillary nodes** (*lymphoglandulae faciales profundae*) are deeply placed beneath the ramus of the mandible on the outer surface of the External

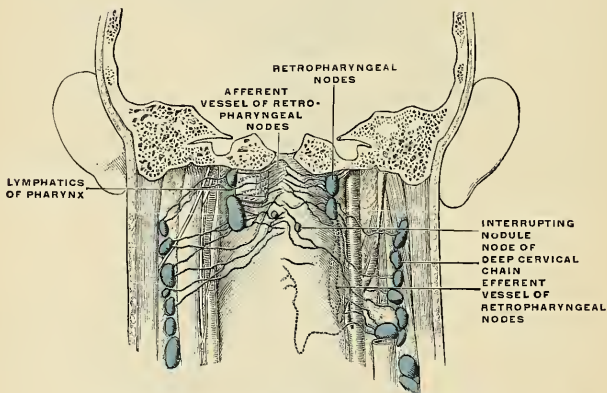


FIG. 558.—The retropharyngeal nodes. (Poirier and Charpy.)

pterygoid, in relation with the internal maxillary artery. Their afferent vessels drain the temporal and zygomatic fossæ and the nasopharynx; their efferents pass to the upper nodes of the deep cervical group and to the submaxillary nodes.

The **lingual nodes** (*lymphoglandulae linguales*) are two or three small nodules lying on the Hyoglossus and under the Geniohyoglossus. They form merely nodal substations in the course of the lymphatic vessels of the tongue.

The **retropharyngeal nodes** (Fig. 558) lie in the buccopharyngeal fascia, behind the upper part of the pharynx and in front of the arch of the atlas, being separated, however, from the latter by the Rectus capitis anticus major. Their afferents drain an extensive area, comprising the nasal fossæ, the nasopharynx, and the Eustachian tube as far as the tympanum; their efferents pass to the upper nodes of the deep cervical group.

The **lymphatic vessels of the scalp** are divisible into (a) those of the frontal region, which terminate in the parotid nodes; (b) those of the temporoparietal region, which end in the parotid and postauricular nodes; and (c) those of the

occipital region, which terminate partly in the occipital nodes and partly in a trunk which runs down along the posterior border of the Sternomastoid to end in the lower group of deep cervical nodes.

The **lymphatic vessels of the pinna and external auditory meatus** are also divisible into three groups: (a) an *anterior*, from the outer surface of the pinna and anterior wall of the canal to the parotid nodes; (b) a *posterior*, from the margin of the pinna, the upper part of its inner surface, the internal surface and posterior wall of the meatus to the postauricular and upper deep cervical nodes; (c) an *inferior*, from the floor of the canal and from the lobule to the external jugular and upper deep cervical nodes.

The **lymphatic vessels of the face** are more numerous than those of the scalp. Those from the eyelids and conjunctivæ terminate partly in the submaxillary, but mainly in the parotid nodes. The vessels from the posterior part of the cheek also pass to the parotid nodes, while those of the anterior portion of the cheek, the side of the nose, the upper lip, and the lateral portions of the lower lip terminate in the submaxillary nodes. The deeper vessels from the temporal and zygomatic fossæ pass to the internal maxillary and upper deep cervical nodes. The deeper vessels of the cheek and lips terminate, like the superficial, in the submaxillary nodes. Both superficial and deep vessels of the central part of the lower lip run to the suprahyoid nodes.

The **lymphatic vessels of the nasal fossæ** can be injected from the subdural and subarachnoid spaces. Those from the anterior parts of the fossæ terminate in the submaxillary nodes; those from the posterior two-thirds of the fossæ and from the communicating air sinuses pass partly to the retropharyngeal nodes and partly to the upper deep cervical nodes.

The **lymphatic vessels of the mouth** terminate as follows: (a) Those of the gums terminate in the submaxillary nodes; (b) those of the hard palate terminate in the upper deep cervical and subparotid nodes; (c) those of the soft palate, in the retropharyngeal and upper deep cervical nodes; (d) those of the anterior part of the floor of the mouth pass through the submental and suprahyoid nodes to the upper deep cervical group; (e) those from the rest of the floor of the mouth terminate in the submaxillary and upper deep cervical nodes.

The **lymphatic vessels of the tongue** (Fig. 559) are drained chiefly into the deep cervical nodes lying between the posterior belly of the Digastric and the posterior belly of the Omohyoid; one node situated at the bifurcation of the common carotid artery is so intimately associated with these vessels that it is known as the **principal node of the tongue**. The apical vessels of the tongue pass to the suprahyoid nodes and principal node of the tongue; the marginal vessels pass partly to the submaxillary and partly to the upper deep cervical nodes. The base of the tongue in the region of the circumvallate papillæ is drained by vessels which terminate in the upper deep cervical nodes.

The **lymph nodes of the neck** include the following groups:

I. The Superficial Cervical, including—

- (a) External Jugular.
- (b) Anterior Cervical (superficial).
- (c) Submaxillary.
- (d) Submental or Suprahyoid.

II. The Deep Cervical, including—

- (a) Anterior Cervical (deep).
- (b) Retropharyngeal.
- (c) Sternomastoid.
- (d) Supraclavicular.

The **superficial cervical nodes** (*lymphoglandulae cervicales superficiales*) (Fig. 557) are composed of two groups, the **external jugular** and the **anterior cervical nodes**.

The **external jugular nodes** (Figs. 557 and 560) are superficial to the Sternomastoid muscle. They are four to six in number and lie along the external jugular vein upon the outer surface of the deep cervical fascia, each node occupying a depression in the fascia. They are usually gathered in a group a little below the parotid gland, but sometimes extend to the middle of the vein. Their afferents drain the lower part of the pinna and parotid region, while their efferents pass around the anterior margin of the Sternomastoid and terminate in the upper deep cervical nodes.

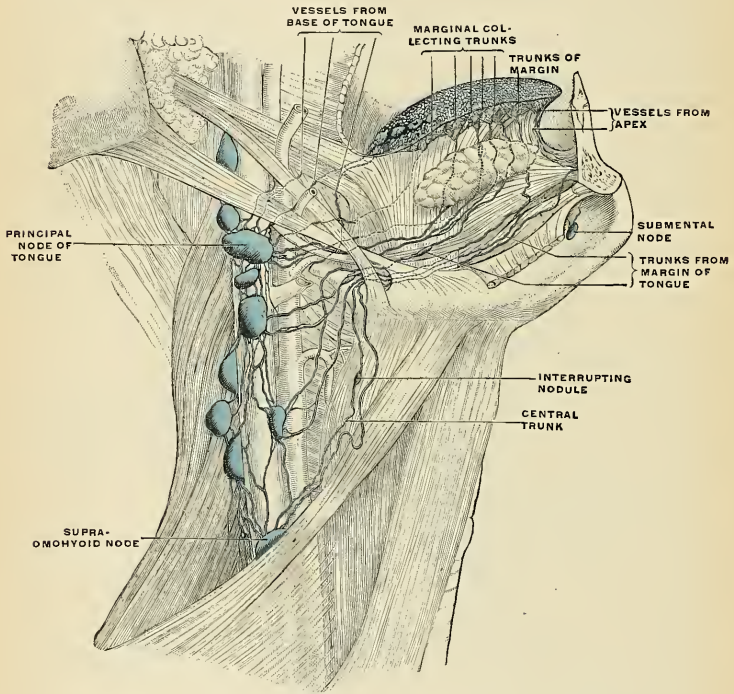


FIG. 559.—The lymphatics of the tongue, lateral view. (Poirier and Charpy.)

The **submaxillary nodes** (*lymphoglandulae submaxillares*) (Figs. 556 and 557), three to six in number, are placed in the submaxillary triangle beneath the body of the mandible in the submaxillary triangle and rest on the superficial surface of the sheath of the submaxillary gland. One node (the **middle gland of Stahr**), which lies on the facial artery as it turns over the mandible, is the most constant of the series. Small lymph nodes are sometimes found on the deep surface of the submaxillary gland. Their afferents drain the inner canthus of the eye, the cheek, the side of the nose, the upper lip, the outer part of the lower lip, the gums, and the anterior part of the margin of the tongue; efferent vessels from the facial and suprahyoid nodes also enter the submaxillary nodes. Their efferent vessels pass to the upper nodes of the deep cervical group.

The **submental** or **suprahyoid nodes** (Figs. 556 and 559) are usually two nodes situated between the anterior bellies of the two Digastric muscles and upon the Mylohyoid muscle. They receive lymph from the cutaneous surface of the chin, from the cutaneous and mucous surfaces of the central portion of the lower lip, from the central portion of the gums, from the floor of the mouth, and from the tip of the tongue. They send some vessels to the submaxillary lymph nodes, and frequently a node is interposed on the anterior belly of the Digastric muscle. They send other vessels to the upper deep cervical nodes.

The **anterior cervical nodes** form an irregular and inconstant group on the front of the larynx and trachea. They may be divided into (a) a **superficial set**, placed on the anterior jugular vein; (b) a **deeper set**, which is further subdivided into **prelaryngeal**, on the cricothyroid membrane, and **pretracheal**, on the front of the trachea. The superficial set receives lymph from the posterior auricular and occipital nodes; their efferents empty into the upper deep cervical nodes. The deeper set drains the lower part of the larynx, the thyroid body, and the upper part of the trachea; their efferents pass to the lower nodes of the upper deep cervical group.

The **retropharyngeal nodes** have been described on page 776.

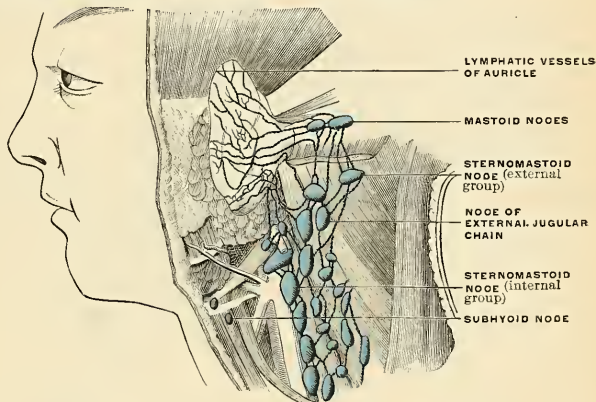


FIG. 560.—Deep cervical chain. (Poirier and Charpy.)

The **deep cervical nodes** (*lymphoglandulae cervicales profundae*) (Figs. 556 and 560) are numerous and of large size; they form a chain along the carotid sheath lying by the side of the pharynx, œsophagus, and trachea, and extending from the base of the skull to the root of the neck. They are usually described in two groups: (1) an **upper** or **substernomastoid** group (*lymphoglandulae cervicales profundae superiores*) lying under the Sternomastoid in close relation with the spinal accessory nerve and the internal jugular vein, some of the nodes lying in front of and others behind the vessel; (2) a **lower** or **supraclavicular** group (*lymphoglandulae cervicales profundae inferiores*) extending beyond the posterior margin of the Sternomastoid into the supraclavicular triangle, where they are closely related to the brachial plexus and subclavian vein. A few minute nodes are situated alongside the recurrent laryngeal nerves on the lateral aspects of the trachea and œsophagus. The **upper** deep cervical nodes drain the occipital portion of the scalp, the pinna, and the back of the neck, the tongue, larynx, thyroid body, trachea, nasopharynx, nasal fossæ, palate, and œsophagus. They

receive also the efferent vessels from all the other nodes of the head and neck, except those from the lower deep cervical group. The lower deep cervical nodes drain the back of the scalp and neck, the superficial pectoral region, part of the arm (see page 783), and occasionally part of the upper surface of the liver. In addition, they receive vessels from the upper group. The efferents of the upper deep cervical nodes pass partly to the lower group and partly to a trunk which unites with the efferent trunk of the lower deep cervical nodes and forms the **jugular trunk** (*truncus jugularis*). This trunk, on the right side, ends in the junction of the internal jugular and subclavian veins, while on the left side it joins the thoracic duct.

The **lymphatic vessels of the skin and muscles of the neck** pass to the deep cervical nodes. From the upper part of the **pharynx** the lymphatic vessels pass to the retropharyngeal, from the lower part to the deep cervical nodes. From the **larynx** two sets of vessels arise, an upper and a lower. The vessels of the upper set pierce the thyrohyoid membrane and join the upper deep cervical nodes. Of the lower set, some pierce the cricothyroid membrane and join the pretracheal and prelaryngeal nodes; others run between the cricoid and first tracheal ring and enter the lower deep cervical nodes. The lymphatic vessels of the **thyroid body** consist of two sets, an upper, which accompanies the superior thyroid artery and enters the upper deep cervical nodes, and a lower, which runs partly to the pretracheal and partly to the small nodes which accompany the recurrent laryngeal nerve. These latter nodes receive also the lymphatic vessels from the cervical portion of the trachea.

Applied Anatomy.—The cervical nodes are very frequently the seat of tuberculous disease. This condition is most usually set up by some lesion in those parts from which they receive their lymph. It is very desirable, therefore, that the surgeon, in dealing with these cases, possess a knowledge of the relation of the respective groups of nodes to the periphery, while in order to eradicate them by operation a long and difficult dissection may be required. Sir Frederick Treves prepared a table to show to what group lymph from each region is sent. The table is practically as follows:

Scalp—Posterior part = suboccipital and mastoid nodes. Frontal and parietal portions = parotid nodes.

Lymphatic vessels from the scalp also enter the superficial cervical set of nodes.

Skin of face and neck = submaxillary, parotid, and superficial cervical nodes.

External ear = superficial cervical nodes.

Lower lip = submaxillary and suprahyoid nodes.

Buccal cavity = submaxillary and upper set of deep cervical nodes.

Gums of lower jaw = submaxillary nodes.

Tongue—Anterior portion = suprahyoid and submaxillary nodes. Posterior portion = upper set of deep cervical nodes.

Tonsils and palate = upper set of deep cervical nodes.

Pharynx—Upper part = parotid and retropharyngeal nodes. Lower part = upper set of deep cervical nodes.

Larynx, orbit, and roof of mouth = upper set of deep cervical nodes.

Nasal fossæ = retropharyngeal nodes, upper set of deep cervical nodes. Some lymphatic vessels from posterior part of the fossæ enter the parotid nodes.

Treves' table indicates the nodes usually involved, but the seat of primary disease cannot invariably be affirmed from a knowledge of the seat of glandular involvement, because the course of the lymphatic vessels is sometimes varied from that which usually maintains; for instance, in some cases lymphatics from the right side of the tongue pass to nodes in the left side of the neck.

A *retropharyngeal abscess* begins laterad of the pharynx. It enlarges toward the centre rather than from it, because the Constrictors of the pharynx limit the outward progress of the pus.

The nodes within the parotid salivary glands not unusually become tuberculous, and the surgeon may be led to believe that the salivary gland is the seat of primary disease.

Sometimes, though seldom, after the extensive removal of lymph nodes the region drained by their tributaries becomes the seat of persistent hard edema (*lymph edema*). It used to be thought that wounds of the thoracic duct were of necessity fatal, but it is now known that, unless close to the vein, they are seldom even very dangerous. It may be possible to suture a partly divided duct. In an unsutured wound of the duct recovery follows if a collateral lymphatic circulation is established.

THE LYMPHATICS OF THE UPPER EXTREMITY.

The Lymph Nodes of the Upper Extremity.

The lymph nodes of the upper extremity are divided into two sets, **superficial** and **deep**.

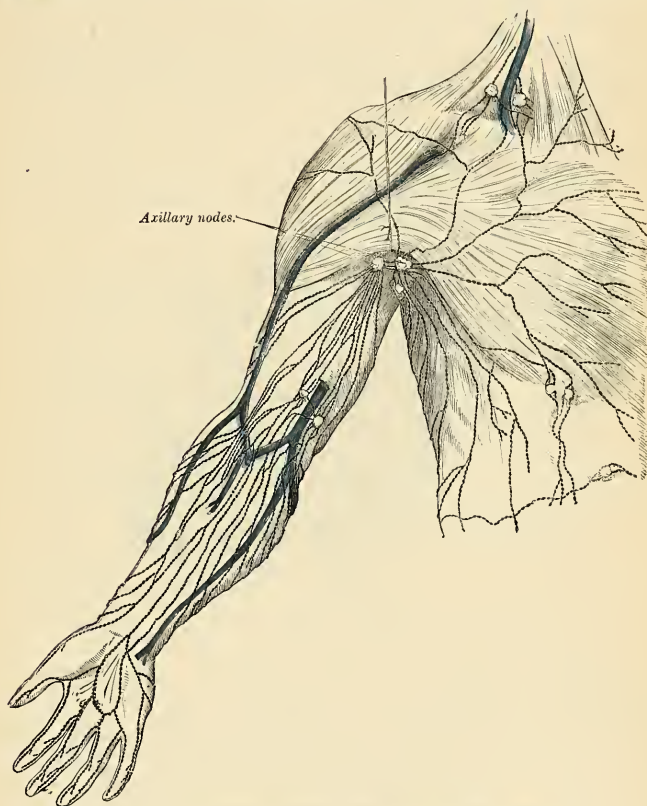


FIG. 561.—The superficial lymphatics and nodes of the upper extremity.

The **superficial lymph nodes** (Fig. 561) of the upper extremity are few in number and small in size. They lie in the subcutaneous tissue. They are not receiving depots of great areas, but interrupt lymphatic vessels here and there. The nodes in the axilla receive all of the lymphatic vessels, superficial and deep.

There may be three sets of superficial nodes. One set, the **antecubital nodes**, lie in front of the elbow. These nodes are often absent. When these nodes are present they receive vessels from the anterior portion of the forearm and the middle

of the palm. The vessels from them pass along the front and inner aspect of the arm.

One or two superficial nodes lie above the internal condyle. This is the **supratrochlear or epitrochlear group of nodes**. There is usually but one node, but there may be two or more. It receives vessels from the three inner fingers, the inner portion of the hand, and the inner portion of the forearm, but, because of free anastomoses, also may receive lymph from any portion of the hand and forearm. Lymph vessels from the supratrochlear node pass up along the basilic vein to the axillary nodes.

There are sometimes several small nodes along the cephalic vein in the groove between the Deltoid and the great Pectoral muscle. These are called **infra-clavicular nodes**, the efferents of which drain into the subclavian nodes.

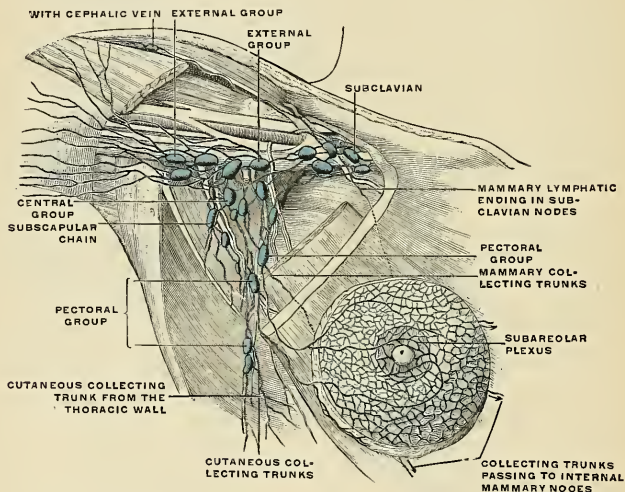


Fig. 562.—Axillary nodes and lymphatics of the breast. (Poirier and Charpy.)

The Deep Lymph Nodes of the Upper Extremity or the Axillary Nodes (*lymphoglandulae axillares*) (Figs. 562 and 563).—The chief deep nodes are situated adjacent to the axillary vessels. There are also a few small nodes along the radial, ulnar, and brachial arteries which receive deep lymphatics from bones, muscles, and ligaments, and send lymphatics to the axillary nodes. The axillary nodes number from fifteen to thirty-five in each axilla. They are embedded in the axillary fat and receive the lymphatic vessels from the upper extremity, from the skin of the upper portion of the thorax, from the Pectoral muscles, and from the mammary gland. They may be arranged in the following groups:

(1) An **external group**, the **humeral chain**, lying on the inner surface of the vessels and nerves, particularly the axillary vein, to the sheath of which they are adherent. Occasionally one or several of these nodes are found beneath the vein. Some of the vessels from these nodes pass into the central group of lymph nodes; others enter the subclavian nodes; others pass above the clavicle and terminate in nodes situated in that region. (2) An **anterior or pectoral group** (*lymphoglandulae pectorales*), situated along the lower border of the Pectoralis minor and in relation

with the long thoracic artery. The afferents of this group drain the skin and muscles of the pectoral and subaxillary regions of the thorax and part of the mammary gland; their efferents pass to the central and subclavicular nodes. (3) A **posterior group**, the **subscapular chain**, lying along the subscapular artery. Their afferents drain the skin and muscles of the lower part of the neck and of the posterior thoracic wall; their efferents pass to the central axillary group of nodes. (4) A **central or intermediate group** of three or four large nodes situated in the adipose tissue near the base of the axilla, their afferents draining all the preceding groups of axillary nodes; their efferent vessels end in the subclavicular nodes. The nodes of the central group in many individuals protrude through the opening in the axillary fascia known as the **foramen of Langer**. (5) A **subclavian group**, situated behind the upper margin of the Pectoralis minor. From the axillary nodes come many vessels which, by anastomosing, form the **infraclavicular plexus**; they then unite into a trunk, the **subclavian trunk** (*truncus subclavius*), which courses between the subclavian vein and Subclavius muscle. On the right side it empties into the junction of the internal jugular and subclavian vein or unites with the jugular trunk to form the right lymphatic duct. On the left side it may empty into the venous junction or into the thoracic duct.

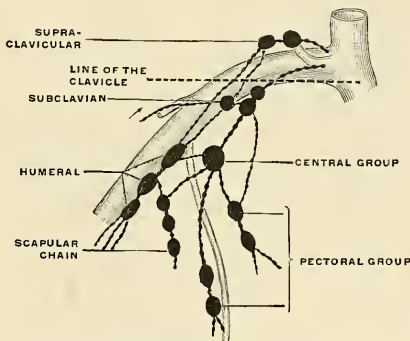


FIG. 563.—Scheme of the axillary nodes. The dotted line indicates the position of the clavicle. (Poirier and Charpy.)

The Lymphatic Vessels of the Upper Extremity (Figs. 561, 564).

The lymphatic vessels of the upper extremity are divided into the **superficial** and the **deep**.

The **superficial lymphatic vessels of the upper extremity** begin as plexuses in the skin and form vessels which ascend in the subcutaneous tissue. These plexuses are particularly plentiful in the palm and palmar surface of the digits (Fig. 564). On each side of each finger two lymph vessels are formed; they ascend toward the hand, cross the dorsum, and anastomose frequently with each other. The vessels from the dorsum of the hand join the lymph vessels of the forearm, which ascend chiefly along the superficial veins. The lymph vessels which ascend with the superficial ulnar vein pass into the supratrochlear node. The vessels which accompany the median veins pass into the antecubital or supratrochlear nodes. Some of the lymph vessels on the radial side of the forearm run up along the cephalic vein and terminate in the infraclavicular nodes. All the other lymph vessels of the upper extremity pass direct to the axillary

nodes. In the forearm there are about thirty vessels, in the middle of the arm there are from fifteen to eighteen (Sappey).

The **deep lymphatic vessels of the upper extremity** convey the lymph from bone, periosteum, muscle, ligament, etc. They pass up the limb with the chief vessels, there usually being two trunks to each artery. In the arm there are two or three vessels. Some few vessels terminate in the small nodes along the radial, ulnar, and brachial arteries, but most of them pass directly to the axillary nodes.

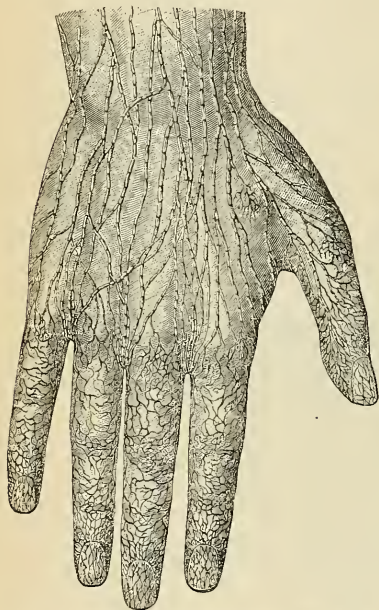


FIG. 564.—Lymphatic vessels of the dorsal surface of the hand. (Sappey.)

piece. By this plan thorough removal is possible, and as lymph vessels containing carcinoma cells are not cut across, the wound is not grafted with malignant epithelial cells. Diseased axillary nodes are apt to adhere to the sheath of the vein. In removing cancerous nodes always excise the sheath of the vein.

Applied Anatomy.—In *malignant diseases*, or other affections implicating the upper part of the back and shoulder, the front of the thorax and mammae, the upper part of the front and side of the abdomen, or the hand, forearm, or arm, the axillary nodes are liable to be found enlarged.

In *secondary syphilis* the supratrochlear node is found to be enlarged. This node is subcutaneous and readily palpable against the subjacent bone when enlarged. Normal axillary nodes cannot be palpated. The axilla is a passageway for structures between the neck or thorax and the upper extremity, and purulent collections or tumors may extend from the neck or thorax into the axilla or from the axilla into the neck or thorax.

The axillary nodes are involved early in cases of cancer of the mammary gland, and later the lower deep cervical nodes are involved, and, as Snow has pointed out, regurgitation of lymph containing cancer cells leads to retrosternal involvement and to secondary cancer of the head of the humerus. In operating for cancer of the breast, follow the principle of Halsted and remove the breast, the skin over it, the muscles and fascia, the lymph vessels, and the axillary nodes in one

THE LYMPHATICS OF THE LOWER EXTREMITY.

The Lymph Nodes of the Lower Extremity.

The lymph nodes of the lower extremity consist of the **anterior tibial node** and the **popliteal and inguinal nodes**, all deeply situated.

The **anterior tibial node** (*lymphoglandula tibialis anterior*) is small and lies on the interosseous membrane in relation to the upper part of the anterior tibial vessels, and constitutes a substation in the course of the anterior tibial lymphatic trunks. Its efferents cross to the inner side of the leg just below the knee and pass to the superficial inguinal nodes.

The **popliteal nodes** (*lymphoglandulae popliteae*), small in size and some six or seven in number, are embedded in the fat contained in the popliteal space.

One lies immediately beneath the popliteal fascia, near the terminal part of the external saphenous vein, and drains the region from which this vein derives its tributaries. Another is placed between the popliteal artery and the posterior ligament of the knee; it receives the lymphatic vessels from the knee-joint together with those which accompany the articular arteries. The others lie at the sides of the popliteal vessels, and receive as afferents the trunks which accompany the anterior and posterior tibial vessels. The efferents of the popliteal nodes pass almost entirely alongside of the femoral vessels to the deep inguinal nodes, but a few may accompany the internal saphenous vein, and end in the nodes of the superficial inguinal group.

The **inguinal nodes** vary from twelve to twenty in number and are arranged in two groups, superficial and deep.

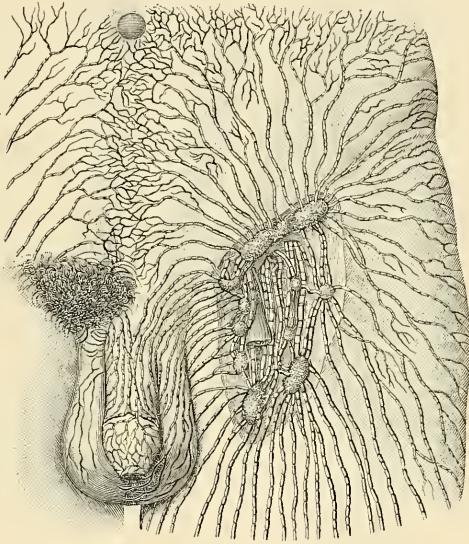


FIG. 565.—Nodes of the inguinal region with the afferent and some of the efferent lymphatics. (Poirier and Charpy.)

The **superficial inguinal lymph nodes** (Figs. 565 and 566), placed immediately beneath the superficial fascia in Scarpa's triangle, are of large size, and vary in number from ten to twenty. It is customary to divide these nodes into groups according to the region in which they are found. A horizontal line carried through the saphenous opening divides the nodes into two groups, a **superior group** and an **inferior group**. The nodes of the superior group (*lymphoglandulae inguinales*) form a chain immediately below Poupart's ligament. They receive as afferents lymphatic vessels from the integument of the penis, scrotum, perineum, buttock, and lower abdominal wall. The nodes of the **inferior group** (*lymphoglandulae subinguinales*) are placed on either side of the upper part of the saphenous vein, and receive as afferents the lymphatic vessels of the lower extremity and also some lymphatics from the penis, scrotum, clitoris, labia, perineum, and buttock.

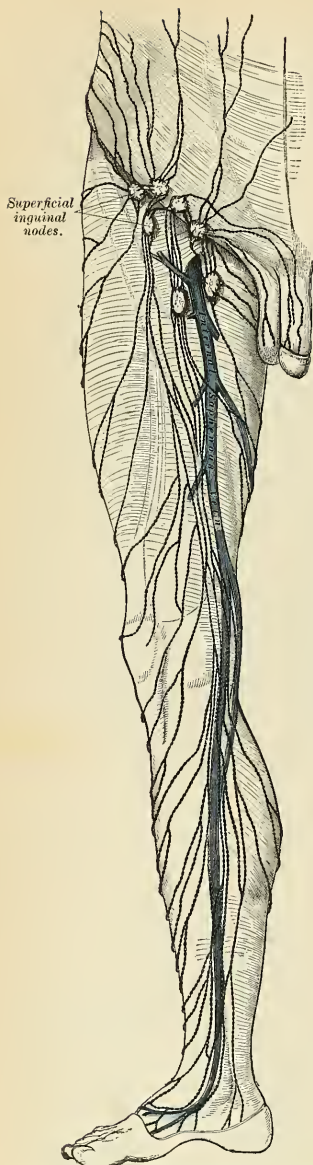

FIG. 566.—The superficial lymphatics and nodes of the lower extremity.

The **deep inguinal nodes** (*lymphoglandulae subinguinales profundae*) (Fig. 565) vary from one to three in number, and are placed under the fascia lata, on the inner side of the femoral vein. When three are present, the lowest is situated just below the junction of the internal saphenous and femoral veins, the middle in the femoral (crural) canal, and the highest in the outer part of the femoral ring. The middle is the most inconsistent of the three, but the highest one, the **node of Cloquet**, or **Rosenmüller**, is also frequently absent. They receive as afferents the deep lymphatic trunks which accompany the femoral vessels, the lymphatics from the glans penis or glans clitoridis, and also some efferents from the superficial inguinal nodes.

Applied Anatomy.—Inflammation and supuration of the popliteal nodes are most commonly due to a sore on the outer side of the heel.

The inguinal nodes frequently become enlarged in diseases implicating the parts from which their lymphatics originate. Thus, in malignant or syphilitic affections of the prepuce and penis, or labia majora, in cancer scroti, in abscess in the perineum, or in similar diseases affecting the integument and superficial structures in those parts, or the subumbilical part of the abdominal wall, or the gluteal region, the upper chain of nodes is almost invariably enlarged, the lower chain being implicated in diseases affecting the lower limb.

The Lymphatic Vessels of the Lower Extremity.

The lymphatic vessels of the lower extremity consist of two sets, superficial and deep, and in their distribution correspond closely with the veins.

The **superficial lymphatic vessels of the lower extremity** are placed beneath the integument in the superficial fascia, and are divisible into three sets—trunks which follow the course of the internal saphenous vein, trunks which accompany the external saphenous, and trunks from the gluteal region. (1) Trunks which follow the course of the internal saphenous vein arise from a plexus on the dorsum of the foot, which plexus obtains lymphatics from all the toes, the sole, and both

borders of the foot. The internal trunks, three or four in number, pass to the superficial inguinal nodes. The external trunks run upward and inward and end in the internal trunks. (2) The trunks which follow the external saphenous vein number two or three, and they take origin from the heel and from the posterior half of the outer edge of the foot. They empty into the superficial inguinal nodes. (3) The lymph trunks from the gluteal region join vessels from the anus and enter the superficial inguinal nodes.

The **deep lymphatic vessels of the lower extremity** are few in number, and accompany the deep bloodvessels. In the leg they consist of three sets, the anterior tibial, peroneal, and posterior tibial, which accompany the corresponding bloodvessels, two or three to each artery; they ascend with the bloodvessels and enter the lymph nodes in the popliteal space; the efferent vessels from these nodes accompany the femoral vein and join the deep inguinal nodes; from these nodes vessels pass beneath Poupart's ligament and communicate with the chain of nodes surrounding the external iliac vessels. The deep lymphatic vessels of the gluteal and sciatic regions follow the course of the bloodvessels, and join the gluteal and sciatic nodes at the great sacrosciatic foramen.

THE LYMPHATICS OF THE PELVIS AND ABDOMEN.

The **lymphatics of the pelvis and abdomen** may be divided from their situation into (*a*) **parietal**, lying retroperitoneally and in close association with the larger bloodvessels; and (*b*) **visceral**, which are found in relation to the visceral arteries.

The **parietal nodes** (Fig. 567) include the following groups:

External iliac.
Internal iliac.
Common iliac.

Lumbar { Lateral aortic.
Preaortic.
Retroaortic.

The **external iliac nodes** form three chains around the external iliac vessels. An **external chain** of three or four nodes lies between the artery and the Psoas muscle. A **middle chain** of three nodes lies upon the front surface of the external iliac vein. An **internal chain** of three or four nodes is placed to the inner side of the external iliac vein. An **obturator node** belongs to the inner chain of external iliac nodes. The external iliac nodes receive vessels from the superficial and deep inguinal nodes, from the glans penis or glans clitoris, deep lymphatics from the umbilicus and lower part of the belly wall, vessels from the superior portion of the vagina, the uterine cervix, the prostate gland, the bladder, the membranous portion of the urethra, and the internal iliac nodes, and the obturator node receives deep lymph vessels from along the course of the obturator vessels. The external iliac nodes send vessels direct to the common iliac nodes and also lymphatics to join vessels from the internal iliac nodes on their way to the common iliac group. The nodes along the epigastric artery and those along the deep circumflex iliac artery are accessory chains to the main group of external iliac nodes.

The **internal iliac or hypogastric nodes** (*lymphoglandulae hypogastricae*) surround the internal iliac vessels, and receive the lymphatics corresponding to the distribution of the branches of the internal iliac artery; *i. e.*, lymphatics from all the pelvic viscera, from the deeper parts of the perineum including the membranous and penile portions of the urethra, from the deep tissues of the posterior portion of the thigh, and from the buttocks. Their efferents pass to the common iliac nodes and also to the external iliac nodes.

The **sacral nodes** belong to this group, but are placed in the concavity of the sacrum; they receive lymphatics from the rectum and posterior wall of the pelvis.

The **common iliac nodes** are found about the common iliac artery and are divided into an **external group**, which lies upon the inner edge of the Psoas muscle; a **middle group**, behind the artery, and an **internal group**, which lies upon the front of the body of the fifth lumbar vertebra or upon the sacrovertebral articulation. They receive vessels from the external and internal iliac nodes and their efferents pass to the lateral aortic nodes.

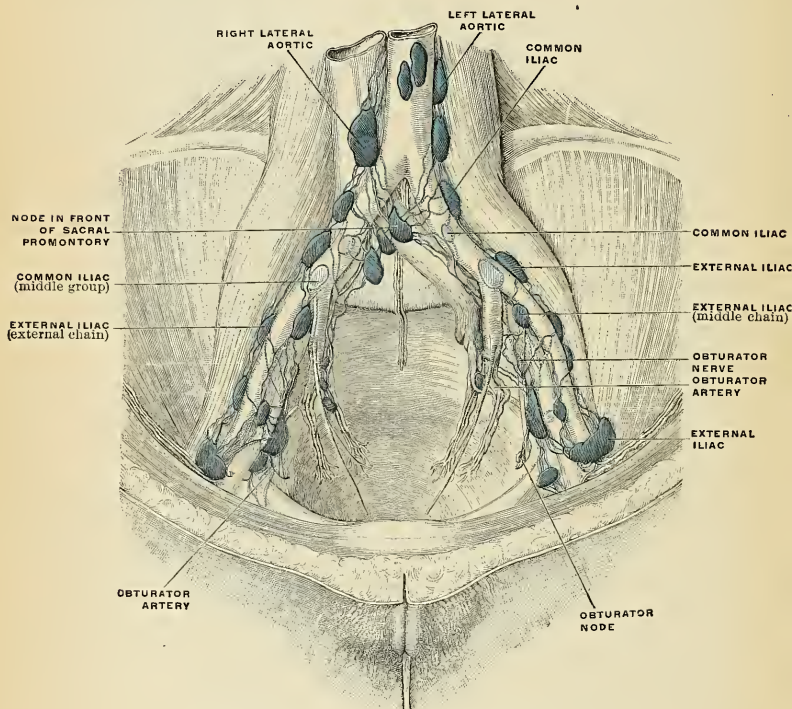


FIG. 567.—Iliopelvic lymph nodes. (Poirier and Charpy.)

The **lumbar nodes** (*lymphoglandulae lumbales*) are very numerous, and consist of right and left lateral aortic, preaortic, and retroaortic groups.

The **right lateral aortic nodes** are situated partly in front of the inferior vena cava, near the termination of the renal vein, and partly behind it on the origin of the Psoas, and on the right crus of the Diaphragm. The **left lateral aortic nodes** form a chain on the left side of the abdominal aorta in front of the origin of the Psoas and left crus of the Diaphragm. The nodes on either side receive (a) the efferents of the common iliac nodes; (b) the lymphatics from the testicle in the male and from the ovary, Fallopian tube, and body of the uterus in the female; (c) the lymphatics from the kidney and suprarenal body; and (d) the

lymphatics draining the lateral abdominal muscles and accompanying the lumbar veins. Most of the efferent vessels of the lateral aortic nodes converge to form the *right and left lumbar trunks* (trunci lumbales) which join the receptaculum chyli, but some enter the preaortic and retroaortic nodes, and others pierce the crura of the Diaphragm to join the lower end of the thoracic duct. The **preaortic nodes** lie in front of the aorta, and may be divided into *celiac*, *superior mesenteric*, and *inferior mesenteric* groups, arranged around the origins of the corresponding

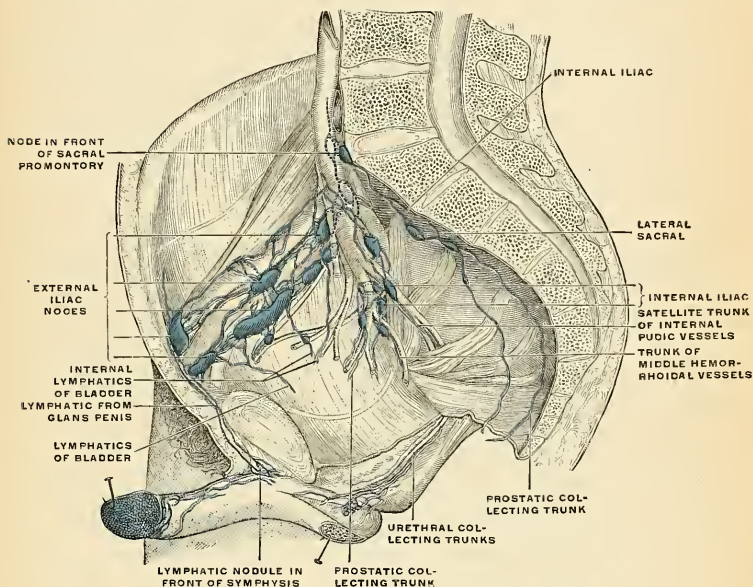


FIG. 568.—The iliopelvic nodes (lateral view). (Poirier and Charpy.)

arteries. They receive a few vessels from the lateral aortic nodes, but their principal afferents are derived from the viscera supplied by the three arteries with which they are associated. Some of their efferents pass to the retroaortic nodes, but the majority unite to form a common trunk, the *truncus intestinalis*, which enters the receptaculum chyli. The **retroaortic nodes** are placed below the receptaculum chyli, on the bodies of the third and fourth lumbar vertebrae. They receive lymphatic trunks from the lateral and preaortic nodes, while their efferents terminate in the receptaculum chyli.

The Lymphatic Vessels of the Abdomen and Pelvis.

The lymphatic vessels of the walls of the abdomen and pelvis may be divided into two sets, superficial and deep.

The **superficial vessels** follow the course of the superficial bloodvessels and converge to the upper group of the superficial inguinal nodes. Those derived from the integument of the front of the abdomen below the umbilicus follow

the course of the superficial epigastric vessels, and those from the sides of the lumbar part of the abdominal wall pass along the crest of the ilium, with the superficial circumflex iliac vessels. The superficial lymphatic vessels of the gluteal region turn horizontally round the outer side of the buttock, and join the superficial inguinal nodes.

The **deep vessels** run alongside the principal bloodvessels. Those of the parietes of the pelvis, which accompany the gluteal, sciatic, and obturator vessels, follow the course of the internal iliac artery, and ultimately join the lateral aortic nodes.

Lymphatic Vessels of the Perineum and External Genitals.—The lymphatic vessels of the perineum and of the integument of the penis, and of the scrotum (or vulva), follow the course of the external pudic vessels, and terminate in the superficial inguinal nodes. Those of the glans penis (or glans clitoridis) terminate partly in the deep inguinal nodes and partly in the external iliac nodes.

The **visceral nodes** are associated with the branches of the celiac axis, superior and inferior mesenteric arteries. Those related to the branches of the celiac axis artery form three chains, gastric, hepatic, and splenic, which accompany the corresponding branches of the artery.

The nodes of the **gastric chain** (*lymphoglandulae gastricae superiores*) are divisible into three groups—viz.: (*a*) **upper gastric**, on the stem of the artery; (*b*) **lower gastric**, accompanying the descending branches of the artery along the cardiac half of the lesser curvature of the stomach, between the two layers of the small omentum; and (*c*) **paracardial**, “outlying members of the coronary chain, disposed in a manner comparable to a chain of beads around the neck of the stomach” (Jamieson and Dobson¹).

The nodes of the gastric chain receive their afferents from the lesser curvature and contiguous surfaces of the stomach; their efferents pass to the celiac group of preaortic nodes.

The nodes of the **hepatic chain** (*lymphoglandulae hepaticae*) (Fig. 574) consist of the following groups: (*a*) **hepatic**, on the stem of the hepatic artery and along the common bile duct, between the two layers of the gastrohepatic omentum as far as the transverse fissure of the liver; the **cystic node**, a member of this group, is placed near the neck of the gall-bladder; (*b*) **subpyloric**, four or five in number, at the bifurcation of the gastroduodenal artery at the angle between the first and second parts of the duodenum; (*c*) one or two **retropyloric** nodes along the pyloric artery; (*d*) **right gastroepiploic** (*lymphoglandulae gastricae inferiores*), four to seven in number, between the two layers of the greater omentum, along the pyloric half of the greater curvature of the stomach. The nodes of the hepatic chain receive afferents from the pyloric portion of the stomach, duodenum, liver, gall-bladder, and the head of the pancreas; their efferents pass to the celiac group of preaortic nodes.

The **splenic nodes** (*lymphoglandulae pancreaticolienales*) accompany the splenic artery and are situated in relation to the dorsal surface and upper border of the pancreas and in the lienorenal ligament. Their afferents are derived from the fundus of the stomach, from the spleen, and from the pancreas; their efferents pass to the celiac group of preaortic nodes.

The **superior mesenteric nodes** comprise three groups—**mesenteric**, **ileocolic**, and **mesocolic**.

The **mesenteric nodes** (*lymphoglandulae mesentericae*) (Fig. 572) lie between the layers of the mesentery, and vary from one hundred to one hundred and fifty in number. One set is situated close to the wall of the small intestine, among the terminal twigs of the superior mesenteric artery; a second is in relation with the

¹ Lancet, April 20 to 27, 1907.

loops and primary branches of the vessel; while a third set of larger nodes lies along the trunk of the artery.

Applied Anatomy.—Enlargement of the mesenteric lymph nodes is seen in most diseased conditions of the intestinal tract, and is well marked in enteric fever, tuberculous ulceration or malignant growths of the bowel. The enlarged nodes can often be palpated through the wall of the abdomen.

The **ileocolic nodes** (Fig. 573), from ten to twenty in number, form a chain around the ileocolic artery, but show a tendency to subdivision into two groups, one near the duodenum and another on the lower part of the trunk of the artery. Where the vessel divides into its terminal branches the chain is broken up into several groups—viz.: (*a*) **ileal**, in relation to the ileal branch of the artery; (*b*) **anterior ileocolic**, usually of three or more nodes, in the ileocolic fold, near the wall of the

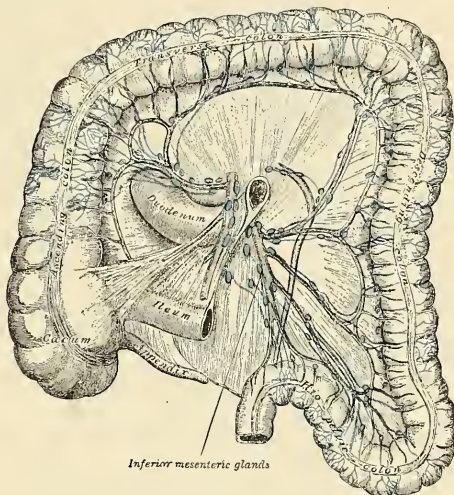


FIG. 569.—Lymphatics of colon. (Jamieson and Dobson.)

cecum; (*c*) **posterior ileocolic**, mostly placed in the angle between the ileum and the colon, but partly lying behind the cecum at its junction with the ascending colon; (*d*) **appendicular**, usually a single node, between the layers of the meso-appendix, near its free edge; (*e*) **right colic**, along the inner side of the ascending colon.

The **mesocolic nodes** are numerous, and lie between the layers of the transverse mesocolon, in close relation to the transverse colon; they are best developed in the neighborhood of the hepatic and splenic flexures. One or two small nodes are occasionally seen along the trunk of the right colic artery, and others are found in relation to the trunk and branches of the middle colic artery.

The superior mesenteric nodes receive afferents from the jejunum, ileum, cecum, appendix, and the ascending and transverse parts of the colon; their efferents pass to the superior mesenteric nodes.

The **inferior mesenteric nodes** (Fig. 569) consist of: (*a*) Small nodes on the branches of the left colic and sigmoid arteries; (*b*) a group in the pelvic mesocolon

around the superior hemorrhoidal artery; and (c) a **pararectal** group in contact with the muscle coat of the rectum. Their afferents drain the descending colon, sigmoid flexure, and upper portion of the rectum; their efferents pass to the inferior mesenteric nodes.

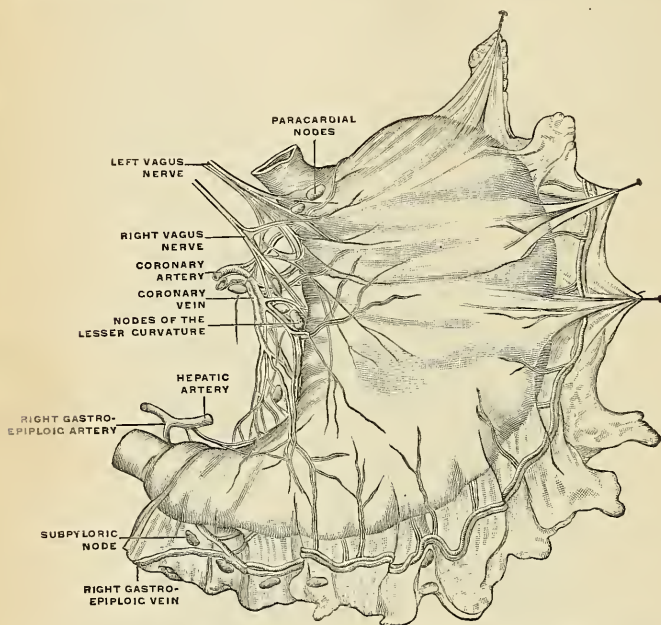


FIG. 570.—General view of the subperitoneal lymphatic plexus of the stomach prepared by the method of Gerota. (Cunéo.)

The Lymphatic Vessels of the Abdominal and Pelvic Viscera.

These consist of: (1) Those of the subdiaphragmatic portion of the alimentary canal and its associated glands, the liver and pancreas; (2) those of the spleen and suprarenal bodies; (3) those of the urinary organs; (4) those of the reproductive organs.

1. **The lymphatic vessels of the subdiaphragmatic portion of the alimentary canal** are situated partly in the mucosa and partly in the seromuscular coats, but as the former system drains into the latter, the two may be considered as one.

The **lymphatic vessels of the stomach** (Fig. 570) are continuous at the cardiac end with those of the œsophagus, and at the pyloric end with those of the duodenum. They mainly follow the bloodvessels, and may be arranged in four sets. Those of the first set accompany the branches of the gastric artery, receiving tributaries from a large area on either surface of the stomach, and terminate in the nodes of the gastric chain. Those of the second set drain the fundus of the stomach, draining the area supplied by the vasa brevia and left gastroepiploic arteries, and ending in the splenic nodes. The vessels of the third set drain

the right portion of the greater curvature and end in the right gastroepiploic nodes, the efferents of which pass to the subpyloric group. Those of the fourth set drain the pyloric canal and pass to the hepatic and subpyloric nodes, and, in part, also to the coronary chain, thence to the celiac group.

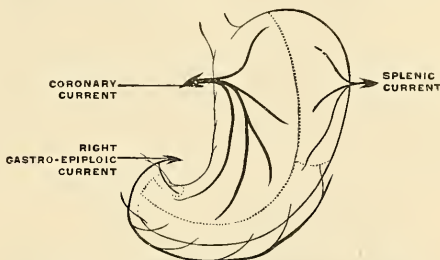


FIG. 571.—Lymphatic areas of the stomach. (Cunéo.)

Applied Anatomy.—Mikulicz pointed out the early infection of the nodes of the lesser curvature in pyloric cancer, and insisted that in operation for pyloric cancer the entire lesser curvature must be removed. Cunéo showed that in pyloric cancer the fundus and two-thirds of the greater curvature usually remain free from disease, because the lymph current is toward the pylorus and not from it. Of course, if the lymphatics become blocked, the lymph current may be reversed (regurgitation), and then infection of these parts can occur. William J. Mayo has noted the "lymphatic isolation" of the dome of the stomach. In operating for cancer of the pylorus, make the section of the stomach as directed by Hartmann, that is, a section which removes all of the lesser curvature and cuts the greater curvature well to the left of the subpyloric nodes.

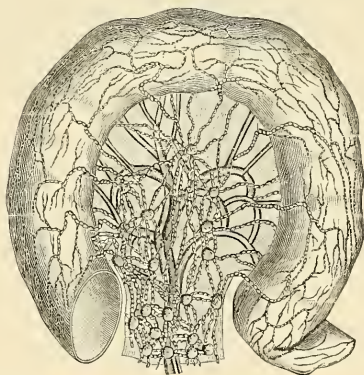


FIG. 572.—Lymphatics of the small intestine. (Poirier and Charpy.)

The **lymphatic vessels of the duodenum** consist of an anterior and a posterior set which open into a series of small **pancreaticoduodenal nodes** on the anterior and posterior aspects of the groove between the head of the pancreas and the duodenum. The efferents from these nodes run in two directions, upward to the hepatic nodes and downward to the superior mesenteric nodes.

The **lymphatic vessels of the small intestine** (Fig. 572) are called **lacteals**, from the milk-white fluid they usually contain. They take origin in the intestinal

villi and in lymphatic sinuses around the bases of the solitary nodules. Lymphatic plexuses exist in the submucous tissue, the muscular coat, and the subserous tissue. The lymphatic vessels pass between the layers of the mesentery, enter the mesenteric nodes, and finally unite to form two or three large trunks which terminate separately in the receptaculum chyli; frequently, however, they unite to form a single large trunk, termed the **intestinal lymphatic trunk** (Figs. 553 and 576).

The **lymphatic vessels of the large intestine** consist of three sets—those of the cecum, ascending and transverse colon, which, after passing through their proper nodes, enter the mesenteric nodes; those of the descending colon and sigmoid flexure, which pass to the lumbar nodes, and those of the rectum and anus, which pass to the sacral and superficial inguinal nodes.

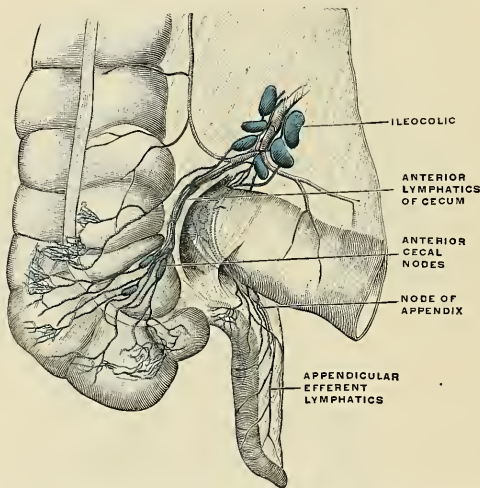


FIG. 573.—Ventral view of the lymphatics of the cecum and appendix. (Poirier and Charpy.)

The **lymphatic vessels of the anus and rectum** take origin from two networks, one from the skin and mucous membrane and the other from the muscular coat. The lymph vessels from the skin at the anal margin pass to the superficial inguinal nodes. Some vessels from the skin of the anus ascend and reach the submucous plexus of the rectum, from which region lymph vessels pass to the pararectal nodes, to the nodes along the middle hemorrhoidal artery, and along the inferior hemorrhoidal artery, and to a pelvic node near the origin of the internal pudic artery. The efferents from these nodes terminate in the inferior mesenteric nodes.

The **lymphatic vessels of the liver** are divisible into two sets, superficial and deep. The former arise in the subperitoneal areolar tissue over the entire surface of the organ, and may be grouped into (a) those on the convex surface, (b) those on the inferior surface.

(a) On the **convex surface**. The vessels from the back part of this surface reach their terminal nodes by three different routes; the vessels of the middle set, five or six in number, pass through the canal opening in the Diaphragm and end in one or two nodes which are situated around the terminal part of the inferior vena cava; a few vessels from the left side pass backward toward

the œsophageal opening, and terminate in the paracardial nodes of the gastric chain; the vessels from the right side, one or two in number, run on the abdominal surface of the Diaphragm, and, after crossing its right crus, terminate in the celiac nodes (*lymphoglandulae coeliacæ*). From the portions of the right and left lobes adjacent to the falciform ligament, the lymphatic vessels converge to form two trunks, one of which accompanies the inferior vena cava through the Diaphragm, and ends in the nodes around the terminal part of this vessel; the other runs downward and forward, and, turning around the anterior sharp margin of the liver, accompanies the upper part of the ligamentum teres, and ends in the upper hepatic nodes. From the anterior surface a few additional vessels turn around the anterior sharp margin to reach the upper hepatic nodes.

Some of the lymph of the upper part of the liver traverses the Diaphragm along several lymphatic vessels which drain into the anterior diaphragmatic nodes on the superior surface of the Diaphragm, just behind the ensiform cartilage and also

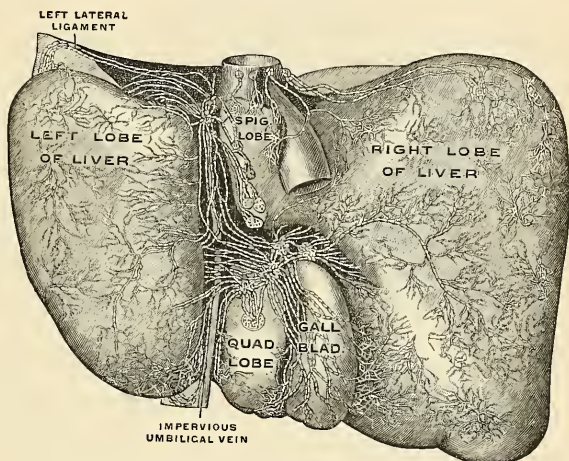


FIG. 574.—Lymphatics of the inferior surface of the liver. (Sappey.)

near the termination of the inferior vena cava, and some to the middle diaphragmatic, some to the posterior mediastinal groups. The efferents from the anterior diaphragmatic nodes pass to the internal mammary chain, a fact which may explain the involvement of the supraclavicular nodes, particularly of the left side,¹ secondary to an abdominal carcinoma.

(b) On the **inferior surface**. The vessels from this surface mostly converge to the transverse fissure, and accompany the deep lymphatics emerging from this fissure to the hepatic nodes; one or two from the posterior parts of the right and Spigelian lobes accompany the inferior vena cava through the Diaphragm, and end in the nodes around the terminal part of this vein.

The **deep lymphatics** of the liver converge to ascending and descending trunks. The ascending trunks accompany the hepatic veins and pass through the Diaphragm to end in the nodes around the terminal part of the inferior vena cava. The descending trunks emerge from the transverse fissure, and end in the hepatic nodes.

The **lymphatic vessels of the gall-bladder** pass to the hepatic nodes in the

¹ Osler, Principles and Practice of Medicine, 7th edition, 1909, page 485.

transverse fissure of the liver; those of the **common bile duct** to the hepatic nodes along the duct and into the upper pancreaticoduodenal nodes.

The **lymphatic vessels of the pancreas** arise from a network about the pancreatic lobules. The collecting trunks anastomose freely among themselves and with the lymphatics of the duodenum, spleen, and in the mesentery and mesocolon;¹ some end in the pancreaticoduodenal nodes, and others in the superior mesenteric nodes.

2. The lymphatics of the spleen and suprarenal glands.

The **lymphatic vessels of the spleen**, both superficial and deep, pass to the splenic nodes in the lienorenal ligament and along the superior border of the pancreas.

The lymphatic vessels of the **suprarenal glands** usually accompany the suprarenal veins, and end in the lateral aortic nodes; occasionally some of them pierce the crura of the Diaphragm and terminate in the nodes of the posterior mediastinum.

3. The lymphatic vessels of the urinary organs.

The **lymphatic vessels of the kidney** form three plexuses—one in the substance of the kidney, a second beneath its fibrous capsule, and a third in the perinephric fat; the second and third communicate freely with each other.

The vessels from the plexus in the kidney substance converge to form four or five trunks which issue at the hilum. Here they are joined by vessels from the plexus under the capsule, and, following the course of the renal vein, end in the lateral aortic nodes. The perinephric plexus is drained directly into the upper lateral aortic nodes.

The **lymphatic vessels of the ureter** run in different directions. Those from its upper portion end partly in the efferent vessels of the kidney and partly in the lateral aortic nodes; those from the portion immediately above the pelvic brim are drained into the common iliac nodes; while the vessels from the intrapelvic portion of the tube join the efferents from the bladder, or terminate in the internal iliac nodes.

The **lymphatic vessels of the bladder** (Fig. 575) originate in two plexuses, an intramuscular and an extramuscular, it being generally admitted that the mucous membrane is devoid of lymphatics.² The efferent vessels are arranged in two groups, one from the anterior and another from the posterior surface of the bladder. The vessels from the *anterior* surface pass to the external iliac nodes, but in their course minute nodes are situated. These minute nodes are arranged in two groups, an *anterior vesical* group, in front of the bladder, and a *lateral vesical*, in relation to the hypogastric artery. The vessels from the *posterior* surface pass to the internal, external, and common iliac nodes; those draining the upper part of this surface traverse the lateral vesical nodes.

The **lymphatic vessels of the prostate** (Fig. 575) terminate chiefly in the internal iliac and sacral nodes, but one trunk from the posterior surface ends in the external iliac nodes, and another from the anterior surface joins the vessels which drain the membranous part of the urethra.

Lymphatic Vessels of the Urethra.—The lymphatics of the *penile* portion of the urethra accompany those of the glans penis, and terminate with them in the deep inguinal and external iliac nodes. Those of the *membranous* and *prostatic* portions, and those of the whole urethra in the female, pass to the internal iliac nodes.

4. The lymphatic vessels of the reproductive organs.

The **lymphatic vessels of the testes** consist of two sets, superficial and deep, the former commencing on the surface of the tunica vaginalis, the latter in the epididymis and body of the testis. They form several large trunks which ascend

¹ P. Bartels, Ueber die Lymphgefäße des Pankreas, Archiv f. Anat. u. Physiol., 1907.

² Some authorities maintain that a plexus of lymphatic vessels does exist in the mucous membrane of the bladder (consult Médecine opératoire des Voies urinaires, par J. Albarran, Paris, 1909).

with the spermatic cord, and, accompanying the spermatic vessels into the abdomen, terminate in the lateral aortic nodes.

The lymphatic vessels of the vas deferens pass to the external iliac nodes; those of the vesiculæ seminales partly to the internal and partly to the external iliac nodes.

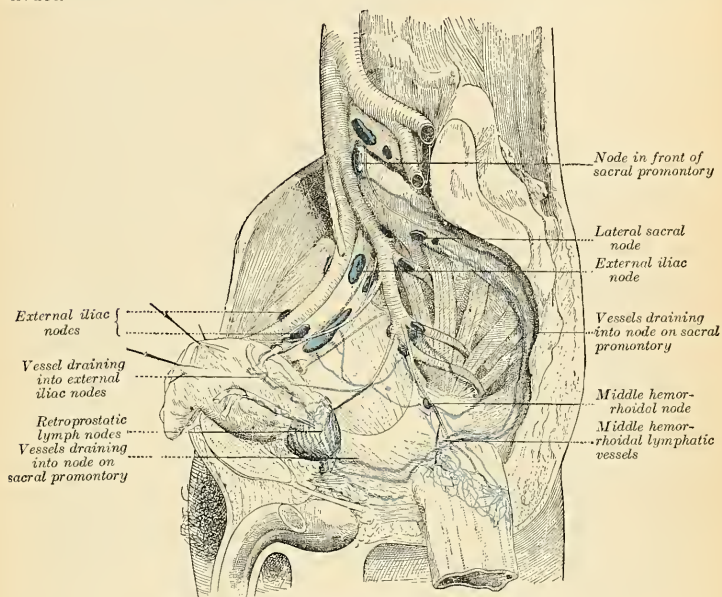


FIG. 575.—Lymphatics of the prostate. (Cunéo and Marcille.)

The lymphatic vessels of the ovary are similar to those of the testicle, and ascend with the ovarian artery to the lateral aortic nodes.

The lymphatic vessels of the Fallopian tube pass partly with those of the ovary and partly with those of the uterus.

The lymphatic vessels of the uterus (Fig. 1149) consist of two sets, superficial and deep, the former being placed beneath the peritoneum, the latter in the substance of the organ. The lymphatics of the cervix uteri run in three directions—transversely to the external iliac nodes, postero-laterally to the internal iliac nodes, and posteriorly to the common iliac nodes. The majority of the vessels of the body and fundus of the uterus pass outward in the broad ligaments, and are continued up with the ovarian vessels to the lateral aortic nodes; a few, however, run to the external iliac nodes, and one or two to the superficial inguinal nodes. In the unimpregnated uterus the lymphatic vessels are very small, but during gestation are greatly enlarged.

The lymphatic vessels of the vagina extend in three directions—those of the upper part to the external iliac nodes, those of the middle part to the internal iliac nodes, and those of the lower part to the common iliac nodes. On the course of those from the middle and lower parts small nodes are situated. Some lymphatics from the lower part of the vagina join those of the vulva and pass to the superficial inguinal nodes. The lymphatics of the vagina anastomose with those of the cervix uteri, vulva, and rectum, but not with those of the bladder.

THE LYMPHATICS OF THE THORAX.

The **lymph nodes of the thorax** may be divided into parietal and visceral—the former being situated in the thoracic wall, the latter in relation to the viscera.

The **parietal lymph nodes** include the internal mammary, intercostal, and diaphragmatic nodes.

1. The **internal mammary nodes** are placed at the anterior extremities of the intercostal spaces, by the side of the internal mammary artery. They derive afferents from the mammary gland, from the deeper structures of the anterior abdominal wall above the level of the umbilicus, from the upper surface of the liver through a small group of nodes which lie behind the ensiform cartilage, and from the deeper parts of the anterior portion of the thoracic wall. Their efferents usually unite to form a single trunk on either side; this may open directly into the junction of the internal jugular and subclavian veins, or that of the right side may join the right subclavian trunk and that of the left the thoracic duct.

2. The **intercostal nodes** (*lymphoglandulae intercostales*) occupy the posterior parts of the intercostal spaces, in relation to the intercostal vessels. They receive the deep lymphatics from the postero-lateral aspect of the thorax; some of these vessels are interrupted by small lateral intercostal nodes. The efferents of the nodes in the lower four or five spaces unite to form the **descending lumbar trunk**, which descends and opens either into the receptaculum chyli or into the commencement of the thoracic duct. The efferents of the nodes in the upper spaces of the left side terminate in the thoracic duct; those of the corresponding right spaces, in the right lymphatic duct.

3. The **diaphragmatic nodes** lie on the thoracic aspect of the Diaphragm, and consist of three sets—*anterior, middle, and posterior*.

The **anterior** set consists of (*a*) two or three small nodes behind the base of the ensiform (xiphisternum), which receive afferents from the convex surface of the liver, and (*b*) one or two nodes on either side near the junction of the seventh rib with its cartilage, which receive lymphatic vessels from the front part of the Diaphragm. The efferent vessels of the anterior set pass to the chain of internal mammary nodes.

The **middle** set consists of two or three nodes on either side close to where the phrenic nerves enter the Diaphragm. On the right side some of the nodes of this group lie within the fibrous sac of the pericardium, in front of the inferior vena cava. The afferents of this set are derived from the middle part of the Diaphragm, those on the right side also receiving afferents from the convex surface of the liver. Their efferents pass to the posterior mediastinal nodes.

The **posterior** set consists of a few nodes situated on the back of the diaphragmatic crura, and connected on the one hand with the lumbar nodes and on the other with the posterior mediastinal nodes.

The **superficial lymphatic vessels of the thoracic wall** ramify beneath the skin and converge to the axillary nodes. Those over the Trapezius and Latissimus dorsi run forward and unite to form ten or twelve trunks which end in the subscapular group. Those over the pectoral region, including the vessels from the skin covering the peripheral part of the mamma, run backward, and those over the Serratus magnus upward, to the pectoral group. Others near the lateral margin of the sternum pass inward between the rib cartilages and end in the internal mammary nodes, while the vessels of opposite sides anastomose across the front of the sternum. A few vessels from the upper part of the pectoral region pass upward over the clavicle to the supraclavicular group of cervical nodes.

The **lymphatic vessels of the mammary gland** (Fig. 562) originate in a plexus in the interlobular spaces and on the walls of the galactiferous ducts. Those from the central part of the gland pass to an intricate plexus beneath the areola (*sub-*

areolar plexus), a plexus which also receives the lymphatics from the skin over the central part of the gland. Its efferents are collected into two trunks which pass to the pectoral group of axillary nodes. The vessels which drain the inner (mesal) part of the gland pierce the thoracic wall and end in the internal mammary nodes, while a vessel may occasionally emerge from the upper part of the gland and, piercing the Pectoralis major, terminate in the subclavian nodes (Fig. 562).

The **deep lymphatics of the thoracic wall** consist of:

1. The lymphatics of the muscles which lie on the ribs; most of these terminate in the axillary nodes, but some from the Pectoralis major pass to the internal mammary nodes.

2. The **intercostal lymphatic vessels** which drain the Intercostal muscles and parietal pleura. Those draining the External intercostal muscles run backward and, after receiving the vessels which accompany the posterior branches of the intercostal arteries, terminate in the posterior intercostal nodes. Those of the Internal intercostal muscles and parietal pleura consist of a single trunk in each space. These trunks run forward in the subpleural tissue and the upper six open separately into the internal mammary nodes or into the vessels which unite them; those of the lower spaces unite to form a single trunk which terminates in the lowest of the internal mammary nodes.

3. The **lymphatic vessels of the Diaphragm**, which form two plexuses, one on its thoracic and another on its abdominal surface. These plexuses anastomose freely with each other, and are best marked on the parts covered respectively by the pleura and peritoneum. That on the thoracic surface communicates with the lymphatics of the costal and mediastinal parts of the pleura, and its efferents consist of three groups: (*a*) *anterior*, passing to the nodes which lie near the junction of the seventh rib with its cartilage; (*b*) *middle*, to the nodes on the œsophagus and to those around the termination of the inferior vena cava; and (*c*) *posterior*, to the nodes which surround the aorta at the point where this vessel leaves the thoracic cavity.

The plexus on the abdominal surface is composed of fine vessels, and anastomoses with the lymphatics of the liver and, at the periphery of the Diaphragm, with those of the subperitoneal tissue. The efferents from the right half of this plexus terminate partly in a group of nodes on the trunk of the corresponding inferior phrenic artery, while others end in the right lateral aortic nodes. Those from the left half of the plexus pass to the preaortic and lateral aortic nodes and to the nodes on the terminal portion of the œsophagus.

Applied Anatomy.—The fact emphasized by Robinson that the peritoneum is a great lymph sac explains the quick absorption of septic material and the rapid spread of infectious processes. If the exudate clots and blocks the lymph channels, absorption is slow and life may be saved. If it does not clot, absorption is rapid and death is certain. Whether it clots or not depends on the nature of the bacteria present. Fowler, impressed by the fact that absorption takes place most rapidly from the diaphragmatic region and least rapidly from the pelvic region, advises placing the victim of peritonitis in bed, with his head and body elevated.

A knowledge of the *lymphatics of the breast* and of the nodes into which the lymphatics drain is of the first importance to a surgeon. Certain surgical deductions from the anatomy of this region are perfectly obvious—viz.: (1) If the skin of the mammary gland is involved in carcinoma, the thoracic group of axillary nodes of the same side is involved. If the skin over the sternal margin of the gland is involved, the nodes of the opposite axilla may be cancerous, as from this point lymph vessels rise and pass across the midline. If the skin of the sternal margin is involved the prognosis is worse than if it is free, the opposite axilla may be cancerous, and the opposite breast may become diseased. (2) When lymphatic vessels become blocked by cancer cells the lymph backs up, flows backward instead of in its proper direction, and may cause infection in the most unsuspected situations. For instance, a block in the cutaneous lymphatics of a portion of the breast may lead to infection of the opposite breast and axilla, though, of course, it is not so likely to as is cancer of the skin of the sternal margin. By regurgitation of lymph

the head of the humerus or the retrosternal structures may become diseased in mammary cancer. (3) If the nipple or areola is cancerous, the entire gland is sure to be diseased, as the lymphatic network of this region empties into the subareolar plexus, and most of the trunks coming from the gland also enter this plexus. (4) If the mammary gland is cancerous, all of the axillary nodes are regarded as diseased, as the main lymphatic channel from the breast reaches the nodes on the inner wall of the axilla upon the third digitation of the *Serratus magnus*. Furthermore, in many cases an accessory lymph channel comes off from the lower portion of the mammary gland and passes directly to the axilla. (5) The subclavian nodes are to be regarded as diseased, because in a certain proportion of cases (the exact proportion being uncertain) an accessory lymph channel comes off from the posterior surface of the mammary gland, passes through the great Pectoral muscle, and ascends between the greater and lesser Pectorals to reach the subclavian nodes. (6) The element which greatly interferes with the cure of mammary carcinoma is the existence of lymph channels which arise from the inner portion of the mammary gland, pierce the greater Pectoral and Internal intercostal muscles, and reach the internal mammary nodes. Mediastinal involvement is apt to be earlier in carcinoma of the inner portion of the breast than in carcinoma of other portions, and the prognosis is particularly bad in cancer of the inner portion of the breast. What is known as the *sternal symptom* of Snow is bulging of the sternum due to involvement of the thymus gland. (7) The sternal portion of the great Pectoral and the tissue between it and the lesser Pectoral muscle are to be regarded as diseased, because in some cases an accessory lymph channel from the breast penetrates the greater Pectoral and ascends to the subclavian nodes. This trunk has several interrupting or satellite nodes, the *retropectoral nodes*, in the tissue back of the great Pectoral muscle. (8) When the great Pectoral muscle is diseased, cancer cells soon spread widely through the sternal portion of the muscle, and this entire portion of the muscle becomes cancerous. The clavicular portion does not suffer early, but escapes until the cancer becomes extensive, as it is anatomically distinct from the sternal portion. If the fibres of the great Pectoral are extensively diseased, the thoracic group of axillary nodes, the subclavian nodes, and possibly the internal mammary nodes are involved. (9) The only operation in cancer of the breast which offers any real hope of cure is one which is done early and is radical. (10) It must be done early, because delay permits involvement of the mediastinum, and if the disease has entered the mediastinum operation is hopeless. If the sternum is bulged operation is useless, and nothing short of amputation at the shoulder-joint could be of help if the head of the humerus is enlarged by the disease. Even this radical procedure is of no avail, because the mediastinum is certainly involved if the head of the humerus is diseased. (11) If the lymph nodes above the clavicle are extensively diseased operation is useless, as in such cases the mediastinum is sure to be involved. (12) A radical operation means the removal of the skin of the breast with the nipple and areola, the subcutaneous tissue of this region, the entire breast, the sternal portion of the great Pectoral with its fascia, the retropectoral nodes and tissue, all the contents of the axilla except vessels and nerves, the nodes and cellular tissue beneath the anterior margin of the *Latissimus dorsi*, and the subclavian nodes. It is probably always wisest to open above the clavicle as well as below to facilitate the removal of nodes. It is seldom necessary to remove the clavicular portion of the greater Pectoral. The lesser Pectoral does not require removal, but it should be taken away, because of the added safety and speed thus obtained in cleaning the great vessels and because its retention does not improve the functional result. The surgeon must remember that the female mammary gland is a much larger organ than we used to think, and all of its irregular projections and outlying lobules must be removed (p. 784). Formerly, surgeons did not completely remove the breast, but only got rid of a large portion of it.

The **visceral lymph nodes** consist of three groups—viz., anterior, mediastinal, posterior mediastinal, and tracheobronchial.

The **anterior mediastinal nodes** (*lymphoglandulae mediastinales anteriores*) are placed in the anterior part of the superior mediastinum, in front of the arch of the aorta and in relation to the innominate veins and the large arterial trunks which arise from the aortic arch. They receive afferents from the thymic nodes; their efferents unite with those of the tracheobronchial nodes, to form the right and left bronchomediastinal trunks.

The **posterior mediastinal nodes** (*lymphoglandulae mediastinales posteriores*) lie behind the pericardium in relation to the œsophagus and descending thoracic aorta. Their afferents are derived from the œsophagus, the posterior part of the pericardium, the Diaphragm, and convex surface of the liver. Their efferents mostly terminate in the thoracic duct, but some join the tracheobronchial nodes.

The **tracheobronchial nodes** form three main groups in relation to the bifurcation of the trachea—one on either side of the trachea above the bronchi and

one in the angle between the bronchi (*lymphoglandulae tracheales*); other nodes, termed **interbronchial** (*lymphoglandulae bronchiales*), are found at the points of division of the larger bronchi. The afferents of the tracheobronchial nodes drain the lungs and bronchi, the thoracic part of the trachea and the heart; some

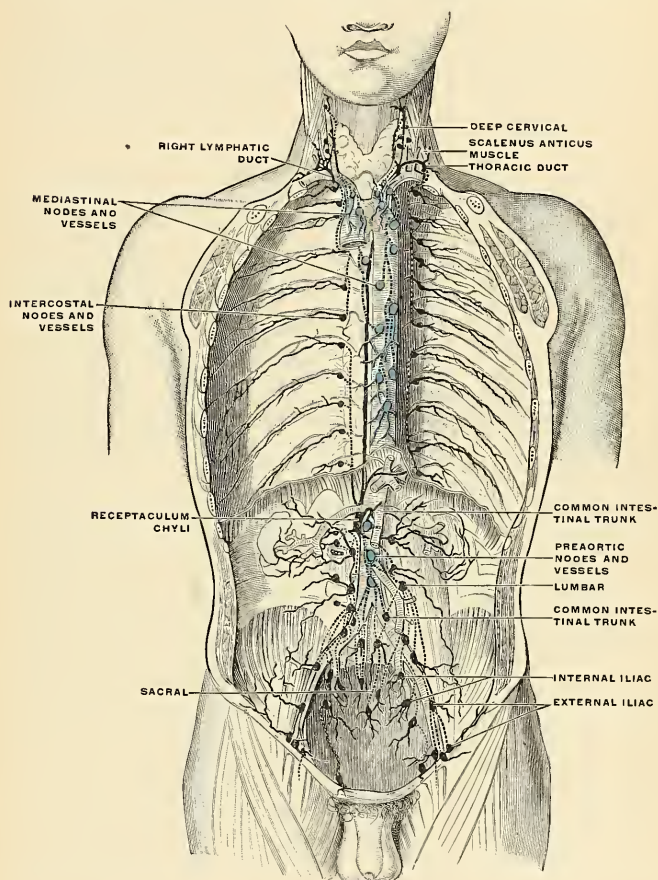


FIG. 576.—Deep lymph nodes and vessels of the thorax and abdomen (diagrammatic). Afferent vessels are represented by continuous lines, and efferent and internodular vessels by dotted lines. (Cunningham.)

of the efferents of the posterior mediastinal nodes also terminate in this group. Their efferent vessels ascend upon the trachea and unite with efferents of the internal mammary and anterior mediastinal nodes to form the **right and left bronchomediastinal trunks**. The right bronchomediastinal trunk may join the right lymphatic duct, and the left the thoracic duct, but more frequently they

open independently of these ducts into the junction of the internal jugular and subclavian veins of their own side.

Applied Anatomy.—In all town dwellers there are continually being swept into those nodes from the bronchi and alveoli large quantities of the dust and black carbonaceous pigment that are so freely inhaled in cities. At first the nodes are moderately enlarged, firm, inky black, and gritty on section; later they enlarge still further, often becoming fibrous from the irritation set up by the minute foreign bodies with which they are crammed, and may break down into a soft slimy mass or may calcify. In tuberculosis of the lungs these nodes are practically always infested; they enlarge, being filled with tuberculous deposits that may soften, or become fibrous, or calcify. Not infrequently an enlarged tuberculous node perforates into a bronchus, discharging its contents into the tube. When this happens there is great danger of acute pulmonary tuberculosis, the infecting node-substance being rapidly spread throughout the bronchial system by the coughing its presence in the air-passages excites.

The **lymphatic vessels of the thoracic viscera** consist of those of the heart and pericardium, lungs and pleura, thymus and œsophagus.

The **lymphatic vessels of the heart** consist of two plexuses: (*a*) deep, immediately under the endocardium, and (*b*) superficial, subjacent to the visceral pericardium. The deep plexus opens into the superficial, the efferents of which form right and left collecting trunks. The *left* trunks, two or three in number, ascend in the anterior interventricular furrow, receiving, in their course, afferents from both ventricles. On reaching the auriculoventricular furrow they are joined by a large trunk from the back of the heart, and then unite to form a single vessel which descends between the pulmonary artery and the left auricle and ends in one of the tracheobronchial nodes. The *right* trunk receives its afferents from the right auricle and from the right border and posterior surface of the right ventricle. It ascends in the posterior auriculoventricular groove and then runs forward in the auriculoventricular groove, and passes up behind the pulmonary artery, to end in one of the tracheobronchial nodes.

The **lymphatic vessels of the lungs** originate in two plexuses, a superficial and a deep. The superficial plexus is placed beneath the visceral pleura. The deep accompanies the branches of the pulmonary vessels and the ramifications of the bronchi. In the case of the larger bronchi the deep plexus consists of two networks, one, submucous, beneath the mucous membrane, and another, peribronchial, outside the walls of the bronchi. In the smaller bronchi there is but a single plexus, which extends as far as the bronchioles, but fails to reach the alveoli, in the walls of which there are no traces of lymphatic vessels. The superficial efferents turn around the borders of the lungs and the margins of their fissures, and converge to end in some nodes situated at the hilum; the deep efferents are conducted to the hilum along the pulmonary vessels and bronchi, and end in the tracheobronchial nodes. Little or no anastomosis occurs between the superficial and deep lymphatics of the lungs, except in the region of the hilus.

The **lymphatic vessels of the pleura** consist of two sets—one in the visceral and another in the parietal part of the membrane. Those of the visceral pleura drain into the superficial efferents of the lung, while the lymphatics of the parietal pleura have three modes of ending—viz.: (*a*) those of the costal portion join the lymphatics of the Internal intercostal muscles and so reach the internal mammary nodes; (*b*) those of the diaphragmatic part are drained by the efferents of the Diaphragm; while (*c*) those of the mediastinal portion terminate in the posterior mediastinal nodes.

The **lymphatic vessels of the thymus gland** terminate in the superior mediastinal, tracheobronchial, and internal mammary nodes.

The **lymphatic vessels of the œsophagus** form a plexus around that tube, the collecting vessels from which drain into the posterior mediastinal nodes.

THE NERVE SYSTEM.

THE SPINAL CORD AND BRAIN, WITH THEIR MENINGES.

THE nerve system of man is an apparatus by means of which he appreciates and becomes influenced by impressions from the outer world, reacts on these impressions, and hence is enabled to adapt himself to his environment. It is the organic substratum for those manifestations of nerve force engaged in the characteristic attributes of animal life—*sensation* and *motion*. Broadly stated, the nerve system connects the various parts of the body with one another and coördinates them into one harmonious whole in order to carry on the bodily functions methodically and to control the physiological division of labor throughout the organism. With the evolution of the higher forms of animal life through an immense phylogenetic past the nerve system has undergone remarkable differentiation and specialization, attaining its maximum as to dominant position and complexity of structure in the human species.

The description of the nerve system is assisted by the accommodation of physiological data to the anatomical basis in order to demonstrate more clearly and to render more practical our knowledge of the mutual relations of its structure and function. The cycle of events which accompanies nerve action is determined by impressions received by the peripheral organs, apperception and reflexes of these impressions in the lower nerve centres, correlation of these with other impressions in higher centres, as well as voluntary reactions or inhibitions, liberated in compliance with the organic or higher needs of the individual.

Conventionally, the nerve system is usually considered as consisting of (1) the **cerebrospinal system**, comprising (*a*) the **central nerve axis** (brain and spinal cord) and (*b*) the **peripheral nerves** (cranial and spinal), and (2) the **sympathetic nerve system**. This subdivision, like others formulated by various authors, is an arbitrary one. No part of the system stands isolated, and the manifold groupings and chainings of the units of the system intimately connect the central nerve organs with the peripheral nerve endings, the organs of special sense and the vegetative organs. The distinction between the central and the sympathetic systems has been too absolute, and the only justification for adhering to the classification given above is based upon the fact that the sympathetic system is preponderatingly related to the interconnection and coördination of the nutritive (digestive, respiratory, and blood and lymph) apparatus, and, therefore, exercises a special control over its activities.

Structurally considered, the nerve system consists of cell-elements peculiarly differentiated from all other tissue cells in that their protoplasm is extended, often to great distances from the nuclear region, in the form of processes. The cell-elements are held in place by supporting tissues, partly of ectodermal and partly of mesodermal origin, and receive an abundant blood supply.

The cell element of the nerve system is called the **neurone**. The neurone is

the *developmental, structural, and functional unit* of the nerve system. It is in reality a single cell presenting unusual structural modifications. It comprises not only the nerve-cell body with its numerous **protoplasmic processes** or **dendrites**, but also the **axone**, which may vary in length from a fraction of a millimetre to fully half a man's stature; so that, despite the delicacy of the axone, its bulk may be almost two hundred times greater than that of the cell body from which it proceeds. The long axones serve to make a connection with a peripheral or distant nerve cell, muscle cell, or gland cell, while the shorter axones of certain neurones divide into terminal branches in the immediate vicinity of its cell body, presumably to come into relation with other nerve cells in the same or adjacent groups.

Neurones, being devoted to the maintenance of functions manifested by various phenomena of nerve force, are differentiated in their polarity, both structurally and dynamically. Receptive neurones are so arranged as to receive afferent nerve impulses from other tissues; emissive or excitator neurones give out efferent nerve impulses. The former are generally termed **sensor neurones**, the latter **motor (excitomotor) neurones** if connected with muscle, **excitoglandular** if connected with gland cells. Were the nerve system made up solely of such initial and terminal neurones, the apparatus would be merely a system of reflex arcs. Such it is in low forms of animal life which, by their very organization, and because of the close juxtaposition of their sensor and motor elements, are compelled to react to stimuli from without. In higher forms, with more profoundly differentiated nerve systems, the sensor impression must pass through an interposed medium which is capable of either transmitting the molecular change in the form of an excitomotor impulse or, on the other hand, is capable of reducing or checking the impulse. In other words, reaction is not imperative; there is a freedom of choice exercised by intermediate neurones endowed with inhibitory function. The simple arc, composed of an afferent sensor neurone and an efferent motor neurone, would act independently of all other arcs were it not for the interposition of this intermediate neurone and of other association neurones which, by their relations toward similar arc elements, produce harmony of action. The basis, then, of the nerve system is a series of neurones, with projecting and association processes, coordinated for the purpose of performing specific actions manifested either by motion, by trophic changes, or by the apperception of stimuli of a chemical, mechanical (tactile and auditory), thermal, or photic nature. When we consider the profoundly complex manifestations of nerve phenomena in the mental and physical life of man it is not surprising to learn that his nerve system is made up of an immense multitude of aggregations of neurones.

Fundamental Facts Regarding the Development of the Nerve System.—

The nerve system is formed by a remarkable metamorphosis of the ectodermic layer of the developing ovum. Along the mid-dorsal line of the embryonic mass a thickening of the ectoderm forms a well-defined layer of cells, the **neural plate**. The proliferative process passes rapidly from the cephalic toward the caudal end, and as development advances it is seen that the most intense growth energy takes place at the cephalic end, indicative of the higher functional potentiality of what is to become the brain. The neural plate undergoes a trough-like formation as its edges become elevated cephalad and laterally to form the **neural groove** (Fig. 577). The edges become more and more elevated and bend toward the median line until the margins of the groove coalesce to form a tube, the **neural tube**, which sinks into the subjacent mesodermal tissues. The fusion of the margins of the neural plate occurs first in the cervical region and rapidly continues both cephalad and caudad. The cephalic portion, destined to become the brain, expands and grows considerably, while the caudal portion elongates to form the spinal cord.

Eventually the neural tube, as it sinks into the subjacent mesodermal tissue,

severs all connection with the ectoderm from which it developed; but for a brief period the continuity is preserved in an attenuated septal mass, the **neural crest** (Fig. 577). The cell elements of this crest subsequently become detached from the superficial ectoderm, the continuity of which is again restored to form the integument. They then pass ventrad to either side of the neural tube, prolifer-

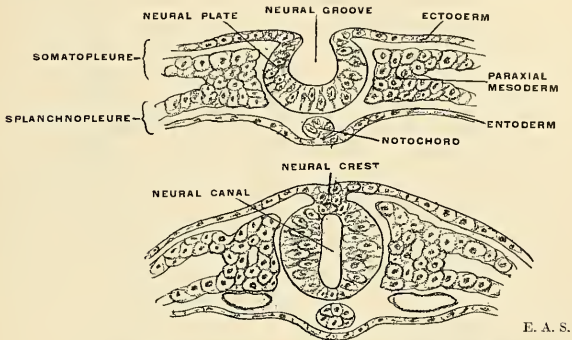


FIG. 577.—Diagrams showing development of neural tube and crest.

ate by mitosis, and accumulate in paired masses, corresponding in number to the segments of the body, to become, in part at least, the **cerebrospinal ganglion** cells of the afferent system, while other similarly paired masses migrate farther ventrad to a prevertebral position to form the **gangliated cord** and widely spread **plexuses of the sympathetic system**. From the tissues of the wall of the neural

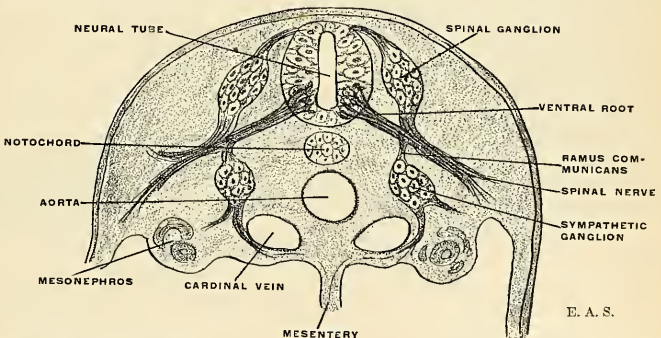


FIG. 578.—Diagram showing development of a spinal nerve and its components, together with the spinal and sympathetic ganglia.

tube and its temporary crest the entire nerve system of complex and intricate structure is developed. The cavity of the tube shares in the developmental growth changes to become the ventricular system of the brain and central canal of the spinal cord. The major details of the development of the principal divisions will be considered in appropriate chapters.

Development of Nerve Tissue. 1. **In the Wall of the Neural Tube.**—The single layer of nucleated epithelial cells of ectodermal origin which makes up the wall of the neural tube early becomes modified into a layer of tall columnar cells called **spongioblasts** (Fig. 579). Their protoplasmic ends undergo differentiation in that the central ends become elongated and attenuated or collapsed to form a series of striated pillars with intervening spaces. The central ends retain their breadth, however, and form an internal limiting membrane. The ectal ends undergo differentiation to form a spongy reticulum (myelospongium network); eventually these spongioblasts become (a) **ciliated ependymal cells** and (b) **neuroglia**.

In the intercellular spaces of the central zone there appear spherical cells of different structure and density. These are the **germinal cells**, seen in very early stages and proliferating rapidly by karyokinesis. They soon lose their spherical form, becoming pear-shaped as a protoplasmic process extends ectad. These pear-shaped cells are now termed **neuroblasts** (Fig. 579), the protons of the neurones, and as development advances they leave the central zone and migrate into the marginal reticulum to the positions in which they are found in the gray substance of the brain and spinal cord. The protoplasmic process is at first slightly bulbous and elon-

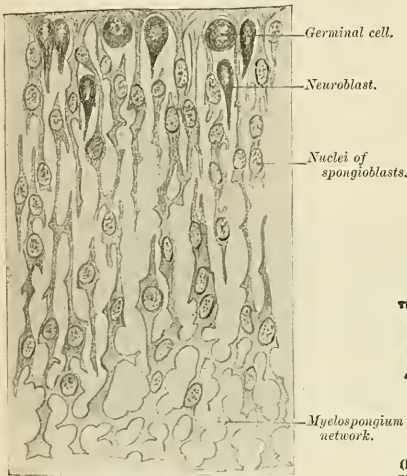


FIG. 579.—Transverse section of the spinal cord of a human embryo at the beginning of the fourth week. Top of figure corresponds to lining of central canal. (After His.)

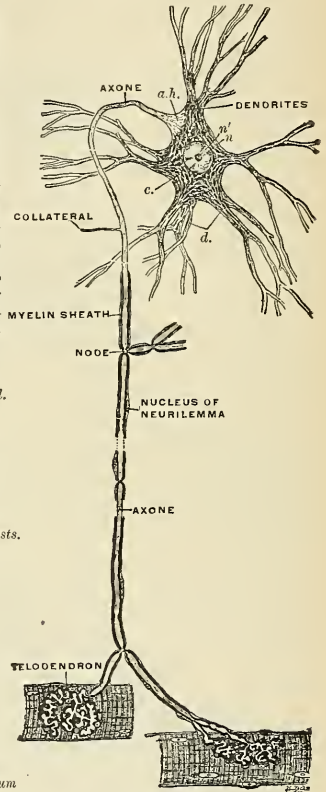


FIG. 580.—Scheme of central motor neurone. (I. type of Golgi.) The motor cell body, together with all its protoplasmic processes, its axis-cylinder process, collaterals, and end ramifications, represent parts of a single cell or neurone. a.h. Axon-hillock devoid of Nissl bodies, and showing fibrillation. c. Cytoplasm showing Nissl bodies and lighter ground substance. n'. Nucleolus. (Barker.)

gates to form the axone extending toward other nerve-cells or to the peripheral tissue elements with which they become associated by the contiguity of the terminal arborizations into which the bulbous extremity develops. The precision with which the axones travel toward their allotted goal is one of the most remarkable manifestations of organic development. An American experimenter, Ross G. Harrison, has devised a method for directly observing the living, growing nerve. In isolated pieces of frog embryos the differentiation of the living nerve elements could be observed from day to day during several weeks. The bulbous end of the outflowing protoplasmic fibre, showing a faint fibrillation, was seen to reveal a continuous change of form particularly in a number of fine simple and branched filaments which were in constant ameboid

movement. Harrison's demonstration¹ is of great significance in connection with the "retraction theory" and other ideas related to the neurone doctrine.

2. **In the Neural Crest Tissues.**—The nerve tissue elements of the sympathetic system and of the ganglia of the cranial nerves and dorsal roots of the spinal nerves are derived from the neural crest. Omitting, for the present, the development of the sympathetic system, it is found that the cells of the paired masses which eventually become the cerebrospinal ganglia are at first somewhat spherical, then oval in form, sending out from either extremity or pole a protoplasmic process. One process migrates centrally, the other toward the tissues of the periphery. The central process penetrates the tissues of the neural tube and, assuming the typical form of an axone with its collaterals and end arborizations, comes into contiguous association with certain cells of the central axis. The peripheral process is in reality an unusually long dendrite, for it is centripetal in function; but owing to the fact that it is usually provided with a myelin sheath it is also termed the **peripheral axone of an afferent (or sensor) neurone**. The central processes of the cells of a single spinal nerve ganglion form the dorsal nerve roots; the peripheral processes constitute the afferent portion of a spinal nerve. The cells themselves are transformed from bipolar into apparently unipolar cells by the migration of the cell body to one side and the consequent approximation of the two processes to form a common pedicle in a T-shaped manner (Fig. 586).

Structure of the Nerve System.—The whole of the nerve system is composed of nerve tissue and supporting connective tissue. The neurones constitute the nerve tissue, while the supporting tissue is composed of the neuroglia and of white fibrous tissue derived either from the investing membrane or from the sheaths of its numerous vascular channels.

The Neurone.—The neurone or nerve cell element, whose individuality has already been pointed out, exhibits remarkable variations as to external characters, dimensions, and form. The neurone presents a concentrated or swollen cell mass and nucleus, formerly known as the **nerve cell** (ganglion cell) and still retaining the name. From this cell body are given off a number of processes of two distinct kinds: (1) **protoplasmic processes** which are commonly branched and generally called the **dendrites**; (2) a single, thinner, and paler process, the **axone** (axis-cylinder process; neuraxone).

Varied Forms of Neurones.—Bearing in mind that each neurone includes not only the cell body and its dendritic processes, but also the axone or axis-cylinder process with all its ramifications, we may consider each of these divisions under separate heads.

1. **Nerve Cell Body. External Morphology.**—The bodies of nerve cells vary much in size, measuring from 4 to 135 microns or more in diameter. The largest cells are found in the ventral horns of the spinal cord, in the spinal ganglia, in the large pyramidal cell layer of the cerebral cortex, in the Purkinjean cell layer of the cerebellum, and in the column of Clarke (dorsal nucleus) of the spinal cord. Very small cells are found in the olfactory bulbs, in the granular layers of the cerebral and the cerebellar cortex, and in the caput gliosum of the cord.

Although all nerve cells begin in the embryonic ectoderm as spherical germinal cells, they later assume, in different regions, very different shapes. These external morphological relations

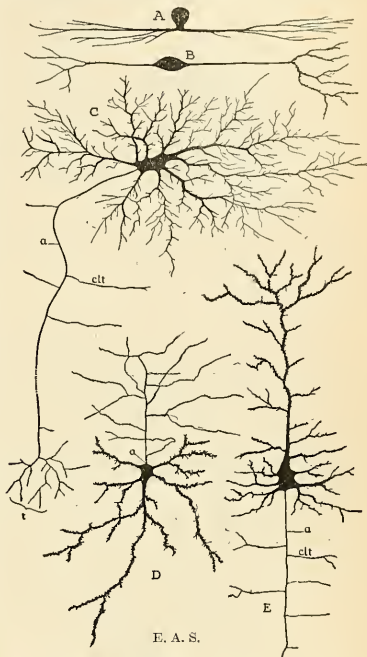


FIG. 581.—Showing some varieties of cell bodies of neurones (diagrammatic.) A. Unipolar (amaerine) cell from the retina. B. Bipolar cell from vestibular ganglion. C. Multipolar cell, with long axone, from spinal cord. D. "Golgi cell," with short axone breaking up into numerous terminal twigs. E. Pyramidal cell from cerebral cortex. a. Axone. clt. Collaterals. t. Telodendria.

¹ American Journal of Anatomy, June 1, 1907, vii, 1. (Anatomical Record, p. 116.)

have been best revealed by the methods of Ehrlich and Golgi. According to the number of processes arising from the cell body, neurones are referred to as (1) **unipolar**, (2) **bipolar**, and (3) **multipolar nerve cells**.

1. **Unipolar cells** are met with frequently in early stages of embryonic development, but are rare in the adult, being found only in the retina, olfactory bulb, and within the baskets of the Purkinjean cells of the cerebellum. They are called **amacrine cells**. The cells of the cerebrospinal ganglia (excepting the cochlear and vestibular) are apparently unipolar, but they are developmentally and functionally of bipolar nature.

2. **Bipolar cells** are found almost exclusively in the peripheral sensor systems, as in the olfactory membrane, in the retina, in the cochlear and vestibular ganglia, and in the cerebrospinal ganglia of the embryo.

3. **Multipolar cells** are the most numerous and form the principal elements of nerve centres throughout the system. They are termed multipolar because of the greater or less number of dendrites given off in addition to the single axone.¹

The terms "unipolar" and "multipolar" must be restricted to the morphological sense; dynamically all nerve cells are bipolar.

According to the relations of the axone we distinguish, after Golgi, two kinds of neurones:

I. Neurones with long axones which become the axis cylinder of a central or peripheral nerve fibre. The axones give off several collaterals which, like the parent stem, break into finely branched terminals or telodendria.

II. Neurones with relatively short axones which do not go into the formation of a nerve fibre, but break up into terminal twigs in the vicinity of the cell-bodies from which they arise. Type II is generally termed, for brevity's sake, the **Golgi cell**.

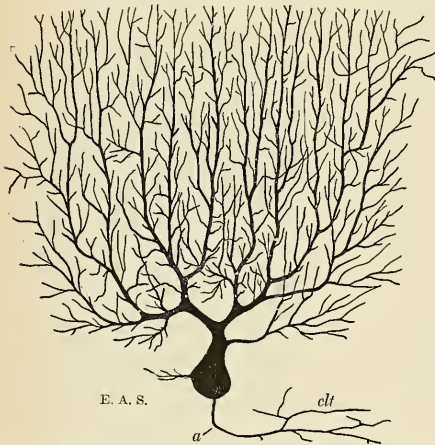


FIG. 582.—Purkinjean cell from human cerebellum, as seen in a plane transverse to the long axis of a cerebellar folium. *a*, Axone, *clt*, Collaterals. (Golgi method.)



FIG. 583.—Profile view of Purkinjean cell, in the plane of the long axis of a cerebellar folium.

According to the morphological relations of the dendrites, neurones are classified as follows:

(a) **Stellate cells**, the dendrites of which spring at intervals from the whole circumference of the cell body and pass toward all directions (motor cells in ventral horn and tract cells of the cord).

(b) Cells with one principal stout dendrite (among other lesser dendrites) which gives off side branches and ends in fine terminal twigs (pyramidal cells of cerebral cortex; mitral cells of olfactory bulb).

(c) **Arboriform cells**, giving off branched dendrites from both base and apex, resembling the roots and the branches of a tree; the axone often springs from the base of one of the root-like dendrites (pyramidal cells of the hippocampus).

¹ Exceptionally, more than one axone has been observed arising from a single cell, as in the Cajal cells of the cerebral cortex.

(d) Cells with **monopolar dendrites**. Several main dendritic stems spring from one pole of the cell and, undergoing frequent subdivision, break up into a fine terminal arborization. The axone springs from the opposite pole (Purkinjean cells of the cerebellum; granular cells of the fasciola cinerea).

2. **Nerve Cell Body. Internal Morphology.**—The nucleus of the nerve cell differs in no essential from the typic nuclear structure. Regarding the organization of the cytoplasm several conflicting views exist. In the present state of our knowledge concerning this still obscure field of investigation it may be said that the nerve cell protoplasm is roughly divided into a **peripheral exoplasmic portion** and a **central endoplasmic portion**. There is shown throughout the cytoplasm a tendency to fibrillar structure, more pronounced in the exoplasmic portion. Within the meshes of a more or less homogeneous ground substance, which pervades the whole, are deposited larger and smaller masses of a granular substance. Nerve cells fixed and stained by the methods of Nissl and Held show that the granule masses are "stainable" (**chromatophiles; tigroid bodies; Nissl bodies**), probably of the nature of a nucleoprotein (MacCallum) and looked upon as a sort of nutritive reserve. Many of the larger cells possess more or less pigmented material, adjacent to the nucleus. The cells of the *substantia nigra (intercalatum)* and of the *locus caeruleus* contain an abundance of such pigment granules.

The "unstainable" homogeneous ground substance of the cytoplasm is probably the more important functionally, for numerous delicate **neurofibrils** have, by special methods, been shown to traverse the cell body and its processes, crossing and interlacing, perhaps anastomosing with each other, and traceable into the axone.¹ Nissl, after years of painstaking investigation, has classified nerve cells into a great many different species in accordance with their reaction to staining agents.

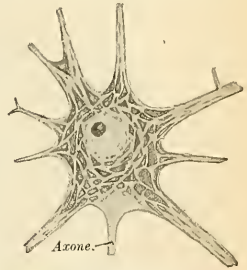


FIG. 584.—Motor nerve cell from ventral horn of spinal cord of rabbit. The angular and spindle-shaped Nissl bodies are well shown. (After Nissl.)

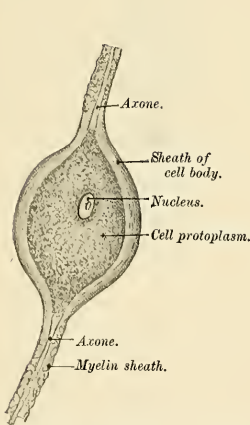


FIG. 585.—Bipolar nerve cell from a spinal ganglion of the pike. (After Kölliker.)

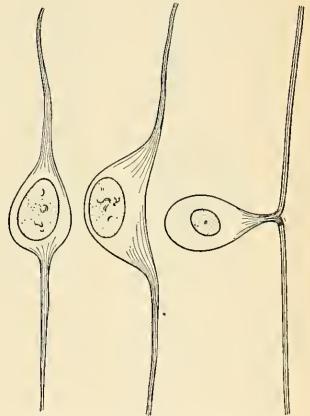


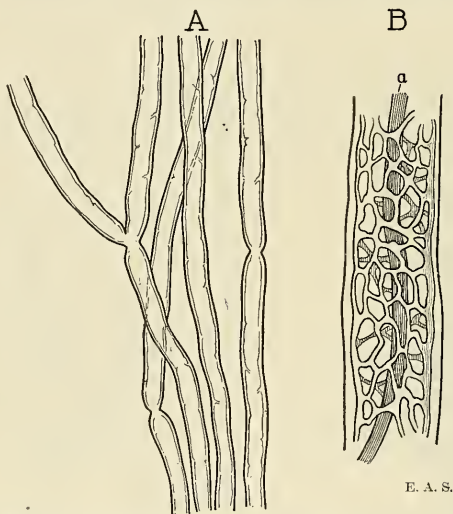
FIG. 586.—Three stages in the development of a cell from a spinal ganglion.

The Dendrites.—The dendrites are attenuated processes, usually numerous, resembling in structure and staining reactions the cytoplasm, of which, as extensions, they increase the functional expanse of the surface of the cell body. Emerging by a broad base, they become

¹ That the neurofibrils form such an intracellular network and that the axones arise therefrom is disputed by Ramón y Cajal, Bielschowsky, and others.

narrower as they divide into many branches in a dichotomous or arborescent manner to end free, according to most observers, or to be joined with the dendrites of other neurones by means of minute fibrillæ (as claimed by Apathy) or by concrescence (Held). The contour of the dendrite, while occasionally irregular in some specimens, with **varicosities** along its course, is, as a rule, beset with numerous lateral buds called **gemmules**. Various hypotheses have been advanced in explanation of these appearances, it being held by some investigators that they are related to conditions of activity as contrasted to those of repose, while others believe them to be artefacts produced by the fixing and staining methods at present employed. However, it is no longer disputed that the function of the dendrites is receptive and conductive (or cellulipetal) for nerve impulses, although they probably serve the nutritional requirements of the cell body as well.

This functional distinction gives the clue to the correct interpretation of the central and peripheral prolongations of the cerebrospinal ganglionic neurones. The cells of these ganglia are at first bipolar in form, but gradually undergo transformation into apparently unipolar cells by the migration of the cell body to one side and the consequent approximation of the two processes to form a common pedicle in a T-shaped manner so typical of the spinal ganglion cell of the adult (Fig. 586). The central branch invariably remains **cellulifugal**, the peripheral branch invariably remains **cellulipetal**, and as such is equivalent to the dendrites of all other neurones. It is merely a *modified* dendrite in that it courses a longer distance without branching until it reaches the periphery and is usually myelinic. Such a peripheral prolongation of the ganglion cell is also termed a **centripetal nerve fibre** or **myelinic (medullated) peripheral axone of an afferent neurone**.



E. A. S.

FIG. 587.—A. Myelinic axones in fresh state, showing a few nodes, B. Portion of a myelinic axone treated with boiling ether and alcohol to remove the myelin and leaving the neurokeratin network. a. Axone.

The Axone.—The axone is usually much longer than any of the dendrites, thin, pale, smooth, emerging from the nerve cell as a direct continuation of the neurofibrillar ground substance of the cell body, and devoid, so far as at present known, of chromatophile granules. Its calibre varies for the different cells, corresponding in general to the length of its course, but it is practically of uniform diameter throughout its extent. Axones may be extremely short or fully a meter in length. Most cells give rise to only one axone (**monaxonic neurones**), but in certain localities **diaxonic** (two axones) and **polyaxonic** (several axones) neurones are found. In a Golgi preparation axones stand out like pieces of black thread, taking a more direct course than do the irregular dendrites, and rarely branching before reaching the ultimate termination, although giving off **collaterals** along their course. The central axones of spinal ganglion (sensor) neurones are the principal exception to this rule in that they bifurcate in a Y-shaped manner after their entrance into the central nerve system. In the case of another group of neurones, **Golgi's Cell, Type II**, the axone is observed to break up into numerous

branches soon after its departure from the cell; such axones are called **dendraxones**. The axones and their collaterals end in terminal arborizations, the **telodendria**.

The axone is the distributive or emissive (cellulifugal) conductor of nerve impulses. There is, therefore, a functional opposition attributable to the two extremities of the neurone, based upon its *dynamic polarity* and upon a physiologic principle which is established by all experiments to which the nerve system is submitted, namely, that nerve impulses pass through the neurone in a definite direction which is invariable and admitting of anatomic localization.

The majority of the peripheral spinal and cerebral axones as well as those constituting the white substance of the brain and cord are invested by a myelin sheath.

The Collaterals (paraxones).—The collaterals are accessory branchings of the axones which are more numerous in the cytoproximal portion and are usually directed at right angles to the parent stem. Some axones possess few or no collaterals, while others possess many. The collaterals, especially those in the gray substance of the central axis, are frequently myelinic. They unquestionably play an important part in the grouping and chaining of neurones within the system, in yielding up to neighboring neurones a portion of the impulse that the cell has received by its dendrites and transmits along its axone to a distance.

Varieties of Axones.—Axones are divided into two main groups depending upon the presence or absence of a myelin sheath—(I) **myelinic axones** and (II) **amyelinic axones**, or **medullated** and **nonmedullated axones**.

Myelinic axones or **medullated axis-cylinder processes** are axones enveloped by a relatively thick sheath composed of semifluid phosphorized fat, which gives to the bundles of these structures their opaque, white appearance. The myelin sheath is in turn invested by a delicate membrane (**neurilemma**) in one group, while another group is devoid of such covering, giving rise to the further subdivision into (a) myelinic axones with a neurilemma; (b) myelinic axones without a neurilemma.

(I, a) **Myelinic axones with a neurilemma** constitute the bulk of the cerebrospinal nerves, and, in lesser proportion, of the sympathetic nerves. The **myelin sheath** (*medullary sheath of Schwann*) (Figs. 587 and 588) does not invest the axone throughout its course nor in a uniform manner. The axone after its emergence from the cell body and likewise in its preterminal portion is naked; and the delicate external membrane or **neurilemma** comes in contact with the axone. The myelin sheath consists of a number of tubular segments demarcated by nodal intersections which are only 0.08 mm. apart in the very small myelinic axones, while for large axones the intervals may be 1 mm. or more. At the **nodes** (*constrictions of Ranvier*) the neurilemma dips into the constriction to come in contact with the axone, and any branches of the axone are invariably given off at such points. The interruptions in the continuity of the myelin sheath have been assumed to be provisions facilitating nutritive diffusion between the axone and the surrounding lymph, and here only may collaterals be given off. Each internodal myelinic segment is further characterized by oblique clefts, irregularly distributed—the **incisures of Schmidt-Lantermann**—seen only in fixed specimens and probably artifacts. Extraction of the fatty substance of the myelin sheath by boiling alcohol and ether brings out a fine network which resists trypsin digestion, and is termed **neurokeratin** on account of its resemblance to the keratin of epidermal structures.

The **neurilemma** (*primitive sheath of Schwann; neurolemma*), a delicate structureless membrane, encloses the myelin and the axone, wherever the myelin sheath is wanting. Against the

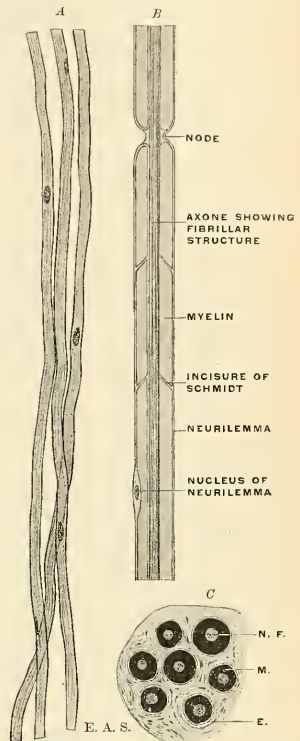


FIG. 588.—A. Amyelinic axones with a neurilemma only, the nuclei of which can be seen. B. Diagram showing structure of a myelinic axon and illustrating two views regarding the relations of the sheaths at the node (compare the two sides). C. Trans-section of a group of myelinic axones, stained with osmic acid, showing: N. F., Axonic neurofibrils, M., Myelin, E., Endoneurium.

inner surface of the neurilemma, and embedded as it were in the myelin, usually midway between two nodes, lies the oval-shaped **nucleus of the neurilemma**.

Myelinic axones are usually from 4 to 10 microns in diameter; the extremes range from 2 to 20 microns.

(I, b) **Myelinic axones without a neurilemma** constitute the white substance of the brain and spinal cord, as well as the optic nerves. They differ from the axones just described in two particulars—the neurilemma is absent and there are no nodes interrupting the continuity of the myelin sheath. A network of neuroglia replaces the neurilemma as a supporting tissue.

(II, a) **Amyelinic axones with a neurilemma** (Remak's fibres; sympathetic nerve fibres) constitute the majority of the sympathetic axones and the axones of the olfactory nerves. The myelin sheath is absent and the axone is invested, more or less completely, by a nucleated cellular sheath or neurilemma.

(II, b) **Amyelinic axones without a neurilemma** are naked axones, most numerous in the central ganglia. Most axones of longer course are devoid of any sheath in the cytoproximal and preterminal portions, whatever investment they may receive in the intermediate portion.

NERVE CELL NIDI OR NUCLEI.

Nerve cells are more or less definitely grouped in the gray substance of the brain and cord to form what are conventionally termed "nuclei." Inasmuch as the term *nucleus* has long been given to the vesicular body in the interior of all cells, ambiguity would be avoided by designating such nerve cell groups by the term *nidi* (plural of *nidus*, "a nest").

"NERVE FIBRES" AND NERVES.

Prior to the general adoption of the neurone concept it was customary to designate the conducting elements of the nerve system by the term **nerve fibres** in distinction from the **nerve cells**. As has been pointed out above, the distinction no longer holds, but the designation "nerve fibre" is still retained in anatomic vocabulary and recurs so frequently in common parlance that, even with the new conception which has been formed of the architecture of the nerve system, the term cannot yet be entirely discarded in favor of "axone," although it probably will eventually.

Nerves are round or flattened bundles of axones which serve to bring the central axis into relation with the periphery and other tissues of the body. The nerves of the body are subdivided into two great classes—the **cerebrospinal**, which are attached to the cerebrospinal axis, and the **sympathetic** or **ganglionic nerves**, which are attached to the ganglia of the sympathetic. The cerebrospinal nerves consist of numerous nerve fibres (**myelinic axones**) collected together into small or large bundles or fasciculi and enclosed in a membranous sheath.

Structure of Nerves.—In structure the common membranous investment, or **sheath** of the whole nerve, which is called the **epineurium**, as well as the **septa** given off from it, and which separate the fasciculi, consists of connective tissue, composed of white and yellow elastic fibres, the latter existing in great abundance. The tubular sheath of the smaller fasciculi composing the nerve trunk, called the **perineurium**, consists of a fine, smooth, transparent membrane, which may be easily separated, in the form of a tube, from the fibres it encloses; in structure it consists of connective tissue which has a distinctly lamellar arrangement, being composed of several lamellæ, separated from each other by spaces containing lymph. The nerve fibres are held together and supported within the *fasciculus* by delicate connective tissue called the **endoneurium** (sheath of Henle). It is continuous with septa which pass inward from the innermost layer of the perineurium, and consists of a ground substance in which are embedded fine bundles of fibrous connective tissue which run for the most part longitudinally. It serves to support the capillary vessels, which are arranged so as to form a network with elongated meshes. The cerebrospinal nerves consist almost exclusively of myelinic axones, the amyelinic axones existing in very small proportions.

The *bloodvessels* supplying a nerve terminate in a minute capillary plexus, the vessels composing which pierce the perineurium and run, for the most part, parallel with the fibres; they are connected by short, transverse vessels, forming narrow, oblong meshes, similar to the capillary system of muscle. Fine amyelinic axones accompany these capillary vessels, the **vasomotor fibres**, and break up into elementary fibrils, which form a network around the vessel. Horsley has also demonstrated certain myelinic fibres as running in the epineurium and terminating in small bulboid **tactile corpuscles** or **end-bulbs of Krause**. These nerve fibres, believed to be sensor, and termed **nervi nervorum**, are considered to have an important bearing upon certain neuralgic pains.

Nerves, in their course, subdivide into branches, and these frequently communicate with branches of a neighboring nerve.

The axones, so far as is at present known, do not coalesce, but pursue an uninterrupted course from the centre to the periphery. In separating a nerve, however, into its component fasciculi, it may be seen that they do not pursue a perfectly insulated course, but occasionally join at a very acute angle with other fasciculi proceeding in the same direction; from this branches are given off, to join again in like manner with other fasciculi. It must be distinctly understood, however, that in these communications the axones do not coalesce, but merely pass into the sheath of the adjacent nerve, become intermixed with its axones, and again pass on, to become blended with the axones in some adjoining fasciculus.

The communications which take place between two or more nerves form what is called a **plexus**. Sometimes a plexus is formed by the primary branches of the trunks of the nerves—as the cervical, brachial, lumbar, and sacral plexuses—and occasionally by the terminal fasciculi, as in the plexuses formed at the periphery of the body. In the formation of a plexus the component nerves divide, then join, and again subdivide in such a complex manner that the individual fasciculi become interlaced most intricately; so that each branch leaving a plexus may contain filaments from each of the primary nerve-trunks which form it. In the formation also of smaller plexuses at the periphery of the body there is a free interchange of the fasciculi and primitive fibres. In each case, however, the individual filaments or axones remain separate and distinct.

It is probable that through this interchange of fibres, every branch passing off from a plexus has a more extensive connection with the spinal cord than if it had proceeded to its distribution without such connections with other nerves. Consequently the parts supplied by these nerves have more extended relations with the nerve centres; by this means, also, groups of muscles may be associated for combined action, as is best exemplified in the formation of the limb plexuses.

The **sympathetic nerves** are constructed in the same manner as the cerebrospinal nerves, but consist mainly of amyelinic axones, collected into fasciculi and enclosed in a sheath of connective tissue. There is, however, in these nerves a certain admixture of myelinic axones, and the amount varies in different nerves, and may be known by their color. Those branches of the sympathetic which present a well-marked reddish-gray color are composed more especially of amyelinic axones, intermixed with a few myelinic axones; while those of a white color contain more of the latter and a few of the former. Occasionally, the gray and white cords run together in a single nerve, without any intermixture, as in the branches of communication between the sympathetic ganglia and the spinal nerves, or in the communicating cords between the ganglia.

The nerves, both of the cerebrospinal and sympathetic systems, convey impressions of a two-fold kind. The **afferent** or **centripetal nerves**, generally called sensor, transmit to the nerve centres impressions made upon the peripheral ends of their components, to produce reflexes in the lower centres while the mind, through the medium of the brain, becomes conscious of environmental conditions or changes. The **efferent** or **centrifugal** (in large part "motor") nerves transmit impulses from the centres to the parts to which the nerves are distributed; these impulses either excite muscle contraction or influence the processes of nutrition, growth, and secretion.

The **ganglia** may be regarded as separate small aggregations of nerve cells, connected with each other, with the cerebrospinal axis, and with the nerves in various situations. They are found on the dorsal root of each of the spinal nerves; on the sensor root of the trigeminus; on the facial and auditory nerves; and on the glossopharyngeal and vagus nerves. They are also found in a connected series along each side of the vertebral column, forming the gangliated cord or trunk of the sympathetic; and on the branches of that nerve, generally in the plexuses or at the point of junction of two or more nerves with each other or with branches of the cerebrospinal system. On section they are seen to consist of a reddish-gray substance, traversed by numerous white nerve fibres; they vary

considerably in form and size; the largest are found on the sensor root of the trigeminus and in the cavity of the abdomen; the smallest, not visible to the naked eye, exist in considerable numbers upon the nerves distributed to the different viscera. The ganglia are invested by a smooth and firm, closely adhering membranous envelope, consisting of dense areolar tissue; this sheath is continuous with the perineurium of the nerves, and sends numerous processes into the interior of the ganglion, which support the bloodvessels supplying its substance.

Origin and Termination of Nerves.—To the central and the peripheral ending of a nerve are usually given the names of "origin" and "termination." These designations have been rendered inappropriate, in many cases, by the newer concept of neuronie arrangement. They have not yet become obsolete, however, particularly in dissecting-room anatomy, and warrant description here with a certain degree of reserve alluded to above.

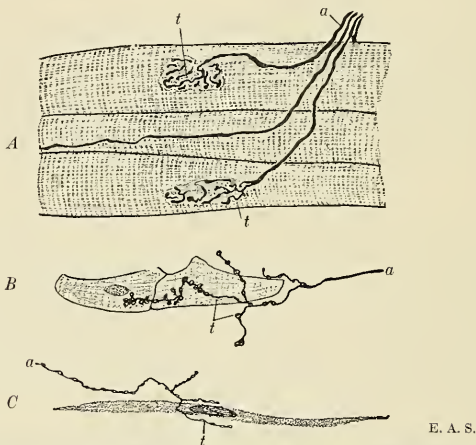


FIG. 589.—Diagrams of motor nerve endings in A. Striated muscle. B. Cardiac muscle. C. Nonstriated muscle. a. Axone. t. Telodendria. (After Huber, Böhm and Davidoff, and others.)

Origin.—The origin in some cases is single—that is to say, the whole nerve emerges from the nerve centre by a single root; in other instances the nerve arises by two or more roots, which come off from different parts of the nerve centre, sometimes widely apart from each other; and it often happens, when a nerve arises in this way by two roots, that the functions of these two roots are different; as, for example, in the spinal nerves, each of which arises by two roots, the ventral of which is motor and the dorsal sensor. The point where the nerve root or roots emerge from the nerve centre is named the **superficial** or **apparent origin**, but the axones of which the nerve consists can be traced for a certain distance into the nerve centre to some portion of the gray substance, which constitutes the **deep** or **real origin** of the nerve. The manner in which these fibres arise at their deep origin varies with their functions. The centrifugal or efferent nerve fibres originate in the nerve cells of the gray substance, the axones of these cells being prolonged to form the fibres. In the case of the centripetal or afferent nerves the axones grow inward either from nerve cells in the organs of special sense (e. g., the retina) or from nerve cells in the ganglia. Having entered the nerve

centre, they branch and send their ultimate twigs among the cells, without, however, uniting with them.

Termination.—Axones terminate peripherally in various ways and may be most conveniently studied in the efferent and afferent systems respectively. The so-called peripheral terminations of afferent neurones are better called **peripheral nerve beginnings**, on account of their functional relations; the impulse is excited in the peripheral end and conducted centrad through the rest of the neurone.

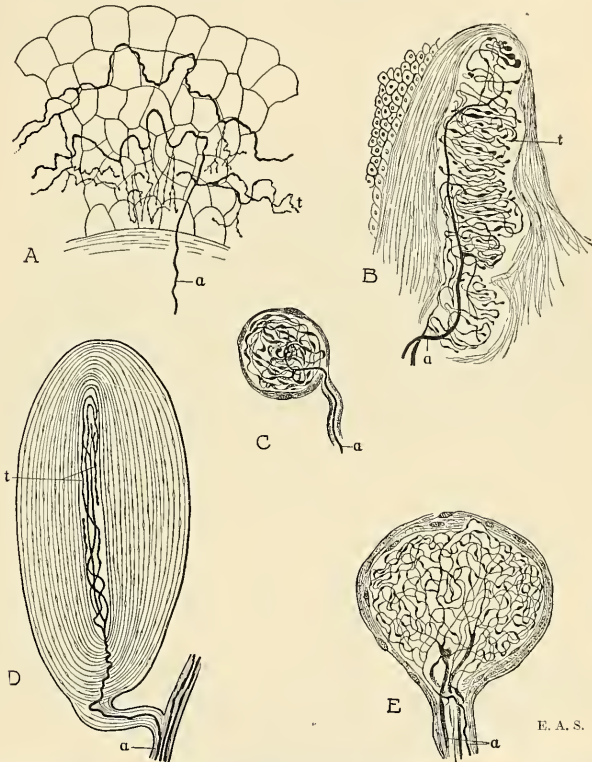


FIG. 590.—Showing some varieties of peripheral terminations of afferent neurones (or "peripheral nerve beginnings"): A. Terminal fibrillae in epithelium (after Retzius). B. Tactile corpuscle (Meissner's, after Dogiel). C. Bulboid corpuscle (Krause's, after Dogiel). D. Lamellated corpuscle (Pacini's, after Dogiel, Sala, and others). E. Genital nerve corpuscle from human glans penis (after Dogiel). a, Axone. t, Telodendria.

Modes of Termination of Axones.—The ultimate terminals of the axones and their collaterals are called **telodendrions** (or telodendria). So far as can be determined by present methods they invariably end "free," commonly by exhaustion through multiple division. This manifold branching presumably puts the neurone in a condition to influence the processes of many other neurones ("avalanche conduction" of Ramón y Cajal). In some localities the formation by axonic terminals of pericellular and peridendritic networks has been observed. Upon muscle

fibres the axone terminals form chains of flattened disks, the **motor end plates**. Among gland cells the terminal fibrils form more or less intricate plexuses.

Peripheral Nerve Beginnings of Centripetal Neurons.—Nerve beginnings of the centripetal (sensor) fibres are found in nearly all the tissues of the body. They are peculiarly differentiated and of various forms in different localities, and their function is apparently the conversion of mechanical, thermal, chemical, and other stimuli into nerve impulses. The organs of vision, hearing, smell, and taste possess variously modified nerve beginnings which are described under appropriate titles in the chapter on the Organs of Special Sense. The organs of the centripetal neurones collecting bodily impressions (tactile sense, muscle sense) and connected with the central axis are often very complicated structures. The principal varieties are:

- | | | |
|-------|------|-----------------------------------|
| | I. { | Terminal (peripheral) fibrillæ. |
| | | Tactile corpuscles (Meissner's). |
| | | "Ruffini's endings." |
| | | Lamellated corpuscles (Pacini's). |
| | | Bulboid corpuscles (Krause's). |
| | | Genital (nerve) corpuscles. |
| | | Articular (nerve) corpuscles. |
| II. { | | Neuromuscular spindles (Ruffini). |
| | | Neurotendinous spindles (Golgi). |

(I, a) **Peripheral fibrillæ** are best demonstrable in the epithelium of the skin, mucous membranes, and cornea. The axone is seen to break up into its constituent fibrillæ, which often present regular varicosities and anastomose with each other in a plexiform manner.

(I, b) **Tactile corpuscles** (*corpuscula tactus*; touch corpuscles of Meissner and Wagner) consist of elongated oval lobules of delicate epithelioid tissue invaded by one or more axones which divide into their primitive fibrils, each terminal branch ending free usually as a somewhat flattened, disk-like plate in among the wedge-shaped cells of the corpuscle. Tactile corpuscles occur in large numbers in the cutaneous papillæ of the finger-tips, in the conjunctiva, and, less abundantly, in the rest of the skin; they appear to be concerned with the finer tactile sensations.

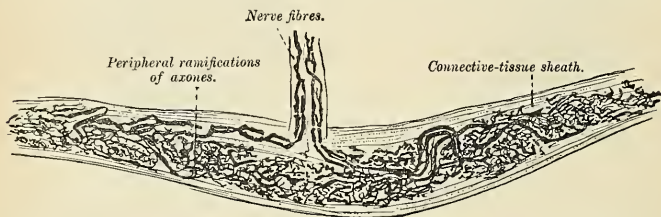


FIG. 591.—Nerve ending of Ruffini. (After Ruffini.)

(I, c) Ruffini has described a special variety of sensor nerve beginning in the subcutaneous tissue of the human finger (Fig. 591). They are principally situated at the junction of the corium with the subcutaneous tissue; they are of oval shape, and consist of a strong connective-tissue sheath within which the axone divides into numerous varicose fibrils ending in small, free knobs.

(I, d) **Lamellated corpuscles** (*corpuscula lamellosa*; Pacinian corpuscles; Vater's corpuscles; Herbst's corpuscles) are among the largest of the tactile end organs and are found chiefly in the palmar surface of the hand, the sole of the foot, the

genital organs, the serous membranes, and many other structures. Each corpuscle consists of a number of capsular connective-tissue lamellæ arranged more or less concentrically around a central granular protoplasmic core, pierced by a single axone which usually divides into two or more branches giving off collaterals of beaded appearance and terminating in rounded knobs.

(I, *e*) **Bulboid corpuscles** (*corpuscula bulboidea*; Krause's end bulbs) are minute cylindrical or oval bodies, consisting of a capsule continuous with the perineurium which encloses a core (inner bulb) of semifluid, finely granular protoplasm. The axone is bulbed peripherally and quite free distally, or, as is frequently observed, divides into a number of branches, to each of which is attached an end bulb.

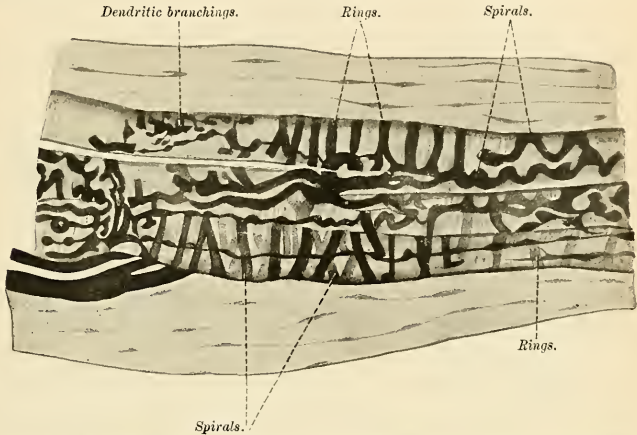


FIG. 592.—Middle third of a terminal plaque in the muscle spindle of an adult cat. (After Ruffini.)

(I, *f*) The **genital corpuscles** (*corpuscula nervorum genitalia*) and the **articular corpuscles** (*corpuscula nervorum articularia*) very much resemble the bulboid corpuscles just described. The genital corpuscles form aggregations of from two to six knob-like masses in the penis and clitoris. The articular corpuscles are found in the synovial membranes of the joints.

II, *a*) **Neuromuscular spindles** (muscle spindles of Kühne) are found in nearly all the skeletal muscles and are most numerous in the Extrinsic muscles of the tongue, in the small muscles of the hand and foot, and in the Intercostal muscles. Most elaborate investigations upon these spindles have been conducted recently by Ruffini in Italy, Sihler, Huber, and De Witt in America. Neuromuscular spindles are usually found in the fibrous septa of the perimysium, and consist of the flattened nerve fibrils of centripetal axones arranged in one or all of three ways: (1) annular, where the fibrils surround the muscle fibres in rings; (2) spiral, and (3) dendritic or branched (Fig. 592). They are doubtlessly concerned with the so-called muscle sense.

(II, *b*) **Neurotendinous Spindles** (organs of Golgi).—The nerves conveying sensor impulses from the tendons have a special modification of the peripheral fibres, in the form of numerous fibrils with branching end plates or of an annular and spiral arrangement resembling the neuromuscular spindles. They usually occur at the junction of the tendon bundles with the muscle fibres (Fig. 593).

The Neurone Doctrine.—The results of the investigations of Golgi, Cajal, Forel, and others prompted Waldeyer to enunciate a theory with regard to the nerve mechanism of the neurone. This hypothesis is generally known as the **neurone theory** and assumes that (1) each neurone is a distinct and separate entity; (2) the collaterals and other terminals of the neurone form no connections among themselves; (3) neurones are associated, and impulses conveyed, by contact or **contiguity** of the axonic terminals of one axone with the cell body or dendrites of another neurone. The theory postulates a nerve cell amebism analogous to the extension and retraction of the pseudopodia of an ameba, and the “retraction theory” has been propounded in explanation of certain functional dissociation phenomena attending nerve force manifestations.

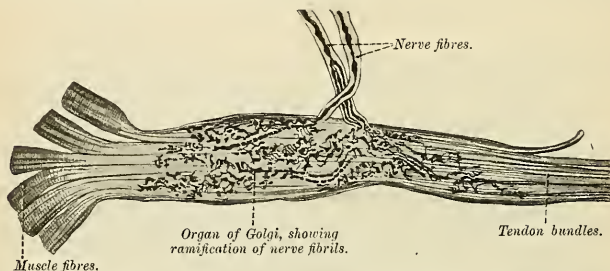


FIG. 593.—Neurotendinous spindle organ of Golgi from the human tendo calcaneus (Achillis). (After Ciaccio.)

Opposed to the “neurone theory” or “contact theory” is the more recent **continuity theory** which is being earnestly advocated by Apathy, Bethe, and Nissl. In behalf of this theory it is claimed that the neurofibrils are continuous not only within the cell and its processes, but through an extracellular network as well. The dispute now being waged does not, however, affect our fundamental ideas regarding the individuality of neurones with regard to their dynamic condition.

The Supporting Tissue Elements of the Nerve System.—A fine meshwork of non-neural tissue, more or less dense in different localities, but apparently restricted to the central axis, serves to support the neurones. This sustentacular tissue is of two kinds: (1) the **neuroglia**; (2) **connective-tissue trabeculae** derived from (a) the pia or (b) **vascular channels**.

The Neuroglia.—The neuroglia consists of **glia cells** of varied forms and **glia fibres**. Glia cells are divisible into two species—**ependymal cells** and **astrocytes** of long-rayed and short-rayed type.

Ependymal cells are the columnar epithelial cells which line the neural canal throughout. In the embryonic condition each cell is seen to project a long multibranched filament toward the periphery of the neural tube, while the free end carries a tuft of cilia. In adult life both the cilia and the radial filament are apparently lost or very much reduced.

Regarding the structure of the glia cells proper as well as of the glia fibres there is a variance of opinion among different investigators. The **astrocytes**, as they are commonly revealed in Golgi preparations, may, as pointed out by Weigert and others, be due to an extension of the silver deposit upon glia-cell nuclei as well as upon adjacent filaments. Huber,¹ Hardesty,² and others regard neuroglia tissue as a syncytium resulting from an early fusion of the protoplasm of the cells of the neural tube which at first were individual and definitely bounded. The filamentous reticulum of glia fibres ordinarily seen in adult tissues seems to result from an increase of the fine threads of the spongioplasmic network of the original cell protoplasm. Neuroglia occurs in both gray and white substances as an all-pervading supporting tissue. In certain localities, as upon the surface of the brain and cord, the neuroglia tissue is disposed in the form of a thin layer.

¹ American Journal of Anatomy, 1901, pp. 45 to 61.

² *ibid.*, 1904, pp. 229 to 268.

Besides the neuroglia, the central nerve system contains as supporting tissues numerous fine and coarse septa or trabeculae derived from the investing pia, or from the sheaths of bloodvessels.

Chemical Composition.—The amount of water in nerve tissue varies with the situation. Thus, in the gray substance of the cerebrum it constitutes about 83 per cent., in the white substance from the same region about 70 per cent., while in the peripheral nerves, such as the sciatic, it may fall to 60 per cent.

The solids consist of neuroalbumins, neuroglobulins, nucleoproteins, neurokeratin (in the gray substance proteins constitute about one-third of the total solids), lecithins, cerebrosides (chiefly phrenosin), cholesterol, unidentified organic sulphocompounds, aminofatty substances, nitrogenous extractives, and inorganic salts with some collagen, fat, etc., in the adherent connective tissue (W. J. Gies).

THE CENTRAL NERVE SYSTEM.

The **central nerve system**, as it is conventionally distinguished from the sympathetic system, is composed of a central axial aggregation of ganglia forming the brain and spinal cord, which are connected with the other tissues of the body by 43 pairs of nerves, of which 12 pairs are attached to the brain and 31 pairs to the spinal cord. The functional relations of the central mechanisms with the periphery are maintained by the essential cell elements of the nerve tissues, the neurones. The chief task in the study and analysis of the structure of the nerve system lies in the dovetailing of features visible to the naked eye with those visible only under high magnifying powers. By the combination of macroscopic with microscopic features the attentive student is enabled to resolve or reconstruct in the three dimensions of space, and see with his mental eye the opaque interior transparently resolved into intricate yet well-defined projecting and associating mechanisms. Assistance in such study may be derived from illustrations depicting hidden structures in accordance with this principle.

Preliminary Considerations. White Substance and Gray Substance.—The central axis of the nerve system contains two categories of substance, their difference to the eye being one of color. They are conventionally designated the **white** and **gray substance**. The **white substance** (*substantia alba*), which forms about two-thirds of the neural axis, is the conducting substance, and its characteristic appearance is due to the myelin sheaths which invest the axones in it.

The **gray substance** (*substantia grisea*; *cinerea*) is the sentient and reacting mass containing the cell bodies of neurones. Its color is due to its translucency, its greater vascularity, and to a certain amount of pigment material in the cell elements. The white and the gray substance is not sharply demarcated everywhere,

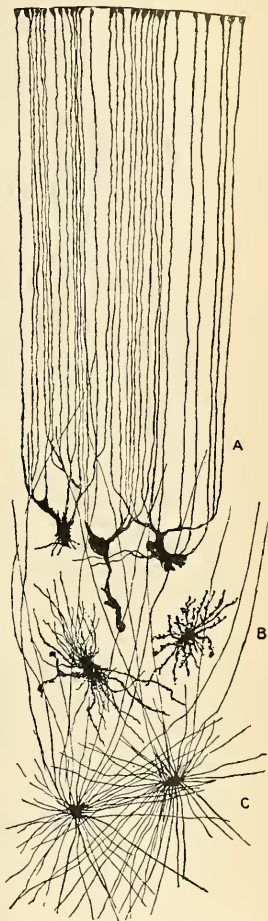


FIG. 594.—Neuroglia cells of brain shown by Golgi's method. A. Cell with branched processes. B. Spider-cell with unbranched processes. (After Andriezen.) (From Schafer's *Essentials of Histology*.)

for although the white substance is exclusively conducting substance, the gray is not exclusively ganglionic, for the former encroaches on the latter; in some localities, as in the ventral horns of the spinal gray, in parts of the cerebral cortex, in the reticular formation of the pons and medulla oblongata, and in the column of Clarke (dorsal nucleus), the admixture of myelinic fibres is considerable. Both white and gray substance is pervaded by the neuroglia.

The specific gravity of the cortical gray substance is 1.021; of the great ganglia, 1.034; of the gray substance in the cerebellum and mesencephalon, 1.040; and of the white substance, 1.028.

For convenience of study, and somewhat in correspondence with phyletic development, the central axis of the nerve system is divided into (1) the **spinal cord** and (2) the **brain**, grossly subdivided into (*a*) **medulla oblongata**, **pons**, and **cerebellum**; (*b*) **mid-brain**; and (*c*) **fore-brain**. This gross subdivision is arbitrary and the interrelations of the parts would be obscured were too much stress laid upon any mode of separation.

THE SPINAL CORD (MEDULLA SPINALIS; MYELON).

The **spinal cord** is the attenuated, nearly cylindrical part of the cerebrospinal axis which lies in the vertebral canal, occupying its upper two-thirds in the adult.

It extends from about the level of the atlantooccipital articulation (or lower border of the pyramid decussation) to the level of the lower border of the body of the first lumbar vertebra, where it terminates in a slender filament of gray substance enveloped by pia, and, further caudad, by a sheath of dura which is attached to the dorsum of the coccyx. The spinal cord is continuous

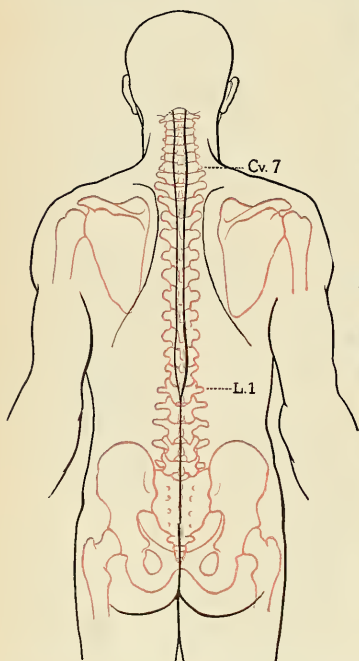


FIG. 595.—Showing the relation of the spinal cord to the dorsal surface of the trunk. The vertebrae are shown in red outlines.

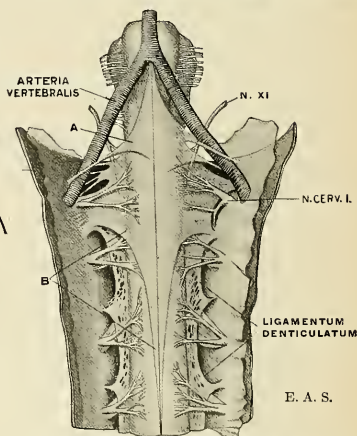


FIG. 596.—Ventral view of medulla oblongata and upper part of spinal cord. Dura and arachnoid cut along median line and folded aside. *A* and *B* are fairly constant velar folds of the arachnoid. (After Key and Retzius.)

cephalad with the medulla oblongata. Its length is 45 cm. (44 to 50 cm.) or eighteen to twenty inches in the male and 43.5 cm. (39.5 to 47 cm.) or sixteen to nineteen inches in the female. In the course of fetal development the spinal cord occupies the entire length of the vertebral canal up to the third month, but after this period it gradually recedes cephalad owing to the more rapid growth of the vertebral column, so that at birth the caudal end of the spinal cord has risen to the level of the third lumbar vertebra.

The spinal cord does not entirely fill the vertebral canal. A wide space or rather a concentric series of spaces intervene between its surface and the walls of the canal, affording a marked freedom of movement of the vertebral column without exerting undue tension upon the spinal cord. These spaces, three in number, which concentrically surround the cord, are demarcated by the three protective membranes—(1) **pia**, (2) **arachnoid**, and (3) **dura**—which are continuous with the like meninges of the brain. The arrangement of the spaces and the membranes may be shown thus:

{ Bony and ligamentous wall of vertebral canal. { Periosteum lining vertebral canal.	Epidural space. (Areolo-fatty tissue and plexus of veins.)	Dura.	Subdural space. (Cerebro-spinal fluid.)	Arachnoid.	Subarachnoid space and subarachnoid reticulum. (Cerebrospinal fluid.)	{ Pia investing spinal cord. { Spinal cord.

The **pia** (*pia mater spinalis*) closely invests the entire surface of the spinal cord and sends septal ingrowths into its substance as well as a fold occupying the anterior median fissure. A leaf-like, serrated fold of pia, the **ligamentum denticulatum**, passes from each lateral border to the inner surface of the dural sheath and helps to support the cord within the subarachnoid space. The arachnoid and the pia are not separable in gross dissection as they merge insensibly, though usually described as distinct membranes. The **arachnoid** (*arachnoidea spinalis*) is in reality an exceedingly delicate and transparent web-like reticulum whose meshes constitute a relatively wide cavity filled with cerebrospinal fluid. The **dura** (*dura mater spinalis*) constitutes the outermost and thickest sheath, while the narrow interval between the dura and the vertebral canal is filled by a fine venous plexus, together with soft, areolofatty tissue. The tubular sheath of dura ends in a pointed *cul-de-sac* at the level of the lower border of the second sacral segment. Of the three spaces which surround the cord, only the two innermost contain fluid, and that of a serous character; the amount in the subdural space is very small, just sufficient to moisten the contiguous endothelial surfaces of the dura and arachnoid; that in the subarachnoidal space is considerable. (For detailed description see section on the Meninges.)

Weight.—The weight of the spinal cord, exclusive of all nerve roots, averages 28 grams, or 1 ounce avoirdupois, being slightly less in the female. Including the nerve roots as ordinarily cut in postmortem procedure, the weight averages 45

grams in the male and 40 grams in the female. The ratio of weight in proportion to that of the brain among mammalia is lowest in the human species, being 1 to 51 in the male and 1 to 49.8 in the female. In the newborn the ratio is 1 to 115. Its specific gravity is 1.038.

External Morphology.—*In situ* the spinal cord exhibits slight curvatures in the sagittal plane, being convex ventrad in the transition from cervical to thoracic portion and slightly concave ventrad to the lumbar portion. Its position varies also according to the degree of curvature of the spinal column, being raised slightly (a few millimeters only) in flexion of the vertebral column.

The intrinsically segmental nature of the spinal cord is expressed by the association of each definite segment with the somatic segment supplied by its nerves. Thirty-one pairs of spinal nerves are commonly enumerated,

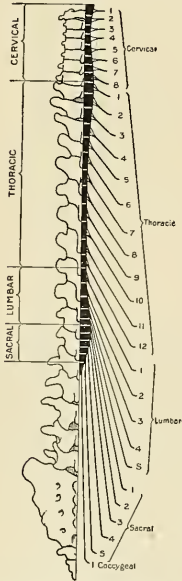


FIG. 597.—Showing the relations of the cord and nerve origins to the levels at which the nerves emerge through the intervertebral foramina (diagrammatic).

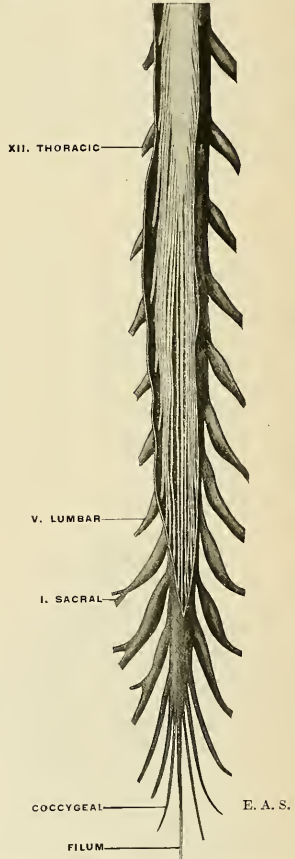


FIG. 598.—The cauda equina exposed within its dural sheath.

although two additional, rudimentary pairs, relics of a tailed vertebrate ancestry, are demonstrable.

The first pair of spinal nerves emerges between the occiput and atlas, and is designated the first cervical; the other cervical pairs are named after the lower of the two vertebræ which form the intervertebral foramen through which the

nerve emerges. Very inconsistently the pair emerging between the seventh cervical and first thoracic vertebræ is called the eighth cervical pair. The remaining spinal nerves are named after the upper of the two vertebræ forming the corresponding foramen. In all there are:

[illegible]

All **spinal nerves** are made up of two roots by which they spring from the lateral aspects of the cord, symmetrically arranged, and these nerve root attachments are the only guides to the demarcation of the various segments of the spinal cord. The two roots are generally termed the **posterior** or **dorsal** (*afferent* or *sensor*) **root**, which enters the cord along the dorsolateral fissure, and the **anterior** or **ventral** (*efferent* or *motor*) **root**, which emerges along the ventrolateral fissure.

Although the cervical nerves pass outward through the intervertebral foramina at nearly a right angle to the long axis of the cord, those of the lower series slope more and more caudad or downward, so that the fifth lumbar pair emerges six vertebral bodies lower than it originates. In fact, the lumbar and sacral nerves descend as parallel bundles in a brush-like manner to form the **cauda equina**, enclosed by the dural sheath as far as about the middle of the sacral canal. The topographical relations of the levels of origin and exit of the spinal nerves to the spinous processes of the vertebra are shown in Fig. 597.

Corresponding with the degree of development of the periphery, the spinal cord is more massive in those segments which are associated with the limbs. Thus in the ground-mole, the cervical portion is very much enlarged in conformity with the powerfully developed forelimbs, while in the kangaroo or the ostrich, with powerful legs, the lumbar portion of the spinal cord is proportionately enlarged. In man, both the cervical and lumbar portions are enlarged, and while the bulk of the lower limbs exceeds that of the upper, the cervical enlargement of the spinal cord is greater because it innervates a limb which is functionally more differentiated, capable of much more skilful and complex movements, and endowed with more acutely developed tactile sensibility.

The Enlargements of the Spinal Cord.—The spinal cord is marked by two spindle-shaped enlargements in its cervical and lumbar portions, while the intervening thoracic portion is nearly cylindrical, being slightly reduced in its antero-posterior diameter. The **cervical enlargement** (*intumescencia cervicalis*) extends from the first or second cervical segment to the level of the second thoracic vertebra, acquiring a maximum breadth (13 to 14 mm.) at the sixth cervical vertebra. At its junction with the medulla oblongata its breadth is about 11 mm. The thoracic portion is about 10 mm. in breadth (minimum at a little below its middle) while its sagittal diameter is 8 mm. The **lumbar enlargement** (*intumescencia lumbalis*) begins at the level of the tenth thoracic vertebra, and acquires its maximum breadth (12 mm.; sagittal diameter = 9 mm.) opposite the twelfth thoracic vertebra. Below the lumbar enlargement the cord gradually tapers to form a cone (**conus**), the apex of which, at the level of the lower border of the body of the first lumbar vertebra, is continuous with the attenuated **filum**.

The cervical enlargement is characterized by a relatively greater breadth than the remaining portions of the cord which, on section, appear nearly circular.

Conus (*conus medullaris*).—The conus is the conical extremity of the cord. The lower three sacral segments and the coccygeal segment are usually included

under this term. Its diameter becomes reduced to 2 mm. ($\frac{1}{12}$ inch), to be continued below as the filum.

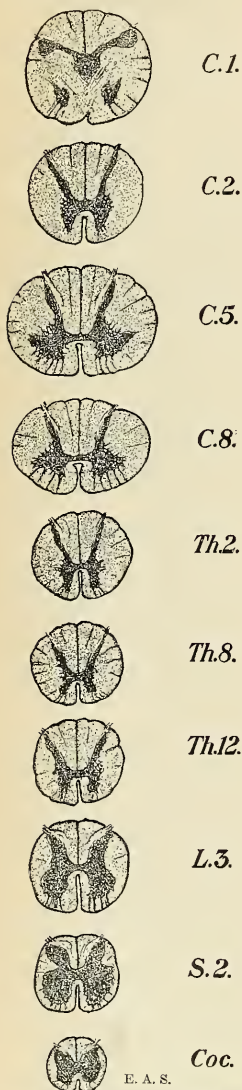


FIG. 599.—Transverse sections of spinal cord at different levels.

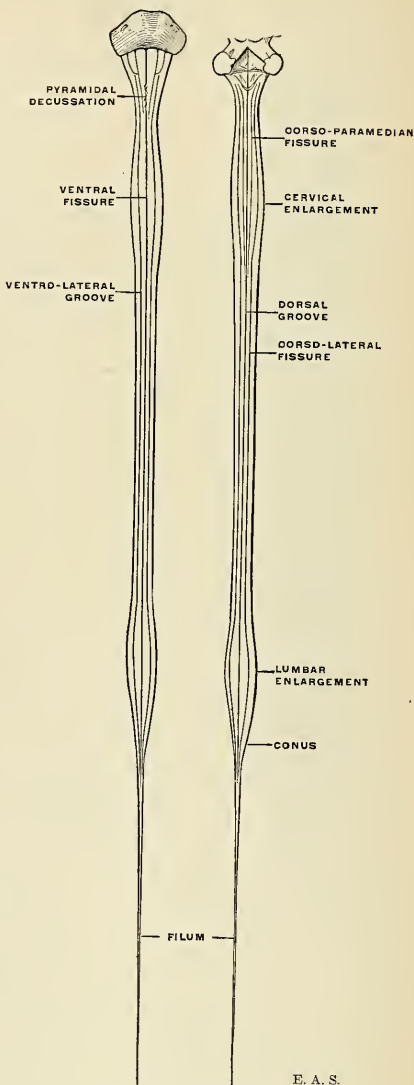


FIG. 600.—Diagram of the spinal cord and its fissures.

Filum (*filum terminale*).—The delicate terminal thread called the filum, continuous with the tapered end of the conus, is about 24 cm. (10 inches) in length. As far as the level of the second sacral vertebral segment it is enclosed, together with the cauda equina, in the tapering sheath of the dura. Within the dural sac it is called the **filum internum**, in contradistinction to the **filum externum**, which is an attenuated process of connective and glia tissue closely invested by a prolongation of the dura, which finally attaches to the periosteum of the dorsum of the coccyx. The filum externum occupies one-third of the total length of the filum. Morphologically, the filum is the caudal representative of the cord, and its intradural portion is usually accompanied by slender fascicles of nerve fibres, which are rudimentary second and third coccygeal pairs of spinal nerves.

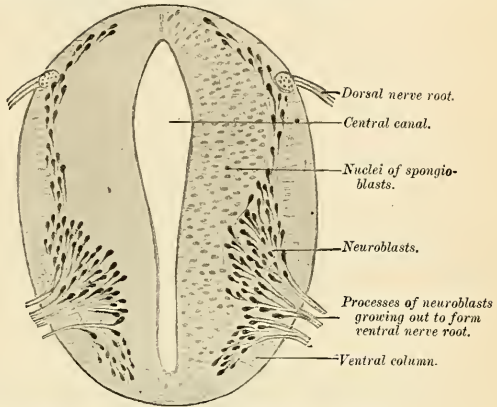
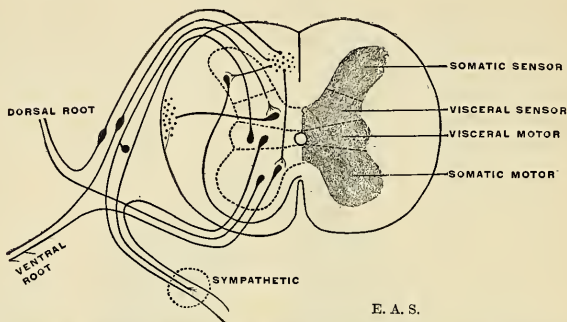


FIG. 601.—Section of spinal cord of a four weeks' embryo. (His.)

Fissures and Grooves.—The spinal cord is a bilaterally symmetrical structure and exhibits a deep ventral fissure and a slight dorsal groove partially subdividing the cord into the right and left halves. The **ventral fissure** (*f. mediana anterior*) extends throughout the entire length of the cord, being shallower in the cervical and thoracic portions (less than one-third of the sagittal diameter) than in the lumbar portion. It is surfaced by a fold of pia which conveys the more important nutritive vessels to the depths of the cord substance. In the depth of this fissure lies the white (ventral) commissure of the cord. The **dorsal groove** (*sulcus medianus posterior*) has been regarded, erroneously, as being analogous to the ventral fissure. Unlike the ventral fissure, however, the pia does not descend into its depths, but passes continuously over it. The shallow groove marks the site of a septum made up of neuroglial and ependymal elements. An actual groove is best demonstrable in part of the lumbar cord and in the medulla oblongata, where it constitutes a veritable fissure between the clavæ.

Each lateral half is marked by the lines of root attachment of the spinal nerves. The dorsal nerve root fascicles enter the cord in linear series and in a depression or true sulcus termed the **dorsolateral fissure** (*sulcus lateralis posterior*). The ventral nerve root fascicles emerge, irregularly scattered, out of a greater circumferential area, and no true ventrolateral fissure can be said to exist. The line of emergence of the outermost fascicles is usually taken as an arbitrary boundary between the ventral and lateral districts of the cord, while the dorsolateral fissure more distinctly maps off the lateral from the dorsal district. An additional fissure,

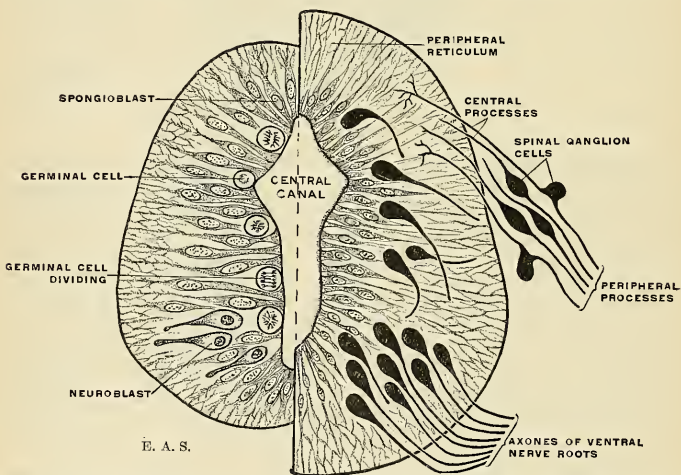
observed most distinctly in the cervical and upper thoracic portions, termed the **dorsoparamedian fissure** (*sulcus intermedius posterior*), demarcates the two principal divisions of the dorsal columns, the **gracile** and the **cuneate columns**. The dorso-



E. A. S.

FIG. 602.—A diagram of the component elements in the spinal cord and the nerve roots in a trunk segment to illustrate the four functional divisions of the nerve system. (After Johnston.)

paramedian fissure is an exceedingly shallow groove and is best denoted in sections of the cord by its continuance as a connective-tissue (*glia*) septum into the substance of the dorsal column. An analogous **ventroparamedian fissure** (*sulcus inter-*



E. A. S.

FIG. 603.—Trans-section through neural tube, early and later stages, diagrammatic. Earliest stages shown on left side. On the right, the maturing neuroblasts are seen sending their axonic processes toward the periphery or to other regions of the central axis, and the central processes of the spinal ganglionic cells are seen to invade the dorsolateral region.

medius anterior) is sometimes observable close to the ventral fissure, demarcating the ventral (or direct) pyramidal fasciculus.

Columns of the Cord (*funiculi medullae spinalis*).—Each half of the spinal cord is thus divided, with respect to its white substance, into three chief columns

or funiculi. The **dorsal column** occupies the area between the dorsal septum and groove and the line of attachment of the dorsal nerve roots; this column in its turn is generally subdivided into the **column of Goll** (*funiculus gracilis*) and the **column of Burdach** (*funiculus cuneatus*) by the shallow dorsoparamedian groove and glia septum referred to above. The **ventral column** (*funiculus anterior*) occupies the area between the ventral fissure and the outermost fascicles of the ventral nerve roots—an arbitrary boundary line. The **lateral column** (*funiculus lateralis*) constitutes the remainder of the cord, between the posterior and anterior nerve root attachments. Each of these columns is subdivided into its component **bundles or fasciculi**, best studied in sections of the cord.

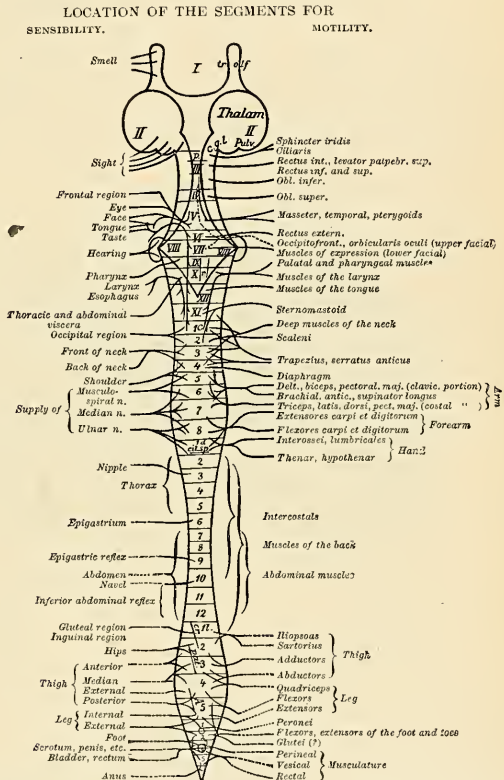


FIG. 604.—Explanation of abbreviations: *tr. olf.*, olfactory tract; *c. g. l.*, lateral geniculate body; *p*, *r*, *cr*, *A*, indicate approximately the location of the reflex centres for the pupillary (*p*), the respiratory (*r*), cremasteric (*cr*), patellar (*pat*), and tendo-Achillis (*A*) reflexes. The vesical centre lies in the third and fourth sacral segments; the anal centre in the fourth and fifth (represented by circles); the centres for erection, ejaculation, labor pains (?) are probably also situated in this region. In reality, the divisions between the various segments are, of course, not so sharp as they are shown in the diagram, so that a given muscle or cutaneous region derives some of its controlling nerve-roots from the segments lying immediately above and below the principal segment. The sensor segment for any given region is regularly somewhat higher than the corresponding motor segment. (Jakob.)

Development of the Spinal Cord.—The elongated posterianal portion of the neural tube becomes the spinal cord, while the primitive cavity within is preserved as the central canal of

the cord. The metamorphosis of the neuroepithelial columnar cells has been described (p. 806). The lateral walls thicken considerably, the central slit-like canal widens as the walls bulge outward in an angular manner, and the central tubular gray becomes a fluted column with dorsal and ventral ridges (or horns) enveloped by a rapidly growing mantle of axone bundles which become myelinic in successive stages. The bulging of the thickening walls in the dorsal and ventral as well as lateral directions produces the ventral fissure and the postseptum.

The segmental nature of the spinal cord has been alluded to before with regard to the segmental derivation of the cerebrospinal ganglia and the disposition of the outgrowing nerve

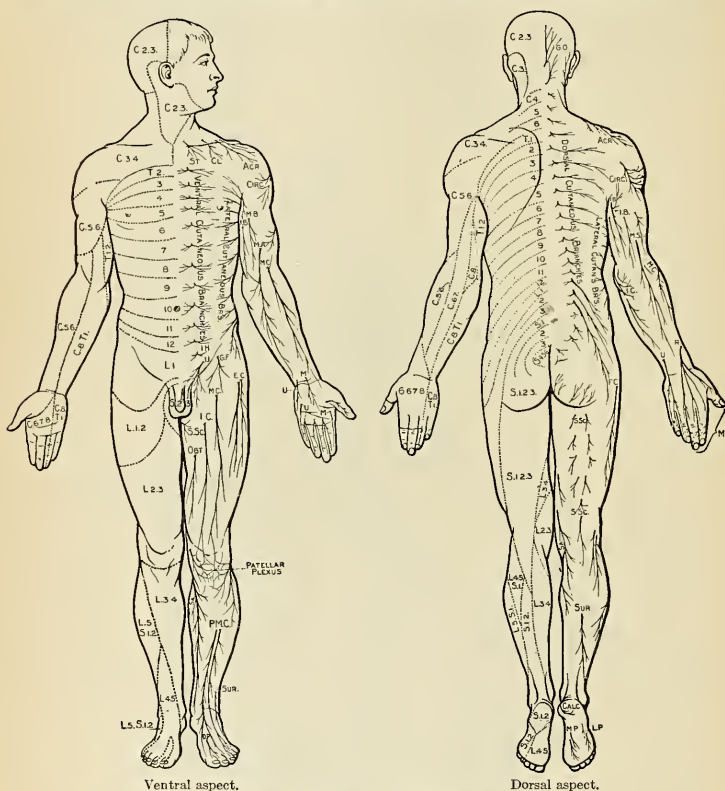


FIG. 605.—Distribution of cutaneous nerves.

bundles. There is a further mode of division into longitudinal systems based upon functional relationships. Two main categories of activity characterize the mechanism of the nerve system and find somatic expression in its architectural plan: First, actions in relation to the external world (**somatic**—involving skin, muscle, skeleton, etc.); second, internal activities concerned with the processes of nutrition and reproduction (**visceral**—involving the alimentary tract, vascular [blood and lymph], excretory, and reproductive systems). In each there is a twofold activity on the part of the nerve system: reception of stimuli and motor responses. In the cord (and to some extent in the brain as well) the following functional divisions may be distinguished and located anatomically (Fig. 602):

Somatic *sensor* elements.
Somatic *motor* elements.

Visceral *sensor* elements.
Visceral *motor* elements.

This functional differentiation of the neural axis into sensor and motor divisions apparently finds organic expression in an important modification of the developing neural tube. Each lateral wall of the neural tube is early demarcated into a **dorsal** and a **ventral lamina** and the slit-like central canal becomes more or less lozenge-shaped on trans-section, owing to the formation of a lateral longitudinal furrow within. The dorsal lamina or zone is preponderantly sensor in function, while the ventral zone is principally motor in function. This fundamental fact has been of the greatest aid in the correct interpretation of many hitherto obscure facts regarding the mechanism of the nerve system, and will be found to underlie our method of description throughout.

The muscular supply from motor segments of the cord is shown in Fig. 604, and the cutaneous supply in Fig. 605.

Internal Structure of the Spinal Cord.—If a transverse section of the spinal cord be made, it will be seen to consist of white and gray nerve substance. The white substance is made up of myelinated axones; the gray contains the cell bodies of neurones and nonmyelinated axones with only few myelinated axones. The color of the gray substance, so-called, varies according to the degree of capillary injection and the age of the individual. It is usually of a faint, reddish-gray tinge, the gray preponderating in older persons, but various shades of red, yellow,

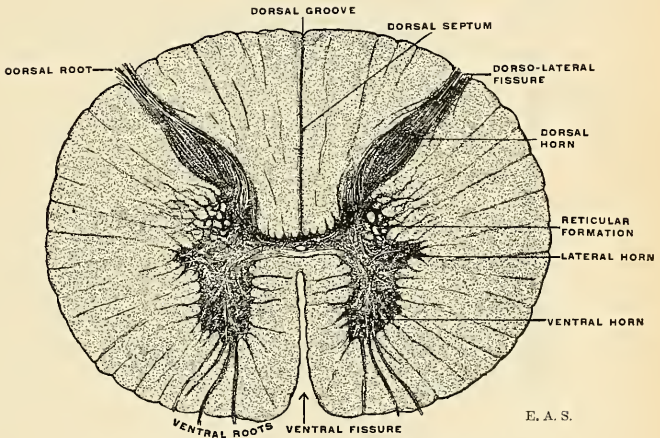


FIG. 606.—Trans-section of the spinal cord at the mid-thoracic region.

and light slate-color may be noted. Nor is the color uniform even in the same section. Around the central canal and at the periphery of the dorsal horn the gray substance is very translucent and is termed, according to its situation, the *gelatinosa centralis* (glia centralis) and *gelatinosa Rolandi* or *caput gliosum* (glia cornualis). The white substance surrounds the gray column as a variously thickened tunic, closely invested by the pia, which sends numerous delicate, vessel-bearing ingrowths into the substance of the cord. The relative area of the white substance, as seen on section, increases cephalad; the absolute area of both white and gray is the largest in the region of the enlargements (Fig. 607).

Gray Substance of the Cord (*substantia grisea centralis*; *entocinerea*).—A plastic conception of the gray substance of the cord is essential to an understanding of the internal architecture. The gray core must be imagined not alone in the relations in which it is conventionally studied, as exposed in trans-sections, but

also as a fluted column having a continuous extent throughout the cord. This gray column is drawn into ventral and dorsal ridges, connected respectively with the ventral and dorsal nerve roots, while the white substance fills out the irregularities and completes the nearly cylindrical outline of the cord (Fig. 608).

On viewing a trans-section, it is seen that the gray substance is so arranged as to present, in each lateral half of the cord, a crescentic or comma-shaped mass, the concavity of which is directed laterad. The two lateral masses are connected by a transverse bar or band of gray substance, termed the **gray commissure** (*commissura cinerea* [*grisea*]), and containing the central canal, which extends the entire length of the cord. The dorsal septum of the cord reaches quite to the

gray commissure, there being but a few white commissural fibres in the dorsal zone. Ventrad, however, a lamina of white substance, the **commissura ventralis alba**, separates the gray commissure from the ventral fissure (Fig. 606).

In trans-sections of the cord it is seen that the lateral crescentic gray masses, united across the middle line by a gray commissure, have the aggregate appearance of the letter H. Each crescentic mass presents projections which are more or less pronounced according to the segment of the cord under consideration. Broadly stated and without reference to special levels, the most marked projections are the **dorsal** and **ventral horns** or **cornua**.

The **dorsal horn**, directed dorsolaterad, is elongated and narrow, and its apex is composed of a translucent, V-shaped mass termed the **caput gelatinosa Rolandi**.

The attenuated apex of the dorsal cornu approaches the surface of the cord along the line of entrance of the dorsal nerve roots. The apex of the dorsal horn is wider in the regions of the enlargements and the gelatinosa is most marked in the higher cervical segments. The base or cervix of the dorsal horn is constricted somewhat except in the thoracic portion, where its greater breadth is due to the presence of **Clarke's column** (*nucleus dorsalis*).

The **ventral horn** is shorter, thicker, and more blunt, and is separated from the ventral and lateral surfaces of the cord by a tolerably thick lamina of white substance. Its margin, in trans-sections, presents a dentate or stellate appearance due to the emergence of fascicles of efferent or ventral root axones on their way to the ventral surface of the cord.

What is known as the **lateral horn** projects as a lateral peninsular extension of the central gray nearly on the line of the gray commissure. It is best marked as a triangular projection in the upper thoracic segments. In the cervical enlargement it is merged with the greatly expanded ventral horn, but it again becomes prominent in the upper cervical segments.

The gray substance of the cord is not everywhere sharply demarcated from the white owing to the invasion of myelinic and amyelinic nerve fibres. Facing the lateral column, in the angle between the dorsal and ventral horns, small fascicles of white fibres are embedded in the gray so that it is broken up in a peculiar basket-work pattern termed the **reticular formation**. This gray network is best

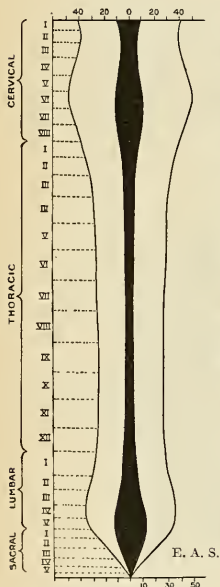


FIG. 607.—Projection upon a plane of the absolute and relative extent of the gray and white substance of the cord as determined by successive sectional areas. Gray substance shown in black. (Adapted from the measurements of Stilling.)

marked in the cervical region and becomes more abundant in the medulla oblongata.

The mode of arrangement of the gray substance and its amount in proportion to the white vary in different parts of the cord. Thus, the dorsal horns are long and narrow in the cervical region; short and narrower in the thoracic; short but wider in the lumbar region. In the cervical region the crescentic portions are small, and the white substance more abundant than in any other region of the cord. In the thoracic region the gray substance is least developed, the white substance being also small in quantity. In the lumbar region the gray substance is more abundant than in any other region of the cord. Toward the lower end of the cord the white substance gradually ceases. The crescentic portions of the gray substance soon blend into a single mass, which forms the only constituent of the lower extremity of the cord.

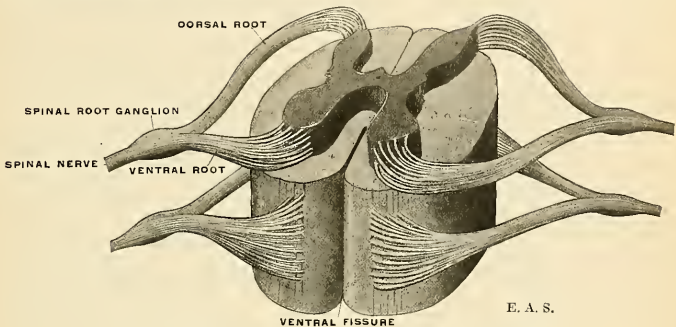


FIG. 608.—Showing origin of two pairs of spinal nerves (schematic).

The **gray commissure** which connects the two crescentic masses of gray substance consists of myelinic and amyelinic nerve fibres and neuroglia. The fibres pass transversely, spreading out at various angles, into the lateral gray masses. In the gray commissure, and extending the whole length of the cord, is a minute channel, the **central canal** (*canalis centralis*; myelocele), which is barely visible to the naked eye, but is proportionately larger in some of the lower vertebrates. Cephalad, in the medulla oblongata, it opens out into the fourth ventricle; caudad it is continued for a short distance into the filum, in which it ends blindly. The canal is very minute, less than 0.1 mm. ($\frac{1}{250}$ inch), except in the terminal part of the conus, where it expands into a fusiform dilatation, the **sinus terminalis**. The central canal is lined by a layer of columnar cells which are seen to be ciliated in the embryo and are in all respects identical with the ependymal cells lining the ventricles of the brain. Surrounding the ependymal lining of the central canal and gradually merging into the spongy substance which constitutes the remainder of the gray commissure is a finely granular and reticulated substance, the **gelatinosa centralis**, almost entirely composed of neuroglia, with a few fine fibrils apparently proceeding from the ependymal cells, and having a translucent, gelatinous appearance.

The gray substance of the cord is composed of (1) the **gelatinosa** or **gliosa**, which envelops the head of the dorsal horn and which encircles the central canal of the cord; (2) the **spongiosa**, which forms the crescentic horns (except the heads of the posterior horns and the envelope of the central canal). Further, it may be stated that the gray substance consists of nerve-fibres of variable but smaller

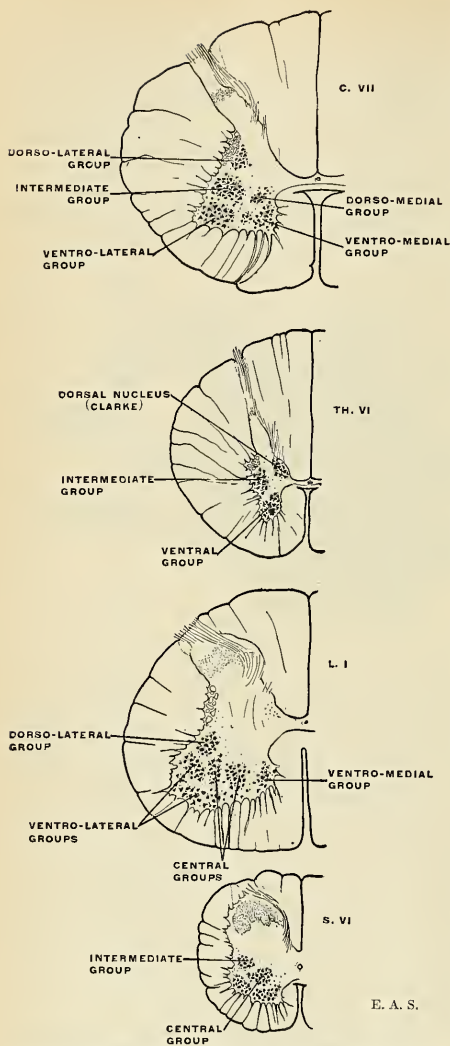


FIG. 609.—Trans-sections of the spinal cord at different levels to show the topographical arrangement of the principal cell groups.

average diameter than those of the white columns; (3) nerve cells of various shapes and sizes, with few or many processes; (4) bloodvessels, lymphatic channels, and connective tissue.

The nerve fibres of the gray substance of the posterior horn are for the most part composed of a dense interlacement of minute fibrils, intermingled with nerves of a larger size. This interlacement is formed partly by the axones and dendrites of the cells of the gray substance, and partly by fibres which enter the gray substance and which come from various sources.

The nerve cells of the gray substance are collected into groups (*nidi* or *nuclei*) as seen on transverse section, but they really form columns of cells placed longitudinally; or else they are found scattered throughout the whole of the gray substance (Fig. 609).

In the ventral horn four main groups of cells may be distinguished which are not wholly represented, however, in all regions of the cord: (1) A **ventral group** of cells, separable in the cervical and lumbar regions into **ventromedial** and **ventrolateral** sub-groups; (2) a **dorsomedial group**, situated in the cervix of the ventral horn, usually demonstrable in the thoracic portion as well as a few contiguous cervical and lumbar segments; (3) a **lateral group**, separable in the lower cervical and lumbar regions

into **ventrolateral** and **dorsolateral** sub-groups, and supplying the muscles of the extremities; (4) a **central group** of cells in the lumbar and sacral regions.

In the **lateral horn**, which is most prominent in the thoracic and upper cervical segments, lies an **intermediate group** of cells, a long, slender column which is nearly restricted to the thoracic portion of the cord, but is seen to reappear in the

upper three cervical and in the third and fourth sacral segments. The axones from these cells probably do not pass out with the ventral nerve roots, but rather course within the cord to terminate at various levels on the same as well as on the opposite side. A close connection with the sympathetic nerve system, and with vasomotor and sweat-gland nerves, has been suggested.

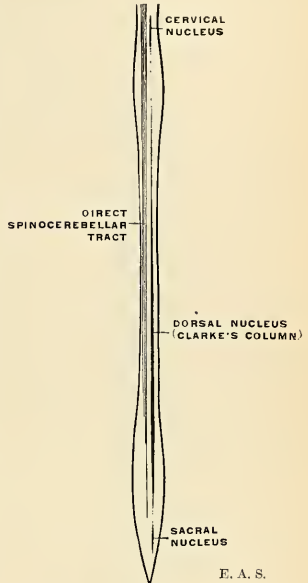
In the **dorsal horn** the most conspicuous group of cells is a columniform nucleus commonly termed **Clarke's column** (*nucleus dorsalis*), which extends between the seventh cervical and second (or third) lumbar segments of the cord. The cells are large and the group presents an oval outline in trans-sections, lying in the medial part of the cervix of the dorsal horn. The axones of these cells pass out of the gray into the lateral column of the cord to form the spinocerebellar tract, and convey tactile impulses to the cerebellum. It is represented in other regions of the cord by scattered cells which are aggregated to form the **cervical nucleus** opposite the third cervical nerve, and a **sacral nucleus** in the middle and lower part of the sacral region. The axones of these cells form the homolateral direct cerebellar tract.

The cells of the dorsal horn are not grouped very definitely, and for the purposes of description they are subdivided according to their location. The cells vary much in form and size and their branched axones pass toward other regions within the gray substance at various levels on the same or on opposite sides, or via the ground bundles. Many fibres of the dorsal nerve roots are in relation with the dorsal horn cells.

The various groups of cells enumerated above are frequently demarcated from neighboring groups by nerve fibre intervals, which may be straight, curved, interlaced, or loop-shaped.

Through the **gelatinosa Rolandi** (*glia cornualis*) pass numerous fine fibrils, chiefly the afferent dorsal nerve root fibres, but in addition this peculiar, gelatinous, and semitranslucent substance contains numerous small, stellate cells; the region is so densely filled with axones and collaterals, as well as neuroglia cells, that until staining methods became sufficiently developed the importance of this substance remained in dispute. In man the gelatinosa Rolandi shows convolutions feebly imitating those of the olivary body, and its structure is analogous. Dorsad of the glia lies the ultimate zone of the dorsal horn; this gray substance resembles the spongiosa in its essential characters.

The White Substance of the Cord (*substantia alba*).—The white substance of the cord, consisting chiefly of longitudinally disposed myelinic fibres, with blood-vessels, neuroglia, and connective-tissue septa, forms a thick mantle which invests the central gray column. When stained with carmine, a transverse section of the white substance is seen to be studded all over with minute dots surrounded by unstained circular areas. The dots are the transversely cut axones; the lighter areas are the myelin sheaths. The mass of white substance is closely invested by



E. A. S.

FIG. 610.—Showing the dorsal nucleus (of Clarke), and its cervical and sacral extensions on one side, and the direct spinocerebellar tract on the other. The fibres of the tract ascend on the same side as the nucleus in which they arise.

a sheath of neuroglia immediately beneath the pia. Numerous septa, derived from the pia, but always coated by a thin layer of neuroglia, pass into the white substance to separate the respective bundles of fibres and are often interwoven between individual nerve fibres, acting as a supporting framework in which they are embedded. In addition to the longitudinal fibres there are shorter and less numerous transverse fibres forming the **white commissure**.

The **longitudinal fibres** constitute the conducting tracts. Although a purely anatomical examination fails to reveal the functional relations in these fibre bundles, the structural alterations which ensue (in accordance with the laws of Waller) in the distal portion of a neurone whose proximal portion has been destroyed, the progressive myelinization of separate tracts in the embryo and infant (as proved by the researches of Meynert and Flechsig), the comparative anatomy method and electrophysiological experimentation have rendered possible the demonstration of the origin and destination of the various conducting systems or tracts with almost mathematical accuracy. While some fibres pursue a lengthy course, serving as conduction paths between the brain centres and the various spinal centres, others are shorter and serve to associate different spinal levels—in juxtaposition or relatively not far distant. It must be borne in mind that the gray substance, intercalated as it is in the course of the impulses which pass to and fro in the cord, contains the neural elements which are either (*a*) the source or (*b*) the destination of these impulses, and thus complete the nerve cycle requisite for the organization of the functions belonging to the cord. The motor and sensor phenomena, though interacting, depend upon distinct nerve elements which, because of their functional relationships, or because of the direction in which they convey impulses, are generally referred to as **motor** or **efferent** and **sensor** or **afferent** neurones; and in the spinal cord usage has sanctioned the employment of the terms **descending** and **ascending** for tracts conveying motor and sensor impulses, respectively. Anatomically speaking, however, it is preferable to describe the tracts with reference to their origins and termini (as cerebrospinal, spinothalamic, etc.), when known, or to their topographical relations as studied in trans-sections of the cord.

For the purposes of description it is convenient to classify the longitudinal fibres into three general systems: (1) The *cerebrospinal system* of axones forming conduction paths for efferent impulses from the cerebrum to the spinal centres for peripheral organs, and axones for afferent impulses received in the spinal centres from the periphery and conveyed in turn to the cerebrum. (2) The *spinocerebellar system*, consisting of conduction paths, afferent and efferent between the cerebellum and the spinal centres. (3) Numberless *association systems* strictly confined within the cord (or only extending into the medulla oblongata), composed of shorter or longer axones which serve to associate not only different levels of the same spinal segment, but also the different segments that are in juxtaposition or more remotely situated. These spinal association axones form bundles in close contact with the central gray column and are termed the **fasciculi proprii** or **ground bundles**.

Tracts of the Spinal Cord.—In the dorsal column there are the following tracts:

Ascending:

1. Fasciculus gracilis (Goll).
2. Fasciculus cuneatus (Burdach).

Descending:

1. Comma tract (Schultze).
2. Median oval tract (Flechsig).

Associating:

1. Fasciculus dorsalis proprius.
2. Dorsal cornucommissural tract.
3. Septomarginal tract (Bruce).

Another tract, usually described as belonging to the lateral column, but functionally more intimately related to the sensor neurone system of the dorsal column is the *fasciculus marginalis* (of Spitzka and Lissauer, described on page 836).

The great majority of the axones constituting the dorsal column are the afferent (sensor) axones arising from the spinal ganglion cells, entering the cord by the dorsal roots. These dorsal root axones bifurcate in the region of the dorsal horn, one branch ascending a little obliquely at first, then vertically, while the other branch takes a similar downward course for a shorter distance (Fig. 613). As additional groups of fibres are contributed by each successive dorsal nerve root the mass of white substance in the dorsal column accumulates as the cord is ascended, though it must be noted that not all of these afferent fibres traverse the whole of the cord above, but end in relation with cells in the gray substance at various levels. The successive accessions of afferent fibres are disposed in a laminated manner so that the lumbar fibres come to lie laterad of the sacral bundle, the thoracic laterad of the lumbar, and so on as the cord is ascended. A section of the cord at its highest level would therefore traverse a collection of bundles derived from all of the dorsal nerve roots of the cord, arranged as shown in Fig. 611.

In the upper segments of the cord it is possible to distinguish a division of the dorsal column into two principal fasciculi owing to the presence of a distinct connective-tissue septum which passes into the substance of the dorsal column along the dorsoparamedian groove. These fasciculi are termed the *fasciculus gracilis*, or *Goll's column*, and the *fasciculus cuneatus*, or *Burdach's column*; in the consideration of the external morphology of the cord, these have already been referred to as the *funiculus gracilis* and *funiculus cuneatus*, respectively.

It has been noted that even in the fresh cord, when sectioned, the gracile bundle has a different tinge and stains more deeply with carmine than does the cuneate bundle.

The caudal or descending branches of the bifurcate dorsal root axones are considerably shorter than the ascending branches. They terminate in the gray substance in relation with its cells and, by numerous collaterals which are shorter or longer and given off at various intervals, serve to associate different levels of the cord. Some of these collaterals cross the median line in the dorsal (gray) commissure to come into relation with neurones of the opposite side. Certain of the longer descending branches show a tendency to collect into a feebly marked bundle along the mesal border of the cuneate fasciculus, called, because of its outline in trans-sections—as seen in cases of descending degeneration from injury at a higher level—the *comma tract* of *Schultze*. A similar bundle, situated along the dorsal septum, best demonstrable in the lumbar cord, and with its fellow

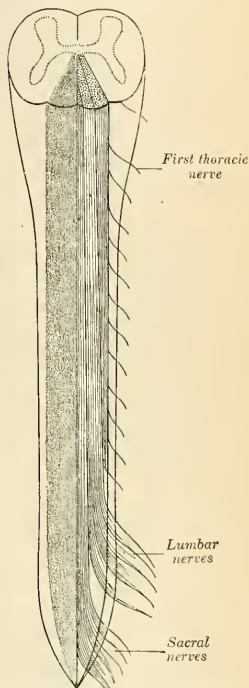
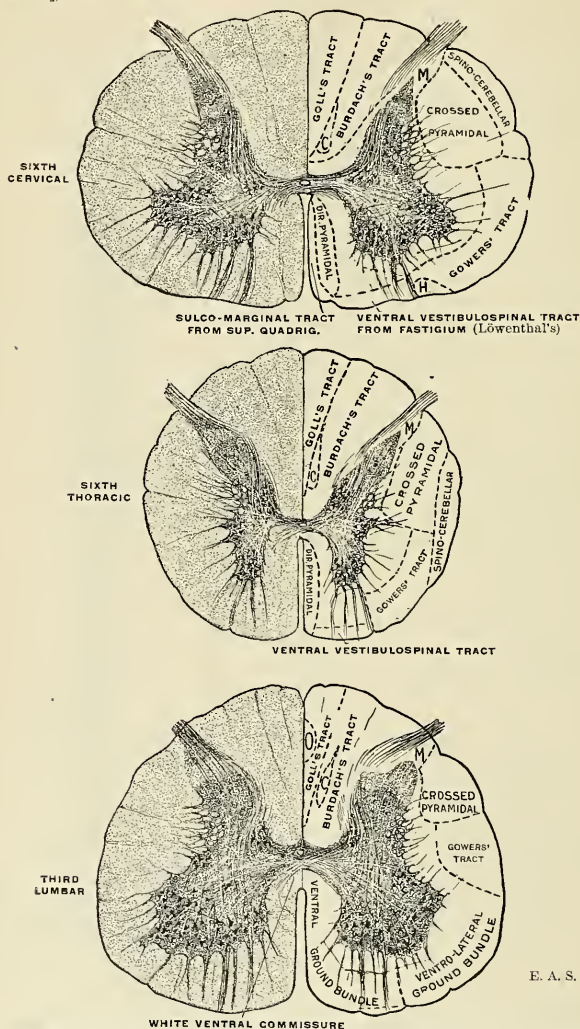


FIG. 611.—Formation of the fasciculus gracilis. Spinal cord viewed from behind. To the left, the fasciculus gracilis is shaded. To the right, the drawing shows that the fasciculus gracilis is formed by the long fibres of the posterior roots, and that in this tract the sacral nerves lie next the mesal plane, the lumbar to their outer side, and the thoracic still more laterally. (Poirier.)

of the opposite side of the oval outline as seen on section, is called the **oval bundle of Flechsig** (*tractus cervicolumbalis* [Edinger]; *dorsomediales Sakralfeld* [Obersteiner]).



E. A. S.

FIG. 612.—Sections of the spinal cord at the level of the sixth cervical, sixth thoracic, and third lumbar segments, the conducting tracts being indicated on the right side of each section: C, Comma tract of Schultze. H, Olivospinal tract of Helweg. M, Marginal tract of Spitzka-Lissauer. O, Oval field of Flechsig.

Marginal Tract.—Not all the axones of the dorsal nerve root enter the dorsal column. Another group elsewhere described passes into the dorsal horn as

well as toward Clarke's column, while a third group of fibres forms the so-called **marginal tract**,¹ situated close to or among the entering fibres of the dorsal roots, but frequently described as lying in the lateral column. The tract is demonstrable in all levels and is made up of successive increments of relatively short axones (traversing not more than three or four segments) to end in relation with the cells in the *gelatinosa Rolandi*.

Ground Bundle of the Dorsal Column.—A zone of fibres contiguous with the dorsal face of the gray column, and termed the **fasciculus dorsalis proprius** or **dorsal**

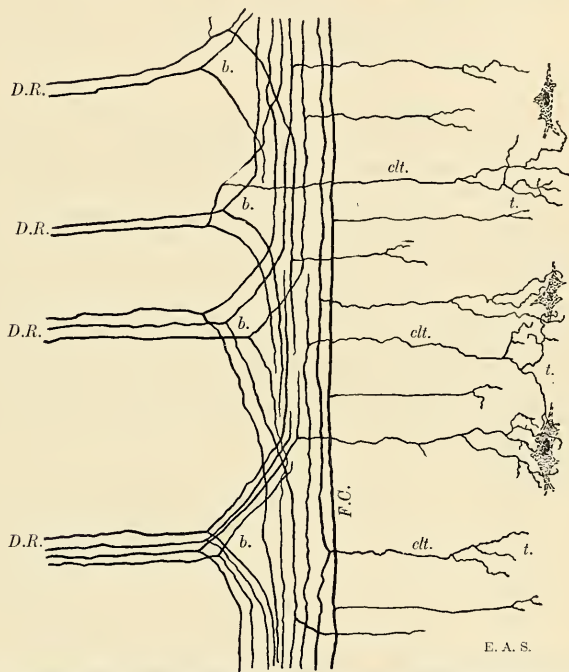


FIG. 613.—Ramifications of the central processes (axones) of afferent neurones entering the spinal cord as seen in longitudinal section (schematic): *D.R.* Axones of dorsal roots. *b.* Their bifurcation. *clt.* Collaterals. *t.* Telodendria ending in proximity of cells in the gray substance. *F.C.* Axones of gracile and cuneate fasciculi.

ground bundle, is composed of axones arising from the smaller cells of the dorsal horn, which, after entering the white substance and bifurcating into ascending and descending branches, come into relation with other levels of the gray column by means of collaterals and terminating in it after a comparatively short course. They are therefore to be regarded purely as association or "longitudinal commissural" fibres. The **dorsal cornucommissural tract** (*ventrales Hinterstrangsbündel* [Strümpell]; *zone cornucommissurale* [Marie]), occupying a triangular interval at the apex of the trans-sectioned dorsal column, and the **septomarginal tract** [of Bruce], in apposition with the postseptum, belong to this category of association bundles. Both tracts are most evident in the lumbar portion of the cord.

¹ First described by E. C. Spitzka (1885) and Lissauer (1886), and usually bearing the name of the latter.

In the **lateral column** the following tracts may be enumerated:

Ascending:

1. Dorsolateral spinocerebellar tract (Flechsig).
2. Superficial ventrolateral spinocerebellar tract (Gowers).
3. Spinothalamic tract.
4. Spinomesencephalic tract.

Descending:

- | | | |
|-----------------------------|---|--------------------------------------------------|
| Internod-
lateral tract. | { | 1. Crossed pyramidal tract. |
| | | 2. Rubrospinal tract. |
| | | 3. Cerebellospinal tract (Marchi and Löwenthal). |
| | | 4. Lateral vestibulospinal tract. |
| | | 5. Olivospinal tract of Helweg. |

Associating:

1. Fasciculus lateralis proprius.

The **dorsolateral spinocerebellar** or **direct cerebellar tract** (*fasc. cerebellospinalis*) lies at the periphery, laterad of the crossed pyramidal tract. Its axones arise from the cells of Clarke's column and ascend uninterruptedly to the medulla oblongata, and thence to the vermis of the cerebellum in its inferior or post-peduncle. The tract becomes more massive as the cord is ascended (Fig. 610).

The **superficial ventrolateral spinocerebellar tract**, or **tract of Gowers** (*fasc. antero-lateralis superficialis* [Gowers]), also courses along the periphery, but farther ventrad. The origin of its axones is yet in dispute; they probably arise from cells in the gray substance of both sides, in the zone between the dorsal and ventral horns as well as from some of the ventral horn cells. The destination of the axones of this tract is equally uncertain, but most of the fibres have been traced through the dorsolateral region of the medulla oblongata and the pontile reticula, whence it turns dorsimesad, to enter the cerebellum through the superior medullary velum and ends in the dorsal vermis. A lesser portion of the tract has been traced to the quadrigeminal bodies, while other groups of axones end in various levels of the gray substance.

The **spinothalamic** and **spinomesencephalic** (tractus spinotectalis) tracts are not gathered into compact bundles, but are rather scattered among the fibres of the lateral column just mesad of the superficial ventrolateral spinocerebellar tract (Gowers). The axones of both systems arise from cells in the dorsal horn and its cervix of the opposite side, coursing through the white ventral commissure and ascending the cord, the spinothalamic fibres ending in the thalamus, the spinomesencephalic fibres ending in the region of the quadrigeminal bodies. The two tracts are collectively called **tractus spinotectalis et thalamicus**.

The **crossed pyramidal tract** (*fasciculus cerebrospinalis lateralis*) occupies an approximately triangular or oval area in the dorsal portion of the lateral column, just mesad of the direct cerebellar tract, except in the lumbar cord, where it lies at the surface. The axones of this tract arise from the pyramidal cells of the cerebral cortex (motor area) of the opposite side. After having descended through the internal capsule, crura, pons, to the pyramis of the medulla oblongata, the major portion (85 to 90 per cent.) of the fibres derived from one-half of the brain decussate with those of the other half, crossing the median line to descend in the lateral column of the cord. The fibres which do not decussate constitute the direct pyramidal tract in the ventral column. As the crossed pyramidal tract descends it diminishes in size as its axones become distributed to the ventral horn, where they terminate either in contiguity with the ventral motor cells which give rise to the fibres of the ventral (motor) nerve roots, or else in contiguity with the dendrites of interposed neurones, which, in turn, convey the impulse to several associated motor neurones presiding over the actions of associated muscles. The bundle becomes exhausted as a distinct strand at the level of the fourth sacral segment.

The **rubrospinal, cerebellospinal, lateral vestibulospinal, and olivospinal tracts** consist of descending axones which are intermingled so that their mutual topographical relations cannot at present be described. Collectively they constitute the **fasciculus intermedius** of Löwenthal and Bechterew (intermediolateral tract of Bruce and Campbell) and they lie ventrad of the crossed pyramidal tract and mesad of the combined spinothalamic and spinomesencephalic tracts.

The **rubrospinal tract** (Monakow's tract; prepyramidal tract) originates in the red nucleus in the tegmentum of the mid-brain of the opposite side and its axones terminate in relation with ventral horn cells. In their course these fibres are seen to invade the area of the crossed pyramidal tract.

The **cerebellospinal tract** (Marchi's tract) is supposed to arise in the cortex of the cerebellar hemispheres, to become distributed to the motor centres in the ventral horn.

The **lateral vestibulospinal tract** arises in the lateral nucleus of the vestibular nerve (Deiters' nucleus), and by its relations with spinal centres establishes a connection with the equilibratory apparatus.

The **olivospinal tract of Helweg** (Helweg's Dreikantenbahn; Bechterew's Olivenbündel) is found only in the higher segments of the cord, at its periphery and just laterad of the emergence of the ventral nerve roots. Its connections and functional direction are uncertain; some investigators have traced its fibres between the olive and certain ventral horn cells; Obersteiner suggests a relationship with the pyramidal tract. The coincidence, in point of time, of the myelinization of both tracts is significant in this connection.

Several other descending tracts ending in the spinal cord and arising in higher centres like the corpora quadrigemina, central gray substance of the mesencephalon, and the cerebellum have been recently described by Held, Boyce, and Bechterew.

Ground Bundle of the Lateral Column (*fasciculus lateralis proprius*).—This lies in the concavity of the lateral aspect of the gray column and consists of axones of neurones having a purely commissural function. In the regions where the reticula is best marked it is subdivided into a group of smaller bundles by numerous glial septa.

In the **ventral column** are described the following tracts:

Descending:

1. Direct pyramidal tract.
2. Sulcomarginal tract.
3. Ventral vestibulospinal tract.

Associating:

1. Association axones between spinal centres and several cranial nerve nuclei.
2. Fasciculus ventralis proprius.

The **direct pyramidal tract** (*fasciculus cerebrospinalis anterior*) is the uncrossed portion of the pyramidal tract below the decussation in the medulla oblongata, and constituting only 10 to 15 per cent. of the fibre system arising in the motor cortex of the same side. It is a small, oblong bundle, as seen on trans-section, lying parallel with the ventral fissure, from which it is separated in the higher segments by the relatively narrow sulcomarginal tract. The tract diminishes in bulk as the cord is descended, to disappear in the thoracic portion of the cord; though, in rare instances, it has been observed to extend throughout the lumbar portion as well. This diminution and eventual disappearance of the tract is due to the successive decussation of its fibres throughout its course, for, with a few exceptions, these cross in the ventral white commissure to come into relation with the ventral horn cells (motor cells) of the opposite side. This partial longitudinal extension of the pyramidal decussation and consequent formation of an uncrossed, ventrally situated pyramidal tract is peculiar to the primate order of vertebrates.

The **sulcomarginal tract** (*tractus tectospinalis*) is a thin bundle whose axones arise in the corpora quadrigemina of the opposite side, immediately decussating and descending through the medulla oblongata, to be distributed to various spinal centres in a manner not yet accurately ascertained. This tract, which is most developed in the cervical region of the cord, is assumed because of its proximity to the lower optic, ocular muscle, and acoustic nuclei.

The **ventral vestibulospinal tract** (Löwenthal's tract; anterior marginal fasciculus; ventral cerebellospinal tract) lies at the periphery of the ventral column, extending, as seen on trans-section, from the ventral root zone to the ventral fissure. Its axones arise from (1) the lateral (Deiters') and (2) superior (Bechterew's) nuclei of the vestibular nerve; and (3) from the nucleus fastigii of the cerebellum. Their termination about the ventral horn cells has been traced as far as the sacral region of the cord.

As in the lateral column, and continuous with the like formation, there is in the ventral column an **intermediate zone** of mixed systems of axones which serve to associate various levels of the cord with ganglionic masses in the medulla oblongata, as well as with the cerebellum and corpora quadrigemina. The nuclei of the trigeminus, facial, auditory, glossopharyngeal, and vagus nerves, together with the olive and the cerebellum, seem most intimately associated with the spinal centres for movements of the head and neck.

Ground Bundle of the Ventral Column.—The white substance of the ventral column contiguous with the central gray is made up of intersegmental axones of association connecting different levels of the cord.

The **ventral (white) commissure** (*commissura anterior alba*) is composed of myelinic fibres which decussate with or cross each other and, on trans-section, are seen to form a narrow band connecting the ventral columns of the two sides. The axones composing it are chiefly (1) those arising from ventral horn cells, which after crossing the midline, course horizontally or cephalad and caudad to come into relation with neurones at the same or at different levels of the gray substance; (2) the decussating axones of the direct pyramidal tract; (3) numerous collaterals from the ventral and lateral column axones. The white commissure is most massive in the enlargements where the associations of the limb centres are necessarily greater in number.

Myelination of the Axones of the Cord.—The acquisition of the myelin sheath is not cotemporary for all axones in the cord, but is characterized by a regular progression in the myelination of separate fasciculi. As a rule, those axone systems which are concerned with simpler or intrinsically spinal reflexes become myelinic or "mature" at an earlier stage of fetal development than do those concerned in the more elaborate connections of the cord with the brain.

According to Flechsig and Trepinski the order of myelination is as follows:

- I. a, b. Ventral and dorsal roots during fifth month.
- II. a, b, c. Ground bundles and intermediolateral tracts during sixth month.
- III. a, b, c. Dorsal columns during fifth to seventh month.
- IV. Direct spinocerebellar tract, seventh month.
- V. Ventral spinocerebellar (Gowers') tract, seventh to eighth month.
- VI. Pyramidal (crossed and direct) tracts, at or soon after birth.
- VII. Olivospinal (Helweg's) tract, ninth month or later.

The order of myelination of the separate fasciculi is indicated in Fig. 614.

Summary.—The Gray Substance.—The gray substance consists, aside from its supporting tissues, of sentient and reacting nerve cells, with their dendrites and axones, and of the terminals of axones entering from without. These nerve cells may be classified as follows:

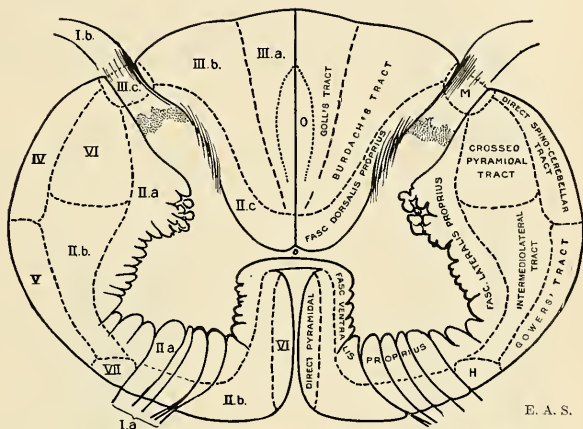
(a) Nerve cells whose axones pass directly out of the cord. These lie in the ventral horn, are "motor" in function, and their axones form the ventral nerve

roots. Certain nerve cells situated in the cervix of the ventral horn are believed to send splanchnic efferent axones in company with the motor axones in the ventral root, while very few similar efferent axones leave by means of the dorsal root.

(b) Nerve cells whose axones pass into the white substance, usually bifurcating into a shorter descending and a longer ascending branch. Two kinds of cells are distinguished:

1. Strand or tract cells whose axones (ascending branches) traverse the cord, to come into relation with higher centres in the brain.

2. Association cells whose axones, after a comparatively brief course in the white substance, reënter the gray substance and serve to coördinate different levels of the cord.



E. A. S.

FIG. 614.—Diagram showing the order of myelination of the various tracts in the spinal cord (cervical level). The tracts are named on the right side; the Roman numerals on the left side correspond with the enumeration given in the text. *H.*, Olivospinal tract of Helweg. *M.*, Marginal tract. *O.*, Oval tract of Flechsig.

The tract cells may be further divided into two categories—**homolateral** and **contralateral tract cells**. Homolateral cells are those whose axones enter the white columns of the same side; contralateral cells are those whose axones traverse the white (ventral) commissure to the other side. Tract cells exist in all parts of the gray substance, and are termed, according to their situation, **ventral**, **lateral**, and **dorsal horn cells**. The contralateral tract cells preponderate in the dorsal horn, its cervix, and in the intermediate zone, and, on account of their course, are also called **commissural cells**.

(c) Nerve cells of Golgi's type II, or cells with short, multibranched axones.

The motor ventral horn cells and the splanchnic efferent cells differ, therefore, from the other categories in that they alone send their axones out of the central axis to the periphery. The tract cells, commissural cells, and the Golgi type II cells are strictly confined to the central axis; the tract cells serve to coördinate the separate units of the spinal neurone system with higher centres; the association cells maintain the paths of conduction between higher and lower cell complexes; while the cells of Golgi's type II are limited to a narrower field of nerve activity as nerve links in the chaining together of neurones.

White Substance.—The white substance consists essentially of axones the great majority of which are disposed longitudinally. These axones comprise:

(a) Axones arising in the cerebral cortex, the gray ganglionic masses in the mid-brain, pons, and cerebellum, and descending to their terminations in different levels of the cord.

(b) Axones which, conversely, arise in the gray substance of the cord (tract cell axones), to terminate in the higher brain centres.

(c) Axones which coördinate different levels of the cord with each other (association cell axones).

(d) Axones which, arising from the spinal ganglion cells of the dorsal nerve roots, enter the cord and ascend in the dorsal columns.

Dissection.—To dissect the cord and its membranes it will be necessary to lay open the whole length of the vertebral canal. For this purpose the muscles must be separated from the vertebral grooves, so as to expose the spinous processes and laminae of the vertebrae; and the latter must be sawed through on each side, close to the roots of the transverse processes, from the third or fourth cervical vertebra above to the sacrum below. The vertebral arches having been displaced by means of a chisel and the separate fragments removed, the dura will be exposed, covered by a plexus of veins and a quantity of loose areolar tissue, often infiltrated with serous fluid. The arches of the upper vertebrae are best divided by means of a strong pair of cutting bone-forceps or by a rachitome.

Applied Anatomy.—*Contusion* of the spine may cause an effusion of blood or traumatic zonal inflammation of the spinal cord with paralysis which may disappear without surgical intervention. *Concussion* ("railway spine") is followed by temporary or rarely permanent impairment of function. *Punctured wounds* are usually caused by the knife, and are most commonly inflicted upon the cervical and upper thoracic divisions and more often involving one-half of the cord. The course is generally an aseptic one; operation is indicated when infection of the cord ensues or when there is a compression from hemorrhage. This may be relieved by lumbar puncture (p. 68) with a large needle. *Hemorrhage* into the substance of the cord (*hematomyelia*) usually occurs in the 4-6 cervical segments. If the hemorrhage is confined to the gray substance, there is wasting of muscle and anesthesia of the pectoral limb; the reflexes below the lesion are abolished. If the white substance is involved, paraplegia below the level of the lesion ensues. The cord may be injured by *fracture or dislocation of vertebrae* (p. 69). *Gunshot wounds* are usually of serious nature. Operation is indicated by symptoms of compression by the bullet or by fragments of bone. If the compression is due to accumulated blood, lumbar puncture may be resorted to.

The cord usually shares in the congenital malformation known as *spina bifida*, resulting from failure of coalescence of the margins or lateral ridges of the neural plate. The defect may be complete (*rachischisis totalis*) or confined to a few segments of the cord. *Tumors* of many varieties, originating in the vertebra, meninges, or even in the substance of the cord itself (glioma, tuberculoma, etc.), give rise to many sensor and motor disturbances which afford a clue to the localization of such growths as indicated on page 831. *Inflammation of the spinal cord (myelitis)* may follow any of the acute specific fevers, occasioning more or less complete paralysis and anesthesia. In *infantile spinal paralysis (acute anterior poliomyelitis)* due to an infection which results in the destruction of ventral horn (motor) cells and consequent permanent paralysis and nutritional disturbances of the limbs whose centres are thus affected. Further, the muscles which normally antagonize the affected groups of muscles tend to assume a state of spastic contraction. The deformity thus produced may be relieved by tenotomy, transplantation of tendons, or even amputation. *Syringomyelia* is a chronic condition in which an abnormal proliferation of the spinal neuroglia takes place, generally near the central canal and in the cervical enlargement, and later this mass becomes absorbed, leaving an irregular cavity in its place. This gives rise to a number of interesting symptoms, such as analgesia (or insensitiveness to pain), inability to distinguish between heat and cold, progressive atrophy of the muscles of the hands and arms, trophic changes in the bones and joints, and painless whitlows.

THE MEMBRANES OF THE CORD.

The membranes which envelop the spinal cord are three in number. The most external is the **dura**, a strong fibrous membrane which forms a loose sheath around the cord. The most internal is the **pia**, a cellulovascular membrane which closely invests the entire surface of the cord. Between the two is the **arachnoid**, an avascular membrane which envelops the cord and is connected to the pia by slender filaments of connective tissue.

The Spinal Dura (Dura Mater Spinalis) (Figs. 615, 617).

The spinal dura represents only the meningeal or supporting layer of the cranial dura. The endocranial or endosteal layer ceases at the foramen magnum dorsally, but reaches as low as the third cervical vertebra ventrad; below these levels its place is taken by the periosteum. The dura forms a loose sheath which surrounds the cord and the cauda equina, and is loosely connected with the vertebral periosteum and the ligaments by a quantity of lax areolar tissue and a plexus of veins, the **meningorachidian veins** (*plexus venosi vertebrales interni*). The space containing the fat and veins is called the **epidural space** (*cavum epidurale*). The situation of the veins between the dura and the periosteum of the vertebra corresponds therefore to that of the cranial sinuses between the endocranial and supporting layers. The dura is attached to the circumference of the foramen magnum and to the axis and third cervical vertebra; it is also fixed to the posterior

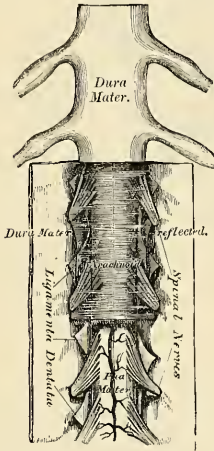


FIG. 615.—The spinal cord and its membranes.

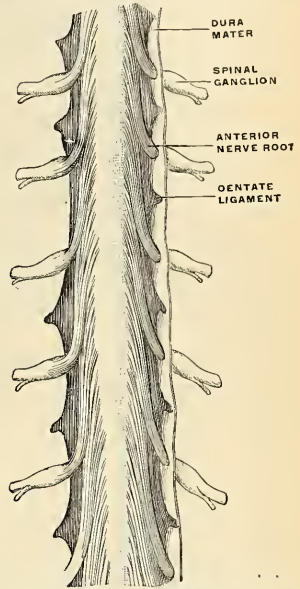


FIG. 616.—The dentate ligament. The dura has been opened and turned back. The ventral surface is seen. (Hirschfeld.)

common ligament, especially near the lower end of the spinal canal, by fibrous slips; it extends below as far as the second or third piece of the sacrum, where its cavity terminates, and, ensheathing the filum terminale, constitutes the **filum duræ matris spinalis** (Fig. 598), and descends to the dorsum of the coccyx, to blend with the periosteum. This part of the dura is called the **coccygeal ligament** (Fig. 617). The dura is much more capacious than is necessary for its contents, and its size is greater in the cervical and lumbar regions than in the thoracic. Its inner surface is smooth. On each side may be seen the double openings which transmit the two roots of the corresponding spinal nerve, the fibrous layer of the dura being continued in the form of a tubular prolongation on them as they pass through these apertures. These prolongations of the dura are short in the upper part of the vertebral column, but gradually become longer below, forming a number of tubes of fibrous membrane, which enclose the sacral nerves, and are contained in the vertebral canal.

The chief *peculiarities* of the dura of the cord, as compared with that investing the brain, are the following: The dura of the cord is not closely adherent to the bones of the vertebral canal, and is not, as is the cranial dura, the internal periosteum of the vertebræ. The vertebræ have an independent periosteum. It does

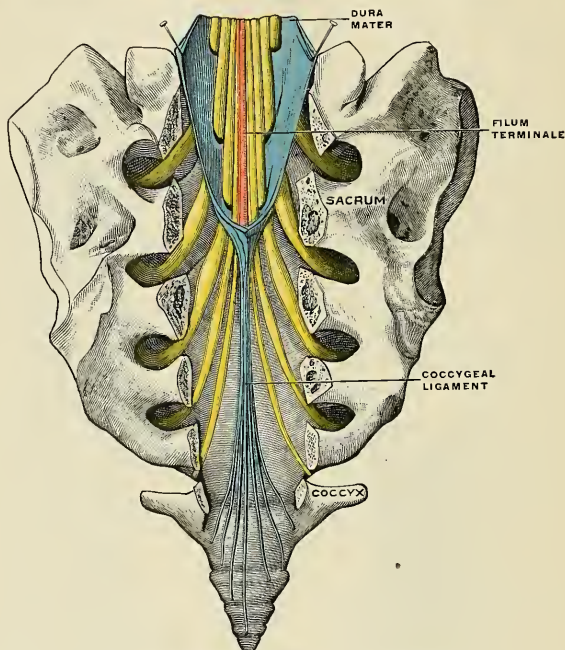


FIG. 617.—The filum terminale (schematic). (Poirier and Charpy.)

not send partitions into the fissures of the cord, as the cranial dura sends partitions into certain fissures of the brain. Its fibrous laminae do not separate to form venous sinuses, as in the cranium. It contains no arachnoid villi (*Pacchionian bodies*).

Structure.—The dura consists of white fibrous and elastic tissue arranged in bands or lamellæ, which, for the most part, are parallel with one another and have a longitudinal arrangement. Each surface is covered by a layer of endothelial cells. It is sparingly supplied with vessels, and some few nerves have been traced into it.

The Arachnoid (*Arachnoidea Spinalis*) (Figs. 596, 615).

The arachnoid is exposed by slitting the dura and reflecting that membrane to either side. It is a thin, delicate, tubular membrane which invests the surface of the cord, and is connected to the pia by slender filaments of connective tissue. Above, it is continuous with the cranial arachnoid; on each side it is continued on the various nerves, so as to form a sheath for them as they pass outward to the intervertebral foramina. The outer surface of the arachnoid is in contact with the inner surface of the dura, and the two are, here and there, joined together by isolated connective-tissue trabeculae. These trabeculae are especially numerous on the dorsal surface of the cord. For the most part, however, these membranes

are not connected together, and the interval between them is named the **subdural space** (*caelum subdurale*). The subdural space contains a very small amount of lymph-like fluid. *There is no communication between the subdural and the sub-arachnoid spaces.* The subdural space is prolonged laterad for a short distance on each emerging nerve and communicates with the lymph tract of the nerve. The inner surface of the arachnoid is separated from the pia by a considerable interval, which is called the **subarachnoid space** (*caelum subarachnoideale*). The space is largest at the lower part of the spinal canal, and encloses the mass of nerves which forms the cauda equina. Cephalad it is continuous with the cranial subarachnoid space, and communicates with the general ventricular cavity of the brain by means of openings in the pia, in the roof of the fourth ventricle, the **foramen of Majendie** or **metapore** and **foramina of Key and Retzius**. It contains an abundant serous secretion, the **cerebrospinal fluid**. This secretion is sufficient in amount to expand the arachnoid, and thus to distend completely the whole of the space included in the dura. The subarachnoid space is occupied by trabeculae of delicate endothelial-covered connective tissue, connecting the pia on the one hand with the arachnoid on the other. This is named **subarachnoid tissue**.

In addition to this the space is partially subdivided by a longitudinal membranous partition, the **septum posticum** or the **dorsal fenestrated septum**, which serves to connect the arachnoid with the pia, opposite the dorsomedian fissure of the spinal cord. It is a partition, but an incomplete and cribriform partition, which consists of bundles of white fibrous tissue interlacing with each other, and is coated with endothelium. The **dentate ligament** (*ligamentum denticulatum*), which runs from the pia to the dura on either side of the cord, divides the subarachnoid space into an **anterior** or **ventral** and a **posterior** or **dorsal space**, which joins like spaces in the cavity of the cranium. The **external spinal veins** (*venae spinales externae*) lie in the subarachnoid space.

Structure.—The arachnoid is a delicate membrane made up of closely arranged interlacing bundles of connective tissue in several layers. It contains many elastic fibers, and is covered on each side by endothelial cells. The arachnoid contains neither vessels nor nerves.

The Pia of the Cord (*Pia Mater Spinalis*).

The pia of the cord is exposed on the removal of the arachnoid (Figs. 615 and 616). It covers the entire surface of the cord, to which it is very intimately adherent, forming its neurilemma, and sending a fold into its ventral fissure. It also forms a sheath for each of the filaments of the spinal nerves, and invests the nerves themselves. A longitudinal fibrous band extends along the middle line on its ventral surface, the **linea splendens**; and a somewhat similar band, which forms the **ligamentum denticulatum**, is situated on each side. At the point where the cord terminates the pia becomes contracted, and is continued caudad as a long, slender filament, the **filum terminale** (Fig. 617), which descends within the sheath of the dura and the arachnoid and through the centre of the mass of nerves forming the **cauda equina**. It unites with the dura and arachnoid about the level of the third sacral vertebra, and as the **central ligament of the spinal cord**, the **coccygeal ligament**, or the **filum duræ spinalis** the fused membranes extend caudad as far as the base of the coccyx, where they blend with the periosteum. It assists in maintaining the cord in its position during the movements of the trunk. It contains a little gray nerve substance, which may be traced for some distance into its upper part, and is accompanied by a small artery and vein. At the upper part of the cord the pia presents a grayish, mottled tint, which is due to yellow or brown pigment cells scattered among the elastic fibres.

Structure.—The pia of the cord is less vascular in structure, but thicker and denser, than the pia of the brain, with which it is continuous. It consists of two layers; an outer, resembling the arachnoid, composed of bundles of connective-tissue fibres, arranged for the most part longitudinally; and an inner (*intima pia*), consisting of stiff circular bundles of the same tissue, which present peculiar angular bends. It is covered on both surfaces by a layer of endothelium. Between the two layers are a number of cleft-like lymphatic spaces which communicate with the subarachnoid cavity, and a number of bloodvessels which are enclosed in perivascular sheaths, derived from the inner layer of the pia, into which the lymphatic spaces open. The pia contains the **anterior or ventral spinal artery** and its branches, the two **posterior or dorsal spinal arteries**, and numerous veins which pass to the external spinal veins. It is also supplied with nerves, which are derived in part from the **sympathetic** and in part from the **cerebrospinal nerves**. These nerves supply the walls of the bloodvessels and enter the cord with the vessels.

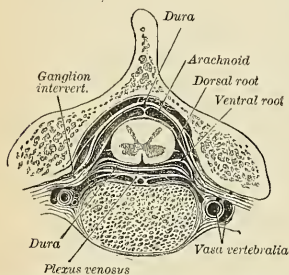


FIG. 618.—Transverse section of the spinal cord and its membranes. (Gegenbaur.)

Both the arachnoid and the pia may be referred to by the compound name **pia-arachnoid**, inasmuch as these meningeal components are with difficulty separable from each other.

The **dentate ligament** (*ligamentum denticulatum*) (Figs. 596 and 616) is a narrow, fibrous band, situated on each side of the spinal cord, throughout its entire length, running from the pia to the dura, and separating the ventral from the dorsal roots of the spinal nerves. It has received its name from the serrated appearance which it presents. Its inner border is continuous with the pia at the side of the cord. Its outer border presents a series of triangular, dentated serrations, the points of which are fixed at intervals to the dura. These serrations are twenty-one in number on each side, the first being attached to the dura opposite the margins of the foramen magnum between the vertebral artery and the hypoglossal nerve, and the last near the lower end of the cord. Its use is to support the cord.

Applied Anatomy.—Evidence of value in the diagnosis of meningitis may be obtained by the operation of **lumbar puncture**, that is, by puncturing the theca of the cord and withdrawing some of the cerebrospinal fluid, and the operation is regarded by some as curative, under the supposition that the draining away of the cerebrospinal fluid relieves the patient by diminishing the intracranial pressure. Lumbar puncture may give important diagnostic aid after a head injury by disclosing bloody cerebrospinal fluid. The operation is performed by inserting a trocar of the smallest size below the level of the fourth lumbar vertebra. In an adult the cord terminates at the lower border of the first lumbar vertebra, and in a child opposite the body of the third lumbar vertebra. The canal may be punctured below the fourth vertebra without much risk of injuring its contents. The point of puncture is indicated by laying the child on its side and dropping a perpendicular line from the highest point of the crest of the ilium; this will cross the upper border of the spine of the fourth lumbar vertebra. In a child the puncture is made just below this spine; in adults, one-half an inch to one side of the end of this spine. However the preliminary puncture is made, the needle penetrates the dura in the midline. In entering the needle it should be directed upward and forward in a child; upward, forward, and slightly inward in an adult.

THE BRAIN OR ENCEPHALON.

The brain is that greatly modified and enlarged portion of the cerebrospinal axis which, with its membranes, almost completely fills the cavity of the cranium. It is a complex organ in which reside the highest functions—consciousness, ideation, judgment, volition, and intellect—together with the centres of special sense and for the mechanisms of life (respiration and circulation), and it is the agent of the will.

General Appearance and Topography of the Brain.—Corresponding to the varieties of cranial form, the shape of the fresh or the successfully preserved brain varies from the ovoid to the nearly spherical form, as viewed dorsally. The frontal pole is usually narrower, though more squarely formed; while the parieto-occipital portion is more massive, but more sharply pointed in each half. The outline is often rather that of an irregular pentagon with its angles rounded off. A dorsal view (Fig. 672) shows only the extensive convex surface of the two great convoluted **cerebral hemispheres** (*hemicerebra*) separated by a median cleft, the **intercerebral fissure** (*fissura longitudinalis cerebri*). On divaricating the cerebral halves it is seen that the separation is not a total one, for in the depths of the fissure a broad commissural mass of white fibres—the **corpus callosum**—joins the cerebral hemispheres. Frontad the longitudinal fissure is continued to the ventral or basal aspect of the brain; caudad it passes into the *fissura transversa cerebri* (tentorial hiatus) or interval, separating the cerebrum from the cerebellum.

In a lateral view (Fig. 673) the continuity of the spinal cord with the medulla oblongata, then the pons and cerebellum are seen in part, overlapped by the cerebrum. Prominent is the temporal lobe with its rounded pole, separated from the frontal and parietal lobes by a deep cleft, the **syLVIAN fissure**, in whose depths—overlapped by the opercula of the adjacent lobes—lies the **island of Reil** or *insula*.

A ventral view (Fig. 619) presents many of the subdivisions of the brain. Here is seen the continuity of the spinal cord, with the short and slightly expanding **medulla oblongata** lying ventrad of the cerebellum and somewhat buried in its vallicula or depression between the lateral hemispheres, which alone are visible. The **cerebellum** is a grayish-colored mass of considerable size and easily recognized by its foliated appearance, due to the numerous parallel and closely set curved fissures. A mass of white fibres, the **pons**, passes transversely from one cerebellar hemisphere to the other, ventrad of the upper portion of the medulla oblongata. Above the pons are seen two large bundles, the **crura cerebri**, one on either side, diverging to pass into the cerebral halves. The interval between the divergent crura cerebri and temporal poles laterad and the orbital portions of the cerebrum frontad contains a number of important structures. Encircling the crura cerebri and meeting in the fore part of the fossa are the **optic tracts**, decussating in the median plane to form the **optic chiasm** and continuing frontad as the **optic nerves**. The arch of the optic tracts and optic chiasm and the crura cerebri enclose the **intercrural space**, in which may be seen (1) the **posterior perforated space** (*substantia perforata posterior*; *postperforatum*); (2) the **corpora albicantia** (*c. mamillaria*); (3) the **tuber cinereum** and the **stalk of the pituitary body**. A groove marking the lateral boundary of the fossa along each crus is termed the **oculomotor sulcus**, as the root fibres of the oculomotor nerve have their superficial origin therein. The **posterior perforated space** is a gray area with numerous minute apertures for the entrance of postperforant branches of the posterior cerebral artery. The **corpora albicantia** are two small, pea-like, white eminences closely set side by side. The **tuber cinereum** is a conical projection between the corpora albicantia and the optic chiasm, to which the hypophysis (pituitary body), resting in the sella of the sphenoid, is attached. In the removal of the brain from the skull the stalk of the hypophysis is usually torn through and an orifice, the **lura**, leading to the infundibular recess of the third ventricle, is thus exposed. In the interval between the optic tract and the orbital surface of each cerebral hemisphere is a small, depressed, triangular area of gray substance leading laterad into the basisylvian fissure and dotted with numerous apertures for the minute basal branches of the middle cerebral artery and called the **anterior perforated space** (*preperforatum*).

If the optic chiasm be drawn somewhat ventrad, a delicate gray lamina, the **lamina terminalis** (*terma*), is seen attached to the dorsal surface of the optic

chiasm and passing dorsad into the intercerebral cleft to the region of the anterior commissure.

Parallel to the mesal border of the orbital surface of each cerebral hemisphere lie the **olfactory tract** and **bulb**, torn away from the fila olfactoria as these pass through the lamina cribrosa of the ethmoid. The olfactory tract may be traced to its root area, the **olfactory trigone**, just frontad of the anterior perforated space.

The superficial origin of nearly all of the **cranial nerves** may be seen upon the basal aspect of the brain (Fig. 619). These nerves, their superficial attachments to the brain, and the foramen of exit in the skull are enumerated in the following table:

TABULATION OF THE CRANIAL NERVES, THEIR SUPERFICIAL ATTACHMENTS TO THE BRAIN, AND THE FORAMINA OF EXIT IN THE SKULL.

NERVE.	SUPERFICIAL "ORIGIN" OR ATTACHMENT TO THE BRAIN.	FORAMEN OF EXIT FROM THE SKULL.
I. Olfactory fila.	Olfactory bulb and tract.	Ethmoidal cribrosa.
II. Optic nerve.	Optic chiasm.	Optic foramen.
III. Oculomotor nerve.	Oculomotor groove along medial border of crus.	Sphenoidal fissure.
IV. Trochlear nerve.	Valve of Vieussens laterad of frenulum.	Sphenoidal fissure.
V. Trigeminal nerve.	Prelateral part of pons.	(a) Ophthalmic ramus, sphenoidal fissure. (b) Maxillary ramus, foramen rotundum. (c) Mandibular ramus, foramen ovale.
VI. Abducent nerve.	Postpontile groove (prepyramidal part).	Sphenoidal fissure.
VII. Facial nerve.	Postpontile groove (laterad of abducent nerve in preolivary part).	Porus acusticus internus; meatus acusticus internus; facial canal; stylomastoid foramen.
VIII. Acoustic nerve.	Postpontile groove (laterad of facial nerve).	Porus acusticus internus.
IX. Glossopharyngeal nerve.	Dorsolateral groove of medulla oblongata.	Jugular foramen.
X. Vagus nerve.	Dorsolateral groove of medulla oblongata.	Jugular foramen.
XI. Spinal Accessory nerve.	(a) Encephalic part: Dorsolateral groove of medulla oblongata. (b) Spinal part: Lateral column of spinal cord, between ventral and dorsal roots of cervical nerves as far as the fifth and sixth cervical nerves.	Jugular foramen.
XII. Hypoglossal nerve.	Pyramido-olivary groove.	Canalis hypoglossi ("anterior condylar foramen").

The olfactory, optic, and acoustic nerves are *afferent* or *sensor nerves*.

The trigeminal, glossopharyngeal, and vagus nerves are *mixed nerves*.

The oculomotor, trochlear, abducent, facial, spinal accessory, and hypoglossal nerves are *afferent* or *motor nerves*.

Dimensions.—The sagittal or occipitofrontal diameter of the white male adult brain averages 16 to 17 cm. (6.4 to 6.8 inches), the maximum width in the parietal region averages 13 to 14 cm. (5.2 to 5.6 inches), while the maximum height is about 12.5 cm. (5 inches). The dimensions of the female brain are usually somewhat less. The brains of dolichocephalic individuals are naturally longer and narrower than those of brachycephalic, and other differences in size and shape are found in conformity with the cranial configuration and other factors.

Weight of the Brain.—The average weight of the brain in the adult male is 1400 grams (49.5 ounces avoirdupois); that of the female, 1250 grams (44 ounces avoirdupois). Among 1500 brains of males the brain weights ranged from 960 grams to over 1900 grams; the great majority of this series ranged from 1250 grams to 1500 grams. The average weight in the newborn is 400 grams (14.1 ounces avoirdupois) in the male and 380 grams (13.4 ounces avoirdupois) in the female. The weight is doubled at the end of the first, and trebled at the end of the fourth or fifth year, the female brain growing less rapidly than the male brain. Brain growth generally ceases in the eighteenth or twentieth year, earlier in the female than the male. After the sixtieth year the brain loses weight, at first slowly, but more rapidly in advanced senescence. Other factors, besides age and sex, which influence brain weight are stature, body weight, cranial form, and race. Persons of large stature average heavier brains than those of short stature in absolute figures, but not relatively. Brachycephalic persons average heavier brains than the dolichocephalic. A most profound influence upon brain weight appears to be exerted by racial differences. Representatives of the white race have heavier brains than those of the other races, although data are not sufficient to make a positive statement. Thus, the few Eskimo brains that have been secured so far are notable for their size and weight. The following table gives approximately accurate averages based upon greater or less numbers of brain weights:

		Males.	Females.
White race	Germans	1425	1260
	Bohemians	1420	1290
	Scots	1420	1260
	Swedes	1415	1260
	Russians	1395	1260
	English	1380	1255
	Italians	1375	1240
	French	1360	1250
Japanese		1365	1215
Chinese		1360	
Negroes (various races)		1390-1200	
Hawaiians		1330	
Papuaans		1250	
Australians		1185	

The intellectual status is in some way reflected in the mass and weight of the brain. The average brain weight of 100 men eminent in the professions, arts, and sciences, with an average age of sixty-two years, was 1470 grams (nearly 52 ounces avoirdupois), exceeding the average weight of the ordinary population of about the same age by more than 100 grams (nearly 4 ounces avoirdupois). A further analysis shows that the brains of men devoted to the higher intellectual occupations, such as the mathematical sciences, involving the most complex mechanisms of the mind, those of men who have devised original lines of research, and those of forceful character are among the heaviest of all.¹

¹ See the editor's memoir: "A Study of the Brains of Six Eminent Scientists and Scholars, etc.," *Trans. Amer. Philos. Soc.*, xxi, iv, 1907.

The brains of the microcephalic idiots are far under the minimal size necessary for mental integrity, which is about 1000 grams (35 ounces avoirdupois) in the male and 900 grams (31.7 ounces avoirdupois) in the female. Certain idiotic individuals possess brains of normal size or even abnormally large brains, but structural defects underlie these forms of idiocy.

The whale, porpoise, dolphin, and elephant possess larger brains than man, but relative to the size and weight of the body the human brain is proportionately larger.

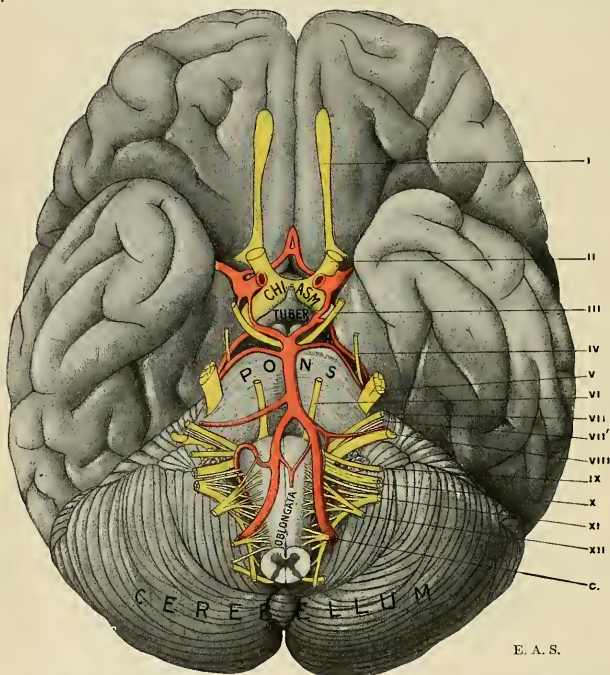


FIG. 619.—Basal aspect of the brain showing the superficial origin of the cranial nerves. The Roman numerals indicate the nerves.

The Development of the Brain and the Usual Classifications of its Subdivisions.—The cephalic region of the embryonic neural plate is characterized, as already pointed out (p. 804), by a rapid process of expansion and intensity of growth energy which seems to indicate the higher functional potentiality of what is to become the brain. The fusion of the margins of the neural plate, proceeding rapidly cephalad and caudad from about the cervical region, soon effects the complete closing in of the brain portion of the neural tube and its complete separation from the overlying ectoderm. For a brief period prior to the completion of the tube formation there exists a minute opening affording communication between the interior of the neural tube and the surrounding amniotic cavity; this temporary passage is called the **neuropore** (Fig. 620), and is morphologically the cephalic end of the tube. Its adult position is probably in the hypophyseal region.

The simple brain tube expands very early in intrauterine life in a sac-like manner, with the formation of three dilatations or pouches—the **primary brain vesicles**—demarcated by two constrictions.¹ The vesicles are designated respectively the

Fore-brain (Prosencephalon).

Mid-brain (Mesencephalon).

Hind-brain (Rhombencephalon or Metencephalon).

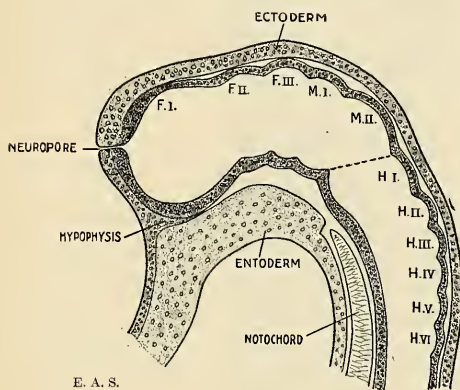


FIG. 620.—Brain tube of embryo salamander, sagittal section, showing neural segmentation (neuromeres): F. I.-III., Fore-brain neuromeres, M. I.-II., Mid-brain neuromeres, H. I.-VI., Hind-brain neuromeres. (Adapted from Kupffer.)

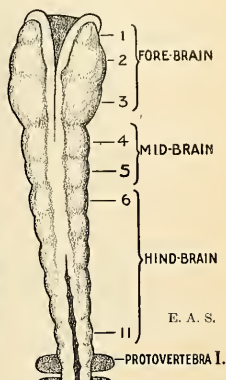


FIG. 621.—Brain tube of chick (25½ hours), showing partly closed brain tube with eleven folds or neuromeres. (After C. Hill.)

This classification has been found acceptable from every comparative standpoint in brain morphology, but attempts have been made to establish a further segmentation into definite anatomical divisions regarding which opinions and usages differ widely and have proved to be a hindrance rather than an aid to the homologization of brain structures in the vertebrate series. The difficulties in formulating a satisfactory schema of the segmental divisions of the brain will be overcome, perhaps, only by distinguishing the **neuromeres** or **neural segments** conforming to the general segmental plan of the vertebrate body. The existence of a neuromerism that is akin to the metamerism or serial segmentation of the body, or to the branchiomerism characterizing the arrangement of the branchial arches, is indicated in several ways, but thus far only the earliest embryonic

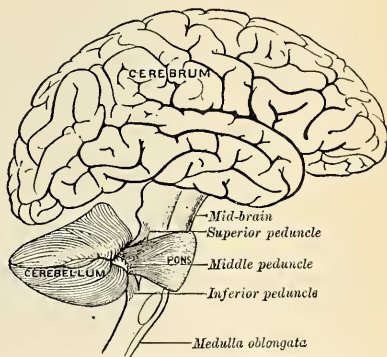


FIG. 622.—Scheme showing the connection of the several parts of the brain.

¹ The constriction between mid- and hind-brain has been called the *isthmus rhombencephali* by Prof. His, and he regards it as coordinate with the other segments recognized by him; the region, however, no more deserves a definitive segmental value than would the cephalic constriction even if it were dignified by the term *isthmus prosencephali*.

stages and the disposition of certain of the cranial nerves afford a clue to the definitive segmentation of the brain. According to the most recent researches, as many as eleven, sixteen, and even more neuromeres have been established in various vertebrate brains. The hind-brain alone shows from six to eight such neural segments (Figs. 620 and 621). The whole matter is yet so obscure that confusion will be avoided by restricting our description to the three primary divisions and their derivatives without insisting upon the recognition of further definitive segments proposed by various authors in consequence of preconceived ideas obtained from the complicated adult structure of the brain. At this transitional period the student is, however, obliged to be familiar with the commonly accepted—yet provisional—schemes of segmentation and a comparative view is given in the following table:

TABLE SHOWING COMPARISON OF THE SEGMENTAL SCHEMAS ADOPTED BY

The Anatomische Gesellschaft in 1895.		The Association of American Anatomists in 1897.	
<i>Partes ventrales.</i>	<i>Partes dorsales.</i>	I. RHINENCEPHALON.	
VI. TELENCEPHALON.		Bulbi olfactorii with their tracts; part of the aula and of the pre- commissure.	
Pars optica hypothalami.	{ Corpus striatum; rhinen- cephalon; pallium.	II. PROSENCEPHALON.	
		Palliums, connected by part of the aula and part of the precommissure.	
V. DIENCEPHALON.		III. DIENCEPHALON.	
Pars mammilaris hypothalami.	{ Thalamus; metathalamus epithalamus.	Thalami, including the chiasm; geniculate bodies.	
IV. MESENCEPHALON.		IV. MESENCEPHALON.	
Pedunculi cerebri.	Corpora quadrigemina.	Crura and quadrigeminum.	
III. ISTHMUS RHOMBENCEPHALI.		V. EPENCEPHALON.	
Pedunculi cerebri.	{ Brachia conjunctiva; ve- lum medullare anterius.	Cerebellum; pons; preoblongata.	
II. METENCEPHALON.		VI. METENCEPHALON.	
Pons.	Cerebellum.	Postoblongata.	
I. MYELENCEPHALON.			
Medulla oblongata.			

Brief Consideration of the Phases of Development of the Brain Tube.

I. **Fore-brain.**—The cephalic or fore-brain vesicle widens and expands most rapidly and attains to a comparatively large size even before the mid- and hind-brain vesicles become markedly defined. A series of remarkable developmental changes ensue in the following order: (a) **Optic vesicles** appear as two diverticula, each budding from either side of the primary fore-brain vesicle, their distal ends growing considerably and coming into contact with the overlying epidermis, while the proximal or attached ends assume a stalk-like shape. The distal sac-like end becomes invaginated and forms the retina of the eye, while the stalk upon obliteration of its cavity forms the optic nerve. It is necessary to state here that as development proceeds the optic stalks become relatively shifted caudad and form more intimate connections with the thalamus and mid-brain.

(b) A second pair of budding vesicles arises cephalad in the dorsal portion of the fore-brain vesicle and is destined to develop into the ponderous cerebral hemi-

spheres with their great ganglia, growing with great rapidity and exceeding in this respect all other parts of the brain. The growth of these **secondary fore-brain vesicles** is principally in the distal parts, and in this manner each forms a great pouch whose interior communicates with the primary neural cavity through a small opening, the **foramen of Monro** (porta). It must be remembered that in

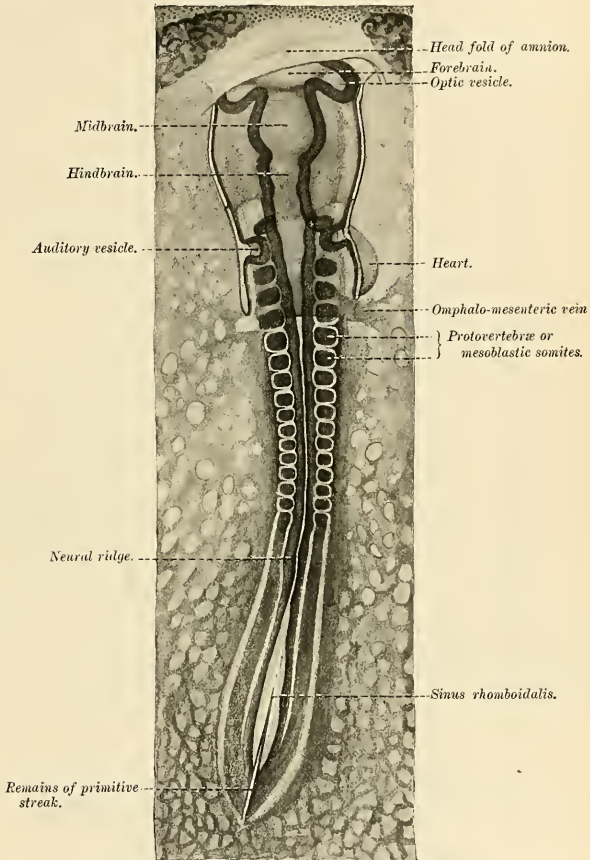


FIG. 623.—Chick embryo of thirty-three hours' incubation, viewed from the dorsal aspect. $\times 30$.
(From Duval's Atlas d'Embryologie.)

these initial stages the vesicles are all extremely thin-walled, but later the walls thicken or hypertrophy to a marked degree, so that the neural cavity becomes relatively small.

(c) Meanwhile (in the fourth week) the most cephalic portion of the fore-brain also becomes differentiated. As the enlarging vesicles of the cerebral hemisphere crowd upon the median, slower-growing portion, there is observed, on either

side, the development of a groove or furrow, the primary arcuate fissure, which demarcates the olfactory region (*rhinencephalon*) into a cephalic and a caudal portion. The cephalic portion develops into a blind tubular diverticulum, which grows cephalad to form the **olfactory bulb and tract**, its central cavity becoming obliterated (persistent in certain other mammals), while the caudal portion forms the roots of the olfactory nerves, the **anterior perforated space** or **preperforatum** and the **subcallosal gyre**.

(d) At the ventral margin of the hemispherical or secondary fore-brain vesicle an excessive proliferation of cells results in the production of several ganglionic masses—the **basal ganglia**, of which the largest are the **lenticular nucleus** (*lenticula*) and **caudate nucleus** (*caudatum*).

(e) The median cephalic terminal wall intervening between the large hemispherical vesicles persists as a thin and relatively undeveloped lamina, the **lamina terminalis**.

(f) The remainder of the fore-brain undergoes great hypertrophy in its lateral walls to form the **optic thalami**, while the ventral portion develops moderately to form the **hypothalamus**, **tuber cinereum**, **posterior lobe of pituitary body**, and **corpora albicantia**. The dorsal wall fails to develop, and remains epithelial except at a point immediately adjacent to the quadrigeminal lamina of the mid-brain; here a diverticulum grows out to form the **pineal body** or **epiphysis** (a rudimentary structure in man, but undoubtedly of functional use in ancestral vertebrates).

(g) The cavity of the primary fore-brain vesicle undergoes alterations in form as the secondary metamorphoses of its walls proceed in the course of development. The hollow cerebral buds so rapidly outstrip all other parts of the brain that their internal cavities, the **lateral ventricles**,

FIG. 624.—Plan showing the mode of formation of the ventricles of the brain and the central canal of the spinal cord: A. Prosencephalon. B. Thalamencephalon. C. Mesencephalon. D. Metencephalon. E. Myelencephalon. F. Central canal of cord. G. Lateral ventricle. H. Foramen of Monro. (After Gerrish.)

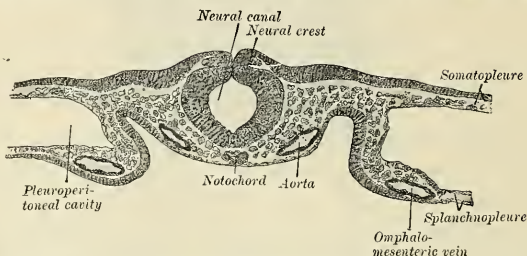
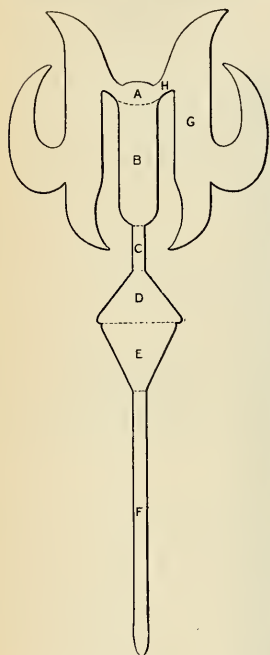


FIG. 625.—Transverse section of a portion of a chick embryo of twenty-nine hours incubation. (From Duval's Atlas d'Embryologie.)

become the most spacious of the ventricular system. The great hypertrophy of the thalamic ganglia in the lateral walls of the primary fore-brain determine the

sagittally placed, slit-like form of the so-called **third ventricle**. The cavities of the optic and olfactory buds become obliterated.

II. **Mid-brain**.—The second primary vesicle becomes somewhat later differentiated and takes a less prominent part in the adult brain. Its dorsal wall goes into the formation of four eminences, the **corpora quadrigemina**, while the lateral and ventral sections grow considerably to form the **crura cerebri**. The neural cavity within the mid-brain persists as the narrow **aqueduct** joining the third and fourth ventricles.

III. **Hind-brain**.—The third primary brain vesicle is demarcated from the mid-brain by a marked constriction to which has been given the term **isthmus rhombencephali**. The hind-brain is specially characterized by the great expansion of its thinned-out, membranous dorsal wall caudad, while cephalad the dorsal wall becomes very much thickened as the **proton** or "**anlage**" of the **cerebellum**.

The ventral and lateral parts undergo thickening to form the **pons** and **medulla oblongata**.

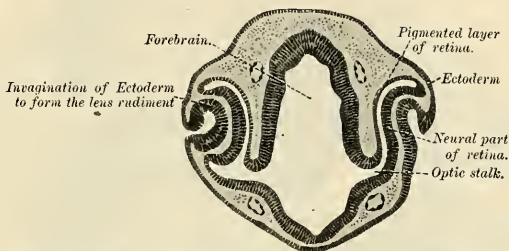

FIG. 626.—Trans-section of head of chick embryo of forty-eight hours' incubation. $\times 55$.
(From Duval's Atlas d'Embryologie.)

Flexures of the Brain Tube.—The difference in growth rate of the different parts of the brain tube and the marked disproportion between the rapid brain growth and slower head growth causes the encephalic neural tube to become sharply bent upon itself at certain points. The first flexure to occur is involved in a bending of the entire head and takes place in the region of the mid-brain; this flexure is termed the **cephalic flexure**. A second bending of the tube occurs at the junction of the spinal cord and hind-brain; this is termed the **cervical flexure**, and is so pronounced in the fifth week of intrauterine life that the brain tube and spinal cord form a right angle with each other. A third flexure is produced, in consequence of the other two, in the region of the future pons, and is therefore called the **pontile flexure**. Subsequently the cervical and pontile flexures are obliterated by a gradual straightening of this portion of the brain axis.

Dorsal and Ventral Laminae or Longitudinal Zones of the Brain.—Quite like the longitudinal division of the developing spinal cord, there is a differentiation of the brain tube into dorsal and ventral zones, though much less clearly shown. The limiting furrow between the two is not demonstrable in the fore-brain; at least it is disputed, on good grounds, that it exists there. It is claimed even that three such longitudinal divisions exist on each side (Kupffer) and the formation of the cranial nerves is not quite comparable to the spinal nerves, although there is a fair homology with their dorsal-sensor and ventral-motor functional differentiation, despite their frequent admixture in some cranial nerves or the total absence of the one category in others. Thus the motor elements do not extend higher than the mid-brain and the dorsal division preponderates in the more highly organized parts of the brain, becoming predominant in the higher vertebrate species—particularly in man.

In its simplest expression the brain is a tube like the rest of the central nerve axis, but a remarkably modified one. There is the same primitive ependymal

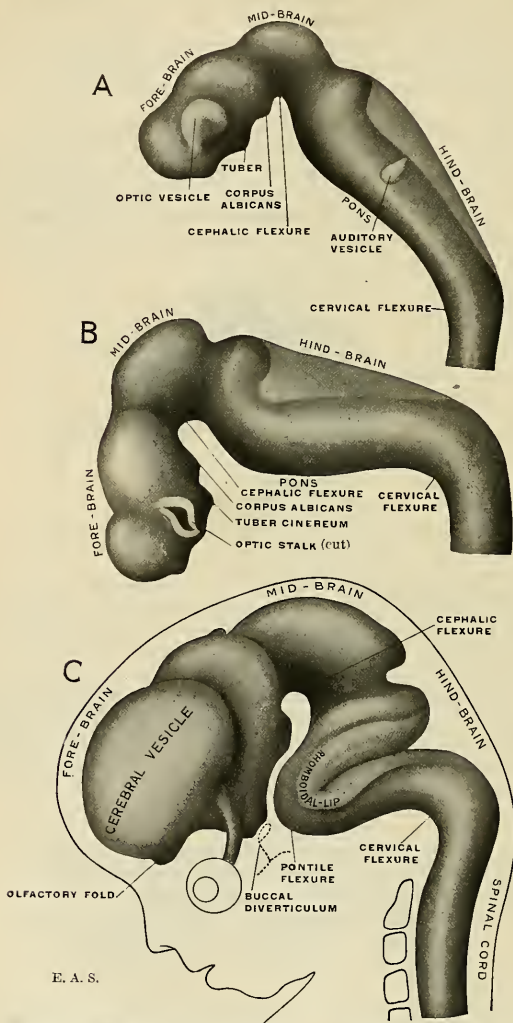


FIG. 627.—Profile view of the brain of human embryos at three several stages, reconstructed from sections. *A.* Brain of an embryo of about fifteen days. *B.* Brain of an embryo about three and a half weeks old. *C.* Brain of an embryo about seven and a half weeks old. (After His.)

lining throughout its interior; there is likewise a central tubular gray mass of ganglionic tissue which, however, undergoes nuclear differentiation in some

portions, atrophies in others, while in certain localities it is crowded away from the central cavity by the intrusion of white fibre masses which are chiefly commissural. A total atrophy occurs in a part of the dorsal wall of both fore-brain and hind-brain; partial atrophy is observable in the floor of the third ventricle, near the optic chiasm, once perhaps the optic centre in the earliest of the ancestral vertebrates, but atrophied in higher forms as the visual tract became secondarily projected in the thalamus and mid-brain. Great hypertrophy characterizes the growth of the ganglionic gray in the floor of the lateral ventricle (cerebral vesicle), resulting in the formation of nugget-like masses, the **caudate**, **lenticular**, and **amygdaline nuclei**. The central gray of the primary fore-brain also undergoes great hypertrophy, but in the lateral walls only, to form the large, compact thalami.

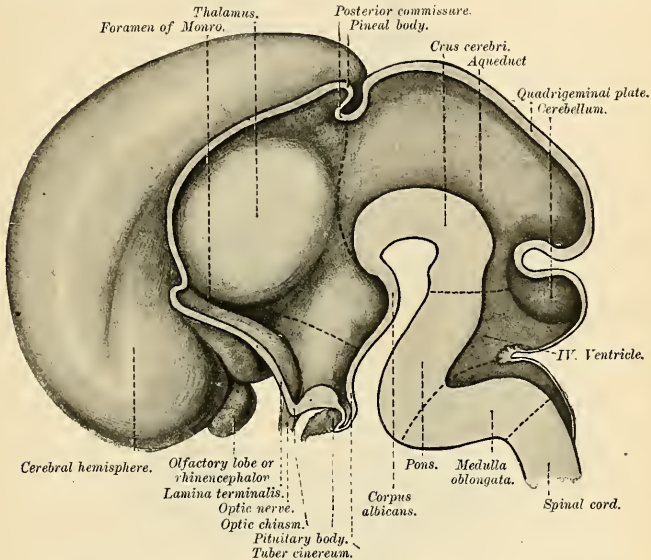


FIG. 628.—Median section of brain of human fetus during the third month. (After His.)

As in the cord, fibre masses develop ectad of the central tubular gray in some localities, while in other regions the ganglionic gray remains at the surface and the white conducting substance is developed on its inner aspect. Thus we have, secondarily, the formation of superficial gray substance as the **cortex** (or rind) of the cerebrum and cerebellum. The isolation of ganglionic gray masses from the primitive central tubular gray and their differentiation into nerve cell midi is also observable in the reticular ganglionic formation of the medulla oblongata and pons as well as in the roof of the mid-brain. Certain aggregations of gray ganglionic tissue are intercalated in the course of fibre strands, receive an admixture of these, and are regarded as terminal, interrupting, or as condensing stations not unlike some very complex relay telegraph system. The **olive**, **dentate nucleus**, **red nucleus**, the **nuclei of the gracile and cuneate funiculi**, the basketwork intercalations of the **reticular** and **lemniscus fields** belong to this intrafascicular type of ganglionic structures.

The plan of structure of the brain differs, therefore, from the comparatively simple arrangement of the gray and white substance in the spinal cord. In the brain the gray substance is not centrally situated throughout, and there is a tendency to nuclear differentiation of great and small ganglionic masses. These are connected with each other and with the centres in the cord by longitudinal strands of fibres of greater and less length, as well as by transverse associating fibres

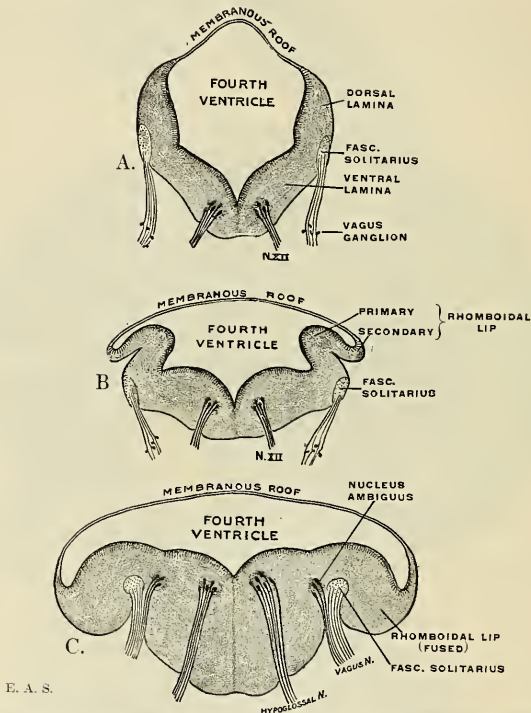


FIG. 629.—Three stages in the development of the medulla oblongata, showing the metamorphosis of the rhomboidal lip. (Modified after His.)

uniting the bilateral nuclei of the same ganglionic category; with the periphery they gain connection through the cranial nerves and (*via* the spinal cord) the spinal nerves.

In tracing the various structures of the brain from the medulla oblongata to the cerebral cortex we follow anatomically what nature has done in the evolution of the highest type of brain from that of the simplest and most ancient vertebrate. In the medulla oblongata lie the centres which exert a very direct influence over those of the entire cord. The striate bodies and the thalami form a connecting link between the higher cerebral cortex and the medulla oblongata and cord below. The extensive cerebral cortex, an aggregation of psychic centres and therefore the seat of the will, controls the activities of the fore-brain ganglia (corpus striatum, thalamus) and the cerebellar cortex, and these in turn preside over the functions

of lower centres, as in the way of motor responses to external impressions; such reactions may be delayed or immediate according to the exercise of the will power residing in the cerebral cortex.

This control by the will is intensified the higher we ascend the animal scale; the pyramidal tract, which originates in the cerebral cortex and threads its way to the motor centres of the spinal cord without interruption along the brain axis, is better developed in man than in any other animal. In the course of evolution the lower or more automatic ganglia and tracts remain relatively about the same in mass as in other mammalia, but the higher, more intellectual ganglia surpass these in growth, so that there is an apparent but not real diminution of the automatic systems observed in the human brain.

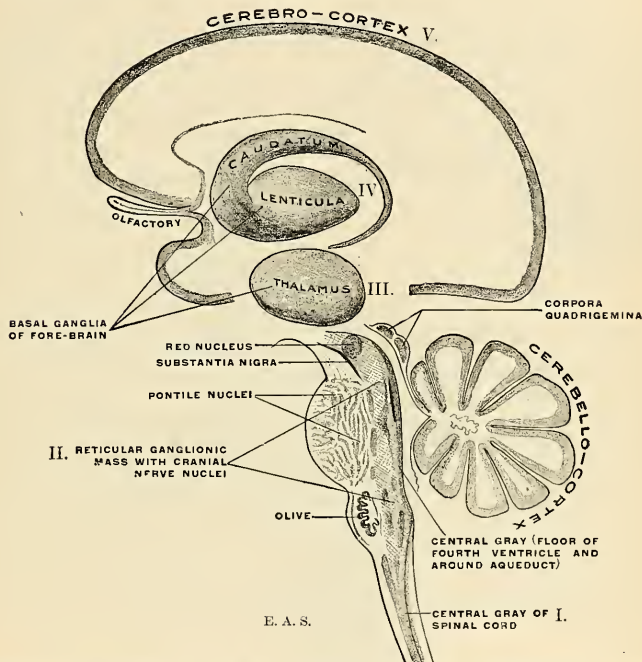


FIG. 630.—Schematic representation of the chief ganglionic categories (I to V). Accurate topographical relations and interconnections are shown in other figures.

It has been seen from the foregoing brief accounts of the development of the nerve system that the most prominent feature is the redundant growth of the cephalic or brain end of the neural tube. Comparative neuroanatomic researches have thrown much light upon the probable genesis of this remarkable characteristic. The ancestral vertebrate, built upon the segmental type, was a swimming animal, and its locomotion took place in the direction of its long axis. In its progress through the water the cephalic (or anterior) segments were those which first encountered the foreign objects floating in the same medium. It was for these segments to determine the quality of the objects encountered—whether

they were inimical or indifferent or beneficial to its individual ends. The sensor periphery, in consequence of the demands of evolution, underwent specialization in the development of olfactory and gustatory organs for testing the quality of the food and of the surrounding medium; optic organs for perceiving rays of light; auditory organs for the appreciation of certain oscillations of the surrounding medium; while others, strictly tactile in nature, underwent elaboration as such in the development of sensitive antennae or tentacles. Motor contrivances, useful in the quest for food or in encounters with the enemy, were developed in the way of powerful jaws and masticatory muscles. In brief, a remarkable specialization

and differentiation of structure attended the development of the head end, and with it the central organ of control kept pace. In the human species we find certain of these structural characteristics in a highly developed condition, while others have dwindled or disappeared in the course of evolution. Thus, in the myxinoid fishes and the lamprey the cerebral hemispheres themselves are mere appendages of the olfactory lobes; the sense of smell was probably the most important in lower animals. In the brain of man conditions are reversed and the olfactory system is seen to have dwindled to an extreme degree as compared with the immense size

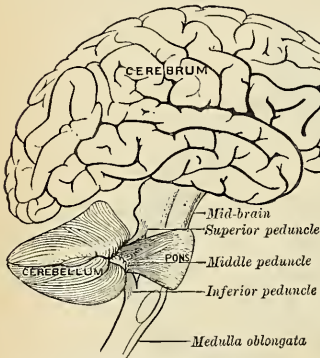


FIG. 631.—Scheme showing the connection of the several parts of the brain.

of the cerebrum; this in conformity with the relatively slight use made of the smell sense in the mental life of man. Other organs of special sense, however, became augmented, and these, together with the nerve mechanisms controlling the vital functions (respiration, circulation), required a more and more elaborate central nerve organ for the harmonious interaction of the several elements. This central organ or brain developed, in bulk and complexity, hand in hand with the increase of the intellectual faculties. Man's most manifest distinction from other animals has resulted from a remarkable evolutionary growth in brain size and brain power; and as the brain is the material organ of mental and moral manifestations, we find in mankind the highest degree of superiority and culture—not only as compared with the nearest related apes, but of the civilized and progressive races as compared with the primitive and unprogressive races.

DESCRIPTIVE ANATOMY OF THE ADULT HUMAN BRAIN.

Morphologically considered, the brain consists of a common trunk (or brain axis) from which the two cerebral hemispheres crop out like swollen terminal buds, while the cerebellum is an excrescence of the trunk itself. The axially situated brain axis or "brain stem"¹ comprises, roughly speaking, the axial parts of all

¹ Also "brain isthmus," a loosely used term. It may here be remarked that most extant accounts of the anatomy of the brain overemphasize the distinction of brain parts from each other. Some authors follow one or another system based upon the theories of the segmentation of the brain tube; others divide the brain into (a) rhombencephalon or hind-brain and (b) cerebrum, comprising mid- and fore-brain. None of the classifications proposed are, as already pointed out, quite satisfactory. The continuity of the parts can only be interrupted arbitrarily, and such procedure leads to a too narrow conception of brain structures single and apart rather than serial and connected.

three primary divisions of the brain tube—(a) **medulla oblongata**, (b) **pons**, (c) **mid-brain**, (d) **thalamic division of fore-brain**. In this brain stem lie the majority of the ganglionic masses enumerated above, together with the nerve tracts uniting the various cell nests in (presumable) automatic coördination as well as the great nerve tracts connecting the spinal gray with the cerebral hemispheres, the thalami, cerebellum, and the ganglia of the medulla oblongata (including the cranial nerve nuclei), and still other tracts connecting the medulla oblongata with the cerebral hemispheres, the cerebellum, and the special ganglia of the pons and mid-brain.

Parts Derived from the Hind-brain (Rhombencephalon). External Morphology.

The Medulla Oblongata (myelencephalon oblongata; spinal bulb; postoblongata of Wilder).—The medulla oblongata is the continuation cephalad of the spinal cord, the transition lying at the level of the foramen magnum and marked by the decussation of the pyramids. Its cephalic limit is sharply defined ventrad by the rounded margin of the pons, while its dorsal surface is sunk into the cerebellar vallecule. The length of the medulla oblongata along its ventral surface is $\frac{4}{5}$ to 1 inch (20 to 25 mm.); its maximum width at the pontile end is $\frac{3}{4}$ inch (17 to 18 mm.), and half as much at its transition into the spinal cord; its maximum

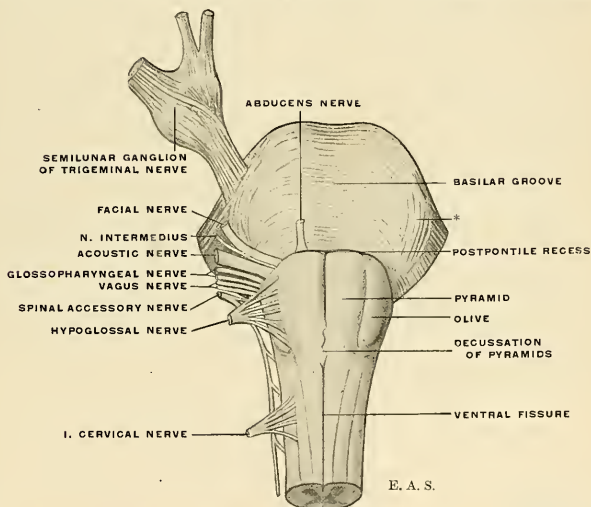


FIG. 632.—Ventral view of pons and medulla oblongata, showing the attachments of certain cranial nerves on one side. * The inter-radicular pons tract or corpus pontobulbare, described in the text.

thickness is about 15 mm. ($\frac{3}{5}$ inch). Its expansion as it approaches the pons gives it the form of a truncated cone. The ventral surface rests upon the basilar groove of the occipital bone.

Fissures.—The ventral and dorsal fissures of the cord are continued upon the medulla oblongata, making it a bilaterally symmetrical structure. The **ventral or ventromedian fissure** (*fissura mediana anterior*) at the level of the foramen magnum is interrupted by a number of obliquely intercrossing fibres, called the

decussation of the pyramids. Beyond this interruption the ventral fissure passes cephalad to end at the ventrocaudal border of the pons in a recess called the **postpontile recess** or **foramen cecum**.

The **dorsal** or **dorsomedian fissure** (*fissura mediana posterior*) is of short extent upon the medulla oblongata, for the neural cavity is here expanded into a rhomboidal fossa whose dorsal wall, profoundly atrophied, is represented only by a delicate membranous lamina; the dorsal fissure rapidly becomes shallower as it ascends, to cease at the caudal apex of the "fourth ventricle."

Like the spinal cord, the surface of each half of the medulla oblongata is divided into three longitudinal districts by fissures called the **ventrolateral** and **dorsolateral fissures**. Of these, the latter only is a continuation of the fissure of the same name in the spinal cord.

The **ventrolateral fissure** (*sulcus lateralis anterior*) of the medulla oblongata demarcates the ventral column (pyramid) from the lateral column as well as the olive, and the roots of the hypoglossal nerve, arranged in linear order, emerge from this fissure.

(The ventrolateral fissure of the spinal cord becomes obscured as it ascends into the oblongatal region, for cephalad of the emergence of the ventral roots of the first cervical nerve a band of superficial arcuate fibres usually obliterates all traces of the furrow.)

The **dorsolateral fissure** (*sulcus lateralis posterior*) of the medulla oblongata is directly continuous with the same-named fissure of the spinal cord, and the root bundles of the spinal accessory, vagus, and glossopharyngeal nerves are attached along the bottom of this fissure. Unlike the dorsal roots of the spinal nerves, the root bundles of these three cranial nerves are not all composed of afferent fibres arising in extraneous ganglionic cells and entering the medulla oblongata, for the accessory nerve is purely efferent and the vagus contains both afferent and efferent fibres.

Areas.—The ventrolateral and dorsolateral fissures with their rows of nerve fascicles divide the surface of the medulla oblongata on each side into three districts which appear to be continuous with the three columns of the spinal cord; they are not so in reality, however, owing to the rearrangement of the fibre tracts and the central ganglionic mass in the myel-oblongatal transition. This portion of the brain axis is sculptured into several eminences and depressions; of the eminences, some, like the olives, the tubercula cineræ, and the clavæ, are due to the accumulation of gray substance beneath the surface at that point; others, like the pyramids and restiform bodies, are due to the prominence at certain points of the surface of the great nerve tracts.

AREAS OF THE MEDULLA OBLONGATA.

- I. Ventral Area:
Pyramid.
- II. Lateral Area:
(a) Lateral tract.
(b) Olive.
- III. Dorsal Area, marked by slight furrows dividing it into:
(a) Funiculus gracilis.
(b) Funiculus cuneatus.
(c) Funiculus lateralis and tuberculum cinereum.

The last three structures mentioned appear to become fused cephalad to continue as the **restiform body** or **restis**; in reality the restiform body is formed in a different manner.

I. The **Pyramids** (*pyramides medullae oblongatae*) constitute the oblongatal portion of the direct cerebrospinal efferent tracts conveying (voluntary) motor impulses from the precentral cortex, through the internal capsule, crista, and ventral pons to descend in the crossed and direct pyramidal tracts to the efferent (motor) cell groups in the ventral horns of the spinal gray. In their external appearance in the medulla oblongata they are moderately constricted at their pontile ends, appear to become somewhat expanded, to again taper as they pass, partly into the ventral columns of the cord, partly, by decussation, into the lateral columns. The pyramids are separated from each other by the ventral (or ventromedian) fissure except where this is more or less completely obliterated by the decussating bundles. Each pyramid is bounded laterally by a slight furrow, the **ventrolateral or pyramido-olivary groove**, in which arise the hypoglossal nerve roots and which separates the pyramid from the olive. The pontile end of each pyramid is frequently traversed by a band of arched fibres (*fibrae arcuatae externae*); ponticulus of Arnold (not the ponticulus of Henle), the **ectal arcuate fibres**.

The **decussation of the pyramids** (*decussatio pyramidum*) is a term given to the obliquely intercrossing bundles seen at the oblongata-mylon transition. The extent to which this decussation occurs and the degree of its visibility varies in different individuals. While in most cases the majority (90 per cent.) of the fibres cross the median line in this decussation to continue as the crossed or lateral pyramidal tract, it is sometimes observed that a larger share of the fibres pass into the direct or uncrossed pyramidal tract with a corresponding reduction of the crossed tract. Occasionally the decussating bundles are so deeply situated in the ventral fissure as not to be visible.

II. The **Lateral Area** of the medulla oblongata is continuous with that of the spinal cord, and is bounded by the dorsolateral and ventrolateral fissures. It is composed of the **tract of Gowers** (*fasciculus anterolateralis superficialis*), the **ventrolateral ground bundle** (*fasciculus proprius anterolateralis*), and the **direct spinocerebellar tract** (*fasciculus cerebellospinalis* [Flechsig]), while it is invaded from above by the crossed pyramidal tract. The olive is interpolated in the cephalic part of this area.

The **olive** (*oliva*; olivary body) is a prominent, elongated oval mass bulging from the cephalic part of the lateral area of the medulla oblongata, bounded by shallow grooves, of which one, for the hypoglossal nerve roots (ventrolateral fissure) separates it from the pyramid, while the other, containing the nerve fascicles of the vagus, glossopharyngeal and spinal accessory nerves, separates the olive from the restiform body. From the pons it is separated by a shallow groove in which a band of arched fibres is sometimes seen. Numerous white fibres (**external or ectal arcuate fibres**) emerging from the ventral fissure and traversing the pyramid loop across the lower parts of the olive to enter the restiform body. The olive is formed by the olivary nucleus, embedded in a thin layer of white substance.

The olive is about 12 mm. ($\frac{1}{2}$ inch) in length and 5 mm. ($\frac{1}{5}$ inch) in breadth.

III. **Dorsal Area.**—(a) The **funiculus gracilis** is the direct continuation of the tract of the same name in the spinal cord. It is a narrow white band placed along the dorsomedian fissure, and separated from the funiculus cuneatus by the **dorso-paramedian furrow** (*sulcus intermedius posterior*). At the caudal apex of the rhomboidal fossa (fourth ventricle) each funiculus gracilis diverges from the median plane, presenting at this point a club-like enlargement, the **clava**. The prominence of the funiculus gracilis (and clava) is due to the gray **nucleus funiculi gracilis** beneath the surface.

(b) The **funiculus cuneatus** is the direct continuation of the tract of the same name in the spinal cord. It enlarges as it ascends, exhibiting a slight eminence or enlargement, the **cuneate tubercle**, which is marked only in the medulla oblongata of young individuals, and is due to the **nucleus funiculi cuneati** beneath the surface.

(c) The **funiculus lateralis** is a longitudinal prominence which gradually enlarges cephalad into a slight tubercle, the **tuberculum cinereum**, marking the approach of the gelatinosa to the surface so as to form a prominence at a level with the lower border of the olive.

The **restiform body** (*corpus restiforme*; *restis*) occupies the upper dorsolateral area of the medulla oblongata on each side, lying between the floor of the fourth ventricle and the roots of the vagus and glossopharyngeal nerves. This structure might at first glance appear to be the continuation of the three funiculi just described. But as a matter of fact it is made up of the **direct spinocerebellar tract**, a set of **external or ectal arcuate fibres** (*fibrae arcuatae externae*) and a set of **internal or ental arcuate fibres** (*fibrae arcuatae internae*). Each restiform body assists in forming the lower part of the lateral boundaries of the fourth ventricle and then enters the cerebellum as the inferior peduncle of that body.

The Pons (*pons* [*Varolii*]).—The pons is a prominent white mass on the ventral aspect of the brain stem which is interposed between the medulla oblongata and the crura cerebri. It is convex from side to side, and its fibres, running chiefly in a transverse arched direction, are gathered into rounded, compact strands on either side, to continue as the middle peduncles into the white substance of the corresponding cerebellar hemisphere. The fibre bundles of the pyramidal tracts thread their way through the pons on either side of the median plane and small aggregations of gray substance (*nuclei pontis*) are packed in the intervals between the transverse pontile and longitudinal pyramidal fibre bundles.

The **Basilar or Ventral Surface** of the pons is in relation with the basilar process of the occipital and the dorsum sellae of the sphenoid. A shallow mesal groove lies between the eminences produced by the pyramidal tracts in their course through the pons. The groove is called the **basilar groove** (*sulcus basilaris*), as the basilar artery is usually accommodated in it; the artery is not, however, a factor in the production of the groove. The large sensor and small motor root bundles of the **trigeminal nerve** pierce the mass of the pons near the anterior pontile border, and a line drawn from this nerve root to that of the facial nerve is usually employed as an arbitrary boundary between the pons proper and the middle peduncle of the cerebellum. The **abducent nerve** emerges from the posterior pontile border (prepyramidal part); the **facial** and **acoustic nerves** are attached farther laterad.

While most of the superficial fibre bundles of the pons are seen to arch transversely, certain small compact bundles¹ are seen to extend in an obliquely longitudinal direction from the region of the trigeminal nerve root to and among the roots of the facial and acoustic nerves.

The Pars Dorsalis Pontis (*pars metencephalica medullae oblongatae*; preoblongata).—The pars dorsalis pontis, or tegmental part, is not sharply demarcated from the medulla oblongata or the tegmentum and crusta of the mid-brain, and the margins of the pons on the ventral surface afford only arbitrary boundary lines; for in the vertebrate series the pons varies greatly in width and its margins can hardly be accepted as the boundaries of a definite brain segment. The dorsal surface of the pars dorsalis pontis is continuous with that of the oblongatal ventricular surface, and its description more properly belongs to a consideration of the anatomy of the fossa rhomboidalis or “floor of the fourth ventricle.”

Fourth Ventricle of the Brain (*ventriculus quartus*).—In a previous section on brain development it has been pointed out how the growth changes and differentiations in the hind-brain differ from those of the rest of the neural tube in that there is a marked disproportion in the degree of growth in the dorsal and ventral walls. While the ventral wall thickens greatly throughout to form the pons-oblon-

¹ Called the *inter-radicular pons tract* by E. C. Spitzka (1884), and more recently described as part of the *corpus pontobulbare* by Essick (American Journal of Anatomy, vii, 1).

gata, the dorsal wall hypertrophies in its cephalic portion to form the cerebellum, while caudad thereof the roof atrophies and expands from side to side, corresponding as to be represented merely by a thin epithelial membrane. The outward folding of the walls of the neural tube in this region creates an expansion of the central cavity in the form of a rhomboidal fossa roofed in by the cerebellum and a thin epithelial layer. A time-honored custom enumerates this as the fourth of a system of ventricles of which the other three lie in the fore-brain.

A cast of the cavity (Fig. 696) shows it to be irregularly pyramidal, with a lozenge-shaped base and ridge-like apex extending from side to side, corresponding to the acute-angled **recessus tecti** in the fastigium ("gable roof") formed by the valve of Vieussens and inferior medullary velum. Such a cast also indicates the ventral extension of the cavity from the lateral angles of the rhomboidal base in the form of the **lateral recesses**.

It is customary to describe for the fourth ventricle a **roof** and a **floor**, although an examination of a sagittal section of a brain hardened *in situ* shows the floor to be in a *vertical plane in the erect attitude*. Caudad the cavity is continuous with the minute central canal of the spinal cord and postoblongata (in part); cephalad it passes into the aqueduct or mesocele. The dorsal wall or "roof" is formed

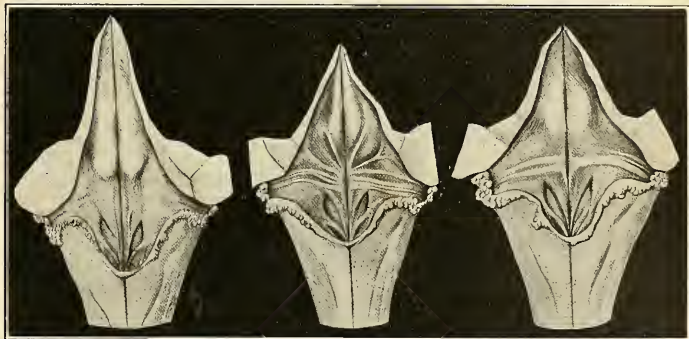


FIG. 633.—Varieties of fourth ventricle.

by the **valvula** (*velum medullare anterius*), the **superior peduncles**, **tela choroidea ventriculi quarti**, and **fastigium of the cerebellum**. The ventral wall or "floor" is the **rhomboidal fossa** occupied by the expanded central gray of the pre- and post-oblongatal portions of the hind-brain.

"Floor" of the Fourth Ventricle (*fossa rhomboidea*).—The "floor" of the fourth ventricle is lozenge-shaped and exhibits regional elevations, depressions, and color differences which are in relation with the deep anatomy of the medulla oblongata and tegmentum of the pons (preoblongata). It is divided longitudinally into symmetrical halves by a median groove, and each lateral half is subdivided into a larger cephalic and a smaller caudal triangle by white, transverse striae, composed of bundles of myelinic fibres connected with the acoustic tract and appearing to sink beneath the surface near the median groove. The portion occupied by these **striae acusticae** (*striae medullares*) is termed by His the **pars intermedia** as distinguished from the **pars superior** and **pars inferior**, or frontal and caudal triangles respectively. Much variation is met with in regard to the course and degree of prominence of the striae acusticae (Fig. 633). There may be none visible or as many as twelve distinct bundles; bilateral symmetry is the exception, and not infrequently one or more bundles run obliquely cephalolaterad—the striae

obliquae (conductor sonorus). This irregularity of the acoustic striæ has led to another mode of division of the "floor" for descriptive purposes—each side to be divided into a median and a lateral area, indicated by a more or less well-marked groove, the *lateral furrow* (*sulcus limitans*), connecting the superior and inferior (*ala cinerea*) foveæ. This groove probably corresponds to one of the interzonal sulci of the embryonic tube, and in a gross way it separates the motor and sensor fields of the "floor." The median area is usually a continuous ridge which is quite accentuated in the cephalic division as the *eminentia abducentis*, while caudad it becomes narrowed as it approaches the closed part of the medulla oblongata. The convergence of the median and lateral furrows at the caudal apex of the rhomboidal fossa gives the appearance of the point of an ancient writing reed or quill pen; hence the term *calamus scriptorius*.

In the caudal quarter triangle a middle area is occupied by an elongated triangular field whose depressed apex is directed frontad. A slight oblique ridge, the *funiculus separans*, composed chiefly of neuroglia, separates the *area postrema* caudally from the *trigonum vagi* or *ala cinerea* of a pronounced grayish color. The whole depression has been termed the *fovea inferior*. Mesally lies a narrow triangular field with its apex directed caudad and with slightly raised surface—the *trigonum hypoglossi*. This area is resolved into two fields by a single or double formation of oblique rugæ affording a "feathered" appearance to the lateral field, the *area plumiformis*. Laterad of the *trigonum vagi* lies the caudal portion of the lateral area of the "floor," also called (in part) the *area vestibularis* (*area acustica*) and crossed over its middle by the *striae acusticae* when these are present. The *area vestibularis* is an irregularly triangular raised surface with its convex base toward the median line, and extending laterally to the attachment of the *tela choroidea* and into the lateral recess. In the fetus and in certain lower vertebrates the area is more prominent and is designated the *tuberculum acusticum* s. *vestibularis*.

The "frontal" division of the floor or triangular quarter-field is marked by a depression at about its middle, the *superior fovea* (*fovea trigemini*), from which the slight "lateral furrow" runs caudad, and but for the intervention of the striæ would reach the inferior fovea. Cephalad of the superior fovea, and continuing some distance along the aqueduct, is the *locus caeruleus*, which owes its color to the refraction of the pigmented cells, the *substantia ferruginea*, by the milky-white ependyma. At this altitude, the medial elevation between the superior fovea and the median sulcus is accentuated into a fairly pronounced eminence, the *eminentia abducentis* (*eminentia medialis*; e. teres), overlying the nucleus of the abducent nerve and the genu of the root of the facial nerve. The portion of the median sulcus intervening between the *eminentia abducentia* is correspondingly depressed to form the *fovea mediana*.

The ventricular features enumerated above correspond in a crude way to the deep structures of the pons-oblongata, and most of the cranial nerve nuclei are held in a rhomboidal frame formed by the superior and inferior peduncles. The surface markings are only imperfect replicas of the subjacent structures; the various cell nests overlap each other more or less and their relations can best be studied in the projection drawing in Fig. 634.

Membranous Portion of the "Roof" of the Fourth Ventricle.—The caudal extension of the hypertrophied cerebellum hides from view the whole of the rhomboidal fossa, but this structure, as before stated, forms but a part of the actual dorsal wall or "roof." This includes the converging *superior peduncles*, the *velum medullare anterius* intervening between these, the *fastigium of the cerebellum*, the *velum medullare posterius*, and the *tela choroidea ventriculi quarti*.

The *velum medullare posterius* is a thin and narrow lamina of white substance continued laterad as the *flocculi* of the cerebellum. At its caudal edge, *i. e.*, where nerve tissue ceases, the ependymal or ventricular lining epithelium and the

pia over this portion coalesce to form a delicate membrane—the *tela choroidea*—attached along the caudolateral boundary line of the rhomboidal fossa. Along this attachment there is another intrusion of nerve substance between the ependymal and pial layers; this reinforced lamina is usually termed the *ligula* and may be traced to the clava and cuneate tubercle, thence laterad over the restiform body to bound the lateral recess. The structure is probably a vestige of the secondary rhomboidal lip and has actually been found to be a part of the pontobulbar body referred to above. Another small semilunar lamina of nerve tissue bridges the caudal apex of the fourth ventricle and is called the *obex*. This structure is often devoid of nerve tissue, and is then a mere membranous lamina.

Except in rare instances, the *tela choroidea* is perforated a short distance from the calamus region. The opening is of variable shape and size; it permits of communication between the ventricular cavity and the subarachnoid space and is termed the *foramen of Majendie* (*apertura medialis ventriculi quarti*; metapore).

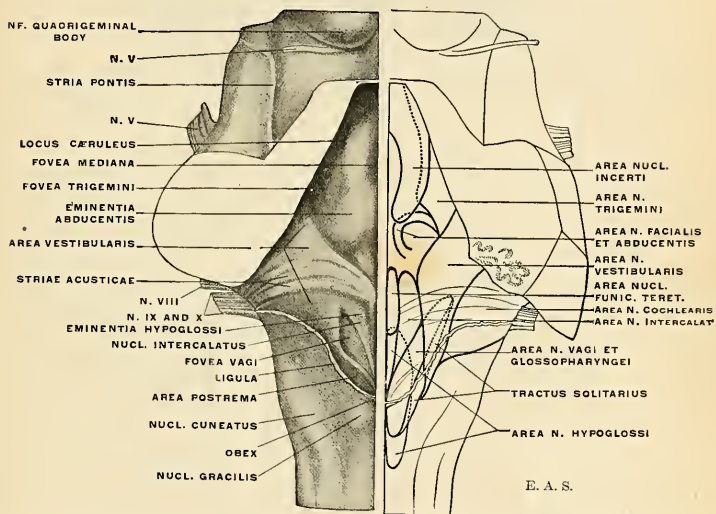


FIG. 634.—Surface markings and topography of the principal nuclei of the floor of the fourth ventricle. (Modified from Streeter.)

Similar apertures at the extremities of the lateral recesses, and called the *foramina Luschkae* (*apertura lateralis ventriculi quarti*) also permit of a tidal flow of the cerebrospinal fluid.

The choroid plexuses of the fourth ventricle (*metaplexuses*) are highly vascular infoldings of the *tela choroidea*, one on either side of the median plane, from each of which offshoots extend laterad into the lateral recesses. As the choroid plexuses of the brain are always formed by infoldings or invaginations of the membranous portions of the brain tube, the ependymal continuity upon them is interrupted only at the margins of the foramina.

Internal Structure of the Medulla Oblongata.—While the spinal cord remains a closed tube with centrally situated gray, the medulla oblongata opens out on the dorsal aspect so as to uncover its part of the neural canal as the “floor” of the fourth

ventricle. This involves a tilting of the functionally differentiated gray segments and, after a gradual transition in the medulla oblongata, the **motor gray** is to be

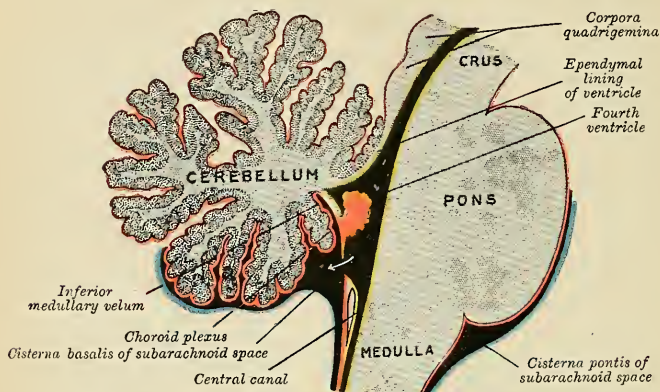


FIG. 635.—Scheme of roof of fourth ventricle. The arrow is in the foramen of Majendie.

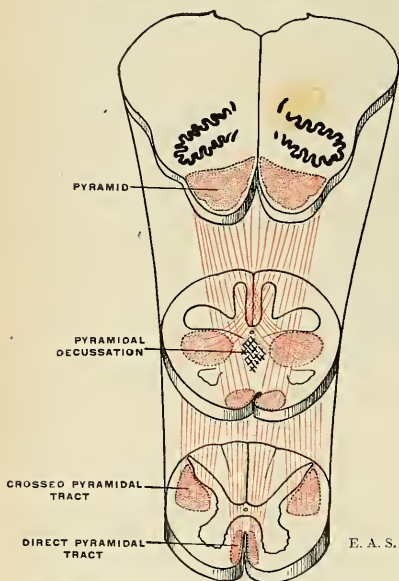


FIG. 636.—Schema of the pyramidal decussation

sought nearest the middle line, the **mixed gray** just ectad, while the **sensor** is the outermost of all. Instead of the ventral, lateral, and dorsal horns of each half of the spinal cord, we have an **ental**, **middle**, and **ectal cornu** in each half of the medulla oblongata. The positions alone have changed; the functional relations to nerve roots having corresponding functions are homologous. Thus, the motor hypoglossal nucleus is placed in the mesal part of the ventricular floor, while the terminal nuclei of the afferent vagus, glossopharyngeal, and auditory nerves lie in the lateral part.

Another cardinal change in the internal structure of the medulla oblongata, accompanying the preponderating development of the cerebrum and great basal ganglia, is caused by interrupting and decussating fibre systems which seek passage through the brain stem and encroach more or less on its primitive architecture.

While in the spinal cord there is a perfect continuity of the central tubular gray, we find in the medulla oblongata more pronounced peninsular and isolated insular nuclei or ganglionic gray masses.

Pyramidal Decussation (*decussatio pyramidum*).—An important change in the internal structure is caused by the passage of the fibres of the pyramidal tract as these pass to the same and opposite sides of the cord, the latter category forming the pyramidal decussation. In consequence of this passage of white (crossed

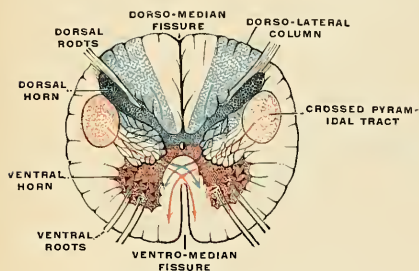


FIG. 637.—Transverse section of the medulla oblongata at its lower end. (Testut.)

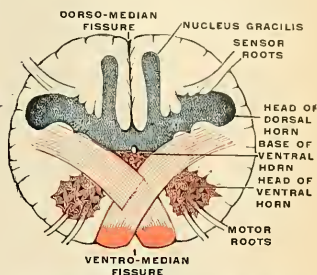
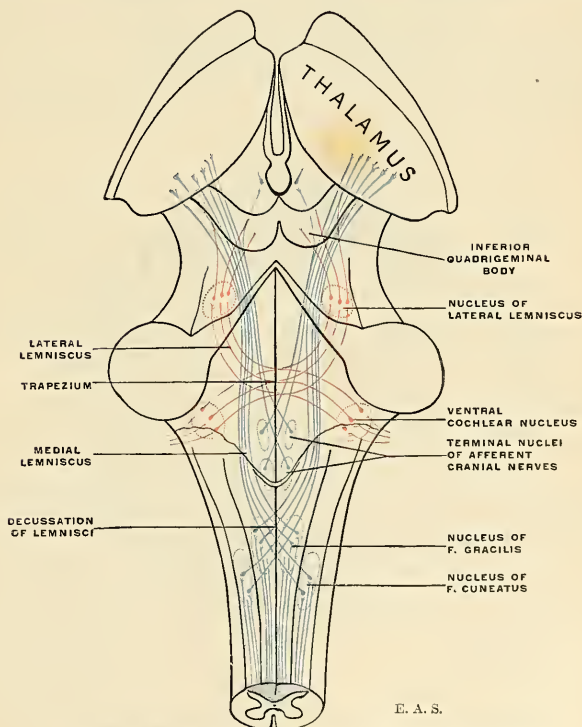


FIG. 638.—Transverse section of the medulla oblongata at the decussation of the pyramids. (Testut, after Duval.)



E. A. S.

FIG. 639.—Diagram showing the course of the lemnisci (fillets) and their decussation.

pyramidal) fibres through its substance the ventral gray horn is broken up into a coarse network, while one portion of it, the **caput cornu**, is entirely separated from the rest; only a small portion of the base of the cornu remains intact close to the ventrolateral aspect of the central canal. The caput cornu, thus separated, is displaced laterally, and comes to lie close to the caput cornu dorsalis, which has also shifted its position. In consequence of this breaking up of the greater part

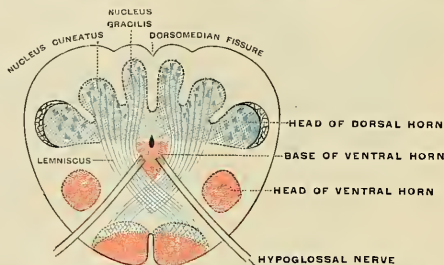


FIG. 640.—Transverse section of the medulla oblongata at the crossing of the lemnisci or fillets. (Testut.)

of the ventral gray cornu by white fibres a coarse network is formed in the anterior and lateral areas of the medulla oblongata, which is named the **formatio reticularis**.

The **gelatinosa Rolandi** (*glia cornualis*) of the dorsal horn is continued into the oblongata, but becomes insignificant, relatively, in the pars dorsalis pontis. The spinal root of the trigeminal nerve is in ectal relation with the gelatinosa Rolandi; at higher levels the spinal root of the vestibular nerve intervenes.

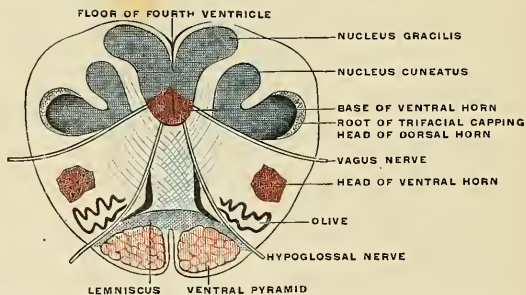


FIG. 641.—Transverse section of the medulla oblongata at the lower end of the olives. The roof of the fourth ventricle is not represented. (Testut, after Duval.)

Decussation of the Lemnisci (fillets).—A similar change, dorsad and cephalad of the pyramidal decussation, is caused by the decussation of axone bundles arising in the nuclei of the gracile and cuneate fasciculi (Goll and Burdach). At this level the base of the dorsal gray cornu undergoes change in the form of two thick dorsal peninsular outgrowths which form the nuclei of termination of the axones in the gracile and cuneate fasciculi; externally these gray masses produce the eminences of the clava and cuneate tubercle. The axones from these nuclei stream mesad and cephalad in a series of concentric arches, decussating in the raphé with the bundles of the opposite side to form the **decussation of the lemnisci**¹ or **sensor decussation**. Cephalad of this decussation the lemnisci are two bundles of fibres coursing on either side of the raphé between the olives, and just dorsad

¹ Also called "mesal lemnisci" in contradistinction to the "lateral lemnisci"—of different origin.

of the pyramids; their further course toward the cerebrum will be described farther on.

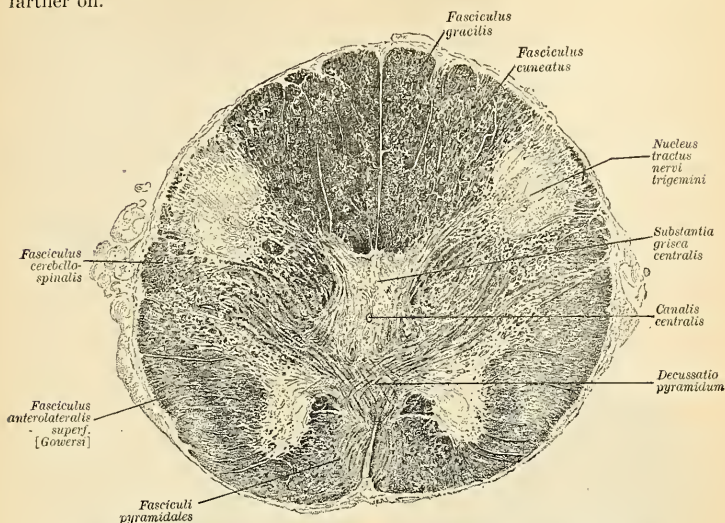


FIG. 642.—Trans-section of the medulla oblongata at the decussation of the pyramidal tracts.

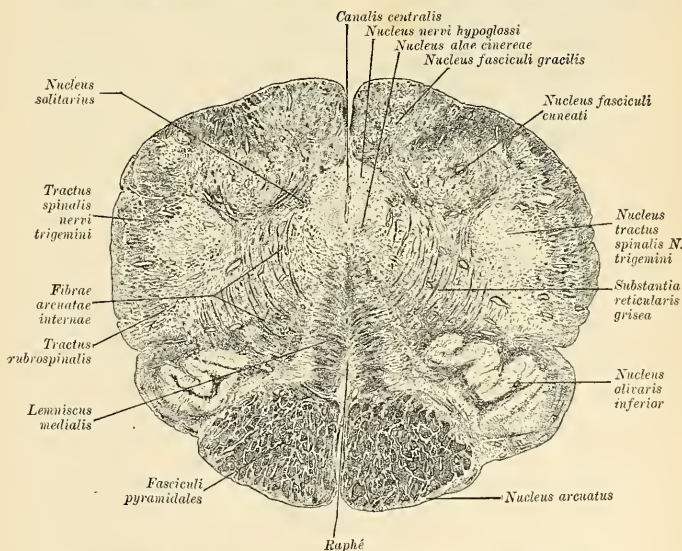


FIG. 643.—Trans-section of the medulla oblongata at the lower end of the olives.

With the extension of the central gray to form the floor of the fourth ventricle, the caput cornu dorsale is displaced ectad so as to almost reach the surface,

where it forms a projection, the **funiculus lateralis (Rolandi)**, which enlarges cephalad into a distinct prominence, the **tuberculum cinereum**. At a higher level the caput is separated from the surface by the **spinal root of the trigeminal nerve** and by the **external arcuate fibres** (Fig. 644). The cervix of the cornu becomes broken up into a reticular formation by the decussating fibres. A portion of the base is placed ectad of the nucleus funiculi cuneati and is called the **accessory cuneate nucleus**, supposed to be a continuation of Clarke's column.

The **formatio reticularis** (Fig. 644) consists of diffusely scattered gray substance in a meshwork of white fibres. It is far more abundant in the medulla oblongata than in the cord. In trans-sections of the medulla oblongata it is seen to be divided by the hypoglossal nerve root fascicles into a mesal and a lateral field. In the mesal field the gray substance is scanty, and white fibres—principally longitudinal ones—preponderate; this is called the **formatio reticularis alba** in contradistinction to the lateral grayer reticulated field, the **formatio reticularis grisea**. Its numerous nerve cells mostly possess short axones and for the most part exercise associative

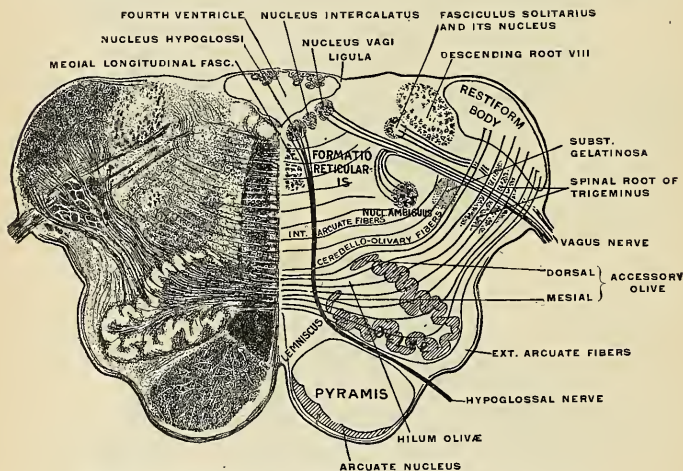


FIG. 644.—Trans-section of the medulla oblongata at about the middle of the olive.

functions for the constantly active centres of respiration (nuclei of the vagus, phrenic, facial, etc.). Certain axones of longer course are collected into a small compact bundle just ventrad of the ventricular floor and central canal (and aqueduct in the mid-brain), and known as the **medial longitudinal fasciculus** (posterior longitudinal bundle). This tract is in intimate association with the cranial nerve nuclei. The **formatio alba** is principally made up of this tract and the **lemniscus** (interolivary stratum).

The **raphé** (Fig. 644) is situated in the middle line of the medulla oblongata above the decussation of the pyramids. It consists of nerve fibres intermingled with nerve cells. The fibres have different directions, which can only be seen in suitable microscopic sections, thus: (1) Some run dorsoventrad; these are continuous with the external or superficial arcuate fibres. (2) Some are longitudinal; these are derived from the arcuate fibres, which on entering the raphé change their direction and become longitudinal. (3) Some are oblique; these are continuous with the internal or deep arcuate fibres which pass from the raphé.

The nerve cells of the raphé are multipolar; some are connected with the dorso-ventral fibres, others with the superficial arcuate fibres.

The **restiform body** succeeds the *gracile and cuneate nuclei* in the dorsolateral part of the medulla oblongata. Its fibres converge from various sources and ultimately enter the cerebellum as its inferior peduncle. For a description of these fibre systems see the section on the "peduncles of the cerebellum."

The **nucleus of the olive** or **inferior olivary nucleus** (*nucleus olivarius inferior*) is a corrugated lamina of gray substance whose extent nearly corresponds to that of the external elevation called the olive. It can be compared to a hollow oval sac or purse, slit on its mesal aspect and the edges of the slit everted. The opening is called the hilum. Numerous fibres stream into the interior through the hilum, while others cut through the lamina to join the fibre arches of the reticular field and then pass toward the restiform body.

What are known as **accessory olivary nuclei** (*nuclei olivarii accessorii*) are smaller detached or semidetached portions of the olivary nucleus named, according to their position, the **dorsal** and **medial accessory olivary nuclei** (*nuclei olivarii accessorii, dorsalis et medialis*).

The olivary nuclei play an important part as relay stations in cerebellar connections. A considerable mass of fibres, the **olivocerebellar fibres** (*fibrae cerebello-olivares*), originate in the olivary nucleus of one side to enter the cerebellum along the restiform body of the opposite side. A much less number of fibres, running contrariwise, reach the olivary nuclei from the opposite cerebellar hemispheres—the **cerebello-olivary** (*vestibulo-olivary tract*) **fibres**. Each olivary nucleus is the terminus of the thalamo-olivary fibres, and Helweg's olivospinal tract is believed to originate therein.

The Arcuate Fibre Systems.—The arcuate fibre systems comprise two sets of fibres according as they course dorsad or ventrad of the olivary nuclei:

1. The **internal** or **deep arcuate fibres** comprise the olivocerebellar fibres, just described, and a number of commissural systems for the association of the tegmental reticular gray ganglia and cranial-nerve nuclei. Others pass cerebralward, others to the cerebellum.

2. The **external** or **superficial arcuate fibres** take origin (*a*) from the gracile and cuneate nuclei and enter the restiform body of the same side; (*b*) from the same nuclei of the opposite side, decussating in the raphé and sweeping ventrad over the pyramid and olive, forming a thin layer over them and ultimately reaching the restiform body. Many of these fibres are interrupted, on each side, in the **nucleus arcuatus**, a thin, isolated lamina of gray substance lying on the ventral aspect of the pyramid.

The **nucleus lateralis** is seen in the lateral column (lower part of medulla oblongata) as a diffuse gray mass lying between the gelatinosa Rolandi and the olive; it gradually disappears cephalad.

The **nucleus intercalatus** (*of Staderini and Van Gehuchten*) forms the elongated, wedge-shaped elevation in the medial triangle of the caudal portion of the ventricular floor called the **area plumiformis** (p. 869); the nucleus derives its name from its (intercalated) position between the hypoglossal and dorsovagal nuclei. Its functional connections are not yet precisely known.

A **nucleus postremus** has been described (J. T. Wilson) as lying subjacent to the area postrema.

The **nucleus funiculi teretis** lies close to the median sulcus in the altitude of the acoustic striæ, and seems to bear an intimate relation to these.

Summary of the Gray Masses in the Medulla Oblongata:

*Central tubular gray (in "closed" part).

*Gray floor of fourth ventricle (in "open" part).

*Gelatinosa Rolandi or gliosa.

*Nucleus funiculi gracilis.

- *Nucleus funiculi cuneatus.
- *Nucleus funiculi cuneati accessorius.
- *Nucleus lateralis.
- *Nucleus olivaris inferior.
- *Nucleus olivaris accessorius dorsalis.
- *Nucleus olivaris accessorius medialis.
- *Nucleus arcuatus.
- Nucleus nervi hypoglossi.
- *Nucleus intercalatus.
- *Nucleus postremus.
- Nucleus vagi (alae cinereae).
- Nucleus vestibularis (spinal division).
- *Nucleus funiculi teretis.
- Nucleus ambiguus.
- Nucleus tractus solitarii.
- Nucleus tractus spinalis n. trigemini.
- *Formatio reticularis.

In the foregoing enumeration of the gray masses of the medulla oblongata, those marked with an asterisk have been described above; the remaining structures relate to the deep connections of the cranial nerves, and will be discussed in detail under that head.

Internal Structure of the Pons and Pars Dorsalis Pontis.—Trans-sections of the pons also pass through the tegmental part of the pons. To consider first the

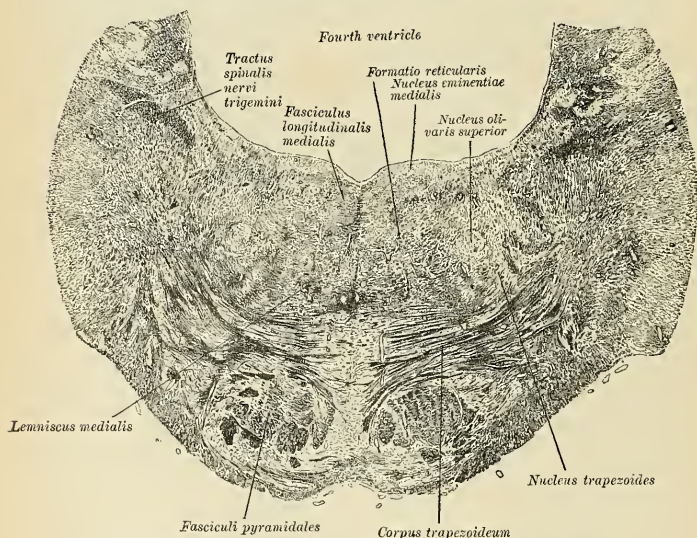


FIG. 645.—Trans-section of the pons at its middle, showing the trapezoid body.

internal structure of the pons proper (or *pars basilaris pontis*): The pons is composed chiefly of (1) transverse fibres arranged in coarse bundles, (2) longitudinal fibres gathered in compact bundles, and (3) diffusely scattered masses of gray substance among the fibre bundles, the nuclei pontis.

The transverse fibres, corresponding to the large size of the cerebellum, are more

abundant in man, relatively, than in any other animal. They form a massive series of bundles coursing ventrad of the brain axis from one cerebellar hemisphere

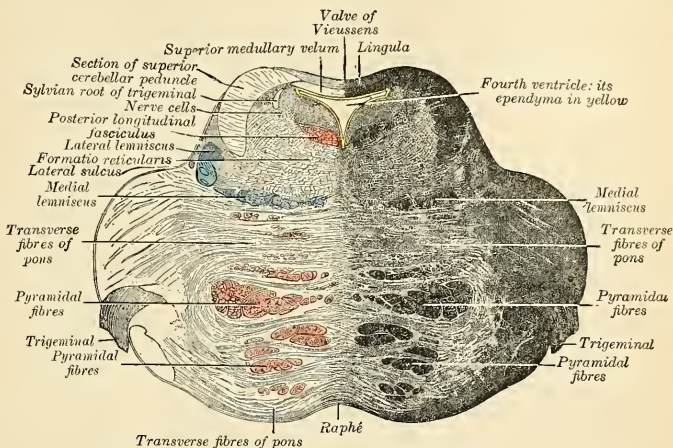


FIG. 646.—Section of the pons, at its upper part.

to the other. At the caudal border of the pons they embrace the pyramidal tracts as well, but farther cephalad the transverse pontile fibres are seen to intersect

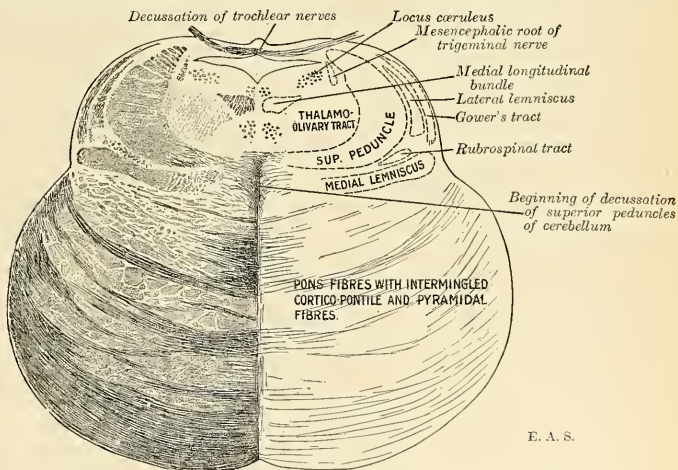


FIG. 647.—Section of the pons near its junction with mid-brain. (Higher level than Fig. 646.)

the pyramidal tracts, breaking these up into pyramidal fasciculi; still farther cephalad the pyramidal tracts are wholly embedded in the mass of transverse pontile fibres, so that these in turn, with reference to the location of the pyramidal

tracts, may be divided into a superficial and a deep set. Laterad they are gathered together to form the middle peduncles (described on p. 890).

The **longitudinal fibres** consist chiefly of the pyramidal tracts, which are solid strands at their entrance to and exit from the pons, but are broken up into lesser bundles at its middle. A certain number of the pyramidal fibres, as well as other cerebropontile fibre tracts, terminate in relation with the cells of the nuclei pontis, as well as certain of the efferent cranial nerve nuclei. This fact accounts for the demonstrable diminution in bulk of the pyramidal tract in its course through the pons.

The **nuclei pontis** are small aggregations of gray substance (which in serial sections show them to be continuations of the arcuate nuclei) diffusely scattered among the fibre systems of the pons proper. They are intercalated in the course (1) of tracts passing from one cerebellar hemisphere to the other, and (2) of descending cerebropontile tracts. The cells of the pontile nuclei send their axones chiefly to the opposite cerebellar hemisphere and play an important part as links in the complex chain of the neurone systems which make the cerebellum such an important organ of sensomotor coördination.

In the contact zone of pons proper and the pontile tegmentum lies a group of transversely decussating fibres with interspersed gray masses with large cells called the **trapezium**. This body will be more fully described in connection with the central auditory paths.

The **tegmental part of the pons** is of much smaller bulk than the pons proper, as seen on trans-sections. On the dorsal surface is spread a layer of gray substance covered by ependyma, which forms the floor of the cephalic part of the fourth ventricle. Beneath this gray substance lies the **formatio reticularis** divided into symmetrical halves by the raphé—continued from the medulla oblongata. Embedded in the formatio reticularis are various isolated masses of gray substance and various more or less compact fibre tracts. Among the gray masses are several of the cranial nerve nuclei, to be described in a separate section, and the following:

The **superior olivary nucleus** (*nucleus olivarius superior*) is a small gray mass or aggregation of several smaller masses situated laterad of the trapezium, intercalated in the path of the trapezial fibres and forming a link in the central acoustic chain (Fig. 651).

The **nucleus incertus** (Streeter) is an aggregation of gray substance in the floor of the fourth ventricle near the median sulcus and forming a slight, rounded elevation which extends to the aqueduct. Its functional relations are unknown.

Fibre Tracts in the Pars Dorsalis Pontis.—Among the fibre tracts in the tegmental part of the pons the chief ones are (1) the **medial lemnisci**, (2) the **lateral lemnisci**, (3) the **medial longitudinal bundle**, and (4) the **superior peduncles of the cerebellum**.

Each **medial lemniscus**, or **medial fillet**, in its passage through the tegmental part of the pons is gathered into a compact, ribbon-like bundle along the contact zone of the tegmentum and pons proper, lateroventrad of the trapezium, some fibres of which traverse it on their way toward the raphé. The medial lemniscus has been described in the medulla oblongata as occupying the field between raphé and inferior olivary nucleus (the interolivary stratum); in its ascent the medial lemniscus gradually trends laterad, so that it almost reaches the surface (Figs. 639 and 647).

The **lateral lemniscus** is a constituent of the central auditory path, and will be described more fully on pages 881 and 898. In trans-sections above the level of the trigeminal nuclei the lateral lemniscus is seen as a flattened band spreading over the surface (externally the **trigonum lemnisci**) ectad of the superior peduncle. Its fibres are interrupted by an intercalated **nucleus of the lateral lemniscus**.

The **medial longitudinal bundle** (posterior longitudinal bundle) maintains its position just ventrad of the central gray, close to the raphé.

The **superior peduncle of the cerebellum** or **prepeduncle** is seen in trans-sections

to be a very compact bundle of crescentic outline with the concavity turned toward the ventricular cavity. Its dorsomesal edge is joined to the superior medullary velum; its ventral border is sunk into the tegmentum, and in its ascent it becomes submerged laterally beneath the lateral lemniscus, dorsally beneath the quadrigeminal plate of the mid-brain.

Summary of the Gray Masses in the Pars Dorsalis Pontis:

Nucleus of Abducent Nerve.

Nucleus of Facial Nerve.

Afferent and Efferent Nuclei of Trigeminal Nerve.

Nucleus of Spinal Root of Trigeminal Nerve.

Nuclei of Acoustic Nerve	{	Cochlear Division	{	Dorsal Nucleus.
		Vestibular Division		Ventral Nucleus.
				Medial Nucleus.
				Lateral Nucleus.
				Superior Nucleus.

*Superior Olivary Nucleus.

Nucleus of Trapezium.

*Reticular Ganglionic Formation.

*Nucleus Incertus.

Nucleus of Lateral Lemniscus.

Those marked with an asterisk have already been described; the remaining structures relate to the deep connections of several cranial nerves to be described in the succeeding section.

Central Connections of the Cranial Nerves Attached to the Hind-brain.—

Eight of the twelve pairs of cranial nerves are attached to the hind-brain portion of the central axis. Their superficial or apparent origin and the cranial foramina of exit are enumerated in the table on page 848. In coördination with the internal descriptive anatomy of the hind-brain the central connections of these eight cranial nerves must now be considered. They comprise:

Purely efferent or motor nerves	{	XII. Hypoglossal nerve.	Motor to muscles of tongue.
		XI. Spinal accessory nerve.	(a) Motor accessory to vagus nerve;
			(b) Motor to Trapezium and Sternomastoid muscles.
		VII. Facial nerve (proper).	Motor to muscles of scalp and face.
Mixed nerves	{	VI. Abducent nerve.	Motor to External rectus muscle of eyeball.
		X. Vagus nerve.	Sensomotor to respiratory tract and upper part of alimentary tract.
		IX. Glossopharyngeal nerve.	Sensor to tongue (and motor?) to Stylopharyngeal muscle.
Purely afferent or sensor nerve	{	V. Trigeminal nerve.	Sensor to face, tongue, teeth; motor to muscles of mastication.
		VIII. Acoustic nerve.	(a) Cochlear division for hearing. (b) Vestibular division for equilibrium.

Another nerve which pursues a remarkably aberrant course, becoming associated with three of the above-mentioned cranial nerves, is the *nervus intermedius*, known peripherally as the *chorda tympani*. It is chiefly sensor (taste) in function, but also contains efferent fibres which are excitoglandular for the submaxillary and sublingual salivary glands.

In the hind-brain axis lie certain gray masses which are functionally homologous with the nuclear masses in the different parts of the spinal central gray.

These defined nests of nerve elements, from their relations to the cranial nerve roots, are called the **cranial nerve nidi** or **nuclei**. Their analogy to the origins of the spinal nerves extends to the shape and character of their cell elements and their differentiation into (a) **nuclei of origin** and (b) **nuclei of termination** or **recipient nuclei**.

The **nuclei of origin** or **motor nuclei** are cell clusters from which arise the axones of efferent nerves or the efferent components of the mixed nerves. Some of these nuclei are in line with the basal portion of the ventral gray horn in the cord below and are termed, owing to their situation near the mesal plane, the **medial nuclei of origin**. Other nuclei are isolated cell columns in the line of the **caput cornu ventrale** detached by the decussation of the pyramids, termed, from their position in the tegmental substance, the **lateral nuclei of origin**. The different nuclei of origin of the efferent cranial nerves are under the dominance of the cerebral cortex by way of the cortico-tegmental (or corticobulbar) path—usually included in the pyramidal tract.

The **nuclei of termination** or sensor cranial nerve nidi are likewise repetitions in structure of the dorsal horn of the spinal gray, but with less regularity and definiteness of position. Thus, while the *gelatinosa* Rolandi of the cord is continuous with the nucleus of the spinal root of the trigeminal nerve, other recipient or afferent nuclei are more or less isolated in the tegmental substance, while the two (lateral and ventral) nuclei of the cochlear nerve actually lie on the surface of the brain stem.

The afferent impulses carried in by the sensor cranial nerves excite impulses in the neurones of the nuclei of termination; their axones enter the tegmental substance as arcuate fibres, cross the mesal plane to join the lemnisci to connect with the thalamus and posterior quadrigeminal body and *via* thalamus and posterior quadrigeminal body with the cerebral

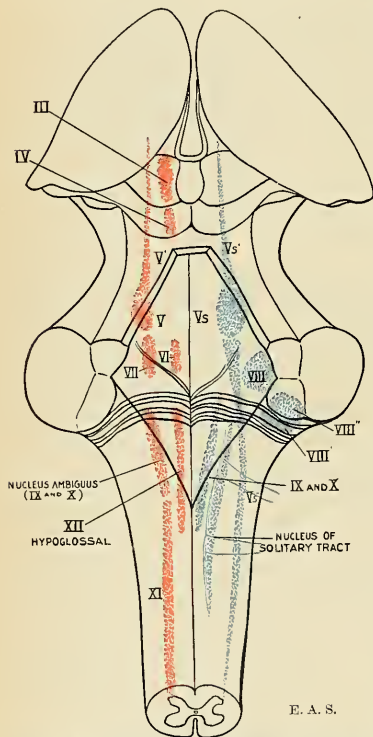


FIG. 648.—The cranial nerve nuclei schematically represented in a supposedly transparent brain stem, dorsal view. Motor nuclei in red; primary terminal nuclei of afferent (sensor) nerves in blue. (Optic and olfactory centres are omitted.)

cortex. The location of the various cranial nerve nuclei in the brain stem may be understood by a reference to the diagrams in Figs. 634, 648, 649, and 650.

Hypoglossal Nerve Nucleus.—The nucleus of origin of the hypoglossal nerve is a rod-like cell column close to the mesal plane, extending for about 7 mm. ($\frac{1}{4}$ inch) in the caudal portion of the fourth ventricle, while its extraventricular portion extends about 5 mm. ($\frac{1}{5}$ inch) caudad of the tip of the calamus. Its efferent axones course ventrad between the *formatio reticularis alba* and *grisea*, thence

between the olivary and medial accessory olivary nuclei, sometimes mesad of the latter, to emerge between pyramid and olive. None of the fibres decussate across the middle line, but the nuclei are coördinated by commissural fibres. Axones from cerebrocortical cells (ventrad third of precentral gyre) terminate in relation with the cells of the hypoglossal nucleus.

The hypoglossal nucleus permits of subdivision into groups: (a) a medial and (b) a lateral sub-group. The lateral group innervates the Palatoglossus and Pharyngoglossus, while the medial nuclear group innervates the remainder of the tongue muscles (Lingualis transversus and inferior, Genioglossus and Hyoglossus).

The Spinal Accessory Nerve Nucleus.—The spinal accessory nerve is also a purely motor or efferent nerve whose axones arise from an attenuated nucleus, with large multipolar cells, in direct continuation with the nucleus ambiguus (of the

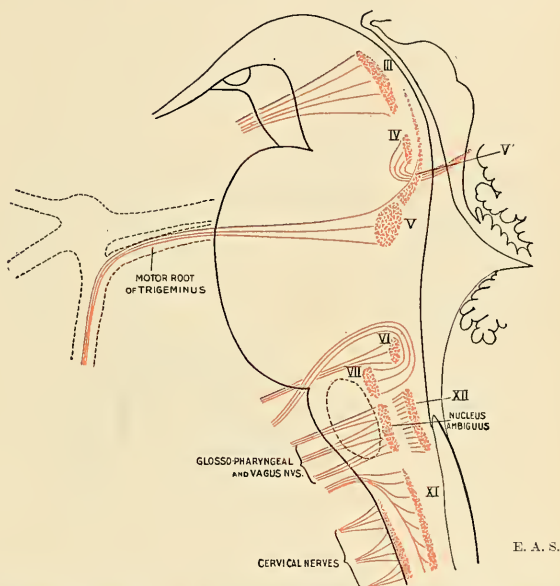


FIG. 649.—Nuclei of origin of the cranial motor nerves schematically represented in a supposedly transparent brain stem, lateral view.

ninth and tenth nerves) cephalad, and with the dorsolateral cell column of the ventral horn of the upper five or six segments of the cord. The **oblongatal portion** of the nucleus gives rise to the encephalic root of the accessory nerve and its axones join the vagus to innervate the laryngeal muscles. Hence it may also be termed the **nidus laryngei** (in contradistinction to the **nidus pharyngei** or **nucleus ambiguus**, whose axones join the vagus and glossopharyngeal nerves to be distributed to the pharynx). The ventrolateral division of this cell column is believed to be the cardioinhibitor centre. The axones from the **spinal nucleus** are distributed to the Trapezius and Sternomastoid muscles.

The nucleus of the spinal accessory nerve is likewise under the dominion of the cerebral cortex by way of the pyramidal tract, and a reflex arc is completed by afferent axones from the dorsal roots of the spinal nerves.

The **Vagus and Glossopharyngeal Nuclei** are usually considered in their aggregate, justified not only by their similarity in origin and central connections, but also by the uncertainty which prevails regarding their peripheral interlacement and complex terminations. Both nerves are in greater part afferent, but also contain efferent axones.

1. **Afferent Portions.**—The afferent axones of the vagus arise from the cells in the **jugular ganglion** and **ganglion nodosum** (ganglion of the trunk); the afferent axones of the glossopharyngeal arise from the cells in its **ganglion superius** and **ganglion petrosum**. The root fascicles of both nerves enter the medulla oblongata along its dorsolateral groove, and the axones then undergo bifurcation into ascending and descending rami, similar to those of the dorsal roots of the spinal nerves.

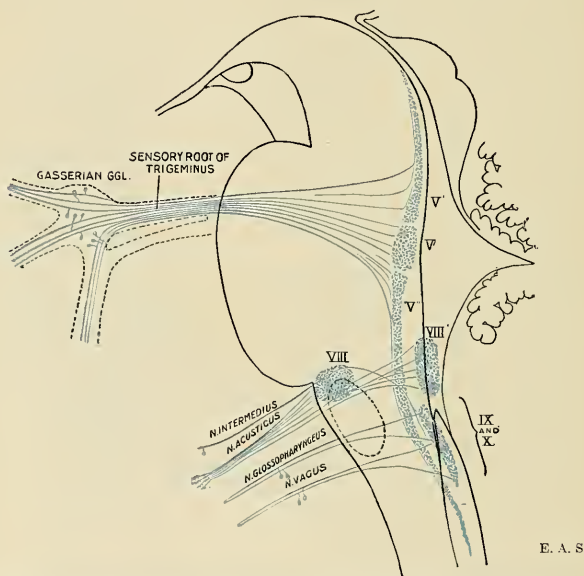


FIG. 650.—Primary terminal nuclei of the afferent (sensor) cranial nerves schematically represented in a supposedly transparent brain stem, lateral view. The optic and olfactory centres are omitted.

The ascending rami end in the **nucleus alae cinereae** (*nucleus vagi et glossopharyngei*); the descending rami collect to form a compact bundle called the **tractus solitarius** or **trineural fasciculus**,¹ and terminating in a gray cell column called the **nucleus of the solitary tract**²—a caudal prolongation of the nucleus alae cinereae. Both tract and nucleus become attenuated caudad, to disappear in the fourth cervical segment (relation with phrenic nerve nucleus), while cephalad it has been traced as far as the region of the locus caeruleus (relation with trigeminal nerve nuclei).

From the cells of the nucleus alae cinereae and nucleus tractus solitarii axones pass across the raphé to the contralateral interolivary stratum to join the medial

¹ There are other "solitary" fasciculi in the nerve system, and the name "trineural fasciculus" aptly characterizes a tract which has for its object the mutual interchange of functions among the central nuclei of the accessory, vagus, and glossopharyngeal nerves.

² The nucleus of the solitary tract lies to the mesal side of the tract. Another nucleus has been described by Mellis, lying laterad of the tract.

lemniscus, establishing connections with the thalamus and cortex; other axones join the tractus nucleocerebellaris.

2. **Efferent Portions.**—The efferent components of the vagus and glossopharyngeal nerves come from two sources—(a) the **dorsal efferent** (vagal) **nucleus** and (b) the **nucleus ambiguus**.

The **dorsal efferent nucleus** lies ventromesad of the principal nucleus alae cinereae and laterad of the hypoglossal nucleus. The axones from its cells pass obliquely ventrolaterad to enter the root fascicles of the vagus and to become distributed to the œsophagus, stomach, trachea, and bronchi. Whether the glossopharyngeal nerve receives efferent axones or not is still in debate.

The **nucleus ambiguus** (*nidus pharyngei*—so termed in contradistinction to the *nidus laryngei*) is a rod-like mass of large, multipolar cells seen, in trans-sections, lying in the gray, reticular formation midway between olive and fasciculus solitarius and apparently a cephalic continuation of the accessory nerve nucleus. The axones arising from its cells run dorsomesad at first, then turn abruptly ectad to join the vagus (and glossopharyngeal?) nerve-root fascicles, becoming distributed to the pharyngeal muscles, œsophagus, Cricothyroid, and the other Laryngeal muscles.

The Acoustic Nerve Nuclei.—The acoustic nerve consists of a cochlear and a vestibular division; the former is concerned with the sense of hearing, the latter with the sense of equilibrium.

1. The **cochlear or true auditory nerve** arises in the bipolar cells of the cochlear spiral ganglion; its axones terminate in (a) the **dorsal nucleus** (tuberculum acusticum), a pyriform mass on the dorsolateral aspect of the restiform body, and (b) the **ventral nucleus**, somewhat detached from the former.

From the dorsal nucleus cells arise the axones which compose the **striae acusticae**, myelinic fibre bundles traversing the ventricular surface to near the median sulcus, dipping into the tegmental substance, crossing to the opposite side in the raphé, and eventually joining the lateral lemniscus to end in the posterior quadrigeminal body and internal geniculate body.

From the ventral nucleus cells arise the axones which course transversely to form the trapezium at the contact zone of the pons proper and tegmentum. Additional axones from cells in the superior olives of both sides and in the trapezium itself increase the bulk of this tract; some of the primary axones end in relation with these cells. These axone groups form the contralateral **lemniscus lateralis**, which contains the intercalated **nucleus of the lateral lemniscus** as a relay station, to be continued to the posterior quadrigeminal and to the internal geniculate bodies and thence to the cortical auditory "centre" in the supertemporal gyre.

2. The **vestibular nerve** axones arise in the bipolar vestibular ganglion cells (G. of Scarpa), enter the brain stem, and bifurcate into ascending and descending rami, which terminate as follows: The ascending rami end in the **medial nucleus** (Schwalbe's); the descending rami end in the **spinal vestibular nucleus**, which extends down to the gracile and cuneate nuclear level; another group of axones ends in the **lateral nucleus** (nucleus magnocellularis) (Deiters'); while a fourth and last group ends in the **superior nucleus** (Bechterew's). From the cells of all these nuclei of termination axones proceed toward the cortex, dentate nucleus, and nucleus fastigii of the cerebellum, as part of the nucleocerebellar tract, to the nuclei of the abducent, trochlear, trigeminal, and oculomotor nerves by collaterals from axones in the medial longitudinal bundle, to the thalamus, and to the ventral horn nuclei of the spinal cord along the tractus vestibulospinalis (ventral and lateral). The far-reaching and complex connections of the vestibular nerve with the cerebellum and the centres for eye muscles and the spinal centres for bodily movements make this cranial nerve a most interesting subject for the active research now going on.

The Facial Nerve Nucleus.—The facial nerve proper is to be distinguished from its so-called **sensor root**, or **pars intermedia**, or **nervus intermedius**.

The axones of the **efferent facial nerve** arise from cells forming the **facial nucleus** in the ventrolateral region of the reticular formation, in line with the nucleus ambiguus or *nidus pharyngei*, a little over 4 mm. ($\frac{1}{6}$ inch) from the ventricular floor. These axones converge toward the ventricular floor to form a compact bundle which curves over the abducens nucleus from behind, overlying it like a horseshoe over a ball (*genu facialis internum*); not as a straight but as a bent horseshoe, bent so that its cephalic branch is directed more laterad than its caudal branch. After having encircled the abducens nucleus, the facial root passes ventrolaterad, passing its own nucleus ectad, and emerging in the **postpontile groove** (*recessus facialis*).¹

Pyramidal fibres from the precentral cortex place this nucleus under the influence of the will; it also receives fibres from the trigeminal and acoustic central systems.

The **nervus intermedius** is a mixed nerve, containing **afferent** (taste) fibres and **efferent** (excitoglandular or secretory) fibres. With respect to its afferent component it may be regarded as an aberrant portion of the glossopharyngeal nerve.

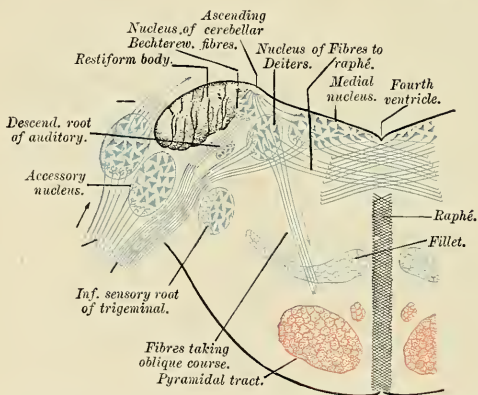


FIG. 651.—Terminal nuclei of the vestibular root of the auditory nerve, with their upper connections. (Schematic.) (Testut.)

1. **Afferent Portion.**—These axones arise from the cells of the **geniculate ganglion**, implanted upon the *genu facialis externum*, and terminate in a nuclear extension cephalad of the **nucleus tractus solitarii**. They probably convey gustatory sense impulses from the anterior two-thirds of the tongue and the pillars of the soft palate.

2. **Efferent Portion.**—A nucleus of origin for the excitoglandular elements has been described as a group of cells extending beneath the ventricular floor from the level of the facial nucleus to that of the motor trigeminal nerve, close to the *raphé*, and called the **nucleus salivatorius**. (Fig. 745).

Peripherally we shall study this nerve as the **chorda tympani**. The mixed nature of the *nervus intermedius* and of the geniculate ganglion makes it probable that they combine the elements of a sympathetic and a spinal ganglion; the nerve, at least, contains both vegetative and sensorial elements.

¹ The peculiar course of the deep root of the facial nerve has been shown by Streeter to be due to a wandering of the facial nucleus in the embryonic period.

The Abducent Nerve Nucleus.—The abducent nerve is a small motor nerve, supplying the External rectus muscle of the eyeball. Its nucleus of origin with large, multipolar cells, lies close to the median plane beneath the eminentia abducentis. The axones from these cells pass ventrad through the tegmentum and trapezium, and laterad of the pyramidal tract, to emerge in the postpontile groove. The nuclei are brought under the dominion of the cerebral cortex by pyramidal fibres of the opposite side. They are likewise brought into intimate relation with the trigeminal, acoustic, and opposite oculomotor nerve nuclei.

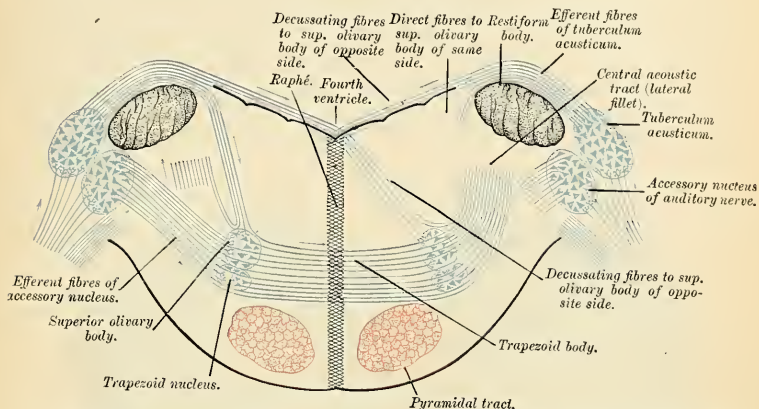


FIG. 652.—Terminal nuclei of the cochlear nerve, with their upper connections. (Schematic.) The vestibular root with its terminal nuclei and thin efferent fibres have been suppressed. On the other hand, in order not to obscure the trapezoid body, the efferent fibres of the terminal nuclei on the right side have been resected in a considerable portion of their extent. The trapezoid body, therefore, shows only one-half of its fibres—viz., those which come from the left. (Testut.)

The Trigeminal Nerve Nucleus.—The trigeminal is relatively enormous and has correspondingly extensive central connections, including nuclei in the mid-brain, pars dorsalis pontis and oblongata, and spinal cord. It is a mixed sensomotor nerve and the afferent and efferent divisions must be considered separately.

1. Afferent Portion.—The axones of the afferent or sensor root arise in the cells of the large *semilunar* (Gasserian) *ganglion*. As in the dorsal roots of the spinal nerves, these axones bifurcate, on entering the brain axis, into ascending and descending rami. These terminate in a cephalic nuclear extension of the *gelatosi Rolandi* of the cord; the ascending rami terminate in the so-called *sensor nucleus* of the trigeminus, the descending rami in the *nucleus of the spinal tract* of the trigeminus, which extends as far as the second cervical segment of the cord. The sensor nucleus, at the level of the entrance of the nerve, is quite massive, becoming attenuated cephalad. The spinal tract, in its descent, likewise decreases rapidly as it gives off its terminal axones to the nucleus of the tract. The cells of these terminal nuclei send out axones which cross the median plane, giving off collaterals to the facial nucleus, to join the medial lemniscus to reach the thalamus, and, *via thalamus*, the somesthetic cerebral cortex. Other axones are distributed (a) to the motor or efferent nucleus of the trigeminus and (b) to the motor or efferent cranial nerve nuclei.

2. Efferent Portion.—The efferent or motor component of the trigeminal nerve consists of axones arising from cells in two *nidi*: (a) the *principal nucleus* in the

dorsolateral part of the pontile tegmentum, dorsomesad of the sensor nucleus; (b) a small, slender, so-called **mesencephalic root nucleus** (*nucleus radialis ascendens nervi trigemini*) extending cephalad of the region of the locus coeruleus to lie along the aqueduct in the mid-brain. The fibres from the principal nucleus supply the muscles of mastication. The distribution of the fibres from the mesencephalic root is not precisely known. Kölliker suggests that they may supply the Tensor veli palatini, Tensor tympani, Mylohyoid, and anterior belly of the Digastric.

Like other motor nuclei, these efferent divisions of the trigeminus are under the dominion of the cerebral cortex *via* pyramidal fibres.

The Cerebellum.—The cerebellum occupies the greater part of the posterior fossa or cerebellar part of the skull, and is the largest portion of the hind-brain. It is overlapped by the occipital poles of the cerebrum, being separated from these by the tentorium. It lies dorsad of the pons oblongata and partly embraces this portion of the brain stem. It is composed of a white central core with scattered gray masses and a surface layer of gray substance that is of darker hue than the cerebral cortex.

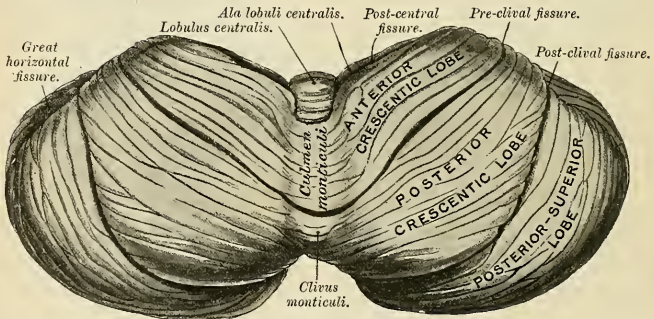


FIG. 653.—Upper surface of the cerebellum. (Schäfer.)

The cerebellum is convoluted on a plan entirely different from that of the cerebrum. Each primary fold is folded by secondary and these in turn by tertiary folds, so that on sagittal section a cypress-leaf appearance is noted, the *arbor vitae cerebelli*. The interior or medullary white substance follows all these branchings and sub-branchings, forming a skeleton of the minute folds which are called *folia*. These folia are demarcated on the surface by numerous curved and more or less parallel fissures of various depths.

The cerebellum is connected to the brain stem by three pairs of peduncles and by vestigial portions of the primitive dorsal wall of the brain tube. Among the latter the medullary vela or laminae are most important; they are the **superior medullary velum** (valvula), and the **inferior medullary velum** (velum) which enter into the formation of the "roof" of the fourth ventricle.

The rounded margin of the cerebellum demarcates two surfaces looking respectively "upward" and "downward," or cephalic and caudal surfaces. Both are convex, the inferior or caudal surface more so than the upper or cephalic. The inferior surface shows a deep median depression, the *vallecule*, into which the medulla oblongata is sunk. The ventral margin is widely notched to partly embrace the **brain stem** (tegmental part of the pons and corpora quadrigemina); a **dorsal notch** (*incisura cerebelli posterior*), which is smaller and narrower and

lodges the cerebellar falx, separates the hemispheres as these project beyond the inferior vermis.

The cerebellum is arbitrarily subdivided into a medial segment, the **vermis** or **worm**, from its annulated appearance, and two lateral portions, commonly called the cerebellar "**hemispheres**." The vermis may, according to the aspect in which it is viewed, be divided into the **superior vermis** or **prevermis** on the upper or cephalic surface, and the **inferior vermis** or **postvermis** on the inferior or caudal aspect. The superior vermis is hardly distinguished from the adjacent sloping surfaces of the hemispheres; occasionally a slight furrow exists on either side. Ordinarily the term is to be restricted to the high median elevation usually called the **monticulus cerebelli**. The inferior vermis is more distinctly bounded by a deep fissure, the **sulcus vallecule**, on each side, separating it from the corresponding lateral hemisphere.

Among the many fissures which traverse the surface of the cerebellum, one is particularly conspicuous as a deep cleft which may be traced along the dorso-lateral margin from the dorsal notch to the point of entrance of the cerebellar

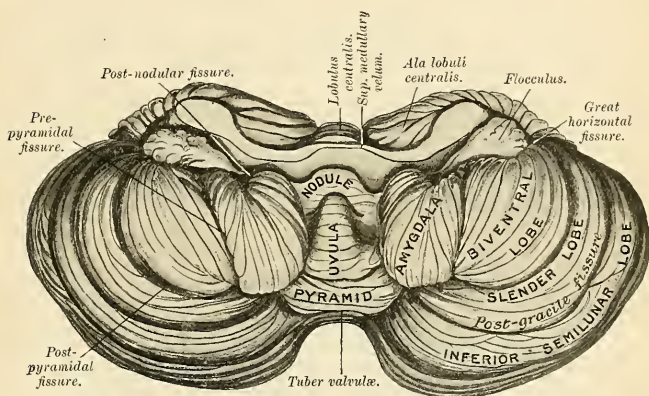


FIG. 654.—Under surface of the cerebellum. (Schäfer.)

peduncles. This is the **peduncular sulcus** or **great horizontal sulcus** (*sulcus horizontalis cerebelli*), and it divides the cerebellum into a cephalic or upper and caudal or lower part. The sulcus is usually quite deep in the hemispherical portion, but it frequently fails to traverse the vermis. Other deep fissures demarcate the lobes or major subdivisions of the intricately convoluted surface of the cerebellum. Conventionally the lobes and fissures or sulci are described upon the "upper" and "lower" surfaces respectively, and this mode of description is partially adhered to here. A better idea of the topographical relations of the lobes and sulci in the vermis and the hemispheres may be gained from a study of the divisions of the cerebellum as if extended in one plane as well as on sagittal sections through the mesal and lateral planes.

Lobes and Fissures of the Cerebellum.—The surface of the cerebellum is traversed by eight more or less curved and deep fissures demarcating nine lobar subdivisions. Distinctive names are given to the portions of each lobe in the hemispheres as contrasted with that in the vermis, although often without warrant, as the two are quite continuous and merit no such distinction. This burdensome nomenclature seems so firmly rooted in descriptive anatomy that the various terms must be

repeated here. The arrangement of the fissures and lobes will be understood by reference to the following schema, in which structures are named from "before backward," or cephalocaudad:

	VERMIS.	HEMISPHERE.
Superior vermis.	Lingula.	Vincula lingualæ.
	← Precentral Fissure. →	
	Lobulus centralis.	Ala lobuli centralis.
	← Postcentral Fissure. →	
	Culmen monticuli.	Anterior crescentic lobe. ¹
	← Preclival Fissure. →	
Inferior vermis.	Clivus monticuli.	Posterior crescentic lobe.
	← Postclival Fissure. →	
	Folium cacuminis.	Superior semilunar lobe.
	← Peduncular Fissure. →	
	Tuber vermis.	{ Inferior semilunar lobe. ← Postgracile fissure. → } Postero-inferior lobule. { Gracile lobe.
	← Postpyramidal Fissure. →	
	Pyramis.	Biventral lobe.
	← Prepyramidal Fissure. →	
	Uvula.	Tonsilla (Amygdala).
	← Postnodular Fissure. →	
	Nodus.	Flocculus.

The *lingula* (*lingula cerebelli*) is a tongue-shaped process of the vermis lying in the ventral cerebellar notch, ventrad of the central lobe, and is partially or completely concealed by it. It consists of five, six, or seven lamellæ lying upon and connected with the dorsum of the *valvula*. At either side the lingula gradually shades off, being prolonged only for a short distance toward the region of the peduncles as the *vincula lingualæ*.

The *central lobe* (*lobulus centralis*) is a small median mass situated in the ventral notch, dorsad of and overlapping the lingula. Its lateral, wing-like prolongation is called the *ala lobuli centralis*.

The *culminal lobe* is much larger than the two lobes just described, and constitutes, with the succeeding lobe (the clival lobe), the bulk of the superior vermis and "upper" surface of the cerebellum. It partly overlaps the central lobe. Its lateral extensions are also termed the *anterior crescentic lobes*.

The *clival lobe* is of considerable size, separated from the culminal lobe by the preclival fissure and from the cacuminal lobe by the postclival fissure. Its lateral extensions are also termed the *posterior crescentic lobes*.

The anterior and posterior crescentic lobes of either side have been described by some writers as the *pars anterior* and *pars posterior* of the *quadrate lobe* or *lobulus quadrangularis*.

The *cacuminal lobe* or *superior semilunar lobe* (*folium vermis*) is a short, narrow band at the dorsal margin of the vermis, which expands in either hemisphere into a lobe of considerable size, of semilunar shape, and bounded caudad by the peduncular fissure.

¹The anterior and posterior crescentic lobes are often called the *pars anterior* and *pars posterior*, respectively, of the "lobulus quadrangularis."

The **tuberal lobe** is of small size in the region of the inferior vermis, but laterally spreads out into the large **inferior semilunar** (*lobulus semilunaris inferior*) and **gracile lobes** demarcated by the intervening postgracile fissure. These lobes comprise at least two-thirds of the "inferior" surface of the cerebellar hemispheres.

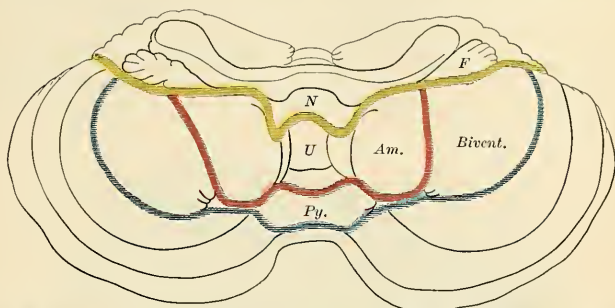


FIG. 655.—Diagram showing fissures on under surface of the cerebellum. F, Flocculus. N, Nodule. U, Uvula. Py, Pyramid. Am, Amygdala or Tonsilla. Bivent, Biventral lobe.

The **gracile lobe** is often divided by an intragracile fissure into pre- and post-gracile lobes.

The **pyramidal lobe** is a conical projection, forming the largest prominence of the inferior vermis. It is continued laterad into the hemisphere as the **biventral lobe** (*lobulus biventer*); the demarcation between the latter and the pyramis proper is accentuated by the deep sulcus valleculæ.

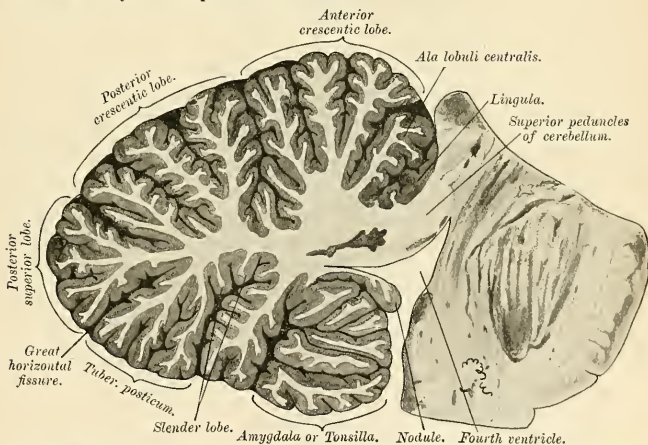


FIG. 656.—Sagittal section of the cerebellum, near the junction of the vermis with the hemisphere. (Schäfer.)

The **uvular lobe** (*uvula vermis*) occupies a considerable portion of the inferior vermis as the **uvula**, while its lateral extension in either hemisphere, the **amygdala** or **tonsilla** (*tonsilla cerebelli*; amygdaline nucleus), is a rounded mass lying in a deep fossa between the uvula and biventral lobe. (This fossa was termed by the

older anatomists the *nidus avis* or "bird's nest" [Reil and Vicq d'Azyr].) The junction of uvula and tonsilla is an attenuated isthmus marked by a few shallow furrows and termed the **furrowed band**.

The **nodular lobe** comprises the **nodulus** (*nodulus vermis*) (in the inferior vermis) and the **flocculus** (*flocculi secundarii*) of each side, connected by a delicate lamina of white substance, the **velum medullare posterius**. Each flocculus lies adjacent to the ventrolateral surface of the peduncular mass, extending into the ventral extremity of the peduncular fissure. The flocculi of the two sides are connected with each other by a band of white substance, termed the **posterior medullary velum** in its medial portion, while its lateral expansions toward the flocculi are termed the **peduncles of the flocculi**.

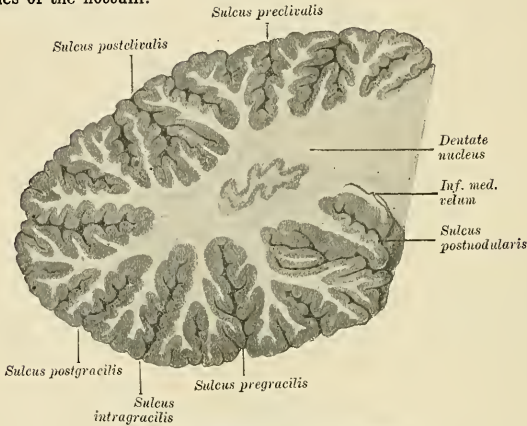


FIG. 657.—Internal structure of the cerebellum.

The Internal Structure of the Cerebellum.—In any section of the cerebellum we may recognize the interior white substance, **corpus medullare**, and the peripheral gray cortex. The white substance in each lateral hemisphere is more bulky than in the median vermis, while the cortex is of more uniform thickness throughout. In a sagittal section in the mesal plane the central white core is seen to divide into two main branches—**anterior ramus** or **preramus** and **posterior ramus** or **postramus**; these main branches divide and subdivide into a series of medullary laminae surmounted by the foliated cortex, and presenting the characteristic appearance known as the **arbor vitae cerebelli**.

Isolated Gray Masses or Nuclei of the Cerebellum.—Embedded in the white matter of the cerebellum are several gray masses. They are four in number on each side:

1. *Dentate nucleus* or *dentatum*.
2. *Nucleus emboliformis* or *embolus*.
3. *Nucleus globosus* or *globulus*.
4. *Nucleus fastigii* or *fastigiatum*.

The **nucleus dentatus** is the largest and best studied of the cerebellar nuclei. It is located in the mesal part of the corresponding cerebellar hemisphere, in the direct prolongation of the superior peduncle of the cerebellum, which appears to enter it. It consists of a folded lamina of gray substance convoluted like the similar nucleus of the olive, and opens cephalomesad where its **hilum** (*hilus nuclei dentati*) permits of the entrance and exit of fibres from various sources.

The **nucleus emboliformis** is a small mass of gray substance, elongated cephalo-caudad, and placed entad of the dentate nucleus, partly covering its hilum.

The **nucleus globosus** consists of several small round or oval masses connected with each other and lying entad of the preceding.

The **nucleus fastigii** (nucleus of the "roof") is second in size to the dentate nucleus, situated close to the mesal plane directly dorsad of the fourth ventricle, or in the fastigium of the cerebellum, and within the inferior vermis. The nuclei of opposite sides approach each other so nearly as almost to fuse.

The Cerebellar Peduncles.—Three pairs of peduncles constitute the chief avenues for the entrance and emergence of the fibres composing the white substance of

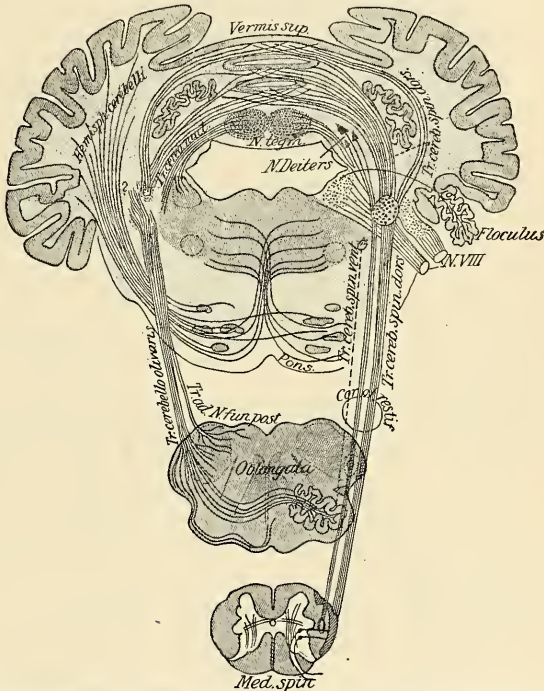


FIG. 658.—Diagram showing the origin and course of the fibres of the peduncles of the cerebellum. (Edinger.)

the cerebellum and connecting adjacent parts of the brain stem therewith. The peduncles are, on each side, the **superior, middle, and inferior peduncles**.

The **inferior peduncle** (*corpus restiforme*; postpedunculus) is the continuation of the restiform body of the medulla oblongata. It contains both afferent and efferent fibres, connecting the cerebellar cortex with structures situated caudad: (1) The **dorsal or direct spinocerebellar tract**, composed of axones arising in Clarke's column (spinal cord) and terminating in the cortex of the superior vermis on both sides of the median line, but chiefly on the opposite side. (2) The **olivocerebellar**

tract, composed of axones (chiefly **internal arcuate fibres**) arising in the (inferior) olivary nuclei—principally from the contralateral or opposite olive, and terminating in the cortex of the superior vermis and adjacent hemispherical portions, as well

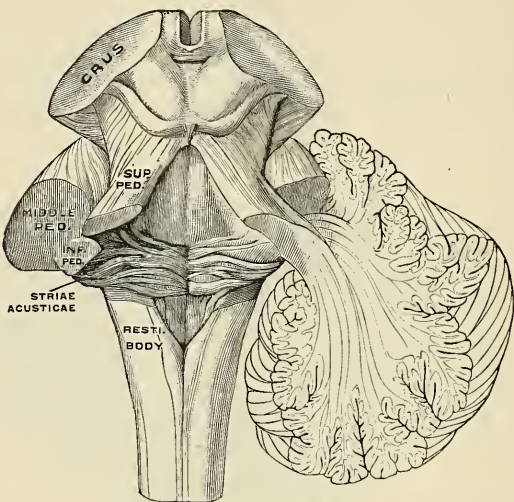


FIG. 659.—The peduncles of the cerebellum. On the left the three peduncles have been cut at their entrance into the cerebellum; on the right side they are shown penetrating the cerebellar hemisphere. (Poirier and Charpy.)

as in the dentate nucleus. (3) **External arcuate fibres** from the homolateral and contralateral nuclei of the gracile and cuneate funiculi. (4) The **nucleocerebellar tract**, composed of axones from the recipient nuclei of certain cranial nerves (*vestibular, trigeminal*). (5) The **cerebellospinal (descending) tract**, terminating in relation with the ventral horn cells at various levels of the spinal cord.

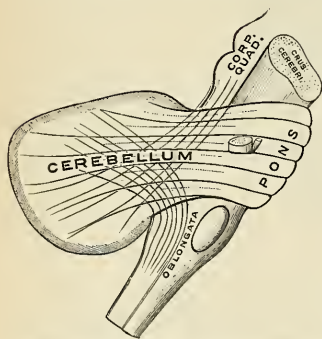


FIG. 660.—Semidiagram of the three cerebellar peduncles. (Testut.)

terminate, however, in the nuclei pontis to convey impulses to the cells therein; these in turn send their axones (*tractus pontocerebellares*) into the opposite middle peduncle, and therefore constitute interrupted commissural systems. A few

The **middle peduncles** (*brachia pontis*; medipedunculi) are the largest of the three pairs. They consist of a mass of curved fibres comprising the pons and entering either cerebellar hemisphere between the parted lips of the ventral end of the peduncular fissure, just caudad of the inferior peduncle. Each peduncle contains axones coursing in opposite directions and in large part may be considered as purely commissural fibres. Some of the axones

fibre systems in the middle peduncles establish relations with certain other structures in the brain stem, notably the nuclei of the oculomotor, trochlear, and abducent cranial nerves.

The **superior peduncles** (*brachia conjunctiva*; *prepedunculi*) emerge cephalad from the cerebellum entad of the middle peduncles. As they extend cephalad they converge to form the lateral boundaries of the fourth ventricle and partly roof it in. On trans-section they appear of oval outline, somewhat concave toward the cavity of the ventricle. The **superior medullary velum** or **valvula**, a thin lamina of white substance, spans the interval between the converging superior peduncles, and thus completes the roofing-in of the cephalic portion of the fourth ventricle.

The superior peduncles consist almost wholly of axones arising from the cells of the dentate nucleus, the ectal part of the nucleus fastigii of the same side, and mesal part of the nucleus fastigii of the opposite side. In their course, converging cephalad, these bundles pass into the tegmentum of the mid-brain ventrad of the inferior corpora quadrigemina, and decussate almost wholly. The fibres of each peduncle terminate in the **red nucleus** of the opposite side, although a few continue to enter the thalamus.

This system of fibres is also called the **tractus cerebellotegmentalis**, and axones of inverse functional direction have been included therein.

The **ventrolateral spinocerebellar tract** (Gowers' tract) is in relation with the superior peduncle and superior medullary velum. Unlike the dorsal or direct spinocerebellar tract, it does not enter the cerebellum along the inferior peduncle. Its fibres pass farther cephalad, through the reticular formation of the pars dorsalis pontis and medulla oblongata, to become reflected dorsocaudad at the level of the isthmus of the hind-brain, and entering the superior medullary velum, proceed with the superior peduncle into the cerebellum.

The **medullary vela** are two thin, relatively undeveloped laminae of white substance, representatives of the mid-dorsal wall of the brain tube adjacent to the cerebellar proton, and in the adult brain appear as prolongations of the white central core of the cerebellum. They are the **anterior** or **superior medullary velum** (*valvula*; or *valve* of Vieussens) and the **posterior** or **inferior medullary velum** (*velum*).

The **superior medullary velum** is a thin lamina of white substance spanning the interval between the converging superior peduncles, and with these assisting in the formation of the "roof" of the fourth ventricle. Caudad it is continuous with the white substance of the cerebellum, while on its dorsal surface lie the five to seven folia of the lingula. Cephalad it narrows as the corpora quadrigemina are approached, and a slight median ridge, the **frenulum**, descends upon the dorsal surface of its apical portion from between the posterior quadrigemina; on either side of the frenulum may be seen the superficial origin of the trochlear nerve. The majority of the fibres in the superior medullary velum are longitudinal; as already described (p. 838), the ventral spinocerebellar (Gowers') tract reaches the cerebellum along the superior medullary velum.

The **inferior medullary velum** is a still thinner lamina of white substance which bears the same relations to the nodulus that the superior medullary velum presents to the lingula. Laterad it extends to the flocculus of either side. The inferior medullary velum ends in a free crescentic edge and its ependymal and pial coverings continue as a fused, delicate membrane, the *tela choroidea ventriculi quarti*.

The superior and inferior medullary vela enter the cerebellum at an acute angle, forming the peaked roof (*fastigium*), while the tent-like recess is called the **recessus tecti**.

The Fibres Proper of the Cerebellum.—The *fibrae propriae* of the cerebellum are of two kinds: (1) **commissural fibres**, which cross the middle line to connect the

opposite halves of the cerebellum, some at the anterior part and others at the posterior part of the vermis; (2) **association fibres**, which are homolateral fibres connecting adjacent laminae with each other.

Microscopic Appearance of the Cerebellar Cortex.—The cerebellar cortex, on section, presents two marked layers—an outer, of a pale gray color, the **molecular layer**, and an inner, of a rusty-brown tint, the **granular layer**. At the contact line of these two layers, but more within the molecular than the granular, are found the characteristic nerve elements of the cerebellum, the **flask-shaped Purkinjean nerve cells**.

The **molecular or ectal layer** consists of cells and delicate fibrillae embedded in a neuroglial network. The cells are small and are characterized by the course of

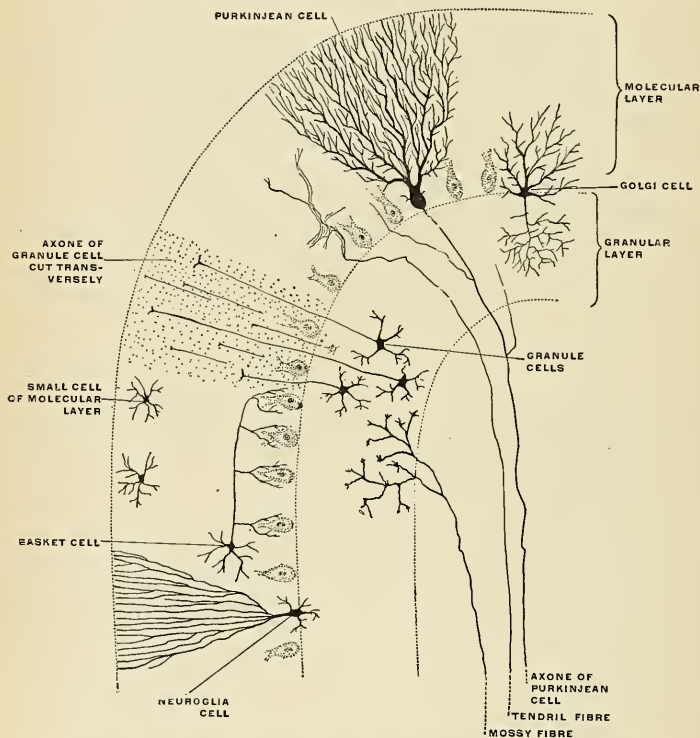


FIG. 661.—Trans-section of a cerebellar folium. (Diagrammatic after Cajal and Kölliker.)

their branching axones which run parallel with the surface of the folium, give off numerous collaterals which pass in a vertical direction toward the cell bodies of the Purkinjean elements and embrace these in a basket-like network. Hence these cells are called **basket cells** (Fig. 661).

The **Purkinjean cells** are flask-shaped, and form a stratum at the junction of the molecular and granular layers, their bases directed toward the latter. Each

cell gives off an axone ectad, while ectad it gives off numerous dichotomously branching dendrites covering a very large field of the molecular layer. The axone, after giving off several collaterals which pass toward different parts of the granular layer, becomes myelinic not far from the cell body and passes into the white substance to establish connections with other folia within the cerebellum or with more distinct brain structures.

The **granular or ental layer** is characterized by containing numerous small nerve cells or granules of a reddish-brown color, together with many nerve fibrils. Most of the cells are nearly spherical and provided with short dendrites, which spread out in a spider-like manner in the granular layer. Their axones pass outward into the molecular layer, and, bifurcating at right angles, run horizontally for some distance. In the outer part of the granular layer are also to be observed some larger cells, of the type termed **Golgi cells** (Fig. 661). Their axones undergo frequent division as soon as they leave the nerve cells, and pass into the granular layer, while their dendrites ramify chiefly in the molecular layer.

Finally, in the gray substance of the cerebellar cortex fibres are to be seen which come from the white centre and penetrate the cortex. The cell origin of these fibres is unknown, though it is believed that it is probably in the gray substance of the spinal cord. Some of these fibres end in the granular layer, by dividing into numerous branches, on which are to be seen peculiar moss-like appendages; hence they have been termed by Ramón y Cajal the **moss fibres** (Fig. 661); they form an arborescence around the cells of the granular layer. Other fibres derived from the medullary centre can be traced into the molecular layer, where their branches cling around the dendrites of Purkinje's cells, and hence they have been named the **clinging or tendril fibres** (Fig. 661).

The cerebellum is an important sensomotor organ, transmuting sensor impressions into motor impulses under the dominance of the cerebral centres. Its connections with other brain portions and the spinal cord are established by the peduncular fibres. It is essentially an apparatus for the coördination of movements and the space-sense perceptions or orientation of the body and its parts in space. These functions depend principally upon the reception of sensor impulses from (1) the vestibular nerve (from the semicircular canals) and (2) the spinocerebellar (ascending) tracts conveying sensor impulses from the skin, muscles and joints. Motor impulses pass along (1) the cerebellospinal (descending) tracts to the ventral horn nuclei of the cervical cord; (2) the tractus rubrospinalis, which arises in the red nucleus—an intercalated ganglionic mass connected with the cerebellar cortex by the superior peduncles, or tractus cerebello-tegmentalis. The tractus rubrospinalis is a tract for voluntary motor impulses next in importance to the pyramidal tract.

Weight of the Cerebellum.—Its average weight in the male is, 165 grams (5.8 ounces avoirdupois) and 155 grams (5.4 ounces avoirdupois) in the female. It attains its maximum between the twenty-fifth and thirty-fifth years, its increase in weight after the fourteenth year being relatively greater in the female than in the male. The proportion between the cerebellum and the cerebrum is as 1 to 7.5; among eminent men it is 1 to 8.5, owing to the preponderance in bulk of the cerebrum or thought-apparatus proper. In the newborn the ratio is as 1 to 20.

The Mid-brain (Mesencephalon).

The mid-brain is the short and constricted portion of the brain which lies in the opening of the tentorium cerebelli (*incisura tentorii*) and which connects the pons with the inter-brain and hemispheres, and hence it is frequently called the **isthmus cerebri**. It is developed from the second brain vesicle, the cavity of which becomes the aqueduct. It comprises the **crura cerebri**, the **corpora quadri-**

gemina, the internal geniculate bodies, and the aqueduct. Its two surfaces are ventral and dorsal. They are free, but concealed; the ventral surface by the apices of the temporal lobes which overlap it; the dorsal, by the overhanging cerebral hemispheres. The *ventral surface*, when exposed by drawing aside the temporal lobes, is seen to consist of two cylindrical bundles of white substance, which emerge from the pons and diverge as they pass forward and outward, to enter the inner and under part of either hemisphere. They are the *crura cerebri*, and between them is a triangular area, the *intercrural space*,¹ near the point of divergence of the crura cerebri the roots of the third nerve are seen to emerge in several bundles from a groove, the *sulcus oculomotorius* (*sulcus nervi oculomotorii*) (Fig. 619). The *dorsal surface* is not visible until a considerable portion of the cerebral hemispheres and other overlying structures have been removed. It then presents four rounded eminences placed in pairs, two cephalad and two caudad, and separated from one another by a crucial depression. These are termed the *corpora*

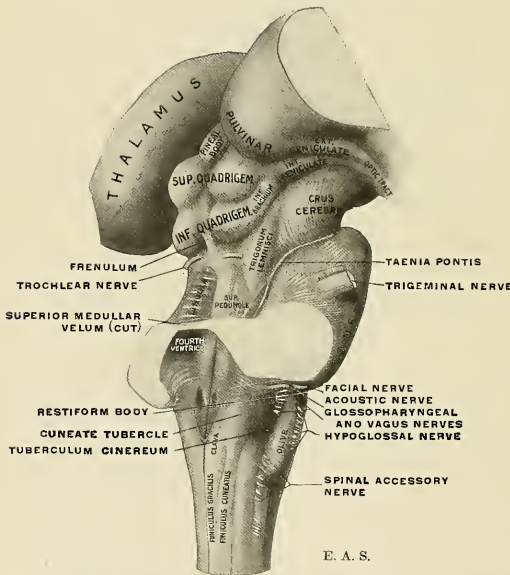


FIG. 662.—The brain stem, showing medulla oblongata, pons, mid-brain, and part of the optic thalami.

quadrigemina (Fig. 662). The ventral and dorsal surfaces meet on the side of the mid-brain, and are separated from each other by a furrow, the *lateral groove* (*sulcus lateralis mesencephali*), which runs caudocephalad (Fig. 662).

External Morphology. Dorsal Surface.—The corpora quadrigemina are four rounded eminences placed in pairs separated by a shallow median groove and a more sharply cut transverse furrow. The cephalic pair, the *superior quadrigeminal bodies* (*superior colliculi*; *pregemina*; the *nates* of older authors), are the larger, and the pineal body rests in the flattened depression between them. The superior quadrigeminal bodies are oval, their long diameter being directed cephalolaterad, and are of a yellowish-gray color. The *inferior quadrigeminal bodies* (*colliculi in-*

¹ Also called interpeduncular space, or posterior perforated space.

feriores; postgemina; the *testes* of older authors) are hemispherical in form and lighter in color than the preceding. The lamina quadrigemina, comprising the whole of the dorsal wall of the mid-brain, extends from the root region (posterior commissure) of the pineal body to the cephalic end of the superior medullary velum.

Each superior and inferior quadrigeminal body is continued lateroventrad in prominent white bands, the brachia. The band from the superior quadrigeminal body is termed the **superior brachium** or **prebrachium**; that from the inferior quadrigeminal body is called the **inferior brachium** or **postbrachium**.

The **superior brachium** or **prebrachium** (*brachium quadrigeminum superius*) proceeds cephaloventrad between the overhanging pulvinar and a light-gray eminence, the internal geniculate body. In reality it is a continuation of a part of the optic tract. The **inferior brachium** or **postbrachium** (*brachium quadrigeminum inferius*) proceeds in a similar direction to disappear beneath the internal geniculate body.

Of the two geniculate bodies, on either side, the external geniculate body belongs rather to the thalamus (p. 905), while the internal geniculate body may properly be considered here among the structures of the mid-brain.

The **internal geniculate body** or **postgeniculum** (*corpus geniculatum mediale*) is a small oval eminence of the lateral surface of the mid-brain in which the mesal root of the optic tract appears to terminate. The inferior brachium likewise appears to run into this body; as a matter of fact, so far as is known, the internal geniculate body is (1) a way-station for auditory impulses in their course toward the cerebrum; (2) the origin and terminus for the **infracommissure of Gudden** (*commissura inferior* [*Guddeni*]), by means of which circuitous path, through the optic chiasm, and along the mesal root of the optic tract, the internal geniculate bodies of the two sides are connected.

The quadrigeminal lamina is continuous caudad with the superior peduncles of the cerebellum and the intervening superior medullary velum. A slight, median ridge-like projection, the **frenulum valvulae**, descends from between the inferior quadrigeminal bodies onto the superior medullary velum; on either side of the frenulum emerge the slender trochlear nerves.

The **crura cerebri** constitute the bulk of this portion of the brain stem. Upon the ventral aspect of the brain they appear as two large, white, rope-like strands emerging from the pons and diverging to either cerebral hemisphere, becoming embraced by the optic tracts. Each crus is composed of a **dorsal tegmental part**—a continuation of the tegmentum of the hind-brain—and a ventral **crusta** or **pes**. These parts are demarcated from each other on the external surface by the **oculomotor sulcus** ventrad (which looks into the intercrural space) and the **sulcus lateralis mesencephali** on the lateral aspect. The lateral surface shows dorsally the superior cerebellar peduncle dipping into the substance of the mid-brain, while between it and the **crusta** is a small triangular field of oblique fibre strands, not always well defined, called the **trigonum lemnisci** because the lateral lemniscus tends to reach the surface of the brain stem at this situation (Fig. 662).

The surface of the crura cerebri shows a rope-like twist in the course of its fibre bundles. Oblique or transverse fasciculi are sometimes seen upon the surface, two of which are fairly constant. They are (1) the **taenia pontis**, and (2) **Gudden's tractus peduncularis transversus** (*cimbia*).

The **taenia pontis**, as Horsley has shown, takes origin contralaterally in the gray substance continuous with the "interpeduncular ganglion," but ventral to it. The taenia then passes over the lateral lemniscus and superior cerebellar peduncle to the dentate nucleus and nucleus fastigii.

The **tractus peduncularis transversus**, or **cimbia**,¹ may be traced from the supe-

¹In architecture, a band or fillet about a column. Also called fasciculus arciformis pedis.

rior quadrigeminal body and internal geniculate body over the surface of the crus cerebri to near the ventromeson, disappearing from view in the oculomotor sulcus.

Internal Structures of the Mid-brain.—If a cross-section be made through the mesencephalon it will be seen that each lateral half is divided into two unequal portions by a lamina of deeply pigmented gray substance, named the **substantia nigra** (intercalatum; ganglion of Soemmering). The postero-superior portion of

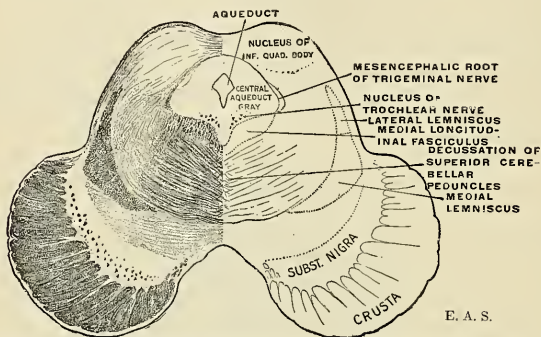


FIG. 663.—Trans-section of the mid-brain through the level of the inferior quadrigeminal body.

the crus is named the **tegmentum**, and the antero-inferior the **crusta** or **pes**. The substantia nigra is curved on section with its concavity upward, and extends from the lateral groove externally to the oculomotor sulcus internally. The two crustæ are in contact in front of the pons, from which point they diverge from each other, but the two halves of the tegmentum are joined to each other in the mesal

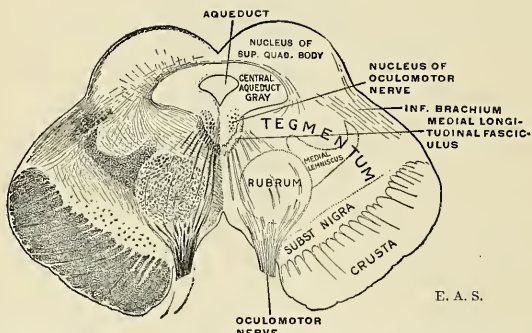


FIG. 664.—Trans-section of the mid-brain through the level of the superior quadrigeminal body.

plane by a forward prolongation of the raphé or median septum of the pons. Laterally the tegmenta are free, but dorsally they blend with the corpora quadrigemina.

Traversing the mid-brain in the median plane and nearer the dorsal surface is the **aqueduct**, surrounded by the central tubular gray, which in this brain seg-

ment has retained the comparatively primitive arrangement of the embryonic brain tube.

The Aqueduct (mesocoele) and Central Aqueduct Gray.—The aqueduct is a narrow canal connecting the third with the fourth ventricle, and demarcating the lamina quadrigemina dorsad from the tegmental zone. Its shape on trans-section varies at different levels, being T-shaped caudad, oval or quadrangular along its middle, and triangular cephalad. It is lined by the ependyma (columnar ciliated epithelium) and surrounded by the central aqueduct gray. The **central gray** is separated dorsally from the corpora quadrigemina by the **stratum lemnisci**; ventrad near the median plane lie the medial longitudinal bundles. Within the gray substance lie certain well-defined cell clusters, the nuclei of origin of the oculomotor and trochlear nerves and the mesencephalic root of the trigeminal nerve. These will be described in detail later.

The **substantia nigra** or **intercalatum** is a crescentic layer of deeply pigmented gray substance interpolated between the crusta and the tegmentum. Mesad it nearly touches its fellow of the opposite side, being separated by the rudimentary ganglionic gray (the posterior perforated substance or postperforatum) in the intercrural space. Its ventral face sends numerous ramifying prolongations among the fasciculi of the crusta. It extends from the cephalic border of the pons to the subthalamic region, while its lateral edge reaches the surface along the lateral sulcus. Its cells are medium-sized, multipolar, their bodies approaching the fusiform or angular in outline. The cells are characterized by a pigment (marked only in man) which varies from a pale brown in the young to an absolute blackness in the very aged. The axones arising from the cells proceed in various directions toward the tegmentum and crusta, but their exact course is not known. Experimental excitation of this ganglionic mass elicits movements of deglutition accompanied by respiratory changes. Mellus has found in the monkey that a portion of the pyramidal tracts is interrupted in the substantia nigra.

The **corpora quadrigemina** are largely composed of gray substance, but the superior and inferior corpora quadrigemina differ distinctly in structure.

The **inferior corpora quadrigemina** or **postgemma** are more homogeneous in texture, comprising a pair of compact ganglia which on trans-section have the shape of biconvex lenses, encapsulated by white substance. The cells are small, multipolar, and very numerous, embedded in a fine molecular groundwork. The white **stratum zonale** is principally derived from the fibres of the lateral lemniscus, which terminate in the central gray of the inferior quadrigeminal body as well as in the internal geniculate body. The axones of the cells in the inferior quadrigeminal body course cephalad in the inferior brachium, dip beneath the internal geniculate body into the tegmentum, and proceed to the thalamus. The inferior quadrigeminal bodies are important links in the chain of the auditory neurone system, and are special localities for the reflexion of auditory impulses.

The **tegmentum** of the mid-brain is continuous with the like formations in the hind-brain stem and consists of longitudinal fibre bundles intersected by transverse arched fibre systems with gray substance irregularly scattered in the interstices, composing the **formatio reticularis**. In its ventral portion, on either side, and at the level of the superior quadrigeminal body, lies a gray ganglionic mass, the **red nucleus**.

The **superior corpora quadrigemina** or **pregemma** present a true cortical type, which is more evident in the optic lobes of lower vertebrates. In man the thin, outermost white layer—the **stratum zonale**—is an expansion of the optic tract. Beneath this lies a gray nucleus, with numerous small cells—the **stratum cinereum**—a cup-like layer of crescentic outline on trans-section. The succeeding ental layer is a white stratum, also derived from the optic tract—the **stratum opticum**. Between this and the underlying stratum lemnisci is a second gray layer, less defined because of the diffuse interlacing of white fibres.

Each superior quadrigeminal body is one of a series of primary centres of vision related more to eye-muscle reflexes resulting from optic and auditory stimuli than to actual light and color perception. Fibres from the retina, for the most part, form the stratum zonale and end in the ganglionic gray; others enter into the formation of the **stratum opticum**. Return fibres from the occipital cortex also enter the stratum opticum. The retinal and occipital fibers determine the formation of the superior brachium. Other fibres reach the superior quadrigeminal body through the lateral and medial lemnisci—from both sides—to end in relation with the deeper cells of the stratum cinereum. The connections of the superior quadrigeminal body with the cochlear centres afforded by the lateral lemniscus establishes the so-called **optic-acoustic reflex path**.

The **red nucleus** or **rubrum** (*nucleus tegmenti*; nucleus ruber), so termed from its reddish tinge in the fresh brain, which it owes to the pigmentation of its cells as well as to its great vascularity, is found subjacent to the superior quadrigeminal body in those section-levels where the substantia nigra has its greatest expansion. In trans-sections its outline is irregularly circular; in sagittal sections an elongated oval. The red nucleus is the end station for the majority of the decussated fibres of the superior peduncles of the cerebellum, for fibres from the cerebral cortex, and from the corpus striatum. These fibre bundles form for the nucleus a capsule which is thicker on its ental surface. From the cells of each of the nuclei arise axones which pass (1) to the thalamus and cerebral cortex (links in the cerebello-cortical neurone-chain), and (2) axones which descend into the spinal cord to form the **tractus rubrospinalis** (Monakow's)—a continuation of an indirect motor path from the cerebral cortex to the peripheral motor nerve. The tracts arising from the red nuclei of the two sides decussate with each other and descend in the tegmentum.

In the intercrural space lies a primitive gray ganglionic mass, the **posterior perforated substance** or **postperforatum**. In this posterior perforated substance, cephalad of the pons and in the median line, lies a cluster of cells, the **interpeduncular nucleus** (Gudden). The **fasciculus retroflexus** (Meynert), whose fibres arise in the habenal ganglion, descends to end in the interpeduncular ganglion.

The principal longitudinal fibre tracts in the tegmentum of the mid-brain are (1) the **medial longitudinal fasciculus**, (2) the **lateral lemniscus**, (3) the **medial lemniscus**, (4) the **decussating superior cerebellar peduncles**, (5) the **decussating rubrospinal tracts**, and (6) the **central tegmental tracts**.

The **medial longitudinal bundle** lies on each side of the median plane, just ventrad of the central aqueduct gray in the mid-brain and continuous throughout the brain stem in its formatio reticularis. It is the continuation and the equivalent, but in a more differentiated form, of the ventral basis bundle of the spinal cord. It is formed by association neurones and acts as an associating agent with regard to many cranial and spinal nerve centres for the performance of certain definite functions. Its neurones receive impulses from afferent elements and transmit them to motor or efferent elements. It particularly brings into relation the sensor cranial nerve nuclei and the corpora quadrigemina with the motor nerves of the eye (III, IV, and VI), of the face (VII), and of the trunk. A special nucleus for the bundle is described as being situated in the gray floor of the third ventricle, at its junction with the aqueduct. The axones from the cells of this nucleus cross to the opposite side through the posterior commissure (Fig. 665).

The **lateral lemniscus**, we have learned, is a continuation of the auditory path in its course to the cerebral cortex. Its formation is described on page 884. In the mid-brain the fibres of the lateral lemniscus course through the lateral part of the tegmentum, near the surface, and most of them end in the *gray* nucleus of the inferior corpora quadrigemina and in the internal geniculate body. A few fibres are carried into the superior quadrigeminal body.

The **medial lemniscus**, or principal conduction path for sensor impulses from the trunk and extremities, and already discussed in the preceding (p. 876), ascends in the tegmentum of the mid-brain in the contact zone with the crusta. In its ascent it is deflected slightly dorsolaterad by the red nucleus. The lateral border of the ribbon-like bundle is in contact with the lateral lemniscus, and forms an angle with it, as seen on trans-section (Figs. 663 and 664).

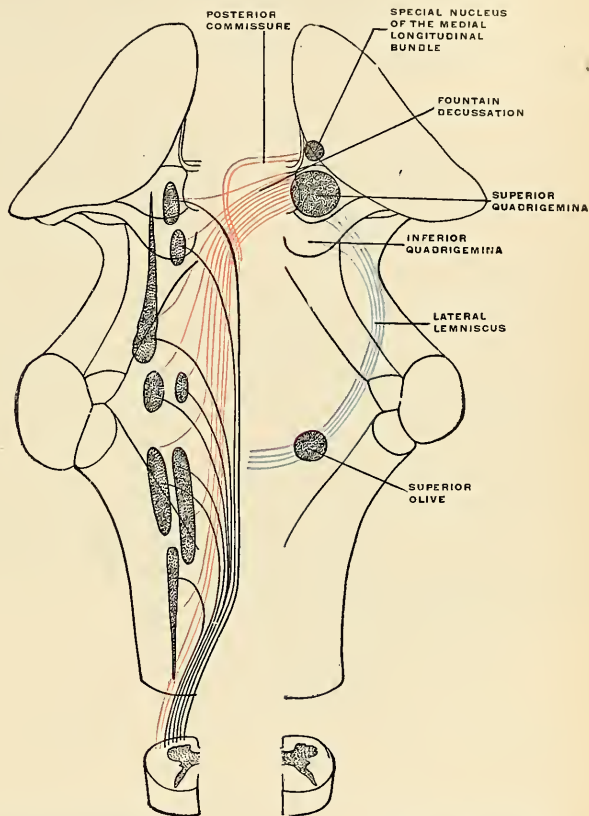


FIG. 665.—The medial longitudinal bundle in black and red. Lateral lemniscus in blue. (The nuclei may be identified by comparison with Fig. 648.)

Many of the fibres of the medial lemniscus terminate in the superior quadrigeminal body; the remainder proceed to the thalamus.

The **superior peduncles** or **prepeduncles of the cerebellum** sink into the mid-brain tegmentum in a cephaloventral direction, the two superior peduncles converging and their fibres undergoing a complete decussation (Wernekinck's commissure) subjacent to the inferior quadrigeminal body. The crossed fibres end, for the most part, in the red nucleus of each side; others circumvent the nucleus forming

a white capsule for it which is thicker on its ental surface, and proceed to the thalamus.

The **tractus rubrospinalis** (Monakow's) is composed of axones arising in the red nucleus, decussating with those of the opposite tract, and descending in the tegmentum to the lateral intermedial fasciculus of the cord, to terminate in relation with ventral-horn cells.

The **central tegmental tract** (*olivary fasciculus*) probably arises in the inferior olivary nucleus and ascends in the tegmentum. In the pars dorsalis pontis it is best seen in trans-sections as a compact longitudinal bundle along the dorsimésal aspect of the superior olive. Cephalad it is said to end in the lenticular nucleus.

Fountain Decussation.¹—A dense decussation may be found in the space between the two red nuclei. The fibres composing the decussating bundles arise from cells in the superior corpora quadrigemina and central aqueduct gray. After having crossed the middle line they descend as the **tectospinal tract**, join the medial longitudinal fasciculus, and give off collaterals to, or terminate in the nuclei of, the eye muscle nerves, as well as to spinal centres for movements of the head and neck.

The **crusta** or **pes** is somewhat crescentic in outline on section and is composed of longitudinal fibre bundles—the continuation of the internal capsule—divisible into three sectors. The middle sector comprises three-fifths of the cross-section area of the crusta, and comprises the **pyramidal tract** on its way from the cerebral cortex (motor area) to cranial and spinal centres below. The ectal sector, or lateral one-fifth, comprises the **temporopontile tract**;¹ its axones arise from the cortical cells in the temporal lobe and end in fine terminal arborizations in relation with cells of the nuclei pontis. The ental sector, or mesal one-fifth of the crusta, comprises the **frontopontile tract**; its axones arise from cells in the cortex of the frontal lobe and terminate in the nuclei pontis.

The **pyramidal tract** is a *direct* voluntary motor tract; the two corticopontile tracts enumerated above are links in a chain of neurones which constitute an indirect motor tract. The series of neurones in the chain of the *indirect motor tract* may be shown in the following order: **Corticopontile tract**; **nuclei pontis**; **cerebello cortex**; **dentate nucleus**; **superior cerebellar peduncle**; **red nucleus**; **tractus rubrospinalis**; **spinal gray**; **spinal nerve**; **muscle**.

Summary of the Gray Masses in the Mid-brain:

*Central aqueduct gray.

(a) Oculomotor n. nucleus.

(b) Trochlear n. nucleus.

Nucleus radialis descendens nervi trigemini.

*Nucleus of medial longitudinal bundle and postcommissure.

*Formatio reticularis.

*Substantia nigra (intercalatum).

*Red nucleus (rubrum).

*Stratum cinereum of superior corpora quadrigemina.

*Nucleus of inferior corpora quadrigemina.

*"Interpeduncular" ganglion.

Structures marked with an asterisk have been considered in the preceding description. The central connections of the oculomotor, trochlear, and trigeminal nerves may now be described.

Deep Origin of Cranial Nerves Arising in the Mid-brain.—The mesencephalic root of the trigeminal nerve has been described on page 884.

¹Decussatio fontinalis, so called because of the resemblance of the scattering strands to the jets of a fountain.

The Trochlear Nerve Nucleus.—The trochlear nerve nucleus is situated in the level of the cephalic half of the inferior quadrigeminal body. It is a small oval mass of gray substance in the ventral part of the central aqueduct gray. The cells are large, sometimes stellate in appearance. The root fibres pursue a peculiar course; they accumulate in the lateroventral angle of the aqueduct gray, run caudad, gradually rising dorsad, and suddenly turn mesad to undergo a complete decussation with the root of the opposite side in the superior medullary velum, emerging laterad of the frenulum, or at the inner border of the superior peduncle.

The nucleus is placed under the dominion of the cerebral cortex by pyramidal fibres, and it is associated with other nuclei in the brain stem by the medial longitudinal bundle.

The Oculomotor Nerve Nucleus.—The oculomotor nerve nucleus is a group of cell clusters in the ventral portion of the aqueduct gray, subjacent to the superior quadrigeminal body, and extending cephalad to become lost in the gray wall of the third ventricle at the slope formed by the opening out of the aqueduct. Its nerve elements are arranged in definite groups. The most cephalic of these is composed of smaller elements, closely crowded and embedded in deeply staining

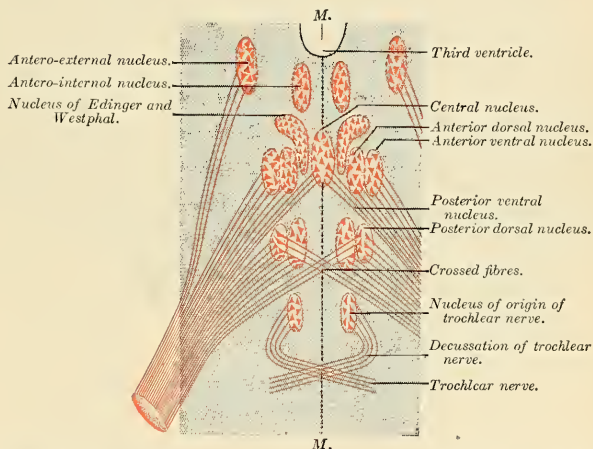


FIG. 666.—Showing the different groups of cells, which constitute, according to Perlia, the nucleus of origin of the oculomotor nerve. (Testut.)

molecular ground substance. In a flat-wise section of the brain stem the outline of this nucleus resembles an inverted L or the tip of a boat hook; the axones from the cells of this nucleus (of Edinger and Westphal) supply the Ciliary muscle and Sphincter iridis (pupillary motion). The main nucleus, composed of several sub-groups, lies caudolaterad of the preceding, and is composed of larger cell elements.

The root fibre bundles from this nuclear group pass ventrad, breaking through the medial longitudinal fasciculus, separating like the strands of a horse's tail by the interference of the red nucleus, to become gathered into more compact bundles between the mesal edge of the substantia nigra and intercrural region, and emerging by eight to twelve fascicles which compose the trunk of the oculomotor nerve.

The origin of each nerve is not limited to the nuclei of its side; a part is decussated and the decussated origin is related to the innervation of the Internal rectus.

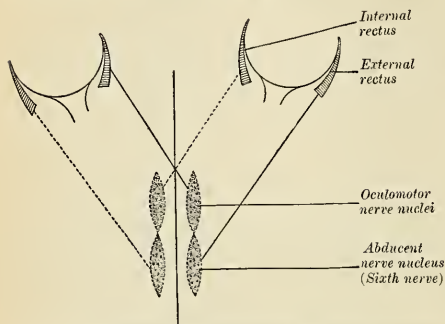


FIG. 667.—Coöperation of the nucleus of origin of the abducent and the nucleus for the Internal Rectus. (Morat.)

By means of association neurones in the medial longitudinal fasciculus the oculomotor and abducens nuclei of one side are brought into relation, affording an organic basis for the synergism existing between the Internal and External recti muscles in the conjugated lateral eye movements.

The paradox of the facial nerve supplying muscles under the reflex dominion of the retina (*Orbicularis oculi*) instead of the oculomotor may be explained by the assumed existence of fibres

emerging from the oculomotor nucleus, entering the medial longitudinal fasciculus and joining the root of the facial.

Parts Derived from the Fore-brain.

The **fore-brain** or **prosencephalon** includes those portions of the brain which are derived from the cephalic one of the three primary brain vesicles. It includes, according to prevailing schemas, a **thalamic portion** (the **thalamencephalon** or **diencephalon**) and the **telencephalon**. The two divisions constitute a structural continuity and exhibit a mutual dependency so close that the arbitrary distinction now in vogue tends to mislead. The relations of "diencephalon" and "telencephalon" are further complicated by the intimate fusion of the sides of the former (thalami) with the floors of the latter; this caudatothalamic fusion, in the adult brain, gives rise to some difficulty in distinguishing the two segments. The internal capsule which intervenes between thalamus and lenticular nucleus also intervenes between lenticular nucleus and caudate nucleus, both telencephalic parts.

External Morphology.—The **diencephalon** or **thalamencephalon** comprises the **thalami**, the **pineal body** or **epiphysis** and **habenulæ**, the **external geniculate bodies**, and the **pars mamillaris hypothalami**. (Other classifications include also the **pars optica**, with **tuber cinereum**, **infundibulum**, **optic chiasm**, and **pituitary body** or **hypophysis**. It is also defined as so much of the fore-brain as does not enter into the formation of the cerebral hemispheres.) Caudad it is continuous with the mid-brain, cephalad with the cerebral hemispheres. Its primitive cavity becomes metamorphosed in the adult into the third ventricle or diacele as the lateral walls hypertrophy to form the thalami. Its ventral surface is the relatively insignificant gray lamina in the intercrural space. Its dorsal surface is concealed from view by the massive hemispheres and their great commissure, the **corpus callosum**, and by the **fornix**. Its actual roof, separating it from the overlapping cerebral parts, is a delicate membranous fold, the **velum interpositum** or **diatela**.

The Thalami.¹—The thalami constitute the bulk of this portion of the brain. They are large ovoid masses of gray substance so named by the ancients after their resemblance to a pair of couches. Each thalamus is smaller frontad than caudad and the caudal ends are more widely separated from each other. The **mesal** or

¹ *Thalamos*, bed or couch; bed-chamber.

ventricular surface is largely free, except for an area, of variable size, by which the two thalami are fused in 90 per cent. of brains. The **thalamic fusion** is also called the **middle commissure** or **medicommisure**. The free surface is covered by ependyma and is of smooth contour. Its dorsal limit is marked by an ependymal ridge, usually torn through in dissection, the **taenia thalami** or **ripa**,¹ fortified by a subjacent narrow band of fibres called the **stria medullaris**, which may be traced to the habenular nucleus and habenular commissure (or "stalk" of the pineal body). Caudad lies a depressed triangular area—the **trigonum habenulae**, situated cephalad of the superior quadrigeminal body.

The **dorsal surface** is usually described as being free, but only a narrow ectal portion can be so described, the ependyma of the lateral ventricle being slightly

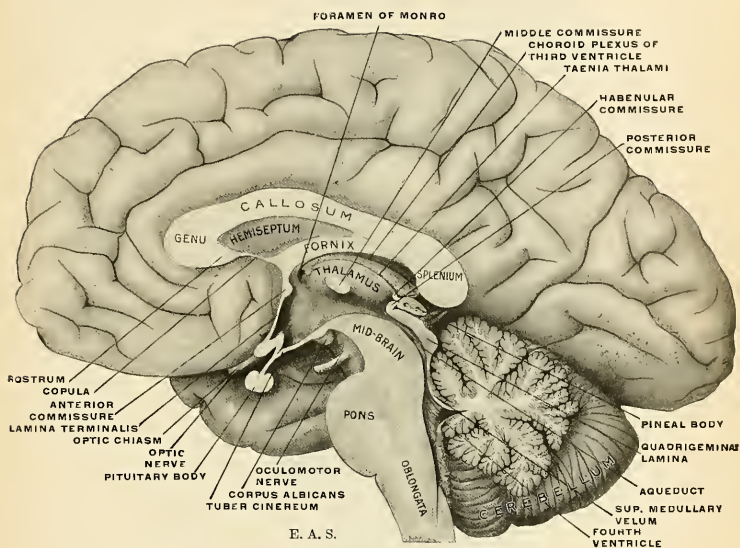


FIG. 668.—Mesal aspect of a brain sectioned in the median sagittal plane.

reflected upon it (the lamina affixa) before entering into the formation of the choroid plexus of the lateral ventricle. The rest of the dorsal surface is not lined by ependyma, but is in contact with the pial fold called the **velum interpositum**. This surface is of a whitish color owing to a thin layer of white fibres, the **stratum zonale**. A faint oblique groove crosses this surface in a caudolateral direction, corresponding to the ectal edge of the fornix. Laterad it is demarcated from the caudate nucleus by a groove which is occupied by the striatal vein and a slender band of fibres, called the **taenia semicircularis** or **stria terminalis**. The surface is not of even contour throughout, usually showing three eminences (in addition to the pulvinar) corresponding to the main nuclear aggregations within the thalamus—viz.: **Tuberculum anterius**, **medialis**, and **lateralis**.

¹The line formed by the rupture of the ependyma along the lines of its reflection from entocœlian (ventricular) surfaces.

The **tuberculum anterius** forms a marked bulging frontal extremity, which helps to form the boundary of the **foramen of Monro** or aperture of communication between lateral and third ventricles.

The caudal extremity of the thalamus is a prominent bolster-like projection which overhangs the brachia of the corpora quadrigemina and is called the **pulvinar**. A smaller oval prominence, situated ventrolaterad of the pulvinar, is termed the **external geniculate body** or **pregeniculum** (*corpus geniculatum laterale*)—a partial end station for the optic tract.

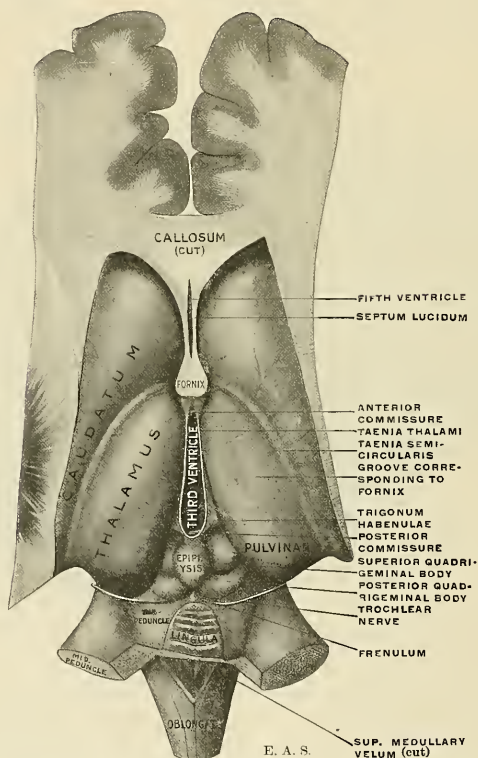


FIG. 669.—Dissection showing the two thalami, the two caudate nuclei, and adjacent parts.

The *lateral surface* of the thalamus is in contact with the internal capsule—that great concentration of fibre tracts coursing to and from cerebral centres and forming the crusta below. To this white stratum the thalamus itself contributes fibres destined to reach the cortex, and in return it receives fibres from the cortex. These thalamocortical and corticothalamic sets of fibres constitute the **thalamic radiation**, forming a more or less distinct reticulated capsular zone (*stratum reticulatum*; external medullary lamina) for the thalamus.

The *ventral* or *inferior surface* is continuous with the hypothalamic tegmental substance and with the central gray substance of the third ventricle lining its sides and floor.

Internal Structure of the Thalamus.—The thalamus is composed of gray substance, with large multipolar cells, which is subdivided into a number of distinct nuclei; twenty such have been described; three are universally recognized. They are separated from each other by a white layer (*lamina medullaris interna*) which runs parallel to the wall of the third ventricle for its greater length; caudally it runs mesad, overlapped by the ectal nucleus, and numerous sub-laminae run into it. Frontad the internal medullary lamina subdivides into two branches, thus permitting the intrusion of the **nucleus anterior** between the two main nuclei (*medial* and *lateral*).

The **nucleus anterior** lies frontodorsad; in it terminate the axones of the **fasciculus thalamomammillaris** (fasciculus albicantiothalami; bundle of Vicq d'Azyr). The **nucleus medialis** is lined mesad by the central gray of the third ventricle and is usually fused with its fellow of the opposite side (middle commissure). A special spheroidal cell cluster in this nucleus is called the **centrum medianum** (Luys). The **nucleus lateralis** is the largest of the three, extending the entire length of the thalamus and including the pulvinar. A special semilunar cluster of cells in the ventral portion of this nucleus is called the **nucleus semilunaris** (Flechsig).

The Connections of the Thalamus.—The thalamus is a ganglion interposed between the sensor tracts in the tegmentum and the cerebral cortex, as well as an important link in the optic path. It also gives rise to motor tracts concerned with instinctive movements of an emotional nature. It is a relay station for the various tracts which convey sensations of touch, temperature, and pain from the body, extremities, head and neck, of muscle sense, and of the special senses. It transmits these impulses to, and, reciprocally, receives impulses from the cerebral cortex. As an "emotional" centre it is also under the inhibitory influence of the cerebral cortex, which, if the emotion be not too strong, prevents its external manifestation.

The **thalamocortical** and **corticothalamic fibres**, with the **internal capsule**, enter into the **corona radiata** or fan-like formation of the white substance of the cerebral hemisphere. Although there is no anatomic subdivision into distinct groups of these fibres as they stream to and from the thalamus, it is customary to distinguish a **frontal**, a **parietal**, an **occipital**, and a **ventral stalk**. The frontal and parietal stalks, as their names indicate, pass between the thalamus and frontoparietal cortex, as well as to the lenticular nucleus and caudate nucleus. The occipital stalk is composed of fibres passing in both directions between the pulvinar and occipital cortex, constituting the so-called **optic radiation**. The ventral stalk comprises the **ansa lenticularis** (*thalamolenticular*) and the **ansa peduncularis** (*thalamotemporal* and *thalamoinsular*). They will be described in detail farther on.

The **external geniculate body**, or **pregeniculum** (*corpus geniculatum laterale*) is an intercalar ganglion proper to the optic nerve, derived from the thalamus. On section it is seen to be characterized by the regular alternation of deeply gray and white laminae. The latter are thicker and composed of fibres which enter the external geniculate body from the optic tract and optic radiation. The nerve cells in the gray substance are large, multipolar, and pigmented.

[NOTE.—The external geniculate body and the more isolated internal geniculate body are generally included under the head of *metathalamus*.]

The **hypothalamic tegmental substance**, continuous with the mid-brain tegmentum, is interpolated between the ventral face of the thalamus, the red nucleus, and a continuation of the substantia nigra known as the **corpus hypothalamicus** or **body of Luys**. Through the hypothalamic tegmentum stream the fibres of

the **medial lemniscus**, of the **superior peduncle** of the cerebellum, and from the red nucleus, to end in relation with thalamic cells. The corpus hypothalamicus is a grayish-brown, lentiform mass which lies in the ideal continuation frontad of the lateral part of the substantia nigra, and, like it, situated between pes and tegmentum. It is made up of fine myelinated fibres crowded in great profusion and confusion, with numerous delicate, coiled capillaries and sparse, multipolar, more or less pigmented, nerve elements of moderate size. The outline of the body is defined by a white capsule, some of the fibres of which are seen to decussate in the floor of the third ventricle with those of the opposite side, dorsocaudad of the corpora albicantia.

The Pineal Body (*corpus pineale*; epiphysis) (Figs. 668 and 669).—The pineal body (from its shape resembling a fir-cone—*pinus*) is a small, reddish-gray body placed between the caudal ends of the thalami and occupying the depression between the two superior quadrigeminal bodies. It is covered by the velum interpositum, which intervenes between it and the splenium of the corpus callosum. It is an outgrowth which is not regarded as an important neural ingredient of the human brain and is generally believed to be a rudimentary relic, representing a cyclopean eye¹ of some extinct ancestral vertebrate, homologous with the parietal organ, resembling a molluscan eye of a living species of Prosaurian (the *Hatteria* of New Zealand). Its attached base is a hollow peduncle divisible into a dorsal and ventral part by the intrusion of the **epiphyseal recess** (*recessus pinealis*) of the third ventricle. The **dorsal stalk** continues on either side and upon each thalamus as the stria medullaris; it is reinforced by commissural fibres joining the habenulae of the two sides; hence another name for the dorsal stalk is the **habenular commissure** (supracommissure of Osborn). The **ventral stalk** is folded over another commissural band—the **posterior commissure**.

Structure.—The pineal body consists of a number of follicles, lined by epithelium and connected by ingrowths of connective tissue. The follicles contain a transparent viscid fluid and a quantity of sabulous matter named **brain sand** (*acervus cerebri*), composed of phosphate and carbonate of lime, phosphate of magnesia and ammonia, with a little animal matter. These concretions are almost constant in their existence, and are present at all periods of life.

In the interval between the pineal body and the caudal end of the thalamus lies a small triangular depression (sometimes an elevation) known as the **trigonum habenulae**, marking the position of the **nidus**, or **ganglion habenulae**, a group of small angular cells. The axones from these cells are collected ventrad into the **fasciculus retroflexus** (Meynert), which courses through the tegmentum mesad of the red nucleus to end in the **interpeduncular ganglion** (Gudden) in the posterior perforated substance. In addition to this fasciculus, the habenula is the reunion point for two other sets of fibres: (1) the **stria medullaris** and (2) **habenular commissure**. The stria medullaris (p. 903) is made up of axones arising from two sources: (1) cells in the hippocampus (*via fornix*) and (2) cells in the ganglion opticum basale. These join near the anterior pillar of the fornix and run caudad on the mesal thalamic surface, to end in the habenular ganglion of the same side and, by crossing in the dorsal stalk of the epiphysis, help to form the habenular commissure, to end in the corresponding nidus habenulae of the opposite side.

The **posterior commissure** is a round band of white fibres crossing from side to side in the ventral stalk of the pineal body bridging the aqueduct at its continua-

¹ Although most vertebrates show a single pineal body or parietal organ, it is double in the lamprey and certain reptiles; the two bodies lie one in front of the other—not side by side (although probably paired organs originally). The frontal organ sends its fibres into the habenular nucleus: the caudal organ to the region of the posterior commissure (tectum opticum).

tion into the third ventricle. The posterior commissure shares relation with both fore-brain and mid-brain structures and is formed of decussating fibres which may be enumerated in the following systems: (a) fibres arising in the special nucleus (described on p. 898) for the **medial longitudinal bundle**; (b) fibres connecting the two **thalami**; (c) fibres connecting the **habenular nuclei**; (d) fibres connecting the **superior quadrigemina**.

[NOTE.—The habenulae, pineal body, and posterior commissure are generally included under the head of *epithalamus*.]

The **posterior perforated substance** or **postperforatum** has been described on page 898. It marks the situation of the “interpeduncular ganglion,” which is small in man, but very large in rodent brains. From the cells in this primitive gray lamina arise the fibre tracts already described as the **taenia pontis** (p. 895), and often visible at the point of emergence from the gray substance of the intercrural space.

The **corpora albicantia** (Fig. 673), or **corpora mamillaria**, are two symmetrical,

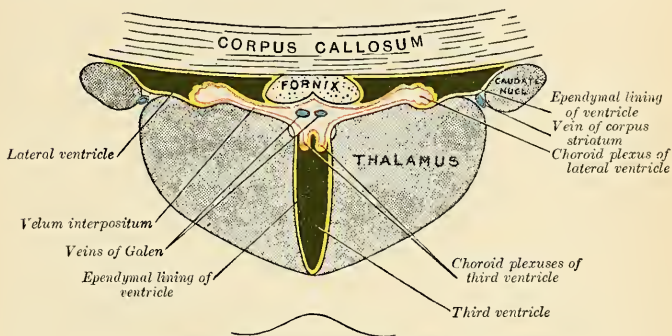


FIG. 670.—Coronal section of lateral and third ventricles. (Diagrammatic.)

small, round, white protuberances situated side by side in the intercrural space cephalad of the posterior perforated substance, at a point where the floor of the third ventricle rapidly decreases in thickness to form the **tuber cinereum**. The color of each corpus albicans is white, owing to a superficial stratum of fibres derived from the fornix. Within lie three nuclear masses—two medial, constituting the main mass, and a smaller lateral nucleus applied against the former, so as to represent a crescent on cross-section.

The fibres of the fornix terminate in the corpus albicans. From its cells arise two fasciculi which have a common neurone origin. Cajal discovered, and Kölliker confirmed the fact, that the axones from the medial nucleus cells bifurcate; one set of limbs passes fronto-dorsad to form the **bundle of Vicq d'Azyr** (*fasciculus thalamomamillaris*), which ends in the nucleus antierius of the thalamus, while the other set of limbs of the primary axones passes caudad to form the **fasciculus pedunculomamillaris** in the mid-brain tegmentum; its destination is doubtful. The axones from the lateral nucleus join the latter bundle.

[NOTE.—The posterior perforated substance and the corpora albicantia are generally included under the head of the *Pars Mamillaris Hypothalami*.]

Third Ventricle (*ventriculus tertius*) (Fig. 668).—The third ventricle is the adult representative of the cavity of the primary fore-brain vesicle, but only so

much of it as is not carried laterad, on either side, in the rapidly growing, eventually huge cerebral hemisphere buds to form the lateral ventricles. It is a narrow, cleft-like interval between the two thalami and hypothalamic gray, limited frontad by the terma, continuous caudad with the aqueduct and laterad, through the foramina of Monro, with the lateral ventricles. Its roof is destitute of nerve tissue and is formed by a delicate, fused ependymal and pial layer, invaginated on either side of the median plane by the plexuses of the lateral ventricle. The pial layer is one of the constituents of the fold known as the velum interpositum. The *floor* of the ventricle is formed by structures already described on the basal aspect in the intercercal space—viz., the tuber cinereum, corpora albicantia, and posterior perforated substance, as well as the optic chiasm and a portion of the tegmentum of the crura cerebri. Much of the floor, it may be noted, is formed by the primitive, undifferentiated central gray; and although the optic vesicle develops from its ventrocephalic portion, the caudal shifting of central optic connections to thalamus and mid-brain has made this portion of the neural tube wall comparatively insignificant. The *lateral walls* are formed in part by the thalami, in part by the hypothalamic gray ventral extension. The fornix may be seen, shining through a thin lamina of gray substance and the ependyma, coursing caudoventrad to the corpus albicans. A slight furrow, the *aulix* or *sulcus of Monro*, may sometimes be traced from the aqueduct to the foramen of Monro, curving ventrad of a bridge-like fusion of the two thalami—the **middle commissure** (medicommisure). (The term commissure is inappropriate, as no commissural fibres appear to pass from one thalamus to the other in this “thalamic fusion”; it is absent in about 10 per cent. of brains examined.)

The cephalic wall is formed by the **lamina terminalis** or *terma*, the rudimentary mediancephalic wall of the neural tube. The terma is attached to the dorsum of the optic chiasm; dorsally it is reinforced by the anterior commissure.

As seen in mesal section or as shown by a cast of the ventricle (Fig. 696) it is seen to be of irregular outline. Frontad is the optic recess, dorsad of the optic chiasm; caudad thereof is the infundibular recess in the tuber. The epiphyseal recess is seen between the habenular commissure and the posterior commissure. Dorsad of the pineal body is a diverticular recess of variable extent (*recessus suprapinealis*).

If the segmentation of the fore-brain into two divisions be adopted ultimately, it will be necessary to allot one portion of the third ventricle (between the thalami) to the diencephalon (hence *diacele*), and the rest to the telencephalon (the medial cavity of which is termed the *aula* by Wilder).

In anticipation of the description of the cerebral hemispheres we may consider here the remaining structures in the floor of the third ventricle, usually included under the head of the **pars optica hypothalami of the telencephalon**, in order to lead up to a description of the cerebral connections of the optic tract.

External Morphology of the Optic Portion of the Hypothalamus.—This includes the tuber cinereum and **pituitary body** or **hypophysis**, the **lamina terminalis**, the **optic chiasm**, and the **optic tracts**.

The **tuber cinereum** (Fig. 668) is a thin-walled conical projection in the intercercal space cephalad of the corpora albicantia. Its apical portion is attenuated to form the stalk of the pituitary body; this is generally termed the **infundibulum**, while the cavity of the funnel-shaped diverticulum is called the **infundibular recess of the third ventricle**. The gray lamina composing the tuber is continuous with the central ventricular gray, and therefore with the **lamina terminalis**.

The **pituitary body** or **hypophysis**¹ is a structure of twofold origin, giving rise to a division into a **prehypophysis** and a **posthypophysis**. The posthypophysis alone is of neural origin, developing as a ventral diverticulum from the primitive neural tube. The prehypophysis or epithelial lobe, develops from the stomodeum, or buccal cavity, as a tubular diverticulum (Rathke's), which eventually loses its connection² with the oral tissues to become included within the cranial cavity and intimately attached to the neural bud. Both pre- and posthypophysis are therefore of ectodermal origin and have developed from a conjunction of surface tissues which have migrated from opposed (ventral and dorsal) parts through the head! The prehypophysis is much the larger and somewhat embraces the posthypophysis; the two are inseparable, however, and together occupy the **fossa hypophyseos** of the sphenoid.

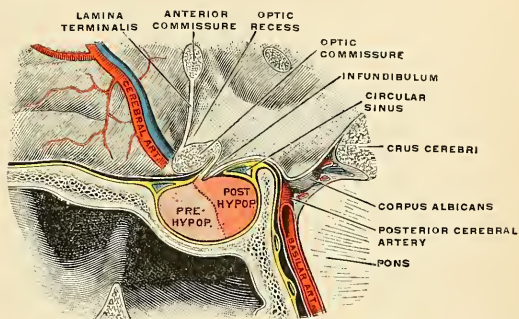


FIG. 671.—The pituitary body, or hypophysis, in position. Shown in median sagittal section. (Testut.)

The two parts of the pituitary body are as distinct in structure as they are in embryonic origin. The posthypophysis consists of a mass of nerve cells, neuroglia, connective tissue, and bloodvessels; the structure of the prehypophysis is distinctly glandular, resembling that of the parathyroid bodies. It is surmised that the latter is the functional part of the pituitary body—concerned with the internal secretions, and usually involved in the pathological form of giantism called **acromegaly**.

The **lamina terminalis** or **terma** (Fig. 668) is a thin, easily torn lamina between the optic chiasm and the anterior commissure, limited laterally by the closely approximated cerebral hemispheres and constituting the primitive, undifferentiated cephalic boundary of the original neural tube.

The Optic Tract and its Central Connections.—In the section on the development of the brain it was learned that the optic nerve is not a peripheral nerve; it is rather a central brain tract extruded from the neural tube. Evidence is at hand that in ancestral vertebrates the general cutaneous sensor system was also capable of light perception. With the recession of the neural tube from the surface and in company with the morphological differentiation of the head end, a light-perceiving pair of organs arose as a special development. The distal end of the optic brain vesicle becomes the retina, in structure like the brain wall, whose cell axones carry afferent impulses to the brain. Although the optic fibres enter the

¹ F. Tiley: Study of the hypophysis cerebri with especial reference to its comparative histology. Memoir No. 2 of Wistar Institute of Anatomy and Biology, 1912.

² Occasionally the channel persists as the *craniopharyngeal canal*.

ventral wall of the brain, the retina is originally derived from the dorsolateral (sensor) wall of the second neuromere (Fig. 627). The parietal organs, also light-perceiving, likewise developed as paired dorsal buds farther caudad, eventually to atrophy, as the more frontal optic organs better subserved the purposes of the organism.

The remarkable and as yet unexplained fact regarding the optic apparatus is that the afferent fibres from the retinal cells pass into the ventral wall to cross to the opposite side, forming a decussation which is total, or nearly so, in vertebrates below the mammals; the more laterally placed the eyes are the more nearly total is the decussation.¹

Although the optic vesicle is a diverticulum of the fore-brain in its cephalic portion, the optic tract in its central connections becomes intimately related with the external geniculate body and pulvinar, the occipital cortex of the cerebrum, and with the superior quadrigeminal body of the mid-brain. Some of these central structures are way-stations in reflex paths; the occipital cortex alone is the actual visual centre, though visual perceptions are here brought into association with tactile, auditory, and other impulses.

Optic Chiasm.—From the retina of each eye the so-called optic nerves converge to partially decussate at the base of the brain to form the **optic chiasm**, a white quadrangular plate which presses in the primitive central gray floor of the third ventricle, as previously described. Approximately one-third of the fibres of each optic nerve do not cross to the opposite side. The optic chiasm is further reinforced by the **infracommissure** (of Gudden) and other lesser fibre tracts (**commissura superior** [Meynerti] and **commissura ansata** [Kölliker]). The fibres in the chiasm are so complexly interwoven that only through exhaustive experimental development and pathological studies has it been possible to understand its structure. Broadly stated, the fibres from the medial (or nasal) halves of the retinae decussate *in toto*, while those from the lateral (or temporal) halves do not cross. Leaving the optic chiasm, the crossed medial and uncrossed lateral fibres form the slightly flattened **optic tracts** coursing caudolaterad, embracing the crura cerebri and dividing in the neighborhood of the lateral geniculate body into two "roots," a mesal and a lateral root. The **mesal root** is in reality not a part of the true optic path; it is a separate fascicular representation of the infracommissure of Gudden, composed of fibres forming a reciprocal bond of union (commissural) between the internal geniculate bodies of the two sides and coursing through the chiasm (Fig. 672). The **lateral root of the optic tract** is the true visual path, composed of (a) the uncrossed fibres from the lateral half of the retina of the same side and (b) the crossed fibres from the mesal half of the retina of the opposite side. The fibres of the lateral root are distributed to the **primary or lower optic centres** as follows: (1) Most fibres end in the external geniculate body; (2) a less number end in the pulvinar; (3) the remainder end in the nucleus of the superior quadrigeminal body.

The **lateral geniculate body** and **pulvinar** are ganglionic way-stations or internodes in which visual impulses are reflected, in large part, to the visual cortex in the occipital lobe; the superior quadrigeminal body, on the other hand, plays no part in the conduction of impulses perceived as light or color; it presides rather over the eye-muscle reflexes to visual² stimuli, and in its turn is under the dominion of the higher cortical centre. Reflex impulses are sent to the oblongata and spinal centres along axones entering into the formation of the medial longitudinal bundle.

¹ Possibly the reflex contraction of the muscles on one side of the body in the ancestral vertebrate followed the perception of a menacing object by the eye of the opposite side; hence the advantage of a decussation.

² And auditory stimuli as well (see p. 898).

The axones of corticifugal neurones proceed to the nucleus of the superior quadrigeminal body along the optic radiation.¹

Some fibres are detached from the optic tract and course through the crus cerebri to the oculomotor nucleus. These fibres are small, and are believed to be afferent branches for the Sphincter pupillæ and Ciliary muscles.

The connections of the external geniculate body and pulvinar with the higher cortical centre of vision are established by neurones, the cells of which lie in the two ganglia just mentioned, and whose axones stream in an arched, more or less

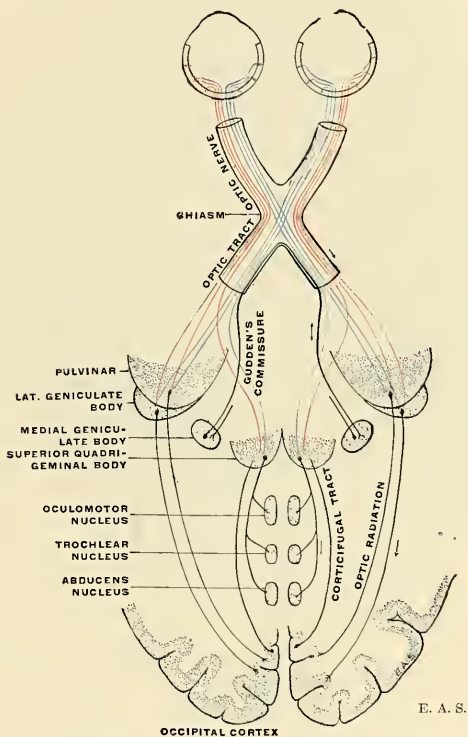


Fig. 672.—Scheme showing central connections of the optic nerve and optic tract.

compact bundle in the white substance of the cerebral hemisphere toward the occipital cortex. Another system of neurones, whose cells lie in the cortex, sends its axones in the reverse direction (corticifugal) to the two lower centres. The cerebral tract thus formed between primary and secondary (cortical) centres is called the **optic radiation** (Fig. 712), to be studied more fully in the sequel. The components of the optic path are delineated schematically in Fig. 672.

¹ Centrifugal fibres ending in the retina, and probably arising from cells in the superior quadrigeminal body, have been discovered in the optic tracts.

The Cerebral Hemispheres.

External Morphology.—Of all the component parts of the brain, the cerebral hemispheres form the largest part, and their preponderance and remarkable specialization underlie the extraordinary manifestations of the intellect so highly amplified in man.

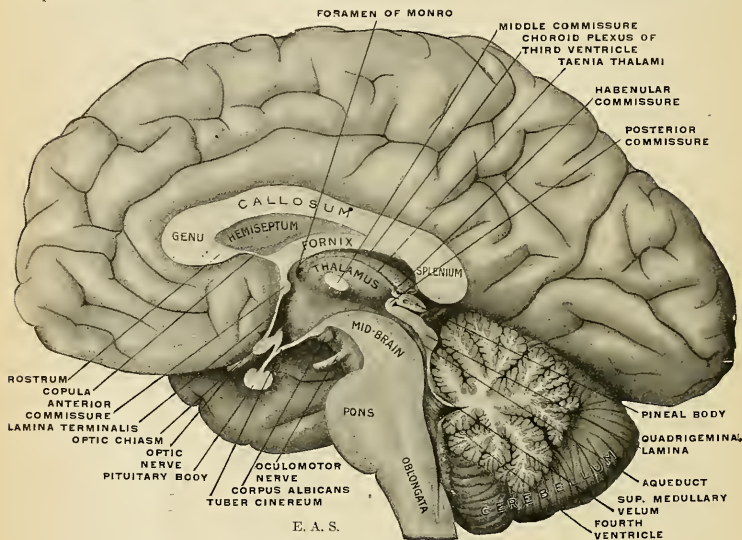


FIG. 673.—Mesal aspect of a brain sectioned in the median sagittal plane.

The term **cerebrum**, often employed loosely as embracing several brain parts, is here intended to include the brain mantle and the olfactory lobe—equivalent to the *telencephalon* of His, with the exception of the *pars optica hypothalami*. As already indicated in the section on brain development, there has occurred, in the evolutionary history of man's vertebrate ancestry, a progressive increase of the secondary fore-brain, with concomitant reduction of the *rhinencephalon*, or *smell brain*—the most archaic portion because of the important relations of the smell sense to the life history of the earliest vertebrates.¹

In a mesal view of a hemisected brain (Fig. 673) may be seen the various parts of the brain stem and the cerebellum overlapped by the preponderatingly greater cerebrum. Among the many notable features exposed to view in this brain section are certain fibre masses, **commissures**, extending across the meson, and therefore divided by the knife in this preparation. Of the commissures pertaining to the cerebrum one is conspicuous for its size and firm consistency. This great fore-brain commissure is the **corpus callosum** already mentioned as being demonstrable in the depths of the intercerebral cleft on divaricating the lips of this fissure. The corpus callosum constitutes a massive system of association fibres for the bilateral coördination of corresponding cortical parts. It is thickened caudally, forming the **splenium of the corpus callosum**; frontad it bends on itself

¹ For a more thorough discussion on the natural subdivision of the fore-brain, based upon comparative morphology, see the paper by G. Elliott Smith, *Journal of Anatomy and Physiology*, 1901.

ventrocaudad to form the **genu** ("knee"), including an interval, between the two limbs, which is flanked on both sides by a thin lamina (hemiseptum) and bounded ventrad by the fornix, constituting a closed cavity, the **pseudocèle** (*cavum septi pellucidi*). The recurved ventral part of the genu tapers into a thinner, beak-shaped part, the **rostrum**. The rostrum is joined to the lamina terminalis, frontad of the anterior commissure, by a thin lamina, the **copula** (*lamina rostralis*).

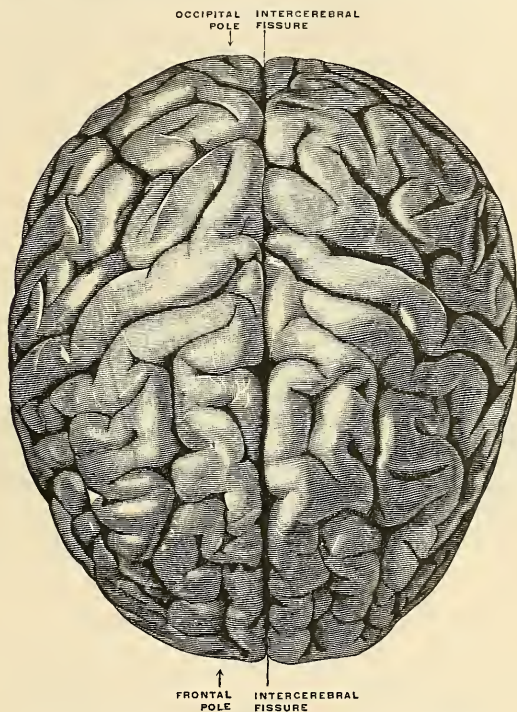


FIG. 674.—The cerebral hemispheres viewed from above. (Spalteholz.)

An arched structure composed of longitudinal fibre bundles comes to view in front of and below the junction of the splenium with the body of the corpus callosum, proceeds frontoventrad with its convexity frontad, to sink from view in the substance of the hypothalamic gray at a point just caudad of the anterior commissure. This white arched bundle is the **fornix**. Between it and the corpus callosum, rostrum, and copula stretches a thin, translucent lamina of nerve tissue—the **hemiseptum**. The hemisepta of the two sides together have usually been termed the **septum pellucidum**, while the enclosed narrow cavity is called the **pseudocèle** or **fifth ventricle**. The subjacent parts revealed in this section have already been described; the morphology and internal relations of the corpus callosum, fornix, and hemiseptum will be described at a later stage.

The cerebral hemispheres together, as viewed from above or dorsally, appear as two symmetrical masses in close apposition, conforming in outline to that of the cranial cavity, which they so nearly fill. The frontal extremities or poles are massive and rounded, preponderatingly so in comparison with the brains of any related primate species. The occipital poles are each more pointed but expand frontad into the widest part of the cerebrum—the **parietal lobes**. The cerebral hemispheres or, briefly, the **hemicerebra** are partially separated from each other by the **intercerebral cleft** or **great longitudinal fissure** (*fissura longitudinalis cerebri*), into which fits a fold of the dura—the **falx cerebri**. By means of a large commissural band of white fibres—the **corpus callosum**—the cerebral halves are joined together in the depths of the intercerebral cleft. All adjacent parts of the brain are overlapped by the ponderous cerebrum so as to entirely conceal the thalamic portion and the mid-brain, while the occipital lobes overlap the cerebellum with

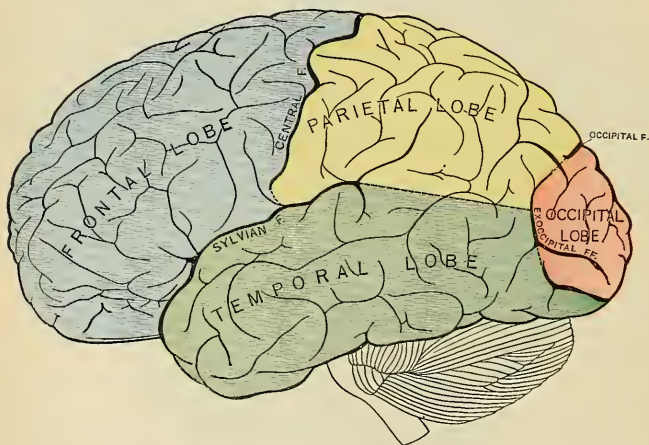


FIG. 675.—Principal fissures and lobes of the cerebrum viewed laterally.

the intervening tentorium—another fold of the dura. Further description will be restricted to each cerebral hemisphere.

Configuration of Each Cerebral Hemisphere.—Each cerebral hemisphere presents an *outer convex surface* (*facies convexa cerebri*), applied to the corresponding half of the cranial vault; a *mesal flattened surface* (*facies medialis cerebri*), which lies in a sagittal plane, applied to the corresponding surface of the opposite cerebral hemisphere, with the great longitudinal fissure intervening, and for the most part in contact with the falx cerebri; and a *basal or ventral surface*, of irregular form, resting frontad upon the floors of the anterior and middle cranial fossæ, and caudad upon the tentorium cerebelli.

Prominent in the lateral and ventral views is the blunt projection of the temporal pole, while at the ventrolateral border, nearer the occipital pole, is a slightly marked indentation usually called the **preoccipital notch**. The deep vallear depression between the orbital surface and the temporal pole accommodates the lesser wing of the sphenoid.

More or less distinct borders demarcate the surfaces. The arched *dorsimesal*

border intervenes between the mesal and the convex surfaces; a straight *mesorbital border* intervenes between the orbital and mesal surfaces of the frontal lobe; a *ventrolateral border* separates the tentorial surface from the lateral, convex surface of the occipital and temporal lobes; while an obtuse border—the *mesoventral* or *internal occipital border*—separates the tentorial from the mesal surfaces.

Cerebral Fissures and Gyres.—The surface of each cerebral hemisphere presents alternating depressions or **fissures** which demarcate gyral elevations—the **convolutions** or **gyres**.¹ The fissures vary in depth from that of a mere shallow groove to as much as 30 mm., and may attain a length of 15 cm. They are more or less sinuous and ramified. They mark the surface with fairly approximate uniformity, that is, one rarely finds an unfissured surface more than 15 to 20 mm. ($\frac{3}{8}$ inch to $\frac{1}{2}$ inch) in width. Numerous functional and mechanical influences must be credited with bringing about the complex foldings of the cerebral surface, principally (a) resistance of the cranium to the expanding brain or “mechanical packing;” (b) differences of growth rate in different parts of the cortical surface; (c) differences of growth rate of different fibre bundles retarding cortical expansion along the fissure lines and elongating to help in the formation of the gyres. The obvious result, whatever the influences may be, is an expansion of the cerebral cortex to an enormous degree, so that, instead of having a surface area of only 60,000 sq. mm. (if unconvoluted), the average adult cerebrum has a cortical area of 200,000 sq. mm. or more. Furthermore, the vascular pia, closely investing the surface and dipping into every fissure, is expanded in a like manner, affording an ample and uniform supply of blood for the entire cerebral cortex.

The cerebral vesicle of the fetal brain presents a smooth surface during the first half of intrauterine life,² except for the depressed fossa at the site of the future island of Reil—destined to become buried in the depths of the sylvian cleft formed by the apposition of the more energetically growing contiguous parts of the cerebral mantle. Some of the cerebral fissures develop early as infoldings of the comparatively thin wall of the vesicle, and hence produce corresponding projections into the cerebral cavity; these are termed the **total** or **complete fissures**. The remaining fissures are only linear depressions of the surface not involving the entire thickness of the wall—the **partial** or **incomplete fissures**. The complete fissures and their correlative projections into the cerebral cavity (lateral ventricle) are:

<i>Fissure.</i>	<i>Internal Eminence.</i>
Hippocampal fissure.	Hippocampus.
Calcarine fissure.	Calcar.
Collateral fissure.	Collateral eminence.
Occipital fissure.	Occipital eminence.

Among the remaining cerebral fissures, of which over fifty have been recognized and named, some are constant in representation in all normal brains, while others are of variable occurrence in different individual specimens. The constant fissures are those which regularly exist as interlobar and intergyral boundary lines forming a common pattern for all normal brains, but these, like all cerebral fissures, are subject to many individual variations as to course, depth, length,

¹ Consistent with the use of the English *lobe* and *lobes* (for *lobus* and *lobi*), the English *gyre* and *gyres* are preferable to *gyrus* and *gyri*. The term *fissure* is here uniformly employed for all anfractuosities of the surface, though *sulcus* (pl. *sulci*) is quite as generally used; sometimes both terms are indiscriminately mixed in other works on this subject.

² The so-called *transitory fissures* of older descriptions may be neglected, since the researches of Retzius, Hochstetter, and Mall have shown these to be in reality artifacts due to postmortem swelling.

mode of branching, and anastomosis with neighboring fissures or manner of interruption by gyral isthmuses. The range of individual variations is so great that no two brains can be said to be exactly alike; in fact, one may find numberless stages of complexity in the cerebral surface configuration from the simply fissured brains of mentally inferior individuals and races to the complexly fissured and more highly organized brains of vigorous thinkers and talented geniuses among the highly intellectual races of man.

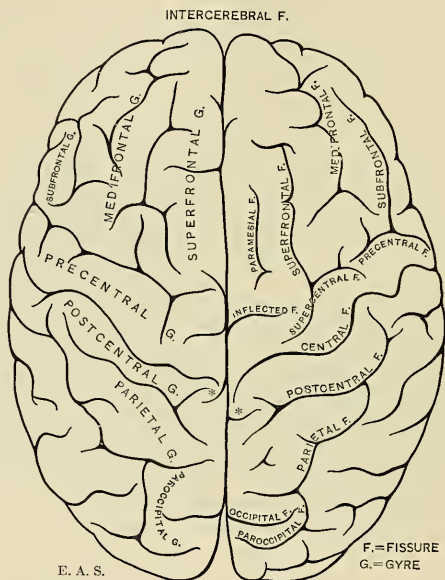


Fig. 676.—Cerebral fissures and gyres viewed dorsally. ** Show constant relations of central and paracentral fissures.

Cerebral Lobes and Fissures.—The cerebral surface is divided into five principal areas, called **lobes**, demarcated by certain constant fissures which are more or less conspicuous, and were therefore selected by the older anatomists as arbitrary boundary lines; these are termed the **interlobar fissures**.

The lobes are: (1) the **frontal**; (2) the **parietal**; (3) the **temporal**; (4) the **occipital**; (5) the **island of Reil or insula**. The interlobar fissures are: (1) the **sylvian**; (2) the **central**; (3) the **occipital**; (4) the **calcarine**; (5) the **circuminsular**. A series of fissures demarcating the rhinencephalon from the pallium or cerebral mantle proper will be considered at a later stage.

The Interlobar Fissures. The Sylvian Fissure and Its Rami (*fissura cerebri lateralis* [*Sylvii*]).—This fissure is a well-marked cleft on the base and side of the cerebral hemisphere. Traced laterad from the region of the anterior perforated substance, it begins as a deep depression between the orbital surface of the frontal lobe and the temporal pole, corresponding to the bony ridge formed by the lesser wing of the sphenoid and extending to the convex surface. This portion of the

fissure is termed the **basisylvian fissure** or **vallecula sylvii**, as far as the **sylvian point**.¹ The sylvian point marks the conjunction of the main portion of the sylvian fissure with its basisylvian part as well as one or two rami. These rami are (1) the **presylvian ramus** and (2) the **subsylvian ramus**.

The **presylvian ramus**² usually proceeds dorsad, slightly inclined frontad, for a distance of 2 to 3 cm. into the subfrontal gyre.

The **subsylvian ramus** (*anterior horizontal limb*) extends frontad for a distance of 1.5 to 2 cm., parallel to the orbitofrontal (superciliary) margin.

These two rami often spring as shorter branches from a common stem, and both may be replaced by a single unbranched limb.

The sylvian fissure proper is the most conspicuous part. It extends from the sylvian point in a caudal direction, inclined slightly dorsad,³ on the lateral surface of the cerebrum for a distance averaging 6 cm. (2½ inches). It separates the temporal lobe wholly from the frontal and partly from the parietal lobe. It usually ends in an upturned manner, in the parietal lobe, the change of direction being oftener abrupt than gradual; this terminal piece receives the name of **epi-sylvian ramus**. Occasionally a short ramus is sent ventrad into the supertemporal gyre and is called the **hyposylvian ramus**.

The sylvian fissure ranges in depth from 15 mm. or less at the presylvian point to 25 or 30 mm. (1 inch to 1½ inches) at the postsylvian point, correlative with the contour of the island of Reil, which lies in its depths. If the lips of the sylvian fissure be divaricated, the island of Reil is revealed as a cortical district, of tetrahedral form, which is normally completely concealed by overlapping portions of the cerebral hemisphere called the **opercula**. These are four in number: (1) the **operculum** proper, (2) the **preoperculum**, (3) the **suboperculum**, and (4) the **postoperculum**.

The **operculum** (frontoparietal operculum) is composed of the adjacent portions of the ventral border of the frontal and parietal lobes, the sylvian fissure intervening between it and the **postoperculum**, which is the overlapping part of the temporal lobe. The **preoperculum** is a small triangular portion embraced by the presylvian and subsylvian rami, and is also called the **pars triangularis** or **Broca's cap**. The **suboperculum** (orbital operculum) is small, demarcated by the subsylvian ramus, and, for the most part, on the orbital face of the frontal lobe, projecting slightly over the frontal part of the island of Reil, with its margin separated from the temporal pole by the basisylvian cleft.

The overlapping opercula are demarcated from the island of Reil by the **circuminsular fissure** (*suleus circularis Reili*).

Development of the Island of Reil and the Sylvian Cleft.—The insular cortical district is topographically correlative with the great gray ganglia of the cerebral hemisphere, particularly the lenticular nucleus, from whose ectal surface the insular cortex is but little removed. As will be learned at a later stage, few if any projection fibres pass to and from the island of Reil; its function is almost wholly associative for adjacent parts of the cerebral mantle. The island of Reil therefore becomes buried beneath the more energetically growing and bulging parts immediately around it. There is at first a slight fossa (observable in the tenth to twelfth week) which, as development proceeds, and as the overhanging opercula encroach upon the island of Reil, becomes more deeply situated as a cleft-like depression until at birth the fossa has become a fissure, with the island of Reil perhaps slightly exposed near its cephalic extremity, where the incomplete apposi-

¹ So called in cranial topography.

² Also called the *anterior ascending limb*. In BNA terms the name for this fissural branch is *Ramus anterior ascendens fissurae cerebri lateralis*.

³ Its inclination to the horizontal plane is called the *sylvian angle*, approximately 15 degrees.

tion of the opercula leaves a triangular space. This space is usually obliterated in childhood, but is commonly met with in certain races (negro, Australian) and in brains showing developmental defects or arrest. The mechanics of the formation of the surface outline of the sylvian fissure by the apposition of the growing and plastic opercula may be understood by a reference to Fig. 682.

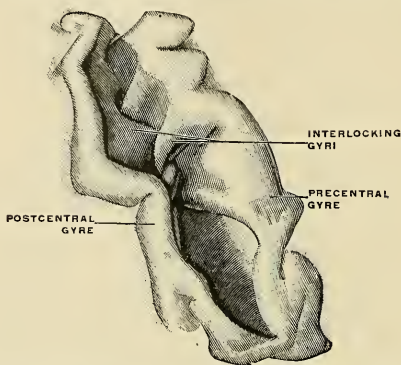


FIG. 677.—Central fissure fully opened up, so as to exhibit the interlocking gyres.

The **central fissure** (*fissure of Rolando* [*sulcus centralis*]) is situated at about the middle of the convex surface, and, coursing obliquely laterofrontad, divides this surface into approximately equal parts, intervening between the frontal and parietal lobes. It may be traced from a point at or near the dorsimesal border, about 1 cm. ($\frac{2}{5}$ inch) caudad of the mid-point of the occipitofrontal arc. It then runs sinuously laterofrontad to within a short distance of the sylvian fissure, about 2 cm. ($\frac{4}{5}$ inch) caudad of the sylvian point; its line of general direction makes an angle of about 70 degrees with the median line (**Rolandic angle**). If measured along its sinuosities, its length averages 10.5 cm. (4 inches). Its curved course may be analyzed into five alternate curves (sometimes more or less), of which three are convex frontad and two caudad. It is rarely very much branched and does not often anastomose with neighboring fissures. Its dorsal end bears a constant relation to the caudal limb of the paracentral, frontad of which it can be found as a hook-like curve (Figs. 676 and 679). If the lips of the central fissure be divaricated, interdigitating sub-gyres are commonly seen in its depths (Fig. 677). These interlocking gyres are often fused to a greater or less degree, and a total interruption of the fissure has, in rare instances, been observed. The central fissure develops at about the end of the fifth month of intrauterine life, not as a single integer, but as the result of the union of two segments—a short dorsal and a longer ventral segment. As development proceeds these segments eventually unite end to end, and at the site of this union a vadium (or shallow uprising of the floor of the fissure) or even a complete isthmus may be demonstrated in the adult brain. Only three cases of *bilateral* interruption are on record.

The **occipital fissure** (*fissura occipitalis*) is a deep cleft across the dorsimesal border transsecting the occipitofrontal arc at about 5 cm. (2 inches) from the occipital pole, and extending upon both the mesal and the convex surfaces. On the meson it attains a length of 3 to 3.5 cm. ($1\frac{1}{5}$ to $1\frac{2}{5}$ inches) (to its junction with the calcarine fissure) while its lateral extent is shorter (2 to 2.5 cm., $\frac{4}{5}$ to 1 inch). It is quite deep throughout and usually shows a number of interdigitating sub-gyres.

The **calcarine fissure** (*fissura calcarina*) is a slightly arched fissure which is usually joined with the occipital fissure at the apex of the cuneus and extends caudad to the occipital pole, ending in a bifurcation. The fissure is composed of two integers which may be partially or completely separated (by a vadum or an isthmus); the caudal segment may then be distinguished as the **postcalcarine fissure**.

The occipital and calcarine fissures join to form a Y-shaped junction; the two limbs of the Y embrace the cuneus, while the stem is continued as the **occipito-calcarine stem** for a distance of about 3 cm. This fissural stem is allotted to the occipital fissure by some and to the calcarine fissure by other authors. As there is no greater frequency of confluence with one as against the other, so far as present statistics go, it is preferable to assign no special relationship for this stem to one or the other principal fissure.

I. Frontal Lobe. FISSURES OF THE FRONTAL LOBE.—1. The *lateral surface* is bounded by the dorsimesal arched border, by the fronto-orbital (or superciliary) border, by the sylvian fissure (in part), and by the central fissure. The principal fissures marking this surface demarcate four gyres: (1) the **precentral**, (2) **superfrontal**, (3) **medifrontal**, and (4) **subfrontal gyres**. The fissures are (1) the **precentral**, (2) **superfrontal**, and (3) **subfrontal fissures**. In addition must be described certain fissures which are intragyral and of more or less constant occurrence.

The Precentral Fissural Complex (*sulcus precentralis*).—Two fissural integers which are sometimes joined extend more or less parallel with the central fissure. The mesally situated piece is usually of zygal (*yoke-shaped*) shape or triradiate, and usually anastomoses with the superfrontal fissure. From its position it is termed the **supercentral** or **superior precentral fissure** (*sulcus precentralis superior*). The laterally situated piece is of longer extent, sometimes straight or slightly sinuous, sometimes arched like an inverted L, or T-shaped. It usually anastomoses with the subfrontal fissure. The two precentral segments demarcate the precentral gyre from the remaining three gyres of the lateral surface of the frontal lobe.

The **superfrontal fissure** (*sulcus frontalis superior*) usually springs from the supercentral and pursues a sinuous course frontad, to become lost, as a rule, in the zigzag or transverse ramifications of the prefrontal region. It is usually quite ramified and often anastomoses with other fissures. It demarcates the superfrontal from the medifrontal gyre.

The **subfrontal fissure** (*sulcus frontalis inferior*) is most often confluent with the precentral, less often with the supercentral fissure. It proceeds frontad in an arched course, to end either in a bifurcation or by anastomosing with other fissures (radiate fissure; orbitofrontal fissure, or medifrontal fissure). The subfrontal fissure demarcates the medifrontal from the subfrontal gyre.

Both the superfrontal and medifrontal gyres are characterized by a more or less pronounced longitudinal subdivision by less constant fissural segments. They are: (1) the **paramesal fissure** occupying an intermediate position between the superfrontal fissure and the dorsimesal border, in the superfrontal gyre, more often composed of a series of short segments which become lost in the more complex configuration of the prefrontal region; (2) the **medifrontal fissure** situated in the prefrontal part of the medifrontal gyre, rarely extending throughout, and usually ending cephalad in a widely spread bifurcation which constitutes the **orbitofrontal fissure** when independent. The medifrontal fissure is usually very much ramified and frequently anastomoses with neighboring fissures. The fissure is a characteristic of human and anthropoid brains only.

By the occurrence of either or both paramesal and medifrontal fissures, the ordinary three-tier type of frontal lobe is converted into a four-tier and five-tier type; the latter more often in the brains of the more highly intellectual—a feature

which is concomitant with the comparatively late phyletic and embryonic development of the two secondary fissures described.

Other, less important, fissures are: (1) the **inflected fissure** (*fissura inflexa*), incising the dorsimesal border between the central fissure and the cephalic limb of the paracentral; (2) the **radiate fissure**, near the lateral orbitofrontal border; (3) the **transprecentral**, a short oblique piece ventrad of the central and usually dipping into the sylvian cleft; and (4) the **diagonal fissure** between the presylvian ramus and the ventral end of the central, and often confluent with the precentral (Fig. 678).

2. The *mesal surface* of the frontal lobe is bounded by the dorsimesal border, the mesorbital border, and the callosal fissure. An arcuate fissure or system of fissures intermediate between the dorsimesal margin and the supercallosal fissure divides this surface into the **superfrontal gyre**, **mesal aspect**, and the **callosal gyre**. The name "**callosomarginal**" was usually applied to this fissure, but an examination of many brains reveals a certain integrality of fissural parts, which are not always connected. One constant segment from its relations with the central fissure is called the **paracentral fissure**, composed of a main stem with a cephalic and a caudal limb, embracing the paracentral gyre. Frontad thereof extends the supercallosal fissure, often in two segments, running a concentric course between the arched dorsimesal border and the genu of the callosum. The supercallosal may be confluent with the paracentral. The supercallosal is,

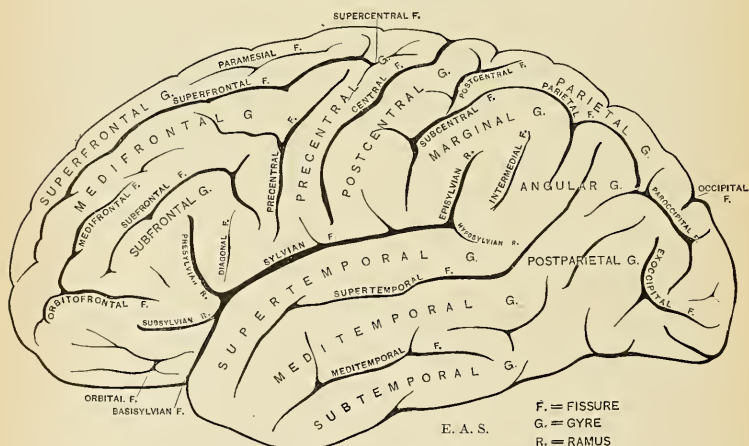


FIG. 678.—Fissures and gyres of the lateral surface of the left hemisphere.

as a rule, quite ramified, its branches transcribing the superfrontal gyre. In the prefrontal region and ventrad of the genu of the corpus callosum lie one or two fissures, more or less parallel to the mesorbital border, and called, respectively, the **rostral** and **subrostral fissures**.

3. The *orbital surface* of the frontal lobe is constantly marked by a straight fissure, the **olfactory fissure** (*sulcus olfactorius*), which runs parallel to the mesorbital border and is occupied by the olfactory bulb and tract. It is about 5 cm. in length and demarcates the **mesorbital gyre** from the remaining orbital gyres. This

orbital surface is marked by a fissural system (*sulci orbitales*) that is usually of zygal type, H-shaped or K-shaped, quadriradiate, or, rarely, triradiate. When the transverse element is sufficiently pronounced it merits the name of **transorbital fissure**, demarcating the preorbital from the postorbital gyral field.

GYRES OF THE FRONTAL LOBE (*lobus frontalis*). 1. *Lateral Surface*.—The **precentral gyre** (*gyrus centralis anterior*), one of the chief motor areas of the cerebral cortex, is a moderately sinuous gyre extending from the dorsimesal border to the sylvian fissure and demarcated by the central and the precentral fissures (supercentral + precentral).

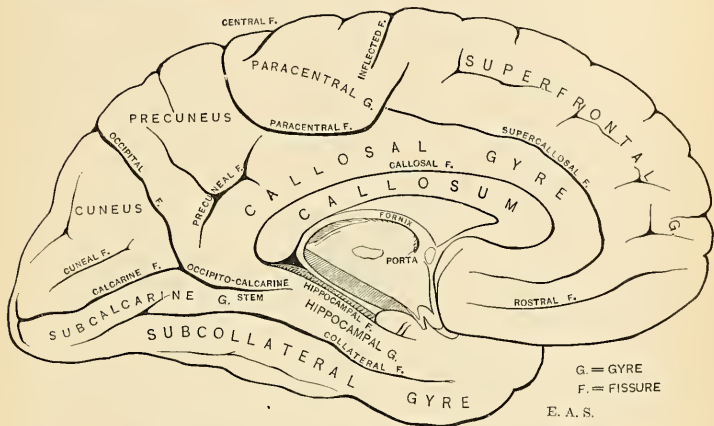


Fig. 679.—Fissures and gyres of the mesal surface of the left hemisphere.

The **superfrontal gyre** is limited laterally by the superfrontal fissure, while it is continuous over the dorsimesal border with its mesal surface.¹ It merges insensibly with the medifrontal gyre in the prefrontal region, while it may be partially subdivided by the paramesal fissure.

The **medifrontal gyre** (*gyrus frontalis medius*) is broader than the preceding, demarcated by the superfrontal and subfrontal fissures, and often marked by the medifrontal fissure in its prefrontal portion.

The **subfrontal gyre** (*gyrus frontalis inferior*) is limited by the subfrontal fissure and the basisylvian + sylvian proper. It is traversed by the presylvian and subsylvian rami, embracing the **preoperculum** or **pars triangularis**. The gyre is of historic importance since Broca, in 1861, declared it to be the seat of speech control. (See Cerebral Localization.)

2. *Mesal Surface*.—On the mesal surface of the frontal lobe and embracing the dorsal end of the central fissure lies an oval lobule or gyre called the **paracentral gyre** (*lobulus paracentralis*), limited by the paracentral fissure with its caudal and cephalic limbs. Frontad thereof extends the large arched mesal surface of the **superfrontal gyre** (*gyrus frontalis superior*), limited by the supercallosal fissure. Between the latter fissure and the callosal fissure, concentrically situated with respect to the superfrontal, lies the **callosal gyre** (the "*gyrus fornicatus*" of other authors).

¹ There being no fissure at this border, it is improper to give the mesal surface of this gyre a different name (i. e., "marginal gyrus" of the authors).

Frontad these two gyres arch around the genu of the corpus callosum, to become merged through the disappearance of the intervening supercallosal fissure, and the rostral fissures alone mark this surface.

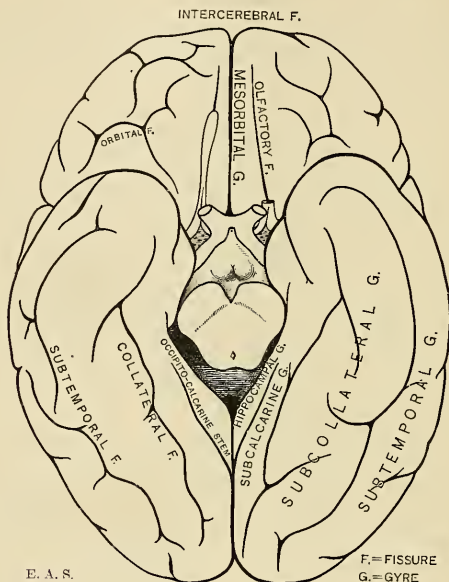


FIG. 680.—Fissures and gyres of the basal surface of the cerebrum.

3. *Orbital Surface*.—The olfactory fissure and the mesorbital border bound the **mesorbital gyre** (*gyrus rectus*). The remaining orbital surface is not regularly divisible on account of the great variability of the orbital fissures; when the trans-orbital fissure is pronounced, a pre- and postorbital gyre may be distinguished.

The **postorbital limbus** is a formation occasionally met with on the orbital surface. It consists of a curved, welt-shaped eminence demarcated by an incisure created by the lesser wing of the sphenoid, and due, apparently, to the intrusion of the postorbital portion into the middle fossa of the skull.

II. *Parietal Lobe* (*lobus parietalis*). **FISSURES OF THE PARIETAL LOBE**.—1. The *lateral surface* is bounded by the dorsimesal border above, by the central fissure in front, and by a part of the sylvian fissure below; it is only partially demarcated from the occipital lobe by the occipital fissure, and merges gradually into the temporal lobe.

The principal fissures marking its surface consist of a group of integral segments showing various degrees of confluence in different individuals and formerly known in the aggregate as the **intraparietal sulcus of Turner** (*sulcus interparietalis*). Two of the fissural segments present much the same parallelism to the central fissure which was noted for the precentral group, and hence these are termed the **postcentral fissural complex**.

The **postcentral fissural complex** comprises a longer mesal and a shorter lateral

(and ventral) segment, which are confluent in about 75 per cent. of brains and then very much resemble in length, continuity, and course the central fissure. This appearance has given rise to reports of alleged duplication of the central; an analysis of the relations of the dorsal ends of the fissures in question with the caudal limb of the paracentral removes all doubt.

The **postcentral fissure** (proper) is the longer mesal (and dorsal) segment. Its dorsal end is frequently bifurcated and then usually embraces the dorsal extension of the caudal limb of the paracentral. The **subcentral fissure** constitutes the shorter lateroventral segment.

The **parietal fissure** is usually a slightly arched fissure inclining mesocaudad, sometimes independent but more often confluent, with one or both of the postcentral segments just described. It demarcates the parietal gyre from the subparietal district.

The **paroccipital fissure**, in whole or in part, probably represents a part of the simian exoccipital or "Affenspalte," isolated by the upgrowth of gyral protons which are totally submerged in the ape brain, but rose to the surface concomitant with the rise in functional dignity of cortical areas so important in the human brain. The fissure is almost invariably of zygal shape, its stem directed sagittally, its ends bifurcated. Its confluence with the parietal fissure seems to be subject to some morphologic law; continuity is the rule on the left side (77 per cent.), and occurs less often on the right. The combination of continuity on the right and separation on the left is a rare one (6 per cent.).

Less constant fissures are the **transparietal**, in the parietal lobe, and the **inter-medial** (Fig. 678). In the subparietal district terminate the upturned ends of the sylvian (*i. e.*, episylvian ramus) of the supertemporal and the meditemporal fissures.

2. The **mesal surface** of the parietal lobe is equivalent to the quadrangular **precuneus**, limited by the paracentral and occipital fissures, while ventrad it is imperfectly separated from the callosal gyre by the **precuneal fissure** (postlimbic sulcus), usually of zygal or triradiate form and occasionally confluent with the paracentral.

GYRES OF THE PARIETAL LOBE. 1. *Lateral Surface.*—The **postcentral gyre** (*gyrus centralis posterior*) is one of the chief somesthetic areas of the cortex. It is a long, more or less sinuous convolution extending obliquely from the dorsimesal border to the sylvian fissure and demarcated by the central and the postcentral + subcentral fissures.

The **parietal gyre** (*lobulus parietalis superior*) lies between the dorsimesal border and the parietal fissure, bounded cephalad by the postcentral, caudad partly by the occipital fissure, the transition to the occipital lobe being maintained by the arched **paroccipital gyre**.

The **subparietal district** or **lobule** (*lobulus parietalis inferior*) is divided into three convolutions which arch around the upturned ends of the sylvian, supertemporal, and meditemporal, and merge insensibly with the adjacent temporo-occipital gyres. The **marginal gyre** (*gyrus supramarginalis*) arches over the extremity of the episylvian ramus and is connected frontad with the postcentral gyre, ventrad with the supertemporal gyre. The **angular gyre** (*gyrus angularis*) arches over the upturned extremity of the supertemporal fissure, and its limbs fuse with the supertemporal and meditemporal gyres. The **postparietal gyre** is not always clearly defined; it arches around the upturned end of the meditemporal or its representative segment; mesally it is bounded by the paroccipital fissure. Variable **intermedial fissures** sometimes help to define the angular gyre from its two neighbors.

2. The **mesal surface** of the parietal lobe has already been described as equiva-

lent to the **precuneus**, from its position in "front" of the **cuneus** or **quadrate lobe** from its general shape. It is sometimes marked by a mesal extension of the **transparietal fissure** or by **intraprecuneal fissures**.

III. Occipital Lobe (*lobus occipitalis*). FISSURES OF THE OCCIPITAL LOBE.—

1. The *lateral surface* of the occipital lobe is imperfectly demarcated from the adjacent parietal and temporal lobes in most brains. The sharply defined **exoccipital fissure** or "Affenspalte" of other primates has, in the ancestry of man, been reduced to a series of fissural segments by the upgrowth of submerged cortical parts. The **paroccipital fissure**, we have already learned, probably represents one of the gaps in the series; another may be the **sulcus lunatus** (Elliott Smith), usually termed the **lateral occipital** by the authors; lastly, a fissure sometimes called the **inferior occipital** (*suboccipital*), and usually embraced, on the occipital pole, by the bifurcate limbs of the postcalcarine, may complete the series. Further researches are necessary to elucidate the morphology of this region.

2. The *mesal surface* is equivalent to the wedge-shaped region embraced by the occipital and calcarine fissures, and called the **cuneus**. A fairly constant **cuneal fissure** traverses its surface parallel to the calcarine.

If it is ever determined that the morphological boundary of the occipital lobe is as outlined above, the lobe is practically excluded from the basal surface of the hemiserebrum.

IV. Temporal Lobe (*lobus temporalis*). FISSURES OF THE TEMPORAL LOBE.—1.

The *lateral surface* of the temporal lobe is bounded by the basisylvian and sylvian fissures and by the ventrolateral border; caudally it merges into the adjacent parietal and occipital lobes.

The **supertemporal fissure** (*sulcus temporalis superior*) is a deep, long (10 to 12 cm.), and usually continuous fissure which begins near the temporal pole, proceeds ventrad of but parallel with the sylvian, to become upturned in the parietal lobe and embraced by the arched angular gyre.

The **meditemporal fissure** (*sulcus temporalis medius*) is rarely continuous; more often it is represented by a series of segments, two, three, or four in number, the caudal segment running more vertically into the parietal lobe to be embraced by the postparietal gyre. The meditemporal fissural segments run nearly parallel with the supertemporal and demarcate the meditemporal from the subtemporal gyre.

2. *Tentorial or Ventral Surface*.—Close to the ventrolateral margin and more or less parallel with it runs the **subtemporal fissure** (*sulcus temporalis inferior*), extending from near the temporal to near the occipital pole. It is rarely continuous, being usually broken up into two or more segments. It demarcates the subtemporal from the subcollateral gyre.

The **collateral fissure** (*fissura collateralis*) is a well-marked, long (8 to 12 cm.), and deep fissure extending from near the occipital to near the temporal pole. Caudally it demarcates the subcalcarine gyre from the subcollateral; frontad it intervenes between the latter gyre and the hippocampal gyre. Its middle part is correlative with the collateral eminence. On the ventromesal aspect of the temporal lobe and near its pole, cephalad of the uncus, is a moderately marked fissure or groove, called, because of its topographic relation to the amygdaline nucleus—a gray, ganglionic mass—the **amygdaline fissure** (*fissura ectorhinalis* s. *postrhinalis*), or **incisura temporalis**.

3. The *dorsal or opercular surface* of the temporal lobe enters into the formation of the sylvian cleft. It is but slightly marked by a few oblique or transverse furrows (**transtemporal fissures**) demarcating slightly elevated **transtemporal gyres**.

GYRES OF THE TEMPORAL LOBE.—The five principal fissures named subdivide the lobe into five gyres. On the lateral surface lie the **supertemporal**, **meditemporal**,

and **subtemporal gyres** (*gg. temporalis superior, medius et inferior*); on the tentorial surface are the **subcalcarine** (*gyrus lingualis*), **subcollateral** (*gyrus fusiformis*; *g. occipitotemporalis*) and part of the **subtemporal**.

The **hippocampal gyre** (*gyrus hippocampi*), formerly included in the "limbic lobe," but morphologically belonging to the neopallium, occupies the dorsimesal part of the ventral surface of the temporal lobe. The longer or shorter extension of the occipitocalcarine stem partially (forming the **isthmus gyri hippocampi**) interrupts its continuity with the callosal gyre. It is demarcated by the collateral fissure (in part) and the hippocampal fissure, broadens out toward the temporal pole, and appears to become bent upon itself dorsally to form the **uncinate gyre** (*unens*). As will be learned in the sequel, the hippocampal gyre is demarcated from the uncus proper by the intervention of the frenulum Giacomini—an extension of the narrow, gray, dentate gyre.

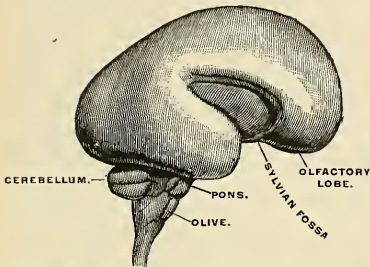


FIG. 681.—Brain of a six-months' human embryo, natural size, right side. The insula is exposed. (Kölliker.)

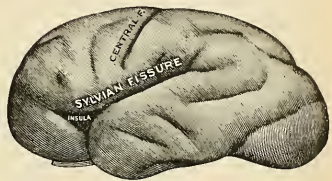


FIG. 682.—Cerebrum of an eight-months' human embryo, left side. The insula is nearly covered in. (Testut.)

Near the temporal pole it is demarcated from the subcollateral gyre by the **fissura rhinica**,¹ or **postrhinal fissure**; this fissure is not infrequently confluent with the collateral.

The surface of the hippocampal gyre, particularly in the zone along the hippocampal fissure, is of a more whitish color than is characteristic of other cerebral gyres; this is due to a white reticular stratum of fibres, the **substantia reticularis alba**. The convex, broader part of the gyre is marked by numerous small, wart-like eminences, resembling the skin of an amphibian, and called by Retzius the **verrucae gyri hippocampi**. Just ventrad of the uncinate portion, or the terminus of the hippocampal fissure, lies a groove marking the impression of the free edge of the tentorium cerebelli.

The Island of Reil (*insula*; central lobe) (Figs. 682, 683).—The island of Reil lies deeply in the Sylvian cleft and can only be seen when the lips of that cleft are widely separated, since it is overlapped by the opercula already described. With the opercula removed, the island of Reil presents a tetrahedral shape with its **apex** or **pole** directed frontoventrad. Its borders are sharply outlined by the **circuminsular fissure** except in the depths of the basisylvian cleft, where the insular cortex is continuous with the gray substance of the anterior perforated substance—the threshold or **limen insulae** (belonging to the rhinencephalon). An oblique **transinsular** or **central insular fissure** divides this district into a larger **preinsula** and a smaller **postinsula**. The postinsula is usually a single long gyre (*gyrus longus insulae*), while the preinsula is subdivided by shallow fissures into three,

¹ Called by Wilder, on account of its correlation with the amygdaline nucleus, the *amygdaline fissure*. Schwalbe calls it (in part) the *incisura temporalis*.

four, or five shorter **preinsular gyres** (*gyri breves insulae*), built upon a radiate plan, converging in the region of the insular pole. As already hinted, the island of Reil represents an area of the brain mantle whose growth did not keep pace with that of the surrounding parts; hence its submergence by them. The close apposition of the insular region to the subjacent basal ganglia, and the failure of development of great masses of projection fibres so prominent elsewhere, were doubtlessly factors therein. The insular cortex is uninterruptedly continuous with the rest of the cortex, but it has become specialized into the purest association centre in the cerebrum, and we shall learn of its intimate relations to the faculty of speech on page 961.

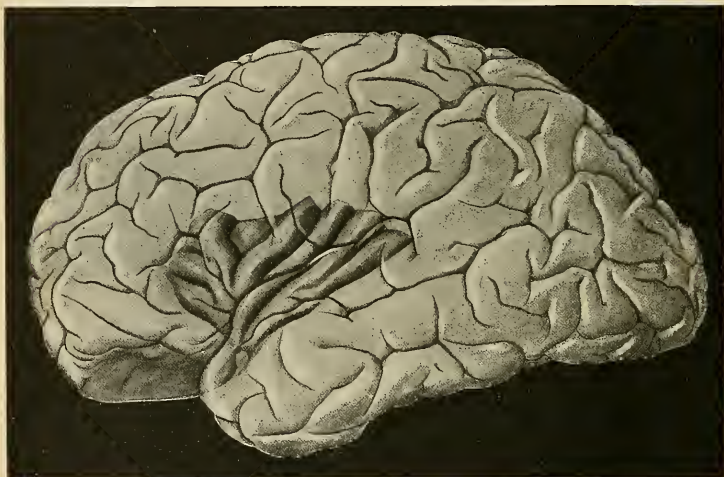


FIG. 683.—The left island of Reil schematically represented in a supposedly transparent cerebral hemisphere, showing how it is concealed from view by the opercula.

The Rhinencephalon, or Olfactory Lobe (*lobus olfactorius*) (Figs. 684, 685).—The grouping of the parts constituting the central olfactory structures under the term “rhinencephalon” as distinguished from the rest of the fore-brain (pallium) was first clearly made by Turner and proved by His to be embryologically well founded and by Edinger to agree with phylogenetic development. More light has been thrown upon the subject recently by Retzius and Elliott Smith. The sense of smell, while highly useful in the quest for food in earlier and lower forms of vertebrates, is relatively little used in the mental life of man. The enormous preponderance of the cerebral mantle and the concomitant atrophy of the rhinencephalon in the human brain afford one of the most striking contrasts in brain morphology. This relatively feeble development in bulk of the olfactory apparatus in the human brain by no means renders its description simple. In fact, not until its development in lower macrosmatic animals was studied could anatomists form even an approximately clear conception of the seemingly disjointed remnants in the human brain of an olfactory apparatus so relatively huge in lower animals. The great expansion of the cerebral hemispheres and of the great commissure which connects them (the corpus callosum) has been an important factor in widely displacing primitively connected parts. The developmental history must be sought for in the writings of Edinger, Retzius, and Elliott Smith.

The Rhinencephalon comprises:

1. Peripheral parts.
2. Central or Cortical parts.

A comprehensive term for the peripheral part is **lobus olfactorius**, divisible into **pre-** and **postolfactory** parts.

- | | | |
|--------------------|---|----------------------------------------------------------------|
| Preolfactory lobe | { | 1. <i>Bulbus olfactorius</i> . |
| | | 2. <i>Tractus olfactorius</i> . |
| | | 3. <i>Tuberculum olfactorium</i> and <i>trigonum</i> . |
| | | 4. <i>Area parolfactoria</i> (Broca). |
| | | 5. <i>Stria olfactoria medialis</i> . |
| | | 6. <i>Stria olfactoria intermedialis</i> . |
| | | 7. <i>Stria olfactoria lateralis</i> . |
| Postolfactory lobe | { | 8. <i>Anterior perforated substance</i> . |
| | | 9. <i>Gyrus subcallosus</i> and <i>Broca's diagonal band</i> . |

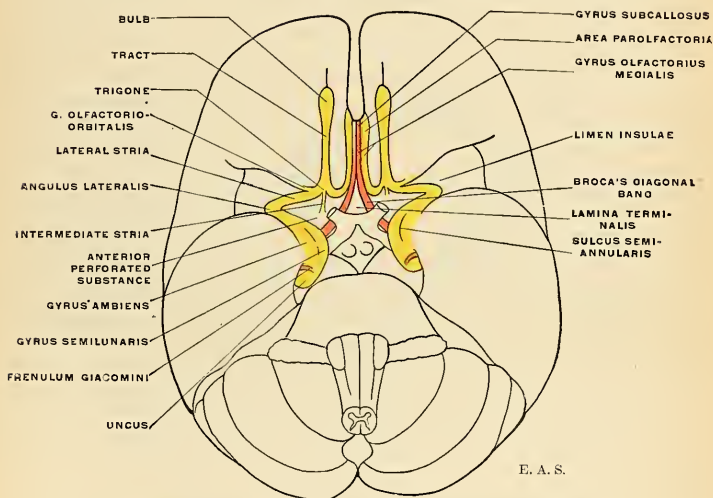


FIG. 684.—Schematic representation of the rhinencephalon, basal aspect.

THE PREOLFATORY DIVISION.—The olfactory bulb and tract form a long and slender band with a bulbous extremity situated on the basal aspect of the frontal lobe and constituting a rudimentary remnant of a relatively large diverticulum, developed from the sensor ectoderm close to the border of the neural plate before it becomes converted into the neural tube and situated on either side of the neuropore at the extreme frontal end. Although hollow at first, the cavity (rhinocele) soon becomes obliterated.

The **olfactory bulb** (*bulbus olfactorius*) is an oval mass of reddish-gray color, which rests on the cribriform plate of the ethmoid and is received in the olfactory fissure on the orbital surface of the frontal lobe. It receives the numerous olfactory nerves (*fila olfactoria*) from the nasal mucous membrane. The **olfactory tract** (*tractus olfactorius*) is a band of white substance, of prismatic outline on

section, its apical ridge fitting into the olfactory fissure. Toward its root region it is somewhat narrowed.

The medial and lateral olfactory gyres are also termed the medial and lateral roots of the tract, and diverge in the region of the trigonum. The **olfactory tubercle** is best seen if the bulb and tract be lifted away from the olfactory fissure; the tubercle appears as a small pyramidal elevation, its apex buried in the olfactory fissure, its irregularly triangular base forming the **trigonum olfactorium**, a small gray area frontad of the anterior perforated substance. This area is marked by ridge-like elevations which appear like radiating roots of the tract, and named, according to their position, the **medial**, **intermediate**, and **lateral roots, striæ or gyres**. The **lateral olfactory stria** is continuous with the **limen insulae** in the depths of the basisylvian cleft, and thence passes to the uncus to end in the **gyrus ambiens** and **gyrus semilunaris**. The sharp turn made at the limen insulae is called the **angulus lateralis**. The **medial olfactory stria**, a narrow gyral band, proceeds mesad and merges with the adjacent cerebral surface; its extension on the mesal surface is known as the **parolfactory area** (Broca) limited frontad by the **anterior parolfactory sulcus** (*sulcus parolfactorius anterior*) and separated from the subcallosal gyre by the **posterior parolfactory sulcus** (*sulcus parolfactorius posterior*).

The **intermediate stria** is not always very distinct; when present it may be traced from the proximal end of the olfactory tract for a short distance over the gray field of the trigonum, to plunge into the gray of the anterior perforated substance.

POSTOLFACTORY DIVISION.—The **anterior perforated substance** or **space** occupies an irregular quadrate field between the olfactory trigone and the optic chiasm and tract. A more or less marked groove (*sulcus parolfactorius posterior*), which is identical with the *fissura prima* (His) of the embryo, separates the trigonum from the anterior perforated substance. Its frontal part, much perforated, is of a darker color than the hind portion; the latter is distinguished by the name of **Broca's diagonal band**. This courses obliquely laterad along the optic tract toward the uncus; mesally the bands of the two sides converge, frontad of the lamina terminalis, and proceed toward the rostrum of the corpus callosum as narrow fields which taper to curve around the genu and continue in the indusium of the corpus callosum as the **striae longitudinales**. The narrow field seen on the mesal aspect frontad of the lamina terminalis and anterior commissure is known as the **gyrus subcallosus** (*formerly peduncle of the corpus callosum*). The continuity of the various parts may be understood by reference to Figs. 684 and 685.

The cortical and central part of the rhinencephalon comprise:

- | | | |
|----------|---|------------------------------------------------------------------------------|
| Cortical | { | 1. The hippocampus. ¹ |
| | | 2. The uncus. |
| | | 3. Gyrus dentatus. |
| | | 4. Fasciola cinerea. |
| | | 5. Indusium, medial and lateral longitudinal striæ upon the corpus callosum. |
| | | 6. Gyri Andreae Retzii. |
| | | 7. Gyri subcallosi. |
| Central | { | 8. Fornix and fimbria. |
| | | 9. Corpus albicans and albicantiothalamic tract. |
| | | 10. Part of anterior commissure (<i>precommissure</i>). |
| | | 11. Part of septum pellucidum. |

¹ Not to be confounded with the *hippocampal gyre* of the pallium.

CENTRAL OR CORTICAL PARTS OF THE RHINENCEPHALON.—Following the suggestion made by Broca in 1878, it has been customary to designate these various parts by the comprehensive term **limbic lobe**. Broca's notion of the limbic lobe in man was founded upon attempts to homologize the human cerebral configurations with those found in lower animals. More recent researches have proved that Broca's "limbic lobe" included parts belonging to the neopallium and not to the rhinencephalon. The term is therefore inappropriate in a morphologic sense.

The **hippocampus** is the submerged, peculiarly folded margin of the cerebral hemisphere produced by the hippocampal fissure. Its architecture can best be understood by referring to a frontal section (Fig. 686). It is seen that the whole cerebral marginal wall is pushed into the ventricular cavity (middle cornu) as a fold caused by the intrusion of the hippocampal fissure. A secondary fold not produced by a fissure, however—constitutes the **gyrus dentatus**. Superimposed lies a prominent white band—the **fimbria**—composed of axones from

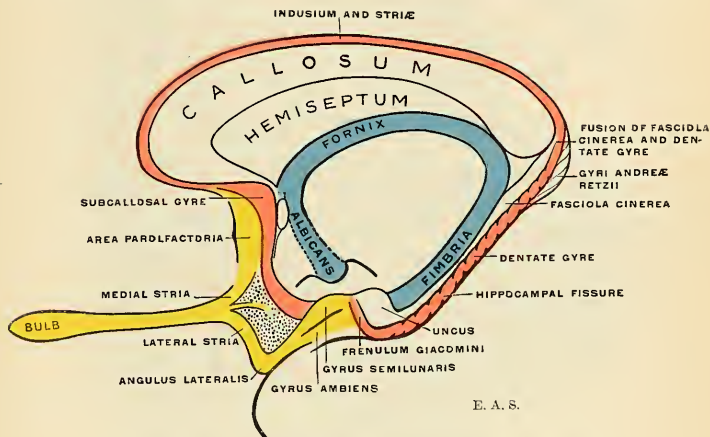


FIG. 685.—Schematic representation of the rhinencephalon, mesal aspect.

the hippocampal cells, assisting in the formation of a white lamina, subjacent to the ependyma of the ventricle, and called the **alveus**. The whole formation is characteristic of this region, and from its fancied resemblance to a ram's horn—a symbol used on the temple of Jupiter Ammon—the name of **cornu ammonis**¹ has been given; the name **hippocampus** was applied because of a fancied resemblance to the marine animal of the same name. The ventricular relations and internal structure of the hippocampus will be given farther on (p. 942).

The **uncus**, with the atrophied lateral olfactory stria, is all that remains in the human brain of the relatively large pyriform lobe of lower forms. It appears to be a hook-like retroflexion of the hippocampal gyre which is partially encircled by the gyrus dentatus. Morphologically speaking, it is only the apical portion, or that which lies caudad of the dentate gyre which is the true uncus (the *gyrus intralimbicus* of Retzius); the remainder is neopallial and a part of the hippocampal gyre. The uncinate or intralimbic gyre may be traced caudad in the

¹ Frequently, but incorrectly, given as *Ammon's Horn*.

depths of the fimbriodentate fissure, along the dentate gyre, the **dentatofasciolar groove** intervening, to be continued as the **fasciola cinerea** (gyrus fasciolaris of Retzius) over the splenium of the corpus callosum.

If the hippocampal gyre be depressed for the purpose of examining the depths of the hippocampal fissure, there is revealed a narrow, gray band whose surface is scored by numerous incisures and whose edge is notched at frequent intervals. This corrugated band is the **dentate gyre** or **fascia dentata**. Partly overlapping it, but farther laterad, lies a white band—the **fimbria**—extending caudad from the uncus to become continued as the fornix.

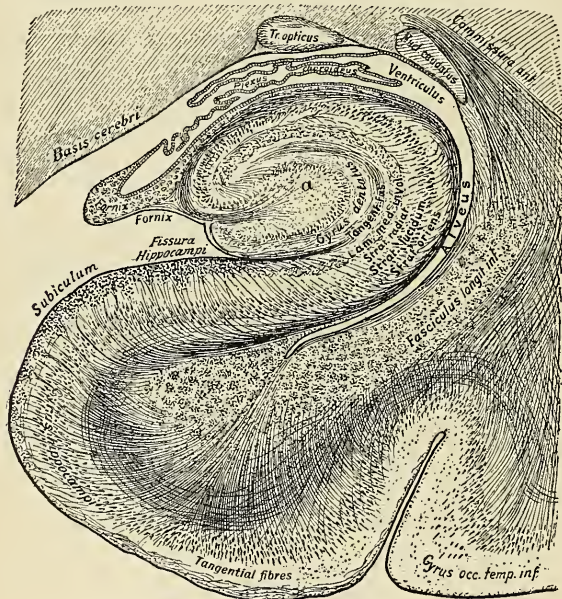


FIG. 686.—Trans-section of the hippocampal gyrus. (Edinger.)

The dentate gyre is demarcated from the hippocampal gyre by the hippocampal fissure, from the fimbria by the fimbriodentate fissure, in whose depths lies the narrow continuation of the uncus or gyrus intralimbicus—the **fasciola cinerea**. Extending caudad, and for the most part parallel with the fimbria, it loses its corrugated appearance on approaching the splenium, then fuses with the fasciola cinerea, parting company with the fimbria (which now becomes fornix), to be continued upon the corpus callosum as a thin, broad plate of gray substance—the **indusium** or **gyrus epicallousus**. At the uncus the dentate gyre makes an abrupt turn to appear upon the mesal surface, out of the depths of the hippocampal fissure, and encircles the neck of the uncus, forming the **frenulum Giacomini**. Beyond this point it can be traced, in rare instances, to the gyrus semilunaris.

The **gyri Andreae Retzii** are rudimentary gyral formations consisting of small, rounded, oval or spirally corrugated eminences situated ventrad of the splenium in the angular interval between the dentate and the hippocampal gyres. Structurally they have been shown to belong to the hippocampal formation.

The **indusium** (gyrus epicallus s. supracallus), considered to be a vestige of the hippocampus, is a thin strip of gray substance superimposed upon the corpus callosum and raised into two paired ridges by longitudinal fibre bundles which constitute the **mesal** and **lateral longitudinal striæ**.¹ The indusium and its striæ are continued cephalad into the gyrus subcallosus; perhaps, also, into the parolfactory area (Fig. 685).

The central connections of the rhinencephalon will be considered in the description of the internal configuration of the hemisphere. (See Fornix, Anterior Commissure, etc.)

Internal Configuration.—Each cerebral hemisphere contains a cavity, the **lateral ventricle** (paracele), an extension of the primitive neural cavity carried outward, its contours modified by the developmental changes in the growth history of the secondary fore-brain vesicle. This central cavity is surrounded by the thick, convoluted walls of nerve tissue which make up the bulky cerebral hemispheres. The cerebral tissue, as elsewhere in the central axis, is made up of gray and white

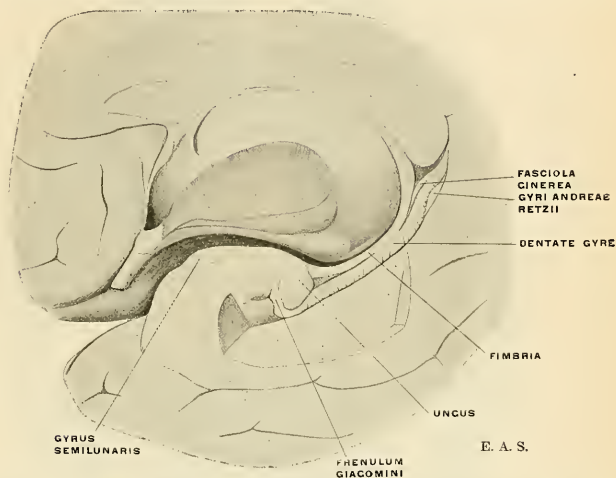


FIG. 687.—Mesal view of a partly dissected cerebral hemisphere, to show the relations of fimbria, fasciola cinerea, dentate gyre, and uncus.

substances. Two well-marked types of gray substance are recognizable: (*a*) the **cortical**, so named because its situation upon an interior white centre invites comparison with the rind (cortex) of a fruit; (*b*) the massive **ganglionic** or nugget-like masses not dissimilar from the thalamus already described, comprising, in this division of the brain, the **caudate**, **lenticular**, and **amygdaline nuclei**. The **white substance** fills out the entire space intervening between the cortex, the cavity of the lateral ventricle, and the great basal ganglia, and is composed of myelinic axones which connect the elements of the cortex with other parts of the nerve system, or with other regions of the cortex of the same or the opposite cerebral hemisphere.

If a brain, resting upon its basal surface, be sliced by successive horizontal sections from above, the peripheral gray and internal white are brought into view.

¹ The mesal striæ are also called *Striæ Lancisii*; the lateral striæ, *Teniae tectae*.

The more superficial sections reveal relatively more gray than white substance; deeper sections show a reverse condition, and a section immediately dorsad of the corpus callosum reveals, in each cerebral hemisphere, a very extensive semioval field of white substance, the **centrum semiovale**, surrounded on all sides by a narrow, convoluted margin of gray substance, the **cortex**. A close examination of the cut surface, in a fresh and normal brain, shows it to be studded with numerous minute red dots (*puncta vasculosa*) produced by the escape of blood from divided blood-vessels.

The Cortex.—The cortex, as revealed in such a section, is not of uniform thickness throughout; different regions show different cortical thicknesses. In general, the cortex is somewhat thicker at the summit of a gyre than in the depths of an adjoining fissure, and it is thicker upon the convex than upon the mesal or basal surfaces. The maximum thickness is observed in the cortex of the central gyres

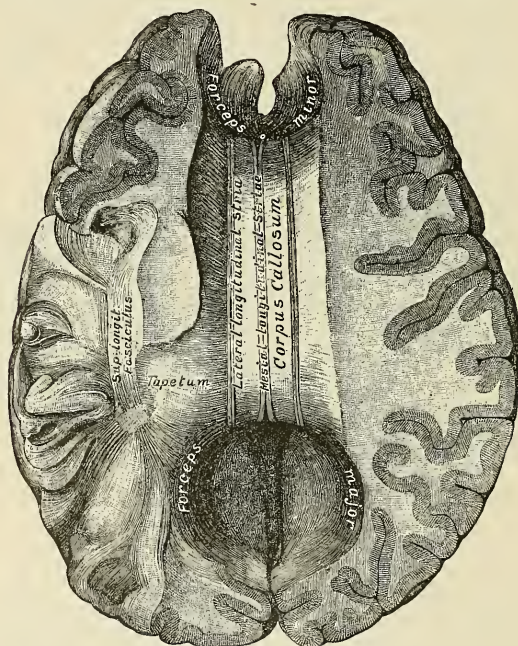


FIG. 655.—Corpus callosum. (From above.)

and the insula; the minimum at the frontal and occipital poles, notably the latter. Not only is the cortex not of uniform thickness, but it is not of homogeneous structure as seen with the naked eye. An alternation of gray and white stripes is discernible, particularly in the occipital cortex, where a white band runs parallel with the cortical surface between two gray strata; this white stripe, first described by Gennari and usually bearing his name, is also called the **band of Vieq d'Azyr**.

The preponderance of white substance over gray substance in the cerebrum is a human characteristic concomitant with the relative increase of the association cortex, in turn demanding a more intricate interconnection of the many nerve cells by a multitude of association neurones. These

coördinating fibre systems are as truly representative of the complexity of man's thought apparatus as the number of interconnecting wires within a telephone "central" station is indicative of the amplitude of connections possible in that system. The proportions of gray and white substances are expressed in the following tabulation:

Gray substance	{ Cortex	33 per cent.
	{ Ganglia	6 per cent.
White substance		61 per cent.

The removal, by successive slices, of the dorsal parts of the cerebrum soon brings into view the large expanse of transverse myelinic fibres, the **corpus callosum**, which connects the two hemispheres.

The Corpus Callosum (*Trabs cerebri; commissura maxima*).—The corpus callosum is a thick stratum of transversely directed nerve fibres, by which almost every part of one cerebral hemisphere is connected with the corresponding part of the other cerebral hemisphere (Figs. 689 and 690). The axones composing it arise from the

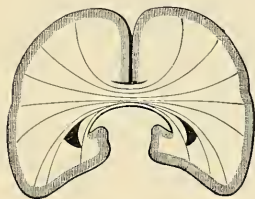


FIG. 689.—Diagram of coronal section of cerebrum to show course of fibres of corpus callosum. (Testut.)

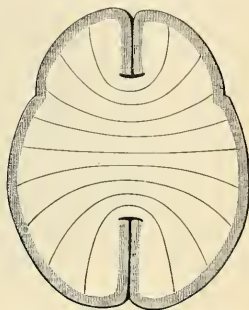


FIG. 690.—Diagram of horizontal section of cerebrum to show course of fibres of corpus callosum. (Testut.)

small pyramidal or the polymorphous cells of the cerebral cortex, or they may be collaterals from the long association or even the projection neurones. They pass in both directions and within the **centrum semiovale** radiate in various directions (**radiatio callosi**) between the fibres of the corona radiata to terminate in the layer of small pyramidal cells of the cortex, thus forming a great transverse commissural system, and at the same time roofing in the greater part of the lateral ventricle in each half. A portion of the dorsal surface is free for a width of about 1 cm. on either side of the mesal plane, partly covered by the indusium and overlapped by the callosal gyres of the two sides, a fold of pia intervening.

The mass of radiating fibres may, for convenience of description, be subdivided into a **pars frontalis**, a **pars parietalis**, and a **pars occipitotemporalis**. The frontal and occipitotemporal portions are compressed or thickened mesally because the fibres cannot pass directly across, but curve, respectively, frontad and caudad in each hemisphericum to form two tong-like bundles, the **forceps anterior s. minor** (preforceps), and **forceps posterior s. major** (postforceps). The pars parietalis constitutes the greater part of the "body" of the corpus callosum. The fibres traversing the **body** (*truncus corporis callosi*) and the adjacent part of the splenium curve around the posterior cornu and trigonum ventriculi of the lateral ventricle, to form a thin but definite white stratum, the **tapetum**, in the roof and ectal wall of these parts of the cavity.

The transverse direction of the fibres is rendered apparent in a dorsal view of the exposed corpus callosum in the form of the **striae transversae**. These are

but little obscured by a thin, gray lamina—the **indusium**—which is thickened longitudinally by two symmetrically situated fibre strands, the **mesal** (striae Lancisii) and **lateral longitudinal striae** (teniae tectae), already mentioned as rudiments of the rhinencephalon.

The best conception of the size and form of the corpus callosum is obtained from a view of a mesal section. It is then seen to be a long, thick, somewhat flattened arch which bends sharply upon itself frontad to form the **genu** (*genu corporis callosi*), while its caudal end is rounded and somewhat folded closely upon itself to form the **splenium**. The corpus callosum ranges in length from 7 to 10 cm., its cross-section area from 5 to 10 sq. cm., being longer and larger in heavier brains and in those of the highly intellectual as compared with smaller and less highly efficient brains. It extends to within 4 cm. of the frontal pole and to within 6 cm. of the occipital pole. The thickness of the “body” averages 5 mm.; of the splenium, 9 mm. or more, while the maximum thickness of the genu is about 13 to 15 mm. The reflected portion or **rostrum** (*rostrum corporis callosi*) gradually tapers into a very thin lamina, the **copula** (*lamina rostralis*), which in turn joins the lamina terminalis frontad of the anterior commissure.

The **splenium** (*splenium corporis callosi*) projects as a rounded welt over the mid-brain, but is separated from it by a pial fold—the **velum interpositum**. Farther frontad the fornix becomes fused to the ventral surface of the corpus callosum for a short distance, to again leave it in its more arched course toward the corpus albicans. Two thin laminae, one on either side of the median plane, but closely applied to each other and frequently partially fused, occupy the interval between corpus callosum and the fornix of each side. The laminae together are termed the **septum lucidum** of the authors, each one being called a **hemiseptum**; the enclosed cavity is called the **fifth ventricle** or **pseudocoele**, though not derived from the original neural cavity.

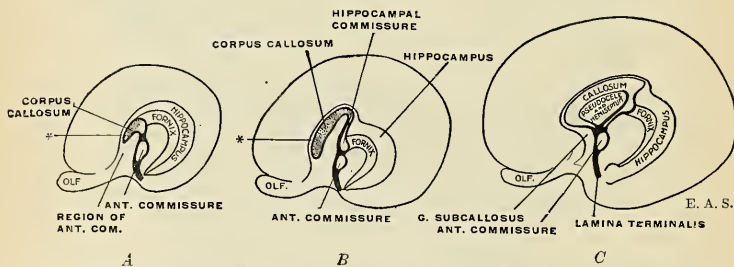


FIG. 691.—Schemata showing the development of the corpus callosum and its relations to hippocampus, fornix, and anterior commissure. Lamina terminalis (terma) in heavy black, corpus callosum dotted. * Represents the attenuated indusium and longitudinal striae already described.

Development.—The corpus callosum develops as a mass of commissural fibres which grow from side to side in the lamina terminalis (terma). The lamina terminalis serves as a matrix for several commissural systems—viz., the hippocampal commissure and the anterior commissure, in addition to the corpus callosum. The last develops rapidly in higher mammalian brains, thrusts aside the hippocampal margin of the pallium so that it atrophies in large part, and stretches out within its sharply bent arch a portion of the precommissural wall of each cerebral vesicle. It thus withdraws a part of the intercerebral cleft, eventually enclosing it entirely as the fifth ventricle. The stages of development are shown schematically in Fig. 691 and its development in the human embryo is shown in Fig. 692. The corpus callosum is most fully developed in man and does not appear below the marsupials. Its growth kept pace with the preponderatingly greater development of the neopallium in higher forms, and it may be looked upon as an index of the elaboration of at least one division of the association systems—those concerned with bilateral coordinations.

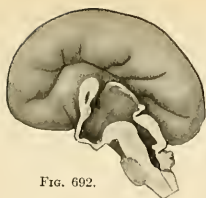

FIG. 692.

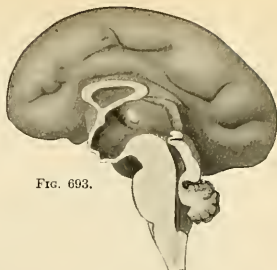

FIG. 693.

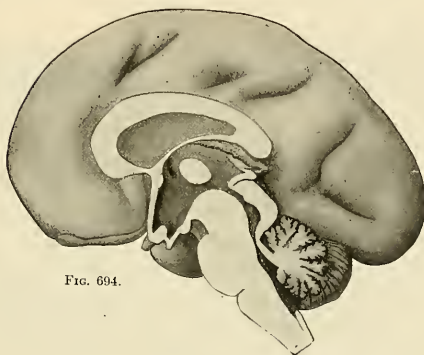


FIG. 694.

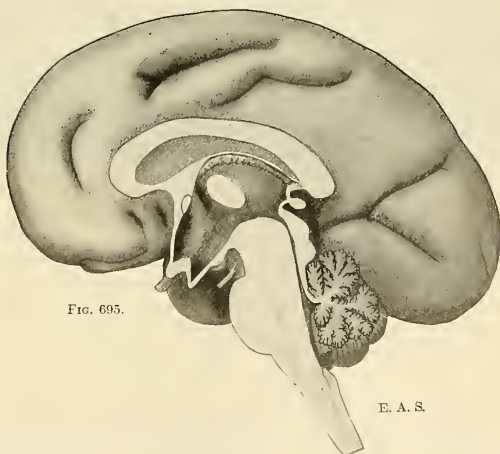


FIG. 695.

E. A. S.

FIGS. 692-695.—Brains of human embryos; mesal aspects of median sagittal section show the development of the corpus callosum. FIG. 692. Fourth month. FIG. 693. Fifth month. FIG. 694. Sixth month. FIG. 695. Seventh month.

The Lateral Ventricles.—An incision through the corpus callosum, on either side of the median plane, will expose two large, irregular, symmetrically situated cavities, the **lateral ventricles**, extending through a great part of each cerebral hemisphere. Each lateral ventricle communicates with the third ventricle through a small opening, the **foramen of Monro**, situated between the fornix-column (anterior pillar of fornix) and frontal end of thalamus. The cavity is lined throughout by ependyma; it is narrow in some and wide in other localities, and contains cerebrospinal fluid.

The shape of the lateral ventricle is best understood by reference to a cast of its interior, and its location within the cerebrum may be appreciated by a study of Figs. 696 and 697. Conventionally the lateral ventricle or paracele is described as being composed of a **body** or **cella** and three horn-like extensions or **cornua**. Viewed laterally its contour corresponds to that of the cerebral hemisphere and its cornua project toward the three poles—viz., frontal, occipital, and temporal.

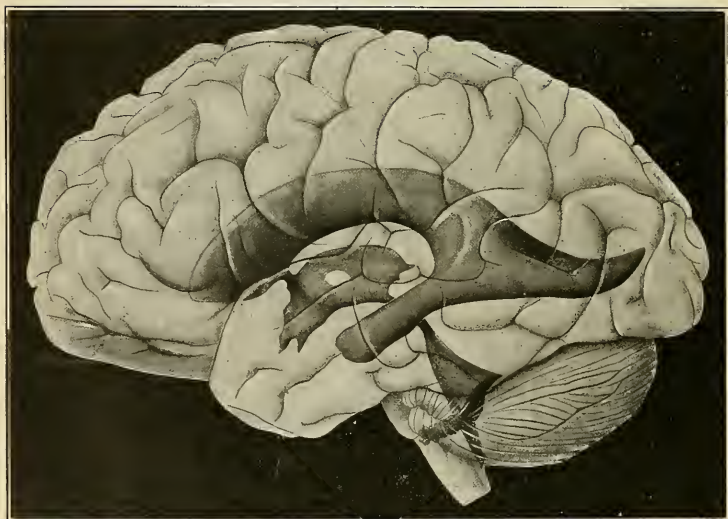


FIG. 696.—Showing the ventricular system of the brain as a solid cast as if seen through a transparent brain.

The **body** (*pars centralis ventriculi lateralis*) or **cella** of the lateral ventricle is defined as that portion which extends from the foramen of Monro to the region of the splenium. Its frontal prolongation is called the **anterior horn** or **precornu**. Near the splenium the cavity may be traced ventrolaterad into a capacious part (*trigonum ventriculi*), from which the **posterior horn** (*postcornu*) and **middle horn** (*medicornu*) are prolonged, respectively, toward the occipital and temporal poles.

The **anterior horn** or **precornu** (*cornu anterius*) passes frontad, inclined slightly ventrolaterad. Its **floor** is the head (*caput*) of the caudate nucleus, forming a rounded incline sloping mesad toward a trench-like recess floored by the rostrum of the corpus callosum. Its **roof** is the anterior forceps of the corpus callosum. Its **mesal wall** is formed by a portion of the hemiseptum of the septum lucidum. Laterally it is limited by the apposition, at an acute angle, of the corpus callosum and the caudate nucleus. Its **apex** reaches the ventricular surface of the genu of

the corpus callosum. The general outline of this part of the ventricle, in a frontal section, is triangular (Fig. 707).

The **body** of the cavity is curved with its convexity dorsad; its outline in trans-sections varies from the triangular to a mere slit which slopes slightly meso-ventrad. It is wholly *roofed* in by the corpus callosum (*pars frontoparietalis*). Its *floor* is formed by the following structures named in order from its ectal toward

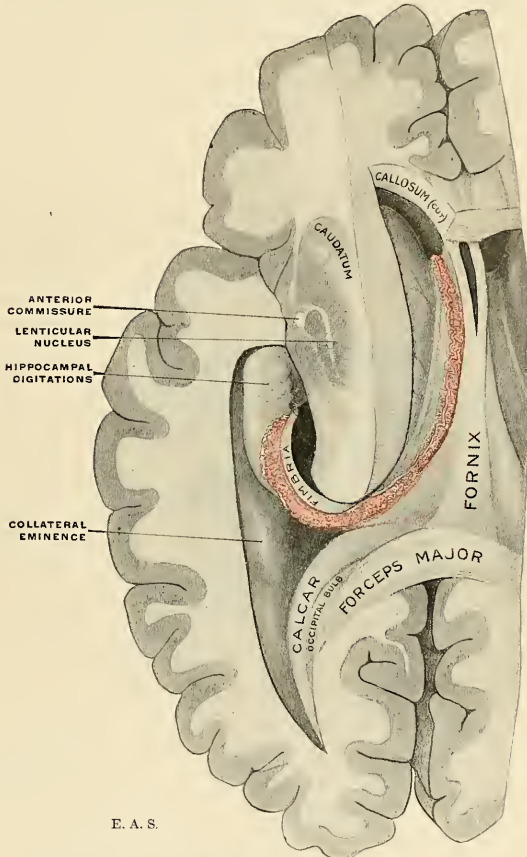


FIG. 697.—Dissection showing the left lateral ventricle (paracele) exposed.

its ental limit: (1) **caudate nucleus** or **caudatum**; (2) a groove which marks the line of coalescence of caudate nucleus and thalamus and lodges the *taenial vein* and a narrow fibre strand—the *taenia semicircularis*, beneath the ependyma; (3) a reflexion of the ependyma onto a narrow area of the thalamus; (4) the **choroid plexus of the lateral ventricle**; (5) the thin, sharp (fimbriated) edge of the **fornix**. The caudate nucleus narrows rapidly as it passes caudad. The taenia

semicircularis, lying along the ental border of the ventricular surface of the caudate nucleus, is a small band of white fibres arching from the amygdaline nucleus (near the temporal pole) to the anterior perforated substance. The entrance of a part of the thalamus into the formation of the floor of the lateral ventricle is apparent enough, but morphologically it should be strictly excluded therefrom. The thalamus is in no way formed from the parietes of the secondary fore-brain vesicles (telencephalon), for it is, in fact, excluded by a layer of ependyma (lamina affixa) reflected onto, and often separable from, the surface of the thalamus, so that it *appears* as a constituent of the floor because of the transparency of the ependymal sheet. The choroid plexus of the lateral ventricle is a richly vascular invagination over which the ependyma is continuous to again become reflected onto the fornix along its sharp edge. A reference to Fig. 670, showing the topographical relations of these structures in a frontal section, may be of assistance.

The cavity is thence continued ventrolaterad in a bold sweep to become expanded as an obliquely pyramidal space of a somewhat triangular outline on section, and placed subjacent to the parietal lobe—the **trigonum ventriculi** (*trigonum collaterale*). A conspicuous feature in its floor is the **collateral eminence**, correlated with the collateral fissure. From the trigonum, the most capacious part of the lateral ventricle, the cavity is prolonged in opposite directions as the middle and posterior cornua.

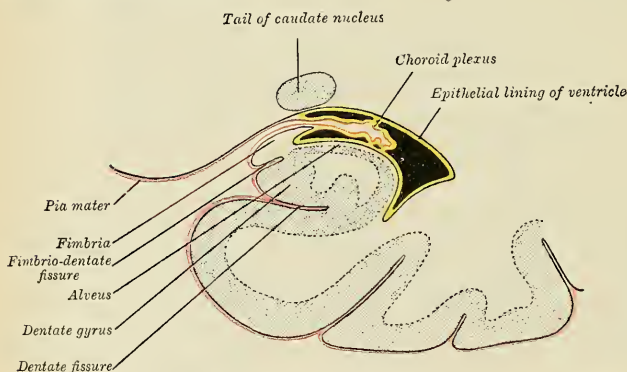


FIG. 69S.—Coronal section of descending horn of the lateral ventricle. (Diagrammatic.)

The **middle horn** or **medicornu** (*cornu inferius*) is a prolongation of the ventricular cavity, from its trigone toward the temporal pole, which pursues a curved course with its convexity directed ventrolaterad (Figs. 696 and 697), corresponding to the curved contour of the temporal lobe, and situated at a depth of about 3 cm. from its lateral surface as well as from the temporal pole. The *roof* is formed by (a) the **tapetum of the corpus callosum**; (b) the **cauda** (tail) of the **caudate nucleus**; (c) the **taenia semicircularis**. The *medial wall* is principally composed of the **hippocampus**, a prominent welt-like eminence bulging into the cavity, largely filling it, and produced by the hippocampal fissure. The hippocampus nearly conceals from view the actual *floor*, which is of variable extent in different brains and usually marked by an extension of the collateral eminence previously described. Surmounting the corrugated hippocampal formation and projecting slightly into the cavity, is the **fimbria**, and from its sharp edge the ventricular ependyma

is reflected upon the invaginated choroid plexus of the lateral ventricle. The choroid plexus of the middle cornu is more voluminous than that of the body of the ventricle, and must be lifted in order to expose the whole of the ventricular aspect of the hippocampus.

At the *apex* of the middle cornu the roof presents a more or less pronounced bulging, the **amygdaloid tubercle**, due to the presence of the amygdaline nucleus, a small mass of ganglionic gray from which the taenia semicircularis arises and in which the caudate nucleus apparently ends.

The **posterior cornu** or **postcornu** is a shorter diverticulum which passes toward the occipital pole in a gently curved course, with its convexity directed laterad. It is not very capacious, usually slit-like on section, and tapers to a point within 2 or 3 cm. of the occipital pole. Its *roof*, slanting lateroventrad, is formed by the

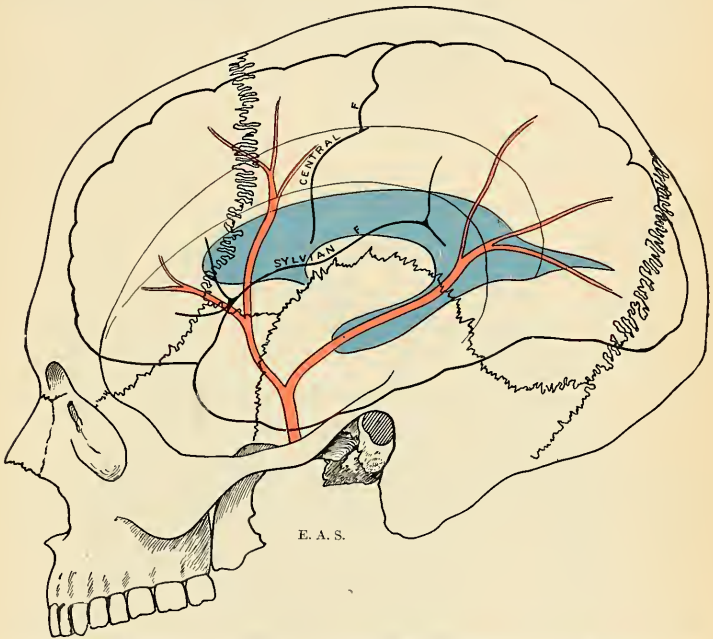


FIG. 699.—Diagram showing the topography of the lateral ventricle, middle meningeal artery, and cerebrum within the cranium.

tapetum of the corpus callosum. On the inner or *mesal wall* two elongated bulgings may be observed. The upper or dorsal elevation, called the **occipital bulb** or **bulb of the cornu** (*bulbus cornu posterioris*, callosal eminence [Wilder]), is formed by the compact arched posterior forceps of the corpus callosum as it curves around the very deep occipital fissure. The occipital bulb is not always well marked. Ventrad of it lies a more constant limbus or welt-like elevation, the **calcar** (*calcar avis*; *hippocampus minor*), a projection produced by the infolding of the cerebral wall along the calcarine fissure. The *floor* is continuous with the col-lateral eminence in front. The choroid plexus does not enter the posterior cornu.

The **choroid fissure** or **rima** (fissure of Bichât) is not a true fissure, and only becomes one when the choroid plexus of the lateral ventricle is torn from its connections. The choroid fissure is nevertheless a gap between the diencephalic part and the overlapping and recurved telencephalon produced by the extension of the secondary fore-brain vesicles in an arcuate manner. It is along this arcuate and fissure-like gap (Fig. 700) that the richly vascular (pial) choroid plexus invaginates the atrophied parietes of the secondary fore-brain to form the choroid plexus which is everywhere covered by ependyma. The choroid fissure extends from the foramen of Monro to near the tip of the middle cornu in an arcuate course, and ependymal reflections everywhere close in this gap except at the foramen of Monro. The manner in which this is accomplished may best be understood by a study of a trans-section showing the ependymal reflections from the ventricular wall onto the invaginated choroid plexus (Figs. 670 and 698). The caudatothalamic fusion and the intrusion of the great fibre masses constituting the cerebral crura play their parts in complicating the relations in brains of higher type.

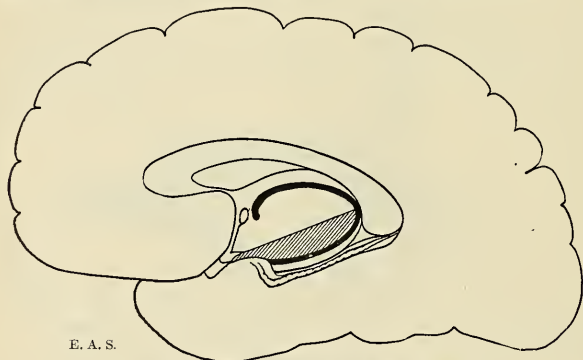
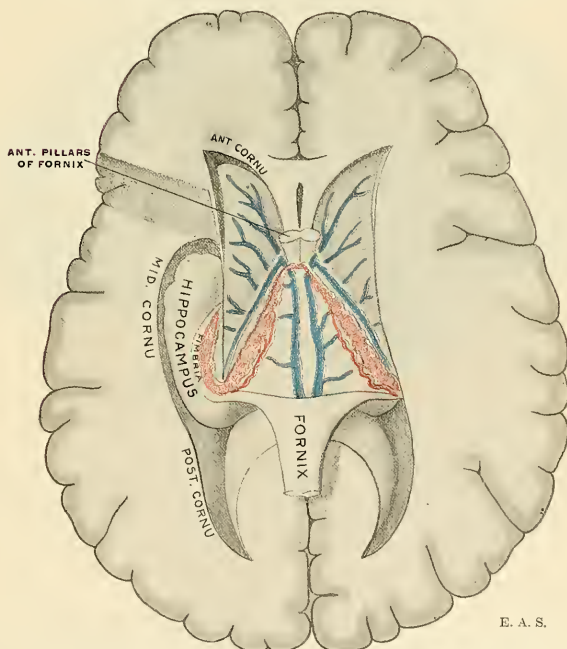


FIG. 700.—Diagram showing the choroid fissure. (Bichât.)

The Choroid Plexus of the Lateral Ventricle and Velum Interpositum.—The **choroid plexus** is a highly vascular, fringe-like structure composed of pia which is invaginated into the lateral ventricle along the choroid fissure, or gap between cerebral hemisphere and diencephalon. The portion of the choroid plexus protruding into the “body” of the lateral ventricle is the fringed vascular border—a triangular fold of pia—the **velum interpositum** (*tela choroidea superior*), which, as its name implies, is interposed between the relatively small primary fore-brain and the enormous overlapping secondary fore-brain, and is produced by the overgrowth of the latter onto the former. Inasmuch as the nerve tissue in the roof of the third ventricle atrophies totally, the ventral fold of the pia comes into contact with the ependyma of that ventricle and here permits a similar vascular invagination in the form of two parallel fringes hanging into the cavity (**diaplexus** or **choroid plexuses of the third ventricle**). The dorsal leaf of the pial fold is in contact with the ventral face of the body of the fornix. Frontad, the velum interpositum tapers toward the region of the two foramina of Monro, where the choroid plexuses of the two sides are continuous with each other. The ventricular surface of the choroid plexuses is everywhere covered by ependyma which is reflected from it to the fimbriated edge of the fornix on the one hand and to the line of the taenia semicircularis (over the thalamus by the lamina affixa) on the other. Its vascular components, in addition to undefined lymphatic channels, are the **anterior choroid artery**, a branch of the internal carotid, entering

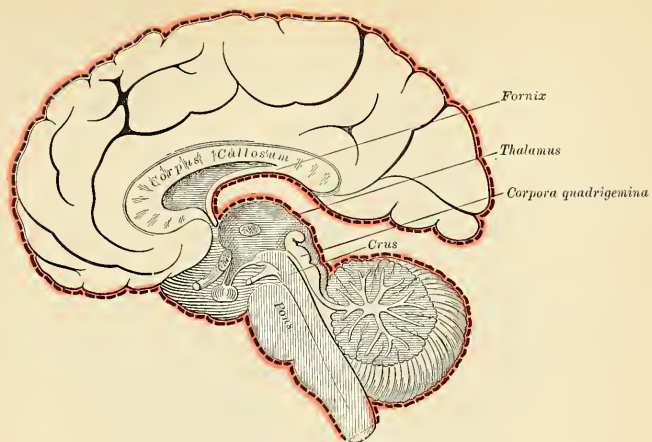

FIG. 701.—Diagram showing the mode of formation of the velum interpositum.



E. A. S.

FIG. 702.—The fornix, velum interpositum, and middle cornu of the lateral ventricle.

the plexus of the middle cornu; and the **posterior choroid artery** from the posterior cerebral artery reaching the choroid plexus in the neighborhood of the splenium. The venules of the plexus join to form a tortuous **middle cornual vein** which terminates frontad by joining one of the **velar veins**.

The **velar veins** (veins of Galen), one on either side close to the median line, running in the fold of the velum interpositum, are formed by the union of the **tenial, striatal, and middle cornual veins**. The two velar veins unite to form a common trunk which empties into the straight sinus.

The Hippocampus and Fornix.—The hippocampus and the fornix merit special description. The **hippocampus**, as seen in the middle cornu, is a white eminence about 5 cm. (2 inches) in length, of a curved elongated form, enlarging cephalad and tapering caudad as the hippocampal fissure decreases in depth. The enlarged extremity is marked by alternate elevations and depressions, usually three in number, the **hippocampal digitations**; because of its resemblance to a lion's paw it is sometimes called the **pes leonis** or **pes hippocampi**. The white appearance of the ventricular aspect of the hippocampus is due to a stratum of white substance, the **alveus**, made up of myelinic axones from hippocampal cells and continued into the fimbria. The fimbria is folded so that its sharp margin is directed

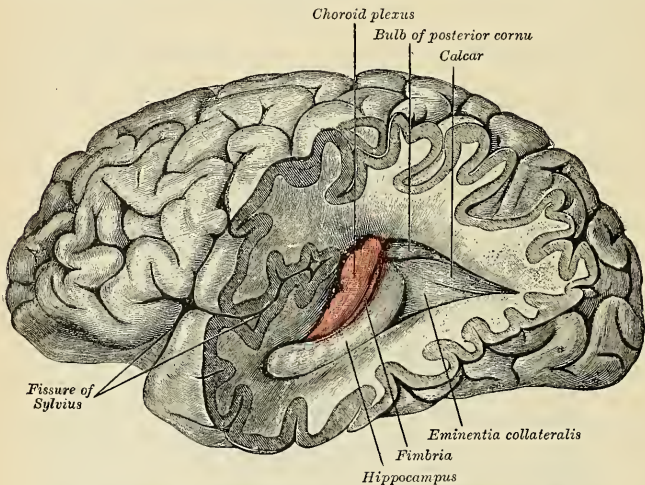


FIG. 703.—Posterior and descending cornua of left lateral ventricle exposed from the side.

toward the cavity of the middle cornu; eventually its fibres will be seen to enter into the formation of the fornix. The formation of the hippocampus is best observed in a coronal section (Fig. 686). In this view it is seen to be a peculiarly folded margin of the cerebral cortex, corrugated by the intrusion of the hippocampal and fimbriodentate fissures. Morphologically it is a vestigial submerged portion of the rhinencephalon, as a part of which it has already been described (p. 929).

The **fornix** (Figs. 704, 705) is really a paired structure consisting of bilaterally symmetrical halves composed of longitudinally directed fibres which arch on each side from the region of the uncus to the corpus albicans. The two lateral parts join each other in the mesal plane along the summit of the arch to form the **body of the fornix** (*corpus fornicis*). Frontad they diverge slightly as they proceed

toward the corpus albicans; caudad they diverge more widely. The paired diverging portions are called respectively the **anterior** and **posterior pillars of the fornix**. The fibres of each half fornix arise from the pyramidal cells in the hippocampus, and their course will be traced from this source to the ending in the corpus

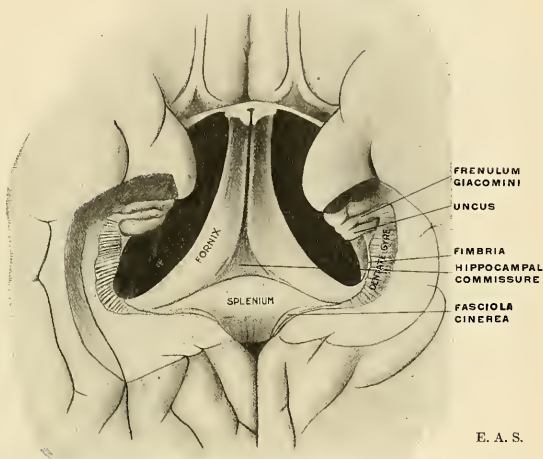


FIG. 704.—The fornix, hippocampal commissure, splenium, and dentate gyrus seen from the basal aspect.

albicans. Beginning at first as a stratum of white substance (*alveus*) constituting the ectal surface of the ventricular bulge of the hippocampus, the fibres become collected along its medial border in a narrow but distinct folded band, the **fimbria**. This increases in diameter as increments are added to it along

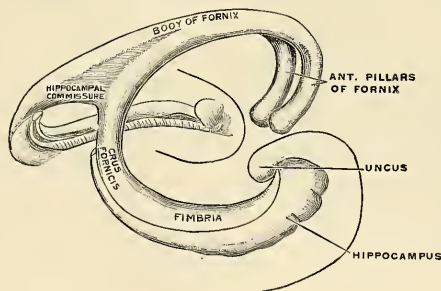


FIG. 705.—Diagram of the fornix. (E. A. S.)

its course, until, at the apical region of the trigonum ventriculi, it leaves the dwindling hippocampus to ascend in a curved course (dorsimesad) toward the subsplenial callosal surface as a thick, flattened band. Once free from the hippocampus on each side, the two converging bands of opposite sides are called the

posterior pillars or crura fornicis. The majority of the fibres continue frontad in each half fornix, but a number course transversely to enter the crus fornicis of the opposite side to end in the hippocampal formation. These fibres, of transverse course, form a thin lamina filling in the small triangular space in the subsplenial region between the converging crura fornicis and constituting the **hippocampal commissure** (lyra; psalterium). Occasionally a small recess called **Verga's ventricle** is formed between the corpus callosum and the hippocampal commissure.

The two half fornices now become joined in the mesal plane and, leaving the subsplenial surface of the corpus callosum, dip frontoventrad in an arch—the **body of the fornix**. Its caudal part is broad and each half is of triangular outline (on section) with a sharp edge directed laterad. Where it is not in contact with the corpus callosum it affords attachment, on each side of the mesal plane, to the hemiseptum of the septum lucidum. Laterad of these lines of attachment the dorsal surface of each fornix enters into the formation of the floor of the lateral

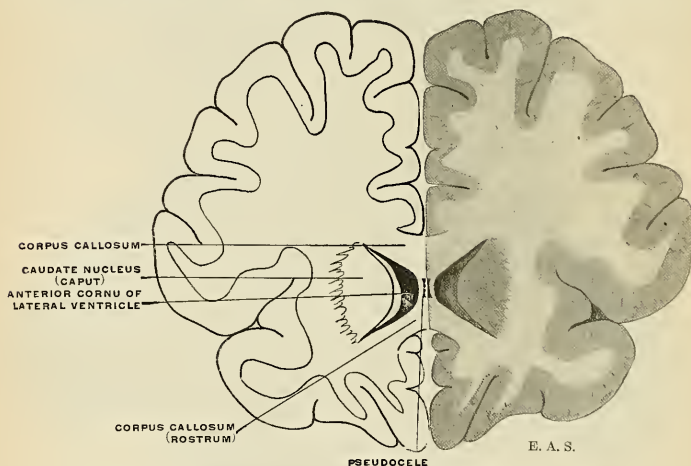


FIG. 706.—A coronal section of the brain slightly caudad of the genu of the corpus callosum.

ventricle and is covered by ependyma (Fig. 697). The ventral surface rests upon the velum interpositum, which separates it from the third ventricle and the dorsal surface of the thalamus (Fig. 670).

Near the region of the anterior commissure the fornix again divides into its constituent lateral halves, separating as rounded strands called the **anterior pillars**. These curve ventrad to form the frontal boundary of the foramen of Monro and thence plunge into the hypothalamic gray, inclined slightly caudad, to end in the corpus albicans. The terminals of the fornix fibres come into relation with the cells of the nucleus of the corpus albicans, which, in turn, give off the bifurcating Y-shaped axone bundles already described (p. 907).

In rare instances each anterior pillar has been seen to divide on approaching the anterior commissure a part passing frontad thereof as an anomalous pre-commissural pillar of the fornix. The fornix, in its course from hippocampus to corpus albicans, gives off, in addition to those described as hippocampal commissural fibres, axones (*a*) to the opposite half fornix, decussating in the fused portion (body), (*b*) to the hemiseptum of the septum lucidum, and (*c*) to

the gray tissues of the anterior perforated substance (Fig. 685). It constitutes an *inner* olfactory arc as distinguished from the epicallosal or outer arc, represented by the atrophied indusium and its longitudinal striae.

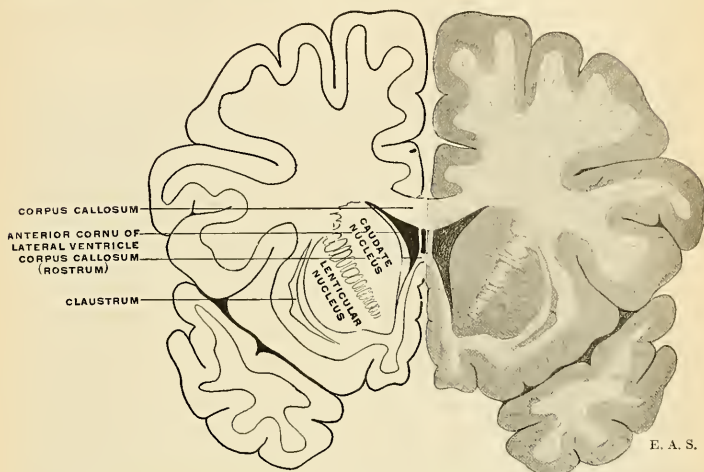


FIG. 707.—A coronal section through the brain in the plane of the junction of caudate and lenticular nuclei.

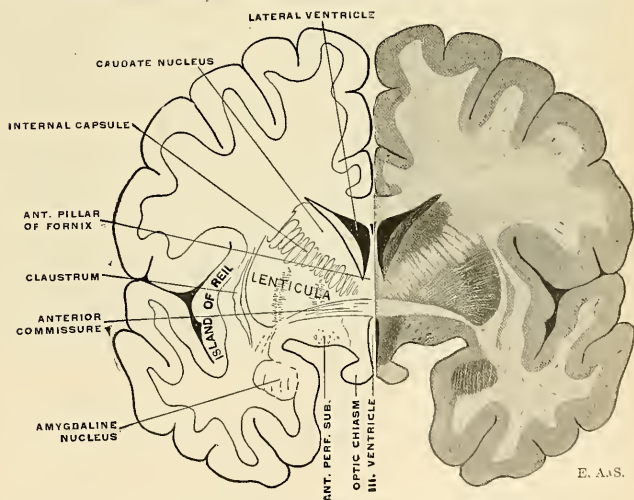


FIG. 708.—A coronal section of the brain in the plane of the anterior commissure.

The Septum Lucidum (*septum pellucidum*).—The so-called septum lucidum really consists of two vertically placed *laminæ* or *hemisepta*. Between them lies a narrow, enclosed space, the *cavum septi pellucidi* (pseudocoele; fifth ventricle),

roofed in by the corpus callosum, while the floor consists of the fused fornices and the rostrum. Each hemiseptum bounds a part of the anterior cornu and body of the lateral ventricle in its mesal wall, and in a lateral view is of triangular outline. The hemisepta represent the thin, undeveloped parts of the mesal walls of the cerebral vesicles, which were enclosed within the rapidly developing arch of the corpus callosum. The cavum septi pellucidi is therefore a closed-off part of the original intercerebral cleft and not a part of the neural cavity, as its older name, "fifth ventricle," seems to imply.

The Anterior Commissure.—The anterior commissure, or **precommissure**, is a bundle of white fibres, of oval outline in a sagittal section, which crosses the midline as a localized reinforcement of the lamina terminalis, slightly bulging into the frontal part (aula) of the third ventricle and clothed by its ependyma. It is a comparatively insignificant intercerebral commissure in the human brain, having become diminished as the corpus callosum increased in mammalian development. It courses from side to side frontad of the anterior pillars of the fornix, ventrad of the head of the caudate nucleus, and passes, in part, through the frontal end of the lenticular nucleus (Fig. 708). Its fibres radiate chiefly to the cortex of the temporal lobe and to certain parts of the rhinencephalon.

The bundle is slightly twisted in each lateral, buried part. Two divisions are distinguishable: (1) The **pars anterior** or **frontal part** (in the median plane) contains two groups of fibres belonging to the olfactory apparatus—(a) fibres arising from the mitral cells in the olfactory bulb of one side to the same layer in the opposite bulb; (b) fibres which associate the uncus of one side with that of the other. (2) The **pars posterior** contains the fibres passing between the cortices of the two temporal lobes.

Gray Masses in the Cerebral Hemisphere.—Aside from the cortex, the cerebral hemisphere contains certain gray ganglionic masses in its interior, more or less embedded in the white centrum, and called, because of their proximity to the base of the cerebrum, the **basal ganglia**. These comprise the **caudate**, the **lenticular**, and the **amygdaline nuclei**. It is usual to include the **claustrum** among the basal ganglia, but morphologically this structure belongs rather to the insular cortex of the island of Reil.

Conventionally the caudate nucleus and lenticular nucleus together are described as the **corpus striatum** (*striatum*), a ganglionic mass which in earlier vertebrate brains bore intimate relations with the olfactory apparatus, but later, with the rise in functional dignity and growth of the neopallium, underwent specialization and differentiation concomitant with the reduction of the rhinencephalon. The intrusion of great projection fibre masses, thrusting the cortical gray outward, has not been everywhere uniform, and we still find, in the human brain, a common ground in which the neopallial cortical gray, the corpus striatum, rhinencephalon, and amygdaline nucleus meet—the site of fusion being in the gray substance of the anterior perforated substance. To the cortical mantle they are regarded as bearing the relation of subordinate (subcortical) centres. In the human brain the **corpus striatum**—so called because of its striated appearance in sections—is composed of two masses, the **caudate** and **lenticular nuclei**, directly continuous with each other at their frontal ends (Fig. 710). The connecting gray bridge becomes broken up into numerous small bands of gray substance as the fibre masses of the internal capsule insinuate themselves between the two nuclei (Fig. 707).

The **caudate nucleus** (*nucleus caudatus*; *caudatum*) (Figs. 709, 710) presents a ventricular and a capsular surface; the ventricular surface, covered by ependyma, forms part of the floor of the body and anterior cornu of the lateral ventricle, while in the middle cornu it is a constituent of its roof, owing to its arched contour in correspondence with the sweeping curve of the ventricle itself. It is of a pyriform

shape with a very much attenuated tail. The large, thick head projects into the anterior cornu, while its thinner tail is prolonged caudolaterad, separated from the thalamus by the narrow taenia semicircularis. Following the curved contour of the ventricle it is prolonged as a narrow gray band in the roof of the middle cornu, where it joins the **amygdaline nucleus**. The nonventricular or capsular surface is embedded in the white substance of the cerebral hemisphere, and is chiefly related to the internal capsule.

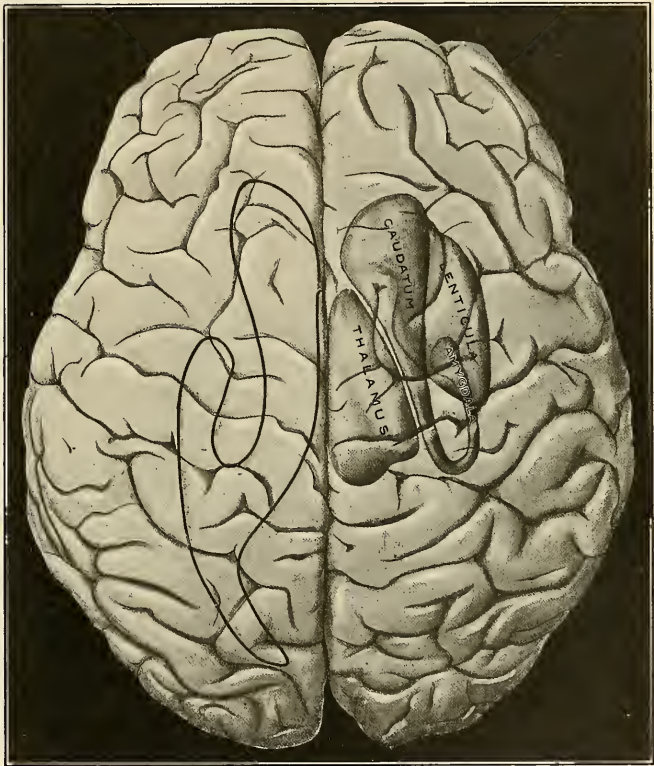


FIG. 709.—The basal ganglia and thalamus schematically represented in a supposedly transparent brain (right side); on the left is shown the outline of the lateral ventricle.

The ventricular surface shows, in microscopic sections, a dense ependymal lining. The capsular face is not sharply outlined, numerous strands of fibres, to and from the internal capsule, entering it obliquely so as to appear as streaks which extend to about the middle of the ganglion, there separating into finer and finer strands which become lost to the naked eye.

The **lenticular nucleus** (lenticula) (Figs. 708 and 709) is wholly embedded in the white substance, and must be studied in sections. In its shape it resembles an irregular triangular pyramid with its convex base directed laterad and parallel with and near to the cortical expanse of the island of Reil and of about the same extent. Its ental, apical portion is directed toward the interval between caudate nucleus

(head) and thalamus. The contour and slope of the surfaces of the ental pyramidal face may be judged from the model pictured in Fig. 710. Its outline, as revealed in sections passing in different planes, is shown in Figs. 708 and 711.

Sections of the lenticular nucleus show it to be composed of three¹ concentric segments separated by two white medullary laminae. The segments are known as **artificuli**; the ectal one is designated the **putamen**; the two ental zones constitute the **globus pallidus** (pallidum). The **putamen** is the larger and of a deeper reddish-gray tint; the two mesal divisions are lighter in color owing to a greater proportion of radiating streaks of white fibres passing to and from the internal capsule. The ectal outline of the putamen is sharply defined against a white lamina, the **external capsule**.

The **amygdaline nucleus** (amygdala) is usually regarded as an hypertrophied aggregation of the temporal cortex which has become nearly isolated from its cortical connection by intruding white substance. It is a rounded, gray, striated mass situated in the fore part of the temporal lobe in the roof of the middle cornu at its apex, where it produces the bulging called the **amygdaloid tubercle**. Caudad it is joined by the tail of the caudate nucleus; frontad it is continuous with the putamen. Except for the marked streaking shown in sections, its structure is like that of the cortex. Its cells apparently give rise to the narrow band of fibres—the **taenia semicircularis**—which courses along the mesal margin of

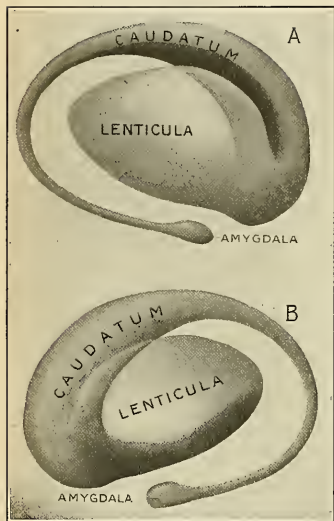


FIG. 710. —Two views of a model of the striatum: A. Lateral aspect. B. Mesal aspect. (E. A. S.)

the ventricular surface of the caudate nucleus throughout its arched course and ends in the gray of the anterior perforated substance, so that it nearly completes a circle.

The **claustrum** is a thin plate of gray substance embedded in the white substance which intervenes between the putamen and the cortex of the island of Reil, and corresponds in extent to these. Its dorsal edge is very much attenuated; traced ventrad it thickens considerably and becomes continuous with the surface gray at the anterior perforated substance. Its ectal surface presents alternate ridges and depressions which correspond to the corrugations of the cortex of the island of Reil. The "external capsule" intervenes between its ental face and the putamen of the lenticular nucleus. From the cortex of the island of Reil proper it is separated by a white lamina which may be termed the **periclastral lamina** or **capsula extrema**. Apparently the claustrum is the thickened and isolated spindle-cell stratum of the cortex of the island of Reil, a feature which may be of significance in relation to the preponderatingly associative function of the insular region.

Internal Capsule² (Fig. 711).—Between the lenticular nucleus on the one hand and the caudate nucleus and thalamus on the other lies the **internal capsule**, a broad

¹ Four and even five have been observed.

² The terms *internal capsule* and *external capsule* owe their derivation to the fact that the lenticular nucleus is almost completely enveloped by white substance in the form of a capsule. Of these the internal or mesal portion is relatively massive, while the external or lateral portion is thin.

band of white fibres which, as seen on horizontal section, appears bent, very much as a leg is bent on the thigh, with the knee (genu) directed mesad. The frontal or caudatolenticular division or limb is confined between the opposed faces of the caudate nucleus and lenticular nucleus. The genu receives the mesal apex of the lenticular nucleus in its hollow, while the caudal or thalamolenticular limb lies between the opposed faces of lenticular nucleus and thalamus. The frontal limb constitutes about one-third, the caudal limb two-thirds of the internal capsule mass.

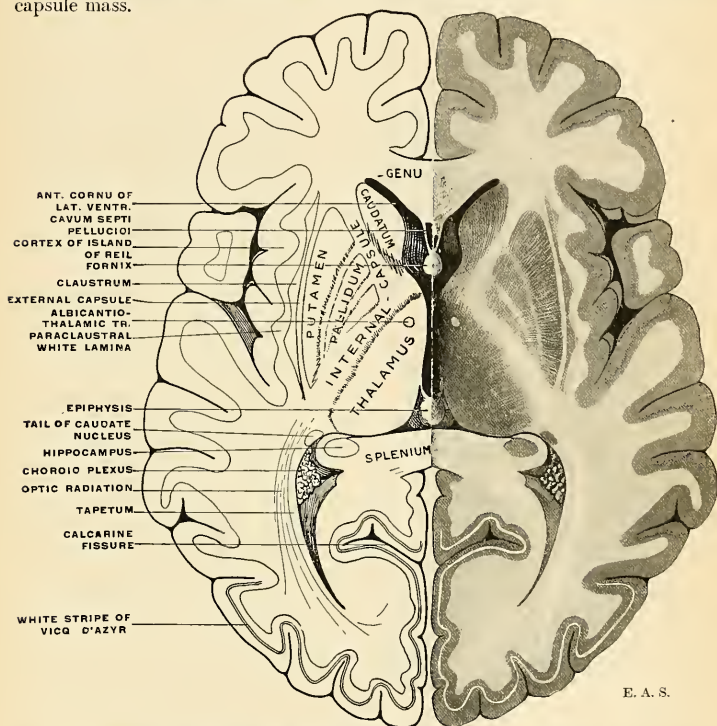


FIG. 711.—Horizontal section through the cerebrum. The various structures are shown in their natural appearance on the right side and are named on the left side.

The term "internal capsule" is often loosely employed and is variously stated to include fibre tracts which do not course between the cerebral cortex and the "lower" brain centres. In a strict sense it is a mass of fibres which converge, like the sticks of a fan, toward the cerebral base and into the crura. Dorsad of the basal ganglia the fibres radiate in various directions, streaming among the radiating callosal fibres and forming the so-called *corona radiata*. Yet other fibre tracts leave and enter the great ganglia at various altitudes along the internal capsule, and we must therefore distinguish the following cerebral fibre systems.

Projecting systems, ascending and descending (in the functional sense), of longer and shorter course, connecting the cerebral cortex with (a) spinal gray centres; (b) mid-brain and pontile nuclei; (c) basal ganglia and thalamus. The

last-mentioned system traverses the internal capsule to a greater or less extent, but does not continue into the crista. These various systems are summarized on page 956. It may here be mentioned that the internal capsule, topographically, exhibits a functional dissociation in that its frontal or lenticulocaudate limb is composed of preponderating corticopetal fibres, while corticifugal fibres form the major portion of the thalamolenticular limb (Fig. 712). In the frontal limb

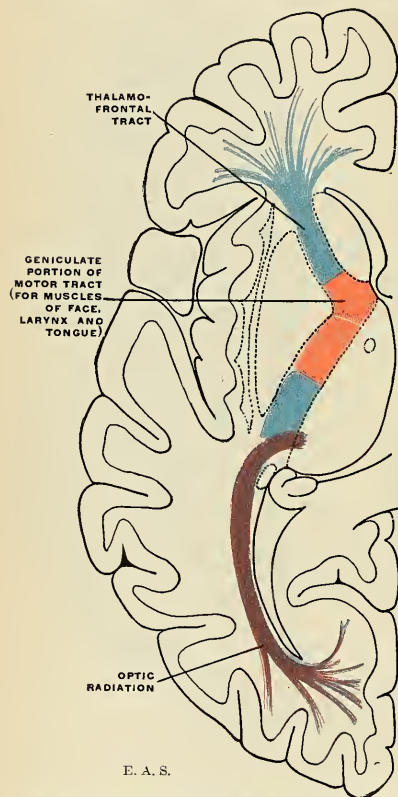


FIG. 712.—Diagram of the tracts in the internal capsule. Motor tract red. The sensor tract (blue) is not direct, but formed of neurones receiving impulses from below in the thalamus and transmitting them to the cortex. The optic radiation (occipitohthalmic) is shown in violet.

are the **thalamofrontal** and **thalamostriate fibres**, the former ending in the cortex of the frontal lobe, the latter in the caudate and lenticular nuclei. The chief corticifugal components are the **frontopontile tract**, and fewer **frontothalamic** and **striatohthalmic fibres**. The frontopontile tract arises in the cortex of the prefrontal region, traverses the frontal limb of the internal capsule, forms the ental sector (one-fifth) of the crista, and ends in the nuclei pontis.

In the genu and the thalamolenticular limb of the internal capsule course several important fibre tracts which are chiefly corticifugal.

The **pyramidal (motor) tract**, in its course from the precentral cortex to the lower motor centres, occupies the frontal half of this limb. The portion in the genu, often designated the **geniculate tract**, comprises the pyramidal fibres which are destined to go to the facial and hypoglossal nerve nuclei; farther caudad lie, in succession, the fibres going to the motor centres for the upper and the lower extremity and trunk. More posteriorly pass the corticopetal fibre-systems conveying sensor impressions from the periphery *via* thalamus (Fig. 712). The most caudal segment (also called the **retrolenticular part**) of the internal capsule contains (a) the **optic radiation**, composed of fibres coursing in both directions

between the occipital cortex and the pulvinar, external geniculate and superior quadrigeminal bodies; (b) the **auditory radiation**, composed of fibres passing in both directions between the cortex of the temporal lobe (auditory centre) and the posterior quadrigeminal and internal geniculate bodies; (c) the **occipitopontile** and **temporopontile tracts** from the occipital and part of the temporal cortex, coursing through the caudal segment of the internal capsule, constituting the ectal (one-fifth) sector of the crista and ending in the nuclei pontis. In addition there are scattered fibre bundles which arise from the ventral portion of

the thalamus, enter the internal capsule to pass toward the cortex, in part through the lenticular nucleus, in part in the sublenticular zone, to form the *ansa lenticularis*. The reinforcement of this sublenticular white-fibre tract by cortico-thalamic fibres from the temporal lobe to thalamus forms the *ansa peduncularis*. The topographic relations of the various tract masses as seen in a flatwise section is schematically shown in Fig. 713; on the whole, they correspond to the cortical areas with which they are connected.

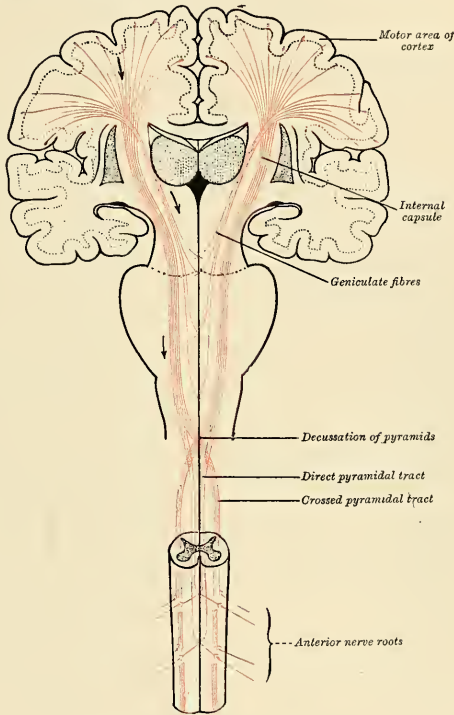


FIG. 713.—The motor tract. (Modified from Poirier.)

The *external capsule* (Fig. 711) is a thin lamina of white substance interposed between the ectal face of the lenticular nucleus and the claustrum. Dorsally, frontad and caudad, at the corresponding borders of the lenticular nucleus, it joins the internal capsule mass, while ventrally it is continuous with the white centrum of the temporal lobe. Its comparatively few projection fibres course to and from the ventral parts of the thalamus; its chief constituents are association axones for the circuminsular cortical areas.

Minute Structure of the Cerebral Cortex and its Special Types in Different Regions (Fig. 714).—A section of the cerebral cortex reveals a tendency on the part of its constituent cells to arrange themselves in layers which alternate with zones less rich in cellular elements. Among the cells course the axones arising from them or terminating in their neighborhood. The axones are chiefly amyelinic, though some are myelinic for a part of their intracortical

course. The cells, of various sizes and shapes, together with their dendrites and axones, are embedded in a matrix of neuroglia.

The nerve cells in a *typical* section of the cortex are arranged in five tangential layers, as follows: (1) the **molecular layer**; (2) the **ectal polymorphous cell layer**; (3) the **layer of small pyramidal cells**; (4) the **layer of large pyramidal cells**; (5) the **ental polymorphous cell layer**.

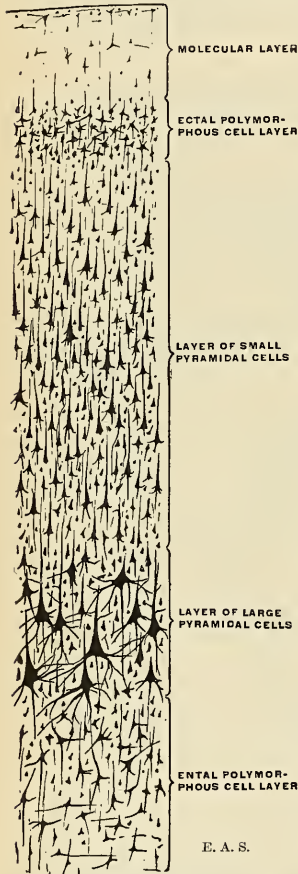


FIG. 714.—Typical arrangement of the cell layers in the cerebral cortex.

The **molecular layer** (*neuroglia layer*) lies immediately subjacent to the pia, and is chiefly made up of glia cells and fibres, among which the dendrites of the subjacent layer of cells intrude.

The **ectal polymorphous layer cells** are polygonal, triangular, and fusiform in shape, and tend to gather in groups in certain cortical regions. The fusiform cells are placed with their long axes parallel (*i. e.*, tangential) to the gyral surface and are presumably associative in function.

The Layer of Small and the Layer of Large Pyramidal Cells.—The cells in the second and third layers may be studied together, since, with the exception of the difference in size and the more superficial position of the smaller cells, they resemble each other. The body of each cell is pyramidal in shape, its base being directed to the deeper parts and its apex toward the surface. It contains granular pigment, and stains deeply with ordinary reagents. The nucleus is nucleolated, of large size, and round or oval in shape. The base of the cell gives off the axone, and this passes into the central white substance, giving off collaterals in its course to be distributed as a projection, commissural, or association fibre. Both the apical and basal parts of the cell give off dendrites. The apical dendrite is directed toward the surface, and ends in the molecular layer by dividing into numerous branches, all of which may be seen to be studded with projecting bristle-like processes when prepared by the silver or methylene-blue method. The larger pyramidal cells, especially in the precentral gyre, may exceed $50\ \mu$ in length and $40\ \mu$ in breadth, and are termed **giant cells**. The chief function of the small pyramidal cells is commissural and associative. The chief function of the large pyramidal cells in the precentral and paracentral cortex is motor, but they have also commissural and associative functions.

Layer of Ental Polymorphous Cells.—The cells in this layer, as their name implies, vary greatly in contour, the commonest varieties being of a spindle, star, oval, or triangular shape. Their dendrites are directed outward, toward, but do not reach, the molecular layer; their axones pass into the subjacent white substance. From this layer come commissural fibres, long association fibres, and some projection fibres.

There are two other kinds of cells in the cerebral cortex, but their axones pass in a direction opposite to that of the pyramidal and polymorphous cells, among which they lie. They are: (a) the **cells of Golgi**, the axones of which do not become myelinated, but divide immediately after their origin into

a large number of branches, which are directed toward the surface of the cortex; (b) the **cells of Martinotti**, which are chiefly found in the polymorphous layer. Their dendrites are short, and may have an ascending or descending course, while their axones pass out into the molecular layer and form an extensive horizontal arborization.

Nerve Fibres in the Cortex.—These fill up a large part of the intervals between the cells. Some of these fibres form fasciculi; some are isolated, and others are arranged in plexuses. They may be myelinic or amyelinic, the latter comprising the axones of the smallest pyramidal cells and the cells of Golgi. In their direction the fibres may be either transverse, the **transverse**

tangential or horizontal fibres, or vertical, the **vertical or radial fibres**. The tangential fibres run parallel to the surface of the hemisphere, intersecting the vertical fibres at a right angle. They consist of several strata, of which the following are the most important: (1) A **stratum of white fibres** covering the superficial aspect of the molecular layer; (2) the **band of Bechterew**, found in certain parts of the superficial portion of the layer of the smaller pyramidal cells; (3) the **external or outer band of Baillarger** or the **band of Gennari**, which runs through the layer of large pyramidal cells; (4) the **internal band of Baillarger**, which intervenes between the layer of large pyramidal cells and the polymorphous layer. According to Cajal, the tangential fibres consist of (a) the collaterals of the pyramidal and polymorphous cells and of the cells of Martinotti; (b) the arborizations of the axones of Golgi's cells; (c) the collaterals and terminal arborizations of the projection, commissural, or association fibres. The **vertical fibres**: Some of these—viz., the axones of the pyramidal and polymorphous cells—are directed toward the central white substance, while others—the terminations of the commissural, projection, or association fibres—pass outward to end in the cortex. The axones of the cells of Martinotti are also ascending fibres.

In certain parts of the cortex this typical structure is departed from. The chief of these regions are (1) the **occipital lobe**, (2) the **transtemporal gyres**, (3) the **hippocampus**, (4) the **dentate gyre**, and (5) the **olfactory bulb**.

Special Types of Gray Substance. 1. **The Occipital Lobe.**—In the cuneus and the calcarine fissure of the occipital lobe Cajal has recently described as many as nine layers. Here the inner band of Baillarger is absent; the outer band of Baillarger or band of Gennari is, on the other hand, of considerable thickness. If a section be examined microscopically, an additional layer is seen to be interpolated between the molecular layer and the layer of small pyramidal cells. This extra layer consists of two or three strata of fusiform cells, the long axes of which are at right angles to the surface. Each cell gives off two dendrites, external and internal, from the latter of which the axone arises and passes into the white central substance. In the layer of small pyramidal cells, fusiform cells, identical with the above, are seen, as well as ovoid or star-like elements with ascending axones, the **cells of Martinotti**. This area of the cortex forms the visual centre, and it has been shown by Dr. J. S. Bolton¹ that in old-standing cases of optic atrophy the thickness of Gennari's band is reduced by nearly 50 per cent.

2. **The Transtemporal Gyres** are distinguished by a reduction of thickness of the pyramidal cell layer with closer approximation of the giant cells to each other, while the fusiform cell layer is more deeply situated than elsewhere. This cortical formation is the end station for cochlear nerve projections.

3. In the **Hippocampus** (Fig. 686) the molecular layer is very thick and contains a large number of Golgi cells. It has been divided into three strata: (a) **S. convolutum** or **S. granulosum**, containing many tangential fibres; (b) **S. lacunosum**, presenting numerous lymphatic or vascular spaces; (c) **S. radiatum**, exhibiting a rich plexus of fibrils. The two layers of pyramidal cells are condensed into one, and these are mostly of large size. The axones of the cells in the polymorphous layer may run in an ascending, descending, or horizontal direction. Between the polymorphous layer and the ventricular ependyma is the white substance of the alveus.

4. **The Dentate Gyre.**—In the rudimentary dentate convolution the molecular layer contains some pyramidal cells, while the pyramidal layer is almost entirely represented by small ovoid elements.

5. **The Olfactory Bulb** (Fig. 715).—In many of the lower animals this contains a cavity which communicates through the hollow olfactory stalk with the cavity of the lateral ventricle. In man the original cavity is filled by neuroglia and its wall becomes thickened, but much more so on its ventral than on its dorsal aspect. Its dorsal part contains a small amount of gray and white substance, but this is scanty and ill defined. A section through the ventral part shows it to consist of the following layers from without inward: (1) A layer of *olfactory nerve fibres*, which are the myelinated axones prolonged from the olfactory cells of the nose, and which reach the bulb by passing through the cribriform plate of the ethmoid bone. At first they cover the bulb, and then penetrate it to end by forming synapses with the dendrites of the mitral cells, presently to be described. (2) *Glomerular layer (stratum glomerulosum)*: This contains numerous spheroidal reticulated enlargements, termed **glomeruli**, which are produced by the branching and arborization of the processes of the olfactory nerve fibres with the descending dendrites of the mitral cells. (3) *Molecular layer*: This layer is formed of a matrix of neuroglia, embedded in which are the **mitral cells**. These cells are pyramidal in shape, and the basal part of each gives off a thick dendrite which descends into the glomerular layer, where it arborizes as above, or, on the other hand, interlaces with similar dendrites of neighboring mitral cells. The axones pass through the next layer into the white substance of the bulb, from which, after becoming bent on themselves at a right angle, they are continued into the olfactory tract. (4) *Nerve fibre layer*: This lies next the central core of neuroglia, and its fibres consist of the axones or afferent processes of the mitral cells which are passing on their way to the brain; some efferent fibres are, however,

¹ Phil. Trans. of Royal Society, Series B, vol. xciii, p. 165.

also present, and terminate in the molecular layer and presumably come *via* the anterior commissure from the mitral cells of the opposite bulb.

The **claustrum**, although usually enumerated among the basal ganglia, is probably the thickened and isolated deepest layer of fusiform cells belonging to the cortex of the island of Reil. The white lamina¹ intervening between it and the cortex proper consists of association axones of longer and shorter course.

Summary of the Cerebral Fibre Systems.—The white substance of the cerebrum consists of myelinic fibres intricately interwoven but permitting of classification into three systems arranged according to the course they take. These systems comprise: (1) **association fibres**, which connect neighboring or distant parts within the same cerebral hemisphere; (2) **commissural fibres**, which unite allied parts in the two cerebral halves and come transversely across the midline to form the commissures; (3) **projection fibres**, which connect the cerebral cortex with lower centres in the brain and spinal cord, and, conversely, those fibres which connect lower centres with the cerebral cortex.

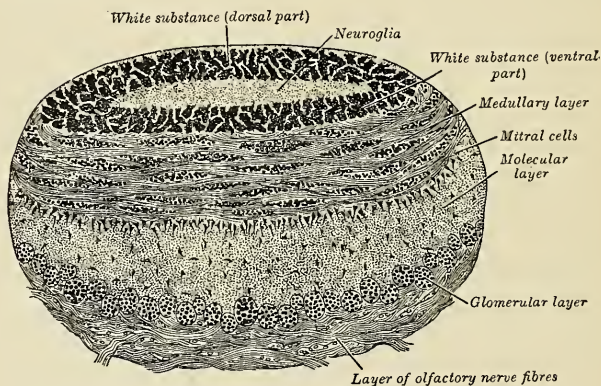


FIG. 715.—Coronal section of olfactory bulb. (Schwalbe.)

1. The **association fibres** (Fig. 716) connect different structures in the same hemispheres, and are in or near to the cortex. They take origin from the small pyramidal and polymorphous cells of the deep layer of the cortex. Their direction is parallel to the surface of the hemisphere, and in their course they cross the projection and commissural fibres. They are of two kinds: (1) Those which unite adjacent convolutions, **short association fibres**; (2) those which pass between more distant parts in the same hemisphere, **long association fibres**.

The **short association fibres** are situated immediately beneath the gray cortex of the hemispheres, and connect adjacent convolutions. They constitute subcortical tracts and are divided into **arcuate fibres** and **tangential fibres**. Thus, some of these fibres connect the "visual sensor area with the visual memory area, and the auditory sensor with the auditory memory area."

The **long association fibres** associate cerebral centres which are far apart. They are gathered into bundles and dip down deep into the centrum ovale. They include the following: (a) the **uncinate fasciculus**; (b) the **superior longitudinal fasciculus**; (c) the **inferior longitudinal fasciculus** (doubtful); (d) the **cingulum**; and (e) the **fasciculus rectus**.

¹ Previously described as the *periclastral lamina* or *capsula extrema* (p. 948).

(a) The **uncinate fasciculus** (*f. uncinatus*) passes between the uncinete gyre and the orbital portion of the frontal lobe; in its course it curves beneath the depths of the basisylvian fissure (Fig. 716).

(b) The **superior longitudinal fasciculus** (*f. longitudinalis superior*) (Fig. 716) is beneath the convex surface of the hemisphere arching over the lenticular nucleus. It joins the frontal cortex with the parietal and temporal cortex and brings into relation the motor speech centres and the centres of auditory and visual memories.

(c) The **inferior longitudinal fasciculus** (*f. longitudinalis inferior*) is usually described as a tract associating the centres of auditory and visual memory. Such association fibres undoubtedly exist, but it is doubtful whether they are collected into a distinct fasciculus. The bundle which is usually designated by this term

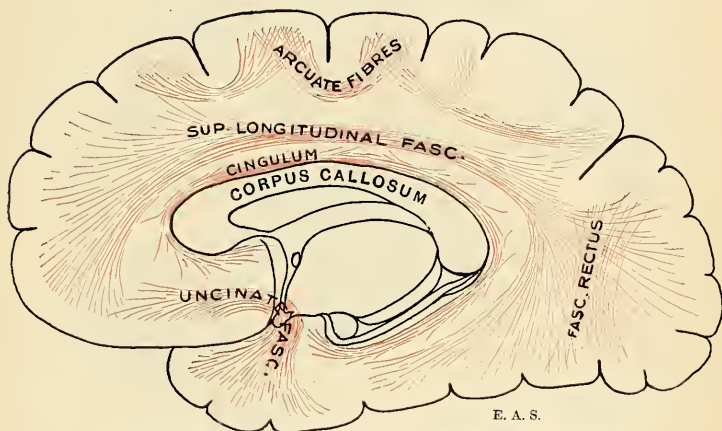


FIG. 716.—Diagram showing the principal systems of associating fibres in the cerebrum.

has been proved to be in part the projection system between the occipital cortex and the thalamus and external geniculate body (E. Redlich) and in part also the fibres from the temporal cortex (meditemporal and subtemporal gyre) to the crista.¹

(d) The **cingulum**, also called the fornix periphericus, is a band of white fibres that course in the white substance of the callosal gyre and runs excentrically to the corpus callosum. Its fibres may be traced frontad into the mesal olfactory stria and the anterior perforated substance, while caudad they radiate into the hippocampus. It may be regarded as an association tract of the rhinencephalon akin to the fornix.

(e) The **fasciculus rectus** or **perpendicular fasciculus** runs dorsoventrad in the occipitoparietal transition and associates the subparietal gyres with the medial and subtemporal gyres; a part of the fasciculus associates the dorsal occipital region with its ventral part and with the subcollateral gyre (Fig. 716).

The **fornix**, previously described, may be enumerated among the long association tracts; it belongs exclusively to the olfactory apparatus.

2. The **commissural fibres** are grouped under the following heads: (a) the **corpus callosum**, described on page 933; (b) the **anterior commissure**, described on page 946; and (c) the **hippocampal commissure**, described on page 944.

¹E. J. Curran (Jour. Comp. Neurol. and Psychol., xix, 6, Dec., 1909) describes a "fasciculus occipitofrontalis inferior" coursing ventrolaterad of the lenticular nucleus.

3. The **projection fibres** connect the cerebral cortex with lower brain centres (caudate and lenticular nuclei, thalamus, hypothalamic region, corpora quadrigemina, pons, medulla oblongata), and with the spinal cord centres. They either project impulses from the cortex to the periphery or bring in impressions from without. Their radiations to and from the cortex, together with the radiations of the callosal fibres, give rise to the characteristic appearance of the **corona radiata**. We may distinguish the projection tracts of long course from those of short course, and, in the functional sense, those that are centrifugal, descending, or motor, from those that are centripetal, ascending, or sensor. The last mode of classification is more desirable.

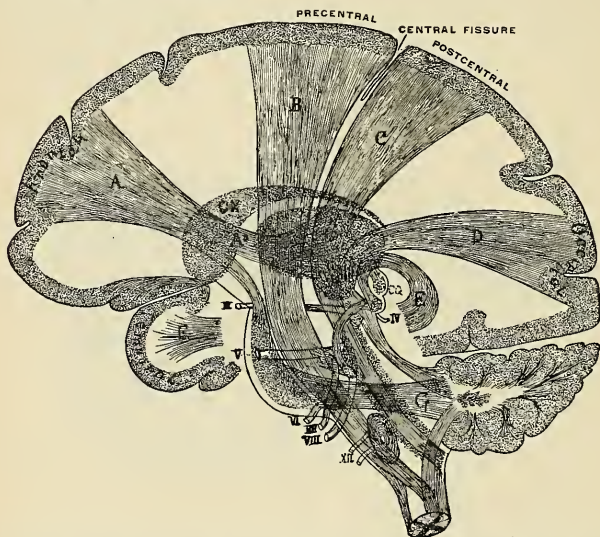

FIG. 717.—The projection tracts joining the cortex with lower nerve centres. Sagittal section showing the arrangements of tracts in the internal capsule: *A*. Tract from the frontal lobe to the frontal half of the capsule, thence in part to the optic thalamus, *A*², and in part to the pons, and thus to the cerebellar hemisphere of the opposite side. *B*. Motor tract from the precentral convolution to the facial nucleus in the pons and to the spinal cord. *C*. Sensor tract from dorsal columns of the cord, through the dorsal part of the medulla oblongata, pons, crus, and capsule to the parietal lobe. *D*. Visual tract from the thalamus (*OT*) to the occipital lobe. *E*. Auditory tract from the internal geniculate body (to which a tract passes from the *VIII N*, nucleus) to the temporal lobe. *F*. Superior peduncle. *G*. Middle peduncle. *H*. Inferior peduncle. *CN*. Caudate nucleus. *CQ*. Corpora quadrigemina. The numerals refer to the cranial nerves. (Starr.)

1. **Descending (corticifugal) tracts** are composed of axones arising from the cortical pyramidal cells.

(a) The **pyramidal or motor tract** from the "motor area," comprising the precentral gyre and paracentral gyre, courses through the genu and frontal two-thirds of the thalamolenticular limb of the internal capsule, forms the middle (three-fifths) sector of the crusta, and passes through the pons into the medulla oblongata and spinal cord. The tract may be subdivided into a **corticobulbar** and a **corticospinal** division.

The **corticobulbar division** is the pyramidal tract to the efferent cranial nerve nuclei. Only those fibres which are destined to go to the facial and hypoglossal can be traced throughout. They originate in the ventral part of the precentral gyre (face and tongue centre), course through the genu of the internal capsule,

and end, contralaterally, in relation with the facial and hypoglossal nerve nuclei (also called the **emissary speech tract**).

The **corticospinal division** arises from the remainder of the motor area, courses through the frontal two-thirds of the posterior limb of the internal capsule, through crusta, pons, and medulla oblongata, to form the pyramids, and, undergoing partial decussation, forms the direct and the crossed pyramidal tracts described in the spinal cord.

(b) The **frontopontile tract** (*Arnold's bundle*) arises in the midfrontal cortex, courses through the internal capsule (caudal part of frontal limb), forms the mesal sector (one-fifth) of the crusta, and ends in the nuclei pontis.

(c) The **temporopontile tract** (*Türk's bundle*) arises in the cortex of the temporal lobe, descends through the internal capsule (caudal segment), forms the ectal (one-fifth) sector of the crusta, and ends in the nuclei pontis. The existence of occipitopontile fibres is denied by Archambault in a recent contribution (1906).

(d) The **occipitomesencephalic tract** arises in the visual area (cuneus and calcarine formation), courses through the retrolenticular part of the internal capsule, to end in the superior quadrigeminal body and in relation with the nuclei for movements of the eyeball.

(e) Part of the fibres composing the **optic radiation** are corticopetal, arising in the occipital cortex and ending in the pulvinar of the thalamus and the external geniculate body.

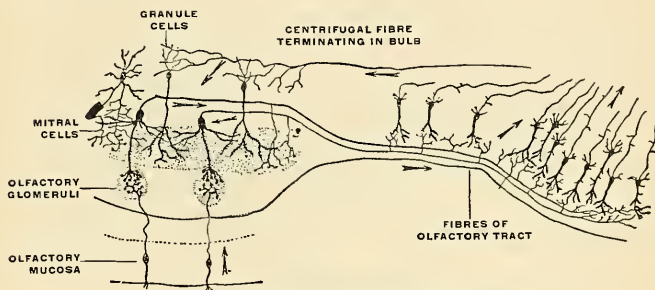


FIG. 71S.—Schema of the olfactory bulb and tract neurones.

2. **Ascending (corticopetal) tracts** arise mostly from the nuclei of the thalamus and hypothalamus, mid-brain, and cerebellum.

(a) The terminal or cerebral part of the **general sensor pathway of the body** comprises the axones arising in the cells of the lateral nucleus of the thalamus and the hypothalamic nucleus—interposed way-stations which transfer the impressions carried along the medial lemniscus from the nuclei of the gracile and cuneate fasciculi in the myeloblongata transition. They convey sensor impressions from the body periphery to the somesthetic area of the cortex—chiefly the postcentral and parietal gyres.

(b) The terminal or cerebral part of the **general sensor pathway of the head and neck** comprises the axones which arise from the afferent cranial nerve nuclei (excepting the auditory) and course along the medial lemniscus to the thalamus and hypothalamic nucleus, to be thence projected to the somesthetic cerebral cortex.

(c) The terminal or cerebral part of the **auditory pathway** from the inferior quadrigeminal body, internal geniculate body, and the interposed nucleus of the lateral lemniscus, ending in the auditory sphere of the cerebral cortex.

(d) The terminal part of the **visual pathway**, described on pages 909–911.

(e) The **terminal (ascending) cerebellocortical pathway**, arising as the fibres of the superior peduncles of the cerebellum, decussating and ending in the red nucleus and lateral nucleus of thalamus, is thence directly projected by new axones to the somesthetic cortical area, or indirectly projected *via* thalamus (lateral nucleus).

Connections of the Corpus Striatum.—The connections of the caudate and lenticular nuclei with each other and with the cortex may be summarized as follows:

(a) Fibres from the cortex to the caudate and lenticular nuclei, entering into the formation of the **corona radiata**.

(b) Fibres from the caudate nucleus and putamen of the lenticular nucleus coursing to the thalamus and hypothalamic region. Those from the caudate nucleus pass through the internal capsule to traverse the globus pallidus, are joined by the fibres from the putamen to again traverse the internal capsule and end in the thalamus, forming the **striothalamic radiation**.

(c) Fibres coursing ventrad in the medullary laminae of the lenticular nucleus, and reinforced by additional fibres from the globus pallidus, course mesad to the hypothalamic region to form the **subthalamic radiation** or **ansa lenticularis** (described on p. 951). This radiation is further reinforced by the ventral stalk of the thalamocortical radiation to form the **ansa peduncularis** (described on p. 951).

The Olfactory Pathways. 1. **Peripheral Pathway.**—Impressions from the upper portion of the Schneiderian mucous membrane pass along the olfactory fila (central processes of the intraepithelial bipolar olfactory cells) to the **glomeruli olfactorii** in the olfactory bulb (Fig. 718).

2. **Central Pathway.**—In the glomeruli the impression is transmitted to the brush-like, dendritic endings of the mitral cells and brush cells; the axones of these cells carry the impression centrad to the gray masses of the olfactory tract, trigonum olfactorium, anterior perforated substance, and adjacent parts (Fig. 713). These constitute the primary centres.

The primary centres are connected with secondary or cortical centres (hippocampus, gyrus dentatus, uncus) by the following tracts: (1) Lateral olfactory striae, from the olfactory trigone to the uncus, ending in the gyrus ambiens and gyrus semilunaris (p. 928). (2) Axones from cells in the olfactory trigonal gray through the fornix to hippocampus. (3) Striae mediales (Lancisii) from the trigone into gyrus subcallosus around the corpus callosum to gyrus dentatus and hippocampus.

The amygdaline nucleus is by some regarded as a cortical centre to which impressions are carried by the taenia semicircularis.

The fornix fibres arise from the pyramidal cells in the hippocampus and the polymorphous cells of the dentate gyre. Some fibres traverse the median plane as the hippocampal commissure to the opposite hippocampus; the remainder end in the corpus albicans, gray nucleus, or, in small part, are retroflexed as the stria medullaris thalami to the habenular ganglion. In the corpus albicans impressions are transmitted to the cells of two nuclear masses; from the medial nucleus arise axones constituting the fasciculus albicans princeps, each axone bifurcating and the diverging bundles forming, respectively, the albicantiothalamic and the albicantiotegmental fasciculi (p. 907).

The *stria medullaris thalami* consists of the following bundles ending in the habenular ganglion: (a) Axones from hippocampus *via* fornix—the cortico-habenular tract; (b) axones from the hemiseptum of the septum lucidum and olfactory gray—the olfactohabenular tract; (c) axones from the thalamus to the habenular ganglion—the thalamohabenular tract. In the habenular ganglion axones arise which pass as a distinct bundle ventrad through the tegmentum to the gray of the posterior perforated substance (*ganglion interpedunculare* [inter-*erurale*] of Gudden)—the *fasciculus retroflexus* of Meynert.

The primary olfactory centres of the two sides are connected by the *pars*

olfactoria of the anterior *commissure*, a bundle of fibres passing from side to side to end in the tract, granular stratum, and glomerular layer of the bulb. Further connections are established with the tuber cinereum, mid-brain, and even spinal centres; one division has been named the *olfactomesencephalic tract* (Wallenberg).

The *cingulum* or *fornix periphericus* is an arcuate association bundle, or rather an arcuate series of short bundles which establishes the connections of the rhinencephalon with the adjacent cortical areas (p. 955).

CORTICAL LOCALIZATION OF FUNCTION.

Patient researches conducted along clinicopathological, experimental, physiological, and developmental lines have furnished us with a topographic map of the somesthetic and sense areas, and, inferentially, of the association areas of the cerebral cortex. The somesthetic and sense areas constitute less than one-third of the cortical area, while the remainder is presumed to be devoted to the elaboration of the higher mental activities manifested by abstract thought, ideation, reasoning, and language. The acquisition of these specifically human mental attributes has been the chief factor in bringing about the superior structure of the human brain, and those cortical regions which were subjected to increased associations rose in functional dignity and increased in size. With over nine billion functional nerve cells in the human cerebral cortex devoted to the mental processes, and less than one-third of these concerned with emissary and receptive functions, the intricacy and capacity of the human brain for the manifold registration of sensations and the numerous transformations that characterize man's mental processes far exceed that of any other animal.

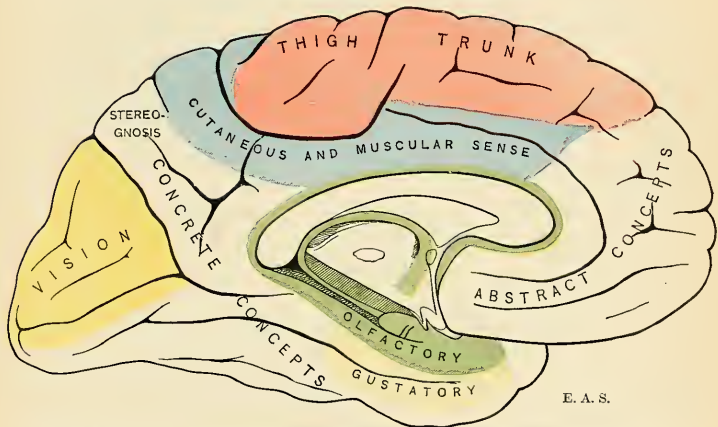


FIG. 719.—Mesal view of left cerebral hemisphere, showing localization of functions. The schema of the fissures and gyres is the same as in Fig. 679.

The delineation of areas called **motor**, **visual**, **auditory**, etc., is not to be deemed as mathematically accurate or sharply defined as the boundaries of a State, county, or township. The areas rather shade off in a diffuse manner, and the arbitrary demarcations employed in the appended figures merely show the maximum concentration of those cortical parts which most distinctly appertain to the function alleged for them.

The principal areas that are known to be functionally differentiated are the following:

1. **Motor Area.**—The motor area comprises the precentral gyre and parts of the frontal gyres adjacent thereto, together with the paracentral gyre and the adjacent portion of the superfrontal gyre on its mesal face. Stimulation of various parts of this area causes movement, while their destruction impairs or abolishes voluntary movements. Within this motor area may be defined districts which are cortical projections of the muscular systems of the body. Thus, movements of the lower limb seem to be controlled by the dorsal part of the precentral and the paracentral gyre; the trunk musculature by the area lying frontad both on the mesal aspect and in the dorsal

superfrontal; the upper limb seems to be controlled by the midportion of the precentral; while the facial musculature is projected in the ventral part. The motor regions for the tongue, larynx, muscles of mastication, and pharynx lie in the frontal opercular part; and the movements of the head and eye are dominated by the medifrontal gyre, adjacent to the precentral. Recalling the fact that the pyramidal (motor) tract decussates in its course to the primary motor centres, it follows that the motor centres in one cerebral hemisphere control the movements of the opposite side of the body. As elsewhere in the cortex, these motor areas gradually pass one into the other and the boundaries are indeterminate. The localization of motor function is rather for coördinated groups of muscles than for individual muscles; as a rule, the most powerful articulation, as the thigh and the shoulder, is localizable frontad in the respective limb centres, while the smaller articulations and those differentiated as regards motility (digits, etc.) are localizable more posteriorly.

2. **Sensor Areas.**—(a) The area for **tactile and temperature impressions** is more intensely localized in the postcentral gyre and in corresponding order with its neighboring precentral motor areas; that is to say, there is the most intimate intercommunication between the sensor and the motor regions which preside over corresponding parts of the body. So closely coupled are the related sensor and motor cells in the highest category of the reflex arc system represented in the cerebral cortex that both sensor and motor areas are included under the term of **somesthetic or sensomotor area**, devoted to the registration of cutaneous impressions, impressions

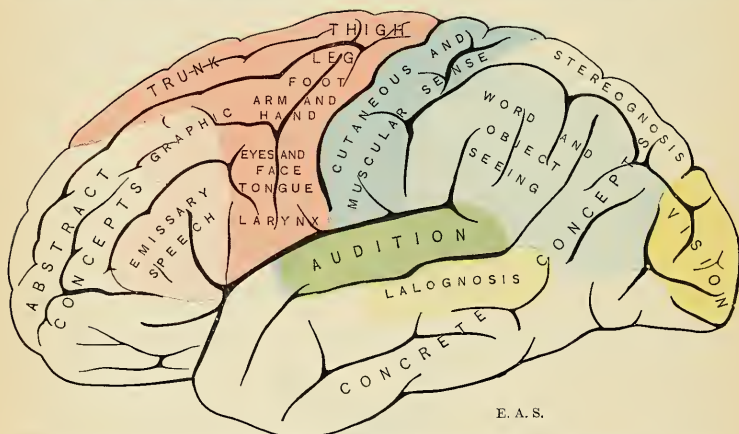


FIG. 720.—Lateral view of left cerebral hemisphere, showing localization of functions. The schema of the fissures and gyres is the same as in Fig. 678.

from the muscles, tendons, and joints; in short, the sense of movement. The cortical area embraced by the parietal gyre, together with its extension in the precuneus on the mesal aspect, appears to be devoted to the concrete perception of the form and solidity of objects, and is therefore termed the **stereognostic sense area**.

(b) The **auditory area** is localized in the middle and posterior thirds of the supertemporal gyre and in the adjacent transtemporal gyres in the sylvian cleft.

(c) The **visual area** is most intensely localizable in the region of the calcarine fissure as well as in the cuneus as a whole. There seems to be an interrelation between the visual function and the special type of cortex already described, and chiefly characterized by the stripe of Gennari.

(d) The **olfactory area** comprises the uncus, frontal part of hippocampus, indusium, subcallosal gyre, parolfactory area, and anterior perforated substance.

(e) The **gustatory area** has not yet been accurately localized; presumably it lies in the neighborhood of the olfactory area in the temporal lobe (uncinate and hippocampal gyre?).

3. **The Language Areas.**—The cortical zone of language comprises certain specialized areas which take part in the intimate relations of speech to thought expression, to memory, in its reading form to sight, in writing to manual muscular innervation, and in "word understanding" to hearing.

(a) The **emissive (articular) centre for speech** is localized in the region of the junction of the subfrontal gyre with the precentral gyre—a region known to be intimately related to the control

of the muscles used in speech (larynx, tongue, jaw muscles). Destruction of this region at least causes a loss or disturbance of articulation of words.

(b) The **auditory perceptive centre**, clinically known as the centre of "word deafness," is localized in the marginal gyre and adjacent parts of the super- and mediotemporal gyres, especially the latter. A patient suffering with a lesion of this area may clearly hear but not understand the spoken word. This division of the centre might also be called the *lalognostic* (word-understanding) centre.

(c) The **visual perceptive centre**, clinically known as the centre of "word blindness," is localized in the angular gyre. Lesion of this area renders the patient incapable of understanding the significance of the words and objects which he sees.

(d) An **emissive "writing" centre**, not positively proved to exist, has been localized in the medifrontal gyre, frontal of the motor area for the upper limb.

(e) Of not a little importance with reference to the intellectual control of the faculty of language is the **island of Reil**, purely an association centre, serving to connect the various receptive sense areas relating to the understanding of the written and spoken word with the somesthetic emissary centre related to articulate speech and writing; in other words, a centre for language-arrangement.

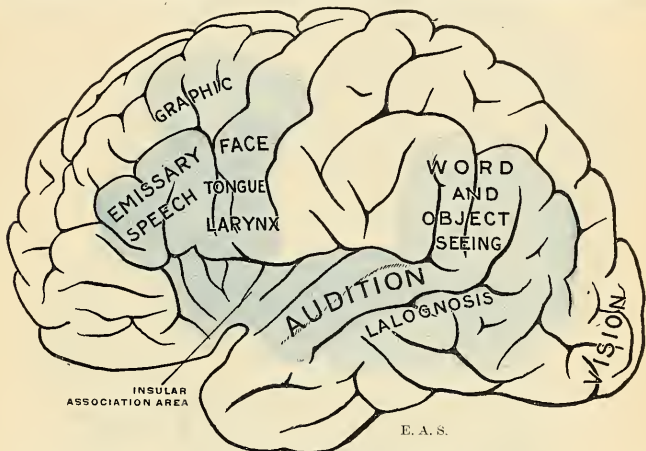


FIG. 721.—Diagram showing the language zone. The opercula are divaricated to expose the island of Reil.

The union of the various centres enumerated above forms the **cortical zone of language**, and is most intensely, if not exclusively, localized, or at least, active, in the left cerebral hemisphere in right-handed persons, and *vice versa* in left-handed persons.

4. **The Association Areas.**—The remaining area of the cerebral cortex is presumably the organic substratum for the higher psychic activities. At the present time not much is known about them, but broadly stated the **frontal association area** is concerned rather with the powers of thought in the abstract—creative, constructive, and philosophic. The **parieto-occipito-temporal association area**, on the other hand, seems to be more concerned with the powers of conception of the concrete, for the comprehension of analogies, comparing, generalizing, and systematizing things heard, observed, and felt.

The great extent of the association areas in the human brain is a somatic expression of man's possession of an associative memory or ability to register and compare sensations far greater than that of the highest ape. The pattern of the fissures and gyres in the brains of the higher anthropoids and man presents the same general features in all these types. In the course of evolution, however, the regions known as association areas assumed a greater energy of growth and expanded in proportion to the rise in functional dignity of these areas. They are regions of "unstable equilibrium" which afford greater and more complex associations as mental development goes on in the species, and concomitant with this great cortical expansion the associating or coördinating fibre systems became more elaborate, complex, and far-reaching.

With the aid of the microscope the maturing of the brain elements can be followed from the earliest stages of embryonic life to the adult period. The Flechsig method has shown how the function of nerve fibres within the brain is only established when the myelin sheath has developed.

But this development of mature nerve fibres does not occur simultaneously throughout the brain, but step by step in a definite order of succession; equally important bundles are myelinated simultaneously, but those of dissimilar importance develop one after another in accordance with *Flechsig's law*. The successive myelinization of fibre bundles to and from the cerebral cortex corresponds to the successive awakenings of mental activities and faculties in the growing child. Flechsig's method of investigation has been of great service in the elucidation of the problems of cerebral localization.

Craniocerebral Topography.—The position of the principal fissures and convolutions of the cerebrum and their relation to the outer surface of the scalp (Fig. 677) have been the subject of much investigation, and many systems have been devised by which one may localize these parts from an exploration of the external surface of the head.

These plans can only be regarded as approximately correct for several reasons; in the first place, because the relations of the convolutions and fissures to the surface are found to be quite

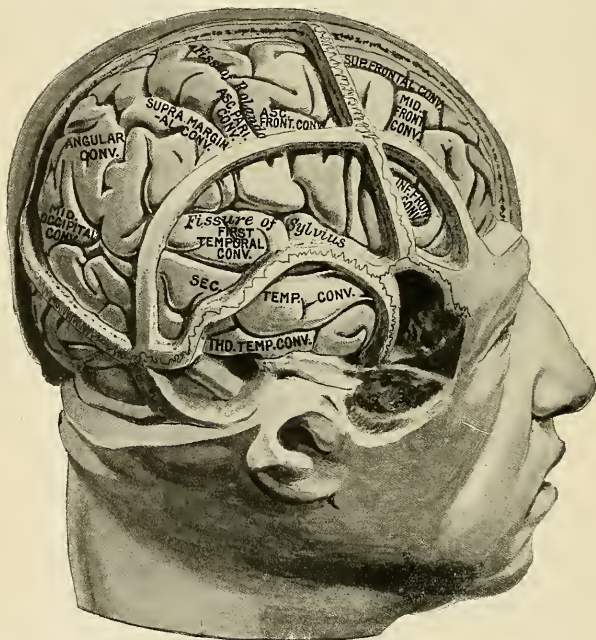


FIG. 722.—Drawing to illustrate craniocerebral topography. (Taken from a cast in the Museum of the Royal College of Surgeons of England, prepared by Professor Cunningham.)

variable in different individuals; secondly, because the surface area of the scalp is greater than the surface area of the brain, so that lines drawn on the one cannot correspond exactly to fissures or convolutions on the other; thirdly, because the fissures and convolutions in two individuals are never precisely alike. Nevertheless, the principal fissures and convolutions can be mapped out with sufficient accuracy for all practical purposes, so that any particular convolution can be generally exposed by removing with the trephine, or by the flap method, a certain portion of the skull. An excellent method is given by Chipault in his *Chirurgie opératoire du système nerveux*, 1894, vol. i. The following systems have been the longest in vogue:

The various landmarks on the outside of the skull, which can be easily felt, and which serve as indications of the position of the parts beneath, have been already referred to, and the relation of the fissures and convolutions to these landmarks is as follows:

Intercerebral or Longitudinal Fissure.—This corresponds to a line drawn from the glabella at the root of the nose to the external occipital protuberance. 1

The Sylvian Fissure.—The position of the sylvian fissure is marked by a line starting from a point 3 cm. ($1\frac{1}{2}$ inches) horizontally behind the external angular process of the frontal bone to a point 2 cm. ($\frac{4}{5}$ inch) below the most prominent point of the parietal eminence. The first 2 cm. ($\frac{4}{5}$ inch) will represent the basisylvian fissure, the remainder the sylvian fissure proper. The sylvian point is therefore 5 cm. (2 inches) behind and about 1 cm. ($\frac{2}{5}$ inch) above the level of the external angular process. The presylvian ramus of the fissure passes upward from this point parallel to, and immediately behind, the coronal suture.

The Tentorial Hiatus or Transverse Fissure.—This is between the cerebrum and cerebellum, and corresponds to a line drawn from theinion to the external auditory meatus.

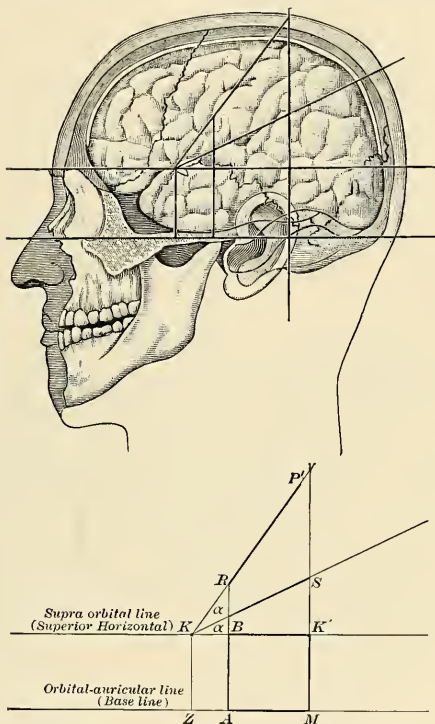


FIG. 723.—Krönlein's method for determining the portions of certain fissures of the brain.

Central Fissure.—To find the dorsal end of the central fissure, a measurement should be taken from the glabella to the external occipital protuberance. The position of the top of the fissure will be, measuring from in front, 55.6 per cent. of the whole distance from the glabella to the external occipital protuberance. Professor Thane adopts a somewhat simpler method. He divides the distance from the glabella to the external occipital protuberance over the top of the head into two equal parts, and, having thus defined the middle point of the vertex, he takes a point half an inch behind it as the top of the sulcus. This is not quite so accurate as the former method; but it is sufficiently so for all practical purposes, and on account of its simplicity is very generally adopted. From this point the fissure runs downward and forward for 9 to 10 cm. ($3\frac{3}{8}$ to 4 inches), its axis making an angle of about 70 degrees with the middle line. In order to mark this groove, two strips of metal may be employed—one, the shorter, being fixed to the middle of the other at the angle mentioned. If the longer strip is now placed along the sagittal suture so that the junction of the two strips is over the point corresponding to the top of the furrow,

the shorter, oblique strip will indicate the direction and 9 to 10 cm. will mark the length of the furrow. Dr. Wilson has devised an instrument, called a cyrtometer, which combines the scale of measurements for localizing the fissure with data for representing its length and direction.¹

The **Occipital Fissure** on the dorsal surface of the cerebrum runs outward at right angles to the great longitudinal fissure for about 2 to 3 cm. ($\frac{3}{8}$ to $1\frac{1}{2}$ inches), from a point 0.5 cm. ($\frac{1}{4}$ inch) in front of the lambda. Reid states that if the sylvian line be continued onward to the sagittal suture, the last 2 to 3 cm. of this line will indicate the position of the fissure.

The **Precentral Fissure** begins 2 cm. ($\frac{3}{8}$ inch) in front of the middle of the central fissure and extends nearly, but not quite, to the sylvian fissure.

The **Superfrontal Fissure** runs backward from the supraorbital notch, parallel with the line of the longitudinal fissure to 1 cm. ($\frac{2}{8}$ inch) in front of the line indicating the position of the central fissure.

The **Subfrontal Fissure** follows the course of the supertemporal ridge on the frontal bone.

The **Intraparietal Fissure**, comprising the parietal, subcentral, and paroccipital fissures, begins on a level with the junction of the middle and lower third of the central fissure, on a line carried across the head from the back of the root of one auricle to that of the other. After passing upward it curves backward, lying parallel to the longitudinal fissure, midway between it and the parietal eminence; then curves downward to end midway between the posterior fontanelle (lambda) and the parietal eminence.

Kronlein's method for determining the portions of certain fissures of the brain is very useful and easy of application (Fig. 723). It is as follows: (1) The base line, ZM , is a horizontal line running at the level of the lower border of the orbit and the upper border of the external auditory meatus. (2) Another horizontal line, KK' , is drawn parallel to ZM . The second horizontal line is on a level with the supraorbital ridge. (3) A vertical line, ZK , is erected from ZM at the middle of the zygoma and is carried to the line KK' . (4) Another vertical line, AR , is erected from the base line at the level of the articulation of the mandible and is carried to R . (5) A third vertical line, MP , is erected from the base line at the posterior border of the mastoid process and is carried to the middle line of the skull, which is marked P . (6) A line is drawn from K to P . The portion of this line between R and P' corresponds to the central fissure. (7) The angle PKK' is bisected by the line KS . KS corresponds to the sylvian fissure, and K is directly over the sylvian point. To reach the anterior branch of the middle meningeal, apply the trephine at K ; to reach the posterior branch, apply it at K' . In abscess of the temporal lobe the trephine should be applied, according to von Bergmann, in the region $AaKM$.

THE MENINGES, OR MENINGEAL MEMBRANES OF THE BRAIN (MENINGES ENCEPHALI).

Dissection.—To examine the brain with its membranes, the skullcap must be removed. In order to effect this, saw through the external table, the section commencing, in front, about 2 cm. ($\frac{1}{2}$ inch) above the margin of the orbits, and extending, behind, to a little above the level of the occipital protuberance. Then break the internal table with the chisel and hammer, to avoid injuring the investing membranes or brain; loosen and forcibly detach the skullcap, and the dura will be exposed. The adhesion between the bone and the dura often is very intimate, particularly along the sutures.

The membranes of the brain are from without inward—the **dura**, **arachnoid**, and the **pia**.

The Dura of the Brain (*Dura Mater Encephali*) (Figs. 724, 729).

The dura of the brain is a thick and dense, inelastic, fibrous membrane which lines the interior of the skull. It is a covering for the brain and is also the internal cranial periosteum. It is composed of two layers closely connected, except in certain situations, where, as already described (p. 721), they separate to form sinuses for the passage of venous blood. Upon the outer surface of the cranial dura, in the situation of the longitudinal sinus, may be seen numerous small whitish bodies, the **glandulae Pacchionii** (*granulationes arachnoideales*). Its outer surface is rough and fibrillated, and adheres closely to the inner surface

of the bones, the adhesion being most marked opposite the sutures and at the base of the skull. Its inner surface is smooth and lined by a layer of endothelium. It sends inward four processes which divide the cavity of the skull into a series of freely communicating compartments, for the lodgement and protection of the different parts of the brain; and it is prolonged to the outer surface of the skull, through the various foramina which exist at the base, and thus becomes continuous with the pericranium; its fibrous layer forms sheaths for the nerves which pass through these apertures. At the base of the skull it sends a fibrous prolongation into the foramen cecum; it sends a series of tubular prolongations around the filaments of the olfactory nerves as they pass through the cribriform plate, and another around the nasal nerve as it passes through the nasal slit; a prolongation is also continued through the sphenoidal fissure into the orbit, and another is carried into the same cavity through the optic foramen, forming a sheath for the optic nerve, which is continued as far as the eyeball. In the posterior fossa it

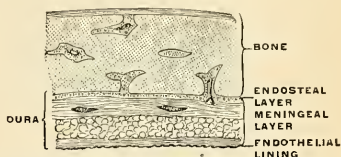


FIG. 724.—The structure of the dura. Section through the cranial vault of a child, slightly enlarged. (Poirier and Charpy.)

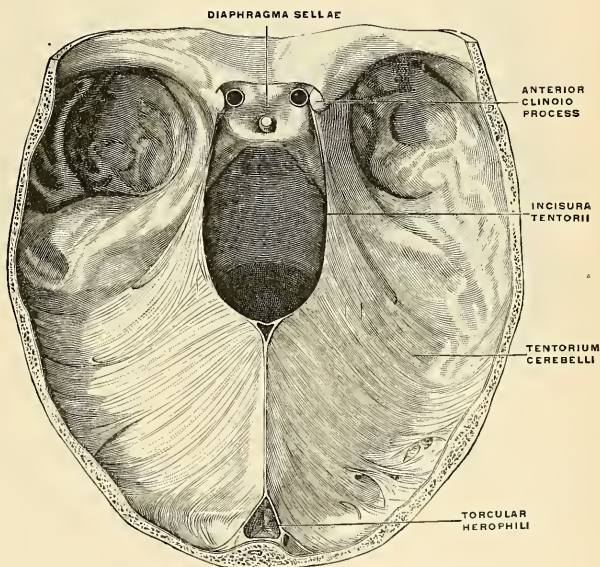


FIG. 725.—The tentorium cerebelli. (Poirier and Charpy.)

sends a process into the internal auditory meatus, ensheathing the facial and auditory nerves; another through the jugular foramen, forming a sheath for the structures which pass through this opening; and a third through the anterior condylar foramen. Around the margin of the foramen magnum it is closely adherent to the bone, and is continuous with the spinal dura.

Processes of the Dura (*processus durae matris*).—The processes of the dura which project into the cavity of the skull are formed by reduplication of the inner or meningeal layer of the membrane, and are four in number—the **falx cerebri**, the **tentorium cerebelli**, the **falx cerebelli**, and the **diaphragma sellae**.

The **falx cerebri** (Figs. 725 and 726), so named from its sickle-like form, is a strong arched process which descends vertically in the intercerebral fissure between the two hemispheres of the brain. It is narrow in front, where it is attached to the crista galli of the ethmoid bone, and broad behind, where it is connected with the upper surface of the tentorium cerebelli. Its upper margin is convex, and attached to the inner surface of the skull, in the middle line, as far back as the internal occipital protuberance; it contains the **superior or great longitudinal sinus** (*sinus sagittalis superior*). Its lower margin is free, concave, and

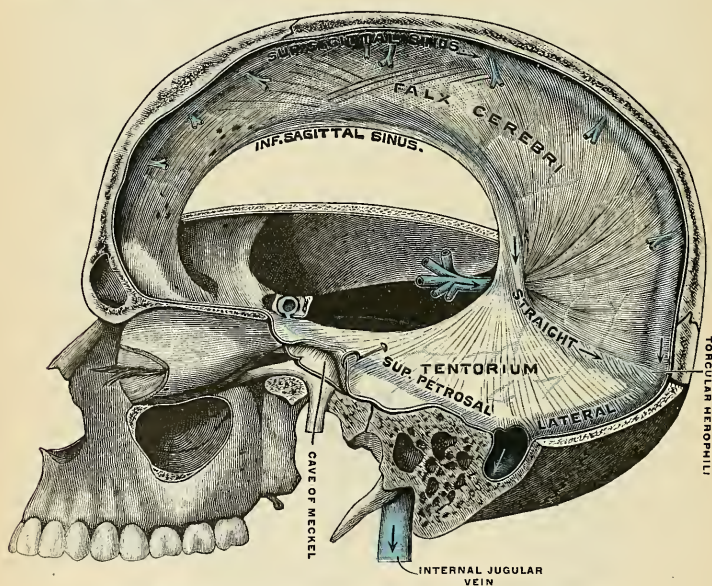


FIG. 726.—Falx cerebri and tentorium cerebelli, left lateral view. (Testut.)

presents a sharp, curved edge, which contains the **falcine or inferior longitudinal sinus** (*sinus sagittalis inferior*). The **tentorial or straight sinus** (*sinus rectus*) is formed by the attachment of the falx cerebri to the tentorium cerebelli.

The **tentorium cerebelli** (Figs. 725 and 726) is an arched lamina of dura, elevated in the middle and slightly inclined toward the circumference. It intervenes between the upper surface of the cerebellum and the occipital lobes of the cerebrum. It is attached, behind, by its convex border to the transverse ridges upon the inner surface of the occipital bone, and there encloses on each side the **transverse or lateral sinus** (*sinus transversus*); forward, to the superior margin of the petrous portion of the temporal bone on either side, there enclosing the **superpetrosal sinus** (*sinus petrosus superior*); and at the apex of this bone the free or internal border and the attached or external border meet, and, crossing one another, are continued forward, to be attached to the anterior and posterior clinoid processes respectively.

Along the middle line of its upper surface the posterior border of the falx is attached, the **tentorial or straight sinus** being placed at their point of junction. Its frontal border is free and concave, and with the dorsum sellae forms a large oval opening. This opening is called the **incisura tentorii** and transmits the mesencephalon.

The **falx cerebelli** (falcula) (Fig. 725) is a small triangular process of dura received into the indentation between the two lateral lobes of the cerebellum behind. Its base is attached, above, to the under and back part of the tentorium cerebelli; its posterior margin, to the lower division of the vertical crest on the inner surface of the occipital bone. As it descends it sometimes divides into two smaller folds, which are lost on the sides of the foramen magnum.

The **diaphragma sellae** (Fig. 725) is a small, circular, horizontal fold, which constitutes a roof for the sella turcica. This almost completely covers the hypophysis, presenting merely a small central opening (*foramen diaphragmatis sellae*) for the passage of the infundibulum.

Structure (Fig. 724).—The dura consists of white fibrous tissue with connective-tissue cells and elastic fibres arranged in flattened laminae, which are imperfectly separated by lacunar spaces and bloodvessels into two layers, **endosteal** and **meningeal**. The **endosteal layer** is the internal periosteum for the cranial bones and contains the bloodvessels for their supply.

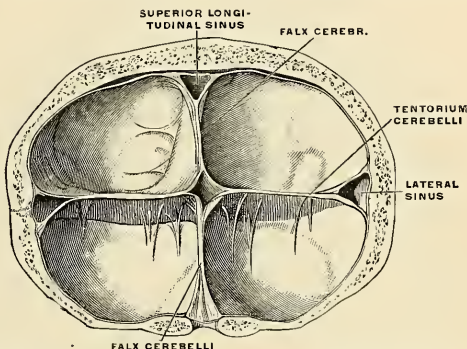


Fig. 727.—Crucial prolongation of the dura. Frontal section passing through the tentorium cerebelli. The torcular herophili is seen in the centre. (Poirier and Charpy.)

At the margin of the foramen magnum it becomes continuous with the periosteum lining the vertebral canal. The **meningeal or supporting layer** is lined on its inner surface by a layer of nucleated endothelium, similar to that found on serous membranes. By its reduplication the meningeal layer forms the **falx cerebri**, the **tentorium cerebelli** and **falx cerebelli**, and the **diaphragma sellae**. The two layers are connected by fibres which intersect each other obliquely.

The **arteries of the dura** (see section on Arteries) are very numerous, but are chiefly distributed to the bones. Those found in the anterior fossa are the **anterior meningeal branches of the anterior and posterior ethmoidal and internal carotid**, and a branch from the **middle meningeal**. Those in the middle fossa are the **middle and small meningeal branches of the internal maxillary**; a branch from the **ascending pharyngeal**, which enters the skull through the foramen lacerum medium; branches from the **internal carotid**, and a **recurrent branch from the lacrimal**. Those in the posterior fossa are **meningeal branches from the occipital**, one of which enters the skull through the jugular foramen, and the other through the mastoid foramen; the **posterior meningeal from the vertebral**; occasional **meningeal branches from the ascending pharyngeal**, which enter the skull through the jugular and anterior condylar foramina; and a branch from the **middle meningeal**.

The **veins** which return the blood from the dura (see p. 717), and partly from the bones, anastomose with the diploic veins (see p. 727). They terminate in the various sinuses, with the exception of two which accompany the middle meningeal artery, and pass out of the skull at the foramen spinosum to join the internal maxillary vein; above, the meningeal veins communicate with the superior longitudinal sinus. The *sinuses* are considered on pages 721 to 727 inclusive.

On either side of the superior longitudinal sinus, especially near its middle, and also near the lateral and straight sinuses, are numerous spaces in the dura which communicate with the sinus, either by a small opening or a distinct venous channel. These spaces are the **parasinoidal sinuses** (*lacunae laterales*). Many of the meningeal veins do not open directly into the sinuses, but indirectly through the parasinoidal sinuses. These venous lacunae are often invaginated by arachnoid villi, and they communicate with the underlying cerebral veins, and also with the diploic and emissary veins.

The nerves of the dura are filaments from the trochlear, the ophthalmic division of the trigeminal, the semilunar or Gasserian ganglion, the vagus, the hypoglossal, and the sympathetic.

The Arachnoid (*Arachnoidea Encephali*) (Fig. 728).

The cranial arachnoid is a delicate membrane which envelops the brain, lying between the pia internally and the dura externally; from this latter membrane it is separated by a very fine slit or space, the **subdural space** (*cavum subdurale*). The subdural space contains a very minute quantity of fluid of the nature of lymph.

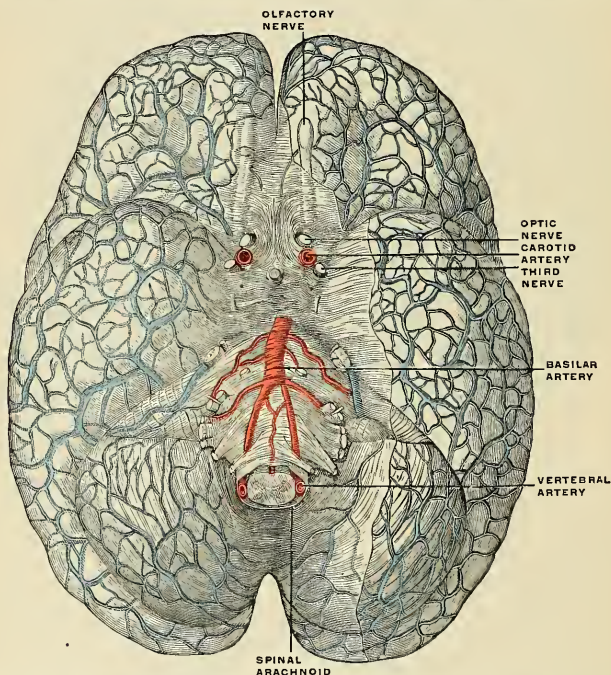


FIG. 728.—The arachnoid upon the base of the brain. On the right the arachnoid has been partly removed to show the cerebrum and cerebellum with their superficial veins. (Poirier and Charpy.)

The arachnoid is prolonged upon emerging nerves and joins the lymph spaces of the nerves. The subdural space does not communicate with the subarachnoid space.

The arachnoid invests the brain loosely, being separated from direct contact with the cerebral substance by the pia, and a quantity of loose areolar tissue, the **subarachnoidean areolar tissue**. On the upper surface of the cerebrum the arachnoid

is thin and transparent, and may be easily demonstrated by injecting a stream of air beneath it by means of a blowpipe; it passes over the convolutions without dipping down into the fissures between them, but does pass into the sylvian and intercerebral fissures and is prolonged upon the nerves as a sheath. At the base of the brain the arachnoid is thicker, and slightly opaque toward the central part; it covers the orbital surface of the anterior lobes and extends across between the two temporal lobes so as to leave a considerable interval between it and the brain, the *cisterna basalis*.

The **subarachnoid space** (*cavum subarachnoideale*) (Fig. 729) is the interval between the arachnoid and pia. It is not only on the surface, but dips between the convolutions. It is not, properly speaking, a *space*, for it is occupied everywhere by a spongy tissue consisting of trabeculæ of delicate connective tissue covered with endothelium, which pass from the pia to the arachnoid, and in the meshes of which the subarachnoid fluid is contained. This so-called space is small on the surface of the cerebrum; but at the base of the brain the subarachnoid tissue is less abundant and its meshes larger.

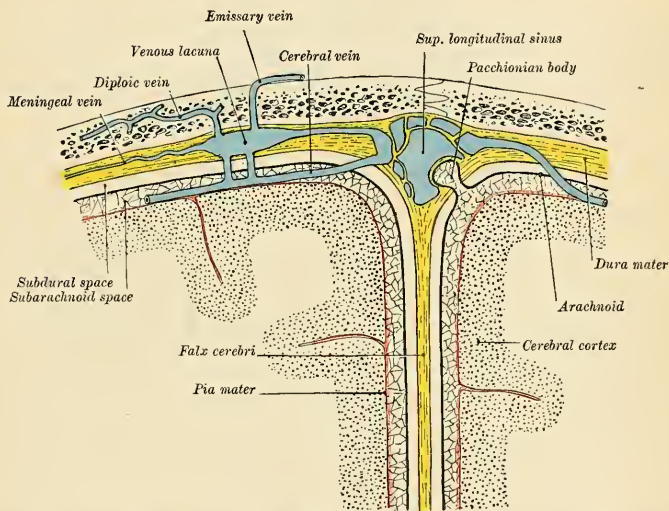


FIG. 729.—Diagrammatic representation of a section across the top of the skull, showing the membranes of the brain, etc. (Modified from Testut.)

In certain regions the arachnoid and pia are farther apart than was previously indicated, and these spaces are called **subarachnoid cisternæ** (*cisternæ subarachnoidales*). The largest space is the continuation of the posterior part of the subarachnoid space of the spinal cord. It is called the **postcisterna** or **cisterna magna** (*cisterna cerebellomedullaris*). It is a space formed by the arachnoid passing across the back and under portions of the medulla oblongata and cerebellum. It communicates with the fourth ventricle by three foramina. The largest opening is the **foramen of Magendie** (*apertura medialis ventriculi quarti*; metapore). It is in the middle line of the tela choroidea. At the end of each recessus lateralis of the fourth ventricle there is also an opening, and each opening is called the **foramen of Luschka** or of **Key and Retzius** (*apertura lateralis ventriculi quarti*). The *cisterna*

pontis is the continuation upward of the anterior part of the subarachnoid space of the cord. About the medulla oblongata it is continuous with the postcisterna, so this important nerve centre is surrounded by a large subarachnoid space. The **cisterna basalis** (*cisterna interpeduncularis*) is formed by the arachnoid extending between the two temporal lobes. There is a cisterna between the inferior edge of the falx cerebri and the superior surface of the corpus callosum which contains the anterior cerebral arteries, a cisterna in the sylvian fissure (*cisterna sylviana*) which contains the middle cerebral artery, and a cisterna between the corpora quadrigemina which contains the vena magna Galeni.

The **cerebrospinal fluid** (coeliolympha; liquor cerebrospinalis) fills the subarachnoid space. It is a clear, limpid fluid, having a saltish taste and a slightly alkaline reaction. According to Lassaigue, it consists of 98.5 parts of water, the remaining 1.5 per cent. being solid matters, animal and saline. It varies in quantity, being most abundant in old persons, and is quickly reproduced. Its chief use is probably to afford mechanical protection to the nerve centres, and to prevent the effects of concussions communicated from without.

Structure.—The arachnoid consists of bundles of connective tissue, the fine fibres of which form one layer and cross each other in every direction. At the level of the large fissures, and especially around the circle of Willis, it is reinforced by thick fibrous tissue. Both surfaces are covered with endothelium. There are no bloodvessels in the arachnoid; the vessels which appear to be in it are really in the pia. There is no positive proof that nerves are present in the arachnoid. It is true that Bochdalek and Luschka long ago described arachnoid nerves, but these observations have never been corroborated.

The Arachnoid Villi or Pacchionian Bodies (*Granulationes Arachnoideales*).

The arachnoid villi, erroneously called glandulae Pacchioni, are numerous small whitish or purplish projections, usually collected into clusters of variable size, which are found in the following situations: (1) Upon the outer surface of the dura, in the vicinity of the superior longitudinal sinus, being received into small depressions on the inner surface of the calvarium. (2) On the inner surface of the dura. (3) In the superior longitudinal sinus and the other sinuses.

A hasty examination would lead us to suppose that these bodies spring from the dura, but, as a matter of fact, they originate from the arachnoid. They are not glandular in structure, but are simply enlarged normal villi of the arachnoid. In their growth they appear to perforate the dura, and when a group of villi is of large size it causes absorption of the bone, and comes to be lodged in a pit or depression (*foveola granularis* [*Pacchioni*]) on the inner table of the skull. Their manner of growth is as follows: At an early period they project through minute holes in the inner layer of the dura, which open into large venous spaces situated in the tissues of the membrane, on either side of the longitudinal sinus and communicating with it. In their onward growth the villi push the outer layer of the dura before them, and this forms over them a delicate membranous sheath. In structure they consist of spongy trabecular tissue, covered over by a membrane, which is continuous with the arachnoid. The space between these two coverings, derived from the dura and arachnoid respectively, corresponds to and is continuous with the subdural space. The spongy tissue of which they are composed is continuous with the trabecular tissue of the subarachnoid space; so that fluid injected into the subarachnoid space finds its way into the Pacchionian bodies, and through their coverings filters into the superior longitudinal sinus. They are supposed to be a means of getting rid of an excess of cerebrospinal fluid when its quantity is increased above normal, or for replenishing the cerebrospinal fluid from the blood plasma when needed. Another means of getting rid of

cerebrospinal fluid is absorption by the lymph spaces of the cranial nerves, which possess sheaths of arachnoid up to the points at which they emerge from the skull.

These bodies are not found in infancy, and very rarely until the third year. They are usually found after the tenth year; and from this period they increase in number as age advances. Occasionally they are wanting.

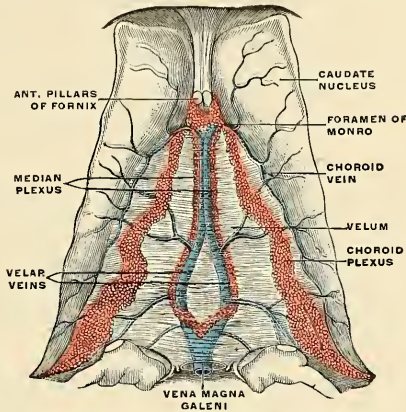


FIG. 730.—Velum interpositum. (Poirier and Charpy.)

The Pia of the Brain (*Pia Mater Encephali*) (Figs. 729, 730).

The pia of the brain is a vascular membrane, and derives its blood from the internal carotid and vertebral arteries. It consists of a minute plexus of blood-vessels held together by an extremely fine areolar tissue. It invests the entire surface of the brain, dipping down between the convolutions and laminae, and is prolonged into the interior, forming the velum interpositum and the choroid plexuses of the lateral and fourth ventricles.

The **velum interpositum** or the **tela chorioidea superior** (*tela chorioidea ventriculi tertii*) (Fig. 730) is the prolongation of the pia into the interior of the brain through the medium of the transverse fissure. It is a double triangular vascular fold, that lies between the body of the fornix above and the thalami and the epithelial roof of the third ventricle below, and passes forward to the foramen of Monro. At each edge of the velum interpositum is the **choroid plexus** (*plexus chorioideus ventriculi lateralis*; *paraplexus*) of the corresponding lateral ventricle. In front the two plexuses join behind the foramen of Monro, and at the point of junction two lesser choroid plexuses pass back along the under surface of the velum interpositum to the third ventricle, the **diaplexus** or **median plexus** (*plexus chorioideus ventriculi tertii*). The **velar veins** or **veins of Galen** (p. 720) are two veins which lie on either side of the middle of the velum interpositum and pass back. Each velar vein is formed by the union of the vein from the corpus striatum and the choroid vein from the choroid plexuses. The two velar veins unite and form the **vena magna** (Galen), which empties into the straight sinus.

The pia of the surfaces of the hemispheres, where it covers the gray substance

of the convolutions, is very vascular, and gives off from its inner surface a multitude of minute vessels, which extend perpendicularly for some distance into the cerebral substance. At the base of the brain, in the situation of the anterior and posterior perforated substance, a number of long, straight vessels are given off, which pass through the white substance to reach the gray substance in the interior. On the cerebellum the membrane is more delicate, and the vessels from its inner surface are shorter. The pia of the spinal cord is thicker, firmer, and less vascular than that of the brain, and as it is traced upward over the medulla oblongata it is seen to preserve these characters. At the upper border of the medulla oblongata it is prolonged over the lower half of the fourth ventricle, forming, before it is reflected onto the under surface of the cerebellum, a covering for the fourth ventricle called the *tela chorioidea inferior* (*tela chorioidea ventriculi quarti*; *metatela*); this carries the **choroid plexus of the fourth ventricle** (*plexus chorioideus ventriculi quarti*).

The **arteries** of the pia (see pp. 614, 617, and 621) (Figs. 450 and 451) are the **anterior, middle, and posterior cerebral, anterior choroid and choroid, superior, anterior inferior, and posterior inferior cerebellar**. (The vessels of the cerebral ganglionic system and of the cortical arterial system are considered on p. 618.)

The **veins** of the pia (see pp. 719, 720, and 721) are the **basilar vein, the velar veins** (Fig. 730), the veins constituting the **choroid plexuses of the third ventricle, the lateral ventricles, and the fourth ventricle; the cerebral veins** (Fig. 728) and the **cerebellar veins** (Fig. 728).

The **nerves** of the pia accompany the branches of the arteries and are derived chiefly from the sympathetic. A few fibres are derived from certain cranial nerves, all of which are probably of the afferent variety.

THE CRANIAL NERVES (NERVI CEREBRALES).

The irregularities of origin and distribution of the cranial nerves, as compared with the relatively simple spinal nerves, are so great and their functions were formerly so little known that the older anatomists contented themselves with numbering them in order, beginning at the frontal end of the brain, and named them with reference to their anatomic connections. The enumeration of the cranial nerves was as variously given, almost, as there were writers upon the subject; the systems of Willis and of Sömmerring were most in vogue for a time, but the latter prevails today. In Sömmerring's arrangement twelve pairs of cranial nerves are recognized, but, on morphological and functional grounds, the nerves of the seventh and eighth pairs should each be considered as being composed of two nerves, the eleventh pair should be included with the nerves of the tenth, and the optic "nerve" is rather a diverticulum of the brain itself than a nerve in the strict sense. Furthermore, while some of the nerves are sensor or motor in a sense strictly comparable with the spinal nerves, others are mixed in function, and yet others constitute nerves of special sense and lack general sensibility. The numerical names, based upon the order in which they pass through the foramina in the base of the cranium, are being abandoned gradually for the more appropriate functional names, but not yet entirely so. Thus *glossopharyngeal* has not yet given way to "*gustatory*;" "*vagus*" is shorter than "*pneumogastric*"—a term which is misleading for a nerve which is distributed not only to lungs and stomach, but also to the meninges, the pharynx and œsophagus, larynx and trachea, heart and pericardium, liver and spleen.

The cranial nerves, as usually enumerated, together with their superficial "origin" or attachment to the brain and their foramina of exit from the skull, are tabulated on page 849. The central olfactory pathway is described on page 958, and the central connections of the optic tracts are given on page 911. The central connections of the remaining cranial nerves are described on pages 877 to 902.

The following is a brief summary of the twelve pairs of cranial nerves, indicating their functional nature:

No.	Name.	Functional nature.
I.	<i>Olfactory (fila).</i>	Smell sense.
II.	<i>Optic.</i>	Visual sense.
III.	<i>Oculomotor.</i>	Motor to muscles of eyeball and orbit.
IV.	<i>Trochlear.</i>	Motor to Superior oblique muscle of eyeball.
V.	<i>Trigeminal.</i>	Mixed: Sensor to face, tongue, and teeth; motor to muscles of mastication.
VI.	<i>Abducent.</i>	Motor to External rectus muscle of eyeball.
VII.	<i>Facial.</i>	Motor to muscles of scalp and face.
	<i>Nervus intermedius.</i>	Mixed: Sensor (gustatory) to tongue; excitoglandular to submaxillary and sublingual salivary glands.
VIII.	<i>Acoustic;</i>	
	I. <i>Cochlearis.</i>	Hearing sense.
	II. <i>Vestibularis.</i>	Equilibratory.
IX.	<i>Glossopharyngeal.</i>	Mixed: Sensor (and gustatory) to tongue and pharynx; motor (?) to Stylopharyngeus muscle.
X.	<i>Vagus.</i>	Mixed: Sensorimotor to respiratory tract and part of alimentary tract.
XI.	<i>Spinal accessory.</i>	
	I. <i>Accessory to vagus.</i>	Motor to muscles of palate, pharynx, etc.; respiratory organs; inhibitory to heart.
	II. <i>Spinal part.</i>	Motor to Trapezius and Sternomastoid muscles.
XII.	<i>Hypoglossal.</i>	Motor to muscles of tongue.

THE FIRST OR OLFACTORY NERVE (N. OLFACTORIUS).

The **olfactory nerves** or **fila** are the special nerves of the sense of smell, and are about twenty in number on each side. These filaments constitute the first or olfactory nerves and are the axones of the **olfactory cells**, lying in the small olfactory region in the upper part of the superior turbinated process of the ethmoid and corresponding portion of the nasal septum and are macroscopically differentiated from the respiratory region in being of a more brownish hue (Fig. 731). The olfactory fila are amyelinic and exhibit a plexiform arrangement in the deeper layers. After piercing the cribriform plate of the ethmoid they become attached to the under surface of the **olfactory bulb**, an oval mass of a grayish color, which rests on the cribriform plate of the ethmoid bone and forms the anterior expanded extremity of a slender process of brain substance, named the **olfactory tract**. The olfactory tract and bulb have already been described (p. 927). The **olfactory tubercle** (*trigonum olfactorium*) is a small triangular mass of gray substance between the diverging roots of the optic tract (p. 928).

Each nerve is surrounded by tubular prolongations from the dura and pia, the former being lost on the periosteum lining the nose, the latter in the neurilemma of the nerve. The nerves, as they enter the nares, are divisible into two groups—an **inner group**, larger than those on the outer wall, spread out over the upper third of the septum; and an **outer set**, which is distributed over the superior turbinated process and the surface of the ethmoid in front of it. As the filaments descend, they appear to unite in a plexiform network, and are believed by most observers to terminate by becoming continuous with the deep extremities of the olfactory cells.

The olfactory nerves differ in structure from other nerves in being composed exclusively of amyelinic fibres. They are deficient in the white substance of Schwann, and consist of axones with a distinct nucleated sheath, in which there are, however, fewer nuclei than in ordinary amyelinic fibres.

The central olfactory pathways are described on page 958).

Applied Anatomy.—Destruction of the olfactory tract of one side causes loss of smell (*anosmia*) on the side of the injury, because the olfactory tract is practically uncrossed. In severe injuries to the head the olfactory bulb may become separated from the olfactory nerves, thus producing loss of the sense of smell, and with this a considerable loss in the sense of taste, as much of the perfection of the sense of taste is due to the sapid substances, being also odorous and

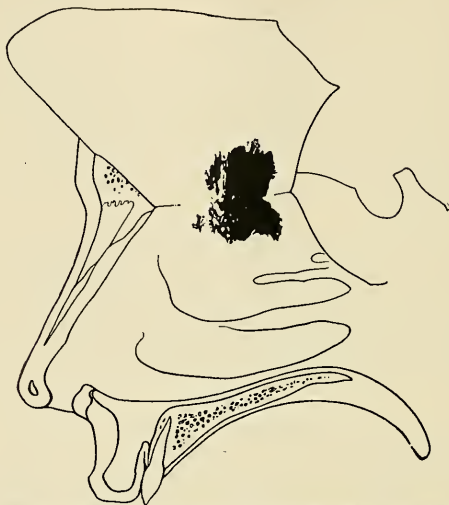


FIG. 731.—Extent of true olfactory mucous membrane. (v. Brunn.)

simultaneously exciting the sense of smell. When the sense of smell is lost, an individual cannot distinguish the *flavor* of food, but he can distinguish that a substance is salt, or sweet, or bitter, or acid. The most usual cause of injury to the olfactory nerve is fracture of the base of the skull, the line of fracture passing through the cribriform plate of the ethmoid bone, but a blow upon the face, forehead, or back of the head which does not produce fracture may injure the nerves.

THE SECOND OR OPTIC NERVE (N. OPTICUS).

The fibres of the optic nerve, the special nerve of the sense of sight, are the central processes of the retinal ganglion cells which, after converging to the optic papilla, leave the eyeball by piercing its fibrous and vascular tunics as a cylindric cord. The point of emergence is situated a little mesad (3 to 4 mm.— $\frac{1}{8}$ to $\frac{1}{6}$ inches) of the posterior pole of the globe. Behind the eyeball the nerve passes backward and inward through the orbital fat and optic foramen to enter the middle fossa of the cranium. The total length of the nerve averages 45 to 50 mm. ($1\frac{4}{5}$ to 2 inches). The two nerves converge to decussate partially, forming the chiasm.

The **optic chiasm** (*chiasma opticum*) (Figs. 732 and 733 and p. 910) is somewhat quadrilateral in form, rests upon the olivary eminence and on the anterior part of the diaphragma sellae, being bounded above by the lamina terminalis; behind by the tuber cinereum; on either side by the anterior perforated substance. Within the commissure the optic nerves of the two sides undergo a partial decussation (Figs. 672 and 733), described in detail on pages 910 and 911.

From the optic chiasm the **optic tracts** wind as flattened bands obliquely caudo-laterad around the crura cerebri to subdivide, each into two bands, one (mesal root) passing to the medial geniculate body and not a true continuation of the optic path (see Gudden's commissure, p. 910), the other (lateral root) passing to the lateral geniculate body, the pulvinar, and the superior quadrigeminal body (p. 910).

The **optic path** has been described on pages 909 to 911.

Applied Anatomy.—The optic nerve is peculiarly liable to become the seat of *neuritis* or undergo *atrophy* in affections of the central nerve system, and, as a rule, the pathological relationship between the two affections is exceedingly difficult to trace. There are, however, certain points in connection with the anatomy of this nerve which tend to throw light upon the frequent association of these affections with intracranial disease: (1) From its mode of development and from its structure the optic nerve must be regarded as a prolongation of the brain substance, rather than as an ordinary cerebrospinal nerve. (2) As it passes from the brain it receives sheaths from the three cerebral membranes—a perineural sheath from the pia, an intermediate sheath from the arachnoid, and an outer sheath from the dura, which is also connected with the periosteum as it passes through the optic foramen. These sheaths are separated from each other by spaces which communicate with the subdural and subarachnoid spaces respectively. The innermost or perineural sheath sends a process around the arteria centralis retinae into the interior of the nerve, and enters immediately into its structure. Thus, inflammatory infections of the meninges or of the brain may readily extend themselves along these spaces or along the interstitial connective tissue in the nerve.

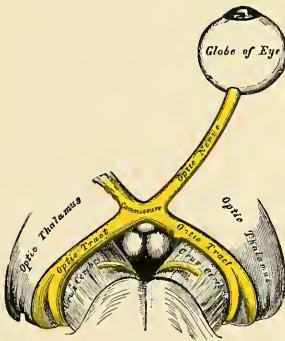


FIG. 732.—The left optic nerve and optic tracts.



FIG. 733.—Course of the fibres in the optic chiasm.

The course of the fibres in the optic chiasm has an important pathological bearing, and has been the subject of much controversy. Microscopic examination, experiments, and pathology all seem to point to the fact that there is a partial decussation of the fibres, each tract supplying the corresponding half of each eye, so that the right tract supplies the right half of each eye, and the left tract the left half of each eye. At the same time, Charcot believes—and his view has met with general acceptance—that the fibres which do not decussate at the optic chiasm will decussate in the corpora quadrigemina, so that lesion of the cerebral centre of one side causes complete blindness of the opposite eye, because both sets of decussating fibres are destroyed. Whereas should one tract—say the right—be destroyed by disease, there will be blindness of the right half of both retinae.

A sagittal section through the optic chiasm would divide the decussating fibres, and would therefore produce blindness of the inner half of each eye; while a section at the margin of the side of the optic chiasm would produce blindness of the external half of the retina of the same side.

The optic nerve may also be affected in injuries or diseases involving the orbit, in fractures of the anterior fossa of the base of the skull, in tumors of the orbit itself, or those invading this cavity from neighboring parts.

THE THIRD OR OCULOMOTOR NERVE (N. OCULOMOTORIUS) (Figs. 734, 735).

The **third or oculomotor nerve** supplies all the muscles of the orbit except the Superior oblique and External rectus; it also supplies, through its connection with the ciliary ganglion, the Sphincter muscle of the iris and the Ciliary muscle. It is a rather large nerve, of cylindric form and firm texture.

Its *apparent origin* is from the oculomotor groove along the ventromesal border of the crus. The deep origin may be traced through the substantia nigra, red nucleus, and tegmentum of the crus to a nucleus situated on either side of the median line beneath the floor of the aqueduct. The nucleus of the oculomotor nerve also receives fibres from the abducent nerve of the opposite side. The nucleus of the oculomotor nerve, considered from a physiological standpoint, can be subdivided into several smaller groups of cells, each group controlling a particular muscle (see p. 901).

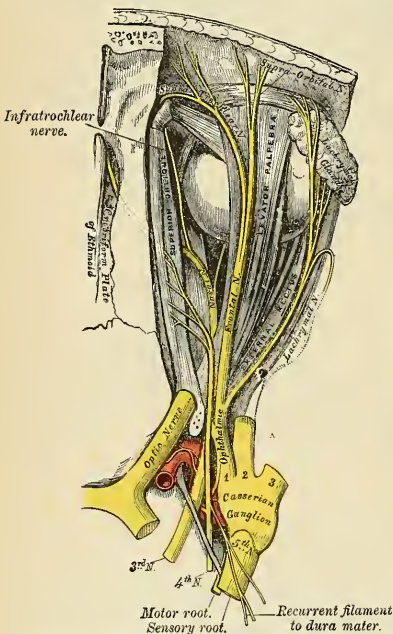


FIG. 734.—Nerves of the orbit, seen from above.

passing through the fissure, the nerve is placed below the trochlear nerve and the frontal and lacrimal branches of the ophthalmic nerve, while the nasal nerve is placed between its two divisions (Fig. 743).

The **superior division** (*ramus superior*) (Fig. 735), the smaller, passes inward over the optic nerve, and supplies the Superior rectus and Levator palpebrae muscles. The **inferior division** (*ramus inferior*) (Fig. 735), the larger, divides into three branches. One passes beneath the optic nerve to the Internal rectus; another, to the Inferior rectus; and the third, the longest of the three, passes forward between the Inferior and External recti to the Inferior oblique. From

On emerging from the brain, the nerve is invested with a sheath of pia, and enclosed in a prolongation from the arachnoid. It passes between superior cerebellar and posterior cerebral arteries, and then pierces the dura in front of and external to the posterior clinoid process, passing between the two processes from the free and attached borders of the tentorium, which are prolonged forward to be connected with the anterior and posterior clinoid processes of the sphenoid bone. It passes along the outer wall of the cavernous sinus (Figs. 505 and 506); above the other orbital nerves, receiving in its course one or two filaments from the cavernous plexus of the sympathetic, and a communicating branch from the first division of the trigeminal nerve. It then divides into two branches, which enter the orbit through the sphenoidal fissure, between the two heads of the External rectus muscle (Fig. 734). On

this latter a short, thick branch, *radix brevis ganglii ciliaris*, is given off to the lower part of the ciliary or lenticular ganglion and forms its *short* or *motor* root (Figs. 735 and 738). All these branches enter the muscles on their ocular surface, except that to the Inferior oblique, which enters its posterior border.

Applied Anatomy.—*Paralysis* of the oculomotor nerve may be the result of many causes: as cerebral disease; conditions causing pressure on the cavernous sinus; periostitis of the bone entering into the formation of the sphenoidal fissure; fracture of the orbit. It results, when complete, in (1) ptosis, or drooping of the upper eyelid, in consequence of the Levator palpebrae being paralyzed; (2) external strabismus, on account of the unopposed action of the External rectus muscle, which is not supplied by the oculomotor nerve, and is not therefore paralyzed; (3) dilatation of the pupil, because the sphincter fibres of the iris are paralyzed; (4) loss of power of accommodation, as the Sphincter pupillae, the Ciliary muscle, and the Internal rectus are paralyzed; (5) slight prominence of the eyeball, owing to most of its muscles being relaxed.

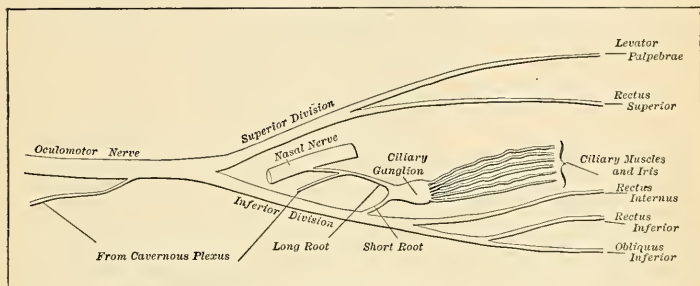


FIG. 735.—Plan of the oculomotor nerve.

Occasionally paralysis may affect only a part of the nerve; that is to say, there may be, for example, a dilated and fixed pupil, with ptosis, but no other signs. *Irritation* of the nerve causes spasm of one or other of the muscles supplied by it; thus, there may be internal strabismus from spasm of the Internal rectus; accommodation for near objects only from spasm of the Ciliary muscle, or contraction of the pupil (myosis), from irritation of the sphincter of the pupil.

The oculomotor nerve is particularly liable to become involved in a syphilitic periarteritis where it passes between the superior cerebellar and posterior cerebral arteries; associated with locomotor ataxia various partial or complete paralyses of the nerve are often seen.

THE FOURTH OR TROCHLEAR NERVE (N. TROCHLEARIS) (Figs. 633, 734).

The **fourth** or **trochlear nerve** is, with the exception of the n. intermedius, the smallest of the cranial nerves, and supplies the Superior oblique muscle.

It *arises* from a nucleus in the floor of the mid-brain aqueduct at the level of the inferior quadrigeminal body. From its origin the nerve runs outward, curving around the central aqueduct gray to turn inward and backward into the superior medullary velum, decussating with the corresponding nerve of the opposite side and *emerging* from the surface laterad of the frenulum veli, immediately behind (or caudad of) the posterior quadrigeminal body.

Emerging from the superior medullary velum, the nerve is directed outward across the superior peduncle of the cerebellum, and then winds forward around the outer side of the crus cerebri, immediately above the pons, pierces the dura in the free border of the tentorium, just behind, and external to, the posterior clinoid process, and passes forward in the outer wall of the cavernous sinus, between the oculomotor nerve and the ophthalmic division of the trigeminal nerve (Figs. 505 and 506). It crosses the oculomotor nerve and enters the

orbit through the sphenoidal fissure (Fig. 743). It now becomes the highest of all the nerves, lying at the inner extremity of the fissure internal to the frontal nerve. In the orbit it passes inward, above the origin of the Levator palpebrae, and finally enters the orbital surface of the Superior oblique muscle.

Branches of Communication.—In the outer wall of the cavernous sinus it forms communications with the cavernous plexus of the sympathetic and with the ophthalmic division of the trigeminal nerve. In the sphenoidal fissure it occasionally gives off a branch to assist in the formation of the lacrimal nerve.

Branches of Distribution.—It gives off a recurrent branch, which passes backward between the layers of the tentorium cerebelli, dividing into two or three filaments which may be traced as far back as the wall of the lateral sinus.

Applied Anatomy.—The trochlear nerve when *paralyzed* causes loss of function in the Superior oblique, so that the patient is unable to turn his eye downward and outward. Should the patient attempt to do this, the eye on the affected side is twisted inward, producing *diplopia* or double vision. Accordingly, it is said that the first symptom of this disease which presents itself is giddiness when going down hill or in descending stairs, owing to the double vision produced by the patient looking at his steps while descending.

THE FIFTH, TRIGEMINAL, OR TRIFACIAL NERVE (N. TRIGEMINUS) (Figs. 737, 738).

The **fifth, trigeminal, or trifacial nerve** is the largest cranial nerve. It resembles a spinal nerve (1) in having two roots, motor and sensor; (2) in having a ganglion developed on its sensor root. It is the great sensor nerve of the head and face and the motor nerve of the muscles of mastication; its upper two divisions are entirely sensor, the third division is partly sensor and partly motor. It *arises* by two roots; of these, the ventral is the smaller, and is the **motor root** (Fig. 649); the dorsal, the larger and **sensor root**. It *emerges* from the side of the pons near the upper border, by a small motor and a large sensor root. The small root consists of three or four bundles; the large root consists of numerous bundles of fibres, varying in number from seventy to a hundred. The two roots are separated from each other by a few of the transverse fibres of the pons. The *deep termination* of the large or sensor root is chiefly in a long tract in the medulla oblongata, the **lower sensor nucleus**, which is continuous below with the substantia gelatinosa Rolandi. The fibres from this nucleus form the so-called **ascending root of the fifth nerve**; they pass upward through the pons and join with fibres from the **upper sensor nucleus** (Fig. 650), which is situated to the outer side of the motor nucleus, from which the lower part of the motor root takes origin. The *deep origin* of the small or motor root is derived partly from a nucleus embedded in the gray substance of the upper part of the floor of the fourth ventricle and partly from a collection of nerve cells situated at the side of the aqueduct from which the fibres pass caudad under the name of the **mesencephalic or descending root of the fifth nerve** (Fig. 650).

The two roots of the nerve pass forward below the tentorium as it bridges over the notch on the inner part of the superior border of the petrous portion of the temporal bone (Fig. 737); they then run between the bone and the dura to the apex of the petrous portion of the temporal bone, where the fibres of the sensor root appear to enter into the formation of the **large semilunar or Gasserian ganglion** (Figs. 736 and 737), while the motor root passes beneath the ganglion without having any connection with it, and joins outside the cranium with one of the trunks derived from it (Figs. 736 and 737).

The **Gasserian or semilunar ganglion**¹ (*ganglion semilunare*) (Figs. 736 and 737) is lodged in an osteofibrous space, the **cavum Meckelii** (Fig. 726), near the

¹ A Viennese anatomist, Rainund Balthasar Hirsch (1765), was the first who recognized the ganglionic nature of the swelling on the sensor root of the fifth nerve, and called it, in honor of his otherwise unknown teacher, Jon. Laur. Gasser, the "Ganglion Gasseri." Julius Casserius, whose name is given to the musculocutaneous nerve of the arm, was professor at Padua, 1545 to 1605. (See Hyrtl, *Lehrbuch der Anatomie*, p. 895 and p. 55.)

apex of the petrous portion of the temporal bone. The ganglion is of somewhat crescentic form, with its convexity turned forward. Its upper surface is intimately adherent to the dura. Besides the small or motor root, the large superficial petrosal nerve lies underneath the ganglion.

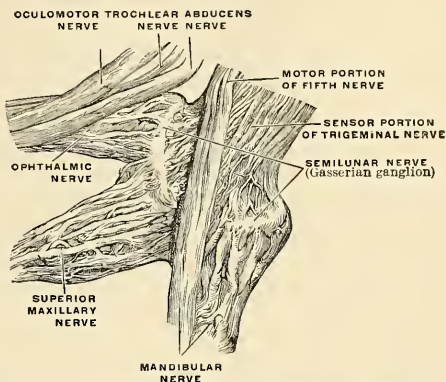


FIG. 736.—The right semilunar or Gasserian ganglion, viewed from the medial side. (Enlarged.) (Spalteholz.)

Branches of Communication.—This ganglion receives on its inner side filaments from the carotid plexus of the sympathetic.

Branches of Distribution.—It gives off minute branches to the tentorium cerebelli and the dura in the middle fossa of the cranium. From its anterior (*convex*) border, which is directed forward and outward, three large branches proceed—the ophthalmic, superior maxillary, and inferior maxillary. The ophthalmic and superior maxillary consist exclusively of fibres derived from the large root and ganglion, and are solely nerves of common sensation. The third division, or inferior maxillary, is joined outside the cranium by the motor root, and is, therefore, strictly speaking, the only portion of the trigeminal nerve which can be said to resemble a spinal nerve.

Associated with the three divisions of the trigeminal nerve are four small ganglia—the ophthalmic, sphenopalatine, otic, and submaxillary ganglia.

The ophthalmic nerve (*n. ophthalmicus*), or first division of the trigeminal, is a sensor nerve. It supplies sensor branches to the cornea, ciliary muscle, and iris, to the lacrimal gland, to a part of the mucous lining of the nasal fossæ, and to the integument of the eyelids, eyebrow, forehead, and nose (Fig. 742). It is the smallest of the three divisions of the fifth, arising from the upper part of the Gasserian ganglion. It is a short, flattened band, about 2 cm. ($\frac{3}{8}$ inch) in length, which passes forward

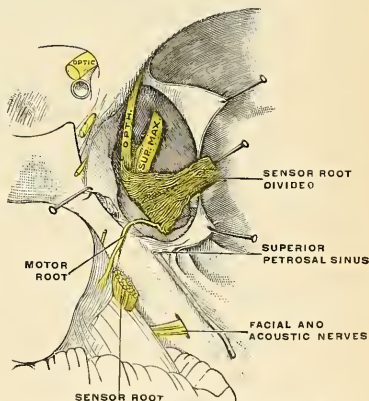


FIG. 737.—The course of the motor root of the trigeminal nerve. (Poirier and Charpy.)

along the outer wall of the cavernous sinus (Figs. 505 and 506), below the oculomotor and trochlear nerves (Fig. 736), and just before entering the orbit, through the sphenoidal fissure, divides into three branches—**lacrimal**, **frontal**, and **nasal**.

Branches of Communication.—The ophthalmic nerve is joined by filaments from the cavernous plexus of the sympathetic, and gives off minute branches to communicate with the oculomotor and abducent nerves, and not infrequently with the trochlear.

Branches of Distribution.—It gives off recurrent filaments (*n. tentorii*) which pass between the layers of the tentorium cerebelli, and then divides into—

Lacrimal.

Frontal.

Nasal.

The **lacrimal nerve** (*n. lacrimonalis*) (Figs. 738 and 739) is the smallest of the three branches of the ophthalmic. It sometimes receives a filament from the trochlear nerve, but this is possibly derived from the branch of communication which passes from the ophthalmic to the trochlear. It passes forward in a separate tube of dura, and enters the orbit through the narrowest part of the sphenoidal fissure (Fig. 743). In the orbit it runs along the upper border of the External rectus muscle, with the lacrimal artery, and communicates with the temporomalar branch of the superior maxillary nerve. It enters the lacrimal gland and gives off several filaments, which supply the gland and the conjunctiva. Finally, it pierces the superior palpebral ligament, and terminates in the integument of the upper eyelid, joining with filaments of the facial nerve. The lacrimal nerve is occasionally absent, when its place is taken by the temporal branch of the superior maxillary. Sometimes the latter branch is absent, and a continuation of the lacrimal is substituted for it.

The **frontal nerve** (*n. frontalis*) (Figs. 734 and 738) is the largest division of the ophthalmic, and may be regarded, both from its size and direction, as the continuation of the nerve. It enters the orbit above the muscles, through the sphenoidal fissure (Fig. 738), and runs forward along the middle line, between the Levator palpebrae and the periosteum. Midway between the apex and the base of the orbit it divides into two branches, **supratrochlear** and **supraorbital**.

The **supratrochlear branch** (*n. supratrochlearis*) (Fig. 734) the smaller of the two, passes inward, above the pulley of the Superior oblique muscle, and gives off a descending filament, which joins with the infratrochlear branch of the nasal nerve. It then leaves the orbit between the pulley of the Superior oblique and the supraorbital foramen, curves up on to the forehead close to the bone, ascends beneath the Corrugator supercilii and Occipitofrontalis muscles, and, dividing into branches which pierce these muscles, it supplies the integument of the lower part of the forehead on either side of the middle line and sends filaments to the conjunctiva and skin of the upper eyelid.

The **supraorbital branch** (*n. supraorbitalis*) (Fig. 743) passes forward through the supraorbital foramen, and gives off, in this situation, **palpebral filaments** to the upper eyelid. It then ascends upon the forehead, and terminates in cutaneous and pericranial branches. The **cutaneous branches**, two in number, an inner and an outer, supply the integument of the cranium as far back as the vertex. They are at first situated beneath the Occipitofrontalis, the inner branch perforating the frontal portion of the muscle, the outer branch its tendinous aponeurosis. The **pericranial branches** are distributed to the pericranium over the frontal and parietal bones.

The **nasal nerve** (*n. nasociliaris*) (Figs. 734 and 738) is intermediate in size between the frontal and lacrimal, and is more deeply placed than the other branches of the ophthalmic. It enters the orbit by way of the sphenoidal fissure (Fig. 743) between the two heads of the External rectus, and passes obliquely inward across the optic nerve, beneath the Superior rectus and Superior oblique muscles,

to the inner wall of the orbit. Here it passes through the anterior ethmoidal foramen, and, entering the cavity of the cranium, traverses a shallow groove on the front of the cribriform plate of the ethmoid bone, and passes down, through the slit by the side of the crista galli, into the nose (Fig. 740), where it divides into two branches, an internal and an external branch. The **internal branch** (*rami nasales mediales*) supplies the mucous membrane near the fore part of the septum of the nose. The **external branch** (*rami nasales laterales*) descends in a groove on the inner surface of the nasal bone, and supplies a few filaments to the mucous membrane covering the fore part of the outer wall of the nares as far as the inferior turbinate process; it then leaves the cavity of the nose, between the lower border of the nasal bone and the upper lateral cartilage of the nose, and, passing down beneath the Compressor nasi, supplies the integument of the ala and the tip of the nose, joining with the facial nerve.

The branches of the nasal nerve are the **ganglionic**, **long ciliary**, and **infratrochlear**.

The **ganglionic branch** or the **long root of the ciliary ganglion** (*radix longa ganglii ciliaris*) (Figs. 735 and 738) is a slender branch, about 1 to 2 cm. in length, which usually arises from the nasal nerve, between the two heads of the External rectus

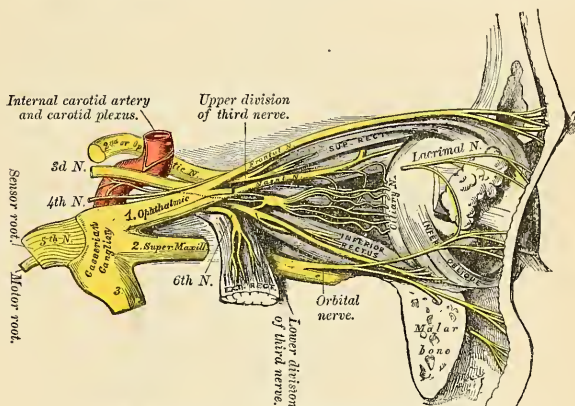


FIG. 738.—Nerves of the orbit and ophthalmic ganglion, side view.

muscle. It passes forward on the outer side of the optic nerve, and enters the postero-superior angle of the ciliary ganglion, forming its long root. It is sometimes joined by a filament from the cavernous plexus of the sympathetic or from the superior division of the oculomotor nerve.

The **long ciliary nerves** (*nn. ciliares longi*), two or three in number, are given off from the nasal as it crosses the optic nerve. They accompany the **short ciliary nerves** (Figs. 735 and 738) from the ciliary ganglion, pierce the posterior part of the sclera, and, running forward between it and the choroid, are distributed to the Ciliary muscle, iris, and cornea.

The **infratrochlear branch** (*n. infratrochlearis*) (Fig. 734) is given off just before the nasal nerve passes through the anterior ethmoidal foramen. It runs forward along the upper border of the Internal rectus muscle, and is joined, beneath the pulley of the Superior oblique, by a filament from the supratrochlear nerve. It then passes to the inner angle of the eye, and supplies the integument of the eyelids and side of the nose, the conjunctiva, the lacrimal sac, and the caruncula lacrimalis.

The **ophthalmic, lenticular, or ciliary ganglion** (*ganglion ciliare*) is a small, quadrangular, flattened ganglion of a reddish-gray color, and about the size of a pin's head, situated at the back part of the orbit between the optic nerve and the External rectus muscle, lying generally on the outer side of the ophthalmic artery. It is enclosed in a quantity of loose fat, which makes its exposure by dissection somewhat difficult.

Its **branches of communication or roots** are three, all of which enter its posterior border. One, the **long or sensor root** (*radix longa ganglii ciliaris*), is derived from the nasal branch of the ophthalmic and joins its postero-superior angle. The second, the **short or motor root** (*radix brevis ganglii ciliaris*), is a short, thick nerve, occasionally divided into two parts, which is derived from the branch of the oculomotor to the Inferior oblique muscle, and is connected with the postero-inferior angle of the ganglion. The third, the **sympathetic root** (*radix sympathetica ganglii ciliaris*), is a slender filament from the cavernous plexus of the sympathetic. This is frequently blended with the long root, although it sometimes passes to the ganglion separately. The ganglion occasionally receives a filament of communication from the **sphenopalatine ganglion**.

Its **branches of distribution** are the **short ciliary nerves** (*nn. ciliares breves*) (Figs. 735 and 738). These are delicate filaments, from six to ten in number, which arise from the fore part of the ganglion in two bundles, connected with its superior and inferior angles; the lower bundle is the larger. They run forward with the ciliary arteries in a wavy course, one set above and the other below the optic nerve, and are accompanied by the long ciliary branches of the nasal nerve. They pierce the sclera at the back part of the globe, pass forward in delicate grooves on its inner surface, and are distributed to the Ciliary muscle, iris, and cornea. One small branch is said to penetrate the optic nerve with the *arteria centralis retinae*.

The **superior maxillary nerve** (*n. maxillaris*) (Figs. 734 and 737), or **second division of the trigeminal**, is a sensor nerve. It is intermediate, both in position and size, between the ophthalmic and inferior maxillary. It commences at the middle of the Gasserian ganglion as a flattened plexiform band, and, passing horizontally forward, it leaves the skull through the foramen rotundum, where it becomes more cylindrical in form and firmer in texture. It then crosses the sphenomaxillary fossa (Fig. 67), inclines outward on the back of the maxilla, and enters the orbit through the sphenomaxillary fissure; it traverses the infra-orbital canal in the floor of the orbit, and appears upon the face at the infra-orbital foramen.¹ At its termination the nerve lies beneath the Levator labii superioris muscle, and divided into a leash of branches, which spread out upon the side of the nose, the lower eyelid, and upper lip, joining with filaments of the facial nerve.

Branches of Distribution.—The branches of this nerve may be divided into four groups: (1) Those given off in the **cranium**. (2) Those given off in the **sphenomaxillary fossa**. (3) Those in the **infraorbital canal**. (4) Those on the **face**.

In the cranium	Meningeal or dural.
Sphenomaxillary fossa . .	{ Orbital or temporomalar.
	{ Sphenopalatine.
	{ Posterior superior dental.
Infraorbital canal	{ Middle superior dental.
	{ Anterior superior dental.
On the face	{ Palpebral.
	{ Nasal.
	{ Labial.

¹ After it enters the infraorbital canal the nerve is usually called the **infraorbital** (*n. infraorbitalis*), and is, therefore, the terminal branch of the superior maxillary nerve (Fig. 742).

The **Meningeal or Dural Branch** (*n. meningeus medius*) is given off from the superior maxillary nerve directly after its origin from the Gasserian ganglion; it accompanies the middle meningeal artery and supplies the dura of the middle fossa of the base of the skull.

The **Orbital or Temporomalar Branch** (*n. zygomaticus*) (Figs. 738 and 739) arises in the sphenomaxillary fossa, enters the orbit by the sphenomaxillary fissure, and divides at the back of that cavity into two branches, temporal and malar.

The **temporal branch** (*ramus zygomaticotemporalis*) runs along the outer wall of the orbit in a groove in the malar bone, receives a branch of communication from the lacrimal, and, passing through a foramen in the malar bone, enters the temporal fossa. It ascends between the bone and the substance of the Temporal muscle, pierces this muscle and the temporal fascia about an inch above the

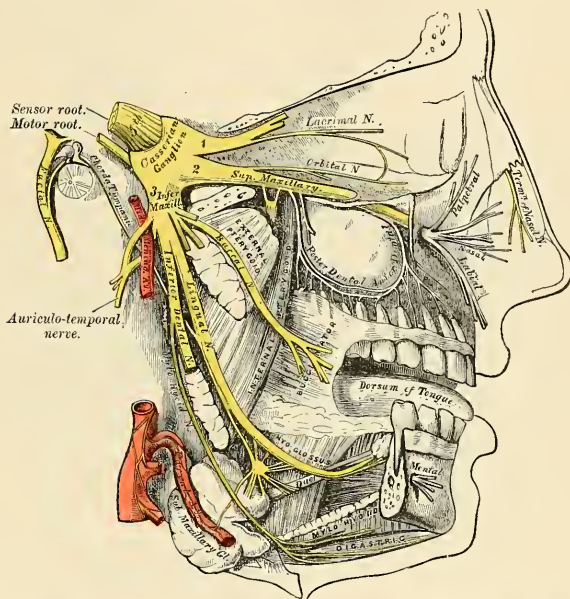


FIG. 739.—Distribution of the second and third divisions of the trigeminal nerve and submaxillary ganglion.

zygoma, and is distributed to the integument covering the temple and side of the forehead, communicating with the facial and the auriculotemporal branch of the inferior maxillary nerve. As it pierces the temporal fascia it gives off a slender twig, which runs between the two layers of the fascia to the outer angle of the orbit. The **malar branch** (*ramus zygomaticofacialis*) passes along the external inferior angle of the orbit, emerges upon the face through a foramen in the malar bone, and, perforating the Orbicularis palpebrarum muscle, supplies the skin on the prominence of the cheek, where it is named the **subcutaneous malæ**. It joins with the facial and the palpebral branches of the superior maxillary.

The **Sphenopalatine Branches** (*nn. sphenopalatini*) (Fig. 739), two in number, descend to the sphenopalatine ganglion, of which ganglion they are the sensor or short roots.

The **Posterior Superior Dental Branches** (*rami alveolares superiores posteriores*) (Fig. 739) arise from the trunk of the nerve just as it is about to enter the infra-orbital canal; they are generally two in number, but sometimes arise by a single trunk, and immediately divide and pass downward on the tuberosity of the maxilla. They give off several twigs to the gums and neighboring parts of the mucous membrane of the cheek, **superior gingival branches** (*rami gingivales superiores*). They then enter the posterior dental canals on the zygomatic surface of the maxilla, and, passing from behind forward in the substance of the bone, communicate with the middle dental nerve by a plexus formation, and give off branches to the lining membrane of the antrum and three twigs to each molar tooth. These twigs enter the foramina at the apices of the fangs and supply the pulp.

The **Middle Superior Dental Branch** (*ramus alveolaris superior medius*) is given off from the superior maxillary nerve in the back part of the infraorbital canal, and runs downward and forward in a special canal in the outer wall of the antrum to supply the two bicuspid teeth. It communicates with the posterior and anterior dental branches by a plexus formation (*plexus dentalis superior*).

At its point of communication with the posterior branch, above the root of the second bicuspid tooth, is a slight thickening which is the so-called **ganglion of Valentin**; and at its point of communication with the anterior branch is a second enlargement, which is called the **ganglion of Bochdalek**. Neither of these is a true ganglion.

The **Anterior Superior Dental Branch** (*ramus alveolaris superior anteriores*), of large size, is given off from the superior maxillary nerve just before its exit from the infraorbital foramen; it enters a special canal in the anterior wall of the antrum, and divides into a series of branches which supply the incisor and canine teeth. It communicates with the middle dental nerve by a plexus, and gives off a **nasal branch**, which passes through a minute canal into the nasal fossa, and supplies the mucous membranes of the fore part of the inferior meatus and the floor of the cavity, communicating with the nasal branches from the sphenopalatine ganglion.

The **Palpebral Branches** (*rami palpebrales inferiores*) pass upward beneath the Orbicularis palpebrarum muscle. They supply the integument and conjunctiva of the lower eyelid, joining at the outer angle of the orbit with the facial nerve and the malar branch of the orbital.

The **Nasal Branches** (*rami nasales interni*) pass inward; they supply the integument of the side of the nose and join with the nasal branch of the ophthalmic.

The **Labial Branches** (*rami labiales superiores*), the largest and most numerous, descend beneath the Levator labii superioris muscle, and are distributed to the integument of the upper lip, the mucous membrane of the mouth, and the labial glands.

All these branches are joined, immediately beneath the orbit, by filaments from the facial nerve, forming an intricate plexus, the **infraorbital plexus**.

The **Sphenopalatine or Meckel's Ganglion** (*ganglion sphenopalatinum*) (Fig. 740), the largest of the ganglia associated with the branches of the trigeminal nerve, is deeply placed in the sphenomaxillary fossa, close to the sphenopalatine foramen. It is triangular or heart-shaped, of a reddish-gray color, and is situated just below the superior maxillary nerve as it crosses the fossa.

Branches of Communication.—Like the other ganglia of the trigeminal nerve, it possesses a motor, a sensor, and a sympathetic root. Its **sensor root** is derived from the superior maxillary nerve through its two sphenopalatine branches (p. 983). These branches of the nerve, given off in the sphenomaxillary fossa, descend to the ganglion. Their fibres, for the most part, pass in front of the ganglion, as they proceed to their destination, in the palate and nasal fossa, and are not incorporated in the ganglionic mass; some few of the fibres, however,

enter the ganglion, constituting its sensor root. Its **motor root** is derived from the facial nerve through the large superficial petrosal nerve, and its **sympathetic root** from the carotid plexus, through the large deep petrosal nerve. These two nerves join together before their entrance into the ganglion to form a single nerve, the Vidian.

The **large or great superficial petrosal branch** (*n. petrosus superficialis major*) (Fig. 744) is given off from the **geniculate ganglion** implanted on the external genu of the facial nerve in the facial canal or aqueductus Fallopii; it passes through the hiatus canalis facialis, enters the cranial cavity, and runs forward, being contained in a groove on the anterior surface of the petrous portion of the temporal bone, and lies beneath the dura. It then enters the cartilaginous substance which fills in the foramen lacerum medium, and, joining with the large deep petrosal nerve, forms the Vidian nerve.

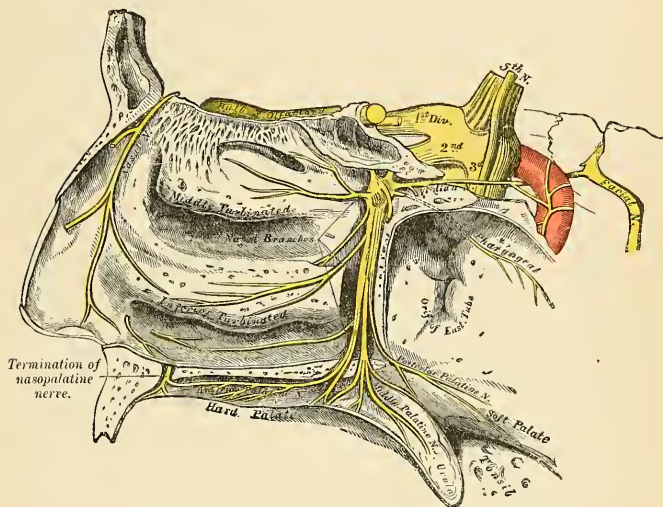


FIG. 740.—The sphenopalatine or Meckel's ganglion and its branches

The **large deep petrosal nerve** (*n. petrosus profundus*) (Fig. 745) is given off from the carotid plexus of the sympathetic upon the internal carotid artery, and runs through the carotid canal on the outer side of the internal carotid artery. It then enters the cartilaginous substance which fills in the foramen lacerum medium, and joins with the large superficial petrosal nerve to form the Vidian.

The **Vidian nerve** (*n. canalis pterygoidei*) (Fig. 740), formed by the junction of the two preceding nerves in the cartilaginous substance which fills in the middle lacerated foramen, passes forward, through the Vidian canal, with the artery of the same name, and is joined by a small ascending nerve branch, the **sphencoidal branch**, from the **otic ganglion**. Finally, it enters the sphenomaxillary fossa, and joins the posterior angle of the sphenopalatine ganglion.

Branches of Distribution of the Sphenopalatine Ganglion.—These are divisible into four groups—**ascending**, which pass to the orbit; **descending**, to the palate; **internal**, to the nose; and **posterior branches**, to the nasopharynx.

The **ascending branches** (*rami orbitales*) are two or three delicate filaments which enter the orbit by the sphenomaxillary fissure, and supply the periosteum and the nonstriated muscle parts of the Levator palpebrae or Superior tarsal muscle, the Inferior tarsal muscle, and the Orbital muscle of Müller. According to Luschka, some filaments pass through foramina in the suture between the os planum of the ethmoid and frontal bone to supply the mucous membrane of the posterior ethmoidal and sphenoidal sinuses.

The **descending or palatine branches** (*nn. palatini*) (Fig. 740) are distributed to the roof of the mouth, the soft palate, tonsil, and lining membrane of the nose. They are almost a direct continuation of the sphenopalatine branches of the superior maxillary nerve, and are three in number—**anterior**, **middle**, and **posterior**.

The **anterior palatine nerve**¹ (*n. palatinus anterior*) descends through the **posterior palatine canal**, emerges upon the hard palate at the posterior palatine foramen, and passes forward in a groove in the hard palate, nearly as far as the incisor teeth. It supplies the gums, the mucous membrane, and glands of the hard palate, and communicates in front with the termination of the **nasopalatine nerve** (see below). While in the posterior palatine canal it gives off **inferior nasal branches** (*rami nasales posteriores inferiores*), which enter the nose through openings in the palate bone and ramify over the turbinated bone and middle and inferior meatuses; and, at its exit from the canal, a palatine branch is distributed to both surfaces of the soft palate.

The **middle palatine nerve** (*n. palatinus medius*) descends through one of the accessory posterior palatine canals, distributing branches to the uvula, tonsil, and soft palate. It is occasionally wanting.

The **posterior palatine nerve** (*n. palatinus posterior*) descends with a minute artery through the posterior palatine canal, and emerges by a separate opening behind the posterior palatine foramen. It supplies the soft palate, tonsil, and uvula. The middle and posterior palatine join with the tonsillar branches of the glossopharyngeal to form a plexus around the tonsil (**circulus tonsillaris**).

The **internal branches** are distributed to the septum and outer wall of the nasal fossae. They are the **superior nasal** and the **nasopalatine**.

The **superior nasal branches** (*rami nasales posteriores superiores*), four or five in number, enter the back part of the nasal fossa by the sphenopalatine foramen. They supply the mucous membrane covering the superior and middle turbinated processes, and that lining the posterior ethmoidal cells, a few being prolonged to the upper and back part of the septum.

The **nasopalatine nerve** (*n. nasopalatinus*) also enters the nasal fossa through the sphenopalatine foramen; it passes inward across the roof of the nose, below the orifice of the sphenoidal sinus, to reach the septum, and then runs obliquely downward and forward along the lower part of the septum, to the anterior palatine foramen, lying between the periosteum and mucous membrane. It descends to the roof of the mouth through the **anterior palatine canal** (Fig. 740). The two nerves are here contained in separate and distinct canals, situated in the intermaxillary suture, and termed the **foramina of Scarpa**, the left nerve being usually anterior to the right one. In the mouth they become united, supply the mucous membrane behind the incisor teeth, and join with the anterior palatine nerves. The nasopalatine nerve furnishes a few small filaments to the mucous membrane of the septum.

Posterior Branch.—The **pharyngeal or pterygopalatine nerve** (Fig. 740) is a small branch arising from the back part of the **sphenopalatine ganglion**. It passes through the pterygopalatine canal with the pterygopalatine artery, and is distributed to the mucous membrane of the upper part of the pharynx, behind the Eustachian tube.

¹ Formerly called the *great palatine nerve*.

The Inferior Maxillary or Mandibular Nerve (*n. mandibularis*) (Figs. 738 and 739).—The inferior maxillary or third division of the trigeminal nerve distributes branches to the teeth and gums of the mandible, the integument of the temple and external ear, the lower part of the face and lower lip, and the muscles of mastication; it also supplies the tongue with a large branch. It is the largest of the three divisions of the trigeminal, and is made up of two roots—a large or sensor root, proceeding from the inferior angle of the Gasserian ganglion; and a small or motor root, which passes beneath the ganglion and unites with the sensor root just after its exit from the skull through the **foramen ovale** (Figs. 736 and 739). Immediately beneath the base of the skull this nerve divides into two trunks, **anterior** and **posterior**. Previous to its division the primary trunk gives off from its inner side a recurrent (meningeal) branch and the nerve to the Internal pterygoid muscle.

The **Recurrent or Meningeal Branch** (*n. spinosus*) is given off directly after its exit from the foramen ovale. It passes backward into the skull through the foramen spinosum with the middle meningeal artery. It divides into two branches, **anterior** and **posterior**, which accompany the main divisions of the artery and supply the dura. The posterior branch also supplies the mucous lining of the mastoid cells. The anterior branch communicates with the dural branch of the superior maxillary nerve.

The **Internal Pterygoid Nerve** (*n. pterygoideus internus*), given off from the inferior maxillary previous to its division, is intimately connected at its origin with the otic ganglion. It is a long and slender branch, which passes inward to enter the deep surface of the Internal pterygoid muscle.

The **anterior** and smaller division of the inferior maxillary nerve, which receives nearly the whole of the motor root of the trigeminal nerve, divides into branches which supply the muscles of mastication. They are the **masseteric**, **deep temporal**, **buccal**, and **external pterygoid branches** (Fig. 739).

The **masseteric branch** (*n. massetericus*) passes outward, above the External pterygoid muscle, in front of the temporomandibular articulation and behind the tendon of the Temporal muscle; it crosses the sigmoid notch with the masseteric artery, to the deep surface of the Masseter muscle, in which it ramifies nearly as far as its anterior border. It gives a filament to the temporomandibular joint.

The **deep temporal branches** (*nn. temporales profundi*), two in number, anterior and posterior, supply the deep surface of the Temporal muscle. The **posterior branch** (*n. temporalis profundus posterior*), of small size, is placed at the back of the temporal fossa. It sometimes arises in common with the masseteric branch. The **anterior branch** (*n. temporalis profundus anterior*) is frequently given off with the buccal nerve; it is reflected upward, at the pterygoid ridge of the sphenoid, to the front of the temporal fossa. Frequently a third branch (**middle deep temporal**) is present.

The **buccal or buccinator branch** (*n. buccinatorius*) passes forward between the two heads of the External pterygoid; and downward beneath or through the fibres of the Temporal muscle; it gives a branch to the External pterygoid during its passage through that muscle, and a few ascending filaments to the Temporal muscle, one of which occasionally joins with the anterior branch of the deep temporal nerve. The **superior or upper branch** supplies the integument and upper part of the Buccinator muscle, joining with the facial nerve around the facial vein. The **inferior or lower branch** passes forward to the angle of the mouth; it supplies the integument and Buccinator muscle, as well as the mucous membrane lining the inner surface of that muscle, and joins the facial nerve.¹

¹ There seems to be no reason to doubt that the branch supplying the Buccinator muscle is entirely a nerve of ordinary sensation, and that the true motor supply of this muscle is from the facial.

The **external pterygoid nerve** (*n. pterygoideus externus*) is most frequently derived from the buccal, but it may be given off separately from the anterior trunk of the inferior maxillary nerve. It enters the muscle on its inner surface.

The **posterior** and larger division of the inferior maxillary nerve is for the most part sensor, but receives a few filaments from the motor root. It divides into three branches—**auriculotemporal**, **lingual**, and **inferior dental** (Fig. 739).

The **auriculotemporal nerve** (*n. auriculotemporalis*) (Fig. 741) generally arises by two roots, between which the middle meningeal artery passes. It runs backward beneath the External pterygoid muscle to the inner side of the neck of the mandible. It then turns upward with the temporal artery, between the external auditory canal and the condyle of the mandible, under cover of the parotid gland, and, escaping from beneath this structure, ascends over the zygoma and divides into two **temporal branches**.

The **branches of communication** of the auriculotemporal nerve are with the facial and with the otic ganglion. The branches of communication with the facial (*rami anastomotici cum n. faciali*), usually two in number, pass forward from behind the neck of the condyle of the mandible, to join this nerve at the posterior border of the Masseter muscle. The filaments of communication with the otic ganglion are derived from the commencement of the auriculotemporal nerve.

The **branches of distribution** are:

Anterior auricular.	Parotid.
Articular.	Superficial temporal.
Branches to the external auditory meatus.	

The **anterior auricular branches** (*nn. auriculares anteriores*) are usually two in number. They supply the front of the upper part of the pinna, being distributed principally to the skin covering the front of the helix and tragus.

A branch to the temporomandibular articulation, the **articular branch**, is usually derived from the auriculotemporal nerve.

The **parotid branches** (*rami parotidei*) supply the parotid gland.

The **superficial temporal branches** (*rami temporales superficiales*) accompany the temporal artery to the vertex of the skull, and supply the integument of the temporal region, communicating with the facial nerve, and with the temporal branch of the temporomalar from the superior maxillary nerve.

The **branches to the external auditory meatus** (*n. meatus auditorii externi*), two in number, enter the canal between the bony and cartilaginous portion of the meatus. They supply the skin lining the meatus; the upper one sending a filament to the membrana tympani (*ramus membranae tympani*).

The **lingual nerve** (*n. lingualis*) (Fig. 739) supplies the papillæ and mucous membrane of the **anterior two-thirds of the tongue**, and is deeply placed throughout the whole of its course. It lies at first beneath the External pterygoid muscle, being placed to the inner side and in front of the inferior dental nerve, and is occasionally joined to this nerve by a branch which may cross the internal maxillary artery. The **chorda tympani nerve** also joins it at an acute angle in this situation. The nerve then passes between the Internal pterygoid muscle and the inner side of the ramus of the mandible, and crosses obliquely to the side of the tongue over the Superior constrictor of the pharynx and the Styloglossus muscles, and then between the Hyoglossus muscle and the deep part of the submaxillary gland; the nerve finally runs across the submaxillary or Wharton's duct, and along the side of the tongue to its apex, lying immediately beneath the mucous membrane.

The **branches of communication** are with the inferior dental and hypoglossal nerves and the submaxillary ganglion, and, apparently only, with the facial through the chorda tympani. The branches to the submaxillary ganglion are two or three

in number; those connected with the hypoglossal nerve form a plexus at the anterior margin of the Hyoglossus muscle.

The **branches of distribution** supply the mucous membrane of the mouth, the gums, the sublingual gland, and the mucous membrane of the anterior two-thirds of the tongue; the terminal filaments communicate at the tip of the tongue, with the hypoglossal nerve. The chorda tympani fibres which join the lingual nerve are probably taste fibres and excitoglandular for the submaxillary and sublingual salivary glands.

The **inferior dental nerve** (*n. alveolaris inferior*) (Fig. 739) is the largest of the branches of the inferior maxillary nerve. It passes downward with the inferior dental artery, at first beneath the External pterygoid muscle, and then between the internal lateral ligament and the ramus of the mandible to the **dental foramen**. It then passes forward in the **dental canal** of the mandible, lying beneath the teeth, as far as the **mental foramen**, where it divides into two terminal branches, incisor and mental.

The **branches of the inferior dental** are the **mylohyoid**, **dental**, **incisor**, and **mental**.

The **mylohyoid** (*n. mylohyoideus*) is derived from the inferior dental just as that nerve is about to enter the **dental foramen**. It descends in a groove on the inner surface of the ramus of the mandible, in which it is retained by a process of fibrous membrane. It reaches the under surface of the Mylohyoid muscle, and supplies it and the anterior belly of the Digastric.

The **dental branches** supply the molar and bicuspid teeth. They correspond in number to the fangs of those teeth, each nerve entering the orifice at the point of the fang and supplying the pulp of the tooth.

The **incisor branch** is continued onward within the bone to the middle line, and supplies the canine and incisor teeth.

The dental branches and the incisor branch form a plexus (*plexus dentalis inferior*), and from this plexus come the branches to the teeth (*rami dentales inferiores*) and to the gums (*rami gingivales inferiores*).

The **mental branch** (*n. mentalis*) emerges from the bone at the **mental foramen**, and divides beneath the Depressor anguli oris muscle into two or three branches; one descends to supply the skin of the chin, and another (sometimes two) ascends to supply the skin and mucous membrane of the lower lip. These branches communicate freely with the facial nerve.

Two small ganglia are connected with the inferior maxillary nerve—the **otic** with the trunk of the nerve, and the **submaxillary** with its lingual branch.

The **Otic Ganglion** (*ganglion oticum*) (Fig. 739) is a small, oval-shaped, flattened ganglion of a reddish-gray color, situated immediately below the foramen ovale, on the inner surface of the inferior maxillary nerve, and surrounding the origin of the internal pterygoid nerve. It is in relation, *externally*, with the trunk of the inferior maxillary nerve, at the point where the motor root joins the sensor portion; *internally*, with the cartilaginous part of the Eustachian tube, and the origin of the Tensor palati muscle; *behind*, it lies in relation with the middle meningeal artery.

Branches of Communication.—This ganglion is connected with the internal pterygoid branch of the inferior maxillary nerve by two or three short, delicate filaments. From this nerve the ganglion may obtain a motor root, and possibly also a sensor root, as these filaments from the nerve to the Internal pterygoid perhaps contain sensor fibres. The otic ganglion communicates with the glossopharyngeal and facial nerves through the **small superficial petrosal nerve** (Figs. 741 and 744) continued from the tympanic plexus, and through this communication it probably receives its sensor root from the glossopharyngeal and its motor root from the facial; its communication with the sympathetic is effected by a filament

from the plexus surrounding the middle meningeal artery. The ganglion also communicates with the auriculotemporal nerve (*ramus anastomoticus cum n. auriculotemporalis*). This communicating filament is probably a branch from the glossopharyngeal which passes to the ganglion, and through it and the auriculotemporal nerve to the parotid gland. A slender filament, the **sphenoidal**, ascends from it to the Vidian nerve.

Branches of Distribution.—Its branches of distribution are a filament to the Tensor tympani (*n. tensoris tympani*) and one to the Tensor palati (*n. tensoris veli palatini*). The former passes backward on the outer side of the Eustachian tube; the latter *arises* from the ganglion, near the origin of the internal pterygoid nerve, and passes forward. The fibres of these nerves are, however, mainly derived from the nerve to the Internal pterygoid muscle.

The **Submaxillary Ganglion** (*ganglion submaxillare*) (Fig. 739) is of small size, fusiform in shape, and situated above the deep portion of the submaxillary gland, near the posterior border of the Mylohyoid muscle, being connected by filaments with the lower border of the lingual nerve.

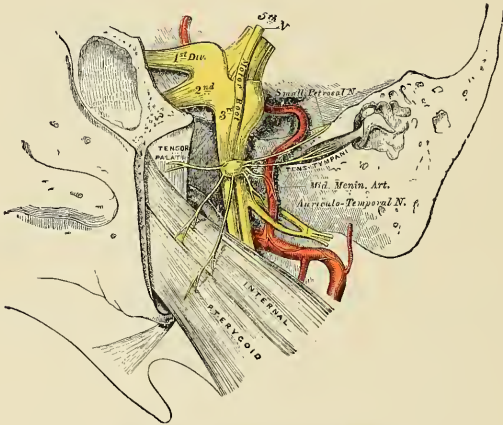


FIG. 741.—The otic ganglion and its branches

Branches of Communication.—This ganglion is suspended from the lingual nerve by two filaments (*rami communicantes cum n. linguali*), which join it separately at its fore and back part. It also receives a branch from the chorda tympani, and communicates with the sympathetic by filaments from the sympathetic plexus around the facial artery.

Branches of Distribution.—These are five or six in number; they *arise* from the lower part of the ganglion, and supply the mucous membrane of the mouth and the submaxillary or Wharton's duct, some being lost in the submaxillary gland (*rami submaxillares*). The branch of communication from the lingual nerve to the fore part of the ganglion is by some regarded as a branch of distribution, by which filaments of the chorda tympani pass from the ganglion to the lingual nerve, and by it are conveyed to the sublingual gland and the tongue.

Surface Marking.—It will be seen from the above description that the three terminal branches of the three divisions of the trigeminal nerve emerge from foramina in the bones of the skull and pass on to the face; the terminal branch of the first division emerging through the

supraorbital foramen; that of the second through the infraorbital foramen; and the third through the mental foramen. The supraorbital foramen is situated at the junction of the internal and middle third of the supraorbital arch. If a straight line is drawn from this point to the lower border of the mandible, so that it passes between the two bicuspid teeth of the mandible, it will pass over the infraorbital and mental foramina, the former being situated about one centimetre (two-fifths of an inch) below the margin of the orbit, and the latter varying in position according to the age of the individual. In the adult it is midway between the upper and lower borders of the mandible; in the child it is nearer the lower border; and in the edentulous jaw of old age it is close to the upper margin.

Applied Anatomy.—In *fracture of the base of the skull* the trigeminal nerve or one of its branches may be injured. It seems certain that occasionally, though seldom, the trigeminal nerve may be actually divided by such an injury. The trigeminal nerve may be affected in its entirety, or its sensor or motor root may be affected, or one of its primary main divisions. In injury to the sensor root there is anesthesia of the half of the face on the side of the lesion, with the exception of the skin over the parotid gland; insensibility of the conjunctiva, followed, if the eye is not temporarily protected with a watch glass, by destructive inflammation of the cornea,

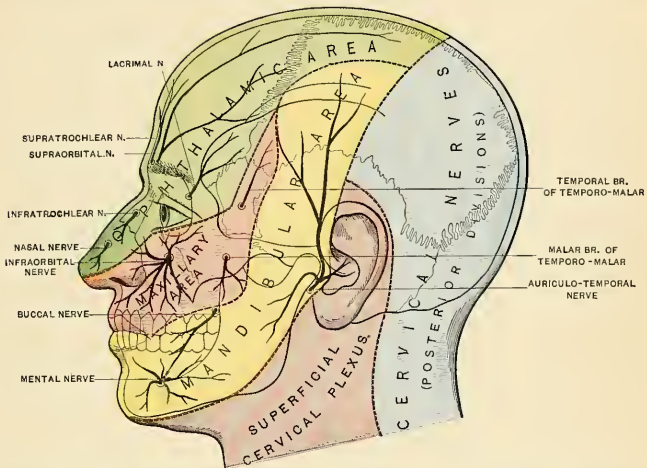


FIG. 742.—Sensor areas of the head, showing the general distribution of the three divisions of the fifth nerve. Gerrish's Anatomy. (Modified from Testut.)

partly, it is held, from loss of trophic influence, and partly it is certain, from the irritation produced by the presence of foreign bodies on it, which are not perceived by the patient, and therefore not expelled by the act of winking; dryness of the nose, loss to a considerable extent of the sense of taste, and diminished secretion of the lacrimal and salivary glands. In injury to the motor root there is impaired action of the mandible from paralysis of the muscles of mastication on the affected side.

The trigeminal nerve is often the seat of *neuralgia*, and each of the three divisions has been divided or a portion of the nerve excised for this affection. The *supraorbital nerve* may be exposed by making an incision an inch and a half in length along the supraorbital margin below the eyebrow, which is to be drawn upward, the centre of the incision corresponding to the supraorbital notch. The skin and Orbicularis palpebrarum having been divided, the nerve can be easily found emerging from the notch and lying in some loose cellular tissue. It should be drawn up by a blunt hook and divided, or, what is better, a portion of it should be removed.

The *infraorbital nerve* has been divided at its exit by an incision on the cheek; or the floor of the orbit has been exposed, the infraorbital canal opened up, and the anterior part of the nerve resected; or the whole nerve, together with Meckel's ganglion as far back as the foramen rotundum, has been removed. This latter operation, though undoubtedly a severe proceeding, appears to have been followed by better results than has nerve resection. The operation is performed as follows. The maxilla is first exposed by a T-shaped incision, one limb of the incision

passing along the lower margin of the orbit, the other from the centre of the first cut vertically down the cheek toward the angle of the mouth. The nerve is then found, is divided, and a piece of silk is tied to it as a guide. A small trephine (one-half inch) is then applied to the bone below, but including the infraorbital foramen, and the antrum opened.* The trephine is now applied to the posterior wall of the antrum, and the sphenomaxillary fossa exposed. The infraorbital canal is now opened up from below by fine cutting pliers or a chisel, and the nerve drawn down into the trephine hole, it being held on the stretch by means of the piece of silk; it is severed with fine curved scissors as near the foramen rotundum as possible, any branches coming off from the ganglion being also divided.¹

The *mental branch of the inferior dental nerve* may be divided at its exit from the foramen through an incision made through the mucous membrane where it is reflected from the alveolar process on to the lower lip; or a portion of the trunk of the *inferior dental nerve* may be resected through an incision on the cheek through the Masseter muscle, exposing the outer surface of the ramus of the mandible. A trephine is then applied over the position of the inferior dental foramen and the outer table removed, so as to expose the inferior dental canal. The nerve is dissected out of the portion of the canal exposed, and, having been divided after its exit from the mental foramen, it is by traction on the end exposed in the trephine hole, drawn out entire, and cut off as high up as possible.² The inferior dental nerve has also been divided through an incision within the mouth, the bony point guarding the inferior dental foramen forming the guide to the nerve. The *buccal nerve* may be divided by an incision through the mucous membrane of the mouth and the Buccinator muscle just in front of the anterior border of the ramus of the mandible (Stimson).

In inveterate neuralgia of one or two of the branches of the trigeminal nerve a peripheral operation may cure the case, but seldom does. It often gives relief, perhaps for months. In neuralgia of the second division or third division, or of the second division *and* third division, Abbe, of New York, opens the skull and divides the nerve or nerves by an intracranial operation, removes a piece of nerve so that the foramen of exit is empty, and covers the foramen with rubber tissue, to hinder regrowth of the nerve. Other operators, after removing a piece from each nerve, have plugged the foramina of the exit with dentists' cement or silver foil.

Rose's method of neurectomy is very valuable for neuralgia of the second division. It is a modification of the Braun-Lossen method. The infraorbital nerve is exposed, a ligature is tied about it, the roof of the infraorbital canal is chiselled open, and the nerve is freed as far back as possible. An incision is made from below the external angular process outward along the zygoma to in front of the lobule of the ear, downward to just above the angle of the mandible, and forward for two inches. The flap is raised and the zygoma is exposed. The roof of the zygoma is drilled at two points, and the zygomatic process of the temporal bone is drilled at two points. The bone is sawed in two places between the drill holes. The freed arch is lifted down and back, the tendon of the Temporal muscle is drawn backward, and the pterygomaxillary fossa is thus exposed. The internal maxillary artery is divided between two ligatures. The External pterygoid muscle is separated from the greater wing of the sphenoid and from the root of the external pterygoid process. The superior maxillary nerve is grasped and twisted off as near the ganglion as possible. The entire nerve is then drawn back from the infraorbital foramen and removed. The wound is then closed. If the third division is also haunted by neuralgia, it too should be removed a few weeks after the performance of Rose's operation.

If a peripheral operation fails, or if all the branches of the trigeminal are involved, the Gasserian ganglion must be removed, or the sensor root of the trigeminal must be divided, as suggested by Frazier and Spiller.

Removal of the Gasserian ganglion was suggested by J. Ewing Mears in 1884, and was first carried out by Rose in 1890. The method chiefly in vogue was devised by Hartley, and was first performed by him in 1891. An osteoplastic flap is made in front of the ear, the dura is exposed and lifted. Following Krause's advice, the third division is exposed and clamped. The second division is exposed and clamped. The nerves are loosened from their beds and then are rolled about the clamps. This twisting pulls out the ganglion intact along with the motor root, and also the sensor root from the pons. A difficulty in the Hartley operation is the danger of division of the middle meningeal artery. If this happens, the surgeon may be able to arrest bleeding and proceed with the operation. If the vessel is torn off at the foramen spinosum, it will be necessary to pack the wound and postpone any further operative manipulation for forty-eight hours. Dr. Harvey Cushing has modified Hartley's operation by trephining the wall of the temporal fossa very low down. He opens the skull *below* the arch of the meningeal vessels, and thus avoids the middle meningeal artery at the foramen spinosum, and also the sulcus arteriosus of the parietal bone. After the removal of the ganglion, Professor Keen, in order to prevent undue inflammation of the eye, sews the eyelids of the affected side together, leaving a space open at each angle, and covers the eye with a watch crystal. Boric acid solution

¹ Carnochan, American Journal of the Medical Sciences, 1858, p. 136.

² Mears, Transactions of the American Surgical Association, vol. ii, p. 469.

is flushed into the opening at the external angle at frequent intervals. The stitches are removed from the lid in from eight to ten days.

The *lingual* nerve is occasionally divided with the view of relieving the pain in cancerous disease of the tongue. This may be done in that part of its course where it lies below and behind the last molar tooth. If a line is drawn from the middle of the crown of the last molar tooth to the angle of the mandible, it will cross the nerve, which lies about half an inch behind the tooth, parallel to the bulging alveolar ridge on the inner side of the body of the bone. If the knife is entered three-quarters of an inch behind and below the last molar tooth and carried down to the bone, the nerve will be divided. Hilton divided it opposite the second molar tooth, where it is covered only by the mucous membrane, and Lucas pulls the tongue forward and over to the opposite side, when the nerve can be seen standing out as a firm cord under the mucous membrane by the side of the tongue and can be easily seized with a sharp hook and divided or a portion excised. This is a simple enough operation on the cadaver, but when the disease is extensive and has extended to the floor of the mouth, as is generally the case when division of the nerve is thought of, the operation is not practicable.

THE SIXTH OR ABDUCENT NERVE (N. ABDUCENS) (Fig. 738).

The **sixth or abducent nerve** supplies the External rectus muscle. Its *superficial origin* is by several filaments from the postpontile groove, between pons and pyramid. Its *deep origin* is from the upper part of the floor of the fourth ventricle, close to the median line, beneath the eminentia abducentis (Fig. 650). From the nucleus of the abducent nerve some fibres are supposed to pass through the medial longitudinal bundle to the oculomotor nucleus of the opposite side and into the oculomotor nerve, along which they are carried to the Internal rectus muscle. See, however, the description already given on page 901).

The nerve pierces the dura on the basilar surface of the sphenoid bone, runs through a notch immediately below the posterior clinoid process, and enters the cavernous sinus. It passes forward through the sinus, lying on the outer side of the internal carotid artery (Fig. 505). It enters the orbit through the sphenoidal fissure, and lies above the ophthalmic vein, from which it is separated by a lamina of dura (Fig. 743). It then passes between the two heads of the External rectus muscle, and is distributed to that muscle on its ocular surface.

Branches of Communication.

—It is joined by several filaments from the carotid and cavernous plexuses, and by one from the ophthalmic nerve.

Relations to One Another of the Oculomotor, Trochlear, Ophthalmic

Division of the Trigeminal, and Abducent Nerves as they Pass to the Orbit.

—The oculomotor, trochlear, the ophthalmic division of the trigeminal, and the abducent nerves, as they pass to the orbit, bear a certain relation to one another in the cavernous sinus, at the sphenoidal fissure, and in the cavity of the orbit, which will now be described.

In the **cavernous sinus** (Figs. 505 and 506) the oculomotor, trochlear, and ophthalmic division of the trigeminal are placed on the outer wall of the sinus, in their numerical order, both from above downward and from within outward. The abducent nerve lies at the outer side of the internal carotid artery. As these nerves pass forward to the sphenoidal fissure, the oculomotor and trigeminal nerves become divided into branches, and the abducent nerve approaches the rest so that their relative position becomes considerably changed.

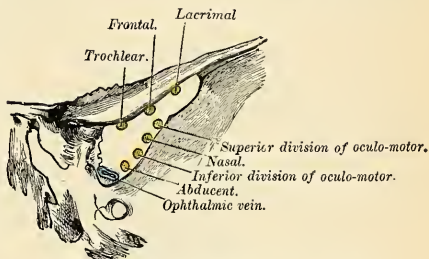


FIG. 743.—Relations of structures passing through the sphenoidal fissure

In the **sphenoidal fissure** (Fig. 743) the trochlear nerve and the frontal and lacrimal branches of the ophthalmic division of the trigeminal lie upon the same plane, the former being most internal, the latter external, and they enter the cavity of the orbit above the muscles. The remaining nerves enter the orbit between the two heads of the External rectus muscle. The superior division of the oculomotor nerve is the highest of these; beneath this lies the nasal branch of the ophthalmic nerve; then the inferior division of the oculomotor nerve; and the abducent nerve lowest of all.

In the **orbit** (Figs. 734 and 738) the trochlear nerve and the frontal and lacrimal divisions of the ophthalmic nerve lie on the same plane immediately beneath the periosteum, the trochlear nerve being internal and resting on the Superior oblique muscle, the frontal nerve resting on the Levator palpebrae muscle, and the lacrimal nerve on the External rectus muscle. Next in order comes the superior division of the oculomotor nerve, lying immediately beneath the Superior rectus muscle, and then the nasal branch of the ophthalmic nerve, crossing the optic nerve from the outer to the inner side of the orbit. Below these is found the optic nerve, surrounded in front by the ciliary nerves, and having the ciliary ganglion on its outer side, between it and the External rectus muscle. Below the optic nerve is the inferior division of the oculomotor nerve and the abducent nerve which lie on the outer side of the orbit.

Applied Anatomy.—It is often stated that the abducent nerve is more frequently involved in *fractures of the base of the skull* than any other of the cranial nerves. As a matter of fact, however, it is injured in only about 2 per cent. of cases of fracture of the skull (Putscher). Cases have been reported in which the nerve was actually severed. The nerve may be injured by traction, pressure of a blood clot, of a tumor, or of an arteriovenous aneurism. The result of paralysis of this nerve is *internal or convergent squint*. When injured so that its function is destroyed, there is, in addition to the paralysis of the External rectus muscle, often a certain amount of contraction of the pupil, because some of the sympathetic fibres to the radiating muscle of the iris pass along with this nerve.

THE SEVENTH OR FACIAL NERVE (N. FACIALIS) (Figs. 744, 745).

The **seventh or facial nerve** is the motor nerve of all the muscles of expression in the face, and of the Platysma and Buccinator; the muscles of the external ear, the posterior belly of the Digastric, and the Stylohyoid. The chorda tympani (or *nervus intermedius*) is referred to as the sensor portion of the facial.

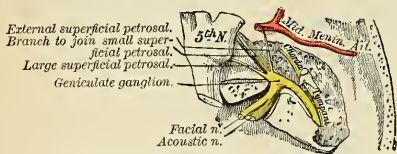


FIG. 744.—The course and connection of the facial nerve in the temporal bone.

Its *superficial origin* is from the upper end of the medulla oblongata, in the groove between the olive and restiform body. Its *deep origin* is from a nucleus situated in the floor of the fourth ventricle, beneath the superior fovea (Fig. 650). The facial nucleus is deeply placed in the reticular formation of the lower part of the pars dorsalis pontis, a little external and ventral to the nucleus of the abducent nerve. From this origin the fibres pursue a curved course in the substance of the pars dorsalis pontis. They first pass backward and inward, and then turn upward and forward, forming the *genu internum*, which with the nucleus abducentis produces an eminence, the *eminentia teres* or *abducentis*, on the floor of the fourth ventricle, and finally bend sharply downward and outward around the upper end of the nucleus of origin of the abducent nerve, to reach their superficial origin between the olive and restiform body. From the nucleus of the oculomotor

nerve some fibres arise which descend in the medial longitudinal bundle and join the facial just before it leaves the pars dorsalis pontis; these fibres are said to supply the anterior belly of the Occipitofrontalis, the Orbicularis palpebrarum, and the Corrugator supercilii, as these museles have been observed to escape paralysis in lesions of the nucleus of the facial nerve.

The **acoustic or auditory nerve** lies to the outer side of the facial nerve; and between the two is a small fasciculus, the **nervus intermedius** or **pars intermedia** of Wrisberg, which apparently *arises* from the medulla oblongata and joins the facial nerve in the internal auditory meatus. The central processes of the ganglion cells, known as the **nervus intermedius**, end in the upper end of the nucleus of the glossopharyngeal nerve. If it is to be classified as part of the facial then the **nervus intermedius** may be regarded as the **sensor root of the facial nerve**, analogous to the sensor root of the trigeminal, and its real nucleus of origin consists of the geniculate ganglion (see p. 882). It will be remembered that a portion of the **nervus intermedius** is efferent (excitoglandular), arising from the nucleus salivatorius (p. 882).

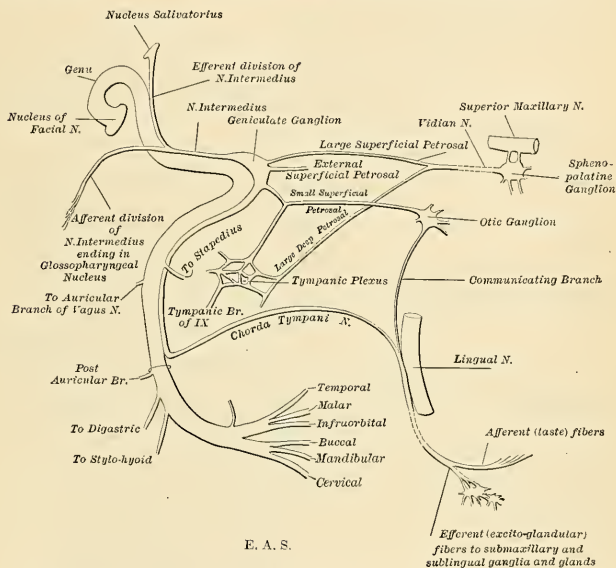


FIG. 745.—Plan of the facial and intermediate nerves and their communication with other nerves.

The facial nerve, firmer, rounder, and smaller than the auditory, passes forward and outward upon the middle peduncle of the cerebellum, and enters the **internal auditory meatus** with the auditory nerve and artery. Within the meatus the facial nerve lies in a groove along the upper and anterior part of the auditory nerve, and the *nervus intermedius* is placed between the two and joins the inner angle of the geniculate ganglion. Beyond the ganglion its fibres are generally regarded as forming the chorda tympani (see p. 997).

At the bottom of the meatus the facial nerve enters the **canalis facialis** or **aqueductus Fallopii** and follows the course of that canal through the petrous portion of the temporal bone, from its commencement at the internal meatus to its termination at the **stylomastoid foramen** (Figs. 50 and 744). It is at first directed outward between the cochlea and vestibule toward the inner wall of the tympanum; it

then bends suddenly backward and arches downward behind the tympanum to the stylomastoid foramen. At the point in the aqueduct of Fallopius where the nerve changes its direction (*geniculum n. facialis*), it presents a reddish, gangli-form swelling, the **geniculate ganglion** (*ganglion geniculi*) or *intumescencia gangli-formis* (Fig. 744). The geniculate ganglion receives a branch from the vestibular division of the auditory nerve. On emerging from the stylomastoid foramen the facial nerve runs forward in the substance of the parotid gland, crosses the external carotid artery, and divides behind the ramus of the mandible into two primary branches, **temporofacial** and **cervicofacial**, from which numerous offshoots are distributed over the side of the head, face, and upper part of the neck, supplying the superficial muscles in these regions. As the primary branches and their offshoots diverge from each other, they present somewhat the appearance of a bird's claw; hence the name of **pes anserinus** is given to the divisions of the facial nerve in and near the parotid gland.

Branches of Communication (Fig. 745).—The communications of the facial nerve may be thus arranged:

In the internal auditory meatus	{	With the acoustic nerve. The nervus intermedius, which is between the facial and acoustic, is supposed to give branches to both. The branch given to the acoustic accompanies it for a certain distance, and then departs from it to join the geniculate ganglion.
From the geniculate ganglion	{	With the acoustic as explained above. With the sphenopalatine ganglion by the large superficial petrosal nerve. With the otic ganglion by the small superficial petrosal nerve. With the sympathetic, on the middle meningeal artery by the external superficial petrosal nerve.
In the canalis facialis or Fallopiian } aqueduct	{	With the auricular branch of the vagus.
At its exit from the stylomastoid } foramen	{	With the glossopharyngeal. With the vagus. With the great auricular. With the auriculotemporal.
Behind the ear	{	With the small occipital.
On the face	{	With three divisions of the trigeminal.
In the neck	{	With the superficial cervical.

In the internal auditory meatus some minute filaments pass between the facial and acoustic nerves.

The **large superficial petrosal nerve** *arises* from the geniculate ganglion and consists chiefly of sensor branches which are distributed to the mucous membrane of the soft palate. It probably also contains a few motor fibres which form the motor root of the sphenopalatine (Meckel's) ganglion. It passes forward through the hiatus canalis facialis (Fallopian) and runs in a groove on the anterior surface of the petrous portion of the temporal bone beneath the Gasserian ganglion to the foramen lacerum medium. It receives a twig from the tympanic plexus, and in the foramen is joined by the great deep petrosal, from the sympathetic plexus on the internal carotid artery, to form the Vidian nerve. This nerve passes through the Vidian canal and ends in the sphenopalatine (Meckel's) ganglion. The geniculate ganglion is connected with the otic ganglion by a branch which

joins the small superficial petrosal nerve; and also with the sympathetic filaments accompanying the middle meningeal artery, by the external petrosal nerve (Bidder). From the gangliform enlargement, according to Arnold, a twig is sent back to the auditory nerve. Just before the facial nerve emerges from the stylomastoid foramen it generally receives a twig of communication from the auricular branch of the vagus.

After its exit from the stylomastoid foramen, it sends a twig to the glosso-pharyngeal, another to the vagus nerve, and communicates with the great auricular branch of the cervical plexus, with the auriculotemporal branch of the inferior maxillary nerve in the parotid gland, with the small occipital nerve behind the ear, on the face with the terminal branches of the three divisions of the fifth, and in the neck with the transverse cervical.

Branches of Distribution (Fig. 745).—The branches of distribution of the facial nerves may be thus arranged:

Within the canalis facialis or aquaeductus Fallopii	{ Tympanic, to the Stapedius muscle. Chorda tympani.
At its exit from the stylomastoid foramen	{ Posterior Auricular. Digastric. Stylohyoid.
On the face	{ Temporofacial . . { Temporal. Malar. Infraorbital. Buccal. Mandibular. Cervical. Cervicofacial . .

The **Tympanic Branch** (*n. stapedius*) (Fig. 745) *arises* from the nerve opposite the pyramid; it passes through a small canal in the pyramid and supplies the Stapedius muscle.

The **Chorda Tympani** (Figs. 744 and 745) is apparently given off from the facial as it passes vertically downward at the back of the tympanum, about 5 mm. ($\frac{1}{5}$ inch) before its exit from the stylomastoid foramen. It passes from below upward and forward in a distinct canal, and enters the cavity of the tympanum through an aperture (*iter chordae posterius*) on its posterior wall between the opening of the mastoid cells and the attachment of the membrana tympani, and becomes invested with mucous membrane. It traverses the cavity of the tympanum, between the fibrous and mucous layers of the membrana tympani, crosses over the handle of the malleus, *emerges* from the cavity through a foramen at the inner end of the Glaserian fissure, which is called the **canal of Huguier** (*iter chordae anterior*). It then descends between the two Pterygoid muscles on the inner aspect of the spine of the sphenoid, which it sometimes grooves, and joins the lingual nerve at an acute angle. A portion of the nerve (excitoglandular division) passes to the submaxillary ganglion; the rest is continued onward through the muscular substance of the tongue to the mucous membrane covering its anterior two-thirds. These constitute the nerves of taste for this portion of the tongue. A few of its fibres probably pass through the submaxillary ganglion to the sublingual gland. Before joining the lingual nerve it receives a small communicating branch from the otic ganglion. As already stated, the chorda tympani nerve is regarded as the peripheral portion of the nervus intermedius (see p. 989).

The **Posterior Auricular Nerve** (*n. auricularis posterior*) (Figs. 745 and 746) *arises* close to the stylomastoid foramen, and passes upward *in front* of the mastoid process and between the mastoid process and the external ear, where it is joined by a filament from the auricular branch of the vagus, and communicates with the

mastoid branch of the great auricular and with the small occipital. As it ascends between the external auditory meatus and the mastoid process it divides into two branches, the auricular and the occipital branches. The **auricular branch** supplies the Retrahens aurem and the small muscles on the cranial surface of the pinna. The **occipital branch** (*ramus occipitalis*), the larger, passes backward along the superior curved line of the occipital bone, and supplies the occipital portion of the Occipitofrontalis.

The **Digastric Branch of the Facial Nerve** (*ramus digastricus*) arises close to the stylo mastoid foramen; it divides into several filaments, which supply the posterior belly of the Digastric; one of these perforates that muscle to join the glossopharyngeal nerve.

The **Stylohyoid Branch** (*ramus stylohyoideus*) frequently arises by a common trunk with the digastric; it is long and slender, and passes inward to enter the Stylohyoid muscle about its middle.

The **Temporofacial Division** (Figs. 745 and 746), the larger of the two terminal branches of the facial, passes upward and forward through the parotid gland, crosses the external carotid artery and temporomaxillary vein, and passes over the neck of the condyle of the mandible, being connected in this situation with the auriculotemporal branch of the inferior maxillary nerve. It breaks up into branches which are distributed over the temple and upper part of the face; these are divided into three sets—**temporal**, **malar**, and **infraorbital**.

The **temporal branches** (*rami temporales*) cross the zygoma to the temporal region, supplying the Attrahens and Attollens aurem muscles, and join with the temporal branch of the temporomalar division of the superior maxillary nerve, and with the auriculotemporal branch of the inferior maxillary nerve. The more anterior branches supply the frontal portion of the Occipitofrontalis, the Orbicularis palpebrarum, and Corrugator supercilii muscles, and join with the supraorbital and lacrimal branches of the ophthalmic.

The **malar branches** (*rami zygomatici*) pass across the malar bone to the outer angle of the orbit, where they supply the Orbicularis palpebrarum muscle and join with filaments from the lacrimal nerve and the malar branch (*subcutaneus malae*) of the superior maxillary nerve.

The **infraorbital branches** of larger size than the rest, pass horizontally forward to be distributed between the lower margin of the orbit and the mouth. The **superficial branches** run beneath the skin and above the superficial muscles of the face, which they supply; some branches are distributed to the Pyramidalis nasi, joining at the inner angle of the orbit with the infratrochlear and nasal branches of the ophthalmic. The **deep branches** pass beneath the Zygomatici and the Levator labii superioris, supplying the Levator anguli oris, the Levator labii superioris alaeque nasi, and the small muscles of the nose, and form a plexus, **infraorbital plexus**, by joining with the branches of the infraorbital branch of the superior maxillary nerve and the buccal branches of the cervicofacial.

The **Cervicofacial Division** of the facial nerve passes obliquely downward and forward through the parotid gland, crossing the external carotid artery. In this situation it is joined by branches from the great auricular nerve. Opposite the angle of the mandible it divides into branches which are distributed on the lower half of the face and upper part of the neck. These may be divided into three sets—**buccal**, **mandibular**, and **cervical**.

The **buccal branches** (*rami buccales*) cross the Masseter muscle. They supply the Buccinator and Orbicularis oris, and join with the infraorbital branches of the temporofacial division of the nerve, and with filaments of the buccal branch of the inferior maxillary nerve.

The **mandibular branch** (*ramus marginalis mandibulae*) passes forward beneath

the Platysma and Depressor anguli oris, supplying the muscles of the lower lip and chin, and communicating with the mental branch of the inferior dental nerve.

The **cervical branch** (*ramus colli*) runs forward beneath the Platysma, and forms a series of arches across the side of the neck over the suprahyoid region. A branch descends vertically to join with the superficial cervical nerve from the cervical plexus; others supply the Platysma.

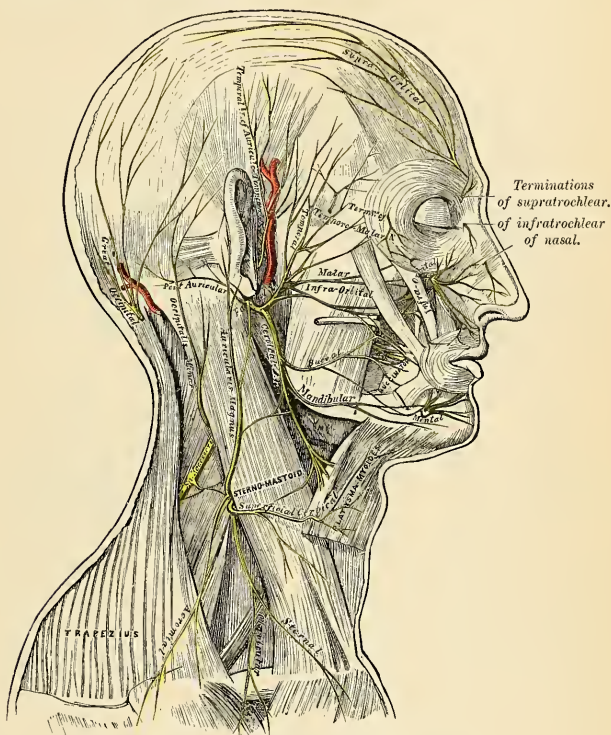


FIG. 746.—The nerves of the scalp, face, and side of the neck.

Applied Anatomy.—The facial nerve is more frequently paralyzed than any of the other of the cranial nerves. The paralysis (*facial palsy*) may depend either upon (1) central causes—*i. e.*, blood clots or intracranial tumors pressing on the nerve before its entrance into the internal auditory meatus. It is also one of the nerves involved in *bulbar paralysis*. Or (2) it may be paralyzed in its passage through the petrous bone by damage due to *middle-ear disease* or by *fractures of the base of the skull*. Or (3) it may be affected at or after its exit from the stylomastoid foramen. This is commonly known as *Bell's paralysis*. It may be due to exposure to cold or to injury of the nerve, either from accidental wounds of the face or during some surgical operation, as removal of parotid tumors, opening of abscesses, or operations on the mandible.

When the cause is central, the abducent nerve is usually paralyzed as well, and there is also hemiplegia on the opposite side. In these cases the electric reactions are the same as in health; whereas, when the paralysis is due to a lesion in the course of the nerve, the reactions of degeneration develop. When the nerve is paralyzed in the petrous bone, in addition to the paralysis of the muscles of expression, there is loss of taste in the anterior part of the tongue, and the patient is

unable to recognize the difference between bitters and sweets, acids and salines, from involvement of the chorda tympani. The mouth is dry, because the salivary glands are not secreting; the sense of hearing is affected from paralysis of the Stapedius, but there is no hemiplegia. When the cause of the paralysis is from fracture of the base of the skull, the acoustic nerve and the petrosal nerves, which are connected with the intumescencia ganglioformis, are also involved. When the injury to the nerve is after its exit from the stylomastoid foramen, all the muscles of expression except the Levator palpebrae, together with the posterior belly of the Digastric and Stylohyoid, are paralyzed. There is smoothness of the forehead, and the patient is unable to frown; the eyelids cannot be closed, and the lower lid droops, so that the punctum is no longer in contact with the globe, and the tears run down the cheek; there is smoothness of the cheek and loss of the nasolabial furrow; the nostril of the paralyzed side cannot be dilated; the mouth is drawn to the sound side, and there is inability to whistle; food collects between the cheek and gum from paralysis of the Buccinator.

The facial nerve is at fault in cases of so-called *histrionic spasm*, which consists in an almost constant and uncontrollable twitching of the muscles of the face. This twitching is sometimes so severe as to cause great discomfort and annoyance to the patient and to interfere with sleep, and for its relief the facial nerve has been *stretched*. The operation is performed by making an incision behind the ear from the root of the mastoid process to the angle of the mandible. The parotid is turned forward, and the dissection carried along the anterior border of the Sternomastoid muscle and mastoid process until the upper border of the posterior belly of the Digastric is found. The nerve is parallel to this on about a level with the middle of the mastoid process. When found, the nerve may be stretched by passing a blunt hook beneath it and pulling it forward and outward. Too great force must not be used, for fear of permanent injury to the nerve. In facial paralysis of extracerebral origin it may be advisable to expose the nerve, cut it across, and anastomose the distal end of the paralyzed nerve to the accessory nerve, or, better, to the hypoglossal nerve (facioaccessory anastomosis or faciohypoglossal anastomosis). The idea was first proposed by Ballance, and has been put in practice by Ballance and Stewart, Keen, Cushing, Paure, Kennedy, and others.

THE EIGHTH OR ACOUSTIC NERVE (N. ACUSTICUS) (Fig. 747).

The **eighth or acoustic or auditory nerve** comprises two distinct sets of fibres which, although both are devoted to the transmission of afferent impulses, differ in their peripheral distribution and in their central connections. The two divisions appear blended in the interval between the medulla oblongata and the internal auditory meatus, running obliquely laterofrontad in company with the facial nerve and internal auditory artery. At the internal auditory meatus the two divisions of the nerve are separable, the **vestibular division** above, the **cochlear** below.

The **cochlear nerve** (*radix cochlearis*) is the true nerve of hearing, lacking general sensibility, however, and therefore a nerve of special sense. The fibres of this division arise from the cells of the **spiral ganglion** of the cochlea as axones of bipolar cells whose dendrites or peripheral processes terminate about the (auditory) hair cells of the organ of Corti (p. 1143). The central connections of the cochlear division are described on page 881.

The **vestibular nerve** (*radix vestibularis*) conducts impulses of equilibratory sense from the semicircular canals, utricle, and saccule to the vestibular nuclei. The ganglion of origin of this nerve differs from ordinary sensor ganglia in that its cells are of bipolar structure, having retained this embryonic characteristic of the ganglion cells throughout life. The central processes of the cells of the **vestibular ganglion** (or **ganglion of Scarpa**) enter the medulla oblongata with the trunk of the cochlear nerve in the postpontile groove, laterad of the facial nerve, to establish central connections already described on page 881. The peripheral processes constitute the two main branches of the nerve—viz., (a) the **utrículo-ampullar** and (b) the **sacculo-ampullar**.

The upper or **utrículo-ampullar branch** divides into:

(a) The **utricular branch**, passing through the superior macula cribrosa of the vestibule to end in the macula acustica of the utricle.

(b) The **superior ampullar branch**, accompanying the utricular branch, to end in the crista acustica of the ampulla of the superior semicircular canal.

(c) The **lateral ampullar**, to the ampulla of the lateral semicircular canal.

The lower or **sacculoampullar branch** is somewhat longer and divides into:

(a) The **posterior ampullar**, passing through the foramen singulare and the inferior macula cribrosa to end in the ampulla of the posterior semicircular canal.

(b) The **saccular branch**, passing through the middle macula cribrosa to end in the macula acustica of the sacculus.

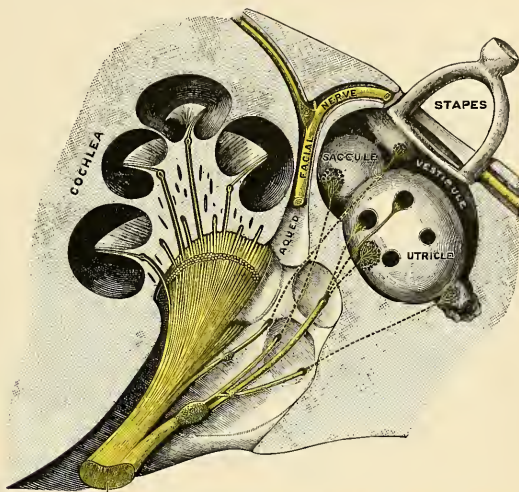


FIG. 747.—Distribution of the acoustic nerve. (Semidiagrammatic.) (Testut.)

Applied Anatomy.—The acoustic nerve is frequently injured, together with the facial nerve, in fractures of the middle fossa of the skull implicating the internal auditory meatus. The nerve may be either torn across, producing permanent deafness, it may be bruised, or it may be pressed upon by extravasated blood or inflammatory exudation, when the deafness will in all probability be temporary. The nerve may also be injured by violent blows on the head without fracture, and deafness may follow loud explosions of dynamite, etc., probably from some lesion of this nerve, which is more liable to be injured than the other cranial nerves on account of its structure. The test that the nerve is destroyed and that the deafness is not due to some lesion of the auditory apparatus is obtained by placing a vibrating tuning-fork on the head. The vibrations will be heard in cases where the auditory apparatus is at fault, but not in cases of destruction of the auditory nerve.

Tinnitus aurium is commonly present in cases of ear disease. The sounds are variable in intensity and nature—buzzing, hissing, whistling, rushing, bell-ringing, and so forth. In the insane, tinnitus is associated with delusions and hallucinations of hearing, and may be due to nothing more than impacted cerumen in the meatus. Menière's disease is discussed in the Applied Anatomy of the Labyrinth.

THE NINTH OR GLOSSOPHARYNGEAL NERVE (N. GLOSSOPHARYNGEUS) (Figs. 748, 749).

The **ninth or glossopharyngeal nerve** is distributed, as its name implies, to the tongue and pharynx, being the nerve of ordinary sensation to the mucous membrane of the pharynx, fauces, and tonsil; and the nerve of taste to all parts of the tongue to which it is distributed.

Its (apparent) *superficial origin* is by three or four filaments, closely connected, from the upper part of the medulla oblongata, in the dorsolateral groove (Fig. 748).

The central connections are described on page 880. The small motor component *arises* from cells in the nucleus ambiguus. The real origin of the sensor fibres of the glossopharyngeal must be looked for in the jugular and petrosal ganglia which are developed from the neural crest.

From its superficial origin it passes outward across the flocculus, and leaves the skull at the central part of the jugular foramen, in a separate sheath of the dura external to and in front of the vagus and spinal accessory nerves (Fig. 749).

In its passage through the jugular foramen it grooves the lower border of the petrous portion of the temporal bone, and at its exit from the skull passes forward between the jugular vein and internal carotid artery, and descends ventrad of the latter vessel, and beneath the styloid process of the temporal bone and the muscles connected with it, to the lower border of the Stylopharyngeus muscle. The nerve now curves inward, forming an arch on the side of the neck, and lying upon the Stylopharyngeus muscle and the Middle constrictor of the pharynx. It then passes beneath the Hyoglossus muscle, and is finally distributed to the mucous membrane of the fauces and base of the tongue, and the mucous glands of the mouth and tonsil.

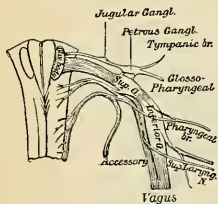


FIG. 748.—Origin, ganglia, and communication of the ninth, tenth, and eleventh cranial nerves.

In passing through the jugular foramen the nerve presents, in succession, two gangliform enlargements. The superior and smaller is called the **jugular ganglion**; the inferior and larger, the **petrosal ganglion** or the **ganglion of Andersch**.

The **superior or jugular ganglion** (*ganglion superius*) is situated in the upper part of the groove in which the nerve is lodged during its passage through the jugular foramen. It is of very small size, and involves only part of the trunk of the nerve. It is usually regarded as a detached portion from the lower ganglion.

The **inferior or petrosal ganglion** (*ganglion inferius*) is situated in a depression in the lower border of the petrous portion of the temporal bone; it is larger than the superior ganglion and involves the whole of the fibres of the nerve. From this ganglion *arise* those filaments which connect the glossopharyngeal with the vagus and sympathetic nerves.

Branches of Communication.—The branches of communication are with the vagus, sympathetic, and facial.

The branches to the vagus are two filaments, arising from the petrosal ganglion, one of which passes to the auricular branch of the vagus, and one to the upper ganglion of the vagus.

The petrosal ganglion is connected by a filament with the superior cervical ganglion.

The branch of communication with the facial perforates the posterior belly of the Digastric muscle. It *arises* from the trunk of the nerve below the petrosal ganglion, and joins the facial just after its exit from the stylomastoid foramen.

Branches of Distribution.—The branches of distribution are the tympanic, carotid, pharyngeal, muscular, tonsillar, and lingual.

The **Tympanic Branch** or **Jacobson's Nerve** (*n. tympanicus*) *arises* from the petrosal ganglion, and enters a small bony canal (*canaliculus tympanicus*) in the lower surface of the petrous portion of the temporal bone, the lower opening of which is situated on the bony ridge which separates the carotid canal from the jugular fossa. It ascends to the tympanum, enters that cavity by an aperture in its floor close to the inner wall, and divides into branches which are contained in grooves upon the surface of the promontory. These branches form a **tympanic**

plexus (*plexus tympanicus*). This plexus gives off (1) the small superficial petrosal nerve (Fig. 745); (2) a branch to join the great superficial petrosal nerve; and (3) branches to the tympanic cavity, all of which will be described in connection with the anatomy of the ear.

The **Carotid Branches** (*n. caroticotympanicus superior* and *n. caroticotympanicus inferior*) descend along the trunk of the internal carotid artery as far as its commencement, communicating with the pharyngeal branch of the vagus and with branches of the sympathetic.

The **Pharyngeal Branches** (*rami pharyngei*) are three or four filaments which unite opposite the Middle constrictor of the pharynx with the pharyngeal branches of the vagus and sympathetic nerves to form the **pharyngeal plexus**, branches from which perforate the muscular coat of the pharynx to supply the muscles and mucous membrane.

The **Muscular Branch** (*ramus stylopharyngeus*) is distributed to the Stylopharyngeus muscle.

The **Tonsillar Branches** (*rami tonsillares*) supply the tonsil, forming a plexus (*circulus tonsillaris*) around this body, from which branches are distributed to the soft palate and fauces, where they communicate with the palatine nerves.

The **Lingual Branches** (*rami linguales*) are two in number; one supplies the circumvallate papillæ and the mucous membrane covering the surface of the base of the tongue; the other perforates its substance, and supplies the mucous membrane and follicular glands of the posterior one-third of the tongue and communicates with the lingual nerve.

The Gustatory Path.—The impressions of taste reach the glossopharyngeal nucleus in the medulla oblongata in two ways. From the posterior one-third of the tongue and from the palate they reach the nucleus by the glossopharyngeal nerve. From the anterior two-thirds of the tongue impulses of taste are conveyed by the chorda tympani or portion of the nervus intermedius. From the glossopharyngeal nucleus gustatory impressions pass by way of the medial fillet to the thalamus of the opposite side, and from the thalamus through ventral thalamo-cortical radiation to the gyrus hippocampi, where the cortical gustatory centre is situated.

Applied Anatomy.—Injury may produce hemorrhage about the roots of the nerve. Bergmann reported such a case. The patient died from edema of the glottis after presenting evidences of disorder of speech and difficulty in swallowing. Disease of the glossopharyngeal nerve alone cannot usually be diagnosed.

THE TENTH, VAGUS, OR PNEUMOGASTRIC NERVE (N. VAGUS)

(Figs. 748, 749).

The **tenth, vagus, or pneumogastric nerve** has a more extensive distribution than any of the other cranial nerves, passing through the neck and thorax to the upper part of the abdomen. It is composed of both motor and sensor fibres. It supplies the organs of voice and respiration with motor and sensor fibres, and the pharynx, œsophagus, stomach, and heart with motor fibres. Its *superficial origin* (Fig. 748) is by eight or ten filaments from the groove between the olive and the restiform body below the glossopharyngeal; its central connections are described on page 880.

The real origin of the sensor fibres of the vagus is to be found in the cells of the ganglia on the nerve—viz., the ganglion of the root and the ganglion of the trunk. The filaments become united and form a flat cord, which passes outward beneath the flocculus to the jugular foramen, through which it emerges from the cranium (Fig. 749). In passing through this opening the vagus accompanies the spinal accessory nerve, being contained in the same sheath of dura with it, a

membranous septum separating them from the glossopharyngeal, which lies in front (Fig. 749). The nerve in this situation presents a well-marked ganglionic

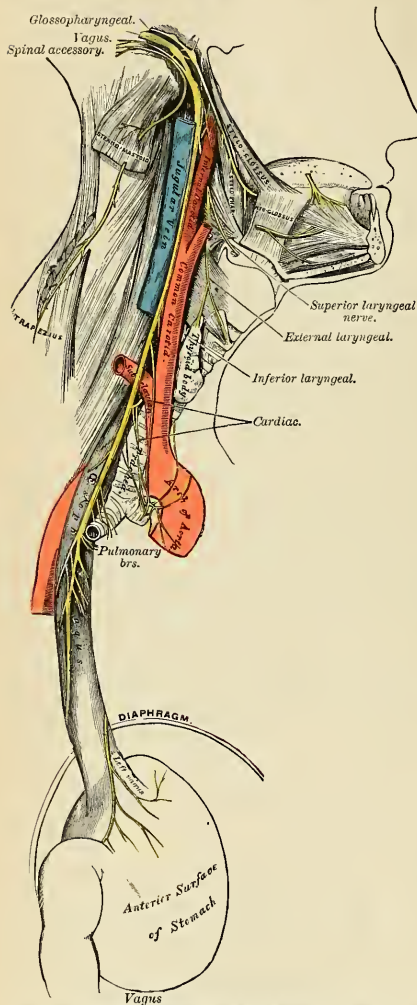


FIG. 749.—Course and distribution of the glossopharyngeal, vagus, and spinal accessory nerves.

enlargement, which is called the **superior ganglion**, or **jugular ganglion**; to it the vagal accessory part of the spinal accessory nerve is connected by one or two filaments. After its exit from the jugular foramen the nerve is joined by the accessory portion of the spinal accessory nerve and enlarges into a second gangliform swelling, called the **inferior ganglion** or the **ganglion of the trunk of the nerve**, through which the fibres of the spinal accessory nerve pass unchanged, being principally distributed to the pharyngeal and superior laryngeal branches of the vagus; but some of the filaments from it are continued into the trunk of the vagus below the ganglion to be distributed with the recurrent laryngeal nerve, and probably also with the cardiac nerves. The vagus nerve passes vertically down the neck within the sheath of the carotid vessels lying between the internal carotid artery and the internal jugular vein as far as the thyroid cartilage, and then between the same vein and the common carotid to the root of the neck (Fig. 749). From here the course of the nerve differs on the two sides of the body.

On the *right side* (Fig. 749) the nerve passes across the subclavian artery between it and the right innominate vein, and descends by the side of the trachea to the back part of the root of the right lung, where it spreads out in a plexiform network, the **posterior pulmonary plexus** (*plexus pulmonalis posterior*), from the lower part

of which two cords descend upon the œsophagus, on which tube they divide, forming, with branches from the opposite nerve, the **œsophageal plexus** (*plexus gulæ*); below, these branches are collected into a single cord, which runs along the back part of the œsophagus, enters the abdomen, and is distributed to the

posterior surface of the stomach, joining the left side of the solar plexus, and sending filaments to the splenic plexus and a considerable branch to the cœliac plexus.

On the *left side* the vagus nerve enters the thorax between the left carotid and subclavian arteries, behind the left innominate vein. It crosses the arch of the aorta and descends behind the root of the left lung, forming the **posterior pulmonary plexus** (*plexus pulmonalis posterior*), and along the anterior surface of the œsophagus, where it unites with the nerve of the right side in forming the **œsophageal plexus**. It passes to the stomach, distributing branches over the anterior surface of that viscus, some extending over the fundus, and others along the lesser curvature. Filaments from these branches enter the gastrohepatic omentum and join the hepatic plexus.

The **ganglion of the root** or the **jugular ganglion** (*ganglion jugulare*) is of a grayish color, circular in form, about 4 mm. or $\frac{1}{8}$ inch in diameter.

Branches of Communication.—To this ganglion the accessory portion of the spinal accessory nerve is connected by several delicate filaments; it also communicates by a twig with the petrous ganglion of the glossopharyngeal, with the facial nerve by means of its auricular branch, and with the sympathetic by means of an ascending filament from the superior cervical ganglion.

The **ganglion of the trunk** or the **inferior ganglion** (*ganglion nodosum*) is a plexiform cord, cylindrical in form, of a reddish color, and about an inch (2 cm.) in length; it involves the whole of the fibres of the nerve, and passing through it is the vagal accessory portion of the spinal accessory nerve, which blends with the vagus below the ganglion, to be then continued principally into its pharyngeal and superior laryngeal branches.

Branches of Communication.—This ganglion is connected with the hypoglossal, the superior cervical ganglion of the sympathetic, and the loop between the first and second cervical nerves.

Branches of Distribution.—The *branches of the vagus* are:

In the jugular fossa . . .	{ Meningeal or dural. Auricular.
In the neck	{ Pharyngeal. Superior laryngeal. Recurrent laryngeal. Cervical cardiac.
In the thorax	{ Thoracic cardiac. Anterior or ventral pulmonary. Posterior or dorsal pulmonary. Œsophageal.
In the abdomen	Gastric.

The **Meningeal or Dural Branch** (*ramus meningeus*) is a recurrent filament given off from the ganglion of the root on the jugular foramen. It passes backward, and is distributed to the dura lining the posterior fossa of the base of the skull.

The **Auricular Branch** or **Arnold's Nerve** (*ramus auricularis*) (Fig. 750) arises from the ganglion of the root, and is joined soon after its origin by a filament from the petrous ganglion of the glossopharyngeal; it passes outward behind the jugular vein, and enters a small canal on the outer wall of the jugular fossa. Traversing the substance of the temporal bone, it crosses the facial canal or aqueductus Fallopii about 4 mm. ($\frac{1}{8}$ inch) above its termination at the stylo-mastoid foramen; here it gives off an ascending branch, which joins the facial. The continuation of the nerve reaches the surface by passing through the auricular fissure between the mastoid process and the external auditory meatus, and divides

into two branches, one of which communicates with the posterior auricular nerve, while the other supplies the integument at the back part of the pinna and the posterior part of the external auditory meatus.

The **Pharyngeal Branch** (*ramus pharyngeus*), the principal motor nerve of the pharynx, arises from the upper part of the ganglion of the trunk of the vagus. It consists principally of filaments from the vagal accessory portion of the spinal accessory nerve; it passes across the internal carotid artery to the upper border of the Middle constrictor of the pharynx, where it divides into numerous filaments which join with those from the glossopharyngeal the superior laryngeal (its external branch), and sympathetic, to form the **pharyngeal plexus** (*plexus pharyngeus*), from which branches are distributed to the muscles and mucous membrane of the pharynx and the muscles of the soft palate, except the Tensor palati. From the pharyngeal plexus a minute filament is given off, which descends and joins the hypoglossal nerve as it winds around the occipital artery.

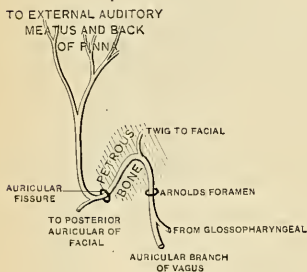


FIG. 750.—Plan of Arnold's nerve. (W. Keiller.)

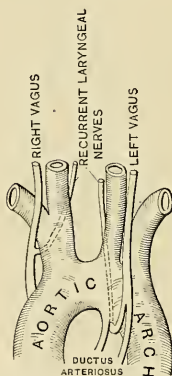


FIG. 751.—Relations of vagus and recurrent laryngeal nerves to the great vessels; (W. Keiller.)

The **Superior Laryngeal Nerve** (*n. laryngeus superior*) (Figs. 748 and 749) is larger than the preceding, and arises from the middle of the ganglion of the trunk of the vagus. In its course it receives a branch from the superior cervical ganglion of the sympathetic. It descends by the side of the pharynx behind the internal carotid artery, where it divides into two branches, the external and internal laryngeal.

The **external laryngeal branch** (*ramus externus*) (Fig. 749) the smaller, descends by the side of the larynx, beneath the Sternothyroid, to supply the Cricothyroid muscle. It gives branches to the pharyngeal plexus and the Inferior constrictor, and communicates with the superior cardiac nerve, behind the common carotid.

The **internal laryngeal branch** (*ramus internus*) descends to the opening in the thyrohyoid membrane, through which it passes with the superior laryngeal artery, and is distributed to the mucous membrane of the larynx. A small branch communicates with the recurrent laryngeal nerve. The branches to the mucous membrane are distributed, some in front to the epiglottis, the base of the tongue, and the epiglottidean glands; while others pass backward, in the arytenoepiglottidean fold, to supply the mucous membrane surrounding the superior orifice of the larynx, as well as the membrane which lines the cavity of the larynx as low down as the vocal cord. The filament which joins with the recurrent laryn-

geal descends beneath the mucous membrane on the inner surface of the thyroid cartilage, where the two nerves become united.

The **Inferior or Recurrent Laryngeal Branch of the Vagus** (*n. recurrens*) Figs. 749 and 751), so called from its reflected course, is the motor nerve of the larynx. It *arises*, on the *right side*, in front of the subclavian artery; winds from before backward around that vessel, and ascends obliquely to the side of the trachea behind the common carotid artery, and either in front of or behind the inferior thyroid artery. On the *left side* it *arises* in front of the arch of the aorta, and winds from before backward around the aorta at the point where the impervious ductus arteriosus is attached, and then ascends to the side of the trachea. The nerve on each side ascends in the groove between the trachea and œsophagus, and, passing under the lower border of the Inferior constrictor muscle, enters the larynx behind the articulation of the inferior cornu of the thyroid cartilage with the cricoid, being distributed to all the muscles of the larynx except the Cricothyroid. It communicates with the superior laryngeal nerve and gives off a few filaments to the mucous membrane of the lower part of the larynx.

The recurrent laryngeal, as it winds around the subclavian artery and aorta, gives off several cardiac filaments, which unite with the cardiac branches from the vagus and sympathetic. As it ascends in the neck it gives off œsophageal branches, more numerous on the left than on the right side, which supply the mucous membrane and muscular coat of the œsophagus; tracheal branches to the mucous membrane and muscular fibres of the trachea; and some pharyngeal filaments to the Inferior constrictor of the pharynx.

The **Cervical Cardiac Branches** (*rami cardiaci superiores*), two or three in number, *arise* from the vagus, at the upper and lower parts of the neck.

The **superior branches** are small, and communicate with the cardiac branches of the sympathetic. They can be traced to the great or deep cardiac plexus.

The **inferior branches**, one on each side, *arise* at the lower part of the neck, just above the first rib. That from the right vagus passes ventrad or by the side of the innominate artery, and communicates with one of the cardiac nerves proceeding to the great or deep cardiac plexus; that from the left runs across the left side of the arch of the aorta and joins the superficial cardiac plexus.

The **Thoracic Cardiac Branches** (*rami cardiaci inferiores*), on the right side, *arise* from the trunk of the vagus as it lies by the side of the trachea, and from its recurrent laryngeal branch, but on the left side from the recurrent nerve only; passing inward, they terminate in the deep cardiac plexus.

The **Anterior or Ventral Pulmonary Branches**, two or three in number, and of small size, are distributed on the anterior aspect of the root of the lungs. They join with filaments from the sympathetic, and form the **anterior pulmonary plexus** (*plexus pulmonalis anterior*).

The **Posterior or Dorsal Pulmonary Branches**, more numerous and larger than the anterior, are distributed on the posterior aspect of the root of the lung; they are joined by filaments from the third and fourth (sometimes also from the first and second) thoracic ganglia of the sympathetic, and form the **posterior pulmonary plexus** (*plexus pulmonalis posterior*). Branches from both plexuses accompany the ramifications of the bronchi through the substance of the lungs (*rami bronchiales anteriores* and *rami bronchiales posteriores*).

The **Œsophageal Branches** (*rami œsophagei*) are given off from the vagus both above and below the pulmonary branches. The lower are more numerous and larger than the upper. They form, together with branches from the opposite nerve, the **œsophageal plexus**. From this plexus branches are distributed to the back of the pericardium.

The **Gastric Branches** (*rami gastrici*) (Fig. 749) are the terminal filaments of the vagus nerve. The nerve on the right side is distributed to the posterior

surface of the stomach. The right vagus sends branches to the *cœliac plexus* (*rami coeliaci*), to the *splenic plexus* (*rami lienales*), and to the *renal plexus* (*rami renales*). The nerve on the left side is distributed over the anterior surface of the stomach and along the lesser curvature. They unite with branches of the right nerve and with the sympathetic, some filaments (*rami hepatica*) passing through the lesser omentum to the *hepatic plexus*.

Applied Anatomy.—It is a well-recognized fact that disease or injury of the vagus may induce serious symptoms. Bruising may cause such symptoms; so may injury of the nerve by a stab, a bullet, or during surgical operations. Either accidental ligation or crushing with clamp forceps is particularly dangerous. Michaux accidentally ligated the vagus, and the patient became comatose and ceased to breathe, but was restored on removing the ligature. Tillmanns, while removing a cancer, accidentally caught and crushed a portion of the nerve in a clamp, and both pulse and respiration ceased. The clamp was removed, the patient was restored with difficulty, and the nerve was sutured. Recovery followed. It thus becomes evident that division of the vagus on one side is not, as was so long taught, a necessarily fatal accident; in fact, it is sometimes undertaken deliberately in removing tumors adherent to the nerve. Division of a nerve which has been long compressed is probably not so dangerous as division of a healthy nerve, as in the former case the opposite vagus has probably assumed some of its colleague's duties. A number of cases of deliberate division have been reported. Twenty-three cases are referred to in the system of surgery by von Bergmann and Mikulicz, and in twelve the patients died, but in none of the deaths was the removal of the vagus the apparent cause of the fatality. Three American cases are notable: One was operated upon by Dr. W. Joseph Hearn, one by Dr. Melvin Franklin, and one by Dr. J. Chalmers Da Costa. All three recovered, and not one presented any serious disturbance, although each had hoarseness and weakness of voice.

One would assume that after division of the vagus below the superior laryngeal nerve and above the recurrent laryngeal nerve (the region usually attacked) there would be paralysis of all the muscles of one side of the larynx, except the Cricothyroid, and widespread aberration evinced by *disturbances* of the heart, stomach, and lungs. As a matter of fact, this has not been the case. It might be and probably would be the case, were a healthy nerve divided; but the surgeon who deliberately divides the nerve does so during the removal of a tumor which has long made pressure. In most cases there is no change in the pulse or respiration. In some cases dysphagia and pneumonia arise, but they may be due to other causes than vagus-nerve injury (the formidable nature and the duration of the operation—the ligation of vessels of large size—the age of the subject).

Laryngeal symptoms, to a greater or less degree, are always noted. The difference in the degree of the palsy is explainable when we recall Exner's statement that the muscles supplied by the recurrent laryngeal also receive some innervation from the superior laryngeal. In fact, Mills points out that a portion of the recurrent laryngeal has been resected without completely paralyzing the muscles supposed to be supplied solely by the recurrent laryngeal. The laryngeal symptoms result from unilateral laryngeal paralysis, in which there is paralysis of the muscles which open the glottis. The voice may be lost or may be hoarse. Usually, after a time, this is, to a great extent, compensated for by the opposite vocal cord, although the voice may always remain weak, and the patient will tire easily on talking. If both vagi were to be divided death would ensue.

The *laryngeal nerves* are of considerable importance in considering some of the morbid conditions of the larynx. When the peripheral terminations of the superior laryngeal nerve are irritated by some foreign body passing over them, *reflex spasm of the glottis* is the result. When the trunk of the same nerve is pressed upon by, for instance, a goitre or an aneurism of the upper part of the carotid, we have a peculiar, dry, brassy cough. When the nerve is paralyzed we have anesthesia of the mucus membrane of the larynx, so that foreign bodies can readily enter the cavity, and, in consequence of its supplying the Cricothyroid muscle, the vocal cords cannot be made tense, and the voice is deep and hoarse. Paralysis of the superior laryngeal nerves may be the result of bulbar paralysis, may be a sequel to diphtheria, when both nerves are usually involved, or it may, though less commonly, be caused by the pressure of tumors or aneurisms, when the paralysis is generally unilateral. Irritation of the inferior laryngeal nerves produces spasm of the muscles of the larynx. When both the recurrent nerves are paralyzed the vocal cords are motionless in the so-called *cadaveric position*—that is to say, in the position in which they are found in ordinary tranquil respiration—neither closed as in phonation, nor open as in deep inspiratory effort. When one recurrent nerve is paralyzed, the cord of the same side is motionless, while the opposite cord crosses the middle line to accommodate itself to the affected one; hence phonation is present, but the voice is altered and weak in timbre. The recurrent laryngeal nerves may be paralyzed in bulbar paralysis or after diphtheria, when the paralysis usually affects both sides; or they may be affected by the pressure of aneurisms of the aorta,

innominate or subclavian arteries; by mediastinal tumors; by bronchocele; or by cancer of the upper part of the œsophagus, when the paralysis is often unilateral.* The nerve may be accidentally divided during the operation for goitre.

THE ELEVENTH OR SPINAL ACCESSORY NERVE (N. ACCESSORIUS) (Figs. 748, 749).

The **eleventh or spinal accessory nerve** consists of two parts, one the accessory part to the vagus, and the other the spinal portion.

The **bulbar or vagal accessory part** (*ramus internus*) is the smaller of the two. It is accessory to the vagus. Its *superficial origin* (Fig. 748) is by four or five delicate filaments from the side of the medulla oblongata, below the roots of the vagus. Its *deep origin* is described in detail on page 879. It passes outward to the jugular foramen, where it interchanges fibres with the spinal portion or becomes united to it for a short distance; it is also connected, in the foramen, with the upper ganglion of the vagus by one or two filaments. It then passes through the foramen (Fig. 749), and becoming again separated from the spinal portion it is continued over the surface of the ganglion of the trunk of the vagus, being adherent to its surface, and is distributed principally to the pharyngeal and superior laryngeal branches of the vagus. Through the pharyngeal branch it probably supplies the Azygos uvulae and Levator palati muscles (see p. 399). Some few filaments from it are continued into the trunk of the vagus below the ganglion, to be distributed with the recurrent laryngeal nerve to supply most of the laryngeal muscles and probably also with the cardiac nerves.

The **spinal portion** (*ramus externus*) is firm in texture. Its *superficial origin* (Fig. 748) is by several filaments or rootlets from the lateral tract of the cord, as low down as the sixth cervical nerve. Its *deep origin* (Fig. 650) may be traced to the intermediolateral tract of the gray substance of the cord. The rootlets of origin join and form a trunk which ascends in the subdural space between the ligamentum denticulatum and the anterior roots of the spinal nerves, enters the skull through the foramen magnum, and is then directed outward to the jugular foramen, through which it passes, lying in the same sheath as the vagus, but separated from it by a fold of the arachnoid. In the jugular foramen it receives one or two filaments from the vagal accessory portion. At its exit from the jugular foramen it passes backward, either in front of or behind the internal jugular vein, and descends obliquely behind the Digastric and Stylohyoid muscles to the upper part of the Sternomastoid muscle. It pierces that muscle, and passes obliquely across the posterior triangle, to terminate in the deep surface of the Trapezius muscle. During its passage through the Sternomastoid muscle it gives several branches to the muscle, and joins in its substance with branches from the second cervical. In the posterior triangle it joins with the second and third cervical nerves, while beneath the Trapezius it forms a sort of plexus with the third and fourth cervical nerves, and from this plexus fibres are distributed to the muscle.

Applied Anatomy.—Division of the external branch of the spinal accessory nerve causes paralysis of the Sternomastoid and Trapezius muscles; not absolute paralysis, for these muscles also receive nerves from the cervical plexus. In cases of *spasmodic torticollis* in which all palliative treatment has failed, division or excision of a portion of the external branch of the spinal accessory nerve has been suggested by Keen. This may be done either along the anterior or posterior border of the Sternomastoid muscle. The former operation is performed by making an incision from the apex of the mastoid process, three inches in length, along the anterior border of the Sternomastoid muscle. The anterior border of the muscle is defined and pulled backward, so as to stretch the nerve, which is then to be sought for beneath the Digastric muscle, about two inches below the apex of the mastoid process. The other operation consists in making an incision along the posterior border of the muscle, so that the centre of the incision corresponds to the middle of this border of the muscle. The superficial structures having been

divided and the border of the muscle defined, the nerve is to be sought for as it emerges from the muscle to cross the occipital triangle. When found, it is to be traced upward through the muscle, and a portion of it is excised above the point where it gives off its branches to the Sternomastoid. In this operation one of the descending branches of the superficial cervical plexus is liable to be mistaken for the nerve.

THE TWELFTH OR HYPOGLOSSAL NERVE (N. HYPOGLOSSUS)

(Figs. 752, 753).

The **twelfth** or **hypoglossal nerve** is the motor nerve of the tongue. Its *superficial origin* is by several filaments, from ten to fifteen in number, from the groove between the pyramidal and olivary bodies of the medulla oblongata, in a continuous line with the ventral roots of the spinal nerves. Its *deep origin* can be traced to a nucleus of gray substance (*nucleus hypoglossi*) in the floor of the fourth ventricle, described on page 878.

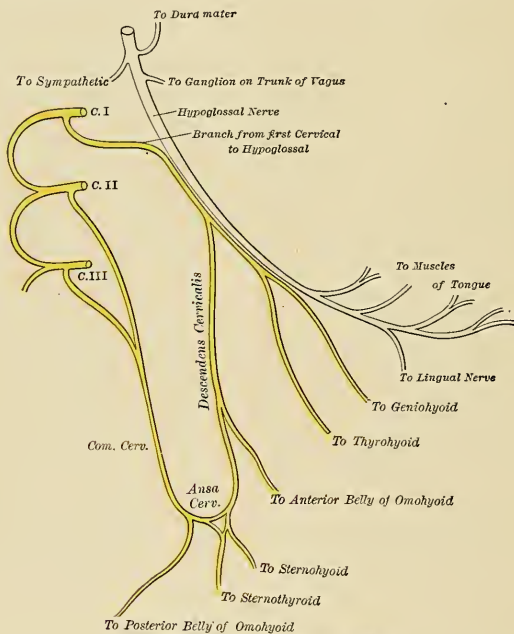


FIG. 752.—Plan of the hypoglossal nerve.

The filaments of this nerve are collected into two bundles, which perforate the dura separately, opposite the anterior condylar foramen, and unite together after their passage through it. In those cases in which the anterior condylar or hypoglossal foramen in the occipital bone is double, these two portions of the nerve are separated by the small piece of bone which divides the foramen. The nerve descends almost vertically to a point corresponding with the angle of the mandible. It is at first deeply seated beneath the internal carotid artery and internal jugular vein, and is intimately connected with the vagus nerve (Fig. 753); it then

passes forward between the vein and artery, and lower down in the neck becomes superficial below the Digastric muscle. The nerve then loops around the occipital artery, and crosses the external carotid and its lingual branch below the tendon of the Digastric muscle. It passes beneath the tendon of the Digastric, the Stylohyoid, and the Mylohyoid muscles, lying between the last-named muscle and the Hyoglossus (Fig. 753), and communicates at the anterior border of the Hyoglossus with the lingual nerve (Fig. 752); it is then continued forward in the fibres of the Geniohyoglossus muscle as far as the tip of the tongue, distributing branches to its muscle substance.

Branches of Communication (Fig. 752).—The branches of communication are with the—

Vagus.
Sympathetic.

First and second cervical nerves.
Lingual.

The communication with the vagus takes place close to the exit of the nerve from the skull, numerous filaments passing between the hypoglossal and the ganglion of the trunk of the vagus through the mass of connective tissue which unites the two nerves. It also communicates with the pharyngeal plexus by a minute filament as it winds around the occipital artery.

The communication with the sympathetic takes place opposite the atlas by branches derived from the superior cervical ganglion, and in the same situation the nerve is joined by filaments derived from the loop connecting the first two cervical nerves.

The communication with the lingual nerve takes place near the anterior border of the Hyoglossus muscle by numerous filaments which ascend upon it.

Branches of Distribution (Fig. 752).—The branches of distribution are:

Meningeal or Dural.
Descendens hypoglossi.

Thyrohyoid.
Muscular.

Of these branches, the descendens hypoglossi and the branches to the Infrahyoid muscles are not actually derived from the hypoglossal nerve, but, as is shown in Fig. 752, are branches from the loop formation (better called *ansa cervicalis*) of the first with the second and third cervical nerves. A part of the loop, commonly called the descendens hypoglossi, is enclosed, for a short distance, in the sheath which invests the hypoglossal nerve.

Meningeal or Dural Branches (Fig. 752).—As the hypoglossal nerve passes through the anterior condylar foramen it gives off, according to Luschka, several filaments to the dura in the posterior fossa of the base of the skull.

The **Descendens Cervicalis** or **Descendens Hypoglossi** (*ramus descendens*) (Figs. 752 and 753) is a long slender branch, which leaves the hypoglossal where it turns around the occipital artery. It consists mainly of fibres which pass along the sheath of the hypoglossal nerve from the first and second cervical nerves in the above-mentioned communication. It descends in front of or within the sheath of the common carotid artery, giving off a branch to the anterior belly of the Omohyoid, and then joins the communicating branches from the second and third cervical nerves, just below the middle of the neck, to form a loop, the *ansa cervicalis* (hypoglossi). From the convexity of this loop branches pass to supply the Sternohyoid, Sternothyroid, and the posterior belly of the Omohyoid.

The **Thyrohyoid Branch** (*ramus thyrohyoideus*) (Fig. 752) is a small branch arising from the hypoglossal near the posterior border of the Hyoglossus; it passes obliquely across the great cornu of the hyoid bone and supplies the Thyrohyoid muscle.

The **Muscular Branches** (Fig. 752) are distributed to the Styloglossus, Hyoglossus, Geniohyoid, and Geniohyoglossus muscles and to the Chondroglossus, when present. At the under surface of the tongue numerous slender branches (*rami linguales*) pass upward into the substance of the organ to supply its Intrinsic muscles.

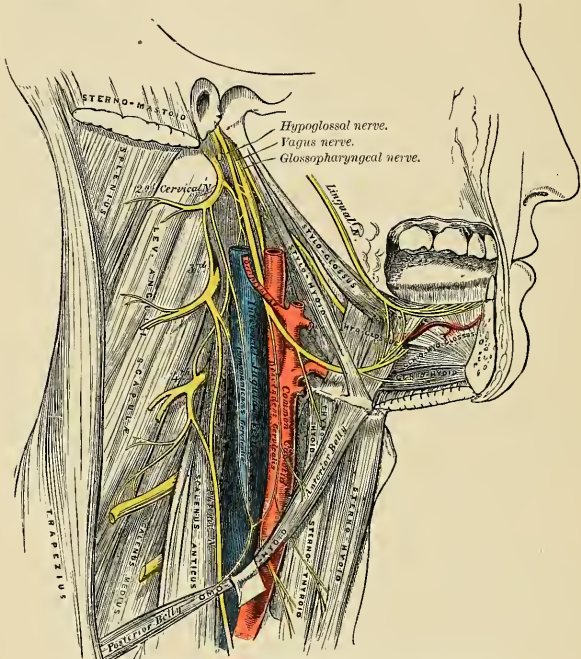


FIG. 753.—Hypoglossal nerve, cervical plexus, and their branches.

Applied Anatomy.—A wound in the submaxillary region may injure the hypoglossal nerve and result in motor paralysis of the corresponding half of the tongue. The hypoglossal nerve is an important guide in the operation of ligation of the lingual artery (see p. 591). It runs forward on the Hyoglossus muscle just above the great cornu of the hyoid bone, and forms the upper boundary of the triangular space (Lesser's triangle) in which the artery is to be sought for by cutting through the fibres of the Hyoglossus muscle.

THE SPINAL NERVES (NERVI SPINALES).

The spinal nerves spring from the spinal cord, and are transmitted through the intervertebral foramina on either side of the spinal column. There are thirty-one pairs of spinal nerves, which are arranged in the following groups, corresponding to the region of the vertebral column through which they pass:

Cervical	8 pairs.
Thoracic	12 “
Lumbar	5 “
Sacral	5 “
Coccygeal	1 pair.

It will be observed that each group of nerves corresponds in number with the vertebrae in that region, except the cervical and coccygeal. Sometimes there is no thirty-first pair. Occasionally below the thirty-first pair there may be one or even two filamentous pairs which do not pass out of the vertebral canal.

Each spinal nerve arises by two roots, an **anterior, ventral, or motor root** and a **posterior, dorsal, or sensor root**, the latter being distinguished by a ganglion termed the **spinal ganglion**.

The Anterior or Ventral Root (*radix anterior*).—The *superficial origin* is from the antero-lateral columns of the cord, corresponding to the situation of the anterior cornu of gray substance. Each root is composed of from four to eight filaments.

The *deep origin* can be traced from cells in the gray substance of the anterior cornu of the same as well as of the opposite side. The majority of the axones arise from the various groups of cells in the anterior cornu of the same side, while others arise from the large cells of the anterior cornu of the opposite side, the axones passing across the median plane in the anterior white commissure. The axone bundles, after leaving the gray substance, penetrate horizontally through the longitudinal bundles of the antero-lateral column to emerge as described above.

The Posterior or Dorsal Root (*radix posterior*).—The *superficial origin* is by filaments (*fila radicularia*), from the postero-lateral fissure of the cord. The *real origin* of these fibres is from the nerve cells in the posterior root ganglion, from which they can be traced into the cord in two main bundles, the course of which has already been studied (p. 835). The posterior or dorsal root of the first cervical nerve is exceptional in that it is smaller than the anterior; it is occasionally wanting.

Within the vertebral canal the nerve roots are separated from each other by the *ligamentum denticulatum* (Fig. 755). In the cervical region the spinal portion of the spinal accessory nerve separates the roots.

The **spinal ganglia** are collections of nerve cells on the posterior root of each of the spinal nerves. Each ganglion is oval in shape and of a reddish color; and its size bears a proportion to that of the nerve root upon which it is situated; it is bifid internally where it is joined by the two bundles of the posterior nerve root. The ganglia are usually placed in the intervertebral foramina, ectad of the point where the nerves perforate the dura. There are, however, exceptions to this rule. Thus, the ganglia upon the first and second cervical nerves lie on the neural arches of the atlas and axis respectively; those of the sacral nerves are placed within the vertebral canal; and that on the coccygeal nerve, also in the canal, is situated at some distance from the apparent origin of the posterior root.

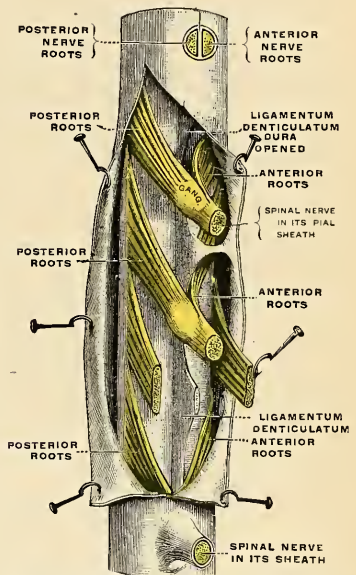


FIG. 754.—A portion of the spinal cord, showing its right lateral surface. The dura is opened and arranged to show the nerve roots. (Testut.)

Structure.—The ganglion in an embryo is composed of bipolar nerve cells. In an adult the bipolar nerve cells by fusion of their two poles form unipolar elements. The process of each unipolar cell divides into two a short distance from the cell. One of the processes from each cell passes to the spinal cord, and the other passes into the spinal nerve. Two other forms of cells are, however, present—viz.: (*a*) the cells of Dogiel, whose axones ramify close to the cell (type II of Golgi), and are distributed entirely within the ganglion; and (*b*) multipolar cells similar to those found in the sympathetic ganglia. On the posterior roots of the lumbar and sacral nerves, between the spinal ganglia and the cord, small cellular masses occasionally exist. They are called **accessory or aberrant ganglia** (*ganglia aberrantia*).

Each typical spinal nerve contains **somatic** and **splanchnic** fibre systems, as well as fibres connecting these systems with each other.

1. The **somatic** fibres are efferent and afferent. The *efferent* fibres originate in the cells of the anterior cornu of the spinal gray substance, and run outward through the anterior nerve roots to the spinal nerve. They convey impulses to the voluntary muscles and are continuous from their origin to their peripheral distribution. The *afferent* fibres (peripheral axones) convey impressions from the skin, etc., and originate in the unipolar nerve cells of the spinal ganglia. The central axones enter the spinal cord through the posterior nerve roots, to be continued to the medulla oblongata, to end in the nuclei of the gracile and cuneate funiculi (Goll and Burdach), or they may end by arborization around efferent neurones in the same or opposite side of the cord, completing in this way reflex arcs.

2. The **sympathetic** fibres are also efferent and afferent. The *efferent* fibres originate in the visceral motor gray substance of the spinal cord and are conveyed through the anterior nerve root and the white ramus communicans to the corresponding ganglion of the sympathetic chain; here they may end by forming synapses around its cells, or may run through the ganglion to end in another of the chain or in a more distally placed ganglion in one of the sympathetic plexuses, the impulses being relayed in other neurones to be carried to the bloodvessels of the trunk and limbs or to the viscera. The *afferent* fibres are derived partly from unipolar and partly from the multipolar cells of the spinal ganglia. Their peripheral processes are carried outward through the white rami communicantes, and after passing through one or more sympathetic ganglia without interruption, terminate in the tissues of the viscera. The central processes of the unipolar cells enter the spinal cord through the posterior nerve root and form synapses around either somatic or visceral efferent neurones, thus completing reflex arcs. The dendrites of the multipolar nerve cells form synapses around the cells of Dogiel in the spinal ganglia, and by this path the original impulse is transferred from the sympathetic to the somatic system, through which it is conveyed to the sensorium.

Points of Emergence of the Spinal Nerves.—The roots of the spinal nerves from their origin in the cord run obliquely caudad to their point of exit from the intervertebral foramina, the amount of obliquity varying in different regions of the spine, and being greater in the lower than in the upper part. The level of their emergence from the cord is within certain limits variable, and of course does not correspond to the point of emergence of the nerve from the intervertebral foramina (Fig. 757).

Each nerve root receives a covering from the pia, and is loosely invested by the arachnoid, the latter being prolonged as far as the points where the roots pierce the dura. The two roots pierce the dura separately, each receiving a sheath from this membrane; this sheath is continuous with the epineurium of the nerve where the roots join to form the spinal nerve.

Divisions.—Immediately beyond the ganglion the two roots coalesce, their fibres intermingle, and the trunk thus formed constitutes the **spinal nerve**; it passes out of the intervertebral foramen, and divides into a **posterior or dorsal primary division** for the supply of the dorsal part of the body, and an **anterior or ventral primary division** for the supply of the ventral part of the body (Fig. 755). Each division contains fibres from both roots.

Before dividing, each spinal nerve gives off a small **recurrent or meningeal branch** (*ramus meningeus*) (Fig. 755) which reënters the vertebral canal through the intervertebral foramen and supplies the membranes and bloodvessels of the cord, the vertebræ, and the vertebral ligaments.

The **posterior or dorsal primary divisions** (*rami posteriores*) (Fig. 755) of the spinal nerves are generally smaller than the anterior; they arise from the trunk

resulting from the union of the roots, in the intervertebral foramina; and, passing dorsad, divide into **internal** or **medial** and **external** or **lateral branches**, which are distributed to the muscles and integument behind the spine. The posterior

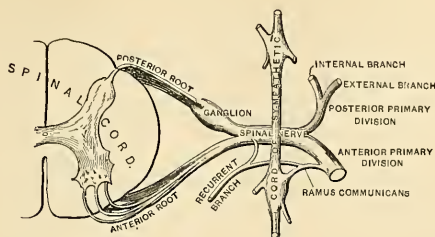


FIG. 755.—Plan of the constitution of a spinal nerve. (W. Keiller, in Gerrish's Text-book of Anatomy.)

primary divisions of the spinal nerves form two small plexuses, the **posterior cervical plexus** and the **posterior sacral plexus**. The first cervical, the fourth and fifth sacral, and the coccygeal nerves do not divide into external and internal branches.

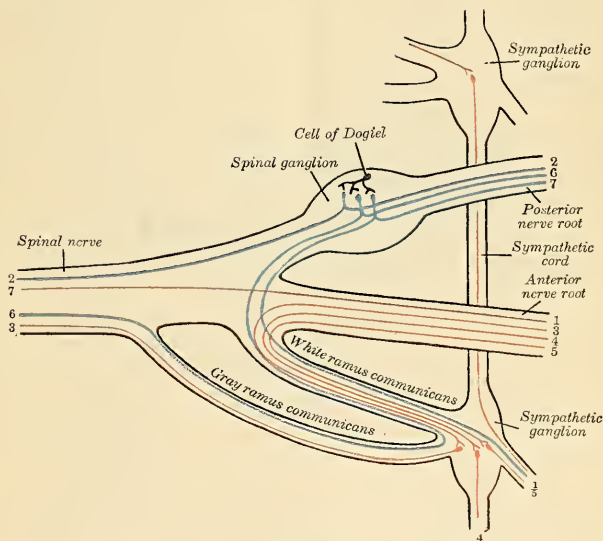


FIG. 756.—Scheme showing structure of a typical spinal nerve.

The **anterior** or **ventral primary divisions** (*rami anteriores*) (Fig. 755) of the spinal nerves supply the parts of the body ventrad of the spine, including the limbs. They are for the most part larger than the posterior primary divisions. Each division, soon after its origin, receives a slender filament from the sympathetic which is called the **gray ramus communicans**. In the thoracic region the anterior

primary divisions of the spinal nerves are quite separate from each other, and are uniform in their distribution; but in the cervical, lumbar, and sacral regions they form intricate plexuses previous to their distribution. The anterior primary divisions of certain thoracic, lumbar, and sacral nerves give off a delicate collection of nerve filaments to the sympathetic cord. These are called the **white rami communicantes** or the **visceral branches of the spinal nerves**.

Posterior or Dorsal Primary Divisions of the Spinal Nerves.—The posterior or dorsal primary divisions are here described together, inasmuch as they do not enter into the formation of the important plexuses (cervical, lumbar, and sacral) exclusively made up of the anterior primary divisions.

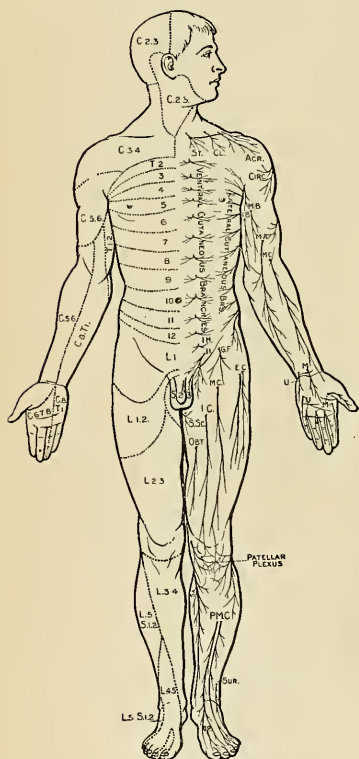


FIG. 757.—Ventral aspect.

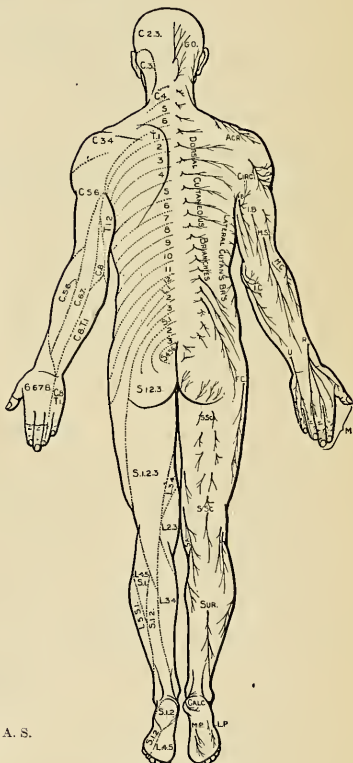


FIG. 758.—Dorsal aspect.

FIGS. 757 and 758.—Distribution of cutaneous nerves.

The Posterior or Dorsal Divisions of the Cervical Nerves (*rami posteriores*).—The posterior division of the first cervical nerve (Fig. 759) differs from the posterior divisions of the other cervical nerves in not dividing into an internal and external branch. It is larger than the anterior division, and escapes from the vertebral canal between the occipital bone and the posterior arch of the atlas and beneath the vertebral artery. It enters the suboccipital triangle formed by

the Rectus capitis posticus major, the Obliquus superior and Obliquus inferior; it gives branches also to the Rectus capitis posticus minor and to the Complexus. From the branch which supplies the Inferior oblique a communicating filament is given off which joins the second cervical nerve. This nerve also occasionally gives off a cutaneous filament, which accompanies the occipital artery and communicates with the occipitalis major and minor nerves.

The **posterior division of the second cervical nerve** is much larger than the anterior division, and is the largest of all the posterior cervical divisions. It emerges from the vertebral canal between the anterior arch of the atlas and lamina of the axis, below the Inferior oblique. It supplies a twig to this muscle, and receives a communicating filament from the first cervical. It then divides into an **internal or medial** and an **external or lateral branch**.

The **internal or medial branch**, called, from its size and distribution, the **great occipital nerve** (*n. occipitalis major*) (Fig. 759), ascends obliquely inward between the Obliquus inferior and the Complexus, and pierces the latter muscle and the Trapezius near their attachments to the occipital bone. It is now joined by a filament from the posterior division of the third cervical nerve, the **anastomotic**, and, ascending on the back part of the head with the occipital artery, divides into two branches, which supply the integument of the scalp as far forward as the vertex, communicating with the occipitalis minor. It gives off an **auricular branch** to the back part of the ear and **muscular branches** to the Complexus.

The **external or lateral branch** is often joined by the external branch of the posterior division of the third cervical nerve, and supplies the Splenius, Trachelomastoid, and Complexus.

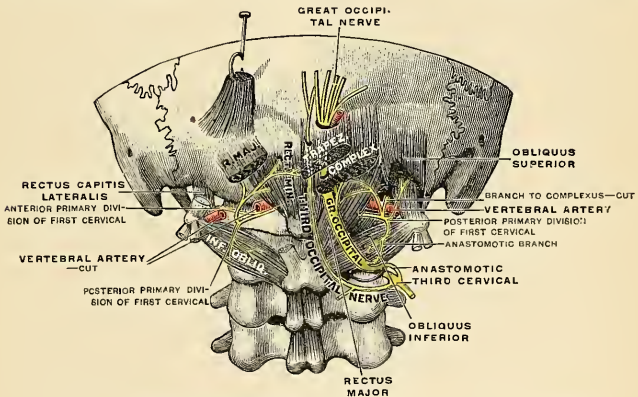


FIG. 759.—Posterior primary divisions of the upper three cervical nerves. (Testut.)

The **posterior division of the third cervical nerve** (Fig. 759) is intermediate in size between those of the second and fourth. Its **internal or cutaneous branch** passes between the Complexus and Semispinalis, and, piercing the Splenius and Trapezius, supplies the skin over the latter muscle; while under the Trapezius it gives off a branch called the **third occipital nerve** (*n. occipitalis tertius*), which pierces the Trapezius and supplies the skin on the lower and back part of the head. It lies to the inner side of the occipitalis major, with which it is connected. The **external branch** often joins that of the second cervical.

The posterior division of the suboccipital nerve and the internal branches of the posterior divisions of the second and third cervical nerves are occasionally

joined beneath the Complexus by communicating loops to form the **posterior cervical plexus** (Cruveilhier).

The **posterior divisions of the lower five cervical nerves** pass dorsad, and divide, behind the Intertransversales muscles, into **internal** or **medial** and **external** or **lateral branches**.

The **internal branches**, the larger, are distributed differently in the upper and lower part of the neck. Those derived from the fourth and fifth nerves pass between the Complexus and Semispinalis muscles, and, having reached the spinous processes, perforate the aponeurosis of the Splenius and Trapezius, and are continued outward to the integument over the Trapezius, while those derived from the three lowest cervical nerves are the smallest, and are placed beneath the Semispinalis colli, which they supply, and then pass into the Interspinalis, Multifidus spinæ, and Complexus, and send twigs through this latter muscle to supply the integument near the spinous processes.

The **external branches** supply the muscles at the side of the neck—viz., the Cervicalis ascendens, Transversalis colli, and Trachelomastoid.

The Posterior Divisions of the Thoracic Nerves (*rami posteriores*).—The posterior divisions of the thoracic nerves are smaller than the anterior, pass dorsad between the transverse processes, and divide into **internal** or **medial** and **external** or **lateral branches**.

The **internal** or **medial branches** of the posterior divisions of the six upper thoracic nerves pass inward between the Semispinalis dorsi and Multifidus spinæ muscles, which they supply, and then, piercing the origins of the Rhomboidei and Trapezius muscles, become cutaneous by the side of the spinous processes and ramify in the integument. The **medial branches** of the six lower thoracic nerves are distributed to the Multifidus spinæ, without giving off any cutaneous filaments.

The **external** or **lateral branches** increase in size from above downward. They pass through the Longissimus dorsi muscle to the cellular interval between it and the Iliocostalis muscle, and supply those muscles, as well as their continuations upward to the head, and also the Levatores costarum muscles; the five or six lower nerves also give off cutaneous filaments, which pierce the Serratus posticus inferior and Latissimus dorsi muscles in a line with the angles of the ribs, and then ramify in the integument.

The **cutaneous branches** of the posterior primary divisions of the thoracic nerves are twelve in number. From each *ramus medialis* of the upper six nerves comes a *ramus cutaneus medialis*, and from each *ramus lateralis* of the lower six nerves comes a *ramus cutaneus lateralis*. The six upper cutaneous nerves are derived from the internal branches of the posterior divisions of the thoracic nerves. They pierce the origins of the Rhomboidei and Trapezius muscles, and become cutaneous by the side of the spinous processes, and then ramify in the integument. They are frequently furnished with gangliform enlargements. The six lower cutaneous nerves are derived from the external branches of the posterior divisions of the thoracic nerves. They pierce the Serratus posticus inferior and Latissimus dorsi muscles in a line with the angles of the ribs, and then ramify in the integument.

The Posterior Divisions of the Lumbar Nerves (*rami posteriores*).—The posterior divisions of the lumbar nerves diminish in size from above downward; they pass postero-laterad between the transverse processes, and divide into **internal** or **medial** and **external** or **lateral branches**.

The **internal branches** (*rami mediales*), the smaller, pass inward close to the articular processes of the vertebræ, and supply the Multifidus spinæ and Interspinales muscles.

The **external branches** (*rami laterales*) supply the Erector spinæ and Intertransverse muscles. The three upper branches give off cutaneous nerves which

pierce the aponeurosis of the Latissimus dorsi muscle and descend over the back part of the crest of the ilium, to be distributed to the integument of the gluteal region, some of the filaments passing as far as the trochanter major (Fig. 778).

The posterior division of the *fifth* lumbar nerve usually sends a branch which forms a loop with the posterior division of the first sacral nerve.

The Posterior Divisions of the Sacral Nerves (*rami posteriores*) (Fig. 779).—The posterior divisions of the sacral nerves are small, diminish in size from above downward, and emerge, except the last, from the sacral canal by the posterior sacral foramina. The *upper three* are covered at their exit from the sacral canal by the Multifidus spinæ muscle, and divide into **internal** or **medial** and **external** or **lateral branches**.

The **internal branches** (*rami mediales*) are small, and supply the Multifidus spinæ muscle.

The **external branches** (*rami laterales*) join with one another, and with the last lumbar and fourth sacral nerves, in the form of loops on the posterior surface of the sacrum, constituting the **posterior sacral plexus**. From these loops branches pass to the outer surface of the great sacrosciatic ligament, where they form a second series of loops beneath the Gluteus maximus muscle. Cutaneous branches from this second series of loops, usually two or three in number, pierce the Gluteus maximus muscle along the line drawn from the posterior superior spine of the ilium to the tip of the coccyx. They supply the integument over the posterior part of the gluteal region.

The *posterior divisions* of the **lower two** sacral nerves are small and lie below the Multifidus spinæ muscle. They do not divide into internal and external branches, but join with each other, and with the posterior division of the coccygeal nerve to form the **posterior sacrococcygeal nerve**, which passes through the sacrosciatic ligament, and forms loops on the back of the sacrum, filaments from which supply the integument over the coccyx.

The Posterior Division of the Coccygeal Nerve.—The coccygeal nerve divides into its anterior and posterior divisions in the vertebral canal. The posterior division is the smaller, and it does not divide into internal and external branches, but receives, as already stated, a communicating branch from the last sacral, and is lost in the integument over the dorsum of the coccyx.

Anterior or Ventral Primary Divisions of the Spinal Nerves.—The **anterior primary divisions of the spinal nerves** (*rami anteriores*) supply the antero-lateral parts of the trunks and the limbs; they are, for the most part, larger than the posterior divisions. In the thoracic region they run independently of one another, but in the cervical, lumbar, and sacral regions they unite near their origins to form **plexuses**.

The Anterior or Ventral Divisions of the Cervical Nerves (*rami anteriores*).—The **anterior primary divisions of the cervical nerves**, with the exception of the first, pass laterad between the anterior and posterior Intertransverse muscles, lying on the grooved upper surfaces of the transverse processes, and emerge between the muscles attached to the anterior and posterior tubercles of these processes. The anterior primary division of the **first** or **suboccipital nerve** issues from the vertebral canal above the posterior arch of the atlas and runs forward around the lateral aspect of its superior articular process, internal to the vertebral artery. In most cases it descends internal to and in front of the Rectus lateralis, but in some cases it pierces the muscle.

The anterior primary divisions of the **upper four cervical nerves** unite to form the **cervical plexus**, and each receives a gray ramus communicans from the superior cervical ganglion of the sympathetic cord. Those of the **lower four cervical**, together with the greater part of the first thoracic, form the **brachial plexus**. They

each receive a gray ramus communicans, those for the fifth and sixth being derived from the middle, and those for the seventh and eighth from the inferior, cervical ganglion of the sympathetic.

THE CERVICAL PLEXUS (PLEXUS CERVICALIS) (Figs. 760, 761).

The cervical plexus is formed by the anterior divisions of the four upper cervical nerves. It is situated opposite the four upper cervical vertebræ, resting upon the Levator anguli scapulae and Scalenus medius muscles, and covered in by the Sternomastoid.

Its branches may be divided into two groups, **superficial** and **deep**, which may be thus arranged:

Superficial	{	Ascending	{	Small occipital	2, C.				
		Transverse	{	Great auricular	2, 3, C.				
				Superficial cervical	2, 3, C.				
	{	Descending or Supraclavicular	{	Sternal	3, 4, C.				
				Clavicular	3, 4, C.				
Deep	{	{	Internal	{	Communicating	{	with hypoglossal	1, 2, C.	
					Muscular	{	with vagus	1, 2, C.	
							with sympathetic	1, 2, 3, 4, C.	
							Rectus lateralis	1, C.	
							Anterior Recti	1, 2, C.	
			External	{	{	Muscular	{	Communicantes hypoglossi	2, 3, C.
								Phrenic	3, 4, 5, C.
								Communicating with spinal accessory	2, 3, 4, C.
								Sternomastoid	2, C.
								Trapezius	3, 4, C.
								Levator anguli scapulae	3, 4, C.
Scalenus medius	3, 4, C.								

The Superficial Branches of the Cervical Plexus.—The **Small Occipital Nerve** (*n. occipitalis minor*) (Fig. 760) arises from the second cervical nerve, sometimes also from the third; it curves around the posterior border of the Sternomastoid, and ascends, running parallel to the posterior border of the muscle, to the back part of the side of the head. Near the cranium it perforates the deep fascia, and is continued upward along the side of the head behind the ear, supplying the integument, and communicating with the great occipital, great auricular, and with the posterior auricular branch of the facial.

This nerve gives off an **auricular branch**, which supplies the integument of the upper and back part of the auricle, communicating with the mastoid branch of the great auricular. The auricular branch is occasionally derived from the great occipital nerve. The small occipital varies in size; it is occasionally double.

The **Great Auricular Nerve** (*n. auricularis magnus*) (Fig. 760) is the largest of the ascending branches. It arises from the second and third cervical nerves, winds around the posterior border of the Sternomastoid, and, after perforating the deep fascia, ascends upon that muscle beneath the Platysma to the parotid gland, where it divides into **facial**, **auricular**, and **mastoid branches**.

The **facial branches** are distributed to the integument of the face over the parotid gland; others penetrate the substance of the gland and communicate with the facial nerve.

The **auricular branches** ascend to supply the integument of the back of the pinna, except at its upper part, communicating with the auricular branches of the facial and vagus nerves. A filament pierces the pinna to reach its outer surface, where it is distributed to the lobule and lower part of the concha.

The **mastoid branch** communicates with the small occipital and the posterior

auricular branch of the facial, and is distributed to the integument behind the ear.

The **Superficial or Transverse Cervical Nerve** (*n. cutaneus colli*) (Fig. 760) arises from the second and third cervical nerves, turns around the posterior border of the Sternomastoid about its middle, and, passing obliquely forward beneath the external jugular vein to the ventral border of the muscle, perforates the deep cervical fascia, and divides beneath the Platysma into two branches, which are distributed to the antero-lateral parts of the neck.

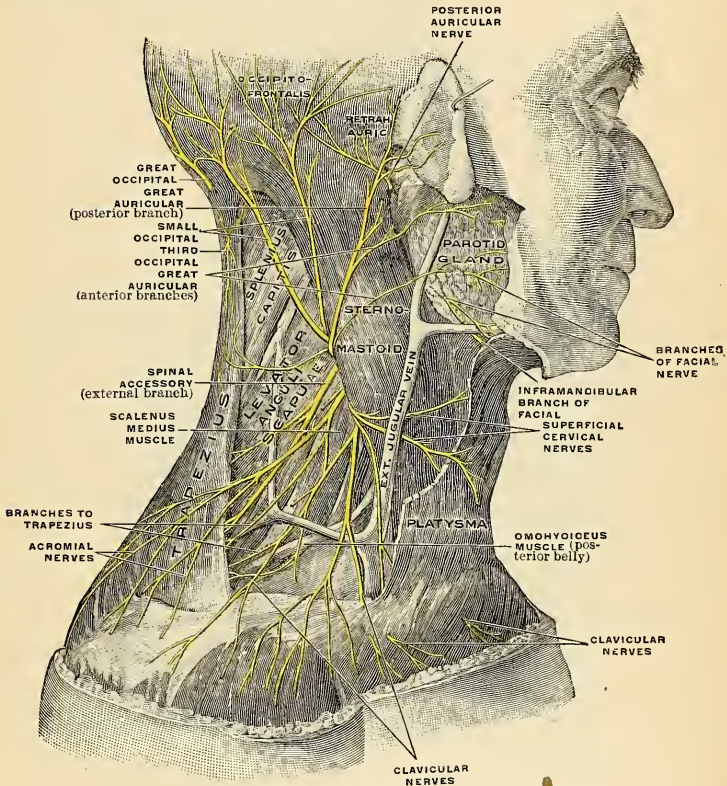


FIG. 760.—The cutaneous branches of the right cervical plexus viewed from the right. The Platysma has been partly removed. (Spalteholz.)

The **ascending branch** (*ramus superior*) gives a filament which accompanies the external jugular vein; it then passes upward to the submaxillary region, and divides into branches, some of which form a plexus with the cervical branches of the facial nerve beneath the Platysma; others pierce that muscle and are distributed to the integument of the upper half of the neck, at its fore part, as high as the chin.

The **descending branches** (*rami inferiores*), usually represented by two or more filaments, pierce the Platysma, and are distributed to the integument of the side and front of the neck, as low as the sternum.

The **Descending or Supraclavicular Branches** (*nn. supraclaviculares*) (Fig. 760) arise from the third and fourth cervical nerves; emerging beneath the posterior border of the Sternomastoid, they descend in the posterior triangle of the neck beneath the Platysma and deep cervical fascia. Near the clavicle they perforate the fascia and Platysma to become cutaneous, and are arranged, according to their position, into three groups.

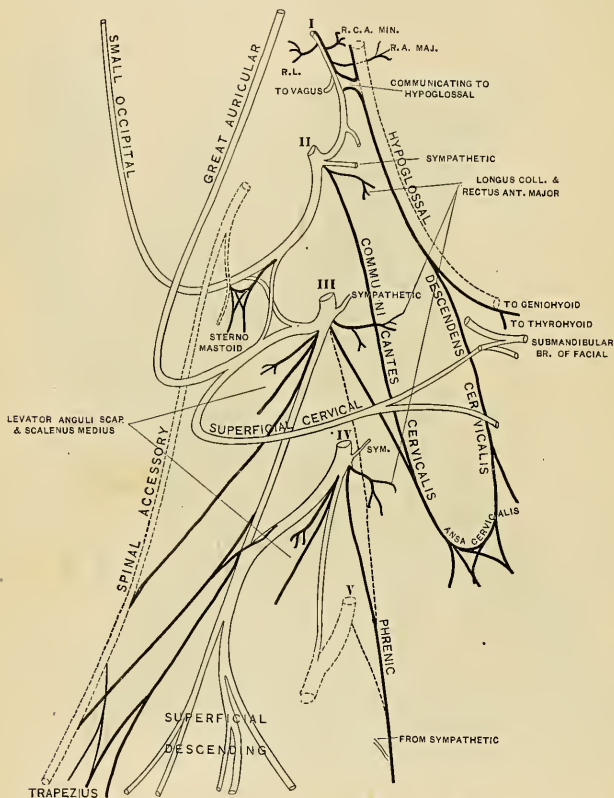


FIG. 761.—Plan of the cervical plexus. (Gerrish.)

The **Inner or Sternal Branches** (*nn. supraclaviculares anteriores*) cross obliquely over the external jugular vein and the clavicular and sternal attachments of the Sternomastoid muscle, and supply the integument as far as the median line. They furnish one or two filaments to the sternoclavicular joint.

The **Middle or Clavicular Branches** (*nn. supraclaviculares medii*) cross the clavicle, and supply the integument over the Pectoral and Deltoid muscles, communicating with the cutaneous branches of the upper intercostal nerves.

The **External or Acromial Branches** (*nn. supraclaviculares posteriores*) pass

obliquely across the outer surface of the Trapezius and the acromion, and supply the integument of the upper and back part of the shoulder.

The Deep Branches of the Cervical Plexus (Fig. 761). **Internal Series.**—The **Communicating Branches** consist of several filaments which pass from the loop between the first and second cervical nerves to the vagus, hypoglossal, and sympathetic. The branch accompanying the hypoglossal in its sheath ultimately leaves

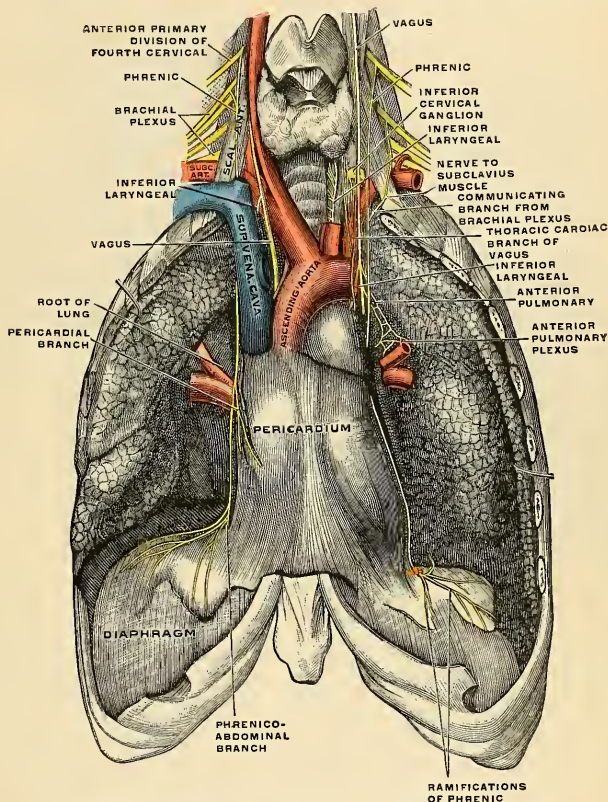


FIG. 762.—The phrenic nerve and its relations with the vagus nerve. (Toldt.)

that nerve as a series of branches—viz., the descendens cervicalis, the nerve to the Thyrohyoid, and the nerve to the Geniohyoid (see p. 1011). Branches (gray rami communicantes) from all four cervical nerves pass to the superior cervical ganglion of the sympathetic, while another communicating branch passes from the fourth to the fifth cervical.

Muscular branches supply the Anterior recti and Rectus lateralis muscles. Those to the Anterior recti proceed from the first cervical nerve, and from the loop formed between it and the second. The Rectus lateralis is supplied by the second, third, and fourth cervical nerves.

The **Communicantes Cervicales** (**Hypoglossi**) (Fig. 761) consist usually of two

filaments, one being derived from the second and the other from the third cervical. These filaments usually join to form the **descendens cervicis**, which passes downward on the outer side of the internal jugular vein, crosses in front of the vein a little below the middle of the neck, and forms a loop (*ansa hypoglossi*; *ansa cervicalis*) with the descendens hypoglossi in front of the sheath of the carotid vessels. Occasionally, the junction of these nerves takes place within the sheath.

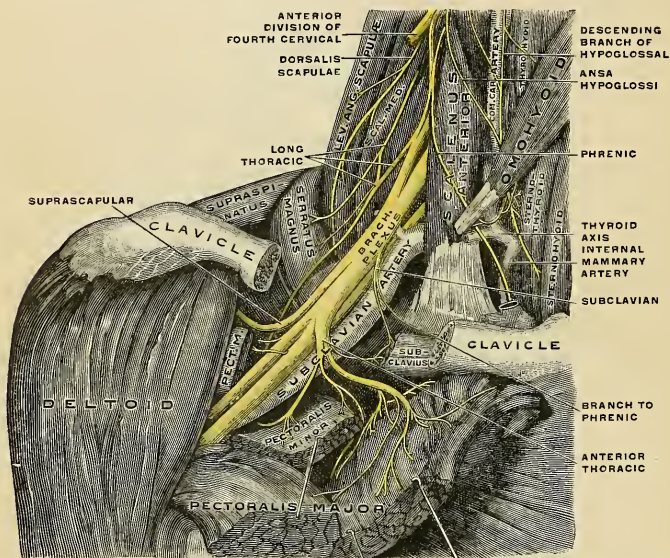


FIG. 763.—The right brachial plexus with its short branches, viewed from in front. The Sternomastoid and Trapezius muscles have been completely, the Omohyoid and Subclavius have been partially, removed; a piece has been sawed out of the clavicle; the Pectoralis muscles have been incised and reflected. (Spalteholz.)

The **Phrenic** or the **Internal Respiratory Nerve of Bell** (*n. phrenicus*) (Figs. 761 and 762) *arises* chiefly from the fourth cervical nerve, with a few filaments from the third and a branch from the fifth, although this branch is occasionally derived from the nerve to the Subclavius. It descends to the root of the neck, running obliquely across the front of the Scalenus anticus, and beneath the Sternomastoid, the posterior belly of the Omohyoid muscles, and the transversalis colli and suprascapular vessels. It next passes over the first part of the subclavian artery, between it and the subclavian vein, and, as it enters the thorax, crosses the internal mammary artery near its origin. Within the thorax it descends nearly vertically in front of the root of the lung and by the side of the pericardium, between it and the mediastinal portion of the pleura, to the Diaphragm, where it divides into branches, some few of which are distributed to its thoracic surface, but most of which separately pierce that muscle and are distributed to its under surface (*rami phrenicoabdominales*). In the thorax it is accompanied by a branch of the internal mammary artery, the *arteria comes nervi phrenici*. The two phrenic nerves differ in their length, and also in their relations at the upper part of the thorax.

The **right phrenic nerve** is situated more deeply, and is shorter and more vertical in direction than the left; it lies on the outer side of the right innominate vein and superior vena cava.

The left phrenic nerve is rather longer than the right, from the inclination of the heart to the left side, and from the Diaphragm being lower on this than on the opposite side. It enters the thorax behind the left innominate vein, and crosses in front of the vagus and the arch of the aorta and the root of the lung.

Each nerve supplies filaments to the pericardium and pleura, and near the thorax is joined by a filament from the sympathetic, and, occasionally, by one from the ansa cervicalis. Branches have been described as passing to the peritoneum.

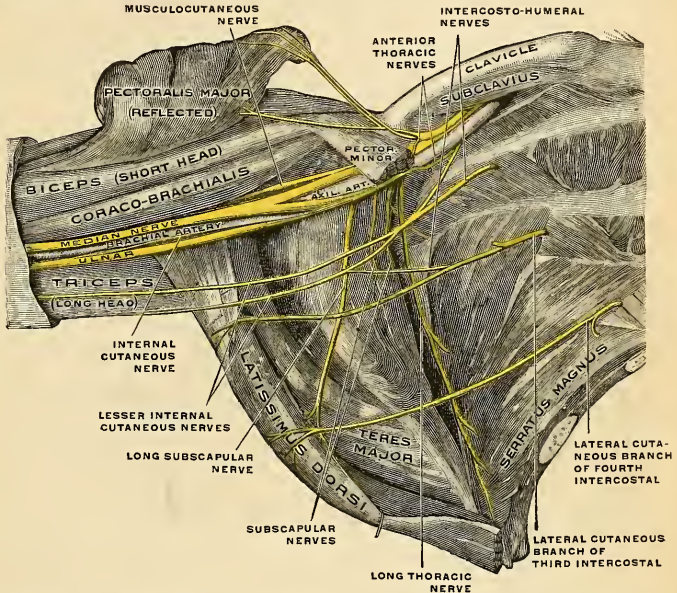


FIG. 764.—The right brachial plexus (infraclavicular portion) in the axillary fossa, viewed from below and in front. The Pectoralis major and minor muscles have been in large part removed; their attachments have been reflected. (Spalteholz.)

From the **right nerve** one or two filaments pass to join in a small ganglion with phrenic branches of the solar plexus; and branches from this ganglion are distributed to the hepatic plexus, the suprarenal gland, and inferior vena cava. From the **left nerve** filaments pass to join the phrenic plexus of the sympathetic, but without any ganglionic enlargement.

Applied Anatomy.—Irritation of the phrenic nerve causes hiccough and persistent cough. Bilateral paralysis of the phrenic causes death from paralysis of the Diaphragm. This form of death is seen by the surgeon in fracture dislocation of the third cervical vertebra. Division of the phrenic on one side is not fatal, and is occasionally practised by the surgeon in removing a tumor of the neck. In Hearn's and Franklin's cases of removal of the vagus the phrenic was also divided. Unilateral division of the phrenic nerve causes paralysis of the corresponding half of the Diaphragm, which is difficult of recognition, because, as Gowers points out, the patient can still take deep inspirations, the thoracic muscles not being paralyzed.

The Deep Branches of the Cervical Plexus. External Series. Communicating Branches.—The deep branches of the external series of the cervical plexus

communicate with the spinal accessory nerve, in the substance of the Sternomastoid muscle, in the posterior triangle, and beneath the Trapezius.

Muscular branches are distributed to the Sternomastoid, Trapezius, Levator anguli scapulae, and Scalenus medius.

The branch for the Sternomastoid is derived from the second cervical; the Trapezius and Levator anguli scapulae receive branches from the third and fourth. The branch for the Scalenus medius is derived sometimes from the third, sometimes from the fourth, and occasionally from both nerves.

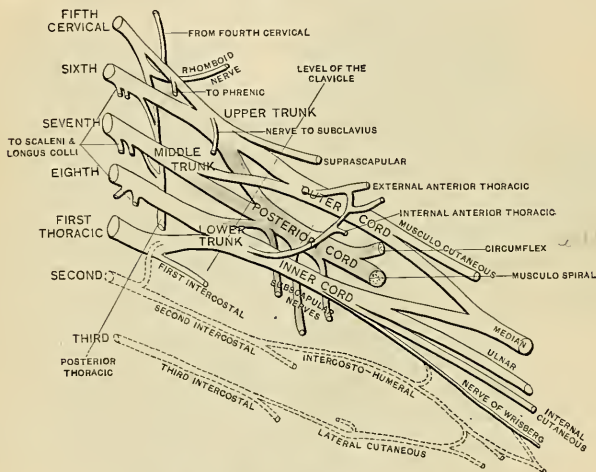


Fig. 765.—Plan of the brachial plexus. (Gerrish.)

Applied Anatomy.—The cervical plexus may be damaged by wounds or contusions, which may or may not be associated with fracture of the clavicle. Paralysis ensues, the extent depending on the degree of damage. After a contusion the paralysis is apt to be temporary and to be followed by pain and muscular spasm in the arm. Paralysis of the arm due to plexus injury may be partial or complete. In some cases there is complete motor palsy and partial sensor palsy, the sensor impulses passing along undamaged collaterals. In certain spasmodic difficulties the surgeon occasionally stretches the cervical plexus. It is reached by an incision at the posterior margin of the Sternomastoid muscle. This incision begins two inches below the level of the tip of the mastoid and is carried downward for three inches.

THE BRACHIAL PLEXUS (PLEXUS BRACHIALIS) (Figs. 763, 764).

The brachial plexus is formed by the union of the anterior primary divisions of the lower four cervical nerves and the greater part of the first thoracic nerve, receiving usually a fasciculus from the fourth cervical nerve, and frequently one from the second thoracic nerve. It extends from the lower part of the side of the neck to the axilla. It is very broad, and presents little of a plexiform arrangement at its commencement. It is narrow opposite the clavicle, becomes broad and forms a more dense interlacement in the axilla, and divides opposite the coracoid process into numerous branches for the supply of the upper limb. The nerves which form the plexus are all similar in size, and their mode of communication is subject to considerable variation, so that no one plan can be given as applying to

every case.¹ The following appears, however, to be the most constant arrangement: **above the clavicle** (*pars supraclavicularis*) the fifth and sixth cervical unite soon after their exit from the intervertebral foramina to form a common trunk. The eighth cervical and first thoracic also unite to form one trunk. So that the nerves

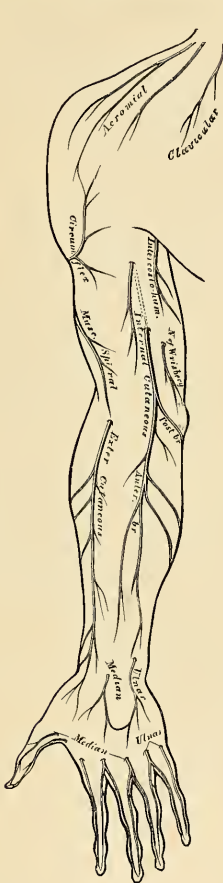


FIG. 766.—Cutaneous nerves of right upper extremity. Anterior view.

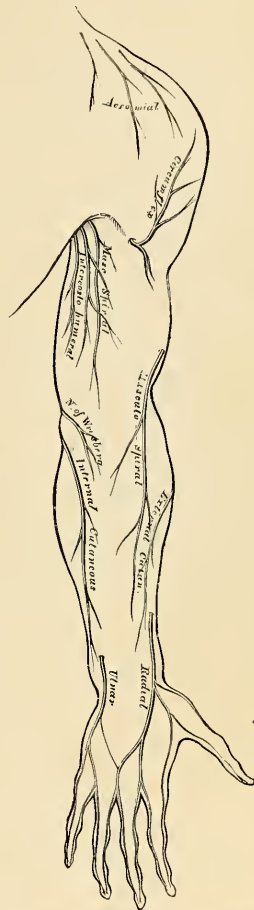


FIG. 767.—Cutaneous nerves of right upper extremity. Posterior view.

forming the plexus, as they lie on the *Scalenus medius* at the outer border of the *Scalenus anticus* muscle, are blended into three **trunks**—an **upper one**, formed

¹ Kerr, Bardeen, and Elting, from a study of 175 brachial plexuses, recognized seven types. In 58 per cent. the outer cord was formed from the fourth to the seventh, the inner cord from the eighth to the ninth spinal nerve, and the posterior or dorsal cord from the fourth to the ninth. In 30 per cent. the outer cord was formed from the fifth to the seventh, the inner cord from the eighth to the ninth, and the posterior cord from the fifth to the ninth.

by the junction of the fifth and sixth cervical nerves; a **middle one**, consisting of the seventh cervical nerve; and a **lower one**, formed by the junction of the eighth cervical and first thoracic nerves. As they pass beneath the clavicle, to compose the **infraclavicular part of the plexus** (*pars infraclavicularis*), each of these three trunks divides into two branches, an **anterior** and a **posterior**. The anterior divisions of the upper and middle trunks then unite to form a common cord, which is situated on the outer side of the middle part of the axillary artery, and is called the **outer cord of the brachial plexus** (*fasciculus lateralis*). The anterior division of the lower trunk passes distally on the inner side of the axillary artery in the middle of the axilla, and forms the **inner cord of the brachial plexus** (*fasciculus medialis*). The posterior divisions of all three trunks unite to form the **posterior cord of the brachial plexus** (*fasciculus posterior*), which is situated behind the second portion of the axillary artery. From this posterior cord are given off the two lower subscapular nerves, the upper subscapular nerve being given off from the posterior division of the upper trunk prior to its junction with the posterior division of the lower and middle trunks. The posterior cord divides into the circumflex and musculospiral nerves.

Branches of Communication.—The brachial plexus communicates with the cervical plexus by a branch from the fourth to the fifth cervical nerve, and with the phrenic nerve by a branch from the fifth cervical, which joins that nerve on the Anterior scalenus muscle; the fifth and sixth cervical nerves are joined by filaments to the middle cervical ganglion of the sympathetic, the seventh and eighth cervical to its inferior ganglion, and the first thoracic nerve to its first thoracic ganglion. Close to their exit from the intervertebral foramina the nerves give off the filaments to the ganglia.

Relations.—**In the neck**, the brachial plexus lies in the posterior triangle, being covered by the skin, Platysma, and deep fascia; it is crossed by the posterior belly of the Omohyoid muscle and by the transversalis colli artery. When the dorsalis scapulae artery arises from the third part of the subclavian it usually passes between the roots of the plexus. The plexus lies at first between the Scalenus anticus and medius, and then above and to the outer side of the subclavian artery; it next passes behind the clavicle and Subclavius muscle, lying upon the first serration of the Serratus magnus, and the Subscapularis muscles. It is in close relation with the apex of the lung (Luschka). **In the axilla** it is placed on the outer side of the first portion of the axillary artery; it surrounds the artery in the second part of its course, one cord lying upon the outer side of that vessel, one on the inner side, and one behind it, and at the lower part of the axillary space gives off its terminal branches to the upper extremity.

Branches of Distribution.—The branches of the brachial plexus are arranged in two groups—viz., those given off **above the clavicle**, and those **below the clavicle**.

SUPRACLAVICULAR BRANCHES.

Communicating	{	with phrenic	5, C.
		with sympathetic	5, 6, 7, 8, C. 1, T.
Muscular . . .	{	Rhomboidei (posterior scapular)	5, C.
		Supraspinatus } Suprascapular	5, 6, C.
	{	Infraspinatus	5, 6, C.
		Subclavius	5, 6, C.
		Serratus magnus (posterior thoracic)	5, 6, 7, C.
		Longus colli	5, 6, 7, 8, C.
		Scaleni	5, 6, 7, 8, C.

The **Communicating Branch** (Figs. 762 and 765) with the **phrenic** is derived from the fifth cervical nerve or from the loop between the fifth and sixth; it joins the phrenic on the Anterior scalenus muscle. The communications with the sympathetic have already been referred to.

The **Muscular Branches** (*rami musculares*) supply the Longus colli, Scaleni, Rhomboidei, and Subclavius muscles. Those for the Longus colli and Scaleni

arise from the four lower cervical nerves at their exit from the intervertebral foramina.

The nerve to the Subclavius (*n. subclavius*) is a small filament which arises from the fifth cervical at its point of junction with the sixth nerve; it descends in front of the third part of the subclavian artery to the Subclavius muscle, and is usually connected by a filament with the phrenic nerve.

The **posterior scapular nerve** (*n. dorsalis scapulae*) (Figs. 763 and 765) arises from the fifth cervical, pierces the Scalenus medius, and passes beneath the Levator anguli scapulae, which it occasionally supplies to the Rhomboid muscles.

The **Long Thoracic** or the **External Respiratory Nerve of Bell** or **Posterior Thoracic Nerve** (*n. thoracalis longus*) (Figs. 763 and 770) supplies the Serratus magnus muscle, and is remarkable for the length of its course. It usually arises by three roots from the fifth, sixth, and seventh nerves, but the root from the seventh may be absent. The roots from the fifth and sixth nerves pierce the Scalenus medius, while that from the seventh emerges in front of that muscle. The nerve passes down behind the brachial plexus and the axillary vessels, resting on the outer surface of the Serratus magnus. It extends along the side of the thorax to the lower border of that muscle, supplying filaments to each of the muscular digitations.

The **Suprascapular Nerve** (*n. suprascapularis*) (Figs. 765 and 770) arises from the trunk formed by the fifth and sixth cervical nerves; passing obliquely outward beneath the Trapezius and the Omohyoid, it enters the supraspinous fossa below the transverse or suprascapular ligament, passes beneath the supraspinatus muscle, and curves around the external border of the spine of the scapula to the infraspinous fossa. In the supraspinous fossa it gives off two branches to the Supraspinatus muscle, and an articular filament to the shoulder-joint; and in the infraspinous fossa it gives off two branches to the Infraspinatus muscle, besides some filaments to the shoulder-joint and scapula.

The **Infraclavicular Branches** (Figs. 764 and 765) are derived from the three cords of the brachial plexus. The fasciculi of which they are composed may be traced through the plexuses to the spinal nerves from which they originate. They are as follows:

Outer cord	{	Musculocutaneous	5, 6, C.
		External anterior thoracic	5, 6, 7, C.
		Outer head of median	6, 7, C.
Inner cord	{	Internal anterior thoracic	8, C. 1, T.
		Internal cutaneous	8, C. 1, T.
		Lesser internal cutaneous	(8, C.) 1, T.
		Ulnar	8, C. 1, T.
		Inner head of median	8, C. 1, T.
Posterior cord	{	Upper subscapular	5, 6, C.
		Middle "	5, 6, 7, C.
		Lower "	5, 6, C.
		Circumflex	5, 6, C.
		Musculospiral	(5), 6, 7, 8, C. (1, T).

These branches from below the clavicle may be arranged according to the parts they supply:

To the thorax	{	Anterior thoracic.
To the shoulder	{	Subscapulars.
	{	Circumflex.
	{	Musculocutaneous.
	{	Internal cutaneous.
To the arm, forearm, and hand	{	Lesser internal cutaneous.
	{	Median.
	{	Ulnar.
	{	Musculospiral.

The **Anterior Thoracic Nerves** (*nn. thoracales anteriores*) (Figs. 764 and 765), two in number, supply the Pectoral muscles.

The **external anterior thoracic nerve** (Figs. 763 and 770), the larger of the two, *arises* from the outer cord of the brachial plexus, through which its fibres may be traced to the fifth, sixth, and seventh cervical nerves. It passes inward, across the axillary artery and vein, pierces the costocoracoid membrane, and is distributed to the under surface of the Pectoralis major muscle. It sends down a communicating filament to join the internal anterior thoracic nerve, and this communicating filament forms a loop around the inner side of the axillary artery.

The **internal anterior thoracic nerve** *arises* from the inner cord and through it from the eighth cervical and first thoracic nerves. It passes behind the first part of the axillary artery, then curves forward between the axillary artery and vein, and joins with the filament from the external nerve. It then passes to the under surface of the Pectoralis minor muscle, where it divides into a number of branches, which supply the muscle on its under surface. Some two or three branches pass through the muscle and reach the Pectoralis major.

The **Subscapular Nerves** (*nn. subscapulares*) (Figs. 764 and 765), three in number, *arise* from the posterior cord of the plexus and supply the Subscapularis, Teres major, and Latissimus dorsi muscles, and give filaments to the shoulder-joint. The fasciculi of which they are composed may be traced to the fifth, sixth, seventh, and eighth cervical nerves.

The **upper or short subscapular nerve**, the smallest, *arises* from the posterior division of the upper trunk of origin of the brachial plexus, and enters the upper part of the Subscapularis muscle; this nerve is frequently represented by two branches.

The **lower subscapular nerve** *arises* from the posterior cord of the brachial plexus, enters the axillary border of the Subscapularis, and terminates in the Teres major. The latter muscle is sometimes supplied by a separate branch.

The **middle or long subscapular nerve** (*n. thoracodorsalis*) (Fig. 764), the largest of the three, *arises* from the posterior cord of the brachial plexus and follows the course of the subscapular artery, along the posterior wall of the axilla to the Latissimus dorsi muscle, through which it may be traced as far as its lower border.

The **Circumflex Nerve** (*n. axillaris*) (Figs. 765 and 771) supplies some of the muscles, the shoulder-joint, and the integument of the shoulder (Figs. 767 and 768). It *arises* from the posterior cord of the brachial plexus, in common with the musculospiral nerve, and its fibres may be traced through the posterior cord to the fifth and sixth cervical nerves. It is at first placed behind the axillary artery, between it and the Subscapularis muscle, and passes downward and outward to the lower border of that muscle. It then winds posteriorly in company with the posterior circumflex artery, through a **quadrilateral space** bounded above by the Teres minor muscle, below by the Teres major muscle, internally by the long head of the Triceps muscle, and externally by the neck of the humerus. The nerve then divides into two branches.

The **upper branch** (Fig. 771) winds posteriorly around the surgical neck of the humerus, beneath the Deltoid, with the posterior circumflex vessels, as far as the anterior border of that muscle, supplying it, and giving off cutaneous branches, which pierce the muscle and ramify in the integument covering its lower part (Fig. 768),

The **lower branch** (Fig. 771). at its origin, distributes filaments to the Teres minor and back part of the Deltoid muscles. Upon the filaments to the former muscle an oval enlargement usually exists. The nerve then pierces the deep fascia, and supplies the integument over the lower two-thirds of the posterior surface of the Deltoid (*n. cutaneus brachii lateralis*), as well as that covering the long head of the Triceps (Fig. 772).

The circumflex nerve, before its division, gives off an **articular filament**, which enters the shoulder-joint below the Subscapularis muscle.

The **Musculocutaneous** (*n. musculocutaneus*) (Figs. 765 and 770) arises from the outer cord of the brachial plexus, opposite the lower border of the Pectoralis minor muscle, receiving filaments from the fifth, sixth, and seventh cervical nerves. It perforates the Coracobrachialis muscle (Fig. 770), passes obliquely between the Biceps and Brachialis anticus muscles to the outer side of the arm, and, a little above the elbow, winds around the outer border of the tendon of the Biceps, and, perforating the deep fascia, becomes cutaneous (Fig. 766). In its course through the arm this nerve supplies the Coracobrachialis, Biceps, and the greater part of the Brachialis anticus muscles. The branch to the Coracobrachialis is given off from the nerve close to its origin, and in some instances as a separate filament from the outer cord of the plexus. The branches to the Biceps and Brachialis anticus are given off after the nerve has pierced the Coracobrachialis. The nerve also sends a small branch to the humerus, which enters the nutrient foramen with the accompanying artery, and a filament from the branch supplying the Brachialis anticus goes to the elbow-joint. The musculocutaneous furnishes the chief nerve supply to this joint.

The cutaneous portion of the musculocutaneous nerve (*n. cutaneus antebrachii lateralis*) passes behind the median cephalic vein, and divides, opposite the elbow-joint, into an anterior and a posterior branch.

The anterior branch descends along the radial border of the forearm to the wrist, and supplies the integument over the outer half of its anterior surface. At the wrist-joint it is placed in front of the radial artery, and some filaments, piercing the deep fascia, accompany that vessel to the dorsum of

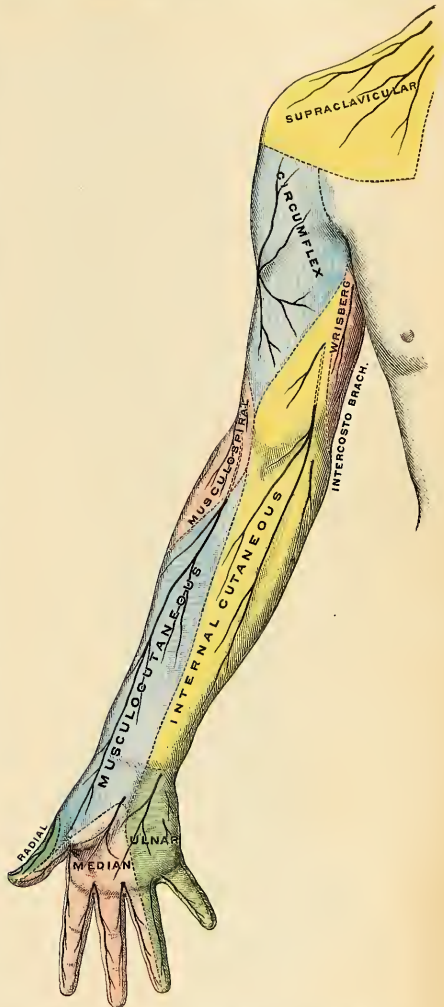


FIG. 76S.—Cutaneous nerves of the upper limb, anterior aspect. (W. Keiller, in Gerrish's Text-book of Anatomy.)

the wrist, supplying the carpus. The nerve then passes downward to the ball of the thumb, where it terminates in cutaneous filaments. It communicates with a

branch from the radial nerve and with the palmar cutaneous branch of the median.

The **posterior branch** passes downward along the back part of the radial side of the forearm to the wrist. It supplies the integument of the lower third of the forearm, communicating with the radial nerve and the external cutaneous branch of the musculospiral. The cutaneous areas supplied by the musculocutaneous nerve are indicated in Figs. 768 and 769.

Variations.—The musculocutaneous nerve presents frequent irregularities. It may adhere for some distance to the median and then pass outward, beneath the Biceps, instead of through the Coracobrachialis. Frequently some of the fibres of the median run for some distance in the musculocutaneous and then leave it to join their proper trunk. Less frequently the reverse is the case, and the median sends a branch to join the musculocutaneous. Instead of piercing the Coracobrachialis muscle the nerve may pass under it or through the Biceps. Occasionally it gives a filament to the Pronator teres muscle, and it has been seen to supply the back of the thumb when the radial nerve was absent.

The **Internal Cutaneous Nerve** (*n. cutaneus antebrachii medialis*) (Figs. 765 and 770). or **medial cutaneous nerve** of the forearm, is one of the smallest branches of the brachial plexus. It *arises* from the inner cord in common with the ulnar nerve and internal head of the median nerve, and, at its commencement, is placed on the inner side of the axillary artery,

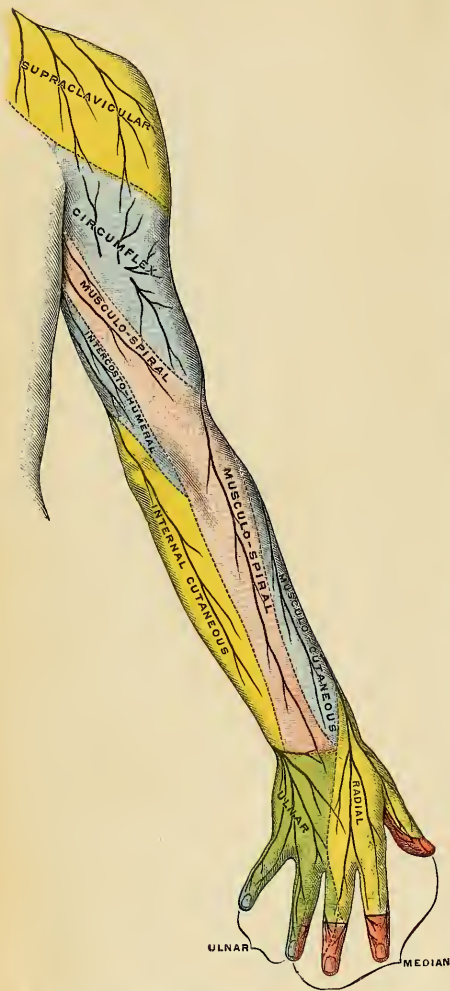
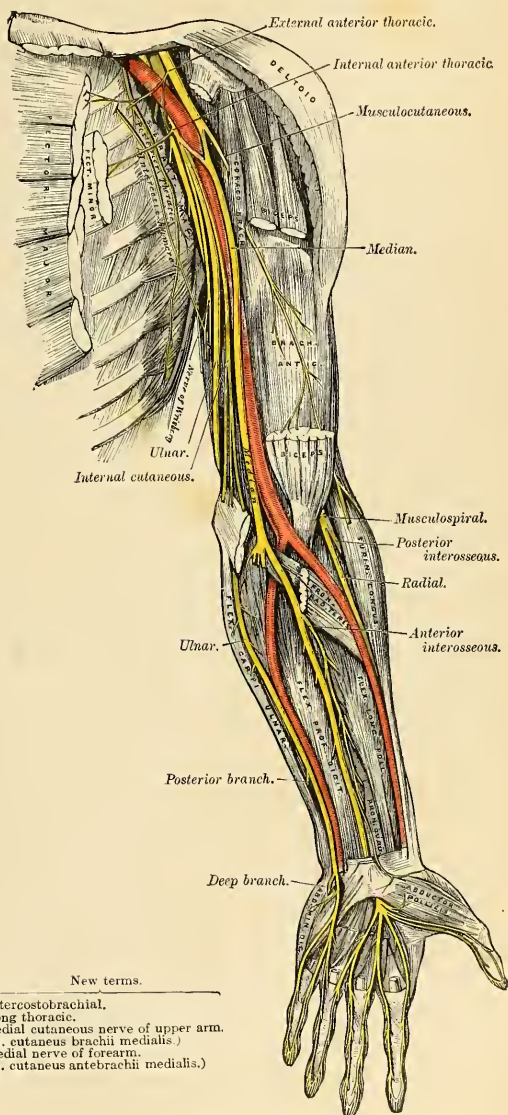


FIG. 769.—Cutaneous nerves of the upper limb, posterior aspect. (W. Keiller, in Gerrish's Text-book of Anatomy.)

and afterward of the brachial artery. It derives its fibres from the eighth cervical and first thoracic nerves. This nerve gives off, near the axilla, a cutaneous filament, which pierces the fascia and supplies the integument covering the Biceps

muscle nearly as far as the elbow. This filament lies a little external to the common trunk, from which it arises. It passes down the inner side of the arm,



Old terms.	New terms.
Intercostohumeral	= Intercostobrachial.
Posterior thoracic	= Long thoracic.
Nerve of Wrisberg	= Medial cutaneous nerve of upper arm. (N. cutaneus brachii medialis.)
Internal cutaneous	= Medial nerve of forearm. (N. cutaneus antebrachii medialis.)

FIG. 770.—Nerves of the left upper extremity.

pierces the deep fascia with the basilic vein, about the middle of the limb, and, becoming cutaneous, divides into two branches, **anterior** and **posterior**.

The **anterior branch**, the larger of the two, passes usually in front of, but occasionally behind, the median basilic vein. It then descends on the anterior surface of the ulnar side of the forearm, distributing filaments to the integument as far as the wrist, and communicating with a cutaneous branch of the ulnar nerve (Fig. 766).

The **posterior branch** passes obliquely downward on the inner side of the basilic vein, passes in front of, or over, the internal condyle of the humerus to the back of the forearm, and descends on the posterior surface of its ulnar side as far as the wrist, distributing filaments to the integument (Fig. 767). It communicates, above the elbow, with the lesser internal cutaneous nerve, the lower external cutaneous branch of the musculospiral, and above the wrist with the posterior cutaneous branch of the ulnar nerve. The cutaneous areas supplied by the internal cutaneous nerve are indicated in Figs. 768 and 769).

The **Lesser Internal Cutaneous Nerve**, or the **Nerve of Wrisberg** (*n. cutaneus brachii medialis*) (Figs. 765 and 770), is distributed to the integument on the inner side of the arm. It is the smallest of the branches of the brachial plexus, and, *arising* from the inner cord, receives its fibres from the first thoracic nerve. It passes through the axillary space, at first lying behind, and then on the inner side of, the axillary vein, and communicates with the intercostohumeral nerve. It descends along the inner side of the brachial artery to the middle of the arm, where it pierces the deep fascia, and is distributed to the integument of the back of the lower third of the arm, extending as far as the elbow (Figs. 767 and 768), where some filaments are lost in the integument in front of the inner condyle, and others over the olecranon. It communicates with the posterior branch of the internal cutaneous nerve.

In some cases the nerve of Wrisberg and the intercostohumeral nerve are connected by two or three filaments which form a plexus at the back part of the axilla. In other cases the intercostohumeral is of large size, and takes the place of the nerve of Wrisberg, receiving merely a filament of communication from the brachial plexus, which filament represents the latter nerve. In other cases this filament is wanting, the place of the nerve of Wrisberg being supplied entirely by the intercostohumeral.

The **Median Nerve** (*n. medianus*) (Figs. 764 and 770) extends along the middle of the arm and forearm to the hand, lying between the ulnar and musculospiral nerves, and the ulnar and the radial nerves. It *arises* by two roots, one from the outer and one from the inner cord of the brachial plexus; these embrace the lower part of the axillary artery, uniting either in front or on the outer side of that vessel. The median nerve receives filaments from the sixth, seventh, and eighth cervical and the first thoracic nerves, and sometimes from the fifth cervical as well. As it descends through the arm, it lies at first on the outer side of the brachial artery, crosses that vessel in the middle of its course, usually in front, but occasionally behind it, and lies on its inner side to the bend of the elbow, where it is situated beneath the bicipital fascia, and is separated from the elbow-joint by the Brachialis anticus muscle. In the forearm it passes between the two heads of the Pronator teres muscle and crosses the ulnar artery, but is separated from that vessel by the deep head of the Pronator teres. It descends beneath the Flexor sublimis muscle, lying on the Flexor profundus muscle, to within two inches (5 cm.) above the annular ligament, where it becomes more superficial, lying between the tendons of the Flexor sublimis and Flexor carpi radialis muscles, beneath, and rather to the radial side or under the tendon of the Palmaris longus, covered by the integument and fascia. It then passes through the **carpal canal** beneath the annular ligament into the palm of the hand. In its course through the forearm it is

accompanied by the *arteria comes nervi mediani*, a branch of the anterior interosseous artery.

Branches.—With the exception of the *nerve to the Pronator teres muscle*, which sometimes arises above the elbow-joint, and filaments to the elbow-joint, the median nerve gives off no branches in the arm. In the forearm its branches are the **muscular, anterior interosseous, and palmar cutaneous**.

The **muscular branches** (*rami musculares*) are derived from the nerve near the elbow and supply all the superficial muscles on the front of the forearm except the Flexor carpi ulnaris.

The **anterior or volar interosseous** (*n. interosseus [antebrachii] volaris*) (Fig. 770) supplies the deep muscles on the front of the forearm, except the inner half of the Flexor profundus digitorum. It accompanies the anterior interosseous artery along the interosseous membrane, in the interval between the Flexor longus pollicis and Flexor profundus digitorum muscles, both of which it supplies, and terminates below in the Pronator quadratus muscle, sending filaments to the inferior radioulnar articulation and the wrist-joint.

The **palmar cutaneous branch** (*ramus cutaneus palmaris n. mediani*) arises from the median nerve at the lower part of the forearm. It pierces the fascia above the annular ligament, and, descending over that ligament, divides into two branches, of which the **outer branch** supplies the skin over the ball of the thumb, and communicates with the anterior cutaneous branch of the musculocutaneous nerve; and the **inner branch** supplies the integument of the palm of the hand, communicating with the cutaneous branch of the ulnar.

In the **palm of the hand** the median nerve is covered by the integument and palmar fascia and is crossed by the superficial palmar arch. It rests upon the tendons of the flexor muscles. In this situation it becomes enlarged, somewhat flattened, of a reddish color, and divides into two branches. Of these, the **external branch** supplies a muscular branch to some of the muscles of the thumb and digital branches to the thumb and radial side of the index finger; the **internal branch** supplies digital branches to the contiguous sides of the index and middle and of the middle and ring fingers. The digital branches, before they subdivide, are called **common palmar digital branches of the median nerve** (*nn. digitales volares communes*).

The **branch to the muscles of the thumb** (*ramus muscularis*) is a short nerve which divides to supply the Abductor, Opponens, and the superficial head of the Flexor brevis pollicis muscles, the remaining muscles of this group being supplied by the ulnar nerve.

The **digital branches** (*nn. digitales volares proprii*) are five in number. The **first** and **second** pass along the borders of the thumb, the external branch communicating with branches of the radial nerve. The **third** passes along the radial side of the index finger, and supplies the First lumbricalis muscle. The **fourth** subdivides to supply the adjacent sides of the index and middle fingers, and sends a branch to the Second lumbricalis muscle. The **fifth** supplies the adjacent sides of the middle and ring fingers, and communicates with a branch from the ulnar nerve.

Each digital nerve, opposite the base of the first phalanx, gives off a dorsal branch, which joins the dorsal digital nerve from the radial nerve and runs along the side of the dorsum of the finger, to end in the integument over the last phalanx. At the end of the finger the digital nerve divides into a palmar and a dorsal branch, the former of which supplies the extremity of the finger, and the latter ramifies around and beneath the nail.

The digital nerves, as they run along the fingers, are placed superficial to the digital arteries. The cutaneous areas supplied by the median nerve are shown in Figs. 768 and 769).

The **Ulnar Nerve** (*n. ulnaris*) (Figs. 764 and 770) is situated along the inner or ulnar side of the upper limb, and is distributed to the muscles and integument of the forearm and hand. It is smaller than the median, behind which it is placed, diverging from it in its course down the arm. It *arises* from the inner cord of the brachial plexus, in common with the inner head of the median and the internal cutaneous nerves, and derives its fibres from the eighth cervical and first thoracic nerves. At its origin it lies to the inner side of the axillary artery, and holds the same relation with the brachial artery to the middle of the arm. Here it pierces the intermuscular septum, runs obliquely across the internal head of the Triceps, and descends to the groove between the internal condyle and the olecranon, accompanied by the inferior profunda artery. **At the elbow** it rests upon the back of the inner condyle, and passes into the forearm between the two heads of the Flexor carpi ulnaris muscle. **In the forearm** it descends in a perfectly straight course along the ulnar side of the extremity, lying upon the Flexor profundus digitorum muscle, its upper half being covered by the Flexor carpi ulnaris muscle, its lower half lying on the outer side of the muscle, being covered by the integument and fascia. In the upper third of its course, it is separated from the ulnar artery by a considerable interval, but in the rest of its extent the nerve lies to the inner side of the artery. **At the wrist** the ulnar nerve crosses the annular ligament on the outer side of the pisiform bone, to the inner side of and a little behind the ulnar artery, and immediately beyond this bone divides into two branches, the superficial and the deep palmar.

Branches.—The branches of the ulnar nerve are:

In the forearm	{	Articular (elbow).	In the hand	{	Superficial palmar.
		Muscular.			Deep palmar.
		Cutaneous.			
		Dorsal cutaneous.			
		Articular (wrist).			

The **articular branches** to the elbow-joint consist of several small filaments. They *arise* from the nerve as it lies in the groove between the inner condyle of the humerus and the olecranon.

The **muscular branches** (*rami musculares*), two in number, *arise* from the trunk of the nerve near the elbow; one supplies the Flexor carpi ulnaris; the other, the inner half of the Flexor profundus digitorum.

The **cutaneous branches** are two in number, **palmar** and **dorsal**.

The **palmar cutaneous branch** (*ramus cutaneus palmaris*) *arises* from the ulnar nerve at about the middle of the forearm and runs downward on the ulnar artery, giving off some filaments entwining around the vessel. Just above the annular ligament it pierces the deep fascia and ends in the integument of the palm, communicating with the palmar cutaneous branch of the median nerve.

The **dorsal cutaneous branch** (*ramus dorsalis manus*) *arises* about two inches above the wrist; it passes posteriorly beneath the Flexor carpi ulnaris, perforates the deep fascia, and, running along the ulnar side of the back of the wrist and hand, divides into branches (*nn. digitales dorsales*); one of these supplies the inner side of the little finger; a second supplies the adjacent sides of the little and ring fingers; a third joins the branch of the radial nerve which supplies the adjoining sides of the middle and ring fingers, and assists in supplying them; a fourth is distributed to the metacarpal region of the hand, communicating with a branch of the radial nerve.

On the little finger the posterior digital branches extend only as far as the base of the terminal phalanx, and on the ring finger as far as the base of the second phalanx; the more distal parts of these digits are supplied by posterior branches derived from the palmar digital branches of the ulnar.

The **superficial palmar branch** (*ramus superficialis n. ulnaris*) supplies the *Palmaris brevis* and the integument on the inner side of the hand, and terminates in two digital branches, which are distributed, one to the ulnar side of the little finger, the other to the adjoining sides of the little and ring fingers, the latter communicating with a branch from the median. The digital branches are distributed to the fingers in the same manner as the digital branches of the median.

The **deep palmar branch** (*ramus profundus n. ulnaris*), accompanied by the deep branch of the ulnar artery, passes between the *Abductor* and *Flexor brevis minimi digiti* muscles; it then perforates the *Opponens minimi digiti* and follows the course of the deep palmar arch beneath the flexor tendons. At its origin it supplies the muscles of the little finger. As it crosses the deep part of the hand it sends two branches to each interosseous space, one for the Dorsal and one for the Palmar interosseous muscle, the branches to the Second and Third palmar interossei supplying filaments to the two inner Lumbrical muscles. At its termination between the thumb and index finger it supplies the *Adductores transversus et obliquus pollicis* and the inner head of the *Flexor brevis pollicis*. It also sends articular filaments to the wrist-joint.

It will be remembered that the inner part of the *Flexor profundus digitorum* muscle is supplied by the ulnar nerve; the two inner Lumbricales, which are connected with the tendons of this part of the muscle, are therefore supplied by the same nerve. The outer part of the *Flexor profundus* is supplied by the median nerve; the two outer Lumbricales, which are connected with the tendons of this part of the muscle, are therefore supplied by the same nerve. Brooks states that in twelve instances out of twenty-one he found that the Third lumbrical received a twig from the median nerve, in addition to its branch from the ulnar. The cutaneous areas supplied by the ulnar nerve are shown in Figs. 768 and 769.

The **Musculospiral Nerve** (*n. radialis*) (Figs. 770 and 771), the largest branch of the brachial plexus, supplies the muscles of the back part of the arm and forearm, and the integument of the same parts, as well as that of the back of the hand (Figs. 768 and 769). It arises from the posterior cord of the brachial plexus, of which it may be regarded as the continuation. Its fibres are derived from the sixth, seventh, and eighth, and sometimes also from the fifth cervical and first thoracic nerves. At its commencement it is placed first behind the axillary artery and then behind the upper part of the brachial artery, passing down in front of the tendons of the *Latissimus dorsi* and *Teres major*. It winds around from the inner to the outer side of the humerus in the musculospiral groove with the superior profunda artery, between the internal and external heads of the *Triceps* muscle (Fig. 771). It pierces the external intermuscular septum, and descends between the *Brachialis anticus* and *Brachioradialis* muscles to the front of the external condyle of the humerus, where it divides into the radial and posterior interosseous nerves.

The branches of the musculospiral nerve are:

Muscular.	Radial.
Cutaneous.	Posterior interosseous.

The **muscular branches** (*rami musculares n. radialis*) are derived from the nerve at the inner side, back part, and outer side of the arm respectively; they supply the *Triceps*, *Anconeus*, *Brachioradialis*, *Extensor carpi radialis longior*, and *Brachialis anticus* muscles. The **internal muscular branches** supply the inner and middle heads of the *Triceps* muscle. That to the inner head of the *Triceps* is a long, slender filament which lies close to the ulnar nerve, as far as the lower third of the arm, and is therefore frequently spoken of as the **ulnar collateral branch**. The **posterior muscular branch**, of large size, arises from the nerve in the groove between the *Triceps* muscle and the humerus. It divides into branches which

supply the outer and inner heads of the Triceps and Anconeus muscles. The branch for the latter muscle is a long, slender filament which descends in the substance of the Triceps to the Anconeus. The **external muscular branches** supply

Suprascapular.

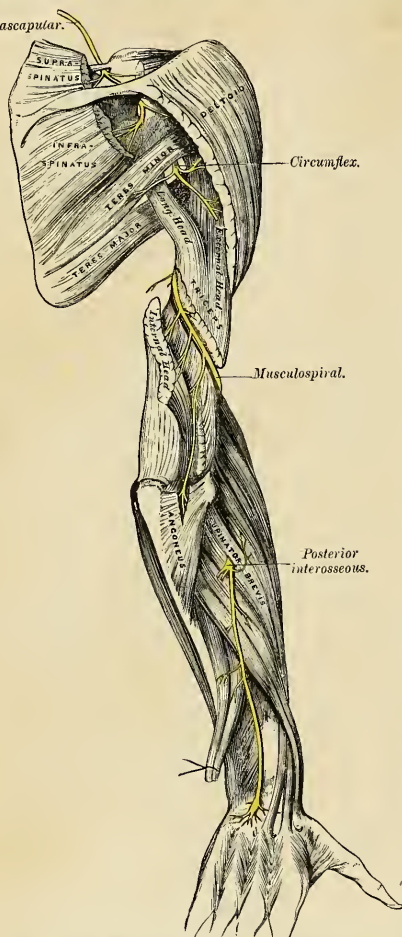


FIG. 771.—The suprascapular, circumflex, and musculospiral nerves.

the Brachioradialis, Extensor carpi radialis longior, and (usually) the outer part of the Brachialis anticus muscles.

The **cutaneous branches** are three in number, one **internal** and two **external**. The **internal cutaneous branch** (*n. cutaneus brachii posterior*) arises in the axillary space with the inner muscular branch. It is of small size, and passes through the axilla to the inner side of the arm, supplying the integument on its posterior aspect nearly as far as the olecranon. In its course it crosses beneath the intercostohumeral nerve, with which it communicates. The **external cutaneous branch** (*n. cutaneus antebrachii dorsalis*) divides into two branches, and each one perforates the outer head of the Triceps muscle at its attachment to the humerus. The **upper** and smaller one passes to the front of the elbow, lying close to the cephalic vein, and supplies the integument of the lower half of the arm on its anterior aspect. The **lower branch** pierces the deep fascia below the insertion of the Deltoid muscle, and passes down along the outer side of the arm and elbow, and then along the back part of the radial side of the forearm to the wrist, supplying the integument in its course, and joining, near its termination, with the posterior cutaneous branch of the musculocutaneous nerve.

The **Radial Nerve** (*ramus superficialis n. radialis*) (Fig. 770), passes along the front of the radial side of the forearm to the commencement of its lower third. It lies at first a little to the outer side of the radial artery, concealed beneath the Brachioradialis. In the middle third of the forearm it lies beneath the same muscle, in close relation with the outer side of the artery. It leaves the artery about three inches above the wrist, passes beneath the tendon of the Brachio-

radialis, and, piercing the deep fascia at the outer border of the forearm, divides into two branches. The **external branch**, the smaller of the two, supplies the integument of the radial side and ball of the thumb, joining with the anterior branch of the musculocutaneous nerve. The **internal branch** communicates, above the wrist, with the posterior cutaneous branch from the musculocutaneous, and on the back of the hand forms an arch with the dorsal cutaneous branch of the ulnar nerve. It then divides into four **digital nerves** (*nn. digitales dorsales*), which are distributed as follows: The first supplies the ulnar side of the thumb; the second, the radial side of the index finger; the third, the adjoining sides of the index and middle fingers; and the fourth, the adjacent borders of the middle and ring fingers.¹ The latter nerve communicates with a filament from the posterior branch of the ulnar nerve.

The **Dorsal or Posterior Interosseous Nerve** (*n. interosseous [antebrachii] dorsalis*) (Figs. 770 and 771) winds to the back of the forearm around the outer side of the radius, passes between the two planes of fibres of the Supinator [*brevis*] muscle, and is prolonged downward, between the superficial and deep layer of muscles, to the middle of the forearm. Considerably diminished in size, it descends on the interosseous membrane, beneath the Extensor longus pollicis muscle, to the back of the carpus, where it presents a gangliform enlargement from which filaments are distributed to the inferior radioulnar articulation, to the wrist-joint, and to the ligaments and articulations of the carpus. It supplies all the muscles of the radial and posterior cubital regions, excepting the Anconeus, Supinator longus, and Extensor carpi radialis longior.

Applied Anatomy.—The brachial plexus may be severed by traction on the limb, leading to complete paralysis. Bristow² has reported three cases of avulsion of the plexus and has described twenty-four cases. In these cases it is generally believed that the lesion is rather a tearing away of the nerves from the spinal cord than a solution of continuity of the nerve fibres themselves. In a case operated upon by Bristow it was found that the plexus had given way where the four cervical nerves and the first thoracic nerve unite to form three trunks. In supra-clavicular division of the brachial plexus, not only will there be motor and sensor paralysis in the limb, but the Serratus magnus muscle will probably be paralyzed, because of injury to the posterior thoracic nerves. In the axilla any of the nerves forming the brachial plexus may be injured by a wound of this part, the median being the one which is most frequently damaged from its exposed position. The musculospiral, on account of its sheltered and deep position, is least often wounded. The brachial plexus in the axilla is often damaged from the pressure of a crutch, producing the condition known as *crutch paralysis*. In these cases the musculospiral is the nerve most frequently implicated; the ulnar nerve being the one that appears to suffer next in frequency.

The *circumflex nerve* is of particular surgical interest. On account of its course around the surgical neck of the humerus, it is liable to be torn in fractures of this part of the bone, and in dislocations of the shoulder-joint, leading to paralysis of the Deltoid, and, according to Erb, inflammation of the shoulder-joint is liable to be followed by a neuritis of this nerve from extension of the inflammation to it.

Hilton takes the *circumflex nerve* as an illustration of a law which he lays down, that "*the same trunks of nerves whose branches supply the groups of muscles moving a joint furnish also a distribution of nerves to the skin over the insertions of the same muscles, and the interior of the joint receives its nerves from the same source.*" In this way he explains the fact that an inflamed joint becomes rigid, because the same nerves which supply the interior of the joint supply the muscles which move that joint.

The *median nerve* is liable to injury in wounds of the forearm. When paralyzed, there is loss of flexion of the second phalanges of all the fingers and of the terminal phalanges of the index and middle fingers. Flexion of the terminal phalanges of the ring and middle fingers can still be effected by that portion of the Flexor profundus digitorum which is supplied by the ulnar nerve. There is power to flex the proximal phalanges through the Interossei. The thumb cannot be flexed or opposed, and is maintained in a position of extension and adduction. All power of pronation is lost. The wrist can be flexed, if the hand is first adducted, by the action

¹ According to Hutchinson, the digital nerve to the thumb reaches only as high as the root of the nail; the one to the forefinger as high as the middle of the second phalanx, and the one to the middle and ring fingers not higher than the first phalangeal joint (London Hospital Gazette, vol. iii, p. 319).

² Annals of Surgery, September, 1902.

of the Flexor carpi ulnaris. There is loss or impairment of sensation on the palmar surface of the thumb, index, middle, and outer half of the ring fingers, and on the dorsal surface of the same fingers over the last two phalanges; except in the thumb, where the loss of sensation is limited to the back of the last phalanx. In order to expose the median nerve for the purpose of *stretching* it an incision should be made along the radial side of the tendon of the Palmaris longus muscle, which serves as a guide to the nerve.

The *ulnar nerve* is liable to be injured in wounds of the forearm. When paralyzed, there is loss of power of flexion in the ring and little fingers; there is impaired power of ulnar flexion and adduction of the hand; there is inability to spread out the fingers from paralysis of the Interossei; and there is inability to adduct the thumb. The fingers cannot be flexed at the first joints, and cannot be extended at the other joints. A *claw hand* develops, the first phalanges being overextended and the others flexed. Sensation is lost or impaired in the skin of the ulnar side of the hand anteriorly and posteriorly, involving the little finger, the ring finger, and the ulnar half of the middle finger posteriorly, and anteriorly involving the little finger and the ulnar half of the ring finger. In order to expose the nerve in the lower part of the forearm, an incision should be made along the outer border of the tendon of the Flexor carpi ulnaris, and the nerve will be found lying on the ulnar side of the ulnar artery.

The *musculospiral nerve* is probably more frequently injured than any other nerve of the upper extremity. In consequence of its close relationship to the humerus as it lies in the musculospiral groove, it is frequently torn or injured in fractures of this bone, or subsequently involved in the callus that may be thrown out around a fracture, and thus pressed upon and its functions interfered with. It is also liable to be squeezed against the bone by kicks or blows; it may be divided by wounds of the arm. When paralyzed, the hand is flexed at the wrist and lies flaccid. This condition is known as *drop wrist*. The fingers are also flexed, and on an attempt being made to extend them the last two phalanges only will be extended through the action of the Interossei, the first phalanges remaining flexed. There is no power of extending the wrist. Supination is completely lost when the forearm is extended on the arm, but is possible to a certain extent if the forearm is flexed so as to allow of the action of the Biceps. The power of extension of the forearm is lost on account of paralysis of the Triceps. Loss of sensation may be considerable or slight. Its area is shown in Fig. 769. The best position in which to expose the nerve for the purpose of stretching is to make an incision along the inner border of the Brachioradialis muscle, just above the level of the elbow-joint. The skin and superficial structures are to be divided and the deep fascia exposed. The white line in this structure indicating the border of the muscle is to be defined, and the deep fascia divided in this line. By now raising the Brachioradialis the nerve will be found lying beneath it, on the Brachialis anticus muscle.

Postanesthetic paralysis. When a person emerges from the influence of a general anesthetic palsy of the arm may be found to exist. The brachial plexus may have been compressed during the operation by drawing the arm strongly from the body or elevating it by the side of the head. In such a case the plexus was compressed by the head of the humerus (Braun).

The median nerve is stretched when the arm is rotated externally and drawn backward and outward. The ulnar nerve is stretched when the forearm is flexed and supinated (Braun). Garrigues believes that in most cases of postanesthetic paralysis the brachial plexus was squeezed between the collar bone and the first rib by the head of the patient being drawn to the opposite side or being allowed to fall back.

The Anterior or Ventral Divisions of the Thoracic Nerves (*rami anteriores*).—The anterior primary divisions of the thoracic nerves are twelve in number on each side. Eleven of them are situated between the ribs, and are therefore termed *intercostal*; the twelfth lies below the last rib. Each nerve is connected with the adjoining ganglion of the sympathetic by one or two filaments (*ramus communicans*). The intercostal nerves are distributed chiefly to the parietes of the thorax and abdomen and differ from the anterior divisions of the other spinal nerves in that there is no plexus formation, each nerve running an independent course. The first two nerves supply fibres to the upper limb in addition to their thoracic branches; the next four are limited in their distribution to the parietes of the thorax; the five lower supply the parietes of the thorax and abdomen; the twelfth thoracic is distributed to the abdominal wall and the skin of the buttock.

The **Anterior Division of the First Thoracic Nerve** divides into two branches; one, the larger, leaves the thorax in front of the neck of the first rib, and enters into the formation of the **brachial plexus**; the other and smaller branch runs along the first intercostal space, forming the **first intercostal nerve** (*n. intercostalis I*),

giving off muscular branches, and terminates on the anterior part of the thorax by forming the **first anterior cutaneous nerve** (*ramus cutaneus anterior n. intercostalis I*) of the thorax. Occasionally this anterior cutaneous branch is wanting. The first intercostal nerve, as a rule, gives off no lateral cutaneous branch, but sometimes a small branch is given off which communicates with the intercostohumeral. It frequently receives a connecting twig from the second thoracic nerve, which passes upward over the neck of the second rib.

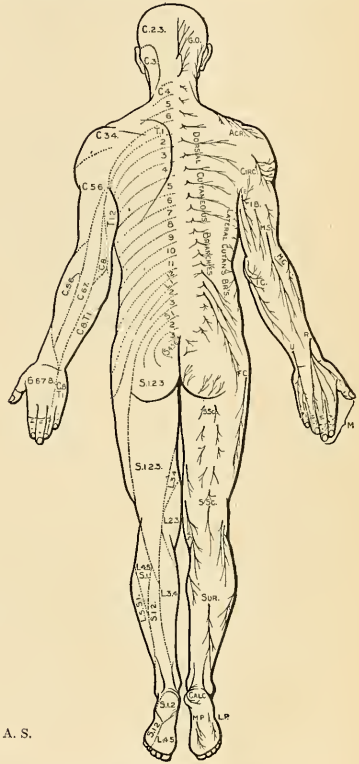
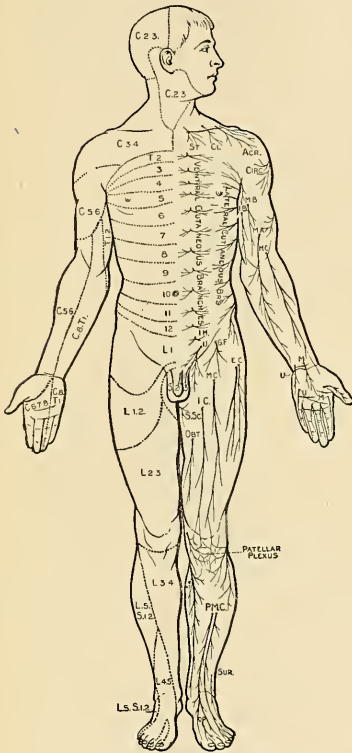


FIG. 772.—Anterior aspect.

FIG. 773.—Posterior aspect.

FIGS. 772 and 773.—Distribution of cutaneous nerves.

The **Anterior Divisions of the Second, Third, Fourth, Fifth, and Sixth Thoracic Nerves** and the **Small Branch from the First Thoracic Nerve** (*nn. intercostales*) are confined to the parietes of the thorax, and are named **thoracic intercostal nerves**. They pass forward in the intercostal spaces below the intercostal vessels. At the back of the thorax they lie between the pleura and the posterior intercostal membrane, piercing the latter, and course between the two planes of Intercostal muscles as far as the middle of the rib. They then enter the substance of the Internal intercostal muscles, and, running amidst their fibres as far as the costal cartilages, they gain the inner surface of the muscles, and lie between them and the pleura.

Near the sternum, they cross in front of the internal mammary artery and Triangularis sterni muscle, pierce the Internal intercostal muscles, the anterior intercostal membrane, and Pectoralis major muscle, and supply the integument of the anterior wall of the thorax and over the mammary gland, forming the anterior cutaneous nerves of the thorax; the branch from the second nerve is joined with the supraclavicular nerves of the cervical plexus.

Branches.—Numerous slender **muscular filaments** (*rami musculares*) supply the Intercostals, the Infracostales, the Levatores costarum, the Serratus posticus superior, and the Triangularis sterni muscles. At the front of the thorax some of these branches cross the costal cartilages from one intercostal space to another.

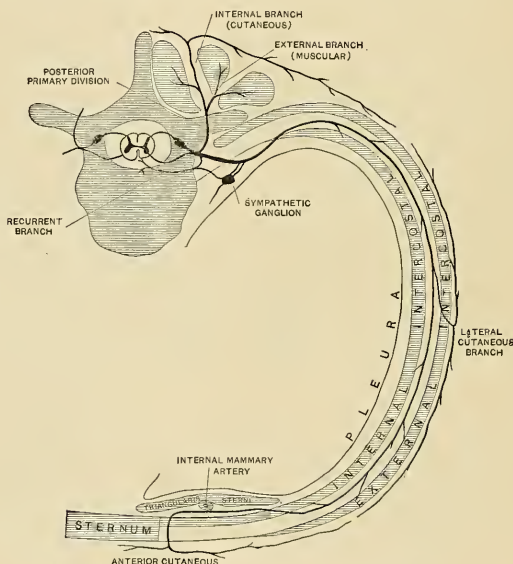


FIG. 774.—Plan of a typical intercostal nerve. (W. Keiller.)

The **lateral cutaneous nerves** (*rami cutanei laterales*) are derived from the intercostal nerves, midway between the vertebræ and sternum; they pierce the External intercostal and Serratus magnus muscles, and divide into anterior and posterior branches. The **anterior branches** (*rami anteriores*) are reflected forward to the side and fore part of the thorax, supplying the skin of the thorax and mamma; those of the fifth and sixth nerves supply the upper digitations of the External oblique. The **posterior branches** (*rami posteriores*) are reflected posteriorly to supply the integument over the scapula and over the Latissimus dorsi muscle.

The **lateral cutaneous branch of the second intercostal nerve** (*n. intercostobrachialis*) is of large size, and does not divide, like the other nerves, into an anterior and a posterior branch. It is named, from its origin and distribution, the **intercostohumeral** or **intercostobrachial nerve** (Figs. 757 and 770). It pierces the External intercostal muscle, crosses the axilla to the inner side of the arm, and joins with a filament from the lesser internal cutaneous nerve of the upper arm (*nerve of Wrisberg*). It then pierces the fascia, and supplies the skin of the upper half of

the inner and back part of the arm (Figs. 768 and 769), communicating with the internal cutaneous branch of the musculospiral nerve. The size of this nerve is in inverse proportion to the size of the other cutaneous nerves, especially the nerve of Wrisberg. A **second intercostohumeral nerve** is frequently given off from the third intercostal. It supplies filaments to the armpit and inner side of the arm. It may or may not send a branch to the intercostohumeral.

The **Anterior Divisions of the Seventh, Eighth, Ninth, Tenth, and Eleventh Thoracic Nerves** are continued anteriorly from the intercostal spaces into the abdominal wall; hence these nerves are named **thoracoabdominal intercostal nerves**. They have the same arrangement as the upper ones as far as the anterior extremities of the intercostal spaces, where they pass behind the costal cartilages, and between the Internal oblique and Transversalis muscles, to the sheath of the Rectus, which they perforate. They supply the Rectus muscle, and terminate in branches which become subcutaneous near the linea alba. These branches are named the **anterior or ventral cutaneous nerves of the abdomen**. They are directed outward as far as the lateral cutaneous nerves, supplying the integument of the front of the belly. The lower intercostal nerves supply the Intercostals, Serratus posticus inferior, and Abdominal muscles, and, about the middle of their course, give off **lateral cutaneous branches** which pierce the External intercostal and External oblique muscles, in the same line as the lateral cutaneous nerves of the thorax, and divide into **anterior and posterior branches**, which are distributed to the integument of the abdomen and back; the ventral branches supply the digitations of the External oblique and extend downward and forward nearly as far as the margin of the Rectus muscle; the posterior branches pass backward to supply the skin over the Latissimus dorsi.

The **Anterior Division of the Last Thoracic Nerve** is larger than that of the other thoracic nerves; it runs along the lower border of the last rib, and passes under the external arcuate ligament of the Diaphragm. It then runs in front of the Quadratus lumborum muscle, perforates the Transversalis muscle, and passes between it and the Internal oblique muscle, to be distributed in the same manner as the lower intercostal nerves. It communicates with the iliohypogastric branch of the lumbar plexus, and is frequently connected with the first lumbar nerve by a slender branch, the **thoracicolumbar nerve**, which descends in the substance of the Quadratus lumborum muscle. It gives a branch to the Pyramidalis muscle.

The **lateral cutaneous branch of the last thoracic** is remarkable for its large size. It does not divide into an anterior and a posterior branch, like the other lateral cutaneous branches of the intercostal nerves, but perforates the Internal and External oblique muscles, passes over the crest of the ilium in front of the iliac branch of the iliohypogastric, and is distributed to the integument of the front part of the gluteal region, some of its filaments extending as low down as the trochanter major.

Applied Anatomy.—The lower seven intercostal nerves and the iliohypogastric from the first lumbar nerve supply the skin of the abdominal wall. They run downward and inward fairly equidistant from each other. The sixth and seventh supply the skin over the "pit of the stomach;" the eighth corresponds to about the position of the middle linea transversa; the tenth to the umbilicus; and the iliohypogastric supplies the skin over the pubes and external abdominal ring. There are several points of surgical significance about the distribution of these nerves, and it is important to remember their origin and course, for in many diseases affecting the nerve trunks at or near their origin the pain is referred to their peripheral origins. Thus, in *Pott's disease of the spine* children will often be brought to the surgeon suffering from pain in the belly. This is due to the fact that the nerves are irritated at the seat of disease as they issue from the vertebral canal. When the irritation is confined to a single pair of nerves, the sensation complained of is often a feeling of constriction, as if a cord were tied around the abdomen; and in these cases the situation of the sense of constriction may serve to localize the disease in

the spinal column. In other cases, where the bone disease is more extensive and two or more nerves are involved, a more diffused pain in the abdomen is complained of. A similar condition is sometimes present in affections of the cord itself, as in *tubercles dorsalis*.

Again, it must be borne in mind that the same nerves which supply the skin of the abdomen supply also the muscles which constitute the greater part of the abdominal wall. Hence it follows that any irritation applied to the peripheral terminations of the cutaneous branches in the skin of the abdomen is immediately followed by reflex contraction of the abdominal muscles. A good practical illustration of this may sometimes be seen in watching two surgeons examine the abdomen of the same patient. One, whose hand is cold, causes the muscles of the abdominal wall to contract at once and the belly to become rigid, and thus not nearly so suitable for examination; the other, who has taken the precaution to warm his hand, examines the abdomen without exciting any reflex contraction. The supply of both muscles and skin from the same source is of importance in protecting the abdominal viscera from injury. A blow on the abdomen, even of a severe character, will do no injury to the viscera if the muscles are in a condition of firm contraction; whereas in cases where the muscles have been taken unawares, and the blow has been struck while they were in a state of rest, an injury insufficient to produce any lesion of the abdominal wall has been attended with rupture of some of the abdominal contents. The importance, therefore, of immediate reflex contraction upon the receipt of an injury cannot be overestimated, and the intimate association of the cutaneous and muscular fibres in the same nerve produces a much more immediate response on the part of the muscles to any peripheral stimulation of the cutaneous filaments than would be the case if the two sets of fibres were derived from independent sources.

Again, the nerves supplying the abdominal muscles and skin are derived from the lower intercostal nerves and are intimately connected with the sympathetic supplying the abdominal viscera through the lower thoracic ganglia from which the splanchnic nerves are derived. In consequence of this, in rupture of the abdominal viscera and in acute peritonitis the muscles of the belly wall become firmly contracted, and thus as far as possible preserve the abdominal contents in a condition of rest.

THE LUMBOSACRAL PLEXUS.

The anterior primary divisions of the lumbar, sacral, and coccygeal nerves form the lumbosacral plexus, the first lumbar nerve being frequently joined by a branch from the twelfth thoracic. For descriptive purposes this plexus is usually divided into three parts—the lumbar, sacral, and pudendal plexuses.

The Anterior or Ventral Divisions of the Lumbar Nerves (*rami anteriores*).—The anterior divisions of the lumbar nerves increase in size from above downward. They are joined, near their origins, by gray *rami communicantes* from the lumbar ganglia of the sympathetic cord. These consist of long, slender filaments, which accompany the lumbar arteries around the sides of the bodies of the vertebræ beneath the Psoas magnus muscle. Their arrangement is somewhat irregular; one ganglion may give rami to two lumbar nerves, or one lumbar nerve may receive rami from two ganglia. The first and second and sometimes the third and fourth lumbar nerves are each connected with the lumbar part of the sympathetic cord by a *white ramus communicans*. The nerves pass obliquely outward behind the Psoas magnus, or between its fasciculi, distributing filaments to it and the Quadratus lumborum muscles. The first three and the greater part of the fourth are connected together in this situation by anastomotic loops, and form the lumbar plexus. The anterior division of the fifth lumbar, joined with a branch from the fourth, descends across the base of the sacrum to join the anterior division of the first sacral nerve and assists in the formation of the sacral plexus. The cord resulting from the union of the fifth lumbar and the branch from the fourth is called the lumbosacral cord (*truncus lumbosacralis*) (Figs. 776 and 781).

The Lumbar Plexus (*plexus lumbalis*) (Figs. 775 and 776).—The lumbar plexus is formed by the loops of communication between the anterior divisions of the four upper lumbar nerves. The plexus is narrow above, and often connected with the last thoracic nerve by a slender branch. The plexus is broad below, where it is joined to the sacral plexus by the lumbosacral cord. The lumbar plexus is situated in the substance of the Psoas magnus muscle near its posterior part, in front of the transverse processes of the lumbar vertebræ.

The mode in which the plexus is arranged varies in different subjects.¹ It differs from the brachial plexus in not forming an intricate interlacement, but the several nerves of distribution arise from one or more of the spinal nerves in the following manner: The first lumbar nerve receives a branch from the last thoracic, gives off a larger, upper branch, which subdivides into the **iliohypogastric** and **ilioinguinal** nerves; and a smaller lower branch which unites with a branch of the second lumbar, to form the **genitofemoral** nerve. The remainder of the second nerve and the third and fourth lumbar nerves divide into **anterior** and **posterior** divisions. The anterior division of the second unites with the anterior division of the third nerve and a part of the anterior division of the fourth nerve to form the **obturator** nerve. The remainder of the anterior division of the fourth nerve passes down to communicate with the fifth lumbar nerve. The posterior divisions of the second and third nerves divide into two branches, a smaller branch from each uniting to form the **external** or **lateral cutaneous nerve**, and a larger branch from each, joining with the posterior division of the fourth lumbar nerve to form the **femoral** or **anterior crural nerve**. The **accessory obturator**, when it exists, is formed by the union of two small branches given off from the third and fourth nerves.

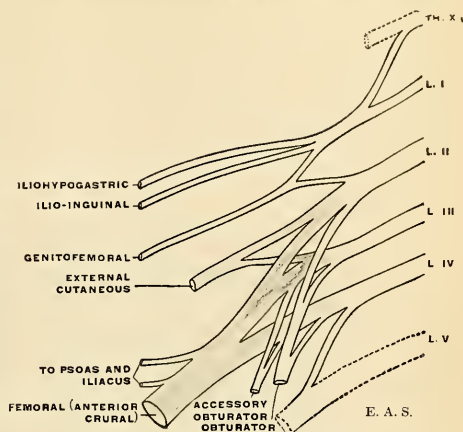


FIG. 775.—Diagram of the lumbar plexus.

The branches of the lumbar plexus may therefore be arranged as follows:

Iliohypogastric	1, L.
Ilioinguinal	1, L.
Genitofemoral	1, 2, L.
Dorsal Divisions.	
External (or lateral) cutaneous	2, 3, L.
Femoral (or anterior crural)	2, 3, 4, L.
Ventral Divisions.	
Obturator	2, 3, 4, L.
Accessory obturator	3, 4, L.

The **Iliohypogastric Nerve** (*n. iliohypogastricus*) (Figs. 775 and 776) arises from the first lumbar nerve. It emerges from the lateral border of the Psoas magnus muscle at its upper part, and crosses obliquely in front of the Quadratus lumborum to the crest of the ilium. It then perforates the Transversalis muscle posteriorly near the crest of the ilium. It gives off **muscular branches** (*rami musculares*) to the abdominal wall, and divides between the Transversalis and the Internal oblique into two cutaneous branches, **iliac** and **hypogastric**.

¹ For statistical studies of the variations encountered in different individuals, see the article by Bardeen, in the American Journal of Anatomy, vol. vi.

male (*nn. scrotales anteriores*) and to the skin covering the mons veneris and labium majus in the female (*nn. labiales anteriores*). The size of this nerve is in inverse proportion to that of the iliohypogastric. Occasionally it is very small, and ends by joining the iliohypogastric; in such cases a branch from the iliohypogastric takes the place of the ilioinguinal, or the ilioinguinal nerve may be altogether absent.

The **genitofemoral or genitocrural nerve** (*n. genitofemoralis*) (Figs. 775 and 776) arises from the first and second lumbar nerves. It passes obliquely through the substance of the Psoas magnus muscle, and emerges from its inner border at a level corresponding to the intervertebral substance between the third and fourth lumbar vertebræ; it then descends on the surface of the Psoas muscle, under cover of the peritoneum, and divides into a **genital** and a **femoral branch**.

The **genital branch or external spermatic nerve** (*n. spermaticus externus*) passes outward on the Psoas magnus, and pierces the fascia transversalis, or passes through the internal abdominal ring; in the male it then descends along the back part of the spermatic cord to the scrotum, and supplies the Cremaster muscle. In the female it accompanies the round ligament, and is lost upon it.

The **femoral branch or lumboinguinal nerve** (*n. lumboinguinalis*) (Fig. 777) descends on the external iliac artery, sending a few filaments around it, and, passing beneath Poupart's ligament to the thigh, enters the sheath of the femoral vessels, lying superficial and a little external to the femoral artery. It pierces the anterior layer of the sheath of the vessels, and, becoming superficial by passing through the fascia lata, it supplies the skin of the anterior aspect of the thigh as far as midway between the pelvis and knee. On the front of the thigh it communicates with the outer branch of the middle cutaneous nerves, derived from the femoral nerve. A few filaments from this nerve may be traced on to the femoral artery; they are derived from the nerve as it passes beneath Poupart's ligament.

The **External or Lateral Cutaneous Nerve** (*n. cutaneus femoris lateralis*) (Figs. 776 and 777) arises from the second and third lumbar nerves. It emerges from the lateral border of the Psoas magnus muscle, about its middle, and crosses the Iliacus muscle obliquely, toward the anterior superior spine of the ilium. It then passes under Poupart's ligament and over the Sartorius muscle into the thigh, where it divides into two branches, **anterior** and **posterior**.

The **anterior branch** descends in an aponeurotic canal formed in the fascia lata, becomes superficial about four inches below Poupart's ligament, and divides into branches which are distributed to the integument along the anterior and outer part of the thigh, as far down as the knee. The terminal filaments of this nerve frequently communicate with the middle and internal cutaneous and with the patellar branch of the long saphenous nerve, forming with them the **patellar plexus**.

The **posterior branch** pierces the fascia lata, and subdivides into branches which pass backward across the outer and posterior surface of the thigh, supplying the integument from the level of the great trochanter to the middle of the thigh.

The **Obturator Nerve** (*n. obturatorius*) (Figs. 776 and 778) supplies the Obturator externus and Adductor muscles of the thigh, the articulations of the hip and knee, and occasionally the integument of the thigh and leg. It arises from the second, the third, and the fourth lumbar nerves. Of these, the branch from the third is the largest, while that from the second is often very small. It descends through the inner fibres of the Psoas magnus muscle, and emerges from its inner border near the brim of the pelvis; it then passes behind the external iliac vessels, which separate it from the ureter, and runs along the lateral wall of the pelvis, above the obturator vessels, to the upper part of the obturator foramen. Here it enters the thigh, and divides into anterior and posterior branches, which are separated by some of the fibres of the Obturator externus muscle, and lower down by the Adductor brevis muscle.

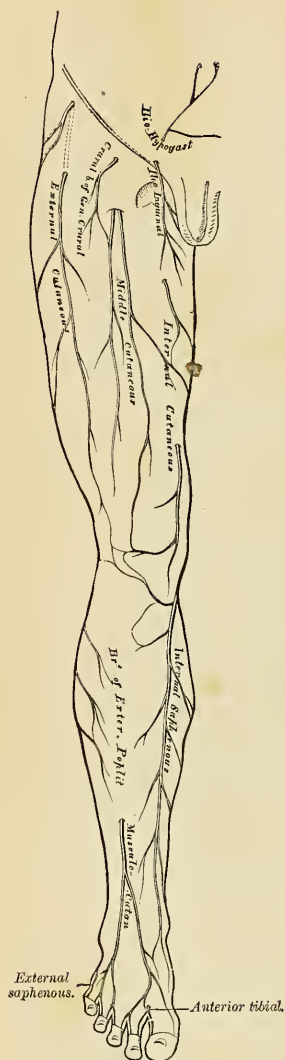


FIG. 777.—Cutaneous nerves of right lower extremity. Front view.

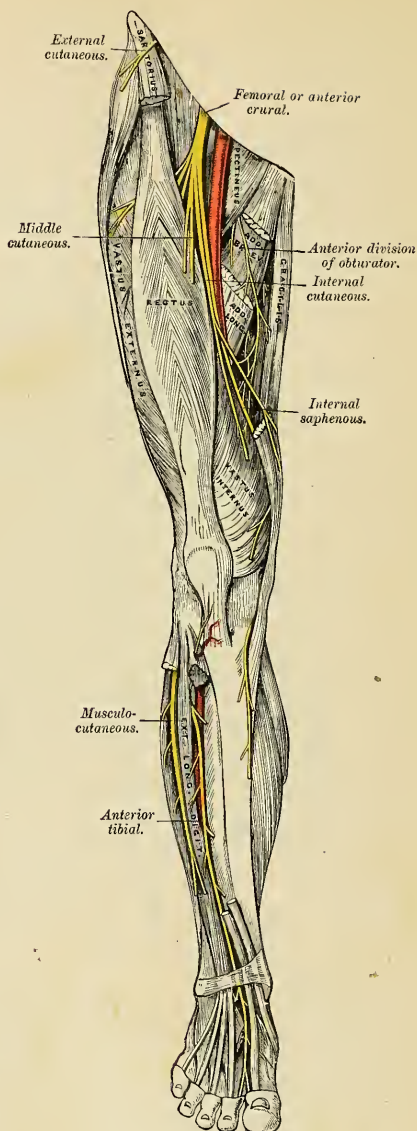


FIG. 778.—Nerves of the right lower extremity. Front view.

The **anterior branch** (*ramus anterior*) (Fig. 778) passes down in front of the Adductor brevis, being covered by the Pectineus and Adductor longus; at the lower border of the latter muscle, it communicates with the internal cutaneous and internal saphenous nerves, forming a kind of plexus. It then descends upon the femoral artery, upon which it is finally distributed. The nerve, near the obturator foramen, gives off an articular branch to the hip-joint. Behind the Pectineus it distributes muscular branches to the Adductor longus and Gracilis, and usually to the Adductor brevis, and in rare instances to the Pectineus, and receives a communicating branch from the accessory obturator nerve when that nerve is present.

Occasionally the communicating branch to the internal cutaneous and internal saphenous nerves is continued down, as a **cutaneous branch** (*ramus cutaneus*), to the thigh and leg. When this is so, it emerges from beneath the lower border of the Adductor longus, descends along the posterior margin of the Sartorius to the inner side of the knee, where it pierces the deep fascia, communicates with the internal or long saphenous nerve, and is distributed to the integument of the inner side of the leg as low down as its middle. When this communicating branch is small its place is supplied by the internal cutaneous nerve.

The **posterior branch** (*ramus posterior*) pierces the anterior part of the Obturator externus, sending branches to supply this muscle, and passes behind the Adductor brevis on the front of the Adductor magnus, where it divides into numerous muscular branches, which supply the Adductor magnus, and the Adductor brevis when the latter does not receive a branch from the anterior division of the nerve. It also gives off a filament to the knee-joint.

The **articular branch for the knee-joint** is sometimes absent; it either perforates the lower part of the Adductor magnus, or passes through the opening which transmits the femoral artery, and enters the popliteal space; it then descends upon the popliteal artery, as far as the back part of the knee-joint, where it perforates the posterior ligament, and is distributed to the synovial membrane. It gives filaments to the artery in its course.

The **Accessory Obturator Nerve** (*n. obturatorius accessorius*) (Fig. 781) is present in about 29 per cent. of cases. It is of small size, and *arises* by separate filaments from the third and fourth lumbar nerves. It descends along the inner border of the Psoas magnus muscle, crosses the ascending ramus of the os pubis, and passes under the outer border of the Pectineus muscle, where it divides into numerous branches. One of these supplies the Pectineus, penetrating its deep surface; another is distributed to the hip-joint; while a third communicates with the anterior branch of the obturator nerve. When this nerve is absent the hip-joint receives two branches from the obturator nerve. Occasionally it is very small, and becomes lost in the capsule of the hip-joint.

The **Femoral or Anterior Crural Nerve** (*n. femoralis*) (Figs. 776 and 778) is the largest branch of the lumbar plexus. It supplies muscular branches to the Iliacus, Pectineus, and all the muscles on the front of the thigh, excepting the Tensor fasciae femoris; cutaneous filaments to the front and inner side of the thigh, and to the leg and foot (Fig. 772); and articular branches to the hip- and knee-joint. It *arises* from the second, third, and fourth lumbar nerves, sometimes from the first or fifth as well. It descends through the fibres of the Psoas magnus, emerging from this muscle at the lower part of its outer border, and passes downward between it and the Iliacus muscle, and beneath Poupart's ligament, into the thigh, where it becomes somewhat flattened, and divides into an anterior and a posterior part. Under Poupart's ligament it is separated from the femoral artery by a portion of the Psoas magnus.

Within the abdomen the femoral nerve gives off from its outer side some small **muscular branches** to the Iliacus, and a branch to the femoral artery which is

distributed upon the upper part of that vessel. The origin of this branch varies; it occasionally arises higher than usual, or it may arise lower down in the thigh.

In the thigh the following branches are given off:

From the Anterior Division.

Middle cutaneous.
Internal cutaneous.
Muscular.

From the Posterior Division.

Long saphenous.
Muscular.
Articular.

The middle and internal cutaneous branches of the femoral nerve are the *rami cutanei anteriores n. femoralis* of the BNA.

The **middle cutaneous nerve** (Figs. 777 and 778) pierces the fascia lata (and generally the Sartorius) about three inches (8 cm.) below Poupart's ligament, and divides into two branches (Fig. 777), which descends in immediate proximity along the fore part of the thigh, to supply the integument as low as the front of the knee. Here they communicate with the internal cutaneous nerve and the patellar branch of the internal saphenous nerve, to form the **patellar plexus**. In the upper part of the thigh the outer division of the middle cutaneous nerve communicates with the femoral branch of the genitofemoral nerve.

The **internal cutaneous nerve** (Fig. 777) passes obliquely across the upper part of the sheath of the femoral artery, and divides in front or at the inner side of that vessel into two branches, **anterior** and **posterior** or **internal**.

The internal cutaneous nerve, before dividing, gives off a few filaments, which pierce the fascia lata (accompanying the long saphenous vein) to supply the integument of the inner side of the thigh. One of these filaments passes through the saphenous opening; a second becomes subcutaneous about the middle of the thigh (Fig. 777); and a third pierces the fascia at its lower third (Fig. 777).

The **anterior branch** runs downward on the Sartorius, perforates the fascia lata at the lower third of the thigh, and divides into two branches, one of which supplies the integument as low down as the inner side of the knee; the other crosses to the outer side of the patella, communicating in its course with the *nervus cutaneus patellae*, a branch of the long or internal saphenous nerve. The **posterior** or **internal branch** descends along the inner border of the Sartorius muscle to the knee, where it pierces the fascia lata, communicates with the long saphenous nerve, and gives off several cutaneous branches. It then passes down to supply the integument of the inner side of the leg. Beneath the fascia lata, at the lower border of the Adductor longus, it joins with branches of the long saphenous and obturator nerves to form a plexiform network (*subsartorial plexus*) (Fig. 778). When the communicating branch from the obturator nerve is large and continued to the integument of the leg, the internal branch of the internal cutaneous is small and terminates in the plexus, occasionally giving off a few cutaneous filaments.

The **Muscular Branches of the Anterior Division** (*rami musculares*).¹ The nerve to the **Pectineus** arises from the femoral nerve immediately below Poupart's ligament, and passes inward behind the femoral sheath to enter the anterior surface of the muscle; it is often duplicated. The nerve to the **Sartorius** arises in common with the middle cutaneous.

The **long or internal saphenous nerve** (*n. saphenus*) (Figs. 777 and 778) is the largest of the cutaneous branches of the femoral nerve. It approaches the femoral artery where this vessel passes beneath the Sartorius, and lies in front of it, beneath the aponeurotic covering of Hunter's canal, as far as the opening in the lower part of the Adductor magnus. It then leaves the artery, and proceeds distally along the inner side of the knee, beneath the Sartorius muscle, pierces the fascia lata opposite the interval between the tendons of the Sartorius and Gracilis muscles, and becomes

subcutaneous. The nerve then passes along the inner side of the leg (Fig. 777), accompanied by the internal saphenous vein, descends behind the internal border of the tibia, and at the lower third of the leg divides into two branches; one continues its course along the margin of the tibia, terminating at the inner ankle; the other passes in front of the ankle, and is distributed to the integument along the inner side of the foot, as far as the great toe, communicating with the internal branch of the musculocutaneous nerve.

The long saphenous nerve *about the middle of the thigh* gives off a communicating branch which joins the subsartorial plexus.

At the inner side of the knee it gives off a large **patellar branch** (*ramus infrapatellaris*), which pierces the Sartorius and fascia lata, and is distributed to the integument in front of the patella. This nerve communicates above the knee with the anterior branch of the internal cutaneous and with the middle cutaneous; below the knee, with other branches of the long saphenous; and on the outer side of the joint, with branches of the external cutaneous nerve, forming a plexiform network, the **patellar plexus**. The patellar branch is occasionally small, and terminates by joining the internal cutaneous, which supplies its place in front of the knee.

Below the knee the branches of the long saphenous nerve are distributed to the integument of the front and inner side of the leg, communicating with the cutaneous branches from the internal cutaneous or from the obturator nerve.

The **Muscular Branches of the Posterior Division** supply the four parts of the Quadriceps extensor muscle.

The **branch to the Rectus femoris** enters its under surface high up, sending off a small filament to the hip-joint.

The **branch to the Vastus externus**, of large size, follows the course of the descending branch of the external circumflex artery to the lower part of the muscle. It gives off an articular filament to the knee-joint.

The **branch to the Vastus internus** is a long branch which runs down on the outer side of the femoral vessels in company with the long saphenous nerve. It enters the muscle about its middle, and gives off a filament which can usually be traced downward on the surface of the muscle to the knee-joint.

The **branches to the Crureus** are two or three in number, and enter the muscle on its anterior surface about the middle of the thigh; a filament from one of these descends through the muscle to the Subcrureus and the knee-joint.

The **articular branch to the hip-joint** is derived from the nerve to the Rectus muscle.

The **articular branches to the knee-joint** are three in number. One, a long slender filament, is derived from the nerve to the Vastus externus muscle; it penetrates the capsular ligament of the joint on its anterior aspect. Another is derived from the nerve to the Vastus internus muscle. It can usually be traced downward on the surface of this muscle to near the joint; it then penetrates the muscle and accompanies the deep branch of the anastomotica magna artery, pierces the capsular ligament of the joint on its inner side, and supplies the synovial membrane. The third branch is derived from the nerve to the Crureus.

The Anterior or Ventral Divisions of the Sacral and Coccygeal Nerves (*rami anteriores*) (Fig. 781).—The anterior primary divisions of the sacral and coccygeal nerves form the sacral and pudendal plexuses. The anterior divisions of the upper four sacral nerves enter the pelvis through the anterior sacral foramina, that of the fifth between the sacrum and coccyx, while that of the coccygeal nerve curves forward below the rudimentary transverse process of the first piece of the coccyx. The first and second sacral are large; the third, fourth, and fifth diminish progressively from above downward. Each nerve receives a *gray ramus communicans* from the corresponding ganglion of the sympathetic cord,

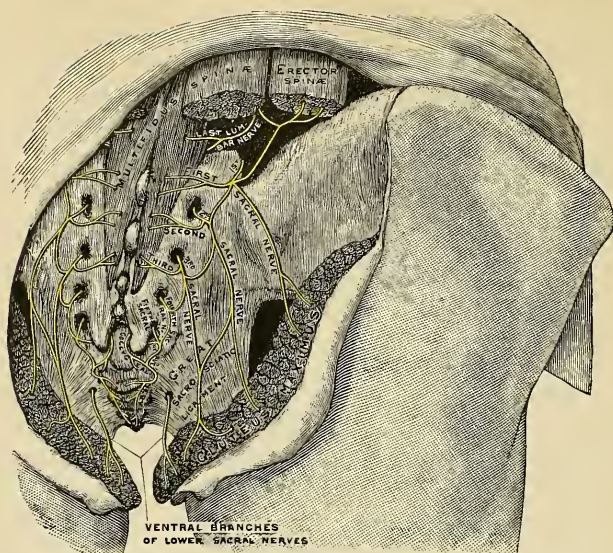


FIG. 779.—The posterior sacral nerves.

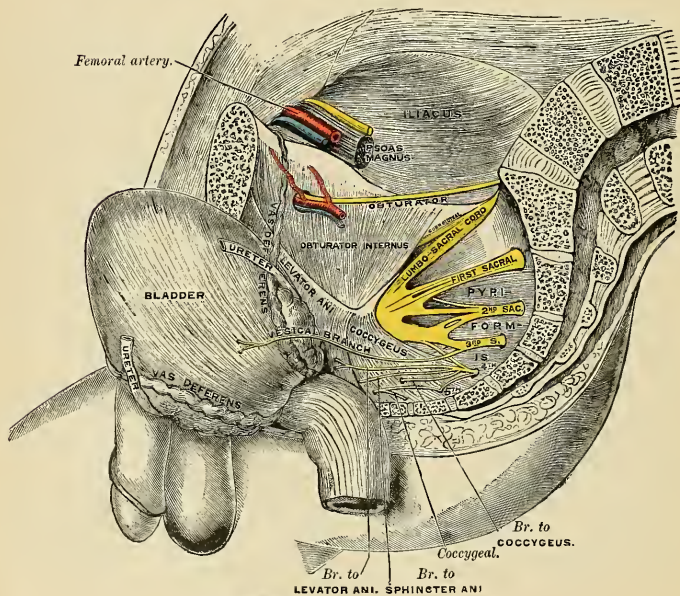


FIG. 780.—Side view of pelvis, showing sacral nerves

while from the third, and frequently from the second and fourth anterior sacral divisions, *white rami communicantes* are given to the pelvic plexuses of the sympathetic.

THE SACRAL PLEXUS (PLEXUS SACRALIS) (Fig. 781).

The *sacral plexus* is formed by the lumbosacral cord, the anterior primary division of the first and portions of the anterior primary divisions of the second and third sacral nerves.

The *lumbosacral cord* comprises the whole of the anterior primary division of the fifth and a part of the anterior primary division of the fourth lumbar nerves, it appears at the inner margin of the Psoas magnus and runs downward (caudad) over the pelvic brim to join the first sacral nerve. The third sacral nerve divides into an upper and a lower branch, the former entering the sacral and the latter the pudendal plexus

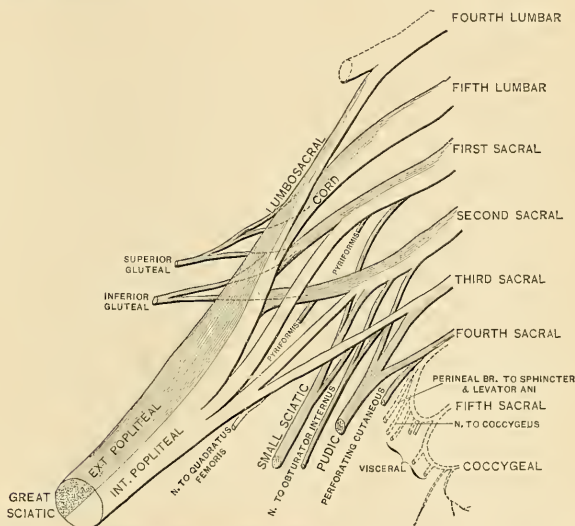


Fig. 781.—Plan of sacral plexus with the pudendal plexus. (Gerrish.) (See text for variations in origin of the perforating cutaneous nerve.)

The branches or divisions forming the sacral plexus converge toward the lower part of the great sacrosciatic foramen, and unite to form a flattened band, from the anterior and posterior surfaces of which several branches arise. The band itself is continued as the *great sciatic nerve*, which splits on the back of the thigh into the *internal* and *external popliteal* nerves; these two nerves sometimes arise separately from the plexus, and in all cases their independence can be shown by dissection.

Relations.—The sacral plexus lies on the anterior or ventral surface of the pelvic part of the Pyriformis and is covered in front by the pelvic fascia, which separates it from the internal iliac vessels, the ureter and the pelvic colon. The gluteal vessels run between the lumbosacral cord and the first sacral nerve, and the sciatic vessels between the second and third sacral nerves.

All the nerves entering the plexus, with the exception of the third sacral, split into anterior and posterior divisions, and the nerves arising from these are as follows:

	Anterior or Ventral Divisions.	Posterior or Dorsal Divisions.
Nerve to Quadratus femoris and Gemellus inferior	4, 5, L. 1, S.	
Nerve to Obturator internus and Gemellus superior	5, L. 1, 2, S.	
Nerve to Piriformis		(1), 2, S.
Superior gluteal		4, 5, L. 1, S.
Inferior gluteal		5, L. 1, 2, S.
Small sciatic	1, 2, 3, S.	
Great sciatic { Internal popliteal	4, 5, L. 1, 2, 3, S.	
{ External popliteal		4, 5, L. 1, 2, S.

The nerve to the **Quadratus femoris and Gemellus inferior** arises from the anterior divisions of the fourth and fifth lumbar and first sacral nerves; it leaves the pelvis through the great sacrosciatic foramen, below the Piriformis, and runs downward beneath the great sciatic nerve, the Gemelli, and the tendon of the Obturator internus, enters the anterior surface of these muscles; it gives off an articular branch to the hip-joint.

The nerve to the **Obturator internus** arises from the anterior divisions of the fifth lumbar and first and second sacral nerves; it leaves the pelvis through the great sacrosciatic foramen below the Piriformis muscle, crosses the ischial spine, reënters the pelvis through the small sacrosciatic foramen, and ends in the Obturator internus, after entering the pelvic surface of that muscle. The branch to the **Gemellus superior** enters the upper part of the posterior surface of that muscle.

The nerve to the **Piriformis** arises from the posterior division of the second, or the posterior divisions of the first and second sacral nerves, and enters the anterior surface of the muscle; this nerve may be double.

The **Superior Gluteal Nerve** (*n. gluteus superior*) (Figs. 781 and 783) arises from the posterior divisions of the fourth and fifth lumbar and first sacral nerves; it leaves the pelvis through the great sacrosciatic foramen above the Piriformis, accompanied by the gluteal vessels, and divides into a superior and an inferior branch. The **superior branch** accompanies the upper branch of the deep division of the gluteal artery, and ends in the Gluteus minimus after giving off branches to supply a part of the Gluteus medius. The **inferior branch** accompanies the lower branch of the gluteal artery across the Gluteus minimus; it gives filaments to the Gluteus medius and Gluteus minimus, and ends in the Tensor fasciæ femoris.

The **Inferior Gluteal Nerve** (*n. gluteus inferior*) (Fig. 781) arises from the posterior divisions of the fifth lumbar and first and second sacral nerves; it leaves the pelvis through the great sacrosciatic foramen, below the Piriformis muscle, and divides into branches, which enter the deep surface of the Gluteus maximus.

The **Small Sciatic** (*n. cutaneus femoris posterior*) (Figs. 781 and 783), or **post-femoral cutaneous nerve** supplies the integument of the perineum and back part of the thigh and leg. It arises partly from the anterior and partly from the posterior divisions of the first, second, and third sacral nerves, and emerges from the pelvis through the great sacrosciatic foramen below the Piriformis. It then descends beneath the Gluteus maximus with the sciatic artery, and passes down the back part of the thigh beneath the fascia lata, and over the long head of the Biceps to the lower part of the popliteal region, here it pierces the fascia and accompanies the external saphenous vein (*v. saphena parva*) to about the middle of the back of the leg, its terminal filaments communicating with the sural or external saphenous nerve.

The branches of the small sciatic nerve are all cutaneous, and are grouped as follows: **gluteal**, **perineal**, and **femoral**.

The **gluteal cutaneous branches** (*nn. clunium inferiores [laterales]*), two or three in number, turn upward around the lower border of the *Gluteus maximus* to supply the skin covering the lower and outer part of that muscle.

The **perineal cutaneous branches** (*rami perineales*) are distributed to the skin at the upper and inner side of the thigh, on its posterior aspect. One branch, longer than the rest, the **inferior pudendal** or **long scrotal nerve** (Fig. 783), curves forward below the ischial tuberosity, pierces the fascia lata, and runs forward beneath the superficial fascia of the perineum to be distributed to the skin of the scrotum in the male and the labium majus in the female, communicating with the superficial perineal and inferior hemorrhoidal nerves.

The **femoral cutaneous branches** consist of numerous descending filaments derived from both sides of the nerve, and are distributed to the back and inner sides of the thigh, to the skin covering the popliteal space, and to the upper part of the leg.

The **Great Sciatic Nerve** (*n. ischiadicus*) (Figs. 781 and 883) supplies nearly the whole of the integument of the leg, the muscles of the back of the thigh, and those of the leg and foot. It is the largest nerve cord in the body, measuring three-quarters of an inch in breadth, and is the continuation of the flattened band of the sacral plexus. It passes out of the pelvis through the great sacrosclatic foramen, below the *Pyriformis* muscle. It descends between the great trochanter of the femur and the tuberosity of the ischium, along the back part of the thigh, to about its lower third, where it divides into two large branches, the **internal popliteal** or **tibial** and **external popliteal** or **peroneal nerves** (Fig. 783). This division may take place at any point between the sacral plexus and the lower third of the thigh. When the division occurs at the plexus (in 10 per cent. of cases) the two nerves descend together side by side; or they may be separated, at their commencement, by the interposition of part or the whole of the *Pyriformis* muscle.

As the nerve descends along the back of the thigh, it rests upon the posterior surface of the ischium, the nerve of the *Quadratus femoris*, and the *External rotator* muscles of the thigh, in company with the small sciatic nerve and artery, and is covered by the *Gluteus maximus*; lower down, it lies upon the *Adductor magnus*, and is covered by the long head of the *Biceps*.

The branches of the nerve, before its division, are **articular** and **muscular**.

The **articular branches** (*rami articulares*) arise from the upper part of the nerve; they supply the hip-joint, perforating the posterior part of its fibrous capsule. These branches are sometimes derived directly from the sacral plexus.

The **muscular branches** (*rami musculares*) are distributed to the flexors of the leg—viz., the *Biceps*, *Semitendinosus*, and *Semimembranosus*, and to the *Adductor magnus*. The nerve to the short head of the *Biceps* comes from the external popliteal part of the great sciatic, while the other muscular branches arise from the internal popliteal portion, as may be seen in those cases where the two popliteal nerves emerge separately on the buttock.

The **Internal Popliteal or Tibial Nerve** (*n. tibialis*) (Figs. 781 and 783), the larger of the two terminal branches of the great sciatic, arises from the anterior primary branches of the last two lumbar and first three sacral nerves. It descends along the back part of the thigh, through the middle of the popliteal space, to the lower part of the *Popliteus* muscle, where it passes with the artery beneath the arch of the *Soleus* and becomes the **posterior tibial**. It is overlapped by the *Hamstring* muscles above, and then becomes more superficial, and lies to the outer side of, and some distance from, the popliteal vessels; opposite the knee-joint it is in close relation with the vessels, and crosses to the inner side of the artery. Below, it is overlapped by the *Gastrocnemius*.

The branches of this nerve are the **articular** and **muscular**, and a cutaneous branch, the **communicans tibialis**.

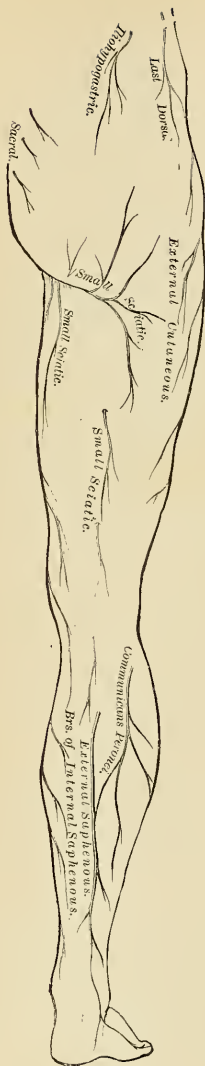

FIG. 782.—Cutaneous nerves of lower extremity. Posterior view.

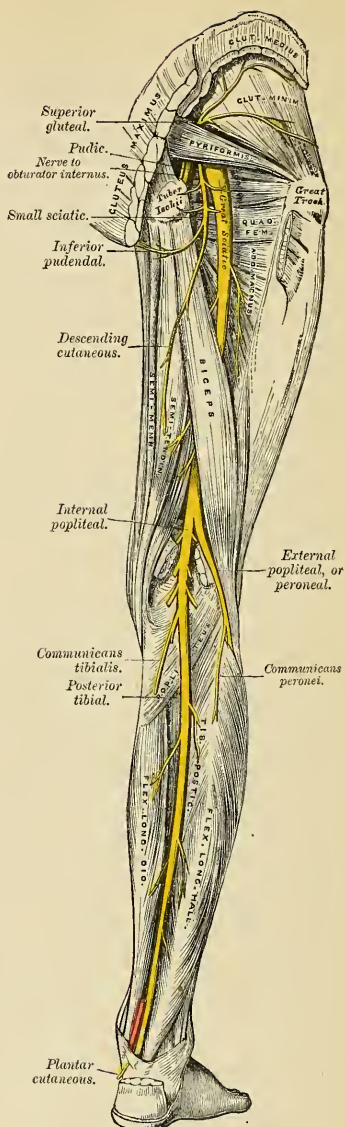


FIG. 783.—Nerves of the lower extremity.¹ Posterior view.

¹N. B.—In this diagram the communicans tibialis and communicans peronei are not in their normal position. They have been displaced by the removal of the superficial muscles. The external saphenous nerve is formed by the junction of the two communicantes.

The articular branches (*rami articulares*), usually three in number, supply the knee-joint; two of these branches accompany the superior and inferior internal articular arteries, and a third, the azygos articular artery.

The **muscular branches** (*rami musculares*), four or five in number, arise from the nerve as it lies between the two heads of the Gastrocnemius; they supply that muscle and the Plantaris, Soleus, and Popliteus. The branch which supplies the Popliteus turns around its lower border and is distributed to the deep surface of the muscle.

The **communicans tibialis** (*n. cutaneus surae medialis*) descends between the two heads of the Gastrocnemius, and about the middle of the back of the leg pierces the deep fascia, and joins a communicating branch (*ramus anastomoticus peronaeus*) from the external popliteal nerve to form the **short or external saphenous nerve** (Fig. 783). The external saphenous nerve, formed by the communicating branches of the internal and external popliteal nerves, passes downward and outward near the outer margin of the tendo Achillis, lying close to the external saphenous vein, to the interval between the external malleolus and the os calcis. It divides into two branches, the posterior of which breaks up into **lateral calcaneal branches** (*rami calcanei laterales*). The **anterior branch** (*n. cutaneus dorsalis lateralis*) winds around the outer malleolus, and is distributed to the integument along the outer side of the foot and little toe, communicating on the dorsum of the foot with the musculocutaneous nerve. In the leg its branches communicate with those of the small sciatic. The cutaneous area supplied by the external saphenous nerve is indicated in Fig. 785.

The **Posterior Tibial Nerve** (Fig. 783), the direct continuation of the internal popliteal nerve, commences at the lower border of the Popliteus muscle, and passes along the back part of the leg with the posterior tibial vessels to the interval between the inner malleolus and the heel, where it divides into the **external and internal plantar nerves**. It lies upon the deep muscles of the leg, and is covered above by the muscles of the calf, lower down by the skin and fascia. In the upper part of its course it lies to the inner side of the posterior tibial artery, but it soon crosses that vessel, and lies to its outer side as far as the ankle. In the lower third of the leg it is placed parallel with the inner margin of the tendo Achillis.

The branches of the posterior tibial nerve are **muscular, internal calcaneal, and articular**.

The **muscular branches** (*rami musculares*) arise either separately or by a common trunk from the upper part of the nerve. They supply the Soleus, Tibialis posterior, Flexor longus digitorum, and Flexor longus hallucis muscles; the branch to the latter muscle accompanies the peroneal artery. The branch to the Soleus enters the deep surface of the muscle, while that from the internal popliteal enters the superficial surface.

The **internal calcaneal branches** (*rami calcanei mediales*) perforate the internal annular ligament, and supply the integument of the heel and inner side of the foot (Fig. 785).

The **articular branch** (*ramus articularis ad articulationem talocruralem*) is given off just above the bifurcation of the nerve and supplies the ankle-joint.

The **Internal Plantar Nerve** (*n. plantaris medialis*) (Fig. 784), the larger of the two terminal branches of the internal popliteal, accompanies the internal plantar artery along the inner side of the foot. From its origin at the inner ankle it passes beneath the Abductor hallucis, and then forward between this muscle and the Flexor brevis digitorum; it divides opposite the bases of the metatarsal bones into **four plantar digital branches** (*nn. digitales plantares communes*) and communicates with the plantar nerve.

Branches.—In its course the internal plantar nerve gives off **cutaneous branches**, which pierce the plantar fascia and supply the integument of the sole of the foot

(Fig. 785); **muscular branches**, which supply the Abductor hallucis and Flexor brevis digitorum; **articular branches**, to the articulations of the tarsus and metatarsus; and **four plantar digital branches** (*nn. digitales plantares proprii*). The first (innermost) branch becomes cutaneous about the middle of the sole, between the Adductor hallucis and Flexor brevis digitorum; the three outer branches pass between the divisions of the plantar fascia in the clefts between the toes. They are distributed in the following manner: The **first** supplies the inner border of the great toe, and sends a filament to the Flexor brevis hallucis muscle; the **second** bifurcates, to supply the adjacent sides of the great and second toes, sending a filament to the First lumbrical muscle; the **third** supplies the adjacent sides of the second and third toes; the **fourth** supplies the corresponding sides of the third and fourth toes, and receives a communicating branch from the external plantar nerve (Fig. 784). Each digital nerve gives off cutaneous and articular filaments; and opposite the last phalanx sends a dorsal branch, which supplies the structures around the nail, the continuation of the nerve being distributed to the ball of the toe. It will be observed that the distribution of these branches is precisely similar to that of the median nerve in the hand.

The **External Plantar Nerve** (*n. plantaris lateralis*) (Fig. 784), the smaller of the two, completes the nerve supply to the structures of the sole of the foot (Fig. 785), being distributed to the little

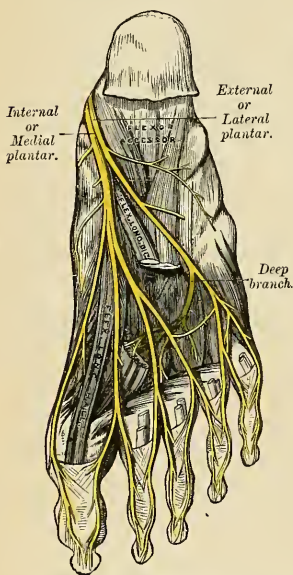


FIG. 784.—The plantar nerves

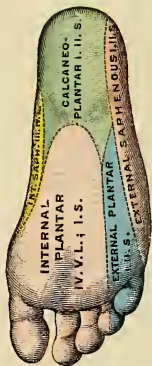

FIG. 785.—Areas of distribution of the cutaneous nerves of the sole (W Keiller, in Gerrish's Text-book of Anatomy.)

toe and outer half of the fourth, as well as to most of the deep muscles, its distribution being similar to that of the ulnar nerve in the hand. It passes obliquely forward with the external plantar artery to the outer side of the foot, lying between the Flexor brevis digitorum and Flexor accessorius; and in the interval between the former muscle and Abductor minimi digiti, divides into a **superficial** and a **deep branch**. Before its division it supplies the Flexor accessorius and Abductor minimi digiti.

The **superficial branch** (*ramus superficialis*) separates into two digital nerves. One, the smaller of the two, supplies the outer side of the little toe, the Flexor brevis minimi digiti, and the two Interosseous muscles of the fourth metatarsal

space; the other and larger digital branch supplies the adjoining sides of the fourth and fifth toes, and communicates with the internal plantar nerve.

The **deep or muscular branch** (*ramus profundus*) accompanies the external plantar artery into the deep part of the sole of the foot, beneath the tendons of the Flexor muscles, and Adductor obliquus hallucis, and supplies all the Interossei (except those in the fourth metatarsal space), the three outer Lumbricales, the Adductor obliquus hallucis, and the Adductor transversus hallucis.

The **External Popliteal or Peroneal Nerve** (*n. peroneus communis*) (Figs. 781 and 783), about one-half the size of the internal popliteal, is derived from the posterior branches of the last two lumbar and first two sacral nerves. It descends obliquely along the outer sides of the popliteal space to the head of the fibula, close to the inner margin of the Biceps muscle. It is easily felt beneath the skin behind the head of the fibula at the inner side of the tendon of the Biceps. It passes between the tendon of the Biceps and outer head of the Gastrocnemius, winds around the neck of the fibula, between the Peroneus longus and the bone, and divides beneath the muscle into the **anterior tibial** and **musculocutaneous nerves**.

The **branches** of the external popliteal nerve, previous to its division, are **articular** and **cutaneous**.

The **articular branches** (*rami articulares*) are three in number: two of these accompany the superior and inferior external articular arteries to the outer side of the knee. The upper one occasionally *arises* from the great sciatic nerve before its bifurcation. The third (*recurrent*) articular nerve is given off at the point of division of the external popliteal nerve; it ascends with the anterior recurrent tibial artery through the Tibialis anticus muscle to the front of the knee, which it supplies.

The **Lateral Cutaneous Branch** (*n. cutaneous surae lateralis*).—There may be two or three of these branches. They supply the integument along the back part and outer side of the leg. The largest **cutaneous** branch of the peroneal is the **communicans peronei** (*ramus anastomoticus peroneus*), which *arises* near the head of the fibula, crosses the external head of the Gastrocnemius to the middle of the leg, and joins with the communicans tibialis to form the external saphenous nerve. This nerve occasionally exists as a separate branch, which is continued as far down as the heel.

The **Anterior Tibial Nerve or Deep Peroneal** (*n. peroneus profundus*) (Fig. 778) commences at the bifurcation of the peroneal nerve, between the fibula and upper part of the Peroneus longus, passes obliquely downward beneath the Extensor longus digitorum muscle to the fore part of the interosseous membrane, and gets into relation with the anterior tibial artery above the middle of the leg; it then descends with the artery to the front of the ankle-joint, where it divides into an **external** and an **internal branch**. This nerve lies at first on the outer side of the anterior tibial artery, then in front of it, and again at its outer side at the ankle-joint.

The **branches** of the anterior tibial nerve in its course through the leg are the **muscular branches** (*rami musculares*) to the Tibialis anticus, Extensor longus digitorum, Peroneus tertius, and Extensor proprius hallucis muscles, and an **articular branch** to the ankle-joint.

The **external or tarsal branch** of the anterior tibial nerve passes outward across the tarsus, beneath the Extensor brevis digitorum, and, having become enlarged like the posterior interosseous nerve at the wrist, supplies the Extensor brevis digitorum muscle. From the enlargement three minute **interosseous branches** are given off which supply the tarsal joints and the metatarsophalangeal joints of the second, third, and fourth toes. The first of these sends a filament to the Second dorsal interosseous muscle.

The **internal branch**, the continuation of the nerve, accompanies the dorsalis pedis artery along the inner side of the dorsum of the foot, and at the first interosseous space divides into two **dorsal digital branches** (*nn. digitales dorsales hallucis lateralis et digiti secundi medialis*), which supply the adjacent sides of the great and second toes, communicating with the internal branch of the musculocutaneous nerve. Before it divides it gives off to the first space an **interosseous branch** which supplies the metatarsophalangeal joint of the great toe and sends a branch to the First dorsal interosseous muscle.

The **Musculocutaneous Nerve** (*n. peroneus superficialis*) (Fig. 778) supplies the muscles on the fibular side of the leg and the integument over the greater part of the dorsum of the foot. It passes forward between the Peronei muscles and the Extensor longus digitorum, pierces the deep fascia at the lower third of the leg on its front and outer side, and divides into two branches. This nerve in its course between the muscles gives off **muscular branches** to the Peroneus longus and brevis, and **cutaneous branches** to the integument of the lower part of the leg.

The **internal dorsal cutaneous branch** (*n. cutaneus dorsalis medialis*) of the musculocutaneous nerve passes in front of the ankle-joint and divides into three **dorsal digital branches** (*nn. digitales dorsales pedis*). The internal branch supplies the skin of the dorsum of the foot and the inner side of the great toe, and communicates with the internal saphenous nerve. The intermediate branch runs to the space between the great and second toes, supplies the adjacent sides of these, and communicates with the anterior tibial nerve. The external branch passes to the space between the second and third toes and supplies the adjacent sides of these.

The **external dorsal cutaneous branch** (*n. cutaneus dorsalis intermedius*), the smaller, passes along the outer side of the dorsum of the foot, and divides into two **dorsal digital branches**, the inner being distributed to the adjacent sides of the third and fourth toes, the outer to the adjacent sides of the fourth and fifth toes. It also supplies the integument of the outer ankle and outer side of the foot and communicates with the external saphenous nerve.

The branches of the musculocutaneous nerve supply all the toes excepting the outer side of the little toe, which is supplied by the small saphenous nerve. The adjoining sides of the great and second toes are also supplied by the internal branch of the anterior tibial. It frequently happens that some of the outer branches of the musculocutaneous are absent, their place being then taken by branches of the external saphenous nerve.

THE PUDENDAL PLEXUS (PLEXUS PUDENDUS).

The **pudendal plexus** (Fig. 781) is not sharply marked off from the sacral plexus, some of the branches which spring from it may arise in conjunction with those of the sacral plexus. It lies on the posterior wall of the pelvis and is usually formed by branches from the ventral primary divisions of the second and third sacral nerves. the whole of the anterior primary divisions of the fourth and fifth sacral nerves, and the coccygeal nerve.

It gives off the following branches:

Perforating cutaneous (variable)	(2, 3, S.) (3, 4, S.) (4, 5, S.)
Pubic	2, 3, 4, S.
Visceral	3, 4, S.
Muscular	4, S.
Anococcygeal	4, 5, S, and Cocc.

The **Perforating Cutaneous Nerve** (Fig. 781) is not always present. It sometimes arises from the second and third sacral nerves, or from the third and fourth, or

even fourth and fifth sacral nerves, and is of small size. When present, it pierces the lower part of the great sacrosciatic ligament, and, winding around the lower border of the Gluteus maximus, supplies the integument covering the inner and lower part of that muscle. When absent, its place is taken either by a cutaneous branch of the small sciatic, or by the *greater coccygeal perforating nerve* of Eisler.

The **Pudic Nerve** (*n. pudendus*) (Figs. 781 and 783) derives its fibres from the anterior branches of the second, third, and fourth sacral nerves. It leaves the pelvis below the Pyramiformis through the great sacrosciatic foramen. It then crosses the spine of the ischium, and enters the pelvis through the lesser sacrosciatic foramen. It accompanies the pudic vessels upward and forward along the outer wall of the ischio-rectal fossa, being contained in a sheath of the obturator fascia, termed **Alcock's canal**, and divides into two terminal branches, the **perineal nerve**, and the **dorsal nerve of the penis or clitoris**. Before its division it gives off the **inferior hemorrhoidal nerve**.

The **inferior hemorrhoidal nerve** (*n. hemorrhoidalis inferior*) is occasionally derived separately from the sacral plexus (3d S.). It passes across the ischio-rectal fossa, with its accompanying vessels, toward the lower end of the rectum, and is distributed to the Sphincter ani externus and to the integument around the anus. Branches of this nerve communicate with the inferior pudendal and superficial perineal nerves at the fore part of the perineum.

The **perineal nerve** (*n. perinei*), the inferior and larger of the two terminal branches of the pudic, is situated below the pudic artery. It accompanies the superficial perineal artery in the perineum, dividing into **cutaneous** and **muscular branches**.

The **cutaneous branches** (*superficial perineal*) are two in number, **posterior** and **anterior**. The **posterior** or **external branch** pierces the base of the triangular ligament of the urethra, and passes forward along the outer side of the urethral triangle in company with the superficial perineal artery; it is distributed to the skin of the scrotum (*nn. scrotales posteriores*) or to the labium majus in the female (*nn. labiales posteriores*). It communicates with the inferior hemorrhoidal, the inferior pudendal, and the other superficial perineal nerve. The **anterior** or **internal branch** also pierces the base of the triangular ligament, and passes forward nearer to the middle line, to be distributed to the inner and back part of the scrotum. Both these nerves supply the labium majus in the female.

The **muscular branches** are distributed to the Transversus perinaei, Accelerator urinae, Erector penis, and Compressor urethrae. A distinct branch is given off from the nerve to the Accelerator urinae, pierces this muscle, and supplies the corpus spongiosum, ending in the mucous membrane of the urethra. This is the **nerve to the bulb**.

The **Dorsal Nerve of the Penis** (*n. dorsalis penis*) is the deepest division of the pudic nerve; it accompanies the pudic artery along the ramus of the ischium; it then runs forward along the inner margin of the ramus of the os pubis, between the superficial and deep layers of the triangular ligament. Piercing the superficial layer, it gives a branch to the corpus cavernosum, and passes forward, in company with the dorsal artery of the penis, between the layers of the suspensory ligament, on to the dorsum of the penis, along which it is carried as far as the glans on which it ends.

In the female the dorsal nerve is very small, and supplies the **clitoris** (*n. dorsalis clitoridis*).

The **visceral branches** arise from the third and fourth, and sometimes the second, sacral nerves and are distributed to the bladder and rectum, and, in the female, to the vagina; they communicate with the pelvic plexuses of the sympathetic.

The **muscular branches** are derived from the fourth sacral, and supply the Levator ani, Coccygeus, and Sphincter ani externus. The branches to the Levator ani

and Coccygeus enter their pelvic surfaces; that to the Sphincter ani externus (*perineal branch*) reaches the ischiorectal fossa by piercing the Coccygeus or by passing between it and the Levator ani. Cutaneous branches from this branch supply the skin between the anus and the coccyx.

Anococcygeal Branches (*nn. anococcygei*).—The fifth sacral nerve receives a communicating branch from the fourth, and unites with the coccygeal nerve to form the **coccygeal plexus** (*plexus coccygeus*). From this plexus the anococcygeal nerves take origin; they consist of a few fine filaments which pierce the great sacrosciatic ligament to supply the skin in the region of the coccyx.

Applied Anatomy.—The lumbar plexus is formed in the Psoas magnus, and, therefore, in *Psoas abscess* any or all of its branches may be irritated, causing severe pain in the parts to which the irritated nerves are distributed. The *genitofemoral nerve* is the one which is most frequently implicated. The nerve is also of importance, as it is concerned in one of the *reflexes* employed in the investigation of diseases of the spine. If the skin over the inner side of the thigh just below Poupart's ligament, the part supplied by the femoral branch of the genitofemoral nerve, be gently tickled in a male child, the testicle will be noticed to be drawn upward through the action of the Cremaster, which is supplied by the genital branch of the same nerve. The same result may sometimes be noticed in adults, and can almost always be produced by severe stimulation. This reflex, when present, shows that the portion of the cord from which the first and second lumbar nerves are derived is in a normal condition.

The *femoral or anterior crural nerve* is in danger of being injured in *fractures of the true pelvis*, since the fracture most commonly takes place through the ascending ramus of the os pubis, at or near the point where this nerve crosses the bone. It is also liable to be injured in *fractures and dislocations of the femur*, and in some *tumors* growing in the pelvis is likely to be pressed upon, and its functions impaired. Moreover, on account of its superficial position, it is exposed to injury in *wounds and stabs in the groin*. When this nerve is *paralyzed*, the patient is unable to flex his hip completely, on account of the loss of motion in the Iliacus; or to extend the knee on the thigh, on account of paralysis of the Quadriceps extensor cruris; there are complete paralysis of the Sartorius and partial paralysis of the Pectineus. There is loss of sensation down the front and inner side of the thigh, except in that part supplied by the femoral branch of the genitofemoral nerve, and by the ilioinguinal nerve. There is also loss of sensation down the inner side of the leg and foot as far as the ball of the great toe.

The *obturator nerve* is of special surgical interest. It is rarely *paralyzed* alone, but occasionally is paralyzed in association with the femoral (anterior crural). The principal interest attached to it is in connection with its supply to the knee; pain in the knee being symptomatic of many diseases in which the trunk of this nerve, or one of its branches, is irritated. Thus, it is well known that in the earlier stages of *hip-joint disease* the patient does not complain of pain in that articulation, but on the inner side of the knee, or in the knee-joint itself, both these articulations being supplied by the obturator nerve, the final distribution of the nerve being to the knee-joint. Again, the same thing occurs in *sacroiliac disease*: pain is complained of in the knee-joint or on its inner side. The obturator nerve is in close relationship with the sacroiliac articulation, passing over it, and, according to some anatomists, distributing filaments to it. Again, in *cancer of the sigmoid flexure*, and even in cases where masses of hardened feces are impacted in this portion of the gut, pain is complained of in the knee. The left obturator nerve lies beneath the sigmoid flexure, and is readily pressed upon and irritated when disease exists in this part of the intestine. Finally, pain in the knee forms an important diagnostic sign in *obturator hernia*. The hernial protrusion as it passes through the opening in the obturator membrane presses upon the nerve and causes pain in the parts supplied by its peripheral filaments. When the obturator nerve is *paralyzed*, the patient is unable to press his knees together or to cross one leg over the other, on account of paralysis of the Adductor muscles. Rotation outward of the thigh is impaired from paralysis of the Obturator externus. Sometimes there is loss of sensation in the upper half of the inner side of the thigh.

The *great sciatic nerve* is liable to be pressed upon by various *pelvic tumors*, giving rise to pain along its trunk, to which the term *sciatica* is applied. Tumors growing from the pelvic viscera, or bones, *aneurisms* of some of the branches of the internal iliac artery, *calculus in the bladder*, when of large size, accumulation of feces in the rectum, may all cause pressure on the nerve inside the pelvis, and give rise to sciatica. Outside the pelvis exposure to cold, violent movements of the hip-joint, *exostoses* or other tumors, growing from the margin of the sacrosciatic foramen, may also give rise to the same condition. When paralyzed there is loss of motion in all the muscles below the knee, and loss of sensation in the same situation, except the upper half of the back of the leg, supplied by the small sciatic and the upper half of the inner side of the leg, when the communicating branch of the obturator is large.

The great sciatic nerve has been frequently cut down upon and *stretched*, or has been acu-

punctured for the relief of sciatica. The nerve has also been stretched in cases of locomotor ataxia, the anesthesia of leprosy, etc. In order to define it on the surface, a point is taken at the junction of the middle and lower third of a line stretching from the posterior superior spine of the ilium to the outer part of the tuber ischii, and a line is drawn from this point to the middle of the upper part of the popliteal space. The line must be slightly curved with its convexity outward, and as it passes downward to the lower border of the *Gluteus maximus* is slightly nearer the tuberosity of the ischium than to the great trochanter, as it crosses a line drawn between these two points. The operation of stretching the sciatic nerve is performed by making an incision over the course of the nerve about the centre of the thigh. The skin, superficial structures, and deep fascia having been divided, the interval between the inner and outer Hamstrings is to be defined, and these muscles respectively pulled inward and outward with retractors. The nerve will be found a little to the inner side of the Biceps. It is to be separated from the surrounding structures, hooked up with the finger, and stretched by steady and continuous traction for two or three minutes. The sciatic nerve may also be stretched by what is known as the "dry" method. The patient is laid on his back, the foot is extended, the leg flexed on the thigh, and the thigh strongly flexed on the abdomen. While the thigh is maintained in this position the leg is forcibly extended to its full extent, and the foot as fully flexed on the leg. This last-named method is uncertain.

The position of the external popliteal nerve, close behind the tendon of the Biceps on the outer side of the ham, should be remembered in *subcutaneous division of the tendon*. After it is divided, a cord often rises up close beside it, which might be mistaken for a small undivided portion of the tendon, and the surgeon might be tempted to reintroduce his knife and divide it. This must never be done, as the cord is the external popliteal nerve, which becomes prominent as soon as the tendon is divided. (See also page 525).

THE SYMPATHETIC NERVE SYSTEM (SYMPATHICUS) (Fig. 786).

The distinction of the sympathetic nerve system from the cerebrospinal system is made merely for reasons of convenience. The two systems are intimately connected and the sympathetic is morphologically a derivative of the central axis disseminated in connection with the nutritive apparatus and establishing relationships among the vegetative organs.

The sympathetic nerve system consists of (1) a series of **central ganglia** (*ganglia trunci sympathici*) connected by a great ganglionic cord, the **gangliated cord** (*truncus sympathicus*), extending from the base of the skull to the coccyx, one gangliated cord on each side of the middle line of the body, ventrolaterad of the vertebral column; (2) of three **great gangliated plexuses** (*plexus sympathici*) or aggregations of nerves and ganglia, situated ventrolaterad of the vertebral column in the thoracic, abdominal, and pelvic cavities respectively; (3) of **smaller or terminal ganglia**, situated in relation with the abdominal viscera;¹ and (4) of numerous **nerve fibres**. These latter are of two kinds—**communicating**, by which the ganglia communicate with each other and with the cerebrospinal nerves; and **distributory**, supplying the internal viscera and the coats of the bloodvessels.

Each gangliated cord may be traced upward from the base of the skull into the cranial cavity by an ascending branch, which passes through the carotid canal, forms a plexus on the internal carotid artery and in the cavernous sinus (Fig. 789), and communicates with certain cranial nerves (p. 1067); the lower ends of the two cords converge and end in a single ganglion, the **ganglion impar** (*ganglion coccygeum impar*), situated ventrad of the coccyx. The ganglia of the cord are distinguished as **cervical**, **thoracic**, **lumbar**, and **sacral**, and except in the neck they closely correspond in number to the vertebræ against which they lie. They are arranged thus:

Cervical portion	3 pairs of ganglia.
Thoracic "	10 to 12 " "
Lumbar "	4 " "
Sacral "	4 or 5 " "

¹ The ciliary, sphenopalatine, otic, and submaxillary ganglia, already described in connection with the trigeminal nerve, may be regarded as belonging to the sympathetic system.

In the neck the ganglia are situated in front of the transverse processes of the vertebræ; in the thoracic region, in front of the heads of the ribs; and in the lumbar region, on the sides of the bodies of the vertebræ; and in the sacral region, in front of the sacrum.

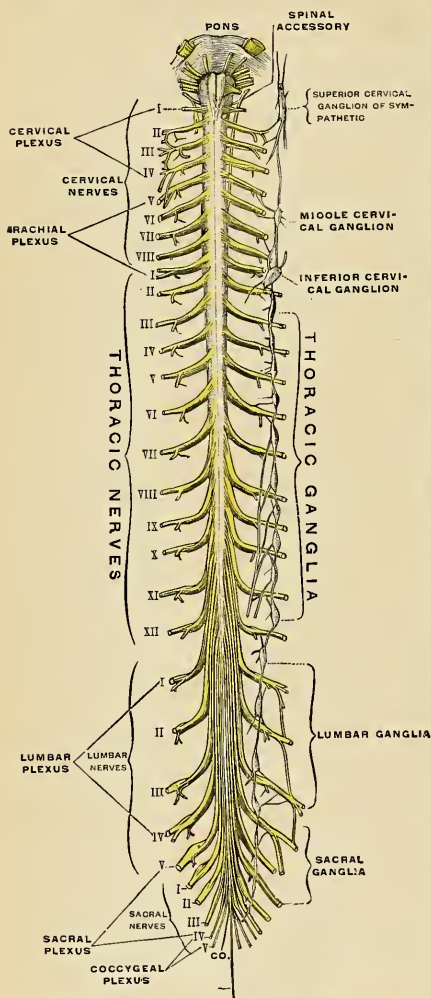


FIG. 786.—Anterior surface of the spinal cord, showing the spinal nerves and their connections with the sympathetic trunk on one side. (Testut.)

Connections with the Spinal Nerves.—Communications are established between the sympathetic and spinal nerves through what are known as **gray and white rami communicantes** (Fig. 786), the gray rami conveying sympathetic fibres into the spinal nerves, and the white rami transmitting afferent and efferent fibres to the sympathetic. Each spinal nerve receives a gray ramus communicans from the gangliated cord of the sympathetic, but white rami are not supplied by all the spinal nerves. The white rami are derived from the first thoracic to the first lumbar, inclusive, while the visceral branches which run from the second, third and fourth sacral nerves directly to the pelvic plexuses of the sympathetic belong to this category. The majority of the fibres which spring from the sympathetic ganglia are amyelinic (*fibres of Remak*); the fibres which reach the sympathetic through the white ramus communicans are myelinated.

The branches of distribution, or sympathetic nerves, derived from the gangliated cords from the prevertebral plexuses, and also from the smaller ganglia, are principally destined for the bloodvessels and thoracic and abdominal viscera, supplying the involuntary muscle fibres of the coats of the vessels and the hollow viscera, and the secreting cells, as well as the muscular coats of the vessels in the glandular viscera. They consist of efferent and afferent

fibres, for the origin and course of which see pages 1014 and 1015 (Fig. 756).

The three great gangliated plexuses (*collateral ganglia*) are situated in front of the vertebral column in the thoracic, abdominal, and pelvic regions, and are named,

respectively, the **cardiac**, the **solar** or **cœliac**, and the **hypogastric plexus**. They consist of collections of nerves and ganglia, the nerves being derived from the gangliated cords and from the cerebrospinal nerves. They distribute branches to the viscera.

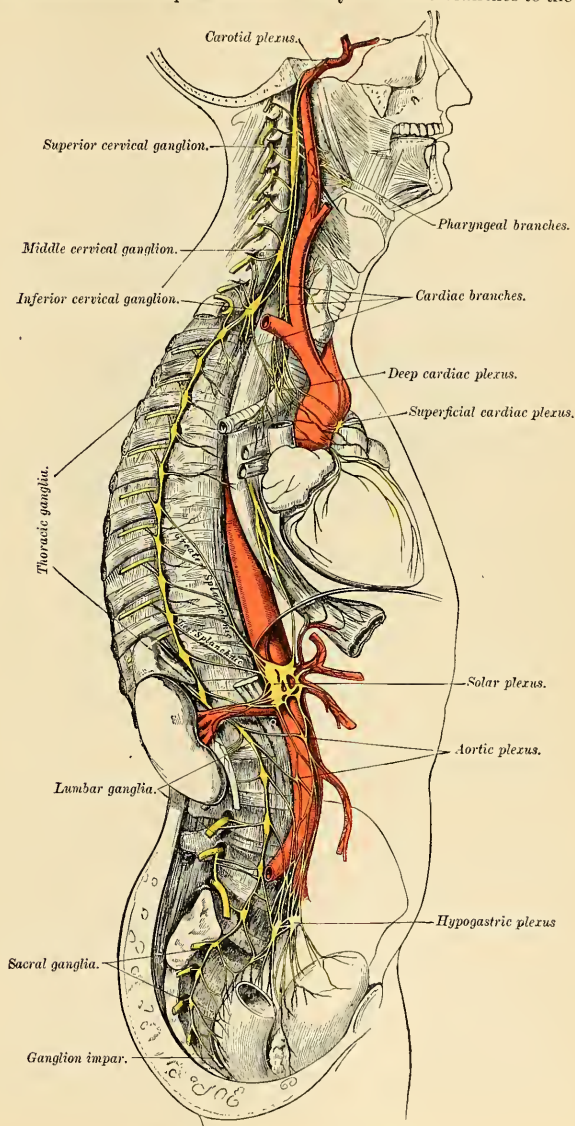


FIG. 787.—The sympathetic nerve system.

THE GANGLIATED CORD (TRUNCUS SYMPATHETICUS).

Cervicocephalic Portion of the Gangliated Cord (Figs. 788, 789).

The cervicocephalic portion of each gangliated cord (*pars cephalica et cervicalis s. sympathici*) consists of three ganglia, distinguished, according to their position, as the superior, middle, and inferior cervical, connected by intervening cords. This portion of the sympathetic cord receives no white rami communicantes from the cervical spinal nerves, its spinal fibres being derived from the white rami of the upper thoracic nerves which enter the corresponding thoracic ganglia of the sympathetic and through these ascend into the cervical portion.

The **superior cervical ganglion** (*ganglion cervicale superius*) (Figs. 787 and 788), the largest of the three, is about three-quarters of an inch in length. It is placed opposite the second and third cervical vertebræ. It is of a reddish-gray color, is usually fusiform in shape, is sometimes broad and flattened, and is occasionally constricted at intervals; it is believed that it is formed by the coalescence of the four ganglia corresponding to the four upper cervical nerves. It is in relation, in front, with the sheath of the internal carotid artery and internal jugular vein; behind, it lies on the *Rectus capitis anticus major*.

Its branches may be divided into **superior, inferior, external, internal, and anterior**.

The **superior branch** (*n. caroticus internus*) (Fig. 744) appears to be a direct prolongation of the ganglion. It is soft in texture and of a reddish color. It ascends by the side of the internal carotid artery, and, entering the carotid canal in the temporal bone, divides into two branches, which lie, one on the outer, and the other on the inner, side of that vessel.

The **outer branch**, the larger of the two, distributes filaments to the internal carotid artery and forms the **carotid plexus**.

The **inner branch** also distributes filaments to the internal carotid artery, and, continuing onward, forms the **cavernous plexus**.

The **Carotid Plexus** (*plexus caroticus internus*) (Figs. 787 and 788) is situated on the outer side of the internal carotid artery. Filaments from this plexus occasionally form a small gangliform swelling, the **carotid ganglion**, on the under surface of the artery. The carotid plexus communicates with the Gasserian ganglion, the abducent nerve, and the sphenopalatine ganglion; it distributes filaments to the wall of the carotid artery, and also communicates with Jacobson's nerve (the tympanic branch of the glossopharyngeal).

The **communicating branches to the abducent nerve** consist of one or two filaments which join that nerve as it lies upon the outer side of the internal carotid artery. The communication with the sphenopalatine ganglion is effected by a branch, the **large deep petrosal nerve** (Fig. 745), given off from the plexus on the outer side of the artery; this branch passes through the cartilage filling up the foramen lacerum medium, and joins the large superficial petrosal from the facial to form the **Vidian nerve** (Figs. 740 and 745). The Vidian nerve then proceeds through the Vidian canal to the sphenopalatine ganglion. The communication with Jacobson's nerve is effected by two branches, one of which is called the **deep petrosal nerve**, and the other the **caroticotympanic nerve**; the latter may consist of two or three delicate filaments.

The **Cavernous Plexus** (*plexus cavernosus*) (Fig. 788) is situated below and internal to that part of the internal carotid which is placed by the side of the sella turcica, in the cavernous sinus, and is formed chiefly by the internal division of the ascending branch from the superior cervical ganglion. It communicates with the oculomotor, the trochlear, the ophthalmic division of the trigeminal,

and the abducent nerves, and with the ciliary or lenticular ganglion, and distributes filaments to the wall of the internal carotid artery, and to the hypophysis. The branch of communication with the oculomotor nerve joins it at its point of division; the branch to the trochlear nerve joins it as it lies on the outer wall of the cavernous sinus; other filaments are connected with the under surface of the trunk of the ophthalmic nerve; and a second filament of communication joins the abducent nerve.

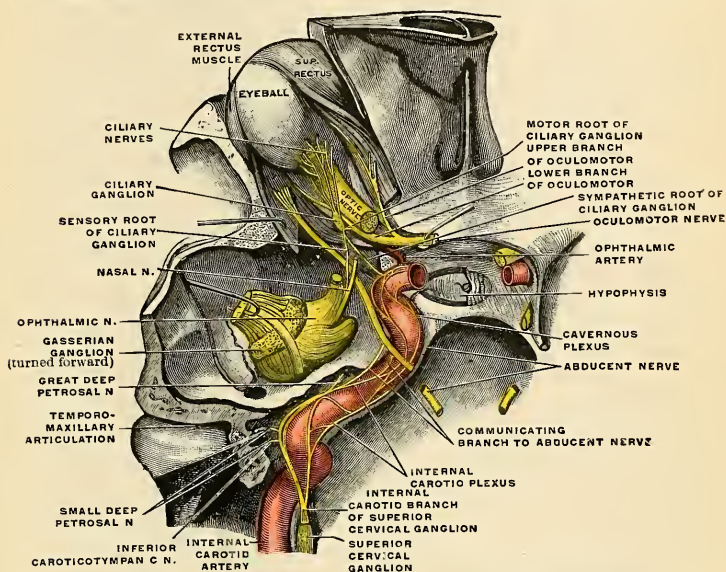


FIG. 788.—The cephalic portion of the sympathetic nerve system, seen obliquely from above and behind. (Toldt.)

The filaments of connection with the ciliary ganglion (Fig. 735) arise from the anterior part of the cavernous plexus and enter the orbit through the sphenoidal fissure; they may join the nasal branch of the ophthalmic nerve or be continued forward as a separate branch.

The terminal filaments from the carotid and cavernous plexuses are prolonged along the internal carotid artery, forming plexuses which entwine around the anterior and middle cerebral arteries and the ophthalmic artery; along the former vessels they may be traced on to the pia; along the latter, into the orbit, where they accompany each of the branches of the vessel. The filaments prolonged to the anterior communicating artery connect the sympathetic nerves of the right and left sides.

The so-called inferior branch of the superior cervical ganglion communicates with the middle cervical ganglion.

The external branches are communicating, and consist of gray rami communicantes to the upper four cervical nerves and to certain of the cranial nerves. Sometimes the branch to the fourth cervical nerve may come from the cord connecting the superior and middle cervical ganglia. The branches to the cranial nerves consist of delicate filaments, which run to the ganglion of the trunk of

the vagus, and to the hypoglossal nerve. A separate filament (*nervus jugularis*) passes upward to the base of the skull, and subdivides to join the petrous ganglion

of the glossopharyngeal, and the ganglion of the root of the vagus in the jugular foramen.

The internal branches are peripheral, and consist of the pharyngeal and laryngeal branches, and the superior cardiac nerve.

The pharyngeal branches (*rami pharyngei*) (Fig. 787) pass inward to the side of the pharynx, where they join with branches from the glossopharyngeal, vagus, and external laryngeal nerves to form the pharyngeal plexus.

The laryngeal branches join the superior laryngeal nerve and its branches.

The superior cardiac nerve (*n. cardiacus superior*) (Figs. 787) arises by two or more branches from the superior cervical ganglion, and occasionally receives a filament from the cord of communication between the first and second cervical ganglia. It runs down the neck behind the common carotid artery, lying upon the *Longus colli*, and crosses in front of the inferior thyroid artery and recurrent laryngeal nerve.

The course of the nerves on

the two sides then differs. The right superior cardiac nerve, at the root of the neck, passes either in front of or behind the subclavian artery, and along the innominate artery, to the back part of the arch of the aorta, where it joins the deep cardiac plexus. It is connected with other branches of the sympathetic; about the middle of the neck it receives filaments from the external laryngeal nerve; lower down it obtains one or two twigs from the vagus, and as it enters the thorax it is joined by a filament from the recurrent laryngeal. Filaments from the nerve communicate with the thyroid branches from the middle cervical ganglion.

The left superior cardiac nerve, in the thorax, runs by the side of the left common carotid artery, and in front of the arch of the aorta to the superficial cardiac plexus.

The anterior branches (*nn. carotici externi*) (Fig. 789) ramify upon the external carotid artery and its branches, forming around each a delicate plexus, on the

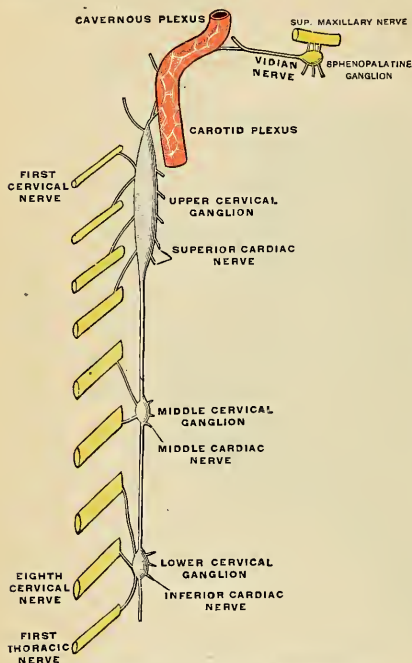


FIG. 789.—Diagram of the cervical sympathetic cord. (Testut.)

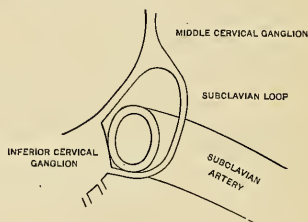


FIG. 790.—The subclavian loop passing from the middle to the inferior cervical ganglia.

nerves composing which small ganglia are occasionally found. The plexuses accompanying some of these arteries have important communications with other nerves. That surrounding the external carotid artery (*plexus caroticus externus*) is connected with the branch of the facial nerve to the Stylohyoid muscle; that surrounding the facial artery communicates with the submaxillary ganglion by one or two filaments; and that accompanying the middle meningeal artery sends an offshoot which passes to the otic ganglion and a second, the external superficial petrosal nerve (Fig. 745), to the geniculate ganglion of the facial nerve.

The **middle cervical ganglion** (*ganglion cervicale medium*) (Figs. 787 and 789) is the smallest of the three cervical ganglia, and is occasionally altogether wanting. It is placed opposite the sixth cervical vertebra, usually upon, or close to, the inferior thyroid artery. It is probably formed by the coalescence of two ganglia corresponding to the fifth and sixth cervical nerves.

It is joined by gray rami communicantes to the fifth and sixth cervical nerves.

It gives off the thyroid and middle cardiac nerves.

The **thyroid branches** are small filaments which accompany the inferior thyroid artery to the thyroid gland, forming the **inferior thyroid plexus** (*plexus thyroideus inferior*); they communicate, on the artery, with the superior cardiac nerve, and, in the gland, with branches from the recurrent and external laryngeal nerves.

The **middle or great cardiac nerve** (*n. cardiacus medius*) (Fig. 787), the largest of the three cardiac nerves, *arises* from the middle cervical ganglion or from the cord between the middle and inferior ganglia. On the right side it descends behind the common carotid artery, and at the root of the neck passes either in front of or behind the subclavian artery; it then descends on the trachea, receives a few filaments from the recurrent laryngeal nerve, and joins the right side of the deep cardiac plexus. In the neck it communicates with the superior cardiac and recurrent laryngeal nerves. On the left side the middle cardiac nerve enters the thorax between the left carotid and subclavian arteries, and joins the left side of the deep cardiac plexus. If the middle cervical ganglion is absent, the above-named branches arise from the gangliated cord.

The **inferior cervical ganglion** (*ganglion cervicale inferius*) (Figs. 787 and 789) is situated between the base of the transverse process of the last cervical vertebra and the neck of the first rib on the inner side of the superior intercostal artery. Its form is irregular; it is larger in size than the preceding, and is frequently joined to the first thoracic ganglion. It is probably formed by the coalescence of two ganglia which correspond to the last two cervical nerves. It is connected to the middle ganglion by two or more cords, one of which forms a loop around the subclavian artery and supplies offshoots to it. This loop is named the *ansa subclavii* (Vieussenii).

The ganglion is joined to the seventh and eighth cervical and the first thoracic nerves by gray rami communicantes.

It gives off the inferior cardiac nerve and offshoots to bloodvessels.

The **inferior cardiac nerve** (*n. cardiacus inferior*) *arises* from the inferior cervical or first thoracic ganglion. It passes down behind the subclavian artery and along the front of the trachea to join the deep cardiac plexus. It communicates freely behind the subclavian artery with the recurrent laryngeal and middle cardiac nerves.

The *offshoots to bloodvessels* accompany the vertebral artery, and form a plexus around it; this plexus (*plexus vertebralis*) supplies filaments to the vessel, and is continued up the vertebral and basilar arteries to the cerebral and cerebellar arteries.

Applied Anatomy.—The situation of the cervical sympathetic makes wounds of it rare. Thirteen cases of traumatic injury to the cervical sympathetics were collected by Seeligmüller. In ten cases paralysis existed; in three, irritation. Tumors of the neck may cause irritation or

paralysis. In *irritation* of the sympathetic the corresponding side of the face becomes pale, the pupil dilates, the palpebral fissure widens, and the eyeball protrudes. In many cases there is acceleration of the heart beats. In *paralysis* of the sympathetic the pupil contracts, the palpebral fissure is narrowed by partial ptosis, the corresponding side of the face reddens, there is an increase in the flow of tears, and recession of the eyeball.

The surgeon occasionally resects the sympathetic. Jonnesco recommends bilateral removal of the superior cervical ganglia for glaucoma, and bilateral removal of all the cervical sympathetic ganglia for epilepsy and for exophthalmic goitre. The results of resection do not appear to justify the operation.

The Thoracic Portion (Pars Thoracalis) of the Gangliated Cord (Fig. 791).

The thoracic portion of the gangliated cord consists of a series of ganglia which usually correspond in number to that of the vertebræ; but, from the occa-

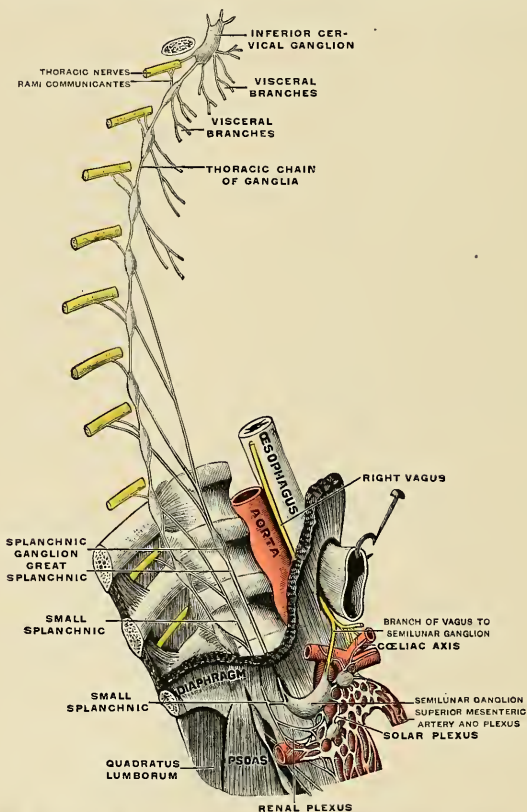


FIG. 791.—Plan of the right sympathetic cord and splanchnic nerves. (Testut.)

sional coalescence of two, their number is uncertain. The ganglia are placed on each side of the spine, resting against the heads of the ribs, and are covered by

the costal pleura; the last two ganglia are, however, anterior to the rest, being placed on the side of the bodies of the eleventh and twelfth thoracic vertebrae. The ganglia are small in size and of a grayish color. The first ganglion, larger than the others, is of an elongated form and is frequently blended with the last cervical ganglion. They are connected by the intervening portions of the cord.

Two rami communicantes, one white and the other gray, connect each ganglion with its corresponding spinal nerve.

The *branches from the upper five ganglia* are very small; they supply filaments to the thoracic aorta and its branches, and to the bodies of the vertebrae and their ligaments. Branches from the second, third, and fourth ganglia enter the posterior pulmonary plexus.

The *branches from the lower seven ganglia* are large, and white in color; they distribute filaments to the aorta, and unite to form the three splanchnic nerves. These are named the **great**, the **lesser**, and the **smallest**, or **renal splanchnic**.

The **great splanchnic nerve** (*n. splanchnicus major*) is white in color, firm in texture, and is *formed* by branches from the thoracic ganglia between the fifth or sixth and the ninth or tenth; but the fibres in the higher roots may be traced upward in the sympathetic cord as far as the first or second thoracic ganglion. These roots unite to form a cord of considerable size. It descends obliquely inward in front of the bodies of the vertebrae along the posterior mediastinum, perforates the crus of the Diaphragm, and terminates in the **semilunar ganglion of the solar plexus** (Fig. 791), distributing filaments to the **renal** and **suprarenal plexuses**. A ganglion (*ganglion splanchnicum*) exists on this nerve opposite the eleventh or twelfth thoracic vertebra.

The **lesser splanchnic nerve** (*n. splanchnicus minor*) is *formed* by filaments from the tenth and eleventh ganglia, and from the cord between them. It pierces the Diaphragm near or with the preceding nerve, and joins the aorticorenal ganglion of the **solar plexus** (Fig. 791). It communicates in the thorax with the great splanchnic nerve, and ends in the solar plexus.

The **least splanchnic nerve** (*n. splanchnicus imus*) *arises* from the last thoracic ganglion, and, piercing the Diaphragm, terminates in the **renal plexus**. It occasionally communicates with the preceding nerve.

A striking analogy appears to exist between the splanchnic and the cardiac nerves. The cardiac nerves are three in number, they *arise* from the three cervical ganglia, and are distributed to a large and important organ in the thoracic cavity. The splanchnic nerves, also three in number, are connected probably with all the thoracic ganglia, and are distributed to important organs in the abdominal cavity.

The Lumbar Portion (Pars Lumbalis) of the Gangliated Cord (Fig. 787).

The lumbar portion of the gangliated cord is situated in front of the vertebral column along the inner margin of the Psoas magnus. It consists usually of four ganglia, connected together by interganglionic cords. It is continuous above with the thoracic portion beneath the internal arcuate ligament of the Diaphragm, and below with the sacral portion behind the common iliac artery. The ganglia are of small size, and placed much nearer the median line than the thoracic ganglia.

Gray rami communicantes connect all the ganglia with the lumbar spinal nerves. There may be two from each ganglion, but the arrangement is not so uniform as in other regions. The first and second, and sometimes the third, lumbar nerves send white rami communicantes to the upper two or three ganglia.

From the situation of the lumbar ganglia these branches are longer than in the other regions. They accompany the lumbar arteries around the sides of the bodies

of the vertebræ, passing beneath the fibrous arches from which some of the fibres of the Psoas magnus arise.

Of the **branches of distribution** some branches pass inward, in front of the aorta, and help to form the **abdominal aortic plexus** (*plexus aorticus abdominalis*) (Fig. 787). Other branches descend in front of the common iliac arteries, and, joining over the promontory of the sacrum, assist in forming the **hypogastric plexus** (*plexus hypogastricus*) (Fig. 787). Numerous delicate filaments are also distributed to the bodies of the vertebræ and the ligaments connecting them.

Pelvic Portion (Pars Pelvina) of the Gangliated Cord (Fig. 787).

The pelvic portion of the gangliated cord is situated in front of the sacrum along the inner side of the anterior sacral foramina. It consists of four or five small ganglia on each side, connected by interganglionic cords. Below, these cords converge and unite on the front of the coccyx by means of a small ganglion, the **coccygeal ganglion** or **ganglion impar** (*ganglion coccygeum impar*) (Fig. 787).

Gray rami communicantes pass from the ganglia to the sacral and coccygeal nerves. No white rami communicantes join this part of the gangliated cord, but the visceral branches which *arise* from the third and fourth, and sometimes from the second, sacral are regarded as homologous with white rami communicantes.

The **branches of distribution** communicate on the front of the sacrum with the corresponding branches from the opposite side; some, from the first two ganglia, pass to join the pelvic plexus, while others form a plexus which accompanies the middle sacral artery, from which plexus filaments pass to the coccygeal gland.

THE GREAT PLEXUSES OF THE SYMPATHETIC SYSTEM.

The great plexuses of the sympathetic are the large aggregations of nerves and ganglia, previously alluded to, situated in the thoracic, abdominal, and pelvic cavities respectively, and named the cardiac, pulmonary, œsophageal, celiac, and hypogastric plexuses respectively. They consist not only of sympathetic fibres derived from the ganglia, but also of fibres from the central nerve system which are conveyed through the white rami communicantes. From them are derived the branches which supply the viscera.

The Cardiac Plexus (Plexus Cardiacus) (Fig. 787).

The cardiac plexus is situated at the base of the heart, and is divided into a **superficial part**, which lies in the concavity of the arch of the aorta, and a **deep part**, which lies between the trachea and aorta. The two plexuses are, however, closely connected.

The **superficial cardiac plexus** lies beneath the arch of the aorta, in front of the right pulmonary artery. It is formed by the left superior cardiac nerve, the left (and occasionally also the right) inferior cervical cardiac branches of the vagus, and filaments from the deep cardiac plexus. A small ganglion, the **cardiac ganglion of Wrisberg** (*ganglion cardiacum [Wrisbergi]*) is occasionally found connected with these nerves at their point of junction. This ganglion, when present, is situated immediately beneath the arch of the aorta on the right side of the ductus arteriosus. The superficial cardiac plexus gives branches to the deep cardiac plexus beneath the arch of the aorta to the right or anterior coronary plexus and to the left anterior pulmonary plexus.

The **deep cardiac plexus** is situated in front of the trachea at its bifurcation,

above the point of division of the pulmonary artery and behind the arch of the aorta. It is formed by the cardiac nerves derived from the cervical ganglia of the sympathetic and the cardiac branches of the recurrent laryngeal and vagus. The only cardiac nerves which do not enter into the formation of this plexus are the left superior cardiac nerve and the inferior cervical cardiac branch from the left vagus.

The branches from the **right side** of this plexus pass, some in front of, and others behind, the right pulmonary artery; the former, the more numerous, transmit a few filaments to the anterior pulmonary plexus, and are then continued onward to form part of the **right coronary plexus**; those behind the pulmonary artery distribute a few filaments to the right auricle, and are then continued onward to form a part of the **left coronary plexus**.

The **left side** of the plexus is connected with the superficial cardiac plexus and gives filaments to the left auricle of the heart, and to the anterior pulmonary plexus, and is then continued to form the greater part of the left coronary plexus.

The **left coronary plexus** (*plexus coronarius posterior*) is larger than the right, and accompanies the left coronary artery; it is chiefly formed by filaments prolonged from the left side of the deep cardiac plexus, and by a few from the right side. It gives branches to the left auricle and ventricle.

The **right coronary plexus** (*plexus coronarius anterior*) is formed partly from the superficial and partly from the deep cardiac plexus. It accompanies the right coronary artery, and gives branches to the right auricle and ventricle.

Although sympathetic filaments enter into the formation of the **anterior** and **posterior pulmonary** and the **œsophageal plexuses**, these are usually regarded as portions of the vagus nerve (p. 1007).

The Cœliac or Solar Plexus (*Plexus Coeliacus*) (Figs. 787, 792).

The cœliac or solar plexus supplies the viscera in the abdominal cavity. It consists of a great network of nerves and ganglia, situated behind the pancreas and the lesser peritoneal cavity and in front of the aorta and crura of the Diaphragm. It surrounds the cœliac axis and root of the superior mesenteric artery, extending downward as low as the pancreas and outward to the suprarenal glands. This plexus, and the ganglia connected with it, receive the **great**, the **small**, and the **least splanchnic nerves** of both sides, and some filaments from the **right vagus nerve**. It distributes filaments which accompany, under the name of plexuses, all the branches from the front of the abdominal aorta.

Of the ganglia of which the solar plexus is partly composed the principal are the two **semilunar ganglia** (*ganglia coeliaca*) (Figs. 792 and 793), which are situated one on each side of the plexus, and are the largest ganglia in the body. They are large, irregular, gangliform masses formed by the aggregation of smaller ganglia, having interspaces between them. They are situated in front of the crura of the Diaphragm, close to the suprarenal glands; the one on the right side lies beneath the inferior vena cava. The upper part of each ganglion is joined by the great splanchnic nerve, and to the inner side of each the branches of the solar plexus are connected. The lower portion of each semilunar ganglion is detached, and is named the **aorticorenal ganglion**.

From the cœliac plexus are derived the following:

Phrenic or Diaphragmatic plexus.
Suprarenal plexus.
Renal plexus.
Spermatic } plexus.
Ovarian }

Gastric plexus.
Splenic plexus.
Hepatic plexus.
Superior mesenteric plexus.
Aortic plexus.

The **Phrenic Plexus** (*plexus phrenicus*) (Fig. 792) accompanies the inferior phrenic artery to the Diaphragm, some filaments passing to the suprarenal gland. It arises from the upper part of the semilunar ganglion, and is larger on the right than on the left side. It receives one or two branches from the phrenic nerve. At the point of junction with the phrenic nerve is a small ganglion, the **phrenic ganglion** (*ganglion phrenicum*) (Fig. 793), which lies on the under surface of the Diaphragm, near the right suprarenal. Its branches are distributed to the inferior vena cava, suprarenal, and hepatic plexus. There is no phrenic ganglion on the left side.

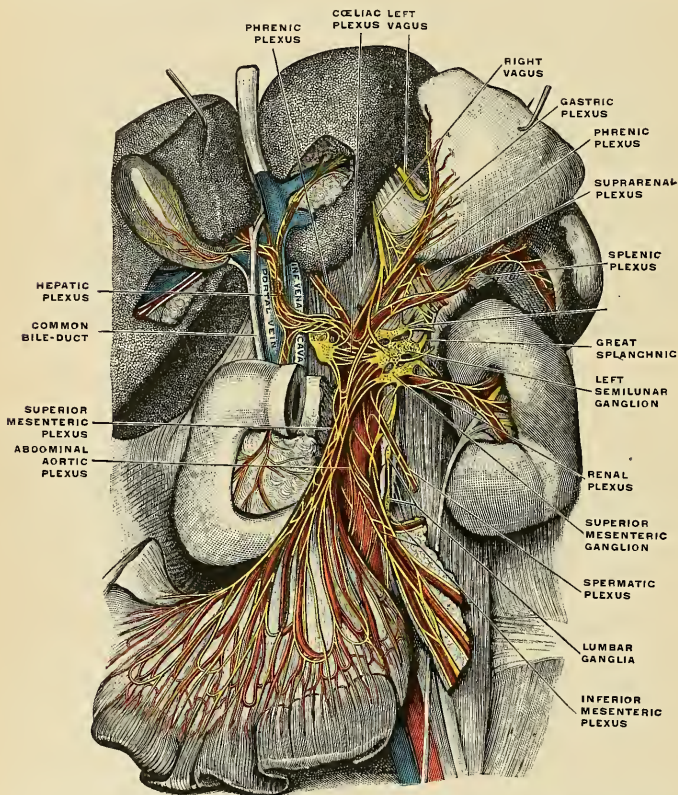


FIG. 792.—The semilunar ganglia with the sympathetic plexuses of the abdominal viscera radiating from the ganglia. (Toldt.)

The **Suprarenal Plexus** (*plexus suprarenalis*) (Fig. 792) is formed by branches from the coeliac plexus, from the semilunar ganglion, and from the phrenic and great splanchnic nerves, a ganglion being formed at the point of junction of the latter nerve. It supplies the suprarenal gland, being chiefly distributed to its medullary portion. The branches of this plexus are remarkable for their large size in comparison with the size of the organ they supply.

The **Renal Plexus** (*plexus renalis*) (Figs. 792 and 793) is formed by filaments from the coeliac plexus, the lower part of the semilunar ganglion (aorticorenal ganglion) and the aortic plexus. It is also joined by the least splanchnic

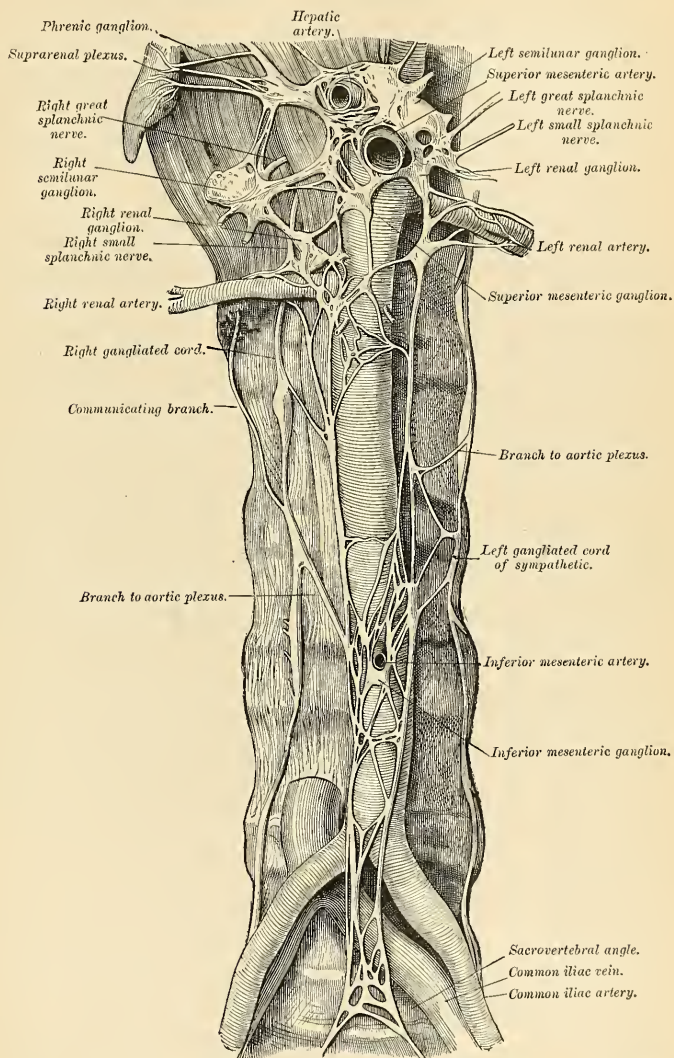


FIG. 793.—Lumbar portion of the gangliated cord, with the coeliac and hypogastric plexuses. (After Henle.)

nerve. The nerves from these sources, fifteen or twenty in number, have numerous ganglia developed upon them. They accompany the branches of the renal artery into the kidney, some filaments on the right side being distributed to the inferior vena cava, and others, on both sides, to the spermatic plexuses.

The **Spermatic Plexus** (*plexus spermaticus*) (Fig. 792) is derived from the renal plexus, receiving branches from the aortic plexus. It accompanies the spermatic vessels to the testis.

In the female the **ovarian plexus** (*plexus arteriae ovaricae*) arises like the spermatic plexus, and is distributed to the ovaries, Fallopian tubes, and fundus of the uterus.

The **Gastric or Coronary Plexus** (*plexus gastricus superior*) (Fig. 792) accompanies the gastric artery along the lesser curvature of the stomach, and joins with branches from the left vagus nerve.

The **Splenic Plexus** (*plexus lienalis*) (Fig. 792) is formed by branches from the celiac plexus, the left semilunar ganglion, and from the right vagus nerve. It accompanies the splenic artery and its branches to the substance of the spleen, giving off, in its course, filaments to the pancreas, the **pancreatic plexus**, and the **left gastroepiploic plexus**, which accompanies the left gastroepiploic artery along the greater curvature of the stomach.

The **Hepatic Plexus** (*plexus hepaticus*) (Fig. 792), the largest offshoot from the celiac plexus, receives filaments from the left vagus and right phrenic nerves. It accompanies the hepatic artery, ramifying in the substance of the liver upon the branches of the portal vein within the substance of the liver.

Branches from this plexus accompany all the divisions of the hepatic artery. Thus, there is a **pyloric plexus** accompanying the pyloric branch of the hepatic, which joins with the gastric plexus and vagi nerves. There is also a **gastro-duodenal plexus**, which subdivides into the **pancreaticoduodenal plexus**, which accompanies the pancreaticoduodenal artery, to supply the pancreas and duodenum, joining with branches from the mesenteric plexus. The **gastroepiploic plexus**, which accompanies the right gastroepiploic artery along the greater curvature of the stomach, and which is said to anastomose with branches from the splenic plexus, is in reality derived from the splenic plexus. A **cystic plexus**, which supplies the gall-bladder, also arises from the hepatic plexus near the liver.

The **Superior Mesenteric Plexus** (*plexus mesentericus superior*) (Fig. 792) is a continuation of the lower part of the great solar plexus, receiving a branch from the junction of the right vagus nerve with the celiac plexus. It surrounds the superior mesenteric artery, which it accompanies into the mesentery, and divides into a number of secondary plexuses, which are distributed to all parts supplied by the artery—viz., **pancreatic branches** to the pancreas; **intestinal branches**, which supply the whole of the small intestine; and **ileocolic, right colic, and middle colic branches**, which supply the corresponding parts of the large intestine. The nerves composing this plexus are white in color and firm in texture; in the upper part of the plexus close to the origin of the superior mesenteric artery is a ganglion (*ganglion mesentericum superius*).

The **Abdominal Aortic Plexus** (*plexus aorticus abdominalis*) (Figs. 792 and 793) is formed by branches derived, on either side, from the celiac plexus, receiving filaments from some of the lumbar ganglia. It is situated upon the sides and front of the aorta, between the origins of the superior and inferior mesenteric arteries. From this plexus arise part of the spermatic, the inferior mesenteric, and the hypogastric plexuses; it also distributes filaments to the inferior vena cava.

The **Inferior Mesenteric Plexus** (*plexus mesentericus inferior*) (Fig. 792) is derived chiefly from the left side of the aortic plexus. It surrounds the inferior mesenteric artery, and divides into a number of secondary plexuses, which are distributed to all the parts supplied by the artery—viz., the **left colic** and **sigmoid plexuses**, which

supply the descending and sigmoid flexure of the colon; and the **superior hemorrhoidal plexus** (*plexus hemorrhoidalis superior*), which supplies the upper part of the rectum and joins in the pelvis with branches from the pelvic plexus.

The Hypogastric Plexus (*Plexus Hypogastricus*) (Figs. 787, 793).

The hypogastric plexus supplies the viscera of the pelvic cavity. It is situated in front of the promontory of the sacrum, between the two common iliac arteries, and is formed by the union of numerous filaments, which descend on each side from the abdominal aortic plexus and from the lumbar ganglia. This plexus contains no evident ganglia; it bifurcates, below, into two lateral portions, right and left, which form the **pelvic plexuses**.

The Pelvic Plexuses.

The pelvic plexuses supply the viscera of the pelvic cavity, and are situated at the side of the rectum in the male, and at the sides of the rectum and vagina in the female. They are formed by a continuation of the hypogastric plexus, by the visceral branches from the second, third, and fourth sacral nerves, and by a few filaments from the first two sacral ganglia. At the points of junction of these nerves small ganglia are found. From these plexuses numerous branches are distributed to the rectum and bladder in the male, and to the rectum, bladder, uterus, and vagina in the female. They accompany the branches of the internal iliac artery. These secondary plexuses are (1) the **inferior hemorrhoidal**, (2) **vesical**, (3) **prostatic**, (4) **vaginal**, and (5) **uterine plexuses**.

The **Inferior Hemorrhoidal Plexus** (*plexus haemorrhoidalis inferior*) arises from the upper part of the pelvic plexus. It supplies the rectum, joining with branches of the superior hemorrhoidal plexus.

The **Vesical Plexus** (*plexus vesicalis*) arises from the fore part of the pelvic plexus. The nerves composing it are numerous, and contain a large proportion of spinal nerve fibres. They accompany the vesical arteries, and are distributed to the side and base of the bladder. Numerous filaments also pass to the vesiculae seminales and vasa deferentia; those accompanying the vas deferens join, on the spermatic cord, with branches from the spermatic plexus.

The **Prostatic Plexus** (*plexus prostaticus*) is continued from the lower part of the pelvic plexus. The nerves composing it are of large size. They are distributed to the prostate gland, seminal vesicles, and erectile tissue of the penis. The nerves supplying the erectile tissue of the penis consist of two sets, the **small** and **large cavernous nerves**. They are slender filaments, which arise from the fore part of the prostatic plexus, and, after joining with branches from the internal pudic nerve, pass forward beneath the pubic arch.

The **small cavernous nerves** (*nn. cavernosi penis minores*) perforate the fibrous covering of the penis, near its root.

The **large cavernous nerve** (*n. cavernosus penis major*) passes forward along the dorsum of the penis, joins with the dorsal nerve of the penis, and is distributed to the corpora cavernosa and corpus spongiosum.

The uterine and vaginal plexuses in reality constitute one plexus, the **utero-vaginal plexus** (*plexus uterovaginalis*).

The **Vaginal Plexus** arises from the lower part of the pelvic plexus. It is distributed to the walls of the vagina, to the erectile tissue of the vestibule, and to the clitoris. The nerves composing this plexus contain, like the vesical, a large proportion of spinal nerve fibres.

The **Uterine Plexus** accompanies the uterine artery to the side of the uterus between the layers of the broad ligament; it communicates with the ovarian plexus.

THE ORGANS OF SPECIAL SENSE.

THE organs of the senses (*organa sensuum*) are five in number—those of smell, sight, hearing, taste, and touch.

THE NOSE.

The nose is the peripheral portion of the organ of smell (*organon olfactus*); by means of the peculiar properties of its nerves it protects the lungs from the inhalation of deleterious gases and assists the organ of taste in discriminating the properties of food. The organ of smell consists of two parts—one external, the **outer nose**, which projects from the centre of the face, and an internal, the **cavum nasi**, which is divided by a septum into the **right** and **left nasal fossæ**.

THE OUTER NOSE (NASUS EXTERNUS).

The outer nose is the more anterior and prominent part of the organ of smell. Of a pyramidal form, it is directed downward, and projects from the centre of the face immediately above the upper lip. Its **root** (*radix nasi*) is connected directly with the forehead. Its **base** (*basis nasi*) presents two elliptical orifices, the **nostrils** or **anterior nares** (*nares*), separated from each other by an antero-posterior septum, the **columna** (*septum mobile nasi*). The margins of the nostrils are provided with a number of stiff hairs or **vibrissæ**, which arrest the passage of foreign substances carried with the current of air intended for respiration. The **point** (*apex nasi*) is the free extremity of the nose. The **lateral surfaces** of the nose form, by their union in the middle line, the **dorsum** (*dorsum nasi*), the direction of which varies considerably in different individuals. The portion of the dorsum over the nasal bones is the **bridge**. Each lateral surface terminates below in a rounded eminence, the **wing** or **ala nasi**, which, by its lower margin (*margo nasi*), forms the outer boundary of the corresponding nostril. Above the ala is a depression, the **alar sulcus**.

Structure.—The nose is composed of a framework of **bones** and **cartilages**, the latter being slightly acted upon by certain muscles. It is covered externally by the integument, internally by mucous membrane, and is supplied with vessels and nerves.

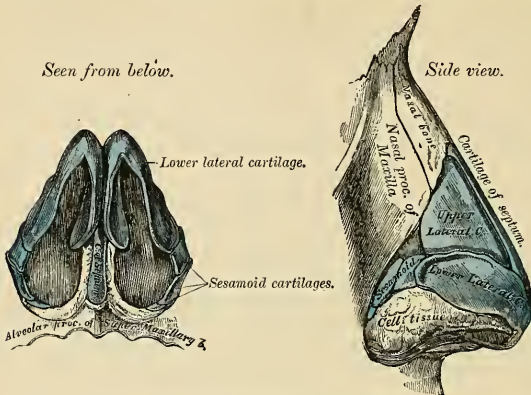
The **bony framework** occupies the upper part of the organ; it consists of the **nasal bones** and the **nasal processes of the maxillæ** (pp. 99 and 104).

The **cartilaginous framework** (*cartilaginee nasi*) (Figs. 794 and 795) consists of five pieces—the **two upper** and the **two lower lateral cartilages** and the **cartilage of the septum**.

The **upper lateral cartilage** (*cartilago nasi lateralis*) of each side is situated below the free margin of the nasal bone and is flat and triangular in shape. Its anterior margin is thicker than the posterior, and continuous above with the cartilage of the septum. Its posterior margin is attached to the nasal process of the maxilla. Its inferior margin is connected by fibrous tissue with the lower lateral cartilage; one surface is turned outward, the other inward toward the nasal cavity.

The **lower lateral cartilage** (*cartilago alaris major*) is a thin, flexible plate situated immediately below the preceding, and bent upon itself in such a manner as to form the inner and outer walls of the orifice of the nostril. The portion which forms the **inner wall** (*crus mediale*), thicker than the rest, is loosely connected with the corresponding portion of the opposite cartilage to

form a small part of the columna. Its inferior border, free, rounded, and projecting, forms, with the thickened integument and subjacent tissue and the corresponding parts of the opposite side, the mobile septum. The part of the cartilage which forms the **outer wall** (*crus laterale*) is



Figs. 794 and 795.—Cartilages of the nose.

curved to correspond with the ala of the nose; it is oval and flattened, narrow behind, where it is connected with the nasal process of the maxilla by a tough fibrous membrane, in which are found three or four small cartilaginous plates, the **sesamoid** or lesser alar cartilages (*cartilagine alares minores*). Above, it is connected by fibrous tissue to the upper lateral cartilage and front part of the cartilage of the septum; below, it falls short of the margin of the nostril; the ala being completed by dense cellular tissue covered by skin. In front the lower lateral cartilages are separated by a notch which corresponds with the point of the nose.

The **cartilage of the septum** (*cartilago septi nasi*) (Figs. 794 and 796) is somewhat quadrilateral in form, thicker at its margins than at its centre, and completes the separation between the nasal fosse in front. Its **anterior margin**, thickest above, is connected with the nasal bones, and is continuous with the anterior margins of the two upper lateral cartilages. Below, it is connected to the inner portions of the lower lateral cartilages by fibrous tissue. Its **posterior margin** is connected with the perpendicular lamella of the ethmoid; its inferior margin with the vomer and the palate processes of the maxillae (Fig. 796).

It may be prolonged backward (especially in children) for some distance between the vomer and perpendicular plate of the ethmoid, forming what is termed the **sphenoidal process** (*processus sphenoidalis septi cartilaginei*). The septal cartilage does not reach as far as the lower part of the nasal septum.

This is formed by the thinnest portions of the

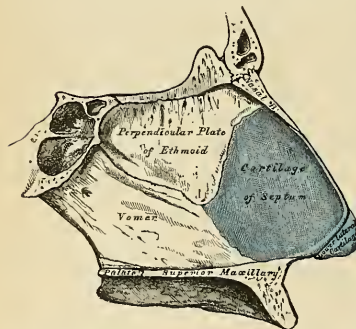


FIG. 796.—Bones and cartilage of septum of the nose. Right side.

lower lateral cartilages and by the skin; it is freely movable, and hence is termed the **mobile septum**.

Along the lower margin of the anterior half of the cartilage of the septum is another cartilage which is attached to the vomer and is known as the **vomerine cartilage**, or **cartilage of Jacobson** (*cartilago vomeronasalis*).

These various cartilages are connected to each other and to the bones by a tough fibrous membrane, which allows the utmost facility of movement between them.

The **muscles of the nose** are situated beneath the integument; they are (on each side) the *Pyramidalis nasi*, the *Levator labii superiores alaeque nasi*, the *Dilatator naris*, anterior and pos-

terior, the Compressor nasi, the Compressor narium minor, and the Depressor alae nasi. They have been previously described (p. 372).

The **integument** covering the dorsum and the sides of the nose is thin, and loosely connected with the subjacent parts; but the integument of the tip and the alae of the nose is thicker and more firmly adherent, and is furnished with a large number of sebaceous follicles, the orifices of which are usually very distinct.

The **mucous membrane** lining the interior of the nose is continuous with the skin externally and with the mucous membrane which lines the nasal fossæ within.

The **arteries of the nose** are the **lateralis nasi** from the facial, and the **inferior artery of the septum** from the superior coronary, which supply the alæ and septum, the sides and dorsum being supplied from the **nasal branch of the ophthalmic** and the **infraorbital**. The **veins of the nose** terminate in the **facial** and **ophthalmic**. The **lymphatics of the outer nose** are shown in Fig. 557. They empty chiefly into the **submaxillary lymph nodes**. The **nerves** for the muscles of the nose are derived from the **facial**, while the skin receives its branches from the **infraorbital**, **infrotrochlear**, and **nasal branches of the ophthalmic**.

THE NASAL FOSSÆ (CAVUM NASI).

The nasal fossæ are two irregular cavities situated in the middle of the face, one on each side of the mesal plane. They open in front, when the soft parts are in place, by the two **nostrils** or **anterior nares**, and terminate, behind, in the nasopharynx by the **posterior nares**.

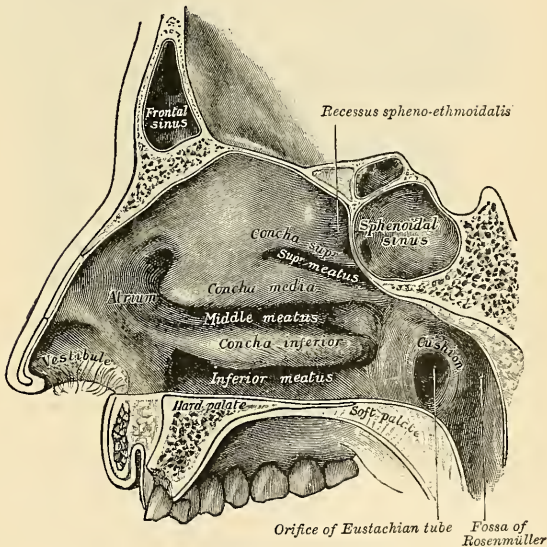


FIG. 797.—Outer wall of nasal fossa.

The **anterior nares** (*nares*) are somewhat pear-shaped apertures, each measuring about one inch (2.5 cm.) antero-posteriorly and half an inch (1.2 cm.) transversely at their widest part. The nasal fossæ in the dry skull open in front by the anterior nasal aperture (*apertura pyriformis*).

The **posterior nares** (*choanae*) are two oval openings, which are smaller in the living or recent subject than in the skeleton, because they are narrowed by the

mucous membrane. Each measures an inch (2.5 cm.) in the vertical and half an inch (1.2 cm.) in the transverse direction in a well-developed adult skull.

For the description of the bony boundaries of the nasal fossæ see page 138.

Inside the aperture of the nostril is a slight dilatation, the **vestibule** (*vestibulum nasi*), which extends as a small pouch, the **ventricle**, toward the point of the nose. Above and behind the vestibule is surrounded by a prominence (*limen nasi*). Below the prominence the vestibule is lined with skin; above and behind it the fossa is lined with mucous membrane. The fossa, above and behind the vestibule, has been divided into two parts—an **olfactory portion** (*regio olfactoria*), a slit-

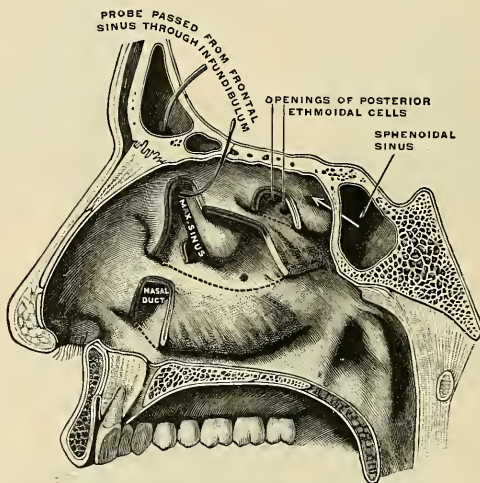


FIG. 798.—External wall of right nasal fossa, parts of the turbinates having been cut away to show the orifices of the sinuses which open into the meatuses. (Testut.)

like cavity, comprising the upper and central part of the septum and the superior turbinated process, and a **respiratory portion** (*regio respiratoria*), which comprises the rest of the fossa.

The Outer Wall (Figs. 797 and 798).—The superior, middle, and inferior meati (*meatus nasi superior, medius, and inferior*) are described on page 141. The sphenoidal air sinus opens into the **sphenoethmoidal recess** (*recessus sphenoethmoidalis*), a narrow recess above the superior turbinated process (Fig. 798). The posterior ethmoidal cells open into the front and upper part of the superior meatus (Fig. 797). Where the middle turbinated process joins the nasal process of the maxilla there is often an elevation, **agger nasi**, presumably a representative of another turbinate. On raising or cutting away the middle turbinated process the outer wall of the middle meatus is fully exposed (Figs. 798 and 799) and presents (1) a rounded elevation, termed the **bulla ethmoidalis**, opening on or immediately above which are the orifices of the middle ethmoidal cells; (2) a deep, narrow, curved groove, in front of the bulla ethmoidalis, termed the **hiatus semilunaris**, into which the anterior ethmoidal cells and the maxillary sinus open, the orifice of the latter being placed near the level of its roof. The middle meatus is prolonged, above and in front, into the **infundibulum**, which leads into the **frontal sinus**. The anterior extremity of the meatus is continued into a depressed area which lies above the vestibule and is named the **atrium** (*atrium meatus medii nasi*).

The **nasal duct** opens into the anterior part of the inferior meatus, the opening being frequently overlapped by a fold of mucous membrane.¹

The Inner Wall (Fig. 799).—The inner wall or septum is frequently more or less deflected from the mesal plane (Fig. 799), thus limiting the size of one fossa and increasing that of the other. Ridges or spurs of bone growing outward from the septum are also sometimes present. Immediately over the incisive foramen at the lower edge of the cartilage of the septum a depression, the **nasopalatine recess** (*recessus nasopalatinus*), may be seen. In the septum close to this recess a minute orifice may be discerned; it leads into a blind pouch, the rudimentary organ of Jacobson (*organon vomeronasale*), which is well developed in some of the lower animals, but is rudimentary in man. The organ is supported by a plate

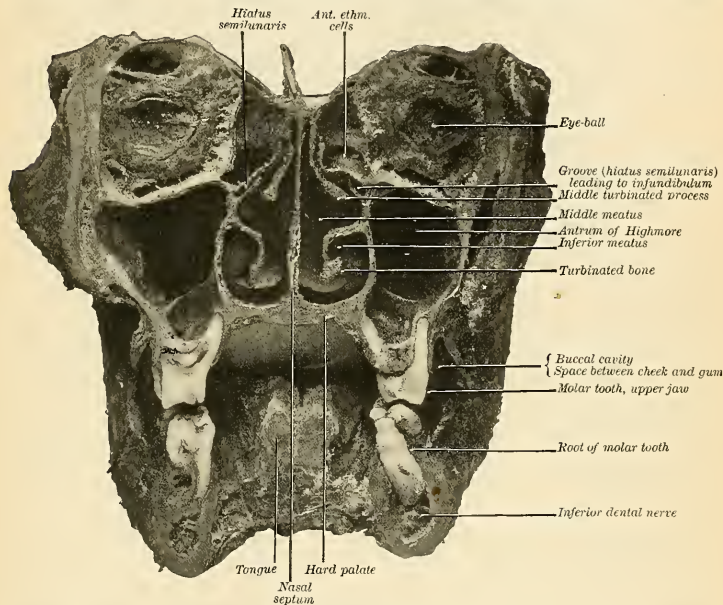


FIG. 799.—Transverse vertical section of the nasal fossæ. The section is made anterior to the superior turbinated processes. (Cryer.)

of cartilage, distinct from the cartilage of the septum, the **cartilage of Jacobson** (p. 1080). The cartilage of Jacobson is to the outer side of the lower edge of the cartilage of the septum. Just below the opening of the blind pouch is an elevation, the **eminence of Jacobson**.

The Mucous Membrane (*membrana mucosa nasi*).—The mucous membrane lining the nasal fossæ is sometimes called the **Schneiderian membrane**.² It is closely adherent to the periosteum or perichondrium, upon which it lies. It is continuous externally with the skin through the anterior nares, and with the mucous membrane of the nasopharynx through the posterior nares. From the nasal fossæ its continuity may be traced with the conjunctiva through the nasal duct and lacrimal canals; with the lining membrane of the tympanum and mastoid cells

¹J. P. Schaeffer: "Types of Ostia Nasolacrimalia, etc.," Amer. Jour. of Anat., vol. xiii, No. 2, 1912.

²After Conrad Victor Schneider (1614–1680), Professor of Anatomy at Wittenberg.

through the Eustachian tube; and with the frontal, ethmoidal, and sphenoidal sinuses, and the maxillary sinus through the several openings in the meatuses. The mucous membrane is thickest and most vascular over the turbinated processes and bone. It is also thick over the septum, but in the intervals between the spongy bones

and on the floor of the nasal fossæ it is very thin. Where it lines the various sinuses it is thin and pale.

Owing to the great thickness of this membrane, the nasal fossæ are much narrower, and the turbinated processes and bones appear larger and more prominent than in the dried skull. From the same circumstance, also, the various apertures communicating with the meatuses are considerably narrowed.

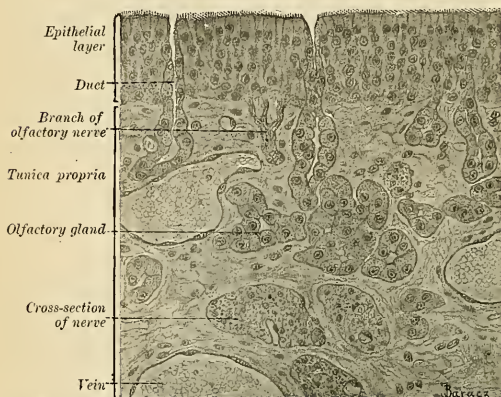


FIG. 800.—Vertical section through the mucous membrane of the regio olfactoria of a rabbit. $\times 360$.

Structure of the Mucous Membrane (Figs. 800 and 801).—The epithelium covering the mucous membrane differs in its character according to the functions of the part of the nose in which it is found. In the respiratory portion of the nasal cavity the epithelium is columnar and ciliated, which is also the type found in the accessory sinuses, with the exception of the maxillary, where the epithelium is of the simple polygonal variety. Interspersed among the columnar ciliated cells are goblet or mucin cells, while between their bases are found smaller pyramidal cells. In this region, beneath the epithelium and its basement membrane, is a fibrous layer infiltrated with leukocytes, so as to form in many parts diffuse lymphoid tissue, which is particularly plentiful in children; beneath this is a nearly continuous layer of smaller and larger glands, some mucous and some serous, the ducts of which open upon the surface. In the respiratory portion of the mucous membrane there is an extensive anastomosing plexus of veins, which in some regions forms a distinct **cavernous tissue** (*plexus cavernosus concharum*). The cavernous tissue is particularly distinct over the inferior turbinated bones. In the olfactory region the mucous membrane is yellowish in color and the epithelial cells are columnar and non-ciliated; they are of two kinds, **supporting cells** and **olfactory cells**.

The **supporting cells** are irregular pigmented elements that contain oval nuclei, situated in the deeper parts of the cells; the free surface of each cell presents a sharp outline, and its deep extremity is prolonged into a process which runs inward, branching to communicate with similar processes from neighboring cells, so as to form a network in the deep part of the mucous membrane. Lying between these central processes of the supporting cells are a large number of spindle-shaped cells, the **olfactory cells**, which consist of a large spherical nucleus surrounded by a small amount of granular protoplasm, and possessing two processes, of which one runs outward between the columnar epithelial cells, and projects on the surface of the mucous membrane as a fine, hair-like process, the **olfactory hair**; the other or deep process runs inward, is frequently beaded, and is continuous with one of the filaments of the olfactory nerves. Beneath the epithelium, extending through the thickness of the mucous membrane, is a layer of tubular,

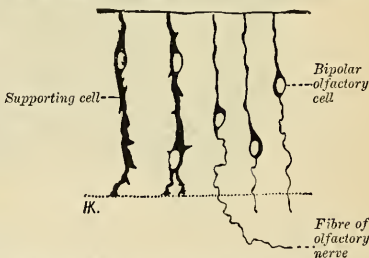


FIG. 801.—From a vertical section through the mucous membrane of the regio olfactoria of a quite young dog. Golgi's method. $\times 450$. (Szymonowicz.)

often branched, glands, the **glands of Bowman** (*glandulæ olfactoriæ*), identical in structure with serous glands.

The **accessory spaces**, **sphenoidal**, **frontal**, **maxillary**, **sinuses**, and **ethmoidal cells** are lined by an extension of the nasal mucosa. The mucosa is thin, and consists of stratified ciliated and goblet cells upon a basement membrane and supported by a thin fibroelastic tunica propria. The glands are few in number and racemose in structure.

The **arteries** of the nasal fossæ are the *anterior* and *posterior ethmoidal*, from the ophthalmic, which supply the ethmoidal cells, frontal sinuses, and roof of the nose; the *sphenopalatine*, from the internal maxillary, which supplies the mucous membrane covering the spongy bones, the meatuses, and septum; the *inferior artery of the septum*, from the superior coronary of the facial; and the *infraorbital* and *alveolar branches* of the internal maxillary, which supply the lining membrane of the antrum. The ramifications of these vessels form a close, plexiform network, beneath and in the substance of the mucous membrane.

The **veins** of the nasal fossæ form a close, cavernous-like network beneath the mucous membrane. This cavernous appearance is especially well marked over the lower part of the septum and over the middle turbinated process and inferior turbinated bones. Some of the veins pass, with those accompanying the sphenopalatine artery, through the sphenopalatine foramen; and others, through the alveolar branch, to join the *facial vein*; some accompany the ethmoidal arteries, and terminate in the *ophthalmic vein*; and, lastly, a few communicate with the veins in the interior of the skull, through the foramina in the cribriform plate of the ethmoid bone, and the foramen cecum.

The **lymphatics** have already been described (p. 777).

The **nerves** of ordinary sensation are the nasal branch of the ophthalmic, filaments from the anterior dental branch of the superior maxillary, the Vidian, the nasopalatine, the large or anterior palatine, and nasal branches of the sphenopalatine ganglion. The *nasal branch of the ophthalmic division of the trigeminal nerve* distributes filaments to the fore part of the septum and outer wall of the nasal fossæ. *Filaments from the anterior dental branch of the superior maxillary* supply the inferior meatus and inferior turbinated bone. The *Vidian nerve* supplies the upper and back part of the septum and superior turbinated process, and the *upper anterior nasal branches* from the *sphenopalatine ganglion* have a similar distribution. The *nasopalatine nerve* supplies the middle of the septum. The *larger or anterior palatine nerve* supplies the *lower nasal branches* to the middle turbinated process and the turbinated bone. The *olfactory nerves*, the special nerves of the sense of smell, are distributed to the olfactory region, and have been already referred to (p. 973).

Applied Anatomy.—Instances of *congenital deformity* of the nose are occasionally met with, such as complete absence of the nose, an aperture only being present; or perfect development on one side, and suppression or malformation on the other; or there may be imperfect apposition of the nasal bones, so that the nose presents a median cleft or furrow. Deformities which have been acquired are much more common, such as *flattening of the nose* (*saddle nose*), the result of *syphilitic necrosis*, imperfect development of the nasal bones in cases of *congenital syphilis*, or a lateral deviation of the nose may result from *fracture*.

The skin over the alæ and tip of the nose is thick and closely adherent to subjacent parts. *Inflammation* of this part is therefore very painful, on account of the tension. The skin is largely supplied with blood, and the circulation here being terminal, vascular engorgement is liable to occur, especially in women at the menopause and in both sexes from disorders of digestion, exposure to cold, etc. The skin of the nose also contains a large number of sebaceous glands, and these, as a result of intemperance, are apt to become affected, and the nose becomes reddened, congested, and irregularly swollen. To this condition the term *grog blossom* is popularly applied. In some of these cases there is enormous hypertrophy of the skin and subcutaneous tissues, producing pendulous masses, termed *lipomata nasi*. Ordinary *epithelioma* and *rodent ulcer* may attack the nose, the latter being the more common of the two. *Lupus* and *syphilitic ulceration* frequently attack the nose, and may destroy the whole of the cartilaginous portion. In fact, *lupus vulgaris* begins more frequently on the alæ of the nose than in any other situation.

Cases of congenital occlusion of one or both nostrils, or adhesion between the alæ and septum may occur, and may require immediate operation, since the obstruction much interferes with nursing. Bony closure of the posterior nares may also occur.

To examine the nasal cavities, the head should be thrown back and the nose drawn upward, the parts being dilated by some form of speculum. The posterior nares can be explored by the aid of reflected light from the mouth, by which the posterior nares can be illuminated. The examination is very difficult to carry out, and, as a rule, sufficient information regarding the presence of foreign bodies or tumors in the nasopharynx can be obtained by the introduction of the finger behind the soft palate through the mouth. The *septum of the nose* is sometimes displaced or *deviates* from the middle line; this may be the result of an injury or some congenital defect in its development; in the latter case the deviation usually occurs along the line of union of the vomer and mesethmoid, and rarely occurs before the seventh year. Sometimes the deviation may be so great that the septum may come in contact with the outer wall of the nasal fossa, and may even become adherent to it, thus producing complete obstruction. *Perforation of the*

septom is not an uncommon affection and may arise from several causes—syphilitic or tuberculous ulceration, blood tumor or abscess of the septum, and especially in workmen exposed to the vapor of bichromate of potash, from the irritating and corrosive action of its fumes. When small, the perforation may cause a peculiar whistling sound during respiration. When large, it may lead to the falling in of the bridge of the nose.

Epistaxis is a very common affection in children. It is rarely of much consequence, and will almost always subside, but in the more violent hemorrhages of later life it may be necessary to plug the posterior nares. In performing this operation it is desirable to remember the size of the posterior nares. A ready method of regulating the size of the plug to fit the opening is to make it of the same size as the terminal phalanx of the thumb of the patient to be operated on.

Foreign bodies, such as boot buttons, are frequently inserted into the nostrils by children, and require some care in their removal, as unskilled attempts only result in pushing the foreign body farther into the nasal fossa. Bodies which remain in the nose any length of time are apt to set up an ulceration of the mucosa, which may spread to the bone; a unilateral nasal discharge in a child is always suggestive of the presence of a foreign body. A foreign body is best removed under anesthesia, placing the left forefinger in the nasopharynx to prevent the passage of the body into the air-passages, and then removing the foreign body through the anterior naris by a suitable scoop or forceps manipulated by the right hand.

Nasal polypus is a very common disease, and presents itself in three forms—the gelatinous, the fibrous, and the malignant. The first is by far the most common. It grows from the mucous membrane of the outer wall of the nasal fossa, where there is an abundant layer of highly vascular submucous tissue; rarely from the septum, where the mucous membrane is closely adherent to the cartilage and bone, without the intervention of much, if any, submucous tissue. The most common seat of gelatinous polyps is probably the middle turbinated process. The fibrous polypus generally grows from the base of the skull behind the posterior nares or from the roof of the nasal fossæ. The malignant polypi, both sarcomatous and carcinomatous, may arise in the nasal cavities and the nasopharynx; or they may originate in the antrum, and protrude through its inner wall into the nasal fossa.

Rhinoliths or nose-stones may sometimes be found in the nasal cavities. They arise from the deposition of phosphate of lime upon either a foreign body or a piece of inspissated secretion.

The nasal passages furnish a secretion of their own and receive secretion from other parts (tears and secretions of the accessory sinuses). The nasal cavities contain the ethmoidal lacryr-rinths, the lateral masses of the ethmoid (which form the superior and middle turbinated processes), and the inferior turbinated bones. The nasal cavity is surrounded by four pairs of pneumatic spaces, the **accessory sinuses**. These are the maxillary sinuses (p. 103), the frontal sinuses (p. 79), the sphenoidal sinuses (p. 99), and the cells of the ethmoidal labyrinth (p. 97). The lacrimal duct opens into the inferior meatus. Inflammation of the air-cells may follow inflammation of the nasal mucous membrane or bone disease. One set of cells or many may suffer. Suppuration may occur; pus may be retained; death of bone may ensue. The most serious conditions may follow (abscess of brain, sinus thrombosis, septicemia), and an operation is necessary to obtain relief.

THE EYE.

The **eyeball** or **globe** (*bulbus oculi*) (Figs. 802 and 804) is contained in the anterior part of the cavity of the orbit. In this situation it is securely protected from injury, while its position is such as to insure the most extensive range of sight. It is acted upon by numerous muscles, by which it is capable of being directed to different parts; it is supplied by vessels and nerves, and is additionally protected in front by the orbital margins, eyelids, etc.

The eyeball is embedded in the fat of the orbit, but is partly surrounded by a thin membranous sac, the **capsule of Ténon**, which isolates it, so as to allow of free movement.

The **Capsule of Ténon** (*fascia bulbi* [*Tenoni*]) (Figs. 802 and 803) consists of a thin membrane which envelops the eyeball from the optic nerve to the ciliary region, separating it from the orbital fat and forming a socket in which it plays. Its inner surface is smooth, and is in contact with the outer surface of the sclera, the **periscleral** or **suprascleral lymph space** only intervening. This lymph space is continuous with the subdural and subarachnoid spaces, and is traversed by delicate bands of connective tissue which extend between the capsule and the sclera. This lymph space forms a flexible pocket, in which the globe rotates. The capsule is perforated behind by the **ciliary vessels** and **nerves** and by the **optic nerve**, being continuous with the sheath of the latter. In front it blends with

the ocular conjunctiva, and with it is attached to the ciliary region of the eyeball. It is perforated by the ocular muscles, and is reflected backward on each as a tubular sheath. The sheath of the Superior oblique is carried as far as the fibrous

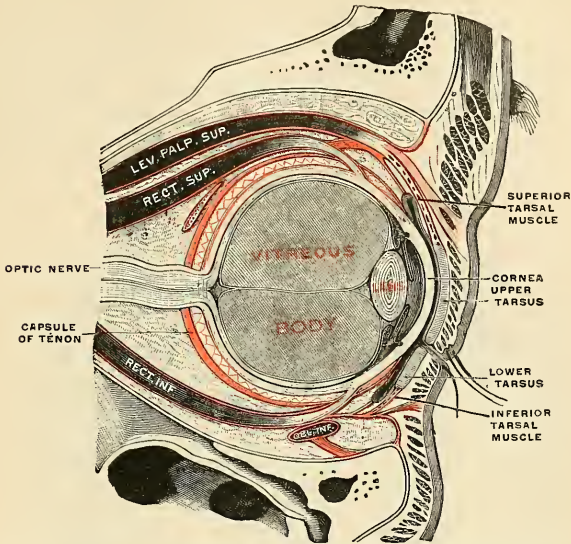


FIG. 802.—The right eye in sagittal section, showing the capsule of Ténon (semidiagrammatic). (Testut.)

pulley of that muscle; that on the Inferior oblique reaches as far as the floor of the orbit, to which it gives off a slip. The sheaths on the Recti are gradually lost in the epimysium, but they give off important expansions. The expansion from the Superior rectus blends with the tendon of the Levator palpebrae; that of the Inferior rectus is attached to the inferior tarsal plate. These two Recti, therefore, will exercise some influence on the movements of the eyelids. The expansions from the sheaths of the Internal and External recti are strong, especially the one from the latter muscle, and are attached to the lacrimal and malar bones respectively. As they probably check the action of these two Recti, they have been named the **internal and external check ligaments**.

Lockwood has also described a thickening of the lower part of the capsule of Ténon which he has named the **suspensory ligament of the eye**. It is slung like a

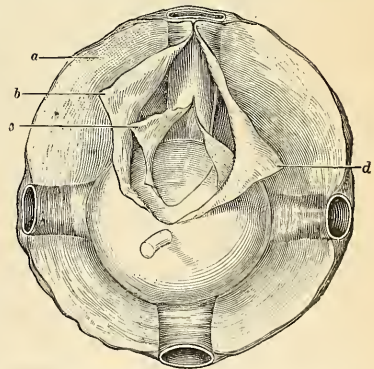


FIG. 803.—The capsule of Ténon. The aponeurosis is seen from behind forward on the posterior hemisphere of the globe. *a*. Cellulofibrous intermuscular lamina. *b*. Deep leaf of the sheath incised at the point where it leaves the muscle to fold itself on the posterior hemisphere when it forms the posterior capsule. *c*. Partly incised. *d*. Serous membrane. (Poirier and Charpy.)

hammock below the eyeball, being expanded in the centre, and narrow at its extremities, which are attached to the malar and lacrimal bones respectively.¹

The anterior one-third of the globe is covered by the **conjunctiva**, or mucous membrane, reflected from the inner surfaces of the lids (Fig. 805). A lateral view of the globe shows that it is composed of **segments of two spheres** of different sizes (Figs. 804 and 805). The **anterior segment** is one of a small sphere, and forms about one-sixth of the eyeball. It is more prominent than the **posterior segment**, which is one of a much larger sphere, and forms about five-sixths of the globe. Between the small, anterior or corneal segment and the large, posterior or scleral segment is a shallow and narrow groove, the **scleral sulcus** (*sulcus sclerae*). The **anterior pole** is the centre of the anterior portion of the cornea. The **posterior pole** is the centre of the posterior portion of the sclera. A straight line joining

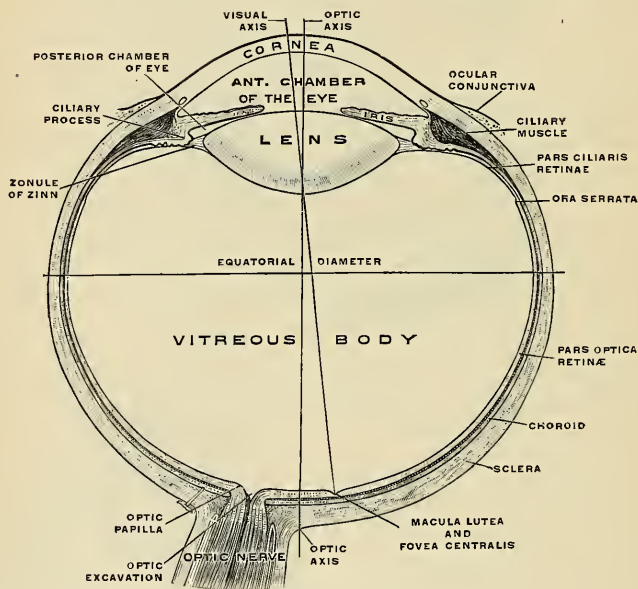


FIG. 804.—The right eye in horizontal section. (Toldt.)

these two poles is the **sagittal or optic axis** (*axis optica*) (Fig. 804). A line drawn around the eyeball equally distant at all points from the two poles is called the **equator** (Fig. 804). The plane of the equator divides the globe in an **anterior** and a **posterior hemisphere**. The **visual axis** (*linea visus*) (Fig. 804) passes in a straight line from the first nodal point on the cornea to the fovea centralis of the yellow spot on the retina. A **nodal point** is the point of intersection of convergent rays with the visual axis. The first nodal point is 6.9685 mm. behind the summit of the cornea. The axes of the eyeballs are nearly parallel to the mesal plane, and therefore do not correspond to the axes of the orbits, which are inclined to this plane, forming with it an anterior angle of about 30 degrees. The optic nerves

¹ See a paper by C. B. Lockwood, *Journal of Anatomy and Physiology*, vol. xx, part i, p. 1.

follow the direction of the axes of the orbits and are therefore not parallel, each nerve either leaves or connects with its eyeball about 1 mm. below and 3 mm. to the inner or nasal side of the posterior pole (Fig. 804). The eyeball measures rather more in its transverse and antero-posterior diameters than in its vertical diameter, the former amounting to about 24 mm. (nearly an inch), the latter to about 23.5 mm. (nine-tenths of an inch). The diameters in the female are somewhat less than in the male. At birth the eyeball has a transverse diameter of about 17.5 mm., while at puberty it measures from 20 to 21 mm.

The eyeball is composed of three investing tunics and of three main refracting media.

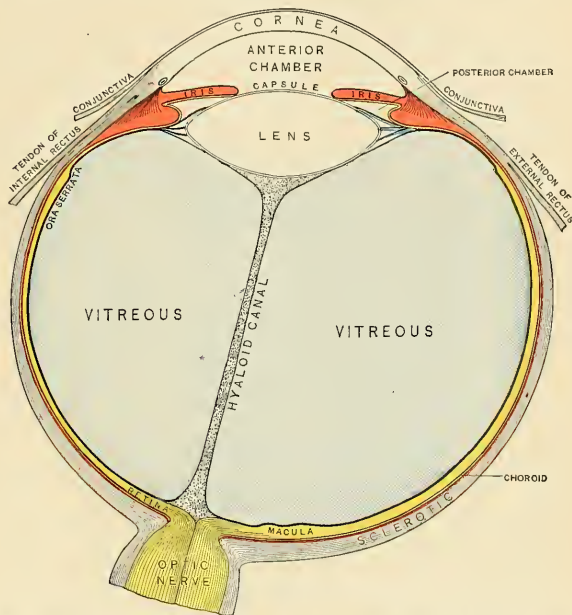


FIG. 805.—Diagram of a horizontal section of the right eye, showing the upper surface of the lower segment. (Testut.)

THE TUNICS OF THE EYE.

From without inward the three tunics are:

- I. Sclera and Cornea.
- II. Choroid, Ciliary Body, and Iris
- III. Retina.

I. The Sclera and Cornea (*Tunica Fibrosa Oculi*).

The sclera and cornea (Figs. 805 and 806) form the external tunic of the eyeball; they are essentially fibrous in structure, the sclera being opaque, and forming the posterior five-sixths of the globe; the cornea, which forms the remaining sixth, is transparent.

The Sclera (*σκληρόν*, hard).—The sclera has received its name from its extreme density and toughness; it is a firm, unyielding, opaque, fibrous membrane serving to maintain the form of the globe. It is much thicker behind than in front. Its *external surface* is of a white color, and is in contact with the inner surface of the capsule of Ténon, a lymph space intervening; it is quite smooth, except one-quarter of an inch back of the sclerocorneal junction, at the points where the Recti and Obliqui muscles are attached to it, and its anterior part is covered by the **conjunctival membrane** (Fig. 829); hence the whiteness and brilliancy of the front of the eyeball. Its *inner surface* is stained a brown color, marked by grooves, in which are lodged the **ciliary nerves** and **vessels** (Figs. 814 and 815); the inner surface of the sclera is loosely connected with the outer surface of the choroid by a layer of exceedingly fine cellular pigmented tissue (*lamina fusca*), which traverses an extensive lymph space, the **perichoroidal space** (*spatium perichoroideale*) (Figs. 814 and 829) intervening between the sclera and choroid. Behind, the sclera is pierced by the **optic nerve** and is continuous with the fibrous sheath of the nerve, which is derived from the dura (Fig. 809). At the point where the optic nerve passes through the sclera, the lamina fusca is represented by an arrangement of the fibrous tissue which forms a thin network, the **cribriform lamina** (*lamina cribrosa sclerae*) (Fig. 819); the minute orifices in this lamina serve for the transmission of nerve filaments, and the fibrous septa dividing them from one another are continuous with the membranous processes which separate the bundles of nerve fibres. One of these openings (*porus opticus*), larger than the rest, occupies the centre of the lamella; it transmits the **arteria centralis retinae** to the interior of the eyeball (Fig. 819). Around the cribriform lamella are numerous small apertures for the transmission of the **ciliary nerves** and the **short ciliary arteries**, and about midway between the margin of the cornea and the entrance of the optic nerve are four or five large apertures, for the transmission of **veins** (*venae vorticosae*) (Fig. 809). In front, the fibrous tissue of the sclera is continuous with the substantia propria of the cornea (Fig. 829), but the opaque sclera slightly overlaps the outer surface of the transparent cornea.

Structure.—The sclera is formed of white fibrous tissue intermixed with fine elastic fibres, and of flattened connective-tissue cells, some of which are pigmented, contained in cell spaces between the fibres (Fig. 819). These fibres are aggregated into bundles, some of which are arranged in layers having an equatorial direction, but most of which are arranged in layers lying in meridian lines. Its vessels (Figs. 809 and 810) are not numerous, the capillaries being of small size and uniting at long and wide intervals. It obtains arterial blood from the **short posterior ciliary** and the **anterior ciliary arteries**. The venous blood is removed by the *venae vorticosae* and the **anterior ciliary veins**. There are lymph spaces between the cells which empty into the *periscleral* (Fig. 802 and p. 1086) and *perichoroidal lymph spaces* (Fig. 814). Its nerves are derived from the **ciliary nerves** (Fig. 808). They lose their myelin sheaths and enter among the bundles of fibrous tissue, but it is not known how they terminate.

The Cornea (Figs. 804 and 809).—The cornea is the projecting transparent part of the external tunic of the eyeball, and forms the anterior sixth of the surface of the globe. It is almost, but not quite, circular in shape, occasionally a little broader in the transverse than in the vertical direction. It is convex anteriorly, and projects forward from the sclera in the same manner that a watch-glass does from the case. Its degree of curvature varies in different individuals, and in the same individual at different periods of life, it being more prominent in youth than in advanced life. Usually the curvature is slightly greater in the vertical plane than in the horizontal plane; at its centre than at its periphery, and at its temporal than at its nasal side. The cornea is dense and of uniform thickness throughout; its *posterior surface* is perfectly circular in outline, and exceeds the anterior surface slightly in extent, as the latter is overlapped by the sclera. The *anterior surface* is covered with conjunctival epithelium (Fig. 814).

Structure (Fig. 806).—The cornea consists of five layers—namely: (1) the anterior or epithelial layer; (2) the anterior elastic membrane; (3) the substantia propria; (4) the posterior elastic membrane; (5) the posterior or endothelial layer.

1. The **anterior layer** (*epithelium corneae*) is composed of stratified epithelium and is continuous with the cells of the conjunctiva at the borders of the cornea. There are from five to eight strata of nucleated cells in the anterior layer. The deepest cells are columnar. Above the columnar cells are several layers of polygonal cells, most of which have finger-like processes and are called *prickle cells*. At the surface the cells and nuclei become flat.

2. The **anterior elastic or anterior limiting membrane, or Bowman's membrane** (*lamina elastica anterior*), is less than half the thickness of the layer of stratified epithelium. It resembles in some respects, but is not, elastic tissue, and is thicker in the centre than at the periphery. It shows evidences of fibrillary structure, and does not display a tendency to curl inward or to undergo fracture when detached from the other layers of the cornea. It consists of extremely close interwoven fibrils, similar to those found in the rest of the cornea proper, but contains no corneal corpuscles. It ought, therefore, to be regarded as a part of the proper tissue of the cornea, apparently representing a basement membrane.

3. The **substantia propria** or proper substance of the cornea forms the main thickness of that structure. It is fibrous, tough, unyielding, perfectly transparent, and continuous with the sclera. It is composed of about sixty flattened lamellae, superimposed one on another. These lamellae are made up of bundles of modified connective tissue, the fibres of which are directly continuous with the fibres of the sclera. The fibres of each lamella are for the most part parallel with each other; those of alternating lamellae at right angles to each other. Fibres, however, frequently pass obliquely from one lamella to the next (*fibræ arcuatae*).

The lamellae are connected with each other by an interstitial cement substance, in which are spaces, the **corneal spaces** (Fig. 807). The spaces are stellate in shape, and have numerous offshoots or **canaliculi** (Fig. 807), by which they communicate with one another. Each space contains a cell, the large **corneal corpuscle** (Fig. 807), which resembles in form the space in which it is lodged, but it does not entirely fill it, the remainder of the space containing lymph. In the aged margin of the cornea becomes opaque gray. This rim is called the **arcus senilis**, and is due to fat deposit in the lamellae and corneal corpuscles.

4. The **posterior elastic membrane, the membrane of Descemet, or of Demours** (*lamina elastica posterior*), which covers the posterior surface of the substantia propria of the cornea, presents no structure recognizable under the microscope. It consists of an elastic and perfectly transparent homogeneous membrane of extreme thinness, which is not rendered opaque by either water, alcohol, or acids. It is very brittle, but its most remarkable property is its extreme elas-

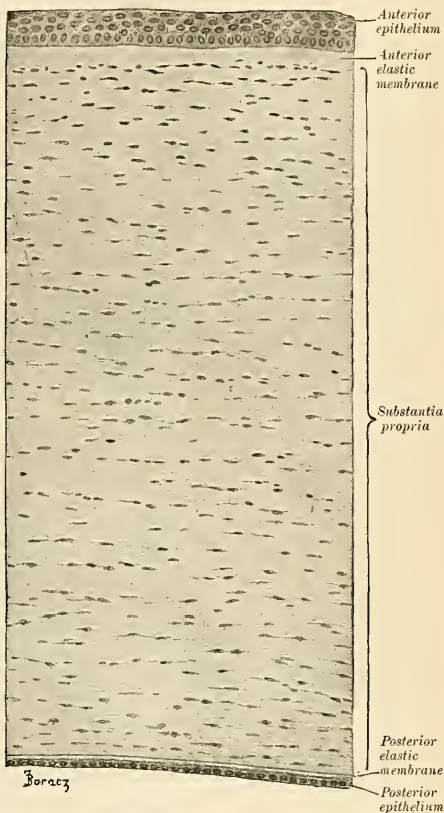


FIG. 806.—Vertical section through the cornea of a newborn child.
× 200. (Szymonowicz.)

ticity and the tendency which it presents to curl up, or roll upon itself, with the attached surface innermost, when separated from the proper substance of the cornea. Its use appears to be "to preserve the requisite permanent correct curvature of the flaccid cornea proper" (Jacob).

At the margin of the cornea this posterior elastic membrane breaks up into fibres to form a reticular structure at the outer angle of the anterior chamber, the intervals between the fibres

forming small cavernous spaces, the **spaces of Fontana** (*spatia anguli iridis*) (Fig. S14). These little spaces communicate with a circular canal in the deeper parts of the corneoscleral junction. This is the **canal of Schlemm** (*sinus venosus sclerae*) (Figs. S14 and S29); it communicates internally with the anterior chamber through the spaces of Fontana, and externally with the scleral veins. Some of the fibres of this reticulated structure are continued into the front of the iris, forming the **ligamentum pectinatum iridis**; while others are connected with the fore part of the sclera and choroid.

5. The **posterior layer** or the **corneal endothelium** (*endothelium camerae anterioris*) lines the aqueous chamber and prevents the absorption of the aqueous

humor. It covers the posterior surface of the elastic lamina, is reflected upon the front of the iris, and also lines the spaces of Fontana. It consists of a single layer of polygonal, flattened, transparent, nucleated cells, similar to those lining other serous cavities.

Arteries and Nerves.—The fetal cornea contains bloodvessels which pass from the margin almost to the centre. The adult cornea contains no bloodvessels, except at its margin. The capillaries from the sclera and conjunctiva form loops at the corneal margin, and many of these loops enter the cornea for a distance of 1 mm. (Fig. S10). The balance of the cornea is non-vascular and obtains its nourishment from the lymph in the *lacunae and canaliculi*. Lymphatic vessels have not as yet been demonstrated in it, but are represented by the channels in which the bundles of nerves run; these channels are lined by endothelium and are continuous with the cell spaces. The nerves are numerous, and they are derived from the ciliary nerves; they form the **annular plexus**, at the corneal margin, and enter the laminated tissue of the cornea, lose their myelin sheaths, and ramify throughout the substantia propria as the **plexus of the stroma**. From this deep plexus come **perforating fibres**, which pass through the anterior elastic lamina and form the **subepithelial plexus**, and from it fibres are given off which ramify between the epithelial cells, forming a network which is termed the **intra-epithelial plexus**. Nerve fibres from the annular plexus and from the plexus of the stroma come into close relation with the corneal corpuscles.

Dissection.—In order to separate the sclera and cornea, so as to expose the second tunic, the eyeball should be immersed in a small vessel of water and held between the finger and thumb. The sclera is then carefully incised, in the equator of the globe, till the choroid is exposed. One blade of a pair of probe-pointed scissors is now introduced through the opening thus made, and the sclera divided around its entire circumference, and removed in separate portions. The front segment being then drawn forward, the handle of the scalpel should be pressed gently against it at its connection with the iris, and, these being separated, a quantity of perfectly transparent fluid will escape; this is the aqueous humor. In the course of the dissection the ciliary nerves (Fig. S08) may be seen lying in the loose cellular tissue between the choroid and sclera or continued in delicate grooves on the inner surface of the latter membrane.

II. The Choroid, Ciliary Body, and Iris (*Tunica Vasculosa Oculi*) (Figs. S08, S29).

The middle tunic of the eye is formed from behind forward by the choroid, the ciliary body, and the iris.

The choroid invests the posterior five-sixths of the globe, and extends as far forward as the *ora serrata* of the retina; the ciliary body connects the choroid

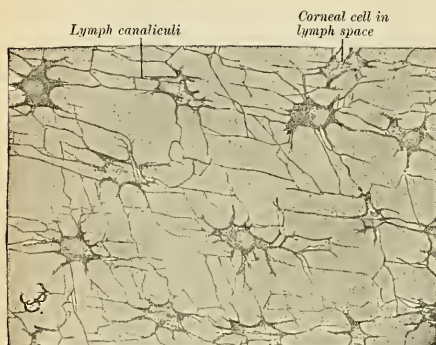


FIG. S07.—From a horizontal section of an ox's cornea. Positive picture of the canal system demonstrated by the gold chloride method, $\times 450$. (Szymonowicz.)

to the circumference of the iris. The iris is the circular septum, which hangs vertically behind the cornea, presenting in its centre a large rounded aperture, the pupil.

The **Choroid** (*chorioidea*) is a thin, highly vascular membrane, of a dark-brown or chocolate color, which invests the posterior five-sixths of the globe, and is pierced behind by the optic nerve, and in this situation is firmly adherent to the sclera. It is thicker behind than in front. Externally, it is loosely connected by the **lamina fusca** with the inner surface of the sclera (p. 1090). Its inner surface is attached to the retina.

Structure.—The choroid consists of a dense capillary plexus and of small arteries and veins, carrying the blood to and returning it from this plexus (Fig. 810), and of branched and pigmented cells which lie in connective tissue. There are three layers in the choroid. Named from without inward, they are the **lamina suprachorioidea**, the **choroid proper**, and **lamina basalis**.

1. The **lamina suprachorioidea** is on the external surface, that is, the surface next to the sclera. It resembles the lamina fusca of the sclera. It is composed of delicate nonvascular lamellæ, each lamella consisting of a network of fine elastic fibres, among which are branched pigment cells. The spaces between the lamellæ are lined by endothelium, and open freely into the perichoroidal lymph space, which, in its turn, communicates with the periscleral space by the perforations in the sclera through which the vessels and nerves are transmitted.

2. The **choroid proper** is internal to the lamina suprachorioidea. In consequence of the small arteries and veins of the choroid proper being arranged on the outer surface of the capillary network, it is customary to describe this as consisting of two layers—the **outer** (*lamina vasculosa*), composed of small arteries and veins, with pigment cells interspersed between them, and the **inner** (*lamina choriocapillaris*), consisting of a capillary plexus. The **external layer of the choroid proper** or the **lamina vasculosa** consists, in part, of the larger branches of the **short posterior ciliary arteries** (Figs. 809 and 812), which run forward between the veins, before they bend inward to terminate in the capillaries; but this layer is formed principally of veins, which have a whorl-like arrangement and empty into four or five large equidistant trunks, the **venæ vorticosæ** (Figs. 809 and 810), which pierce the sclera midway between the margin of the cornea and the attachment of the optic nerve. Interspersed between the vessels are dark star-shaped pigment-cells, the processes of which, communicating with similar branchings from neighboring cells, form a delicate network of stroma, which toward the inner surface of the choroid loses its pigmentary character. The **inner layer of the choroid proper** consists of an exceedingly fine capillary plexus, formed by the short ciliary vessels (Fig. 810), and is known as the **membrane of Ruysch** (*lamina choriocapillaris*). The network is close, and finer at the hinder part of the choroid than in front. About 1.2 cm. behind the cornea its meshes become larger, and are continuous with those of the ciliary processes. These two laminæ are connected by an **intermediate stratum** (*boundary zone*), which is destitute of pigment cells and consists of fine elastic fibres. On the inner surface of the lamina choriocapillaris is a very thin, structureless, or faintly fibrous membrane, called the **lamina basalis** (**membrane of Bruch**); it is closely connected with the stroma of the choroid, and separates it from the pigmentary layer of the retina; the cells of the latter are found attached to this membrane.

Dissection.—The ciliary body should now be examined. It may be exposed either by detaching the iris from its connection with the Ciliary muscle or by making a transverse section of the globe and examining it from behind.

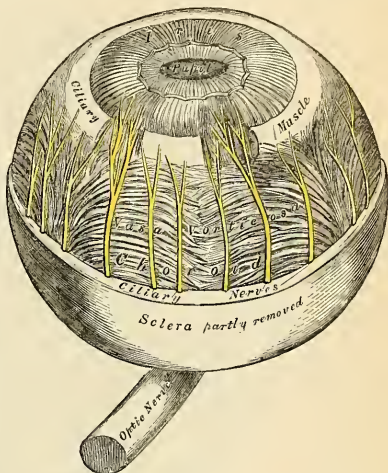


FIG. 808.—The choroid and iris. (Enlarged.)

The **Ciliary Body** (*corpus ciliare*) (Fig. 813) joins the choroid to the margin of the iris. It is in reality a process of the choroid and comprises the **orbicularis ciliaris**, the **ciliary processes**, and the **Ciliary muscle**.

The **orbiculus ciliaris** (Figs. 811 and 812) is a zone of about 4 mm. ($\frac{1}{6}$ inch) in width, directly continuous with the anterior part of the choroid; it presents numerous ridges arranged in a radial manner. The depressions between the ridges are filled with retinal pigment epithelium (Szymonowicz). The orbiculus contains no lamina choriocapillaris.

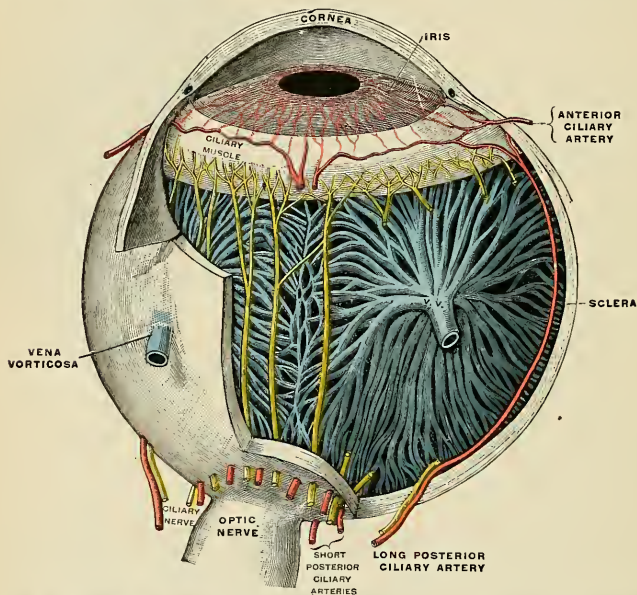


FIG. 809.—Vessels and nerves of the choroid and iris, seen from above. The sclera and cornea have been largely removed. (Testut.)

The **ciliary processes** (*processus ciliares*) (Figs. 813 and 829) are formed by the plaiting and folding inward of the various layers of the choroid (*i. e.*, the choroid proper and the lamina basalis) at its anterior margin, and are received between corresponding foldings of the suspensory ligament of the lens, thus establishing a connection between the choroid and inner tunic of the eye. They are arranged in a circle, and form a sort of plaited frill, the **corona ciliaris**, behind the iris, round the margin of the lens (Figs. 813 and 829). They vary between sixty and eighty in number, lie side by side, and may be divided into large and small; the latter, consisting of about one-third of the entire number, are situated in the spaces between the former, but without regular alternation. The larger processes are each about 2.5 mm. (one-tenth of an inch) in length, and are attached by their periphery to three or four of the ridges of the orbiculus ciliaris, and are continuous with the layers of the choroid; the opposite margin is free, and rests upon the circumference of the lens. Their anterior surface is turned toward the back of the iris, with the circumference of which they are continuous. The posterior surface is connected with the suspensory ligament of the lens.

Structure.—The ciliary processes are similar in structure to the choroid, but the vessels are larger, and have chiefly a longitudinal direction. They constitute the most vascular portion of the eyeball. The processes are covered on their inner surface by two strata of black pigment cells, which are continued forward from the retina, and are named the *pars ciliaris retinae* (Fig. 814). In the stroma of the ciliary processes there are also stellate pigment cells, which, however, are not so numerous as in the choroid itself.

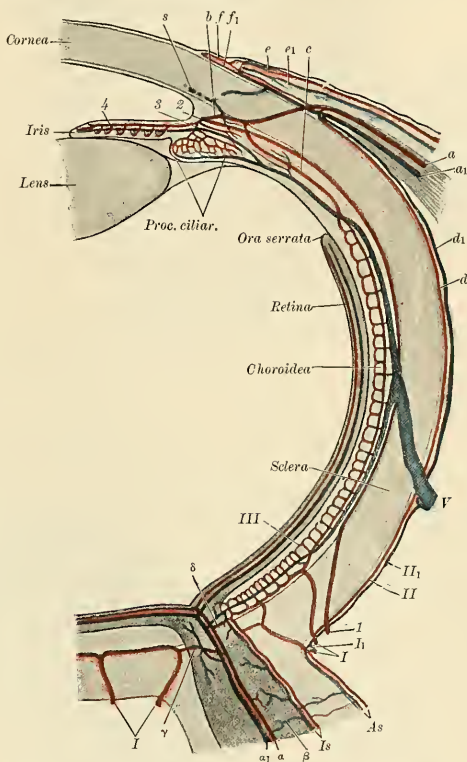


FIG. 810.—Diagram of the bloodvessels of the eye, as seen in a horizontal section. (Leber, after Stöhr.)

Course of vasa centralia retinae: *a*. Arteria. *a*₁. Vena centralis retinae. *β*. Anastomosis with vessels of outer coats. *γ*. Anastomosis with branches of short posterior ciliary arteries. *δ*. Anastomosis with chorioidal vessels.

Course of vasa ciliar, postic, brev.: *l*. Arteriae, and *l*₁. Venae ciliar, postic, brev. *II*. Episcleral artery. *II*₁. Episcleral vein. *III*. Capillaries of lamina choriocapillaris.

Course of vasa ciliar, postic, long.: *l*. *a*, ciliar, post, longa. *2*. Circulus iridis major cut across. *3*. Branches to ciliary body. *4*. Branches to iris.

Course of vasa ciliar, ant.: *a*. Arteria. *a*₁. Vena ciliar, ant. *b*. Junction with the circulus iridis major. *c*. Junction with lamina choriocapill. *d*. Arterial, and *d*₁. Venous episcleral branches. *e*. Arterial, and *e*₁. Venous branches to conjunctiva sclerae. *f*. Arterial, and *f*₁. Venous branches to corneal border. *V*. Vena vorticiosa. *S*. Transverse section of sinus venosus sclerae.

The **Ciliary muscle** (Bowman's muscle) (*m. ciliaris*) (Figs. 814 and 816) consists of unstriated fibres; it forms a grayish, semitransparent, circular band, about 3 mm. (one-eighth of an inch) broad, on the outer surface of the fore part of the choroid, between the choroid and the iris and back of the sclerocorneal junction. It is thickest in front and gradually becomes thinner behind. It consists of two sets of fibres, **radial** and **circular**. The **radial fibres** (*fibræ meridiales*) (Figs.

814 and 829), the more numerous, arise at the point of junction of the cornea and sclera, and partly also from the ligamentum pectinatum iridis, and, passing backward, are attached to the choroid opposite to the ciliary processes. One bundle, according to Waldeyer, is continued backward to be inserted into the sclera. The **circular fibres** (*fibrae circulares* [Muller]) (Figs. 814 and 829) are

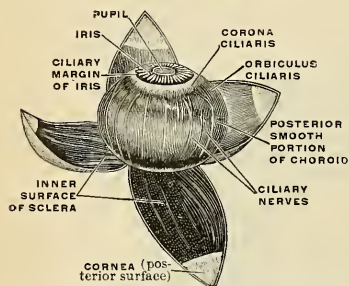


FIG. 811.—The middle or vascular coat of the eyeball exposed from without. Left eye, seen obliquely from above and before. (Toldt.)

internal to the radial ones and to some extent unconnected with them, and have a circular course around the attachment of the iris. They are sometimes called the “ring muscle” of Müller, and were formerly described as the **ciliary ligament**. They are well developed in hypermetropic, but are rudimentary or absent in myopic eyes. The Ciliary muscle is admitted to be the chief agent in accommodation—*i. e.*, in adjusting the eye to the vision of near objects. When the Ciliary muscle contracts, it draws the choroid forward, and relaxes the suspensory ligament. The elasticity of the lens at once allows it to bulge forward until

it is again checked by the tension of the capsule;¹ the pupil is at the same time slightly contracted.

The **Iris** (*iris*, a rainbow) (Figs. 815 and 817) has received its name from its various colors in different individuals. It is a thin, circular contractile curtain, suspended in the aqueous humor between the cornea and the lens, being perforated a little to the nasal side of its centre by a circular aperture, the **pupil** (*pupilla*) (Fig. 817), for the transmission of light. The pupil of a living person varies in size under the influence of light and in efforts at accommodation. In looking at a near object the pupil is small; in looking at a distant object it is large. In light the pupil contracts, in darkness it dilates; hence the pupil is a window which permits light to pass into the interior of the eye. The size of this window depends on the contraction or relaxation of the iris. The iris divides the **aqueous chamber** (the space between the cornea and lens) into an **anterior chamber** and a **posterior chamber** which communicate through the pupil (Fig. 804). By its **circumference** or **ciliary margin** (*margo ciliaris*) (Figs. 814 and 815) the iris is continuous with the ciliary body, and it is also connected with the posterior elastic lamina of the cornea by means of the **pectinate ligament** (*ligamentum pectinatum iridis*) (Fig. 829). The pectinate ligament of the iris is derived from the posterior

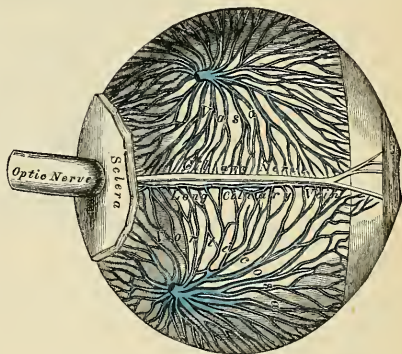


FIG. 812. The veins of the choroid and iris. The sclera has been mostly removed. (Enlarged.)

¹ Stewart, Manual of Physiology.

elastic layer of the cornea. In this ligament are numerous lymph spaces, the **spaces of Fontana** (*spatia anguli iridis*) [*Fontanae*] (Fig. 814), and they join the canal of

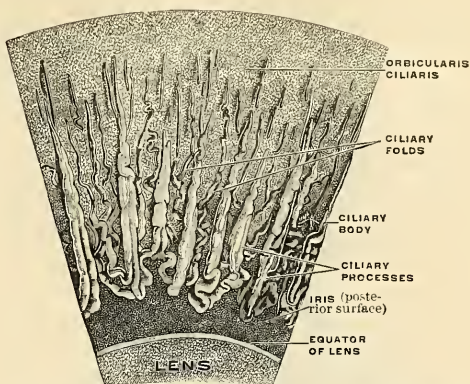


FIG. 813.—A portion of the corona ciliaris magnified. The ciliary processes and the ciliary folds. (Toldt.)

Schlemm to the anterior chamber of the eye. The inner or free edge of the iris forms the margin of the pupil, and is called the **pupillary margin** (*margo pupillaris*) (Fig. 815). The surfaces of the iris are flattened, and look forward and backward, the anterior toward the cornea, the posterior toward the ciliary processes and lens.

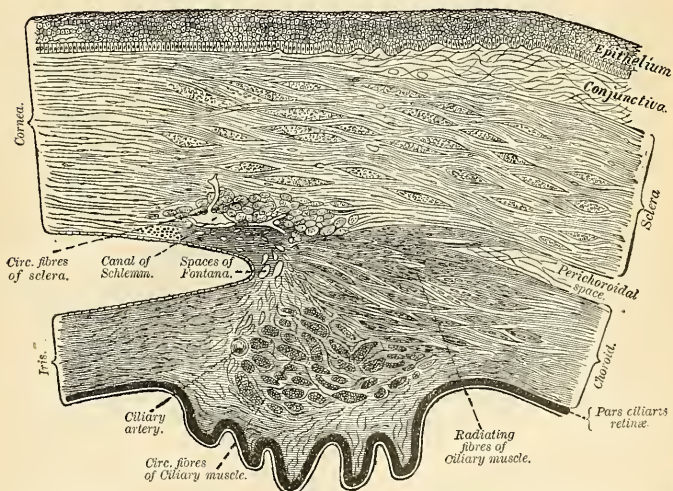


FIG. 814.—Section of the eye, showing the relations of the cornea, sclera, and iris, together with the ciliary muscle and the cavernous spaces near the angle of the anterior chamber. (Waldeyer.)

The iris is pigmented and the color of an individual's eyes depends upon this pigment. The anterior surface (*facies anterior*) (Figs. 815 and 829) of the iris

is variously colored in different individuals, and is marked by lines which converge toward the pupil. The **posterior surface** (*facies posterior*) (Figs. 813 and 829) is of a deep purple tint, from being covered by two layers of pigmented, columnar epithelium, which layers are continuous posteriorly with the pars ciliaris retinae. This pigmented epithelium is termed the **pars iridica retinae**, though it is sometimes named **uvea**, from its resemblance in color to a ripe grape.

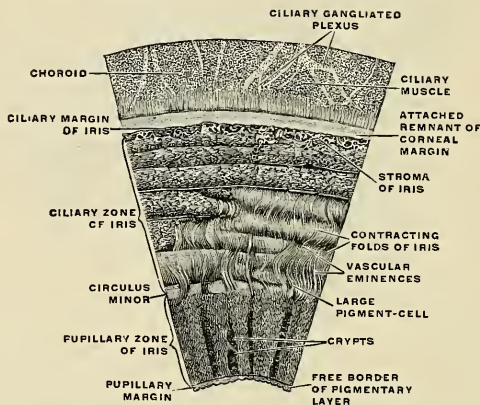


FIG. 815.—Section of the iris. Anterior surface magnified. (Toldt.)

Structure.—The iris is composed of the following structures:

1. In front is a layer of flattened endothelial cells placed on a delicate hyalin basement membrane. This layer is continuous with the endothelial layer covering the membrane of Descemet, and in men with dark-colored irides the cells contain pigment granules.

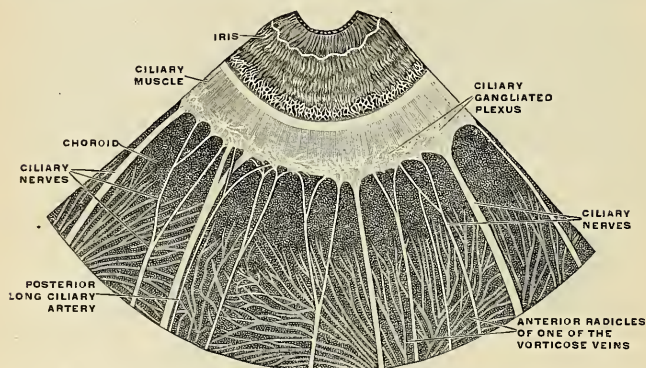


FIG. 816.—The ciliary ganglionic plexus and the ciliary nerves entering the plexus. Outer surface of the middle or vascular coat of the eyeball. (Toldt.)

2. The **stroma** (*stroma iridis*) consists of fibres and cells. The former are made up of fine, delicate bundles of fibrous tissue, of which some few fibres have a circular direction at the circumference of the iris, but the chief mass consists of fibres radiating toward the pupil. They form, by their interlacement, delicate meshes, in which the vessels and nerves are contained. Interspersed between the bundles of connective tissue are numerous stellate cells with fine processes.

Many of them in dark eyes contain pigment granules, but in blue eyes and the pink eyes of albinos they are unpigmented. The **muscle fibres** are unstriated and consist of **circular** and **radial fibres**. The **circular fibres** (*m. sphincter pupillae*) surround the margin of the pupil on the posterior surface of the iris, like a sphincter, forming a narrow band about one-thirtieth of an inch (0.8 mm.) in width, those near the free margin being closely aggregated; those more external somewhat separated, and forming less complete circles. The **radial fibres** (*m. dilatator pupillae*) converge from the circumference toward the centre, and blend with the circular fibres near the margin of the pupil. These fibres are regarded by some as elastic, not muscular.

3. **Pigmented epithelium** (*pars iridica retinae*). This is a continuation of the *pars ciliaris retinae*, and consists of two layers of pigmented, columnar epithelial cells. The situation of the pigment differs in different irides. In the various shades of blue eyes the only pigmentation is that of the pigmented epithelium. The color of the eye in these individuals is due to this coloring matter showing more or less through the texture of the iris. In the albino even this pigment is absent. In the gray, brown, and black eye there are, as mentioned above, pigment granules to be found in the connective tissue cells of the stroma and in the endothelial layers on the front of the iris; to these the dark color of the eye is due.

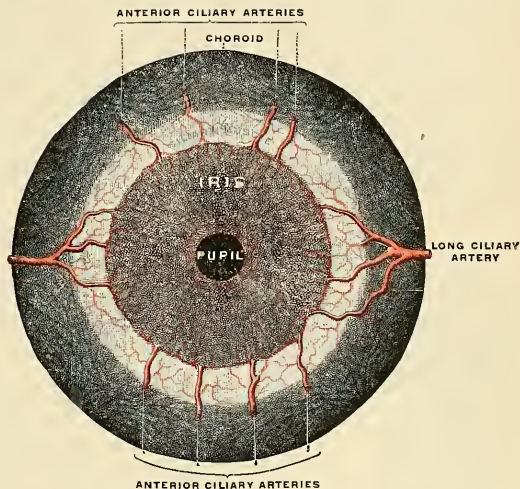


FIG. S17.—Iris, front view. (Testut.)

The **arteries** of the Choroid and Iris (Figs. S09 and S17).—The **short posterior ciliary arteries**, from six to twelve in number, arise from the ophthalmic, or some of its branches; they pass forward around the optic nerve to the posterior part of the eyeball, pierce the sclera around the entrance of the nerve, and supply the choroid coat and ciliary processes. The arteries of the iris are derived from the *long posterior ciliary* and *anterior ciliary arteries* and from the vessels of the ciliary processes (see p. 613). The **long posterior ciliary arteries** (Figs. S09 and S10), two in number, pass through the sclera, one on the inner and one on the outer side of the optic nerve, and pass forward between the sclera and choroid, and, having reached the attached margin of the iris (Figs. S09 and S17), divide into an upper and a lower branch, and, encircling the iris, anastomose with corresponding branches from the opposite side; into this vascular zone (*circulus iridis major*) (Fig. S29) the **anterior ciliary arteries** (Fig. S29), from the **lacrimal** and **anterior ciliary** from the muscular branches of the ophthalmic, pour their blood. From this zone vessels converge to the free margin of the iris, and these communicate by branches from one to another and thus form a second zone (*circulus iridis minor*) in this situation. The **veins** pass toward the ciliary margin and communicate with the veins of the ciliary processes and of the canal of Schlemm (Figs. S09 and S10).

The **nerves** of the Choroid and Iris (Fig. S08) are the **short ciliary**, the **ciliary branches** of the **lenticular ganglion**, and the **long ciliary** from the **nasal branch** of the ophthalmic division of the **trigeminal**. They pierce the sclera around the entrance of the optic nerve, and run for-

ward in the perichoroidal lymph space, in which they form a plexus, from which plexus filaments pass to supply the bloodvessels of the choroid. After reaching the iris they form a plexus around its attached margin; from this are derived amyelinic fibres which terminate in the circular and radial muscle fibres. Their exact mode of termination has not been ascertained. Other fibres from the plexus terminate in a network on the anterior surface of the iris. The fibres derived from the motor root of the lenticular ganglion (oculomotor nerve) supply the circular fibres, while those derived from the sympathetic supply the radial fibres.

Membrana Pupillaris.—In the fetus the pupil is closed by a delicate transparent vascular membrane, the **membrana pupillaris**, which divides the space into which the iris is suspended into two distinct chambers. This membrane contains numerous minute vessels, continued from the margin of the iris to those on the front part of the capsule of the lens. These vessels have a looped arrangement, and converge toward each other without anastomosing. Between the seventh and eighth months the membrane begins to disappear, by gradual absorption from the centre toward the circumference, and at birth only a few fragments remain. It is said sometimes to remain permanent and produce blindness.

III. The Retina, or Tunica Interna (Figs. 808, 809).

The retina is a delicate nerve membrane, in which the fibres of the optic nerve are spread out and upon the surface of which the images of external objects are received. Its outer surface is in contact with the choroid; its inner with the vitreous body. Behind, it is continuous

with the optic nerve; it gradually diminishes in thickness from behind forward; and, in front, extends nearly as far as the ciliary body, where it appears to terminate in a jagged margin, the **ora serrata** (Figs. 810 and 829). Here the nerve tissues of the retina end, but a thin prolongation of the membrane extends forward over the back of the ciliary processes and iris, forming the **pars ciliaris retinae** and **pars iridica retinae**, already referred to. This forward prolongation consists of the pigmentary layer of the retina, together with a stratum of columnar epithelium. The retina is soft, semi-transparent, and of a purple tint in the fresh state, owing to the presence

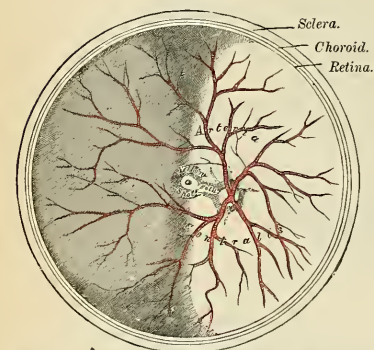


FIG. 818.—The arteria centralis retinae, yellow spot, etc., the anterior half of the eyeball being removed. (Enlarged.)

of a coloring material named **rhodopsin** or **visual purple**; but it soon becomes clouded, opaque, and bleached when exposed to sunlight. Exactly in the centre of the front surface of the posterior part of the retina, corresponding to the visual axis, and at a point in which the sense of vision is most perfect, is an oval yellowish spot, called the **yellow spot** (*macula lutea*) (Figs. 804 and 818), having a central depression, the **fovea centralis**. The retina in the situation of the fovea centralis is exceedingly thin, and the dark color of the choroid is distinctly seen through it. It exists only in man, the quadrumana, and some saurian reptiles. About 3 mm. (one eighth of an inch) to the nasal side of the yellow spot, and about 1 mm. below it, is the point of attachment of the optic nerve, the **optic disk** (*porus opticus*) (Figs. 818 and 819), the circumference of which is slightly raised so as to form

an eminence, the **optic papilla** (*colliculus nervi optici*); the central portion is depressed and is called the **optic cup** (*excavatio papillae nervi optici*). The *arteria centralis retinae* pierces its centre. This is the only part of the surface of the retina from which the power of vision is absent, and is termed the **blind spot**.

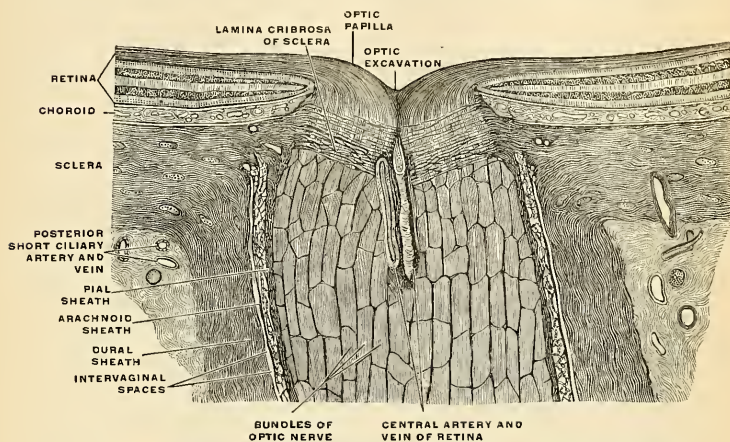


FIG. S19.—The terminal portion of the optic nerve and its entrance into the eyeball, in horizontal section. (Toidt.)

Structure.—The retina is an exceedingly complex structure, and, when examined microscopically by means of sections made perpendicularly to its surface, is found to consist of many layers of nerve elements bound together and supported by the **sustentacular fibres**. The layers of the retina are:

1. *Membrana limitans interna*.
2. Layer of nerve fibres (*stratum opticum*).
3. Ganglionic layer, consisting of nerve cells.
4. Inner plexiform layer.
5. Inner nuclear layer, or outer ganglionic layer.
6. Outer plexiform layer.
7. Outer nuclear layer, or layer of outer granules.
8. *Membrana limitans externa*.
9. Jacob's membrane (layer of rods and cones).
10. Pigmentary layer (*tapetum nigrum*).

1. The **membrana limitans interna** is the most internal layer of the retina and is in contact with the hyaloid membrane of the vitreous humor. It is derived from the supporting framework of the retina, with which tissue it will be described.

2. The **layer of the nerve fibres** consists of the axones proceeding from the nerve cells in the inner ganglionic layer. They are amylonic, and, concentrating at the porus opticus, pass through all the layers of the retina except the *membrana limitans interna*. On passing through the lamina cribrosa of the sclera these axones acquire myelin sheaths and leave the eyeball as a compact rounded bundle called the optic nerve. A few of the fibres in this layer are centrifugal, being axones of ganglion cells within the brain, to terminate in the inner plexiform and outer ganglionic layers. The layer of nerve fibers is thickest at the optic nerve exit and gradually diminishes in thickness toward the ora serrata.

3. The **ganglionic layer** consists of a single layer of large ganglion cells, except in the macula lutea, where there are several strata. The cells are somewhat flask-shaped, the rounded internal surface of each cell resting on the preceding layer and sending off an axone which is prolonged as a nerve fibre into the fibre layer. From the opposite extremity numerous dendrites extend into the inner plexiform layer, where they branch out into flattened arborizations at different levels (Fig. S20). The ganglion cells vary much in size, and the dendrites of the smaller ones,

as a rule, arborize in the inner plexiform layer as soon as they enter it; while the processes of the larger cells ramify close to the inner nuclear layer.

4. The **inner plexiform layer** is made up of a dense reticulum of minute fibrils, formed by the interlacement of the dendrites of the ganglion cells with those of the cells contained in the next layer, immediately to be described. Within the reticulum formed by these fibrils, a few branched spongioblasts are sometimes embedded.

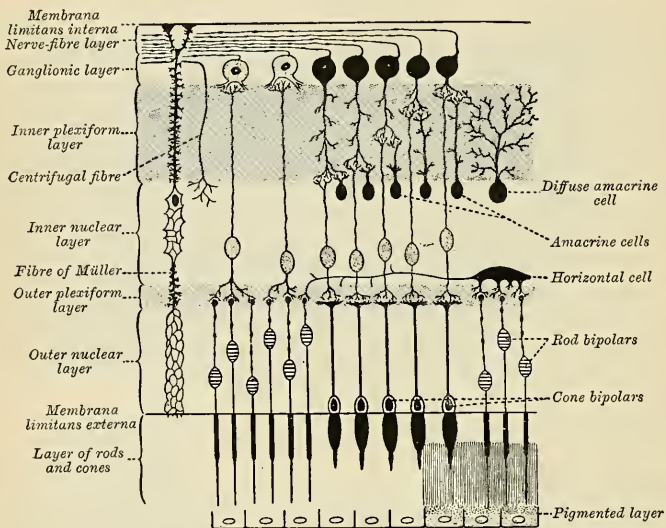


FIG. 820.—Plan of retinal neurones. (After Cajal.)

5. The **inner nuclear** or **inner granular layer** consists of a number of closely packed cells, of which there are three varieties—viz.: (1) A large number of oval cells, which are commonly regarded as **bipolar nerve cells**, and are much more numerous than either of the other kind. They each consist of a large oval body placed vertically to the surface, and containing a distinct nucleus. The protoplasm is prolonged into two processes; one of these passes inward into the inner plexiform layer, is varicose in appearance, and ends in a terminal ramification, which is often in close proximity to the ganglion cells. The outer process passes outward into the outer plexiform layer, and there breaks up into a number of branches. There are two varieties of these bipolar cells—one in which the outer process arborizes around the knobbed ends of the rod fibres, and the inner around the cells of the ganglionic layer; these are called **rod bipolars** (Fig. 820); the others are those in which the outer process breaks up in a horizontal ramification, in contact with the end of a cone fibre; these are the **cone bipolars**, and their inner process breaks up into its terminal ramification in the inner molecular layer. (2) At the innermost part of this inner nuclear layer is a stratum of cells, which are named **amacrine cells** (of Cajal), from the fact that they have no axis-cylinder process, but they give a number of short protoplasmic processes which extend into the inner plexiform layer and there ramify (Fig. 820). There are also at the outermost part of this layer some cells, the processes of which extend into and ramify in the outer molecular layer. These are the **horizontal cells** (of Cajal). (3) Some few cells are also found in this layer, connected with the fibres of Müller, and will be described with those structures.

6. The **outer plexiform layer** is much thinner than the inner plexiform layer; but, like it, consists of a dense network of minute fibrils, derived from the processes of the horizontal cells of the preceding layer and the outer processes of the bipolar cells, which ramify in it, forming arborizations around the ends of the rod fibres and with the branched foot plates of the cone fibres. In the neighborhood of the macula lutea, elongations from the inner segments of rod fibres and cone fibres form the so-called **Henle's fibre layer**.

7. The **outer nuclear** or **outer granular layer**, like the inner nuclear layer, contains several strata of clear oval nuclear bodies; they are of two kinds, and on account of their being respectively connected with the rods and cones of Jacob's membrane (rod fibres and cone fibres) are named **rod granules** and **cone granules**. The **rod granules** are much the more numerous, and are placed at different levels throughout the layer. Their nuclei present a peculiar cross-striped appearance, and prolonged from either extremity of the granule is a fine process; the outer process is continuous with a single rod of Jacob's membrane; the inner passes inward toward the outer plexiform layer and terminates in an enlarged extremity, and is embedded in the tuft into which the outer process of the rod bipolars break up. In its course it presents numerous varicosities. The **cone granules**, fewer in number than the rod granules, are placed close to the *membrana limitans externa*, through which they are continuous with the cones of Jacob's membrane. They do not present any cross-stripping, but contain a pyriform nucleus which almost completely fills the cell. From their inner extremity a thick process passes inward to the outer plexiform layer, upon which it rests by a somewhat pyramidal enlargement, from which are given

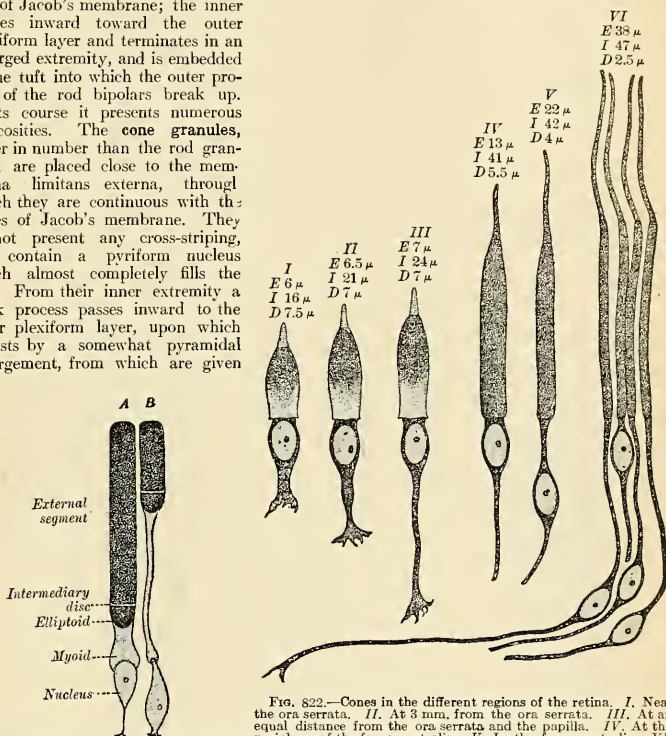


FIG. 821.—The cells of the rods of the retina in the frog. A. Red rod. B. Green rod. (Poirier and Charpy.)

FIG. 822.—Cones in the different regions of the retina. I. Near the ora serrata. II. At 3 mm. from the ora serrata. III. At an equal distance from the ora serrata and the papilla. IV. At the periphery of the fovea centralis. V. In the fovea centralis. VI. At the centre of the fovea centralis. E. Length of the external segment. I. Length of the internal segment. D. Diameter of the internal segment. (Poirier and Charpy.)

off numerous fine fibrils, which enter the outer plexiform layer, where they come in contact with the outer processes of the cone-bipolars.

8. The **membrana limitans externa**, like the *membrana limitans interna*, is derived from the fibres of Müller, with which structures it will be described.

9. **Jacob's membrane**, or the **layer of rods and cones**, consists of **visual cells**, and the elements which compose it are of two kinds, **rod cells** and **cone cells**, the former being much more numerous than the latter. The **rod cells** (Fig. 821) are of nearly uniform size, and arranged perpendicularly to the surface. A rod cell consists of a **rod** and a **rod fibre**, and the fibre contains the nucleus. The rods are cylindrical and each consists of two portions, an **outer segment** and an **inner segment**, which are of about equal length. The segments differ from each other as regards refraction and in their behavior with coloring reagents, the inner portion becoming stained by carmine, iodine, etc., the outer portion remaining unstained with these reagents, but staining yellowish brown with osmic acid. The outer portion of each rod is marked by trans-

verse striae, and is made up of a number of thin disks superimposed on one another. It also exhibits faint longitudinal markings. The inner portion of each rod, at its deeper part where it is joined to the outer process of the rod granule, is indistinctly granular; its more superficial part presents a longitudinal striation, being composed of fine, bright, highly refracting fibres. The visual purple, or *rhodopsin*, is found only in the outer segments of the rods. At its inner end each rod is prolonged into a very fine fibre, the **rod fibre**, which contains a nucleus, and which terminates in the outer nuclear layer, being somewhat enlarged at its termination.

The **cone cells** (Fig. 822) are conical, or flask-shaped, their broad ends resting upon the *membrana limitans externa*, the narrow pointed extremity being turned to the choroid. Each cone cell consists of two parts, the **cone** and the **cone fibre**. The **outer segment** or cone is a short conical process, which, like the outer segment of a rod, presents transverse striae. The **inner segment (cone fibre)** resembles the inner portion of the rods in structure, but differs from it in size, being shorter and bulged out laterally in a flask-shaped manner, and at the junction of the cone with the fibre is the nucleus of the cone cell. The cone fibre passes to the outer nuclear layer, and terminates as an expansion from which very minute fibrils are given off. The chemical and optical characters of the rod cells and cone cells are identical.

10. The **pigmentary layer or tapetum nigrum**, the most external layer of the retina, formerly regarded as a part of the choroid, consists of a single layer of hexagonal epithelial cells, loaded with pigment granules. Each cell contains a flattened nucleus in the outer portion of the cell which is free from pigment at this point. These cells are smooth externally, where they are in contact with the choroid, but internally they are prolonged into fine, straight processes, which extend between the rods, this being especially the case when the eye is exposed to light. The pigment changes its position under the influence of light, and is distributed through the entire cell. In the eyes of albinos, the cells of the pigmentary layer are present, but they contain no coloring matter.

Supporting Framework of the Retina.—Almost all these layers of the retina are connected by a supporting framework, formed by the **supporting cells** or **supporting fibres of Müller** or **radiating fibres**, from which the *membrana limitans interna et externa* are derived. These fibres are found stretched between the two limiting layers, "like columns between a floor and a roof," and they pass through all the neural layers except Jacob's membrane. Each commences on the inner surface of the retina by a conical hollow base, which sometimes contains a spheroidal body which stains deeply with hematoxylin, the edges of the bases of adjoining fibres being united and thus forming a boundary line, which is the *membrana limitans interna*. As they pass through the nerve fibre and ganglionic layers they give off few lateral branches; in the inner nuclear layer they give off numerous lateral processes for the support of the inner granules, while in the outer nuclear layer they form a network, the **fibre baskets**, around the rod and cone fibrils, and unite to form the external limiting membrane at the bases of the rods and cones. In the inner nuclear layer each fibre of Müller presents a clear oval nucleus, which is sometimes situated at the side of, sometimes altogether within, the fibre. The supporting framework of the retina contains neuroglia cells.

The Path of Light Stimuli.—The stimulus is supposed to be first received by the rod and cone cells (the visual cells), and is transmitted to the bipolar cells of the inner nuclear layer and then to the cells of the ganglionic layer, which send fibres by way of the optic nerve and tract to the brain (see p. 909).

Macula Lutea and Fovea Centralis.—The structure of the retina at the yellow spot presents some modifications. In the macula lutea (1) the nerve fibres are wanting as a continuous layer; (2) the ganglionic layer consists of several strata of cells, instead of a single layer; (3) in Jacob's membrane there are no rods, but only cones, and these are longer and narrower than in other parts; and (4) in the outer nuclear layer there are only cone fibres, which are very long and arranged in curved lines. At the fovea centralis the only parts which exist are the cones of Jacob's membrane, the outer nuclear layer, the cone fibres of which are almost horizontal in direction, and an exceedingly thin inner granular layer, the pigmentary layer, which is thicker and its pigment more pronounced than elsewhere. The color of the macula seems to imbue all the layers except Jacob's membrane; it is of a rich yellow, deepest toward the centre, and does not appear to consist of pigment cells, but simply a staining of the constituent parts.

At the **ora serrata** (Fig. 810) the nerve layers of the retina terminate abruptly, and the retina is continued onward as a single layer of elongated columnar cells covered by the pigmentary layer. This prolongation is known as the **pars ciliaris retinae** (Fig. 814), and can be traced forward from the ciliary processes on to the back of the iris, where it is termed the **pars iridica retinae** or **uvea**.

From the description given of the nerve elements of the retina it will be seen that there is no direct continuity between the structures which form its different layers except between the ganglionic and nerve fibre layers, the majority of the nerve fibres being formed of the axones of the ganglionic cells. In the inner molecular layer the dendrites of the ganglionic layer interlace with those of the cells of the inner nuclear layer, while in the outer molecular layer a

like synopsis occurs between the processes of the inner granules and the rod and cone elements.

The **arteria centralis retinae** (Fig. 810) and its accompanying vein, **vena centralis retinae**, pierce the optic nerve, and enter the globe of the eye through the porus opticus. They bifurcate on the surface of the papilla or just beneath it into an upper and a lower branch, and each of these again divides into an inner or nasal, and an outer or temporal branch; these at first run between the hyaloid membrane and the nerve layer; but they soon enter the latter, and pass forward, dividing dichotomously. From these branches a minute capillary plexus is given off, which does not extend beyond the inner nuclear layer. The macula receives small twigs from the temporal branches and others directly from the central artery; these do not, however, reach as far as the fovea centralis, which has no bloodvessels. The branches of the arteria centralis retinae do not anastomose with each other—in other words, they are “terminal arteries.” In the fetus, a small vessel passes forward, through the **hyaloid canal** in the vitreous body, to the posterior surface of the capsule of the lens (Fig. 805).

THE REFRACTING MEDIA.

The Refracting media are three—viz.:

Aqueous humor.

Vitreous body.

Crystalline lens,

I. The Aqueous Humor (**Humor Aqueus**).

The aqueous humor completely fills the lymph space known as the **aqueous chamber**, the space which is bounded in front by the cornea and behind by the lens and its suspensory ligament and the ciliary body (Fig. 829). The aqueous chamber is partly divided by the iris into two communicating parts, the **anterior** and **posterior chambers** (Figs. 805 and 829). The **posterior chamber** (*camera oculi posterior*) is only a narrow chink between the peripheral part of the iris, the suspensory ligament of the lens, and the ciliary processes. The **anterior chamber** (*camera oculi anterior*) is bounded in front by the cornea and behind by the iris. The external angle of the anterior chamber is bounded by the periphery of the cornea and of the iris. It is called the **angle** or the **filtration angle** (*angulus iridis*). It is by way of the filtration angle that any excess of aqueous humor passes by way of the spaces of Fontana and the canal of Schlemm (Fig. 814) to the anterior ciliary veins and relieves tension. The aqueous humor is small in quantity, has an alkaline reaction, in composition is little more than water, less than 2 per cent. of its weight being solid matter, chiefly sodium chloride.

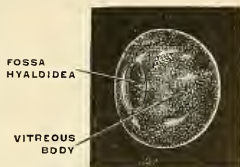

FIG. 823.—The vitreous body removed from the eye in the fresh state, with the saucer-shaped hollow (*fossa hyaloidea*) in which the lens lies. Seen obliquely from the side and before. (Toldt.)

II. The Vitreous Body (**Corpus Vitreum**) (Figs. 805, 825).

The **vitreous body** occupies about four-fifths of the entire globe. It is composed of a jelly-like tissue containing 98 per cent. water, some salts, and a little albumin, and called the **vitreous humor** (*humor vitreus*), connective-tissue fibres, and connective-tissue cells. It fills the concavity of the retina, and is hollowed in front, forming a deep concavity, **fossa hyaloidea** (Fig. 823), for the reception of the lens. It is perfectly transparent, of the consistence of thin jelly, and is composed of an albuminous fluid enclosed in a delicate transparent membrane, the **hyaloid membrane** (*membrana hyaloidca*), the outside of which is in contact with the *membrana limitans interna* of the retina. In the fetus a peculiar fibrous texture pervades the mass, the fibres joining at the numerous points, and presenting minute nuclear

granules at their point of junction. In the centre of the vitreous humor, running from the entrance of the optic nerve to the posterior surface of the lens, is a canal, filled with fluid and lined by a prolongation of the hyaloid membrane. This is the **hyaloid canal** (*canalis hyaloideus*) (Fig. 805), which in the embryonic vitreous humor conveyed the minute vessel from the central artery of the retina to the back of the lens.

The **hyaloid membrane** encloses the whole of the vitreous humor. In front of the ora serrata it is thickened by the accession of radial fibres and is termed the **zonule of Zinn** (*zonula ciliaris*) (Figs. 824 and 829). Here it presents a series of radially arranged furrows, in which the ciliary processes are accommodated and to which they are adherent, as evidenced by the fact that when removed some of their pigment remains attached to the zonule.¹ The zonule of Zinn splits into two

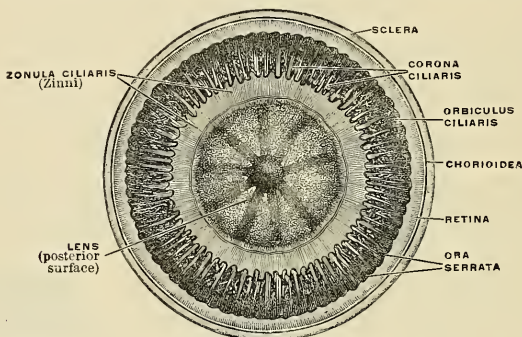


FIG. 824.—The zonule of Zinn or the suspensory ligament of the lens viewed from behind in connection with the lens and the ciliary body. (Toldt.)

layers, one of which is thin and lines the fossa hyaloidea; the other is named the **suspensory ligament of the lens**; it is thicker, and passes over the ciliary body to be attached to the capsule of the lens a short distance in front of its equator. Scattered and delicate fibres are also attached to the region of the equator itself. This ligament retains the lens in position, and is relaxed by the contraction of the radial fibres of the Ciliary muscle, so that the lens is allowed to become more convex. Behind the suspensory ligament there is a sacculated canal, the **canal of Petit** (*spatia zonularia*), which encircles the margin of the lens and which can be easily inflated through a fine blowpipe inserted through the suspensory ligament. It is bounded in front by the anterior layer of the suspensory ligament of the lens, behind by the membrana hyaloidea, and internally by the capsule of the lens. The canal of Petit is a lymph space. All of the spaces of the canal of Petit communicate with the posterior chamber of the eye.

No vessels penetrate the vitreous body, although a lymph channel remains; so that its nutrition must be carried on by the vessels of the retina and ciliary processes, situated upon its exterior.

III. The Crystalline Lens (*Lens Crystallina*) (Figs. 825, 826).

The **crystalline lens**, enclosed in its *capsule*, is situated immediately behind the pupil, in front of the vitreous body, and is encircled by the ciliary processes, which slightly overlap its margin.

¹ F. A. Woll: A Simple Technique for the Removal of the Hyaloid Membrane with Contents and Attachments Intact. *Anat. Rec.*, vol. 6, No. 9, September, 1912.

The **capsule of the lens** (*capsula lentis*) (Fig. 785) is a transparent, highly elastic, and brittle membrane, which closely surrounds the lens, and is composed in part of cuticular and in part of connective tissues. It is not white fibrous tissue, and is not true elastic tissue (Szymonowicz). Its outer surface is composed of lamellae and possesses transverse striations. It rests, *behind*, in the fossa hyaloidea in the fore part of the vitreous body (Fig. 823); in *front*, it is in contact with the free border of the iris, this latter receding from it at the circumference, thus forming the **posterior chamber of the eye** (Fig. 829); and it is retained in its position chiefly by the suspensory ligament of the lens, already described (Fig. 829). The capsule is much thicker in front than behind, and when ruptured the edges roll up with the outer surface innermost, like the elastic lamina of the cornea.

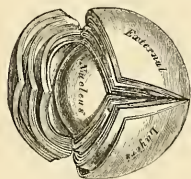

FIG. 825.—The crystalline lens, hardened and divided. (Enlarged.)

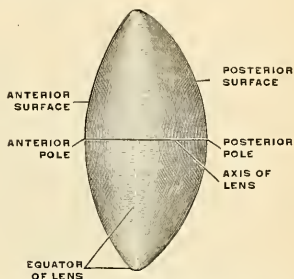


FIG. 826.—The terms used in the orientation of the lens. (Toldt.)

The *lens* is a transparent, biconvex body, the convexity of the posterior surface being greater than that of the anterior. The central points of these surfaces are termed respectively the **anterior** and **posterior poles** (*polus anterior et polus posterior lentis*). A line connecting the poles constitutes the **axis** of the lens (*axis lentis*), while the marginal circumference is termed the **equator** (*aequator lentis*). The lens measures from 9 to 10 mm. in the transverse and vertical diameters and about 4 mm. from anterior to posterior pole.

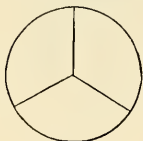

FIG. 827.

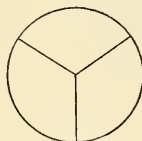


FIG. 828.

FIGS. 827 AND 828.—Diagram to show the direction and arrangement of the radiating lines on the front and back of the fetal lens. Fig. 827. From the front. Fig. 828. From the back.

Structure.—The lens consists of an outer, soft part, easily detached (*substantia corticalis*), and a central, firm part (*nucleus lentis*) (Fig. 825). Faint lines (*radii lentis*) radiate from the poles to the equator. In the adult there may be six or more of these lines, but in the fetus they are only three in number and diverge from each other at angles of 120 degrees (Figs. 827 and 828). On the anterior surface one line ascends vertically and the other two diverge downward and outward. On the posterior surface one ray descends vertically and the other two diverge upward. They correspond with the free edges of an equal number of **septa** composed of an amorphous substance, which dip into the substance of the lens. When the lens has been hardened (as in alcohol), it is seen to consist of concentric layers, or **laminae**, each of which is interrupted at the septa. Each lamina is built up of a number of parallel, hexagonal **lens fibres** (*fibræ lentis*), the edges of which are serrated to fit similar serrations of adjacent lens fibres, while the ends of the fibres

come into apposition with the septa. The fibres run in a curved manner from the septa on the anterior surface to those on the posterior surface. No fibres pass from pole to pole, but they are arranged in such a way that fibres which commence near the pole on the one aspect of the lens terminate near the peripheral extremity of the plane on the other, and *vice versa*. Each fibre of the outer layers of the lens contains a nucleus, and these nuclei form a layer, the **nuclear layer**, on the surface of the lens. The nuclear layer is most distinct toward the circumference of the lens. The anterior surface of the lens is covered by a single layer of transparent, columnar, nucleated epithelial cells (*epithelium lentis*). At the equator these cells become elongated and their gradual transition into lens fibres can be traced.

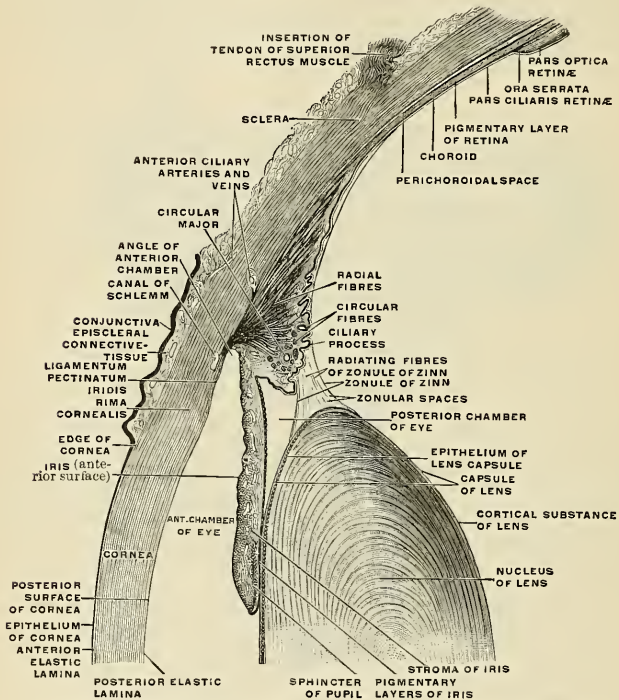


FIG. 829.—The upper half of a sagittal section through the front of the eyeball. (Toldt.)

The changes produced in the lens by age are the following:

In the **fetus** its form is nearly spherical, its color of a slightly reddish tint, it is not perfectly transparent, and is so soft as to disintegrate readily on the slightest pressure. A small branch from the arteria centralis retinae runs forward, as already mentioned, through the vitreous humor to the posterior part of the capsule of the lens, where its branches radiate and form a plexiform network, which covers its surface, and they are continuous around the margin of the capsule with the vessels of the pupillary membrane and with those of the iris.

In the **adult** the posterior surface is more convex than the anterior; it is colorless, transparent, firm in texture, and devoid of bloodvessels.

In **old age** it becomes flattened on both surfaces, slightly opaque, of an amber tint, and increases in density.

Vessels and Nerves of the Globe of the Eye.—The arteries of the globe of the eye are the short posterior ciliary, long posterior ciliary, and anterior ciliary arteries, and the arteria centralis retinae. They have been already described (p. 613).

The *ciliary veins* are seen on the outer surface of the choroid, and are named from their arrangement, the *venae vorticosae* (p. 1094). They converge to four or five equidistant trunks, which pierce the sclera midway between the margin of the cornea and the porus opticus. Another set of veins accompanies the anterior ciliary arteries and opens into the ophthalmic vein.

The Lymphatic Passages of the Eyeball.—The conjunctiva contains lymph vessels. The eyeball contains lymph spaces, but no lymph vessels. There are two sets of lymph spaces in the eyeball, the anterior and posterior. The **anterior lymph spaces** are the spaces of the cornea, of the iris, of the anterior chamber, and of the posterior chamber. The lymph from the intralaminar lymph spaces of the cornea enters the conjunctival lymphatics at the margin of the cornea. The lymph spaces of the iris open into the anterior chamber by the crypts of the iris, and at the margin of the iris join the spaces of Fontana. The aqueous humor fills the anterior and posterior chambers, but is furnished by the vessels in the posterior chamber; in part by the vessels of the ciliary body, and in part by the vessels of the posterior surface of the iris. The lymph passes by way of the pupil into the anterior chamber, and then is taken up by the spaces of Fontana, the canal of Schlemm, and the anterior ciliary veins.

The **posterior lymph spaces** are the hyaloid canal, the perichoroidal lymph space, the space of Ténon, the intervaginal space of the optic nerve, and the supravaginal space.

The **hyaloid canal** (Figs. 802 and 805). passes between the posterior surface of the lens and the optic disk. The hyaloid canal opens into the intervaginal space of the optic nerve. Between the sclera and the choroid is the **perichoroidal lymph space** (Fig. 829). It is around the choroid vessels and the *venae vorticosae*, and empties into Ténon's space by means of openings through the sclera about the *venae vorticosae*. **Ténon's space** (Figs. 802 and 803) is between the sclera and the capsule of Ténon. It receives lymph from the perichoroidal space, and empties into the supravaginal space.

The optic nerve (Fig. 819) has a sheath of dura and a sheath of pia, and between these sheaths is the **intervaginal lymph space**. It is divided by a prolongation of the cerebral arachnoid into a **subdural space** and a **subarachnoid space**, which empty into the corresponding spaces of the membranes of the brain. The **supravaginal space** is between the dural portion of the sheath of the optic nerve and a posterior prolongation of Ténon's capsule.¹

The Nerves of the Globe of the Eye.—The **long ciliary nerves** (*nn. ciliares longi*), two in number, are derived from the nasal branch of the ophthalmic, and the **short ciliary nerves** (*nn. ciliares breves*), twelve to fifteen in number, are derived from the ciliary or ophthalmic ganglion. Both the long and short ciliary nerves perforate the sclera in the neighborhood of the optic nerve (Fig. 809). They pass along the perichoroidal lymph space, forming a plexus which sends filaments to the choroidal vessels. In front of the Ciliary muscle they form a second plexus, and from it come branches which go to the Ciliary muscle and the muscle fibres and vessels of the iris, sclera, choroid, ciliary body, and iris (Fig. 816). The ciliary nerves supply the cornea. The circular fibres of the iris are innervated by the oculomotor nerve and the radial fibres by the sympathetic.

Applied Anatomy.—From a surgical point of view the cornea may be regarded as consisting of three layers: (1) Of an external epithelial layer, developed from the ectoderm, and continuous with the external epithelial covering of the rest of the body, and therefore its lesions resemble those of the epidermis; (2) of the cornea proper, derived from the mesoderm, and associated in its diseases with the fibrovascular structures of the body; and (3) the posterior elastic layer with its endothelium, also derived from the mesoderm and having the characters of a serous membrane, so that inflammation of it resembles inflammation of the other serous and synovial membranes of the body.

The *cornea* contains no bloodvessels, except at its periphery, where numerous delicate loops, derived from the anterior ciliary arteries, may be demonstrated on the anterior surface of the cornea. The rest of the cornea is nourished by lymph, which gains access to the proper substance of the cornea and the posterior layer through the spaces of Fontana (*spatia anguli iridis*). This lack of direct blood supply renders the cornea very apt to become inflamed in the cachectic and ill-nourished. In spite of the absence of bloodvessels, wounds of the cornea usually heal rapidly. A wound which penetrates the cornea opens the anterior chamber, and aqueous humor escapes. An *ulcer* may also open the anterior chamber. Through a wound or a perforated ulcer the papillary margin of the iris may prolapse. A trivial injury of the cornea is repaired by transparent tissue. A severe injury is repaired by fibrous tissue, and *opacity* results. A slight opacity resembling a cloud of gray smoke is called *nebula*; a more marked white opacity is called *leucoma*. In *abscess of the cornea* pus gravitates between the layers to the lower part of the cornea and the purulent collection assumes a crescentic shape (*ouph*). The *areus senilis*, seen in the aged, is a condition of haziness or opacity at the corneal margin due to fatty degeneration of the tissues of the cornea. It signifies interference with the blood supply, because of senile degeneration of adjacent vessels. In cases of *trachoma* there is a peculiar affection of the cornea, called *pannus*, in which the anterior layers of the cornea become vascularized, and a rich network

¹ For the lymphatic channels of the eyeball see Deaver's Surgical Anatomy, vol. ii, p. 392.

of bloodvessels may be seen on the cornea; and in *interstitial keratitis* new vessels extend into the cornea, giving it a pinkish hue, to which the term *salmon patch* is applied. The cornea is richly supplied with nerves, derived from the ciliary nerves, which enter the cornea through the fore part of the sclera and form plexuses in the stroma, terminating between the epithelial cells by free ends or in corpuscles. In cases of *glaucoma* the ciliary nerves may be pressed upon as they course between the choroid and sclera (Fig. 808), and in consequence of the pressure upon them, the cornea, to which they are distributed, becomes anesthetic. When a scar forms on the cornea and the iris becomes adherent, the scar and the iris, and sometimes even the lens, may bulge forward from intraocular tension. This condition is *staphyloma of the cornea*. In conditions of impaired nutrition the cornea may be bulged forward by intraocular pressure. The line of least resistance is a little below the centre of the cornea, and it is bulged forward and strongly curved. This condition is known as *conical cornea*.

The sclera has very few bloodvessels and nerves. The bloodvessels are derived from the anterior ciliary, and form an open plexus in its substance. As they approach the corneal margin this arrangement is peculiar. Some branches pass through the sclera to the ciliary body; others become superficial and lie in the episcleral tissue, and form arches, by anastomosing with each other, some little distance behind the corneal margin. From these arches numerous straight vessels are given off, which run forward to the cornea, forming its marginal plexus. In *inflammation of the sclera and episcleral tissue* these vessels become conspicuous, and form a pinkish zone of straight vessels radiating from the corneal margin, commonly known as the *zone of ciliary injection*. In *inflammation of the iris and ciliary body*, this zone is present, since the sclera speedily becomes involved when these structures are inflamed. But in *inflammation of the cornea* the sclera is seldom much affected, though the cornea and sclera are structurally continuous. This would appear to be due to the fact that the nutrition of the cornea is derived from a different source from that of the sclera. The sclera may be *ruptured subcutaneously* without any laceration of the conjunctiva, and the rupture usually occurs near the corneal margin, where the tunic is thinnest. It may be complicated with lesions of adjacent parts—laceration of the choroid, retina, iris, or suspensory ligament of the lens—and is then often attended with hemorrhage into the anterior chamber, which masks the nature of the injury. In some cases the lens has escaped through the rent in the sclera, and has been found under the conjunctiva. *Wounds of the sclera*, if they do not perforate, usually heal readily. If they extend through the sclera they cause diminished tension, are always dangerous, and are often followed by inflammation, suppuration, and by sympathetic ophthalmia. The sclera may be weakened by injury, inflammation, etc., and the weakened portion may bulge from intraocular pressure, and even a healthy sclera may bulge from excessive intraocular pressure. According to its situation the lesion is known as *ciliary staphyloma*, *equatorial staphyloma*, or *posterior staphyloma*.

One of the functions of the *choroid* is to provide nutrition for the retina and to convey vessels and nerves to the ciliary body and iris. *Inflammation of the choroid* is therefore followed by grave disturbance in the nutrition of the retina, and is attended with early interference with vision. *Purulent choroiditis* is not confined to the choroid; the retina, the vitreous, and the entire uveal tract become involved, and even other structures may suffer. In its diseases it bears a considerable analogy to those which affect the skin, and, like it, is one of the places from which *melanotic sarcomata* may grow. These tumors contain a large amount of pigment in their cells, and grow only from those parts where pigment is naturally present. The *choroid* may be *ruptured* without injury to the other tunics, as well as participating in general injuries of the eyeball. In cases of uncomplicated rupture the injury is usually at its posterior part, and is the result of a blow on the front of the eye. It is attended by considerable hemorrhage, which for a time may obscure vision, but in most cases this is restored as soon as the blood is absorbed.

The *iris* is the seat of a malformation, termed *coloboma*, which consists in a deficiency or cleft, which in a great number of cases is clearly due to an arrest in development. In these cases it is found at the lower aspect, extending directly downward from the pupil, and the gap frequently extends through the choroid to the attachment of the optic nerve. In some rarer cases the gap is round in other parts of the iris, and is then not associated with any deficiency of the choroid. The *iris* is abundantly supplied with bloodvessels and nerves, and is therefore very prone to become *inflamed*. When inflamed, in consequence of the fact that the iris and ciliary body are continuous, and that their vessels communicate, *iritis* is usually associated with *eyclitis*, the disease being called *iridoeyclitis*. And, in addition, inflammation of adjacent structures, the cornea and sclera, is apt to spread into the iris. The iris is covered with endothelium, and partakes of the character of a serous membrane, and, like these structures, is liable to pour out a plastic exudation when inflamed, and contract adhesions, either to the cornea in front (*synechia anterior*), or to the capsule of the lens behind (*synechia posterior*). In *iritis* the lens may become involved, and the condition known as *secondary cataract* may be set up. *Tumors* occasionally commence in the iris; of these, *cysts*, which are usually congenital and *sarcomatous tumors*, are the most common and require removal. *Gummata* are not infrequently found in this situation. In some forms of injury of the eyeball, as the impact of a spent shot, a flying cork, the rebound of a twig, or a blow with a whip, the iris may be *detached* from the Ciliary muscle, the amount of detach-

ment varying from the slightest degree to the separation of the whole iris from its ciliary connection.

The *Argyll-Robertson pupil* shows no reaction to light, but retains reaction to accommodation and vision remains good.

The *retina*, with the exception of its pigment layer, and its vessels is perfectly transparent, and is invisible when examined by the ophthalmoscope, so that its diseased conditions are recognized by its loss of transparency. In *retinitis*, for instance, there is more or less dense and extensive opacity of its structure, and not infrequently extravasations of blood into its substance. Hemorrhages may also take place into the retina from rupture of a bloodvessel without inflammation. In *optic neuritis*, *papillitis*, or *choked disk*, the ophthalmoscope shows increase in vascularity, and swelling and opacity of the nerve, which extend beyond the disk margins. Optic atrophy is apt to follow. (Fig. 830 shows a normal optic disk.) The *retina* may become displaced from effusion of serum between it and the choroid or by blows on the eyeball, or may occur without apparent cause in *progressive myopia*, and in this case the ophthalmoscope shows an opaque, tremulous cloud. *Glioma*, a form of sarcoma, and essentially a disease of early life, is occasionally met with in connection with the retina.

The *lens* has no bloodvessels, nerves, or connective tissue in its structure, and therefore is not subject to those morbid changes to which tissues containing these structures are liable. It does, however, present certain morbid or abnormal conditions of various kinds. Thus, variations in shape, absence of the whole or a part of the lens, and displacements are among its *congenital defects*. *Opacities* may occur from injury, senile changes, malnutrition, or errors in growth or development. An opacity of the capsule, of the lens, or of both, is known as a *cataract*. *Senile changes* may take place in the lens, impairing its elasticity and rendering it harder than in youth,

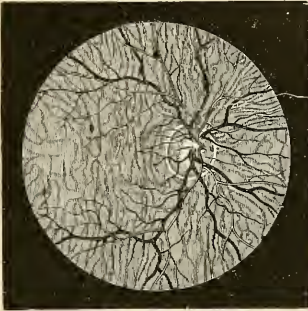


FIG. 830.—Ophthalmoscopic appearance of healthy fundus in a person of very fair complexion. Scleral ring well marked. Left eye, inverted image. (Wecker and Jaeger.)

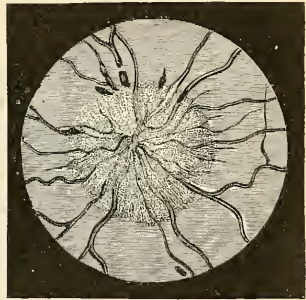


FIG. 831.—Ophthalmoscopic appearance of severe recent papillitis. Several elongated patches of blood near border of disk. (After Hughlings Jackson.)

so that its curvature can only be altered to a limited extent by the Ciliary muscle. And, finally, the lens may be *dislocated* or displaced by blows upon the eyeball, and its relations to surrounding structures altered by adhesions or the pressure of newgrowths.

There are two particular regions of the eye which require special notice; one of these is known as the "filtration area," and the other as the "dangerous area." The *filtration area* is the circumcorneal zone immediately in front of the iris. Here are situated the cavernous spaces of Fontana, which communicate with the canal of Schlemm, through which the chief transudation of fluid from the eye is now believed to take place. The *dangerous area of the eye* is the region in the neighborhood of the ciliary body, and wounds or injuries in this situation are peculiarly dangerous; for inflammation of the ciliary body is liable to spread to many of the other structures of the eye, especially to the iris and choroid, which are intimately connected by nerve and vascular supplies. Moreover, wounds which involve the ciliary region are especially liable to be followed by sympathetic ophthalmia, in which destructive inflammation of one eye is excited by some irritation in the other.

Emmetropia is normal vision. In normal vision the practically parallel light rays from distant objects focus on the retina without effort; divergent rays from near objects are focussed on the retina by an effort of accommodation.

Hyperopia or *hypermetropia* is far-sightedness. In this condition the retina is in front of the principal focus when the eye is at rest. The patient endeavors to correct the failure by constant

and tiresome efforts at accommodation. The condition is usually due to inordinate shortness of the axis of the eye, but may be due to loss of the lens, decreased convexity of the refractive surfaces, or lessened refractive power in the refractive media of the eye. It is corrected by the use of convex glasses.

Myopia is near-sightedness. In this condition the rays of light come to a focus in front of the retina, and the patient is subjected to continued eye-strain. It is usually due to too great length of the axis of the eye, but may result from increase in refractive power of refractive media. It is corrected by concave glasses. Sometimes, as a person with hyperopia begins to age, an increased refractive power of the lens causes myopia. The occurrence of myopia in a hyperopic eye is called *second sight*, and it enables the individual to cease wearing convex glasses.

Exenteration of the contents of the orbit means removal of all the contents except those at the orbital apex. Even the periosteum is taken away. It is performed for malignant disease.

Evisceration of the eyeball is performed by making a circular incision at the corneal margin and removing the internal and middle coats and the contents of the globe. The sclera is not removed. A glass ball is inserted into the scleral sheath, and the sclera is closed over the ball by vertical stitches, and the conjunctiva is closed over it by transverse stitches. The operation is performed for leucoma or staphyloma of the cornea. An artificial eye (a shell) is placed over the stump when healing is complete.

Enucleation, or *excision of the eyeball*, differs from *exenteration of the orbital contents* in the fact that only the eyeball is removed. A circular incision through the ocular conjunctiva is carried around and near to the corneal margin. The conjunctiva and capsule of Ténon are pushed back and the Rectus muscles are clamped and divided back of the clamp. Traction is made upon the globe in a forward and inward direction, and the optic nerve and adjacent structures are cut with scissors from the outer aspect of the globe. The eye is then pulled out of the orbit, and all structures which tend to retain it are divided. The stumps of the Recti muscles are sewed together.

THE APPENDAGES OF THE EYE (ORGANA OCULI ACCESSORIA).

The appendages of the eye include the **eyebrows**, the **eyelids**, the **conjunctiva**, and the **lacrimal apparatus**—viz., the **lacrimal gland**, the **lacrimal sac**, and the **nasal duct**.

The **Eyebrows** (*supercilia*) are two arched eminences of integument which surmount the upper circumference of the orbit on each side, and support numerous short, thick hairs, directed obliquely on the surface. The hairs may entangle foreign bodies and lessen somewhat the force of blows. In structure the eyebrows consist of thickened integument, connected beneath with the Orbicularis palpebrarum, Corrugator supercilii, and Occipitofrontalis muscles. These muscles serve, by their action on this part, to control to a certain extent the amount of light admitted into the eye.

The **Eyelids** (*palpebrae*) (Figs. 832 and 833) are two thin, movable folds placed in front of the eye, and protecting it from injury by their closure. The eyelids are composed of skin, superficial fascia, and areolar tissue, fibres of the Orbicularis palpebrarum muscle, palpebral and orbitotarsal ligaments, tarsal plates, and conjunctiva. The upper lid also contains the Levator palpebrae superioris muscle. In the lids are bloodvessels, lymph vessels, nerves, and Meibomian glands. There are two lids, the **upper** (*palpebra superior*) and the **lower** (*palpebra inferior*); the groundwork of both lids is made up of a fascial membrane called the **orbital septum** (*septum orbitale*). The upper lid is the larger and the more movable of the two, and is furnished with a separate elevator muscle, the **Levator palpebrae superioris**. The orbital septum, in each lid, consists of two portions. The part near the orbital margin is called the **orbital portion**. The part in which the tarsus lies is called the **tarsal portion**. Between the two portions in each lid is a sulcus, called, in the upper lid, the **superior orbitopalpebral sulcus**, and in the lower lid, the **inferior orbitopalpebral sulcus**. When the eyelids are opened an elliptical space, the **interpallpebral slit** (*rima palpebrarum*), is left between their

margins, the angles of which correspond to the junction of the upper and lower lids, and are called **canthi**.

The **outer canthus** (*commissura palpebrarum lateralis*) is more acute than the inner, and the lids here lie in close contact with the globe; but the **inner canthus** (*commissura palpebrarum medialis*) is prolonged for a short distance inward toward the nose, and the two lids are separated at the inner canthus by a triangular space, the **lacus lacrimalis**. At the commencement of the lacus lacrimalis, on the margin of each eyelid, is a small conical elevation, the **lacrimal papilla**, the apex of which is pierced by a small orifice, the **punctum lacrimale** (Fig. 837), the commencement of the lacrimal canal (Fig. 835). When the lids are closed a space remains between them and the globe to permit of the flow of tears inward (*rivus lacrimalis*).

The **Eyelashes** (*cilia*) (Fig. 833) are attached to the free edges of the eyelids; they are short, thick, curved hairs, arranged in a double or triple row at the margin of the lids; those of the upper lid, more numerous and longer than the lower, curve upward; those of the lower lid curve downward. Because of this arrangement the two sets do not interlace in closing the lids. Near the attachment of the eyelashes are the openings of **sebaceous glands** (*glandulae sebaceae*) (Fig. 833) and of a number of glands, **glands of Moll** (*glandulae ciliares [Molli]*) (Fig. 833), arranged in several rows close to the free margin of the lid. They are regarded as enlarged and modified sweat glands.

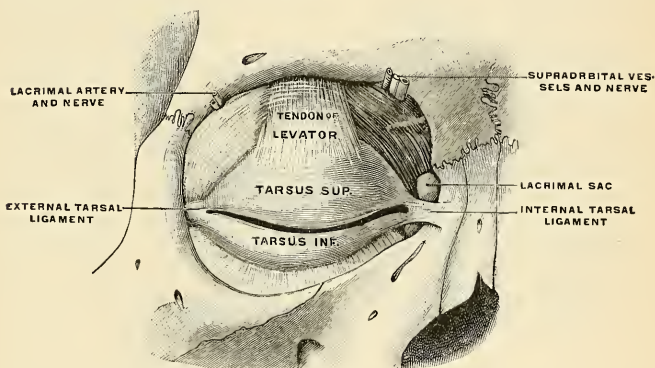


FIG. 832.—The tarsi and their ligaments. Right eye, front view. (Testut.)

Structure of the Eyelids (Fig. 791).—The eyelids are composed of the following structures, taken in their order from without inward: Integument, areolar tissue, fibres of the Orbicularis muscle, tarsal plate, and its ligament, Meibomian glands, and conjunctiva. The upper lid has, in addition, the aponeurosis of the Levator palpebrae, while both lids contain a certain amount of non-striated muscle, called, respectively, the **Superior and Inferior tarsal muscles** (see p. 369) (Fig. 802). The **integument** is extremely thin, and continuous at the margin of the lids with the conjunctiva. The **subcutaneous areolar tissue** is very lax and delicate, seldom contains any fat, and is extremely liable to serous infiltration. The **Palpebral fibres of the Orbicularis oculi muscle** (*m. ciliaris [Riolani]*) are thin, pale in color, and possess an involuntary action.

The **tarsal plates** (Fig. 832) are two thin, elongated, wedge-shaped plates of dense connective tissue about 2.5 cm. (1 inch) in length. They are placed one in each lid, beneath the conjunctival surface, contributing to their form and support. The **superior tarsal plate, superior tarsus, or superior tarsal body** (*tarsus superior*) (Fig. 832), the larger, is of a semilunar form, about 8 mm. ($\frac{1}{3}$ inch) in breadth at the centre, and becoming gradually narrowed at each extremity. To the anterior surface of this plate the aponeurosis of the Levator palpebrae is attached. The **inferior tarsal plate, inferior tarsus, or inferior tarsal body** (*tarsus inferior*)

(Fig. S32), the smaller of the two, is thinner and of an elliptical form. The **free** or **ciliary margin** of these plates is thick, and presents a perfectly straight edge. The **attached** or **orbital margin** is connected to the circumference of the orbit by the fibrous membrane of the lids, with which it is continuous. The outer angle of each plate is attached to the malar bone by the **external tarsal ligament** (*raphe palpebralis lateralis*) (Fig. S32). The inner angles of the two plates terminate at the commencement of the lacus lacrimalis; they are attached to the nasal process of the superior maxilla by the **internal tarsal ligament** or the **tendo oculi** (*ligamentum palpebrale mediale*) (Fig. S32). In reality these so-called ligaments are fascial expansions situated one in each lid, and are attached marginally to the edge of the orbit, where they are continuous with the periosteum. The superior ligament blends with the tendon of the Levator palpebrae, the inferior with the inferior tarsal plate. Externally, the superior and inferior ligaments fuse to form the external tarsal ligament just referred to; internally they are much thinner, and, becoming separated from the internal tarsal ligament, are fixed to the lacrimal bone immediately behind the lacrimal sac. The whole fascial sheet spanning the orbit, and reinforced by these ligaments, constitutes the **orbital septum** (*septum orbitale*), which is perforated by the vessels and nerves which pass from the orbital cavity to the face and scalp.

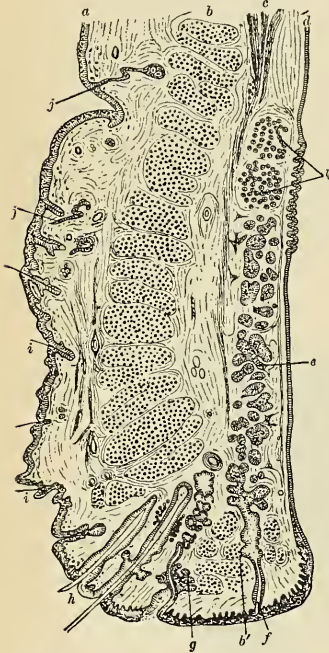


FIG. S33.—Vertical section through the upper eyelid. *a*, Skin. *b*, Orbicularis palpebrarum. *b'*, Marginal fasciculus of Orbicularis (ciliary bundle). *c*, Levator palpebrae. *d*, Conjunctiva. *e*, Tarsal plate. *f*, Meibomian gland. *g*, Sebaceous gland. *h*, Eye-f lashes. *i*, Small hairs of skin. *j*, Sweat-glands. *k*, Accessory lacrimal glands. (After Waldeyer.)

stratified epithelium; the deeper parts of the tubes and the alveoli are filled with polyhedral cells. They are thus identical in structure with the sebaceous glands.

The **Conjunctiva** (Figs. S34 and S35) is the mucous membrane of the eye. It lines the inner surface of the eyelids, is reflected over the fore part of the sclera and cornea, and joins the lids to the eyeball. In each of these situations its structure presents some peculiarities.

The **palpebral portion**, (*tunica conjunctiva palpebrarum*) (Fig. S35) of the conjunctiva lines the posterior surface of the lids. It is thick, opaque, highly vascular, and covered with numerous papillæ, its deeper parts presenting a considerable amount of lymphoid tissue. At the margins of the lids it becomes continuous

The **Meibomian** or **Tarsal Glands** (*glandulae tarsales* [Meibomi]) (Figs. S33 and S35) are situated in the tarsal plates, and may be distinctly seen through the conjunctiva on everting the eyelids, presenting the appearance of parallel strings of pearls. They are about thirty in number in the upper eyelid, and somewhat fewer in the lower. They correspond in length with the breadth of each plate, and are, consequently, longer in the upper than in the lower eyelid. Their ducts open on the free margin of the lids by minute foramina, which correspond in number to the follicles. The use of their secretion is to prevent adhesions of the lids.

Structure.—These glands are a variety of the cutaneous sebaceous glands, each consisting of a single straight tube or duct, having a cecal termination, and with numerous small alveoli opening into it. The tubes consist of basement membrane, lined at the mouths of the tubes by

with the lining membrane of the ducts of the Meibomian glands, and, through the lacrimal canals, with the lining membrane of the lacrimal sac and nasal duct. At the outer angle of the upper lid the lacrimal ducts open on its free surface; and at the inner angle of the eye it forms a semilunar fold, the *plica semilunaris* (*plica semilunaris conjunctivae*) (Fig. 837). The folds formed by the reflection of the conjunctiva from the lids on to the eye are called the **superior and inferior palpebral folds**, the former being the deeper of the two. These folds form the **superior and inferior conjunctival fornix** (Fig. 834).

The Bulbar Portion (*tunica conjunctiva bulbi*).—Upon the sclera the conjunctiva is loosely connected to the globe; it becomes thinner, loses its papillary structure, is transparent, and only slightly vascular in health. Upon the *cornea* the conjunctiva consists only of epithelium, constituting the anterior layer of the cornea (conjunctival epithelium) already described (p. 1091). Lymphatics arise in the conjunctiva in a delicate zone around the cornea, from which the vessels run to the ocular conjunctiva.

Fornices of Conjunctiva.—At the line of reflection of each fold of the conjunctiva from each lid on to the globe of the eye a pocket or arch is formed. These arches are termed the **fornices conjunctivae**, **superior and inferior** (Fig. 834).

Glands of Conjunctiva.—In the conjunctiva there are a number of mucous glands (*gl. mucosae* [Krause]) which are much convoluted. They are chiefly found in the upper lid. Other glands, analogous to lymphoid follicles, and called by Henle **trachoma glands**, are found in the conjunctiva, and, according to Stromeyer, are chiefly situated near the inner canthus of the eye.

The **caruncula lacrimalis** is a small, reddish, conical-shaped body, situated at the inner canthus of the eye, and filling up the small triangular space in this situation, the **lacus lacrimalis**. It consists of an island of skin containing sebaceous and sweat glands, and is the source of the whitish secretion which constantly collects at the inner angle of the eye. A few slender hairs are attached to its surface. On the outer side of the caruncula is a slight semilunar fold of conjunctiva, the concavity of which is directed toward the cornea; it is called the **plica semilunaris** (Fig. 837). Müller found smooth muscle fibres in this fold, and in some of the domesticated animals a thin plate of dense white fibrous tissue has been discovered. This structure is considered to be the rudiment of the third eyelid in birds, the **membrana nictitans**.

The **nerves** in the conjunctiva are numerous and form rich plexuses. According to Krause they terminate in a peculiar form of tactile corpuscle, the "terminal bulb."

The **Lacrimal Apparatus** (*apparatus lacrimalis*) (Figs. 835 and 837) consists of the lacrimal gland, which secretes the tears, and its excretory ducts, which convey the fluid to the surface of the eye. This fluid is carried away by the lacrimal canals into the lacrimal sac, and along the nasal duct into the cavity of the nose.

The **Lacrimal Gland** (*glandula lacrimalis*) is lodged in a depression at the upper and outer angle of the orbit, on the inner side of the external angular process of the frontal bone. It is of an oval form, about the size and shape of an almond. Its upper convex surface is in contact with the periosteum of the orbit, to which it is connected by a few fibrous bands. Its under concave surface rests upon the convexity of the eyeball and upon the Superior and External recti muscles. Its vessels and nerves enter its posterior border, while its anterior margin is closely adherent

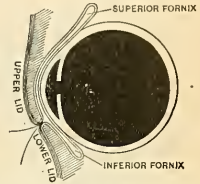


FIG. 834.—Sagittal section of eye, showing superior and inferior fornices of the conjunctiva. (Testut.)

to the back part of the upper eyelid, where it is covered to a slight extent by the reflection of the conjunctiva. The fore part of the gland is separated from the rest by a fibrous septum; hence it is sometimes described as a separate lobe, called the **inferior lacrimal gland** (*glandula lacrimalis inferior*), the back part of the gland then being called the **superior lacrimal gland** (*glandula lacrimalis superior*). The ducts of the lacrimal gland, from six to twelve in number, run obliquely beneath the mucous membrane for a short distance, and, separating from each other, open by a series of minute orifices on the upper and outer half of the conjunctiva near its reflection on to the globe. These orifices are arranged in a row, so as to disperse the secretion over the surface of the membrane.

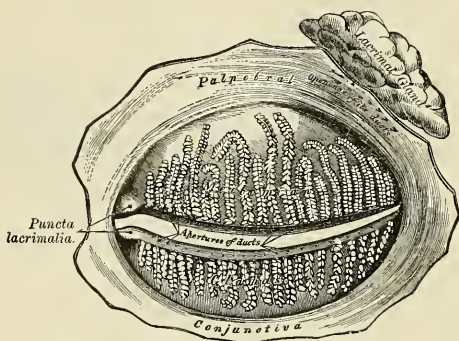


FIG. 835.—The Meibomian glands, etc., seen from the inner surface of the eyelids.

Structure.—In structure and general appearance the lacrimal resembles the serous salivary glands. In the recent state the cells are so crowded with granules that their limits can hardly be defined. Each cell contains an oval nucleus, and the cell protoplasm is finely fibrillated.

The **Lacrimal Canals** (Fig. 837) commence at the minute orifices, **puncta lacrimalia**, on the summit of small conical elevations, the **lacrimal papillæ** (*papillæ lacrimalis*), seen on the margin of the lids at the outer extremity of the lacus lacrimalis. The **superior canal** (*ductus lacrimalis superior*), the smaller and shorter

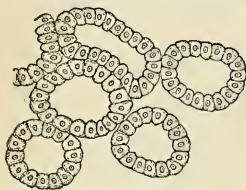


FIG. 836.—Alveoli of lacrimal gland.

of the two, at first ascends, and then bends at an acute angle, and passes inward and downward to the ampulla of the lacrimal sac. The **inferior canal** (*ductus lacrimalis inferior*) at first descends, and then passes almost horizontally inward to the ampulla. These canals are dense and elastic in structure and somewhat dilated at their angles. The mucous membrane is covered with stratified epithelium upon a basement membrane. Outside the latter is a layer of striped muscle continuous with the Tensor tarsi. The two canals join in a dilatation, the **ampulla** (*ampulla ductus lacrimalis*), which empties into the lacrimal sac.

The **Lacrimal Sac** (*saccus lacrimalis*) (Fig. 837) is the upper dilated extremity of the **nasal duct**, and is lodged in a deep groove formed by the lacrimal bone and the nasal process of the maxilla bone. It is oval in form, its upper extremity being closed in and rounded, while below it is continued into the nasal duct. It is covered by a fibrous expansion derived from the tendo oculi, and on its deep

surface it is crossed by the *Tensor tarsi* muscle (Horner's muscle, p. 367), which is attached to the ridge on the lacrimal bone.

Structure.—The lacrimal sac consists of a fibrous elastic coat, lined internally by mucous membrane, the latter being continuous, through the ampulla and lacrimal canals, with the mucous lining of the conjunctiva, and, through the nasal duct, with the mucous membrane of the nose.

The **Nasal Duct** (*ductus nasolacrimalis*) (Fig. 837) is a membranous canal, about 2 cm. (three-quarters of an inch) in length, which extends from the lower part of the lacrimal sac to the inferior meatus of the nose, where it terminates by a somewhat expanded orifice, provided with an imperfect valve, the **valve of Hasner** (*plica lacrimalis [Hasneri]*), formed by a fold of mucous membrane. It is contained in an osseous canal formed by the maxilla, the lacrimal, and the turbinated bones, is narrower in the middle than at each extremity, and takes a direction downward, backward, and a little outward. It is lined by mucous membrane, which is continuous below with that of the nasal fossæ. The membrane in the lacrimal sac and nasal duct is covered with columnar epithelium, as in the nose; this epithelium is in places ciliated.

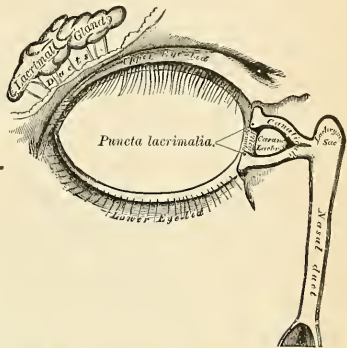


FIG. 837.—The lacrimal apparatus. Right side.

Surface Form.—The *palpebral fissure*, or opening between the eyelids, is elliptic in shape, and differs in size in different individuals and in different races of mankind. In the Mongolian races, for instance, the opening is very small, merely a narrow fissure, and this makes the eyeball appear small in these races, whereas the size of the eye is relatively very constant. The normal direction of the fissure is slightly oblique, in a direction upward and outward, so that the outer angle is on a slightly higher level than the inner. This is especially noticeable in the Mongolian races, in whom, owing to the upward projection of the malar bone and the shortness of the external angular process of the frontal bone, the tarsal plate of the upper lid is raised at its outer part and gives an oblique direction to the palpebral fissure. When the eyes are directed forward, as in ordinary vision, the upper part of the cornea is covered by the upper lid, and the lower margin of the cornea corresponds to the level of the lower lid, so that about the lower three-fourths of the cornea is exposed under ordinary circumstances.

On the margin of the lids, about 1 cm. from the inner canthus, are two small openings, the *puncta lacrimalia*, the commencement of the lacrimal canals. They are best seen by everting the eyelids. In the natural condition they are in contact with the conjunctiva of the eyeball, and are maintained in this position by the *Tensor tarsi* muscle, so that the tears running over the surface of the globe easily find their way into the lacrimal canals. The position of the *lacrimal sac* into which the canals open is indicated by a little tubercle, which is plainly to be felt on the lower margin of the orbit. The lacrimal sac lies immediately above and to the inner side of this tubercle, and a knife passed through the skin in this situation would open the cavity. The position of the lacrimal sac may also be indicated by the *tendo oculi* or *internal tarsal ligament*. If both lids be drawn outward, so as to tighten the skin at the inner angle, a prominent cord will be seen beneath the tightened skin. This is the *tendo oculi*, which lies immediately over the lacrimal sac, bisecting it, and thus forming a useful guide to its situation. A knife entered immediately beneath the tense cord would open the lower part of the sac. A probe introduced through this opening can be readily passed downward through the duct into the inferior meatus of the nose. The direction of the duct is downward, outward, and backward, and this course should be borne in mind in passing the probe, otherwise the point may be driven through the thin bony walls of the canal. A convenient plan is to direct the probe in such a manner that if it were pushed onward it would strike the first molar tooth of the lower jaw on the same side of the body. In other words, the surgeon standing in front of his patient should carry in his mind the position of

the first molar tooth, and should push his probe onward in such a way as if he desired to reach this structure.

Beneath the internal angular process of the frontal bone the pulley of the *Superior oblique muscle* of the eye can be plainly felt by pushing the finger backward between the upper and inner angle of the eye and the roof of the orbit; passing backward and outward from this pulley, the tendon can be felt for a short distance.

Applied Anatomy.—The eyelids are composed of various tissues, and consequently are liable to a variety of diseases. The skin which covers them is exceedingly thin and delicate, and is supported on a quantity of loose and lax subcutaneous tissue which contains no fat. In consequence of this it is very freely movable, and is liable to be drawn down by the contraction of neighboring cicatrices. Such contractions may produce an eversion of the lid known as *ectropion*. Inversion of the lids (*entropion*) from spasm of the *Orbicularis palpebrarum* or from chronic inflammation of the palpebral conjunctiva may also occur. In some individuals there is an extra row of eyelashes on the inner margin of the lid, directed toward the cornea (*distichiasis*). *Trichiasis* is a condition in which the lashes are directed toward the eye, but there is not inversion of the lid. The eyelids are richly supplied with blood, and are often the seat of vascular growths, such as *navi*. *Rodent ulcer* also frequently commences in this situation. The loose cellular tissue beneath the skin is liable to become extensively infiltrated either with blood or inflammatory products, producing very great swelling. Even from very slight injuries to this tissue the extravasation of blood may be so great as to produce considerable swelling of the lids and complete closure of the eye, and the same is the case when the inflammatory products are poured out. The follicles are liable to become inflamed, constituting the disease known as *marginal blepharitis*, *blepharitis ciliaris*, or “*blear-eye*.” Irregular or disorderly growth of the eyelashes not infrequently occurs, some of them being turned toward the eyeball and producing inflammation and follicles of the eyelashes, or the sebaceous glands associated with these follicles may be the seat of inflammation, constituting the ordinary *hordeolum* or “*sty*.” The Meibomian glands are affected in the so-called “*tarsal tumor*,” the tumor, according to some, being caused by the retained secretion of these glands; by others it is believed to be a neoplasm connected with the gland. The *Orbicularis palpebrarum* may be the seat of *spasm* (*blepharospasm*), either in the form of slight quivering of the lids or repeated twittings, most commonly due to errors of refraction in children, or more continuous spasm, due to some irritation of the trigeminal or facial nerves. The *Orbicularis* may be *paralyzed*, generally associated with paralysis of the other facial muscles. Under these circumstances the patient is unable to close the lids, and if he attempts to do so, rolls the eyeball upward under the upper lid. The tears overflow from displacement of the lower lid, and the conjunctiva and cornea, being constantly exposed and the patient being unable to wink, become irritated from dust and foreign bodies. As a result there may be ulceration of the cornea, and possibly eventually complete destruction of the eye. In *paralysis of the Levator palpebrae superioris* there is drooping of the upper eyelid (*ptosis*) and other symptoms of implication of the oculomotor nerve. The eyelids may be the seat of *bruises*, *wounds*, or *burns*. After wounds or burns adhesions of the margins of the lids to each other or adhesion of the lids to the globe may take place. The eyelids are sometimes the seat of *emphysema* after fracture of some of the thin bones forming the inner wall of the orbit. If shortly after such an injury the patient blows his nose, air is forced from the nostrils through the lacerated structure into the connective tissue of the eyelids, which suddenly swell up and present the peculiar crackling on pressure which is characteristic of this affection.

Foreign bodies frequently get into the *conjunctival sac* and cause great pain, especially if they come in contact with the corneal surface, during the movements of the lid and the eye on each other. The conjunctiva is frequently involved in severe injuries of the eyeball, but is seldom ruptured alone; the most common form of injury to the conjunctiva alone is from a *burn*, either from fire, strong acids, or lime. In these cases the union is apt to take place between the eyelid and the eyeball. The conjunctiva is often the seat of *inflammation* arising from many different causes, and the arrangement of the conjunctival vessels should be remembered as affording a means of diagnosis between this condition and injection of the sclera, which is present in inflammation of the deeper structures of the globe. The inflamed conjunctiva is bright red; the vessels are large and tortuous, and greatest at the circumference, shading off toward the corneal margin; they anastomose freely and form a dense network, and they can be emptied by gentle pressure.

The *lacrimal gland* is occasionally, though rarely, the seat of *inflammation* (*dacryoadenitis*). either acute or chronic; it is also sometimes the seat of *tumors*, benign or malignant, and for these may require removal. This may be done by an incision through the skin just below the eyebrow; and the gland, being invested with a special capsule of its own, may be isolated and removed without opening the general cavity of the orbit. The *canals* may be *obstructed*, either as a congenital defect or by some foreign body, as an eyelash or a dacryolith, causing the tears to run over the cheek. The canals may also become occluded as the result of *burns* or *injury*; overflow of tears may, in addition, result from *deviation of the puncta* or from chronic inflammation of the lacrimal sac. When there is failure of the lacrimal tubes to drain off the tears and the

fluid gathers beneath and flows over the lids, the condition is known as *epiphora* or *stillicidium*. This latter condition is set up by some obstruction to the nasal duct frequently occurring in tuberculous subjects. In consequence of this the tears and mucus accumulate in the lacrimal sac, distending it. *Suppuration in the lacrimal sac (dacryocystitis)* is sometimes met with; this may be the sequel of a chronic inflammation; or may occur after some of the eruptive fevers in cases where the lacrimal passages were previously quite healthy. It may lead to *lacrimal fistula*.

THE EAR (ORGANON AUDITUS).

The organ of hearing is divisible into three parts—the external ear, the middle ear or tympanum, and the internal ear or labyrinth.

THE EXTERNAL EAR (AURIS EXTERNA).

The external ear consists of an expanded portion named *pinna* or *auricula*, and the *auditory canal* or *meatus*. The former serves to collect the vibrations of the air by which sound is produced; the latter conducts those vibrations to the tympanum.

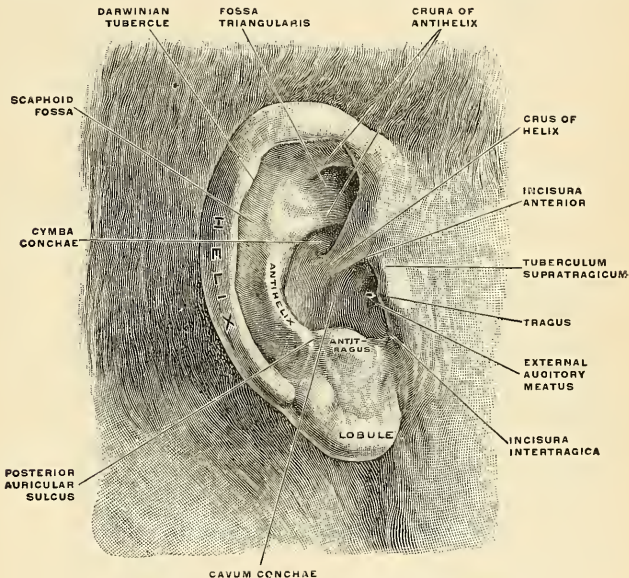


FIG. 838.—The right pinna, viewed from without. (Spalteholz.)

The **Pinna**, or **Auricula** (Fig. 838), is attached to the side of the head midway between the forehead and occiput. It is of an ovoid form, with its larger end directed upward. Its *outer surface* is irregularly concave, directed slightly forward, and presents numerous eminences and depressions which result from the foldings of its fibrocartilaginous element. To each of these, names have been assigned. Thus, the external prominent rim of the auricle is called the **helix**. Another curved prominence, parallel with and in front of the helix, is called the

antihelix; this bifurcates above and forms the **crura** (*crura anthelics*), which enclose a triangular depression, the **fossa of the antihelix** (*fossa triangularis [auriculæ]*). The narrow curved depression between the helix and antihelix is called the **fossa of the helix** or the **scaphoid fossa** (*scapha*); the antihelix describes a curve

around a deep, capacious cavity, the **concha auriculæ**, which is partially divided into two parts by the **crus of the helix** (*crus helicis*), or the commencement of the helix; the upper part is termed the **cymba conchæ**, the lower part the **cavum conchæ**. In front of the concha, and projecting backward over the meatus, is a small pointed eminence, the **tragus**, so called from its being generally covered on its under surface with a tuft of hair resembling a goat's beard. Opposite the tragus, and separated from it by a deep notch (*incisura intertragica*), is a small tubercle, the **antitragus**. Below this is the **lobule** (*lobulus auriculæ*), composed of tough areolar and adipose tissue, wanting the firmness and elasticity of the rest of the pinna. Sometimes the lobule does not hang freely, but is adherent.

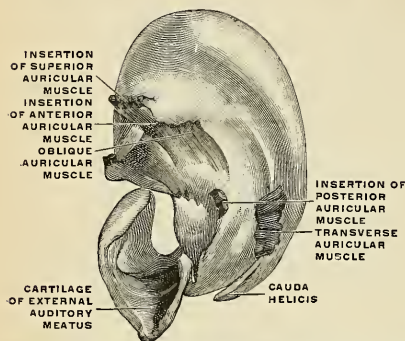


FIG. 839.—The cartilage of the right pinna, isolated, with the muscles, viewed from the inside. (Spalteholz.)

Where the helix turns downward a small tubercle, **tubercle of Darwin** (*tuberculum auriculæ [Darwini]*), is frequently seen. This tubercle is very evident about the sixth month of fetal life; at this stage the human pinna has a close resemblance to that of some of the adult monkeys.

The **cranial surface** of the pinna presents elevations which correspond to the depressions on its outer surface and after which they are named, *e. g.*, **eminentia conchæ**, **eminentia fossæ triangularis**, etc.

Structure.—The pinna is composed of a thin plate of yellow fibrocartilage, covered with integument and connected to the surrounding parts by the extrinsic ligaments and muscles, and to the commencement of the external auditory canal by fibrous tissue.

The **integument** is thin, closely adherent to the cartilage, and covered with hairs furnished with sebaceous glands which are most numerous in the concha and scaphoid fossa. The hairs are most numerous and largest on the tragus and antitragus.

The **cartilage of the pinna** (*cartilago auriculæ*) (Fig. 840) consists of one single piece; it gives form to this part of the ear, and upon its surface are found all the eminences and depressions above described. It does not enter into the construction of all parts of the pinna; thus, it does not form a constituent part of the lobule; it is deficient also between the lamina of the tragus and beginning of the crus helix, the notch between them (*incisura terminalis auris*) being filled up by dense fibrous tissue. At the front part of the pinna, where the helix bends upward, is a small projection of cartilage, called the **spine of the helix** (*spina helicis*), while the lower part of the helix is prolonged downward as a tail-like process, the **cauda helicis**; this is separated from the antihelix by a fissure, the **fissura antitragohelicina**. The cranial aspect of the cartilage

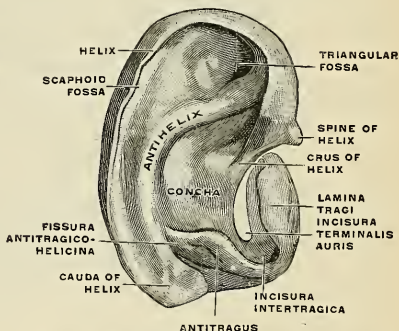


FIG. 840.—The right ear cartilage, isolated, viewed from without. (Spalteholz.)

is a small projection of cartilage, called the **spine of the helix** (*spina helicis*), while the lower part of the helix is prolonged downward as a tail-like process, the **cauda helicis**; this is separated from the antihelix by a fissure, the **fissura antitragohelicina**. The cranial aspect of the cartilage

exhibits a transverse furrow, the **sulcus antihelicus transversus**, which separates the prominence produced by the concha from that caused by the fossa triangularis. A vertical ridge (*ponticulus*) upon the eminentia conchae gives attachment to the Retrahens aurem muscle. The fissure of the helix is a short vertical slit, situated at the fore part of the pinna. Another fissure, the **fissure of the tragus**, is seen upon the anterior surface of the tragus. Anteriorly and inferiorly the cartilage of the pinna is continuous with the cartilage of the external auditory canal by a **cartilaginous isthmus** (*isthmus cartilaginis auris*). Some authors regard the tragus as part of the cartilage of the canal. The cartilage of the pinna is very pliable, elastic, of a yellowish color, and belongs to that form of cartilage which is known under the name of yellow fibrocartilage.

The **ligaments** of the pinna (*ligamenti auricularia* [Valsalvæ]) consist of two sets: 1. The extrinsic set, or those connecting it to the side of the head. 2. The intrinsic set, or those connecting the various parts of its cartilage together. The **extrinsic ligaments**, the most important, are three in number—**superior, anterior, and posterior**. The **superior ligament** (*ligamentum auriculare superius*) extends from the supramental spine to the spine of the helix. The **anterior ligament** (*ligamentum auriculare anterius*) extends from the spina helices and tragus to the root of the zygoma. The **posterior ligament** (*ligamentum auriculare posterius*) passes from the posterior surface of the concha to the outer surface of the mastoid process of the temporal bone. The chief **intrinsic ligaments** are: (1) A strong fibrous band stretching across from the tragus to the commencement of the helix, completing the meatus in front, and partly encircling the boundary of the concha; and (2) a band which extends between the antihelix and the cauda helices. Other less important bands are found on the cranial surface of the pinna.

The **muscles** of the pinna (Figs. 839 and 841) consist of two sets: (1) The *extrinsic*, which connect it with the side of the head, moving the pinna as a whole—viz., the Attollens, Attrahens, and Retrahens aurem (p. 366). (2) The *intrinsic*, which extend from one part of the auricle to another—viz.:

Helicis major.
Helicis minor.
Tragicus.

Antitragicus.
Transversus auriculæ.
Obliquus auriculæ.

The *Helicis major* (*m. helicis major*) is a narrow vertical band of muscle fibres, situated upon the anterior margin of the helix. It arises, below, from the spina helices, and is inserted into the anterior border of the helix, just where it is about to curve backward.

The *Helicis minor* (*m. helicis minor*) is an oblique fasciculus which covers the crus helices.

The *Tragicus* (*m. tragicus*) is a short, flattened band of muscle fibres situated upon the outer surface of the tragus, the direction of its fibres being vertical.

The *Antitragicus* (*m. antitragicus*) arises from the outer part of the antitragus; its fibres are inserted into the cauda helices and antihelix. This muscle is usually very distinct.

The *Transversus auriculæ* (*m. transversus auriculæ*) is placed on the cranial surface of the pinna. It consists of scattered fibres, partly tendon and partly muscle, extending from the convexity of the concha to the prominence corresponding with the groove of the helix.

The *Obliquus auriculæ* (Tod) (*m. obliquus auriculæ*) consists of a few fibres extending from the upper and back part of the concha to the convexity immediately above it.

The **arteries** of the pinna are the posterior auricular from the external carotid, the anterior auricular from the temporal, and an auricular branch from the occipital artery. The **veins** of the pinna accompany the corresponding arteries. The

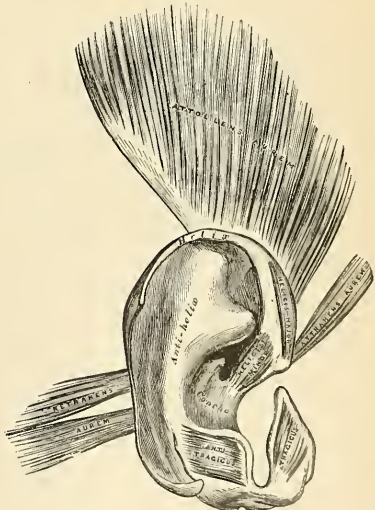


FIG. 841.—The muscles of the pinna.

lymphatics enter into the preauricular nodes and the nodes upon the Sternomastoid muscle at its insertion. The **nerves** of the pinna are the great auricular, from the cervical plexus; the auricular branch of the vagus; the auriculotemporal branch of the inferior maxillary nerve; the small occipital from the cervical plexus, and the great occipital or internal branch of the dorsal division of the second cervical nerve. The muscles of the pinna are supplied by the facial nerve.

The **Auditory Canal**, or **Meatus** (*meatus acusticus externus*), extends from the bottom of the concha to the membrana tympani (Figs. 842 and 843). It is about 3.7 cm. (an inch and an half) in length if measured from the tragus; from the bottom of the concha its length is about 2.5 cm. (an inch). It forms a sort of S-shaped curve, and is directed at first inward, forward, and slightly upward (*pars externa*); it then passes inward and backward (*pars media*), and lastly is carried inward, forward, and slightly downward (*pars interna*). It forms an oval cylindrical canal, the greatest diameter being in the vertical direction at the external orifice,

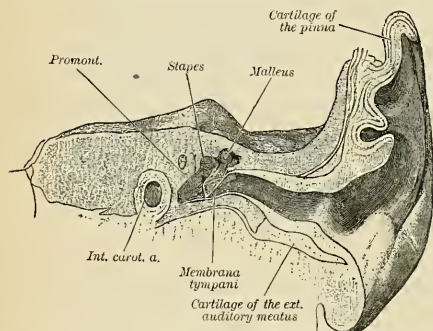


FIG. 842.—Transverse section of external auditory canal and tympanum. Left side. (Gegenbaur.)

but in the transverse direction at the tympanic end. It presents two constrictions, one near the inner end of the cartilaginous portion, and another, the **isthmus**, in the osseous portion, about 2 cm. (three-quarters of an inch) from the bottom of the concha. The **membrana tympani** (Figs. 842 and 843), which closes the inner end of the canal, is directed obliquely, in consequence of which the floor of the canal is longer than the roof, and the anterior wall longer than the posterior. The auditory canal is formed partly by cartilage and membrane, partly by bone, and is lined by perichondrium and periosteum, covered by skin.

The **cartilaginous portion** (*meatus acusticus externus cartilagineus*) is about 8 mm. (one-third of an inch) in length; it is formed by the cartilage of the pinna, prolonged inward, and firmly attached to a greater portion of the circumference of the auditory process of the temporal bone. The cartilage is deficient at its upper and back part, its place being supplied by a fibrous membrane. This part of the canal is rendered extremely movable by two or three deep fissures, the **fissures of Santorini** (*incisurae cartilaginis meatus acustici externi* [Santorini]), which extend through the cartilage in a vertical direction.

The **osseous portion** (*meatus acusticus externus osseus*) is about 16 mm. (two-thirds of an inch) in length, and narrower than the cartilaginous portion. It is directed inward and a little forward, forming a slight curve in its course, the convexity of which is upward and backward. Its inner end, which communicates, in the dry bone, with the cavity of the tympanum, is smaller than the outer and sloped, the anterior wall projecting beyond the posterior about 4 mm. (one-sixth of an inch); it is marked, except at its upper part, by a narrow groove, the **tympanic sulcus** (*sulcus tympanicus*), in which the circumferential margin of the membrana tympani is attached. Its outer edge is dilated and rough in the greater part of its circumference, for the attachment of the cartilage of the pinna. Its transverse section is oval, the greatest diameter being from above downward and backward. The front and lower parts of this canal are formed by a curved plate of bone,

the tympanic plate, which, in the fetus, exists as a separate ring (*annulus tympanicus*), incomplete at its upper part. (See Section on Osteology, p. 87.)

The **skin** lining the meatus is very thin, adheres closely to the cartilaginous and osseous portions of the tube, and covers the surface of the membrana tympani, forming a very thin outer layer. After maceration the thin pouch of epidermis, when withdrawn, preserves the form of the canal. In the thick subcutaneous tissue of the cartilaginous part of the meatus are numerous **ceruminous glands** (*glandulae ceruminosae*) which secrete the *ear wax* or *cerumen*. They resemble in structure sweat glands, and their ducts open on the surface of the skin.

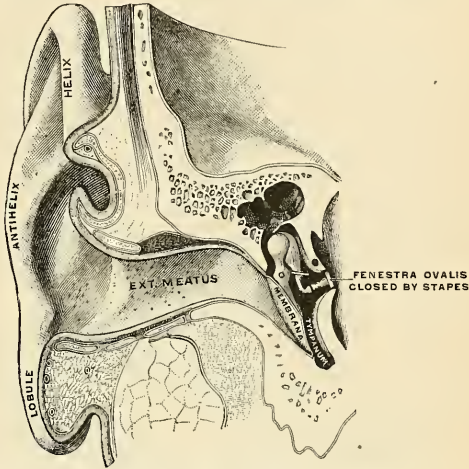


FIG. 843.—Vertical section through the external auditory canal and tympanum, passing in front of the fenestra ovalis. (Testut.)

Relations of the Canal.—In front of the osseous part is the *glenoid fossa*, which receives the *condyle of the mandible* (Fig. 100), which, however, is separated from the cartilaginous part by the retromandibular part of the *parotid gland*. The movements of the mandible influence to some extent the lumen of the cartilaginous portion. Behind the osseous part are the *mastoid air cells* (*cellulae mastoideae*), separated from it by a thin layer of bone (Fig. 845).

The **arteries** supplying the external canal are branches from the posterior auricular, internal maxillary, and superficial temporal.

The **veins** of the external canal accompany the corresponding arteries and pass to the internal maxillary, temporal, and posterior auricular veins. The **lymphatics** accompany the veins and enter the parotid and posterior auricular lymph nodes. The **nerves** are chiefly derived from the auriculotemporal branch of the inferior maxillary nerve, the *auricularis magnus*, and the auricular branch of the *vagus*.

The point of junction of the osseous and cartilaginous portions of the tube is an obtuse angle, which projects into the canal at its antero-inferior wall. This produces a sort of constriction in this situation, and renders it the narrowest portion of the canal—an important point to be borne in mind in connection with the presence of foreign bodies in the ear. The cartilaginous is connected to the bony part by fibrous tissue, which renders the outer part of the tube very movable, and therefore by drawing the pinna upward and backward the canal is rendered almost straight. At the external orifice are a few short crisp hairs which serve to prevent the entrance of small particles of dust, flies, or other insects. In the external auditory canal the secretion of the ceruminous glands serves to catch any small particles which may find their way into the canal, and prevent their reaching the membrana tympani, where their presence might excite irritation. In young children the canal is short, the osseous part being very deficient, and consisting merely of a bony ring (*annulus tympanicus*), which supports the membrana tympani. In the fetus the osseous part is entirely absent. The shortness of the canal in children

should be borne in mind in introducing the aural speculum, so that it shall not be pushed in too far, at the risk of injuring the *membrana tympani*; indeed, even in the adult the speculum should never be introduced beyond the constriction which marks the junction of the osseous and cartilaginous portions. In using this instrument it is advisable that the pinna should be drawn upward, backward, and a little outward, so as to render the canal as straight as possible, and thus assist the operator in obtaining, by the aid of reflected light, a good view of the *membrana tympani*. Just in front of the membrane is a well-marked depression, situated on the floor of the canal and bounded by a somewhat prominent ridge; in this foreign bodies may become lodged. By aid of the speculum, combined with traction of the auricle upward and backward, the whole of the *membrana tympani* is rendered visible. It is a pearly-gray membrane, slightly glistening in the adult, placed obliquely, so as to form with the floor of the canal a very acute angle (about 55 degrees), while with the roof it forms an obtuse angle. At birth it is more horizontal—being situated in almost the same plane as the base of the skull. About midway between the anterior and posterior margins of the membrane, and extending from the centre obliquely upward, is a reddish-yellow streak; this is the handle of the malleus, which is attached to the membrane (Fig. 846). At the upper part of this streak, close to the roof of the canal, a little white rounded prominence is plainly to be seen; this is the *processus brevis* of the malleus, projecting against the membrane. The *membrana tympani* does not present a plane surface; on the contrary, its centre is drawn inward, on account of its connection with the handle of the malleus, and thus the external surface is rendered concave.

The connections of the nerves of the auditory canal explain the fact that the occurrence, in cases of any irritation of the canal, of constant coughing and sneezing from implication of the vagus, or of yawning from implication of the auriculotemporal, of vomiting which may follow syringing the ears of children, and the occasional heart failure similarly induced in elderly persons. No doubt also the association of *earache* with *toothache* in cancer of the tongue is due to implication of the inferior maxillary, which supplies also the teeth and the tongue. The upper half of the *membrana tympani* is much more richly supplied with blood than the lower half. For this reason, and also to avoid the chorda tympani nerve and ossicles, *incisions through the membrana* should be made at the lower and posterior part.

Applied Anatomy.—*Malformations*, such as imperfect development of the external parts, absence of the canal, or supernumerary auricles, are occasionally met with. Or the pinna may present a *congenital fistula*, which is due to defective closure of the first visceral cleft, or rather of that portion of it which is not concerned in the formation of the Eustachian tube, tympanum, and meatus. In some cases the cephaloauricular angle is almost absent; in others, it is nearly a right angle. *Projecting ears* and *long ears* are said by some observers to be more common among degenerates, criminals, and the insane than among the normal, the non-criminal, and the sane. The skin of the auricle is thin and richly supplied with blood, but in spite of this it is frequently the seat of *frost-bite*, due to the fact that it is much exposed to cold, and lacks the usual underlying subcutaneous fat found in most other parts of the body. A collection of blood is sometimes found between the cartilage and perichondrium (*hematoma auris*), usually the result of traumatism, but not necessarily due to this cause. It is said to occur most frequently in the ears of the insane. *Keloid* sometimes grows in the auricle around the puncture made for ear-rings, and *epithelioma* occasionally affects this part. Deposits of *urate of soda* are often met with in the pinna in gouty subjects.

The external auditory canal can be most satisfactorily examined by light reflected through a funnel-shaped speculum; by gently moving the latter in different directions and by gently drawing the pinna upward, backward, and a little outward, so as to render the canal as straight as possible, the whole of the canal and *membrana tympani* can be brought into view. The points to be noted are the presence of wax or foreign bodies, the size of the canal, and the condition of the *membrana tympani*. The *accumulation of wax* (impacted cerumen) is often the cause of deafness, and may give rise to very serious consequences, causing ulceration of the membrane and even absorption of the bony wall of the canal. *Foreign bodies* are not infrequently introduced into the ear by children, and, when situated in the first portion of the canal, may be removed with tolerable facility by means of a minute hook or loop of fine wire, the parts being illuminated with reflected light; but when they have slipped beyond the narrow middle part of the meatus, their removal is in nowise easy, and attempts to effect it, in inexperienced hands, may be followed by destruction of the *membrana tympani* and possibly injury of the contents of the tympanum. The caliber of the external auditory canal may be narrowed by *inflammation* of its lining membrane, running on to *suppuration*; by *periostitis*; by *polypi*, *sebaceous tumors*, and *exostoses*.

THE MIDDLE EAR, DRUM, OR TYMPANUM (AURIS MEDIA)

(Figs. 844, 848).

The middle ear or tympanum is an irregular cavity, compressed laterally, and situated within the petrous portion of the temporal bone. It is placed above

the jugular fossa; the carotid canal lying in front, the mastoid cells behind, the external auditory canal externally, and the labyrinth internally. It is lined with mucous membrane, is filled with air, and communicates with the mastoid cells, through the mastoid antrum, and with the nasopharynx by the Eustachian tube. The tympanum is traversed by a chain of movable bones, which connect the membrana tympani with the labyrinth, and serve to convey the vibrations communicated to the membrana tympani across the cavity of the tympanum to the internal ear. In shape it is roughly biconcave, the concave surfaces being placed vertically and forming the external and internal walls. The cavity forms an angle of 45 degrees with the sagittal plane.

The **Tympanic Cavity** (*cazum tympani*) (Figs. 848 and 849) consists of two parts—the **atrium** or **tympanic cavity proper** (Fig. 849), opposite the tympanic membrane, and the **attic** or **epitympanic recess** (*recessus epitympanicus*) (Figs. 847 and 848), above the level of the upper part of the membrane; the latter contains the upper half of the malleus and the greater part of the incus. The diameter of the tympanic cavity, including the attic, measures about 15 mm. (three-fifths of an inch) vertically and anteroposteriorly. From without inward it measures about 6 mm. (one-quarter of an inch) above and 4 mm. (one-sixth of an inch) below; opposite the centre of the tympanic membrane it is only about 2 mm. (one-twelfth of an inch). It is bounded *externally* by the membrana tympani and meatus; *internally*, by the outer surface of the internal ear; it communicates *behind* with the mastoid antrum and through it with the mastoid cells, and *in front* with the Eustachian tube.

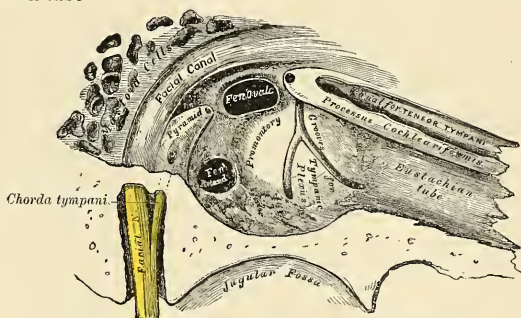


FIG. 844.—View of the inner wall of the tympanum (enlarged).

The **roof of the tympanum** (*paries tegmentalis*) is broad, flattened, and formed of a thin plate of bone (*tegmen tympani*) (Fig. 848), which separates the cranial and tympanic cavities. It is situated on the anterior surface of the petrous portion of the temporal bone, close to its angle of junction with the squamous portion of the same bone, and is prolonged backward so as to roof in the mastoid antrum; it is also carried forward to cover in the canal for the Tensor tympani muscle. Its outer edge corresponds with the remains of the petrosquamous suture.

The **floor** (*paries jugularis*) (Fig. 848) is narrow, and is separated by a thin plate of bone (*fundus tympani*) from the jugular fossa. It presents, near the inner wall, a small aperture, the opening of the **canaliculus tympanicus**, for the transmission of Jacobson's nerve (*n. tympanicus*). On the floor near the posterior wall there is often to be found a slight bony projection (*prominentia styloideae*).

The **outer wall** (Fig. 843) is formed mainly by the membrana tympani, partly by the ring of bone into which this membrane is inserted. This ring of bone is incomplete at its upper part, forming a notch (*incisura tympanica* [*Rivini*])

(Fig. 844), close to which are three small apertures—the *iter chordae posterius*, the *Glaserian fissure*, and the *iter chordae antierius*.

The *iter chordae posterius* (*canaliculus chordae tympani*) (Fig. 804) is in the angle of junction between the posterior and external walls of the tympanum, immediately behind the *membrana tympani* and on a level with the upper end of the handle of the malleus; it leads into a minute canal, which descends in front of the facial canal and terminates in the aqueduct near the stylomastoid foramen. Through it the *chorda tympani* nerve enters the tympanum.

The *Glaserian* or *petrotympanic fissure* (*fissura petrotympanica*) [*Glaseri*] (Fig. 847) opens just above and in front of the ring of bone into which the *membrana tympani* is inserted; in this situation it is a mere slit about 2 mm. in length. It lodges the long process and anterior ligament of the malleus, and gives passage to the tympanic branch of the internal maxillary artery.

The *iter chordae antierius* or *canal of Huguier* (Fig. 847) is seen at the inner end of the preceding fissure; through it the *chorda tympani* nerve leaves the tympanum.

The *inner wall of the tympanum* (*paries labyrinthica*) (Figs. 844 and 848) is adjacent to the labyrinth; it is vertical in direction, and looks directly outward. It presents for examination the following parts:

Fenestra ovalis.

Promontory.

Fenestra rotunda.

Ridge of the facial canal.

Prominence of the lateral semicircular canal.

The *fenestra ovalis* (*fenestra vestibuli*) (Fig. 844) is a reniform opening leading from the tympanum into the vestibule of the internal ear. Its long diameter is directed horizontally, and its convex border is upward. In the recent state it is occupied by the base of the stapes (Figs. 843 and 849), the circumference of which is connected to the margin of the foramen by an annular ligament.

The *fenestra rotunda* (*fenestra cochleae*) (Fig. 844) is situated below and a little behind the *fenestra ovalis*, from which it is separated by a rounded elevation, the *promontory*; at its border is a narrow ridge of bone (*crista fenestrae cochleae*). The *fenestra rotunda* is closed in the recent state by a membrane (*membrana tympani secundaria*); this membrane is concave toward the tympanum, convex toward the cochlea. It consists of three layers—the external or mucous, derived from the mucous lining of the tympanum; the internal, from the lining membrane of the cochlea; and an intermediate or fibrous layer.

The *promontory* (*promontorium*) (Fig. 848) is a rounded hollow prominence, formed by the projection outward of the first turn of the cochlea; it is placed between the fenestrae, and is *furrowed* on its surface (*sulcus promontorii*) for the lodgement of the *tympanic plexus*. A minute spicule of bone frequently connects the promontory to the pyramid.

The *prominentia canalis facialis* (Fig. 848) indicates the position of the bony canal in which the facial nerve is contained; this canal traverses the inner wall of the tympanum above the *fenestra ovalis*, and behind that opening curves nearly vertically downward along the posterior wall.

The *posterior wall of the tympanum* (*paries mastoidea*) (Fig. 848) is wider above than below, and presents for examination the—

Opening of the antrum.

Fossa incudis.

Pyramid.

The *opening of the antrum* is a large irregular aperture, which extends backward from the epitympanic recess and leads into a considerable air space, the *mastoid antrum* (*antrum tympanicum*) (see p. 83). The antrum communicates

with large irregular cavities contained in the interior of the mastoid process, the **mastoid air cells**. These cavities vary considerably in number, size, and form; they are lined by mucous membrane continuous with that lining the cavity of the tympanum.

The **fossa incudis** (Fig. 848) is placed in the posterior and inferior part of the epitympanic recess. It lodges the short process of the incus.

The **pyramid** (*eminentia pyramidalis*) (Fig. 844) is a conical eminence situated immediately behind the fenestra ovalis, and in front of the vertical portion of the facial canal; it is hollow in the interior, and contains the Stapedius muscle; its summit projects forward toward the fenestra ovalis and presents a small aperture which transmits the tendon of the muscle. The cavity in the pyramid is prolonged into a minute canal, which communicates with the facial canal and transmits the twig from the facial nerve which supplies the Stapedius.

The **anterior wall of the tympanum** (*paries carotica*) is wider above than below; it corresponds with the carotid canal, from which it is separated by a thin plate of bone (Fig. 848), perforated by the **caroticotympanic canaliculus**, which transmits the tympanic branch of the internal carotid artery and the caroticotympanic nerves. It presents for examination the—

Canal for the Tensor tympani.

Orifice of the Eustachian tube.

The processus cochleariformis.

The orifice of the canal for the Tensor tympani and the orifice of the Eustachian tube are situated at the upper part of the anterior wall, being incompletely separated from each other by a thin, delicate, horizontal plate of bone, the **processus cochleariformis** (*septum canalis musculotubarii*) (Figs. 844 and 848). The canalis musculotubarius is divided by this long process into the canal for the Tensor tympani and the canal for the Eustachian tube. These canals run from the tympanum forward, inward, and a little downward, to the angle between the squamous and petrous portions of the temporal bone.

The **canal for the Tensor tympani** (*semicanalis m. tensoris tympani*) (Figs. 844 and 848) is the superior and the smaller of the two; it is rounded and lies beneath the forward prolongation of the tegmen tympani. It extends on to the inner wall of the tympanum and ends immediately above the fenestra ovalis. The processus cochleariformis passes backward below this part of the canal, forming its outer wall and floor; it expands above the anterior extremity of the fenestra ovalis and terminates by curving outward so as to form a pulley over which the tendon passes. The bony wall of this canal is incomplete, and the osseous vacancy is filled by tough connective tissue.

The **Eustachian tube** (*tuba auditiva* [*Eustachii*]) (Figs. 844 and 845) is the channel through which the tympanum communicates with the nasopharynx. Its length is 36 mm. (an inch and a half), and its direction downward, inward, and forward, forming an angle of about 45 degrees with the sagittal plane and one of from 30 to 40 degrees with the horizontal plane. The **canal for the Eustachian tube** (*semicanalis tubae auditivae*) (Fig. 845) is formed partly of bone, partly of cartilage and fibrous tissue.

The **osseous portion** (*pars ossea tubae auditivae*) is about 12 mm. (half an inch) in length. It is the outer portion of the tube. It commences in the anterior wall of the tympanum, below the processus cochleariformis, and, gradually narrowing, terminates at the angle of junction of the petrous and squamous portions of the temporal bone, its extremity presenting a jagged margin which serves for the attachment of the cartilaginous portion.

The **cartilaginous portion** (*pars cartilaginea tubae auditivae*), about 2.5 cm. (an inch) in length, is formed of a triangular plate of elastic fibrocartilage (*cartilago*

tubae auditivae), the apex of which is attached to the margin of the inner extremity of the osseous canal, while its base lies directly under the mucous membrane of the nasopharynx, where it forms an elevation or cushion above and behind the pharyngeal orifice of the tube. The upper edge of the cartilage is curled upon itself, being bent outward so as to present on transverse section the appearance of a hook (*lamina lateralis*); a groove or furrow is thus produced, which opens below and externally, and this part of the canal is completed by fibrous membrane. On transverse section the cartilage exhibits the laminae which above are continuous with each other—the hard, thick lamina medialis and the thin and hooked lamina lateralis. The cartilage of the Eustachian tube, with a hood plate of cartilage, forms the posterior portion of the inner wall (the *lamina medialis*). The cartilage is fixed to the base of the skull, and lies in a groove (*sulcus tubae auditivae*) between

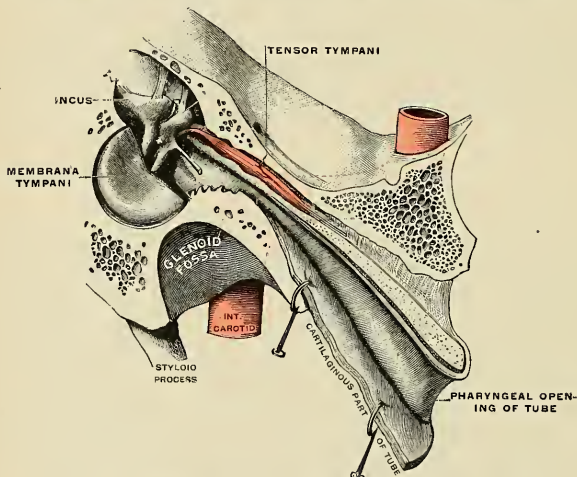


FIG. 845.—Eustachian tube, laid open by a cut in its long axis. (Testut.)

the petrous portion of the temporal and the greater wing of the sphenoid; this groove ends opposite the middle of the internal pterygoid plate, in a projection, the **processus tubarius**. The cartilaginous and bony portions of the tube are not in the same plane, the former inclining downward a little more than the latter. They join each other at a large obtuse angle, open below. The diameter of the canal is not uniform throughout, being greatest at the pharyngeal orifice and least at the junction of the bony and cartilaginous portions, where it is named the **isthmus** (*isthmus tubae auditivae*); it again expands somewhat as it approaches the tympanic cavity. The position and relations of the pharyngeal orifice are described with the anatomy of the nasopharynx. The mucous membrane of the tube is continuous in front with that of the nasopharynx, and behind with that which lines the tympanum; it is covered with ciliated epithelium and is thin in the osseous portion, while in the cartilaginous portion it contains many mucous glands and near the pharyngeal orifice a considerable amount of lymphoid tissue, which has been named by Gerlach the **tubal tonsil**. The tube is opened during deglutition by the Salpingopharyngeus and Dilator tubae muscles.

The **Membrana Tympani** (Figs. 846 and 847) separates the cavity of the tympanum from the bottom of the external canal. It is a thin, semitransparent

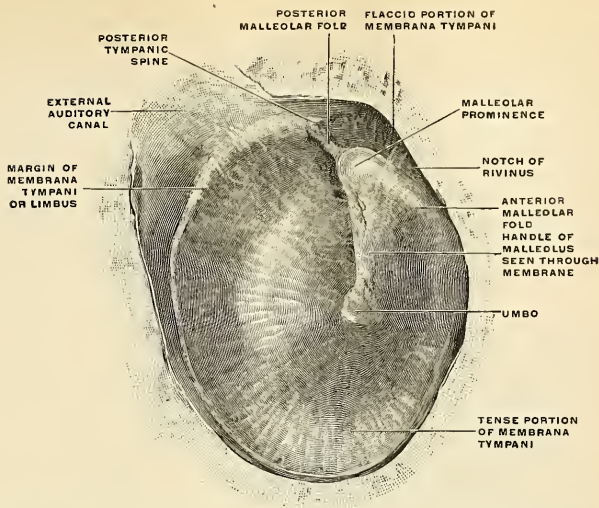


FIG. 846.—The right membrana tympani, viewed from the outside, from in front, and from below. (Spalteholz.)

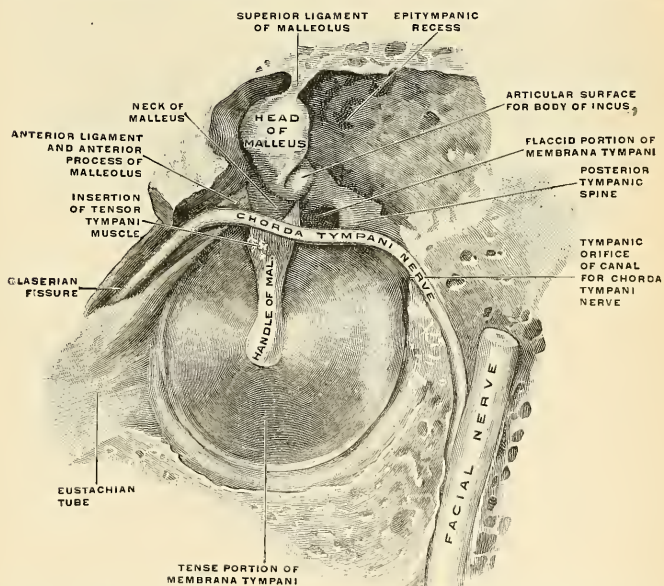


FIG. 847.—The right membrana tympani with the hammer and the chorda tympani, viewed from within, from behind, and from above. (Spalteholz.)

membrane, nearly oval in form, somewhat broader above than below, and directed very obliquely downward and inward, so as to form an angle of about 55 degrees with the floor of the canal (Fig. 843). The antero-inferior portion is, therefore, placed at the greatest distance from the external orifice of the meatus. In a newborn child the *membrana tympani* is almost horizontal. The greatest diameter of the *membrana tympani* is from 9 to 10 mm.; its least diameter is from 8 to 9 mm. The greater part of its circumference (*limbus membranae tympanae*) is thickened and fixed in a groove, the **sulcus tympanicus**, at the inner extremity of the external meatus. This sulcus is deficient superiorly at the incisure or **notch of Rivinus** (Fig. 846). From the extremities of the notch two folds, the **anterior** and **posterior malleolar folds**, are prolonged to the short process of the malleus (Fig. 846). The small, somewhat triangular part of the membrane situated

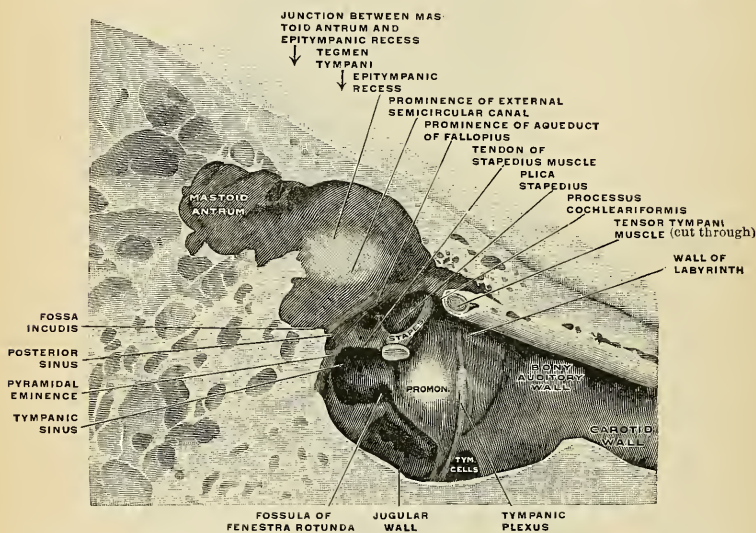


FIG. 848.—The medial wall and part of the posterior and anterior walls of the right tympanic cavity, lateral view. (Spalteholz.)

above these folds is lax and thin, and is named the **membrana flaccida of Shrapnell** (Figs. 846 and 847); in it a small orifice is sometimes seen. The larger lower portion of the tympanic membrane is stretched tightly, and is called the **tense portion** or **pars tensa** (Figs. 846 and 847).

The handle of the malleus is firmly attached to the inner aspect of the *membrana tympani* as far as its centre (Fig. 847), which it draws inward toward the tympanic cavity. The most depressed part of the concavity is called the **umbo** (*umbo membranae tympanae*) (Fig. 846). On the outer surface of the drum membrane a light stripe (*stria malleolaris*) is seen. It runs from in front and above downward and backward, and is produced by the handle of the malleus, showing through the membrane (Fig. 846).

Structure.—The **tympanic membrane** is composed of three layers—an **external** (*cuticular*), a **middle** (*fibrous*), and an **internal** (*mucous*). The **cuticular layer** (*stratum cutaneum*) is derived from the integument lining the external canal. The **fibrous** or **middle layer** (*membrana propria*)

consists of two strata—an external, of **radiating fibres** (*stratum radiatum*), which diverge from the handle of the malleus, and an internal, of **circular fibres** (*stratum circulare*), which are plentiful around the circumference, but sparse and scattered near the centre of the membrane. **Branched or dendritic fibres**, as pointed out by Grüber, are also present, especially in the posterior half of the membrane.

The **arteries** are derived from the deep auricular branch of the internal maxillary, which ramifies beneath the cuticular layer and from the stylomastoid branch of the posterior auricular and tympanic branch of the internal maxillary, which are distributed on the mucous surface. The arteries of the cutaneous set anastomose with the arteries of the mucous set by minute branches which penetrate the drum membrane near its margin. The **superficial veins** open into the external jugular; those on the mucous surface drain partly into the lateral sinus and veins of the dura and partly into a plexus on the Eustachian tube. The outer surface of the drum membrane receives its **nerve supply** from the auriculotemporal branch of the inferior maxillary and the auricular branch of the vagus. The inner surface is supplied by the tympanic branch of the glossopharyngeal.

There are two sets of **lymphatics**, the cutaneous and mucous, which freely communicate. The spaces between the dendritic fibres of Grüber are lymph spaces (Kessel).

The Ossicles of the Tympanum (*ossicula auditus*) (Fig. 849).—The tympanum contains in its upper part a chain of movable bones, three in number, the **malleus**, **incus**, and **stapes**. The first is attached to the membrana tympani, the last to the fenestra ovalis, the incus being placed between the two, and connected to both by delicate articulations.

The **Malleus** (Fig. 850), so named from its fancied resemblance to a hammer, is placed farthest in front and outward. It consists of a **head**, **neck**, and three processes—the **handle**, or **manubrium**, the **processus gracilis**, and the **processus brevis**.

The **head** (*capitulum mallei*) is the large upper extremity of the bone, and is situated in the epitympanic recess (Fig. 847). It is oval in shape, and articulates posteriorly with the incus, being free in the rest of its extent. The facet for articulation with the incus is covered by cartilage; it is constricted near the middle, and is divided by a ridge into an upper, greater, and a lower, lesser part; which form nearly a right angle with each other. Opposite the constriction the lower margin of the facet projects in the form of a process, the **cog tooth**, or **spur of the malleus**. On the back of the head below the spur is a crest (*crista mallei*), to which the posterior ligament of the malleus is attached.

The **neck** (*collum mallei*) is the narrow contracted part just beneath the head; below this is a prominence, to which the various processes are attached. The chorda tympani nerve crosses the inner surface (Fig. 847).

The **handle** (*manubrium mallei*) is a vertical process of bone, which is connected by its outer margin with the fibrous layer of the membrana tympani, its entire length being fastened to the fibrous layer of the drum membrane by its own periosteum and by a layer of cartilage (Figs. 847 and 849). It is directed downward, inward, and backward; it decreases in size toward its extremity, where it is curved slightly forward, and is flattened from within outward. The handle forms a variable angle with the head of the hammer. It averages about 130 degrees, but is always greater in the right ear than in the left. It forms an angle with the

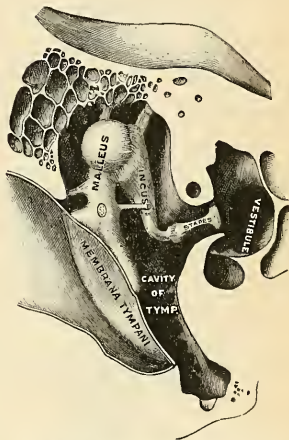


FIG. 849.—Chain of ossicles and their ligaments, seen from the front in a vertical, transverse section of the tympanum. (Testut.)

horizontal, averaging on the right side 50 degrees and on the left side 45 degrees (Spalteholz). Internally the handle is covered by the mucous membrane of the tympanum. On the inner side, near its upper end, is a slight projection, into which the tendon of the Tensor tympani is inserted (Fig. 847).

The **processus gracilis** (*processus anterior* [*Folii*]) is a long and delicate process, which springs from the eminence below the neck and is directed forward and outward to the Glaserian fissure, to which it is connected by ligamentous fibres. In the fetus this is the longest process of the malleolus, and is in direct continuity with the cartilage of Meckel.

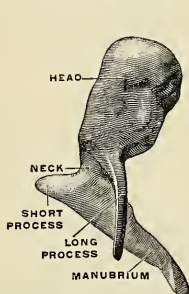


FIG. 850.—Viewed from in front.

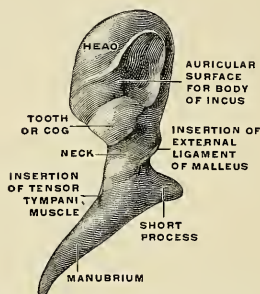


FIG. 851.—Viewed from behind. (Spalteholz.)

FIGS. 850 and 851.—The right malleus (enlarged).

The **processus brevis** (*processus lateralis*) is a slight conical projection, which springs from the root of the manubrium; it is directed outward and is attached to the upper part of the tympanic membrane by cartilage and to the margins of the notch of Rivinus by the two tympanomalleolar folds.

The **Incus** (Figs. 852 and 853) has received its name from its supposed resemblance to an anvil, but it is more like a bicuspid tooth with two roots,

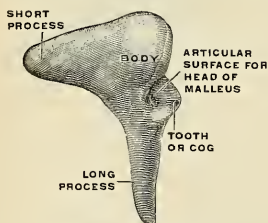


FIG. 852.—Lateral view.

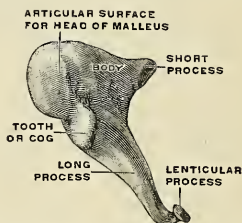


FIG. 853.—Medial and front view. (Spalteholz.)

FIGS. 852 and 853.—The right incus (enlarged.)

which differ in length, and are widely separated from each other. It consists of a **body** and **two processes**. The body and the short process are placed in the epitympanic recess (Fig. 849).

The **body** (*corpus incudis*) is somewhat quadrilateral, but compressed laterally. On its anterior surface is a deeply concavo-convex facet, which articulates with the head of the malleus, and the lower part is hollowed for the spur of the malleus.

The **two processes** diverge from each other at an angle of from 90 to 100 degrees.

The **short process** (*crus breve*), somewhat conical in shape, projects almost horizontally backward, and articulates with a depression, the **fossa incudis**, in the lower and back part of the epitympanic recess.

The **long process** (*crus longum*), longer and more slender than the preceding, descends nearly vertically behind and parallel to the handle of the malleus, and, bending inward, terminates in a rounded globular projection, the **os orbiculare** or **lenticular process** (*processus lenticularis*), which is tipped with cartilage, and articulates with the head of the stapes. In the fetus the os orbiculare exists as a separate bone.

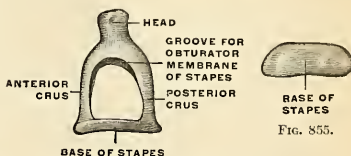


FIG. 854.

FIGS. 854 AND 855.—The right stapes (enlarged). FIG. 854. Viewed from above. FIG. 855. Medial view. (Spalteholz.)

The **Stapes** (Figs. 854 and 855), so called from its close resemblance to a stirrup, consists of a **head**, **neck**, two **crura**, and a **base**. The stapes is the only one of the tympanic ossicles that has a marrow cavity.

The **head** (*capitulum stapedis*) presents a depression, tipped with cartilage, which articulates with the os orbiculare.

The **neck**, the constricted part of the bone succeeding the head, receives the insertion of the Stapedius muscle.

The two **crura** (*crus anterior* and *crus posterior*) diverge from the neck and are connected at their extremities by a flattened, oval-shaped plate, the **base** (*basis stapedis*), which forms the foot-plate of the stapes and is fixed to the margin of the fenestra ovalis by ligamentous fibres. The foot-plate almost fills the oval window (Fig. 843). Of the two crura, the anterior is shorter and less curved than the posterior. In a recent specimen a membrane will be observed filling the space between the crura and the foot-plate. This membrane is connective tissue and is called the *membrana obturatoria stapedis*. The stapes lies practically horizontal.

Articulations of the Ossicles of the Tympanum (*articulationes ossiculorum auditus*) (Fig. 840).—These small bones are connected with each other and with the walls of the tympanum by ligaments, and are moved by small muscles. The articular surfaces of the malleus and incus and the orbicular process of the incus and head of the stapes are covered by cartilage, connected by delicate capsular ligaments and lined by synovial membrane.

Ligaments Connecting the Ossicula with the Walls of the Tympanum (*lig. assiculorum auditus*).—The malleus is fastened to the wall of the tympanum by three ligaments—the anterior, superior, and external ligaments.

The **anterior ligament of the malleus** (*lig. mallei anterioris*) is attached by one extremity to the neck of the malleus just above the processus gracilis, and by the other to the anterior wall of the tympanum, close to the Glaserian fissure, some of its fibres being prolonged through the fissure to reach the alar spine of the sphenoid.

The **superior ligament of the malleus** (*lig. mallei superioris*) is a delicate round bundle of fibres which descends perpendicularly from the roof of the epitympanic recess to the head of the malleus. It is sometimes called the **suspensory ligament**.

The **external ligament of the malleus** (*lig. mallei laterale*) is a triangular plane of fibres passing from the posterior part of the notch in the tympanic ring to the head of the malleus. The malleus rotates around an axis composed of the external and anterior ligaments, hence these two ligaments constitute what Helmholtz called the **axis ligament of the malleus**.

The incus is fastened to the wall of the tympanum by two ligaments, the **posterior** and the **superior**.

The **posterior ligament of the incus** (*lig. incudis posterioris*) is a short, thick, ligamentous band which connects the extremity of the short process of the incus to the posterior and lower part of the epitympanic recess, near the margin of the opening of the mastoid cells.

A **superior ligament of the incus** (*lig. incudis superioris*) has been described, but it is little more than a fold of mucous membrane.

The vestibular surface and the circumference of the base of the stapes are covered by hyaline cartilage, and the **annular ligament of the stapes** (*lig. annulare bascos stapedis*) connects the circumference of the base to the margin of the fenestra ovalis.

The muscles of the tympanum (*m. ossiculorum auditus*) are two:¹

Tensor tympani.

Stapedius.

The **Tensor tympani** (*m. tensor tympani*) (Fig. 848), the larger, is contained in the bony canal above the osseous portion of the Eustachian tube, from which it is separated by the processus cochleariformis. It arises from the under surface of the petrous bone, from the cartilaginous portion of the Eustachian tube, and from the osseous canal in which it is contained. Passing backward through the canal, it terminates in a slender tendon which enters the tympanum and makes a sharp bend outward around the extremity of the processus cochleariformis, and is inserted into the handle of the malleus near its root. Its nerve supply is from the motor root of the trigeminal nerve by way of the otic ganglion.

The **Stapedius** (*m. stapedius*) (Fig. 848), the smallest constant muscle in the body, weighing only 1 grain, arises from the side of a conical cavity hollowed out of the interior of the pyramid; its tendon emerges from the orifice at the apex of the pyramid, and, passing forward, is inserted into the neck of the stapes. Its surface is aponeurotic, its interior fleshy, and its tendon occasionally contains a slender bony spine, which is constant in some mammalia. It is supplied by the tympanic branch of the facial nerve.

Actions.—The *Tensor tympani* draws the handle of the malleus inward and thus increases the tension of the tympanic membrane. When the *Stapedius* contracts it draws the head of the stapes backward, and in consequence the anterior end of the foot-plate passes outward toward the tympanum, and the posterior end inward toward the vestibule, and the annular ligament is made tense. It probably compresses the contents of the vestibule.

Movements of the Ossicles of the Tympanum.—The chain of bones is a lever-like arrangement, by means of which the vibrations of the membrana tympani are transferred to the membrane covering the oval window, and from this to the perilymph in the labyrinth. When the tympanic membrane moves inward, the handle of the malleus moves with it. The movement of the malleus moves the incus, and the movement of the incus drives the foot of the stapes toward the labyrinth. When the handle of the malleus moves inward, the spur on the head becomes locked with the body of the incus. During outward movement it is unlocked. The ordinary outward movement of the drum membrane causes the above-described movements to be reversed. When there is overforceful outward movement the incus does not go outward quite as far as the malleus, but slides at the joint between the malleus and incus. This reluctance of the incus saves the foot of the stapes from being pulled away from the oval window.

The **mucous membrane of the tympanum** (*tunica mucosa tympanica*) is continuous with that of the nasopharynx through the Eustachian tube. It invests the ossicles, and the muscles and nerves contained in the tympanic cavity, forms the internal layer of the membrana tympani, and is reflected into the mastoid antrum and air cells, which it lines throughout. It forms several vascular folds (*plicæ*), which extend from the walls of the tympanum to the ossicles, enveloping these as well as the chorda tympani nerve and the Tensor tympani muscle.

The **anterior malleolar fold** (*plica malleolaris anterior*) comes off from the membrana tympani between the anterior edge of the notch of Rivinus and the handle of the malleus, envelops the processus gracilis of the malleus, the anterior ligament of the malleus, and the anterior portion of the chorda tympani nerve, and terminates in a free concave edge. The **posterior malleolar fold** (*plica malleolaris posterior*) is the larger of the two. It comes off from the margin of the notch of Rivinus, envelops the external ligament of the malleus, the posterior part of the chorda tympani nerve, is attached to the handle of the malleus, and ends in a free concave margin. The **fold of the incus** (*plica incudis*) takes origin from the roof of the epitympanic recess and passes to the body and short process of the incus; and a similar fold passes from the head of the malleus to the anterior wall of the epitympanic recess. The entire stapes, with its obturator membrane, is enveloped by the **fold of the stapes** (*plica stapedis*). This fold also ensheaths the tendon of the Stapedius muscle and often reaches to the posterior wall of the cavity of the tympanum. These folds separate off pouch-like cavities, and give the interior of the tympanum a somewhat honeycombed appearance.

The **inferior external pouch of the tympanum** or the **pouch of Prussak** (*recessus membranae tympani superior*) is between the flaccid portion of the membrana tympani, the external ligament of the malleus, and the neck of the malleus. The anterior and posterior malleolar folds with the tympanic membrane form two pouches. These are the **anterior** and **posterior pouches** or **recesses of Troeltsch** (*recessus membranae tympani, anterior and posterior*). The anterior pouch is blind above and has a slit-like opening below. The posterior pouch is continued into the blind superior pouch of the tympanic membrane. In the tympanum this membrane is pale, thin, slightly vascular, and covered for the most part with columnar ciliated epithelium, but that

¹ Two additional muscles have been described as the *Mm. laxator tympani major et minor*; they correspond to the anterior and lateral ligaments of the malleus, but often show striated muscle tissue. (D. G. Metheny.)

covering the pyramid, ossicula, and membrana tympani possesses a flattened, nonciliated epithelium. In the antrum and mastoid cells its epithelium is also nonciliated. In the osseous portion of the Eustachian tube the membrane is thin, but in the cartilaginous portion it is very thick, highly vascular, covered with ciliated epithelium, and provided with numerous mucous glands.

Vessels and Nerves.—The arteries supplying the tympanum are six in number. Two of them are larger than the rest—viz., the tympanic branch of the internal maxillary, which enters by way of the petrotympanic or Glaserian fissure and supplies the membrana tympani; and the stylomastoid branch of the posterior auricular, which passes through the stylomastoid foramen and the facial canal, and supplies the inner wall and floor of the tympanum, the mastoid cells and antrum, and the Stapedius muscle. This vessel anastomoses around the tympanic membrane with the tympanic. The middle meningeal sends a small branch to the Tensor tympani muscle near its origin. The petrosal branch of the middle meningeal enters the tympanum by way of the hiatus canalis facialis. Minute branches from the posterior branch of the middle meningeal pass through the petrosquamous fissure and are distributed to the antrum and epitympanic recess. Two tympanic branches come off from the internal carotid artery in its course through the carotid canal. A branch from the ascending pharyngeal and another from the Vidian accompany the Eustachian tube. The two tympanic branches from the internal carotid are given off in the carotid canal and perforate the thin anterior wall of the tympanum. The **veins of the tympanum** terminate in the pterygoid plexus, the middle meningeal vein, and the superior petrosal sinus.

The **nerves of the tympanum** constitute the **tympanic plexus** (*plexus tympanicus* [*Jacobsoni*]), which ramifies upon the surface of the promontory (Fig. 848). The plexus is formed by (1) the tympanic branch of the glossopharyngeal; (2) the small deep petrosal nerve; (3) the small superficial petrosal nerve; and (4) a branch which joins the great superficial petrosal.

The **tympanic branch of the glossopharyngeal** or **Jacobson's nerve** (*n. tympanicus*) enters the tympanum by an aperture in its floor close to the inner wall and divides into branches, which ramify on the promontory and enter into the formation of the plexus. The **small deep petrosal nerve** (*n. petrosus profundus*), from the carotid plexus of the sympathetic, passes through the wall of the carotid canal, and joins the branches of Jacobson's nerve. The branch to the great superficial petrosal passes through an opening on the inner wall of the tympanum in front of the fenestra ovalis. The **small superficial petrosal nerve** (*n. petrosus superficialis minor*), derived from the otic ganglion, passes through a foramen (*canaliculus innominatus*) in the middle fossa of the base of the skull (sometimes through the foramen ovale), passes backward and enters the petrous bone through a small aperture, situated external to the hiatus canalis facialis on the anterior surface of this bone; it then courses downward through the bone, and, passing by the geniculate ganglion, receives a connecting filament from it (Fig. 845) and enters the tympanic cavity, where it communicates with Jacobson's nerve, and assists in forming the tympanic plexus.

The **branches of distribution** of the tympanic plexus are supplied to the mucous membrane of the tympanum; one special branch passing to the fenestra ovalis, another to the fenestra rotunda, and a third to the Eustachian tube. The small superficial petrosal may be looked upon as the continuation of the tympanic nerve (Jacobson's) through the plexus to the otic ganglion.

In addition to the tympanic plexus there are the nerves supplying the muscles. The Tensor tympani is supplied by a branch from the third division of the trigeminal through the otic ganglion, and the Stapedius by the tympanic branch of the facial.

The **chorda tympani** (Figs. 835 and 838) crosses the tympanic cavity. It is apparently given off from the facial as it passes vertically downward at the back of the tympanum, about 6 mm. (a quarter of an inch) before its exit from the stylomastoid foramen. It passes from below upward and forward in a distinct canal, and enters the cavity of the tympanum through an aperture, **iter chordae posterius**, already described (p. 1126), and becomes invested with mucous membrane. It passes forward, through the cavity of the tympanum, crossing internal to the membrana tympani and over the handle of the malleus to the anterior inferior angle of the tympanum, and emerges from that cavity through the **iter chordae anterior** or **canal of Huguier** (p. 1126).

Applied Anatomy.—The principal point in connection with the *surgical anatomy of the tympanum* is its relations to other parts. Its roof is formed by a thin plate of bone, which, with the dura, is all that separates it from the temporal lobe of the brain. Its floor is immediately above the *jugular fossa* and the *carotid canal*, the fossa being behind and the canal in front. Its posterior wall presents the opening of the *mastoid cells*. On its anterior wall is the opening of the *Eustachian tube*. Thus, it follows that in disease of the middle ear we may get *subdural abscess*, *septic meningitis*, or *abscess of the cerebrum or cerebellum* from extension of the inflammation through the bony roof; *thrombosis of the lateral sinus*, with or without pyemia, by extension through the floor; or *mastoid abscess* by extension backward. In addition to this, there may be fatal hemorrhage from the internal carotid in destructive changes of the middle ear; and in throat disease we may get the inflammation extending up the Eustachian tube to the

middle ear. The Eustachian tube is accessible from the nose. If the nose and mouth be closed and an attempt made to expire air, a sense of pressure with dulness of hearing is produced in both ears, from the air finding its way up the Eustachian tube and bulging out the membrana tympani. During the act of swallowing, the pharyngeal orifice of the tube, which is normally closed, is opened, probably by the action of the Dilator tubæ muscle. This fact was employed by Politzer in devising an easy method of inflating the tube. The nozzle of a rubber syringe is inserted into the nostril; the patient takes a mouthful of water and holds it in his mouth, both nostrils are closed with the finger and thumb to prevent the escape of air, and the patient is then requested to swallow; as he does so the surgeon squeezes the bulb and the air is forced out of the syringe into the nose, and is driven into the Eustachian tube, which is now open. The impact of the air against the membrana tympani can be heard by the surgeon, if the membrane is intact, sound being conveyed by means of a piece of rubber tubing, one end of which is inserted into the meatus of the patient's ear, the other into that of the surgeon. The direct examination of the Eustachian tube is made by the Eustachian catheter. This is passed along the floor of the nostril, close to the septum, with the point touching the floor, to the posterior wall of the pharynx. When this is felt, the catheter is to be withdrawn about half an inch, and the point rotated outward through a quarter of a circle, and pushed again slightly backward, when it will enter the orifice of the tube, and will be found to be caught, and air forced into the catheter will be heard impinging on the tympanic membrane if the ears of the patient and surgeon are connected by a rubber tube.

THE INTERNAL EAR, OR LABYRINTH (AURIS INTERNA).

The internal ear is the essential part of the organ of hearing and of orientation in space. It is called the **labyrinth**, from the complexity of its shape, and consists of two parts, the **osseous labyrinth**, a series of cavities channelled out of the substance of the petrous portion of the temporal bone, and the **membranous labyrinth**, the latter being contained within the former.

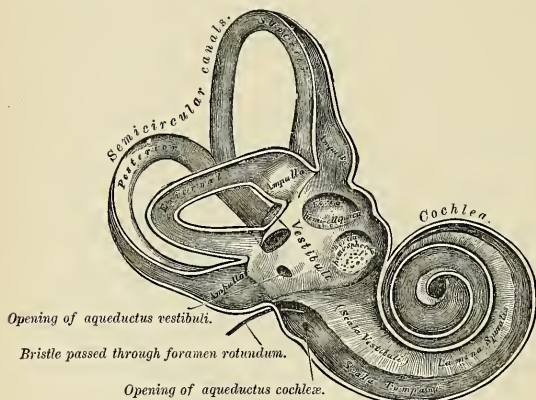


FIG. 856.—The osseous labyrinth laid open (enlarged.)

The **Osseous Labyrinth** (*labyrinthus osseus*) (Fig. 856) consists of three parts—the **vestibule**, **semicircular canals**, and **cochlea**. These are cavities hollowed out of the substance of the bone, and lined by periosteum and endothelium. A clear fluid is contained in the space between the osseous labyrinth and the membranous labyrinth. The space is called the **perilymph space**, and the fluid is called **perilymph**.

The **Vestibule** (*vestibulum*) (Figs. 849 and 856) is the common central cavity of communication between the parts of the internal ear. It is situated on the inner side of the tympanum, behind the cochlea, and in front of the semicircular canals.

It is somewhat ovoid in shape, flattened from within outward, and measures about 5 mm. (one-fifth of an inch) from before backward, as well as from above downward, and about 3 mm. (one-eighth of an inch) from without inward. On its *outer* or *tympanic wall* is the **fenestra ovalis** (*fenestra vestibuli*), closed, in the recent state, by the base of the stapes, and its annular ligament. On its *inner wall*, at the fore part, is a small circular depression, the **spherical recess** (*recessus sphaericus*), in which the sacculæ is placed. This recess is perforated, at its anterior and inferior part, by about a dozen minute holes (*macula cribrosa media*), for the passage of filaments of the vestibular nerve to the sacculæ. Above and behind this depression is an oblique ridge, the **crista vestibuli**, the anterior extremity of which is called the **pyramid** (*pyramis vestibuli*). This ridge bifurcates posteriorly to enclose a small depression, the **recessus cochlearis**, which is perforated by eight small holes for the passage of filaments of the auditory nerve which supply the basal end of the ductus cochlearis. An oval depression is placed in the roof and inner wall of the vestibule above and behind the crista vestibuli. It is called the **fovea hemielliptica**, **elliptical recess**, or **spherical recess** (*recessus ellipticus*), and receives the utricle. The pyramid and the adjacent elliptical recess are perforated by numerous minute foramina (*macula cribrosa superior*). The openings in the pyramid transmit filaments from the vestibular nerve to the utricle; the openings in the elliptical recess transmit filaments from the vestibular nerve to the ampullæ of the superior and lateral semicircular canals. Below and behind the elliptical recess is a groove which deepens into a canal and is called the **aquæ-ductus vestibuli**. This canal passes to the posterior surface of the petrous portion of the temporal bone and opens as a mere crack between the internal auditory meatus and the groove for the lateral sinus. It transmits a small vein, and contains a tubular prolongation of the lining membrane of the vestibule, the **ductus endolymphaticus**, which ends in a *cul-de-sac* between the layers of the dura mater within the cranial cavity. *Behind*, the semicircular canals open into the vestibule by five orifices. In *front* is an elliptical opening, which communicates with the scala vestibuli of the cochlea by an orifice, **apertura scalæ vestibuli cochleæ**. This opening is bounded below by a thin plate of bone (*lamina spiralis ossea*), which takes origin from the vestibular floor external to the spherical recess and in the cochlea forms the bony portion of the partition between the scala tympani and the scala vestibuli. In the anterior portion of the vestibular floor is a fissure (*fissura vestibuli*), which passes into the bony part of the canal of the cochlea. The external boundary of this fissure is a small, thin plate of bone (*lamina spiralis secundaria*).

The **Bony Semicircular Canals** (*canales semicirculares ossei*) (Fig. 856) are three bony canals situated above and behind the vestibule. They are of unequal length, compressed from side to side, and each describes the greater part of a circle. They measure about 0.8 mm. (one-thirtieth of an inch) in diameter, and each presents a dilatation at one end, called the **ampulla ossea**, which measures more than twice the diameter of the tube. These canals open into the vestibule by five orifices, one of the apertures being common to two of the canals.

The **superior semicircular canal** (*canalis semicircularis superior*), 15 to 20 mm. in length, is vertical in direction, and is placed transversely to the long axis of the petrous portion of the temporal bone, on the anterior surface of which its arch forms a round projection. It describes about two-thirds of a circle. Its outer extremity, which is ampullated, communicates by a distinct orifice with the upper part of the vestibule; the opposite end of the canal, which is not dilated, joins with the corresponding part of the posterior canal to form the **crus commune**, which opens into the upper and inner part of the vestibule.

The **posterior semicircular canal** (*canalis semicircularis posterior*), also vertical in direction, is directed backward, nearly parallel to the posterior surface of the

petrous bone; it is the longest of the three, measuring from 18 to 22 mm.; its ampullated end commences at the lower and back part of the vestibule, its opposite end joining to form the common canal already mentioned. In the wall of the ampulla of the posterior canal are a number of small openings (*macula cribrosa inferior*) for the passage of nerves to the ampulla.

The **lateral** or **horizontal canal** (*canalis semicircularis lateralis*) is the shortest of the three. It measures from 12 to 15 mm., and its arch is directed outward and backward; thus each semicircular canal stands at right angles to the other two. Its ampullated end corresponds to the upper and outer angle of the vestibule, just above the fenestra ovalis, where it opens close to the ampullary end of the superior canal; its opposite end opens by a distinct orifice at the upper and back part of the vestibule.

The **cochlea** (Figs. 856 and 857) bears some resemblance to a common snail-shell; it forms the anterior part of the labyrinth, is conical in form, and placed almost horizontally in front of the vestibule; its apex (*cupula*) is directed forward and outward, with a slight inclination downward, toward the upper and front part

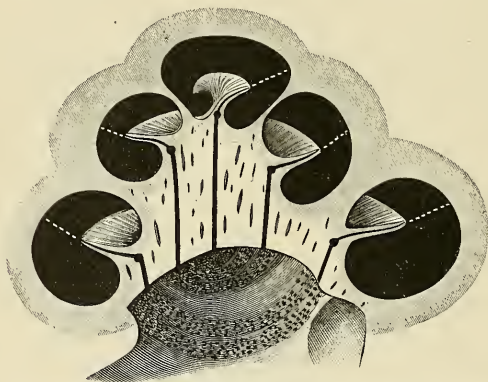

FIG. 857.—Osseous cochlea in vertical section. The broken, white lines indicate the position of the basilar membrane of the canal of the cochlea. Semidiagrammatic. (Testut.)

of the inner wall of the tympanum; its base (*basis cochleae*) corresponds with the anterior depression at the bottom of the internal auditory meatus, and is perforated by numerous apertures for the passage of the cochlear divisions of the auditory nerve. It measures nearly a quarter of an inch (5 mm.) from base to apex, and its breadth across the base is somewhat greater (about 9 mm.). It consists of a conical-shaped central axis, the **modiolus**; of a canal, the **bony canal of the cochlea**, the inner wall of which is formed by the central axis, wound spirally around it for two turns and three-quarters, from the base to the apex, and of a delicate lamina, the **lamina spiralis ossea**, which projects from the modiolus, and, following the windings of the canal, partially subdivides it into two. In the recent state a membrane, the **membrana basilaris**, stretches from the free border of this lamina, to the outer wall of the cochlea, and separates this canal into two passages, except where they communicate with each other at the apex of the modiolus by a small opening, named the **helicotrema**.

The **Modiolus** (Figs. 858 and 859) is the central axis or pillar of the cochlea. It is conical in form, and extends from the base to the apex of the cochlea. Its base (*basis modioli*) is broad, and appears at the bottom of the internal auditory

meatus, where it corresponds with the area cochleae. It is perforated by numerous orifices, which transmit filaments of the cochlear division of the auditory nerve, the nerves for the first turn and a half being transmitted through the foramina of the **tractus spiralis foraminosus**; those for the apical, turn through the

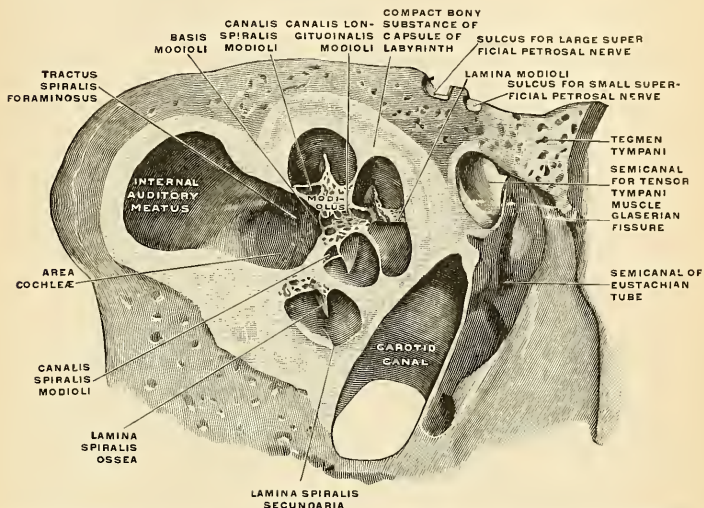


FIG. 858.—Vertical section through the right cochlea, medial portion, viewed from the lateral side. (Spalteholz).

foramen centrale. The foramina of the tractus spiralis foraminosus pass up through the modiolus and successively bend outward to reach the attached margin of the lamina spiralis ossea. Here they become enlarged, and by their apposition form a **spiral canal** (*canalis spiralis modioli*), which follows the course of the attached

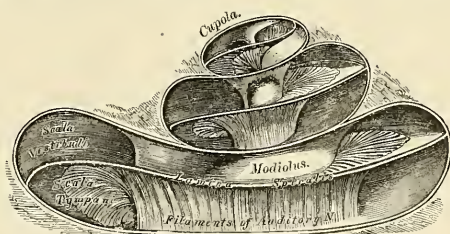


FIG. 859.—The cochlea laid open (enlarged).

margin of the lamina spiralis ossea and lodges the **ganglion spirale** (of Corti) (*ganglion spirale cochleae*). The **foramen centrale** is continued as a canal up the middle of the modiolus to its apex, and from this canal numerous minute foramina pass outward to the unattached edge of the lamina spiralis. In the foramina are vessels and nerves. The modiolus diminishes rapidly in size in the second and succeeding coil.

The **bony canal** or the **spiral canal of the cochlea** (*canalis spiralis cochleae*) (Fig. 859) takes two turns and three-quarters around the modiolus. The first turn of the canal is called the **basal coil**, the second is called the **central coil**, the third turn is called the **apical coil**. The promontory on the inner wall of the tympanic cavity is caused by the basal coil. The bony canal of the cochlea is a little over an inch (about 30 mm.) in length, and diminishes gradually in size from the base to the summit, where it terminates in the **cupola** (*cupula*), which forms the apex of the cochlea. The commencement of this canal is about a tenth of an inch (2.5 mm.) in diameter; it diverges from the modiolus toward the tympanum and vestibule, and presents three openings. One, the **fenestra rotunda**, communicates with the tympanum; in the recent state this aperture is closed by a membrane, the **membrana tympani secundaria**. Another aperture, of an elliptical form, opens into the vestibule. The third is the aperture of the **aquaeductus cochleae**, leading to a minute funnel-shaped canal, which opens on the basilar surface of the petrous bone internal to the jugular fossa, and transmits a small vein, and also forms a communication between the subarachnoidean space of the skull and the perilymph space in the scala tympani.

The **lamina spiralis ossea** is a bony shelf or ledge which projects outward from the modiolus into the interior of the spiral canal, and, like the canal, takes nearly two and three-quarter turns around the modiolus. It reaches about half-way toward the outer wall of the spiral canal, and partially divides its cavity into two passages or **scalae**, of which the upper is named the **scala vestibuli**, while the lower is termed the **scala tympani**. Near the summit of the cochlea the lamina terminates in a hook-shaped process, the **hamulus** (*hamulus laminae spiralis*), which assists in forming the boundary of a small opening, the **helicotrema**, by which the two **scalae** communicate with each other. From the *canalis spiralis modioli* numerous foramina pass outward through the osseous spiral lamina as far as its outer or free edge. In the lower part of the first turn a second bony lamina (*lamina spiralis secundaria*) projects inward from the outer wall of the bony tube; it does not, however, reach the primary osseous spiral lamina, so that if viewed from the vestibule a narrow fissure, the **fissura vestibuli**, is seen between them.

The fundus of the internal auditory meatus is described on page 85.

The **Membranous Labyrinth** (*labyrinthus membranaceus*) (Figs. 860 and 861) is contained within the bony cavities just described, having the same general form as the cavities in which it is contained, though considerably smaller, being separated from the bony walls by a quantity of fluid, the **perilymph** (*perilymph*). It does not, however, float loosely in this fluid, but in places is fixed to the walls of the cavity. The membranous sac contains fluid, the **endolymph** (*endolymph*), and on the sac the ramifications of the auditory nerve are distributed.

Within the osseous vestibule the membranous labyrinth does not quite preserve the form of the bony cavity, but presents two membranous sacs, the **utricle** and the **sacculle**.

The **Utricle** (*utricleus*) is the larger of the two, of an oblong form, compressed laterally, and occupies the upper and back part of the vestibule, lying in contact with the fovea semielliptica and the part below it. The highest portion of the utricle is called the **recess** (*recessus utriculi*); it is placed in the elliptical recess, and opening into it are the ampullæ of the superior and lateral semicircular canals. The central portion of the recess of the utricle receives upon the side the lateral semicircular canal. This opening has no ampulla. The **superior sinus** is a prolongation upward and backward from the central portion of the utricle and in the superior sinus the crus commune and the superior and posterior semicircular canals open. The lower and inner portion of the utricle is the **inferior sinus**, and into it the ampulla of the posterior semicircular canal opens. The floor and anterior wall of the recess of the utricle are much thicker than else-

where, and form the **macula acustica utriculi**, which receives the utricular filaments of the auditory nerve and has attached to its internal surface a layer of calcareous particles which are called **otoliths**. The cavity of the utricle communicates behind

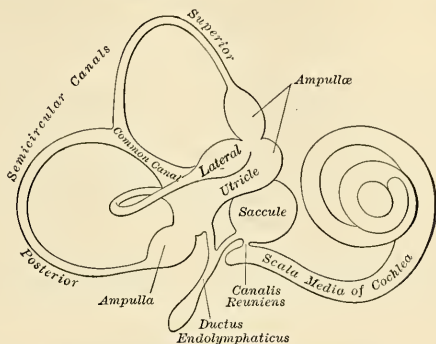


FIG. 860.—The membranous labyrinth (enlarged).

with the membranous semicircular canals by five orifices. From its anterior wall is given off a small canal (*ductus utriculosaccularis*), which joins with a canal from the saccule, the **ductus endolymphaticus**.

The **Saccule** (*sacculus*) is the smaller of the two sacs; it is globular in form, lies in the recessus sphaericus near the opening of the **scala vestibuli** of the coch-

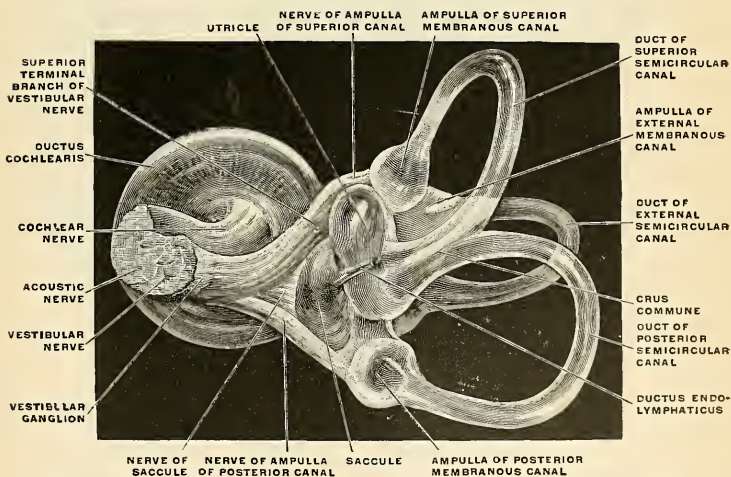


FIG. 861.—The right membranous labyrinth of an adult, isolated, medial and posterior view. (Spalteholz.)

lea. Its anterior part exhibits an oval thickening, the **macula acustica sacculi**, to which are distributed the saccular filaments of the auditory nerve. Its cavity does not directly communicate with that of the utricle. From the pos-

terior wall is given off a canal, the **ductus endolymphaticus**. This duct is joined by the ductus utriculosaccularis, and then passes along the aquaeductus vestibuli and ends in a blind pouch on the posterior surface of the petrous portion of the temporal bone, where it is in contact with the dura. From the lower part of the sacculæ a short tube, the **canalis reuniens of Hensen** (*ductus reuniens* [*Henseni*]), passes downward and outward to open into the ductus cochlearis near its vestibular extremity.

The **Membranous Semicircular Canals** (*ductus semicirculares*) are about one-third the diameter of the osseous canals, but in number, shape, and general form they are precisely similar, and each presents at one end an ampulla (*ampullæ membranaceæ*). The canals open by five orifices into the utricle, one opening being common to the inner end of the superior and the upper end of the posterior canal. In the ampullæ the wall is thickened, and projects into the cavity as a fiddle-shaped, transversely placed elevation, the **septum transversum**, in which the nerves end.

The utricle, sacculæ, and membranous canals are attached here and there to the bone by numerous fibrous bands, the so-called ligaments (*ligamenta labyrinthi canaliculorum*).

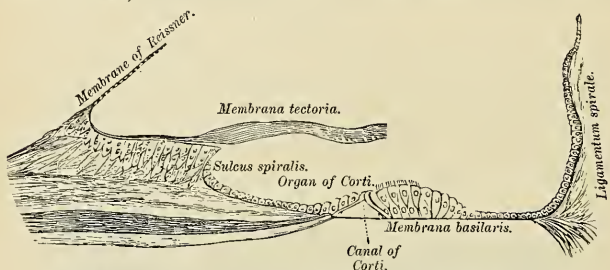


FIG. 862.—Floor of scala media, showing the organ of Corti, etc.

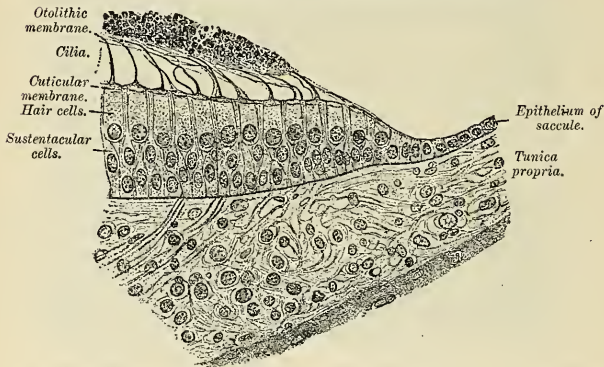


FIG. 863.—Trans-section of the margin of the maculi sacculi of a guinea-pig. $\times 325$. (After Kolliker.)

Structure.—The walls of the utricle, sacculæ, and membranous semicircular canals consist of three layers. The *outer layer* is a loose and flocculent structure, apparently composed of ordinary fibrous tissue, containing bloodvessels and pigment cells. The *middle layer*, thicker and more transparent, bears some resemblance to the hyaloid membrane, but it presents on its internal surface, especially in the semicircular canals, numerous papilliform projections, and, on the

addition of acetic acid, presents an appearance of longitudinal fibrillation and elongated nuclei. The *inner layer* is formed of simple polygonal epithelial cells. In the maculae of the utricle and saccule, and in the transverse septa of the ampullae of the canals, the middle coat is thickened; the epithelium is columnar, is increased in height, and passes into the neuroepithelium. The **neuroepithelium** consists of supporting cells and hair cells.

1. The **supporting cells** are long and fusiform, and contain an oval nucleus. Their deep ends are attached to the membrana propria, while their free extremities are united to form a thin cuticle. The protoplasm contains yellowish pigment granules.

2. The **hair cells** are columnar, with bulged lower ends and free upper ends. The bulged lower ends, each of which contains a spherical nucleus, do not reach higher than the middle of the epithelial layer. Each free upper end is surmounted by a long, tapering filament. These filaments constitute **auditory hair**, and they project into the cavity. Each filament is found to consist of many fine hairs. The filaments of the auditory nerve enter these parts, and, having pierced the outer and thickened middle layer, they lose their myelin sheaths, and their axones divide into three or four branches at the larger and deeper ends of the hair cells. These branches form a horizontal plexus (*stratum plexiforme*).

Numerous small prismatic bodies termed **statoliths**, **otoconia**, or **otoliths**, and consisting of a mass of minute crystalline grains of carbonate of lime, held together in a gelatinous substance, are contained in the walls of the utricle and saccule opposite the distribution of the nerves. The membrane is called the **otolith membrane**. A calcareous material is also, according to Bowman, sparingly scattered in the cells lining the ampullae of the semicircular canals. The conical thickening in the ampulla corresponds to the otolith membrane.

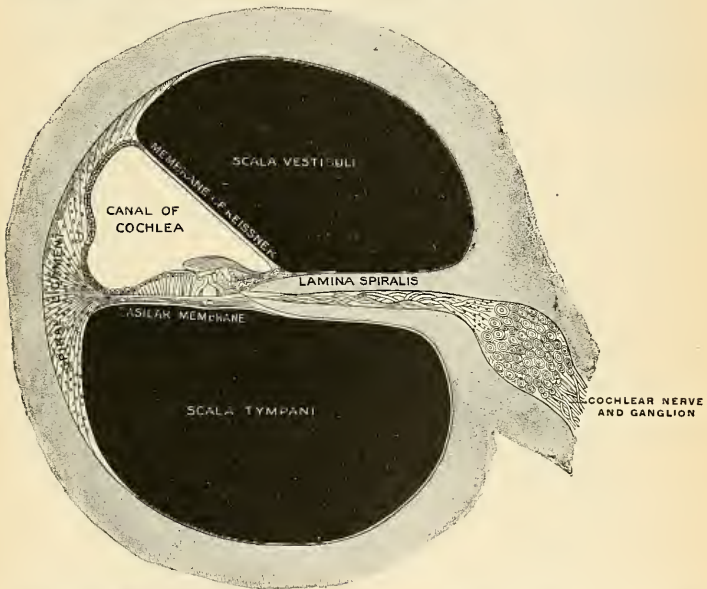


FIG. 864.—Cochlea in transverse section. Observe especially the canal of the cochlea, which is a part of the membranous labyrinth. (Testut.)

The **membranous cochlea**, **ductus cochlearis**, or **scala media** consists of a spirally arranged tube enclosed in the bony canal of the cochlea and lying along its outer wall.

The osseous spiral lamina, as already stated, extends only part of the distance between the modiolus and the outer bony wall of the cochlea. A membrane, the **basilar membrane** (*membrana basilaris*) (Fig. 862), stretches from its free edge

to the outer wall of the cochlea, and completes the roof of the scala tympani. A second and more delicate membrane, the **membrane of Reissner** (*membrana vestibularis* [*Reissneri*]) (Fig. 862), extends from the thickened periosteum covering the lamina spiralis ossea, at an angle of about 45 degrees, to the outer wall of the cochlea, to which it is attached at some little distance above the membrana basilaris. A canal is thus shut off between the scala tympani below and the scala vestibuli above; this is the **membranous canal of the cochleæ** (*ductus cochlearis* or *scala media*) (Fig. 863). It is triangular on transverse section, its roof being formed by the membrane of Reissner, its outer wall by the periosteum which lines the bony canal, and its floor by the membrana basilaris, and the outer part of the lamina spiralis ossea, on the former of which is placed the organ of Corti. Reissner's membrane is thin and homogeneous, and is covered on its upper and under surfaces by a layer of epithelium. The periosteum, which forms the outer

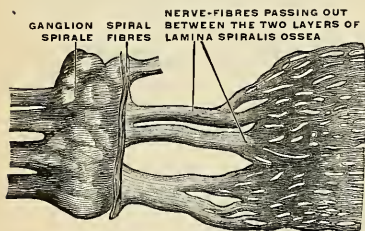


FIG. 865.—Part of the cochlear nerve, highly magnified. (Henle.)

will of the ductus cochlearis, is greatly thickened and altered in character; forming what is called the **spiral ligament of the cochlea** (*ligamentum spirale cochleæ*) (Fig. 862). It projects inward below as a triangular prominence, the **crista basilaris**, which gives attachment to the outer edge of the membrana basilaris, and immediately above which is a concavity, the **sulcus spiralis externus** (Fig. 862). The upper portion of the ligamentum spirale contains numerous capillary loops and small bloodvessels within

the epithelium, and forms what is termed the **stria vascularis**. The stria is limited below by a prominence (*prominentia spiralis*), in which a bloodvessel (*vas prominens*) is distinctly visible.

The **lamina spiralis ossea** (Fig. 863) consists of two plates of bone extending outward; between these are the canals for the transmission of the filaments of the auditory nerve. On the upper plate of that part of the osseous spiral lamina which is outside Reissner's membrane the periosteum is thickened to form the **limbus laminae spiralis**, and this terminates externally in a concavity, the **sulcus spiralis internus**, which presents, on section, the form of the letter C; the upper part of the letter, formed by the overhanging extremity of the limbus, is named the **labium vestibulare**; the lower part, prolonged and tapering, is called the **labium tympanicum**, and is perforated by numerous foramina (*foramina nervosa*) for the passage of the component parts of the cochlear nerve. Externally, the labium tympanicum is continuous with the membrana basilaris. The upper surface of the labium vestibulare is intersected at right angles by a number of furrows, between which are numerous elevations; these present the appearance of teeth along the free margin of the labium, and have been named by Huschke the **auditory teeth**. The basilar membrane may be divided into two areas, inner and outer. The inner is thin, and is named the **zona arcuata** or **zona tecta** (Fig. 862); it supports the organ of Corti. The outer is thicker and striated, and is termed the **zona pectinata**. The under surface of the membrane is covered by a layer of vascular connective tissue. One of these vessels is somewhat larger than the rest, and is named the **vas spirale** (Fig. 866); it lies below Corti's tunnel.

The **organ of Corti**¹ (*organon spirale* [*Corti*]) (Figs. 866 and 867) is situated upon the inner part of the membrana basilaris within the canal of the ductus

¹ Corti's original paper is in the Zeitschrift f. Wissen. Zool., iii, 109.

cochlearis and appears as a ridge (*crista spiralis*), winding spirally throughout the whole length of the ductus cochlearis. It is seen to be composed of a remarkable arrangement of cells, which may be likened to the keyboard of a piano. Of these cells, the central ones are rod-like bodies and are called the **inner and outer rods or pillars of Corti**. Their bases are expanded and placed on the basilar membrane,

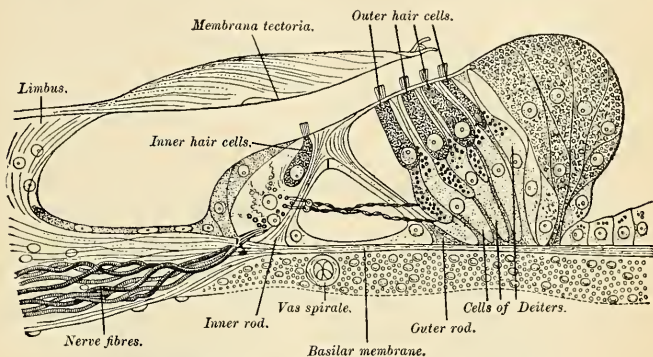


FIG. 866.—Section through the organ of Corti. Magnified. (G. Retzius.)

at some little distance from each other, while their intermediate portions are inclined toward each other, so as to meet at their opposite extremities, and form a series of arches roofing over a minute tunnel, the **canal or tunnel of Corti**, between them and the basilar membrane, which ascends spirally through the whole length of the cochlea.

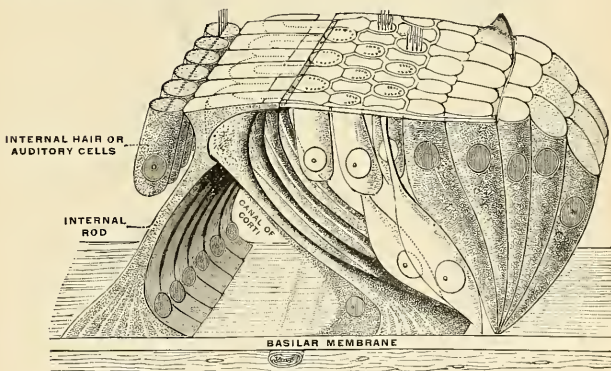


FIG. 867.—Organ of Corti. Diagrammatic view of a small portion. (Testut.)

The **inner rods** (Fig. 866), some 6000 in number, are more numerous than the outer ones, and rest on the basilar membrane, close to the labium tympanicum; they project obliquely upward and outward, and terminate above in expanded extremities which resemble in shape the upper end of the ulna, with its sigmoid cavity, coronoid and olecranon processes. On the outer side of the rod, in the

angle formed between it and the basilar membrane, is a nucleated mass of protoplasm; while on the inner side is a row of epithelial cells, the **inner hair cells** (Fig. 866), surmounted by a brush of fine, stiff, hair-like processes. On the inner side of these cells are two or three rows of columnar supporting cells, which are continuous with the cubical cells lining the sulcus spiralis internus.

The **outer rods** (Fig. 866), numbering about 4000, also rest by broad foot-plates on the basilar membrane; they incline upward and inward, and their upper extremity resembles the head and bill of a swan; the back of the head fitting into the concavity—the analogue of the sigmoid cavity—of one or more of the internal rods, and the bill projecting outward as a phalangeal process of the membrana reticularis, presently to be described.

In the head of these outer rods is an oval portion, where the fibres of which the rod appears to be composed are deficient, and which stains more deeply with carmine than the rest of the rod. At the base of the rod, on its internal side—that is to say, in the angle formed by the rod with the basilar membrane—is a similar protoplasmic mass to that found on the outer side of the base of the inner

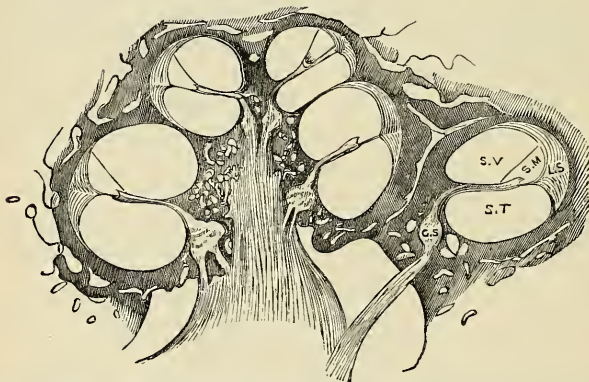


FIG. 868.—Longitudinal section of the cochlea, showing the relations of the scala, the ganglion spirale, etc. S.V. Scala vestibuli. S.T. Scala tympani. S.M. Scala media. L.S. Ligamentum spirale. G.S. Ganglion spirale.

rod; these masses of protoplasm are probably the undifferentiated portions of the cells from which the rods are developed. External to the outer rod are three or four successive rows of epithelial cells, more elongated than those found on the internal side of the inner rod, but, like them, furnished with minute hairs or cilia. These are termed the **outer hair cells**, in contradistinction to the inner hair cells above referred to. There are about 12,000 outer hair cells, and about 3500 inner hair cells.

The hair cells are somewhat oval in shape; their free extremities are on a level with the heads of Corti's rods, and from each some twenty fine cilia project and are arranged in the form of a crescent, the concavity of which opens inward. The deep ends of the cells are rounded and contain large nuclei; they reach only as far as the middle of Corti's rods, and are in contact with the ramifications of the nerve filaments. Between the rows of the outer hair cells are rows of supporting cells, called the **cells of Deiters**; their expanded bases are planted on the basilar membrane, while their opposite ends present a clubbed extremity or **phalangeal process**. Immediately to the outer side of Deiters' cells are some

five or six rows of columnar cells, the **supporting cells of Hensen**. Their bases are narrow, while their upper parts are expanded and form a rounded elevation on the floor of the ductus cochlearis. The columnar cells lying outside Hensen's cells are termed the **cells of Claudius**. A space is seen between the outer rods of Corti and the adjacent hair cells; this is called the **space of Nuel**.

The **lamina reticularis**, or **membrane of Kölliker**, is a delicate framework perforated by rounded holes. It extends from the inner rods of Corti to the external row of the outer hair cells, and is formed by several rows of "minute fiddle-shaped cuticular structures" called **phalanges**, between which are circular apertures containing the free ends of the hair cells. The innermost row of phalanges consists of the phalangeal processes of the outer rods of Corti; the outer rows are formed by the modified free ends of Deiters' cells.

Covering over these structures, but not touching them, is the **membrana tectoria** or **membrane of Corti** (Figs. 862 and 866), which is attached to the vestibular surface of the lamina spiralis close to the attachment of the membrane of Reissner. It is thin near its inner margin, and overlies the auditory teeth of Huschke. Its outer half is thick, and along its lower edge, opposite the inner hair cells, is a clear band, named **Hensen's stripe**. Externally, the membrane becomes much thinner, and is attached to the outer row of Deiters' cells (Retzius). It is made up of multitudes of delicate fibres embedded in a transparent matrix of a soft, transparent collagenous character with marked adhesiveness (Hardesty).

The **osseous labyrinth** is lined by an exceedingly thin fibroserous membrane, analogous to a periosteum, from its close adhesion to the inner surfaces of these cavities, and performing the office of a serous membrane by its free surface. It lines the vestibule, and from this cavity is continued into the semicircular canals and the scala vestibuli of the cochlea, and through the helicotrema into the scala tympani. A delicate tubular process is prolonged along the aqueduct of the vestibule to the inner surface of the dura. This membrane is continued across the fenestra ovalis and fenestra rotunda, and consequently has no communication with the lining membrane of the tympanum. Its attached surface is rough and fibrous, and closely adherent to the bone; its free surface is smooth and pale, covered with a layer of epithelium, and secretes a thin, limpid fluid, the **perilymph**.

The **scala media** (*ductus cochlearis*) is closed above and below. The upper blind extremity is termed the **lagena**, and is attached to the cupola at the upper part of the helicotrema; the lower end is lodged in the recessus cochlearis of the vestibule. Near this blind extremity, the scala media receives the **canalis reuniens of Hensen** (Fig. 860), a very delicate canal, by which the ductus cochlearis is brought into continuity with the saccule.

The **auditory nerve** (*n. acusticus*), the special nerve of the senses of hearing and of equilibrium, divides, at the bottom of the internal auditory meatus, into two branches, the **cochlear** and **vestibular**.

The **vestibular nerve** (*n. vestibularis*), the posterior of the two, presents, as it lies in the internal auditory meatus, a ganglion, the **vestibular ganglion** or the **ganglion of Scarpa** (*ganglion vestibulare*); the nerve divides into three branches which pass through minute openings at the upper and back part of the bottom of the meatus (*area vestibularis posterior*), and, entering the vestibule, are distributed to the utricle and to the ampulla of the external and superior semicircular canals. The nerve filaments enter the ampullary enlargements opposite the septum transversum, and arborize around the hair cells. In the utricle and saccule the nerve fibres pierce the membrana propria of the maculae, and end in arborizations around the hair cells.

The **cochlear nerve** (*n. cochlearis*) gives off the branch to the saccule, the filaments of which are transmitted from the internal auditory meatus through the foramina of the *area vestibularis inferior*, which lies at the lower and back part

of the floor of the meatus. It also gives off the branch for the ampulla of the posterior semicircular canal, which leaves the meatus through the **foramen singulare**.

The rest of the cochlear nerve divides into numerous filaments at the base of the modiolus; those for the basal and middle coils pass through the foramina in the tractus foraminosus, those for the apical coil through the canalis centralis, and the nerves bend outward to pass between the lamellæ of the osseous spiral lamina. Occupying the spiral canal of the modiolus is the **spiral ganglion**, or **ganglion of Corti** (*ganglion spirale*), consisting of bipolar nerve cells, which really constitute the true cells of origin of this nerve, one pole being prolonged centrally to the brain and the other peripherally to the hair cells of Corti's organ. Reaching the outer edge of the osseous spiral lamina, the nerve fibres pass through the foramina in the labium tympanicum. Some of these fibres end by arborizing around the bases of the inner hair cells, while others pass between Corti's rods and across the tunnel, to terminate in a similar manner in relation to the outer hair cells.

The **arteries** of the labyrinth are the **internal auditory**, from the basilar, and the **stylomastoid**, from the posterior auricular. The internal auditory divides at the bottom of the internal auditory meatus into two branches, cochlear and vestibular. The **cochlear artery** divides into numerous minute branches, which enter foramina in the tractus spiralis foraminosa and course in the lamina spiralis ossea to reach the membranous structures. The largest of the cochlear branches is in the canalis centralis. The **vestibular branches** accompany the nerves, and supply the membranous structures in the vestibule and semicircular canals. Two arteries go to each canal. The two vessels enter opposite extremities of the canal, and anastomose at the summit of the canal. The vestibular vessels form a minute capillary network in the substance of each membranous labyrinth.

The **veins** of the vestibule and semicircular canals, the **auditory veins**, accompany the arteries, and receive those of the cochlea at the base of the modiolus, to form the **internal auditory vein** (*vv. auditivæ internæ*), which opens into the posterior part of the inferior petrosal sinus or into the lateral sinus.

THE ORGANS OF TASTE (ORGANON GUSTUS).

The peripheral organs of the sense of taste consist of certain flask-shaped groups of modified epithelial cells, termed **taste buds** (*calyculi gustatorii*), situated on the tongue and adjacent parts. They occupy nests in the stratified epithelium

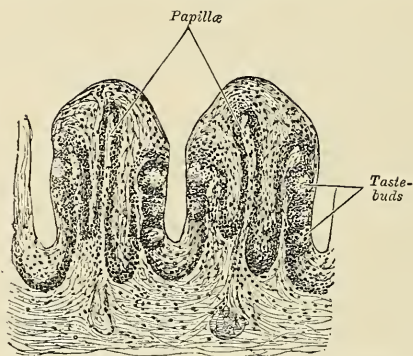


FIG. 869.—Section of part of the papilla foliata of a rabbit. (Magnified.)

and are present in large numbers on the sides of the circumvallate papillæ (Fig. 869), and to a less extent on their opposed walls. They are also found on the fungiform papillæ over the back part and sides of the tongue, and in the general

epithelial covering of the same areas. They are very plentiful over the fimbriae linguae, and are also present on the under aspect of the soft palate, uvula, and on the lingual surface of the epiglottis.

Each **taste bud** is flask-like in shape, its broad base resting on the corium, and the neck opening by an orifice, the gustatory pore, between the cells of the epithelium. The bud is formed by two kinds of cells, supporting cells and gustatory cells. The **supporting cells** are mostly arranged like the staves of a cask, and form an outer envelope for the bud. Some, however, are found in the interior of the bud between the gustatory cells. The **gustatory cells** occupy the central portion of the bud; they are spindle-shaped, and each possesses a large spherical nucleus near the middle of the cell. The peripheral end of the cell terminates at the gustatory pore in a fine, hair-like filament, the **gustatory hair**. The central process passes toward the deep extremity of the bud, and there ends in a single or bifurcated varicose filament, which was formerly supposed to be continuous with the terminal fibril of a nerve; the investigations of Lenhossék and others would seem to prove, however, that this is not so, but that the nerve fibrils after losing their myelin sheaths enter the taste bud, and terminate in fine extremities between

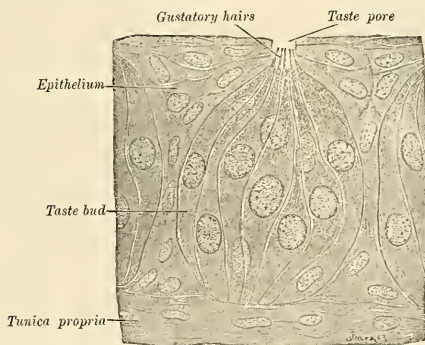


FIG. 870.—Taste buds from the papilla foliata of a rabbit. $\times 850$. (Szymonowicz.)

the gustatory cells. Other nerve fibrils may be seen ramifying between the supporting cells and terminating in fine extremities; these, however, are believed to be nerves of ordinary sensation, and not gustatory. "The latest researches have shown that dendrites of sensor neurones (sensor nerves) enter the taste buds and end free in telodendria. The latter surround the neuroepithelial, and, to some extent, the sustentacular cells, their relations depending on contact."¹

Nerves of Taste.—The chorda tympani nerve is generally regarded as the nerve of taste for the anterior two-thirds of the tongue; the nerve for the posterior third is the glossopharyngeal.

THE SKIN (INTEGUMENTUM COMMUNE).

The skin covers the body surface and is continuous with the mucous membrane at the origin and termination of the alimentary canal and at the openings of other canals. The skin is a protective coat, a regulator of body temperature, contains multitudes of the terminations of sensor nerves, and is the seat of the **organ of**

¹ Journal of Anatomy and Physiology, 1891.

touch (*organon tactus*). These nerve organs are connected with nerve fibres of temperature, pressure, and pain. Connected with the skin are sweat glands which have important excretory functions and sebaceous glands. From its superficial part come appendages, the hairs, and nails. The skin is elastic and varies in thickness from 0.5 mm. to 4 mm. ($\frac{1}{50}$ to $\frac{1}{6}$ inch). It is thinnest in the eyelids and prepuce, and thickest over the back of the neck, back of the shoulders, palms of the hands, and soles of the feet. Its color depends in part on the blood within it, and in part upon pigment. The deepest hue is about the anus, in the genital region, in the axillæ, over the mammary glands, and in the parts exposed to air, light, and varied temperatures. The color varies with age, being pinkish in extreme youth and becoming yellow in old age. It varies with

exposure and with climate, being deepest in those who brave all weathers and temperatures and in those who dwell beneath a tropical sun. It also varies with race, and this is so well recognized that races are classified by the color of the skin into the White, Yellow, Brown, and Black races. The color of the skin is also affected in certain diseases; being extremely pale in anemia, brown in Addison's disease, yellow in jaundice, etc.

In most situations the skin is movable, but in some it is attached closely to underlying structures, and is consequently immovable on the scalp, the palms of the hands, the soles of the feet, and the outer portion of the pinna of the ear. The skin is fairly smooth, but close examination dis-

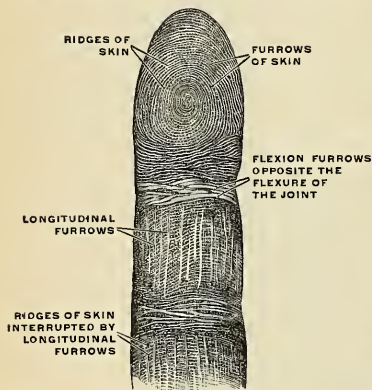


FIG. 871.—The furrows and ridges of the surface of the skin from the palm or surface of the middle finger. (Toldt.)

closes multitudes of openings, creases, furrows, depressions, folds, and hairs. Hair follicles open upon the surface, and the ducts of sebaceous glands and of sweat glands perforate the skin.

About the joints are **folds of skin** (*retinacula cutis*), and temporary folds or wrinkles are created by the contraction of superficial muscles. The *facial wrinkles* of advancing years are due to habitual expression and loss of skin elasticity. A *dimple* is a permanent pit or depression due to adhesion of the surface to parts beneath. The ridges and furrows on the palms, soles, and flexor aspects of the digits are permanent, and over the palmar surface of the digits they are arranged in definite forms which endure through life and are so distinctive that they have been utilized by police officials in determining the identity of individuals. These folds are due to the papillæ of the skin being arranged in rows; some of the papillæ proliferate, and linear depressions occur in the horny layer (Philippon).

Fig. 871 shows **skin ridges** (*cristae cutis*), **skin furrows** (*sulci cutis*), furrows opposite joints due to acts of flexion, and called **flexure furrows**, and **longitudinal furrows**.

When the skin is punctured by a round awl it tends to split in a definite direction, which direction varies with the region stabbed. These clefts are known as the **cleavage lines of Langer** (Figs. 872 and 873), and depend upon the arrangement of the connective-tissue bundles of the corium. These connective-tissue bundles certainly influence the formation of folds and furrows. In many portions of the body the cutaneous surface is divided by linear furrows into irregularly

shaped areas (Fig. 874). The skin consists of two layers: a superficial layer, the **epidermis**, and a deep layer, the **corium** or **dermis**.

The **Cuticle**, **Scarf Skin**, or **Epidermis** (Figs. 875 and 876) is composed of layers of epithelium and is derived from the ectoderm. The epithelium is strati-

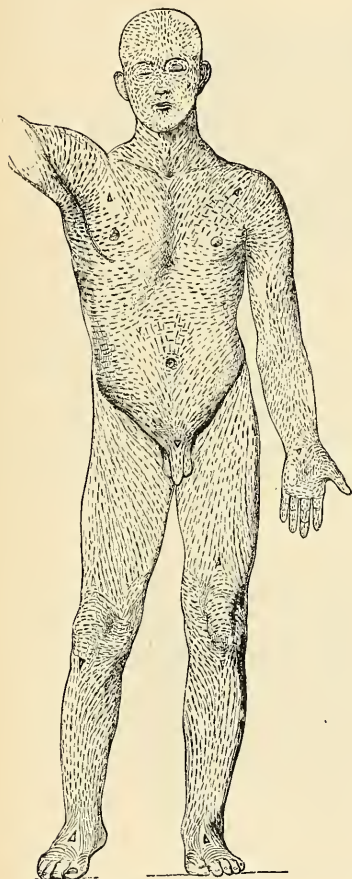


FIG. 872.—Anterior surface.

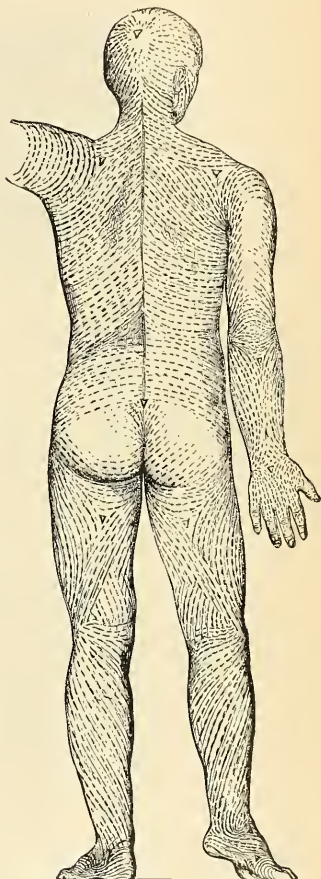


FIG. 873.—Posterior surface.

The general course of the connective-tissue bundles of the corium, determined by the direction assumed by the linear clefts made in the skin when it is punctured by a round awl. (Langer.)

fied, and is devoid of bloodvessels. Two layers can be readily made out, the **superficial** or **horny layer** and the **deeper** or **Malpighian layer**.

The **horny layer** (*stratum corneum*) is formed by several layers of non-nucleated scaly cells. The cells consist of keratin. The surface cells of the horny layers

are being constantly rubbed off, and are being replaced by cells from the Malpighian layer, which are converted into keratin as they approach the surface.

The **Malpighian layer** (*stratum Malpighii*) of the epidermis is divided into four layers, named, from without inward, the **stratum lucidum**, the **stratum granulosum**, the **stratum mucosum**, and the **stratum germinativum**.




FIG. 874.—The furrows of the skin and the areas which these furrows delimit, reproduced from an impression of the dorsal surface of the wrist. (Toldt.)

The **stratum lucidum** is the most superficial part of the Malpighian layer. It consists of several layers of flat cells, the nuclei of which are beginning to disappear. The cells contain eleidin granules. In regions where the epidermis is thin the stratum lucidum is absent.

The **stratum granulosum** consists of several layers of nucleated flat cells, containing keratohyaline granules. These granules are probably formed from the disintegrating nucleus, and in the stratum lucidum are converted into eleidin, an intermediate substance in the formation of keratin. It is best developed in the sole and palms.

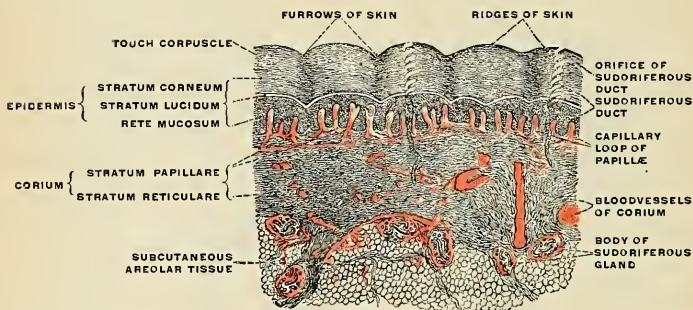


FIG. 875.—Vertical section through the skin of the finger-tip. The layers of the epidermis and of the corium. The subcutaneous areolar tissue. The sudoriferous or sweat-gland. (Toldt.)

The **mucous layer** or the **stratum mucosum** consists of numerous layers of nucleated, polygonal, spine-shaped cells known as **prickle cells** or **finger cells**. Between the cells of the stratum mucosum are spaces containing pigment granules and leukocytes. Processes from the prickle cells join adjacent cells. This layer contains numerous connective-tissue fibres arranged in a network, and known as **epidermic fibrils**.

The **stratum cylindricum** or **stratum germinativum** is composed of cylindrical or prickle cells, the points of which are directed downward. Fine fibrils pass up

from the corium between the cells, and there is cement substance as well between them.

The **Corium, Cutis Vera, Dermis, or True Skin** (Figs. 876 and 880) is a connective-tissue structure which arises from the mesoderm. It consists especially of connective tissue and elastic fibres; it contributes elasticity to the skin, and is the seat of the sense organs. The corium is composed of two layers, the **papillary** and the **reticular**.

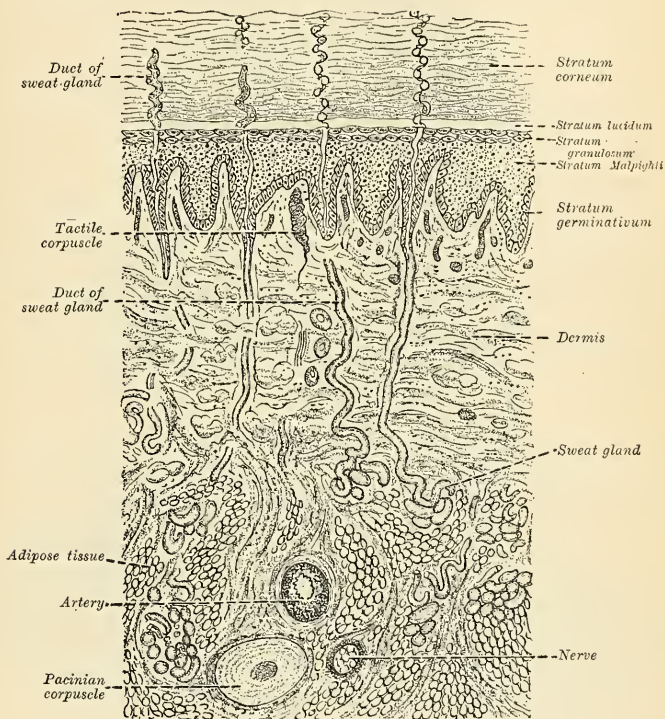


FIG. 876.—Diagrammatic sectional view of the skin. (Magnified.)

The superficial or papillary layer or **corpus papillare of the corium** (*stratum papillare*) lies just beneath the epidermis, contains the papillæ, and is composed of a network of fine bundles of fibrous tissue. The papillæ are composed of fine strands of connective tissue and elastic tissue. They project from the corium beneath the epidermis and enter into depressions of the epidermis. They vary greatly in size, averaging $\frac{1}{100}$ of an inch in height and $\frac{1}{200}$ of an inch in width at the base. In the face, especially in the eyelids, they are insignificant. On the glans penis, the palms of the hands, and the soles of the feet, and in the nipples, they are large. In the palmar surfaces of the hands and fingers and the plantar surfaces of the feet and toes they produce permanent ridges (Fig. 879). A ridge is composed of two or more rows of papillæ, and the ducts of sweat glands emerge

between rows of papillæ, and open on the curved surface ridges (Fig. 875). Most of the papillæ contain loops of capillaries, and are called **vascular papillæ**. Some contain nerve terminations, and are called **nerve papillæ**. Between the papillary

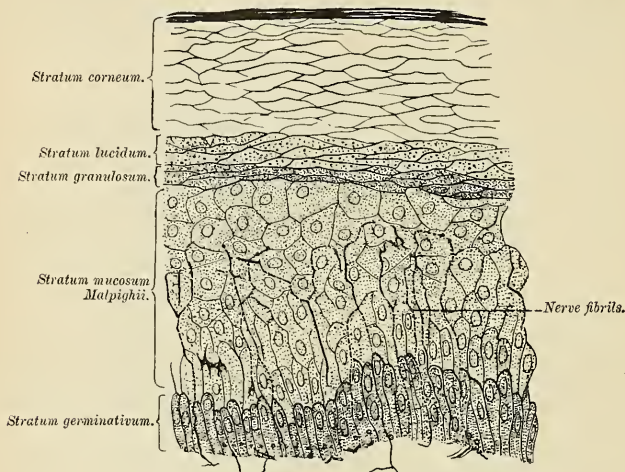


FIG. 877.—Section of epidermis. (Ranvier.)

layer of the corium and the epidermis is a very thin and structureless membrane called the **basal membrane**.

The **deep** or **reticular layer** (*stratum reticulare*) rests upon the subcutaneous tissue. It passes superficially into the papillary layer, and at most places into the subcutaneous tissue without a sharp line of differentiation. At some places, for instance in the nipple, the deep layer of the corium rests upon a layer of muscle tissue. In the face this muscle tissue is striated and sends prolongations to the papillary layer; in the nipple and scrotum it is nonstriated. The reticular layer is composed of bundles of white fibrous tissue, arranged in a network. In the meshes of the network are fat, bloodvessels, lymphatics, sebaceous glands, sweat glands, and hair follicles.

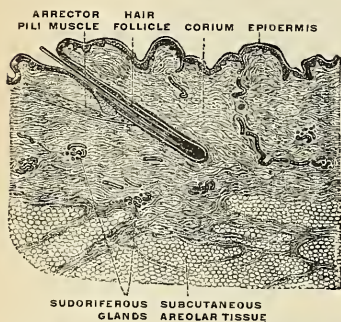


FIG. 878.—Vertical section through the skin of the trunk in the region of the arch of the ribs. One of the small hairs is seen in longitudinal section. (Toldt.)

The **subcutaneous areolar tissue**, or **tela subcutanea** (*panniculus adiposus*), connects the skin to the parts beneath; it is composed of bundles of connective tissue which cross repeatedly and form spaces. In almost all regions the spaces contain fat, but in the scrotum, external ear, penis, and eyelid they do not contain fat. When the connective-tissue fibres of the panniculus adiposus are long and nearly parallel to the skin surface,

the skin becomes wrinkled; when they are short and nearly at right angles to the surface, the skin cannot wrinkle.

Pigmentation of the Skin.—As previously stated, in certain regions the skin of the white race is brown because of pigmentation (areolæ, nipples, around the anus,

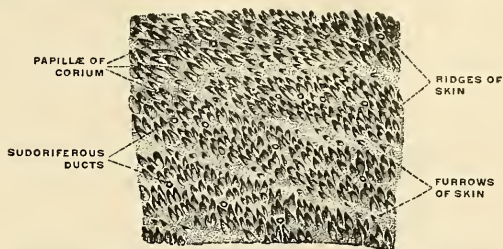


FIG. 879.—The furrows and ridges of true skin on the palmar surface of one of the fingers, the epidermis having been removed. (Toldt.)

axillæ, serotum, labia majora). This is due to pigment within the epithelial and connective-tissue cells of the papillary layer of the corium, and in the basal cells of the epidermis. There are few or none of these pigmented cells in the stratum corneum of one of the Caucasian race.

“In negroes and other colored races the deep pigmentation is due to a similar distribution of the pigment granules in the entire epidermis; but even here the

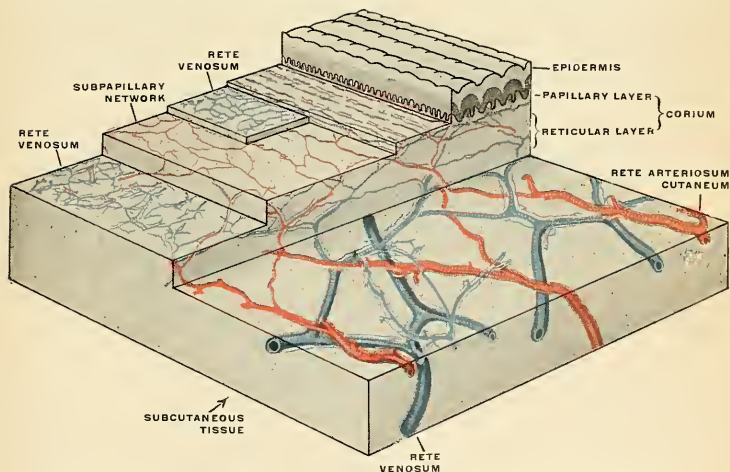


FIG. 880.—The distribution of the bloodvessels in the skin of the sole of the foot. (Spalteholz.)

pigmentation decreases toward the surface, although the uppermost cells of the stratum corneum always contain some pigment. The nuclei of the cells are always free from coloring matter. The question as to the origin of the pigment is as yet unsolved.”¹

¹ A Text-book of Histology. By A. A. Böhm and M. von Davidoff. Translated and edited by G. Carl Huber.

The **arteries** supplying the skin vary in number, and vary much in size, being largest in regions exposed to pressure, as the skin of the palms, soles, and buttocks. The arteries enter the skin from a network in the subcutaneous tissue, and by an anastomosis in the deepest part of the corium form a network (*rete arteriosum cutaneum*). The vessels send branches to the fat and to the sweat glands. Branches from the network just described ascend and form a second network in the corium beneath the papillæ. This is called the **subpapillary network** (*rete arteriosum subpapillare*). From this network fine capillary vessels pass into the papillæ, forming, in the smaller papillæ, a single capillary loop, but in the larger a more or less convoluted vessel. From this network branches go to the hair follicles and sebaceous glands. The blood from the papillæ passes into a plexus (*rete venosum*) beneath the papillæ. This communicates with another plexus between the corium and subcutaneous tissue. In some regions one or more retia are interposed between these two. The **veins** from the sweat glands, sebaceous glands, superficial fat, and hair follicles are received by the *retia venosa*. From the deepest rete veins pass to the subcutaneous tissue, and these veins enter the large subcutaneous veins.

There are numerous **lymphatics** supplied to the skin which form two networks, superficial and deep, communicating with each other and with the lymphatics of the subcutaneous tissue by oblique branches. They originate in the cell spaces of the tissue.

The **nerves** of the skin terminate partly in the epidermis (Fig. 867) and partly in the cutis vera (Fig. 876). The former are prolonged into the epidermis from a dense plexus in the superficial layer of the corium and terminate between the cells in bulbous extremities; or, according to some observers, in the deep epithelial cells themselves. The latter terminate in end bulbs, touch corpuscles, or Pacinian bodies (Figs. 590 and 866), in the manner already described (p. 815), and, in addition to these, a considerable number of fibrils are distributed to the hair follicles, which are said to entwine about the follicle in a circular manner. Other nerve fibres are supplied to the smooth muscle fibres (*mm. arrectores pilorum*) of the hair follicles and to the muscle coat of the bloodvessels. These are probably amyelinic fibres.

THE APPENDAGES OF THE SKIN.

The appendages of the skin are the nails, the hairs, the sudoriferous and sebaceous glands, and their ducts.

The nails and hairs are peculiar modifications of the epidermis, consisting essentially of the same cellular structure as that tissue.

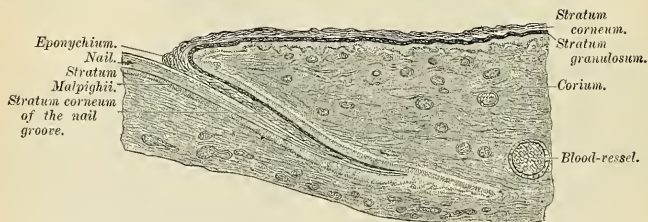


FIG. 881.—Longitudinal section through human nail and its nail groove (sulcus). (From Böhm and Davidoff's Histology.)

The **Nails** (*ungues*) (Figs. 881 and 884) are flattened, elastic structures of a horny texture, placed upon the dorsal surface of the terminal phalanges of the fingers and toes. Each nail is convex on its outer surface, concave within. Its chief mass, called the **body** (*corpus unguis*), lies upon the nail bed. The **free edge** is called the *margo liber*. Each **lateral margin** (*margo lateralis*), like the proximal **short edge of the nail** (*margo occultus*), lies in a groove of the cutis, the **ungual sulcus** (*sulcus matricis unguis*). The **ungual wall** (*vallum unguis*) overlies the lateral and posterior edges. The nail is implanted by means of a portion, called the **root** (*radix unguis*), into a groove in the skin. The root is beneath the ungual wall and is composed of cells which have not yet become horny. It is white in color. The nail has a very firm adhesion to the cutis vera, being accurately moulded

upon the surface of the true skin, as the epidermis is in other parts. The part of the cutis beneath the body and root of the nail is called the **matrix** (*matrix unguis*), because it is the part from which the nail is produced. Corresponding to the body of the nail, the matrix is thick, and raised into a series of **longitudinal ridges** (*cristae matricis unguis*), which are very vascular, and the color is seen through the transparent tissue. Behind this, near the root of the nail, the papillae are small, less vascular, and have no regular arrangement, and here the tissue

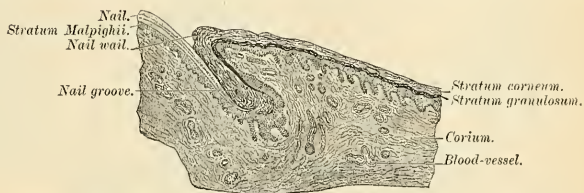

FIG. 882.—Transverse section through human nail and its sulcus. (From Böhm and Davidoff's Histology.)

of the nail is somewhat more opaque; hence this portion is of a whiter color, and is called the **lunula** on account of its crescentic shape.

The cuticle, as it passes forward on the dorsal surface of the finger or toe, is attached to the surface of the nail, a little in advance of the nail root; at the extremity of the finger it is connected with the under surface of the nail a little behind its free edge. The cuticle and the horny substance of the nail (both epidermic structures) are thus directly continuous with each other. The nails consist of a greatly thickened stratum lucidum, the stratum corneum forming merely

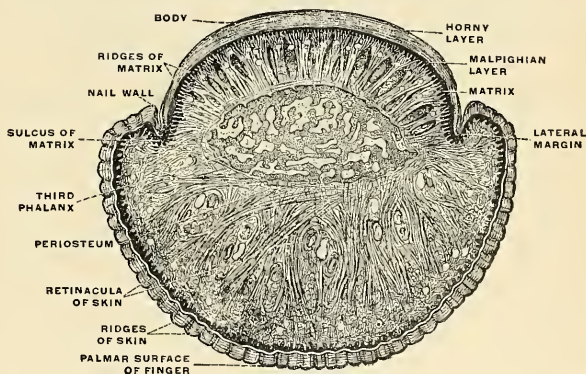


FIG. 883.—Transverse section through the nail and the terminal portion of the ring finger. (Toldt.)

the thin cuticular fold (*eponychium*) which overlaps the lunula. The cells have a laminated arrangement, and are essentially similar to those composing the epidermis. The deepest layer of cells, which lie in contact with the papillae of the matrix, are columnar in form and arranged perpendicularly to the surface; those which succeed them are of a rounded or polygonal form, the more superficial ones becoming broad, thin, and flattened, and so closely compacted as to make the limits of each cell very indistinct. It is by the successive growth of new cells at the root and under surface of the body of the nail that it advances forward and

maintains a due thickness, while, at the same time, the growth of the nail in the proper direction is secured. As these cells in their turn become displaced by the growth of new ones, they assume a flattened form and finally become closely

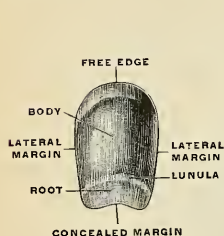


FIG. 884.—The finger-nail completely isolated, seen from the convex side. (Toldt.)

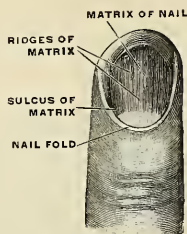


FIG. 885.—The matrix of the nail or nail bed, with the nail fold and nail walls displayed by the removal of the epidermic portion of the nail or nail proper and the surrounding epidermis. (Toldt.)

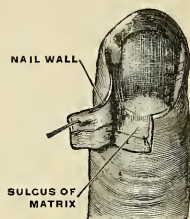


FIG. 886.—Matrix of the nail with partly opened marginal groove of the nail bed. (Toldt.)

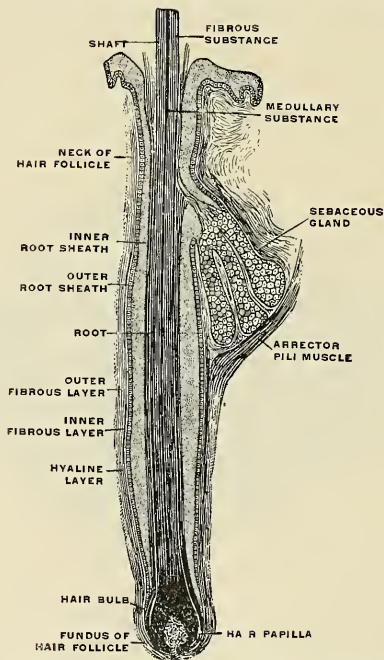


FIG. 887.—A hair of the head still in the course of growth, with hair bulb in longitudinal section. (Toldt.)

compacted together into a firm dense, horny texture. In *chemical composition* the nails resemble the upper layers of the epidermis, containing, however, a somewhat larger proportion of carbon and sulphur (Mulder).

The **Hairs** (*pili*) (Figs. 888 and 889) are peculiar modifications of the epidermis, and consist essentially of the same structure as that membrane. They are found on nearly every part of the surface of the body, excepting the palms of the hands, soles of the feet, the nipples, the inner surface of the prepuce, and the glans penis. Hairs include **hairs of the head** (*capilli*); of the **eyebrows** (*supercilia*); of the **beard** (*barba*); of the **ears** (*tragi*); of the **nostrils** (*vibrissæ*); the **eyelashes** (*cilia*); hairs of the **axilla** (*hirci*); of the **pubes** (*pubes*); and the small hairs of the **skin** or **woolly hairs** (*lanugo*). They vary much in length, thickness, and color in different parts of the body and in different races of mankind. In some parts, as in the skin of the eyelids, they are so short as not to project beyond the follicles containing them; in others, as upon the scalp, they are of considerable length; again, in other parts, as the eyelashes, the hairs of the pubic region, and the whiskers and beard, they are remarkable for their thickness. Straight hairs are stronger

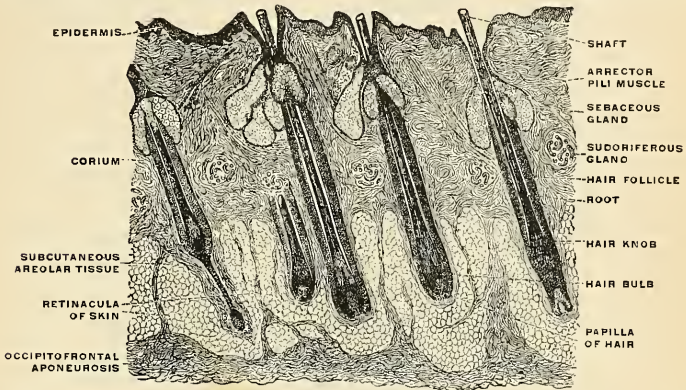


FIG. 888.—Vertical section through the skin of the head. The hairs of the head in longitudinal section. (Toldt.)

than curly hairs, and present on transverse section a cylindrical or oval outline; curly hairs, on the other hand, are flattened. The hairs are usually oblique to the surface from which they arise (Fig. 888). Their direction depends upon the region from which they spring, being fairly regular in certain regions. Thus are formed **hair streams** (*flumina pilorum*) and **hair whirlpools** (*vortices pilorum*).

A hair consists of the **root**, the part implanted in the skin; the **shaft**, the portion projecting from its surface; and the **point**.

The **root of the hair** (*radix pili*) presents at its extremity a bulbous enlargement, the **hair bulb** (*bulbus pili*) (Fig. 887), which is whiter in color and softer in texture than the shaft, and is lodged in a follicular involution of the epidermis called the **hair follicle** (*folliculus pili*) (Fig. 878). When the hair is of considerable length the follicle extends into the subcutaneous cellular tissue. The hair follicle commences on the surface of the skin with a funnel-shaped opening, and passes inward in an oblique or curved direction—the latter in curly hair—to become dilated at its deep extremity or **fundus** (*fundus folliculi pili*), where it corresponds with the bulbous condition of the hair which it contains. It has opening into it, near its free extremity, the orifices of the ducts of one or more sebaceous glands (Figs. 887 and 888). At the bottom of each hair follicle is a small, conical, vascular eminence or papilla, the **hair papilla** (*papilla pili*) (Figs. 887 and 888), similar in every respect to the papillæ found upon the surface of the corium; it is continuous with the dermic layer of the follicle, is highly vascular, and is probably supplied

with nerve fibrils. In structure the hair follicle consists of two root sheaths—an **outer or dermic**, and an **inner or epidermic** (Figs. 887 and 889).

The **outer or dermic root sheath** is formed mainly of fibrous tissue; it is continuous with the corium, is highly vascular, and is supplied by numerous minute nerve filaments. It consists of three layers. The most internal, the **cuticular lining of the follicle**, consists of a hyaline basement membrane, the **hyaline layer**, having a glassy, transparent appearance, which is well marked in the larger hair follicles, but is not very distinct in the follicles of minute hairs. It is continuous with the basement membrane of the surface of the corium. External to this is the **inner fibrous layer**, a compact layer of fibres and spindle-shaped cells arranged circularly around the follicle. This layer extends from the bottom of the follicle as high as the entrance of the ducts of the sebaceous glands. Externally is the **outer fibrous layer**, a thick layer of connective tissue, arranged in longitudinal bundles, forming a more open texture and corresponding to the reticular part of the corium. In this are contained the bloodvessels and nerves.

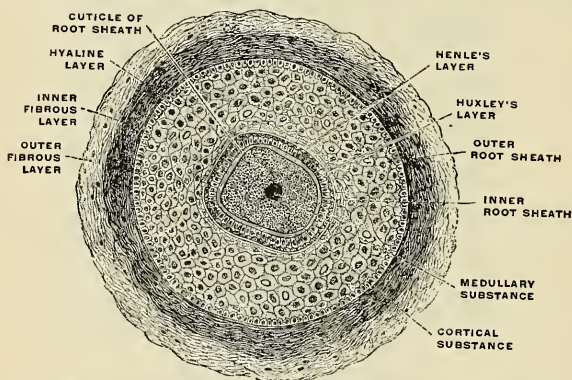


FIG. 889.—A moustache hair with its hair follicle in transverse section. (Toldt.)

The **inner or epidermic layer** is closely adherent to the root of the hair, so that when the hair is plucked from its follicle this layer most commonly adheres to it and forms what is called the **root sheath**. It consists of two strata, named respectively the **outer and inner root sheaths**; the former of these corresponds with the Malpighian layer of the epidermis, and resembles it in the rounded form and soft character of its cells; at the bottom of the hair follicles these cells become continuous with those of the root of the hair. The inner root sheath consists of a delicate cuticle next the hair, composed of a thin layer of imbricated scales having a downward direction, so that they fit accurately over the upwardly directed imbricated scales of the hair itself; then of one or two layers of horny, flattened nucleated cells, known as **Huxley's layer**; and finally of a single layer of horny oblong cells without visible nuclei, called **Henle's layer**.

The hair follicle contains the **root of the hair**, which terminates in a bulbous extremity, and is excavated so as to exactly fit the papilla from which it grows. The bulb is composed of polyhedral epithelial cells, which as they pass upward into the root of the hair become elongated and spindle-shaped, except some in the centre, which remain polyhedral. Some of these latter cells contain pigment granules, which give rise to the color of the hair. It occasionally happens that these pigment granules completely fill the cells of the medullary substance in the centre of the bulb, which gives rise to the dark tract of pigment often found, of greater or less length, in the axis of the hair.

The **shaft of the hair** (*scapus pili*) (Fig. 887) consists of a central pith or **medulla**, the fibrous part of the hair, and the true cuticle externally. The **medulla** (*substantia medullaris pili*) occupies the centre of the shaft and ceases toward the point of the hair. It is usually wanting in the fine hairs covering the surface of the body, and commonly in those of the head. It is found in the shafts of all thick hairs and in the deeper parts of the root of most hairs. It is more opaque and deeper colored when viewed by transmitted light than the fibrous part; but when viewed by reflected light it is white. It is composed of rows of polyhedral cells, which contain granules of eleidin and frequently air spaces. The **cortical substance of the hair** (*substantia corticalis pili*) constitutes the chief part of the shaft; its cells are elongated and unite to form flattened fusiform cells. Between the cells are found minute spaces which contain either pigment granules in dark hair or minute air spaces in white hair. In addition to this there is also a diffused pigment contained in the cells. The cells which form the **outer hair membrane** or **true cuticle** (*cuticula pili*) consist of a single layer which surrounds those of the cortical part; they are converted into thin, flat scales, having an imbricated arrangement.

Connected with the hair follicles are minute bundles of involuntary muscle fibres, termed **Arrectores pilorum** (*mm. arrectores pilorum*) (Figs. 878 and 887). They arise from the superficial layer of the corium, and are inserted into the outer surface of the hair follicle, below the entrance of the duct of the sebaceous gland. They are placed on the side toward which the hair slopes, and by their action elevate the hair.¹ When the hair is elevated a depression forms over the seat of origin of the muscle, and the parts about the hair are elevated. This condition is known as **goose skin**. It is probable that the contraction of these muscles aids in emptying sebaceous glands.

Bloodvessels and Nerves (Fig. 878).—A hair follicle possesses a rich network of capillaries about the hyaline membrane, and capillary loops pass to the papilla. We have little knowledge as to nerve terminations of the human hair.

The **Sebaceous Glands** (*glandulae sebaceae*) are small, sacculated, glandular organs, lodged in the substance of the corium. They are found in most parts of the skin, but are especially abundant in the scalp and face; they are also very numerous around the apertures of the anus, nose, mouth, and external ear, but are wanting in the palms of the hands and soles of the feet. Each gland consists of a single duct, more or less capacious, which terminates in a cluster of small secreting pouches or saccules. The sacculi connected with each duct vary in number, as a rule, from two to five, but in some instances may be as many as twenty. They are composed of a transparent, colorless membrane, enclosing a number of epithelial cells. Those of the outer or marginal layer are small and polyhedral, and are continuous with the lining cells of the duct. The remainder of the sac is filled with larger cells, containing fat, except in the centre, where the cells have become broken up, leaving a cavity containing their debris and a mass of fatty matter, which constitutes the sebaceous secretion. The orifices of the ducts open most frequently into the hair follicles, but occasionally upon the general surface, as in the labia minora and the free margins of the lips. On the nose and face the glands are of large size, distinctly lobulated, and often become much enlarged from the accumulation of pent-up secretion. The largest sebaceous glands are those found in the eyelids—the Meibomian glands.

The **Sudoriferous or Sweat Glands** (*glandulae sudoriferae*) (Figs. 878 and 888) are the organs by which a large portion of the aqueous and gaseous materials

¹ Arthur Thomson suggests that the contraction of these muscles on follicles which contain weak, flat hairs will tend to produce a permanent curve in the follicle, and this curve will be impressed on the hair which is moulded within it, so that the hair, on emerging through the skin, will be curled. Curved hair follicles are characteristic of the scalp of the Bushman.

is excreted by the skin. They are found in almost every part of this structure, being absent on the red border of the lips, the glans penis, and inner surface of the prepuce. On the eyelids they are somewhat modified, and are called **ciliary glands** (*glandulae ciliares* [Molli]); about the anus they are extremely large, and are called **circumanal glands** (*glandulae circumanales*). The sweat glands are situated in small pits below the under surface of the corium, or, more frequently, in the subcutaneous areolar tissue, surrounded by a quantity of adipose tissue. They are small, lobular, reddish bodies, consisting of a single convoluted tube, from which the efferent duct (*ductus sudoriferus*) proceeds outward through the corium and cuticle, becomes somewhat dilated at its extremity, and opens on the surface of the cuticle by an oblique valve-like aperture (*porus sudoriferus*). The duct, as it passes through the epidermis, presents a spiral arrangement, being twisted like a corkscrew, in those parts where the epidermis is thick; where, however, the epidermis is thin, the spiral arrangement does not exist. In the superficial layers of the corium the duct is straight, but in the deeper layers it is convoluted or even twisted. The spiral course of these ducts is especially distinct in the thick cuticle of the palm of the hand and sole of the foot. The size of the glands varies. They are especially large in those regions where the flow of perspiration is copious, as in the axillæ, where they form a thin, mamillated layer of a reddish color, which corresponds exactly to the situation of the hair in this region; they are large also in the groin. Their number varies. They are most numerous on the palm of the hand, presenting, according to Krause, 2800 orifices on a square inch of the integument, and are rather less numerous on the sole of the foot. In both of these situations the orifices of the ducts are exceedingly regular, and open on the curved surface ridges. In other situations they are more irregularly scattered, but the number in a given extent of surface presents a fairly uniform average. In the neck and back they are least numerous, their number amounting to 417 on the square inch (Krause). Their total number is estimated by the same writer at 2,381,248, and supposing the aperture of each gland to represent a surface of $\frac{1}{670}$ of an inch in diameter, he calculates that the whole of these glands would present an evaporating surface of about eight square inches. Each gland consists of a single tube intricately convoluted, terminating at one end by a blind extremity, and opening at the other end upon the surface of the skin. The wall of the duct is thick, the lumen seldom exceeding one-third of the diameter of the tubes. The tube, both in the gland and where it forms the excretory duct, consists of two layers (except in the epidermis, where the epithelium of this layer forms the wall)—an outer, formed by fine areolar tissue, and an inner layer of epithelium. The external coat is thin, continuous with the superficial layer of the corium, and extends only as high as the surface of the corium. The epithelial lining in the distal part of the coiled tube consists of a single layer of cubical cells, supported on a basement membrane. Between the epithelium and the fibrocellular coat lies a layer of longitudinally or obliquely arranged involuntary muscle fibres, the contraction of which aid in the expulsion of the sweat. In the proximal part there are two or more layers of polyhedral cells lined on the internal surface (next the lumen of the tube) by a delicate membrane devoid of muscle fibres. The contents of the smaller sweat glands is quite fluid; but in the larger glands the contents are semifluid and opaque, and contain a number of colored granules and cells which appear analogous to epithelial cells.

The **bloodvessels** are branches from the subcutaneous vessels and the arterial plexus of the deep part of the corium. Numerous amyelinic **nerve fibres** lie upon the membrana propria of a sweat gland. From them fibrils pass inward and terminate by end bulbs upon the cells of the gland.

THE ORGANS OF VOICE AND RESPIRATION.

THE respiratory organs (*apparatus respiratorius*) consist of the **larynx**, or organ of voice, the **trachea**, **bronchi**, **lungs**, and **pleuræ**.

THE LARYNX.

The **larynx**, or organ of voice, is placed at the upper part of the air passage. It is situated between the trachea and base of the tongue, at the upper and fore part of the neck, where it forms a considerable projection in the middle line. On *either side* of it lie the great vessels of the neck; *behind*, it forms part of the boundary of the pharynx, and is covered by the mucous membrane lining that cavity. Its vertical extent corresponds to the fourth, fifth, and sixth cervical vertebrae, but it is placed somewhat higher in the female and also during childhood.

According to Sappey, the average measurements of the adult larynx are as follows:

	In males.	In females.
Vertical diameter	44 mm.	36 mm.
Transverse diameter	43 “	41 “
Antero-posterior diameter	36 “	26 “
Circumference	136 “	112 “

Until puberty there is no marked difference between the larynx of the male and that of the female. In the latter its further increase in size is only slight, whereas in the former the increase is great; all the cartilages are enlarged, and the thyroid becomes prominent as the pomum Adami in the middle line of the neck, while the length of the glottis is nearly doubled.

The larynx is broad above, where it presents the form of a triangular box, flattened behind and at the sides, and bounded in front by a prominent vertical ridge. Below, it is narrow and cylindrical. It is composed of cartilages, which are connected by ligaments and moved by numerous muscles. It is lined by mucous membrane, which is continuous above with that lining the pharynx and below with that of the trachea. On each side internal to the thyroid cartilage a small recess, the **recessus pyriformis**, extends forward from the cavity of the pharynx (p. 1231).

The **Cartilages of the Larynx** (*cartilagine laryngis*) are nine in number, three single and three pairs:

Thyroid.	Two Arytenoid.
Cricoid.	Two Cornicula Laryngis.
Epiglottis.	Two Cuneiform.

The **Thyroid Cartilage** (*cartilago thyroidea*) (Figs. 891 and 892) is the largest cartilage of the larynx. It consists of two lateral **lamellæ** or **alæ**, united at an acute angle in front, forming a vertical projection in the midline, which is prominent

above and called the **pomum Adami** (*prominentia laryngea*). This prominence is subcutaneous, is more distinct in the male than in the female, and is often separated from the integument by a bursa, the **bursa subcutanea prominentiae laryngeae**. The anterior borders of the alæ of the thyroid cartilage which are continuous below are separated above by a V-shaped notch, the **thyroid notch** (*incisura thyroidea superior*). The posterior borders are free, rounded, and somewhat thickened, and are extended in the form of superior and inferior cornua.

The *outer surface* of each ala (Fig. 891) presents an **oblique ridge** (*linea obliqua*), which passes downward and forward from a tubercle situated near the root of the superior cornu, the **superior tubercle** (*tuberculum thyroideum superius*), to a small tubercle near the anterior part of the lower border, the **inferior tubercle** (*tuberculum thyroideum inferius*). This ridge gives attachment to the Sternothyroid and Thyrohyoid muscles, and the portion of cartilage included between it and the posterior border gives attachment to part of the Inferior constrictor muscle.

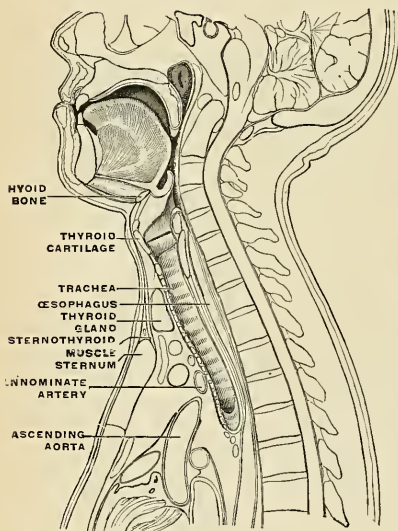


FIG. 890.—Sagittal section of a man twenty-one years of age.
(After W. Braune.)

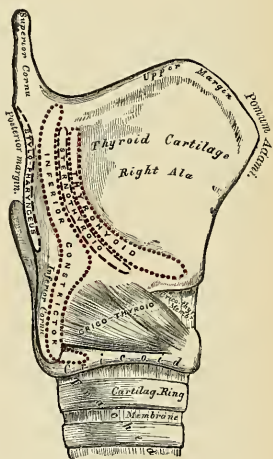


FIG. 891.—Side view of the thyroid and cricoid cartilages.

The *inner surface* (Fig. 892) of each ala is smooth, slightly concave, and covered by the mucous membrane of the outer wall of the sinus pyriformis above and behind; but in front, in the receding angle formed by the junction of the alæ, are attached the epiglottis, the true and false vocal cords, the Thyroarytenoid and Thyroepiglottidean muscles, and the thyroepiglottidean ligament.

The *upper border* (Fig. 891) is sinuously curved, being concave at its posterior part, then rising into a convex outline in front; it gives attachment throughout its whole extent to the **thyrohyoid membrane**.

The *lower border* (Fig. 892) is nearly straight in front, but behind, close to the cornu, it is concave, the two parts being separated by the inferior tubercle. A small part of it, in and near the median line, is connected to the cricoid cartilage by

the middle portion of the **cricothyroid membrane** (*membrana cricothyroides*); and, on either side, by the Cricothyroid muscle.

The **posterior borders** (Fig. 892) are thick and rounded, and each terminates above, in a **superior cornu** (*cornu superius*), and below, in an **inferior cornu** (*cornu inferius*). The two superior cornua are long and narrow, directed upward, backward, and inward, and terminate in conical extremities, which give attachment to the lateral thyrohyoid ligaments. The two inferior cornua are short and thick; they pass downward, with a slight inclination forward and inward, and each presents on its inner surface a small oval articular facet for articulation with the side of the cricoid cartilage (Fig. 891). The posterior border receives the insertion of the Stylopharyngeus and Palatopharyngeus muscles on each side.

During infancy the alae of the thyroid cartilage are joined to each other by a narrow, lozenge-shaped strip, named the **intrathyroid cartilage**. This strip extends from the upper to the lower border of the thyroid cartilage in the middle line, and is distinguished from the alae by being more transparent and more flexible.

The **Cricoid Cartilage** (*cartilago cricoidea*) (Figs. 891 and 892) is so called from its resemblance to a signet ring (*χοιζος*, a ring). It is smaller, but thicker and stronger than the thyroid cartilage, and forms the lower and back part of the cavity of the larynx. It is hyaline cartilage, and consists of two parts—a **quadrate portion**, situated behind, and a narrow ring, or **arch**, one-fourth or one-fifth the depth of the posterior part, situated in front. The posterior square portion rapidly narrows at the sides of the cartilage, at the expense of the upper border, into the anterior portion.

Its **posterior portion**, or **lamina** (*lamina cartilaginæ cricoideæ*), is very deep and broad, and measures from above downward about an inch (2.5 cm.); it presents, on its posterior surface, in the middle line, a vertical ridge for the attachment of the longitudinal fibres of the œsophagus, and on either side a broad depression for the Cricoarthyenoideus posticus muscle.

Its **anterior portion**, or **arcus** (*arcus cartilaginæ cricoideæ*), is narrow and convex, and measures vertically about one-fourth or one-fifth of an inch (6 to 5 mm.); it affords attachment externally in front and at the sides to the Cricothyroid muscles, and, behind, to part of the Inferior constrictor.

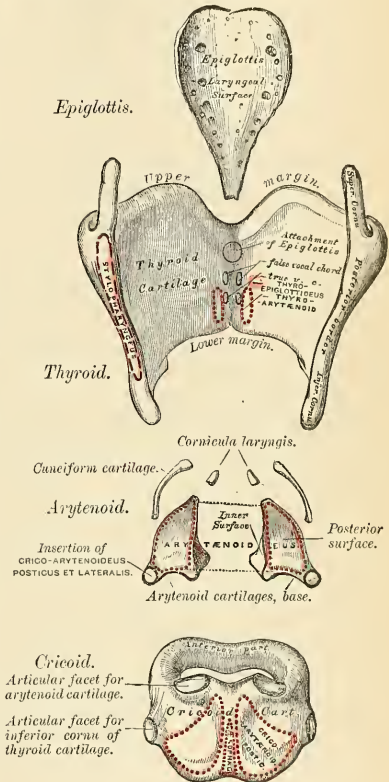


FIG. 892.—The cartilages of the larynx. Posterior view.

At the junction of the posterior quadrate portion with the rest of the cartilage is a small round articular eminence, for articulation with the inferior cornu of the thyroid cartilage.

The **lower border** of the cricoid cartilage is horizontal, and connected to the uppermost ring of the trachea by fibrous membrane (Figs. 891 and 892).

Its **upper border** is directed obliquely upward and backward, owing to the great depth of the posterior surface. It gives attachment, in *front*, to the middle portion of the cricothyroid membrane; at the sides, to the lateral portion of the same membrane and to the lateral Cricothyroid muscle; *behind*, it presents, in the middle, a shallow notch, and on *each side* of this is a smooth, oval surface, directed upward and outward, for articulation with the base of an arytenoid cartilage.

The **inner surface** of the cricoid cartilage is smooth, and covered by mucous membrane.

The **Arytenoid Cartilages** (*cartilagine arytenoideae*) (Fig. 892) are two in number, and situated at the upper border of the cricoid cartilage, at the back of the larynx in the interval between the posterior borders of the alae of the thyroid cartilages. Each cartilage is in form a three-sided pyramid, and presents for examination **three surfaces**, a **base**, and an **apex**.

The **posterior surface** is triangular, smooth, concave, and gives attachment to the transverse portion of the Arytenoid muscle.

The **antero-external surface** is somewhat convex and rough. It presents, near its apex, a small elevation, the **colliculus**; from this a **ridge** (*crista arcuata*) passes backward and then forward and downward into a sharp-pointed process, the **vocal process**. This ridge separates a deep depression above, the **fovea triangularis**, from a broader and shallower depression below, the **fovea oblonga**. A short distance above the base a small tubercle on the anterior border gives origin to the ligament of the false vocal cord, the superior thyroarytenoid ligament. To the outer part of the ridge, as well as the surface above and below, is attached the Thyroarytenoid muscle.

The **internal surface** is narrow, smooth, and flattened, and forms the lateral boundary of the respiratory part of the glottis.

The **base** (*basis*) of each cartilage is broad, and presents a concave smooth surface, for articulation with the cricoid cartilage. Two of its angles require special mention: The **external angle**, which is short, rounded, and prominent, projects backward and outward, and is termed the **muscular process** (*processus muscularis*), from receiving the insertion of the Posterior and Lateral cricoarytenoid muscles. The **anterior angle**, also prominent, but more pointed, projects horizontally forward, and gives attachment to the inferior thyroarytenoid ligament, the supporting ligament of the true vocal cord. This angle is called the **vocal process** (*processus vocalis*).

The **apex** of each cartilage is pointed, curved backward and inward, and surmounted by a small conical, cartilaginous nodule, the **corniculum laryngis**, articulated with or united to the arytenoid cartilage.

The **Cornicula Laryngis** or **Cartilages of Santorini** (*cartilagine corniculatae*) (Figs. 892 and 898) are two small conical nodules, consisting of yellow elastic cartilage, which articulate with the summits of the arytenoid cartilages and serve to prolong them backward and inward. They are situated in the posterior parts of the arytenoepiglottic folds, and are sometimes united to the arytenoid cartilages.

The **Cuneiform Cartilages** or **Cartilages of Wrisberg** (*cartilagine cuneiformes*) (Figs. 892 and 897) are two small, elongated pieces of yellow elastic cartilage, placed one on each side, in the arytenoepiglottic fold (*plica aryepiglottica*) (Fig. 897), where they give rise to small whitish elevations on the inner surface of the mucous membrane, just in front of the arytenoid cartilages.

The **Epiglottis** (*cartilago epiglottica*) (Figs. 892 and 893) is a thin, flexible lamella of fibrocartilage, of a yellowish color, shaped like a leaf, and projecting behind the tongue in front of the superior opening of the larynx. The projecting extremity is broad and rounded; its attached part or apex (*petiolus epiglottidis*) is long, narrow, and connected to the receding angle between the two alae of the thyroid cartilage, just below the median notch, by a ligamentous band, the **thyroepiglottic ligament** (Fig. 894). The lower part of its anterior surface is connected to the upper border of the body of the hyoid bone by an elastic ligamentous band, the **hyoepiglottic ligament**.

Its **anterior or lingual surface** is curved forward, toward the tongue, and covered at its upper, free part by mucous membrane, which is reflected on to the sides and base of the organ, forming a median and two lateral folds, the **glossopiglottic folds** (Fig. 897); the lateral folds are partly attached to the wall of the pharynx. The depressions between the epiglottis and base of the tongue on each side of the median fold are named the **valleculæ**. The lower part of the anterior surface of the epiglottis lies behind the hyoid bone, the thyrohyoid membrane, and upper part of the thyroid cartilage, but is separated from these structures by a mass of fatty tissue.

Its **posterior or laryngeal surface** is smooth, concave from side to side, concavo-convex from above downward; its lower part projects backward as an elevation, the **tubercle or cushion** (*tuberculum epiglotticum*) (Fig. 893). When the mucous membrane is removed, the surface of the cartilage is seen to be indented by a number of small pits, in which mucous glands are lodged. To its sides the **arytenoepiglottic folds** are attached (Fig. 897).

Structure.—The cornicula laryngis and cuneiform cartilages, the epiglottis, and the apices of the arytenoids at first consist of hyaline cartilage, but later elastic fibres grow in from the perichondrium, and eventually they are converted into yellow fibrocartilage; they show little tendency to calcification. The thyroid, cricoid, and the greater part of the arytenoids consist of hyaline cartilage, and become more or less ossified as age advances. Ossification commences about the twenty-fifth year in the thyroid cartilage, somewhat later in the cricoid and arytenoids; by the sixty-fifth year these cartilages may be completely converted into bone.

Ligaments.—The ligaments of the larynx are *extrinsic*—i. e., those connecting the thyroid cartilage and epiglottis with the hyoid bone, and the cricoid cartilage with the trachea; and *intrinsic*, those which connect the several cartilages of the larynx to each other.

Extrinsic Ligaments.—The ligaments connecting the thyroid cartilage with the hyoid bone are four in number—the thyrohyoid membrane, the two lateral thyrohyoid ligaments, and the hyoepiglottic ligament.

The **Thyrohyoid Membrane** (*membrana hyothyroidea*) (Fig. 894) is a broad, fibroelastic, membranous layer, attached below to the upper border of the thyroid cartilage, and above to the upper margin of the posterior surface of the body and greater cornua of the hyoid bone, thus passing behind the posterior surface of the hyoid, and being separated from it by a synovial bursa (*bursa m. sternohyoidei*), which facilitates the upward movement of the larynx during deglutition. It is thicker in the middle line than at either side. This thickening is due to elastic fibres, and constitutes the **middle thyrohyoid ligament** (*ligamentum hyothyroideum medium*). On each side the posterior extremity of the membrane is thickened by elastic fibres, constituting the **lateral thyrohyoid ligament** (*ligamentum hyothyroideum laterale*). The thyrohyoid membrane is pierced on each side by the superior laryngeal vessels and the internal branch of the superior laryngeal nerve. The anterior surface of the thyrohyoid membrane is in relation with the Thyrohyoid, Sternohyoid, and Omohyoid muscles and with the body of the hyoid bone. The two lateral ligaments are rounded, elastic cords, which pass between the superior

cornua of the thyroid cartilage and the extremities of the greater cornua of the hyoid bone. A small cartilaginous nodule (*cartilago triticea*), sometimes bony, is frequently found in each.

The ligament connecting the epiglottis with the hyoid bone is the *hyoepiglottic*. In addition to this extrinsic ligament, the epiglottis is connected to the tongue by the three glossoepiglottic folds of mucous membrane, which may also be considered as extrinsic ligaments of the epiglottis. The **hyoepiglottic ligament** (*ligamentum hyoepiglotticum*) is an elastic band, which extends from the anterior surface of the epiglottis, near its apex, to the upper border of the body of the hyoid bone.

The **cricotracheal ligament** (*ligamentum cricotracheale*) connects the cricoid cartilage with the first ring of the trachea. It resembles the fibrous membrane which connects the cartilaginous rings of the trachea.

Intrinsic Ligaments.—The ligaments connecting the thyroid cartilage to the cricoid are three in number—the **cricothyroid membrane** and the two **capsular ligaments**.

The **Cricothyroid Membrane** (*conus elasticus*) (Figs. 891 and 901) is composed mainly of yellow elastic tissue. It consists of three parts, a central triangular portion and two lateral portions. The *central part* (*ligamentum cricothyroideum medium*) is thick and strong,

narrow above and broadening out below. It connects the contiguous margins of the thyroid and cricoid cartilages. It is convex, concealed on each side by the Cricothyroid muscle, but subcutaneous in the middle line; it is crossed horizontally by a small anastomotic arterial arch, formed by the junction of the two cricothyroid arteries. The *lateral portions* are thinner and lie close under the mucous membrane of the larynx. They extend from the superior border of the cricoid cartilage to the inferior margin of the true vocal cords with which they are continuous. These cords may therefore be regarded as the free borders of the lateral portions of the cricothyroid membrane; they

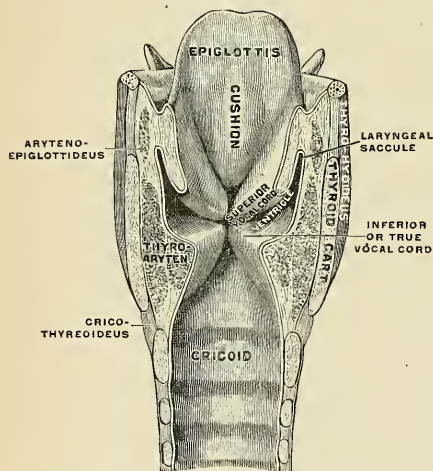


FIG. 893.—Coronal section of larynx, rear view of front half. (Testut.)

extend from the vocal processes of the arytenoid cartilages to the receding angle of the thyroid cartilage near its centre. The lateral portions are lined internally by mucous membrane, and are separated from the thyroid cartilage by the Cricoaarytenoideus lateralis and Thyroarytenoideus muscles.

A **capsular ligament**, strengthened posteriorly by a well-marked fibrous band, encloses the articulation of the inferior cornu of the thyroid with the cricoid cartilage on each side. The articulation is lined by synovial membrane.

Each arytenoid cartilage is connected to the cricoid by a **capsular ligament** (*capsula articularis cricoarytaenoidea*) and a **posterior cricoarytenoid ligament** (*ligamentum cricoarytenoideum posterius*). The capsular ligament is thin and loose, and is attached to the margin of the articular surfaces, and lined by synovial

membrane. The **posterior cricoarytenoid ligament** extends from the cricoid to the inner and back part of the base of the arytenoid cartilage.

The **thyroepiglottic ligament** (*ligamentum thyroepiglotticum*) (Fig. 894) is a long, slender elastic cord which connects the apex of the epiglottis with the internal surface of the receding angle of the thyroid cartilage, immediately beneath the median notch, above the attachments of the false and true vocal cords.

Movements.—The articulation between the inferior cornu of the thyroid and the cricoid cartilage on either side is a diarthroidal one, and permits of rotary and gliding movements. The rotary movement is one in which the inferior cornua of the thyroid cartilage rotate upon the cricoid cartilage around an axis passing transversely through both joints. The gliding movement consists in a limited shifting of the cricoid on the thyroid in different directions.

The articulation between the arytenoid cartilages and the cricoid is also a diarthroidal one, and permits of two varieties of movement—one a rotation of the arytenoid on a vertical axis, whereby the vocal process is moved outward or inward and the opening of the rima glottidis increased or diminished; the other is a gliding movement and allows the arytenoid cartilages to approach or recede from each other; from the direction and slope of the articular surfaces outward gliding is accompanied by a forward and downward movement. The two movements of gliding and rotation are associated, the gliding inward being connected with inward rotation, and the gliding outward with outward rotation. The posterior cricoarytenoid ligaments limit the forward movement of the arytenoid cartilages on the cricoid.

Interior of the Larynx (Figs. 893, 894, and 897).—The **cavity of the larynx** (*cavum laryngis*) extends from the superior aperture of the larynx to the lower border of the cricoid cartilage. It is divided into two parts by the projection

inward of the true vocal cords, between which is a narrow triangular fissure or chink, the **rima glottidis**. The portion of the cavity of the larynx above the true vocal cords, sometimes called the **vestibule** (*vestibulum laryngis*), is wide and triangular in shape, its base or anterior wall presenting, however, about its centre the backward projection of the cushion of the epiglottis. It contains the false vocal cords (*plicae ventriculares*), and between these and the true vocal cords are the ventricles of the larynx. The portion below the true vocal cords is at first of an elliptical form, but lower down it widens out, assumes a circular form, and is continuous with the tube of the trachea.

The **Superior Aperture of the Larynx** (*aditus laryngis*) (Figs. 893 and 897) is a triangular or cordiform opening, wide in front, narrow behind, and sloping obliquely downward and backward. It is bounded, in *front*, by the epiglottis; *behind*, by the apices of the arytenoid cartilages and the cornicula laryngis; and

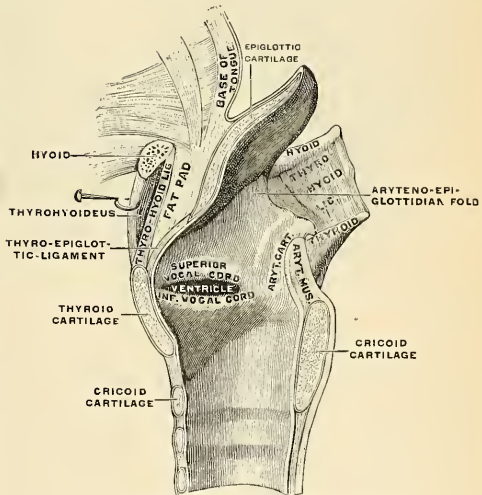


FIG. 894.—Sagittal section of larynx, right half. (Testut.)

laterally, by a fold of mucous membrane, enclosing ligamentous and muscle fibres, stretched between the side of the epiglottis and the apex of the arytenoid cartilage; this is the **arytenoepiglottic fold** (Figs. 894 and 897), on the margin of which the cuneiform cartilage forms a more or less distinct whitish prominence.

The **superior or false vocal cords** (*plicae ventriculares*) (Figs. 893 and 894), so called because they are not directly concerned in the production of the voice, are two thick folds of mucous membrane, each enclosing a very narrow band of connective tissue, the so-called **superior thyroarytenoid ligament**. This is attached in front to the angle of the thyroid cartilage immediately below the attachment of the epiglottis, and behind to the antero-external surface of the arytenoid cartilage. The lower border of this ligament, enclosed in mucous membrane, forms a free crescentic margin, which constitutes the upper boundary of the ventricle of the larynx.

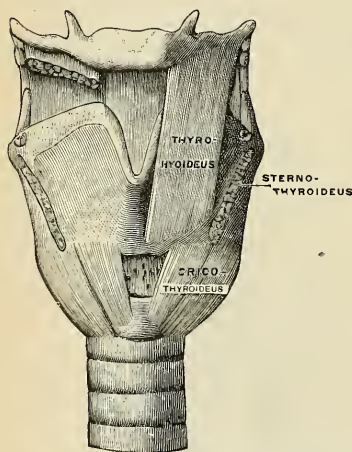


FIG. 895.—Muscles of larynx, front view. The Sternalthyroids and right Thyrohyoid have been removed. (Testut.)

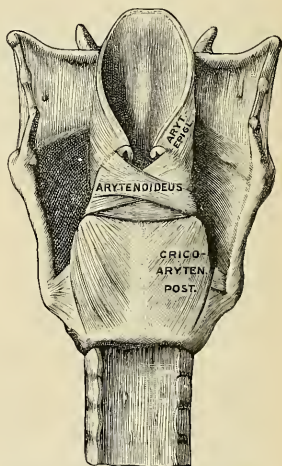


FIG. 896.—Muscles of larynx, from behind. (Testut.)

The **inferior or true vocal cords** (*plicae vocales*) (Figs. 893 and 894), so called from their being concerned in the production of sound, are two strong bands named the **inferior thyroarytenoid ligaments**. Each ligament consists of a band of yellow elastic tissue, attached in front to the depression between the alae of the thyroid cartilage, and behind to the vocal process at the base of the arytenoid. Its lower border is continuous with the thin lateral part of the cricothyroid membrane. Its upper border forms the lower boundary of the ventricle of the larynx. Externally, the Thyroarytenoideus muscle lies parallel with it. It is covered internally by mucous membrane, which is extremely pale, thin, and closely adherent to its surface. The node-like attachment of the ligament to the thyroid cartilage appears as a yellow spot (*macula flava*); the vocal process also shines through the mucosa as a yellowish spot.

The **ventricle of the larynx or laryngeal sinus** (*ventriculus laryngis* [Morgagnii]) (Figs. 893 and 894) is an oblong fossa, situated between the superior and inferior vocal cords on each side, and extending nearly their entire length. This fossa is bounded, *above*, by the free crescentic edge of the false vocal cord; *below*, by the straight margin of the true vocal cord; *externally*, by the mucous membrane cover-

ing the corresponding Thyroarytenoideus muscle. The anterior part of the ventricle leads up by a narrow opening into a cecal pouch of mucous membrane of variable size, called the **laryngeal saccule**.

The **laryngeal saccule** (*appendix ventriculi*) (Fig. 893), or laryngeal pouch, is a membranous sac, placed between the superior vocal cord and the inner surface of the thyroid cartilage, occasionally extending as far as its upper border or even higher; it is conical in form, and curved slightly backward. On the surface of its mucous membrane are the openings of sixty or seventy mucous glands, which are lodged in the submucous areolar tissue. This sac is enclosed in a fibrous capsule, continuous below with the superior thyroarytenoid ligament; its laryngeal surface is covered by a few delicate muscle fasciculi which arise from the apex of the arytenoid cartilages and become lost in the fold of mucous membrane extending between the arytenoid cartilage and the side of the epiglottis (they were named by Hilton the *compressor sacculi laryngis*); while its exterior is covered by the Thyroarytenoideus and Thyroepiglottideus muscles. These muscles compress the laryngeal saccule, and express the secretion it contains upon the vocal cords to lubricate their surfaces. The saccule assists in imparting resonance to the voice.

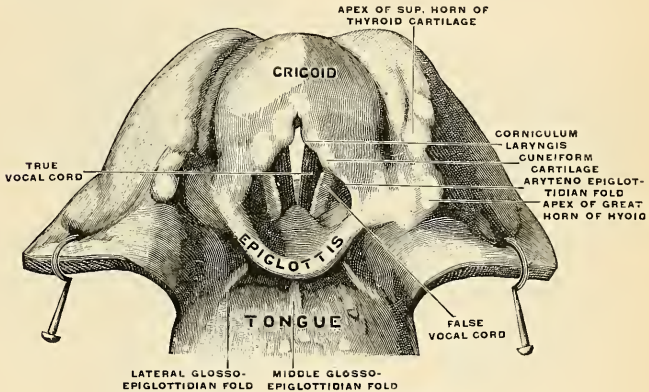


FIG. 897.—Larynx, viewed from above. (Testut.)

The **Rima Glottidis** (Figs. 893 and 897) is the elongated fissure or chink between the true vocal cords in front, and between the bases and vocal processes of the arytenoid cartilages behind. It is therefore frequently subdivided into an anterior, interligamentous or **vocal portion**, the **glottis vocalis** (*pars intermembranacea*), and a posterior, intercartilaginous or **respiratory portion**, the **glottis respiratoria** (*pars intercartilaginea*). Posteriorly it is limited by the mucous membrane passing between the arytenoid cartilages. The vocal portion averages about three-fifths of the length of the entire aperture. It is the narrowest part of the cavity of the larynx, and its level corresponds to the bases of the arytenoid cartilages. Its length, in the male, measures rather less than an inch (23 mm.); in the female it is shorter (16 to 20 mm.). The width and shape of the rima glottidis vary with the movements of the vocal cords and arytenoid cartilages during respiration and phonation. In the condition of rest—*i. e.*, when those structures are uninfluenced by muscular action, as in quiet respiration, the glottis vocalis is triangular, with its apex in front and its base behind, the latter being represented by a line

about 8 mm. ($\frac{1}{3}$ inch) long, connecting the anterior extremities of the vocal processes, while the inner surfaces of the arytenoids are parallel to each other, and hence the glottis respiratoria is rectangular. During extreme adduction of the cords, as in the emission of a high note, the glottis vocalis is reduced to a linear slit by the apposition of the cords, while the glottis respiratoria is triangular, its apex corresponding to the anterior extremities of the vocal processes of the arytenoids, which are approximated by the inward rotation of the cartilages. Conversely in extreme abduction of the cords, as in forced inspiration, the arytenoids and their vocal processes are rotated outward, and the glottis respiratoria is triangular in shape, but with its apex directed backward. In this condition the entire glottis is somewhat lozenge-shaped, the sides of the glottis vocalis diverging from before backward, those of the glottis respiratoria diverging from behind forward, the widest part of the aperture corresponding with the attachment of the cords to the vocal processes.

Muscles of the Larynx.—The *extrinsic* muscles are those which pass between the larynx and parts around—these have been described on pages 387 to 389. The *intrinsic* muscles, confined entirely to the larynx, are:

Cricothyroideus.

Cricoarytenoideus lateralis.

Cricoarytenoideus posticus.

Arytenoideus.

Thyroarytenoideus.

The Arytenoideus is a single muscle, the other four are paired.

Dissection.—In order to expose the Lateral cricothyroid and Thyroarytenoid muscles the thyroid cartilage of one side must be removed. Begin by taking away the Cricothyroid muscle, then dividing the lateral thyrohyoid ligament, disarticulate the inferior cornu of the thyroid cartilage from the cricoid cartilage, then carefully cut through the thyroid cartilage a short distance from its union with its twin.

The **Cricothyroid** (*m. cricothyreoideus*) (Figs. 898 and 899) is triangular in form, and situated at the fore part and side of the cricoid cartilage. It *arises* from the front and lateral part of the cricoid cartilage; its fibres diverge, passing obliquely upward and outward to be *inserted* into the lower border of the thyroid cartilage and into the anterior border of the lower cornu. The inner borders of these two muscles are separated in the middle line by a triangular interval occupied by the central part of the cricothyroid membrane.

The **Posterior Cricoarytenoid** (*m. cricoarytaenoideus posterior*) (Figs. 898 and 899) *arises* from the broad depression occupying each lateral half of the posterior surface of the cricoid cartilage; its fibres pass upward and outward, converging to be *inserted* into the outer angle (muscular process) of the base of the arytenoid cartilage. The upper fibres are nearly horizontal, the middle oblique, and the lower almost vertical.

The **Lateral Cricoarytenoid** (*m. cricoarytaenoideus lateralis*) (Figs. 898 and 899), a paired muscle, is smaller than the preceding, and of an oblong form. It *arises* from the upper border of the side of the cricoid cartilage, and, passing obliquely upward and backward, is *inserted* into the muscular process of the arytenoid cartilage in front of the posterior Cricoarytenoid muscle. The deep surface is applied to the cricothyroid membrane, its external or superficial surface is subjacent to the thyroid cartilage.

The **Arytenoideus** (Figs. 898 and 899) is a single muscle filling up the posterior concave surface of the arytenoid cartilages. It *arises* from the posterior surface and outer border of one arytenoid cartilage, and is inserted into the corresponding parts of the opposite cartilage. It consists of three planes of fibres, two oblique and one transverse. The *oblique fibres* (*m. arytenoideus obliquus*),

the most superficial, form two fasciculi, which pass from the base of one cartilage to the apex of the opposite one, and which, therefore, cross each other like the limbs of the letter X. The **transverse fibres** (*m. arytaenoides transversus*), the deepest and most numerous, pass transversely across between the two cartilages. A few of the oblique fibres are continued around the outer margin of the cartilage, and blend with the Thyroarytenoid in the arytenoepiglottic fold, and are called the **Aryepiglotticus** muscle.

The **Thyroarytenoid** (*m. thyroarytenoideus*) (Figs. 898 and 899), a paired muscle, is broad and flat. It lies parallel with the outer side of the true vocal cord. It arises in front from the lower half of the receding angle of the thyroid cartilage, and from the cricothyroid membrane. Its fibres pass backward and outward, to be inserted into the base and antero-external surface of the arytenoid cartilage. This muscle consists of two fasciculi.¹ The **inner portion** (*m. vocalis*) is a triangular band which is inserted into the vocal process of the arytenoid cartilage, and into the adjacent portion of its antero-external surface; it lies parallel with the true vocal cord, to which it is adherent. This fasciculus on its deeper surface

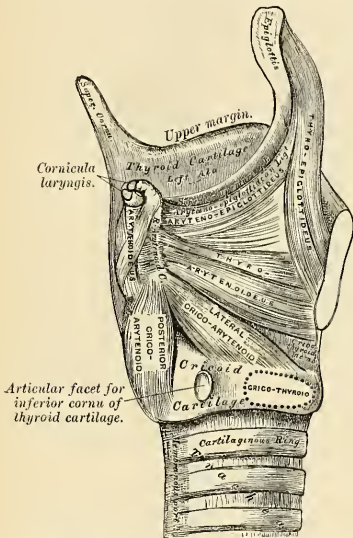


FIG. 898.—Muscles of larynx. Side view. Right ala of thyroid cartilage removed.

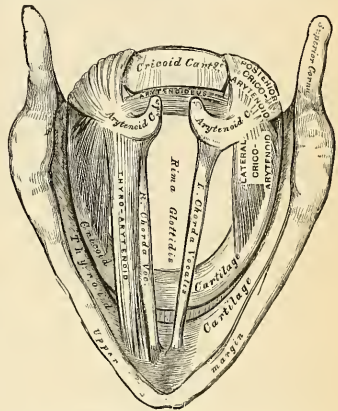


FIG. 899.—Interior of the larynx, seen from above. (Enlarged.)

gives off some fibres which are attached to the true vocal cord. These are called the **Aryvocalis** (Ludwig). The **outer portion** (*m. thyroarytenoideus*), the thinner, is inserted into the antero-external surface and outer border of the arytenoid cartilage above the preceding fibres; it lies on the outer side of the laryngeal sacculæ, immediately beneath the mucous membrane.

A considerable number of the fibres of the Thyroarytenoideus are prolonged into the arytenoepiglottic fold, where some of them become lost, while others are continued forward to the margin of the epiglottis. They have received a distinctive name, **Thyroepiglotticus** (*m. thyroepiglotticus*), and are sometimes described as a separate muscle.

¹ Henle describes these two portions as separate muscles, under the names of the External and Internal thyroarytenoids.

Actions.—In considering the action of the muscles of the larynx, they may be conveniently divided into two groups—viz.: (1) Those which open and close the glottis. (2) Those which regulate the degree of tension of the vocal cords.

1. The muscles which open the glottis are the two Posterior cricoarytenoids; and those which close it are the Arytenoideus and the two Lateral cricoarytenoids.

2. The muscles which regulate the tension of the vocal cords are the two Cricothyroids, which render tense and elongate them, and the two Thyroarytenoids, which relax and shorten them.

The *Posterior cricoarytenoids* separate the chordæ vocales, and consequently open the glottis, by rotating the arytenoid cartilages outward around a vertical axis passing through the cricoarytenoid joints, so that their vocal processes and the vocal cords attached to them become widely separated.

The *Lateral cricoarytenoids* close the glottis by rotating the arytenoid cartilages inward so as to approximate their vocal processes.

The *Arytenoideus muscle* approximates the arytenoid cartilages, and thus closes the opening of the glottis, especially at its back part.

The *Cricothyroid muscles* produce tension and elongation of the vocal cords. This is effected as follows: the thyroid cartilage is fixed by its Extrinsic muscles; then the Cricothyroid muscles, when they act, draw upward the front of the cricoid cartilage, and so depress the posterior portion, which carries with it the arytenoid cartilages, and thus elongate the vocal cords.

The *Thyroarytenoid muscles*, consisting of two parts having different attachments and different directions, are rather complicated as regards their action. Their main use is to draw the arytenoid cartilages forward toward the thyroid, and thus shorten and relax the vocal cords. But, owing to the connection of the inner portion with the vocal cord, this part, if acting separately, is supposed to modify its elasticity and tension, and the outer portion, being inserted into the outer part of the anterior surface of the arytenoid cartilage, may rotate it inward, and thus narrow the rima glottidis by bringing the two cords together.

The manner in which the superior aperture of the larynx is closed during deglutition is referred to on page 399.

The **mucous membrane of the larynx** is continuous above with that lining the mouth and pharynx, and it is prolonged through the trachea and bronchi into the lungs. It lines the posterior surface and the anterior part of the upper surface of the epiglottis, to which it is closely adherent. In the rest of the larynx, above the true vocal cords, it is lax and rests upon a considerable submucous layer. The mucous membrane, with the submucous coat, ligamentous and muscular fibres, forms the arytenoepiglottic folds, which folds are the lateral boundaries of the superior aperture of the larynx. It lines the whole of the cavity of the larynx, forms by its reduplication the chief part of the superior or false vocal cord, and, from the ventricle, is continued into the laryngeal sacculæ. It is then reflected over the true vocal cords, where it is thin and very intimately adherent; covers the inner surface of the cricothyroid membrane and cricoid cartilage; and is ultimately continuous with the lining membrane of the trachea. The fore part of the anterior surface and the upper half of the posterior surface of the epiglottis, the upper part of the arytenoepiglottic folds, and the true vocal cords are covered by stratified squamous epithelium; the rest of the laryngeal mucous membrane is covered by stratified ciliated cells.

The mucous membrane above the rima glottidis is extremely sensitive, and during life the lightest touch of a foreign body produces cough.

Glands.—The mucous membrane of the larynx is furnished with numerous muciparous glands, the orifices of which are found in nearly every part; they are very numerous upon the epiglottis, being lodged in little pits in its substance; they are also found in large numbers along the posterior margin of the arytenoepiglottic fold, in front of the arytenoid cartilages, where they are termed the **arytenoid glands**. They exist also in large numbers upon the inner surface of the laryngeal sacculæ. None are found on the surface of the true vocal cords.

Vessels and Nerves.—The arteries of the larynx (Fig. 900) are the laryngeal branches derived from the superior and inferior thyroid. The superior laryngeal artery from the superior thyroid accompanies the internal branch of the superior laryngeal nerve; the inferior laryngeal artery from the inferior thyroid courses along with the recurrent laryngeal nerve. The veins accompany the arteries; those accompanying the superior laryngeal artery join the superior thyroid vein, which opens into the internal jugular vein; while those accompanying the inferior laryngeal artery join the inferior thyroid vein, which opens into the innominate vein. The lymphatics consist of two sets, superior and inferior. The superior accompany the superior laryngeal artery, pierce the thyrohyoid membrane, and terminate in the nodes situated at the bifurcation of the carotid artery. Of the inferior lymphatics, some pass through the cricothyroid membrane to terminate in a node lying in front of that membrane or in front of the upper part of the trachea, while others pass to the deep cervical nodes and to the nodes along the inferior thyroid artery.

The nerves are derived from the internal and external laryngeal branches of the superior laryngeal nerve, from the inferior or recurrent laryngeal, and from the sympathetic. The

internal laryngeal nerve is almost entirely sensor, but some motor filaments are said to be carried by it to the Arytenoideus muscle. It divides into a branch which is distributed to both surfaces of the epiglottis, a second to the arytenoepiglottic folds, and a third, the largest, which supplies the mucous membrane over the back of the larynx and communicates with the recurrent laryngeal. The external laryngeal branch supplies the Cricothyroid muscle. The recurrent laryngeal passes upward under the lower border of the Inferior constrictor, and enters the larynx between the cricoid and thyroid cartilages. It supplies all the muscles of the larynx except the Cricothyroid and part of the Arytenoideus. The sensor branches of the laryngeal nerves form subepithelial plexuses, from which fibres ascend to end between the cells covering the mucous membrane. Sympathetic filaments accompany all of the laryngeal nerves.

Over the posterior surface of the epiglottis, in the arytenoepiglottidean folds, and less regularly in some other parts, taste buds, similar to those in the tongue, are found.

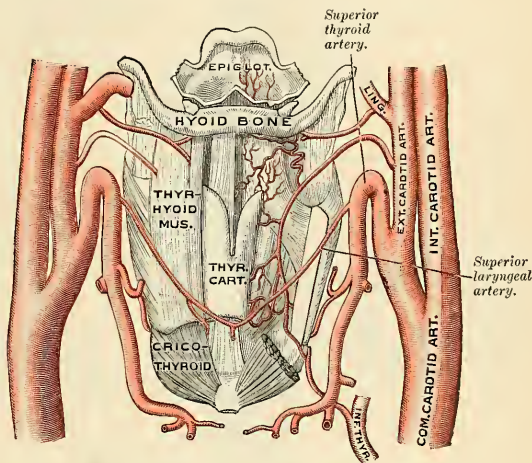


FIG. 900.—The origin and distribution of the arteries of the larynx. (Luschka.)

THE TRACHEA AND BRONCHI (Fig. 901).

The **trachea**, or **windpipe**, is a cartilaginous, membranous, elastic, cylindrical tube, flattened posteriorly, which extends from the lower part of the larynx, on a level with the sixth cervical vertebra, to opposite the body or upper border of the fifth thoracic vertebra, where it divides (*bifurcatio tracheae*) into **two stem bronchi**, one for each lung. The trachea is nearly, but not quite, cylindrical, being flattened posteriorly (Fig. 903). The largest diameter of the tube is at the middle; from this point the diameter diminishes toward the bronchi and toward the laryngeal end. The trachea measures about four inches and a half (11 cm.) in length; its diameter, in the cadaver, from side to side is from three-quarters of an inch to an inch (19 to 25 mm.), being always greater in the male than in the female. Its calibre is not quite uniform throughout; the middle third is somewhat wider than the rest of the tube, while just below, before its bifurcation, the trachea is slightly diminished in diameter where it is in relation with the arch of the aorta. In the living subject, owing to the muscle tone of the wall, the transverse diameter is 12.5 mm. (0.5 inch); the antero-posterior, 11 mm. (0.44 inch).

Relations.—The anterior surface of the trachea is convex, and covered in the neck, from above downward, by the isthmus of the thyroid gland, the inferior thyroid veins, the arteria thyroidea ima (when that vessel exists), the Sternohyoid and Sternothyroid muscles, the cervical

fascia, and, more superficially, by the anastomosing branches between the anterior jugular veins; in the **thorax** it is covered from before backward by the first piece of the sternum, the remains of the thymus gland, the left innominate vein, the arch of the aorta, the innominate and left common carotid arteries, and the deep cardiac plexus. *Posteriorly*, it is in relation with the œsophagus; *laterally, in the neck*, it is in relation with the common carotid arteries, the lateral lobes of the thyroid gland, the inferior thyroid arteries, and recurrent laryngeal nerves; and, in the **thorax**, it lies in the upper part of the **interpleural space** (*superior mediastinum*), and is in relation on the right with the pleura and right vagus, and near the root of the neck with the innominate artery; on its left side are the recurrent laryngeal nerve, the aortic arch, the left common carotid and subclavian arteries.

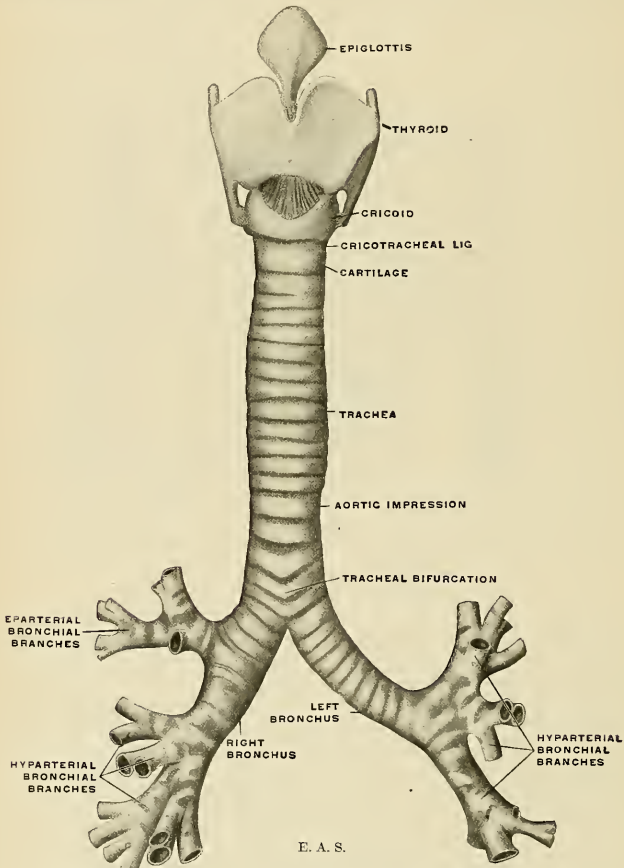


FIG. 901.—Front view of cartilages of larynx, the trachea and bronchi.

The **Right Bronchus** (*bronchus dexter*) (Fig. 901), wider, shorter, and more vertical in direction than the left, is about an inch in length (2.5 cm.), and enters the hilum of the right lung opposite the fifth thoracic vertebra. It forms an angle

to the median plane of about 25 degrees. The vena azygos major arches over it from *behind*; and the right pulmonary artery lies *below* and then in *front* of it. About one inch from its commencement it gives off a branch to the upper lobe of the right lung. This is termed the **eparterial branch bronchus** (*ramus bronchialis eparterialis*), because it is given off above the right pulmonary artery. The bronchus now passes below the artery, is known as the **hyparterial branch bronchus** (*ramus bronchialis hyparterialis*), and divides into two branches for the middle and lower lobes.

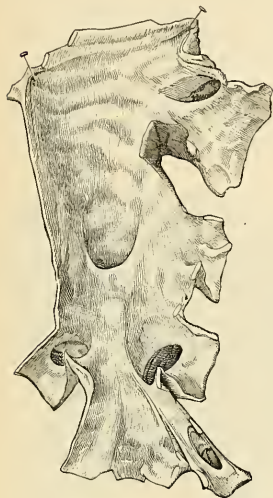


FIG. 902.—Internal surface of the bronchi. (Poirier and Charpy.)

The **Left Bronchus** (*bronchus sinister*) (Fig. 901) is smaller and longer than the right, being nearly two inches in length. It forms an angle to the median plane of about 46 degrees. It is slightly curved and enters the root of the left lung, opposite the sixth thoracic vertebra, about an inch lower than the right bronchus. It passes beneath the arch of the aorta, crosses in front of the oesophagus, the thoracic duct, and the descending aorta, and has the left pul-

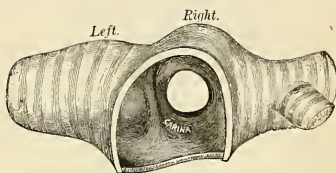


FIG. 903.—Transverse section of the trachea, just above its bifurcation, with a bird's-eye view of the interior, showing the carina tracheae.

monary artery lying at first above, and then behind it. The left bronchus has no branch corresponding to the eparterial branch of the right bronchus in the sense that it is given off above the pulmonary artery. The first hyparterial branch bronchus of the left side is the morphological equivalent of the right eparterial branch bronchus, as shown by Huntington.¹

The further subdivision of the bronchi will be considered with the anatomy of the lung.

If a transverse section of the trachea is made a short distance above its point of bifurcation, and a bird's-eye view taken of its interior (Fig. 903), the septum (carina tracheae) placed at the bottom of the trachea and separating the two bronchi will be seen to occupy the left of the median line, and the right bronchus appears to be a more direct continuation than the left, so that any solid body dropping into the trachea would naturally be directed toward the right bronchus. This tendency is aided by the larger size of the right tube as compared with its fellow. This fact serves to explain why a foreign body in the trachea more frequently falls into the right bronchus than into the left.²

Structure of the Trachea.—The trachea is composed of incomplete cartilaginous rings, fibrous membrane, muscle fibres, mucous membrane, and glands.

The **Cartilages** vary from sixteen to twenty in number; each forms an incomplete ring, which surrounds about two-thirds of the cylinder of the trachea, being imperfect behind, where the

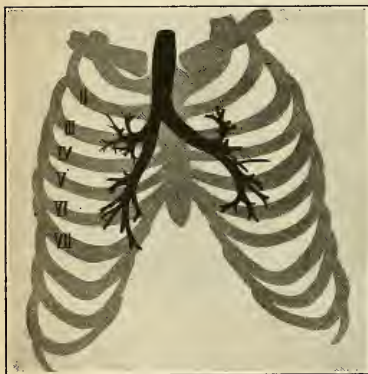
¹The Eparterial Bronchial System of the Mammalia, *Annals N. Y. Acad. Sci.*, 1898.

²Reigel asserts that the entrance of a foreign body into the *left* bronchus is by no means so infrequent as is generally supposed. See also *Med.-Chir. Transactions*, vol. lxxi, p. 121.

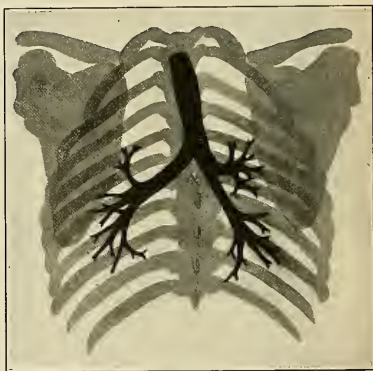
tube is completed by muscle and fibrous tissue. The cartilages are placed horizontally above each other, separated by narrow intervals bridged by fibroelastic tissue. They measure about $\frac{1}{2}$ of an inch in depth, and $\frac{3}{8}$ of an inch in thickness, tapering at their posterior ends. Their outer surfaces are flattened, but internally they are convex, from being thicker in the middle than at the margins. Two or more of the cartilages often unite, partially or completely, and are sometimes bifurcated at their extremities. They are highly elastic, but sometimes become calcified in advanced life. In the right bronchus the cartilages vary in number from six to eight; in the left, from nine to twelve. They are shorter and narrower than those of the trachea. The peculiar cartilages of the trachea are the first and the last.

The **first cartilage** is broader than the rest, and sometimes divided at one end; it is connected by fibrous membrane with the lower border of the cricoid cartilage, with which or with the succeeding cartilage it is sometimes blended.

The **last cartilage** is thick and broad in the middle, in consequence of its lower border being prolonged into a triangular hook-shaped process which curves downward and backward between the two bronchi. It terminates on each side in an imperfect ring which encloses the commencement of the bronchi. The cartilage above the last is often somewhat broader than the rest at its centre.



Ventral view.



Dorsal view.

FIGS. 904 AND 905.—Radiographs of trachea and bronchi filled with fusible metal. (After J. A. Blake.)

The Fibrous Membrane.—The cartilages are enclosed in a fibroelastic membrane which forms a double layer, one layer, the thicker of the two, passing over the outer surface of the ring, the other over the inner surface; at the upper and lower margins of the cartilages these two layers blend together to form a single membrane, which intervenes between the rings. They are thus, as it were, embedded in the membrane. In the space behind, between the extremities of the rings, the membrane forms a single distinct layer.

The **muscle fibres** are disposed in two layers, **longitudinal** and **transverse**.

The **longitudinal fibres** are external, and consist merely of a few scattered longitudinal bundles of fibres.

The **transverse fibres**, the **Trachealis muscle of Todd and Bowman**, form a thin internal layer which extends transversely between the ends of the cartilages and the intervals between them, thus extending the entire length of the posterior part of the trachea. The muscle fibres are of the unstriated variety.

The **mucous membrane** is continuous above with that of the larynx, and below with that of the bronchi. Microscopically, it consists of stratified ciliated epithelial cells, among which a number of goblet cells are seen; the basal cells are often branched and rest upon the basement membrane, beneath which is a layer of fibroelastic tissue containing diffuse lymphoid tissue. The tunica propria blends with the next coat, the submucosa, and here are found the cartilage rings and a number of mucous glands, the tracheal glands.

The **tracheal glands** (*glandulae tracheales*) are found in great abundance at the posterior part of the trachea. They are racemose glands, and consist of a basement membrane lined by columnar mucus-secreting cells. They are situated at the back of the trachea, outside the layer of muscle tissue, between it and the outer fibrous layer. Their excretory ducts pierce the

muscle and inner fibrous layers, and pass through the submucous and mucous layers to open on the surface of the mucous membrane. Some glands of smaller size are also found at the sides of the trachea, between the layers of fibrous tissue connecting the rings, and others immediately beneath the mucous coat. The secretion from these glands serves to lubricate the inner surface of the trachea.

Vessels and Nerves.—The trachea is supplied with blood by the inferior thyroid arteries. The veins terminate in the thyroid venous plexus. The nerves are derived from the vagus and its recurrent branches and from the sympathetic.

Lymph Nodes.—The trachea is surrounded by lax connective tissue which contains numerous lymph nodes, known as the **peritracheobronchial nodes**. They are divided into four groups (Baréty). A group to the **right side**, in the angle between the trachea and right bronchus and ascending to the region of the subclavian vessels. A group to the **left side**, in the angle formed by the trachea and left bronchus, and ascending to about the arch of the aorta and the recurrent laryngeal nerve. The two groups just described are usually called **tracheal nodes** (*lymphoglandulae tracheales*). A third group is in the angle formed by the bifurcation of the trachea. These constitute the **bronchial nodes** (*lymphoglandulae bronchiales*), ten or twelve in

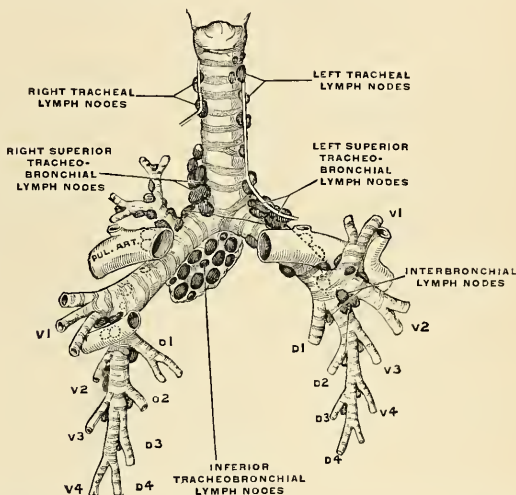


FIG. 906.—The tracheobronchial and interbronchial lymph nodes, seen from in front. The dotted lymph nodes and lymph vessels are not visible from in front: d^1 , d^2 . First and second dorsal branch bronchi. v^1 , v^2 . First and second ventral branch bronchi. (Sukienikow.)

number. A fourth group, the **interbronchial nodes**, are found in angles of bifurcation of the larger bronchi in the lung parenchyma. Very early in life the peritracheobronchial nodes become dark or even black from the deposition of carbonaceous substance brought by the leukocytes from the bronchial tubes. This condition is called **anthracosis**.

Surface Form.—In the middle line of the neck some of the cartilages of the larynx can readily be distinguished. In the angle below the chin the hyoid bone can easily be distinguished, and a finger's breadth below it is the pomum Adami, the prominence between the upper borders of the two alae of the thyroid cartilage. About an inch below this, in the middle line, is a depression corresponding to the cricothyroid space, in which the operation of laryngotomy is performed. This depression is bounded below by a prominent arch, the anterior ring of the cricoid cartilage, below which the trachea can be felt, though it is only in the emaciated adult that the separate rings can be distinguished. The lower part of the trachea is not easily observed, for as it descends in the neck, following the curvature of the vertebral column, it takes a deeper position, and is farther removed from the surface. The level of the vocal cords corresponds to the middle of the anterior margin of the thyroid cartilage.

With the *laryngoscope*, the following structures can be seen. The base of the tongue and the lingual surface of the epiglottis, with the glossoepiglottic ligaments; the superior aperture of

the larynx, bounded on either side by the arytenoepiglottidean folds, in which may be seen two rounded eminences corresponding to the cornicular and cuneiform cartilages. Beneath these, the false and true vocal cords, with the ventricle between them. Still deeper, the cricoid cartilage and some of the anterior parts of the rings of the trachea, and sometimes, in deep inspiration, the bifurcation of the trachea.

Applied Anatomy.—*Foreign bodies* often find their way into the air passages. These may be large, soft substances, as a piece of meat, which may become lodged in the upper aperture of the larynx or in the rima glottidis, and cause speedy suffocation unless rapidly got rid of, or unless an opening is made into the air passages below, so as to enable the patient to breathe. Smaller bodies, frequently of a hard nature, such as cherry- or plum-stones, small pieces of bone, buttons, etc., may find their way through the rima glottidis into the trachea or bronchus, or may become lodged in the ventricle of the larynx. The dangers then depend not so much upon the mechanical obstruction as upon the spasm of the glottis which they excite from reflex irritation. When lodged in the ventricle of the larynx, they may produce very few symptoms beyond sudden loss of voice or alteration in the voice sounds, immediately following the inhalation of the foreign body. When, however, they are situated in the trachea, they are constantly striking against the vocal cords during expiratory efforts, and produce attacks of dyspnea from spasm of the glottis. When lodged in the bronchus, they usually become fixed there, and, occluding the lumen of the tube, cause a loss of the respiratory murmur on the affected side, which is, as stated above, more often the right.

Beneath the mucous membrane of the upper part of the air passages there is a considerable amount of submucous tissue which is liable to become much swollen from effusion in inflammatory affections, constituting the disease known as "*edema of the glottis*." This effusion does not extend below the level of the true vocal cords, on account of the fact that the mucous membrane is closely adherent to these structures, without the intervention of any submucous tissue. So that, in cases of this disease in which it is necessary to open the air passages to prevent suffocation, the operation of laryngotomy is sufficient.

Chronic laryngitis is an inflammation of the mucous membrane of the larynx, which occurs in those who speak much in public, and is due to the dryness induced by the large amount of cold air drawn into the air passages during prolonged speaking, which incites increased activity in the mucous glands to keep the parts moist, and this eventually terminates in inflammation of these structures.

Ulceration of the larynx may occur from syphilis, either as a superficial ulceration, or from the softening of a gumma; from tuberculous disease (laryngeal phthisis), or from malignant disease (epithelioma).

The air passages may be opened surgically in two different situations—through the cricothyroid membrane (*laryngotomy*), or in some part of the trachea (*tracheotomy*); and to these some surgeons have added a third method—opening the cricothyroid membrane and dividing the cartilage with the upper ring of the trachea (*laryngotracheotomy*).

Laryngotomy is anatomically the more simple operation; it can readily be performed, and should be employed in those cases where the air passages require opening in an emergency for the relief of some sudden obstruction to respiration. The cricothyroid membrane is very superficial, being covered in the middle line only by the skin, superficial fascia, and the deep fascia. On each side of the middle line it is also covered by the Sternohyoid and Sternothyroid muscles, which diverge from each other at their upper parts, leaving a slight interval between them. On these muscles rest the anterior jugular veins. The only vessel of any importance in connection with this operation is the cricothyroid artery, which crosses the cricothyroid membrane, and which may be wounded, but rarely gives rise to any trouble. The operation is performed thus: The head being thrown back and steadied by an assistant, the finger is passed over the front of the neck, and the cricothyroid depression felt for. A vertical incision is then made through the skin, in the middle line over this spot, and carried down through the fascia until the cricothyroid membrane is exposed. A cross-cut is then made through the membrane, close to the upper border of the cricoid cartilage, so as to avoid, if possible, the cricothyroid artery, and a tracheotomy tube is introduced. It has been recommended, as a more rapid way of performing the operation, to make a transverse instead of a longitudinal cut, through both the superficial and deep structures, and thus to open at once the air passages. It will be seen, however, that in opening in this way the anterior jugular veins would be in danger of being wounded.

Tracheotomy may be performed either above or below the isthmus of the thyroid body, or this structure may be divided and the trachea opened behind it.

The isthmus of the thyroid gland usually crosses the second and third rings of the trachea; along its upper border is frequently to be found a large transverse communicating branch between the superior thyroid veins; and the isthmus itself is covered by a venous plexus formed between the thyroid veins of the opposite sides. Theoretically, therefore, it is advisable to avoid dividing this structure in opening the trachea.

Above the isthmus the trachea is comparatively superficial, being covered by the skin, superficial fascia, deep fascia, Sternohyoid and Sternothyroid muscles, and a second layer of the deep

fascia, which, attached above to the lower border of the hyoid bone, descends beneath the muscles to the thyroid body, where it divides into two layers and encloses the isthmus.

Below the isthmus the trachea lies much more deeply, and is covered by the Sternohyoid and the Sternothyroid muscles and a quantity of loose areolar tissue in which is a plexus of veins, some of them of large size; they converge to two trunks, the inferior thyroid veins, which descend on either side of the median line on the front of the trachea and open into the innominate vein. In the infant the thymus gland ascends a variable distance along the front of the trachea, and opposite the episternal notch the windpipe is crossed by the left innominate vein. Occasionally, also, in young subjects, the innominate artery crosses the tube obliquely above the level of the sternum. The thyroidea ima artery, when that vessel exists, passes from below upward along the front of the trachea.

From these observations it must be evident that the trachea can be more readily opened above than below the isthmus of the thyroid body.

Tracheotomy above the isthmus is performed thus: The patient should, if possible, be laid on his back on a table in a good light. A pillow is to be placed under the shoulders and the head thrown back and steadied by an assistant. The surgeon, standing on the right side of his patient, makes an incision from an inch and a half to two inches in length in the median line of the neck from the top of the cricoid cartilage. The incision must be made exactly in the middle line, so as to avoid the anterior jugular veins, and after the superficial structures have been divided the interval between the Sternohyoid muscles must be found, the raphé divided, and the muscles drawn apart. The lower border of the cricoid cartilage must now be felt for, and the upper part of the trachea exposed from this point downward in the middle line. Bosc has recommended that the layer of fascia in front of the trachea should be divided transversely at the level of the lower border of the cricoid cartilage, and, having been seized with a pair of forceps, pressed downward with the handle of the scalpel. By this means the isthmus of the thyroid gland is depressed, and is saved from all danger of being wounded, and the trachea is cleanly exposed. The trachea is now transfixed with a sharp hook and drawn forward in order to steady it, and is then opened by inserting the knife into it and dividing the two or three upper rings from below upward. If the trachea is to be opened below the isthmus, the incision to expose it must be made from a little below the cricoid cartilage to the top of the sternum.

In the child the trachea is smaller, more deeply placed, and more movable than in the adult. In fat or short-necked people, or in those in whom the muscles of the neck are prominently developed, the trachea is more deeply placed than in others.

A portion of the larynx or the whole of it has been removed for malignant disease, *laryngectomy*. Some surgeons do preliminary tracheotomy, insert a Trendelenburg cannula to prevent the flow of blood downward into the lungs, and then remove the larynx. Other surgeons do not employ preliminary tracheotomy. Perier's method of laryngectomy is as follows: Make a vertical incision in the median line from the level of the hyoid bone to below the level of the cricoid cartilage. Make a transverse incision at each end of the vertical incision. This makes an I-shaped wound. Separate the soft parts from the larynx and upper part of the trachea, and separate these two structures from the œsophagus. After arresting bleeding, divide the trachea below the cricoid cartilage, introduce a special cannula, complete the removal of the larynx, suture the opening of the trachea to the lower angle of the wound, and close the rest of the wound after securing drainage. In malignant disease of the larynx the associated lymph nodes must be removed. Partial laryngectomy, according to Sir F. Semon, is the removal of not less than one wing of the thyroid cartilage. Removal of a lesser piece of the thyroid or of a bit of the arytenoid or cricoid he considers with the operation of thyrotomy.

THE PLEURÆ (Figs. 889, 919).

Each lung is invested by an exceedingly delicate serous membrane, the **pleura**, which encloses the organ as far as its root, and is then reflected on to the pericardium, thoracic wall, and Diaphragm. The portion of the serous membrane investing the surface of the lung and dipping into the fissures between its lobes is called the **visceral layer of the pleura** (*pleura pulmonalis*) (Fig. 907), while that which lines the inner surface of the thorax is called the **parietal layer of the pleura** (*pleura parietalis*) (Fig. 907). The space between these two layers is called the **cavity of the pleura** (*cavum pleurae*), and contains a very little clear fluid. It must be borne in mind that in the healthy condition the two layers are in contact, and there is no real cavity. When the lung becomes collapsed a separation of it from the wall takes place and a cavity results. Each pleura is therefore a shut

sac, one occupying the right, the other the left half of the thorax, and they do not communicate with each other. The two pleuræ do not meet in the middle line

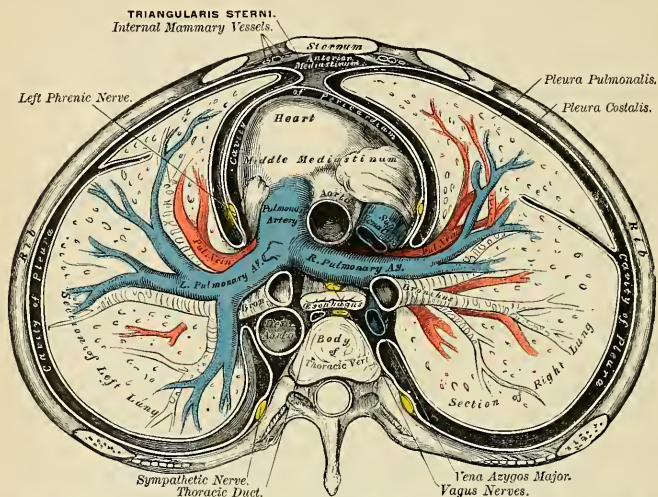


FIG. 907.—A transverse section of the thorax, showing the relative position of the viscera and the reflections of the pleuræ.

of the thorax, excepting anteriorly opposite the second and third pieces of the sternum. The region left between them contains all the thoracic viscera excepting the lungs, and is named the **mediastinum** or **interpleural septum**.

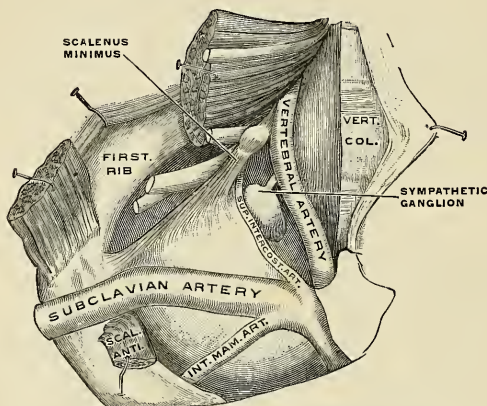


FIG. 908.—The dome of the pleura. (Poirier and Charpy.)

Different portions of the parietal pleura have received special names which indicate their position; thus, that portion which lines the inner surfaces of the ribs

and Intercostal muscles is the **costal pleura** (*pleura costalis*); that which covers the convex surface of the Diaphragm is the **diaphragmatic pleura** (*pleura diaphragmatica*); that which rises in the neck, over the apex of the lung, is the **cervical pleura** (*cupula pleuræ*); and that which is applied to the adjacent structures of the mediastinum is the **mediastinal pleura** (*pleura mediastinalis*).

Reflections of the Pleuræ (Fig. 907).—Commencing at the sternum, the pleura passes laterad, covers the inner surfaces of the ribs and costal cartilages, and Internal intercostal muscles, and at the back part of the thorax passes over the gangliated cord of the sympathetic and its branches, and is reflected upon the sides of the bodies of the vertebræ where it is separated by a narrow interval, the **posterior mediastinum** (*cavum mediastinale posterius*), from the opposite pleura. From the vertebral column the pleura passes to the side of the pericardium, which it

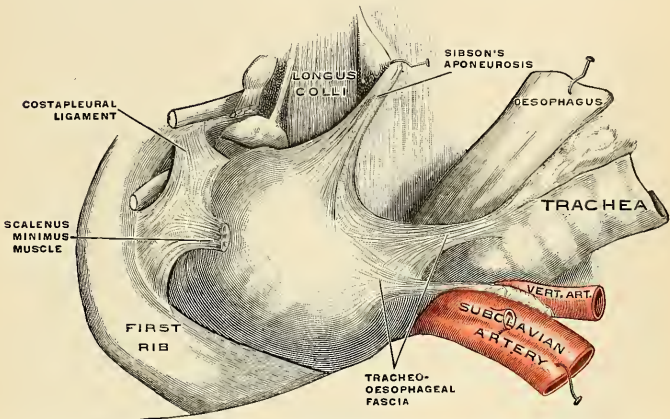


FIG. 909.—The supports of the pleural dome. The oesophagus, trachea, and arteries have been cut and pulled aside to show the pleural reinforcements. (Poirier and Charpy.)

covers to a slight extent; it then covers the back part of the root of the lung, from the lower border of which a triangular sheet descends vertically by the side of the posterior mediastinum to the Diaphragm, but is not attached thereto. This sheet is the posterior layer of a wide fold, known as the **broad ligament of the lung** (*ligamentum pulmonale* or *ligamentum latum pulmonis*). From the posterior aspect of the lung root, the pleura may be traced over the convex surface of the lung, the apex, and base, and also into the fissures between the lobes, on to its inner surface and the front part of its root; it is continued from the lower margin of the root as the anterior layer of the broad ligament, and from this it is reflected on to the pericardium, and from it to the back of the sternum. *Below*, it covers the upper surface of the Diaphragm, and extends, *in front*, as low as the costal cartilage of the seventh rib; *at the side* of the thorax, to the lower border of the tenth rib on the left side and to the upper border of the same rib on the right side; and *behind*, it reaches as low as the twelfth rib, and sometimes even as low as the transverse process of the first lumbar vertebra. *Above*, its apex projects, through the superior aperture of the thorax into the neck, extending from one to two inches (2.5 to 5 cm.) above the anterior extremity of the first rib; this portion of the sac is strengthened by a dome-like expansion of fascia (**Sibson's fascia**) (Fig. 909), attached in front to the inner border of the first rib, and behind to the ante-

rior border of the transverse process of the seventh cervical vertebra. This is covered and strengthened by a few spreading muscle fibres derived from the Scaleni.

In the front of the thorax, where the parietal layer of the pleura is reflected backward to the pericardium, the two pleural sacs are nearly in contact for a short distance (Fig. 919). At the upper part of the thorax, behind the manubrium, they are not in contact, the point of reflection being represented by a line drawn from the sternoclavicular articulation to the midpoint of the junction of the manubrium with the body of the sternum. From this point the two pleurae descend in close contact to the level of the fourth costal cartilages, and the line of reflection on the *right side* is continued downward in nearly a straight line to the lower end of the gladiolus, and then turns outward, while on the *left side* the line of reflection diverges slightly outward and is continued downward, close to the left border of the sternum as far as the sixth costal cartilage. The inferior limit of the pleura is on a considerably lower level than the corresponding limit of the lung, but does not extend to the attachment of the Diaphragm, so that below the line of reflection of the pleura from the thoracic wall on to the Diaphragm the latter is in direct contact with the rib cartilages and the Internal intercostal muscles. In ordinary inspiration the thin margin of the base of the lung does not extend as low as the line of pleural reflection, with the result that the costal and diaphragmatic pleura are here in contact, the narrow slit between the two being termed the *costophrenic sinus* (*sinus phrenicocostalis*) (Fig. 910). A similar condition exists behind the sternum and rib cartilages, where the anterior thin margin of the lung falls short of the line of pleural reflection, and where the slit-like cavity between the two layers of pleura forms what is sometimes called the *costomediastinal sinus* (*sinus costomediastinalis*).

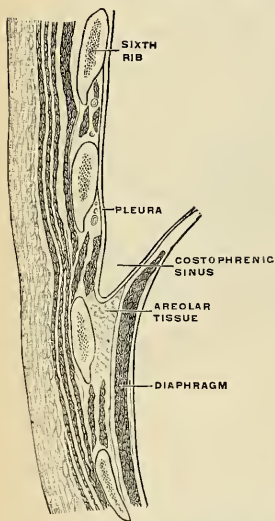


FIG. 910.—Section of the wall of the thorax, showing the phrenicocostal sinus. (Poirier and Charpy.)

of the *left pleura* follows at first the ascending part of the sixth costal cartilage, and in the rest of its course is slightly higher than that of the right side.

The free surface of the pleura is smooth, polished, and moistened by a serous fluid; its attached surface is intimately adherent to the surface of the lung, and to the pulmonary vessels as they emerge from the pericardium; it is also adherent to the upper surface of the Diaphragm; throughout the rest of its extent it is somewhat thicker, and may be separated from the adjacent parts with extreme facility.

The right pleural sac is shorter, wider, and reaches higher in the neck than the left.

Ligamentum Latum Pulmonis.—From the above description it will be seen that the root of the lung is covered in front, above, and behind by the pleura, and that at its lower border the investing layers come into contact. Here they form a sort of mesenteric fold, the *ligamentum latum pulmonis* (*lig. pulmonale*), which extends

as far as the Diaphragm (but is not attached thereto) between the pericardium and the lower part of the inner surface of the lung, having a free falciform border below, between the lung and the Diaphragm. It serves to retain the lower part of the lung in position (Figs. 913 and 914).

Structure of the Pleura.—The pleura is composed of fibroelastic connective tissue, its free surface being covered with a single layer of flat endothelial cells. It is fastened to adjacent structures by subserous fibroelastic tissue. The subserous tissue of the visceral pleura is continuous with the fibroelastic tissue of the lung.

Vessels and Nerves.—The arteries of the pleura are derived from the intercostal, the internal mammary, the musculophrenic, thymic, pericardiac, and bronchial arteries. The veins correspond to the arteries. The lymphatics are very numerous in the pleura and subserous tissue. The lymphatics of the visceral layer empty into the superficial pulmonary trunks; the lymphatics of the costal pleura empty into the intercostal trunks; of the diaphragmatic pleura, into the diaphragmatic trunks; of the mediastinal pleura, into the posterior mediastinal nodes. The nerves are derived from the phrenic and sympathetic (Luschka).

Applied Anatomy.—In operations upon the kidney it must be borne in mind that the pleura may sometimes extend below the level of the last rib, and may therefore be opened in these operations, especially when the last rib is removed, in order to give more room. It is best to keep the incision at least one inch below the last rib, enlarging the wound afterward, when the finger can be introduced as a guide.

In wounds of the Diaphragm the pleura may be injured. In operations about the root of the neck, especially in the removal of lymph nodes and the ligation of the first part of the subclavian artery, the pleura may be injured.

Punctured wounds of the root of the neck are apt to reach the pleura.

Empyema is a surgical disease. In acute empyema the treatment is drainage. A portion of the fifth or sixth rib in the axillary line is removed by subperiosteal resection, the pleura is opened, and a tube is introduced. In chronic empyema the lung is contracted and adherent and cannot expand; hence drainage will not cure it. It is necessary to perform multiple rib resection in order to permit the thoracic wall to sink in and obliterate the cavity, which, as the lung is unable to expand, it cannot do. The necessary operation may be the one of either Estlander, Schede, or Fowler (p. 168).

If a large wound admits suddenly a quantity of air into the pleura, dangerous or fatal *pneumothorax* arises, and the lung collapses. This is usually met during operations by using the Fell-O'Dwyer apparatus for artificial respiration, as advised by Matas.¹ This apparatus keeps the lung expanded, in spite of the entrance of air into the pleural sac. A surgeon can open the pleura widely without any fear of the lung collapsing if he operates in a Sauerbruch chamber. The pressure within this chamber is negative. The patient's head is outside of the chamber, his body is within it. The bronchioles are distended by the patient inhaling air at the ordinary pressure, but the exposed lung is subjected to negative pressure, hence the lung does not collapse in spite of a large wound in the pleura. In surgical pneumothorax the lung may be sutured to the thoracic wall, so as to block the opening. Sometimes, in order to arrest dangerous pulmonary bleeding, a surgeon deliberately induces pneumothorax, in the hope that the collapse of the lung will arrest bleeding.

When an abscess of the liver is posterior and on the dorsum, *transpleural hepatotomy* is performed. A portion of the tenth and eleventh ribs below the angle of the scapula is removed. As a rule, the pleura is found obliterated at this point. If it is opened, it is at once sutured or closed with gauze packing. The exposed Diaphragm is incised, and, as it is usually adherent to the liver, the abscess cavity is entered. If it is not adherent, the liver is exposed and the abscess sought for with an aspirating needle.

Grocco's sign is the presence of a triangular area of paravertebral dullness above the level of the twelfth rib on the side opposite to a pleural effusion. The dullness is believed to be due to a displacement of the contents of the posterior mediastinum by the fluid.

THE MEDIASTINUM, OR INTERPLEURAL SPACE.

The mediastinum is the space left in the median portion of the thorax by the non-apposition of the two pleuræ. In reality it is an "interpleural septum." It extends from the sternum in front to the vertebral column behind, and contains all the thoracic viscera excepting the lungs. The mediastinum may be divided for purposes of description into two parts—an upper portion, above the upper level

¹ Annals of Surgery, April, 1899.

of the pericardium, which is named the **superior mediastinum**; and a lower portion, below the upper level of the pericardium. This lower portion is again subdivided into three—that part which contains the pericardium, its contents, and other structures below this plane: the **middle mediastinum**; that part which is in front of the pericardium, the **anterior mediastinum**; and that part which is behind the pericardium, the **posterior mediastinum**.

The **superior mediastinum** (Fig. 911) is that portion of the interpleural space which lies between the manubrium sterni in front and the upper thoracic vertebrae behind. It is bounded *below* by a plane passing backward from the junction of the manubrium and gladiolus sterni to the lower part of the body of the fourth thoracic vertebra, and laterally by the lungs and pleuræ. It contains the origins of the Sternohyoid and Sternothyroid muscles and the lower ends of the Longus colli muscles; the arch of the aorta; the innominate, the thoracic portion of the left carotid and subclavian arteries; the upper half of the superior vena cava and

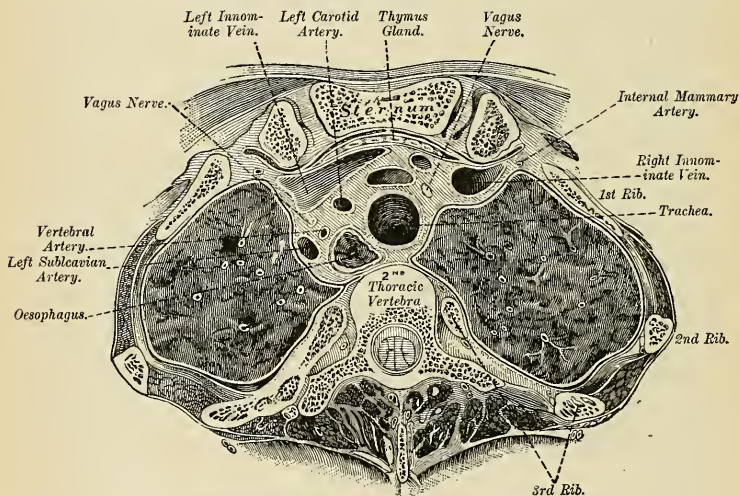


FIG. 911.—Transverse section through the second thoracic vertebra. (Braune.)

the innominate veins, and the left superior intercostal vein; the vagus, cardiac, phrenic, and left recurrent laryngeal nerves; the trachea, oesophagus, and thoracic duct; the remains of the thymus gland and some lymph nodes.

The **anterior mediastinum** (Fig. 907) is bounded in *front* by the sternum, laterally by the pleuræ, and *behind* by the pericardium. It is narrow above, but widens out a little below, and, owing to the oblique course taken by the left pleura, it is directed from above obliquely downward and to the left. Its anterior wall is formed by the left Triangularis sterni muscle and the fifth, sixth, and seventh left costal cartilages. It contains a quantity of loose areolar tissue, some lymphatic vessels which ascend from the convex surface of the liver, two or three lymph nodes (anterior mediastinal glands), and the small mediastinal branches of the internal mammary artery.

The **middle mediastinum** (Fig. 907) is the broadest part of the interpleural space. It contains the heart enclosed in the pericardium, the ascending aorta, the lower half of the superior vena cava, with the vena azygos major opening into

it, the bifurcation of the trachea and the two bronchi, the pulmonary artery dividing into its two branches and the right and left pulmonary veins, the phrenic nerves, and some bronchial lymph nodes.

The **posterior mediastinum** (Figs. 907 and 912) is an irregular triangular space running parallel with the vertebral column; it is bounded in *front* by the peri-

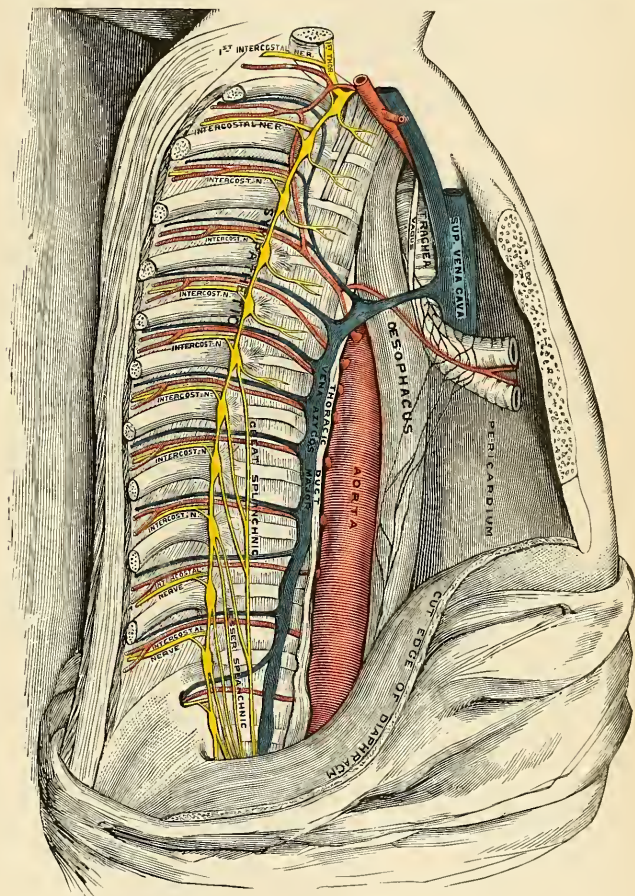


FIG. 912.—The posterior mediastinum.

cardium above, and by the posterior surface of the Diaphragm below, *behind* by the vertebral column from the lower border of the fourth to the twelfth thoracic vertebra, and *on either side* by the pleura. It contains the descending thoracic aorta, the venae azygos major and minor, the vagus and splanchnic nerves, the oesophagus, the thoracic duct, and some lymph nodes.

Applied Anatomy.—*Primary tumors* of the mediastinum are usually lymphomata or lymphosarcomata arising from the thymus or from the bronchial or posterior mediastinal lymph nodes; sarcomata, dermoid cysts, and embryomata, occur more rarely. These tumors give rise to pain, deformity of the thorax, and symptoms of pressure on the various nerves, bloodvessels, air passages, lymphatics, and on the œsophagus, as these various structures pass through the thorax. They may produce physical signs very much like those of an aortic aneurism, so that diagnosis between the two is often difficult. The prognosis is bad, life usually ending within a few months or a year of the onset of the symptoms.

Inflammation of the mediastinum due to wounds, or to the spread of inflammation from adjacent parts (*e. g.*, the œsophagus, the pericardium), is sometimes acute, leading to abscess formation. A more chronic form associated with adhesions and inflammation of the pericardium—the so-called chronic adhesive mediastinopericarditis—gives rise to obscure symptoms suggesting gradual heart failure, and leads to death slowly but surely.

THE LUNGS (PULMONES) (Figs. 913, 914).

The **lungs** are the essential organs of respiration; they are two in number, placed one on each side of the thorax, separated from each other by the heart and other contents of the mediastinum. A healthy lung hangs free within the pleural cavity. It is suspended by the root and by the ligamentum pulmonale. In many

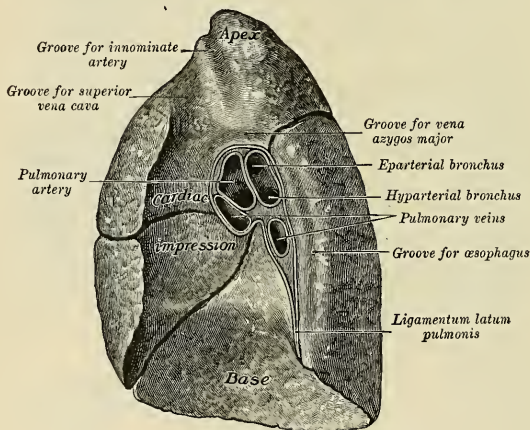


FIG. 913.—Mediastinal surface of right lung.

cases examined the lung does not hang free, but, as a result of former pleurisy, an area of the pulmonary pleura is adherent to the parietal pleura. Each lung is conical in shape, and presents for an examination an **apex**, a **base**, three **borders**, and three **surfaces**.

The **apex** (*apex pulmonis*) is rounded, and extends into the root of the neck about an inch to two inches (2.5 to 5 cm.) above the level of the anterior end of the first rib. A furrow produced by the subclavian artery as it curves outward in front of the pleura runs upward and outward immediately below the apex. The brachial plexus is in close proximity to this portion of the lung.

The **base** (*basis pulmonis*) or **diaphragmatic surface** is broad, concave, and rests upon the convex surface of the Diaphragm, which separates the right lung from the upper surface of the right lobe of the liver and the left lung from the

upper surface of the left lobe of the liver, the fundus of the stomach, and the spleen. Since the Diaphragm extends higher on the right than on the left side, it follows that the concavity on the base of the right lung is deeper than that of the left. Laterally and behind, the base is bounded by a thin, sharp margin which projects for some distance into the costophrenic sinus of the pleura, between the lower ribs and the costal attachment of the Diaphragm. The base of the lung descends during inspiration and ascends during expiration; its relation to the thoracic wall is indicated in Figs. 919 and 920.

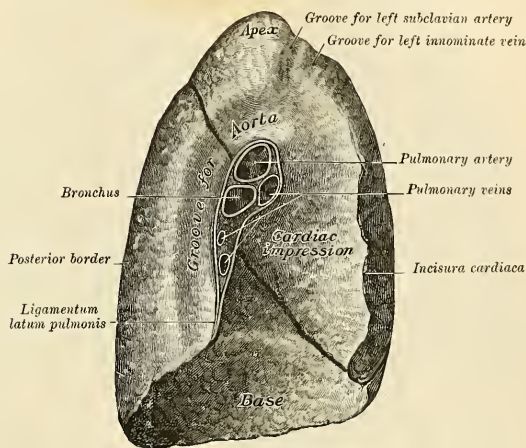


FIG. 914.—Mediastinal surface of left lung.

Surfaces.—The **external, costal, or thoracic surface** (*facies costalis*) (Figs. 917 and 918) is smooth, convex, of considerable extent, and corresponds to the form of the cavity of the thorax, being deeper behind than in front. It is in contact with the costal pleura, and presents, in a hardened specimen, slight grooves corresponding to the overlying ribs.

The **inner or mediastinal surface** (*facies mediastinalis*) (Figs. 913 and 914) is in contact with that portion of the pleura which forms the lateral boundary of the mediastinal space. It presents a deep concavity which accommodates the pericardial sac; this is larger and deeper on the left than on the right lung, on account of the heart projecting farther to the left than to the right of the mesal plane. Above and behind this concavity is a triangular depression named the **hilum** (*hilus pulmonis*), where the structures which form the root of the lung enter and leave the viscus.

On the **right lung** (Fig. 915), immediately above the hilum, is an arched furrow which accommodates the vena azygos major, while running upward, and then arching outward some little distance below the apex, is a wide groove for the superior vena cava and right innominate vein; and behind this, nearer the apex, is a second furrow for the innominate artery. Along the back part of the inner surface is a vertical groove for the œsophagus; this groove becomes less distinct below, owing to the inclination of the lower part of the œsophagus to the left of the middle line. In front and to the right of the lower part of the œsophageal groove, the inner surface is applied to the pleural covering of the right and posterior aspects

of the thoracic parts of the inferior vena cava; this vessel being accommodated in a deep concavity.

On the *left lung* (Fig. 914), immediately above the hilum, is a well-marked curved furrow produced by the arch of the aorta, and running upward from this toward the apex is a groove accommodating the subclavian artery; a slight impression in front of the latter and close to the margin of the lung lodges the left innominate vein. Behind the hilum and pericardial depression is a vertical furrow produced by the descending thoracic aorta, and in front of this, near the base of the lung, the lower part of the œsophagus causes a shallow depression.

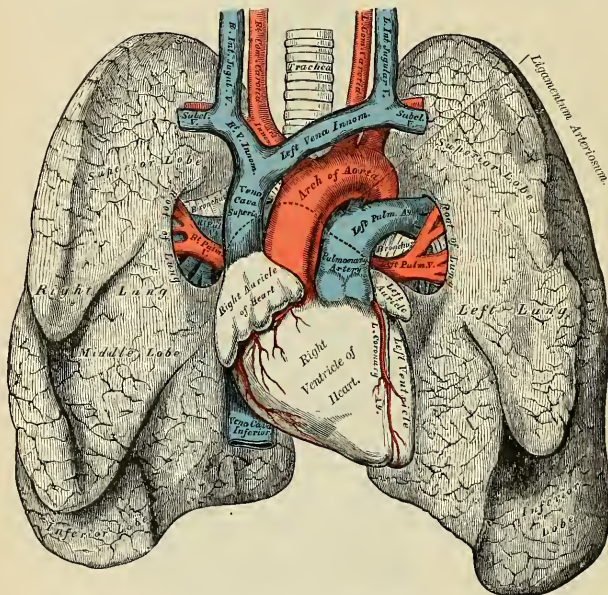


FIG. 915.—Front view of the heart and lungs.

Borders.—The **posterior border** (*margo posterior*) is broad and rounded, and is received into the deep concavity on either side of the vertebral column. It is much longer than the anterior border.

The **inferior border** (*margo inferior*) is the sharp margin of the base separating the costal and diaphragmatic surfaces. It projects, below, into the upper part of the costophrenic sinus.

The **anterior border** (*margo anterior*) is thin and sharp, overlaps the front of the pericardium, and is projected into the costomediastinal sinus of the pleura. The anterior border of the right lung is almost vertical; that of the left presents, below, an angular notch, the *incisura cardiaca*, into which the heart and pericardium are received. A projection from the upper lobe comes forward beneath the cardiac notch; it is called the *lingula pulmonis*.

Fissures and Lobes of the Lung.—The **left lung** is divided into two lobes, an upper and a lower, by an *oblique fissure* (*incisura interlobaris*), which extends from the outer to the inner surface of the lung both above and below the hilum.

As seen on the surface, this fissure commences on the inner aspect of the lung at the upper and posterior part of the hilum, and runs backward and upward

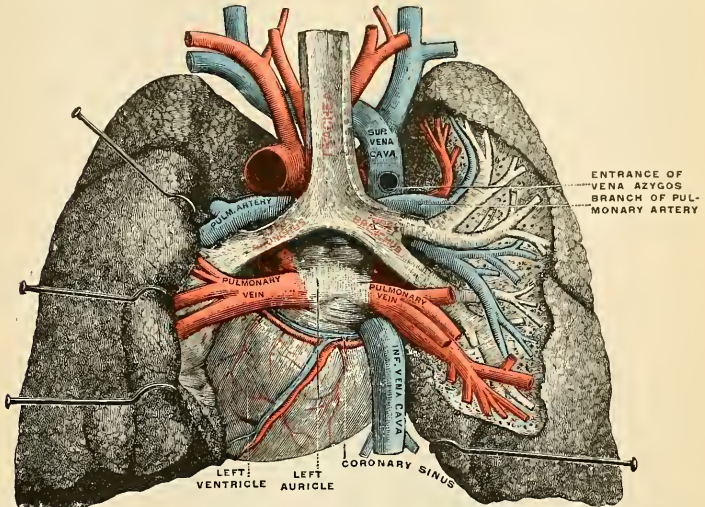


FIG. 916.—Pulmonary veins, seen in a dorsal view of the heart and lungs. The lungs have been pulled away from the median line, and a part of the right lung has been cut away to display the air ducts and bloodvessels. (Testut.)

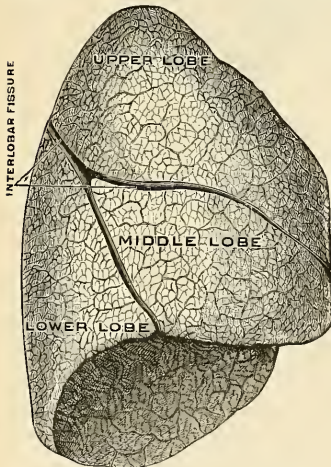


FIG. 917.—The right lung. The outer or costal surface. (Toldt.)

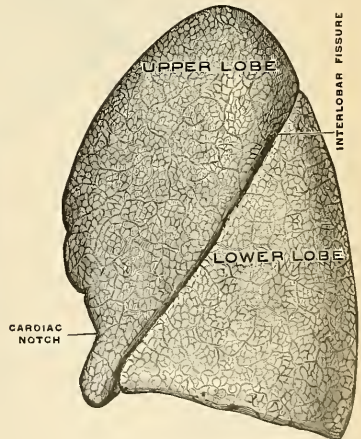


FIG. 918.—The left lung. The outer or costal surface. (Toldt.)

to the posterior border, which it crosses about two and a half inches (6.5 cm.) below the apex. It then extends downward and forward over the outer surface and

reaches the lower border a little behind its anterior inferior extremity, and its further course can be followed upward and backward across the inner surface as far as the lower part of the hilum. The **upper lobe** (*lobus superior*) lies above and in front of this fissure, and includes the apex, the anterior border, and a considerable part of the outer surface and the greater part of the inner surface of the lung. The **lower lobe** (*lobus inferior*), the larger of the two, is situated below and behind this fissure, and comprises almost the whole of the base, a large portion of the outer surface, and the greater part of the posterior border.

The **right lung** is divided into three lobes, upper, middle, and lower, by an oblique and a horizontal fissure. The **oblique fissure** separates the lower from the middle

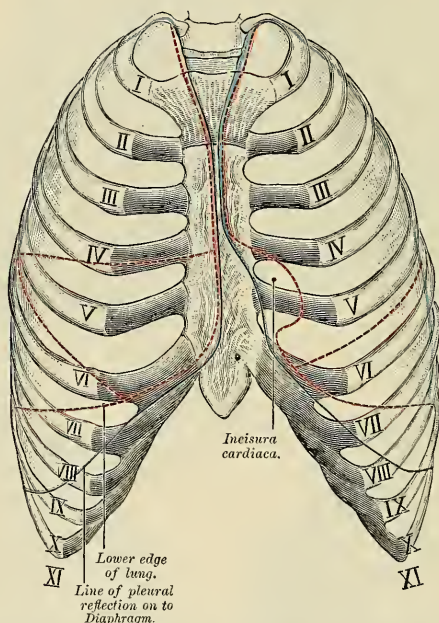


FIG. 919.—Front view of thorax, showing relations of pleuræ and lungs to the thoracic wall. The blue lines indicate the lines of the reflection of the pleuræ; the red, the outlines of the lungs and their fissures.

and upper lobes, and corresponds closely with the fissure of the left lung. Its direction is, however, more vertical, and it cuts the lower border about three inches from the anterior margin. The **horizontal fissure** separates the upper from the middle lobe. It begins in the oblique fissure near the posterior border of the lung and, running horizontally forward, cuts the anterior border at the level of the sternal end of the fourth costal cartilage; on the inner surface it may be traced backward to the hilum. The **middle lobe** (*lobus medius*), the smallest of the lobes of the right lung, lies between the horizontal fissure and the lower part of the oblique fissure; it is wedge-shaped and includes the lower part of the anterior border and the anterior part of the base of the lung.

The right lung is the larger and heavier; it is broader than the left, owing to

the inclination of the heart to the left side; it is also shorter by an inch, in consequence of the Diaphragm rising higher on the right side to accommodate the liver.

The Root of the Lung (*radix pulmonis*) (Figs. 913 and 914).—A little above the middle of the inner surface of each lung, and nearer its posterior than its anterior

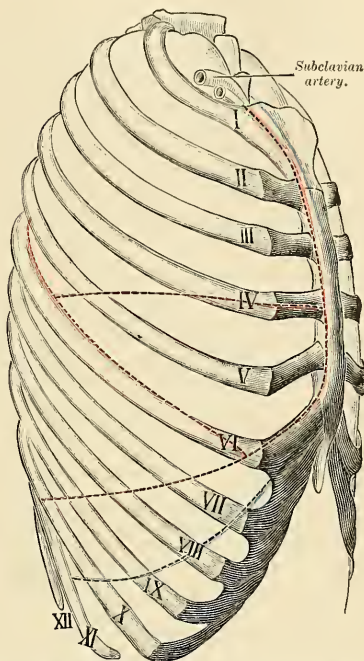


FIG. 920.—Lateral view of thorax, showing relations of right pleura and lung to the thoracic wall. The blue line indicates the line of pleural reflection; the red lines, the outline of the lung and its fissures.

border, is its root, by which the lung is connected to the heart and the trachea. The root is formed by the bronchial tube, the pulmonary artery, the pulmonary veins, the bronchial arteries and veins, the pulmonary plexus of nerves, lymphatics, bronchial lymph nodes, and areolar tissue, all of which are enclosed by a reflection of the pleura. The root of the right lung lies behind the superior vena cava and ascending portion of the aorta, and below the vena azygos major. The root of the left lung lies beneath the arch of the aorta and in front of the descending aorta; the phrenic nerve and the anterior pulmonary plexus lie in front of each, and the vagus and posterior pulmonary plexus behind each; below each is the broad pulmonary ligament.

The chief structures composing the root of each lung are arranged in a similar manner from before backward on both sides—viz., the two pulmonary veins in front, the pulmonary artery in the middle, and the bronchus, together with the bronchial vessels, behind. From above downward, on the two sides, their arrangement differs, thus:

On the *right* side their position is—bronchus, pulmonary artery, pulmonary veins; but on the *left* side their position is—pulmonary artery, bronchus, pulmonary veins. It should be noted that the entire right bronchus does not lie above the right pulmonary artery, but only its eparterial branch (see p. 1177), which passes to the upper lobe of the right lung; the divisions of the bronchus for the middle and lower lobes lie below the artery.

Divisions of the Bronchi.—Just as the lungs differ from each other in the number of their lobes, so the bronchi differ in their mode of subdivision.

The *right* bronchus gives off, about an inch from the bifurcation of the trachea, a branch for the upper lobe. This branch arises above the level of the pulmonary artery, and is therefore named the **eparterial bronchus**. All the other branch bronchi come off below the pulmonary artery, and consequently are termed **hyparterial bronchi**. The first of these is distributed to the middle lobe, and the main tube then passes downward and backward into the lower lobe, giving off in its course a series of large ventral and small dorsal branches. The ventral and dorsal branches arise alternately, and are usually eight in number—four of each kind. The branch to the middle lobe is regarded as the first of the ventral series.

The *left* bronchus passes below the level of the pulmonary artery before it divides, and hence all its branches are **hyparterial**; it may therefore be looked upon as equivalent to that portion of the right bronchus which lies on the distal side of its eparterial branch. The first branch of the left bronchus arises about two inches from the bifurcation of the trachea, and is distributed to the upper lobe. The main stem then enters the lower lobe, where it divides into ventral and dorsal branches similar to those in the right lung. The branch to the upper lobe of the left lung is regarded as the first of the ventral series.

The true **weight** of the human lungs as ascertained in the bodies of criminals executed by electricity, in which the mode of death is attended by a nearly bloodless condition of the lungs, is 215 grams (7½ ounces) for the left lung and 240 grams (8½ ounces) for the right lung (E. A. Spitzka, *Amer. Jour. of Anat.*, iii, 1, p. v). Ordinarily, with the vascular channels more or less filled with blood and serum, the two lungs together weigh about 42 ounces, the right lung being 2 ounces heavier than the left, but much variation is met with according to the amount of blood or serous fluid they may contain. The lungs are heavier in the male than in the female. The specific gravity of the lung tissue varies from 0.345 to 0.746.

The **color** of the lungs at birth is a pinkish white; in adult life a dark slate-color, mottled in patches; and as age advances this mottling assumes a black color. The coloring matter consists of granules of carbonaceous substance deposited in the areolar tissue near the surface of the organ. It increases in quantity as age advances, and is more abundant in males than in females. The posterior surface of the lung is usually darker than the anterior.

The **surface** of the lung is smooth, shining, and marked out into numerous polyhedral spaces, indicating the lobules of the organ; the area of each of these spaces is crossed by numerous lighter lines.

The **substance** of the lung is of a light, porous, spongy texture; it floats in water and crepitates when handled, owing to the presence of air in the tissue; it is also highly elastic; hence the collapsed state of these organs when they are removed from the closed cavity of the thorax.

The Fetal Lung.—After respiration has been established, the lung fills the pleural cavity. In the stillborn fetus, as the lung has never been distended with air and has never received a large amount of blood, it is gathered into a small mass at the back of the thorax. It will sink in water and feels solid to the touch.

Structure.—The structure of the lung is such that the blood brought by the pulmonary artery comes into close relation with the air which enters from the bronchioles. The blood gives materials to the air, and the air gives elements to the blood, and the process of respiration causes the dark blood brought from the heart by the pulmonary artery to return to the heart as red blood in the pulmonary veins. The lungs are composed of an **external serous coat**, a **subserous areolar tissue**, and the **pulmonary substance** or **parenchyma**.

The **serous coat** is thin, transparent, and invests the entire organ as far as the root. It is composed of a layer of endothelial cells resting upon a thin layer of fibroelastic tissue, and is continuous with the subserous tissue. It is known as the pulmonary pleura (p. 1181).

The **subserous areolar tissue** contains a large proportion of elastic fibres; it invests the entire surface of the lung, and extends inward between the lobules.

The **parenchyma** is composed of **lobules** which, although closely connected by an interlobular areolar tissue, are quite distinct from one another. The lobules vary in size from 0.3 cm. to 3 cm. ($\frac{1}{8}$ inch to $1\frac{1}{2}$ inches); those on the surface are large, of pyramidal form, with the bases turned toward the surface; those in the interior are smaller and of various forms. Each lobule is composed of one of the ramifications of a **bronchiole** (about 1 mm. in diameter) and its terminal air cells, and of the ramifications of the pulmonary and bronchial vessels, lymphatics, and nerves, all of these structures being connected by fibroelastic tissue.

The **bronchus** upon entering the lung divides like the ducts of a gland, the terminal tubules, about 1 mm. in diameter, constituting the **bronchioles**. Each bronchiole forms a lobule that is separated and closed from its neighbor. The bronchiole diminishes in diameter to about 0.5 mm. and divides into several tubules (0.3 to 0.4 mm. in diameter), the **respiratory bronchioles**, upon the sides of which some minute depressions, **alveoli**, may be seen. Each respiratory bronchiole further subdivides into several **alveolar ducts** (0.2 mm. in diameter), along which alveoli are numerous. The alveolar ducts lead into individual dilated spaces, the **alveoli**, **air sacs**, or **infundibula** (0.3 to 5 mm. in diameter), upon the sides of which are **alveoli** or **sacculi** (0.05 to 0.1 mm. in diameter). The alveoli are partially separated from one another by low partitions or **septa**, of the same structure as the alveolar wall.

Changes in Structure of the Bronchus and Its Divisions.—Each main **bronchus** resembles the trachea in structure. Within the lung the bronchial tubes are circular in outline. As the bronchus divides and redivides monopodially, changes occur in the various coats. The mucous coat presents a corrugated appearance and the cartilage in the submucosa changes to a complete investing layer composed of a number of individual plates. With this change the smooth muscle tissue, internal to the cartilage, increases so as to form a complete layer. As the smaller tubes are approached the cartilage decreases in amount, while the muscle increases relatively. The mucous glands in mucosa disappear in those tubules of 1 mm. in diameter, while the cartilage persists until a diameter of about 0.5 mm. is reached.

Each **bronchiole** consists of a layer of simple columnar and goblet epithelial cells resting upon a basement membrane and a fibroelastic tunica propria; external to this is found a layer of smooth muscle tissue, and beyond this a layer of white fibrous tissue containing the main vessels and nerves of the tubules. The **respiratory bronchiole** is lined by simple ciliated cells, that gradually give way to nonciliated columnar and cuboidal cells, and lastly flattened epithelium (the **respiratory epithelium**). Some muscle tissue is still present, and the elastic tissue increases in quantity. The **alveolar ducts** are lined by simple epithelial plates resting upon a basement membrane supported by elastic tissue. At the end of this tubule the muscle tissue disappears. The **air sacs** are composed of the **alveoli** or **sacculi** lined by respiratory epithelium that rests upon a basement membrane supported by a meshwork of elastic tissue containing the densest capillary plexus of the body. This elastic tissue allows the alveoli to increase from two to three times their ordinary diameters. Separating one alveolus from another is a low **septum** that has the same structure as the alveolar wall.

Vessels of the Lungs.—The **pulmonary artery** (Figs. 915 and 916) conveys the venous blood to the lungs; it divides into branches which accompany the bronchial tubes, and terminates in a dense capillary network upon the walls of the air cells. In the lung the branches of the pulmonary artery are usually above and in front of a bronchial tube, the vein below. The pulmonary arteries are the nutrient vessels of the respiratory epithelium.

The **pulmonary capillaries** form plexuses which lie immediately beneath the epithelium of the walls and septa of the air cells and of the alveoli. In the septa between the air cells the capillary network forms a single layer. The capillaries form a very minute network, the meshes of which are smaller than the vessels themselves; their walls are also exceedingly thin. The arteries of neighboring lobules are independent of one another, but the veins freely anastomose.

The **pulmonary veins** commence in the pulmonary capillaries, the radicles coalescing into larger branches, which run along through the substance of the lung, independently from the minute arteries and bronchi. After freely communicating with other branches they form large vessels, which ultimately come into relation with the arteries and bronchial tubes, and accompany them to the hilum of the organ. Finally, they open into the left auricle of the heart, conveying oxygenated blood to be eventually distributed to all parts of the body by the aorta.

The **bronchial arteries** supply blood for the nutrition of bronchial tubes and vessels of the lung. The thoracic aorta usually gives off two left bronchial arteries. The single right bronchial artery usually arises from the first right aortic intercostal, but sometimes from the superior left bronchial artery, or from the aorta. In the root of the lung they are posterior to the bronchus, they accompany the bronchial tubes, supply the bronchial tubes and surrounding interlobular tissue, and give branches to the walls of the larger pulmonary vessels, the œsophagus, pericardium, and bronchial lymph nodes. Those supplying the bronchial tubes form a capillary plexus in the muscular coat, from which branches are given off to form a second plexus in the mucous coat. This plexus anastomoses with branches of the pulmonary artery, and empties

into the pulmonary vein. Others are distributed in the interlobular areolar tissue, and terminate partly in the deep, partly in the superficial, bronchial veins. Lastly, some ramify upon the surface of the lung beneath the pleura, where they form a capillary network. There may be but one bronchial artery; there may be three or four.

The **bronchial veins** are not found in the walls of the very small bronchi. The small bronchial veins run along by the front and back of the medium sized and larger tubes, and form two trunks at the root of each lung. These vessels terminate on the right side in the vena azygos major, and on the left side in the superior intercostal or left upper azygos vein. Tracheal and posterior mediastinal veins open into the bronchial veins. The venous blood from the smaller tubes passes to the pulmonary veins.

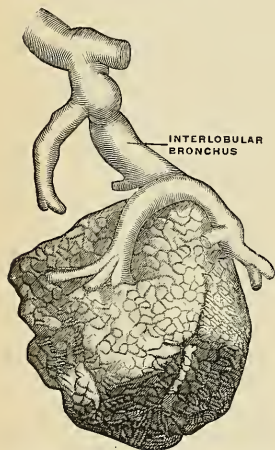


FIG. 921.—A pulmonary lobule. (Poirier and Charpy.)

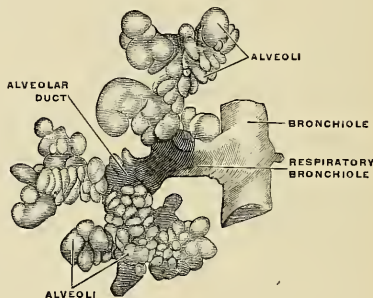


FIG. 922.—The terminal bronchial tubes. The respiratory bronchiole and alveoli. (Poirier and Charpy.)

The **lymphatics** begin in networks about the lobules and form networks about the bronchi and beneath the bronchial mucous membrane. The superficial collecting trunks arise about the lobules and beneath the pleura. According to Sappey, the superficial trunks from the upper lobe begin on the costal surface; one set passes around the anterior border, another set around the posterior border, and a third into the incisura interlobaris. The same observer says that the superficial trunks from the middle lobe unite with the trunks from the upper and lower lobes; and the superficial trunks from the lower lobe, like those of the upper lobe, are in three sets. One set passes around the posterior margin, one around the anterior margin, and one into the interlobar fissure. All of the superficial trunks convey lymph to the nodes of the hilum. Some of the deep collecting trunks begin by the side of the small bronchi; others course along by the pulmonary veins or pulmonary arteries. All of them pass to the nodes of the hilum. The nodes of the hilum are in communication with the peritracheobronchial nodes.

Nerves.—The lungs are supplied from the **anterior and posterior pulmonary plexuses**, formed chiefly by branches from the **sympathetic** and **vagus**. The filaments from these plexuses accompany the bronchial tubes, and are lost upon them. Small ganglia are found upon these nerves.

Surface Form.—The apex of the lung is situated in the neck, behind the interval between the two heads of origin of the Sternomastoid muscle. The height to which it rises above the clavicle varies very considerably, but is generally about one inch. It may, however, extend as much as an inch and a half or an inch and three-quarters, or, on the other hand, it may scarcely project above the level of this bone. In order to mark out the anterior margin of the lung, a line is to be drawn from the apex point, one inch above the level of the clavicle, and rather nearer the posterior than the anterior border of the Sternomastoid muscle, downward and inward across the sternoclavicular articulation and first piece of the sternum until it meets, or almost meets, its fellow of the other side opposite the articulation of the manubrium and gladiolus. From this point the two lines are to be drawn downward, one on either side of the mesal line and close to it, as far as the level of the articulation of the fourth costal cartilages to the sternum. From here the two lines diverge; the left is to be drawn at first passing outward with a slight inclination downward, and then taking a bend downward with a slight inclination outward to the apex

of the heart, and thence to the sixth sternochondral articulation. The direction of the anterior border of this part of the left lung is denoted with sufficient accuracy by a curved line with its convexity directed upward and outward from the articulation of the fourth right costal cartilage of the sternum to the fifth intercostal space, an inch and a half below and three-quarters of an inch internal to the left nipple in the male. The continuation of the anterior border of the right lung is marked by a prolongation of its line from the level of the fourth costal cartilages vertically downward as far as the sixth, when it slopes off along the line of the sixth costal cartilage to its articulation with the rib.

The lower border of the lung is marked out by a slightly curved line with its convexity downward from the articulation of the sixth costal cartilage to its rib to the spinous process of the tenth thoracic vertebra. If vertical lines are drawn downward from the middle of the clavicle, from the deepest part of the axilla, and from the apex of the scapula, while the arms are raised from the sides, they should intersect this convex line, the first at the sixth, the second at the eighth, and the third at the tenth rib. It will thus be seen that the pleura extends farther down than the lung, so that it may be wounded, and a wound may pass through its cavity into the Diaphragm, and the abdominal viscera may be injured without the lung being involved.

The posterior border of the lung is indicated by a line drawn from the level of the spinous process of the seventh cervical vertebra, down either side of the vertebral column, corresponding to the costovertebral joints as low as the spinous process of the tenth thoracic vertebra. The trachea bifurcates opposite the spinous process of the fourth thoracic vertebra, and from this point the two bronchi are directed outward.

"The position of the great fissure of the lungs may be indicated by a line drawn from the third thoracic spine obliquely downward in such a manner as to reach the sixth rib close to the mid-clavicular line. The interlobar fissure between the upper and middle lobes of the right lung corresponds to a line drawn from the apex of the axilla almost horizontally to the sternum, reaching the latter at about the level of the fourth costal cartilage" (Ehrendrath).

Applied Anatomy.—The lungs may be wounded or torn in three ways: (1) By compression of the thorax, without any injury to the ribs. (2) By a fractured rib penetrating the lung. (3) By stabs, gunshot wounds, etc.

The first form, where the lung is *ruptured by external compression* without any fracture of the ribs, is very rare, and usually occurs in young children, and affects the root of the lung—*i. e.*, the most fixed part—and thus, implicating the great vessels, is frequently fatal. It would seem to be a most unusual injury, and the exact mode of its causation is difficult to understand. The probable explanation is that immediately before the compression is applied a deep inspiration is taken and the lungs are fully inflated; owing then to spasm of the glottis at the moment of compression, the air is unable to escape from the lung, the lung is not able to recede, and consequently gives way.

In the second variety, when the *wound in the lung* is produced by the *penetration of a broken rib*, both the pleura costalis and the pleura pulmonalis must necessarily be injured, and consequently the air taken into the wounded air cells may find its way through these wounds into the cellular tissue of the parietes of the thorax. This it may do without collecting in the pleural cavity; the two layers of the pleura are so intimately in contact that the air may pass straight through from the wounded lung into the subcutaneous tissue. *Emphysema* constitutes, therefore, an important sign of injury to the lung in cases of fracture of the ribs. *Pneumothorax*, or air in the pleural cavity, is much more likely to occur in injuries to the lung of the third variety; that is to say, from *external wounds*, from stabs and gunshot injuries, in which cases air passes either from the wound of the lung or from an external wound into the cavity of the pleura during the respiratory movements. In these cases there is generally no *emphysema* of the subcutaneous tissue unless the external wound is small and valvular, so that the air drawn into the wound during inspiration is then forced into the cellular tissue during expiration because it cannot escape from the external wound. Occasionally in wounds of the parietes of the thorax no air finds its way into the cavity of the pleura, because the lung at the time of the accident protrudes through the wound and blocks the opening. This occurs where the wound is large, and constitutes a so-called *hernia* of the lung. *True hernia* of the lung occurs, though very rarely, after wounds of the thoracic wall, when the wound has healed and the cicatrix subsequently yields from the pressure of the viscus behind. It forms a globular, elastic, crepitating swelling, which enlarges during expiratory efforts, falls during inspiration, and disappears on holding the breath. Wounds of the lung may produce dangerous or fatal *hemorrhage* into the pleural sac. In many cases the bleeding is spontaneously arrested; in others the surgeon must interfere to save life. In some cases air has been admitted by intercostal incision and the insertion of a tube, and pulmonary collapse has arrested bleeding. In other cases it is necessary to resect portions of several ribs, and stop bleeding by ligatures or suture ligatures. J. Chalmers Da Costa reports a case in which a furious secondary hemorrhage followed a gunshot wound. He resected several ribs, packed the pleural cavity about the lung with sterile gauze, to obtain a base for support, and then arrested the bleeding by packing iodoform gauze against the firmly supported lung. This patient recovered.

Incision of the lung (*pneumotomy*) is performed for pulmonary abscess (either tuberculous or pyogenic), pulmonary gangrene, hydatid cysts, and bronchiectasis. In pulmonary abscess, locate the area by physical signs and the *x*-rays, resect a portion of a rib over it, and note if the pleura is adherent. If it is adherent, continue the operation. If it is not adherent, insert stitches of catgut through the two layers of pleura and the superficial part of the lung, so as to encircle a considerable area, and then wait several days for adhesions to form. Adhesions protect the pleura from infection, and, by keeping air from the pleural sac, prevent pneumothorax. When ready to continue the operation, locate the abscess with an aspirating needle and syringe, open it with a cautery at a dull red heat, and drain by means of a tube.

Pneumotomy is very unsatisfactory in tuberculous cavities and bronchiectasis. In tuberculosis, excision of the diseased area (*pneumectomy*) has been employed, but it is not to be advised.

Operations upon the lungs can be most safely performed with the patient in a Sauerbruch chamber. The danger of collapse of the lung is thus eliminated.

The routine methods of physical examinations—inspection, palpation, percussion, and auscultation—are nowhere more important than they are in the diagnosis of diseases of the lungs. It is essential, too, that in every case the two sides of the thorax should be compared with each other, and that the wide variations that may be met with under normal conditions in different persons and at different ages should be kept in mind when the thorax is being examined.

On *inspection* the thorax will be seen to be enlarged and barrel-shaped in emphysema, in which the volume of the lungs is increased by dilatation of their alveoli, or in an acute attack of asthma, or when a large pleural effusion or mediastinal tumor is present. The thoracic wall will be flattened or sunken, on the other hand, over an area of lung that has collapsed or become fibrosed, as often happens in chronic pulmonary tuberculosis. The respiratory movements of the thoracic wall will be lessened, or even absent, over a part or the whole of the affected side in such acute disorders as pleurisy, pneumonia, or pleural effusion, or in more chronic disease where the underlying lung is fibrosed, or is crushed to one side by a mediastinal tumor; and by the use of the *x*-rays a corresponding loss of movement or displacement of the Diaphragm on the affected side can often be observed. Under normal conditions the intercostal spaces are a little depressed; but they may be obliterated or even bulging on that side when a large effusion or newgrowth fills up one of the pleural cavities.

On *palpation*, the hand can be used to verify the eye's impressions as to the degree of movement on respiration of any part of the thoracic wall. The facility with which the vibrations produced by the voice are conducted from the larynx by the underlying lung to the hand (in the form of *vocal fremitus*) can also be tested. The vocal fremitus is commonly much increased over the consolidated area in pneumonia or in fibrosis of the lung, and much diminished over a pleural effusion when the lung is pushed up by the fluid toward the top of the pleural cavity. It is also diminished, but to a less extent, in emphysema, and in bronchitis when the bronchi are blocked by secretion. In bronchitis the bubbling of the secretion in the tubes can often be felt by a hand placed on the thoracic wall as the patient breathes; and in chronic pleurisy the friction of the two roughened pleural surfaces against each other can sometimes be felt in the same way.

On *percussion*, the normal resonance of the pulmonary tissue is found to be increased in emphysema, and in pneumothorax this hyperresonance may be still further increased. The resonance is lessened in any condition causing collapse or solidification of the lung tissue, or when its place is taken by fluid (pleural effusion) or some solid growth (mediastinal tumor). Thus, dullness on percussion at the bases of the lungs is common in the hypostatic congestion of the bases seen in heart failure; dullness at the right base is often due to compression of the lung by enlargement of the liver; some dullness at the apex of a lung is frequently met with in tuberculosis of that part, before the disease has progressed very far. Complete dullness over one side of the thorax, back and front alike, except at the apex, is common when a large pleural effusion has taken the lung's place. Von Kórányi, Grocco, and others, have drawn attention to a triangular patch of dullness along the vertebral column (the paravertebral triangle of dullness) on the unaffected side in pleural effusion; this triangle of dullness is said to be absent in other conditions causing loss of pulmonary resonance on percussion, and is due to shifting over of the contents of the posterior mediastinum toward the sound side. The apex of this triangle is in the middle line at the upper level of the fluid effusion; its base, some two to four inches in length, runs horizontally outward from the middle line at the level where the pulmonary resonance normally comes to an end.

On *auscultation* of the lungs, both in health and disease, the variety of sounds to be heard is very great. It is impossible to give adequate consideration to them here, and for further information reference should be made to the text-books dealing with the subject.

THE ORGANS OF DIGESTION.

THE Apparatus for the Digestion of the Food (*apparatus digestorius*) consists of the **alimentary canal** and of certain **accessory organs**.

The **alimentary canal** is a musculomembranous tube, about thirty feet, or nine meters, in length, extending from the mouth to the anus, and lined throughout the entire extent by mucous membrane. It has received different names in the various parts of its course; at its commencement, the **mouth**, we find provision made for the mechanical division of the food (*mastication*), and for its admixture with a fluid secreted by the salivary glands (*insalivation*); beyond this are the **pharynx** and the **œsophagus**, the organs which convey the food (*deglutition*) into that part of the alimentary canal, the **stomach**, in which the principal chemical changes occur, and in which the reduction and solution of the food take place in digestion; in the **small intestine** the nutritive principles of the food are separated, by its admixture with the bile, pancreatic and intestinal fluids, from that portion which passes into the **large intestine**, most of which is expelled from the system through the **rectum** and **anal canal**.

Alimentary Canal.

Mouth.	Small intestine	{ Duodenum.
Pharynx.		{ Jejunum.
Œsophagus.		{ Ileum.
Stomach.	Large intestine	{ Cecum and appendix.
		{ Colon.
		{ Rectum.
		{ Anal canal.

Accessory Organs.

Teeth.		
Tongue.		
Salivary glands	{ Parotid.	Liver.
	{ Submaxillary.	Pancreas.
	{ Sublingual.	

THE MOUTH, ORAL OR BUCCAL CAVITY (CAVUM ORIS).

The mouth is placed at the commencement of the alimentary canal; it is a nearly oval-shaped cavity, in which the mastication and insalivation of the food take place (Figs. 923 and 924).

The **aperture of the mouth** (*rima oris*) is bounded by the lips. The **angle of the mouth** (*angulus oris*) is formed on each side by the meeting of the upper and lower lips (*commissura labiorum*). When at rest with the lips in contact, the rima is a slightly curved line. Every movement which the lips make alters the shape of the rima. When the mouth is closed the floor and roof are usually in contact and its sides are approximated to the dental arches. The mouth consists of two parts—an outer, smaller portion, the **vestibule**, and an inner, larger part, the **cavity proper of the mouth**.

The **Lips** (*labia oris*) are two fleshy folds which surround the orifice of the mouth formed externally by integument and internally by mucous membrane, between which are found the Orbicularis oris muscle (Fig. 292), the labial vessels, some nerves (Fig. 439), areolar tissue, and fat, and numerous small labial glands. The upper lip is called the **labium superius**; the lower lip is called the **labium inferius**. The inner surface of each lip is connected in the middle line to the gum of the corresponding jaw by a fold of mucous membrane, the **frenulum** (*frenulum labii superioris* and *frenulum labii inferioris*), the upper being the larger of the two.

The **labial glands** (*glandulae labialis*) (Fig. 439) are situated between the mucous membrane and the Orbicularis oris muscle around the orifice of the mouth. They are circular in form and of small size; their ducts open by minute orifices upon the surface of the mucous membrane. In structure they resemble the salivary glands.

The **vestibule** (*vestibulum oris*) is a slit-like space, bounded in *front* and *laterally* by the lips and cheeks; *behind* and *internally* by the gums and teeth. *Above*

and *below* it is limited by the reflection of the mucous membrane from the lips and cheeks to the gum covering the upper and lower alveolar arch respectively. It receives the secretion from the parotid, buccal, molar, and labial glands, and communicates, when the jaws are closed, with the cavum oris by an aperture on each side behind the wisdom teeth, and by narrow clefts between opposing teeth (interdental spaces).

The **Cheeks** (*buccae*) form the sides of the face and are continuous in front with the lips. They are composed externally of integument, internally of mucous membrane, and between the two of a layer of muscle, besides a large quantity of fat, areolar tissue, vessels, nerves, and buccal glands.

The Mucous Membrane.—The mucous membrane lining the cheek is reflected above and below upon the gums, where its color becomes lighter; it is continuous behind with the lining membrane of the soft palate. It is composed of stratified squamous epithelial cells that rest upon a basement membrane and papillated tunica propria that consists of fibroelastic tissue supporting the smaller vessels and nerves. Opposite the second molar tooth of the upper jaw is a **papilla**, the summit of which presents the aperture of the **parotid duct** (*ductus parotideus* [Stenonis]) (Fig. 958). The

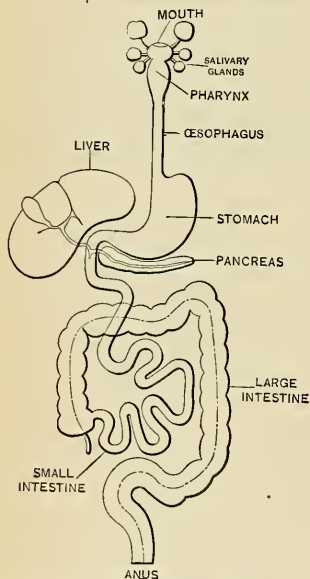


FIG. 923.—Diagram of the alimentary tube and its appendages. (Testut.)

principal muscle of the cheek is the Buccinator, but numerous other muscles enter into its formation—viz., the Zygomatici, Risorius, and Platysma.

The Buccal Glands (*glandulae buccales*).—The buccal glands are placed in the submucous tissue between the mucous membrane and Buccinator muscle; they are similar in structure to the labial glands, but smaller. Four or five glands of larger size than the previously mentioned glands are placed beneath the mucous membrane in the neighborhood of the last molar tooth. They are called the **molar glands** (*glandulae molares*). Their ducts open into the mouth opposite the last molar tooth. The fat pad of the cheek (*corpus adiposum buccae*) has been described on page 376.

The **Gums** (*gingivae*) are composed of a dense fibrous tissue, closely connected to the periosteum of the alveolar processes and surrounding the necks of the teeth. They are covered by smooth and vascular mucous membrane, which is remarkable

for its limited sensibility. Around the necks of the teeth the fibroelastic portion presents numerous fine papillæ; from here it is reflected into each alveolus, where it is continuous with the periosteal membrane lining that cavity.

The **cavity of the mouth proper** (*cavum oris proprium*) is bounded *laterally* and in *front* by the alveolar arches with their contained teeth; *behind*, it communicates with the pharynx by a constricted aperture termed the **isthmus faucium**. It is *roofed* in by the hard and soft palate. The greater part of the *floor* is formed by the tongue, the remainder being completed by the reflection of the mucous membrane from the sides and under surface of the tongue to the gum lining the inner aspect of the mandible. It receives the secretion from the submaxillary, sublingual, and lingual glands.

Floor of the Mouth.—If the tongue be lifted out of its resting-place, the true floor of the mouth, or sublingual region, may be examined. In the middle a fold

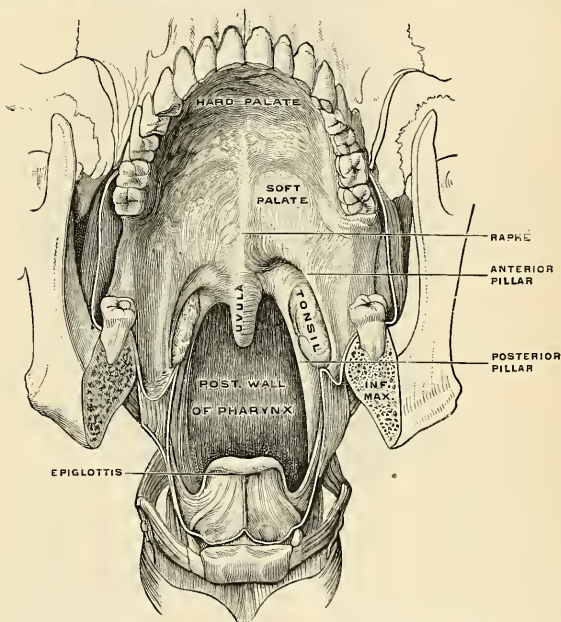


FIG. 924.—Antero-inferior surface of the soft palate. The tongue has been removed, so that the pharyngeal isthmus is distinctly seen. (Luschka.)

of mucous membrane, the **frenum linguae**, extends from the under surface of the tongue to the floor. On each side of the frenum is a papilla, the **caruncula sublingualis**, on the summit of which is the small orifice of the submaxillary (Wharton's) duct. Extending backward from these caruncles, between the tongue and the alveolar arches on each side, is a carunculated fold, the **plica sublingualis**, which becomes lost posteriorly. The carunculated elevations, of variable number, present the orifices of the sublingual ducts.

Structure.—The *mucous membrane* lining the mouth is continuous with the integument at the free margin of the lips and with the mucous lining of the pharynx behind; it is of a rose-pink tinge during life, and very thick where it covers the hard parts bounding the cavity. It is covered by stratified squamous epithelium. In the subepithelial fibroelastic tissue are seen many small accessory salivary glands.

The **Palate** (*palatum*) forms the roof of the mouth; it consists of two portions: the **hard palate**, about two-thirds in front; the **soft palate**, about one-third behind.

The **hard palate** (*palatum durum*) (Figs. 924 and 925) is bounded in front and at the sides by the upper alveolar arches and gums; behind, it is continuous with the soft palate. It is formed by the palate processes of the maxillæ and the palate processes of the palate bones (Fig. 72). It is covered by a dense structure formed by the periosteum and mucous membrane of the mouth, which are intimately adherent, particularly to the front and sides, by means of a layer of fibrous

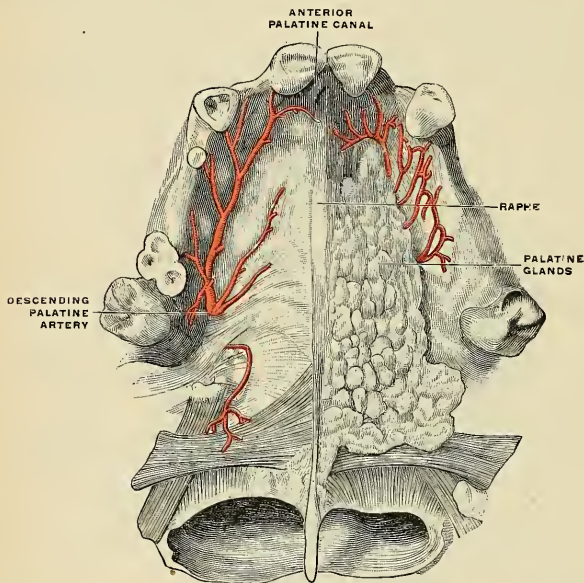


FIG. 925.—The palatine vault on the right side of the mucous membrane has been removed. The left side shows the mucous membrane and the glandular layer. (Poirier and Charpy.)

tissue. Along the middle line is a **linear ridge** or **raphé** (*raphe palati*), which terminates anteriorly in a small papilla, the **incisive papilla** (*papilla incisiva*), corresponding with the inferior opening of the anterior palatine fossa. On either side and in front of the raphé the mucous membrane is thick, pale in color, and corrugated; these corrugations, which are composed of fibrous tissue, are the **palatine rugæ** (*plicae palatinae transversae*). In very young children the rugæ are distinct and definite. In the aged they are indistinct. Behind, it is thin, smooth, and of a deeper color; it is covered with stratified squamous epithelium and the fibrous tissue beneath it contains many mucous glands, the **palatine glands** (*glandulae palatinae*). The palatine vessels and nerves lie in the fibrous tissue beneath the mucous membrane.

The **soft palate** (*palatum molle*) (Figs. 924 and 925) is a movable slanting fold suspended from the posterior border of the hard palate, and forming an incomplete septum between the mouth and pharynx. It consists of a fold of mucous mem-

¹ Concerning the etymology of *palatal* and *palatine*, see footnote on page 109.

brane enclosing muscle fibres, an aponeurosis, vessels, nerves, lymphoid tissue, and mucous glands. When occupying its usual position it is relaxed and pendent, and its oral surface is concave, continuous with the roof of the mouth, and marked by a **median ridge** or **raphé**, which indicates its original separation into two lateral halves. Its pharyngeal surface is convex, and continuous with the mucous membrane covering the floor of the posterior nares. Its anterior or upper border is attached to the posterior margin of the hard palate, and its sides are blended with the pharynx. Its posterior or lower border is free. The posterior portion of the soft palate (*velum palatinum*) terminates posteriorly and externally on each side in a free margin, the posterior arch of the palate, and bounds the isthmus of the pharynx.

Hanging from the middle of its lower border is a small, cone-shaped, pendulous process, the **uvula** (*uvula palatina*). The uvula varies greatly in length in different individuals. It is composed of glands and connective tissue, contains a prolongation of the Azygos uvulæ muscle and is covered with mucous membrane, and arching outward and downward from the base of the uvula on each side are two curved folds of mucous membrane, containing muscle fibres, called the **arches** or **pillars of the soft palate** or **pillars of the fauces** (*arcus palatini*).

The **anterior pillar** (*arcus glossopalatinus*) (Fig. 924) on each side runs downward, outward, and forward to the side of the base of the tongue, and is formed by the projection of the Palatoglossus muscle, covered by mucous membrane.

The **posterior pillar** (*arcus pharyngopalatinus*) (Fig. 924) is larger and projects farther inward than the anterior; it runs downward, outward, and backward to the sides of the pharynx, and is formed by the projection of the Palatopharyngeus muscle, covered by mucous membrane. The anterior and posterior pillars are separated below by a triangular interval (*tonsillar sinus*), in which the tonsil is lodged.

The aperture by which the mouth communicates with the pharynx is called the **isthmus of the fauces** (*isthmus faucium*). It is bounded, *above*, by the free margin of the soft palate; *below*, by the back of the tongue; and on *each side*, by the pillars of the fauces and the tonsils.

The **aponeurosis of the soft palate** is a thin but firm fibrous layer attached above to the posterior border of the hard palate, and becoming thinner toward the free margin of the soft palate. Laterally, it is continuous with the pharyngeal aponeurosis. It forms the framework of the anterior half of the soft palate, and is joined by the tendons of the Tensor palati muscles.

The **muscles of the soft palate** are found in its posterior half, and are six on each side—the **Levator palati**, **Tensor palati**, **Azygos uvulæ**, **Palatoglossus**, **Palatopharyngeus**, and **Salpingopharyngeus** (see p. 397). The following is the relative position of these structures in a dissection of the soft palate from the posterior or nasopharyngeal to the anterior or oral surface: Immediately beneath the pharyngeal mucous membrane is a thin stratum of muscle tissue, the posterior fasciculus of the **Palatopharyngeus muscle**, joining with its fellow of the opposite side in the middle line. This posterior fasciculus is joined by the Salpingopharyngeus muscle. Beneath this are the **Azygos uvulæ** and **Salpingopharyngeus muscles**, consisting of two rounded fleshy fasciculi, placed side by side in the median line of the soft palate. Next comes the aponeurosis of the **Levator palati**, joining with the muscle of the opposite side in the middle line. Fourthly, the anterior fasciculus of the **Palatopharyngeus**, thicker than the posterior, and separating the Levator palati from the next muscle, the **Tensor palati**. This muscle terminates in a tendon which, after winding around the hamular process of the internal pterygoid plate of the sphenoid bone, expands into a broad aponeurosis in the soft palate, anterior to the other muscles so far enumerated. Finally, we have a thin muscular stratum, the **Palatoglossus muscle**, placed in front of the aponeurosis of the Tensor palati, and separated from the oral mucous membrane by lymphoid tissue.

The **mucous membrane of the soft palate** is thin, and covered with stratified squamous epithelium on both surfaces, excepting near the orifice of the Eustachian tube, where its epithelium is stratified and ciliated.¹ Beneath the mucous membrane on the oral surface of the soft palate

¹ According to Klein, the mucous membrane on the nasal surface of the soft palate in the fetus is covered throughout by columnar ciliated epithelium, which subsequently becomes squamous; and some anatomists state that it is covered with columnar ciliated epithelium, except at its free margin, throughout life.

is a considerable amount of lymphoid tissue. The palatine glands form a continuous layer on the pharyngeal surface and around the uvula.

The **arteries** supplying the palate are the **descending palatine branch of the internal maxillary artery** (*a. palatina descendens*), the **ascending or palatine branch of the facial artery** (*a. palatina ascendens*), and sometimes a palatine branch of the ascending pharyngeal. The **veins** terminate chiefly in the pterygoid and tonsillar plexuses. The **lymphatic vessels** pass to the superior deep cervical nodes.

The **motor nerves** are chiefly derived from the pharyngeal plexus, the Tensor palati, however, receiving a special branch from the otic ganglion. The **sensor nerves** are derived from the descending palatine, nasopalatine, and from the glossopharyngeal.

Development of the Mouth.—The mouth is developed partly from the stomodeum, the depression between the head end of the embryo and the pericardial area, and partly from the floor of the extreme end of the foregut. The floor of the stomodeum is the thin, buccopharyngeal membrane, formed by the apposition of ectoderm and entoderm; this membrane wholly disappears after the second week of embryonic life, and a communication is established between the mouth and future pharynx. With the development of the face the nasal passages are separated from the mouth proper by the coalescence of the maxillary and palatal processes of the first visceral arch with the lateral nasal and globular processes forming the maxillæ and palate.

The development of the teeth is described on page 1212.

Applied Anatomy.—*Cleft palate* is by no means a rare congenital deformity, and may be partial or complete. Most of the cleft is in the middle line. It may be a mere cleft of the uvula, it may be limited to the soft palate, or it may involve the hard palate to but not include the alveolus. It may pass through the alveolus, but if it does so it ceases to be median at this point, and follows the line of suture between the incisive bone and the maxilla (pp. 106 and 152). Complete cleft palate is likely to be accompanied by *harelip*. This cleft in the lip is not median, but is at the termination of the palate cleft. If the cleft of a cleft palate runs along each side of the incisive bone, the bone is isolated from the maxilla and the cleft is Y-shaped. In such a case *double harelip* is present.

The **Teeth** (*dentes*).—The human subject is provided with two sets of teeth, which make their appearance at different periods of life.

Those of the first set appear in childhood, and are called the **temporary, deciduous, or milk teeth**. Those of the second set are named **permanent or succedaneous teeth**.

The **temporary teeth** are twenty in number—four incisors, two canines, and four molars in each jaw (Figs. 926 and 947).

The **permanent teeth** are thirty-two in number—four incisors (two central and two lateral), two canines, four bicuspid, and six molars in each jaw (Figs. 928 and 932).

The dental formulæ may be represented as follows:

<i>Temporary Teeth.</i>							} Total, 20.		
Upper jaw	Molar.	Canine.	Incisor.	Incisor.	Canine.	Molar.			
. . .	2	1	2	2	1	2			
Lower jaw	2	1	2	2	1	2			
<i>Permanent Teeth.</i>							} Total, 32.		
Upper jaw	Molar.	Bicuspid.	Canine.	Incisor.	Incisor.	Canine.		Bicuspid.	Molar.
. . .	3	2	1	2	2	1		2	3
Lower jaw	3	2	1	2	2	1		2	3

General Characters (Fig. 933).—Each tooth consists of three portions—the **crown or body** (*corona dentis*), projecting above the gums; the **root or fang** (*radix dentis*), entirely concealed within the alveolus; and the **neck** (*collum dentis*), the constricted portion between the root and crown, covered by the gum.

The **roots** of the teeth are firmly implanted within the **sockets or alveoli of the jaws** (*alveoli dentales*) (see pp. 104 and 117). These depressions are lined with periosteum, which is reflected on to the tooth at the apex of the root and covers

¹ According to Klein, the mucous membrane on the nasal surface of the soft palate in the fetus is covered throughout by columnar ciliated epithelium, which subsequently becomes squamous; and some anatomists state that it is covered with columnar ciliated epithelium, except at its free margin, throughout life.

it as far as the neck. This is the **root-**, or **pericemental membrane** (*periosteum alveolare*). At the margin of the alveolus the periosteum becomes continuous with the fibrous structure of the gums.

Surfaces.—In consequence of the curve of the dental arch, such terms as anterior, posterior, internal, and external, as applied to the teeth, are misleading and confusing. Special terms are therefore applied to the different surfaces of a tooth: That which looks toward the lips and cheek is the **labial** or **buccal surface** (*facies*

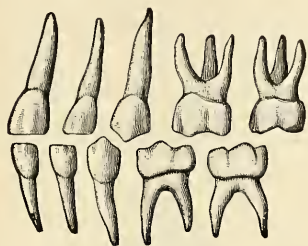


FIG. 926.—Deciduous teeth of left side. Labial view.

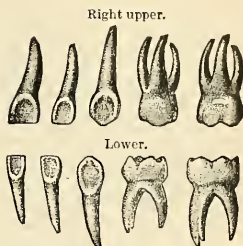


FIG. 927.—Deciduous teeth. Lingual view.

labialis); that toward the tongue is the **lingual surface** (*facies lingualis*); that surface which is directed toward the mesal plane, supposing the teeth were arranged in a straight line outward from the central incisor, is known as the **proximal surface**, looks toward predecessor; while that directed away from the mesal plane is called the distal surface, looks toward successor. The surface which comes in contact with the teeth of the opposite jaw is the **grinding, masticating, or occlusal surface** (*facies masticatoria*).

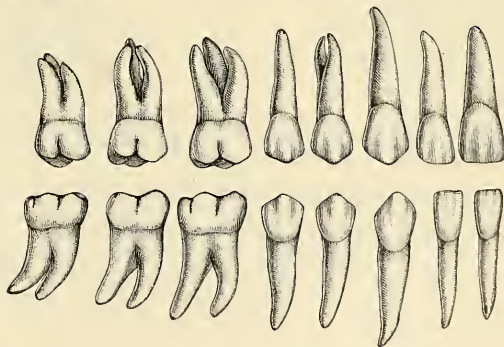


FIG. 928.—Permanent teeth, right side. (Burchard.)

The **Temporary, Deciduous, or Milk Teeth** (*dentes decidui*) (Figs. 926 and 927) are smaller, but resemble in form those of the permanent set. The neck is more marked, owing to the greater degree of convexity of the labial and lingual surfaces of the crown. The last of the two temporary molars is the largest of all the deciduous teeth, and is succeeded by the second bicuspid. The first upper molar has only three cusps—two labial, one lingual; the second upper molar has four cusps. The first lower molar has four cusps; the second lower molar has five.

The roots of the temporary molar teeth are smaller and more diverging than those of the permanent set, but in other respects bear a strong resemblance to them.

Permanent Teeth (*dentes permanentes*) (Fig. 928).—The **incisors** or **cutting teeth** (*dentes incisivi*) are so named from their presenting a sharp cutting edge, adapted for incising the food. They are eight in number, and comprise the four front teeth in each jaw.

The **crown** is directed vertically and is chisel-shaped, being bevelled at the expense of its lingual surface, so as to present a sharp horizontal cutting edge. Before being subjected to attrition this edge presents three small elevations. The **labial surface** is convex, smooth, and highly polished. The **lingual surface** is concave, and is marked by two marginal ridges extending from an encircling ridge at the neck to the angles of the cutting edge of the tooth. The ridge at the neck is termed the **cingulum** or **basal ridge**. The **neck** of the tooth is constricted. The **root** is long, single, conical, transversely flattened, thicker before than behind, and slightly grooved on either side in the longitudinal direction. The root may be curved.

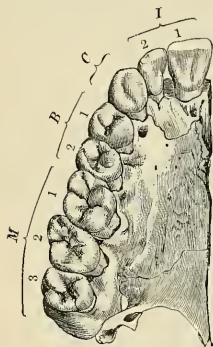


FIG. 929.—Right half of upper jaw (from below), with the corresponding teeth. The letters and numbers point to the classes of teeth and the numbers in classes.

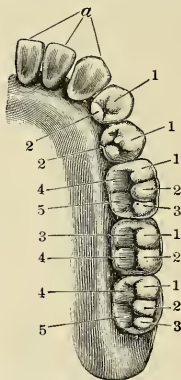


FIG. 930.—Right half of lower jaw, with the corresponding teeth. The letter and numbers point to the various cusps or their modifications on the different teeth. (Burchard.)

The **incisors of the upper jaw** are altogether larger and stronger than those of the lower jaw, the central incisors being larger and flatter than the lateral incisors. They are directed obliquely downward and forward.

The **incisors of the lower jaw** are smaller and flatter than the upper, and the elevations upon their lingual faces are not marked. The two central are smaller than the two lateral incisors, being the smallest of all the teeth. The **roots** of these teeth are flattened laterally.

The **Canine Teeth** (*dentes canini*) are four in number, two in the upper, two in the lower jaw—one being placed distal to each lateral incisor. They are larger and stronger than the incisors, especially in the roots, which are deeply implanted and each causes a well-marked prominence of the process at the place of insertion.

The **crown** is large, of spear-head form, and its very convex labial surface is marked by three longitudinal ridges. The concave lingual surface is also marked by three ridges which unite at a basal ridge. The **point** or **cusp** is longer than in the other teeth, and is the point of division between a short proximal and a long distal cutting edge. These two edges form an obtuse angle with each other.

The **root** is single, oval, or elliptical on transverse section, and is longer and more prominent than the roots of the incisors.

The **upper canines**, popularly called the **eye teeth**, are larger and longer than the two lower, and in occlusion are distal to them to the extent of half the width of the crown.

The **lower canines**, popularly called the **stomach teeth**, have the general form of the upper canines, but their lingual surfaces are much more flattened, owing to the absence of the elevations marking the upper teeth. Their roots are more flattened and may be bifid at their apices.

The **bicuspid teeth**, or the **premolars** (*dentes premolares*) are eight in number, four in each jaw; they are placed distal to the canine teeth, two upon each side of the jaw.

The **crown** is surmounted by two cusps, one buccal and one lingual, separated by a groove, the buccal being more prominent and larger than the lingual. The lower bicuspid is not truly bicuspid, the first having but a primitive lingual cusp, the second having the lingual cusp divided into two sections—i. e., it is usually tricuspid. The **necks** of the teeth are oval; the **roots** are single and laterally compressed, that of the first upper bicuspid being frequently bifid. The first upper bicuspid is usually the largest of the series. The roots of the lower bicuspid are less compressed and more rounded.

The **Molar Teeth** (*dentes molares*) are the largest and strongest teeth of the permanent set, and are adapted by their forms for the crushing and grinding of the food. They are twelve in number, six in each jaw, three being placed posterior to each second bicuspid.

The **crowns** are cuboidal in form, are convex buccally and lingually; they are flattened proximally and distally. They are formed by the fusion of three primitive cusps in the upper and four in the lower. To these are added in the first and second upper molars a **distolingual tubercle**, and in the first and third molars of the lower jaw a **distobuccal tubercle**. The unions of the primitive forms are marked by sulci. The **necks** of these teeth are large and rhomboidal in form. The **roots** of the upper molars are three in number—one large **lingual or palatal root**, and two smaller **buccal roots**. In the lower molars, two roots are found, a proximal and a distal, each of which is much flattened from before backward.

The **first molar teeth** are the largest of the dental series; they have four cusps on the upper and five in the lower—three buccal and two lingual. The **second molars** are smaller; the crowns of the upper are compressed until the distolingual cusp is reduced. The crowns of the lower are almost rectangular, with a cusp at each angle. The **third molars** are called the wisdom teeth, or *dentes sapientiae* (*dentes serotini*), from their late eruption; they have three cusps upon the upper and five upon the lower. The three roots of the upper are frequently fused together, forming a grooved cone, which is usually curved backward. The roots of the lower, two in number, are compressed together, and curve backward.

Of the permanent teeth, all but the molars represent succedaneous teeth, that is, teeth that succeed those of the temporary set. The molars are primary teeth, as they possess no predecessors in the temporary set.

Arrangement of the Teeth.¹—The human teeth are arranged in two parabolic arches, the **upper row** or **arch** (*arcus dentalis superior*) being larger, its teeth overlapping the **lower row** or **arch** (*arcus dentalis inferior*). The average distance between the centres of the condyles of the mandible is about four inches, which is also the distance from either of these points to the line of junction between the lower incisor teeth. Whether the jaw be large or small, the equilateral triangle

¹ After Dr. W. G. A. Bonwill.

indicated is included in it; the range of size is between three and one-half and four and one-half inches.

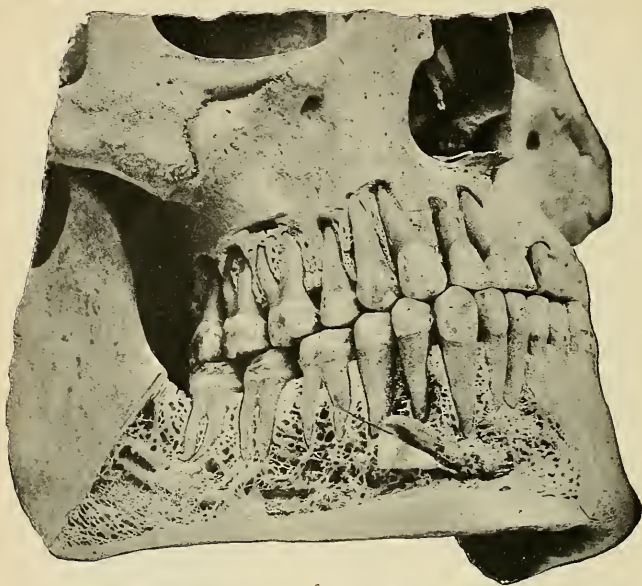


FIG. 931.—View of teeth *in situ*, with the external plates of the alveolar processes removed. (Cryer.)

Owing to the smaller sizes of the lower incisors, the teeth of the mandible are each one-half a tooth in advance of its upper fellow, so that each tooth of the dental

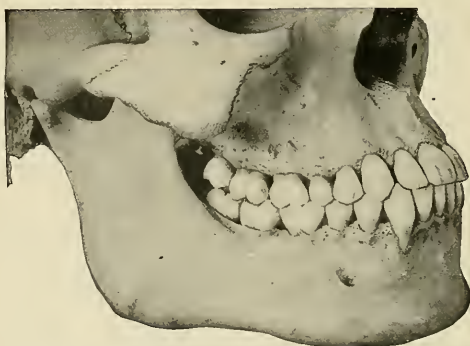

FIG. 932.—Front and side views of the teeth and jaws. (Cryer.)

series has two antagonists, with the exception of the lower central incisors and upper third molars (Figs. 931 and 932).

The grinding faces of the upper bicuspid and molars curve progressively upward and point outward, the first molar being at the lowest point of the curve, the third molar at the highest. The curve of the lower dental arch is the reverse, the first molar at its deepest part, the third molar at its extremity. The greater the depth to which the upper incisors overlap the lower, the more marked this curve and the more pointed are the cusps of the grinding teeth.

The movement of the human mandible is forward and downward, the resultant of these directions being an oblique line, upon an average of 35 degrees from the horizontal plane.¹

When the mandible is advanced until the cutting edges of the incisors are in contact, the jaws are separated, but at the highest point of the lower arch its third molar advances, and meets and rests upon a high point, the second molar of the upper arch, and thus undue strain upon the incisors is obviated.

In the lateral movements of the mandible but one side is in effective action at one time; the oblique positions of the cusps of the opposite teeth are such that when either side is in action the other is balanced at two or more points.

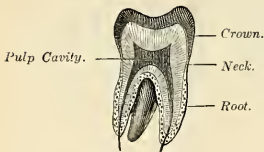


FIG. 933.—Vertical section of molar tooth.

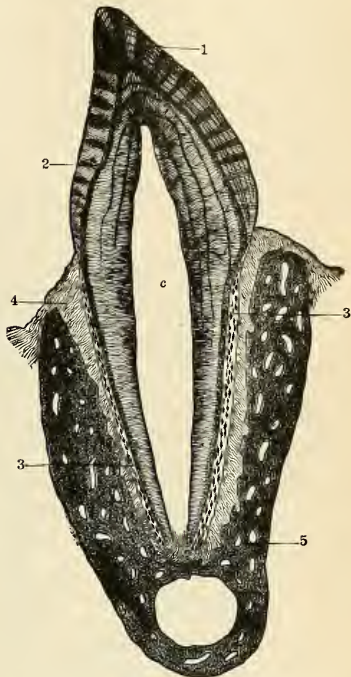


FIG. 934.—Vertical section of a tooth *in situ* (15 diameters). *c* is placed in the pulp cavity, opposite the cervix, or neck of the tooth; the part above is the crown, that below is the root (fang). 1. Enamel with radial and concentric markings. 2. Dentin with tubules and incremental lines. 3. Cementum or crusta petrosa, with bone corpuscles. 4. Pericemental membrane. 5. Bone of mandible.

There is an anatomical correspondence between the forms and arrangement of the teeth, the form of the condyle of the mandible, and the muscular arrangement. Individuals who have teeth with long cusps have the head of the bone much rounded from before backward, and have a preponderance of the direct over the oblique muscles of mastication, and *vice versa*; teeth with short or no cusps are associated with a flattened condyle and strong oblique muscles.

Very great aberrations in the dental arrangement are frequently followed by accommodative changes in the condyles of the mandible.

Structure of the Teeth.—A longitudinal section of a tooth will show the presence of a central chamber having the general form of the crown of the tooth, and called the **pulp chamber** or **pulp cavity** (*cavum dentis*). The solid portion of the tooth exhibits three hard tissues: one, the

¹ W. E. Walker, Dental Cosmos, 1896.

proper dental substance, called **dentin** or **ivory** sheathed upon the exposed crown by a layer called the **enamel**, while the dentin of the root is enclosed in a distinct tissue, the **cementum** or **crusta petrosa**. Both enamel and cementum are thinnest at the neck and thickest upon their distal portions.

The **enamel** (*substantia adamantina*) (Figs. 934, 935, and 938) is the hardest and most compact part of a tooth, and forms a thin crust over the exposed part of the crown, as far as the commencement of the root. It is thickest on the grinding surface of the crown until worn away by attrition, and becomes thinner toward the neck. It consists of a congeries of minute hexagonal rods, columns, or prisms, known as **enamel fibres** or **prisms** (*prismata adamantina*) (Fig. 938). In general they lie parallel with one another, resting by one extremity upon the dentin, which presents a number of minute depressions for their reception, and forming the free surface of the crown by the other extremity. There are additional shorter (*supplemental*) prisms filling in the spaces between the long diverging prisms. There are occasional collections of prisms which run diagonally. The prisms are directed vertically on the summit of the crown, horizontally at the sides; they are about $\frac{1}{3500}$ inch in diameter, and pursue a more or less wavy course. By reflected light radial striations are visible, best marked near the dentin. These are **Schreger's lines** and are due to the fact that the prisms take an undulatory course

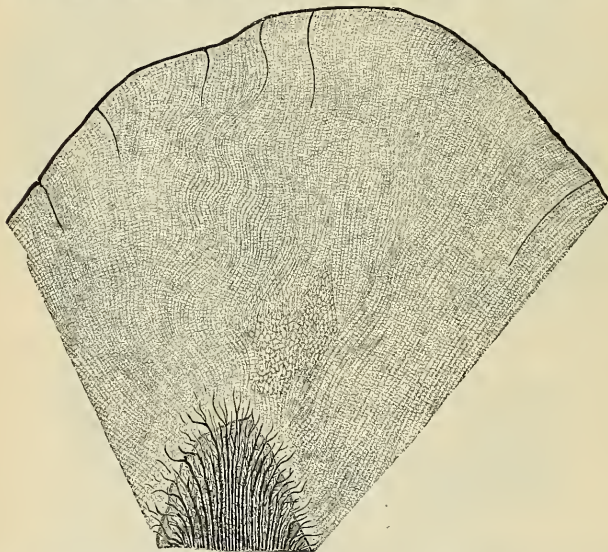


FIG. 935.—Longitudinal ground section through the apex of a canine tooth from a three-and-a-half-year-old boy. The entrance of the dental canaliculi between the enamel prisms and the course taken by the latter are shown. $\times 135$. (Szymonowicz.)

and those of two layers may have opposite directions. Another series of lines, having a brown appearance from pigmentation, and denominated the **parallel striæ** or **brown striæ** of **Retzius**, or the **colored lines**, are seen on a section of the enamel. These lines are concentric, and *cross* the enamel rods. They are caused by the mode of enamel deposition. Inasmuch as the enamel columns, when near the dentin, cross each other and only become parallel farther away, a series of radial markings, light and dark alternately, is obtained (Fig. 934). The enamel prisms are themselves calcified and are fixed to each other by a very small amount of cement substance. Numerous minute interstices intervene between the enamel fibres near their dentinal surface. It is noted that some of the dentinal canals at the crown penetrate a certain distance between the rods of the enamel; this is considered pathological by some (Fig. 935). No nutritive canals exist in the enamel, except the very few dentinal canals which at the crown penetrate a short distance, and these are found only in a small area.

Chemical Composition.—According to Bibra, enamel consists of 96.5 per cent. of earthy matter and 3.5 per cent. of animal matter. The earthy matter consists of the phosphate and

the carbonate of calcium, with traces of fluoride of calcium, phosphate of magnesia, and other salts.

The enamel of a recently erupted tooth is covered by a membrane, the thickness of which is $\frac{1}{2000}$ inch. It is known as **enamel cuticle** or **Nasmyth's membrane** (*cuticula dentis*). It is probably the remains of the enamel organ, though some consider it the continuation of the cementum.

The **dentin** or **ivory** (*substantia eburnea*) (Fig. 937) forms the principal mass of the tooth. It represents modified bone, but differs from the latter in that its cells are upon the surface of the pulp and not in the substance of the dentin. The important parts are: dentinal tubules, dentinal sheaths, matrix, and dentinal fibres.

The **dentinal tubules** are minute canals which have a spiral course, more or less perpendicular to the pulp cavity, and extending from this cavity to the enamel or to the cementum. The diameter at the pulpal end is about $\frac{1}{4500}$ of an inch, and this diminishes as the tubules branch. The tubules usually end blindly near the enamel; some, however, terminate in the interglobular spaces or anastomose with other tubules. The dentinal tubules contain the **dentinal fibres**, which represent the peripheral processes of the odontoblastic cells, and their branches follow the divisions of the tubules. The tubule branches are most numerous near the enamel or the cementum.

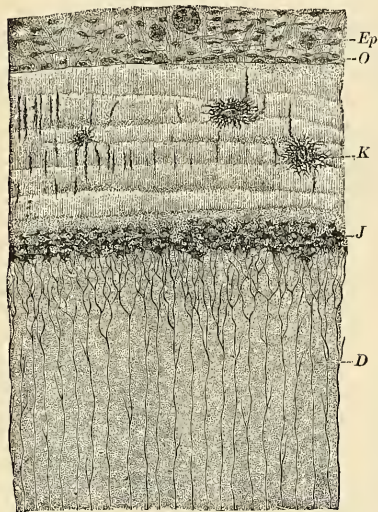


FIG. 936.—Ground section through the root of a human premolar. D. Dentin. K. Cement corpuscles. O. Osteoblasts. Ep. Remains of Hertwig's epithelial sheath, 200 diameters. J. Interglobular spaces. (Rose.)




FIG. 937.—From a ground section through the parts of a dentin, near the pulp, of a human canine tooth which has been impregnated with pigment. The dental canaliculi are cut across and are joined together by side branches. $\times 400$.

The **dentinal sheaths**, or **Neumann's sheaths**, are tubes of markedly resistant dentin surrounding and bounding the dentinal tubules. They branch and curve as do the tubules.

The **matrix**, or **intertubular dentin**, is less dense than that of the sheaths. It fills the spaces between the sheaths, and seems to be composed of lamellae that run parallel to the pulp chamber. Fibrils have been found in the matrix. Scattered in the matrix, and especially near the enamel, are numerous spaces filled with a gelatinous substance; these are the **interglobular spaces** (*spatia interglobulares*), representing areas of incomplete calcification. Between the dentin and cementum the spaces are very numerous, but small; these constitute **Tomes' granular layer**.

In a *dry* tooth a section of dentin often displays a series of lines—the **incremental lines of Salter**—which are parallel with the laminae above mentioned. These lines are caused by two facts: (1) The imperfect calcification of the dentinal laminae immediately adjacent to the line. (2) The drying process, which reveals these defects in the calcification. These lines are wide or narrow according to the number of laminae involved, and along their course, in consequence of the imperfection in the calcifying process, little irregular cavities are left, which are the **interglobular spaces** already referred to. They have received their name from the fact that they are surrounded by minute nodules or globules of dentin. Other curved lines may be seen parallel to the surface. These are the **concentric lines of Schreger**, and are due to the optical effect of simultaneous curvature of the dentinal tubules.

Chemical Composition.—According to Berzelius and Bibra, dentin consists of twenty-eight parts of animal and seventy-two of earthy matter. The animal matter is resolvable by boiling into gelatin. The earthy matter consists of phosphate and carbonate of calcium, with a trace of fluoride of calcium, phosphate of magnesia, and other salts.

The **cementum**, or **crusta petrosa** (*substantia ossea*) (Fig. 934), is disposed as a thin layer on the roots and neck of a tooth, from the termination of the enamel as far as the apex of the root, where it is usually very thick. At the neck it overlies a slight margin of enamel. In structure and chemical composition it is true bone. It consists of a number of lamellæ that are thicker near the apex than the neck of the tooth in young teeth. In older teeth there are additional shorter supplemental lamellæ at the apex. Between the lamellæ are the lacunæ and canaliculi, and it is claimed that in thick cementum even Haversian systems may be found. It is composed of about 66 per cent. organic matter and 34 per cent. inorganic matter. The teeth of the young usually contain Haversian systems in the thicker portions of the cementum. The neck of the tooth does not contain lacunæ. Sharpey's fibres (p. 38) are very numerous. Some of the lacunæ of the cementum receive dentinal tubes from the dentine.

As age advances the cement increases in thickness, and gives rise to those bony growths, or exostoses, so common in the teeth of the aged; the pulp cavity becomes also partially filled by a hard substance intermediate in structure between dentin and bone (the *ostedentin* of Owen; the *secondary dentin* of Tomes). It is formed by the odontoblasts, the dental pulp lessening in volume.

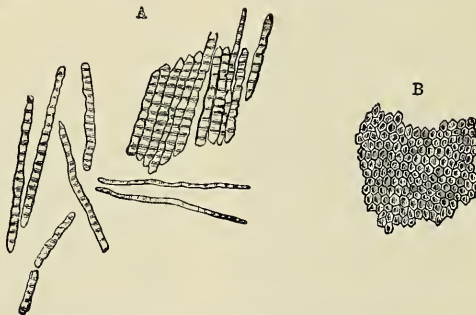


FIG. 938.—Enamel prisms (350 diameters). A. Fragments and single fibres of the enamel isolated by the action of hydrochloric acid. B. Surface of a small fragment of enamel, showing the hexagonal ends of the fibres.

The **pulp** (*pulpa dentis*) occupies the **pulp cavity** or **chamber**. This chamber communicates with the outside through a minute canal in the apex of each fang, called the **root canal** (*canalis radialis dentis*). The foramen at the apex is called the **apical foramen** (*foramen apicis dentis*). The **pulp** is a highly vascular and sensitive mass of mucous connective tissue connected with the nutrition and sensitiveness of the tooth. It consists of a network of delicate fibrils supporting spindle-shape, stellate, and spheroidal cells, and, lastly, the **odontoblasts**, which are arranged in a single row upon the surface of the pulp; each odontoblast is a cylindrical or flask-shaped cell possessing several processes, of which the peripheral becomes the **dentinal fibre**. The bloodvessels of the pulp break up into innumerable capillary loops which lie beneath the layer of odontoblasts. The nerve fibrils break up into numberless myelinic filaments, which spread out beneath the odontoblasts, and probably send terminal filaments to the extreme periphery of the pulp outside the odontoblasts. The matrix cells and their processes are irregularly arranged in the body of the pulp, but in the canal portion the fibrillæ are in the direction of the axis of the root.

The **peridental membrane** (*pericementum*) is a vascular and sensitive fibrous tissue membrane that holds the tooth in place. Upon its internal surface it forms cementum, while upon its outer surface it forms the bone of the alveolar process of maxilla or mandible. It is thickest at the apical and gingival regions of the tooth and thin in the middle. Upon its inner surface are seen cementoblasts, and upon its outer surface are found osteoblasts. The *arteries* are derived from the apical artery, and ultimately form a capillary plexus beneath the cemental and alveolar surfaces of the membrane. The venous channels converge at the apex to empty into the apical vein.

Lymphatics are said to be absent.

Development of the Teeth (Figs. 939 to 945).—The teeth are an evolution from the dermoid system, and not of the bony skeleton; they are developed from two of the blasto-

dermic layers, the ectoderm and mesoderm. From the former the enamel is developed; from the latter the dentinal pulp, dentin, cementum, and periodontal membrane. It is customary to view the development of the permanent and temporary teeth as separate studies.

The earliest evidence of tooth formation in the human embryo is observed about the sixth week. The epithelium covering the embryonic jaws is seen to rise as a ridge along the summit of each jaw. This ridge is the **maxillary rampart of Kolliker and Waldeyer**. A transverse section through the jaw will show the elevation to be due to a linear and outlined activity of the germinal epithelial layer; a corresponding epithelial growth is seen to sink as a band into the mesodermal tissue beneath. This band is called the **dental lamina or dental shelf**. The local

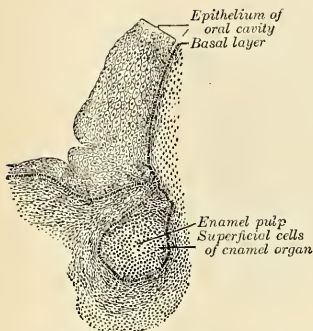


FIG. 939.—Anlage of the enamel germ connected with the oral epithelium by the enamel ledge. $\times 110$.

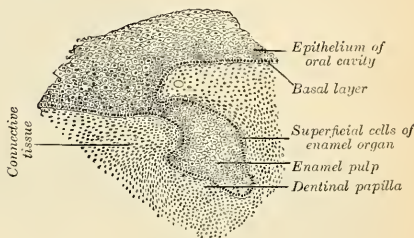


FIG. 940.—First trace of the dentinal papilla. $\times 110$.

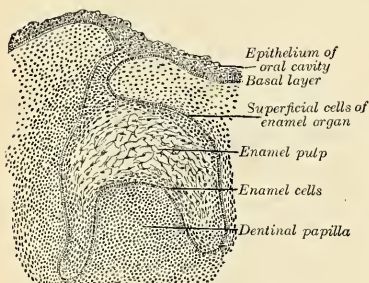


FIG. 941.—Advanced stage with larger papilla and differentiating enamel pulp. $\times 110$.

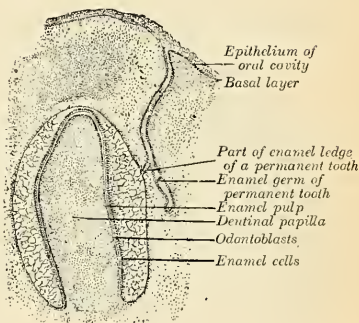


FIG. 942.—Budding from the enamel ledge of the anlage of the papilla, which later goes to form the enamel of a permanent tooth; at the periphery of the papilla the odontoblasts are beginning to differentiate. $\times 40$.

FIGS. 939 TO 942.—Four stages in the development of a tooth in a sheep embryo (from the lower jaw) (From Böhm and Davidoff.)

cell activity continues, and in its descent the band appears to meet with a resistance which causes a flattening of its extremity into a continuous lamina. From the outer or labial surface of the shelf epithelial buds are given off successively, ten in number, one for each temporary tooth; the earliest (central incisors) appear about the seventh to the eighth week.

The growth of each bud continues, and each expands into a flask-like form, the walls covered by a layer of germinal cells, its interior composed of stellate cells. The bulb is now seen to flatten upon its deep surface, as though it had met with an outlined resistance from the mesodermal

tissue beneath. The mesoderm at the base of each enamel organ condenses, and seems to force the adjacent part of the enamel germ toward the apex of the organ, producing thus a sac-like structure, the **enamel organ**; the latter now consists of three layers, outer columnar layer, middle, stellate reticulum, and inner, enamel-forming cells, the **membrana adamantina**. The papilla-like mass of mesoderm that extends into the enamel organ is called the **dental papilla**.

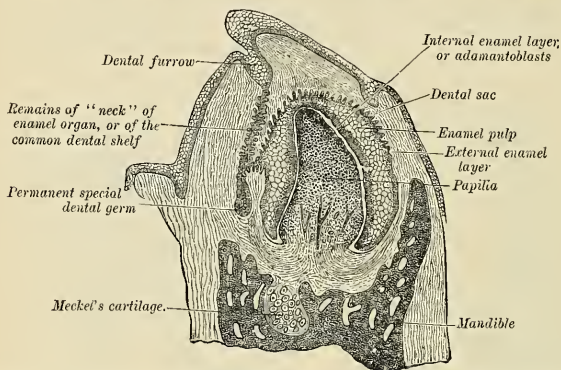


FIG. 943.—Vertical section of the mandible of an early human fetus. (Magnified 25 diameters.)

The mesoderm peripheral to the enamel organ condenses to form a sheath called the **dental sac** or **follicle**. In the meantime the dental shelf becomes attenuated and tends to disappear, and bone is being deposited in the intervals around and between the teeth, so that the latter soon lie in a gutter of bone.

The cells of the enamel organ now undergo a series of differentiations. The inner layer, arranged as columnar epithelium, are the **enamel cells**, or **ameloblasts**. The layer is called the

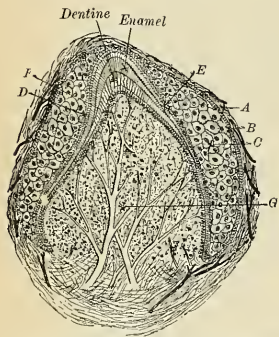


FIG. 944.—Section through tooth follicle—human canine seven and one-half months. A. Follicular wall. B. Outer epithelial coat. C. Stellate reticulum. D. Stratum intermedium. E. Ameloblasts. F. Odontoblasts. G. Pulp.

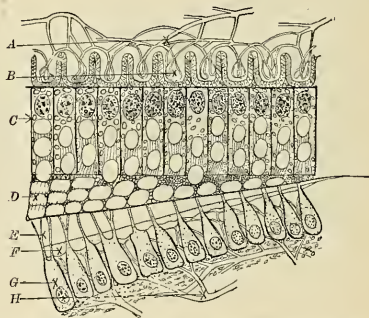


FIG. 945.—Diagram after Williams (Dental Cosmos, 1896), mode of enamel deposition. A. Blood supply to B, secreting papillae. C. Layer of ameloblasts containing enamel globules and droplets of calcoglobulin. D. Enamel globules deposited. E. Formed dentin. F. Forming dentin. G. Layer of odontoblasts. H. Blood supply to odontoblastic layer.

ameloblastic or **enamel-forming layer** (Figs. 944, 945, and 946). The cells of the outer wall remain cuboidal; the cells which lie between become much distended, and on account of their appearance when seen in section this portion of the organ is called the **enamel jelly** or the **stellate reticulum**. The layer of cells immediately contiguous to the ameloblasts forms a layer called the **stratum intermedium** (Fig. 944, D).

The enclosed **mesoblastic papilla** (the *future dental pulp*) has its peripheral cells, which are called **odontoblasts**, differentiated into columnar bodies disposed as a layer, each cell having a large nucleus. The vascular supply of the pulp is now well marked. A section of a follicle at this period will exhibit the follicular wall springing from the base of the dental papilla and having a well-marked blood supply. The bony alveolar walls are well outlined, and evidences of a periosteum appear (Figs. 943, 944, and 945).

Development of Enamel (Fig. 945).—In point of time, the deposition of dentin actually begins before that of enamel, so that the first-formed layer of enamel is deposited against a layer of immature dentin, and is formed from within outward, so that the youngest enamel is upon the surface of the tooth. The enamel is built up of two distinct substances—globules of uniform size which are formed by the ameloblasts, and a cementing substance, probably an albuminate of calcium (calcoglobulin), the basis of all the calcified tissues. In the ends of the ameloblasts, next to the dentin, the secretion of calcoglobulin is deposited, and into the plastic mass the enamel globules are extruded, each globule remaining connected with the ameloblasts by plasmic strings, which also join the globules laterally.¹

The first deposit of enamel begins in the tips of the cusps, and is quickly followed by a disappearance of the stellate reticulum at that point; the stellate reticulum appears to atrophy, so that the vascular follicular wall is brought into direct apposition with the stratum intermedium, which becomes differentiated into a glandular (secreting) tissue which elaborates the calcic albuminous basis of the enamel. The secretion passes from the cells of the stratum intermedium through a membrane into the ameloblasts, where it is in part combined with the cellular globules, and irregular masses of it are extruded as cementing substance. The deposition continues until the enamel cap has its typical form. The deposition of the layers of globules is indicated by parallel lines transverse to the axes of the enamel rods. At the completion of amelification the ameloblasts are partially calcified and form the **enamel cuticle** or **Nasmyth's membrane** (*cuticula dentis*).

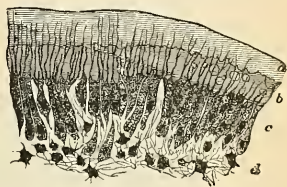


FIG. 946.—Part of section of developing tooth of young rat, showing the mode of deposition of the dentin (highly magnified). a. Outer layer of fully calcified dentin. b. Uncalcified matrix with a few nodules of calcareous matter. c. Odontoblasts with processes extending into the dentin. d. Pulp. The section is stained with carmine, which colors the uncalcified matrix, but not the calcified part.

Formation of Dentin.—The layer of columnar cells bounding the periphery of the pulp, the **odontoblasts**, are in apposition with the plexus of capillary vessels (Fig. 946). Each cell is a secreting body which selects the material for dentin building. Against the layer of ameloblasts, the *membrana eboris*, covering the dental papilla, the odontoblasts deposit globules of the calcium albuminate, and reeding as the deposits are made, leave one or more protoplasmic processes in the calcic deposit. These are known as **Tomes' or dentinal fibres**. The process continues until the normal dentin thickness is formed. The deposit is laid down in a scaffolding of finely fibrillated tissue, and begins about the sixteenth week. The layer of formative cells remains constant. The remains of the dentinal papilla constitute the **pulp** and lie in the pulp cavity (p. 1212).

Formation of Cementum.—As the enamel organ continues to grow the dental follicle covering atrophies, while that over the future root region continues to grow. Upon its dentinal surface the stellate cells constitute the **cementoblasts**. Upon its outer surface the stellate cells are **osteoblasts** that form the alveolar bone. The cementum of the tooth is not formed until the dentin has extended below the enamel cap, while the cementum of the apex is usually not completed until after the eruption of the tooth.

Formation of Alveoli.—By the time the crowns of the teeth have formed, each is enclosed in a loculus of bone which has developed around it and at some distance from it; the developing permanent tooth is contained in the same loculus, but is later separated from the temporary tooth by a growth of bone. The alveolar process is not completed until after the eruption of the teeth. During eruption that portion of the process overlying the crown undergoes absorption, and as soon as the immature tooth is erupted the alveolar process has developed about the root, whose formation is also completed after eruption.

Development of the Permanent Teeth.—The permanent teeth as regards their development may be divided into two sets: (1) Those which replace the temporary teeth, and which, like them, are ten in number; these are the **successional permanent teeth**; and (2) those which have no temporary predecessors, but are superadded at the back of the dental series. These are three in number on either side in each jaw, and are termed the **superadded permanent teeth**. They are the three molars of the permanent set, the molars of the temporary set being replaced by the premolars or bicuspid of the permanent set.

¹ J. L. Williams, Dental Cosmos, 1896.

The **Development of the Successional Permanent Teeth**—the ten anterior ones in either jaw—will be first considered. The germs for these teeth are developed from the lingual side of the dental shelf, opposite to the corresponding temporary teeth. The germ for the central incisor appears at about the *seventeenth week*, and the others follow successively in order of their eruption. The deposition of enamel, dentin, and cementum occurs as in the temporary teeth. The sac of each permanent tooth is also connected with the fibrous tissue of the gum by a slender band of the **gubernaculum**, which passes to the margin of the jaw behind the corresponding milk tooth (see above).

The **Superadded Permanent Teeth**—three on each side in each jaw—develop as primary teeth. The enamel germ for the first molar tooth appears during the *sixteenth week from the end of the dental shelf*. The enamel germ for the second molar tooth appears about the *fourth month after birth* from the neck of the enamel sac of the first molar tooth, while that for the third molar or wisdom tooth does not appear until the *third year after birth*, from the enamel sac of the second molar tooth.

Eruption.—When the teeth are ready to erupt the bone between them and the gum is absorbed as well as that covering the labial surface of the crown, until one-half of the enamel is exposed. The bone covering the lingual surface is more slowly absorbed, as it protects the permanent tooth germ beneath. As a result of this process the tooth is exposed chiefly by the removal of the bone around the crown, and not by a growth upward of the tooth itself. In the replacement of the temporary teeth by the permanent set the roots of the temporary teeth are gradually absorbed until merely the enamel cap and contained dentin remain. The hold of the tooth upon the jaw is weakened so that it may readily be removed or lost.

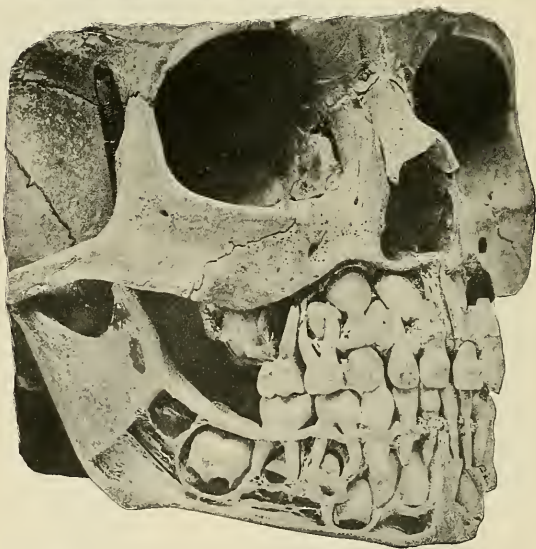


FIG. 947.—The milk teeth in a child aged about four years. The permanent teeth are seen in their alveoli. (Cryer.)

Calcification of the permanent teeth proceeds in the following order: First molar, soon after birth; the central incisor, lateral incisor, and canine, about six months after birth; the bicuspid, at the second year or later; second molar, end of second year; third molar, about the twelfth year.

The **Eruption of the Temporary Teeth** commences at the seventh month, and is complete about the end of the second year.

The periods for the eruption of the temporary set are (C. S. Tomes):

Lower central incisors	6 to 9 months.
Upper incisors	8 to 10 “
Lower lateral incisors and first molars	15 to 21 “
Canines	16 to 20 “
Second molars	20 to 24 “

The **Eruption of the Permanent Teeth** takes place at the following periods, the teeth of the lower jaw preceding those of the upper by a short interval:

6½ years, first molars.	10th year, second bicuspid.
7th year, two middle incisors.	11th to 12th year, canine.
8th year, two lateral incisors.	12th to 13th year, second molars.
9th year, first bicuspid.	17th to 21st year, third molars.

THE TONGUE (LINGUA) (Fig. 948).

The **tongue** is a very mobile muscular organ, undergoing changes in length and width at every contraction of its muscle. It is one of the organs of the special sense of taste, and is also an organ of speech, and assists in insalivation, mastication, and deglutition. It is situated in the floor of the mouth, in the interval between the two lateral portions of the body of the mandible, and when at rest is about three and one-half inches (8.75 cm.) in length. We describe the **body**, **base**, **apex**, **dorsum**, **margin**, and **inferior surface**.

The **body** (*corpus linguae*) forms the great bulk of the organ and is composed of striated muscle.

The **base** or **root** (*radix linguae*) is directed backward and connected with the hyoid bone by the Hyoglossi and Geniohyoglossi muscles and the hyoglossal membrane; with the epiglottis by three folds, **glossoepiglottic folds**, of mucous membrane; with the soft palate by means of the anterior pillars of the fauces; and with the pharynx by the Superior constrictor muscles and the mucous membrane.

The **apex** or **tip** (*apex linguae*) is free, thin, and narrow, and is directed forward against the inner surface of the lower incisor teeth.

The **dorsum** of the tongue (*dorsum linguae*) of a living person, when at rest, is markedly arched from before backward. On the dorsum is a **median longitudinal raphé** (*sulcus medianus linguae*). This slight depression terminates posteriorly in the depression known as the **foramen cecum** (*foramen caecum linguae* [*Morgagni*]), from which a shallow, V-shaped groove, the **sulcus terminalis** of His, runs outward and forward on each side to the lateral margin of the tongue. The part of the dorsum of the tongue in front of this groove, known as the **anterior**, **apical**, or **oral part**, forming about two-thirds of its upper surface, looks upward, is practically horizontal, and is rough and covered with papillæ; the **posterior** or **basal third** of the dorsum is vertical and looks backward, is smoother, and contains numerous muciparous glands and lymphoid nodules.

The **margin of the tongue** (*margo lateralis linguae*) is free in front of the anterior arch of the palate. Just in front of the arch are several vertical folds, the **folia linguae**.

The **under or inferior surface** (*facies inferior linguae*) of the tongue is connected with the mandible by the Geniohyoglossi muscles; from its sides the mucous membrane is reflected to the inner surface of the gums, and from its under surface on to the floor of the mouth, where, in the middle line, it is elevated into a distinct vertical fold, the **frenum linguae** (*frenulum linguae*). To each side of the frenum is a slight fold of the mucous membrane, the **plica fimbriata**, the free edge of which exhibits a series of fringe-like processes.

The tip of the tongue, part of the under surface, its sides, and dorsum are free.

Structure of the Tongue.—The tongue is partly invested by mucous membrane and a sub-mucous fibrous layer surrounding the central muscle tissue. It consists of symmetrical halves, separated from each other, in the middle line, by an incomplete fibrous septum. Each half is composed of muscle fibres arranged in various directions (p. 393), containing many glands and much interposed fat, and supplied by vessels and nerves.

The **mucous membrane** (*tunica mucosa linguae*) invests the entire extent of the free surface of the tongue. On the dorsum it is thicker behind than in front, and is continuous with the

sheath of the muscles attached to it, through the submucous fibrous layer. On the under surface of the organ, where it is thin and smooth, it can be traced on each side of the frenum through the ducts of the submaxillary and the sublingual glands. As it passes over the borders of the organ it gradually assumes a papillary character. That covering the under surface of the organ is thin, smooth, and identical in structure with that lining the rest of the oral cavity. The mucous membrane covering the tongue behind the foramen cecum and sulcus terminalis is thick and freely movable over the subjacent parts.

The mucosa consists of stratified squamous epithelial cells resting upon a basement membrane, and this upon a papillated tunica propria of fibroelastic tissue containing the capillary loops and nerves. Upon the apical two-thirds of the dorsum of the tongue the projections of the mucosa are seen, and these are the papillæ. They vary in number, size, form, and location; they are the **filiform papillæ**, **fungiform papillæ**, and **circumvallate papillæ**.

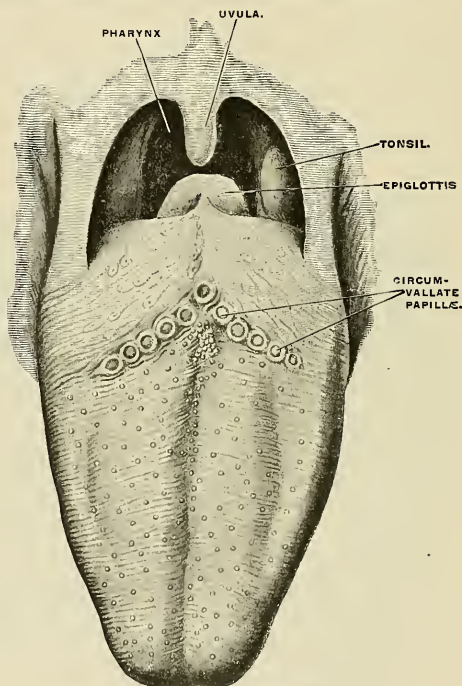


FIG. 948.—Upper surface of the tongue.

The **filiform** or **conical papillæ** (*papillae filiformes*) are small and scattered over the apical two-thirds (dorsum and margin) of the tongue, and are arranged in parallel lines that are directed outward and forward, especially posteriorly. Minute *secondary* papillæ of a whitish color project from these filiform structures.

The **fungiform papillæ** (*papillae fungiformes*) (Fig. 949) are scattered sparingly over the dorsum of the tongue, and are more numerous at the sides and apex. They are larger in size but less numerous than the preceding, and are readily recognized by their large size and deep red color. Their bases are narrow and constricted, while the free ends are large and blunt; the whole papilla is above the general epithelial surface of the tongue. These papillæ possess secondary papillæ, and in their epithelium *taste buds* are at times seen.

The **circumvallate papillæ** (*papillae vallatae*) (Fig. 949) are of large size, but only eight to twelve in number. They are arranged like a letter V at the junction of the apical two-thirds and basal one-third of the dorsum, with the apex at the foramen cecum and the arms directed out-

ward and forward just in front of the sulcus terminalis. These papillæ are partially or wholly submerged, that is, lie in depressions. Each consists of a narrow base, attached at the bottom of the depression, while the remainder is surrounded by the vallum or ditch. Each papilla is from $\frac{1}{10}$ to $\frac{1}{8}$ inch in width and possesses secondary papillæ. In the epithelium of the sides are found the *taste buds*.

The **foramen cecum**, according to His, represents the remains of the evagination that formed the middle lobe of the thyroid body and the upper end of the supposed **thyroglossal duct** (*ductus thyroglossus*). This may exist as a canal, at times extending toward the hyoid bone.

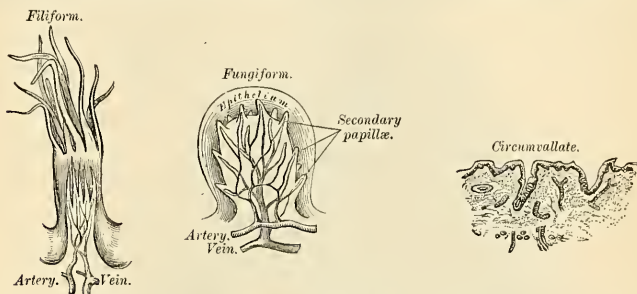


FIG. 949.—Filiform papillæ, FIG. 950.—Fungiform papillæ, magnified. FIG. 951.—Circumvallate papillæ, magnified.

Upon the **posterior** or **basal** one-third of the dorsum of the tongue papillæ are not found. The surface is irregular, however, due to the presence of nodular collections of lymphoid tissue, that produce rounded elevations of the mucosa. Each nodule possesses a little pit or crypt, and collectively the follicles are termed the **lingual tonsil** (*tonsilla lingualis*). Each crypt is lined by stratified squamous epithelial cells upon basement membrane and tunica propria; in the latter are numerous solitary nodules arranged around the pit, and each group is isolated from the neighboring collection. These groups constitute the lingual tonsils.

Beneath the tunica propria of the mucosa is the **muscle tissue of the tongue**. This muscle tissue is of the voluntary striated variety and is divided into two sets of muscles—Intrinsic and Extrinsic (described on p. 393).

Scattered throughout the tongue, but especially located in definite areas, are glands of a mucous and serous character. The mucous glands are found behind the circumvallate papillæ and along the margins, and an especial group at the apex, called the **apical glands** or **glands of Nuhn and Blandin** (*glandulæ linguales anteriores of Nuhn and Blandin*) (Fig. 953). Each gland is situated at the side of the frenulum and is covered by a fasciculus of muscle fibres derived from the Styloglossus and Inferior lingualis muscles. Each gland is from one-half inch to nearly an inch in length (1 to 2 cm.) and about one-third of an inch broad (8 mm.). Each gland has from four to six ducts, which open on the under surface of the apex. The serous glands, or glands of von Ebner, occur in the basal part of the tongue, the ducts opening chiefly into the fossæ around the circumvallate papillæ. Both mucous and serous glands resemble the other salivary glands in structure (p. 1226).

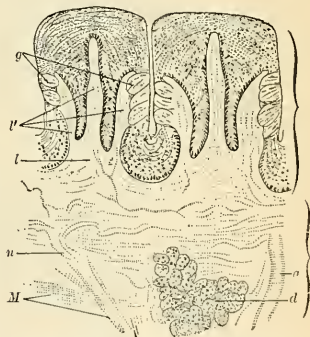


FIG. 952.—Circumvallate papillæ of tongue of rabbit, showing position of taste goblets. *g*. Duct of gland. *d*. Serous gland. *g*. Taste buds. *l*. Primary septa, and *v'*, secondary septa, of papillæ. *n*. Myelinated nerve. *M*. Muscle fibres. (Stöhr.)

The Vessels of the Tongue.—The arteries of the tongue are derived from the lingual, the facial, and ascending pharyngeal. The veins of the tongue open into the internal jugular.

The **lingual artery** (Fig. 955) on each side passes forward beneath the Hyoglossus muscle and courses to the apex of the tongue, between the Genioglossus and the Inferior lingual muscles, about one-eighth of an inch from the surface. It divides into the **ranine** (Fig. 953) and sub-

lingual (Fig. 955). Near the apex a branch is given off from the ranine artery, which penetrates the septum and joins a like branch from the other side. The **dorsalis linguae** is a branch of the lingual supplying the posterior part of the tongue, and rami from the **tonsillar branch of the facial** go to the same region. A network of capillary vessels is placed beneath the epithelium.

The **ranine veins** lie to the side of the frenum underneath the mucous membrane. Each ranine vein runs backward, superficial to and upon the Hyoglossus muscle and near to the

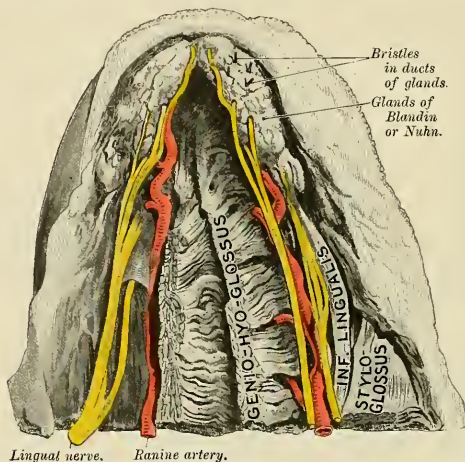


FIG. 953.—Under surface of tongue, showing position and relations of gland of Blandin or Nuhn. (From a preparation in the Museum of the Royal College of Surgeons of England.)

hypoglossal nerve. The venae comites of the lingual artery usually join the ranine vein, and the trunk opens into the internal jugular vein, but the vessels may open separately into the jugular vein (Fig. 496).

The Lymphatic Vessels of the Tongue (Fig. 559).—The lymphatic vessels from the anterior half of the tongue pass to the **submaxillary lymph nodes**.

Lymph vessels from the posterior half of the tongue are connected with satellite **nodes** on the Hyoglossus muscle and terminate in the **deep cervical nodes**. The last-named lymph vessel accompanies the ranine vein. The lingual lymphatics arise from a network beneath the

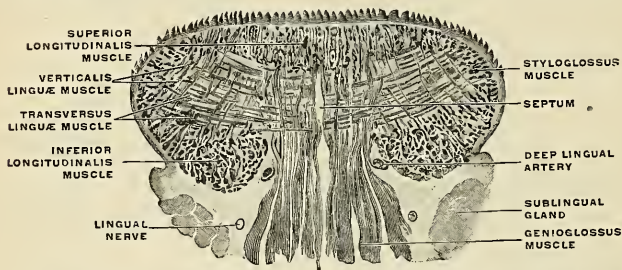


FIG. 954.—Frontal section through the body of the tongue of a newborn babe. $\times 3$. (Spalteholz.)

epithelium. Across the anterior two-thirds of the tongue there is little or no lymphatic connection between the two sides; in the posterior one-third there is free connection, due to absence of septum here.

The Nerves of the Tongue (Fig. 955).—The nerves of the tongue are five in number in each half—the **lingual branch of the inferior maxillary division of the trigeminal**, which is distributed to the papillæ at the fore part and sides of the tongue, and forms the nerve of ordinary sensibility for its anterior two-thirds; the **chorda tympani**, which runs in the sheath of the lingual, is generally regarded as the nerve of taste for the same area (p. 997); the **lingual branch of the glossopharyngeal**, which is distributed to the mucous membrane at the base and sides of the tongue, and to the papillæ circumvallatæ, and which supplies both sensor and gustatory filaments to this region; the **hypoglossal nerve**, which is the motor nerve to the muscular substance of the tongue; and the **internal laryngeal branch of the superior laryngeal**, which sends some fine branches to the root near to the epiglottis. **Sympathetic** filaments also pass to the tongue from the *nervi molles* on the lingual and other arteries supplying it. Some of the nerves end free between the cells of epithelium; others terminate as end organs (Meissner's corpuscles and the end-bulbs of Krause), and in taste buds as sensor dendrites (p. 1149).

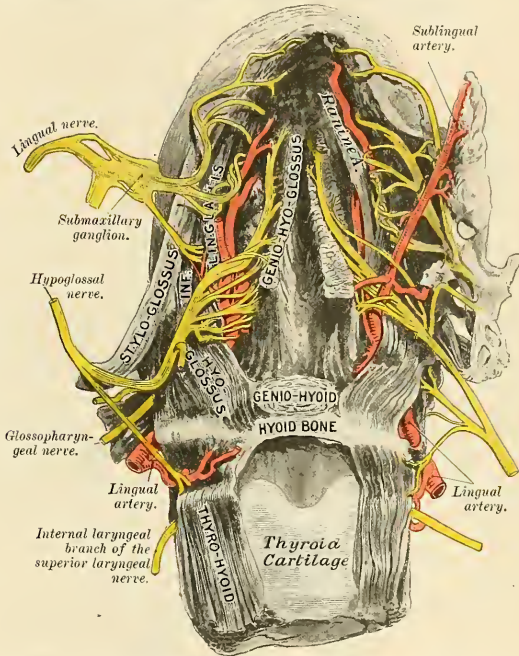


FIG. 955.—Under surface of tongue, showing the distribution of nerves to this organ. (From a preparation in the Museum of the Royal College of Surgeons of England.)

The Development of the Tongue (Figs. 956 and 957).—The tongue is developed in the floor of the pharynx. The rudiment of the anterior or buccal portion appears during the third week as a rounded elevation, immediately behind the ventral ends of the mandibular arches. This elevation is named the **tuberculum impar** (Figs. 956 and 957); it extends forward on the oral surface of the mandibular arch, and increases markedly in size by the development of a pair of lateral tongue elevations, which raise themselves from the inner surfaces of the mandibular arches, and, blending with the tuberculum impar, form the tip and greater portion of the buccal part of the tongue. These lateral growths correspond with similar structures which were described by E. Kallius in the development of the tongue of the lizard. From the ventral ends of the fourth arch there arises a second and larger elevation, in the centre of which is a median groove or furrow. This elevation is named the **furcula** (Fig. 956), and is at first separated from the

tuberculum impar by a depression, but later by a ridge formed by the forward growth and fusion of the ventral ends of the second and third arches. The posterior or pharyngeal part of the tongue is developed from this ridge, which extends forward in the form of a V, so as to embrace between its two limbs the tuberculum impar (Figs. 956 and 957). At the apex of the V a pit-like invagination occurs, to form the middle thyroid rudiment, and this depression is represented in the adult by the *foramen cecum* of the tongue. In the adult the union of the anterior and posterior parts of the tongue is marked by a V-shaped depression (*sulcus terminalis*), the apex of which is at the foramen cecum, while the two limbs run outward and forward, parallel to, but a little behind, the circumvallate papillae. The prominent anterior part of the furcula forms the epiglottis; the furrow behind it is the entrance to the larynx; and the anterior parts of its lateral margins constitute the arytenoepiglottidean folds.

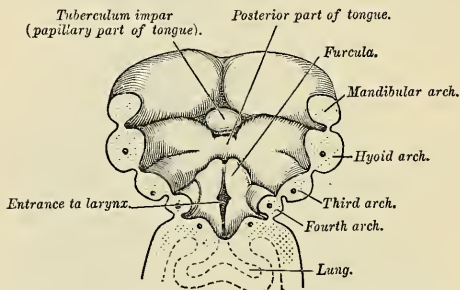


FIG. 956.—The floor of the pharynx of a human embryo about twenty-three days old. $\times 30$. (From His.)

Applied Anatomy.—The diseases to which the tongue is liable are numerous, and its applied anatomy is of importance, since any or all the structures of which it is composed—muscles, connective tissue, mucous membrane, glands, vessels, nerves, and lymphatics—may be the seat of morbid changes. It is not often the seat of congenital defects, though a few cases of *vertical cleft* have been recorded, and it is occasionally, though much more rarely than is commonly supposed, the seat of *tongue-tie*, from shortness of the frenum.

There is, however, one condition which must be regarded as congenital, though not uncommonly it does not exhibit the significant changes until a year or two after birth. This is an enlargement of the tongue which is due primarily to a dilatation of the lymph channels and a greatly increased development of the lymphatic tissue throughout the tongue (*macroglossia*). This is often aggravated by inflammatory changes induced by injury or exposure, and the tongue may

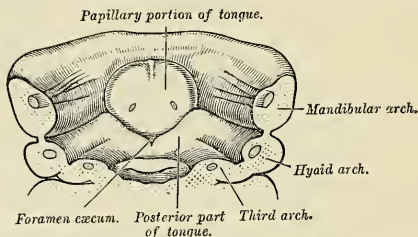


FIG. 957.—Floor of mouth of an embryo slightly older than that shown in Fig. 956. $\times 16$. (From His.)

assume enormous dimensions and hang out of the mouth, giving the child an imbecile expression. The treatment consists in excising a V-shaped portion and bringing the cut surfaces together with deeply placed silver sutures. Acute inflammation of the tongue (*acute glossitis*) may be caused by injury or the introduction of some septic or irritating matter, and it is attended by great swelling from infiltration of the connective tissue of the tongue; this connective tissue is present in considerable quantity. The great swelling renders the patient incapable of swallowing or speaking, and may seriously impede respiration. The condition may eventuate in

suppuration and the formation of an *acute abscess*. *Chronic abscess*, which has been mistaken for cancer, may also occur in the substance of the tongue.

The mucous membrane of the tongue may become chronically inflamed, and presents different appearances in different stages of the disease, to which the terms *leukoplakia*, *psoriasis*, and *ichthyosis* have been given.

The tongue, being very vascular, is often the seat of *nevroid growths*, and these have a tendency to grow rapidly.

The tongue is frequently the seat of *ulceration*, which may arise from many causes, as from the irritation of jagged teeth, dyspepsia, *tuberculosis*, *syphilis*, and *cancer*. Of these, the cancerous ulcer is the most important, and probably also the most common. The variety is the *squamous epithelioma*, which soon develops into an ulcer with an indurated base. It produces great pain which speedily extends to all parts supplied with sensation by the trigeminal nerve, especially to the region of the ear. The pain in these cases is conducted to the ear and temporal region by the lingual nerve, and from this nerve pain radiates to the other branches of the inferior maxillary nerve, especially the auriculotemporal. Possibly pain in the ear itself may be due to implication of the fibres of the glossopharyngeal nerve, which by its tympanic branch reaches the tympanic plexus. Cancer of the tongue spreads through the organ very rapidly because of the almost constant muscular movements.

Cancer of the tongue may necessitate removal of a part or the whole of the organ, and many different methods have been adopted for its excision. The better method is by the scissors, usually known as Whitehead's method. The mouth is widely opened with a gag, the tongue is transfixed with a stout silk ligature, by which to hold and make traction on it and the reflection of mucous membrane from the tongue to the jaw, and the insertion of the Geniohyoglossi first divided with a pair of curved blunt scissors. The Palatoglossi are also divided. The tongue can now be pulled well out of the mouth. The base of the tongue is cut through by a series of short snips, each bleeding vessel being dealt with as soon as divided, until the situation of the ranine artery is reached. The remaining undivided portion of tissue is to be seized with a pair of Wells' forceps, the tongue removed, and the vessel secured. In the event of the ranine artery being accidentally injured early in the operation, hemorrhage can be at once controlled by passing two fingers over the dorsum of the tongue as far as the epiglottis and dragging the root of the tongue forcibly forward.

In cases where the disease is confined to one side of the anterior portion of the tongue this operation may be modified by splitting the tongue down the centre and removing only the affected half. If the posterior portion of the tongue is attacked by cancer the entire tongue must be removed, even if but one side of the organ is *apparently* involved. The exchange of lymph between the halves of the posterior portion of the tongue makes it certain that the opposite half becomes involved soon after the origin of the disease. Whatever operation is performed for cancer of the tongue, the lymph nodes must be removed from *both sides of the neck*. This is to be done, even if but one side of the tongue is removed.

Finally, where both sides of the floor of the mouth are involved in the disease, or where very free access is required on account of the extension backward of the disease to the pillars of the fauces and the tonsil, or where the mandible is involved, the operation recommended by Syme must be performed. This is done by an incision through the central line of the lip, across the chin, and down as far as the hyoid bone. The mandible is sawed through at the symphysis, and the two halves of the bone forcibly separated from each other. The mucous membrane is separated from the bone, the Geniohyoglossi detached from the bone, and the Hyoglossi divided. The tongue is then drawn forward and removed close to its attachment to the hyoid bone. Adjacent lymph nodes can be removed, and if the bone is implicated in the disease, it can also be removed by freeing it from the soft parts externally and internally, and making a second section with the saw beyond the diseased part.

THE SALIVARY GLANDS (Fig. 95S)

The principal salivary glands communicating with the mouth, and pouring their secretion into its cavity, are the *parotid*, *submaxillary*, and *sublingual*.

The **Parotid Gland** (*glandula parotis*) is the largest of the three salivary glands, varying in weight from half an ounce to an ounce. It lies upon the side of the face, immediately below and in front of the external ear. The main portion of the gland is superficial, somewhat flat and quadrilateral in form, and is placed between the ramus of the mandible in *front* and the mastoid process and Sternomastoid muscle *behind*, overlapping, however, both boundaries. *Above*, it is limited by the zygoma; *below*, it extends to about the level of a line joining the tip of the mas-

toid process to the angle of the mandible. The remainder of the gland is wedge-shaped, and extends deeply inward toward the pharyngeal wall.

The gland is enclosed within a capsule continuous with the deep cervical fascia; the layer covering the outer surface is dense and closely adherent to the gland; a portion of the fascia, attached to the styloid process and the angle of the mandible, is thickened to form the stylomandibular ligament which intervenes between the parotid and submaxillary glands.

The *anterior surface* of the gland is moulded on the posterior border of the ramus of the mandible with the attached Internal pterygoid and Masseter muscles, and advances forward between the two Pterygoid muscles and overlaps the Masseter. A part of the overlapping portion, immediately below the zygoma, is usually detached, and is named the *solia parotidis* (*gl. parotis accessoria*).

The *outer or superficial surface*, slightly lobulated, is covered by the integument, the superficial fascia containing the facial branches of the great auricular nerve and some small lymph nodes, and the fascia which forms the capsule of the gland.

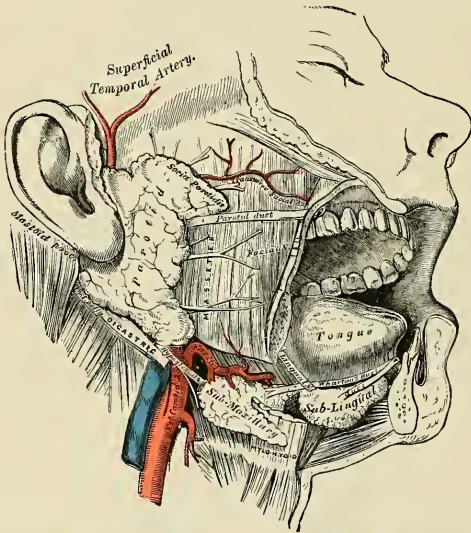


FIG. 958.—The salivary glands. (Note that the deep process of the submaxillary gland lies upon the deep surface of the Mylohyoid.)

The *inner or deep surface* extends inward by means of two processes, one of which lies on the styloid process and the styloid group of muscles and projects under the mastoid process and Sternomastoid muscle; the other is situated in front of the styloid process and passes into the posterior part of the glenoid fossa behind the temporomandibular joint. The deep surface is in contact with the internal and external carotid arteries, the internal jugular vein, and the vagus and glossopharyngeal nerves.

The *anterior border* lies on the superficial surface of the Masseter; the *posterior* abuts on the external auditory canal and the mastoid process, and overlaps

the anterior edge of the Sternomastoid. The *superior border* is in contact with the zygomatic arch, and the *inferior* overlaps the posterior belly of the Digastric. The *inner border* at the junction of the anterior and inner surfaces is in relation with the styloid process and styloid muscles, and is separated from the pharyngeal wall by some loose connective tissue.

Structures within the Gland.—The *external carotid artery* lies at first in contact with the deep surface, and then in the substance of the gland. The artery gives off its *posterior auricular* branch which emerges from the gland behind; it then divides into its terminal branches, the *internal maxillary* and *superficial temporal*; the former runs inward behind the neck of the mandible; the latter runs upward across the zygoma and gives off its *transverse facial* branch which emerges from the front of the gland. Superficial to the arteries are the *temporal* and *internal maxillary veins*, uniting to form the *temporomaxillary vein*; in the lower part of the gland this vein divides into anterior and posterior divisions. The anterior division emerges from the gland to join the facial vein; the posterior unites in the gland with the posterior auricular vein to form the external jugular vein (Fig. 495). On a still more superficial plane is the *facial nerve*, the *branches* of which emerge at the upper and anterior borders of the gland. Branches of the *great auricular nerve* pierce the gland to join the facial, and the *auriculotemporal branch* of the *inferior maxillary nerve* emerges from the upper part of the gland.

Lymph nodes, known as the **parotid nodes**, are in and about the parotid gland, some being embedded in the outer surface of the parotid fascia, others being in the inner surface of the fascia, others in the gland itself, particularly along the temporomaxillary vein and external carotid artery (see p. 775).

The **Duct of the Parotid Gland**, or **Stenson's Duct** (*ductus parotideus* [*Stenonis*]) (Fig. 958), is about two inches and a half (5 to 6 cm.) in length. It commences by numerous branches from the anterior part of the gland, crosses the Masseter muscle, and at its anterior border turns inward nearly at a right angle and passes into the substance of the Buccinator muscle, which it pierces; it then runs for a short distance obliquely forward between the Buccinator muscle, and the mucous membrane of the mouth, and opens upon the inner surface of the cheek by a small orifice, opposite the second upper molar tooth (Fig. 936). While crossing the Masseter it receives the duct of the *socia parotidis*. In this position it has the transverse facial artery above it and some branches of the facial nerve below it.

The parotid duct is dense, it is of considerable thickness, and its canal is about the size of a crowquill; but at its orifice on the inner aspect of the cheek its lumen is greatly reduced in size. The duct corresponds to the middle third of a line drawn across the face from the lower margin of the external auditory meatus to midway between the red margin of the upper lip and the columella of the nose.

Vessels and Nerves.—The **arteries** supplying the parotid gland are derived from the external carotid, and from the branches given off by that vessel in or near its substance. The **veins** empty into the external jugular through some of its tributaries. The **lymphatics** terminate in the superficial cervical and the deep cervical nodes, passing in their course through two or three lymph nodes placed on the surface and in the substance of the parotid. The **nerves** are derived from the plexus of the **sympathetic** on the external carotid artery, the **nervus intermedius**, the **auriculotemporal**, and the **great auricular nerves**. It is probable that the branch from the auriculotemporal nerve is derived from the **glossopharyngeal** through the **otic ganglion**. At all events, in some of the lower animals this has been proved experimentally to be the case.

The **Submaxillary Gland** (*glandula submaxillaris*) (Fig. 958) is irregular in form and weighs about two drams (eight to ten grams). A considerable part of it is situated in the submaxillary triangle, reaching forward to the anterior belly of the Digastric and backward to the stylohyoid ligament which intervenes

between it and the parotid gland. *Above*, it extends under cover of the body of the mandible; *below*, it usually overlaps the intermediate tendon of the Digastric and the insertion of the Stylohyoid, while from its deep surface a tongue-like **deep process** extends forward and inward above the Mylohyoid muscle.

The *deep surface* is in relation with the Mylohyoid, Hyoglossus, Styloglossus, Stylohyoid, and posterior belly of the Digastric muscles; in contact with it are the mylohyoid nerve and the mylohyoid and submental vessels.

The facial artery is embedded in a groove in the posterior border of the gland.

The *deep process* of the gland extends forward and inward between the Mylohyoid below and externally, and the Hyoglossus and Styloglossus internally; above it is the lingual nerve; below it, the hypoglossal nerve and ranine vein.

The **duct of the submaxillary gland**, or **Wharton's duct** (*ductus submaxillaris* [Wharton]), is about two inches (5 cm.) in length, and its wall is much thinner than that of the parotid duct. It begins by numerous branches from the deep portion of the gland which lies on the upper surface of the Mylohyoid muscle, and runs forward and inward between the Mylohyoid and the Hyoglossus and Geniohyoglossus muscles, then between the sublingual gland and the Geniohyoglossus muscle, and opens by a narrow orifice on the summit of a small papilla (*caruncula sublingualis*) at the side of the frenum linguae. On the Hyoglossus muscle it lies between the lingual and hypoglossal nerves, but at the anterior border of the muscle it is crossed by the lingual nerve.

Vessels and Nerves.—The arteries supplying the submaxillary glands are branches of the **facial and lingual**. Its veins follow the course of the arteries. The lymphatics drain into the **submaxillary lymph nodes**. The nerves are derived from the **submaxillary ganglion**, through which it receives filaments from the **chorda tympani** and from the **lingual branch of the inferior maxillary**, sometimes from the **mylohyoid branch of the inferior dental** and from the **sympathetic**.

The **Sublingual Gland** (*glandula sublingualis*) (Fig. 958) is the smallest of the salivary glands. It is situated beneath the mucous membrane of the floor of the mouth, at the side of the frenum linguae, in contact with the inner surface of the mandible, close to the symphysis. It is narrow, flattened, in shape somewhat like an almond, and weighs about a dram. It is in relation, *above*, with the mucous membrane; *below*, with the Mylohyoid muscle; in *front*, with the mandible and its fellow of the opposite side; *behind*, with the deep part of the submaxillary gland; and *internally*, with the Geniohyoglossus, from which it is separated by the lingual nerve and submaxillary duct. Its **excretory ducts** or **ducts of Rivinus** (*ductus sublingualis minores*) are from eight to twenty in number; some join the submaxillary duct, others open separately into the mouth, on the elevated crest of mucous membrane (*plica sublingualis*) caused by the projection of the gland on either side of the frenum linguae. One or more join to form a tube which opens into the submaxillary duct; this is called the **duct of Bartholin** (*ductus sublingualis major*).

Vessels and Nerves.—The sublingual gland is supplied with blood from the **sublingual and submental arteries**. Its nerves are derived from the **lingual**.

Structure of Salivary Glands (Fig. 959).—The salivary glands are compound tubuloracemose or racemose glands, surrounded by a capsule of white fibrous connective tissue that divides the gland into numerous lobes and lobules. The tissue between the lobules supports blood-vessels, nerves, lymphatics, and ducts. Each lobule consists of the ramifications of a single duct, dividing frequently like the branches of a tree, the branches terminating in either rounded or tubular ends, the **acini** or **alveoli**, around which the capillaries are distributed. Each alveolus or acinus consists of a single layer of columnar or pyramidal epithelial cells resting upon a **basement membrane**, further supported by the fibroelastic *tunica propria*, in which the capillaries and nerves are found. Within the lobule are found **intralobular ducts** that collect the secretion from the alveoli and empty it into the **interlobular ducts** between the lobules. The latter join, to ultimately form the **excretory duct** of the gland.

The **main** or **excretory duct** of each gland consists of **mucous, muscle, and fibrous coats**. The **mucous coat** is composed of either simple columnar or stratified columnar epithelial cells

that rest upon a basement membrane, and fibroelastic tunica propria. The muscle coat consists of circularly arranged smooth muscle tissue. The fibrous coat consists of fibroelastic tissue and serves to support the other coats.

The salivary glands are **mucous**, **serous**, and **mixed**. The **mucous** glands secrete a thick viscid fluid and the cells of the acini stain lightly. The alveoli are tubular in form and the cells large and of a columnar shape, cloudy to transparent, and may even be striated in appearance. At intervals peculiar, darkly staining crescent-shaped cells or cell groups are seen between the above epithelium and the basement membrane; these are the **demilunes of Heidenhain** or **crescents of Gianuzzi** (Fig. 959), by some regarded as mucous cells in the resting stage, and by others as distinctly separate cells. These glands are the small unnamed glands of lips, cheek, pharynx, cesophagus, and tongue (especially the glands of Nuhn and Blandin).

Serous glands are those that secrete a thin, watery fluid, and the cells of the acini stain darkly. The acini are grape-like and the cells are somewhat pyramidal in form, smaller than mucous cells, and possess richly granular protoplasm. These glands are the parotid and many small unnamed glands in the tongue and lips.

Mixed glands are those in which some of the alveoli are tubular (mucous) and others grape-like (serous), representing both of the above varieties in one capsule. Here belong the sublingual and submaxillary glands.

The **arteries** enter the capsule and divide into branches that enter the interlobular tissues; from these vessels branches enter the lobules and form capillary plexuses around the alveoli in close proximity to the basement membrane. The **veins** return the blood in vessels parallel to the arteries.

The **nerves** enter with the vessels and ultimately form plexuses in the interlobular and intra-lobular tissue, the latter sending filaments that end in relation to the epithelial cells and blood-vessels. In the submaxillary gland small ganglia are found in connection with the interlobular nerve plexus.

Development of the Salivary Glands.—The salivary glands arise as diverticula from the epithelial lining of the mouth, and their rudiments appear in the following order—viz., the parotid during the fourth week, the submaxillary in the sixth week, and the sublingual during the ninth week (Hammar).

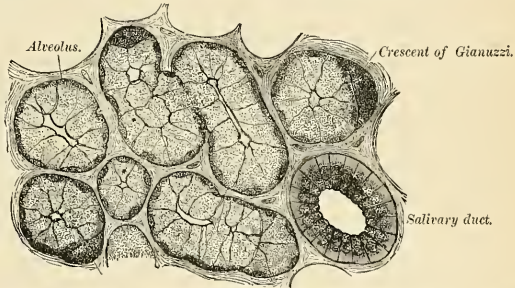


FIG. 959.—A highly magnified section of the submaxillary gland of the dog, stained with carmine. (Kölliker.)

Surface Form.—The orifice of the mouth is bounded by the *lips*, two thick, fleshy folds covered externally by integument and internally by mucous membrane, and consisting of muscles, vessels, nerves, areolar tissue, and numerous small glands. The size of the orifice of the mouth varies considerably in different individuals, but seems to bear a close relation to the size and prominence of the teeth. Its corners correspond pretty accurately to the outer border of the canine teeth. In the Ethiopian tribes the front teeth are large and inclined forward, the mouth is large; and this, combined with the thick and everted lips which appear to be associated with prominent teeth, gives to the negro's face much of the peculiarity by which it is characterized. The smaller teeth and the slighter prominence of the alveolar arch of the more highly civilized races render the orifice of the mouth much smaller, and thus a small mouth is an indication of intelligence, and is regarded as an evidence of the higher civilization of the individual.

Upon looking into the mouth, the first thing we may note is the tongue, the upper surface of which will be seen occupying the floor of the cavity. This surface is convex, and is marked along the middle line by a raphé which divides it into two symmetrical portions. The anterior two-thirds is rough and studded with papillae; the posterior third, smooth and tuberculated, contains numerous lymphoid structures which project from the surface. Upon raising the

tongue the mucous membrane which invests the upper surface may be traced covering the sides of the under surface, and then reflected over the floor of the mouth on to the inner surface of the mandible, a part of which it covers. As it passes over the borders of the tongue it changes its character, becoming thin and smooth and losing the papillæ which are to be seen on the upper surface. In the middle line the mucous membrane on the under surface of the tip of the tongue forms a distinct fold, the *frenum linguae*, by which this organ is connected to the symphysis of the mandible. Occasionally it is found that this frenum is rather shorter than natural, and, acting as a bridle, prevents the complete protrusion of the tongue. When this condition exists and an attempt is made to protrude the organ, the tip will be seen to remain buried in the floor of the mouth, and the dorsum of the tongue is rendered very convex, and more or less extruded from the mouth; at the same time a deep furrow will be noticed to appear in the middle line of the anterior part of the dorsum. Sometimes, a little external to the frenum, the ranine vein may be seen immediately beneath the mucous membrane. The corresponding artery, being more deeply placed, does not come into view, nor can its pulsation be felt with the finger. On either side of the frenum, in the floor of the mouth, is an elevation or ridge, produced by the projection of the sublingual gland, which lies immediately beneath the mucous membrane. And close to the attachment of the frenum to the tip of the tongue may be seen on either side the slit-like orifices of the *submaxillary ducts*, into which a fine probe may be passed without much difficulty. By everting the lips the smooth mucous membrane lining them may be examined, and may be traced from them on to the outer surface of the alveolar arch. In the middle line, both of the upper and lower lip, a small fold of mucous membrane passes from the lip to the bone, constituting the *frena*; these are not so large as the frenum linguae. By pulling outward the angle of the mouth, the mucous membrane lining the cheeks can be seen, and on it may be perceived a little papilla which marks the position of the orifice of the *parotid duct*. The exact position of the orifice of the duct will be found to be opposite the second upper molar tooth. The introduction of a probe into this duct is attended with considerable difficulty. The teeth are the next objects which claim our attention upon looking into the mouth. These, are, as stated above, ten in either jaw in the temporary set, and sixteen in the permanent set. The gums, in which they are implanted, are dense, firm, and vascular.

At the back of the mouth is seen the *isthmus of the fauces*, or, as it is popularly called, "the throat;" this is the space between the pillars of the fauces on either side, and is the means by which the mouth communicates with the pharynx. Above, it is bounded by the soft palate, the anterior surface of which is concave and covered with mucous membrane, which is continuous with that lining the roof of the mouth. Projecting downward from the middle of its lower border is a conical-shaped projection, the *uvula*. On either side of the isthmus of the fauces are the anterior and posterior pillars, formed by the Palatoglossus and Palatopharyngeus muscles, respectively, covered over by mucous membrane. Between the two pillars on either side is situated the *tonsil*.

When the mouth is wide open a prominent tense fold of mucous membrane may be seen and felt, extending upward and backward from the position of the fang of the last molar tooth to the posterior part of the hard palate. This is caused by the *pterygomaxillary ligament*, which is attached by one extremity to the apex of the internal pterygoid plate, and by the other to the posterior extremity of the mylohyoid ridge of the lower jaw. It connects the Buccinator with the Superior constrictor of the pharynx. The fang of the last molar tooth indicates the position of the *lingual nerve* where it is easily accessible, and can with readiness be divided in cases of cancer of the tongue (see p. 993). On the inner side of the last molar tooth we can feel the hamular process of the internal pterygoid plate of the sphenoid bone, around which the tendon of the Tensor palati plays. The exact position of this process is of importance in performing the operation of *staphylorrhaphy*. About one-third of an inch (8 mm.) in front of the hamular process, and the same distance directly inward from the last molar tooth, is the situation of the opening of the posterior palatine canal, through which emerges the posterior or descending palatine branch of the internal maxillary artery and one of the descending palatine nerves from Meckel's ganglion. The exact position of the opening on the subject may be ascertained by driving a needle through the tissues of the palate in this situation, when it will be at once felt to enter the canal. The artery emerging from the opening runs forward in a groove in the bone just internal to the alveolar border of the hard palate, and may be wounded in the operation for the cure of cleft palate. Under these circumstances the palatine canal may require plugging. By introducing the finger into the mouth the anterior border of the coronoid process of the mandible can be felt, and it is especially prominent when the jaw is dislocated. By throwing the head well back a considerable portion of the posterior wall of the pharynx may be seen through the isthmus faucium, and on introducing the finger the anterior surface of the bodies of the upper cervical vertebræ may be felt immediately beneath the thin muscular stratum forming the wall of the pharynx. The finger can be hooked around the posterior border of the soft palate, and by turning it forward the posterior nares, separated by the septum, can be felt, or the presence of any adenoid or other growths in the nasopharynx can be ascertained.

Applied Anatomy.—The duct of a salivary gland may be blocked by a *calculus*, and the condition is often productive of severe pain.

A *wound* of the parotid duct or of the parotid gland may be followed by a *salivary fistula*.

The parotid recess is completely lined by fascia, except above. "Between the anterior edge of the styloid process and the posterior border of the External pterygoid muscle there is a gap in the fascia, through which the parotid space communicates with the connective tissue about the pharynx."

This explains why there is frequently swelling of the parotid region in postpharyngeal abscess. A *parotid abscess* rarely bursts through the skin; it may pass into the temporal fossa, may enter the zygomatic fossa, may advance toward the mouth, pharynx, or neck. Because of the situation of the gland, a parotid abscess may cause inflammation of the temporomandibular joint or periostitis of the bone about the canal, and may even burst into the external auditory canal (Treves).

The facial nerve passes through the gland, and inflammation or tuberculosis of the gland may cause *facial palsy*. Some enlargements of the parotid region are due to inflammation of the parotid lymph nodes, and these nodes may become *tuberculous*.

Mumps is characterized by acute inflammation of the parotid gland.

Various *tumors* occur in the parotid (fibroma, sarcoma, carcinoma, enchondroma, etc.). Most parotid tumors contain more or less cartilage. Complete extirpation of the parotid gland surgically is certainly extremely difficult, and Treves and others maintain that it is impossible.

THE PHARYNX (Figs. 964, 965).

The **pharynx** is that part of the alimentary canal which is placed behind, and communicates with the nose, mouth, and larynx. It is a musculomembranous tube, somewhat conical in form, with the base upward and the apex downward, extending from the under surface of the skull to the level of the cricoid cartilage in front and that of the sixth cervical vertebra behind.

The cavity of the pharynx (*cavum pharyngis*) is about five inches in length, and broader in the transverse than in the antero-posterior diameter. Its greatest breadth is immediately below the base of the skull, where it projects on either side, behind the orifice of the Eustachian tube, as a recess termed the fossa of Rosenmüller; its narrowest part is at its termination in the œsophagus. It is limited above by the body of the sphenoid as well as by the basilar process of the occipital; *below*, it is continuous with the œsophagus; *posteriorly*, it is connected by loose areolar tissue with the cervical portion of the vertebral column and the Longus colli and Rectus capitis anticus muscles; this areolar tissue is contained in what is called the **retropharyngeal space**; *anteriorly*, it is incomplete, and is attached in succession to the Eustachian tube, the internal pterygoid plate, the pterygomandibular ligament, the posterior termination of the mylohyoid ridge of the mandible, the mucous membrane of the mouth, the base of the tongue, hyoid bone, the thyroid and cricoid cartilages; *laterally*, it is connected to the styloid processes and their muscles, and is in contact with the common and internal carotid arteries, the internal jugular veins, and the glossopharyngeal, vagus, hypoglossal, and sympathetic nerves, and above with a small part of the Internal pterygoid muscles. Seven openings communicate with it—viz., the two posterior nares, the two Eustachian tubes, the mouth, larynx, and œsophagus. The cavity of the pharynx may be subdivided from above downward into three parts—**nasal**, **oral**, and **laryngeal**.

The **Nasal Part**, or **Nasopharynx** (*pars nasalis pharyngis*) (Fig. 964), lies behind the nose and above the level of the soft palate; it differs from the two lower parts of the tube in that its cavity always remains patent. In front it communicates through the **posterior nares** (*choanae*) (Fig. 965) with the nasal fossæ. On its lateral wall is the **pharyngeal orifice of the Eustachian tube** (*ostium pharyngeum tubae auditivæ*) (Figs. 960 and 961), somewhat triangular in shape and bounded behind by a firm prominence, the **Eustachian cushion** (*torus tubarius*), caused by

the inner extremity of the cartilage of the tube which elevates the mucous membrane (Fig. 961). At the pharyngeal end of the tube is a collection of lymphoid tissue called by Gerlach the **tubal tonsil**. The orifice is about one-third to one-half inch behind the inferior turbinated bone. A vertical fold of mucous membrane, the **salpingopharyngeal fold** (*plica salpingopharyngea*) (Fig. 961), stretches from the lower part of the cushion to the pharynx; it contains the Salpingopharyngeus muscle. A second and smaller fold, the **salpingopalatine fold** (*plica salpingopalatina*) (Fig. 949), stretches from the upper part of the cushion to the palate. Behind the orifice of the Eustachian tube is a deep recess, the **lateral recess or fossa of Rosenmüller** (*recessus pharyngeus*) (Fig. 961), which represents the remains of the upper part of the second inner branchial cleft. The posterior wall of the nasopharynx is directed upward and forward, and it meets the superior wall at an angle constituting the **vault of the pharynx** (*fovnix pharyngis*). On the posterior wall, above the level of the orifices of the Eustachian tubes, is a prominence, best marked in childhood, produced by a mass of lymphoid tissue which is known as the **pharyngeal tonsil** (*tonsilla pharyngea*) (Fig. 960). In the pharyngeal vault, in the middle line, an irregular flask-shaped depression of the mucous membrane is sometimes seen extending up as far as the basilar process of the occipital bone. It is known as the **pharyngeal bursa**, a possible vestige of the pharyngeal tonsil. The floor of the nasopharynx is formed by the upper surface of the sloping soft palate; in front the floor is continuous with that of the nasal cavities, while behind it ends at the free margin of the soft palate, which bounds the **isthmus of the pharynx** (*isthmus pharyngonasalis*).

The **Oral Part** (*pars oralis pharyngis*) of the pharynx reaches from the under surface of the soft palate to about the level of the hyoid bone. It opens anteriorly, through the isthmus faucium, into the mouth, while in its lateral wall, between the two pillars of the fauces, is the tonsil.

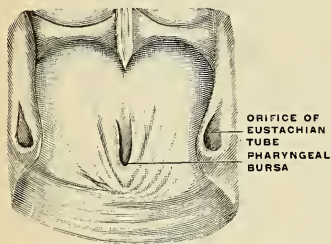


FIG. 960.—Pharyngeal tonsil in an adult. (Escat.)

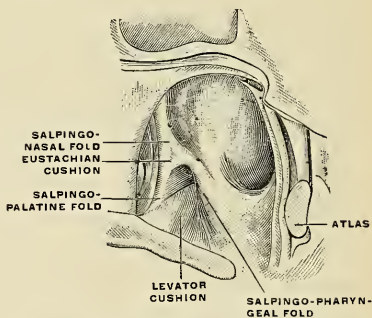


FIG. 961.—The posterior lateral cavity of the nasopharynx. (Escat.)

The **Tonsils** (*tonsilla palatina*) (Figs. 963 and 964) are two lymphoid bodies situated one on each side of the fauces, between the anterior and posterior pillars of the soft palate, corresponding in position externally to the angle of the mandible. They are usually of an oval form as viewed from their oral aspect, and vary considerably in size in different individuals. As seen in horizontal sections in hardened heads, the form of each tonsil is rather that of a Brazil nut, with *anterior*, *lateral*, and *posterior* surfaces, and an *upper* and a *lower* pole.¹ A recess,

¹ Cf. George Fetterolf's article: "The Anatomy and Relations of the Tonsil in the Hardened Body," etc., American Journal of the Medical Sciences, July, 1912.

the **supratonsillar fossa** (*fossa supratonsillaris*) may be seen, directed upward, outward, and backward above the tonsil, the recess being the remains of the second inner visceral cleft. The space below the tonsil, between the tongue in front and the posterior pillar behind, is called the **tonsillar sinus**. The tonsil is encased within a thin fibrous capsule over its lateral and posterior surfaces. An extension of the tonsillar capsule, inward and backward beyond the anterior pillar of the fauces, with its free surface covered by mucous membrane and partly covering the antero-internal surface of the tonsil is called the **plica triangularis**. "Of its three sides the anterior is attached apparently to the anterior pillar, the posterior runs downward and backward over the tonsil, and the inferior either is inserted into the side of the tongue, or, in the case of a small tonsil and a large fossa, fades away in the lower part of the tonsillar sinus."¹

The fibrous capsule covering the lateral and posterior surfaces of the tonsil lies in contact with the aponeurosis of the Superior constrictor muscle of the pharynx; external to this is a mass of areolar tissue with the ascending palatine artery and, more laterally, the Internal pterygoid muscle. The internal carotid artery lies behind and to the outer side of the tonsil, and nearly an inch (20 to 25 mm.) distant from it. The Palatoglossus courses along the anterior margin, while the Palatopharyngeus is in contact with the capsule investing the posterior surface of the tonsil.

The free or antero-internal surface of the tonsil is directed toward the cavity of the oropharynx and presents from twelve to fifteen orifices, each leading into small recesses or **crypts** (*fossulae tonsillares*). From the crypts numerous follicles branch out into the substance of the tonsil by means of very irregular channels. As indicated above, this surface of the tonsil is partially covered by the plica triangularis, which may be free or attached.

Structure.—The tonsil is covered externally by a capsule of white fibrous tissue that separates it from the surrounding organs and tissues, and is continued into the plica triangularis. This capsule sends in trabeculae that divide the organ into irregular compartments. Within the compartments is the delicate framework and reticulum in the meshes of which are found diffuse lymphoid tissue and solitary nodules or follicles. The internal surface presents twelve to fifteen depressions or **crypts** that extend into the organ in the form of irregular, blindly ending, tortuous channels or follicles. The internal surface of the tonsils and the crypts and follicles are lined by stratified squamous cells, exhibiting in places marked degenerative changes, and in others leukocytes that are passing through the epithelial layer to the crypts.

The **arteries** supplying the tonsil are all derived from branches of the external carotid. According to the observations of J. Leslie Davis,² they usually enter the tonsil at what is commonly called the hilum, just behind and about a quarter of an inch from the margin of the anterior pillar, about midway between the upper and lower poles. Fetterolf³ enumerates: (1) an **anterior tonsillar artery**, a branch from the dorsalis linguae; (2) the **superior tonsillar artery**, from the descending palatine; (3) the **posterior tonsillar artery**, a branch of the ascending pharyngeal, and (4) three **inferior tonsillar arteries**, of which one is a branch of the dorsalis linguae, while the other two are offshoots from the tonsillar branches of the facial.

The **veins** of the tonsil terminate in the **tonsillar plexus** on the lateral and posterior surfaces of the tonsil, and the tonsillar plexus joins the pharyngeal plexus which communicates with the pterygoid plexus of the internal jugular or the facial vein. While most of the veins leave at the hilum, there is usually a large vein coursing downward along the posterior surface of the tonsil, to the outer side of the Palatopharyngeus.

Surrounding each follicle is a close plexus of *lymphatic vessels*. From these plexuses the lymphatic vessels pass to the submaxillary lymph nodes below the angle of the mandible. From the submaxillary nodes lymph passes to the deep cervical nodes.

The Nerves of the Tonsil.—A branch from the **glossopharyngeal nerve** by uniting with branches from the middle and posterior palatine branches from the sphenopalatine ganglion forms the **tonsillar plexus**.

¹ G. Fetterolf, loc. cit.

² "Tonsillectomy, Why, When, and How," etc., Pennsylvania Medical Journal, November, 1911.

³ G. Fetterolf, loc. cit.

Development.—The tonsils are developed from the lower parts of the second inner visceral clefts, immediately behind the anterior pillars of the fauces. The endoderm which lines these

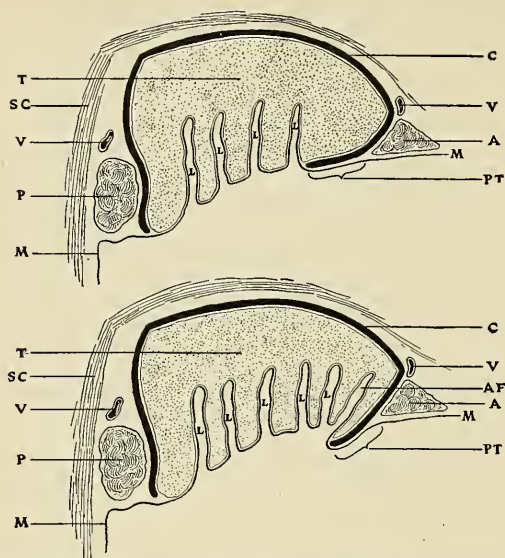


FIG. 962.—Diagrams of horizontal sections of left tonsillar region, viewed from above, the upper one showing the attached form of plica and the lower one the free form: *T*, Tonsil; *C*, capsule; *PT*, plica triangularis; *M*, *M*, mucous membrane; *L*, *L*, lacunae; *AF*, anterior tonsillar fossa; *SC*, superior constrictor; *A*, Palato-glossus; *P*, Palato-pharyngeus; *V*, *V*, main veins of tonsillar plexus. (Fetterolf.)

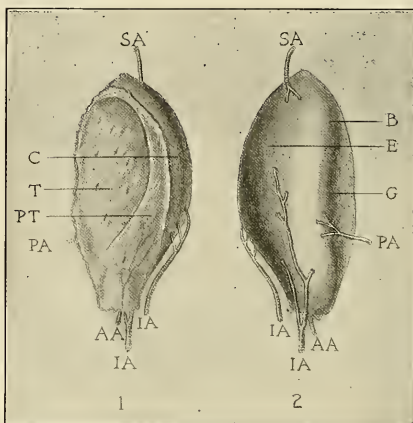


FIG. 963.—Actual shape of (left) tonsil, with arterial supply: 1, Mesal aspect; 2, postero-lateral aspect; *E*, lateral surface; *B*, posterior surface; *G*, groove for Palato-pharyngeus; *T*, tonsil tissue; *PT*, plica triangularis; *C*, capsule; *AA*, anterior tonsillar artery; *PA*, posterior tonsillar artery; *SA*, superior tonsillar artery; *IA*, inferior tonsillar arteries. (Fetterolf.)

clefs grows in the form of a number of solid buds into the surrounding mesoderm. These buds become hollowed out by the degeneration and casting off of their central cells, and by this means the tonsillar crypts are formed. Lymphoid cells accumulate around the crypts, and become grouped to form the lymphoid follicles; the latter, however, are not well defined until after birth.

Applied Anatomy.—The tonsils can be easily inspected by instructing the patient to throw the head back with mouth wide open, the tongue being depressed by a spatula or tongue depressor. The normal tonsil should not project inward beyond the plane of the anterior pillar of the fauces. When enlarged they make deglutition and respiration troublesome. The *deafness* which so often attends hypertrophy of the tonsil is not due to blocking of the Eustachian orifice by the tonsil, but is due to the attendant thickening of the mucous membrane lining the tube itself. The tonsils may be the seat of *acute inflammation*, which may run on to suppuration, requiring evacuation of the pus. The incision into the tonsil should always be made from in front backward and inward. Another form of acute inflammation of the tonsil is *follicular tonsillitis*, due to the lodgment of micro-organisms in the tonsillar crypts.

Tonsillectomy is the complete enucleation of the gland. In this operation, profuse bleeding may be avoided by the use of dissectors designed to keep to the outer surface of the capsule and by the use of the snare and tenaculum. Successful methods are those of Fetterolf¹ and Davis,² whereby enucleation is complete without inflicting damage upon surrounding structures, such as the faucial pillars, which, if injured, may cause discomfort and affect the voice, and also avoiding injury to the *ascending pharyngeal artery* or one of the palatine arteries lying without the capsule of the tonsil.

The tonsil may be the seat of malignant growth, either an *epithelioma* or a *lymphosarcoma*.

The **Laryngeal Part** of the pharynx (*pars laryngea pharyngis*) is that division which lies behind the larynx; it is wide above where it is continuous with the oral portion, while below at the lower border of the cricoid cartilage it becomes continuous with the oesophagus. In front it presents the triangular aperture of the larynx, the base of which is directed forward and is formed by the epiglottis, while its lateral boundaries are constituted by the arytenoepiglottic folds. On either side of the laryngeal orifice is a recess, termed the *sinus pyriformis* (*recessus pyriformis*) (Fig. 964); it is bounded internally by the arytenoepiglottic fold, externally by the thyroid cartilage and thyrohyoid membrane. In the anterior part of the sinus pyriformis is a fold (*plica nervi laryngei*), which passes downward and inward. Extending outward from the epiglottis on each side is a fold, the **pharyngoepiglottic fold** (*plica pharyngoepiglottica*). This ascends in the lateral wall of the pharynx, nearly to the posterior arch of the fauces.

Structure.—The pharynx is composed of **mucous, fibrous, and muscular coats**.

The **mucous coat** (*tunica mucosa*) is continuous with that lining the Eustachian tubes, the nasal fossæ, the mouth, and the larynx. In the nasopharynx it is covered by stratified ciliated epithelium; in the buccal and laryngeal portions the epithelium is of the stratified squamous variety. In the tunica propria considerable diffuse lymphoid tissue, pharyngeal tonsil, and **mucous glands** (*glandulae pharyngeae*) are found; the latter are especially numerous at the upper part of the pharynx around the orifices of the Eustachian tubes.

The **pharyngeal aponeurosis** or **fibrous coat** is situated between the mucous and the muscle layers, and consists of large bundles of white fibrous connective tissue. It is thick above, where the muscle fibres are wanting, and is firmly connected to the periosteum of the basilar process of the occipital and petrous portion of the temporal bones. As it descends it diminishes in thickness, and is gradually lost. It is strengthened posteriorly by a strong fibrous band, which is attached above to the pharyngeal spine on the under surface of the basilar portion of the occipital bone, and passes downward, forming a **median raphe**, which gives attachment to the Constrictor muscles of the pharynx.

The **muscular coat** has been already described (pp. 394 to 397).

The *motor nerves* are derived chiefly from the pharyngeal plexus; the Tensor palati, however, receives a special branch from the otic ganglion. The *sensor* filaments are derived from the descending palatine, nasopalatine, and from the glossopharyngeal nerve.

¹ G. Fetterolf, loc. cit.

² J. Leslie Davis, loc. cit.

The Lymphatic Pharyngeal Ring.—This name was applied by Waldeyer to the lymphatic structures gathered into a sort of ring about the pharynx. There are four chief collections of this tissue on each side. The first is known as the **lingual tonsil** (p. 1219); the second as the **palatal tonsil** (p. 1230); the third as the **pharyngeal tonsil** (p. 1230); and the fourth as the **tubal tonsil** (pp. 1128, 1230).

Development of the Pharynx (Figs. 956, 957).—The pharynx develops from the cephalic portion of the foregut, flanked by the five branchial (visceral) arches, with four intervening branchial clefts (visceral pouches). These have become retrogressively modified in that they have

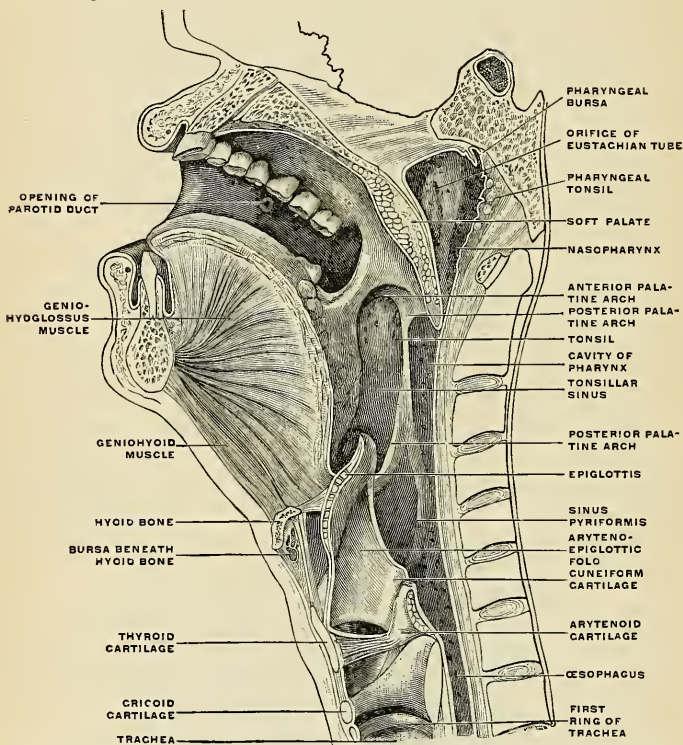


FIG. 964.—Sagittal median section of the head and neck. The head is thrown backward into complete extension, which explains the relations between the lower jaw and the hyoid bone as seen in the figure. (Luschka.)

lost their respiratory function (as gills), but recur in the development of each individual for the purpose of forming organs not entirely vestigial. Thus, the first or most cephalic branchial arch assists in the formation of the jaws, the malleus, incus, sphenomandibular ligament, and part of the external ear. The second arch forms the styloid process, lesser cornu of hyoid and the intervening stylohyoid ligament, the stapes, a part of the external ear, and a part of the posterior one-third of the tongue. From the third arch are formed the body and greater cornu of the hyoid bone, and part of the posterior one-third of the tongue. The fourth and fifth arches share in forming the thyroid cartilage. The inner furrows or clefts, lined by entoderm, contribute to the formation of important structures. Thus, the first inner furrow becomes the middle-ear cavity and Eustachian tube, the "closing membrane" persisting as the tympanic membrane

separating the inner from the outer furrow, which becomes the external auditory meatus. The second inner furrow becomes the lateral recess of the pharynx, and its entodermal lining gives rise to the tonsil. From the third inner furrow are developed the thymus and the inferior parathyroid gland, while the fourth gives rise to the lateral lobes of the thyroid and the superior parathyroid glands. The isthmus of the thyroid is derived by a median ventral evagination of the entoderm arising between the tuberculum impar and the second visceral bar. Another median ventral evagination occurs at the level of the fourth visceral arch to form the respiratory apparatus. The tuberculum impar forms the papillary portion of the tongue.

Applied Anatomy.—The *internal carotid artery* is in close relation with the pharynx, so that its pulsations can be felt through the mouth. It has been occasionally wounded by sharp-pointed instruments introduced into the mouth and thrust through the wall of the pharynx.

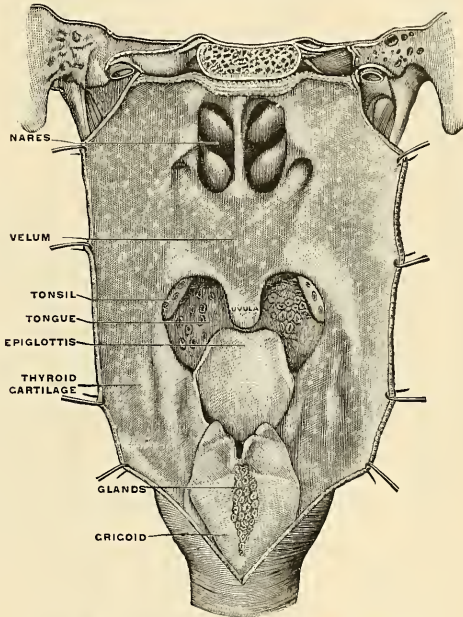


FIG. 965.—The anterior surface of the pharynx. (Sappey.)

In *aneurism* of this vessel in the neck the tumor necessarily bulges into the pharynx, as this is the direction in which it meets with the least resistance, nothing lying between the vessel and the mucous membrane except the thin Constrictor muscle, whereas on the outer side there is the dense cervical fascia, the muscles descending from the styloid process, and the margin of the Sternomastoid muscle.

The mucous membrane of the pharynx is very vascular, and is often the seat of *inflammation*, frequently of a septic character, and dangerous on account of its tendency to spread to the larynx. On account of the tissue which surrounds the pharyngeal wall being loose and lax, the inflammation is liable to spread through it far and wide, extending downward into the posterior mediastinum along the œsophagus. *Abscess* may form in the connective tissue behind the pharynx, between it and the vertebral column, constituting what is known as *retropharyngeal abscess*. This is most commonly due to caries of the cervical vertebrae, but may also be caused by supuration of a lymph node which is situated in this position opposite the axis, and which receives lymphatics from the nares, or by *gunna* or by *acute pharyngitis*. In these cases the pus may be easily evacuated by an incision, with a guarded bistoury, through the mouth, but, for aseptic

reasons, it is desirable that the abscess should be opened from the neck. In some instances this is perfectly easy; the abscess can be felt bulging at the side of the neck and merely requires an incision for its relief; but this is not always so, and then an incision should be made along the posterior border of the Sternomastoid and the deep fascia should be divided. A director should now be inserted into the wound, the forefinger of the left hand being introduced into the mouth and pressure made upon the swelling. This acts as a guide, and the director is to be pushed onward

until pus appears in the groove. A pair of sinus forceps are now inserted along the director and the opening into the cavity dilated.

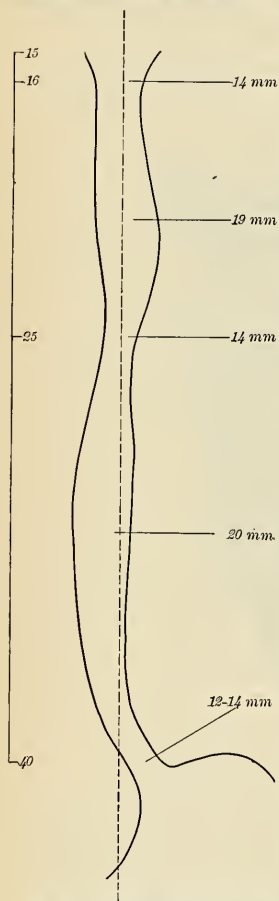
Foreign bodies not infrequently become lodged in the pharynx and most usually at its termination at about the level of the cricoid cartilage, just beyond the reach of the finger, as the distance from the arch of the teeth to the commencement of the œsophagus is about six inches.

Hypertrophy of the lymphoid tissue of the nasopharynx produces groups of hypertrophic masses known as *adenoids*. A child with adenoids has a cough, and when awake or asleep, breathes noisily and with the mouth open. The voice is muffled, the hearing is impaired, the expression is vacant, the mind is dull, and the tonsils are enlarged.

THE ŒSOPHAGUS (Figs. 966, 967).

The *œsophagus*, or *gullet*, is a musculomembranous canal, about nine or ten inches in length, extending from the pharynx to the stomach. It commences at the upper border of the cricoid cartilage, opposite the sixth cervical vertebra, descends along the front of the vertebral column through the posterior mediastinum, passes through the Diaphragm, and, entering the abdomen, terminates at the cardiac orifice of the stomach, opposite the eleventh thoracic vertebra, about an inch (2.5 cm.) to the left of the median plane. The general direction of the œsophagus is vertical, but it presents two or three slight curves in its course. At its commencement it is placed in the median line, but it inclines to the left side as far as the root of the neck, gradually passes to the middle line again, and finally deviates to the left as it passes forward to the œsophageal opening of the Diaphragm (*hiatus œsophageus*). The œsophagus also presents antero-posterior flexures, corresponding to the curvature of the cervical and thoracic portions of the vertebral column. It is the narrowest part of the alimentary canal, being most contracted at its commencement, at about the level of the third thoracic vertebra, and at the point where it passes through the Diaphragm (Fig. 966).

FIG. 966.—Contour of the œsophagus. On the left the distances of the constrictions from the incisor teeth are given in centimeters; on the right are given the diameters in millimeters. (Half natural size.)



When empty, the œsophagus is contracted so that its anterior and posterior walls come in contact and the lumen is stellate on account of the longitudinal foldings of the inelastic mucous membrane loosely held by the submucosa. The calibre

of the lumen varies between half an inch to an inch or more, depending upon the absence or presence of swallowed substances. The average distance from the upper incisor teeth to the beginning of the gullet is about six inches (15 cm.); the average distance from the incisor teeth to the cardiac opening of the stomach is fifteen or sixteen inches (40 cm.). The portion of the œsophagus which is in the neck is called the **cervical portion** (*pars cervicalis*); the portion in the thorax, the **thoracic portion** (*pars thoracalis*); and the portion which lies in the œsophageal groove of the liver, and therefore below the Diaphragm, is the **abdominal portion**. The abdominal portion of the œsophagus (*pars abdominalis*) is not over half an inch in length, and is limited to the small portion of the anterior and left lateral surface observed when a stomach which is completely empty is drawn downward with considerable force. The abdominal portion of the œsophagus is covered by perito-

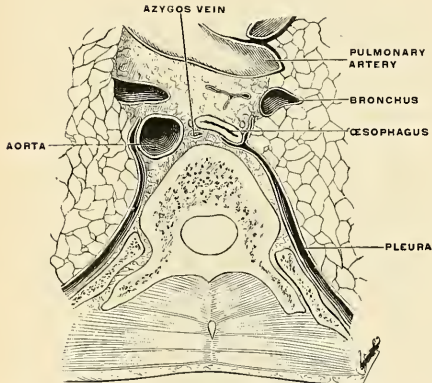


FIG. 967.—Pleural cul-de-sac of the posterior mediastinum. Level of sixth thoracic vertebra.

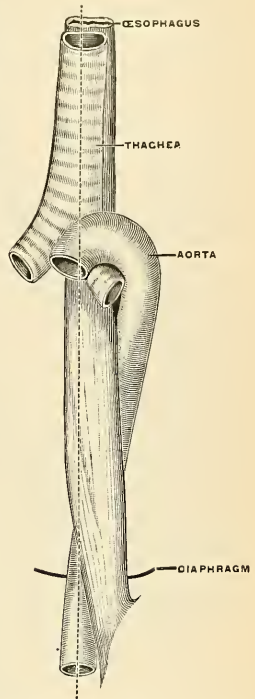


FIG. 968.—The relations of œsophagus, trachea, and aorta in an infant. (Poirier and Charpy.)

neum only on its ventral and left aspects. It is somewhat conical, with its base toward the stomach, and is known as the *antrum cardiacum*.

Relations.—The **cervical portion** of the œsophagus is in relation, *in front*, with the trachea, and at the lower part of the neck, where it projects to the left side, with the thyroid gland; *behind*, it rests upon the vertebral column and Longus colli muscles; *on either side*, it is in relation with the common carotid artery (especially the left, as it inclines to that side) and part of the lateral lobe of the thyroid gland; the recurrent laryngeal nerves ascend between it and the trachea; to its left side is the thoracic duct.

The **thoracic portion** of the œsophagus is at first situated a little to the left of the median line; it then passes behind the aortic arch, separated from it by the trachea, and descends in the posterior mediastinum, along the right side of the aorta, then runs in front and a little to the left of the aorta, and enters the abdomen through the Diaphragm at the level of the tenth thoracic vertebra. Just before it passes through the Diaphragm it presents a distinct dilatation or *bulb*. It is in relation, *in front*, with the trachea, the left bronchus, the pericardium, and the Diaphragm; *behind*, it rests upon the vertebral column, the Longus colli muscles, the right intercostal arteries, the thoracic duct, and the vena azygos minor veins; and *below*, near the Diaphragm, upon the

front of the aorta. On its *left* side, in the superior mediastinum, are the terminal part of the arch of the aorta, the left subclavian artery, the thoracic duct, and left pleura, while running upward in the angle between it and the trachea is the left recurrent laryngeal nerve; *below*, it is in relation with the descending thoracic aorta. On its *right* side are the right pleura and the vena azygos major, which it overlaps. The vagus nerves descend in close contact with it, the right nerve passing down behind, and the left nerve in front of it; the two nerves uniting to form a plexus (*plexus oesophageus s. gular*) around the tube.

In the lower part of the posterior mediastinum the thoracic duct lies to the right side of the oesophagus; higher up, it is placed behind it, and, crossing about the level of the fourth thoracic vertebra, is continued upward on its left side.

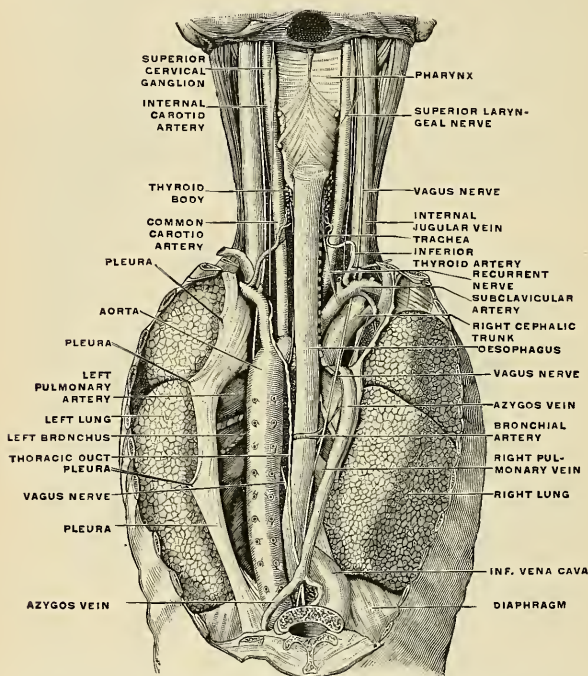


FIG. 969.—The position and relation of the oesophagus in the cervical region and in the posterior mediastinum. Seen from behind. (Poirier and Charpy.)

Structure.—The oesophagus has four coats—an **external** or **fibrous**, a **muscular**, a **sub-mucous**, and an **internal** or **mucous** coat.

The **fibrous coat** consists of white fibrous connective tissue that supports the other coats and assists in connecting the oesophagus to the surrounding tissues or organs.

The **muscular coat** (*tunica muscularis*) is composed of two planes of considerable thickness, an **external longitudinal** and an **internal circular**.

The **longitudinal fibres** are arranged, at the commencement of the tube, in three fasciculi—one in front, which is attached to the vertical ridge on the posterior surface of the cricoid cartilage, and one at each side, which is continuous with the fibres of the Inferior constrictor of the pharynx; as they descend they blend together and form a uniform layer, which covers the outer surface of the tube.

Accessory slips of muscle tissue pass between the oesophagus and the left pleura, where the latter covers the thoracic aorta, or the root of the left bronchus, or the back of the pericardium (Fig. 970).

The **circular fibres** are continuous above with the Inferior constrictor of the pharynx; their direction is transverse at the upper and lower parts of the tube, but oblique in the intermediate part. Below, the circular fibres pass into the circular and oblique fibres of the stomach.

The muscle fibres in the upper part of the œsophagus are of a red color, and consist chiefly of the striped variety, but below they consist for the most part of involuntary muscular fibres.

The **submucous coat** (*tela submucosa*) connects loosely the mucous and muscular coats.

The **mucous coat** (*tunica mucosa*) is thick, of a reddish color above and pale below. It is disposed in longitudinal folds, which disappear on distention of the tube. Its surface is studded with minute papillæ, and is covered throughout with a thick layer of stratified pavement epithelium. Beneath the mucous membrane, between it and the submucous coat, is a layer of longitudinally arranged nonstriped muscle tissue. This is the **muscularis mucosae** (*lamina muscularis mucosae*). At the commencement of the œsophagus it is absent, or only represented by a few scattered bundles; lower down it forms a considerable stratum.

The **œsophageal glands** are small compound racemose glands of the mucous type; they are lodged in the submucous tissue and each opens upon the mucous surface by a long excretory duct.

Vessels and Nerves.—The larger vessels are in the submucosa and send branches to the mucosa and muscularis. The **arteries** supplying the œsophagus are derived from the **inferior thyroid branch of the thyroid axis of the subclavian**, from the **descending thoracic aorta** and the **bronchial arteries**, and from the **gastric branch of the cœliac axis**, and from the **left inferior phrenic of the abdominal aorta**. They have for the most part a longitudinal direction. The **veins** are gathered into a plexus on the outer surface of the œsophagus. This plexus receives the venous blood from the walls of the tube. From the lower portion of the plexus branches go to the **coronary vein of the stomach**. Higher up branches go to the **azygos veins** and **thyroid veins**. In this manner a communication is opened between the portal vein and the systemic veins.

The **lymphatics** drain into the inferior deep cervical nodes and the nodes of the posterior mediastinum.

The **nerves** are derived from the **vagus** and from the **sympathetic**; they form a plexus in which are groups of ganglion cells between the two layers of the muscular coat. From this fibres pass to supply the muscle, and others go to the submucous tissue to form a secondary plexus. It is usual to regard the plexus as consisting of two parts, an **anterior œsophageal plexus**, derived from the left vagus, and a **posterior œsophageal plexus**, derived from the right vagus. These two plexuses are in the posterior mediastinum; they communicate with each other and contain sympathetic fibres.

Applied Anatomy.—The relations of the œsophagus are of considerable practical interest to the surgeon, as he is frequently required, in cases of *stricture* of this tube, to dilate the canal by a bougie, when it is of importance that the direction of the œsophagus and its relations to surrounding parts should be remembered. In cases of *malignant disease* of the œsophagus, where its tissues have become softened from infiltration of the morbid deposit, the greatest care is requisite in directing the bougie through the strictured part, as a false passage may easily be made, and the instrument may pass into the mediastinum, or into one or the other pleural cavity, or even into the pericardium.

One should also remember that obstruction of the œsophagus, and consequent symptoms of stricture, are occasionally produced by *aneurism* of some part of the aorta pressing upon the tube. In such a case the passage of a bougie could only hasten the fatal issue.

In passing a bougie the left forefinger should be introduced into the mouth and the epiglottis felt for, care being taken not to throw the head too far backward. The bougie is then to be passed beyond the finger until it touches the posterior wall of the pharynx. The patient is now asked to swallow, and at the moment of swallowing the bougie is passed gently downward, all violence being carefully avoided.

It occasionally happens that a *foreign body* becomes impacted in the œsophagus and can neither be brought upward nor moved downward. When all ordinary means for its removal have failed, and the body is lodged above the lower one-third of the gullet, external *œsophago-*

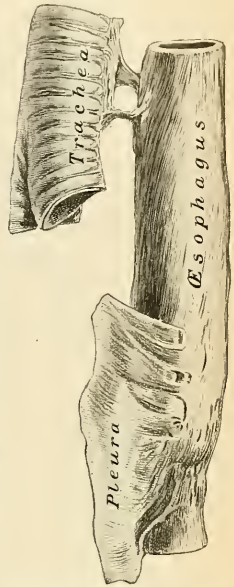


FIG. 970.—Accessory muscle slips between the œsophagus and pleura, and œsophagus and trachea. (From a preparation in the Museum of the Royal College of Surgeons of England.)

gotomy is performed. If the foreign body is lodged in the lower one-third of the gullet, the stomach is opened (*gastrotomy*) and the foreign body is extracted. If the foreign body is allowed to remain lodged in the œsophagus, extensive inflammation and ulceration may ensue. In one case the foreign body ultimately penetrated the intervertebral substance, and destroyed life by inflammation of the membranes and substance of the spinal cord.

The operation of *œsophagotomy* is thus performed: The patient being placed upon his back, with the head and shoulders slightly elevated, an incision, about four inches in length, should be made on the left side of the trachea, from the thyroid cartilage downward, dividing the skin, Platysma, and deep fascia. The edges of the wound being separated, the Omohyoid muscle should, if necessary, be divided, and the fibres of the Sternohyoid and Sternothyroid muscles drawn inward; the sheath of the carotid vessels, being exposed, must be drawn outward, and retained in that position by retractors; the œsophagus will now be exposed, and should be divided over the foreign body, which can then be removed. Great care is necessary to avoid wounding the thyroid vessels, the thyroid gland, and the laryngeal nerves.

The œsophagus may be obstructed not only by foreign bodies, but also by changes in its coats, producing *stricture*, or by pressure on it from without of *new growths* or *aneurisms*, etc.

The different forms of *stricture* are: (1) the *spasmodic*, occurring in neurotic individuals, and intermittent in character, so that the dysphagia is not constant. Spasmodic stricture of the œsophagus sometimes occurs in cases of cancer of the stomach and cancer of the liver; (2) *fibrous*, due to cicatrization after injuries, such as swallowing corrosive fluids or boiling water; and (3) *malignant*, usually epitheliomatous in its nature. Cancer is most common either at the upper end of the tube, opposite to the cricoid cartilage, or at its lower end at the cardiac orifice. Cicatricial stricture may be treated by gradual dilatation. If a stricture is impassable from above, the stomach may be opened, an instrument passed from below, and a string used to divide the stricture. The operation of *œsophagostomy* has occasionally been performed, but if any operative interference is undertaken for stricture, with the idea of forming an orifice for the introduction of food, it is better to perform *gastrotomy*. In malignant stricture, gastrotomy is the only operation to be thought of.

THE ABDOMEN.

The **abdomen** is that portion of the trunk which lies below the Diaphragm, and it contains the largest cavity in the body. It is of an oval form, the extremities of the oval being directed upward and downward; the upper one is formed by the under surface of the Diaphragm, the lower end is limited by the structures

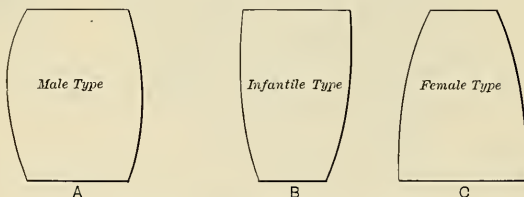


FIG. 971.—Schematic outlines of the abdomen.

which clothe the inner surface of the bony pelvis, principally the Levatores ani and the Coccygei muscles on either side. These muscles are sometimes termed the **Diaphragm of the pelvis**. In order to facilitate description, it is artificially divided into two parts, an upper and larger part, the **abdomen proper**, and a lower and smaller part, the **pelvis**. The cavities of these divisions are not separated from each other, but the limit between them is marked by the brim of the true pelvis. The cavity is wider above than below, and measures more in the vertical than in the transverse diameter.

The **abdomen proper** differs from the other great cavities of the body in being bounded for the most part by muscles and fasciæ, so that it can vary in capacity and shape according to the condition of the viscera which it contains; but, in

addition to this, the abdomen varies in form and extent with age and sex (Fig. 971). In the adult male, with moderate distention of the viscera, it is oval or barrel-shaped, but at the same time flattened from before backward. In the adult female, with a fully developed pelvis, it is conical with the apex above, and in young children it is conical with the apex below.

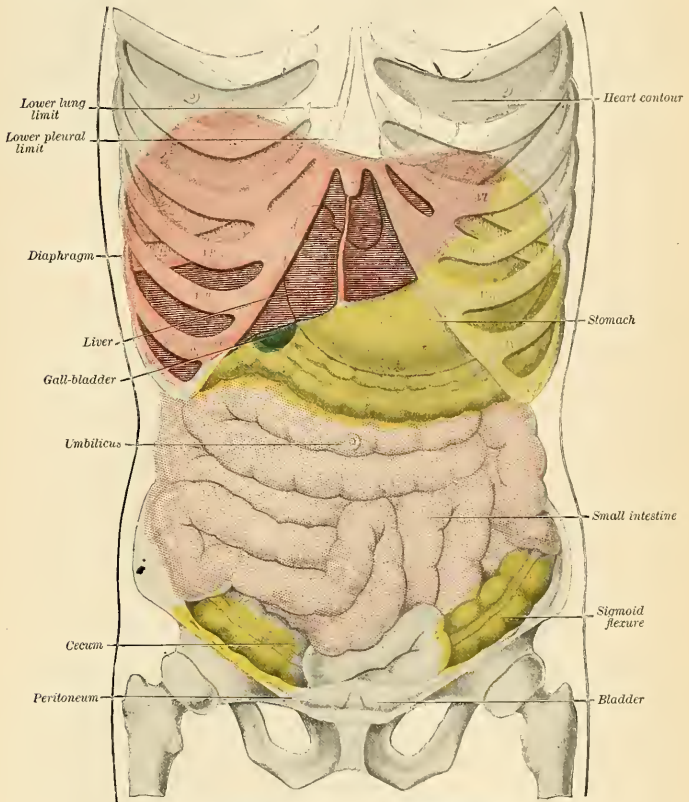


FIG. 972.—Topography of thoracic and abdominal viscera.

Boundaries.—The boundary between the thorax and abdomen is the Diaphragm, which extends as a dome over the abdomen, so that the cavity extends high into the bony thorax, reaching on the *right* side, in the midclavicular line, to the upper border of the fifth rib; on the *left* side it falls below this level by about half an inch or more. The abdomen proper is bounded *in front* and *at the sides* by the lower ribs, the abdominal muscles, and the iliac fossae; *behind*, by the vertebral column and the Psoas and Quadratus lumborum muscles; *above*, by the Diaphragm; *below*, by the plane of the inlet or brim of the pelvis. The muscles forming the boundaries of the cavity are lined upon their inner surface by a layer of fascia, differently named, according to the part which it covers.

The abdomen contains (Fig. 972) the greater part of the alimentary canal; some of the accessory organs to digestion—viz., the liver and pancreas; the spleen, the kidneys, and adrenals, or suprarenal capsules. Most of these structures, as well as the wall of the cavity in which they are contained, are covered by an extensive and complicated serous membrane, the **peritoneum** (Fig. 1004).

The Apertures in the Walls of the Abdomen.—The apertures found in the walls of the abdomen, for the transmission of structures to or from it, are the **umbilicus**, for the transmission (in the fetus) of the umbilical vessels; the **caval opening** in the Diaphragm, for the transmission of the inferior vena cava; the **aortic opening**, for the passage of the aorta, vena azygos major, and thoracic duct; and the **œsophageal opening**, for the œsophagus and vagus nerves. *Below*, there are two apertures on each side, one for the passage of the femoral vessels, and the other for the transmission of the spermatic cord in the male, and the round ligament in the female.

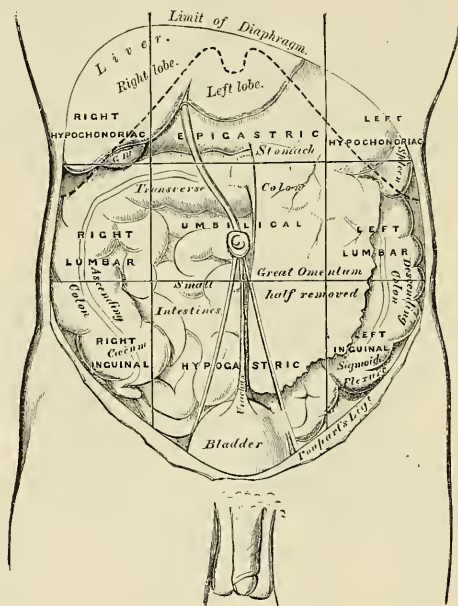


FIG. 973.—The regions of the abdomen and their contents. Edges of costal cartilages in dotted outline.

Regions (Fig. 973).—For convenience of description of the viscera, as well as of reference to the morbid conditions of the contained parts, the abdomen is artificially divided into nine regions by imaginary planes, two horizontal and two sagittal, passing through the cavity, the edges of the planes being indicated by lines drawn on the ventral surface of the body. Of the horizontal planes, the upper or *infracostal* is indicated by a line encircling the body at the level of the lowest points of the tenth costal cartilages, the lower by a line carried around the trunk at the level of the summits of the iliac crests. The lower plane closely corresponds to the *intertubercular plane* passing through the trunk at the level of the prominent and easily defined tubercle on the iliac crest about two inches behind

the anterior superior iliac spine. By means of these imaginary planes the abdomen is divided into three zones, which are named, from above downward, *subcostal*, *umbilical*, and *hypogastric* zones. Each of these is further subdivided by two sagittal planes, which are indicated on the surface by lines drawn vertically through points half way between the anterior superior iliac spines and the symphysis pubis. The regions as outlined by the BNA Commission are shown in Fig. 974.¹

The middle region of the upper zone is called the **epigastric**, and the two lateral regions, the **right** and **left hypochondriac**. The central region of the middle zone is the **umbilical**; and the two lateral regions, the **right** and **left lumbar**. The middle region of the lower zone is the **hypogastric** or **pubic region**; and the lateral regions are the **right** and **left iliac** or **inguinal**.

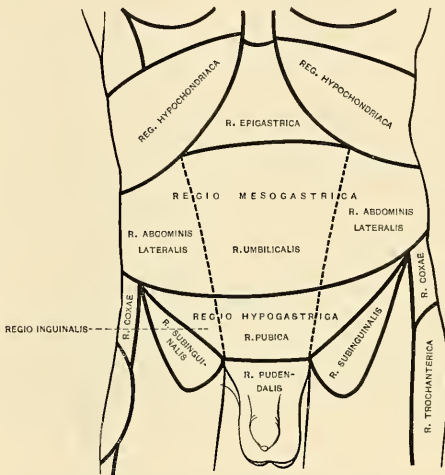


FIG. 974.—Regions of the abdomen, according to the BNA Commission.

The **pelvic cavity** is that part of the abdominal cavity which lies below and behind a plane passing through the promontory of the sacrum, the iliopectineal lines and the pubic crests. It is bounded *behind* by the sacrum, coccyx, Pyriformis muscles, and the great sacrospinous ligaments; in *front* and *laterally* by the pubes and ischia and Obturator internus muscles; *above*, it communicates with the cavity of the abdomen; *below*, it is closed by the Levatores ani and Coccygei muscles and the triangular ligament. The pelvic cavity contains the urinary bladder, the sigmoid colon, the rectum, a few coils of small intestine, and some of the generative organs.

If the anterior abdominal wall is reflected in the form of four triangular flaps by means of vertical and transverse incisions—the former from the ensiform cartilage to the symphysis pubis, the latter from flank to flank at the level of the umbilicus—the abdominal or peritoneal cavity is freely opened and the contained

¹ Anatomists are far from agreed as to the best method of subdividing the abdominal cavity. Addison (Journal of Anatomy and Physiology, vols. xxxiv and xxxv), in a careful analysis of the abdominal viscera in forty subjects, adopts the following lines: (1) a median, from the symphysis pubis to the ensiform cartilage; (2) two lateral lines drawn vertically through a point midway between the anterior superior iliac spine and the symphysis pubis; (3) an upper transverse line half way between the symphysis pubis and the suprasternal notch; and (4) a lower transverse line midway between the last and the upper border of the symphysis pubis. The upper transverse line corresponds with what he has termed the *transpyloric plane*, from the fact that in most cases this plane traverses the pylorus.

viscera are in part exposed. Above and to the right side is the **liver**, situated chiefly under the shelter of the right ribs and their cartilages, but extending across the middle line, and reaching for some distance below the level of the ensiform cartilage. To the left of the liver is the **stomach**, from the lower border of which an apron-like fold of peritoneum, the **greater omentum**, descends for a varying distance, and obscures, to a greater or less extent, the other viscera (Fig. 1002). Below it, however, some of the coils of the **small intestine** can generally be seen, while in the right and left iliac regions respectively the **cecum** and the **sigmoid flexure** of the colon are exposed. The **bladder** occupies the anterior part of the pelvis, and, if distended, will project above the symphysis pubis; the **rectum** lies in the concavity of the sacrum, but is usually obscured by the coils of the small intestine. The sigmoid colon lies between the rectum and the bladder.

If the stomach is followed from left to right it will be found to be continuous with the first part of the small intestine, or **duodenum**, the point of continuity being marked by a thickened ring which indicates the position of the **pyloric sphincter**. The duodenum passes toward the under surface of the liver, and then, curving downward, is lost to sight. If, however, the great omentum be thrown upward over the thorax, the terminal part of the duodenum will be observed passing across the vertebral column toward the left side, where it becomes continuous with the **coils of the small intestine**. These measure some twenty feet in length, and if followed downward will be seen to end in the right iliac fossa by opening into the **cecum**, the commencement of the **large intestine**. From the cecum the large intestine takes an arched course, passing at first upward on the right side, then across the middle line and downward on the left side, and forming respectively the **ascending, transverse, and descending parts of the colon**. In the left iliac region it assumes the form of a loop, the **sigmoid flexure**, then follows the curve of the sacrum and terminates in the **rectum and anal canal**.

The **spleen** lies behind the stomach in the left hypochondriac region, and may be in part exposed by pulling the stomach over toward the right side.

The glistening appearance of the deep surface of the abdominal wall and of the exposed viscera is due to the fact that the former is lined and the latter more or less completely covered by a serous membrane, the **peritoneum**.

THE PERITONEUM (TUNICA SEROSA).

The **peritoneum** is the largest serous membrane in the body, and consists, in the male, of a closed sac, a part of which is applied against the abdominal parietes, while the remainder is reflected more or less completely over the contained viscera. In the female the peritoneum is not a closed sac, since the free extremities of the Fallopian tubes open directly into the peritoneal cavity. The part which lines the parietes is named the **parietal peritoneum**; that which is reflected over the viscera, the **visceral peritoneum**. The **free surface** of the membrane is smooth, covered by a layer of flattened endothelium, and lubricated by a small quantity of serous fluid. Hence the viscera can glide freely against the wall of the cavity or upon one another with the least possible amount of friction. The **attached surface** is rough, being connected to the viscera and inner surface of the parietes by means of areolar tissue termed the **subserous areolar tissue** (*tela subserosa*). The parietal portion is loosely connected with the fascia lining the abdomen and pelvis, but more closely to the under surface of the Diaphragm and also in the middle line of the abdomen.

The space between the parietal and visceral layers of the peritoneum is named the **peritoneal cavity**; but it must be remembered that under normal conditions this cavity is a potential one, since the parietal and visceral layers are in contact.

The peritoneal "cavity" is subdivided into a **greater** and a **lesser cavity** or **sac**, which communicate through the foramen of Winslow (*foramen epiploicum*). The greater sac is opened when the ventral abdominal wall is pierced; the lesser is situated behind the stomach and adjoining structures, and may be regarded as a diverticulum of the greater sac.

The disposition of the peritoneum as it is applied to the parietes and also reflected over the viscera contained in the abdominal cavity is best understood after tracing the developmental (embryologic) history of the peritoneum and the alimentary tract.

Development of the Peritoneum and Alimentary Tract.¹—The segmenting ovum, at an early stage, becomes a blastodermic vesicle with two layers of cells composing its wall, named, from without inward, ectoderm and entoderm. The cavity of the vesicle is filled with the nutritive yolk (*vitellus*). Only a part of the ovum is destined to form the embryo, the remainder being used up in the formation of membranes and other appendages which are concerned in protection and nutrition; the ovum may, therefore, be divided into its *embryonic area* and *extra-embryonic portion*. In the embryonic area, in its caudal part, appears the transitory *primitive streak* and *groove* produced by an axial thickening of the ectoderm. From the head process of the primitive streak a third layer of cells, the *mesoderm*, extends in all directions between ectoderm and entoderm, extending alongside the neural tube and notochord. The extension of the mesoderm takes place throughout the whole of the embryonic and extra-embryonic areas of the ovum except in certain regions. One such area, devoid of mesoderm, is seen

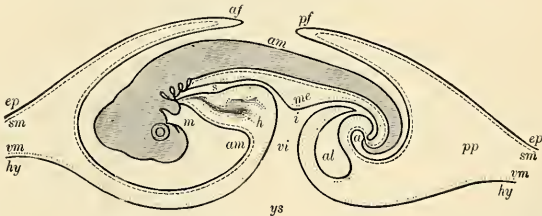


FIG. 975.—Diagrammatic outline of a longitudinal vertical section of the chick on the fourth day. *ep*, Ectoderm. *sm*, Somatic mesoderm. *hy*, Entoderm. *vm*, Visceral mesoderm. *af*, Cephalic fold. *pf*, Caudal fold. *am*, Cavity of true amnion. *ys*, Yolk sac. *i*, Intestine. *s*, Foregut. *a*, Future anus, still closed. *m*, The mouth. *me*, The mesentery. *al*, The allantoic vesicle. *pp*, Space between inner and outer folds of amnion. (From Quain's Anatomy, Allen Thomson.)

immediately cephalad of the neural tube. This is named the *buccopharyngeal area*, since it afterward forms the temporary septum between the primitive mouth and primitive pharynx. This membrane extends from the head to the pericardial area. A similar area devoid of mesoderm is seen immediately caudad of the embryonic area, and is named the *cloacal membrane*, since it afterward forms the temporary septum between the anal pit and the primitive hindgut.

While the paraxial mesoderm extends along the neural tube and notochord and in all directions, its lateral portion splits into two concentric layers; the outer or *somatic* layer becomes applied to the ectoderm, and with it forms the **somatopleure** or body wall; the inner or *splanchnic* layer adheres to the entoderm, and with it forms the **splanchnopleure**, from which the greater portion of the digestive tract is formed. The space created between the layers of the mesoderm is termed the **coelom** or **body cavity**. A portion of this space is later enclosed within the embryo, and is called the **embryonic coelom**, while the portion of the coelomic

¹ In the preparation of this chapter the editor has consulted several original treatises, notably G. S. Huntington's "Anatomy of the Human Peritoneum and Abdominal Cavity," 1903.

cavity left outside the embryo, the *extra-embryonic cœlom*, envelops the vitelline or yolk sac.

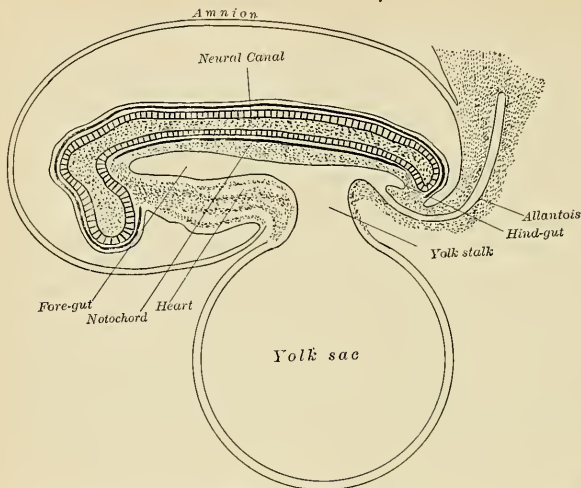
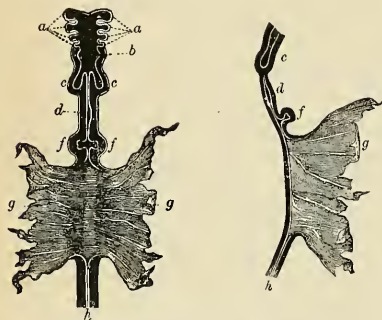


FIG. 976.—Diagram of a longitudinal section of a mammalian embryo. Very early. (After Quain.)

The relatively slow growth of the margin of the embryonic area and the relatively rapid growth of the axial parts soon come to form a ring of constriction between the embryo and the yolk sac, and a part of the latter—that is, a part of its splan-

nopleural wall and part of the cavity—becomes enclosed within the embryo to form the primitive alimentary canal (Fig. 976). At the same time a part of the cœlom becomes enclosed within the embryo by the relative approximation of the lateral, cephalic, and caudal folds, and the embryonic cœlom cavity forms the rudiment of the pleural, pericardial, and peritoneal cavities. The abdominal cavity is separated from the other cavities by the septum transversum, the proton of the Diaphragm. The embryo grows more rapidly in length than in width, and its cephalic and caudal extremities are bent ventrad; the forward growth of the head tilts the areas situated cephalad so that the positions of the buccopharyngeal and



FIGS. 977 and 978.—Early form of the alimentary canal. In Fig. 977 a front view, and in Fig. 978 an antero-posterior section are represented. *a*. Four pharyngeal or visceral pouches. *b*. The pharynx. *c, c*. The commencing lungs. *d*. The stomach. *f, f*. The diverticula connected with the formation of the liver. *g*. The yolk sac, into which the middle intestinal groove opens. *h*. The hind gut. (From Kölliker, after Bischoff.)

pericardial areas become reversed; the same inversion takes place with regard to the cloacal membrane.

The alimentary tube, now in its simplest form, is nearly straight and may be divided into three portions: (a) the *foregut* between the pericardium and noto-

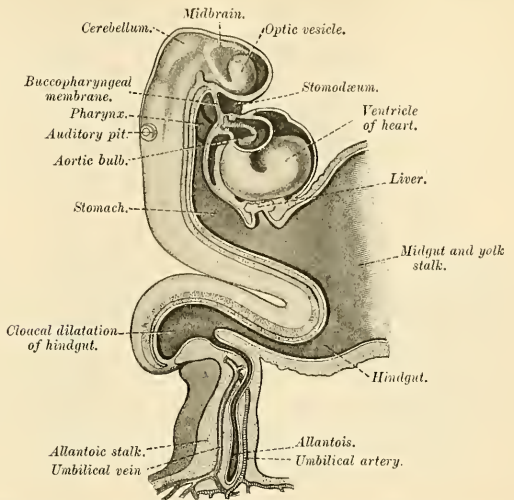
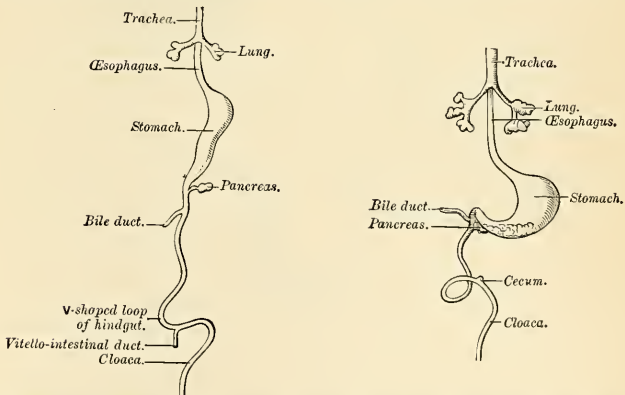


FIG. 979.—Human emryo, about fifteen days old. Brain and heart represented from right side; alimentary canal and yolk sac in mesal section. (After His.)

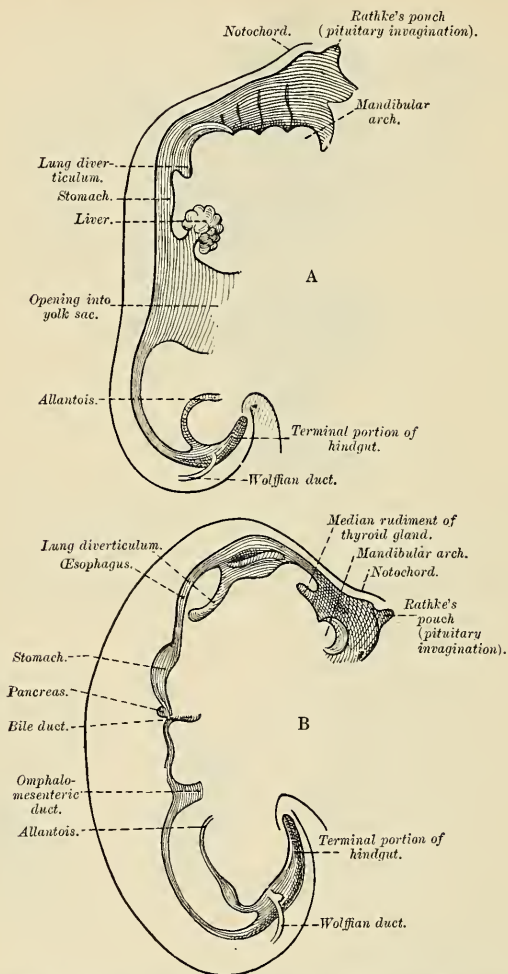
chord; (b) the *midgut*, opening directly into the yolk sac; and (c) the *hindgut*, contained within the caudal fold. The passage between the midgut and the



FIGS. 980 and 981.—Front view of two successive stages in the development of the alimentary canal. (His.)

yolk sac is at first relatively wide, but it is subsequently narrowed and lengthened to become the tubular *vitelline duct* (to wholly disappear eventually).

In its course from the head to the tail the primitive alimentary canal is held to the body axis (notochord) by a broad mass of mesoderm, from which the common



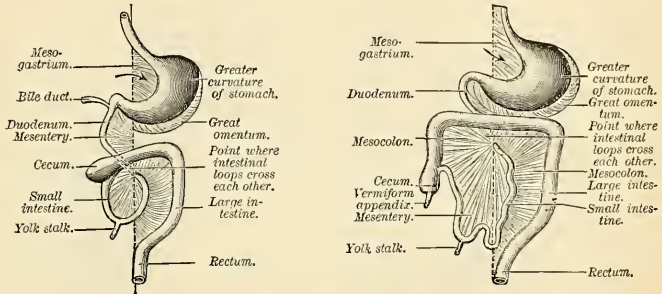
FIGS. 982 and 983.—Sketches in profile of two stages in the development of the human alimentary canal. Fig. 982, A $\times 30$. Fig. 983, B $\times 20$. (His.)

mesentery of the gut is subsequently developed. The foregut¹ is also held by a ventral mesentery, the thoracic portion of which becomes modified by the development of the heart and lungs, while the abdominal portion serves as a matrix for the developing liver, and ultimately becoming the falciform ligament and gastro-

¹ The junction of the foregut with the midgut is generally understood to be at the level of the orifice of the common bile duct, or site of origin of the liver diverticulum.

hepatic omentum. The mesoderm lining the body cavity as well as the free surfaces of the mesenteries soon assumes the character of a serous membrane, and is then called the peritoneum. Topographically, this membrane may be subdivided into: (a) *Parietal peritoneum*, investing the inner surface of the abdominal cavity; (b) *visceral peritoneum*, investing the alimentary tube and its derivatives; (c) *mesenteric peritoneum*, connecting the two former, as a suspensory support for the alimentary tract, and carrying the vessels and nerves to it.

The pharynx, œsophagus, stomach, and part of the duodenum are developed from the foregut; the descending and sigmoid parts of the colon, the rectum, and the tubular diverticulum of the allantois are developed from the hindgut; the midgut gives origin to the remainder of the alimentary tube.



FIGS. 984 AND 985.—Illustrating two stages in the development of the human alimentary canal and its mesentery. The arrow indicates the entrance to the bursa omentalis. (Hertwig.)

The upper part of the foregut becomes dilated in the form of branchial pouches to form the pharynx; the succeeding part remains tubular¹ and with the descent of the stomach becomes elongated to form the œsophagus. About the fifth week a funnel-form dilatation, the future stomach, makes its appearance. The stomach, together with a succeeding part of the duodenum, has a ventral mesentery, called the *ventral mesogastrium*, in addition to its dorsal attachment, the *dorsal mesogastrium*. In the base of the dorsal mesogastrium courses the aorta which supplies a series of branches, embedded in the mesoderm, to the alimentary tube. The stomach undergoes a further dilatation, and its two curvatures can be recognized, the greater directed dorsad and the lesser ventrad, while its two surfaces look to the right and left respectively. The midgut undergoes great elongation and forms a loop which projects downward and forward; from the arch of the loop the vitelline duct passes to the umbilicus. For a time a part of the loop extends beyond the abdominal cavity into the umbilical cord, but is withdrawn into the cavity by the end of the third month.

About the sixth week a lateral diverticulum makes its appearance on the caudal part of the loop a short distance from the vitelline duct, and indicates the future cecum and appendix. The part of the loop on the distal side of the cecal diverticulum increases in diameter and forms the future ascending and transverse portions of the large intestine. The cecal diverticulum shares only partially in this increase in calibre, its pendant portion remaining rudimentary and forming the appendix.

The stomach and intestine, with their mesenteries, undergo changes of position determined by several growth factors, such as the elongation of the intestine, and

¹ The epithelium of the œsophagus and certain other portions of the gut increases so greatly in thickness by active proliferation of the cells that the lumen is nearly or wholly closed during the second month, to be restored about one month later (Congenital stenosis).

the development of such organs as the liver, pancreas, and spleen. Such developmental changes, with subsequent displacements, adhesions, and absorptions, serve to form all the mesenteries, omenta, and peritoneal folds of the adult, so that, while in the primitive condition the intestinal tube is suspended by a dorsal mesentery and freely movable, certain portions of it become later, by secondary adhesion, firmly connected with the parietes (retroperitoneal) or with other portions of the tract.

Rotation of Stomach and Intestine.—The stomach rotates so that its greater (dorsal) curvature with the attached dorsal mesogastrium is carried downward and to the left, so that the right surface of the stomach is now directed backward and the left surface forward (ventrad)—a change in position which explains why the left vagus nerve is found on the front of the stomach and the right vagus on the back of it. As the stomach rotates, the dorsal mesogastrium is necessarily elongated; this elongation is, however, augmented in further development, so that a large pouch, the *bursa omentalis* or *lesser sac* is formed. The entrance to this pouch constitutes the future *foramen of Winslow*. The duodenum, developed from that part of the tube which immediately succeeds the stomach, undergoes

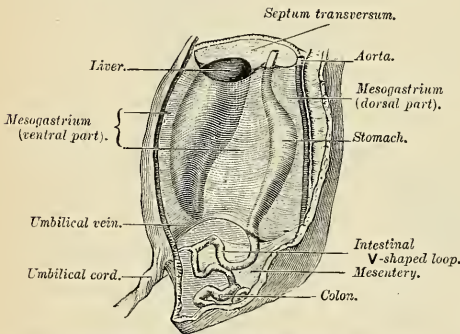


FIG. 986.—The primitive mesentery of a six weeks' human embryo, half schematic. (Kollmann.)

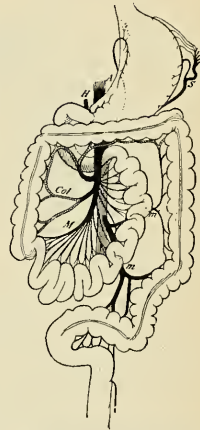


FIG. 987.—Final disposition of the intestines and their vascular relations. A. Aorta. H. Hepatic artery. S. Splenic artery. M, Col. Branches of superior mesenteric artery. m, m'. Branches of inferior mesenteric artery. (Jonnesco.)

little elongation. It is at first suspended by a mesentery (mesoduodenum) and projects forward in the form of a loop. The loop is subsequently displaced backward by the transverse colon, so that the right surface of the mesoduodenum is swung back, and, adhering to the parietal peritoneum partly in front of the right kidney, is obliterated; in this way the duodenum, together with the pancreas which has invaded the dorsal mesoduodenum, become retroperitoneal. It is further fixed in position by the liver and pancreas which arise as diverticula from it. The liver, developing between the layers of the ventral mesogastrium, comes to occupy the upper right portion of the abdominal cavity, and thus reduces the entrance to the omental bursa to the small foramen of Winslow.

The remainder of the alimentary canal becomes elongated, and as a consequence the tube becomes complexly coiled on itself, and this elongation demands a corresponding increase in the width of the intestinal attachment of the mesentery, which becomes folded.

Rotation of the Intestine.—At an early stage the small and large intestines are attached to the dorsal wall of the abdomen by a common mesentery, the coils

of the small intestine falling to the right, while the large intestine lies on the left side.¹

The gut now becomes rotated upon itself, so that the large intestine is carried over in front of the small intestine, and the cecum is placed immediately below the liver; about the sixth month the cecum descends into the right iliac fossa,² and the large intestine now forms an arch consisting of the ascending, transverse, and descending portions of the colon—the transverse portion crossing in front of the duodenum and lying just below the greater curvature of the stomach; within this arch the coils of the small intestine are disposed (Figs. 984 and 985). The intestine in its rotation twists the mesentery in a funnel-shaped manner, so that

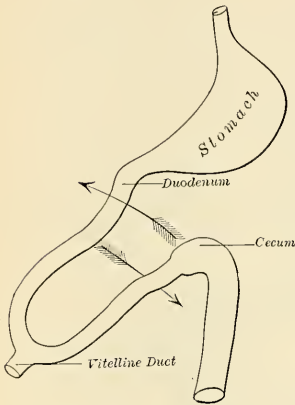


FIG. 988.—Torsion of the umbilical loop.
Initial position. (Jonnesco.)

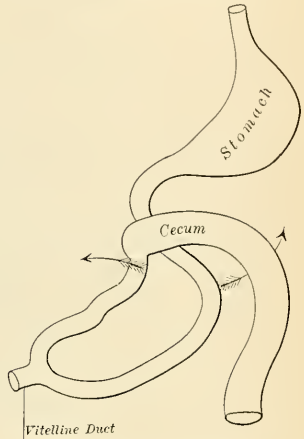


FIG. 989.—Torsion of the umbilical loop.
Acquired position. (Jonnesco.)

the original right leaf of the mesentery of the small intestine has become the left, and *vice versa*. The mesentery of the small intestine assumes the oblique attachment characteristic of its adult conditions. All divisions of the large intestine are at first freely movable, being suspended by a free mesocolon; but subsequently the ascending and descending portions become fixed retroperitoneal structures in consequence of adhesion of the opposed surfaces of the ascending and descending mesocolons and of the dorsal parietal peritoneum. Occasionally the descending mesocolon, more rarely the ascending, persists so that the bowel is more or less movable in these divisions. The sigmoid colon usually remains movable throughout life.

The omental bursa, which at first reaches only as far as the greater curvature of the stomach, grows downward as a double-layered, pouch-like fold, the interior layer derived from the right leaf of the primitive mesogastrium, its exterior layer from the left leaf. This omental sac or **greater omentum** extends downward as an apron-like fold in front of the transverse colon and the coils of the small intestine. The anterior layer of the transverse mesocolon is at first quite distinct from the

¹ Sometimes this condition persists throughout life, and it is then found that the duodenum does not cross from the right to the left side of the vertebral column, but lies entirely on the right side of the mesal plane, where it is continued into the jejunum; the arteries to the small intestine (*rami intestini tenuis*) also arise from the right instead of the left side of the superior mesenteric artery.

² Sometimes the downward progress of the cecum is arrested, so that in the adult it may be found lying immediately below the liver instead of in the right iliac region.

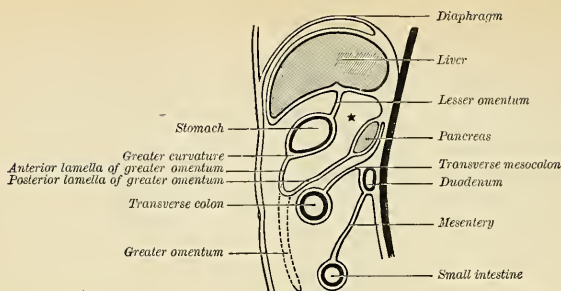


FIG. 990.—Illustrating the development of the bursa omentalis, cavity of the greater omentum or lesser sac. Fetal stage. * Lesser sac. (Hertwig.)

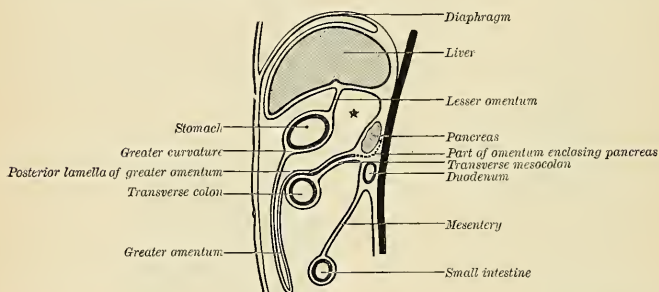


FIG. 991.—Development of bursa omentalis. Infantile stage. Greater omentum covers the intestines and has fused with the transverse mesocolon. Pancreas is free from peritoneum posteriorly. (Hertwig.)

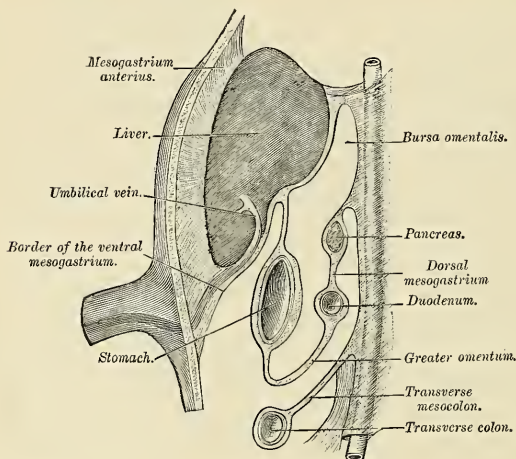


FIG. 992.—Schematic figure of the bursa omentalis, etc. Human embryo of eight weeks. (Kollmann.)

posterior layer of the bursa omentalis, but ultimately the two blend, and hence the greater omentum appears as if attached to the transverse colon (Figs. 990, 991, and 992).

The **lesser omentum** is formed by a thinning of the mesoderm of the ventral mesogastrium which attaches the stomach and part of the duodenum to the ventral abdominal wall. By the subsequent growth of the liver this leaf is divided into two parts—viz., the falciform and coronary ligaments between the liver and the abdominal wall and Diaphragm; and the lesser or gastrohepatic omentum, between the liver and the stomach.

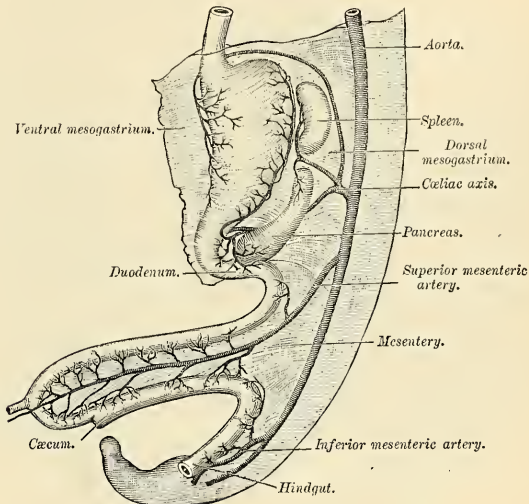


FIG. 993.—Abdominal part of alimentary canal and its attachment to the primitive or common mesentery. Human embryo of six weeks. (Kollmann.)

Vertical Disposition of the Greater Sac (Fig. 995).—It is convenient to trace the greater sac from the back of the abdominal wall at the level of the umbilicus.

On following the parietal peritoneum upward from this level it is seen to be reflected around a fibrous cord, the **ligamentum teres** or **impervious umbilical vein** (Figs. 998 and 1087), which reaches from the umbilicus to the under surface of the liver. This reflection forms a somewhat triangular fold, the **falciform** or **suspensory ligament of the liver** (*ligamentum falciforme hepatis*), attaching the upper and anterior surfaces of the liver to the Diaphragm and abdominal wall. With the exception of the line of attachment of this ligament the peritoneum covers the whole of the under surface of the anterior part of the Diaphragm and is continued from it on to the upper surface of the right lobe of the liver as the **superior layer of the coronary ligament**, and on to the upper surface of the left lobe as the **superior layer of the left lateral ligament** of the liver. Covering the upper and anterior surfaces of the liver it is continued around its sharp margin on to its under surface, where it presents the following relations: (a) It covers the under surface of the right lobe and is reflected from the back part of this to the upper extremity of the right kidney, forming in this situation the **inferior layer of the coronary ligament**; from the kidney it is carried downward to the duodenum and hepatic flexure of the colon and inward to the inferior vena cava,

where it is continuous with the posterior wall of the lesser sac. Between the two layers of the coronary ligament there is a triangular surface of the liver which is devoid of peritoneal covering; this is named the **bare area of the liver**, and is attached to the Diaphragm by areolar tissue. Toward the right margin of the liver the two layers of the coronary ligament gradually approach each other, and ultimately fuse to form a small triangular fold connecting the right lobe of the liver to the Diaphragm, and named the **right lateral ligament** of the liver. The

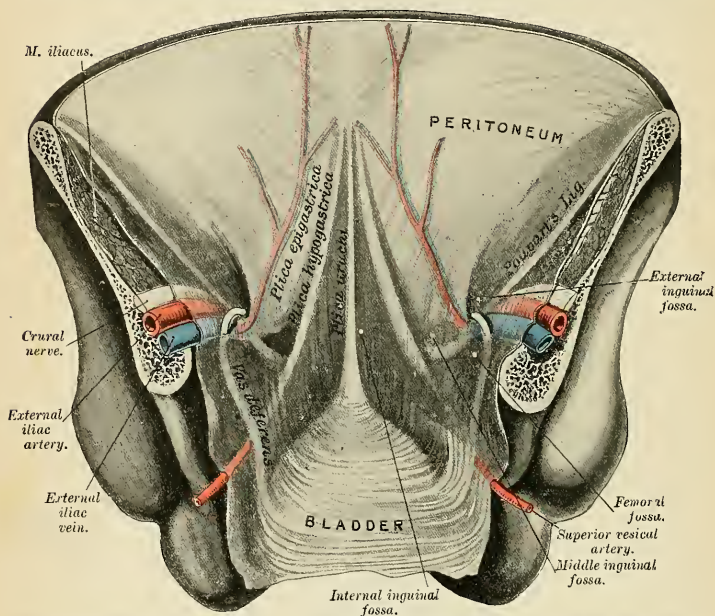


FIG. 994.—Posterior view of the anterior abdominal wall in its lower half. The peritoneum is in place, and the various cords are shining through. (After Joessel.)

apex of the triangular bare area corresponds to the point of meeting of the two layers of the coronary ligament, its base with the fossa of the inferior vena cava. (b) It covers the lower surface of the quadrate lobe, the under and lateral surfaces of the gall-bladder, and the under surface of the posterior border of the left lobe; it is then reflected from the upper surface of the liver to the Diaphragm as the **inferior layer of the left lateral ligament**, and from the transverse fissure and the fissure for the ligamentum venosum to the lesser curvature of the stomach as the anterior layer of the **gastrohepatic, or lesser omentum**. If this layer of the lesser omentum be followed to the right it will be found to turn around the hepatic artery, bile duct, and portal vein and become continuous with the anterior wall of the lesser sac, forming a free folded edge of peritoneum.

Traced downward it covers the antero-superior surface of the stomach and the commencement of the duodenum, and is carried down from the greater curvature of the stomach into a large free fold, the **gastrocolic or greater omentum** (Figs. 996 and 1002). Reaching the free edge of this fold, it is reflected upward to cover the under and posterior surfaces of the transverse colon, and thence to the pos-

terior abdominal wall as the inferior layer of the **transverse mesocolon** (Fig. 995). It reaches the abdominal wall at the upper border of the third part of the duodenum, and is then carried down on the superior mesenteric vessels to the small intestine as the anterior layer of the *mesentery*. It encircles the intestine, and

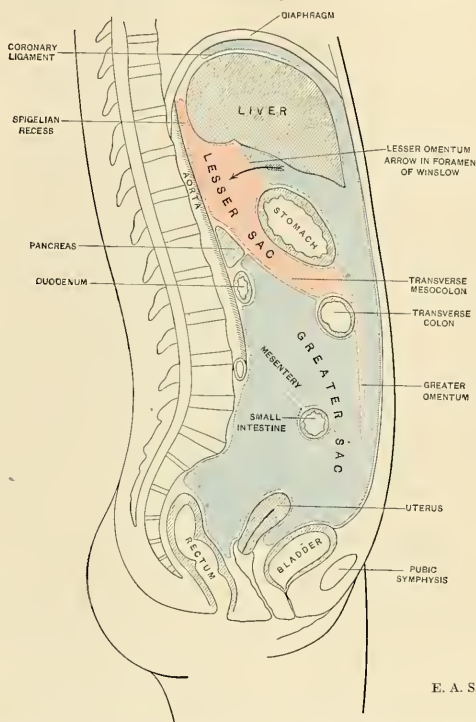


FIG. 995.—Diagram showing the vertical disposition of the peritoneum. Lesser sac in red; greater sac in blue.

subsequently may be traced, as the posterior layer of the mesentery, upward and backward to the abdominal wall. From this it sweeps down over the aorta into the pelvis, where it invests the sigmoid colon, its reduplication forming the **sigmoid mesocolon** (Fig. 1004). Leaving first the sides and then the front of the rectum, it is reflected on to the base of the bladder, and, after covering the upper surface of that viscus, is carried along the urachus and impervious hypogastric arteries to the back of the abdominal wall, from which a start was made.

Between the rectum and the bladder the peritoneum forms, in the *male*, a pouch, the **rectovesical pouch** (*excavatio rectovesicalis*), bounded on the sides by two crescentic or semilunar folds (*plicae rectovesicales*), which pass from the posterior surface of the bladder to the sides of the rectum; the bottom of this pouch is about on a level with the middle of the seminal vesicles—*i. e.*, three inches or so from the orifice of the anus. When the bladder is distended the peritoneum is carried up with the expanded viscus, so that a considerable part of the anterior surface of the latter lies directly against the abdominal wall without the intervention of

the peritoneal membrane. When the bladder is empty the peritoneum forms a transverse fold over its upper surface (*plica vesicalis transversa*).

In the *female* the peritoneum is reflected from the rectum to the upper part of the posterior vaginal wall, forming the **rectovaginal pouch** or **pouch of Douglas** (*excavatio rectouterina*) (Fig. 996). It is continued over the posterior surface and fundus of the uterus on to its anterior surface, which it covers as far as the junction of the body and cervix uteri, forming here a second but shallower depression, the **utero-vesical pouch** (*excavatio vesicouterina*). It is also reflected from the sides of the uterus to the lateral wall of the pelvis on each side as two expanded folds, the **broad ligaments of the uterus** (*ligamenta lata uteri*), in the free margin of each of which is the Fallopian tube.

Vertical Disposition of the Lesser Sac (Fig. 995).—A start may be made in this case on the posterior abdominal wall above the pancreas. From this region the peritoneum may be followed upward on to the inferior surface of the Diaphragm, and thence on to the Spigelian and caudate lobes of the liver to the fissure for the ligamentum venosum and the transverse fissure; this *cul-de-sac* is the **Spigelian recess**. Traced laterally, it is continuous over the inferior vena cava with the posterior wall of the greater sac. From the liver it is carried downward to the lesser curvature of the stomach as the posterior layer of the gastrohepatic omentum, and is continuous on the right, around the hepatic artery, bile duct, and portal vein, with the greater sac. The posterior layer of the gastrohepatic omentum is carried down to the greater curvature of the stomach as a covering for the postero-inferior surface of this viscus, and from the greater curvature is continued downward as the deep layer of the greater or gastrocolic omentum. From the free margin of this fold it is reflected upward on itself to the anterior and superior surfaces of the transverse colon and thence as the superior layer of the transverse mesocolon to the upper border of the third part of the duodenum, from which it may be followed over the front of the pancreas to the level at which a start was made. It will be seen that the loop formed by the wall of the lesser sac below the transverse colon follows, and is closely applied to, the deep surface of that formed by the greater sac, and that the greater omentum or large fold of peritoneum which hangs in front of the small intestine therefore consists of four layers, two anterior and two posterior, separated by the potential cavity of the lesser sac though inseparably blended, as a rule, in the adult.

Horizontal Disposition of the Peritoneum.—Below the transverse colon the arrangement is extremely simple, as it includes only the greater sac (Fig. 997); above the level of the transverse colon it is more complicated on account of the existence of the two sacs. Below the transverse colon it may be considered in three regions—viz., in the pelvis and in the abdomen proper, upper and lower portions.

1. *In the Pelvis.*—The peritoneum here follows closely the surfaces of the pelvic viscera and the irregularities of the pelvic walls and presents important differences in the two sexes: (*a*) *In the male* it encircles the sigmoid flexure, from which it is reflected to the posterior wall as a fold, the *sigmoid mesocolon*. It then leaves the sides and, finally, the front of the rectum, and is continued to the bladder; on either side of the rectum it forms a fossa, the *pararectal fossa*, which varies in size with the distention of the rectum. In front of the rectum the peritoneum forms the *rectovesical pouch*, which is limited laterally by peritoneal folds extending from the sides of the bladder to the rectum and sacrum. These folds are known from their position as the *rectovesical* or *sacro-genital folds*. The peritoneum of the anterior pelvic wall covers the superior surface of the bladder, and on either side of this viscus forms a depression, termed the *paravesical fossa*, and limited externally by the fold of peritoneum covering the vas deferens. The size of this fossa is dependent on the state of distention of the bladder; when the bladder is empty, a variable fold of peritoneum, the *plica vesicalis transversa*, divides the

fossa into two portions. On the peritoneum between the paravesical and pararectal fossæ the only elevations are those produced by the ureters and the internal iliac vessels. (b) *In the female*, pararectal and paravesical fossæ similar to those in the male are present; the outer limit of the paravesical fossa is the peritoneum investing the round ligament of the uterus. The rectovesical pouch is, however,

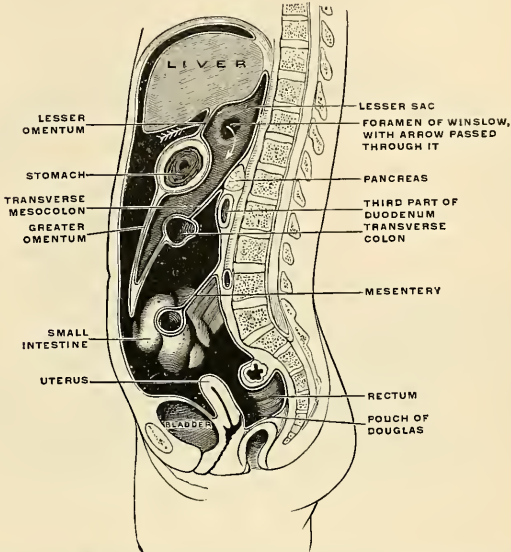


FIG. 996.—Diagrammatic mesal section of the female body, to show the peritoneum on vertical tracing. The greater sac of the peritoneum is black and is represented as being much larger than in nature; the lesser sac is very darkly shaded; the peritoneum on section is shown as a white line, and a white arrow is passed through the foramen of Winslow from the greater into the lesser sac. (Cunningham.)

divided by the uterus and vagina into a small anterior *utero-vesical* and a large, deep, posterior *recto-vaginal pouch* or *pouch of Douglas*. The sacrogenital folds form the margins of the latter, and are continued on to the back of the uterus to form a transverse fold, the *torus uterinus*. The *broad ligaments* extend from the sides of the uterus to the lateral walls of the pelvis; they contain in their free margins the Fallopian tubes, and on their posterior surface the ovaries attached by the mesovaria. Below, the broad ligaments are continuous with the peritoneum on the lateral walls of the pelvis. On the lateral pelvic wall behind the attachment of the broad ligament, in the angle between the elevations produced by the diverging internal and external iliac vessels, is a slight fossa, the *ovarian fossa*, in which the ovary normally lies.

2. *In the Lower Abdomen* (Fig. 997).—Starting from the linea alba, below the level of the transverse colon, and tracing the continuity in a horizontal direction to the right, the peritoneum covers the inner surface of the abdominal wall almost as far as the outer border of the Quadratus lumborum; it encloses the cecum and appendix, and is reflected over the sides and anterior surface of the ascending colon; it may then be traced over the Psoas muscle and the inferior vena cava toward the middle line, whence it passes along the mesenteric vessels to invest the small intestine, and back again to the large vessels in front of the vertebral

column, forming the **mesentery**, between the layers of which are contained the mesenteric bloodvessels, nerves, lacteals, and lymph nodes. It is then continued over the left Psoas muscle; it covers the sides and anterior surface of the descending colon, and, reaching the abdominal wall, is continued on it to the middle line.

3. *In the Upper Abdomen* (Fig. 998).—Above the transverse colon the peritoneum can be traced, forming the greater and lesser sacs, and their communication through the foramen of Winslow can be demonstrated.

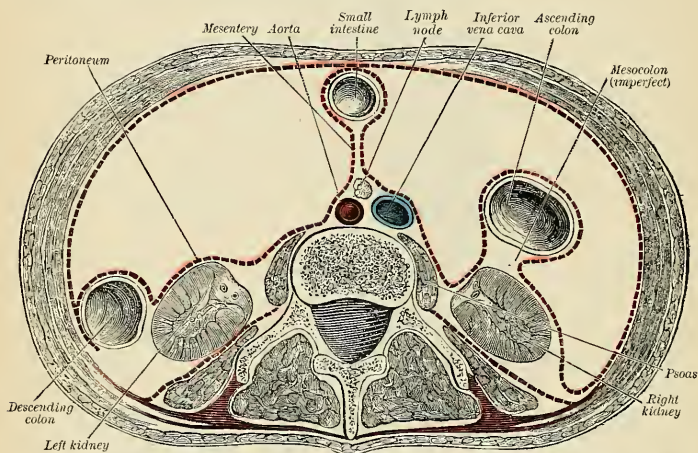


FIG. 997.—Peritoneal reflection in transverse section of lumbar region below the transverse colon. Seen from above. Schematic. (Tillaux.)

(a) **Greater Sac.**—Commencing on the posterior abdominal wall at the inferior vena cava, the membrane may be followed to the right over the front of the upper part of the right kidney on to the antero-lateral abdominal wall. From the middle of the anterior wall a backwardly directed fold encircles the impervious umbilical vein and forms the falciform ligament of the liver. Continuing to the left, the peritoneum lines the lateral abdominal wall and covers the outer part of the front of the left kidney, and is reflected to the posterior border of the hilus of the spleen as the posterior layer of the lienorenal ligament (Fig. 1001). It can then be traced over the surface of the spleen to the front of the hilus, and thence to the cardiac extremity of the stomach as the anterior layer of the gastrosplenic omentum. It covers the antero-superior surface of the stomach and first part of the duodenum and extends up from the lesser curvature of the stomach to the liver, the latter portion forming the anterior layer of the gastrohepatic omentum.

(b) **Lesser Sac.**—On the posterior abdominal wall the peritoneum of the greater sac is continuous with that of the lesser sac in front of the inferior vena cava. Starting from here, the lesser sac may be traced across the aorta and over the inner part of the front of the left kidney to the hilus of the spleen as the anterior layer of the lienorenal ligament. From the spleen it is reflected to the stomach as the posterior layer of the gastrosplenic omentum. It covers the postero-inferior surfaces of the stomach and commencement of the duodenum, and from the lesser curvature of the stomach extends upward to the liver as the posterior layer of the gastrohepatic omentum; the right margin of this layer is continuous around the hepatic artery, bile duct, and portal vein with the wall of the greater sac.

The **foramen of Winslow** (*foramen epiploicum*) is the passage of communication

between the greater and lesser sacs. It is bounded in *front* by the free border of the gastrohepatic omentum, with the hepatic artery, common bile duct, and portal vein between its two layers; *behind* by the peritoneum covering the inferior vena cava; *above* by the peritoneum on the caudate lobe of the liver, and *below* by the peritoneum covering the commencement of the duodenum and the hepatic artery, the latter passing forward below the foramen before ascending between the two layers of the gastrohepatic omentum (Fig. 998).

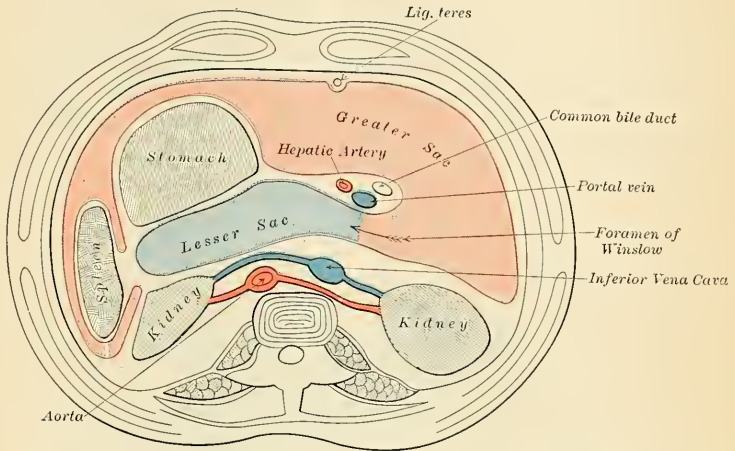


FIG. 998.—Transverse section of peritoneum above the transverse colon. The arrow points to the lesser sac and passes through the foramen of Winslow.

The *boundaries of the lesser sac* will now be evident. It is bounded in *front*, from above downward, by the Spigelian lobe of the liver, the gastrohepatic omentum, the stomach, and the anterior two layers of the greater omentum; *behind*, it is limited, from below upward, by the two posterior layers of the greater omentum, the transverse colon, and the ascending layer of the transverse mesocolon, the upper surface of the pancreas, the left suprarenal gland, and the upper end of the left kidney. *Laterally*, the lesser sac extends from the foramen of Winslow to the spleen (*recessus lienalis*) (Fig. 1001), where it is limited by the lienorenal ligament and the gastrosplenic omentum.

In the fetus the lesser sac reaches as far as the free margin of the great omentum, but in the adult its vertical extent is usually more limited, owing to adhesions between the layers of the omentum. It should be stated that during a considerable part of fetal life the transverse colon is suspended from the posterior abdominal wall by a mesentery of its own—the two posterior layers of the greater omentum passing, at this stage, in front of the colon (Fig. 990). This condition sometimes persists throughout adult life, but, as a rule, adhesion occurs between the mesentery of the transverse colon and the posterior layer of the greater omentum, with the result that the colon appears to receive its peritoneal covering by the splitting of the two posterior layers of the latter fold. In the adult the lesser sac intervenes between the stomach and the structures on which that viscus lies, and performs, therefore, the functions of a serous bursa for the stomach.

Numerous peritoneal folds extend between the various organs or connect them to the parietes. They serve to hold them in position, and, at the same time,

enclose the vessels and nerves proceeding to them. Some of these folds which connect certain viscera with the parietes are called **ligaments**, such as the ligaments of the liver and the false ligaments of the bladder. Others, which connect certain parts of the intestine with the abdominal wall, constitute the **mesenteries**; and lastly, those which proceed from the stomach to certain viscera in its neighborhood are called **omenta**.

The **ligaments**, formed by folds of the peritoneum, include those of the liver, spleen, bladder, and uterus. They will be found described with their respective organs.

The **omenta** are the **lesser omentum**, the **greater omentum**, and the **gastrosplenic omentum**.

The **lesser or gastrohepatic omentum** (*omentum minus*) (Figs. 996 and 999) is the duplicature which extends between the transverse fissure of the liver and the right side of the abdominal portion of the œsophagus, the lesser curvature of the stomach, and the upper portion of the superior surface of the duodenum.

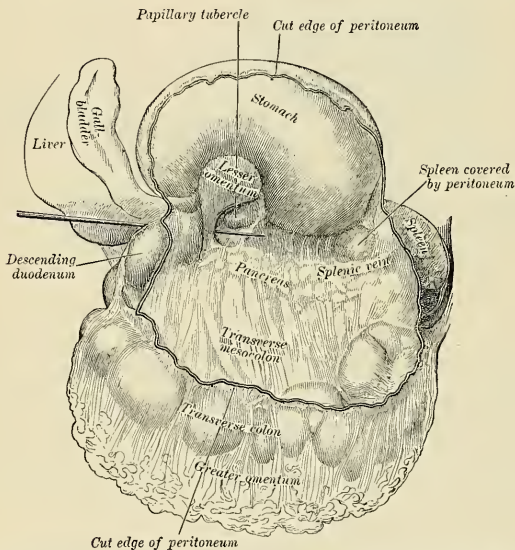


FIG. 999.—Bursa omentalis, or lesser sac, opened from the front by an incision through the gastrocolic omentum. A probe passes through the foramen of Winslow and rests on the gastropancreatic fold. (Henle.)

The portion going to the œsophagus and stomach is called the **hepatogastric ligament** (*ligamentum hepatogastricum*). The division of the ligament which goes to the œsophagus is strong and dense; the division which goes to the lesser curvature of the stomach is thin and relaxed. The portion of the lesser omentum which goes to the duodenum is continuous with the first-named portion. It is called the **hepatoduodenal ligament** (*ligamentum hepatoduodenale*). The right margin of this ligament is free and concave. The **hepatocolic ligament** (*ligamentum hepatocolicum*) is not invariably present. It is a fold of the hepatoduodenal ligament and runs from the posterior surface of the gall-bladder to the descending portion of the duodenum or possibly to the transverse colon.

The **lesser omentum** is thin, and is continuous with the two layers which cover respectively the anterior and posterior surfaces of the stomach. When the two layers reach the lesser curvature of the stomach, they join and ascend as the double

fold to the transverse or portal fissure of the liver; to the left of this fissure the double fold is attached to the bottom of the fissure for the ligamentum venosum, along which it is carried to the Diaphragm, where the two layers separate to embrace the end of the œsophagus. At the right border the two layers are continuous and form a free margin which constitutes the anterior boundary of the foramen of Winslow. Between the two layers, close to this free margin, are the **hepatic artery**, the **common bile duct**, the **portal vein**, **lymphatics**, and the **hepatic plexus of nerves** (Fig. 1000)—all these structures being enclosed in loose areolar tissue which is continuous with Glisson's capsule. Between the layers where they are attached to the stomach lie the **gastric artery** and the **pyloric branch of the hepatic artery**.

The **greater or gastrocolic omentum** (*omentum majus*) (Figs. 996 and 1002) is the largest peritoneal fold. It consists of a double sheet of peritoneum, folded on itself so that it is made up of four layers. The two layers which descend from the stomach pass in front of the small intestines, sometimes as low down as the pelvis; they then turn upon themselves, and ascend again as far as the transverse colon, where they separate and enclose that part of the intestine. These separate layers may be easily demonstrated in the young subject, but in the adult they are more,

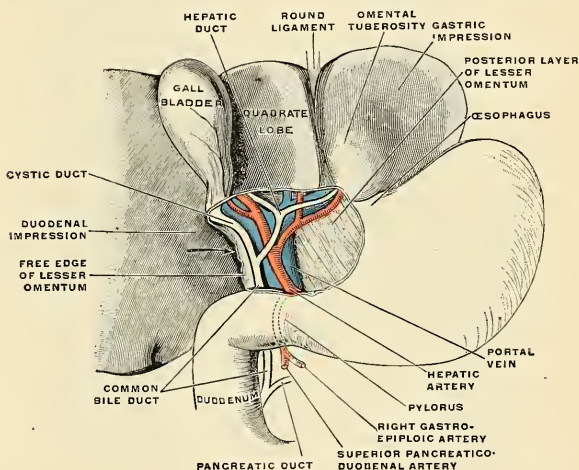


FIG. 1000.—Structures between the layers of the lesser omentum. The liver has been raised up, and the anterior layer of the omentum removed. Semidiagrammatic. (Cunningham.)

or less inseparably blended. The left border of the greater omentum is continuous with the gastrosplenic omentum; its right border extends only as far as the duodenum. The greater omentum is usually thin, presents a cribriform appearance, and always contains some adipose tissue, which in fat persons accumulates in considerable quantity. Between its two anterior layers is the anastomosis between the right and left gastroepiploic arteries. In opening the abdomen the greater omentum is rarely found spread out evenly over the intestines. It often projects between intestinal coils, or is largely gathered in some one region, or is pushed in front of the stomach by distention of the colon.

The **gastrosplenic omentum** is the fold which connects the margins of the hilum of the spleen to the stomach, being continuous by its lower border with the greater omentum. It contains the *vasa brevia*.

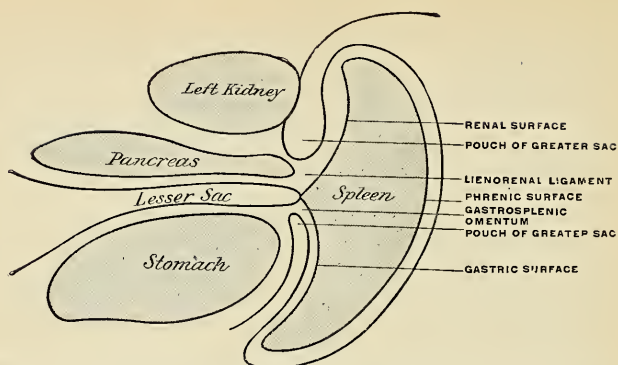


FIG. 1001.—Horizontal section through the stomach, pancreas, spleen, and the left kidney to show peritoneal reflections at the hilum of the spleen. (G. S. H.)

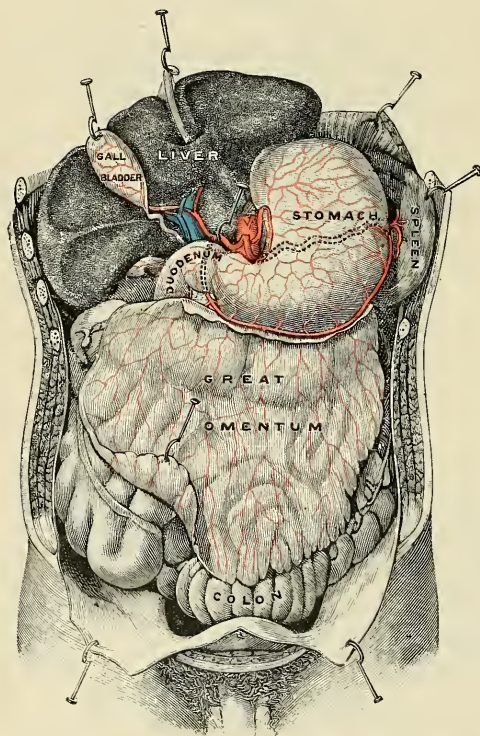


FIG. 1002.—The greater omentum as seen from the front. (Testut.)

mesocolon, and the mesentery of the vermiform appendix. In addition to these there are sometimes present an ascending and a descending mesocolon.

The **mesentery** (*mesenterium*) (Figs. 1003 and 1004), is the broad, fan-shaped fold of peritoneum which connects the convolutions of the jejunum and ileum with

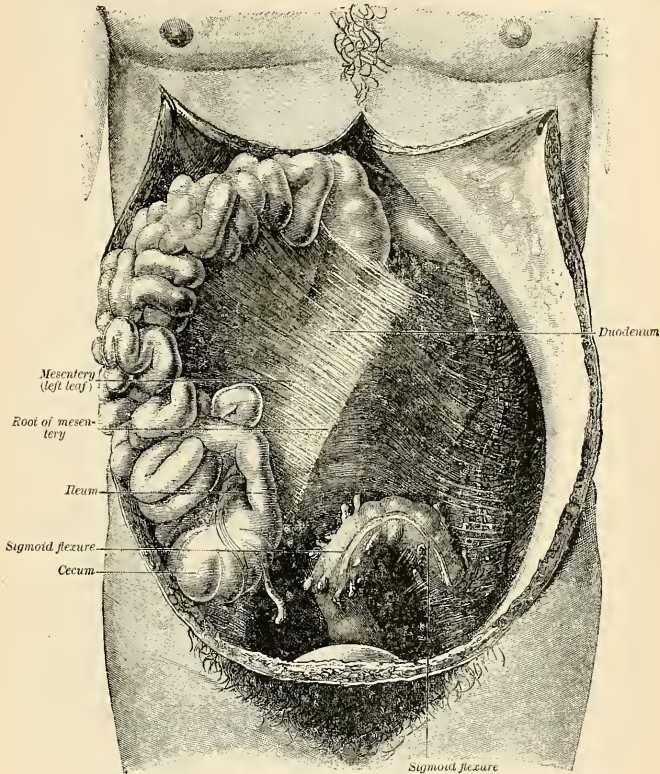


FIG. 1003.—Mesentery. Small intestine pushed upward to the right. (Tillaux.)

the posterior wall of the abdomen. Its **root** (*radix mesenterii*), the part connected with the structures in front of the vertebral column, is narrow, about six inches in length, and directed obliquely from the left side of the second lumbar vertebra to the right iliac fossa (Fig. 1004). Its **intestinal border** is about twenty feet in length, and here the two layers separate so as to enclose the intestine and form its peritoneal coat. Its breadth, between its vertebral and intestinal border, is about eight inches. Its **upper border** is continuous with the under surface of the transverse mesocolon; its **lower border**, with the peritoneum covering the cecum and ascending colon. It serves to retain the small intestines in their position, and contains between its layers the **mesenteric vessels and nerves**, the **lymphatic vessels**, and **mesenteric lymph nodes**. These nodes number from 50 to 150. The mesentery is somewhat translucent, particularly at its upper part, but in stout individuals it becomes opaque on account of the fat deposited between its layers.

In most cases the peritoneum covers only the front and sides of the ascending

and descending parts of the colon. Sometimes, however, these are surrounded by the serous membrane and attached to the posterior abdominal wall by an **ascending mesocolon** (*mesocolon ascendens*) and a **descending mesocolon** (*mesocolon descendens*) respectively. At the place where the transverse colon turns downward to form the descending colon, a fold of peritoneum is continued to the under surface of the Diaphragm opposite the tenth and eleventh ribs. This is the **phrenocolic ligament** (*ligamentum phrenicocolicum*); it passes below the spleen, and serves to support this organ, and therefore it has received the name of **sustentaculum lienis**.

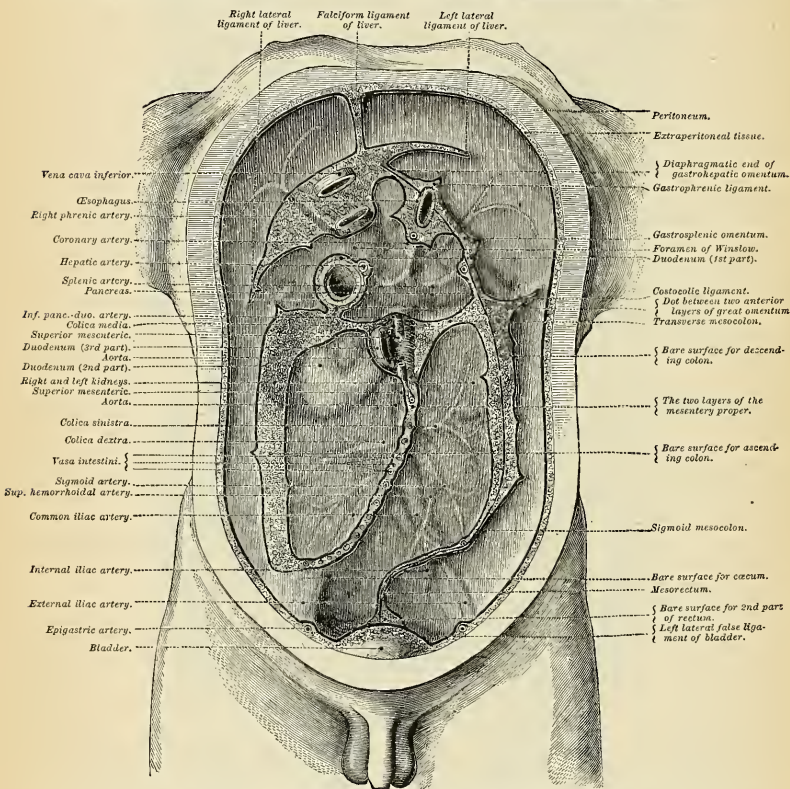


FIG. 1004.—Diagram devised by Dr. Delépine to show the lines along which the peritoneum leaves the wall of the abdomen to invest the viscera.

The **transverse mesocolon** (*mesocolon transversum*) (Fig. 1004) is a broad fold which connects the transverse colon to the posterior wall of the abdomen. It is formed by the two posterior layers of the greater omentum, which, after separating to surround the transverse colon, join behind it, and are continued backward to the vertebral column, where they diverge in front of the anterior border of the pancreas. This fold contains between its layers the vessels which supply the transverse colon.

The **sigmoid mesocolon** (*mesocolon sigmoidicum*) (Fig. 1004) is the fold of peritoneum which retains the sigmoid flexure in connection with the pelvic wall. Its line of attachment forms a V-shaped curve, the apex of the curve being placed

about the point of division of the left common iliac artery. The curve begins on the inner side of the left Psoas, and runs upward and backward to the apex, from which it bends sharply downward and inward, and ends in the mesal plane at the level of the third sacral segment. Between the two layers of this fold run the sigmoid and superior hemorrhoidal vessels.

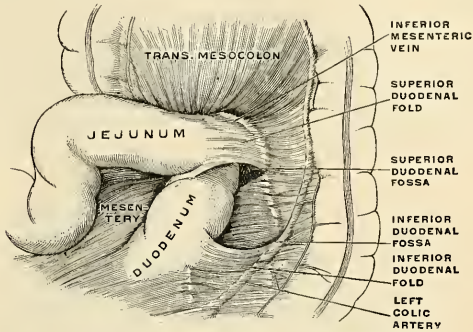


FIG. 1005.—Superior and inferior duodenal fossæ. (Poirier and Charpy.)

The **mesoappendix** or **mesentery of the vermiform appendix** (*mesenterium processus vermiformis*) (Fig. 1008) is a double fold of peritoneum derived from the left leaf of the mesentery. In the majority of cases it is triangular in shape and usually extends along the entire length of the appendix. Between its two layers lie the appendicular artery (Fig. 1055), a branch of the ileocolic artery, some connective tissue, and lymph vessels and nerves.

The **appendices epiploicæ** are small pouches of the peritoneum filled with fat and situated along the colon and upper part of the rectum. They are chiefly appended to the transverse colon.

Retroperitoneal Fossæ.—In certain parts of the abdominal cavity there are recesses of peritoneum forming *culs-de-sac* or pouches, which are of surgical interest in connection with the possibility of the occurrence of retroperitoneal hernia. One of these is the lesser sac of the peritoneum (Figs. 996 and 998), which may be regarded as a recess of peritoneum through the foramen of Winslow, in which a hernia may take place, but there are several others, of smaller size, which require mention.

These recesses, or fossæ, may be divided into three groups—viz.: (1) the **duodenal fossæ**; (2) **pericecal fossæ**; and (3) the **intersigmoid fossa**.

1. **Duodenal Folds and Fossæ.**—Moynihan has described no less than nine fossæ as occurring in the neighborhood of the duodenum. Three of these are fairly constant. Five of the fossæ are here considered: (a) The **inferior duodenal fossa**, or **fossa of Treitz** (Fig. 1005), is the most constant of all the peritoneal fossæ in this region, being present in from 70 to 75 per cent. of cases. It is situated opposite the third lumbar vertebra on the left side of the ascending portion of the duodenum. Its opening is directed upward, and is bounded by a thin, sharp fold of peritoneum with a concave free upper margin, called the **inferior duodenal fold** (*plica duodenomesocolica*). The tip of the index finger introduced into the fossa under the fold passes some little distance behind the ascending or fourth portion of the duodenum. (b) The **superior duodenal fossa** (Fig. 1005) is the next most constant pouch or recess, being present in from 40 to 50 per cent. of cases. It often coexists with the inferior one, and its orifice looks downward, in the opposite direction to the preceding fossa. It lies to the left of the ascending portion

of the duodenum. It is bounded by the free edge of the **superior duodenal fold** (*plica duodenojejunalis*), which presents a semilunar margin; to the right it is blended with the peritoneum covering the ascending duodenum, and to the left with the peritoneum covering the perirenal tissues. The fossa is bounded in front by the superior duodenal fold; behind by the second lumbar vertebra; to the right by the duodenum. (c) The **duodenojejunal fossa** or **mesocolic fossa** (*recessus duodenojejunalis*) is formed where the duodenojejunal angle enters the root of the transverse mesocolon. There are two forms: (1) a single fossa and (2) a double fossa. It can be seen by pulling the jejunum downward and to the right after the transverse colon has been pulled upward. It will appear as an almost circular opening, looking downward and to the right, and bounded by two free borders or folds of peritoneum, the **duodenomesocolic ligaments**. The opening

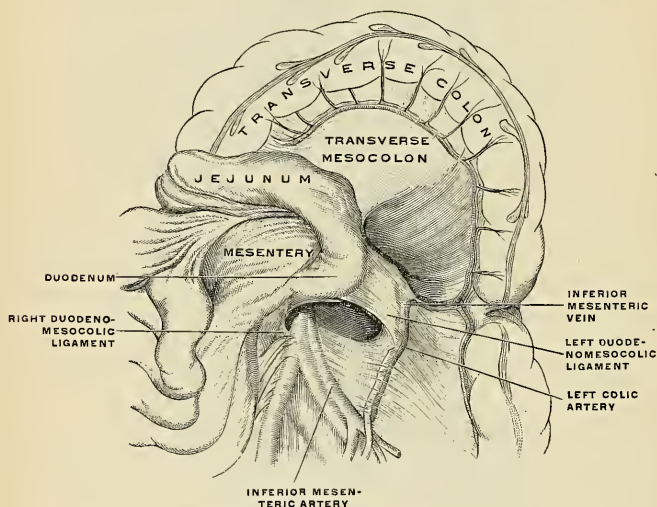


FIG. 1006.—Duodenojejunal fossa. (Poirier and Charpy.)

admits the little finger into the fossa to the depth of from four-fifths to one and one-fifth inches, or 2 to 3 cm. The fossa is bounded above by the pancreas, to the right by the aorta, and to the left by the kidney; beneath is the left renal vein. The fossa exists in from 15 to 20 per cent. of cases, and has never yet been found in conjunction with any other form of duodenal fossa. (d) **Paraduodenal fossa** or the **fossa of Landzert** (*recessus duodenojejunalis*) is most distinct in the infant, and is to the left of the ascending portion of the duodenum. The fold of peritoneum to its outer side and above is produced by the inferior mesenteric vein. Its lower limit is a fold called the **mesentericomesocolic fold**. (e) The **retro-duodenal fossa** (Fig. 996) was described in 1893 by Jonnesco. It is a peritoneal *cul-de-sac*, sometimes found behind the horizontal and ascending portions of the duodenum.

2. Pericecal Folds and Fossæ.—There are at least three pouches or recesses to be found in the neighborhood of the cecum, which are termed **pericecal fossæ**. (1) The **ileocolic fossa** or **superior ileocecal** (*recessus ileocecalis superior*) (Fig. 1007) is formed by a fold of peritoneum, the **ileocolic fold**, arching over the branch of the ileocolic artery which supplies the ileocolic junction. The fossa is a narrow

chink situated between the ileocolic fold in front, and the mesentery or the small intestine, the ileum, and a small portion of the cecum behind. (2) The **ileocecal** or **ileoappendicular fossa** (*recessus ileocecalis inferior*) (Fig. 1067) is situated behind the angle of junction of the ileum and cecum. It is formed by a fold of peritoneum, the **ileocecal fold** (*plica ileocecalis*), or "bloodless fold" of Treves, the upper border of which is attached to the ileum, opposite its mesenteric attachment, while the lower border, passing over the ileocecal junction, joins the mesentery of the appendix, and sometimes the appendix itself; hence this fold is sometimes called the **ileoappendicular fold**. Between this fold and the mesentery of the vermiform appendix is the **inferior ileocecal fossa**. It is bounded *above* by the posterior surface of the ileum and the mesentery; in *front* and *below* by the ileocecal fold and *behind* by the upper part of the mesentery of the appendix. (3) The **retrocecal** or **subcecal fossa** (*recessus retrocecalis*) (Fig. 1008) is situated

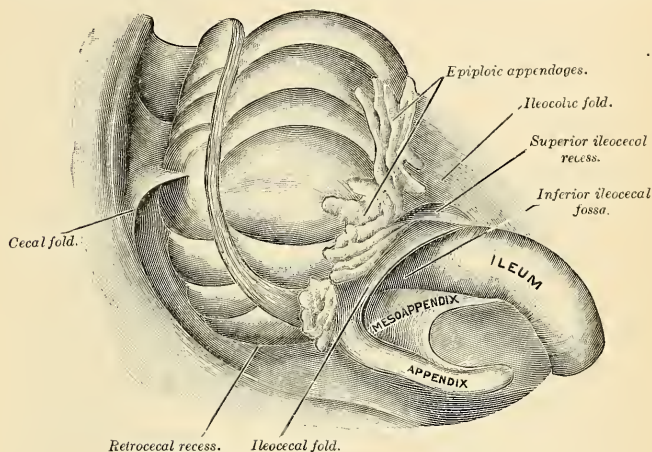


FIG. 1007.—The pericecal folds and fossæ.

behind the cecum, which has to be raised to bring the fossa into view. It varies much in size and extent. In some cases it is sufficiently large to admit the index finger and extends upward behind the ascending colon in the direction of the kidney; in others it is merely a shallow depression. It is bounded and formed by two folds: one, the **external parietocolic fold**, or the **superior cecal fold**, which is attached by one edge to the abdominal wall from the lower border of the kidney to the iliac fossa and by the other to the postero-external aspect of the colon; and the other, the **inferior cecal** or **mesentericoparietal fold**, which is in reality the insertion of the mesentery into the iliac fossa. In some instances the subcecal fossa is double.

3. The **intersigmoid fossa** (*recessus intersigmoideus*) is constant in the fetus and common during infancy, but disappears in a large percentage of cases as age advances. Upon drawing the sigmoid flexure upward, the left surface of the sigmoid mesocolon is exposed, and on it will be seen a funnel-shaped recess of the peritoneum, lying on the external iliac vessels, in the interspace between the Psoas and Iliacus muscles. This is the orifice leading to the fossa intersigmoidea, which lies behind the sigmoid mesocolon, and in front of the parietal peritoneum. The fossa varies in size; in some instances it is a mere dimple, whereas in others it will admit the whole of the index finger.

Any of these fossæ may be the site of a **retroperitoneal hernia**. The pericecal fossæ are of especial interest, because hernia of the vermiform appendix frequently takes place into one of them, and may there become strangulated. The presence of these pouches also explains the course which pus has been known to take in cases of perforation of the appendix, where it travels upward behind the ascending colon as far as the Diaphragm.¹

Applied Anatomy.—Study of the peritoneum by Robinson and others shows that *absorption* takes place more rapidly from the region of the Diaphragm, less rapidly but still very actively from the region of the small intestine, slowly from the pelvic region. Clinically we know that pelvic

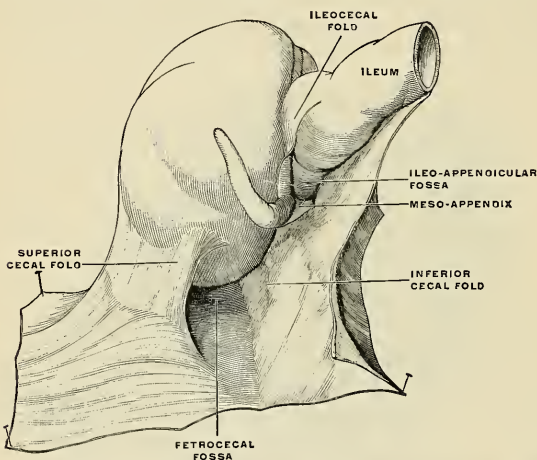


FIG. 1008.—The retrocecal fossa. The ileum and cecum are drawn backward and upward. (Souligoux.)

peritonitis is not nearly so dangerous as peritonitis in the small intestine or Diaphragm areas, and that peritonitis in the region of the Diaphragm is the most fatal form of the infection. After *abdominal operations* in infected cases, it is well to elevate the head of the bed (*Fowler's position*), so as to obtain the aid of gravity in draining septic fluids away from the dangerous region and toward the safer region.¹ In areas in which absorption is rapid, protective exudation is not apt to form. In areas in which absorption is slow, inflammatory exudation is apt to circumscribe the area and prevent diffusion. After an operation in a noninfected case, if salt solution has been left in the abdominal cavity because of *shock* or *hemorrhage*, raising the foot of the bed will aid rapid absorption of the fluid by favoring the natural current toward the Diaphragm and hurrying the fluid to a region in which absorption is rapid. Dr. John B. Murphy's plan of treating general peritonitis has proved remarkably successful. He does not remove the exudation of lymph which is seen upon the peritoneum. This exudation is conservative, blocks up lymph spaces, and lessens the absorption of dangerous toxins. He inserts a drainage tube into the peritoneal cavity above the pubes, puts the patient erect or semierect in bed (*Fowler's position*), and administers salt solution continuously by low pressure proctolysis. According to Murphy, the lymph circulation is reversed and the peritoneum becomes a secreting surface. Certain it is that the salt solution absorbed from the rectum reaches the peritoneal cavity in large amounts and flows out of the drainage tube.

The *greater omentum* stores up fat, and, being movable, it is able to pass to different parts of the peritoneal cavity. Dr. Robinson, in his work on the *Peritoneum*, describes its functions as follows: "The omentum is the great protector against peritoneal infectious invasions. It builds barriers of exudates to check infection. It is like a man-of-war, ready at a moment's notice to move to invaded parts. It circumscribes abscesses, it repairs visceral wounds, and prevents

¹ On the anatomy of these fossæ, see the Arris and Gale Lectures by Moynihan, 1899.

² George R. Fowler, in Medical Record, April 14, 1900.

adhesions of mobile viscera to the anterior abdominal wall. It resists infectious invasions by typical peritoneal exudates, and not by succumbing to absorbed sepsis. It is a director of peritoneal fluids, a peritoneal drain."

In *abdominal wounds* the greater omentum often protrudes. This structure frequently constitutes or is part of a *hernia*, and is almost invariably present in umbilical hernia. As a result of *inflammation*, it may become adherent to adjacent structures. *Adhesions* may be of service by matting together the intestines and circumscribing infections. They may be harmful by constricting the bowels and producing obstruction. A portion of the omentum may become adherent to some other part and form a *band*, and under this band the gut may be caught and *strangulated*. The omentum may adhere to and plug a perforation in a hollow viscus, and the surgeon may utilize it for the same purpose, or to cover a raw surface or overlie a suture line. The omentum may be in the surgeon's way while operating. If it is, the patient is placed in the *Trendelenburg position* (pelvis elevated).

Any *tear* or opening found by the surgeon in the greater omentum must be closed with sutures, because of the danger that intestine might enter and be caught in such an opening. A tumor cut off from its proper blood supply, for instance, an ovarian cyst with a twisted pedicle, may continue to receive nourishment from adherent omentum, and gangrene may thus be prevented.

The lax character and shifting tendency of the subserous tissue explains the occurrence of *ptosis of the abdominal viscera and kidneys*.

The vast number of nerves in the peritoneum accounts for the profound shock which follows a wound, attends an intraperitoneal calamity, or which develops from infection. An infective process of any portion of the peritoneum produces pain and reflex symptoms (vomiting, abdominal rigidity, intestinal paresis, etc.).

The parietal peritoneum is very sensitive to pain, but not to touch; hence, after injecting a local anesthetic and opening the abdomen, a fairly satisfactory exploration can be made with the finger.

The intestine, the mesentery, the stomach, the anterior margin of the liver, and the gall-bladder are insensitive, and may be cut or even burned without pain.¹ Viscera which obtain their innervation purely from visceral nerves are insensitive; those which receive branches from somatic nerves are sensitive (Lennander).

The oblique origin of the mesentery causes this structure to form a sort of shelf. A hemorrhage or extravasation into the abdomen, to the right of the mesentery, tends to flow into the right iliac fossa; one occurring on the left side flows into the pelvis. Monks shows how the mesentery can be utilized to determine the direction of an intestinal loop:

"Now, let us suppose that the surgeon has between his fingers a loop of bowel, and wishes to determine its direction. He knows that one side of the loop is the left side of the intestine, and that the corresponding side of the mesentery, if closely followed down to the mesenteric root, will conduct him into the left fossa; he also knows that the other side of the bowel is its right side, and that the mesentery on that side will conduct him into the right fossa. Now, if his finger goes into the great fossa on the left side of the abdomen, after having closely followed the mesentery down to its root and arranged his loop to be parallel with that root, he then knows that the left and right sides of the intestine face to the left and right sides of the abdomen respectively, and that the end of the loop which points downward is the end nearest the ileocecal valve. He can determine the direction of the gut in a similar way in case his finger enters the right fossa. All this would seem very simple were it not for the twists in mesentery and intestine, which tend to mislead one. A little practice will usually enable one to recognize a twist in the mesentery. This should be untwisted by rotation of the gut, after which the direction is determined by another palpation of the mesenteric root."²

The studies made of the arrangement and variations of the loops of the mesenteric vessels by Dr. Thomas Dwight³ have been utilized and expanded by Dr. George H. Monks in laying down rules for the determination of the exact portion of small intestine which may be in the surgeon's hand.⁴ His views are as follows:

"General Vascularity of the Mesentery near the Bowel.—Opposite the upper part of the bowel the mesenteric vessels are distinctly larger than opposite any other part of it. These vessels grow smaller and smaller as we pass downward until the lower third of the gut is reached, where they remain about the same size as far as the ileocecal valve. The arrangement of the mesenteric vessels has some features which intimately concern the subject in hand, and which I shall describe with some detail. Diagrammatically speaking, the main branches of the superior mesenteric artery unite with each other by means of loops, which are called for convenience 'primary loops;' in some parts of the tube, 'secondary loops,' and even, occasionally, 'tertiary loops,' are superimposed upon these. From these loops little straight vessels—the vasa recta already referred to—run to the bowel, upon which they ramify, alternating, as a rule, as to the side of the intestine which they supply. The mesenteric veins are arranged in a manner somewhat similar to the arteries.

¹ Dr. K. E. L. Lennander, in *Mitteilungen aus dem Grenzgebieten der Medicin und Chirurgie*, Band x, Heft, 1, 2.

² *Intestinal Localization*, by George H. Monks, *Annals of Surgery*, October, 1903.

³ *Reports of the Meeting of American Anatomists*, 1897.

⁴ *Annals of Surgery*, 1903.

"*The Loops of the Mesenteric Vessels.*—Opposite the upper part of the bowel there are only primary loops. Occasionally a secondary loop appears, but it is small and insignificant as compared with the primary loops, which are large and quite regular. As we proceed down the bowel, secondary loops become more numerous, larger, and approach nearer to the bowel than the primary loops in the upper part. As a rule, secondary loops become a prominent feature at about the fourth foot. As we continue farther downward, the secondary loops (and, possibly, tertiary loops) become still more numerous and the primary loops smaller, the loops all the time getting nearer and nearer to the gut. Opposite the lower part of the gut the loops generally lose their characteristic appearance, and are represented by a complicated network.

"*The Vasa Recta.*—Opposite the upper part of the intestine the vasa recta are from three to five centimetres long, when the loop of small intestine to which they run is lifted up so as to put them gently on the stretch. They are straight, large, and regular, and rarely give off branches in the mesentery. In the lower third they are very short, being generally less than 1 cm. in length. Here they are less straight, smaller, less regular, and have frequent branches in the mesentery."

THE STOMACH (GASTER; VENTRICULUS) (Figs. 972, 1010).

The stomach is one of the principal organs of digestion, and serves as a temporary receptacle for food. It is the most dilated part of the alimentary canal and is situated between the termination of the œsophagus (*cardia*) and the commencement of the small intestine.

It lies more or less obliquely or horizontally in the epigastric, umbilical, and left hypochondriac regions of the abdomen, and occupies a recess or chamber called the **stomach chamber** (Fig. 999). When distended the viscus completely fills the space. When the stomach is empty it lies upon the floor of the chamber, and the portion it has vacated is occupied by the transverse colon, which ascends in front of the stomach and finally gets above it. The **anterior and left wall** of the stomach chamber is formed by the anterior abdominal wall and Diaphragm. The **roof** is formed by the under surface of the Diaphragm and the under surface of the left lobe of the liver. The **floor** is formed by the left suprarenal gland and the summit of the left kidney, the gastric surface of the spleen, the upper surface of the pancreas, the transverse mesocolon, and the colon.

The shape and position of the stomach are so greatly modified by changes within itself and in the surrounding organs that no one form can be described as typical. The chief modifications are determined by (1) the amount of the stomach contents, (2) the stage which the digestive process has reached, (3) the degree of development or functional power of the gastric musculature, and (4) the condition of the adjacent intestines.

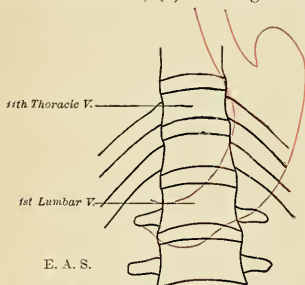


FIG. 1009.—Form and topography of the stomach when empty and contracted, as seen immediately after death in an executed individual.

When empty and contracted, as after a period of rest,¹ the stomach is sickle- or sausage-shaped, as shown in Fig. 1009. At an early stage of gastric digestion the stomach commonly consists of two segments—(a) a large globular portion on the left, and (b) a narrow tubular portion on the right, corresponding to the fundus and pyloric portions, and forming an angle with each other, the axis of the fundus being directed downward and inward while the pyloric portion curves upward and to the right.

The stomach presents two openings, two borders or curvatures, and two surfaces.

¹An opportunity to view this condition is given by the immediate examination of the organ *in situ* in executed criminals who have not eaten for some time.

Openings.—The opening by which the œsophagus communicates with the stomach is known as the **cardiac orifice**, and is situated at the level of the eleventh thoracic vertebra, nearly an inch from the midline, corresponding to the seventh left chondrosternal junction. The short intra-abdominal portion of the œsophagus (*antrum cardiacum*) is conical in shape and curved sharply to the left, the base of the cone being continuous with the cardiac orifice of the stomach. The right margin of the œsophagus is continuous with the lesser curvature of the stomach, while the left margin joins the greater curvature at an acute angle, the **incisura cardiaca**.

The **pyloric orifice** communicates with the duodenum, and its position is indicated on the surface by a circular groove, the **duodenopyloric constriction**. This orifice lies to the right of the middle line at the level of the first lumbar vertebra; it may be from one to two inches to the right of the middle line, depending upon the degree of distention of the stomach. Its position on the ventral surface of the body would be indicated by a point in the transpyloric plane (see p. 1243) about one inch to the right of the middle line.

Curvatures.—The **lesser curvature** (*curvatura ventriculi minor*), extending between the cardiac and pyloric orifices, forms the right or posterior border of the stomach. It descends as a continuation of the right margin of the œsophagus in front of the left crus of the Diaphragm, and then, turning to the right, it crosses the first lumbar vertebra and ends at the pylorus. Nearer its pyloric than its cardiac end is a well-marked notch, the **incisura angularis**, which varies somewhat in position with the state of distention of the viscus, it serves to separate the stomach into a right and left portion. The lesser curvature gives attachment to the two layers of the gastrohepatic omentum, and between these two layers are the gastric artery and the pyloric branch of the hepatic artery. It is from three to four inches (8–10 cm.) in length.

The **greater curvature** (*curvatura ventriculi major*) is directed mainly forward and to the left, and is three or four times as long as the lesser curvature (twelve to sixteen inches, or 30 to 40 cm.); starting from the cardiac orifice at the **incisura cardiaca** it forms an arch backward, upward, and to the left; the highest point of the convexity is on a level with the sixth left costal cartilage or tenth thoracic vertebra. From this level it may be followed downward and forward with a slight convexity to the left as low as the cartilage of the ninth rib; it then turns to the right to end at the pylorus. Directly opposite the **incisura angularis** of the lesser curvature the greater curvature presents a dilatation, the **pyloric vestibule** or **antrum**, which is limited on the right by a slight groove, the **sulcus intermedius**; this sulcus is about an inch from the duodenopyloric constriction. The portion between the **sulcus intermedius** and the duodenopyloric constriction is termed the **pyloric canal**. At its commencement the greater curvature is covered by peritoneum continuous with that covering the front of the organ. The left part of the curvature gives attachment to the gastrosplenic omentum, while to its anterior portion are attached the two anterior layers of the great omentum, separated from each other by the gastroepiploic vessels.

Surfaces.—When the stomach is in the slightly dilated condition, its surfaces are directed more upward and downward respectively, but when the viscus is distended they are directed more forward and backward. They may, therefore, be described as antero-superior and postero-inferior.

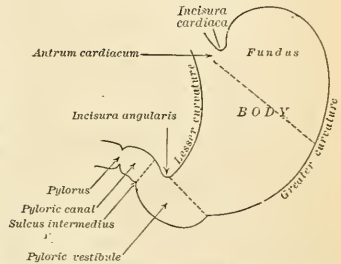


FIG. 1010.—Outlines of the stomach, showing its anatomical landmarks.

Antero-superior Surface.—The left half of this surface is in contact with the Diaphragm, which separates it from the base of the left lung, the pericardium, the seventh, eighth, and ninth ribs, and intercostal spaces of the left side. The right half is in relation with the left and quadrate lobes of the liver and with the ventral abdominal wall. When the stomach is empty the transverse colon may be found lying on the front part of this surface. The whole surface is covered by peritoneum.

The **Postero-inferior Surface** (*paries posterior*) is in relation with the Diaphragm, the gastric surface of the spleen, the left suprarenal gland, the upper part of the front of the left kidney, the anterior surface of the pancreas, the splenic flexure of the colon, and the upper layer of the transverse mesocolon. These structures form a shallow concavity ("*stomach bed*"), on which the stomach rests. The transverse mesocolon intervenes between the stomach and the duodenojejunal flexure and small intestine. The postero-inferior surface is covered with peritoneum, except over a small area close to the cardiac orifice; this area is limited by the lines of attachment of the *gastrophrenic ligament*, and lies in contact with the Diaphragm and frequently with the upper portion of the left adrenal gland.

Component Parts of the Stomach.—The stomach may be divided into a left portion or **body** and a right or **pyloric portion** or **antrum** by a plane passing through the incisura angularis and the left limit of the opposed dilatation (*pyloric vestibule*) on the greater curvature. The left portion of the body (*corpus ventriculi*) is known as the **fundus**, while that which is adjacent to the cardiac orifice is known as the **cardiac antrum**. The pyloric antrum is divided into a right part, the **pyloric canal**, and a left, the **pyloric vestibule**, by a plane passing through the sulcus intermedius at right angles to the axis of this portion (Fig. 1010).

The *size* of the stomach varies considerably in different subjects. When moderately distended its greatest length, from the top of the fundus to the lowest part of the greater curvature, is from ten to twelve inches and its diameter at the widest part from four to five inches. The distance between the two orifices, when the stomach is *in situ*, is three to four inches, and the measurement from the anterior to the posterior wall three and one-half inches. Its *weight*, according to Clendinning, is about four ounces and a half, and its *capacity* in the adult male is five to eight pints. The stomach of a newborn child holds about one ounce.

Alterations in Position.—There is no organ in the body the position and connections of which present such frequent alterations as the stomach. When *empty*, it lies at the back part of the abdomen, some distance from the ventral abdominal wall, and is in the left hypochondriac region and the left portion of the epigastric region. Its fundus is directed upward and backward toward the Diaphragm. The long axis of the viscus is quite oblique. Its pyloric end is directed toward the right, covered in front by the left lobe of the liver, and on a level with the first lumbar vertebra. When empty and contracted the stomach assumes a more or less cylindrical form, especially noticeable at its pyloric end, and resembles a piece of thick-walled intestine. When the stomach is *distended*, its surfaces become convex and the shape becomes pyriform, its long axis being downward, forward, and to the right. The greater curvature is elevated and carried forward, so that the anterior surface is turned more or less upward and the posterior surface downward, and the stomach is brought well against the anterior wall of the abdomen. Its fundus expands and rises considerably above the level of the cardiac orifice; in doing this the Diaphragm is forced upward, contracting the cavity of the thorax; hence the dyspnea complained of as inspiration is impeded. The apex of the heart is also tilted upward; hence the oppression in this region and the palpitation experienced in extreme distention of the stomach. The left lobe of the liver is pushed toward the right. When the stomach becomes distended the change in the position of the pylorus may be considerable; it is shifted to the right as much as two inches from the median line, and lies under cover of the liver, near the neck of the gall-bladder. In consequence of the distention of the stomach the pyloric antrum bulges in front of the pylorus, concealing it from view, and causing it to undergo a rotation, so that its orifice is directed backward. When the stomach is greatly distended its lower border may enter the umbilical and the left lumbar regions. During *inspiration* the stomach is displaced downward by the descent of the Diaphragm, and it is elevated by the pressure of the abdominal muscles during *expiration*. Pressure from without, as from tight lacing, pushes the stomach down toward the pelvis. In fact, in the female, because of tight lacing, the body of the stomach may be to the left

side of the vertebral column and nearly vertical in direction, the pyloric portion being sharply angled upward toward the pylorus, which lies underneath the liver. Besides the angulation, the stomach may have a median constriction, and there may even be an *hour-glass stomach*. In disease the position and connection of the stomach may be greatly changed, from the accumulation of fluid in the thoracic cavity or abdomen, or from alteration in size of any of the surrounding viscera.

Variations According to Age.—In an early period of development the stomach is vertical, and in the newborn child it is more vertical than later on in life, as owing to the large size of the liver it is pushed over more to the left side of the abdomen, and the whole of the anterior surface is covered by the left lobe of this organ.

Interior of the Stomach.—When examined after death, the stomach is usually fixed at some temporary stage of the digestive process. A common form is that shown in Fig. 1011. If the viscus be laid open by a section through the plane of its two curvatures, it is seen to consist of the two segments already described—viz., a large globular portion to the left, comprising the body and fundus, and the tubular pyloric portion to the right. The mucous membrane lining the interior is soft and velvety, red or reddish brown in the body and fundus, and of a pinkish tinge at the pyloric end. It is thrown into numerous folds or *rugæ*, chiefly longitudinal in direction and most marked toward the pyloric end and along the greater curvature. To the left of the cardiac orifice is the *incisura cardiaca*; the projection of this notch into the cavity of the stomach increases as the organ distends, and has been supposed to act as a valve preventing regurgitation into the œsophagus. In the pyloric portion are seen (a) the elevation corresponding to the *incisura angularis*, and (b) the circular projection from the duodenopyloric constriction which forms the pyloric valve. The separation of the pyloric vestibule from the pyloric canal is scarcely indicated, but the manner in which the pylorus is invaginated into the duodenum is evident.

The **pyloric valve** (*valvula pylori*) (Fig. 1013) is formed by a reduplication of the mucous membrane of the stomach, containing numerous circular fibres, which are aggregated into a thick circular ring, the **Pyloric Sphincter** (*m. sphincter pylori*); some of the deeper longitudinal fibres turn in and interlace with the circular fibres

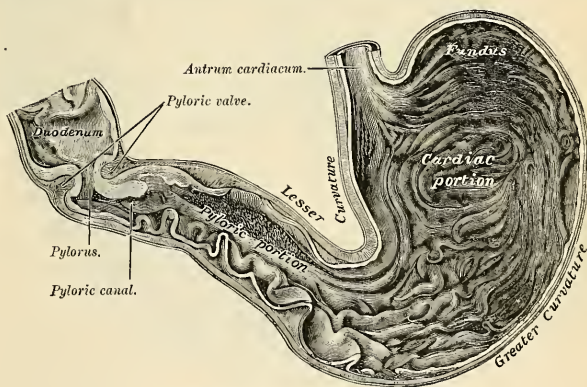


FIG. 1011.—Interior of the stomach.

of the valve. The pylorus is normally kept closed by the action of this Sphincter muscle. During the early stage of digestion it remains closed, but after a time opens now and then, this relaxation becoming more frequent and the period of patency more prolonged as digestion advances.

Structure.—The wall of the stomach consists of four coats—serous, muscular, submucous, and mucous, together with vessels and nerves.

The **serous coat** (*tunica serosa*) is derived from the peritoneum, and covers the entire surface of the organ, excepting along the greater and lesser curvatures, at the points of attachment of the greater and lesser omenta; here the two layers of peritoneum leave a small triangular space uncovered by peritoneum along which the nutrient vessels and nerves pass. On the posterior surface of the stomach, close to the cardiac orifice, there is also a small triangular area uncovered by peritoneum, where the organ is in contact with the under surface of the Diaphragm.

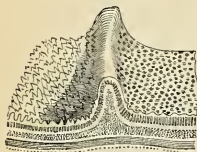


FIG. 1012.—Diagrammatic view of the coats of the stomach, duodenum, and pylorus. The ridge is the pyloric valve. (Allan Thomson.)

The **muscular coat** (*tunica muscularis*) (Figs. 1014 and 1015) is situated immediately beneath the serous covering, to which it is closely connected. It consists of three sets of smooth muscle tissue—longitudinal, circular, and oblique, from without inward, in the order named.

The **longitudinal fibres** (*stratum longitudinale*) are the most superficial, and are arranged in two sets. The first set consists of fibres continuous with the longitudinal fibres of the oesophagus; they radiate in a stellate manner from the cardiac orifice and are practically all lost before the pyloric portion is reached. The second set commences on the body of the stomach and passes to the right, its fibres becoming more closely collected as they approach the pylorus. Some of the more superficial fibres of this set pass on to the duodenum, but the deeper fibres dip in and interlace with the circular fibres of the pyloric valve Sphincter. The bundles of longitudinal

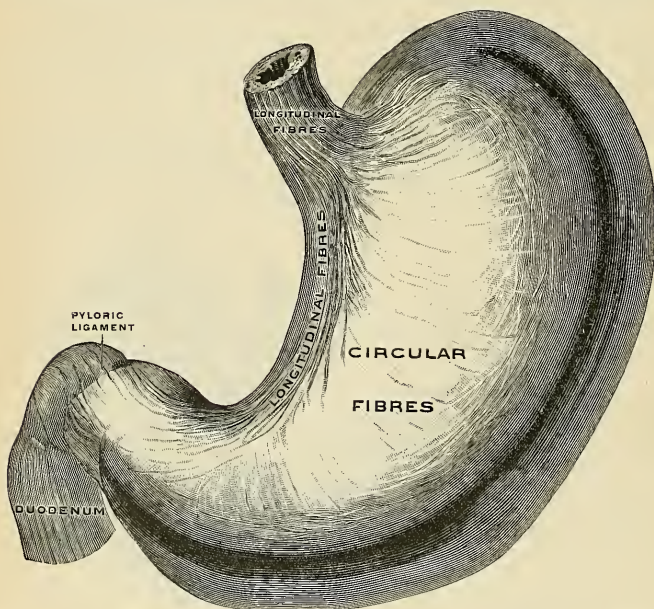


FIG. 1013.—The superficial muscular layer of the stomach, viewed from above and in front. (Spalteholz.)

muscle fibre on the upper and lower surfaces of the pylorus are particularly firm and distinct, and are called the **pyloric ligaments** (*ligamenta pylori*).

The **circular fibres** (*stratum circulare*) form a uniform layer throughout the whole extent of the stomach internal to the longitudinal fibres. They begin as tiny rings at the left extremity of

the fundus and pass over into larger and larger rings to encircle the entire organ. At the pylorus they are most abundant, and are aggregated into a **circular ring** or **Sphincter**, which projects into the cavity, and forms, with the fold of mucous membrane covering its surface, the **pyloric valve** (Fig. 1012). The circular fibre stratum is continuous with the circular layer of the œsophagus, the fibres being interlaced at the transition.

The **oblique fibres** (*fibrae obliquæ*) arise at the left side of the cardia from the circular fibres of the œsophagus. The fibres pass down in the anterior and posterior walls, and almost reach the pylorus. Certain oblique muscular fibres encircle the fundus of the stomach in a series of rings.

The **submucous coat** (*tela submucosa*) consist of loose areolar tissue, connecting the mucous and muscular coats. It supports the large bloodvessels previous to their distribution to the mucous membrane; hence it is sometimes called the **vascular coat**.

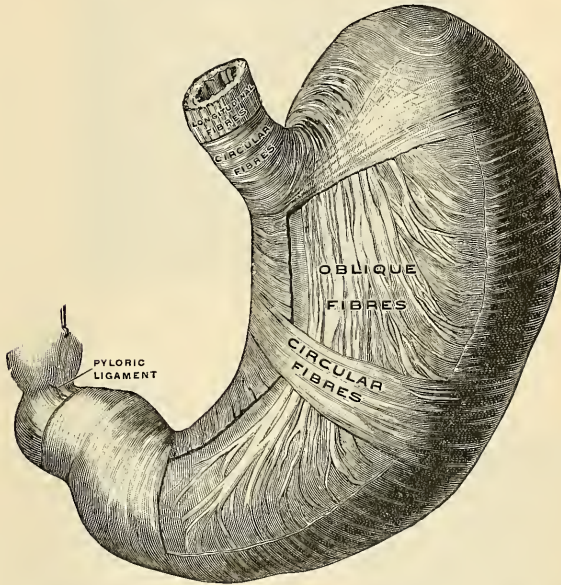


FIG. 1014.—The middle and deep muscular layer of the stomach, viewed from above and in front. (Spalteholz.)

The **mucous membrane** (*tunica mucosa*) (Figs. 1015, 1016, 1017, and 1018) is thick, its surface smooth, soft, and velvety. In the fresh state it is of a pinkish tinge at the pyloric end, and of a red or reddish-brown color over the rest of the surface. In infancy it is of a brighter hue, the vascular redness being more marked. It is thin at the cardiac extremity, but thicker toward the pylorus. During the contracted state of the organ it is thrown into numerous folds or **rugæ** (*plicæ mucosæ*) (Figs. 1015 and 1016), which for the most part have a longitudinal direction, and are most marked toward the pyloric end of the stomach and along the greater curvature. These folds consist of mucous and submucous coats, and are entirely obliterated when the organ becomes fully distended.

Structure of the Mucous Membrane.—When examined with a lens the inner surface of the mucous membrane presents a peculiar honeycomb appearance, from being covered with small shallow depressions, the **gastric crypts** or **pits** (*foveolæ gastricae*) (Figs. 1015 and 1018) of a polygonal or hexagonal form, which vary from $\frac{1}{100}$ to $\frac{1}{200}$ of an inch in diameter, and are separated by slightly elevated ridges (*plicæ villosæ*). The pits in the cardiac and fundal portions of the stomach extend through about one-sixth the thickness of the mucosa, while in the pyloric end they extend through about one-half the mucous coat. In the bottom of the crypts are seen three to seven orifices of minute tubes, the **gastric glands** (Fig. 1018), which are placed per-

pendicularly side by side throughout the entire substance of the mucous membrane. The surface of the mucous membrane of the stomach is covered by a single layer of **columnar epithelium** and a few **goblet cells**; it lines the crypts, and also for a certain distance the mouths of the gastric glands; in the glands the character of the epithelium changes. This epithelium com-

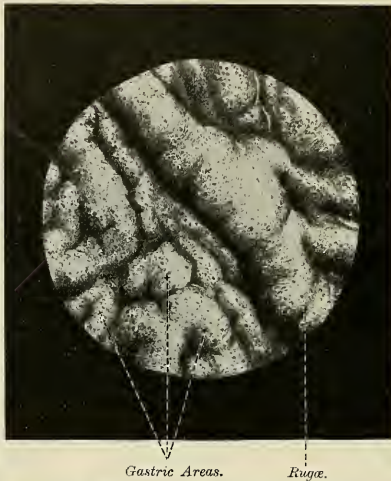


FIG. 1015.—Mucous membrane of the stomach, from the pars pylorica, viewed from the surface. $\times 5$. (Spalteholz.)

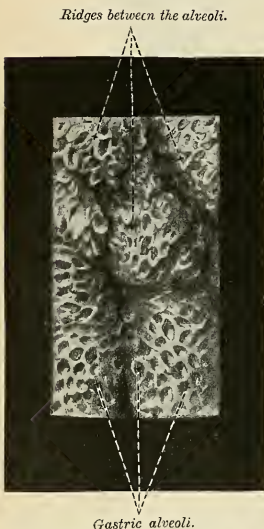


FIG. 1016.—Mucous membrane of the stomach, from the pars pylorica, viewed from the surface. $\times 16$. (Spalteholz.)

mences very abruptly at the cardiac orifice, where the cells suddenly change in character from the **stratified epithelium** of the cesophagus.

The Gastric Glands.—The gastric glands are of three kinds—the **true gastric glands**, the **pyloric glands**, and the **cardiac glands**.

The **true gastric glands** (Fig. 1020) are called also the **oxyntic glands**, the **fundus glands**, and the **peptic glands** (*glandulae gastricae propriae*). They are distributed throughout the entire fundus and body, and may be found even at the pylorus. They are mainly of the simple tubular variety, and are lined by simple epithelial cells resting upon a delicate basement membrane supported by the tunica propria. The duct, or mouth, however, in these glands is shorter than in the other variety, sometimes not amounting to more than one-sixth of the whole length of the gland; it is lined throughout by columnar epithelium. At the point where the terminal tubes open into the mouth, and which is termed the **neck**, the epithelium alters, and consists of short columnar or polyhedral, granular cells, which almost fill the tube, so that the lumen becomes suddenly constricted, and is continued down as a very fine channel. They are known as the **chief** or the **peptic** or the **central cells of the glands**, and furnish pepsin. Between these cells and the basement membrane are found other darker granular-looking cells, studded throughout the tubes at intervals, and giving it a beaded or varicose appearance. The **fundus** is the blind extremity of the gland, and here the chief cells predominate. These are known as the **acid**, **parietal**, or **oxyntic cells**. Some of the parietal

cells empty directly into the lumen of the gland by secretory capillaries; others empty by a channel which divides into secretory capillaries. The parietal cells secrete the acid of the

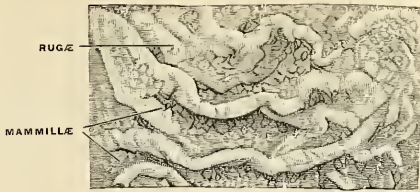


FIG. 1017.

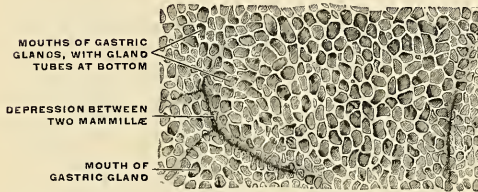


FIG. 1018.

FIGS. 1017 and 1018.—The mucous membrane of the stomach. Fig. 1017. Natural size. Fig. 1018. Magnified 25 diameters. In Fig. 1017 the rugæ and the mamillated surfaces are shown. In Fig. 1018 the gland mouths (foveolæ gastricae), with the gland tubes leading from some of them, and the ridges separating the mouths (plicae villosae) are seen. (Cunningham.)

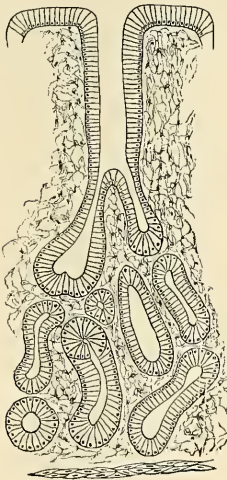


FIG. 1019.—Pyloric gland.

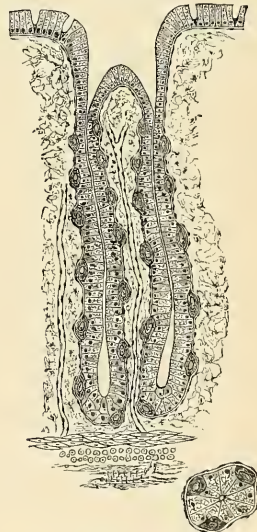


FIG. 1020.—Peptic gastric gland.

gastric juice. Between the glands the tunica propria consists of fibroelastic connective-tissue framework with lymphoid tissue and a rich capillary plexus. In places this latter tissue, especially in early life, is collected into little masses, which to a certain extent resemble the

solitary nodules of the intestine, and are by some termed the **lenticular follicles of the stomach**. They are not, however, so distinctly circumscribed as the solitary follicles.

The **pyloric glands** (*glandulae pyloricae*) (Fig. 1019) are the branched tubular glands, and secrete mucus and pepsin.

They are placed most plentifully about the pylorus, but between the fundus and pylorus, in the region known as the **transitional or intermediate zone**, both true gastric glands and pyloric glands are found. Each pyloric gland consists of two or three short tubes opening into a common

mouth or duct, the external orifice of which is situated at the bottom of a crypt. The tubes are wavy, and are of about equal length with the duct. The tubes and duct are lined throughout with simple epithelium, the duct being lined by columnar cells continuous with the epithelium lining the surface of the mucous membrane of the stomach, the tubes with tall, broad, and pale-staining cells, which are finely granular. The pyloric glands branch more frequently, are more curved in direction, and open into deeper foveolæ than the true gastric glands (Szymonowicz). They contain only chief or peptic cells and do not possess parietal cells. These glands, at times, extend into the submucous coat.

The **cardiac glands** are found about the oesophageal orifice. They resemble the glands of the oesophagus and are mucous in character.

External to the tunica propria of the mucous membrane, and between it and the submucous coat, is a thin stratum of involuntary muscle tissue (*muscularis mucosae*), which in some parts

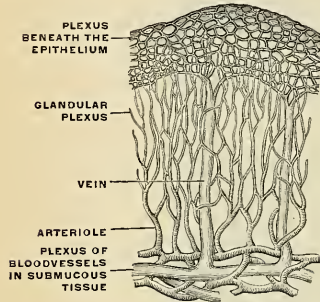


FIG. 1021.—Terminations of the bloodvessels in the mucous membrane of the stomach. (Poirier and Charpy.)

consists only of a single longitudinal layer; in others, of two layers, an inner circular, and an outer longitudinal.

Vessels and Nerves.—The arteries supplying the stomach are the gastric, the pyloric, and the right gastroepiploic branch of the gastroduodenal, the left gastroepiploic and vasa brevia from the splenic. The gastric artery passes to the lesser curvature just below the cardia. It gives off the oesophageal branch, and passes from left to right along the lesser curvature of the stomach beneath the peritoneum between the two layers of the lesser omentum and upon the wall of the stomach. It may in this course be a single vessel, or may divide into two branches,

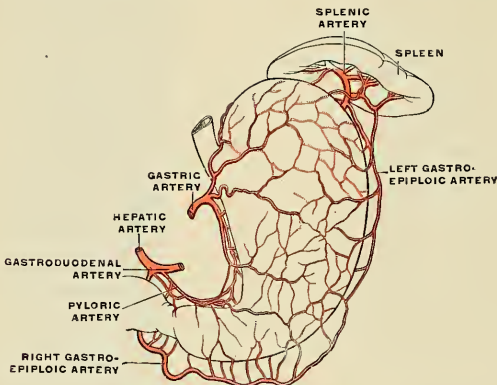


FIG. 1022.—The arteries of the anterior surface of the stomach. (Poirier and Charpy.)

which run along each side of the lesser curvature (Fig. 1022). If there is a single artery, it gives off six or seven descending branches to the anterior wall and about the same number to the posterior wall of the stomach. It also gives branches to the lesser omentum. If two **vascular arches** form, one gives branches to the anterior wall of the stomach, the other to the posterior

wall, and both to the lesser omentum. The termination of the gastric anastomoses with the pyloric branch or two rami of the pyloric branch of the hepatic artery. From each arch six or seven **descending branches** come off to the anterior and posterior walls of the stomach. The **gastrooduodenal artery** is given off by the hepatic. From the gastrooduodenal comes the right gastroepiploic. The left gastroepiploic comes from the splenic. The **right gastroepiploic artery** passes from right to left in the gastrocolic omentum below the greater curvature of the stomach. The **left gastroepiploic artery** passes forward in the gastrosplenic omentum to below the greater curvature of the stomach, and passes from left to right along that curvature in the greater omentum, and joins the right gastroepiploic artery. The gastroepiploic arteries are not upon but are distinctly below the stomach wall. From them numerous gastric branches are sent to the anterior and posterior walls of the stomach, and they anastomose with branches of the gastric and pyloric. *Vasa brevia*, four or five in number, arise from the splenic, pass forward in the gastrosplenic omentum, and supply the fundus. The arteries of the stomach lie first beneath the peritoneum, but soon enter the muscular coat, supply it, pierce it, ramify in the submucous coat, and are finally distributed to the mucous membrane. The arrangement of the vessels in the mucous membrane is somewhat peculiar (Fig. 1021). The arteries break up at the base of the gastric tubules into a plexus of fine capillaries which run upward between the tubules, anastomosing with each other, and ending in a plexus of larger capillaries, which surround the mouths of the tubes and also form hexagonal meshes around the crypts.

The capillary network about the glands gives origin to the **veins**. The various small **veins unite and form a plexus in the submucous tissue** (Fig. 1021). From this plexus come branches which pass through the muscular coat and terminate in the **right gastroepiploic branch of the superior mesenteric**, the **left gastroepiploic branch of the splenic**, the veins to the splenic which correspond to the *vasa brevia* arteries, and the **gastric or coronary branch of the portal**.

The **lymphatics** (Figs. 570 and 571) arise in the mucous membrane and terminate in a network in the submucous tissue. From this network trunks arise which perforate the muscular coat in the regions of the curvatures and terminate in the seromuscular collecting trunks. The details of the lymphatic drainage of the stomach are given on page 792.

The **nerves of the stomach** come from the **right and left vagi** and from the **solar plexus of the sympathetic**. The left vagus passes to the front of the stomach, and the right nerve passes to the back, and they unite with the fibres of the sympathetic. The fibres thus formed are mostly amyelinic. They form **Auerbach's plexus** in the muscular coat between the circular and longitudinal fibres and **Meissner's plexus** in the submucous coat, the latter plexus being formed by fibres from the former. Auerbach's plexus supplies the muscular coat of the stomach, while fibres from Meissner's plexus ramify in the submucous coat and terminate in the muscularis mucosae and the mucous membrane, branches passing to the gastric glands and to just beneath the epithelium. (See nerve supply of small intestine, p. 1295).

Relations of the Stomach.—The antero-superior surface is in relation with the left and quadrate lobes of the liver, the ventral abdominal parietes, and the costal portion of the Diaphragm. The postero-inferior surface is in relation with the lumbar portion of the Diaphragm, the pancreas, and the transverse mesocolon, while the fundus may come into contact with the left kidney and suprarenal gland, the spleen, and splenic flexure of the colon. The lesser curvature is directed toward the transverse fissure of the liver, while the greater curvature may be in contact with the transverse colon.

Movements and Innervation of the Stomach.

Movements.—It has apparently been demonstrated that the stomach "consists of two parts physiologically distinct."¹ The cardiac portion of the stomach is a food reservoir in which salivary digestion continues; the pyloric portion is the seat of active gastric digestion. Cannon affirms that there are no peristaltic waves in the cardiac portion, but that as the food passes from the pyloric portion into the intestines, tonic contraction of the muscles of the fundus squeezes the contents of the pyloric portion. Moritz, Levan, and Cannon assert that muscular activity is chiefly manifested in the pyloric portion. In this portion during digestion there is a succession of peristaltic waves, which waves in the human being pass at the rate of three per minute (Moritz). Cannon points out that the efficiency of peristalsis in mixing the food depends upon the contraction of the pyloric sphincter. So long as the sphincter holds, each constriction ring coursing from the middle to the end of the stomach presses the food into a blind pouch; the food, unable to escape through the pyloric opening, has as its only outlet the opening in the advancing ring. This is an admirable device for bringing the food under the influence of the glandular secretions of the pyloric region. For, as a constriction occurs, the secreting surface enclosed by the narrowed muscular ring is pressed close around the food within the ring. As the constriction advances it continually presses inward fresh glandular surfaces, and further-

¹ Walter B. Cannon, *Medical News*, May 20, 1905.

more, as the constriction advances, a thin stream of food is continuously forced back through the ring and thus past the mouths of the glands. The old view that the pyloric sphincter only opens after several hours' continuance of the process of digestion, and that then the stomach empties at once, is incorrect. It is emptied in small amounts, which escape at frequent intervals because of the intermittent opening of the pylorus. When the pylorus is open a wave of peristalsis forces some of the material from the stomach into the duodenum (Cannon).

Cannon is of the opinion that the pyloric sphincter is caused to relax by the presence of free hydrochloric acid in the pyloric portion of the stomach. When the pylorus is open acid chyme passes into the duodenum, and acid in the duodenum causes the pylorus to close. The acid in the duodenum causes a flow of alkaline pancreatic juice and the acid is neutralized. "As the neutralizing proceeds, the stimulus closing the pylorus is weakened until the acid in the stomach again opens the sphincter."¹

Innervation.—The stomach, as previously shown, has nerve plexuses in its walls and is connected to the cerebrospinal and sympathetic systems. It is probable that gastric peristalsis is due to a local reflex from Auerbach's plexus (Magnus), the local reflex being inaugurated by local stimulation, which stimulation, in the words of Bayliss and Starling, "produces excitation above and inhibition below the excited spot."² Reversed peristalsis cannot occur if "the reflex mechanism is intact" (Cannon). Cannon in the previously quoted article states that cutting the vagi or splanchnic nerves does not destroy the reflex mechanism of the pylorus, but, nevertheless, it is markedly affected by the central nerve system.

Surface Form (see p. 1241).—The cardiac orifice corresponds to the articulation of the seventh left costal cartilage with the sternum. The pyloric orifice of the empty stomach is about an inch to the right of the midline in the transpyloric line. According to Braune, when the stomach is distended, the pylorus moves considerably to the right, sometimes as much as three inches. The fundus of the stomach reaches, on the left side, as high as the level of the sixth costal cartilage of the left side, being a little below and behind the apex of the heart. The portion of the distended stomach which is in contact with the abdominal walls, and is therefore accessible for opening in the operations of gastrotomy and gastrostomy, is represented by a triangular space, the base of which is formed by a line drawn from the tip of the tenth costal cartilage on the left side to the tip of the ninth costal cartilage on the right, and the sides by two lines drawn from the extremity of the eighth costal cartilage on the left side to the end of the base line. What is commonly termed the **semilunar space of Traube** is that portion of the stomach which is not covered by neighboring viscera. It is bounded above by the left lobe of the liver and the inferior margin of the left lung, posteriorly and to the left by the spleen; on percussion, this area is normally tympanitic.

Applied Anatomy.—Operations on the stomach are frequently performed, ulcers are excised, malignant growths are removed with the associated lymphatic involvement, the entire stomach may be removed for cancer, etc. By "*gastrotomy*" is meant an incision into the stomach for the removal of a foreign body, or the arrest of hemorrhage, or for exploration, the opening being immediately afterward closed—in contradistinction to "*gastrostomy*," the making of a more or less permanent fistulous opening. *Gastrotomy* is probably best performed by an incision in the linea alba, especially if the foreign body is large. The cut may reach from the ensiform cartilage to the umbilicus. The incision may be made over the foreign body itself, where this can be felt, or by one of the incisions for gastrostomy, to be mentioned shortly. The peritoneal cavity is opened, and the point at which the stomach is to be incised decided upon. This portion is then brought out of the abdominal wound and sponges carefully packed around. The stomach is now opened by a transverse incision and the foreign body extracted. The wound in the stomach is then closed by *Lambert sutures*—i. e., by sutures passed through the peritoneal, muscular, and submucous coats in such a way that the peritoneal surfaces on each side of the wound are brought into apposition. *Gastrostomy* was formerly done in two stages by the *direct* method. The first stage consisted in opening the abdomen, drawing up the stomach into the external wound, and fixing it there; and the second stage, performed from two to four days afterward, consisted in opening the stomach. The operation is now done by a *valvular* method. The following plan is known as the *Sabanejew-Frank* operation. An incision is commenced opposite the eighth intercostal space, two inches to the left of the median line, and carried downward for three inches. By this incision the fibres of the Rectus muscle are exposed and these are separated from one another in the same line. The posterior layer of the sheath, the transversalis fascia, and the peritoneum are then divided, and the peritoneal cavity is opened. Instead of the above incision, the curved incision of Fenger can be made at the margin of the left costal cartilages. The anterior wall of the stomach is now seized and drawn out of the wound and a silk suture passed through its submucous, muscular, and serous coats at the point selected for opening the viscus. This is held by an assistant so that a long conical diverticulum of the stomach protrudes from the external wound, and the parietal peritoneum and the posterior layer of the sheath of the Rectus are sutured to the base of the cone. A second incision is made through

¹ Walter B. Cannon, Medical News, May 20, 1905.

² Ibid.

the skin, over the margin of the costal cartilage, *above and a little to the outer side* of the first incision. If Fenger's incision were used, the second incision should be above the margin of the cartilages. With a pair of dressing forceps a track is made under the skin through the subcutaneous tissue from the one opening to the other and the diverticulum of the stomach is drawn along this track by means of this suture inserted into it; so that its apex appears at the second opening. A small perforation is now made into the stomach through this protruding apex and its margin carefully and accurately sutured to the margin of the external wound. The remainder of this incision and the whole of the first incision are then closed in the ordinary way and the wound dressed.

In cases of *gastric ulcer*, *perforation* sometimes takes place, and this was formerly regarded as an almost fatal complication. In the present day, by opening the abdomen and closing the perforation, which is generally situated on the anterior surface of the stomach, a considerable percentage of cases are cured, provided the operation is undertaken within twelve to fifteen hours after the perforation has taken place. The opening is best closed by bringing the peritoneal surfaces on either side into apposition by means of Lembert sutures.

Pylorotomy or excision of the pylorus is performed, particularly for early cancer, but is also done for cicatricial stricture and for ulcer. The mortality after operation for cancer was, until recently, very great, but of late years it has been notably reduced, though it is still much higher than that which follows operations for any non-malignant condition.

In operating for cancer, bear in mind Cunéo's study of the lymphatics (p. 792). These observations indicate that the fundus and two-thirds of the greater curvature are free from lymphatic involvement in pyloric cancer.¹ In every operable case of cancer of the pylorus the entire lesser curvature must be removed up to the gastric artery (Mikulicz's point), and the greater curvature must be removed to the left of the involved lymph nodes (Hartmann's rule).

Gastroenterostomy is an operation which establishes a fistulous communication between the stomach and jejunum. The operation is often called *gastrojejunostomy*. The opening may be made upon either the anterior or the posterior wall of the stomach, between the cardia and the seat of pyloric disease. The operation is employed for stricture of the pylorus (benign or malignant), and occasionally for ulcer of the stomach.

Hypertrophy and spasm of the circumferential muscular coat of the pylorus coming on during the first few weeks of life, and somewhat erroneously described as *congenital hypertrophic stenosis of the pylorus*, is a rare but serious disorder of infancy. It is characterized by abdominal pains and obstinate vomiting coming on after food has been given, and gastric peristalsis can be observed by inspection of the child's epigastrium after it has been fed and before vomiting has occurred. Progressive wasting for want of nourishment and death from exhaustion tend to ensue. Treatment should be by washing out the stomach, and the administration at frequent intervals of small quantities of easily digested food. Surgical interference—*pyloroplasty* or *pylorotomy*—entailing a severe operation, gives less favorable result.

Total gastrectomy is the removal of the entire stomach. It is only used for cancer. It was first performed by Conner, of Cincinnati. The first successful operation was done by Schlatter, of Zurich, in 1898. A number of successes have been reported. It is a justifiable operation only in a case in which almost the entire stomach is cancerous, in which the viscus is movable, in which there are no secondary deposits, and no irremovable diseased lymph nodes.

Gastrogastrostomy is an operation employed in hour-glass stomach. In this operation an anastomosis is made between the pyloric and cardiac ends of the stomach.

Gastroplication is the operation of suturing the stomach wall into folds or reefs, in order to lessen its size. It is employed in some cases of gastric dilatation.

Gastroptosis is a condition in which the stomach is displaced downward. In some of these cases the greater curvature almost reaches the level of the symphysis pubis, and the lesser curvature is midway between the umbilicus and ensiform cartilage. The condition is usually associated with *enteroptosis* and *movable kidney* (nephroptosis). In this condition the gastrohepatic omentum is pulled upon and lengthened. The best operation for gastroptosis was devised by Beyer. He applies sutures so as to make folds in and thus shorten the stretched omentum. Thus the stomach is elevated to its proper position, and its mobility is not lessened, as it is in other operations which suture it to the abdominal wall.

THE SMALL INTESTINE (INTESTINUM TENUE).

The *small intestine* is a convoluted tube, extending from the pylorus to the ileocecal valve, where it terminates in the large intestine. It is about twenty feet

¹ William J. Mayo, *Annals of Surgery*, March, 1904.

(6 m.) in length,¹ and gradually diminishes in size from its commencement to its termination. It is contained in the central and lower part of the abdominal cavity, and is surrounded above and at the sides by the large intestine; a portion of it extends below the brim of the pelvis and lies in front of the rectum. It is in relation, in front, with the great omentum and abdominal parietes, and the greater part of it is connected to the vertebral column by a fold of peritoneum, the **mesentery** (p. 1263). The small intestine is divisible into three portions—the **duodenum**, the **jejunum**, and the **ileum**.

The Duodenum (Figs. 1023, 1030).

The **duodenum** has received its name from being about equal in length to the breadth of twelve fingers (ten inches). It is the shortest, the widest, and the most fixed part of the small intestine, and has no mesentery, being only partially invested by peritoneum. Somewhat more than the upper half of the duodenum is placed in the epigastric region; the remainder is in the umbilical region. Its course prevents a remarkable curve, somewhat of the shape of an incomplete circle, so that its termination is not far removed from its beginning.

In the adult the *course* of the duodenum is as follows: Commencing at the pylorus it passes backward, upward, and to the right, beneath the quadrate lobe of the liver to the neck of the gall-bladder, varying slightly in direction according to the degree of distention of the stomach; it then takes a sharp curve and descends along the right margin of the head of the pancreas, for a variable distance, generally to the level of the upper border of the body of the fourth lumbar vertebra. It now takes a second bend, and passes from right to left across the front of the vertebral column, having a slight inclination upward; and to the left side of the vertebral column it ascends for about an inch, and then terminates opposite the second lumbar vertebra in the jejunum. As it unites with the jejunum it turns abruptly forward, forming the **duodenojejunal flexure**. From the above description it will be seen that the duodenum may be divided into four portions—**superior**, **descending**, **transverse**, and **ascending**.

The **first or superior portion** (*pars superior*) (Figs. 1023 and 1024) is about two inches (5 cm.) in length. Beginning at the pylorus, it ends at the level of the neck of the gall-bladder. It is the most movable of the four portions. It is almost completely covered by peritoneum derived from the two layers of the lesser omentum, but a small part of its posterior surface near the neck of the gall-bladder and the inferior vena cava is uncovered (Fig. 1024). It is in such close relation with the gall-bladder that it is usually found to be stained by bile after death, especially on its anterior surface. It is in relation *above* and in *front* with the quadrate lobe of the liver, lying in a slight concavity, the **impressio duodenalis**, and the gall-bladder; *behind*, with the gastroduodenal artery, the common bile duct, and the portal vein; and *below*, with the head of the pancreas.

The **second or descending portion** (*pars descendens*) (Figs. 1023 and 1025) is between three and four inches (7.5 to 10 cm.) in length, and extends from the neck of the gall-bladder on a level with the first lumbar vertebra along the right side of the vertebral column as low as the body of the fourth lumbar vertebra. It is crossed in its middle third by the transverse colon, the posterior surface of which is uncovered by peritoneum and is connected to the duodenum by a small quantity of connective tissue. The portions of the descending part of the duodenum above and below this interspace are named the **supracolic** and **infracolic portions**, and are

¹ Treves states that in one hundred cases the average length of the small intestine in the adult male was 22 feet 6 inches, and in the adult female 23 feet 4 inches; but that it varies very much, the extremes in the male being 31 feet 10 inches in one case and 15 feet 6 inches in another, a difference of over 15 feet. He states that he has convinced himself that the length of the bowel is independent, in the adult, of age, height, and weight.

covered in front by peritoneum (Fig. 1025). The infracolic part is covered by the right leaf of the mesentery. Posteriorly the descending portion of the duodenum

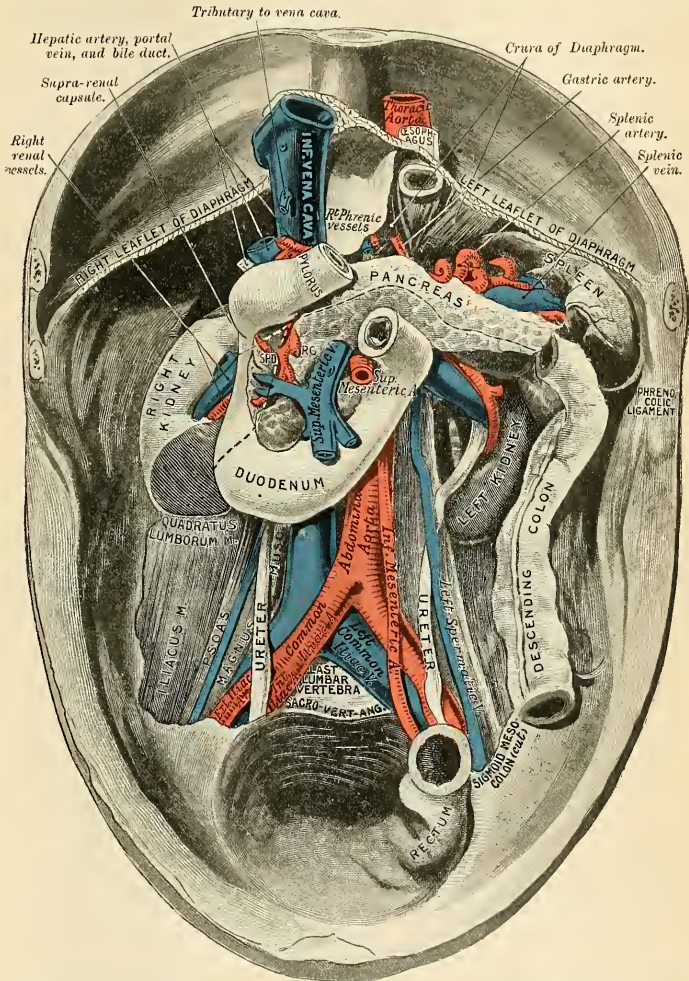


FIG. 1023.—Relations of duodenum, pancreas, and spleen. (From a cast by Professor Birmingham.)¹ The broken line represents the line of attachment of the transverse mesocolon.

is not covered by peritoneum. It is in relation, in *front*, with the transverse colon, and above this with the right lobe of the liver, where it lies in the *impressio duo-*

¹ In the subject from which the cast was taken the left kidney was lower than usual.

denalis for the second part of the duodenum; *behind*, with the inner part of the right kidney, to which it is connected by loose areolar tissue, the right renal vessels, and the inferior vena cava; at its *inner side* is the head of the pancreas and the common bile duct; to its *outer side* is the hepatic flexure of the colon. The common bile duct passes downward behind the first portion of the duodenum, descends to the

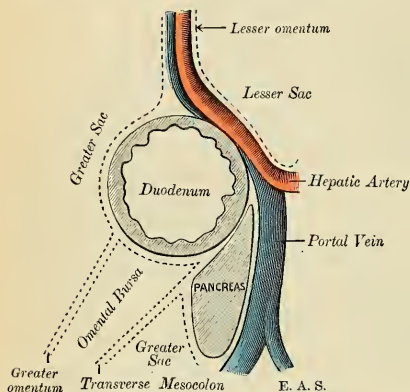


FIG. 1024.—Diagram of cross-section of the first part of the duodenum, to show its peritoneal relations. (Gerrish.)

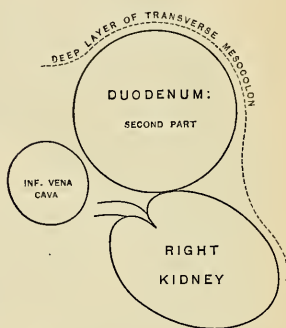


FIG. 1025.—Diagram of cross-section of the second part of the duodenum, to show its peritoneal relations. (Gerrish.)

inner side of the second portion, is joined by the pancreatic duct, and the two together perforate the inner side of this portion of the intestine obliquely, and empty into the duodenum by a common opening or by two openings at the summit of a papilla, some three and a half or four inches (9 to 10 cm.) beyond the pylorus.

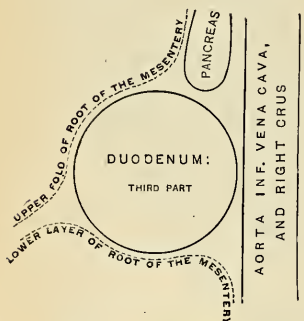


FIG. 1026.—Diagram of the third part of the duodenum, to show its peritoneal relations. (Gerrish.)

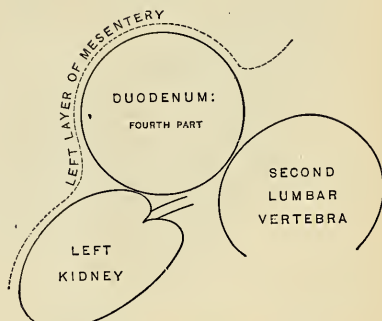


FIG. 1027.—Diagram of the fourth part of the duodenum, to show its peritoneal relations. (Gerrish.)

The relations of the second part of the duodenum to the right kidney present considerable variations.

The **third, preaortic, or transverse portion** (*pars horizontalis inferior*) (Figs. 1023 and 1026) is from two to three inches in length. It commences at the right side of the upper border of the fourth lumbar vertebra and passes from right

to left, with a slight inclination upward, in front of the great vessels and crura of the Diaphragm, and ends in the fourth portion in front of or just to the left of the abdominal aorta. It is crossed by the superior mesenteric vessels and the mesentery. Its *ventral* surface is covered by peritoneum, except near the middle line, where it is crossed by the superior mesenteric vessels (Fig. 1026). Its *posterior surface* rests upon the aorta, the inferior vena cava, and the crura of the Diaphragm. Its upper surface is in relation with the head of the pancreas.

The **fourth or ascending portion of the duodenum** (*pars ascendens*) (Figs. 1023 and 1027) is about an inch (2.5 cm.) long. It ascends on the left side of the vertebral column and aorta, as far as the level of the upper border of the second lumbar vertebra, where it turns abruptly forward to become the jejunum, forming the **duodenojejunal flexure** (*flexura duodenojejunalis*) (Fig. 1028). It lies in front of the left Psoas muscle and left renal vessels, and is covered in front and partly at the sides by peritoneum, continuous with the left portion of the mesentery (Fig. 1027). The left side of the termination of the ascending portion is also covered by peritoneum, and in this region some of the **duodenal fossæ** are found (p. 1265).

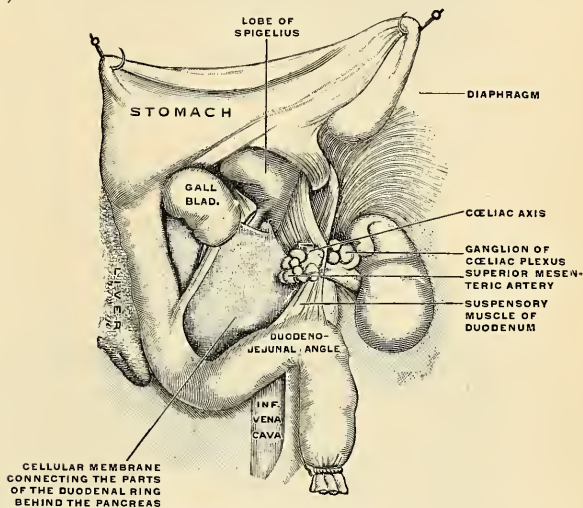


FIG. 1028.—Suspensory muscle of the duodenum or muscle of Treitz. (Poirier and Charpy.)

The first part of the duodenum, as stated above, is somewhat movable, but the rest is practically fixed and is bound down to neighboring viscera and the posterior abdominal wall by the peritoneum. In addition to this, the fourth part of the duodenum and the duodenojejunal flexure is further bound down and fixed by a structure called the **Suspensory muscle of the duodenum** or the **suspensory ligament of Treitz** (*m. suspensorius duodeni*) (Fig. 1028). This structure commences in the connective tissue around the celiac axis and left crus of the Diaphragm, and passes downward to be inserted into the superior border of the duodenojejunal curve and a part of the ascending duodenum, and from this it is continued into the mesentery. It possesses, according to Treitz, some few nonstriated muscle fibres mixed with the fibrous tissue, of which it is principally made up. It is of little importance as a muscle, but acts as a suspensory ligament.

Interior of the Duodenum (Fig. 1029).—The proximal part of the duodenum is comparatively smooth. Valvulae conniventes begin to appear in the distal half

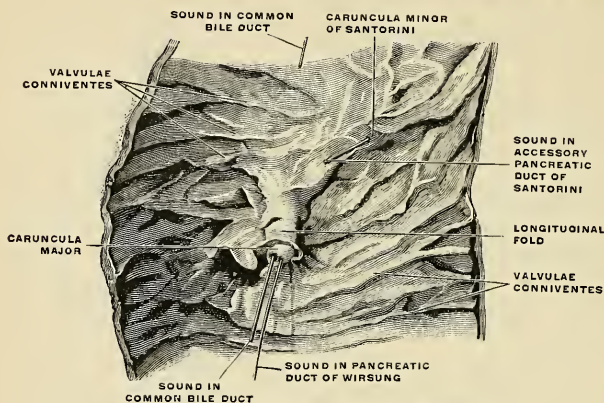


FIG. 1029.—The interior of the duodenum. (Spalteholz.)

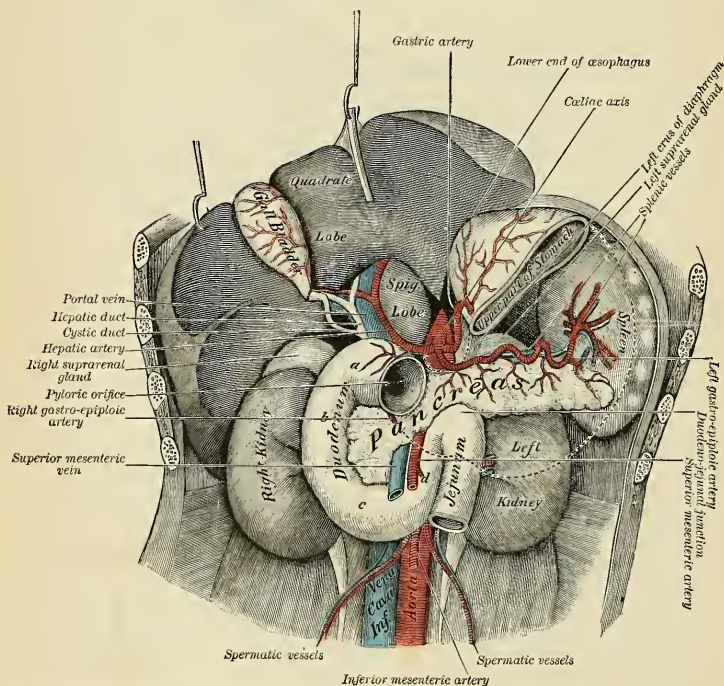


FIG. 1030.—The duodenum, its four parts marked a, b, c, d. The liver is lifted up; the greater part of the stomach is removed, broken lines indicating its former position. (Testut.)

of the first portion, being at first trivial elevations irregularly placed. They become higher, regular, and more numerous farther on, and near the termination of the duodenum are strongly marked and closely placed transverse or spiral folds (Fig. 1029 and p. 1289). In the descending portion (Fig. 1029), to the side and rear, is a longitudinal fold (*plica longitudinalis duodeni*), which is formed by the projection of the bile duct and pancreatic duct beneath the mucous membrane.

The **caruncula major of Santorini** or the **bile papilla** is a projection in the lower part of the longitudinal fold. At the summit of this papilla the bile duct and pancreatic duct empty into the duodenum. One inch above and half an inch or more in front of the bile papilla is a much smaller papilla, the **caruncula minor of Santorini** (*papilla duodeni* [Santorini]), on the summit of which the accessory pancreatic duct of Santorini opens when present.

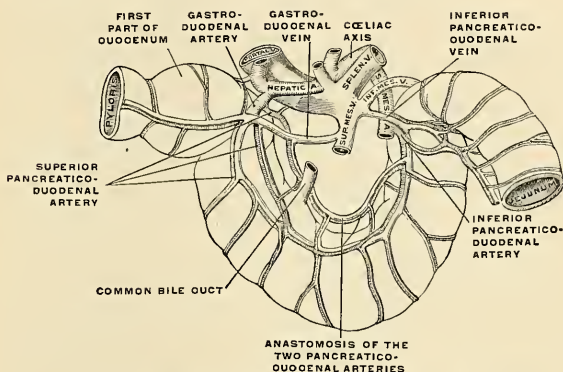


FIG. 1031.—The bloodvessels of the duodenum. (Poirier and Charpy.)

Structure of the Duodenum.—(See Structure of the Small Intestine, p. 1289.)

Vessels and Nerves.—The arteries (Fig. 1031) supplying the duodenum are the pyloric and pancreaticoduodenal branches of the hepatic, and the inferior pancreaticoduodenal branch of the superior mesenteric. The veins (Fig. 1031) correspond to the arteries. The superior duodenal vein passes into the superior mesenteric, and the inferior duodenal vein passes into the portal. The lymphatics pass along with the pancreaticoduodenal arteries, lymph nodes being present here and there, and terminate in the nodes about the coeliac axis. The nerves are derived from the solar plexus.

Applied Anatomy.—*Ulcer of the duodenum* is more common than used to be thought. The portion of the duodenum between the pylorus and the bile papilla is about four inches in length, and is called by the Mayo brothers the *vestibule of the duodenum*. Here the acid gastric juice enters and may produce an ulcer. The portion of the duodenum below the vestibule is not liable to ulcer, because it is protected by the alkaline bile and pancreatic juice.

A duodenal ulcer may perforate a large duodenal vessel and cause death from hemorrhage, or may perforate the intestine and produce septic peritonitis. A perforated ulcer is treated by laparotomy and closure of the perforation. Occasionally ulceration of the duodenal glands (*Curling's ulcer*) may occur in cases of extensive burns of the skin, but is not a very common complication.

The Jejunum and Ileum (Figs. 972, 1003).

The remainder of the small intestine from the termination of the duodenum comprises the **jejunum** and **ileum**; the former name being given to the upper two-fifths and the latter to the remaining three-fifths. Spalteholz and others call all of the small intestine below the duodenum the **intestinum tenue mesenteriale**. There

is no morphological line of distinction between the jejunum and ileum, and the division is arbitrary; but at the same time it must be noted that the character of the intestine gradually undergoes a change from the commencement of the jejunum to the termination of the ileum, so that a portion of the bowel taken from these two situations would present characteristics and marked differences. These are briefly as follows:

	Jejunum.	Ileum.
Calibre	larger ($1\frac{1}{2}$ inches).	smaller (1 inch).
Wall	thicker, heavier.	thinner, lighter.
Color	red, more vascular.	pale, less vascular.
Valvulae conniventes	prominent.	smaller and fewer.
Lymphoid tissue	diffuse and few nodules.	diffuse and many Peyer's patches.
Villi	numerous, short, and broad.	fewer, slender, filiform.
Intestinal glands	more numerous.	less numerous.

The Jejunum (*intestinum jejunum*).—The jejunum is wider, its diameter being about one inch and a half (3.75 cm.), and is thicker, more vascular, and of a deeper color than the ileum, so that a given length weighs more. Its valvulae conniventes are large and thickly set and its villi are larger than in the ileum. The patches of Peyer are almost absent in the upper part of the jejunum, and in the lower part are less frequently found than in the ileum, and are smaller and tend to assume a circular form. Brunner's glands are only found in the duodenum. By grasping the jejunum between the finger and thumb the valvulae conniventes can be felt through the walls of the gut; these being absent in the lower part of the ileum, it is possible in this way to distinguish the upper from the lower part of the small intestine.

The Ileum (*intestinum ileum*).—The ileum is narrower, its diameter being one inch (2.5 cm.) or a little more, and its coats are thinner and less vascular than those of the jejunum. It possesses but few valvulae conniventes, and they are small and disappear entirely toward its lower end, but Peyer's patches are larger and more numerous. The jejunum for the most part occupies the umbilical and left iliac regions, while the ileum occupies chiefly the umbilical, hypogastric, right iliac, and pelvic regions, and terminates in the right iliac fossa by opening into the inner side of the commencement of the large intestine. The jejunum and ileum are attached to the posterior abdominal wall by an extensive fold of peritoneum, the **mesentery** (p. 1263), which allows the freest motion, so that each coil can accommodate itself to changes in form and position. The mesentery is fan-shaped; its posterior border or root, about six inches (15 cm.) in length, is attached to the posterior abdominal wall from the left side of the body of the second lumbar vertebra to the right iliac fossa, crossing successively the third part of the duodenum, the aorta, the inferior vena cava, the right ureter, and the right Psoas muscle (Fig. 1004). Its breadth between its vertebral and intestinal borders is about eight inches (20 cm.) from its commencement to its termination at the intestine, and it is greater in the middle than at either end of the bowel. According to Lockwood, it tends to increase in length as age advances. Between the two layers of which it is composed are contained bloodvessels, nerves, lacteals, and lymph nodes, together with a variable amount of fat.

Meckel's Diverticulum (*diverticulum ilei*).—This consists of a pouch which projects from the lower part of the ileum in about 2 per cent. of subjects. Its average position is about three feet from the ileocolic junction, and its average length about two inches. Its calibre is generally the same as that of the ileum. Sometimes only a portion of the proximal end has a lumen and the balance of the structure is impervious and shrunk to a fibrous cord. In other cases the diverticulum is actually of greater diameter than the intestine. It usually is at a right angle to the intestine, but may take almost any direction. Its blind extremity may be unattached or may be connected with the abdominal wall or with some other

portion of the intestine by a fibrous band. It represents the remains of the vitelline or omphalomesenteric duct, the duct of communication between the umbilical vesicle and the alimentary canal in early fetal life.

Structure of the Small Intestine, Including the Duodenum.—The wall of the small intestine is composed of four coats—serous, muscular, submucous, and mucous.

The Serous Coat (*tunica serosa*).—The relation of the peritoneum to the duodenum has been described. The remaining portion of the small intestine is surrounded by the peritoneum, excepting along its attached or mesenteric border; here a space is left for the vessels and nerves to pass to the gut.

The muscular coat (*tunica muscularis*) consists of two layers of fibres, an **external** or **longitudinal layer** and an **internal** or **circular layer**.

The **longitudinal fibres** (*stratum longitudinale*) are thinly scattered over the surface of the intestine, and are more distinct along its free border.

The **circular fibres** (*stratum circulare*) form a thick, uniform layer; they surround the cylinder of the intestine in the greater part of its circumference, and are composed of smooth muscle cells of considerable length. The muscular coat is thicker at the upper than at the lower part of the small intestine.

The **submucous coat** (*tela submucosa*) connects the mucous and muscular layers. It consists of loose, filamentous areolar tissue, which forms a bed for the subdivisions of the nutrient vessels, previous to their distribution to the mucous surface, also for the lymph channels and nerves.

The submucous coat contains **lymph nodules** (*noduli lymphatici*). Each nodule is pyramidal or pear-shaped, and the apex lies in the mucous membrane and forms a rounded elevation. These rounded elevations mark the **solitary follicles** and **Peyer's patches** (Figs. 1033 and 1040), and nowise resemble villi. In the duodenum the submucous tissue contains the **duodenal glands**. The submucous tissue is prolonged into the **valvulae conniventes**. It contains bloodvessels, Meissner's plexus of nerves, and lymph vessels.

The **mucous membrane** (*tunica mucosa*) is thick and highly vascular at the upper part of the small intestine, but somewhat paler and thinner below. It consists of the following structures: next the areolar or submucous coat is a layer of unstriped muscle tissue, the **muscularis mucosae**; internal to this is a quantity of retiform tissue, enclosing in its meshes lymph corpuscles (diffuse lymphoid tissue), and in which the bloodvessels and nerves ramify. Lastly, a basement membrane, supporting a single layer of columnar epithelial and goblet cells. They are granular in appearance, and each possesses a clear, oval nucleus. At their superficial or unattached end they present a distinct layer of highly refracting material, the **cuticular border**, marked by vertical striae.

The mucous membrane presents for examination the following structures contained within it or belonging to it:

Valvulae conniventes.

Villi.

Intestinal glands.

Lymphatic nodules { Solitary follicles.
Peyer's or agminated follicles.

The **valvulae conniventes** or the **valves of Kerkring** (*plicae circulares* [*Kerkringi*]) (Fig. 1032) are large folds or valvular flaps projecting into the lumen of the bowel. They are composed of reduplications or folds of the mucous membrane, the two layers of the fold being bound together by submucous tissue; they contain no muscular fibres, and, unlike the folds in the stomach, they are permanent, and are not obliterated when the intestine is distended. The majority extend transversely across the cylinder of the intestine for about one-half or two-thirds of its circumference, but some form complete circles, and others have a spiral direction; the latter usually extend a little more than once around the bowel, but occasionally two or three times. The larger folds are about one-third of an inch in depth at the broadest part; but the greater number are of smaller size. The larger and smaller folds alternate with each other. They are not found at the commencement of the duodenum, but begin to appear about one or two inches beyond the pylorus. In the lower part of the descending portion,

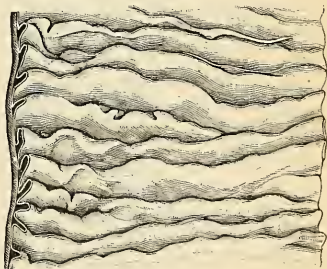


FIG. 1032.—Valvulae conniventes in the upper part of the small intestine. (Poirier and Charpy.)

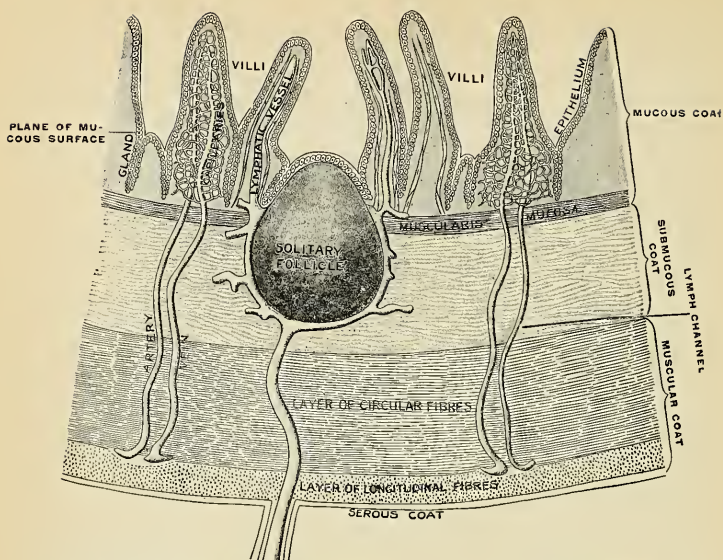


FIG. 1033.—Mucosa of small intestine in ideal vertical cross-section. (Testut, after Heitzmann.)

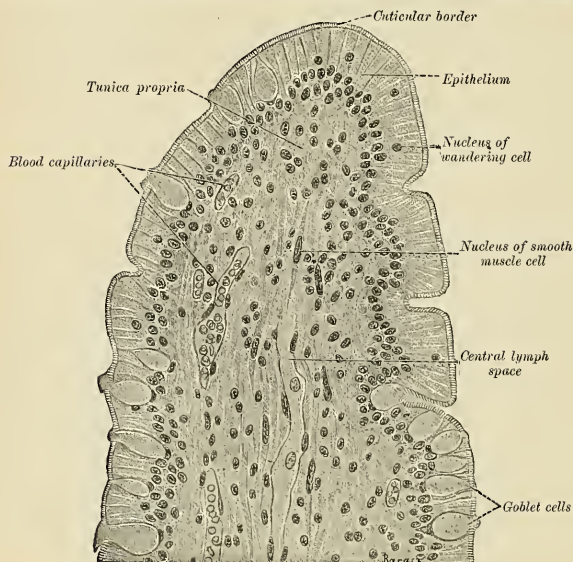


FIG. 1034.—Longitudinal section through the end of a villus from the small intestine of a cat. $\times 450$.

below the point where the bile and pancreatic ducts enter the intestine, they are very large and closely approximated. In the transverse portion of the duodenum and upper half of the jejunum they are large and numerous; and from this point, down to the middle of the ileum, they diminish considerably in size. In the lower part of the ileum they almost entirely disappear; hence the comparative thinness of this portion of the intestine as compared with the duodenum and jejunum. The *valvulae conniventes* retard the passage of the food along the intestine, and afford a more extensive surface for absorption.

The **villi** (*villi intestinalis*) (Figs. 1034 and 1035) are minute, highly vascular processes, never larger than 1 millimeter, projecting from the mucous membrane of the small intestine throughout its whole extent, and giving to its surface a velvety appearance. They spring from the *valvulae conniventes* and also from the spaces between them. In shape, according to Rauber, they are short and leaf-shaped in the duodenum, tongue-shaped in the jejunum, and filiform in the ileum. They are largest and most numerous in the duodenum and jejunum, and become fewer and smaller in the ileum. Kraus estimates their number in the upper part of the small intestine at from fifty to ninety in a square line; and in the lower part from forty to seventy, the total number for the whole length of the intestine being about four millions.

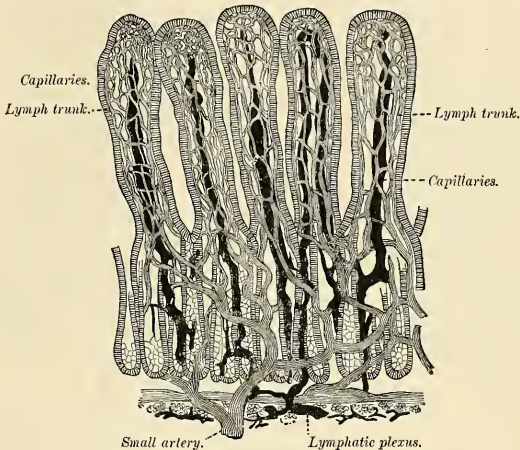


FIG. 1035.—Villi of small intestine. (Cadiat.)

Structure of the Villi (Figs. 1034 and 1035).—The structure of the villi has been studied by many eminent anatomists. We shall here follow the description of Watney,¹ whose researches have a most important bearing on the physiology of that which is the peculiar function of this part of the intestine, the absorption of fat.

The essential parts of a villus are the lacteal vessel, the bloodvessels, the epithelium, the basement membrane, and muscle and lymphoid tissues of the mucosa, these structures being supported and held together by retiform tissue.

These structures are arranged in the following manner: Situated in the centre of the villus is a space, the **lacteal**, terminating near the summit in a blind extremity; running beside this vessel are unstriated muscle fibres; surrounding it is a meshwork of fibroelastic tissue supporting a plexus of capillary vessels and diffuse lymphoid tissue, the whole being enclosed by a basement membrane, and covered by simple columnar epithelium and goblet cells. Nerve fibres are contained within the villi; they form ramifications throughout the reticulum.

The **lacteals** are in some cases double, and in some animals *multiple*. Situated in the axis of a villus, each commences by a dilated cecal extremity near to, but not quite at, the summit of the villus. The walls are composed of a single layer of endothelial cells, the interstitial substance between the cells being continuous with the reticulum of the matrix. The **muscle fibres** are derived from the muscularis mucosae, and are arranged in bundles around the lacteal vessel,

¹ Phil. Trans., vol. clxv, part ii.

extending from the base to the summit of the villus, and giving off laterally individual muscle cells, which are enclosed by the reticulum, and by it are attached to the basement membrane.

The **bloodvessels** form a plexus between the lacteal and the basement membrane, and are enclosed in the reticular tissue; in the interstices of the capillary plexus, which they form, are contained the cells of the villus.

The **intestinal glands, crypts** or **glands of Lieberkühn** (*glandulae intestinales* [*Liebrkühni*]) (Figs. 1036 and 1040), are found in considerable numbers over every part of the mucous membrane of the small intestine. They consist of minute simple tubular depressions of the mucous membrane, arranged perpendicularly to the surface, upon which they open by small circular apertures. They may be seen with the aid of a lens, their orifices appearing as minute dots seen at the base of the villi. Their walls are thin, consisting of a basement membrane lined by simple columnar epithelium and goblet cells, and are surrounded by capillary vessels. In the glands of the ileum and also to a certain extent those of the jejunum are seen some coarsely granular cells, the **cells of Paneth**. They seem to be cells of special secretion.

The **duodenal** or **Brunner's glands** (*glandulae duodenales* [*Brunneri*]) are limited to the duodenum. They are small, branched, tubular glands in the submucous coat, and open upon the surface of the mucous membrane by minute excretory ducts. They are most numerous and largest near the pylorus. They resemble the pyloric glands in appearance, and are believed to be a direct continuation of those glands. The cells are clear and pale staining, and Stöhr states that cells resembling parietal cells are occasionally seen.

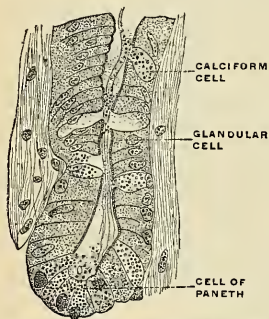


FIG. 1036.—Section of a gland of Lieberkühn in the mouse. (Paneth.)

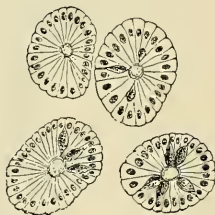

FIG. 1037.—Transverse section of crypts of Lieberkühn. (Klein and Noble Smith.)

The **lymph nodules** (*noduli lymphatici*) are small pyriform structures. The bodies of the nodes are in the submucous coat; the apices are in the mucous membrane, which is thrown by them into rounded elevations. They are divided into **solitary follicles** and **Peyer's patches**.

The **solitary follicles** (*noduli lymphatici solitarii*) (Fig. 1033) are found scattered throughout the mucous and submucous coats of the small intestine and the large intestine. In the small intestine they are most numerous in the lower part of the ileum, upon and between the valvulae conniventes. They are small, round, whitish bodies, from one-twenty-fourth of an inch to one-quarter of an inch (1 to 6 mm.) in diameter. Their free surface is free of villi, and each follicle is surrounded by the openings of the glands of Lieberkühn. They are now recognized as lymph nodules. They consist of a dense interlacing retiform tissue closely packed with lymph corpuscles and permeated with an abundant capillary network. The interspaces of the retiform tissue are continuous with larger lymph spaces at the base of the nodule, through which they communicate with the lacteal system. Each consists of a lighter central area, the **germinal centre**, where the leukocytes are reproducing, and a peripheral darker zone, where the cells are more numerous and closely packed.

Peyer's patches, the **agminated follicles**, or the **tonsillae intestinales** (*noduli lymphatici aggregati* [*Peyeri*]) (Figs. 1038, 1039, and 1040) may be regarded as aggregations of solitary follicles, forming circular or oval patches from ten to sixty in number, and varying in length from half an inch to four inches (1.25 to 10 cm.). They are largest and most numerous in the ileum. In the lower part of the jejunum they are small, of a circular form, and few in number. They are occasionally seen in the duodenum. They are placed lengthwise in the intestine, and are situated in the portion of the tube most distant from the attachment of the mesentery. Each patch is formed of a group of the above-described solitary follicles covered with mucous membrane, and in almost every respect are similar in structure to them. They do not, however, as a rule,

possess villi on their free surface nor glands. Each patch is surrounded by a circle of the crypts of Lieberkühn. They are best marked in the young subject, becoming indistinct in middle age and sometimes altogether disappearing in advanced life. They are largely supplied with blood

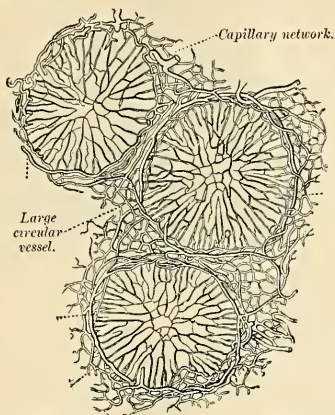


FIG. 1038.—Transverse section through the equatorial plane of three of Peyer's follicles from the rabbit.

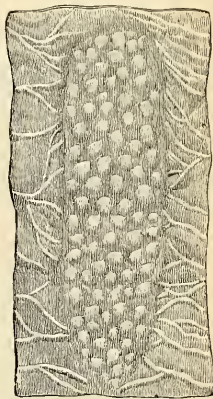


FIG. 1039.—Free surface of a Peyer's patch. (After Quain.)

vessels, which form an abundant plexus around each follicle and give off fine branches which permeate the lymphoid tissue in the interior of the follicle. The lacteal plexuses which are found throughout the small intestine are especially abundant around these patches; here they form rich plexuses with sinuses around the glands (Fig. 1024). In typhoid fever there is ulceration of Peyer's patches.

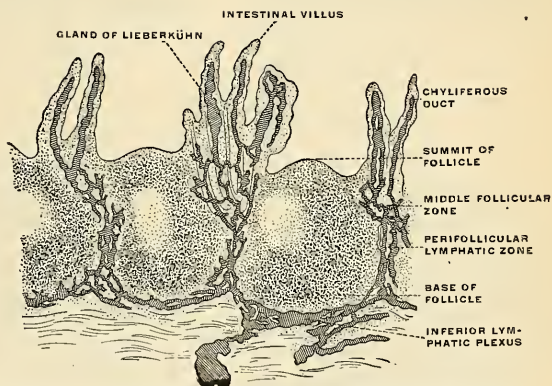
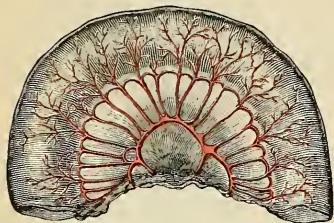


FIG. 1040.—Vertical section of a Peyer's patch in a man with the lymphatic vessels injected. (Frey.)

Vessels and Nerves.—The arteries (*vasa intestini tenuis*) are branches of the superior mesenteric (Fig. 470) and course within the mesentery, forming single, double, or even tertiary loops (Figs. 1041, 1042, 1043, 1044, 1045, and 1046). The terminal branches reach the intestine, and each branch divides into two, one going to each side of the intestine and passing transversely around it. At first they are directly beneath the peritoneum, but after a time they pass to the

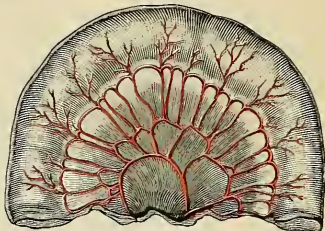
submucosa and form a plexus, from which branches go to the mucous membrane. Some of these enter the villi; others form plexuses about the glands of Lieberkuhn (Birmingham). The details of the arterial blood supply of the small intestines are given on page 663.

FIG. 1041



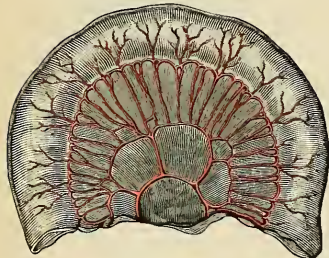
Three feet.

FIG. 1042



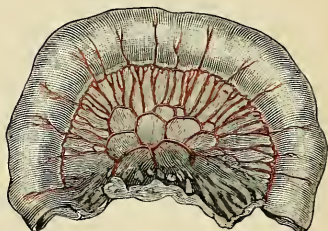
Six feet.

FIG. 1043



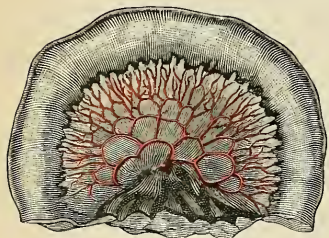
Nine feet.

FIG. 1044



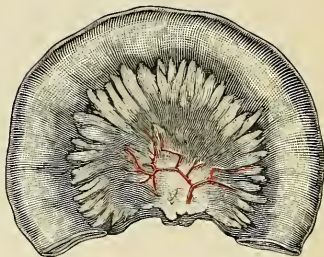Twelve feet.

FIG. 1045



Seventeen feet.

FIG. 1046



Twenty feet.

FIGS. 1041, 1042, 1043, 1044, 1045, 1046.—Diagrams showing the arrangement and variations of the loops of the mesenteric vessels for various segments of the small intestine of average length. Nearest the duodenum the mesenteric loops are primary, the vasa recta are long and regular in distribution, and the translucent spaces (lunettes) are extensive. Toward the ileocolic junction, secondary and tertiary loops are observed, the vessels are smaller and become obscured by numerous fat-tabs. (After Monks.) (See p. 1269 for detailed description.)

The **veins** correspond to the arteries, and the venous blood passes to the **superior mesenteric vein**, which, it will be remembered, unites with the splenic vein to form the portal vein. The mesenteric veins are devoid of valves.

The **lacteals** are **lymphatics** (Figs. 1033 and 1040) which arise in the villi. Lymphatics also begin in sinuses at the base of the solitary follicles and in Peyer's patches. There is an extensive lymphatic plexus in the submucous coat, another in the muscular coat, another under the peritoneum. The submucous plexus is formed by lymphatics from the villi and mucous membrane. This plexus is joined by lymphatics from the bases of the solitary follicles, and the lymph passes by vessels to larger vessels at the mesenteric border of the gut. The muscular lymphatics are placed between the two muscular layers. They form a plexus and communicate freely with the lymphatics from the mucous membrane, and empty themselves in the same manner into the commencement of the lacteal vessels at the attached border of the gut. The vessels from all sources of lymphatic supply pass up between the two layers of the mesentery, being connected with the **mesenteric nodes** (Fig. 572), and unite to form a trunk, the **intestinal lymphatic trunk**, which opens into the receptaculum chyli, or the vessels unite to form several trunks, which open separately into the receptaculum chyli.

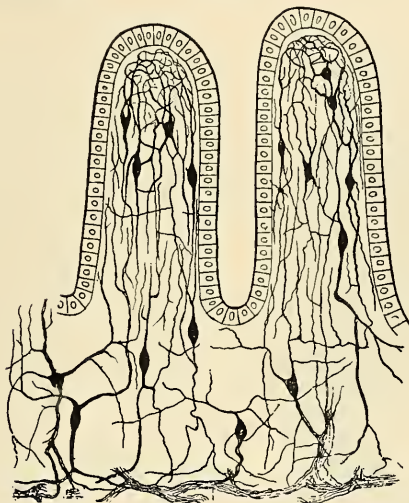


FIG. 1047.—Meissner's plexus. (Ramón y Cajal.)

The **nerves of the small intestine** (Fig. 1047) are derived from the **celiac plexus** about the superior mesenteric artery. They pass along within the mesentery with the superior mesenteric artery and reach the intestine. They pass to the plexus of nerves and ganglia situated between the circular and longitudinal muscular fibres (**Auerbach's plexus**), from which the nerve branches are distributed to the muscular coats of the intestine. From this plexus a secondary plexus is derived (**Meissner's plexus**). It is formed by branches which have perforated the circular muscular fibres. This plexus lies in the submucous coat. It is also gangliated, and from it the ultimate fibres pass to the muscularis mucosae, to the villi, and to the mucous membrane. The nerves of the intestine are amyelinic, and some of the fibres are derived from the vagus.

Applied Anatomy.—The applied anatomy of the small intestine, especially the surgical anatomy of the **hernias**, is given on page 1315.

THE LARGE INTESTINE (INTESTINUM CRASSUM) (Figs. 977, 1078).

The large intestine extends from the termination of the ileum to the anus. It is about five feet or more in length, being one-fifth of the whole extent of the intestinal canal. It is largest at its commencement at the cecum, and gradually

diminishes as far as the rectum, where there is a dilatation of considerable size just above the anal canal. It differs from the small intestine in its greater size, its more fixed position, its sacculated wall, and in possessing certain appendages to its external coat, the **appendices epiploicae** (Fig. 1048), little peritoneal pouches containing fat.

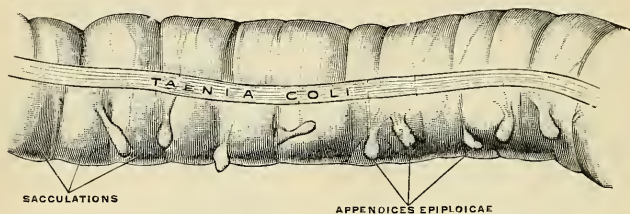


FIG. 1048.—Large intestine. A piece of transverse colon from a child two years old. The three chief characteristics of the large intestine—sacculations, tæniæ, and appendices epiploicae—are shown. (Cunningham.)

Further, the longitudinal muscle fibres of the large intestine do not form a continuous layer around the gut, but are arranged in three **longitudinal bands** or **tæniæ** (*taeniae coli*) (Fig. 1048). The large intestine, in its course, describes an arch which surrounds the convolutions of the small intestine. The segment of the intestinal tract where the small intestine joins the large is termed the **ileocecal** or **ileocolic junction**. The large intestine commences in the right inguinal region,

in a dilated part, the **cecum**, together with a rudimentary structure, the **appendix**. It ascends through the right lumbar and right hypochondriac regions to the under surface of the liver; here it takes a bend to the left (**hepatic flexure**), and passes transversely across the abdomen on the confines of the epigastric and umbilical regions, to the left hypochondriac region; it then bends again (**splenic flexure**), and descends through the left lumbar region to the left iliac fossa, where it becomes convoluted, and forms the **sigmoid flexure**; finally it enters the pelvis and descends along its posterior wall to the anus. The large intestine is divided into the **cecum**, **colon**, **rectum**, and **anal canal**.

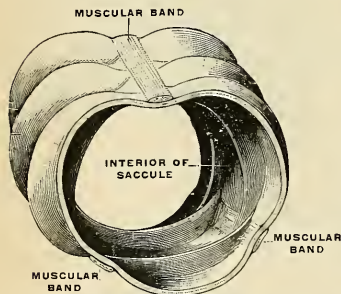


FIG. 1049.—Segment of large intestine, showing the characteristic feature of its structures. (Testut.)

The Cecum.

The **cecum** (*intestinum cecum*) (Figs. 1050 and 1051–1054), the commencement of the large intestine, is the large blind pouch situated below the ileocecal valve. Its blind end or fundus is directed downward, and its open end upward, communicating directly with the colon, of which this blind pouch appears to be the beginning or head, and hence the old name **caput cecum coli** was applied to it. Its size is variously estimated by different authors, but on an average it may be said to be two and one-half inches (6.25 cm.) in length and three (7.5 cm.) in breadth.¹

¹ In 435 careful autopsies, Robinson found the cecum and appendix congenitally absent in one case (St. Louis Courier of Medicine, October–December, 1902). Sometimes a very large, sometimes an exceedingly small, cecum is encountered. A large cecum may be four inches in width, entirely surrounded by peritoneum, and usually is excessively mobile. An adult cecum may be only one inch in width and one-half an inch in length, and it is usually devoid of mobility.

It is situated in the right iliac fossa, above the outer half of Poupart's ligament; it rests on the Iliopsoas muscle, and lies immediately behind the abdominal wall. As a rule, it is entirely enveloped on all sides by peritoneum, but in a certain number of cases (6 per cent., according to Berry) the peritoneal covering is not complete, so that a small portion of the upper end of the posterior surface is uncovered and connected to the iliac fossa by connective tissue. The cecum lies quite free in the abdominal cavity and is capable of a considerable amount of movement, so that it may become herniated down the right inguinal canal, and has occasionally been found in an inguinal hernia on the left side.¹

The cecum varies in shape, but, according to Treves, in man it may be classified under one of four types (Figs. 1051-1054). In early fetal life it is short, conical, and broad at the base, with its apex turned upward and inward toward the ileocecal junction. It then resembles the cecum of some of the monkey tribe, *e. g.*, Mangabey monkey. As the fetus grows the cecum increases in length more than in breadth, so that it forms a longer tube than in the primitive form and without the broad base, but with the same inclination inward of the apex toward the ileocecal junction. This form is seen in others of the monkey tribe, *e. g.*, the spider monkey. As development goes on, the lower part of the tube ceases to grow and the upper part becomes greatly increased, so that at birth there is a narrow tube, the **vermiform appendix**, hanging from a conical projection, the **cecum**. This is the **infantile form**, and as it persists throughout life, in about 2 per cent. of cases it is regarded by Treves as the *first* of his four types of human ceca. The cecum is conical and the appendix rises from its apex. The three longitudinal bands start from the appendix and are equidistant from each other. In the *second* type, the conical cecum has become quadrate by the growing out of a saccule on either side of the anterior longitudinal band. These sacculae are of equal size, and the appendix arises from between them instead of from the apex of a cone. This type is found in about 3 per cent. of cases. The *third* type is the normal type of man. Here the two sacculae, which in the second type were uniform, have grown at unequal rates, the right with greater rapidity than the left. In consequence of this an apparently new apex has been formed by the growing downward of the right saccule, and the original apex, with the appendix attached, is pushed over to the left toward the ileocecal junction. The three longitudinal bands still start from the base of the appendix, but they are now no longer equidistant from one another, because the right saccule has grown between the anterior and postero-external bands, pushing them over to the left. This type occurs in about 90 per cent. of cases. The *fourth* type is merely an exaggerated condition of the third; the right saccule is still larger, and at the same time the left saccule has been atrophied, so that the original apex of the cecum, with the appendix, is close to the ileocecal junction, and the anterior band courses inward to the same situation. This type is present in about 4 per cent. of cases.

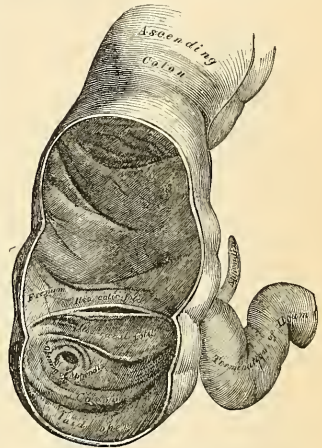
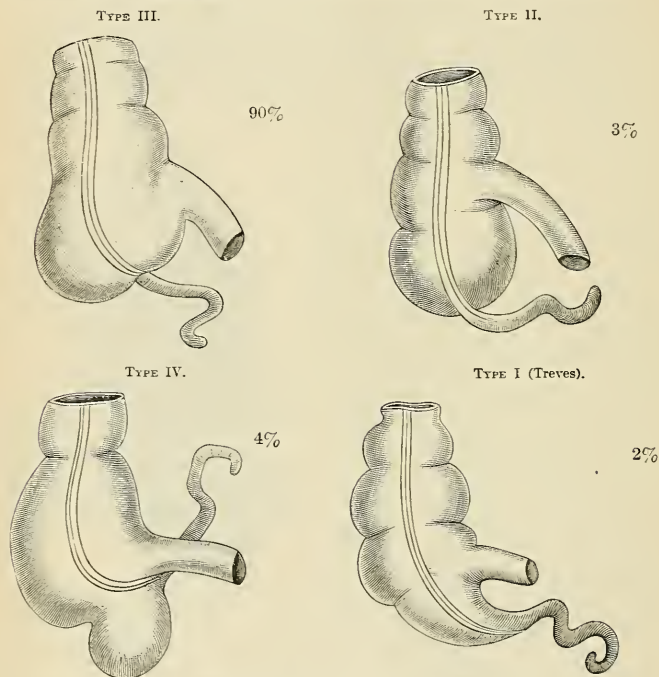


FIG. 1050.—The cecum and colon laid open to show the ileocecal valve.

¹ In 310 adult males, Robinson found 8 per cent. with undescended cecum and appendix. Nondescent was found in less than 4 per cent. of females. A partly descended cecum usually lies upon the right kidney.

The Interior of the Cecum.—Corresponding to the surface sacculations are seen the pouch-like depressions (*haustra*) bounded by the **semilunar folds** (*plicae semilunares coli*) (Fig. 1050), corresponding to the surface constrictions which mark off the saccules. The interior of the cecum is continued into the colon above, and the orifice of the ileum and of the appendix open into it. These orifices, guarded respectively by the ileocecal valve and by the valve of Gerlach, are described on pages 1299 and 1301.

Pericecal Folds and Fossæ.—See page 1266, and Figs. 1007 and 1008.



FIGS. 1051 TO 1054.—The four types of cecum.

The Vermiform Appendix (*processus vermiformis*) (Figs. 1056 and 1062).—The vermiform appendix is found only in man, the higher apes, and the wombat, although in certain rodents a somewhat similar arrangement exists. In carnivorous animals the cecum is very slightly developed; in herbivorous animals (with a simple stomach) it is, as a rule, extremely large. It has been suggested that the vermiform process in man is the degenerated remains of the herbivorous cecum, which has been replaced by the carnivorous form. The vermiform appendix is a long, narrow, worm-shaped, musculomembranous tube, which starts from what was originally the apex of the cecum. After development has advanced the vermiform appendix comes off, as a rule, from the inner side of the posterior wall of the cecum, below and behind the termination of the ileum. This origin usually corresponds to **McBurney's point** on the abdominal wall, two to three inches from the anterior superior iliac spine on a line from this process to the umbilicus, and which is the usual seat of the greatest tenderness in appendicitis. The origin of the

appendix varies with the type of cecum present. These variations are shown in Figs. 1051–1054. The movable portion of the appendix may be met with in different situations. It may pass upward and in front of the cecum and colon, upward and behind the cecum, and even behind the colon between the two layers of the mesocolon; upward and to the inner side or upward and to the outer side of the cecum and colon. It may pass to the left under the ileum and mesentery, upward and to the left or downward and to the left into the true pelvis. It may pass directly downward under the cecum. It may pass to the right in front of or back of the cecum. It may occupy any one of the pericecal fossæ (p. 1266), but most often enters the ileocecal fossa. When the cecum is mobile the appendix may be found almost anywhere within the abdomen. When the cecum is undescended, the appendix of course shares in the failure to descend, and may be below the gall-bladder or in front of the right kidney, and may pass in several directions—upward behind the cecum, to the left behind the ileum and mesentery; or downward and inward into the true pelvis. It varies from one-

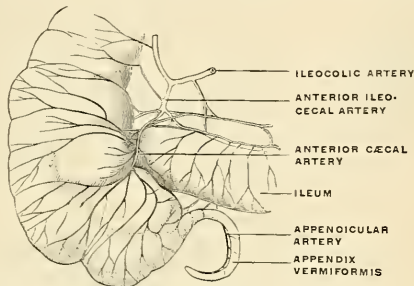


FIG. 1055.—Arteries of the cecum and of the appendix vermiformis and of the terminal portion of the ileum. (Poirier and Charpy.)

half an inch to nine inches in length (1.25 to 22.5 cm.) its average being about three inches (7.5 cm.). Its diameter is from one-eighth inch to one-quarter inch (3 to 6 mm.). The operating surgeon may occasionally fail to find an appendix buried in one of the cecal fossæ, and may conclude that the diverticulum is absent. In rare instances the appendix has been found absent. It is retained in position by a fold of peritoneum derived from the left leaf of the mesentery, which forms a mesentery for it, and is called the **mesoappendix** (p. 1265 and Figs. 1007 and 1008). This fold, in the majority of cases, is more or less triangular in shape, and, as a rule, extends along the entire length of the tube. In color the healthy appendix is yellowish-pink and is soft and smooth to the touch. The **canal of the appendix** is small and extends throughout the whole length of the organ. The walls of the healthy diverticulum are thick, and the diameter of the lumen is usually trivial as compared with the diameter of the appendix itself. The lumen of the appendix communicates with the cecum by an orifice which is placed below and behind the ileocecal opening (Fig. 1060). It is sometimes guarded above and to the left side by a semilunar fold of mucous membrane, the **valve of Gerlach** (*valvula processus vermiformis*). The valve is inconstant, and is never perfect. It is stated that the lumen of the appendix tends to undergo obliteration in advanced age as an involution change in a supposedly functionless organ. The lumen rarely contains foreign bodies after death, but often contains fecal concretions. Certain it is that in 25 per cent. of necropsies upon adults or elderly persons the lumen is found to be partially or completely occluded.

Structure of the Appendix (Fig. 1058).—The coats of the appendix correspond to the coats of the bowel—**serous**, **muscular** (the outer layer of longitudinal, the inner of circular fibres), **submucous**, and **mucous**.

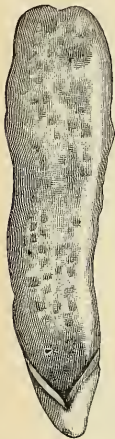


FIG. 1056.—The internal surface of the vermiform appendix. (Donany and Broca.)

The **outer** or **serous coat** forms a complete investment for the appendix except along the narrow line of attachment of its mesentery in its proximal two-thirds or more.

The **longitudinal muscle layer** is thin and irregularly distributed, and in certain regions may be exceedingly thin or actually absent, so that the peritoneal and submucous coats are contiguous over small areas.

The **circular muscle layer** is a much thicker layer than the preceding, and at the blind extremity forms a dome-like collection of interlacing fibres. Both layers have openings at intervals for the passage of bloodvessels.

The **submucous coat** varies greatly in thickness. It contains bloodvessels, nerves, and lymphatics, and a large number of lymphoid follicles (300 to 400) and, at times, adipose tissue.

The **mucous membrane** (Fig. 1056) is lined by columnar epithelium and contains numerous solitary lymph follicles, glands of Lieberkühn (about 25,000), surrounded by diffuse lymphoid tissue, bloodvessels, lymphatics, and nerves.

The **muscularis mucosae** may be absent, may be scanty, or may be distinct. The **lymphoid follicles** are visible to the naked eye (Fig. 1056). Some of them are in the submucosa, some of them chiefly in the mucosa, the bases of the latter, however, being in the submucosa.

The **arteries of the cecum and appendix** are derived from the ileocolic branch of the superior mesenteric artery. Close to the ileocecal junction the ileocolic artery gives off *anterior* and *posterior ileocecal* branches to the terminal part of the ileum and beginning of the large intestine. The terminal branches to the cecum are called *anterior* and *posterior cecal* arteries. The appendix is supplied by the *appendicular artery*, a branch of the posterior ileocecal artery (see p. 664).

The **veins** of the appendix are numerous, thin walled, and large. Veins from the submucous plexus pass through the muscular gaps and enter the subperitoneal plexus. Veins from the subperitoneal plexus pass into the veins in the mesoappendix which correspond to but do not really

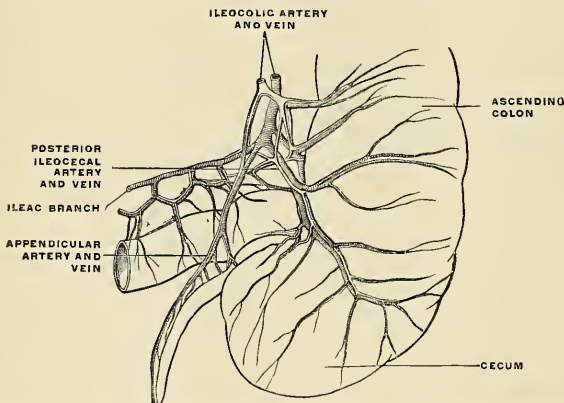


FIG. 1057.—Arteries and veins of the cecum and vermiform appendix seen from behind. (Poirier and Charpy.)

accompany the arteries (Lockwood). Most of the veins of the mesoappendix pass to the **posterior ileocecal vein**, though some pass directly to the **cecal vein**. These veins are radicles of the portal system.

The **lymphatics** of the cecum and appendix are described on page 794.

The Ileocecal Valve (*valvuli coli*) (Figs. 1060 and 1061).—The lower end of the ileum terminates by opening into the inner and back part of the large intestine, at the point of junction of the cecum with the colon. The opening is guarded by a valve, consisting of two semilunar segments, an **upper or colic segment** (*labium superius*) and a **lower or cecal segment** (*labium inferius*), which project into the

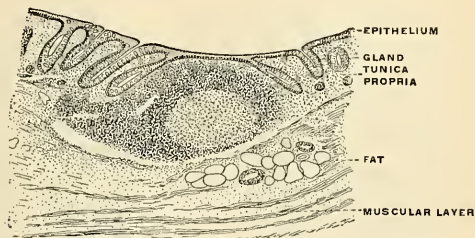


FIG. 1058.—Transverse section of the vermiform appendix of man. (Kölliker.)

lumen of the large intestine. The upper one, nearly horizontal in direction, is attached by its convex border to the point of junction of the ileum with the colon; the lower segment, which is more concave and longer, is attached to the point of junction of the ileum with the cecum. At each end of the aperture the two segments

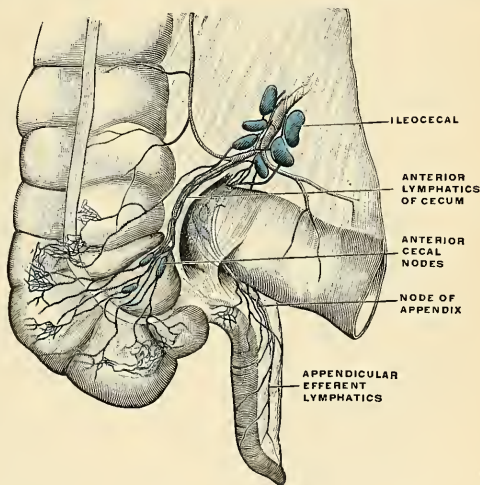


FIG. 1059.—Lymphatics of the cecum and appendix, anterior view. (Poirier and Charpy.)

of the valve coalesce, and are continued as a narrow membranous ridge around the canal for a short distance. Each **ridge** is known as the **frenulum of the valve** (*frenulum valvulae coli*). The left or anterior part of the aperture is rounded; the right or posterior is narrow and pointed. In the formation of the valve the termination of the small intestine invaginates for a short distance into the lumen

of the large intestine (Fig. 1061), the invaginated portion of the wall of the small intestine uniting with a corresponding portion of the wall of the large intestine. Each segment of the valve is formed by a reduplication of the mucous membrane and of the circular muscle fibres of the intestine, the longitudinal fibres and peritoneum being continued uninterruptedly across the one portion of the intestine to the other.

The surface of each segment of the valve directed toward the ileum possesses villi, and presents the characteristic structure of the mucous membrane of the

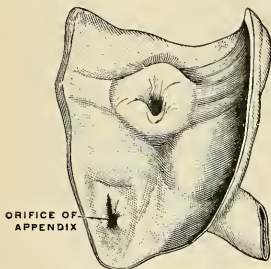


FIG. 1060.—Ileocele valve of the circular type. (Poirier.)

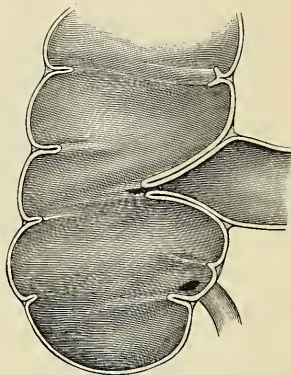


FIG. 1061.—Vertical section through the cecum and ileocecal valve. (Gegenbaur.)

small intestine; while that turned toward the large intestine is destitute of villi, and marked with the orifices of the numerous tubular glands peculiar to the mucous membrane of the large intestine. These differences in structure continue as far

as the free margins of the valve. When the cecum is distended it is supposed that the margins of the opening are approximated so as to prevent reflux into the ileum. It is known, however, that a very large enema which distends the cecum and colon may in part enter the ileum, being driven there by waves of reversed peristalsis. The valve resists, but a certain amount of pressure overcomes it. Some believe that the so-called ileocecal valve is not a valve, but a distinct sphincter. This has been demonstrated to be true in cats and dogs, but lacks demonstration in man (p. 1313).

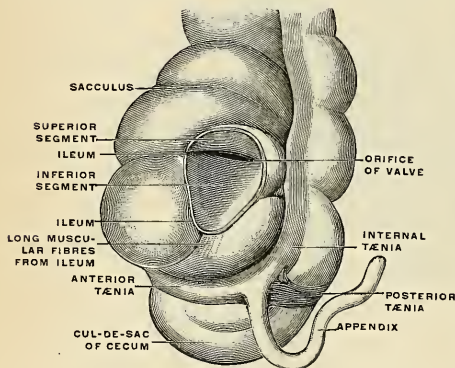


FIG. 1062.—Cecum and vermiform appendix; ileum cut through. (Sappey.)

Applied Anatomy.—The vermiform appendix is very liable to become inflamed, the condition being known as *appendicitis*. The condition may be set up by a catarrhal inflammation arising in the appendix or derived from the colon. It may remain catarrhal and then subside. It may become purulent or may be purulent from the beginning. Anything which lessens vital

resistance makes the appendix a ready prey to bacteria. Among causes which lessen resistance are fecal concretions, twists of the mesoappendix cutting off the blood supply, bruises inflicted by the Psoas muscle (Byron Robinson), blocking of the outlet of the appendix by catarrhal exudate, concretions, proliferated lymphoid tissue, or adhesions. Appendicitis may arise by the appendix becoming twisted, owing to the shortness of its mesentery, in consequence of distention of the cecum. As the result of inflammation, its blood supply, which is mainly through one large artery running in the meso-appendix, becomes interfered with. Again, in rarer cases, the inflammation is set up by the impaction of a solid mass of feces or a foreign body in the appendix. The inflammation may result in ulceration and perforation, or in gangrene of the appendix the appendix may be blocked and full of pus, or abscess may form outside of it (*appendicular abscess*). These conditions require prompt operative interference, and in cases of recurrent attacks of appendicitis it is advisable to remove this diverticulum between the attacks.

The cecum and appendix may be implicated in cases of strangulated hernia, giving rise to serious symptoms of obstruction. An obstruction in the distal part of the large bowel causes distention, particularly of the cecum, which sometimes assumes enormous dimensions, and has been known to rupture, causing fatal peritonitis.

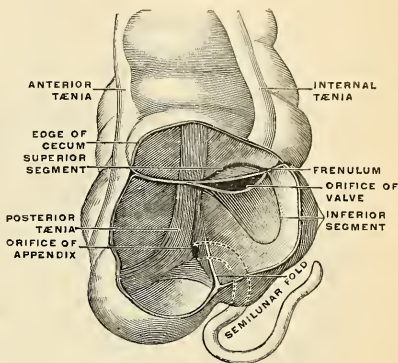


FIG. 1063. — Ileocecal valve. (Sappey.)

The Colon.

The colon is divided into four parts—the **ascending**, **transverse**, and **descending colon** and the **sigmoid flexure**.

The **ascending colon** (*colon ascendens*) is smaller than the cecum, with which it is continuous. It passes upward, from its commencement at the cecum, opposite the ileocecal valve, to the under surface of the right lobe of the liver, on the right of the gall-bladder, where it is lodged in a shallow depression on the liver, the **impressio colica**; here it bends abruptly forward and inward to the left, forming the **hepatic flexure** (*flexura coli dextra*). It is retained in contact with the posterior wall of the abdomen by the peritoneum, which covers its anterior surface and sides, its posterior surface being connected by loose areolar tissue with the Quadratus lumborum muscle, and with the front of the lower and outer part of the right kidney (Fig. 1064). Sometimes the peritoneum almost completely invests it, and forms a distinct but short mesocolon¹ (p. 1251). It is in relation, in front, with the convolutions of the ileum and the abdominal parietes.

The **transverse colon** (*colon transversum*) (Fig. 999), the longest and most movable part of the large intestine, passes transversely from the right hypochondriac region across the abdomen, within the confines of the epigastric and umbilical zones, into the left hypochondriac region, where it curves downward beneath the lower end of the spleen, forming the **splenic flexure** (*flexura coli sinistra*). In its course the transverse colon describes an arch, the concavity of

¹ Treves states that after a careful examination of one hundred subjects, he found that in fifty-two there was neither an ascending nor a descending mesocolon. In twenty-two there was a descending mesocolon, but no trace of a corresponding fold on the other side. In fourteen subjects there was a mesocolon to both the ascending and the descending segments of the bowel; while in the remaining twelve there was an ascending mesocolon, but no corresponding fold on the left side. It follows, therefore, that in performing lumbar colostomy a mesocolon may be expected on the left side in 36 per cent. of all cases, and on the right in 26 per cent. (The Anatomy of the Intestinal Canal and Peritoneum in Man, 1885, p. 55.)

which is directed backward toward the vertebral column and a little upward. It is almost completely invested by peritoneum, and connected to the posterior

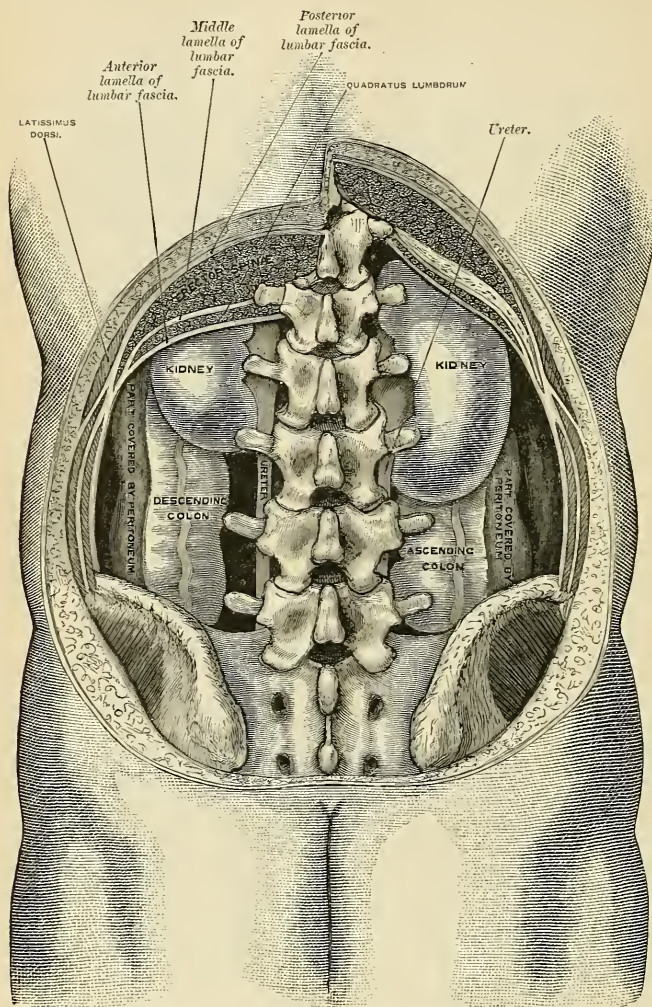


FIG. 1064.—Diagram of the relations of the large intestine and kidneys, from behind.

abdominal wall by a large and wide duplicature of that membrane, the **transverse mesocolon** (Fig. 1013). The transverse colon is in relation, by its upper surface, with the liver and gall-bladder, the greater curvature of the stomach, and the lower

end of the spleen; by its under surface, with the small intestines; by its anterior surface, with the anterior layers of the greater omentum and the abdominal parietes; its posterior surface on the right side is in relation with the second portion of the duodenum, and on the left side is in contact with some of the convolutions of the jejunum and ileum.

The *splenic flexure* is in relation with the lower end of the spleen and the tail of the pancreas. It lies at a higher level than, and on a plane posterior to, the hepatic flexure, and is attached to the Diaphragm opposite the tenth and eleventh ribs, by a peritoneal fold, the **phrenocolic ligament** (see p. 1264).

The **descending colon** (*colon descendens*) passes downward through the left hypochondriac and lumbar regions along the outer border of the left kidney. At the lower end of the kidney it turns

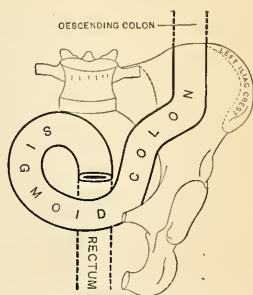


FIG. 1065.—Sigmoid colon, front view. Seruodiagrammatic. (Testut.)

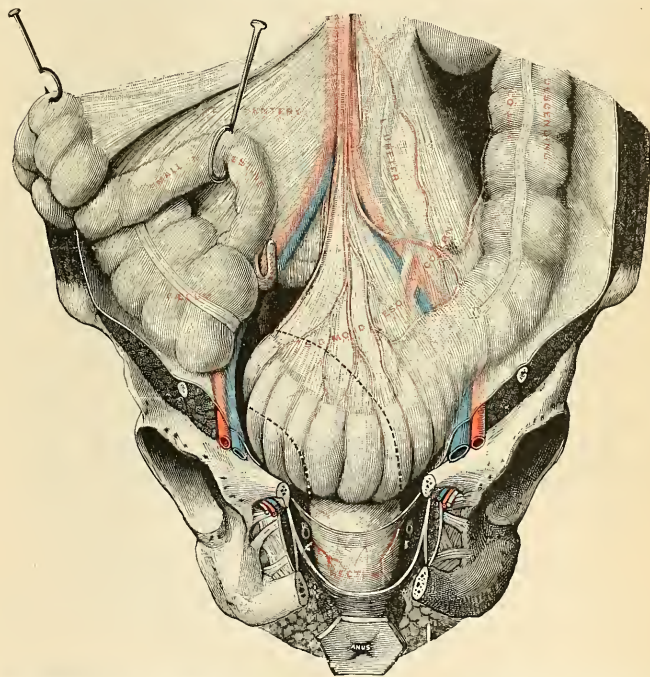


FIG. 1066.—Sigmoid colon and rectum, front view. The broken lines indicate the situation of the concealed part of the sigmoid colon. The small intestine is drawn away, and the anus is turned forward. (Testut.)

inward toward the outer border of the Psoas muscle, along which it descends to the crest of the ilium, where it terminates in the sigmoid flexure. It is retained

in position by the peritoneum, which covers its anterior surface and sides, its posterior surface being connected by areolar tissue with the outer border of the left kidney, and the Quadratus lumborum muscle (Fig. 1004). It is smaller in calibre and more deeply placed than the ascending colon, and is more frequently covered with peritoneum on its posterior surface than the ascending colon (Treves).

The **sigmoid flexure, pelvic colon, or sigmoid colon** (*colon sigmoideum*) (Figs. 1065 and 1066) is the narrowest part of the colon; it is situated in the left iliac fossa, commencing from the termination of the descending colon, at the margin of the crest of the ilium, and then forming a loop, which varies in length and position, and which terminates in the rectum at the level of the attachment of the mesentery upon the front of the third sacral vertebra. It passes downward about two inches (5 cm.) parallel to the outer border of the Psoas muscle, then taking a transverse direction enters the cavity of the pelvis, crosses this cavity from left to right and a little upward to the lower margin of the right iliac fossa; thence it passes downward, backward, and inward along the anterior surface of the sacrum to its junction with the rectum. It is surrounded by the peritoneum and is attached to the posterior abdominal wall by the **mesosigmoid**. When the sigmoid is lifted upward and to the right and the mesosigmoid is put slightly on the stretch the intersigmoid fossa (p. 1267) is brought into view. When the sigmoid flexure is empty most of it falls into the rectovesical or rectovaginal space (Fig. 1066). When distended it mounts up into the abdomen, reaching to or even above the umbilicus. The sigmoid flexure is in relation in front with the small intestine and abdominal parietes. The sigmoid mesocolon is attached to a line running downward and inward from the crest of the ilium, across the left Psoas muscle, left external iliac artery and vein, left spermatic or ovarian vessels, and the left ureter (Fig. 1004).

Applied Anatomy.—The diameter of the large intestine gradually diminishes from the cecum, which has the greatest diameter of any part of the bowel, to the point of junction of the sigmoid flexure with the rectum, at or a little below which point stricture most commonly occurs and diminishes in frequency as one proceeds upward to the cecum. When distended by some *obstruction* low down, the outline of the large intestine can be defined throughout nearly the whole of its course—all, in fact, except the hepatic and splenic flexures, which are more deeply placed; the distention is most obvious in the two flanks and on the front of the abdomen just above the umbilicus. The cecum, however, is that portion of the bowel which is, of all, most distended (see p. 1297). The hepatic flexure and the right extremity of the transverse colon are in close relationship with the liver, and abscess of this viscus sometimes bursts into the gut in this situation. The gall-bladder may become adherent to the colon, and gallstones may find their way through into the gut, where they may become impacted or may be discharged per anum. The mobility of the sigmoid flexure renders it more liable to become the seat of a *volvulus* or twist than any other part of the intestine. It generally occurs in patients who have been the subjects of habitual constipation, and in whom, therefore, the mesosigmoid is elongated. The gut at this part being loaded with feces, from its weight falls over the gut below, and so gives rise to the twist.

The Rectum (*Intestinum Rectum*) (Figs. 1067, 1068).

The rectum is continuous with the sigmoid flexure, while below it ends in the anal canal. From its origin at the level of the third sacral vertebra it passes downward, lying in the sacrococcygeal curve, and extends for about an inch (2.5 cm.) in front of, and a little below, the tip of the coccyx, as far as the apex of the prostate gland. It then bends sharply backward to continue as the anal canal.

It therefore presents two antero-posterior curves. An upper, with its convexity backward, is due to the conformation of the sacrococcygeal column. The lower one has its convexity forward, and is angular. Two lateral curves are also described—the one to the right, opposite the junction of the third and fourth sacral

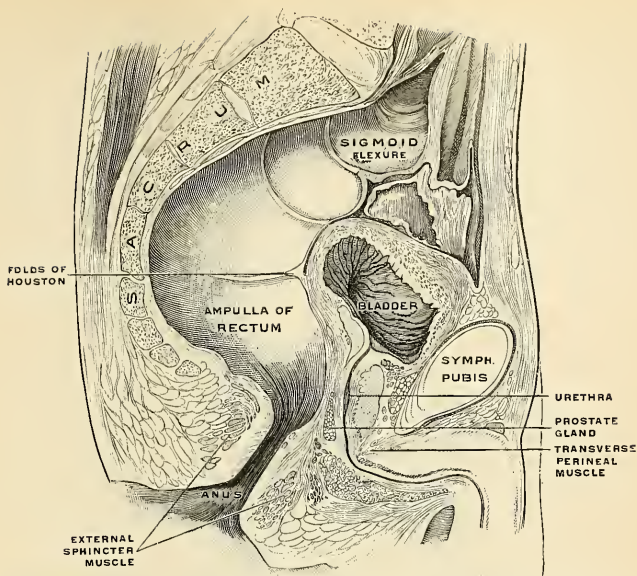


FIG. 1067.—Sagittal section in the median line of the male pelvis. Rectum distended. (Poirier and Charpy.)

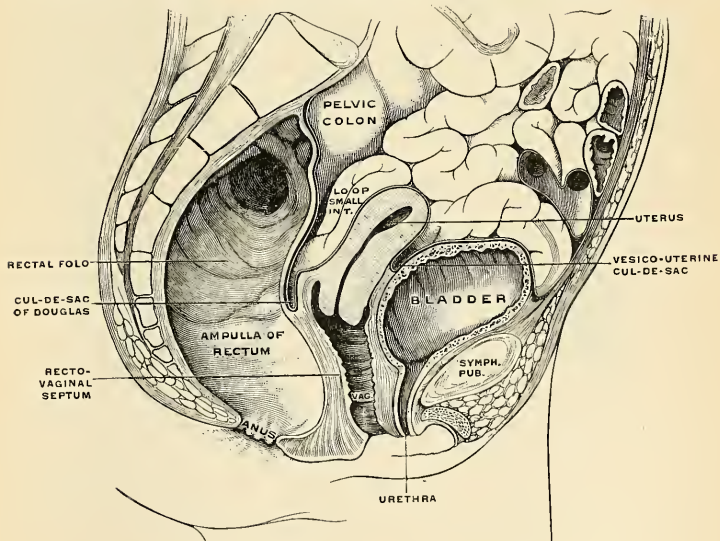


FIG. 1068.—Median sagittal section of the female pelvis. Rectum distended. (Luschka.)

vertebræ; the other to the left, opposite the sacrococcygeal articulation. They are, however, of little importance.

The adult rectum measures about five inches (12.5 cm.) in length, and at its commencement its calibre is similar to that of the sigmoid flexure, but near its termination it is dilated to form the **rectal ampulla**. The rectum has no sacculations comparable to those of the colon, but a sacculated condition, due to the presence in its interior of valves (shortly to be described), is sometimes seen.

The peritoneum is related to the upper two-thirds of the rectum, covering at first its front and sides, but lower down its front only; from the latter it is reflected on to the seminal vesicles in the male and the posterior vaginal wall in the female, forming the vesico-uterine cul-de-sac of Douglas.

The level at which the peritoneum leaves the anterior wall of the rectum to be reflected on to the viscus in front of it is of considerable importance from a surgical point of view, in connection with removal of the lower part of the rectum. It is higher in the male than in the female. In the former the height of the rectovesical pouch is about three inches (7.5 cm.); that is to say, the height to which an ordinary index finger can reach from the anus. In the female the height of the rectovaginal pouch is about two and a quarter inches (5.2 cm.) from the anal orifice. The rectum is surrounded by a dense tube of fascia derived from the *fascia endopelvina*, but fused behind with the fascia covering the sacrum and coccyx. The fascial tube is loosely attached to the rectal wall by areolar tissue in order to allow the viscus to distend.

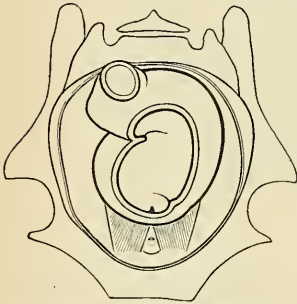


Fig. 1069.—Diagram of rectum, showing Hous-ton's valves in the interior. (Cunningham.)

separate it from the anterior surfaces of the sacral vertebræ; in its lower part it lies directly on the sacrum, coccyx, and Levatores ani, a dense fascia alone intervening; *in front*, it is separated above, in the male, from the posterior surface of the bladder; in the female, from the posterior surface of the uterus and its appendages by some convolutions of the small intestine (Fig. 1068). To the sides below the peritoneal reflections, the rectum is surrounded by cellular tissue in which on each side lie the lateral sacral artery and the bifurcated hypogastric plexus of

Relations of the Rectum.—

The upper part of the rectum is in relation, *behind*, with the superior hemorrhoidal vessels, the left Pyriformis muscle, and left sacral plexus of nerves, which

RECTAL VALVES

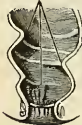

Fig. 1070.

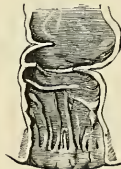

Fig. 1071.

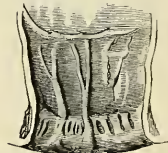


Fig. 1072.

FIGS. 1070-1072.—The anal canal and lower part of the rectum in the fetus. Fig. 1070. Aged four to five months. Fig. 1071. Six months. Fig. 1072. Nine months. In each the anal canal is distinctly marked off from the rectum proper; the columns of Morgagni and the rectal valves are distinct. (Cunningham.)

the sympathetic. This portion of the rectum is separated from the sacrum and coccyx by an interval, the **retrorectal space**, which is filled with cellular tissue. The lower or prostatic portion in the male is in relation anteriorly with the triangular portion of the base of the bladder, the seminal vesicles, vasa deferentia, and, more anteriorly, with the prostate gland; in the female, with the posterior wall of the vagina.

The Anal Canal (*pars analis recti*) (Figs. 1070–1073).—The anal canal is the terminal portion of the large intestine. It begins at the level of the apex of the prostate, is directed downward and backward, and ends at the anus. It forms an angle with the lower part of the rectum and measures an inch to an inch and a half (2.5 to 3.75 cm.) in length. It has no peritoneal covering, but is invested by the Internal sphincter, supported by the Levatores ani muscles, and surrounded at its termination by the External sphincter; in the empty condition it presents the appearance of a longitudinal slit. Behind is a mass of muscle and fibrous tissue, the **anococcygeal body**; in front of it, *in the male*, are the membranous portion and bulb of the urethra, and the base of the triangular ligament, and *in the female* it is separated from the lower end of the vagina by a mass of muscle and fibrous tissue, named the **perineal body**.

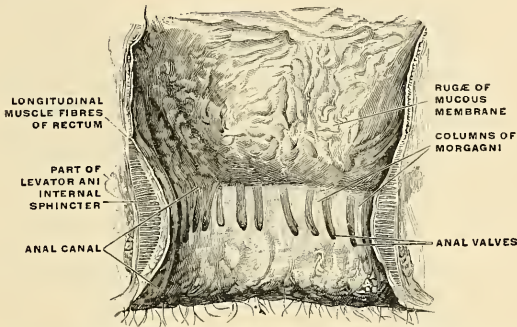


FIG. 1073.—The interior of the anal canal and lower part of the rectum, showing the columns of Morgagni and the anal valves between their lower ends. The columns were more numerous in the specimen than usual. (Cunningham.)

The **Anal Orifice** or **Anus** is the external opening of the anal canal, formed by pigmented skin containing numerous sebaceous and sudoriparous glands (*glandulae circumanales*) and furnished with hairs. While the anus is closed, the skin around it is thrown into radial folds by the contraction of the External sphincter.

Structure of Large Intestine.—The large intestine has four coats—serous, muscular, sub-mucous, and mucous. The serous coat is derived from the peritoneum, and invests the different portions of the large intestine to a variable extent. The cecum is completely covered by the serous membrane, except in a small percentage of cases (5 or 6 per cent.), where a small portion of the upper end of the posterior surface is uncovered. The ascending and descending colon are usually covered only in front and at the sides; a variable amount of the posterior surface is uncovered.¹ The transverse colon is almost completely invested, the parts corresponding to the attachment of the great omentum and transverse mesocolon being alone excepted. The sigmoid flexure is completely surrounded, except along the line to which the sigmoid mesocolon is attached. The upper two-thirds of the rectum is covered in front and laterally by the peritoneum, but not posteriorly, between the two posterior folds of peritoneum, the so-called mesorectum; later it is covered only on its anterior surface; and the lower portion is entirely devoid of any serous covering. In the course of the colon the peritoneal coat is thrown into a number of small pouches filled with fat, called **appendices epiploicae**. They are chiefly appended to the transverse colon, and are particularly numerous along the anterior band.

The **muscular coat** consists of an **external longitudinal** and an **internal circular layer** of smooth muscle tissue.

The **longitudinal fibres** do not form a uniform layer over the whole surface of the large intestine. In the cecum and colon they are especially collected into three flat **longitudinal bands**

¹ See footnote, page 1303.

or *taeniæ* (*taeniæ coli*) (Figs. 1048 and 1049), each being about half an inch (12 mm.) in width, and named, respectively, the mesocolic, omental, and free longitudinal bands or *taeniæ*. These bands commence at the base of the vermiform appendix, which structure is surrounded by a uniform layer of longitudinal muscular fibres. The bands pass from the base of the appendix to the rectum. At this point they broaden, fuse, and surround the rectum. On the ascending, descending, and sigmoid colon the **mesocolic band** (*taenia mesocolica*) is posterior and internal; the **omental band** (*taenia omentalis*) is posterior and external; the **free band** (*taenia libera*) is anterior. On the transverse colon the *taenia libera* is inferior; the *taenia mesocolica* is posterior; the *taenia omentalis* is anterior and superior. These bands are one-sixth shorter than the other coats of the intestine to which they are applied, and serve to produce the **sacculi** (Fig. 1049), which are characteristic of the cecum and colon; accordingly, when they are dissected off, the tube can be lengthened, and its sacculated character becomes lost. There are three rows of the sacculations separated from each other by the longitudinal bands. These pouches are also subdivided by transverse furrows which correspond to concave folds of mucous membrane, called **semilunar folds** (*plicæ semilunares coli*). In the sigmoid flexure the longitudinal fibres become more scattered, and around the rectum they spread out and form a layer which completely encircles this portion of the gut, but is thicker on the anterior and posterior surfaces than on the lateral surfaces. In addition to the muscular fibres of the bowels, two bands of smooth muscle fibres arise from the second and third coccygeal vertebrae, and pass downward and forward to blend with the longitudinal muscle tissue on the posterior wall of the anal canal. They are known as the **rectococcygeal muscles** (*m. rectococcygeus*).

The **circular fibres** form a thin layer over the cecum and colon, being especially accumulated in the intervals between the sacculi. In the rectum the circular fibres constitute a thick layer, and in the anal canal they become numerous and constitute the **Internal sphincter**.

The **submucous coat** (*tela submucosa*) connects the muscular and mucous layers closely together. Solitary follicles are quite numerous here.

The **mucous membrane**, in the cecum and colon, is pale, smooth, destitute of villi, and raised into numerous crescentic folds which correspond to the intervals between the sacculi. In the rectum it is thicker, of a darker color, more vascular, and connected loosely to the muscular coat, as in the œsophagus. It consists of simple columnar and goblet cells resting upon a basement membrane, beneath which is seen the tunica propria, which contains the capillaries and a considerable amount of diffuse lymphoid tissue. Externally, is seen the muscularis mucosae. Simple tubular glands, lined chiefly by goblet cells, are present. They are much broader than those of the small intestine.

When the lower part of the rectum is contracted, its mucous membrane is thrown into a number of folds, which are longitudinal in direction and are effaced by the distention of the gut. Besides these, are certain permanent horizontal folds, of a semilunar shape, known as the **rectal** or **Houston's valves** (Figs. 1070 to 1072). They are usually three in number; sometimes a fourth is found, and occasionally only two are present.¹ One is situated near the commencement of the rectum, on the right side; a second extends inward from the left side opposite the middle of the sacrum; a third, the largest and most constant, projects backward from the forepart of the rectum, opposite the base of the bladder. When a fourth is present, it is situated nearly an inch (2.5 cm.) above the anus on the left and posterior wall of the tube. These folds are about half an inch (12 mm.) in width and contain some of the circular fibres of the gut. In the empty state of the intestine they overlap each other so effectually that they render the introduction of a bougie or the finger somewhat difficult, and their use seems to be "to support the weight of fecal matter, and prevent its urging toward the anus, where its presence always excites a sensation demanding its discharge."

The lumen of the anal canal presents, in its upper half, a number of vertical folds, produced by an infolding of the mucous membrane and some of the muscle tissue. They are known as the **columns of Morgagni** or **anal columns** (columnæ rectales [Morgagni]) (Figs. 1073 and 1074). There are from five to ten of these folds, each of which is about half an inch long. They are most prominent when the Sphincter contracts. The outer angle of each column below passes into a semilunar valve. The grooves between the columns are shallow above and deeper below, and end in the anal valves. The **valves of Morgagni** or **anal valves** (Figs. 1073 and 1074) are folds which stretch from the base of one column to another, and form the **anal pockets** or **crypts of Morgagni** (*sinus rectales*). Just below the anal valves is the junction of the mucous membrane of the anal canal with the skin; this is indicated by the so-called **white line of Hilton** or **anocutaneous line of Hermann** (Fig. 1074).

Vessels and Nerves of the Large Intestine.—The **arteries** (see also p. 664) supplying the large intestine give off large branches, which ramify between the muscular coats supplying them, and, after dividing into small vessels in the submucous tissue, pass to the mucous membrane. The cecum, the appendix, and the ileocecal valve are supplied by the branches from the anastomotic loops between the **right colic** and **ileocolic** branches of the superior mesenteric artery

¹ Dublin Hospital Reports, vol. v, p. 163.

(Fig. 1075). The ascending colon is supplied by the **right colic**, and the transverse colon by the **middle colic branch of the superior mesenteric**. The descending colon is supplied by the



FIG. 1074.—Inner wall of the lower end of the rectum and anus. On the right the mucous membrane has been removed to show the dilatation of the veins and how they pass through the muscular wall to anastomose with the external hemorrhoidal plexus. (Luschka.)

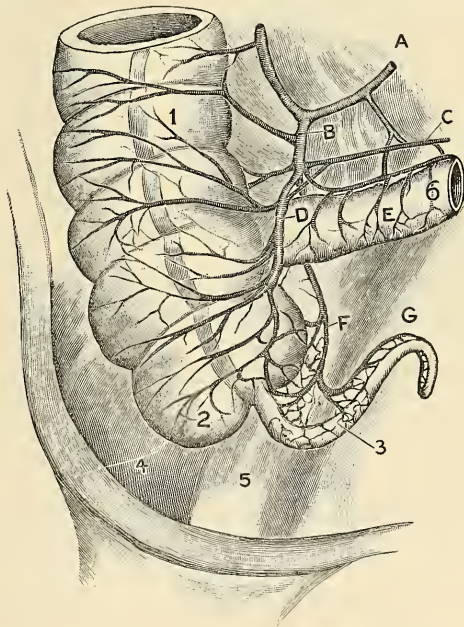


FIG. 1075.—The arterial blood supply of the anterior (ventral) surface of the cecum and appendix: A. Ileocolic artery. B. Cecal artery. D. Anterior cecal artery. F and G. Appendicular artery. Note that the cecal and appendicular arteries anastomose by fine capillaries, both ventrally and dorsally. C. Iliac artery. 1. Right colon. 2. External sacculus of cecum (to right of taenium coli). 3. Appendix. 4. Iliac muscle. 5. Psoas muscle. (Robinson.)

left colic branch of the inferior mesenteric, and the sigmoid flexure by the sigmoid branches of the inferior mesenteric. The rectum (Fig. 1076) is supplied mainly by the superior hemorrhoidal branch of the inferior mesenteric, but also at its lower end by the middle hemorrhoidal

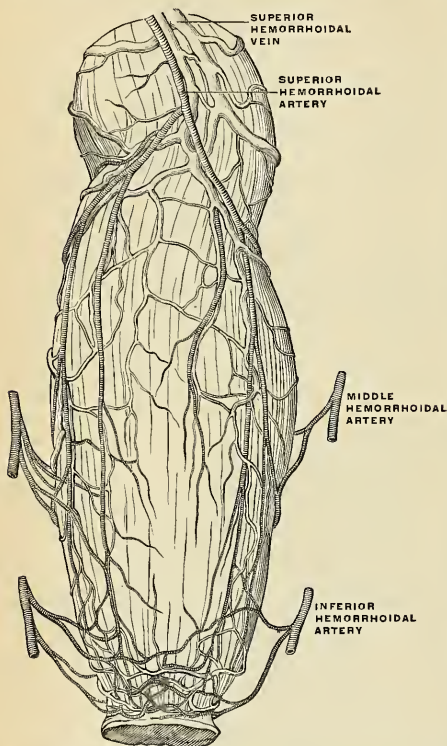


FIG. 1076.—The bloodvessels of the rectum and anus, showing the distribution and anastomosis on the posterior surface near the termination of the gut. (Poirier and Charpy.)

veins at its commencement, and thus a communication is established between the systemic and portal circulations. The inferior hemorrhoidal veins empty into the internal pudic veins, and the middle hemorrhoidal veins empty into the internal iliac veins.

The lymphatics of the large intestine are described on page 794.

The nerves are derived from the sympathetic plexuses around the branches of the superior and inferior mesenteric arteries. They are distributed in a similar way to those found in the small intestine. The spinal centre for the nerves of the anus and rectum is situated in the first and second sacral segments of the spinal cord.

Movements and Innervation of the Intestines.

Movements.—As the *small intestine* is devoid of any sphincter arrangement, peristalsis cannot mix the food as it does in the pyloric portion of the stomach. The process by which the food is mixed with the secretions and is brought against the intestinal wall for absorption is called by Cannon "rhythmic segmentation." Rhythmic motions "mix the food and expose it to the

from the internal iliac, and the inferior hemorrhoidal from the internal pudic artery. The superior hemorrhoidal, the continuation of the inferior mesenteric, divides into two branches, which run down either side of the rectum to within about five inches (12.5 cm.) of the anus; they here split up into about six branches, which pierce the muscular coat and descend between it and the mucous membrane in a longitudinal direction, parallel with each other as far as the Internal sphincter, where they anastomose with the other hemorrhoidal arteries and form a series of loops around the anus. The veins of the large intestine correspond to the arteries and join the superior and inferior mesenteric veins which join the portal vein. The veins of the rectum (Fig. 1076) commence in a plexus of vessels which surrounds the lower extremity of the intestinal canal. In the vessels forming this plexus are small saccular dilations just within the margin of the anus (Figs. 1074 and 1076); from it about six vessels of considerable size are given off. These ascend between the muscular and mucous coat for about five inches (12.5 cm.), running parallel to each other; they then pierce the muscular coat, and, by their union, form a single trunk, the superior hemorrhoidal vein, which empties into the inferior mesenteric tributary of the portal vein. This arrangement is termed the **hemorrhoidal plexus** (Fig. 523); it communicates with the tributaries of the middle and inferior hemorrhoidal

mucosa without advancing it *appreciatively* along the canal."¹ In this process constrictions occur in the circular fibres, with the result that a collection of stationary food is divided into a number of segments. In the middle of each segment constrictions appear and the earlier constrictions relax. Then the latter constrictions relax and the earlier reappear, and so on until the food is thoroughly mixed with digestive secretions. Finally, the food is driven on by peristalsis, coming again to rest, and being again subjected to "rhythmic segmentation." Cannon says that in the duodenum "rhythmic segmentation" lasts for several minutes, but in other parts of the intestine it may continue for half an hour or more, the food which is being subjected to it scarcely moving along the canal. It is probable that in man there are from seven to eight segmentations per minute in a given area. It is also probable that there is a sphincter action at the ileocecal opening.

Cannon divides the large intestine into two parts—a distal part, in which the material is hard and lumpy and is "advanced by rings of tonic contraction," and a proximal part, in which the material is soft. In this part "the common movements are waves of constriction running backward toward the cecum." The resistance of the valve or sphincter enables reversed peristalsis or antiperistalsis to mix the food. When more food enters from the small intestine, antiperistalsis ceases, tonic contraction of the cecum and proximal portion of the colon occurs, some of the food is merged into the transverse colon, and antiperistalsis again begins to act on what remains. The above facts have been observed in animals and are probably true in man.

Innervation.—The vagus fibres of the small intestine seem to excite contraction of the circular fibres after a brief preliminary period of inhibition.² Some observers maintain that the splanchnic fibres are inhibitory, but others claim that they are also motor. The local reflex of the small intestine is in Auerbach's plexus. Cannon quotes Bayliss and Starling to the effect that the pelvic visceral nerves to the large intestine, "arising like the vagus from the central nerve system, are augmentary nerves, whereas the supply from the sympathetic system is purely inhibitory in its action." It is further contended that the pelvic visceral nerves are distributed to the distal colon only. "The region of antiperistalsis does not, therefore, receive motor impulses from the pelvic nerves."

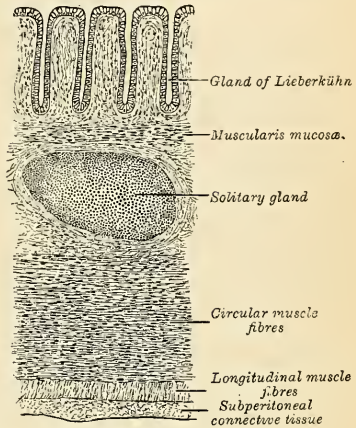


FIG. 1077.—Transverse section of wall of large intestine.

Surface Form.—The coils of the small intestine occupy the front of the abdomen below the transverse colon, and are covered more or less completely by the great omentum. For the most part the coils of the jejunum occupy the left side of the abdominal cavity—*i. e.*, the left lumbar and inguinal regions and the left half of the umbilical region—while the coils of the ileum are situated to the right, in the right lumbar and inguinal regions, in the right half of the umbilical region, and also in the hypogastric region. The cecum is situated in the right inguinal region. Its position varies slightly, but the mid-point of a line drawn from the anterior superior spinous process of the ilium to the symphysis pubis will about mark the middle of its lower border. It is comparatively superficial. From it the ascending colon passes upward through the right lumbar and hypochondriac regions, and becomes more deeply situated as it ascends to the hepatic flexure, which is deeply placed under cover of the liver. The transverse colon crosses the belly transversely on the confines of the umbilical and epigastric regions, its lower border being on a level slightly above the umbilicus, its upper border just below the greater curvature of the stomach. The splenic flexure of the colon is situated behind the stomach in the left hypochondrium, and is on a higher level than the hepatic flexure. The descending colon is deeply seated, passing down through the left hypochondriac and lumbar regions to the sigmoid flexure, which is situated in the left inguinal region, and which can be felt in thin persons, with relaxed abdominal walls, rolling under the fingers when empty, and when distended forming a distinct bulge. The usual position of the base of the vermiform appendix is indicated by a point on the cutaneous surface two to three inches (5–7.5 cm.) from the anterior superior spinous process of the ilium, on a line drawn from this process to the umbilicus. This is known as **McBurney's point**. Another mode of defining the position of the base of the appendix is to draw a line between the anterior superior spines of the ilia and marking the point where this line intersects the right semilunar line.

¹ Medical News, May 20, 1905.

² Bayliss and Starling, *Journal of Physiology*, 1899.

Upon introducing the finger into the rectum, the membranous portion of the urethra can be felt, if an instrument has been introduced into the bladder, exactly in the middle line; behind and above this the prostate gland can be recognized by its shape and hardness and any enlargement detected; above the prostate the fluctuating wall of the bladder when full can be felt, and if thought desirable it can be tapped in this situation; on either side and behind the prostate the seminal vesicles can be readily felt, especially if enlarged by tuberculous disease. Behind, the coccyx is to be felt, and on the mucous membrane one or two of Houston's folds. The ischio-rectal fossæ can be explored on either side, with a view to ascertaining the presence of deep-seated collections of pus. Finally, it will be noted that the finger is firmly gripped by the sphincter for about an inch (2.5 cm.) up the bowel.

Applied Anatomy.—The small intestine is much exposed to injury, but, in consequence of its elasticity and the ease with which one fold glides over another, it is not so frequently ruptured as would otherwise be the case. Any part of the small intestine may be ruptured, but probably the most common situation is the transverse duodenum, on account of its being more fixed than other portions of the bowel, and because it is situated in front of the bodies of the vertebræ, so that if this portion of the intestine is struck a sharp blow, as from the kick of a horse, it is unable to glide out of the way, but is compressed against the bone and lacerated. Wounds of the intestine sometimes occur. If the wound is a small puncture, under, it is said, one-quarter of an inch (6 mm.) in length, there may be no extravasation of the contents of the bowel. The mucous membrane becomes everted and perhaps plugs the little opening. The bowels, therefore, may be punctured with a fine capillary trocar, in cases of excessive distention of the intestine with gas, without much danger of extravasation. A longitudinal wound gapes more than a transverse wound, owing to the greater thickness of the circular muscular coat. In closing a wound of the intestine, use Lembert's inversion sutures, which bring the peritoneal surfaces in contact. Halsted showed that these sutures must include the tough submucous coat. The portions of intestine which lie in the pelvis are inflamed in *pelvic peritonitis* and become embedded in adhesions. The portions of intestine which may be present are the termination of the ileum, the portion of small intestine with the largest mesentery (Treves), the rectum, and the pelvic colon. The small intestine, and most frequently the ileum, may become *strangulated* by internal bands, or through apertures, normal or abnormal. The bands may be formed in several different ways: they may be old peritoneal adhesions from previous attacks of peritonitis; or adherent omentum from the same cause; or the band may be formed by *Meckel's diverticulum*, which has contracted adhesions at its distal extremity; or the band may be the result of the abnormal attachment of some normal structure, as the adhesion of two appendices epiploicæ, or an adherent vermiform appendix or Fallopian tube. *Intussusception* or invagination of the small intestine may take place in any part of the jejunum and ileum, but the most frequent situation is at the ileocecal valve, the valve forming the apex of the entering tube. This form may attain great size, and it is not uncommon in these cases to find the valve projecting from the anus. *Stricture*, the *impaction of foreign bodies*, and twisting of the gut (*volvulus*) may lead to intestinal obstruction. Volvulus is most common in the sigmoid flexure. Meckel's diverticulum may itself become twisted and strangulated.

Resection of a portion of the intestine may be required in cases of gangrene of the bowel; in cases of intussusception; for the removal of a newgrowth in the bowel; in dealing with artificial anus; and in cases of rupture. The operation is termed *enterectomy*, and is performed as follows: The abdomen having been opened and the amount of bowel requiring removal having been determined upon, the gut must be clamped on either side of this portion in order to prevent the escape of any of the contents of the bowel during the operation. The portion of bowel is then separated above and below by means of scissors. If the portion removed is small, it may be simply removed from the mesentery at its attachment and the bleeding vessels tied; but if it is large, it will be necessary to remove also a triangular piece of the mesentery, and having secured the vessels, suture the cut edges of this structure together. The surgeon then proceeds to unite the cut ends of the bowel. He may do it by the operation termed *end-to-end anastomosis*. There are many ways of doing this, which may be divided into two classes—one, where the anastomosis is made by means of some mechanical appliance, such as Murphy's button, or one of the forms of decalcified bone bobbins; and the other, where the operation is performed by simply suturing the ends of the bowel in such a manner that the peritoneum covering the free divided ends of the bowel is brought into contact, so that speedy union may ensue.

In some cases after resection each open end of the gut is closed, the side of the terminal portion is sutured to the side of the initial portion, a fistula is made in each, and the suturing is completed so as to cause the two fistulæ to correspond. A permanent side-to-side opening is thus made. *Lateral anastomosis* without resection may be practised between two pieces of intestine, in order to side-track an intervening portion, which is the seat of malignant disease or of an artificial anus. *Complete exclusion* of a portion of intestine is performed for irremovable tumors or persistent fecal fistulæ of the large intestine. The intestine is cut through above and below the diseased area and the ends of the healthy gut are united to each other, or the larger end is closed, an opening is made into the side of the larger end and the smaller end is implanted in it

(*lateral implantation*). The two ends of the excluded portion are fastened to the skin and are left open.

In ascites resulting from cirrhosis of the liver, benefit occasionally follows the performance of *Talma's operation* (*epiploexy*). The abdomen is opened and the omentum is sutured to the anterior abdominal wall or in the abdominal wound, in the hope of establishing a more free communication between the portal and systemic circulations, thus lowering portal pressure.

Hernia.—The two chief sites at which external hernia may take place are the *inguinal region* and the *crural canal*. The description of the inguinal canal and its relations will be found on pages 437 to 439 and that of the crural canal on pages 503 and 684. Some points in regard to the disposition of the peritoneum in these regions may, however, be recapitulated here.

Between the upper margin of the front of the pelvis and the umbilicus, the peritoneum, when viewed from behind, will be seen to be raised into fine folds with intervening depressions, by more or less prominent bands which converge to the umbilicus. The urachus, situated in the middle line, is covered by a fold of peritoneum known as the *plica urachi*. On either side of this a fold of peritoneum around the impervious hypogastric artery forms the *plica hypogastrica*. To either side of these three cords is the deep epigastric artery covered by the *plica epigastrica*. Between these raised folds are depressions constituting the so-called *fosse*. The most internal, between the *plica urachi* and *plica hypogastrica*, is known as the **internal inguinal fossa** (*fovea suprapresacalis*). The middle one is situated between the *plica hypogastrica* and *plica epigastrica*, and is termed the **middle inguinal fossa** (*fovea inguinalis medialis*). The external one is external to the *plica epigastrica* and is known as the **external inguinal fossa** (*fovea inguinalis lateralis*). Occasionally the deep epigastric artery corresponds in position to the impervious hypogastric artery, and then there is but one fold on each side of the middle line. In the usual position of the parts the floor of the external inguinal fossa corresponds to the internal abdominal ring, and into this fossa an oblique inguinal hernia descends. To the inner side of the *plica epigastrica* are the two internal *fosse*, and through either of these a direct hernia may descend. The whole of the space between the deep epigastric artery, the margin of the Rectus and Poupart's ligament, is known as **Hesselbach's triangle**. Below the level of Poupart's ligament is a small depression corresponding to the position of the crural ring. It is known as the **femoral fossa**, and into it a femoral hernia descends.

Inguinal Hernia.—Inguinal hernia is that form of protrusion which makes its way through the abdomen in the inguinal region. There are two principal varieties of it—external or oblique, and internal or direct.

In **oblique inguinal hernia** the intestine escapes from the abdominal cavity at the internal ring, pushing before it a pouch of peritoneum which forms the hernial sac. As it enters the inguinal canal it receives an investment from the extraperitoneal tissue and is enclosed in the infundibuliform fascia. In passing along the inguinal canal it displaces upward the arched fibres of the Transversalis and Internal oblique, and receives a covering of Cremaster muscle and cremasteric fascia. It then passes along the front of the spermatic cord and escapes from the inguinal canal at the external ring, becoming invested by intercolumnar fascia. Lastly, it descends into the scrotum, receiving coverings from the superficial fascia and the integument.

The seat of stricture in oblique inguinal hernia is at either the external or internal abdominal ring; most frequently in the latter situation. If it is situated at the external ring, the division of a few fibres at one point of the circumference is all that is necessary for the replacement of the hernia. If at the internal ring, it is necessary to divide the aponeurosis of the External oblique so as to lay open the inguinal canal; in dividing the aponeurosis the incision should be directed parallel to Poupart's ligament, and the constriction at the internal ring should then be divided directly upward.

When the intestine passes along the inguinal canal and escapes from the external ring into the scrotum, it is called complete oblique inguinal or scrotal hernia. If the intestine does not escape from the external ring, but is retained in the inguinal canal, it is called incomplete inguinal hernia or bubonocoele. In each of these cases the coverings which invest it will depend upon the extent to which it descends in the inguinal canal.

There are some other varieties of oblique inguinal hernia (Figs. 1078 to 1082) depending upon congenital defects in the processus vaginalis, the pouch of peritoneum which precedes the descent of the testis. Normally this pouch is closed before birth, closure commencing at two points—viz., at the internal abdominal ring and at the top of the epididymis, and gradually extending until the whole of the intervening portion is converted into a fibrous cord. From failure in the completion of this process, variations in the relation of the hernial protrusion to the testis and tunica vaginalis are produced; these constitute distinct varieties of inguinal hernia—viz., congenital, infantile, encysted, and hernia of the funicular process.

Where the processus vaginalis remains patent throughout, the cavity of the tunica vaginalis communicates directly with that of the peritoneum. The intestine descends along this pouch into the cavity of the tunica vaginalis which constitutes the sac of the hernia, and the gut lies in contact with the testis. Though this form of hernia is termed *congenital*, the term does not imply that the hernia existed at birth, but merely that a condition is present which may allow of the

descent of the hernia at any moment. As a matter of fact, congenital herniæ frequently do not appear until adult life.

Where the processus vaginalis is occluded at the internal ring only and remains patent throughout the rest of its extent, two varieties of oblique inguinal hernia may be produced—viz., infantile

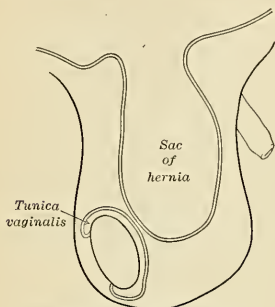


FIG. 1078.—Common scrotal hernia.

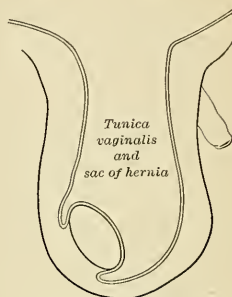


FIG. 1079.—Congenital hernia.

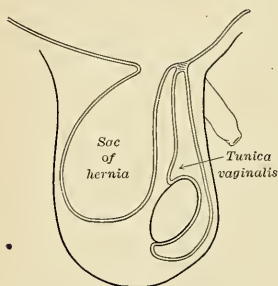


FIG. 1080.—Infantile hernia.

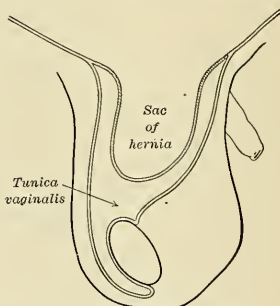


FIG. 1081.—Encysted hernia.

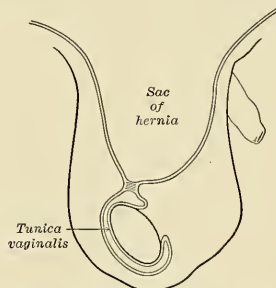


FIG. 1082.—Hernia into the funicular process.

FIGS. 1078 to 1082.—Varieties of oblique inguinal hernia.

and encysted herniæ. In the *infantile* form (Fig. 1080) the bowel pressing upon the septum and the peritoneum in its immediate neighborhood causes it to yield and form a sac which descends behind the tunica vaginalis; so that in front of the bowel there are three layers of peritoneum,

the two layers of the tunica vaginalis and its own sac. In the *encysted* form (Fig. 1060) pressure at the occluded spot causes the septum to yield and form a sac which projects into the tunica vaginalis, forming thus a sac within a sac, so that in front of the bowel there are two layers of peritoneum, one from the tunica vaginalis and one from its own sac.

Where the processus vaginalis is occluded at the lower point only, *i. e.*, just above the testis, the intestine descends into the pouch of peritoneum as far as the testis, but is prevented from entering the sac of the tunica vaginalis by the septum which has formed between it and the pouch. This is known as *hernia into the funicular process*; it resembles the congenital form except that instead of enveloping the testis it lies above it.

In **direct inguinal hernia** the protrusion makes its way through some part of Hesselbach's triangle, either through (*a*) the outer part, where only extraperitoneal tissue and transversalis fascia intervene between the peritoneum and the aponeurosis of the External oblique; or through (*b*) the conjoined tendon which stretches across the inner two-thirds of the triangle between the artery and the middle line. In the former the hernial protrusion escapes from the abdomen on the outer side of the conjoined tendon, pushes before it the peritoneum, extraperitoneal tissue, and transversalis fascia, and enters the inguinal canal. It passes along nearly the whole length of the canal and finally emerges from the external ring, receiving an investment from the inter-columnar fascia. The coverings of this form of hernia are similar to those of the oblique form, except that a portion derived from the general layer of transversalis fascia replaces the infundibuliform fascia.

In the second form, which is the more frequent, the hernia is either forced through the fibres of the conjoined tendon, or the tendon is gradually distended in front of it so as to form a complete investment for it. The intestine then enters the lower end of the inguinal canal, escapes at the external ring lying on the inner side of the cord, and receives additional coverings from the external spermatic fascia, the superficial fascia, and the integument. The coverings of this form, therefore, differ from those of the oblique form in that the conjoined tendon is substituted for the cremaster, and the infundibuliform fascia is replaced by a portion of the general layer of the transversalis fascia.

The seat of stricture in both varieties of direct hernia is usually found either at the neck of the sac or at the external ring. In that form which perforates the conjoined tendon it not infrequently occurs at the edges of the fissure through which the gut passes. In all cases of inguinal hernia, whether direct or oblique, it is proper to divide the stricture directly upward; by cutting in this direction the incision is made parallel to the deep epigastric artery—external to it in the oblique variety, internal to it in the direct form of hernia; all chance of wounding the vessel is thus avoided. Direct inguinal hernia is of much less frequent occurrence than the oblique, and is found more often in men than in women. The main differences in position between it and the oblique form are: (*a*) it is placed over the pubis and not in the course of the inguinal canal; (*b*) the deep epigastric artery runs on the outer or iliac side of the neck of the sac; and (*c*) the spermatic cord lies along its external and posterior sides, not directly behind it, as in oblique inguinal hernia.

Femoral Hernia.—In femoral hernia the protrusion of the intestine takes place through the crural ring. As already described (p. 503), this ring is closed by the septum crurale, a partition of modified extraperitoneal tissue; it is, therefore, a weak spot in the abdominal wall, and especially in the female, where the ring is larger and where profound changes are produced in the tissues of the abdomen by pregnancy. Femoral hernia is, therefore, more common in women than in men.

When a portion of intestine is forced through the femoral ring it carries before it a pouch of peritoneum which forms the hernial sac. It receives an investment from the extraperitoneal tissue or septum crurale and descends along the femoral canal, or inner compartment of the sheath of the femoral vessels, as far as the saphenous opening; at this point it changes its course, being prevented from extending farther down the sheath on account of the narrowing of the latter, and its close contact with the vessels, and also from the close attachment of the superficial fascia and femoral sheath to the lower part of the circumference of the saphenous opening. The tumor is consequently directed forward, pushing before it the cribriform fascia, and then curves upward over Poupart's ligament and the lower part of the External oblique, being covered by the superficial fascia and integument. While the hernia is contained in the femoral canal it is usually of small size owing to the resisting nature of the surrounding parts, but when it escapes from the saphenous opening into the loose areolar tissue of the groin it becomes considerably enlarged. The direction taken by a femoral hernia in its descent is at first downward, then forward and upward; in the application of taxis for the reduction of a femoral hernia, therefore, pressure should be directed in the reverse order.

The coverings of a femoral hernia, from within outward, are peritoneum, septum crurale, femoral sheath, cribriform fascia, superficial fascia, and integument. Sir Astley Cooper has described an investment for femoral hernia under the name of *fascia propria*, lying immediately external to the peritoneal sac but frequently separated from it by some adipose tissue. Surgically it is important to remember the frequent existence of this layer on account of the ease with

which an inexperienced operator may mistake the fascia for the peritoneal sac and the contained fat for omentum, as there is often a great excess of subperitoneal fatty tissue enclosed in the "fascia propria." In many cases it resembles a fatty tumor, but on further dissection the true hernial sac will be found in the centre of the mass of fat. The fascia propria is merely modified extraperitoneal tissue which has been thickened to form a membranous sheet by the pressure of the hernia.

When the intestine descends along the femoral canal only as far as the saphenous opening the condition is known as incomplete femoral hernia. The small size of the protrusion in this form of hernia, on account of the firm and resisting nature of the canal in which it is contained, renders it an exceedingly dangerous variety of the disease from the extreme difficulty of detecting the existence of the swelling, especially in corpulent subjects. The coverings of an incomplete femoral hernia would be, from without inward, integument, superficial fascia, superior falciform process of fascia lata, femoral sheath, septum crurale, and peritoneum.

The seat of stricture of a femoral hernia varies; it may be in the peritoneum at the neck of the hernial sac; in the greater number of cases it is at the point of junction of the superior falciform process with the free edge of Gimbernat's ligament; or it may be at the margin of the saphenous opening. The stricture should in every case be divided in a direction upward and inward for a distance of about one-sixth to one-quarter of an inch. All vessels or other structures of importance in relation to the neck of the sac will thus be avoided.

The spine of the pubis forms an important landmark in serving to differentiate the inguinal from the femoral variety of hernia. The inguinal protrusion is above and to the inner side of the spine, while the femoral is below and to its outer side.

By the term *internal hernia*, we mean hernia into the foramen of Winslow, into the retro-duodenal fossa, into the retrocecal fossa, or into the intersigmoid fossa. Such a hernia produces the symptoms of acute strangulation of the intestine.

In *typhoid fever* there is ulceration of Peyer's patches. One of these ulcers may *perforate*. The only chance for life is immediate laparotomy and closure of the perforation. This saves one-fifth, or possibly one-third, of the cases. The incision is made to expose the lower ileum, as in the vast majority of cases the perforation is in this portion of the gut.

The surgical anatomy of the rectum is of considerable importance. There may be congenital malformation due to arrested or imperfect development. Thus, there may be no invagination of the ectoderm, and consequently a complete absence of the anus; or the hind gut may be imperfectly developed, and there may be an absence of the rectum, though the anus is developed; or the invagination of the ectoderm may not communicate with the termination of the hind gut from want of solution of continuity in the septum which in early fetal life exists between the two. The mucous membrane is thick and but loosely connected to the muscular coat beneath and thus favors *prolapse*, especially in children. The vessels of the rectum are arranged as mentioned above, longitudinally, and are contained in the loose cellular tissue between the mucous and muscular coats, and receive no support from surrounding tissues, and this favors varicosity. Moreover, the veins, after running upward in a longitudinal direction for about five inches in the submucous tissue, pierce the muscular coats, and are liable to become constricted at this point by the contraction of the muscular wall of the gut. In addition to this there are no valves in the superior hemorrhoidal veins, and the vessels of the rectum are placed in a dependent position, and are liable to be pressed upon and obstructed by hardened feces. The anatomical arrangement, therefore, of the hemorrhoidal vessels explains the great tendency to the occurrence of piles. The presence of the Sphincter ani is of surgical importance, since it is the constant contraction of this muscle which prevents an *ischio-rectal abscess* from healing and tends to cause a fistula. Also, the reflex contraction of this muscle is the cause of the severe pain complained of in *fissure of the anus*. The relations of the peritoneum to the rectum are of importance in connection with the operation of removal of the lower end of the rectum for malignant disease. The membrane gradually leaves the rectum as it descends into the pelvis; first leaving its posterior surface, then the sides, and then the anterior surface, to become reflected in the male on to the posterior wall of the bladder, forming the rectovesical pouch, and in the female on to the posterior wall of the vagina, forming Douglas' pouch. The rectovesical pouch of peritoneum extends to within three inches (7.5 cm.) from the anus, so that it is not desirable to remove more than two and a half inches (6.25 cm.) of the entire circumference of the bowel, for fear of the risk of opening the peritoneum. When, however, the disease is confined to the posterior surface of the rectum, or extends farther in this direction, a greater amount of the posterior wall of the gut may be removed, as the peritoneum does not extend on this surface to a lower level than five inches from the margin of the anus. The rectovaginal or Douglas' pouch in the female extends somewhat lower than the rectovesical pouch of the male, and therefore it is advisable to remove a less length of the tube in this sex. Of recent years, however, much more extensive operations have been done for the removal of cancer of the rectum, and in these the peritoneal cavity has necessarily been opened. If, in these cases, the opening is plugged with iodoform gauze until the operation is completed, and then the edges of the wound in the peritoneum are accurately brought together with sutures, no evil result appears to follow. For cases

of cancer of the rectum which are too low to be reached by abdominal section, and too high to be removed by the ordinary operation from below, Kraske has devised an operation which goes by his name. The patient is placed on his right side and an incision is made from the second sacral spine to the anus. The soft parts are now separated from the back of the left side of the sacrum as far as its left margin, and the greater and lesser sacrosciatic ligaments are divided. A portion of the lateral mass of the sacrum, commencing on the left border at the level of the third posterior sacral foramen, and running downward and inward through the fourth foramen to the cornu, is now cut away with a chisel. The left side of the wound being now forcibly drawn outward, the whole of the rectum is brought into view, and the diseased portion can be removed, leaving the anal portions of the gut, if healthy. The two divided ends of the gut can perhaps then be approximated and sutured together. Kraske's operation is in many cases preceded by the performance of iliac colostomy. In cancer high up in the rectum removal of the growth through the abdomen is sometimes practised, the divided lower end of the rectum being sutured to the divided upper end (Weir's operation).

The colon frequently requires opening in cases of intestinal obstruction, and by some surgeons this operation is performed in cases of cancer of the rectum, as soon as the disease is recognized, in the hope that the rate of growth may be retarded by removing the irritation produced by the passage of fecal matter over the diseased surface. The operation of *colostomy* may be performed either in the inguinal or lumbar region; but *inguinal colostomy* (Maydl's operation) has at the present day superseded the lumbar operation. The main reason for preferring this operation is that a spur-shaped process of the mesocolon can be formed, which prevents any fecal matter finding its way past the artificial anus and becoming lodged on the diseased structures below. The sigmoid flexure being surrounded by peritoneum, a coil can be drawn out of the wound, and when it is opened transversely a spur is formed, and this prevents any fecal matter finding its way from the gut above the opening into that below. The operation is performed by making an incision two or three inches in length from a point one inch internal to the anterior superior spinous process of the ilium, parallel to Poupart's ligament. The various layers of abdominal muscles are cut through, and the peritoneum opened and sewed to the external skin. The sigmoid flexure is now sought for, and pulled out of the wound and fixed by pushing a glass bar through a slit in the mesocolon. The two parts of the loop are sutured together. The intestine is now sutured to the parietal peritoneum. The wound is dressed, and either immediately or between the second to the fourth day, according to the requirements of the case, the protruded coil of intestine is opened. It is opened transversely with the Paquelin cautery.

The loose connective tissue around the rectum is occasionally the site of an abscess, the active focus of which, however, may be located elsewhere. This form of abscess may be described as the *superior pelvic rectal*; it is placed above the pelvic diaphragm, but beneath the peritoneum. The acute variety is generally due to ulceration or perforation of the bowel (possibly produced by a foreign body) above the level of the attachment of the Levator ani. The abscess may also occur above a stricture (simple or malignant) of the rectum; occasionally it arises from suppuration around the prostate, and more rarely follows abscess of the seminal vesicles. Chronic abscesses also appear in the same region either from caries of the anterior surface of the sacrum or from caseation of the presacral lymph nodes, while in other cases an abscess finds its way down into the pelvis from disease of the anterior surfaces of the bodies of the lumbar vertebral.

THE LIVER (HEPAR) (Figs. 1083, 1084).

The liver is the largest gland in the body and is situated in the upper and right part of the abdominal cavity, occupying almost the whole of the right hypochondrium, the greater part of the epigastrium, and not uncommonly extending into the left hypochondrium as far as the midclavicular line. In the male it weighs from fifty to sixty ounces; in the female, from forty to fifty. It is relatively much larger in the fetus than in the adult, constituting, in the former, about one-eighteenth, and in the latter, about one-thirty-sixth of the entire body weight. Its greatest transverse measurement is from eight to nine inches (20 to 22 cm.). Vertically, near its lateral or right surface, it measures about six or seven inches (15 to 18 cm.), while its greatest antero-posterior diameter is on a level with the upper end of the right kidney and is from four to five inches (10 to 12 cm.). Opposite the vertebral column its measurement from before backward is reduced to about three inches (7.5 cm.). Its consistence is that of a soft solid; it is, however, friable and easily lacerated; its color is a dark reddish brown, and its specific gravity is 1.05.

To obtain a correct idea of its shape, it must be hardened *in situ*, and it will then be seen to present the appearance of a wedge, the base of which is directed to the right and the thin edge toward the left. Symington describes its shape as that "of a right-angled triangular prism with the right angles rounded off."

Surfaces.—The liver possesses five surfaces—viz., a **superior**, **inferior**, **anterior**, **posterior**, and a **right lateral surface**. A sharp, well-defined margin divides the inferior from the anterior and lateral surfaces, but the other surfaces are separated from one another by thick, rounded borders. The superior and anterior surfaces are separated from each other by a thick rounded border, and are attached to the Diaphragm and anterior abdominal wall by a triangular or falciform fold of peritoneum, the **suspensory or falciform ligament**, in the free margin of which is a rounded cord, the **ligamentum teres** or impervious umbilical vein. The line of attachment of the falciform ligament divides the liver into two unequal parts, termed the **right and left lobes**, the right being much the larger. The inferior and posterior surfaces are divided into five lobes by five fissures, which are arranged in the form

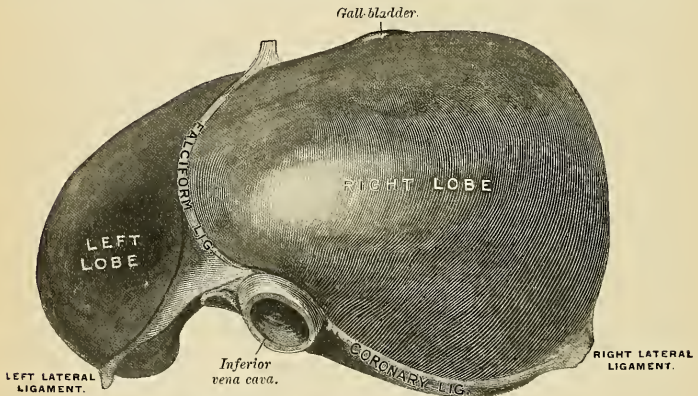


FIG. 1083.—The liver. Upper surface. (Drawn from His' model.)

of the letter H. The left limb of the H marks on these surfaces the division of the liver into right and left lobes; it is known as the **longitudinal fissure**, and consists of two parts—viz., the **umbilical fissure** in front and the **fissure for the ductus venosus** behind. The right limb of the H is formed in front by the **fissure or fossa for the gall-bladder**, and behind by the **fissure for the inferior vena cava**; these two fissures are separated from one another by a band of liver substance, termed the **caudate lobe**. The bar connecting the two limbs of the H is the **transverse or portal fissure**; in front of it is the **quadrate lobe**, behind it is the **Spigelian lobe**.

The **superior surface** (*facies superior*) (Fig. 1083) comprises a part of both lobes, and, as a whole, is convex, and fits under the vault of the Diaphragm; its central part, however, presents a shallow depression, the **cardiac depression** (*impressio cardiaca*), which corresponds with the position of the heart on the upper surfaces of the Diaphragm. It is separated from the anterior, posterior, and lateral surfaces by thick, rounded borders. Its left extremity is continued into the under surface by a prominent sharp margin. Except along the lines of attachment of the falciform ligament this surface is completely covered by peritoneum.

The **anterior surface** is large, triangular in shape, and comprises also a part of both right and left lobes. It is directed forward, and the greater part of it is in

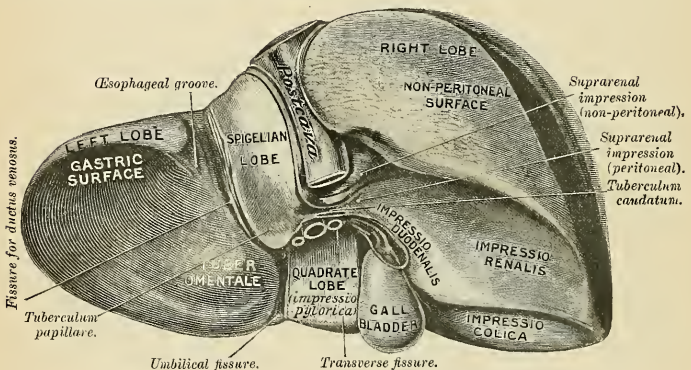
contact with the Diaphragm, which separates it on the right from the sixth to the tenth ribs and their cartilages, and on the left from the seventh and eighth costal cartilages. In the middle line it lies behind the ensiform cartilage, and in the angle between the diverging rib cartilages of opposite sides the anterior surface is in contact with the abdominal wall. It is separated from the inferior surface by a sharp margin, and from the superior and lateral surfaces by thick rounded borders. It is completely covered by peritoneum except along the line of attachment of the falciform ligament.

The **lateral or right surface** (Figs. 1083 and 1084) is convex from before backward and slightly so from above downward. It is directed toward the right side, forming the base of the wedge, and lies against the lateral portion of the Diaphragm, which separates it from the lower part of the right pleura and lung, outside which are the right costal arches from the seventh to the eleventh inclusive.

The **inferior or visceral surface** (*facies inferior*) (Figs. 1084 and 1085) is uneven, concave, directed downward, backward, and to the left, and is in relation with the stomach and duodenum, the hepatic flexure of the colon, and the right kidney and suprarenal glands. The surface is divided by a longitudinal fissure into a right and a left lobe, and is almost completely invested by peritoneum; the only parts where this covering is absent are where the gall-bladder is attached to the liver and at the transverse fissure, where the two layers of the lesser omentum are separated from each other by the bloodvessels and duct of the viscus. The under surface of the left lobe presents to the right and near the centre a rounded eminence, the **omental tuberosity** (*tuber omentale*) (Fig. 1084), which is in contact with the lesser omentum. It is surrounded by a broad depression, the **gastric surface or impression** (*impressio gastrica*), with which the stomach is in contact. Between the gall-bladder and the left lobe is the **quadrate lobe**. The quadrate lobe is bounded to the left by the **umbilical fissure** or the **fissure for the umbilical vein** (*fossa venae umbilicalis*), which is the anterior portion of the longitudinal fissure and lodges the **round ligament**. The under surface of the right lobe is divided into two unequal portions by a fossa, which lodges the gall-bladder and is called the **fossa vesicalis** (*fossa vesicae felleae*). The portion to the left, the smaller of the two, is the **quadrate lobe**, and is in relation with the pyloric end of the stomach (*impressio pylorica*) and the first portion of the duodenum. The portion of the under surface of the right lobe to the right of the fossa vesicalis presents two shallow concave impressions, one situated behind the other, the two being separated by a ridge. The anterior of these two impressions, the **colic impression** (*impressio colica*), is produced by the hepatic flexure of the colon; the posterior, the **renal impression** (*impressio renalis*), is occupied by the upper end of the right kidney and lower part of the suprarenal gland (Fig. 1084). To the inner side of the renal impression is a third and slightly marked impression, lying between it and the neck of the gall-bladder. This is caused by the second portion of the duodenum, and is known as the **duodenal impression** (*impressio duodenalis*). Just in front of the inferior vena cava is a narrow strip of liver tissue, the **caudate lobe**, which connects the right inferior angle of the Spigelian lobe to the under surface of the right lobe. It forms the upper boundary of the foramen of Winslow.

The **posterior surface** (*facies posterior*) (Fig. 1085) is rounded and broad behind the right lobe, but narrow on the left. Over a large part of its extent it is not covered by peritoneum; this **uncovered area** (Fig. 1084) is about three inches (7.5 cm.) broad, and is in direct contact with the Diaphragm, being united to it by areolar tissue. It is marked off from the upper surface by the line of reflection of the upper or anterior layer of the coronary ligament and from the under surface of the liver by the line of reflection of the lower layer of the coronary ligament (Fig. 1086). The central part of the posterior surface presents a deep concavity which is moulded on the vertebral column and crura of the Diaphragm. To the

right of this the inferior vena cava is lodged in an indentation in the liver substance, lying between the uncovered area and the Spigelian lobe. Close to the right of this indentation and immediately above the renal impression is a small triangular depressed area, the **suprarenal impression** (*impressio suprarenalis*) (Fig. 1084), the greater part of which is devoid of peritoneum; it lodges the right suprarenal gland, which is inserted between the liver and Diaphragm. To the left of the fossa for the inferior vena cava is the **Spigelian lobe**, which lies between the fissure for the inferior vena cava and the fissure for the ductus venosus. Below and in front it projects and forms part of the posterior boundary of the transverse fissure. Here, to the right, it is connected with the under surface of the right lobe of the liver by the caudate lobe, and to the left it presents a tubercle, the **tuberculum papillare** (Fig. 1084). It is opposite the tenth and eleventh thoracic vertebræ, and rests upon the aorta and crura of the Diaphragm, being covered by the peritoneum of the lesser sac. On the posterior surface to the left of the Spigelian lobe is a groove, the **œsophageal groove** (*impressio œsophagea*), indicating the position of the abdominal portion of the œsophagus (Fig. 1084).



* FIG. 1084.—The liver. Posterior and inferior surfaces. (Drawn from His' model.)

The **inferior border or margin** (*margo inferioris*) is thin and sharp, and marked opposite the attachment of the falciform ligament by a deep notch, the **umbilical notch** (*incisura umbilicalis*), and opposite the cartilage of the ninth rib by a second notch for the fundus of the gall-bladder (*incisura vesicae felleae*). In adult males this border generally corresponds with the lower margin of the thorax in the right midclavicular line; but in women and children it usually projects below the ribs.

The **left extremity of the inferior margin of the liver** is thin and flattened from above downward.

Fissures.—Five fissures are seen upon the under and posterior surfaces of the liver, which serve to divide it into its five lobes. They are: the **umbilical fissure**, the **fissure for the ductus venosus** (forming together the longitudinal fissure), the **transverse fissure**, the **fissure for the gall-bladder**, and the **fissure for the inferior vena cava**.

The **longitudinal fissure** (*fossa longitudinalis sinistra*) is a deep groove, which extends from the notch on the anterior margin of the liver to the upper border of the posterior surface of the organ. It separates the right and left lobes, the transverse fissure (Fig. 1084) joins it, at right angles, and divides it into two parts. The anterior part, or **umbilical fissure** (*fossa venae umbilicalis*), lodges the umbilical

The **transverse or portal fissure** (*porta hepatis*) (Fig. 1084) is a short but deep fissure, about two inches (5 cm.) in length, extending transversely across the under surface of the left portion of the right lobe, nearer to its posterior surface than its anterior border. It joins, nearly at right angles, with the longitudinal fissure, and separates the quadrate lobe in front from the caudate and Spigelian lobes behind. By the older anatomists this fissure was considered the gateway (*porta*) of the liver; hence the large vein which enters at this fissure was called the **portal vein** (Fig. 1085). Besides this vein, the fissure transmits the hepatic artery and nerves, and the hepatic duct and lymphatics. At their entrance into the fissure, the hepatic duct lies in front and to the right, the hepatic artery to the left, and the portal vein behind and between the duct and artery.

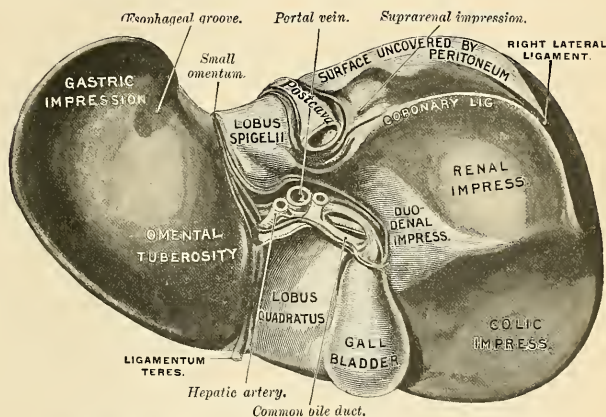


FIG. 1085.—Posterior and under surfaces of the liver. (Drawn from His' model.)

The fossa or fissure for the gall-bladder (*fossa vesicae felleae*) is a shallow, oblong fossa, placed on the under surface of the right lobe, parallel with the longitudinal fissure. It extends from the anterior free margin of the liver, which is notched for its reception, to the right extremity of the transverse fissure.

The fissure for the inferior vena cava (*fossa venae cavae*) (Fig. 1084) is a short, deep fissure, in some cases a complete canal, in consequence of the substance of the liver occasionally surrounding this vessel. It extends obliquely upward from the lobus caudatus, which separates it from the transverse fissure on the posterior surface of the liver, and is situated between the Spigelian lobe and the bare area of the liver. On slitting open the inferior vena cava the orifices of the hepatic veins will be seen opening into this vessel at its upper part, after perforating the floor of this fissure.

Lobes.—The lobes of the liver, like the ligaments and fissures, are five in number—the **right lobe**, the **left lobe**, the **lobus quadratus**, the **lobus Spigelii**, and the **lobus caudatus**, the last three being merely parts of the right lobe.

The **right lobe** (*lobus hepatis dexter*) (Figs. 1083 and 1084) is much larger than the left, the proportion between them being as six to one. It occupies the right hypochondrium, and is separated from the left lobe, on its upper and anterior surfaces, by the falciform ligament; on its under and posterior surfaces by the longitudinal fissure; and in front by the umbilical notch. It is of a somewhat quadrilateral form, its under and posterior surfaces being marked by three fissures—the transverse fissure, the fissure for the gall-bladder, and the fissure for the inferior vena cava, which separate its left part into three smaller lobes—the *lobus Spigelii*, *lobus quadratus*, and *lobus caudatus*. On it are seen four shallow impressions—one in front, for the hepatic flexure of the colon; a second behind, for the right kidney; a third internal, between the last-named and the gall-bladder, for the second part of the duodenum; and a fourth on its posterior surface, for the suprarenal gland.

The **lobus quadratus** (Figs. 1084 and 1085) is situated on the under surface of the right lobe, is bounded in front by the inferior margin of the liver; behind, by the transverse fissure; on the right, by the fissure of the gall-bladder; on the left, by the umbilical fissure. It is oblong in shape, its antero-posterior diameter being greater than its transverse.

The **lobus Spigelii** (*lobus caudatus* [*Spigelii*]) (Figs. 1084 and 1085) is situated upon the posterior surface of the right lobe of the liver. It looks directly backward, and is nearly vertical in direction. It is bounded below by the transverse fissure, on the right by the fissure for the inferior vena cava, and on the left by the fissure for the ductus venosus. It is longer from above downward, and is somewhat concave in the transverse direction. Its lower end usually projects in the form of a rounded process, the **tuber papillare** (*processus papillaris*).

The **lobus caudatus** (*processus caudatus*) (Fig. 1084), or tailed lobe, is a small elevation of the hepatic substance extending obliquely outward, from the lower extremity of the Spigelian lobe to the under surface of the right lobe. It is situated behind the transverse fissure, and separates the fissure for the gall-bladder from the commencement of the fissure for the inferior vena cava.

The **left lobe** (*lobus hepatis sinister*) (Figs. 1083 and 1084) is smaller and more flattened than the right. It is situated in the epigastric and left hypochondriac regions. Its upper surface is slightly convex; its under surface is concave, and presents a shallow depression for the stomach, the **gastric impression**. This is situated in front of the groove for the œsophagus, and is separated from the longitudinal fissure by the **omental tuberosity**, which lies against the small omentum and lesser curvature of the stomach. The posterior end of the left lobe frequently exhibits a flat projection, composed of connective tissue, and called the **appendix fibrosus hepatis**. In the adult, portions only of bile ducts are present in it. In the newborn it is a definite portion of secreting liver substance, which later undergoes connective-tissue transformation.

Ligaments.—The liver is connected to the under surface of the Diaphragm and the anterior walls of the abdomen by five ligaments, four of which are peritoneal folds; the fifth is round, fibrous cord, resulting from the occlusion of the umbilical vein. These ligaments are the **falciform**, two **lateral**, **coronary**, and **round**. It is also attached to the lesser curvature of the stomach by the gastro-hepatic or small omentum (p. 1260).

The **falciform ligament** (*ligamentum falciforme hepatis*) (Figs. 1086 and 1087) is a broad and thin antero-posterior peritoneal fold, falciform in shape, its base being directed downward and backward, its apex upward and backward. It is attached by one margin to the under surface of the Diaphragm, and the posterior surface of the sheath of the right Rectus muscle as low down as the umbilicus; by its hepatic margin it extends from the notch on the anterior margin of the liver, as far back as its posterior surface. It is composed of two layers of peritoneum closely united. Its free edge contains the round ligament of the liver.

The **coronary ligament** (*ligamentum coronarium hepatis*) (Figs. 1083 and 1086) connects the posterior surface of the liver to the Diaphragm. It consists of two layers. The *upper layer* is formed by the reflection of the peritoneum from the upper margin of the bare area of the liver to the under surface of the Diaphragm, and is continuous with the right layer of the falciform ligament. The *lower layer* is reflected from the lower margin of the bare area on to the right kidney and suprarenal gland.

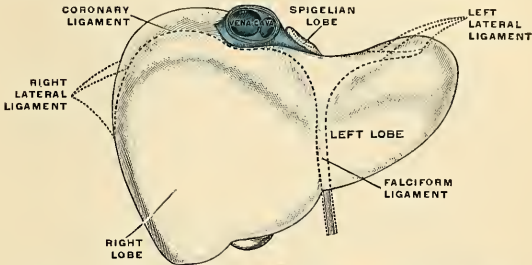


FIG. 1086.—The peritoneal ligaments of the liver. (Schematic.) (Poirier and Charpy.)

The **lateral ligaments** (Figs. 1083 and 1086) are two in number, and are called the **right** and **left lateral ligaments**.

The **right lateral ligament** (*ligamentum triangulare dextrum*) (Figs. 1083 and 1086) is in reality the right extremity of the coronary ligament. This ligament is triangular in form, runs from the liver to the Diaphragm, and is formed by the apposition of the upper and lower layers of the coronary ligament.

The **left lateral ligament** (*ligamentum triangulare sinistrum*) (Figs. 1083 and 1086) is a fold of some considerable size, which connects the posterior part of the upper surface of the left lobe to the Diaphragm; its anterior layer is continuous with the left layer of the falciform ligament.

The **round ligament** (*ligamentum teres hepatis*) (Figs. 1085 and 1087) is a fibrous cord resulting from the occlusion of the fetal umbilical vein. It ascends from the umbilicus, in the free margin of the falciform ligament, to the notch in the anterior border of the liver, from which it may be traced along the umbilical fissure on the inferior surface of the liver; on the posterior surface it is continued upward as the impervious ductus venosus (*lig. venosum*) as far as the inferior vena cava.

Support and Movability of the Liver.—The liver is movable within certain narrow limits. It moves with respiration. On inspiration it moves down with the Diaphragm to distinctly below the costal arch in the right midclavicular line.

Its fixation to the under surface of the Diaphragm by means of connective tissue gives it its strongest support.

The surface relations of the liver are given on page 1334.

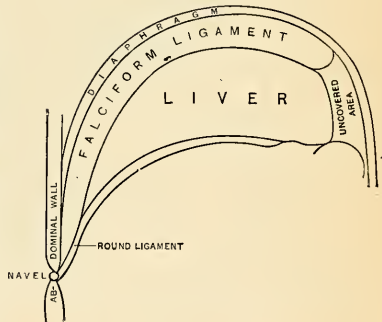


FIG. 1087.—Diagram to show the relations of the falciform or suspensory and round ligaments to the liver and the abdominal wall. (Gerrish.)

Abnormalities of the Liver.—The liver may be divided into many lobules, and such lobulation is most evident on the parietal surface of the right lobe. Lobulation is probably a pathological change. Occasionally the right lobe is small and the left large.

Accessory Livers are fragments of hepatic tissue or vestiges, which are entirely separated from the liver. They are seldom met with. When they do exist their most common situation is in the suspensory ligament, but they have been found in the great omentum, in the peritoneum, wall of the gall-bladder, and in other situations. They may be congenital or may be due to atrophy of the pedicle of an accessory lobe or of a pedunculated lobe. **Tight lacing** alters the shape and position of the liver (Fig. 1088). It may flatten the dome and increase the length of the anterior surface, this change being especially obvious in the right lobe, and a costal groove may be formed by the pressure of a rib. "When the elongated right lobe passes over the right kidney, there is atrophy of the hepatic substance and thickening of the capsule, which is opaque and forms a hinge-like ligament between the main part of the right lobe above the constricted lower portion. This lobe is variously termed **partial hepatoptosis**, **constriction lobe**, or the **sustentacular formation of the right lobe** (Hertz). The constriction furrow is produced by the pressure of the corset in front and the resistance of the kidney behind. The constriction lobe tapers to a point, so that the shape of the liver, as seen from the front, is that of a right-angled triangle, with the apex downward."¹ Such a constriction lobe is known as **Riedel's lobe**. The left lobe may also project down, but not so markedly. Tight lacing may cause the entire organ

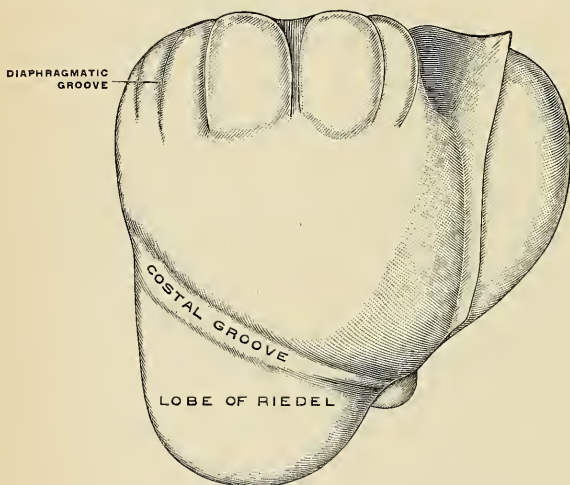


FIG. 1088.—Deformed female liver. (Poirier and Charpy.)

to occupy a level higher than normal. Such a liver is thick and excessively convex above and thin below, and reaches to or laps over the spleen. In severe cases the superior surface is thrown into antero-posterior creases or folds. Riedel's lobe (Fig. 1088) may be congenital, may be due to tight lacing, or may arise in cholelithiasis or cholecystitis from the traction of adhesions. Such a lobe comes off from the right lobe. It may be a tapering mass of liver tissue, it may have a thin pedicle of liver tissue, or its pedicle may be merely a double fold of peritoneum. The gall-bladder may lie upon its under surface, or may be placed to the left of it.

Vessels.—The bloodvessels connected with the liver are the **hepatic artery**, the **portal vein**, and the **hepatic veins**.

The **hepatic artery** and **portal vein** (Figs. 467, 468, 557, and 1089), accompanied by numerous lymphatics and nerves, ascend to the transverse fissure between the layers of the gastrohepatic omentum, and in front of the foramen of Winslow. The **hepatic duct**, lying in company with them, descends from the transverse fissure between the layers of the same omentum. The relative position of the three structures in the lesser omentum (Fig. 1000) is as follows: The hepatic

¹ Rolleston, on Diseases of the Liver.

duct lies to the right, the hepatic artery to the left, and the portal vein behind and between the other two. They enter the transverse fissure in the above-described order, but in that fissure undergo rearrangement, the duct being in front, the artery in the middle, and the vein behind. The artery, the vein, and the duct divide into a right and left branch and several smaller branches, and within the organ the vessels from the three sources accompany each other and divide at the

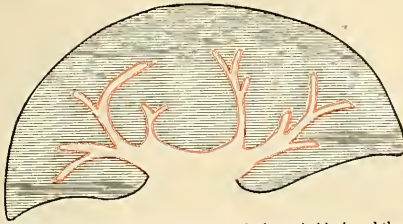


FIG. 1089.—Schematic section of the liver. The fibrous tunic is shown in black and the capsule of Glisson in red

same points; so each branch of the portal vein is accompanied by a branch of the hepatic artery and of the duct. They are enveloped in a loose areolar tissue, the **capsule of Glisson** (Fig. 1089), which accompanies the vessels in their course through the *portal canals* in the interior of the organ.

The **hepatic veins** (Fig. 471) convey the blood from the liver. They commence in the substance of the liver, in the capillary terminations of the portal vein and hepatic artery; these tributaries, gradually uniting, usually form three veins, which converge toward the posterior surface of the liver and open into the portion of the inferior vena cava situated in the groove at the back part of this organ. Of these three veins, one from the right and another from the left lobe open obliquely into the inferior vena cava, that from the middle of the organ and lobus Spigelii having a straight course.

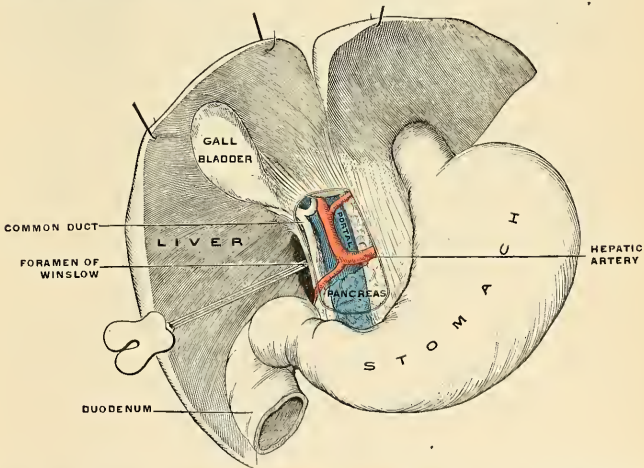


FIG. 1090.—The relations of the vessels as they pass into the transverse fissure of the liver. (Poirier and Charpy.)

The hepatic veins have very little cellular investment; what there is binds their parietes closely to the walls of the canals through which they run; so that, on section of the organ, these veins remain widely open and solitary (Fig. 1092), and may be easily distinguished from the branches of the portal vein (Fig. 1093), which are more or less collapsed, and always accompanied by an artery and duct; the hepatic veins are destitute of valves.

Structure.—The substance of the liver is composed of **lobules** held together by extremely fine areolar tissue, and of the ramifications of the portal vein, hepatic duct, hepatic artery, hepatic veins, lymphatics, and nerves, the whole being invested by a serous and fibrous coat.

The **serous coat** (*tunica serosa*) is derived from the peritoneum, and invests the greater part of the surface of the organ. It is intimately adherent to the fibrous coat.

The **areolar or fibrous coat** (*capsula fibrosa* (Glissoni)) lies beneath the serous investment and covers the entire surface of the organ; it is called the **capsule of Glisson**; the latter term has also been retained for the heavy fibrous tissue, at the portal fissure, that envelops and accompanies the vessels into the liver. It is difficult of demonstration, excepting where the serous coat is deficient. The areolar tissue which surrounds and binds together the liver lobules is continuous with the areolar coat.

The Lobules (*lobuli hepatis*) (Fig. 1096).—The lobules form the chief mass of the hepatic substance; they may be seen either on the surface of the organ or by making a section through the gland. They are small granular bodies about the size of a millet seed, measuring from one-twentieth to one-tenth of an inch in diameter. In the human subject their outline is very irregular, but in some of the lower animals (for example, the pig) they are well defined, and when divided transversely have a polygonal outline. If divided longitudinally they are more or less foliated or oblong. The bases of the lobules are clustered around the smallest radicles of the hepatic veins (*sublobular veins*), to which each is connected by means of a small branch which issues from the centre of the lobule (*intralobular vein*). The remaining part of the surface of each lobule is imperfectly isolated from the surrounding lobules by a thin stratum of areolar tissue in which are **ducts** and a plexus of vessels, the **interlobular plexus** (Figs. 1094 and 1095). In some animals, as the pig, the lobules are completely isolated from one another by this interlobular areolar tissue.

If one of the sublobular veins be laid open, the bases of the lobules may be seen through the thin wall of the vein on which they rest, arranged in the form of a tessellated pavement, the centre of each polygonal space presenting a minute aperture, the mouth of an intralobular vein (Fig. 1092).

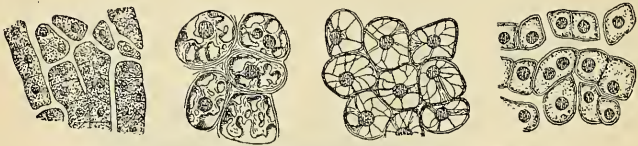

FIG. 1091.—The hepatic cells at different stages of digestion. (Heidenhain.)

Microscopic Appearance.—Each lobule is composed of irregular, anastomosing chains of cells, **hepatic cells** (Fig. 1091), surrounded by a dense capillary plexus, composed of vessels which penetrate from the circumference to the centre of the lobule, and terminate in a single straight central vein, which runs through its centre, to open at its base into one of the radicles of the hepatic vein. These structures are supported by a delicate meshwork of retiform connective tissue. Within the chains of the cells are the minute commencements of the bile ducts. Therefore, in the lobule we have all the essentials of a secreting gland; that is to say, (1) **cells**, by which the secretion is formed; (2) **bloodvessels**, in close relation with the cells, containing the blood from which the secretion is derived; and (3) **ducts**, by which the secretion, when formed, is carried away. Each of these structures will have to be further considered.

1. The **hepatic cells** are epithelial in nature and of more or less cuboidal or polygonal form. They vary in size from the $\frac{1}{10000}$ to the $\frac{1}{20000}$ of an inch in diameter; they consist of a granular protoplasm without any cell wall, and contain one or sometimes two distinct nuclei. In the nucleus is a highly refracting nucleolus with granules. Embedded in the protoplasm are numerous brownish particles, the coloring matter of the bile, oil globules, and glycogen granules in varying quantities. Secretory capillaries are to be found in the cells. The cells adhere together by their surfaces so as to form rows, which radiate from the centre to the circumference of the lobules. As stated above, they are the chief agents in the secretion of the bile.

2. The **Bloodvessels**.—The blood in the capillary plexus around the liver cells is brought to the liver principally by the portal vein, but also to a certain extent by the hepatic artery. For the sake of clearness the distribution of the blood derived from the hepatic artery may be considered first.

The **hepatic artery**, entering the liver at the transverse fissure with the portal vein and hepatic duct, ramifies with these vessels through the portal canals. It gives off **vaginal branches** which

¹ According to Mall (Jour. of Anat., vol. v, No. 3), the lobule as here described is not his *structural unit*, which refers to all the tissue surrounding each terminal branch of the portal vein.

ramify in the interlobular tissue, and appear to be destined chiefly for the nutrition of the coats of the large vessels, the ducts, and the investing membrane of the liver. It also gives off **capsular branches** which reach the surface of the organ, terminating in the fibrous coat in stellate plexuses. Finally, it gives off **interlobular branches** (*rami arteriosi interlobulares*) which form a plexus of capillaries (*interlobular capillaries*) on the outer side of each lobule, to supply its wall and the accompanying bile ducts. From this plexus some lobular branches enter the lobule and end in the capillary network between the cells.

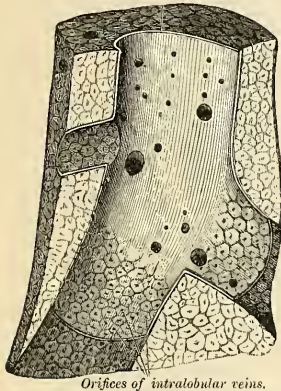


FIG. 1092.—Longitudinal section of an hepatic vein. (After Kiernan.)

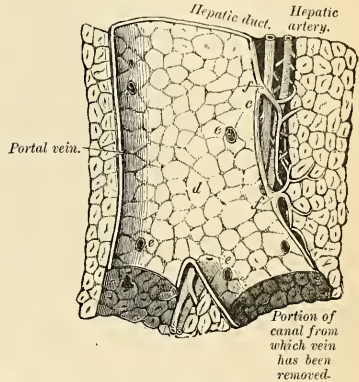


FIG. 1093.—Longitudinal section of a small portal vein and canal. (After Kiernan.)

The **portal vein** also enters at the transverse fissure and runs through the portal canals, dividing into branches in its course, which finally break up into a plexus, the **interlobular plexus**, in the interlobular connective tissue. In their course these branches receive the vaginal and capsular veins, corresponding to the vaginal and capsular branches of the hepatic artery (Fig. 1094). Thus it will be seen that all the blood carried to the liver by the portal vein and hepatic

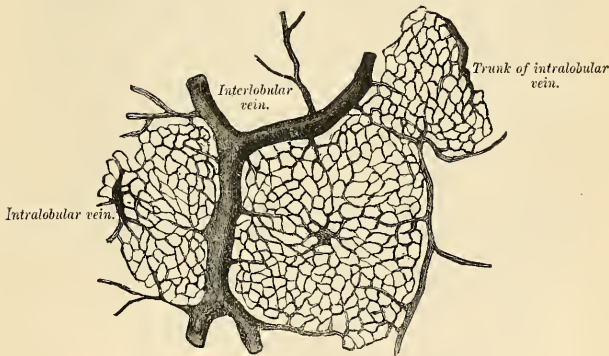


FIG. 1094.—Horizontal section of injected liver (dog).

artery, except perhaps that derived from the interlobular branches of the hepatic artery, directly or indirectly finds its way into the interlobular plexus. From this plexus the blood is carried into the lobule by fine branches which pierce its wall and then converge from the circumference to the centre of the lobule, forming a number of converging vessels, **intralobular capillaries**, which are connected by transverse branches (Figs. 1095 and 1096). In the interstices of the network

of vessels thus formed are situated, as before said, the liver cells; and here it is that the blood is brought into intimate connection with the liver cells and the bile is secreted. The endothelium of

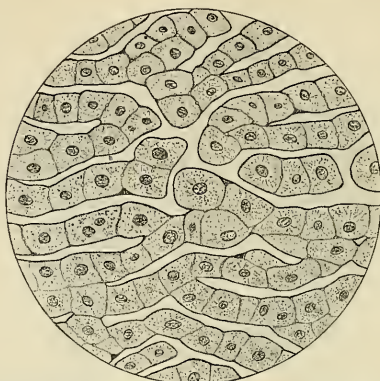


FIG. 1095.—Magnified section of a human liver, placed in preservative a few minutes after death (electrocution). The sinusoidal endothelium is seen closely applied to the hepatic epithelial cells. The cell elements of the blood in the sinusoids have been omitted, but in this as in other similarly obtained preparations numerous bell-shaped forms of red blood cells were seen.

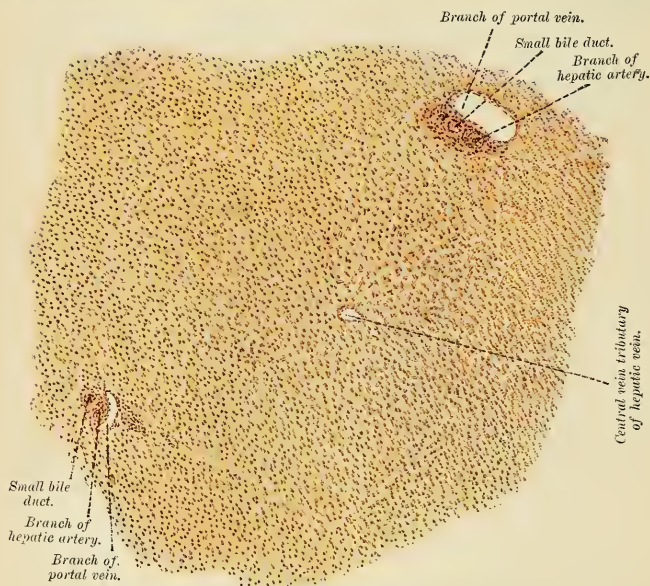


FIG. 1096.—A lobule of human liver. (After Rauber-Kopsch.)

the capillaries and the epithelial cells are closely adherent to each other, forming **sinusoids**. Arrived at the centre of a lobule, all these minute vessels empty themselves into one vein, of

considerable size, which runs down the centre of the lobule from apex to base and is called the **intralobular** or **central vein** (*vena intralobularis*) (Fig. 1096). At the base of the lobule this vein opens directly into the **sublobular vein**, with which the lobule is connected, and which, as before mentioned, is a radicle of the hepatic vein. The sublobular veins, uniting into larger and larger trunks, end at last in the hepatic veins, which do not receive any intralobular veins directly. Finally, the hepatic veins, as mentioned on page 751, converge to form three large trunks which open into the inferior vena cava, while that vessel is situated in the fissure appropriated to it at the back of the liver. The portal vein is the nutritive vessel of the parenchyma of the liver, while the hepatic artery nourishes the vessels, ducts, and interlobular connective tissue.

3. **The Ducts.**—Having shown how the blood is brought into intimate relation with the hepatic cells in order that the bile may be secreted, it remains now only to consider the way in which the secretion, having been formed, is carried away. Several views have prevailed as to the mode of origin of the hepatic ducts; it seems, however, to be clear that they commence by little passages, which are formed between the cells and which have been termed **intercellular biliary passages**, **bile capillaries**, or **bile canaliculi** (*ductus biliferi*). These passages are merely little channels or spaces left between the contiguous surfaces of two cells or in the angle where three or more liver cells meet, and it seems doubtful whether there is any delicate membrane forming the wall of the channel. Heidenhain, however, thinks they have coats. The channels thus formed radiate to the circumference of the lobule, and empty into small interlobular ducts between the lobules. These are lined by low epithelial cells supported by a basement membrane and a little fibrous tissue. The **interlobular ducts** pass into the portal canals, become enclosed in Glisson's capsule, and, accompanying the portal vein and hepatic artery (Fig. 1096), join with other ducts to form two main trunks, the right and left branches of the hepatic duct, which leave the liver at the transverse or portal fissure, and by their union form the hepatic duct. The larger interlobular ducts possess some circularly arranged smooth muscle tissue, while the main ducts possess three coats—**mucous**, **muscular**, and **fibrous**. The **mucous coat** consists of tall columnar epithelial cells, basement membrane, and tunica propria. The **muscular coat** consists of smooth muscle tissue circularly arranged. The **fibrous coat** consists of loose white fibrous tissue supporting the other coats.

The **lymphatics**, in the substance of the liver (Fig. 569), commence in lymphatic spaces around the capillaries of the lobules; they accompany the vessels of the interlobular plexus, often enclosing and surrounding them. These unite and form larger vessels, which run in the portal canals, enclosed in Glisson's capsule, and emerge at the portal fissure to be distributed in the manner described. Other superficial lymphatics arise from the superficial lobules, pass under the peritoneum, and form a close plexus, where this membrane covers the liver. The first-named group of lymphatics gives origin to the deep collecting trunks, the second to the superficial collecting trunks. One group of deep collecting trunks accompanies the portal vein, there being fifteen to eighteen of them emerging from the transverse fissure. They empty into the lymph nodes of the hilum. Another group accompanies the hepatic veins. There are five or six trunks which pass through the Diaphragm and terminate in the lymph nodes about the inferior vena cava (*intrathoracic nodes*). The superficial trunks of the superior surface are divided into posterior, anterior, and superior trunks. Some of the posterior trunks terminate in the nodes about the celiac axis, others in the nodes about the lower portion of the inferior vena cava in the thorax; others in the nodes about the abdominal portion of the esophagus. The anterior trunks which are limited to the right lobe pass to the nodes of the hilum. The superior trunks ascend in the suspensory ligament. Some pass to the nodes about the inferior vena cava, just above the Diaphragm; others to the hepatic nodes. The balance unite to form a very large trunk, which passes through the Diaphragm and divides into branches which enter the nodes back of the base of the ensiform cartilage.

The **nerves** of the liver are derived from the **left vagus** and **sympathetic**. The branches of the left vagus ascend from in front of the stomach within the lesser omentum. The sympathetic nerves pass along the hepatic artery, enter the liver at the transverse fissure, and accompany the vessels and ducts to the interlobular spaces. Here, according to Korolkow, the myelinic fibres are distributed almost exclusively to the coats of the bloodvessels, while the amyelinic fibres enter the lobules and ramify between the cells.

The Excretory Apparatus of the Liver.

The excretory apparatus of the liver consists of (1) the **hepatic duct**, formed, as we have seen, by the junction of the two main ducts, which pass out of the liver at the transverse fissure; (2) the **gall-bladder**, which serves as a reservoir for the bile; (3) the **cystic duct**, or the duct of the gall-bladder; and (4) the **common bile duct**, formed by the junction of the hepatic and cystic ducts.

The Hepatic Duct (*ductus hepaticus*) (Figs. 1097 and 1098).—Two main trunks of nearly equal size issue from the liver at the transverse fissure, one from the **right**, the other from the **left lobe**; these unite to form the hepatic duct, which then passes downward and to the right for about an inch and a half or two inches (3.75 to 5 cm.), between the layers of the lesser omentum, where it is joined at an acute angle by the cystic duct, and so forms the common bile duct (*ductus communis choledochus*). The hepatic duct is accompanied by the hepatic artery and portal vein (Fig. 1090).

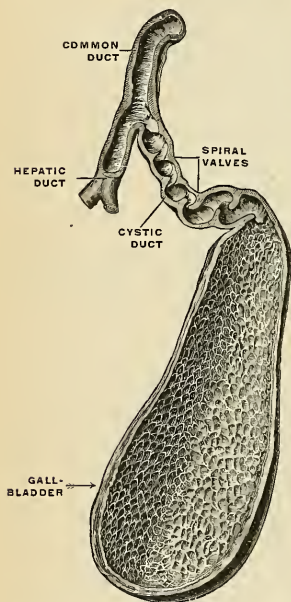


FIG. 1097.—The gall-bladder and bile ducts, opened up. (Spalteholz.)

The Gall-bladder (*vesica fellea*) (Figs. 1084 and 1097).—The gall-bladder is the reservoir for the bile; it is a conical or pear-shaped musculomembranous sac, lodged in a fossa on the under surface of the right lobe of the liver, and fixed in it by connective tissue, and extending from near the right extremity of the transverse fissure to the anterior border of the organ. It is from three to four inches (7.5 to 10 cm.) in length, one inch (2.5 cm.) in breadth at its widest part, and holds from eight to ten drams (30 to 40 c.c.). It is divided into a fundus, body, and neck. The **fundus** (*fundus vesicae felleae*), or broad extremity, is directed downward, forward, and to the right, and projects beyond the anterior border of the liver; the **body** (*corpus vesicae felleae*) and **neck** (*collum vesicae felleae*) are directed upward and backward to the left. The neck of the gall-bladder is on a slightly higher level than the lowest point of the gall-bladder; thus the weight of the bile is away from rather than toward the outlet. The upper surface of the gall-bladder is attached to the liver by connective tissue and vessels. The under surface is covered by peritoneum, which is reflected on to it from the surface of the liver. Occasionally the whole of the organ is invested by the serous membrane, and is then connected to the liver by a kind of mesentery.

Relations.—The **body of the gall-bladder** is in relation, by its upper surface, with the liver, to which it is connected by areolar tissue and vessels; by its under surface, with the commencement of the transverse colon; and farther back, with the upper end of the descending portion of the duodenum or sometimes with the pyloric end of the stomach or the first portion of the duodenum. The **fundus** is completely invested by peritoneum; it is in relation, in front, with the abdominal parietes, immediately below the ninth costal cartilage; behind, with the transverse arch of the colon. The **neck** is narrow, and curves upon itself like the letter S; at its point of connection with the cystic duct it presents a well-marked constriction.

When the gall-bladder is distended with bile or filled with calculi, the fundus may be felt through the abdominal parietes, especially in an emaciated subject; the relations of this sac will also serve to explain the occasional occurrence of abdominal biliary fistulae, through which biliary calculi may pass out, and of the passage of calculi from the gall-bladder into the stomach, duodenum, or colon, which occasionally happens.

Structure.—The gall-bladder consists of three coats—**serofibrous**, **muscular**, and **mucous**. The **external or serofibrous coat** (*tunica serosa vesicae felleae*) consists of white fibrous tissue that surrounds the muscle coat; the fundus is completely covered by peritoneum, while the body and neck are covered on their under surfaces only.

The **muscular coat** (*tunica muscularis vesicae felleae*) is a thin but strong layer which forms

the framework of the sac, consisting of dense fibrous tissue which interlaces in all directions and is mixed with plain muscle fibres which are disposed chiefly in a longitudinal direction, a few running transversely.

The **internal** or **mucous coat** (*tunica mucosa vesicae felleae*) is loosely connected with the fibrous portion of the preceding coat. It is generally tinged with a yellowish-brown color, and is everywhere elevated into minute **rugæ**, by the union of which numerous meshes are formed, the depressed intervening spaces having a polygonal outline. The meshes are smaller at the fundus and neck, being most developed about the centre of the sac. Opposite the neck of the gall-bladder the mucous membrane projects inward in the form of oblique ridges or folds, forming a spiral valve (Fig. 1097).

The mucous membrane is covered with columnar epithelium, and secretes an abundance of thick viscid mucus; it is continuous through the hepatic duct with the mucous membrane lining the ducts of the liver, and through the ductus communis choledochus with the mucous membrane of the duodenum. Mucous glands may be found in this coat, as well as diffuse lymphoid tissue and solitary follicles.

The Cystic Duct (*ductus cysticus*).—The cystic duct, the smallest of the three biliary ducts, is about an inch and a half (3.75 cm.) in length. It passes obliquely downward and to the left from the neck of the gall-bladder, and joins the hepatic duct to form the common bile duct. It lies in the gastrohepatic omentum in front of the portal vein, the hepatic artery lying to its left side. The mucous membrane lining its interior is thrown into a series of crescentic folds, from five to twelve in number, similar to those found in the neck of the gall-bladder. They project into the duct in regular succession, and are directed obliquely around the tube, presenting much the appearance of a continuous spiral valve (*valvula spiralis* [*Heisteri*]) (Fig. 1097). When the duct is distended, the spaces between the folds are dilated, so as to give to its exterior a twisted appearance.

The **common bile duct** (*ductus choledochus*) (Figs. 1097 and 1098), the largest of the three, is the common excretory duct of the liver and gall-bladder. It is about three inches in length, is of the diameter of a goose-quill, and is formed by the junction of the cystic and hepatic ducts.

It descends along the right border of the lesser omentum behind the first portion of the duodenum, in front of the portal vein, and to the right of the hepatic artery (Fig. 1000); it then passes between the head of the pancreas and descending

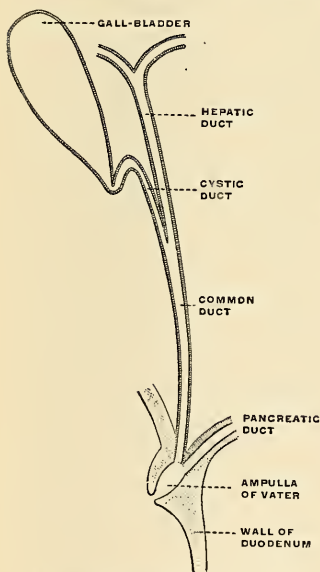


FIG. 1098.—The biliary ducts. (Schematic.) (Poirier and Charpy.)

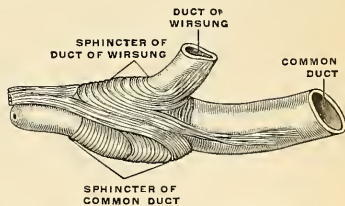


FIG. 1099.—The sphincter of the common bile duct. (Poirier and Charpy.)

portion of the duodenum, and, running for a short distance along the right side of the terminal part of the pancreatic duct, passes with it obliquely through the wall of the descending portion of the duodenum between the mucous and muscular

coats in the submucous tissue for one-half to three-quarters of an inch (1.25 to 2 cm.). The two ducts usually unite just before opening into the duodenum (Figs. 1098 and 1099), but may remain independent throughout (in about 10 per cent. of individuals). The **ampulla of Vater** (Fig. 1098) is the conical cavity formed by the fusion of the two ducts, and is much larger than the opening on the bile papilla. It averages 9.3 mm. in length. The average diameter of the orifice is 2.5 mm. (Opie). The two ducts open by a common orifice if there is an ampulla, or by two separate orifices if there is no ampulla, upon the summit of a papilla, situated at the inner side of the descending portion of the duodenum, a little below its middle and about three or four inches (7.5 to 10 cm.) below the pylorus. Circular muscle fibres, continuous with the longitudinal fibres of the ducts, surround the termination of the two ducts in the ampulla. These fibres constitute the so-called **sphincter of Oddi** (Fig. 1099).

Structure.—The coats of the large biliary ducts are an **external** or **fibrous**, a **middle** or **muscular**, and an **internal** or **mucous**. The **fibrous coat** is composed of strong fibroareolar tissue. The **muscular coat** consists chiefly of circularly arranged smooth muscle tissue. The **mucous coat** is continuous with the lining membrane of the hepatic ducts and gall-bladder, and also with that of the duodenum; and, like the mucous membrane of these structures, its epithelium is of the simple columnar variety. It is provided with numerous mucous glands, which are lobulated and open by minute orifices scattered irregularly in the larger ducts. It is questionable if the smallest biliary ducts, which lie in the interlobular spaces, have any coats. Heidenhain thinks they have a connective-tissue coat, in which are muscle cells arranged both circularly and longitudinally, and an epithelial layer, consisting of short columnar cells.

Dimensions of the Bile Ducts.—The hepatic duct is about two inches (5 cm.) in length, and its lumen is one-sixth of an inch (4 mm.) in diameter. The cystic duct is about one and one-half inches (3.75 cm.) in length, and its lumen is one-twelfth of an inch (2 mm.) in diameter. The common duct is about three inches (7.5 cm.) in length, and its lumen is one-quarter of an inch (6 mm.) in diameter. The duodenal opening is smaller than the common duct. The ducts are capable of considerable distention, but the duodenal opening cannot be dilated (Hyrtl).

Bloodvessels, Lymphatics, and Nerves of the Gall-bladder and Bile Ducts.—The **cystic artery** (Fig. 467), a branch from the right division of the hepatic, supplies the gall-bladder and cystic duct with blood. It passes along the cystic duct, and on reaching the gall-bladder divides into an upper branch and a lower branch. The upper branch lies between the gall-bladder and the liver and sends branches to each. The lower branch is between the peritoneum and the wall of the gall-bladder. The **cystic veins** empty into the portal vein. The common duct receives branches from the **superior pancreaticoduodenal artery**. There is a **submucous lymphatic network** and a **muscular lymphatic network**. The lymphatics are much less numerous at the fundus of the gall-bladder than at the neck or in the extrahepatic ducts. The collecting trunks end in lymph nodes along the cystic and common ducts, and these glands are in communication with the duodenal lymphatics and the lymphatics from the head of the pancreas. The **nerves** of the gall-bladder and bile ducts come from the **cœliac plexus** of the sympathetic.

The Bile (fel).—The bile is a reddish-brown or greenish fluid. It contains pigments (bilirubin and biliverdin), fats and soaps, cholesterin, sodium salts of glycocholic and taurocholic acid, lecithin, and nucleoalbumin furnished by the mucous membrane. There are also present CO₂; chlorides, carbonates, phosphates, and sulphates of the alkalies and of calcium, and iron. The amount normally secreted is from one pint to one and one-half pints in the twenty-four hours.

Surface Relations.—The liver is situated in the right hypochondriac and the epigastric regions, and is moulded to the arch of the Diaphragm. In the greater part of its extent it lies under cover of the lower ribs and their cartilages, but in the epigastric region it comes in contact with the abdominal wall, in the subcostal angle. The *upper limit of the right lobe of the liver* may be defined in the middle line by the junction of the mesosternum with the ensiform cartilage; on the right side the line must be carried upward as far as the fifth rib cartilage in the midclavicular line and then downward to reach the seventh rib at the side of the thorax. The *upper limit of the left lobe* may be defined by continuing this line to the left with an inclination downward to a point about 7 cm. to the left of the mesal plane on a level with the sixth left costal cartilage. The *lower limit of the liver* may be indicated by a line drawn half an inch below the lower border of the thorax on the right side as far as the ninth right costal cartilage, and thence obliquely upward across the subcostal angle to the eighth left costal cartilage. A slight curved line with its convexity to the left from this point—i. e., the eighth left costal cartilage—to the termination of the line indicating the upper limit will denote the left margin of the liver. The fundus of the gall-bladder approaches the surface behind the anterior extremity of the ninth costal cartilage, close to the outer margin of the right Rectus muscle.

It must be remembered that the liver is subject to considerable alterations in position, and the student should make himself acquainted with the different circumstances under which this occurs, as they are of importance in determining the existence of enlargement or other diseases of the organ.

Its position varies according to the posture of the body. In the erect position in the adult male the edge of the liver projects about half an inch below the lower edge of the right costal cartilages, and its anterior border can be often felt in this situation if the abdominal wall is thin. In the supine position the liver gravitates backward and recedes above the lower margin of the ribs, and cannot then be detected by the finger. In the prone position it falls forward, and can then generally be felt in a patient with loose and lax abdominal walls. Its position varies also with the ascent or descent of the Diaphragm. In a deep inspiration the liver descends below the ribs; in expiration it is raised behind them. Again, in emphysema, where the lungs are distended and the Diaphragm descends very low, the liver is pushed down; in some other diseases, as phthisis, where the Diaphragm is much arched, the liver rises very high up. Pressure from without, as in tight lacing, by compressing the lower part of the thorax, displaces the liver considerably, its anterior edge often extending as low as the crest of the ilium; and its convex surface is often at the same time deeply indented from the pressure of the ribs. Again, its position varies greatly according to the greater or less distention of the stomach and intestines. When the intestines are empty the liver descends in the abdomen, but when they are distended it is pushed upward. Its relations to surrounding organs may also be changed by the growth of tumors or by collections of fluid in the thoracic or abdominal cavities.

Applied Anatomy.—*Movable liver* or *hepatoptosis* is a rare condition, in which the liver moves or can be moved from its normal position. It is due to lessened tone of the abdominal muscles and relaxation of the liver supports. In movable liver the organ may be rotated on its vertical axis or on its transverse axis. Tongue-like lobes have been referred to. On account of its large size, its fixed position, and its friability, the liver is more frequently *ruptured* than any other of the abdominal viscera. The rupture may vary considerably in extent, from a slight scratch to an extensive laceration completely through its substance, dividing it into two parts. Sometimes an *internal rupture* without laceration of the peritoneal covering takes place, and such injuries are most susceptible of repair; but small tears of the surface may also heal; when, however, the laceration is extensive, death usually takes place from hemorrhage, on account of the fact that the hepatic veins are contained in rigid canals in the liver substance and are unable to contract, and are, moreover, unprovided with valves. The liver may also be torn by the end of a broken rib perforating the Diaphragm. The liver may be injured by *stabs* or other *punctured wounds*, and when these are inflicted through the chest wall both pleural and peritoneal cavities may be opened up and both lung and liver be wounded. In cases of *wound of the liver* from the front, protrusion of a part of this viscus may take place, but can generally easily be replaced. In cases of laceration of the liver, when there is evidence that bleeding is going on, the abdomen must be opened, the laceration sought for, and the bleeding arrested. This may be done temporarily by introducing the forefinger into the foramen of Winslow and placing the thumb on the gastrohepatic omentum and compressing the hepatic artery and portal vein between the two. Any bleeding points can then be seen. Bleeding is, if possible, arrested by suture ligatures. The edges of a small laceration are simply brought together and sutured by means of a blunt, curved, round needle passed from one side of the wound to the other. All sutures must be passed before any are tied, and this must be done with the greatest gentleness, as the liver substance is very friable. If suture fails the actual cautery may succeed. When the laceration is extensive, the liver is sutured to the abdominal wall to hold it firm when pressure is applied, and then the laceration is packed with a piece of iodoform gauze, the end of which is allowed to hang out of the external wound. *Abscess of the liver* is of not infrequent occurrence, and may open in many different ways on account of the relations of this viscus to other organs. Thus, it may burst into the lung, the pus being coughed up, or into the stomach, the pus perhaps being vomited; it may burst into the colon or into the duodenum, or, by perforating the Diaphragm, it may empty itself into the pleural cavity. Frequently it makes its way forward, and points on the anterior abdominal wall, and finally it may burst into the peritoneal or pericardiac cavity. Abscesses of the liver require opening, and this must be done by an incision in the abdominal wall, in the thoracic wall, or in the lumbar region, according to the direction in which the abscess is tracking. The incision through the abdominal wall is to be preferred when possible. The abdominal wall is incised over the swelling, and unless the peritoneum is adherent, gauze is packed all around the exposed liver surface and the abscess opened, if deeply seated, preferably by the thermo-cautery. *Hydatid cysts* are more often found in the liver than in any other of the viscera. The reason of this is not far to seek. The embryo of the egg of the *tenia echinococcus* being liberated in the stomach by the disintegration of its shell, bores its way through the gastric walls and usually enters a bloodvessel, and is carried by the blood stream to the hepatic capillaries, where its onward course is arrested, and where it undergoes development into the fully formed hydatid. *Tumors of the liver* have recently been subjected to surgical treatment by removal of a portion of the organ. The abdomen is opened and the diseased portion of liver exposed; the circula-

tion is controlled by compressing the portal vein and the hepatic artery in the gastrohepatic omentum and a wedge-shaped portion of liver containing the tumor removed; the divided vessels are ligated, and the cut surfaces brought together and sutured in the manner directed on page 1333.

When the *gall-bladder* or one of its main ducts is *ruptured*, which may occur independently of laceration of the liver, death usually occurs from peritonitis. If the symptoms have led to the performance of a laparotomy and a small rent is found, it should be sutured; if an extensive opening is found the gall-bladder should be removed. If the cystic duct is torn, its distal end must be closed and the gall-bladder removed. In rupture of either of the other ducts, simply provide for free drainage.

The gall-bladder may become distended with bile in cases of *obstruction of its duct* or of the *common bile duct*, or it may become distended from a collection of *gallstones* within its interior, thus forming a large tumor. The swelling due to distention with bile is pear-shaped, and projects downward and forward to the umbilicus. It moves with respiration, since it is attached to the liver. To relieve a patient of *gallstones*, the gall-bladder must be opened and the gallstones removed. The operation is performed by an incision two or three inches long in the right semilunar line, commencing at the costal margin. The peritoneal cavity is opened, and, the tumor having been found, gauze pads are packed around it to protect the peritoneal cavity, and it is aspirated. When the contained fluid has been evacuated the flaccid bladder is drawn out of the abdominal wound and its wall incised to the extent of an inch; any gallstones in the bladder are now removed and the interior of the sac sponged dry. If the case is one of obstruction of the duct, an attempt must be made to dislodge the stone by manipulation through the wall of the duct; or it may be crushed from without by the fingers or carefully padded forceps. If this does not succeed, the safest plan is to incise the duct, extract the stone, close the incision in the duct by fine sutures in two layers, and employ drainage. After all obstruction has been removed, four courses are open to the surgeon: (1) The wound in the gall-bladder may be at once sewed up, the organ returned into the abdominal cavity, and the external incision closed. (2) The edges of the incision in the gall-bladder may be sutured to the fascia of the external wound, and a fistulous communication established between the gall-bladder and the exterior; this fistulous opening usually closes in the course of a few weeks. (3) The gall-bladder may be connected with the intestinal canal, preferably the duodenum, by means of a lateral anastomosis; this is known as *cholecystenterostomy*. (4) The gall-bladder may be completely removed (*cholecystectomy*).

If a stone blocks the ampulla of Vater and if the common bile duct and the pancreatic duct empty into the diverticulum, it is evident that both ducts will be blocked. It has been demonstrated that in such a case the pressure urging the bile onward is sufficient to overcome the pressure in the pancreatic duct and drive bile into the ducts of the pancreas, the result, perhaps, being disastrous inflammation of the pancreas.

Septic trouble arises more rapidly when a stone is blocked in the duct than when stones merely block the gall-bladder, because the first-named part is richer in lymphatics (Murphy).

THE PANCREAS (Figs. 1100, 1102).

Dissection.—The pancreas may be exposed for dissection in three different ways: (1) By raising the liver, drawing down the stomach, and tearing through the gastrohepatic omentum and the ascending layer of the transverse mesocolon. (2) By raising the stomach, the arch of the colon, and greater omentum, and then dividing the inferior layer of the transverse mesocolon and raising its ascending layer. (3) By dividing the two layers of peritoneum, which descend from the greater curvature of the stomach to form the greater omentum; turning the stomach upward, and then cutting through the ascending layer of the transverse mesocolon (see Fig. 996).

The **pancreas** is a compound racemose gland, analogous in its structure to the salivary glands, though softer and less compactly arranged than those organs. It is long and irregularly prismatic in shape, and of a reddish-white color. Its right extremity, being broad, is called the **head**, and is connected to the main portion of the organ, the **body**, by a slight constriction, the **neck**; while its left extremity gradually tapers to form the **tail**. It is situated transversely across the posterior wall of the abdomen, at the back of the epigastric and left hypochondriac regions. Its length varies from five to six inches (12.5 to 15 cm.), its breadth is an inch and a half (3.75 cm.), and its thickness from half an inch to an inch (1.25 to 2.5 cm.), being greater at its right extremity and along its upper border. Its weight varies from two to three and one-half ounces (60 to 100 grams).

The **head** (*caput pancreatis*) (Fig. 1100) is flattened from before backward, and is lodged within the curve of the duodenum. The upper border is in contact with the first part of the duodenum, and its lower overlaps the third part; its right

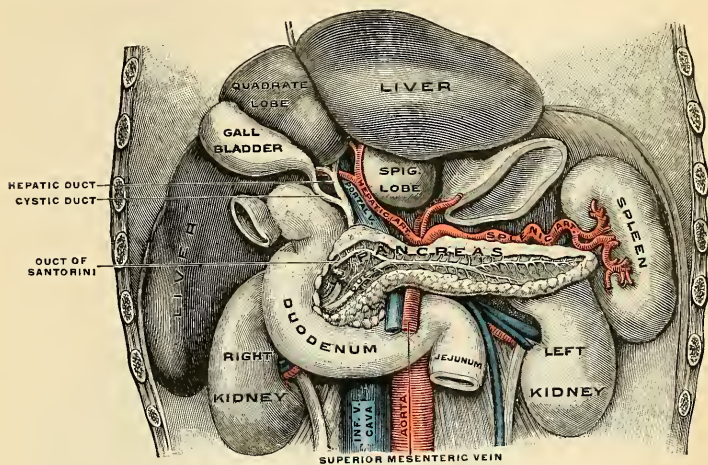


FIG. 1100.—Position and relations of pancreas.

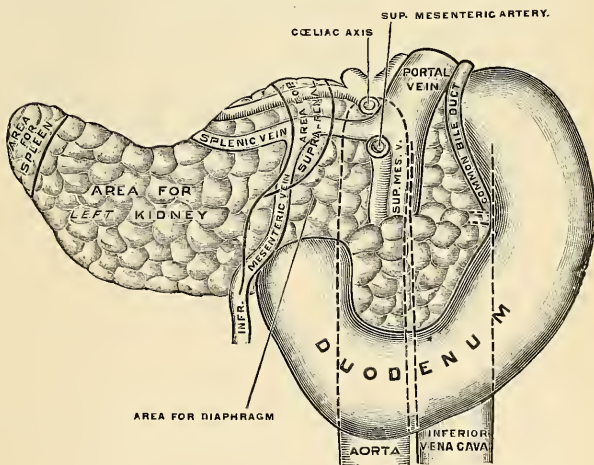


FIG. 1101.—The pancreas and duodenum from behind. (Drawn from His' model.)

and left borders overlap in front, and insinuate themselves behind, the second and fourth parts of the duodenum respectively. The angle of junction of the lower and left lateral borders forms a prolongation, termed the **processus uncinatus**. In the groove between the duodenum and the right lateral and lower borders in

front are the anastomosing superior and inferior pancreaticoduodenal arteries; the common bile duct descends behind, along the right border, to its termination in the second part of the duodenum.

The greater part of the right half of the **anterior surface** is in contact with the transverse colon, only areolar tissue intervening. From its upper part the neck originates, its right limit being marked by a groove for the gastroduodenal artery. The lower part of the right half, below the transverse colon, is covered by peritoneum continuous with the inferior layer of the transverse mesocolon, and is

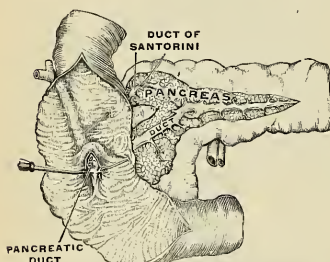


FIG. 1102.—Duodenal orifice of the pancreatic duct and of the duct of Santorini.

in contact with the coils of the small intestine. The superior mesenteric artery passes down in front of the left half across the uncinate process; the superior mesenteric vein runs upward along the right side of the artery, and, behind the neck of the pancreas, joins with the splenic vein to form the portal vein.

The **posterior surface** is in relation with the inferior vena cava, the renal veins, the right crus of the Diaphragm, and the aorta.

The **neck** springs from the right upper portion of the front of the head. It is about an inch (2.5 cm.) long, and is directed, at first, upward and forward,

and then upward and to the left to join the body; it is somewhat flattened from above downward and backward. Its antero-superior surface supports the pylorus; its postero-inferior surface is in relation with the commencement of the portal vein; on the right it is grooved by the gastroduodenal artery.

The **body** (*corpus pancreatis*) is somewhat prismatic in shape, and has three surfaces—**anterior**, **posterior**, and **inferior**.

The **anterior surface** (*facies anterior*) is somewhat concave, and is directed forward and upward; it is covered by the postero-inferior surface of the stomach which rests upon it, the two organs being separated by the lesser sac of the peritoneum. Where it joins the neck extremity there is a well-marked prominence, called the **omental tuberosity** (*tuber omentale*), which abuts against the posterior surface of the small omentum.

The **posterior surface** (*facies posterior*) (Fig. 1101) is devoid of peritoneum, and is in contact with the aorta, the splenic vein, the left kidney and its vessels, the left suprarenal gland, the crura of the Diaphragm, and the origin of the superior mesenteric artery.

The **inferior surface** (*facies inferior*) (Fig. 1101) is narrow on the right, but broader on the left, and is covered by peritoneum; it lies upon the duodenojejunal flexure and on some coils of the jejunum; its left extremity rests on the splenic flexure of the colon.

The **superior border** (*margo superior*) of the body is blunt and flat to the right; narrow and sharp to the left, near the tail. It commences to the right in the omental tuberosity, and is in relation with the celiac axis, from which the hepatic artery courses to the right just above the gland, while the splenic branch runs toward the left in a groove along this border.

The **anterior border** (*margo anterior*) separates the anterior from the inferior surface, and along this border the two layers of the transverse mesocolon diverge from each other; one passing upward over the anterior surface, the other backward over the inferior surface.

The **inferior border** (*margo inferior*) separates the posterior from the inferior surface; the superior mesenteric vessels emerge under its right extremity.

The **tail** (*cauda pancreatis*) is narrow; it extends to the left as far as the lower part of the gastric surface of the spleen, and it is in contact with the splenic flexure of the colon.

Birmingham describes the body of the pancreas as projecting forward as a prominent ridge into the abdominal cavity and forming a sort of shelf on which the stomach lies. He says: "The portion of the pancreas to the left of the middle line has a very considerable antero-posterior thickness; as a result the anterior surface is of considerable extent, it looks strongly upward, and forms a large and important part of the shelf. As the pancreas extends to the left toward the spleen it crosses the upper part of the kidney, and is so moulded on to it that the top of the kidney forms an extension inward and backward of the upper surface of the pancreas and extends the bed in this direction. On the other hand, the extremity of the pancreas comes in contact with the spleen in such a way that the plane of its upper surface runs with little interruption upward and backward into the concave gastric surface of the spleen, which completes the bed behind and to

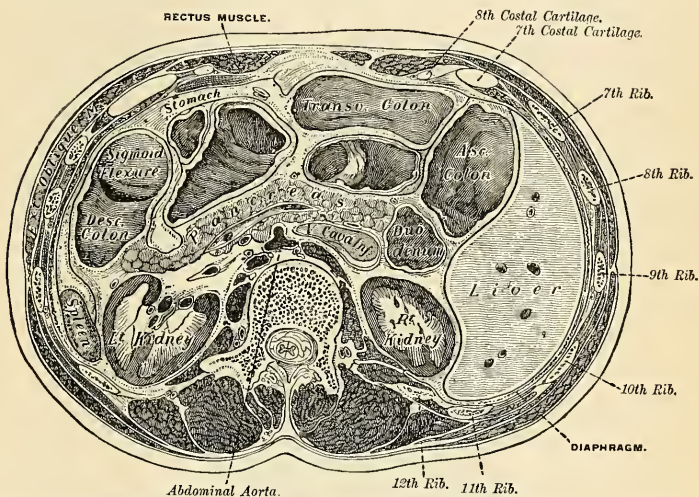


FIG. 1103.—Transverse section through the middle of the first lumbar vertebra, showing the relations of the pancreas. (Braune.)

the left, and, running upward, forms a partial cap for the wide end of the stomach.

The principal excretory duct of the pancreas, called the **pancreatic duct** or **canal of Wirsung** (*ductus pancreaticus* [*Wirsungi*]) (Figs. 1100 and 1102), extends transversely from left to right through the substance of the pancreas. In order to expose it, the superficial portion of the gland must be removed. It commences by the junction of the small ducts of the lobules situated in the tail of the pancreas, and, running from left to right through the body, it constantly receives the ducts of the various lobules composing the gland. Considerably augmented in size, it reaches the neck, and, turning obliquely downward, backward, and to the right, it comes into relation with the common bile duct, lying to its left side; leaving the head of the gland, it passes very obliquely through the mucous and muscular coats of the duodenum, and usually terminates by an orifice common to it and the

common bile duct upon the summit of an elevated papilla, situated at the inner side of the descending portion of the duodenum, three or four inches (7.5 to 10 cm.) below the pylorus (Figs. 1098 and 1099).

Sometimes the pancreatic duct and common bile duct open separately into the duodenum (Fig. 1029). Frequently there is an accessory duct, which is given off from the canal of Wirsung in the neck of the pancreas and passes horizontally to the right to open into the duodenum about an inch above the orifice of the main duct. This is known as the **duct of Santorini** (*ductus pancreaticus accessorius* [Santorini]) (Fig. 1102).

The **pancreatic duct**, near the duodenum, is about the size of an ordinary quill; its walls are thin, consisting of three coats, an **external fibrous**, a **middle muscular**, and an **internal mucous**; the latter is smooth, and furnished near its termination with a few scattered follicles.

Structure.—In structure, the pancreas resembles the salivary glands. It differs from them, however, in certain particulars, and is looser and softer in its texture. It is not enclosed in a distinct capsule, but is surrounded by areolar tissue, which dips into its interior, and connects the various lobules of which it is composed. Each lobule, like the lobules of the salivary glands, consists of one of the ultimate ramifications of the main duct, terminating in a number of cecal pouches or alveoli, which are mainly grape-like. The minute ducts connected with the alveoli are narrow and lined with flattened cells. The alveoli are almost completely filled with secreting cells, so that scarcely any lumen is visible. In the centre of the end-tubules flat cells are frequently found. They are continuations into the tubules of the duct epithelium. These cells are known as the **centro-acinar cells of Langerhans**. The true secreting cells which line the wall of the alveolus are very characteristic. They are pyramidal or rounded in shape and present two zones—an outer one clear and finely striated next the basement membrane, and an inner granular one next the lumen. The highly refracting granules are known as **zymogen granules**. During digestion the granules gradually disappear and the cells become clear. During fasting the granular zone occupies more than one-half of the cell (Szymonowicz). In some secreting cells of the pancreas is a spherical mass, staining more easily than the rest of the cells;

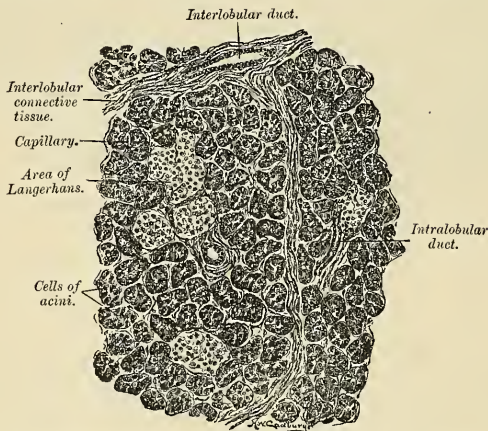


FIG. 1104.—Section of human pancreas, showing pancreatic islands. (Radasch.)

this is termed the **paranucleus**, and it is believed to be an extension from the nucleus. The connective tissue among the gland tubules and alveoli presents in certain parts collections of cells, which are termed **interalveolar cell islets**, or **islands of Langerhans**. Opie points out that they are most common in the splenic end of the pancreas. The cells of the islands are smaller and paler than the secreting cells of the alveoli, and are arranged in layers with intervening spaces. The islands are sharply demarcated from the alveoli, are much larger than the latter, and are

very vascular. There are no ducts in the islands of Langerhans. Their function is to furnish the internal secretion of the pancreas.

Bloodvessels, Lymphatics, and Nerves.—The arteries of the pancreas come from the superior pancreaticoduodenal branch of the gastroduodenal; the inferior pancreaticoduodenal branch of the superior mesenteric; the inferior pancreatic branch of the superior mesenteric; pancreatic branches of the hepatic and pancreatic branches of the splenic. In a few cases a large artery, the *pancreatica magna*, accompanies the pancreatic duct. In most cases there is no such vessel. The veins are the anterior pancreaticoduodenal branch of the superior mesenteric; the posterior pancreaticoduodenal branch and other pancreatic branches of the portal; and pancreatic branches of the splenic. The lymphatics arise in a network about the lobules. Numerous collecting trunks pass to the surface of the pancreas, anastomose with each other, and enter into nodes about the pancreas. The splenic nodes receive most of the trunks. Others are received by nodes along the aorta (Sappey), nodes at the origin of the superior mesenteric artery, and nodes along the pancreaticoduodenal vessels. The nerves come from the celiac, superior mesenteric, and splenic plexuses.

The Pancreatic Juice.—The pancreatic juice is a clear, somewhat viscid alkaline liquid. Its specific gravity is about 1.030. The solid matter consists chiefly of proteids, and amounts to about 10 per cent. of a sample of the juice. The juice contains a ferment which breaks up fat, a ferment which converts starch into sugar, and a ferment which digests proteid material.

Surface Form.—The pancreas lies in front of the second lumbar vertebra, and can sometimes be felt, in emaciated subjects, when the stomach and colon are empty, by making deep pressure in the middle line about three inches above the umbilicus.

Applied Anatomy.—Of late years our knowledge of the structure, functions, and diseases of the pancreas has been notably increased, and surgeons have begun to operate for certain pancreatic diseases. It is occasionally the seat of *cancer*, which usually affects the head or duodenal end, and therefore often speedily involves the common bile duct, leading to persistent jaundice. Cancer of the pancreas may be primary or secondary. *Primary sarcoma* is very unusual; secondary sarcoma is more common, but cancer is far commoner than either form of sarcoma. *Adenoma* may also occur. Cases are on record of the successful removal of tumors of the pancreas, but the operations are very dangerous, are extremely difficult, and are seldom attempted. The pancreas may be the seat of *syphilitic* or *tuberculous disease*. As a result of pancreatic injury, there may be *effusion into the lesser peritoneal cavity*. The lesser cavity becomes distended, and the fluid of this *pseudocyst* may contain pancreatic juice (Jordan Lloyd). *True cysts* of the pancreas are occasionally found. Pancreatic cysts may result from blocking of the duct, from epithelial proliferation, from traumatism and hemorrhage, or from hydatid disease. *Con genital cysts* may occur, and *cystic carcinoma* is sometimes encountered. Cysts of the pancreas may present in the epigastric region above and to the right of the umbilicus. The fluid in these cysts contains some of the pancreatic secretion. A pancreatic cyst is best treated by opening the abdomen, suturing the cyst to the skin, opening the cyst, and providing for drainage. Complete extirpation of the cyst is invariably difficult and is usually impossible. It has been said that the pancreas is the only abdominal viscus which has never been found in a hernial protrusion; but even this organ has been found, in company with other viscera, in rare cases of *diaphragmatic hernia*. The pancreas has been known to become invaginated into the intestines and portions of the organ have sloughed off. In cases of *excision of the pylorus* great care must be exercised to avoid wounding the pancreas, as the escape of the pancreatic fluid may be attended with serious and even with fatal results, peritonitis and *fat necrosis*, and gangrene being caused.

Rupture of the pancreas as a solitary result of traumatism is very unusual, but is more common in violent injuries which rupture the liver and spleen as well. An injury which lacerates the pancreas and permits blood and pancreatic juice to flow into the lesser peritoneal cavity is usually rapidly fatal, but may not be. The foramen of Winslow may be occluded by inflammation, and a pseudocyst may form. In severe laceration of the pancreas alone it would be proper to open the abdomen, ligate bleeding vessels, suture the pancreas, and drain the lesser peritoneal cavity posteriorly. A *gunshot wound of the pancreas* requires posterior drainage. Every effort must be made in a pancreatic wound to rapidly get rid of pancreatic fluid by drainage from the wound area, as this fluid is extremely irritant and may cause gangrene.

Inflammation of the pancreas is due to infection. Occasionally it seems to follow the entrance of bile into the pancreatic duct, because of plugging of the ampulla with a calculus (Halsted, Opie). Hemorrhage into the pancreas is frequent in acute pancreatitis, and fat necrosis is common in the fat of the mesentery, subperitoneal tissue, omentum, and other parts. Acute pancreatitis may be recovered from if the abdomen is opened, the pancreas incised, and drainage employed.

In *chronic interstitial pancreatitis* of the head of the pancreas the bile duct is apt to become blocked, and the disease is frequently mistaken for cancer. Cure may follow opening and drainage of the gall-bladder.

Extensive fibrosis of the islands of Langerhans is one of the commonest lesions found post mortem in cases of *diabetes mellitus*.

THE URINOGENITAL ORGANS.¹

THE urinogenital organs (*apparatus urogenitalis*) consist of (a) the urinary organs for the excretion of the urine, and (b) the genital organs which are concerned with the process of reproduction.

THE URINARY ORGANS.

The urinary organs comprise the **kidneys**, which secrete the urine; the **ureters** or ducts which convey it to the **bladder**, where it is for a time retained; and the **urethra**, through which it is discharged from the body.

THE KIDNEYS (RENES) (Figs. 1105, 1107).

The **kidneys** are situated in the posterior part of the abdomen, one on each side of the vertebral column, *behind* the peritoneum, and are surrounded by a mass of fat and loose areolar tissue. Their upper extremities are on a level with the upper border of the twelfth thoracic vertebra, the lower extremity on a level with the third lumbar vertebra. The right kidney is usually on a slightly lower level than the left, probably on account of the vicinity of the liver. In the female the kidneys are a little lower than in the male. The long axis of each kidney is directed from above downward and outward, the transverse axis from within backward and outward.

Each kidney is about four and one-half inches (11.5 cm.) in length, two to two and one-half inches (5.5 cm.) in breadth, and about one and one-half inches (3.7 cm.) in thickness. The left is somewhat longer and narrower than the right. The weight of the kidney in the adult male varies from four and one-half ounces to six ounces (130 to 170 grams); in the adult female, from four ounces to five and one-half ounces (115 to 155 grams). The specific gravity is about 1.052. The kidney has a characteristic form, resembling that of a lima bean, and presents for examination two surfaces, two borders, and an upper and a lower extremity. The combined weight of the two kidneys in proportion to the body is about 1 to 240.

Relations.—The **anterior surface** (*facies anterior*) of each kidney is convex, and looks forward and outward. Its relations to adjacent viscera differ so completely on the two sides that separate descriptions are necessary.

(a) **Anterior Surface of Right Kidney.**—A narrow portion at the upper extremity is in relation with the suprarenal gland. Immediately below this a large area, involving about three-fourths of the surface, lies in the renal impression on the inferior surface of the liver, and a narrow but somewhat variable area near the inner border is in contact with the second part of the duodenum. The lower part of the anterior surface is in contact externally with the hepatic flexure of the

¹ Usage has sanctioned the employment of *urogenital* as the equivalent of *urinogenital*, although the latter form only is philologically correct.

colon, and internally with the small intestine. The areas in relation with the liver and intestine are covered by peritoneum; the suprarenal, duodenal, and colic areas are devoid of peritoneum.

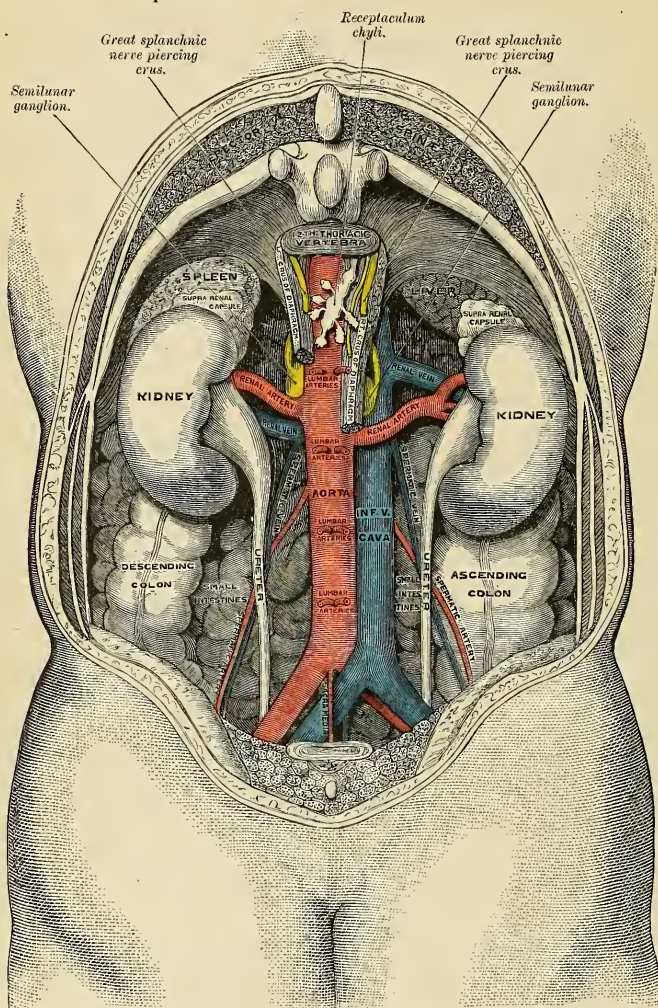


FIG. 1105.—The relations of the viscera and large vessels of the abdomen. (Seen from behind, the last thoracic vertebra being well raised.)

(b) **Anterior Surface of Left Kidney.**—A small area along the upper part of the inner border is in relation with the suprarenal gland, and close to the outer border is a narrow strip in contact with the renal impression on the spleen. A broad,

somewhat quadrilateral field, about the middle of the anterior surface, marks the site of contact with the body of the pancreas, on the deep surface of which are the splenic vessels. Above this is a small triangular portion, between the suprarenal and splenic areas, in contact with the postero-inferior surface of the stomach. Below the pancreatic area the outer part is in relation with the splenic flexure of the colon, the inner with the small intestine. The area in contact with the stomach is covered by the peritoneum of the lesser sac, while that in relation to the small intestine is covered by the peritoneum of the greater sac; behind the latter are some branches of the left colic vessels.

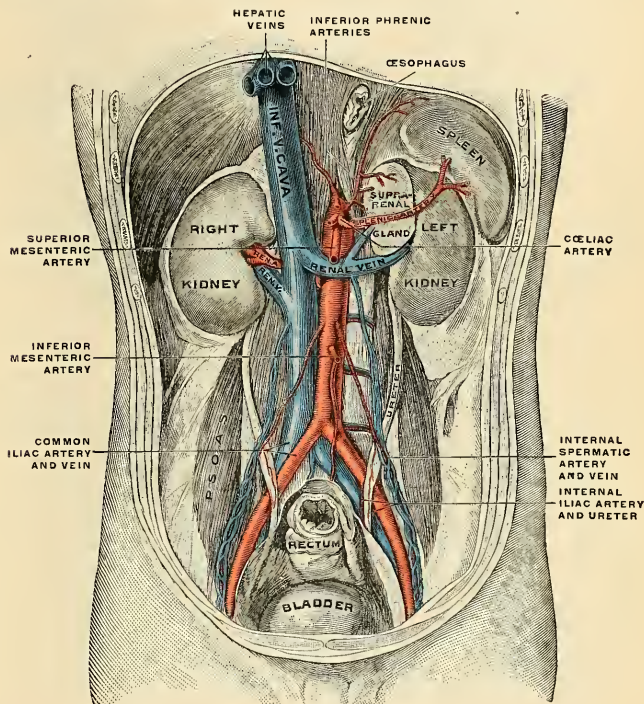


FIG. 1106.—Posterior abdominal wall, after removal of the peritoneum, showing kidneys, suprarenal capsules, and great vessels. (Corning.)

The Posterior Surface (*facies posterior*) (Fig. 1108).—The posterior surface of the kidney is flatter than the anterior and is directed backward and inward. It is entirely devoid of peritoneal covering, being embedded in areolar and fatty tissues. It lies upon the Diaphragm, the anterior layer of the lumbar aponeurosis, the external and internal arcuate ligaments, the Psoas and Transversalis muscles, one or two of the upper lumbar arteries, the last thoracic, iliohypogastric, and ilioinguinal nerves. The **lumbocostal ligaments** overlies the posterior surface of the kidney (Fig. 993). The right kidney rests upon the twelfth rib (Fig. 993), the left usually on the eleventh and twelfth ribs. The Diaphragm separates the

kidney from the pleura as the pleura dips down to form the **phrenicocostal sinus** (Fig. 910), but frequently the muscle fibres of the Diaphragm are defective or

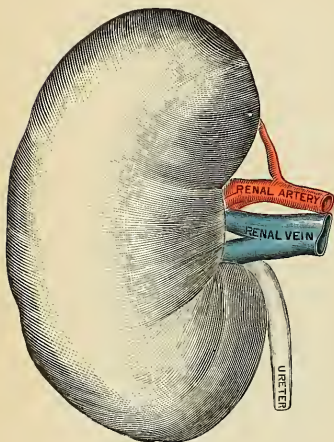


FIG. 1107.—Right kidney. Anterior view.

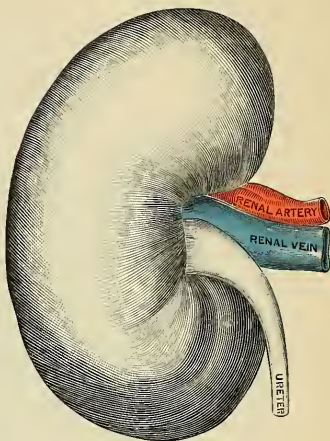


FIG. 1108.—Left kidney. Posterior view.

absent over a triangular area immediately above the external arcuate ligament, and when this is the case the perirenal areolar tissue is in immediate apposition

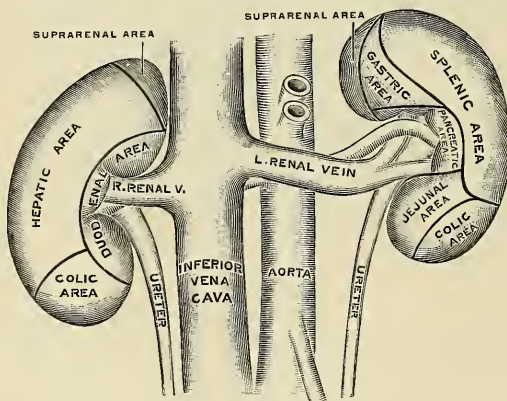


FIG. 1109.—The anterior surfaces of the kidneys, showing areas of contact of neighboring viscera.

with the diaphragmatic pleura. In the lower part of the posterior surface of the kidney is an impression produced by the *Quadratus lumborum* muscle and called

the *impressio muscularis*. A little internal to this a flattening, caused by the *Psoas* muscle, is often recognizable.

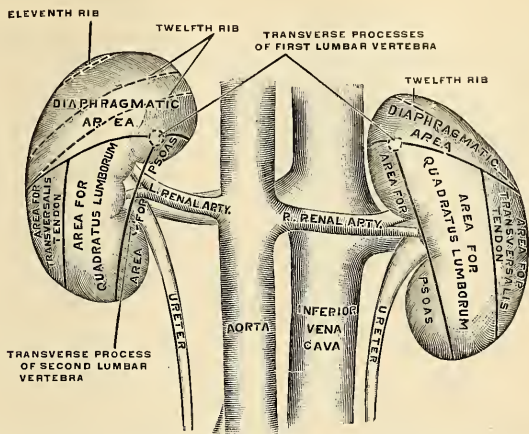


FIG. 1110.—The posterior surfaces of the kidneys, showing areas of relation to the parietes.

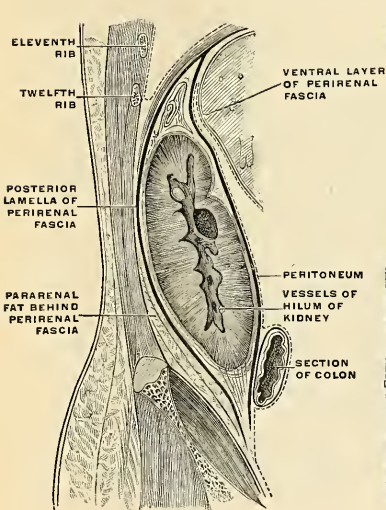


FIG. 1111.—Longitudinal section, showing the arrangement of the renal fascia. (After Gerota.)

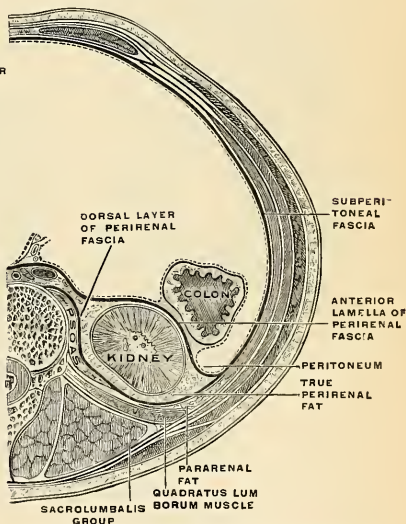


FIG. 1112.—Transverse section, showing the relations of the renal fascia and the two layers of fat. (After Gerota.)

Borders.—The external border (*margo lateralis*) (Figs. 1107 and 1108) is convex, and is directed outward and backward, toward the postero-lateral wall of the

abdomen. On the left side it is in contact, at its upper part, with the spleen (Fig. 1106).

The **internal border** (*margo medialis*) (Figs. 1107 and 1108) is concave, and is directed forward, inward, and a little downward. It presents a deep longitudinal fissure, bounded by a prominent overhanging anterior and posterior lip. This fissure is named the **hilum** (*hilus renalis*) (Fig. 1108), and allows of the passage of the vessels, nerves, and ureter into and out of the kidney.

At the hilum of the kidney the relative position of the main structures passing into and out of the kidney is as follows: The vein is in *front*, the artery in the *middle*, and the duct or ureter *behind* and toward the lower part (Fig. 1107). By a knowledge of these relations the student may distinguish between the right and left kidney. The kidney is to be laid on the table before the student on its posterior surface, with its lower extremity toward the observer—that is to say, with the ureter *behind* and *below* the other vessels; the hilum will then be directed to the side to which the kidney belongs. Frequently, however, the branches of both artery and vein are placed behind the ureter.

Extremities.—The **superior extremity** (*extremitas superior*) (Figs. 1107 and 1108) is directed slightly inward as well as upward, being situated about 4 cm. from the mesal plane. It is thick, broad, bulky, and rounded, and is surmounted by the suprarenal gland (Fig. 1113), which covers also a small portion of the anterior surface.

The **inferior extremity** (*extremitas inferior*) (Figs. 1107 and 1108), directed a little outward as well as downward, is smaller and thinner and usually more pointed than the superior. It is situated about 6 cm. from the mesal plane, and extends to within two inches (5 cm.) of the crest of the ilium.

Fixation of the Kidney (Figs. 1111 and 1112).—The kidney and its vessels are embedded in a mass of fatty tissue termed the **perirenal fat** (*capsula adiposa*), which is thickest at the margins of the kidney and is prolonged through the hilum into the renal sinus. The kidney and the capsula adiposa are enclosed in a sheath of fibrous tissue continuous with the subperitoneal fascia, and named the **fascia renalis**. At the outer border of the kidney the fascia renalis splits into an anterior and a posterior layer. The anterior layer is carried inward in front of the kidney and its vessels, and is continuous over the aorta with the corresponding layer of the opposite side. The posterior layer extends inward behind the kidney

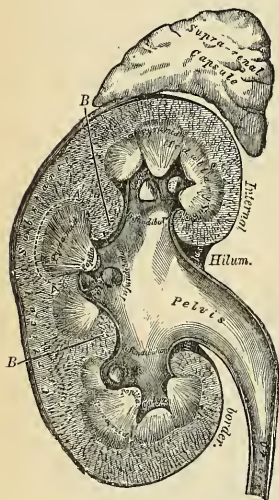


FIG. 1113.—Vertical section of kidney.

and blends with the fascia on the Quadratus lumborum and Psoas muscles and through this fascia is attached to the vertebral column. At the upper margin of the suprarenal gland the two layers of the fascia renalis fuse, and unite with the fascia of the Diaphragm; below they remain separate, and are gradually lost in the subperitoneal fascia of the iliac fossa (Fig. 1111). The fascia renalis is connected to the fibrous capsule of the kidney by numerous trabeculae, which traverse the adipose capsule and are strongest near the lower end of the organ. The **perirenal fat** does not look like the fat in other regions, but is soft, delicate, and of a canary-yellow color. Behind the fascia renalis is a considerable quantity of fat which constitutes the

pararenal or Transversalis fat. The kidney is held in position through the attachments of the fascia renalis and by the apposition of the neighboring viscera.

General Structure of the Kidney.—

The kidney is invested by a capsule of interlacing bundles of fibrous connective tissue (*tunica fibrosa*), which forms a firm, smooth covering for the organ. The capsule can be easily stripped off, but in doing so, numerous fine processes of connective tissue and small bloodvessels are torn through. Beneath this coat, a thin wide-meshed network of unstriated muscle fibres forms an incomplete covering. When the capsule is removed, the surface of the kidney is found to be smooth and even, and of a very deep red color. In infants, fissures extending for some depth may be seen on the surface of the organ, a remnant of the lobular construction of the gland (Fig. 1105). The kidney is dense in texture, but is easily lacerable by mechanical force. If a vertical section of the kidney be made from its convex to its concave border, and the loose tissue and fat removed from around the vessels and the excretory duct, it will be seen that the organ consists of a central cavity surrounded, except

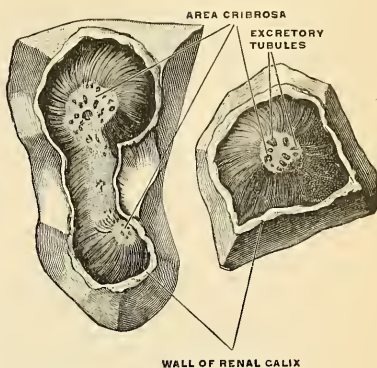


FIG. 1114.—Area cribrosa of renal papilla. (Toldt.)

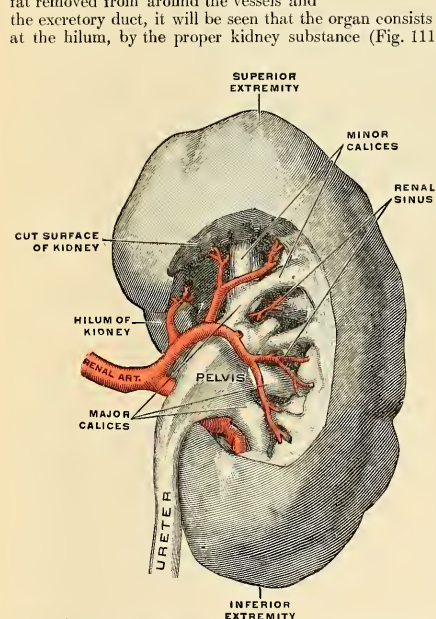


FIG. 1115.—The right kidney with the pelvis of the ureter exposed, and showing dorsal branch of the renal artery, viewed from behind. (Spalteholz.)

and surrounded by blood- and lymph vessels and nerves.

It is readily divisible into an outer third, the **cortex**, about one-third to one-half of an inch (8 to 12 mm.) in thickness, and an inner two-thirds, the **medulla**, two-thirds to three-quarters of an inch (16 to 20 mm.) in thickness.

This central cavity is called the **renal sinus** (*sinus renalis*) and is lined by a prolongation of the capsule, which is continued around the lips of the hilum. Through the hilum the bloodvessels of the kidney and its excretory duct pass, and therefore these structures, upon entering the kidney, are contained within the sinus.

The **excretory duct** or **ureter** begins as a funnel-shaped sac, the **pelvis of the ureter** (*pelvis uretericus s. renalis*). The pelvis begins at the renal papillæ in the form of a number of truncated cup-shaped infundibular divisions, the **calices minores**, into each of which usually one papilla projects. These minor calices vary from ten to twenty in number. Several minor calices unite to form larger divisions, the **calices majores** (Fig. 1115), which are usually two in number, though more may be present. These major calices unite to form the main compartment of the pelvis, which becomes narrowed below at the level of the second lumbar vertebra to be continued as the ureter proper (Fig. 1115).

The **kidney substance** or **parenchyma** consists of very irregular tubules, the **uriniferous tubules**, which are supported by a framework of retiform connective tissue

The **cortex** is reddish brown in color and soft and granular in consistence. It lies immediately beneath the capsule, arches over the bases of the pyramids, and dips in between adjacent pyramids toward the renal sinus in the form of **renal columns** (*columnae renales* [Bertini]). If a section of the cortex be examined with a lens, it will be seen to consist of a series of lighter colored, ray-like prolongations of straight tubules from the medulla, called the **medullary rays** (*pars radiata*). The darker colored intervening substance composing the remainder of the cortex, from the complexity of its structure, is called the **labyrinth** (*pars convoluta*), and contains the convoluted portions of the uriniferous tubules and the Malpighian corpuscles. The medullary rays gradually taper toward the circumference of the kidney, but do not reach the capsule.

The **medulla** consists of reddish, striated, conical masses, the **medullary pyramids** (*pyramides renales* [Malpighii]), the number of which, varying from ten to twenty, corresponds to the number of lobes of which the organ is composed in the fetal state. The pyramids are composed of straight tubes which pass from the base to the apex. The sides of the pyramids are contiguous with the renal columns, while the apices, known as the **renal papillae**, project into the minor calices of the ureteral pelvis, each calix receiving one, two, or three papillae. Each papilla shows

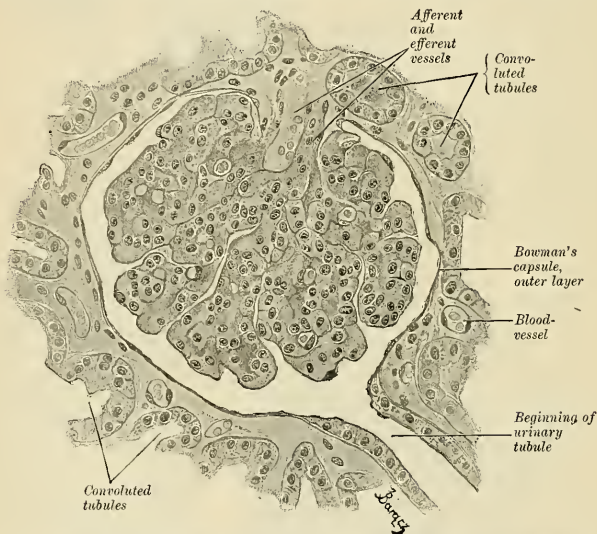


FIG. 1116.—A section through the cortex of an ape's kidney. A Malpighian corpuscle, together with the beginning of the tubule, is shown. $\times 350$. (Szymonowicz.)

upon its apex a number (16 to 20) of minute orifices of the excretory ducts of the pyramid; this perforated area of the apex is called the **area cribrosa** (Fig. 1114).

The **renal columns** (of Bertin) separate the pyramids from one another and consist of cortical masses extending toward the renal sinus. At the sinus ends they contain a considerable amount of white fibrous and adipose tissue. They serve as a passageway for the main bloodvessels, lymphatics, and nerves to and from the parenchyma of the organ.

Minute Anatomy.—The **uriniferous tubules** (*tubuli renales*) are in part very convoluted and in part straight and regular. They arise in the cortex, pass into the medulla, return to the cortex, and end at the area cribrosa of the renal papilla. Each tubule starts at the **glomerulus** or **renal corpuscle** (*Malpighian body*), a small, round, reddish mass, which measures 120 to 200 μ . Each of these little bodies is composed of two parts, a central glomerulus of vessels, called a **Malpighian tuft** and a membranous envelope, the **Malpighian capsule**, or **capsule of Bowman**, which is the small pouch-like commencement of a uriniferous tubule.

The **Malpighian tuft**, or vascular glomerulus, is a network of convoluted capillary bloodvessels, held together by scanty connective tissue. This capillary network is derived from a small arterial twig, the **afferent vessel**, which pierces the wall of the capsule, generally at a point opposite to that at which the latter is connected with the tube; and the resulting vein, the **efferent vessel**,

that at which the latter is connected with the tube; and the resulting arteriole, the *effluent vessel*, emerges from the capsule at the same point. The afferent vessel is usually the larger of the two (Fig. 1116). The *Malpighian* or *Bowman's capsule*, which surrounds the glomerulus, is formed of a hyaline membrane, supported by a small amount of connective tissue, which is continuous with the connective tissue of the tube. It is lined on its inner surface by a single layer of squamous epithelial cells, which are reflected from the lining membrane to the glomerulus, at the point of entrance or exit of the afferent and efferent vessels. The whole surface of the glomerulus is covered with a continuous layer of the same cells, which rests on a delicate supporting membrane (Fig. 1116). Thus, between the glomerulus and the capsule a space is left, forming a cavity lined by a continuous layer of squamous cells; this cavity varies in size according to the state of secretion and the amount of fluid present in it. In the fetus and young subject the cells are polyhedral or even columnar.

At the junction of a tubule with the Malpighian capsule there is a somewhat constricted portion which is termed the **neck** (Fig. 1118). Beyond this the tubule becomes convoluted, and pursues a considerable course in the cortical structure, constituting the **proximal** or **first convoluted tubule** (Figs. 1118 and 1121). After a time the convolutions disappear, and the tubule approaches the medullary portion of the kidney in a more or less spiral manner. This section of the tubule has been called the **spiral tube** of *Schachowa*. Throughout this portion of their course the tubuli uriniferi are contained entirely in the cortical structure, and present a fairly uniform calibre. They now enter the medullary portion, suddenly become much smaller,

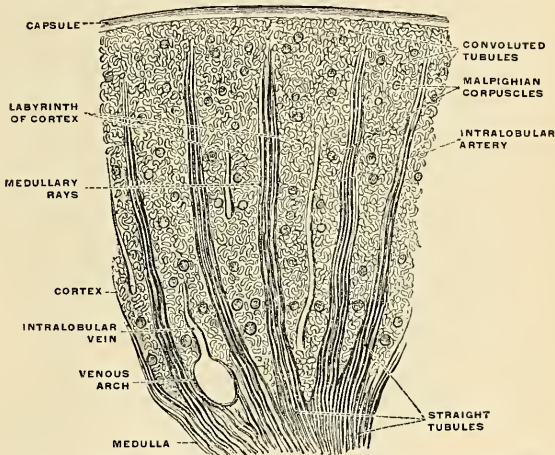


FIG. 1117.—Part of a section through the cortex of the kidney in the direction of the straight tubules. (Toldt.)

quite straight in direction, and dip down for a variable depth into the pyramids, constituting the **descending limb of Henle's loop**. Bending on themselves, they form what is termed the **loop of Henle**, and re-ascending, they become suddenly enlarged and again spiral in direction, forming the **ascending limb of Henle's loop**, and reënter the cortical structure. In the cortex the tubule again becomes slightly convoluted, and is called the **distal** or **second convoluted tubule** (Fig. 1116). This terminates in a narrow **arched collecting** or **junctional tubule**, which enters the **straight collecting tubule**.

Each **straight collecting tubule** (*tubulus renalis recta*) passes from the cortex into the medulla, receiving at various intervals in the cortical part of its course several arched collecting tubules. In the medullary pyramid, several straight collecting tubules unite to form from sixteen to twenty **papillary** or **excretory ducts**, which empty at the area cribrosa of the renal papilla. As they approach the papilla, their diameter gradually increases.

It will be seen from the above description that there is a continuous series of tubes from their commencement in the Malpighian bodies to their termination at the orifices on the apices of the pyramids of Malpighi, and that the urine, the excretion of which commences in Bowman's capsule, finds its way through these tubes into the calices of the ureter.

Structure of the Uriniferous Tubule.—The uriniferous tubule consists throughout of

a single layer of epithelial cells resting upon a basement membrane which is supported by a delicate meshwork of retiform connective tissue. The tissue contains the vessels, nerves, and lymphatics. The diameter of the tubule and the size of the cells vary in the different portions. The capsule of Bowman is lined with *simple squamous cells*, and the renal corpuscle has a diameter of 120 to 200 microns; the neck is lined by *simple squamous cells*, and has a diameter of about 15 microns; the proximal convoluted and spiral tubules are lined with *irregular columnar cells*;

the lumen of the tubule is irregular and the diameter averages about 40 microns; the descending limb of Henle's loop is lined with *simple squamous cells*, and the diameter is from 10 to 13 microns; the loop and ascending limb are lined with *regular cuboidal cells*, and the diameter averages from 23 to 28 microns; the distal convoluted tubule is lined with *irregular columnar cells*, the lumen is irregular, and the diameter about 45 microns; the arched connecting tubule is lined with *simple cuboidal cells*, and the diameter is about 45 microns; the straight collecting tubule is lined by *columnar cells*, and the diameter increases from 45 to 75 microns; the papillary ducts are lined with *tall columnar cells*, and the diameter reaches 200 to 300 microns. The protoplasm of these cells is granular at the basal end, while the luminal end is striated.

The parts of the kidney in which the various portions of the uriniferous tubules lie are as follows:

Cortex.—In the labyrinth are found the renal corpuscles, the neck, and the proximal and distal convoluted tubules.

In the medullary rays are found the upper ends of the descending and ascending limbs of Henle's loop, the arched collecting tubules, and the upper ends of the straight collecting tubules.

Medulla.—Here are found the lower ends of the descending and ascending limbs of Henle's loop, the loop, the straight collecting tubules, and the papillary ducts.

The Renal Bloodvessels.—The kidney is plentifully supplied with blood by the renal artery

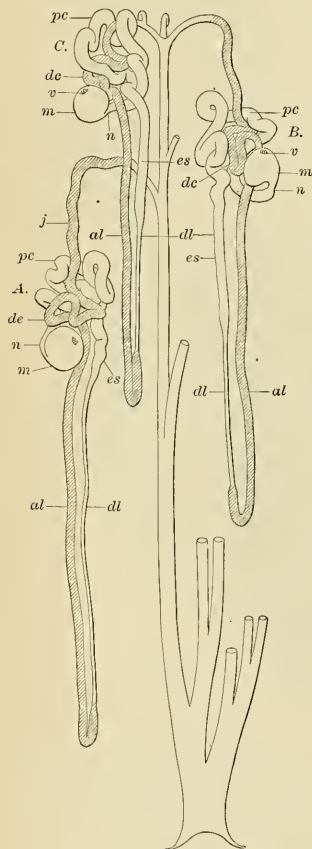


FIG. 1118.—Diagram of three uriniferous tubules and their relation to a collecting tubule. A. Of a tubule, the Malpighian corpuscle of which is situated in the lowermost portion of the cortex. B. About the middle of the cortex. C. In the outer portion of the cortex. m, Malpighian corpuscle. v, Vessel porta. n, Neck. pc, Proximal convoluted portion. es, End segment. dl, Descending limb. al, Ascending limb of the loop of Henle. dc, Distal convoluted portion. j, Junctional tubule. c, Collecting tubule. (Huber.)



FIG. 1119.—Longitudinal section of Henle's descending limb. a, Cylindrical or cubical epithelium. b, Membrana propria.



FIG. 1120.—Longitudinal section of straight tube. a, Cylindrical or cubical epithelium. b, Membrana propria.

(Figs. 1107 and 1115); a large branch of the abdominal aorta given off at the level of the articular disk between the first and second lumbar vertebræ. The importance of the kidney as an excre-

tory organ is evidenced by the fact that the artery is three times as large as is necessary for the nutrition of an organ of the size of the kidney. Previously to entering the kidney, each artery divides into four or five branches, which are distributed to its substance. At the hilum these branches lie between the renal vein and ureter, the vein being in front, the ureter behind. Each vessel gives off a small branch to the suprarenal glands, the ureter, and the surrounding tissue and muscles. It has been pointed out by Hyrtl (p. 665) that the renal artery gives off a branch which divides and supplies the dorsal portion of the kidney and a larger branch which divides and supplies the ventral portion of the kidney. Between these two vascular systems is a nonvascular

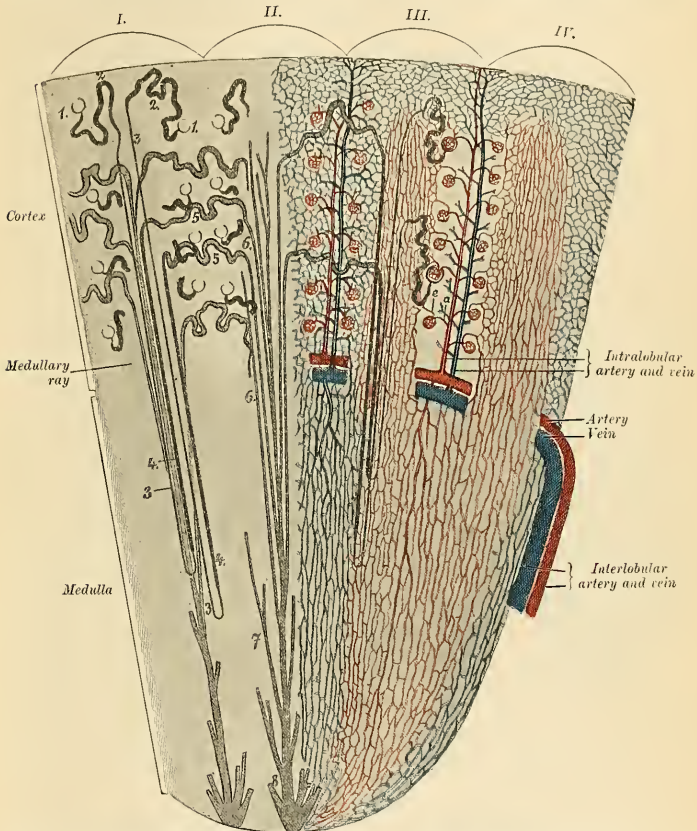


FIG. 1121.—Diagrammatic representation of the course of the uriniferous tubules (left) and the kidney vessels (right). The arteries are red, the veins blue; capsules of Bowman, convoluted tubules I order and loops of Henle are black; convoluted tubules II order and collecting tubules gray. 1, II, III, IV. Four kidney lobules. a, Vas afferens. c, Vas efferens. 1, Bowman's capsule. 2, Convoluted tubule I order. 3, Descending limb of loop of Henle. 4, Ascending limb of loop of Henle. 5, Convoluted tubule II order. 6, 7, Collecting tubules. 8, Papillary duct. (Szymonowicz.)

zone, called by Robinson the **exsanguinated renal zone of Hyrtl**. It "is one-half inch dorsal to the external border of the kidney." Frequently there is a second renal artery, which is given off from the abdominal aorta at a lower level, and supplies the lower portion of the

kidney. It is termed the **accessory renal artery**. Within the sinus the renal artery divides into four or five branches, about three-fourths of the blood going to the anterior pyramids and the remainder to the posterior pyramids. Each extremity of the kidney is supplied by a branch which divides into anterior, middle, and posterior branches, which do not anastomose with each other. The branches of the renal arteries pass to the kidney substance between the pyramids and are known as **interlobar arteries** (*arteriae interlobares renis*) (Fig. 1117). At the junction of the cortical and medullary portions (the boundary zone) these vessels turn and for a short distance pursue a course parallel to the kidney surface. There are thus formed a series of incomplete vascular arches across the bases of the pyramids, the **arcuate arteries** (*arteriae arciformes*) (Figs. 1113 and 1121). From these arches two sets of vessels come. The vessels of one set go to the periphery and enter the cortex, the **intralobular, or cortical arteries**, those of the other set pass toward the sinus and enter the medulla. These last vessels are the **arteriolae recti** (Figs. 1117 and 1121). As the **intralobular arteries** pass toward the capsule they give off branches to each renal corpuscle, the **vasa afferentia or afferent arterioles**. As the arteriole enters the corpuscle it divides into several branches, each of which forms a capillary plexus. The blood from each plexus is collected by a small branch which joins with its fellows to form the **vas efferens or efferent arteriole**. These various plexuses constitute a **glomerulus or Malpighian Tuft** (Fig. 1116). On leaving the glomerulus the arteriole forms a capillary network around the adjacent portions of the uriniferous tubule. The blood is collected by various channels and emptied into the intralobular vein, which starts in the *venae stellatae*, beneath the capsule, and empties its blood into the arcuate vein.

The **arteriolae rectae** supply the medulla and are smaller in diameter than the intralobular arteries, and soon form a rich capillary plexus around the tubules of the medulla. The blood is collected by the **venae rectae**, which empty into the **arcuate vein** (*vena arciformis*) at the boundary zone. The blood is carried to the columns of Bertin, where it continues toward the sinus in the **interlobular veins**. In the sinus these veins unite to form the **renal vein** (*vena renalis*) (Fig. 1107).

The **nerves** of the kidney, although small, are about fifteen in number. They have small ganglia developed upon them, and are derived from the **renal plexus**, which is formed by branches from the solar plexus, the lower and outer part of the semilunar ganglion and aortic plexus, and from the lesser and smallest splanchnic nerves. They communicate with the spermatic plexus, a circumstance which may explain the occurrence of pain in the testicle in affections of the kidney. So far as they have been traced, they seem to accompany the renal artery and its branches, and they have been traced to the epithelium, but their exact mode of termination is not known.

The **Lymphatics** are described on page 796.

Variations and Abnormalities.—Congenital absence of the kidney has been observed. Not unusually one kidney is considerably larger than the other; occasionally one is very large and the other is very small, from atrophy, the large organ having become large in response to a functional need, which causes it to compensate for the insufficiency of the small kidney. If a kidney is removed surgically, the other kidney enlarges. As previously stated, the kidneys of the fetus and of the young child show distinct fissures which make each organ lobulated (Fig. 1122). The adult kidneys frequently exhibit remains of these fissures. A **horseshoe kidney** is a condition in which the lower extremities of the two kidneys are united by kidney structure, the bond

of union crossing the middle line. The strip of kidney tissue which effects the junction may be slight, considerable, or extensive in amount. Sometimes the two kidneys are completely fused together into one large organ with two ureters.

Surface Form.—The kidneys, being situated at the back part of the abdominal cavity and deeply situated, cannot be felt unless enlarged or misplaced. They are situated on the confines of the epigastric and umbilical regions internally, with the hypochondriac and lumbar regions externally. The left is somewhat higher than the right. According to Morris, the position of the kidney may be thus defined: *Anteriorly*: "(1) A horizontal line through the umbilicus is below the lower edge of each kidney. (2) A vertical line carried upward to the costal arch from the middle of Poupart's ligament has one-third of the kidney to its outer side and two-thirds to its inner side—i. e., between this line and the median line of the body." In adopting these lines it must be borne in mind that the axes of the kidneys are not vertical, but oblique, and if continued upward would meet about the ninth thoracic vertebra. *Posteriorly*: The upper end of the left kidney would be defined by a line drawn horizontally outward from the spinous process of the eleventh thoracic vertebra, and its lower end by a point two inches (5 cm.) above the iliac crest.

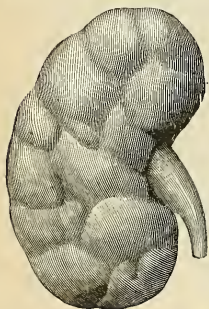


FIG. 1122.—Fetal kidney, showing lobulation. (Testut.)

The right kidney would be half to three-quarters of an inch lower. Morris lays down the following rules for indicating the position of the kidney on the posterior surface of the body: "(1) A line parallel with, and one inch from, the vertebral column, between the lower edge of the tip of the spinous process of the eleventh thoracic vertebra and the lower edge of the spinous process of the third lumbar vertebra. (2) A line from the top of this first line outward at right angles to it for two and three-quarter inches. (3) A line from the lower end of the first transversely outward for two and three-quarter inches. (4) A line parallel to the first and connecting the outer extremities of the second and third lines just described."

The hilum of the **right** kidney is two inches from the mesal plane; the hilum of the **left** one and one-half inches from the mesal plane. A line joining the two hili crosses the vertebral column opposite the disk between the first and second lumbar vertebrae.

Applied Anatomy.—Cases of *congenital absence* of a kidney, of *atrophy* of a kidney, and a *horseshoe kidney* are of great importance, and must be duly taken into account when nephrectomy is contemplated. A more common malformation is where the two kidneys are *fused together*. They may be only joined together at their lower ends by means of a thick mass of renal tissue, so as to form a horseshoe-shaped body, or they may be completely united, forming a disk-like kidney, from which two ureters descend into the bladder. These fused kidneys are generally situated in the middle line of the abdomen, but may be misplaced as well.

One or both kidneys may be *misplaced* as a congenital condition, and remain fixed in this abnormal position. They are then very often misshapen. They may be situated higher or lower than normal or removed farther from the spine than usual or they may be displaced into the iliac fossa, over the sacroiliac joint, on to the promontory of the sacrum, or into the pelvis between the rectum and bladder or by the side of the uterus. In these latter cases they may give rise to very serious trouble. The kidney may also be misplaced as a congenital condition, but may not be fixed. It is then known as a *floating kidney*. It is believed to be due to the fact that the kidney is completely enveloped by peritoneum, which then passes backward to the vertebral column as a double layer, forming a *mesonephron*, which permits of movements taking place. The kidney may also be misplaced as an acquired condition; in these cases the kidney is mobile in the tissues by which it is surrounded, either moving in or moving with its fatty capsule. This condition is known as *movable kidney* (*nephroptosis*), and is more common in the female than in the male, and on the right than the left side. If a displaced kidney becomes fixed in an abnormal position, it is said to be *dislocated*. Movable kidney cannot be distinguished from floating kidney until the kidney is exposed by incision. Other malformations are the persistence of the fetal lobulation; the presence of two pelves or two ureters to the one kidney. In some rare instances a third kidney may be present.

The kidney is embedded in a large quantity of loose fatty tissue, and is but partially covered by peritoneum; hence *rupture* of this organ is not nearly so serious an accident as rupture of the liver or spleen, since the extravasation of blood and urine which follows is, in the majority of cases, outside the peritoneal cavity. Occasionally the kidney may be *bruised* by blows in the loin or by being compressed between the lower ribs and the ilium when the body is violently bent forward. This is followed by a little transient *hematuria*, which, however, speedily passes off. Occasionally, when rupture involves the pelvis of the ureter or the commencement of the ureter, this duct may become blocked, and *hydronephrosis* follows.

The loose cellular tissue around the kidney may be the seat of suppuration, constituting *perinephritic abscess*. This may be due to injury, to disease of the kidney itself, or to extension of inflammation from neighboring parts. The abscess may burst into the pleura, causing empyema; into the colon or bladder; or may point externally in the groin or loin. *Tumors of the kidney*, of which, perhaps, *sarcoma* in children is the most common, may be recognized by their position and fixity; by the resonant colon lying in front of it; by their not moving with respiration; and by their rounded outline, not presenting a notched anterior margin like the spleen, with which they are most likely to be confounded. The *examination of the kidney* should be bimanual; that is to say, one hand should be placed in the flank and firm pressure made forward, while the other hand is buried in the abdominal wall, over the situation of the organ. Manipulation of the kidney frequently produces a peculiar sickening sensation and some faintness.

The kidney is frequently attacked surgically. It may be exposed and opened for exploration or the evacuation of pus (*nephrotomy*); it may be incised for the removal of stone (*nephrolithotomy*); it may be sutured when wounded (*nephrorrhaphy*); it may be fixed in place by sutures (*nephropexy*) or gauze pads when movable or floating; or it may be removed (*nephrectomy*).

The kidney may be exposed either by a *lumbar* or *abdominal incision*. The operation is best performed by a lumbar incision, except in a case of very large tumor or of wandering kidney with a loose mesonephron, on account of the advantages which it possesses of not opening the peritoneum and of affording admirable drainage. It may be performed either by an oblique, a vertical, or a transverse incision. A common incision for exposing the kidney begins an inch below the twelfth rib, at the margin of the Erector spinae muscle, and passes obliquely down-

ward and forward, exposing the anterior border of the *Latissimus dorsi* and the posterior border of the *Internal oblique*. The surgeon divides the posterior leaflet of the lumbar fascia, draws aside or incises the *Quadratus lumborum*, and cuts the anterior leaflet of the lumbar fascia and also the *transversalis fascia*. He opens the fatty capsule down to the kidney and strips it from the true capsule, bringing the kidney outside of the body for inspection. The vertical incision at the edge of the *Erector spinae* muscle is frequently used. A gridiron or muscle-splitting operation is used by some in order to avoid the division of nerves, vessels, and muscle fibres.

The abdominal operation is best performed by an incision in the *linea semilunaris* on the side of the kidney to be removed, as recommended by *Langenbuch*; the kidney is then reached from the outer side of the colon, ascending or descending, as the case may be, and the vessels of the colon are not interfered with. If the incision were made in the *linea alba*, the kidney would be reached from the inner side of the colon, and the vessels running to supply the colon would necessarily be interfered with. The incision is made of varying length according to the size of the kidney, and commences just below the costal arch. The abdominal cavity is opened. The intestines are held aside, and the outer layer of the *mesocolon* incised, so that the fingers can be introduced behind the peritoneum and the renal vessels are sought for. These vessels are then to be ligated; if tied separately, care must be taken to ligate the artery first. The kidney must now be enucleated, and the vessels and the ureter divided, and the latter disinfected and tied, and, if it is thought necessary, stitched to the edge of the wound.

THE URETERS (Figs. 1106, 1115).

The ureters are the two tubes which convey the urine from the kidneys into the bladder. Each ureter commences within the sinus of the corresponding kidney by a number of short cup-shaped branches, the **minor calices** or **infundibula**, which unite either directly or indirectly to form a dilated pouch, the **pelvis** (Fig. 1115), from which the ureter, after passing through the hilum of the kidney, descends to the bladder. The **minor calices** encircle the apices of the renal papillæ; but inasmuch as one calix may include two or even more papillæ, their number is generally less than the pyramids themselves. The minor calices vary in number from ten to twenty or more. These calices converge into two or three tubular divisions, the **major calices**, which by their junction form the **pelvis** or **dilated portion of the ureter**, which is situated behind the renal vessels and which lies partly within and partly outside the renal sinus. It is usually placed on a level with the spinous process of the first lumbar vertebra.

The **ureter proper** is a cylindrical membranous tube, about ten to twelve inches (25 to 30 cm.) in length and about one-sixth inch (4 mm.) in diameter, directly continuous near the lower end of the kidney with the tapering extremity of the **pelvis**. Its walls are from 1 to 2 mm. thick, and its calibre varies. It exhibits four main constrictions—(1) at its junction with its **pelvis**; (2) as it passes over the brim of the **pelvis**; (3) as it enters the bladder; (4) at its termination. Its course is obliquely downward and inward through the lumbar region (*pars abdominalis*) (Fig. 1106), into the cavity of the **pelvis** (*pars pelvina*) (Fig. 1124), where it passes downward, forward, and inward across that cavity to the base of the bladder, into which it then opens by a constricted orifice (*orificium ureteris*) (Fig. 1134), after having passed obliquely for nearly an inch between the vesical muscular and mucous coats (Fig. 1123). The lower part of the abdominal portion of the ureter exhibits a spindle-shaped dilatation.

Relations (Fig. 1124).—The *abdominal part* lies behind the peritoneum on the inner part of the *Psoas* muscle, and is crossed obliquely by the spermatic or ovarian vessels. It enters the pelvic cavity by crossing either the termination of the common, or the commencement of the external, iliac vessels.

At its origin the **right** ureter is usually covered by the second part of the duodenum, and in its

course downward lies to the right of the inferior vena cava and is crossed by the right colic artery, while near the pelvic brim it passes behind the lower part of the mesentery and the terminal part of the ileum. The **left ureter** is crossed by the left colic artery, and near the brim of the pelvis passes behind the sigmoid colon and its mesentery.

The **pelvic part** runs at first downward on the lateral wall of the pelvic cavity under cover of the peritoneum, lying in front of the internal iliac vessels and on the inner side of the impervious part of the hypogastric artery and the obturator nerve and vessels. Opposite the lower part of the great sacrosciatic foramen it inclines inward behind the vas deferens (which crosses to its inner side) and reaches the base of the bladder, where in the **male** it is situated in front of the upper end of the seminal vesicle and at a distance of about two inches from the opposite ureter. Finally, the ureters run obliquely for about three-quarters of an inch through the wall of the bladder and open by slit-like apertures into the cavity of that viscus at the lateral angles of the trigone. When the bladder is distended the openings of the ureters are about two inches apart, but when it is empty and contracted the distance between them is diminished by one-half. Owing to their oblique course through the coats of the bladder, their upper and lower walls become closely applied to each other when the viscus is distended, and, acting as a valve, prevent regurgitation of urine from the bladder.

In the **female**, the ureter forms, as it lies in relation to the wall of the pelvis, the posterior boundary of a shallow depression named the ovarian fossa, in which the ovary is situated. It then runs inward and forward on the lateral aspect of the cervix of the uterus and of the upper part of the vagina to reach the base of the bladder. In this part of its course it is accompanied for

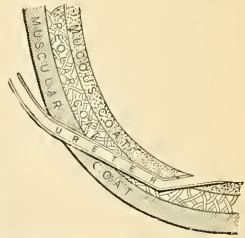

FIG. 1123. — Diagram showing method of entrance of the ureter into the bladder. (F. H. Gerrish.)

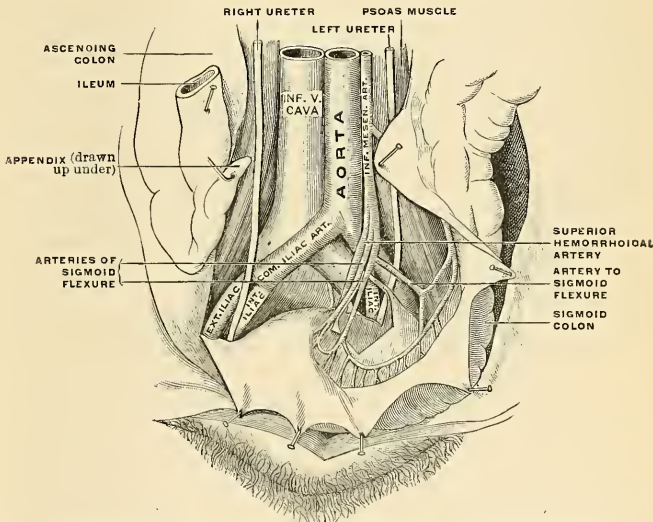


FIG. 1124. — The relations of the pelvic mesocolon with the wall, the iliac, sigmoid, and superior hemorrhoidal arteries, and the ureter. (Poirier and Charpy.)

about an inch by the uterine artery, which then crosses in front of the ureter and ascends between the two layers of the broad ligament. The ureter is distant about three-quarters of an inch from the lateral aspect of the neck of the uterus.

The ureter is sometimes double, and the two tubes may remain distinct as far as the base of the bladder. On rare occasions they open separately into the bladder cavity.

Structure.—The ureter is composed of three coats—**fibrous, muscular, and mucous.**

The **fibrous coat** (*tunica adventitia*) is the same throughout the entire length of the duct, being continuous at one end with the fibrous capsule of the kidney at the floor of the sinus, while at the other it is lost in the fibrous structure of the bladder.

In the pelvis of the ureter the **muscular coat** (*tunica muscularis*) consists of two layers, an internal longitudinal and an external circular; the **longitudinal** fibres become lost upon the sides of the papillæ at the extremities of the calices; while the circular fibres become more prominent and resemble a small sphincter. In the ureter proper the muscle layers are very distinct, and are three in number—an **external longitudinal** (*stratum externum*), a **middle circular** (*stratum medium*), and an **internal longitudinal layer** (*stratum internum*). The external longitudinal layer is found more prominent in the lower half or lower third of the ureter.

The **mucous coat** (*tunica mucosa*) is smooth, and presents a few longitudinal folds which become effaced by distention. It is continuous with the mucous membrane of the bladder below, while above it is prolonged over the papillæ of the kidney. Its epithelium is of a peculiar character, and resembles that found in the bladder. It is known by the name of **transitional epithelium**. It consists of several layers of cells, of which the innermost—that is to say, the cells in contact with the urine—are quadrilateral in shape, with concave margins on their outer surface, into which fit the rounded ends of the cells of the second layer. These, the intermediate cells, more or less resemble columnar epithelium, and are pear-shaped, with a rounded internal extremity, which fits into the concavity of the cells of the first layer, and a narrow external extremity which is wedged in between the cells of the third layer. The external or third layer consists of conical or oval cells varying in number in different parts, and presenting processes which extend down into the basement membrane. A few racemose glands are at times seen in the mucous coat.

Vessels and Nerves.—The arteries supplying the ureter are branches from the **renal, spermatic, internal iliac, and inferior vesical.**

The nerves are derived from the **inferior mesenteric, spermatic, and pelvic plexuses.**

Applied Anatomy.—*Subcutaneous rupture* of the ureter is not a common accident, but occasionally occurs from a sharp direct blow on the abdomen, as from the kick of a horse. The ureter may be either torn completely across, or only partially divided, and, as a rule, the peritoneum escapes injury. If torn completely across, the urine collects in the retroperitoneal tissues; if it is not completely divided, the lumen of the tube may become obstructed and hydronephrosis or pyonephrosis results. The ureter may be accidentally wounded in some abdominal operations; if this should happen, the divided ends must be sutured together, or, failing to accomplish this, the upper end must be implanted into the bladder or the intestine.

Stones (*calculi*) not uncommonly become impacted in the ureter. This may occur at any part, but most commonly either at the point where the tube is crossing the pelvic brim or at the termination, where it is passing obliquely through the muscular wall of the bladder. In the former case, an incision with its centre opposite and one inch internal to the anterior superior spine of the ilium dividing all the structures down to the peritoneum, enables the operator to reach the ureter by pushing the unopened peritoneum inward; the stone can then be felt in the ureter, the wall of which is incised, and the stone extracted, free drainage being provided for the escaping urine. When the stone is impacted at the vesical end of the tube a preliminary incision into the bladder is required, and by scratching through the mucous membrane overlying it the calculus can then be removed.

The diagnosis of ureteral calculus is sometimes made by an x-ray examination. In identifying any shadows in the picture thus secured, caution must be exercised not to mistake similar shadows thrown by *periureteral phleboliths* in the pelvic veins as ureteral calculi.¹

THE URINARY BLADDER (VESICA URINARIA) (Figs. 1127, 1128).

The **urinary bladder** is a musculomembranous sac situated in the pelvis, behind the pubes, and in front of the rectum in the male, the cervix uteri and vagina intervening between it and that intestine in the female. The shape, position, and relations of the bladder are greatly influenced by age, sex, and the degree of distention of the organ. *During infancy* it is conical in shape, and projects above the symphysis pubis into the hypogastric region. *In the adult cadaver*, when quite empty and collapsed (Figs. 1125 and 1126), it is cup-shaped, and on vertical median section its cavity, with the adjacent portion of the urethra, presents a Y-shaped cleft, the stem of the Y corresponding to the urethra. It is placed

¹ Consult article by George O. Clark in *Annals of Surgery*, 1909, p. 913.

deeply in the pelvis, flattened from before backward, and reaches as high as the upper border of the symphysis pubis. When empty and contracted, and as seen immediately after death (as after electrocution), the bladder is nearly spherical in shape. When slightly distended, it has a rounded form, and is still contained within the pelvic cavity (Fig. 1126), and when greatly distended (Figs. 1126 and 1182), it is ovoid in shape, rising into the abdominal cavity, and often extend-

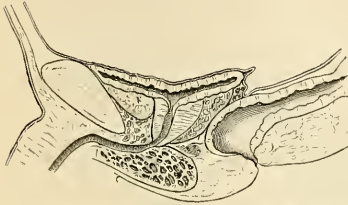


FIG. 1125.—The empty bladder. (Poirier and Charpy.)

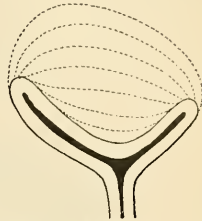


FIG. 1126.—Modifications of form of the bladder during distention. (Poirier and Charpy.)

ing nearly as high as the umbilicus. It is larger in its vertical diameter than from side to side, and its long axis is directed from above obliquely downward and backward, in a line directed from some point between the symphysis pubis and umbilicus (according to its distention) to the end of the coccyx. The bladder, when distended, is slightly curved forward toward the anterior wall of the abdomen, so as to be more convex behind than in front. When moderately distended, it measures about five and one-half inches (14 cm.) in the vertical diameter, four and one-half inches (12 cm.) across, and three inches (10 cm.) antero-posteriorly. In the *female* it is larger in the transverse than in the vertical diameter, and its capacity is said to be greater than in the male. The ordinary amount which it can contain without serious discomfort is about a pint.

The bladder is divided for purposes of description into a **superior**, an **antero-inferior**, and two **lateral** surfaces, a **base** or **fundus**, and a **summit** or **apex**.

Surfaces.—The **superior** or **abdominal surface** (Figs. 994 and 1106) is entirely free, and is invested throughout by peritoneum. It looks almost directly upward into the abdominal cavity, and extends in an antero-posterior direction from the apex to the base of the bladder. It is in relation with the small intestine and sometimes with the sigmoid flexure, and, in the *female*, with the uterus. On each side, in the *male*, a portion of the vas deferens is in contact with the hinder part of this surface, lying beneath the peritoneum. In the relaxed and empty condition of the bladder a transverse fold of peritoneum (*plica vesicalis transversa*) is formed on this surface.

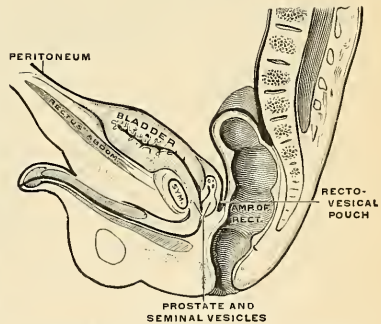


FIG. 1127.—Mesal section through pelvis of newborn male. (Corning.)

The **antero-inferior** or **pubic surface** (Figs. 337 and 1128) looks downward and forward. In the undistended condition it is uncovered by peritoneum, and is in relation with the Obturator internus muscle on each side, with the rectovesical fascia, and anterior true ligaments of the bladder. It is separated from the body of the pubis by a triangular interval, occupied by fatty tissue, the **pubovesical space of Retzius**. As the bladder ascends into the abdominal cavity during distention the distance between its apex and the umbilicus is necessarily diminished, and the urachus (Figs. 994 and 1128) is thus relaxed; so that, instead of passing directly upward to the umbilicus, it descends first on the upper part of the anterior surface of the bladder, and then curving upward, ascends on the back of the abdominal wall. The peritoneum, which follows the urachus, thus comes to form a pouch of varying depth between the anterior surface of the viscus and the

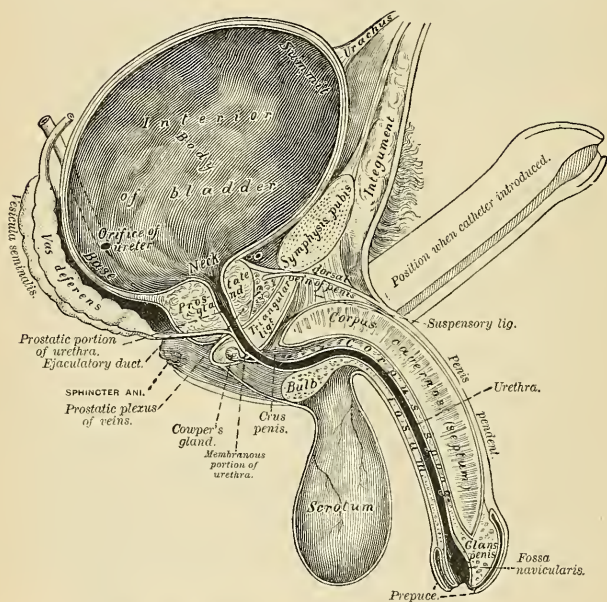


FIG. 1128.—Vertical section of bladder, penis, and urethra.

abdominal wall (Fig. 337). The pouch passes to the neighborhood of the internal abdominal rings. Thus, when the bladder is distended, the upper part of its anterior surface is in relation with the urachus and is covered by peritoneum. The lower part of its anterior surface, for a distance of about two inches above the symphysis pubis, is devoid of peritoneum, and is in contact with the abdominal wall.

The **lateral surfaces** are invested behind and above by peritoneum, which extends as low as the level of the impervious hypogastric artery; below and in front of this, these surfaces are uncovered by peritoneum, and are separated from the Levatores ani muscles and the walls of the pelvis by a quantity of loose areolar tissue containing fat. In front this surface is connected to the rectovesical fascia by a broad expansion on either side, the **lateral true ligaments**. The vas deferens crosses the

hinder part of the lateral surface obliquely, and passes between the ureter and the bladder. When the bladder is empty the peritoncum descends on the pelvic wall as low as the lateral border of the bladder and enters a groove known as the **paravesical fossa**. The lateral surfaces, the pubic surface, and the abdominal surface together constitute the **body of the bladder** (*corpus vesicae*).

The **fundus** or **base** (*fundus vesicae*) (Figs. 1128 and 1152) is directed downward and backward, and is partly covered by peritoneum. In the *male* the upper portion, to within about an inch and a half of the prostate, is covered by the **rectovesical pouch of peritoneum** (Fig. 998). The lower part is in direct contact with the anterior wall of the second part of the rectum, the seminal vesicles, and the vasa deferentia (Figs. 1128 and 1135). The ureters enter the bladder at the upper part of its base, about an inch and a half above the base of the prostate gland (Fig. 1128).

The portion of the bladder in relation with the rectum corresponds to a triangular space, bounded *below*, by the prostate gland; *above*, by the **rectovesical fold of the peritoneum**; and on *each side*, by the seminal vesicles and the vas deferens. It is separated from direct contact with the rectum by the **rectovesical fascia**. When the bladder is very full, the peritoneal fold is raised with it, and the distance between its reflection and the anus is about four inches; but this distance is much diminished when the bladder is empty and contracted. In the *female*, the base of the bladder is connected to the anterior aspect of the cervix uteri by areolar tissue, and is adherent to the anterior wall of the vagina (Fig. 996). Its upper surface is separated from the anterior surface of the body of the uterus by the **utero-vesical pouch of the peritoneum** (Fig. 996).

The so-called **neck** or **cervix of the bladder** (*collum vesicae*), the fixed portion of this viscus, is the point of commencement of the urethra; there is, however, no tapering part, which would constitute a true neck, but the bladder suddenly contracts to the opening of the urethra (Fig. 337). In the *male* it is surrounded by the prostate gland and its direction is oblique when the individual is in the erect posture (Figs. 337 and 1128). In the *female* its direction is obliquely downward and forward. The so-called neck is the most fixed portion of the bladder, and is located one inch (2.5 cm.) behind the junction of the inferior and middle thirds of the symphysis pubis; or two inches (5 cm.) behind and below the superior border of the symphysis.

The **summit** or **apex** (*vertex vesicae*) is the portion of the bladder which when that organ is empty or nearly empty is nearest to the upper border of the symphysis. It is directed upward and forward. In a distended bladder the apex is well above the pubes in the abdominal cavity.

The **urachus** or **middle umbilical ligament** (*ligamentum umbilicale medium*) (Fig. 994) is the impervious remains of the tubular canal of the **allantois**, which existed in the embryo, and a portion of which expanded to form the bladder. It passes upward, from the apex of the bladder, between the transversalis fascia and peritoneum, to the umbilicus, becoming thinner as it ascends. It is composed of fibrous tissue, mixed with plain muscle fibres.

The urachus causes the formation of a peritoneal fold, the **plica umbilicalis media** (Fig. 994). On each side of it is placed a fibrous cord, the impervious portion of the **hypogastric artery**, which, passing upward from the side of the bladder, approaches the urachus above its summit. Over each cord is the fold known as the **plica umbilicalis lateralis** (Fig. 994). In the infant, at birth, the urachus is occasionally found pervious, so that the urine escapes at the umbilicus, and calculi have been found in its canal.

Ligaments.—The bladder is retained in its place by ligaments, which are divided into true and false. The true ligaments are *five* in number—two anterior, two lateral, and the urachus. The false ligaments, also *five* in number, consist of folds of the peritoneum.

The two **anterior true ligaments** or **puboprostatic ligaments** (*ligamenta pubo-prostatica*) extend from the back of the ossa pubis, one on each side of the symphysis, to the front of the neck of the bladder, over the anterior surface of the prostate gland.

The two **lateral true ligaments**, formed by expansions from the fascia lining the lateral wall of the pelvis, are broader and thinner than the preceding. They are attached to the lateral parts of the prostate gland and to the sides of the base of the bladder.

The **urachus** or **middle umbilical ligament** is the fibromuscular cord already mentioned, extending between the summit of the bladder and the umbilicus.

The two **posterior false ligaments** pass forward, in the *male*, from the sides of the rectum (*plicae rectovesicales*); in the *female*, from the sides of the uterus (*plicae vesicouterinae*), to the posterior and lateral aspect of the bladder; they form in the *male* the lateral boundaries of the **rectovesical pouch** (*excavatio rectovesicalis*) (Figs. 337 and 1067); in the *female* the peritoneum is reflected from the rectum to the upper part of the posterior vaginal wall, forming the *rectovaginal pouch*

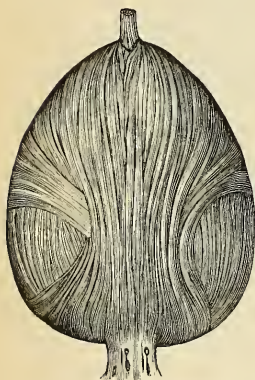

FIG. 1129.—Fibres of the external longitudinal layer. (Poirier and Charpy.)

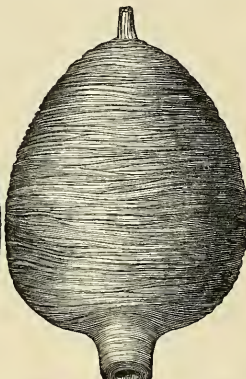


FIG. 1130.—Fibres of the middle or circular layer. (Poirier and Charpy.)

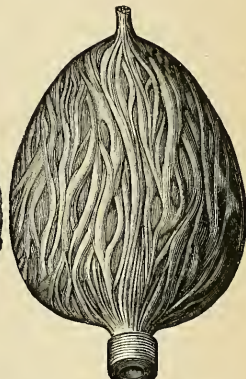


FIG. 1131.—Fibres of the internal longitudinal layer. (Poirier and Charpy.)

or *pouch of Douglas* (Fig. 1068). It is continued over the posterior surface and fundus of the uterus on to its anterior surface and then to the bladder, forming here a second but shallower pouch, the *utero-vesical pouch*, bounded on either side by the utero-vesical or posterior false ligaments of the bladder. The posterior false ligaments contain the impervious hypogastric arteries and the ureters, together with vessels and nerves. In the base of each fold is smooth muscle fibre, the **Rectovesical muscle** (*m. rectovesicalis*).

The two **lateral false ligaments** are reflections of the peritoneum, from the iliac fossæ and lateral walls of the pelvis to the sides of the bladder. Each lateral false ligament (*ligamentum umbilicale laterale*) passes in front into the **plica umbilicalis lateralis** over the corresponding hypogastric artery. The two lateral reflections of peritoneum are continuous in front of the apex of the bladder, at which point the peritoneum passes upon the urachus.

The **superior or anterior false ligament** (*plica umbilicus media*; suspensory ligament) is the prominent fold of peritoneum extending from the summit of the bladder to the umbilicus. It is carried off from the bladder by the urachus. The

peritoneal fold over each impervious hypogastric artery is called the *plica umbilicalis lateralis* (Fig. 994), and is the prolongation forward of the *ligamentum umbilicale laterale*. Besides the true and false ligaments, the bladder receives support from the fibrous tissue and unstriated muscle about the seminal vesicles, and terminations of the ureters and vasa deferentia. In the female the connection with the anterior vaginal wall supports the base of the bladder. In both sexes the most solidly fixed part of the bladder is about the internal orifice of the urethra.

Structure.—The bladder is composed of three coats—**fibrous, muscular, and mucous.**

The **fibrous coat** (*tunica fibrosa*) consists of white fibrous tissue, which supports the other coats. It is partially invested by peritoneum.

The **muscular coat** (*tunica muscularis*) (Figs. 1129, 1130, and 1131) consists of three incompletely differentiated layers of unstriated muscular fibre—an **external layer**, composed of fibres having for the most part a longitudinal arrangement; a **middle layer**, in which the fibres are arranged, more or less, in a circular manner; and an **internal layer**, in which the fibres have a general longitudinal arrangement.

The **fibres of the external longitudinal layer** (*stratum externum*) arise from the posterior surface of the body of the os pubis in both sexes (*m. pubovesicalis*), and in the male arise also from the adjacent part of the prostate gland and its capsule. They pass, in a more or less longitudinal manner, up the anterior surface of the bladder, over its apex, and then descend along its posterior surface to its base, where they become attached to the prostate in the male and to the front of the vagina in the female. At the sides of the bladder the fibres are arranged obliquely and intersect one another. The external longitudinal layer has been named the **Detrusor urinæ muscle**.

The **middle circular layers** (*stratum medium*) are very thinly and irregularly scattered on the body of the organ, and, though to some extent placed transversely to the long axis of the bladder, are for the most part arranged obliquely. Toward the lower part of the bladder, around the neck and the commencement of the urethra, they are disposed in a thick circular layer, forming the **sphincter vesicæ**, which is continuous with the muscle fibres of the prostate gland.

The **internal longitudinal layer** (*stratum internum*) is thin, and its fasciculi have a reticular arrangement, but with a tendency to assume for the most part a longitudinal direction. Two bands of oblique fibres, originating behind the orifices of the ureters, converge to the back part of the prostate gland, and are *inserted*, by means of a fibrous process, into the so-called middle lobe of that organ. They are the **muscles of the ureters**, described by Sir C. Bell, who supposed that during the contraction of the bladder they served to retain the oblique direction of the ureters, and so prevent the reflux of the urine into them.

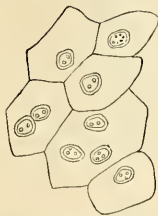

FIG. 1132.—Superficial layer of the epithelium of the bladder. Composed of polyhedral cells of various sizes, each with one, two, or three nuclei. (Klein and Noble Smith.)

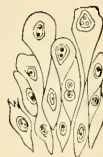

FIG. 1133.—Deep layers of epithelium of bladder, showing large club-shaped cells above, and smaller, more spindle-shaped cells below, each with an oval nucleus. (Klein and Noble Smith.)

The **mucous coat** (*tunica mucosa*) is thin, smooth, and of a pale rose color. It is continuous above through the ureters with the lining membrane of the uriniferous tubes, and below with that of the urethra. Except at the trigone, it is connected very loosely to the muscular coat by a layer of areolar tissue, and is therefore thrown into folds or rugæ when the bladder is empty (Fig. 1135). The epithelium covering it is of the transitional variety, consisting of a superficial layer of polyhedral flattened cells, each with one, two, or three nuclei (Fig. 1132); beneath these is a stratum of large club-shaped cells with the narrow extremity of each cell directed downward and wedged in between smaller spindle-shaped cells, each with an oval nucleus (Fig. 1133). There are no true glands in the mucous membrane of the bladder, though certain mucous follicles

which exist, especially near the neck of the bladder, have been regarded as such. The epithelial cells rest upon a basement membrane, beneath which is the fibroelastic tunica propria, which contains diffuse lymphoid tissue, and in which solitary nodules have been found.

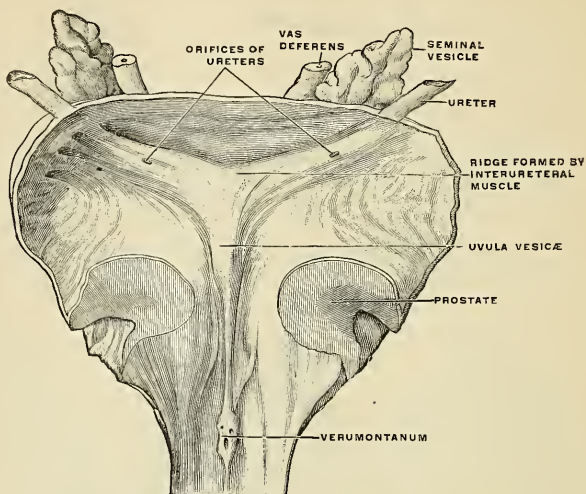


FIG. 1134.—The interior of the bladder, showing the vesical trigone. (Poirier and Charpy.)

The Interior of the Bladder.—Upon the inner surface of the bladder are seen the mucous membrane, orifices of the ureters, the trigone, and the commencement of the urethra.

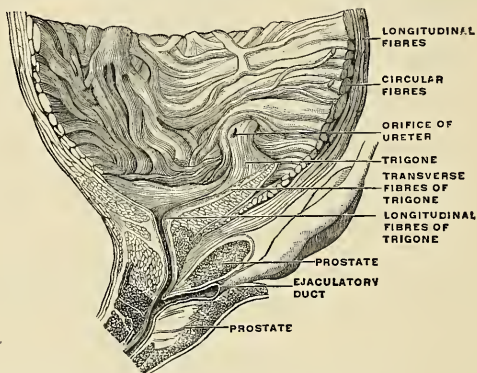


FIG. 1135.—The internal surface of the bladder. (Poirier and Charpy.)

The mucous membrane of the empty bladder is thrown into folds or *rugæ*, except over the trigone, where it is firmly adherent to the muscular coat and is smooth (Figs. 1134 and 1135). The folds disappear when the bladder is distended.

The **vesical trigone** or the **trigonum vesicae** (Fig. 1135) is a smooth, triangular surface, with the apex directed forward, situated at the base of the bladder, immediately behind the urethral orifice. It represents an equilateral triangle, the sides measuring about one inch in the empty bladder and increasing to about one and one-half inches in the distended bladder. It is paler in color than the rest of the interior, and never presents any rugæ, even in the contracted condition of the organ, owing to the intimate adhesion of its mucous membrane to the subjacent tissue. It is bounded at each basal angle by the orifice of a ureter, and at its apex by the orifice of the urethra. Projecting from the lower and anterior part of the bladder, and reaching to the orifice of the urethra, is a slight elevation of mucous membrane, particularly prominent in old persons, called the **uvula vesicae**.

Stretching from one ureteral opening to the other is a smooth, slightly curved ridge (*torus interuretericus*), the convexity of which is toward the urethra. It is produced by transverse muscle fibres beneath the mucous membrane. The outer prolongations of this ridge beyond the ureteral orifices are called the **ureteral folds** (*plicae uretericae*). They are formed by the ureters as they traverse the bladder wall. About the urethral orifice are slight radial folds of mucous membrane, which are continuous with the longitudinal folds of the prostatic urethra.

The **internal urethral orifice** (*orificium urethrae internum*) is sickle-shaped and is surrounded by a circular prominence (*annulus urethralis*), which is most distinct in the male.

Vessels and Nerves.—The arteries (Fig. 472) supplying the bladder are the **superior, middle, and inferior vesical** in the male, with additional branches from the **uterine and vaginal** in the female. They are all derived from the **anterior trunk of the internal iliac**. The **obturator and sciatic arteries** also supply small visceral branches to the bladder. The **veins** form a complicated plexus around the neck, sides, and base of the bladder (Fig. 524). The veins communicate below with the plexus about the prostate and terminate in the internal iliac vein.

The **lymphatics** are few in number; they form two plexuses, one in the muscular and another in the deep tissue of the mucous coat, and accompany the bloodvessels. The subepithelial portion of the mucous membrane of the bladder contains no lymphatics whatever (Sappey). The muscular tissue contains a few lymphatics. The subperitoneal tissues contain the usual number. The collecting trunks from the anterior surface terminate in the **external iliac nodes**. The trunks from the posterior surface terminate in the **internal iliac nodes**, the **hypogastric nodes**, and the nodes in front of the **sacral promontory**.

The **nerves** are derived from the **pelvic plexus of the sympathetic** and from the **third and fourth sacral nerves**; the former supplying the upper part of the organ, the latter its base and neck. According to F. Darwin, the sympathetic fibres have ganglia connected with them, which send branches to the vessels and to the muscular coat.

Surface Form.—The surface form of the bladder varies with its degree of distention and under other circumstances. In the young child it is represented by a conical figure, the apex of which, even when the viscus is empty, is situated in the hypogastric region, about an inch above the level of the symphysis pubis. In the adult, when the bladder is empty, its apex does not reach above the level of the upper border of the symphysis pubis, and the whole organ is situated in the pelvis; the neck, in the *male*, corresponding to a line drawn horizontally backward through the symphysis a little below its middle. As the bladder becomes distended, it gradually rises out of the pelvis into the abdomen, and forms a swelling in the hypogastric region, which is perceptible to the hand as well as to percussion. In extreme distention it reaches into the umbilical region. Under these circumstances the lower part of its anterior surface, for a distance of about two inches above the symphysis pubis, is closely applied to the abdominal wall, without the intervention of peritoneum, so that it can be tapped by an opening in the middle line just above the symphysis pubis, without any fear of wounding the peritoneum. When the rectum is distended, the prostatic portion of the urethra is elongated and the bladder lifted out of the pelvis and the peritoneum pushed upward. Advantage is taken of this by some surgeons in performing the operation of suprapubic cystotomy. The rectum is distended by a rubber bag, which is introduced into this cavity empty, and is then filled with ten or twelve ounces of water. If, now, the bladder is injected with about half a pint of some antiseptic fluid it will appear above the pubes plainly perceptible to the sight and touch. The peritoneum will be pushed out of the way, and an incision three inches long may be made in the *linea alba*, from the symphysis pubis upward, without any great risk of wounding the peritoneum. Other

surgeons object to the employment of this bag, as its use is not unattended with risk, since it causes pressure on the prostatic veins and hence produces congestion of the vessels over the bladder and a good deal of venous hemorrhage.

When distended, the bladder can be felt in the male, from the rectum, behind the prostate, and fluctuation can be perceived by a bimanual examination, one finger being introduced into the rectum and the distended bladder being tapped on the front of the abdomen with the finger of the other hand. This portion of the bladder—that is, the portion felt in the rectum by the finger—is uncovered by peritoneum.

Applied Anatomy.—A certain defect of development in which the bladder is implicated is known under the name of *extroversion of the bladder*. In this condition the lower part of the abdominal wall and the anterior wall of the bladder are wanting, so that the posterior surface of the bladder presents on the abdominal surface, and is pushed forward by the pressure of the viscera within the abdomen, forming a red, vascular protrusion, on which the openings of the ureters are visible. The penis, except the glans, is rudimentary, and is cleft on its dorsal surface, exposing the floor of the urethra—a condition known as *epispadias*. The pelvic bones are also arrested in development (see p. 220).

The bladder may be *ruptured* by violence applied to the abdominal wall when the viscus is distended without injury to the bony pelvis, or it may be torn in case of fracture of the pelvis. The rupture may be either intraperitoneal or extraperitoneal, that is—may implicate the superior surface of the bladder in the former case, or one of the other surfaces in the latter. Rupture of the antero-inferior surface alone is, however, very rare. Until recently intraperitoneal rupture was uniformly fatal, but now abdominal section and suturing the rent with Lembert sutures often saves the patient. The sutures are inserted only through the peritoneal and muscular coats in such a way as to bring the serous surfaces at the margin of the wound into apposition, and one is also inserted just beyond each end of the wound. The bladder should be tested as to whether it is water-tight before closing the external incision.

The muscular coat of the bladder undergoes *hypertrophy* in cases in which there is any persistent obstruction to the flow of urine. Under these circumstances the bundles of which the muscular coat consists become much increased in size, and, interlacing in all directions, give rise to what is known as the *fasciculated bladder*. Between these bundles of muscle fibres the mucous membrane may bulge out, forming sacculi, constituting the *sacculated bladder*, and in these little pouches phosphatic concretions may collect, forming *encysted calculi*. The mucous membrane is very loose and lax, except over the trigone, to allow of the distention of the viscus.

Various forms of *tumors* have been found springing from the wall of the bladder. The *innocent tumors* are the *papilloma* and the *mucous polypus*, arising from the mucous membrane; the *fibrous tumor*, from the deep mucous tissue; and the *myoma*, originating in the muscle tissue; and, very rarely, *dermoid tumors*, the exact origin of which it is difficult to explain. Of the *malignant tumors*, *epitheliomata* are the most common, but *sarcomata* are occasionally found in the bladders of children.

Puncture of the bladder is performed above the pubes without wounding the peritoneum. *Suprapubic cystotomy* is considered above under the heading of Surface Form. This operation may be employed to permit of the removal of a calculus, and is then called *suprapubic lithotomy*.

THE MALE URETHRA (URETHRA VIRILIS) (Figs. 1136, 1137).

The *urethra* in the *male* extends from the neck of the bladder at the **internal orifice of the urethra** (*orificium urethrae internum*) to the **meatus urinarius**, the **external orifice of the urethra** (*orificium urethrae externum*), at the end of the penis. The internal orifice has been described (p. 1363). The urethra presents a double curve in the flaccid state of the penis (Fig. 1128), but in the erect state of this organ it forms only a single curve, the concavity of which is directed upward. It presents three important constrictions—(1) at the beginning, (2) in the membranous portion, (3) at the end. Its length varies from seven to eight inches (17 to 20 cm.); and it is divided into three portions, the **prostatic**, **membranous**, and **spongy**, the structure and relations of which are essentially different. Except during the passage of the urine or semen, the urethra is a mere transverse, T-shaped, or crescentic cleft or slit (Fig. 1137), with its upper and under surfaces in contact. At the meatus urinarius the slit is vertical, and in the prostatic portion somewhat arched (Fig. 1137).

The **prostatic portion** (*pars prostatica*) (Figs. 1136 and 1171), the widest part of the canal, is about an inch in length. It is between the internal orifice

of the urethra and the deep layer of the triangular ligament and lies within the pelvic cavity. It passes almost vertically through the prostate gland from its base to its apex, lying nearer its anterior than its posterior surface. The gland *seems* to completely surround this portion of the urethra (Fig. 1166), but the glandular substance proper does not (Fig. 1169). The gland is like a clasp open in front, and the open part of the clasp is closed by the prostatic muscle. The form of the canal is spindle-shaped, being wider in the middle than at either extremity, and narrowest below, where it joins the membranous portion. Except during the passage of fluid, the canal is in a collapsed state and is horseshoe-shaped on trans-section, the anterior wall resting upon the posterior wall (Fig. 1137), and the mucous membrane exhibiting longitudinal folds. When distended, the largest portion of the prostatic urethra in the cadaver has a diameter of about one-half inch (12 mm.).

Upon the **posterior wall or floor** of the canal is a narrow longitudinal ridge, the **verumontanum** or **caput gallinaginis** (Figs. 1136 and 1171) (*crista urethralis*), formed by an elevation of the mucous membrane and its subjacent tissue (Fig. 1170). It is about 16 mm. in length and about 3 mm. in height, and contains, according to Kobelt, muscle and erectile tissues. On either side of the verumontanum is a slightly depressed fossa, the **prostatic sinus**, the floor of which is perforated by numerous apertures, the **orifices of the prostatic ducts** (Figs. 1136 and 1171), from the lateral lobes of the glands; the ducts of the middle lobe open behind the verumontanum. At the forepart of the verumontanum, in the middle line, is a depression, the **sinus pocularis** (*utriculus prostaticus*) (Figs. 337 and 1171), upon the margins of which are the slit-like openings of the **ejaculatory ducts** (Fig. 1171). The sinus pocularis forms a *cul-de-sac* about a quarter of an inch in length, which runs upward and backward in the substance of the prostate into the so-called middle lobe; its prominent anterior wall partly forms the verumontanum. Its walls are composed of fibrous tissue, muscle fibres, and mucous membrane, and numerous small glands open on its inner surface. It has been called the **uterus masculinus**, because it is developed from the united lower ends of the atrophied Müllerian ducts, and therefore is homologous with the uterus and vagina in the female.

The **membranous portion** (*pars membranacea*) (Figs. 1128 and 1136) lies between the two layers of the triangular ligament, and extends downward and forward between the apex of the prostate and the bulb of the corpus spongiosum. It is the narrowest part of the canal (excepting the meati), has a calibre of about one-third of an inch (8 mm.), and measures about half an inch (10 to 12 mm.) in length. Its anterior concave surface is placed about an inch below and behind

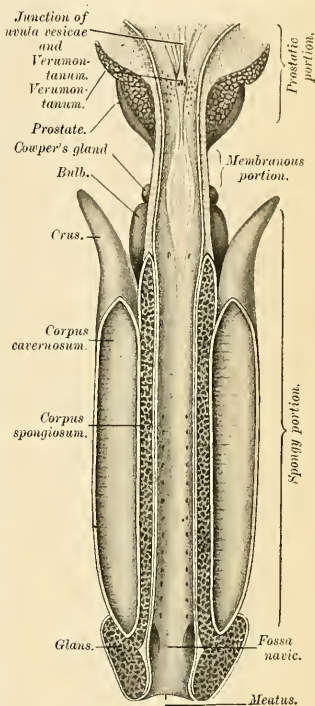


FIG. 1136.—The male urethra, laid open on its anterior (upper surface). (Testut.)

the pubic arch, from which it is separated by the dorsal vessels and nerve of the penis, and some muscle fibres. Its posterior convex surface is separated from the rectum by a triangular mass of tissue which constitutes the perineal body. As it pierces the superficial layer of the triangular ligament the fibres around the opening are prolonged over the tube and fix the two structures firmly to each other. The membranous urethra is surrounded by cavernous tissue and by the Compressor urethrae muscle (*m. sphincter urethrae membranaceae*) (Fig. 338). On the floor of the membranous urethra is the anterior extremity of the verumontanum.

Behind this part of the urethra, on each side of the middle line, are Cowper's glands (Figs. 334 and 1128). When the urethra is empty the mucous membrane of this part is thrown into longitudinal folds, which are obliterated by distention.

The penile or spongy portion (*pars cavernosa*) (Figs. 1136 and 1138) is the longest part of the urethra, and is contained in the corpus spongiosum. It is about six inches (15 cm.) in length, and extends from the termination of the membranous portion to the meatus urinarius. Its proximal end is fixed in position and unchangeable in direction. Its distal end is movable and changeable in direction. Commencing just below the triangular ligament it is first directed forward through the bulb; it then passes downward and forward, the turn beginning at the point of attachment of the suspensory ligament of the penis (Fig. 1128). The direction of the spongy portion of the urethra is changed by alterations in the position of the penis. When the canal is closed the anterior and posterior walls are in contact (roof and floor), except in the glans penis, where the lateral walls

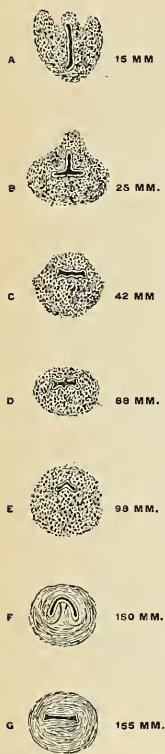


FIG. 1137. — Cross-section of the male urethra at various distances from its free end, showing marked alterations of form. (Testut.)

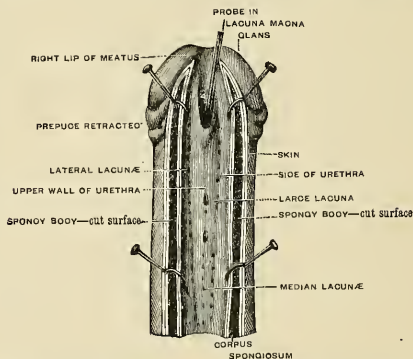


FIG. 1138.—The distal portion of the male urethra, laid open on its posterior (under) surface, showing the lacunæ. (Testut.)

come together. The calibre of the spongy urethra varies in different portions of the tube. It is narrow and of uniform size in the body of the penis, measuring about one-third of an inch (9 mm.) in diameter; it is dilated behind, within the bulb (13 to 14 mm.), and again anteriorly within the glans penis (12 to 14 mm.), where it forms the fossa navicularis (*fossa navicularis urethrae*). In the roof of the fossa navicularis there is a transverse fold of mucous membrane,

the **valve of Guerin** (*valvulae fossae navicularis*), guarding a recess, the **lacuna magna**. The urethra opens anteriorly by the **meatus urinarius**.

The **bulbous portion** is a name sometimes given to the posterior part of the spongy portion contained within the bulb.

The **meatus urinarius** or **external orifice of the urethra** (*orificium urethrae externum*) (Figs. 1136 and 1138) is the most contracted part of the urethra. Its calibre averages about 7 mm. It is a vertical slit (Fig. 1137), bounded on each side by a small lip or **labium**.

The inner surface of the living membrane of the urethra, especially on the floor of the spongy portion, presents the orifices of numerous mucous glands (Fig. 1138) situated in the subepithelial tissue, and named the **glands of Littre** (*glandulae urethrales*). Besides these there are a number of little recesses or follicles, of varying sizes, called **lacunae** (*lacunae urethrales*). Their orifices are directed forward, so that they may easily intercept the point of a catheter in its passage along the canal. One of these lacunae, larger than the rest, is situated in the upper surface of the fossa navicularis, about half an inch from the orifice; it is called the **lacuna magna** (Fig. 1138). Into the bulbous portion are found opening the ducts of Cowper's glands.

Structure.—The male urethra is composed of three coats—**mucous, muscular, and fibrous**.

The **mucous coat** forms part of the urinogenital mucous membrane. It is continuous with the mucous membrane of the bladder, ureters, and kidneys; externally with the integument covering the glans penis; and is prolonged into the ducts of the glands which open into the urethra—viz., Cowper's glands and the prostate gland—into the vasa deferentia and the seminal vesicles through the ejaculatory ducts. The mucous membrane is arranged in longitudinal folds when the tube is empty. Small papillae are found upon it near the orifice, and its epithelial lining varies in the different divisions. The **prostatic portion** is lined by **transitional cells**, continued from the bladder, the **membranous portion** by **stratified columnar cells**, and the **penile portion** by **simple columnar epithelium**, except in the *fossa navicularis*, where **stratified squamous cells** are found. The cells rest upon a **basement membrane** supported by the *tunica propria*, composed of fibroelastic tissue. In the latter are found diffuse lymphoid tissue and racemose glands, the **urethral glands** (*glands of Littre*).

The **muscular layer** is continuous with the muscle of the prostate and bladder, and lies external to the mucous coat. It is composed of nonstriated muscle arranged in an outer layer of **circular fibres** (*stratum circulare*) and an inner layer of **longitudinal fibres** (*stratum longitudinale*). These layers are prominent in the prostatic urethra, less so in the membranous portion, and ultimately disappear in the spongy part. The longitudinal fibres, when contracted, shorten the urethra and increase its diameter. The circular fibres are in a state of tonic contraction and close the urethra, constituting, apparently, a real **sphincter** (Zeissl, Zuckerkandl). The so-called sphincter of the urethra, the **Accelerator urinæ**, is a voluntary muscle and is not the real sphincter. Outside of the muscle layer of the urethra is the tissue of the corpus spongiosum.

The **fibrous coat** (*tunica fibrosa*) consists chiefly of white fibrous tissue supporting the preceding coats.

Applied Anatomy.—The urethra may be **ruptured** by the patient falling astride of any hard substance and striking his perineum, so that the urethra is crushed against the pubic arch. Bleeding will at once take place from the urethra, and this, together with the bruising in the perineum and the history of the accident, will at once point to the nature of the injury.

Rupture of the urethra leads to **extravasation of urine**. In rupture back of the superior layer of the triangular ligament the urine usually follows the rectum and reaches the margin of the anus. Rupture of the membranous part liberates urine between the two layers of the triangular ligament, where it remains until a path of exit is made by suppurating or the surgeon's knife. In rupture superficial to the anterior layer of the ligament the urine passes into the scrotum and may mount up to the abdomen between the symphysis and the pubic spine, between which points the deep layer of the superficial fascia is not attached. It cannot pass to the thigh nor cross the midline, because the fascia is attached to the fascia lata and at the midline.

The applied anatomy of the urethra is of considerable importance in connection with the passage of instruments into the bladder. Otis was the first to point out that the urethra is capable of great dilatation, so that, excepting through the external meatus, an instrument corresponding to 20 to 28 French gauge can usually be passed without damage. The orifice of the urethra is not so dilatable, and therefore may require slitting, although the introduction of the Oberlander dilator, which is expanded after introduction, renders slitting of the meatus seldom necessary in cases of chronic gonorrhœa. A recognition of this dilatability caused Bige-

low to very considerably modify the operation of lithotripsy and introduce that of litholapaxy. In passing a fine catheter, the point of the instrument after it has passed the lacuna magna should be kept as far as possible along the upper wall of the canal, as the point is otherwise very liable to enter one of the lacunæ. *Stricture of the urethra* is a disease of very common occurrence, and is generally situated in the spongy portion of the urethra, most commonly in the bulbous portion just in front of the membranous urethra, but in a very considerable number of cases in the penile part of the canal. Even in a normal urethra, and very markedly in an inflamed urethra, a bougie encounters resistance behind the bulb. This is usually supposed to be due to spasm of the Compressor urethræ muscle.

In irrigation of the urethra by gravity fluid tends to block at the same point, especially if it is thrown in suddenly or forcibly. If a reservoir is raised seven and one-half feet from the floor, and if a patient sits on a chair or lies upon a bed, fluid can be readily made to pass by hydraulic pressure from the meatus to the bladder. Spasm may temporarily prevent the inflow, but the weight of the column of fluid soon tires out the muscle and causes it to relax. Relaxation is favored by having the patient take slow, deep breaths, and make efforts at urination (Valentine).

Chronic gonorrhea is frequently kept up by persistent inflammation of the ducts and follicles in the mucous membrane. This condition is known as *chronic glandular urethritis* or *para-urethritis*. In these crypts and glands gonococci may remain when gonorrhea appears to have passed away, and from time to time reinfection of the urethra may arise from such a source.

Median urethrotomy or *perineal section* is opening of the membranous urethra. Through such an opening the bladder can be drained and explored, and the operation is sometimes called *median cystotomy*.

In *lateral lithotomy* the knife enters the membranous urethra and strikes the groove of the staff. Its edge is then turned toward the left ischial tuberosity and is carried along the groove into the bladder, dividing the membranous urethra, the prostatic urethra, the posterior layer of the triangular ligament, the Compressor urethræ muscle, anterior fibres of the Levator ani muscle and the left lobe of the prostate gland.

THE FEMALE URETHRA (URETHRA MULIEBRIS).

The female urethra is a narrow membranous canal, about an inch and a half in length, extending from the internal urethral orifice at the neck of the bladder to the *meatus urinarius*. It is placed behind the symphysis pubis, embedded in the anterior wall of the vagina, and its direction is obliquely downward and forward; its course is slightly curved and the concavity directed forward and upward. Ordinarily the wall is collapsed so that the lumen is of stellate outline; the urethra may be dilated to about a quarter of an inch (6 to 8 mm.); toward the bladder the calibre increases slightly. The urethra perforates both layers of the triangular ligament, and its external orifice is situated directly in front of the vaginal opening and about an inch behind the glans clitoridis.

Structure.—The female urethra consists of three coats—*mucous*, *muscular*, and *fibrous*.

The *mucous coat* (*tunica mucosa*) is pale, continuous externally with that of the vulva, and internally with that of the bladder. It is thrown into longitudinal folds, one of which, placed along the floor of the canal, extends from the vesical trigone almost to the external orifice of the urethra. It is called the *crest* (*crista urethralis*). The outline of the urethra is stellate when collapsed, because of the formation of numerous longitudinal folds. It is lined by laminated epithelium, which becomes transitional near the bladder. Many mucous glands open into the urethra, and there are numerous lacunæ. On either side of the terminal portion of the urethra lie a group of mucous glands (*glandulæ paraurethrales*), each lateral group opening into the vestibule by a common duct (*ductus paraurethralis*) at the side of the urinary meatus. These glands are regarded as being homologous with the prostate in the male.

The mucous coat is lined by *stratified squamous* cells resting upon a *basement membrane* and by papillated *tunica propria*; the latter consists of fibroelastic tissue containing the smaller vessels, some lymphoid tissue, and a few racemose glands. In the deeper portion of the tunica propria the structure is very vascular, is of a spongy nature, and constitutes the *erectile tissue*.

The *muscular coat* (*tunica muscularis*) is continuous with that of the bladder; it extends the whole length of the tube, and consists of an internal layer of *nonstriated longitudinal fibres* (*stratum longitudinale*) and an external layer of *nonstriated circular fibres* (*stratum circulare*). In addition to these, between the two layers of the triangular ligament, the female urethra is surrounded by the Compressor urethræ muscle, as in the male.

The **fibrous coat** consists of white fibrous tissue which supports the other coats.

The urethra, because it is not surrounded by dense resisting structures, as in the male, admits of great dilatation, which enables the surgeon to remove with considerable facility calculi or other foreign bodies from the cavity of the bladder.

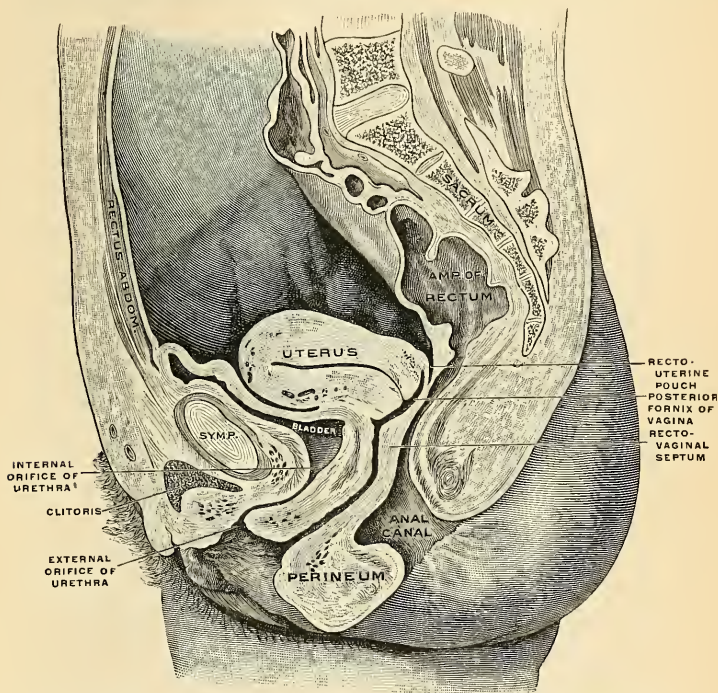


FIG. 1139.—Mesal section through the pelvis of a woman, aged twenty-one years. Peritoneum in blue. (Corning.)

THE MALE REPRODUCTIVE ORGANS.

The male reproductive organs (*organa genitalia virilia*) include the testes, the vasa deferentia, the seminal vesicles, the ejaculatory ducts, and the penis, together with the following accessory structures—viz., the prostate and Cowper's glands.

THE TESTICLES (TESTES) AND THEIR COVERINGS (Figs. 1140, 1141).

The testes are two glandular organs, which secrete the spermatozoa; they are situated in the scrotum, being suspended by the spermatic cords. At an early period of fetal life the testes are contained in the abdominal cavity, behind the peritoneum. Before birth they descend to the inguinal canal, along which they pass with the spermatic cord, and emerging at the external abdominal ring, they descend into the scrotum, becoming invested in their course by coverings derived

from the serous, muscular, and fibrous layers of the abdominal parietes as well as by the scrotum proper.

The coverings of the testis are the following:

- Skin
- Dartos } Scrotum.
- Intercolumnar or External spermatic fascia.
- Cremasteric fascia.
- Infundibuliform or Internal spermatic fascia.
- Tunica vaginalis.

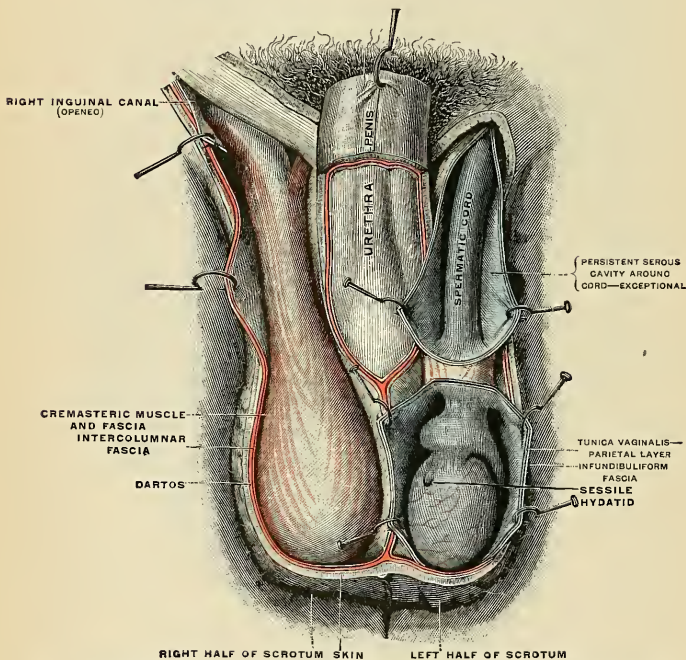


FIG. 1140.—The scrotum. On the left side the cavity of the tunica vaginalis has been opened; on the right side only the layers superficial to the Cremaster have been removed. (Testut.)

The **scrotum**¹ (Figs. 1140 and 1141) is a cutaneous pouch which contains the testes and part of the spermatic cords. It is divided on its surface into two lateral portions by a median line or **raphé** (*raphe scroti*), which is continued forward to the under surface of the penis and backward along the middle line of the perineum to the anus. Of these two lateral portions, the left is usually longer than the right, to correspond with the usual greater length of the left spermatic cord. Its external aspect varies under different circumstances; thus, under the influence of warmth and in old and debilitated persons it becomes elongated and flaccid but under the influence of cold or sexual excitement and in the young

¹ Originally *scortum*, a bag of leather or skin; through a blunder two of the letters in the word have become transposed.

and robust it is short, corrugated, and closely applied to the testes. The wrinkles in the scrotum are called *rugæ*.

The scrotum consists of two layers, the *integument* and the *dartos*.

The *integument* is very thin, of a brownish color, and generally thrown into folds or *rugæ*. It is provided with sebaceous follicles, the secretion of which has a peculiar odor, and is beset with thinly scattered, crisp hairs, the roots of which may be seen through the skin.

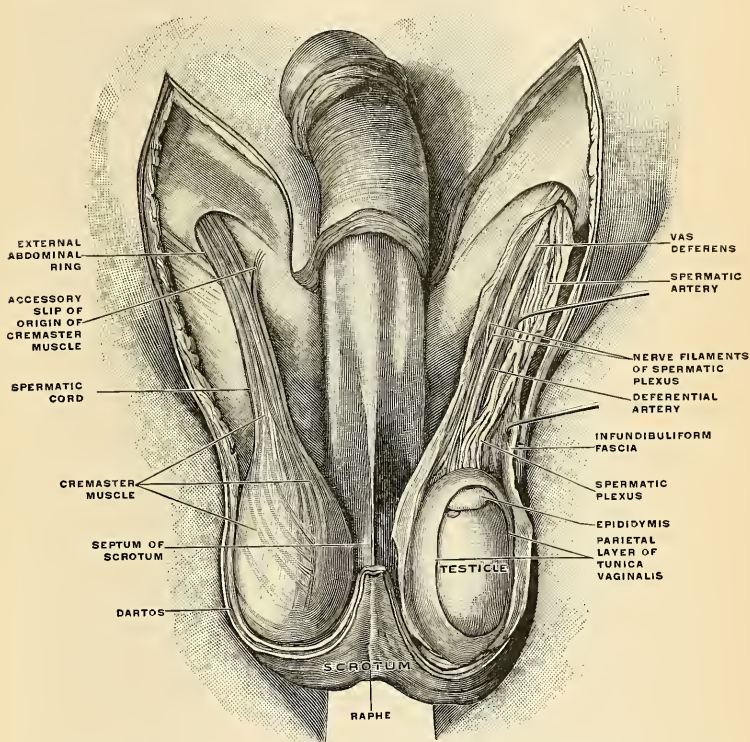


FIG. 1141.—The scrotum. The penis has been turned upward, and the anterior wall of the scrotum has been removed. On the right side, the spermatic cord, the infundibuliform fascia, and the Cremaster muscle are displayed; on the left side, the infundibuliform fascia has been divided by a longitudinal incision passing along the front of the cord and the testicle, and a portion of the parietal layer of the tunica vaginalis has been removed to display the testicle and a portion of the head of the epididymis, which are covered by the visceral layer of the tunica vaginalis. (Toldt.)

The *dartos* (*tunica dartos*) (Figs. 1140 and 1142) is a thin layer of loose vascular tissue, containing smooth muscle tissue, but no fat; it forms the proper tunic of the scrotum, is continuous around the base of the scrotum, with the two layers of the superficial fascia of the groin and perineum, and sends inward a distinct mesal septum, the *septum of the scrotum* (*septum scroti*) (Fig. 1140), which divides it into two cavities for the two testes, the septum extending between the raphe and the under surface of the penis as far as its root.

The dartos is closely united to the skin externally, but connected with the subjacent parts by delicate areolar tissue, upon which it glides with the greatest facility.

The **intercolumnar** or **external spermatic fascia** (Fig. 1140) is a thin membrane derived from the margin of the pillars of the external abdominal ring, during the descent of the testis in the fetus, which is prolonged downward around the surface of the cord and testis. It is separated from the dartos by loose areolar tissue, which allows of considerable movement of the latter upon it, but is intimately connected with the succeeding layers.

The **cremasteric fascia** (*fascia cremasterica*) (Figs. 1140 and 1141) consists of scattered bundles of muscle fibres, the **cremaster muscle** (*m. cremaster*) (Figs. 1140 and 1141) derived from the lower border of the Internal oblique and collected within a continuous covering by intermediate areolar tissue.

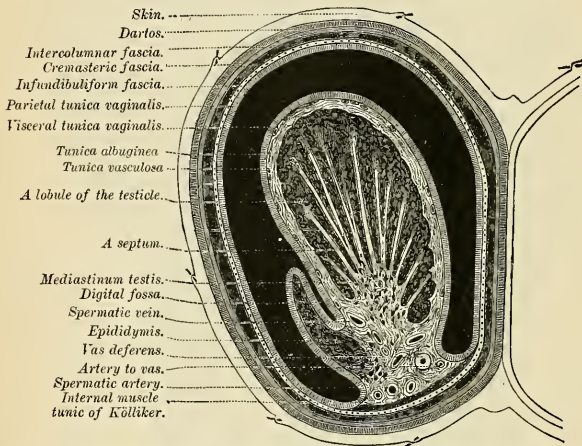


FIG. 1142.—Transverse section through the left side of the scrotum and the left testis. The sac of the tunica vaginalis is represented in a distended condition. (Delépine.)

The **infundibuliform fascia** (*tunica vaginalis communis* [*testis et funiculi spermatici*]) (Figs. 1140 and 1141) is a thin membranous layer, which loosely invests the surface of the cord. It is a continuation downward of the fascia transversalis. Beneath it is a quantity of loose connective tissue which connects this layer of fascia with the spermatic cord and posterior parts of the testicle. This connective tissue is continuous above with the subserous areolar tissue of the abdomen. These two layers, the infundibuliform fascia and the tissue beneath it, are known collectively as the **fascia propria**. The infundibuliform fascia completely encloses the testicle and epididymis and is fused with the parietal lamina of the tunica vaginalis propria testis.

The **tunica vaginalis** (*tunica vaginalis propria testis*) is described with the testis (p. 1379).

Vessels and Nerves.—The arteries supplying the coverings of the testis are the superficial and deep external pudic, from the femoral; the superficial perineal branch of the internal pudic; and the cremasteric branch from the deep epigastric. The veins follow the course of the corresponding arteries. The lymphatics terminate in the inguinal nodes. The nerves are the ilioinguinal and genital branch of the genitofemoral nerve and of the lumbar plexus, the two superficial perineal branches of the internal pudic nerve, and the inferior pudendal branch of the small sciatic nerve.

The **inguinal** or **spermatic canal** (*canalis inguinalis*) (Figs. 330 and 1124) contains the spermatic cord in the male and the round ligament in the female. It is an oblique canal, about an inch and a half in length, directed downward and inward and placed parallel with, and a little above, Poupart's ligament. It commences above at the internal or deep abdominal ring, which is the point where the cord enters the inguinal canal, and terminates below at the external or superficial ring. It is bounded, *in front*, by the integument and superficial fascia, by the aponeurosis of the External oblique throughout its whole length, and by the Internal oblique for its outer third; *behind*, by the triangular fascia, the conjoined tendon of the Internal oblique and Transversalis, transversalis fascia, and the subperitoneal fat and peritoneum; *above*, by the arched fibres of the Internal oblique and Transversalis; *below*, by the union of the transversalis fascia with Poupart's ligament.

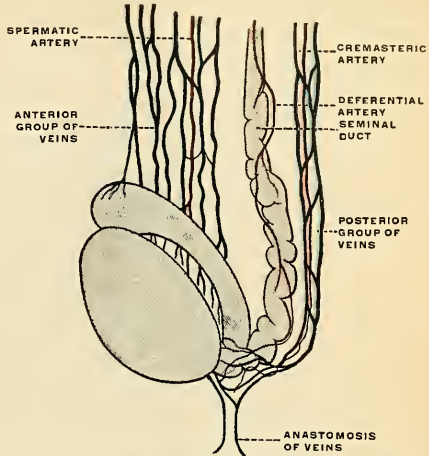


FIG. 1143.—The arteries of the testis and the cord. (Poirier and Charpy.)

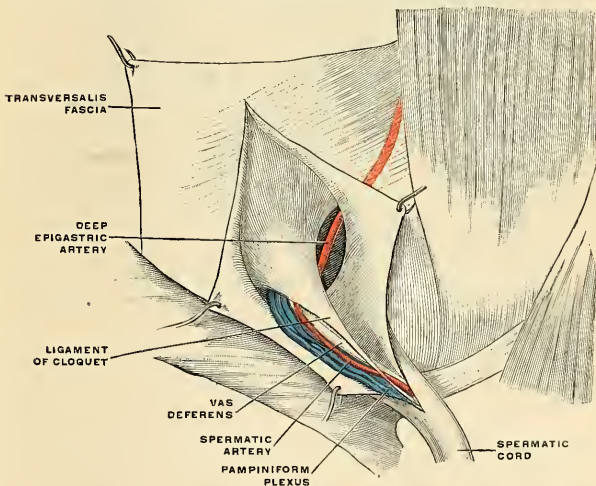


FIG. 1144.—The spermatic cord and the ligament of Cloquet. (Poirier and Charpy.)

The **spermatic cord** (*funiculus spermaticus*) (Figs. 1140 and 1144) extends from the internal abdominal ring, where the structures of which it is composed

converge, to the back part of the testicle. In the abdominal wall the cord passes obliquely along the inguinal canal, lying at first beneath the Internal oblique muscle and upon the fascia transversalis; but nearer the pubes it rests upon Poupart's ligament, having the aponeurosis of the External oblique in front of it and the conjoined tendon behind it. It then escapes at the external ring, and descends nearly vertically into the scrotum. The left cord is usually rather longer than the right, consequently the left testis generally hangs somewhat lower than its fellow.

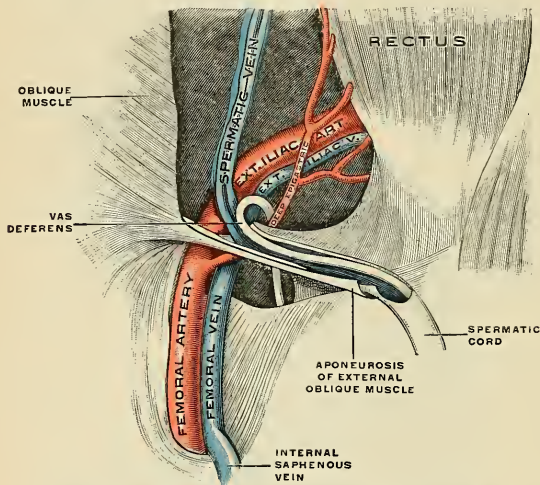


FIG. 1145.—The spermatic cord in the inguinal canal. (Poirier and Charpy.)

Structure.—The spermatic cord contains the spermatic duct or vas deferens, the deferential artery and veins, the spermatic artery, the pampiniform plexus of veins, the spermatic plexus, and the deferential plexus of the sympathetic nerve, lymphatics, and the cord-like remnant of the funicular process of peritoneum called the **ligament of Cloquet** (Fig. 1144). All the above structures are held together by connective tissue. These structures are ensheathed by the **infundibuliform process of the transversalis fascia** (Fig. 1144 and p. 1374). This fascia is thin above and thicker below, and encloses the testicle and epididymis, as well as the cord, being firmly adherent to the parietal layer of the vaginal tunic of the testicle and with the posterior portion of the testicle and epididymis. Upon this fascia are the fibres of the Cremaster muscle, which spring from the Internal oblique, and in this fascia are the cremasteric artery, the genital branch of the genitofemoral nerve, and external spermatic veins. This fascia is surrounded by the **intercolumnar or spermatic fascia**, which is distinct above, but not below.

Vessels and Nerves of the Spermatic Cord.—The **arteries** (Figs. 1141 and 1143) of the cord are the spermatic, from the aorta; the artery of the vas deferens, from the superior vesical; the cremasteric, from the deep epigastric.

The **spermatic artery** (*a. spermatica interna*) arises from the abdominal aorta below the renal artery, descends by the Psoas muscle, crosses the ureter and external iliac vessels, meets the vas deferens at the internal abdominal ring, escapes from the abdomen at the internal or deep abdominal ring, and lying in front of the vas deferens accompanies the other constituents of the spermatic cord along the inguinal canal and through the external abdominal ring into the scrotum. It then descends to the testis, and, becoming tortuous, divides into several branches, two or three of which, the **epididymal branches**, accompany the vas deferens and supply the epididymis, anastomosing with the artery of the vas deferens and the cremasteric artery; others, the **glandular branches**, pierce the back of the tunica albuginea and supply the substance of the testis.

The **artery of the vas deferens** (*a. deferentialis*), a branch of the superior vesical, is a long slender vessel which accompanies the vas deferens, ramifying upon the coats of that duct, and anastomosing with the spermatic artery and the cremasteric artery near the testis.

The **cremasteric artery** (*a. spermatica externa*) is a branch of the deep epigastric artery. It accompanies the spermatic cord and supplies the Cremaster muscle and other coverings of the cord, anastomosing with the spermatic and deferential arteries.

The **spermatic veins** (Figs. 523 and 1146) emerge from the back of the testis and receive tributaries from the epididymis; they unite and form a convoluted plexus, the **pampiniform plexus** (*plexus pampiniformis*), which forms the chief mass of the cord; the vessels composing this plexus are very numerous, and ascend along the cord in front of the vas deferens; below the external or superficial abdominal ring they unite to form three or four veins, which pass along the inguinal canal, and, entering the abdomen through the internal or deep abdominal ring, coalesce to form two veins. These again unite to form a single vein, which opens on the right side into the inferior vena cava at an acute angle, and on the left side into the left renal vein at a right angle.

The **lymphatic vessels** of the scrotum terminate in the superficial inguinal nodes. The lymphatics of the testicle join the lymphatics of the epididymis and of the visceral layer of the vaginal tunic of the testicle, and ascend in the spermatic cord. They reach the lumbar region along the spermatic bloodvessels and terminate in the **lateral aortic nodes**, and sometimes in the nodes in front of the aorta. The lymphatics of the seminal duct pass to the external iliac nodes.

The **nerves** are the **spermatic plexus** from the sympathetic, joined by filaments from the **pelvic plexus** which accompany the artery of the vas deferens.

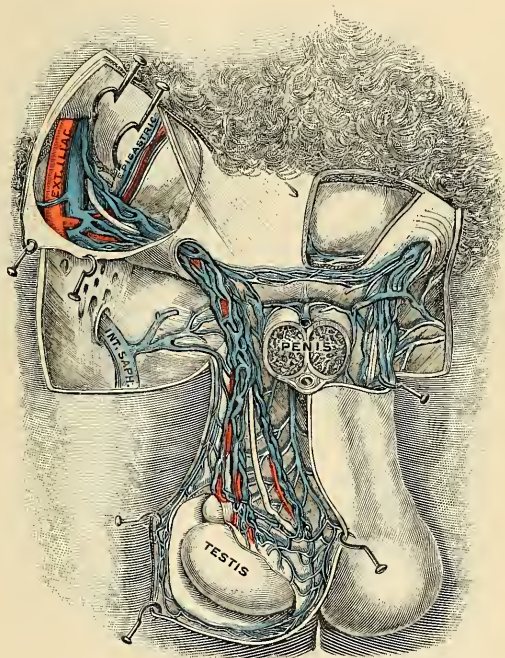


FIG. 1146.—Spermatic veins. (Testut.)

The **testes** (Figs. 1141 and 1146) are suspended in the scrotum by the spermatic cords, the left testis hanging somewhat lower than its fellow. The average dimensions of this gland are from one and a half to two inches (4 cm.) in length, one inch (2.5 cm.) in breadth, and an inch and a quarter (3 cm.) in the antero-posterior diameter, and the weight varies from six to eight drams (25 to 30 grams). It is of a grayish-white color, and of resilient consistency. Each gland is of an oval

form, compressed laterally, and having an oblique position in the scrotum, the **upper extremity** (*extremities superior*) being directed forward and a little outward, the **lower extremity** (*extremities inferior*), backward and a little inward; the **anterior convex border** looks forward and downward; the **posterior or straight border** (*margo posterior*), to which the cord is attached, backward and upward.

The **anterior border** (*margo anterior*) and **lateral surfaces** (*facies lateralis et facies medialis*), as well as both extremities of the organ, are convex, free, smooth, and invested by the visceral layer of the tunica vaginalis. The posterior border, to which the cord is attached, receives only a partial investment from that membrane. To the inferior part of the posterior border is attached the **gubernaculum testis** (see p. 1424), which anchors the testis firmly to the scrotum. Lying upon the outer edge of this posterior border is a long, narrow, flattened body, named, from its relation to the testis, the **epididymis** (Figs. 1147 and 1148), which curves outward and backward.

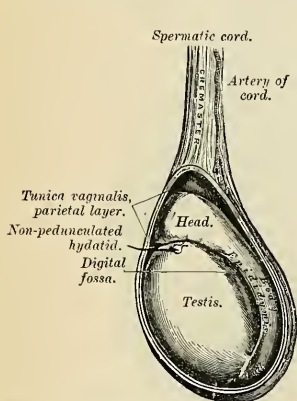


FIG. 1147.—The left testis *in situ*, the tunica vaginalis having been laid open.

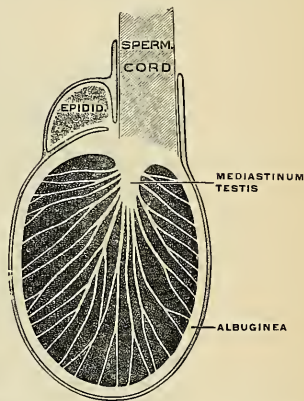


FIG. 1148.—Frontal section of the testis and epididymis. (Poirier and Charpy.)

The **epididymis** consists of a **central portion** or **body** (*corpus epididymidis*); an upper enlarged extremity, the **head** or **globus major** (*caput epididymidis*); and a lower pointed extremity, the **tail** or **globus minor** (*cauda epididymidis*). The globus major is directed inward and is intimately connected with the upper end of the testicle by means of its efferent ducts, and the globus minor is connected with its lower end by cellular tissue and a reflection of the tunica vaginalis. The globus minor bends suddenly and passes into the **seminal duct**, the direction of which is upward and backward. The outer surface and upper and lower ends of the epididymis are free and covered by serous membrane; the body is also completely invested by it, excepting along its inner border, and between the body and the posterior part of the outer surface of the testis is a pouch or *cul-de-sac*, named the **digital fossa** (*sinus epididymidis*). Above this fossa is a fold of the tunica vaginalis, which is called the **ligamentum epididymidis superior**, and below it is another fold, the **ligamentum epididymidis inferior**. The epididymis is connected to the back of the testis by a fold of the serous membrane. Attached to the upper end of the testis, close to the globus major, is a small body; it is oblong in shape and has a broad base, and is called the **sessile hydatid** (*appendix testis* [Morgagni]) (Figs. 1140 and 1147). Attached to the globus major of the epi-

didymis is another small, pear-shaped body—the **pedunculated hydatid** (*appendix epididymidis*). These bodies are the remains of embryonic structures. When the testis is removed from the body, the position of the vas deferens, on the posterior surface of the testis and inner side of the epididymis, marks the side to which the gland has belonged.

Structure of the Epididymis.—The epididymis is surrounded by a capsule of white fibrous tissue. The globus major consists of from ten to fifteen tubules, which are convoluted and lined by stratified ciliated epithelial cells. The body and globus minor are composed of the convolutions of a single tubule, which if straightened would measure upward of twenty feet. These parts are lined by stratified ciliated cells and continue as the vas deferens.

The Tunics of the Testicle.—The testis is invested by two tunics—the **tunica vaginalis** and the **tunica albuginea**.

The **tunica vaginalis** (*tunica vaginalis propria testis*) (Figs. 1147 and 1150) is the serous covering of the testis and epididymis. It is a pouch of serous membrane, derived from the peritoneum (*processus vaginalis peritoneaei*) during the descent of the testis in the fetus from the abdomen into the scrotum. After its descent that portion of the pouch which extends from the internal ring to near the upper part of the gland, the *funicular process*, becomes obliterated, the lower portion remaining as a shut sac, which invests the outer surface of the testis, and is reflected to the internal surface of the scrotum; hence it may be described as consisting of a visceral and parietal portion.

The **visceral portion** (*lamina visceralis*) of the tunica vaginalis propria covers the outer surface of the testis, as well as the epididymis, connecting the latter to the testis by means of a distinct fold. From the posterior border of the gland it is reflected to the internal surface of the infundibuliform process of the transversalis fascia, and between the tunic and the fascia is a layer of unstriated muscle fibres, the **Internal cremaster muscle** (Fig. 1142).

The **parietal portion** (*lamina parietalis*) of the tunica vaginalis propria is the reflected portion. It is far more extensive than the visceral portion, extending upward for some distance in front and on the inner side of the cord, and reaching below the testis. The inner surface of the tunica vaginalis is free, smooth, and covered by a layer of endothelial cells. The interval between the visceral and parietal layers of this membrane constitutes the **cavity of the tunica vaginalis** and contains a small amount of serous fluid.

The obliterated portion of the pouch may generally be seen as a fibrocellular thread, the **ligament of Cloquet** (*rudimentum processus vaginalis*) (Fig. 1144), lying in the loose areolar tissue around the spermatic cord; sometimes this may be traced as a distinct band from the upper end of the inguinal canal, where it is

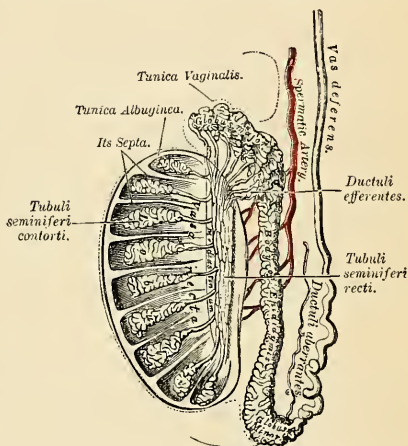


FIG. 1149.—Vertical section of the testis, to show the arrangement of the ducts.

connected with the peritoneum, down to the tunica vaginalis; sometimes it gradually becomes lost on the spermatic cord. Occasionally no trace of it can be detected. In some cases it happens that the pouch of peritoneum does not become obliterated, but the peritoneal cavity communicates with the tunica vaginalis. This may give rise to one of the varieties of oblique inguinal hernia or hydrocele; or in other cases the pouch may contract, but not become entirely obliterated; it then forms a minute canal leading from the peritoneum to the tunica vaginalis.

The **tunica albuginea** (Figs. 1148 and 1149) is the fibrous covering of the testis. It is a dense fibrous membrane, of a bluish-white color, composed of bundles of white fibrous tissue, which interlace in every direction. Its outer surface is covered by the tunica vaginalis, except at the points of attachment of the epididymis to the testis, and along its posterior border, where the spermatic vessels enter the gland. It consists of two portions, the **tunica fibrosa** and the **tunica vasculosa**; the former is the thicker of the two and contains few vessels, while the latter contains many small vessels. The tunica vasculosa sends septa into the organ which divide it into compartments. These septa converge and end at the mediastinum. This membrane surrounds the glandular structure of the testis, and at its posterior border forms a projection, triangular in shape and cellular in structure, which is reflected into the interior of the gland, forming an incomplete vertical septum, called the **mediastinum testis**.

The **mediastinum testis** (**corpus Highmori**) (Figs. 1148 and 1149) extends from the upper, nearly to the lower, extremity of the gland, and is wider above than below. From the front and sides of this septum numerous slender fibrous cords and imperfect septa—*septula testis* (Fig. 1149)—are given off, which radiate toward the surface of the organ, and are attached to the inner surface of the tunica albuginea. This scaffolding of connective tissue divides the **parenchyma** (*parenchyma testis*) of the organ into a number of incomplete spaces, which are somewhat cone-shaped, being broad at their bases at the surface of the gland, and becoming narrower as they converge to the mediastinum. The mediastinum supports the bloodvessels, lymphatics, and ducts of the testis in their passage to and from the substance of the gland, and contains numerous fine canals, into which open the very small tubules of the proper substance of the testis.

Structure of the Testis (Fig. 1149).—The glandular structure of the testis consists of numerous **lobules** (*lobuli testis*). Their number, in a single testis, is estimated to be about 200. They differ in size according to their position, those in the middle of the gland being larger and longer. The lobules are pyramidal in shape, the base of each being directed toward the circumference of the organ, the apex toward the mediastinum. Each lobule is contained in one of the intervals between the fibrous cords and vascular processes which extend between the mediastinum testis and the tunica albuginea, and consists of from one to three or more minute convoluted tubes $2\frac{1}{2}$ feet in length and 140 to 200 μ in diameter, the **tubuli seminiferi contorti**, which usually end blindly beneath the tunica albuginea. The contorted tubes unite at the apex of the lobules and form several **straight tubes** (*tubuli recti*), which pass into the mediastinum testis and form the network known as the **rete testis** (Fig. 1149). The **efferent ducts** (*ductuli efferentes testis*) (Fig. 1149), about twelve to fifteen in number, arise from the rete and continue into the globus major as the **coni vasculosi**. The total number of tubes is considered by Lauth to be about 840. The tubuli recti and rete testes are lined by simple squamous or cuboidal cells, while the vasa efferentia are lined by simple columnar cells which are either ciliated or non-ciliated. The convoluted tubules are pale in color in early life, but in old age they acquire a deep yellow tinge from containing much fatty matter. Each tube consists of a basement layer, formed of epithelial cells united edge to edge, outside of which are other layers of flattened cells arranged in interrupted laminae, which give to the tube an appearance of striation in cross-section. The cells of the outer layers gradually pass into the interstitial tissue. Within the basement membrane are epithelial cells arranged in several irregular layers, which are not always clearly separated, but which may be arranged in different groups that do not form clearly defined layers. The various groups cannot be seen in a single cross-section, but may be discerned in successive sections. Among these cells may be seen the **spermia** in different stages of development. (1) Lining the basement membrane and forming the outer zone is a layer of cubical cells, **spermatogonia**, containing small nuclei and pyramidal cells, the **columns of Sertoli**. The

nucleus of the former may be seen to be in the process of indirect division (*karyokinesis*), and in consequence of this daughter cells are formed, which constitute the second zone. (2) Within this first layer is to be seen a number of larger cells with clear nuclei, arranged in two or three strata; these are the **spermatocytes of the first order**, or **mother cells**. Most of the cells are in a condition of karyokinetic division, and the cells which result from this division form those of the next layer, the **spermatocytes of the second order**, or **daughter cells**. (3) The latter by division give rise to the **spermids**, which change into the **spermia** or **spermatozoa**. In addition to these three layers of cells, others are seen, which are termed the **supporting cells**, or **cells of Sertoli**. They are elongated and columnar, and project inward from the basement membrane toward the lumen of the tube. They give off numerous lateral branches, which form a reticulum for the support of the three groups of cells just described. As development of the spermia proceeds, the latter group themselves around the inner extremities of the supporting cells. The nuclear part of the spermid, which is partly embedded in the supporting cell, is differentiated to form the head of the spermium, while the cell protoplasm becomes lengthened out to form the middle piece and tail, the latter projecting into the lumen of the tube. Ultimately the heads are separated from the column of Sertoli and the spermia are set free.

The process of spermatogenesis bears a close relation to that of maturation of the ovum. The spermatocyte is equivalent to the immature ovum. It undergoes subdivision, and ultimately gives origin to four spermia, each of which contains, therefore, only one-fourth of the chromatin elements of the nucleus of the spermatocyte (see Ovum, p. 1400).

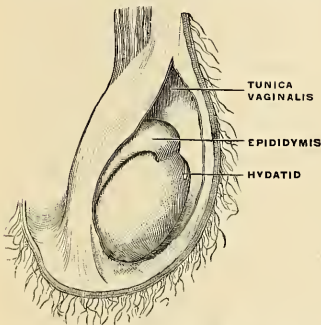


Fig. 1150.—Vaginal tunics of the right testicle. (Poirier and Charpy.)

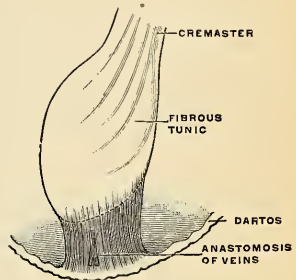


Fig. 1151.—Ligament of the scrotum or gubernaculum testis. (Poirier and Charpy.)

The tubules are enclosed in a delicate plexus of capillary vessels, and are held together by an intertubular connective tissue, which presents large interstitial spaces lined by endothelium, which are believed to be the rootlets of lymphatic vessels of the testis. In this interstitial tissue are groups of large granular cells, the **interstitial cells**. These contain pigment, fat, and crystalloids, and are more numerous before and after sexual activity.

The **aberrant ducts of the epididymis** (*ductuli aberrantes*) are tortuous and end in blind extremities. The **superior aberrant duct** (*ductus aberrans superior*) is in the globus major and joins the rete testis. The **inferior aberrant duct** (*ductus aberrans inferior*) (Fig. 1149) is in the tail of the epididymis, and takes origin from the duct of the epididymis or the seminal duct. It is a persistent canal of the Wolffian body. It extends up the cord for two or three inches and terminates by a blind extremity, which is occasionally bifurcated. It may be as much as fourteen inches in length when unravelled. Its structure is similar to that of the vas deferens.

The **descent of the testis** will be described on page 1424.

The Semen.—The semen is the viscid, whitish, or opalescent fluid, of alkaline reaction and characteristic odor, which is secreted by the testes, prostate, seminal vesicles, and Cowper's glands. It contains water and about 18 per cent. of solid matter, chiefly consisting of proteids, salts, and nitrogenous substances. The semen serves to convey and maintain the vitality of the spermia in their course along the seminal passages.

The **Spermatozoa**, or **Spermia**, are present in enormous numbers in the seminal fluid. Each consists of a **head**, **neck**, **body**, and **tail**.

The **head** is oval, but flattened so that when viewed in profile it is pear-shaped. Its anterior part is covered by a layer of modified tissue called the *head-cap* or *perforator*.

The **neck** and **body** together form a cylindric or rod-like segment, the neck containing the two centrosomes. From the posterior centrosome proceeds the *axial filament*, which in the body of the spermium is encircled by a *spiral thread*.

The **tail** is about four times the combined length of the head and body, and consists of the axial filament surrounded by a delicate sheath of protoplasm. The terminal portion of the tail is named the *end piece*, and consists of the axial filament only.

By virtue of their tails, which act as propellers, the spermia, in the fresh condition, are capable of free movement, and if placed in favorable surroundings (e. g., in the female passages) may retain their vitality for several days.

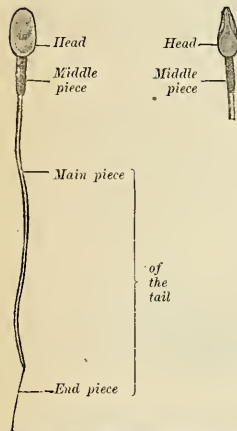


FIG. 1152.—Spermium of man. At the left a surface view is shown; at the right a lateral view. $\times 1200$. (Szymonowicz, after Retzius.)

Applied Anatomy.—The scrotum forms an admirable covering for the protection of the testicle. This body, lying suspended and loose in the cavity of the scrotum, and surrounded by a serous membrane, is capable of great mobility, and can therefore easily slip about within the scrotum, and thus avoid injuries from blows or squeezes. The skin of the scrotum is very elastic and capable of great distention, and on account of the looseness and amount of subcutaneous tissue, the scrotum becomes greatly enlarged in cases of *edema*, to which this part is especially liable on account of its dependent position. The scrotum is frequently the seat of *epithelioma*; this is no doubt due to the rugæ on its surface, which favor the lodgement of dirt, and this, causing irritation, is the exciting cause of the disease. Cancer was especially common in chimney-sweeps from the lodgement of soot. The scrotum is also the part most frequently affected by *elephantiasis*.

On account of the looseness of the subcutaneous tissue considerable *extravasations of blood* may take place from very slight injuries. It is therefore generally recommended never to apply leeches to the scrotum, since they may lead to considerable *ecchymosis*, but rather to puncture one or more of the superficial veins of the scrotum in cases where local bloodletting from this part is judged to be desirable. The muscle tissue in the dartos causes contraction and considerable diminution in the size of a *wound of the scrotum*, as after the operation of castration, and is of assistance in keeping the edges together and covering the exposed parts.

Abnormalities in the formation and in the descent of the testes may occur. The testis may fail to be developed, or it may be fully developed and the vas deferens may be undeveloped in whole or in part; or, again, both testes and vas deferens may be fully developed, but the duct may not become connected to the gland. The testis may fail in its descent (*cryptorchismus*) or it may descend into some abnormal position (*ectopia testis*). Thus, it may be retained in the position where it was primarily developed, below the kidney; or it may descend to the internal abdominal ring, but fail to pass through this opening; it may be retained in the inguinal canal, which is, perhaps, the most common position; or it may pass through the external abdominal ring and remain just outside it, failing to pass to the bottom of the scrotum. On the other hand, it may get into some abnormal position; it may pass the scrotum and reach the perineum, or it may fail to enter the inguinal canal, and may find its way through the femoral ring into the crural canal, and present itself on the thigh at the saphenous opening. Ectopia testis is due to the absence, overdevelopment, or malposition of some portion of the gubernaculum. There is still a third class of cases of abnormality in the position of the testis, where the organ has descended in due course into the scrotum, but is malplaced. The most common form of this is where the testis is *inverted*; that is to say, the organ is rotated, so that the epididymis is connected to the front of the scrotum, and the body, surrounded by the tunica vaginalis, is directed backward. In these cases the vas deferens is to be felt in the front of the cord. The condition is of importance in connection with hydrocele and hematocele, and the position of the testis should always be carefully ascertained before performing any operation for these affections. Again, more rarely, the testis may be *reversed*. This is a condition in which the top of the testis, indicated by the globus

major of the epididymis, is at the bottom of the scrotum, and the vas deferens comes off from the summit of the organ.

The testis may require removal for *malignant disease, tuberculous disease, cystic disease*, in cases of large *hernia testis*, and in some instances of *incompletely descended or misplaced testes*. The operation of *castration* is a comparatively simple one. An incision is made into the cavity of the tunica vaginalis from the external ring to the bottom of the scrotum. The coverings are shelled off the organ, and the mesorchium, stretching between the back of the testis and the scrotum, divided. The cord is then isolated, and an aneurism needle, armed with a double ligature, passed under it, as high as is thought necessary, and the cord tied in two places, and divided between the ligatures. Sometimes, in cases of malignant disease, it is desirable to open the inguinal canal and tie the cord as near the internal abdominal ring as possible.

A collection of serous fluid in the sac of the vaginal tunic of the testicle is known as an *ordinary or testicular hydrocele*. In *congenital hydrocele* a communication remains between the tunica vaginalis testis and the peritoneal cavity. This communication should have closed during development. In *infantile hydrocele* the tunica vaginalis and part of the funicular process are distended with fluid, but the funicular process is closed above and the cavity of the hydrocele does not communicate with the peritoneal cavity. In *encysted hydrocele of the cord* the funicular process is closed above and below, but between these points is not obliterated. In *funicular hydrocele* the funicular process is closed below and open above. Congenital hydrocele can usually be cured by the application of a truss. This obliterates the upper end of the funicular process, and the obliteration once begun may proceed to completion. If it does not, the condition has become an *infantile hydrocele*. An *infantile hydrocele* can usually be cured by multiple puncture or tapping. The same is true of *encysted hydrocele of the cord*. In *hydrocele of the funicular process* a truss should be worn for a time and the fluid then evacuated by tapping. In *ordinary testicular hydrocele* incise and pack, or incise and suture the cut edge of the parietal layer of the tunic to the skin, or extirpate the parietal layer of the tunic. A successful method is that of Longuet. He makes an incision, pulls out the testis, and allows all the coats except the skin to fall behind and make a sheath for the cord. These coats are held behind by one catgut suture. A bed is made for the testis beneath the skin toward the septum of the scrotum. The testicle is rotated on its long axis, and placed in the bed, and the skin is sutured above it. This operation is known as *extraserous transposition*. If a portion of bowel enters an open vaginal process the condition is *congenital hernia*.

In *infantile hernia* the funicular process is closed above but not below, and the hernia descends in a special sac back of the vaginal tunic. If the hernia pushes down on the vaginal process and causes it to double on itself the condition is *encysted infantile hernia*.

THE VAS DEFERENS (DUCTUS DEFERENS) (Figs. 1145, 1153).

The **vas deferens**, or **seminal duct**, the excretory duct of the testis, is the continuation of the epididymis. Commencing at the lower part of the globus minor, it ascends along the posterior border of the testis and inner side of the epididymis, and along the back part of the spermatic cord, through the inguinal canal to the internal or deep abdominal ring. From the ring it curves around the outer side of the deep epigastric artery, and ascends for about an inch in front of the external iliac artery. It is next directed backward and slightly downward, and, crossing the external iliac vessels obliquely, enters the pelvic cavity, where it lies between the peritoneal membrane and the lateral wall of the pelvis, and passes on the inner side of the impervious hypogastric artery and the obturator nerve and vessels. It then crosses in front of the ureter, and, reaching the inner side of this tube, bends at an acute angle, and runs inward and slightly forward between the base of the bladder and the upper end of the seminal vesicle. Reaching the inner side of the seminal vesicle, it is directed downward and inward in contact with this structure and gradually approaches the vas of the opposite side. Here the vas deferens lies between the base of the bladder and the rectum, where it is enclosed, together with the seminal vesicle, in a sheath derived from the rectovesical fascia.

At the base of the bladder it becomes enlarged and sacculated, forming the **ampulla** (*ampulla ductus deferentis*) (Fig. 1153), and then, becoming narrowed at the base of the prostate, it is joined by the duct of the seminal vesicle to form

the ejaculatory duct (Fig. 1154). The vas deferens offers a hard and cord-like sensation to the fingers; it is about two feet in length if unravelled, of cylindrical form, and about 3 mm. in diameter. Its walls are dense, measuring 0.7 mm., and its canal is extremely small, measuring about 0.5 mm.

Structure.—The vas deferens consists of three coats: (1) An **external** or **areolar coat** (*tunica adventitia*). (2) A **muscular coat** (*tunica muscularis*), which in the greater part of the tube consists of three layers of unstriated muscle tissue, an **inner** layer of thin longitudinal fibres (*stratum internum*), a thick **middle** layer of circular fibres (*stratum medium*), and a thick **external** layer of longitudinal fibres (*stratum externum*). (3) An **internal** or **mucous coat** (*tunica mucosa*), which is pale, and arranged in longitudinal folds; its epithelial cells are chiefly of the stratified columnar variety of which the superficial layer is ciliated.

Organ of Giralde's (*paradidymis*).—This term is applied to a small body of rounded shape in the lower end of the spermatic cord, in front of the bloodvessels. It consists of a small collection of minute vesicles and a small collection of convoluted tubules. These tubes are lined with columnar ciliated epithelium, and probably represent the remains of a part of the Wolffian body.

THE SEMINAL VESICLES (VESICULAE SEMINALES) (Figs. 1152, 1153).

The **seminal vesicles** are two convoluted membranous pouches placed between the base of the bladder and the rectum, serving as reservoirs for the spermia, and secreting a fluid to be added to the secretion of the testes. Each sac is some-

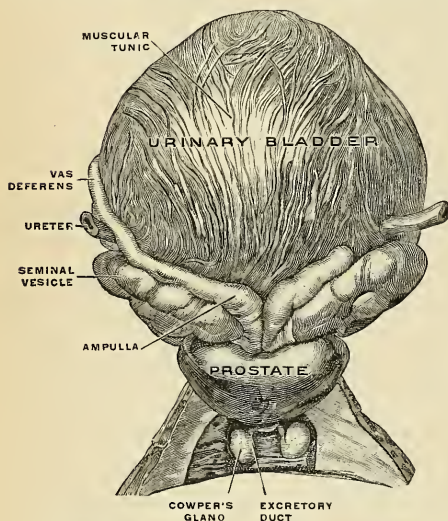


FIG. 1153.—The urinary bladder, distended, with surrounding structures, viewed from behind. (Spalteholz.)

what pyramidal in form, the broad end being directed backward and the narrow end forward toward the prostate. It measures about two and a half inches (6.25 cm.) in length, about 10 mm. in breadth, and 4 to 6 mm. in thickness. They vary, however, in size, not only in different individuals, but also in the same individual on the two sides. The **anterior surface** is in contact with the base of the bladder, extending from near the termination of the ureters to the base of the prostate gland. The **posterior surface** rests upon the rectum, from which it is separated by the rectovesical fascia. Their **upper extremities** diverge from each other. Their **lower extremities** are pointed, and converge toward the base

of the prostate gland, where each joins with the corresponding vas deferens to form the ejaculatory duct. Along the inner margin of each vesicle runs the ampulla of the vas deferens. The inner border of the vesicle and the correspond-

ing vas deferens form the lateral boundaries of a triangular space, limited behind by the rectovesical peritoneal fold; the portion of the bladder included in this space rests on the rectum.

Each vesicle consists of a single tube, coiled upon itself and giving off several irregular cecal diverticula (Fig. 1154), the separate coils, as well as the diverticula, being connected by fibrous tissue. When uncoiled this tube is about the diameter of a quill, and varies in length from four to six inches (10 to 15 cm.); it terminates above in a *cul-de-sac*; its lower extremity becomes constricted into a narrow straight duct, the **excretory duct** (*ductus excretorius*) (Fig. 1154), which joins with the corresponding vas deferens to form the ejaculatory duct.

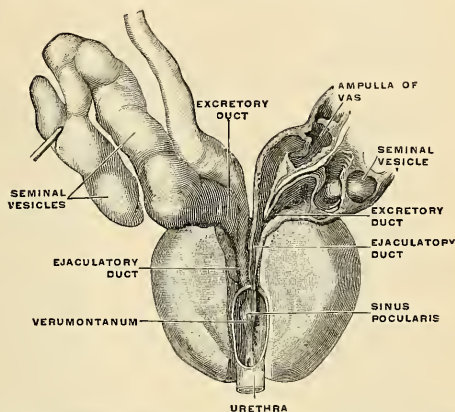


FIG. 1154.—The ejaculatory ducts viewed from in front and above. (Spalteholz.)

Structure.—The seminal vesicles are composed of three coats—an **external** or **fibrous** (*tunica adventitia*); a **middle** or **muscular coat** (*tunica muscularis*), which is thinner than in the seminal duct, and is arranged in two layers, an *outer*, longitudinal, and an *inner*, circular; an **internal** or **mucous coat** (*tunica mucosa*), which is usually thrown into waves or folds, and which is pale, of a whitish-brown color, and of a delicate reticular structure, like that seen in the gall-bladder. The epithelium is of the columnar variety, and, in the diverticula, goblet cells are present, the secretion of which increases the bulk of the seminal fluid.

Vessels and Nerves.—The arteries supplying the seminal vesicles are derived from the **middle** and **inferior vesical** and **middle hemorrhoidal**. The **veins** and **lymphatics** accompany the arteries. The lymphatics anastomose on the surface of the vesicle. The trunks from this network anastomose with the lymphatics of the bladder and prostate, and pass to the **external** and **internal iliac nodes**. The **nerves** are derived from the **pelvic plexus**.

Applied Anatomy.—The seminal vesicles are often the seat of an extension of the disease in cases of *tuberculosis* of the testis, and should always be examined through the rectum before coming to a decision with regard to castration in this affection. The vesicles have been deliberately *extirpated* for local tuberculosis. In gonorrhea the seminal vesicles may become acutely inflamed (*acute seminal vesiculitis*). *Chronic seminal vesiculitis* may follow the acute form or may arise insidiously during gonorrhea.

THE EJACULATORY DUCTS (DUCTUS EJACULATORII) (Fig. 1154).

The **ejaculatory ducts** are two in number, one on each side. Each duct is formed by the junction of the duct of the seminal vesicle with the vas deferens. Each duct is about three-quarters of an inch (2 cm.) in length; it commences at the base of the prostate, and runs forward and downward between the middle and lateral

lobes of that gland, and along the side of the sinus pocularis, to terminate by a separate slit-like orifice close to the margins of the sinus. The ducts diminish in size and also converge toward their terminations.

Structure.—The coats of the ejaculatory ducts are extremely thin. They are an **outer fibrous layer**, which is almost entirely lost after the entrance of the duct into the prostate; a **layer of muscle fibres**, consisting of an *outer* thin circular and an *inner* longitudinal layer; and the **mucous membrane**, lined by simple columnar epithelial cells.

THE PENIS (Figs. 1155, 1156).

The **penis** is a pendulous organ suspended from the front and sides of the pubic arch and containing the greater part of the urethra. In the flaccid condition it is cylindrical in shape, but when erect assumes the form of a triangular prism with rounded sides, one side of the prism forming the dorsum. It is composed of three cylindrical masses of erectile tissue bound together by fibrous tissue and covered with skin. Two of the masses are lateral, and are known as the **corpora cavernosa**; the third is median, and is termed the **corpus spongiosum** (Figs. 1155 and 1163).

The **two corpora cavernosa** (*corpora cavernosa penis*) (Figs. 1155 and 1156) form the greater part of the body of the penis. They consist of two fibrous cylindrical tubes, placed side by side, and intimately connected along the median line for their anterior three-fourths, while at their back part they separate from each other to form the **crura penis**, which are two strong tapering fibrous processes or **roots** firmly connected to the rami of the os pubis and ischium (Figs. 1155 and 1156). Each **crus** commences by a blunt-pointed process in front of the tuberosity of the ischium, and before its junction with its fellow to form the body of the penis it presents a slight enlargement, named by Kobelt the **bulb of the corpus cavernosum**. Just beyond this point they become constricted, and retain an equal diameter to their anterior extremity, where they form a single rounded end (*digital process*) which is received into a fossa in the base of the glans penis (Fig. 1155). A median groove on the upper surface lodges the dorsal arteries, nerves, and veins of the penis (Figs. 1161 and 1163), and the groove on the under surface receives the corpus spongiosum (Fig. 1155).

The corpora cavernosa are surrounded by a strong fibrous envelope (*tunica albuginea*) consisting of superficial and deep fibres. The *superficial* fibres are longitudinal in direction, being common to the two corpora cavernosa, and investing them in a common covering; the other, *deep*, circular in direction, and being proper to each corpus cavernosum. The internal circular fibres of the two corpora cavernosa form, by their junction in the mesal plane, an incomplete partition or septum (*septum penis*) between the two bodies. This is thick and complete behind, but in front it is incomplete, and consists of a number of vertical bands, which are arranged like the teeth of a comb. It is therefore named the **septum pectiniforme**. These bands extend between the dorsal and the urethral surface of the corpora cavernosa. The fibrous investment of the corpora cavernosa is extremely dense, of considerable thickness, and consists of bundles of shining white fibres, with an admixture of well-developed elastic fibres, so that it is possessed of great elasticity.

The **corpus spongiosum** (*corpus cavernosum urethrae*) (Figs. 1155 and 1156) contains the urethra, and is situated in the groove on the under surface of the corpora cavernosa penis. Behind, it is expanded to form the **urethral bulb** (*bulbus urethrae*) and lies in apposition with the superficial layer of the triangular ligament, from which it receives a fibrous investment. The urethra enters the bulb nearer to the upper than to the lower surface. On the latter there is a depressed

median **raphé** (*sulcus bulbi*), from which a thin fibrous septum projects into the substance of the bulb and divides it imperfectly into two lateral lobes or **hemispheres** (*hemisphaeria bulbi urethrae*).

The portion of the corpus spongiosum in front of the bulb lies in a groove on the under surface of the conjoined corpora cavernosa. It is cylindrical in form and tapers slightly from behind forward. Its anterior extremity is expanded in the form of an obtuse cone, flattened from above downward. This expansion, termed

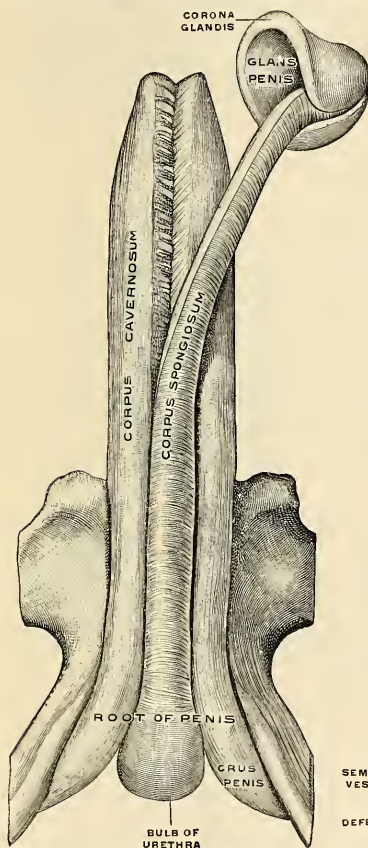


FIG. 1155.—The penis, with the pubic bones, seen from before and below. (Toldt.)

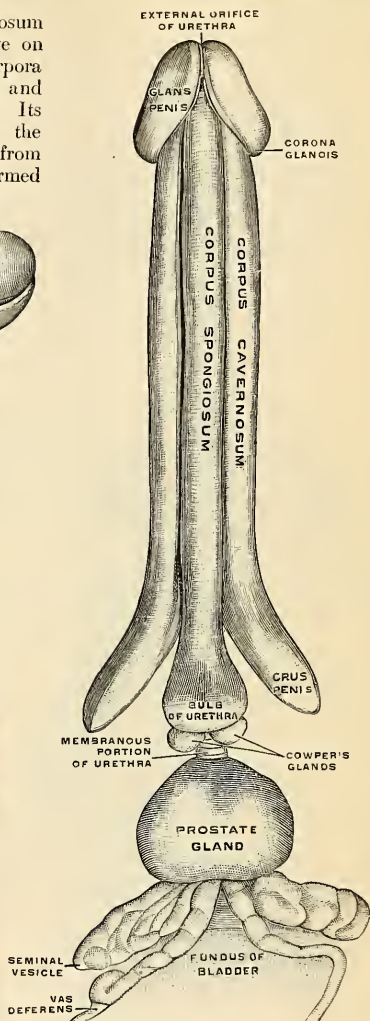


FIG. 1156.—The penis, with the urethra, Cowper's glands, the prostate gland, and the seminal vesicles seen from below and behind. (Toldt.)

the **glans penis**, is moulded on the rounded ends of the corpora cavernosa, extending farther on their upper than on their lower surfaces. At the summit of the glans

is the vertical, slit-like urethral orifice or **meatus**. The circumference of the base of the glans forms a rounded projecting border, the **corona glandis**, overhanging a deep sulcus (*sulcus retroglandularis*), behind which is the **neck** of the penis (*collum penis*).

For descriptive purposes it is convenient to divide the penis into three parts—the root, the body, and the extremity.

The **root** (*radix penis*) of the penis is triradiate in form, consisting of the diverging crura, one on either side, and the mesal bulb of the corpus spongiosum. Each crus is covered by the Erector penis muscle, while the bulb is surrounded by the Accelerator urinae muscle. The root of the penis lies in the perineum between the superficial layer of the triangular ligament and the fascia of Colles. In addition to being attached to the pubic rami and to the triangular ligament, the root is bound to the front of the symphysis pubis by the **suspensory ligament** (*lig. suspensorium penis*). The upper fibres of this ligament pass downward from the lower end of the linea alba, and the lower fibres from the symphysis pubis; together they form a strong, fibrous band which extends to the upper surface of the root, where it splits into two fasciculi and blends with the fascial sheath of the organ.

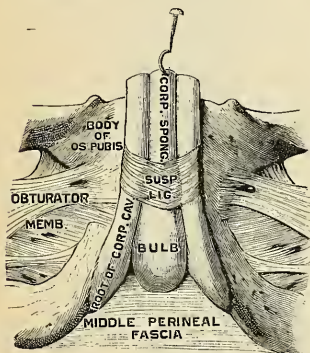


FIG. 1157.—The penis, proximal portion, seen from below. (Testut.)

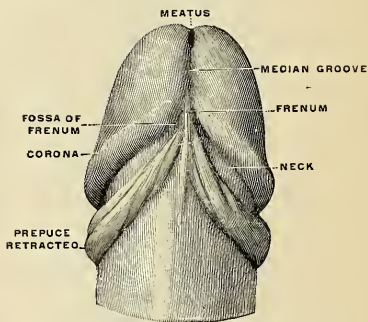


FIG. 1158.—Glans penis, under surface. (Testut.)

The **body of the penis** (*corpus penis*) extends from the root to the ends of the corpora cavernosa between the root and extremity. In the flaccid condition of the organ it is cylindrical, but when erect it has a triangular prismatic form with rounded angles, the broadest side being turned upward, and called the **dorsum penis**. The lower surface of the body of the penis is called the **urethral surface** (*facies urethralis*). The body is covered by integument, and contains in its interior a large portion of the urethra.

The **extremity** is formed by the glans penis, the expanded anterior (distal) end of the corpus spongiosum. It is separated from the body by the constricted neck, which is surmounted by the corona glandis.

The integument covering the penis is remarkable for its thinness, its dark color, its looseness of connection with the deeper parts of the organ, and for the absence of adipose tissue. At the root of the penis the integument is continuous with that upon the pubes, scrotum, and perineum. At the neck of the glans it leaves the surface and becomes folded upon itself to form the **prepuce** (*præputium*) (Fig. 1161). The internal layer of the prepuce is directly continuous, along the line of the neck, with the integument over the glans. Immediately behind the

urinary meatus it forms a small, secondary reduplication, attached along the bottom of a depressed median raphé, which extends from the meatus to the neck; this fold is termed the **frenulum** (*frenulum praeputii*). The integument covering the glans is continuous with the urethral mucous membrane at the meatus; it is devoid of hairs, but projecting from its free surface are a number of small,

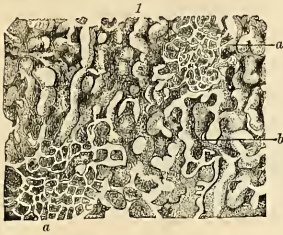

FIG. 1159.—a. Capillary network.
b. Cavernous spaces.

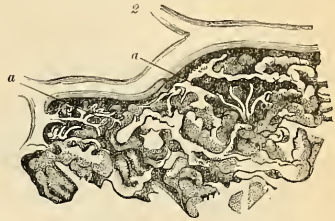


FIG. 1160.—Connection of the arterial twigs (a) with the cavernous spaces.

FIGS. 1159 AND 1160.—From the peripheral portion of the corpus cavernosum penis under a low magnifying power. (Copied from Langer.)

highly sensitive papillæ. In the retroglandular sulcus numerous small glands, the **glandulæ Tysonii odoriferae** (*glandulæ praeputii*) have been described. They secrete a sebaceous material of very peculiar odor, called *smegma praeputii*, which probably contains casein, and readily undergoes decomposition.

The prepuce covers a variable amount of the glans and is separated from it by a potential sac—the *preputial sac*—which presents two shallow recesses (*fossæ frenuli*), one on either side of the frenulum.

Structure.—From the internal surface of the fibrous envelope of the corpora cavernosa, as well as from the sides of the septum, are given off a number of bands or cords which cross the interior of each crus in all directions, subdividing it into a number of separate compartments, and giving the entire structure a spongy appearance. These bands and cords are called **trabeculae corporum cavernosum**, and consist of white fibrous tissue, elastic fibres, and smooth muscle tissue. In them are continued numerous arteries and nerves.

The component fibres of which the trabeculae are composed are larger and stronger around the circumference than at the centre of the corpora cavernosa; they are also thicker behind than in front. The interspaces, on the contrary, are larger at the centre than at the circumference their long diameter being directed transversely; they are largest anteriorly. They are called **cavernous spaces** and are occupied by blood during erection, and are lined by a layer of flattened endothelial cells (Fig. 1159).

The arteries bringing the blood to these spaces are the **arteries of the corpora cavernosa** and branches from the **dorsal artery of the penis**, which perforate the fibrous capsule, along the upper surface, especially near the fore part of the organ.

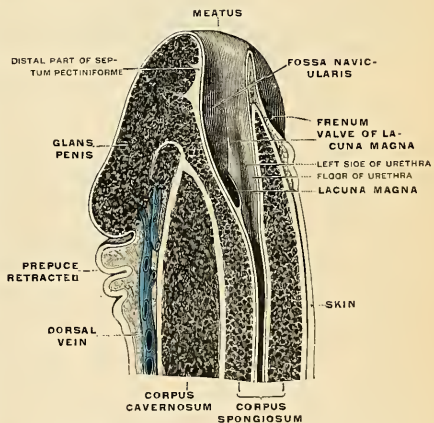


FIG. 1161.—The penis, distal end, in sagittal section 2 mm. at left of middle line. (Testut.)

On entering the cavernous structure the arteries divide into branches which are supported and enclosed by the trabeculae. Some of these terminate in a capillary network, the branches of which open directly into the cavernous spaces (Fig. 1160); others assume a tendril-like appearance, and form convoluted and somewhat dilated vessels, which were named by Müller *helicine arteries* (*arteriae helicinae*). They project into the spaces, and from them are given off small capillary branches to supply the trabecular structure. They are bound down in the spaces by fine fibrous processes, and are more abundant in the back part of the corpora cavernosa.

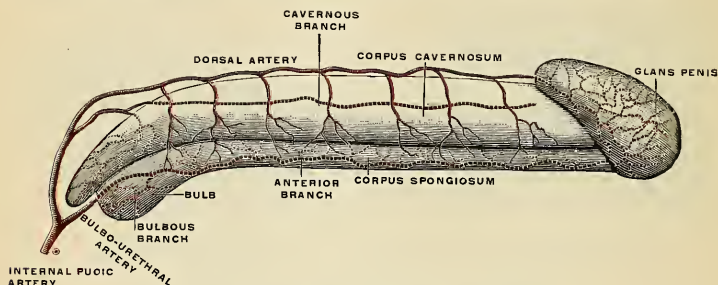


FIG. 1162.—Diagram of the arteries of the penis. (Testut.)

The blood from the cavernous spaces is returned by a series of vessels, some of which emerge in considerable numbers from the base of the glans penis and converge on the dorsum of the organ to form the **deep dorsal vein**; others pass out on the upper surface of the corpora cavernosa and join the dorsal vein; some emerge from the under surface of the corpora cavernosa, and, receiving branches from the corpus spongiosum, wind around the sides of the penis to terminate in the dorsal vein; but the greater number pass out at the root of the penis and join the **prostatic plexus**.

The fibrous envelope of the corpus spongiosum is thinner, whiter in color, and more elastic than that of the corpora cavernosa. The trabeculae are more delicate, more nearly uniform in size, and the meshes between them smaller than in the corpora cavernosa, their long diameter, for the most part, corresponding with that of the penis. The external envelope or outer coat of the corpus spongiosum is formed partly of unstripped muscle tissue, and a layer of the same tissue immediately surrounds the canal of the urethra. The corpus spongiosum receives its blood through the bulbourethral branch of the internal pudic artery.

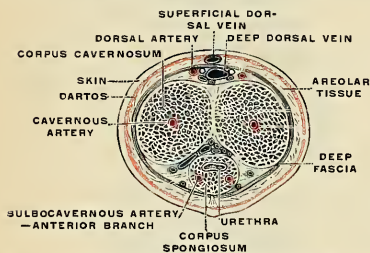


FIG. 1163.—The penis in transverse section, showing the bloodvessels. (Testut.)

the cutaneous nerves have Pacinian bodies connected with them, and, according to Krause, many of them terminate in peculiar end-bulbs (see p. 817).

Applied Anatomy.—It is occasionally necessary to remove a penis for malignant disease. Usually, removal of the antescrotal portion is all that is necessary, but sometimes it is requisite to remove the whole organ from its attachment to the rami of the ossa pubis and ischia. The former operation is performed either by cutting off the whole of the anterior part of the penis with one sweep of the knife, or, what is better, cutting through the corpora cavernosa from the dorsum, and then separating the corpus spongiosum from them, dividing it at a level nearer the glans penis. The mucous membrane of the urethra is then slit up, and the edges of the flap attached to the external skin, in order to prevent contraction of the orifice, which would other-

The **lymphatics** of the skin of the penis terminate in the inguinal nodes. The lymphatics of the *penile* portion of the urethra accompany those of the glans penis and terminate with them in the deep inguinal and external iliac nodes. Those of the *membranous* and *prostatic* portions pass to the internal iliac nodes.

The **nerves** are derived from the internal pudic nerve and the pelvic plexus. On the glans and bulb some filaments of

wise take place. The vessels which require ligation are the two dorsal arteries of the penis, the arteries of the corpora cavernosa, and the artery of the septum. When the entire organ requires removal the patient is placed in the lithotomy position, and an incision is made through the skin and subcutaneous tissue around the root of the penis, and carried down the median line of the scrotum as far as the perineum. The two halves of the scrotum are then separated from each other, and a catheter having been introduced into the bladder as a guide, the spongy portion of the urethra below the triangular ligament is separated from the corpora cavernosa and divided, the catheter having been withdrawn just behind the bulb. The suspensory ligament is now severed, and the crura separated from the bone with a periosteum scraper, and the whole penis removed. The membranous portion of the urethra, which has not been removed, is now to be attached to the skin at the posterior extremity of the incision in the perineum. The remainder of the wound is to be brought together, free drainage being provided for.

THE PROSTATE GLAND (PROSTATA) (Figs. 1153, 1156, 1166).

The prostate gland is a structure accessory to the true generative organs and secretes a viscid, opalescent secretion in which spermia will live and which furnishes a medium in which they maintain the motile activity necessary to carry them to their destination. It is a pale, firm, partly glandular and partly muscular body, which is placed immediately below the neck of the bladder and about the commencement of the urethra.

It is situated in the pelvic cavity below the lower part of the symphysis pubis, above the deep layer of the triangular ligament, and in front of the rectum, through which it may be distinctly felt, especially when enlarged. It is about the size of a horse chestnut and somewhat conical in shape, and presents for examination a base, an apex, an anterior, a posterior, and two lateral surfaces.

The **base** (*basis prostatae*) is directed upward, and is applied to the under surface of the bladder. The greater part of this surface is directly continuous with the bladder wall; the urethra penetrates it nearer to its anterior than to its posterior border.

The **apex** (*apex prostatae*) is directed downward and rests upon the deep layer of the triangular ligament. The apex is fixed, except for the slight mobility of the triangular ligament; the rest of the gland is somewhat movable.

Surfaces.—The **posterior surface** (*facies posterior*) is flattened from side to side and convex from above downward; it rests upon the rectum, and is distant about an inch and a half from the anus. Near its upper border there is a depression through which the two common ejaculatory ducts enter the prostate. This depression serves to divide the posterior surface into a lower larger and upper smaller part. The upper smaller part constitutes the so-called "**middle lobe**" of the prostate and intervenes between the ejaculatory ducts and the urethra; it varies greatly

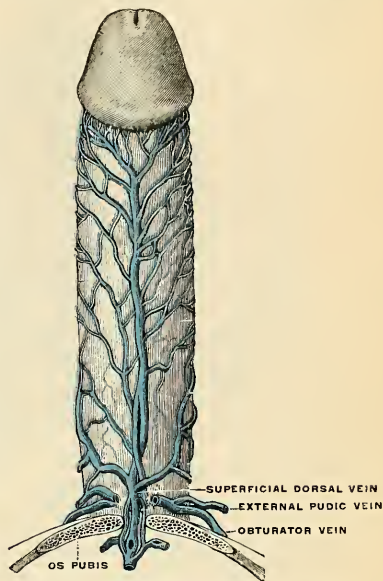


FIG. 1164.—Veins of the penis. (Testut.)

in size and in some subjects is destitute of glandular tissue. The lower larger portion sometimes presents a shallow median furrow which imperfectly separates it into a *right* and a *left lateral lobe*; these form the main mass of the gland and are

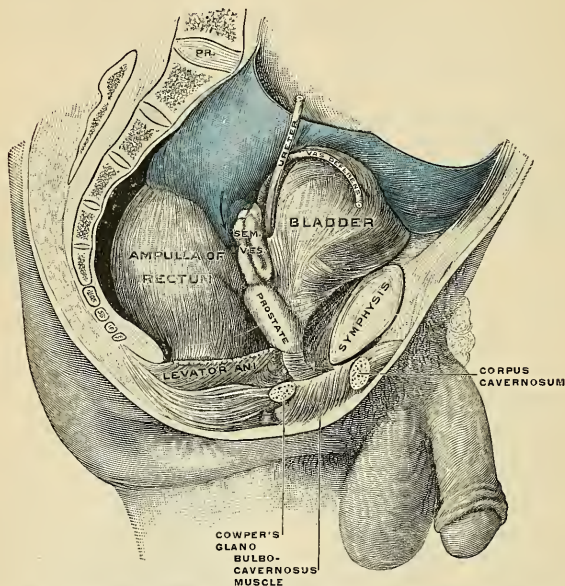


FIG. 1165.—Male pelvic organs seen from right side. Bladder and rectum distended; relations of peritoneum to the bladder and rectum shown in blue. The arrow points to the rectovesical pouch. (Corning.)

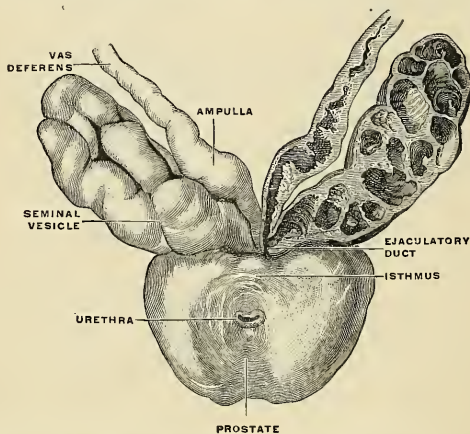


FIG. 1166.—Prostate with seminal vesicles and seminal ducts, viewed from in front and above. (Spalteholz.)

directly continuous with each other behind the urethra. In front of the urethra they are connected by a band which is named the **anterior commissure**; this consists of the same tissues as the capsule and is devoid of glandular substance.

The **anterior surface** (*facies anterior*) measures about one inch (2.5 cm.) from above downward, but is narrow and convex from side to side. It is placed about three-fourths of an inch behind the pubic symphysis, from which it is separated by a plexus of veins and a quantity of loose fat. It is connected to the pubic bone on either side by the **puboprostatic ligaments**. The urethra emerges from this surface a little above and in front of the apex of the gland.

The **lateral surfaces** are prominent, and are covered by the anterior portions of the Levatores ani muscles, which are, however, separated from the gland by a plexus of veins.

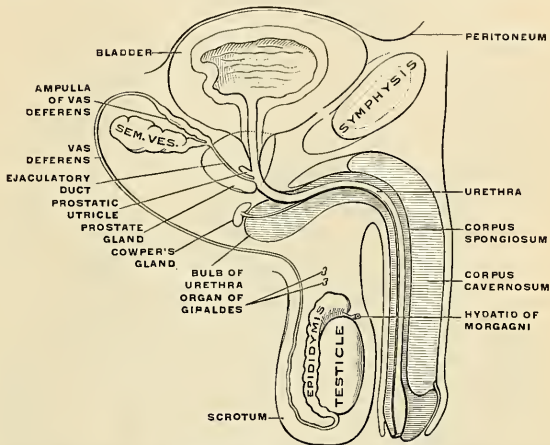


FIG. 1167.—Diagrammatic representation of the male organs of reproduction and their relations to the bladder and the urethra. Lateral view. (Toldt.)

The prostate measures about an inch and a half (3.75 cm.) transversely at the base, three-quarters of an inch (1.8 cm.) in its antero-posterior diameter, and an inch and a quarter (3 cm.) in its vertical diameter. Its weight is about four and a half drams (18 grams). It is held in position by the **anterior ligaments of the bladder** (*ligamenta puboprostatica*); by the deep layer of the triangular ligament, which invests the commencement of the membranous portion of the urethra and prostate gland; and by the anterior portions of the Levatores ani muscles, which pass backward from the os pubis and embrace the sides of the prostate. These portions of the Levatores ani, from the support they afford to the prostate, are named the **Levatores prostatae**.

The prostate gland is perforated by the urethra and the ejaculatory ducts. The urethra usually lies along the junction of its anterior with its middle third. The ejaculatory ducts pass obliquely downward and forward through the posterior part of the prostate, and open into the prostatic portion of the urethra.

Structure.—The prostate is immediately enveloped by a thin but firm musculo-fibrous **capsule**, distinct from the *prostatic fascia* derived from the rectovesical fascia, and separated from it by a plexus of veins. The capsule is firmly adherent to the prostate and is structurally continuous with the stroma of the gland, being composed of the same tissues—viz., smooth muscle and fibrous tissue. The prostatic fascia, distinct and dense, does not cover the apex and at the

attachment of the base to the under surface of the bladder. The substance of the prostate is of a pale, reddish-gray color, of great density, and not easily torn. It consists of glandular substance and muscle tissue.

The **muscle tissue**, according to Kölliker, constitutes the proper stroma of the prostate, the connective tissue being very scanty, and simply forming thin trabeculae between the muscle fibres, in which the vessels and nerves of the gland ramify. The muscle tissue is arranged as follows: Immediately beneath the fibrous capsule is a dense layer, which forms an investing sheath for the gland; secondly, around the urethra, as it lies in the prostate, is another dense layer of circular fibres, continuous *above* with the internal layer of the muscle coat of the bladder, and *below* blending with the fibres surrounding the membranous portion of the urethra. Between these

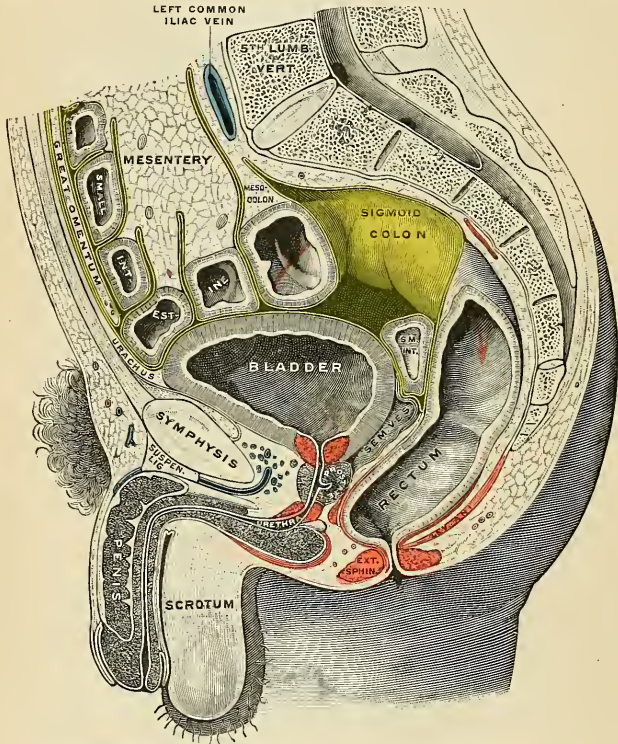


FIG. 1168.—Sagittal section of the lower part of a male trunk, the right segment. (Testut.)

two layers strong bands of muscle tissue, which decussate freely, form meshes in which the glandular structure of the organ is embedded. In that part of the gland which is situated in *front* of the urethra the muscle tissue is especially dense, and there is here little or no gland tissue; while in that part which is *behind* the urethra the muscle tissue presents a wide-meshed structure, which is densest at the base of the gland—that is, near the bladder—and becomes looser and more sponge-like toward the apex of the organ.

The **glandular substance** is composed of lobules containing numerous branched tubular glands opening into elongated canals, which join to form from twelve to twenty small excretory ducts. The glands are held together by areolar tissue, supported by prolongations from the fibrous capsule and muscle stroma, and enclosed in a delicate capillary plexus. The epithelium which lines the canals and the terminal tubules is of the columnar variety. The prostatic ducts

open into the floor of the prostatic portion of the urethra, and are lined by two layers of epithelium, the inner layer consisting of columnar and the outer of small cubical cells.

Vessels and Nerves.—The arteries supplying the prostate are derived from the **internal pudic, inferior vesical, and middle hemorrhoidal**. Branches of the vessels enter the gland in the septa between the lobules and send off minute branches to the lobules (Walker). The veins form a plexus around the sides and base of the gland between the layers of the fascial sheath; they receive in front the **dorsal vein of the penis**, and terminate in the **internal iliac vein**. The lymphatics of the prostate are described on page 796. The nerves are derived from the pelvic plexus.

Applied Anatomy.—The relation of the prostate to the rectum should be noted; by means of the finger introduced into the rectum the surgeon detects enlargement or other disease of the prostate; he can feel the apex of the gland, which is the guide to *Cock's operation* for stricture; he is enabled also by the same means to direct the point of a catheter when its introduction is attended with difficulty either from injury or disease of the membranous or prostatic portions of the urethra. When the finger is introduced into the bowel the surgeon may, in some cases, especially in boys, learn the position, as well as the size and weight, of a calculus in the bladder. In the operation for the removal of a calculus, if, as is not infrequently the case, the stone should be lodged behind an enlarged prostate, it may be displaced from its position by pressing upward the base of the bladder from the rectum. The prostate gland is occasionally the seat of *suppuration*,

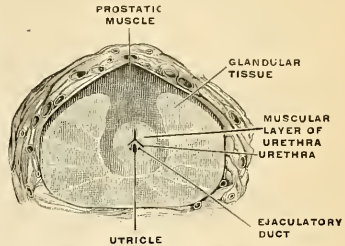


FIG. 1169.—Section of the prostate. (Jarjavay.)

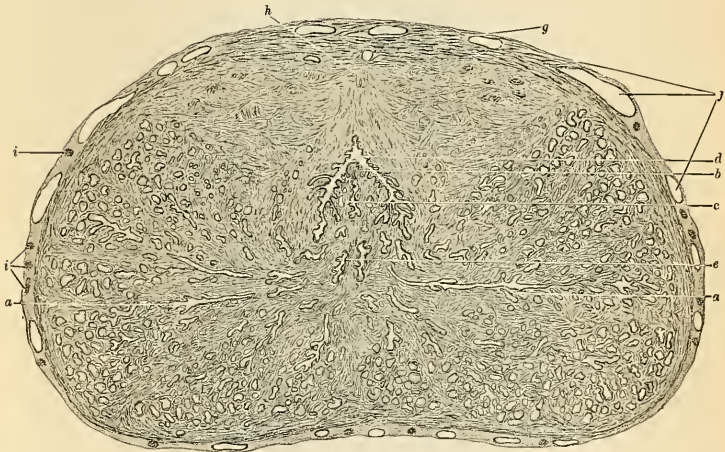


FIG. 1170.—Transverse section of normal prostate through the middle of the verumontanum, from a subject aged nineteen years: *a*. Longitudinal section of ducts leading from the lobules of the prostatic glands. *b*. Verumontanum. *c*. Sinus peculiaris. *d*. Urethra. *e*. Ejaculatory ducts. *f*. Arteries, veins, and venous sinuses in sheath of prostate. *g*. Nerve trunks in sheath. *h*. Point of origin of fibromuscular bands encircling urethra. *i*. Zone of striated voluntary muscle on superior surface. (Drawn with Edinger projection apparatus.) (Taylor.)

either due to injury, gonorrhea, or tuberculous disease. The gland is enveloped in a dense unyielding capsule, which determines the course of an abscess, and also explains the great pain which is present in acute inflammation. The abscess most frequently bursts into the urethra, the direction in which there is least resistance, but may occasionally burst into the rectum, or more rarely in the perineum. In advanced life the prostate often becomes considerably *enlarged*, and may project into the bladder so as to impede the passage of the urine. According to Dr. Messer's

researches, conducted at Greenwich Hospital, it would seem that such obstruction exists in 20 per cent. of all men over sixty years of age. The prostate may be enlarged by the growth of *innocent tumors*, adenomata, fibromata, myomata, and myofibromata. The entire gland may be *hypertrophied*. A tumor may be encapsulated, but often is surrounded by an area of hyperplasia of prostatic tissues, and usually the area of hyperplasia is much more extensive than the tumor. A tumor may be beneath the mucous membrane, deep in the gland, or beneath the sheath. The growth called the *third lobe* is submucous. In some cases the enlargement affects principally the lateral lobes, which may undergo considerable enlargement without causing much inconvenience. In other cases it would seem that the nodule forms the so-called middle lobe, and even a small enlargement of this character may act injuriously, by forming a sort of valve over the urethral orifice, preventing the passage of the urine, and the more the patient strains, the more completely will it block the opening into the urethra. In consequence of the enlargement of the prostate a *pouch* is formed at the base of the bladder behind the projection, in which urine collects and cannot be entirely expelled. The urine becomes decomposed and ammoniacal, and leads to cystitis. If the prostate enlarges the urethra is lengthened, often dilated, altered in shape, or distorted.

The relation of the enlarged prostate to the neck of the bladder is greatly altered from the relation of the normal prostate. Normally, it is extravescical; when enlarged it may encapsule "the neck of the bladder in a cuff-like manner, extending several inches upward on its wall," and often it protrudes "into the vesical cavity, carrying on its surface the mucosa vesicae." In many cases of prostatic enlargement the gland should be removed (*prostatectomy*). One method is enucleation through a suprapubic incision; another method is enucleation through a perineal incision; another method is carried out by both incisions (the combined method).

In elderly individuals the gland tubules may form round, indurated, and sometimes calcified masses, about 1 mm. in diameter, and called *prostatic stones*.

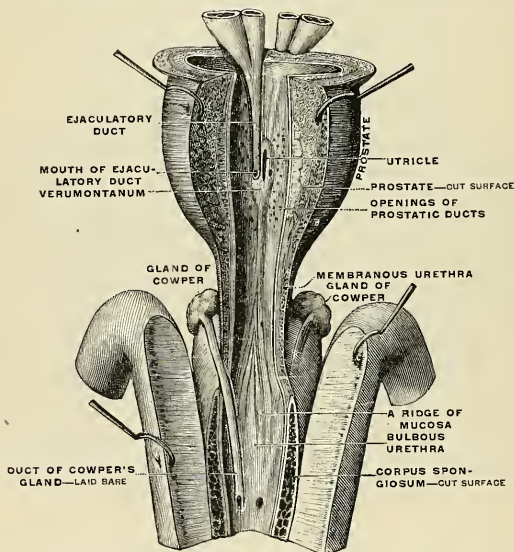


FIG. 1171.—Proximal portion of the urethra, laid open by a median, anterior cut. (Testut.)

COWPER'S GLANDS (GLANDULAE BULBOURETHRALES) (Fig. 1171).

Cowper's glands are two small, rounded, and somewhat lobulated bodies of a yellow color, about the size of peas, placed behind the fore part of the membranous portion of the urethra, between the two layers of the triangular ligament.

They lie close above the bulb, and are enclosed by the transverse fibres of the Compressor urethræ muscle. Their existence is said to be constant; they gradually diminish in size as age advances.

The **excretory duct** of each gland, nearly an inch in length, passes obliquely forward beneath the mucous membrane, and opens by a minute orifice on the floor of the bulbous portion of the urethra.

Structure.—Each gland consists of several lobules held together by a fibrous investment. Each lobule consists of a number of acini lined by columnar epithelial cells, opening into one duct, which, joining with the ducts of other lobules outside the gland, form the single **excretory duct**.

THE FEMALE REPRODUCTIVE ORGANS.

The **female reproductive organs** (*organa genitalia muliebria*) consist of an internal and an external group. The *internal organs* are situated within the pelvis, and consist of the ovaries, the Fallopian tubes or oviducts, the uterus, and the vagina. The *external organs* are placed superficial to the triangular ligament of the urethra and below and in front of the pubic arch. They comprise the mons veneris, the labia majora et minora, the clitoris, the bulbi vestibuli, and the glands of Bartholin.

THE OVARIES (OVARIA) (Figs. 1172, 1177).

The **ovaries** are homologous with the testes in the male. They are two nodular, oval-shaped bodies of an elongated form, situated one on either side of the uterus, in the posterior layer of the broad ligament behind and below the Fallopian tube.

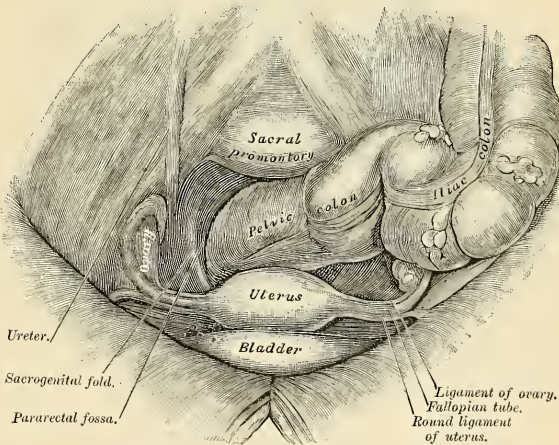


FIG. 1172.—Female pelvis and its contents, seen from above and in front.

The ovaries are of a grayish-pink color, and present either a smooth or a puckered, uneven surface. They are each about an inch and a half (3.75 cm.) in length three-quarters of an inch (2 cm.) in width, and about a third of an inch (8 mm.) thick, and weigh from one to two drams (4 to 8 grams).

Each ovary (*ovarium*) presents an outer and an inner surface, an upper and a lower extremity, and an anterior and a posterior border. It lies in a shallow depression, named the *fossa ovarii*, on the lateral wall of the pelvis; this fossa is bounded above by the external iliac vessels, in front by the impervious hypogastric artery, and behind by the ureter. The exact position of the ovary has been the subject of considerable difference of opinion, and the description here given applies to the nulliparous woman. The ovary becomes displaced during the first pregnancy and probably never again returns to its original position.

In the erect posture the long axis of the ovary is nearly vertical. The *upper* or *tubal extremity* is near the external iliac vein; to it is attached the ovarian fimbria of the Fallopian tube and a fold of peritoneum, the **suspensory ligament of the ovary**, which is directed upward over the iliac vessels and contains the ovarian vessels. The *lower* or *uterine end* is directed toward the pelvic floor; it

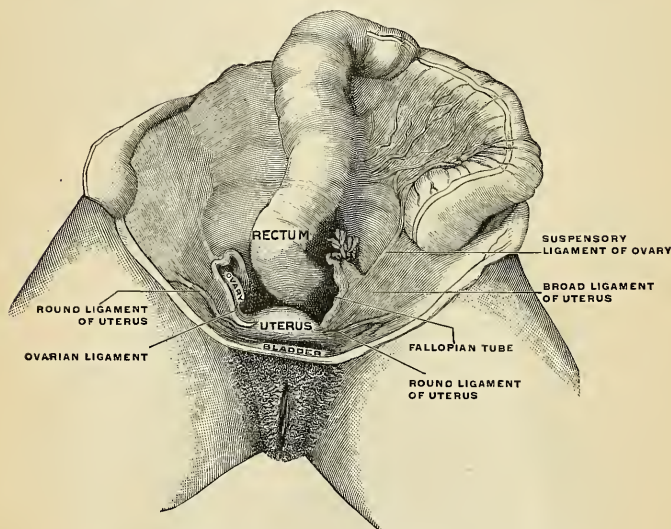


FIG. 1173.—Female pelvic organs *in situ*, seen from above. (Bardeleben.)

is usually narrower than the upper end and is attached to the lateral angle of the uterus, immediately behind the Fallopian tube, by a rounded cord termed the **ligament of the ovary**, which lies within the broad ligament and contains some non-striated muscle fibres. The *outer surface* is in contact with the parietal peritoneum which lines the fossa ovarii, the *inner surface* is to a large extent covered by the fimbriated extremity of the Fallopian tube. The *anterior* or *straight border* is directed toward the impervious hypogastric artery, and is attached to the back of the broad ligament by a short fold named the **mesovarium**. Between the two layers of this fold the bloodvessels and nerves pass to enter the hilum of the ovary. The *posterior* or *convex border* is free and is directed toward the ureter. The Fallopian tube arches over the ovary, running upward in relation to its anterior border, then curving over its upper or tubal pole, and finally passing downward on its posterior border and inner surface.

The Descent of the Ovary is described on page 1425.

The Ovary at Different Ages.—The ovary of childhood is smooth and even. The scars of many ruptured Graafian follicles cause this surface of the ovary to become pitted, puckered, fibrous, and uneven in old age. The surface of the ovary is grayish red in color. The corpus luteum of a nonpregnant woman slowly degenerates and disappears. The corpus luteum of an impregnated woman enlarges during pregnancy.

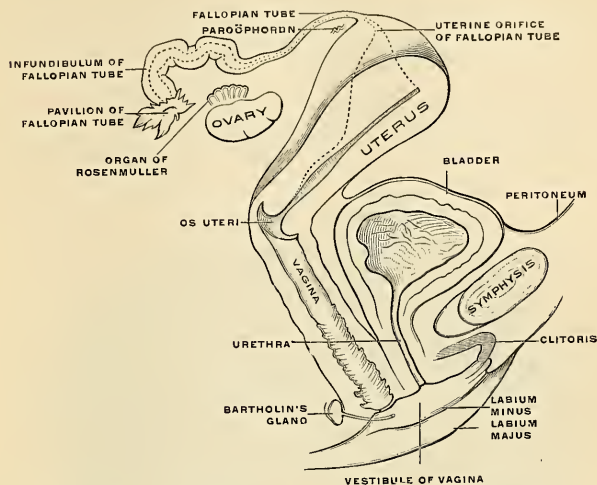


FIG. 1174.—Diagrammatic representation of the female reproductive organs and their relations to the bladder and urethra, lateral view. (Toldt.)

Structure (Figs. 1175, 1176, and 1184).—The ovary consists of the cortex and medulla, in the former of which are found the Graafian follicles and their remains and the hilum of the ovary. The **cortex** consists of stroma and **Graafian follicles**. Peripherally, the stroma is condensed to form a **capsule**, the **tunica albuginea**, which is covered by a layer of cuboidal epithelial cells called the **germinal epithelium**, and is often referred to as the serous covering of the organ. These cells are sharply marked off by a whitish line, at the hilum of the ovary, from the endothelium of the peritoneum. The **stroma** consists of a delicate white fibrous tissue meshwork, containing many small blood-vessels and groups of large polygonal epithelial cells called **interstitial cells**.

In the stroma are found the **Graafian follicles** (Fig. 1175) and their remains. The follicles are of different sizes; the smallest are beneath the tunica albuginea, the medium-sized follicles are found toward the medulla, while the largest extend from the innermost part of the cortex and beyond its ordinary limit, thus causing the nodular appearance of the surface of the ovary. A large follicle consists of a sheath of stroma called the **theca folliculi**, the inner portion of which is quite vascular. Lining the theca are several layers of granular cells, the **zona granulosa**. The greater part of the follicle is devoid of cells, but contains a liquid, the **liquor folliculi**, and the

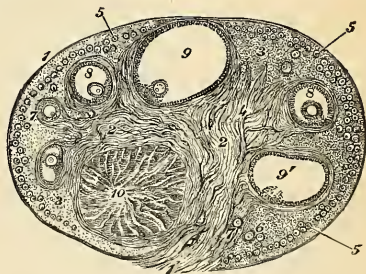


FIG. 1175.—Section of the ovary: 1. Outer covering, 1'. Attached border. 2. Central stroma. 3. Peripheral stroma. 4. Bloodvessels. 5. Graafian follicles in their earliest stage. 6, 7, 8. More advanced follicles. 9. An almost mature follicle. 9'. Follicle from which the ovum has escaped. 10. Corpus luteum. (After Schron.)

space occupied by this is termed the **antrum**. At one point the zona granulosa forms a mass which projects into the antrum; this mass, the **discus proligerus**, contains the ovum and its membrane. Beneath the granular cells of the discus is a layer of radially placed tall columnar cells, the **corona radiata**, within which lies a broad clear membrane, the **zona pellucida**, or **zona radiata**. Between the zona pellucida and the ovum, which lies within it, is said to exist a narrow space, the **perivitelline space**.

The ovum consists of an outer membrane, the **vitelline membrane**, internal to which is the protoplasm or **vitellus**. Embedded in the latter is a large, pale-staining, eccentrically placed nucleus, the **germinal vesicle**, which contains a large, deeply staining nucleolus, or **germinal spot**. Although the ovum is usually described as a typic cell, the matured ovum, since it does not contain a centrosome, cannot be so designated.

When a follicle enlarges it ruptures and the ovum usually escapes into the oviduct. This process constitutes **ovulation**. When the ovum escapes, the vessels of the follicle rupture and fill the antrum with blood and form thus the **corpus hemorrhagicum**. As this becomes organized, the hemoglobin is absorbed and this body becomes yellowish, due to the presence of a great number of large yellow elements, the **lutein cells**, and thus the **corpus luteum** is formed. If pregnancy

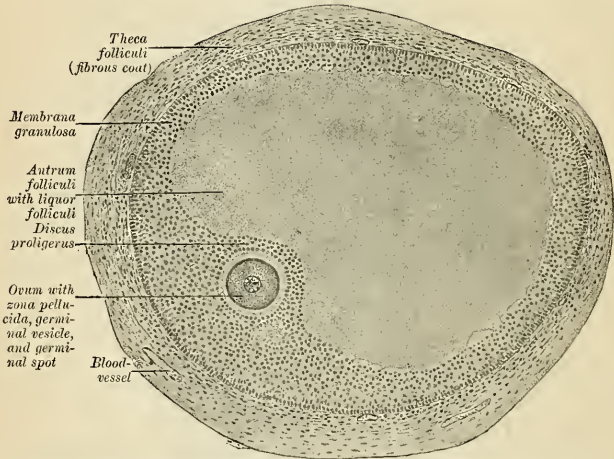


FIG. 1176.—Section through a Graafian follicle from an ape's ovary. $\times 90$. (Szymonowicz.)

supervenes, this body persists almost the entire period of gestation; if the ovum is not impregnated, the corpus luteum soon becomes contracted and whitish, and forms the **corpus albicans**.

The **medulla** consists of a loose network of coarse bundles of white fibrous tissue, which supports many large bloodvessels; here are also seen *smooth muscle* tissue and **interstitial cells**.

The **hilum** is a scar-like depression at which the medulla comes to the surface; here the vessels, nerves, and lymphatics enter and emerge.

Each ovum, before it can be fertilized, must undergo **maturation**. In this process the oöcyte undergoes two divisions, resulting in four cells, each of which contains one-fourth the amount of chromatin in the form of *one-half the number of chromosomes*. Three of these, the **polar bodies**, are small and unimportant and disappear. The fourth is the large **matured ovum**.

The development and maturation of the Graafian vesicles and ova continue uninterruptedly from puberty to the end of the fruitful period of woman's life, while their formation commences before birth. Before puberty the ovaries are small, the Graafian vesicles contained in them are disposed in a comparatively thick layer in the cortical substance; here they present the appearance of a large number of minute closed vesicles, constituting the early condition of the Graafian vesicles; many, however, never attain full development, but shrink and disappear. At puberty the ovaries enlarge and become more vascular, the Graafian vesicles are developed in greater abundance, and their ova are capable of fecundation.

Vessels and Nerves.—The arteries of the ovaries (Figs. 1185 and 1187) are the **ovarian** from the aorta, corresponding to the spermatic arteries in the male. The ovarian artery on each side enters the pelvis in the fold of broad ligament known as the suspensory ligament of the ovary and enters the attached border, or hilum, of the ovary. The ovarian vessels anastomose about the hilum with branches of the **uterine artery**. The **veins** follow the course of the arteries; they form a plexus near the ovary, the **pampiniform plexus**, corresponding to a like structure near the testis of the male. The **lymphatics** (Fig. 1186) terminate in the nodes to the corresponding side of the aorta, and they anastomose in their course with trunks from the uterine fundus and oviduct. The **nerves** come from the **ovarian plexus**, which is a continuation of the **renal plexus** along the ovarian artery, and from the **aortic plexus**.

The **epoöphoron**, **parovarium** or **organ of Rosenmüller** (Figs. 1177, 1180, and 1181) is placed in the mesosalpinx, between the ovary and tube. It consists of a number of epithelial-lined closed tubes. This structure can be readily seen if the mesosalpinx is stretched and held in front of the light. One of these tubes runs parallel to the Fallopian tube, and is called **Gärtner's duct** (*ductus epoophori longitudinalis*). A number of tubes (*ductuli transversi*) ascend from near the ovary and each empties into Gärtner's duct at a right angle. Gärtner's duct is a portion of the Wolffian duct, which has persisted and is represented in the male by the canal of the epididymis. The tubules which join the duct are persistent mesonephric tubules and are the homologues of the vasa efferentia and coni vasculosi of the testis, and probably also the aberrant ducts of the canal of the epididymis.

The **paroöphoron** is within the mesosalpinx, but is nearer to the uterus than is the epoöphoron. It consists of several small tubules, which can be seen in an adult only by the aid of a pocket lens. They are visible to the naked eye in a child at birth. It represents the organ of Giralde's in the male and is derived from the mesonephros.

Applied Anatomy.—An ovary may fail to descend and remain well above the pelvic brim; it may *prolapse* into Douglas' pouch; it may enter the sac of a hernia; it may inflame; a *tumor* or *cyst* may arise from it. A *solid tumor* of the ovary may be a fibroma, a sarcoma, or a carcinoma. "Cysts may originate in any part of the tuboövarian structure; as the cortical, medullary, or parenchymatous portions of the ovary; in the structure between the tube and ovary known as the Rosenmüller organ or parovarian structures; and in the hydatid of Morgagni." Cysts may be simple, proliferating, or dermoid; unilocular or multilocular. Glandular proliferous cysts, papillary proliferous cysts, dermoid cysts, and parovarian cysts may attain a large or even an enormous size. The operation for the removal of an ovarian cyst is one of the most successful of the major procedures of surgery.

THE FALLOPIAN TUBE, OR OVIDUCT (TUBA UTERINA [FALLOPII]) (Figs. 1177, 1178).

The **Fallopian tubes** or **oviducts** convey the ova from the ovaries to the cavity of the uterus. They are two in number, one on each side, situated in the upper margin of the broad ligament, extending from each superior angle of the uterus to the side of the pelvis. Each tube is about four inches (10 cm.) in length, and is described as consisting of three portions—(1) the **isthmus** (*isthmus tubae uterinae*) (Fig. 1177), or inner constricted third; (2) the **ampulla** (*ampulla tubae uterinae*) (Fig. 1177), or outer dilated portion, which curves over the ovary; and (3) the **infundibulum** (*infundibulum tubae uterinae*), the funnel-like expansion of the tube, at the bottom of which is the **abdominal orifice** or **pavilion** (*ostium abdominale tubae uterinae*) (Fig. 1177). The abdominal orifice has a small diameter (2 mm. when relaxed to its full extent). The margin of the infundibulum is rendered irregular by the presence of numerous small processes, the **fimbriae** (*fimbriae tubae*). This end of the tube is called the **fimbriated extremity** (Fig. 1177), because of these processes. The surfaces of the fimbriae looking into the cavity of the infundibulum are covered with mucous membrane continuous with the tubal mucous membrane. The outer surfaces are covered with peritoneum. One of the fimbriae is attached to the ovary and is called the **ovarian fimbria** (*fimbria ovarica*) (Fig. 1177). The uterine opening (*ostium uterinum tubae*) is even smaller than the abdominal opening, and will admit only a small bristle. In connection with the fimbriae of the Fallopian tube or with the broad ligament close to them

there are frequently one or more small pedunculated vesicles. These are termed the **hydatids of Morgagni** (*appendices vesiculosi*).

The course pursued by the Fallopian tube has been given in its relations to the ovary on page 1398.

Structure.—The Fallopian tube consists of three coats—**serous, muscular, and mucous.**

The **external or serous coat** (*tunica serosa*) is peritoneal. Beneath this lies the **tunica adventitia**, composed of lax connective tissue.

The **middle or muscular coat** (*tunica muscularis*) consists of an **external longitudinal layer** (*stratum longitudinale*), and an internal **circular layer** (*stratum circulare*) of smooth muscle fibres continuous with those of the uterus; near the uterine end of the tube an **inner longitudinal layer** is found.

The **internal or mucous coat** (*tunica mucosa*) is continuous with the mucous lining of the uterus and, at the free extremity of the tube, with the peritoneum. It is thrown into branched **longitudinal folds or villi** (*pliae tubariae*), which in the outer, larger part of the tube or **ampulla** (*pliae ampullares*) are much more extensive than in the narrow canal of the isthmus (*pliae isthmicae*). The lining epithelium is simple ciliated. This form of epithelium is also found on the inner surface of the fimbriae, while on the outer or serous surfaces of these processes the epithelium gradually merges into the endothelium of the peritoneum.

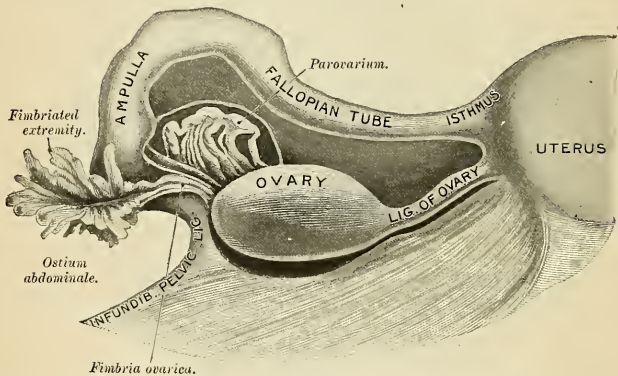


Fig. 1177.—Dissection of uterine appendages, seen from behind. (Henle.)

Vessels and Nerves.—The chief artery of the tube is the **tubal branch of the uterine artery** (*ramus tubarius*) (Fig. 1185). It also receives branches from the ovarian (Fig. 1185). Some of the **tubal veins** empty into the uterine veins, some into the ovarian veins. The **lymphatics** (Fig. 1186) coming from the tube unite with the trunks coming from the uterus and ovary and terminate in the lateral aortic nodes. The **nerves** come from the same plexuses that send branches to the uterus and ovary.

Applied Anatomy.—*Extrauterine pregnancy* most commonly occurs in the ampulla of the tube. The product of the conception may escape through the ostium abdominale or the walls of the tube may rupture, a violent hemorrhage resulting. *Pelvic peritonitis* is a not uncommon sequence of tubal disease. *Salpingitis* is inflammation of the mucous coat of the tube—*interstitial salpingitis* of the middle coat; *perisalpingitis* of the peritoneal coat. If inflammation closes the uterine and the abdominal ends of the tube, mucus gathers and distends the tube (*hydrosalpinx*). If purulent matter gathers, the condition is known as *pyosalpinx*.

THE UTERUS, OR WOMB (Figs. 1178, 1181).

The **uterus** is the organ of gestation, receiving the fecundated ovum in its cavity, retaining and supporting it during the development of the fetus, and becoming the principal agent in its expulsion at the time of parturition. It is a hollow

muscular organ. The nonpregnant uterus is contained in the cavity of the pelvis between the bladder and the rectum (Figs. 1183 and 1188). It is rarely placed exactly in the midline, but inclines to one side or the other, more often to the left than to the right. The walls of the organ are extremely thick. The uterus is movable as a whole, and the body of the uterus is movable upon the neck. Its position varies with the condition of adjacent parts, especially of the bladder and rectum. The cervix is more firmly fixed than the body and fundus, and hence the latter vary more in position than the former. Normally, in an erect individual, with the bladder and rectum empty, the external os is at the level of the upper surface of the pubic symphysis (Fig. 1174) and in a frontal plane passing through the ischiatic spines. The long axis of the uterus is directed forward and upward (Fig. 1174) and is angled where the body and cervix join. Hence, normally, with the bladder empty, the uterus is *anteverted* and *anteflexed*. When the bladder fills, the anteversion and anteflexion are almost abolished. If the bladder is overdistended and the rectum is empty, the uterus is pushed strongly backward; so that its long axis corresponds to the long axis of the vagina; in other words, it is *retroverted*.

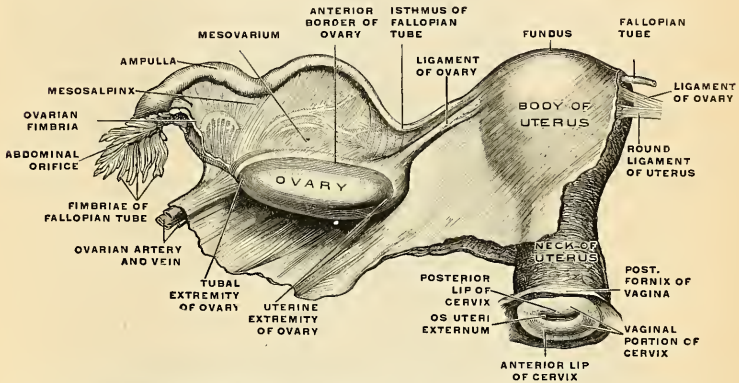


FIG. 1178.—The uterus, the left Fallopian tube, and the left ovary in their connection with the broad ligament of the uterus, which has been fully unfolded. Seen from behind. From a virgin, aged nineteen years. (Toldt.)

In the virgin state it is pear-shaped, flattened from before backward, and is retained in its position by the round and broad ligaments on each side, and projects into the upper end of the vagina below (Figs. 1178 and 1179). Its upper end, or base, is directed upward and forward; its lower end, or apex, downward and backward, in the line of the axis of the inlet of the pelvis. It therefore forms an angle of about 110 degrees with the vagina, since the direction of the vagina corresponds to the axis of the cavity and outlet of the pelvis. The nonpregnant adult uterus measures about three inches (7.5 cm.) in length, two inches (5 cm.) in breadth at its upper part, and nearly an inch (2.5 cm.) in thickness, and it weighs from an ounce to an ounce and a half (30 to 45 grams).

It consists of *two* parts (Fig. 1178): (1) An upper and larger portion, consisting of the body and fundus. This portion is flattened from before backward. (2) A lower, smaller, and cylindrical portion, the cervix.

On the surface, about midway between the base and apex, a slight constriction, known as the *isthmus uteri*, and a corresponding narrowing of the uterine cavity, the internal os, serve to demarcate the two portions.

The **fundus** (*fundus uteri*) (Fig. 1178) is the upper broad extremity of the uterus. If a line is drawn from the uterine opening of one Fallopian tube to the other, the portion above the line is the fundus. The fundus is directly continuous with the body.

The **body of the uterus** (*corpus uteri*) (Fig. 1178) gradually narrows from the fundus to the isthmus. In outline, when seen from in front or behind, it resembles a triangle, the base being above and the apex being absent. The **anterior surface** (*facies vesicales*) is so slightly rounded as to appear flattened. It is covered by

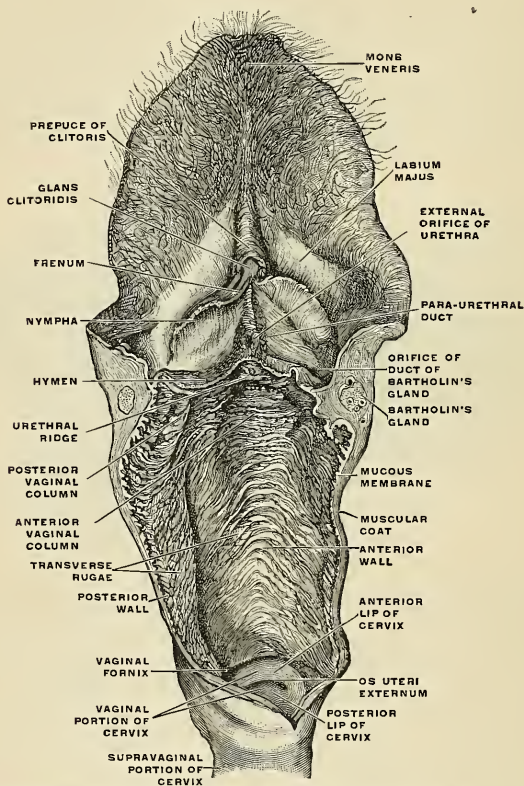


FIG. 1179.—The external genital organ of a virgin attached to the vagina, which has been isolated and opened, and a portion of the cervix uteri. (Toldt.)

peritoneum (Fig. 1178), which becomes reflected from it at its isthmus to form the **utero-vesical pouch**, which lies between the uterus and bladder (Fig. 1182). Its posterior surface is more rounded than the anterior, being convex transversely. It is covered by peritoneum throughout except along the attachments of the layers of the broad ligament (Fig. 1183), and is separated from the rectum by some convolutions of the small intestine (Fig. 1182). The peritoneum which

covers the posterior surface forms most of the anterior wall of Douglas' *cul-de-sac* (Figs. 1181 and 1182, and p. 1407). Its lateral margins (Figs. 1178 and 1181) are slightly convex. At the upper angle the Fallopian tube joins the body of the uterus; immediately below this the round ligament is attached, and behind the latter is the attachment of the ligament of the ovary; behind both of

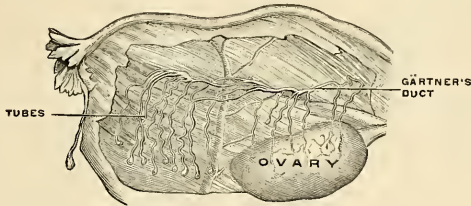


FIG. 1180.—The parovarium. The mesosalpinx is partly removed. (Poirier and Charpy.)

these structures, and from the side of the womb the broad ligament passes. The division between the body and the cervix is indicated externally by the isthmus and by the reflection of the peritoneum from the anterior surface of the uterus on to the bladder, and internally by a narrowing of the canal called the **internal os** (Fig. 1181).

The **neck** or **cervix uteri** (Figs. 1178 and 1181) is the lower constricted segment of the uterus; around its circumference is attached the upper end of the vagina (Figs. 1178 and 1182), which extends upward a greater distance behind than in front. The neck is spindle-shaped in the nulliparous and cylindrical in parous women.

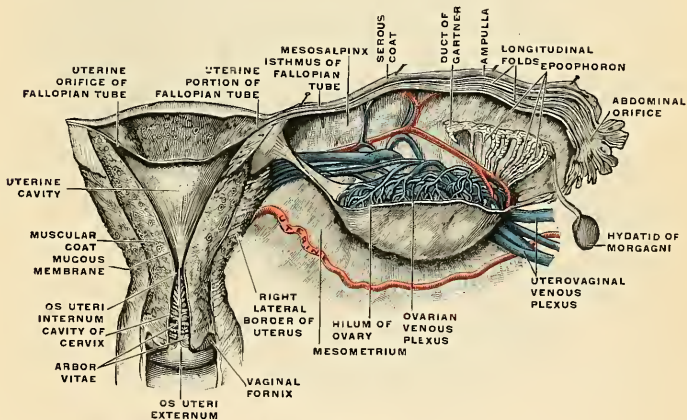


FIG. 1181.—The uterus and the right Fallopian tube opened from behind. (Toldt.)

The **supravaginal portion** (*portio supravaginalis [cervicis]*) (Figs. 1178 and 1182) is not covered by peritoneum in front; a pad of cellular tissue is interposed between it and the bladder. Behind, the peritoneum is extended over it.

The **vaginal portion** (*portio vaginalis [cervicis]*) (Figs. 1178 and 1182) is the lower end projecting into the vagina. It is circular or elliptical, the long axis of the

ellipse being transversely placed. On its surface is a small aperture, the *external os* or *os uteri* (*orificium externum uteri*) (Figs. 1178 and 1181), generally linear in shape, but sometimes oval or almost circular. If a woman has borne children, the opening is transverse and the margins are irregular. The margin of the opening is, in the absence of parturition or disease, quite smooth. This aperture divides the vaginal portion of the cervix into two lips, an *upper* or *posterior* lip (*labium posterius*) and an *anterior* lip (*labium anterius*). On each side of the cervix and upper portion of the vagina there is a space containing bloodvessels and filled with loose cellular tissue. This loose tissue passes upward between the layers of

the broad ligament, and is called **parametrium**. On each side of the cervix and three-quarters of an inch away is the terminal portion of the corresponding ureter.

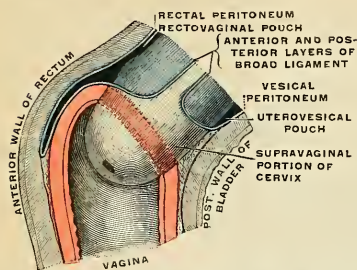


FIG. 1182.—The cervix uteri and upper end of the vagina, showing their relations to the peritoneum. Diagrammatic. (Testut.)

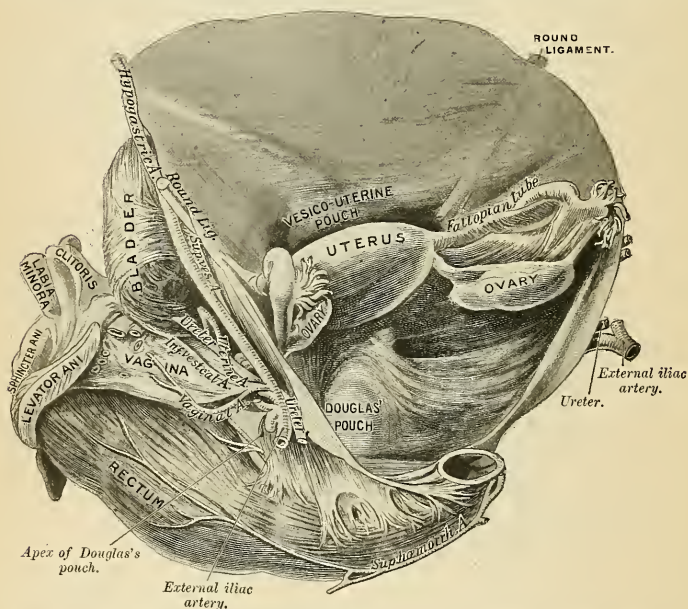


FIG. 1183.—Douglas' pouch. (From a preparation in the Museum of the Royal College of Surgeons of England.)

Folds and Ligaments.—The ligaments of the uterus are eight in number. Some are simple folds of peritoneum; others contain connective tissue and muscle. The ligaments are as follows: one anterior, one posterior, two lateral or broad,

two sacrouterine—all these being formed of peritoneum—and, lastly, two round ligaments.

The **anterior ligament** or the **utero-vesical fold** is reflected on to the bladder from the front of the uterus, at the junction of the cervix and body. It forms the **utero-vesical pouch** (*excavatio vesicouterina*) (Figs. 1182 and 1183).

The **posterior ligament** or the **rectovaginal fold** passes from the posterior wall of the uterus over the upper fourth of the vagina, and thence on to the rectum and sacrum. It thus forms a pouch, called the **rectovaginal pouch** or **Douglas' pouch** (Figs. 1182 and 1183), the boundaries of which are, *in front*, the posterior wall of the uterus, the supravaginal portion of the cervix, and the upper fourth of the vagina; *behind*, the rectum and sacrum; *above*, the small intestine; and *laterally*, the folds of Douglas or rectouterine folds, which contain the sacrouterine ligaments.

The **broad ligament** (*ligamentum latum uteri*) (Figs. 1183 and 1184) is a peritoneal fold which passes from each side of the uterus to the lateral wall of the pelvis as high as the external iliac vein. From this region comes the peritoneal fold called the suspensory ligament of the ovary (Fig. 1173). The two broad ligaments form a septum across the pelvis, which divides that cavity into two portions. In the anterior part are contained the bladder, urethra, and vagina; in the posterior part, the rectum. With the uterus normally placed the anterior surface of the broad ligament faces forward and downward, and the posterior surface faces upward and backward. The ligament is more nearly vertical at its pelvic attachment. The two layers of the broad ligament are mostly near to each other, to the side and below they separate and pass into the peritoneum of the lateral pelvic wall, the bladder, and the rectum. Between the two layers of each broad ligament are contained (1) the Fallopian tube superiorly; (2) the round ligament; (3) the ovary and its ligament; (4) the parovarium or organ of Rosenmüller, and the paroöphoron; (5) loose connective tissue, which is called **parametrium**; (6) unstriped muscle tissue; and (7) bloodvessels and nerves. The Fallopian tube is in the free edge of the broad ligament, and is contained in a special fold, which is attached to the part of the ligament near the ovary, and is known by the name of the **mesosalpinx** (Figs. 1181 and 1184). If the mesosalpinx is spread out, it is seen to be roughly triangular; the base of the triangle is outward, the apex at the upper and outer angle of the uterus; the upper boundary is the Fallopian tube, and the lower boundary is the ovary and its ligament. Between the two layers of the mesosalpinx are the parovarium and the paroöphoron. Between the fimbriated extremity of the tube and the lower attachment of the broad ligament is a concave rounded margin, called the **infundibulopelvic ligament** (Fig. 1177).

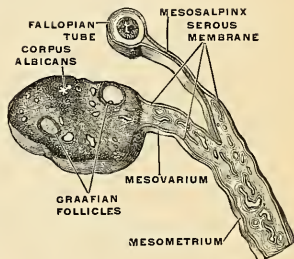


FIG. 1184.—The broad ligament of the uterus, with the mesovarium, the mesosalpinx, the ovary, and the Fallopian tube in transverse section. (Toldt.)

If the mesosalpinx is spread out, it is seen to be roughly triangular; the base of the triangle is outward, the apex at the upper and outer angle of the uterus; the upper boundary is the Fallopian tube, and the lower boundary is the ovary and its ligament. Between the two layers of the mesosalpinx are the parovarium and the paroöphoron. Between the fimbriated extremity of the tube and the lower attachment of the broad ligament is a concave rounded margin, called the **infundibulopelvic ligament** (Fig. 1177).

The **mesovarium** passes upward from the posterior surface of the broad ligament (Fig. 1184). Beneath the mesovarium is a larger and thicker portion of the broad ligament, called the **mesometrium** (Fig. 1184).

The **sacrouterine** or **rectouterine ligaments** (*plicae rectouterinae*) are contained in the peritoneal folds of Douglas. They pass from the second and third segments of the sacrum, downward and forward on the lateral aspects of the rectum, to be attached one on each side of the uterus at the junction of the supravaginal cervix and the body, this point corresponding internally to the position of the os internum.

They contain fibrous tissue and unstriated muscle fibre. Muscle fibres from the uterine wall to the rectal wall constitute the **Rectouterinus muscle** (*musculus rectouterinus*). This muscle is part of the sacrouterine ligaments.

A **round ligament** (*ligamentum teres uteri*) (Figs. 1178 and 1183) is attached on each side of the uterus. The two ligaments are rounded cords between four and five inches in length, each situated between the layers of the broad ligament in front of and below the Fallopian tube. Commencing at the superior angle of the uterus, this ligament passes forward, upward, and outward through the internal abdominal ring, along the inguinal canal, to the labium majus, in which it becomes lost. The round ligament consists principally of muscle tissue prolonged from the uterus; also of some fibrous and areolar tissue, besides bloodvessels and nerves, enclosed in a duplicature of peritoneum, which in the fetus is prolonged in the form of a tubular process for a short distance into the inguinal canal. This process is called the **canal of Nuck**. It is generally obliterated in the adult, but sometimes remains pervious even in advanced life. It is analogous to the peritoneal pouch which precedes the descent of the testis.

The **cavity of the uterus** (*cavum uteri*) (Fig. 1181) is small in comparison with the size of the organ, because of the great thickness of the wall. That portion of the cavity which corresponds to the body is triangular, flattened from before backward, so that its anterior and posterior walls are closely approximated, and having its base directed upward toward the fundus. At each superior angle is the minute orifice of the Fallopian tube. At the inferior angle of the uterine cavity is a small constricted opening, smaller and more nearly circular than the external os uteri, the **internal os uteri** (*orificium internum uteri*) (Fig. 1181), which leads into the cavity of the cervix.

The **cavity of the cervix** (*canalis cervicis uteri*) (Fig. 1181) extends from the internal os uteri to the external os uteri. It is somewhat fusiform, flattened from before backward, broader at the middle than at either extremity, and communicates below with the vagina. The wall of the canal presents, anteriorly and posteriorly, a longitudinal column, from which proceed a number of small oblique columns, giving the appearance of branches from the stem of a tree; and hence the name **uterine arbor vitæ** (*plicæ palmatæ*) applied to it. The longitudinal ridges are not exactly apposed, but fit against each other so as to close the cervical canal. These folds usually become very indistinct after the first labor.

The total length of the uterine cavity from the external os to the fundus is about two and a half inches.

The Uterus at Different Ages.—The uterus of the fetus is in the abdominal cavity projecting above the brim of the pelvis. The cervix is considerably larger than the body. At birth the cervix is larger relatively than in the adult; there is no distinct internal os distinguishing the cavity of the body of the uterus from the cavity of the cervix. The arbor vitæ is distinct and extends to the upper part of the cavity of the organ. The growth of the uterus is slow until puberty is almost reached, when for a time the growth is rapid. The growth of the uterine body causes the mucous membrane of this part to lose its folds, hence the arbor vitæ disappears from the body. In a woman who has had children the uterine cavity is larger than in a woman who has never borne a child. In advanced years the uterine wall becomes paler and hard and rigid from atrophic fibrous changes. A more distinct constriction separates the body and cervix. The internal os frequently and the external os occasionally are obliterated in old age.

Abnormalities.—Very rarely the uterine cavity is divided into two by a septum. Occasionally the condition known as **bicornate uterus** exists. In this condition each lateral angle is prolonged into a horn or cornu. The uterus is formed by the union of the two ducts of Müller, and failure of fusion of these ducts makes a double uterus or a bicornate uterus.

Changes at a Menstrual Period.—For several days before the menstrual flow begins the mucous membrane increases in thickness and vascularity and its surface is cast into folds. After these preparatory changes the superficial portions of the mucous membrane break down and are cast off, and bleeding begins. At the termination of menstruation the mucous membrane rapidly regenerates. At each menstrual period from four to five fluidounces of blood are discharged. The meaning of menstruation is uncertain. Pflüger believes the wall of the uterus

is made raw, so that if an impregnated ovum arrives it will adhere. Reichert believes that menstruation means that no impregnated ovum has arrived in the womb, and hence no bed is needed for one.

Changes Induced by Pregnancy.—The muscle fibres hypertrophy enormously and become vastly longer and broader. There is a great increase in connective tissue, and new connective-tissue fibres pass between bundles of muscle. The peritoneal coat undergoes hyperplasia. It remains closely adherent to the uterus, except over the lower segment, from which region it can be easily stripped. The bloodvessels become large and tortuous. The nerves are increased in length and new filaments form. The lymphatics undergo hypertrophy and hyperplasia. The uterus becomes spherical, and after the fourth month ovoidal. Early in pregnancy the increase in weight causes the uterus to descend in the pelvis. After the third month it rises progressively, and during the ninth month the fundus reaches the epigastrium. "Before term (four weeks in primiparæ, ten days or one week in multiparæ) the fundus sinks again, as the presenting part and lower uterine segment become engaged in the pelvic cavity. This phenomenon is explained by contraction of the overstretched abdominal walls." The womb is acutely anteфлекed during the first three months of pregnancy. After this period, as the womb rises, the anteфлекion is diminished, but some degree remains, because the abdominal walls are too lax to hold the organ straight. The uterus passes somewhat to the right side and undergoes a rotation on its longitudinal axis, so that the anterior surface looks front and to the right. These changes in position are caused by fecal distention of the sigmoid. The intestines are above and back of the uterus. During the first four months the cervix softens and enlarges somewhat. The length of the cervical canal is not altered during pregnancy, and the canal does not dilate until labor begins. During pregnancy the cervical glands secrete thick mucus, which coagulates and occludes the cervical canal; the round ligaments become stronger, and the layers of the broad ligaments are separated toward their inner portions by the enlarging womb.

After parturition the uterus nearly regains its former size, usually weighing something over one and a half ounces; but its cavity is larger than in the virgin state, the external orifice is more marked, its edges present a fissured surface, its vessels are very tortuous, and its muscle layers are more defined.

Structure.—The uterus is composed of three coats—an **external** or **serous coat**, a **middle** or **muscular coat**, and an **internal** or **mucous coat**.

The **serous coat** or **perimetrium** (*tunica serosa*) is derived from the peritoneum; it invests the fundus and the whole of the posterior surface of the uterus; but covers the anterior surface only as far as the junction of the body and cervix. In the lower fourth of the posterior surface the peritoneum, though covering the uterus, is not closely connected with it, being separated from it by a layer of loose cellular tissue and some large veins. At the lateral margins of the uterus the serous coat passes on to the broad ligaments. The serous coat adheres closely to the uterus, and it is very difficult to separate it from the muscle.

The **muscular coat** (*tunica muscularis*) (Fig. 1181) forms the chief bulk of the substance of the uterus. In the unimpregnated state it is dense, firm, of a grayish color, and cuts almost like cartilage. It is thick opposite the middle of the body and fundus, and thin at the orifices of the Fallopian tubes. It consists of bundles of unstriped muscle tissue, disposed in layers, intermixed with areolar tissue, bloodvessels, lymphatic vessels, and nerves. The muscle tissue is disposed in three layers—**external**, **middle**, and **internal**.

The **external layer** is placed beneath the peritoneum, disposed as a thin plane on the anterior and posterior surfaces. It consists of fibres which pass transversely across the fundus, and, converging at each superior angle of the uterus, are continued on the Fallopian tube, the round ligament, the ligament of the ovary; some passing at each side of the broad ligament, and others running backward from the cervix into the sacrouterine ligaments. The fibres of the external portion of the outer layer (*stratum suberosum*) are longitudinal. The fibres of the inner portion of the outer layer (*stratum supravasculare*) are partly circular and partly longitudinal.

The **middle layer of fibres** (*stratum vasculare*), which is thickest, presents bundles of circular fibres closely connected with bloodvessels. In this layer are most of the large bloodvessels. The circular fibres about the internal os form a distinct sphincter. Those which surround the orifices of the Fallopian tubes are arranged in the form of two hollow cones, the apices of which surround the orifices of the Fallopian tubes, their bases intermingling with one another on the middle of the body of the uterus.

The **internal or deep layer** (*stratum mucosum*) consists of longitudinal fibres. Some consider the deeper portion of the muscle tissue of the uterus to be the muscularis mucosæ. But the deep portion of the muscle substance is continuous with the more superficial portion, and there is no submucous coat between the muscle and the mucous membrane. The deeper layer of muscle fibres of the uterus contains connective tissue and elastic fibres. The muscle tissue of the cervix contains more connective and elastic tissue than does the body of the uterus; hence, the cervix is harder and stiffer than the body.

The **mucous membrane** (*tunica mucosa*) (Fig. 1181) is thin, smooth, and closely adherent to the subjacent muscle tissue. It is continuous, through the fimbriated extremity of the Fallopian tubes, with the peritoneum, and through the os uteri with the lining of the vagina.

In the body of the uterus it is smooth, soft, of a pale red color, lined with simple ciliated epithelium, and presents, when viewed with a lens, the orifices of numerous tubular glands arranged perpendicularly to the surface. It is not provided with any submucosa, but is intimately connected with the innermost layer of the muscular coat. In structure its tunica propria differs from ordinary mucous membrane, consisting of an embryonic nucleated and highly cellular form of connective tissue, in which run numerous large lymphatics. In it are the tube-like **uterine glands** (*glandulae uterinae*), which are of small size in the unimpregnated uterus, but shortly after impregnation become enlarged and elongated, presenting a contorted or waved appearance toward their closed extremities, which reach into the muscularis, and may be single or bifid. The uterine glands consist of a delicate membrane, lined with epithelium, which becomes ciliated toward the orifices.

In the **cervix** the mucous membrane is sharply differentiated from that of the uterine cavity. It is thrown into numerous oblique ridges, which diverge from an anterior and posterior longitudinal raphé, presenting an appearance which has received the name of **arbor vitae** (*plicae*

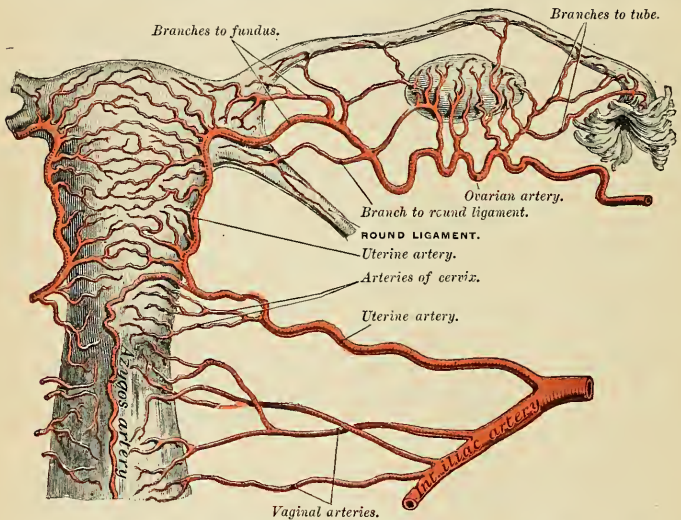


FIG. 1185.—The arteries of the internal reproductive organs of the female, seen from behind. (After Hyrtl.)

palmatae). In the upper two-thirds of the canal the mucous membrane is provided with numerous deep glands (*glandulae cervicales uteri*), which secrete a clear viscid alkaline mucus; and in addition, extending through the whole length of the canal, are a variable number of little cysts, presumably glands, which have become occluded and distended with retained secretion. They are called the **ovules of Naboth**. The mucous membrane covering the lower half of the cervical canal presents numerous papillæ. The epithelium of the upper two-thirds is ciliated, but below this it loses its cilia, and close to the external os gradually changes to squamous epithelium.

Vessels and Nerves (Fig. 1185).—The **arteries of the uterus** are the **uterine**, from the internal iliac, and the **ovarian**, from the aorta. They are remarkable for their tortuous course in the substance of the organ and for their frequent anastomoses. The uterine artery reaches the lower part of the uterus at the side and is prolonged as a large artery to the body and fundus, which ascends between the layers of the broad ligament. The uterine artery gives off a smaller branch, the **cervical**, which descends to supply the cervix and sends **cervicovaginal** branches to the vagina. The **azygos arteries of the vagina** come from the cervicovaginal reinforced by branches of the vaginal arteries (Fig. 1187). A median longitudinal vessel is formed in front and behind, which descends in the vaginal wall. The termination of the ovarian artery meets the termination of the uterine artery, and forms an anastomotic trunk from which branches are given off to

supply the uterus. Dr. Robinson, instead of describing the uterine and ovarian arteries as two vessels, describes them as parts of one vessel, the *arteria uterina ovarica* (p. 673). The veins are of large size, and correspond with the arteries. In the impregnated uterus these vessels form the **uterine sinuses**, consisting of the lining membrane of the veins adhering to the walls of the canals channelled through the substance of the uterus. They terminate in the **uterine plexuses**, which empty into the **internal iliac veins**. The **lymphatics** (Fig. 1186) are described on page 797. The nerves come chiefly from the **uterovaginal plexus**, which continues into the **hypogastric plexus** and receives filaments from the **third and fourth sacral nerves**. The uterus also receives direct fibres from the **hypogastric plexus** and from the **vesical plexus**.

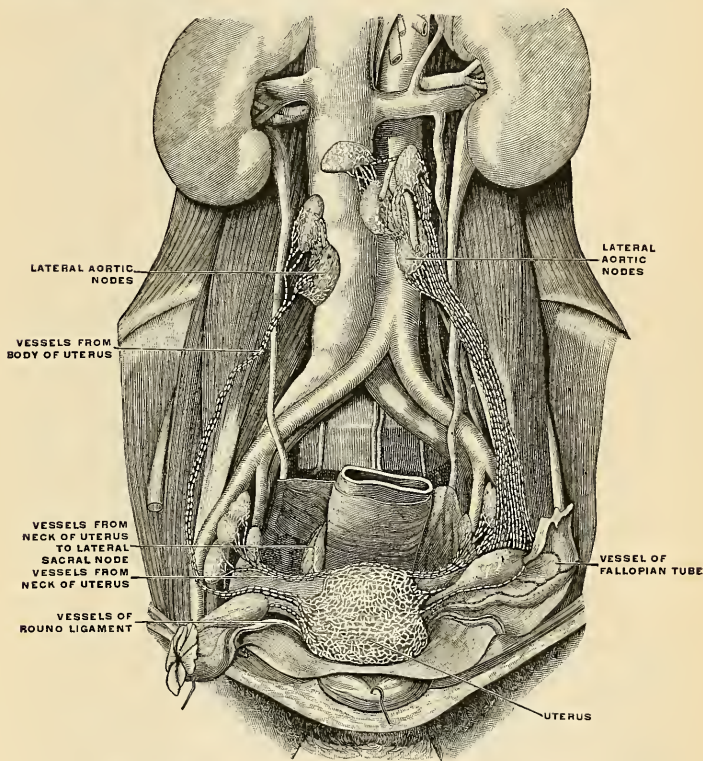


FIG. 1186.—The lymphatics of the internal organs of generation in the female. (Poirier and Charpy.)

Applied Anatomy.—*Pelvic cellulitis (parametritis)* is inflammation of the pelvic cellular tissue. It is due to sepsis, and its usual antecedent is uterine sepsis. A laceration of the cervix may admit bacteria. An abscess may form. If it points in the vagina it should be incised through the vaginal wall. The uterus may require removal (*hysterectomy*) in cases of *malignant disease* or for *fibroid tumors*. *Carcinoma* is the most common form of malignant disease of the uterus, though cases of *sarcoma* do occur. *Carcinoma* may show itself either as a columnar carcinoma or as a squamous carcinoma, the former commencing either in the cervix or body of the uterus, the latter always commencing in the epithelial cells of the mucous membrane covering of the vaginal surface of the cervix. The columnar form may be treated in the early stage, before fixation has taken place, by removal of the uterus, either through the vagina or by means of abdominal section. The former operation is attended by the smaller death rate. Vaginal hysterectomy

may be performed in any case in which the uterus or the uterus and tumor are not too large to be withdrawn through the vagina. It is difficult in this operation to deal with adhesions and other complications in the upper part of the pelvis, and for this reason many surgeons prefer the abdom-

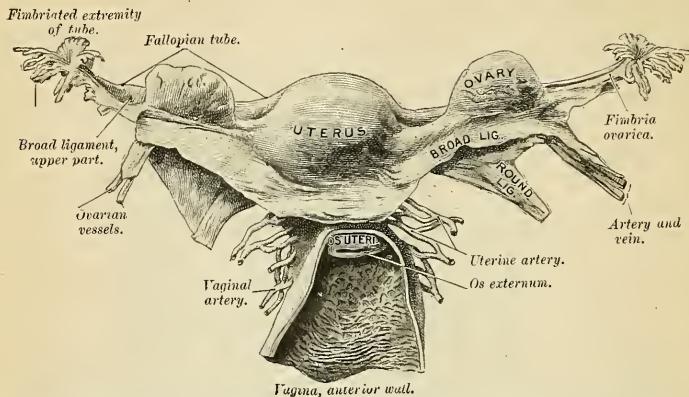


FIG. 1187.—The uterus and its appendages. Posterior view. The parts have been somewhat displaced from their proper position in the preparation of the specimen; thus, the right ovary has been raised above the Fallopian tube, and the fimbriated extremities of the tube have been turned upward and outward. (From a preparation in the Museum of the Royal College of Surgeons of England.)

inal operation. *Vaginal hysterectomy* is performed by placing the patient in the lithotomy position and introducing a large duckbill speculum into the vagina. The cervix is then seized with a volsellum and pulled down as far as possible and the mucous membrane of the vagina incised around the cervix as near to it as the disease will allow, especially in front, where the ureters are in danger of being wounded. A pair of dressing forceps are then pushed through into Douglas'

pouch and opened sufficiently to allow of the introduction of the two forefingers, by means of which the opening is dilated laterally as far as the sacrouterine ligaments. A somewhat similar proceeding is adopted in front, but here the bladder has to be separated from the anterior wall of the uterus for about an inch before the vesicouterine fold of peritoneum can be reached. This is done by carefully burrowing upward with a director and stripping the tissues from the anterior uterine wall. When the vesicouterine pouch has been opened and the opening dilated laterally, the uterus remains attached only by the broad ligaments, in which are contained the vessels that supply the uterus. Before division of the ligaments these vessels have to be dealt with. The forefinger of the left hand is introduced into Douglas' pouch and an aneurism needle, armed with a long silk ligature, is inserted into the vesicouterine pouch, and is pushed through the broad ligament of one side about an inch above its lower level and at some distance from the uterus. One end of the ligature is now pulled through the anterior opening, and in this way we have the lowest inch of the broad ligament, in which is contained the uterine artery,

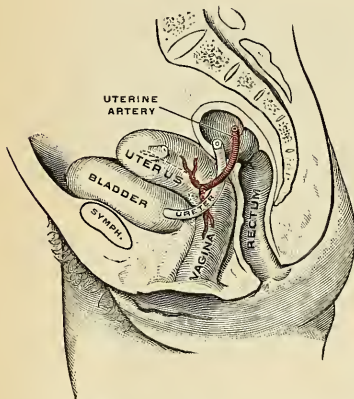


FIG. 1188.—Relations between uterus, ureter, and uterine artery. (Schematic.)

enclosed in a ligature. This is tied tightly, and the operation is repeated on the other side. The broad ligament is then divided on either side, between the ligature and the uterus, to the extent to which it has been constricted. By traction on the volsellum which grasps the cervix, the uterus

can be pulled considerably farther down in the vagina, and a second inch of the broad ligament is treated in a similar way. This second ligature will embrace the pampiniform plexus of veins, and, when the broad ligament has been divided on either side, it will be found that a third ligature can be made to pass over the Fallopian tube and top of the broad ligament, after the uterus has been dragged down as far as possible. After the third ligature has been tied and the structure between it and the uterus divided, this organ will be freed from all its connections and can be removed from the vagina. This canal is then sponged out and lightly dressed with gauze, no sutures being used. The gauze may be removed at the end of the second day. In squamous epithelioma, amputation of the cervix is done by some in those cases where the disease is recognized before it has invaded the walls of the vagina or the neighboring broad ligaments. The operation consists in removing a wedge-shaped piece of the uterus, including the cervix, through the vagina and attaching the cut surface of the stump to the anterior and posterior vaginal walls, so as to prevent retraction. In view, however, of the continuity of the lymphatic network of the cervix with the lymphatics of the body, the operation is insufficient and should be condemned. Complete *abdominal hysterectomy* is rarely necessary, except for malignant disease. In this operation the entire uterus is removed. The preliminary introduction of bougies into the ureters as practised by Kelly and Clark enables the surgeon to readily recognize the situations of these tubes. After the abdomen has been opened the uterine vessels are secured and the broad ligaments divided in a similar manner to that employed in vaginal hysterectomy, except that the proceeding is commenced from above. When the first two ligatures have been tied and the broad ligament divided, it will be found that the uterus can be raised out of the pelvis. A transverse incision is now made through the peritoneum, where it is reflected from the anterior surface of the uterus on to the back of the bladder and the serous membrane peeled from the surface of the uterus until the vagina is reached. The anterior wall of this canal is cut across. The uterus is now turned forward and the peritoneum at the bottom of Douglas' pouch incised transversely, and the posterior wall of the vagina cut across until it meets the incision on the anterior wall. The uterus is now almost free, and is held only by the lower part of the broad ligament on either side, containing the uterine artery. A third ligature is made to encircle this, and, after having been tied, the structures are divided between the ligature and the uterus. The organ can now be removed. The vagina is plugged with gauze, and the external wound closed in the usual way. The vagina acts as a drain, and therefore the opening into it is usually left unsutured. In some cases of uterine fibroid the abdomen is opened and the tumor is removed, but the uterus is not taken away. This operation is called *myomectomy*. This operation is suited only to solitary subperitoneal or interstitial tumors (Penrose).

The common operation for uterine fibroids is *supravaginal amputation*. The uterus is cut away and the cervical flaps are sutured. Before the technique of hysterectomy was perfected and before myomectomy was devised the favorite operation for uterine fibroids was *salpingo-oöphorectomy*, and by it a large majority of cases operated upon were cured. When it succeeds, a premature menopause is induced and the tumor shrinks. The operation is useless if a woman is past the menopause, and is likely to fail if the tumor is very soft or very large.

THE VAGINA (Figs. 1174, 1192).

The **vagina** (*vulvouterine canal*) is a musculomembranous passage, which extends from the vulva to the uterus. It is situated in the cavity of the pelvis, behind the bladder and in front of the rectum. Its direction is curved upward and backward, at first in the line of the pelvic outlet, and afterward in that of the axis of the cavity of the pelvis. Its walls are ordinarily in contact, and its usual shape on transverse section is that of an H, the transverse limb being slightly curved forward or backward, while the lateral limbs are somewhat convex toward the median line. Its length is about two and a half inches (6.25 cm.) along its anterior wall (*paries anterior*), and three and a half inches (8.75 cm.) along its posterior wall (*paries posterior*), and its wall is about 2 mm. thick. It is constricted at its commencement, and becomes dilated medially, and narrowed near its uterine extremity; it surrounds the vaginal portion of the cervix uteri, a short distance from the os, its attachment extending higher up on the posterior than on the anterior wall of the uterus (Fig. 1182). To the recess behind the cervix the term **posterior fornix** is applied, while the smaller recess in front is termed the **anterior fornix**.

Relations (Figs. 1174 and 1192).—The upper part of the anterior wall of the vagina is in relation with the base of the bladder, being separated from that viscus by lax connective tissue. Lower down the middle line of the anterior wall and closely joined to it is the urethra. The upper part of the posterior wall, near the middle line, is covered for a quarter of an inch or more with peritoneum, which forms the anterior wall of the depths of the **rectovaginal pouch of peritoneum** or **pouch of Douglas** (*excavatio rectouterina* [Douglas]) (Fig. 1182), between the uterus and vagina and the rectum. The portion of the posterior wall below the level of the pouch of Douglas is placed close to the rectum, a layer of pelvic fascia intervening. As the vaginal orifice is approached, the rectum and vagina separate, and interposed between them is a mass of fibro-fatty tissue called the **perineum** or **perineal body**. Its sides are enclosed between the Levatores ani muscles. The ureter toward its termination (Fig. 1183) lies near the lateral wall of the vagina, passing at this point in a direction downward, inward, and slightly forward to reach the bladder. The vagina near its termination passes through the triangular ligament, and upon its sides are the bulbs of the vestibule, the glands of Bartholin, and the Bulbocavernous muscle.

Structure.—The vagina consists of an **internal mucous lining**, a **muscular coat**, and a **fibrous coat**; between the first two is found a **layer of erectile tissue**.

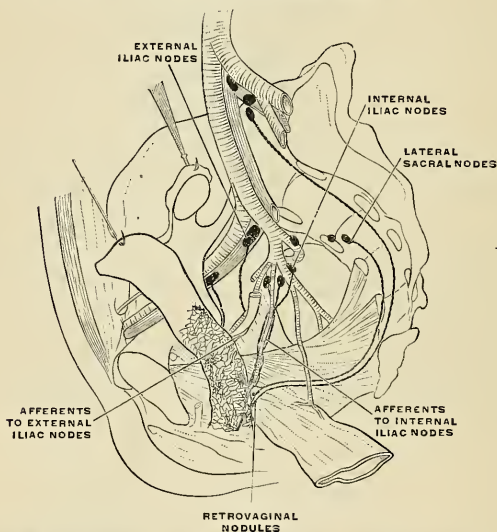


FIG. 1189.—The lymphatics of the vagina. Schematic. (Poirier and Charpy.)

The **mucous membrane** (*tunica mucosa*) (Fig. 1179) is continuous above with that lining the uterus. Its inner surface presents, along the anterior and posterior walls, a longitudinal ridge or raphé, called the **rugous columns of the vagina** (*columna rugarum anterior et posterior*). The anterior column extends downward as far as the external orifice of the urethra, forming the **carina urethralis vaginae**. Numerous transverse ridges or **rugæ** (*rugæ vaginales*) extend outward from the raphe on either side. These rugæ are separated by furrows of variable depth, giving to the mucous membrane the appearance of being studded over with conical projections or papillæ; they are most numerous near the orifice of the vagina, especially in women before parturition. The epithelium covering the mucous membrane is of the stratified squamous variety. The subepithelial tissue is very loose and contains numerous large veins, which by their anastomoses form a plexus, together with smooth muscle fibres from the muscular coat; it is regarded by Gussenbauer as an erectile tissue. It contains a number of mucous crypts, but no true glands.

The **muscular coat** (*tunica muscularis*) consists of two layers, an external longitudinal, which is far the stronger, and an internal circular layer. The longitudinal fibres are continuous with the superficial muscle fibres of the uterus. The strongest fasciculi are those attached to the rectovesical fascia on each side. The two layers are not distinctly separable from each other, but

are connected by oblique decussating fasciculi which pass from the one layer to the other. Above the triangular ligament the fibres are nonstriated; in the region of the ligament they show striations. In addition to this, the vagina at its lower end is surrounded by a band of striped muscle tissue, the **Sphincter vaginae** (p. 445).

The **fibrous coat** is composed of dense white fibrous connective tissue, which connects the vagina to the surrounding organs. It contains a large plexus of bloodvessels.

The **erectile tissue** consists of a layer of loose connective tissue situated between the mucous membrane and the muscular coat; embedded in it is a plexus of large veins, and numerous bundles of unstriated muscular fibres derived from the circular muscular layer. The arrangement of the veins is similar to that found in other erectile tissues.

Bloodvessels, Nerves, and Lymphatics.—The arteries of the vagina are branches of the vesicovaginal artery, the vaginal branch of the uterine artery (p. 672) and branches of the internal pudic and middle hemorrhoidal. The veins form an abundant plexus around the wall of the vagina and pass to the internal iliac veins. The lymphatics (Fig. 1189) arise from two communicating networks, one of which is beneath the mucous membrane, the other in the muscular wall. There is a third network around the vaginal wall, from which the collectors arise. The trunks from the upper third of the vagina pass to the external iliac nodes; those from the middle third pass to the internal iliac nodes; those from the lower third terminate in the nodes at the promontory of the sacrum or in the lateral sacral nodes. The nerves come from the third and fourth sacral nerves and from the uterovaginal and vesical plexuses of the sympathetic.

THE EXTERNAL ORGANS (PARTES GENITALES EXTERNAE MULIEBRES).

The external reproductive organs in the female are the **mons Veneris**, the **labia majora** and **minora**, the vestibule, the clitoris, the vaginal bulb, and the glands of Bartholin. The term **vulva** (*pudendum muliebre*), as generally applied, includes all of these parts. In examining the structures entering into the formation of the vulva we find the homologues of most of the structures which make up the male genitals.

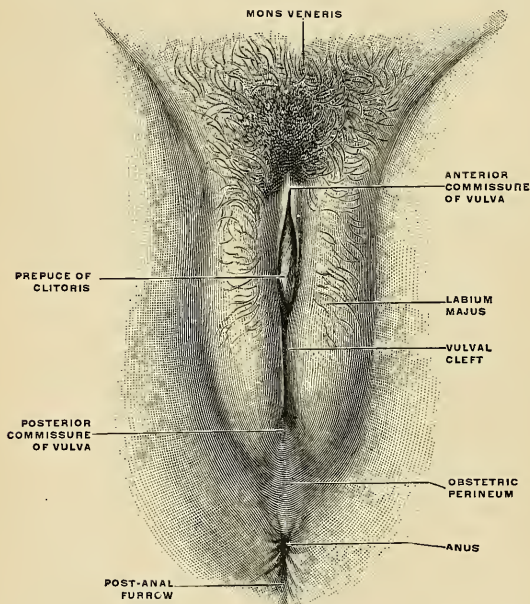
Labia majora	=	Scrotum.
Clitoris	=	Corpora cavernosa.
Bulbus vestibuli	=	Corpus spongiosum.
Vestibular glands (of Bartholin).	=	Bulbourethral glands (of Cowper).

The **mons Veneris** (*commissura labiorum anterior*) is the rounded eminence in front of the pubic symphysis formed by a collection of fatty tissue beneath the integument. It becomes covered with hair at the time of puberty.

The **labia majora** (*labia majora pudendi*) (Figs. 1190 and 1191) are two prominent longitudinal cutaneous folds, narrow behind, but fuller and larger toward the mons Veneris, and bounding the **pudendal slit** (*rima pudendi*) or common urinogenital opening. Each **labium majus** has two surfaces, an outer, which is covered by pigmented skin with numerous sebaceous glands and strong, crisp hairs, and an inner, which is smooth and moist and is continuous with the genitourinary mucous tract. In the subcutaneous areolofatty tissue of each labium majus the round ligament of the uterus ends. The labia are joined with each other anteriorly by the mons Veneris or anterior commissure. Posteriorly they appear to become lost in the neighboring integument, although sometimes connected by a slight transverse fold in front of the anus, the **posterior commissure** (*commissura labiorum posterior*), or posterior boundary of the vulvar orifice. The interval between the posterior commissure and the anus, about an inch in length, constitutes the obstetric perineum.

Bloodvessels, Nerves, and Lymphatics.—The arteries of the labia majora are derived from the superficial external pudic arteries and from perineal branches of the internal pudic arteries. Homologous with the scrotum, the nerve supply is derived from branches of the ilioinguinal, internal pudic, and perineal branches of the small sciatic. The lymphatics drain into the superficial inguinal and internal iliac lymph nodes.

The **labia minora**, or **nymphæ** (*labia minora pudendi*) (Figs. 1191, 1192), are two smaller, narrower longitudinal folds, with a delicate covering of modified skin, and usually hidden from view unless the labia majora are separated. They end posteriorly by gradually joining the labia majora, although in the young there is usually a transverse fold, the **fourchette** or **frenulum** (*frenulum labiorum pudendi*). Traced forward each labium minus divides into an outer and an inner portion or limb. The outer parts of the two labia unite over the glans clitoridis to form the **prepuce of the clitoris** (*præputium clitoridis*) (Fig. 1191). The internal limbs unite at an acute angle beneath the glans clitoridis and are attached to the under surface of the glans to form the **frenulum clitoridis**. The two labia minora are in contact, flanked by the labia majora, and are covered by modified skin,

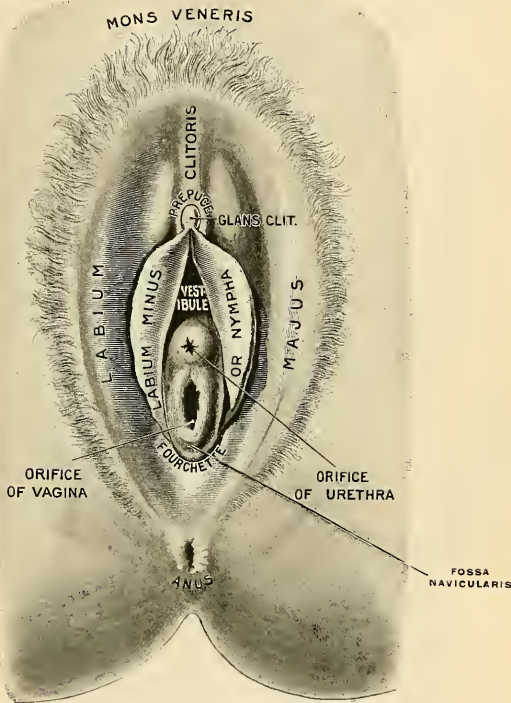


1190.—The female pudendum or vulva with the labia majora. (Toldt.)

with numerous, sebaceous glands (*glandulae vestibulares minores*), resembling the smooth, moist, pink-colored integument of the inner surface of the labia majora. The cleft between the labia minora is called the **vestibule**, the structures of which are seen only on separating the labia.

The **vestibule** (*vestibulum vaginae*) (Figs. 1174 and 1191) is the cleft between the labia minora, between the glans clitoridis in front and the fourchette behind. On separating the labia minora the following structures in the vestibule are seen: (1) The external urethral orifice and the minute openings, one on each side, of the paraurethral ducts; (2) the vaginal orifice; and (3) the openings of the ducts of the vestibular glands (of Bartholin). The recess between the fourchette and the vaginal orifice is called the **fossa navicularis**.

The **external orifice of the urethra**, or **urinary meatus** (*orificium urethrae externum*) (Figs. 1191 and 1194), is situated immediately in front of the vaginal orifice and about an inch behind the glans clitoridis. The orifice usually presents the appearance of a vertical slit, and is surrounded by a prominent elevation of the mucous membrane. On each side of the urinary meatus there may sometimes be seen the minute orifice of the duct of the paraurethral glands, supposed to be the homologues of the prostate.



1191.—The vulva. External female organs of generation.

The **vaginal opening** is situated behind the urethral orifice, and its appearance varies with the condition of the hymen, a membranous fold which more or less closes the aperture in the virgin.

The **hymen** varies much in shape. Its commonest form is that of a ring, generally broadest posteriorly; sometimes it is represented by a semilunar or crescentic fold, with its concave margin turned toward the pubes. A complete septum stretched across the lower part of the vaginal orifice is called an **imperforate hymen**. Occasionally the hymen is *eribriform*, or its free margin forms a *membranous fringe*, or it may be entirely *absent*. It may persist after copulation, so that it cannot be considered as a test of virginity. After rupture of the hymen the small

rounded nodular elevations known as the *carunculae myrtiformes* (*carunculae hymenales*) are found as the remains of the structure.

The **clitoris** (Figs. 1191, 1192) is an erectile structure which is the morphologic homologue of the penis; unlike the penis, however, it is not traversed by the urethra. It is situated beneath the anterior commissure (or *mons Veneris*) and is partly hidden between the anterior extremities of the labia minora. It is composed of a body and two crura; the extremity of the body is surmounted by a small glans.

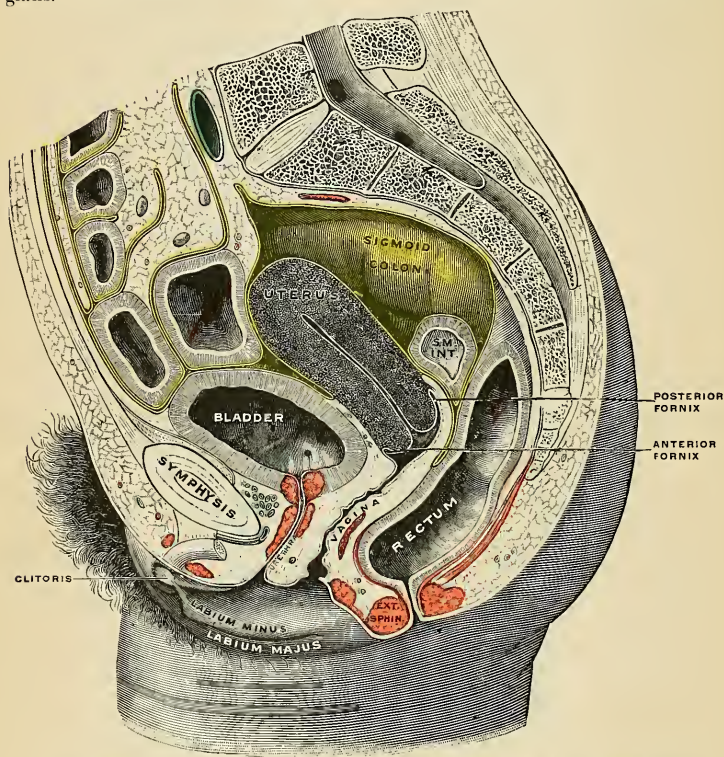
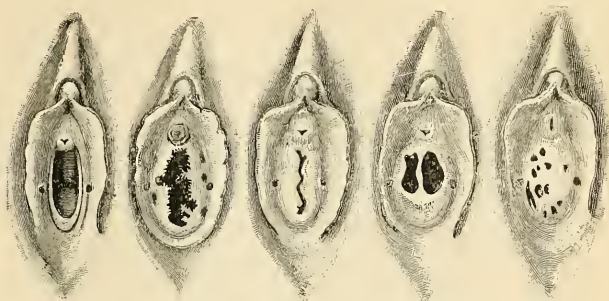

FIG. 1192.—Sagittal section of the lower part of a female trunk, right segment. SM. INT. Small intestine. (Testut.)

The **body of the clitoris**, composed of erectile tissue, is about an inch and a quarter in length (3 cm.), and is bent upon itself so that the angle opens downward. It tapers toward the glans, is enclosed by a dense fibrous coat, and is divided by an incomplete *septum corporum cavernosorum* into two semicylindrical *corpora cavernosa clitoridis*, homologous with the *corpora cavernosa* of the male. A **suspensory ligament** passes from the pubic symphysis to the fibrous coat of the body of the clitoris. Each corpus cavernosum diverges from its fellow to form the **crus clitoridis**. Each crus is attached to the pubic arch (pubis and ischium) and is covered by the Ischiocavernosus muscle (*m. erector clitoridis*).

The **glans clitoridis** is a minute mass of erectile tissue, surmounting the tapering apex of the body of the clitoris. It is covered by a very sensitive epithelium, and its erectile tissue, like that of the glans penis, is continuous with the erectile tissue



CRESCENTIC

FRINGED

BILABIAL

BIPERFORATE

CRIBRIFORM

FIG. 1193.—Varieties of hymen. (Testut, after Rose.)

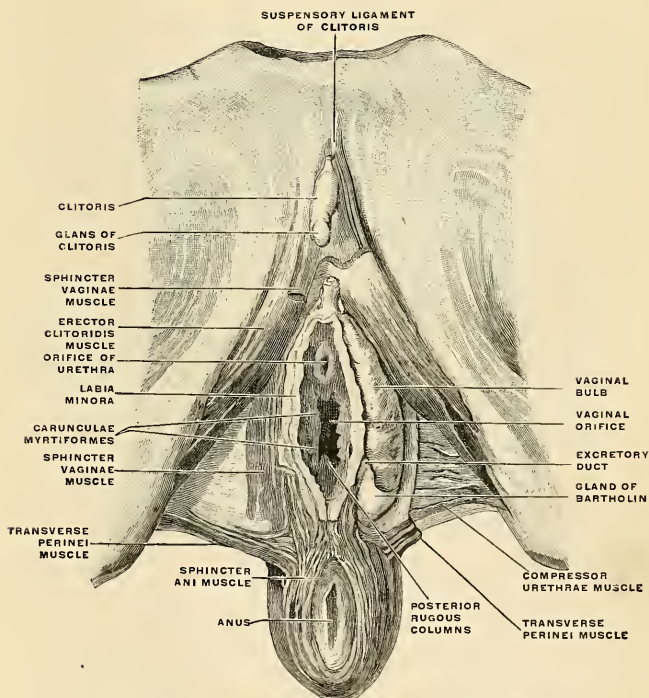


FIG. 1194.—The female external organs of generation dissected. (Spalteholz.)

of the bulbus vestibuli, the homologue of the corpus spongiosum of the male. The **præputium clitoridis** and the **frenulum clitoridis** have already been described (p. 1416) as divisions of the labia minora.

Arteries and Nerves of the Clitoris.—The body and the crura of the clitoris derive their blood supply from the **deep artery of the clitoris** (*arteria profunda clitoridis*), a branch of the **internal pudic artery**. Another branch of this artery, the **dorsal artery of the clitoris** (*arteria dorsalis clitoridis*) supplies the glans. The nerve supply is derived from the **dorsal nerve of the clitoris**, from the internal pudic, and from the **hypogastric sympathetic plexus**.

The **vaginal bulb** (*bulbus vestibuli*) (Fig. 1194) may be regarded as the homologue of the bulb portions of the corpus spongiosum of the male. The principal morphological difference lies in the fact that the two halves are fused in the male, but remain separated in the female. The bulbus vestibuli consists of a mass of minute convoluted bloodvessels, of such plexiform arrangement as to be often called erectile tissue, arranged in two halves, one on either side of the vaginal and urethral orifices. Each half is thicker or more massive posteriorly, while anteriorly it is attenuated and joins its fellow of the opposite side to form the **pars intermedia**, continuous with the erectile tissue of the **glans clitoridis**. Each half of the bulbus vestibuli rests against the lateral wall of the vagina and lies superficial to the triangular ligament. Externally and inferiorly it is covered by the Bulbocavernosus muscle.

Arteries and Nerves of the Bulbus Vestibuli.—The blood is supplied by the **artery to the bulb** (*arteria bulbi vestibuli*), a branch of the **internal pudic artery**. The nerve supply is by branches of the **hypogastric sympathetic plexus**.

The Glands of Bartholin (*glandula vestibularis major* [Bartholini]) (Fig. 1194).—On each side of the posterior part of the commencement of the vagina is a round or oblong body, of a reddish-yellow color, and of the size of a horse-bean, analogous to Cowper's gland in the male. It is called the **gland of Bartholin**, the **gland of Duverney**, the **vulvovaginal gland**, or the **suburethral gland**. Bartholin's gland lies partly in the inferior or anterior leaf of the triangular ligament. The posterior portion of the bulbus vestibuli and the Bulbocavernosus muscle partly cover it. Each gland opens by means of a long single duct immediately external to the hymen, in the angle or groove between it and the nymphæ (Fig. 1193).

DEVELOPMENT OF THE URINARY AND GENERATIVE ORGANS.

The permanent organs of the adult are preceded by a set of purely embryonic structures which, with the exception of their ducts, almost entirely disappear before birth. These embryonic structures, all developed from the intermediate cell mass of mesodermal tissue, are on either side; the pronephros, the mesonephros, the Wolffian (mesonephric) duct, and the Müllerian duct (oviduct). The pronephros disappears very early; the structural elements of the mesonephros mostly atrophy, but in their place is developed the genital gland, in association with which the mesonephric duct remains as the duct of the male genital gland, the oviduct as that of the female.

The **pronephros** is an early embryonic structure in all vertebrates. It develops at about the level of the heart by a proliferation of the mesodermal cells of the intermediate cell mass. In it appear (a) a longitudinal cord of cells, which later acquires a lumen to form the **pronephric duct**; (b) two transverse **pronephric tubules** develop as invaginations of the cœlomic mesothelium. Of these, the cephalic one acquires a lumen and opens into the cœlomic cavity; the other remains a solid cord of cells. Neither tubule becomes connected with the pronephric duct. The pronephric duct remains to become the Wolffian duct of the next stage, while the tubules are represented, in the adult, by the hydatids at the fimbriated end of the Fallopian tube in the female, and by the stalked hydatid at the upper end of the testis in the male.

The Mesonephros, Müllerian Duct, and Genital Gland.—On the inner side of the Wolffian duct a series of tubules, the *Wolffian tubules*, are developed. Each tubule opens laterally into the duct, while its middle part is invaginated by a tuft of capillary bloodvessels to form a glom-

erulus. These tubules increase in number, and collectively constitute the **mesonephros** or **Wolffian body** (Figs. 1195, 1196). At the beginning of the second month this body forms an elongated spindle-shaped structure, which projects into the coelomic cavity at the side of the dorsal mesentery, and reaches from the septum transversum cephalad to the fifth lumbar somite caudad. The Wolffian body persists and forms the permanent kidney in fishes and amphibians,

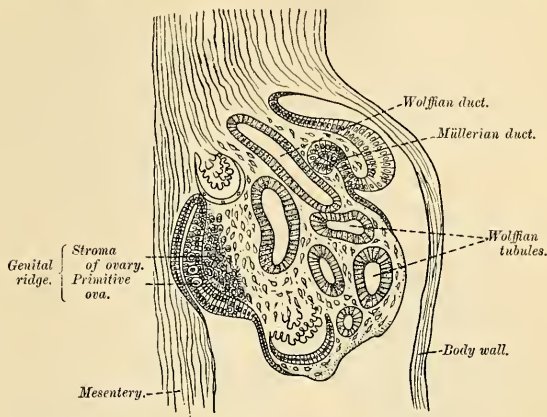


FIG. 1195.—Section of the urinogenital area of a chick embryo of the fourth day. (Waldeyer.)

but in reptiles, birds, and mammals it is superseded by the *metanephros*, which forms the permanent kidney in these animals. The cephalic tubules of the Wolffian body become attached to the sexual eminence or *genital ridge*, from which the ovary in the female and the testicle in the male are developed. During the development of the permanent kidneys the Wolffian bodies atrophy, and this process proceeds to a much greater extent in the female than in the male.

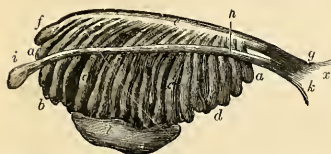


FIG. 1196.—Enlarged view from the front of the left Wolffian body before the establishment of the distinction of sex. *a, b, c, d*, Tubular structure of the Wolffian body. *e*, Wolffian duct. *f*, Its upper extremity. *g*, Its termination in *x*, the urinogenital sinus. *h*, The duct of Müller. *i*, Its upper, funnel-shaped extremity. *k*, Its lower end, terminating in the urinogenital sinus. *l*, The mass of blastema for the reproductive organ, ovary, or testicle. (From Farre, after Kobelt.)

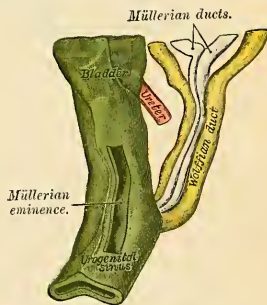


FIG. 1197.—Urinogenital sinus of female human embryo of eight and a half to nine weeks old.

In the *male*, the Wolffian duct persists, and forms the tube of the epididymis, the vas deferens, and common ejaculatory duct, while the seminal vesicle arises as a lateral diverticulum from its caudal end. The cephalic Wolffian tubules form the rete testis, vasa efferentia, and conus vasculosi of the testis; while the caudal tubules atrophy or are represented by the occasional vasa aberrantia of the globus minor and by the paradidymis.

In the *female*, the Wolffian bodies and ducts atrophy. The remains of the Wolffian tubules are represented by the epoöphoron and the paroöphoron (p. 1407), while the cephalic portion of the Wolffian duct sometimes persists as the functionless duct of Gärtner (Fig. 1181).

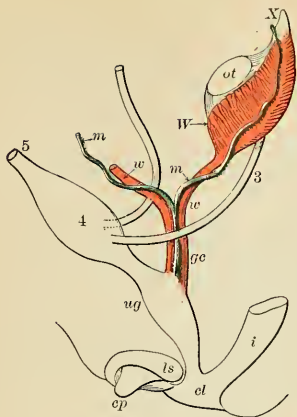


FIG. 1198.—Diagram of the primitive urino-genital organs in the embryo previous to sexual distinction. 3. Ureter. 4. Urinary bladder. 5. Urachus. *d*. Cloaca. *cp*. Elevation which becomes clitoris or penis. *i*. Lower part of intestine. *ls*. Fold of integument from which the labia majora or scrotum are formed. *m, m*. Right and left Müllerian ducts uniting and running with the Wolffian ducts in *gc*, the genital cord. *ot*. The genital ridge from which either the ovary or testicle is formed. *up*. Sinus urogenitalis. *W*. Left Wolffian body. *w, w*. Right and left Wolffian ducts.

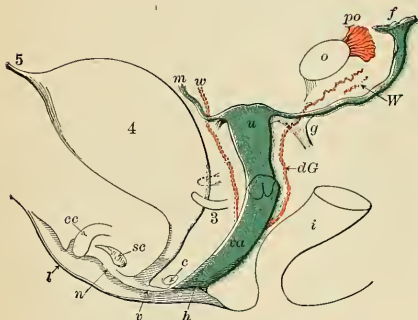


FIG. 1199.—Diagram of the female type of sexual organs. *e*. Gland of Bartholin, and immediately above it the urethra. *cc*. Corpus cavernosum clitoridis. *dG*. Remains of the left Wolffian duct, such as give rise to the duct of Gartner, represented by dotted lines; that of the right side is marked *w*. *f*. The abdominal opening of the left Fallopian tube. *g*. Round ligament corresponding to gubernaculum. *h*. Situation of the hymen. *i*. Lower part of the intestine. *l*. Labium. *n*. Nympha. *o*. The left ovary. *po*. Parovarium (epioöphoron of Waldeyer). *sc*. Vascular bulb or corpus spongiosum. *u*. Uterus. The Fallopian tube of the right side is marked *m*. *v*. Vulva. *va*. Vagina. *W*. Scattered remains of Wolffian tubes near it (paroöphoron of Waldeyer).

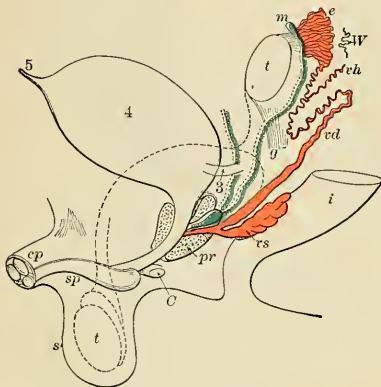

FIG. 1200.—Diagram of the male type of sexual organs. *C*. Cowper's gland of one side. *cp*. Corpora cavernosa penis cut short. *e*. Caput epididymis. *g*. The gubernaculum. *i*. Lower part of the intestine. *m*. Müllerian duct, the upper part of which remains as the hydatid of Morgagni; the lower part, represented by a dotted line descending to the prostatic vesicle, constitutes the occasionally existing cornu and tube of the uterus masculinus. *pr*. The prostatic gland. *s*. Scrotum. *sp*. Corpus spongiosum urethrae. *t*. Testicle in the place of its original formation. *t'*. Together with the dotted lines above, indicates the direction in which the testicle and epididymis descend from the abdomen into the scrotum. *vd*. Vas deferens. *vh*. Vas aberrans. *vs*. The vesicula seminalis. *W*. Scattered remains of the Wolffian body, constituting the organ of Giralde's, or the paradidymis of Waldeyer.

The Müllerian Ducts.—Shortly after the formation of the Wolffian ducts a second pair of ducts is developed. These are named the **Müllerian ducts**. Each arises on the outer aspect of the corresponding Wolffian body as a tubular invagination of the cells lining the coelom (Fig. 1194). The orifice of the invagination remains patent, and undergoes enlargement and modification to form the abdominal ostium of the Fallopian tube. The ducts pass caudad on the outer aspects of the Wolffian bodies, but toward the posterior end of the embryo they cross to the inner side of the Wolffian ducts, and thus come to lie side by side between and behind the latter—the four ducts forming what is termed the *genital cord* (Fig. 1197).

Ultimately, the Müllerian ducts open into the ventral part of the cloaca between the orifices of the Wolffian ducts, and terminate on an elevation named the *Müllerian eminence* (Fig. 1197).

In the male the Müllerian ducts atrophy, but traces of their cephalic ends are represented by the sessile hydatids of the epididymis, while their terminal fused portions form the uterus masculinus or sinus pularis in the floor of the prostatic portion of the urethra (Fig. 1200).

In the female, the Müllerian ducts persist and undergo further development. The portions which lie in the genital cord fuse to form the uterus and vagina; the parts cephalad of this cord remain separate, and each forms the corresponding Fallopian tube—the abdominal ostium of which is developed from the anterior extremity of the original tubular invagination from the coelom (Fig. 1199). The fusion of the Müllerian ducts begins in the third month, and the septum formed by their fused mesal walls disappears from below upward, and thus the cavities of the vagina and uterus are produced. About the fifth month an annular constriction marks the position of the neck of the uterus, and after the sixth month the walls of the uterus begin to thicken. The development of the vagina in the manner just described would necessitate the growth of a septum between it and the urethra; but Wood-Jones maintains that no such septum exists, and that “the vagina is, for a great part of fetal life, a solid rod, and not an open canal at all.” He says: “Early in the history of the embryo the Müllerian ducts open into the urogenital sinus at its upper part; late in its history they open at the hind-end of the vagina, and for a considerable interval they have no opening at all—the old one being lost and the new one not yet formed. No septal division is employed in this change; but as the hindgut, when its cloacal opening is lost, reestablishes communication with the exterior by a new downgrowth, so the Müllerian ducts, when their cloacal opening becomes obliterated, tunnel a new passage to the hind end.”

Genital Gland.—The first appearance of the genital gland is essentially the same in the two sexes, and consists in a thickening of the epithelial layer which lines the peritoneal or body cavity on the inner side of the Wolffian ridge. Beneath the thickened epithelium an increase in the mesoderm takes place, forming a distinct projection. This is termed the *genital ridge* (Fig. 1135), and from it the testis in the male and the ovary in the female are developed. At first the Wolffian body and genital ridge are suspended by a common mesentery, but as the embryo grows the genital ridge gradually becomes pinched off from the Wolffian body, with which it is at first continuous, though it still remains connected to the remnant of this body by a fold of peritoneum, the *mesorchium* or *mesovarium* (Fig. 1201). About the seventh week the distinction of sex in the genital ridge begins to be perceptible.

The **ovary**, thus formed from the genital ridge, consists of a central part of connective tissue covered by a layer of epithelium, the *germinal epithelium*. Between the cells of the germinal epithelium a number of larger cells, the *primitive ova*, are found, and these are carried into the subjacent stroma by bud-like ingrowths of the germinal epithelium, the cells of which surround the primitive ova; in this manner the primitive Graafian follicles are formed. The rest of the germinal epithelium on the surface of the ovary forms the permanent epithelial covering of this organ (Fig. 1202). According to Beard, the primitive ova are early set apart during the segmentation of the ovum and migrate into the germinal ridge.

Waldeyer taught, and for many years his views have been accepted, that the primitive germ cells are derived from the “germinal epithelium” covering the genital ridge. Beard, on the

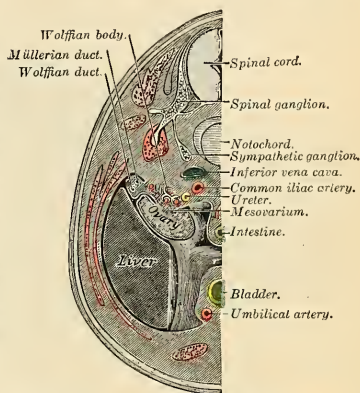


FIG. 1201.—Transverse section of human embryo of eight and a half to nine weeks old. (From model by Keibel.)

other hand, maintains that in the skate they are not derived from this epithelium, but are probably formed during the later stages of cell cleavage, before there is any trace of an embryo; and a similar view was advanced by Nussbaum as to their origin in amphibia. Beard says: "At the close of segmentation many of the future germ cells lie in the segmentation cavity just beneath the site of the future embryo, and there is no doubt they subsequently wander into it." The germ cells, "after they enter the resting phase, are sharply marked off from the cells of the embryo by entire absence of mitoses among them." They can be further recognized by their irregular form and amoeboid processes, and by the fact that their cytoplasm has no affinity for ordinary stains, but assumes a brownish tinge when treated by osmic acid. The path along which they travel into the embryo is a very definite one—viz., "from the yolk sac upward between the splanchnopleure and gut in the hinder portion of the embryo." This pathway, named by Beard the *germinal path*, "leads them directly to the position which they ought finally to take up in the 'germinal ridge.'" A considerable number apparently never reach their proper destination, since "vagrant germ cells are found in all sorts of places, but more particularly on the mesentery." Some of these may possibly find their way into the germinal ridge; some probably undergo atrophy, while others may persist and become the seat of dermoid tumors.

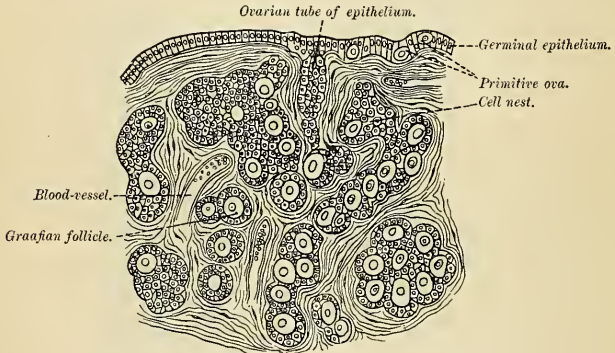


FIG. 1202.—Section of the ovary of a newborn child. (Waldeyer.)

The **testis** is developed in a very similar way to the ovary. Like the ovary, in its earliest stages it consists of a central mass of connective tissue covered by germinal epithelium, among which larger cells, the *primitive sperm cells*, are seen. These are carried into the subjacent stroma by tubes of germinal epithelium, which form the lining of the seminiferous tubules, while the primitive sperm cells form the spermatogonia. The seminiferous tubules become connected with outgrowths from the Wolffian body, which, as before mentioned, form the rete testis and vasa efferentia.

Descent of the Testes.—The testes, at an early period of fetal life, are placed at the back part of the abdominal cavity, behind the peritoneum and a little below the kidneys; their anterior surfaces and sides are invested by peritoneum. About the third month of intrauterine life a peculiar structure, the **gubernaculum testis**, makes its appearance. This is at first a slender band, extending from that part of the skin of the groin which afterward forms the scrotum through the inguinal canal to the body and epididymis of the testis, and is then continued upward in front of the kidney toward the Diaphragm. As development advances, the peritoneum covering the testis encloses it and forms a mesentery, the *mesorchium*, which encloses also the gubernaculum and forms two folds, one above the testis and the other below it. The one above the testis is the *plica vascularis*, and contains ultimately the spermatic vessels; the one below, the *plica gubernatrix*, contains the lower part of the gubernaculum, which has now grown into a thick cord; it terminates below at the internal ring in a tube of peritoneum, the *processus vaginalis*, which protrudes itself down the inguinal canal. The lower part of the gubernaculum by the fifth month has become a thick cord, while the upper part has disappeared. The lower part can now be seen to consist of a central core of unstriped muscle fibre, and outside this of a firm layer of striped elements, connected, behind the peritoneum, with the abdominal wall. As the scrotum develops, the main portion of the lower end of the gubernaculum is carried with the skin to which it is attached to the bottom of this pouch; other bands are carried to the inner side of the thigh and to the perineum. The fold of peritoneum, constituting the *processus vaginalis*, projects itself downward into the inguinal canal, and emerges at the external abdominal ring,

pushing before it a part of the Internal oblique and the aponeurosis of the External oblique, which form, respectively, the Cremaster muscle and the external spermatic fascia. It forms a gradually elongating pouch or *cul-de-sac*, which eventually reaches the bottom of the scrotum, and behind this the testis is drawn by the growth of the body of the fetus, for the gubernaculum does not grow commensurately with the growth of other parts, and therefore the testis, being attached by the gubernaculum to the bottom of the scrotum, is prevented from rising as the body grows, and is drawn first into the inguinal canal and eventually into the scrotum. It seems certain also that the gubernacular cord becomes shortened as development proceeds, and this assists in causing the testis to reach the bottom of the scrotum. By the eighth month the testis has reached the scrotum, preceded by the lengthened pouch of peritoneum, the processus vaginalis, which communicates by its upper extremity with the peritoneal cavity. Just before birth the upper part of the pouch usually becomes closed, and this obliteration extends gradually downward to within a short distance of the testis. The process of peritoneum surrounding the testis is now entirely cut off from the general peritoneal cavity and constitutes the *tunica vaginalis*.¹

In the female there is also a gubernaculum, which effects a considerable change in the position of the ovary, though not so extensive a change as in that of the testis in the male. The gubernaculum in the female, as it lies on either side in contact with the fundus of the uterus, contracts adhesions to this organ, and thus the ovary is prevented from descending below this level. The

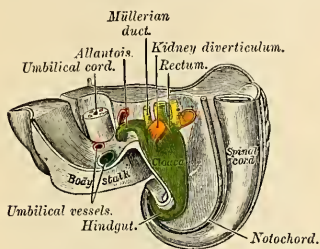


FIG. 1203.—Tail end of human embryo of twenty-five to twenty-nine days old. (From model by Keibel.)

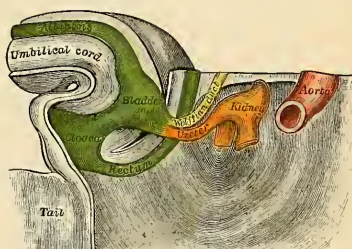


FIG. 1204.—Tail end of human embryo of thirty-two to thirty-three days old. (From model by Keibel.)

upper part of the gubernaculum, *i. e.*, the part between the ovary and the uterus, becomes ultimately the rounded ligament of the ovary, while the lower part, *i. e.*, the part between the attachment of the cord to the uterus and its termination in the labium majus, ultimately forms the round ligament of the uterus. A pouch of peritoneum accompanies it along the inguinal canal, analogous to the processus vaginalis in the male; it is called the *canal of Nuck*. In rare cases the gubernaculum may fail to contract adhesions to the uterus, and then the ovary descends through the inguinal canal into the labium majus, extending down the canal of Nuck, and under these circumstances its position resembles that of the testis in the male.

The Metanephros or Permanent Kidney.—The rudiments of the permanent kidneys make their appearance about the end of the first or beginning of the second month. Each arises as a diverticulum from the hind end of the Wolffian duct, close to where the latter opens into the cloaca (Figs. 1203, 1204). This diverticulum grows cephalad into the posterior part of the intermediate cell mass, where its blind or cephalic extremity becomes dilated and subsequently divides into several buds, which form the rudiments of the pelvis and calices of the ureter. By further subdivisions it gives rise to the collecting tubules of the kidney. The secretory tubules are developed from condensations of the nephrogenic tissue. At first these are spherical masses of cells which become hollowed, forming the *renal vesicles*. These become elongated and S-shaped; one end of the S-shaped tube becomes continuous with the lumen of a renal diverticular branch, the other end becomes cup-shaped and then spherical, being invaginated by a tuft of capillaries derived from the renal artery to form a glomerulus. The intervening portions of the tube become convoluted and looped to form the uriniferous tubule. The mesoderm around the subdivisions of the diverticulum becomes condensed to form the connective tissue and vessels of the kidney. The diverticulum is elongated to form the ureter, the posterior extremity of which opens at first into the hind end of the Wolffian duct; after the sixth week it separates from the Wolffian duct, and opens independently into the part of the

¹ The obliteration of the process of peritoneum which accompanies the cord, and is hence called the *funicular process*, is often incomplete.

cloaca which ultimately becomes the bladder (Fig. 1205). The manner in which this separation is brought about is not fully known.¹

The secretory tubules of the kidney become arranged into pyramidal masses or lobules, and the lobulated condition of the kidneys exists for some time after birth, while traces of it may be found even in the adult. The kidney of the ox and many other animals remains lobulated throughout life.

The Urethra.—In the female the urethra is formed from the upper part of the urinogenital sinus—viz., that part which lies above the openings of the Wolffian and Müllerian ducts. The portion of the sinus below these openings becomes gradually shortened, and it is ultimately opened out to form the vestibule, and in this manner the urethra and vagina come to open separately on the surface. Wood-Jones regards the female urethra as “the cloacal remnant in its simplest form,” and points out that “it does not remain tubular throughout fetal life, but is for a time obliterated more or less completely by the proliferation of the vaginal bulbs.” Developmentally considered, the male urethra consists of two parts—(1) the prostatic and membranous portions, which are derived from the urinogenital sinus, and correspond to the whole of the female urethra; (2) the penile portion, which is formed by the fusion of the inner genital folds.

The prostate gland originally consists of two separate portions, each of which arises as a series of diverticular buds from the epithelial lining of the urinogenital sinus, between the third and fourth months. These buds become tubular, and form the glandular substance of the two

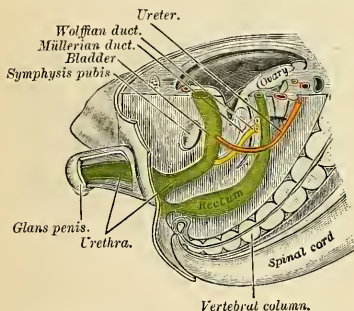


FIG. 1205.—Tail end of human embryo, from eight and a half to nine weeks old. (From model by Keibel.)

lobes, which ultimately meet and fuse behind the urethra and also extend on to its ventral aspect. The third or middle lobe is formed as an extension of the lateral lobes between the common ejaculatory ducts and the bladder. Skene's ducts in the female urethra are regarded as the homologues of the prostatic glands.

The glands of Cowper in the male, and of Bartholin in the female, also arise as diverticula from the epithelial lining of the urogenital sinus.

The Urinary Bladder.—The trigone of the bladder is formed from the upper part of the urinogenital sinus; the remainder of the viscus is developed from the part of the cloaca which lies above the sinus (Fig. 1204). The bladder is at first tubular in shape, its canal being continuous with that of the allantois, but after the second month its cavity expands to form a sac, from the summit of which the tube of the allantois extends to

the umbilicus; this tube undergoes obliteration to form the fibrous cord of the urachus. In some cases the allantoic canal remains patent, and urine may escape by it at the umbilicus. If the urethra be looked upon as the remnant of the cloaca, then the bladder, with the exception of the trigone, must be regarded as being developed by a dilatation of the proximal part of the allantois.

The external organs of generation (Fig. 1206), like the internal, pass during development through an indifferent stage in which there is no distinction of sex. It is therefore necessary to describe this stage, and then follow the development of the female and male organs, respectively.

The cloacal membrane, which is composed of ectoderm and entoderm, originally extends from the umbilicus to the tail. The mesoderm around the cloacal chamber gradually extends between the layers of the membrane, stopping short, however, around the margins of the entodermal cloaca, so that the bilaminar cloacal membrane is limited to this part. About the fifth week a prominence, the genital tubercle, arises in front of the cloacal membrane, while at the sides the edges of the mesoderm are elevated to form the labioscrotal or outer genital folds.

Along the under surface of the genital tubercle the ectoderm is thickened, and at the apex of the tubercle projects forward as an epithelial horn. In this ectodermal thickening a longitudinal

¹ The separation of the uterus from the Wolffian duct may be brought about by the absorption of the hinder end of the latter into the genitourinary chamber, and by the growth of the wall of this chamber between the openings. Robinson (Proceedings of the Anatomical Society of Great Britain and Ireland, May, 1903, p. 63) states, regarding an embryo of about seven weeks, that “from the posterior or lower opening of the Wolffian duct a grooved ridge, the Wolffian ledge, runs caudally on the wall of the genitourinary chamber and gradually disappears at the junction of the Wolffian angle with the body of the chamber. The lateral margins of the groove are continuous anteriorly with the lateral margins of the Wolffian duct, and apparently fuse together to form the ventral wall of the lower part of the duct. Obviously, if the lateral margins of the groove were to fuse from before backward, the aperture of the Wolffian duct would be carried farther backward in the chamber, and its distance from the opening of the ureter increased.”

groove, the genital groove, appears, and into its lips the mesoderm extends to form the *inner genital folds*. After the rupture of the cloacal membrane this groove becomes continuous with the urogenital sinus. With the formation of these parts the *indifferent stage* of the external genital organs is reached.

In the *female* this stage is largely retained; the lower part of the urinogenital sinus persists as the vestibule, the genital tubercle forms the clitoris, the labioscrotal folds the labia majora, and the inner genital folds the labia minora.

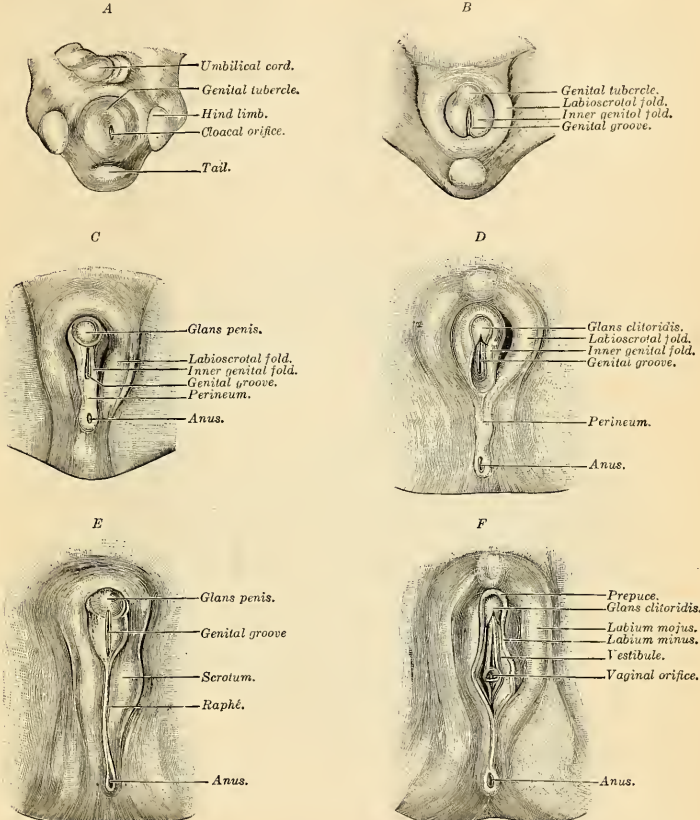


FIG. 1206.—Stages in the development of the external sexual organs in the male and female. (Drawn from the Ecker-Ziegler models.)

In the *male* the changes are greater on account of the development of the penile portion of the urethra. The genital tubercle enlarges to form the corpora cavernosa and glans penis. The lips of the inner genital folds meet and fuse from behind forward to form the penile urethra, the bulb, and the corpus spongiosum. The part of the urethral groove on the glans penis is closed independently, and the last part of the urethral tube to be completed is that at the junction of the glans and body of the penis. If the lips of the groove fail to close, the condition known as *hypospadias* results.

The labioscrotal folds meet and unite in the middle line to form the scrotum, their line of union being indicated by the median raphé.

The *prepuce* is formed by the growth of a solid plate of ectoderm into the superficial part of the genital tubercle; on coronal section this plate presents the shape of a horseshoe. By the breaking-down of its more centrally situated cells this plate is split into two lamellæ and a cutaneous fold, the prepuce,¹ is liberated and forms a hood over the glans. "Adherent prepuce is not an adhesion really, but a hindered central desquamation" (Berry Hart, *op. cit.*).

The homologies of the different parts of the sexual organs may be stated in tabular form as follows:

INOIFFERENT STAGE.	MALE.	FEMALE.
Genital Ridge. .	Testis (secretory portion).	Ovary.
Wolfian body. .	Rete testis, vasa efferentia, coni vasculosi, paradidymis.	Epoöphoron or organ of Rosenmüller. Paroöphoron.
Wolfian duct. .	Canal of epididymis, vas deferens, common ejaculatory duct. Seminal vesicle.	Hydatid of Morgagni. (Duct of Gärtner.)
Müllerian ducts. .	Sessile hydatids of epididymis. Uterus masculinus.	Fallopian tubes, uterus, vagina.
Genital tubercle. .	Corpora cavernosa and glans penis.	Clitoris.
Urinogenital sinus	Prostatic and membranous parts of urethra.	Urethra. Vestibule.
Inner genital folds	Penile urethra, bulb, and corpus spongiosum.	Labia minora.
Labioscrotal folds	Scrotum.	Labia majora.

THE MAMMARY GLAND (MAMMA) (Figs. 1208, 1210).

The **breasts**, **mammary glands** or **mammæ**, secrete the milk, and are accessory glands to the organs of reproduction. They develop fully in the female, but usually remain rudimentary in the male. There are two of these glands, and they are situated in the superficial fascia of the anterior portion of the thorax.

Description of a Well-developed Breast.—Each gland appears as a hemispherical body projecting from the front of the thorax beneath the skin and lying over a portion of the Pectoralis major muscle and a smaller portion of the Serratus magnus muscle. The hemispherical projection extends usually from the margin of the sternum to the axilla and from the level of the second rib to the level of the sixth rib, or from the third rib to the seventh rib, but this does not represent the real size of the gland. The gland is much larger than this, being rendered so by tails or prolongations of breast tissue, which will be described later (p. 1430).

The **nipple** (*papilla mammae*) (Figs. 1207 and 1210) projects from a little below and to the median side of the summit of the hemisphere at or above the level of the fifth rib, and is covered with thin skin. The right nipple may not exactly correspond in situation and direction to the left nipple. The nipple varies considerably in height and shape. In the virgin it is usually cylindrical and is directed forward and slightly upward and outward. The apex of the

¹ Spicer (Journal of Anatomy and Physiology, vol. xliii, 1909) describes the prepuce as arising in the form of an annular hood of mesoblastic tissue which proceeds forward *within the substance of the surrounding epithelium*. "The main portion of this hood springs from mesoblastic tissue considerably posterior to the cervix glandis, is in the form of a crescentic swelling, or collar, and this creeps forward, burrowing always in the epithelial layers, bridging over the groove of the cervix which is filled with epidermal cells, and finally overlaps the body of the glans. This hood is the prepuce."

"The epidermis covering the glans thus becomes divided into two layers—an outer, which forms the superficial covering of the prepuce, and an inner, which remains as a more or less solid layer between the prepuce and the glans until after birth. From it is differentiated a basal layer of cubical or cylindrical epithelium to line the inner aspect of the prepuce, and another to cover the surface of the glans, while central desquamation ensues later and prepares the way for a movable prepuce."

nipple is rendered rough by fissures (Fig. 1207), it exhibits a depression in which are the openings of the milk ducts (Fig. 1209), and its circumference is thrown into concentric ridges (Fig. 1209). The nipple is surrounded by a darker circular wrinkled area, the **areola** (*areola mammae*) (Figs. 1207 and 1208), which contains sweat glands and on which are twelve or fifteen small rounded elevations. These elevations are caused by cutaneous sebaceous glands which in structure represent a transition between sebaceous and mammary glands. They are probably rudimentary portions of the mammary gland and are known as the **glands of Montgomery** (*glandulae areolares*) (Fig. 1209). The color of the nipple and areola varies with the complexion of the individual. In brunettes it is darker than in blondes. The usual color of the nipple in a young woman is rosy pink, the areola being of a darker shade. During the early months of pregnancy the nipple and areola become dark brown in color, the areola becomes larger in circumference, and the glands of Montgomery increase in size (Fig. 1210). The nipple contains nonstriated muscle, and mechanical irritation or sexual excitement makes it stiff and erect. The skin covering the breast is clear, soft, and delicate, and subcutaneous veins are often visible. The skin of the nipple and areola is particularly delicate.

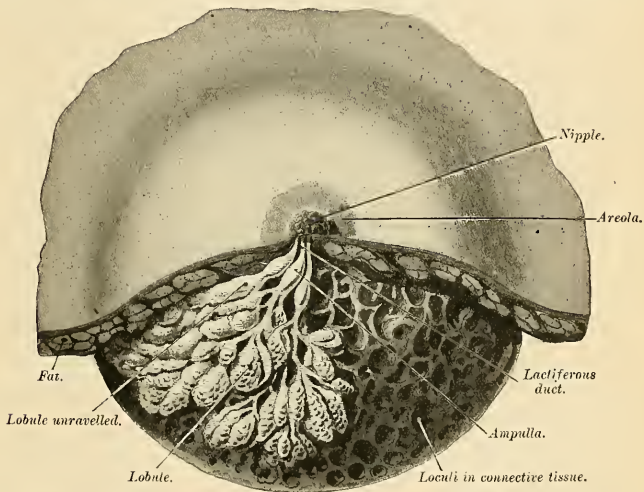


FIG. 1207.—Dissection of the lower half of the female breast during the period of lactation. (From Luschka.)

Variations in the Mammæ.—Before puberty the glands are small, are of the infantile type, grow slowly, and differ but slightly from the male organs. The nipple is small, flat, and pale. At puberty the increase in the size of the breast is rapid and considerable, due to growth of gland tissue and of subcutaneous fat. In the young virgin the breasts are of hemispherical form and of firm consistency. During pregnancy the breasts enlarge greatly and remain very large throughout lactation. This enlargement is due to new gland tissue and increased vascularity. Numerous blue veins are visible in the skin, the areola darkens, and the glands of Montgomery enlarge (Fig. 1210). After the termination of lactation the breasts diminish in size. They do not become as small as the virgin breast, are apt to lose their hemispherical outlines, and become soft and

flabby. They droop as flaccid pendulous masses, the subcutaneous fat is largely gone, and the outlines of the lobular breast tissue can be seen and felt. The nipple is long and hangs down like a teat. At the menopause the breast usually shrinks. In some cases, however, it actually increases in size. In such a case, although the gland atrophies, there is an extensive deposit of fat. In old age the glands undergo atrophy and largely disappear, the skin is flabby and thrown into wrinkles, and the breasts contain very little glandular structure, and are hard from the presence of fibrous tissue. The nipples become pigmented and corrugated. Women vary greatly in the development of the breasts. In some women they are large, firm, and well proportioned; in others they are small, flat, or atrophy occurs in the course of certain bodily diseases, as in phthisis, and in certain mental diseases, as melancholia. If the ovaries are ill-developed the breasts remain flat and small. The outline and direction of the breast and also of the nipple may be altered by corsets. The left mamma is usually somewhat larger than the right.

One gland or both glands may be entirely absent, the nipple being also absent. One or both glands may be absent, one or both nipples being present. When there is only one nipple, it is apt to be the left. The term **polymazia** (*mammæ accessorie muliebris*) means the presence of supernumerary breasts, with or without nipples. **Polythelia** means the presence of supernumerary nipples, the associated glandular structure being rudimentary. There may be one, two, or several supernumerary breasts, and when more than one exists, are usually asymmetrical. If one is functionally active, it enlarges during pregnancy and furnishes milk.

Supernumerary *mammæ* may secrete milk or may be without function. The most common situation is on the part of the chest below and to the inner side of the normally placed gland. They may also exist in the axilla, the abdomen, the groin, the back and the thigh. Many cases of supposed supernumerary glands have been really instances in which moles, warts, or sebaceous cysts have been mistaken for nipples, but some cases are undoubted.

Prolongations of Mammary Tissue.—As previously stated, the outlines of the breast are not regular, but here and there tails, prolongations, or cusps come off from and are true portions of the gland. Two or even more prolongations pass to the edge of the sternum; others pass toward the axilla, the clavicle, and the origin of the External oblique muscle from the ribs. Underneath the mammary gland prolongations of mammary tissue penetrate the pectoral fascia (Heidenhain). If one of the glandular cusps is of considerable size it is called an **outlying lobule**.

Structure of Mammary Gland and Nipple (Figs. 1207 and 1208).—The **glands of the breast** (*corpus mammæ*) rest by a smooth posterior surface upon the loose pectoral fascia, which fastens the breast to the muscle beneath, but so loosely that the breast is movable. The mamma consists of gland tissue; of fibrous tissue, connecting its lobes, of fatty tissue in the intervals between the lobes, of retinacula, and of skin. The gland tissue, when freed from fibrous tissue and fat, is of a pale reddish color, firm in texture, generally globular in form, with prolongations here and there, flattened from before backward, thicker in the centre than at the circumference, and presenting several inequalities on its surface, especially in front. On the anterior surface there are many irregular elevated processes with deep spaces between them. From the summits of the elevations connective-tissue strands (*retinacula cutis*) pass to the true skin. The glandular structure consists of numerous glands divided into **lobes** (*lobi mammæ*), and these are composed of **lobules** (*lobuli mammæ*), connected by areolar tissue, which contains the bloodvessels and ducts. The smallest lobules consist of a cluster of rounded **alveoli** (Fig. 1207), which open into the smallest branches of the excretory ducts; these ducts, uniting, form larger ducts, which terminate in single canals. Each canal is called a **lactiferous, galactophorous, or mamillary duct** (*ductus lactiferus*) (Fig. 1207). The alveoli are tubular in form and are lined by low columnar epithelial cells which rest upon a basement membrane.¹ Each glandular area possesses one lactiferous duct. This passes to the apex of the lobe and then into the nipple. The lactiferous ducts are white and cord-like, and contrast with the yellowish-red tissue of the gland itself. The number of excretory ducts varies from fifteen to twenty, each representing an individual gland. They converge toward the areola, beneath which each duct possesses a spindle-shaped

¹ According to Lacroix and Benda, there is a thin layer of nonstriated muscle between the basement membrane and the secreting cell.

dilatation, the **ampulla** (*sinus lactiferans*) (Fig. 1207). The ampullæ serve as reservoirs for the milk. At the base of the nipple the ducts become contracted and pursue a straight course to its summit, perforating it by separate orifices considerably narrower than the ducts themselves. Each orifice (*porus lactiferus*) is the orifice of a tube which drains an individual gland. The ducts are composed of areolar tissue, with longitudinal and transverse elastic fibres and some muscle tissue derived from that of the nipple; their mucous lining is continuous, at the point of the nipple, with the integument. The epithelium of the mammary gland differs according to the state of activity of the organ. In the gland of a woman who is not pregnant or nursing the alveoli are very small, few in number, solid, and filled with a mass of granular polyhedral cells. During pregnancy the alveoli increase in number and enlarge and the cells undergo rapid multiplication. At the commencement of lactation the cells in the centre of an alveolus undergo fatty degeneration, and are eliminated in the first milk as **colostrum corpuscles**. The peripheral cells of the alveolus remain, and form a single layer of granular, short columnar cells lining the limiting *membrana propria*. The single nucleus of each cell divides and forms two.

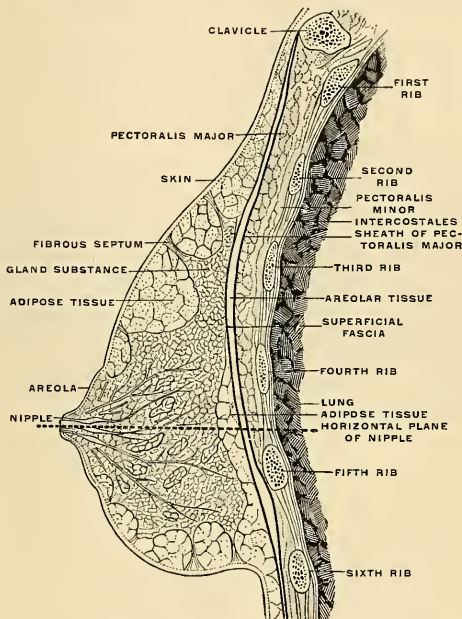


FIG. 1208.—Right breast in sagittal section, inner surface of outer segment. (Testut.)

In the protoplasm, especially in the end of the cells toward the alveolus, drops of fat appear and the nucleus toward this end of the cell also becomes fatty.

The end of the cell toward the alveolus breaks down, and the liberated material constitutes "the albuminous ingredients of the milk, while the drops of fat become the milk globules. The portion of the cell which remains forms new cytoplasm, and the same process is repeated over and over again. The cells also secrete water and the salts which are found in the milk."¹

After lactation a number of the alveoli atrophy and disappear, while the remainder become much reduced in size. The gland then consists mainly of adipose and fibrous tissues.

The **fibrous tissue** (Fig. 1208) invests the entire surface of the breast, and sends down septa between its lobes, which serve to hold them together.

The **fatty tissue** (Figs. 1207 and 1208) surrounds the surface of the gland and occupies the intervals between its lobes. It usually exists in considerable abundance, and determines the form and size of the gland. There is no fat immediately beneath the areola and nipple.

¹ Human Physiology. By Joseph Howard Raymond.

Vessels and Nerves.—The arteries supplying the mammary gland are derived from the perforating branches of the internal mammary, the long thoracic branches of the axillary, and branches from the intercostals. The veins describe an anastomotic circle around the base of the nipple, called by Haller the *circulus venosus*. From this large branches transmit the blood to the circumference of the gland and end in the axillary and internal mammary veins. The lymphatics of the mammary gland (Fig. 562) and mammary region have been previously described (pp. 782 and 797). The nerves are derived from the fourth, fifth, and sixth intercostal nerves, and sympathetic filaments from the thoracic cord pass to the breast along the branches of the intercostal nerves.

Applied Anatomy.—Occasionally the mammary gland undergoes enormous *hypertrophy*. This may occur in any age, even in the virgin. The physiological enlargement of puberty may become excessive or the physiological enlargement of pregnancy and lactation may continue and increase after the termination of lactation. The chief elements in the enlargement are fat and connective tissue, and it is doubtful if there is extensive reproduction of glandular tissue.

Abscess of the breast may occur at any age, but is most common by far in nursing women. The portals are opened to infection by a crack in the nipple and bacteria are carried inward by the lymph vessels. In some cases the pus gathers beneath the skin (*supramammary abscess*), in others in the breast tissue (*intramammary abscess*). In rare cases pus gathers beneath the breast (*retromammary abscess*). In intramammary abscess the pus burrows through the fibrous septa or fascia and forms numerous channels, and such a channel is constricted in hour-glass shape at the point where it passes through fascia or a fibrous septum.

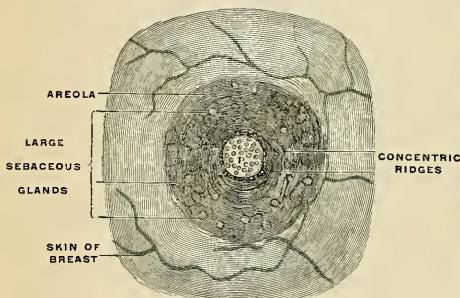


FIG. 1209.—Nipple and areola of a virgin. (Testut.)

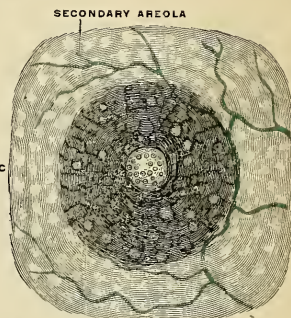


FIG. 1210.—Nipple and areolæ of a pregnant woman. (Testut.)

In every patient suffering from abscess the nipple should be examined for a sore or crack, and the area when found should be treated antiseptically. A supramammary abscess should be opened by an incision radiating from the nipple.

In intramammary abscess follow the advice of Sheild: Open the abscess by an incision radiating from the nipple, insert the index finger, and when possible pass it to the bottom of the abscess and carry the tip from the depths of the abscess to as near the surface as possible. At this point make a counter opening. The finger breaks down septa which cause constriction and thus converts the tracking sinuses into one large cavity.¹ Drain by tubes.

A retromammary abscess is opened by an incision, following the outline of the breast at the thoracomammary junction, the finger being pushed through the incision and up under the gland.

Tuberculosis of the breast may occur, and if it does, *cold abscess* is apt to form. The best treatment is removal of the gland and the associated lymph nodes.

Chronic mastitis is a condition of mammary fibrosis, most common in neurotic single women, and apt to be associated with ovarian or uterine disease.

Malignant dermatitis or *Paget's disease* of the nipple is a chronic condition consisting of epithelial proliferation, induration, desquamation, and ulceration, and it is apt to be followed by epithelioma.

Chanere of the nipple is occasionally met with.

Secondary and tertiary syphilitic lesions are seen upon the skin of the breast, the nipple, and the areola.

Cysts and tumors are common in the breast. There may be *cystic degeneration* of the gland in women near the menopause (*involution cysts*); a *lactal cyst*; a *hydatid cyst*; an *adenoma*

¹ Diseases of the Breast. By A. Marmaduke Sheild.

may become cystic. The nipple may suffer from *epithelioma*, *myoma*, *myxoma*, *angioma*, *papilloma*, or *fibroma*. The innocent tumors of the breast are *fibroadenoma*, *cystic adenoma*, *myxoma*, and *angioma*. The skin of the breast may suffer from any form of growth or cyst which could arise from the skin of another part. Malignant tumors of the glandular structure are ten times as frequent as innocent tumors. *Sarcoma* is rare; *carcinoma* is very common.

Carcinoma of the breast has occupied much of the attention of surgeons during recent years. The old operation was uniformly followed by recurrence. The modern radical operation has been evolved from the studies of Moore, the younger Gross, Heidenhain, Stiles, Banks, Halsted, and others. The modern operation always removes at least the skin and subcutaneous tissue over the hemispherical portion of the breast, the outlying lobules of the breast, the pectoral fascia, and the sternal portion of the great Pectoral muscle, the lymphatic tracts from the breast, the lymphatic nodes and cellular tissue from the axilla, and from beneath the Latissimus dorsi muscle. The pectoral fascia and the sternal portion of the great Pectoral muscle must come away in every case, because breast tissue may pass through the fascia. The entire breast must be removed, because even in a recent case the entire breast is regarded as infected. The clavicular portion of the great Pectoral muscle is anatomically distinct from the sternal portion and its removal is not imperative. Some operators remove the lesser Pectoral muscle. To leave it is of no value to the arm, and it frequently causes an annoying rigid band anterior to the axilla. To take it away gives ready access to the axillary vessels at a desirable point above. The sheath of the axillary vein should be removed with the nodes and cellular tissue of the axilla. The nodes receiving lymph from the cancerous area must be removed, of course. In view of the fact that in an undetermined percentage of cases a lymph tract passes direct to the subclavian nodes, it is evident that these nodes may become infected by this route instead of, as is more usual, secondarily to axillary infection; hence it seems wiser in every case to remove the cellular tissue and nodes from the subclavian triangle. All of these structures should be removed as one piece, in order to avoid cutting across lymph tracts and flooding the wound with carcinoma cells which might adhere, grow, and reproduce cancer.

Halsted's operation is the method adopted by most surgeons. The wound cannot be completely closed, and the raw spot is covered at once or later with Thiersch's skin grafts. (For surgical considerations regarding the lymphatics in mammary carcinoma see page 804).

The **male breast** (*mamma virilis*) is a small, flat structure, consisting chiefly of connective tissue, but containing some branched tubules. Under normal circumstances it remains permanently of the infantile type. It possesses a nipple which is much smaller than that of the female breast, and which usually lies over the fourth intercostal space, but may lie over the fourth or fifth rib. The nipples of the two sides are rarely placed quite symmetrically. Accessory glands and accessory nipples are as common among males as females. The male breast may exhibit some evidence of temporary functional activity at birth and at puberty. Cases have been recorded of actual lactation by the male breast.

Applied Anatomy.—The male breasts may undergo enormous hypertrophy (*gynecomazia*). In these cases the penis is often small and the testicles may be atrophied. The breasts may be absent in the male. Disease of the male breast is not nearly so frequent as disease of the female breast. The organ may be the seat of syphilis, tuberculosis, acute or chronic mastitis, abscess or tumor. A number of cases of cancer of the male breast have been recorded.

THE DUCTLESS GLANDS.

THERE are certain organs, in various situations, which are very similar to secreting glands, but differ from them in one essential feature—viz., they do not possess any ducts by which their secretion is discharged. These organs are known as the **ductless glands**. They are capable of *internal secretion*—that is to say, of forming, from materials brought to them by the blood, substances which have a certain influence upon the nutritive and other changes going on in the body. This secretion is carried into the blood stream, either directly by the veins or indirectly through the medium of the lymphatics.

These glands include the thyroid and the parathyroids, the thymus, the spleen, the suprarenal glands, and the small carotid, coccygeal, and parasympathetic bodies, which will be described in this section. They also include the lymph and hemolymph nodes (or glands) which have already been described on pages 768 to 802; and the epiphysis (pineal gland) and hypophysis (pituitary) described with the brain on pages 906 and 909. Certain isolated cell masses in the pancreas, the testicle, and ovary, apparently engaged in internal secretion, are described with those organs.

THE THYROID GLAND OR BODY (GLANDULA THYREOIDEA) (Fig. 1211).

The **thyroid gland** is a highly vascular organ, situated at the front and sides of the neck, and extending upward upon each side of the larynx; it consists of two **lateral lobes** connected across the middle line by a narrow transverse portion, the **isthmus**.

The **weight** of the gland is somewhat variable, but is usually about one ounce. It is somewhat heavier in the female, in whom it becomes enlarged during menstruation and pregnancy.

The **lateral lobes** are conical in shape, the apex of each being directed upward and outward as far as the junction of the middle with the lower third of the thyroid cartilage; the base looks downward, and is on a level with the fifth or sixth tracheal ring. Each lobe is about two inches (5 cm.) in length, its greatest width is about one inch and a quarter (3 cm.), and its thickness about three-quarters (2 cm.) of an inch. The summit of the lateral lobe is not unusually pointed and reaches to the level of the oblique line upon the ala of the thyroid cartilage or even higher. The right lobe is, as a rule, somewhat larger than the left. The lower portion of the gland, when the head is extended, is about one inch above the upper margin of the sternum; when the head is flexed, it is at the level of the upper border of the sternum or even below and behind it.

The **external or superficial surface** is convex, and covered by the skin, the superficial fascia, the deep fascia, the Sternomastoid, the anterior belly of the Omohyoid, the Sternohyoid, and Sternothyroid muscles, and beneath the last-named muscles by the pretracheal layer of the deep fascia, which forms a capsule for the gland (Fig. 297).

The **deep or internal surface** is moulded over the underlying structures—viz., the thyroid and cricoid cartilages, the trachea, the Inferior constrictor and pos-

terior part of the Cricothyroid muscles, the œsophagus (particularly on the left side of the neck), the superior and inferior thyroid arteries, and the recurrent laryngeal nerves.

The deep surface of each lobe is fixed by bands of fibrous tissue passing from the capsule of the isthmus and lateral lobes to the sides of the cricoid cartilage and the posterior fascia of the trachea. These bands are called the **lateral** or

suspensory ligaments. Because of this fixation to the larynx and trachea by the capsule and by the lateral ligaments, the thyroid gland moves with the trachea and ascends during the act of swallowing. The recurrent laryngeal nerve on each side is in contact with the outer and posterior surface of the suspensory ligament.

The **anterior border** is thin, and inclines obliquely from above downward and inward toward the middle line of the neck, while the **posterior border** is thick and overlaps the common carotid artery.

The **isthmus** (*isthmus glandulae thyroidea*) connects the lower two-thirds of the two lateral lobes; it measures about half an inch in breadth and the same in depth, and usually covers the second and third rings of the trachea, but sometimes also the first and fourth rings. Its situation and size present, however, many variations, a point of importance in the operation of tracheotomy. In the middle line of the neck it is covered by the skin and fascia, and close to the middle line, on either side, by the Sternohyoid muscle. Across its upper border run branches of the superior thyroid artery and vein; at its lower border is a branch of the inferior thyroid veins. Sometimes the isthmus is altogether wanting.

The **third, pyramidal** or **middle lobe** frequently arises from the upper part of the isthmus, or from the adjacent portion of either lobe, but most commonly from the left lobe, and ascends in front of the thyroid cartilage in the direction of the middle of the hyoid bone. It may reach the bone or may not reach it. If it reaches the bone it is attached to it. If it does not reach the bone, fibrous tissue, which often contains muscle, is prolonged from the tip of the pyramid to the back of the bone or to the thyrohyoid membrane. The pyramid is occasionally quite detached, or divided into two or more parts.

A few muscle bands, derived from the Thyrohyoid muscles, are occasionally found attached, above, to the body of the hyoid bone, and below to the isthmus of the gland or its pyramidal process. These form a muscle, which was named by Soemmerring the *Levator glandulae thyroideae*.

Accessory Thyroids (*glandulae thyroideae accessoriae*).—Frequently small isolated masses of thyroid tissue exist. They are found particularly about the lateral lobes of the thyroid gland in the sides of the neck or just above the hyoid bone, and are called **accessory thyroids**.

Structure of the Thyroid (Fig. 1212).—The thyroid body is invested by a capsule of connective tissue which projects into its substance as a framework and imperfectly divides it into

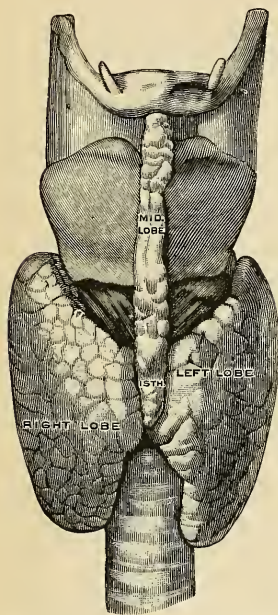


FIG. 1211.—The thyroid gland. (Spalteholz.)

masses of irregular form and size, known as lobes and lobules. More slender septa separate the secretory alveoli from one another. While the anterior portion of the capsule is thin and easily torn, the posterior portion is thick and dense. When the organ is cut into, it is of a brownish-red color, and is seen to be made up of a number of closed vesicles or alveoli containing a yellow glairy fluid and separated from each other by intermediate connective tissue.

It is a compound tubular gland, each lobule of which consists of a number of short closed tubules or alveoli, which are surrounded by the interstitial reticulum.

According to Baber, who has published some important observations on the minute structure of the thyroid, the vesicles of the thyroid of the adult animal are generally closed cavities; but in some young animals (*e. g.*, young dogs) the vesicles are more or less tubular and branched. This appearance he supposes to be due to the mode of growth of the gland, and merely indicating that an increase in the number of vesicles is taking place. Each vesicle is lined by a single layer of cuboidal epithelial cells which rest upon a delicate basement membrane. Between the tubules exists a delicate reticulum. The vesicles are of various sizes and shapes, and contain as a normal product a viscid, homogeneous, semifluid, slightly yellowish material which frequently contains red corpuscles in various stages of disintegration and decolorization, the yellow tinge being probably due to the hemoglobin, which is thus set free from the colored corpuscles. This normal product is known as **colloid material**, and it is secreted by the epithelium. What part if any the

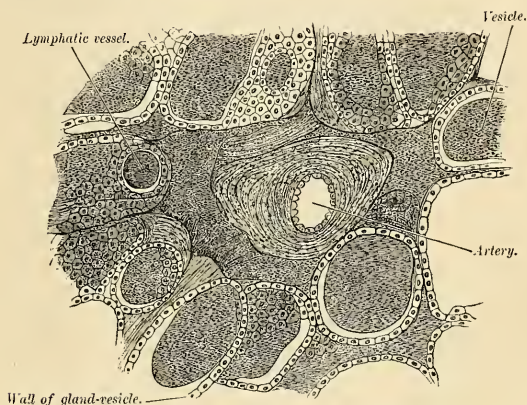


FIG. 1212.—Minute structure of the thyroid. From a transverse section of the thyroid of a dog. Semi-diagrammatic. (Baber.)

colloid plays in the formation of the internal secretion of the gland is not known. It is quite possible that the colloid corresponds to the external secretion of glands with ducts and that the true internal secretion passes directly into the capillaries which form a network about the alveoli (Szymonowicz), or passes into the lymphatics. In the thyroid gland of the dog, Baber has found large round cells, **parenchymatous cells**, each provided with a single oval-shaped nucleus, which migrate into the interior of the gland vesicles. Between the thyroid vesicles in the human being are collections of **round cells**. They are, in reality, miniature immature vesicles, and are much more numerous in youth than in old age.

The capillary bloodvessels form a dense plexus in the connective tissue around the vesicles, between the epithelium of the vesicles and the endothelium of the lymph spaces, which latter surround a greater or smaller part of the circumference of the vesicles. These lymph spaces empty themselves into lymphatic vessels which run in the interlobular connective tissue, not uncommonly surrounding the arteries which they accompany, and communicate with a network in the capsule of the gland. Small glands may be connected with this network. Baber has found in the lymphatics of the thyroid a viscid material which is morphologically identical with the normal constituent of the vesicle.

Vessels and Nerves.—The arteries (Figs. 444 and 499; see also p. 592) supplying the thyroid are the **superior thyroid** from the **external carotid**, and the **inferior thyroid** from the **thyroid axis** of the first part of the subclavian. Sometimes there is an additional vessel, the **thyroidea media** or **ima**, usually arising from the innominate artery, but sometimes from the arch of the aorta or the common carotid. It ascends upon the front of the trachea. The superior thyroid

artery reaches the summit of the upper horn of the gland, and usually at this point gives off a vessel which courses down the posterior surface of the gland. The main trunk passes downward and inward at the junction of the inner and anterior border of the upper horn, giving branches to adjacent structures and sending branches over the anterior surface of the thyroid gland. It reaches the isthmus and crosses the isthmus at its upper border to anastomose with the artery from the other side. The inferior thyroid artery, which is usually larger than the superior, after it has passed posterior to the sheath of the carotid and the sympathetic nerve, reaches the posterior surface of the gland. At this point branches are given off; some pass into the hilum; the others go to the posterior surface of the gland. The relation of the artery to the recurrent laryngeal nerve is very important to the surgeon. "Usually the main trunk of the artery passes behind the nerve; sometimes the artery breaks up before reaching the nerve; in this case one or more of the branches may pass in front of it. Much less commonly the main trunk or all its branches will be found to lie in front of the nerve."¹ If the thyroidea ima is present it goes to the lower part of the gland. The larger branches of the thyroid arteries are beneath the capsule and upon the surface of the gland; smaller branches pass to the interior of the gland (Berry). The arteries are remarkable for their large size and frequent anastomoses.

The **thyroid veins** (Figs. 498 and 499; see also p. 715) form a plexus upon the surface of the gland and beneath the capsule. Here and there veins pass through the capsule and go to adjacent venous trunks. Berry, accepting Kocher's description, notes the following veins: The **superior thyroid vein** runs with the superior thyroid artery and passes to the internal jugular vein. A **transverse vein** of the upper border of the isthmus joins the two superior thyroid veins. A single vein, the **middle thyroid**, sometimes emerges from the side of the gland and passes to the internal jugular. Usually, however, instead of this single vein there are two veins, the **superior** and **inferior accessory thyroids**. The **superior accessory thyroid** emerges from the outer side of the upper horn, below the apex, and passes to the internal jugular. The **inferior accessory thyroid** emerges from the posterior and inferior portion of the gland and passes to the internal jugular. The veins from the lower border of the gland vary greatly. A vein passes vertically down on each side in front of the trachea from the isthmus and from the inner side of the inferior horn. It is called by Kocher the **thyroidea ima**. The vein of the left side passes to the left innominate; the vein of the right side passes to the right innominate or left innominate. As Berry points out, the vein of one side may be small or may be absent, or the two veins may unite and form one vein which enters the left innominate. An **inferior thyroid vein** is often present. It is of small size, emerges at the inferior and external part of the gland, and passes to the corresponding innominate vein.²

The **lymphatics** are numerous and of large size. Collecting trunks arise from a network within the capsule. Some trunks ascend from the upper margin of the isthmus and reach the **node in front of the larynx**; others ascend along the superior thyroid artery and reach the **nodes at the bifurcation of the carotid**. Descending trunks from the lower margin of the isthmus reach the **nodes in front of the trachea**; trunks from the side of the gland descend to the **nodes about the recurrent laryngeal nerve**.³

The **nerves** of the thyroid are amyelinic and are derived from the middle and inferior ganglia of the sympathetic. They reach the gland by following the thyroid arteries.⁴

Applied Anatomy.—The thyroid gland may be congenitally absent, and when it is the individual suffers from the worst form of *cretinism*. One lobe may be congenitally absent, but this will provoke no trouble unless the other lobe undergoes atrophy.

Complete removal of the thyroid and parathyroids will produce operative *myxedema* (*cachexia strumipriva*), unless accessory thyroids enlarge and perform the functions of the thyroid.

The thyroid gland may be congenitally enlarged. The gland tends to atrophy in old age. It is atrophied in myxedema and cretinism. Some forms of thyroid enlargement are called *goitre*.

When all parts of the gland enlarge the condition is known as *parenchymatous goitre*.

Adenomatous goitre consists of an adenoma or of adenomata. In *cystic goitre* there are one or more cysts due to cystic degeneration of adenomata or to fusion of adjacent tubules.

A *pulsating goitre* is one which receives impulses from the carotid pulsations. In a *fibroid goitre* there is increase of interstitial connective tissue. A goitre which passes back of the sternum is known as *substernal* or *intrathoracic*. A goitre may extend back of the trachea or back of the oesophagus.

Exophthalmic goitre, Graves' disease or Basedow's disease, is a remarkable disease. Its three chief symptoms are enlargement of the thyroid, or *goitre*; prominence of the eyeballs, or *exophthalmos* (see p. 372); and very rapid pulse, or *tachycardia*. Dyspnea, tremor, and various other symptoms are usually found. The thyroid gland may be the seat of a *carcinoma* or *sarcoma* (*malignant goitre*), *syphilitic* or *tuberculous* disease, ordinary *inflammation*, *suppuration*, or

¹ Diseases of the Thyroid Gland. By James Berry.

² The Lymphatics. By Poirier, Cunéo, and Delamere. Translated and edited by Cecil H. Leaf.

⁴ D. A. Rhinehart: Amer. Jour. of Anat., vol. xiii, May 15, 1912.

³ Ibid.

hydatid disease. For the relief of ordinary goitre various methods have been employed. Tapping, injection of astringents, simple incision, and the seton are obsolete. Ligation of the thyroid arteries is rarely performed as a curative measure. The superior and inferior thyroids of one side have been tied in some cases; all four thyroids in other cases. Jaboulay has performed *exothyropexy*. In this operation the gland is dislocated from its bed, brought out of the wound, and left exposed, in hope that it will atrophy.

Division of the isthmus is occasionally practised to relieve dyspnea. The operation sometimes succeeds, but often fails.

Extirpation of one-half or two-thirds of the gland is a very successful operation. Removal of the entire gland will be followed by operative myxedema. Removal or injury of the parathyroids causes tetany.

In *extirpating* a lobe of the thyroid by the method until recently in vogue, great care must be taken to avoid tearing the capsules, as if this happens the gland tissue bleeds profusely. The thyroid arteries should be ligated on the diseased side before an attempt is made to remove the mass, and in ligating the inferior thyroid the position of the recurrent laryngeal nerve must be borne in mind, so as not to include it in the ligature. In order to preserve the parathyroids from injury, C. H. Mayo recommends that after the vessels entering and leaving the thyroid have been double clamped and divided, the entire lobe should be elevated, the capsule split along the side of the gland and pushed back with gauze, and the gland lifted and removed without disturbing the posterior portion of the capsule. As pointed out before, the posterior portion of the capsule is so thick and strong that it is easier to leave it *in situ* than to bring it out of the wound with the gland.

A cystic or solid tumor of the thyroid may be removed by *intraglandular enucleation*. If operation becomes necessary in exophthalmic goitre, partial extirpation is usually preferred. Bilateral extirpation of the cervical ganglia of the sympathetic (*sympathectomy* or *Jonnesco's operation*) has been practised by some surgeons for exophthalmic goitre. The value of the procedure is uncertain.

THE PARATHYROID GLANDS (Fig. 1213).

The **parathyroid glands** are small, brownish-red bodies, situated near the thyroid gland, but differing from it in structure, being composed of masses of cells arranged in a more or less reticular fashion with numerous intervening bloodvessels. They measure on an average about a quarter of an inch (6 mm.) in length, and from an eighth to a sixth of an inch (3 to 4 mm.) in breadth, and usually present the appearance of flat oval disks. They are classified according to their position into *superior* and *inferior*. The superior, usually two in number, are the more constant in position, and are situated, one on either side, at the level of the lower border of the cricoid cartilage, behind the junction of the pharynx and œsophagus, and in front of the prevertebral fascia. The inferior, also usually two in number, may be applied to the lower edge of the lateral lobe, or may be placed at some little distance below the thyroid body, or may be found in relation with one of the inferior thyroid veins. Although there are usually four parathyroids, there may be but three, or there may be six or even eight. Parathyroid tissue may exist within the thyroid gland even when the superior parathyroids are present. Accessory parathyroids may be found over a wide area. Rogers and Fergusson found one in the middle of the posterior portion of the pharynx. Ogle found a gland in the thorax which was partly parathyroid.

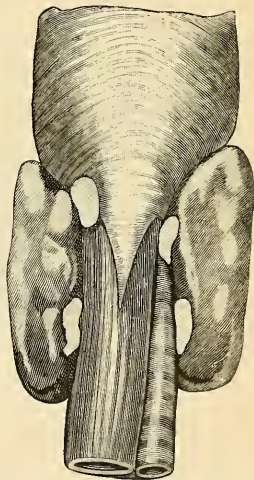


FIG. 1213.—The position of the parathyroid glands. Viewed from behind. (Zuckerkindl.)

Structure.—The structure of the parathyroids is different from that of the thyroid. They are composed of groups of epithelial cells arranged in a chain-like fashion with numerous intervening capillaries. There is a certain type of cell, but the form varies. These variations result from changes due to episodes of rest and activity (Verebely). MacCallum's studies seem to lead to the same conclusion. Thomson¹ states that he finds only one type of cell in the infant gland, and that in the adult there is primarily but one type of cell, the other cells noted being modifications of the principal cell due to degeneration or hyperfunction. There is much lymphoid tissue in the interstitial connective tissue. The capillaries are of the sinusoidal variety. The nerves of the parathyroids are derived from the sympathetic system. Each parathyroid gland is supplied by a parathyroid artery. The inferior parathyroid artery is always a branch of the inferior thyroid artery or of the anastomosing channel between the superior and inferior thyroid arteries of one side (Geist). The superior parathyroid artery may be a branch of the superior thyroid (Poole), but it is usually a branch of the inferior thyroid or of the anastomosing channel. Ginsburg² has shown that each of the glands has an accessory blood supply, by anastomotic channels from the opposite side.

Embryology.—The parathyroids develop chronologically in advance of the thyroid. They are derived from the third and fourth branchial clefts of each side. An independent accessory parathyroid may develop from the fifth cleft (Getzowa, Michand). Some have regarded the parathyroids as embryonic portions of the thyroid, but, as MacCallum says, "there is no histological proof that parathyroid tissue can ever become converted into thyroid tissue." Most observers regard the parathyroids as distinct glands possessed of a special function. Certain it is, as Gley³ and others have shown, removal of the parathyroids from herbivora, leaving the thyroid intact, is followed by spasms, tetany, etc., just as complete thyroidectomy is followed by such symptoms in carnivora.

Applied Anatomy.—Surgeons have become convinced that removal of the parathyroids in man causes tetany, and that damage to them may produce serious symptoms. Because of this danger most surgeons now prefer to remove a goitre from within the capsule of the thyroid gland, after the plan of the Mayos, and thus avoiding the parathyroids.

THE THYMUS GLAND (Fig. 1214).

The **thymus gland** is a temporary organ, attaining its full size at the end of the second year, when it ceases to grow and remains practically stationary until puberty, at which period it rapidly degenerates. It does not entirely disappear,

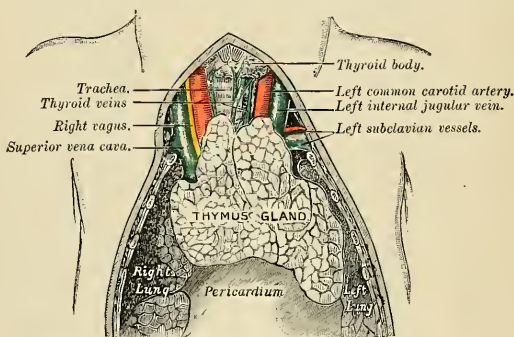


FIG. 1214.—The thymus gland of a full-time fetus exposed *in situ*.

for the shrunken and degenerated mass, even later in life, maintains a likeness to the original form and retains within its substance small portions of thymus tissue (Waldeyer). If examined when its growth is most active, it will be found to con-

¹ Internal Secretions. By William Hanna Thomson. New York Medical Journal, November 19, 1904.

² University of Pennsylvania Medical Bulletin, January, 1905.

³ American Journal of the Medical Sciences, 1907, n. s., cxxxiv, p. 562.

sist of two lateral lobes placed in close contact along the middle line, situated partly in the superior mediastinum, partly in the neck, and extending from the level of the fourth costal cartilage upward as high as the lower border of the thyroid gland. It is covered by the sternum and by the origins of the Sternohyoid and Sternothyroid muscles. *Below*, it rests upon the pericardium, being separated from the arch of the aorta and great vessels by a layer of fascia. In the neck it lies on the *front* and *sides* of the trachea, *behind* the Sternohyoid and Sternothyroid muscles. The two lobes generally differ in size; they are occasionally united so as to form a single mass, and are sometimes separated by an intermediate lobe. The thymus is of a pinkish-gray color, is soft, and is lobulated on its surfaces. It is about two inches (5 cm.) in length, one and a half inches (3.75 cm.) in breadth below, and about a quarter of an inch (6 mm.) in thickness. At birth it weighs about half an ounce.

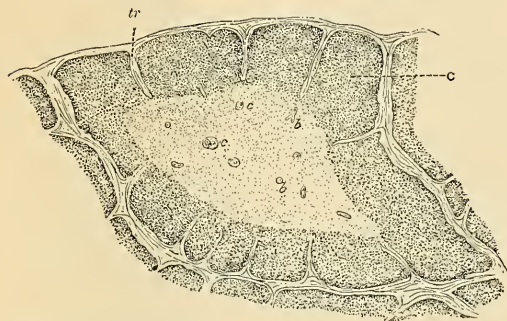


FIG. 1215.—A lobule of the thymus of a child, as seen under low power. C, Cortex. c, Concentric corpuscles within medulla. b, Bloodvessels. tr, Trabeculae. (Schäfer.)

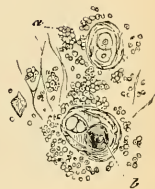

FIG. 1216.—Elements of the thymus. $\times 300$. a, Lymph corpuscles. b, Concentric corpuscle. (Schäfer, after Cadot.)

Structure (Figs. 1195 and 1197).—Each lateral lobe is composed of numerous lobules held together by delicate areolar tissue, the entire gland being enclosed in an investing capsule of a similar but denser structure. The primary lobules vary in size from a pin's head to a small pea, and are made up of a number of small nodules which are irregular in shape and are more or less fused together, especially toward the interior of the gland. Each lobule consists of a cortical and medullary portion, which differ in many essential particulars from each other. The **cortical portion** is mainly composed of **dense lymphoid tissue**, consisting chiefly of lymphocytes and hyaline cells supported by a delicate reticulum. In addition to this reticulum, of which traces only are found in the medullary portion, there is also a network of finely branched cells which is continuous with a similar network in the medullary portion. This network forms an adventitia to the bloodvessels. The **medullary portion** consists of **diffuse lymphoid tissue** (granular cells) and **concentric corpuscles** (corpuscles of Hassall). The granular cells are rounded or flask-shaped masses attached (often by fibrillated extremities) to bloodvessels and to newly formed connective tissue. The concentric corpuscles are composed of a central mass consisting of one or more granular cells, and of a capsule which is formed of concentrically arranged epithelioid cells which seem to be continuous with the branched cells forming the network mentioned above.

Each lobule is surrounded by a capillary plexus from which vessels pass into the interior and radiate from the periphery toward the centre, and form a second zone just within the margin of the medullary portion. In the centre of the medulla there are very few vessels, and they are of minute size.

Watney has made the important observation that hemoglobin is found in the thymus either in cysts or in cells situated near to or forming part of the concentric corpuscles. This hemoglobin varies from granules to masses exactly resembling colored blood corpuscles, oval in the bird, reptile, and fish; circular in all mammals except in the camel. Dr. Watney has also discovered in the lymph issuing from the thymus similar cells to those found in the gland, and, like them, containing hemoglobin either in the form of granules or masses. From these facts

he arrives at the physiological conclusion that the thymus is one source of the colored blood corpuscles.

Vessels and Nerves.—The arteries supplying the thymus are derived from the **internal mammary** and from the **superior and inferior thyroid**. The veins terminate in the two **innominate veins**, and in the **internal mammary** and the **thyroid veins**. The **lymphatics** are of large size, arise in the substance of the gland, and are said to terminate in the **internal jugular vein**. The **nerves** are exceedingly minute; they are derived from the **vagus** and **sympathetic**. Branches from the **descendens hypoglossi** and **phrenic** reach the investing capsule, but do not penetrate into the substance of the gland.

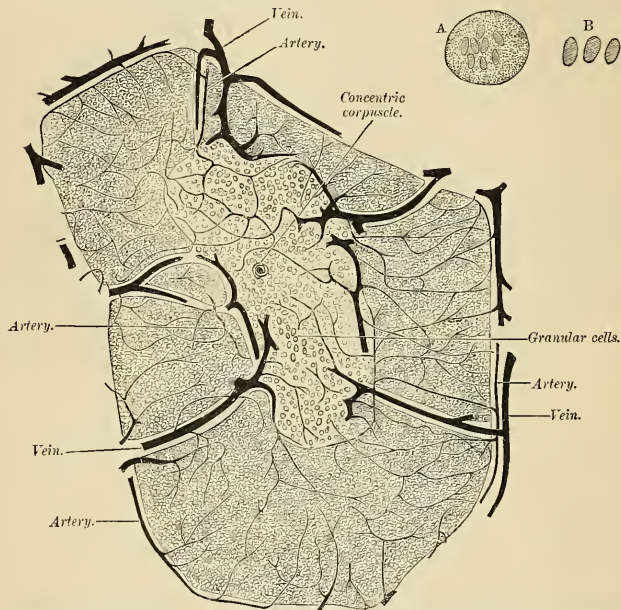


FIG. 1217.—Minute structure of the thymus gland. Lobule of injected thymus from a calf, four days old, slightly diagrammatic, magnified about 50 diameters. The large vessels are disposed in two rings, one of which surrounds the lobule, the other lies just within the margin of the medulla. A and B. From thymus of camel, examined without addition of any reagent. Magnified about 400 diameters. A. Large, colorless cells containing small masses of hemoglobin. Similar cells are found in the lymph nodes, spleen, and medulla of bone. B. Colored blood corpuscles. (Watney.)

Applied Anatomy.—Sudden death—"thymus death"—with heart failure, and with or without acute respiratory embarrassment, has been recorded in a number of infants and children in whom the thymus was enlarged, and the lymphatic tissues throughout the body showed general hypertrophy, but who showed no other evidence of disease. Such deaths have often occurred during the administration of anesthetics.

Primary tumors of the thymus are rare forms of mediastinal newgrowth, and are usually dermoids or lymphosarcomas.

THE SPLEEN (LIEN) (Figs. 1218, 1219).

The **spleen** is situated principally in the posterior portion of the left hypochondriac region, its upper and inner extremity extending into the epigastric region; it lies between the fundus of the stomach and the Diaphragm. It is obliquely placed, its long axis following the obliquity of the tenth rib. If the abdomen is

opened a spleen of ordinary size is not visible from the front, as it is placed between the left kidney, Diaphragm, and stomach. It moves with the respiratory

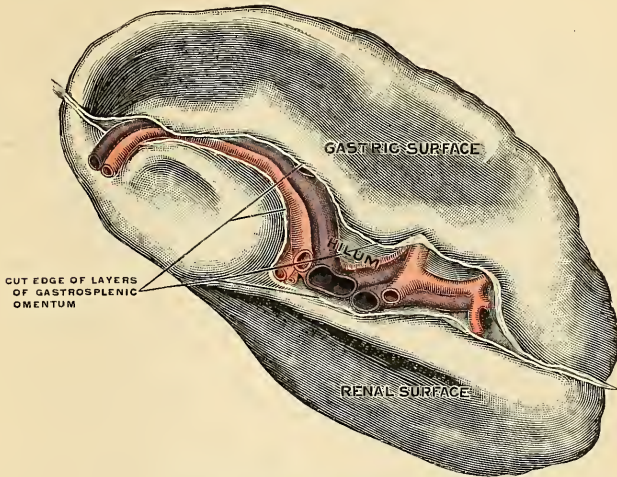


FIG. 1218.—The spleen. Internal or visceral surface.

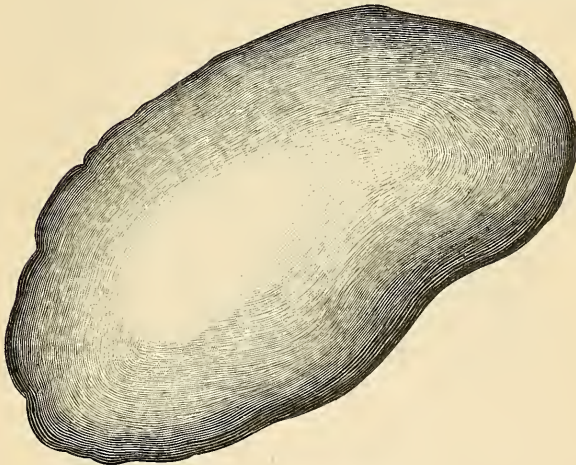


FIG. 1219.—The spleen. Diaphragmatic surface.

movements and with the movements of the stomach. It is the largest of the so-called ductless glands, and varies greatly in size. Usually it measures some five

inches in length. It is of an oblong, flattened, tetrahedral form, soft, of very friable consistence, highly vascular, and of a dark-purplish color.

Relations.—The **external** or **phrenic surface** (*facies diaphragmatica*) is convex, smooth, and is directed upward, backward, and to the left, except at its upper end, where it is directed slightly inward. It is in relation with the under surface of the Diaphragm, which separates it from the ninth, tenth, and eleventh ribs of the left side, and the intervening lower border of the left lung and pleura.

The **internal surface** is concave, and divided by a ridge into an **anterior** or **gastric**, and a **posterior** or **renal portion**.

The **gastric surface** (*facies gastrica*), which is directed forward and inward, is broad and concave, and is in contact with the posterior wall of the fundus of the stomach; and below this with the tail of the pancreas. It presents near its inner border a long fissure, termed the **hilum** (*hilus lienis*), in which are several irregular apertures, for the entrance and exit of vessels and nerves.

The **renal surface** (*facies renalis*) is directed inward and downward. It is somewhat flattened, is considerably narrower than the gastric surface, and is in relation with the upper part of the outer surface of the left kidney and occasionally with the left suprarenal gland.

The **upper end of the spleen** (*extremitas superior*) is directed inward, toward the vertebral column, where it lies on a level with the eleventh thoracic vertebra, within one and one-half to two inches of the midline. The **lower end** (*extremitas inferior*), sometimes termed the **basal surface**, is flat, triangular in shape, and rests upon the splenic flexure of the colon and the phrenocolic ligament, and is generally in contact with the tail of the pancreas. The **anterior border** (*margo anterior*) is free, sharp, and thin, and is often notched, especially below; it separates the phrenic surface from the gastric surface. The **posterior border** (*margo posterior*), more rounded and blunter than the anterior, separates the renal from the phrenic surface; it corresponds to the lower border of the eleventh rib and lies between the Diaphragm and left kidney. The **internal border**, or intermediate margin, is the ridge which separates the renal and gastric portions of the internal surface.

The spleen, with the exception of its hilum, is completely invested with peritoneum, which is firmly adherent to the capsule of the organ. Two folds of peritoneal tissue—the **lienorenal ligament** and the **gastrosplenic omentum**—serve to hold the organ in position. The lienorenal ligament (Figs. 998 and 1001) is derived from the layers of the peritoneum forming the greater and lesser sacs where they come into contact between the left kidney and the spleen. Between these two layers the splenic vessels pass. The **gastrosplenic omentum** (*ligamentum gastrosplenicum*) is also formed of two layers, derived from the greater and lesser sacs, respectively, where they meet between the spleen and the fundus of the stomach (Fig. 1001). Between these two layers run the *vasa brevia* and the left gastroepiploic branches of the splenic artery and vein. The spleen is also supported by the **phrenocolic ligament** (see p. 1263).

The size and weight of the spleen are liable to extreme variations at different periods of life in different individuals, and in the same individual under different conditions. *In the adult*, in whom it attains its greatest size, it is usually about five inches (12 cm.) in length, three inches (7.5 cm.) in breadth, and an inch or an inch and a quarter (3 cm.) in thickness, and weighs about six and one-half ounces (195 gm.) *At birth* its weight, in proportion to the entire body, is almost equal to what is observed in the adult, being as 1 to 350; while in the adult it varies from 1 to 320 to 1 to 400. *In old age* the organ not only decreases in weight, but decreases considerably in proportion to the entire body, being as 1 to 700. The size of the spleen is increased during and after digestion, and varies considerably according to the state of nutrition of the body, being large in well-fed, and small in starved animals. In intermittent and other fevers it becomes much enlarged, weighing occasionally from eighteen to twenty pounds.

Frequently in the neighborhood of the spleen, and especially in the gastrosplenic and great omenta, small nodules of splenic tissue may be found, either isolated, or connected to the spleen by thin bands of splenic tissue. Every such nodule is known as a **supernumerary** or **accessory spleen** (*lien accessorius*). Accessory spleens vary in size from that of a pea to that of a plum.

Support and Mobility of the Spleen.—The spleen is normally movable within certain narrow limits. It moves with respiration and with the stomach movements. It is supported by ligaments (p. 1258). An unduly mobile spleen is called a **movable spleen**. In order that a spleen shall become unduly movable, the ligaments must stretch, and this stretching is often effected when the organ is greatly enlarged, but even an apparently normal spleen may become movable. Movable spleen is usually associated with movable left kidney.

Structure.—The spleen is invested by a **capsule** consisting of an **external serous** and an **internal fibromuscular layer**.

The **external** or **serous layer** (*tunica serosa*) is derived from the peritoneum; it is thin, smooth, and in the human subject is intimately adherent to the fibromuscular layer. It invests the entire organ, except at the places of its reflection on to the stomach and Diaphragm and at the hilum.

The **fibromuscular layer** (*tunica albuginea*) forms the framework of the spleen. It is composed of white fibrous connective tissue containing smooth muscle cells and elastic fibres, and it invests the organ as a capsule, and at the hilum is reflected inward upon the vessels in the form of sheaths. From these sheaths, as well as from the inner surface of the fibromuscular layer,

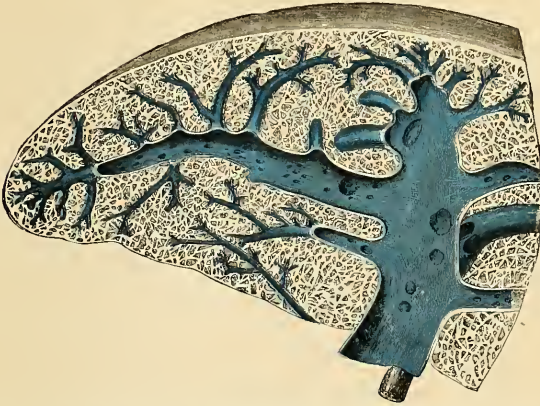

FIG. 1220.—Transverse section of the spleen, showing the trabecular tissue and the splenic vein and its tributaries.

numerous small fibrous bands, **trabeculae** (*trabeculae lienis*) (Figs. 1220 and 1221), are given off in all directions; these uniting with the bands from the vessel sheaths constitute the framework of the spleen. This framework resembles a sponge-like material, consisting of a number of small spaces or areolae. The spaces of the areolae contain the lymphoid material known as **splenic pulp** (*pulpa lienis*).

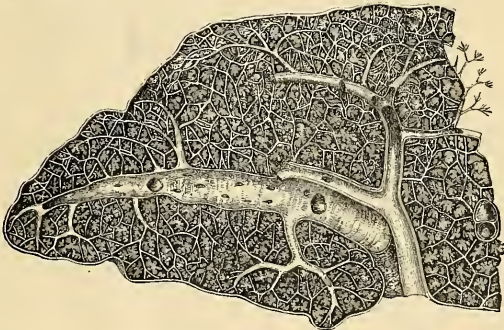


FIG. 1221.—Transverse section of the human spleen, showing the distribution of the splenic artery and its branches.

Within the capsule is the **parenchyma**, consisting of the **splenic pulp** and **splenic (Malpighian) corpuscles**. The **splenic pulp** is dark reddish brown in color and consists of a delicate *reticulum*, upon the fibres of which are seen stellate connective-tissue cells. In the meshes of the reticulum are **diffuse lymphoid tissue**, **erythrocytes**, erythroblasts, disintegrating erythrocytes, **pigment granules**, **branched cells**, and certain large polynuclear elements, **splenic cells**. The lymphoid tissue consists of *leukocytes*, mainly lymphocytes, and hyaline cells scattered throughout the reticulum. The erythrocytes are on their way to or from the blood current; the erythroblasts

are newly formed red blood cells that have as yet not lost their nuclei. The disintegrating red cells are useless cells that by their disintegration contribute the coloring matters to the bile. The branched cells are large, flattened, stellate elements, the processes of which seem to anastomose to assist in forming the reticular substance, and also seem to connect with the endothelial cells of the capillaries. The **splenic cells** are large polynuclear elements possessing the power of ameboid movements. They often contain pigment granules and red cells in their protoplasm, thus indicating *phagocytosis*. The **trabeculae** are continuations of the capsule, and consist of white fibrous connective tissue and smooth muscle tissue.

The **splenic (Malpighian) corpuscles** are dense, spherical or cylindrical collections of lymphoid tissue (*solitary nodules*) surrounding an arteriole. Each corpuscle shows a lighter **germinal centre** and a darker peripheral zone where the leukocytes are more numerous and more closely packed. Each corpuscle usually exhibits an excentrically placed arteriole, as the lymphoid tissue is collected in the adventitial sheath of the vessel. These bodies are visible to the naked eye, and appear as whitish dots.

Bloodvessels of the Spleen.¹—The **splenic artery** enters the hilum and divides into branches that follow the trabeculae. Of these, some quickly pass to the pulp, while others follow the trabeculae to their smallest divisions. The external coats of these arterioles, at first consisting of ordinary connective tissue, undergo a transformation, becoming much thickened and converted into lymphoid tissue. The spleen is divided into circulatory lobules about 1 mm. in diameter, each of which is divided into histological units, one for each terminal vessel, or *ampulla*. These terminal vessels are large endothelial channels surrounded by lymphoid tissue, called the *ellipsoidal sheath*. These terminal ampullae are porous and continue as veins, that collect the blood and empty it into the splenic vein at the hilum.

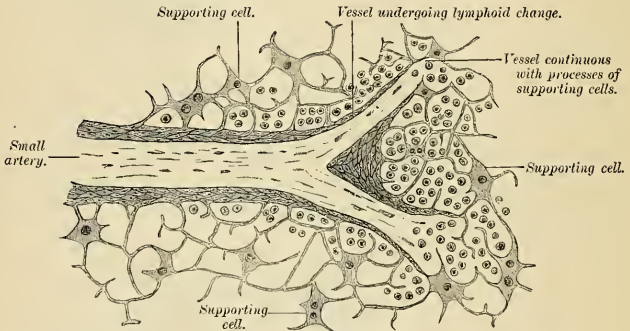


FIG. 1222.—Section of spleen, showing the termination of the small bloodvessels.

The spleen is subject to rhythmical contractions, one per minute; during a contraction the organ is reduced about 18 per cent. in volume. These contractions are produced by the contractions of the smooth muscle tissue in the capsule and trabeculae of the pulp. When the cardiac impulse sends the blood into the arterial channels the blood passes through the porous walls of the ampullae into the pulp. When the rhythmical contractions occur the blood is forced into the veins through the pores of the ampullae, and at the same time the arteries are closed.

The **lymphatics** originate in two ways—*i. e.* from the sheath of the arteries and in the trabeculae. The former trunks are the **deep collecting trunks**, and accompany the bloodvessels; the latter pass to the **superficial lymphatic plexus**, which may be seen on the surface of the organ. Lymphatic channels do not exist in the pulp. The deep trunks at the hilum number from five to ten, and terminate in the **splenic nodes**. The superficial trunks also pass to the hilum and terminate in the splenic nodes.

The **nerves** are derived from the **splenic plexus**, which is a part of or connected with the solar plexus. The nerves enter the spleen with the vessels.

Surface Form.—The spleen is situated under cover of the lower ribs of the left side, being separated from them by the Diaphragm, and above by a small portion of the lower margin of the left lung and pleura. Its position corresponds to the ninth, tenth, and eleventh ribs. It is placed very obliquely. "It is oblique in two directions—*viz.*, from above downward and outward, and also from above downward and forward" (Cunningham). "Its highest and lowest points are on a level respectively with the ninth thoracic and first lumbar spines; its inner end is dis-

¹F. P. Mall, Amer. Jour. of Anat., 1903, vol. ii, No. 3.

tant about an inch and a half from the median plane of the body, and its outer end about reaches the midaxillary line" (Quain).

Applied Anatomy.—Injury of the spleen is less common than that of the liver, on account of its protected situation and connections. It may be *ruptured* by direct or indirect violence, torn by a broken rib, or injured by a punctured or gunshot wound. When the organ is enlarged the chance of rupture is increased. The great risk is *hemorrhage*, owing to the extreme vascularity of the organ, and the absence of a proper system of capillaries. The injury is not, however, necessarily fatal, and this would appear to be due in a great measure to the contractile power of its capsule, which narrows the wound and thus antagonizes the escape of blood. In cases in which the symptoms suggest such an injury and indicate danger to life, laparotomy must be performed; and if the hemorrhage cannot be arrested by ordinary surgical methods the spleen must be removed. The spleen may become displaced, producing great pain from stretching of the vessels and nerves, and this dislocation may render necessary removal of the organ. The spleen may become enormously *enlarged* in certain diseased conditions, such as *ague*, *leukemia*, *syphilis*, valvular disease of the heart, or without any obtainable history of previous disease. It may also become enlarged in *lymphadenoma* as a part of a general blood disease. In these cases the mass may fill the abdomen and extend into the pelvis, and may be mistaken for ovarian or uterine disease.

The spleen is sometimes the seat of *cystic tumors*, especially *hydatids*, and of *abscess*. These cases require treatment by incision and drainage; and in abscess great care must be taken if there are no adhesions between the spleen and abdominal cavity, to prevent the escape of any of the pus into the peritoneal cavity. If possible, the operation should be performed in two stages. *Sarcoma* and *carcinoma* are occasionally found in the spleen, but very rarely as a primary disease. In *movable spleen*, if the organ is normal, follow the advice of Rydygier and loosen the parietal peritoneum to make a pocket, place the spleen in the pocket, and pass sutures through the parietal peritoneum and splenic ligaments. A movable diseased spleen should be removed.

Extirpation of the spleen has been performed for wounds or injuries, floating spleen, simple hypertrophy, and leukemic enlargement; but in the latter case the operation is now regarded as unjustifiable, as it is practically certain to terminate fatally. The incision is best made in the left semilunar line; the spleen is isolated from its surroundings, and the pedicle transfixed and ligated in two portions, before the tumor is turned out of the abdominal cavity, if this is possible, so as to avoid any traction on the pedicle, which may cause tearing of the splenic vein and which inevitably induces grave shock. In applying the ligatures the surgeon must not include the tail of the pancreas, and in lifting out the organ care must be taken to avoid rupturing the capsule.

THE SUPRARENAL GLANDS, OR ADRENAL CAPSULES (GLANDULAE SUPRARENALIS) (Figs. 1223, 1224).

The **suprarenal glands** are two small flattened bodies, of a yellowish color, situated at the back part of the abdomen, behind the peritoneum, and immediately above and in front of the upper extremity of each kidney; hence their name. The *right* one (Fig. 1223) is somewhat triangular in shape, bearing a resemblance to a cocked hat; the *left* (Fig. 1224) is more semilunar, usually larger and placed at a higher level than the right. They vary in size in different individuals, being sometimes so small as to be scarcely detected; their usual size is from an inch and a quarter to nearly two inches (3 to 5 cm.) in length, rather less in width, and one-quarter of an inch (6 mm.) in thickness. Their average weight is from one to one and one-half drams (6 grams) each.

Relations.—The relations of the suprarenal glands differ on the two sides of the body.

The **right suprarenal** (Fig. 1223) is situated behind the inferior vena cava and the right lobe of the liver, and in front of the Diaphragm and the upper end of the right kidney. It is roughly triangular in shape, and its **base**, directed downward, is in contact with the inner and anterior aspects of the upper end of the right kidney. It presents two surfaces for examination, an anterior and a posterior. The **anterior surface** (*facies anterior*) presents two areas, separated by a furrow, the **hilum** (*hilus glandulae suprarenalis*); one area, occupying about one-third of the

whole surface, is situated above and internally; it is depressed, uncovered by peritoneum, and is in contact in front with the posterior surface of the right lobe of the liver, and along its inner border with the inferior vena cava; the remaining area is elevated, and is divided into a nonperitoneal portion, in contact with the hepatic flexure of the duodenum, and a portion covered by peritoneum forming the hepatorenal fold. The **posterior surface** (*facies posterior*) is divided into an upper and a lower part by a curved ridge; the upper, slightly concave, rests upon the Diaphragm; the lower, or **base** (*basis glandulae suprarenalis*) is concave, and is in contact with the upper end and the adjacent part of the anterior surface of the kidney.

The **left suprarenal** (Fig. 1224), slightly larger than the right, is crescentic in shape, its concavity being adapted to the inner border of the upper extremity of the left kidney. It presents an inner border which is convex, and an outer which is concave; its upper border is narrow; and its lower rounded. Its **anterior**

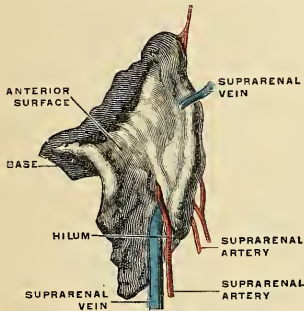


FIG. 1223.—The right suprarenal gland.
(Spalteholz.)

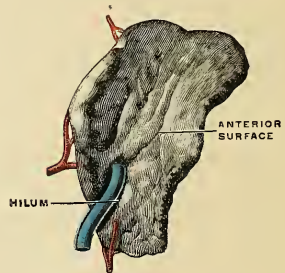


FIG. 1224.—The left suprarenal gland.
(Spalteholz.)

surface presents two areas—an upper one, covered by the peritoneum forming the lesser sac, which separates it from the cardiac end of the stomach and to a small extent from the superior extremity of the spleen; and a lower one, which is in contact with the pancreas and splenic artery, and is, therefore, not covered by the peritoneum. A hilum is present, as in the right suprarenal. Its **posterior surface** presents a vertical ridge, which divides it into two areas. The ridge lies in the sulcus between the kidney and crus of the Diaphragm, while the area on either side of it lies on these parts respectively; the outer area, which is thin, resting on the kidney, and the inner and smaller area resting on the left crus of the Diaphragm.

The surface of the suprarenal gland is surrounded by areolar tissue containing much fat, and closely invested by a thin fibrous coat, which is difficult to remove, on account of numerous fibrous processes and vessels which enter the organ through the furrows on its anterior surface and base.

Accessory suprarenal glands (*glandulae suprarenales accessoriae*) are often to be found in the connective tissue around the suprarenals. The smaller of these, on section, show a uniform surface, but in some of the larger a distinct medulla can be made out.

Structure (Fig. 1225).—On making a perpendicular section, the suprarenal gland is seen to consist of two substances—surrounded by a **capsule**—the **external** or **cortical** and the **internal** or **medullary**. The former, which constitutes the chief part of the organ, is of a deep-

yellow color. The medullary substance is soft, pulpy, and of a dark-brown color. In the centre is often seen a space, not natural, but formed after death by the disintegration of the medullary substance.

The **capsule** consists of white fibrous connective tissue in which some smooth muscle tissue is seen. From the capsule and vessel sheaths the framework of the organ is derived.

The **cortical portion** consists of epithelial cells arranged in three zones. The **zona glomerulosa**—the outermost—consists of oval or round cell groups surrounded by capillary plexuses and reticulum. The cells are polyhedral in shape with clear nuclei; the protoplasm is granular and contains many fat globules. The **zona fasciculata**—or middle zone—consists of columns of epithelial cells (usually two cells wide) supported by reticulum containing bloodvessels and lymphatics. These cells resemble the above, but the nuclei are in the peripheral portion of the cells. The **zona reticularis**, the innermost of the three, consists of anastomosing columns or chains of cells. These cells are smaller than the preceding, are distinct in outline, and possess a granular and pigmented protoplasm.

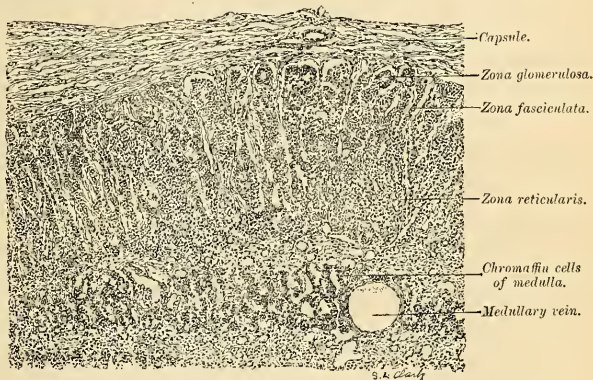


FIG. 1225.—Section of human suprarenal gland. (Radach.)

The **medullary portion** (*substantia medullaris*) (Fig. 1225). is usually separated from the cortex by a layer of large smooth cells. Beneath this layer the epithelial cells are arranged in irregular groups and chains, surrounded by reticulum and capillaries. The cells are small and their outlines are indistinct. They color deeply with chromium salts, and are called *chromaffin cells*. Many sympathetic nerve cells are present.

Vessels and Nerves.—The numerous arteries which enter the suprarenal bodies from the sources mentioned below form plexuses in the capsule and penetrate the cortical part of the gland, where they break up into capillaries in the fibrous septa, and these converge to the very numerous thin-walled veins of the medullary portion. These veins usually empty directly into the large central veins. The medullary vessels are derived from the cortical vessels, and pass to the medulla without branching to form plexuses of capillaries around the cells. The veins in this region converge to form from two to four central veins, which unite to become the suprarenal vein, which in turn emerges as a single vessel from the centre of the gland.

The **arteries** supplying the suprarenal glands are three in number and of large size; they are derived from the **aorta**, the **phrenic**, and the **renal**; they subdivide into numerous minute branches previous to entering the substance of the gland.

The **suprarenal vein** returns the blood from the medullary venous plexus, and receives several branches from the cortical substance; it emerges from the hilum and opens on the right side into the inferior vena cava, on the left side into the renal vein.

The **lymphatics** form several collections which are about the beginning of the suprarenal vein. They terminate in the nodes at the corresponding side of the aorta.

The **nerves** are myelinated and amyelinated, are exceedingly numerous, and are derived from the **solar** and **renal plexuses**, and, according to Bergmann, from the **phrenic** and **vagus nerves**. They enter the lower and inner part of the gland. A plexus in the gland sends branches into the cortex, where plexuses are formed around the vessels. Branches are also sent to the medulla, where rich plexuses are formed around the cells and vessels. Many sympathetic ganglia are seen there.

THE CAROTID GLANDS, OR CAROTID BODIES (GLOMUS CAROTICUM).

The **carotid bodies**, two in number, are situated one on either side of the neck, behind the common carotid artery at its point of bifurcation into the internal and external carotid trunks. They are reddish brown in color and oval in shape, the long diameter measuring about one-fifth of an inch (5 mm.) Each is invested by a fibrous capsule and consists of spherical or irregular masses of cells—the masses being more or less isolated from each other by septa which extend inward from the capsule. A network of large capillaries from the carotid artery ramifies among the cell masses, together with numerous sympathetic nerve fibres. The cells are polyhedral in shape, and each contains a large nucleus embedded in finely granular protoplasm which is stained yellow by chromic salts.

Applied Anatomy.—*Tumors* may arise in this structure. Such a tumor is apt to be above the level of the upper margin of the thyroid cartilage, and in most cases it moves with each arterial beat.

THE COCCYGEAL GLAND OR BODY, OR LUSCHKA'S GLAND (GLOMUS COCCYGEUM).

Lying near the tip of the coccyx in a small tendinous interval formed by the union of the Levator ani muscles and just above the coccygeal attachment of the Sphincter ani is a small conglobate body about as large as a millet seed, first described by Luschka, and named by him the **coccygeal gland**. Its most obvious connections are with the middle sacral artery.

Structure.—It consists of a congeries of small arteries with little aneurismal dilatations derived from the middle sacral and freely communicating with each other. The gland is surrounded by a capsule of white fibrous connective tissue which sends in septa to form the framework of the organ and to divide it into spaces which contain groups of polyhedral cells. Each cell contains a large round or oval nucleus, the protoplasm surrounding which is clear and is not stained by chromic salts.¹ Nerves pass into this little body from the sympathetic, but their mode of termination is unknown. Macalister believes the glomerulus of the vessels "consists of the condensed and convoluted metamerie dorsal arteries of the caudal segments embedded in tissue which is possibly a small persisting fragment of the neurenteric canal."

THE PARASYMPATHETIC BODIES (ORGANA PARASYMPATHETICA; PARAGANGLIA LUMBALE).

The **parasympathetic bodies** were discovered in 1901 by Zuckerkandl. They are from one to four in number, situated retroperitoneally, ventrad of the abdominal aorta at the level of the third and fourth lumbar vertebrae. Each parasympathetic body is from 6 to 10 mm. in length and from 2 to 4 mm. in width, and is surrounded by a capsule of fibrous tissue. In the meshes of the reticulum are found groups of polyhedral or cuboidal epithelial cells, closely packed and of the chromaffin type. These bodies are usually supplied by fine arterial twigs from the aorta. They are best developed in the fetus and in infancy, apparently being absent in the adult.

¹Consult J. W. T. Walker, "Ueber die menschliche Steissdrüse," Arch. f. mikr. Anat. u. Entwicklgesch., 1904

INDEX.

A

- ABDOMEN**, 1240
 boundaries of, 1241
 fasciæ of, 424
 triangular, 425, 428
 lymphatic vessels of, 789, 790
 lymphatics of, 787
 muscles of, 423
 regions of, 1242
 veins of, 739
 walls of, apertures in, 1242
Abdominal aorta, 657
 applied anatomy of, 658
 surface marking of, 657
aortic plexus of nerves, 1076
 furrow, 439
 ring, 426, 436, 437
 viscera, lymphatic vessels of, 792
Abdominothoracic arch, 166
Abducent nerve, 993
 applied anatomy of, 994
 nucleus, 883
Abduction, 267
Abductor hallucis muscle, 538
 indiciæ muscle, 494
 minimi digiti muscle, foot, 539
 surface form of, 544
 hand, 493
 pollicis longus muscle, 485
 muscle, 489
Aberrant ganglion, 1014
Accelerator urinae muscle, 443
Accessory cephalic vein, 731
 ganglion, 1014
 ligament, 275
 liver, 1326
 obturator nerve, 1049
 olivary nuclei, 873
 posterior palatine canals, 110,
 128
 pudic artery, 675
 suprarenal glands, 1448
 thyroid gland, 1436
 veins, 717
Acervus cerebri, 906
Acetabulum, 213
 fossa of, 213
 transverse ligament of, 325
Acid cells, 1276
Acoustic nerve, 1000
 applied anatomy of, 1001
 nuclei, 881
Acromial angle, 177
 artery, 638
 bursa, 303
 nerve, 1022
 region, muscles of, 462
Acromioclavicular articulation,
 297
 applied anatomy of, 299
 surface form of, 299
 ligaments, 297
Acromion, 175
 angle, 177
 process, 175
Acromiothoracic artery, 638
Adduction, 267
Adductor brevis muscle, 514
 canal, 685
 longus muscle, 513
Adductor longus muscle, applied
 anatomy of, 515
 surface form of, 543
magnus muscle, 514
 applied anatomy of, 515
 surface form of, 543
minimus muscle, 514
obliquus hallucis muscle, 541
 pollicis muscle, 492
transversus hallucis muscle,
 541
 pollicis muscle, 492
 surface form of, 497
 tubercle, 225
Aditus laryngis, 1169
Adminiculum linæ albae, 428
Adrenal capsule, 1447
Aequator lentis, 1107
Afferent lymphatic vessels, 768
 root of spinal cord, 823
Agger nasi, 1082
Agminated follicles, 1292
Air sacs, 1195
 sinus, frontal, 79
Ala cinerea, 866
 lobuli centralis cerebelli, 886
 nasi, 1079
 sacrotis, 61
Alae of ethmoid, 96
 magna, 92
 parvae, 93
 of sphenoid, 92
 of vomer, 114, 138
Alar cartilage, 1080
 thoracic artery, 639
Alcock's canal, 450, 675
Alimentary canal, 1199
 tract, development of, 1245
Alisphenoids, 95
Alveolar artery, 601
 index of skull, 147
 point of skull, 146
 process of maxilla, 104
Alveoli dentales, 104, 117, 1204
 of lungs, 1195
Alveus, 929, 942
Ameloblasts, 1214
Amphiarthrosis, 264, 266
Ampulla ductus deferentis, 1383
 lacrimalis, 1116
 of Fallopian tube, 1401
 of lacrimal canal, 1116
 of rectum, 1308
 tubae uterinae, 1401
 of vas deferens, 1383
 of Vater, 1334
Ampullae membranaceae, 1142
 ossea, 1137
Ampullar nerve, 1001
Amygdala, 887, 948
Amygdaline fissure, 924
 nucleus, 948
Amygdaloid tubercle, 939, 948
Anal canal, 1309
 fascia, 446, 454
 orifice, 1309
 pockets, 1310
 valves, 1310
Anastomosis of arteries, 572
 circumpatellar, 696
 between portal and systemic
 veins, 754
Anastomosis, crucial, 678, 690
 of veins, 706
Anastomotie vein of Trolard, 720
Anastomotica magna of brachial,
 643
 of femoral, 691
Anatomical neck of humerus,
 178
Anconeus muscle, 482
 surface form of, 496
Andersch, ganglion of, 1002
Angiology, definition of, 34
Angle, acromial, 177
 filtration, 1105
 of jaw, 118
 lateral, inferior, 60
 of Ludwig, 157, 166
 nasal, 100
 of pubis, 212
 of ribs, 163
 Rolandic, 918
 sacrovertebral, 58
 subcostal, 156
 subscapular, 172
Angular gyre, 923
 processes, 77, 135
 vein, 710
Angulus costae, 163
 frontalis, 76
 inferior, 176
 infrasternalis, 156
 iridis, 1105
 lateralis, 176
 Ludovici, 157, 166
 mandibulæ, 118
 mastoidæus, 76
 medialis, 176
 occipitalis, 76
 oris, 1199
 sphenoidalis, 76
Ankle bone, 244
Ankle-joint, 342
 applied anatomy of, 346
 surface form of, 346
Anlage of cerebellum, 855
Annuli fibrosi, 562
Annulus femoralis, 428, 503, 685
 fibrosus, 270, 558
 dexter, 558
 sinister, 560
inguinalis abdominis, 437
 subcutaneous, 426
 crus inferius, 427
 superius, 427
 ovalis, 557
 tendineus communis, 370
 tympanicus, 1123
 urethralis, 1365
Anococcygeal body, 1309
 nerves, 1062
 raphé, 451, 453
Ansa cervicalis, 1024
 hypoglossi, 1024
 lenticularis, 905, 951
 peduncularis, 905, 951
 subclaviæ [Vieussensii], 1069
Antecubital fossa, 641
 lymph nodes, 781
Antihelix of ear, 1120
Antitragicus muscles, 1121
Antitragus of ear, 1120
Antrum cardiacum, 1237, 1271

- Antrum of Highmore, 101, 103
 mastoid, 83
 opening of, 1126
 tympanicum, 1126
 Anus, 1309
 lymphatic vessels of, 794
 Aorta, 575
 abdominal, 657
 abdominalis, 657
 arch of, 579
 applied anatomy of, 580
 development of, 761
 ascendens, 576
 ascending, 576
 descending, 653
 dorsal, 762
 primitive, 755
 surf-line of, 580
 thoracalis, 653
 rami mediastinales, 654
 pericardiaci, 654
 thoracic, 653
 transverse, 579
 ventral, 761
 Aortenspindel, 580
 Aortic arches, 761
 bulb, 757, 759
 isthmus, 762
 lymph nodes, 788
 opening of diaphragm, 419
 septum, 759, 760
 spindle, 762
 stem, primitive, 757, 759
 valve, 560
 Aorticorenal ganglion, 1073
 Apertura externa aquaeductus
 vestibuli, 86
 canaliculi cochleae, 86
 lateralis [ventriculi quarti], 867,
 969
 medialis [ventriculi quarti], 867,
 969
 pelvis [minoris] inferior, 217
 superior, 215
 pyriformis, 135, 138, 1081
 scalae vestibuli cochleae, 1137
 sinus sphenoidalis, 91, 95
 superior canaliculi tympanici,
 84
 thoracis inferior, 156
 superior, 155
 Apex capiti *fibulae*, 236
 linguae, 1217
 nasi, 1079
 oss. sacri, 61
 patellae, 231
 prostaticae, 1391
 pulmonis, 1188
 pyramidis, 84
 Apical foramen, 1212
 glands, 1219
 Aponeuroses, 360
 epicranial, 363
 of external oblique, 425
 gluteal, 516
 of internal oblique, 428
 lumbar, 409
 palatal, 397
 pharyngeal, 395
 of soft palate, 1203
 suprahyoid, 389
 vertebral, 404, 408
 Aponeurosis *palmaris*, 488
 plantaris, 537
 Aponeurotic fascia, 361
 Apophysis of bone, 37
 Apparatus *digestorius*, 1199
 lacrimalis, 1115
 respiratorius, 1163
 Appendices *epiploicae*, 1265,
 1296, 1309
 vesiculosi, 1402
 Appendicular artery, 664
 lymph nodes, 791
 planes of body, 34
- Appendix, ensiform, 159
 epididymidis, 1379
 testis [Morgagni], 1378
 ventriculi, 1171
 veriform, 1298
 xiphoid, 159
 Applied anatomy of abdominal
 aorta, 658
 of abducent nerve, 994
 of acoustic nerve, 1001
 of acromioclavicular articu-
 lation, 299
 of adductor longus muscle,
 515
 magnus muscle, 515
 of ankle-joint, 346
 of anterior tibial artery, 697
 of arch of aorta, 580
 of articulations of elbow-
 joint, 309
 of hip-joint, 329
 of phalanges of foot, 256
 of shoulder-joint, 304
 of tarsus, 351
 of vertebral column, 278
 of wrist-joint, 315
 of ascending pharyngeal
 artery, 597
 of auditory canal, 1124
 of axilla, 634
 of axillary artery, 637
 veins, 732
 of azygos veins, 737
 of bladder, 1366
 of bone, 46
 of bones of foot, 256
 of brachial artery, 641
 plexus of nerves, 1039
 of carotid glands, 1450
 of carpal bones, 205
 of cavernous sinuses, 724
 of cervical fascia, 384
 ganglion, 1069
 lymph nodes, 780
 of choroid, 1110
 of clavicle, 172
 of colon, 1306
 of common carotid artery,
 586
 iliac arteries, 669
 of conjunctiva, 1118
 of cornea, 1109
 of coronary artery, 578
 of costal cartilages, 167
 of crystalline lens, 1111
 of deep epigastric artery,
 681
 definition of, 33
 of deltoid muscle, 463
 of descending palatine ar-
 tery, 602
 of dorsalis pedis artery, 699
 of duodenum, 1287
 of emissary veins, 727
 of external abdominal ring,
 427
 carotid artery, 588
 iliac artery, 680
 of eyelids, 1118
 of facial artery, 595
 nerve, 999
 veins, 711
 of femoral artery, 687
 of femur, 229
 of fibula, 239
 of glossopharyngeal nerve,
 1003
 of hamstring muscles, 525
 of heart, 568
 of hemorrhoidal plexus of
 veins, 745
 of humerus, 184
 of hyoid bone, 154
 of hypoglossal nerve, 1012
 of iliotibial band, 508
- Applied anatomy of inferior
 calcanoscaphoid liga-
 ment, 349
 vena cava, 748
 of innominate artery, 582
 of intercostal arteries, 657
 of internal calcanoscaphoid
 ligament, 349
 carotid artery, 608
 iliac artery, 671, 679
 jugular vein, 717
 of intestines, 1295, 1314
 of iris, 1110
 of kidneys, 1355
 of knee-joint, 338
 of lacrimal gland, 1118
 sac, 1119
 of lateral sinus, 724
 of liver, 1335
 of lumbar plexus of nerves,
 1062
 of lymph nodes of lower
 extremity, 786
 of upper extremity, 784
 of lymphatic vessels, 770
 of diaphragm, 799
 of stomach, 793
 of male breast, 1433
 urethra, 1369
 of mammary gland, 1432
 of mediastinum, 1188
 of middle meningeal artery,
 600
 of mouth, 1204
 of muscles, 359
 of back, 416
 of cranial region, 365
 of femoral region, 512, 515
 of leg, 535
 of lower extremity, 544
 of orbital region, 371
 of palatal region, 399
 of radioulnar region, 478,
 485
 of tongue, 394
 of upper extremity, 497
 of nasal duct, 1119
 of nose, 1084
 of oculomotor nerve, 977
 of oesophagus, 1239
 of olfactory nerve, 974
 of optic nerve, 975
 of ovaries, 1401
 of palmar fascia, 489
 of pancreas, 1341
 of parathyroid glands, 1440
 of patella, 231
 of pelvis, 220
 of penis, 1390
 of pericardium, 550
 of peritoneum, 1268
 of pharynx, 1235
 of phrenic nerve, 1025
 of plantar arch, 704
 of pleurae, 1185
 of popliteal artery, 693
 of portal veins, 754
 of posterior tibial artery, 701
 of pronator teres muscle,
 473
 of prostate gland, 1395
 of psoas magnus muscle, 505
 of pulmonary artery, 575
 veins, 708
 of pyloric artery, 662
 of quadriceps extensor
 muscle, 512
 of radial artery, 646
 of radius, 192
 of rectus femoris muscle, 512
 of retina, 1111
 of ribs, 167
 of salivary glands, 1229
 of saphenous veins, 741
 of scapula, 178

- Applied anatomy of sclera, 1110
 of serotum, 1382
 of seminal vesicles, 1385
 of serratus magnus muscle, 461
 of skull, 149
 of spermatic veins, 750
 of spinal accessory nerve, 1009
 arteries, 621
 cord, 842
 pia, 846
 of spleen, 1447
 of sternoclavicular articulation, 297
 of sternomastoid muscle, 386
 of sternum, 167
 of stomach, 1280
 of subclavian artery, 627
 of superficial palmar arch, 652
 of superior mesenteric lymph nodes, 791
 radioulnar articulation, 311
 thyroid artery, 590
 of synovial membranes of wrist, 487
 of temporal artery, 598
 of temporomandibular articulation, 281
 of testes, 1383
 of thoracic aorta, 654
 duct, 774
 of thorax, 167
 of thymus gland, 1442
 of thyroid gland, 1438
 of tibia, 239
 of tongue, 1222
 of tonsil, 1233
 of trachea, 1180
 of tracheobronchial lymph nodes, 802
 of triceps muscles, 471
 of trigeminal nerve, 991
 of trochlear nerve, 978
 of tympanum, 1135
 of ulna, 192
 of ulnar artery, 649
 of ureters, 1358
 of uterus, 1411
 of vaginal artery, 673
 of vagus nerve, 1008
 of vermiform appendix, 1302
 of vertebral artery, 620
 column, 68
- Aquaeductus cochleae*, 86, 131, 1140
Fallopia, 85
vestibuli, 86, 128, 1137
- Aqueduct of midbrain, 896
- Aqueous chamber, 1105
 humor, 1105
- Arachnoid of brain, 968
 villi of, 970
 spinal, 844
- Arachnoidea encephali*, 968
spinalis, 844
- Arbor vitae cerebelli*, 886
- Arboriform nerve cells, 808
- Arch, abdomin thoracic, 166
 of aorta, 579
 of atlas, 50, 51
 axillary, 407
 crural, 684
 femoral, 436
 nasal, of veins, 710
 palmar, 645, 652
 plantar, 704
 pubic, 217
 supraorbital, 77
 tarsal, 612
- Arches, aortic, 761
- Arcuate fibres, 873
 of medulla oblongata, 863
- Arcuate ligaments, 419
- Arcus aortae*, 579
- cartilaginis cricoideae*, 1165
- dentalis inferior*, 1207
superior, 1207
- glossopalatinus*, 1203
- lumbocostalis lateralis*, 419
medialis, 419
- palatini*, 1203
- pharyngopalatinus*, 1203
- plantaris*, 704
rami perforantes anteriores, 704
posteriores, 704
- pubis*, 217
- superciliares*, 77, 79
- tarsus inferior*, 612
superior, 612
- tendineus*, 449, 450
- venosi digitales*, 728, 729
- venosus dorsalis pedis*, 739
plantaris, 741
- vertebrae*, 48
- volaris profundus*, 645
superficialis, 652
- Area acustica*, 866
cribrosa, 85
media, 85
superior, 85
plumiformis, 873
vestibularis inferior, 1147
posterior, 1147
- Areola mammae*, 1429
 of mammary gland, 1429
- Areolar tissue*, subcutaneous, 1154
- Arm, bones of, 178
 fascia of, 461, 467
 muscles of, 461, 467
- Arnold, bundle of, 957
- nerve of, 1005
- ponticulus of, 863
- Arrectores pilorum*, 1161
- Arteria alveolaris inferior*, 601
ramus mylohyoideus, 601
superior posterior, 601
- angularis*, 594
- anonyma*, 582
- appendicularis*, 664
- arcuata*, 699
- auditiva interna*, 622
- auricularis posterior*, 596
ramus auricularis, 596
mastoideus, 596
profunda, 600
- axillaris*, 635
- rami pectorales*, 638
- ramus acromialis*, 638
clavicularis, 638
deltoides, 638
- basilaris*, 622
rami ad pontem, 622
- brachialis*, 640
- buccinatoria*, 601
- bulbi urethrae*, 675
vestibuli, 1420
- canalis pterygoidei*, 602
- carotis communis*, 583
dextra, 583
sinistra, 583
externa, 588
interna, 606
ramus caroticotympanicus, 609
- centralis retinae*, 613, 1090, 1105
- cerebelli inferior anterior*, 622
posterior, 621
superior, 622
- cerebri anterior*, 614
media, 616
posterior, 622
- cervicalis ascendens*, 629
profunda, 633
- chorioidea*, 617
- Arteria ciliares*, 613
- circumflexa femoris lateralis*, 690
medialis, 690
ramus acetabuli, 690
profundus, 690
superficialis, 690
- humeri anterior*, 639
posterior, 639
- ilium profunda*, 682
superficialis, 689
- scapulae*, 639
- coeliaca*, 659
- colica dextra*, 664
media, 664
sinistra, 666
- collateralis ulnaris inferior*, 643
superior, 643
- comes nervi phrenici*, 1024
- comitans nervi ischiadici*, 677
- communicans anterior*, 615
posterior, 617
- coronaria [cordis] dextra*, 578
sinistra, 578
- cystica*, 661
- deferentialis*, 1376
- dorsalis clitoridis*, 676, 1420
hallucis, 700
nasi, 612
pedis, 698
penis, 676
- epigastrica inferior*, 680
ramus pubicus, 681
superficialis, 689
superior, 633
- ethmoidalis anterior*, 611
posterior, 611
- femoralis*, 683
- frontalis*, 612
- gastrica dextra*, 661
sinistra, 660
- rami aesophagei*, 661
- gastroduodenalis*, 661
- gastroepiploica dextra*, 661
rami epiploici, 661
sinistra, 662
- genu inferior lateralis*, 695
medialis, 695
media, 695
superior lateralis, 695
mediatis, 694
- suprema*, 691
ramus musculoarticularis, 691
- saphenus*, 691
- glutaea inferior*, 677
superior, 678
- ramus inferior*, 678
superior, 678
- hemorrhoidalis inferior*, 675
media, 672
superior, 667
- hepatica*, 661
- hypogastrica*, 669
- ileocolica*, 664
- iliaca externa*, 679
- ilolumbalis*, 678
- ramus iliacus*, 678
lumbalis, 678
spinalis, 678
- infraorbitalis*, 602
- interossea communis*, 650
dorsales, 650
recurrens, 651
volaris, 650
- labialis inferior*, 593
superior, 594
- lacrimalis*, 610
- linguea superior*, 590
- lienalis*, 661
- rami pancreatica*, 662
- ligamenti teretis uteri*, 680
- lingualis*, 590
ramus hyoidicus, 591
dorsalis linguae, 591

- Arteria magna*, 575
 hallucis, 700
 malleolaris anterior lateralis, 698
 medialis, 698
 posterior medialis, 703
 mammaria interna, 631
 rami intercostales, 632
 perforantes, 632
 sternales, 632
 masseterica, 601
 maxillaris externa, 592
 rami glandulares, 593
 ramus tonsillaris, 593
 interna, 598
 mediana, 650
 meningeae anterior, 609
 media, 600
 posterior, 597
 mentalis, 601
 mesenterica inferior, 665
 superior, 663
 musculophrenica, 632
 nutricia fibulae, 702
 humeri, 643
 tibiae, 702
 ramus communicans, 703
 obturatoria, 673
 ramus anterior, 674
 iliacus, 673
 posterior, 674
 pubicus, 673
 vesicalis, 673
 occipitalis, 595
 rami musculares, 595
 occipitales, 596
 ramus auricularis, 596
 descendens, 596
 meningicus, 596
 mastoideus, 596
 ophthalmica, 610
 ovaricae, 665
 palatina ascendens, 593, 1204
 descendens, 602, 1204
 pancreaticoduodenalis inferior, 663
 superior, 661
 perforans prima, 691
 secunda, 691
 tertia, 691
 pericardiacophrenica, 632
 perinei, 675
 peroneae, 701
 ramus calcaneus lateralis, 702
 communicans, 702
 perforans, 702
 pharyngea ascendens, 597
 rami pharyngei, 597
 plantaris lateralis, 703
 medialis, 703
 ramus superficialis, 703
 poplitea, 691
 princeps cervicis, 596
 hallucis, 709
 pollicis, 647
 profunda brachii, 641
 rami musculares, 644
 clitoridis, 676, 1420
 femoris, 689
 ramus ascendens, 690
 descendens, 690
 linguae, 591
 penis, 676
 putidena externa profunda, 689
 superficialis, 689
 interna, 674
 pulmonalis, 574
 ramus dexter, 575
 sinister, 575
 radiatis, 644
 rami musculares, 646
 perforantes, 648
 ramus carpeus dorsalis, 647
 volaris, 647
 volaris superficialis, 647
- Arteria recurrens radialis*, 646
 tibialis anterior, 698
 posterior, 698
 recurrentes ulnaris anterior, 650
 posterior, 650
 sacralis lateralis, 678
 rami spinales, 678
 sigmoideae, 667
 spermatica externa, 680, 1377
 interna, 665, 1376
 sphenopalatina, 602
 spinalis anterior, 621
 posterior, 621
 sternocleidomastoidea, 595
 stylomastoidea, 596
 subclavia, 623
 sublingualis, 591
 submental, 593
 subscapularis, 639
 supraorbitalis, 610
 suprarenalis inferior, 665
 media, 662
 tarsae lateralis, 699
 temporalis media, 598
 profunda anterior, 601
 posterior, 601
 superficialis, 597
 rami auriculares anteriores, 598
 ramus frontalis, 598
 parietalis, 598
 thoracalis lateralis, 638
 suprema, 638
 thyroidea ima, 582
 inferior, 629
 rami oesophagi, 629
 tracheales, 629
 superior, 589
 rami glandulares, 590
 ramus anterior, 589
 cricothyroideus, 590
 hyoideus, 590
 posterior, 589
 sternocleidomastoideus, 590
 tibialis anterior, 696
 posterior, 700
 transversa colli, 630
 ramus ascendens, 630
 descendens, 630
 faciei, 598
 scapulae, 629
 ramus acromialis, 630
 tympánica anterior, 600
 inferior, 597
 superior, 600
 ulnaris, 648
 rami musculares, 651
 ramus carpeus dorsalis, 651
 volaris, 651
 volaris profundus, 651
 urethralis, 676
 uterina, 672
 ramus ovarii, 672
 vaginalis, 672
 vertebralis, 619
 rami spinales, 620
 ramus meningicus, 621
 vesiculis inferior, 672
 medialis, 672
 superior, 671
 volaris indicis radialis, 647
 zygomaticoorbitalis, 598
- Arteriae alveolares superiores anteriores*, 602
 arciformes, 1354
 bronchiales, 654
 ciliares anteriores, 613
 posteriores breves, 613
 longae, 613
 digitales dorsales, 647, 699
 plantares, 704
 valeres communes, 652
 propriae, 652
 gastricae breves, 662
- Arteriae ileae*, 663
 iliacae communes, 668
 intercostales, 655
 rami cutanei laterales, 656
 musculares, 656
 ramus posterior, 655
 interlobares renis, 1354
 intestinales, 663
 jejunales, 663
 lumbales, 662
 ramus dorsalis, 663
 spinalis, 663
 mediastinales anteriores, 632
 metacarpeae dorsales, 647
 volares, 648
 metatarsae dorsales, 699
 plantares, 704
 oesophageae, 654
 palpebrales laterales, 610
 mediales, 612
 phrenicae inferiores, 658
 rami suprarenales superiores, 659
 receptaculi, 609
 renales, 665
 surales, 694
 tunica adventitia, 573
 intima, 573
 media, 573
- Arterial sheath*, 574
Arteriola recti, 1354
Arterioles, 547
 precapillary, 573
Artery or Arteries, 572
 acromial, 638
 acromiothoracic, 638
 of ala, 574
 alveolar, 601
 anastomosis of, 572
 around elbow-joint, 644
 circumpatellar, 696
 crucial, 678, 690
 anastomatica magna of brachial, 643, 644
 of femoral, 691
 angular, 592, 594
 of ankle-joint, 345
 antero-lateral ganglionic, 617
 antero-median ganglionic, 614
 aorta, 575
 abdominal, 657
 arch of, 579
 ascending, 576
 descending, 653
 thoracic, 653
 appendicular, 664
 articular, 694, 695
 of auditory canal, 1123
 internal, 622
 auricular, 596
 anterior, 598
 deep, 600
 posterior, 596
 axillary, 635
 azygos, articular, 695
 of vagina, 672
 basilar, 622
 of bile ducts, 1336
 of bladder, 1365
 brachial, 640
 brachiocephalic, 582
 of brain, 617
 bronchial, 582, 654
 buccal, 601
 of bulb, 675
 bulbar, 622
 calcaneal, 702, 703
 capsular, 662
 carotid, common, 583
 external, 588
 internal, 609
 of cecum, 664, 1300
 central ganglionic system of, 618
 of retina, 613

- Artery or Arteries, cerebellar, 621, 622
- cerebral, anterior, 614
- hemorrhage, 617
- middle, 616
- posterior, 622
- cervical, 629, 630
- cervicoouterine, 672
- cervicovaginal, 672
- choroid, 617, 622, 1099
- ciliary, 613
- circle of Willis, 617
- circumflex, 639, 690
- circumpatellar, anastomosis of, 696
- clavicular, 638
- of clitoris, 1420
- coats of, 573
- coccygeal, 677
- coeliac, 659
- colic, 664, 666
- communicating, anterior, 614, 650
- of dorsalis pedis, 700
- of peroneal, 702
- posterior, 617
- of cornea, 1092
- coronary, 578, 660
- of corpus cavernosum, 676
- cortical system of, 619
- cranial, from occipital, 596
- cremasteric, 680
- cricothyroid, 590
- cystic, 661
- dental, 601, 602
- development of, 761
- digital, 652
- collateral, 652
- plantar, 704
- ulnar, 652
- dorsal, of penis, 676
- dorsalis hallucis, 700
- indiciis, 647
- linguae, 591
- nasi, 613
- pedis, 698
- pollicis, 647
- scapulae, 639
- of duodenum, 1287
- dural, from ascending pharyngeal, 597
- from occipital, 596
- of elbow-joint, 308
- epigastric, deep, 680
- superficial, 689
- superior, 633
- ethmoidal, 611
- facial, 592
- transverse, 598
- of Fallopiian tube, 1402
- femoral, 683, 689
- fibular, 698
- frontal, 598, 612, 615, 617
- of gall-bladder, 1335
- ganglionic, 614, 617, 618
- gastric, 660
- gastroduodenal, 661
- gastroepiploic, 661
- glandular, 593
- of globe of eye, 1108
- gluteal, 678
- of head, 583
- of heart, 565
- hemorrhoidal, 672, 675
- hepatic, 661
- of hip-joint, 327
- histology of, 573
- humeral, 638
- hypogastric, 570, 669, 763
- impervious, 671
- ileal, 664
- ileocecal, 664
- ileocolic, 664
- iliac, common, 668
- deep circumflex, 682
- internal, 669
- superficial circumflex, 689
- iliolumbar, 678
- infrahyoid, 590
- infraorbital, 602
- infrascapular, 639
- innominate, 582
- inoculation of, 572
- intercostal, 632, 655
- interosseous, foot, 699, 700
- hand, 647, 648
- recurrent, 651
- ulnar, 650
- of iris, 1099
- of kidneys, 1352
- of knee-joint, 337
- of labia majora, 1415
- labial coronary, 593, 594
- lacrimal, 610
- of large intestines, 1310
- laryngeal, 590, 629, 1174
- lateralis nasi, 594
- lenticulostriate, 617
- lingual, 590, 591, 601
- of liver, 1326
- of lower extremity, 682
- lumbar, 662
- lymphatics of, 574
- malar, 610
- malleolar, 698, 703
- mammary, 631, 638
- masseteric, 601
- mastoid, from occipital, 596
- from posterior auricular, 596
- maxillary, 598
- mediastinal, 632, 654
- medidural, 600
- medullary, 619
- of membrana tympani, 1131
- meningeal, anterior, 609
- from ascending pharyngeal, 597
- from occipital, 596
- middle, 600
- posterior, 597, 621
- small, 600
- mental, 601
- mesenteric, 663, 666
- metatarsal, 699
- musculophrenic, 632
- mylohyoid, 601
- nasal, 612, 613
- nasopalatine, 602
- of neck, 583
- nerves of, 574
- of nose, 1081
- nutrient, of fibula, 702
- of humerus, 643
- of tibia, 702
- obturator, 673
- occipital, 595, 623
- oesophageal, 629, 654, 1239
- ophthalmic, 610
- orbital, 598
- ovarian, 665, 1401
- palatine, 596, 597, 602, 1204
- palpebral, 610, 612
- pancreatic, 662, 1341
- pancreaticoduodenal, 661, 663
- parietal, 617
- of parotid gland, 1225
- parvidural, 600
- of penis, 1389
- perforating, 690
- of foot, 704
- fourth, 689
- of hand, 648
- pericardiac, 632, 654
- perineal, 675
- perirenal, 665
- peroneal, 701, 702
- petrosal, 600
- pharyngeal, 597
- of pia of brain, 972
- of spinal cord, 846
- of pinna of ear, 1121
- plantar, 700, 703
- of pleurae, 1185
- pontile, 622
- popliteal, 691
- postdural, 597
- postero-median ganglionic, 617
- prevertebral, 597
- princeps hallucis, 700
- pollicis, 647
- profunda femoris, 689
- inferior, 643
- superior, 642
- of ulnar, 651
- of prostate gland, 1395
- pterygoid, 601
- pterygopalatine, 602
- pubic, 681
- pubic, accessory, 675
- external, 689
- internal, 674, 676
- pulmonary, 574
- pyloric, 661
- radial, 644
- carpal, 647
- radialis indicis, 647
- ranine, 591
- recurrent, radial, 646
- tibial, 698
- ulnar, 650
- renal, 665
- sacral, 669, 678
- of salivary glands, 1227
- scapular, 630
- sciatic, 677
- of seminal vesicles, 1385
- of septum, 594, 602
- of shoulder-joint, 303
- sigmoid, 667
- of skin, 1156
- of small intestine, 1293
- spermatic, 665, 1376
- spinal, 620, 621
- splenic, 661, 1446, 1449
- splenopalatine, 602
- sternal, 632
- sternomastoid, 590, 595
- of stomach, 1278
- stylomastoid of posterior auricular, 596
- subclavian, 623
- sublingual, 591
- submaxillary, 593, 1226
- submental, 593
- subpleural, mediastinal plexus of, 632
- subscapular, 630, 639
- superficial volae, 647
- supra-acromial, 630
- suprahyoid, 591
- supraorbital, 610
- suprarenal, 662
- suprascapular, 629
- suprasternal, 629, 630
- sural, 694
- tarsal, 699
- temporal, 600, 617
- anterior, 598, 623
- deep, 601
- middle, 598
- posterior, 598, 623
- superficial, 597
- of temporomandibular articulation, 281
- terminal, definition of, 573
- thoracic, 638, 639
- thymic, 582, 1442
- thyroid axis, 628
- inferior, 629
- superior, 589
- thyroidea ima, 582
- tibial, 696, 700

- Artery or Arteries, of tongue, 1219
 tonsillar, 593, 1231
 tracheal, 629, 1179
 of trunk, 653
 tympanic, 609
 anterior, 600
 from ascending pharyngeal, 597
 superior, 600
 ulnar, 648, 651
 umbilical, 570
 of upper extremity, 623
 ureteral, 665, 1358
 urethral, 676
 uterine, 672, 1410
 vaginal, 672, 1415
 bulb, 1420
 of vas deferens, 671
 vasa brevia, 662
 intestini tenuis, 663
 of vermiform appendix, 1300
 vertebral, 619, 628
 vesical, 671, 672
 Vidian, 602, 609
 of voluntary muscles, 356
 of wrist-joint, 315
Arthrodia, 264, 265, 266
 Articular arteries, 694, 695
 cartilage, 260
 disks, 260
 triangular, 312
 eminence of zygomatic process
 of temporal bone, 81
 facet of clavicle, 171
 fibrocartilage, 260
 lamella of bone, 259
 meniscus, 280
 nerve corpuscles, 817
 processes of atlas, 51
 surfaces of axis, 52
 of sacrum, 60
 synovial membrane, 261
Articulatio acromioclavicularis, 297
allantoepistrophica, 273
allantooccipitalis, 275
calcanecuboides, 347
carpometa carpeae pollicis, 317
coxae, 322
cubiti, 306
cuboidonavicularis, 350
genu, 331
humcri, 301
intercarpeae, 315
mandibularis, 279
radiocarpeae, 314
radioulnaris, 310
distalis, 312
sacroiliaca, 290
sternoclavicularis, 295
talocalcanea, 347
talocruralis, 342
tarsi transversa [*Choparti*], 349
tibiofibularis, 340
Articulatio capitolorum, 282
carpometa carpeae, 317, 318
costotransversariae, 284
costovertebrales, 282
digitorum manus, 321
pedis, 354
interchordales, 288
intermetacarpeae, 319
intermetarsaeae, 352
intertarsaeae, 347
metacarpophalangeae, 320
metatarsophalangeae, 353
ossiculorum auditus, 1133
sternocostales, 286
tarsometatarsaeae, 351
 Articulations, 259
 acromioclavicular, 297
 of astragalus with scaphoid, 349
 of atlas with axis, 273
 with occipital bone, 275
 of axis with occipital bone, 277
 biaxial, 264, 265
 Articulations, calcaneo-astragal-
 oid, 347
 calcaneocuboid, 347
 calcaneoscaphoid, 348
 carpometa carpal, 318
 of carpus, 315
 of cartilages of ribs with each
 other, 288
 costocentral, 282, 285
 costosternal, 286
 costotransverse, 284, 285
 costovertebral, 282
 of cuneiform bones with each
 other, 350
 of elbow-joint, 306
 of external cuneiform bone
 with cuboid, 351
 of hip-joint, 322
 immovable, 263
 intercuneiform, 350
 interneural, 271
 of knee-joint, 331
 of lower extremity, 322
 mediotarsal, 349
 metacarpophalangeal, 320
 of metatarsal bones with each
 other, 352
 metatarsophalangeal, 353
 mixed, 264
 movable, 264
 of ossicles of tympanum, 1133
 of pelvis, 290
 of phalanges of foot, 354
 of hand, 321
 polyaxial, 264
 of pubic bones, 294
 radiocarpal, 314
 radioulnar, 310
 of ribs with their cartilages,
 288
 with vertebrae, 282
 sacroiliac, 290
 of sacrum and coccyx, 292
 and ilium, 290
 of scaphoid with cuboid, 350
 with cuneiform, 349
 of scapula, 299
 scapuloclavicular, 297
 of shoulder-joint, 301
 sternoclavicular, 295
 of sternum, 288
 tarsometatarsal, 351
 of tarsus, 347
 temporomandibular, 133, 279
 tibiofibular, 340
 tibiotalarsal, 342
 transverse tarsal, 349
 of trunk, 268
 of upper extremity, 295
 of vertebral column, 268
 with cranium, 275
 with pelvis, 289
 of wrist-joint, 314
 Aryepiglottic muscles, 1173
 Arytenoepiglottic fold, 1167,
 1170
 Arytenoid cartilage, 1166
 Arytenoideus muscles, 1172
 Ascending aorta, 576
 colon, 1303
 mesocolon, 1264
 Association nerve fibers, 954
 Asterion, 133, 146
 Astragaloscaphoid ligament, 349
 Astragalus, 244
 articulation of calcaneus and,
 347
 of scaphoid with, 349
 Astrocytes, 818
 Atlanto-axial ligaments, 274
 Atlanto-odontoid joint, 274
 Atlas, 50
 accessory ligament of, 275
 articulation of, with axis, 273
 with occipital bone, 275
 Atlas, development of, 63
 transverse ligament of, 274
 Atrium, 1125
 dextrum, 554
 maxillary, orifice of, 141
 meatus medii, 141
 nasi, 1082
 of nasal meatus, 141
 sinistrum, 559
 Attic, 1125
 Attollens aurem muscle, 366
 Attrahens aurem muscle, 366
 Auditory artery, internal, 622
 canal, 1122
 applied anatomy of, 1124
 arteries of, 1123
 cartilaginous portion of,
 1122
 lymphatics of, 1123
 nerves of, 1123
 osseous portion of, 1122
 skin of, 1123
 veins of, 1123
 hair, 1143
 meatus, 1122
 external, 88, 133, 1122
 lymphatic vessels of, 777
 internal, 85, 128
 nerve, 1000
 nuclei, 881
 teeth, 1144
 vesicles, 142
 Auerbach's plexus of nerves, 1279
 Aula, 908
 Aulix, 908
 Auricles of ear, 1119
 of heart, fibres of, 562
 left, 559
 right, 554
 primitive, 757
 Auricula, 1119
 dextra, 554
 sinistra, 559
 Auricular appendix, 554, 559
 artery, 596, 598, 600
 canal, 757
 fissure, 131
 lymph nodes, 774
 nerve, anterior, 988
 from vagus, 1005
 great, 1020
 posterior, 997
 point of skull, 146
 region, muscles of, 365
 systole, 565
 vein, 712
 Auriculotemporal nerves, 988
 Auriculoventricular bundle of
 His, 564
 opening, 557, 559
 Auris interna, 1136
 Avalanche conduction of Ramón
 y Cajal, 815
 Axes of pelvis, 218
 Axial planes of body, 34
 Axilla, 633
 applied anatomy of, 634
 dissection of, 455
 ligaments of, 456
 Axillary arch, 407
 artery, 635
 applied anatomy of, 637
 fascia, 456, 633
 lymph nodes, 782
 sheath, 636
 veins, 731
 applied anatomy of, 732
 Axis, 52
 articulation of, with occipital
 bone, 277
 coeliac, 659
 of crystalline lens, 1107
 development of, 64
 optic, 1088
 sagittal, 1088

Axis, thyroid, 628
 visual, 1088
Axialis lentis, 1107
optica, 1088
pctvis, 218
 Axis-cylinder process, 807, 811
 Axones, 810
 amyelinic, 812
 myelinic, 811
 of spinal cord, myelination of, 840
 Azygos arteries of vagina, 672
 articular artery, 695
 uvulae muscle, 398
 veins, 736
 applied anatomy of, 737

B

BACK, fascia of, 404
 muscles of, 403
 applied anatomy of, 416
 first layer, 413
 first layer, 404
 fourth layer, 410
 second layer, 407
 surface form of, 416
 third layer, 408
 Baillarger, fibre band of, 953
 Ball-and-socket joint, 264
 Band of Vicq d'Azyr, 932
Barba, 1159
 Bartholin, duct of, 1226
 glands of, 1420
 Basihyal, 153
 Basilar artery, 622
 groove, 73
 of pons, 864
 membrane, 1143
 process, 71
 sinus, 727
 suture, 122
 vein, 720
 Basilic vein, 730
 Basion, 131, 146
Basis cochleae, 1138
cordis, 551
glandulae suprarenalis, 1448
mandibulae, 117
modioli, 1138
nasi, 1079
ossa metacarpalia, 201
metatarsalia, 250
sacri, 61
patellae, 231
phalangis, 204
prostaticae, 1391
pulmonis, 1188
 Basisylvian fissure, 917
 Basket cells, 892
 Basophiles, 40
 Berchterew, fibre band of, 953
 Bell, respiratory nerve of, external, 1029
 internal, 1024
 Bertin, ligament of, 323
 Biaxial articulations, 264
 Biceps brachii muscles, 469
 femoris muscle, 522
 applied anatomy of, 525
 bursa of, 524
 surface form of, 543
 flexor cubiti muscle, 469
 muscle, 469
 surface form of, 495
 Bichât, fissure of, 940
 Bicipital fascia, 469, 730
 groove, 180
 tuberosity, 191
 Bicornate uterus, 1408
 Bicuspid teeth, 1207
 valve, 561
Bifurcatio tracheae, 1175
 Bigelow, ligament of, 324

Bile, 1334
 duct, 1333
 arteries of, 1334
 lymphatics of, 796, 1334
 nerves of, 1334
 veins of, 1334
 papilla, 1287
 Bipolar nerve cells, 808, 1102
 "Bird's nest" of cerebellum, 888
 Biventer cervicis muscles, 413
 Biventral lobes, 887
 muscle, 358
 Bladder, 1358
 applied anatomy of, 1366
 arteries of, 1365
 cervix of, 1361
 development of, 1426
 interior of, 1364
 ligaments of, 1361
 true, 1362
 lymphatics of, 796, 1365
 mucous membrane of, 1364
 nerves of, 1365
 rugae of, 1364
 surface form of, 1365
 trigone of, 1365
 veins of, 1365
 Blind spot, 1101
 Blood cells, 40
 circulation of, 547
 islands, 755
 Blood-vascular system, 547
 development of, 755
 Bloodvessels of bone, 40
 of nerves, 813
 BNA, definition of, 33
 Bochdalek, ganglion of, 984
 Bodies, carotid, 1450
 Nissl, 809
 parasympathetic, 1450
 quadrigenal, 894
 tigroid, 809
 Body, ciliary, 1094
 coccygeal, 1450
 geniculate, external, 905
 internal, 895
 lateral, 910
 of Luys, 905
 pineal, 906
 pituitary, 909
 thyroid, 1435
 vitreous, 1105
 Bone or Bones, acetabulum, 213
 ankle, 244
 apophysis of, 37
 applied anatomy of, 46
 of arm, 178
 astragalus, 244
 atlas, 50
 axis, 52
 bloodvessels of, 40
 breast, 157
 calcaneus, 239
 calcification of, 44
 calf, 236
 cambium layer of, 46
 canaliculi of, 39
 cancellous, 40
 carpus, 195
 of cerebral cranium, 70
 chemical composition of, 41
 of chest, 154
 clavicle, 169
 coccyx, 61
 collar, 169
 compact, 38
 covering, 142
 of cranium, 70
 cuboid, 245
 cuneiform, of foot, 247
 of hand, 197
 dense, 38
 dermal, 142
 destroyers, 44
 diaphysis of, 35

Bone or Bones, of elbow, 185
 endosteum of, 39
 epactal, 144
 epiphyses of, 35
 epipteric, 144
 ethmoid, 96
 extremities of, 35
 of face, 99
 femur, 221
 fibers of, 38
 fibula, 236
 flat, 36
 of foot, 239
 of forearm, 185
 formers, 44
 frontal, 76
 growth of, 42
 of hand, 194
 lower row, 198
 upper row, 196
 heel, 239
 hip, 207
 humerus, 178
 hyoid, 153
 ilium, 207
 interparietal, 74
 irregular, 36
 ischium, 210
 knee-cap, 230
 lacrimal, 106
 lesser, 107
 lacuna of, 39, 259
 lamellae of, 39
 articular, 259
 of leg, 230
 lingual, 153
 long, 35
 of lower extremity, 207
 jaw, 115
 lymphatics of, 41
 malar, 107
 mandible, 115
 marrow of, 40
 maxillae, 100
 medullary canal of, 35
 metacarpus, 201
 metatarsal, 249
 nasal, 99
 navicular, of foot, 246
 of hand, 196
 nerves of, 41
 occipital, 70
 os calcis, 239
 coxal, 207
 innominatum, 207
 magnum, 199
 pubis, 207, 212
 trigonum, 245
 osseous tissue of, 38
 ossification of, 42
 palate, 109
 parietal, 74
 patella, 230
 of pelvis, 215
 periosteum of, 38
 phalanges of foot, 252
 of hand, 204
 pisiform, 198
 premaxillary, 105
 proliferation of, 44
 pubis, 212
 radius, 190
 ribs, 161
 rider's, 229, 360, 515
 sacrum, 58
 scaphoid, of foot, 246
 of hand, 196
 scapula, 172
 semilunar, 197
 sesamoid, 257
 shaft of, 35
 shin, 231
 short, 36
 shoulder blade, 172
 girdle, 169

- Bone or Bones, of skull, 69
 sphenoid, 89
 spine, 48
 sternum, 157
 supernumerary, 144
 sutural, 144
 tarsus, 239
 temporal, 80
 thigh, 220
 of thorax, 154
 tibia, 231
 trapezium, 198
 trapezoid, 199
 turbinate, 113, 139
 ulna, 185
 unciform, 200
 of upper extremity, 168
 jaw, 100
 vascularization of, 45
 vertebrae, 48
 cervical, 49
 coccygeal, 58
 lumbar, 56
 sacral, 58
 thoracic, 53
 vomer, 114
 wedge, 247
 Wormian, 144
- Bony semicircular canals, 1137
- Born, ostium primum of, 759
 secundum of, 759
- Bowman, capsule of, 1350, 1351
 membrane of, 1091
- Brachia conjunctiva*, 891
pontis, 890
- Brachial artery, 640
 applied anatomy of, 641
 surface marking of, 641
 fascia, 467
 plexus of nerves, 1026
 applied anatomy of, 1039
 veins, 731
- Brachialis anticus muscle, 469
 surface form of, 496
- Brachiocephalic artery, 582
 veins, 733
- Brachioradialis muscle, 479
 surface form of, 496
- Brachium quadrigeminum inferius*, 895
superius, 895
- Brachycephalic cranium, 146
- Brain, 846
 adult human, 860
 arachnoid of, 968
 villi of, 970
 areas of, 959
 arteries of, 617
 cerebellum, 854
 development of, 850
 dimensions of, 849
 dura of, 964
 fourth ventricle of, 864
 hind, 861
 isthmus, 860 (note)
 laminae of, 855
 localization of function of, 959
 medulla oblongata, 861
 meninges of, 964
 nuclei of, 857
 Pacchionian bodies of, 970
 pia of, 972
 pons, 864
 structure of, plan of, 858
 topography of, 847
 tube, development of, 852
 flexures of, 855
 vesicle, primary, 851
 weight of, 849
 zones of, 855
- Breast bone, 157
 female, 1428
 male, 1433
- Bregma*, 76, 123, 146
- Bregmatic fontanelle, 143
- Brim of pelvis, 215
- Broad ligament of lung, 1183
 of uterus, 1407
- Broca's cap, 917
 diagonal band, 928
- Bronchi, 1175
 left, 1177
 right, 1176
- Bronchial artery, 582, 654
 veins, 737
- Bronchioles, respiratory, 1195
- Bronchiomediastinal lymph nodes, 801
- Bronchus dexter*, 1176
ramus bronchialis eparterialis, 1177
hyparterialis, 1177
sinister, 1177
- Bruce and Campbell, intermedio-lateral tract of, 839
- Bruch, membrane of, 1093
- Bruns, falciform margin of, 508
- Bryant's triangle, 329
- Buccae*, 1200
- Buccal artery, 601
 cavity, 1199
 glands, 1200
 lymph nodes, 776
 nerve, 987, 998
 region, muscles of, 374
- Buccinator muscle, 375
 nerve, 987
- Buccopharyngeal fascia, 377, 394
- Bulb, aortic, 759
 artery of, 675
 of corpora cavernosa, 1386
 of internal jugular vein, 714
 occipital, 939
 olfactory, 927
 urethral, 1386
- Bulbar arteries, 622
- Bulboid corpuscles, 817
- Bulbous aortae*, 576
- Bulbus cordis*, 757, 759
cornu posterioris, 939
oculi, 1086
olfactorius, 927
pili, 1159
urethrae, 1386
vena jugularis inferior, 714
superior, 714
vestibuli, 1420
- Bulla ethmoidalis*, 1082
- Burdach, column of, 827
- Bursa or Bursae, about knee-joint, 336
 of biceps femoris muscle, 524
 deep infrapatellar, 336
 of elbow-joint, 308
 gluteofemoral, 327
 of gluteus maximus muscle, 516
 medius muscle, 517
 of greater trochanter, 327
 of hand, 487
 of hip-joint, 327
 iliopectineal, 327
 infrapatellar, deep, 336
 infrapatellar, 303
 ischiofemoral, 327
 of knee-joint, 336
 obturator, 327, 518
 olecranon, 308
 patellar, deep, 512
 prepatellar, 336, 512
 of pyriformis muscle, 517
 of quadriceps femoris muscle, 521
 of shoulder-joint, 303
 subacromial, 303, 462
 subcutaneous acromial, 303
 tibial, 336
 trochanteric, 327
 subdeltoid, 303, 462
- Bursa or Bursae, subscapular, 303
 subtendinous iliac, 327
 suprapatellar, 336, 511
 synovial, subcutaneous, 262
 subtendinous, 262
 thecal, 262
 of tendo Achillis, 530
 tensoris veli palati, 397
 of tibialis anticus muscle, 526
 of wrist, 487
- Bursa or Bursae, anserina*, 513, 524
bicipitogastrocnemialis, 524
bicipitoradialis, 308
gluteofemorales, 327, 516
iliaca subtendinea, 327, 504
iliopectinea, 327, 504
infrapatellaris profunda, 336, 512
intermetacarpophalangeae, 487
intratendinea olecrani, 308
ischiofemorales, 327, 516
maximi, 327, 516
mucosae subcutaneae, 262
subtendineae, 262
musculi poplitei, 337
musculus bicipitis femoris inferior, 524
infrapatinati, 465
oburatorii interni, 327, 518
pectinei, 513
piriformis, 517
recti femoris, 510
sartorii propria, 509
sternohyoides, 1167
subscapularis, 464
tensoris veli palati, 397
tertius majoris, 466
praepatellaris subcutanea, 336, 506, 512
subfacialis, 336
subtendinea, 336
sternohyoides, 387
subacromialis, 462
subcutanea calcanea, 530
digitorum dorsales, 487
epicondylj humeri lateralis, 308
medialis, 308
olecrani, 308
prominentiae laryngeae, 1164
tuberositatis tibiae, 336
subdeltoides, 462
subtendinea musculus tibialis anterioris, 526
olecrani, 308
suprapatellaris, 336, 511
tendinis calcanei, 530
trochanterica musculus glutaei maximi, 516
medii anterior, 517
posterior, 517
minimi, 517
subcutanea, 327, 506
- Bursal synovial membrane, 262
- C**
- CACUMINAL lobes, 886
- Cajal, nerve cells of, 1102
- Calcaneal arteries, 702, 703
 nerves, 1057
- Calcaneo-astragaloid articulation, 347
 ligaments, 347
- Calcaneocuboid articulation, 347
 ligaments, 348
- Calcaneoscapoid articulation, 348
 ligaments, 348
- Calcaneus, 239
 articulation of astragalus and, 347
 of scaphoid and, 348

- Calcaneus, articulation with cuboid, 347
 Calcar, 939
 avis, 939
 femorale, 227
 Calcarine fissure, 919
 Calf bone, 236
 Colices *maiores*, 1349
 minores, 1349
 of ureters, 1356
 Callosal eminence, 939
 gyre, 920, 921
Calyculi gustatorii, 1148
Camera oculi anterior, 1105
 posterior, 1105
 Camper, fascia of, 424
 Canal or Canals, adductor, 685
 Alcock's, 450, 675
 alimentary, 1199
 anal, 1309
 auditory, 1122
 auricular, 757
 carotid, 131
 of Corti, 1145
 crural, 684
 dental, 102, 117
 diploic, 718
 ethmoidal, 79, 98
 for Eustachian tube, 1127
 femoral, 503, 684
 Haversian, 39
 of Huguier, 84, 88, 997, 1126
 Hunter's, 511, 515, 685
 hyaloid, 1106
 incisor, 105
 infraorbital, 102, 136
 inguinal, 437, 1375
 lacrimal, 1116
 malar, 108
 medullary, of bone, 35
 membranous, of cochlea, 1144
 for nasal duct, orifice of, 141
 nasopalatine, 114
 of Nuck, 1408
 nutrient, of fibula, 237
 of metacarpal bones, 201
 of radius, 191
 of ulna, 189
 obturator, 517
 palatine, anterior, 139
 posterior, 102, 110, 134
 accessory, 110, 128
 palatamaxillary, 102
 of Petit, 1106
 pterygoid, 130
 pterygopalatine, 92, 130, 134
 pyloric, 1272
 sacral, 61
 of Schlemm, 1092
 semicircular, bony, 1137
 membranous, 1142
 spermatic, 437, 1375
 of spinal cord, central, 831
 for tensor tympani, 1127
 of vermiform appendix, 1299
 vertebral, 49, 67
 Vidian, 93, 130, 134
 Volkmann's, 39
 of Wirsung, 1339
Canales diploici [Brescheti], 718
 palatina, 110
 semicirculares ossei, 1137
 lateralis, 1138
 posterior, 1137
 superior, 1137
 Canaliculi of bone, 39
 caroticotympanici, 86
Canaliculus chordae tympani, 88, 1126
 innominatum, 92, 127, 1135
 tympanicus, 87, 1125
Canalis adductorius [Hunteri], 511, 515, 685
 centralis cochleae, 85
 medullae spinalis, 831
Canalis cervicis uteri, 1408
 condyloideus, 71
 ethmoidale anterior, 98
 posterior, 98
 facialis, 85
 femoralis, 503, 684
 hyaloideus, 1106
 hypoglossi, 71
 inguinalis, 437, 1375
 ioannidis, 104
 mandibulae, 117
 musculotubarius, 87
 nasolacrimalis, 102
 obturatorius, 517
 pterygoideus, 93
 pterygopalatinus, 110
 radicis dentis, 1212
 reunions of Hensen, 1142
 sacralis, 61
 spiralis cochleae, 1140
 modioli, 1139
 vertebralis, 49
 Cancellous bone, 40
 Canine eminence, 101
 fossa, 101, 135
 teeth, 1206
 Canthi of eyelids, 1113
 Capillaries, 547, 573
Capilli, 1159
Capitellum, 182
Capitulum costae, 162
 fibulae, 236
 humeri, 182
 mallei, 1131
 mandibulae, 118
 ossa metacarpalia, 201
 metatarsalia, 250
 radii, 190
 stapedis, 1133
 ulnae, 189
Capsula adiposa, 1348
 articularis cricoarytaenoidea, 1168
 extrema, 948
 lentis, 1107.
Capsulae articulares. See Individual joints.
Capsular artery, 662
 ligaments. See Individual joints.
Capsule, adrenal, 1447
 of Bowman, 1350, 1351
 of crystalline lens, 1107
 external, 951
 internal, 948
 Malpighian, 1350, 1351
 of Ténon, 371, 1086
Caput cecum coli, 1297
 epididymidis, 1378
 femoris, 221
 gallinaginis, 1367
 gelatinosa Rolandi, 830
 ghiosum, 829
 humeri, 178
 obliquum musculus adductoris hallucis, 541
 pancreaticis, 1337
 transversum musculus adductoris hallucis, 541
 Cardiac cycle, 565
 Ganglion of Wrisberg, 1072
 glands, 1278
 muscle fibers, 355, 357
 muscles, 355
 nerves, cervical, 1007
 inferior, 1069
 superior, 1068
 thoracic, 1007
 orifice, 1271
 plexus of nerves, 1072
 revolution, 565
 veins, 708
 anterior, 556
Carina urethralis vaginae, 1414
 Caroticotympanic nerve, 1066
 Carotid arteries, common, 583
 applied anatomy of, 586
 left, 583
 right, 583
 surface marking of, 586
 external, 588
 applied anatomy of, 588
 surface marking of, 588
 internal, 606
 applied anatomy of, 608
 cavernous portion of, 608
 cerebral portion of, 608
 cervical portion of, 607
 petrous portion of, 607
 bodies, 1450
 canal, 131
 foramen, 84, 86
 ganglion, 1066
 glands, 586, 1450
 groove, 126
 nerve, 1003
 plexus of, 1069
 sheath, 383
 triangle, 388, 603, 604
 Carpal arch, 647
 artery, radial, 647
 ulnar, 651
 bones, 195
 applied anatomy of, 205
 common characters of, 196
 surface form of, 205
 meniscus, 317
 Carpo-metacarpal articulations, 317
 Carpus, 195
 articulations of, 315
 ligaments of, 315
 Cartilage, 259
 alar, lesser, 1080
 articular, 260
 arytenoid, 1166
 costal, 165
 cricoid, 1165
 cuneiform, 1166
 elastic, 261
 epiphyseal, 44
 hyaline, 260
 intrathyroid, 1165
 of Jacobson, 1080, 1083
 of larynx, 1163
 matrix, 260
 Meckel's, 118
 of nose, 1079
 parachordal, 141
 of pinna of ear, 1120
 of Santorini, 1166
 sesamoid, 1080
 thyroid, 1163
 of trachea, 1177
 vomeric, 1080
 of Wrisberg, 1166
Cartilagineae alares minores, 1080
 arytenoideae, 1166
 basis, 1166
 crista arcuata, 1166
 fovea oblonga, 1166
 triangularis, 1166
 processus muscularis, 1166
 vocalis, 1166
 corniculatae, 1166
 cuneiformes, 1166
 laryngis, 1163
 nasi, 1079
 Cartilaginous ear capsules, 141
Cartilago alaris major, 1079
 crus laterale, 1079
 mediale, 1079
 auriculae, 1120
 costalis, 165
 cricoidae, 1165
 epiglottica, 1167
 nasi lateralis, 1079
 scripti nasi, 1080
 thyreoidea, 1163
 triticea, 1168

- Cartilago tubae auditivae*, 1128
lamina lateralis, 1128
medialis, 1128
vomeronasalis, 1080
Caruncula lacrimalis, 1115
sublingualis, 1201, 1226
Carunculae hymenales, 1418
myrtiformes, 1418
Cauda epididymidis, 1378
equina, 823, 845
helicis, 1120
pancreatis, 1339
Caudate lobe of liver, 1324
nucleus, 937, 946
Caudatum, 854, 937, 946
Cavernous groove, 91
nerves, 1077
plexus of, 1066
sinuses, 724
Cavitas glenoidalis, 176
Cavity or Cavities, cotyloid, 213
glenoid, 176
of heart, 553
of mouth, 138
nasal, 138
of pelvis, 216
pulp, 1212
sigmoid, of radius, 192
of ulna, 187
of thorax, 157
tympanic, 1125
Cavum articulare, 294
[*genae*], 336
conchae, 1120
dentis, 1209
epidurale, 843
laryngis, 1169
mediastinale posterius, 1183
nasi, 138, 1081
regio olfactoria, 1082
respiratoria, 1082
oris, 1199
proprium, 1201
pharyngis, 1229
pleurae, 1181
septi pellucidi, 913, 945
subarachnoideale, 845, 969
thoracis, 154, 157
tympani, 1125
paries carotica, 1127
jugularis, 1125
labyrinthica, 1126
mastoidea, 1126
tegumentalis, 1125
uteri, 1408
Cecal arteries, 664, 1300
fold, 1267
Cecum, 1296
arteries of, 664, 1300
interior of, 1298
lymphatics of, 1300
mucous membrane of, 1300
veins of, 1300
Cell or Cells, acid, 1276
air, mastoid, 1127
basket, 892
centro-acinar, of Langerhans, 1340
of Claudius, 1147
commissural, of cord, 841
of Deiters, 1146
enamel, 1214
ependymal, 818
ethmoidal, 79, 97, 98, 141
ganglion, 807
of Golgi, 952
gustatory, 1149
hair, 1143
outer, 1146
of Hensen, 1147
interstitial, 1399
islets, interalveolar, 1340
of lateral ventricles, 936
lutein, 1400
of Martinotti, 952, 953
Cell or Cells, mastoid, 83
nerve, arboriform, 808
bipolar, 808, 1102
of cerebral cortex, 952
ciliated ependymal, 806
germinal, 806
glia, 818
Golgi, 808
multipolar, 808
of spinal cord, 832
stellate, 808
unipolar, 808
oxyntic, 1276
parenchymatous, 1437
parietal, 1276
polymorphous, 952
Purkinjean, 892
pyramidal, 952
splenic, 1445
Cellulae ethmoidales, 97
mastoideae, 83, 1123
Cementum of teeth, 1212
Centripetal nerve fiber, 810
Centro-acinar cells of Langerhans, 1340
Centrum semiovale, 932
tendineum [diaphragma], 419
Cephalic fixture of brain, 855
index of skull, 146
vein, 730
accessory, 731
Ceratohyals, 154
Cerebellar artery, anterior inferior, 622
posterior inferior, 621
superior, 622
hemispheres, 885
tract of spinal cord, 838
veins, 720
Cerebello-olivary fibers, 873
Cerebellospinal tract of cord, 839
Cerebellum, 884
anlage of, 855
"bird's nest" of, 885
cortex of, microscopic appearance of, 892
fibers of, 891
fissures of, 885
flocculus of, 888
peduncles of, 888
folia of, 884
frenulum of, 891
furrowed band of, 888
gray masses of, 888
lingula of, 886
lobes of, 885
nuclei of, 888
peduncles of, 889
peduncular sulcus of, 885
postramus of, 888
preramus of, 888
proton of, 885
ramus of, 888
vermis of, 885
weight of, 883
worm of, 885
Cerebral artery, anterior, 614
middle, 616
posterior, 622
cortex, 932
nerve cells of, 952
fibres of, 952
cranium, bones of, 70
fibre systems, summary of, 954
fissures, 915
gyres, 915
hemispheres, 912
configuration of, 914
gray masses in, 946
hemorrhage, artery of, 617
lobes, 916
veins, 719
Cerebrospinal fluid, 845, 970
tract, ventral, 840
Cerebrum, 912
Cerumen, 1123
Cervical arteries, 629, 630
cardiac nerve, 1007
curve of vertebral column, 66
enlargement of spinal cord, 823
fascia, applied anatomy of, 884
flexure of brain, 855
ganglion, 1066, 1069
lymph nodes, 777, 779
nerves, division of, 1016
nucleus of spinal cord, 833
pleura, 1183
plexus of nerves, 1018, 1020
applied anatomy of, 1026
rib, 53, 64
veins, 717, 718
vertebrae, 49
seventh, 53
Cervicalis ascendens muscle, 412
Cervicofacial nerve, 996
Cervicouterine artery, 672
Cervicovaginal artery, 672
Cervix uteri, 1405
portio supravaginalis, 1405
vaginalis, 1405
Chassaignac's tubercle, 68
Check ligaments, 1087
Cheeks, 1200
Chemproscope skull, 146
Chest, 154. See Thorax.
Chiasma opticum, 974
Choanae, 138, 1081, 1229
Chondrin, 260
Chondroblasts, 259
Chondroglossus muscle, 392, 393
Chondrosternal ligaments, 286, 287
Chondroxiphoid ligaments, 288
Chorda obliqua, 311
tympani, 877, 882, 997
Chordae tendineae, 558, 561
Wilms', 721
Chorioidea, 1093
Choroid, 1093
applied anatomy of, 1110
artery of, 617, 1099
fissure, 940
nerves of, 1099
plexuses of fourth ventricle, 867
of lateral ventricles, 940
of third ventricle, 940
vein, 720
Chromatophiles, 809
Chyle, 767
Chyliferous vessels, 767
Cilia, 1113, 1159
Ciliary arteries, 613
body, 1094
ganglion, 982
glands, 1162
ligament, 1096
muscle, 1095
nerves, 981, 982
processes, 1094
Ciliated ependymal nerve cells, 806
Cinerea, 819
Cingulum, 955, 1206
Circle of Willis, 617, 618
Circular sinus, 726
Circulation of blood, 547
fetal, 568
placental, 755, 756
pulmonary, 548
systemic, 548
umbilical, 756
vitelline, 755
Circulus arteriosus, 617
iridis major, 1099
minor, 1099
tonsillaris, 1003
Circumanal glands, 1162
Circumduction, 267
Circumference of pelvis, 215, 217

- Circumferentia articularis*, 191
Circumferential lamella of bone, 39
Circumflex arteries, 639, 690
 iliac vein, 742
 nerve, 1030
Circuminsular fissure, 925
Circumpatellar anastomosis, 696
Cisterna basalis, 969
Cerebellomedullaris, 969
 cylis, 770, 772
 interpeduncularis, 970
 pontis, 969
Cisternae subarachnoidales, 969
Clarke's column, 830, 833
Claudius, cells of, 1147
Clastrum, 948, 954
Clava, 863
Clavicle, 169
 applied anatomy of, 172
 surface form of, 171
Clavicula, 169
Clavicular artery, 638
 facet, 157
 nerve, 1022
Clavipectoral fascia, 456, 459
Cleavage lines of Langer, 1150
Cleft palate, 151
Clinoid processes, 90, 94, 126
Clitoris, 1418
 arteries of, 1420
 frenulum of, 1416
 nerves of, 1420
 prepuce of, 1416
Clival lobes, 886
Clivus, 73, 90
Cloquet, ligament of, 1376, 1379
 lymph nodes of, 786
 septum crurale of, 504
Club foot, 256
Coaptation, 267
Coccygeal artery, 677
 body, 1450
 ganglion, 1072
 gland, 1450
 ligament, 843, 845
 nerves, 1019
 divisions of, 1051
 plexus of, 1062
 vertebra, 58
Coccygeus muscle, 453
Coccyx, 61
Cochlea, 1138
 bony canal of, 1138, 1140
 membranous canal of, 1144
Cochlear nerve nuclei, 881
Cochleariform process, 1127
Cochlear artery, 659
 axis, 659
 plexus of nerves, 1008, 1073
Cæliolympha, 970
Cælom, 1245
Cohnheim's fields, 356
Colic arteries, 664, 666
 impression of liver, 1321
 lymph nodes, 791
 plexus of nerves, 1076
Collar bone, 169
Collateral circulation, definition of, 573
 eminence, 938
 fissure, 924
Colles, fascia of, 424, 441
 fracture, 193
 passive motion after, 268
Colliculi inferiores [corpora quadrigemini], 894
 superiores [corpora quadrigemini], 894
Colliculus nervi optici, 1101
Collum anatomicum, 178
 chirurgicum, 178
 costae, 162
 dentis, 1204
 femoris, 221
 Collium mallei, 1131
 mandibulac, 118
 radii, 191
 scapulae, 176
 tali, 245
 vesicae, 1361
 fellae, 1332
Colon, 1303
 applied anatomy of, 1306
 ascendens, 1303
 descendens, 1305
 hepatic flexure of, 1303
 mucous membrane of, 1310
 sigmoid flexure of, 1306
 sigmoideum, 1306
 splenic flexure of, 1303
 transversum, 1303
Colostrum corpuscles, 1431
Column of Burdach, 827, 835
 Clarke's, 830, 833
 of Goll, 827, 835
 of Sertoli, 1380
 of spinal cord, 826
Columna rugorum anterior, 1414
 posterior, 1414
 vertebrolis, 48, 66
Columnae carnae, 558, 561
 renales [Bertini], 1350
 pars convoluta, 1350
 radiata, 1350
Comes nervi ischiadici artery, 677
 mediana artery, 650
 phrenici artery, 632
Comma tract of Schultze, 835
Commissura anterior alba, 840
 cinerea [grisea], 830
 inferior [Guddeni], 895
 labiorum, 1199
 anterior, 1415
 posterior, 1415
 maxima, 933
 palpebrarum lateralis, 1113
 medialis, 1113
 ventralis alba, 830
Commisural cells of cord, 841
Commissure, anterior, 946
 of Gudden, 895
 habenular, 906
 hippocampal, 944
 middle, 903
 posterior, 906
 of spinal cord, gray, 830, 831,
 white, 834
Communicantes hypoglossi nerve, 1023
Communicating artery, anterior, 614, 650
 of dorsalis pedis, 700
 of peroneal, 702
 posterior, 617
 of tibia, 703
 peroneal nerve, 1059
Complexus muscle, 412
Compressor narium minor muscle, 372
 urethrae muscle, 448
Concentric corpuscles, 1441
 lamella of bone, 39
Concha auriculæ, 1120
 nasalis inferior, 113
 media, 98
 superior, 98
Conchae sphenoidales, 91, 95
Conductor sonorus, 866
Condylar foramen, 71, 127, 128, 132
 fossa, 132
 Condyle, external, 182
 internal, 182
Condyles of bones. See Bones.
Condylod joint, 264, 265
 process of mandible, 118
Condylus lateralis femoris, 225
 tibiae, 233
Condylus medialis femoris, 225
 tibiae, 233
 occipitalis, 71
Confluence of sinuses, 72, 724
Confluens sinuum, 72, 724
Conjugal ligaments, 271
Conjugata, 215
Conjugate diameter of pelvis, 215
Conjunctiva, 1114
 applied anatomy of, 1118
 fornices of, 1115
 glands of, 1115
 nerves of, 1115
Conoid ligament, 298
 tubercle, 169
Constriction lobe of liver, 1326
Constrictions of Ranvier, 811
Constrictor isthmi faucium muscle, 391 (note)
 muscles, 394, 395
 urethrae muscle, 448
Contralateral tract cells of cord, 841
Corus arteriosus, 557, 574
 elosticus, 1168
 medullaris, 823
Cooper, ligament of, 428, 456
Cor, 551
 facies diaphragmatica, 552
 sternocostalis, 551
 margo acutus, 552
 obtusius, 552
 sulci longitudinales, 553
 sulcus coronarius, 553
 longitudinalis anterior, 553
 posterior, 553
Coracoclavicular ligament, 299
Coracobrachialis muscle, 468
 surface form of, 495
Coracoclavicular ligament, 298
Coracohumeral ligament, 302
Coracoid process, 176
Cord, gangliated, 1066
 spermatic, 437, 1375
 spinal. See Spinal cord.
Corium of skin, 1153
 stratum papillare, 1153
 reticulare, 1154
Cornea, 1090
 applied anatomy of, 1109
 arteries of, 1092
 dissection of, 1092
 nerves of, 1092
Corneal corpuscle, 1091
 spaces, 1091
Corniculum laryngis, 1166
Cornu ammonis, 929
Cornua coccygea, 62
 of coccyx, 62
 of lateral ventricles, 936
 majora ossi hyoidei, 154
 minora ossi hyoidei, 154
 sacral, 59
 of spinal cord, 830
Cornucommissural tract, 837
Corona ciliaris, 1094
 dentis, 1204
 glandis, 1388
 radiata, 905, 949
Coronal planes of body, 34
 suture, 76, 121
Coronary arteries, 578, 660
 ligament of knee-joint, 336
 plexus of nerves, 1073, 1076
 sinus, 555, 708
 valve, 555, 708
 veins, 709
Coronoid fossa, 182
 process of mandible, 118
Corpora albicantia, 907
 Arantii, 561
 cavernosa, 1386
 bulb of, 1386
 clitoridis, 1418
 penis, 1386

- Corpora mammillaria*, 847
quadrigemina, 894, 897
Corpus adiposum buccae, 376, 1200
albicans, 1400
Arantii, 559
callosum, 912, 933
 development of, 934
 genu of, 934
 peduncle of, 928
 rostrum of, 934
 splenium of, 934
 tapetum of, 938
cavernosum, artery of, 676
 urethrae, 1386
ciliare, 1094
costae, 163
epididymidis, 1378
femoris, 224
fibulae, 236
fornicis, 942
geniculatum laterale, 904, 905
 mediale, 895
hemorrhagicum, 1400
Higbini, 1380
humeri, 180
hypothalamicus, 905
incudis, 1132
linguae, 1217
luteum, 1400
mammulae, 1430
mandibulae, 115
mandibulae, 101
medullare, 888
os sphenoidale, 90
ossa metacarpalia, 201
 metatarsalia, 250
ossei hyoidei, 153
ossis ischii, 210
 pubis, 212
pancreatis, 1338
phalangis, 204
restiforme, 864, 889
spongiosum, 1386
sterni, 157
striatum, 946
tibiae, 234
ulnae, 187
unguis, 1156
uteri, 1404
 facies vesicles, 1404
ventriculi, 1272
vertebrae, 48
vesicae, 1361
 fellae, 1332
vitreum, 1105
Corpuscles, articular, 817
 bulboid, 817
 colostrum, 1431
 concentric, 1441
 corneal, 1091
 genital, 817
 of Hassal, 1441
 Herbst's, 816
 lamellated, 816
 Malpighian, 1445
 Pacinian, 816
 renal, 1350
 splenic, 1445
 tactile, 816
 touch, of Meissner and Wagner, 816
 Vater's, 816
Corpuscula bulboidea, 817
lamellosa, 816
neorum articularia, 817
 genitalia, 817
 tactus, 816
Corrugator cutis ani muscle, 453
 supercilii muscle, 367
Cortex, cerebral, 932
 of kidneys, 1349
Corti, canal of, 1145
 ganglion of, 1148
Corti, ganglion of, spirale of, 1139
 membrane of, 1147
 organ of, 1144
 rods of, 1145
Cortical arterial system, 619
Corticopontile tract, 900
Corticothalamic fibers, 905
Costae, 161
 spuriae, 161
 verae, 161
Costal cartilages, 165
 pleura, 1183
 process, 50
Costoaxillary veins, 732
Costocentral articulations, 285
Costoclavicular ligament, 296
Costocoracoid ligament, 460
 membrane, 459
Costomediastinal sinus, 1184
Costophrenic sinus, 1184
Costosternal articulations, 286
Costotransverse articulations, 284
 ligaments, 284, 285
 foramen, 50
Costovertebral articulations, 282
 ligament, 282
Cotyloid cavity, 213
 ligament, 325
 notch, 213
Cowper's glands, 1396
 development of, 1426
Cranial branches of occipital artery, 596
 fossa, 138
 indices, 146
 nerves, 972
 periosteum, 364
 region, fascia of, 363
 muscles of, 362
 applied anatomy of, 365
Craniocerebral topography, 962
Craniology, 144
Cranium, articulations of vertebral column with, 275
 bones of, 70
 brachycephalic, 146
 cerebrale, 70
 dolichocephalic, 146
 muscles of, 362
 membranous, primordial, 141
Cremaster muscle, 430
Cremasteric arteries, 680
 fascia, 430, 1374
Crescentic lobes of cerebellum, 886
Crest, ethmoidal, 91
 falciform, 85
 frontal, 78, 124
 of ilium, 210
 incisor, 105
 of lacrimal bone, 137
 nasal, 105, 110, neural, 805
 obturator, 213
 occipital, 70, 72, 132
 of pubis, 212
 supramastoid, 81
 temporal, 74
 of tibia, 234
 turbinated, 102, 104, 110
Cribiform fascia, 506, 508
 lamina, 1090
 plate of ethmoid, 96
Cricoaerotenoid ligaments, 1169
 muscles, 1172
Cricoid cartilage, 1165
Cricothyroid artery, 590
 membrane, 1165, 1168
 muscles, 1172
Cricotracheal ligaments, 1168
Crista anterior corpus fibulae, 237
 tibiae, 234
 basilaris, 1144
 capituli, 162
Crista colli castae, 162
 conchal, 102, 110
 ethmoidalis, 104, 110
 fenestrae cochleae, 1126
 frontalis, 78
 iliaca, 210
 infratemporalis, 92
 interossea, 189
 corpus fibulae, 237
 tibiae, 234
 intertrochanterica, 224
 lacrimalis posterior, 107
 lateralis corpus fibulae, 237
 mallei, 1131
 medialis corpus fibulae, 237
 nasalis, 105, 110
 oblutatoria, 113
 occipitalis externa, 70
 interna, 72
 sacralis media, 59
 sphenoidalis, 91
 spiralis, 1145
 supraventricularis, 557
 terminalis [His], 758
 atrii dextri, 554, 551, 557
 transversa, 85
 urethralis, 1370
 vestibuli, 1137
Cristae cutis, 1150
 matricis unguis, 1157
 sacrales articulares, 59
 laterales, 60
Cristi galli, 96, 124
Crucial anastomosis, 678, 690
 ligaments, 333
 ridge, 71
Cruciform ligament, 275
Crura anethicis, 1120
 cerebri, 847, 895
 of diaphragm, 419
 of ear, 1120
 fornicis, 944
 of penis, 1386
Crural arch, 684
 canal, 684
 cisterna, 969
 nerve, 1049
 ring, 428, 685
 sheath, 683
Cruentus muscle, 511
 surface form of, 543
Crus clitoridis, 1418
 helicis, 1120
Crusta of midbrain, 900
 petrosa, 1212
Cruveilhier, glenoid ligament of, 321
Crypts of Lieberkühn, 1292
 of Morgagni, 1310
 of tonsils, 1231
Crystalline lens, 1106
 applied anatomy of, 1111
Cuboid bone, 245
 articulation of calcaneus with, 347
 of scaphoid with, 350
Culminal lobes, 886
Cuneal fissure, 924
Cuneate columns of spinal cord, 826
Cuneiform bones, articulation of scaphoid with, 349
 of foot, 247, 248
 of hand, 197
 cartilage, 1166
Cupola, 1140
Cupula, 1138, 1140
 pleurae, 1183
Curvatura ventriculi major, 1271
 minor, 1271
Cusps of mitral valve, 561
Cutaneous nerve, external, 1045
 femoral, 1055
 from external popliteal, 1059

- Cutaneous nerve, gluteal, 1055
 internal, 1032, 1050
 lesser, 1034
 lateral, 1045
 middle, 1050
 perforating, 1060
 perineal, 1055
 postfemoral, 1054
- Cuticle of skin, 1151
Cuticula dentis, 1211
pili, 1161
- Cutis vera, 1153
- Cuvier, duct of, 550, 764
- Cymba conchae*, 1120
- Cystic artery, 661
 duct, 1333
 lymph nodes, 790
 plexus of nerves, 1076
 vein, 754
- D**
- DACRYON, 137, 146
- Dartos of scrotum, 1373
- Darwin, tubercle of, 1120
- Deciduous teeth, 1205
- Decussata pyramidum*, 863, 869
- Decussation of lemnisci, 870
 of pyramids of medulla oblongata, 869
- Deglutition, muscles of, 397, 399
- Deiters' cells, 1146
 nucleus, 839
- Deltoid impression, 180, 181
 ligament, 343
 muscle, 462
 applied anatomy of, 463
 surface form of, 495
 tubercle, 169
- Demours, membrane of, 1091
- Dendraxones, 811
- Dendrites, 804, 809
- Dense bone, 38
- Dental arteries, 601, 602
 canal, anterior, 102
 inferior, 117
 posterior, 102
 follicle, 1214
 lamina, 1213
 nerves, 984, 989
 papilla, 1214
 sac, 1214
 shelf, 1213
- Dentate fascia, 930
 gyre, 930
 gray substance of, 953
 ligament, 846
- Dentatofasciolar groove, 930
- Dentes*, 1204
canini, 1206
decidui, 1205
facies labialis, 1205
lingualis, 1205
masticatoria, 1205
incisivi, 1206
molars, 1207
permanentes, 1206
premolars, 1207
scrofini, 1207
- Dentin, intertubular, 1211
 of teeth, 1211
- Dentinal fibres, 1211
 sheaths, 1211
 tubules, 1211
- Depression, infrasternal, 166
 Pacchionian, 74
 pterygoid, 118
 trigeminal, 84
- Depressor alae nasi muscle, 372
 anguli oris muscle, 374
 labii inferioris muscle, 374
- Dermal bones, 142
- Dermis, 1153
- Descemet, membrane of, 1091
- Descendens hypoglossi nerve, 1014
- Descending aorta, 653
 colon, 1305
 mesocolon, 1264
- Detrusor urinae muscle, 1363
- Development of alimentary tract, 1245
 of aortic arches, 761
 of arteries, 761
 of atlas, 63
 of axis, 64
 of bladder, 1426
 of blood-vascular system, 755
 of brain, 850
 of carpal bones, 206
 of clavicle, 171
 of coccyx, 65
 of common iliac veins, 764
 of corpus callosum, 934
 of Cowper's glands, 1426
 of dorsal aorta, 762
 of ductus venosus, 764
 of ethmoid bone, 99
 of femur, 228
 of fibula, 238
 of frontal bone, 80
 of generative organs, 1420
 of heart, 755, 760
 of humerus, 183
 of hyoid bone, 154
 of ilium, 214
 of inferior vena cava, 765
 of ischium, 214
 of island of Reil, 917
 of jugular veins, 764
 of lacrimal bone, 107
 of lymphatic vessels, 769
 of malar bone, 109
 of mandible, 118
 of maxilla, 105
 of metacarpal bones, 206
 of metatarsal bones, 254
 of mouth, 1204
 of nerve system, 804
 tissue, 806
 of occipital bone, 73
 of os innominatum, 214
 of palate bone, 112
 of parathyroid glands, 1440
 of parietal bone, 76
 veins, 764
 of patella, 231
 of peritoneum, 1245
 of phalanges of foot, 254
 of hand, 207
 of pharynx, 1234
 of portal veins, 764
 of prostate gland, 1426
 of pubis, 214
 of radius, 192
 of ribs, 165
 of sacrum, 65
 of salivary glands, 1227
 of scapula, 176
 of skeletal muscles, 361
 of skull, 141
 of sphenoid bone, 95
 of spinal cord, 827
 of sternum, 159
 of sylvian cleft, 917
 of tarsal bones, 254
 of teeth, 1212
 of temporal bone, 88
 of tibia, 235
 of tongue, 1221
 of tonsil, 1232
 of turbinated bone, 114
 of ulna, 190
 of urethra, 1426
 of urinary organs, 1420
 of valves of heart, 760
 of veins, 763
 of ventral aorta, 761
 of vertebrae, 63
- Development of vomer, 115
- Diagonal fissures, 920
- Diameter obliqua pelvis minoris*, 216
transverse pelvis minoris, 215
- Diameters of pelvis, 215, 216
- Diaphragm, 418
 crura of, 419
 ligaments of, 419
 lymphatic vessels of, 799
 openings of, 419, 421
 of pelvis, 1240
- Diaphragma*, 418
sellae, 967
urogenitale, 446
- Diaphragmatic lymph nodes, 798
 pleura, 1183
- Diaphysis of bone, 35
- Diaplexus, 940
- Diarthrosis*, 264, 266
- Diastole, ventricular, 565
- Diastolic neurones, 810
- Dienecephalon*, 902
- Digastric fossa, 82, 117, 131
 muscle, 388
 nerve from facial, 998
- Digital arteries of foot, 704
 of hand, 652
 fossa, 223, 1376
 veins, dorsal, 728, 739
 plantar, 741
- Dilator naris muscles, 372
- Diploë, 36
 veins of, 718
- Diploic canals, 718
- Discus articularis*, 280, 296, 298, 312
 proligerus, 1400
- Disks, articular, 260
 interpubic, 294
 optic, 1100
- Dissection of axilla, 455
 of ciliary body, 1093
 of cornea, 1092
 of costocoracoid membrane, 459
 of deep layer of muscles of forearm, 476
 of inferior mesenteric artery, 666
 of internal oblique muscle, 428
 of left auricle of heart, 559
 ventricle of heart, 560
 of meninges of brain, 964
 of muscles of abdomen, 423
 of anterior femoral region, 505
 humeral region, 467
 scapular region, 463
 tibiofibular region, 525
 of arm, 461
 of auricular region, 366
 of back, 404, 407, 408, 410, 413
 of buccal region, 374
 of cranial region, 362
 of fibular region, 534
 of forearm, 471
 of gluteal region, 515, 516
 of hand, 486
 of infrahyoid region, 386
 of internal femoral region, 512
 of larynx, 1172
 of lingual region, 391
 of mandibular region, 374
 of orbital region, 368
 of palatal region, 397
 of palpebral region, 366
 of pectoral region, 455
 of pharyngeal region, 394
 of plantar region, 538, 539
 of posterior femoral region, 522

Dissection of muscles of posterior scapular region, 464
 tibiofibular region, 528
 of pterygomandibular region, 379
 of radial region, 479
 of shoulder, 461
 of superficial cervical region, 381
 of suprahyoid region, 388
 of mylohyoid muscle, 390
 of pancreas, 1336
 of pectoralis muscles, 459
 of popliteal space, 691
 of rectus abdominis muscle, 433
 of right auricle of heart, 555
 ventricle of heart, 557
 of spinal cord, 842
 of superior mesenteric artery, 663
 of temporal muscle, 378
 of transversalis muscle, 432
 Distobuccal tubercle, 1207
 Distolingual tubercle, 1207
Diverticulum ilei, 1288
 Meckel's, 1288
 Dobies' line, 356
 Dolichocephalic cranium, 146
 Dolichofacial skull, 146
 Dorsal artery of penis, 676, 1463
 nerve of penis, 1061
 region of foot, fascia of, 537
 muscle of, 537
 root of spinal cord, 823
 veins of penis, 746
 Dorsales pollicis arteries, 647
 Dorsalis hallucis artery, 700
 indicis artery, 647
 linguae artery, 591
 nasi artery, 613
 pedis artery, 698
 applied anatomy of, 699
 surface marking of, 699
 scapulae artery, 639
 Dorsal-epitrochlear muscle, 407
 Dorsolateral fissure of medulla oblongata, 862
 of spinal cord, 825
 spinocerebellar tract of cord, 838
 Dorsomediales Sakralfeld [Obersteiner], 836
 Dorsomedian fissure of medulla oblongata, 862
 Dorsoparamedian fissure of spinal cord, 826
 furrow of medulla oblongata, 863
 Dorsum illi, 207
linguae, 1217
nasi, 1079
 sellae, 90, 126
 Douglas, pouch of, 1256, 1362, 1407
 semilunar fold of, 430
 Drum of ear, 1124
 Duct of Bartholin, 1226
 bile, 1333
 of Cuvier, 550, 764
 cystic, 1333
 ejaculatory, 1385
 excretory, 1385
 galactophorous, 1430
 Gärtner's, 1401
 hepatic, 1332
 interlobular, 1226
 intralobular, 1226
 lactiferous, 1430
 lymphatic, right, 773
 mamillary, 1430
 Müllerian, 1423
 nasal, 1117
 canal for orifice of, 141

Duct, pancreatic, 1339
 parotid, 1200
 gland, 1225
 pronephric, 1420
 of Rivinus, 2261
 of Santorini, 1340
 seminal, 1383
 Stenson's, 1225
 of submaxillary gland, 1226
 thoracic, 771
 thyroglossal, 1219
 Wharton's, 1226
 Ductless glands, 1435
Ductuli aberrantes, 1381
efferentes testis, 1380
Ductus aberrans inferior, 1381
 superior, 1381
arteriosus, 569, 575
cochlearis, 1144
coledochus, 1333
cysticus, 1333
deferens, 1383
stratum externum, 1384
internum, 1384
medium, 1384
tunica adventitia, 1384
mucosa, 1384
muscularis, 1384
ejaculatorii, 1385
endolymphaticus, S6, 1137, 1141
excretorius, 1385
hepaticus, 1332
lacrimalis inferior, 1116
 superior, 1116
lactiferus, 1430
lymphaticus dexter, 773
nasolacrimalis, 1117
pancreaticus [Wirsung], 1339
accessorius, 1339
paraurethralis, 1370
parotideus [Stenonis], 1200, 1225
reunions [Hensen], 1142
semicirculares, 1142
sublingualis major, 1226
 minores, 1226
submaxillaris [Wharton], 1226
sudoriferus, 1162
thoracicus, 771
thyroglossus, 1219
venosus, 764
 Duodenal fossae, 1265
 glands, 1289
 impression of liver, 1321
 Duodenojejunal flexure, 1282, 1285
 fosse, 1265
 Duodenomesocolic ligaments, 1265
 Duodenopyloric constriction, 1270
 Duodenum, 1282
 applied anatomy of, 1287
 arteries of, 1287
 interior of, 1286
 lymphatic vessels of, 793, 1287
 nerves of, 1287
pars ascendens, 1285
descendens, 1282
horizontalis inferior, 1284
 superior, 1282
 suspensory muscle of, 1285
 Dura of brain, 964
 arteries of, 967
 nerves of, 968
 veins of, 967
mater encephali, 964
spinialis, 843
 of spinal cord, 843
 Dural artery, 596, 597
 nerves, 983, 1005, 1011
 veins, 719
 Duverney, glands of, 1420

E

EAR, 1119
 antihelix of, 1120
 fossa of, 1120
 antitragus of, 1120
 auditory canal, 1122
 meatus, 1122
 auricula of, 1119
 capsules, cartilaginous, 141
 cochlea of, 1138
 crura of, 1120
 drum of, 1124
 external, 1119
 helix of, 1119
 incus of, 1132
 internal, 1136
 labyrinth of, 1136
 malleus of, 1131
 membrana tympani, 1128
 middle, 1124
 modiolus of, 1138
 pinna of, 1119
 sacule of, 1141
 semicircular canals of, bony, 1137
 membranous, 1142
 stapes of, 1133
 tragus of, 1120
 tympanum, 1124
 utricle of, 1140
 vestibule of, 1136
 Ectal arcuate fibres of medulla oblongata, 863
 Efferent root of spinal cord, 823
 Eighth nerve, 1000
 Ejaculatory ducts, 1385
 Elastic cartilage, 261
 lamina, 573
 tissue, yellow, 261
 Elbow, bend of, 641
 bones of, 185
 joint, anastomosis of arteries around, 644
 articulation of, 306
 applied anatomy of, 309
 surface form of, 309
 bursae of, 308
 Eleventh nerve, 1009
 thoracic vertebra, 55
 Elliptical recess, 1137
 Embryology, definition of, 33
 Eminence, callosal, 939
 canine, 101
 collateral, 938
 frontal, 76
 hypothetic, 486
 iliopectineal, 210, 213
 of Jacobson, 1083
 olivary, 90
 parietal, 74
 thenar, 486
Eminencia abducentis, 866, 994
arcuata, 84
articularis, 81, 131
conchae, 1120
fossae triangulares, 1120
iliopectinea, 210, 213
intercondyloidea, 233
medialis, 866
pyramidalis, 1127
teres, 866, 994
Emissaria, 727
Emissarium condyloideum, 727
mastoideum, 727
occipitale, 727
parietale, 727
 Emmissary speech tract, 957
 veins, 727
 Enamel cells, 1214
 jelly, 1214
 of teeth, 1210
Enarthrosis, 264, 265, 266
 Encephalocele, 149
 Encephalon, 846

- End-bulbs of Krause, 813, 817
 Endocardial cushions, 758
 Endocardium, 562
 Endognathion, 106
 Endolymph, 1140
 Endomysium, 355
 Endoneurium, 812
 Endoskeleton, 35
 Endosteum of bone, 39
Endothelium cameræ anterioris, 1092
 Ensiform appendix, 159
 Entocinerea, 829
 Eosinophiles, 40
 Epactal bones, 145
 Eparterial branch bronchus, 1177
 Ependymal cells, 818
Epicardium, 549, 565
Epicondylus lateralis, 182, 226
medialis, 182, 226
 Epicranial aponeurosis, 363
Epidermis, 1151
stratum corneum, 1151
germinativum [*Malpighii*], 1152
 Epididymis, 1378
 Epidural space, 843
 Epigastric artery, deep, 680
 applied anatomy of, 681
 superficial, 689
 superior, 633
 vein, 742
 Epiglottis, 1167
Epimysium, 355
 Epineurium, 812
 Epitotic portion of temporal bone, 88
 Epiphyseal cartilage, 44
 recess, 906
 Epiphyses of bone, 35
 Epiphysis, 906
 Epipteric bone, 145
 Episternal centres, 160
Epistropheus, 52
 Episylian ramus, 917
Epithalamus, 907
Epithelium corneæ, 1091
 germinal, 1399
lentis, 1108
 respiratory, 1195
 Epitrochlear lymph nodes, 782
 Epitympanic recess, 1125
 Eponymichium, 1157
 Epöphoron, 1401
 Erector clitoridis muscle, 446
 penis muscle, 444
 spinæ aponeurosis, 410
 muscle, 410
 surface form of, 416
 Erythroblasts, 40, 755
 Ethmoid bone, 96
 Ethmoidal arteries, 611
 canals, 79, 98
 cells, 79, 97, 98, 139
 crest, 91
 foramen, structures trans-
 mitted by, 125, 137
 infundibulum, 99
 notch, 79
 process, 114
 sinuses, 99
 spine, 90, 125
 Eustachian cushion, 1229
 tube, 1127
 canal for, 1127
 valve, 555
Excavatio papillæ nervi optici, 1101
rectouterina [*Douglas*], 1256, 1414
rectovesicalis, 1255, 1362
vesicouterina, 1256, 1407
 Excitoglandular neurones, 804
 Excitomotor neurones, 804
 Excretory apparatus of liver, 1331
 duct, 1385
 Exognathion, 106
 Exoskeleton, 35
 Expression, muscles of, 380
 Exsanguinated renal zone of Hyrtl, 665
 Extensor brevis digitorum muscle, 537
 pollicis muscle, 483
 carpi radialis brevis muscle, 479
 longior muscle, 479
 ulnaris muscle, 482
 coccygis muscle, 414
 communis digitorum muscle, 480
 indicis muscle, 484
 longus digitorum muscle, 527
 surface form of, 544
 pollicis muscle, 484
 minimi digiti muscle, 481
 ossis metacarpi pollicis muscle, 482
 proprius hallucis muscle, 527
 surface form of, 544
 Extracranial lymphatics, 774
 Extravertebral veins, 737
Extremitas acromialis, 171
sternalis, 171
 Extrinsic ligaments of larynx, 1167
 muscles of tongue, 393
 Eye, 1086
 appendages of, 1112
 aqueous humor of, 1105
 choroid, 1093
 ciliary body, 1094
 cornea of, 1090
 crystalline lens of, 1106
 globe of, arteries of, 1108
 lymphatics of, 1109
 nerves of, 1109
 veins of, 1109
 iris, 1096
 refracting media of, 1105
 retina of, 1100
 sclera of, 1090
 suspensory ligament of, 1087
 tumes of, 1089
 vitreous body of, 1105
 Eyeball, 1086
 fascia of, 371
 Eyebrows, 1112
 Eyelashes, 1113
 Eyelids, 1112
 applied anatomy of, 1118
 canthi of, 1113
 structure of, 1113
 surface form of, 1117
 F
 FACE, bones of, 69, 99
 exterior of, veins of, 710
 lymph nodes of, 777
 lymphatic vessels of, 777
 muscles of, 362
 surface form of, 380
 Facet, acromial, of clavicle, 171
 articular, of clavicle, 171
 costal, 171
 Facial artery, 592
 applied anatomy of, 595
 transverse, 598
 nerve, 994
 applied anatomy of, 999
 nucleus, 882
 suture, transverse, 121
 vein, 710
 applied anatomy of, 711
 common, 710
 deep, 712
 Facial vein, transverse, 712
Facies anterior, 101
corpus fibulæ, 237
lateralis, 181
medialis, 181
articularis acromialis, 171
anterior, 52
calcanei anterior, 242, 245
media, 242, 245
posterior, 239, 245
carpea, 192
cuboidæ, 243
fibularis, 233
inferior, 51, 235
malleoli, 238
navicularis, 245
patellæ, 230
posterior, 52
sternalis, 171
superior, 52, 233
tuberculi costæ, 162
auricularis, 60, 210
cerebralis, 74, 78, 79, 92
convexa cerebri, 914
costalis, 172
diaphragmatica cordis, 552
dorsalis, 59, 172, 189
corpus radii, 191
frontalis, 76
infratemporalis, 101
lateralis corpus fibulæ, 237
radii, 191
tibiæ, 234
lunata, 213
malaris, 107
malleolaris lateralis, 245
medialis, 245
maxillaris, 111
medialis, 189
cerebri, 914
corpus fibulæ, 237
tibiæ, 234
nasalis, 102, 109, 110
orbitalis, 79, 102, 108
palatina, 109
parietalis, 74
patellaris, 225
pelvina, 58
posterior, 181
corpus fibulæ, 237
tibiæ, 234
sternocostalis cordis, 551
temporalis, 107
urethralis, 1388
volaris, 189
corpus radii, 191
 Falciiform crest, 85
 ligament, 1320, 1324
 margin of Bruns, 508
 process of fascia lata, 508
 of sacrosciatic ligament, 291
 Falena, 967
 Fallopian tube, 1401
 ampulla of, 1401
 applied anatomy of, 1402
 arteries of, 1402
 fimbriae of, 1401
 infundibulum of, 1401
 isthmus of, 1401
 lymphatic vessels of, 797, 1402
 nerves of, 1402
 pavilion of, 1401
 structure of, 1402
 veins of, 1402
 False pelvis, 215
 suture, 264
Falx cerebelli, 967
cerebri, 914, 966
 Fascia or Fasciæ, 355, 360
 of abdomen, 424, 428
 anal, 446, 450
 antebrachial, 471
 aponeurotic, 361
 of arm, 461, 467

- Fascia** or **Fasciæ**, axillary, 456, 633
 of back, 404
 bicipital, 469, 730
 brachial, 467
 buccopharyngeal, 377, 394
 of Camper, 424
 cervical, 382, 383
 clavipectoral, 459
 of Colles, 425, 441
 covering quadratus lumborum, 439
 of cranial region, 363
 cremasteric, 430, 1374
 cribriform, 506, 508
 deep, 361
 dentate, 930
 endopelvina, 450
 of eyeball, 371
 of foot, 536
 dorsal region, 537
 of forearm, 471
 of hand, 486
 of hip, 515
 iliac, 502
 infrapinnatus, 464
 infundibuliform, 436, 1374
 intercolumnar, 427, 1374
 intercostal, 417
 ischiofrenal, 446
 of leg, 525
 of lower extremity, 501
 lumbar, 409
 masseteric, 377
 of neck, 380
 nuchæ, 406
 obturator, 448
 orbital, 371
 palmar, 488
 parotid, 377
 pectoral, 456
 pelvic, 448
 of pelvic outlet, 440
 plantar, 537
 pretracheal, 384
 prevertebral, 384
 propria, 1374
 of pyriformis, 448
 rectovesical, 1361
 renal, 1348
 of Scarpa, 424
 of shoulder, 461
 Sibson's, 1183
 spermatic, 427, 437, 1374
 subscapular, 463
 superficial, 360
 supraspinatus, 464
 temporal, 378
 of thigh, 506
 of thoracic region, 455, 456
 of thorax, 416
 triangular, 425, 428
 of trunk, 403
 of upper extremity, 454
Fascia or **Fasciæ**, *antibrachii*, 471
axillaris, 456, 633
brachii, 467
buccopharyngea, 377, 394
bulbi [Tenon], 1086
colli, 382
coracoclavicularis, 459
cremasterica, 430, 1374
cribrosa, 506
cruris, 503
diaphragmatis urogenitalis inferior, 446
dorsalis pedis, 537
iliaca, 502
inferior diaphragmatis pelvis, 454
infrapinnata, 464
lata, 506
porotidomasseterica, 377
prævertebralis, 384
Fascia or **Fasciæ**, *subscapularis*, 463
supraspinata, 464
temporalis, 378
transversalis, 436
Fasciculus *albicans* *thalamii*, 905
antrolateralis superficialis [Gowers], 838
atrioventricularis, 564
cerebellospinatus, 838
cerebrospinalis anterior, 839
lateralis, 838
cuneatus [Burdach], 835
gracilis [Goll], 835
intermedius of Löwenthal and Bechterew, 839
lateralis proprius, 839
longitudinalis inferior, 955
superior, 955
marginalis, 835
pedunculomammillaris, 907
perpendicular, 955
rectus, 955
retroflexus, 898, 906
thalamomammillaris, 905, 907
uncinatus, 955
Fasciola *cinerea*, 930
Fat collagen, 42
Fauces, isthmus of, 1203
 pillars of, 1203
Female breast, 1428
 reproductive organs, 1397
 urethra, 1370
Femoral arches, 427, 436
 artery, 683
 applied anatomy of, 687
 deep, 689
 surface marking of, 687
 canal, 503, 684
 fossa, 1315
 hernia, 1317
 ligament, 508
 nerves, cutaneous, 1055
 region, anterior, muscles of, 505
 applied anatomy of, 512
 internal, muscles of, 512
 applied anatomy of, 515
 posterior, muscles of, 522
 ring, 428, 685
 sheath, 503, 683
 spur, 227
 vein, 742
Femur, 221
 applied anatomy of, 229
 condyles of, 225
 distal extremity of, 225
 linea aspera, 224
 quadrati, 224
 popliteal surface of, 224
 proximal extremity of, 221
 ridges of, 224
 shaft of, 224
 spiral line of, 224
 surface form of, 228
 trochanters of, 222
 trochlea of, 225
 tubercle of, 224
 tuberosities of, 226
Fenestra *cochleæ*, 1126
ovalis, 1126, 1137
rotunda, 85, 1126, 1140
vestibuli, 85, 1126, 1137
Fenestrated membrane of Henle, 573
Fetal circulation, 570
 left superior vena cava, 550
 lungs, 1194
Fetus, hypogastric artery in, 670
 pelvis in, 219
 vascular system in, peculiarities of, 568
Fibræ *arcuatae*, 1091
externæ, 863, 864
Fibræ *arcuatae internæ*, 864
cerebello-olivares, 873
intercurvales, 427
lenticæ, 1107
Fibres, arcuate, 873
 of medullæ oblongata, 863
 of auricles of heart, 562
 cerebello-olivary, 873
 of cerebellum, 891
 corticothalamic, 905
 dentinal, 1211
 frontothalamic, 950
 intercolumnar, of external abdominal ring, 427
 muscle, cardiac, 355
 plain, 355
 unstriated, 355
 nerve, centripetal, 810
 of cerebral cortex, 952
 glia, 818
 of spinal cord, 832, 834
 olivocerebellar, 873
 osteogenetic, 42
 Purkinje's, 357, 565
 Remak's, 812
 striothalamic, 950
 thalamocortical, 905
 thalamofrontal, 950
 thalamostriate, 950
 tracts of midbrain, 900
 in pars dorsalis pontis, 876
 in tegmentum of midbrain, 898
 of ventricles of heart, 563
Fibrillæ, 356
 peripheral, 816
 terminal, 816
Fibrocartilages, 259, 260
 articular, 260
 circumferential, 261
 connecting, 261
 intervertebral, 269
 semilunar, 334, 335
Fibrocartilaginæ *intervertebrales*, 269
Fibroelastic tissue, subendothelial, 573
Fibrous pericardium, 548
 sheaths of flexor tendons, 539
Fibula, 236
 applied anatomy of, 239
 nutrient artery of, 702
 canal of, 237
 foramen of, 237
 surface form of, 238
Fibular artery, 698
 region, muscles of, 534
Fifth lumbar vertebra, 57
 nerve, 978
 ventricle, 934, 945
Fila *olfactoria*, 927
radicularia, 1013
Filaments, temporomalar, 109
Filtration angle, 1105
Filum *duræ spinalis*, 843, 845
externum, 825
internum, 825
terminale, 825
Fimbria, 929, 930, 943
ovarica, 1401
tubæ, 1401
First nerve, 973
 thoracic vertebra, 54
Fissura *antitragohelicina*, 1120
calcarina, 919
cerebri lateralis [Sylvii], 916
collateralis, 924
ectothalamic, 924
inflexa, 920
longitudinalis cerebri, 847, 914
mediana anterior [medullæ oblongatæ], 861
medullæ spinalis, 825
posterior [medulla oblongata], 862

- Fissura occipitalis*, 918
orbitalis inferior, 134
paraoccipital, 923
petrooccipitalis, 122
petrotympanica [Glaser], 1126
postrhinalis, 924
rhinica, 925
sphenoccipitalis, 122
sphenopectrosa, 122
transversa cerebri, 847
tympanomastoidea, 87
vestibuli, 1137, 1140
- Fissure or Fissures, amygdaline, 924
 antitragohelicina, 1120
 auricular, 131
 basisylvian, 917
 of Bichât, 940
 ealcarine, 919
 central, 918
 of cerebellum, 885
 cerebral, 915
 choroid, 940
 circuminsular, 917, 925
 collateral, 924
 cuneal, 924
 diagonal, 920
 of frontal lobe, 919
 Glaserian, 88, 1126
 infected, 920
 interlobar, 916
 intermedial, 923
 intraprecuneal, 924
 of liver, 1322
 of lungs, 1190
 medifrontal, 919
 mediotemporal, 924
 of medulla oblongata, 861
 occipital, 918, 924
 olfactory, 920
 orbital, 93
 orbitofrontal, 919
 paracentral, 920
 paranesal, 919
 parietal, 923
 petrosphenoidal, 122
 petrotympanic, 88, 1126
 postcalcarine, 919
 postcentral, 923
 postinsular, 925
 postrhinal, 925
 precentral, 919
 precuneal, 923
 preinsula, 925
 pterygomaxillary, 134
 radiate, 920
 rhinica, 925
 of Rolando, 918
 rostral, 920
 of Santorini, 1122
 sphenoidal, 93, 126, 134
 sphenomaxillary, 109, 134, 137
 of spinal cord, 825
 sternal, 161
 subcentral, 923
 subfrontal, 919
 subrostral, 920
 subtemporal, 924
 supercentral, 919
 superfrontal, 919
 sylvian, 916
 of temporal lobe, 924
 of tragus of ear, 1121
 transinsular, 925
 transorbital, 921
 transparietal, 923
 transprecentral, 920
 transtemporal, 924
 tympanomastoid, 87
- Fixation muscles, 359
- Flat bones, 36
- Flechsiz, nucleus semilunaris of, 905
- oval bundle of, 836
- Flexor accessorius muscle, 539
- Flexor brevis digitorum muscle, 538
 surface form of, 544
 hallucis muscle, 541
 minimi digiti muscle, foot, 541
 band, 494
 pollicis muscle, 490, 492
 (note)
 carpi radialis muscle, 473
 surface form of, 496
 ulnaris muscle, 474
 surface form of, 496
 longus digitorum muscle, 533
 hallucis muscle, 532
 pollicis muscle, 476
 profundus digitorum muscle, 476
 sublimis digitorum muscle, 475
 surface form of, 496
 tendons, fibrous sheaths, of, 539
 at wrist, synovial membranes of, 486
- Flexura coli dextra*, 1303
sinistra, 1303
duodenojejunalis, 1285
- Flexures of brain tube, 855
 of colon, 1303
 hepatic, 1296, 1303
 sigmoid, 1296, 1303
- Floating ribs, 161
- Floccular fossa, 86, 128
- Flocculi secundarii*, 888
- Flocculus of cerebellum, 888
 peduncles of, 888
- Flood's ligament, 302
- Floor of fourth ventricle of
 brain, 865
- Flumina pilorum*, 1159
- Folia, 884
 linguae, 1217
- Folium vermis*, 886
- Follicles, agminated, 1292
 solitary, 1292
- Folliculus pili*, 1159
- Fontana, spaces of, 1092, 1097
- Fontanelles, 143
 anterior, 76, 142
 bregmatic, 143
 lateral, 144
 posterior, 76, 143
- Foot, arch of, longitudinal, 254
 transverse, 255
 arteries of, 699, 703
 bones of, 239
 applied anatomy of, 256
 surface form of, 255
 club, 256
 construction of, as a whole, 254
 fascia of, 536
 flat, 255
 muscles of, 536
 phalanges of, 252
 articulations of, 354
 veins of, 739, 741
- Foramen, apical, 1212
 caroticeum externum, 86
 internum, 84
 carotid, 84, 86
 cecum, 78, 96, 124, 862, 1217
 condylar, 71, 127, 128, 132
 costotransverse, 50
 ethmoidal, 137
 of Huschke, 89
 incisor, 105
 infraorbital, 101, 136
 intervertebral, 49
 jugular, 71, 131
 of Key and Retzius, 845, 969
 of Langer, 783
 of Luschka, 867, 969
 of Majendie, 845, 867, 969
- Foramen, malar, 107, 136
 of mandible, 117
 mastoid, 82, 128, 133
 mental, 116, 136
 of Monro, 936
 nasal, 99
 nutrient, of clavicle, 170
 of fibula, 237
 of metacarpal bones, 201
 of radius, 191
 of tibia, 234
 of ulna, 189
 obturator, 213
 olfactory, 138, 139
 optic, 90, 94, 126
 palatine, 121
 parietal, 74
 pterygospinous, 383
 sacral, 59
 sacrosclatic, great, 211, 292
 lesser, 211, 292
 of Scarpa, 105, 128
 sphenopalatine, 112, 134, 138, 140
 spinal, 49
 of Stenson, 105, 128
 sternal, 159, 161
 stylomastoid, 87, 131
 supracondylar, 181 (note)
 supraorbital, 135
 supratrochlear, 182
 temporomalar, 109
 thyroid, 213
 transverse, 50
 vertebral, 49
 vertebrarterial, 50
 Vesalii, 92, 127
 of Winslow, 1259
- Foramen apicis dentis*, 1212
caecum linguae [Morgagni], 1217
caecum, 78, 96, 124, 862, 1217
diaphragmatis sellae, 967
epiploicum, 1245, 1258
ethmoidale anterius, 79
posterius, 79
infraorbitale, 101
ischiodicicum majus, 211, 292
minus, 211, 292
jugulare, 127
lacerum, 127
anterius, 93, 126
medium, 127, 131
posterius, 71, 73, 127
magnum, 71, 127, 131
mandibulare, 117
mastoideum, 82
mentale, 116
nasale, 99
obturatum, 213
occipitale magnum, 71
opticum, 90
ovale, 92, 127, 131, 557, 759
parietale, 74
rotundum, 92, 127, 134
singulare, 85, 1148
sphenopalatinum, 112
spinousum, 92, 127, 131
stylomastoideum, 87
transversarium, 50
vena cava, 421
vertebrale, 49
zygomaticotemporale, 108
- Foramina alveolaria*, 102
intervertebralia, 48, 49
sacralia anteriosa, 59
posteriosa, 60
venarum minimarum [Thebesii], 555
- Forearm, bones of, 185
 fascia of, 471
 muscles of, 471
- Forebrain, 902
 development of, 852
 structure of, 902

Forebrain, thalami of, 902
 Foregut, 1247
Formatio reticularis, 872, 897
 alba, 872
 grisea, 872
Fornices conjunctivae, 1115
 Fornicolumns, 954
 Fornix, 913, 942
 body of, 942
 periphericus, 959
 pharyngis, 1230
 pillars of, 943, 944
 Fossa of acetabulum, 213
 antecubital, 641
 of antihelix of ear, 1120
 canine, 101, 136
 condylar, 131
 coronoid, 182
 cranial, 138
 digastric, 82, 117, 131
 digital, 223, 1376
 duodenal, 1265
 duodenojejunal, 1266
 femoral, 1315
 floccular, 86, 128
 glenoid, 87, 137
 hyaloidea, 1105
 hypophyseous, 90, 909
 iliac, 209
 ileoappendicular, 1267
 ileocecal, 1267
 iliocolic, 1266
 incisive, 101, 135
 incisor, 116
 incus, 1127
 infraspinous, 172
 inguinal, 1315
 intersigmoid, 1267
 ischio rectal, 454
 jugular, 86, 87
 lacrimal, 79
 of Landzert, 1266
 mesocolic, 1266
 nasal, 138, 1081
 occipital, 128
 olecranon, 182
 orbital, 138
 palatine, 105, 128
 paraduodenal, 1266
 pararectal, 1256
 paravesical, 1361
 pericecal, 1266
 pterygoid, 94, 109
 radial, 182
 retroduodenal, 1266
 retroperitoneal, 1265
 rhomboidal, 865
 of Rosenmüller, 1230
 scaphoid, 94, 130, 1120
 sigmoid, 82
 of skull, anterior, 123
 inferior occipital, 128
 middle, 125
 posterior, 127
 sphenomaxillary, 109, 134
 subcecal, 1267
 sublingual, 117
 submaxillary, 117
 subscapular, 172
 supraspinous, 172
 supratonsillar, 1231
 temporal, 92, 134
 of Treitz, 1265
 trochanteric, 223
 trochlear, 79
 vesicalis, 1321
 zygomatic, 92, 101, 130, 134
Fossa acetabuli, 213
 canina, 101
 condyloidea, 71
 coronoidea, 182
 cranii anterior, 123
 media, 125
 posterior, 127
 digastrica, 117

Fossa ductus venosi, 1323
glandulae lacrimales, 79
iliaca, 209
infraspinoia, 172
infratemporalis, 133
intercondyloidea, 225
 anterior, 233
 posterior, 233
ischio rectalis, 454
jugularis, 86, 87
longitudinalis sinistra, 1322
mandibularis, 87
mastoidea, 82
navicularis, 1368, 1416
 urthrae, 1368
olecrani, 182
ovatis, 508, 557
 margo falciformis, 508
ovarum, 1398
pterygopalatina, 134
radialis, 182
rhomboidea, 865
sacci lacrimales, 107
scaphoidea, 94
 subarcuato, 86
subscapularis, 172
supraspinata, 172
supratonsillar, 1231
temporalis, 92, 134
triangularis [auriculae], 1120
trochanterica, 223
venae cavae, 1323
 umbilicalis, 1321
 vesicae felleae, 1321
Fossae frenuli, 1389
Fossulae tonsillares, 1231
 Fountain decussation, 900
 Fourchette, 1416
 Fourth nerve, 977
 ventricle of brain, 864
Fovea articularis superior, 51
capitis femoris, 221
capituli radii, 190
centralis, 1100, 1104
costalis inferior, 53
 superior, 53
 transversalis, 54
 dentis, 50
 hemielliptica, 1137
 inferior, 866
 inguinalis lateralis, 1315
 medialis, 1315
 supravesicalis, 1315
 mediana, 866
 pterygoidea, 118
 sublingualis, 117
 submaxillaris, 117
 superior, 866
 trigemini, 866
 trochlearis, 79
Foveola granularis [Pacchioni], 970
Foveolae gastricae, 1275
granulares [Pacchioni], 74
 Frankfort, horizontal line of, 146
 Frenulum of cerebellum, 891
 clitoridis, 1416
 of clitoris, 1416
 Giacomini, 930
 of ileocecal valve, 1301
 labii inferioris, 1200
 superioris, 1200
 labiorum pudendi, 1416
 linguae, 1217
 of penis, 1389
 praeputii, 1389
 valvulae, 895
 coli, 1301
Frenum linguae, 1201, 1217
 Frontal air sinus, 79
 artery, 598, 612
 anterior internal, 615
 ascending, 617
 inferior external, 617
 internal, 615

Frontal artery, middle internal, 615
 posterior internal, 615
 bone, 76
 crest, 78, 124
 diploic vein, 718
 eminence, 76
 lobe, 919
 fissures of, 919
 gyre of, 921
 nerve, 980
 planes of body, 34
 process of malar bone, 108
 suture, 121
 vein, 710
 Frontalis muscle, 363
 Frontoethmoidal suture, 122
 Frontolacrimal suture, 122
 Frontomalar suture, 121
 Frontomaxillary suture, 122
 Frontoparietal operculum, 917
 suture, 121
 Frontopontile tract, 900, 950, 957
 Frontosphenoidal suture, 121
 Frontothalamic fibers, 950
 Fundiform ligament of Retzius, 536
Fundus folliculi pili, 1159
 glands, 1276
 tympani, 1125
 uteri, 1404
 vesiculae, 1361
 felleae, 1332
 Funicular process, 1379
Funiculi medullae spinalis, 826
Funiculus anterior, 827
 cuneatus, 827, 835, 863
 gracilis, 827, 835, 863
 lateralis, 817, 835, 864
 [Rolandi], 872
 separans, 866
 spermaticus, 437, 1375
 Furcula, 1221
 Fusiform muscles, 358

G

GALACTOPHOROUS duct, 1430
Galea aponeurotica, 363
 Galen, veins of, 720, 943
 Gall-bladder, 1332
 arteries of, 1334
 lymphatic vessels of, 795, 1334
 nerves of, 1334
 veins of, 1334
Ganglia aberrantia, 1014
coeliaca, 1073
trunci sympathici, 1063
 Gangliated cord, 1066
 cervicocephalic, 1066
 lumbar, 1071
 thoracic, 1070
 Ganglion, aberrant, 1014
 accessory, 1014
 of Andersch, 1002
 aorticorenal, 1073
 of Boeddalek, 984
 cardiac, of Wrisberg, 1072
 carotid, 1066
 cell, 807
 cervical, 1066, 1069
 ciliary, 982
 coccygeal, 1072
 of Corti, 1148
 Gasserian, 978
 geniculate, 996
 inferior, 1002
 interpeduncular, 906
 jugular, 1002
 lenticular, 982
 Meckel's, 984
 ophthalmic, 982

- Ganglion, otic, 989
 petrous, 1002
 phenic, 1074
 of Scarpa, 1000, 1147
 semilunar, 978, 1073
 of Sömmerring, 986
 sphenopalatine, 982, 984, 986
 spinal, 1016
 spiral, 1000, 1148
 of Corti, 1139
 submaxillary, 990
 superior, 1002
 of Valentin, 984
 vestibular, 1000
Ganglion cardiacum [Wrisberg], 1072
 cervicale inferius, 1069
 medium, 1069
 superius, 1066
 ciliare, 982
 radix brevis ganglii ciliaris, 982
 longa ganglii ciliaris, 981, 982
 sympathetica ganglii ciliaris, 982
 coccygeum impar, 1063, 1072
 geniculi, 996
 habenulae, 906
 jugulare, 1005
 mesentericum superius, 1076
 nodosum, 880, 1005
 oticum, 989
 ramus anastomaticus cum n. auriculotemporalis, 990
 petrosus, 880
 phenicum, 1074
 semilunare [Gasser], 978
 sphenopalatinum, 984
 rami nasales posteriores inferiores, 986
 superiores, 986
 orbitales, 986
 spirale, 1148
 cochleae, 1139
 splanchnicum, 1071
 submaxillare, 990
 rami communicantes cum n. linguati, 990
 submaxillares, 990
 superius, 880
 vestibulare, 1147
 Ganglionic arteries, 614, 617, 618
 Gärtner's duct, 1401
 Gasserian ganglion, 978
Gaster, 1270
 Gastric artery, 660
 crypts, 1275
 glands, 1276
 impression of liver, 1321
 lymph nodes, 790
 nerve, 1007
 pits, 1275
 plexus of nerves, 1076
 veins, 753
 Gastrocnemius muscle, 528
 surface form of, 544
 Gastrocolic omentum, 1254, 1261
 Gastroduodenal artery, 661
 plexus of nerves, 1076
 Gastroepiploic arteries, 661
 lymph nodes, 790
 plexus of nerves, 1076
 veins, 753
 Gastrohepatic omentum, 1254, 1260
 Gastrosplenic omentum, 1261
Gelatinosa centralis, 829, 831
 Rolandi, 829, 833
 Gemellus inferior muscle, 520
 superior muscle, 520
 Gemmules, 810
 Generative organs, development of, 1420
 Genial tubercles, 117
 Geniculate body, external, 905
 internal, 895
 lateral, 910
 ganglion, 996
 tract, 950
Geniculum n. facialis, 996
 Geniohyoglossus muscle, 391
 Geniohyoid muscle, 390
 Genital corpuscles, 817
 gland, 1423
 ridge, 1423
 Genitals, external, lymphatic vessels of, 790
 Gennari, fiber band of, 953
Genu corporis callosi, 934
 facialis internum, 882
 Gerlach, valve of, 1299
 Germinal centre, 1292
 epithelium, 1399
 nerve cells, 806
 spot, 1400
 vesicle, 1400
 Gianuzzi, crescents of, 1227
 Gimbernat's ligament, 426, 428
Gingivae, 1200
Ginglymus, 264, 265
 Giraldés, organ of, 1384
 Glabella, 77, 134, 146
 Gladiolus, 159
 Glands, apical, 1219
 of Bartholin, 1420
 buccal, 1200
 cardiac, 1278
 carotid, 586, 1450
 ciliary, 1162
 circumanal, 1162
 coccygeal, 1450
 of conjunctiva, 1115
 Cowper's, 1396
 ductless, 1435
 duodenal, 1289
 of Duverney, 1420
 fundus, 1276
 gastric, 1276
 genital, 1423
 intestinal, 1292
 labial, 1200
 lacrimal, 1115
 of larynx, 1174
 of Lieberkühn, 1292
 of Littre, 1369
 Luschka's, 1450
 lymphatic. See Lymph nodes.
 mammary, 1428
 Meibomian, 1114
 molar, 1200
 of Moll, 1113
 of Montgomery, 1429
 of Nuhn and Blandin, 1219
 oesophageal, 1239
 oxyntic, 1276
 palatine, 1202
 parathyroid, 1439
 parotid, 1223
 peptic, 1276
 prostate, 1391
 pyloric, 1278
 salivary, 1223
 sebaceous, 1113, 1161
 serous, 1219
 sublingual, 1226
 submaxillary, 1225
 suburethral, 1420
 sudoriferous, 1161
 suprarenal, 1447
 sweat, 1161
 tarsal, 1114
 thymus, 1440
 thyroid, 1435
 of trachea, 1178
 trachoma, 1115
 of von Ebner, 1219
 Glands, vulvovaginal, 1420
Glandula lacrimalis, 1115
 inferior, 1116
 superior, 1116
 parotis, 1223
 accessoria, 1224
 sublingualis, 1226
 submaxillaris, 1225
 thyreoidea, 1435
 accessoriae, 1436
 vestibularis major [Bartholini], 1420
Glandulae areolares, 1429
 buccales, 1200
 bulbourethralis, 1396
 ceruminosae, 1123
 cervicales uteri, 1410
 ciliares [Mölli], 1113, 1162
 circumanales, 1162, 1309
 duodenales [Brunneri], 1292
 gastricae propriae, 1276
 intestinales [Lieberkühni], 1292
 labialis, 1200
 linguales anteriores, 1219
 molares, 1200
 mucosae [Krause], 1115
 olfactoriae, 1085
 palatinae, 1202
 paraurethrales, 1370
 pharyngeae, 1233
 praeputii, 1389
 pyloricae, 1278
 sebaceae, 1113, 1161
 sudoriferae, 1161
 suprarenales accessoriae, 1448
 facies anterior, 1447
 posterior, 1448
 suprarenalis, 1447
 tarsales [Meibomi], 1114
 tracheales, 1178
 Tysonii odoriferae, 1389
 urethrales, 1369
 uterinae, 1410
 vestibulares minores, 1416
 Glangular artery, 593
Glans clitoridis, 1419
 penis, 1387
 Glaserian fissure, 88, 1126
 Glenohumeral ligament, 302
 Glenoid fossa, 87, 131
 ligament, 176, 303
 of Cruveilhier, 321
 surface of scapula, 176
 Glia cells, 818
 fibers, 818
 Gliding joints, 264
 Gliosa centralis, 829
 cornualis, 829, 833, 870
 Globus pallidus, 948
Glomus caroticum, 1450
 coccygeum, 1450
 Glossoepiglottic fold, 1167
 Glossopharyngeal nerve, 1001
 applied anatomy of, 1003
 nucleus, 880
 Gluteal aponeurosis, 516
 artery, 678
 nerves, 1054, 1055
 region, muscles of, 515
 ridge, 224
 veins, 743
 Gluteofemoral bursa, 327
 Gluteus maximus muscle, 515
 bursa of, 516, 517
 surface form of, 543
 medius muscle, 516
 surface form of, 543
 Gnathic index of skull, 147
 Golgi, cells of, 808, 952
 organs of, 817
 Goll, column of, 827, 835
 Gomphosis, 264
 Gonion, 146
 Gower's, tract of, 838
 Graafian follicles, 1399

Gracile column of spinal cord, 826
lobes, 887
Gracilis muscle, 512
bursa of, 513
surface form of, 543
Granulationes arachnoidales [Pachion], 721, 970
Gray commissure of spinal cord, 830
masses of cerebellum, 888
substance of spinal cord, 829
Grooves, auriculovertebral, 553
basilar, 73
of pons, 864
bicipital, 180
carotid, 126
cavernous, 91
dentofascicular, 930
infraorbital, 102, 136
interauricular, 553
interventricular, 553
lacrimar, 102, 104, 107, 137, 138
musculospiral, 180
mylohyoidan, 117
nasopalatine, 114
obturator, 211, 213, 214
occipital, 82, 131
oesophageal, 421
optic, 90, 126
peroneal, 246
popliteal, 226
pterygopalatine, 110, 111
pyramido-olivary, 863
sacral, 60
of spinal cord, 825
subclavian, 171
subcostal, 163
ulnar, 182
vertebral, 67
Growth of bone, 42
Gubernaculum testis, 1378
Gudden, infraommissure of, 895
tractus peduncularis transversus, 895
Guerin, valve of, 1369
Gullet, 1236
Gums, 1200
Gustatory areas of brain, 960
cells, 1149
hair, 1149
path, 1003
Gyre, angular, 923
callosal, 920, 921
cerebral, 915
dentate, 930
hippocampal, 925
marginal, 923
medifrontal, 921
mediotemporal, 924
mesorbital, 920, 922
olfactory, 928
paracentral, 921
paraoccipital, 923
parietal, 923
postcentral, 923
postparietal, 923
precentral, 921
preinsular, 926
subcalcarine, 925
subcallosal, 928
subcollateral, 925
subfrontal, 921
subtemporal, 925
superfrontal, 920, 921
supertemporal, 924
transtemporal, 924
uncinate, 925
Gyri Andreae Retzii, 930
Gyrus ambicus, 928
angularis, 923
breves insulae, 926
centralis anterior, 921
posterior, 923

Gyrus dentatus, 929
epicallosus, 930
fasciolaris, 930
fornicatus, 921
frontalis inferior, 921
medius, 921
superior, 921
fusiformis, 925
hippocampi, 925
lingualis, 925
longus insulae, 915
occipitotemporalis, 925
rectus, 922
semilunaris, 928
subcallosus, 928
supracallosus, 931
supramarginalis, 923
temporalis inferior, 925
medius, 925
superior, 925

H

HABENULAR commissure, 906

Hairs, 1159

auditory, 1143
bulb, 1159
cells, 1143
outer, 1146
follicle, 1159
fundus of, 1159
gustatory, 1149
papilla, 1159
root of, 1159
sheaths of, 1160
streams, 1159
whirlpools, 1159

Hallucis, etymology of, 525

Hamstring muscles, 522

applied anatomy of, 525

Hamular process, 94, 107, 130

Hamulus, 1140

lacrimalis, 107
laminae spiralis, 1140
ossis hamati, 200
pterygaideus, 94

Hand, arteries of, 647

bones of, 194
lower row, 198
upper row, 196

bursae of, 487
fasciae of, 486
ligaments of, 315
muscles of, 486
phalanges of, 204
articulations of, 321
veins of, plexus of, 729
superficial, 728

Hard palate, 1202

Harelip, 151

Hasner, valve of, 1117

Hassal, corpuscles of, 1441

Haversian canal, 39

lamella of bone, 39

Head, arteries of, 583
lymph nodes of, 774
muscles of, surface form of, 380
veins of, 710

Heart, 551

apex of, 551
applied anatomy of, 565
arteries of, 565
auricles of, fibers of, 562
left, 559
right, 554
base of, 551
beat, myogenic theory of, 566
neurogenic theory of, 566
cavities of, 553
capacity of, 561
component parts of, 553
development of, 755, 760
endocardium, 562

Heart, grooves of, auriculovertebral, 553
interauricular, 553
interventricular, 553
infundibulum of, 557
left, 553
lymphatic vessels of, 565, 802
margins of, 552
muscular filters of, 562
myocardium, 562
nerves of, 565
position of, 551
pulmonary, 553
right, 553
rudiments of, 755
size of, 552
surface form of, 567
surfaces of, 551
systemic, 553
valves of, action of, 565
development of, 760
veins of, 565
ventricles of, fibers of, 563
left, 560
right, 557
weight of, 552
Hebenuia, 906
Heel bone, 239
Heidenhain, demilunes of, 1227
Helicis major muscle, 1121
minor muscle, 1121
Helicotrema, 1138, 1140
Helix of ear, 1119
Helweg, olivospinal tract of, 839
Hemicerebra, 847
Hemiseptum, 934
Hemisphaeria bulbi urethrae, 1387
Hemispheres, cerebral, 912
Hemolymph nodes, 768
Hemorrhoidal artery, inferior, 675
middle, 672
superior, 667
nerve, inferior, 1061
plexus of nerves, 1077
veins, 744, 753
plexus of, 745
Henle, fenestrated membrane of, 573
layer of nerve fiber of, 1103, 1160
ligament of, 433
loop of, 1351
sheath of, 812
spine of, 81
Hensen, canal is reuniens of, 1142, 1147
cells of, 1147
membrane of, 356
stripe of, 1147
Hepar, 1319
capsula fibrosa [Glissoni], 1328
facies inferior, 1321
posterior, 1321
superior, 1320
impresso cardiaca, 1320
colica, 1321
duodenalis, 1321
gastrica, 1321
oesophagea, 1322
pylorica, 1321
renal, 1321
suprarenalis, 1322
marginal inferior, 1322
tunica serosa, 1328
Hepatic artery, 660
duct, 1332
flexure of colon, 1296
lymph nodes, 790
plexus of nerves, 1076
veins, 751
Hepatocolic ligaments, 1260
Hepatoduodenal ligaments, 1260
Hepatogastric ligaments, 1260
Herbst's corpuscles, 816

- Hernia, 1315
 femoral, 1317
 inguinal, 1315
- Hesselbach, ligament of, 433
 triangle of, 437, 1315
- Hey, ligament of, 508
- Hiatus aorticus diaphragma*, 419
- canalalis facialis*, 84
- Fallopian*, 84
- maxillaris*, 102, 103
- oesophageus*, 1236
- diaphragma*, 421
- sacralis*, 59, 61
- scutularis*, 1081
- tentorial, 837
- Highmore, antrum of, 101, 103
- Hilum of kidneys, 1348
 of nucleus dentatus, 888
 of suprarenal glands, 1448
- Hilus glandulae suprarenalis*, 1448
- lucis*, 1444
- nuclei dentati*, 888
- pulmonis*, 1189
- renalis*, 1348
- Hindbrain, 861
 development of, 855
 structure of, 861
- Hindgut, 1247
- Hinge-joint, 264, 265
- Hip bone, 207
 fasciae of, 515
 -joint, arteries of, 327
 articulations of, 322
 applied anatomy of, 329
 surface form of, 329
 burse of, 327
 movements of, 328
 muscles of, 326, 515
 nerves of, 327
 synovial membrane of, 326
- Hippocampal commissure, 944
- gyre, 925
- Hippocampus, 942
 gray substance of, 953
- Hirci*, 1159
- His, auriculoventricular bundle of, 564
 crista terminalis of, 758
 spina vestibuli of, 758
 sulcus terminalis of, 1217
- Histology, definition of, 33
- Homolateral tract cells of cord, 841
- Homologies of sexual organs, 1428
- Horner's muscle, 367
- Horns of spinal cord, 830
- Horny layer of skin, 1151
- Horseshoe kidney, 1354
- Houston's valves, 1310
- Howship's foveolae, 39
- Huguier, canal of, 88, 997, 1126
- Humeral artery, 638
 ligament, 303
 lymph nodes, 782
 region, muscles of, 467, 470
- Humerus, 178
 applied anatomy of, 184
 development of, 183
 head of, 178
 neck of, anatomical, 178
 surgical, 178
 shaft of, 180
 surface form of, 184
 tuberosities of, 180
- Humor aquicus*, 1105
- vitreus*, 1105
- Hunter's canal, 511, 515, 685
- Huschke, foramen of, 89
- Huxley's layer, 1160
- Hyaline cartilage, 260
- Hyaloid canal, 1106
 membrane, 1106
- Hydatids of Morgagni, 1402
- Hydatids, pedunculated, 1379
 sessile, 1378
- Hydronecephalocoele, 149
- Hymen, 1417
 imperforate, 1417
- Hyoepiglottic ligaments, 1167
- Hyoglossus muscle, 391
- Hyoid bone, 153
 applied anatomy of, 154
 development of, 154
 elevators of, 388
 surface form of, 154
- Hyparterial branch bronchus, 1177
- Hypogastric arteries, 570, 669, 763
 in fetus, 670
 impervious, 671
 lymph nodes, 787
 plexus of nerves, 1077
 vein, 743
- Hypoglossal nerve, 1010
 applied anatomy of, 1012
 nucleus, 878
- Hypophysis*, 909
- Hyposylvian ramus, 917
- Hypothalamic tegmental substance, 905
- Hypothalamus, structure of, 908
- Hypothenar eminence, 486
- Hyrtl, exsanguinated renal zone of, 665
- I**
- ILEAL artery, 664
 lymph nodes, 791
- Ileoappendicular fold, 1267
 fossa, 1267
- Ileocecal arteries, 664
 fossa, 1267
 junction, 1296
 valve, 1301
- Ileocolic fold, 1266
 fossa, 1266
 junction, 1296
 lymph nodes, 791
 plexus of nerves, 1076
- Ileum, 1288
- Iliac arteries, common, 668
 applied anatomy of, 669
 surface marking of, 669
 deep circumflex, 682
 external, 679
 applied anatomy of, 680
 surface marking of, 680
 internal, 669
 applied anatomy of, 671, 679
 surface marking of, 679
 superficial circumflex, 689
- bursa, subtendinous, 327
- fascia, 502
- fossa, 209
- furrow, 219, 439
- lymph nodes, 787, 788
- region, muscles of, 502
- veins, common, 747
 development of, 764
 deep circumflex, 742
 external, 742
 internal, 743
- Iliacus muscle, 504
- Iliococcygeus muscles, 452
- Iliocolic arteries, 664
- Iliocostalis muscle, 410
- Iliofemoral ligament, 323
- Iliolumbar artery, 678
 ligament, 290
 veins, 748
- Iliopectineal bursa, 327
 eminence, 210, 213
 ligament, 503
 line, 209, 212
- Iliopsoas muscle, 504 (note)
- Iliosacralis muscles, 452
- Iliotibial band, 507
 applied anatomy of, 508
- Iliotrochanteric ligament, 324
- Ilium, 207
 crest of, 210
 curved lines of, 207, 208
 spinous processes of, 210
 lips of, 210
 intermediate space of, 210
- Impervious hypogastric artery, 671
- Impressio trigemini*, 84, 85
- Impression, deltoid, 180, 181
 rhomboid, 171
- Incisive fossa, 101, 135
 papilla, 1202
- Incisor canal, 105
 crest, 105
 foramina, 105
 fossa, 116
- Incisura acetabuli*, 213
- cardiaca*, 1190
- cerebelli posterior*, 884
- clavicularis*, 157
- costalis I*, 157
- II*, 159
- VII*, 159
- ethmoidalis*, 79
- frontalis*, 77
- interlobaris*, 1190
- intertragica*, 1120
- ischiadica minor*, 211
- jugularis*, 71, 157
- lacrimalis*, 102
- mandibulae*, 118
- mastoidea*, 82
- poplitea*, 233
- radialis*, 187
- scapulae*, 175
- semilunaris*, 187
- sphenopalatine*, 112
- supraorbitalis*, 77
- tentorii*, 893
- terminalis auris*, 1120
- thyreoidea superior*, 1164
- tympanica [Rivini]*, 1125
- ulnaris*, 192
- umbilicalis*, 1322
- vertebralis inferior*, 49
 superior, 49
- vesicae felleae*, 1322, 1323
- Incisurae cartilaginis meatus acustici externi [Santorini]*, 1122
- Incisures of Schmidt-Lantermann, 811
- Incus, 1132
 crus breve, 1133
 longum, 1133
 processus lenticularis, 1133
- Indices, cranial, 146
- Indusium*, 930, 931, 934
- Inflected fissures, 920
- Infraclavicular lymph nodes, 782, 783
 nerve, 1029
- Infracommissure of Gudden, 895, 910
- Infracostales muscles, 417
- Infraglenoid tubercle, 175
- Infrahyoid artery, 590
 region, muscles of, 386
- Intraorbital artery, 602
 canal, 102, 136
 foramen, 101, 136
 groove, 102
 nerve, 982 (note), 998
 plexus of nerves, 984, 998
- Infrapatellar bursa, 336
 pad, 336
- Infraseapular arteries, 639
- Infraspinatus bursa, 303
 fascia, 464
 muscle, 465
- Infraspinous fossa, 172

- Infrasternal depression, 166
 Infratrochlear nerve, 981
 Infundibula of lungs, 1195
 of ureters, 1356
 Infundibuliform fascia, 436, 437, 1374
 Infundibulopelvic ligament, 1407
 Infundibulum, 141, 760, 909
 ethmoidal, 99
 ethmoidale, 99
 of Fallopiian tube, 1401
 of heart, 557
 tuber uterinae, 1401
 Inguinal canal, 437, 1375
 fossæ, 1315
 hernia, 1315
 lymph nodes, 785
 Inion, 146
 Inlet of pelvis, 215
 of thorax, 155
 Innervation of intestines, 1313
 of stomach, 1280
 Innominate artery, 582
 veins, 733
 Inosculation of arteries, 572
Inscriptiones tendineae, 433
Insula, 925
 Integument of nose, 1081
 of scrotum, 1373
Integumentum commune, 1149
 Interaleveolar cell islets, 1340
 Interauricular groove, 553
 septum, 559
 Interbronchial lymph nodes, 801, 1179
 Intercalatum of midbrain, 897
 Intercavernous sinuses, 726
 Interacellular lymph spaces, 767
 substance of bone, 39
 Interchondral ligaments, 288
 Interclavicular ligament, 296
 Intercolumnar fascia, 427, 1374
 fibers of external abdominal ring, 427
 Intercondyloid notch, 225
 Intercoastal arteries, 655
 anterior, 632
 applied anatomy of, 657
 superior, 633
 fascia, 417
 lymph nodes, 798
 lymphatic vessels, 799
 muscles, 417
 nerves, 1040
 applied anatomy of, 1043
 space, 155
 veins, 735, 736
 Intercostobrachial nerve, 1042
 Intercostohumeral nerves, 1042
 Intercuneiform articulations, 350
 Interdigital veins, 739
 Interlobular spaces, 1211
 Interlobar fissures, 916
 Interlobular ducts, 1226
 Intermaxillary suture, 135
 Intermedial fissures, 923
 Intermediate lamella of bone, 39
 space of ilium, 210
 Intermidolateral tract of Bruce and Campbell, 839
 Intermuscular septum of arm, 467
 of thigh, 507, 508
 Internasal suture, 135
 Internuclear articulations, 271
 Interosseal muscles, foot, 541
 hand, 494
 surface form of, 497
 Interosseous arteries, foot, 699, 700
 hand, 647, 650
 recurrent artery, 651
 veins, 729
 Interpalpebral slit, 1112
 Interparietal bone, 74
 Interparietal suture, 121
 Interpeduncular ganglion, 906
 nucleus, 898
 Interpleural space, 1185
 Interpublic disk, 294
 Intersigmoid fossa, 1268
 Interspinales muscle, 414
 Interspinous ligament, 272
 Intesternal ligaments, 288
 Interstitial cells, 1399
 lamella of bone, 39
 Intertransversales laterales muscle, 414
 mediales muscle, 414
 Intertransverse ligaments, 272, 293
 Intertrochanteric line, 224
 Intertubular dentin, 1211
 Interventricular grooves, 553
 septum, 557, 561
 Intervertebral fibrocartilage, 269
 foramina, 49
 notches, 49
 substance, structure of, 270
 veins, 738
 Intestinal glands, 1292
 lymphatic trunks, 772
 plexus of nerves, 1076
 Intestines, applied anatomy of, 1314
 innervations of, 1313
 large, 1295
 arteries of, 1310
 lymphatic vessels of, 794, 1312
 nerves of, 1312
 veins of, 1312
 movements of, 1312
 relations of, 1250
 small, 1281
 applied anatomy of, 1314
 arteries of, 1293
 lymphatic vessels of, 793, 1295
 mucous membrane of, 1289
 nerves of, 1295
 veins of, 1295
 villi of, 1291
 structure of, 1291
 surface form of, 1313
Intestinum cecum, 1296
 crassum, 1295
 ileum, 1288
 jejunum, 1288
 rectum, 1306
 pars analis recti, 1309
 tenuis, 1281
 mesenteriale, 1287
 pliae circulares [Kerkring], 1289
 tela submucosa, 1289
 tunica mucosa, 1289
 mucularis, 1289
 stratum circulare, 1289
 longitudinale, 1289
 serosa, 1289
 Intra-articular ligament, 283
 Intracartilaginous ossification, 42
 Intracranial lymphatics, 774
 Intrajugular process, 73
 Intralobular ducts, 1226
 veins, 751
 Intramembranous ossification, 42
 Intraparietal sulcus of Turner, 922
 Intraprecuneal fissure, 924
 Intrathyroid cartilage, 1165
 Intravertebral veins, 738
 Intrinsic ligaments of larynx, 1168
 muscles of tongue, 393
Intumescentia cervicalis, 823
 gangliofornis, 996
 lumbalis, 823
 Involuntary muscles, 355, 357
- Iris, 1096
 applied anatomy of, 1110
 arteries of, 1099
 epithelium of, pigmented, 1099
 muscle fibers of, 1099
 nerves of, 1099
 stroma of, 1098
 structure of, 1098
 Irregular bones, 36
 Ischiobulbosus muscle, 444
 Ischioapsular ligament, 323
 Ischiogluteal bursa, 327
 Ischiorectal fascia, 446
 fossa, 454
 region, muscles of, 453
 Ischium, 210
 obturator groove of, 211
 ramus of, 212
 spine of, 211
 tuberosity of, 211
 Islands of Langerhans, 1340
 of Reil, 925
 development of, 917
Isthmus aortae, 580
 cartilaginis auris, 1121
 of Fallopiian tube, 1401
 of fauces, 1201, 1203
 faucium, 1201, 1203
 glandulae thyroidea, 1436
 gyri hippocampi, 925
 pharyngonasalis, 1230
 of pharynx, 1230
 rhombencephali, 855
 tubae auditivae, 1128
 uterinae, 1401
 Iter chordae, 1126
 Ivory of teeth, 1211
- J**
- JACOB'S membrane, 1103
 Jacobson, cartilage of, 1080, 1083
 eminence of, 1083
 nerves of, 1002
 Jaw, angle of, 118
 lower, bones of, 115
 upper, bones of, 100
 Jejunum, 1288
 Joints. See Articulations.
 Jugular foramen, 71, 131
 fossa, 86
 ganglion, 1002
 lymph nodes, 778
 process, 71, 131
 sinus, 713
 tubercle, 73
 veins, 713
 development of, 764
- K**
- KERKING, valves of, 1289
 Key and Retzius, foramen of, 845, 969
 Kidneys, 1343
 abnormalities of, 1354
 applied anatomy of, 1355
 arteries of, 1352
 columns of, 1349
 convolutions of, 1351
 cortex of, 1349
 fixation of, 1348
 glomerulus of, 1350
 hilum of, 1348
 horsehoe, 1349
 labyrinth of, 1349
 lymphatic vessels of, 796, 1354
 medulla of, 1349
 minute anatomy of, 1350
 nerves of, 1354
 parenchyma of, 1349

- Kidneys, permanent, 1425
relations of, 1343
structure of, 1349
substance, 1349
surface form of, 1354
tubules of, 1351
veins of, 1354
- Kneecap, 230
- Knee-joint, applied anatomy of, 338
arteries of, 337
bursa of, 336
ligaments of, 331
movements of, 337
nerves of, 337
structures around, 337
surface form of, 338
synovial membrane of, 336
- Krause, end-bulbs of, 813, 817
membrane of, 356
- Kühne, muscle spindles of, 817
- L**
- LABIA majora, 1415
minora, 1416
pudendi, 1416
oris, 1200
- Labial artery, 593
coronary arteries, 594
glands, 1200
nerves, 984
- Labium externum eristi iliaca*, 210
glenoidale, 303, 325
inferius, 1200
internum crista iliaca, 210
laterale [linea aspera], 224
mediale [linea aspera], 224
superius, 1200
tympanicum, 1144
vestibulare, 1144
- Labyrinth of ear, 1136
membranous, 1140
structure of, 1142
osseous, 1136
of ethmoid, 97
of kidneys, 1349
- Labyrinthus ethmoidalis*, 97
membranaceus, 1140
osceus, 1136
- Lacertus fibrosus*, 469
- Lachrymal. See Lacrimal.
- Lacrimal apparatus, 1115
artery, 610
bone, 106
crests of, 137
lesser, 107
canal, 104, 107, 1116
ampulla of, 1116
fossa, 79
gland, 1115
applied anatomy of, 1118
groove, 102, 104, 137, 138
nerve, 980
notch, 102
papilla, 1113, 1116
process, 114
sac, 1116
applied anatomy of, 1119
sulcus, 107
tubercle, 104
- Lactals, 767
- Lactiferous duct, 1430
- Lacuna of bone, 39, 259
magna, 1369
musculorum, 503
rasorum, 503
- Lacunae, 39
laterales, 721
urthrales, 1369
- Lacus lacrimalis*, 1113, 1115
- Lagena, 1147
- Lambda*, 76, 123, 146
- Lambdoid suture, 73, 76, 121
- Lamella of bone, 39
- Lamellated corpuscles, 816
- Lamina basalis*, 1093
of brain, 885
cartilaginis ericoideae, 1165
choriocrapillaris, 1093
cribriform, 1090
cribrosa, 85
sclerae, 1090
clastica anterior, 1091
posterior, 1091
fibrocartilaginea interpubica, 294
fusca, 1090
horizontal, of ethmoid, 96
lateralis processus pterygoidei, 94
medialis processus pterygoidei, 94
medullaris interna, 905
papyracea, 98
periclastral, 948
perpendicularis, 97
reticular, 1147
reticularis, 1147
rostralis, 913
spiralis ossea, 1138, 1140, 1144
secundaria, 1137, 1140
suprachoroidea, 1093
terminalis, 847, 908, 909
vasculosa, 1093
- Landzert, fossa of, 1266
- Langer, cleavage lines of, 1150
foramen of, 783
- Langerhans, centro-acinar cells
of, 1340
islands of, 1340
- Larugo*, 1159
- Laryngeal artery, inferior, 629
superior, 590
nerve, 1078
inferior, 1007
recurrent, 1007
superior, 1006
sinus, 1170
veins, 735
- Larynx, 1163
arteries of, 1174
cartilages of, 1163
glands of, 1174
interior of, 1169
ligaments of, 1167
movements of, 1169
mucous membrane of, 1174
muscles of, 1172
nerves of, 1174
veins of, 1174
ventricles of, 1170
- Lateralis nasi artery, 594
- Latissimus dorsi muscle, 406
surface form of, 416
- Leg, bones of, 230
fasciae of, 525
muscles of, 525
applied anatomy of, 535
- Lemnisc, decussation of, 870
- Lemniscus lateralis*, 876
medialis, 876
- Lens crystallina*, 1106
crystalline, 1106
ligament of, suspensory, 1106
- Lenticula, 854, 947
- Lenticular ganglion, 982
nucleus, 947
- Lenticulostriate arteries, 617
- Leptoprosopie skull, 146
- Lesser's triangle, 591, 1012
- Leukocytes, 40
- Levator anguli oris muscle, 373
scapulae muscle, 407
surface form of, 416
ani muscle, 450
costarum muscle, 417
glandulae thyroideae muscle, 1436
- Levator labii superioris alaeque
nasi muscle, 372
muscle, 373
menti muscle, 374
palati muscle, 397
palpebrae superioris muscle, 369
prostaticae muscle, 452
- Lieberkühn, crypts of, 1292
glands of, 1292
- Lien, 1442
extremitas inferior, 1444
superior, 1444
facies diaphragmatica, 1444
gastrica, 1444
renalis, 1444
margo anterior, 1444
posterior, 1444
tunica albuginea, 1445
serosa, 1444
- Ligamenta accessoria plantaria*, 354
alaris, 277, 336
basium ossis metacarp. dorsalis, 319
interossea, 319
volaris, 319
metatars. dorsalis, 352
interossea, 352
plantaria, 352
brevia, 476
carpometaearpeae dorsalis, 315
volaris, 318
collateralis, 321
articulationes digitorum pedis, 354
metatarsophalangeae, 354
columnae vertebrales, 268
cruciata genu, 333
cuncometatarsea interossea, 352
intercarpea dorsalis, 315, 316, 317
interossea, 315, 316
volaris, 315, 316
intercostalis externa, 288
interna, 288
intercruralis, 271
intercuneiformia dorsalis, 350
interossea, 350
plantaria, 350
interspinalia, 272
intertransversaria, 272
labyrinthi canaliculorum, 1142
lata uteri, 1256
longa, 476
navicularicuneiformia dorsalis, 350
plantaria, 350
puboprostatica, 1362, 1393
pylori, 1274
sacroiliaca anteriora, 290
subflava, 271
tarsometatarsea dorsalis, 352
plantaria, 352
- Ligamenti auricularia [Valsalvae]*, 1121
- Ligamentous action of muscles, 267
- Ligaments, 259, 261
accessory, 275
acromioclavicular, 297
annular, anterior, 486, 536
external, 537
internal, 536
posterior, 487
of radius, 310
arcuate, 419
astragaloscaphoid, 349
atlanto-axial, 274
of axilla, suspensory, 456
of Bertin, 323
of Bigelow, 324
of bladder, 1361
true, 450
broad, 1183, 1407

Ligaments, calcaneo-astragaloid, 347
 calcaneocuboid, 348
 calcaneoscaphoid, 348
 capsular. See Individual joints.
 of carpus, 315
 check, 1087
 chondrosteral, 286, 287
 chondroxiphoid, 288
 ciliary, 1096
 of Cloquet, 1876, 1379
 coxycgeal, 843, 845
 common, anterior, 268
 posterior, 269
 conjugal, 271
 conoid, 298
 of Cooper, 428
 coracacromial, 299
 coracoclavicular, 298
 coracohumeral, 302
 coronary, of knee-joint, 336
 costoclavicular, 296
 costocoracoid, 460
 costotransverse, 284, 285
 costovertebral, 282
 cotyloid, 325
 cricoarytenoid, 1169
 cricotracheal, 1168
 crucial, 333
 cruciform, 275
 deltoid, 343
 dentate, 846
 of diaphragm, 419
 duodcnomesocolic, 1266
 falciform, 1320, 1324
 femoral, 508
 of fingers, 319
 Flood's, 302
 fundiform, of Retzius, 536
 Gimbernati's, 426, 428
 glenohumeral, 302
 glenoid, 176, 303
 of Cruveilhier, 321
 of hand, 315
 of Henle, 433
 hepatocolic, 1260
 hepatoduodenal, 1260
 hepatogastric, 1260
 of Hesselbach, 433
 of Hey, 508
 of hip, 322
 hyoepiglottic, 1167, 1168
 iliofemoral, 323
 iliohumeral, 290
 iliopectineal, 503
 iliotrochanteric, 324
 of ineus, 1133
 infundibulopelvic, 1407
 interchondral, 288
 interclavicular, 296
 interosseous. See Individual joints.
 interspinous, 272
 intersternal, 288, 289
 intertransverse, 272, 293
 intra-articular, 283
 ischioapsular, 323
 of knee-joint, 331
 lateral. See Individual joints.
 of liver, 1324
 lumbosacral, 289, 1345
 malleus, 1133
 oblique, 311
 obturator, 295
 occipito-atlantal, 275, 276
 occipito-axial, 277
 odontoid, 277, 278
 orbicular, 310
 of patella, 331
 phrenocolic, 1305
 of pinna of ear, 1121
 Poupart's, 426, 427
 pterygomandibular, 376, 383
 pterygo-spinous, 383

Ligaments, pubic, 294
 pubofemoral, 323
 puboprostic, 450
 pyloric, 1274
 radioulnar, 312
 rhomboid, 296
 round, 437
 sacrocoxycgeal, 293
 sacroiliac, 290
 sacrosciatic, 291, 292
 sacrouterine, 1407
 of scapula, 299, 300, 301
 Schlemm's, 302
 spinal, 268
 spinoglenoid, 301
 of stapes, 1133
 stellate, 282
 sternoclavicular, 296
 sternocostal, 286
 stylohyoid, 389
 stylomandibular, 280, 382
 superficial transverse, of fingers, 489
 suprascapular, 300
 supraspinous, 272
 suspensory, of bladder, 1362
 of Cooper, 456
 of eye, 1087
 of lens, 1106
 of penis, 424
 of Treitz, 1285
 sutural, 121, 259
 synovial, 262
 tarsal, 366
 thyroarytenoid, 1170
 thyroepiglottic, 1167, 1169
 thyrohyoid, 1167
 tibiotarsal, 343
 transverse, of acetabulum, 325, 326
 of atlas, 274
 humeral, 303
 of knee-joint, 336
 metatarsal, 353
 pelvic, 446
 trapezoid, 298
 triangular, deep layer of, 449
 in female, 446
 in male, 446
 true, of bladder, 450
 umbilical, 1361
 uterosacral, 1407
 of uterus, 1406
 of vertebral bodies, 268
 volar, 315
 of Winslow, 332
 of Wrisberg, 336
 of wrist-joint, 314
 Y, 324
 of Zinn, 370
Ligamentum acromioclaviculare, 297
annulare bascos stapedius, 1133
radii, 310
apicis dentis, 278
arcuatum externum, 439
pubis, 294
arteriosum, 570, 575
auriculare anterius, 1121
 posterius, 1121
 superius, 1121
bifurcatum, 348
calcaneocuboidum dorsale, 348
 plantare, 348
calcaneofibulare, 344
calcaneonaviculare plantare, 348
calcaneotibiale, 343
capituli costae interarticularae, 283
 radiatum, 282
capitulum ossis metacarpalium transversum, 320
carpi dorsale, 487
 fasciculi transversi, 489
 transversum, 486

Ligamentum collaterale carpi radiale, 314
 ulnare, 314
fibulare, 333
radiale, 308
tibiale, 332
ulnare, 307
colli costae, 284
conoideum, 298
coracacromiale, 299
coracoclavicular, 298
coracohumeral, 302
coronarium hepatis, 1325
costoclavicular, 296
costotransversarium anterius, 284
 posterius, 285
costoxiphoidum anterius, 288
cricocarytenoideum posterius, 1168
cricothyroideum medium, 1168
cricotracheale, 1168
crucium anterius, 333
 atlantis, 275
 cruris, 536
 posterius, 333
cuboideonaviculare dorsale, 350
 plantare, 350
cuneocuboidum dorsale, 351
 interosseum, 350, 351
 plantare, 351
deltoidum, 343
denticulatum, 821, 845, 846, 1013
epididymidis inferior, 1378
 superior, 1378
falciforme hepatis, 1253, 1324
gastrolienal, 1444
hepatocolicum, 1260
hepatoduodenale, 1260
hepatogastricum, 1260
hyoepiglotticum, 1168
hyothyroideum laterale, 1167
 medium, 1167
iliofemorale, 323
iliohumale, 290
incutis posterius, 1133
 superius, 1133
inguinale, 427
 reflexum, 428
interclavicular, 296
interfoveolare, 433
ischioapsulare, 323
laciniatum, 536
locunare, 428
laterale externum breve seu posticum, 333
latum pulmonis, 1184
 uteri, 1407
longitudinale anterius, 268
 posterius, 269
mallei anterius, 1133
 laterale, 1153
 superius, 1153
malleoli lateralis anterius, 341
 posterius, 342
mucosum, 336
nuchae, 272, 406
ossiculorum auditus, 1133
palpebrale mediale, 367, 1114
patellae, 331
pectinatum iridis, 1092, 1096
phrenocolicum, 1264
pisohamatum, 316
pisometacarpum, 316
plantare longum, 348
popliteum obliquum, 332
pubicum superius, 294
pubocapsulare, 323
pulmonale, 1184
radiocarpum dorsale, 314
 volare, 314
sacrocoxycgeum anterius, 293
 posterius, 293

- Ligamentum sacrococcygeum posterius profundum*, 293
superficiale, 293
sacroiliacum posterius, 290
breve, 290
longum, 290
sacrospinous, 292
sacroctuberosum, 291
sphenomandibulare, 279
spirale cochleae, 1144
sternoclaviculare, 296
sternocostale intercartilagineum, 287
radiatum, 286
sternopericardica, 518
stylohyoideus, 389
stylomandibulare, 280
supraspinale, 272
suspensorium penis, 1388
talocalcarum anterius, 347
interossum, 347
laterale, 347
mediale, 347
posterius, 347
talofibulare anterius, 344
posterius, 344
talotibiale anterius, 343
posterius, 343
temporomandibulare, 279
teres, 324, 752, 764
femoris, 324
hepatis, 1325
utriculi, 437, 1408
thyroepiglotticum, 1169
tibionaviculare, 343
transversum acetabuli, 326
atlantis, 274
cruris, 536
genu, 336
pelvis, 446
scapulae inferius, 301
superius, 300
trapezoidum, 298
triangulare dextrum, 1325
sinistrum, 1325
umbilicale laterale, 671, 1362
medium, 1361
vaginale, 321
vena cavae sinistras, 550
venosum, 752, 1325
 Light stimuli, path of, 1104
 Limbic lobe, 929
Limbus fossae ovalis [Viusseni], 557
laminae spirales, 1144
membranae tympanicae, 1130
Limen insulae, 925
nasi, 1082
 Line, ilipectineal, 209
 intertrochanteric, 224
 spiral, of femur, 224
Linca alba, 426, 435, 439
arcuata, 209, 212
aspera, 224
glutaea anterior, 207
inferior, 208
posterior, 207
intercondyloidea, 226
intermedia crista iliaca, 210
intertrochanterica, 224
mylohyoidea, 117
nuchae inferior, 70
superior, 70
suprema, 70
obliqua, 117, 1164
pectinea, 224
poplitea, 224
quadrata, 224
semicircularis, 430, 435
semilunaris, 439
 of abdomen, 436
splendens, 845
temporalis inferior, 74
superior, 74
transversae, 439
visus, 1088
Lincae musculares, 172
semilunares, 436
transversae, 58
Lingula, 1217
facies inferior, 1217
margo lateralis, 1217
tunica mucosa, 1217
 Lingual arteries, 590, 591, 601, 1219
 bone, 153
 lymph nodes, 776
 muscles, 393
 nerves, 988
 from glossopharyngeal, 1003
 region, muscles of, 391
 septum, 393
 tonsil, 1219
 veins, 715
Lingula, 91, 117, 867, 886
cerebelli, 886
mandibulae, 117
pulmonis, 1190
sphenoidalis, 91
 Lips, 1200
Liquor cerebrospinalis, 970
 folliculi, 1400
 Littre, glands of, 1369
 Liver, 1319
 abnormalities of, 1326
 accessory, 1326
 applied anatomy of, 1335
 arteries of, 1326
 colic impression of, 1321
 constriction lobe of, 1326
 duodenal impression of, 1321
 excretory apparatus of, 1331
 fissures of, 1322
 gastric impression of, 1321
 ligaments of, 1324
 ligamentum venosum of, 764
 lobes of, 1323
 lobules of, 1328
 lymphatic vessels of, 794, 1331
 movability of, 1325
 nerves of, 1331
 omental tuberosity of, 1321
 renal impression of, 1321
 Riedel's lobe of, 1326
 structure of, 1328
 support of, 1325
 suprarenal impression of, 1322
 surface relations of, 1334
 surfaces of, 1320
 veins of, 1327
 Lobe or Lobes, biventral, 887
cacuminal, 886
central, 886
 of cerebellum, 885
cerebral, 915
clival, 886
erectile, 886
culminal, 886
frontal, 919
gracile, 887
limbic, 929
 of lungs, 1190
nodular, 888
occipital, 924
olfactory, 926
parietal, 922
pyramidal, 887
quadrate, 886
semilunar, 887
temporal, 924
tuberal, 887
uvular, 887
Lobi mammae, 1430
 Lobules of liver, 1328
 of lungs, 1195
Lobuli hepatis, 1328
mammae, 1430
testis, 1380
Lobulus auricularis, 1120
biventer cerebelli, 887
centralis cerebelli, 886
Lobulus paracentralis, 921
parietalis inferior, 923
superior, 923
semilunaris inferior [cerebelli], 887
Lobus cavatus [Spigeli], 1324
frontalis, 921
hepatis dexter, 1324
sinister, 1324
occipitalis, 924
olfactorius, 926
parietalis, 922
temporalis, 924
 Lockwood, tendon of, 370
Locus caeruleus, 866
 Longissimus dorsi muscle, 412
 Longitudinal fasciculus, 955
 vertebral veins, 738
 zones of brain, 855
 Longus colli muscle, 401
 Löwenthal and Bechterew, fasciculus intermedius of, 839
 tract of eord, 840
 Lower, tubercle of, 557
 Ludwig, angle of, 157, 166
 Lumbar aponeurosis, 409
 arteries, 662
 curve of vertebral column, 66
 enlargement of spinal cord, 823
 fascia, 409
 lymph nodes, 788
 lymphatic trunks, 772
 nerves, 1019
 divisions of, 1018, 1044
 plexus of nerves, 1044
 applied anatomy of, 1062
 portion of gangliated cord, 1071
 puncture, 68
 veins, 749
 ascending, 736, 749
 vertebrae, 56
 fifth, 57
 Lumbosacral ligament, 289, 1345
 plexus of nerves, 1044
 Lumbricales muscle, foot, 540
 hand, 493
 Lungs, 1188
 alveoli of, 1195
 applied anatomy of, 1197
 arteries of, 1195
 borders of, 1190
 broad ligament of, 1183
 color of, 1194
 fetal, 1194
 fissures of, 1190
 infundibula of, 1195
 lobes of, 1190
 lobules of, 1195
 lymphatic vessels of, 802, 1196
 nerves of, 1196
 parenchyma of, 1195
 root of, 1193
 saecules of, 1195
 septa of, 1195
 structure of, 1194
 substance of, 1194
 surface form of, 1196
 surfaces of, 1189
 veins of, 1195
 weight of, 1194
 Lunula, 1157
 of nails, 1157
Lunulae valvularum semilunarium, 559, 561
 Lushka, foramen of, 867, 969
 gland of, 1450
 Lutein cells, 1400
 Luys, body of, 905
 centrum medium of, 905
 Lymph, 767
 nodes, antecubital, 781
 aortic, 788
 appendicular, 791
 auricular, posterior, 774

Lymph nodes, axillary, 782
 bronchiomediastinal, 801
 buccal, 776
 cervical, 777, 779
 of Cloquet, 786
 colic, 791
 cystic, 790
 definition of, 768
 diaphragmatic, 798
 epitrochlear, 782
 of face, 774, 776
 gastric, 790
 gastroepiploic, 790
 of head, 774
 hepatic, 790
 humeral, 782
 hypogastric, 787
 ileal, 791
 ileocolic, 791
 iliac, 787, 788
 infraclavicular, 782, 783
 inguinal, 785, 786
 interbronchial, 801, 1179
 intercostal, 798
 jugular, 778
 lingual, 776
 of lower extremity, 784
 lumbar, 788
 mammary, 798
 mandibular, 776
 mastoid, 774
 maxillary, 776
 mediastinal, 800
 mesenteric, 790, 791
 mesocolic, 791
 middle, of Stahr, 778
 of neck, 774, 777
 obturator, 787
 occipital, 774
 pancreaticoduodenal, 793
 paracardial, 790
 parietal, 787, 798
 parotid, 774
 pectoral, 782
 peritracheobronchial, 1179
 popliteal, 784
 preaortic, 789
 preauricular, 774
 prelaryngeal, 779
 pretracheal, 779
 retroaortic, 789
 retropharyngeal, 776
 retropyloric, 790
 of Rosenmüller, 786
 sacral, 788
 splenic, 790
 subclavian, 783
 submaxillary, 778
 submental, 779
 subparotid, 776
 subpyloric, 790
 subscapular, 783
 substernomastoid, 779
 supraclavicular, 779
 suprahyoid, 779
 supratrochlear, 782
 of thorax, 798
 tibial, 784
 of trachea, 1179
 tracheobronchial, 800
 of upper extremity, 781, 782
 visceral, 790, 800
 sinuses, 768
 spaces, 767
 periscleral, 1086
 perivascular, 707
 suprasccleral, 1086
 -vascular system, 547
 Lymphatic or Lymphatics, 767
 applied anatomy of, 770
 duct, right, 773
 extracranial, 774
 glands. See Lymph nodes.
 intracranial, 774
 origin of, 769

Lymphatic or Lymphatics, pas-
 sages of eyeball, 1109
 pharyngeal ring, 1234
 sacs, primary, 770
 structure of, 769
 terminations of, 769
 trunks, intestinal, 772
 lumbar, 772
 vessels of abdomen, 787, 789,
 790
 of abdominal viscera, 792
 afferent, 768
 of anus, 794
 of arteries, 574
 of auditory meatus, exter-
 nal, 777
 of bladder, 796
 of bone, 41
 of cecum, 1300
 of common bile-duct, 796
 development of, 769
 of diaphragm, 799
 of duodenum, 793
 efferent, 768
 of external genitals, 790
 of face, 774, 777
 of Fallopian tube, 797
 of gall-bladder, 795
 of head, 774
 of heart, 802
 intercostal, 799
 of intestine, large, 794
 small, 793
 of kidney, 796
 of labia majora, 1415
 of liver, 794
 of lower extremity, 786, 787
 of lungs, 802
 of mammary gland, 798
 of membrana tympani, 1131
 of mouth, 777
 of muscles of neck, 780
 of nasal fossæ, 777
 of neck, 774, 780
 of nose, 1081
 of oesophagus, 802
 of ovaries, 797
 of pancreas, 796
 of parotid gland, 1225
 of pelvic viscera, 792
 of pelvis, 789, 790
 of penis, 1390
 of perineum, 790
 of pinna, 777
 of pleura, 802
 of prostate, 796
 of rectum, 794
 of reproductive organs, 796
 of scalp, 776
 of seminal vesicles, 797
 of skin, 1156
 of spermatic cord, 1377
 of spleen, 796, 1446
 of stomach, 792, 1279
 of submaxillary gland, 1226
 of suprarenal glands, 796,
 1449
 of testes, 796
 of thoracic viscera, 802
 wall, 798
 of thorax, 798
 of thymus gland, 802
 of thyroid gland, 1438
 of tongue, 777
 of tonsil, 1231
 of upper extremity, 783, 784
 of ureter, 796
 of urethra, 796
 of urinary organs, 796
 of uterus, 797
 of vagina, 797
 of vas deferens, 797
 of vermiform appendix, 1300
 Lymphoglandulæ, 768
 auriculares anteriores, 775

Lymphoglandulæ auriculares pos-
 teriores, 774
 axillares, 782
 bronchiales, 801, 1179
 cervicales profundæ, 779
 inferiores, 779
 superficiales, 777
 superiores, 779
 coeliacæ, 795
 faciales profundæ, 776
 gastricæ inferiores, 790
 superiores, 790
 hepaticæ, 790
 hypogastricæ, 787
 inguinales, 785
 intercostales, 798
 linguales, 776
 lumbales, 788
 mediastinales anteriores, 800
 posteriores, 800
 mesentericæ, 790
 occipitales, 774
 pancreaticolienales, 790
 parotideæ, 774
 pectorales, 782
 popliteæ, 784
 subinguinales, 785
 profundæ, 786
 submaxillares, 778
 tibialis anterior, 784
 tracheales, 801, 1179

M

McBURNER'S point, 1298, 1313
 Macewen's suprameatal triangle,
 81, 151
 Macula acustica sacculi, 1141
 butea, 1100, 1104
 utriculi, 1141
 Majendie, foramen of, 845, 867,
 969
 Malar arteries, 610
 bone, 107
 canal, 108
 foramen, 107, 136
 nerve, 998
 of superior maxillary, 983
 process of maxillæ, 101, 104
 Male breast, 1433
 reproductive organs, 1371
 urethra, 1366
 Malleolar arteries, 698, 703
 folds, 1130
 sulcus, 238
 Malleolus, external, 237
 internal, 235
 lateralis, 237
 medialis, 235
 Malleus, 1131
 ligaments of, 1133
 processus anterior [Folik], 1132
 lateralis, 1132
 Malpighian body, 1350
 capsule, 1350
 corpuscles, 1445
 layer of skin, 1152
 tuft, 1350
 Mamma virilis, 1433
 Mammæ accessoridæ muliebri,
 1430
 Mammary artery, external, 638
 internal, 631
 gland, 1428
 applied anatomy of, 1432
 areola of, 1429
 arteries of, 1432
 lymphatic vessels of, 798,
 1432
 nerves of, 1432
 prolongation of, 1430
 variations in, 1429
 veins of, 1432
 lymph nodes, internal, 798

- Mammary veins, 734
 Mamillary duct, 1430
 Maudible, 115
 changes produced in, by age, 119
 condyle of, 118
 condyloid process of, 118
 coronoid process of, 118
 depressors of, 388
 oblique line of, 117
 perpendicular portions of, 117
 side views of, at different periods of life, 119
 symphysis of, 115
 Mandibula, 115
 Mandibular lymph nodes, 776
 nerve, 987
 from facial, 998
 region, muscles of, 374
 Manubrium mallei, 1131
 sterni, 157
 Marclou's tract of cord, 839
 Margin of orbit, 101
 Marginal cusp of mitral valve, 561
 gyre, 923
 tract of spinal cord, 836
 veins, 709
 Margo acutus, 552
 azillaris, 175
 ciliaris, 1096
 dorsalis corpus radii, 191
 ulnae, 187
 frontalis, 76
 infraorbitalis, 101, 137
 lambdoides, 73
 lateralis, 180
 mastoides, 73
 medialis, 180
 corpus tibiae, 234
 nasi, 1079
 obtusus, 552
 occipitalis, 76
 pupillaris, 1097
 sagittalis, 76
 squamosus, 76
 supraorbitalis, 77, 137
 vertebralis, 175
 volaris corpus radii, 191
 ulnae, 187
 Marrow, bone, 40
 cells, 40
 Marshall, oblique vein of, 550, 709
 vestigial fold of, 550
 Martinotti, cells of, 952, 953
 Massae laterales, 51
 Masseter muscle, 377
 surface form of, 380
 Masseteric artery, 601
 fascia, 377
 nerve, 987
 Mastoid air cells, 1127
 antrum, 83
 artery, 596
 bone, sigmoid fossa of, 82
 cells, 83
 foramen, 82, 128, 133
 lymph nodes, 774
 portion of temporal bone, 82
 process of temporal bone, 82
 Masto-occipital suture, 73, 122
 Mastoparietal suture, 122
 Matrix of nails, 1157
 unguis, 1157
 Maxilla, 100
 alveolar process of, 104
 malar process of, 104
 nasal process of, 104
 palatal process of, 104
 Maxillary artery, 598
 atrium, orifice of, 141
 hiatus, 102
 lymph nodes, 776
 Maxillary nerve, 982, 987
 process of palate bone, 111
 of turbinated bone, 114
 region, muscles of, 373
 sinus, 101, 103
 tuberosity, 102
 vein, 712
 Meatus acusticus externus, 1122
 cartilagineus, 1122
 osseous, 1122
 pars externa, 1122
 interna, 1122
 media, 1122
 internus, 85
 auditory, 1122
 external, 88, 133
 internal, 85, 128
 nasi inferior, 1082
 medius, 1082
 superior, 1082
 of nose, 98, 110
 atrium of, 141
 urinarius, 1369
 Meckel's cartilage, 118
 diverticulum, 1289
 ganglion, 984
 Median nerves, 1034
 veins, 730
 Mediastinal arteries, 632, 654
 lymph nodes, 800
 pleura, 1183
 plexus, subpleural, 632
 Mediastinum, 1185
 applied anatomy of, 1188
 testis [corpus Highmori], 1380
 Medial commissure, 903
 Mediocornu, 938
 Mediodural artery, 600
 Medifrontal fissures, 919
 gyre, 921
 Mediotarsal articulation, 349
 Medipodunculi, 890
 Mediotemporal fissure, 924
 gyre, 924
 Medulla of kidneys, 1349
 oblongata, 861
 areas of, 862
 fissures of, 861
 funiculus of, 863
 olive of, 863
 pyramids of, 863, 869
 restis of, 864
 tuberculum cinereum of, 864
 veins of, 721
 ossium rubra, 40
 spinalis, 820
 Medullary arteries, 619
 body, 888
 canal of bone, 35
 cavity, formation of, 45
 pyramids, 1349
 rays, 1349
 sheath of Schwann, 811
 velum, inferior, 884, 891
 posterior, 888
 superior, 884, 891
 Medullated axis-cylinder processes, 811
 Megacephalic skulls, 145
 Meibonian glands, 1114
 Meissner and Wagner, touch corpuscles of, 816
 Meissner's plexus of nerves, 1279
 Membrana adamantina, 1214
 atlantooccipitalis anterior, 275
 posterior, 276
 basilaris, 1138, 1143
 ericothyroidea, 1165
 flaccida of Shrapnell, 1130
 hyaloidea, 1105
 hyothyroidea, 1167
 interossea antibrachii, 312
 cruvis, 341
 mucosa nasi, 1083
 nictitans, 1115
 Membrana obturatoria, 517
 stapedis, 1133
 pupillaris, 1100
 sacciformis, 318
 sterni, 286
 tectoria, 277, 1147
 tympani, 87, 1122, 1128
 arteries of, 1131
 lymphatics of, 1131
 nerves of, 1131
 secundaria, 1126, 1140
 stratum circulare, 1131
 mucosum, 1130
 radiatum, 1131
 veins of, 1131
 vestibularis [Reissner], 1144
 Membrane, basilar, 1143
 Bowman's, 1091
 of brain, 964
 of Bruch, 1093
 of Corti, 1147
 costocoracoid, 459
 ericothyroid, 1165, 1168
 of Demours, 1091
 of Descemet, 1091
 of Henle, fenestrated, 573
 of Hensen, 356
 hyaloid, 1106
 intercostal, 417
 of Kölliker, 1147
 of Krause, 356
 Nasmyth's, 1211
 otohith, 1143
 peridental, 1212
 of Reissner, 1144
 of Ruysch, 1093
 Schneiderian, 1083
 serous, of diaphragm, 421
 of spinal cord, 842
 sutural, 263
 synovial, 259, 261
 thyrohyoid, 1161, 1167
 tympanic, 1128
 vitelline, 1400
 Membranous canal of cochlea, 1144
 labyrinth of ear, 1140
 primordial cranium, 141
 semicircular canals, 1142
 Meningeal artery, 596, 597
 anterior, 609
 middle, 600
 posterior, 597, 621
 small, 600
 nerve, 983
 from hypoglossal, 1011
 from internal maxillary, 987
 from vagus, 1005
 veins, 719
 Meninges of brain, 964
 encephali, 964
 Meningocele, 149
 Meningoarachidian veins, 843
 Menisci, 334
 articulares, 260
 Meniscofemoral joint, 338
 Meniscotibial joint, 338
 Meniscus lateralis, 335
 medialis, 334
 Mental artery, 601
 foramen 116, 136
 point of skull, 146
 process, 116, 135
 tubercles, 116
 Mesal plane of skull, 146
 Mesencephalic root nuclei, 884
 Mesencephalon, 893
 Mesenteric arteries, 663, 666
 lymph nodes, 790
 peritoneum, 1249
 plexus of nerves, 1076
 veins, 753
 Mesentericomesocolic fold, 1266
 Mesentericoparietal fold, 1267

- Mesenteriolium processus vermiciformis*, 1265
Mesenterium, 1263
 Mesentery, 1263
 of vermiform appendix, 1265
Mesoappendix, 1265, 1299
Mesocele, 897
Mesoccephalic skull, 145
Mesocolic band, 1310
 fossæ, 1266
 lymph nodes, 791
Mesocolon, ascending, 1264
 descending, 1264
 sigmoid, 1264
 transverse, 1264
Mesocolon ascendens, 1264
 descendens, 1264
 sigmoideum, 1264
 transversum, 1264
Mesogastrium, 1249
Mesognathion, 106
Mesometrium, 1407
Meson planes of body, 34
Mesonephros, 1420
Mesorbital gyre, 920, 922
Mesorchium, 1423
Mesosigmoid, 1306
Mesosternum, 157
Mesovarium, 1398, 1407, 1423
Metacarpal bones, 201
 of index finger, 202
 of little finger, 203
 of middle finger, 202
 nutrient canal of, 201
 foramen of, 201
 peculiar characters of, 202
 of ring finger, 203
 of thumb, 202
 spaces, 202
Metacarpophalangeal articulations, 320
 surface form of, 321
Metacarpus, 201
Metanephros, 1425
Metapore, 845, 867, 969
Metasternum, 157
Metatarsal artery; 699
 articulation, synovial membrane in, 353
 bones, 249
 articulations of, 252, 352
 common characters of, 250
 fifth, 252
 first, 250
 fourth, 251
 peculiar characters of, 250
 second, 251
 third, 251
 ligament, transverse, 353
 veins, 741
Metatarsophalangeal articulations, 353
Metopic suture, 121
Meynert, fasciculus retroflexus of, 906
Microcephalic skulls, 145
Midbrain, 893
 aqueduct of, 897
 central aqueduct gray, 897
 crusta of, 900
 development of, 855
 fiber tracts of, 899, 900
 gray masses in, summary of, 900
 intercalatum of, 897
 pes of, 900
 structure of, 894, 896
 substantia nigra of, 897
 tegumentum of, 896
Midgut, 1247
Milk teeth, 1205
Mitral orifice, 560
 valve, 561
Mixed articulation, 264
Moderator band, 558
Modiolus, 1138, 1139
Molar glands, 1200
 teeth, 1207
Moll, glands of, 1113
Monakow's tract of cord, 839
Monaxonie neurones, 810
Monro, foramen of, 936
Mons Veneris, 1415
Montgomery, glands of, 1429
Monticulus cerebelli, 885
Morgagni, crypts of, 1310
 hydatids of, 1402
 sinus of, 395
 valves of, 1310
Moss fibers of Ramón y Cajal, 893
Motor area of brain, 959
 end plates, 816
 neurones, 804
 root of spinal cord, 823
Mouth, 1199
 angle of, 1199
 aperture of, 1199
 applied anatomy of, 1204
 cavity of, 138, 1201
 development of, 1204
 floor of, 1201
 lymphatic vessels of, 777
 structure of, 1201
 vestibule of, 1200
Movable articulations, 264
Mucous membranc of bladder, 1364
 of cecum, 1310
 of cheeks, 1200
 of colon, 1310
 of larynx, 1174
 of nasal fossæ, 1083
 of nose, 1081
 of small intestine, 1289
 of soft palate, 1203
 of stomach, 1275
 of tongue, 1217
 of trachea, 1178
 of tympanum, 1134
 of uterus, 1410
 of vagina, 1414
Müller, muscle of, 371
 nerve fibers of, 1104
 ring muscle of, 1096
Müllerian duct, 1423
Multifidus spinæ muscle, 413
Multipenniform muscle, 358
Multipolar nerve cells, 808
Muscle or Muscles, 355
 of abdomen, antero-lateral, 423
 posterior, 439
 abductor hallucis, 538
 indicial, 494
 minimi digiti, foot, 539
 hand, 493
 pollicis, 489
 longus, 485
 accelerator urinae, 443
 of acromial region, 462
 adductor brevis, 514
 longus, 513
 magnus, 514
 minimus, 514
 obliquus hallucis, 541
 pollicis, 492
 transversus hallucis, 541
 pollicis, 492
 anconeus, 482
 anomalous, 361
 antitragicus, 1121
 applied anatomy of, 359
 of arm, 461, 467
 arrectores pilorum, 1161
 of articulations of elbow-joint, 308
 of shoulder-joint, 303
 aryepiglottic, 1173
 arytenoideus, 1172
Muscle or Muscles, attachment of, 357
 attollens aurem, 366
 atrahans aurem, 366
 of auricular region, 365
 azygos uvulae, 398
 of back, 403
 biceps, 469
 femoris, 522
 flexor cubiti, 469
 biventer cervicis, 413
 biventral, 358
 brachialis anticus, 469
 brachioradialis, 479
 of buccal region, 374
 buccinator, 375
 cardiac, 355
 cervicalis ascendens, 412
 chondroglossus, 393
 ciliary, 1095
 coccygeus, 453
 complexus, 412
 compressor bulbi, 444
 hemisphaerium bulbi, 444
 naris, 372
 narium minor, 372
 urethrae, 448
 constrictor, inferior, 394
 middle, 395
 radicis penis, 444
 superior, 395
 urethrae, 448
 coracobrachialis, 468
 corrugator cutis ani, 453
 supercilii, 367
 of cranial region, 362
 of cranium, 362
 cremaster, 430
 cricoarytenoid, 1172
 cricothyroid, 1172
 crureus, 511
 of deglutition, 397
 deltoid, 462
 depressor alae nasi, 372
 anguli oris, 374
 labii inferioris, 374
 detrusor urinae, 1363
 development of, 361
 of diaphragm, 418
 digastric, 388
 dilator naris, anterior, 372
 posterior, 372
 of dorsal region, 537
 erector clitoridis, 446
 penis, 444
 spinæ, 410
 of expression, 380
 extensor brevis digitorum, 537
 pollicis, 483
 carpi radialis brevis, 479
 longior, 479
 ulnaris, 482
 coccygis, 414
 communis digitorum, 480
 indicial, 484
 longus digitorum, 527
 pollicis, 484
 minimi digiti, 481
 ossis metacarpi pollicis, 482
 proprius hallucis, 527
 of face, 362
 of femoral region, anterior, 505
 internal, 512
 posterior, 522
 fibers, 355
 of fibular region, 534
 fixation, 359
 flexor accessorius, 539
 brevis digitorum, 538
 hallucis, 541
 minimi digiti, foot, 541
 hand, 493
 pollicis, 490, 492 (note)
 carpi radialis, 473
 ulnaris, 474

- Muscle or Muscles, flexor longus
 digitorum, 533
 hallucis, 532
 pollicis, 476
 profundus digitorum, 476
 sublimis digitorum, 475
 of foot, 536
 of forearm, 471
 form of, 357
 frontalis, 364
 fusiform, 358
 gastrocnemius, 528
 gemelli, 520
 geniohyoglossus, 391
 geniohyoid, 390
 of gluteal region, 515
 gluteus maximus, 515
 medius, 516
 minimus, 517
 gracilis, 512
 hamstring, 522
 of hand, 486
 helix major, 1121
 minor, 1121
 of hip, 515
 Horner's, 367
 of humeral region, 467, 470
 hyoglossus, 391
 of iliac region, 502
 iliacus, 504
 iliococcygeus, 452
 iliocostalis, 410
 iliopsoas, 504 (note)
 iliosacralis, 452
 incisivus, 375
 inferior oblique, 370
 infracostales, 417
 of infrahyoid region, 386
 infraspinalis, 465
 insertion of, definition of, 359
 intercostal, 417
 interossei, foot, 541
 of hand, 494
 interspinales, 414
 intertransversales, 414
 involuntary, 355
 nonstriated, bloodvessels of, 357
 nerves of, 357
 ischiobulbosus, 444
 of ischiofemoral region, 453
 of larynx, 1172
 latissimus dorsi, 406
 of leg, 525
 levator anguli oris, 373
 scapulae, 407
 ani, 450
 glandulae thyroideae, 1436
 labii superioris, 373
 alaeque nasi, 372
 menti, 374
 palati, 397
 palpebrae superioris, 369
 penis, 444
 prostatae, 452
 levatores costarum, 417
 ligamentous action of, 367
 of lingual region, 391
 lingualis, 393
 longissimus dorsi, 412
 longus colli, 401
 of lower extremity, 501
 lumbricales, foot, 540
 hand, 493
 of mandibular region, 374
 masseter, 377
 of maxillary region, 373
 Müller's, 371
 multifidus spinae, 413
 multipennate, 358
 mylohyoid, 389
 of nasal region, 372
 nasolabialis, 375
 of neck, 380
 of nose, 1081
- Muscle or Muscles, oblique, as-
 cending, 428
 descending, 424
 external, 424
 internal, 428
 obliquus auriculae, 1121
 inferior, 415
 superior, 415
 obturator externus, 521
 internus, 518
 occipitalis, 363
 occipitofrontalis, 363
 omohyoid, 388
 opponens minimi digiti, foot, 541
 hand, 493
 pollicis, 490
 orbicular, 358
 orbicularis oris, 374
 palpebrarum, 366
 orbital, 368, 371
 origin of, definition of, 359
 of palatal region, 397
 palatoglossus, 398
 palatopharyngeus, 398
 of palmar region, 493
 palmaris brevis, 492
 longus, 474
 of palpebral region, 366
 papillary, 558
 pectineus, 513
 pectoralis major, 456
 minor, 460
 of pelvic outlet, 440
 penniform, 358
 of perineum in female, 445
 in male, 442
 peroneus brevis, 535
 longus, 534
 tertius, 527
 of pharyngeal region, 394
 of pinna of ear, 1121
 of plantar region, 537
 plantaris, 530
 platysma, 381
 popliteus, 531
 pronator quadratus, 478
 teres, 472
 psoas magnus, 504
 parvus, 504
 pterygoid, 379, 380
 of pterygomandibular region, 379
 pubocavernosus, 444
 pubococcygeus, 452
 puborectalis, 452
 pyramidalis, 435
 nasi, 372
 pyriformis, 517
 quadratus femoris, 520
 lumborum, 439
 menti, 374
 quadriceps extensor, 509
 quadrilateral, 358
 of radial region, 479, 489
 of radioulnar region, 472, 480
 recti, 370
 rectococcygeal, 1311
 rectouterinus, 1408
 rectovesical, 1362
 rectus abdominis, 433
 capitis anticus, 400
 lateralis, 400
 posticus, 414
 femoris, 510
 retrahens aurem, 366
 rhomboideus, 407
 ring, of Müller, 1096
 risorius, 377
 rotatores spinae, 413
 salpingopharyngeus, 399
 sartorius, 508
 scalenus anticus, 401
 medius, 401
 posticus, 402
- Muscle or Muscles of scapular
 region, 463, 464
 semimembranosus, 524
 semispinalis colli, 413
 dorsi, 413
 semitendinosus, 524
 serratus magnus, 461
 posticus, 408
 of shoulder, 461
 skeletal, 355
 of soft palate, 1203
 soleus, 529
 spinalis colli, 412
 dorsi, 412
 sphincter, 358
 ani, 453, 454
 recti, 452
 urethrae membranaceae, 448
 vaginae, 445
 spicule, 357
 spindles of Kühne, 817
 splenius capitis, 409
 colli, 409
 stapedius, 1134
 sternalis, 459
 sternohyoid, 386
 sternomastoid, 385
 sternothyroid, 387
 striated, 355
 striations of, cross, 356
 longitudinal, 356
 striped, 355
 styloglossus, 392
 stylohyoid, 389
 stylopharyngeus, 396
 subacromius, 471
 subclavius, 460
 suberucosus, 512
 subscapularis, 464
 substance, 356
 of superficial cervical region, 381
 superior oblique, 370
 supinator [brevis], 482
 longus, 479
 of suprahoid region, 388
 supraspinales, 414
 supraspinatus, 464
 suspensory, of duodenum, 1285
 synergic, 359
 tarsal, 369, 370
 temporal, 378
 of temporomandibular region, 377
 tensor fasciae femoris, 508
 palati, 397
 tarsi, 367
 teres major, 466
 minor, 466
 of thigh, 505
 of thoracic region, 455, 461
 of thorax, 416
 thyroarytenoid, 1173
 thyroepiglotticus, 1173
 thyrohyoid, 387
 tibialis anticus, 526
 posticus, 533
 of tibiofibular region, anterior, 525
 posterior, 528
 of tongue, 393
 trachealis, of Todd and Bowman, 1178
 trachelomastoid, 412
 tragus, 1121
 transversalis, 432
 capitis, 412 (note)
 cervicis, 412
 transverse perineal, 442, 445
 transversus auriculae, 1121
 perinei profundus, 448
 trapezius, 404
 triangular, 358
 triangularis sterni, 417
 triceps, 470

- Muscle or Museles, triceps ex-
 tensor cubiti, 470
 of trunk, 403
 of tympanum, 1134
 of ulnar region, 492
 unstriated, 355
 of upper extremity, 454
 of ureters, 1363
 variable, 361
 vastus externus, 510
 internus, 511
 vegetative, 355
 of vertebral region, 400, 401
 voluntary, 355
 arteries of, 356
 nerves of, 357
 veins of, 357
 zygomatius major, 373
 minor, 373
- Musculus arrectores pilorum**, 1161
intercostales externi, 417
 interni, 417
interossei, 493
 dorsales, 494
 volares, 494
interspinales, 414
intertransversarii, 414
laxator tympani major et mi-
nor, 1134
levator costarum, 417
lumbicales, 493
papillares, 558, 561
pectinati, 554, 557, 559
rotatores, 413
subcostales, 417
supraspinales, 414
- Musculocutaneous nerve**, 1060
Musculophrenic artery, 632
Musculospiral groove, 180
 nerve, 1037
- Musculus abductor digiti quinti**,
 492, 539
 brevis, 493
 hallucis, 538
 pollicis brevis, 489
 longus, 482
accessorius, 410
adductor brevis, 514
 longus, 513
 magnus, 514
 minimus, 514
 pollicis, 490
 transversus pollicis, 492
anconaeus, 482
antitragicus, 1121
articularis genu, 512
auricularis anterior, 366
 posterior, 366
 superior, 366
arytenoideus obliquus, 1172
 transversus, 1173
biceps brachii, 469
 caput breve, 469
 longum, 469
 femoris, 522
 caput breve, 523
 longum, 522
bipennatus, 358
biventer cervicis, 413
brachialis, 469
brachioradialis, 479
buccinator, 375
bulbocavernosus, 443, 445, 675
caninus, 373
capitis posterior major, 414
 minor, 414
chondroglossus, 392
ciliaris, 1095
 fibrae circulares, 1096
 meridionales, 1095
coccygeus, 453
compressor bulbi, 444
 hemisphaerium bulbi, 444
constrictor isthi faucium, 391
 (note)
- Musculus constrictor pharyngis**
 inferior, 394
 medius, 395
 superior, 395
 radicis penis, 444
coracobrachialis, 468
cremaster, 430, 1374
cricothyrenoideus lateralis, 1172
 posterior, 1172
cricothyrenoideus, 1172
deltoideus, 462
depressor scpti, 372
digastricus, 388
dilatator pupillae, 1099
epicranius, 363
erector clitoridis, 1418
extensor carpi radialis brevis,
 479
 longus, 479
 digiti quinti proprius, 481
 digitorum brevis, 537
 communis, 480
 longus, 527
 hallucis longus, 527
 inducis proprius, 484
 pollicis brevis, 483
 longus, 484
flexor carpi radialis, 473
 ulnaris, 474
 caput humerale, 474
 ulnare, 474
 digiti quinti brevis, 541
 digitorum brevis, 538
 longus, 533
 profundus, 476
 sublimis, 475
 caput humerale, 475
 radiale, 475
 ulnare, 475
 pollicis brevis, 490
 longus, 476
frontalis, 363
gastrocnemius, 528
 caput laterale, 528
 mediale, 528
gemellus inferior, 520
 superior, 520
genioglossus, 391
geniohyoideus, 390
glossopalatinus, 398
gluteus maximus, 515
 medius, 516
 minimus, 517
gracilis, 512
hallucis longus, 532
helicis major, 1121
 minor, 1121
hyoglossus, 391
iliacus, 504
iliococcygeus, 452
iliocostalis cervicis, 412
 dorsi, 410
 lumborum, 410
iliosacralis, 452
incisivus inferior, 375
 superior, 375
infraspinatus, 465
interossei, 541
 dorsales, 541
 plantares, 542
ischio bulbosus, 444
ischio cavernosus, 444, 446, 675
latissimus dorsi, 406
levator scapulae, 407
veli palatini, 397
longissimus capitis, 412
 cervicis, 412
 dorsi, 412
longitudinalis inferior, 393
 superior, 393
longus capitis, 400
 colli, 401
lumbicales, 540
masseter, 377
mentalis, 374
- Musculus multifidus**, 413
mylohyoideus, 389
nasalis, 372
nasolabialis, 375
obliquus auricularis, 1121
 capitis inferior, 415
 superior, 415
 externus abdominis, 424
 internus abdominis, 428
 oculi inferior, 370
 superior, 370
obturator externus, 521
 internus, 518
occipitalis, 363
omohyoideus, 388
opponens digiti quinti, 493
 pollicis, 490
orbicularis oculi, 366
 oris, 374
orbitale, 371
ossiculorum auditus, 1134
palmaris brevis, 492
 longus, 474
pectineus, 513
pectoralis major, 456
 minor, 460
peroneus brevis, 535
 longus, 534
 tertius, 527
pharyngopalatinus, 398
piriformis, 517
plantaris, 530
platysma, 381
pophiteus, 531
procerus, 372
pronator quadratus, 478
 teres, 472
 caput humerale, 472
 ulnare, 472
psaos major, 504
 minor, 504
pterygoideus externus, 379
 internus, 380
pubocavernosus, 444
pubococcygeus, 452
puborectalis, 452
pubovesicalis, 1363
pyramidalis, 435
quadratus femoris, 520
 labii inferioris, 374
 lumborum, 439
 plantae, 539
quadriceps femoris, 509
rectococcygeus, 1310
rectouterinus, 1408
rectovesicalis, 1362
rectus abdominis, 433
 capitis anterior, 400
 lateralis, 400
 femoris, 510
rhomboideus major, 407
 minor, 407
risorius, 377
sacrospinalis, 410
salpingopharyngeus, 399
sartorius, 508
scolenus anterior, 401
 medius, 401
 posterior, 402
semimembranosus, 524
semispinalis capitis, 412
 cervicis, 413
 dorsi, 413
semitendinosus, 524
serratus anterior, 461
 posterior inferior, 408
 superior, 408
soleus, 529
sphincter ani externus, 453
 internus, 454
 pupillae, 1099
 pylori, 1273
 recti, 452
 urethrae membranacea, 448,
 1368

Musculus spinalis cervicis, 412
dorsi, 412
splenius capitis, 409
cervicis, 409
stapedius, 1134
sternocleidomastoideus, 385
sternohyoideus, 386
sternothyreoideus, 387
styloglossus, 392
stylohyoideus, 389
stylopharyngeus, 396
subclavius, 460
subscapularis, 464
supinator, 482
supraspinatus, 464
suspensorius duodenum, 1285
temporalis, 378
tensor fasciae latae, 508
veli palatini, 397
terci major, 466
minor, 466
thyreoarytenoideus, 1173
thyreocapiglotticus, 1173
thyreohyoideus, 387
tibialis anterior, 526
posterior, 533
transversalis capitis, 412 (note).
transversus abdominis, 432
auricular, 1121
linguae, 393
menti, 374 (note)
perinei superficialis, 442, 445
thoracis, 417
trapezius, 405
triangularis, 374
triceps brachii, 470
caput laterale, 470
longum, 470
mediale, 470
unipennatus, 358
uvulae, 398
vastus intermedius, 511
lateralis, 510
medialis, 511
verticalis linguae, 393
vocalis, 1173
zygomaticus, 373
Myelencephalon, 861
Myelin sheath, 811
Myelocle, 831
Myelocytes, 40
Mylohyoid artery, 601
muscle, 389
nerves, 989
ridge, 117
Mylohyoid groove, 117
Myocardium, 562
Myogenic theory of heart beat, 566
Myology, definition of, 34

N

Nails, 1156
lunula of, 1157
matrix of, 1157
Nares, 1081
anterior, 1081
posterior, 138, 1081
Nasal angle, 100
aperture, anterior, 138
arch of veins, 710
artery, 612
transverse, 613
bones, 99
cavity, 138
crest, 105, 110
duct, 1117
applied anatomy of, 1119
canal for orifice of, 141
foramen, 99
fossae, 1081
arteries of, 1085
inner wall of, 1083

Nasal fossae, lymphatic vessels
of, 777, 1085
mucous membrane of, 1083
nerves of, 1085
outer wall of, 1082
veins of, 1085
index of skull, 146
meatus, atrium of, 141
inferior, 141
middle, 140
superior, 139
nerve, 980, 984
process of maxillae, 104
region, muscles of, 372
sinus, septum of, 139
slit, 139
spine, 79
anterior, 135, 139
posterior, 129, 139
surface of maxillae, 102
Nasion, 134, 146
Nasmyth's membrane, 1211
Nasofrontal suture, 122
vein, 725
Nasomaxillary suture, 135
Nasopalatine artery, 602
canal, 114
groove, 114
nerve, 986
Nasopharynx, 1229
Nasus externus, 1079
Nasular bone, foot, 246
hand, 196
Neck, arteries of, 583
fascia of, 380
lymphatics of, 774
muscles of, 380
lymphatic vessels of, 780
surface form of, 402
skin of, lymphatic vessels of, 780
triangles of, 385, 602
veins of, 719, 713
Nélaton's line, 229, 329
Nerve or Nerves, 812
abducent, 993
acoustic, 1000
acromial, 1022
ampullar, 1001
of ankle-joint, 345
anococcygeal, 1062
Arnold's, 1005
of arteries, 574
articular, from external popliteal, 1059
from great sciatic, 1055
from internal popliteal, 1057
from posterior tibial, 1057
from ulnar, 1036
of articulations of elbow-joint, 308
of shoulder-joint, 303
auditory, 1000
of auditory canal, 1123
auricular, anterior, 988
from vagus, 1005
great, 1020
posterior, 997
auriculotemporal, 988
beginnings, peripheral, 815
of bile ducts, 1334
of bladder, 1365
bloodvessels of, 813
of bone, 41
buccal, 987, 998
buccinator, 987
calcaneal, 1057
cardiac, cervical, 1007
great, 1069
inferior, 1069
middle, 1069
superior, 1068
thoracic, 1007
of cardiac muscle, 357
carotico tympanic, 1066
Nerve or Nerves, carotid, 1003
cavernous, 1077
cell, bipolar, 1102
body, 807
arboriform, 808
bipolar, 808
central endoplastic portion, 809
Golgi, 808
peripheral exoplastic portion, 809
multipolar, 808
stellate, 808
unipolar, 808
of cerebral cortex, 952
ciliated ependymal, 806
germinal, 806
glia, 818
nidi, 812
nuclei, 812
of spinal cord, 832
cervical, 1021
cervicofacial, 998
chemical composition of, 819
chorda tympani, 997
of choroid, 1099
ciliary, 981, 982
circumflex, 1030
clavicular, 1022
of clitoris, 1420
coccygeal, 1019
cochlear, 1000
communicans tibialis, 1057
communicantes hypoglossi, 1023
of conjunctiva, 1115
of cornea, 1092
corpuscles, 816, 817
cranial, 972
crural, anterior, 1049
cutaneous of abdomen, 1043
external, 1047
femoral, 1055
from external popliteal, 1059
from musculospinal, 1038
gluteal, 1055
internal, 1032, 1050
lesser, 1034
lateral, 1047
middle, 1050
palmar, 1036
perforating, 1060
perineal, 1055
postfemoral, 1054
dental, 984, 989
descendens hypoglossi, 1011
digestic, from facial, 998
digital dorsal, 1060
dorsal, of clitoris, 1061
of penis, 1061
of duodenum, 1287
of dura of brain, 968
dural, 983
from hypoglossal, 1041
from vagus, 1005
eighth, 1000
eleventh, 1009
facial, 994
of Fallopien tube, 1402
femoral, 1049
fibers, 812
association, 954
centripetal, 810
of cerebral cortex, 952
commissural, 955
glia, 818
projection, 956
radiating, 1104
of spinal cord, 832, 834
supporting, of Müller, 1104
sympathetic, 812
vasomotor, 813
fifth, 978
first, 973
fourth, 977

- Nerve or Nerves, frontal, 980
 of gall-bladder, 1334
 ganglion of, of Andersch, 1002
 aorticorenal, 1073
 of Bochdalek, 984
 cardiac, of Wrisberg, 1072
 carotid, 1066
 cervical, 1069
 ciliary, 982
 coccygeal, 1072
 Gasserian, 978
 geniculate, 996
 impar, 1072
 inferior, 1002, 1005
 jugular, 1002, 1005
 lenticular, 982
 Meckel's, 984
 ophthalmic, 982
 otic, 989
 petrous, 1002
 of Scarpa, 1000
 semilunar, 978, 1073
 sphenopalatine, 982, 984,
 986
 spiral, 1000
 submaxillary, 990
 superior, 1002
 of Valentin, 984
 vestibular, 1000
 gastric, 1007
 genitocrural, 1047
 genitotemoral, 1047
 gingival, 984
 glossopharyngeal, 1001
 gluteal, 1054
 granules, 1103
 of heart, 565
 hemiorrhoidal, inferior, 1061
 of hip-joint, 327
 hypogastric, 1046
 hypoglossal, 1010
 iliac, 1046
 iliohypogastric, 1045
 ilioinguinal, 1046
 infraclavicular, 1029
 infraorbital, 982 (note), 998
 infratrochlear, 981
 intercostal, 1040
 intercostobrachial, 1042
 intercostohumeral, 1042
 interosseous, anterior, 1036
 volar, 1036
 of involuntary striated muscle,
 357
 of iris, 1099
 Jacobson's, 1002
 of kidneys, 1354
 of knee-joint, 337
 of labia majora, 1415
 labial, 984
 lacrimal, 980
 of large intestine, 1312
 laryngeal, 1068
 inferior, 1007
 recurrent, 1007
 superior, 1006
 of larynx, 1174
 lingual, 988
 from glossopharyngeal, 1003
 of liver, 1331
 lumbar, 1020
 lumbinguinal, 1047
 of lungs, 1196
 malar, 998
 of superior maxillary, 983
 from facial, 998
 of mammary gland, 1432
 mandibular, 987
 from facial, 998
 masseteric, 987
 maxillary, inferior, 987
 superior, 982
 median, 1034
 of membranous tympani, 1131
 meningeal, 983
- Nerve or Nerves, meningeal,
 from hypoglossal, 1011
 from inferior maxillary, 987
 from vagus, 1005
 muscular, of brachial plexus,
 1028
 from glossopharyngeal, 1003
 from great sciatic, 1055
 from hypoglossal, 1012
 from internal plantar, 1059
 popliteal, 1057
 from median, 1035
 from musculospinal, 1037
 from posterior tibial, 1057
 from ulnar, 1036
 musculocutaneous, 1031, 1060
 musculospinal, 1037
 mylohyoid, 989
 nasal, 980, 984
 fossae, 1085
 nasopalatine, 986
 ninth, 1001
 of nose, 1081
 obturator, 1047
 accessory, 1049
 occipital, great, 1017
 small, 1020
 third, 1017
 oculomotor, 976
 of oesophagus, 1239
 olfactory, 973
 ophthalmic, 979
 optic, 974
 orbital, 983
 origin of, 814
 of ovaries, 1401
 palatine, 986
 palpebral, 984
 of pancreas, 1341
 papilla, 1154
 parotid, 988
 of parotid glands, 1225
 patellar, 1051
 of penis, 1390
 pericranial, 980
 perineal, 1061
 peroneal, 1057, 1059
 petrosal, 985
 deep, 1066
 superficial, 989, 996
 pharyngeal, 986, 1003, 1006,
 1068
 phrenic, 1024
 of pia of brain, 970
 plantar, 1057, 1058
 of pleura, 1185
 plexus of abdominal aortic,
 1076
 Auerbach's, 1279
 brachial, 1026
 cardiac, 1072
 carotid, 1066
 cavernous, 1066
 cervical, 1018, 1020
 coccygeal, 1062
 coliac, 1008, 1073
 colic, 1076
 coronary, 1073, 1076
 cystic, 1076
 gastric, 1076
 gastroduodenal, 1076
 gastroepiploic, 1076
 hemiorrhoidal, 1077
 hepatic, 1076
 hypogastric, 1077
 ileocolic, 1076
 infraorbital, 984, 998
 intestinal, 1076
 lumbar, 1044
 lumbosacral, 1044
 Meissner's, 1280
 mesenteric, 1076
 oesophageal, 1007, 1073,
 1075
 ovarian, 1076
- Nerve or Nerves, plexus, pan-
 creatic, 1076
 pancreatoduodenal, 1076
 patellar, 1051
 pelvic, 1077
 pharyngeal, 1003, 1006
 phrenic, 1074
 prostatic, 1077
 pudendal, 1060
 pulmonary, 1073
 posterior, 1005
 pyloric, 1076
 renal, 1008, 1075
 sacral, 1053
 sigmoid, 1076
 solar, 1073
 spermatic, 1076
 splenic, 1008, 1076
 suprarenal, 1074
 thyroid, 1069
 tympanic, 1002
 uterine, 1077
 vaginal, 1077
 vertebral, 1069
 vesical, 1077
 pneumogastric, 1003
 popliteal, 1055, 1059
 of prostate gland, 1395
 pterygoid, 987, 988
 pterygopalatine, 986
 pudendal, 1055
 pudic, 1061
 pulmonary, 1007
 radial, 1038
 recurrent, 987
 respiratory, of Bell, 1024, 1029
 sacral, 1019
 of salivary glands, 1226
 saphenous, 1056, 1057
 scapular, posterior, 1029
 sciatic, 1054, 1055
 serotal, long, 1055
 second, 974
 of seminal vesicles, 1385
 seventh, 994
 sheath of, 812
 sixth, 993
 of skin, 1156
 of small intestine, 1295
 spermatic, 1047
 sphenoidal, 990
 sphenopalatine, 983
 spinal, 1012
 accessory, 1009
 spindles, 817
 splanchnic, 1071
 of spleen, 1446, 1449
 sternal, 1022
 of stomach, 1279
 structure of, 812
 stylohyoid, 998
 subcutaneous malae, 983
 of submaxillary gland, 1226
 subscapular, 1030
 supraclavicular, 1022
 supraorbital, 980
 suprascapular, 1029
 supratrochlear, 980
 system, 803
 central, 819
 development of, 804
 structure of, 807
 supporting tissue elements
 of, 818
 sympathetic, 1063
 tarsal, 1059
 of taste, 1149
 temporal, from facial, 998
 from internal maxillary, 987
 from superior maxillary, 983
 temporofacial, 998
 temporomalar, 983
 of temporomandibular articu-
 lation, 281
 tenth, 1003

Nerve or Nerves, termination of, 817
 third, 976
 thoracic, 1018
 anterior, 1030
 long, 1029
 posterior, 1029
 thoracicolumbar, 1043
 thoracoabdominal intercostal, 1043
 of thymus gland, 1440
 thyrohyoid, 1011
 thyroid, 1069
 of thyroid gland, 1438
 tibial, 1055
 anterior, 1059
 posterior, 1057
 tissue, development of, 806
 of tongue, 1221
 of tonsil, 1231
 tonsillar, 1003
 tract, cerebellospinal, 838
 Löwenthal's, 840
 ventral cerebrospinal, 840
 Monakow's, 839
 pyramidal, 839
 trifacial, 978
 trigeminal, 978
 trochlear, 977
 twelfth, 1010
 tympanic, from facial, 997
 from glossopharyngeal, 1002
 of tympanum, 1135
 ulnar, 1036
 of ureters, 1358
 of uterus, 1411
 utricular, 1000
 utriculoampullar, 1000
 of vagina, 1415
 of vaginal bulb, 1420
 vagus, 1003
 vestibular, 1000
 Vidian, 985, 1066
 of voluntary muscles, 357
 of Wrisberg, 1034
 of wrist-joint, 315
Nervi anococcygei, 1062
auriculares anteriores, 988
 rami parotidei, 988
 temporales superficiales, 988
carotici externi, 1068
cavernosi penis minores, 1077
cerebrales, 972
ciliares breves, 982
 longi, 981
clunium inferiores [laterales], 1055
digitales dorsales hallucis lateralis, 1060
 pedis, 1060
 plantares communes, 1057
 proprii, 1058
 volares communes, 1035
 proprii, 1035
digiti secundi medialis, 1060
intercostales, 1041
 rami anteriores, 1042
 cutanei laterales, 1042
 musculares, 1042
 postiores, 1042
labiales anteriores, 1047
 posteriores, 1061
nervorum, 813
palatini, 986
palatinus anterior, 986
 medius, 986
 posterior, 986
scrotales anteriores, 1047
 posteriores, 1061
sphenopalatini, 983
spinales, 1012
 radix anterior, 1013
 posterior, 1013
 rami anteriores, 1015

Nervi spinales rami posteriores, 1014
 ramus communicans, 1015
 meningus, 1014
 subscapulares, 1030
 suprascapulares, 1022
 anteriores, 1022
 medii, 1022
 posteriores, 1022
 temporalis profundus, 987
 thoracales anteriores, 1030
Nervus abducens, 993
accessorius, 1009
 ramus externus, 1009
 internus, 1009
acusticus, 1000, 1147
 radix cochlearis, 1000
 vestibularis, 1000
alveolaris inferior, 989
auricularis magnus, 1020
 posterior, 997
 ramus occipitalis, 998
auriculotemporalis, 988
rami anastomotica cum n. faciali, 988
axillaris, 1030
buccinatorius, 987
canalis pterygoidei, 985
cardiacus inferior, 1069
 medius, 1069
 superior, 1068
caroticotympanicus inferior, 1003
 superior, 1003
caroticus internus, 1066
cavernosus penis major, 1077
cochlearis, 1147
cutaneus antibrachii dorsalis, 1038
 lateralis, 1031
 medialis, 1032
brachii lateralis, 1030
 medialis, 1034
 posterior, 1038
colli, 1021
 rami inferiores, 1021
 ramus superior, 1021
 dorsalis intermedius, 1060
 medialis, 1060
femoris lateralis, 1047
 posterior, 1054
 rami perineales, 1055
surae lateralis, 1059
ramus anastomoticus peronaeus, 1059
 medialis, 1057
ramus anastomoticus peronaeus, 1057
dorsalis chlorididis, 1061
 penis, 1061
 scapulae, 1029
facialis, 994
 genu internum, 994
 rami buccales, 998
 temporales, 998
 zygomatice, 998
 ramus colli, 999
 digastricus, 998
 marginalis mandibulae, 998
 stylohyoideus, 998
femoralis, 1049
frontalis, 980
geniofemoralis, 1047
glossopharyngeus, 1001
ganglion inferius, 1002
 superius, 1002
gluteus inferior, 1054
 superior, 1054
hemorrhoidalis inferior, 1061
hyoglossus, 1010
 rami linguales, 1012
 ramus descendens, 1011
 thyrohyoideus, 1011
iliohypogastricus, 1045

Nervus iliohypogastricus rami musculares, 1045
 ramus cutaneus anterior, 1046
 lateralis, 1046
ilioinguinalis, 1046
 rami musculares, 1046
infratrochlearis, 981
intercostalis I, 1040
 ramus cutaneus anterior, 1041
intercostobrachialis, 1042
intermedius, 877, 882, 955, 995
interosseus [antebrachii] dorsalis, 1039
 volaris, 1035
ischiodiadicus, 1055
 rami articulares, 1055
 musculares, 1055
jugularis, 1068
lacrimalis, 980
laryngeus superior, 1006
 ramus externus, 1006
 internus, 1006
lingualis, 988
lumboinguinalis, 1047
mandibularis, 987
massetericus, 987
maxillaris, 982
 rami alveolares superiores posteriores, 984
 rami gingivales superiores, 984
 labiales superiores, 984
 nasales interni, 984
 palpebrales inferiores, 984
 ramus alveolaris superior anteriores, 984
 medius, 984
meatus auditorii externi, 988
 ramus membranacei tympani, 988
medianus, 1034
 rami musculares, 1035
 ramus cutaneus palmaris n. mediani, 1035
meningus medius, 983
mentalis, 989
musculocutaneus, 1031
mylohyoideus, 989
 rami dentales inferiores, 989
 gingivales inferiores, 989
nasociliaris, 980
 rami nasales laterales, 981
 mediales, 981
nasopalatinus, 986
obturatorius, 1047
 accessorius, 1049
 ramus anterior, 1049
 cutaneus, 1049
 posterior, 1049
occipitalis major, 1017
 minor, 1020
 tertius, 1017
oculomotorius, 976
 radix brevis ganglii ciliaris, 977
 ramus inferior, 976
 superior, 976
olfactorius, 973
ophthalmicus, 979
opticus, 974
perineus, 1061
peronaeus communis, 1059
 rami articulares, 1059
 profundus, 1059
 rami musculares, 1059
 superficialis, 1060
petrosus profundus, 985, 1135
 superficialis, 1135
 major, 985
phrenicus, 1024
plantaris lateralis, 1058
 ramus profundus, 1059
 superficialis, 1058

Nervus plantaris medialis, 1057
pterygoideus externus, 988
internus, 987
pubendus, 1061
radialis, 1037
rami musculares, 1037
ramus superficialis, 1038
nn. digitales dorsales, 1039
recurrens, 1007
rami cardiaci inferiores, 1007
superiores, 1007
saphenus, 1050
ramus infrapatellaris, 1051
spermaticus externus, 1047
spinus, 987
splanchnicus imus, 1071
major, 1071
minor, 1071
stapedius, 997
subclavius, 1029
subscapularis, 1029
supraorbitalis, 980
supratrochlearis, 980
temporalis profundus anterior, 987
posterior, 987
thoracalis longus, 1029
thoracodorsalis, 1030
tibialis, 1055
rami articulares, 1057
musculares, 1057
calcanei laterales, 1057
mediales, 1057
ramus articularis ad articulationem talocruralem, 1057
trigemini, 978
trochlearis, 977
typanicus, 1002, 1125, 1135
rami linguales, 1003
pharyngei, 1003
tonsillares, 1003
ramus stylopharyngeus, 1003
ulnaris, 1036
rami musculares, 1036
ramus cutaneus palmaris, 1036
dorsalis manus, 1036
nn. digitales dorsales, 1036
profundus, 1037
superficialis, 1037
vagus, 1003
rami coeliac, 1008
gastrici, 1007
hepatici, 1008
lianales, 1008
oesophagei, 1007
renales, 1008
ramus auricularis, 1005
meningeus, 1005
pharyngeus, 1006
vestibularis, 1147
zygomaticus, 983
ramus zygomaticofacialis, 983
zygomaticotemporalis, 983
Neumann's sheaths, 1211
Neural crest, 805
segments, 851
Neuraxone, 807
Neurilemma, 811
nucleus of, 812
Neuroblasts, 806
Neurocentral suture, 63
Neuroepithelium, 1143
Neurofibrils, 809
Neurogenic theory of heart beat, 566
Neuroglia, 806, 818
Neurology, definition of, 34
Neuromeres, 851
Neuromuscular spindles, 817
Neurons, 803, 807
centripetal, peripheral nerve beginnings of, 816

Neurons, diaxonic, 810
 excitoglandular, 804
 excitomotor, 804
 monaxonic, 810
 motor, 804
 polyaxonic, 810
 sensor, 804
 theory of, 818
 varied forms of, 807
Neurotendinous spindles, 817
Nidus, 832
Nidus avis, 888
habenulae, 906
laryngei, 879
pharyngei, 879, 881
Ninth nerve, 1001
thoracic vertebra, 54
Nipple, 1428
Nissl bodies, 809
Nodes, hemolymph, 768
lymph, 768
Parrot's, 151
of Ranvier, 811
of Tawara, 564
Noduli lymphatici aggregati [Pey-eri], 1292
solitarii, 1292
Nodulus, 888
valvulae semilunaris [Arantii], 559, 561
vermis, 888
Norma basalis, 128
frontalis, 134
lateralis, 132
verticalis, 123
Nose, 1079
applied anatomy of, 1085
arteries of, 1081
cartilage of, 1079
framework of, bony, 1079
cartilaginous, 1079
integument of, 1081
lymphatics of, 1081
meatus of, 110
mucous membrane of, 1081
muscles of, 1081
nerves of, 1081
septum of, 138
artery of, 602
cartilage of, 1080
veins of, 1081
Nostrils, 1081
Notch, cotyloid, 213
ethmoidal, 79
intercondyloid, 225
intervertebral, 49
lacrimal, 102
popliteal, 233
preoccipital, 914
presternal, 157, 166, 171
pterygoid, 94
of Rivinus, 1130
sacrosciotic, 210, 211
sigmoid, 118
sphenopalatine, 112
supraorbital, 77, 135
suprascapular, 175
suprasternal, 403
Nuck, canal of, 1408
Nuclei, 832
of abducent nerve, 883
of acoustic nerve, 881
of auditory nerve, 881
of brain, 857
of cerebellum, 888
of cochlear nerve, 881
of facial nerve, 882
of glossopharyngeal nerve, 880
of hypoglossal nerve, 878
of oculomotor nerve, 901
olivarii accessorii, 873
dorsalis, 873
medialis, 873
of olive, 873
pontis, 864, 876

Nuclei radialis ascendentes nervi trigemini, 883
of solitary tract, 880
of spinal accessory nerve, 879
cord, cervical, 833
Deiters', 839
sacral, 833
of tegmentum, 897
of trigeminal nerve, 883
of trochlear nerve, 901
of vagus nerve, 880
of vestibular nerve, 881
Nucleus ambiguus, 881
amygdaline, 948
anterior, 905
thalami, 905
arcuatus, 973
caudate, 937, 946
caudatus, 946
dentatus, 888
dorsalis [Clarkii], 830, 833
emboliformis, 889
fastigi, 889
funiculi cuneati, 863
gracilis, 863
teretis, 873
globosus, 889
globulus, 889
glossopharyngei, 880
hypoglossi, 1010
incertus, 876
intercalatus, 873
interpeduncular, 898
lateralis, 873, 905
thalami, 905
lenticular, 947
lenticis, 1107
magnocellularis, 881
medialis, 905
mesencephalic root, 884
olivarius inferior, 873
superior, 876
olivary, 873
postremus, 873
pulposus, 270
red, 898
salivatorius, 882
semilunaris [Flechsig], 905
segmenti, 898
tractus solitarii, 882
vagi, 880
Nuel, space of, 1147
Nuhn and Blandin, glands of, 1219
Nutrient artery of brachial, 643
of fibula, 702
of tibia, 702
canal of fibula, 237
of metacarpal bones, 201
of radius, 191
of ulna, 189
foramen of fibula, 237
of metacarpal bones, 201
of radius, 191
of tibia, 234
of ulna, 189
Nymphæ, 1416

O

OBELION, 123, 146
Obez [ventriguli] quarti, 867
Oblique diameter of pelvis, 216
foramen of mandible, 117
inguinal hernia, 1315
ligament, 311
line of clavicle, 169
of mandible, 117
of radius, 191
of tibia, 234
of trapezium, 199
muscles, ascending, 428
descending, 424
external, 424

- Oblique muscles, internal, 428
 sacroiliac ligament, 290
 sinus of pericardium, 549
 vein of Marshall, 550, 709
- Obliquus auricularis muscles, 1121
 inferior muscle, 415
 superior muscle, 415
- Oblongata, 861
- Obstetric perineum, 1415
- Obturator artery, 673
 bursa, 327
 canal, 517
 crest, 213
 externus muscle, 521
 fascia, 448
 foramen, 213
 groove, 211, 213, 214
 internus muscle, 518
 bursa of, 518
 ligament, 295
 membrane, 517
 nerve, accessory, 1049
 vein, 744
- Occipital artery, 595
 bone, 70
 articulation of atlas with, 275
 of axis with, 277
 bulb, 939
 crest, external, 70, 132
 internal, 72, 128
 diploic vein, 719
 fissure, 918
 fossa, inferior, 128
 groove, 82, 131
 lobe, 924
 fissures of, 924
 gray substance of, 953
 lymph nodes, 774
 nerves, 1017, 1020
 point of skull, 146
 protuberance, 70, 72, 132
 sinus, 723
 triangle, 388, 605
 vein, 713
- Occipitalis muscle, 363
- Occipito-atlantal ligaments, 275
- Occipito-axial ligament, 277
- Occipitofrontalis muscle, 363
- Occipitomesencephalic tract, 957
- Occipitoparietal suture, 121
- Occipitopontile tracts, 950
- Oculomotor nerve, 976
- Odontoblasts, 1212, 1215
- Odontoid ligaments, 277, 278
- Oesophageal arteries, 629, 654
 glands, 1239
 groove, 421
 opening of diaphragm, 421
 plexus of nerves, 1005
- Oesophagus, 1236
 applied anatomy of, 1239
 arteries of, 1239
lamina macularis mucosae, 1239
 lymphatic vessels of, 802, 1239
 nerves of, 1239
pars abdominalis, 1237
cervicalis, 1237
thoracalis, 1237
 relations of, 1237
tela submucosa, 1239
tunica mucosa, 1239
muscularis, 1238
 veins of, 735, 1239
- Olecranon, 185
 bursa, 308
 fossa, 182
- Olfactory areas of brain, 960
 bulb, 927
 gray substance of, 953
 fissure, 920
 foramina, 138
 gyre, 928
 lobe, 926
- Olfactory nerve, 973
 applied anatomy of, 974
 pathways, 958
 tract, 927
 tubercler, 928, 973
- Olive*, 863
- Olivary body, 863
 eminence, 90
fasciculus, 900
 nucleus, accessory, 873
 inferior, 873
 superior, 876
 process, 126
- Olive of medulla oblongata, 863
- Olivocerebellar fibers, 873
- Olivospinal tract of Helweg, 839
- Omental band, 1310
 tuberosity of liver, 1321
- Omentum, gastrocolic, 1254, 1260
 gastrohepatic, 1254, 1260
 gastrosplenic, 1261
 greater, 1251, 1261
 lesser, 1253, 1260
 majus, 1261
 minus, 1260
- Omohyoid muscle, 388
 surface form of, 403
- Operculum*, 917
- Ophryon, 143
- Ophthalmic artery, 610
 ganglion, 982
 nerve, 979
 veins, 725
- Opisthion, 132, 146
- Opisthotic portion of temporal bone, 88
- Opponeus minimi digiti muscle, foot, 541
 hand, 493
 pollicis muscles, 490
- Optic-acoustic reflex path, 898
- Optic axis, 1088
 chiasm, 910, 974
 cup, 1101
 disk, 1100
 foramen, 90, 126
 groove, 90, 126
 nerves, 974
 papilla, 1101
 radiation, 905
 tract and its central connections, 909
 vesicles, 852
- Ora serrata*, 1100, 1104
- Oral cavity, 1199
- Orbicular ligament, 310
 muscle, 358
- Orbicularis oris muscle, 374
 palpebrarum muscle, 366
 surface form of, 380
- Orbicularis ciliaris*, 1094
- Orbit, 136
 fascia of, 371
 margin of, 101
- Orbita*, 136
- Orbital artery, 598
 fascia, 371
 fossa, 138
 index of skull, 146
 muscle, 371
 sheaths of, 371
 nerve, 983
operculum, 917
 plates, 79
 portion of frontal bone, 79
 process of malar bone, 108
 of palate bone, 112
 region, muscles of, 368
 applied anatomy of, 371
 septum, 368, 1112
 sinus, 112
 veins, 712
 wings of sphenoid bone, 93
- Orbitofrontal fissures, 919
- Orbitopalpebral sulcus, 1112
- Orbitosphenoids, 95
- Organ of Corti, 1144
 of digestion, 1199
 of Giralde's, 1384
 of Golgi, 817
 reproductive, female, 1397
 male, 1371
 of respiration, 1163
 of Rosenmüller, 1401
 of taste, 1148
 of touch, 1150
 urinary, 1343
 urogenital, 1343
 of voice, 1163
- Organa genitalia muliebria*, 1397
 virilia, 1371
- oculi accessoria*, 1112
parasympathetica, 1450
sensuum, 1079
- Organon auditus*, 1119
gustus, 1148
olfactus, 1079
spirale [Corti], 1144
tactus, 1150
vomeronasale, 1083
- Orifice of canal for nasal duct, 141
 of maxillary atrium, 141
 mitral, 560
 tricuspid, 556
- Orificium externum uteri*, 1406
labium anterius, 1406
 posterius, 1406
internum uteri, 1408
uteris, 1356
urethrae externum, 1366, 1369, 1417
 internum, 1365, 1366
- Os ac tabuli*, 213, 214
 calcis, 239
capitulum, 199
centrale, 206
coccygis, 61
cordis, 562
coxae, 207
cuboidum, 245
cuneiforme primum, 247
 secundum, 248
 tertium, 248
 external, 1406
frontale, 76
homatum, 200
hyoideum, 153
ilium, 207
incae, 74
incisivum, 105
innominatum, 207
 internal, 1405
ischii, 210
lacrimal, 106
 magnum, 199
metacarpale, I, 202
 II, 202
 III, 202
 IV, 203
 V, 203
metatarsale, I, 250
 II, 251
 III, 251
 IV, 251
 V, 252
multangulum majus, 198
 minus, 199
naviculare manus, 196
 pedis, 246
occipitale, 70
palatinum, 109
parietale, 74
piriforme, 198
planum, 98
pubis, 212
sacrum, 58
sphenoidale, 89
temporale, 80

Os trigonum, 245
triquetrum, 197
 uteri, 1406
Osborn, supracondylar process of, 906
Ossa carpi, 95
faciei, 99
metacarpalia, 201
metatarsalia, 249
nasalia, 99
sessamoides, 257
tarsi, 239
triquetra, 144
unguis, 106
Ossein, 42
Ossaceous labyrinth of ear, 1136
 tissue of bone, 38
Ossicles of tympanum, 1131
 articulations of, 1133
 movements of, 1134
Ossicula auditus, 1131
Ossification of bone, 42
 centre of, 44
 intra-articular, 42
 intramembranous, 42
Osteoblasts, 39, 40, 44
Osteogenetic fibers, 42
Osteology, definition of, 34
Ostium abdominale tubae uterinae, 1401
arteriosum, 560
pulmonis, 558
pharyngeum tubae auditivae, 1229
 primum of Born, 759
 secundum of Born, 759
uterinum tubae, 1401
venosum dextrum, 556
ventriculi dextri, 557
sinistri, 559, 560
Otic ganglion, 989
 vesicles, 141
Otoconia, 1143
Otoliths, 1141, 1143
 membrane, 1143
Outlet of pelvis, 217
Oval bundle of Flechsig, 836
Ovaria, 1397
discus proligerus, 1400
ligament folliculi, 1399
theca folliculi, 1399
tunica albuginea, 1399
zona granulosa, 1399
pellucida, 1400
radiata, 1400
Ovarian plexus of nerves, 1076
Ovaries, 1397
 applied anatomy of, 1401
 arteries of, 665, 1401
 cortex of, 1399
 descent of, 1398
 at different ages, 1399
 fimbriae of, 1401
 hilum of, 1400
 lymphatic vessels of, 797, 1401
 medulla of, 1400
 nerves of, 1401
 suspensory ligament of, 1398
 veins of, 751, 1401
Ovarium, 1398
Oviduct, 1401
Ovoid depression of femur, 221
Ovulation, 1400
Ovules of Naboth, 1410
Owen, osteodentum of, 1212
Oxyntic cells, 1276
 glands, 1276

P

PACCHIONIAN bodies of brain, 970
 depressions, 74
Pacinian corpuscles, 816
Pad, sucking, 376
Palatal aponeurosis, 397

Palatal process of maxillae, 102, 104
 region, muscles of, 397
 applied anatomy of, 399
Palate, 1202
 arteries, 1204
 bone, 109
 cleft, 151
Palatine artery, 597
 ascending, 593
 descending, 602
 applied anatomy of, 602
 canal, anterior, 138, 139
 posterior, 102, 110, 111, 134
 accessory, 110, 128
 foramen, posterior, 128
 fossa, anterior, 128
 glands, 1202
 nerves, 986
 rugae, 1202
 spine, 110
Palatoglossus muscle, 398
Palatomaxillary canal, 102
Palatopharyngeus muscle, 398
Palatum, 1202
durum, 1202
molle, 1202
Pallidum, 948
Palmar arch, deep, 645
 superficial, 652
 applied anatomy of, 652
 surface marking of, 652
 cutaneous nerve, 1036, 1037, 1039
 fascia, 488
 interosseous muscles, 494
 interosseous arteries, 648
 plexus of veins, 729
 region, muscles of, 493
 veins, 731
Palmaris brevis muscle, 492
 surface form of, 497
 longus muscle, 474
 surface form of, 496
Palpebrae, 1112
Palpebral arteries, 610, 612
 nerves, 984
 region, muscles of, 366
Pancreas, 1336
 applied anatomy of, 1341
 arteries of, 662, 1341
facies anterior, 1338
inferior, 1338
posterior, 1338
 lymphatic vessels of, 796, 1341
margo anterior, 1338
inferior, 1338
superior, 1338
 nerves of, 1341
 surface form of, 1341
 veins of, 753, 1341
Pancreatic duct, 1340
 juice, 1341
 magna, 662
 plexus of nerves, 1076
Pancreaticoduodenal arteries, 661, 663
 lymph nodes, 793
 plexus of nerves, 1076
 veins, 753
Panniculus adiposus, 360, 1154
Papilla, bile, 1287
duodeni [Santorini], 1287
incisiva, 1202
lacrimal, 1113
mammæ, 1428
 renal, 1349
Papillae filiformes, 1218
fungiformes, 1218
lacrimalis, 1116
 of tongue, 1218
vallatae, 1218
Papillary layer of skin, 1153
 muscles, 558

Paracardial lymph nodes, 790
Paracardial fissure, 920
 gyre, 921
Parachordal cartilages, 141
Paradidymis, 1384
Paraduodenal fossa, 1266
Paramesal fissures, 919
Parametrium, 1406, 1407
Paramucleus, 1341
Paraoccipital fissure, 923
Paraplexus, 940, 971
Pararectal fossa, 1256
Parasinoidal spaces, 721
Parasympathetic bodies, 1450
Parathyroid glands, 1439
 applied anatomy of, 1440
 development of, 1440
Paravesical fossa, 1361
Paraxones, 811
Parachyma of kidneys, 1349
 of lungs, 1195
 of spleen, 1445
 of testes, 1380
Parenchymatous cells, 1437
Parietal artery, ascending, 617
 bone, 74
 cells, 1276
 eminence, 74
 foramen, 74
 fissure, 923
 lobe, 922
 fissures of, 922
 gyres of, 923
 lymph nodes, 787, 798
 peritoneum, 1244
 veins, development of, 764
Parietocolic fold, 1267
Parietotemporal artery, 617
Parotid gland, 928
 sulcus, anterior, 928
Parotidophoron, 1401
Parotid duct, 1200
 fascia, 377
 glands, 1223
 arteries of, 1225
 duct of, 1225
 lymphatics of, 1225
 nerves of, 1225
 veins of, 1225
 lymph-nodes, 774, 1225
 nerves, 988
Parovarium, 1401
Parrot's nodes, 151
Pars basilaris, 71
pontis, 874
calcaneocuboidea ligamenti bifurcati, 348
calcaneonavicularis ligamenti bifurcati, 348
ciliaris retinae, 1100
diaphragmatica fasciae pelvis, 454
dorsalis pontis, 864
 fiber tracts in, 876
iridis retinae, 1098, 1099, 1100
lacrimalis musculus orbicularis oculi, 367
metencephalica [medullae oblongatae], 864
orbitalis musculus orbicularis oculi, 366
palpebralis musculus orbicularis oculi, 366
tympanica, 87
Partes genitales externae muliebres, 1415
petrosa et mastoidea, 81
Parumbilical veins, 754
Parivulvar artery, 600
Patella, 230
 applied anatomy of, 231
 ligaments of, 331
 surface form of, 231
Patellar bursa, 512

- Patellar plexus of nerves, 1051
 Pavilion of Fallopian tube, 1401
 Pectineus muscle, 513
 Pectoral fascia, 456
 lymph nodes, 782
 region, dissection of, 455
 Pectoralis major muscle, 456
 surface form of, 495
 minor muscle, 460
 surface form of, 495
 muscles, dissection of, 459
 Peculiar ribs, 163
 thoracic vertebrae, 54
 Peduncle of cerebellum, 889
 of corpus callosum, 928
 Peduncular sulcus of cerebellum, 885
 Pedunculated hydatid, 1379
 Pelvic colon, 1306
 curve of vertebral column, 66
 fascia, 448
 ligament, transverse, 446
 outlet, fasciae of, 440,
 muscles of, 440
 plexuses of nerves, 1077
 viscera, lymphatic vessels of,
 792
 Pelvis, 215
 applied anatomy of, 220
 articulations of, 290
 vertebral column with, 289
 axes of, 218
 brim of, 215
 cavity of, 216
 axis of, 218
 circumference of, 215, 217
 diameters of, 215, 217
 diaphragm of, 1240
 difference between male and
 female, 218
 false, 215
 in fetus, 219
 inlet of, 215
 axis of, 218
 plane of, 218
 lymphatics of, 787, 789, 790
 major, 215
 minor, 215
 outlet of, 217
 axis of, 218
 position of, 217
 surface form of, 219
 true, 215
 of ureter, 1349, 1356
 uretericus s. renalis, 1349
 veins of, 739
 white line of, 449
 Penis, 1386
 applied anatomy of, 1390
 arteries of, 1389
 dorsal, 676
 dorsum of, 1388
 frenulum of, 1389
 lymphatics of, 1390
 nerves of, 1390
 dorsal, 1061
 prepuce of, 1388
 suspensory ligament of, 1388
 tunica albuginea, 1386
 urethral surface of, 1388
 veins of, 1390
 dorsal, 746
 Peniform muscle, 358
 Peptic glands, 1276
 Perforated space, anterior, 928
 posterior, 898
 Perforating arteries of foot, 704
 of thigh, 690
 cutaneous nerve, 1060
 Pericardium, 548
 applied anatomy of, 550
 arteries of, 550, 632, 654
 fibrous, 548
 nerves of, 550
 serous, 549
 Pericardium, sinus of, 550
 vestigial fold of, 550
 Pericecal fossa, 1266
 Pericellular lymph spaces, 767
 Perichondrium, 44, 259
 Perichoroidal space, 1090
 Pericardial lamina, 948
 Pericranial nerves, 980
 Peridental membrane, 1212
 Perilymph, 1136
 space, 1136
 Perimedullary lamella of bone, 39
 Perimetrium, 1409
Perimysium, 355
 Perineal arteries, 675
 body, 1309
 fascia, 446
 muscle, superficial transverse,
 442, 445
 nerves, 1061
 cutaneous, 1055
 Perineum, central tendinous
 point of, 442
 in female, muscles of, 445
 lymphatic vessels of, 790
 in male, muscles of, 442
 Perineural lymph spaces, 767
 Perineurium, 812
 Periosteal lamella of bone, 39
Periosteum alveolare, 1205
 of bone, 38, 44
 cranial, 364
 Peripheral axone of an afferent
 neuron, 807
 fibrillae, 816
 lamella of bone, 39
 nerve beginnings, 815
 Perirenal arteries, 665
 fat, 1348
 Periscleral lymph spaces, 1086
 Peritoneal cavity, 1244
 Peritoneum, 1244
 applied anatomy of, 1268
 development of, 1245
 mesenteric, 1249
 parietal, 1244
 rectovesical fold of, 1361
 pouch of, 1361
 uterovesical pouch of, 1361
 visceral, 1244
 Peritracheobronchial lymph
 nodes, 1179
 Perivascular lymph spaces, 707,
 767
 Perivittelline space, 1400
 Peroneal arteries, 701, 702
 groove, 246
 nerve, 1059
 spine, 242
 Peroneus brevis muscle, 535
 surface form of, 544
 longus muscle, 534
 surface form of, 544
 tertius muscle, 527
 surface form of, 544
 Perpendicular plate of palate
 bone, 110
 portions of mandible, 117
 Pes anserinus, 996
 hippocampi, 942
 leonis, 942
 of midbrain, 900
Petrolus epiglottidis, 1167
 Petromastoid portion of tem-
 poral bone, 82
 Petro-occipital suture, 73, 122,
 127
 Petrosal artery, 600
 nerves, 985
 deep, 1066
 superficial, 989, 996
 process, 90
 sinus, 715, 726
 Petrosphenoidal fissure, 122
 suture, 131
 Petrosquamous sinus, 723
 suture, 84
 Petrotympenic fissure, 88, 1126
 Petrous ganglion, 1002
 portion of temporal bone, 83
 Peyer's patches, 1293
Phalanges digitorum manus, 204
 pedis, 252
 of foot, 252
 applied anatomy of, 256
 articulations of, 354
 surface form of, 354
 of hand, 204
 applied anatomy of, 206
 articulations of, 321
 development of, 207
 surface form of, 205
 ungual, 205
Phalanx prima digitorum pedis,
 252
 secunda digitorum pedis, 253
 tertia digitorum pedis, 253
 Pharyngeal aponeurosis, 395
 artery, ascending, 597
 nerve, 986, 1003, 1006, 1068
 plexus of nerves, 1003, 1006
 of veins, 715
 region, muscles of, 394
 ring, lymphatic, 1234
 spine, 71, 131
 tonsil, 1230
 veins, 715
 Pharyngoepiglottic fold, 1233
 Pharynx, 1229
 applied anatomy of, 1235
 development of, 1234
 isthmus of, 1230
 pars laryngea, 1233
 nasalis, 1229
 oralis, 1230
 tunica mucosa, 1233
 Philtrum, 375
 Phrenic arteries, 658
 ganglion, 1074
 nerve, 1024
 applied anatomy of, 1025
 plexus of nerves, 1074
 veins, 734, 751
 Phrenicocostal sinus, 1346
 Phrenocolic ligament, 1305
 Pia of brain, 971
 arteries of, 972
 nerves of, 972
 veins of, 972
 mater cnecephali, 971
 spinalis, 845
 of spinal cord, 845
 applied anatomy of, 846
 arteries of, 846
 Pigmentation of skin, 1155
Pili, 1159
 Pillars of external abdominal
 ring, 427
 Pineal body, 906
 Pinna of ear, 1119
 arteries of, 1121
 cartilage of, 1120
 integument of, 1120
 ligaments of, 1121
 lymphatics of, 777, 1122
 muscles of, 1121
 veins of, 1121
 Pisiform bone, 198
 Pisometacarpal ligament, 316
 Piso-uncinate ligament, 316
 Pit of stomach, 166
 Pituitary body, 909
 Pivot-joint, 264, 265
 Placental circulation, 755
 Planes of body, 84
 Plantar arch, 704
 arteries, 703
 surface marking of, 704
 metatarsal veins, 741
 nerves, 1057, 1058

- Plantar region, fascia of, 537
 muscles of, 538
 veins, 741
- Plantaris muscle, 530
- Plantum popliteum*, 224
- sternale*, 159
- Plate, cribriform, of ethmoid, 96
 horizontal, of palate bone, 109
 perpendicular, of palate bone, 110
- pterygoid, 94
 tympanic, 131
- vertical, of ethmoid, 97
 of palate bone, 110
- Platysma muscle, 381
 surface form of, 402
- Pleura costalis*, 1183
diaphragmatica, 1183
mediastinalis, 1183
parietalis, 1181
pulmonalis, 1181
- Pleurae, 1181
 applied anatomy of, 1185
 arteries of, 1185
 cavity of, 1181
 cervical, 1183
 costal, 1183
 diaphragmatic, 1183
 lymphatic vessels of, 802, 1185
 mediastinal, 1183
 nerves of, 1185
 reflections of, 1183
 veins of, 1185
- Plexus of arteries, subpleural mediastinal, 632
- choroid, of fourth ventricle, 867
 of lateral ventricles, 940
 of third ventricle, 940
- of nerves, abdominal aortic, 1076
 brachial, 1026
 cardiac, 1072
 carotid, 1066
 cavernous, 1066
 cervical, 1018, 1020
 coccygeal, 1062
 coeliac, 1008, 1073
 colic, 1076
 coronary, 1073, 1076
 cystic, 1076
 gastric, 1076
 gastroduodenal, 1076
 gastroepiploic, 1076
 hemorrhoidal, 1077
 hepatic, 1008, 1076
 hypogastric, 1077
 ileocolic, 1076
 infraorbital, 984, 998
 intestinal, 1076
 lumbar, 1044
 lumbosacral, 1044
 mesenteric, 1074
 oesophageal, 1005, 1007, 1073
 ovarian, 1076
 pancreatic, 1076
 pancreaticoduodenal, 1076
 patellar, 1051
 pelvic, 1077
 pharyngeal, 1003, 1006
 phrenic, 1074
 prostatic, 1077
 pudendal, 1060
- pulmonary, 1073
 posterior, 1005, 1007
 pyloric, 1076
 renal, 1068, 1075
 sacral, 1053
 sigmoid, 1076
 solar, 1076
 spermatic, 1076
 splenic, 1008, 1076
 suprarenal, 1074
 thyroid, 1069
 tympanic, 1002
- Plexus of nerves, uterine, 1077
 vaginal, 1077
 vesical, 1077
- of veins of foot, 739
 of hand, 729
 hemorrhoidal, 745
 palmar, 729
 pampiniformis, 750
 pharyngeal, 715
 pterygoid, 712
 spermatic, 750
 on thyroid body, 734
 uterine, 747
 vaginal, 747
 vertebral, 737
 vesical, 745
 vesicoprostatic, 745
- Plexus aorticus abdominalis*, 1072, 1076
arteriae ovaricae, 1076
basilares, 727
brachiales, 1026
fasciculus lateralis, 1028
medialis, 1028
posterior, 1028
pars infraclavicularis, 1028
supraclavicularis, 1027
rami musculares, 1028
cardiacus, 1072
caroticus externus, 1069
internus, 1066
cavernosus, 1066
concharum, 1084
cervicalis, 1020
chorioideus ventriculi lateralis, 971
quarti, 972
terti, 971
coccygeus, 1062
coeliacus, 1073
coronarius anterior, 1073
posterior, 1073
dentalis inferior, 989
superior, 984
gastricus superior, 1076
gulae, 1004, 1238
haemorrhoidalis inferior, 1077
hepaticus, 1076
hypogastricus, 1072, 1077
lienalis, 1076
lumbalis, 1044
lumbosacralis, 1044
rami anteriores, 1044
mesentericus inferior, 1076
superior, 1076
oesophageus, 1238
pampiniformis, 750
pharyngeus, 1006
phrenicus, 1074
prostaticus, 1077
pudendus, 1060
pulmonalis anterior, 1007
posterior, 1004, 1005, 1007
rami bronchiales anteriores, 1007
posteriores, 1007
renalis, 1075
sacralis, 1053
spermaticus, 1076
suprarenalis, 1074
sympathici, 1063
thyroidicus, 1069
tympanicus, 1002
 [Jacobson], 1135
utero vaginalis, 1077
venosi pampiniformis, 1377
ptyergoideus, 712
thyroideus impar, 734
vertebrales, 717
anteriores, 737
externi, 737
interni, 738, 843
posteriores, 737
venosus caroticus internus, 714, 727
- Plexus vertebralis*, 1069
vesiculis, 1077
- Plica arypegloptica*, 1166
duodenojejunalis, 1266
duodeno mesocolica, 1265
fimbriata, 1217
ileocecalis, 1267
lacrimalis [Hasner], 1177
longitudinalis duodeni, 1287
neri laryngis, 1233
pharyngoepiglottica, 1233
salpingopalatina, 1230
salpingopharyngea, 1230
semilunaris conjunctivae, 1115
sublingualis, 1201, 1226
synovialis patellaris, 336
triangularis, 1231
umbilicalis, 1361
lateralis, 1361, 1363
media, 1361, 1362
vesicalis transversa, 1256, 1359
- Plicae alares*, 336
palatinae transversae, 1202
palmae, 1408, 1410
rectouterinae, 1407
rectovesicales, 1255, 1362
semilunares coli, 1298, 1310
uretericae, 1365
ventriculares, 1170
vesicouterinae, 1362
vocales, 1170
- Pneumogastric nerve, 1003
- Polus anterior lentis*, 1107
posterior lentis, 1107
- Polyaxonic neurones, 810
- Polymazia, 1430
- Polymorphous cells, 952
- Polynuclear cells, 40
- Polythelia, 1430
- Pomum Adami, 1164
- Pons, 864
 basilar surface of, 864
 tegmental part of, 876
 tract, inter-radicular, 864
 varolii, 864
 veins of, 720
- Ponticulus of Arnold, 863
- Pontile arteries, 622
 flexure of brain, 855
- Popliteal artery, 691
 applied anatomy of, 693
 surface marking of, 693
 groove, 226
 lymph nodes, 784
 nerves, 1055, 1059
 notch, 233
 space, 691
 boundaries of, 692
 contents of, 692
 position of contained parts, 692
 vein, 742
- Popliteus muscle, 531
- Porta, 853
hepatis, 1323
- Portal vein, 751
 applied anatomy of, 754
 development of, 764
- Porus lactiferus*, 1431
opticus, 1090, 1100
sudoriferus, 1162
- Postbrachium, 895
- Postcalcarine fissure, 919
- Postcapillary veins, 706
- Postcardinal veins, 764
- Postcava, 748
- Postcentral fissures, 923
 gyre, 923
- Postcisterna, 969
- Postcornu, 939
- Postdural artery, 597
- Postfemoral cutaneous nerve, 1054
- Postforceps, 933
- Postgemma, 897

- Postgeniculum, 895
 Postglenoid process, 81
 Posthypophysis, 909
 Postinsula, 925
 fissure, 925
 Postoblongata of Wilder, 861
 Postoperculum, 917
 Postorbital limbus, 922
 Postparietal gyre, 923
 Postpedunculus, 889
 Postperforatum, 847, 898
 Postpontile recess, 862
 Postramus of cerebellum, 888
 Postrhinal fissure, 925
 Postvermis, 885
 Poupart's ligament, 426, 427
Praeputium, 1388
clitoridis, 1416, 1420
 Preacrotic lymph nodes, 789
 Preauricular lymph nodes, 775
 Prebrachium, 895
 Precapillary arteriole, 573
 Precardinal veins, 764
 Precava, 735
 Precentral fissures, 919
 gyre, 921
 Precommissure, 946
 Precornu, 936
 Precuneal fissures, 923
 Precuneus, 924
 Preforeps, 933
 Pregemina, 894, 897
 Pregeniculum, 904
 Prehypophysis, 909
 Preinsula, 925
 fissure, 925
 Preinsular gyres, 926
 Prelaryngeal lymph nodes, 779
 Premaxillary bones, 105
 centre, 106
 Preoblongata, 864
 Preoccipital notch, 914
 Preoperculum, 917
 Prepatellar bursa, 336, 512
 Prepedunculi, 891
 Preperforatum, 847, 928
 Prepuce of clitoris, 1416
 of penis, 1388
 Prepyramidal tract of cord, 839
 Preramus of cerebellum, 888
 Presternal notch, 157, 166, 171
 Presternum, 157
 Presylvian ramus, 917
 Pretracheal fascia, 384
 lymph nodes, 779
 Prevermis, 885
 Prevertebral artery, 597
 fascia, 384
 Primitive sheath of Schwann, 811
 Princeps hallucis artery, 700
 pollicis artery, 647
Prismata adamantina, 1210
 Process or Processes, acromion, 175
 alveolar, of maxillæ, 104
 angular, 77, 78, 135
 of atlas, 51
 of axis, 52
 axis cylinder, 807
 medullated, 811
 noumedullated, 812
 basilar, 71
 of calcaneus, 242
 ciliary, 1094
 clinoid, 90, 94, 126
 cochleariform, 1127
 condyloid, of mandible, 118
 coracoid, 176
 coronoid, of mandible, 118
 costal, 50
 ethmoidal, 114
 falciiform, 508
 frontal, of malar, 108
 funicular, 1379
 Process or Processes, hamular, 94, 107, 130
 intrajugular, 73
 jugular, 71, 131
 lacrimal, 114
 malar, 101, 104
 mastoid, of temporal bone, 82, 133
 maxillary, 111, 114
 mental, 116, 135
 nasal, of maxillæ, 104
 olivary, 126
 orbital, of malar, 108
 of palate bone, 112
 palatal, of maxillæ, 102, 104
 petrosal, 99
 postglenoid, 81
 pterygoid, of sphenoid bone, 94
 sphenoidal, 1080
 of palate bone, 112
 turbinated, 91, 95
 spinous, of ilium, 210
 stylohyal, 89
 styloid, 88, 131
 of fibula, 236
 of radius, 192
 of ulna, 189
 supracondylar, 181 (note)
 transverse, 71
 turbinated, middle, 98, 139
 sphenoidal, 138
 superior, 98
 tympanohyal, 88
 unciform, 200
 of ethmoid, 98
 vaginal, of sphenoid, 92, 94, 95
 zygomatic, of malar, 109
 of temporal bone, 81
Processus accessorius, 57
 alveolaris, 104
 articularis inferior, 49
 superior, 49
 caudatus, 1324
 ciliaries, 1094
 clinoidi medii, 90
 posterior, 90
 clinoides anterior, 94
 condyloides, 118
 coracoideus, 176
 coronoideus, 118, 185
 costarius, 57
 duræ matris cnecephali, 966
 ethmoidalis concha nasalis inferior, 114
 falciiformis ligamentum sacrotuberiosum, 291
 frontalis, 104
 frontosphenoidalis, 108
 inferior tegmenti tympani, 88
 intrajugularis, 71, 73
 jugularis, 71
 lacrimalis concha nasalis inferior, 114
 lateralis tuberis calcanei, 242
 mamillar, 57
 mastoides, 82
 maxillaris, 111
 concha unalis inferior, 114
 medialis tuberis calcanei, 242
 orbitalis, 112
 palatinus, 102, 104
 papillaris, 1324
 posterior tali, 245
 pterygoidei, 94
 pyramidalis, 111
 sphenoidalis, 112
 septi cartilaginei, 1080
 spinosus, 49
 styloideus, 189, 192
 os metacarpale III, 203
 temporalis, 109
 trochlearis, 242
 tubarus, 94, 1128
 uncinatus, 98, 1337
Processus vaginalis peritonaci, 1379
 processus pterygoidei, 95
 vermiformis, 1298
 xiphoideus, 157
 zygomatikus, 104
 Profunda arteries, 642, 643, 651, 689
Prominentia canalis facialis, 1126
 laryngea, 1164
 spiralis, 1144
 styloideae, 1125
Promontorium, 58, 1126
 Promontory of sacrum, 58
 of temporal bone, 85
 of tympanum, 1126
 Pronator quadratus muscle, 478
 teres, 472
 applied anatomy of, 473
 surface form of, 496
 Pronephric duct, 1420
 tubules, 1420
 Pronephros, 1420
 Pro-otic portion of temporal bone, 88
Proscenephalon, 902
Prostata, 1391
 fasciæ anterior, 1393
 posterior, 1391
 Prostate gland, 1391
 applied anatomy of, 1395
 arteries of, 1395
 development of, 1426
 lymphatics of, 796, 1395
 nerves of, 1395
 veins of, 1395
 Prostatic ducts, orifice of, 1367
 plexus of nerves, 1077
 sinus, 1367
 Prosthion, 146
 Proton of cerebellum, 855
 Protuberance, occipital, 70, 72, 131
Protuberantia mentalis, 116
 occipitalis externa, 70
 interna, 72
 Prussak, pouch of, 1134
 Psalterium, 944
 Pseudocele, 934, 945
 Psoas magnus muscle, 504
 applied anatomy of, 505
 parvus muscle 504
 Pterion, 76, 133, 146
 ossicle, 80, 144
 Pteriotic portion of temporal bone, 88
 Pterygoid artery, 601
 canal, 130
 depression, 118
 fossa, 94, 109
 muscles, 379, 380
 nerves, 987, 988
 notch, 94
 plates, 94
 plexus of veins, 712
 processes of sphenoid bone, 94
 ridge, 92, 132
 tubercle, 95
 Pterygomandibular ligament, 376
 region, muscles of, 379
 Pterygomaxillary fissure, 134
 Pterygopalatine artery, 602
 canal, 92, 130, 134
 groove, 110, 111
 nerve, 986
 Pterygospinous foramen, 383
 ligament, 382
Pubes, 1159
 Pubic arch, 217
 artery, 681
 bones, articulation of, 294
 ligaments, 294
 vein, 743
 Pubis, 212

Pubis, angle of, 212
 body of, 212
 crest of, 212
 ramus of, 213, 214
 spine of, 212
 Pubococcygeus muscles, 452
 Pubofemoral ligament, 323
 Puboprostatic ligament, 450
 Puborectalis muscles, 452
 Pubovesical space of Retzius, 1360
 Pudendal nerve, inferior, 1055
 plexus of nerves, 1060
Pudendum muliebre, 1415
 Pudic artery, accessory, 675
 external, 689
 internal, 674, 676
 nerves, 1061
 veins, internal, 744
 Pulmonary artery, 574
 applied anatomy of, 575
 left, 575
 opening of, 557
 right, 575
 circulation, 548
 heart, 553
 nerves, 1007
 plexus of nerves, 1005, 1007, 1073
 sinuses of Valsalva, 559, 561
 valve, 559
 veins, 559, 707
 applied anatomy of, 708
Pulmones, 1188
facies costalis, 1189
mediastinalis, 1189
lobus inferior, 1192
medius, 1192
superior, 1192
margo anterior, 1190
inferior, 1190
posterior, 1190
 Pulp cavity, 1212
 chamber, 1212
Pulpia dentis, 1212
lensis, 1445
Pulvinar, 904, 910
Puncta lacrimalia, 1116
Punctum lacrimale, 1113, 1116
 Pupil of eye, 1096
Pupilla, 1096
 Pupillary margin, 1097
 Purkinje fibers, 357, 565
 Purkinje cells, 892
 Putamen, 948
 Pyloric artery, 661
 applied anatomy of, 662
 canal, 1272
 glands, 1278
 ligaments, 1274
 orifice, 1271
 plexus of nerves, 1076
 sphincter, 1273
 valve, 1273
 vein, 754
 vestibule, 1272
 Pyramid of medulla oblongata, 863
 of vestibule of ear, 1137
 Pyramidal cells, 952
 lobes, 887
 tract of brain, 900
 of cord, crossed, 838
 direct, 839
 Pyramidalis muscle, 435
 nasi muscle, 372
 surface form of, 380
Pyramides [medullae oblongatae], 863
renales [Malpighii], 1350
 Pyramido-olivary groove, 863
Pyramis vestibuli, 1137
 Pyriformis muscle, 517
 bursa of, 517
 fascia of, 448

Q

QUADRATE lobes of brain, 886
 of liver, 1324
 Quadratus femoris muscle, 520
 bursa of, 521
 lumborum muscle, 439
 fascia covering, 439
 menti muscle, 374
 tubercle of, 224 (note)
 Quadriceps extensor muscle, 509
 applied anatomy of, 512
 surface form of, 543
 tendons of, 512
 Quadrigeminal bodies, 894, 897
 Quadrilateral muscles, 358
 Quiet respiration, 423

R

RADIAL artery, 644
 applied anatomy of, 646
 surface marking of, 646
 carpal arteries, 647
 fossa, 182
 nerve, 1038
 recurrent artery, 646
 region, muscles of, 479, 489
 veins, 730
 Radialis indicis artery, 647
 Radiate fissures, 920
Radiatio callosi, 933
Radii lentis, 1107
 Radiocarpal articulation, 314
 Radioulnar articulation, 310
 inferior, 312
 middle, 311
 superior, 310
 applied anatomy of, 311
 surface form of, 311
 surface form of, 314
 synovial membrane of, 313
 ligaments, 312
 region, anterior, muscles of, 472
 applied anatomy of, 478
 posterior, muscles of, 480
 applied anatomy of, 485
 Radius, 190
 applied anatomy of, 192
 oblique line of, 191
 shaft of, 191
 sigmoid cavity of, 192
 surface form of, 192
Radix arcus vertebrae, 48
dentis, 1204
linguae, 1217
mesenterii, 1263
nasi, 1079
penis, 1388
pili, 1159
pulmonis, 1193
unguis, 1156
Rami calcanei mediales, 703
perforantes anteriores [arcus plantaris], 704
posteriores [arcus plantaris], 704
[venae mammae internae], 734
sternales [venae mammae internae], 734
Ramus carpcus dorsalis [arteria radialis], 647
 of cerebellum, 888
communicans [arteria nutricia tibiae], 703
 episylvian, 917
 hyposylvian, 917
inferior ossis ischii, 212
 pubis, 213
 of ischium, 212
 of mandible, 117
plantaris profundus, 700

Ramus, presylvian, 917
 of pubis, 212, 213
 subsylvian, 917
superficialis [arteria plantaris medialis], 703
superior ossis pubis, 212
 Ranine artery, 591
 vein, 715
 Ranvier, constrictions of, 811
 nodes of, 811
Raphé, 872
palati, 1202
palpebralis lateralis, 367, 1114
pterygomandibularis, 376
scroti, 1372
 Receptaculum chyli, 771, 772
 Recess, elliptical, 1137
 epitympanic, 1125
 spheno-ethmoidal, 140
 spherical, 1137
Recessus duodenojejunalis, 1266
epitympanicus, 1125
ileocecalis inferior, 1267
superior, 1266
intersigmoideus, 1267
lienalis, 1259
membranae tympani anterior, 1134
posterior, 1134
superior, 1134
nasopalatinus, 1083
pharyngeus, 1230
pinealis, 906
pyriformis, 1163, 1233
retrocecalis, 1267
sacciformis, 308, 313
sphenoethmoidalis, 140, 1082
suprapinealis, 908
utriculi, 1140
 Rectal valves, 1310
 Recti muscles, 370
 Rectococcygeal muscles, 1310
 Rectouterinus muscle, 1408
 Rectovaginal fold, 1407
 pouch, 1256, 1362, 1407
 Rectovesical fascia, 1361
 fold of peritoneum, 1256, 1361
 muscle, 1362
 pouch of peritoneum, 1255, 1361, 1362
 Rectum, 1306
 ampulla of, 1308
 lymphatic vessels of, 794
 relations of, 1308
 Rectus abdominis muscle, 433
 surface form of, 439
capitis anticus major muscle, 400
 minor muscle, 400
lateralis muscle, 400
posticus major muscle, 414
 minor muscle, 414
femoris muscle, 510
 applied anatomy of, 512
 surface form of, 543
 sheath, 434
 Recurrent artery, radial, 646
 tibial, 698
 ulnar, 650
 Red nucleus, 898
 Reil, island of, 925
 Reissner, membrane of, 1144
 Remak's fibers, 812
 Renal arteries, 665
 columns, 1349
 corpuscles, 1350
 fascia, 1348
 impression of liver, 1321
 papilla, 1349
 plexus of nerves, 1008, 1075
 sinus, 1349
 veins, 751
 zone of Hyrtl, exsanguinated, 665, 1353
 Renes, 1343

- Reus extremities inferior*, 1348
superior, 1348
facies anterior, 1343
posterior, 1345
impressio muscularis, 1347
margo lateralis, 1347
medialis, 1348
tunica fibrosa, 1349
- Reproductive organs, female, 1397
 male, 1371
- Respiration, forced, 423
 mechanism of, 422
 organs of, 1163
 quiet, 423
- Respiratory bronchioles, 1195
 epithelium, 1195
 nerves of Bell, 1024, 1029
- Restiform body, 873
- Rostis*, 862, 864
- Retc arteriosum cutaneum*, 1156
subpapillare, 1156
venosum, 1156
canalis hypoglossi, 727
carpi dorsale [arteria radialis], 647
[arteria ulnaris], 651
volare [arteria radialis], 647
foraminis ovalis, 727
testis, 1380
venosum dorsale manus, 729
pedis cutaneum, 739
plantare cutaneum, 739
- Retia mirabilia, 573
- Reticular formation of spinal cord, 830
 layer of skin, 1154
- Retina, 1100
 applied anatomy of, 1111
 central artery of, 613
 layers of, 1101
 nerve fibers of, 1101
 supporting framework of, 1104
 yellow spot of, 1100
- Retinacula cutis*, 1150, 1430
- Retinaeulcum of capsular ligament of hip, 322
musculi peroneorum inferius, 537
superius, 537
patellae laterale, 331, 510
mediale, 331, 511
- Retrahens aurem muscle, 366
- Retroaortic lymph nodes, 789
- Retrocecal fossa, 1267
- Retroduodenal fossa, 1266
- Retroperitoneal fossae, 1265
- Retropharyngeal lymph nodes, 776
 space, 384, 1229
- Retrorrectal space, 1308
- Retzius, brown stria of, 1210
 fundiform ligament of, 536
 pubovesical space of, 1360
- Rhinencephalon, 926
- Rhodopsin, 1100
- Rhomencephalon*, 861
- Rhomboid impression, 171
 ligament, 296
- Rhomboidal fossa, 865
- Rhomboideus major muscle, 407
 surface form of, 416
 minor muscle, 407
 surface form of, 416
- Ribs, 161
 applied anatomy of, 167
 articulations of, with vertebrae, 282
 cervical, 53, 64, 167
 common characters of, 162
 false, 161
 floating, 161
 peculiar, 163
 true, 161
 tubercle of, 162
- Ribs, vertebral, 161
 vertebrochondral, 161
 vertebrosteral, 161
- Ridel's lobe of liver, 1326
- Rider's bone, 229
- Ridge, crucial, 71
 gluteal, 224
 mylohyoid, 117
 pterygoid, 92, 132
 superciliary, 77, 79, 134
 supracondylar, 180
 supraorbital, 135
 temporal, of frontal bone, 78
 of parietal bone, 74
 trapezoid, 169
- Rima glottidis*, 1171
pars intercartilaginea, 1171
intermembranacea, 1171
oris, 1199
pulprebrum, 1112
puclendi, 1415
- Ring muscle of Müller, 1096
- Ripa, 903
- Risorius muscle, 377
- Rivinus, duct of, 1226
 notch of, 1130
- Rivus lacrimalis*, 1113
- Rods of Corti, 1145
- Rolandic angle, 918
- Rolando, fissure of, 918
- Rosenmüller, fossa of, 1229
 lymph nodes of, 786
 organ of, 1401
- Rostral fissure, 920
- Rostrum corporis callosi*, 934
 of corpus callosum, 934
 of sphenoid, 92
sphenoidalis, 92
- Rotary joint, 265
- Rotation in joints, 267
- Rotatores spinæ muscle, 413
- Rubrospinal tract of cord, 839
- Rubrum, 898
- Rudimental third trochanter, 224
- Rudimentum processus vaginalis*, 1379
- Ruyae vaginales*, 1414
- Ruysch, membrane of, 1093
- S**
- Sac, lacrimal, 1116
- Saccule, 1141
 laryngeal, 1171
 of lungs, 1195
- Sacculi, 1310
- Sacculus*, 1141
- Saccus lacrimalis*, 1116
- Sacral arteries, 669, 678
 canal, 61
 cornua, 59
 foramina, 59
 groove, 60
 lymph nodes, 788
 nerves, 1019
 divisions of, 1019, 1051
 nucleus of spinal cord, 833
 plexus of nerves, 1053
 veins, 744, 748
 vertebra, 58
- Sacrocoxygeal ligaments, 293
- Sacrogenital folds, 1257
- Sacroiliac articulation, 290
 surface form of, 290
 ligaments, 290
- Sacrosciatic foramen, 292
 great, 211
 lesser, 211
 ligaments, 291, 292
 notch, 210, 211
- Sacrospinous ligaments, 1407
- Sacrovertebral angle, 58
- Sacrum, 58
- Sacrum, ala of, 61
 articulations of, 61, 290, 292
 difference between male and female, 61
 promontory of, 58
 variations in, 61
- Saddle-joint, 264, 265
- Sagittal axis, 1088
 planes of body, 34
 sinus, 74, 124, 721
 sulcus, 72, 78
 suture, 121
- Salivary glands, 1223
 applied anatomy of, 1229
 arteries of, 1227
 development of, 1227
 nerves of, 1227
 surface form of, 1227
 veins of, 1227
- Salpingopalatine fold, 1230
- Salpingopharyngeal fold, 1230
- Salpingopharyngeus muscle, 399
- Santorini, cartilage of, 1166
 earuncula of, 1287
 duct of, 1340
 fissures of, 1122
- Saphenous nerves, 1050, 1057
 opening, 508
 veins, 740, 741
- Sarcolemma, 356
- Sarcomere, 356
- Sarcoplasm, 356
- Sarcostyle, 356
- Sarcous elements of muscle, 356
- Sartorius muscle, 508
 surface form of, 543
- Scala tympani*, 1140
vestibuli, 1140
- Scalenus anticus muscle, 401
 medius muscle, 401
 posticus muscle, 402
- Scalp, lymphatic vessels of, 776
 skin of, 363
- Scapha*, 1120
- Scaphoid, articulation of astragalus with, 349
 of calcaneus and, 348
 with cuboid, 350
 with cuneiform, 349
 bone of foot, 246
 of hand, 196
 fossa, 94, 130, 1120
- Scapula, 172
 applied anatomy of, 178
 head of, 176
 ligaments of, 299
 neck of, 176
 anatomical, 178
 surgical, 178
 spine of, 174
 surface form of, 177
- Scapular artery, posterior, 630
 nerve, posterior, 1029
 region, muscles of, anterior, 463
 posterior, 464
- Scapuloclavicular articulation, 297
- Scapus pili*, 1161
- Scarf skin, 1151
- Scarpa, fascia of, 424
 foramina of, 105, 128
 ganglion of, 1000, 1147
 triangle of, 509, 685
- Schachowa, spiral tube of, 1351
- Schindylesis, 264
- Schlemm, canal of, 1092
 ligament of, 302
- Schmidt-Lantermann, incisures of, 811
- Schneiderian membrane, 1083
- Schreger, concentric lines of, 1211
- Schultze, comma tract of, 835
- Schwann, sheaths of, 811
- Sciatic artery, 677

- Sciatic nerves, 1054
veins, 744
- Sclera, 1090
applied anatomy of, 1110
- Scleral sulcus, 1088
- Scrobiculus cordis*, 166
- Scrotal nerve, 1055
- Scrotum, 1372
applied anatomy of, 1382
dartos of, 1373
integument of, 1373
septum of, 1373
- Sebaceous glands, 1113, 1161
- Second nerve, 974
- Sella turcica, 90, 126
- Semen, 1381
- Semicanalis musculus tensoris tympani*, 1127
tubae auditivae, 1127
- Semicircular canals, bony, 1137
membranous, 1142
- Semilunar bone, 197
fibrocartilages, 334, 335
fold of Douglas, 430
ganglion, 978, 1073
hiatus, 730
lobe, inferior, 887
- Seminembranous muscle, 524
surface form of, 544
- Seminal duct, 1383
vesicles, 1384
applied anatomy of, 1385
arteries of, 1385
lymphatics of, 797, 1385
nerves of, 1385
veins of, 1385
- Semispinalis colli muscle, 413
dorsi muscle, 413
- Semitendinous muscle, 524
surface form of, 543
- Sensor area of brain, 960
neurones, 804
root of spinal cord, 823
- Septa of lungs, 1195
- Septomarginal tract of cord, 837
- Septum, aortic, 759, 760
dorsal, fenestrated, 845
interauricular, 559
interventricular, 557, 561
lingual, 393
of nasal sinus, 139
nasi osseum, 139
of nose, 138
artery of, 602
orbital, 368, 1112
pectiniforme, 1386
of scrotum, 1373
secundum, 759
spurium, 758
ventricular, 759
- Septum atriorum, 559
canalis musculotubarii, 1127
corporum cavernosorum, 1418
femorale [*Cloqueti*], 504
inferius, 759
intermedium, 759
intermusculare laterale, 508
mediale, 508
linguae, 393
lucidum, 934, 945
membranaceum ventriculorum, 561
mobile nasi, 1079
musculare ventriculorum, 561
orbitale, 1112
pellucidum, 913, 945
penis, 1386
primum, 759
scroti, 1373
sinuum frontalem, 79
sphenoidalium, 91
ventriculorum, 557, 561
- Serous membranes of diaphragm, 421
pericardium, 549
- Serratus magnus muscle, 461
applied anatomy of, 461
surface form of, 495
posticus muscles, 408
surface form of, 416
- Sertoli, columns of, 1380
- Sesamoid bones, 257
cartilage, 1080
- Sessile hydatid, 1378
- Seventh nerve, 994
- Sharpey's fibers, 38
- Sheath, axillary, 636
crural, 683
femoral, 683
of Henle, 812
myelin, 811
of nerves, 812
of orbital muscle, 371
rectus, 434
of Schwann, 811
- Shin bone, 231
- Shoulder blade, 172
fascia of, 461
girdle, 169
-joint, articulations of, 301
applied anatomy of, 304
arteries of, 303
bursa of, 303
muscles of, 303
nerves of, 303
surface form of, 304
synovial membrane of, 303
muscles of, 461
- Shrapnell, membrana flaccida of, 1130
- Sibson's fascia, 1183
- Sigmoid arteries, 667
cavity of radius, 192
of ulna, 187
flexure, 1297
fossa, 82
mesocolon, 1264
notch, 118
plexus of nerves, 1076
sinus, 723
- Sinus or Sinuses, 707
of aorta, great, 576
basilar, 727
cavernous, 723
circlear, 726
confluence of, 723
coronary, 555, 708
costomediastinal, 1184
costophrenic, 1184
definition of, 77 (note)
of dura, 721
epididymis, 1378
ethmoidal, 99
facialis, 721
frontal air, 79
intercavernous, 726
of internal jugular vein, 714
jugular, 713
laryngeal, 1170
lateral, 722
lymph, 768
maxillary, 101, 103
of Morgagni, 395
occipital, 723
orbital, 112
of pericardium, 550
petrosal, 715, 726
petrosquamous, 723
phrenicocostal, 1346
prostatic, 1367
pyriformis, 1233
renal, 1349
sagittal, inferior, 721
superior, 74, 124, 721
sigmoid, 723
sphenoidal, 91, 139
sphenoparietal, 725
straight, 722
tentorial, 722
terminalis, 831
- Sinus or Sinuses, of Valsalva, 576
pulmonary, 559, 561
venous, 554, 757
venous, 707
- Sinus or Sinuses, cavernosus, 724
circularis, 726
coronarius, 555, 708
costomediastinalis, 1184
durac matris, 721
epididymidis, 1378
frontalis, 79
intercavernosus anterior, 726
posterior, 726
lactiferans, 1431
maxillaris, 103
occipitalis, 723
petrosus inferior, 726
superior, 726, 966
phrenicocostalis, 1184
pocularis, 1367
rectales, 1310
rectus, 722, 966
renalis, 1349
sagittalis inferior, 721, 966
superior, 721, 966
sphenoidales, 91
sphenoparietalis, 725
tarsi, 239
tentorii, 722
transversus, 722, 727, 966
pericardii, 550
venarum, 554
venosus sclerae, 1092
vertebrales longitudinales, 738
- Sinusoids, 573, 751, 763
- Sixth nerve, 993
- Skeletal muscles, 355
- Skin, 1149
appendages of, 1156
arteries of, 1156
of auditory canal, 1123
bloodvessels of, 1161
corium of, 1153
cuticle of, 1151
folds of, 1150
furrows, 1150
lymphatics of, 1156
nerves of, 1156, 1161
pigmentation of, 1155
ridges, 1150
of scalp, 363
scarf, 1151
true, 1153
veins of, 1156
- Skull, anterior region of, 134
applied anatomy of, 149
base of, 123
bones of, 69
brachyfacial, 146
chemoprosopoe, 146
development of, 141
differences in, due to age, 143
to sex, 144
dolichofacial, 146
fossa of, anterior, 123
condylar, 131
digastric, 131
floccular, 128
glenoid, 131
inferior occipital, 128
middle, 125
posterior, 127
scaphoid, 130
sphenomaxillary, 134
temporal, 132
zygomatic, 130, 133
index of, 146, 147
lateral regions of, 132
leptoprosopoe, 146
measurements of, 146
megacephalic, 145
mesal plane of, 146
mesocephalic, 145
microcephalic, 145
surface form of, 147

- Skull, sutures of, 124
obliteration of, 144
tables of, 36
vertex of, 123
Smegma praeputii, 1389
Socia parotidis, 1224
Soft palate, 1202
aponeurosis of, 1203
mucous membrane of, 1203
muscles of, 1203
pillars of, 1203
Solar plexus of nerves, 1073
Sole plate, 357
Soleus muscle, 529
surface form of, 544
Solitary follicles, 1292
Somatopleure, 1245
Sömmerring, ganglion of, 896
Space, epidural, 843
of Fontana, 1097
intercostal, 155
intermediate, of ilium, 210
interpleural, 1185
metacarpal, 202
of Nuel, 1147
perilymph, 1136
popliteal, 691
retropharyngeal, 384
semilunar, of Traube, 1280
subarachnoid, 845
subdural, 845
suprasternal, 383
Spacia anguli iridis [Fontana], 1092, 1097
interglobulares, 1211
interossea metacarpi, 202
zonularia, 1106
Spacium intercostale, 155
perichoroidente, 1090
suprasternal, 383
Speech tract, emissary, 957
Spermatic arteries, 665, 1376
canal, 437, 1375
cord, 437, 1375
arteries of, 1376
lymphatics of, 1377
nerves of, 1377
veins of, 1377
fascia, external, 427, 1374
internal, 437
nerve, 1047
plexus of nerves, 1076
of veins, 750
veins, 750
Spermatoocytes, 1381
Spermatogonia, 1380
Spermatozoa, 1381
Spermia, 1381
Sphenoethmoidal recess, 140
Sphenofrontal suture, 122
Sphenoid bone, 89
rostrum of, 92, 130
Sphenoidal fissure, 93, 126, 134
foramen, structures transmitted by, 126
nerves, 990
process, 1080
of palate bone, 112
sinuses, 91, 139
spine, 92
turbinate processes, 91, 95, 138
Sphenomaxillary fissure, 109, 134, 137
fossa, 109, 134
Sphenopalatine foramen, 112, 134, 138, 139
ganglion, 982, 984, 986
nerve, 983
notch, 112
Sphenoparietal sinuses, 725
suture, 122
Spherical recess, 1137
Sphincter ani muscles, 453, 454
muscle, 358
Sphincter, pyloric, 1273
recti muscle, 452
urethrae membranaceae, 448
vaginae muscle, 415
Spigelian lobe of liver, 1324
recess, 1256
Spina angularis, 92
bifida, 68
helicis, 1120
iliaca anterior inferior, 210
superior, 210
posterior inferior, 210
superior, 210
ischiadica, 211
nasalis anterior, 105
posterior, 110
scapulae, 174
vestibuli of His, 758
Spinac mentales, 117
Spinal accessory nerve, 1009
nucleus of, 879
arteries, 620, 621
bulb, 861
column, 48
cord, 820
applied anatomy of, 842
arachnoid of, 844
axones of, myelination of, 840
central canal of, 831
ligament of, 845
columns of, 826
dorsal, ground bundle of, 837
lateral, ground bundle of, 839
ventral, ground bundle of, 840
commissure of, gray, 831
white, 834
conus, 823
cornua of, 830
development of, 827
dura of, 843
enlargements of, 823
filum, 825
fissures, 825
grooves of, 825
horns of, 830
membranes of, 842
morphology of, 822, 829
nerve cells of, 832
fibers of, 832, 834
nucleus of, 834
pia of, 845
reticula of, 830
roots of, 823
substance of, gray, 829, 840
white, 833, 841
tracts of, 834
veins of, 739
weight of, 821
foramen, 49
ganglia, 1013
nerves, 1012
connections of sympathetic with, 1064
divisions of, 1014, 1019
points of emergence of, 1014
roots of, 1013
veins, external, 845
Spinalis colli muscle, 412
dorsi muscle, 412
Spindles, muscle, of Kühne, 817
neuromuscular, 817
neurotendinous, 817
Spine, 48
ethmoidal, 90, 125
of helix of ear, 1120
of Henle, 81
of ischium, 211
nasal, 79
anterior, 105, 135, 139
posterior, 129, 139
palatine, 110
Spine, peroneal, 242
pharyngeal, 71, 131
of pubi, 212
of scapula, 174
sphenoidal, 92
of tibia, 233
Spinoglenoid ligament, 301
Spinomesencephalic tract of cord, 838
Spinothalamic tract of cord, 838
Spinous processes of ilium, 210
Spiral ganglion, 1039
line of femur, 224
tube of Schachowa, 1351
Splanchnic nerves, 1071
Splanchnology, definition of, 31
Splanchnopleure, 1215
Spleen, 1442
applied anatomy of, 1447
arteries of, 1446, 1449
lymphatic vessels of, 796, 1416, 1449
mobility of, 1444
nerves of, 1446, 1449
parenchyma of, 1445
relations of, 1444
supports of, 1444
surface form of, 1446
trabeculae of, 1445
veins of, 752, 1446, 1449
Splenic centre, 119
Splenic artery, 661
cells, 1445
corpuscles, 1445
lymph nodes, 790
plexus of nerves, 1008, 1076
pulp, 1445
Splenium corporis collosi, 934
of corpus callosum, 934
Splenius capitis muscle, 409
colli muscle, 409
surface form of, 416
dorsi muscle, surface form of, 416
Spongiblasts, 806
Squamoparietal suture, 122
Squamosphenoidal suture, 122
Squamous portion of temporal bone, 80
temporalis, 80
Stahr, middle lymph node of, 778
Stapedius muscles, 1134
Stapes, 1133
crura of, 1133
crus anterior, 1133
posterior, 1133
head of, 1133
ligament of, 1133
neck of, 1133
Statoliths, 1143
Stellate ligament, 282
nerve cells, 808
Stenson, duct of, 1225
foramina of, 105, 128
Stephanion, 133, 146
Sternal arteries, 632
fissure, 161
foramen, 159, 161
furrow, 166
nerve, 1022
Sternoclavicular articulation, 295
applied anatomy of, 297
surface form of, 297
synovial membranes of, 296
ligaments, 296
Sternocostal ligament, 286
Sternohyoid muscle, 386
Sternomastoid artery, 590, 595
muscle, 385
applied anatomy of, 386
surface form of, 402
Sternothyroid muscles, 387
Sternum, 157
applied anatomy of, 167
articulations of, 161, 288

- Sternum, ensiform appendix of, 159
 gladiolus of, 159
 ligaments of, 288, 289
 manubrium of, 157
 xiphoid appendix of, 159
- Stomach, 1270
 alterations in position of, 1272
 applied anatomy of, 1280
 arteries of, 1278
 chamber, 1270
 component parts of, 1272
 curvatures of, 1271
 fundus of, 1270
 innervation of, 1280
 interior of, 1273
 lymphatic vessels of, 792, 1279
 movements of, 1279
 mucous membrane of, 1273
 nerves of, 1279
 openings of, 1271
 pit of, 166
 relations of, 1279
 rugæ, 1273
 surface form of, 1280
 surfaces of, 1271
 teeth, 1207
 veins of, 1279
- Stomata, 573, 767
- Straight sinus, 722
- Stratum cinereum*, 897
leuisci, 897
opticum, 897, 898
reticulatum, 904
zonale, 897
- Stria malleolaris*, 1130
medullaris, 903, 906
thalami, 958
terminalis, 903
vascularis, 1144
- Striae acustice, 865, 866
- Lancisi, 934
 longitudinales, 928
metallares, 865
 oblique, 866
- Striate veins, 720
- Striated muscles, 355, 357
 involuntary, nerves of, 357
 structure of, 355
- Striatohalamic fibers, 950
- Striped muscles, 355
- Stroma iridis*, 1098
 of iris, 1098
- Structure of arachnoid of brain, 970
 of bile duct, 1334
 of bladder, 1363
 of bone, 35
 of cartilages of larynx, 1167
 of cerebellum, 888
 of cerebral cortex, 951
 hemispheres, 912, 931
 of choroid, 1093
 of ciliary processes, 1095
 of clavicle, 171
 of coccygeal gland, 1450
 of coccyx, 63
 of cornea, 1091
 of Cowper's glands, 1397
 of crystalline lens, 1106
 of duodenum, 1289
 of dura of brain, 967
 of spinal cord, 844
 of ejaculatory ducts, 1386
 of epididymis, 1379
 of eyelids, 1113
 of Fallopian tube, 1402
 of female urethra, 1370
 of femur, 226
 of forebrain, 902
 of frontal bone, 80
 of gall-bladder, 1332
 of heart, 562
 of hindbrain, 861
 of humerus, 182
- Structure of vertebral substance, 270
 of iris, 1098
 of kidneys, 1349
 of lacrimal gland, 1116
 sac, 1117
 of large intestine, 1309
 of liver, 1328
 of lungs, 1194
 of lymphatics, 769
 of male urethra, 1369
 of mammary gland, 1430
 of medulla oblongata, 867
 of Meibomian glands, 1114
 of membrana tympani, 1130
 of membranous labyrinth, 1142
 of midbrain, 894, 896
 of mouth, 1201
 of mucous membrane of nasal fossæ, 1084
 of muscle fiber, 356
 of nerve system, 807
 of nerves, 812
 of nipple, 1430
 of nose, 1079
 of occipital bone, 73
 of œsophagus, 1238
 of os innominatum, 214
 of ovaries, 1399
 of pancreas, 1340
 of parathyroid glands, 1440
 of parotid gland, 1225
 of pars dorsalis pontis, 874
 of patella, 231
 of penis, 1389
 of pharynx, 1231
 of pineal body, 906
 of pinna of ear, 1120
 of pituitary body, 909
 of pleura, 1185
 of pons, 874
 of prostate gland, 1393
 of radius, 192
 of retina, 1101
 of ribs, 165
 of sacrum, 63
 of salivary glands, 1226
 of scapula, 176
 of sclera, 1090
 of seminal vesicles, 1385
 of small intestine, 1289
 of spermatid cord, 1376
 of spinal arachnoid, 845
 cord, 822, 829
 nerves, 1014
 pia, 846
 of spleen, 1444
 of sternum, 159
 of stomach, 1274
 of striated muscle, 355
 of suprarenal glands, 1448
 of tarsal glands, 1114
 of teeth, 1209
 of temporal bone, 88
 of testes, 1380
 of thalamus, 905
 of thoracic duct, 773
 of thymus gland, 1441
 of thyroid gland, 1436
 of tibia, 235
 of tongue, 1217
 of tonsils, 1231
 of trachea, 1177
 of ulna, 190
 of uriniferous tubules, 1351
 of uterus, 1409
 of vagina, 1414
 of vas deferens, 1384
 of vermiform appendix, 1300
 of vertebrae, 62
 of villi of small intestine, 1291
- Styloglossus muscle, 392
- Stylohyal process, 89
- Stylohyoid ligament, 389
- Stylohyoid muscle, 389
 nerve, 998
- Styloid process of fibula, 236
 of radius, 192
 of ulna, 189
- Stylomandibular ligament, 280, 382
- Stylomastoid artery, 596
 foramen, 87, 131
- Stylopharyngeus muscle, 396
- Subacromial bursa, 303
- Subanconeus muscle, 471
- Subarachnoid cisterna, 969
 space, 845, 969
 tissue, 845
- Subarachnoid areolar tissue, 968
- Subarcuate fossa, 86
- Subcalcarine gyre, 925
- Subcapsular lymph sinus, 768
- Subcardinal veins, 765
- Subcecal fossa, 1267
- Subcentral fissures, 923
- Subcerebellar veins, 720
- Subclavian artery, 623
 applied anatomy of, 627
 left, 625
 right, 623
 surface marking of, 626
 groove, 171
 lymph nodes, 783
 triangle, 388, 605
 vein, 732
- Subclavius muscle, 460
- Subcollateral gyre, 925
- Subcoracoid centre, 177
- Subcostal angle, 156
 groove, 163
- Subcutaneous acromial bursa, 303
 areolar tissue, 1154
 malac nerve, 983
 synovial bursa, 262
 tibial bursa, 336
 trochanteric bursa, 327
- Subdeltoid bursa, 303, 462
- Subdural space, 845
- Subendothelial fibroelastic tissue, 573
- Subfrontal fissures, 919
 gyre, 921
- Sublingual artery, 591
 fossa, 117
 gland, 1226
- Sublobular veins, 751
- Submaxillary artery, 593
 fossa, 117
 ganglion, 990
 gland, 1225
 arteries of, 1226
 duct of, 1226
 lymphatics of, 1226
 nerves of, 1226
 veins of, 1226
 lymph nodes, 778
 triangle, 604
- Submental artery, 593
 lymph nodes, 779
- Subnasal point of skull, 146
- Suboccipital triangle, 415, 620
- Suboperculum, 917
- Subparotid lymph nodes, 776
- Subpleural mediastinal plexus, 632
- Subpubic ligament, 294
- Subpyloric lymph nodes, 790
- Subrostral fissure, 920
- Subscapular angle, 172
 artery, 630, 639
 bursa, 303
 fascia, 463
 fossa, 172
 lymph nodes, 783
 nerve, 1030
- Subscapularis muscle, 464

- Substantia adamantina*, 1210
alba medulla spinalis, 819, 833
compacta, 38
corticalis, 1107
pili, 1161
eburnea, 1211
feruginea, 866
gelatinosa [Rolandi], 829
grisea centralis, 829
medulla spinalis, 819
medullaris pili, 1161
nigra, 897
ossea, 1212
perforata posterior, 847
reticularis alba, 925
spongiosa, 38
- Substernomastoid lymph nodes, 779
- Subsylvian ramus, 917
- Subtemporal fissure, 924
 gyro, 925
- Subtendinous iliac bursa, 327
 synovial bursa, 262
- Suburethral glands, 1420
- Sucking pad, 376
- Sudoriferous glands, 1161
- Sulci cutis*, 1150
longitudinales, 553
orbitales, 921
- Sulcomarginal tract of cord, 840
- Sulcus, intraparietal, of Turner, 922
 lacrimal, 107
 lunatus, 924
 of Monro, 908
 orbitopalpebral, 1112
 parolfactory, 928
 peduncular, of cerebellum, 885
 sagittal, 72, 78
 scleral, 1088
 tympanic, 87, 1122, 1130
- Sulcus antihelicis transversus*, 1121
arteria occipitalis, 82
arteriae vertebralis, 51
basilaris [pontis], 864
bulbi, 1387
calcanei, 239
carotidis, 91
centralis [Rolandi], 918
chiasmatis, 90
circularis [Reili], 917
coronarius, 553
costae, 163
frontalis inferior, 919
superior, 919
horizontalis cerebelli, 885
infraorbitalis, 102
intermedius anterior [medullae spinalis], 826
posterior [medullae spinalis], 826
interparietalis, 922
intertubercularis, 180
lacrimalis, 107
lateralis anterior [medullae oblongatae], 862
mesencephali, 894
posterior [medullae oblongatae], 862
 [medullae spinalis], 825
limitans [fossae rhomboideae], 866
longitudinalis anterior, 553
m. flexoris hallucis longi, 245
m. peronei longi, 246
malleolaris, 235, 238
matricis unguis, 1156
medianus linguae, 1217
posterior [medullae spinalis], 825
mylohyoideus, 117
nervi oculomotorii, 894, 897
radialis, 180
ulnaris, 182
- Sulcus obturatorius*, 213, 214, 920
parolfactorius anterior, 928
posterior, 928
praeccentralis, 919
superior, 919
promontorii, 1126
pterygopalatinus, 92, 95, 110
retroglandularis, 1388
sagittalis, 72, 78
sclerae, 1088
spinalis, 1144
externus, 1144
internus, 1144
subclaviae, 163
tali, 245
temporalis inferior, 924
medius, 924
superior, 924
terminalis, 554
atrii dextri, 554
transversus, 72
tubae auditivae, 1128
tympanicus, 87, 1122, 1130
- Supercentral fissures, 919
- Supercilia*, 1112, 1159
- Superciliary ridge, 77, 79, 134
- Superfrontal fissures, 919
 gyro, 921
- Supernumerary bones, 144
- Spinator [brevis] muscle, 482
 longus muscle, 479
- Supra-acromial artery, 630
- Supracardinal veins, 765
- Supraclavicular lymph nodes, 779
 nerve, 1022
 Supracommissure of Osborn, 906
- Supracondylar process, 181 (note)
 ridge, 180
- Supracondyloid foramen, 181 (note)
- Suprahyoid aponeurosis, 389
 artery, 591
 lymph nodes, 779
 region, muscles of, 388
 triangle, 605
- Supramastoid crest, 81
- Suprameatal triangle of MacEwan, 81, 151
- Supraorbital arch, 77
 artery, 610
 foramen, 135
 nerve, 980
 notch, 77, 135
 ridge, 135
 vein, 710
- Suprapatellar bursa, 336
- Suprarenal artery, 662
 glands, 1446
 accessory, 1448
 hilum of, 1447
 lymphatic vessels of, 796
 impression of liver, 1322
 plexus of nerves, 1074
 veins, 751
- Suprascapular artery, 629
 ligament, 300
 nerve, 1029
 notch, 175
- Suprascleral lymph spaces, 1086
- Supraspinales muscle, 414
- Supraspinatus fascia, 464
 muscle, 464
- Supraspinous fossa, 172
 ligament, 272
- Suprasternal artery, 629
 notch, 403
 space, 383
- Supratonsillar fossa, 1231
- Supratrochlear foramen, 182
 lymph nodes, 782
 nerve, 980
- Sural artery, 694
- Sural veins, 742
- Surface form of abductor hallucis muscle, 544
 minimi digiti muscle, 544
 of acromioclavicular articulation, 299
 of adductor longus muscle, 543
 magnus muscle, 543
 transversus pollicis muscle, 497
 of anconeus muscle, 496
 of ankle-joint, 346
 of articulations of elbow-joint, 309
 of hip-joint, 329
 of phalanges of foot, 354
 of shoulder-joint, 304
 of biceps femoris muscle, 543
 muscle, 495
 of bladder, 1365
 of bones of foot, 255
 of brachialis anticus muscle, 496
 of brachioradialis muscle, 496
 of carpal bones, 205
 of clavicle, 171
 of coracobrachialis muscle, 495
 of crureus muscle, 543
 of deltoid muscle, 495
 of digastric muscle, 403
 of erector spinae muscle, 416
 of extensor brevis digitorum muscle, 544
 longus digitorum muscle, 544
 proprius hallucis muscle, 544
 of external oblique muscle, 439
 of eyelids, 1117
 of femur, 228
 of fibula, 238
 of flexor brevis digitorum muscle, 544
 carpi radialis muscle, 496
 ulnaris muscle, 496
 sublimis digitorum muscle, 496
 of foot, 255
 of gastrocnemius muscle, 544
 of gluteus maximus muscle, 543
 medius muscle, 543
 of gracilis muscle, 543
 of heart, 567
 of humerus, 184
 of hyoid bone, 154
 of interossei muscle, 497
 of intestines, 1313
 of kidneys, 1354
 of knee-joint, 338
 of latissimus dorsi muscle, 416
 of levator anguli scapulae muscle, 416
 of lumbricales muscle, 497
 of lungs, 1196
 of masseter muscle, 389
 of metacarpal bones, 205
 of metacarpophalangeal articulations, 321
 of muscles of face, 380
 of head, 380
 of lower extremity, 543
 of neck, 402
 of upper extremity, 495
 of omohyoid muscle, 403
 of orbicularis palpebrarum muscle, 380

- Surface form of palmaris brevis muscle, 497
 longus muscle, 496
 of pancreas, 1341
 of patella, 231
 of pectoralis muscles, 495
 of pelvis, 219
 of peroneus muscles, 544
 of phalanges, 205
 of platysma muscle, 402
 of pronator teres muscle, 496
 of pyramidalis nasi muscle, 380
 of quadriceps extensor muscle, 543
 of radioulnar articulation, 314
 of radius, 192
 of rectus abdominis muscle, 439
 femoris muscle, 543
 of rhomboideus muscles, 416
 of sacroiliac articulation, 290
 of salivary glands, 1227
 of sartorius muscle, 543
 of scapula, 177
 of semimembranous muscle, 544
 of semitendinous muscle, 543
 of serratus magnus muscle, 495
 posticus muscles, 416
 of skull, 147
 of soleus muscle, 544
 of spleen, 1446
 of splenius colli muscle, 416
 dorsi muscle, 416
 of sternoclavicular articulation, 297
 of sternomastoid muscle, 402
 of stomach, 1281
 of suburens muscle, 543
 of superior radioulnar articulation, 311
 of temporal muscle, 380
 of temporomandibular articulation, 281
 of tensor fasciæ femoris muscle, 543
 of teres major muscle, 495
 of thorax, 166
 of tibia, 236
 of tibialis muscles, 544
 of trachea, 1179
 of trachelomastoid muscle, 416
 of trapezius muscle, 416
 of triceps muscle, 496
 of ulna, 190
 of vastus externus muscle, 543
 internus muscle, 543
 of vertebral column, 67
 of wrist-joint, 315
 marking of abdominal aorta, 657
 of anterior tibial artery, 697
 of axillary artery, 637
 of brachial artery, 641
 of common carotid artery, 586
 iliac arteries, 669
 of dorsalis pedis artery, 699
 of external carotid artery, 588
 iliac artery, 680
 of femoral artery, 687
 of internal iliac artery, 679
 of plantar arteries, 704
 of popliteal artery, 693
 of posterior tibial artery, 701
 of radial artery, 646
- Surface marking of subclavian artery, 626
 of superficial palmar arch, 652
 of trigeminal nerve, 990
 of ulnar artery, 649
 relations of liver, 1334
 Surf-line of aorta, 580
 Surgical anatomy. See Applied anatomy,
 neck of humerus, 178
 Suspensory ligament of axilla, 456
 of clitoris, 1418
 of Cooper, 456
 of eye, 1087
 of lens, 1106
 of liver, 1325
 of malleus, 1133
 of mamma, 456
 of ovaries, 1398
 of penis, 1388
 of Treitz, 1285
 muscle of duodenum, 1285
Sustentaculum lentis, 1264
tali, 242
Sutura, 263
coronalis, 121
dentata, 264
frontalis, 121
frontoethmoidalis, 122
frontolacrimalis, 122
frontomaxillaris, 122
harmonia, 264
intermaxillaris, 135
internasalis, 135
lamblodea, 121
limbosa, 264
nasofrontalis, 122
nasomaxillaris, 135
occipitomastoidæ, 122
parietomastoidæ, 122
sagittalis, 121
serrata, 264
sphenofrontalis, 121
sphenoparietalis, 122
sphenosquamosa, 122
squamosa, 264
vera, 264
zygomaticofrontalis, 121
 Sutural bones, 144
 ligament, 121, 259
 membrane, 263
 Sutures, 121
 basilar, 122
 coronal, 76, 121
 false, 264
 frontal, 121
 fronto-ethmoidal, 122
 frontolacrimal, 122
 frontomalar, 121
 frontomaxillary, 122
 frontoparietal, 121
 frontosphenoidal, 121
 intermaxillary, 135
 internasal, 135
 interparietal, 121
 lambdoid, 73, 76, 121
 lateral, 121
 masto-occipital, 73, 122
 mastoparietal, 122
 metopic, 121
 nasofrontal, 122
 nasomaxillary, 135
 neurocentral, 63
 obliteration of, 144
 occipitoparietal, 121
 petro-occipital, 73
 petrosphenoidal, 131
 petrosquamous, 84
 sagittal, 76, 121
 sphenofrontal, 122
 sphenoparietal, 122
 squamoparietal, 122
 squamosphenoidal, 122
- Sutures, transverse, 122, 139
 facial, 121
 true, 264
 zygomaticofrontal, 122
 Sweat glands, 1161
 Sylvian fissure and its rami, 916
 development of, 917
 veins, 720
 Sympathetic nerve system, 1063
 Synphysis of mandible, 115
ossium pubis, 294
sacrocoecygeæ, 292
Synarthrosis, 263, 266
Synchondrosis, 264
sphenooccipitalis, 122
sternalis, 157
 Syndesmosis, definition of, 34
Syndesmosis tibiofibularis, 341
 Syndesmo-odontoid joint, 274
 Synergie muscles, 359
 Synovia, 261
 Synovial bursæ, subcutaneous, 262
 subtendinous, 262
 thecal, 262
 ligaments, 262
 membrane, 259, 261
 of acromioclavicular articulation, 298
 of ankle-joint, 345
 articular, 261
 of articulations of carpus, 317
 of elbow-joint, 308
 of shoulder-joint, 303
 bursal, 262
 of calcaneo-astragaloid articulation, 347
 of calcaneocuboid articulation, 348
 of carpometacarpal articulations, 318
 of costocentral articulations, 283
 of costosternal articulations, 288
 of flexor tendons at wrist, 486
 of hip-joint, 326
 of inferior tibiofibular articulation, 342
 of knee-joint, 336
 in metatarsal joint, 353
 of radioulnar articulations, 313
 of sternoclavicular articulation, 296
 of superior tibiofibular articulation, 341
 in tarsal joint, 353
 of tarsometatarsal articulation, 352
 of temporomandibular articulation, 280
 vaginal, 262
 pads, 262
 sheath, 262
 villi, 262
 Systemic circulation, 548
 veins, 708
 Systole, auricular, 565
 ventricular, 565

T

- TABLES of skull, 36
 Tactile corpuscles, 816
Toenia coli, 1310
libera, 1310
mesocolica, 1310
orientalis, 1310
pontis, 895
semicircularis, 937, 938
thalami, 903

- Taenia coli*, 1296
Talus, 241
Tapetum of corpus callosum, 933, 938
Tarsal arch, inferior, 612
 superior, 612
 artery, 699
 articulations, synovial membrane in, 353
 transverse, 349
 bones, development of, 254
 glands, 1114
 ligaments, 366
 muscles, 369, 370
 nerve, 1059
 plates, 1113
Tarsometatarsal articulations, 351
 synovial membrane of, 352
Tarsus, 239
 articulations of, 347
Taste buds, 1149
 nerves of, 1149
 organs of, 1148
Tawara, node of, 564
Tectospinal tract, 900
Teeth, 1204
 auditory, 1144
 bicuspids, 1207
 calcification of, 1216
 canine, 1206
 cementum of, 1212
 chemical composition of, 1210
 deciduous, 1205
 dentin of, 1211
 development of, 1212
 eruption of, 1216
 enamel of, 1210
 ivory of, 1211
 milk, 1205
 molar, 1207
 permanent, 1206
 premolar, 1207
 stomach, 1207
 structure of, 1209
 temporary, 1205
Tegmen tympani, 84, 1125
Tegmental part of pons, 876
 tract, 900
Tegmentum, 896, 897
 of midbrain, 897
 fiber tracts in, 898
 nucleus of, 898
Tela choroidea, 867, 971
 superior, 940
ventriculi quarti, 865, 867, 972
tertii, 971
 subcutanea, 1154
Telencephalon, 902
 pars optica hypothalami of, 908
Telodendria, 811, 815
Temporal arteries, 597, 598, 600, 601, 617
 bone, 80
 crest, 74
 diploic veins, 718
 fascia, 378
 fossa, 92, 132
 lobe, 924
 fissures of, 924
 gyres of, 924
 muscle, 378
 surface form of, 380
 nerve from facial, 998
 from internal maxillary, 987
 from superior maxillary, 983
 ridge of frontal bone, 78
 of parietal bone, 74
 veins, 712
 wings of sphenoid, 92
 temporofacial nerve, 996
Temporomalar filaments, 109
 foramen, 109
Temporomalar nerve, 983
Temporomandibular articulation, 133, 279
 applied anatomy of, 281
 surface form of, 281
 synovial membrane of, 280
 region, muscles of, 377
Temporomaxillary vein, 712
Temporopontile tract, 900, 950, 957
Tendo, 360
Achillis, 530
 bursa of, 530
calcaneus [*Achillis*], 530
oculi, 366, 367
Tendons, 360
 of diaphragm, 419
 flexor, fibrous sheaths of, 539
 at wrist, synovial membranes of, 486
 of Lockwood, 370
 of quadriceps extensor muscle, 512
 of triceps muscle, 470
 of Zinn, 370
Ténon's capsule, 371
Tensor fasciae femoris muscle, 508
 surface form of, 543
palati muscle, 397
tarsi muscle, 367
 tympani, canal for, 1127
Tenth nerve, 1003
 thoracic vertebra, 54
Tentorial hiatus, 847
 sinus, 732
Tentorium cerebelli, 966
Teres major muscle, 466
 surface form of, 495
 minor muscle, 466
Terma, 847, 908, 909
Terminal arteries, 573, 618
 fibrillar, 816
Testes, 1371, 1377. See also Testicle.
 applied anatomy of, 1383
 descent of, 1424
 efferent ducts of, 1380
extremities inferior, 1378
 superior, 1378
facies lateralis, 1378
medialis, 1378
 lymphatic vessels of, 796
margo anterior, 1378
 posterior, 1378
 parenchyma of, 1380
 structure of, 1380
tunica albuginea, 1380
dartos, 1373
fibrosa, 1380
vaginalis communis, 1374
propria, 1374, 1379
lamina parietalis, 1379
visceralis, 1379
vasculosa, 1380
Testicle, 1371
 coverings of, 1372
 tunics of, 1379
Thalamencephalon, 902
Thalami, 902
Thalamofrontal fibers, 950
Thalamostriate fibers, 950
Thebesius, valve of, 555, 708
 veins of, 709
Theca folliculi, 1399
Thecal synovial bursa, 262
Thenar eminence, 486
Thigh, fascia of, 505
 muscles of, 505
Third nerve, 976
 occipital nerve, 1017
 ventricle, 907
Thoracic aorta, 653
 applied anatomy of, 654
 arteries, 638, 639
Thoracic cardiac nerve, 1007
 curve of vertebral column, 65
 duct, 771
 applied anatomy of, 771
 tributaries of, 772
 nerve, 1018
 anterior, 1030
 divisions of, 1018, 1010
 long, 1029
 posterior, 1029
 portion of gangliated cord, 1070
 region, fasciae of, 155
 muscles of, 455, 161
 vein, long, 732
 vertebrae, 53
 viscera, lymphatic vessels of, 802
 wall, lymphatic vessels of, 798
Thoracicogastric vein, 732
Thoracicolumbar nerves, 1043
Thoracoabdominal intercostal nerves, 1043
Thorax, 154
 applied anatomy of, 167
 fasciae of, 416
 inlet of, 155
 lymph nodes of, 798
 muscles of, 416
 surface form of, 166
 veins of, 727
Thymic artery, 582, 1442
Thymus gland, 1440
 applied anatomy of, 1442
 arteries of, 1442
 lymphatic vessels of, 802, 1442
 nerves of, 1442
 veins of, 1442
Thyroarytenoid ligaments, 1170
 muscles, 1173
Thyroglossal duct, 1219
Thyrohyals, 154
Thyrohyoid ligaments, 1167
 membrane, 1164, 1167
 muscle, 387
 nerve, 1011
Thyroid artery, inferior, 629
 superior, 589
 axis, 628
 body, 1435
 plexus of veins on, 734
 cartilage, 1163
 foramen, 213
 gland, 1435
 accessory, 1436
 applied anatomy of, 1438
 arteries of, 1437
 lymphatics of, 1438
 nerves of, 1438
 structure of, 1436
 veins of, 1438
 nerve, 1069
 plexus of, 1069
 vein, inferior, 734
 middle, 716
 superior, 715
Thyroidea ima artery, 582
 vein, 735
Tibia, 231
 crest of, 234
 internal malleolus of, 235
 nutrient artery of, 702
 foramen of, 231
 oblique line of, 234
 popliteal notch of, 233
 spine of, 233
 structure of, 235
 surface form of, 236
 tubercle of, 233
Tibial artery, anterior, 696

- Tibial artery, anterior, applied anatomy of, 697
 recurrent, 698
 surface marking of, 697
 posterior, 700
 applied anatomy of, 701
 recurrent, 698
 surface marking of, 701
 bursa, subcutaneous, 336
 lymph node, 784
 nerves, 1055, 1057, 1059
- Tibialis anticus muscle, 526
 bursa of, 526
 surface form of, 544
 posticus muscle, 533
 surface form of, 544
- Tibiofibular articulations, 340, 341
 region, muscles of, 525, 528
- Tibiotalar articulation, 342
 ligaments, 343
- Tigroid bodies, 809
- Tissue, fibroelastic, subendothelial, 573
 spaces, 767
 subarachnoid, 845
- Todd and Bowman, trachealis muscle of, 1178
- Tomes, granular layer of, 1211
 secondary dentin of, 1212
- Tongue, 1217
 applied anatomy of, 1222
 arteries of, 1219
 development of, 1221
 lymphatic vessels of, 777, 1220
 mucous membrane of, 1217
 muscles of, 393
 nerves of, 1221
 papillae of, 1218
 veins of, 1219
- Tonsilla, 887
cerebelli, 887
intestinalis, 1292
lingualis, 1219
palatina, 1230
pharyngea, 1230
- Tonsillar artery, 593
 nerve, 1003
- Tonsils, 1230
 applied anatomy of, 1233
 arteries of, 1231
 development of, 1232
 lingual, 1219
 lymphatics of, 1231
 nerves of, 1231
 pharyngeal, 1230
 tubal, 1128
 veins of, 1231
- Topographic anatomy, definition of, 33
- Topography, craniocerebral, 962
- Torcular, 72, 128
- Herophilii, 724
- Torus intervertebricus*, 1365
tubarius, 1229
uterinus, 1257
- Touch corpuscles of Meissner and Wagner, 816
 organ of, 1150
- Trabeculae carneae*, 558
carparum cavernosum, 1389
cranii, 141
linis, 1445
 of spleen, 1445
- Trabs cerebri, 933
- Trachea, 1175
 applied anatomy of, 1180
 arteries of, 629, 1179
 cartilages of, 1177
 glands of, 1178
 lymph nodes of, 1179
 mucous membrane of, 1178
 relations of, 1175
 surface form of, 1179
 veins of, 735, 1179
- Tracheal lymph nodes, 1179
- Trachealis muscle of Todd and Bowman, 1178
- Trachelomastoid muscle, 412
 surface form of, 416
- Tracheobronchial lymph nodes, 801
- Trachoma glands, 1115
- Tract, ascending, 957
 cells of spinal cord, 841
 corticopontile, 900
 descending, 956
 frontopontile, 900, 951, 957
 geniculate, 950
 nerve, cerebrospinal, S38
 Löwenthal's, 840
 ventral cerebrospinal, 840
 Marchi's, 839
 Monakow's, 839
 prepyramidal, 839
 occipitomesencephalic, 957
 occipitopontile, 950
 olfactory, 927
 pyramidal, 900
 solitary, nucleus of, 880
 speech, emissary, 957
 of spinal cord, 834
 tectospinal, 900
 tegmental, 900
 temporo-pontile, 900, 950, 957
- Tractus cervicalumbalis*, 836
iliatibialis [Maissiat], 507
olfactorius, 927
peduncularis transversus, 895
pontocerebellares, 890
rubrospinalis, 898
solitarius, 880
spinotectalis, S38
spiralis foraminosus, 85, 1139
thalamicus, 838
tectospinalis, 840
- Tragi*, 1159
- Tragicus muscles, 1121
- Tragus*, 1120
- Transinsula fissure, 925
- Transorbital fissure, 921
- Transparietal fissure, 924
- Transprecentral fissures, 920
- Trans temporal fissure, 924
 gyre, 924
 gray substance of, 953
- Transversalis capitis* muscles, 412
cervicis muscle, 412
fascia, 436
muscle, 432
- Transverse aorta, 579
 colon, 1303
 mesocolon, 1264, 1304
- Transversus auriculæ* muscles, 1121
perinei profundus, 448
suleus antihelicis, 1121
- Trapezium, 876
 bone, 198
- Trapezius muscle, 404
 surface form of, 416
- Trapezoid bone, 199
 ligament, 298
 ridge, 169
- Treitz, fosse of, 1265
 suspensory ligament of, 1285
- Triangle, carotid, 388, 603, 604
 of election, 604
 Hesselbach's, 437
 Lesser's, 591, 1012
 of necessity, 603
 of neck, 386, 602, 603, 605
 occipital, 388, 605
 Petit, 407, 426
 Scarpa's, 509, 685
 subclavian, 388, 605
 submaxillary, 604
 suboccipital, 415, 620
 suprahyoid, 605
- Triangle, suprameatal, 81
- Triangular articular disk, 312
 fascia, 425, 428
 ligament in female, 446,
 in male, 446
 muscles, 358
- Triangularis sterni muscle, 417
- Triceps extensor cubiti muscle, 470
 muscle, 470
 applied anatomy of, 471
 surface form of, 496
 tendon of, 470
- Tricuspid orifice, 557
 valve, 558
- Trifacial nerve, 978
- Trigeminal depression, 84
 nerve, 978
 applied anatomy of, 991
 nucleus of, 883
 surface marking of, 990
- Trigone of bladder, 1367
- Trigonom callaterale*, 938
femorale, 685
fibrosus, 562
habenulae, 903, 906
hypoglossi, 866
lumbale, 426
olfactorium, 928, 973
vagi, 866
ventriculi, 938
vesicae, 1365
- Trineural fasciculus, 880
- Trochanter, greater, 222
 bursa of, 327
 lesser, 223
majar, 222
minor, 223
 rudimental third, 224
tertius, 224
- Trochanteric bursa, 327
 fossa, 223
- Trochlea, 182
 of femur, 225
humeri, 182
phalangis, 205
 of superior oblique muscle, 370
tali, 245
- Trochlear fossa, 79
 nerve, 977
 nucleus, 901
- Trochoid, 264, 265
- Troeltsch, recesses of, 1134
- Trolard, anastomotic vein of, 720
- True pelvis, 215
 skin, 1153
 suture, 264
- Trunci lumbales, 772, 789
- Truncus corporis callosi*, 933
costocervicalis, 633
intestinalis, 772, 789
jugalaris, 780
lumbosacralis, 1044
subclavius, 783
sympatheticus, 1066
pars cephalica, 1066
cervicatis, 1066
sympathici, 1066
thyrocervicalis, 628
- Trunk, arteries of, 653
 articulations of, 268
 fasciae of, 403
 muscles of, 403
- Tuba auditiva* [Eustachii], 1127
pars cartilaginæa, 1127
ossea, 1127
interna [Fallapii], 1401
stratum circulare, 1402
longitudinale, 1402
tunica mucosa, 1402
plicae ampullares, 1402
isthmicae, 1402
tubariae, 1402
mucularis, 1402
serosa, 1402

- Tubal tonsil, 1128
 Tube, Eustachian, 1127
Tuber calcanei, 243
cinereum, 847, 908
frontale, 76
ischiodiaphragm, 211
maxillare, 102
mentale, 1321, 1338
parietale, 74
 Tuberal lobes, 887
 Tubercle, adductor, 225
 amygdaloid, 939, 948
 of calcaneus, 242
 Chassaignae's, 68
 conoid, 169
 of Darwin, 1120
 deltoid, 169
 distobuccal, 1207
 distolingual, 1207
 of femur, 224
 genial, 117
 of ilium, 210
 infraglenoid, 175
 jugular, 73
 lacrimal, 104
 of Lower, 557
 mental, 116
 olfactory, 928, 973
 pterygoid, 95
 of quadratus, 224 (note)
 supraglenoid, 176
 of tibia, 233
 of ulna, 187
 zygomatic, 81
Tubercula mentalia, 116
Tuberculum acusticum, 866, 881
 anterior, 50, 904
 thalami, 904
 auriculæ [Darwin], 1120
 cinereum, 864
 costae, 162
 epiglotticum, 1167
 intercondyloideum laterale, 233
 mediale, 233
 interosseum [Lower], 557
 jugulare, 73
 majus, 180
 minus, 180
 obturatorium anterius, 214
 posterius, 214
 ossis multanguli majoris, 199
 navicularis, 196
 papillare, 1322
 pharyngeum, 71
 posterius, 51
 pubicum, 212
 sculenti, 163
 sellae, 90
 thyroideum inferius, 1164
 superius, 1164
 vestibularis, 866
Tuberositas coracoidea, 169
 costae II, 165
 costalis, 171
 deltoides, 181
 glutaea, 224
 iliaco, 210
 infraglenoidalis, 175
 ossis cuboidei, 246
 metatarsalis I, 251
 V, 252
 navicularis, 247
 radii, 191
 sacralis, 60
 supraglenoidalis, 176
 tibiae, 233
 ulnae, 187
 unguicularis, 205
 Tuberosity, bicipital, 191
 of femur, 226
 of humerus, 180
 of ischium, 211
 maxillary, 102
 of palate bone, 111, 128
 of ribs, 162
 Tuberosity of scaphoid bone of
 foot, 247
 of tibia, 233
 Tubules, pronephric, 1420
Tubuli recti, 1380
 renales, 1350
 seminiferi contorti, 1380
Tubulus renalis rectus, 1351
 Tunica albuginea, 1380
 conjunctiva bulbi, 1115
 palpebrarum, 1114
 fibrosa, 1380
 oculi, 1089
 intima, 573
 mucosa tympani, 1134
 plica incutis, 1134
 malleolaris anterior, 1134
 posterior, 1134
 stapedis, 1134
 serosa, 1244
 tela subserosa, 1244
 vaginalis, 1379
 vasculosa, 1380
 oculi, 1092
 Tunics of eye, 1089
 of testicle, 1379
 Turbinate bone, 113
 crests, 102, 101, 110
 process, middle, 98, 139
 sphenoidal, 91, 95, 139
 superior, 98
 Türk's bundle, 957
 Turner, intraparietal sulcus of, 922
 Twelfth nerve, 1010
 thoracic vertebrae, 55
 Tympanic arteries, 597, 600, 609
 cavity, 1125
 membrane, 87, 1128
 nerve from facial, 997
 from glossopharyngeal, 1002
 plate, 131
 plexus of nerves, 1002
 portion of temporal bone, 87
 sulcus, 87, 1122, 1130
 Tympanohyal process, 88
 Tympanum, 1124
 applied anatomy of, 1135
 arteries of, 1135
 floor of, 1125
 mucous membrane of, 1134
 muscles of, 1134
 nerves of, 1135
 ossicles of, 1131
 promontory of, 1126
 roof of, 1125
 veins of, 1135
 wall of, anterior, 1127
 inner, 1126
 outer, 1125
 posterior, 1126
- U
- ULNA, 185
 applied anatomy of, 192
 surface form of, 192
 Ulnar artery, 648
 carpal arteries, 651
 groove, 182
 nerve, 1036
 recurrent arteries, 650
 region, muscles of, 492
 veins, 729
 Umbilical arteries, 570
 circulation, 756
 ligament, 1361
 vein, 764
 Umbilicus, 435
Umbo membranae tympanae, 1130
 Ulniform bone, 200
 process, 200
 of ethmoid, 98
 Uncinate fasciculus, 955
 Uncinate gyre, 925
Unicus, 929
 Ungual phalanges, 205
Ungues, 1156
 margo lateralis, 1156
 liber, 1156
 occultus, 1156
 Unipolar nerve cells, 808
 Unstriated muscles, 355, 357
 Unstriated muscle, 355
Urachus, 1360
 Urethral folds, 1365
 orifice, 1365
 Ureters, 1356
 applied anatomy of, 1358
 arteries of, 1358
 calices of, 1356
 infundibula of, 1356
 lymphatic vessels of, 796
 muscles of, 1363
 nerves of, 1358
 pars abdominalis, 1356
 pelvina, 1356
 pelvis of, 1349, 1356
 relations of, 1356
 stratum externum, 1358
 internum, 1358
 tunica adventitia, 1358
 mucosa, 1358
 muscularis, 1358
 Urethra, arteries of, 676
 development of, 1426
 female, 1370
 lymphatic vessels of, 796
 male, 1366
 applied anatomy of, 1369
 bulbous portion, 1369
 membranous portion, 1367
 penile portion, 1368
 prostatic portion, 1366
 spongy portion, 1368
muliebris, 1370
 stratum circulare, 1370
 longitudinale, 1370
 tunica mucosa, 1370
 muscularis, 1370
 orifice of, 1369
 virilis, 1366
 pars cavernosa, 1368
 membranacea, 1367
 prostatica, 1366
 stratum circulare, 1369
 longitudinale, 1369
 tunica fibrosa, 1369
 Urethral bulb, 1386
 Urinary bladder, 1358
 meatus, 1417
 organs, 1343
 development of, 1420
 lymphatic vessels of, 796
 Uriniferous tubules, structure of, 1351
 Urinogenital organs, 1343
 Uterine arbor vitae, 1408
 plexus of nerves, 1077
 plexus of veins, 747
 Uterosacral ligaments, 1407
 Uterovesical fold, 1407
 pouch, 1256, 1362, 1404, 1407
 Uterus, 1402
 abnormalities of, 1408
 applied anatomy of, 1411
 arteries of, 672, 1410
 bicornate, 1408
 changes in, at menstrual
 period, 1408
 by pregnancy, 1409
 at different ages, 1408
 folds of, 1406
 ligaments of, 1406
 lymphatic vessels of, 797, 1411
 muscularis, 1367
 mucous membrane of, 1410
 nerves of, 1411
 tunica mucosa, 1410

- Utricus tunica muscularis*, 1409
stratum mucosum, 1409
subserosum, 1409
supravascular, 1409
vascular, 1409
scrota, 1409
 veins of, 747, 1411
Utricle, 1140
Utricular nerve, 1000
Utriculoampullar nerves, 1000
Utriculus, 1140
prostaticus, 1367
Uvea, 1098
Uvula, 1203
palatina, 1203
vernis, 887
vesicae, 1365
Uvular lobes, 887
- V**
- VAGINA**, 1413
 arteries of, 672, 1415
 applied anatomy of, 673
 lymphatic vessels of, 797, 1415
mucosa intertubercularis, 303
tendinis, 262
 mucous membrane of, 1414
musculus recti abdominis, 434
 nerves of, 1415
paries anterior, 1413
 posterior, 1413
 relations of, 1414
 rugous column of, 1414
tunica mucosa, 1414
 muscularis, 1414
 veins of, 747, 1415
 vestibule of, 1416
Vaginal bulb, 1420
 arteries of, 1420
 nerves of, 1420
 plexus of nerves, 1077
 of veins, 747
 process of sphenoid, 92, 94
 synovial membrane, 262
Vagus nerve, 1003
 applied anatomy of, 1008
 nucleus, 880
Valentin, ganglion of, 984
Vallecula, 884, 1167
 sylvii, 917
Valleculae, 1167
Vallum unguis, 1156
Valsalva, sinuses of, 576
 pulmonary, 559, 561
Valve, anal, 1310
 aortic, 561
 bicuspid, 561
 coronary, 555, 708
 Eustachian, 555
 of Gerlach, 1299
 of Guerin, 1369
 of Hasner, 1117
 of heart, action of, 565
 development of, 760
 Houston's, 1310
 ileocecal, 1301
 of Kerkring, 1289
 mitral, 561
 of Morgagni, 1310
 pulmonary, 559
 pyloric, 1273
 rectal, 1310
 of Thebesius, 555, 708
 tricuspid, 558
 venous, 758
 of Vieussens, 891
Valvula, 884, 891
 bicuspidalis, 561
 cuspid anterior, 561
 posterior, 561
 pylori, 1273
 spiralis [Heisteri], 1333
 tricuspidalis, 558
 cuspid anterior, 558
- Valvula tricuspidalis cuspid medi-*
alis, 558
 posterior, 558
venae cavae inferioris [Eus-
tachii], 556
Valvulae conniventes, 1289
 fossa navicularis, 1369
 semilunares aortae, 561
 arteria pulmonalis, 559
 sinus coronarii [Thebesii], 556
Valvuli coli, 1301
 labium inferius, 1301
 superius, 1301
Vas deferens, 1383
 ampulla of, 1383
 arteries of, 671
 lymphatic vessels of, 797
 efferens, 768
Vasa aberrantia, 641
 afferentia, 768
 brevia arteries, 662
 intestini tenuis, 663, 1293
Vascular papillae, 1154
 system, changes in, at birth, 571
 in fetus, peculiarities of, 568
Vascularization of bone, 45
Vasomotor nerve fibers, 813
Vastus externus muscle, 510
 surface form of, 543
 internus muscle, 510
 surface form of, 543
Vater, ampulla of, 1334
 corpuscles of, 816
Vegetative muscle, 355
Vein or Veins, 705
 of abdomen, 739
 accessory cephalic, 731
 adventitia of, 706
 anastomosis of, 706
 between portal and sys-
 temic, 754
 anastomotic, posterior, 720
 of Trolard, 720
 angular, 710
 of auditory canal, 1123
 auricular, 712
 axillary, 731
 azygos, 736
 basilar, 720
 basilic, 730
 of bile ducts, 1334
 of bladder, 1365
 of bodies of vertebrae, 738
 braehial, 731
 braehiocephalic, 733
 bronchial, 737
 cardiac, 708
 anterior, 556
 of cecum, 1300
 cephalic, 730, 731
 cerebellar, 720
 cerebral, 719
 cervical, 717
 choroid, 720
 companion, 731
 coronary, 709
 costoaxillary, 732
 cystic, 754
 definition of, 548
 development of, 763
 digital, 728, 739, 741
 of diploe, 718
 dorsal, of penis, 746
 of dura of brain, 967
 dural, 719
 emissary, 727
 epigastric, 742
 extravertebral, 737
 of face, exterior of, 710
 facial, 710, 712
 of Fallopian tube, 1402
 femoral, 742
 of fingers, superficial, 728
 of foot, 739, 741
 frontal, 710
- Vein or Veins*, of Galen, 720, 942
 of gall-bladder, 1334
 gastric, 753
 gastroepiploic, 753
 of globe of eye, 1109
 gluteal, 743
 of hand, 728
 of head, 710
 of heart, 565
 hemorrhoidal, 744
 hepatic, 751
 histology of, 706
 iliac, 742, 743, 747
 iliolumbar, 748
 innominate, 733
 intercostal, 735, 736
 interdigital, 739
 interosseous, 731, 739
 intervertebral, 738
 intima of, 706
 intralobular, 751
 intravertebral, 738
 jugular, 713, 714
 of kidneys, 1354
 of large intestine, 1312
 laryngeal, 735
 of larynx, 1174
 of left ventricle, 709
 lingual, 715
 of liver, 1328
 of lower extremity, 739, 741
 lumbar, 749
 ascending, 736, 749
 of mammary gland, 734, 1432
 marginal, 709
 maxillary, 712
 media of, 706
 median, 721, 730
 of medulla oblongata, 721
 membrana tympani, 1131
 meningeal, 719
 meningorachidian, 843
 mesenteric, 753
 metatarsal, 741
 nasal arch of, 710
 fossae, 1085
 nasofrontal, 725
 of neck, 710, 713
 of nose, 1081
 oblique, of Marshall, 550, 709
 obturator, 744
 occipital, 713
 oesophageal, 735, 1239
 ophthalmic, 725
 orbital, 712
 ovarian, 751, 1401
 palmar, 731
 pancreatic, 753, 1341
 pancreaticoduodenal, 753
 parietal, development of, 764
 of parotid gland, 1225
 paraumbilical, 754
 of pelvis, 739
 of penis, 1390
 pharyngeal, 715
 phrenic, 734, 751
 of pia of brain, 972
 of pinna of ear, 1121
 plantar, 741
 of pleura, 1185
 plexus of, of foot, 739
 of hand, 729
 hemorrhoidal, 745
 palmar, 729
 pharyngeal, 715
 pterygoid, 712
 spomatic, 750
 on thyroid body, 734
 uterine, 747
 vaginal, 747
 vesical, 745
 vesicoprostatic, 745
 vertebral, 737
 of pons, 720
 popliteal, 742

- Vein or Veins, portal, 751
 postcapillary, 706
 postcardinal, 764
 postcava, 748
 precardinal, 764
 precava, 735
 of prostate gland, 1395
 pubic, 743
 pudic, 744
 pulmonary, 559, 707
 pyloric, 754
 radial, 730, 731
 ranine, 715
 renal, 751
 sacral, 744, 748
 of salivary glands, 1227
 saphenous, 740, 741
 sciatic, 744
 of seminal vesicles, 1385
 of skin, 1156
 of small intestine, 1295
 spermatic, 750
 spinal, external, 845
 of spinal cord, 739
 splenic, 752, 1446, 1449
 of stomach, 1279
 striate, inferior, 720
 subcardinal, 765
 subcerebellar, 720
 subclavian, 732
 sublobular, 751
 of submaxillary gland, 1226
 supracardinal, 765
 supraorbital, 710
 suprarenal, 751
 sural, 742
 sylvian, 720
 systemic, 708
 temporal, 712
 temporomaxillary, 712
 of Thebesius, 709
 thoracic, long, 732
 thoracicoepigastric, 732
 of thorax, 727
 of thymus gland, 1442
 thyroid accessory, 717
 inferior, 734
 gland, 1438
 middle, 716
 superior, 715
 thyroidea ima, 735
 tibial, 742
 of tongue, 1220
 of tonsil, 1231
 tracheal, 735, 1179
 of tympanum, 1135
 ulnar, 729
 umbilical, 752, 764
 of upper extremity, 727, 728, 731
 uterine, 747, 1411
 vaginal, 747, 1415
 vena capitis lateralis, 766
 cava, inferior, 748
 applied anatomy of, 748
 development of, 765
 opening for, in dia-
 phragm, 421
 superior, 735
 of vermiform appendix, 1300
 vertebral, 717, 737
 of voluntary muscles, 357
Villicula cerebelli, 884
Velum, 884
 interpositum, 884, 903, 934,
 940, 971
 medullare anterius, 865
 posterius, 866, 888
 palatinum, 1203
Vena anonyma dextra, 733
 sinistra, 734
 arciformis, 1354
 auditiuae internae, 1148
 auricularis posterior, 712
 axillaris, 731
Vena azygos, 736
 basilica, 730
 basivertebralis, 738
 capitis lateralis, 766
 cava inferior, 555, 748
 sinistra, 550
 superior, 555, 735
 cephalica, 730
 accessoria, 731
 cerebri magna, 720
 cervicalis profunda, 713, 718
 choroidea, 720
 circumflexa ilium profunda, 742
 colica dextrae, 753
 media, 753
 cordis magna, 709
 media, 709
 parva, 709
 coronaria ventriculi, 753
 corporis striati, 720
 cystica, 754
 diplex frontalis, 718
 occipitalis, 719
 temporalis anterior, 718
 posterior, 718, 719
 epigastrica inferior, 742
 facialis anterior, 710
 communis, 710
 posterior, 712
 femoralis, 742
 frontalis, 710
 gastroepiploica dextra, 753
 sinistra, 753
 hemiazygos, 736
 accessoria, 737
 hemorrhoidalis media, 744
 superior, 753
 hypogastrica, 743
 iliaca communis dextra, 748
 sinistra, 748
 externa, 742
 intercostalis suprema dextra,
 735
 sinister, 735
 jugularis anterior, 713
 externa, 713
 interna, 714
 posterior, 713
 laryngea inferior, 735
 linealis, 752
 lumbalis ascendens, 736, 737,
 749
 magna Galeni, 720
 maxillaris interna, 712
 mediana basilica, 730
 cephalica, 730
 cubiti, 730
 mesenterica inferior, 753
 superior, 753
 nasofrontalis, 710, 725
 obliqua atris sinistri [Marshalli],
 550, 709
 obturatoria, 744
 occipitalis, 713
 ophthalmica inferior, 726
 superior, 725
 poplitea, 742
 portae, 751
 posterior ventriculi sinistri, 709
 profunda femoris, 742
 radialis, 730
 renalis, 1354
 sacralis media, 748
 saphena magna, 740
 parva, 741
 subclavia, 732
 supraorbitalis, 710
 thoracalis lateralis, 732
 thoracoeipigastrica, 732
 thyroidea ima, 735
 superioris, 715
 vertebralis, 717
Venae anonymae, 733
 auditiuae internae, 723, 726
 basilis [Rosenhah], 720
Venae basis vertebrae, 48
 brachiales, 731
 branchiales anteriores, 737
 posteriores, 737
 cerebelli inferiores, 720
 superiores, 720
 cerebri, 719
 inferiores, 720
 internae, 720
 media, 720
 superiores, 719
 commes, 697, 707, 731
 cordis, 708
 anteriores, 709
 minimae, 709
 costoaxillares, 732
 digitales communes pedis, 739
 dorsales propriae, 728
 pedis dorsalis, 739
 plantares, 741
 volares propriae, 729
 gastricae breves, 753
 glutacae inferiores, 744
 superiores, 743
 hemorrhoidales inferiores, 744
 hepaticae, 751
 iliolumbales, 748
 intercapitulares, 729, 739
 intercostalis, 736
 intervertebrales, 737, 738
 intestinales, 753
 linguales, 715
 lumbales, 749
 mammariae internae, 734
 rami perforantes, 734
 sternales, 734
 meningae, 719
 metacarpeae dorsales, 729
 metatarsae dorsales pedis, 741
 plantares, 741
 minimae cordis, 555, 559
 oesophagae, 735
 ovaricae, 751
 pancreaticae, 753
 pancreatoduodenales, 753
 parumbilicales, 754
 pharyngeae, 715
 phrenicae inferiores, 751
 pulmonales, 707
 rectae, 1354
 renales, 751
 revehentes, 764
 sacrales laterales, 744
 saphena parva, 1054
 sigmoideae, 753
 spermaticae, 750
 spinales, 739
 externae, 845
 suprarenales, 751
 thyroideae inferiores, 734
 tibialis anteriores, 742
 posteriores, 742
 tracheales, 735
 uterinae, 747
 vorticosae, 725, 1090, 1093
Venous arches of fingers, 728
 mesocardium, 549
 valves, 758
*Venter anterior musculus digas-
tricus*, 389
 inferior musculus omohyoideus,
 388
 posterior musculus digastricus,
 388
 *superior musculus omohyoid-
eus*, 388
Ventral aorta, 761
 cerebrospinal tract, 840
 column of cord, 827
 ground bundle of, 840
 fissure of medulla oblongata,
 861
 of spinal cord, 825
 horn of spinal cord, 834
 lamina of brain, 555

- Ventral root of spinal cord, 823
 spinal artery, 621
 Ventrals Hinderstrangsbandel
 [Strümpell], 837
 Ventricle of brain, fifth, 934, 945
 fourth, 864
 choroid plexus of, 867
 floor of, 865
 furrows of, 866
 roof of, 866
 of heart, fibers of, 563
 left, 560
 right, 557
 of larynx, 1170
 lateral, 936
 left, vein of, 709
 primitive, 757
 third, 907
 Ventricular diastole, 565
 septum, 759
 systole, 565
 Ventriculus, 1270
 dexter, 557
 laryngis [Morgagnii], 1170
 lateralis, 936
 cornu anterius, 936
 inferius, 938
 pars centralis, 936
 frontoparietalis, 937
 paries posterior, 1272
 plicae mucosae, 1275
 villosae, 1275
 quartus, 864
 sinister, 560
 tela submucosa, 1275
 tertius, 907
 tunica mucosa, 1275
 muscularis, 1274
 fibrae obliquae, 1275
 stratum circulare, 1274
 longitudinale, 1274
 serosa, 1274
 Ventrolateral fissure of medulla
 oblongata, 862
 Ventromedian fissure of medulla
 oblongata, 861
 Ventroparamedian fissure of
 spinal cord, 826
 Venules, 547, 706
 Verga's ventricle, 944
 Vermiform appendix, 1298
 applied anatomy of, 1302
 arteries of, 1300
 canal of, 1299
 lymphatics of, 1300
 mesentery of, 1265
 veins of, 1300
 Vermis, 885
 Verrucae gyri hippocampi, 925
 Verumontanum, 1367
 Vertebra, 48
 cervical, 49
 atlas of, 50
 axis of, 52
 seventh, 53
 lumbar, 56
 structure of, 62
 thoracic, 53
 Vertebrae cervicales, 49
 coccygeae, 61
 lumbales, 56
 prominens, 50, 53, 67
 thoracales, 53
 Vertebral aponeurosis, 404, 408
 artery, 619, 628
 applied anatomy of, 620
 bodies, ligaments of, 268
 canal, 49, 67
 column, 48
 applied anatomy of, 68
 articulations of, 268
 applied anatomy of, 278
 with cranium, 275
 with pelvis, 289
 with ribs, 282
 Vertebral column, movements of,
 272
 surface form of, 67
 as a whole, 66
 foramen, 49
 groove, 67
 region, muscles of, 400
 ribs, 161
 veins, 737
 Vertebralarterial foramen, 50
 Vertebrochondral ribs, 161
 Vertebro-sternal ribs, 161
 Vertex of skull, 123
 vesicae, 1361
 Vesica fellea, 1332
 tunica mucosa, 1333
 muscularis, 1332
 serosa, 1332
 urinaria, 1358
 stratum externum, 1363
 internum, 1363
 medium, 1363
 tunica fibrosa, 1363
 mucosa, 1363
 muscularis, 1363
 Vesical arteries, 671, 672
 plexus of nerves, 1077
 of veins, 745
 Vesicles, auditory, 141
 optic, 852
 otic, 141
 Vesicoprostatic plexus of veins,
 745
 Vesiculae seminales, 1384
 tunica adventitia, 1385
 mucosa, 1385
 muscularis, 1385
 Vestibular ganglion, 1000
 nerve, 1000
 nuclei, 881
 Vestibule of ear, 1136
 of vagina, 1416
 Vestibulospinal tracts of cord,
 839, 840
 Vestibulum, 1136
 macula cribrosa inferior, 1138
 media, 1137
 superior, 1137
 nasi, 1082
 oris, 1200
 recessus cochlearis, 1137
 ellipticus, 1137
 sphaericus, 1137
 vaginac, 1416
 Vestigial fold of Marshall, 550
 Vibrissae, 1159
 Vicq d' Azyr, bundle of, 905
 Vidian artery, 602, 609
 canal, 93, 130, 134
 nerve, 985, 1066
 Vieussens, valve of, 891
 Villi intestinales, 1291
 of small intestine, 1291
 Vincula accessoria tendinum, 476
 lingulae cerebelli, 886
 tendinene, 476
 Visceral lymph nodes, 790, 799
 peritoneum, 1244
 veins, 763
 Visual axis, 1088
 purple, 1100
 Vitelline circulation, 755
 membrane, 1400
 veins, 763
 Vitellus, 755
 Vitreous body, 1105
 humor, 1105
 table of skull, 36
 Vocal cords, 1170
 Voice, organs of, 1163
 Volar interosseous nerve, 1036
 ligament, 319
 Volkmann's canals, 39
 Voluntary muscles, 355
 Vomer, 114
 Vomer, ala of, 114, 138
 Vomerine cartilage, 108
 Von Ebner, glands of, 1219
 Vortices pilorum, 1159
 Vulvovaginal glands, 1420
- ## W
- Wedge bones, 247
 Weight of brain, 849
 of spinal cord, 821
 Wernick's commissure, 899
 Wharton's duct, 1226
 White blood cells, 40
 commissure of spinal cord, 834
 line of pelvis, 449
 substance of spinal cord, 833,
 841
 Wilder, postoblongata of, 801
 Willis, circle of, 617, 618
 Winslow, foramen of, 1258
 posterior ligament of, 332
 Wirsung, canal of, 1339
 Wolfian body, 1421
 Womb, 1402
 Worm of cerebellum, 885
 Wormian bones, 144
 Wisberg, cardiac ganglion of,
 1072
 cartilage of, 1166
 ligament of, 336
 nerves of, 1034
 pars intermedia of, 995
 Wrist, articulations of, 311
 applied anatomy of, 312
 bursa of, 487
 flexor tendons at, synovial
 membranes of, 486
 -joint, arteries of, 315
 nerves of, 315
 surface form of, 315
 synovial membrane of, 315
 ligaments of, 314
- ## X
- Xiphoid appendix, 159
- ## Y
- Y-LIGAMENT, 324
 Yellow elastic tissue, 261
 spot of retina, 1100
- ## Z
- ZINN, ligament of, 370
 zonule of, 1106
 Zona arcuata, 1144
 fasciculata, 1449
 glomerulosa, 1449
 granulosa, 1399
 orbicularis, 322
 pectinata, 1144
 pellucida, 1400
 radiata, 1400
 reticularis, 1449
 tecta, 1144
 Zone of brain, 855
 cornu commissurale [Marie],
 837
 exsanguinated renal, of Hyrtl,
 665
 Zonula ciliaris, 1106
 Zonule of Zinn, 1106
 Zygopophyses, 49
 Zygonia, 80
 Zygomatic fossa, 92, 101, 130,
 133
 process of malar bone, 101
 of temporal bone, 80
 tubercle, 81
 Zygomaticofrontal suture, 122
 Zygomaticus muscles, 373
 Zymogen granules, 1340

COLUMBIA UNIVERSITY

This book is due on the date indicated below, or at the expiration of a definite period after the date of borrowing, as provided by the rules of the Library or by special arrangement with the Librarian in charge.

DATE BORROWED	DATE DUE	DATE BORROWED	DATE DUE
	FEB 2 1940	APR 1 3 1944	
	MAR 1 1940		
	JUN 18 1940	JAN 31 1945	
	OCT 12 1940	FEB 2 1945	
	JAN 29 1941	MAY 25 1945	
	FEB 27 1941		
	MAY 2 1941		
	MAY 29 1941		
	JUN 27 1941	JUN 27 1948	
	FEB 1 1942		
	FEB 1 1942		
	FEB 1 1942		
	MAY 1 1942	JUN 10 1955	
	AUG 9 1943	JUN 18 1954	
		JUN 22 1954	

QM23

G79

Gray

1913

