

University of Gondar
College Of Veterinary Medicine and Animal Sciences
Unit of Biomedical Sciences
A Course Guide for the Veterinary Gross Anatomy I

I. GENERAL INFORMATION

A Course Guide for the Veterinary Gross Anatomy I	Course Title: Veterinary Gross Anatomy I	
Module Name: Veterinary Anatomy & Embryology	Course Code: Vetm1081	
Module Code: Vetm-M011	Course ECTS : 7 ECTS	
Module Number: 01	Course Weight:	
Status Of The Module: Major Area Course	Prepared By: Dr. Bemrew A. and Dr. Atnaf A.	
Module ECTS: 27 ECTS Year : 1	Instructors' Contact Details: 1. <u><i>Dr. Atnaf A.; atnaf.alebie@yahoo.com</i></u> 2. <u><i>Dr. Bemrew A.; vet27admasu@gmail.com</i></u>	Lab. Assistants: 1. Mr. Yibeltal
Semester: II	Office Hours ❖ Monday - Friday: 8:30 AM - 5:00 PM	
Target Groups: Year 1st Veterinary Medicine Students	COURSE LOGISTICS: ❖ Location: Class room _____ ❖ Laboratory class: CVMAS Gross Anatomy Lab.	

➤ **Teaching Method and Assessment**

Summary of teaching-learning methods:	Summary of assessment methods:
Brainstorming	Quizzes, Tests
gapped lecture	Assignments (individual and group)
Lecture	Practical/lab reports
Practical demonstration using model within the laboratory	Practical examination
Group and buzz group discussion	Final examination

➤ **STUDENTS WORKLOAD**

Contact Hours Per Week	Effective Lecture Hours	Practical Hours	Home Based Activities	Total
4	48Hrs	48Hrs	93Hrs	189 Hrs

I. COURSE DESCRIPTION

The course, Veterinary Gross Anatomy I, deals with the study of gross structure of the body of animals. Studying the gross structure of the body of an animal is the basis for understanding gross pathological lesions, surgical operations, diagnostic procedures etc. Chapters included in Veterinary Gross Anatomy I are: general account of anatomy (definition, classification, and methods of studying anatomy), classification and gross study of bones, joints and muscles, coelomic cavities and serous membranes, anatomy of the digestive system and the respiratory system. Important species differences will be described with special emphasis given to those anatomical features important from clinical and production points of view. Dissection of fresh and preserved cadavers, use of mounted skeletons and plastic models make the basis of practical demonstrations. Gross study of skeletons, joints, muscles, gastrointestinal and respiratory organs using ruminants as model species and comparison with other domestic animals will be done.

The practical sessions will cover the demonstrations of: bone/skeletal system and joints; muscles (cutaneous muscles, muscles of the head, muscles of the neck region, muscles of vertebral column, muscles of chest/brisket region, muscles of the thorax, muscles of the abdomen, muscles of thoracic and pelvic limb muscles) Coelomic cavity and serous membrane, structures or organs in the digestive system and accessory digestive organs, structures or organs of the respiratory system.

III. COURSE OBJECTIVES

After completing this course, students will be able to:

- Understand the basic principles of Veterinary Gross Anatomy and describe topographic terms; Define medical terms and concepts related to the structural morphology of animals;
- Understand and reflect the Gross anatomy of animal skeleton: types of bone, classification of bone and the relationships among different components of the skeletal system;
- Identify the types, location and relationships of joint structures with other structures in animal body;
- Describe the types, nomenclature, structure, location, regional classification, and relationship of different muscular structures in the animal body;
- Differentiate the different digestive structures or organs with their respective species;
- Describe gross anatomical structure, location, and relationship of structures or organs of respiratory the respiratory system;
- Explain the normal gross bodily structures, the relationship of the different organs, systems and morphology of the animal body;
- Dissect and describe the normal gross structure, location and relationship with different organs studied;
- Describe anatomical differences between different species of domestic animals;
- Demonstrate the application of the learned material in practical situations and in different disciplines of Veterinary Medicine.

IV. Grading Policy, ECTS Grading System

Raw mark interval- [100%]	Corresponding fixed number grade	Corresponding letter grade	Status description
[90-100]	4.0	A ⁺	Excellent
[85-90)	4.0	A	
[80-85)	3.75	A ⁻	
[75-80)	3.5	B ⁺	Very good
[70-75)	3.0	B	
[65-70)	2.75	B ⁻	Good
[60-65)	2.5	C ⁺	
[50-60)	2.0	C	Satisfactory
[45-50)	1.75	C ⁻	Unsatisfactory
[40-45)	1.0	D	Very poor
[30-40)	0	F _x	Fail
[<30)	0	F	Fail

EXPLANATIONS:

- **Excellent** = refers to out- standing performance and a few minor errors.
- **Very good** = refers to above the average standard, but some errors.
- **Good** = refers to good, solid overall performance, but some noticeable errors.
- **Satisfactory** = refers to the performance that satisfies minimum requirement.
- **Failed (F_x)** = refers to improvements are required before the credit can be awarded.
- **Failed (F)** = refers to considerable future work is required.

VII. COURSE POLICIES

1. Ground Rules:

The course is delivered based on the rules and regulations of the University and the following rules must be kept for classroom purpose:

- ✓ Attending all class is a must;
- ✓ Punctuality in class and assignment is mandatory;
- ✓ Active participation is required at most;
- ✓ Misbehaving at class is highly forbidden;
- ✓ Disabling a cellular phone is a must

2. Academic honesty policy: Students are responsible for their work only. Students who cheat on exams, by whatever method, or guilty of plagiarism will, or may be given an " F" for course and dismissed permanently from class.

3. Late work

Students may take any missed exam by the consent of the department members and students are expected to provide their evidence for missing exam since 5 days after the onset of the exam.

4. Disclaimer

This syllabus represent a best plan for the course ,but ,as withmost plans, itis subject to changes made necessary by time ,space and personal constraints as the course progresses.

Week	Contents	References
1	1. General introduction 1.1. Definition of Anatomy 1.2. Classification of anatomy 1.3. Methods of studying anatomy 1.4. Descriptive and/or Topographic terms	Rowen D. Frandson, W. Lee Wilke and Anna Dee Fails (2005). Anatomy and Physiology of Farm Animals; 6 th edition. A John Wiley & Sons, Inc., Publication; Wiley-Blackwell. Dyce, K., M, Sack W., O. and Wensing C., J., G. (2010). Textbook of Veterinary Anatomy; 4 th edition. by Saunders, an imprint of Elsevier Inc.
2	2. Osteology 2.1. Introduction 2.2. Structures of bones 2.3. Morphological and functional classification of bones	Rowen D. Frandson, W. Lee Wilke and Anna Dee Fails (2005). Anatomy and Physiology of Farm Animals; 6 th edition. A John Wiley & Sons, Inc., Publication; Wiley-Blackwell. Dyce, K., M, Sack W., O. and Wensing C., J., G. (2010). Textbook of Veterinary Anatomy; 4 th edition. By Saunders, an imprint of Elsevier Inc. Boyd J.S., 2001: Color Atlas of Clinical Anatomy of the Dog & Cat, 2 nd edition.
3	2.4. Regional classification of bones 2.4.1. Axial skeleton 2.4.2. Appendicular skeleton 2.4.3. Comparative osteology 2.4.4. Splanchnic skeleton	
4 & 5	3. Arthrology 3.1. Introduction 3.2. Classification of joints 3.2.1. Fibrous joints Cartilaginous joints 3.2.2. Synovial joints 3.2.2.1. Articulation of axial skeleton 3.2.2.2. Articulation of appendicular skeleton	Thomas O. McCracken, Robert A. Kainer and Thomas L. Spurgeon (1999). Spurgeon's Color Atlas of large Animal Anatomy: The Essentials; Lippincott Williams and Wilkins.
6	4. Myology 4.1. Introduction 4.2. Classification of muscle tissue 4.3. Organization of skeletal muscles	Rowen D. Frandson, W. Lee Wilke and Anna Dee Fails (2005). Anatomy and Physiology of Farm Animals; 6 th edition. A John Wiley & Sons, Inc., Publication; Wiley-Blackwell. Dyce, K., M, Sack W., O. and Wensing C., J., G. (2010). Textbook of Veterinary Anatomy; 4 th edition. by Saunders, an imprint of Elsevier Inc.
7	4.4. Regional classification of skeletal muscles 4.4.1. Coetaneous muscle	

	<p>4.4.2. Muscles of the head 4.4.3. Muscles of the neck 4.4.4. Muscles of the back and loin 4.4.5. Muscles of the chest</p>	<p>Kenneth V. Kardong (2012). Vertebrates: Comparative Anatomy, Function, Evolution; 6th edition; The McGraw-Hill Companies, Inc. Thomas O. McCracken, Robert A. Kainer and Thomas L. Spurgeon (1999). Spurgeon's Color Atlas of large Animal Anatomy: The Essentials; Lippincott Williams and Wilkins.</p>
8 & 9	<p>4.4.6. Muscles of the thorax 4.4.7. Muscles of the abdomen</p>	
	<p>4.4.8. Muscle of the thoracic limb 4.4.9. Muscles of the pelvic limb</p>	
10	<p>5. Coelomic Cavities and Serous Membranes 5.1. Introduction 5.2. Thoracic cavity 5.3. Abdominal cavity 5.4. Pelvic cavity 5.5. Serous membranes</p>	<p>Rowen D. Frandson, W. Lee Wilke and Anna Dee Fails (2005). Anatomy and Physiology of Farm Animals; 6th edition. A John Wiley & Sons, Inc., Publication; Wiley-Blackwell. Schummer, A., 1973: The Viscera of the Domestic Mammals, 5th edition. Dyce, K., M, Sack W., O. and Wensing C., J., G. (2010). Textbook of Veterinary Anatomy; 4th edition. by Saunders, an imprint of Elsevier Inc.</p>
11 & 12	<p>6. The digestive system 6.1. Introduction 6.2. Mouth, tongue and teeth 6.3. Pharynx 6.4. Esophagus 6.5. Stomach 6.5.1. Non ruminant stomach 6.5.2. Ruminant stomach</p>	<p>Rowen D. Frandson, W. Lee Wilke and Anna Dee Fails (2005). Anatomy and Physiology of Farm Animals; 6th edition. A John Wiley & Sons, Inc., Publication; Wiley-Blackwell. Dyce, K., M, Sack W., O. and Wensing C., J., G. (2010). Textbook of Veterinary Anatomy; 4th edition. by Saunders, an imprint of Elsevier Inc. Paul Mills (2003). Comparative Animal Anatomy; Teaching and Educational Development Institute, the University of Queensland; the University of Queensland.</p>
13 & 14	<p>6.6. Small intestine 6.7. Large intestine 6.8. Accessory digestive organs 6.8.1. Salivary glands 6.8.2. Liver 6.8.3. Pancreas</p>	<p>Thomas O. McCracken, Robert A. Kainer and Thomas L. Spurgeon (1999). Spurgeon's Color Atlas of large Animal Anatomy: The Essentials; Lippincott Williams and Wilkins.</p>
15 & 16	<p>7. The respiratory system 7.1. Nasal cavity 7.2. Larynx 7.3. Trachea</p>	<p>Rowen D. Frandson, W. Lee Wilke and Anna Dee Fails (2005). Anatomy and Physiology of Farm Animals; 6th edition. A John Wiley & Sons, Inc., Publication; Wiley-Blackwell. Dyce, K., M, Sack W., O. and Wensing C., J., G. (2010). Textbook of Veterinary Anatomy; 4th edition. by Saunders, an imprint of Elsevier Inc.</p>

References

1. Dyce, K., M, Sack W., O. and Wensing C., J., G. (2010). Textbook of Veterinary Anatomy; 4th edition. Saunders, an imprint of Elsevier Inc.
2. Thomas O. McCracken, Robert A. Kainer and Thomas L. Spurgeon (1999). Spurgeon's Color Atlas of large Animal Anatomy: The Essentials; Lippincott Williams and Wilkins.
3. Kenneth V. Kardong (2012). Vertebrates: Comparative Anatomy, Function, Evolution; 6th edition; The McGraw-Hill Companies, Inc.
4. Rowen D. Frandson, W. Lee Wilke and Anna Dee Fails (2005). Anatomy and Physiology of Farm Animals; 6th edition. A John Wiley & Sons, Inc., Publication; Wiley-Blackwell.
5. Paul Mills (2003). Comparative Animal Anatomy; Teaching and Educational Development Institute, the University of Queensland; the University of Queensland.

Other Suggested reading materials

1. Boyd J.S., 2001: Color Atlas of Clinical Anatomy of the Dog & Cat, 2nd edition.
2. Burdas K. *et al.*, 2003: Anatomy of the horse, an illustrative text, 4th edition.
3. Clayton H.M., 1996: Color atlas of large animal applied Anatomy.
4. Constantinescu G.M., 2001: Guide to Regional Ruminant Anatomy Based on the Dissection of the Goat.
5. Done S.H., Goody P.C., Evans S.A., Stickland N.C., 1996: Color Atlas of Veterinary Anatomy. The Dog and Cat. Volume III.
6. Bone J.F., 1988: Animal Anatomy and Physiology, 3rd edition.
7. Getty R.,; Sissons and Gross man's the Anatomy of Domestic Animals, Volume I & II.
8. Messonnier, S.P., 2000: Veterinary Neurology; the practical veterinarian.
9. Schummer, A., 1973: The Viscera of the Domestic Mammals, 5th edition.



**UNIVERSITY OF GONDAR,
GONDAR, ETHIOPIA**

**College Veterinary Medicine and
Animal sciences**

Department of Biomedical sciences

GROSS VET. ANATOMY I

**BY: Bemrew Admassu (DVM, MSC in
comparative vertebrate Morphology)**

February, 2020

1. Introduction

- **The doctrine of morphology as the scientific study of the form and structure of organisms was founded by Aristotle.**
- **He defined morphology as the search for a common constructional plan for all structures.**

Continue

- Since A⁺ dissections were the only possibility of studying the principles of form and function,
- *Claudius Galenus*, became the most famous and influential doctor in Rome.
- His research laid the unchallenged foundation of anatomical knowledge.
- However, his understanding of anatomy and physiology was based up on Aristotle's publications.

Continue

- **Some of his extrapolations were erroneous (suspected that the Rete Mirabile epidurale would also found in human).**
- **Further he concluded that humans have a ceacum and uterus with cotyledons.**
- **Veterinary anatomy as a prerequisite for practicing vet. Med. has developed only in the last few centuries as an independent teaching and research subject.**

Cont...

- The clinical relevance of the topographical approach was soon integrated in to the teaching of anatomy.
- Then after, the importance of anatomy became visible, it was integrated as a discipline to new veterinary school in European.
- Consequently, it was not until 1822 that the first comprehensive anatomy text or handbook was published.
- Yet veterinary anatomy - the dedicated study of the structure of the major domestic species - gained momentum rather more slowly, as the veterinary profession developed in Britain and around the world.
- subject has here always had strong roots in developmental and evolutionary biology .

Definition of Anatomy:

- **Origin:** Is a Greek word, which comes from **anatoma**
- **Ana-**means **apart**, and **tomy-**means cut (signifies cutting apart of the body!)
- -Is the branch of biological science that deals with the structure and organization (form) of living things.
- -It inputs the art of dissecting, the different parts of any organized body, to discover their **situation**, **structure**, and **economy**
- **Physiology** - The study of body **function**

Cont'....

Study of the function of a living organism and its component parts

- Includes all chemical and physical processes
- Cannot be completely separated from anatomy
- Each type of **life** has its own characteristics:
 - viral, bacterial, plant, animal, human, etc

Importance

- Physiology is important because
 - the foundation upon which we build our knowledge of what "life" is, how to treat disease, and how to cope with stresses imposed upon our bodies by new environments.

Physiological studies of normal biological function provide the basis for understanding the abnormal function seen in animal and human disease (pathophysiology)

and for developing new methods for treating those diseases (translational research).

Characteristics of Living things

- **Metabolism** is sum of all chemical reactions taking place in a living body
- **Organization:** of progressively complex levels
- **Growth:** living things grow by changing food into living matter
- **Reproduction:** all living things produce young ones
- **Responsiveness:** respond to changes in surroundings (stimuli; singular is stimulus)
- **Movements:** all living things spontaneously move their parts



The Hierarchy of Structural Organization

- **Chemical level** – atoms form molecules
- **Cellular level** – cells and their functional subunits
- **Tissue level** – a group of cells performing a common function
- **Organ level** – a discrete structure made up of more than one tissue
- **Organ system** – organs working together for a common purpose
- **Organismal level** – the result of all simpler levels working in unison

Cellular Anatomy

Different cells in the body, each with characteristic structure and function

Differentiation

- All animals begin life as a single cell (fertilized egg)
- Through differentiation, cells take on more than 200 in multicellular organisms
 - different shapes and functions Ex. bone and muscle cells are elongated for support and movement; mucus cells are circular for absorption
- Each cell inherits same DNA, but no one cell uses all of it



Cellular Anatomy

Components of Cell:

- Cell membrane
- Cytoplasm
- Organelles
- Cytosol
- Nucleus

Cell Membrane

Function:

- Separates cell from ECF
- Barrier and gateway
- Regulates exchange between cell and ECF
- Structure:
 - 7.5 nm thick bilayer of phospholipid molecules
 - Studded with proteins

Cytoplasm

Everything inside cell except **nucleus**

- **Cytosol**
- Dissolved nutrients
- Ions
- Waste Products
- Organelles

Membranous like:

- Mitochondria, Golgi apparatus, lysosomes, peroxisomes

Non-membranous organelles like

- Ribosomes, cytoskeleton

Non-membranous Organelles

■ Ribosomes

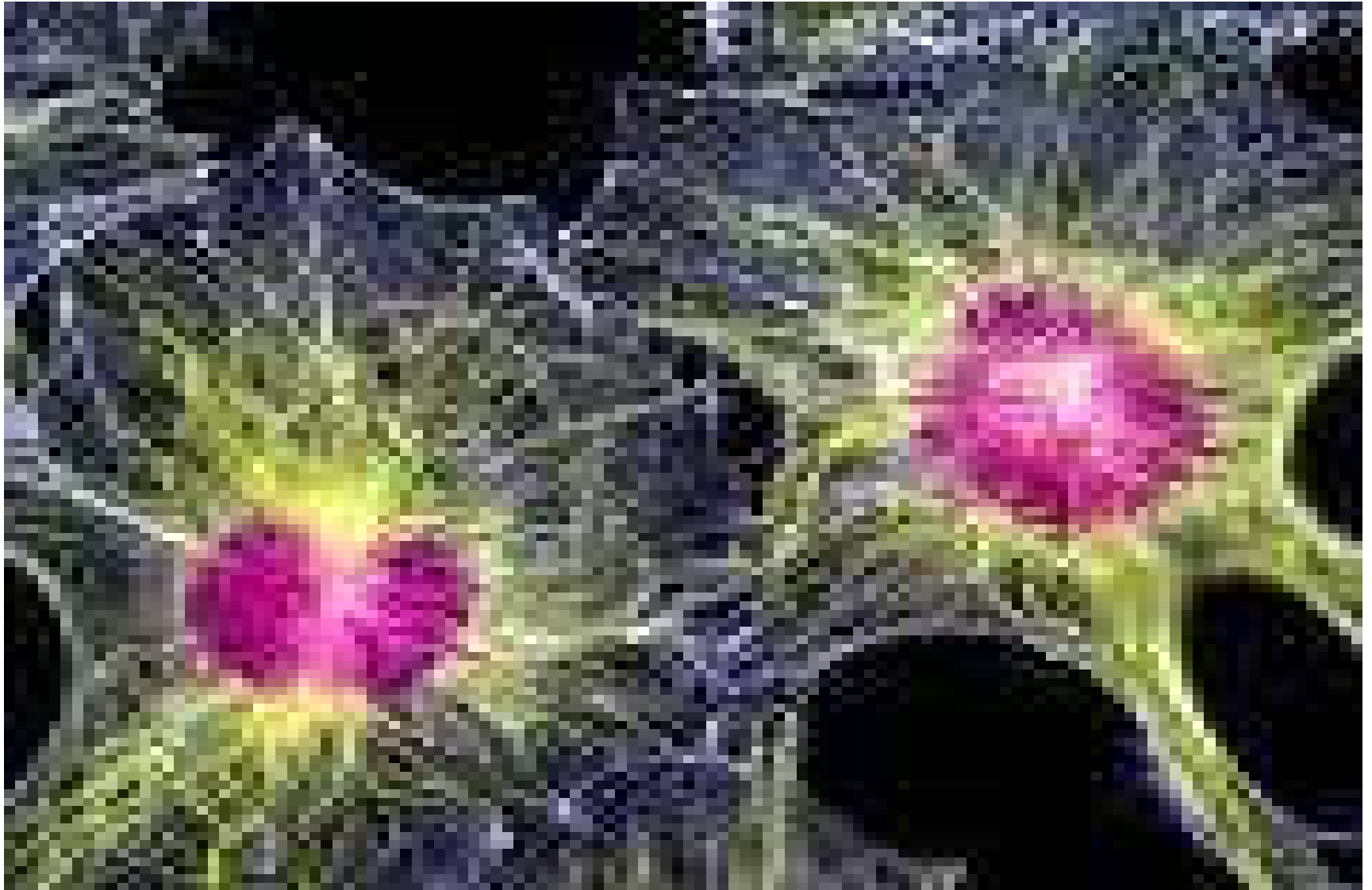
- Small dense granules of RNA and protein
- Manufacture proteins under direction of cell's DNA
- Most are attached to ER – fixed ribosomes
- Some float freely in cytoplasm
- Numerous in cells that make lots of protein

Cont'd...

Cytoskeleton

- Flexible, changeable, internal scaffolding of the cell
- Provides mechanical strength
- Helps transport material into cell and within cytoplasm
- Links cells to each other
- Responsible for cell motion
- Includes:
 - ✓ Actin microfilaments
 - ✓ Myosin and keratin intermediate filaments
 - ✓ Thick Filaments
 - ✓ Microtubules

Image



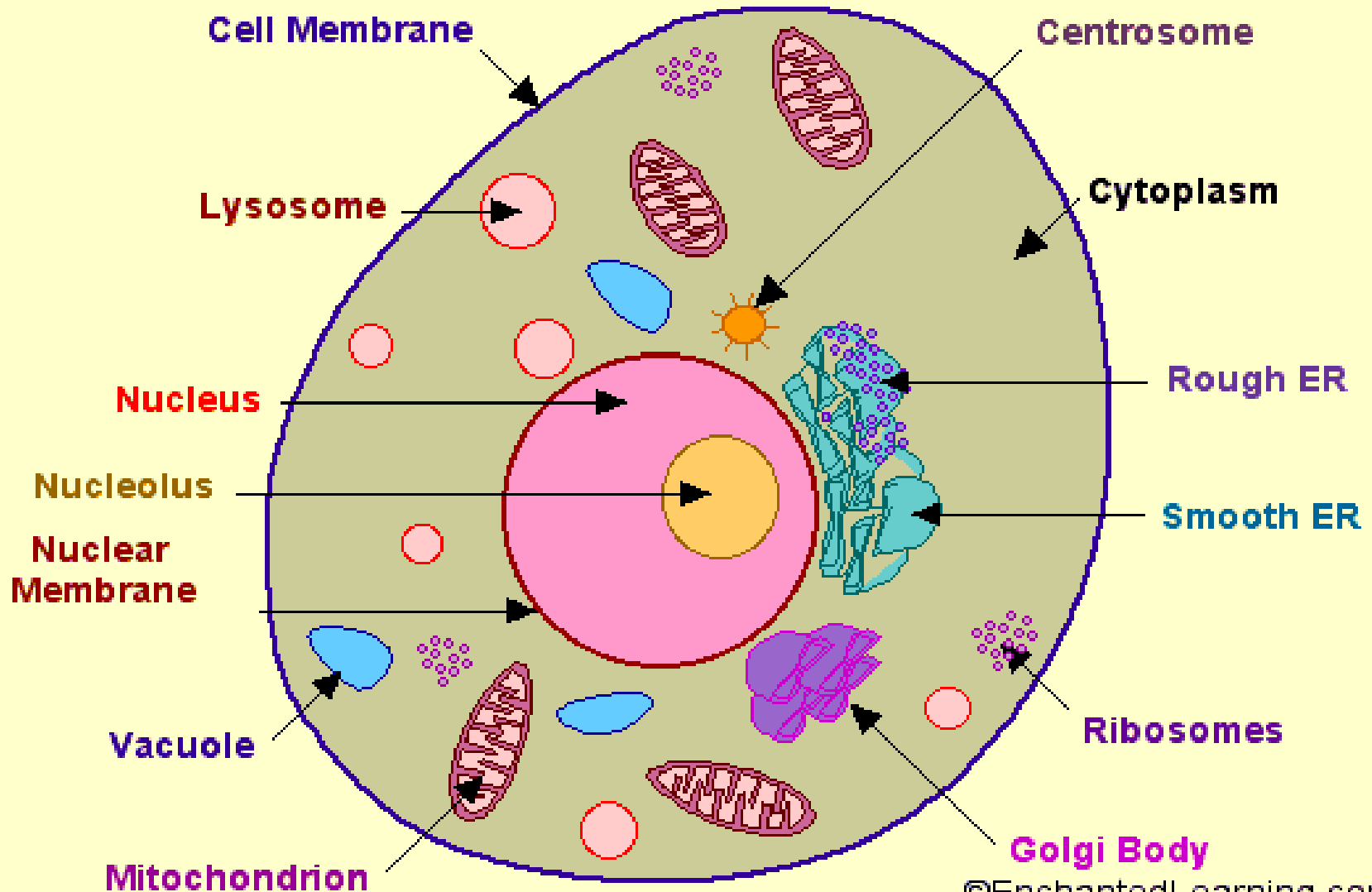
Membranous Organelles

Separated from cytosol by a **phospholipid membrane**

Include:

- Mitochondria
- ER
- Golgi apparatus
- Lysosomes
- Peroxisomes

Cross-Section of an Animal Cell



Cont'd

Mitochondria

- Elliptical organelle with **double** membrane
- Inner membrane folded into cristae
- Inside inner membrane:
 - Mitochondrial matrix
 - Contains enzymes, ribosomes, mitochondrial DNA
 - Between inner and outer membrane:
 - Inter-membrane space
 - Plays an important role in ATP production
 - Number of mito in a cell:
 - Depends on the cell's energy needs

Membranous Organelles

Endoplasmic Reticulum

- Site of **protein** and **lipid** synthesis
- Network of interconnected membrane tubes
- Continuation of nuclear outer membrane

Two types:

- Rough
- Dotted with ribosomes
- Main site for **protein** synthesis
- Smooth
- Main site for **lipid** synthesis
- Proteins packaged into membrane bound vesicles and shuttled to outside



Membranous Organelles

- Golgi Apparatus
- Modifies proteins and packs them into membrane bound vesicles

Membranous Organelles

Lysosomes

- Intracellular digestive system
- Small membrane bound storage vesicles
- Contain powerful enzymes that break down biomolecules
- Destroy damaged organelles
- Kill bacteria
- Activated only under very **acidic conditions**



Membranous Organelles

Peroxisomes

- Contain enzymes that neutralize toxins
- Smaller than lysosomes
- Degrade long chain fatty acids and toxic foreign molecules

Nucleus

- Contains DNA
- Surrounded by nuclear envelope
- Two membrane structure
- Outer membrane is connected to ER
- Ions and small molecules can freely move across nuclear membrane
- Protein and RNA must be transported through in a process that uses energy
- Usually contain nucleoli

Contain **genes** and **proteins** that control syntehsis of RNA for ribosomes

Histology 'introduction'

- **"Histology"** is derived from the Greek word for a tissue "*Histos*", and "*-logos*" = the study of.
- The concept of Histology as a subject includes far more than just the study of tissues, includes understanding of the **structure** and **function** of **cells**, **tissues**, **organs** and **organ systems**, which can better be described as "**Microscopic Anatomy**".
- It is evident that the study of Histology or Microscopic Anatomy involves the use of **microscopes** (**light** and **electron**) as basic tools.

Cont'...

- In addition to understanding the histology and ultrastructure of cells, tissues and organs, it is also necessary to complement the **morphological observations** with an understanding of the **biochemistry**, **physiology** and **biophysics** of these structures.

■ **BASIC TISSUES**

Histogenesis results in four tissue types:

- ✓ Epithelial Tissues –from all three germ layers
- ✓ Supporting (**Connective**) Tissues –from mesoderm
- ✓ Muscle Tissues - from mesoderm
- ✓ Nervous Tissues –from ectoderm

Cont' ...

- Epithelium –sheet like coverings with one surface free, one surface attached

Occurrence: wherever free surfaces exist

Skin

Conjunctiva (in part)

Cornea

External acoustic meatus

urogenital system.

Digestive system

Respiratory system

- Supporting tissues –connect, bind, support
- Muscle tissues –respond to stimuli –contract
- Nervous tissues –irritable –conduct nervous impulses – waves of excitation

BASIC TECHNIQUES

Preparation of histological sections

Has to be sectioned

In order to prepare thin sections for examination by **microscopy**, it is necessary to

- **Fix** :preserve the tissues and
- **Embed**: implant them in a supporting medium (such as **paraffin wax** or resins) prior to sectioning.

Sections are usually stained in order to provide contrast.

Fixation

■ Adv.

- ✓ preserves the tissues and prevent structural change or breakdown of the components of the tissues as close as possible to the living state.
- ✓ The fixatives commonly stabilize or denature proteins.
- ✓ A widely used fixative is formaldehyde, which has the advantage of being cheap and penetrates tissues rapidly.
- ✓ For better fixation, it is necessary to use pH buffers in the fixative.

2. Embedding

- The most commonly used embedding or support medium is **paraffin wax**, with a melting point of about **56°C**.
- Prior to infiltration of the tissue with molten wax, it is necessary to remove all the water from the tissue (**dehydration**).
- Dehydration is achieved using an ascending series of alcohols (**70%, 95%, 100%**).
- This is followed by tissue immersion in a wax solvent such as **xylene** or **chloroform**. The tissue is then transferred to molten paraffin wax (in an embedding oven) for a **couple of hours**.
- The tissue is then placed in a square or rectangular mold, and orientated in the required position, prior to adding hot wax to form a **wax block**.

3. Microtomy

- the tissue embedded in the wax block are cut on a machine, known as a **microtome**
- Typically series of sections are cut at a thickness of **6-8mm**.
- The sections are transferred to the surface of a hot water bath (where the sections flatten and lose any wrinkles).
- Sections are collected on **glass microscope slides** (standard dimensions of 3 x 1 inches).
- In order for the sections to adhere to the slides they are dried for up to 24 hours in a drying oven (at a temperature of about 40°C).
- This prevents sections falling off the slides in the later stages of preparation.

4. Staining

- The most common staining technique is known as **Hematoxylin** and **Eosin** (or H&E) staining.
- In order to stain the sections the wax needs to be removed.
- This is done using a wax solvent such as xylene.
- The slide is then hydrated using a series of descending alcohols (100%, 95%, 70%) and then water.
- The slide is then immersed in Hematoxylin stain, rinsed in running water (preferably alkaline), followed by staining with Eosin, and rinsing in water.

STAINING TECHNIQUES

■ Hematoxylin and Eosin (H&E)

This is the most commonly used staining technique for histological and histopathological sections.

The Hematoxylin is a **basic dye** that **stains acidic** components of cells a **blue color**.

This characteristic is known as **basophilia**.

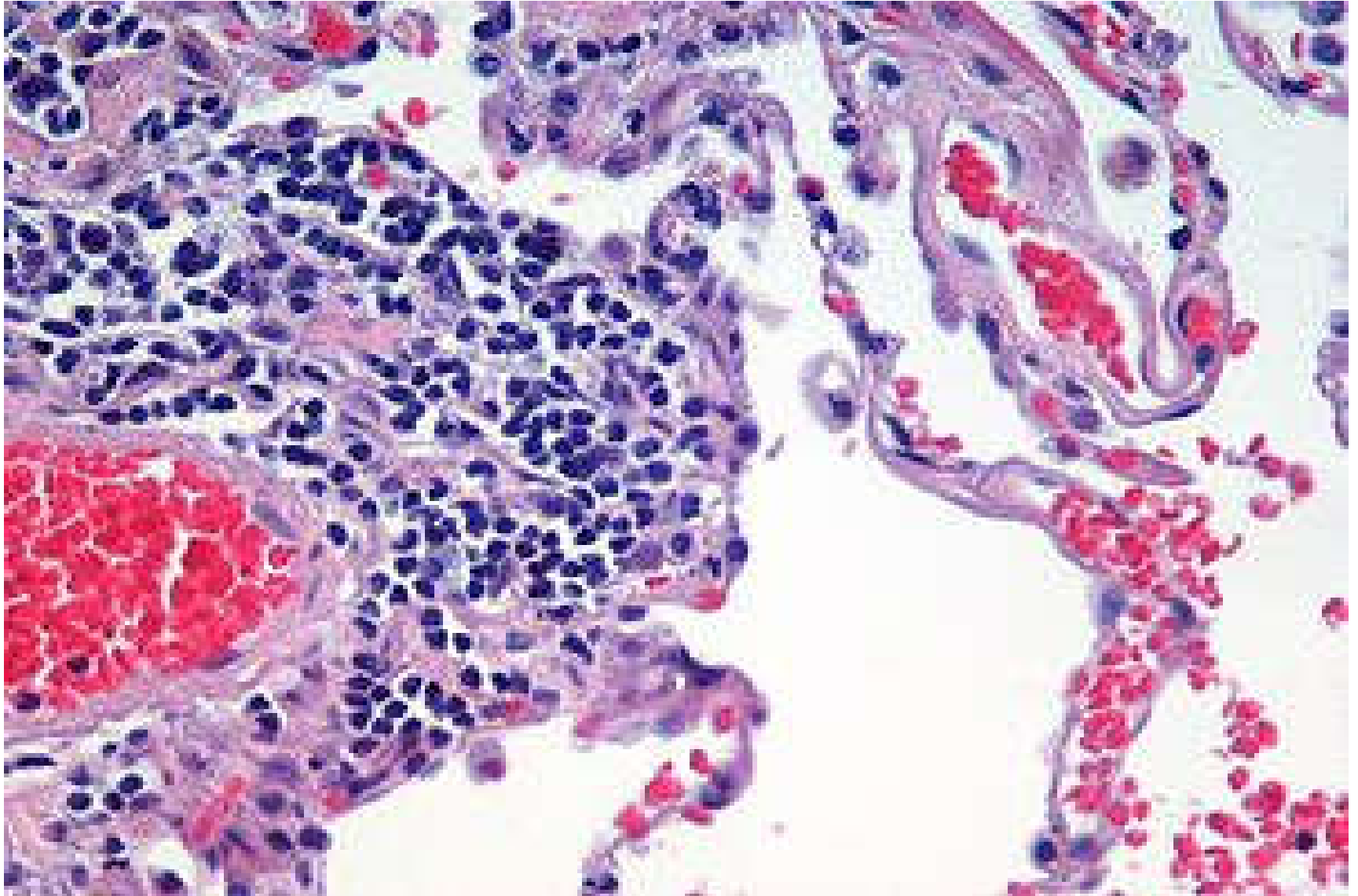
Hematoxylin stains the **nuclei of cells**, and the **RER of the cytoplasm**.

Eosin is an **acidic dye** that stains the **basic** components of the cells a **reddish-pink color**.

This characteristic is known as **acidophilia**. Most of the **cytoplasm** of cells is stained by eosin.

Exam. Bone matrix is also stained by eosin

Lung tissue stained with hematoxylin and eosin.



5. Permanent Mounting

- After staining the sections are again dehydrated with ascending alcohols (95%, 100%) and xylene, prior to covering with a mountant and a glass coverlip.
- Mountants need to have good optical properties.
- The slide is left for at least 24 hours for the mountant to dry.
- The finished (permanent) slide with its stained tissues can then be examined under the microscope.

Frozen sections

- Embedding in paraffin wax is a lengthy process and during the embedding many components (such as lipids) are dissolved and lost.
- Enzymatic activities are also largely destroyed.
- A rapid alternative to wax embedding is to prepare frozen sections and in a cryostat (a microtome operated in a low temperature cabinet, usually about -30°C).
- Frozen sections can then be stained or used for enzyme histochemistry, and mounted in a suitable water-soluble mountant.

Total preparations

- In some cases the tissue to be examined is a very thin membrane.
- In such cases the tissue does not need cutting on a microtome, but can be stained, mounted and examined directly. This is known as a **total preparation**.
- Total preparations are not as 2-dimensional as histological sections, and adjustment of focus is necessary during examination.

Cell Smears

- Cell smears are a form of histological preparation that does not require sectioning.
- Smears can be made for example of the blood or bone marrow.
- Smears are also common for swabs or scrapings of epithelial cells (e.g. from the oral cavity, cervix uteri).

2. Periodic acid-Schiff (PAS) staining

- PAS is a widely used staining technique that stains the neutral sugars of **glycosaminoglycans** a **pink color**.
- Common components stained positively with PAS include mucus, the basal lamina, glycogen.

Other staining are

✓ **Orcein**

stains elastic fibers a **dark brown-purple** color.
(show the elastic components in the walls of arteries)

✓ **Osmium tetroxide**: used to **stain** lipids a **dark black** color. It is very useful for demonstrating the myelin of myelinated nerves, or lipid droplets in the liver or steroid-secreting cells.

✓ **Oil Red O**: Oil Red O is used to stain lipids a red-orange color in unfixed frozen sections.



Cont'...

✓ **Vital staining**

Vital staining refers to the uptake of dyes (usually particulate) by cells. If we inject Trypan blue into experimental animals, the dye is rapidly engulfed by specific macrophages.

We can use such vital staining to demonstrate the **Kupffer** cells of the liver.

3. The Importance

- **To identify and characterize the physical or internal structure of an organism (primary goal).**
- **Appreciation of nutrition, physiological processes, conventional approaches to conditions etc. broadens our awareness.**
- **Dialogue with Practitioners: enables us to dialogue more eloquently (expressively) and effectively.**

Branches of Anatomy:

- The need for the expansion of the scope of the science and anatomical knowledge has necessitated the subdivisions of the anatomical science and new terms.

- Some are:



A. **Macroscopic Anatomy:**

- Is the study of the form and relation of the structure of the body, which can be seen with unaided eye.

B. **Microscopic Anatomy:**

- is a branch of anatomy, which deals with the study of those tissues and cells that can be seen with the aid of a **Microscope**



C. Developmental Anatomy:

- is the study of the stages through which the organism evolves from conception through birth.

D. Special Anatomy:

- is the branch that deals with the structure of a single type or species of animal.

E. Comparative Anatomy:

- is the description and comparison of the structure of animals, and forms the basics for the classification of this anim. into their family, genus or species.
- This is a list of **superficial anatomical** features. That is to say, externally visible parts of the body in humans and animals.

F. Superficial Anatomy

- also called **surface anatomy**
- is a descriptive science dealing with anatomical features that can be studied by sight without dissecting an organism.

Are the form and proportions of the animal body and the surface landmarks which correspond to deeper structures hidden from view, both in static pose and in motion.

It is also called "visual anatomy".

- Remark: Veterinary anatomy is usually persuade with regard to professional requirements and is therefore largely descriptive in character.

Methods of studying anatomy

Among the methods that have been employed for a years are:

- **Systemic anatomy:**

- in this method of study:

- The body is regarded as consisting of systems of organs
- This are similar in origin and structures and are associated in the performance of certain function.
- Is the study of the **systems of the body**.



Cont'...

Regional anatomy:

is the study of limited portions or region of the body.

Accordingly, the body is broken down in to four regions:

- ✓ head and neck,
- ✓ thorax and forelimb,
- ✓ abdomen, and pelvic region and
- ✓ hind limb.



Cont...

Topographic anatomy:

is the study of part of systems in relation to the surrounding parts, so as to determine their relative position in the body.

The use of bony and soft tissue landmarks on the surface of the body to indicate the known location of deeper structures.



Cont...

Applied anatomy:

is the method of studying anatomy, which deals with the consideration of anatomical facts in their relation to surgery, physical diagnoses and other practical branches.

Topographic Terms:

- In order to indicate precisely
 - the position
 - direction of parts of the body certain descriptive terms are used.

In the explanation, they are applied to **quadruped** in the normal standing position.

- The following arbitrary planes are used as frames of references in locating any given parts of animal body.



Cont'...

Median

Sagittal

Transverse

Frontal

Median Plane:

- is an imaginary plane that passes through the long axis of the body and divides the body into two equal halves.
 - ❖ a primary plane of reference.
 - ❖ Single plane.
 - ❖ All other planes are constructed in relationship to it.

Sagittal Plane:

Are those planes parallel to the median plane.

Transverse Plane:

- is located at right angles to the median plane.
- Divides the body into cranial and caudal Portions.
- A cross section of the body would be made on the transverse plane.
- Helps during meat inspection and post-mortem examination.

Frontal Plane:

- is a plane at right angle to both the median and transverse planes.
- It divides the body into dorsal and ventral segments.
- In addition to these planes of references, there are certain descriptive terms, which are valuable in locating an area we wish to focus at.
- Some of these terms include:

Directional terms

- **Cranial-** is a part (direction) towards the head.
Ex. the horn is cranial to the hump.
- **Rostral-** relative position of the head structures toward the **muzzle**.
- **Caudal-** direction towards the tail.



Cont...

- **Medial-** close to or toward the median plane
- **Lateral-** away from the median plane
- **Dorsal** -- directed toward the back

Cont...

- **Ventral** - directed toward the belly .
- **Proximal** - directed toward the body [limbs & tail]. Relatively close to the given parts, body or center of gravity.
Structures that lie toward the junction with the body are proximal.
Ex. the knee is proximal to the foot.
- **Distal** - directed away from the body (vertebral column) [limbs & tail].
Ex. The hoof is distal to the knee.

Cont...

- **Palmar-**

caudal surface of the **forelimb** distal to the **elbow**.

- **Dorsal-**

when used to the forelimb refers to the opposite palmar side.

- **Plantar-**

caudal surface of the **hind** limb below the **hock** or the sole surface of the rear foot.

Cont...

- **Dorsal-**

when used to the hind limb refers to directly the opposite plantar side.

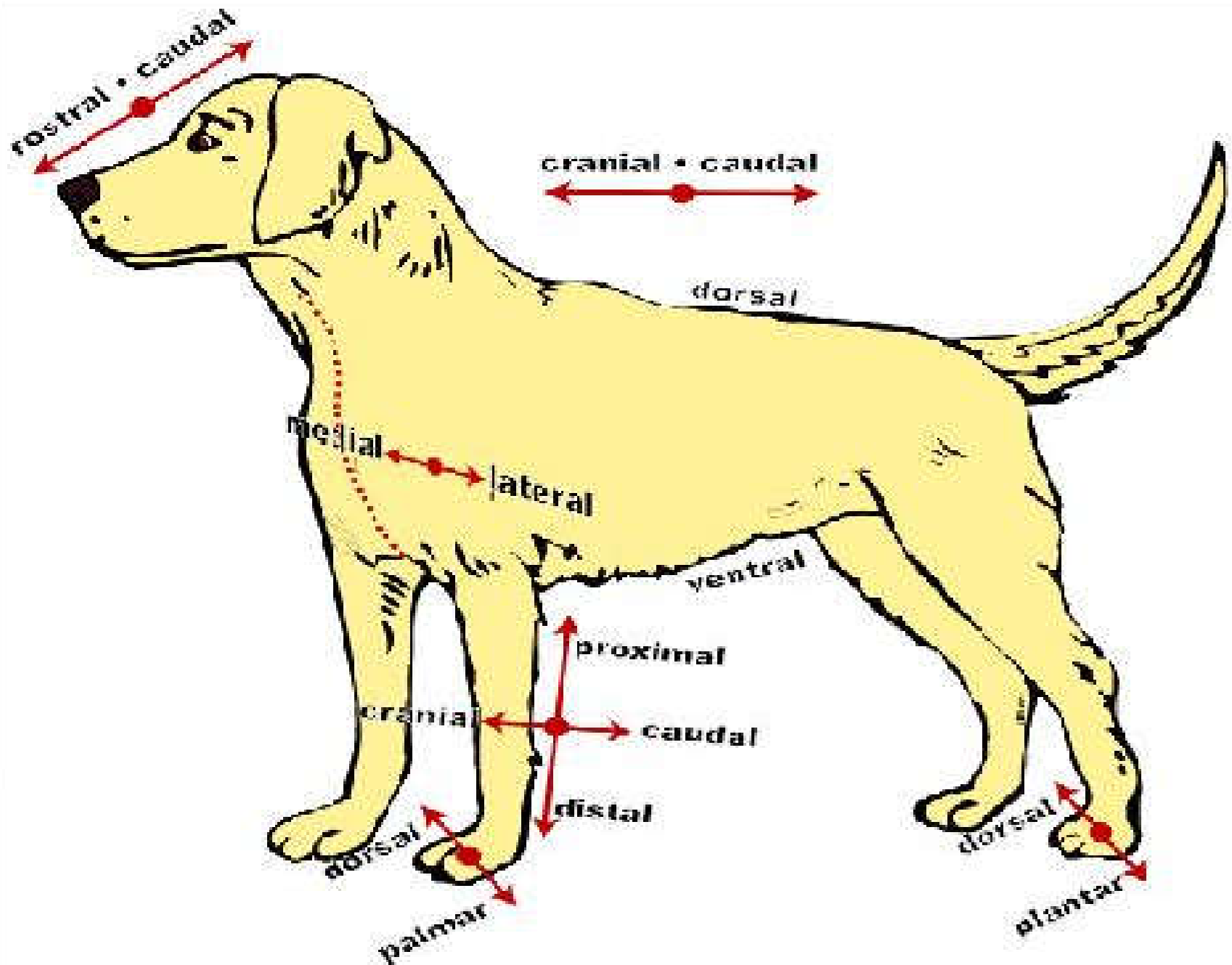
- **Superficial-**

implies proximity to the skin or the surface of the body.

- **Deep-**

implies closeness to the center of gravity or to the center of extremity.

Directional Terms



UNIVERSITY OF GONDAR, GONDAR, ETHIOPIA

College Veterinary Medicine and Animal sciences

Department of Biomedical sciences

Gross Anatomy for DVM 1st YEAR students

Dr. Bemrew Admassu & Dr Gashaw Getaneh

2020

CHAPTER 2

SKELETON SYSTEM

- The **skeleton** is a strong and often a rigid framework that supports the body of an animal.
- Holds it upright and giving it shape and strength.
-
- The skeleton is the flexible, bony framework found in all vertebrate animals.
- **In higher animals, it includes bones and cartilages.**

2 OSEOLOGY

2.1 Introduction

- **Osteology** → Is the study of structure, form and function of bones.
- **Osteon** → bone
- **Osteocyte** → bone cells
- **Osteon** → is a hard connective tissue of the body. It makes up the skeleton. It also supports and protects vital organs.
- Embryologic origin of osteon → **mesoderm**.
- **Importance of studying skeletal system:**
 - ❖ **To understand the disease condition of locomotory system.**
 - ❖ **In interpretation of radiological results(results of x-rays).**

2.2. Structures, physical and chemical composition of bones

- ✓ Bone is a living structure having blood and nerve supply.
- ✓ Bone can grow, be diseased and heal from fracture.
- ✓ It can be weakened & reduced by disuse → **atrophy**

✓ *Chemically* bones have *organic and inorganic* matter in the ratio of approximately 1:2.

1. Organic matter

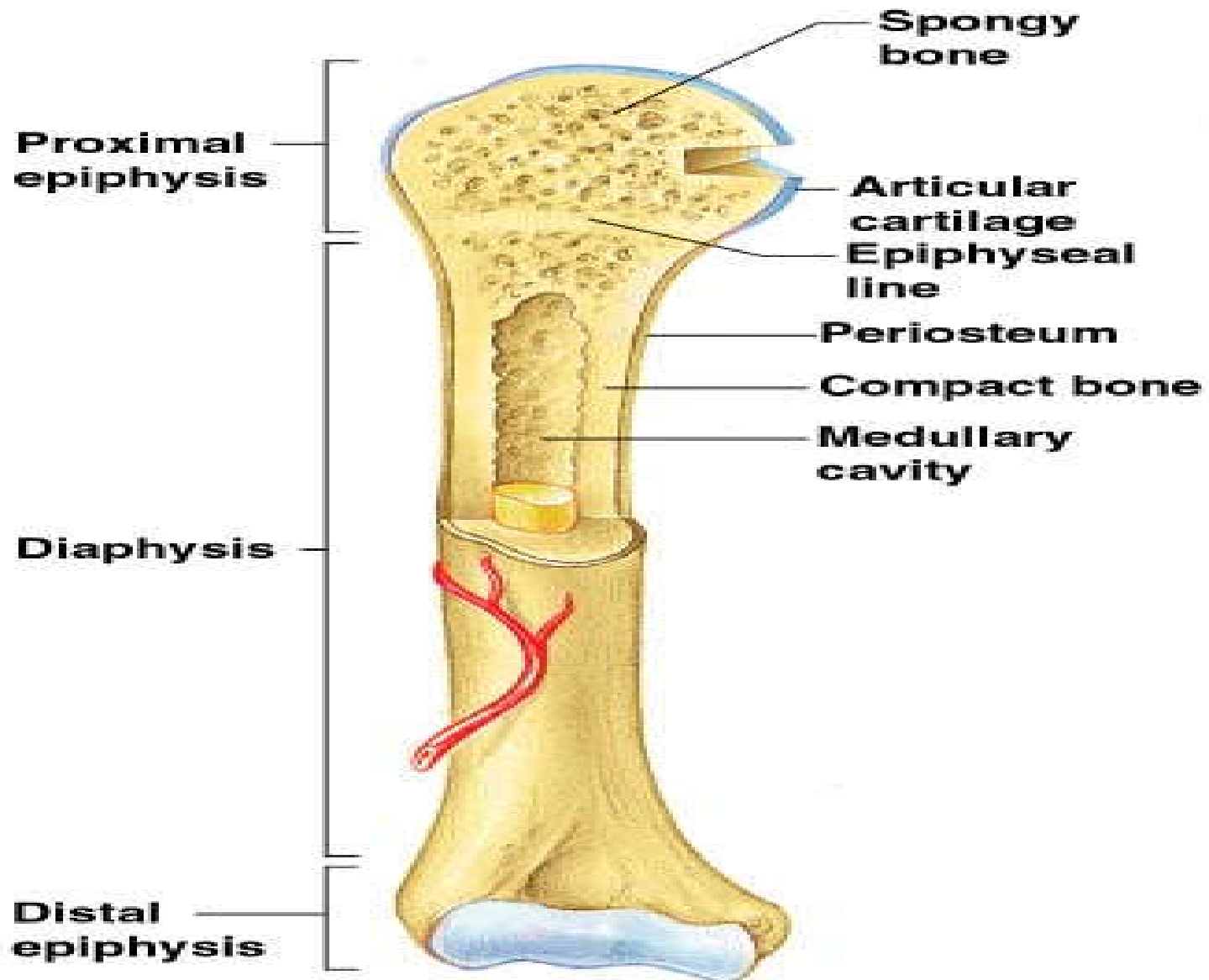
- responsible for **flexibility** of bone.
- It Includes **bone cells-(osteoblasts, osteocytes, and osteoclasts)** and Fibrous proteins like **collagen, ossein** and **chondroitin sulphate**.

2. Inorganic matter

- Includes mainly calcium phosphate (85%), calcium carbonate (10%), magnesium phosphate, sodium carbonate and sodium chloride.
- Responsible for the **rigidity and hardness** of bone.

- ❖ A longitudinal or transverse sectioning of a bone reveals:
 - An external fibrous covering → ***Periosteum***.
 - Tightly packed dense layer † ***Compact (cortical bone)***.
 - More loosely arranged layer— ***Sponge (Cancellous bone)***.
 - An internal thin fibrous layer— ***Endosteum***
 - Hollow structure ► ***Medullary cavity /marrow cavity***.

- Periosteum, Compact bone, Spongy bone, endosteum and Marrow cavity of bone are reflected with the next diagram.



A. The periosteum

❑ The outer membrane, which has the outer protective fibrous layer and inner cellular osteogenic layer.

- Inner osteogenic layer is important for bone formation and repair.

❑ Is firmly attaches and covers the surface of the bone except at **articular cartilage**.

❑ is absent in area where bone is covered by articular cartilage.

B. The Compact bone/layer

- It is dense layer of the bone.

• Bone matrix deposited in layer called “lamellae” (thin sheet of tissue).

- The hardest and strongest part of the bone.

• Consists uniform cavities/ spaces → **lacunae** → this cavities are filled with osteocytes.

C. Spongy bone/ cancellous bone

- ❖ Inner part composed of delicate/ soft bony plates arranged to form porous networks. These spaces are filled with bone marrow.
- ❖ Spongy bone forms the bulk of **short bone and extremities of long bone.**
- ❖ Honey comb structure that makes the bone light.

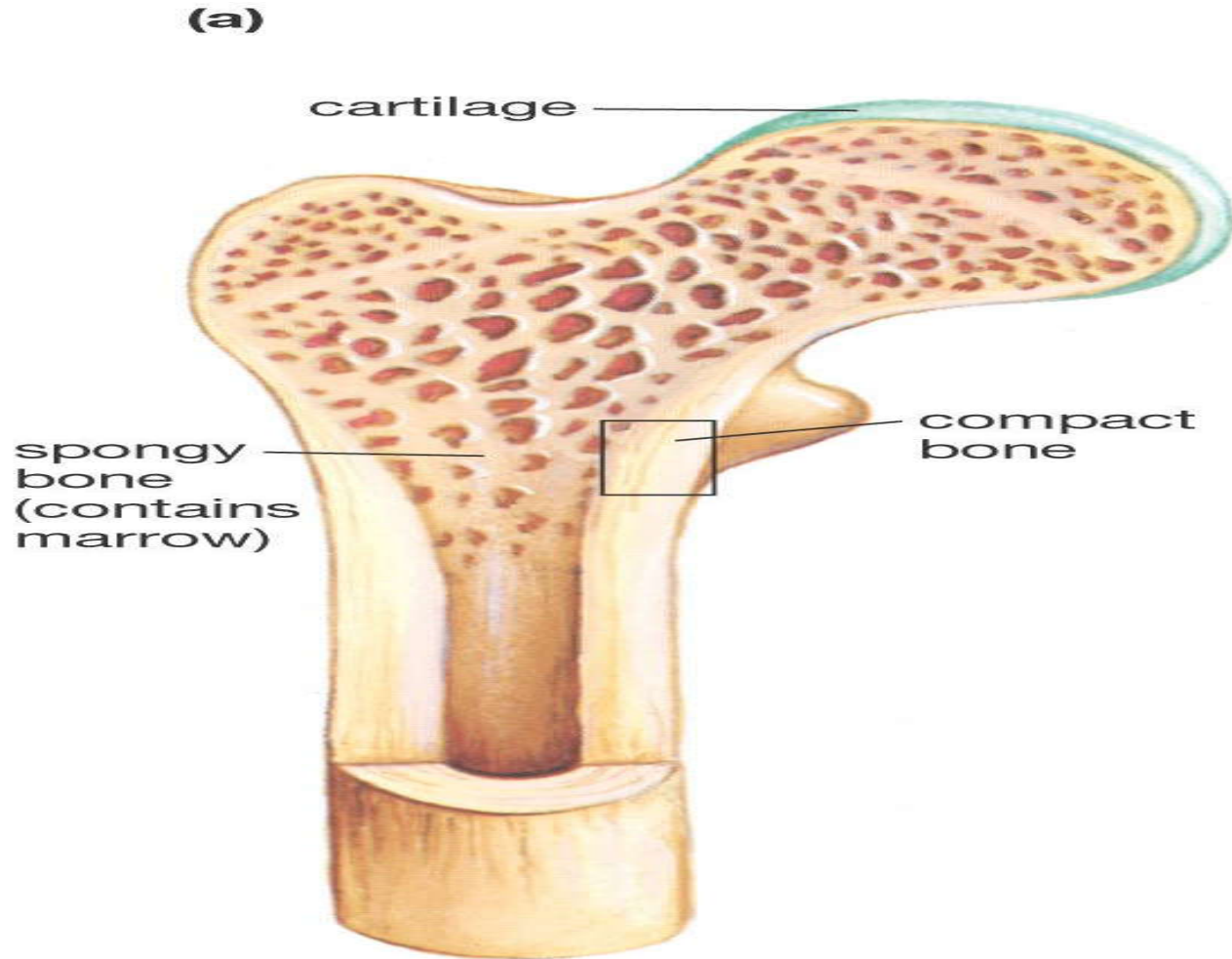
D. The endosteum

- thin fibrous membrane that lines the marrow/ medullary cavity.

E. Marrow cavity

- Is a space usually surrounded by compact bone of long bone which is usually filled by bone marrow.
- Continuous with the spaces of spongy bone

Diagram showing compact and spongy bone



–Bone marrow is a specialized type of soft connective tissue **WHICH Fills the cavities of bones**. The main function of bone marrow is production of blood cells.

–There are two types of bone marrow :

A. Red bone marrow

1.Function in production of red blood cells.

2.It is red b/c it contains oxygen carrying molecule known as hemoglobin.

3.Found in most bone marrow of infants and young. At the old age it can be replaced by yellow bone marrow.

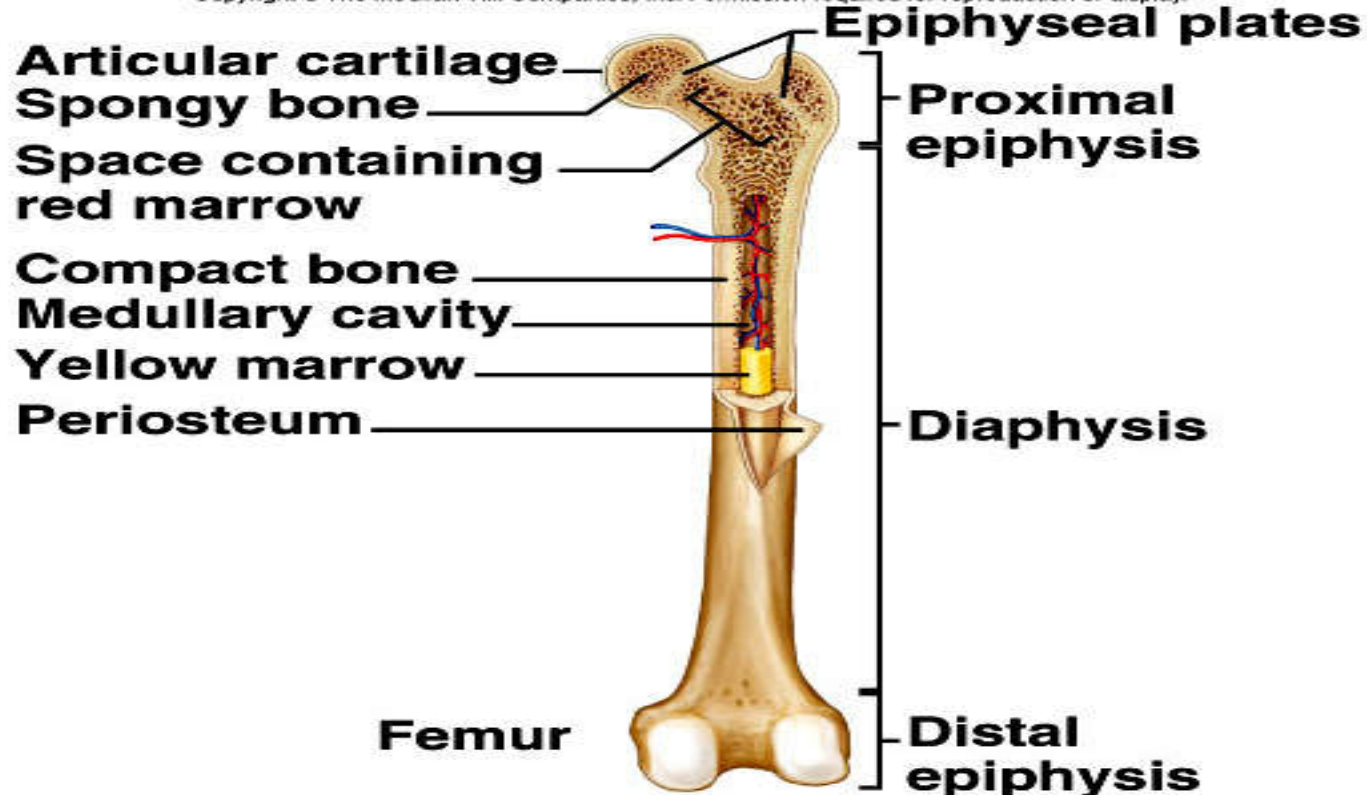
B. Yellow bone marrow

1.Function in storage of fat. So, it is inactive in blood cell formation.

2.Found in old animals.

Diagram showing red bone marrow and yellow bone marrow

Copyright © The McGraw-Hill Companies, Inc. Permission required for reproduction or display.



Functions of Bones

Bones have many functions, including.

--very dynamic organ that is constantly remodeling and -
-changing shape to adapt to the daily forces placed upon it.

--Shape — Bones provide a frame to keep the body supported.

Support. Bones provide a framework for the attachment of muscles and other tissues.

Protection. Bones such as the skull and rib cage protect internal organs from injury.

Sound transduction - Bones are important in the mechanical aspect of [hearing](#).

Movement. Bones enable body movements by acting as levers and points of attachment for muscles.

Mineral storage. Bones serve as a reservoir for calcium and phosphorus, essential minerals for various cellular activities throughout the body.

Detoxification - Bone tissues can also store heavy metals and other foreign elements, removing them from the blood and reducing their effects on other tissues.

These can later be gradually released for excretion.

Blood cell production. The production of blood cells, or **hematopoiesis**, occurs in the red marrow found within the cavities of certain bones.

Energy storage. Lipids (fats) stored in adipose cells of the yellow marrow serve as an energy reservoir.

Morphological and Functional Classification of Bones

Depending on their shape, structure and function, bone can be classified into six types.

A. Long bones (*ossa longa*)

- ❖ Are elongated and cylindrical form with enlarged extremities.
- ❖ They develop from at least **three centers** of ossification: one from the Shaft (diaphysis), another from each extremities (epiphysis).
- ❖ They are greater in one dimension than any other.
- ❖ They contains marrow cavity.
- ❖ Components of long bone:
 - ✓ **Epiphysis** → refers to extremities of long bone.
 - ✓ **Diaphysis** → cylindrical shaft of long bone situated between epiphysis

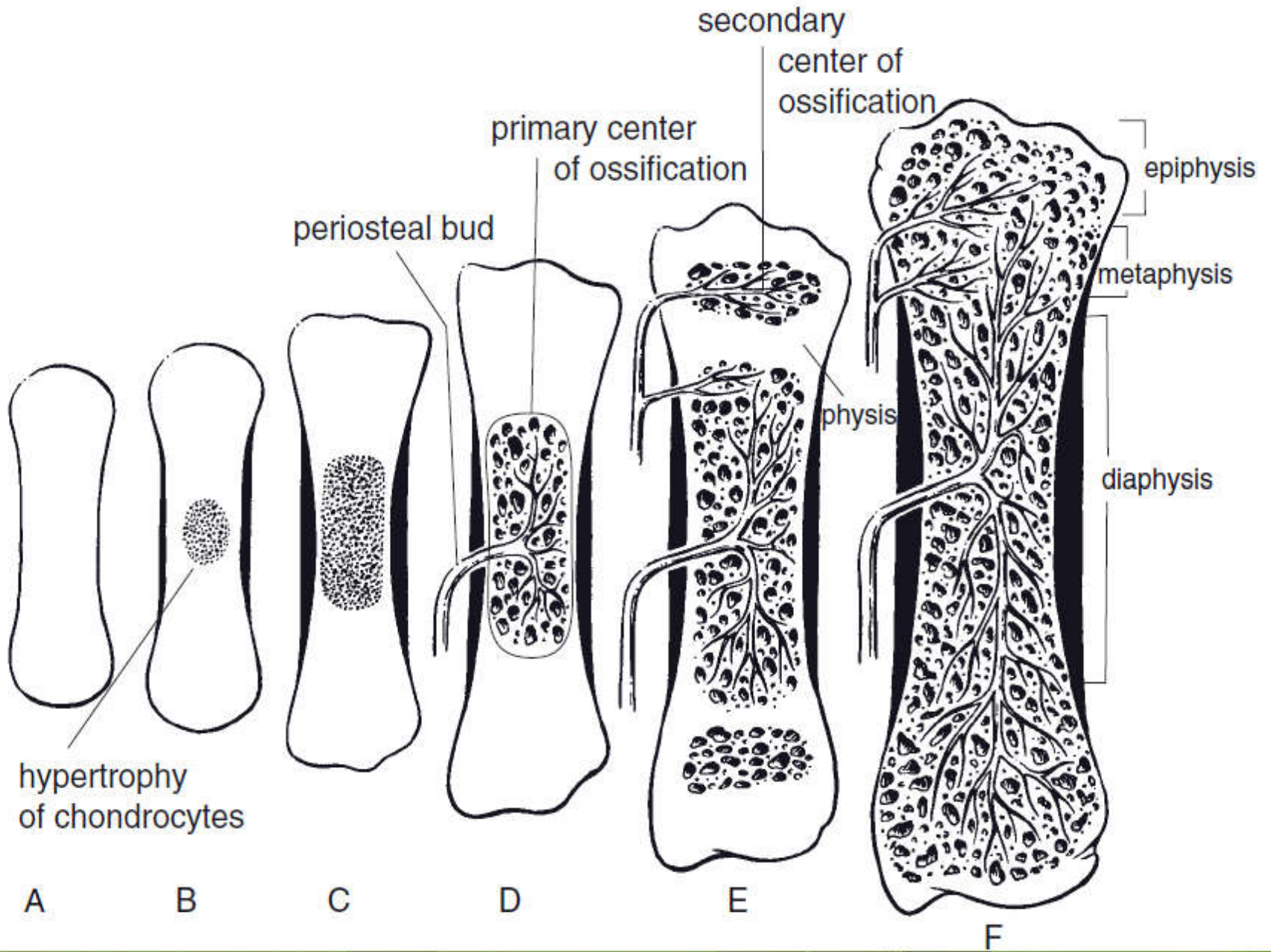
✓ Epiphysial cartilage(metaphysis) →it is layer of **hyaline cartilage** that separates diaphysis from epiphysis. It is the only area in which bone can increase in length.

Long bone functions chiefly as

- lever and aid in locomotion and prehension.
- Both ends of the bone are covered in **hyaline cartilage** to help protect the bone and its cancellous bone aid in **shock absorption**.

Examples of long bone:

- Pelvic limb→ Femur, tibia and fibula, metatarsus and phalanges.
- Pectoral/ forelimb→ humerus, radius and ulna, metacarpal and phalanges.



The above Figure shows that. The stages of endochondral ossification of a long bone. A) *A cartilage model forms initially.*

B) The chondrocytes in the center of the model hypertrophy.

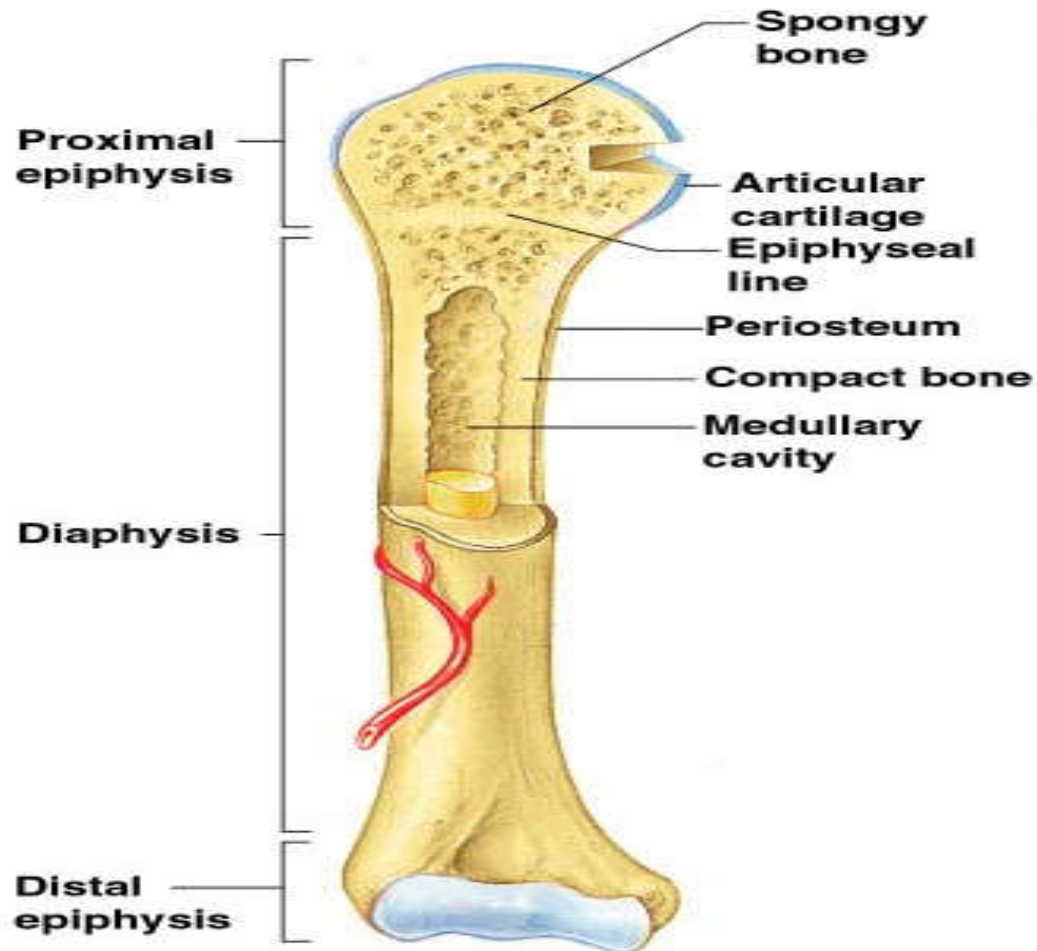
C) A bony collar begins to form around the cartilage model.

D) Blood vessels from the periosteum (periosteal bud) invade the cartilage model, bringing bone-forming cells to initiate the primary center of ossification.

E) The physis and secondary centers of ossification are established.

F) The growth plate closes in the mature bone, and a confluent marrow cavity from the epiphysis to the diaphysis is formed.

Diagram showing Epiphysis, Metaphysis (epiphysial line or epiphysial cartilage) and Diaphysis of bone



B. Short bones (**Ossa brevia**)

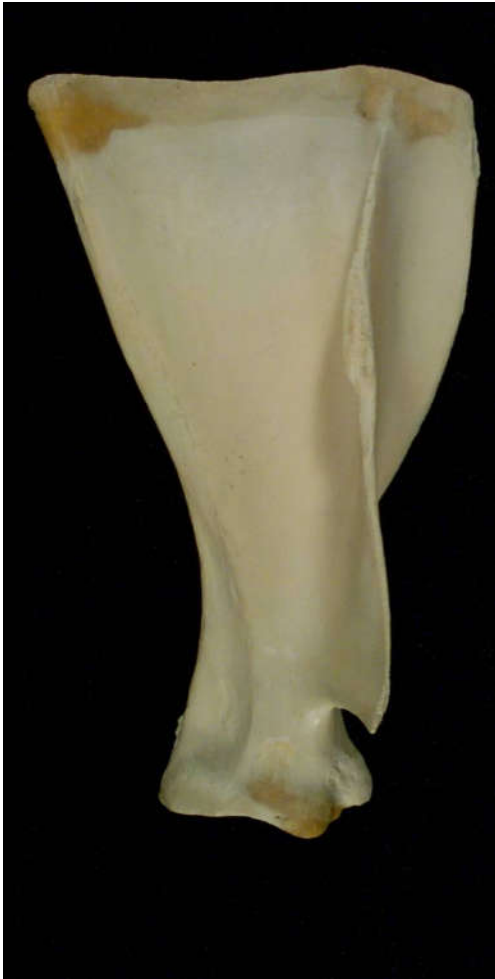- ❖ are cuboid, approximately equal in all dimensions.
- ❖ no marrow cavity.
- ❖ found in complex joints of **carpus** (knee joint of fore limb) and **tarsus** ([hock joint of the hind limb](#)).

C. Flat bones (**Ossa plana**)

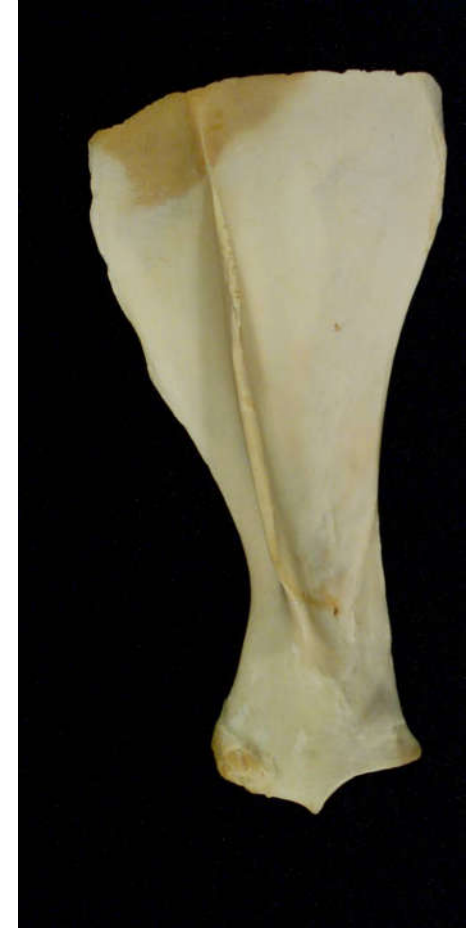- ❑ Relatively thin and expanded in two dimensions.
- ❑ Function chiefly for protection of vital organs such as brain, the heart and the lung.
- ❑ Examples → skull, scapula, and os- coxae.

Diagram showing scapula and carpal bones

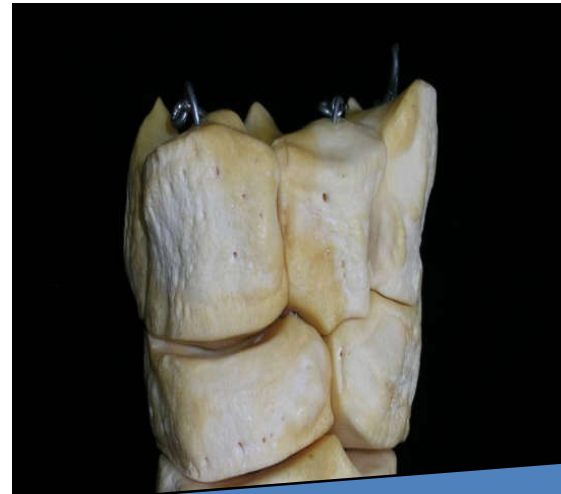
Bovine left scapula



Equine left scapula



Short bones



The acromion process is absent in the pig and the horse.

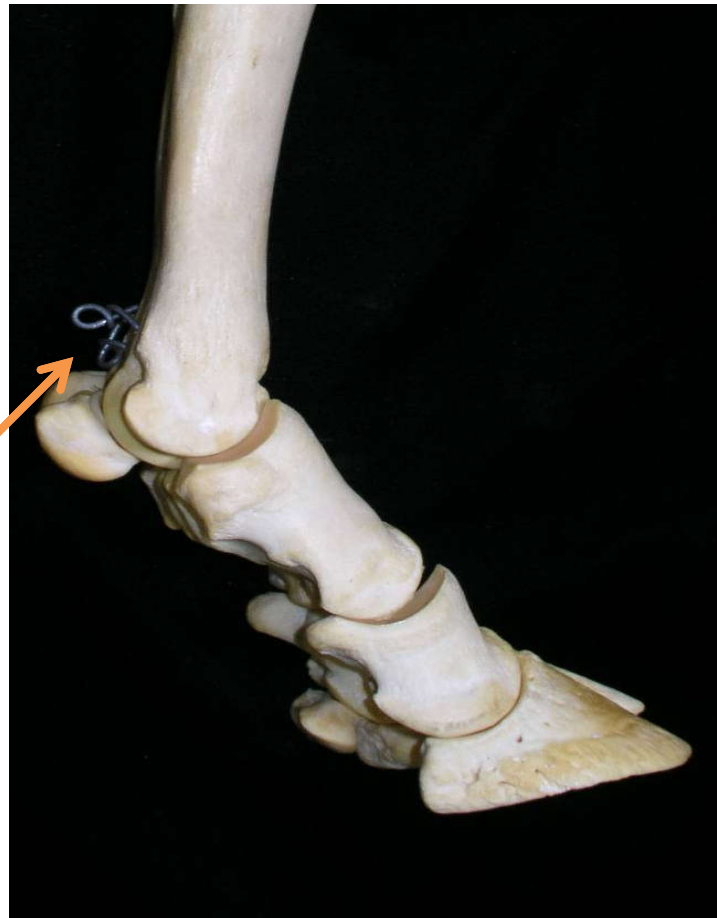D. Sesamoid bones

- ✓ sesamoid bones are so called because of their resemblance with “sesame seed.”
- ✓ are found along the course of tendons to reduce friction.
- ✓ The **patella (Knee cap)** is the largest sesamoid bone in the body (found on hind limb attached with the distal end of femur).

E. Pneumonic bones

- Found on the face region which contains air spaces or sinuses that communicate with the external environment.
- E.g., **Bones of the skull such as frontal and maxillary bone.**

Diagram showing Sesamoid bones

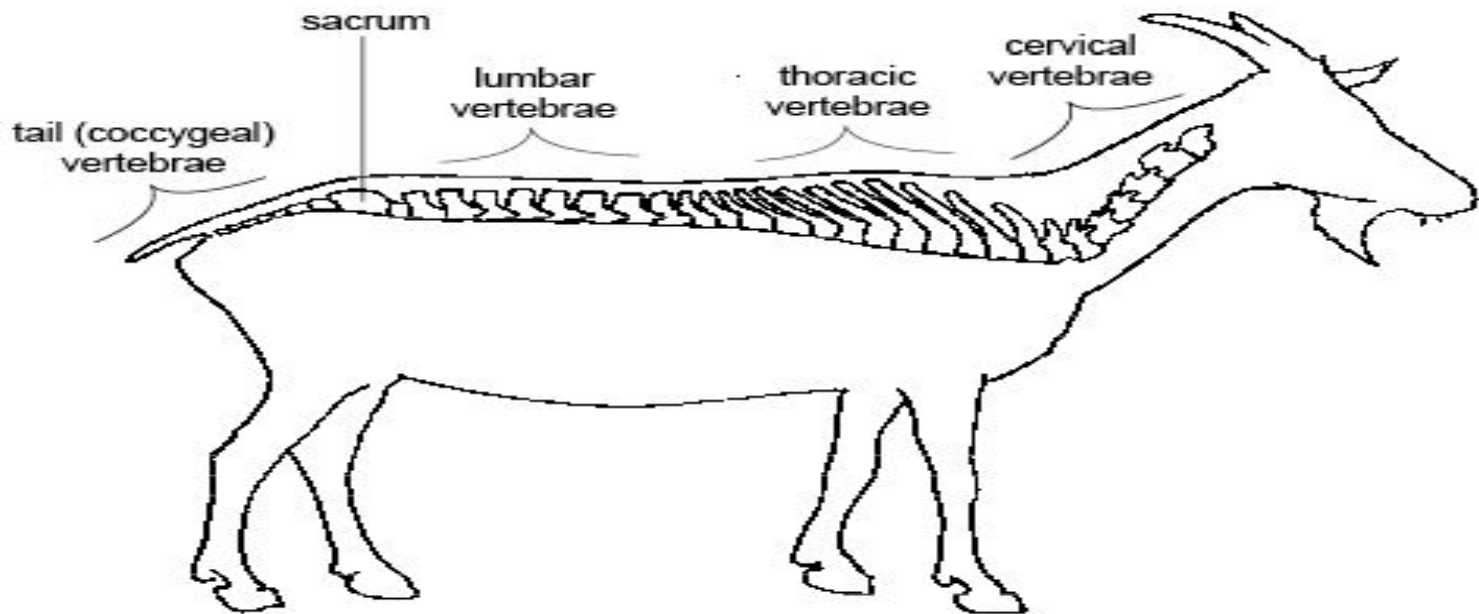


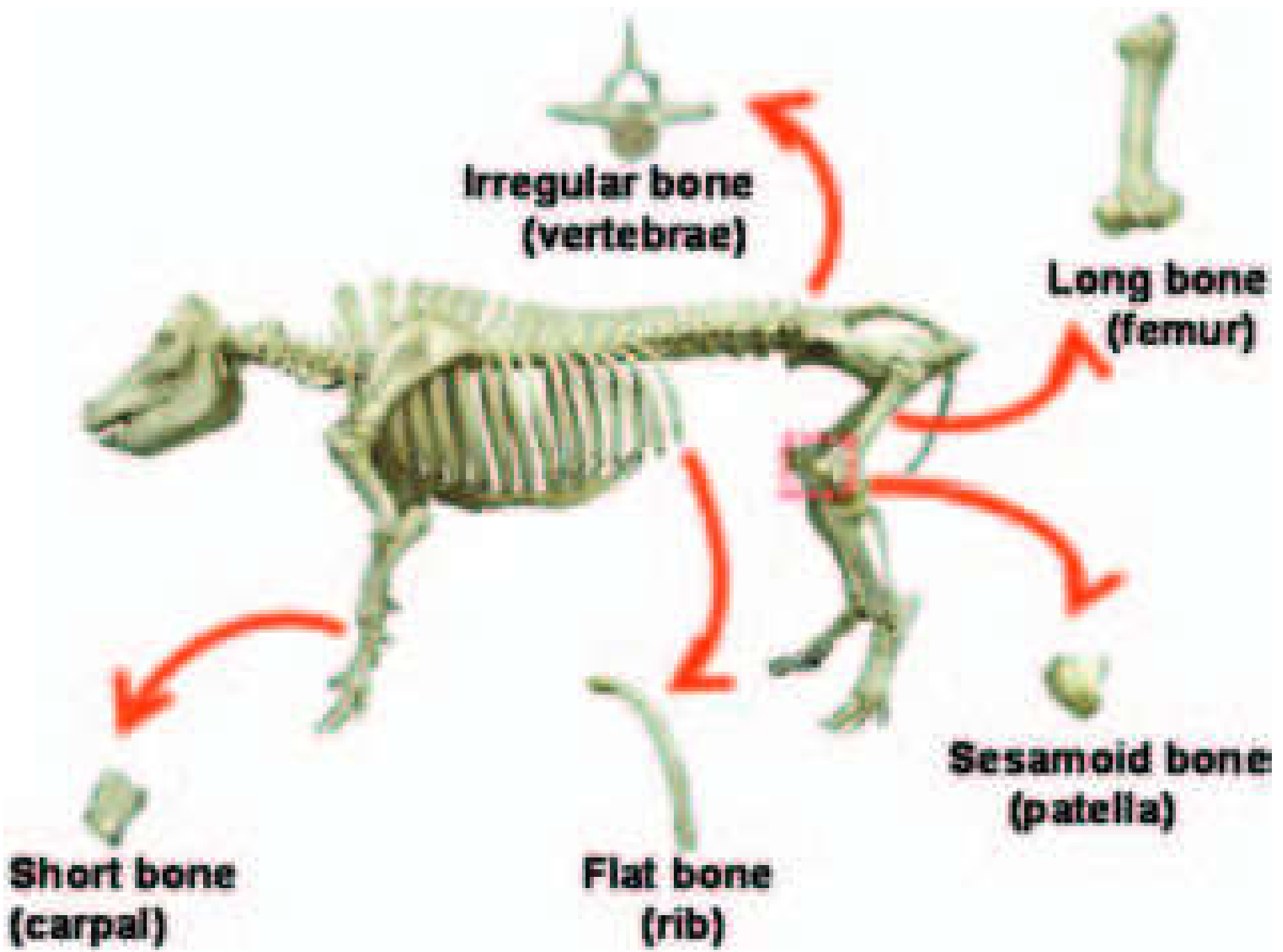
**Sesamoid
bone**

**Bovine left
Thoracic limb
Lateral view**

F. Irregular bones

- Have complicated shape that can not be classified as long, short or flat.
- Usually found on median plane and are unpaired bones.
- They includes the vertebrae, and some unpaired bones of the skull.





**Irregular bone
(vertebrae)**

**Long bone
(femur)**

**Sesamoid bone
(patella)**

**Flat bone
(rib)**

**Short bone
(carpal)**

Terminologies in osteology

- 1. Projection** → outward growth of bone
 - 2. Depression** → structures that are found as concavity, tunnel or circumscribed hole on bone. It is simply indentation on the bone.
 - 3. Articular** → bony structures that participate in joint formation(articulation).
 - 4. Non-articular** → bony structures that don't participate in joint formation(articulation).
- ❖ **Projection may be articular or non-articular.**
- A. Articular projection** → categories:
- i. Head** → is spherical projection, e.g. head of femur.

- Type of head:
 - ✓ a). **Condyle/ condylus** → is cylindrical articular mass , joint forming mass. E.g., occipital condyle, mandibular condyle, femoral condyle.
 - ii. **Facet** → are out ward growth of the bone and they have relatively flat surface as compared to head. E.G., B/n adjacent carpal bone, thoracic vertebrae.

B. Non- articular projection → categories:

- 1. Process →** out ward projection of bone that don't participate in joint formation. e.g., **spinous and transverse process of vertebrae.**
- 2. Tuberosity(tuber) →** large non articular bony projection which is important for muscle attachment. e.g., **Deltoid tuberosity of humerus** on its shaft.
- 3. Tubercle/ tuberculum →** small projection on the proximal end of long bone, but don't participate in joint formation. e.g., **greater and lesser tubercle of humerus.**
- 4. Epicondyle →** small projection above the condyle at the distal extremity of long bone. It is important in muscle attachment.

5. **Trochanter** → large non-articular projection. It is important in muscle attachment. It is greater than tubercle and tuberosity. e.g., greater and lesser trochanter of femur.
6. **Spine** → it is pointed projection on the bone. e.g., **spine of scapula.**
7. **Crest** → outward projection of bone and they are sharp narrow ridge. It is important for muscle attachment.e.g., **medial crest of sacral bone.**
8. **Neck**→ is a type of projection with cylindrical appearance to which head is attached. e.g., **neck of ribs.**
9. **Line**→ small ridge or mark formed by the pull of muscle. It is found in any bone that attaches to the muscle.

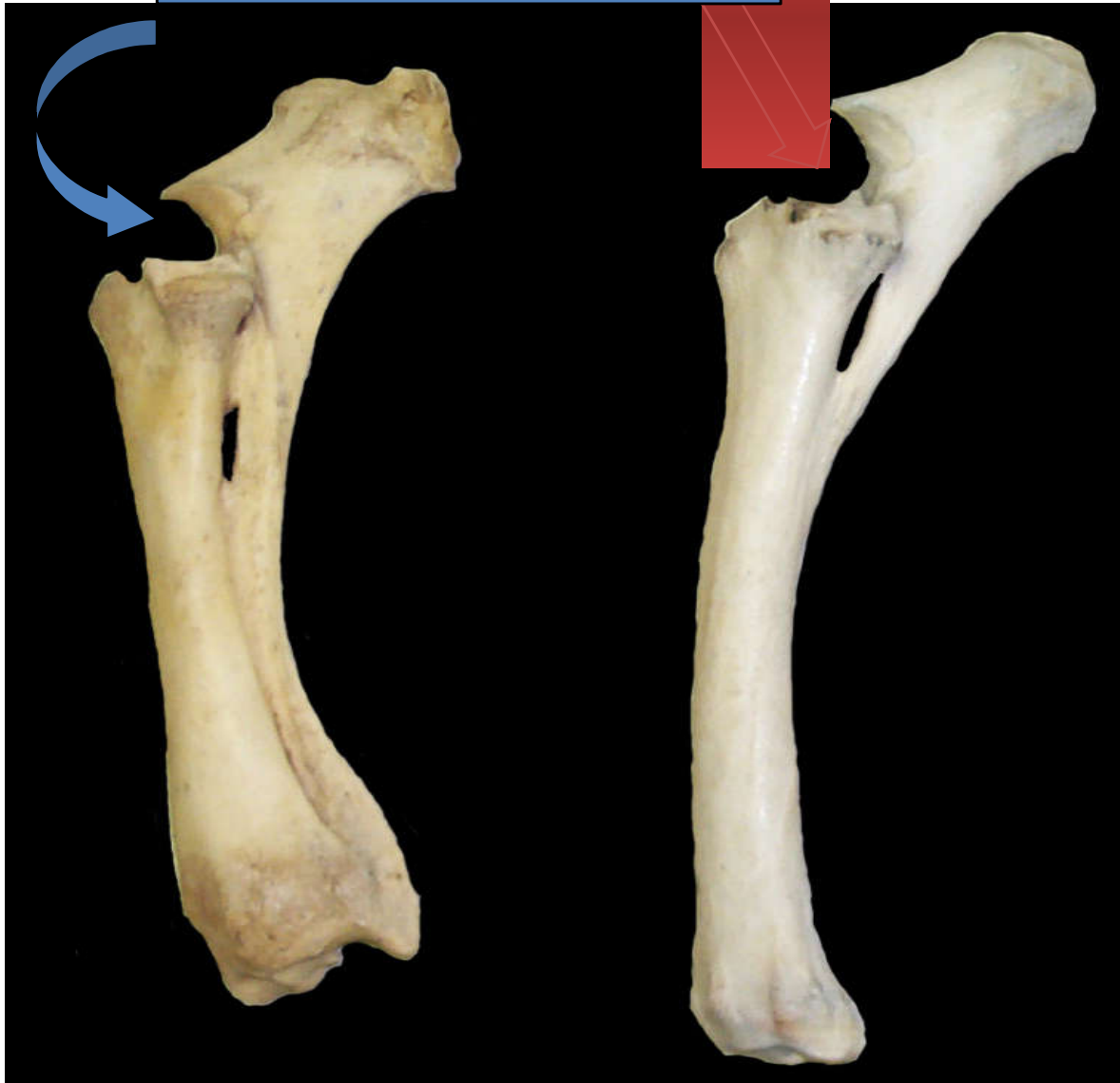❖ **Depression can be articular or non-articular.**

A. Articular depression → categories:

- 1. Glenoid cavity → It is a shallow articular concavity. E.g.,
glenoid cavity of scapula.**
- 2. Condylod cavity → relatively deep concavity. E.g.,
acetabulum(it is a cavity in which the head of femur is
inserted to it).**
- 3. Notch → v- shaped depression. e.g., semilunar notch of
ulna.**

Semilunar notch of ulna.

**Bovine left
Radius/ulna
Lateral View**

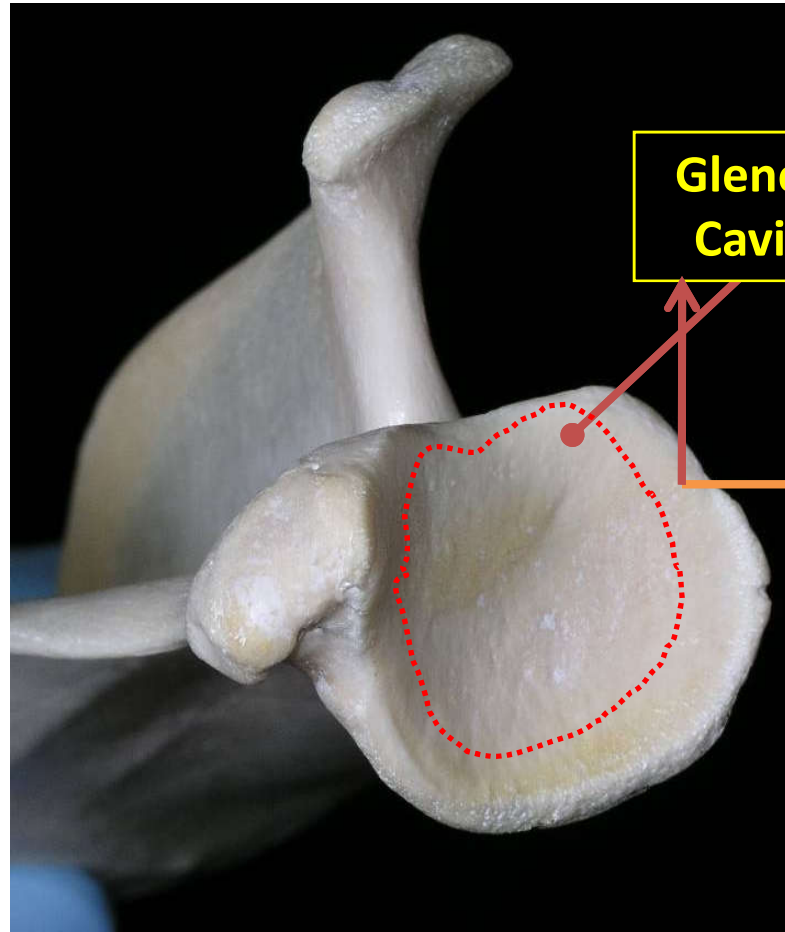
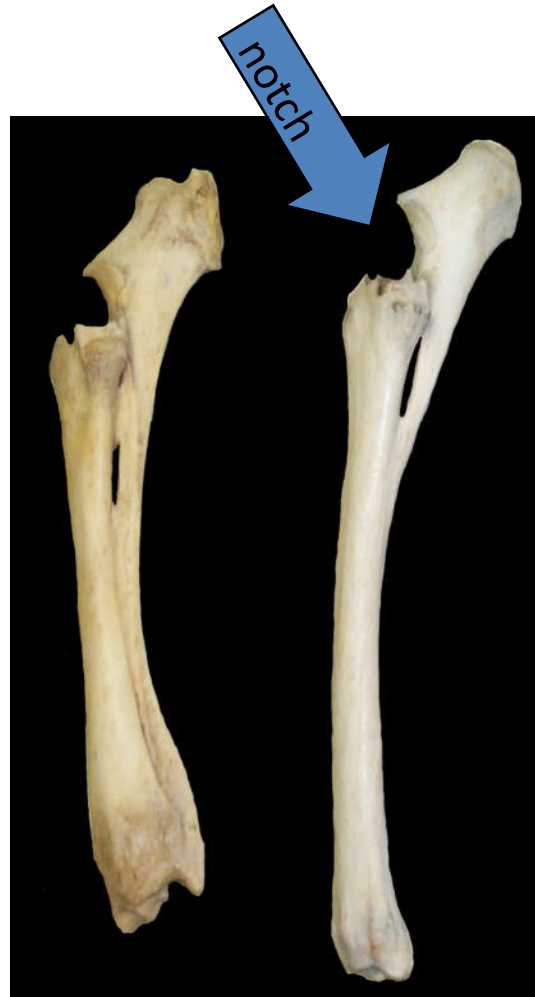

**Equine left
Radius/ulna
Lateral View**

B. Non- articular depression → categories:

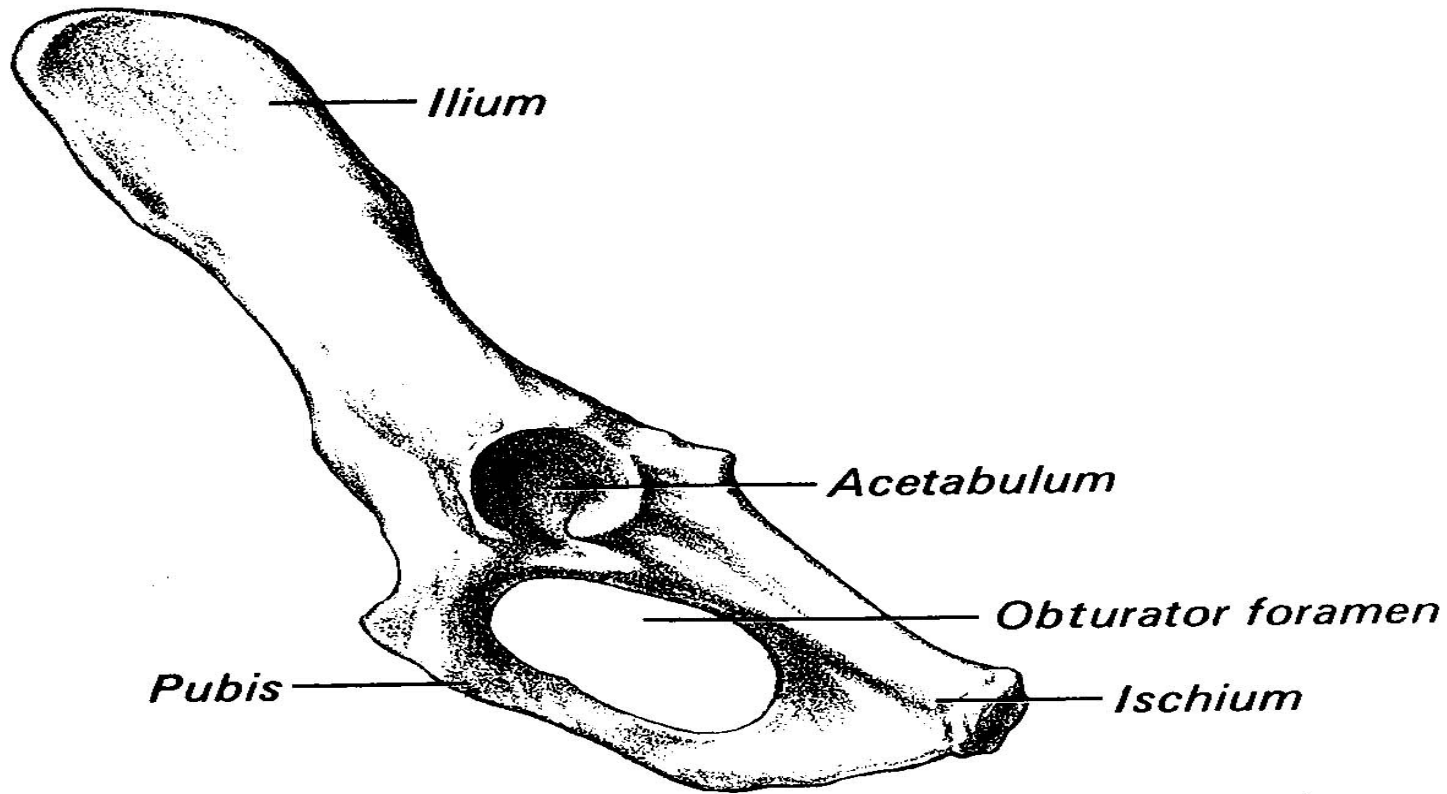
- 1. Fossa** → it is relatively large non articular depression. E.g.,
Supraspinous fossa.
- 2. Fovea** → relatively small non-articular depression. e.g.,
fovea capitis on the head of femur.
- 3. Foramen** → circumscribed hole /perforation on the bone.
There is no bone that comes to attach. e.g., **foramen magnum(found in occipital bone), obturator foramen(found in os- coxae).**
- 4. Canal** → tunnel through one or more bone. e.g., vertebral canal → spinal cord can pass through this canal.

Diagram showing the glenoid cavity on the scapula and notch on the ulna (which is a kind of articular depression)



**Canine left
Scapula
Ventral View**

Diagram showing the acetabulum (articular depression) and obturator foramen (non-articular depression) of os coxae.



2.4. Regional classification of the skeleton

- Depending on the region that the bone found, skeleton can be divided into three parts:

I. Axial skeleton:

- skull
- Vertebral column
- Ribs
- Sternum

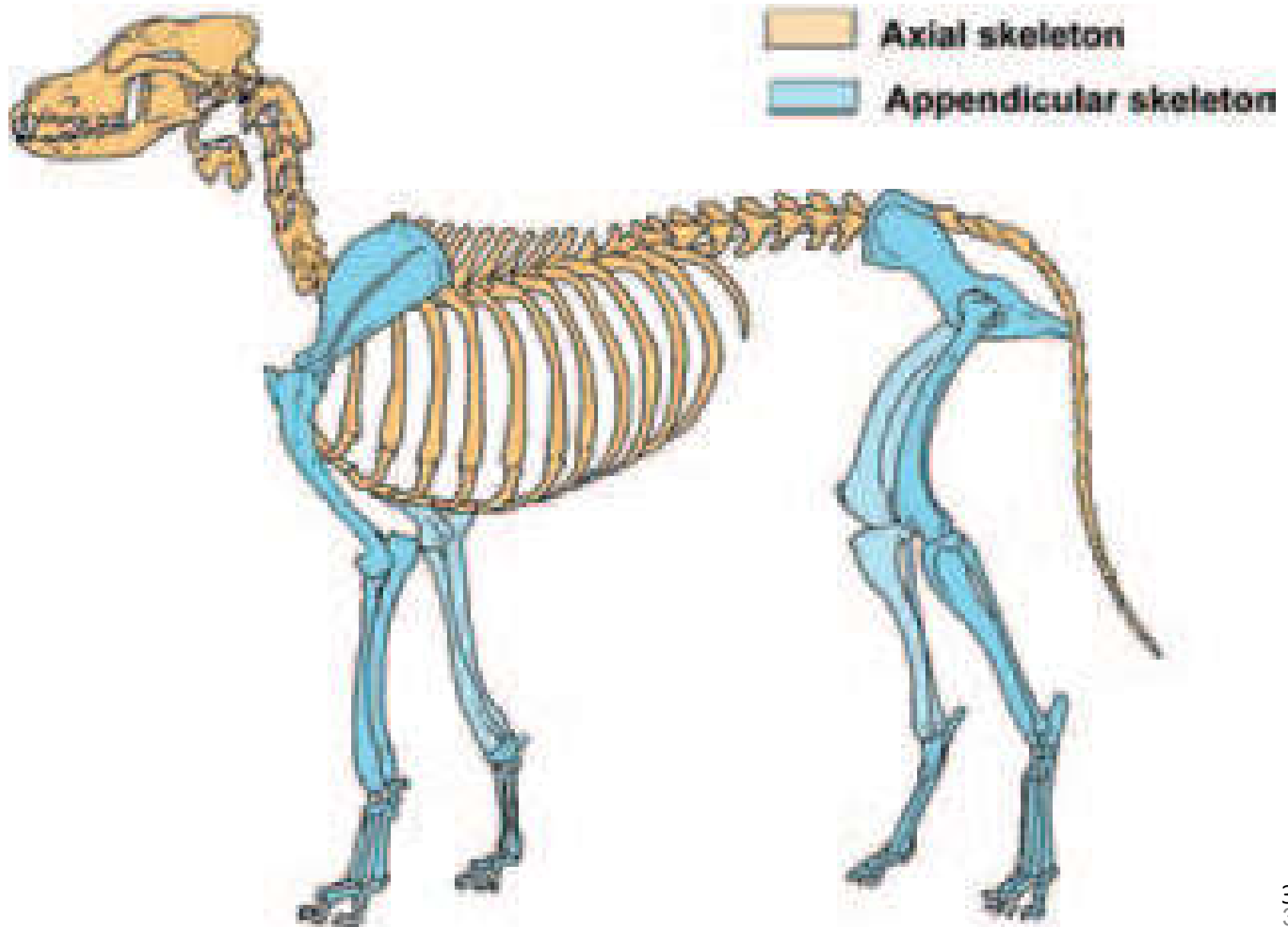
II. Appendicular skeleton:

- bones of limbs
 - Pectoral /thoracic/fore limbs
 - Bone of the hind limbs

III. Splanchnic or visceral skeleton:

- Are types of bone found deeply embedded by muscle at visceral organs. E.g. Os penis in the penis of dog, os-cordis in the heart of bovine.

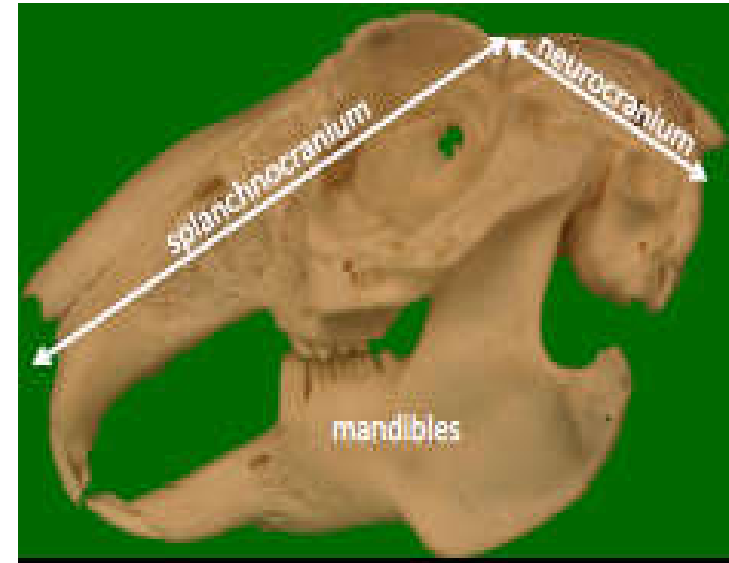
Axial and appendicular skeleton



2.4.1. Axial skeleton

1. Skull

- ✓ The skull is the part of the skeleton that shapes the head and face.
- ✓ Usually head is composed of 50 individual bone which are complex in shape.
- ✓ Provide protection for brain, organs of special sense like sight, hearing and balance, smell and taste.
- ✓ The skull is composed of two groups of bone parts:
 - i). Bones of cranium (Cranial part)*
 - surrounds the brain
 - ii). Bones of face (Facial part)*
 - cover the nose, teeth and other related structures



Bones of cranium

- Could be paired or unpaired. Most unpaired bones are found on median part of the skull. These bones includes:
 - » Occipital bone
 - » Ethmoid bone
 - » Sphenoid bone
- Those **paired cranial bones** are found on the **lateral part** of an animal. These includes:
 - » Interparietal bone
 - » Parietal bone
 - » Frontal bones
 - » Temporal bones

Unpaired Bones of cranium

A. Occipital bone

- Found at the caudal part of cranium.
- most caudal roof and floor of the cranium.
- The occipital bone has the following structures:
 - » **Foramen magnum**: - large foramen at the center through which the spinal cord passes.
 - » **Occipital condyles**:- cylindrical bony projections that articulates with the atlas.
 - » **Jugular (paramastoid) process**: - non articular bony projections for muscle attachment.
 - » **Nuchal crest**: - is the prominent ridge on the dorsal external aspect of the occipital bone.

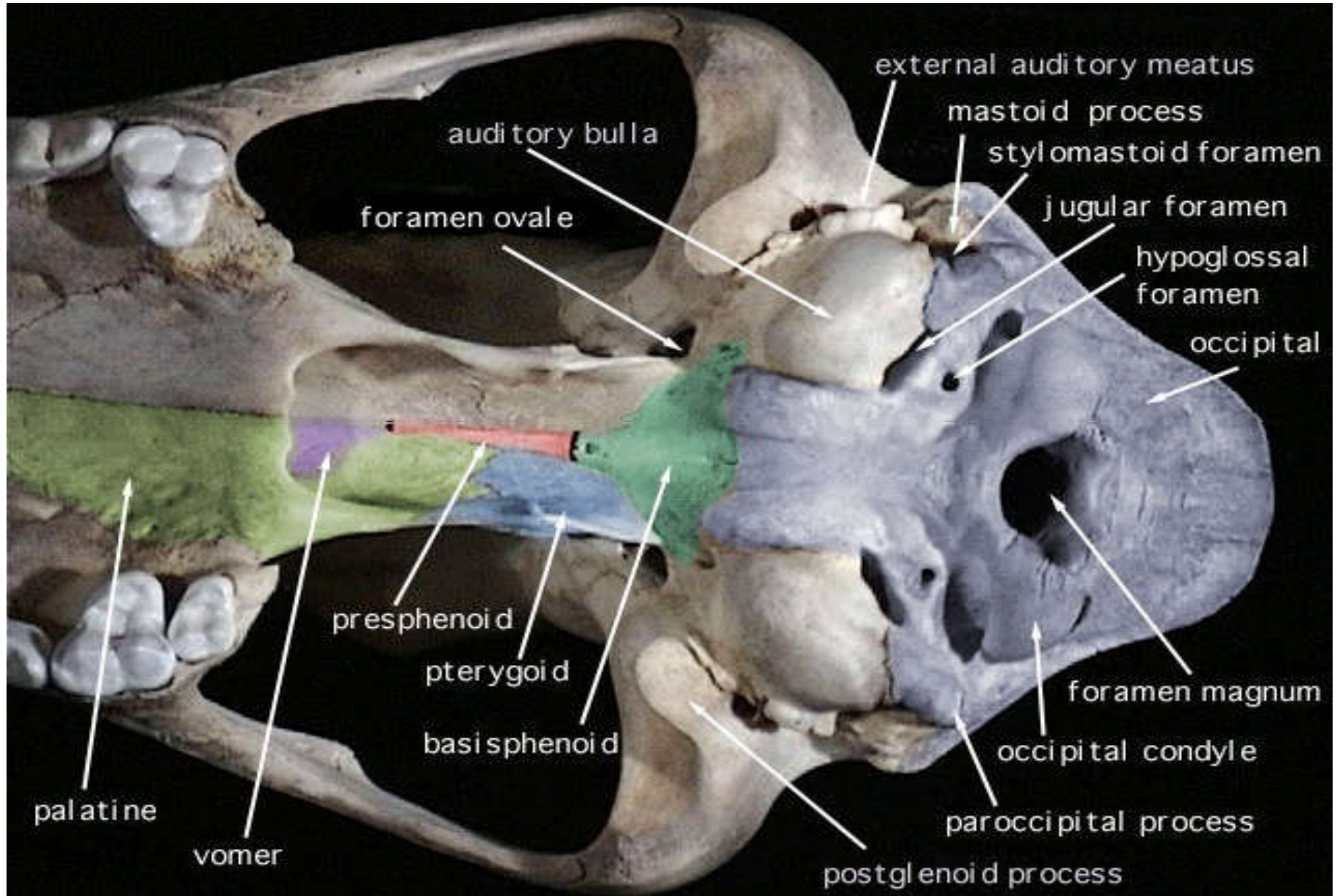
B. Sphenoid bone

- lies on the floor of the cranium.
- It is a place where the pituitary gland is found.
- ❖ a special place on sphenoid bone where pituitary gland is found is called **sella turcica**.

C. Ethmoid bone

- Forms rostral part of the cranial cavity.
- It consists of **cribriform plate (sieve like appearance)** for the passage of olfactory nerves towards the nose.

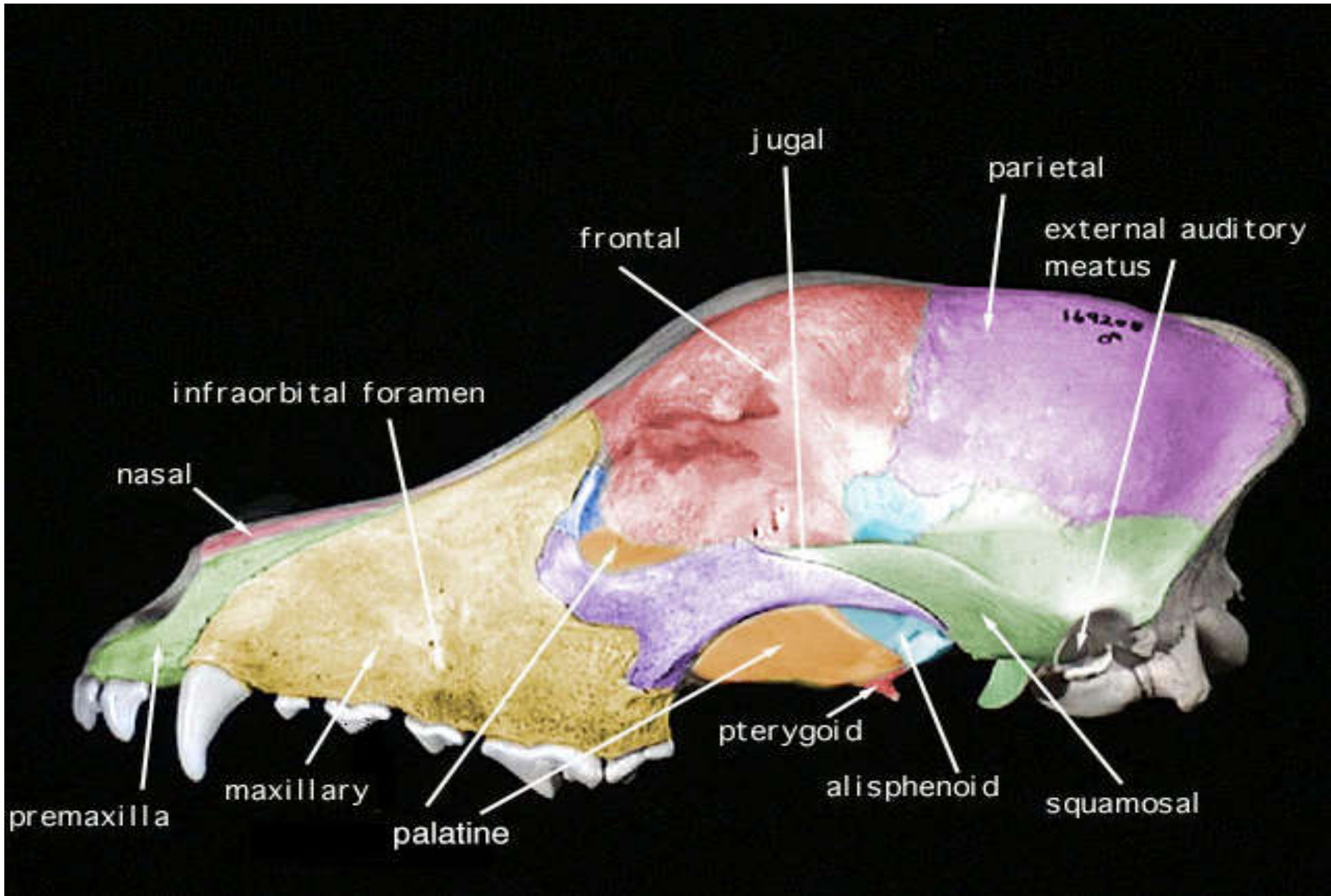
DIAGRAM SHOWING OCCIPITAL BONE AND SPHENOID BONE

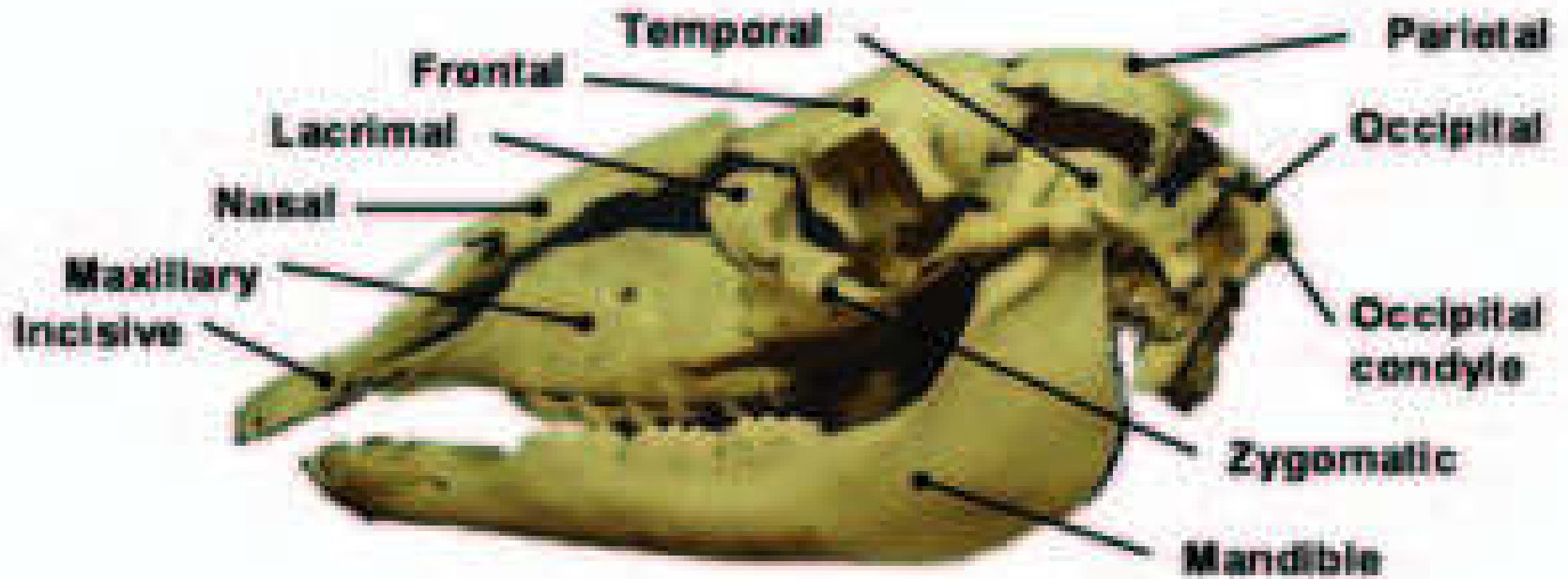
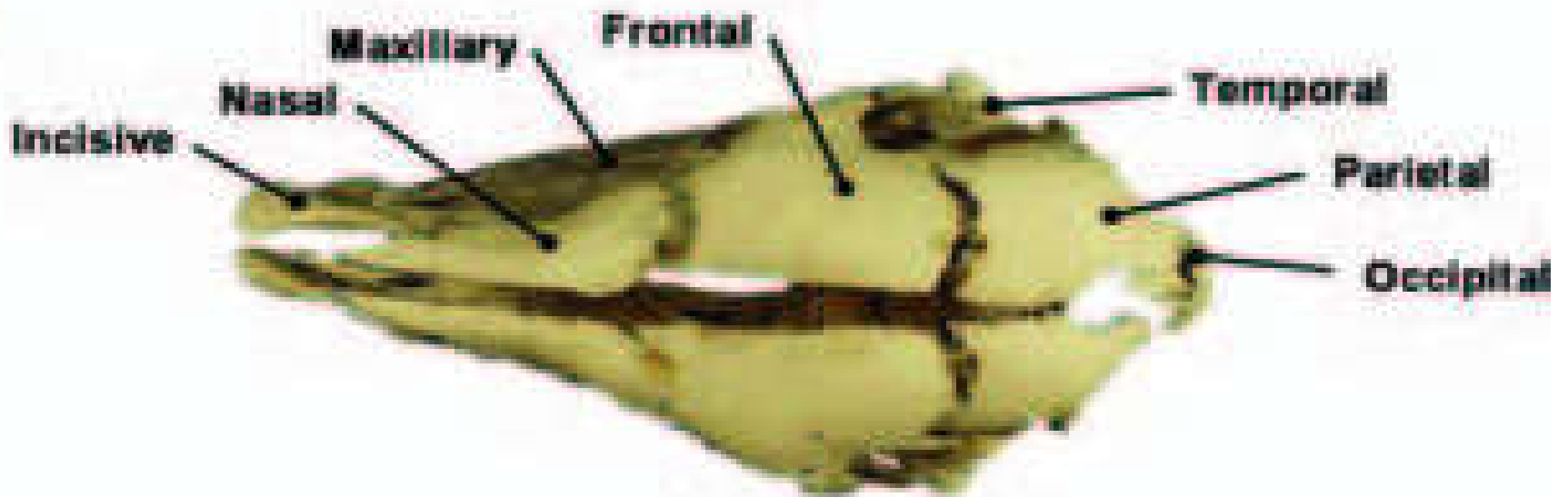


Paired bones of cranium

- A. Interparietal bone** → situated centrally b/n parts of parietal and occipital bone.
- B. Parietal bone** → compose the greatest proportion of vault of cranium.
- C. Frontal bone** → situated b/n parietal and nasal bone. It forms the roof of cranial cavity and encloses frontal sinuses (air space).it consists of:
- **Zygomatic process** → projection of bone that forms the arch of orbit.
 - **Corunal process** → forms the bony core for horn.
 - **Supra orbital foramen** → usually are paired.
 - **Frontal sinus** → air space inside the bone.
- D. Temporal bone** → They form the greater portion of the lateral wall of cranium.

Paired bones of cranium



A**B**

Bones of the face:

- **Consists of paired and unpaired bone.**

Bones of the face	
Paired bones	Unpaired bones
Maxilla	Vomer
Premaxilla (incisive)	Mandible
Palatine	Hyoid bone
Nasal	
pterygoid	
lacrimal	
Zygomatic (molar)	
conchae (turbinate, meatus) : four types (Dorsal, middle, ventral and common)	

Paired Bones of the face

A. *Maxilla* → basal part of the upper jaw and forms sockets for upper cheek and canine teeth. It consists of zygomatic process, maxillary sinuses, facial crest and two infraorbital foramen.

B. *Incisive bone* → found on the rostral part of the upper jaw. It forms the bony base of the upper incisive bone.

C. *Palatine bone* → found at the caudal side of nares.

D. *Pterygoid bone* → two very small flattened bones situated at either side of caudal nares.

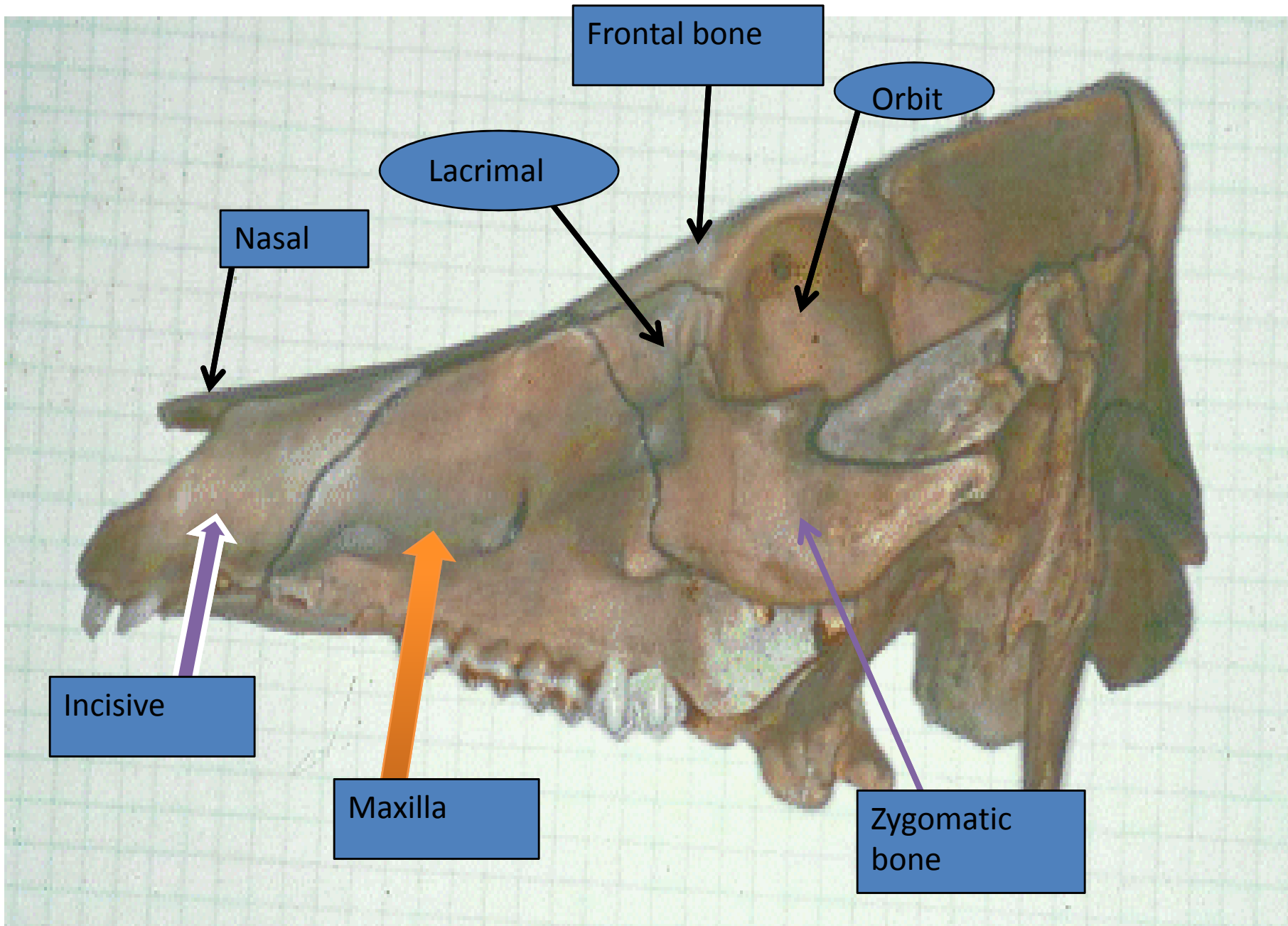
E. *Nasal bone* → forms the major parts of the roof of the nasal cavity.

F. Lacrimal bone → is found on the rostroventral part of the orbit. They are perforated by lacrimal foramen through which tear is easily passed out to the environment.

❖ The bony socket that protect the eye is called **orbit**. It is surrounded by portions of *frontal, lacrimal and zygomatic bones*.

G. Zygomatic bone → found on the rostro-lateral to the lacrimal bone.

H. Turbinate/conchae → Are very thin bones rolled into scroll like formation which are covered by mucus membrane. They helps in filtering and warming up of the air.

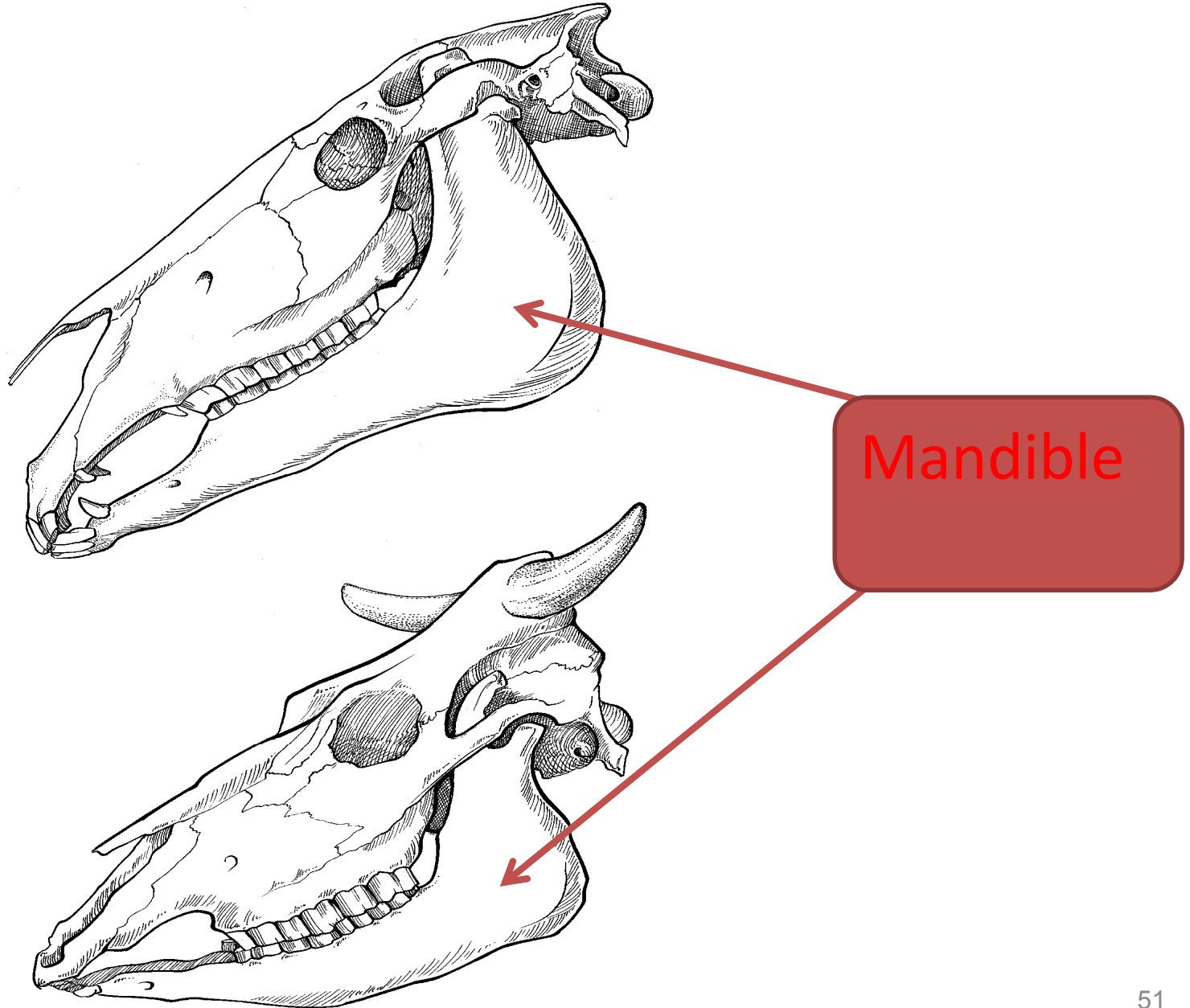


Unpaired bone of the face

A. Mandible:

- The **largest bone** of the face and forms the lower jaw.
- Composed of two halves that fuse anteriorly at the **mandibular symphysis**.
- It contains all lower teeth.
- It Consists of **body(horizontal part)** and **two rami(ventral part)**.
- It Consists of **two mental foramen** that are located laterally on the body.
- It also consists of **two mandibular foramen** located medially above half way of the rami.

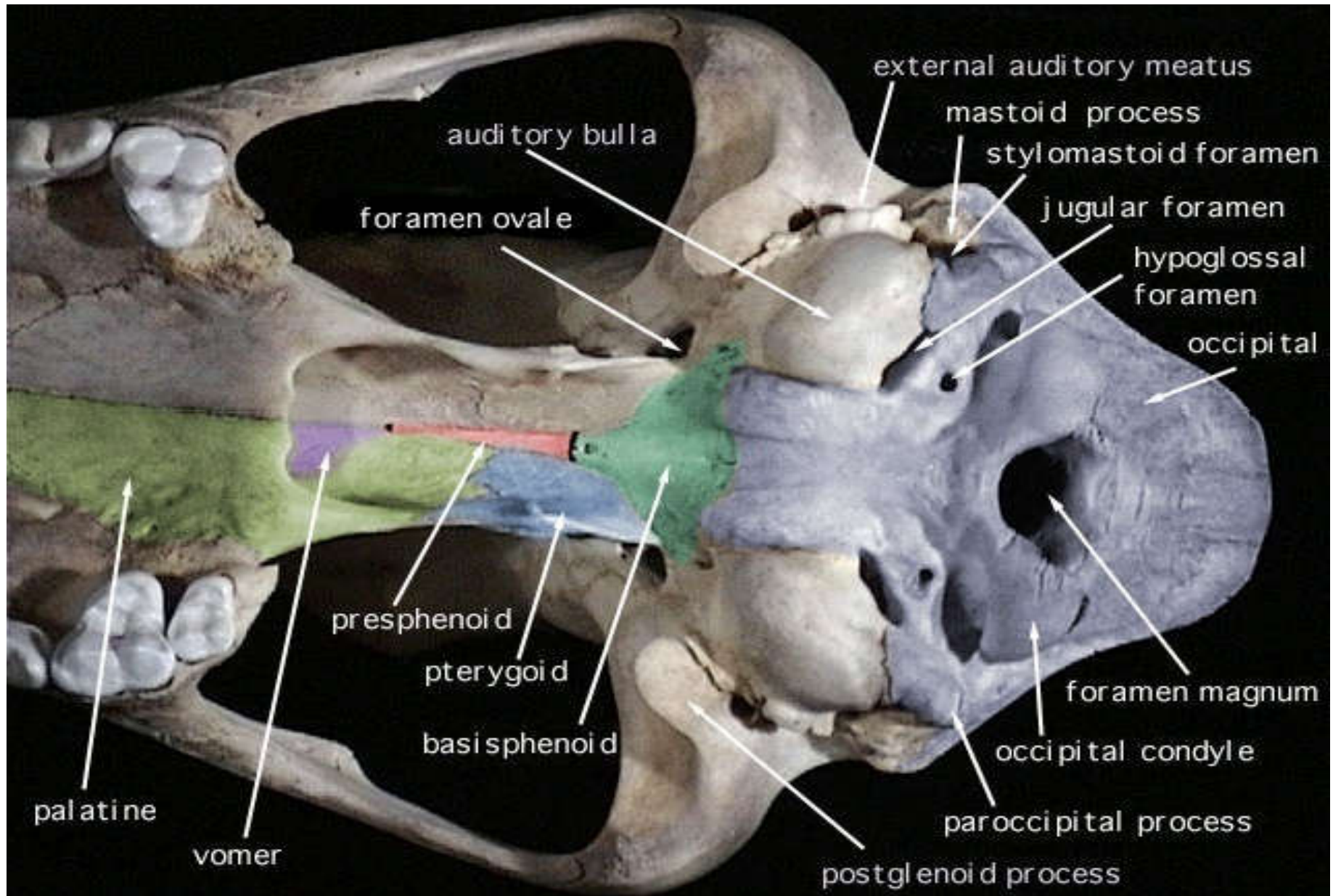
Diagram showing the mandible



B. *Vomer* → is a median bone that forms the ventral Part of the nasal cavity. It separates the right and left of the nasal passages with a [cartilaginous septum](#).

C. *The hyoid apparatus (hyoid bone)* → is a bony framework that gives support to the pharynx (throat), larynx and tongue. It is found between the right and left portions of the mandible.

DIAGRAM SHOWING VOMER



2. Vertebral column

- Extends from the base of the skull to the tip of the tail.
- Consists of a chain of *median, unpaired, irregular* bones called *vertebrae*.
- The vertebral column encloses and protects the spinal cord .
- The **Vertebral** column is sub-divided in to **five** regions,
 - named according to the **part of the body** in which the vertebrae are situated.

– These are:

» Cervical Vertebrae(C) → neck region

» Thoracic Vertebrae (T) → thorax region

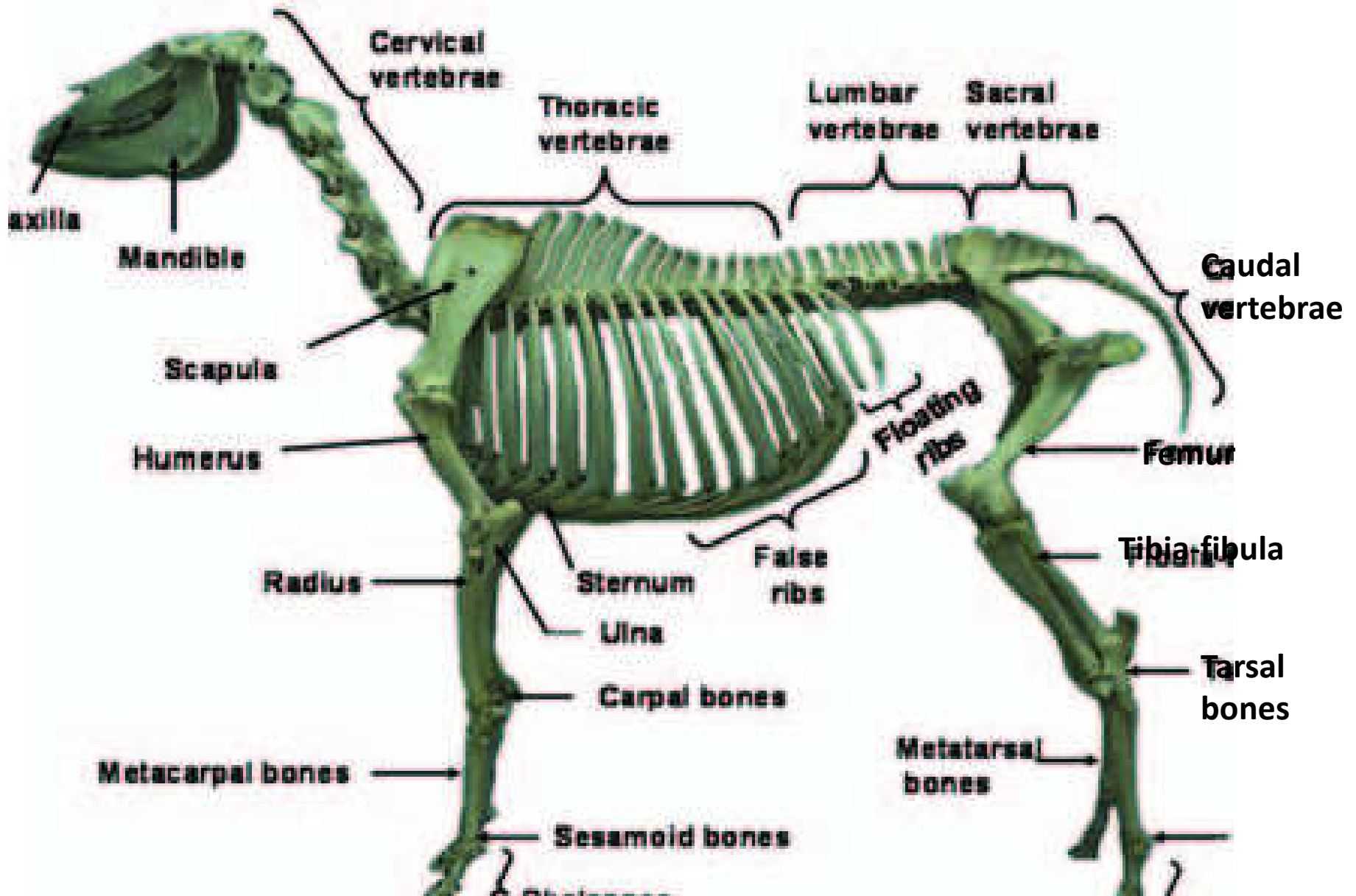
» Lumbar Vertebrae (L)→ Loin region

» Sacral Vertebrae (S) → Croup region

» Caudal (coccygeal) Vertebrae (Cd)(Cy) → tail region

- Usually the number of vertebrae in each of the vertebrae that composes each region varies with species. Due to that each animal species do have their own *vertebral formula*.

<i>Species</i>	<i>Cervical (C)</i>	<i>Thoracic (T)</i>	<i>Lumbar (L)</i>	<i>Sacral (S)</i>	<i>Caudal (Cd/Cy)</i>
Horse	7	18	6	5	15-20
Cattle	7	13	6	5(found fused)	18-20
Sheep	7	13	6-7	4	16-18
Goat	7	13	7	4	12
Camel	7	12	7	4	18-20
Pig	7	14-15	6-7	4	20-23
Dog	7	13	7	3	20-23
Chicken	14	7	14(lumbo sacral)	-	6



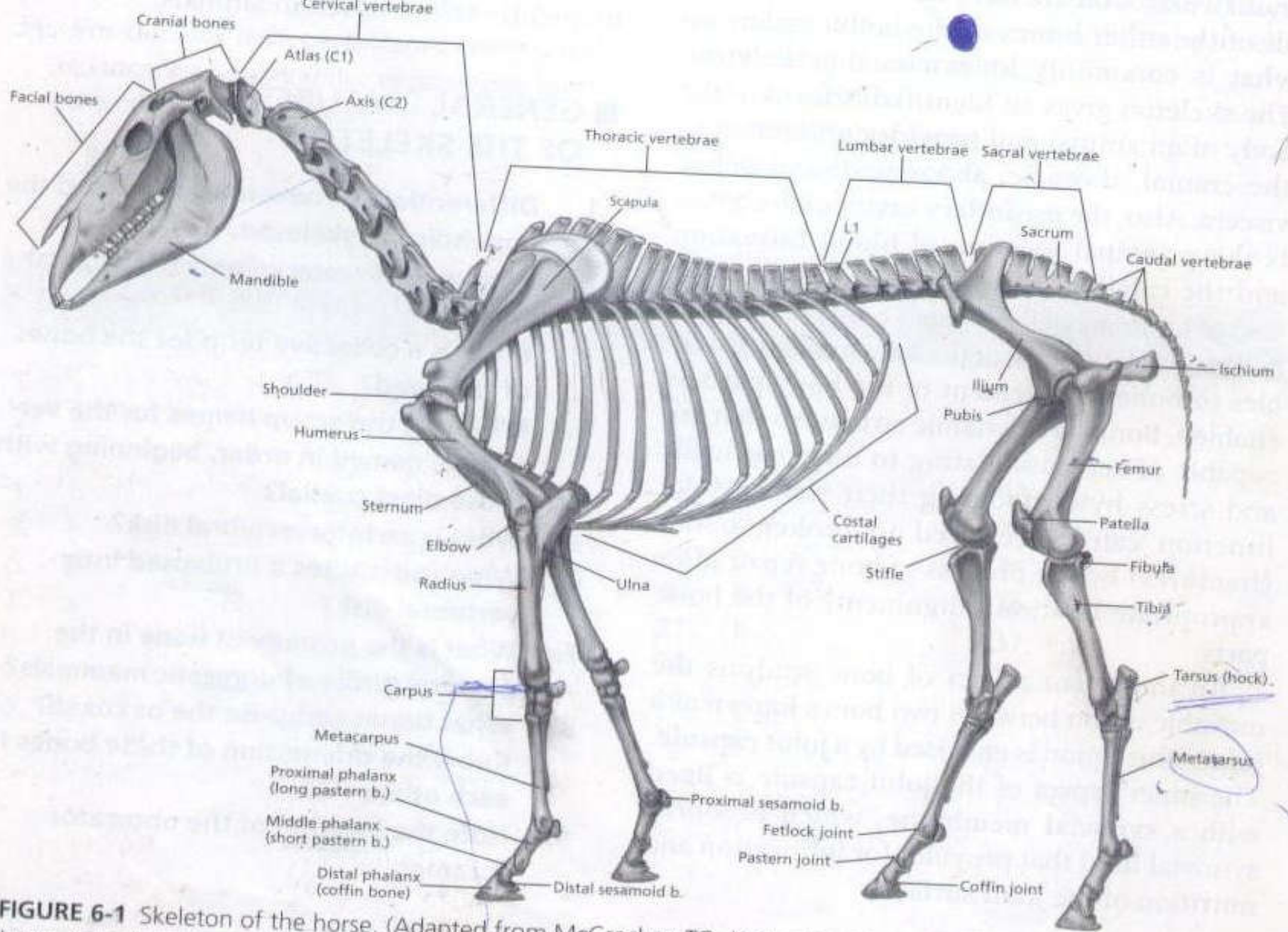
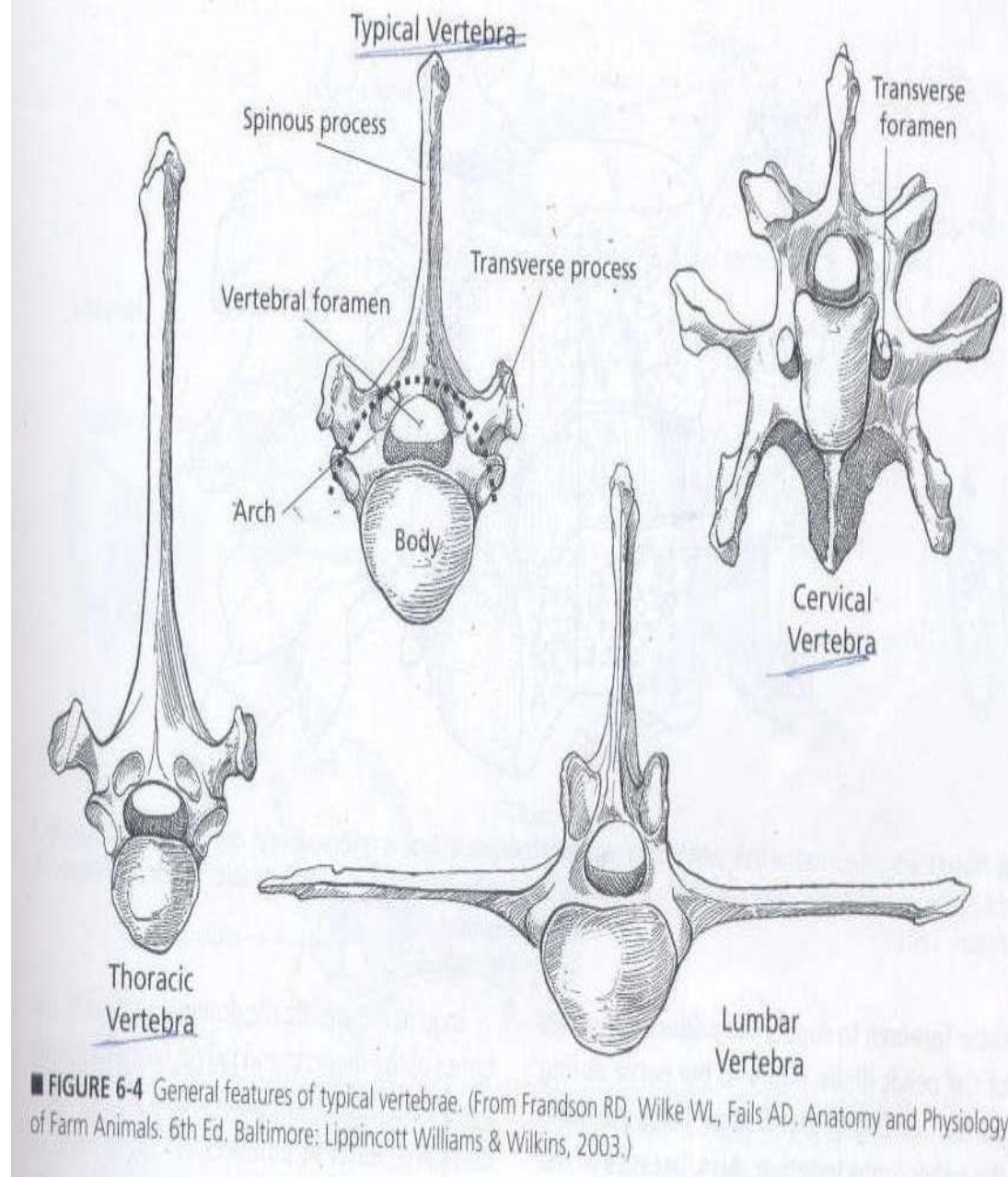


FIGURE 6-1 Skeleton of the horse. (Adapted from McCracken TO, Kainer RA, Spurgeon TL. Spurgeon's Color Atlas of Large Animal Anatomy: The Essentials. Baltimore: Lippincott Williams & Wilkins, 1999.)

2.1. Vertebrae:

- ✓ Typical vertebrae is characterized by:
 - *Body*
 - *Arch*
 - *Process*
- ✓ The part of a vertebrae consists of these structures with variable **size**, and **shape** depending on the **region**.



❖ **Body (Corpus):**

- Is cylindrical mass forming the ventral part of the vertebrae.
- Do have cranial and caudal part. Cranial part of the body is *convex* . Caudal part is *concave* which attached with the adjacent vertebrae by:
 - » *intervertebral fibro cartilaginous structure.*
- Do have dorsal and ventral part. The dorsal part is flattened and participates in the formation of the **vertebral canal (vertebral foramen)**. Where as the ventral part is round.
- **Thoracic vertebrae** contains two pairs of **facets** on cranial and caudal part that articulate with part of head of successive pairs of ribs.

❖ Arch:

- constructed on the dorsal aspect of the body that forms bony ring together with it and enclose the vertebral canal (foramen).

❖ Process :

- Non- articular bony projection.
- There are **three** main processes in vertebrae:
 - A. *Spinous process* : projects dorsally from the middle of the arch.
 - » It is single.
 - B. *Transverse process* :- projects laterally from the side of the arch or junction between body and arch.
 - » It is **two** in number.

C. Articular process : - Projects from the border of the arch.

» usually four in number (two cranial, two caudal).

❑ **There are different openings in vertebral column.**

- serves for the passage of spinal nerves and blood vessels.

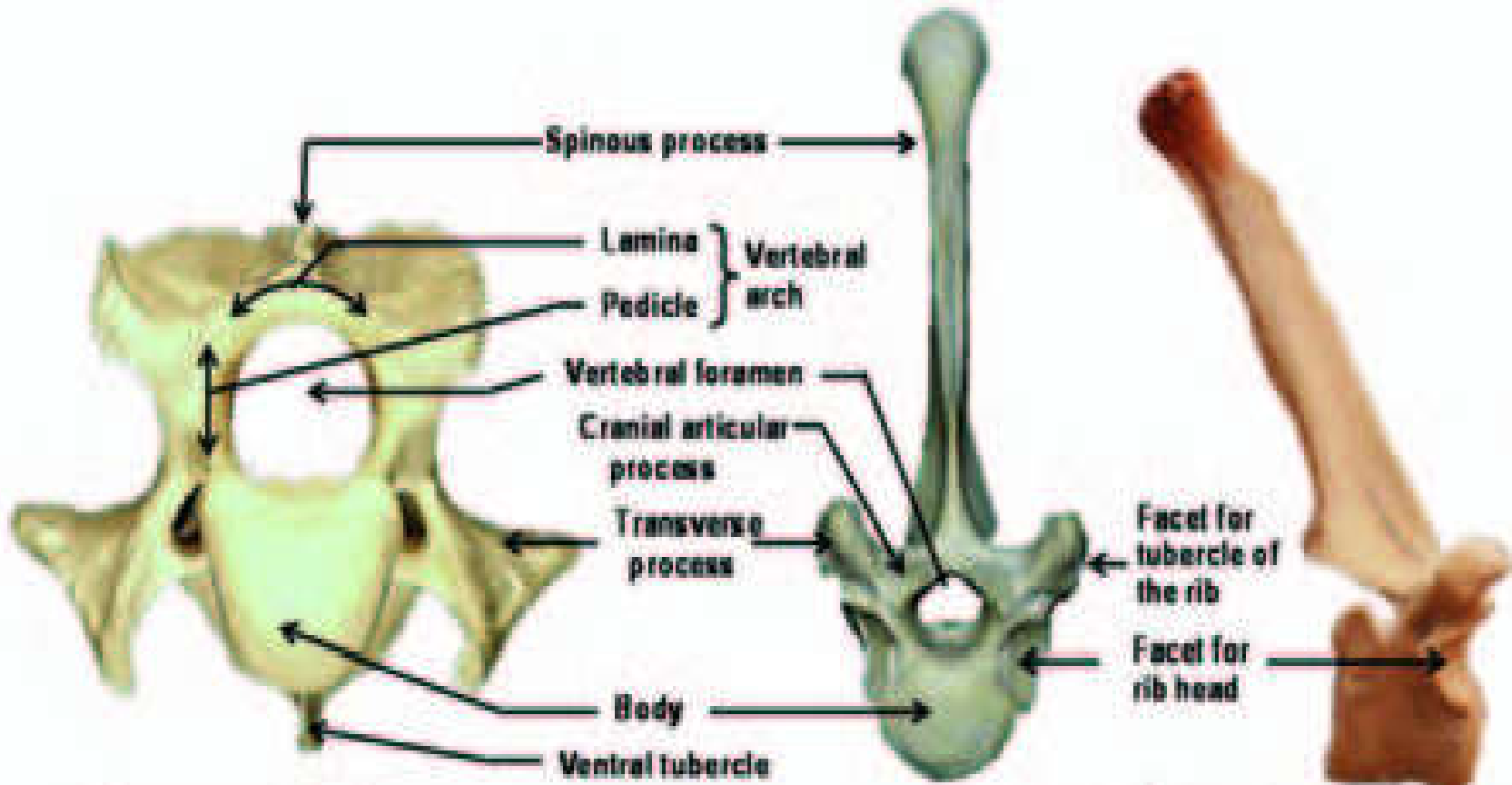
❑ These openings may be:

a) Between two adjacent vertebrae:

- Called **inter-vertebral foramen.**

b) On transverse process:

- called **transverse foramen.**



Cervical vertebra

Thoracic vertebra



Lumbar vertebra



Sacral vertebra

A. Cervical vertebrae:

- Vertebrae of the neck region.
- All domestic animals have seven (7) cervical vertebrae except chicken.
- The first two, **atlas** and **axis**, are much more modified to allow **free movement of the head.**

I. Atlas:

- is the first cervical vertebra (C1).
- Body and spinous process are absent.
- Consists of two lateral mass which is known as wing of atlas.
- It articulates with :
 - » occipital condyles of the skull cranially and
 - » the dens of the axis caudally.

II. Axis

- is the second cervical vertebrae (C2).
- Its spinous process is long as compared to atlas.
- Its body has a cranial projection called the “dens” which articulate with atlas.

III. The next four cervical vertebrae :

- Are similar to one another with large articular and transverse process and poorly developed spinous process.
- The transverse process branches in to dorsal and ventral tubercles.
- These vertebrae have paired transverse foramen and single vertebral foramen for the passage of nerve and blood vessels.

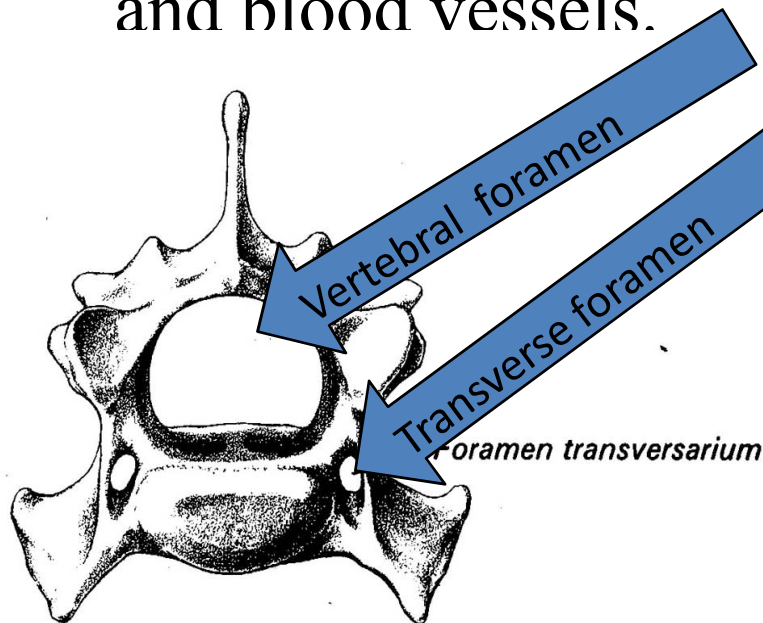
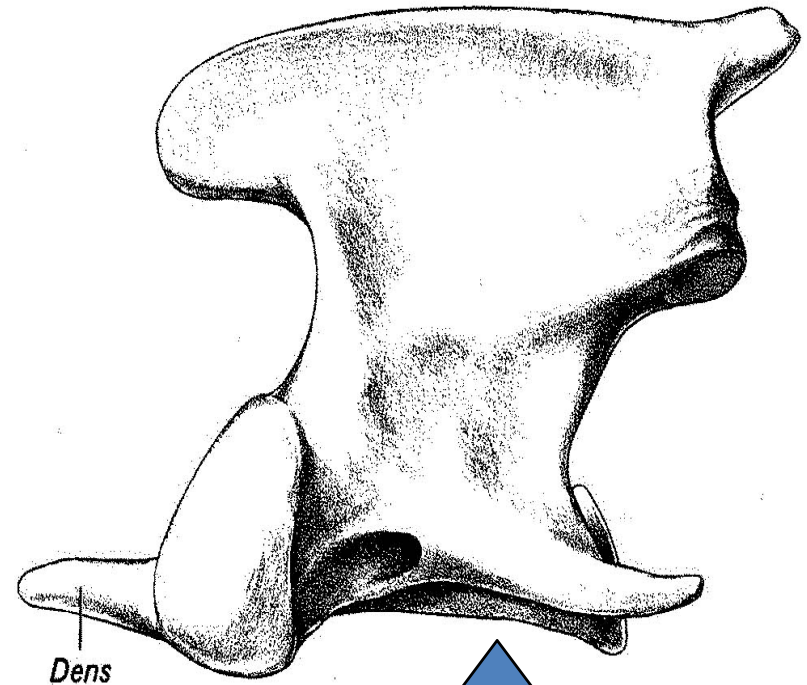
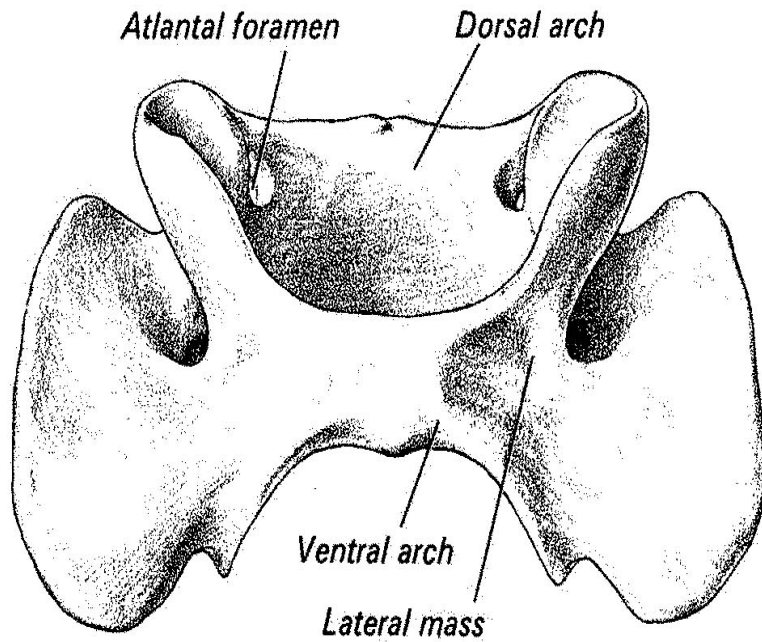


Diagram showing vertebral foramen and transverse foramen

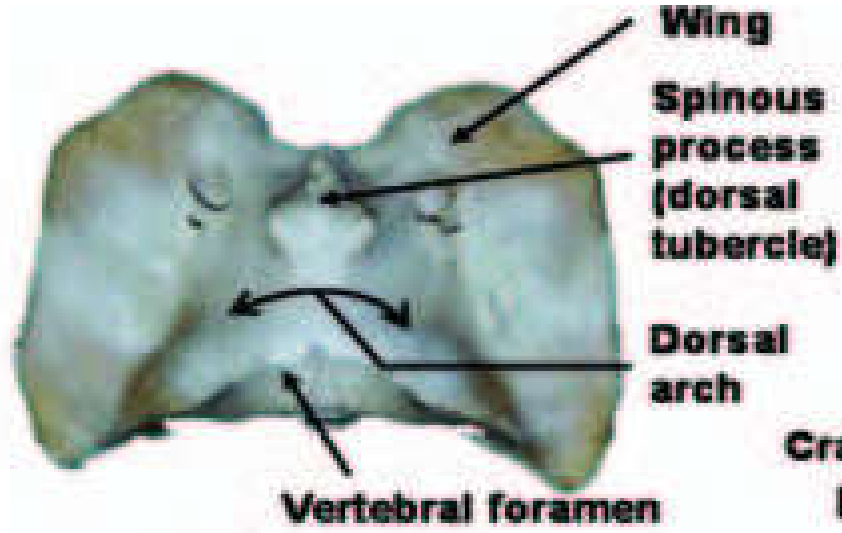
Atlas and axis: first two cervicals

Atlas

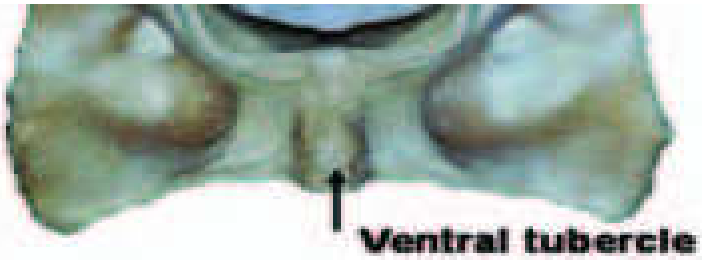

Axis

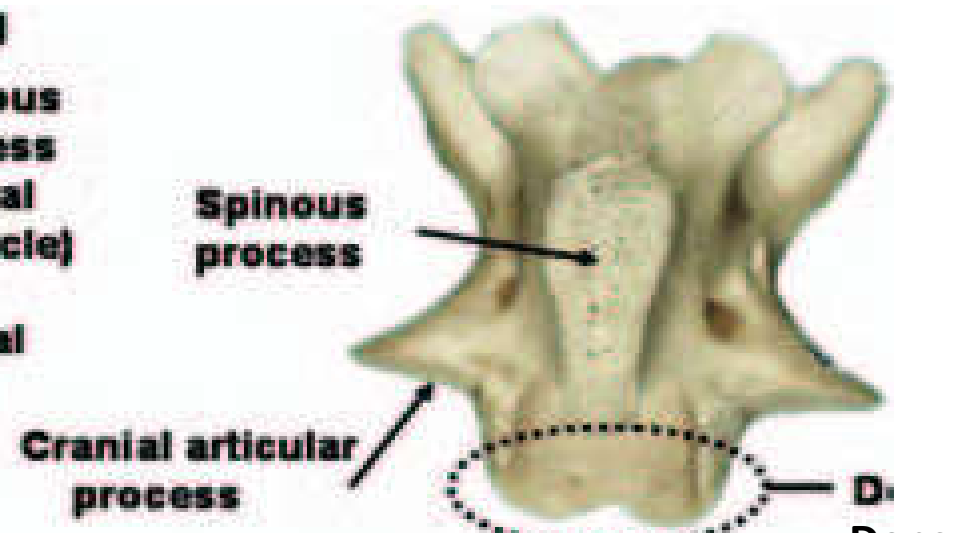
Atlas



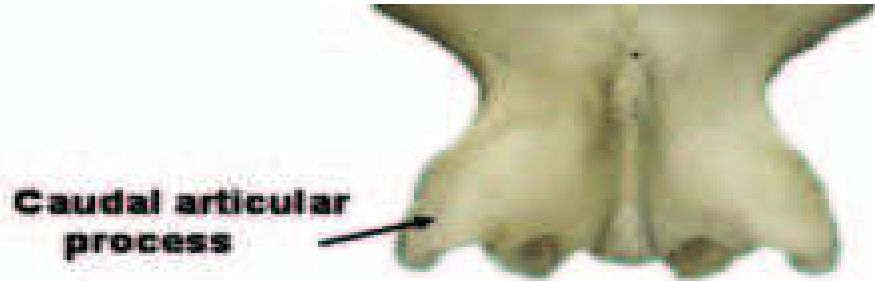

Dorsal view



Axis



Dorsal view



IV. The seventh cervical vertebra :

- » Is the transition between cervical and thoracic vertebrae.
- » Is distinguished by its taller spinous process.
- » Has **no transverse foramen** on its transverse process.
- » On the caudal extremity, its body possess **facets** for articulation with the first pair of ribs.

B. Thoracic Vertebrae

- » are characterized by **well-developed spinous processes** and **articular facets**.
- » have short **body** consisting for articulation with the **head of ribs**.
- » **Transverse process** is relatively shorter, thick and has costal facets for articulation of the **tubercle of ribs**.

C. Lumbar Vertebrae:

- » distinguished by large and flattened transverse processes that project laterally.
- » have no costal facets and have short spinous process.
- » The body and caudal articular process of the last lumbar vertebra articulate with the **sacrum**.

D.Sacral Vertebrae (Fused vertebrae = false vertebrae)

– are fused to form a single wedge-shaped bone called “*Sacrum*” which is wider cranially, narrower caudally.

– articulates with :

» the last lumbar vertebrae cranially,

» the first coccygeal vertebra caudally and

» pelvic bone cranio- laterally.

- In most species ,dorsal surface has spinous process, but no incase of **pigs**.
- In dogs and horses **spinous process present separately**.
- In ruminants spinous process fused together to form **median sacral crest**.
- Lateral side of fused transverse process forms the **lateral sacral crest**.

- ❖ The inter-vertebral foramens in this region are many, which are called **sacral foramen**,
 - from caudal and ventral side of the bone
 - give the passage of **spinal nerves**.

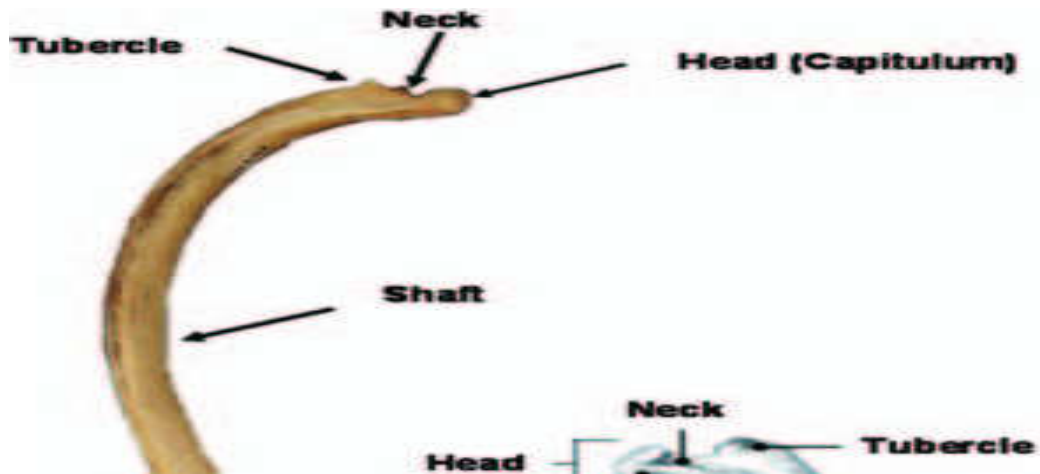
E. Coccygeal (Caudal) Vertebrae:

- form the bony basis of the tail.
- The numbers of vertebrae depends on:
 - the length of the tail,
 - The type of species
- The size of the vertebrae decreases in caudal direction up to small rods of bones.

3. Ribs (costae)

- ✓ The ribs (costae) are long curved bone that form the lateral wall of the *thoracic cage(cavity)*.
- ✓ Usually the number of pairs of ribs is the same as the number of thoracic vertebrae.
- ✓ A typical ribs consists of:
 - vertebral extremity dorsally
 - Shaft and
 - Sternal extremity ventrally,
- ✓ Except for the last one or two pairs of ribs,
 - the sternal extremity is connected to the sternum by the **costal cartilage**.

- ✓ The vertebral extremity consists of :
 - ✓ spherical head
 - ✓ constricted neck and
 - ✓ tubercle.



✓ Depending on the **connection** with sternum, ribs can be grouped in to **three as:**

I. Sternal (true) Ribs:

- Their costal cartilage articulates directly to the sternum.

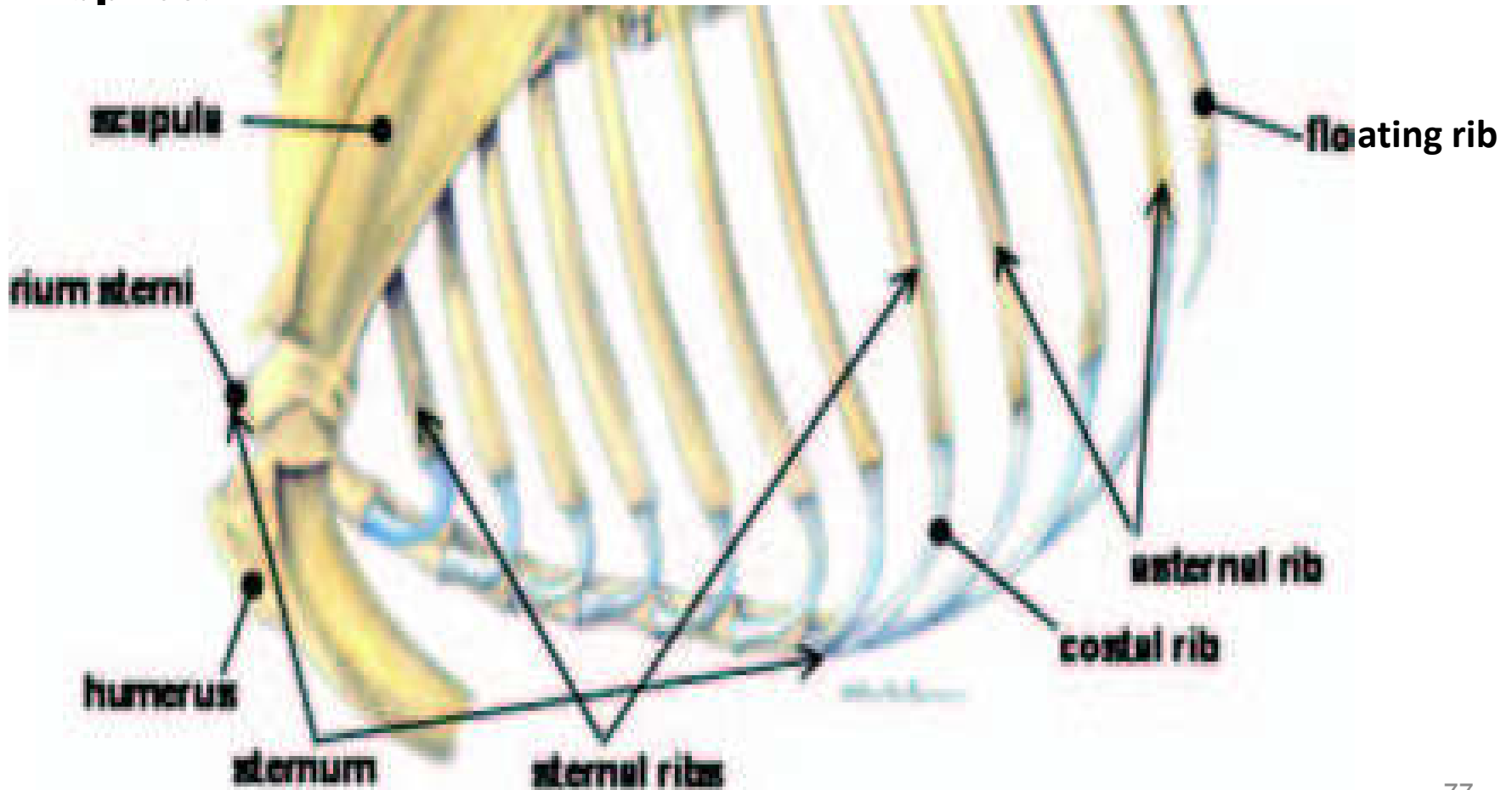
II. Asternal (false) ribs:

- Their cartilage is not directly articulate to the sternum.
- They have indirect connection; their cartilage overlaps and forms the costal arch. So that it articulates with sternum by this single costal arch.

III. Floating ribs:

- Their cartilage has no any contact with sternum.

✓ The space between individual adjacent ribs is called **intercostal space**.



4. **Sternum (breast bone)**

- ✓ The sternum forms the floor of the thoracic cage.
- ✓ It has three parts:
 - a) **Manubrium (pre-sternum)**
 - b) **Meso-sternum (Body)**
 - c) **Xiphoid process**

a) **Manubrium (pre-sternum)**

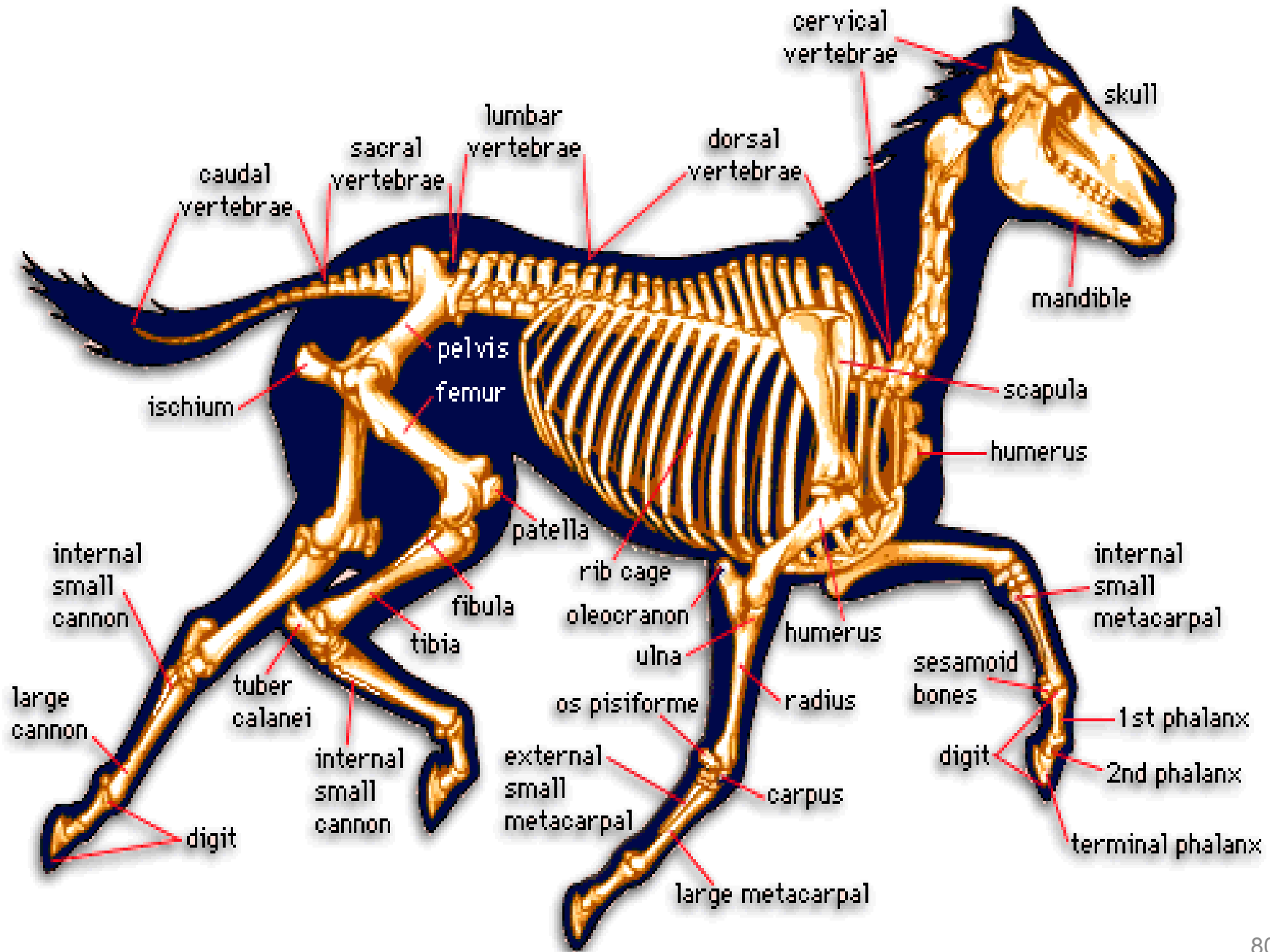
- It is the most cranial part of sternum where by the cartilages of the first ribs articulate.

b) Meso-sternum (Body)

- Situated at the medial part of sternum.
- Composed of several segments of bones called **sternebrae** that tend to fuse as **age advances**.
- The number of sternebrae varies with the species.
 - E.g. ruminants and horse (5), pig (4) and dog (6).
- Each sternebrae laterally composed of a series of **depression** for articulation of **costal cartilage**.

c) Xiphoid process

- the caudal part which is a **flat cartilage**.



2.4.2. Appendicular skeleton

❖ The appendicular skeleton is made up of bones of the limbs (forelimbs and hind limbs).

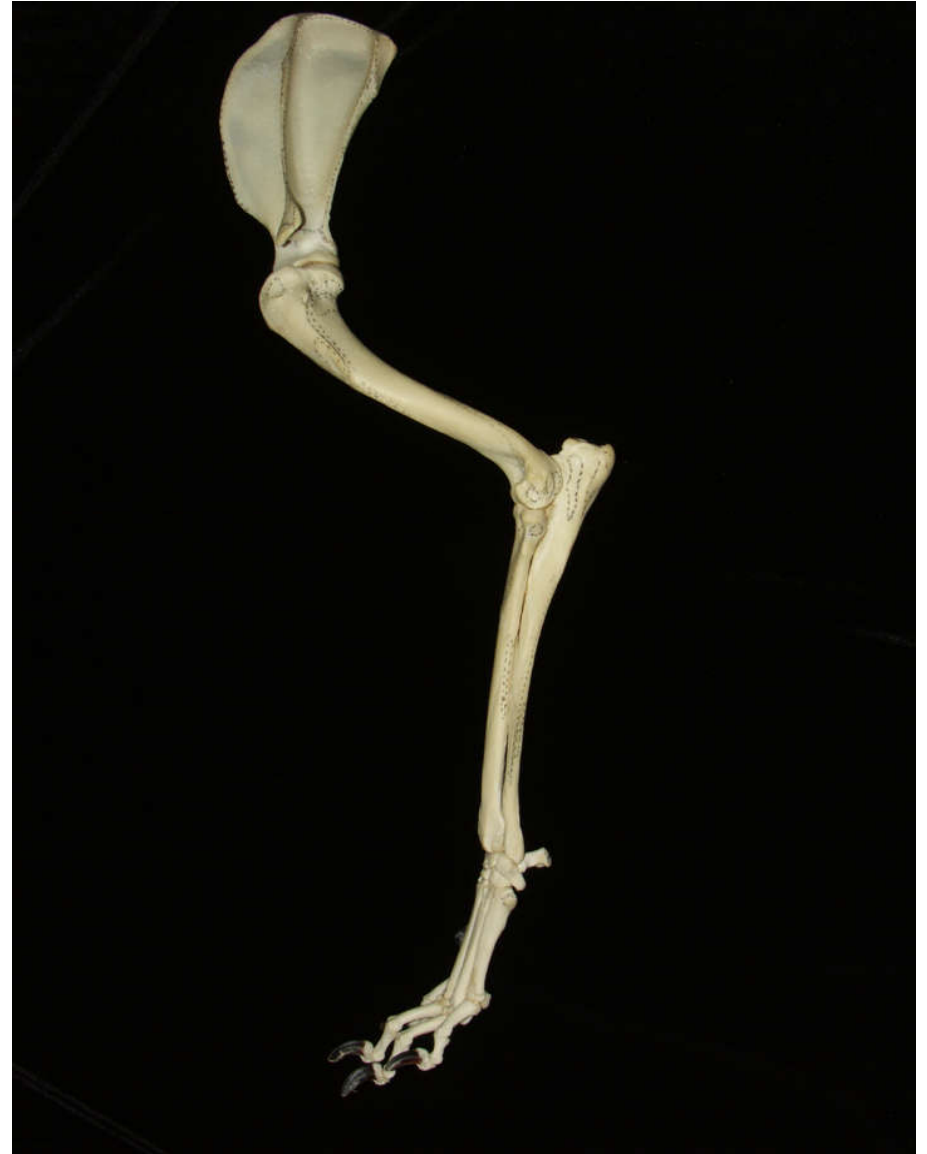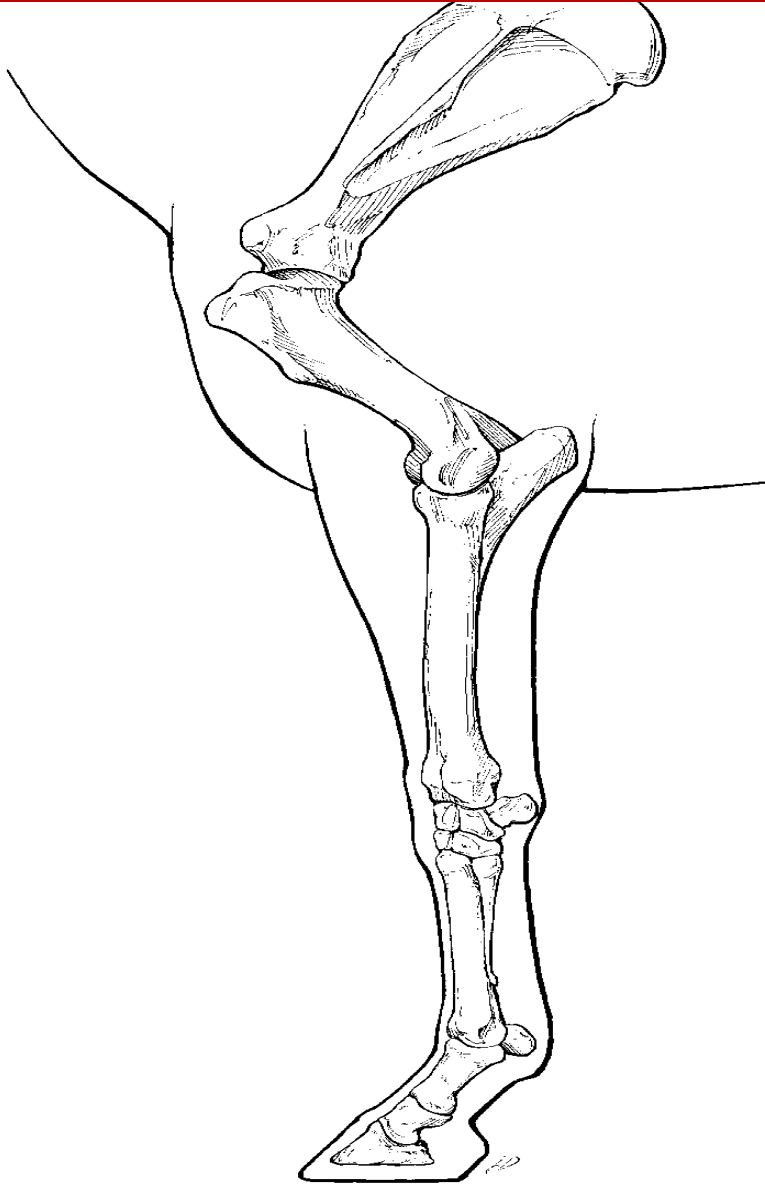
■ Pectoral (thoracic, fore, front) limbs :

✓ The thoracic limb consists of four chief segments:

<u>Segment</u>	<u>bone</u>
----------------	-------------

1. Shoulder girdle ----- Scapula, *clavicle and coracoid bones.*
2. Arm-----Humerus
3. Forearm -----Radius and Ulna.
4. Manus -----Carpal, Metacarpus and Digits.

Pectoral (thoracic, fore, front) limbs



1. Shoulder girdle

- ✓ When the shoulder girdle is fully developed, it consists of three bones:
 - *scapula (shoulder blade)*,
 - *coracoid bone*,
 - *clavicle (collar)*.
- ✓ Fully developed shoulder girdle is found in **birds**.
- ✓ Higher primates
 - have scapula and clavicle on shoulder girdle
- ✓ In domestic animals
 - only the **scapula** a large, flat bone is well developed.

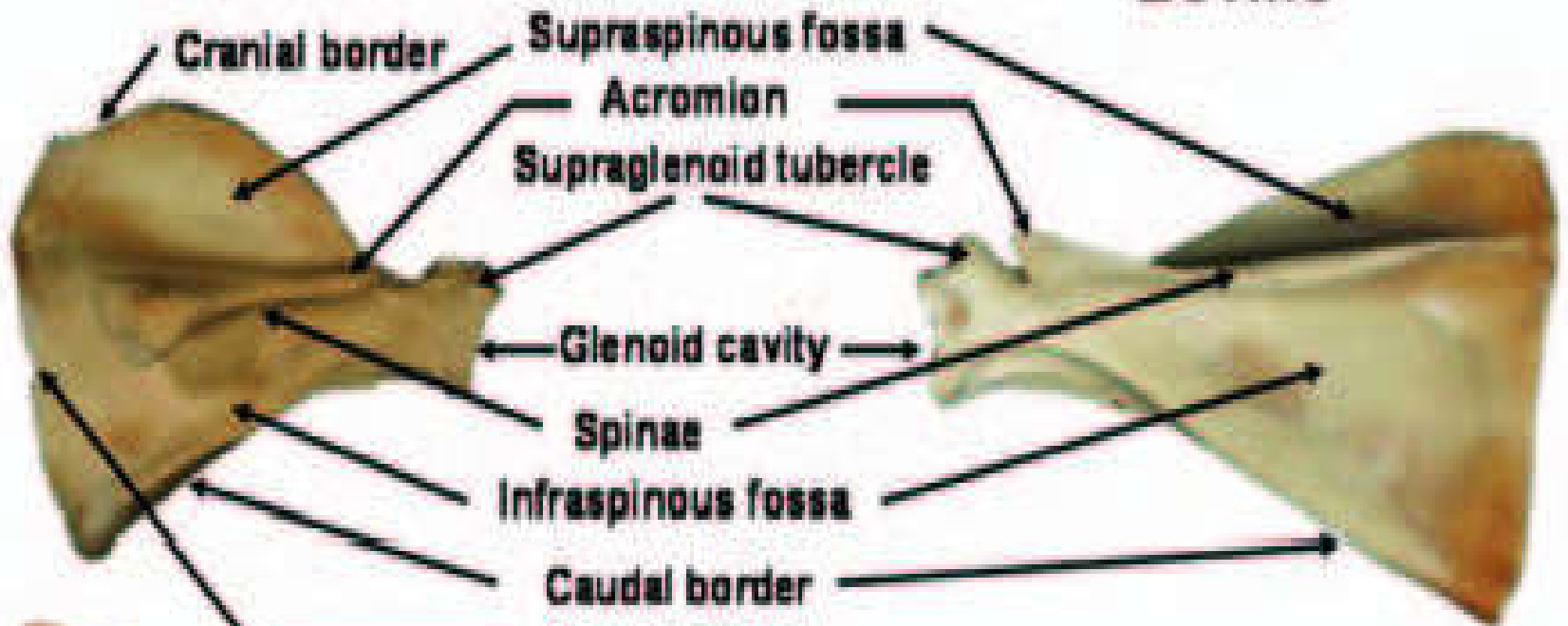
A. Scapula (shoulder blade):

- Found in all domestic animals.
- is large, flat and somewhat triangular bone.
- It has two surfaces,
 - *medial and lateral surface.*
- The medial surface
 - is flat whereas,
- The lateral surface
 - is divided in to two fossa as (Supraspinous fossa and Infraspinous fossa) by *scapular spine(scapular crest)*.
- It has two extremities,
 - Proximal/dorsal extremity and
 - Distal/ventral extremity.

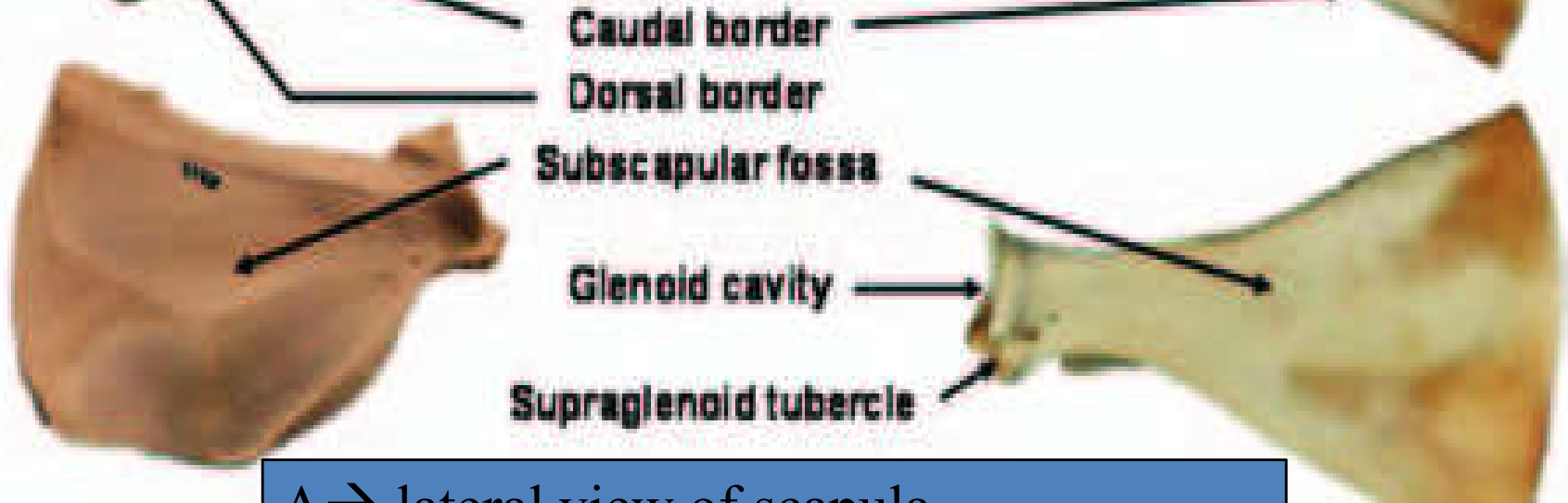
Porcine

Bovine

A.

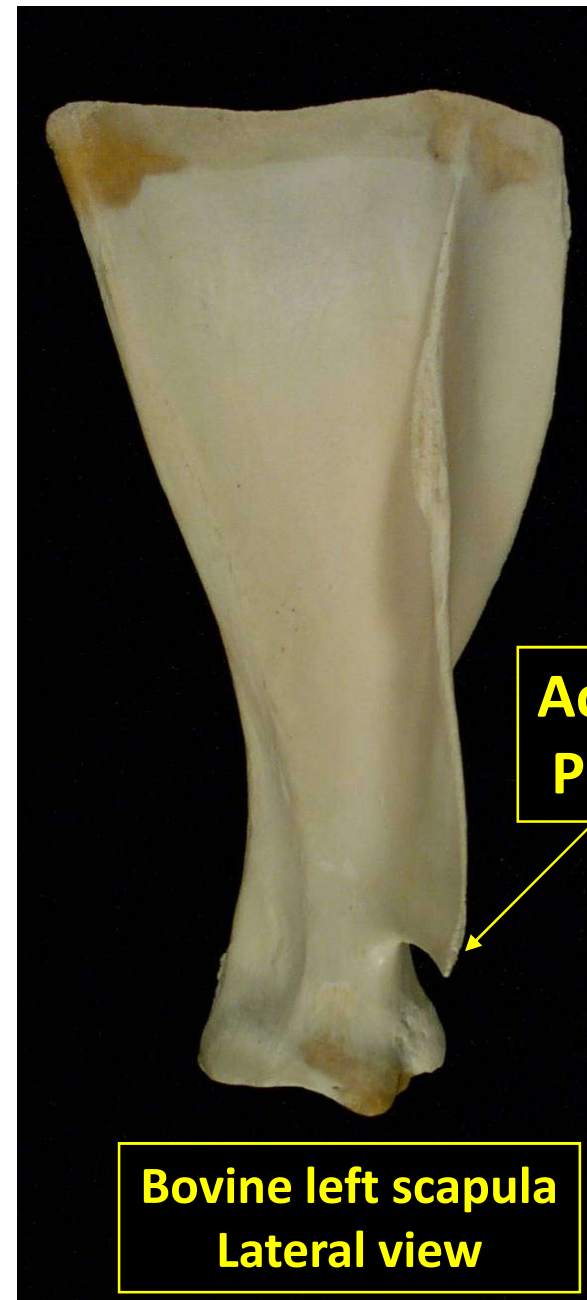


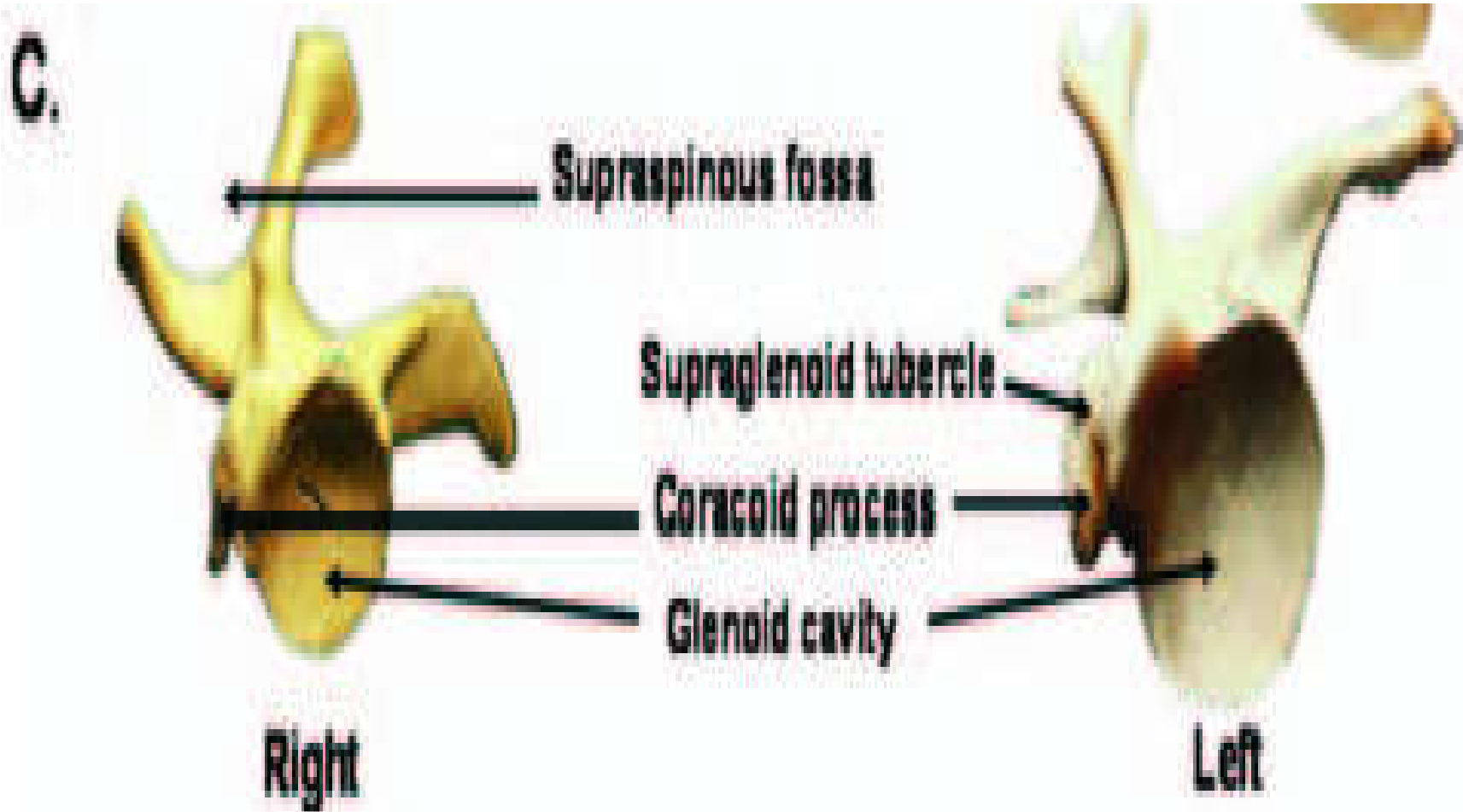
B.



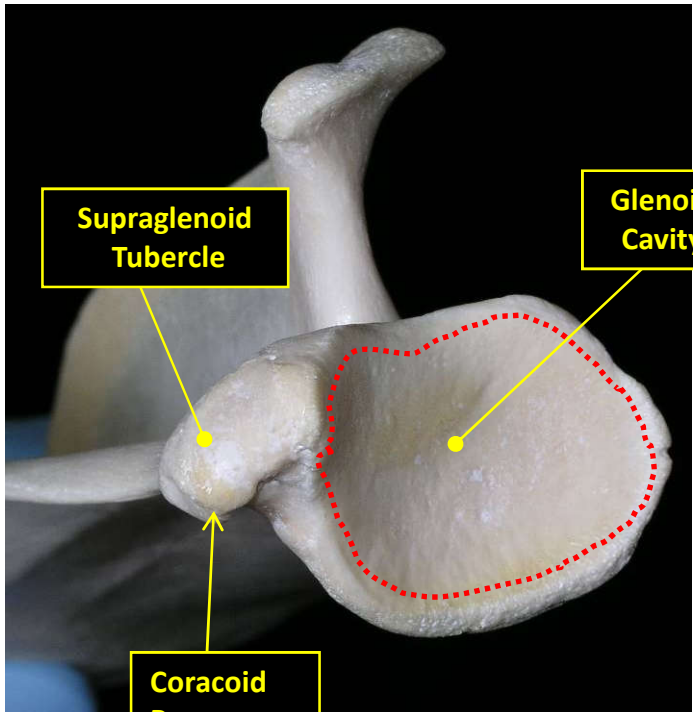
A → lateral view of scapula
B → medial view of scapula

- Dorsally the scapula is wider and has a cartilage called **scapular cartilage**.
- The distal end of the scapular spine is flattened to form ***acromion process***.
- The distal end has:
 - *coracoid process and*
 - *supra glenoid tubercle*
- Between the processes there is a depression called *glenoid cavity* which articulates with the head of the humerus.





C → Distal/ventral view of scapula

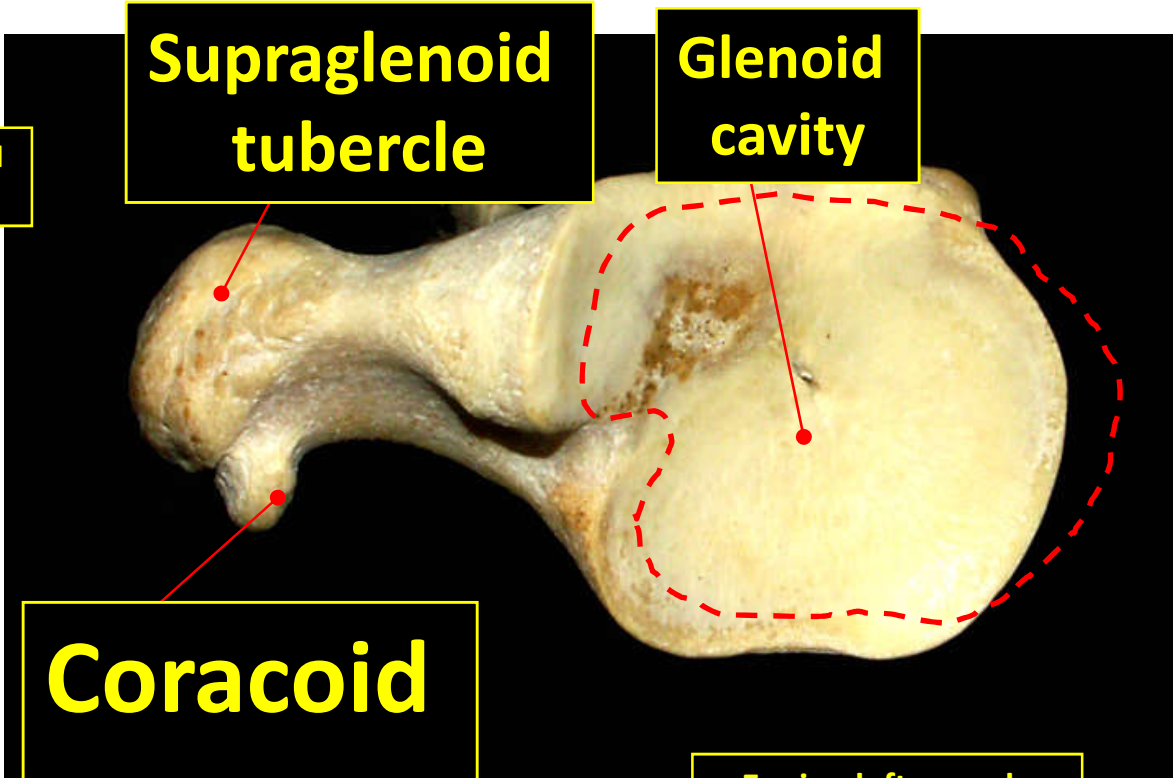


Supraglenoid Tubercle

Glenoid Cavity

Coracoid Process

Canine left Scapula Distal / Ventral View



Supraglenoid tubercle

Glenoid cavity

Coracoid process

Equine left scapula Distal / Ventral view

B. Coracoids bone

- ✓ Only birds have well developed type of coracoid bone. but, in human beings & other domestic animals it is very much reduced and found only as coracoid process.

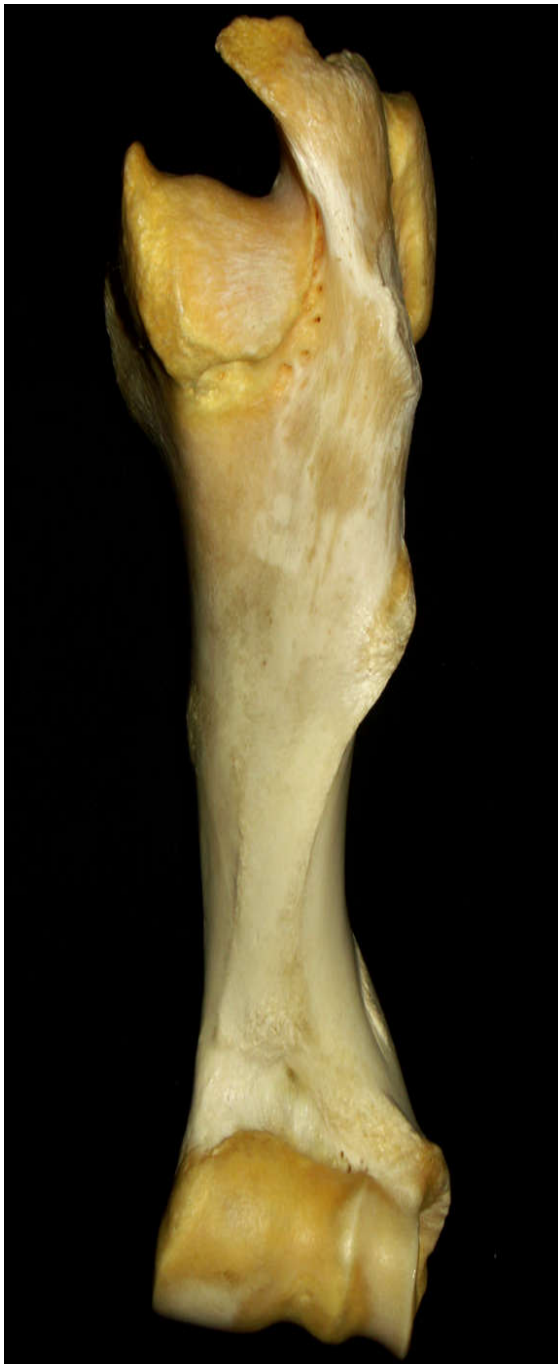C. Clavicle

- ✓ Is well developed in **birds, man, dog, cat** and **fox**.
- ✓ In these animals, clavicle forms joint with **sternum** and **scapula**.
- ✓ In most quadrupeds, clavicle is absent but represented by **clavicular tendon**.
- ✓ The clavicle in case of birds is found fused ventrally. The fused clavicle is called **furcula/wish bone**.

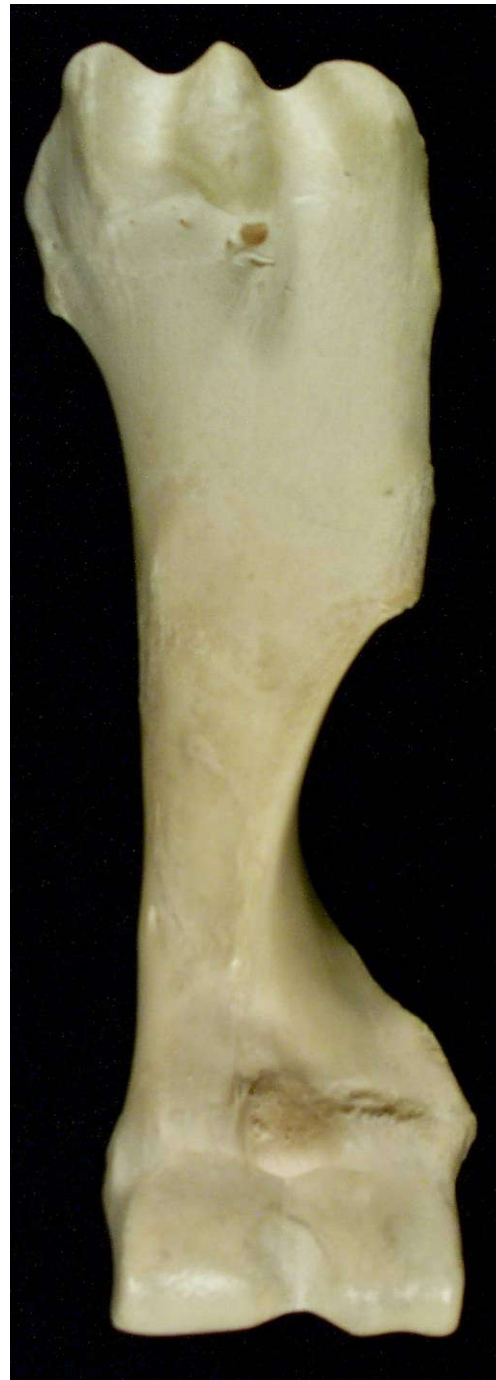2. Arm (Brachium)

- Contains a single long bone → the **humerus** (**arm bone**).
- Has a shaft and two extremities (the proximal and distal).
- The proximal extremity has spherical head which articulate with scapula at glenoid cavity.
- ***The shaft is slightly twisted and grooved medially.***
- ***The distal extremity:***
 - » Is the caudal part of the distal humerus which consists of articular condyles named as **lateral capitulum**, and **medial trochlea**.
 - » It has a **groove** called ***olecranon fossa*** which receives an ulnar process (olecranon process).

**Bovine
Left humerus
Cranial View**



**Equine
Left humerus
Cranial View**



3. Forearm (ante-brachium)

- The forearm has **two** bones:
 - **Radius** and
 - **Ulna**
- In most species of animals radius is larger than ulna, but in birds ulna is larger than radius.
- On standing position,
 - » the *radius* is more **cranial** and **lateral** but the *ulna* is **caudal**.

Radius:

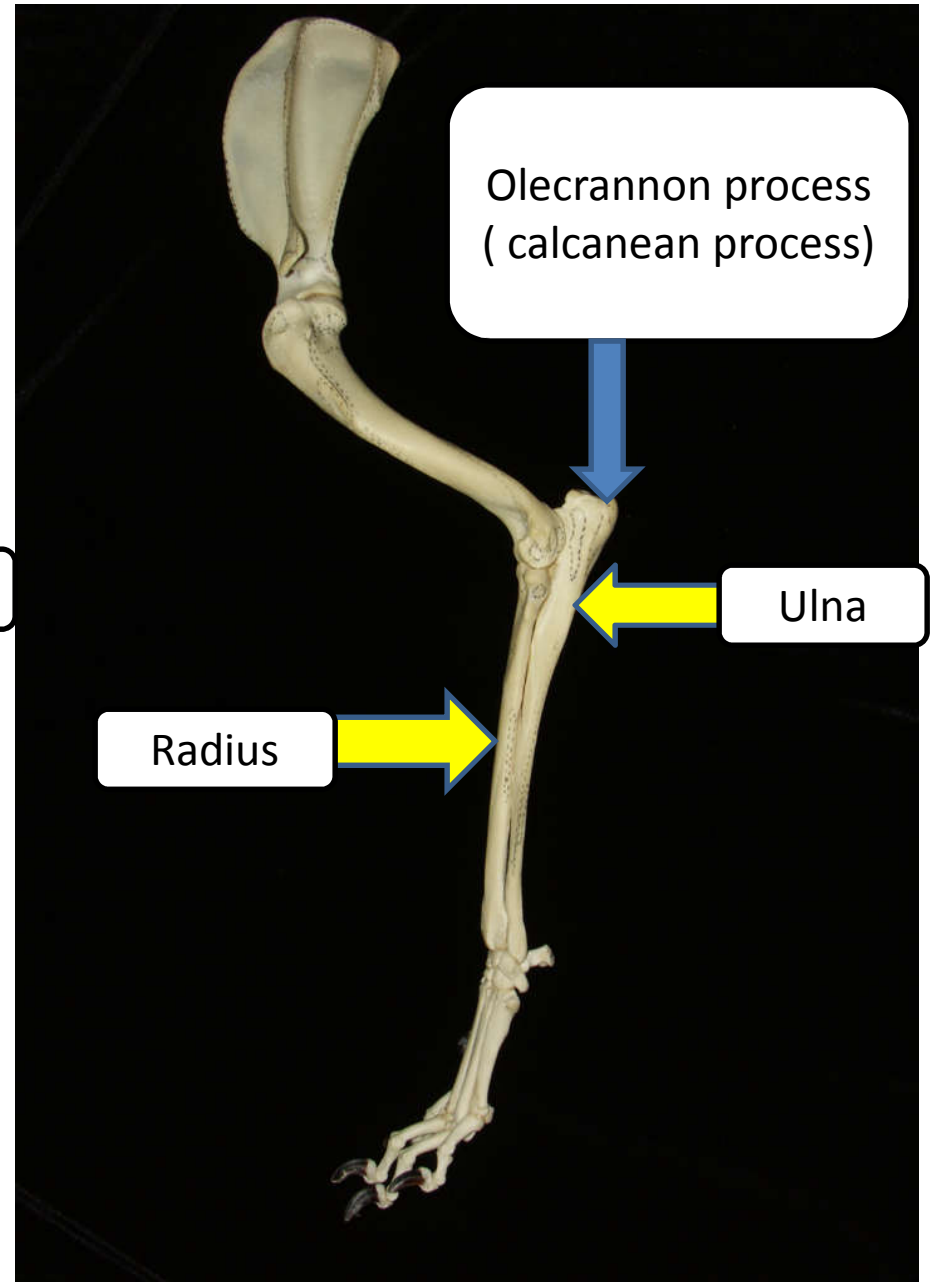
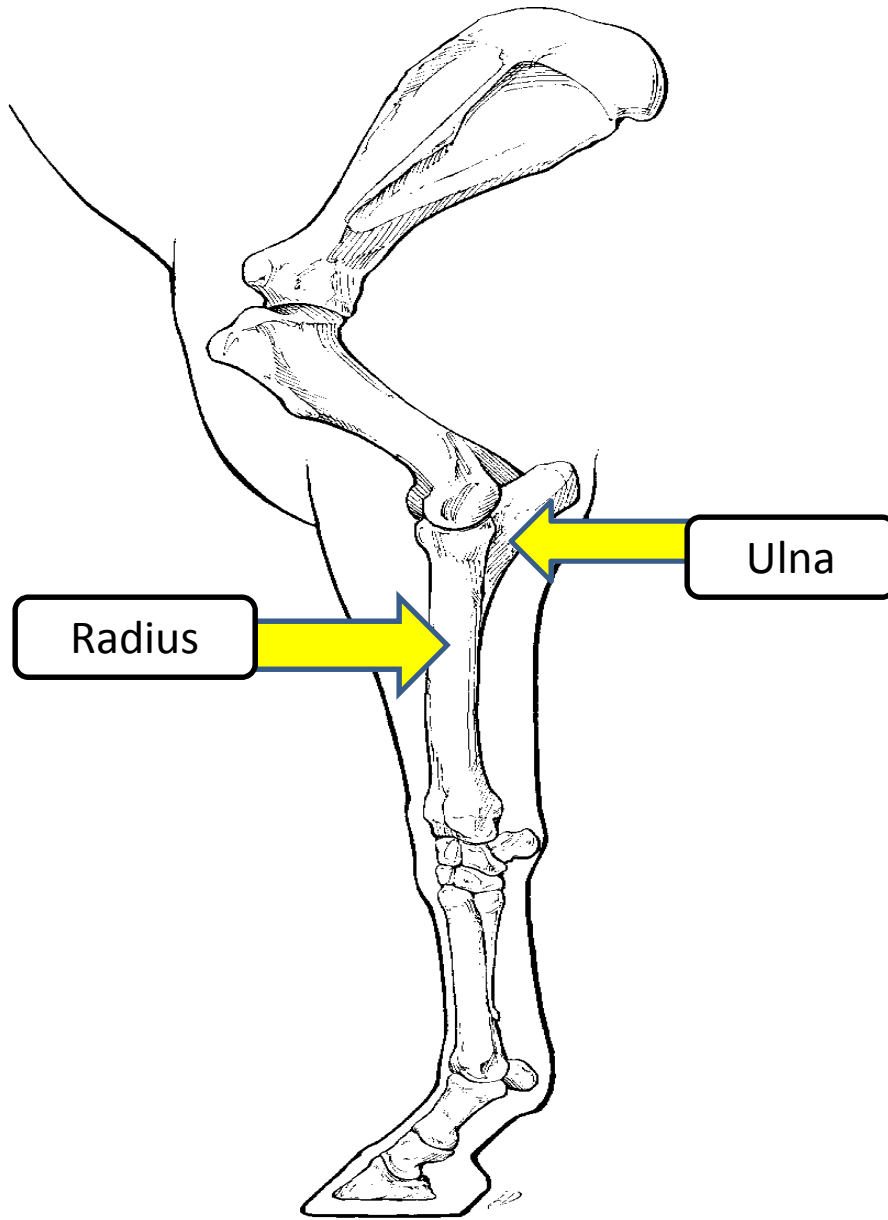
- is simple rod- like bone of fore-arm.
- The proximal extremity
 - widened and articulate with the **condyles of humerus**.
- The distal extremity make an articulation with **carpal bones**.

Ulna:

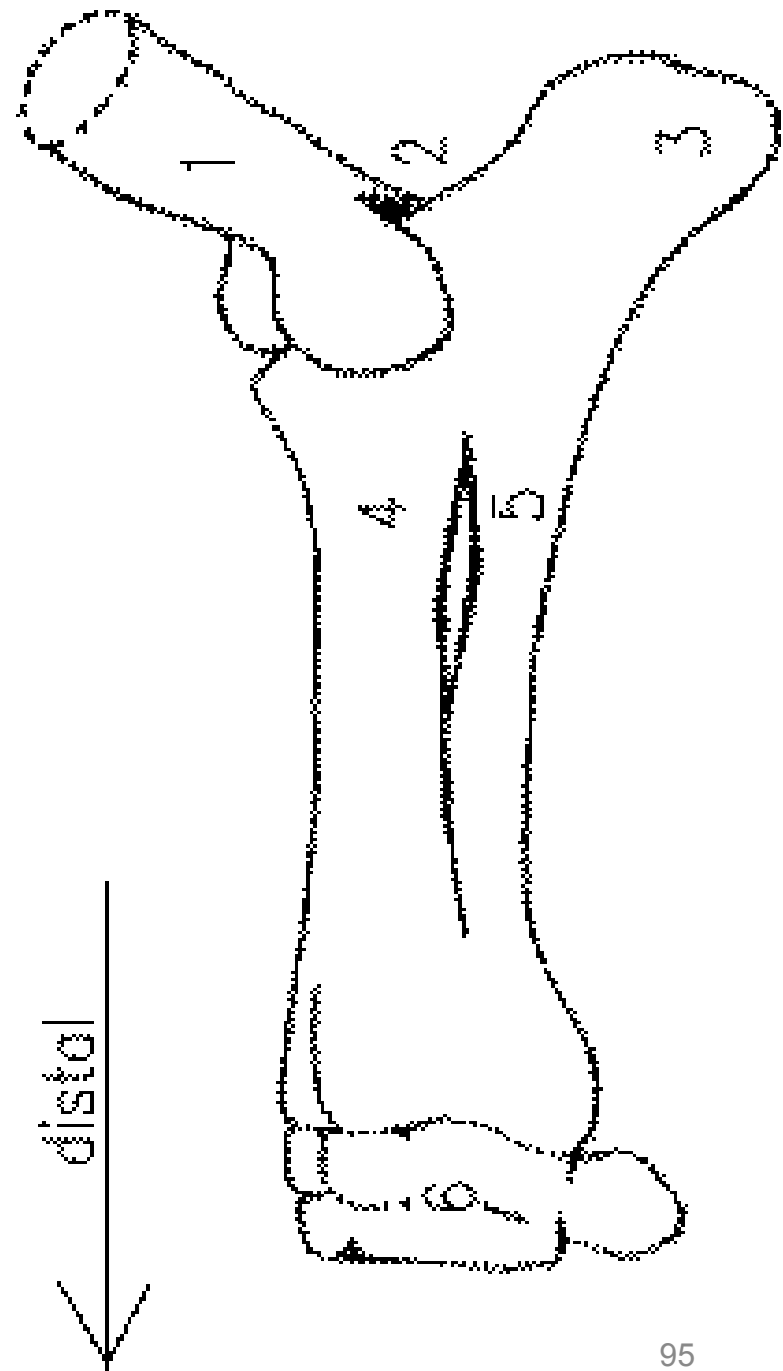
- has proximal projection called **olecranon process** (point of the elbow joint).
- Olecranon process fits with the depression found between **condyles of the humerus known as olecranon fossa.**

☐ **Species variation in radius and ulna**

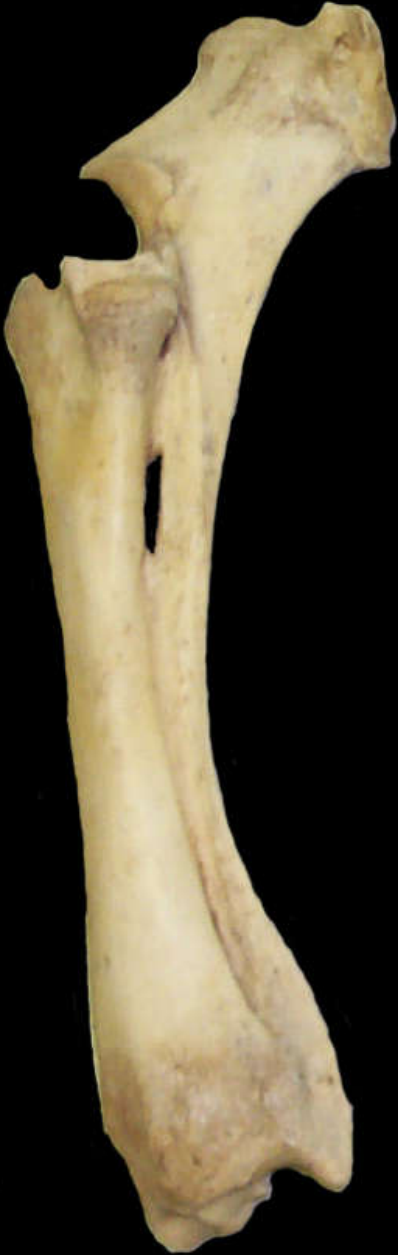- ❖ **Horse** → proximal portion of the shaft of ulna fuses with the radius.
- ❖ **Cow, sheep, goat and pig** → ulna is completely fused with radius and there is groove in b/n.
- ❖ **Cats and dogs** → has separate ulna and radius with considerable movement.



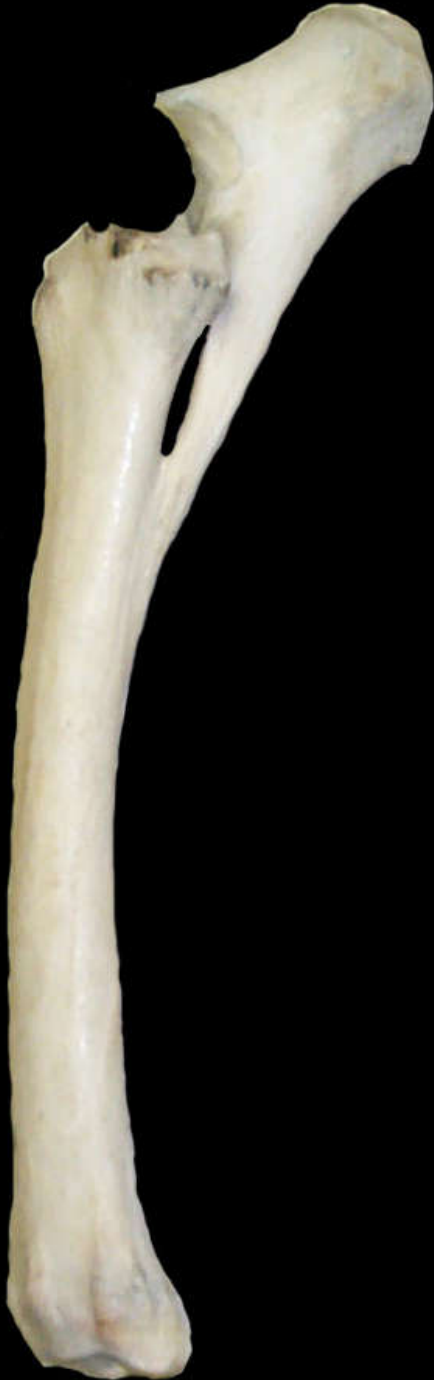- 1, Distal end of humerus
- 2, Olecranon fossa
- 3, Olecranon process
- 4, Radius
- 5, Ulna
- 6, Carpal bones



**Bovine left
Radius/ulna
Lateral View**



**Equine left
Radius/ulna
Lateral View**




D. Manus

- Manus is homologous of the **hand**.
- consists of three subdivisions (**Carpus, Metacarpus, Digits**).

1. Carpus

- Contain group of short bones arranged in two transverse rows (proximal and distal rows).
- **The proximal rows** comprise the following carpal bones in medio- lateral sequence.
 - » *Radial carpal bone,*
 - » *Intermediate carpal bone,*
 - » *Ulnar carpal bone, and*
 - » *Accessory carpal bone.*

four in no.

- **The distal rows** - are numbered from **I** to **IV** in mediolateral sequence.
 - » Therefore, when the carpus is fully developed, there are a total of **eight** (8) bones.
 - » However, in ruminant,
 - the first is absent and
 - the second & the third are fused
- } 2 in no.
- ❖ (Two bones on the distal row & four bones in proximal row totally  **six** carpal bones).

➡ Comparative features:

- ✓ **Pigs** → 8 separate carpal bones
- ✓ **Carnivores** → radial and intermediate carpal bones are fused = 7 carpal bones.
- ✓ **Ruminants** (sheep, goat and cattle) → the first carpal bones are absent and the second and third are fused= 6 carpal bones.
- ✓ **Equines** (horse, donkey and mule) → the first carpal bone is absent = 7 carpal bones.

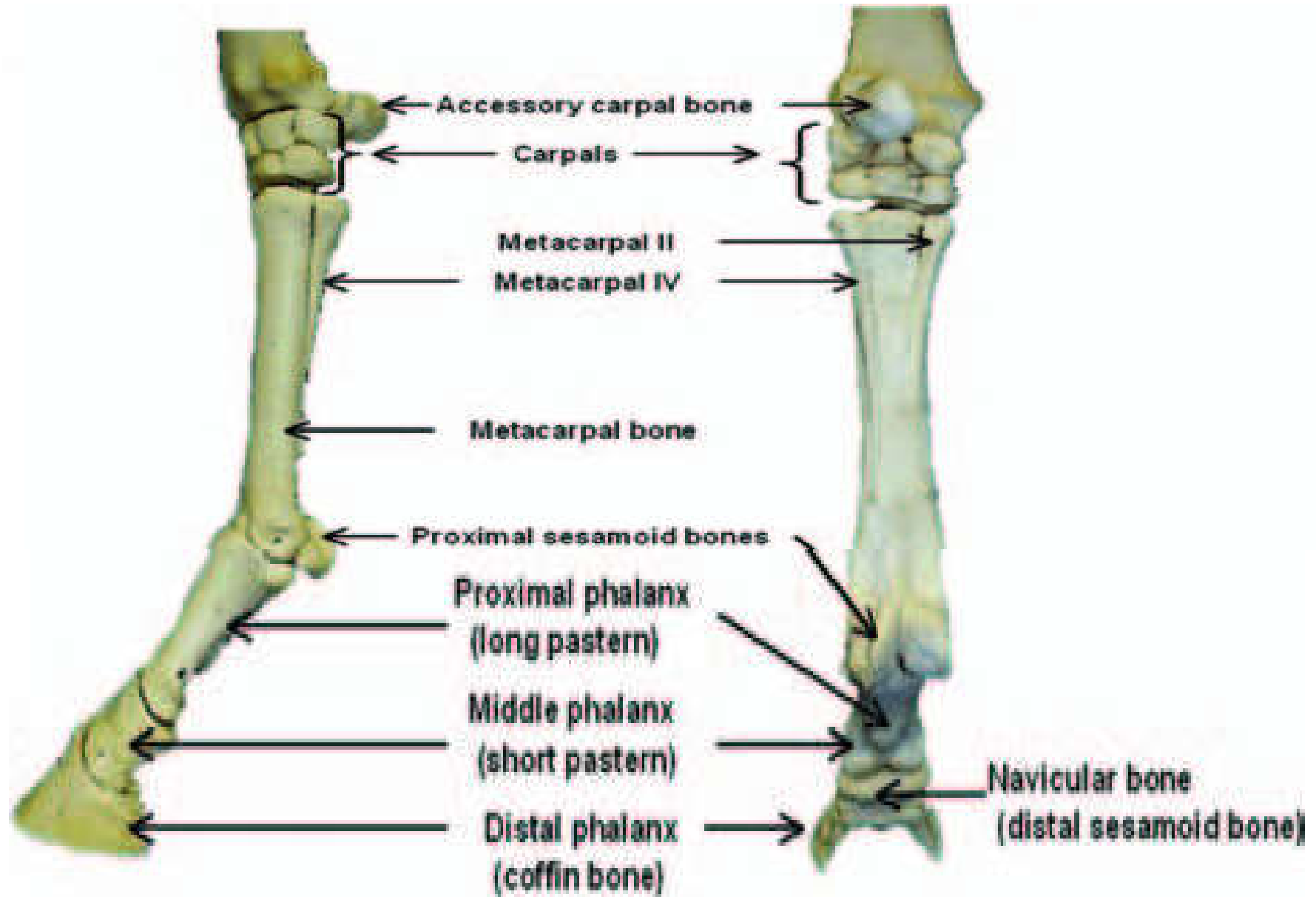
2. Metacarpus

- Contains **five bones** when fully developed designated medio-laterally as **I to V**.

❖ Comparative features

- **Equines:**
 - Have **one** large metacarpal bone and is known as **cannon bone** (3rd metacarpal bone) .
 - The 1st and 5th are absent.
 - The 2nd and 4th are very much reduced to form **splint bones**.

Diagram showing the manus



- **Ruminants:**
 - The **3rd** and **4th** metacarpal bones are fused to form a single bone known as **cannon bone**.
 - **No splint bones** in ruminants.
- **Pigs:**
 - The first is absent.
 - The second and the fifth are reduced in size.
Totally have **four** metacarpal bones

3. Digits

- Homologous to human fingers.
- Are results of extension of metacarpal bones.
- Are numbered from I to V mediolaterally.
- **Each** complete digit made up of **three phalanges**
 - » **Proximal, Middle and Distal phalanges** and
 - » Two sesamoid bones (proximal and distal sesamoid bone).
 - » proximal sesamoid bones are found b/n the distal end of metacarpal bone and proximal phalanges. Whereas, the distal one is found b/n middle and distal phalanges. The other name of distal sesamoid bone is **navicular bone**.

❖ **Comparative features:**

✓ **Horse** → 1

✓ **Ruminant & camel** → 2

✓ **Pigs** → 4

✓ **Carnivores** → 5

❖ Camels do have two proximal sesamoid bones but no distal sesamoid bone.

❖ In any animal the third phalanges known as **coffine bone** is found to be enclosed by **hoof**.

■ **Bones of the hind limbs:**

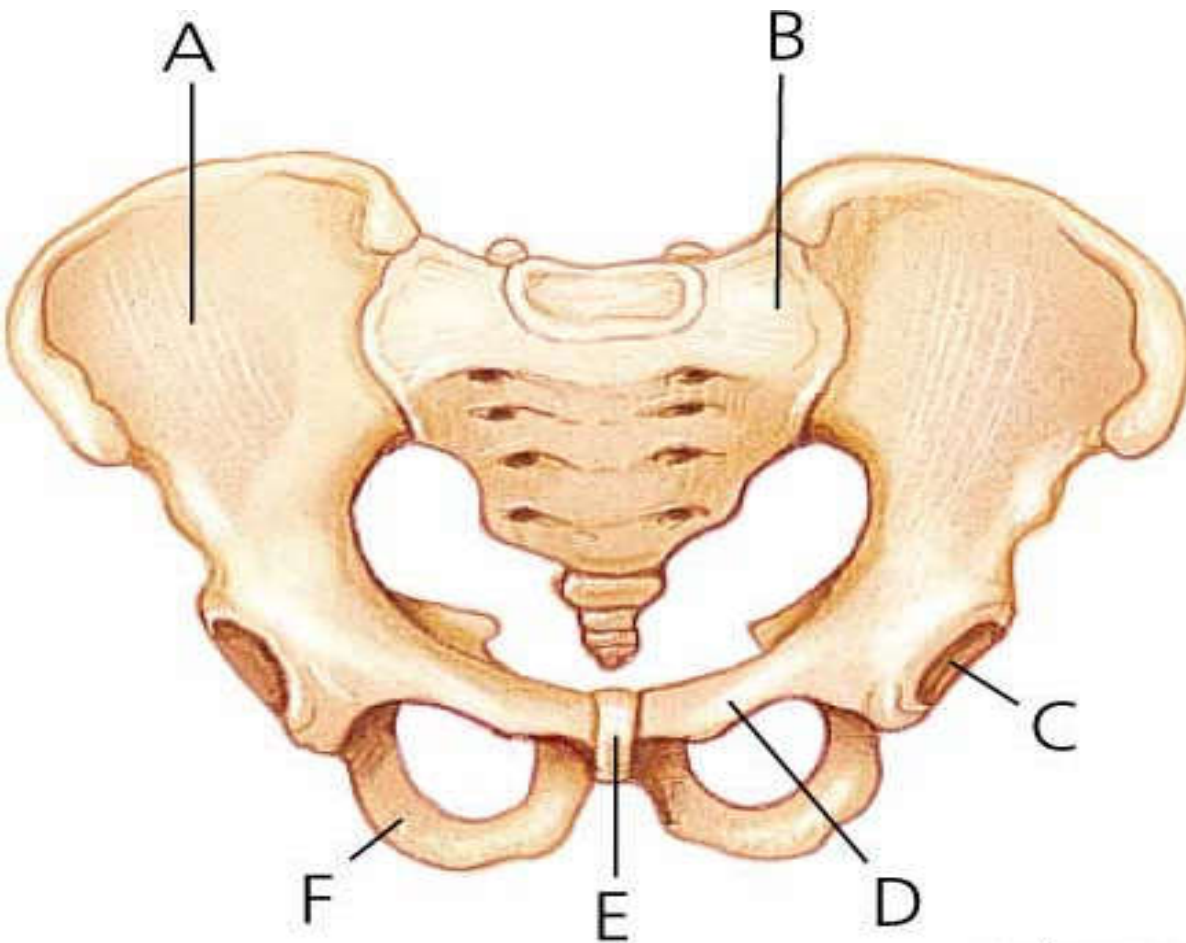
– Hind limbs (pelvic limbs) like the thoracic limb consists of four segments:

- ✓ **Pelvic girdle..... (Ilium, Ischium and Pubis)**
- ✓ **Thigh..... (Femur and Patella)**
- ✓ **Leg (crus)..... (Tibia and Fibula)**
- ✓ **Pes..... (Tarsus, Metatarsus and Digits)**

1. Pelvic girdle

- ✓ Three bones are components of the pelvic girdle.
 1. the dorsal **ilium**, which articulates with one or more sacral vertebrae,
 2. the ventral **pubis**, and
 3. the caudal **ischium**.
- ✓ Three bones are completely **fused** in adults to form a single bone called **Os coxae (pelvic bone) (hip bone)**.
 - **Os coxae is the largest flat bone.**
- ✓ Of the os coxae, both pubis and ischium are firmly attached to one another to form **pelvic symphysis** ventrally.

- Three bones participate in the formation of **acetabulum** (a cup shaped articular cavity).
 - » a depression in which **head** of the **femur enters** to form **a hip joint**.



- A. Ilium**
- B. Sacrum**
- C. Acetabulum**
- D. Ischium**
- E. Pubic symphysis**
- F. Pubis**

Carlyn Iverson

❖ **Ilium:**

- It is the largest and most dorsal of the pelvic bones.
- The broad and flat portion of ilium is known as **wing of ilium**.
- Lateral boarder of the wing of ilium is known as **tuber coxae**.
- It Participate in the formation of **acetabulum**.

❖ **Ischium:**

- forms the caudal part of the hipbone or Os coxae and
- participates in the formation of the **acetabulum, obturator foramen** and **pubic symphysis**.

❖ **Pubis :**

- is the smallest of the three which forms the cranial floor of the pelvic cavity.
- participates in the formation of **acetabulum, obturator foramen** and **pubic symphysis**.

➤ **All these three bones participate in the formation of the acetabulum.**

2. Thigh

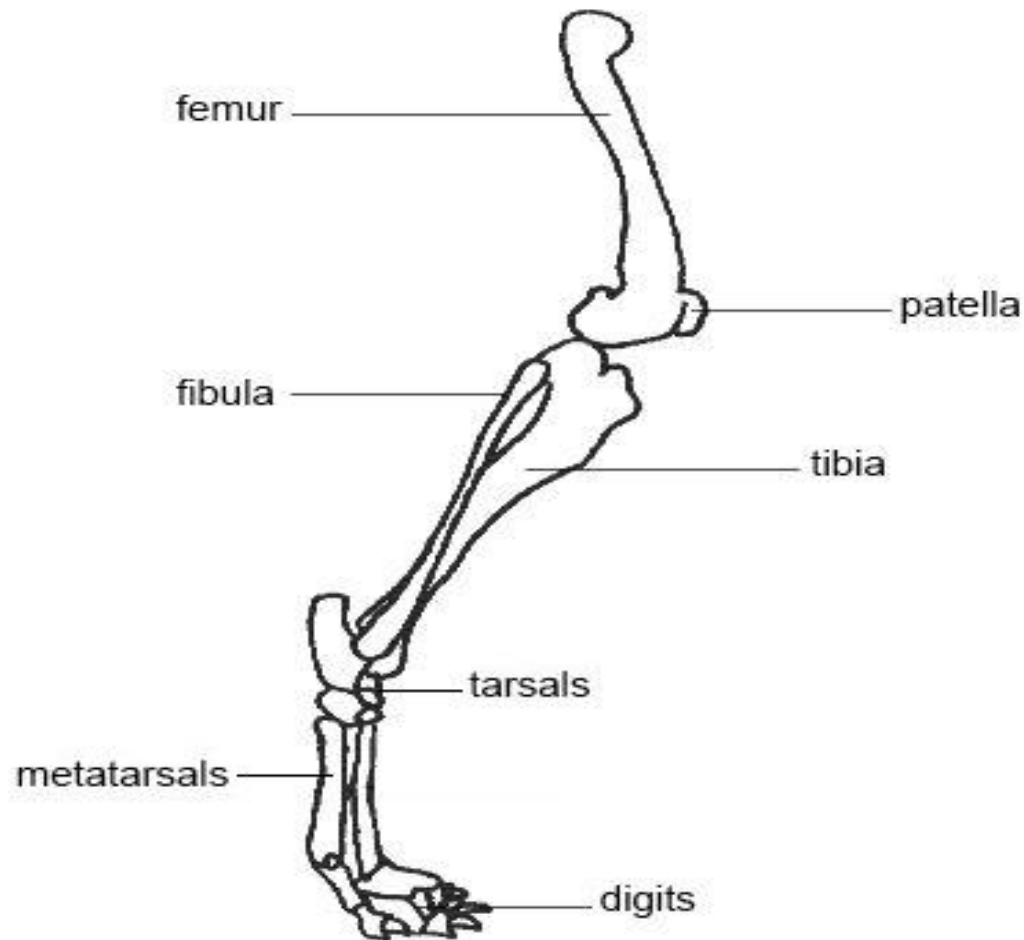
– is composed of the **femur** and **patella**.

2.1. Femur:

- Long bone that articulate with acetabulum proximally and with tibia & patella distally.
- has **two** expanded *extremities* and a *body*.
- *Proximal extremity*:
 - » has spherical head with small depression called *fovea capitis*.
- **The shaft of the femur is nearly circular(*round*)**.
- *Distal extremity*:
 - » has **two condyles** (medial and lateral) and trochlea for articulation with the tibia and patella respectively.

2.2. *Patella (knee cap):*

- Is the largest **sesamoid** bone, which articulates with the trochlea of the distal femur.



3. Leg (crus):

- The skeleton of the leg comprises **two** bones:
 - » *tibia* and *fibula*.

A). *Tibia*:

- is always larger than fibula.
- articulate with
 - » patella and femur proximally,
 - » tarsus distally and
 - » fibula laterally.

B). *Fibula*:

- Is rudimentary long bone located at the lateral side of tibia.
- The proximal extremity has spherical projection (head), which attaches with lateral condyle of the tibia.
- **doesn't articulate with femur.**

❖ Comparative feature:

- ✓ **In horse** → the shaft is incomplete (i.e., the proximal end and a portion of the shaft of fibula is present).
- ✓ **In Ruminants** → the shaft is completely absent & only a vestige of the proximal end of the fibula is found fused to tibia.
- ✓ **In Pigs and dogs** → fibula is a complete bone but smaller than tibia (the fibula extends from the proximal end of the tibia to the lateral aspect of the hock).

4. **Pes:**

- The skeleton of the pes is the homologue of the human **foot**.
- consists of three subdivisions:

» *Tarsus*

» *Metatarsus* &

» *digits*

A. Tarsus (hock):

- contain a group of short bones.
- ranges from 5-7 depending on the species.
- are arranged in three rows.

I). The proximal row

- consists of **two** relatively large bones:
 - ***Talus* (tibiotarsal bone)** → is relatively large, pulley like bone situated on the tip of tibial bones.
 - ***Calcaneus* (fibulotarsal bone)** → largest tarsal bone situated at the fibular bone. It has a long bony process known as **calcaneal tubercle**.

II). The middle row:

- Consists of only one central bone (**central tarsal bone**).

III). The distal row:

- Consists up to four bones which are numbered in mediolateral sequence as I to IV.

❖ Comparative features:

- ✓ **Ruminants** → tarsal bones are 5 in number due to the fusion of the central & 4th tarsal bone and 2nd & 3rd tarsal bone.
- ✓ **Equines** → tarsal bones are 6 in number due to the fusion of 1st and 2nd tarsal bones.

B. Metatarsal bone:

- ✓ are long bones located between distal rows of tarsal bones and proximal part of the digit.
- ✓ Structurally similar to the metacarpal bones except in most domestic animals the metatarsal bones are longest but less massive than metacarpal bones.

C. Digits:

- ✓ Consists of phalanges and sesamoid bones.
- ✓ They are similar characteristically with front limb digits.
But, their difference from that of front digits are:
 - The proximal **phalange** is a little bit shorter, wider proximally and narrower distally.
 - The middle **phalange** is narrower and slightly longer than thoracic counterpart.
 - Sesamoid bone → Proximal sesamoid bones are a little bit smaller than that of the thoracic sesamoid bones.
 - Distal sesamoid bone is narrower and shorter than the thoracic counterpart.

2.4.3. Splanchnic or visceral skeleton

- Visceral skeletons consists of bones that develop in soft tissue of certain organs such as:
 - ✓ **Os cordis** → in heart of ox.
 - ✓ **Os penis** → in the penis of dog.
 - ✓ **The scleral ring** → in eyes of birds.



THANK YOU VERY MUCH

CHAPTER 3

Arthrology

BEMREW A(Dr.) and GASHAW G.(Dr.)
March,2020

1. Introduction

- **Arthrology (Syndesmology):**
 - is the study of articulations (unions) between two or more bones which are commonly called joints.
- **Joint(arthrosis):**
 - is the area where two bones are attached for the purpose of motion of body parts.

ARTHROLOGY....

➤ **Importance of studying Arthrology:**

- ✓ To know the normal physiology of joints.
- ✓ To differentiate the abnormal joint.
- ✓ To take samples for diagnosis.
- ✓ To identify the proper site for treatment of joints.

Joint Functions

1. Hold the skeletal bones together
2. Allow the skeleton some flexibility so gross movement can occur
3. Make bone growth possible

Classification of joints

Joints can be classified by various ways:

I. Motility (degree of movement) [physiological].

– On this basis, three general groups can be identified.

a) Synarthroses:

- are immovable joints, allow **no** movement.
✓ Eg. suture

b) Amphiarthroses:

- are slightly movable joints, allow **slight** movement.
✓ Eg. intervertebral disc.

c) Diarthroses:

- are freely movable joints
✓ Eg. most joints with in the skeletal system are freely movable.

Classification of joints

II. The **numerical** system [biomechanical] :

- simple joint
 - with **2** articular surface and
- composite (compound joints) joints
 - with **>2** articular surfaces.

III. Based on their **geometry** (structure or tissue or anatomy) and uniting medium:

- A. Fibrous,
- B. Cartilaginous,
- C. Synovial joints.

Classification of joints

A. Fibrous joints:

- Bones are united by fibrous tissue.
- Have no joint cavity.
- Allow no movement
- The **three** common groups of fibrous joints are:

1) *Suture:*

- narrow strip of fibrous tissue (ligament) unite the margin of two bones.

2) *Gomphosis:*

- is the **specialized** articulation of **teeth** in their **alveoli** (sockets).
- The fibrous tissue that joins the tooth to the socket is termed as ***periodontal ligament***.

3) *Syndesmoses:*

- joined by white connective tissue (ligaments).
- E.g.
 - ✓ joint between metacarpal bones,
 - ✓ joint between radius and ulna, fibula and tibia

Classification of joints

B. Cartilaginous joints:

- are united by cartilage & related tissue.
- have no intervening joint cavity and allow no or a little movement.
- **Two types of cartilaginous joints are:**

i) Synchondrosis:

- United by hyaline cartilage.
- E.g. union of diaphysis & epiphysis of long bone.

ii). Symphysis (fibro cartilaginous) :

- united by fibrocartilage tissue.

Classification of joints

C. Synovial joints:

- Bones are separated by fluid-filled spaces (the joint cavity).
- The fluid is called *synovium* (“white egg”) that reduce friction.
- They allow variable degree of movements.

Structures of synovial joints

Structures that participate for the formation of synovial joints are:

***i).* Articular surface**

- is specialized layer of bone on the surfaces that articulate with other bones.

***ii).* Articular cartilage**

- is a layer of hyaline cartilage covering the articular surface.

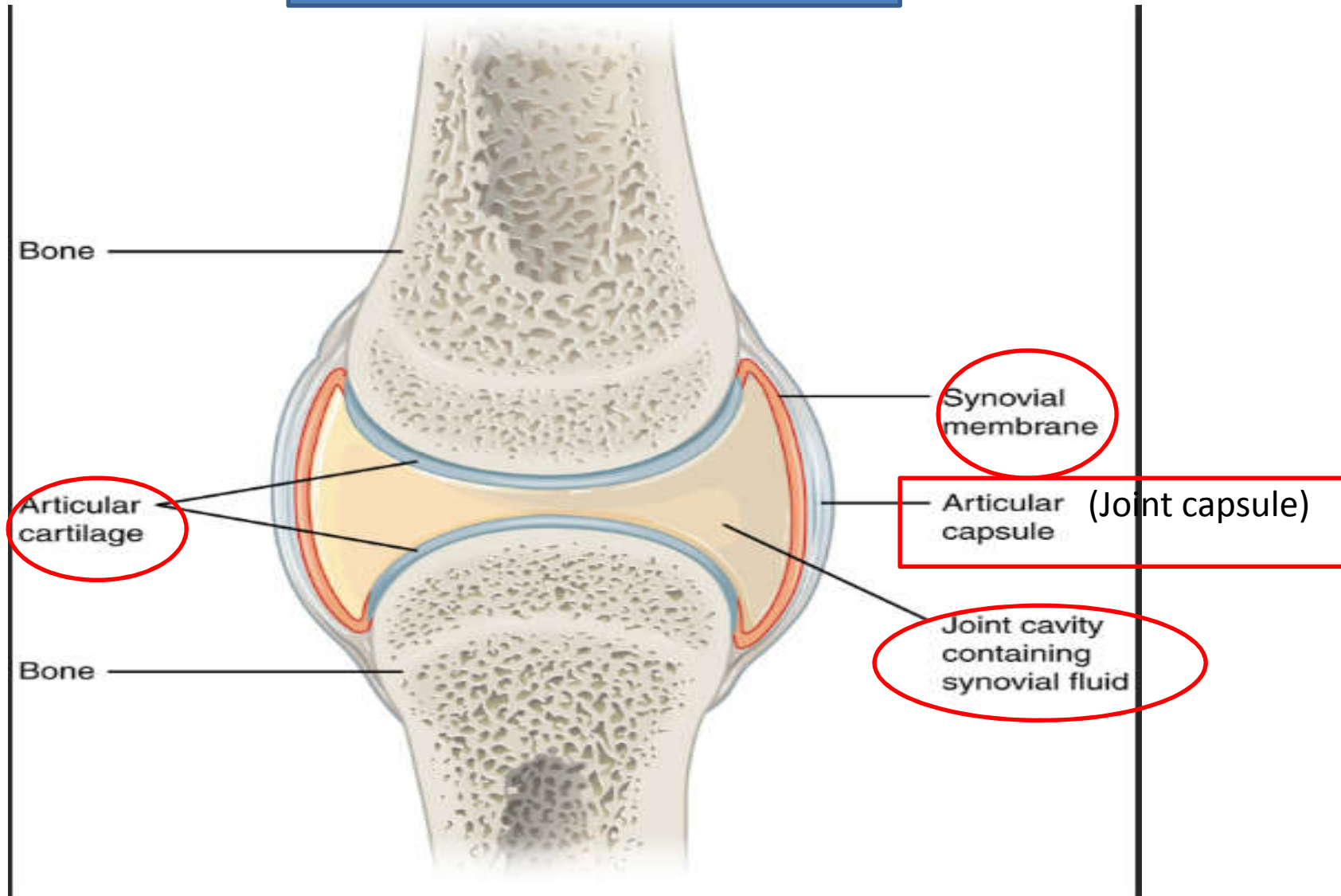
***iii).* Articular cavity**

- is a space between the adjacent bones of the joint surrounded by joint capsule.
- filled with synovial fluid.
- It is a viscous fluid, its colour ranges from pale straw to slight brownish.

***iv).* Joint capsule**

- Between surfaces, there are interposed fibro-cartilage names as *discs* (*meniscus*).
- E.g. in the stifle & in the temporomandibular joint.

Synovial joint structures



Movements of synovial joints

- Synovial joints may exhibit one or more of the following movements.
 - A. Gliding or sliding: only allow sliding movement
 - movement occurs between flat surfaces in plane joints.
 - E.g. joint between Carpal bones
 - B. Flexion:
 - movement to decrease the angle between segments making up a joint.
 - C. Extension:
 - is the reverse of flexion and tends to increase the angle between segments forming the joint.
 - D. Hyper extension:
 - is the movement in which the angle between segments is increase beyond **180°** or straight line (excessive extension)

Movements of synovial joints

E. Rotation:

- a twisting movement of a segment around its own axis.
- Shaking the head (between atlas & axis).

F. Adduction:

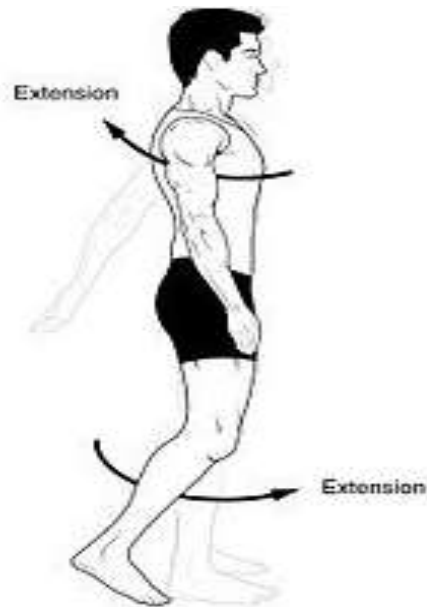
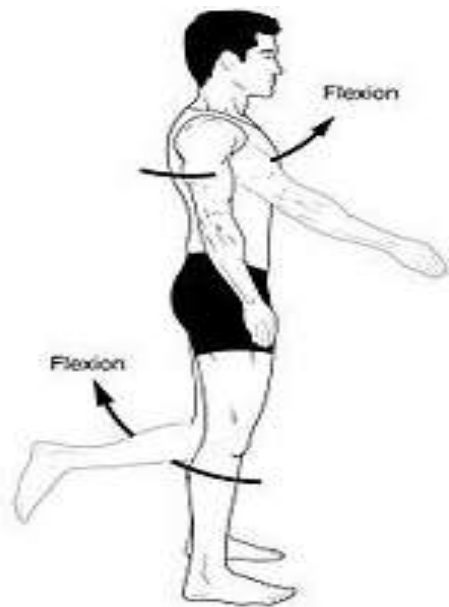
- is movement of an extremity toward the median plane.

G. Abduction:

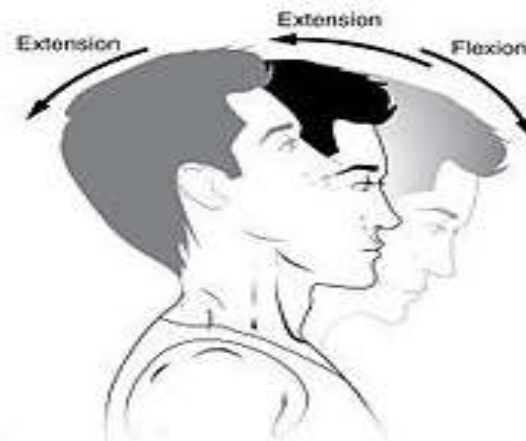
- is movement of an extremity away from median plane.

H. Circumduction:

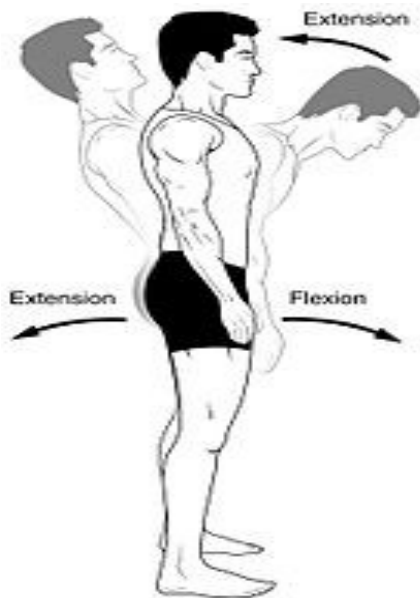
- combines the other types of movement except rotation, moving a part so that its end follows a circular path.



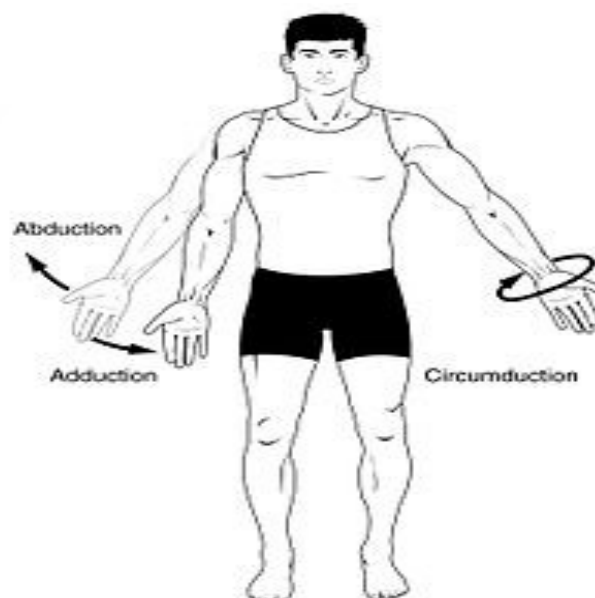(a) and (b) Angular movements: flexion and extension at the shoulder and knees



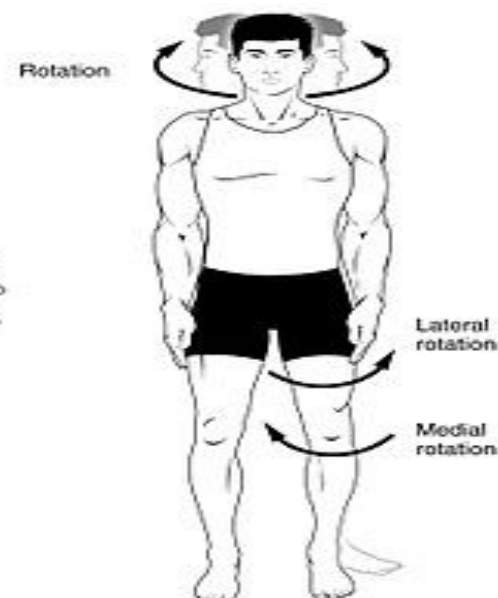
(c) Angular movements: flexion and extension of the neck



(d) Angular movements: flexion and extension of the vertebral column



(e) Angular movements: abduction, adduction, and circumduction of the upper limb at the shoulder



(f) Rotation of the head, neck, and lower limb

Classification of synovial joints

Classification of synovial joints

- Seven (7) types of synovial joints in domestic animals based on their Geometry.
- a) **Plane joint (Arthrodial):**
 - joint between relatively two flat apposed surfaces, allow only slight gliding movement.
 - E.g. between articular processes of adjacent cervical vertebrae, between carpal bones
- b) **Hinge joints (ginglymus):**
 - has one articular surface shape like a segment of a cylinder, the other excavated to receive it.
 - It moves only in their sagittal plane such as flexion, and extension.
 - E.g. Fetlock joint (metacarpophalangeal)
- c) **Pivot joint (articulatio-trochoidea):**
 - comprises a peg fitted with in a ring.
 - Rotation is the typical movement for this type of joint

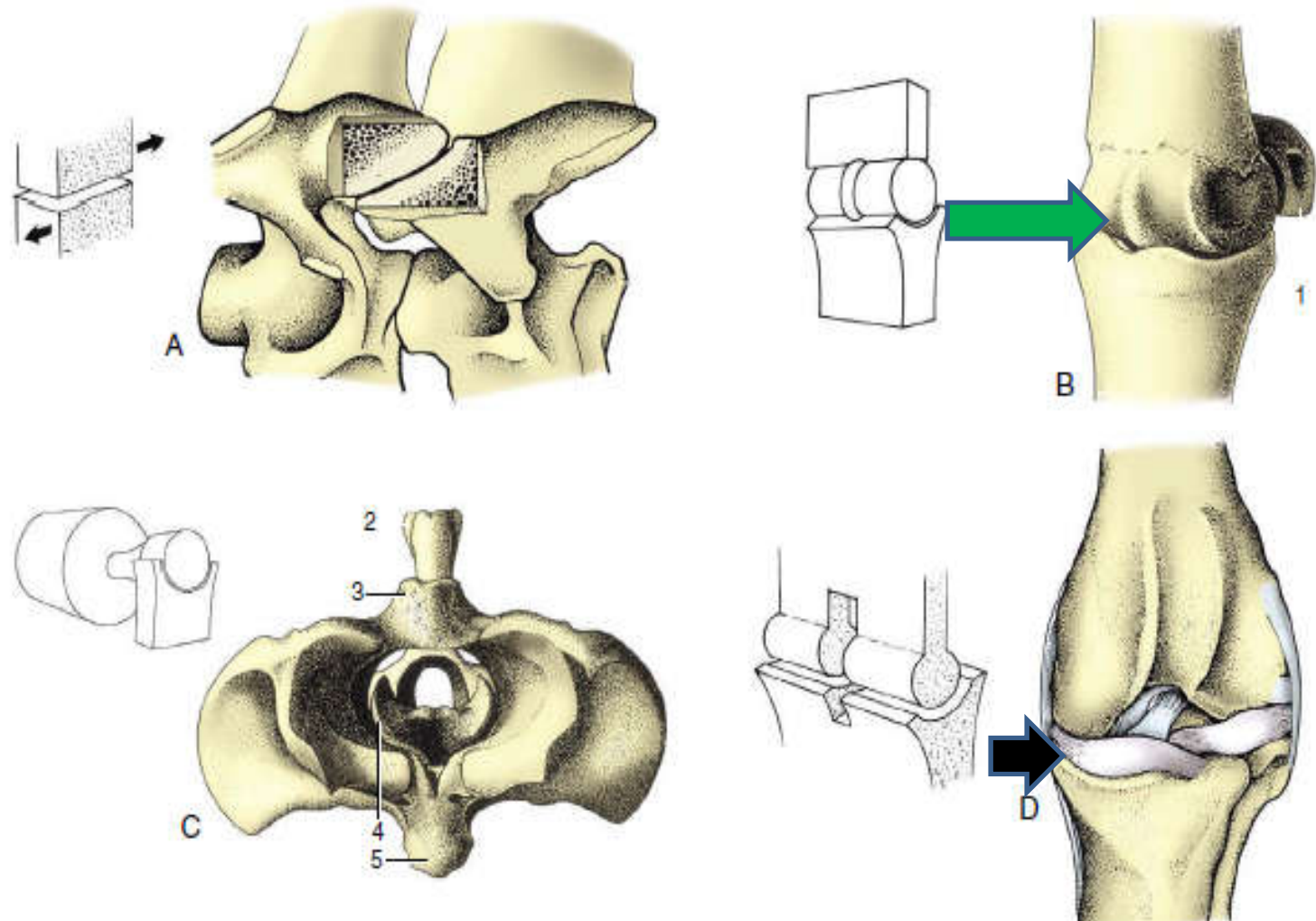
Classification of synovial joints

- d) **Condylar joint: flexion, extension, abduction, and adduction movements**
- one convex articular condyles articulate with the other somewhat concave articular surface.
 - E.g. temporomandibular joint, Stifle joint
- e) **Ellipsoidal joints:**
- The ellipsoidal joints present an ovoid convex surface that fit into a corresponding concavity forming an ellipse.
 - Eg. radio-carpal joint

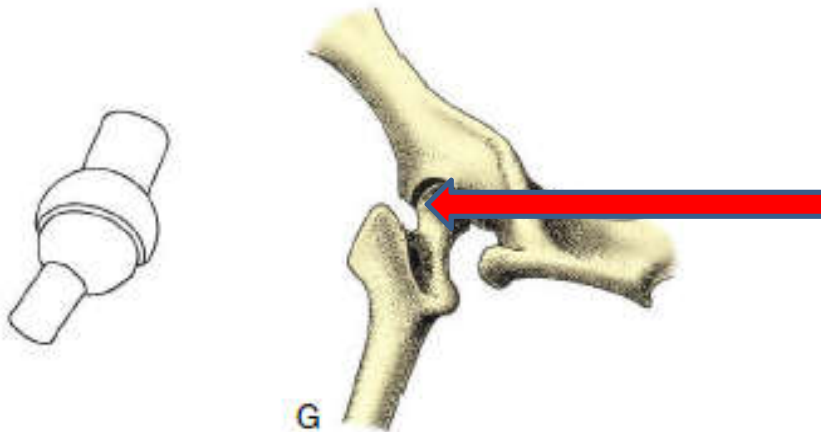
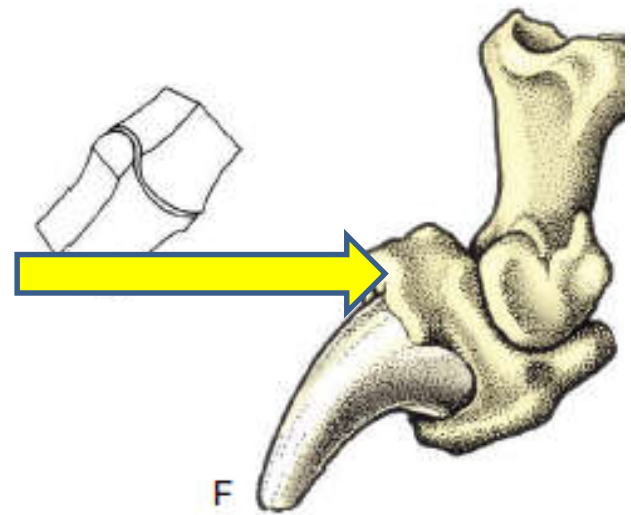
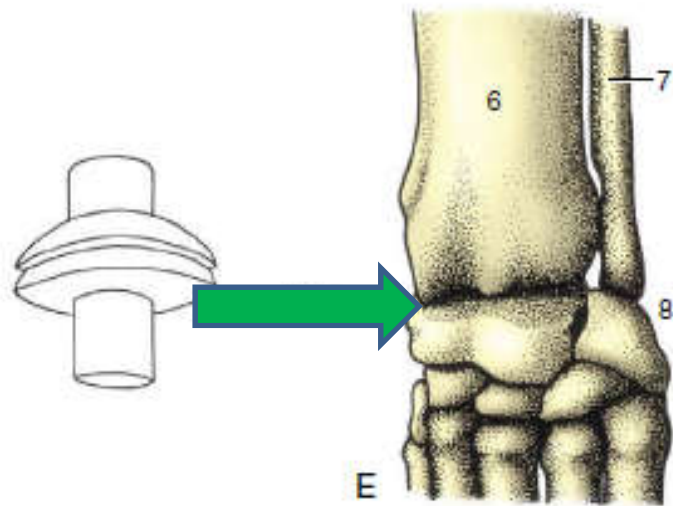
Classification of synovial joints

- f) **Saddle joint (Articulo sellaris):** permit the same movement as condyloid joints and combine with them to form compound joints
- each bone is convex in one direction and concave in a second direction at 90^0 to the first.
 - E.g. Carpo-metacarpal joint
- g) **Ball and socket or spheroidal joint (enarthrodial):**
- A spherical head on one bone fits into a cap shaped depression in the other segment of the joint.
 - allows all possible movements, except gliding.
 - E.g.
 - hip joint (head of femur, units with acetabulum of pelvic bone)
 - shoulder joint in man (head of humerus with glenoid cavity of scapula)

Summary: Fig. showing geometrical classification of joints



A. Plane joint: cervical vertebrae AP; B. hinge: metacarpophalangeal joints; C. pivot: atlantoaxial joint; D. condylar: femorotibial, stifle.



E. Ellipsoidal joint: radiocarpal joints ; F. saddle joints: distal interphalangeal joints; G. Spheroidal/ball and socket joint: hip joint

3.2.3.1. Articulation of axial skeleton

I. Articulation of the skull

- The joints of the skull are chiefly **suture type**.
- **Symphysis** → is also found in the skull which is found b/n the two halves of the mandible which later becomes ossified.
- **Synchondrosis** → is found b/n the sphenoid and occipital bone.
- **Temporo-mandibular joint** → it is the only freely movable joints b/n the ramus of the mandible and the temporal bone of the skull. It performs two types of movements.
 - ✓ **Gliding or sliding movement**
 - ✓ **Angular movement**

II. Articulation of the vertebrae/ joints of vertebrae

1. **Atlanto- occipital joint:**

- ✓ It is the joint b/n atlas and occipital condyles of the occipital bone.
- ✓ It performs angular type of movement.
- ✓ So, the possible movements in atlanto-occipital joint are **flexion and extension.**
- ✓ It is **”YES joint.”**

2. **Atlanto-axial joint:**

- ✓ Formed by the atlas and dens of axis.
- ✓ The **dens of axis** projects into the vertebral foramen of **atlas** where it held by the annular ligament.
- ✓ It is **”NO joint.”**

- **Symphyseal /fibro- cartilaginous/ joint:**
 - Formed b/n the adjacent vertebrae through out the rest of a vertebral column exhibiting little movement (**from 3rd cervical vertebrae – coccygeal vertebrae**).

III. Articulation of thorax

- The ribs are attached to the vertebral column and consists of two types of joint.
 - ✓ **Pivot / Trochoid joint** → is formed b/n the **heads of the ribs and the bodies of the adjacent thoracic vertebrae.**
 - ✓ **Arthroidal / Plane joint** → formed b/n the **tubercle of the ribs and the transverse process of the thoracic vertebrae.**

3.2.3.2. Articulation of appendicular skeleton

I. Joints of forelimb

1. **Synsarcosis joint:**

- ✓ the scapula has no any bony connection with the thorax. It is held in place by **ligament and muscle**.

2. **Shoulder joint:**

- ✓ Is the joint b/n the distal end of scapula and the proximal end of Humerus.
 - This joint is formed b/n the glenoid cavity of scapula and head of Humerus.
- ✓ The possible type of movement are flexion and extension.

3. Elbow joint:

- ✓ Is a true ginglymus joint formed by the distal end of the humerus and proximal end of the radius and ulna.
- ✓ The possible type of movements are flexion and extension.

4. Carpal joint:

- ✓ Is a joint formed by the distal end of radius and ulna, carpal bones and proximal end of metacarpal bones.
- ✓ The possible movement b/n radius and ulna and metacarpal bones are flexion and extension.
- ✓ B/n carpal bones and proximal end of metacarpal bones is plane movement (gliding or sliding movement).

5. Fetlock joint:

- ✓ Formed by the distal end of metacarpal bone and the proximal end of the first phalange and two proximal sesamoid bones.
- ✓ The possible movements are extension, flexion, hyperextension(ginglymus type joint).

6. Pastern joint:

- ✓ Formed by the first and middle phalanges.

7. Coffine joint:

- ✓ Formed by 2nd and 3rd and distal sesamoid bone. They are largely enclosed by the hoof.

II. Joints of hind limb

1. Sacroiliac joint:

- ✓ It is the only bony connection b/n axial and appendicular skeleton.
- ✓ It is formed b/n **wing of ileum** and **sacrum**.
- ✓ Movement is allowed during parturition.

2. Hip/ Coxo- femoral joint:

- ✓ Formed b/n the acetabulum of the os-coxae and head of the femur.
- ✓ It is spheroidal type of joint.

conti

- The joint capsule of the hip joint is extensive, but not so extensive as that of the shoulder. The ***ligament of the femoral head*** (formerly ***round ligament***) connects the head of the femur with a nonarticular area within the acetabulum.
- Movements in nearly all directions are possible in the hip joint, but as in the shoulder joint, extension and flexion are the movements chiefly employed in normal locomotion.

3. STIFLE JOINT

- The *stifle joint* corresponds to the human knee. It comprises the:
 - condyles of the distal femur,
 - the patella, and
 - the proximal tibia.

CONT..

- The ***patella (kneecap)*** is a sesamoid bone embedded in the tendon of insertion of the large cranial muscles of the thigh. This muscle group is a powerful extensor of the stifle, acting through its connection to the cranial aspect of the proximal tibia via one (pig) or three (horses and ruminants) strong ***patellar ligaments***. In the horse, the ***medial patellar ligament*** is attached to the medial aspect of the patella via a large, hook-shaped fibrocartilage.

4. TARSAL JOINTS

- The *tarsus (hock) joint*, like the carpus, is a composite joint. The ginglymus portion is formed between the distal end of the tibia and the talus. This portion of the joint is held together by strong medial and lateral collateral ligaments of the hock.


CONT..

- The calcaneus projects proximad and caudad to form a lever for attachment of the ***common calcaneal tendon (Achilles tendon)***, which is the common insertional tendon of the extensor muscles of the hock. The calcaneus is firmly attached to the other tarsal bones by many short, strong ligaments.

CONT..

- The ligaments are less extensive over the craniomedial aspect of the hock. In this location, the joint capsule is immediately beneath the skin, and distension of this joint results in an obvious soft bulge commonly called a ***bog spavin***.. In the horse, movement between adjacent tarsal bones is limited to a very small degree of gliding. However, in the ox, sheep, and pig, the proximal intertarsal joint has some hinge movement. Distal to the hock, the joints are similar to those of the forelimb.

FACTORS INFLUENCING JOINT STABILITY



- **A). The shape of articular surfaces.**
- **B). Ligaments**
- **C). Muscle Tone**

Exercise!!!

- Make four groups containing 8-9 students.
(15 minutes)

1. Define “arthrology” and “Joint”?
2. Classify joints based on:
 - *Motility*?
 - *Numeric*?
 - *Geometry(structure)*?
3. List some among the **7** types of synovial joints?
4. List the movements of synovial joints?
5. List structures that participate for the formation of synovial joints ?(if possible with **figure!!!**)

Answers

Define Arthrology

Classification: Joints can be classified by various ways


A. *Motility* (degree of movement). On this basis, three general groups can be identified.

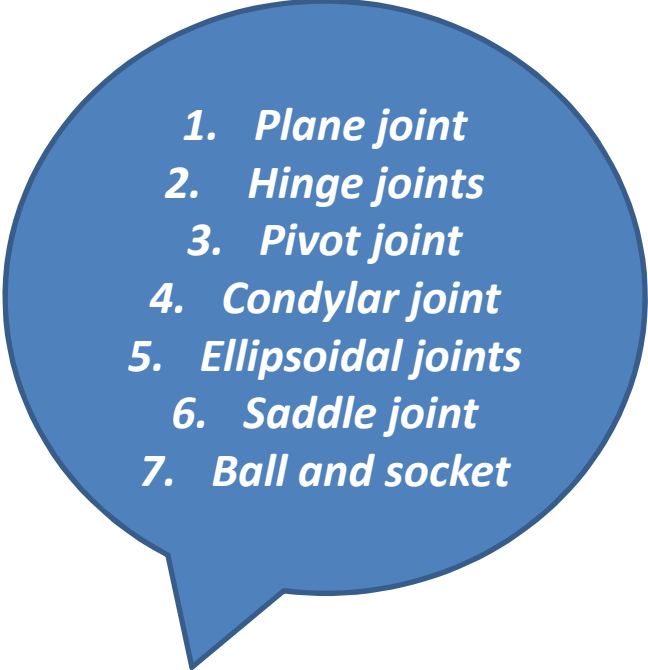
- *Synarthroses:*
- *Amphiarthroses:*
- *Diarthroses:*

B. The numerical system

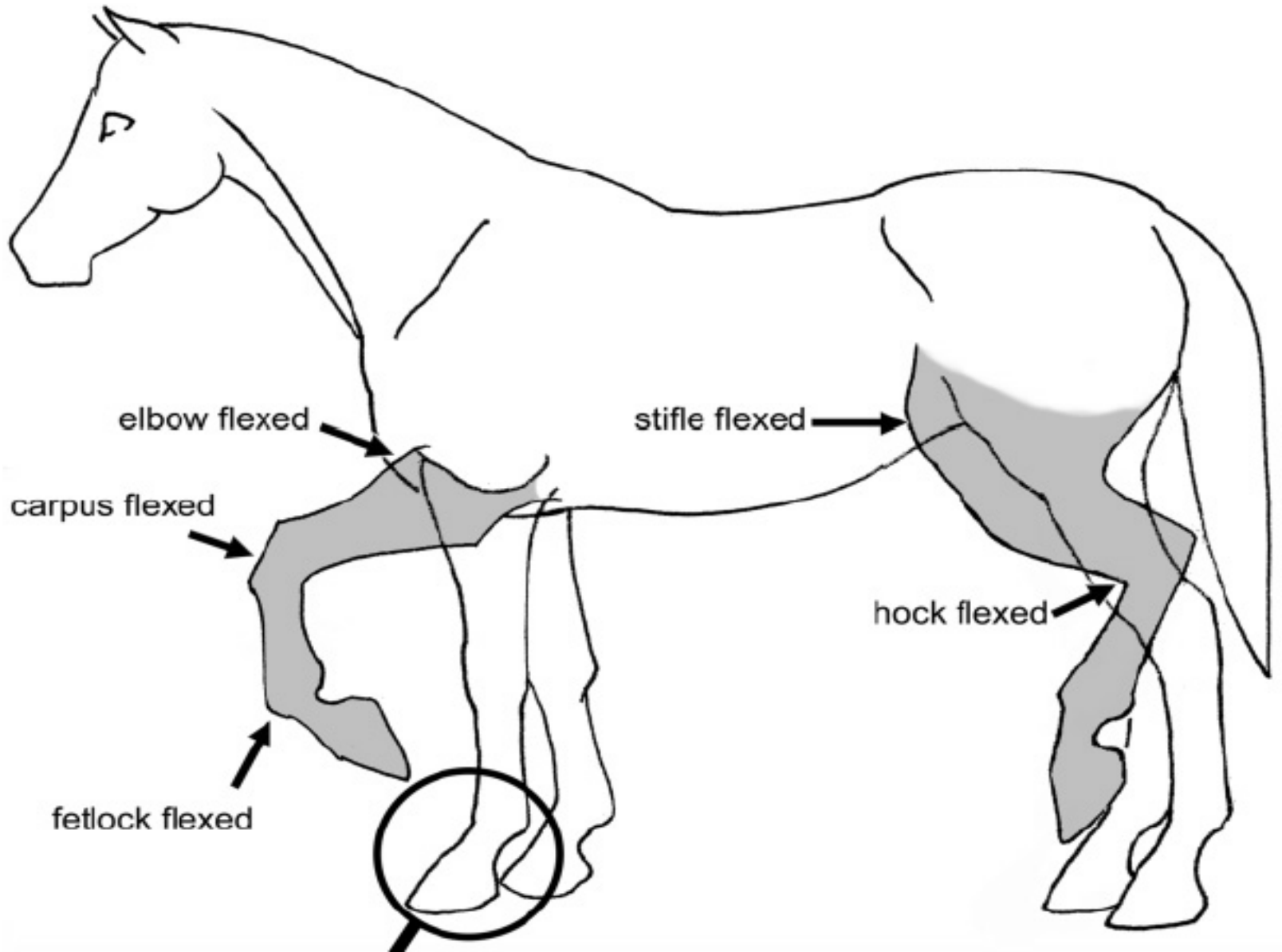
- *simple* joint
- *composite* (compound joints)

C. geometry (structure) and uniting medium:

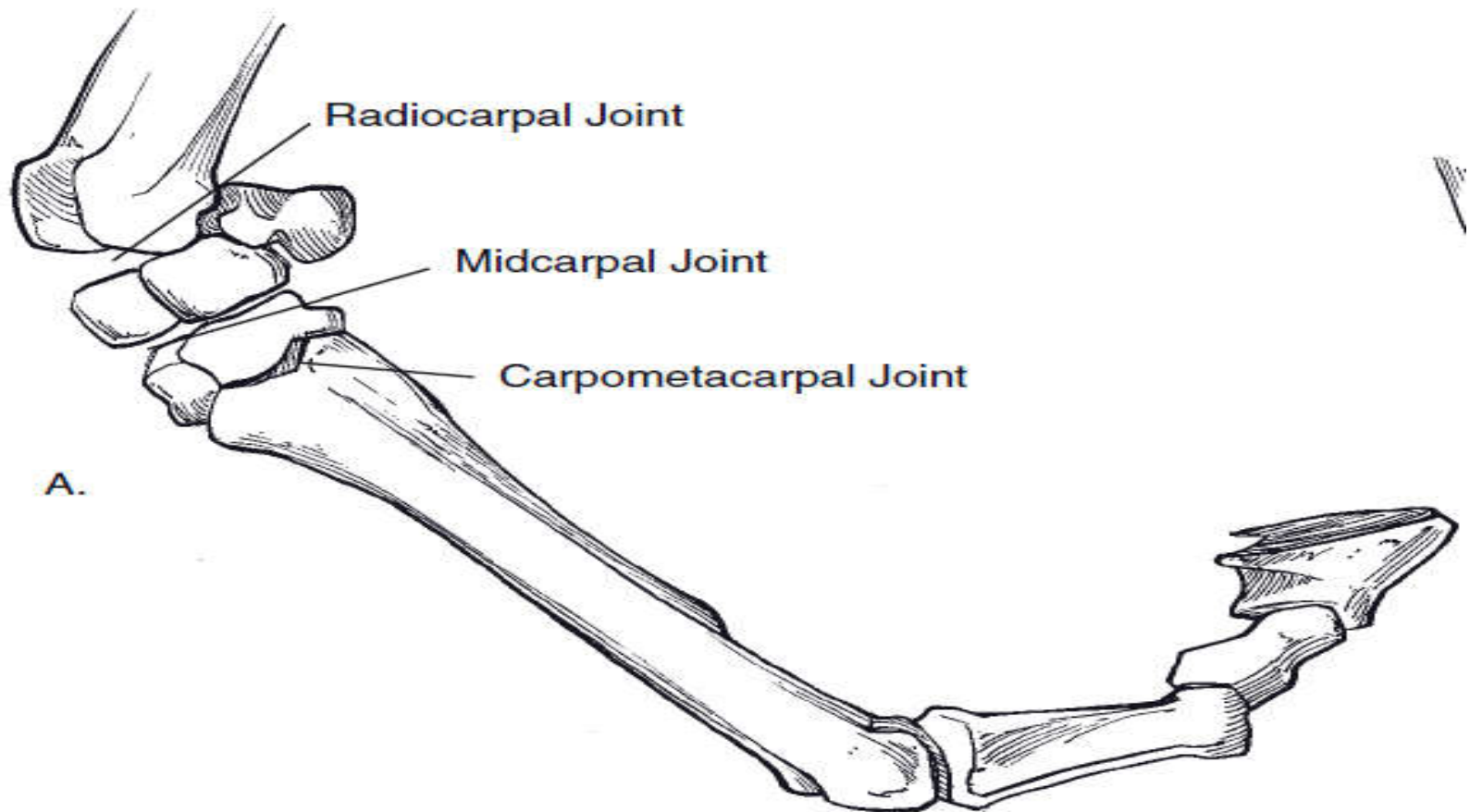
- *fibrous,*
 - *Suture*
 - *Gomphosis*
 - *Syndesmoses*
- *cartilaginous,*
 - *Synochondrosis*
 - *Symphysis (fibro cartilaginous)*
- *synovial joints.* 
 - Structures **- movements** (*Gliding or sliding, Flexion, Extension, Hyperext, Rotation, Adduction, Abduction..*)
 - *Articular surface*
 - *Articular cartilage*
 - *Articular cavity*
 - *Joint capsule*

- 
1. *Plane joint*
 2. *Hinge joints*
 3. *Pivot joint*
 4. *Condylar joint*
 5. *Ellipsoidal joints*
 6. *Saddle joint*
 7. *Ball and socket*

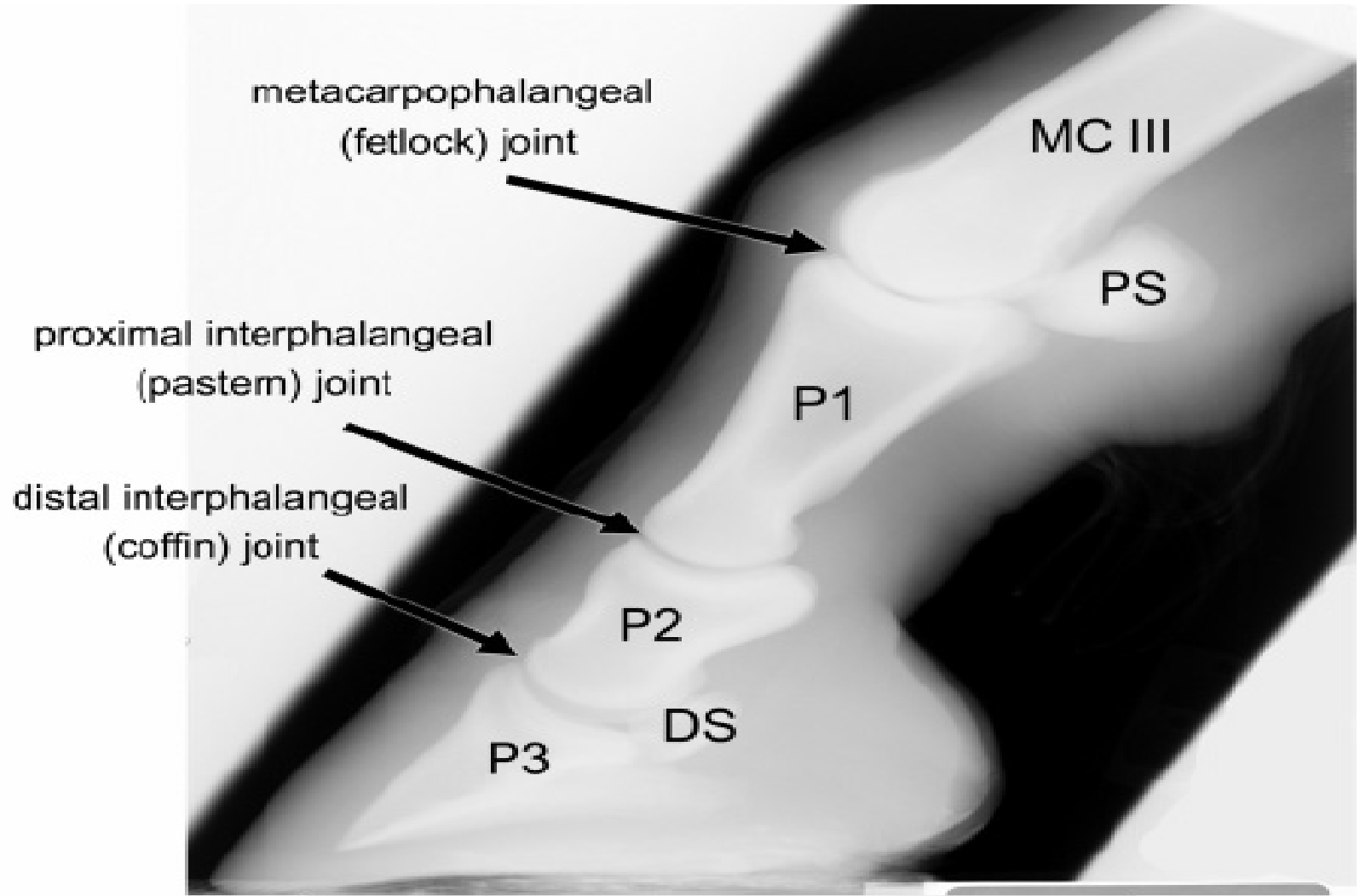
Joint....



figure



Cont--



UNIVERSITY OF GONDAR

*College of Veterinary Medicine and Animal
Sciences*

Unit of Biomedical Sciences

Lecture Note:

*On: Veterinary Gross Anatomy I
(Myology Part)*

To: Veterinary Medicine Year 1st Students

Compiled By:

Bemrew. (DVM, MSC)

APRIL, 2020

Gondar, Ethiopia

CHAPTER 4: MYOLOGY

Objective(s)

- ❖ At the end of this chapter, each student should be able to:
 - Classify muscle tissue of animal body in to different types.
 - Explain the organization, attachment, functional grouping and nomenclature of skeletal muscle.
 - Understand the different muscular structures act in locomotion and body function; and actions of muscles;
 - Identify the structure and relation of muscles found on different parts of animal body and describe their action.
 - Understand muscular structures considered during some clinical and other practices such as in surgical procedures, IM injection, meat inspection, etc.

Introduction

- ❖ Myology is the study of the structural and functional organization of muscle tissue and related structures.

Muscle tissue is:

- specialized for contraction;
 - responsible for body movements and changes in size and shape of internal organs;
 - the major component of the body of an individual.
- ❖ In multicellular organisms, muscle cells possess properties of:
 - Contractility; excitability; extensibility and elasticity.

Cont...

- ❖ The muscular system, in conjunction with the skeletal system
 - allows the movement of internal structures, limbs, and the body as a whole.

- ❖ Muscles make things happen;
 - supply force for movement, and together with skeletal system, act as movers and levers that make an animal act,
 - ✓ Just as important, muscles restrain motion.

Cont...

Importance of Studying the Muscular System

- ❖ To understand muscular structures act in locomotion and body function;
- ❖ To identify those muscular structures encountered during surgical procedures;
- ❖ To understand those muscles commonly considered in meat inspection;
- ❖ To know common muscles used for IM injection etc.

Cont...

Functions of Muscles

- ❖ Produce movement (volunteer and involunteer)
- Locomotion
- Help blood movement through blood vessels & food through GIT
 - ❖ Maintain posture
 - ❖ Stabilize joints and Restrain movement
 - ❖ Generating heat:
 - Regulate body temperature homeostasis
- by shivering (movement produces heat energy).

Cont...

□ Generally, muscles play role in:

- Respiration,
- Digestion, regurgitation, Defecation,
- Movement/locomotion
- Urination
- Parturition
- Circulation,
- Vision,
- Temperature regulation etc.

Classification of Muscle Tissue

- ❖ Most commonly used criteria used to classify muscles include:
 1. Muscles are classified according to their color (i.e. red and white muscles).
 - This classification has fallen out of favor.
 2. Muscles are classified according to their location;
 - **Somatic muscles**: move bones (or cartilages), and
 - **visceral muscles**: control the activities of organs, vessels, and ducts.

Cont...

3. Muscles are classified by the way in which they are controlled by the nervous system;

- **Voluntary muscles:** are under immediate conscious control,
- **involuntary muscles:** are not under immediate conscious control.

Cont...

4. Muscles are classified according to their embryonic origin

- Mesenchymal origin: ↔ Smooth muscles within the walls of blood vessels and some viscera arise from mesenchyme.,
- Hypomeral origin., ↔ smooth muscle layers of the alimentary tract and its derivatives.
 - ✓ Cells of the hypomere also form the cardiac muscle of the tubular heart.
- Mesodermal origin (i.e. paraxial) ↔ most skeletal muscles develop.

5. Muscles are classified by their general microscopic appearance;

➤ skeletal,

➤ cardiac, and Smooth muscles.

❖ **Generally**, muscle tissue can be classified; both morphologically and functionally in to three basic types:

➤ Smooth muscle (non-striated, involuntary)

➤ Cardiac muscle (striated, involuntary)

➤ Skeletal muscle (striated, voluntary)

I. Smooth (visceral) muscle tissue

➤ Makes up walls of :

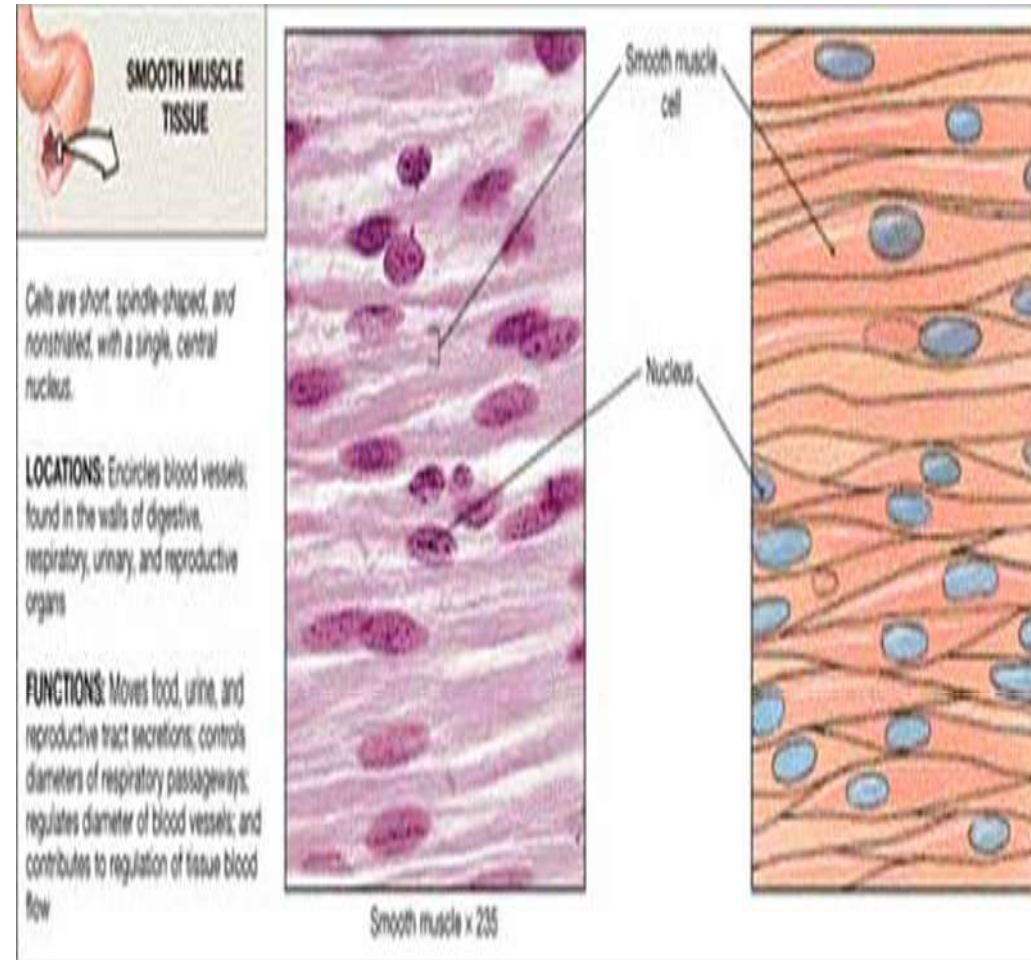
✓ hollow organs & blood vessels

✓ organs of digestive and urogenital systems

✓ Most blood vessels & in certain glands, spleen, eye ball and hair follicles.

Cont...

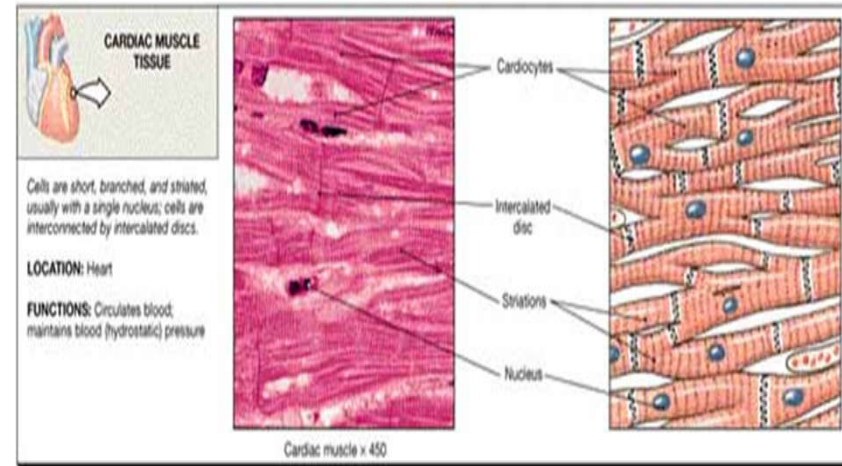
- Cells are short, spindle-shaped & have a single nucleus
- Tissue is non-striated & involuntary
- Tissue is extremely extensible, while still retaining ability to contract
 - ✓ i.e. due to intrinsic property of the fibers (spontaneous contraction).



Cont...

II. Cardiac muscle tissue

- ❖ Involuntarily & striated muscle;
- ❖ Found in the heart (Myocardium);
- ❖ Makes up the majority of the walls of the cardiac chamber (atria and ventricles);
- ❖ Microscopically appears striated;
- ❖ Cells are short, branching & have a single nucleus;
- ❖ Cells are connect to each other at intercalated discs.



Cont...

III. Skeletal muscle tissue

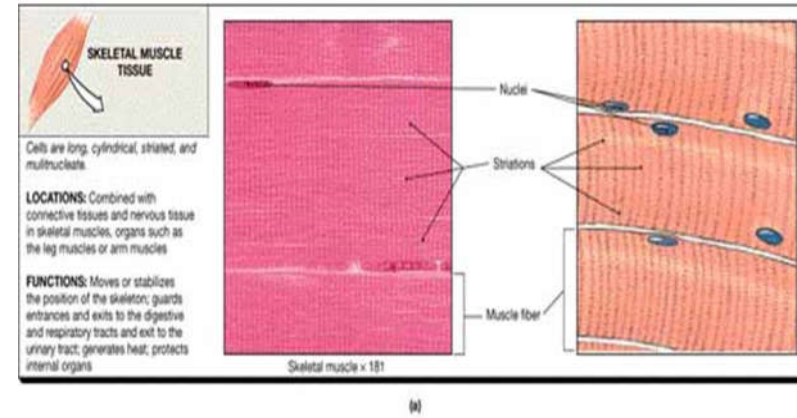
- ❖ Associated with & attached to bones of the skeleton

=> Skeletal muscle.

- ❖ Constitutes the flesh (bulk of muscle) of the animal body

=> Butcher's meat.

- ❖ Microscopically the tissue appears striated.
- ❖ Under conscious (voluntary) control.
- ❖ Cells are long, cylindrical & multinucleate.

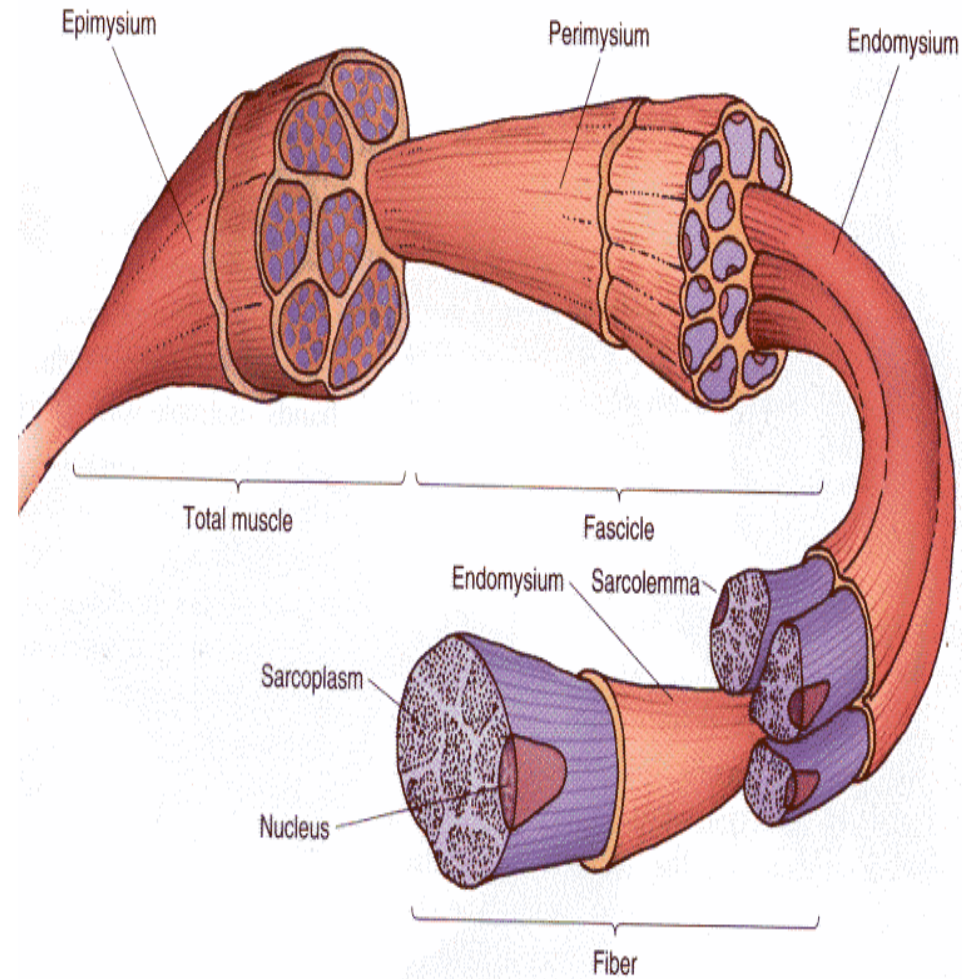


Organization of Skeletal Muscles

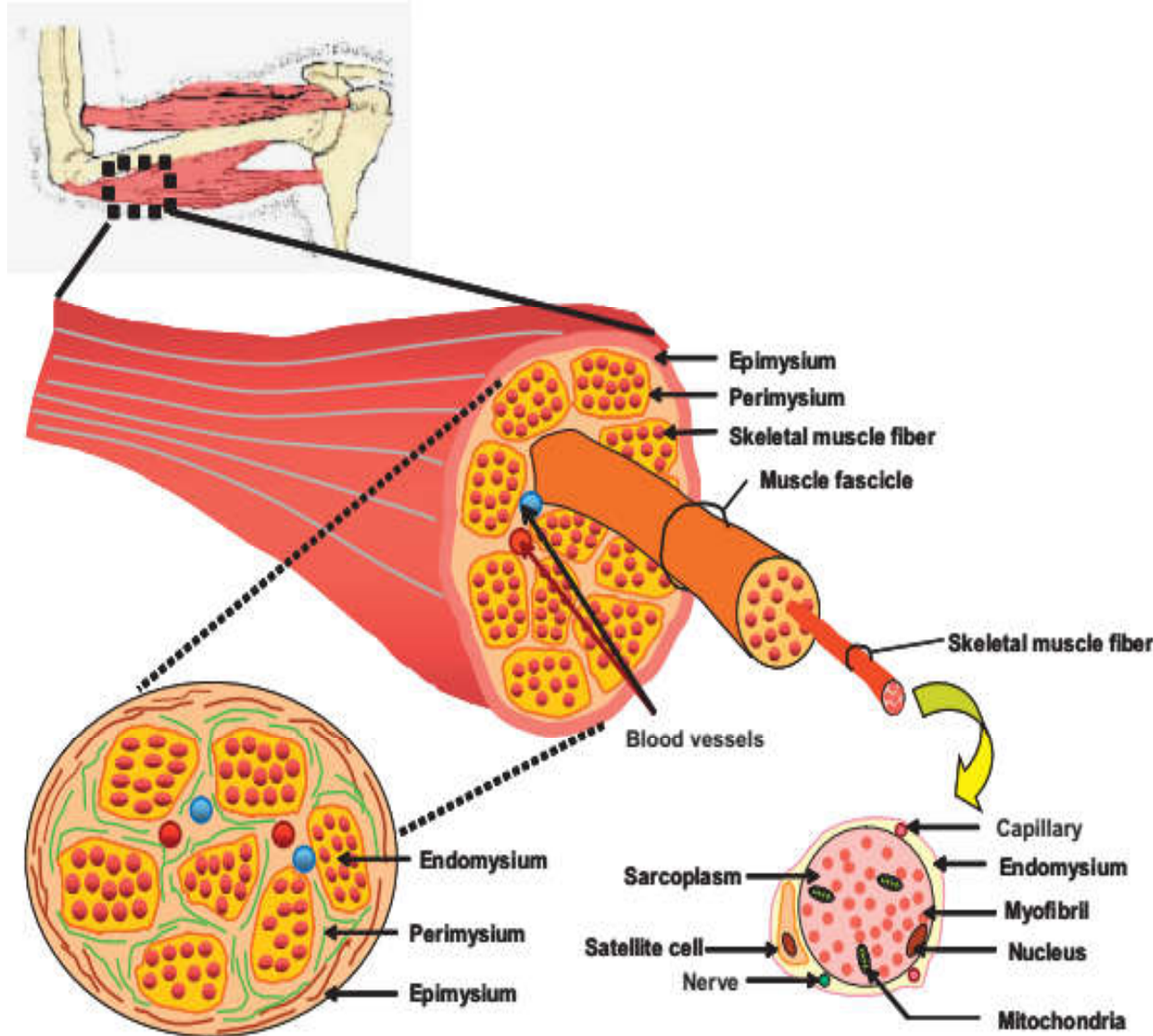
- ❖ Each muscle is composed of many cells (muscle fibers)
- ❖ Muscle fiber is surrounded by a film of connective tissue covering => Endomysium
- ❖ The group of skeletal muscle fibers form bundles (known as Fascicles)
- ❖ Fascicles are ensheathed and bound together by a connective tissue => Perimysium
- ❖ The entire groups of muscle fascicles are surrounded by fibrous connective tissue => Epimysium
 - Epimysium forms the muscle visible as flesh.
 - The epimysium is the outer covering of entire muscles.

Cont...

- The epimysium is the outer covering of entire muscles.
- ✓ The CT that form the bundles and ensheath the muscle tissue are interconnected and continuous to one another and come together at the extremities of a muscle to form tendons;
- ✓ The CT membrane separating muscles from each other and binding them into position is called **Fascia**.



Cont...




- Fig:** CT sheaths in skeletal muscle;
- Each skeletal muscle represents skeletal muscle fibers grouped into a muscle surrounded by a thin CT sheath called the epimysium;
 - Within the muscle are groupings of muscle fibers called fascicles, which are surrounded by the perimysium;
 - Within each fascicle are individual muscle fibers surrounded by the endomysium.

Arrangement of Muscle Fibers

- ❖ Arrangement of muscle fibers, within the muscle, varies greatly and they may be arranged in:
 - Parallel (strap muscle),
 - Spindle-shaped (fusiform) and
 - Pennate (penniform) form.

1. Parallel (strap) muscle:

- ❖ The fibers run parallel to the long axis and throughout the length of the muscle, which is completed by very short tendons of attachment.
- ❖ Muscle fibers join the tendon in a parallel manner.
Example: Abdominal muscles, Sartorius muscle of thigh.

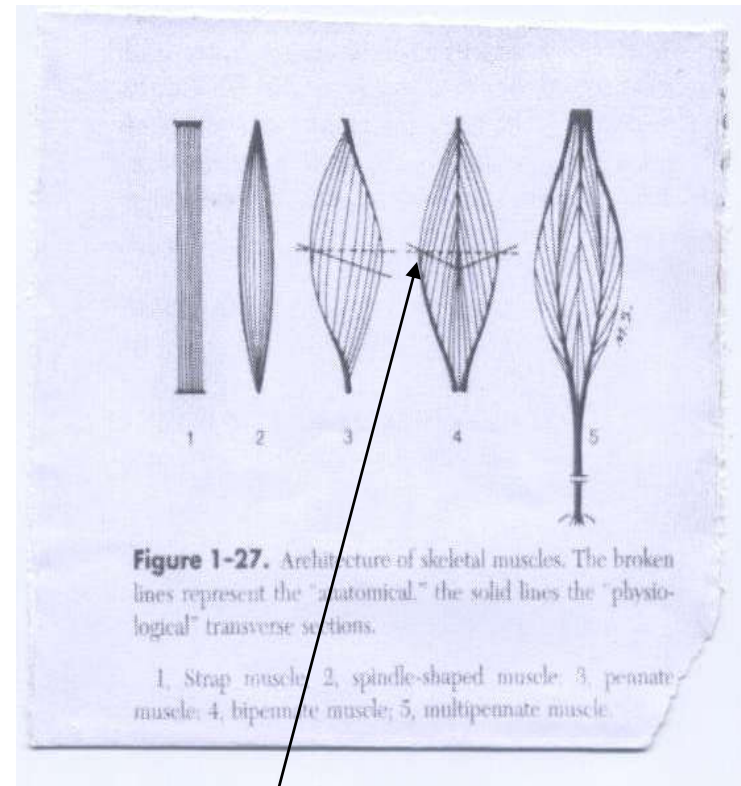


Parallel Fibers
"Strap Muscle"

Cont...

2. Spindle shaped (fusiform):

- ❖ Occurs when tendons are found at both ends.
- ❖ The wider part is called a belly.
- ❖ Some muscles have two bellies (digastricus), when interrupted by a narrow band (tendon).



Belly

Cont...

3. Pennate (penniform): Feather like arrangement with intervening tendon.

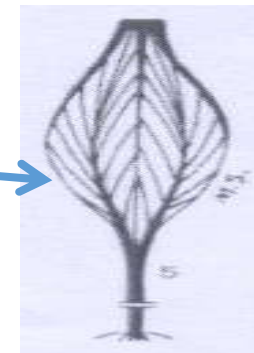
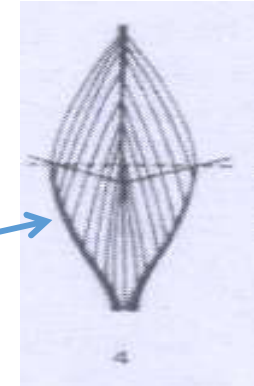

❖ The muscle fibers join the tendons at an angle.

❖ Depending on the **direction of fibers** and the **intermediate tendon**, pennate arrangement can be unipennate, bipennate and multipennate.


3.1. Unipennate: Muscle fibres are coming only in one direction and no intermediate tendon.

3.2. Bipennate: Muscle fibres come from two directions and there is one intermediate tendon.


3.3. Multipennate: Muscle fibres come from three or more directions and there is more than one intermediate tendon. Tendons represent the quill and muscle fibers represent the vane of the feather.



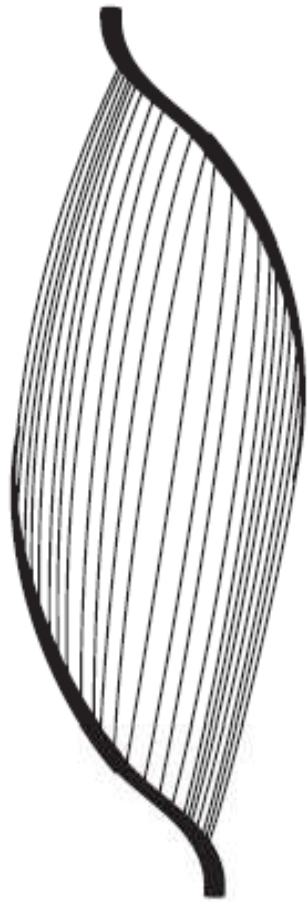
Cont...



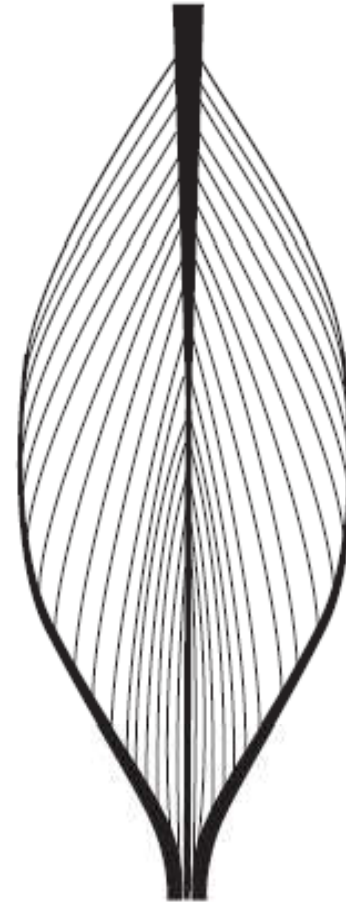
Parallel Fibers
"Strap Muscle"



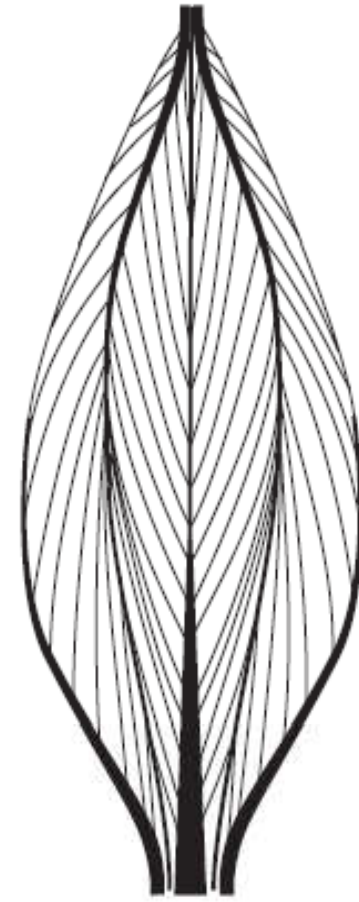
Fusiform



Unipennate



Bipennate



Multipennate

Attachment of Muscles

1. Fleshy Attachment:

- ❖ Attachment of muscle directly to the bone; i.e.
- when a muscle appears to come from the bone or directly to the bone; Ex. Muscles attaching the scapula.

2. Tendinous attachment:

- ❖ Fibrous CT at the end of the muscle form tendons;
- which attach to periosteum of bone or may even penetrate the surface of the bone for short distance.

Eg. *Musculus biceps brachii*.

- ❖ Muscles may attach directly to the periosteum of the bone; ex. Masseter muscle.

Cont...

3. Aponeurosis attachment:

- ❖ Attachment forming a flat sheet of fibrous connective tissue,
- ❖ usually associated with flat muscles.
- ❖ Attaches the muscles to bone or with other muscles.

Example: abdominal muscles.

- **Linea Alba** runs lengthwise between the muscles on the animals ventral midline and connects the abdominal muscles from each side together.

Muscle Terminology

Origin and Insertions

❖ Muscles are always attached to other structures at either end;

➤ Generally, one end is in a fixed position; while

➤ the other end moves toward it when the muscle is contracted;

Origin of muscle:

➤ more stable attachment sites of the muscle and

➤ does not move much when the muscle contracts;

➤ denotes the more proximal attachment in extremities.

Cont...

Insertion of muscle:

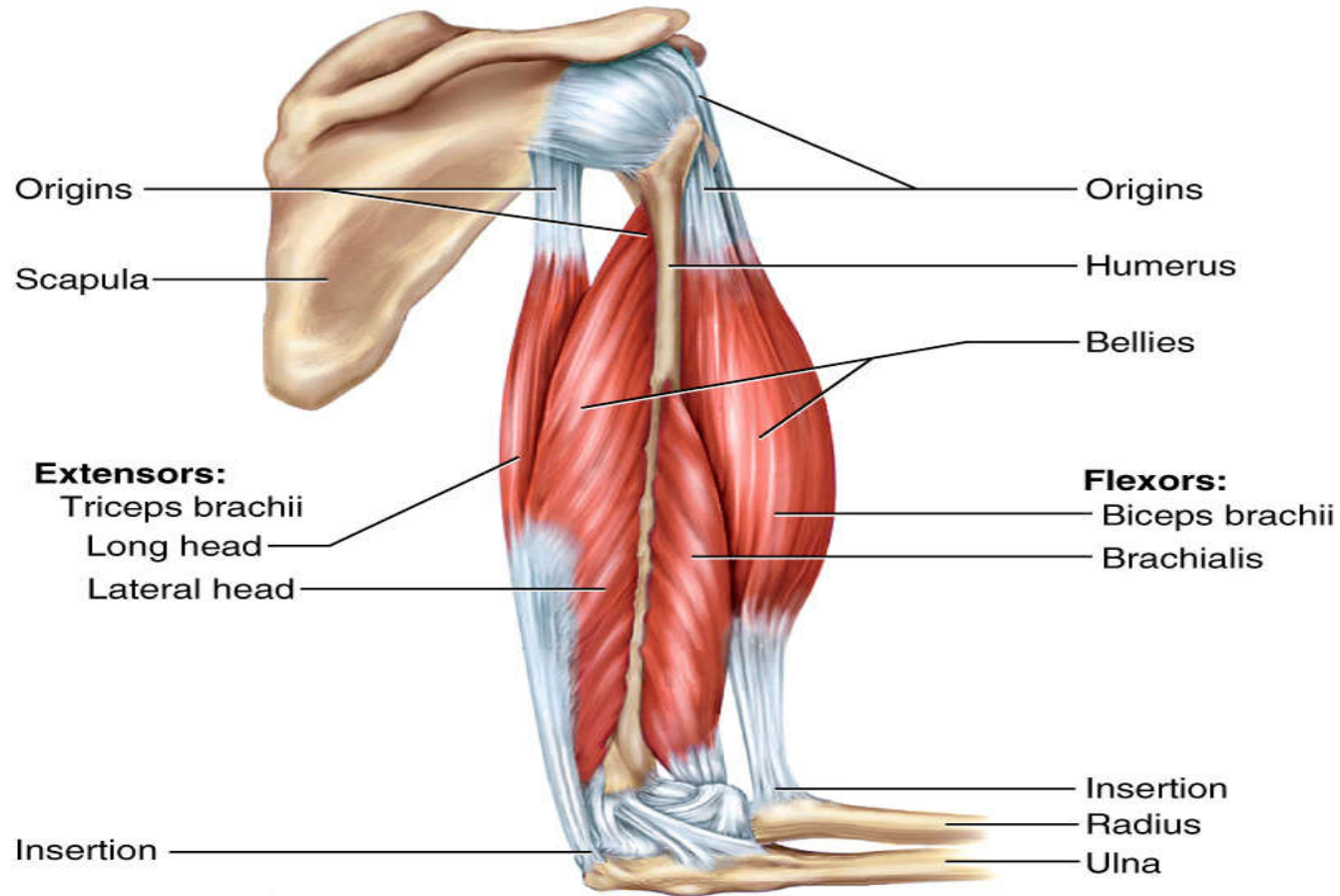
- more movable attachment site of a muscle and
- undergoes most of the movement when a muscle contracts;
- denotes the more distal attachment in extremities.

NB: Some muscles have distinctive divisions, called **heads**, which have separate origins.

Ex: *m. biceps brachii* has multiple heads (three heads).

Cont...

Copyright © The McGraw-Hill Companies, Inc. Permission required for reproduction or display.



NB: Since the only thing a muscle can actively do is contract, it nearly always tends to bring its ***origin*** and ***insertion*** closer together, causing one or both of the bones to move.

Actions

- ❖ The movements of the skeleton caused by muscle contraction involve:
 - flexion or extension, adduction or abduction,
 - protraction or retraction, elevation or depression,
 - rotation, circumduction, pronation or supination, inversion or eversion.
- ❖ Muscles typically work in groups rather than individually;
 - For example;
 - ✓ the *m. biceps brachii* and *m. brachialis* cause flexion of the elbow, and
 - ✓ the *m. triceps brachii*, *m. tensor fasciae anterbrachii*, and *m. anconeus* cause extension of the elbow.

Cont....

<i>Term</i>	<i>Description</i>
Abduction	Movement of a structure or limb or away from the median plane of the body (e.g., spreading the toes or moving a limb away from the center of the body)
Adduction	Movement of a structure or limb toward the median plane of the body (e.g., bringing the toes together or moving a limb toward the center of the body)
Antagonist	Opposes the movement of the prime mover (e.g., the triceps brachii, which extends the elbow joint, is the antagonist of the <i>biceps brachii</i> , which flexes the elbow joint)
Circumduction	Circular movement of an extremity describing the surface of a cone; involves successive flexion, abduction, extension, and adduction (e.g., moving a limb in a circular motion)
Depression	Moving a structure in a ventral direction (e.g., dropping the shoulders)
Elevation	Moving a structure in a dorsal direction (e.g., shrugging the shoulders upward)
Eversion	Twisting the foot to face the sole outward
Extension	Increasing the angle between bones. Ex: extending fingers from a curled position, or straightening the stifle (knee)

Cont....

Flexion	Decreasing the angle between bones. Ex: Bending the elbow toward a 90° angle.
Trunk lateral flexion	Bending to the side
Trunk flexion	Bending forward
Shoulder flexion	Swinging the limb backward (in humans, it is swinging the limb forward)
Plantar flexion	Movement of the ankle joint to push the sole of the foot downward
Dorsiflexion	Flexion of the ankle joint in order to raise the top of the foot upward
Insertion	The more movable of the two attachments. In the limbs, this is usually the more distal attachment
Inversion	Twisting motion of the foot to face the sole inward
Origin	The less movable of the two attachments. In the limbs, it is usually the more proximal attachment
Pronation	Movement of the palmar side of the paw downward
Protraction	Moving a part of the body cranially in the horizontal plane. Ex: Pushing the shoulders forward

Cont....

Retraction	Moving a part of the body caudally. Ex: Pulling the shoulders back
Rotation	Movement around the long axis
Lateral rotation	The cranial surface of a limb turns away from the long axis of the trunk (e.g., Gemelli)
Medial rotation	The cranial surface of a limb turns toward the long axis of the trunk
Supination	Movement of the forearm (radius and ulna) so the palmar side is rotated upward or forward as when a cat laps milk off its paw.
Synergist	A muscle that indirectly aids the action of the prime mover. Ex. Teres major muscle is a synergist to the latissimus dorsi muscle

Functional (Action) Groupings of Muscles

1. Flexor muscles:

- ❖ are muscles that bend the joint
- ❖ Located on the side of the bone toward which joint bends.
 - Ex: *m. biceps brachii*: flexor of the elbow joint.

2. Extensor muscles:

- ❖ are muscles that straightens the joint
- ❖ Located on the side of the bone toward which the joint stretches (extends).
 - Ex: *Triceps brachii* muscle: extensor of the elbow joint.

NB: Flexion and extension apply chiefly to limbs.

3. Adductor muscles:

- ❖ are muscles that tend to pull a part toward the median plane.
- Example: Pectoral muscles are adductors of the forelimb.

4. Abductor muscles:

- ❖ are muscles that tend to move the part away from the median plane.
- Example: *musculus deltoides* is abductor of the forelimb.

NB: Adduction and abduction are most often used to describe motion of the limb relative to the body.

5. Levators:

❖ are muscles that elevate the part of the body.

➤ Example: *musculus levator nasolabialis*.

NB: applied to jaw action:

➤ **Levators** (a special kind of adductor) close the jaws;

➤ **Depressors** (a special kind of abductor) open the jaws.

Cont...

6. Sphincters/constrictors: muscles that surround the openings of the body.

❖ Striated or smooth muscle.

Examples:

- *Pyloric sphincter:* smooth muscle that surrounds the opening between the stomach and intestine;
- *Orbicularis oculi:* striated muscle fibers in the eyelids;
- *Orbicularis oris:* around the oral opening;
- *Anal sphincter:* around the anal opening;
- *Cardiac sphincter:* entrance of the esophagus to the stomach;
- *Urethral sphincter:* around the neck of the urinary bladder.

7. Agonists (primary movers):

- ❖ are muscles that are directly responsible for producing desired action.

Example:

- If desired action is flexion of the elbow: *musculus biceps brachii* and *musculus brachialis* become agonists;
- If desired action is extension of the elbow joint: *musculus triceps brachii* becomes an agonist.

8. Antagonists

- ❖ are muscles that oppose the desired action.
- ❖ They have actions directly opposite to the agonists.

Example:

I. In the extension of the elbow;

- *M. biceps brachii* and *M. brachialis* are antagonists,
✓ i.e. produce the opposite action (flexion of the elbow).

II. In flexion of the elbow joint, the *M. triceps brachii* becomes antagonist,

i.e. produces the opposite action.

9. Synergists:

- ❖ Are muscles that act together to produce motion in the same general direction.
- ❖ Muscles that oppose any undesired action of the agonists.
- ❖ Eliminate an unwanted side effect of agonist and
- ❖ Assist in carrying out the action of agonist.

Example:

supraspinatus and
brachiocephalicus

} muscles are synergists.

Cont...

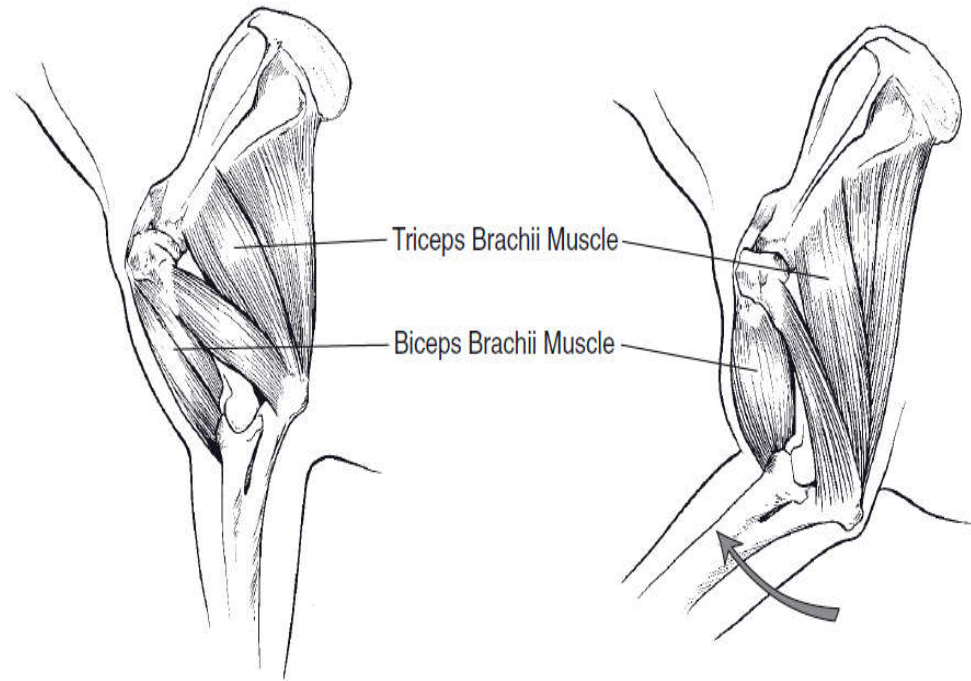


Figure : Functional grouping of muscles.

- ❖ The *m. biceps brachii* is a flexor of the elbow, and the *m. triceps brachii* is an extensor.
- ❖ In this case, the *m. biceps brachii* is an agonist for elbow flexion, and the *m. triceps brachii* acts as an antagonist.
- ❖ Any muscles that assist elbow flexion indirectly by stabilizing other joints are considered synergists of that movement.

Cont...

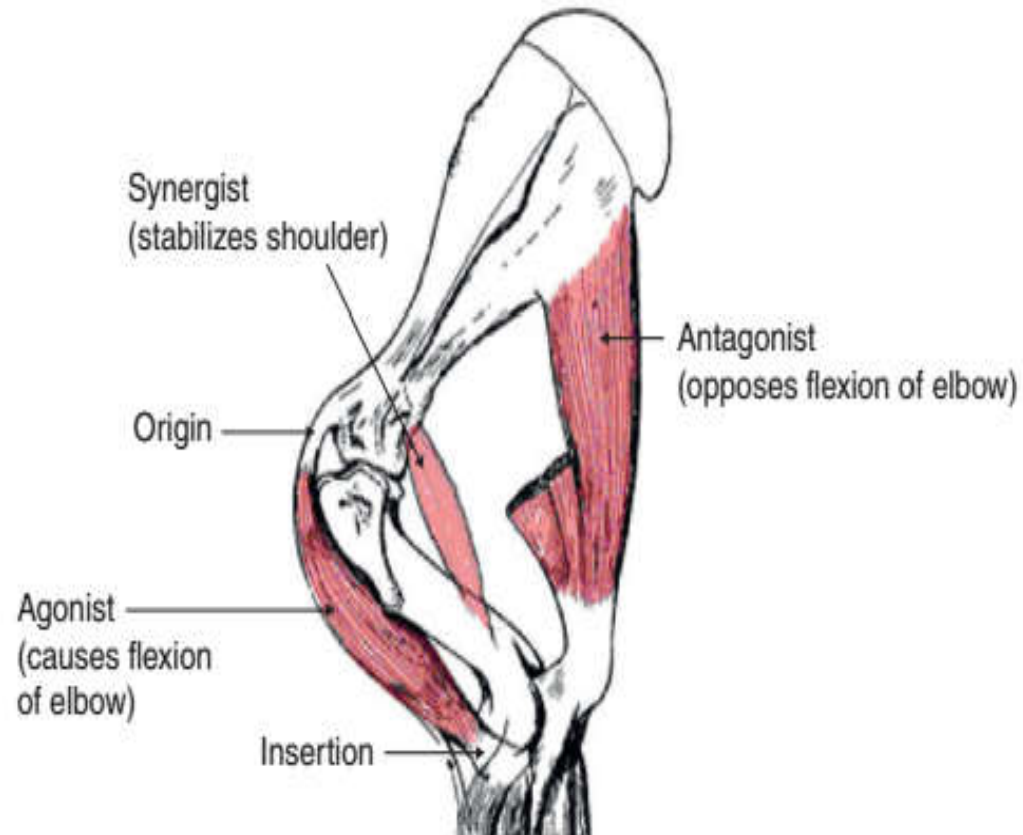


Fig: Muscle functions and attachments.

❖ Using the thoracic limb of the horse, this figure demonstrates the origin and insertion of muscles, as well as the agonist and antagonist functions with regards to the elbow.

Nomenclature of Skeletal Muscles

- ❖ The name of muscles is usually written in Latin rather than in English;
- ❖ Latin names are highly descriptive of the function and/or appearance of the muscles.
- ❖ In Latin, the noun is written first followed by adjectives.

Example:

- *M. triceps brachii*: three headed muscle of the arm,
- *M. flexor digitarum profundus*: deep digital flexor muscle.

Cont....

□ Names of muscles may be derived from the following physical characteristics of muscles:

1. Their action;

❖ A portion of muscles name is often related to its function.

Example: Flexor muscles flex the part when they contract
superficial digital flexor muscles: flexes the digit.

Action	Description	Example
Adductor	Adducts the part	<i>M. adductors</i>
Depressor	Depresses the part	<i>M. Depressor labi maxillaris</i>
Extensor	Extend the part	<i>M. extensor carpi radialis</i>
Levator	Elevate the part	<i>M. levator nasolabialis</i>
Flexor	Flexes the part	<i>M. flexor carpi-radialis</i>

Cont...

2. Their overall shape:

❖ a muscle's name can reflect its distinctive shape.

Example: *Musculus deltoides*: Deltoid shape (triangular shape) muscle of shoulder area.

Shape	Description	Example
Orbicularis	circular shaped	<i>M. orbicularis oris</i>
Quadratus	square shaped	<i>M. quadratus femoris</i>
Rhomboideus	diamond shape	<i>M. rhomboideus</i>
Trapezius	trapezoidal shape	<i>M. trapezius</i>

Cont...

3.Their location: a muscles name can indicate its physical location in the body.

Ex: *M. biceps brachii*: located in the brachial region,
M. biceps femoris: located on Femur.

4. Their direction of muscle fibers

Example: *Musculus rectus abdominis* is straight muscle that runs parallel to the midline (Rectus means straight).

Dxn of fibers	Description	Example
Oblique	Diagonal to the body's mid line	<i>M. obliquus carpiradialis</i>
Rectus	Straight (parallel to the mid line)	<i>M. rectus abdominis</i>
Transversus	At the right angle to the mid line	<i>M. transversus abdominis</i>

5. Their attachment sites (Origin and insertion sites):

- ❖ Origin and insertion sites are used to name some muscles

Example:

- *M. sternocephalicus* = the origin is the sternum and insertion is the head;
- *Musculus brachiocephalicus* = the origin is head and insertion is the forearm.

6. Their relative position:

Example:

↻ Externus → external

↻ Profundus → deep

↻ Caudalis → caudal

↻ Internus → internal

↻ Superficialis → superficial

↻ Lateralis → lateral.

7. Their relative size:

Size	Description	Example
Brevis	Short	<i>M. peroneus brevis</i>
Longus	Long	<i>M. peroneus longus</i>
Medius	Medium	<i>M. gluteus medius</i>

Regional Classification of Skeletal Muscles

1. Cutaneous Muscles

- ❖ Thin muscular layer occurring in the superficial fascia between the skin and the deep fascia;
- ❖ Located under the skin and cover skeletal muscles;
- ❖ No attachment to bone;
- ❖ Enable animals to twitch the skin;
- ❖ It is attached to the skin and
- ❖ Responsible for movement of the skin.

Cont...

❖ Divided into: ⇨ Facial,

⇨ cervical (neck),

⇨ omobrachial (shoulder and arm),

⇨ abdominal and hind (femoral);

I. The facial part (*musculus cutaneous faciei*)

- Muscle extending over the mandibular space and the masseter muscle;

II. The cervical part (*musculus cutaneous colli*)

- Muscle situated along the ventral region of the neck

III. Omobrachial part (*musculus cutaneus omobrachialis*)

- Covers the lateral surface of the shoulder and arm.

IV. The abdominal part (*musculus cutaneus trunci*)

- Muscle covers a large part of the body of animal caudal to the shoulder and arm;
- Runs from the ventromedial linea alba towards the dorsum.

Cont...

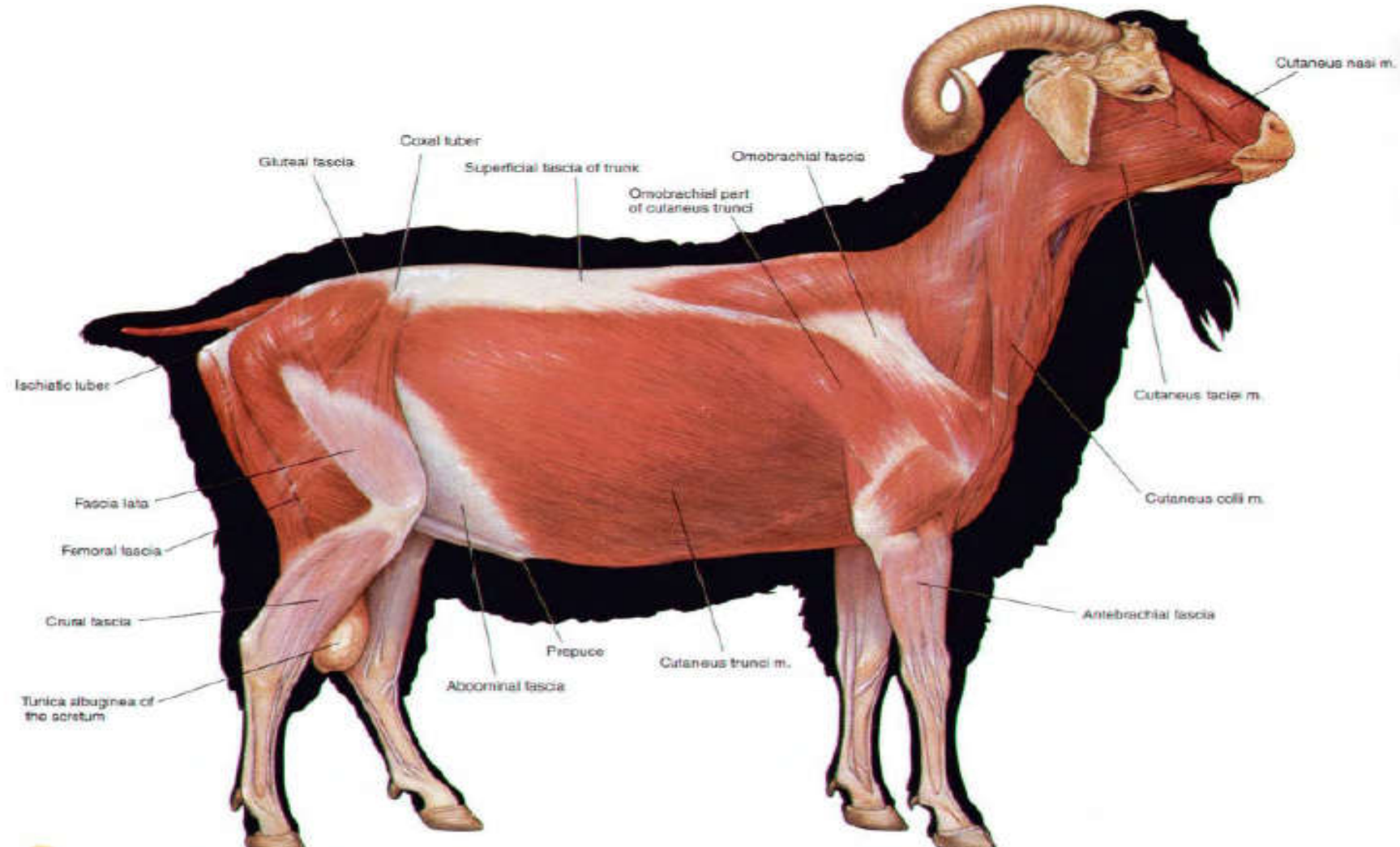


Figure: cutaneous muscles and major fasciae of the trunk. Right lateral view.

2. Muscles of the Head

- ❖ The roles of muscles of the head are to:
 - control facial expression,
 - enable chewing (mastication) and
 - move sensory structures, such as the eyes and ears.

Cont...

- ❖ Include muscles that are found in association with

§ mouth area (muzzle, lips), § nose, § orbit,

§ mandible, § hyoid apparatus, § tongue and ears.

- ❖ Muscles of the head are grouped into:

Ψ muscles of mastication, Ψ muscles of facial expression,

Ψ muscles of the tongue and Ψ muscles of hyoid apparatus.

Cont...

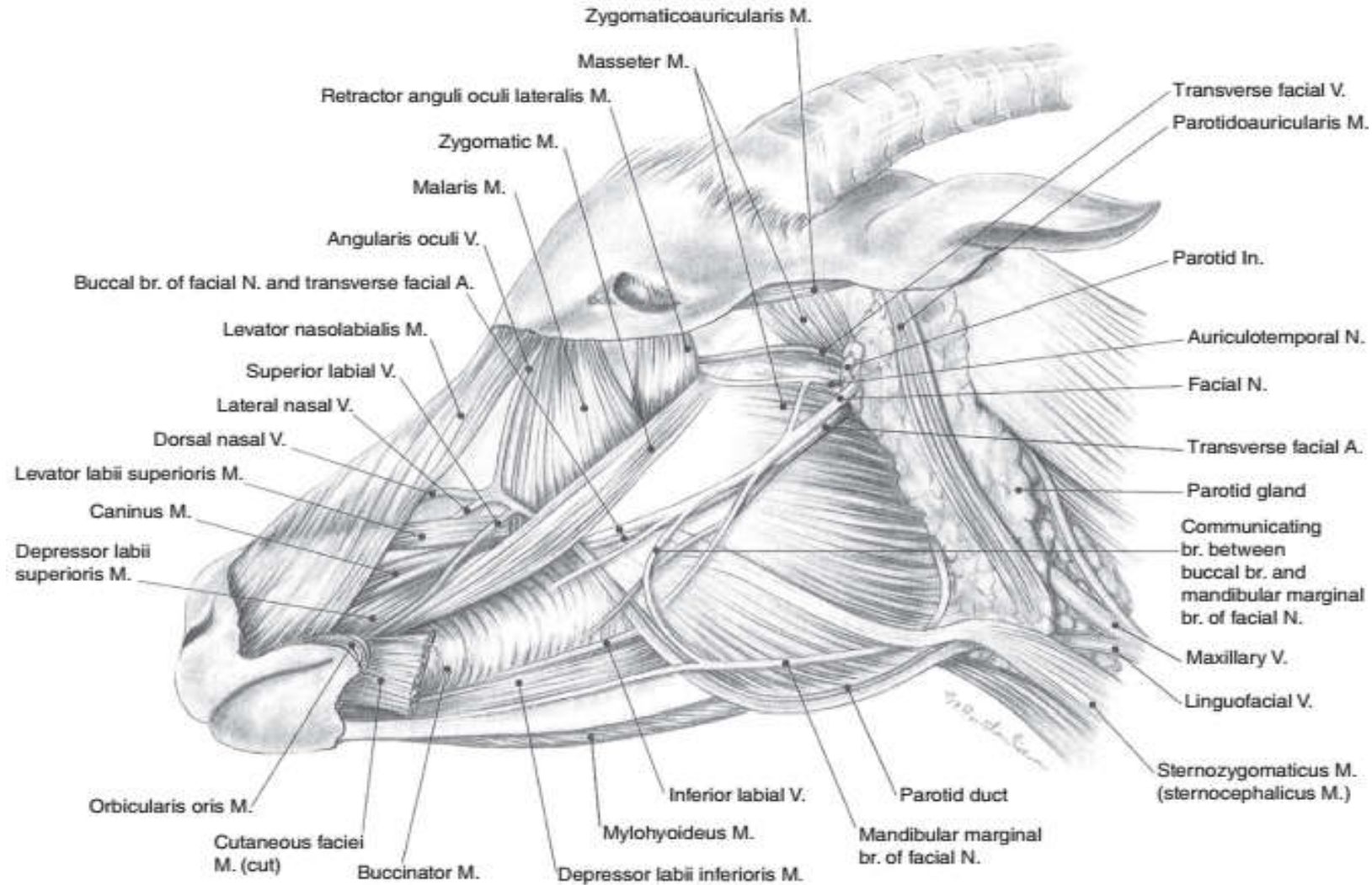


Fig: Superficial muscles of the neck of the goat. A, artery; br, branch; V, vein; In, lymph node; M, muscle; N, nerve.

2.1. Muscles of Mastication

❖ These group of muscles:

- arise from maxilla and the cranium and
- insert in to the mandible.

❖ Their contraction produces the jaw movements associated with chewing of food.

I. *Musculus temporalis*:

- is a strong muscle that occupies the temporal fossa.
- Largest muscle on the head.
- Lateral and dorsal aspect of the skull.

Cont...

- ❖ Fan-shaped muscle covering part of temporal, frontal and parietal bones
- Originates from the sagittal crest and the expansive temporal fossa of the lateral cranium and
- inserts into coronoid process of the mandible.

Action: elevates and retracts mandible to close mouth.

- ✓ elevating the mandible: brings the upper and lower teeth together.

Cont...

II. Masseter muscle:

- ❖ Powerful masticator muscle and
- ❖ Occupies majority of the cheek area of the head.
- ❖ Lies lateral to the mandible (lateral surface of the ramus).
- ❖ Largest muscle found ventral to the zygomatic arch.
- ❖ It is well developed in **herbivores**.
 - arises from maxillary region of face and zygomatic arch;
 - Inserts into caudal mandible.

Action: elevates and draws the mandible laterad.

III. *Musculus digastricus*:

- ❖ Thin, superficial, strap-like muscle.
 - ❖ Ventral caudal edge of mandible.
 - ❖ composed of two fusiform flattened bellies, united by a round tendon.
-
- Originates from the region caudal to TMJ;
 - Inserts into the angle of the mandible.

Action: brings forceful depression of the mandible ↔ opens mouth.

IV. *M. pterygoideus*:

- ❖ they are two in number (i.e. lateral and medial);
- ❖ Are located medial to the mandible;
- ❖ Occupy the medial surfaces of ramus of the mandible similar to masseter laterally.
 - *Arises* from ventral parts of the skull;
 - ✓ i.e. from pterygoid and palatine bones.
 - *Inserts* into the mandible.

Action:

- Assist in closing the mandible and
- Play a role in the side to side gliding movements typical of herbivore mastication.

Cont...

2.2. Muscles of Facial Expression (Mimetic Musculature)

- ❖ These are muscles that move the:
 - skin of face and
 - head to express feelings.
- ❖ Generally, they are thin cutaneous muscles and composed of:
 - I. Muscles of the muzzles, nostril, lips and cheeks
 - II. Muscles of the eyelid and eyeball;
 - III. Muscles of the ear.

I. Muscles of the muzzles, nostril, lips and cheeks

❖ The principal muscles of the lips and cheeks are the:

➤ *M. Zygomaticus*

➤ *M. buccinator,*

➤ *M. orbicularis oris,*

➤ *M. caninus,*

➤ *M. levator nasolabialis,*

➤ *M. levator labii superioris,* and

➤ *M. depressor labii inferioris;*

A. *M. Zygomaticus*:

- ❖ Muscle running diagonally from cheek bones to corner of mouth;
- ❖ From its caudal border transverse muscle bundles pass toward the mandibular space.
- ❖ lies immediately under the skin of cheek;
- ❖ Origin: Zygomatic bone near zygomaticomaxillary suture;
- ❖ Insertion: Angle of the mouth; radiates into the orbicularis oris.

Action: Retracts and elevates corners of mouth;

B. *Musculus levator nasolabialis*:

- ❖ a thin muscle found on the lateral surface of nasal region that elevates maxillary lip and commissure;
- ❖ arises over the dorsum of the nose and
- ❖ Inserts:
 - partly on the wing of the nostril and
 - partly into the lateral part of the upper lip.

Action: It is able to:

- dilate the nostril and
- elevate and retract the upper lip.

C. *M. levator labii superioris*:

- ❖ Lies on dorsolateral aspect of the face;
- ❖ Origin: Bones of the side of the face (in front of the eye in the horse; lower, at the end of the facial crest in the ox; above the large molar in the dog).
- ❖ Insertion:
 - Horse and ox: Skin on the front of the upper lip, by common tendon with the same muscle of the other side.
 - Dog: Front end of the upper lip and the side of the nostril.

Cont...

Action:

Horse and ox: 1. Muscles of both sides: Lift the front of the upper lip; by continued action, evert the lips, exposing the front teeth.

2. One side only: Lifts and pulls the upper lip slightly to that side.

- Dog: Lifts the upper lip and widens the nostril opening.
 - it elevates maxillary lip at the fullest extent;
 - results in eversion of the lip.

Cont...

D. *M. Caninus*:

- ❖ thin triangular muscle that lies on lateral region of cheek
- ❖ arises ventral to the infraorbital foramen and
- ❖ radiates into the wing of the nostril and the upper lip.
- ❖ It dilates the nostril and elevates the corner of the mouth in the snarling gesture, especially in the dog;

E. *M. Orbicularis oris*:

- ❖ surrounds the mouth opening, where it is closely attached to the skin and mucosa of the lips.
- ❖ It closes the opening of the mouth by pursing the lips and is important in sucking.
- ❖ is sphincter muscle of the mouth,

Cont...

F. *M. buccinator*:

- ❖ Muscle contained within the wall of the cheek;
- ❖ Is lateral wall of the mouth (forms the basis of the cheek)
- ❖ Origin and insertion: fascia of cheek wall;
- ❖ extends from the angle of the mouth to the maxilla;
- ❖ dorsal to *M. depressor labi mandibularis* and
- ❖ passes b/n the margins of the upper and lower jaws;
- ❖ is partly covered by the masseter;
- ❖ it flattens the cheek, thus pressing food between the teeth;
- ❖ Holds the cheeks toward the mouth when chewing;



Cont...

- ❖ *M. buccinator* acts in opposition to the tongue;
- preventing food from collecting in the vestibule by returning it to the central cavity of the mouth;
- ❖ it also retracts the mouth.

G. *M. depressor labii inferioris*:

- lies on lateral surface of mandible and
- depresses and retracts mandibular lip.

NB: most muscles of the face are innervated by branches from facial nerve.

Cont...

II. Muscles of the Eyelid and Eyeball

A. *M. orbicularis oculi*: is a flat sphincter muscle;

- ❖ Surrounds the palpebral fissure, the opening between the lids.
- ❖ It is anchored at the medial and lateral commissures and therefore narrows the opening to a horizontal slit when it contracts.
- ❖ Its contraction squeezes the eyelids shut and produces a forceful closure of the fissure.

Cont...

B. *M. malaris*:

- ❖ It is a thin muscle that depresses the lower eye lid, enlarging the eye opening.
- ❖ it extends from facial rostral orbit to lower lid.
- ❖ Originates from Deep fascia of the face and
- ❖ Inserts into the Lower eyelid
- ❖ Draws the lower eyelid ventrally.

NB: levator anguli oculi raises the upper lid.

Cont...

C. *M. levator palpebrae superioris*:

- ❖ is the primary lifter of the upper eyelid.
- ❖ It arises between the origins of the dorsal oblique and dorsal rectus muscles and
- ❖ inserts via a wide tendon in the connective tissue within the upper eyelid.

Action: retracts and elevates the superior lid.

D. *Musculus rectus* (superior, inferior, lateral and medial)

- ❖ Are the muscles of the ocular bulb (eyeball);
- ❖ the rectus muscles move the eyeball medially toward the nose or laterally toward the temporal region, as well as dorsally and ventrally.

E. Ventral and dorsal oblique muscles

- ❖ The muscles of the ocular bulb (eyeball);
- ❖ The *m. obliquus dorsalis* (*dorsal oblique m.*)
 - lies between the dorsal and medial recti muscles and
 - tapers to a thin tendon at the level of the posterior pole of the eyeball.

Cont...

- ❖ The *mm. obliquus dorsalis* and *ventralis*:
 - produce inward and outward rotation of the bulb respectively;
 - When the dorsal oblique muscle contracts, the dorsal part of the eyeball is pulled toward the medial portion of the orbit;
 - ✓ i.e., the left eyeball rotates counterclockwise and the right rotates clockwise).

Cont...

- ❖ The *m. obliquus ventralis* (*ventral oblique m.*):
 - originates from a fossa in the ventral portion of the orbital rim;
 - it runs dorsolaterad, ventral to the insertion of the ventral rectus muscle; and
 - it inserts via two short tendons on the lateral aspect of the globe.
 - The ventral oblique muscle rotates the globe opposite to the rotation produced by the dorsal oblique muscle.

F. Retractor muscle

- ❖ The *m. retractor bulbi* arises in the caudal part of the orbit, lateral to the optic nerve, and
- ❖ divides into four flat muscle bellies that insert on the equator of the eyeball in a nearly complete muscular cone.
- ❖ Contraction of the *m. retractor bulbi* results in retraction of the eyeball into the orbit.

III. Muscles of the ear (Auricular muscles)

- ❖ Are roughly divided into a rostral and a caudal group.

Action:

- production of the range of ear movements characteristic of domestic animals.

Cont...

2.3. Muscles of the tongue: extrinsic/intrinsic

❖ Musculus genioglossus:

- Extrinsic muscle of the tongue (arises from outside the tongue);
- arises from the rostral part of the mandible (the genu) and
- inserts in the base of the tongue.

❖ M. styloglossus

- draws up the sides of the tongue to create a trough for swallowing.
- Aids in retracting the tongue /brings tongue in/.

Action: it draws the entire tongue rostrad/i.e. protraction/.

❖ Musculus hyoglossus:

- arises from the hyoid apparatus and
- inserts in the base of the tongue;

Action: it draws the tongue caudad.

Cont...

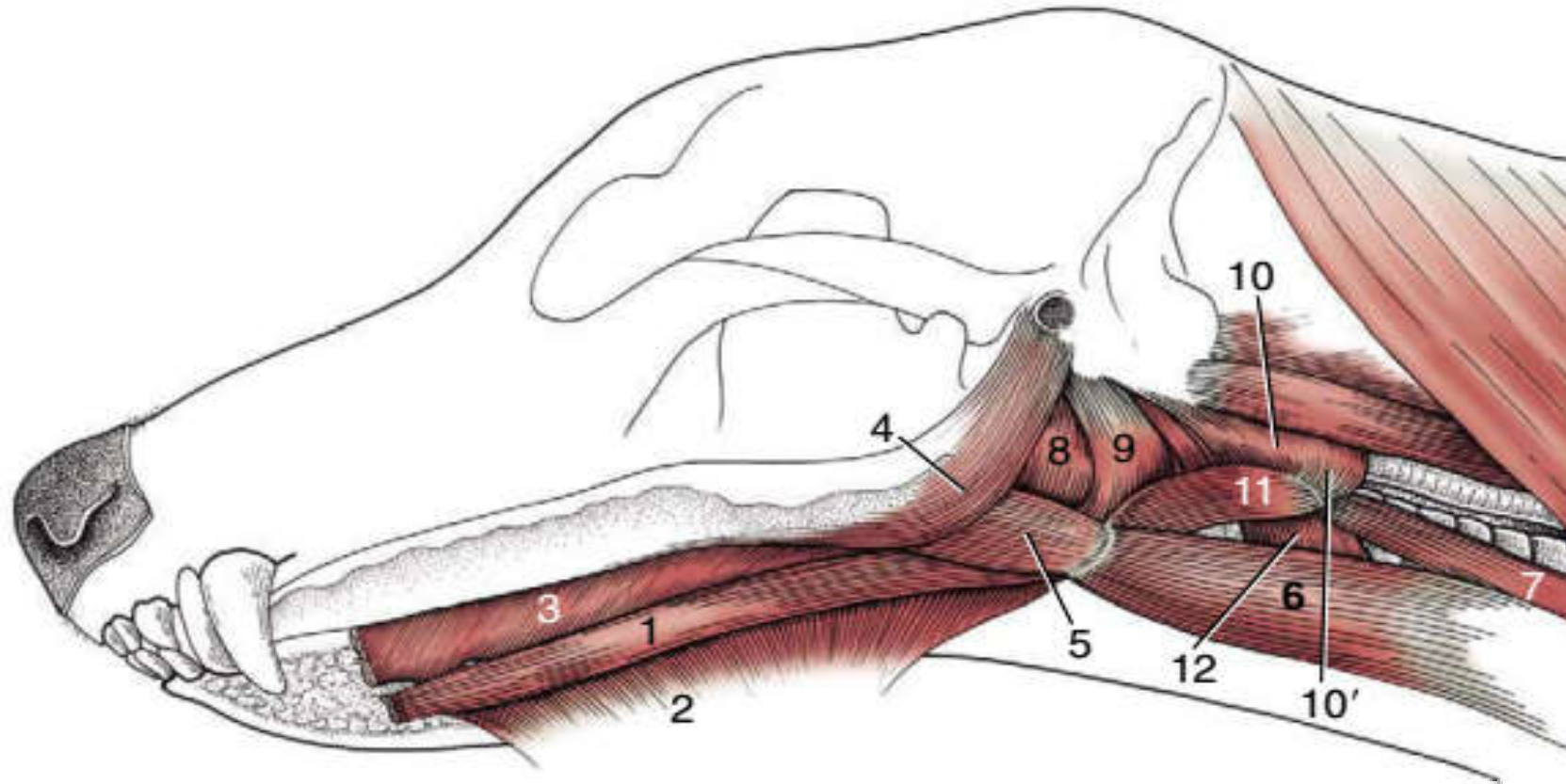


Fig: Muscles of the tongue and pharynx of the dog.

1, Geniohyoideus; 2, mylohyoideus; 3, genioglossus; 4, styloglossus; 5, hyoglossus; 6, sternohyoideus; 7, sternothyroideus; 8,9, hyopharyngeus (two parts); 10, thyropharyngeus; 10' cricopharyngeus; 11, thyrohyoideus; 12, cricothyroideus.

2.4. Muscles of hyoid apparatus

❖ *M. mylohyoideus*

- Thin sheet, fibers running transverse direction.
- Forms sling for the tongue.

Action: raises the floor of the mouth.

❖ *M. stylohyoideus*

Action: Help to raise or draw the base of the tongue or hyoid bone.

Cont...

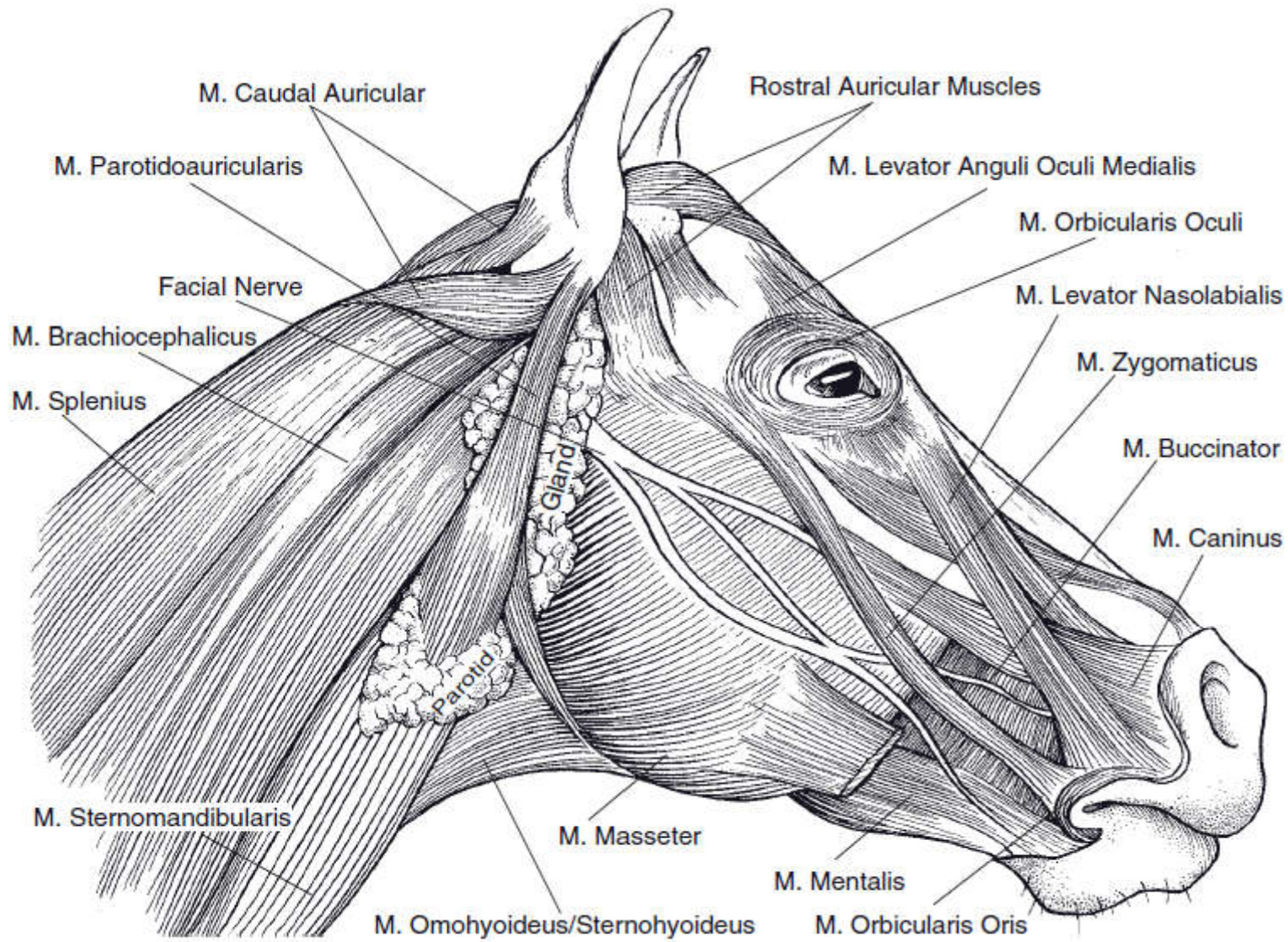


Figure: Muscles of the equine head.

Cont...

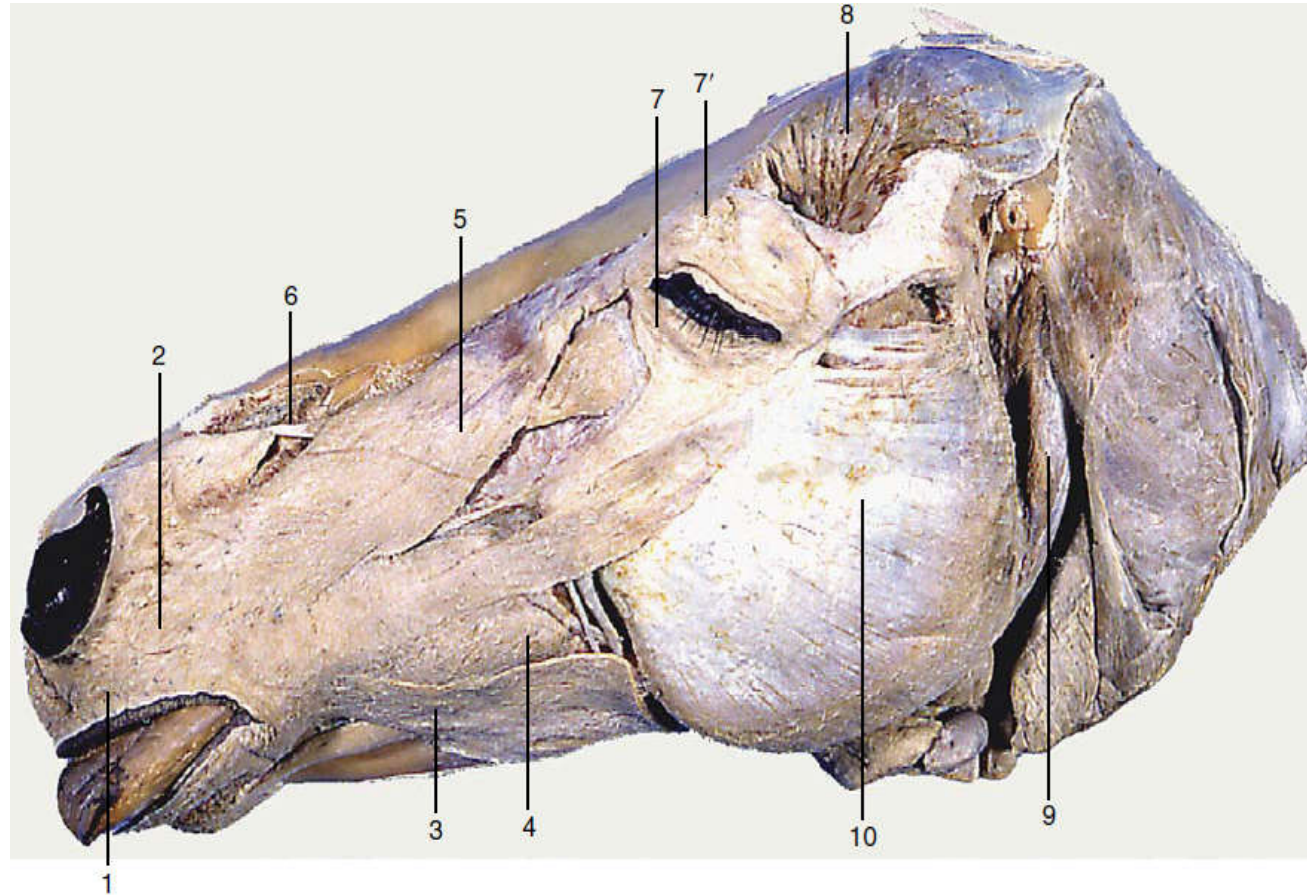


Figure: Superficial muscles of the equine head.

1, Orbicularis oris; 2, caninus; 3, depressor labii inferioris; 4, buccinator; 5, levator nasolabialis; 6, levator labii superioris; 7, orbicularis oculi; 7', levator anguli oculi medialis; 8, temporalis; 9, occipitomandibular part of digastricus; 10, masseter.

3. Muscles of the Neck Region

- ❖ These groups of muscles support the head and
 - allow the head and neck to flex, extend and move laterally;
- ❖ Divided into **ventral cervical muscles** and **dorsolateral cervical muscles**.

3.1. Ventral Cervical Muscles

- ❖ Muscles situated on the ventral part of the neck.
- ❖ a region of considerable **clinical importance** on account of the numerous visceral, vascular, and nervous structures that traverse it. *For example*: ...

I. *Musculus sternocephalicus*:

- ❖ A smaller, strap like muscle; most ventral of the other muscles;
- ❖ Joins with *m. brachiocephalicus* to form the jugular groove;
- ❖ Forms the ventral boarder of the jugular groove;
- ❖ In carnivores, consists of sternomastoid and sternooccipitalis;
- ❖ In ox and goats, the sternooccipitalis is replaced by the sternomandibularis;
- ❖ The horse has only sternomandibularis;

Cont...

- ❖ Origin: manubrium of the sternum and
- ❖ Insertion: angle of the mandible and/or mastoid process of the skull (varies with species of animal);

Parts: *sternomastoid*, *sternooccipitalis* and *sternomandibularis*;

Action:

- Unilateral contraction draws the head and neck to that side;
- Bilateral contraction flexes the head and neck ventrally;
- In species with a mandibular insertion, the sternocephalicus may assist in opening the mouth.

II. *Musculus sternothyroideus* and *sternohyoideus*:

- ❖ Thin muscles covering trachea.
 - ❖ Are combined at their origin from the sternum but branch into slips that diverge to attach to the thyroid cartilage and the basihyoid.
 - ❖ originate from cartilage of the sternum,
 - ❖ insert on caudal side of the lamina of the larynx, (near the angle of the mandible) and on the hyoid bone.
- Action:** retract and depress the hyoid bone and the base of the tongue as in deglutition (swallowing).

III. *Musculus omohyoideus*

- ❖ A thin, ribbon-like muscle;
- ❖ extends between the medial aspect of the shoulder and the basihyoid;
- ❖ forms the floor of the jugular groove.
- ❖ arises from the subscapular area and
- ❖ Inserts into hyoid bone.
- ❖ Absent in carnivores.

Action: retract the hyoid bone and the root of the tongue

IV. *M. longus colli* and *M. longus capitis*

- ❖ Induce flexion (lowering) of the head and neck downward.

3.2. Dorsolateral Cervical Muscles

- ❖ on either side of the neck and form a thick layer.
- ❖ Commonly used for **IM injection** of drugs (medicine).

1. Musculus brachiocephalicus:

- ❖ Forms lateral portion of jugular groove.
- ❖ Extends along the side of the neck - from the head to the arm;
- ❖ Parts: cleidocephalicus, cleidobrachialis, cleidomastoideus.

Origin: temporal bone; wing of atlas; transverse process of the 2nd to 4th cervical vertebrae.

Insertion: deltoid tuberosity of humerus.

Action: pulls limb forward and extends shoulder.

→extend the head and neck and incline them to the side (laterally).

Cont...

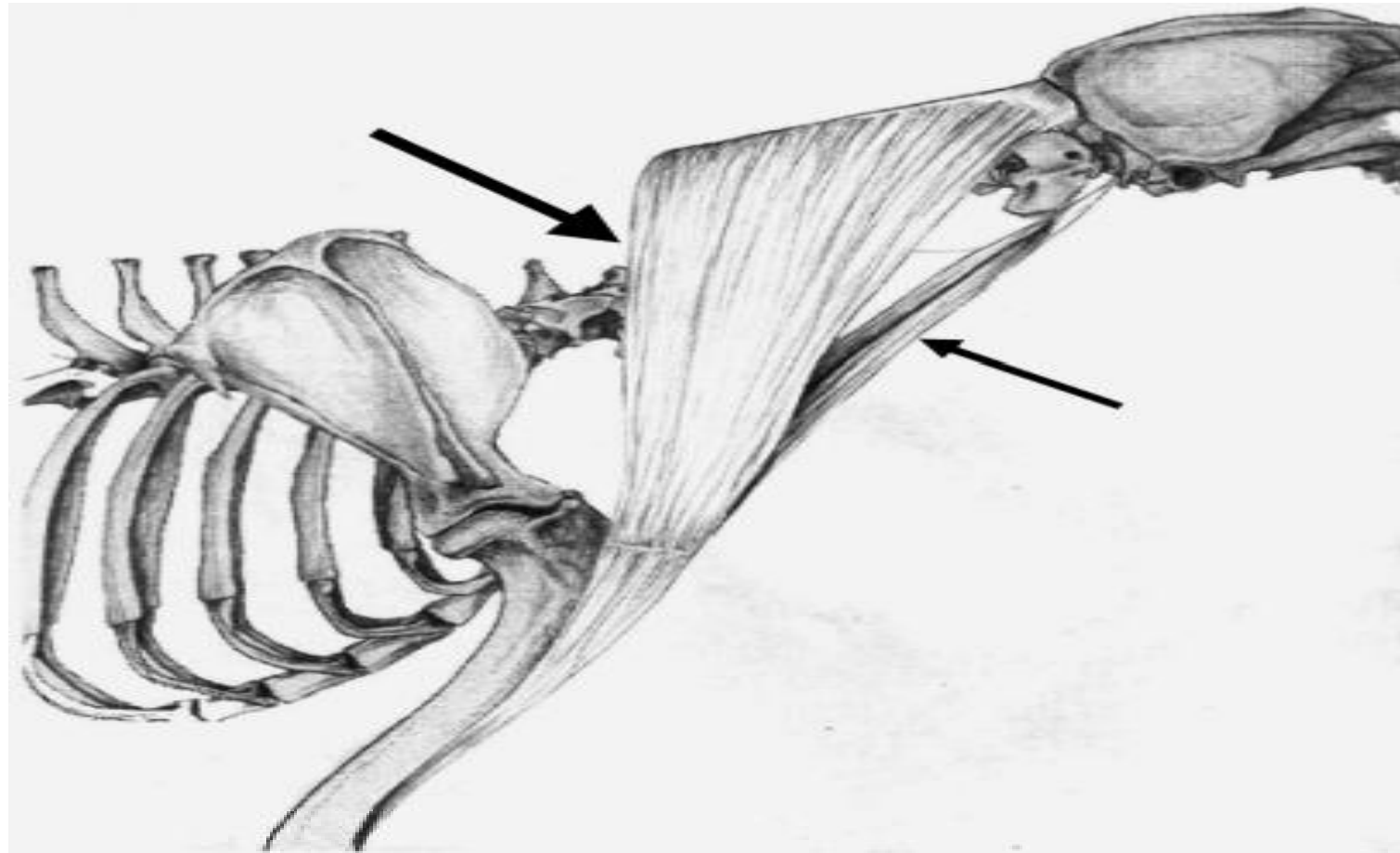


Fig: Schematic drawing illustrating the anatomical relationships and organization of the two heads of brachiocephalicus: the cleidomastoideus (CM), which inserts on the deep-mastoid part of temporal bone (small arrow), and the cleidocervicalis (CC), which inserts on the fibrous raphe of the cranial half of the neck (large arrow).

Cont...

II. *Musculus omotransversarius*

- Strap-like muscle;
- Partially covered by the *m. brachiocephalicus*;
- originates from the transverse processes of the more cranial cervical vertebrae and
- ends at the clavicular intersection;
- Its dorsal edge is connected to the *m. trapezius* by the superficial fascia.

Action: advances the limb and/or pulls the head and neck to the side.

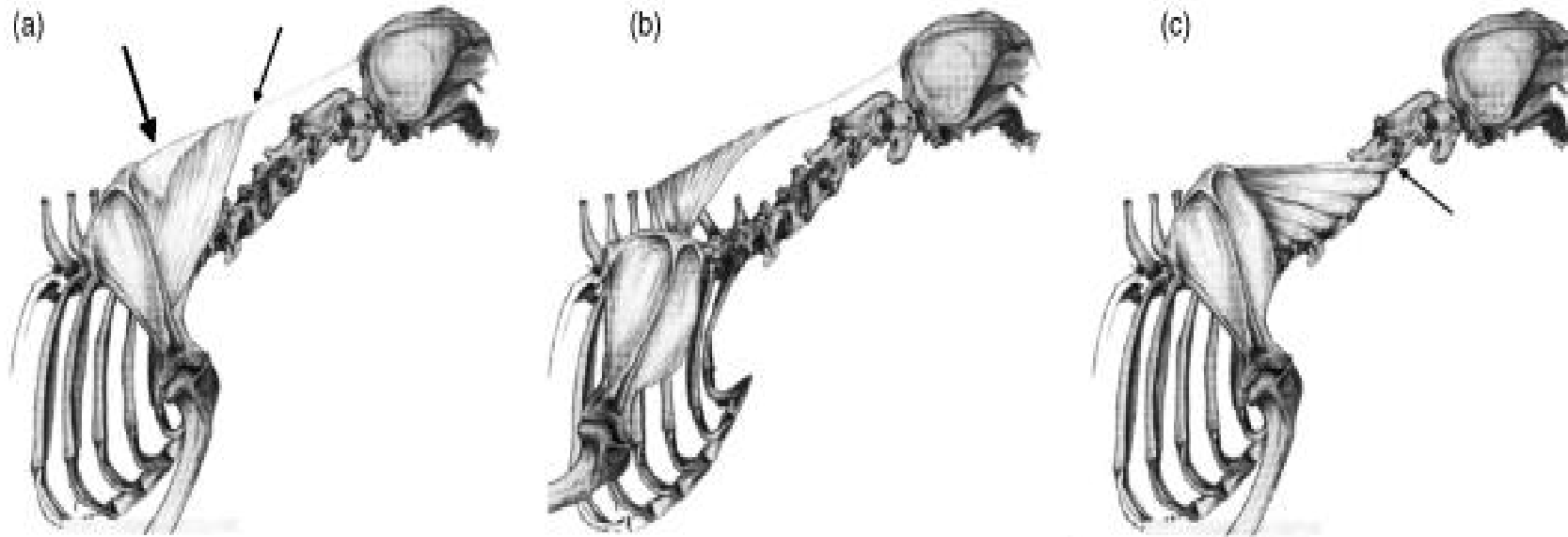
III. *Musculus trapezius*:

- ❖ Thin triangular-shaped muscle;
 - ❖ extending from the dorsal midline of neck and thorax to the spine of the scapula;
 - ❖ Cervical portion (*M. trapezius cervicis*) - cranial to the scapula and
 - ❖ Thoracic portion (*M. trapezius thoracis*) - caudal to the scapula.
-
- ❖ Origin: Cervicis: Median fibrous raphe of neck
Thoracis: Spines of T3-T8 or T9;
 - ❖ Insertion: Spine of scapula (for both the muscles)

Action:

- Both concurrently: Elevate shoulder;
- Cervicis only: rotate scapula cranially;
- Thoracis only: rotate scapula caudally.

Cont...



Schematic drawing illustrating the anatomical relationships of muscles originating from the cervical vertebrae and inserting on the shoulder girdle.

- (a) The trapezius (TR) is attached to the midline by an aponeurotic sheet at the centre of its vertebral origin (C4–C7) (Large arrow). Fascicles are longest at the cranial end of the muscle (small arrow), and become progressively shorter and less angled toward the tendinous band.
- (b) The cervical portion of the rhomboideus cervicis (RC) is separated from the thoracic portion along a line extending dorsally from the scapular spine. Its fascicles are longest at the cranial end, and become shorter and progressively less angled caudally.
- (c) The cervical portion of the serratus ventralis (SV) in four dogs had an additional division, which originated cranially on the facies serrata and inserted on the transverse process of C2 (arrow).

IV. *M. rhomboideus*:

- Lies deep to the trapezius muscle.
- Holds the dorsal border of the scapula close to the body;
- Extrinsic muscle lying deep to the trapezius;
- extends between dorsal medial scapula and midline from head or neck to cranial thorax;
- It arises from 2nd cervical - 2nd thoracic vertebrae;

Origin: Dorsal neck and thorax; nuchal crest of skull;

Insertion: Dorsal border of scapula and scapular cartilage;

Action:

- elevates the neck and forelimb;
- Rotates (capitis and cervicis) or adducts the scapula (thoracis);

Cont...

V. *Musculus serratus*

- ❖ *M. serratus ventralis* is a large fan-shaped muscle that takes an extensive origin by separate digitations from the fourth cervical vertebra to the tenth rib.
- ❖ *M. serratus ventralis cervicis* inserts craniodorsal to the axis of scapular rotation,
 - projected from the cervical vertebrae to cartilage of scapula.

Action:

- draws the neck to that side (When acting unilaterally);
- raises the neck (when acting bilaterally);
- May retract the limb.

Cont...

VI. *Musculus splenius:*

- is a flat triangular muscle;
- originates from the:
 - ✓ spinocostotransverse fascia;
 - ✓ spinous processes of the first three thoracic vertebrae, and
 - ✓ nuchal ligament and
- inserts on: the nuchal crest and the mastoid process.

Action: elevates the head and neck ↔ inclines the head and neck to the side of contracting muscle.

Cont...

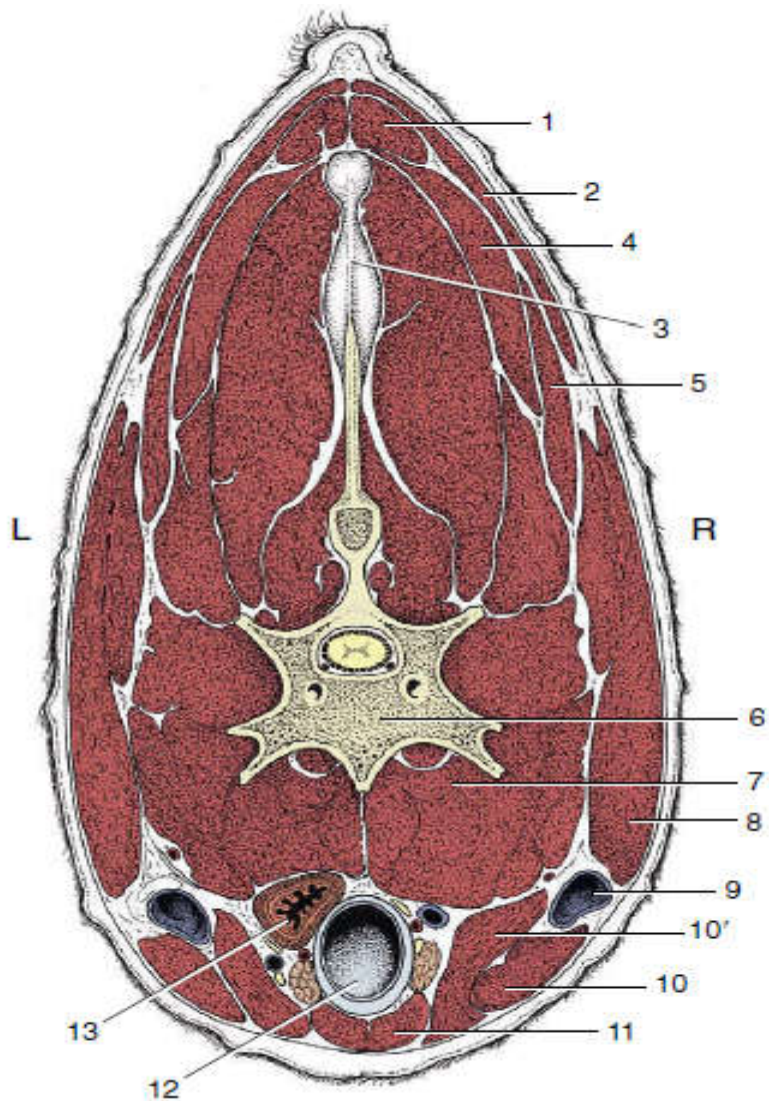


Figure: Transverse section of the bovine neck.

- 1, Rhomboideus;
- 2, trapezius;
- 3, nuchal ligament;
- 4, splenius;
- 5, omotransversarius;
- 6, vertebra;
- 7, longus colli;
- 8, brachiocephalicus;
- 9, external jugular vein in jugular groove;
- 10, 10' sternocephalicus, mandibular, and mastoid parts;
- 11, combined sternohyoideus and sternothyroideus;
- 12, trachea;
- 13, esophagus (ventral to it, nerves, blood vessels, and thymus).

Cont...

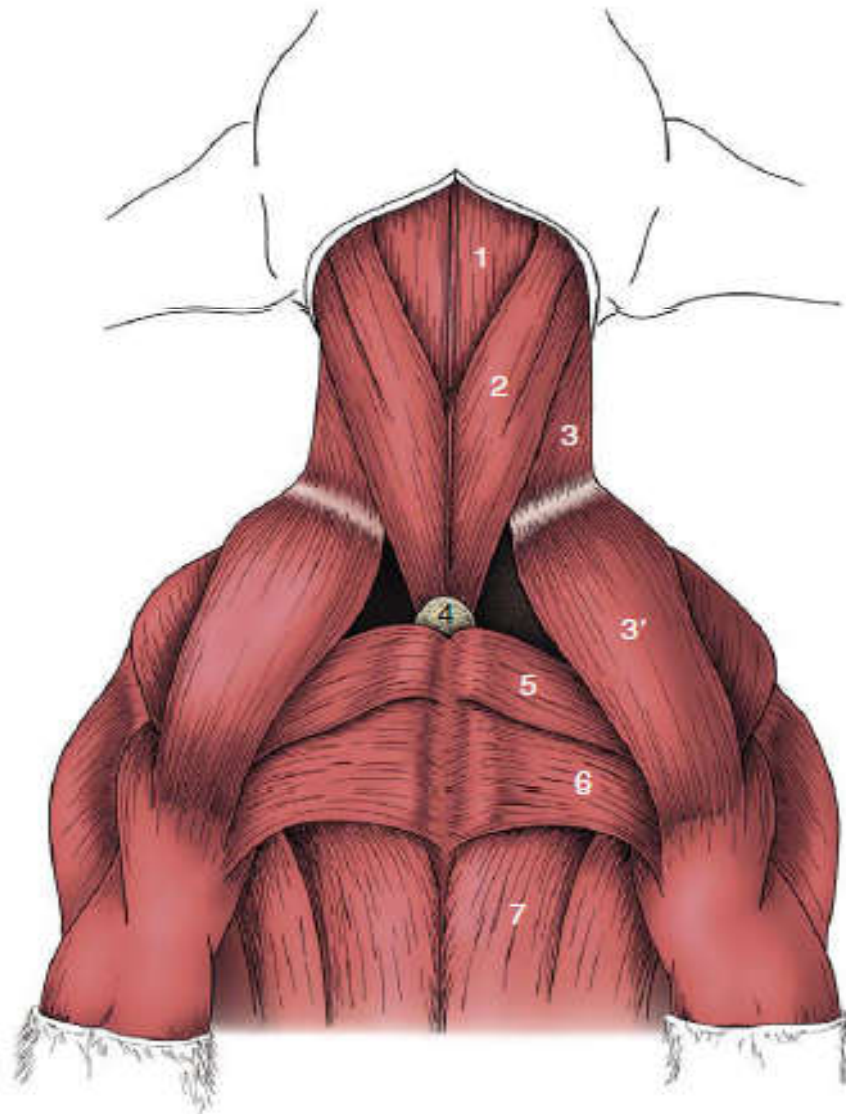


Figure: Ventral muscles of the canine neck and thorax.

1, Combined sternohyoideus and sternothyroideus;

2, sternocephalicus;

3, 3', brachiocephalicus: cleidocervicalis, cleidobrachialis;

4, manubrium of sternum;

5, pectoralis descendens;

6, pectoralis transversus;

7, pectoralis profundus.

Cont...

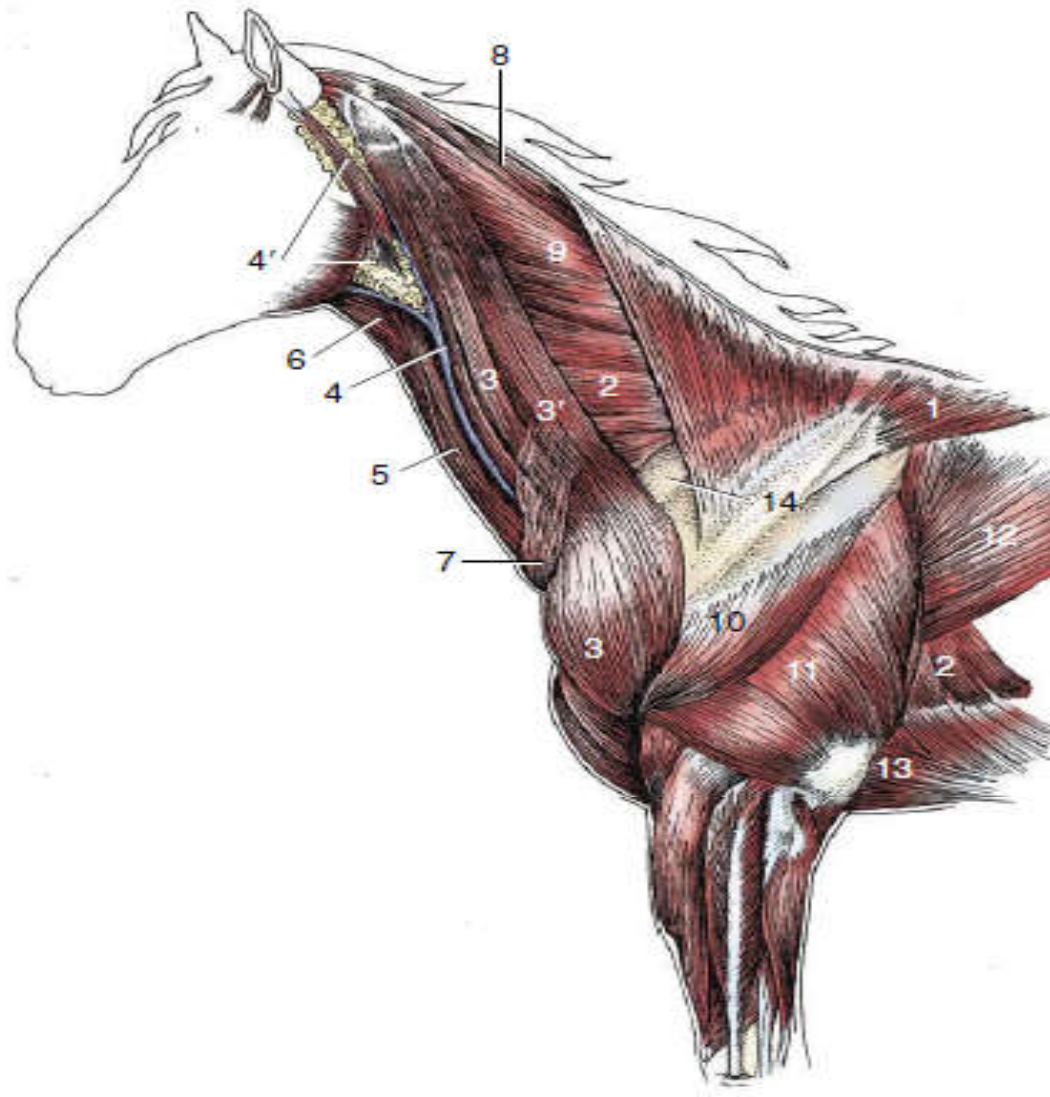


Figure: Superficial dissection of the neck and shoulder region.

- 1, Trapezius;
- 2, serratus ventralis;
- 3, brachiocephalicus;
- 3', omotransversarius;
- 4, external jugular vein;
- 4', parotid gland;
- 5, sternocephalicus;
- 6, omohyoideus;
- 7, cutaneous colli;
- 8, rhomboideus cervicis;
- 9, splenius;
- 10, deltoideus;
- 11, triceps;
- 12, latissimus dorsi;
- 13, pectoralis ascendens;
- 14, subclavius.

Cont...

4. Muscles of Vertebral Column (back and Loin)

- ❖ It includes all muscles situated along the vertebral column.
- ❖ Directly associated with the neck and back;
 - mainly extend between points on the vertebrae (and ribs);
 - some also attach to the skull, the ilium, and, where the psoas group is concerned, the femur.
- ❖ divided into two divisions; these are:
 - **Epaxial** and **Hypaxial** muscles.

Cont...

4.1. Epaxial muscles

- ❖ These are muscles placed:
 - dorsal to the line of the transverse processes of vertebrae; on either side of spinous processes.
- ❖ They are erector spinae muscles and extensors of the vertebral column;
- ❖ Relatively more powerful in animals that make use of a bounding gait when traveling at speed;
- ❖ Comprise three longitudinal systems; arranged in three parallel columns: i.e.
 - *M. iliocostalis*, *M. longissimus*, and *M. transversospinalis*;

I. *M. iliocostalis* system (**Lateral column**):

- ❖ Arises from the ilium and transverse processes of the lumbar vertebrae and
- ❖ inserts on the more cranial lumbar vertebrae and ribs;
- ❖ Composed of many fascicles that overlap; for the most part they span about four vertebrae;
- ❖ is lateral to the longissimus system and
- ❖ is covered by the dorsal serratus and the origins of the latissimus and abdominal oblique muscles.
- ❖ Its lateral position makes it effective in bending the trunk to the side.

Cont...

II. *M. longissimus* system (**Middle column**)

- ❖ The largest, longest and strongest muscle, extends from the ilium to the skull,
- ❖ Located just medial to the *m. iliocostalis*;
- ❖ The most powerful extensor of the back and loin;
- ❖ Some of its more cranial parts are independent;

Origins (conventionally): from the ilium, the sacrum, and the mamillary processes and

Insertions: to the transverse processes and ribs.

Cont...

❖ Its different parts include:

➤ *M. longissimus lumborum*;

➤ *M. longissimus dorsi*;

➤ *M. longissimus cervicis*;

➤ *M. longissimus atlantis*, and

➤ *M. longissimus capitis*, but usually the generic term is sufficient.

❖ The muscle tends to fuse with its medial and lateral neighbors in the lumbar region.

Cont...

- ❖ The cervical part of the longissimus is closely associated with the more superficial *splenius*.
 - This passes from the highest spines of the withers and thoracolumbar fascia to the occipitomastoid region of the skull.
 - is covered by *m. trapezius* and *m. rhomboideus*.
- ❖ The longissimus complex also includes:
 - certain small muscles passing between adjacent transverse processes
 - as well as the dorsal (sacrocaudal) muscles of the tail: *are fleshy at their origin and are continued by tendons that run the length of the tail.*

Cont...

III. *M. transversospinalis* system (medial column)

- ❖ More intimately related to the vertebrae and *is the most complex*.
- ❖ lies on and between the medial parts of the vertebral arches and the spinous processes.
- ❖ Extends from the sacrum to the cervical region.

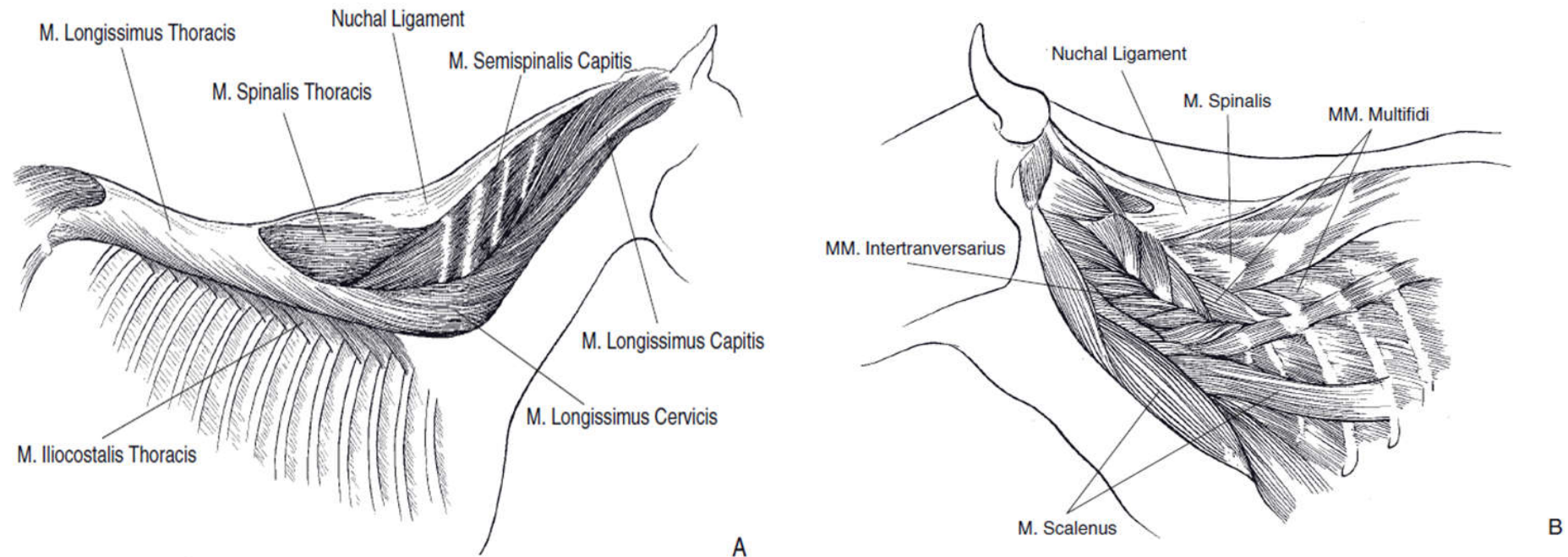


Fig: Epaxial mm. A) Superficial mm. of the horse; B) Deeper mm. of the ox.

4.2. Hypaxial Muscles

❖ lie ventral to transverse processes of vertebrae and include:

□ *Longus colli*: runs from the cranial thoracic region to the atlas, covering the ventral surfaces of the vertebral bodies.

➤ complemented by the *rectus capitis ventralis and longus capitis*

□ *Rectus capitis ventralis*: extends from the atlas to the ventral aspect of the skull.

Cont...

- ❑ *Longus capitis*: lies lateral to the longus colli and extends from the transverse processes of the midcervical vertebrae to the skull;
- ❑ *Scalenus group*: occupies a similar position in relation to the caudal cervical vertebrae.
 - passes to the first one or few ribs, helps stabilize during inspiration.
 - In some Spp., readily divisible into dorsal, middle, and ventral parts.

The Hypaxial Muscles are flexor muscles of the neck or tail.

5. Muscles of Chest (Brisket Region)

- ❖ The pectoral muscles form the substance of the brisket.
 - They originate from the sternum and insert mainly on the proximal part of the humerus;
 - commonly, they are divided into the:
 - ✓ superficial pectoral muscle (*m. pectoralis superficialis*);
 - ✓ deep pectoral muscle (*m. pectoralis profundus*).
 - pectoral muscles are strong adductors of the forelimb, and
 - the deep pectoral muscle also advances the trunk when the limb is fixed on the ground (weight bearing).

Cont...

❖ *M. pectoralis superficialis*

- broad triangular portion of the pectoral muscle;
- Are two; cranial (descending) and caudal (transverse);
 - ✓ arise, one behind the other, from the cranial part of the sternum;
- Cranial muscle (*m. pectoralis descendens*) terminates on the crest of the humerus, distal to the deltoid tuberosity;

Cont...

- Caudal muscle (*m. pectoralis transversus*) descends over the medial aspect of the arm and in the larger species continues distally over the elbow joint, covering the median artery and nerve;
- ✓ to insert into the medial fascia of the forelimb;
- Both muscles adduct the limb,

Action: it draws the arm/forelimb towards the chest.

Cont...

The *m. pectoralis profundus*:

- ❖ may be considered as having cranial and caudal parts;
- ❖ The cranial part, well formed only in the horse and pig;
- probably corresponds to the subclavius of other mammals;
- ❖ Both parts (or muscles) arise from the ventral aspect of the length of the sternum and adjacent cartilages, and the most caudal fibers extend beyond this onto the abdominal floor;
- ❖ In the horse and pig the subclavius passes dorsally along the leading edge of the scapula, attaching to the supraspinatus;

Cont...

- ❖ The larger caudal part, *m. pectoralis ascendens*, inserts on the lesser tubercle of the humerus;
- ❖ Both play a role, secondary to that of the *m. serratus ventralis*, in slinging the trunk between the forelimbs;
- ❖ They may also act as retractors of the forelimb when this is free;
- ❖ When the limb is advanced and fixed, they draw the trunk forward, toward the limb.

6. Muscles of the Thorax

- ❖ Primarily concerned with respiration;
- ❖ Inspiratory muscles enlarge the thoracic cavity; causing air to flow into the lungs.
- ❖ Expiratory muscles diminish the thoracic cavity; forcing air out of the lungs.
- ❖ Muscles of the thorax comprise:
 - muscles that fill the spaces between the ribs,
 - certain muscles placed lateral to the ribs and
 - diaphragm.

Cont...

6.1. Intercostal Muscles

- ❖ are arranged in three layers that correspond to the layers of the abdominal wall (theoretically); Viz:
 - external intercostal muscles
 - internal intercostal muscles
 - subcostal layer: is so weak and so inconsistently developed that it may be ignored.
- ❖ fill the spaces between the ribs.

Cont...

I. External intercostals muscle:

- ❖ Outermost layer and each of these muscles is confined to a single intercostal space;
- ❖ The fibers run caudoventrally from caudal borders of the ribs to cranial borders of succeeding ribs; i.e:
 - originate on one rib and terminate on the following rib;
 - fill the spaces from the upper ends to the costochondral junctions and sometimes beyond these;
 - ✓ but fail to reach the sternum.

Action:

- rotate the ribs upward and forward;
 - increasing the size of the thorax.

II. Internal Intercostal Muscles

- ❖ Placed more deeply within the intercostal spaces and
- ❖ Run cranioventrally, approximately perpendicular to the course of the external muscles.
- ❖ They do not occupy the most dorsal parts of the spaces,
 - But, they do reach the margin of the sternum.
- ❖ Arise from cranial borders of ribs and their cartilage(s);
- ❖ Insert at the caudal border of succeeding ribs and their cartilage(s).

Action:

- draw the ventral part of ribs downward;
 - decreasing the space of the thoracic cavity;
- reducing the volume of the thorax and therefore
 - aiding in forced expiration.

6.2. *Transversus thoracis*:

- ❖ a triangular sheet that arises from and covers the dorsal surface of the sternum.
- ❖ The apex points cranially, and the muscle splits into slips that run caudolaterally to insert on the sternal ribs close to the costochondral junctions.
- ❖ It is morphologically the equivalent of the ventral part of the transversus abdominis.

6.3. *Rectus thoracis*:

- ❖ Lies on the lateral surface of thoracic wall.
- ❖ a small quadrilateral sheet of muscle placed over the lower ends of the first four ribs in continuation of *m. rectus abdominis*.

Cont...

6.4. *M. serratus dorsalis:*

- ❖ lies over the dorsal parts of the ribs on lateral surface of thoracic wall.
- ❖ Originates from the fascia of the back and
- ❖ inserts on the ribs by a series of slips.
 - The slips of the cranial part of the muscle slope caudoventrally, and
 - those of the caudal part slope cranioventrally, which points to antagonistic functions;
 - The two parts are sometimes quite widely separated.

6.5. *Musculus scalenus:*

- has an attachment to the first rib;
- in some species, it also passes quite extensively over the rib cage.

6.5. Diaphragm:

- ❖ A sheet of muscle extending across the caudal part of the rib cage;
 - ❖ Chief muscle of inspiration and increases the longitudinal diameter of the chest;
 - ❖ Separates the thoracic cavity from the abdominal cavity;
 - ❖ Has three openings:
 - **Aortic hiatus:** passage for aorta & thoracic duct;
 - **Esophageal hiatus:** passage for esophagus & blood vessels;
 - **Foramen of vena cava:** conveys caudal vena cava;
- Origin: sternal, costal and lumbar regions and
Insertion: central tendon.
- ❖ Action: Draws the central tendon caudad during inspiration and increases the volume of the thoracic cavity.

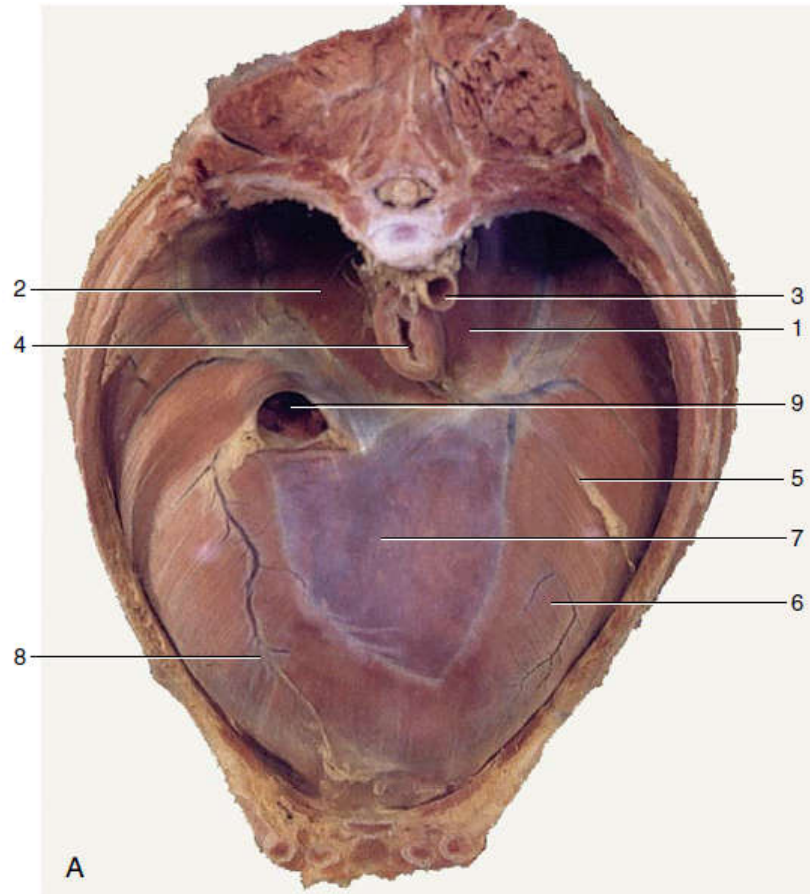
❖ Attachements:

- The sternal part to dorsal surface of xiphoid cartilage;
- The costal part to cartilages of 8th -10th ribs;
- The lumbar part to the first to 4th or 5th lumbar vertebrae.

❖ Diaphragm has thoracic and abdominal surfaces.

- The thoracic surface is related to pleura, pericardium and the base of the lungs and ribs;
- The abdominal surface is covered by peritoneum and it is related to liver, stomach, intestine, spleen, pancreas, kidney and adrenal glands.

Cont...



- 1, Left crus;
- 2, right crus;
- 3, aorta;
- 4, esophagus;
- 5, attachment of caudal mediastinum to diaphragm;
- 6, sternal and costal parts of diaphragm;
- 7, tendinous center;
- 8, attachment of plica venae cavae;
- 9, caudal vena cava.

Figure: Cranial view of the canine diaphragm.

7. Muscles of the Abdomen

❖ Abdominal muscles:

- support the organs in abdominal cavity;
- empty the contents of:
 - ✓ the digestive tract (defecation);
 - ✓ urinary tract (urination), and
 - ✓ female reproductive tract at birth (parturition) and
- serve for forced expiration of air from the lungs,
 - ✓ as seen during coughing or sneezing;
 - ✓ by forcing the abdominal viscera against the diaphragm, decreasing the size of the thorax.
- used in the adjustment of posture and in progression .

Cont...

- ❖ Abdominal muscles are arranged in layers;
- ❖ Muscle fibers run in different directions into broad aponeurotic insertions that meet at mid-ventral line
 - forming the linea alba (white line).

Linea alba (white line):

- is a median fibrous cord,
 - extends or runs in the ventral midline from the xiphoid cartilage to the cranial end of the pelvic symphysis (prepubic tendon).
- ❖ Abdominal muscles may be divided into two groups; viz:
 - ventrolateral group and
 - dorsal (sublumbar) group.

7.1. Ventro-lateral Group of Abdominal Muscles

- ❖ Comprise muscles of the flanks and abdominal floor;
- ❖ Have particular importance; encountered and incised in almost all surgical approaches to access abdominal organs. *For example ...*
- ❖ Each muscle of the group is continued ventrally by aponeurotic tendon (inserted on the linea alba);
- ❖ The muscles of the ventrolateral group include:
 - I. External abdominal oblique muscle
 - II. Internal abdominal oblique muscle
 - III. Rectus abdominis muscle
 - IV. Transversus abdominis muscle

Cont...

I. *Musculus obliquus externus abdominis*

- ❖ Outermost (superficial) and extensive muscle of the group;
- ❖ Arises from the last few ribs and thoracolumbar fascia and
- ❖ Inserts by means of a broad flat tendon (aponeurosis) that meets the insertion of the muscle from the opposite side at the linea alba.
- ❖ The fibers of the muscle run obliquely; caudoventrally;
- ❖ Superficially related with skin and cutaneous muscle and deeply with internal abdominal oblique muscle;
- ❖ Caudally, the muscle is continued by an aponeurosis, sometimes called the ***inguinal ligament***, at the junction of abdominal wall to pelvic limb.

Cont...

II. *Musculus obliquus internus abdominis*

- ❖ Immediately deep to the external abdominal oblique m.;
- ❖ Arises from coxal tuber and the tips of the lumbar transverse process and
- ❖ Inserts on the linea alba.
- ❖ The fibers of the muscle run cranioventrally;
- ❖ related:
 - superficially with external abdominal oblique muscle;
 - deeply with rectus abdominis, transversus abdominis and peritoneum.

Cont...

- ❖ In some animals, this muscle forms the deep wall of the inguinal canal and also the ***deep inguinal ring***;
- ❖ The most caudal group of fibers from the internal abdominal oblique muscle:
 - passes through the inguinal canal with the spermatic cord and
 - attaches to the outer covering of the testicle.
- ✓ This slip of muscle constitutes the *cremaster m.*, which pulls the testicle toward the inguinal canal.

III. *Musculus transversus abdominis*

- ❖ Deepest of the abdominal muscles;
- ❖ Originates from the deepest layer of thoracolumbar fascia;
- ❖ The fibers are directed perpendicular to the long axis of the body;
- ❖ Fibers insert on the linea alba.
- ❖ related:
 - superficially with external, internal abdominal muscles and rectus abdominis muscle; and
 - Deeply with transverse fascia and peritoneum.

Cont...

IV. *Musculus rectus abdominis*:

- ❖ Forms a broad band to the side of the linea alba in the abdominal floor;
- ❖ Arises from the ventral surfaces of the rib cartilages and sternum and
- ❖ Inserts on pubic brim by means of a prepubic tendon;
- ❖ The fleshy part:
 - is widest about the middle of the abdomen;
 - divided into a series of segments by irregular transverse septa (tendinous intersections) that recall its polysegmental origin.

Cont...

Functions (actions) of abdominal muscles

- ❖ **Support expiration**; by assisting the forward recovery of the diaphragm when breathing is labored.
- ❖ **Let animals strain**:
 - Occurs when the abdominal muscles are contracted against a fixed diaphragm;
 - ✓ Results in an increase in intraabdominal pressure;
 - This may reinforce the efforts of visceral muscle to expel urine, feces, or a fetus.
- ❖ **Protect the abdominal viscera**; via the rigidity of the abdominal wall produced by contraction of the muscles.
- ❖ **Used in the adjustment of posture and in progression**; i.e.
 - Acting unilaterally, the muscles of the flank bend the trunk to that side;
 - Acting bilaterally, they may assist in arching the back.

Cont...

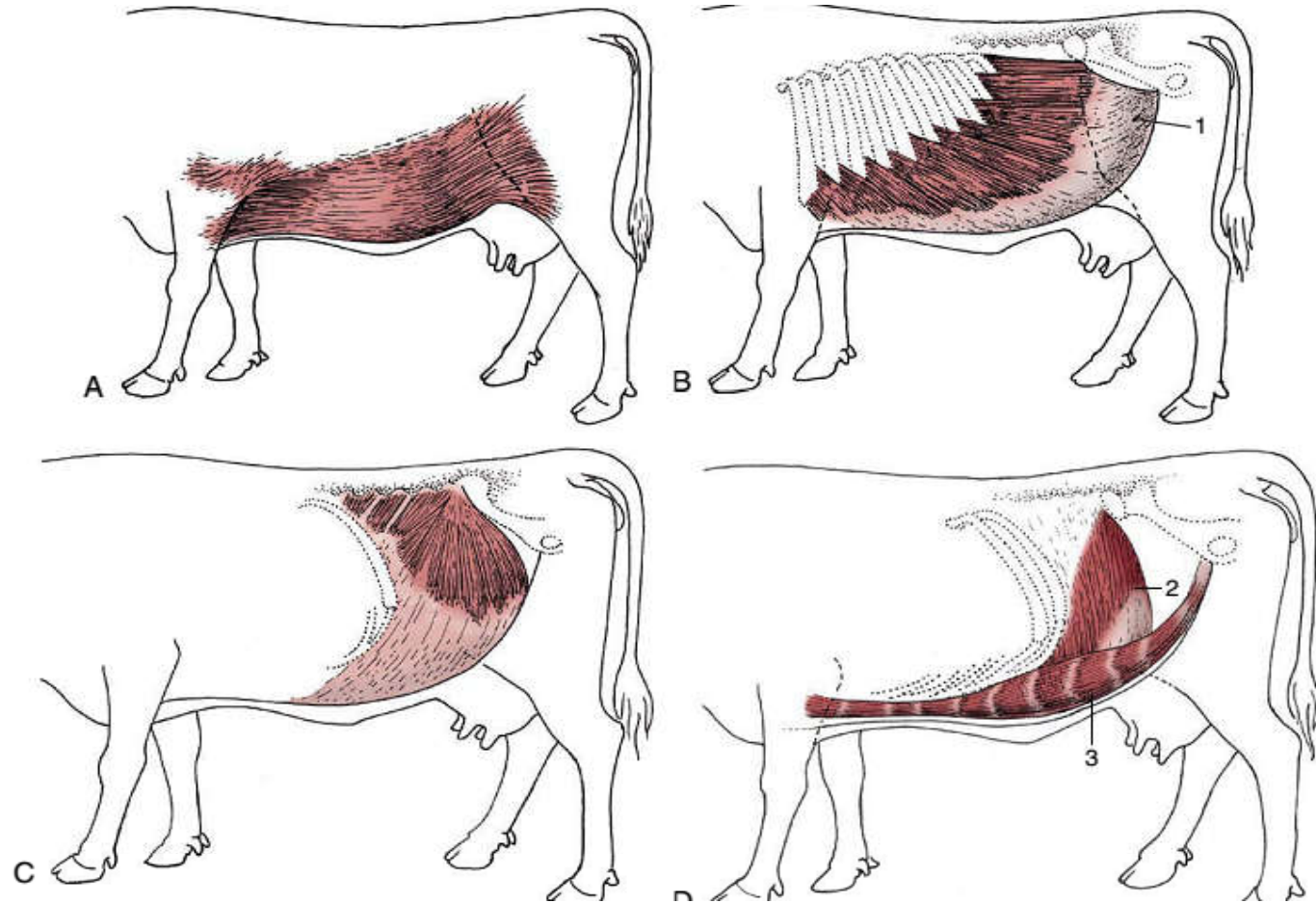


Fig: Cutaneous trunci and abdominal muscles.

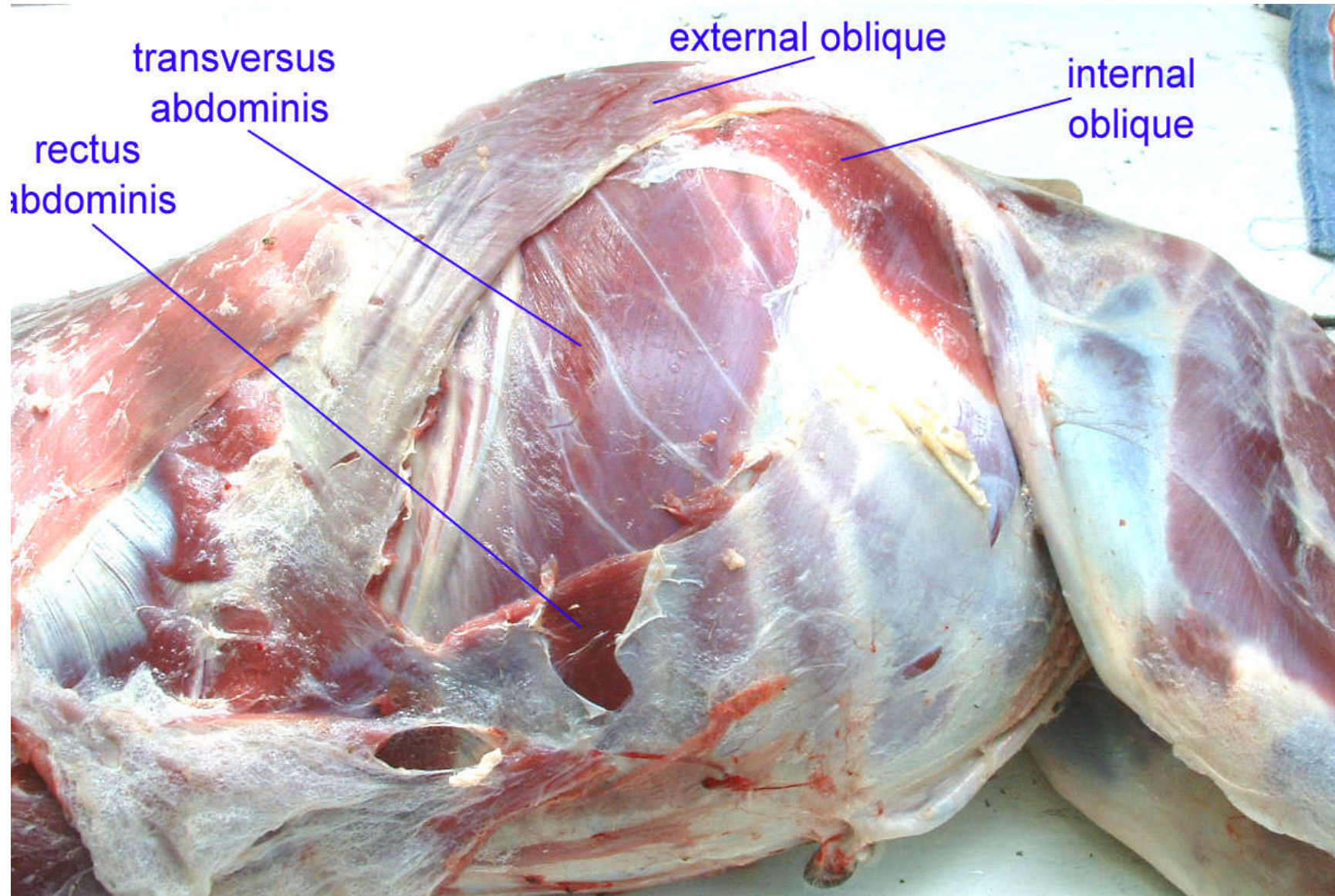
A, Cutaneous trunci, especially well-developed ventrally.

B, External abdominal oblique with superficial inguinal ring (1) in its aponeurosis.

C, Internal abdominal oblique. **D,** Transversus abdominis (2) and rectus abdominis (3).

Note the reduction in the thickness of the wall along the caudal part of the rectus margin.

Cont...



7.2. Dorsal (Sublumbar) groups of abdominal muscles

❖ *Psoas minor*:

- arises from the bodies of the thoracolumbar vertebrae;
- inserts on the psoas minor tubercle on the ilium;
- Much tendon is intermingled in the flesh, which supports the contention that the muscle is probably mainly employed to stabilize the vertebral column;
- It may also rotate the pelvis at the sacroiliac joint.

❖ *psoas major and iliacus muscles*:

- may be regarded as vertebral and pelvic heads of a single muscle, iliopsoas that terminates on the lesser trochanter of the femur.

Cont...

- ❖ Psoas major arises from the bodies and ventral surfaces of the transverse processes of the lumbar vertebrae lateral to the psoas minor.
- ❖ iliacus arises from the ventral aspect of wing and shaft of the ilium.
 - The tendons of the two heads combine shortly before insertion;
 - ❖ iliopsoas is a flexor of the hip and an outward rotator of the thigh;
 - ❖ The psoas head probably also contributes to the stability of the vertebral column;

m. quadratus lumborum:

- ❖ arises from the last ribs and from the transverse processes of the lumbar vertebrae and
- ❖ inserts on the wing of the sacrum (sometimes also on the ilium).
- ❖ stabilizes the lumbar portion of the vertebral column.

Cont...

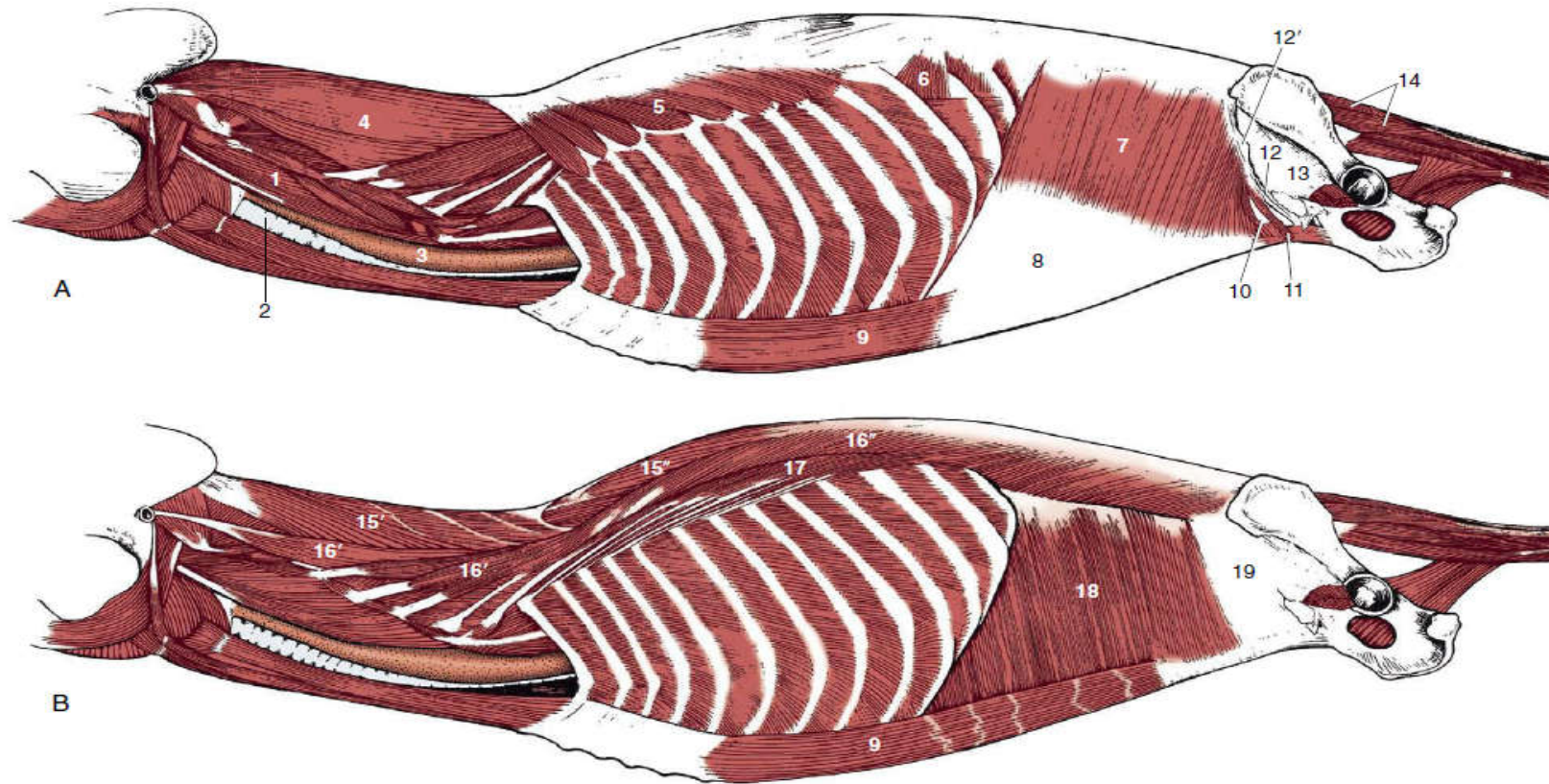


Figure: A and B, Trunk muscles of the dog, deeper layers.

1, Longus capitis; 2, trachea; 3, esophagus; **4, splenius**; 5, 6, serratus dorsalis cranialis and caudalis; **7, internal abdominal oblique**; 8, its aponeurosis; **9, rectus abdominis**; 10, caudal free border of internal abdominal oblique; 11, cremaster; **12, inguinal ligament**; **12', external abdominal oblique aponeurosis, cut and reflected**; **13, fascia iliopsoas**; 14, dorsal sacrocaudal muscles; **15, transversospinalis system**; 15', semispinalis capitis; 15'', spinalis et semispinalis; 16, longissimus system; 16', longissimus capitis and cervicis; **16'', longissimus thoracis**; **17, iliocostalis**; **18, transversus abdominis**; 19, transverse fascia.

8. Muscles of Limbs

8.1. Muscles of Thoracic Limbs

- ❖ Function mainly in locomotion ↔ allowing the animal to walk and run.
- ❖ Consist of two major groups; viz:
 - extrinsic muscles and
 - intrinsic muscles.

I. Extrinsic muscles of the shoulder

- Consist those muscles which connect thoracic limb with:
 - ✓ head, neck and trunk; forming the so-called synsarcosis.

Cont...

❖ These muscles:

- include muscles that hold the scapula in place;
- contribute to the swinging (forward and backward) movement of the distal end of the bone;

❖ Consists of two layers:

1. Superficial layer; includes:

- ❖ *m. trapezius, m. omotransversarius,*
- ❖ *m. brachiocephalicus, m. latissimus dorsi* and
- ❖ *m. pectoralis superficialis.*

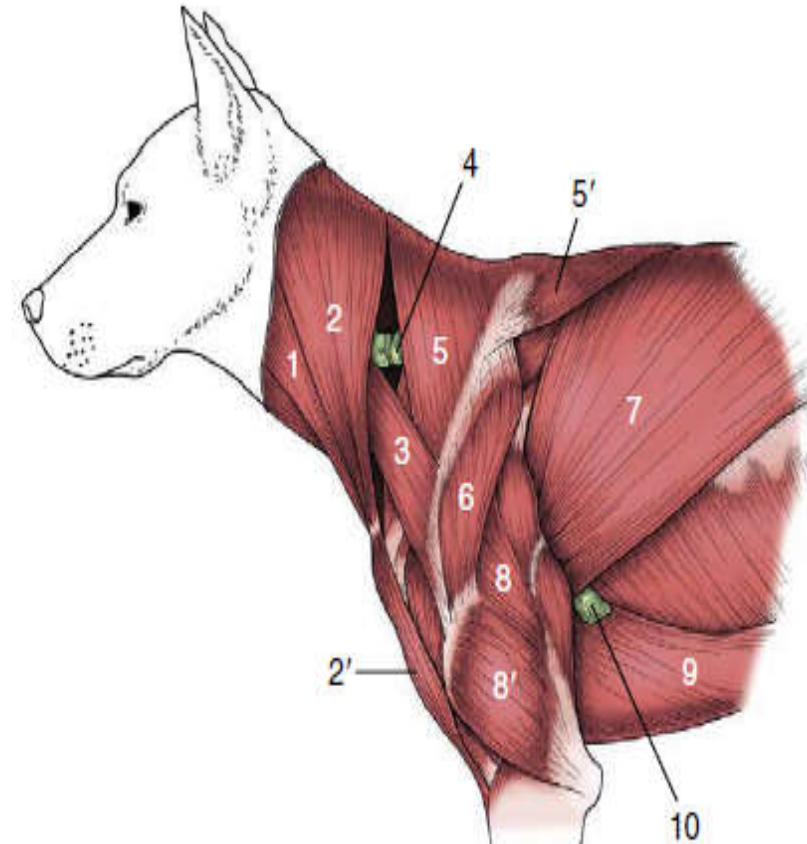
2. Deep layer; includes:

- ❖ *m. rhomboideus, m. serratus ventralis* and *m. pectoralis profundus.*

Cont...

Fig: Superficial muscles of the shoulder and arm.

- 1, Sternocephalicus;
- 2,2',brachiocephalicus:
cleidocervicalis and cleidobrachialis;
- 3, omotransversarius;
- 4, superficial cervical lymph node;
- 5, 5', cervical and thoracic parts of
trapezius;
- 6, deltoideus;
- 7, latissimus dorsi;
- 8, 8', long and lateral heads of triceps;
- 9, pectoralis profundus (ascendens);
- 10, accessory axillary lymph node.



Cont...

❖ *Musculus trapezius*:

- ✚ Thin triangular and the most superficial flat muscle;
- ✚ Located on the dorsal aspect of the cervicothoracic junction (shoulder area);
- ✚ It has cervical and thoracic parts.

Action: Raises the scapula against the trunk;

Swing the ventral angle of the bone cranially.

Cont...

➤ *musculus omotransversarius*:

- is a separate muscle of the shoulder region in most domestic species;
- originates from the transverse processes of the more cranial cervical vertebrae and
- inserts on the distal part of the spine of the scapula (clavicular tendon in the horse).
- With these attachments, it usually pulls the distal end of the scapula forward,
 - with the limb in weight bearing position, it instead assists lateral flexion of the neck.

Action: It assists in advancement of the limb.

Cont...

➤ *m. brachiocephalicus*:

M. Cleidobrachialis; *M. cleidomastoideus*; *M. cleidocephalicus*;

- ❖ extends from the head to the arm;
- ❖ originates from the occipital bone of the skull and transverse processes of the cervical vertebrae;
- ❖ inserts on the lateral side of the proximal part of the humerus proximal to the deltoid tuberosity;
- ❖ the heavy muscle covering the cranial aspect of the point of the shoulder.

Action:

- raises and advances the shoulder
- principal extensor of the shoulder and
- acts as a lateral flexor of the neck when the limb is weight bearing.

➡ *M. latissimus dorsi*:

- Wide muscle having right angled triangle shape;
- Lies on the lateral wall of the thorax from vertebral spine to the arm/forelimb;
- Origin: Thoracolumbar region;
- Insertion: Teres tuberosity of humerus;

Action: drawing the humerus dorsally and caudally and thus flexes the shoulder joint.

B. Deeper layer muscles include:

➤ *M. rhomboideus*:

- It forms the hump of bovine and consists of two parts.
 - ✓ *M. rhomboideus cervicis* and *M. rhomboideus thoracis*;
- A heavy muscle immediately deep to the *m. trapezius*;
- It acts to draw the scapula dorsally and cranially.

➤ *M. serratus ventralis*:

- lies on the lateral surface of thorax and neck and
- has cervical and thoracic parts.
- Situated deep to *m. lattissimus dorsii*.

II. Intrinsic Muscles of Shoulder

- ❖ Grouped by their common location and actions;
- ❖ Include the following muscles:

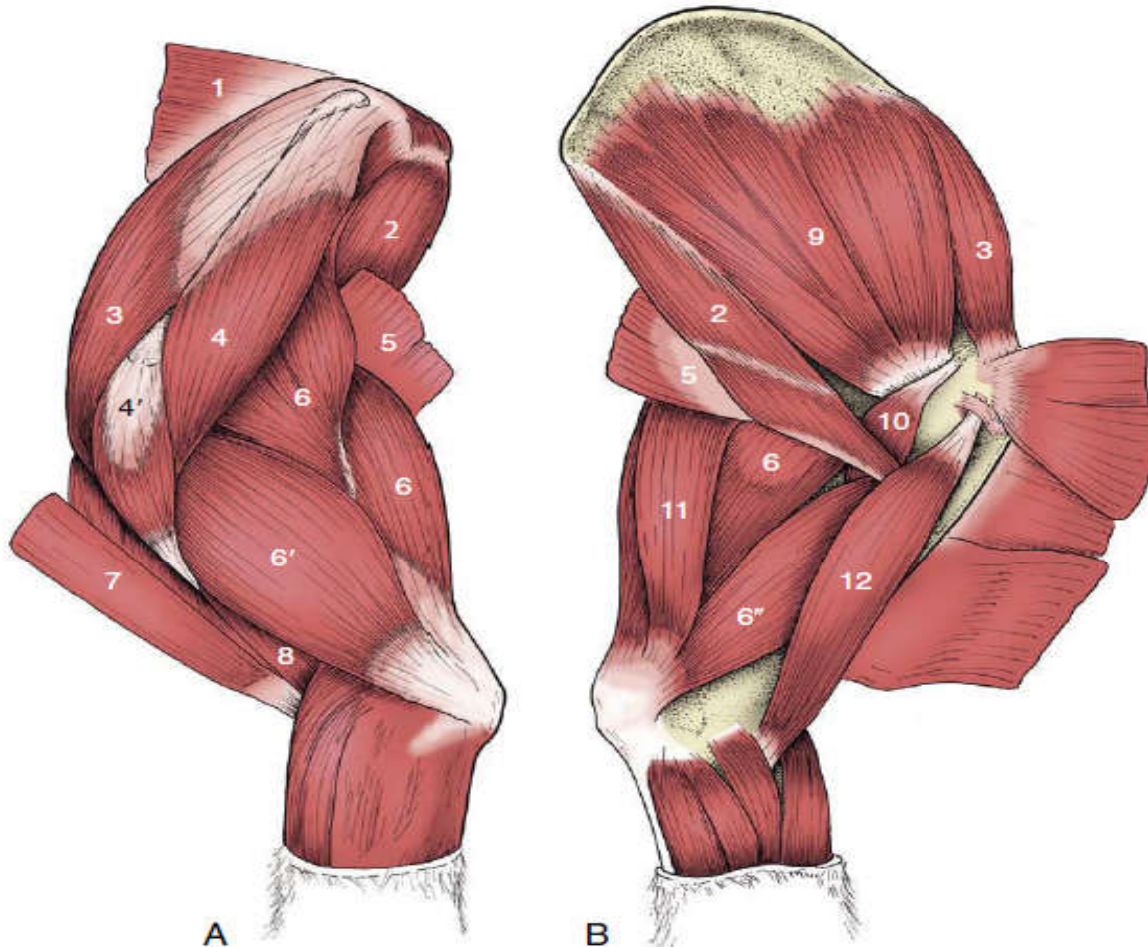


Fig: Intrinsic muscles of the left shoulder and arm of the dog, lateral (A) and medial (B) views.

- 1, *m. rhomboideus*;
- 2, *m. teres major*;
- 3, *m. supraspinatus*;
- 4, 4', scapular and acromial parts of deltoideus;
- 5, *m. latissimus dorsi*;
- 6, 6', 6'', long, lateral, and medial heads of triceps;
- 7, *m. brachiocephalicus*;
- 8, *m. brachialis*;
- 9, *m. subscapularis*;
- 10, *m. coracobrachialis*;
- 11, *m. tensor fasciae antebrachii*;
- 12, *m. biceps brachii*.

A. Muscles acting on the shoulder joint

1. Extensors of the shoulder joint:

- ❖ These are muscles on cranial side of the shoulder joint;
- ❖ The muscles acting on the shoulder joint are arranged in lateral, medial, and caudal groups;

I. *Musculus brachiocephalicus*:

- ❖ principal extensor of the shoulder and
- ❖ acts as a lateral flexor of the neck when the limb is weight bearing.

B. *Musculus supraspinatus*:

- ❖ Found on the lateral surface of scapula, cranial to the spine;
- ❖ Origin: Supraspinous fossa of scapula;
- ❖ Insertion: on the greater tubercle (both greater and lesser in the horse) of the humerus;
- ❖ Action: extends the shoulder; and chiefly acts as stabilizing ligament of the shoulder joint.

2. Flexors of the shoulder joint

❖ These are muscles on caudal side of the shoulder joint.

A: *m. teres major:*

- ❖ originates from the dorsal part of the caudal border of the scapula and
- ❖ inserts on the teres major tuberosity on the medial side of the shaft of the humerus.
- ❖ It is a strong flexor of the shoulder joint.

B: *m. infraspinatus:*

- ❖ Originates from the infraspinous fossa just caudal and ventral to the spine of the scapula.
- ❖ Inserts into the caudal part of the greater tubercle of the humerus.
- ❖ acts as a strong collateral ligament of the shoulder joint and may abduct, flex, and outwardly rotate the shoulder.
- ❖ This muscle also atrophies in cases of sweeny.

Cont...

C: *m. teres minor*

- ❖ lies just distal to the *m. infraspinatus* and has the same action as the *m. infraspinatus*.
- ❖ Originates from the distal caudal border of the scapula and
- ❖ inserts on the teres minor tuberosity of the humerus just distal to the greater tubercle of the humerus.

d: *m. deltoideus*

- ❖ extends from the spine of the scapula to the deltoid tuberosity of the humerus.
- ❖ It is an abductor and flexor of the shoulder joint.

e: *m. latissimus dorsi*

3. Adductors of the shoulder joint

a: Pectoral muscles:

- ❖ both superficial and deep pectoral muscles are adductors of the shoulder joint.

b: *m. coracobrachialis*:

- ❖ is a small muscle that extends:
 - from the coracoid process on the medial side of the scapula
 - to the medial side of the shaft of the humerus.

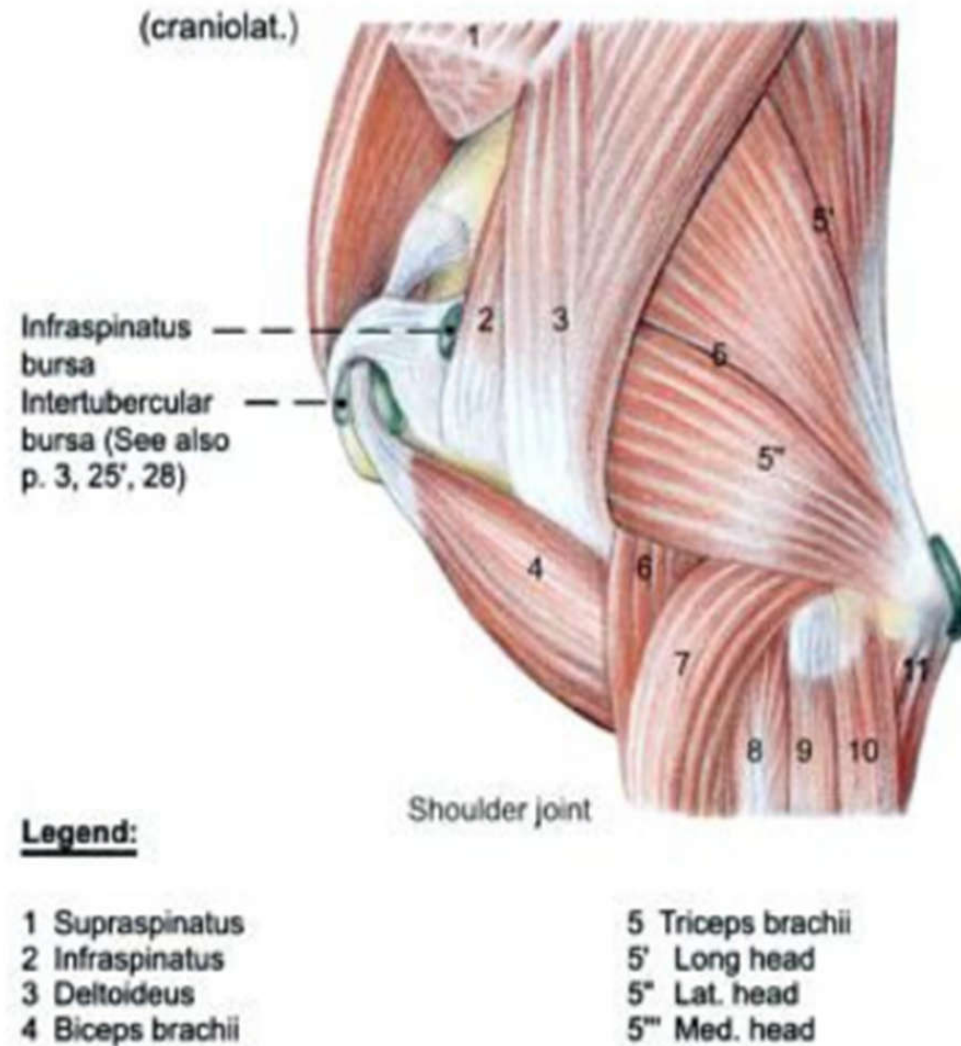
Cont...

c: *m. subscapularis*:

- ❖ stabilizes the shoulder on the medial side.
- ❖ provides some adduction to the shoulder joint.

4. Abductor muscles of the shoulder joint

As an example; *musculus deltoideus* is an abductor and flexor of the shoulder joint.



Muscles Acting on the Elbow Joint

- ❑ This group of muscles are either extensors or flexors.
- ❑ In quadrupeds, the extensors are stronger than the flexors... ???

A. Extensor muscles of the elbow

I. *m. triceps brachii*:

- ❖ is a three headed (long, medial, lateral) muscle located on caudal part of humerus;
- ❖ The long head originates from the caudal border of the scapula, and
- ❖ the medial and lateral heads originate from the respective sides of the humeral diaphysis;
- ❖ Carnivores have an accessory head that also originates from the humerus between the medial and lateral heads.

Cont...

- ❖ All heads insert on the olecranon process of the ulna.
- ❖ The triceps is the strongest extensor of the elbow.
- ❖ The long head may also act to flex the shoulder.

II. m. anconeus:

- ❖ deep to the *m. triceps brachii*,
- ❖ is a small muscle that covers the caudal aspect of the joint capsule of the elbow.
- ❖ It originates from the humerus,
- ❖ inserts on the olecranon process, and
- ❖ extends the elbow.

Cont...

III. *m. tensor fasciae antibrachii*

- ❖ thin sheet, partly muscular, partly aponeurotic, that lies over the medial aspect of the long head of the triceps;
- ❖ extending from the scapula to the olecranon;
- ❖ Originates via a thin aponeurosis that is blended with the long head of the *m. triceps* and the *m. latissimus dorsi*;
 - The flattened muscle belly lies on the caudomedial aspect of the arm and
- ❖ Inserts via a second aponeurosis on the olecranon and antebrachial fascia;
- ❖ it tenses antebrachial fascia,
- ❖ assists the *m. triceps* in extension of the elbow.

B. Flexor muscles of the elbow

1. *M. biceps brachii*:

- ❖ is a two headed muscle lies on the cranial surface of humerus;
- ❖ originates on the supraglenoid tubercle just dorsal and cranial to the articular surface of the scapula;
- ❖ inserts on
 - (1) the radial tuberosity on the cranial aspect of the proximal radius;
 - (2) the medial collateral ligament of the elbow, and
 - (3) the antebrachial fascia.
- ❖ The tendinous blending with the antebrachial fascia forms a palpable cordlike structure on the flexor surface;
- ❖ assists in holding the shoulder joint in apposition and may extend it to some extent;
- ❖ Its chief action is flexion of the elbow.

Cont...

2. *Musculus brachialis*:

- ❖ purely fleshy and crosses only one joint, the elbow.
- ❖ Arises from the caudoproximal part of the humerus, winds laterally within a spiral groove, and then crosses the flexor aspect of the elbow and
- ❖ insert on the craniomedial part of the proximal radius.
- ❖ Proximally, the muscle is covered by the triceps, but its distal part is superficial and may be palpated.

3. *m. pronator teres*

- ❖ a small, weak muscle in ruminants and pigs.
- ❖ In these species, it acts primarily as a flexor of the elbow.
- ❖ originates on the medial epicondyle of the humerus and
- ❖ Inserts on the medial side of the radius.
- ❖ reduced to a ligament in horses.

Cont...

Muscles Acting on the Carpal Joint

A. Extensor muscles of the carpal joint

1. *m. extensor carpi radialis*:

- the largest extensor of the carpus and the most medial.
- Origin: lateral epicondyle of the humerus
- Insertion: middle metacarpal bone.
- is the most prominent muscle on the front of the forearm and
- is the most cranial muscle of the group.
- Action: extends the carpal joint and flexes the elbow joint.

Cont...

2. *m. extensor carpi ulnaris*

- ❖ formerly *Musculus ulnaris lateralis*;
- ❖ is the most caudal of the extensor muscles;
- ❖ Originates from the lateral epicondyle of the humerus, passes downward over the lateral side of the carpus and
- ❖ inserts on the most lateral metacarpal bone.

3. *Musculus carpi obliquus*:

- ❖ is a flat triangular extensor of the carpus;
- ❖ Lies deep to the digital extensor muscles of the antebrachium;
- ❖ arises from the craniolateral aspect of the distal half of the radius (and ulna in species with a complete ulna);
- ❖ Inserts *on the most* medial metacarpal bone.

Cont...

B. Flexor muscles of carpal joint

1. m. flexor carpi radialis:

- ❖ On the medial side of the forearm, just caudal to the radius;
- ❖ palpable directly beneath the skin;
- ❖ originates from the medial epicondyle of the humerus and
- ❖ inserts on the palmar aspect of the proximal end of the metacarpus (medial side).

2. m. flexor carpi ulnaris

- ❖ On the caudal side;
- ❖ exerts considerable leverage as a flexor of the carpus by inserting on the accessory carpal bone, which projects in a palmar direction from the lateral aspect of the carpus.

Cont...

Muscles Acting on the Digit

A. Extensor muscle of digit

1. *m. extensor digitorum communis*

- ❖ It is the longest extensor muscle in the thoracic limb;
- ❖ The origin is lateral epicondyle of humerus close to extensor carpiradialis muscle,
- **its tendinous** insertion is on the extensor process of the distal phalanx and on the proximal ends of the middle and proximal phalanges;
- The tendon is single in the horse; double in the cow, sheep, and goat; and split into four separate tendons in the pig and carnivores;
- This muscle is an extensor of all joints of the digit, including the fetlock;
- It may also assist in extending the carpus and even in flexing the elbow.

Cont...

2. *M. extensor digitorum lateralis*

- ❖ Origin: just caudal to the common digital extensor m. on the lateral collateral ligament of the elbow and lateral radius and ulna.
- ❖ Insertion: varies according to the number of digits present, and there are interspecific differences regarding to which phalanx the tendon attaches.
 - In pigs: it inserts on the fourth and fifth digits;
 - in ruminants: on the middle phalanx of the fourth digit;
 - in the horse: on the proximal phalanx of the third digit.

B. Flexor Muscles of Digit

❖ In all animals the principal digital flexors are the superficial and the deep digital flexor muscles.

1. *m. flexor digitorum profundus*:

❖ Lies closest to the metacarpal bones.

❖ Originates from the humerus, radius, and ulna.

❖ Its long, stout tendon extends distad through the carpal canal, then along the palmar side of the metacarpus;

❖ inserts on the palmar surface of the distal phalanges.

Cont...

- ❖ the number of insertions depend on:
 - the number of digits, with the main tendon dividing into individual slips, one per digit, just proximal to the fetlock.
- ✓ is the only muscle that flexes the distal interphalangeal joint;
- ✓ Secondly, it also flexes the more proximal joints of the digit and the carpus;
- ✓ important in supporting the fetlock.

Cont...

2. *M. flexor digitorum superficialis*

- It is similar to the deep digital flexor muscle,
 - ✓ but it inserts primarily on the proximal part of the middle phalanx of each digit.
- In the horse, the superficial digital flexor tendon inserts on the palmar aspects of the :
 - ✓ proximal end of the middle phalanx and
 - ✓ distal end of the proximal phalanx.
- Tendons of both the superficial and deep digital flexor muscles can be palpated palmar to the cannon bone.

❑ Short Digital Muscles

Interosseous muscles

- ❖ Support the metacarpophalangeal joints;
- ❖ show marked species differences in number, structure (they are largely tendinous in the large species), and function.
- ❖ arise from the palmar aspect of the proximal ends of the metacarpal bones and
- ❖ Initially insert on the sesamoid bones at the metacarpophalangeal joints; and
 - are continued by distal sesamoidean ligaments that:
 - ✓ attach to the phalanges and
 - ✓ by extensor branches that wind around to the dorsal aspect of the digit to join the extensor tendons.

Cont...

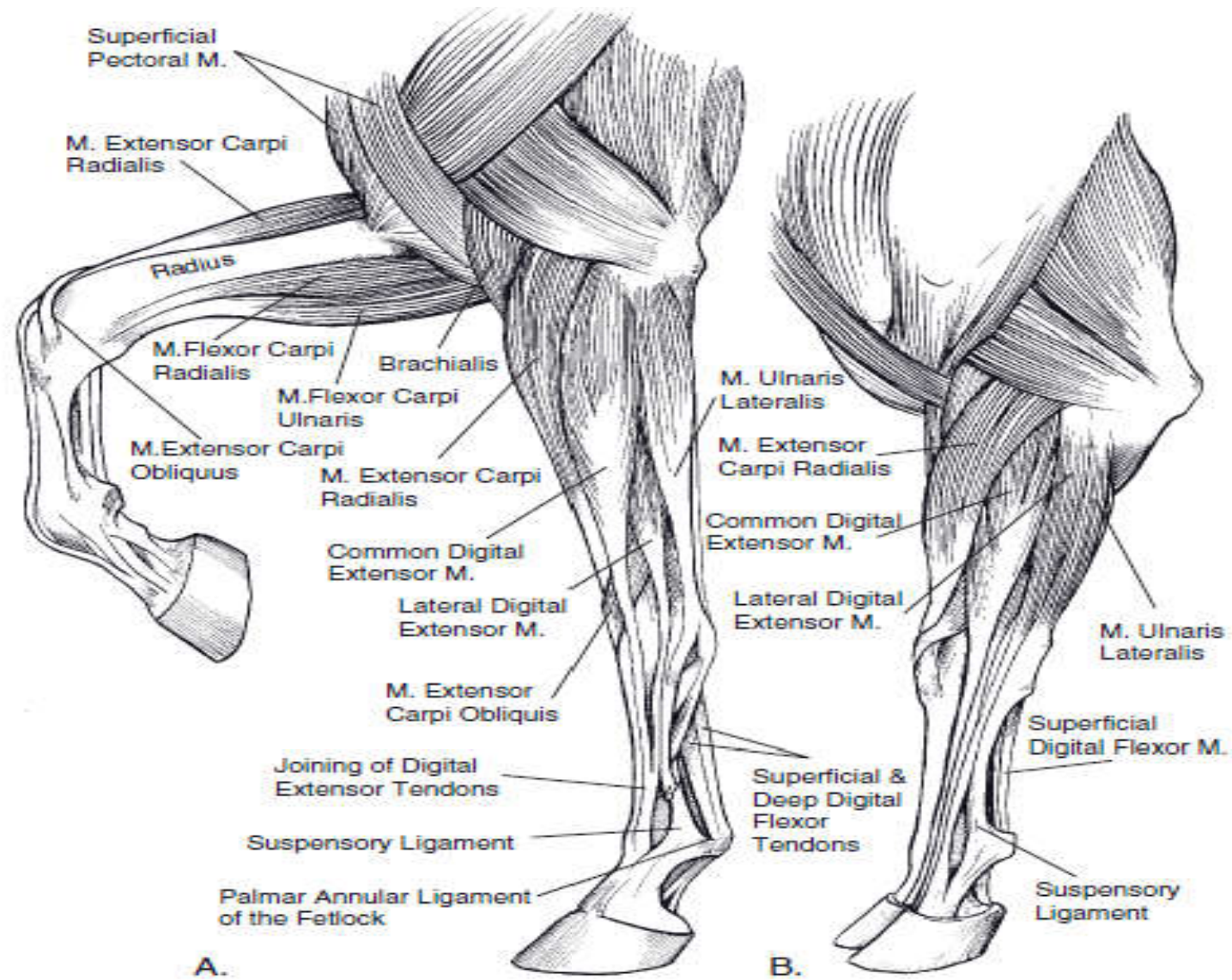


Figure: Muscles of the thoracic limb. *A) Equine. B) Bovine.*

8.2. Muscles of the Pelvic Limb

- ❖ Function mainly in locomotion;
- ❖ Muscles in this group include:

1. Muscles Acting on the Hip Joint

- ❖ The muscles acting at the hip are arranged in; a classification based primarily on topography:
 - A. Gluteal group:** comprises superficial, middle, and deep gluteal muscles and the *m. tensor fasciae latae*;
 - B. Caudal** (hamstring) groups:
 - C. Medial:** includes; *adductors* (gracilis, pectineus, adductor, external obturator) and sartorius,
 - D. Deep:** includes; obturator internus, gemelli, quadratus femoris, and articularis coxae.

Cont...

A. Gluteal muscles group

❖ Generally the gluteal muscles extend from the bones of the pelvis down to the trochanter of the femur.

➤ Clinically important for IM injection.

❖ Gluteal muscles group includes the following:

I. *m. tensor fasciae latae*:

- Originates on the coxal tuber and
- ends by a broad aponeurosis (fascia lata) that inserts on:
 - ✓ the patella,
 - ✓ the lateral patellar ligament, and
 - ✓ the cranial border of the tibia.
- The cranial border of the fleshy part is related to the subiliac lymph nodes;
- flexor of the hip & helps to advance the limb;

Cont...

II. *m. gluteus superficialis*:

- ❖ lies between the tensor and *m. biceps femoris*.
- ❖ has separate origins from:
 - the coxal tuber and
 - the gluteal fascia,
 - ✓ but the two parts combine at a common insertion on the third trochanter;
 - this projection is broken off, and it is then displaced dorsally by the attaching muscle.

Action:

- potential flexor of the hip and
- abductor of the thigh.

Cont...

III. *m. gluteus medius*

- ❖ is a muscle of exceptional size and power;
 - ❖ Origin: it spreads from *m. longissimus dorsi*:
 - over the coxal tuber and iliac wing;
 - to the sacrum and adjacent part of the sacrosciatic ligament;
 - ❖ Insertion: principally to the caudal part of the greater trochanter;
- Action: primarily an extensor of the hip,
✓ an abductor of the thigh, secondary function.
Its association with the *m. longissimus dorsii* makes it an effective participant in rearing.

Cont...

IV. m. gluteus profundus:

- ❖ Lies deep to the caudal part of the *m. gluteus medius*.
- ❖ Origin:
 - arises from and around the ischial spine and
 - passes more or less transversely;
- ❖ insertion: on the cranial part of the greater trochanter.
- ❖ Extends hip, abducts limb;

B. Hamstring Muscles Group

- ❖ This group of muscles extends from ischial tuber to proximal end of tibia, fibula or calcanus of the tarsus.
- ❖ Clinically important for injection of medicaments intramuscularly (IM), in:
 - small ruminants (sheep, goat) and
 - calves.
- ❖ They flesh the caudal part of the thigh.
- ❖ Hamstring muscles are the chief extensors of the hip.

Cont...

❖ Hamstring group includes three muscles; located on the back of the thigh region:

1. *m. biceps femoris*: the most lateral of the caudal muscles of the thigh;

2. *m. semitendinosus*: the middle muscle of the caudal group;

3. *m. semimembranosus*: the medial muscle of this group.

1. *m. biceps femoris*:

- ❖ In the horse and in ruminants, but not in the dog, it has both vertebral and pelvic heads;
- ❖ In the lower part of the thigh:
 - the united muscle divides into insertions that attach to the patella and ligaments of the stifle joint both proximal and distal to the joint space;
 - an additional insertion to the point of the hock is achieved through a contribution (tarsal tendon) to the common calcanean tendon.
- ❖ In ruminant species, the biceps femoris muscle is blended with the superficial gluteal muscle and named as musculus gluteobiceps.
 - It is a powerful extensor of the hip.

Cont...

2. *m. semitendinosus*:

- ❖ Forms the caudal contour of the thigh.
- ❖ It has a vertebral head only in the horse and pig.
- ❖ The insertion is to the medial aspect of the proximal extremity of the tibia and to the calcaneus.

3. *m. semimembranosus*:

- ❖ Most medial and has a vertebral head only in the horse.
- ❖ The insertion is divided between a cranial part attaching to the medial femoral condyle and a caudal part attaching to the medial tibial condyle.
- The division between these muscles can be seen as a vertical groove (popliteal fossa) in live animals that are not very fat.

C. medial group

- ❖ Is principally employed to adduct the hindlimb.

1. m. gracilis,

- ❖ a broad but thin muscle, takes an aponeurotic origin from the symphyseal region of the pelvis;
- ❖ Its insertion, also aponeurotic, merges with the crural fascia through which it finds attachment to the tibial crest and other medial structures of the stifle region.

II. *m. pectineus*:

- ❖ is a small fusiform muscle.
- ❖ arises from the cranial branch of the pubis and from the prepubic tendon;
- ❖ inserts on the proximal part of the medial “rough line” of the femur.
- ❖ In the larger species, a considerable part of the tendon of origin decussates with its fellow within the prepubic tendon.

Cont...

III. m. adductor

- ❖ is often divided into several individually named parts.
- ❖ arises over the ventral aspect of the pelvic floor and
- ❖ Inserts:
 - along the distal two thirds of the medial “rough line” of the femur and
 - to the fascia and ligaments of the medial aspect of the stifle.

IV. m. obturator externus

- ❖ arises from the ventral surface of the pelvic floor, over and around the obturator foramen, and
- ❖ inserts within the ventral part of the trochanteric fossa.
- ❖ an adductor and potential outward rotator of the thigh.

Cont...

V. m. sartorius

- ❖ It is superficial and follows the craniomedial aspect of the thigh;
- ❖ arises from the iliac fascia on the abdominal roof (in the horse), from the iliac crest (in other animals) and
- ❖ Inserts to the medial structures of the stifle region.
- ❖ Flexion of the hip→main action,
- ❖ Also adduction of the thigh and extension of the stifle.

The superficial space between the caudal margin of the sartorius and the pectineus is often designated the *femoral canal*.

Cont...

D. Deep Muscles Group

- ❖ *form a rather heterogeneous* community of small and essentially trivial muscles.

I. m. obturator internus:

- ❖ Originates on the dorsal surface of the hip bone in the vicinity of the obturator foramen; and
- ❖ ends in the trochanteric fossa.
- ❖ is an external rotator of the thigh.

II. M. gemelli

- ❖ two small “twin” bundles that pass from the ischial spine to the trochanteric fossa.
- ❖ Are also external rotators.

Cont...

III. m. quadratus femoris:

- ❖ *passes from the ventral aspect* of the ischium to end on the femoral shaft close to the trochanteric fossa.

IV. M. articularis coxae:

- ❖ *lies on the capsule over the* cranial aspect of the hip and protects this from being nipped between the femoral and acetabular surfaces.

Cont...

2. Muscles Acting Primarily on the Stifle Joint

❖ extensor and flexor groups.

l. m. quadriceps femoris,

❖ the principal extensor of the stifle,

❖ forms the mass of muscle cranial to the femur.

❖ consists of four parts, separate at their origins but joined distally.

➤ One, the rectus femoris, arises from the shaft of the ilium immediately cranial to the acetabulum.

➤ The others, vastus medialis, intermedius, and lateralis, arise from the medial, cranial, and lateral aspects of the femoral shaft.

➤ common insertion: patella and tibial tuberosity (i.e. muscle is continued distal to the patella by the patellar ligament(s)).

Cont...

- ❖ The rectus femoris has the potential secondary action of flexion of the hip, although it is ill-placed for this purpose.

II. M. popliteus

- ❖ lies directly over the caudal aspect of the joint.
- ❖ takes a tendinous and confined origin from the lateral condyle of the femur and fans out to a broad fleshy insertion on the proximal third of the caudal surface of the tibia.
- ❖ flexor of the stifle, and rotates the distal part of the limb.

Cont...

3. Muscles Acting on Tarsal and Digital Joints

- ❖ These comprise:
 - extensors and flexors of the hock and
 - extensors and flexors of the digits.
- ❖ They are grouped in two masses:
 - A.** craniolateral to the tibia and
 - B.** caudal to the tibia.
- A. Craniolateral Muscles of the Leg:**
 - ❖ comprises muscles with an action confined to flexion of the hock and others that have this action but continue to extend the digits.
 - ❖ it would comprise the tibialis cranialis, peroneus tertius, peroneus longus, and peroneus brevis.

Cont...

i. M. tibialis cranialis,

- ❖ *always substantial, lies immediately* cranial to the subcutaneous medial surface of the tibia.
- ❖ *originates from the lateral* condyle of the tibia and
- ❖ inserts on the mediodistal tarsal and adjacent metatarsal skeleton.
- ❖ It is a flexor of the hock with a secondary supinator role.

ii. M. peroneus tertius

- ❖ *is most important in the horse,*
 - *constitutes* an essential component of the so-called reciprocal mechanism.

Cont...

❖ *M. peroneus longus*

- arises from and around the distal part of the lateral collateral ligament of the stifle joint;
- crosses the lateral aspect of the tarsus before turning medially, over the plantar aspect, and
- end on the proximal parts of the medial metatarsal bone.
- Is primarily a pronator of the foot but may also flex the hock.
- **Important in ruminants, pig and dog.**

❖ *M. peroneus brevis* is of no practical importance, except little importance in carnivores.

The number and the arrangement of the extensor muscles of the digits are naturally correlated with the digital pattern.

Cont...

iii. long digital extensor muscle

- ❖ *arises from the distal extremity of the femur and*
- ❖ follows the lateral border of the tibialis cranialis.
- ❖ Its tendon crosses the dorsal surface of the hock and splits into branches, one for each functional digit.
- ❖ Each branch inserts on the extensor process of a distal phalanx.

iv. lateral digital extensor

- ❖ *arises from* the head of the fibula,
- ❖ crosses the lateral aspect of the hock, and
- ❖ enters the most lateral functional digit, & terminates either:
 - on the proximal phalanx (dog) or
 - by joining the long extensor tendon (horse).

Cont...

B. Caudal Muscles of the Leg:

- ❖ *The caudal group comprises the:*
 - twin-bellied gastrocnemius,
 - soleus, and
 - superficial and deep digital flexors.
- ❖ The gastrocnemius and the soleus are sometimes collectively known as the *triceps surae*;
- ❖ extensors of the hock,
- ❖ a potential flexor of the stifle; stifle and hock (proximal attachment), normally move in unison.

Cont...

- ❖ suggested prime function of the muscle is not to move either joint but to oppose bending of the tibia, ensuring that the strain is always directed along its long axis.

ii. superficial digital flexor muscle

- ❖ *Arises* from a supracondylar fossa or tubercle on the caudal aspect of the femur, close to the origin of the gastrocnemius.
- ❖ It first runs deeply, between the two parts of the gastrocnemius;
- ❖ its tendon later winds around the medial border of the gastrocnemius tendon to gain the more superficial position.

Cont...

iii. deep digital flexor muscles

- ❖ *Are three* (lateral and medial flexors, and tibialis caudalis);
 - *their* independence varies among species;
 - lie close together and originate on the caudal surface of the tibia (and fibula).
- ❖ In the ungulates,
 - the tendons of the lateral muscle and the tibialis caudalis unite above the tarsus and
 - then run over the plantar aspect of the joint, medial to the calcaneus;
 - ✓ this common tendon is then joined in the upper part of the metatarsus by that of the medial muscle, which descends over the medial malleolus;
 - ✓ The combined deep flexor tendon ends as the corresponding tendon of the forelimb.

Cont...

- ❖ In carnivores,
 - only the lateral and medial muscles unite.
 - small tibialis caudalis remains aloof and inserts separately on the hock;
 - ✓ this truncated course transforms it into an extensor of the hock and supinator of the foot.

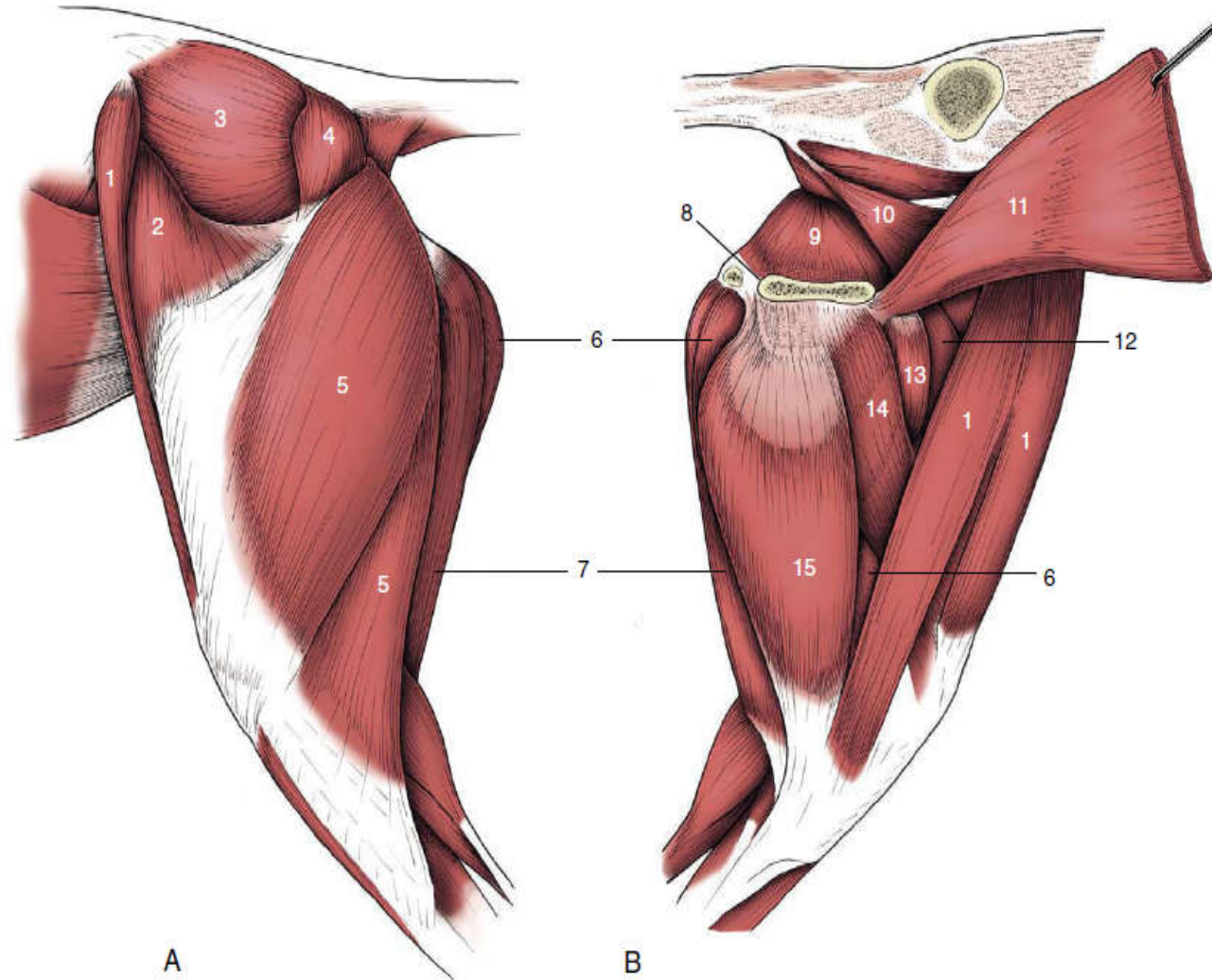
4. Short digital muscles

- ❖ The most important short muscles are the interossei, which resemble those of the forelimb.
- ❖ A number of other small muscles that occur, especially in the dog, are of trivial significance.

Cont...

Figure: Muscles of the canine hindquarter and thigh, lateral (A) and medial (B) views.

- 1, Sartorius;
- 2, tensor fasciae latae;
- 3, gluteus medius;
- 4, gluteus superficialis;
- 5, biceps;
- 6, semimembranosus;
- 7, semitendinosus;
- 8, pelvic symphysis;
- 9, internal obturator;
- 10, levator ani;
- 11, rectus abdominis;
- 12, quadriceps;
- 13, pectineus;
- 14, adductor;
- 15, gracilis.



A

UBMSs

UoG

B

189

Cont...

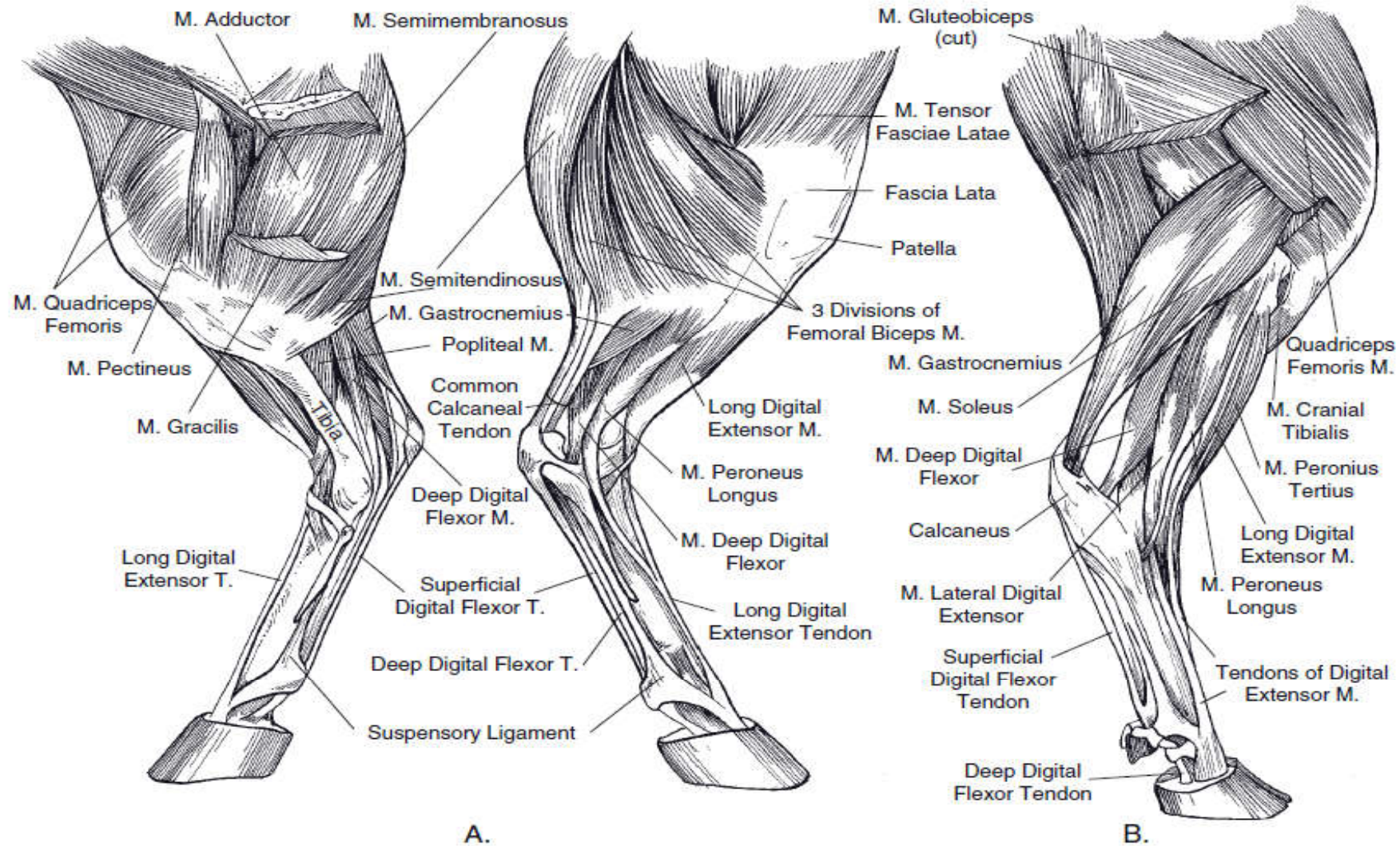


Figure: Muscles of the pelvic limb. A) Equine. Left) medial view. Right) lateral view. B) Bovine: lateral view.

Important Figures for Myology

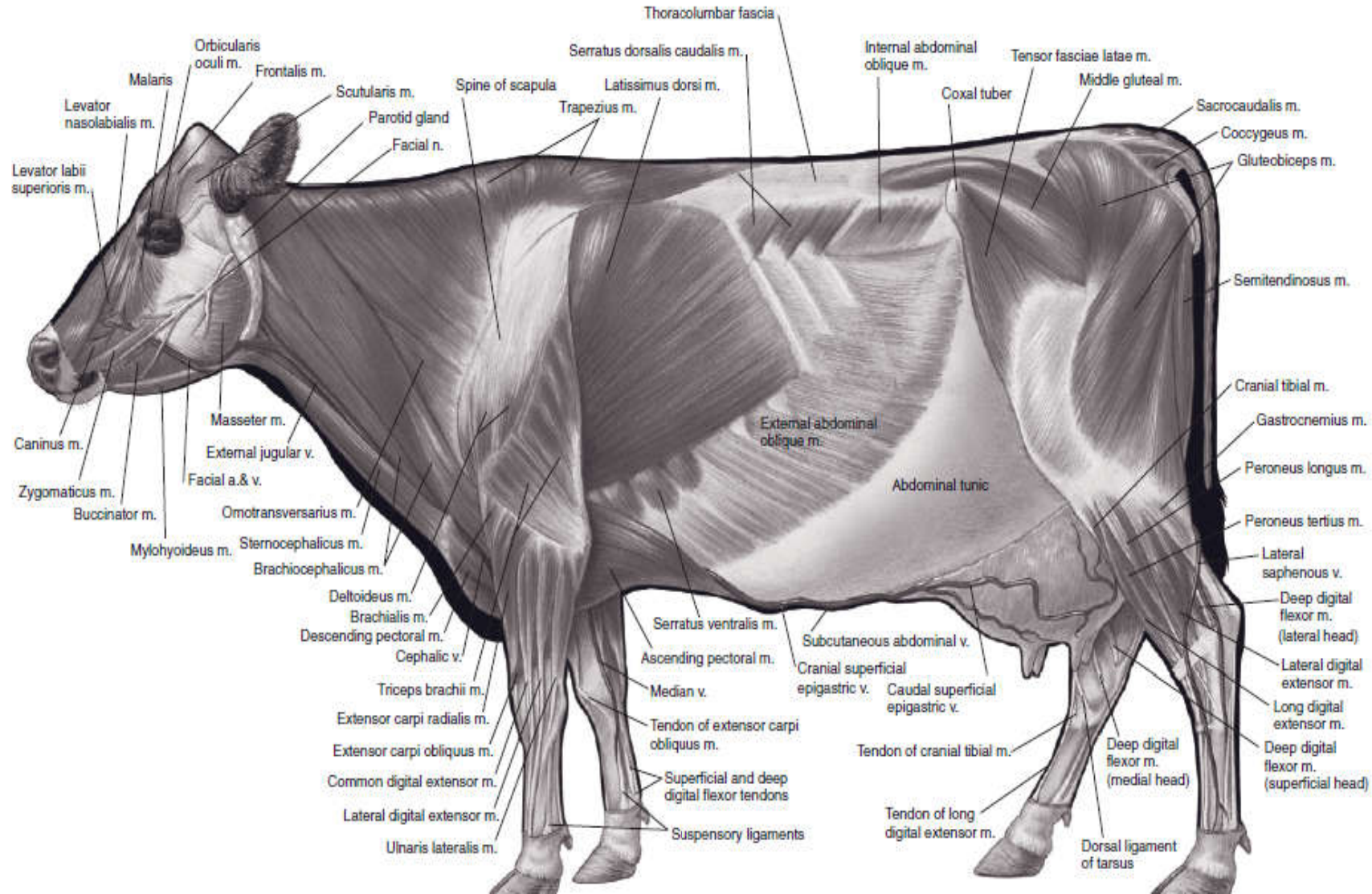


Figure: Superficial muscles of the cow.

Cont...

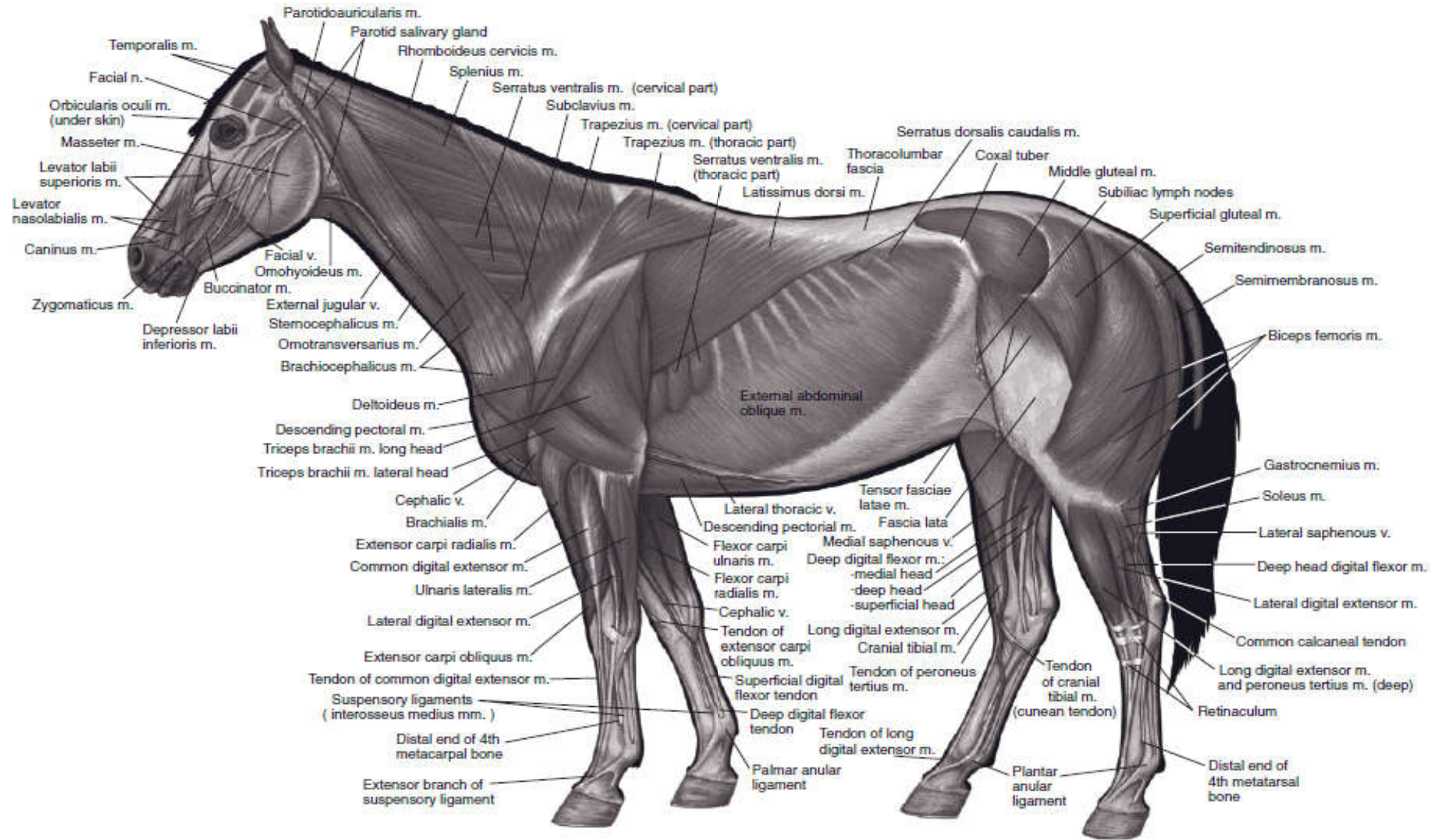


Figure: Superficial muscles of the horse.

Cont...

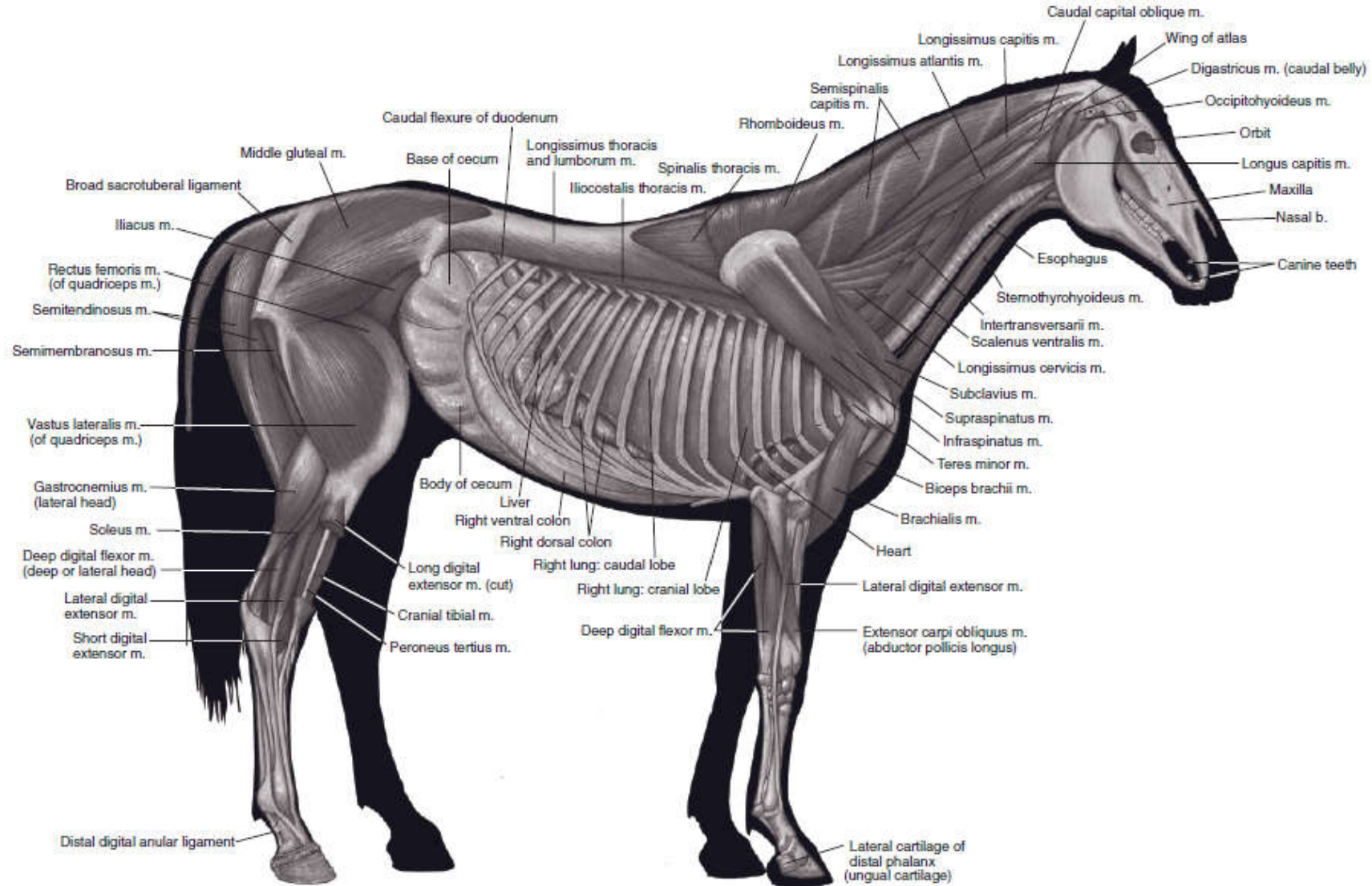
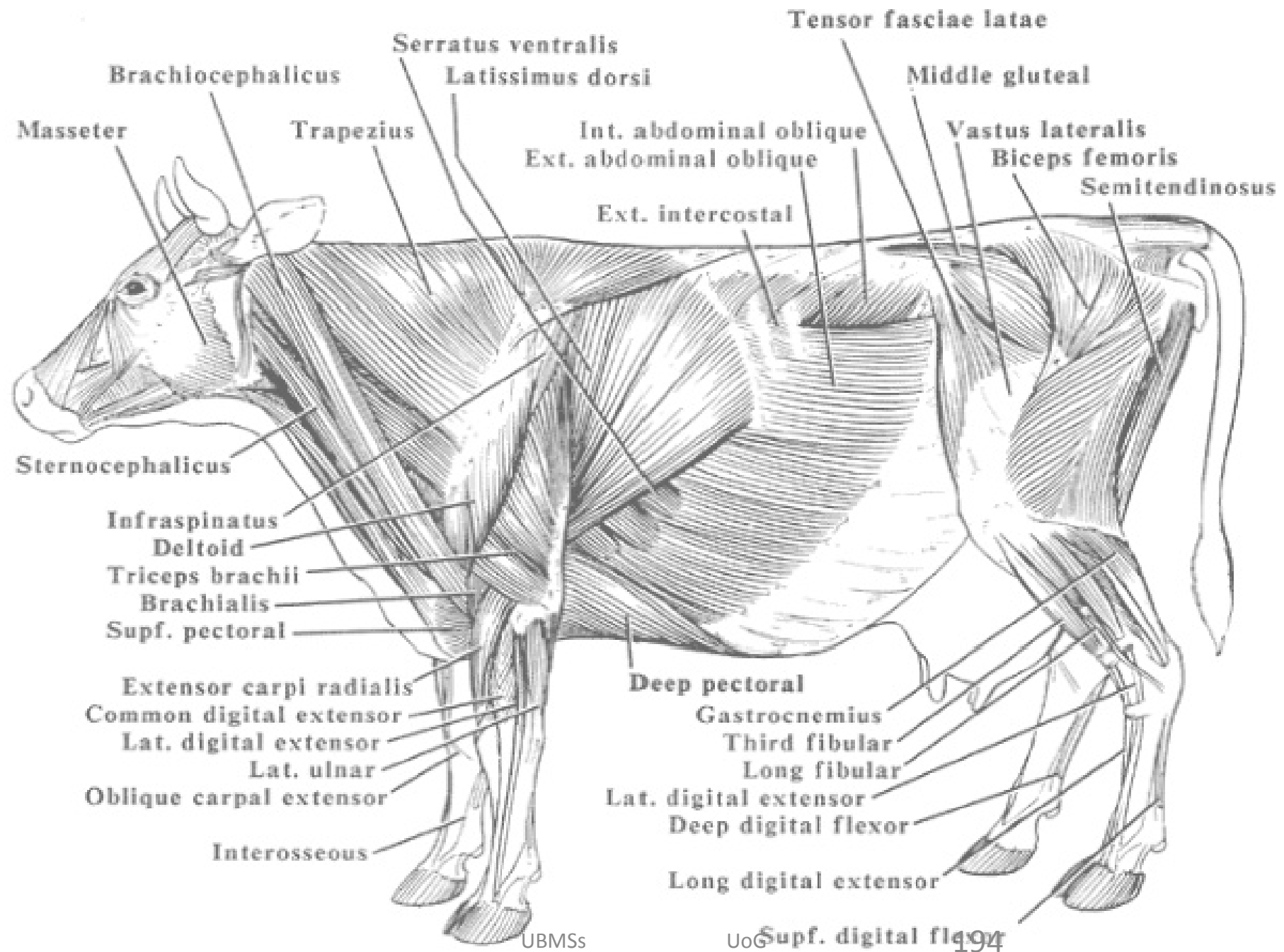


Figure: Deeper muscles of the horse.



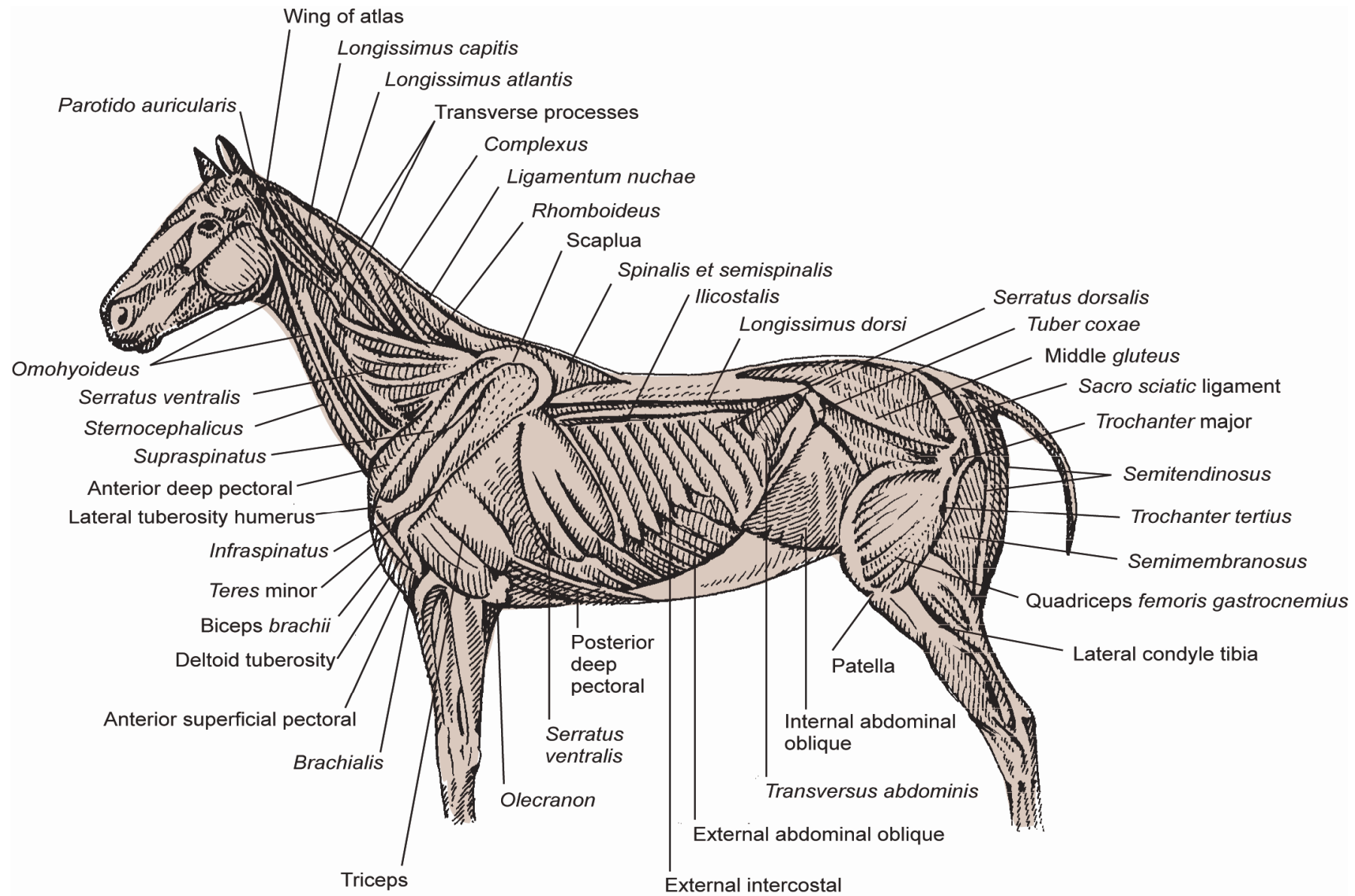


Figure: Muscles of the horse.

Begin with the end in mind!

the end

thank you !!!
thank you !!!

Tabular Presentation of some Skeletal Muscles of the Body

<i>Muscle</i>	<i>Description</i>	<i>Origin (O)/Insertion (I)</i>	<i>Action</i>
Muscles of Facial Expression and Mastication			
Buccinator	Muscle contained within the wall of the cheek	O—Fascia of cheek wall I—Fascia of cheek wall	Holds the cheeks toward the mouth when chewing
Masseter	Most powerful muscle for closing jaw	O—Zygomatic arch I—Masseteric fossa of mandible	Elevates mandible (closes mouth)
Mentalis	Major muscle making bulk of muscle mass of chin	O—Rostral end of mandible I—Skin of chin	Elevates and protrudes lower lip
Orbicularis oris	Multilayered muscle of the lips	O—Lips I—Lips	Purses lips
Pterygoid			
Medial	Two-headed muscle running along internal surface of mandible	O—Sphenoid and pterygoid bones I—Medial surface of mandible	Acts with temporalis and masseter muscle to elevate mandible (close mouth)
Lateral	Two-headed muscle lying superior to medial pterygoid muscle	O—Sphenoid bone I—Neck of condyle of mandible	Protrudes mandible; in herbivores, cross jaw-action
Platysma	“Grimace” and “neck-cording” muscle	O—Skin of neck I—Angle of lips	Retract lips
Temporalis	Fan-shaped muscle covering part of temporal, frontal and parietal bones	O—Temporal fossa I—Coronoid process of mandible	Closes mouth; elevates and retracts mandible
Zygomaticus	Muscle running diagonally from cheek bones to corner of mouth	O—Zygomatic bone near zygomaticomaxillary suture I—Angle of the mouth	Retracts and elevates corners of mouth

Cont...

Muscles of the Neck

Brachiocephalicus

Cleidobrachialis

Complex muscle acting on head and/or limb

O—Clavicle or its remnant
I—Cranial humerus

Cleidomastoideus

O—Clavicle or its remnant
I—Mastoid process of skull

Cleidocephalicus

O—Clavicle or its remnant
I—Dorsal midline of neck

Sternocephalicus

In carnivores, consists of sternomastoid and sternooccipitalis. In ox and goats, the sternooccipitalis is replaced by the sternomandibularis. The horse has only sternomandibularis.

O—Cranial part of the sternum (manubrium)

Depending on which end is fixed (not moved), and whether one or both sides (right and left) contract: Advances forelimb, turns head to the side, or flexes neck ventrally

Flexes the head and neck and inclines them to one side. Sternomandibularis may also help open the mouth.

Sternomastoid

I—Mastoid process of skull

O—Sternum (manubrium)
I—Mastoid process of skull

Sternooccipitalis (dog and cat)

O—Sternum (manubrium)
I—Occipital region of skull

Sternomandibularis

O—Sternum (manubrium)
I—Angle of the mandible

Cont...

<i>Muscle</i>	<i>Description</i>	<i>Origin (O)/Insertion (I)</i>	<i>Action</i>
Extrinsic Muscles of Thoracic Limb¹			
Brachiocephalicus	This is a wide muscle running from the head and neck to the front limb. The clavicular intersection divides the muscle into the cleidocephalicus and cleidobrachialis		Draws the lifted forelimb forward or draws the head to the side
Cleidocephalicus		O—Occipital and dorsal midline of neck I—Clavicle	Pulls humerus forward
Clavodeltoid		O—Clavicle I—Cranial border of humerus	Pulls humerus forward
Pectoralis	A broad flat muscle extending from the sternum to the humerus		
Pectoralis superficialis		O—Sternum I—Humerus (greater and lesser tubercles)	Adducts and retracts limb (flex shoulder)
Pectoralis profundus		O—Sternum I—Cranial surface of the humerus	Flexes shoulder and draws humerus caudally

Cont...

<i>Muscle</i>	<i>Description</i>	<i>Origin (O)/Insertion (I)</i>	<i>Action</i>
Rhomboideus Cervicis Thoracis	Extrinsic muscle lying deep to the trapezius extends between dorsal medial scapula and midline from head or neck to cranial thorax	O—Dorsal neck and thorax; nuchal crest of skull I—Dorsal border of scapula and scapular cartilage	Rotates (capitis and cervicis) or adducts the scapula (thoracis)
Trapezius Cervicis Thoracis	Triangular-shaped muscle extending from the dorsal midline of neck and thorax to the spine of the scapula	O—Cervicis: Median fibrous raphe of neck Thoracis: Spines of T ₃ -T ₈ or T ₉ I—(both parts)—Spine of scapula	Both concurrently: Elevate shoulder Cervicis only: rotate scapula cranially Thoracis only: rotate scapula caudally
Latissimus dorsi	Broad, flat, fan-shaped muscle extending from dorsal thoracolumbar region to medial side of humerus	O—Thoracolumbar fascia of thorax and lumbar region; and some caudal ribs I—Teres tuberosity of humerus	Pulls humerus caudally; medially rotates and adducts the shoulder
Intrinsic Muscles of Shoulder²			
Biceps brachii	One headed (Two-headed in humans) fusiform muscle	O—Supraglenoid tubercle of scapula I—Radial tuberosity; also ulnar tuberosity in some species	Extension of the shoulder
Coracobrachialis	Small muscle crossing medial side of shoulder joint	O—Coracoid process of scapula I—Proximal shaft of humerus	Stabilizes and potentially flexes shoulder joint
Deltoideus	Extends from scapular spine over shoulder joint to the deltoid tuberosity of the humerus	O—Spine of scapula; acromion process of scapula I—Deltoid tuberosity of humerus	Flexes shoulder joint; slightly abducts humerus
Supraspinatus	Fills the supraspinous fossa of the scapula	O—Supraspinous fossa of scapula I—Greater and lesser tubercle of humerus	Extends shoulder joint
Infraspinatus	Fills the infraspinous fossa of the scapula	O—Infraspinous fossa of scapula I—Infraspinous tubercle of humerus	Abducts and rotates humerus, may flex humerus depending on position
Teres major	Extends from caudal border of scapula and inserts on latissimus dorsi muscle on medial side of humerus	O—Proximal 2/3 of caudal border of scapula I—Teres tuberosity of humerus	Flexes shoulder joint
Teres minor	Small muscle ventral to the tendon of the infraspinatus muscle	O—Distal third of caudal border of scapula I—Teres minor tuberosity of humerus	Flexes/stabilizes shoulder
Subscapularis	Large muscle filling most of the space on the medial scapular surface and inserting on humerus	O—Subscapular fossa of scapula I—Lesser tubercle of humerus	Adducts shoulder joint

Cont...

Intrinsic Flexor Muscles of Leg²

Biceps brachii	Spans cranial surface of humerus	O—Supraglenoid tubercle of scapula I—Radial tuberosity; also ulnar tuberosity in carnivores	Action distal to shoulder is to flex shoulder; also supinates paw in carnivores
Brachialis	Extends from caudal part of humerus to the radius	O—Proximal lateral humerus I—Radial tuberosity	Flexes elbow

Intrinsic Extensor Muscles of Leg²

Triceps brachii	Multi-headed muscle crossing shoulder and caudal leg		
Long Head		O—Caudal border of scapula I—Olecranon process of ulna	Extends elbow joint
Lateral Head		O—Lateral surface of humerus I—Olecranon process of ulna	Extends elbow joint
Medial Head		O—Medial surface of humerus I—Olecranon process of ulna	Extends elbow joint
Accessory Head (carnivores only)		O—Proximal caudal humerus I—Olecranon process of ulna	Extends elbow joint
Tensor faciae antebrachii	Thin, insignificant muscle arising from the latissimus muscle	O—Latissimus dorsi I—Olecranon process of ulna and antebrachial fascia	Extends elbow joint
Anconeus	Small muscle filling olecranon fossa	O—Epicondyles of humerus I—Olecranon process of ulna	Lifts joint capsule out of joint space on full elbow extension

Cont...

<i>Muscle</i>	<i>Description</i>	<i>Origin (O)/Insertion (I)</i>	<i>Action</i>
Sublumbar Muscles¹			
Psoas minor	A long, thin muscle extending from lumbar vertebral bodies to ilium	O—Vertebrae T ₁₃ -L ₅ I—Iliopubic tubercle	Stabilize back; flex vertebral column
Iliopsoas (psoas major and iliacus)	Fused psoas major and iliacus muscle; chief flexor of hip	O—Lumbar vertebrae I—Lesser trochanter of femur	Flexes hip when leg is free; flexes vertebral column when leg is fixed
Quadratus lumborum	Lies along underside of transverse processes of lumbar vertebrae	O—Transverse processes of lumbar vertebrae I—Wing of sacrum and ilium	Stabilizes lumbar vertebrae
Rump Muscles²			
Gluteal muscle			
Superficial	Smallest, thinnest gluteal muscle	O—Sacral vertebrae I—Third trochanter	Abducts limb of femur
Medial	Largest gluteal muscle	O—Wing of ilium I—Greater trochanter of femur	Extends hip, abducts limb
Deep	Moderately sized, fan shaped	O—Body of ilium I—On or near greater trochanter	Extends hip, abducts limb
Tensor fasciae latae	Triangular-shaped	O—Tuber coxae I—Lateral femoral fascia, patella	Tense lateral femoral fascia and thus flex hop joint and extend stifle

Cont...

Pelvic-Associated Muscles³

Obturator

External	Fan-shaped muscle covering obturator foramen externally	O—Ventral surface of pubis and ischium surrounding obturator foramen I—Trochanteric fossa of femur	Adducts thigh
Internal	Fan-shaped muscle covering covering obturator foramen inside pelvic cavity	O—Interior (floor) of pelvis surrounding obturator foramen I—Trochanteric fossa of femur	Rotates femur laterally
Gemelli	Fairly insignificant hip rotator	O—Ischium I—Trochanteric fossa of femur	Rotates femur laterally
Quadratus femoris	Small rectangular muscle that extends from ileum to femur	O—Ventral surface of the caudal ischial tuberosity I—Intertrochanteric crest, just distal to intertrochanteric fossa	Outward rotation of the hip; minor action in extending hip

Body Wall

Abdominal obliques	Four muscles forming ventrolateral abdominal wall		
External	Sheet-like muscle extending cranially and ventrally from ribs and thoracolumbar fascia	O—Last several ribs and thoracolumbar fascia I—Midventral	Support the abdominal wall; assist forced expiration/urination/defecation; twist trunk
Internal	Sheet-like muscle deep to the external abdominal oblique	O—Tuber coxae and thoracolumbar fascia I—Ventral midline at the linea alba	Support the abdominal wall; assist forced expiration/urination/defecation; twist trunk
Gracilis	Broad, superficial muscle extending from pelvic symphysis to medial thigh and inserting on the tibia	O—Symphyseal tendon (ventral pelvic symphysis) I—Medial surface of knee/leg	Adducts thigh

Cont...

<i>Muscle</i>	<i>Description</i>	<i>Origin (O)/Insertion (I)</i>	<i>Action</i>
Rectus abdominis	Tow long, straight muscles running from sternum to prepubic tendon	O—Sternum I—Prepubic tendon	Support/balance
Thigh Muscles⁴			
Hamstrings			
Biceps femoris	Largest and most lateral of caudal thigh muscles	O—Ischial tuberosity I—Lateral surface of knee/leg	Extends thigh, flexes leg
Semimembranosus	Arises with semitendinosus muscle from ischiatic tuberosity. Splits into two bellies.	O—Ischial tuberosity I—Posterior surface of femur and tibia	Extends hip, flex or extend knee (stifle)
Semitendinosus	The longest hamstring; forms caudal border of thigh.	O—Ischial tuberosity I—Tibia and calcanean tuberosity	Extends hip and tarsus, flexes knee (stifle)
Pectinius	Long, spindle-shaped muscle on medial thigh	O—Pubic tendon I—Femoral shaft	Adducts limb and flexes hip
Quadriceps femoris	Large muscle covering lateral, medial and cranial surfaces of femur		Main stifle (knee) joint extensor
Vastus lateralis		O—Cranial and inferior to greater trochanter of femur and along linea aspera I—Tibial tuberosity via patellar ligament	Extends knee (stifle)
Vastus intermedius		O—Cranialateral surface of femur and linea aspera of femur I—Tibial tuberosity via patellar ligament	Extends knee (stifle)
Vastus medialis		O—Entire length of linea aspera of femur I—Tibial tuberosity via patellar ligament	Extends knee (stifle)
Rectus femoris		O—Rectus femoris area of ilium I—Tibial tuberosity via patellar ligament	Extends knee (stifle); flexes hip
Sartorius	A strap-like muscle on medial thigh	O—Ilium I—Knee	Flexes hip joint and extends knee

Reading assignment!!!

The Muscles of the Pelvic Outlet

i. m. coccygeus

- ❖ *essentially a muscle of the tail.*
- ❖ Rhomboidal in outline,
- ❖ it arises from the ischial spine, crosses the sacrotuberous ligament medially, and
- ❖ inserts on and about the transverse processes of the first few tail vertebrae.

ii. levator ani

- ❖ *thinner and more extensive and*
- ❖ runs more obliquely in a dorsocaudal direction;
- ❖ only partly covered by the coccygeus.

Cont...

- The two muscles arise close together or by a common tendon in ungulates.
 - ❖ In the dog, the levator has a more widely spread origin
 - that continues from the iliac shaft over the cranial ramus of the pubis to follow the pelvic symphysis.
 - ❖ *The insertion is divided* between the:
 - fascia and vertebrae of the tail (extending distal to the insertion of the coccygeus) and
 - fascia about the anus and external anal sphincter.

Action:

- ❖ The coccygeus
 - flexes the tail laterally or,
 - when acting in concert with its fellow, draws the tail ventrally to cover the perineum, an attitude familiar in the nervous dog.

Cont...

- The action of the levator varies with species' differences.
 - In the goat it is active whenever the intraabdominal pressure is raised,
 - ✓ presumably to oppose the tendency to displace pelvic organs caudally.
 - Although it involves in other visceral functions, it has a very definite relationship to defecation;
 - ✓ it is active before the event (when it may fix the position of the anus against the contraction of the smooth muscle of the colon),
 - ✓ becomes inactive during the event, and regains activity following the event (when it may restore the parts to their resting positions).
 - The jerky movements of the dog's tail after defecation are probably evidence of levator activity in this species.

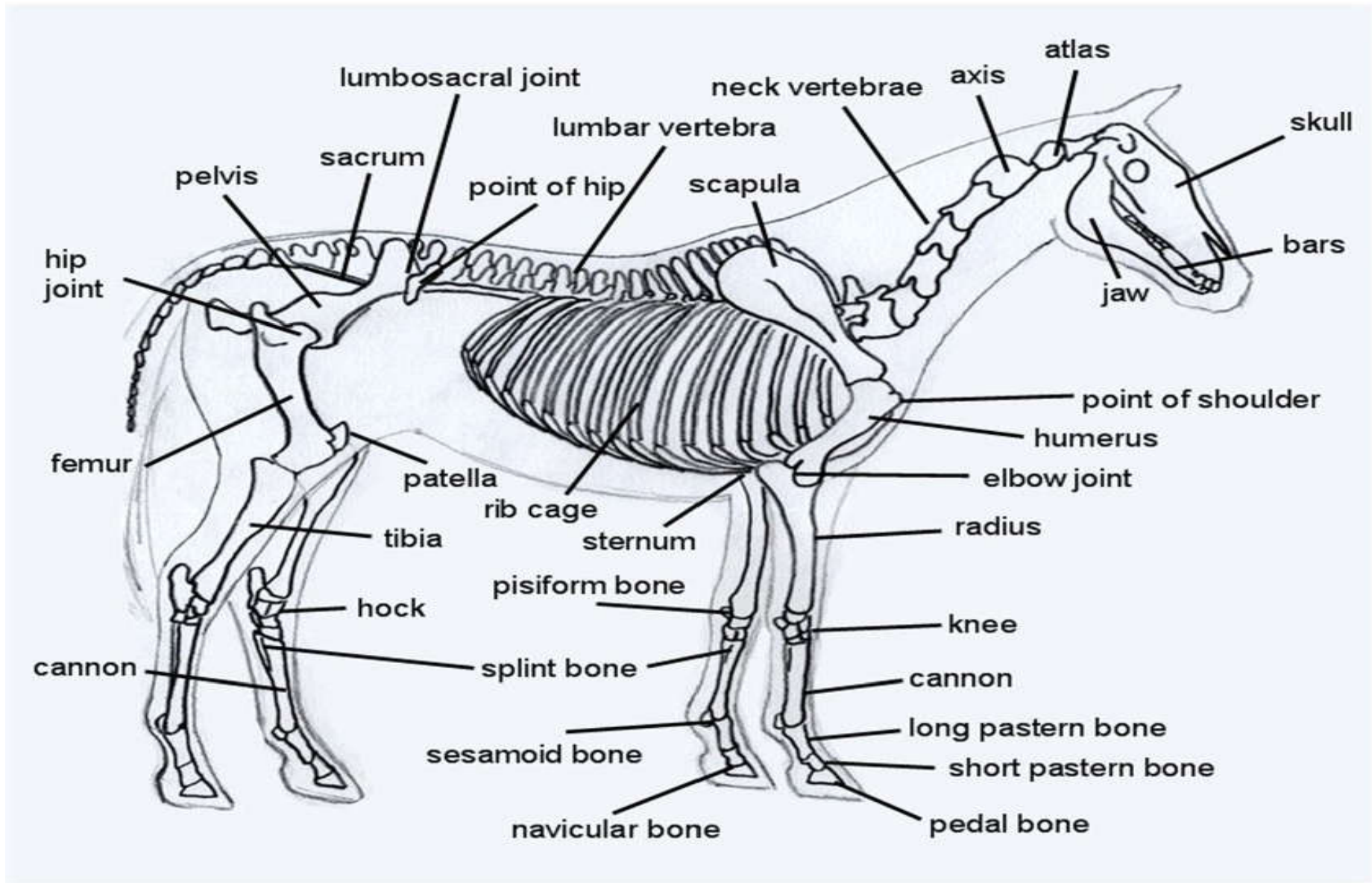
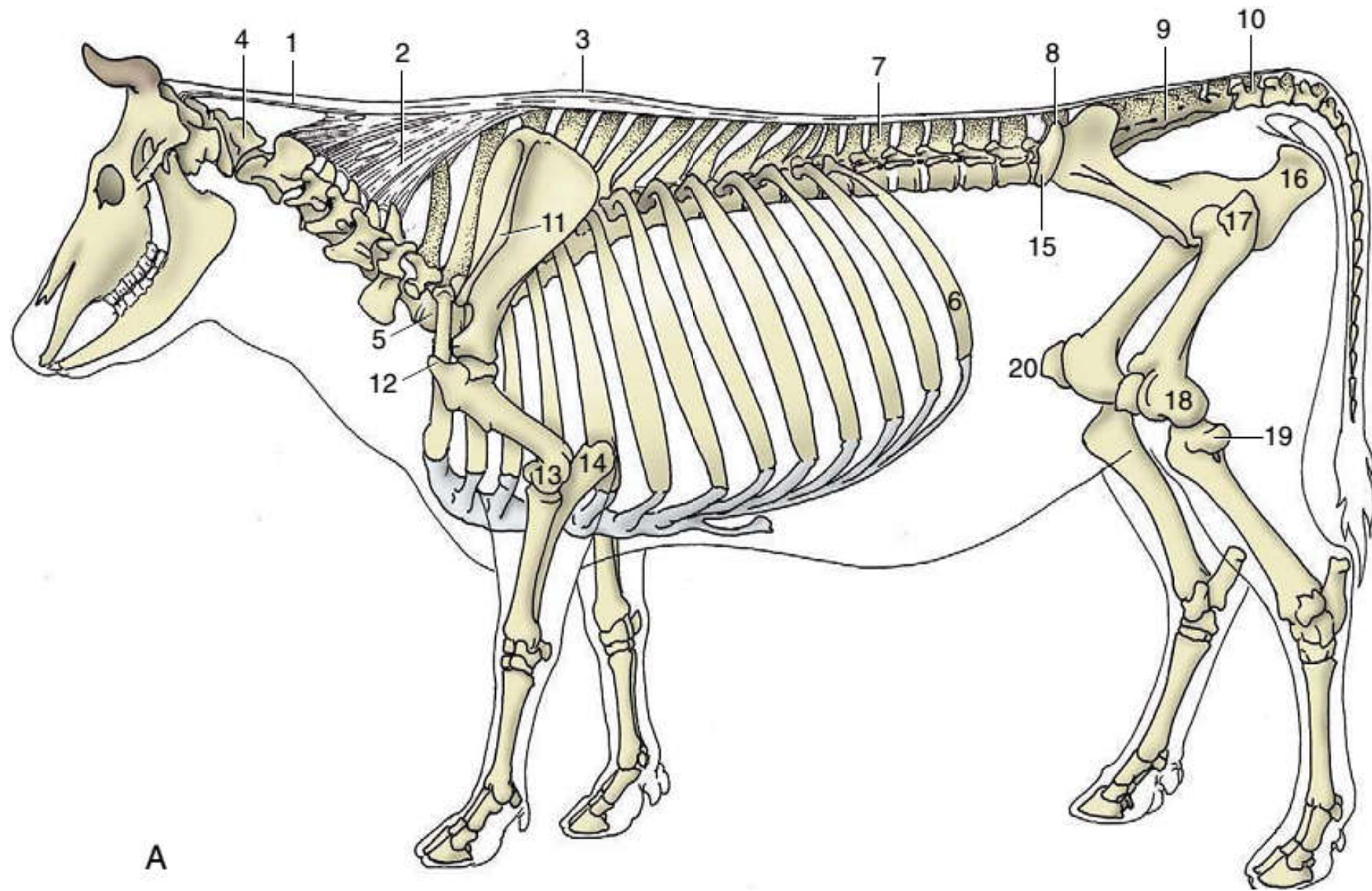


Fig: horse-skeleton-illustration.



A



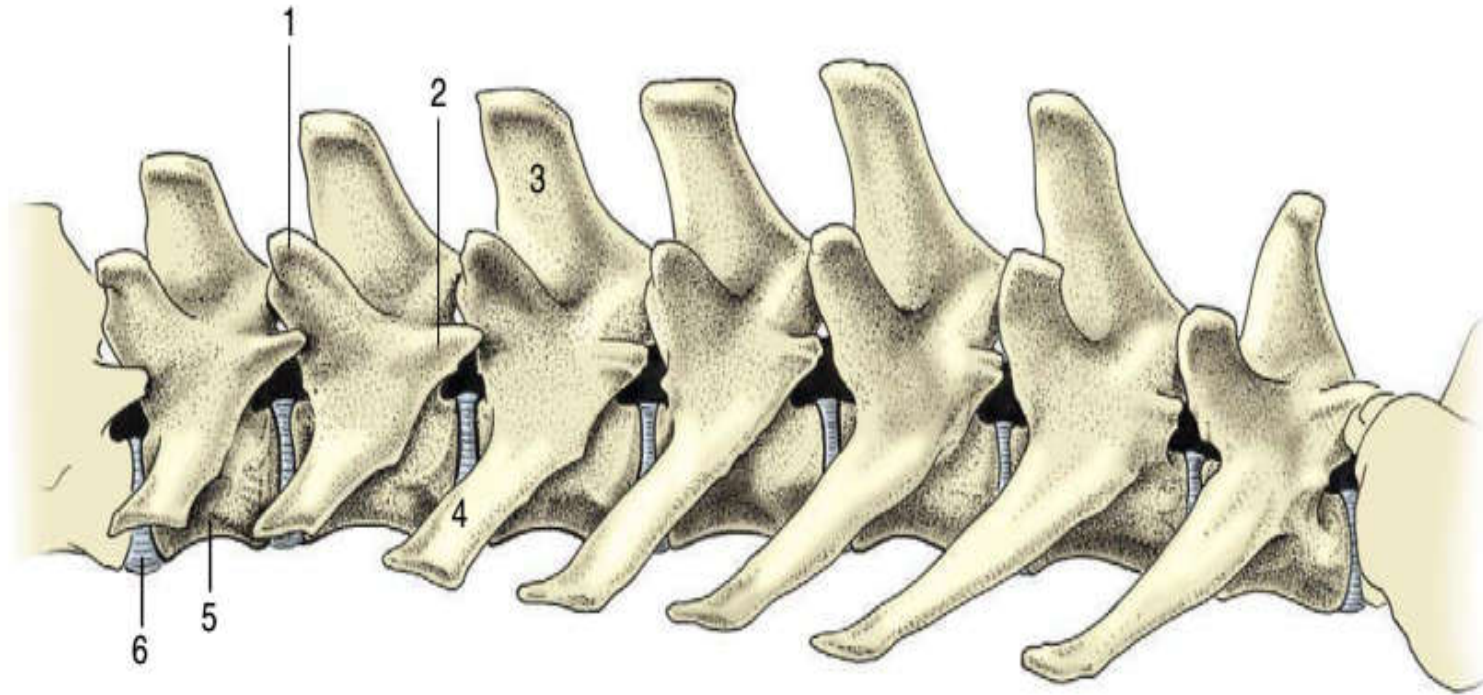
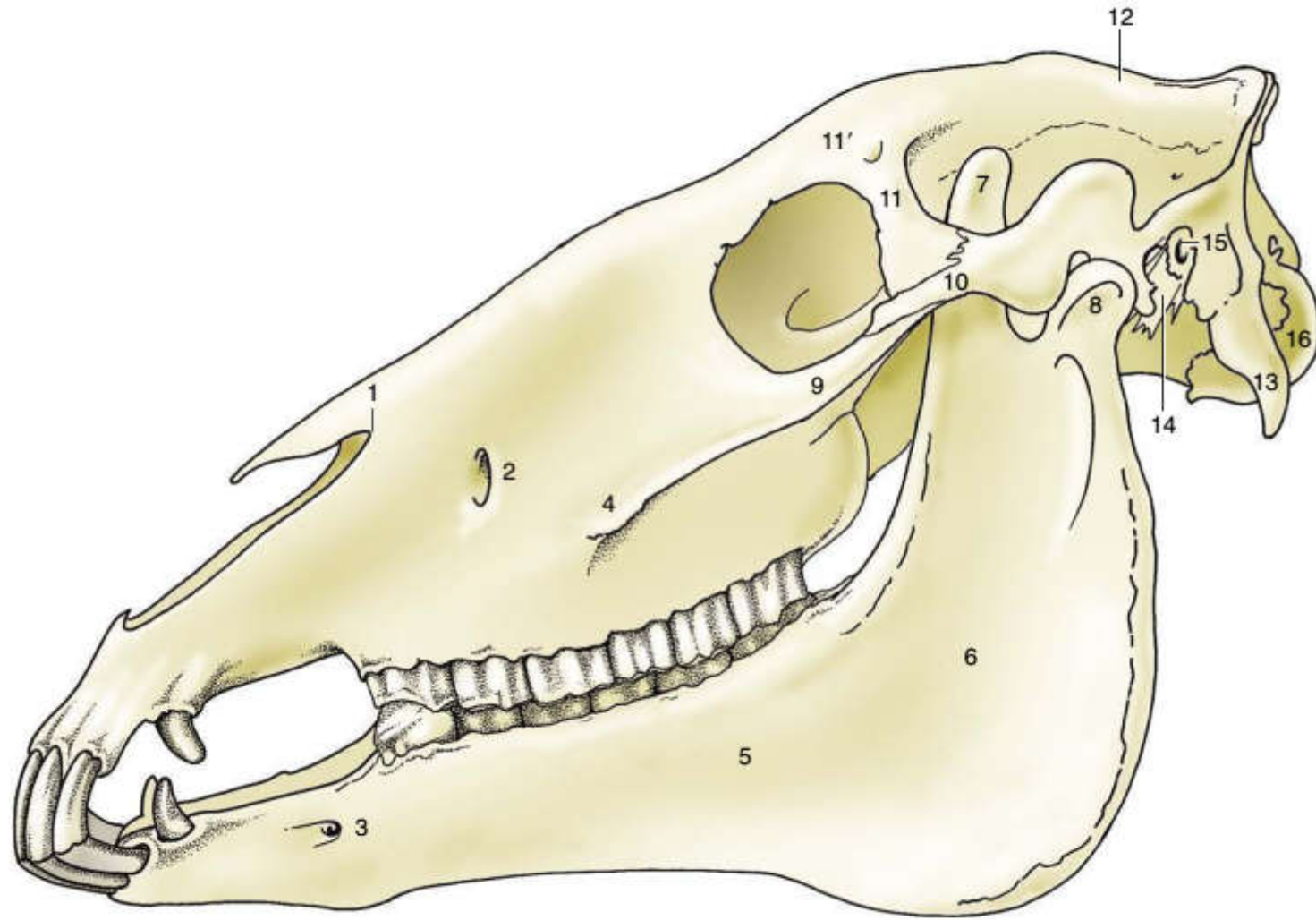
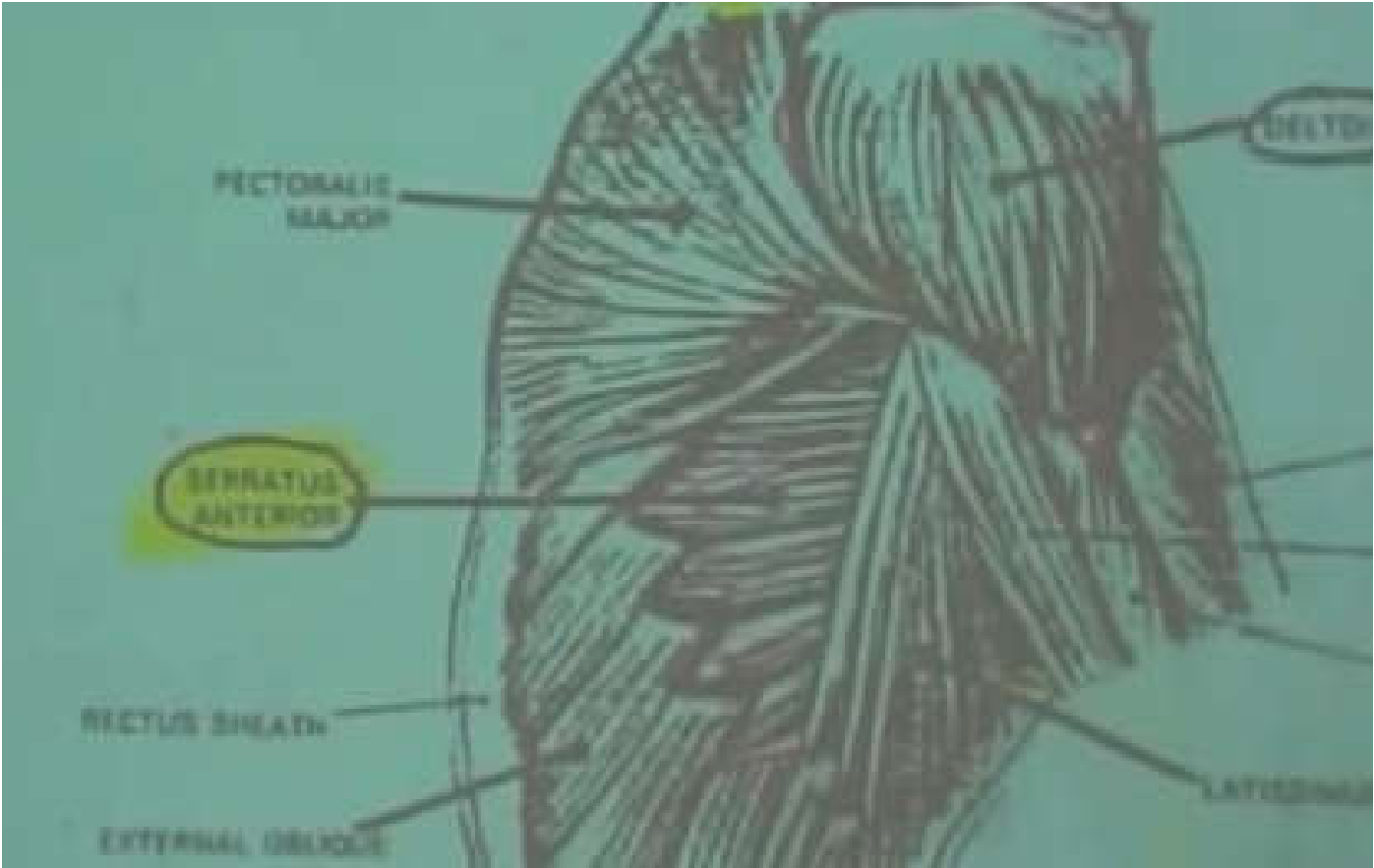


Figure 2-11 Lumbar vertebrae of the dog, left lateral view. 1, Mamillary process; 2, accessory process; 3, spinous process; 4, transverse process; 5, body; 6, intervertebral disk.

- ❖ **The mamillary processes** are short dorsal projections of the transverse processes that first appear at the third thoracic vertebra and, from the eleventh, migrate dorsally to surmount the cranial articular processes;
- ❖ The accessory processes arise from the caudal border of the pedicle and are present from the midthoracic to midlumbar regions; they are confined to the last three thoracic vertebrae in cats

Figure 18–6 Lateral view of the skull. 1, Nasoincisive notch; 2, infraorbital foramen; 3, mental foramen; 4, facial crest; 5, body of mandible; 6, ramus of mandible; 7, coronoid process; 8, condylar process; 9, temporal process of zygomatic bone; 10, zygomatic process of temporal bone; 11, zygomatic process of frontal bone; 11', supraorbital foramen; 12, external sagittal crest; 13, paracondylar process; 14, styloid process; 15, external acoustic meatus; 16, occipital condyle.





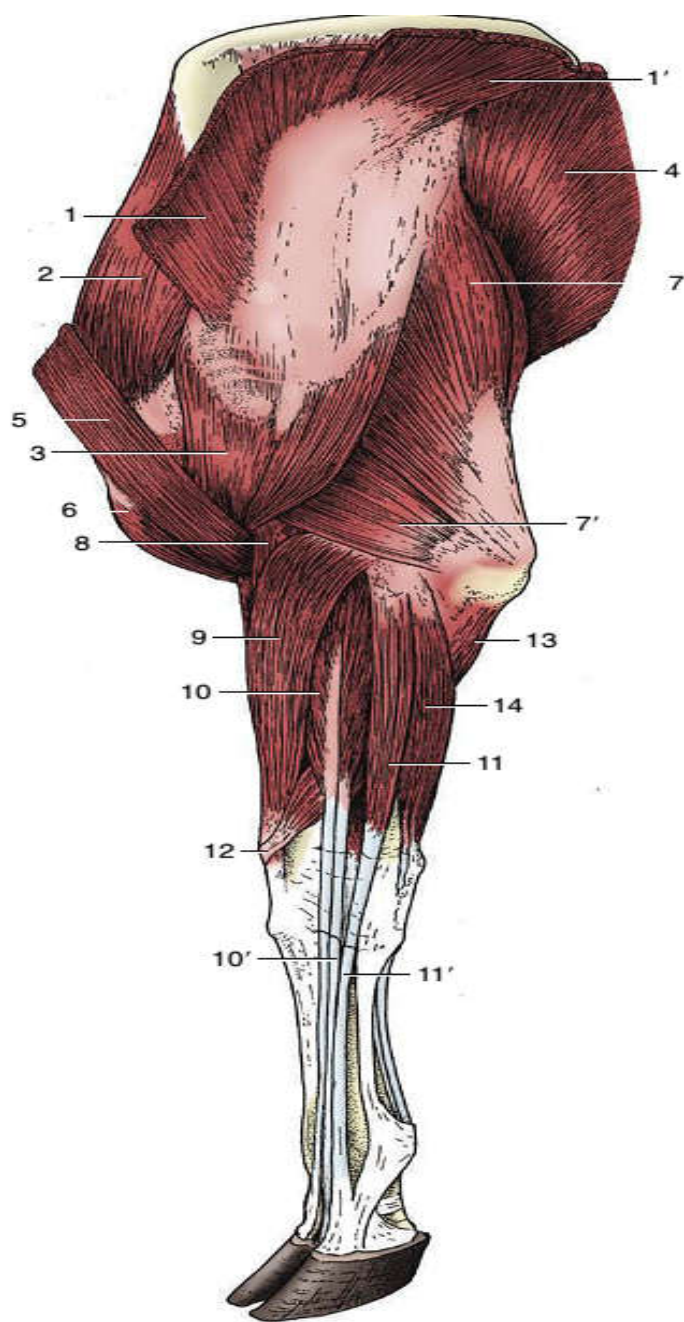


Fig: Muscles of the bovine forelimb, lateral view.

- 1, 1',Trapezius;
- 2,supraspinatus;
- 3,deltoideus;
- 4,latissimus dorsi;
- 5,brachiocephalicus;
- 6,biceps;
- 7, 7',long and lateral heads of triceps;
- 8,brachialis;
- 9,extensor carpi radialis;
- 10, common digital extensor; 10',tendon of lateral belly;
- 11, 11', lateral digital extensor and its tendon;
- 12, extensor carpi obliquus;
- 13, ulnar head of deep digital flexor;
- 14, ulnaris lateralis.

UNIVERSITY OF GONDAR

Faculty of Veterinary Medicine

Unit of Biomedical Science

*Lecture Note: On Chapter 5: Anatomy of Coelomic
Cavity*

To: Veterinary Medicine Year 1st Students

Compiled By:

Bemrew A. (DVM, MSC)

April, 2020

Gondar, Ethiopia

Coelomic Cavity and serous membrane

Objectives

- ❖ Students need to know the body cavities
- ❖ They need to know organs circumscribed in these cavities
- ❖ They have to understand the concepts of serous membrane

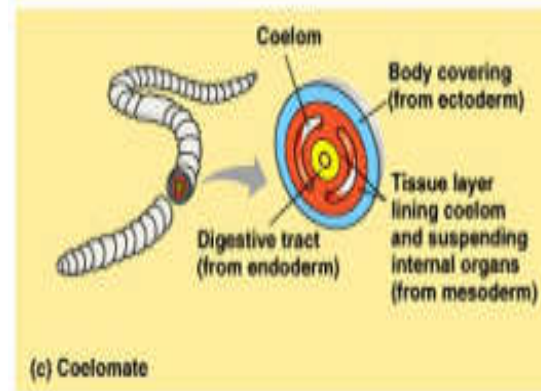
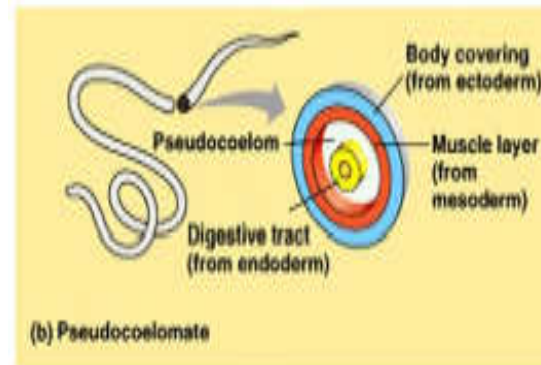
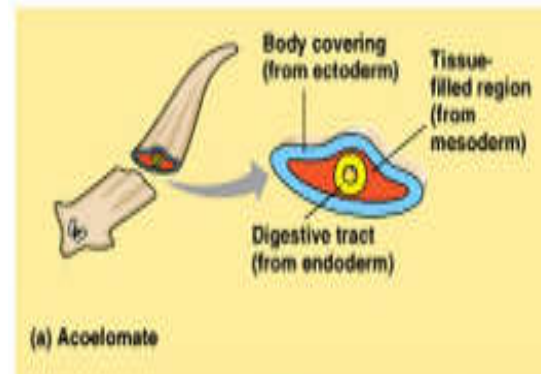
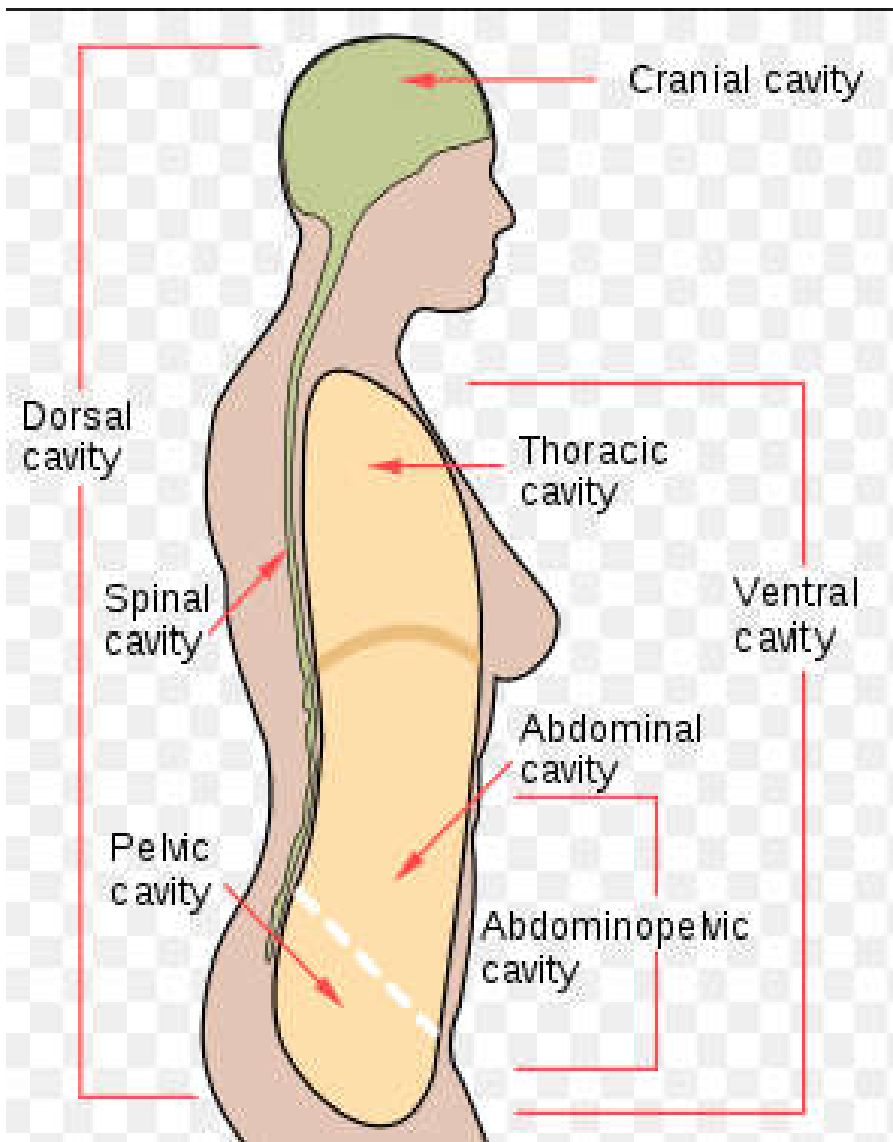
Coelomic (Body) Cavities & Serous Membranes

- ❖ Embryologically **coelomic cavities** are originated from the **mesoderm**.
- ❖ **Coelomic cavities** → refers to the cavities of the body which contain visceral organs.
- ❖ **Serous membranes** → are the membranes that line body cavities and suspend visceral organs.

Importance

The knowledge of these cavities and serous membranes is important during surgical procedures involving these areas including:

- _abdominocentesis
- thoracocentesis
- clinical examination of the thoracic and abdominal area.



Copyright © Pearson Education, Inc., publishing as Benjamin Cummings

- Coelom:
- Fluid-filled body cavity lined by cells from the mesoderm
- In mammals it forms the peritoneal, pleural and pericardial cavities

□ **Viscera (singular; viscus)** → refers to internal soft organs of the body with or without cavity.

❖ Those with cavity are the **hollow viscera** and

❖ Those with full of mass of tissues without having such a cavity, are the **parenchymatous viscera**.

□ **Layers of hollow organs:**

❖ **connective tissue-subserosal → outer**

❖ **Muscular layer → middle**

❖ **connective tissue (submucosa), and**

❖ **Mucous membrane → inner.**

Coelomic(body) Cavities

- ❑ the **trunk**: refers to the large part of the carcass that remains after the removal of the head and neck, the tail, and the limbs (simply; **body of the animal**).
- ❑ The trunk consists of three segments; i.e. thorax, abdomen, and pelvis → which are not clearly divided externally.
- ❑ Each segment of trunk is bounded by the body wall, and each contains a cavity:
 - 1.Thoracic cavity
 2. Abdominal cavity, and
 - 3.Pelvic cavity.

1. Thoracic Cavity

- ❖ Thoracic cavity lies cranial to the diaphragm,
- ❖ Contains the:
 - *pericardial sac*, which surrounds the heart,
 - *two pleural sacs*, which surround the two lungs, and
 - Mediastinum, **divides the thoracic cavity in to two chambers.**
- ❖ It has the shape of laterally flattened cone open at both ends;
 - the cranial -*thoracic inlet*
 - the caudal- *thoracic outlet*.
- ❖ It is the 2nd largest cavity.
- ❖ Its wall is lined by *endothoracic fascia*.

Cont...

- ❖ The **dorsal wall** is formed by:
 - Thoracic vertebrae and
 - ligaments and muscles
- ❖ The **lateral wall** is formed by:
 - Ribs and
 - intercostal muscles.
- ❖ The **ventral wall** is formed by:
 - Sternum and
 - cartilages of the sternal ribs and
 - the muscles in connection with these structures.
- ❖ The **caudal wall** is formed by:
 - Diaphragm;

2. Abdominal Cavity

- ❖ It is the largest cavity, and bordered.
- ❖ Cranially - with TC by diaphragm
- ❖ Caudally-continued **pelvic cavity**.
- ❖ The demarcation b/n the abdominal and pelvic cavities is known as **terminal line (brim of the pelvis)**. It is formed by
 1. The **base of the sacrum dorsally**
 2. The **arcuate line (ileopectinal line)** found on the wing of the ilium **laterally**
 3. The cranial border of the **pubis ventrally**.

Cont...

Borders forming the abdominal cavity:

- ❖ **Dorsal wall (roof)** → by the **lumbar vertebrae**, associated **muscles** and lumbar extension of the **diaphragm**.
- ❖ **Lateral side** → by **abdominal muscles** (both oblique and transversus), abdominal fascia, cranial part of the ilium and the iliac muscle, the cartilages of the sternal ribs.
- ❖ **Ventral side** → by the rectus abdominis muscle, the aponeurosis of the oblique and transversus muscles, abdominal fascia and the xiphoid cartilage.
- ❖ **Cranial side** → formed of the diaphragm.

❖ The wall of this cavity has a number of openings through which vessels and other tubular organs enter or leave.

➤ Three of them found in the diaphragm & include:

✓ **Aortic hiatus=aorta**

✓ **Oesophageal hiatus=oesophagus**

✓ **Foramen venae cavae= vena cavae**

❖ **Organs of the abdominal cavity include the stomach, liver, gallbladder, spleen, pancreas, small intestine, kidneys, some portion of large intestine, and adrenal glands.**

Cont...

- ❖ For accurate description of the organs in the abdomen, the abdominal cavity may be divided into three transverse segments.

- i. Cranial abdominal region,
- ii. Middle abdominal region,
- iii. Caudal abdominal region,

i. Cranial abdominal region:

- ❖ Extends from the diaphragm to a transverse plane at the most caudal point on the costal arc.
- ❖ dome shaped configuration of the diaphragm
 - the organs -cranial portion covered by the lungs and thoracic wall makes difficult to examine by external palpation.

ii. Middle abdominal region:

- ❖ Extends from caudal most point on the **costal arc** to the most cranial point on the **tuber coxae**.
- ❖ This region consists of:
 - **The flank** (part of the lateral wall; the soft tissues or muscles with out bone)
 - **The umbilical region**; on the ventral mid line.
 - In the **dorsal part** of the flank is the **paralumbar fossa**:
 - ✓ which is a triangular depressed area on both sides of the animal; bounded by:
 - a. The tips of the lumbar transverse processes **dorsally**.
 - b. The part of the internal abdominal oblique muscle passing from the tuber coxae to the last rib **ventrally** and
 - c. The last rib **cranially**.

Cont...

iii. Caudal abdominal region

- ❖ Begins from the caudal most point on the tuber coxae and extends to the pelvic inlet.
- ❖ This region consists of:
 - a **median pubic region** (the area in front of the pubic bones) and
 - the **inguinal region** (which extends laterally to the fold of the flank and thigh).

Cont...

3. The Pelvic Cavity

- ❖ It communicates cranially with the abdominal cavity.
- ❖ Enclosed by the caudal part of the trunk known as **pelvis**.
- ❖ Boundaries forming the pelvic cavity:
 - **Dorsal wall:** by the sacrum and the first three or four caudal vertebrae.
 - **Lateral wall:** by the ilium caudal to the arcuate line.
 - **Ventral wall:** by the pubis and ischium.

Cont...

- ❖ The entrance to the pelvic cavity (**pelvic inlet**), is an osseous oval ring known as **linea terminalis** which consists of:
 - The base of the sacrum **dorsally**,
 - The body of the ilium **laterally** and
 - The pecten of the pubis **ventrally**.
- ❖ The **pelvic outlet** is formed:
 - **Dorsally** by the **3rd/4th caudal vertebrae**,
 - **Laterally** by the **sacrotuberal part of the sacrospinous ligament** and
 - **Ventrally** by the **ischial arc**.

Cont...

- ❖ The pelvic outlet is greater than the pelvic inlet, Except in carnivores, and
 - by the time of parturition, it is the outlet which slightly enlarges; but the inlet, as it is osseous.
- ❖ The pelvic cavity is covered by the **pelvic fascia** and some part (cranial part) of it by the **peritoneum**.
- ❖ Organs located with in the pelvic cavity include:
 - Rectum and anal canal;
 - Urinary bladder;
 - Pelvic urethra and accessory genital glands and
 - The caudal part of the female genital tract.
- ❖ The **retroperitoneal** part of the pelvic cavity, which is essentially the body wall that closes the pelvic outlet, is known as the **perineum**.

Cont...

- ❖ Its principal component is the **pelvic diaphragm** consisting of:
 - the **levator ani** and **coccygeal muscles**, and
 - layer of internal and external fascia on each side of these muscles.

NB: The pelvic diaphragm:

- in **man**, with erect posture, carries the viscera and prevents prolapse of the anus, or the vagina and uterus.
- **But in quadrupeds**, the pelvic organs are supported principally by the **bony floor of the pelvis**, and hence the pelvic diaphragm is not as well developed as in man.
 - ✓ functions to contain pelvic viscera during abdominal press, i.e., during defecation, urination, copulation, parturition, labored breathing, and in draft animals when pulling heavy loads.
 - ✓ If it functions inadequately during such stresses, prolapse of rectum or of the vagina and uterus may occur.

Serous Membranes

- ❖ Are thin, moist and transparent membranes covering walls of the body cavities and visceral organs.
 - Line the body cavities and suspend organs.
 - serous membrane lining the wall of body cavity is designated as **parietal**;
 - while serous membrane covering the viscera is called **visceral**.
 - **connecting (intermediate)** serous membranes that may run b/n parietal and visceral components are named depending on the organ to which they are attached.
Examples;
 - ✓ Mesentery → for intestine;
 - ✓ Meso-ovarium → for ovary.

Cont...

Serous cavities:

- ✓ Are potential spaces between parietal and visceral serous membranes containing lubricating serous fluids (i.e. Pleural fluid, Pericardial fluid and Peritoneal fluid) for each cavity.
- ❖ Include: peritoneal, pleural and pericardial cavities.
- ❖ Fluid avoids:
 - Friction b/n organs (e.g., Lung and heart) and
 - b/n the organs and the wall.
- ❖ The visceral and intermediate serous membranes form pathway for the blood vessels, lymphatic vessels, and nerves:
 - for vascularization and innervations of organs.

Cont...

- ❖ Depending on specific location, serous membranes can be divided into three; i.e: **Pleura, Pericardium, Peritoneum.**

1. Pleurae

- ❖ Are two continuous serous membranes (*parietal* and *visceral*) that cover thoracic wall and lungs.
- ❖ Each forms a pleural sac.

i. Parietal Pleura

- ❖ lines each half of the thoracic cavity.

Cont...

ii. Mediastinal Pleura

- ❖ Connecting pleura on each side enclosing on the mediastinum.
- ❖ **Mediastinum:**
- ❖ is a longitudinal septum which divides the thoracic cavity in to two chambers (pleural cavities).
- ❖ Contains thoracic organs other than the lungs; such as: the heart, esophagus, trachea, blood vessels, lymph nodes and ducts, thymus, nerves and adipose tissue.

Cont...

iii. Visceral Pleura:

- ❖ The immediate serous membrane covering lungs/covers each lung;
- ❖ also called **pulmonary pleura**.

Pleural cavity:

- ❖ the cavity between the parietal and visceral pleura.
- ❖ Contains pleural fluid.
- ❖ It is divided in to two chambers; separated by the mediastinum forming the left and right pleural sacs,
 - the right is larger than the left.

Cont...

2. Pericardium

- ❖ It is the heart sac or serous membrane which almost completely covers the heart (doesn't cover the whole part).
- ❖ has got two layers:
 - **Visceral Pericardium/Epicardium**: the visceral layer that covers the heart.
 - ✓ covers the heart and reflects around the base of the heart and great vessels to become continuous with the parietal pericardium.
 - **Parietal Pericardium**.
- ❖ The space between the visceral and the parietal pericardium is called **pericardial cavity**; and
- ❖ The serous fluid filling the pericardial cavity is called **pericardial fluid**.

Cont...

3. Peritoneum

- ❖ a thin serous membrane which forms the **peritoneal cavity** with in the abdominal and pelvic cavities;
 - more or less covering the viscera found with in these two cavities.
- ❖ (**paries = wall, in Latin**).
- ❖ Consists three continuous parts; viz: **parietal, connecting and visceral peritoneums**.

i. Parietal peritoneum

- ❖ Lines the abdominal cavity and cranial part of the pelvic cavity.

ii. Connecting peritoneum

- ❖ Reflects from the parietal peritoneum and suspends organs in a double fold containing vessels and nerves as it extends into an organ.

Cont...

❖ It is indicated by:

- Mes- (Greek 'mesos' which means 'middle') and
- The Latin or Greek name of the organ.

Example: mesentery = mes- + Greek word 'enteron' → small intestine.

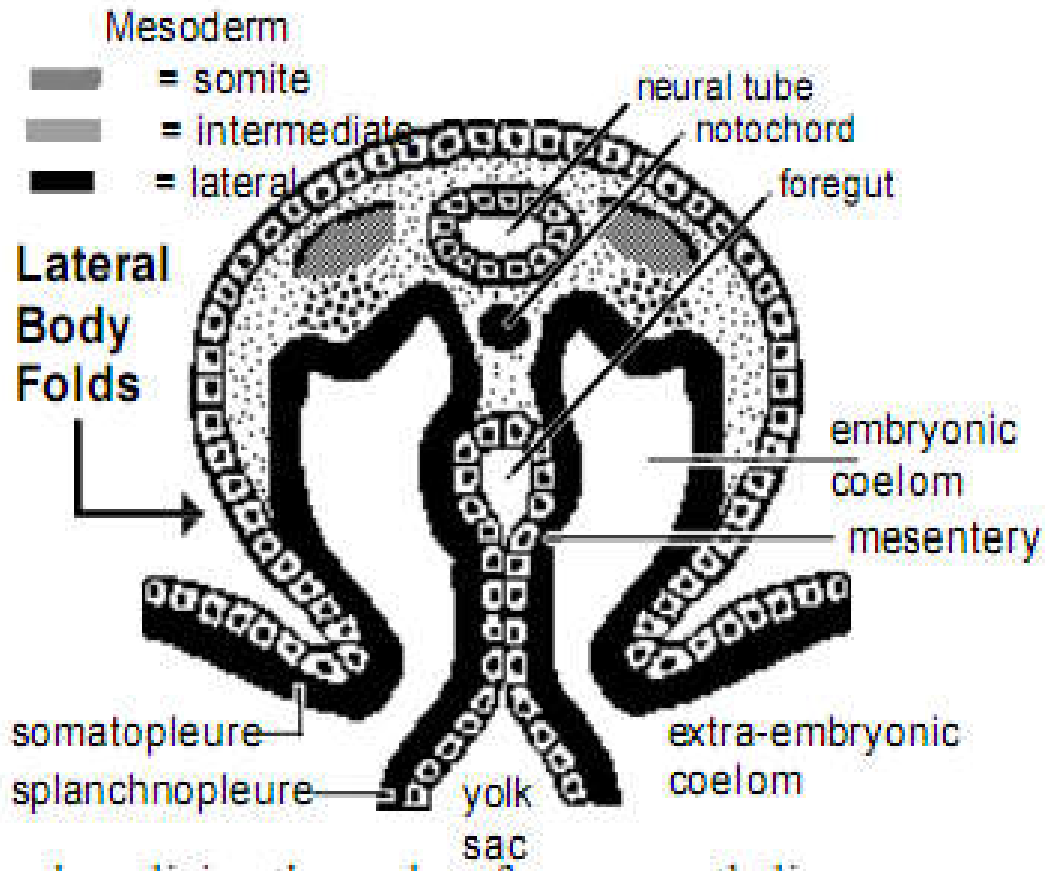
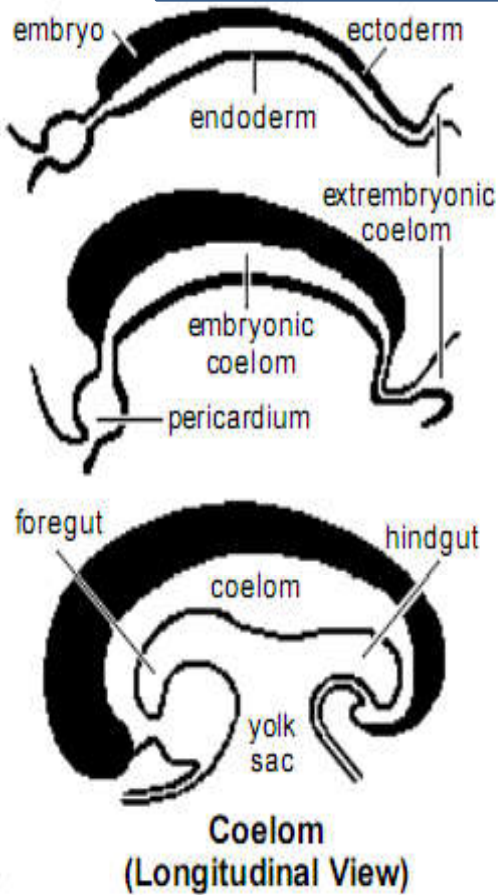
❖ Connects the visceral and parietal peritoneum; example:

- **Omentum:** attaches the stomach with the parietal layer.
- **Mesentery:** attaches the intestine with the parietal layer.
- **Mesocolon:** attaches the colon with the parietal layer.
- **Mesorectum:** attaches the rectum.
- **Mesoovarium:** broad ligament w/c suspends the ovary,
- **Mesosalpinx:** broad ligament enveloping the uterine tube
- **Mesometrium:** support the horn and the body of the uterus.

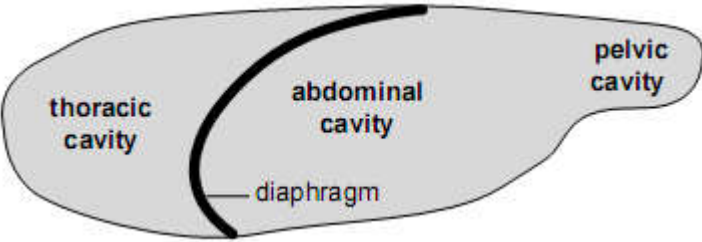
iii. Visceral peritoneum:

❖ It is continuous with connecting peritoneum, encircling a viscus (large internal organ).

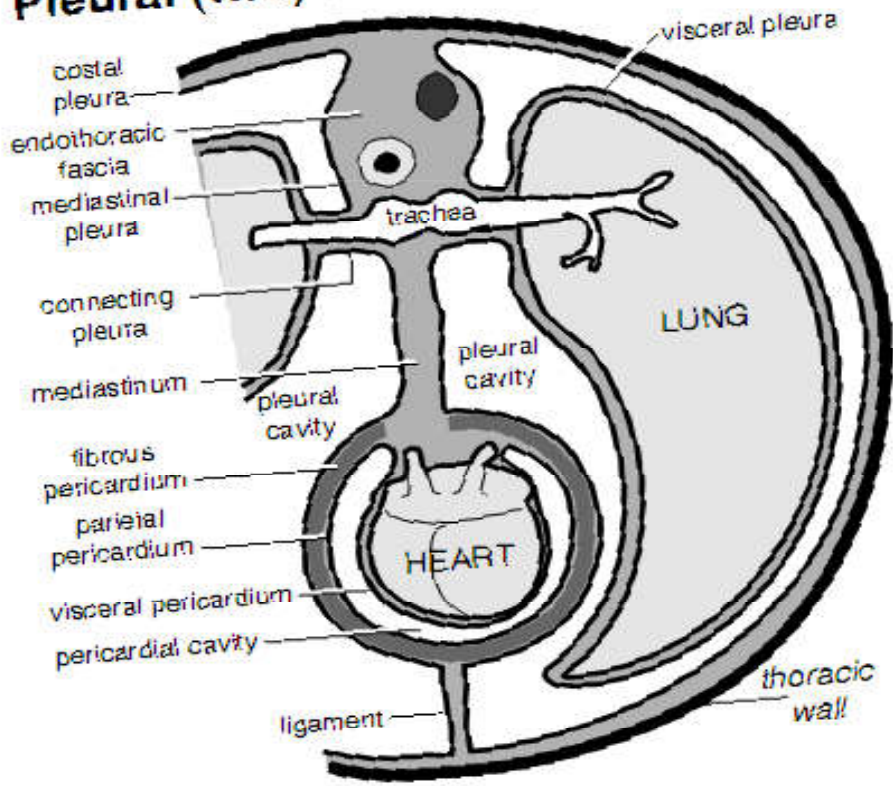
Coelom development



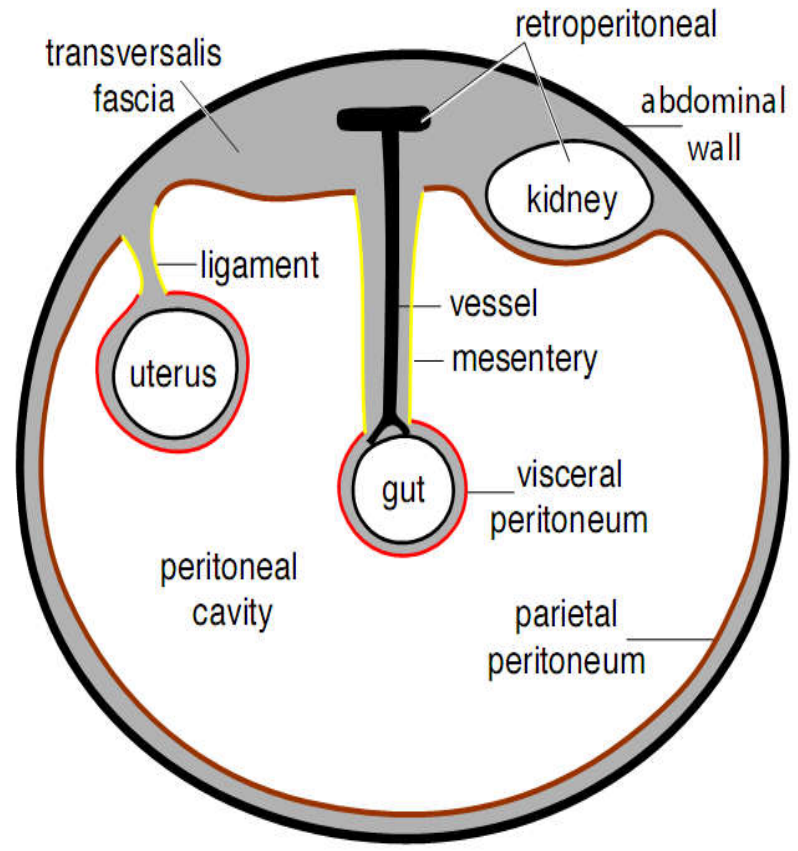
Serous Cavities



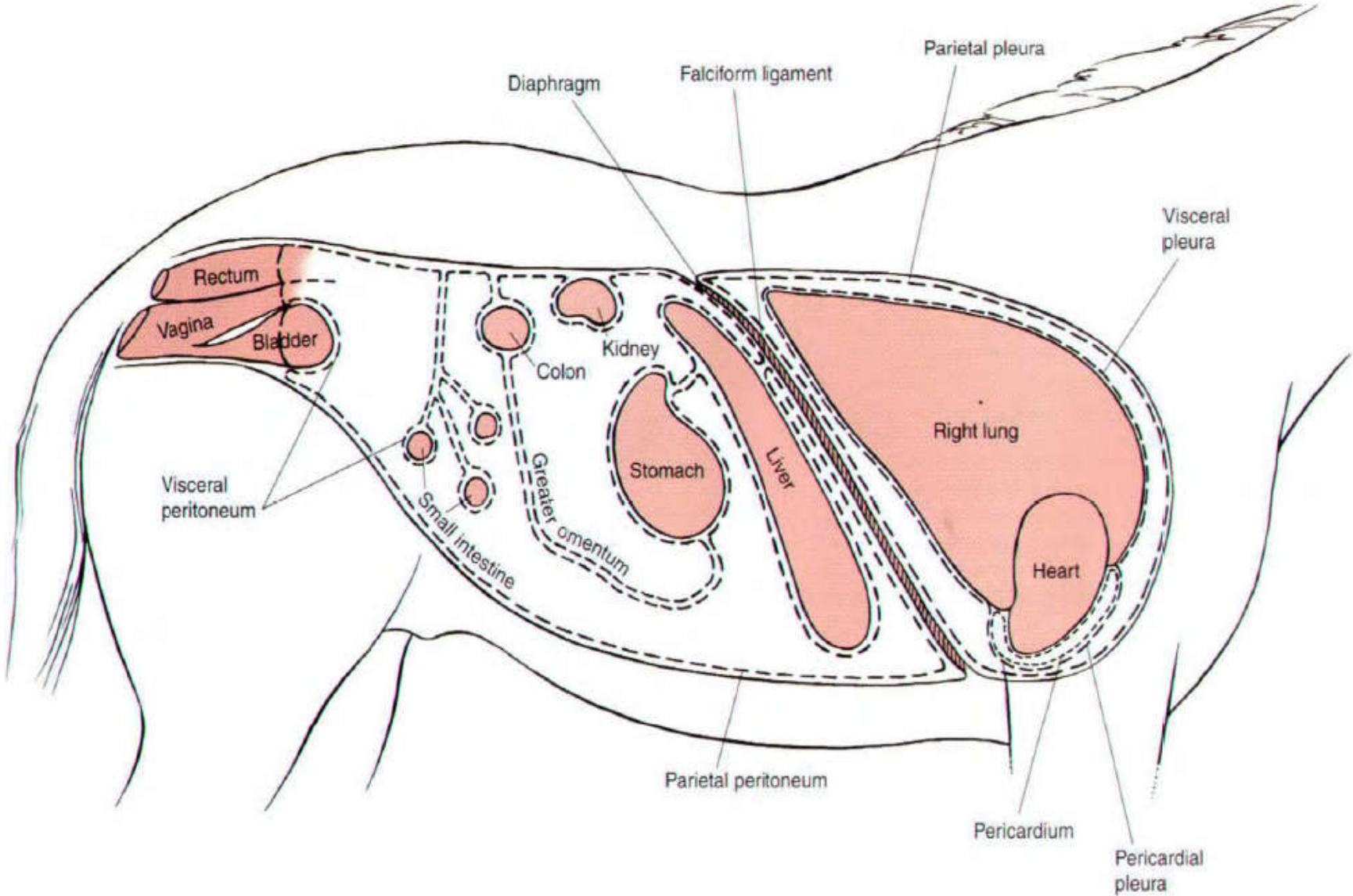
Pleural (two) & Pericardial Cavities



Peritoneal Cavity



Cont...



Cont...

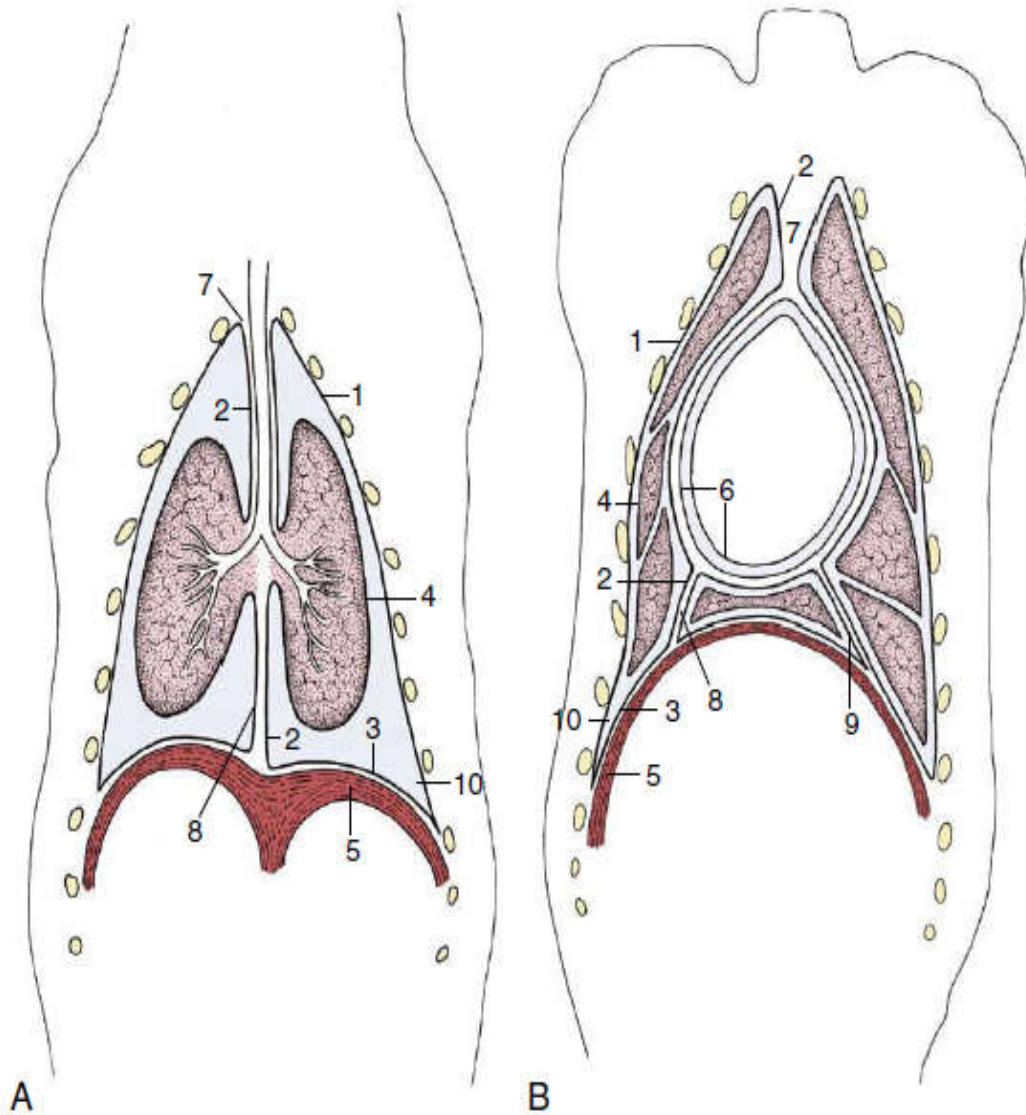


Figure: Schematic dorsal sections of the pleural cavities (dog); at the level of the tracheal bifurcation (A) and at the level of the heart (B).

1–3, Parietal pleura, later subdivided; 1, costal pleura; 2, mediastinal pleura; 3, diaphragmatic pleura;

4, visceral pleura;

5, diaphragm;

6, parietal and visceral pericardium;

7, cranial mediastinum;

8, caudal mediastinum;

9, plica venae cavae;

10, costodiaphragmatic recess.

Retroperitoneal vs Peritoneal Organs

- A useful for **mnemonic** to remember which organs are retroperitoneal is:
- SAD PUCKER

Reminder

- **S:** suprarenal (adrenal) gland
- **A:** aorta
- **D:** duodenum (second and third part)
- **P:** pancreas (except tail)
- **U:** ureters
- **C:** colon (ascending and descending)
- **K:** kidneys
- **E:** (o)esophagus
- **R:** rectum

UNIVERSITY OF GONDAR

Faculty of Veterinary Medicine

Unit of Biomedical Science

Lecture Note: On Chapter 6. ANATOMY OF THE DIGESTIVE SYSTEM

To: Veterinary Medicine Year 1st Students

Compiled By:

Bemrew A.(DVM, MSC)

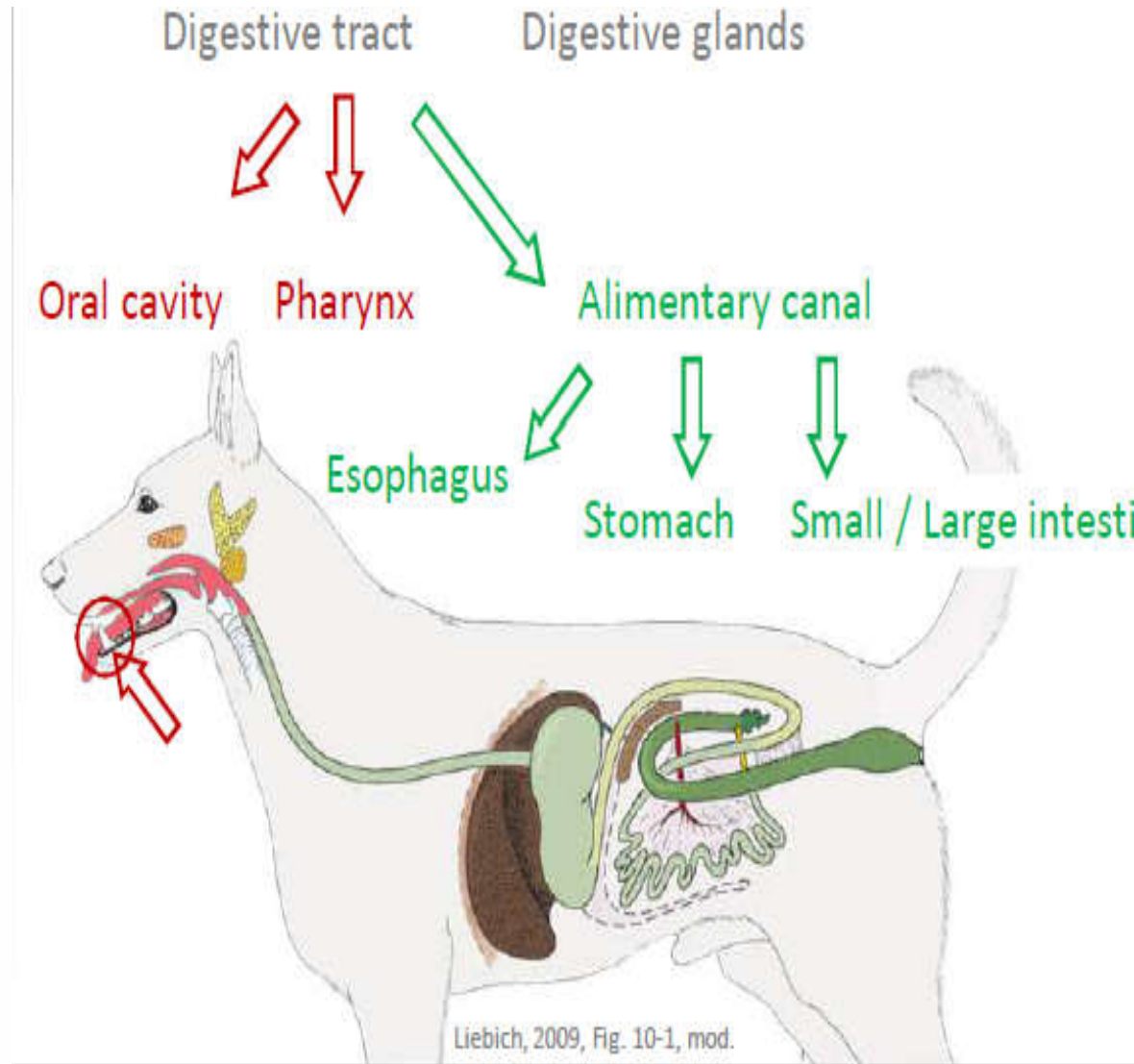
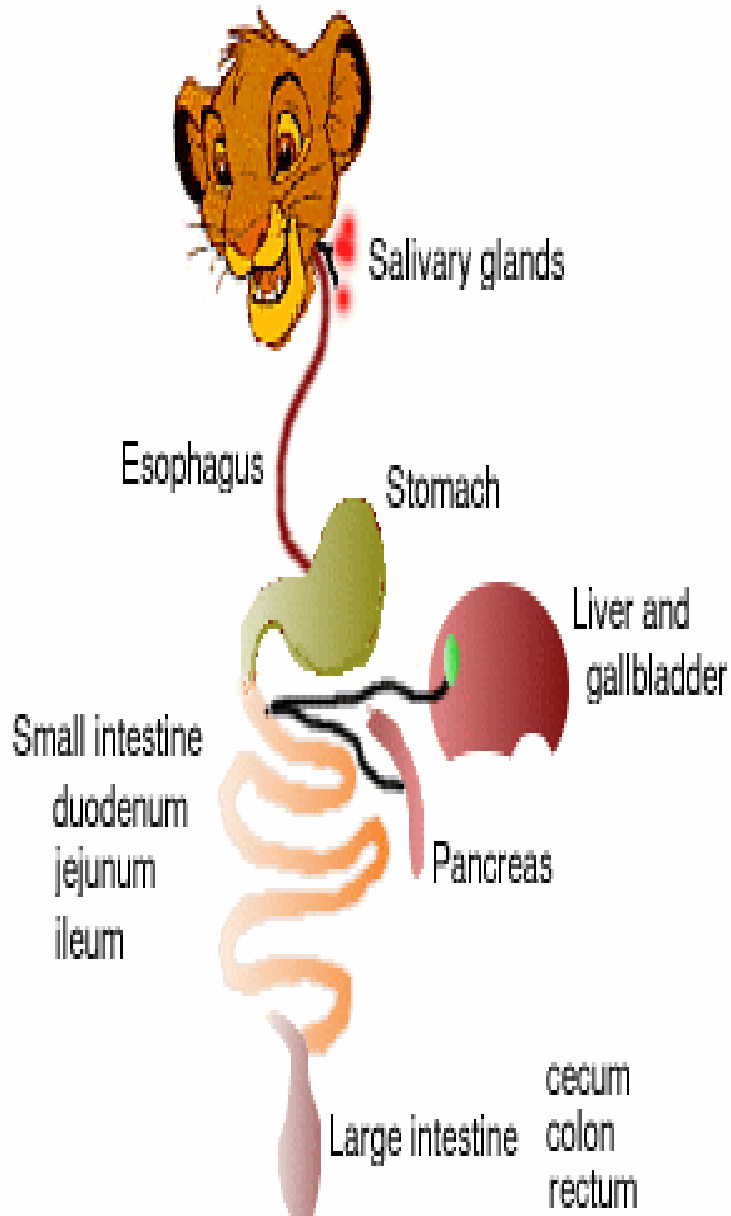
March, 2020

Gondar, Ethiopia

Objective of the session

- Students need to understand basic Anatomy of the digestive system(DST)
- They need to explain different segment of the DST
- They should clearly know the species variation of the tract
- They need to know the accessory digestive organs

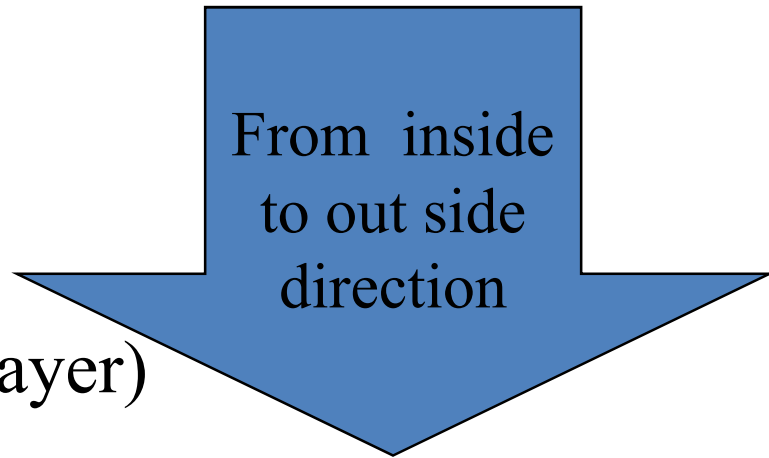
6. ANATOMY OF THE DIGESTIVE SYSTEM



6.1. INTRODUCTION

- The **digestive system** consists of:
 - *Alimentary tract* that extends from **mouth** to **anus** (mouth, oesophagus, stomach, small and large intestine).
 - *Accessory glands* → *closely related with digestion function* (**Salivary gland, Liver and Pancreas**).
- The primary functions of digestive system includes:
 - **Prehension** → the act of bringing the food to the mouth.
 - **Mastication (chewing)** → Mechanical breakdown of food.
 - **Digestion** → the process of reduction of feed particles to molecules that can be absorbed into the blood.
 - **Absorption of food** and
 - **Elimination of solid waste (defecation).**

- Embryologically:
 - Mouth → is derived from **ectoderm**.
 - Remaining digestive organs are primarily originated from the **endoderm**.
 - Muscles and connective tissues that support the epithelium are from **mesoderm**.
- The wall of alimentary tract is formed by four layers :
 - » Mucosal layer
 - » Sub mucosal layer
 - » Muscular layer
 - » Serous layer(fibrous layer)



6.2. Mouth, tongue and teeth

A. The mouth (Oris, Os)

- ✓ The term mouth (*oris, os*) includes:
 - The **cavity** (i.e., oral cavity (buccal cavity)) and its wall.
 - Accessory structures that project from the wall (like teeth and tongue)
 - Structure that drain to it (salivary glands).
- ✓ The mouth plays a roll in **prehension, mastication, insalivations of food and aggression or defense.**
- ✓ The entrance of mouth is defined by the **lips (labia oris)**.
 - The mobility of the lips varies with the species.
 - » **Horse, camel and shoats** lips are soft and mobile.
 - » **Bovine** lips are less mobile.

- ✓ The mouth is bounded by:
 - **Cheeks** laterally,
 - **Soft palate and hard palate** dorsally,
 - **Body of the mandible** ventrally.
- ✓ The oral cavity is sub-divided by the teeth and margins of the jaw in to two cavities.
 - a. **Vestibule**
 - b. **Mouth cavity proper**

A. Vestibule → is the cavity external to the teeth and **alveolar process** (the bony portion of the maxilla and mandible where the teeth are embedded) → Bounded by:

- ✓ Lips and cheeks externally and
- ✓ Gums and teeth internally

B. Mouth cavity proper → is the cavity within the dental arches.

- ✓ Roofed by palates (soft and hard palates).
- ✓ Floored by the tongue.
- ✓ Bounded laterally by teeth, gum and margins of the jaw.

□ Lips (labia oris)

- ✓ Are two musculo-membraneous folds which surround the orifices of the mouth and contains glands .
- ✓ Each the upper and lower lips presents surfaces:
 - External surfaces → skin covered with fine tactile hairs.
 - Intermediate surfaces → muscles, tendons and glands.
 - Internal surface → mucous membrane
- ✓ The skin of the lip and its mucosa meet at the margins of the lips (**muco-cutaneous junction**).
- ✓ The upper and the lower lips meet at the angle of the mouth:
 - Left commissure
 - Right commissure

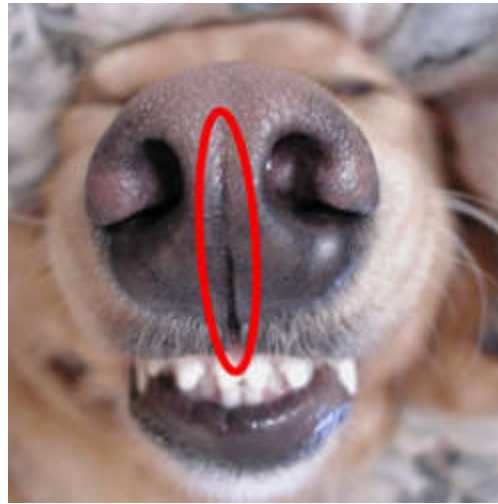


- ✓ In bovine, there is moist and glandular area in the upper lip called:
 - **Naso-labial plate (muzzle)** which does have clinical importance in diagnosing febrile condition of the animal.
- ✓ **In bovine the upper lip is hairless but in equines it is covered by hairy integument.**
- ✓ The upper lips of **carnivores, small ruminants and camels** is divided by a median cleft (groove) called **philtrum**.

MUZZLE



- The upper lip of the carnivores and the small ruminants is divided by the median cleft, philtrum.
- In pig and horse the philtrum may be indistinct or absent.



- In camels, both lips are extremely mobile and on the upper lip there is a well developed philtrum. The lower lip presents a round prominence called the chin (mentum).

Cheeks (buccae)

✓ The structures are:

- **Skin**
- **Muscular layer**
- **Glandular layer and**
- **Mucous membrane.**

✓ Forms the side of the mouth and continuous rostrally with lips.

Gums(gingivae)

✓ Composed of dense regular connective tissue which is intimately united with the periosteum of alveolar process.

✓ It constitutes glands and covered by smooth mucous membrane with a low degree of sensitivity.

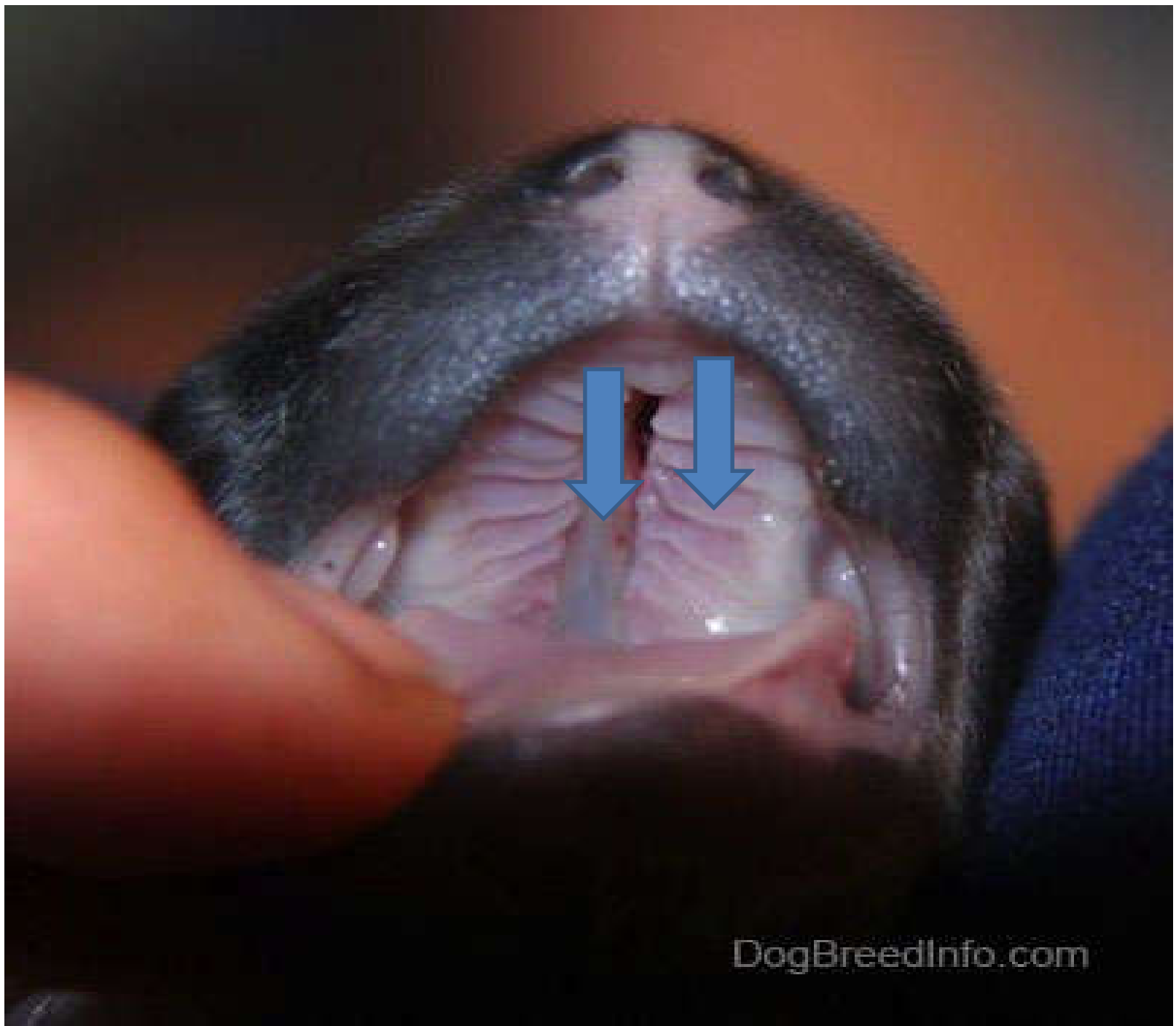☐ Hard palate

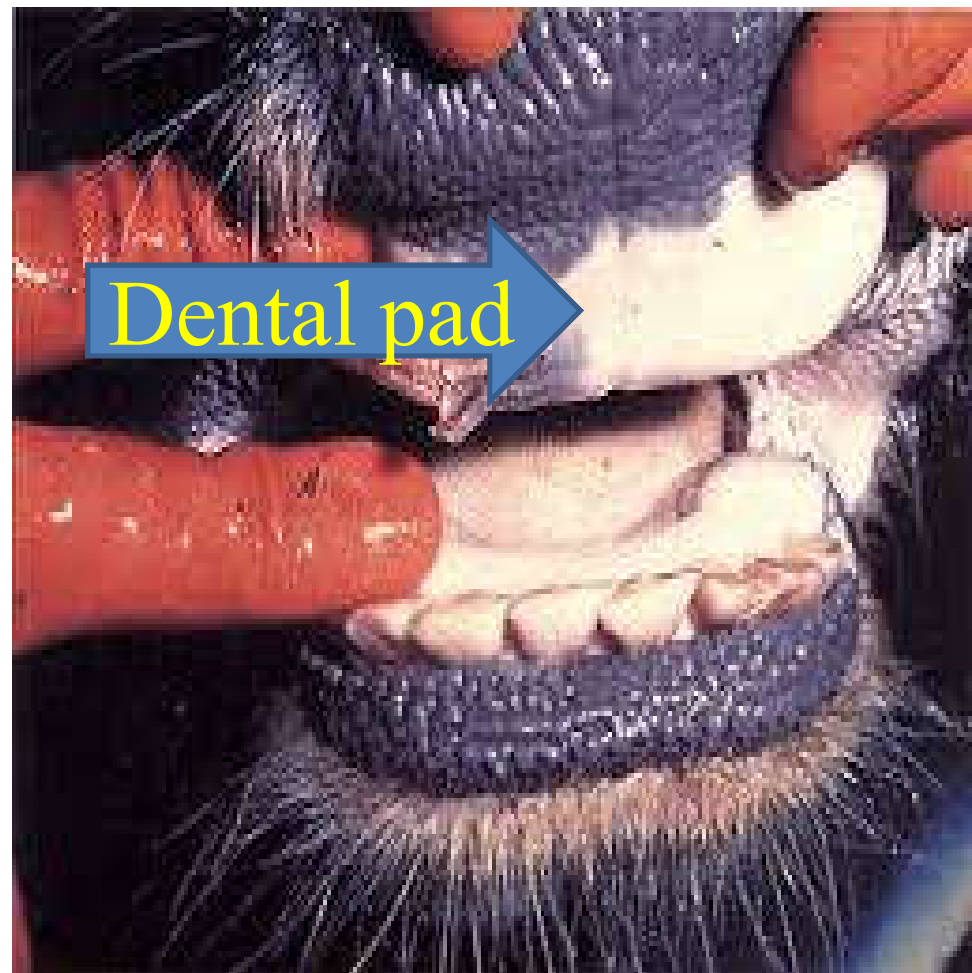
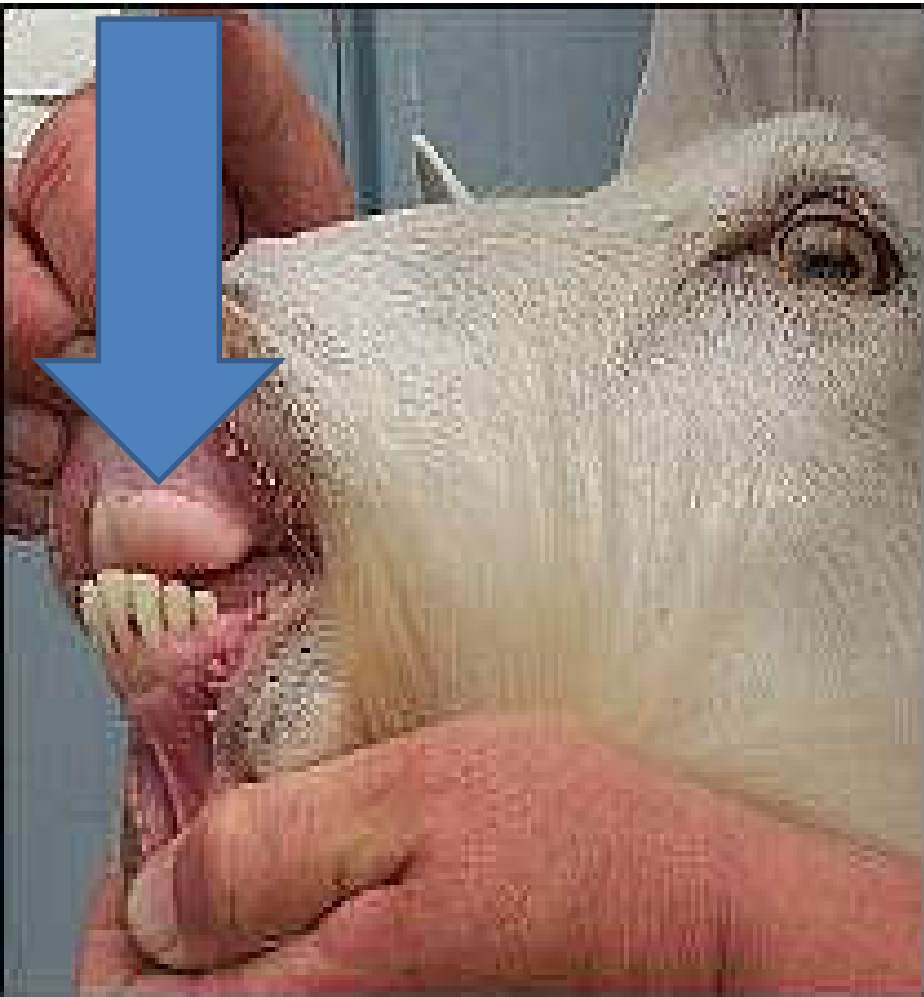- ✓ Is the dorsal wall of the oral cavity.
- ✓ Is continuous with soft palate caudally with out any external demarcation.
- ✓ The mucosa of the hard palate represents a longitudinal fold called *palatine raphae (central raphae)* which divided the surface in to two portion.
- ✓ It has a series of transverse folds called *palatine rugae*.
- ✓ The bony shelf of the hard palate is formed from:
 - **Incisive bone**
 - **Maxillary bone and**
 - **Palatine bone**

- ✓ **In ruminants**, the position generally occupied by the **upper incisor teeth** in equines, is replaced by thick layer of connective tissue called **dental pad**.
- ✓ Small prominence caudal to the incisor teeth or dental pad (in ruminants) is referred to as **incisive papillae**.
- ✓ Mucosal projections on the mucous membrane of the cheek especially towards the lip is called **buccal papillae**.

☐ **Soft palate**

- ✓ Is a musculo-mucosal sheet that extends toward the base of the **epiglottis** separating the mouth cavity from the **pharynx** except during **swallowing**.





- ✓ It is a caudal continuation of hard palate and slopes ventral and caudal from its junction.
- ✓ In equine, soft palate is well developed in length and makes contact with epiglottis that may prevent:
 - **Mouth breathing and**
 - **Introduction of stomach tube through the mouth.**
- ✓ During **vomiting** the ejected matter will escape usually through the nasal cavity since it will be prevented by this long curtain like soft palate from going to the oral cavity.
- ✓ **So, vomiting is fatal for horse and intubation is possible only using the nostril.**

❖ The **equine soft palate is exceptionally long** and the horse is uniquely unable to lift the soft palate so as to permit passage of air from oral cavity to the larynx **hence mouth breathing is not common.**

□ For this reason, horses are obligate **nose**
breathers.

B. Tongue

- ✓ Composed of a mass of muscle covered by mucous membrane.
- ✓ It consists of intrinsic and extrinsic skeletal muscles.
- ✓ The intrinsic muscles are arranged in bundles running longitudinally, vertically and transversely forming the bulk of the tongue (permitting the tongue a wide range of movements) and blend with extrinsic muscles that attached the tongue with the surrounding tissues.
- ✓ It has **three** parts:
 - *Root (radix linguae)*
 - *Body (corpus linguae)*
 - *Apex*

- *The root (radix linguae)* → Located caudally, attached and supported by the *hyoid bones, soft palate* and *pharynx*.
- *The body (corpus linguae)* → middle and meaty part attached to the mandible and supported by paired myohyoideus muscles.
- *The apex:* → free and rostral part which is spatula in shape.
- ✓ The **dorsal surface** of the tongue
 - is characterized by large number of projections called **papillae**.
 - » **Filiform papillae**
 - » **Fungiform papillae**
 - » **Vallate (Circumvalate) papillae**
 - » **Foliate papillae**

1. Filiform papillae

- Are thread(hair) like projections scattered on the dorsal & lateral side of the body and tip of tongue.
- They are soft and short in horse than other domestic animals giving the tongue of horse its **velvety** feeling.
- In cattle, they are sharp and cornified which makes the tongue **rough**.
- They **do not bear taste buds**.

2. Fungiform papillae

- So called because they resemble to a tiny mushroom.
- Found usually on lateral and dorsal surface of the tongue **among** filiform papillae.

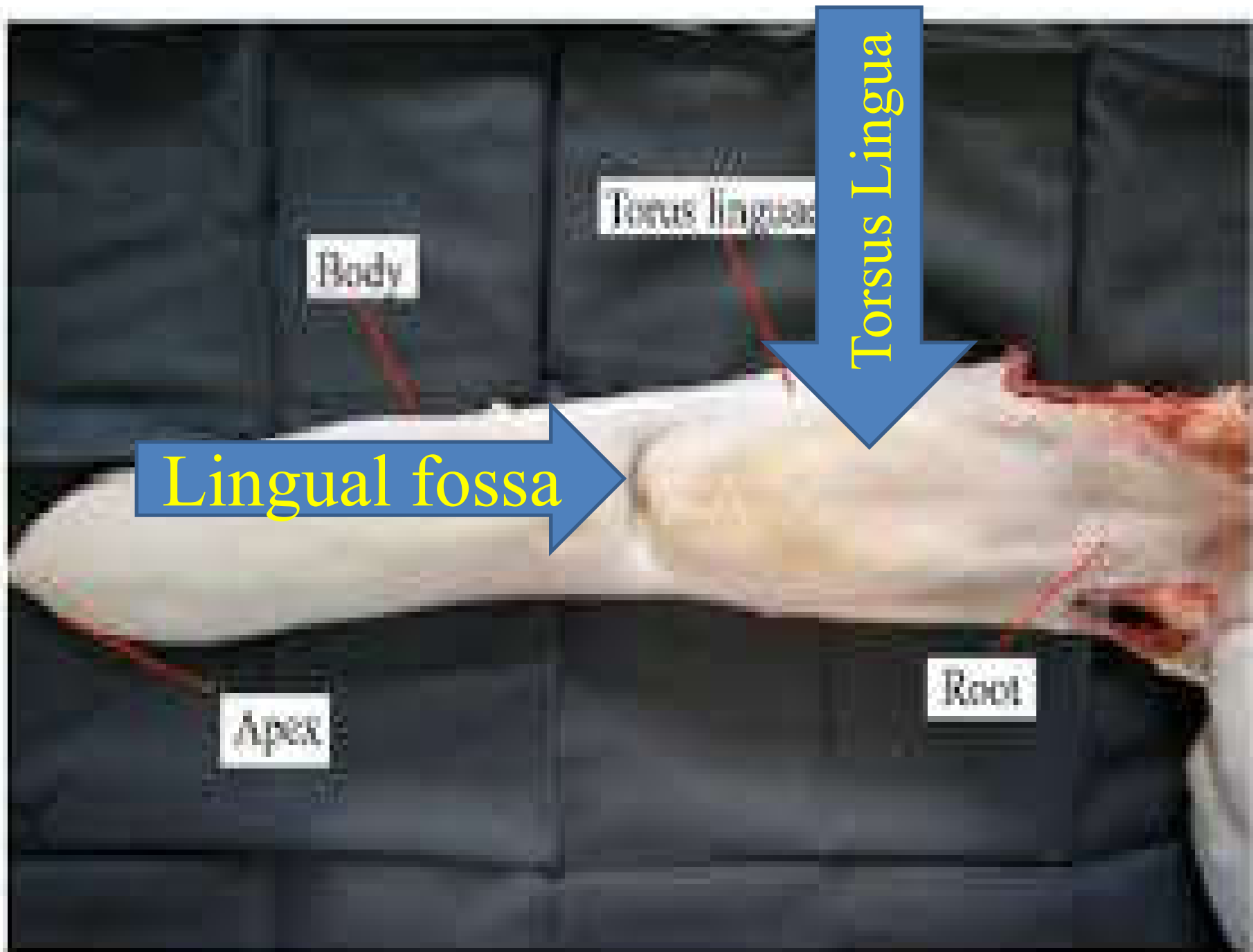
3. Vallate (Circumvalate) papillae

- Are larger circular projections surrounded by a deep groove.
- They contains **serous** glands in all domestic animals and **mucous** gland in horse.
- These papillae are arranged in a V shape on the caudal part of the tongue and demarcate the morphologic division between the body and the root of the tongue.

4. Foliate papillae

- Resemble leaves of the plant.
- Located on the lateral margin adjacent to where the **root** of the tongue is connected to the soft palate by a mucous membrane fold, the *palatoglossal arch*.

- ❖ Filiform, fungiform and vallate(circumvalate) papillae are found in **all domestic animals**.
- ❖ **Foliate papillae** are found in equines, carnivores and pigs **but not in ruminants**.
- ❖ Fungiform, foliate and vallate(circumvallate) papillae have taste buds but filiform papillae have **no taste buds**. (Receptors for the sense of taste are taste buds).



Body

Torus Lingualis

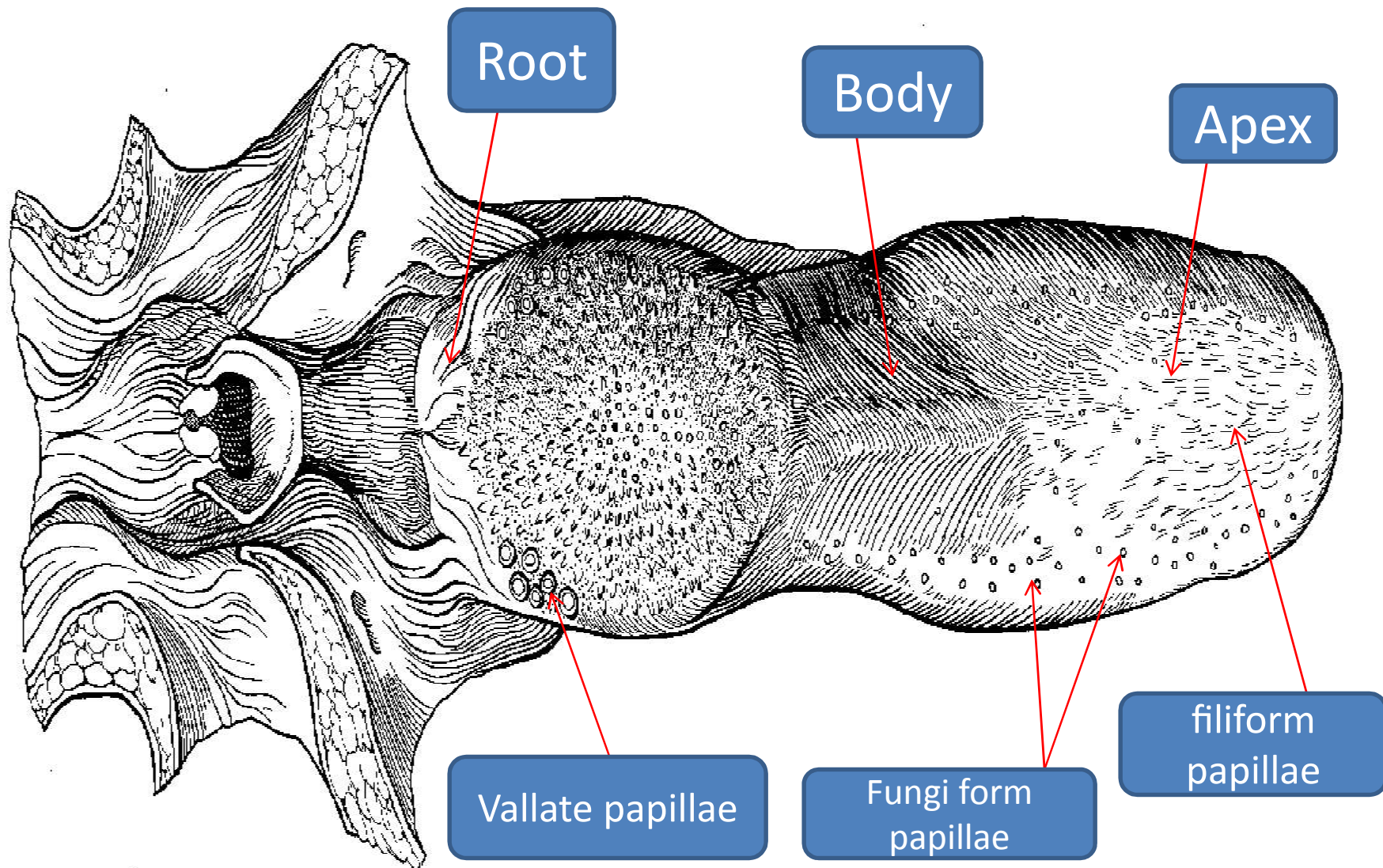
Torsus Lingua

Lingual fossa

Apex

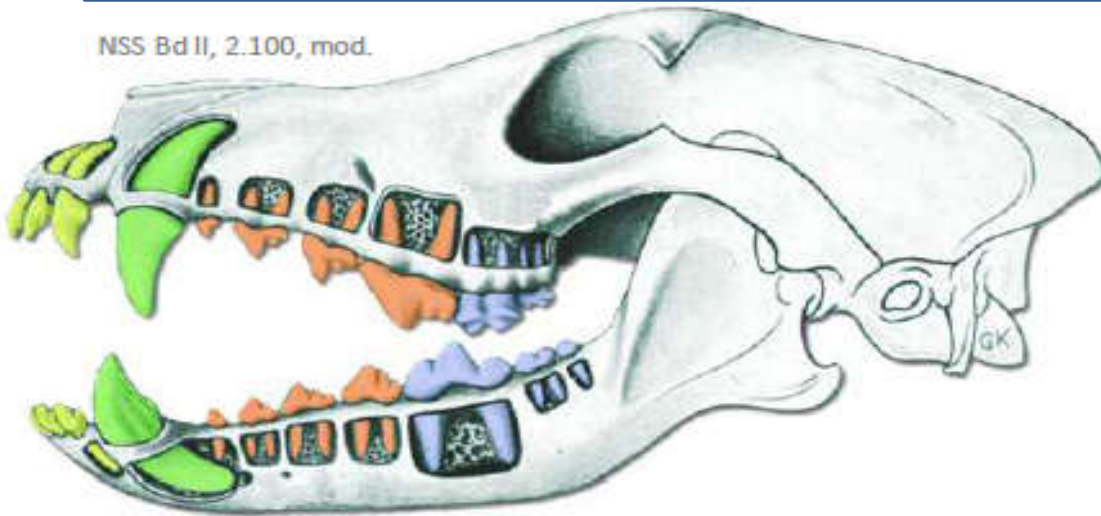
Root

Tongue of ox, dorsal view



C. Teeth

NSS Bd II, 2.100, mod.



Incisors

Canine teeth

Premolars

Molars

Dentes incisivi

Dens caninus

Dentes premolares

Dentes molares

Incisivi

Caninus

Prämolaren

Molaren

I1 – I2 – I3

C

P1 – P2 – P3 – P4

M1 – M2 – M3

Crown

„Corona dentis“



Enamel

Pulp

Neck

„Cervix“ dentis

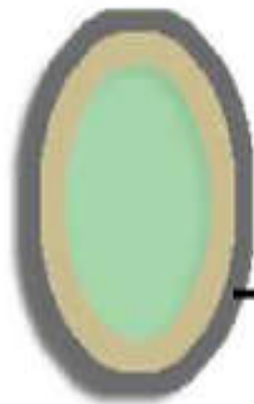


Dentin

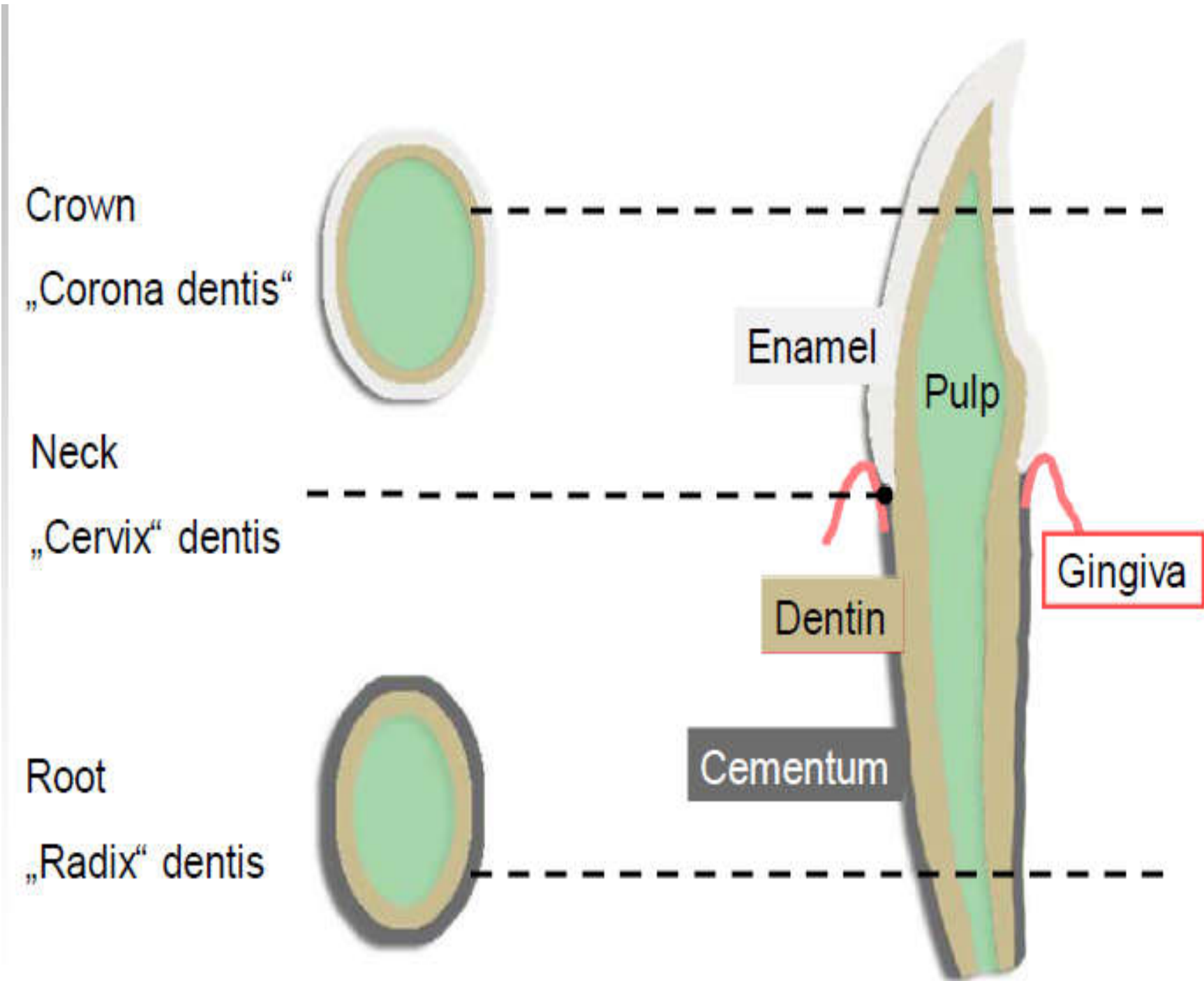
Gingiva

Root

„Radix“ dentis



Cementum



Teeth are part of the *skeletal system* structurally and *digestive system* functionally.

- ✓ Teeth are arranged in two *dental arcades*:
 - the teeth of the *upper jaw* form *the upper dental arch* (associated with the incisor and maxillary bones).
 - The teeth of *lower jaw* form *the lower dental arch* (associated with the *mandible*).
- ✓ Farm animals typically have a gap in each arch between the front teeth (incisors) and the cheek teeth.
 - » such a physiological gap is called *diastema* (*important for animal handling*).

✓ The type and anatomy of the teeth can be classified according to **permanency, manner of growth and function.**

A. According to the permanency → mammalian teeth are classified in to two as:

✓ Temporary teeth (milk teeth, baby teeth deciduous, draft teeth) or

✓ Permanent teeth (adult teeth)

❖ Animals whose teeth are replaced once during their life is called **diphyodont** (most domestic animals).

❖ Those animals that can replace their teeth more than one time are called **polyphyodont**.

1. Deciduous teeth

- ✓ Are present at birth.
- ✓ Can persist from a few weeks to several years depending on the species (in bovine it may stay up to 2 years).
- ✓ They fall out and replaced with *permanent teeth*.
- ✓ They are **weaker** in strength and **fewer** in number than permanent teeth.

2. Permanent teeth

- ✓ Persist throughout the life of the individual.

B. According to the manner of growth, mammalian teeth can be: -

- » **True teeth**
- » **Constantly growing teeth**
- » **Constantly erupting teeth**

➤ **True teeth**

- Posses crown, neck and root.
- Found in carnivorous, omnivorous and incisor teeth of ruminants.
- Grow to adult size and then wear away without further growth.

➤ Constantly growing teeth

- These teeth continue to grow throughout the life of an animal.
- They don't possess a definite root or neck.
- They are considered to be rootless teeth, simply growing active persistent **pulp**.
 - » E.g. **Canine** tooth of pigs and **Incisor** teeth of rodents.

➤ Constantly erupting teeth

- Possess extremely long **root** and with no definite neck.
 - E.g. equine teeth, cheek teeth (premolar and molar teeth) of other species.

C. According to the function, the teeth of domestic animals fall in to the following groups:

» Cutting teeth (incisors)

» Tearing or seizing teeth (canines)

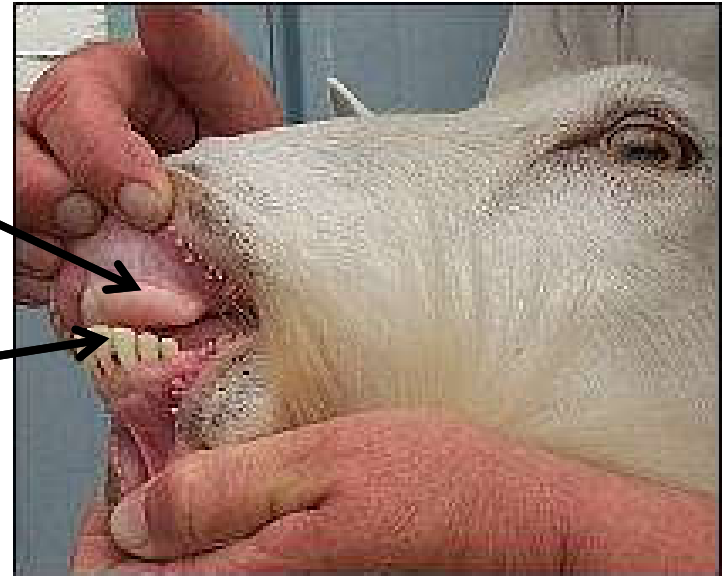» Grinding or shearing teeth (molar or premolar)

□ So mammals typically exhibit **heterodonty** (various types of teeth with different function).

1. Incisor teeth (I)

- ✓ Are front teeth used for cutting.
- ✓ Are embedded in the incisive bone and rostral part of the mandible.
 - **Ruminants lack incisors on the upper dental arcade,**
 - Instead the area is modified as keratinized area called **dental pad**,

Lower incisor
teeth



2. Canine teeth (C)

- ✓ Also called **eye teeth, bridle teeth, tusks.**
- ✓ Are well developed in canine but **Ruminants lack canine teeth.**

3. Premolar (P) and Molar (M)

- They are also called as **cheek teeth.**
- Only premolar teeth are preceded by deciduous teeth.

➤ *Dental Formula*

- ✓ It is the short hand method of listing the type and number of teeth.
- ✓ In writing dental formula, incisors (I) are indicated first, canines (C) second, premolars (P) third, and finally molars (M), giving I:C:P:M.

Dental formula for different species

Species	Temporary teeth	Permanent teeth
Ruminants	$2(I^0_4 C^0_0 P^3_3) = 20$	$2(I^0_4 C^0_0 P^3_3 M^3_3) = 32$
Horse	$2(I^3_3 C^0_0 P^3_3) = 24$	$2(I^3_3 C^1_1 P^{3/4}_3 M^3_3) = 40/42$
Dog	$2(I^3_3 C^1_1 P^3_3) = 28$	$2(I^3_3 C^1_1 P^4_4 M^2_3) = 42$
Pigs	$2(I^3_3 C^1_1 P^3_3) = 28$	$2(I^3_3 C^1_1 P^4_4 M^3_3) = 44$
Camel	$2(I^1_3 C^1_1 P^3_3) = 22$	$2(I^1_3 C^1_1 P^3_2 M^3_3) = 34$
Human	$2(I^2_2 C^1_1 P^3_3) = 24$	$2(I^2_3 2C^1_1 P^2_2 M^3_3) = 32$

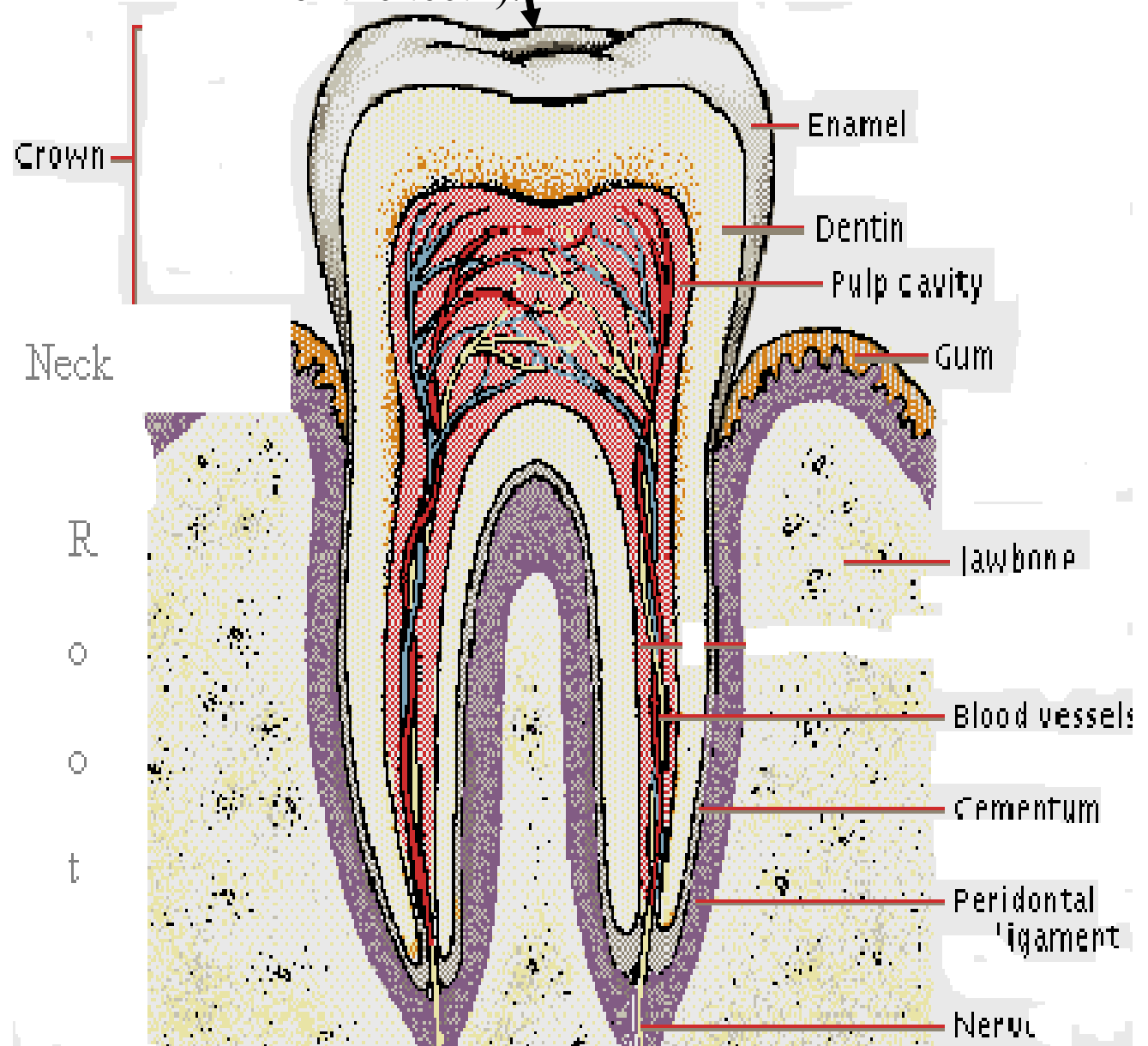
✓ Tooth is composed of **three parts:**

- **Crown**

- **Neck**

- **Root**

Table surface(is the outer most surface of the teeth).



➤ **Crown:**

- Is the visible part of the tooth above the mucous membrane of the gum.
- A tooth having a *short crown* separated from the root by a *distinct neck* is described as **brachyodont teeth**.

» **E.g., Incisor teeth of Ruminant.**

- A tooth having a long and straight crown with no visible neck is called **hypsodont teeth**.

» **E.g., Incisor and cheek teeth of horse.**

➤ **Neck :**

- It is the part of tooth found at the gum line.

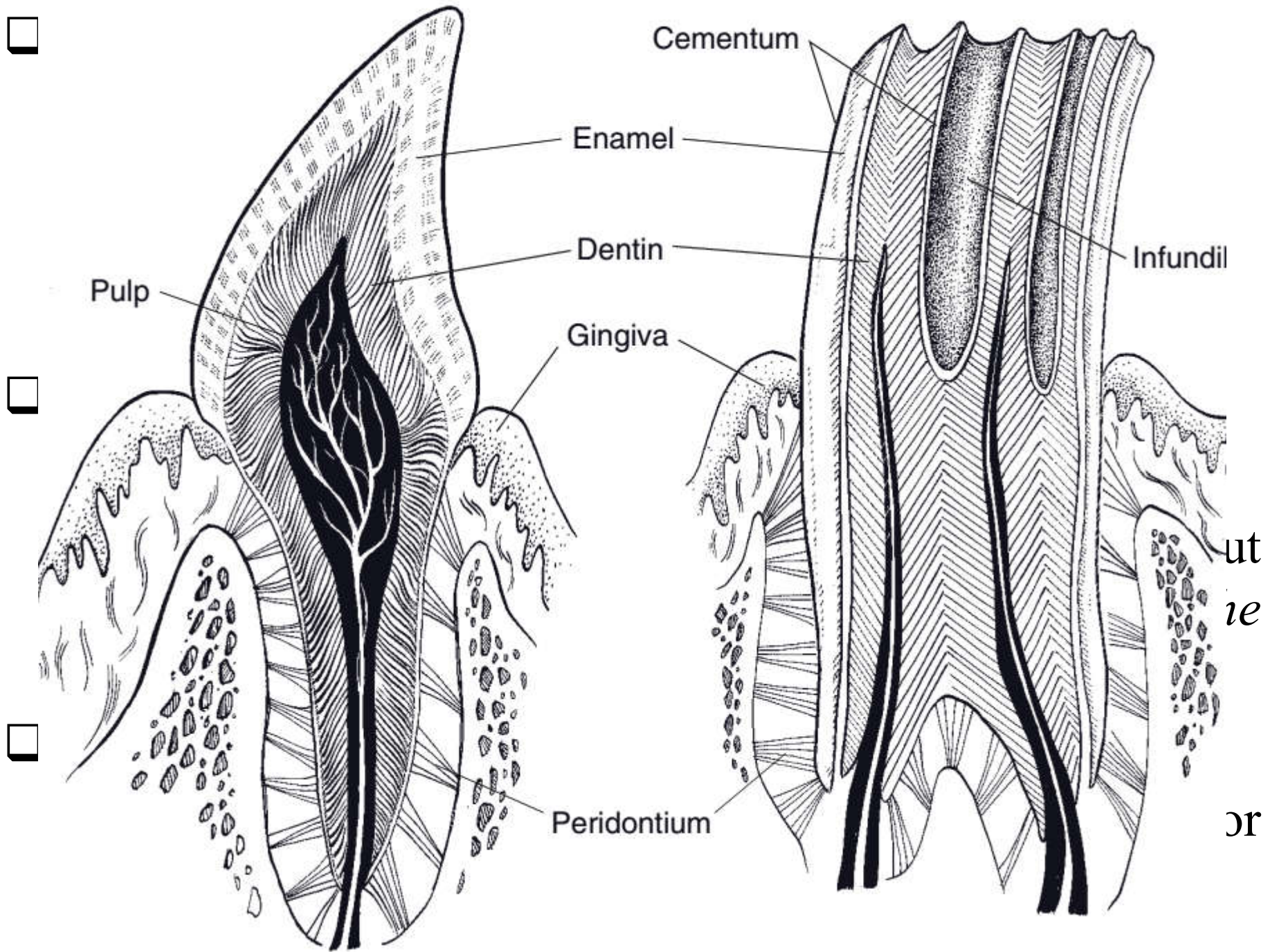
➤ ***The root:*** -

- Is the part embedded in a socket of bone called **alveoli**.
- It may be *single* as incisor and canine or
- It may be *paired* or *multiple* as premolar and molar.

❑ ***Dental cavity or Pulp cavity :***

- is the central cavity extending from the *base of the root* to up to a variable distance into the *crown*.
- It contains dental pulp, vessels and nerves.

❑ ***Pulp:*** is delicate connective tissue inside the pulp cavity and it is highly vascularised.



Pulp

Enamel

Dentin

Gingiva

Peridontium

Cementum

Infundil

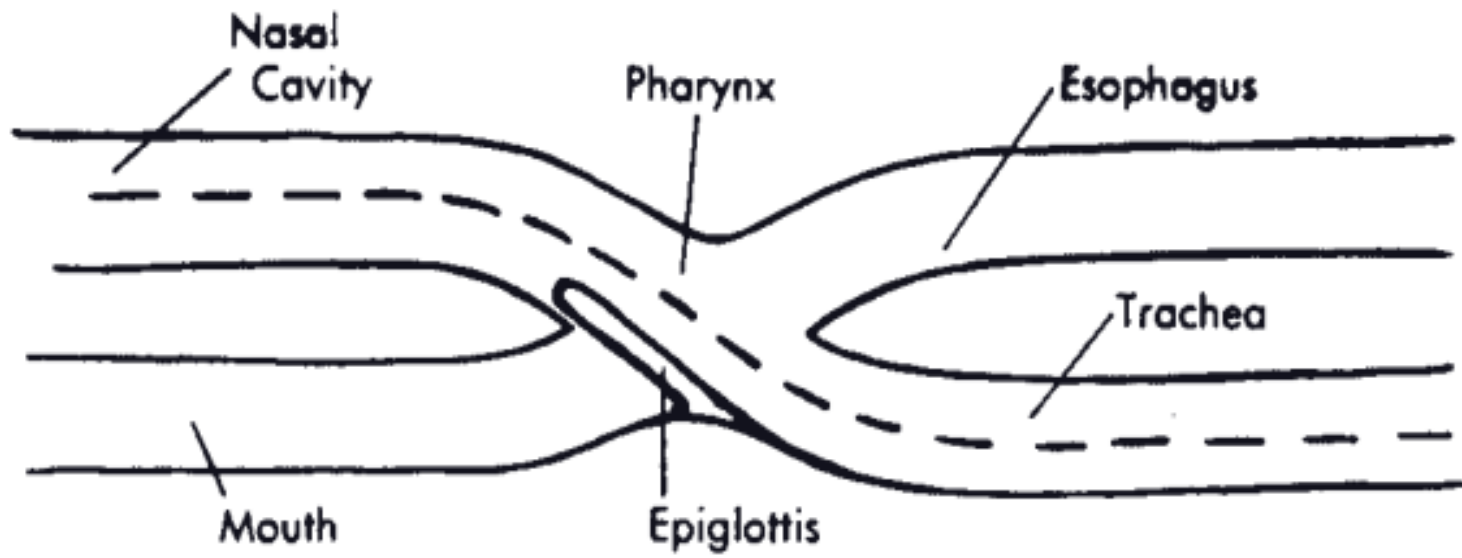
ut
ie

or

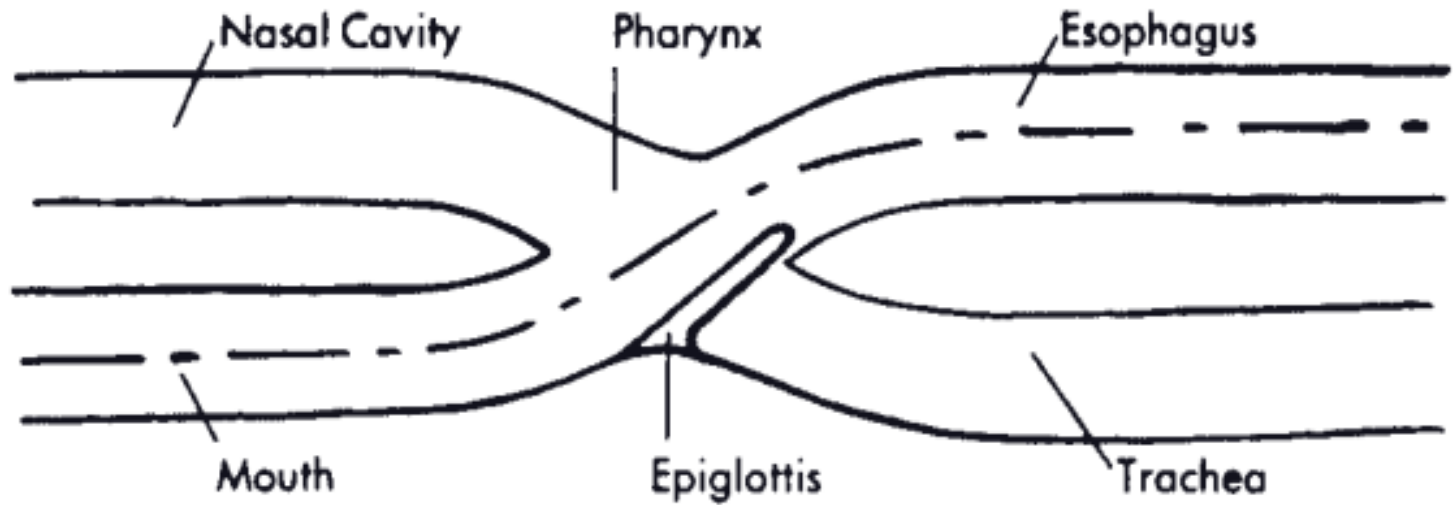
6.3. Pharynx(Throat)

- ✓ A funnel shaped musculo-membranous organ belonging to both digestive and respiratory systems.
- ✓ It connects the oral cavity with the oesophagus.
- ✓ The enlarged opening of the funnel faces *rostrally* and opens in to the *mouth* and *nasal cavity* while the small end is continued by the oesophagus.
- ✓ The pharynx is bounded by:
 - the base of the cranium dorsally
 - larynx and oesophagus ventrally
- ✓ Air and food passages cross in the pharyngeal cavity. So, it is the task of the pharynx to direct air and food properly to avoid choking.

- ✓ The pharynx has several **openings**:
 - **Oral opening** → to the oral cavity.
 - **Nasal opening** → to the nasal cavity.
 - **Two Eustachian tubes** → to the middle ear.
 - **Oesophageal opening** → to the digestive tract (always closed except during swallowing).
 - **Laryngeal opening** → to the respiratory tract (always opened except during swallowing).
- ✓ The pharynx can be divided into three from the outside to inside part:
 - » *Oropharynx*
 - » *Nasopharynx* and
 - » *Laryngopharynx*



A. Normal Respiration



B. Swallowing

6.4. Oesophagus

- ✓ It is a musculo-membranous tube extending from the *pharynx* to the cardia of *stomach*.
- ✓ It has **three** parts:
 - Cervical part
 - Thoracic part and
 - Abdominal part .
- ✓ It passes dorsal to the trachea and usually inclines somewhat to the left in the middle of the neck (mid-cervical region).
- ✓ It passes through the diaphragm at the oesophageal hiatus and joins the stomach within the abdominal cavity at the cardia.

- ✓ The mucosa of the oesophagus:
- has prominent longitudinal folds that permit considerable cross sectional dilation of the lumen to accommodate the bolus of food.
 - The middle layer is **muscular** with **longitudinal, oblique, and circular arranged fibres**.
 - The lumen is closed by **longitudinal folds** when it is empty.

6.5. Stomach

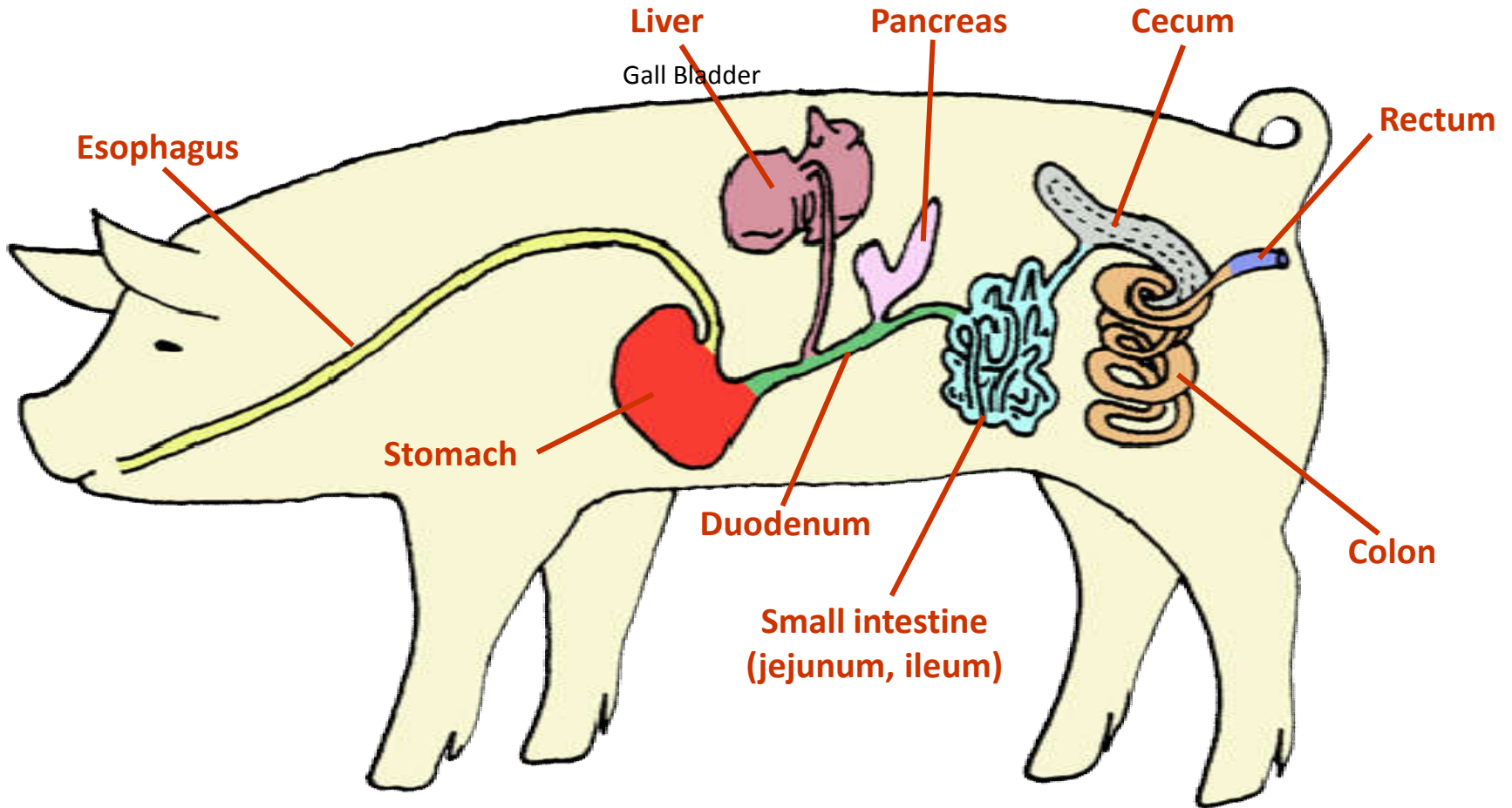
- ✓ Is the dilated part of the digestive tract, interposes between *oesophagus* and the *small intestine*.
- ✓ There is a considerable variation in the *form* and *structure* of the stomach in our domestic animals.
 - **Simple stomach or monogastric** → the stomach is one organ without subdivisions.
 - » **E.g., Stomach of horse, donkey, dog, cat and pig.**
 - **Compound stomach or polygastric** → the stomach is divided into four chambers (rumen, reticulum, omasum and abomasum).
 - » **E.g., Stomach of Cattle, Sheep, Goat and Camel.**

- **Gastric complex of birds** → the stomach is divided into three parts (crop, proventriculus and ventriculus).

6.5.1. Non ruminant stomach

- ✓ Is a simple stomach or monogastric having one organ without subdivisions.
- ✓ It is a large specialized dilation located just caudal to the diaphragm more to the left side of the body b/n **esophagus** and **small intestine**.
- ✓ Grossly, the mucosa has prominent gastric folds (**rugae**), allow the stomach volume to expand to accommodate meals.
- ✓ The simple stomach is grossly sub-divided into:
 - » ***Cardiac region*** (entrance) → due to its proximity to the heart.
 - » ***Fundus*** (body)
 - » ***Pyloric regions***
- ✓ The **oesophagus** joins the stomach at the **cardia**.

Digestive Tract of Pig



- ✓ At the entrance , there is thickening of muscle that act as a *sphincter*, called **cardiac sphincter** which is used to prevent the *back flow of food* to the oesophagus.
 - ❖ It is *well developed* in the **horse** where its *strength* and *configuration* make it difficult or impossible for the horse to **vomit**.
- ✓ Another strong sphincter called **pyloric sphincter** regulates the *out flow* of the stomach content into the small intestine.
- ✓ The cardia and the pylorus are quite close together, giving the stomach a '**J**' shape.
 - This arrangement results in a very short concave side between the cardia and the pylorus known as *lesser curvature* and a much longer convex side called as *greater curvature*.

1. *The cardiac region*

- is covered by stratified squamous epithelium and non-glandular.
- It is expanded in horses as *saccus cecus* (blind sac).

2. *The fundic region*

- is glandular and more expanded than cardiac region.

3. *The pyloric region*

- It is also glandular and has *two parts*
 - the proximal wider part is called *pyloric antrum*,
 - the distal narrow part is *pyloric canal*, near the duodenum.
- It ends at **pyloric sphincter**.

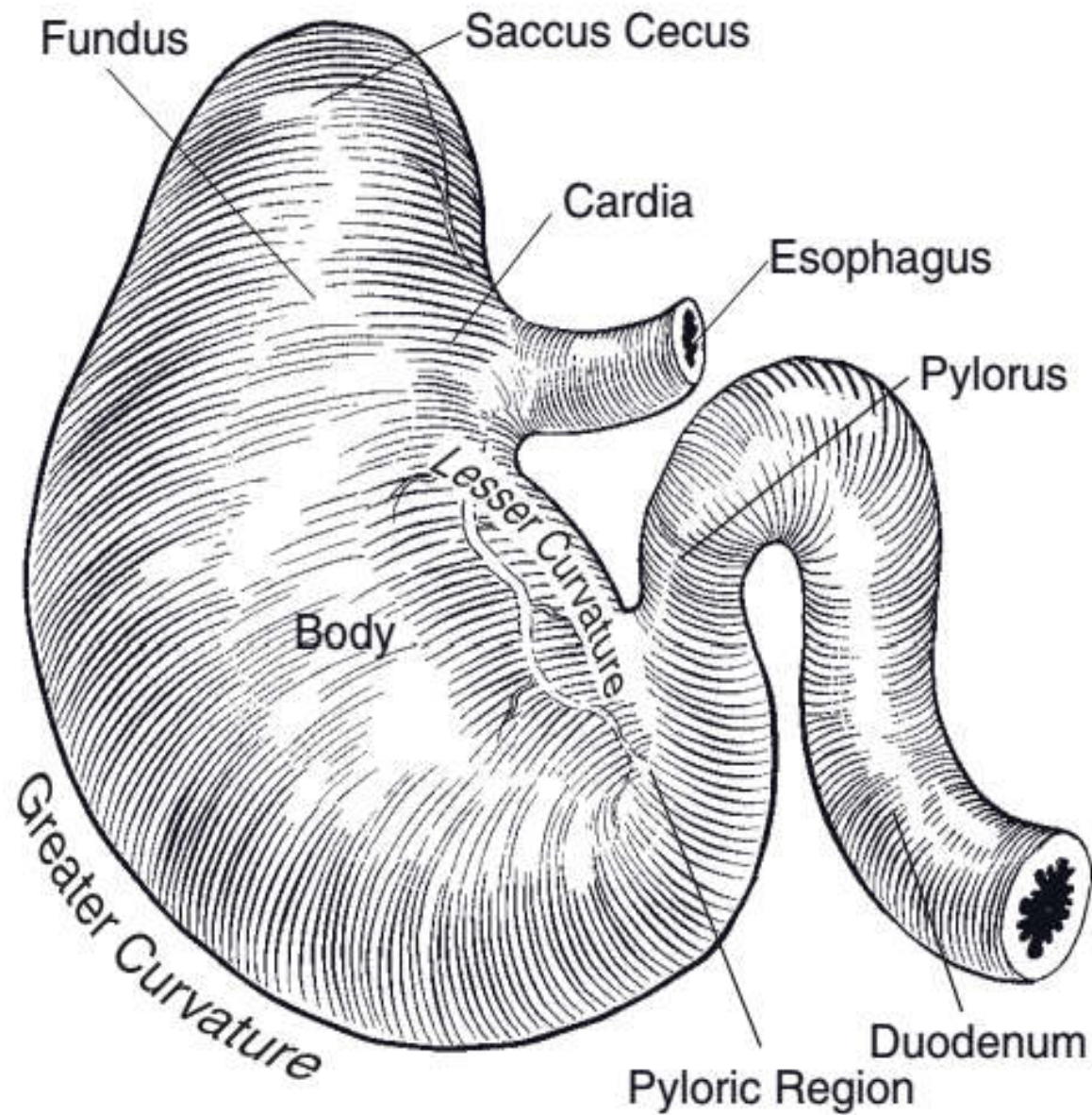
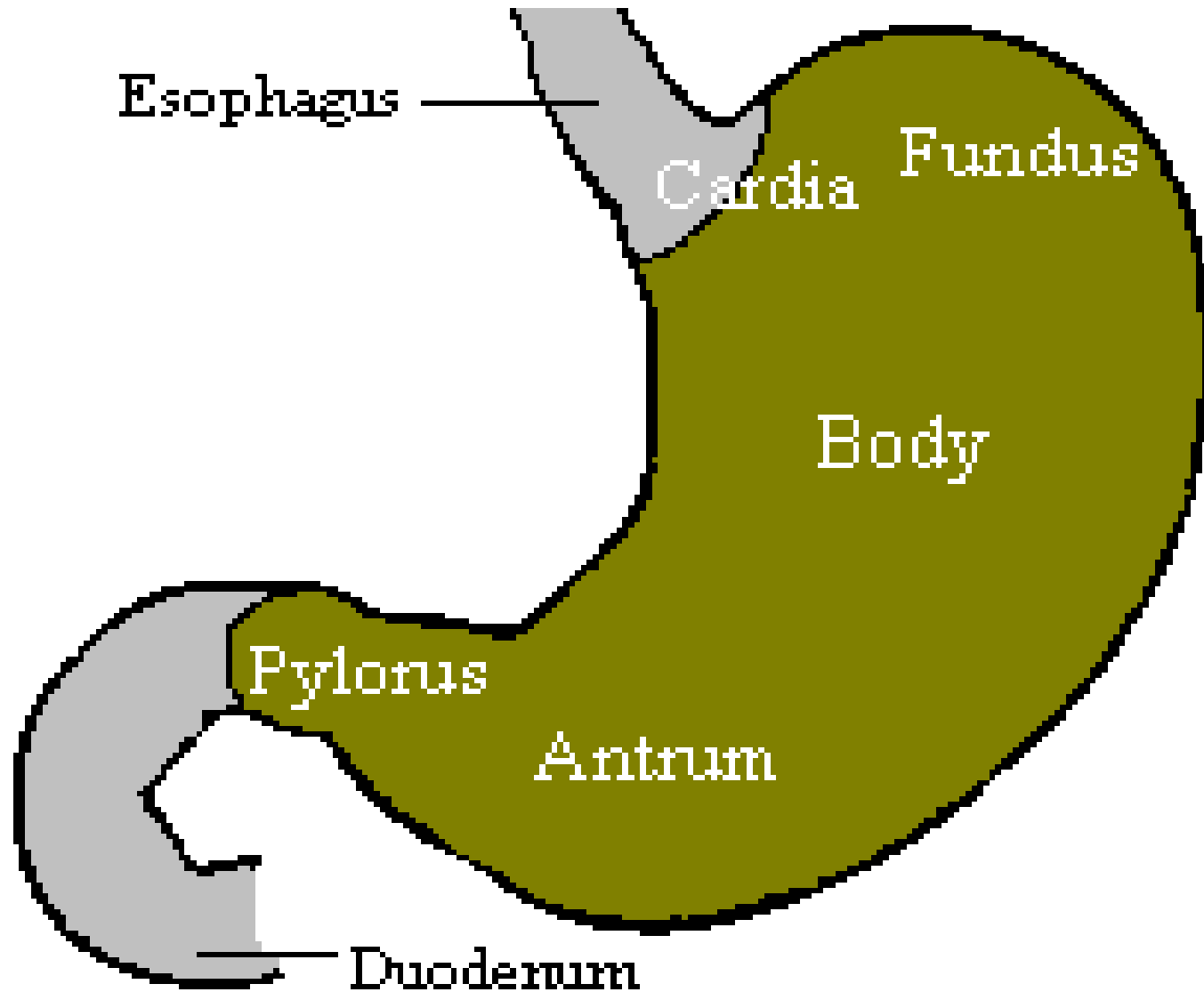


Figure 20-8. External anatomy of the equine simple stomach. Dorsal view.

Non-ruminant stomach (Simple stomach)



6.5.2. Ruminant stomach

- ✓ It is a compound stomach having four compartment:
 - » Rumen → the pouch
 - » Reticulum → the honey comb
 - » Omasum → many plies
 - » Abomasum → true stomach (glandular stomach)
- ✓ Cattle, Sheep and Goat are **true ruminants**, but **camels are not true ruminants**.
 - » Because the omasum is not present in case of camels.

- ✓ The true stomach contains glandular structure that secretes *enzymes* and HCL like the stomach of monogastric animals.
- ✓ The proportion of different compartments (chambers) *in adult* animal is as follows:

» Rumen	75-80%
» Reticulum	5-8%
» Omasum	4-8%
» Abomasum	7-8%

1. Rumen

- ✓ The rumen is the largest sac of the adult compound stomach.
- ✓ In young animal it is poorly developed (Not functional at birth).
- ✓ The *long axis* of the rumen extends
 - ✓ from 7th intercostal space or 8th ribs to the pelvic inlet.
- ✓ The rumen has a very thick muscular wall.
- ✓ It fills most of the left-side of the abdomen.
- ✓ It opens to the reticulum and the line of demarcation b/n rumen and reticulum is called *rumino-reticular fold*.

- ✓ The fold of mucous membrane called *esophageal groove* extends from the cardia to the opening b/n reticulum and omasum.
 - In young animal it can be stimulated by suckling reflux to form a tube called milk groove or milk canal to bypass the rumen.
- ✓ Rumen has:
 - Two surfaces → parietal and visceral
 - Two curvatures → dorsal and ventral curvature
 - Two extremities → cranial and caudal extremities

✓ The rumen is subdivided internally into sub-compartments by *muscular pillars* that correspond with **grooves** visible externally.

– There are **two types** of grooves /**pillars**/

▪ *Coronary groove*: - divide the rumen into cranial and caudal parts.

▪ *Longitudinal groove*: - separate the rumen into dorsal and ventral sac.

➤ *The dorsal sac*: -

» is the largest compartment and it is non-blind sac since it communicates with the reticulum.

» Caudally it is subdivided by *dorsal coronary pillars* which form an incomplete circle bounding the *dorsal blind sac*.

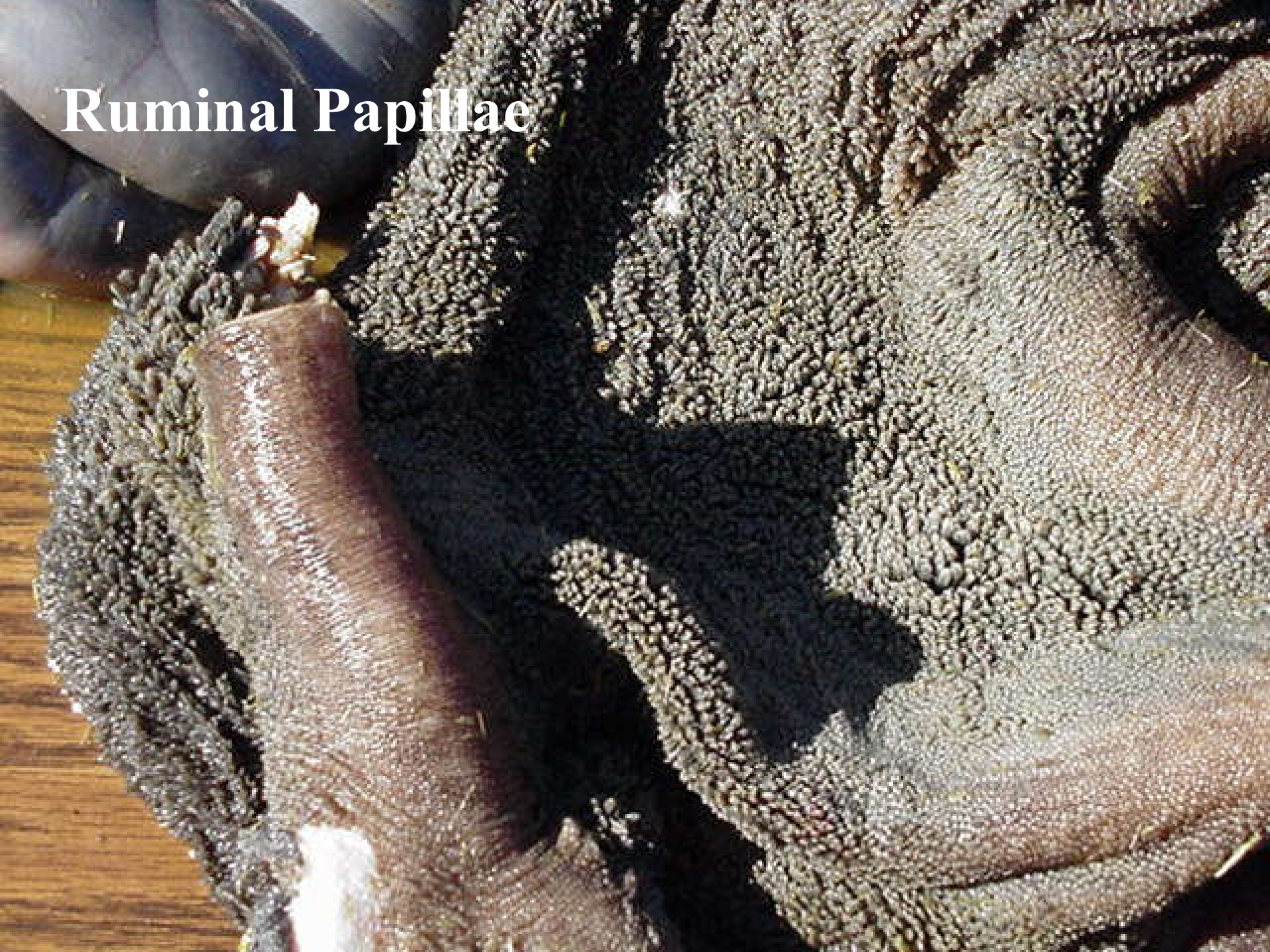➤ *The ventral sac*

» is blind and the caudal part of the ventral sac forms a diverticulum by caudal coronary grooves.

➤ The most ventral parts of both sacs of the rumen contain numerous leathery papillae → **ruminal papillae**.

➤ Ruminal papillae are absent on the dorsal part of the rumen.

Ruminal Papillae





Ruminal papillae

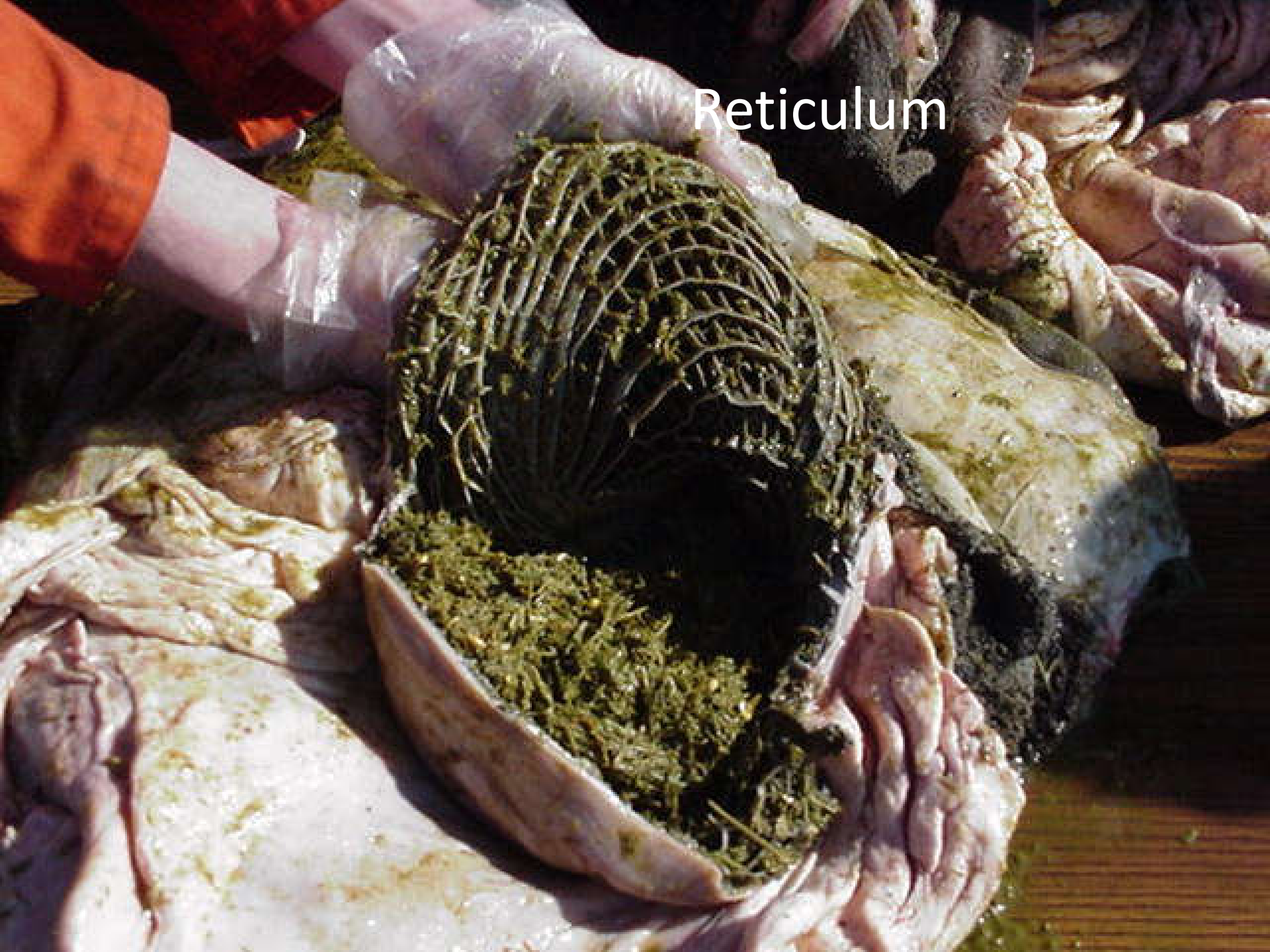- The wall of the rumen composed of *smooth muscle* arranged in **two layers**.
- the *superficial layer*
 - » runs in *cranio-caudal* direction and bridges most of the ruminal grooves where as
- the *inner layer*
 - » runs transversely and makes up **the substance of the pillars**.

2. Reticulum

- ✓ Is the *smallest* section of the four compartments, comprises about 5-7% of the total volume.
- ✓ Is the most cranial compartment of the fore stomach that lies entirely to the left of the median plane.
- ✓ Is located immediately behind the *diaphragm* almost in apposition to the heart.
 - So any foreign sharp metallic objects tend to lodge in the reticulum.
 - The foreign objects pierce the diaphragm and then pericardium affecting the heart at the time of *contraction* of the reticulum resulting in ***traumatic reticulopericarditis*** (hard ware disease).

- ✓ The mucosa of the reticulum has *intersecting ridges* that give the reticulum common name, the *honey comb*, they are *hexagonal* in shape.
- ✓ Numerous small papillae stud the interior floors of these ridges.
- ✓ It communicates with the rumen through *rumino-reticular opening* and rumen and reticulum are ventrally divided by *ruminoreticular fold*.

Reticulum



Interior surface of Reticulum, honey-combed appearance.



3. Omasum

- ✓ It is a spherical organ filled with many *muscular laminae* having different size which look like pages of book (giving the omasum a common name '**book stomach**' or **butcher's bible**).
- ✓ There are also short *blunt papillae* on the surface of the laminae that grind the roughage before it passes into abomasum.
- ✓ The omasum lies ventrally to the right of the median plane and just caudal to the liver.
- ✓ It communicates with
 - ✓ reticulum through *reticulo-omasal opening* and with that of the
 - ✓ abomasum through *omasoabomasal opening*.

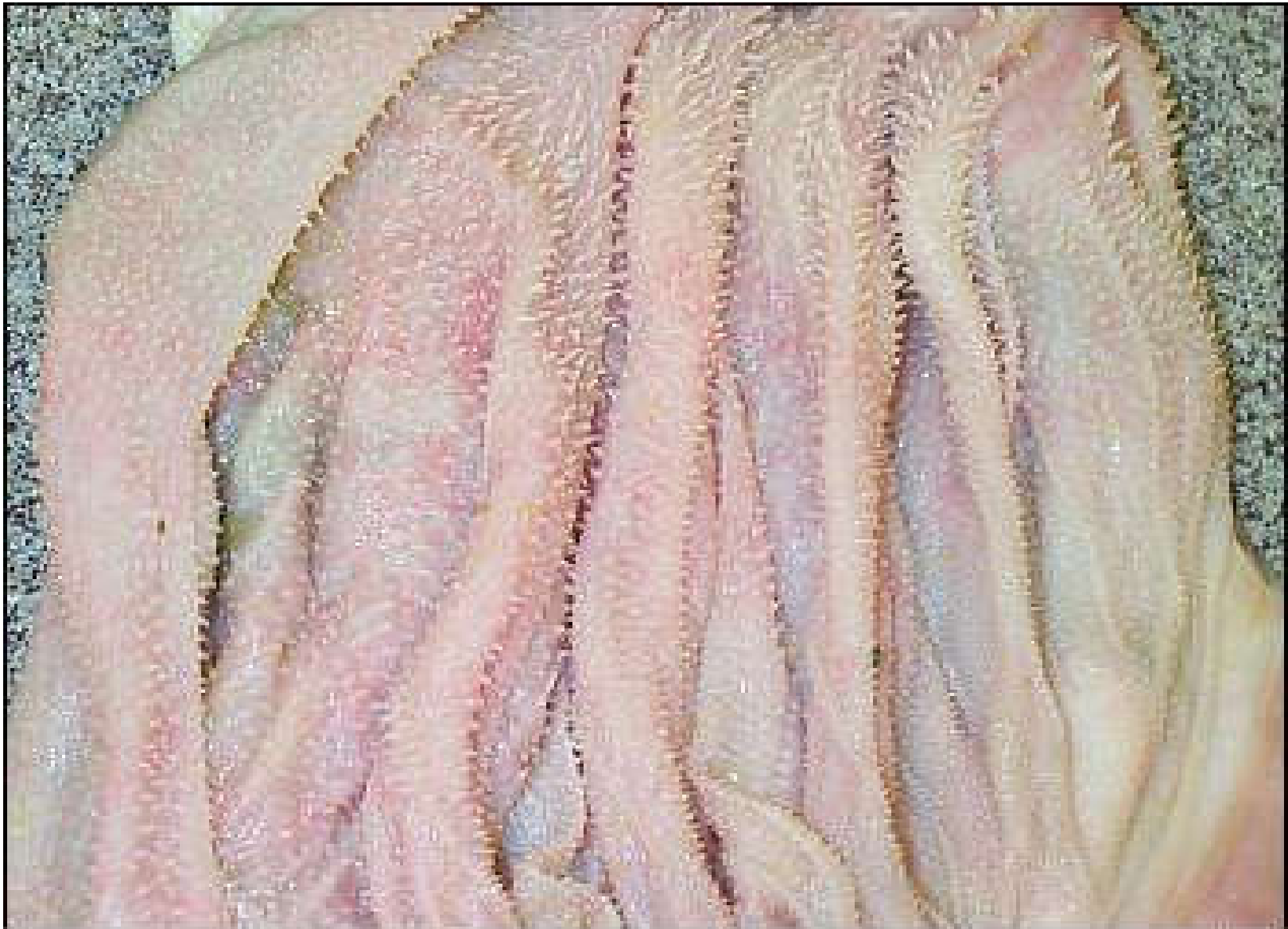Omasum - full



Omasum is a heavy, hard organ with a lining that has many folds (leaves).

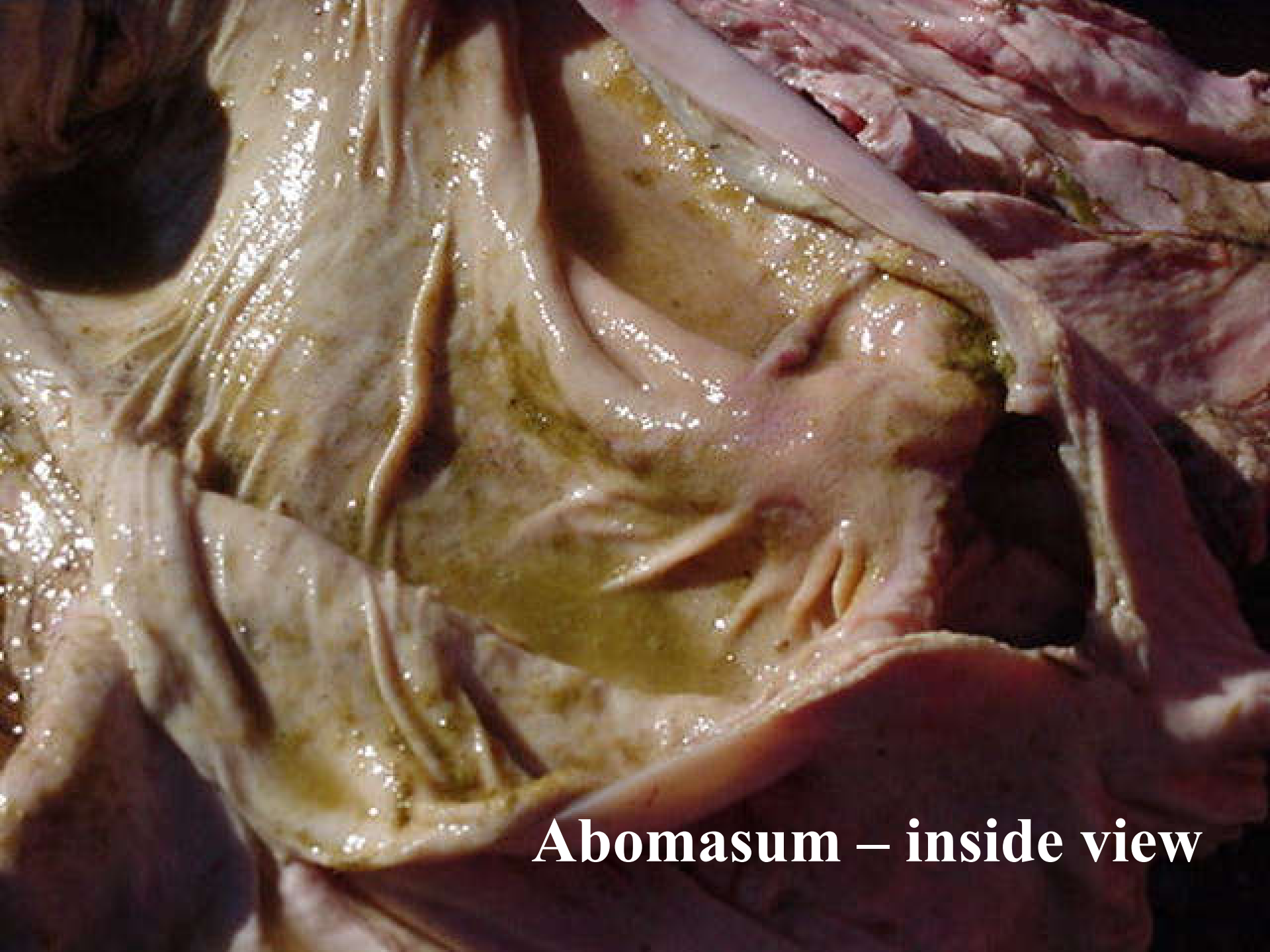

The inside of the **omasum** has longitudinal folds(muscular laminae).



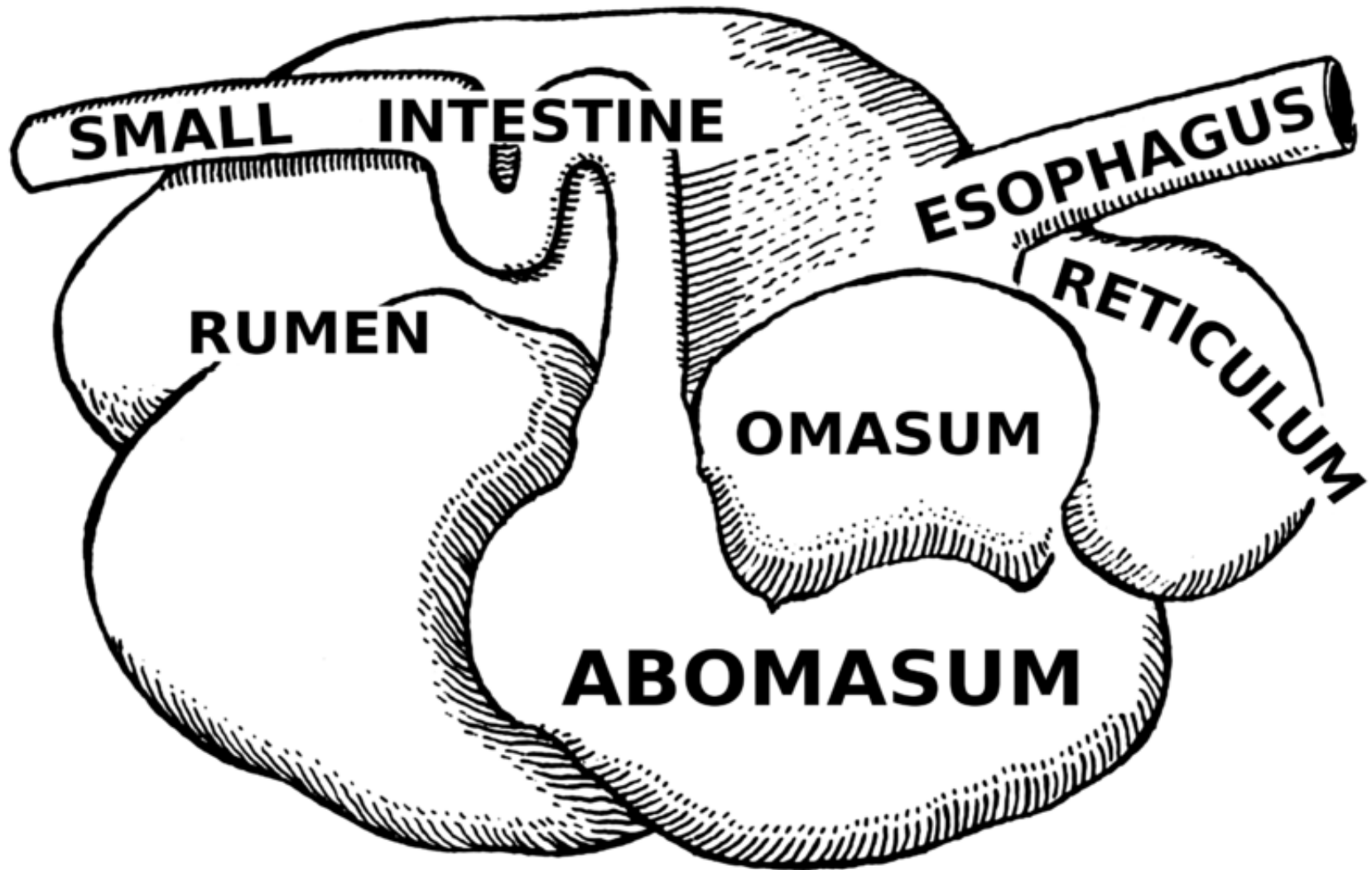
4. Abomasum

- ✓ It is an elongated sac which lies chiefly on the abdominal floor.
- ✓ It is also called "True stomach" that secretes enzymes from its walls.
- ✓ Glandular stomach like monogastric fundic region.
- ✓ It is divided into a *fundus* (region of the proper gastric glands), *body* and a *pylorus* parts and it has greater and lesser curvature.
- ✓ It is an elongated pear-shaped sac lying on the floor of the abdomen, on the right-hand side.
- ✓ The lumen has pink numerous folds (pink glandular mucosa) to increase the surface area.
- ✓ The fundus lies on the abdominal floor caudal to the reticulum.

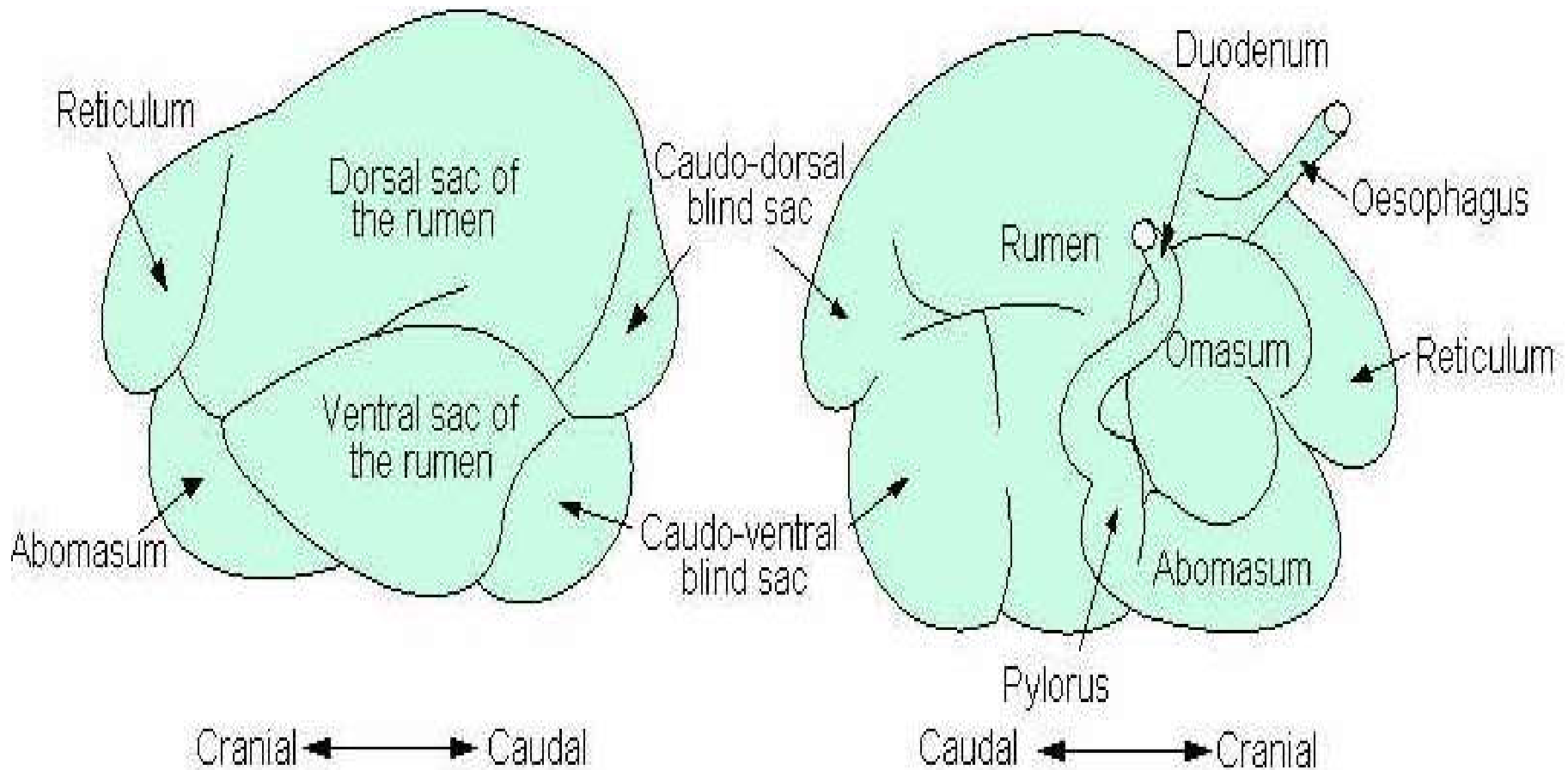


Abomasum – inside view

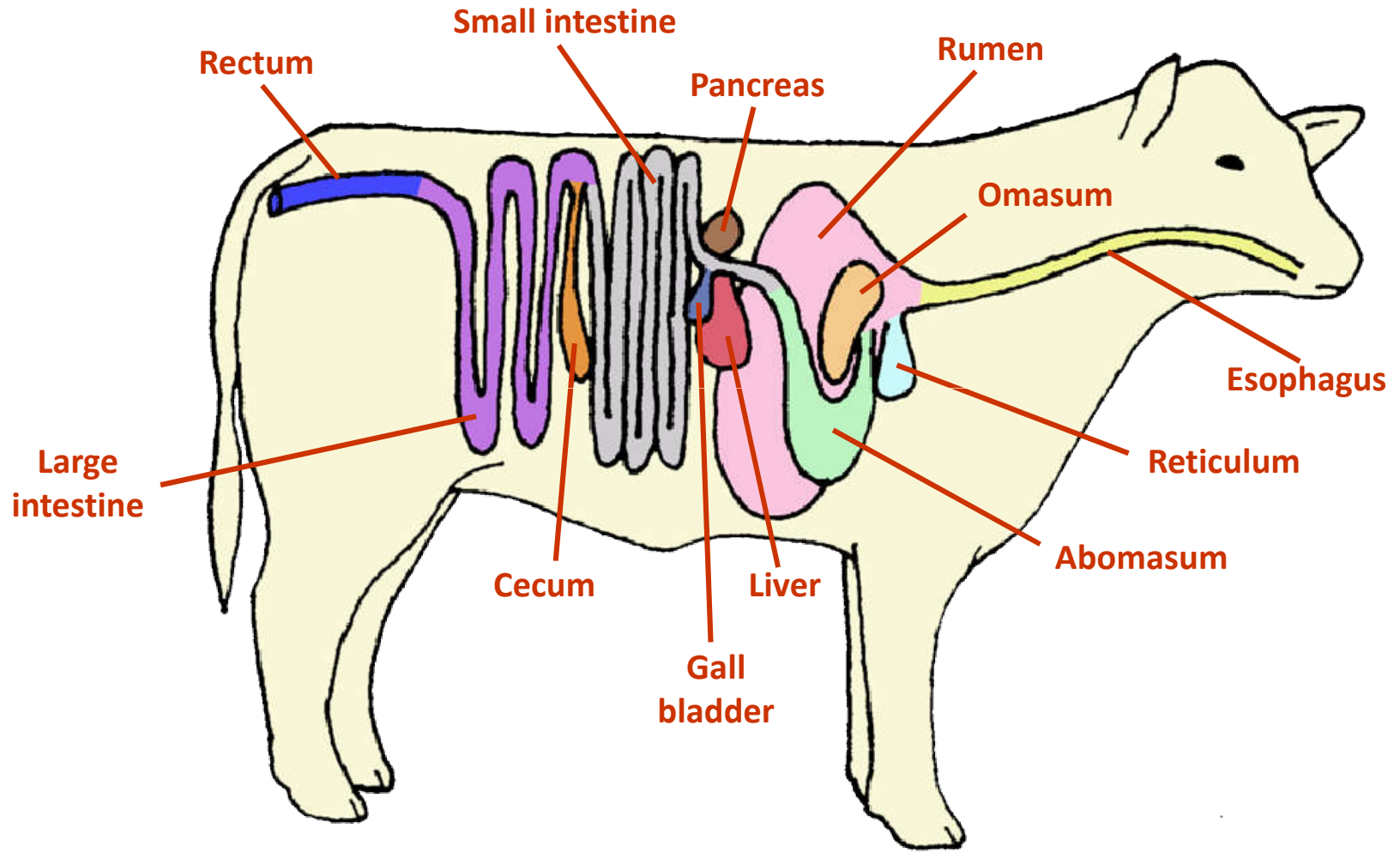
Components of ruminant stomach

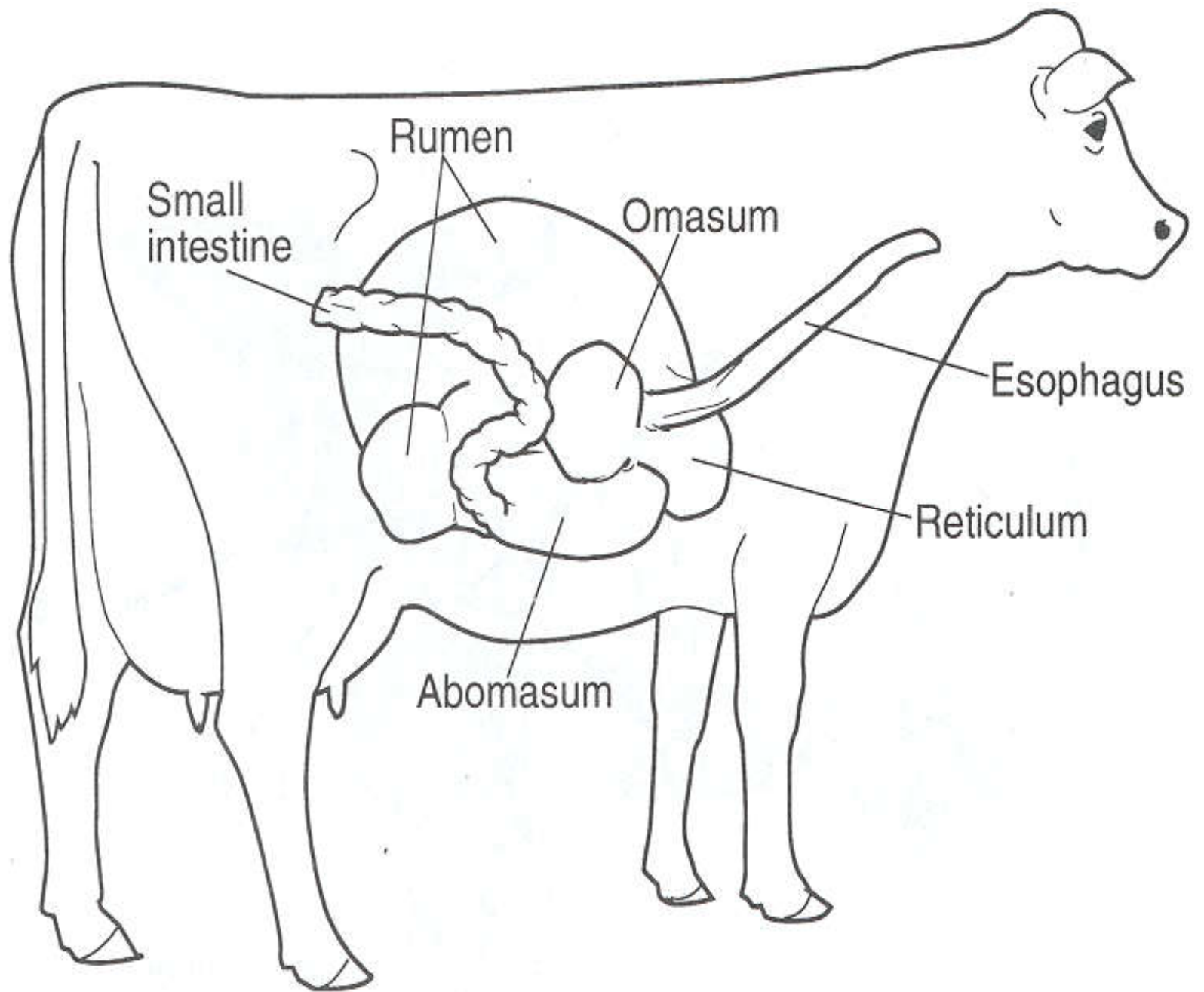


Ruminant stomach



Digestive Tract – Beef Cattle





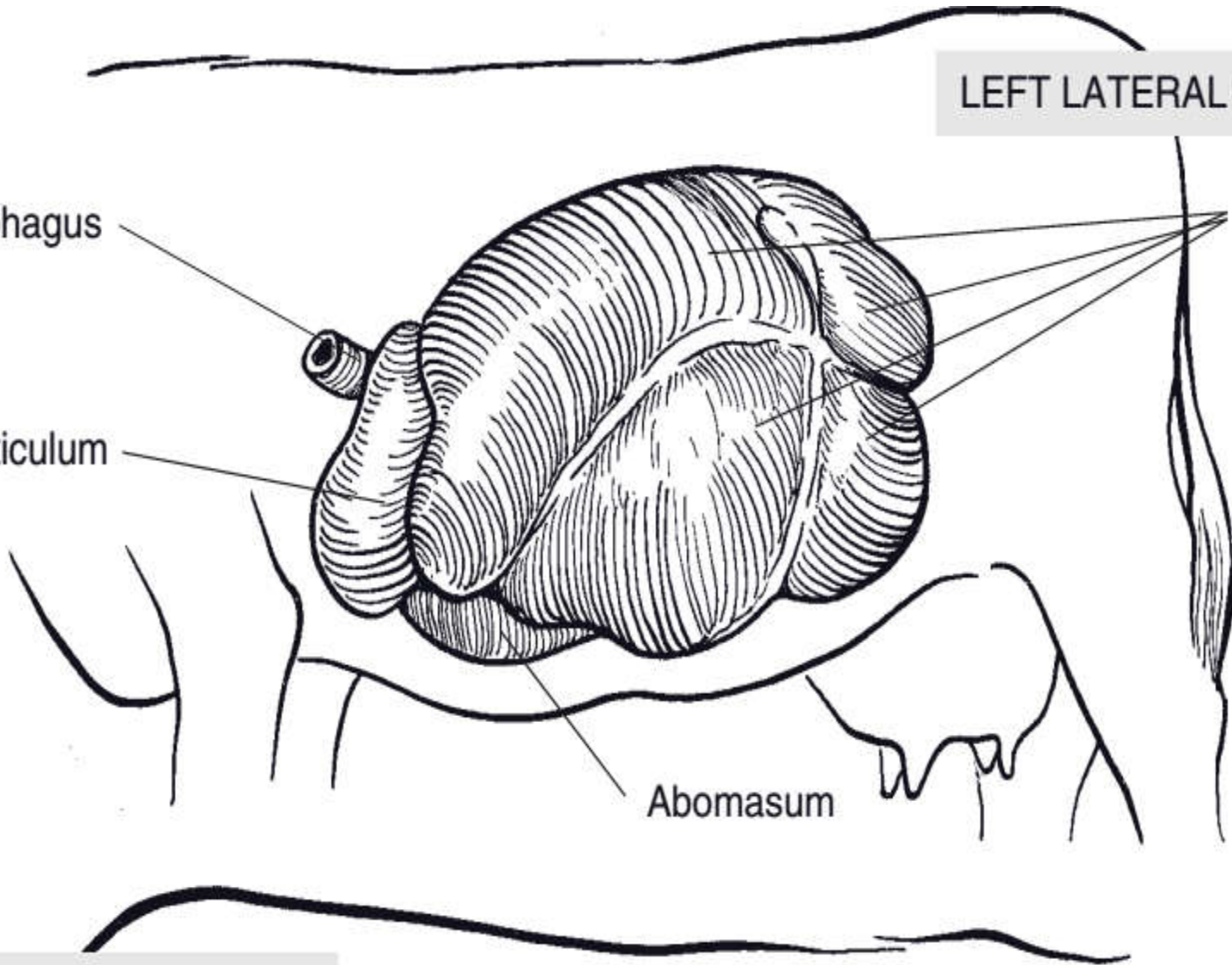
LEFT LATERAL SURFACE

Esophagus

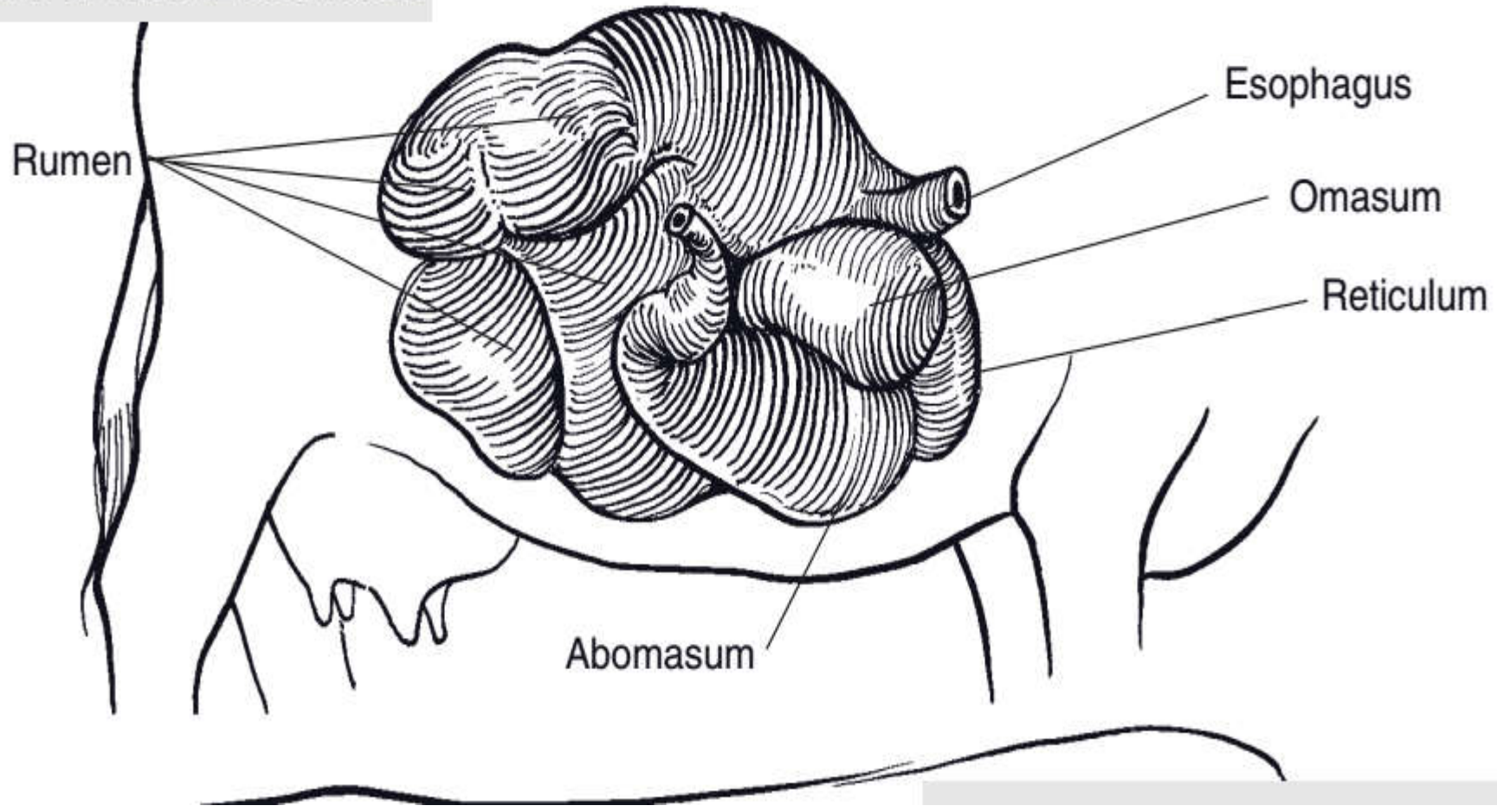
Reticulum

Rumen

Abomasum



RIGHT LATERAL SURFACE



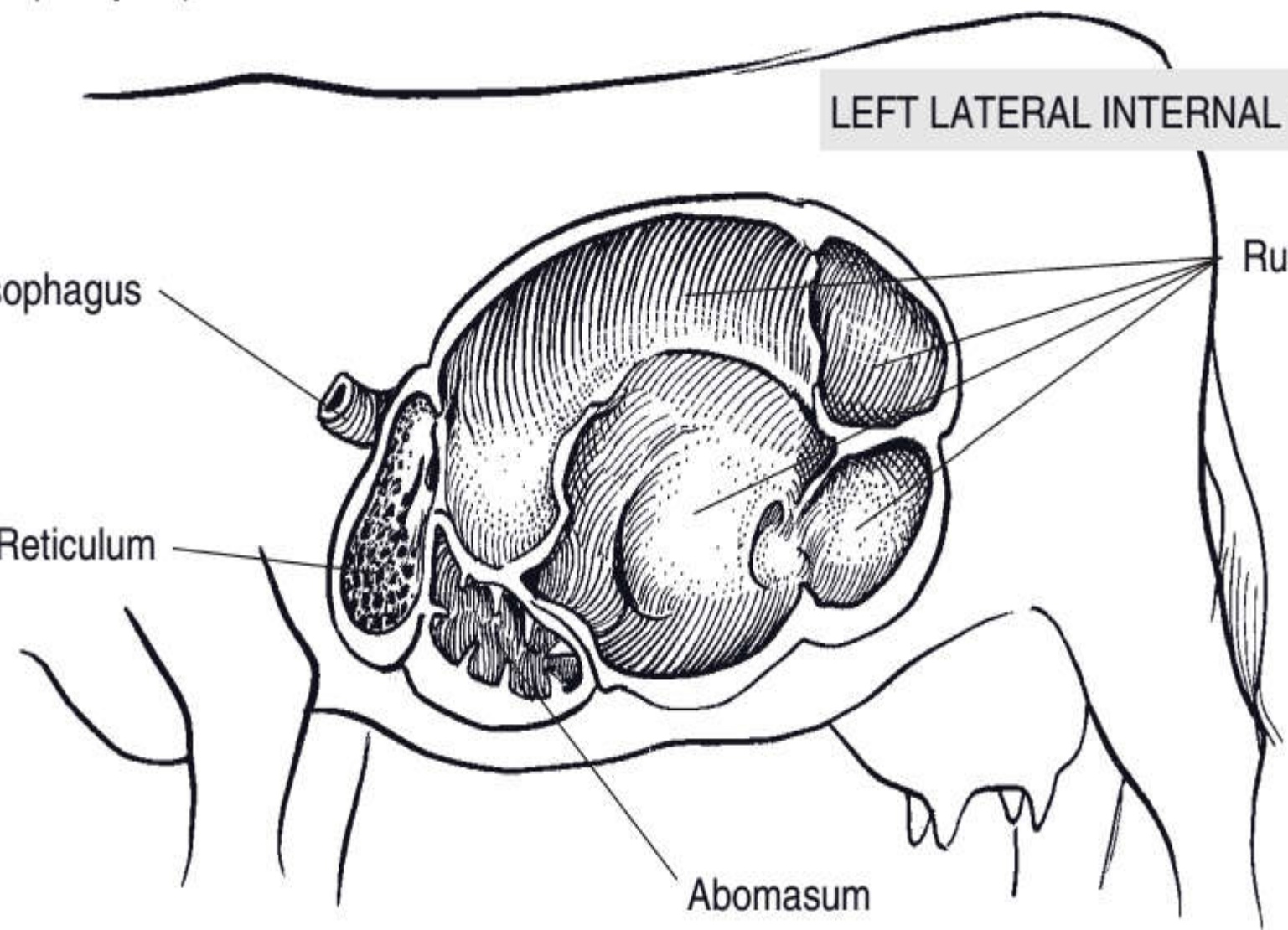
LEFT LATERAL INTERNAL VIEW

Esophagus

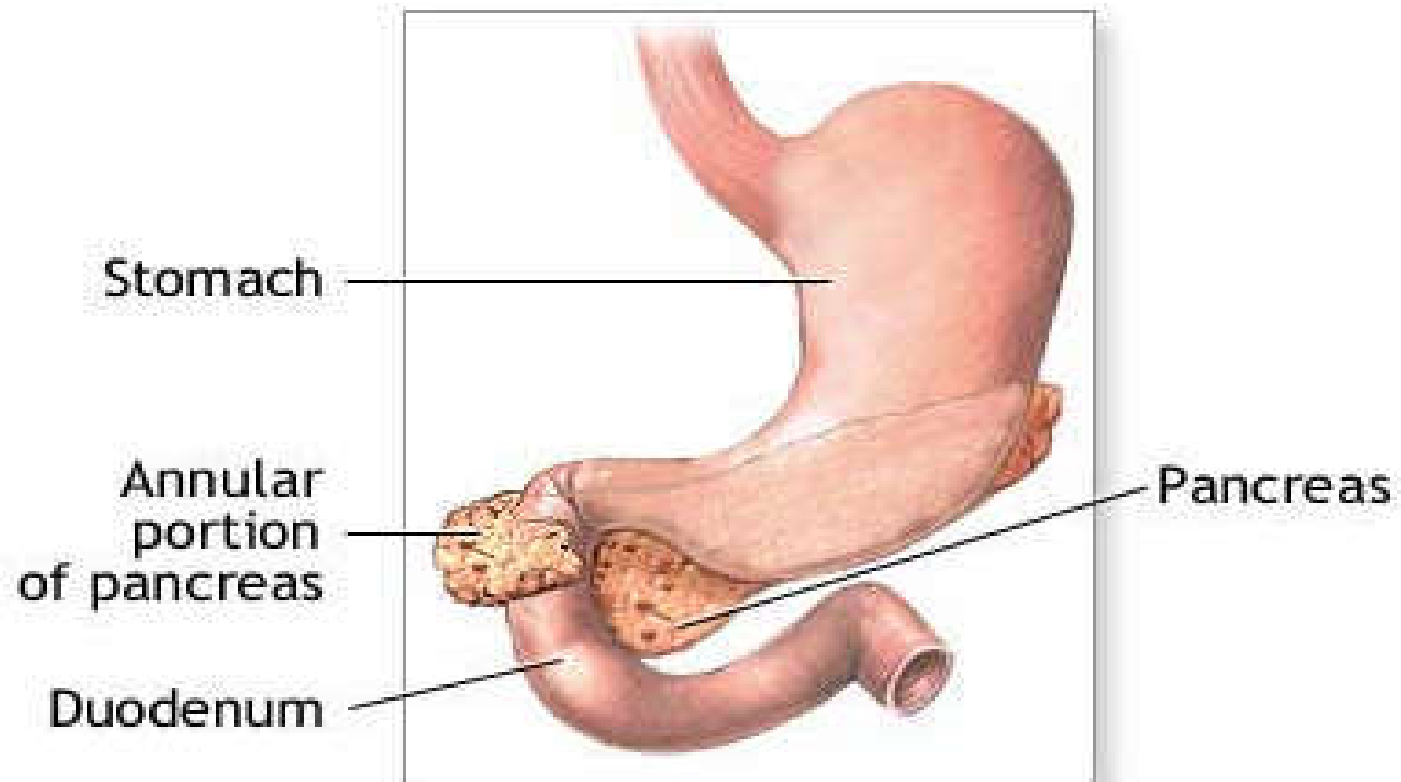
Rumen

Reticulum

Abomasum



6.6. Small intestine



Is a tube connecting the stomach to the large intestine (usually at the junction between caecum and colon, **cecocolic junction**).

- ✓ It is the proximal part of intestine with narrow lumen.
- ✓ It consists of three parts:
 - » *Duodenum*
 - » *Jejunum* and
 - » *Ileum*.
- ✓ The length is about:
 - 20 m in horse
 - 40 m in ox and
 - 25 m in shoat.

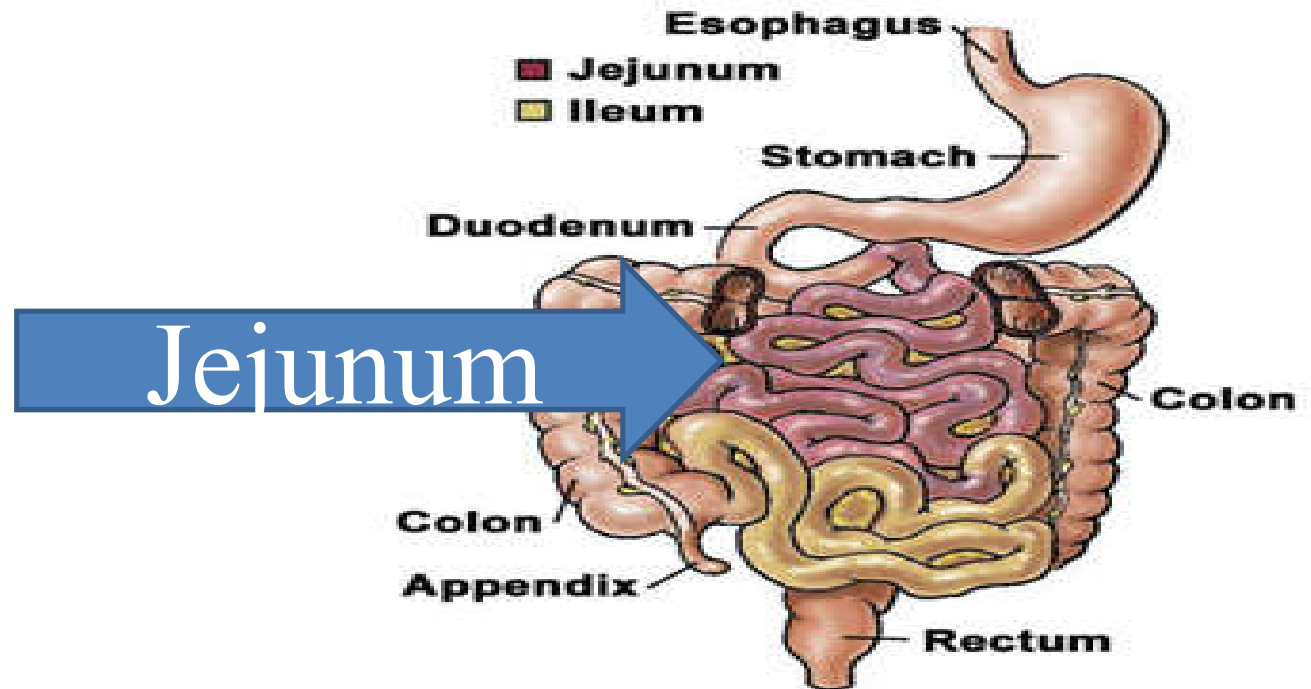
❑ Duodenum

- ✓ Is the first part of the small intestine that forms 'S' or curve shaped.
- ✓ It is closely attached to the right side of the dorsal body wall by a short mesentery, **mesoduodenum**.
- ✓ It also contains **pancreas** at its curvature and the ducts from the pancreas and liver open on the first part of the duodenum.
- ✓ It passes caudal on the right side of the abdominal cavity toward the pelvic inlet.

❑ Jejunum

- ✓ It is the *longest* part of the small intestine and occupies the ventral side of the abdominal cavity.

- **Jejunum:** is attached by the mesentery and forms numerous close coils arranged in a fashion around the border of the mesentery.
- The jejunum is the longest part of the small intestine.



□ Ileum

- ✓ Ileum is the *shortest* and the last part of the small intestine.
- ✓ The ileum joins the cecum in horse and empties into the ascending colon in all other animals.
- ✓ The ileal epithelium features numerous **goblet (mucus) cells** and aggregates of lymph nodes (**peyer's patch**) in this region are more abundant than in other part of small intestine.
- ✓ **There is no gross demarcation between the different parts of the small intestine.**

- ✓ The mesenteries that suspend the small intestine from the dorsal wall are named according to the part of the intestine suspended.
 - ✓ Mesoduodenum → duodenum
 - ✓ Mesojejunum → jejunum
 - ✓ Mesoileum → ileum
- ✓ The size of the mesoduodenum is short so the location of the duodenum is relatively fixed.
- ✓ The mesentery that supports the jejunum and ileum is long and it is sometimes named as **greater mesentery**.

6.7. large intestine

It extends from the termination of the ileum to the anus.

✓ It consists of:

- *Caecum*
- *Colon*
- *Rectum and*
- *Anal canal.*

☐ Caecum

- ✓ It is a blind sac that arises from the junction of the ileum and colon.
- ✓ It is very *large* in **horses** which has **comma shape(,)** and **three** parts,
 - **The base, body and apex.**
- ✓ It is the primary site of fermentation in horses (post-gastric fermentation).
- ✓ The **caecum in horses** extends from right side of the pelvic inlet to the floor of the abdominal cavity where the apex lies just caudal to the diaphragm, near the xiphoid cartilage of the sternum.
- ✓ In **ruminants**, the caecum with its blind end projects caudal as the pelvic inlet and the dorsal end is continuous with colon.

□ Colon

- ✓ It follows the caecum, and is twisted structure.
- ✓ It is divided in to three parts:
 - *Ascending colon*
 - *Transverse colon* and
 - *Descending colon.*
- The *ascending colon and transverse colon* together constitute the *large colon*; the *descending colon* is the *small colon*.

- ✓ The proximal part of the colon(ascending colon) in ruminants is modified into series of *three loops*:
 - *Proximal loop (ansa proximalis) → S shape*
 - *Spiral loop (ansa spiralis) → the main and the middle*
 - *Distal loop (ansa distalis) → connect the spiral loop with the transverse colon.*

❑ Rectum

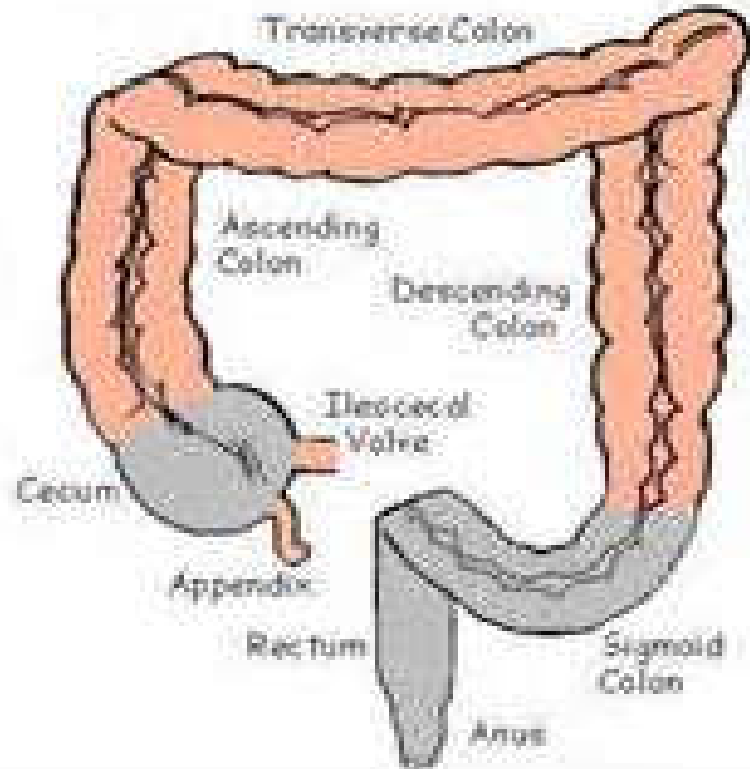
- ✓ It is relatively straight portion of LI and readily dilated for storage of faeces.
- ✓ It continues from the *descending colon* in the pelvic cavity and ends at *anal canal*.

□ Anal canal

- ✓ *The* anal canal is the short termination of the digestive tract.
 - Orifice at the end of the anal canal is the **anus**.
 - ✓ The anus has sphincter → **anal sphincter**.
- ✓ Dogs and cats possess **two anal sacs**.
 - located ventrolaterally to the anus between the internal and external anal sphincter which may be engorged by foul smelling fluid.

Cecum

- ◆ is a sac intercalated between the small intestine and the colon
- ◆ *It has a remarkable size in equine, about 1.28m* which
- ◆ The med



6.8. Accessory Digestive Organs

- ✓ These includes: **Salivary gland, Liver, and Pancreas.**
 - *Which* secrete **enzymes** and **fluid** that facilitate the digestive process in addition to the numerous glands located in the wall of the stomach and intestine.

6.8.1. Salivary glands

- ✓ Located in and around the mouth cavity.
- ✓ There are numerous salivary glands that drain their product(saliva) into the *oral cavity*.
 - ✓ Saliva:
 - Keeps the mouth moist
 - When mixed with food facilitates mastication
 - Lubricates the oesophagus during swallowing.

✓ Salivary glands are classified depending on the nature of their secretion (saliva) as:

- *Serous*

- *Mucous or*

- *Mixed (seromucous).*

- **Serous** means *whely like watery clear fluid* whereas

- **Mucous** is a *viscid tenacious material* that acts as a protecting covering of the surface of mucous membrane.

- **Mixed glands** secrete both *mucous* and *serous* fluid.

✓ There are **three** main salivary glands :

- ***Parotid*** salivary glands
- ***Mandibular*** salivary glands *and*
- ***Sublingual*** salivary glands.

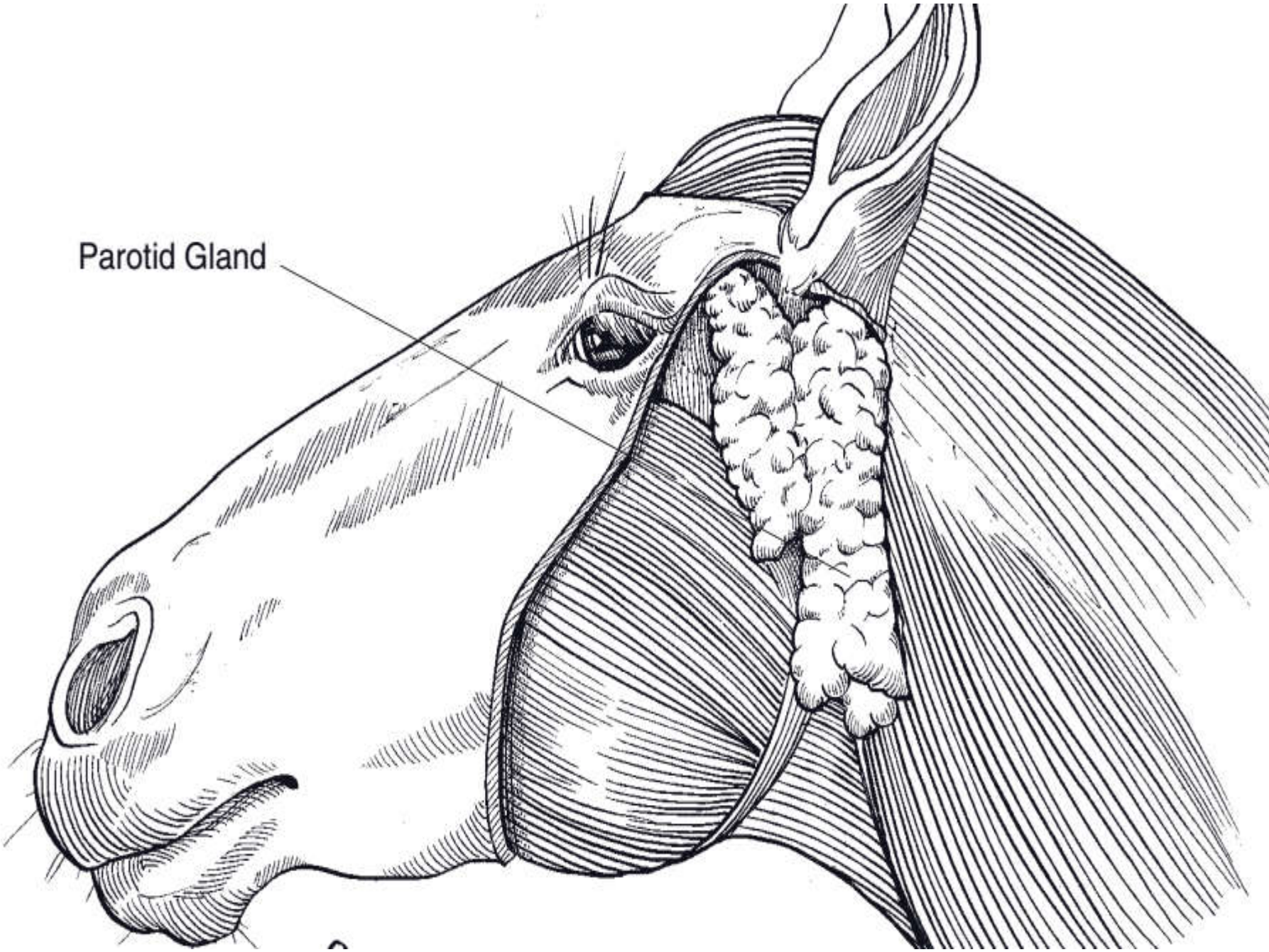
A). The parotid salivary gland

- It is located ventral to the ear in relation to the caudal border of the mandible.
- It is purely ***serous*** in most species (except in dogs).

B). The mandibular salivary gland

- It is located ventral to the parotid gland very close to the angle of the mandible.
- It produces a ***mixed*** mucous and serous secretion.

Parotid Gland

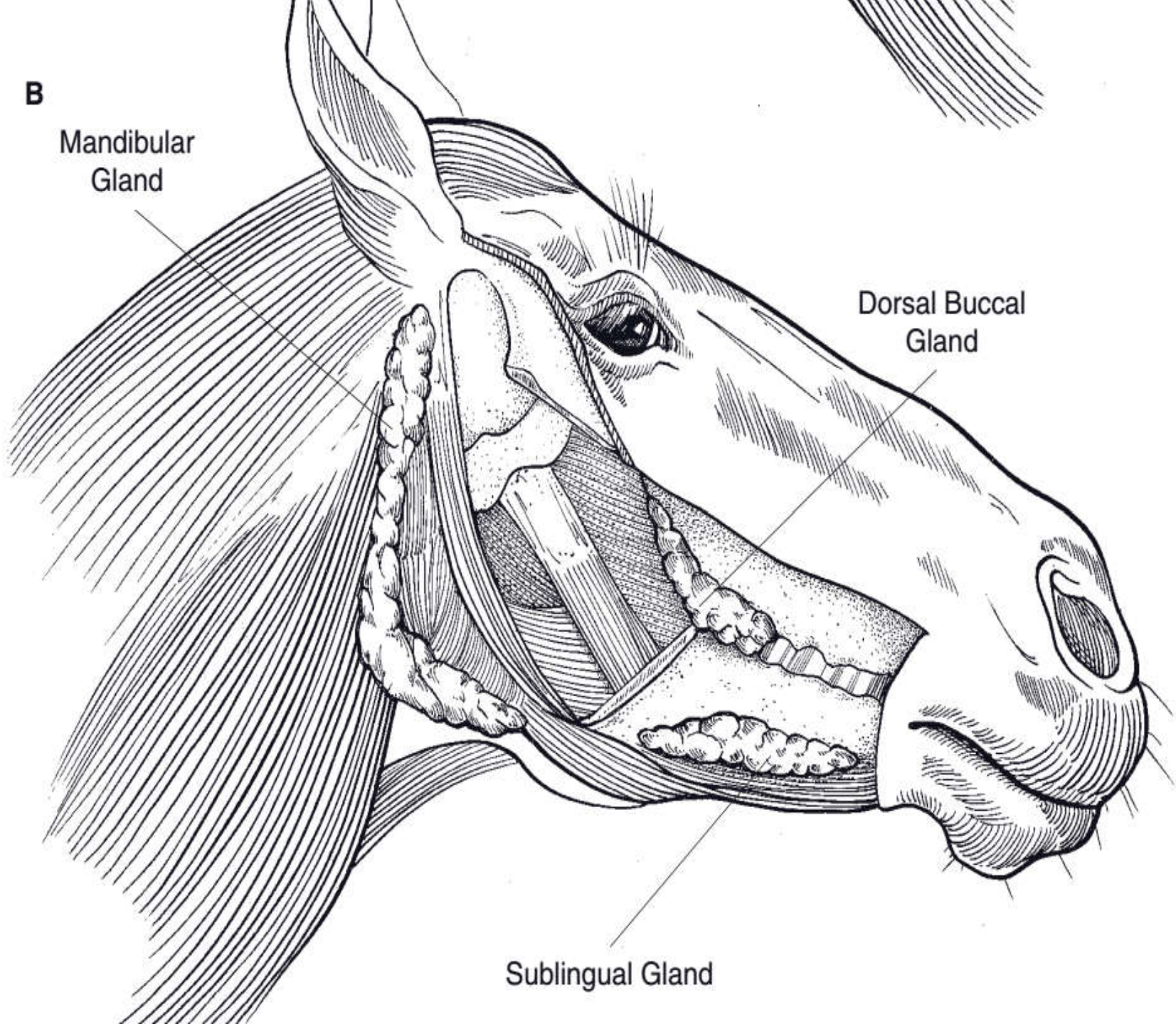


B

Mandibular
Gland

Dorsal Buccal
Gland

Sublingual Gland



C). *Sub-lingual salivary gland*

- It is located along the ventral side of the lateral surface of the tongue near the floor of the mouth.
- It produces a *mixed* mucous and serous secretion.

6.8.2. Liver (Hepar)

- ✓ It is the *largest gland* in the body and performs many vital functions important for life like:
 - Production of bile which play a great roll in protein, carbohydrate and fat metabolism.
 - Filtration of blood especially from toxic substances.

✓ Location:

- Liver is located in the most cranial part of the abdomen immediately behind the diaphragm to the right of the median plane but in **carnivores** it is central in relation to the median plane.

✓ size:

- There is a variation in size of the liver between species in relation to their body weight.
 - 3-5% of the body weight in carnivores.
 - 2-3% of body weight in omnivores.
 - 1.5% of the body weight in herbivores.

✓ The liver is substantially **heavier** in the *young* animal than in the *adult*.

- It is often shows considerable decrease in size (atrophy) in **old age**.

✓ Shape

- Mostly *irregular* in shape with **two** surfaces:
 - ***Diaphragmatic*** surface → which is convex and related to the diaphragm.
 - ***Visceral surface***, which is related to the stomach, duodenum, colon, jejunum and right kidney.

✓ Color

- Vary depending on the *amount of blood* it contains. But generally fresh liver has **brownish-red** color and covered by a connective tissue capsule.

✓ Consistency → it is soft and friable in consistency.

✓ Lobes:

– The liver is divided by *fissure* in to different **lobes**.

➤ In *ruminants*:

- Left lobe
- Right lobe
- Quadrate lobe and
- Caudate lobe

➤ In *equine* :

- Left lobe
- Right lobe and
- Quadrate lobe

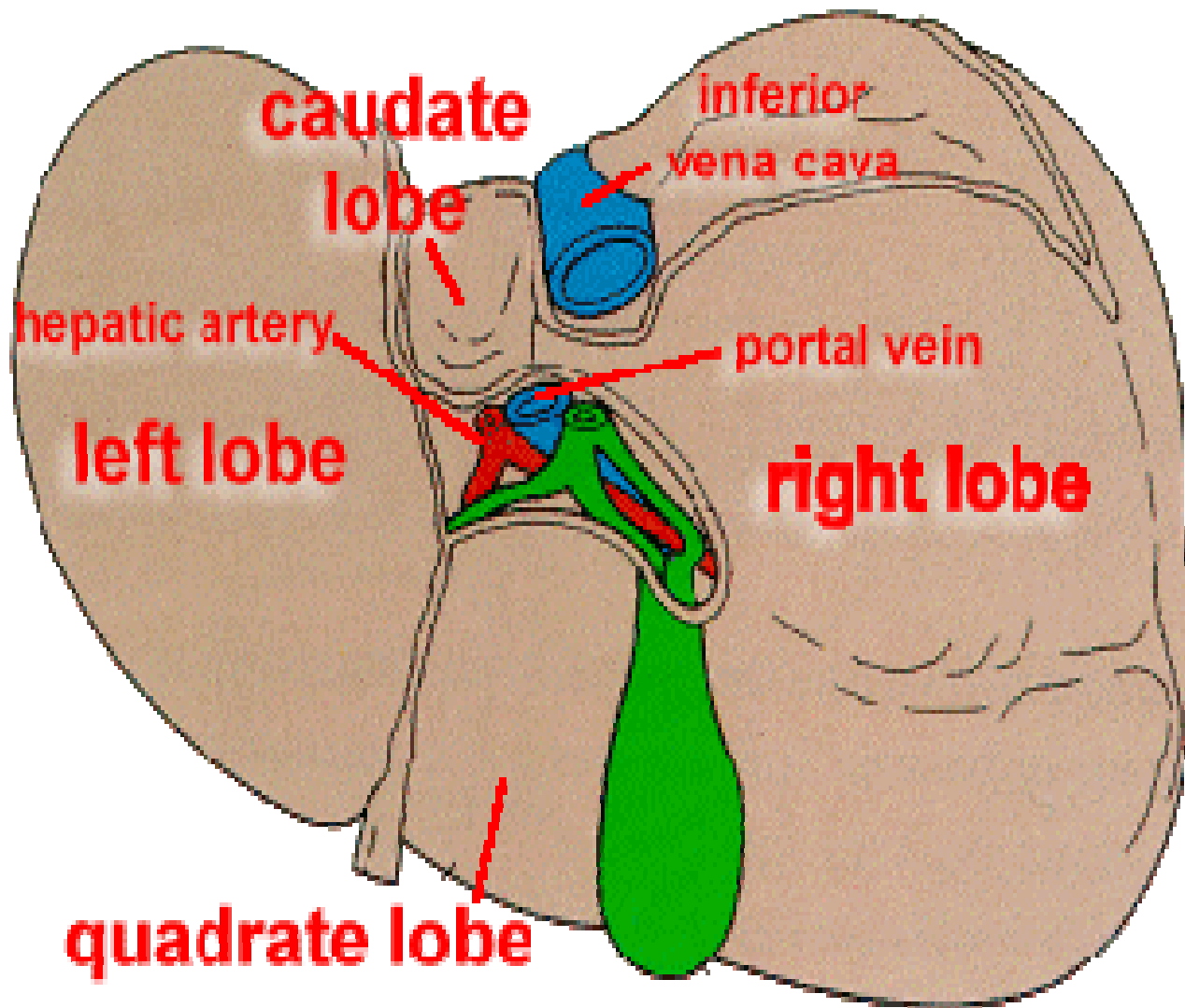
✓ Ligaments

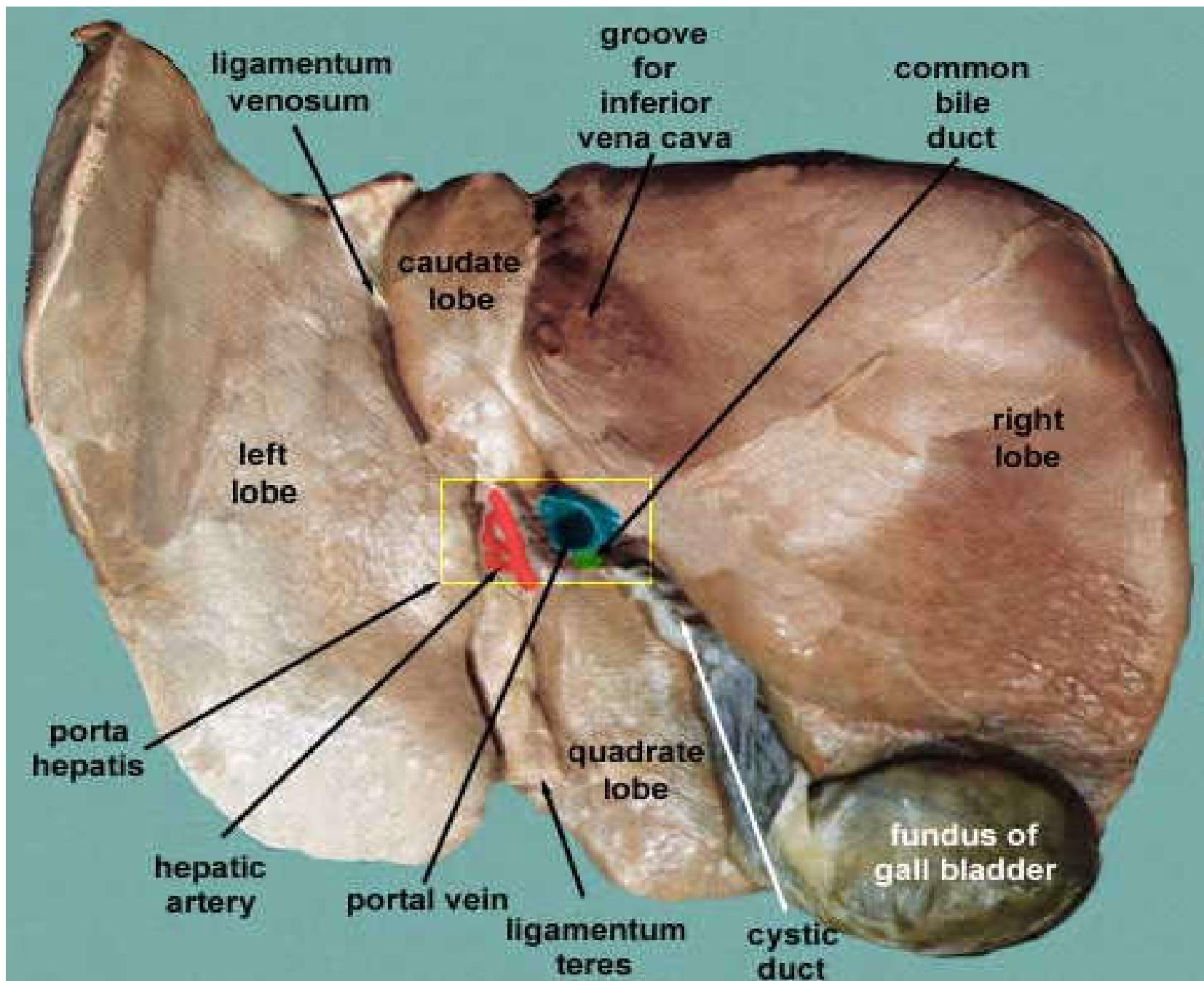
- it is used to fix the liver in permanent position which are attached to the diaphragm or other vital organs.
- In ruminants → 6 type of ligaments:
 - *Coronary ligaments*
 - *Falciform ligaments*
 - *Round ligaments*
 - *Right ligaments*
 - *Lateral ligaments and*
 - *Caudate ligaments*

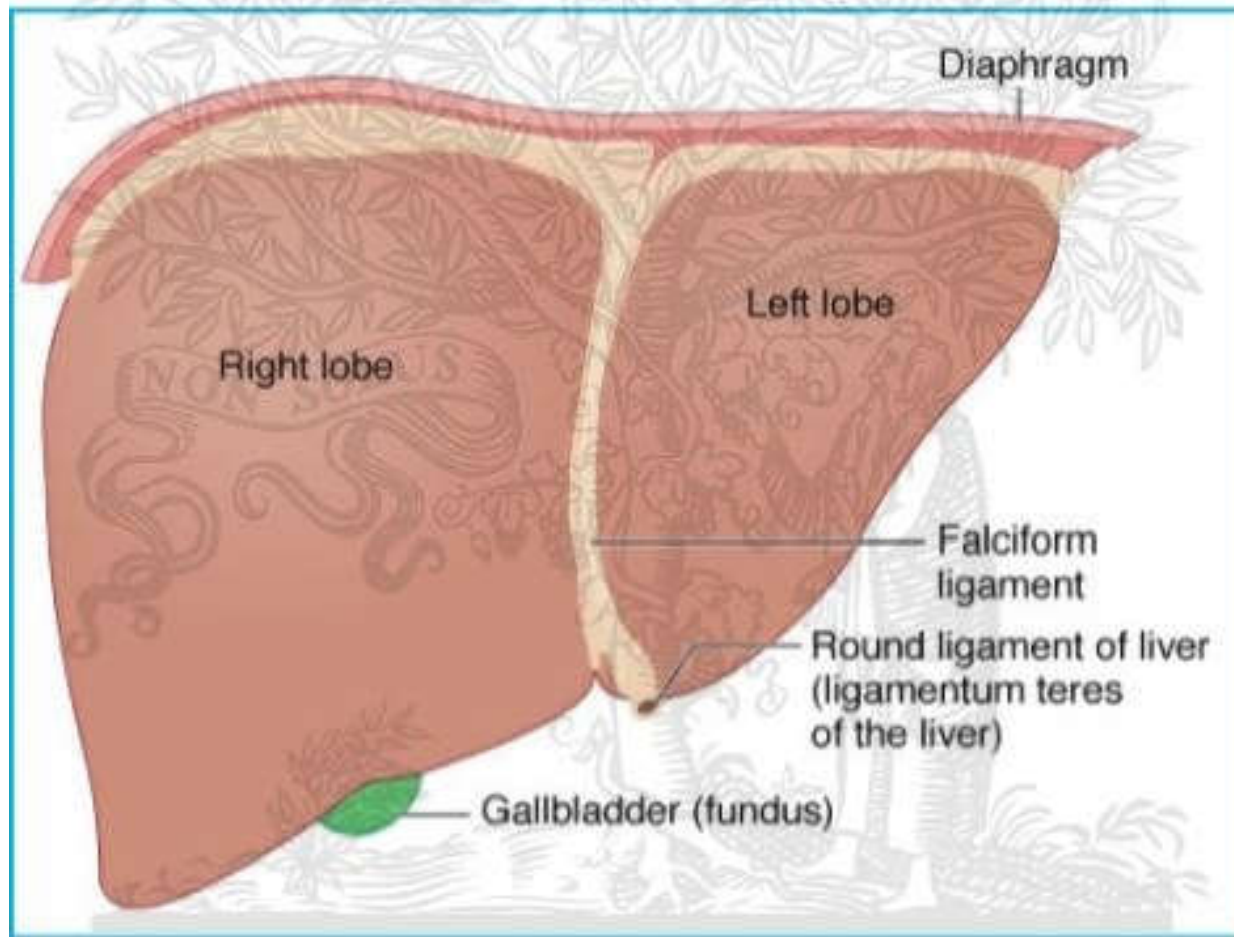
- In horses → **also 6** type of ligaments:
 - *Coronary ligaments*
 - *Falciform ligaments*
 - *Round ligaments*
 - *Right ligaments*
 - *Left ligaments and*
 - *Caudate ligaments*

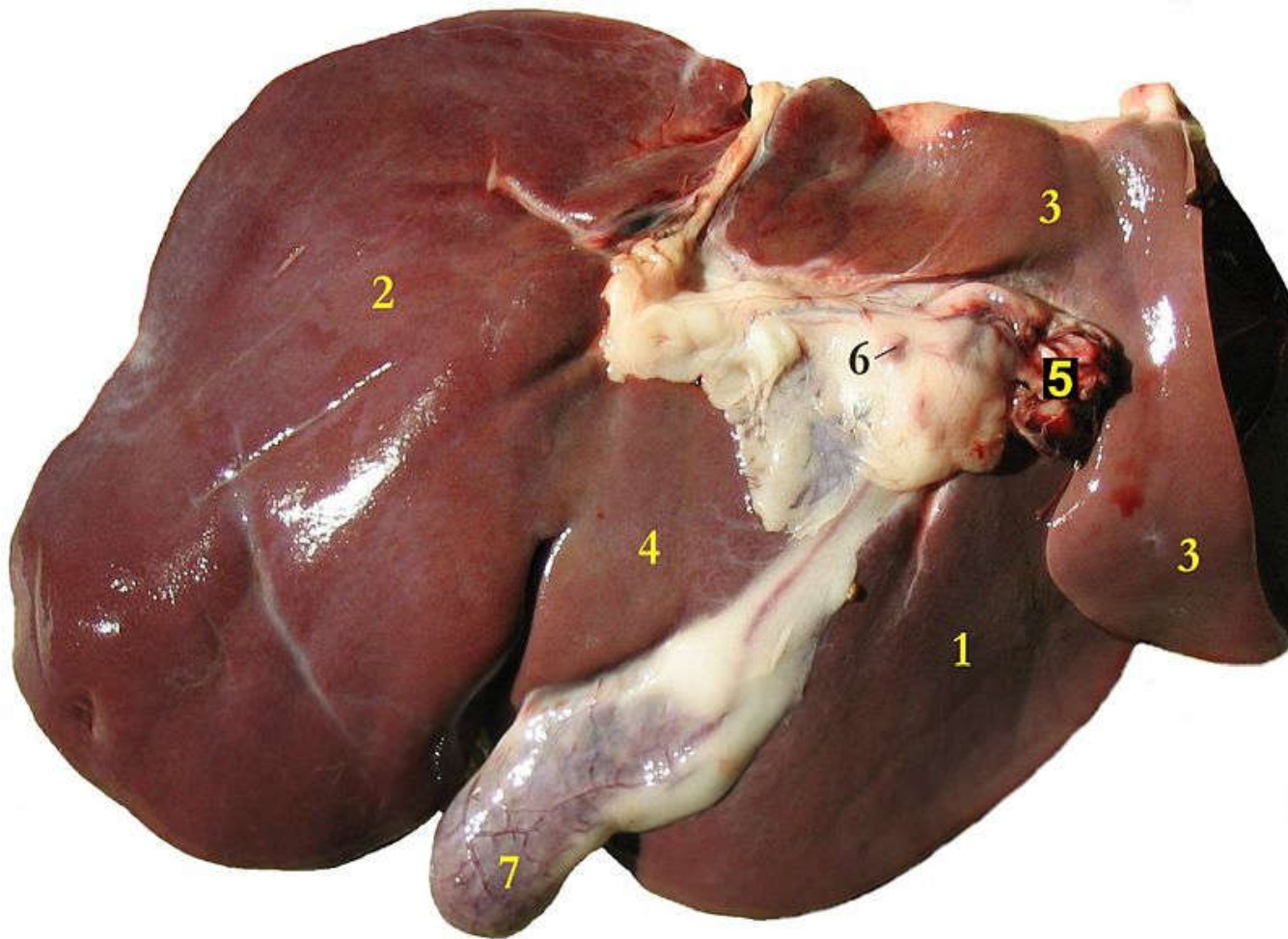
✓ **Gall bladder**

- Is a pear shaped sac used to store bile.
- It lies on the visceral surface of liver.
- All domestic animals except **horse and camel** have gall bladder for storage of bile. So, there is continuous digestion of food due to the presence of continuous flow of bile in case of horses and camels.





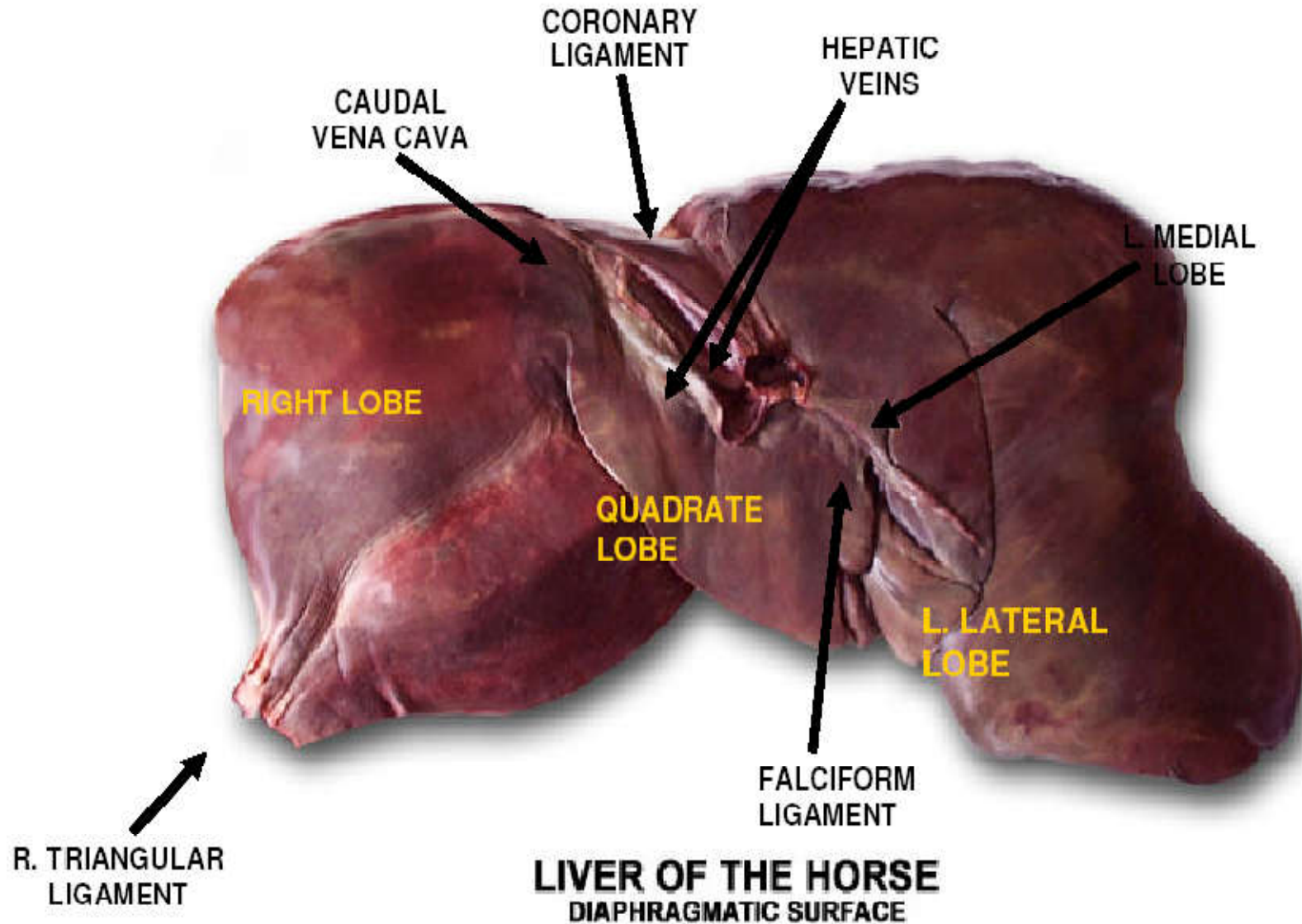




Liver of a sheep (its visceral surface):

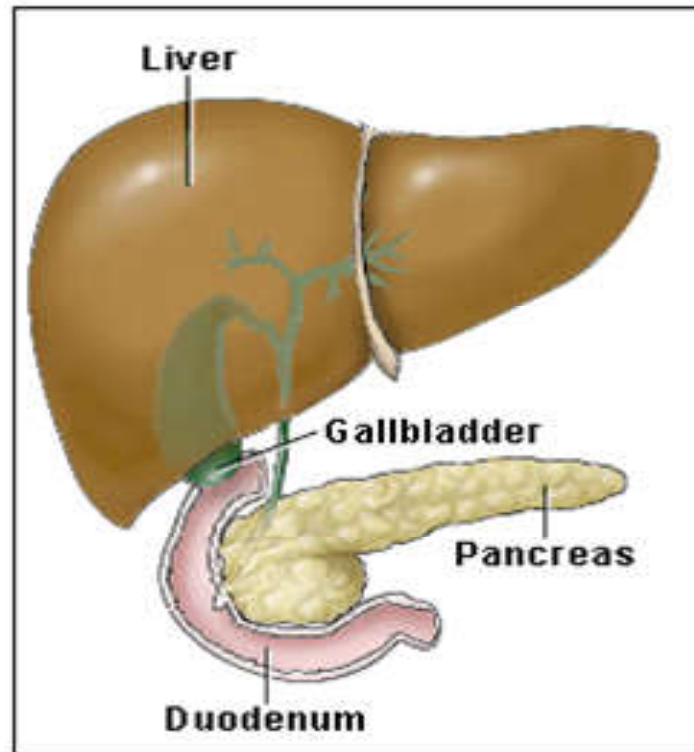
(1) right lobe, (2) left lobe, (3) caudate lobe, (4) quadrate lobe,
(5) hepatic artery and portal vein, (6) hepatic lymph nodes, (7)
gall bladder

There is no gall bladder associated with the liver of the horse, hence there is no cystic duct.



6.8.3. Pancreas

- ✓ Is a gland located near the stomach and attached to the wall of the first part of the small intestine (i.e., duodenum).
- ✓ It appears grossly as an irregular lobulated organ, yellowish in color.



- ✓ The pancreas has two major functions.
 - It produces hormones to aid in the maintenance of a proper blood sugar (glucose) level.
 - It also produces important enzymes to aid in the digestion of protein and fats (lipids).
 - These enzymes travel from the pancreas to the duodenum through a small tube called the **pancreatic duct**.
- ✓ The pancreas have both endocrine and exocrine portions which is also called as compound gland for that. The **exocrine** portion is the larger of the two parts.
- ✓ The functional units of the endocrine part are the *islets of Langerhans*.
- ✓ The endocrine cells are scattered between exocrine cells and they are the source of **insulin and glucagon**.

- ❖ Hormonal or endocrine function (insulin and glucagon)
 - The glucose-regulating hormones produced by the pancreas are insulin and glucagon. When starches and carbohydrates are eaten → broken down into the sugar glucose → The glucose is absorbed through the wall of the digestive tract → joins the bloodstream.
 - Insulin allows glucose to leave the bloodstream and enter the body's tissues. Glucose can then be utilized as energy for the cells.
 - When glucose levels are high, glucagon causes the glucose to be stored in the liver and muscles as glycogen. If not enough insulin is produced, diabetes mellitus can occur.

- ❖ Digestive or exocrine function (trypsin, chymotrypsin, and lipases)
 - The pancreas produces the protein-digesting enzymes **trypsin** and **chymotrypsin**.
 - It also produces fat digesting enzymes called **lipases**.

- Digestion is the great secret of life!!!!
- Thanks in advance for your attention and good commitment and dedication
- Wish you all the best for academic journey