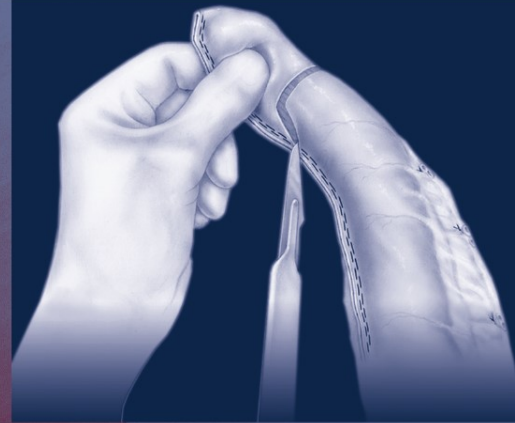

J. R. IZBICKI  
D. C. BROERING  
E. F. YEKEBAS  
A. KUTUP

A. F. CHERNOUSOV  
Y. I. GALLINGER  
P. M. BOGOPOLSKI  
N. SOEHENDRA  
Editors

# Surgery of the Esophagus

Textbook and Atlas  
of Surgical Practice



STEINKOPFF  
VERLAG



Springer

# **Surgery of the Esophagus**

---

**Textbook and Atlas of Surgical Practice**

**Editors**

J. R. IZBICKI  
D. C. BROERING  
E. F. YEKEBAS  
A. KUTUP

A. F. CHERNOUSOV  
Y. I. GALLINGER  
P. M. BOGOPOLSKI  
N. SOEHENDRA

# **Surgery of the Esophagus**

**Textbook and Atlas  
of Surgical Practice**

WITH 394 DRAWINGS IN 564 SEPARATE ILLUSTRATIONS

STEINKOPFF  
VERLAG

 Springer

## Drawings

FRANZISKA VON ASPERN

PETER VON ASPERN

ALFONS EUGEN DREWS

KATHARINA SCHUMACHER

S. STÄMPFLI

M. LÜCK

## ISBN 978-3-7985-1309-9 Steinkopff Verlag

Bibliographic information published by Die Deutsche Nationalbibliothek  
Die Deutsche Bibliothek lists this publication in the Deutsche Nationalbibliografie;  
detailed bibliographic data is available in the Internet at <http://dnb.d-nb.de>.

This work is subject to copyright. All rights are reserved, whether the whole or part of the material is concerned, specifically the rights of translation, reprinting, reuse of illustrations, recitation, broadcasting, reproduction on microfilm or in any other way, and storage in data banks. Duplication of this publication or parts thereof is permitted only under the provisions of the German Copyright Law of September 9, 1965, in its current version, and permission for use must always be obtained from Steinkopff Verlag. Violations are liable for prosecution under the German Copyright Law.

Steinkopff Verlag  
a member of Springer Science+Business Media

[www.steinkopff.com](http://www.steinkopff.com)

© Steinkopff Verlag 2009  
Printed in Germany

The use of general descriptive names, registered names, trademarks, etc. in this publication does not imply, even in the absence of a specific statement, that such names are exempt from the relevant protective laws and regulations and therefore free for general use.

Product liability: The publishers cannot guarantee the accuracy of any information about the application of operative techniques and medications contained in this book. In every individual case the user must check such information by consulting the relevant literature.

Medical Editors: Dr. med. Gertrud Volkert, Petra Elster  
Production Editor: Klemens Schwind  
Cover design: Erich Kirchner, Heidelberg  
Typesetting: K+V Fotosatz GmbH, Beerfelden  
Printing and binding: Stürtz GmbH, Würzburg

SPIN 10783278

105/7231-5 4 3 2 1 0 – Printed on acid-free paper

Dedicated to

Prof. Dr. med. Dr. h.c.

HANS-WILHELM SCHREIBER (1924–2004)

pioneer in upper gastrointestinal surgery

---

# Preface

While a surgeon many decades ago treated diseases from head to toe, this concept has evolved, and today some degree of specialization is the rule worldwide. In many countries various boards for sub-specializations are designed, and after a broad training in general surgery, many young surgeons move on further into a specific field.

Knowledge of anatomy and precise surgical technique remain the foundation of high quality surgery. A knowledgeable surgeon, equipped with excellent theoretical and clinical skills, will only be accomplished when he or she masters the operative techniques of the practice of surgery. The legacy of an academic surgeon or a surgical teacher relies in great part on the transmission of his or her surgical abilities. Significant influence on the development in esophageal surgery arises from the surgical understanding of the anatomical and functional structures of the esophagus as well as the ongoing developments in the multidisciplinary management in this challenging field of surgery.

In bringing forth this atlas, we were motivated by the desire to create a comprehensive and educational atlas on esophageal diseases, emphasizing all details of pathophysiologies, diagnostic strategies, pre- and postoperative management, and operative techniques covering minimally invasive and open procedures ranging from straightforward to more complex procedures.

This Textbook and Atlas is intended for residents in surgery and for fellows specializing in esophageal surgery preparing themselves for the operation, and will be useful for specialists and general surgeons, who may compare their techniques with the one described herein or find some additional help or tricks when performing rare procedures.

In summary, we hope that specialists as well as surgeons at various levels of training will benefit from this huge effort, combining the work of many experts, gifted artists, and the publisher.

THE EDITORS

# Contents

## Basic Principles of Esophageal Surgery

<b>1</b>	<b>Surgical Anatomy of the Esophagus</b> .....	3
	D. C. BROERING, J. WALTER, Z. HALATA	
	■ Topography of the esophagus .....	3
	■ Development of the esophagus .....	4
	■ Structure of the esophagus .....	9
<b>2</b>	<b>The Esophagus</b>	
	<b>Diagnostic Methods of Examination</b> .....	11
	G. KRUPSKI, V. NICOLAS	
	■ Conventional methods of examination .....	11
	■ Diverticula .....	11
	■ Achalasia .....	12
	■ Gastroesophageal reflux and hernias .....	13
	■ Varices .....	13
	■ Foreign bodies .....	14
	■ Esophageal tumors .....	14
	■ CT and MRI .....	16
<b>3</b>	<b>Endoscopic Examination of the Esophagus</b> .....	19
	K. F. BINMOELLER, B. BRAND, N. SOEHENDRA	
	■ Introduction .....	19
	■ Equipment and normal anatomy .....	19
	■ Malignant tumors .....	19
	■ Benign tumors .....	20
	■ Esophagitis .....	21
	■ Complications of esophagitis .....	22
	■ Varices and other sources of upper gastrointestinal bleeding .....	22
	■ Diverticula .....	23
	■ Achalasia and other motor disorders .....	23
	■ References .....	24

<b>4</b>	<b>Role of Endoscopic Ultrasound for Diagnosis and Staging of Esophageal Cancer</b> .....	25
	A. FRITSCHER-RAVENS, M.X. PELLING	
■	Introduction .....	25
■	Principles of EUS tumor staging .....	25
■	Examination technique and instrumentation .....	27
■	EUS compared to other imaging techniques .....	29
■	EUS and tumor stenosis .....	30
■	EUS and re-staging of esophageal cancer .....	31
■	Endoscopic ultrasound in early tumor stages .....	31
■	Endoscopic ultrasound guided fine needle aspiration .....	32
■	Conclusion .....	34
■	References .....	34
<b>5</b>	<b>Preoperative Evaluation of the Operative Risk Profile</b> .....	39
	K. A. GAWAD, C. BUSCH, D.C. BROERING, E. F. YEKEBAS	
■	Introduction .....	39
■	Definition of “risk” .....	39
■	Methods of risk ascertainment .....	39
■	Measures for preoperative risk minimization .....	40
■	References .....	41
<b>6</b>	<b>Perioperative and Postoperative Management</b> .....	43
	J. SCHOLZ, P.H. TONNER, G. VON KNOBELSDORFF	
■	Preoperative evaluation .....	43
■	Postoperative phase .....	48
■	References .....	49
<b>7</b>	<b>Pathophysiology of Gastroesophageal Reflux Disease and Indication for Surgical Therapy</b> .....	51
	K.-H. FUCHS	
■	Introduction .....	51
■	Definition .....	51
■	The antireflux barrier .....	52
■	Esophageal peristalsis .....	53
■	Mucosal resistance .....	54
■	Duodeno-gastroesophageal reflux .....	54
■	Gastroduodenal disorders .....	54
■	Indication for surgery .....	54
■	Conclusions .....	55
■	References .....	55



<b>8</b>	<b>Gastroesophageal Reflux and its Surgical Management</b> . . . . .	59
	G. G. JAMIESON, D. I. WATSON	
	■ Introduction . . . . .	59
	■ Which patients should be considered for antireflux surgery? . . . . .	59
	■ What are the advantages and disadvantages of antireflux surgery? . . . . .	60
	■ Operations available . . . . .	61
	■ Traditional open fundoplication . . . . .	61
	■ Laparoscopic fundoplication . . . . .	62
	■ Laparoscopic versus open surgery . . . . .	64
	■ Randomized trials of laparoscopic antireflux surgery . . . . .	65
	■ Controversies and questions in regard to laparoscopic antireflux surgery	65
	■ Why do antireflux operations sometimes fail . . . . .	66
	■ When do antireflux operations fail? . . . . .	67
	■ Re-operative surgery for failed antireflux procedures . . . . .	67
	■ References . . . . .	68
<b>9</b>	<b>Pathologic Classification of the Esophageal Carcinoma</b> . . . . .	71
	P. HERMANEK	
	■ Tumor classification . . . . .	71
	■ Tumor site . . . . .	71
	■ Typing . . . . .	72
	■ Grading . . . . .	72
	■ TNM/pTNM classification . . . . .	73
	■ Requirement for pTNM classification of esophageal carcinoma (UICC 2002, 2003) . . . . .	73
	■ Additional descriptors and optional categories of the TNM system . . . . .	76
	■ Residual tumor (R) classification . . . . .	77
	■ Grading of histological regression after neoadjuvant treatment . . . . .	78
	■ Preconditions for adequate histopathological tumor classification . . . . .	79
	■ References . . . . .	79
<b>10</b>	<b>Lymphatic Dissemination and Principles of Lymph Node Dissection</b> . . . . .	81
	J. R. IZBICKI, A. REHDERS, A. KUTUP, C. BUSCH	
	■ Anatomy of the lymphatic system . . . . .	82
	■ Operative procedure . . . . .	85
	■ References . . . . .	86

<b>11</b>	<b>Rationale for Type of Resection in Cancer of the Esophagus and Gastroesophageal Junction</b> .....	89
	W. T. KNOEFEL, I. ALLDINGER, J. R. IZBICKI	
■	Tumor typing .....	89
■	Anatomic location .....	90
■	Cervical esophagus .....	90
■	Upper thoracic esophagus .....	90
■	Lower thoracic esophagus .....	91
■	Tumors of the gastroesophageal junction .....	91
■	Limited resections .....	93
■	Palliative esophageal resection .....	93
■	Recurrences .....	93
■	Summary .....	93
■	References .....	93
<b>12</b>	<b>Results of Extended en bloc Esophagectomy in Treatment of Patients with Esophageal Cancer</b> .....	97
	D. I. WATSON, G. G. JAMIESON	
■	Rationale for extended en bloc esophagectomy .....	97
■	Proposed advantages and disadvantages for extended en bloc esophagectomy .....	98
■	Results of standard esophagectomy .....	98
■	Results of 2 field (en bloc) esophagectomy .....	99
■	Results of extended 3 field esophagectomy .....	100
■	Case selection and peri-operative outcomes for 3 field esophagectomy .	100
■	Complications following 3 field esophagectomy .....	101
■	Lymph node metastases to the cervical nodes found by 3 field lymphadenectomy .....	101
■	Survival following esophagectomy .....	101
■	Randomized trials of extended 3 field esophagectomy versus 2 field en bloc esophagectomy .....	102
■	Use of 3 field en bloc esophagectomy for adenocarcinoma of the esophagus .....	104
■	Conclusions .....	104
■	References .....	104

## Surgical Techniques

- 13 Blunt Transhiatal Subtotal Esophagectomy with Gastroplasty and Cervical Anastomosis** ..... 109  
 E. F. YEKEBAS, A. F. CHERNOUSOV, D. C. BROERING, P. M. BOGOPOLSKI,  
 C. F. EISENBERGER, A. KUTUP, J. R. IZBICKI
- Blunt transhiatal esophagectomy and substitution by gastric tube ..... 109
  - Complications of transhiatal blunt esophageal dissection and gastric pull-up ..... 155
- 14 Partial Abdominothoracic Resection of the Esophagus with Gastroplasty and Intrathoracic Anastomosis** ..... 157  
 A. F. CHERNOUSOV, A. KUTUP, P. M. BOGOPOLSKI, D. C. BROERING
- Indications ..... 157
- 15 Abdominothoracic Subtotal en bloc Esophagectomy and Reconstruction with Gastric Tube Transposition** ..... 171  
 J. R. IZBICKI, D. C. BROERING, P. KAUDEL, A. KUTUP, E. F. YEKEBAS
- 16 Fundus Rotation Gastroplasty** ..... 181  
 M. K. SCHILLING, M. W. BUECHLER
- 17 Proximal Gastrectomy with Distal Esophagectomy (Proximal Resection)** ..... 185  
 A. F. CHERNOUSOV, O. ZEHLER, P. M. BOGOPOLSKI, D. C. BROERING,  
 H. W. SCHREIBER†
- 18 Transhiatal Esophagogastrectomy** ..... 199  
 J. R. IZBICKI, D. C. BROERING, A. KUTUP, E. F. YEKEBAS
- 19 Colon Interposition after Total and Subtotal Esophagectomy** ..... 205  
 J. R. IZBICKI, K. STEFFANI, A. F. CHERNOUSOV, P. M. BOGOPOLSKI,  
 D. C. BROERING, H. W. SCHREIBER †
- Complications after subtotal or total esophagectomy with colonic interposition ..... 222
- 20 Intrathoracic Esophagoplasty by Colon Interposition** ..... 223  
 A. F. CHERNOUSOV, P. M. BOGOPOLSKI, H. W. SCHREIBER†, D. C. BROERING
- 21 Reconstruction of Gastrointestinal Continuity by Jejunal Interposition following Total and Subtotal Esophagectomy** ..... 233  
 A. F. CHERNOUSOV, P. SCHURR, P. M. BOGOPOLSKI, D. C. BROERING,  
 H. W. SCHREIBER†

<b>22</b>	<b>Limited en bloc Resection of the Gastroesophageal Junction with Isoperistaltic Jejunal Interposition</b> . . . . .	247
	J.R. IZBICKI, W.T. KNOEFEL, D.C. BROERING	
<b>23</b>	<b>Conventional Cardiomyotomy in Achalasia</b> . . . . .	253
	K.A. GAWAD, D.C. BROERING, C. BUSCH	
<b>24</b>	<b>Surgical Technique in Gastroesophageal Reflux Disease – Conventional Approach</b> . . . . .	259
■	Introduction and Techniques in gastroesophageal reflux . . . . .	259
	K.A. GAWAD, D.C. BROERING, C. BLOECHLE, C. BUSCH	
■	Techniques in peptic stricture and hiatal hernia . . . . .	264
	A.F. CHERNOUSOV, P.M. BOGOPOLSKI, K.A. GAWAD	
<b>25</b>	<b>Conventional Resection of Esophageal Diverticula</b> . . . . .	275
	A.F. CHERNOUSOV, C.F. EISENBERGER, P.M. BOGOPOLSKI, J.R. IZBICKI, H.W. SCHREIBER †	
■	Epiphrenic diverticulum . . . . .	278
■	Preparation of a diaphragmatic flap for enforcement of the esophageal wall after resection of an epiphrenic diverticulum . . . . .	280
<b>26</b>	<b>Local Excision of Benign Esophageal Tumors</b> . . . . .	281
	A.F. CHERNOUSOV, A. KUTUP, P.M. BOGOPOLSKI, H.W. SCHREIBER †	
<b>27</b>	<b>Surgical Treatment of Esophageal Fistula and Perforation</b> . . . . .	283
	A.F. CHERNOUSOV, N. ROCH, P.M. BOGOPOLSKI, D.C. BROERING, H.W. SCHREIBER †	
■	Fistulas of the esophagus . . . . .	284
■	Cervical fistulas of the esophagus . . . . .	284
■	Intrathoracic esophago-tracheal fistula . . . . .	286
■	Intrathoracic fistulas . . . . .	287
■	Intraabdominal fistulas of the esophagus . . . . .	288
■	Esophagopleural fistulas . . . . .	289
<b>28</b>	<b>Techniques of Local Esophagoplasty</b> . . . . .	293
	A.F. CHERNOUSOV, A. KUTUP, P.M. BOGOPOLSKI, H.W. SCHREIBER †	

<b>29</b>	<b>Minimal Invasive Surgery of the Esophagus</b> . . . . .	297
	H. FEUSSNER, R. BUMM, T. OLAH	
	■ Introduction . . . . .	297
	■ Diverticula of the esophagus . . . . .	297
	■ Minimal invasive treatment of esophageal motility disorders . . . . .	301
	■ Antireflux surgery . . . . .	303
	■ Excision of benign tumors . . . . .	307
	■ Minimally invasive procedures in esophageal carcinoma . . . . .	308
<b>30</b>	<b>Endoscopic Technique in the Treatment of Esophageal Diseases</b> . . . . .	315
	Y.I. GALLINGER, M. REHNER, F.M. STEICHEN, N. SOEHENDRA	
	■ Hemorrhage and esophageal varices . . . . .	315
	■ Foreign bodies and bolus obstruction . . . . .	324
	■ Resection of tumors . . . . .	327
	■ Photodynamic therapy of tumors (PDT) . . . . .	333
	■ Obstructions by malignant tumors . . . . .	335
	■ Esophageal fistula . . . . .	341
	■ Dilatation of benign stenoses . . . . .	345
	■ Stenotic esophageal anastomoses and membranes (webs) . . . . .	348
	■ Achalasia . . . . .	351
	■ Diverticula . . . . .	355
	■ References . . . . .	357
<b>31</b>	<b>Post-operative Complications of the Esophagus and Esophagus Bridge Graft</b> . . . . .	361
	D.C. BROERING, J.R. IZBICKI, Y. VASHIST, A.F. CHERNOUSOV, P.M. BOGOPOLSKI, E.F. YEKEBAS	
	■ Early post-operative complications . . . . .	361
	■ Late post-operative complications . . . . .	367
	<b>Subject Index</b> . . . . .	373

## Editors and Authors

INGO ALLDINGER, MD  
Department of General-,  
Visceral- and Pediatric Surgery  
Heinrich-Heine-University of Düsseldorf  
Moorenstrasse 5  
40225 Düsseldorf, Germany

KENNETH F. BINMOELLER, MD  
Center for Complex Digestive  
2333 Buchanan Street  
San Francisco, CA 94115, USA

CHRISTIAN BLOECHLE, MD  
Department of General  
and Visceral Surgery  
Sana Kliniken Lübeck GmbH  
Kronsfordter Allee 71-73  
23560 Lübeck, Germany

PAVEL M. BOGOPOLSKI, MD  
Department for Thoracic  
& Abdominal Surgery  
National Research Centre of Surgery  
Abrikosovski pereulok 2  
Moscow, 119992, Russia

BORIS BRAND, MD  
Medical Center Hammoniabad  
Lerchenfeld 14  
22081 Hamburg, Germany

DIETER C. BROERING, MD  
Department of General  
and Thoracic Surgery  
Christian-Albrechts-University Kiel  
Olshausenstrasse 40  
24118 Kiel, Germany

MARKUS W. BUECHLER, MD  
Department of General,  
Visceral and Transplantation Surgery  
Universitätsklinikum Heidelberg  
Im Neuenheimer Feld 672  
69120 Heidelberg, Germany

RUDOLF BUMM, MD  
Department of Surgery  
Klinikum rechts der Isar  
TU München  
Ismaninger Strasse 22  
81675 München, Germany

CHRISTOPH BUSCH, MD  
Department of General,  
Visceral and Thoracic Surgery  
University Hospital Hamburg Eppendorf  
Martinistrasse 52  
20246 Hamburg, Germany

ALEXANDR F. CHERNOUSOV, MD  
Department for Thoracic  
& Abdominal Surgery  
National Research Centre of Surgery  
Abrikosovski pereulok 2  
Moscow, 119992, Russia

CLAUS F. EISENBERGER, MD  
Department of General-,  
Visceral- and Pediatric Surgery  
Heinrich-Heine-University of Düsseldorf  
Moorenstrasse 5  
40225 Düsseldorf, Germany

HUBERTUS FEUSSNER, MD  
Department of Surgery  
Klinikum rechts der Isar  
TU München  
Ismaninger Strasse 22  
81675 München, Germany

ANNETTE FRITSCHER-RAVENS, MD  
St. Mary's Hospital  
Imperial College  
Praed Street  
London W2 1NY, UK

KARL-HERMANN FUCHS, MD  
Department of Surgery  
Markus-Krankenhaus  
Frankfurter Diakonie-Kliniken  
Wilhelm-Epstein-Straße 2  
60431 Frankfurt am Main, Germany

YURY I. GALLINGER, MD  
Department for Endoscopic Surgery  
National Research Centre of Surgery  
Abrikosovsky pereulok 2  
Moscow, 119992, Russia

KARIM A. GAWAD, MD  
Department of General,  
Visceral and Thoracic Surgery  
University Hospital Hamburg Eppendorf  
Martinistrasse 52  
20246 Hamburg, Germany

ZDENĚK HALATA, MD  
Institute of Anatomy  
First Medical Faculty  
Charles University in Prague  
U Nemocnice 3  
128 00 Praha 2, Czech Republic

PAUL HERMANEK, MD  
Department of Surgery  
University Hospital Erlangen  
Krankenhausstrasse 12  
91054 Erlangen, Germany

JAKOB R. IZBICKI, MD  
Department of General,  
Visceral and Thoracic Surgery  
University Hospital Hamburg Eppendorf  
Martinistrasse 52  
20246 Hamburg, Germany

GLYN G. JAMIESON, MD  
Discipline of Surgery  
University of Adelaide  
Royal Adelaide Hospital  
North Terrace  
Adelaide, S.A. 5000 Australia

PHILIPP KAUDEL, MD  
Department of General,  
Abdominal and Transplant Surgery  
Hannover Medical School  
Carl-Neuberg-Strasse 1  
30625 Hannover, Germany

GEORG VON KNOBELSDORFF, MD  
Department of Anaesthesiology  
St. Bernward Krankenhaus  
Treibstrasse 9  
31134 Hildesheim, Germany

WOLFRAM T. KNOEFEL, MD  
Department of General-,  
Visceral- and Pediatric Surgery  
Heinrich-Heine-University of Düsseldorf  
Moorenstrasse 5  
40225 Düsseldorf, Germany

GERRIT KRUPSKI-BERDIEN, MD  
Department of Radiology  
Hospital Reinbek St. Adolph-Stift  
Hamburgerstrasse 41  
21465 Reinbek, Germany

ASAD KUTUP, MD  
Department of General,  
Visceral and Thoracic Surgery  
University Hospital Hamburg Eppendorf  
Martinistrasse 52  
20246 Hamburg, Germany

VOLKMAR NICOLAS, MD  
Department of Radiology  
and Nuclear Medicine  
University Bochum  
Bürkle de la Camp-Platz 1  
44789 Bochum, Germany

TIBORNÉ OLAH, MD  
Department of Surgery  
University Szeged  
Kalvaria sgt. 57  
6725 Szeged, Hungary

MARK X. PELLING, MD  
St. Mary's Hospital  
Imperial College  
Praed Street  
London W2 1NY, UK

ALEXANDER REHDERS, MD  
Department of General-,  
Visceral- and Pediatric Surgery  
Heinrich-Heine-University of Düsseldorf  
Moorenstrasse 5  
40225 Düsseldorf, Germany

MANFRED REHNER, MD  
Rehmkoppel 39b  
22391 Hamburg, Germany

NADINE ROCH, MD  
Department of General,  
Visceral and Thoracic Surgery  
University Hospital Hamburg Eppendorf  
Martinistrasse 52  
20246 Hamburg, Germany

MARTIN K. SCHILLING, MD  
Department of General Surgery,  
Abdominal and Vascular Surgery  
and Paediatric Surgery  
Saarland University Hospital  
Kirrberger Straße  
66421 Homburg/Saar, Germany

JENS SCHOLZ, MD  
Department of Anaesthesiology  
and Operative Medicine  
University Hospital Schleswig-Holstein,  
Campus Kiel  
Schwanenweg 21  
24105 Kiel, Germany

HANS-WILHELM SCHREIBER †, MD  
Department of General,  
Visceral and Thoracic Surgery  
University Hospital Hamburg Eppendorf  
Martinistrasse 52  
20246 Hamburg, Germany

PAULUS SCHURR, MD  
Department of General,  
Visceral and Thoracic Surgery  
University Hospital Hamburg Eppendorf  
Martinistrasse 52  
20246 Hamburg, Germany

NIB SOEHENDRA, MD  
Department of Interdisciplinary Endoscopy  
University Hospital Hamburg Eppendorf  
Martinistrasse 52  
20246 Hamburg, Germany

KATHARINA STEFFANI, MD  
Department of General,  
Visceral and Thoracic Surgery  
University Hospital Hamburg Eppendorf  
Martinistrasse 52  
20246 Hamburg, Germany

FELICIEN M. STEICHEN, MD  
Institute for Minimally Invasive Surgery  
303 North Street, Suite 103  
White Plains  
New York, 10605, USA

PETER H. TONNER, MD  
Department of Anaesthesiology  
Herzzentrum Bremen  
Klinikum Links der Weser  
Senator-Weßling-Straße 1  
28277 Bremen, Germany

YOGESH VASHIST, MD  
Department of General,  
Visceral and Thoracic Surgery  
University Hospital Hamburg Eppendorf  
Martinistrasse 52  
20246 Hamburg, Germany

JESSICA WALTER, MD  
Department of General and Thoracic Surgery  
Christian-Albrechts-University Kiel  
Olshausenstrasse 40  
24118 Kiel, Germany

DAVID I. WATSON, MD  
Discipline of Surgery  
University of Adelaide  
Royal Adelaide Hospital  
North Terrace  
Adelaide, S.A. 5000 Australia

EMRE F. YEKEBAS, MD  
Department of General,  
Visceral and Thoracic Surgery  
University Hospital Hamburg Eppendorf  
Martinistrasse 52  
20246 Hamburg, Germany

OLIVER ZEHLER, MD  
Department of General,  
Visceral and Thoracic Surgery  
University Hospital Hamburg Eppendorf  
Martinistrasse 52  
20246 Hamburg, Germany



# **Basic Principles of Esophageal Surgery**

---

The esophagus is a part of the alimentary tract. It is a muscular tube approximately 25 cm long extending from the pharynx to the stomach. The esophagus begins at the lower margin of the cricoid cartilage opposite the sixth cervical vertebra and enters the gastric orifice at the level of the twelfth thoracic vertebra.

There are some morphological and physiological differences between the esophagus and the remaining parts of the gastrointestinal tract. The esophagus is the narrowest of the digestive tubes and is collapsed under resting conditions. The main function is to provide a proper transit of the food bolus from the pharynx into the stomach. Positioned in the posterior mediastinum, the esophagus is surrounded only by adventitial tissue. The muscular tube remains under permanent tension and is proximally secured by the upper esophageal sphincter and distally by the lower esophageal sphincter. These sphincters create a high-pressure zone of 2 to 4 cm in length. The upper sphincter prevents any continuous air flow into the digestive tube. The lower sphincter functions as a barrier against reflux of gastric juice into the esophagus. The closure of the upper and the lower sphincter is optimized by a submucous venous plexus. Both sphincters and additionally the passage through the muscular diaphragm describe 3 narrowings. Above these narrowings diverticula may occur due to areas of weakness in the muscular wall.

After deglutition starts with a pharyngeal phase, the esophageal phase of swallowing continues with a progressing peristaltic wave. The contraction is initiated in the external longitudinal muscle layer and results in shortening and dilating the esophagus simultaneously. Secondly, the circular muscle layer narrows the diameter of the esophagus. The peristaltic con-

traction moves down from oral to aboral at 2 to 4 cm per second. The transit time depends on the consistence of the food. The passage of liquids lasts for at least 1 to 2 seconds, mashed food for at least 5 seconds, and solid food needs a transit time of about 9 seconds to reach the cardiac orifice of the stomach.

## Topography of the esophagus

The esophagus passes through three compartments: the neck, the chest, and the abdomen. Therefore, it can be divided into a cervical, thoracic and abdominal segment.

■ **The cervical segment** ( $C_6$ - $Th_1$ ) of the esophagus begins as a continuation of the pharynx about 15 cm from the incisors. Lying prevertebral between the deep and the middle cervical fascia and anteriorly attached to the trachea, the course of the esophagus deviates slightly to the left.

■ **Relations.** Anteriorly, the trachea passes the cervical esophagus. The esophageal adventitia is attached to connective tissue of the membranous wall of the trachea and anchored to the trachea and the pleura by fibromuscular tissue bands. Posteriorly, the cervical esophagus is related to the longissimus cervicis muscles under the prevertebral fascia. Bilaterally, there are the common carotid arteries, the internal jugular veins, and the vagal nerves. The left side of the esophagus lies somewhat closer to the carotid bundle than the right. The dorsal parts of the thyroid gland are located bilaterally between the esophagus and the carotid arteries. The thoracic duct ascends for a short distance

along the left side of the esophagus before arriving to the left venous confluence. In a groove between the trachea and the esophagus, the recurrent nerves ascend on each side to the larynx.

■ **The thoracic segment** (Th<sub>1</sub>–Th<sub>10</sub>) of the esophagus descends from the superior mediastinum to the lower posterior mediastinum and turns slightly to the right of the spine. It courses behind the trachea from the superior mediastinum downward, where it is attached to the left main bronchus. The aortic arch which becomes the descending thoracic aorta runs on the left side of the esophagus. The thoracic aorta gives rise to branches from which this portion of the esophagus directly receives its blood supply.

■ **Relations.** The ventral thoracic esophagus is covered by the trachea and the left main stem bronchus. While descending, it passes the right pulmonary artery and touches the pericardium of the adjacent left atrium. Below the tracheal bifurcation a vagal plexus surrounds the esophageal wall. At the level of the diaphragm hiatus, the plexus gives rise to an anterior and a posterior vagal trunk. The anterior trunk passes downward on the ventral surface of the tube, and the posterior trunk runs on the dorsal esophageal wall.

In the superior mediastinum, the last part of the aortic arch with the left subclavian artery lies left of the esophagus. Further to the left, there are the thoracic duct and the left mediastinal pleura.

The thoracic aorta descends on the left side of the esophagus in the lower dorsal mediastinum. On the right side there is the mediastinal pleura and the azygos vein ascending from dorsal right to the upper mediastinum and draining into the superior vena cava.

The vertebral column, the thoracic duct, and the intercostal arteries are located dorsally. Directly above the diaphragm, the last part of the thoracic aorta crosses behind the esophagus.

■ **The abdominal segment** (Th<sub>10</sub>–Th<sub>11</sub>) is about 1.2–2.5 cm in length, it takes a conical course while running below the diaphragm from the esophageal hiatus to enter the cardiac part of the stomach. This abdominal portion lies in-

traperitoneal and is surrounded by a serosa coat.

■ **Relations.** Ventrally runs the anterior vagal trunk, the posterior vagal trunk is placed on the dorsal muscular wall. To its right, the esophagus lies in close contact to the left lobe of the liver, which forms an esophageal groove.

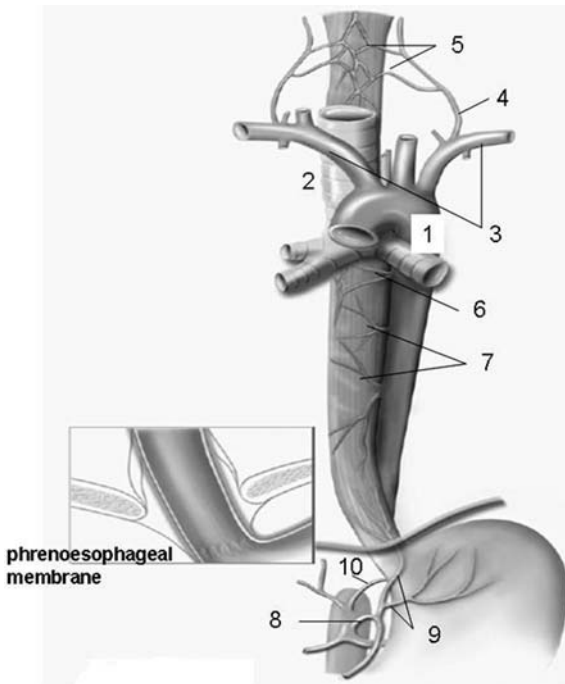
While running through the diaphragm, the esophagus is surrounded and attached by the phrenoesophageal membrane. This ligament consists endothoracically of the pleura, the subpleural fascia, and the phrenoesophageal fascia of Laimer. The subdiaphragmatic portion of the membrane consists of peritoneum and the transversalis fascia, blending into the adventitial coat of the abdominal esophagus. This membranous arrangement allows elastic mobility of the distal esophagus.

## Development of the esophagus

The esophagus is derived from the caudal part of the foregut just below the germ of the pharynx. In the fourth week of development, the caudal portion of the foregut builds a fusiform enlargement to mark the site of the future stomach. Above this dilatation, the tracheo-bronchial diverticula develop ventrally. In later periods, the development of a tracheoesophageal septum partitions the future trachea from the future esophagus. The trachea originates from the ventral part, the esophagus from the dorsal part of the membranous septum.

The endoderm of the primitive gut gives rise to the mucosal epithelium. The remaining layers are derived from mesenchyme of the caudal branchial arches and from the segmental splanchnic mesenchyme. Two thirds of the muscular esophageal wall contains striated muscle fibers. In the middle third both smooth and striated muscle fibers are represented. The lower third of the muscle coat is dominated by smooth muscle fibers only.

The **arterial blood supply** (Fig. 1.1) represents the complicated development and segmentation of the esophagus. The *cervical esophagus* receives its blood supply mainly from the inferior thyroïdal artery of the thyrocervi-



**Fig. 1.1.** Arterial supply of the esophagus. **1** Thoracic aorta; **2** trachea; **3** left and right subclavian artery; **4** inferior thyroid artery with (**5**) esophageal branches; **6** bronchial artery; **7** aortic esophageal arteries; **8** left gastric artery; **9** ascending branches of the left gastric artery; **10** ascending branches of the phrenic artery.

cal trunk and from the superior thyroidal artery. Together with branches of the tracheoesophageal artery, the vessels build a dense network of collateral anastomoses on both the anterior and posterior esophageal wall. In rare cases, the subclavian artery may give rise to an esophageal branch. The *thoracic esophageal segment* is proximally supplied by two to three bronchial arteries originating from the arch and the upper descending aorta. Distally, one or two esophageal arteries arise directly from the thoracic aorta. These vessels divide into one ascending and one descending branch some distance before entering the esophageal wall. The *abdominal esophagus* receives its arterial blood from the ascending branches of the left gastric and inferior phrenic arteries. The branches of the left gastric artery run on the lateral side of the cardia following the longitudinal axis of the esophagus. The dorsal wall of the distal esophagus is supplied by branches of the inferior phrenic arteries and

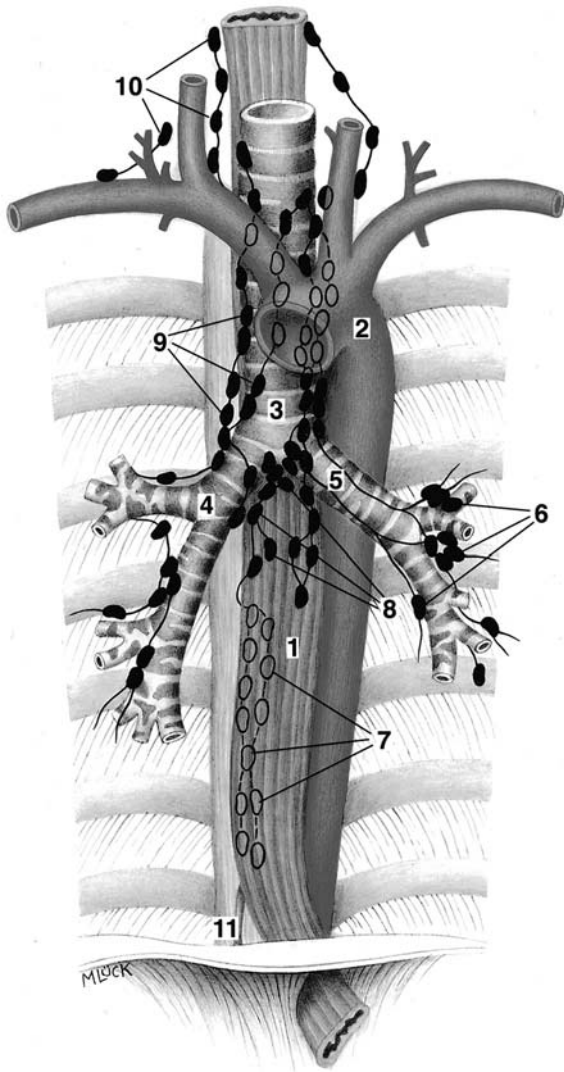
by branches of the splenic artery. All of the main esophageal arterial branches follow the longitudinal course of the esophagus after entering the submucosal layer. They form a longitudinal network and give rise to minute branches at right angles which surround the circumference to communicate with the opposite side. Altogether, the cervical, thoracic, and abdominal esophageal arterial branches are connected by a dense anastomosing submucosal network of small vessels. This network provides an adequate circulation during surgical mobilization.

The **venous drainage** continues the division into three segments. The veins of the cervical portion drain into the inferior thyroid vein. In the thoracic region, the blood empties into the azygos, hemiazygos, and the accessory hemiazygos veins. Caudally, the venous plexi of the abdominal esophagus return blood into the left gastric vein, and into the coronary vein. This communication belongs to the portocaval anastomoses. In case of portal venous obstruction, collateralization through the venous plexus may occur and result in esophageal varices.

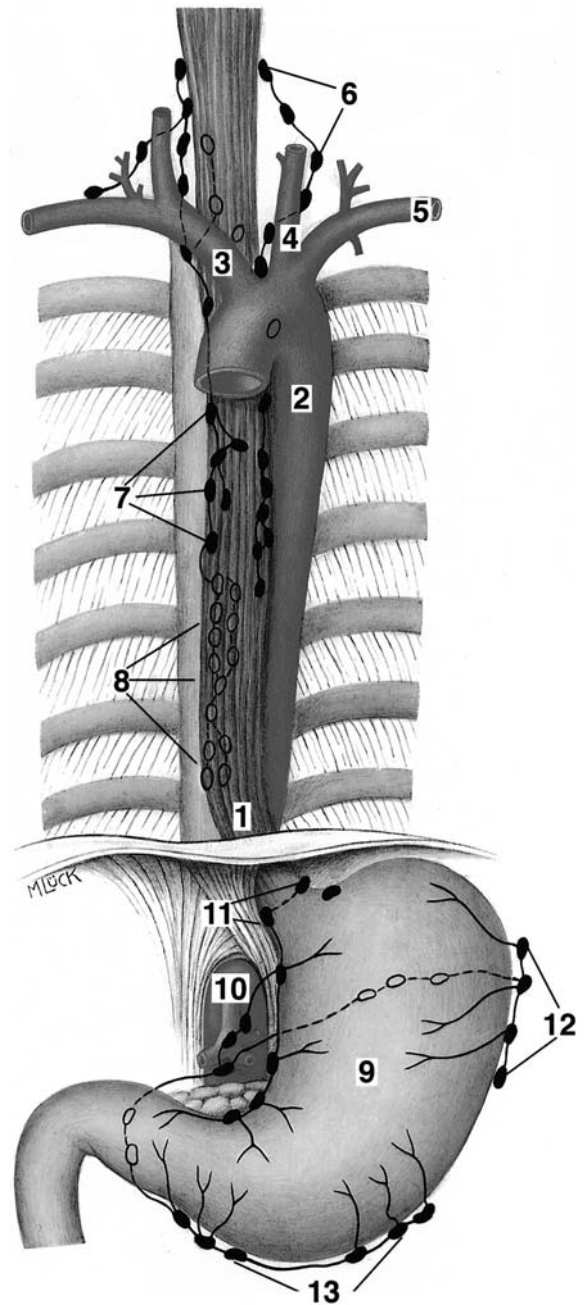
For clinical aspects and especially for therapy of malignant tumors, knowledge of the **lymphatic vessels** (Figs. 1.2–1.5, Table 1.1 and 1.2) and the regional lymph nodes is of immense importance. The lymphatic capillary vessels form a plexus in the submucosal layer of the esophageal wall. The flow of lymph runs mainly in a longitudinal direction. During contraction of the muscular tube, the lymph can flow bidirectionally, cranial and caudal. There can be a direct connection from lymphatic capillary vessels to the thoracic duct in the middle part of the esophagus.

Lymph ducts of the cervical esophagus drain mainly into the paraesophageal lymph nodes, lying laterally to the esophagus, and into the retropharyngeal lymph nodes, which are positioned behind the pharynx on the prevertebral fascia. These lymph nodes drain into the cervical lymph nodes, running with the external and internal jugular veins.

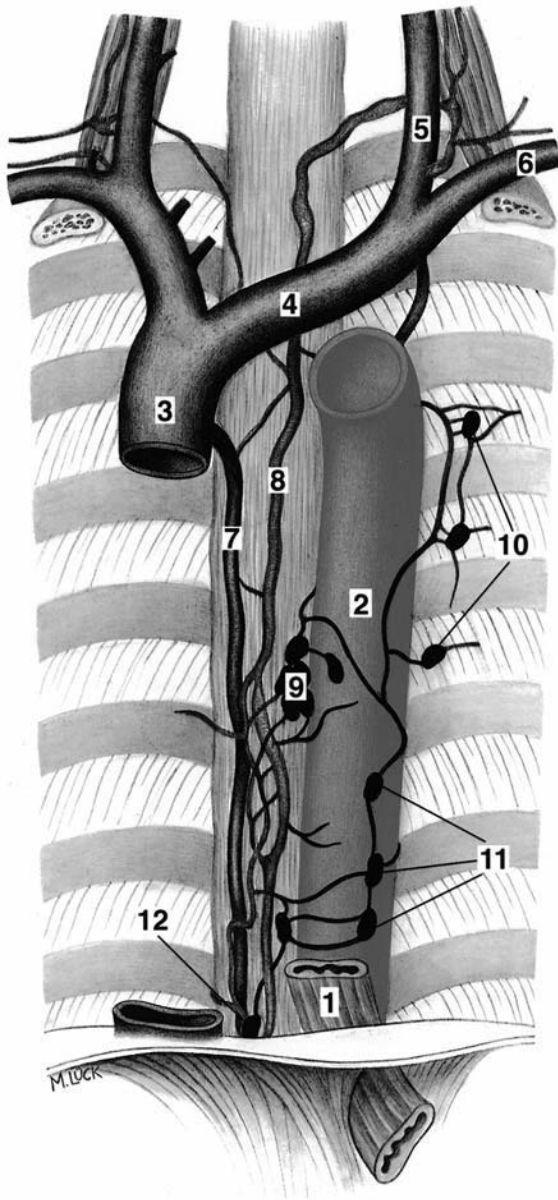
Lymph flow from the upper third of the mediastinal compartment enters the superior paraesophageal lymph nodes which are laterally attached to the esophagus, and the prevertebral lymph nodes, located caudally. In common, lymphatic drainage of the mid-third



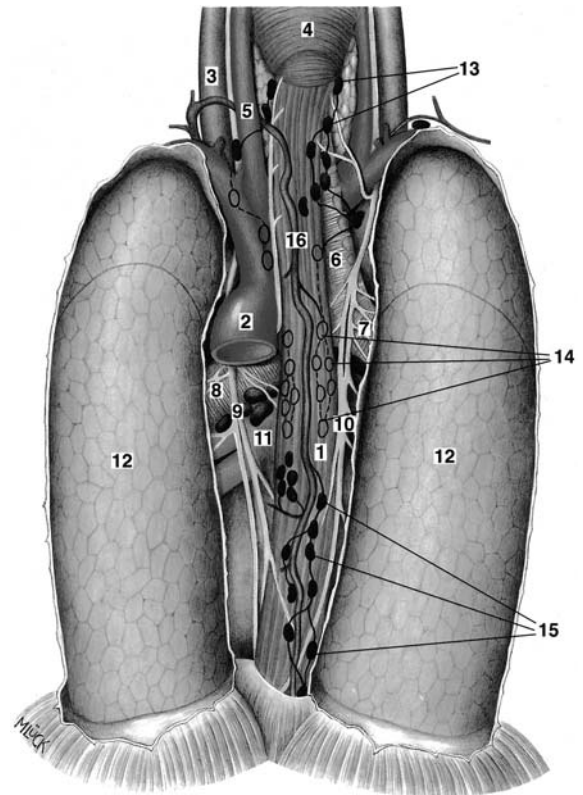
**Fig. 1.2.** Mediastinum – ventral view including esophagus (1), thoracic aorta (2) and trachea (3). 4 Right principal bronchus; 5 left principal bronchus; 6 nodi lymphatici bronchopulmonales; 7 nodi lymphatici juxtaesophageales pulmonales; 8 nodi lymphatici tracheobronchiales inferiores; 9 nodi lymphatici tracheobronchiales superiores; 10 nodi lymphatici mediastinales anteriores; 11 thoracic duct.



**Fig. 1.3.** Mediastinum – ventral view including esophagus (1) and thoracic aorta (2). 3 Brachiocephalic trunk; 4 left common carotid artery; 5 left subclavian artery; 6 nodi lymphatici mediastinales anteriores; 7 nodi lymphatici juxtaesophageales pulmonales; 8 nodi lymphatici prevertebrales; 9 anterior facies of the stomach; 10 celiac trunk with nodi lymphatici coeliaci; 11 nodi lymphatici gastrici sinistri; 12 nodi lymphatici pancreaticolienales; 13 nodi lymphatici gastroenterales.



**Fig. 1.4.** Mediastinum – ventral view including thoracic aorta (2) and thoracic duct (8). 1 Esophagus; 2 thoracic aorta; 3 superior vena cava; 4 brachiocephalic veins; 5 external jugular veins; 6 subclavian veins; 7 azygos vein; 8 thoracic duct; 9 nodi lymphatici prevertebrales (UICC-108 – nodi lymphatici paraesophageales mediales); 10 (nodi lymphatici intercostales – not constantly); 11 nodi lymphatici aortici; 12 nodi lymphatici phrenici.



**Fig. 1.5.** Mediastinum – dorsal view. 1 Esophagus; 2 descending aorta; 3 internal jugular vein; 4 pharynx; 5 common carotid artery; 6 trachea; 7 right principal bronchus; 8 left principal bronchus; 9 left vagus nerve; 10 right vagus nerve; 11 left pulmonary artery; 12 left and right lung; 13 nodi lymphatici retropharyngeales and nodi lymphatici paraesophageales; 14 nodi lymphatici tracheobronchiales inferiores; 15 nodi lymphatici juxtaesophageales pulmonales; 16 thoracic duct.

**Table 1.1.** Lymph nodes of the esophagus

Draining region	UICC	Anatomical nomenclature	Position
■ Cervical compartment	100	Nodi lymphatici cervicales laterales:	
	100	– superficiales	along the external jugular vein
	102	– profundi	along the internal jugular vein
	101	(Nodi lymphatici paraesophageales) Nodi lymphatici retropharyngeales	beside the esophagus inbetween the dorsal aspect of the pharynx and the prevertebral fascia
	103		
	104	Nodi lymphatici supraclaviculares	the lowest of the deep cervical lymph nodes
■ Mediastinal compartment	105, 108, 110	Nodi lymphatici prevertebrales	beside and
	105	(Nodi lymphatici paraesophageales superiores)	above
	108	(Nodi lymphatici paraesophageales mediales)	beside and behind the esophagus in the middle
	110	(Nodi lymphatici paraesophageales inferiores)	beside and behind the esophagus below
	106	Nodi lymphatici paratracheales	along the trachea
	107	Nodi lymphatici tracheobronchiales	inbetween the bifurcation of trachea along the principal bronchi
	109	Nodi lymphatici bronchopulmonales and hilares	at the pulmonary hilum
	111	Nodi lymphatici diaphragmatici superiores	along the attachment of the pericardium with the diaphragm
	112	Nodi lymphatici prevertebrales	along the caudal thoracic aorta
■ Perigastrical compartment	1 and 2	Nodi lymphatici gastrici sinistri	right and left to the cardia
	3	Nodi lymphatici gastrici dextri	along the lesser curvature
	4	Nodi lymphatici gastromentales	along the greater curvature
	5 and 6	Nodi lymphatici pylorici	above and below the pylorus
	7	Nodi lymphatici preaortici (coeliaci)	along the left gastric artery

courses into the medial paraesophageal lymph nodes and into the paratracheal, tracheobronchial and bronchopulmonary lymph nodes. However, it can also enter the thoracic duct directly in rare cases. Another course for the lymphatic pathway can be to the lymph nodes of the cranial or caudal compartment. The lymphatic flow from the lower mediastinal third runs to the inferior paraesophageal and prevertebral lymph nodes. Additionally, the superior diaphragmatic lymph nodes have to be mentioned. They rest on the diaphragm along the dorsal connection between the pericardium and the diaphragm.

Lymphatic flow from the abdominal segment empties into the left and right gastric lymph nodes along the lesser curvature and into the gastroomental, pyloric, and/or coeliacal lymph nodes along the greater curvature. The lymphatic pathways, the UICC and the anatomical nomenclature are summarized in a table.

The **innervation** of the esophagus is provided by both sympathetic and parasympathetic fibers. The sympathetic nerve supply is through the cervical and thoracic sympathetic chain. Commonly, the branches run with the arterial vessels. The parasympathetic nerve is primarily through the recurrent laryngeal

**Table 1.2.** Lymph nodes of the mediastinum

Anatomical nomenclature	Position	Draining region
■ Nodi lymphatici parasternales	along the internal thoracic vessels	Thoracic wall, mamma, diaphragm, pericardium, prepericardial lymph nodes
■ Nodi lymphatici mediastinales anteriores	aortic arch, brachiocephalic vein	Pericardium, thymus, parasternal lymph nodes
■ Nodi lymphatici prepericardiales	inbetween the sternum and the pericardium	Pericardium
■ Nodi lymphatici mediastinales posteriores:		
■ Nodi lymphatici juxtaesophageales pulmonales	along the esophagus	Esophagus, lung
■ Nodi lymphatici bronchopulmonales	pulmonary hilum	Lung and bronchi
■ Nodi lymphatici tracheobronchiales inferiores	inbetween the bifurcation of trachea	Lung, bronchi, trachea
■ Nodi lymphatici tracheobronchiales superiores	in the angle between the trachea and the principal bronchi	Lung, bronchi, trachea
■ Nodi lymphatici paratracheales	along the trachea	Trachea, esophagus
■ Nodi lymphatici prevertebrales	posterior mediastinum between the thoracic spine and the esophagus	Dorsal thoracic wall, esophagus
■ Nodi lymphatici phrenici	right and left on the diaphragm inbetween the tendinous center and the costalic part	Diaphragm, pericardium, right side of the liver, left side of the pericardium
■ Nodi lymphatici gastrici	around the gastric vessels along the lesser curvature of the stomach	Esophagus, liver, gall bladder, stomach

nerve and the esophageal plexus arising from the vagus nerve.

Due to the close relationship to the respiratory tract and an extending increase of mucosal epithelium, malformations can occur in several cases. Most common are esophageal stenosis, atresia, fistula, and diverticula.

### Structure of the esophagus

The esophageal wall consists of four layers. It is comprised of a characteristic tissue texture of the mucosa – the internal mucous coat (tunica mucosa), the submucosal (tela submucosa), and the muscular layer (tunica muscularis). The external layer is an adventitial coat (tunica adventitia) composed of loose connective tissue.

The mucous layer consists of three layers:

- the lamina epithelialis, characterized by stratified, non-keratinizing squamous epithelium
- the lamina propia mucosae, and
- the lamina muscularis mucosae, containing a small layer of smooth muscle fibers.

The submucosa consists of loose fibrous connective tissue and contains mucous and tubular glands, arterial and venous blood vessels as well as lymphatic vessels. The fine lymph capillaries run in a longitudinal direction. Consequently, lymph flow may empty both cranially and caudally into regional lymph nodes. In the upper two thirds of the esophagus, the lymph flow courses mainly cephalad and caudad in the lower third. Lymph from the middle part may directly drain into the thoracic duct. In rare cases, lymphatic follicles can be found in the submucosal layer.



The submucosal layer also contains a network of nerves, representing parasympathetic innervation through the vagus nerve and sympathetic innervation. Innervation of glands, smooth and striated muscle fibers is given through vegetative neural branches of this network.

The muscular coat can be divided into an internal circular-oriented muscle layer and an external muscle layer of longitudinal orientation. In the superior third of the esophagus, these layers are exclusively composed of striated muscle fibers. In the middle third the striated muscle fibers dominate, but smooth muscle fibers are intermingled. In the lower third, smooth muscle fibers predominate. Most likely, the striated muscle originates from the mesenchyme of the caudal branchial arches, and the smooth muscle develops from the surrounding segmental mes-

enchyme. A somewhat helical direction of the muscular layer has been described. This observation together with the longitudinal course of the lymphatic vessels in the submucous layer could explain the spreading of carcinoma cells over a long distance before entering the regional lymph nodes both superiorly and inferiorly.

The nerve supply of the esophageal muscles is through both vagus nerves and their branches and the sympathetic nervous system. There are no muscle spindles in between the striated muscle fibers. Stretching of the muscular wall is detected by specific mechanoreceptors which are similar to the Ruffini bodies of the locomotor apparatus.

The esophagus is enveloped and connected with its surrounding structures by loose connective tissue, the tunica adventitia.

## 2 The Esophagus

### Diagnostic Methods of Examination

G. KRUPSKI, V. NICOLAS

#### Conventional methods of examination

To judge the anatomy, the function, as well as pathologic findings in the esophagus, contrast esophagographies are needed. Applied contrast media are the barium swallow and water soluble contrast media. For the diagnostic routine examination, viscous barium suspensions are required in order to judge motor disorders, the mucous membrane, and lateral boundaries. If perforation, rupture or postoperative suture dehiscence is suspected, water soluble contrast media or contrast media used in bronchography should be taken. These contrast media should also be used in case of suspected esophago-tracheal fistula and where risk of aspiration is present. The double contrast of the esophagus can be improved by mixing the usual contrast medium with gas, or if necessary with intravenous application of anticholinergic substances.

For the investigation of dysphagia, a 100 mm camera should be applied or cinefluorography is required; with the use of these techniques, especially proximal tumors can be demonstrated and documented. The patient can be examined in an upright or a lying position. The latter is used to slow down the passage of contrast media. To get an impression of the organs of the thorax, a roentgenoscopy should be performed first. Abnormalities of the lungs, the diaphragm, and the heart can be seen with the use of this technique.

The standard projections are frontal, right oblique and lateral positions, as well as target radiography in two planes of pathological organ regions. The esophagogram is the method of first choice to detect diverticula, hernias, varices, and achalasia.

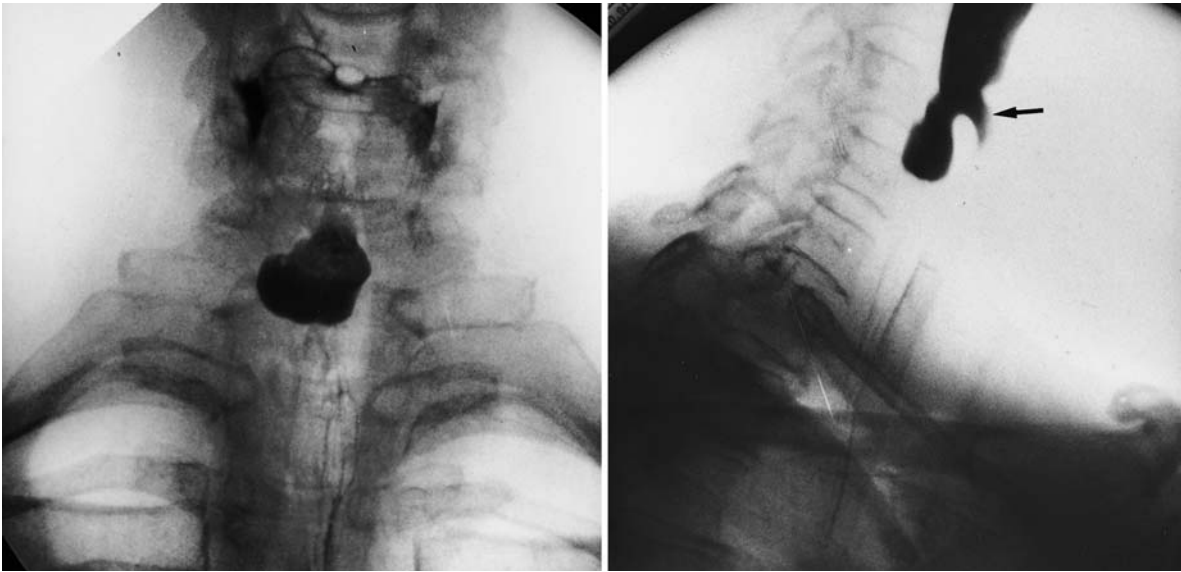
#### Diverticula

Depending on their origin pulsion-, traction- and mixed diverticula can be detected as well as cervical, thoracic and epiphrenic diverticula.

■ **Cervical diverticula** show a progression in complaints with increasing size of the diverticulum during the course of the disorder. Initially the patients complain of a sensation of a foreign body and difficulty in swallowing. Congestion, regurgitation, and the linked danger of aspiration take place only with progression of disease. In the beginning the complaints may be misinterpreted as of cardiac origin. Depending on its size, a diverticulum usually lies on the left side of the neck. Occasionally distension of the neck or even a palpable tumor is evident. A diverticulum may be compressed in order to limit further filling.

Posterior pharyngeal diverticula (Zenker's diverticulum), in most cases, lie on the left hand side. With progression of the disease, it may reach such a size that the esophagus may be compressed and displaced. In this case, we refer to a false diverticulum created by pulsation in the region of Killian's triangle. This is a region with a scarce amount of muscle above the *M. cricopharyngeus*, but it is more likely due to a failure of opening of the *M. cricopharyngeus*. It may occur as a result of an error in the coordination between the closure of the sphincter and the emptying of the pharynx. Piriform diverticula fill during swallowing earlier than the esophagus and usually show a neck.

These characteristically show retention of food. Since the neck of the diverticulum is situated quite cranially, the diverticulum is often seen as a mass lesion within air fluid levels in plain radiographs.



**Fig. 2.1.** Typical depiction of a cervical esophageal diverticulum (Zenker) in a.p. and lateral projection after barium swallow. On the lateral film the esophagus is compressed and

shows ventral displacement (→). Therefore, it can be classified as stage II according to Brombard.

■ **Traction diverticula** are usually found arising from the anterior or lateral wall of the esophagus, at the level of the tracheal bifurcation. The cause is thought to be inflammatory, lymph nodes as a result of e.g. tuberculosis. This infiltrates the wall of the esophagus and, with remission of disease, a cicatricial retraction of the esophagus wall occurs. The x-ray findings tend to show clearly defined 0.5–1 cm deep extrusions of the esophagus wall, usually with a pointed apex and a broad base. Traction diverticula generally are incidental findings, since the patient usually has no symptoms or suffers from non-specific symptoms only. They can be missed on x-ray, if the examination is performed in an upright position with a minimal filling of the diverticulum, or if a patient has not been examined in the oblique or lateral position especially if the diverticulum is the anterior extrusions of the esophagus.

■ **Epiphrenic diverticula**, as their name implies, are situated near the diaphragm arising from the right posterolateral aspect of the esophagus. They develop due to mal- or dysfunction of the esophagus. If the diverticula is in combination with achalasia, diffuse spasm of the

esophagus or hypertonic sphincter may be associated findings. Dysphagia, nocturnal heartburn due to emptying of the diverticulum in the horizontal position, and epigastric abdominal pain are the resulting symptoms. The absence of gastric mucosa in the diverticulum as well as the connection to the esophagus allows the diverticulum to be differentiated from a prolapsed part of the stomach.

## Achalasia

Dysfunction in the esophageal body and lower esophageal sphincter serve as a guide to the clinical picture of achalasia. The causative agent of achalasia (cardio spasm, mega esophagus) is unknown. The rare mega esophagus congenitus must be separated from the mega esophagus of achalasia. The predominant guiding symptom of achalasia is difficulty in swallowing. The sensation of food sticking or cramping pain is often projected retrosternally or around the xiphoid process. As the disease progresses the patients present with regurgitation and weight loss. There is a risk of aspiration and bronchopulmonary complications.

Depending on the severity of the disease, on plain chest x-rays broadening of the mediastinal silhouette located on the right side due to a distended esophagus may be visible. On the lateral view, the retrocardial space is often opacified and the trachea is anteriorly displaced. After the swallow there is a slow filling of the dilated esophagus and the barium contrast medium mixes with retained food resulting in an inhomogenous image. The esophageal wall appears smooth. With varying prestenotic dilatation of the esophagus in its distal part, there is a smooth narrowing in the gastroesophageal junction. To rule out a malignant stenosis, the proof of the continuity of the longitudinal esophageal fold is essential. Suction of remaining food and additional application of glucagons may help to distinguish achalasia from other conditions.

### Gastroesophageal reflux and hernias

The term *reflux disease* summarizes clinical findings resulting from reflux of gastric acid and aggressive duodenal secretors into the esophagus. In association with food intake and position of the body, the leading symptoms of retrosternal pain or burning sensations as well as projected pain in the epigastrium or throat are reported. The diagnosis of gastroesophageal reflux is primarily made from the typical clinical findings with proof of either reflux of inflammatory mucosal reactions being achieved by endoscopy or radiology.

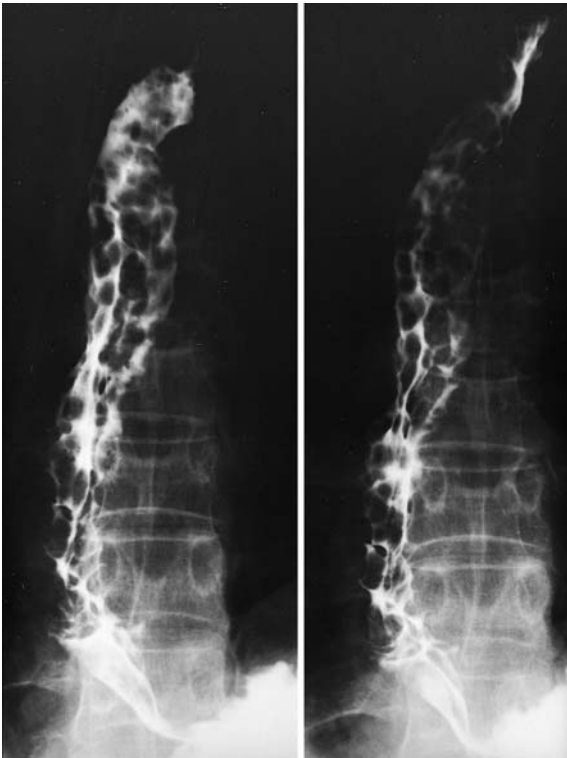
The radiological examination of gastroesophageal reflux or hiatus hernia is performed with the patient head down or prone. Valsalva maneuver followed by deep inspiration and coughing can provoke gastroesophageal contrast media reflux and herniation. The early stage of the disease often lacks clear signs. Additional findings are disturbed motility (tertia 1 contractions) and swollen folds. Evidence of a short esophagus or hiatus hernia supports the diagnosis. Minor ulceration is not normally detectable radiologically but is seen by endoscopy. However more extensive ulceration is

seen as contour irregularities or a niche particularly using a double contrast technique. Peptic stenosis resulting in a shortened esophagus and post-inflammatory scarring of the esophageal wall is the final stage of the disease. The involvement of the esophageal musculature in the disease becomes obvious by spastic changes in stenotic areas and disturbed motility in prestenotic dilatation proximal to tubular stenoses. These causes reduce contrast media outflow on x-rays.

There are no specific clinical findings in hiatus hernia. Most of the patients are completely free of symptoms, and the hernia is detected as an incidental finding in gastrointestinal examinations for other reasons. Large hernias may already have been diagnosed from a plain chest x-ray as translucencies in the right pericardial angle or retrocardial and paravertebral space, respectively. The surrounding margin is formed by the gastric wall and shows varying air fluid levels. Using oral contrast media, hiatus hernias can be classified and clearly differentiated from hernias of the diaphragm. For a sliding hiatus hernia the level of pretubular esophagus, gastroesophageal vestibulum, and Schatzki-ring (mucosal border of esophagus and stomach) (if present) as well as an intrathoracic and infradiaphragmal stomach have to be described. For all types of hernias (sliding, paraesophageal, mixed, upside-down-stomach) primary or acquired brachyoesophagus has to be ruled out prior to surgery.

### Varices

The examination for the detection of *esophageal varices* is performed in a supine position in expiration. Submucosal varices present with linear, nodular, and pearly thickenings in the lower third of the esophagus. In the same examination fundal varices in the stomach should be ruled out as well. If varices are limited to the upper third of the esophagus, thrombosis or stenosis of the SVC should be considered and further investigations such as CT or angiography are necessary.



**Fig. 2.2.** Esophageal varices: round-shaped filling defects lined up like pearls.

## Foreign bodies

The localization of ingested foreign bodies is an important radiological examination. Retained foreign bodies in the esophagus or throat cause vomiting and coughing and may disturb swallowing. Before using contrast agents plain x-rays should be taken from the neck and chest region in at least two planes. One has to look for air trapping in soft tissues, frontal positioning of the pharyngoesophageal segment, broadening of the mediastinum, disturbed motility of the diaphragm, atelectasis, pleural effusion, or free intraperitoneal air as markers for complications of foreign body ingestion. Most foreign bodies are trapped in the upper third of the esophagus by its strong musculature. The esophageal lumen is flattened at this level by the cricoid cartilage anteriorly and at the 6th cervical vertebra posteriorly. Flat foreign bodies tend to become positioned in a frontal plane which plays an important role for the differentiation from tracheal for-

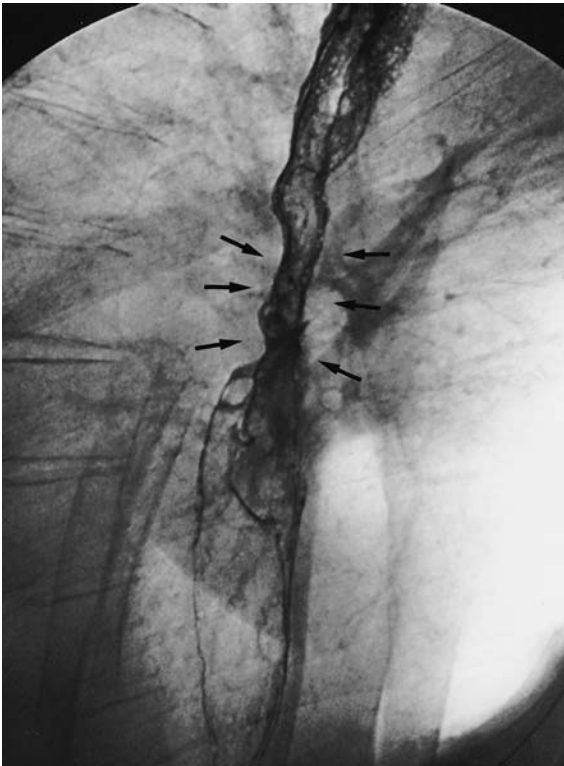
eign bodies because these tend to be positioned in a sagittal plane. The precise localization of either endotracheal or esophageal foreign bodies needs a lateral view. After oral application of water soluble contrast media, the foreign body becomes smoothly covered. Large foreign bodies, such as a bit of meat, might block the contrast passage completely. Swallowing of a cotton pad previously dipped into contrast media can enable visualization of previously invisible foreign bodies. Apart from the direct demonstration of foreign bodies, the oral contrast application facilitates the detection of associated mucosal ulceration, fistulas, or perforations which determine further therapeutic approaches.

## Esophageal tumors

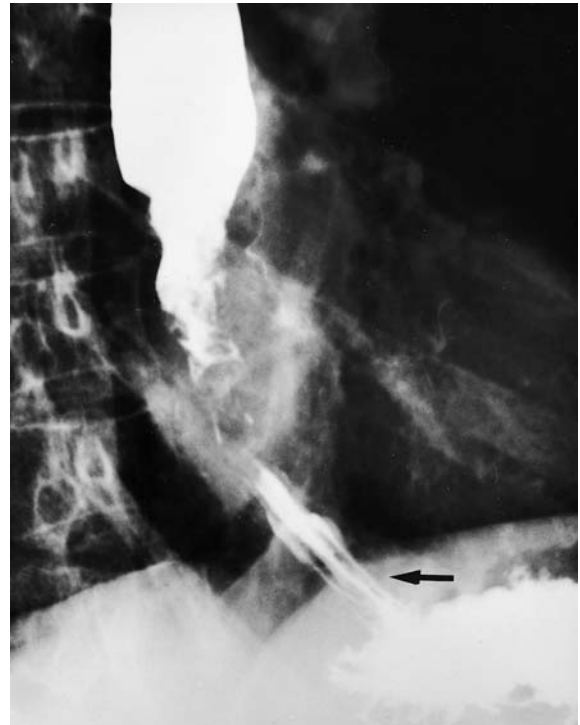Dysphagia is the first and most common clinical sign of an *esophageal carcinoma*. Quite often the disease starts with uncharacteristic burning sensations or retrosternal pressure while swallowing. Surprisingly, patients can precisely localize the level of obstruction. In contrast to esophagitis or esophageal spasm, pain sensations are well described and localized. The diagnosis of an esophageal carcinoma is made by radiology, endoscopy, and biopsy. Characteristic findings in the esophagogram often enable the differentiation between malignant and benign lesions. Depending on the extent and growth, the appearance may vary. Based on x-ray morphology there are three main types:

- *Scirrhus carcinoma* with intramural growth and early stenosis
- the *ulcerated or medullary carcinoma* with ulceration
- the *exophytic, polypoid carcinoma* with intraluminal growth and filling defect with irregular surface at the periphery.

Plaque-like lesions are an early sign of an infiltrating growth. For the detection of small lesions, a multiplanar examination using double contrast is obligatory. Mucosal folds tend to be only slightly thickened and can be disrupted. There might be remaining contrast depots in lesions. In the early stages motility and



**Fig. 2.3.** Platelet-cell carcinoma of the thoracic esophagus demonstrated in double-contrast technique. Apple-core shaped filling defect of the otherwise adequately distended esophagus with an irregular and ulcerated surface (→).



**Fig. 2.4.** Distal adenocarcinoma of the esophagus (Barrett carcinoma) positioned in the esophagogastric junction. A small rim of the distal esophagus in the hiatus shows residual normal epithelial folds (→).

flexibility of the esophagus are normal. Depending on their growth, advanced tumors result in rigidity of the esophagus wall, destruction of the normal fold architecture, intraluminal filling defects, and stenoses with prestenotic dilatation. Due to ulceration and loss of small tumor parts, the radiological aspect can vary from examination to examination. Fibrous types of the esophageal carcinoma are very difficult to detect in the early stage because minimal wall deformities are easily missed. In the advanced stages hourglass-like circular stenoses develop which primarily have smooth margins (increasing infiltration and ulceration finally leads to irregular contours).

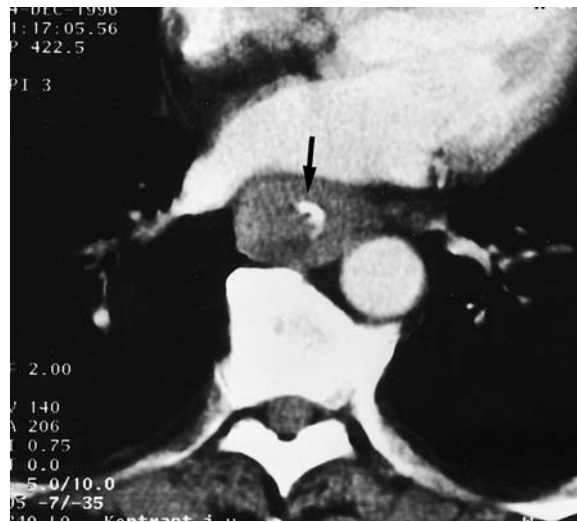
■ **Benign esophageal tumors** (0.6%) are rare compared with malignant tumors. The presentation of symptoms and signs depend on the site, extent, configuration, and growth direction of the tumor. Most benign tumors are asymptomatic. Dysphagia is the leading symp-

tom for submucosal and intraluminal growth when the lumen becomes obliterated. Intramural and extraesophageal growth can lead to very large tumor size before symptoms become clinically apparent (dysphagia, vomiting, retrosternal pain). Depending on their growth pattern, benign esophageal tumors can be classified as intraluminal (papilloma, adenoma, carcinoid, hemangioma, fibrovascular polyp, granular cell myoblastoma), intramural (leiomyoma) and cysts. After histological examination 50–70% of benign tumors are found to be leiomyomas which are located in the mid and lower third in 90% of cases. Radiologically they present with well defined round filling defects without disruption of the mucosa. Compared with the normal esophagus there might be a slight flattening of the folds in the neoplastic area. Peristalsis is normal. With circular growth prestenotic dilatation and a mega esophagus can result in rare cases. Sometimes, there is ulceration which can be difficult to differentiate from

malignant lesions such as carcinomas or sarcomas or polyps (a short course of the disease, weight loss and rapid deterioration with diffuse leiomyomatosis, diverticula, gastric carcinoma and a synchronous malignant lesion in benign esophageal tumors. Hence on barium swallow only intraluminal growth can be observed. Periesophageal growth has to be demonstrated using cross sectional imaging techniques: CT, MRI, and endosonography.

## CT and MRI

Indications for a CT examination in esophageal disease are: diagnosis of lymphatic and hematogenous metastatic spread, periesophageal tumor extent, and tumor localization for irradiation. For the detection of the longitudinal extent of a tumor the esophagogram is superior. The application of water soluble oral contrast media for the demonstration of the esophageal lumen has shown to be of value. In the CT infiltrative or medullary growing scirrhous carcinomas might present with a thickening and demarcation of the periesophageal tissues. Proximal to a stenotic tumor a fluid-air level can be seen. In polypoidly growing tumors the intraluminal tumor or an eccentric wall thickening might strike ones eyes. Wrong estimation of tumor size and lymph node staging are common in cachectic patients or after surgery and irradiation, respectively. In cachectic patients the differentiation of the esophagus from surrounding tissues might be almost impossible due to reduction of mediastinal fatty tissue. In this situation the missing fat pad does not necessarily suggest an infiltration of the adjacent structures or vessels. The  $90^\circ$  rule is helpful to decide whether there is a vascular infiltration: if the contact area of tumor and aorta lies above  $1/4$  of the circumference of the vessel (which equals an angle of  $90^\circ$ ) there is an infiltration of the aorta in 80% of the cases. However, with an area less than  $45^\circ$  ( $1/8$  of the circumference) there is no infiltration to be expected. Preoperative irradiation leads to increased fatty tissue densities and therefore impossibility to differentiate such changes from infiltration.

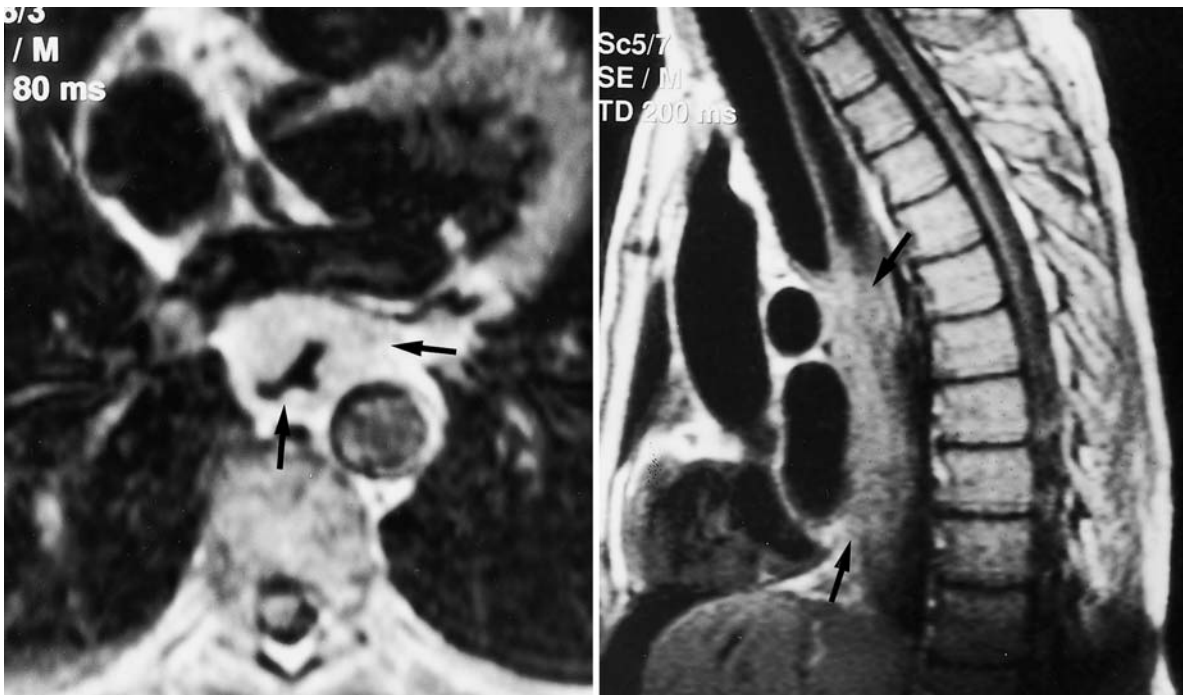


**Fig. 2.5.** Cross-sectional CT-image of the thorax in a patient with esophageal platelet-cell carcinoma (same case as in Fig. 2.3.). After barium swallow, a narrowed residual lumen is visible ( $\rightarrow$ ) surrounded by tumor mass.

With the introduction of multislice CT-imaging slight improvements in the imaging of esophageal tumors could be achieved for primary and secondary staging as well as detection of distant metastasis (Figs. 2.1–2.3). Nevertheless this still cannot be called a true breakthrough.

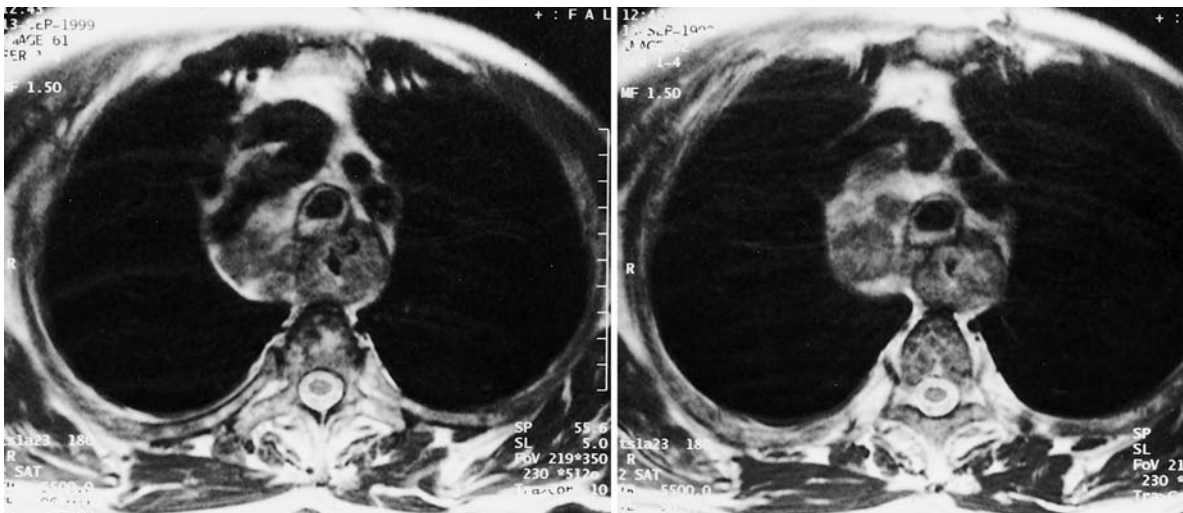
Indications for MRI are equal to CT, but coronal and sagittal image planes allow sufficient differentiation for longitudinal tumor extent definition. Nevertheless, in all publications to date, there is no evidence that MRI is superior to CT in the imaging of malignant esophageal disease. Since the T1 and T2 weighted images, esophageal musculature is equal to skeletal muscle or a good differentiation from tumor can be expected in T2 weighted sequences. However, due to low signal to noise ratios and motion artifacts in long acquisitions, the anatomical spatial resolution is worse. To enhance the differences in relaxation of tumor and surrounding tissue the application of i.v. Gadolinium DTPA can be advantageous. Because of diaphragmatic motion, particularly the inferior part of the esophagus and the esophagogastric junction are difficult to image on MRI (Figs. 2.4–2.6).

The lymphatic spread of malignant esophageal tumors follows the esophageal wall to locoregional paraesophageal lymph nodes. Depending on the localization of the tumor, low, cervical and supraclavicular lymph node sta-



**Fig. 2.6.** T1-weighted axial and sagittal MR images of the mid esophagus in a patient with platelet-cell carcinoma

(same patient as in Figs. 2.3 and 2.5). In both planes the tumor extent can clearly be outlined (→).



**Fig. 2.7.** Axial T2-weighted MR image in a patient with proximal platelet-cell carcinoma of the esophagus presenting with suspicious paratracheal lymphoma. In addition, there is an infiltration of the pars membranacea of the trachea (proven

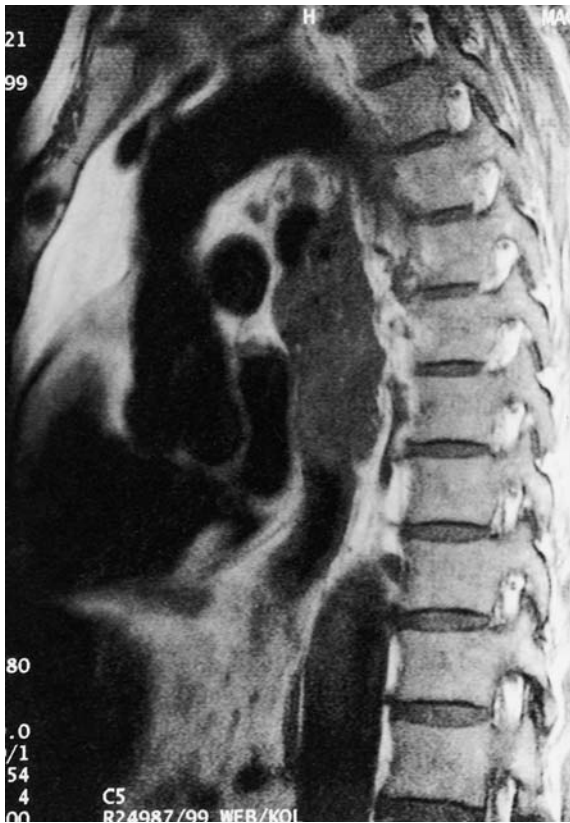by tracheoscopy and biopsy) best seen on the left image (disruption of the low signal intensity outer margin of the trachea). The tumor has to be staged as T4 N2.

tions have to be included in CT examinations. They can be visualized from 5–10 mm depending on slice thickness. Normal lymph nodes may reach a diameter of up to 10 mm. Diameters above 15 mm are suspect for metastatic

infiltration but cannot be differentiated from reactive lymph node enlargement in e.g. associated pulmonary diseases.

In the literature the accuracy for the T-staging in CT is 60% and 47–74% for the N-stag-





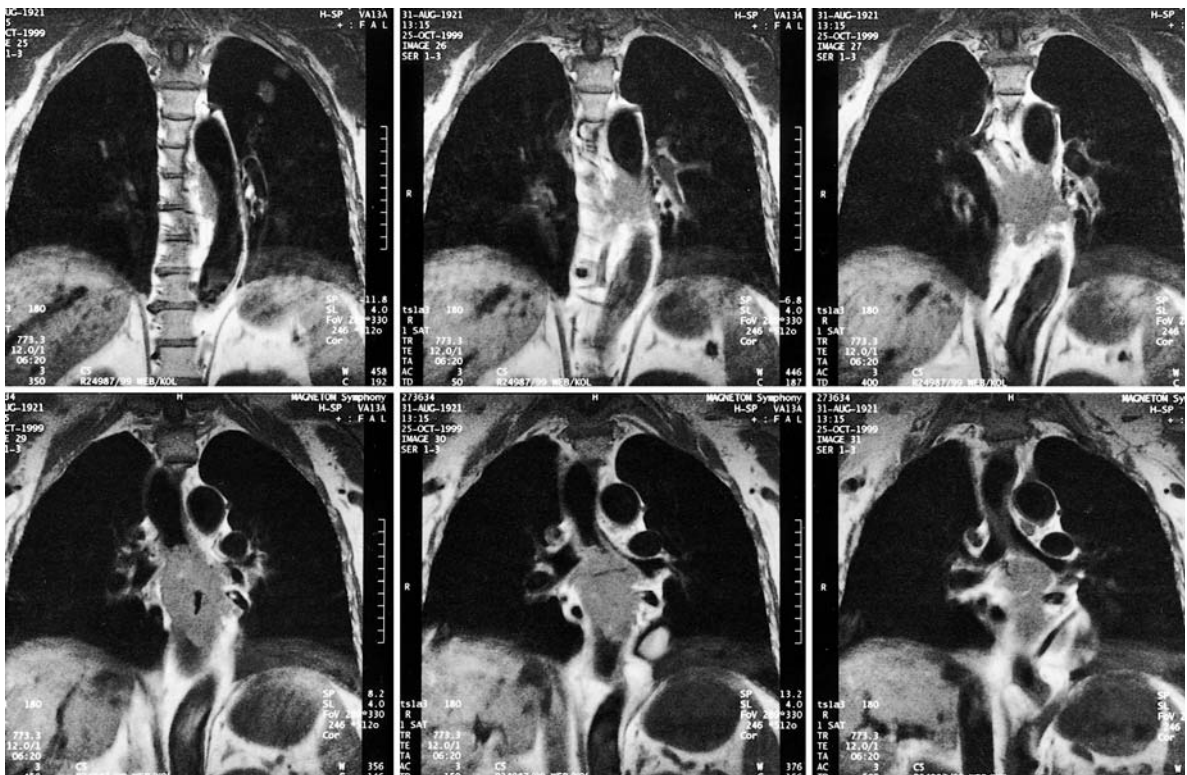
▶ **Fig. 2.8.** Sagittal T1-weighted image of a large esophageal carcinoma from a modern 1.5 T MRI: both proximal and distal tumor borders are visible.

ing, whereas endosonography is doubtlessly better with an accuracy of 73–95% and 73–80%, respectively. Although the accuracy of CT and MRI is insufficient for N- and T-staging, in esophageal malignant disease both are obligate for detection of hepatic and pulmonary metastases.

### ■ Perspectives in imaging

New imaging techniques are subsequently introduced and applied in the diagnosis of esophageal disease. Promising first results were presented using e.g. intraluminal MRI probes and PET (Figs. 2.7, 2.8). The latter seems to bear a certain impact on early detection of non-responding tumors undergoing neoadjuvant treatment regimes.

▶ **Fig. 2.9.** Sagittal T1-weighted MR images in advanced esophageal carcinoma of the middle third. Both tumor mass and pulmonary metastases of the left apical lung lobe as well as multiple suspicious lymph nodes are displayed with a sequence.



## Introduction

Endoscopy is well established in the evaluation of esophageal disease. With the widespread availability of endoscopy in nearly every hospital around the world, it has largely supplanted radiological examination as the primary investigation of choice. The major advantage over radiological examination is that the endoscopist can directly visualize the mucosa and obtain targeted biopsy specimens. Furthermore, endoscopic treatment (e.g., balloon dilatation for achalasia or stent inception for esophageal carcinoma) can often be performed immediately after the diagnostic examination. Conventional endoscopy has most recently been complemented by endoscopic ultrasonography, which adds a new dimension to endoscopic diagnostic capability. Using an endoscope equipped with a miniaturized ultrasound transducer at its tip (echoendoscope), or catheter ultrasound probes ('miniprobes') that can be inserted through the working channel of a standard endoscope, the endoscopist is able to sonographically "look" into and beyond the esophageal wall.

## Equipment and normal anatomy

Videoendoscopes that use an electronic CCD (charge-coupled device) or chip for generation of an image are rapidly replacing the older fiberoptic endoscopes. The videoendoscopes produce clear high-resolution color images of the luminal wall lining that are displayed on a television monitor. Since videoendoscopic images can be viewed by multiple observers, it has improved coordination between endosco-

pist and assistant, such as the timely opening and closing of biopsy forceps. Videoendoscopy has also significantly improved the teaching of endoscopy.

The normal color of the wall is a pale salmon pink. On close inspection, tiny vessels can be seen shimmering through the mucosa. Small whitish papules are commonly sometimes seen along the mucosa and represent a benign entity without clinical significance (glycogenic acanthoses). In the proximal esophagus an isolated patch of reddish mucosa may be seen, which histologically represents heterotopic gastric (columnar) mucosa. The upper and lower esophageal sphincters (at approximately 15 cm and 40 cm from the incisors, respectively) can be recognized endoscopically as regions of luminal constriction that can be easily passed with gentle advancement of the endoscope. Occasionally, neighboring organs such as the aorta can impinge on the esophagus and cause mild luminal narrowing. This may mimic a submucosal tumor. In this case endosonography is helpful.

The transition of the squamous epithelium of the esophagus to the columnar epithelium of the stomach is always sharp and readily identified by an abrupt change in the color and appearance of the mucosa from a glossy pale pink (squamous epithelium) to a velvety deep red (columnar epithelium). This transition is referred to as the Z-line, derived from its irregular zig-zag appearance.

## Malignant tumors

Because esophageal carcinoma originates from the mucosal layer, it is easily recognized on endoscopic examination. Patients usually pre-

sent at an advanced stage of disease when stenosis has resulted in dysphagia and weight loss. Most esophageal malignancies are squamous cell carcinoma, but the incidence of adenocarcinoma has been steadily rising. The endoscopic appearance may vary, but typically presents as a lumen-occluding ulcerating polypoid lesion. There is often increased vascularity and contact friability. The sudden onset of a coughing spell or respiratory distress during endoscopy should alert the endoscopist to the possibility of an esophago-tracheal fistula, which can be confirmed by a radiographic gastrograffin study or bronchoscopy. Stenosing tumors that cannot be traversed with a thin-caliber endoscope (e.g., pediatric gastroscope) will require preliminary bougienage, which should be done cautiously in graduated steps. Rarely, a diffusely infiltrating scirrhous cancer may present as thickening and rigidity of the esophageal wall of variable length. This may be falsely interpreted to represent fibrosis of chronic esophageal reflux disease. It is important to recognize that the visible tumor may not represent its true extent. A tumor may spread submucosally and even establish satellite lesions far removed from the primary lesion.

Although carcinomas are easily accessible to endoscopic biopsy and brushings for histocytological confirmation, the diagnosis may be missed if faulty biopsy technique is used. Multiple biopsies and brushings should be taken from different sites of the tumor, avoiding areas of obvious necrosis. When 6 to 10 biopsy specimens are obtained, the diagnostic accuracy has been reported to be around 80%. The type of forceps selected may improve the tissue yield; if possible, large-cupped biopsy forceps with a needle should be used. Forceps that open laterally are preferable for flat lesions that are approached tangentially.

Endoscopic detection of early or superficial cancer in the esophagus is difficult to diagnose and is often overlooked in the asymptomatic patient. Their detection requires mass screening programs, as have been established in Japan where the incidence is around 40% (compared to <5% in Europe and the United States where screening is absent). In line with the Japanese experience, early malignancy is subdivided into three main macroscopic types ac-

ording to the tumor's height in relation to the neighboring normal epithelial surface:

- Type I, elevated or protruded type
- Type II, superficial flat type
- Type III, depressed or excavated type.

Type II is divided into three subtypes:

- Type II a, flat with elevation
- Type II b, flat without elevation or depression
- Type II c, flat with depression.

The typical appearance of an early cancer is a circumscribed polypoid lesion (Type I), but the lesion may appear as a patch of mucosal discoloration (Type II).

Chromoscopy using dye stains such as Lugol's solution and methylene blue may be used to facilitate the detection of early carcinomas or Barrett's epithelium. Lugol's solution stains glycogen components of normal nonkeratinized squamous epithelium and will fail to stain severely dysplastic and carcinomatous tissue ("negative staining"). Methylene blue stains absorptive epithelium and will identify regions of intestinal metaplasia or dysplasia [3].

## Benign tumors

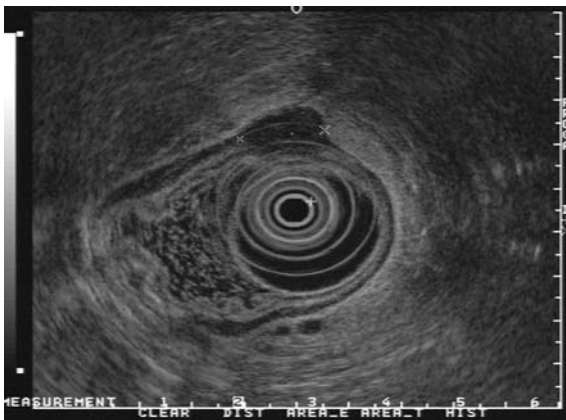
Benign non-epithelial tumors include leiomyomas, lipomas, granular cell tumors, neurofibromas and fibrovascular tumors. All of these typically appear on endoscopic examination as a "submucosal" tumor, i.e., a rounded, raised mass with normal appearing overlying mucosa.

The most common benign tumor of the esophagus is a leiomyoma, which arises from smooth muscle cells in the muscularis propria or less commonly the muscularis mucosa. Palpation of this solid mesenchymal tumor with an endoscopic accessory (e.g., closed biopsy forceps) reveals the submucosal lesion to be firm in consistency. The overlying mucosa is normal and can be moved against the underlying tumor. Forceps biopsies are usually too superficial to establish a diagnosis.

Hemangiomas, composed of numerous capillary or cavernous channels lined with endothelial cells within the mucosa or submucosa,

typically appear as a nodular mass with a blue or plum hue. In contrast to leiomyomas and other mesenchymal tumors, they are soft to instrumental palpation. Endoscopic biopsies of these lesions have been reported without significant bleeding.

EUS is the procedure of choice to evaluate submucosal lesions. EUS is capable of defining the origin of the lesion relative to the histologic layers of the gastrointestinal tract and the extent of its spread. Genuine submucosal tumors can be distinguished from extramural structures that can compress the esophageal wall and thereby mimic a submucosal tumor (e.g., aorta, bronchogenic cyst, lymph node). Although EUS cannot provide a histologic diagnosis, the layer of origin and the echogenicity of the lesion are often highly suggestive of the diagnosis. Leiomyomas present characteristically as a well demarcated hypoechoic mass originating from the muscularis propria or muscularis mucosae layer (Fig. 3.1). A leiomyoma can be differentiated from a leiomyosarcoma with reasonable certainty by assessing sonographic features such as size, homogeneity, and margins, and following these features longitudinally over time. Lipomas are typically well demarcated hyperechoic structures originating from the submucosal layer.



**Fig. 3.1.** Benign leiomyoma; hypoechoic mass originating from the muscularis propria or muscularis mucosae layer.

## Esophagitis

Gastroesophageal reflux disease (GERD) leads to inflammation of the esophageal mucosa that can be detected on endoscopy. The most reliable endoscopic markers of inflammation are erosions and ulcers. Erythema alone is often a nonspecific finding and poorly reproducible among examiners. Numerous classification schemes have been proposed to grade the severity of esophagitis, but the most commonly used is that of Savary Miller:

- 0 normal
- 1 Erythema or edema
- 2 noncircumferential erosions
- 3 Circumferential erosions
- 4 Ulcerations

Savary Miller stage '0' is GERD without endoscopic evidence of esophagitis. The diagnosis of GERD is established by histologic evidence of esophagitis or 24-hour pH manometry. Reflux is usually acid in nature, but may be alkaline, such as after a partial Billroth-II gastrectomy.

Complications of GERD include ulcerations, peptic stenosis, and Barrett's esophagus.

GERD is often associated with a hiatal hernia, which may contribute to incompetency of the lower esophageal sphincter. The axial sliding hernia is the most common type, but occasionally a paraesophageal hernia (stomach fundus herniated into the thorax alongside the esophagus) is encountered, of which the "upside-down" stomach is an extreme variant.

Endoscopy is the method of choice for the detection of nonreflux-induced esophagitis. The most common cause of infectious esophagitis is *Candida*. The diagnosis is usually suggested by the typical endoscopic appearance showing multiple isolated or confluent yellow-whitish plaques. The proximal esophagus is preferentially involved. At an advanced stage, these plaques become circumferential and may result in luminal narrowing. The diagnosis is established by brush cytology.

Viral esophagitis due to cytomegalovirus (CMV) and herpes simplex virus (HSV) cause mucosal ulcerations. The appearance can vary considerably depending on the cause of immunodeficiency and severity of disease. The ear-

liest lesion of HSV is the vesicle, usually seen in the oropharynx, but occasionally encountered in the esophagus. HSV ulcers are superficial and often scattered throughout the esophagus. By contrast, CMV ulcers tend to be large and more well-circumscribed with sparing of intervening mucosa. Brushings of HMV lesions for cytology are usually diagnostic, whereas the diagnosis of HMV requires large forceps biopsies taken from the ulcer base.

---

### Complications of esophagitis

■ **Peptic strictures.** Peptic strictures may occur in as many as 10–20% of patients with chronic GERD. The endoscopic appearance is typically that of a concentrically fixed narrowing that does not distend with air insufflation at or slightly above the level of the cardia. The length of the stricture is rarely greater than 1–2 cm, and the mucosa appears scarred. Inflammatory mucosal changes are usually present.

Tissue sampling is mandatory to exclude malignancy.

■ **Barrett's esophagus.** Barrett's esophagus is defined as metaplastic change of squamous epithelium to columnar lined epithelium caused by chronic GERD. The diagnosis is a histological one and requires the identification of goblet cells on histopathology to establish the presence of intestinal metaplasia. The entity is more common in men than women, and the frequency of Barrett's esophagus in patients undergoing endoscopy for clinical indications approaches 1% for men [1, 2]. The entity is widely regarded as pre-malignant owing to a risk of developing cancer that is 30- to 100-fold higher than healthy controls. However, the actual likelihood of an individual with Barrett's esophagus over a lifetime is difficult to define. Prospective series define an incidence of adenocarcinoma ranging from 1 in 52 patient years of follow-up to 1 in 278 patient years. The prognostic significance of Barrett's esophagus will depend on whether dysplasia is present and what the estimated life expectancy is (patient's biological age and comorbid condition). Barrett's esophagus has received greater attention in recent years due to the rising inci-

dence of adenocarcinoma relative to squamous cell carcinoma of the esophagus.

Barrett's esophagus should be suspected when the squamocolumnar junction (Z-line) is proximally displaced from the gastroesophageal (GE) junction. This may be difficult to diagnose when the Z-line is obscured – as may be the case with accompanying inflammation – or the GE junction is obscured – as may be the case with an accompanying hiatal hernia or tortuous anatomy. Barrett's epithelium typically appears as “tongues” of velvety red mucosa that extends into the tubular esophagus. However, a long circumferential segment of Barrett's can mimic normal squamous epithelium.

Barrett's esophagus has been defined in the past as metaplastic tissue extending 3 cm into the tubular esophagus. However, recently “short segment” (<3 cm) and “ultrashort segment” (at the gastric cardia) Barrett's esophagus have been found to have malignant potential. Endoscopically inapparent but histologically confirmed Barrett's metaplasia has received greater appreciation as endoscopists have begun to systematically evaluate for Barrett's with biopsies. The use of vital dyes such as methylene or toluidine blue, which specifically stain intestinalized epithelium, can help to identify Barrett's change.

---

### Varices and other sources of upper gastrointestinal bleeding

In the patient with upper gastrointestinal bleeding, endoscopy is indicated as a first-line procedure to localize the bleeding source. Vomiting of fresh blood suggests variceal bleeding as the most likely source. Other less frequent sources may be hemorrhagic esophagitis or a Mallory-Weiss tear, the latter a linear mucosal tear at the cardia caused by violent retching. A deep tear may result in perforation (Boerhaave's syndrome) with signs of mediastinitis or mediastinal emphysema. Hematemesis may also be caused by swallowed blood from the nose or hypopharynx, mimicking gastrointestinal bleeding.

Dilated esophageal veins may be seen in patients with portal hypertension and do not

pose any risk for bleeding. By contrast, visible varices may rupture and bleed, as they are located in the mucosa (lamina propria mucosa). Varices are typically seen in the lower third of the esophagus and are categorized according to their risk of bleeding in 3 grades:

- Grade 1: discretely protruding into the lumen
- Grade 2: protruding into the lumen and persisting even after maximal insufflation of air
- Grade 3: filling the variceal lumen with no normal mucosa between columns.

Additional signs that correlate with an increased risk of bleeding are red spots over varices ('red color signs') and small venules over varices ('blue wale sign').

Esophageal varices are usually a complication of portal hypertension (pre-, intra- and posthepatic block). Rarely, varices may complicate mediastinal compression with obstruction of venous emptying ('down-hill' varices in the upper third of the esophagus). In northern Europe portal hypertension is most commonly caused by alcoholic liver cirrhosis and in southern Europe by posthepatic cirrhosis (especially hepatitis B and C). Portal hypertension caused by a liver tumor is characterized by recurrent bleeding.

Endoscopic hemostasis is the procedure of choice for acute variceal bleeding. The injection of Histoacryl (Braun-Melsungen) to obliterate the bleeding varix is the best endoscopic treatment [4]. After hemostasis is achieved, endoscopic ligation with rubber bands and paravariceal sclerotherapy are well established as effective treatments to prevent variceal rebleeding, the risk of which is very high and associated with significant mortality. After variceal eradication, endoscopic follow-up examinations are indicated to treat new varices. Varices that have not previously bled are generally treated by beta-blockers to prevent first-time bleeding. Variceal band ligation is undergoing investigation as a possible treatment for the primary prevention of variceal bleeding.

## Diverticula

Diverticula are outpouchings of the esophageal wall. True diverticula comprise all layers of the esophageal wall (e.g., the typically asymptomatic mid-esophageal traction diverticula), whereas pseudodiverticula are herniations of the mucosa through the muscle layer (e.g., Zenker diverticula of the proximal esophagus, whereby the diverticulum protrudes posteriorly through the muscle fibers of the Killian triangle and can cause severe symptoms of dysphagia and regurgitation of food). Epiphrenic diverticula are often found in association with esophageal motility disorders (see below).

## Achalasia and other motor disorders

Endoscopy is a relatively insensitive method for assessing esophageal motility disorders, as the anatomy and mucosal lining of the esophagus do not show pathognomonic changes. However, the diagnosis may be suggested in advanced cases. Achalasia, an acquired neurodegenerative disease of the esophagus, in which there is a selective loss of inhibitory neurons to the ganglion cells of the Auerbach's plexus, has several characteristic findings. Firstly, the esophagus proximal to the gastroesophageal (GE) junction may be dilated and filled with food or secretions. Stasis may result in varying degrees of inflammatory changes. Secondly, the GE junction may show a puckered appearance without evidence of fibrosis or tumor. Characteristically, the endoscope will "pop" through the tight opening with pressure. It is imperative to distinguish primary achalasia from secondary achalasia due to malignancy involving the cardia. The careful examination of the cardia region, including a retroflexed view from the stomach, is required, and biopsies should be liberally taken from any suspicious area.

As a rule, manometric studies should be obtained to confirm the diagnosis of primary achalasia. Manometric studies may also suggest other motility disorders such as diffuse esophagospasm, nutcracker esophagus, or scleroderma, all of which can mimic achalasia. It must be emphasized that motility disorders are a diagnosis of exclusion, and that all patients should undergo an endoscopy to exclude malignancy and GERD. The diagnosis of reflux disease is of importance, as this can be easily and effectively treated.

## References

1. Cameron AJ, Zinsmeister AR, Ballard DJ, Carlen JA (1990) Prevalence of columnar-lined (Barrett's) esophagus. Comparison of population-based clinical and autopsy findings. *Gastroenterology* 99:918–922
2. Eloubeidi MA, Provenzale D (2001) Clinical and demographic predictors of Barrett's esophagus among patients with gastroesophageal reflux disease: a multivariable analysis in veterans. *J Clin Gastroenterol* 33(4):306–309
3. Shim CS (1999) Staining in gastrointestinal endoscopy: clinical applications and limitations. *Endoscopy* 31:487–496
4. Soehendra N, Grimm H, Nam VC, Berger B (1987) N-butyl-2-cyanoacrylate: a supplement to endoscopic sclerotherapy. *Endoscopy* 19:221–224

# Role of Endoscopic Ultrasound for Diagnosis and Staging of Esophageal Cancer

A. FRITSCHER-RAVENS, M. X. PELLING

## Introduction

Despite radical and aggressive combination chemotherapy, the prognosis for esophageal cancer remains poor.

Any decision about the best and/or most suitable treatment with curative or palliative intent is dependent on the depth of penetration of the primary tumor and on the presence or absence of local or distant lymph node metastases.

Computer tomography remains the “gold standard” for pre-operative staging of esophageal cancer. Measurements of wall thickness serve as criteria for depth of invasion by the primary tumor. A wall thickness of less than 1 cm is classified as T1–T2 and a wall thickness greater than 1 cm as T3. The limited spatial resolution of CT and its inability to visualize the layers of the esophageal wall make it unreliable for detection and staging of early cancers, although the accuracy of CT improves in advanced disease.

To improve preoperative staging, including evaluation of depth of invasion and involvement of local nodes, it is necessary to use an imaging technique that is able to resolve the different layers of the esophageal wall, as well as the surrounding tissues. Over the past 20 years endoscopic ultrasound (EUS) has developed and become established as a high-resolution technique for the evaluation of upper gastrointestinal lesions. At present it is the only imaging modality able to demonstrate the detailed anatomy and layers of the esophageal wall. This allows correct tumor staging, which can be correlated with the post-operative histology.

In many centers it is now standard practice to perform precise staging with endoscopic ul-

trasound after CT has been obtained. Also, endoscopic ultrasound has emerged as the most important new tool for pre-operative treatment decision.

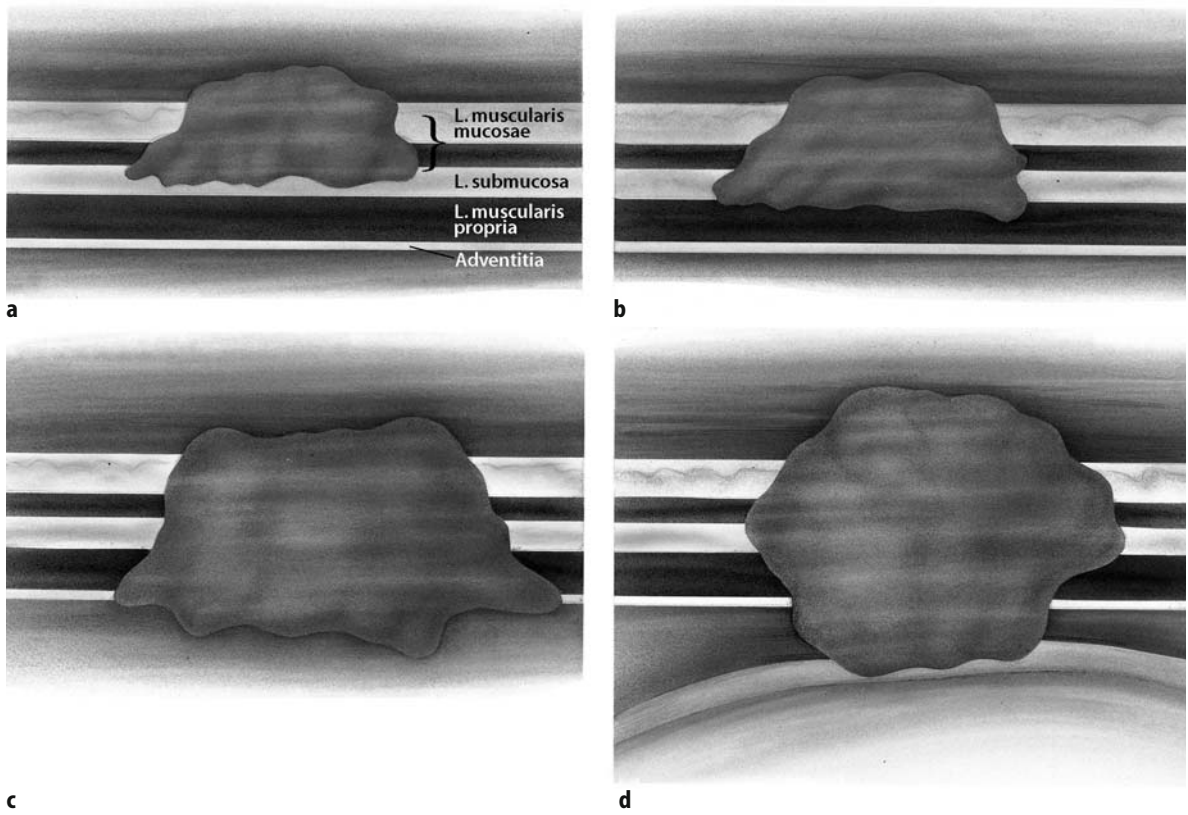
## Principles of EUS tumor staging

Endoscopic ultrasound with 5–10 MHz probes enables visualization of 5 different layers of the wall of the upper gastrointestinal tract, which makes tumor staging (T-staging) according to the UICC TNM classification possible [4, 5, 82] (Table 4.1, Fig. 4.1). The T-staging is based on the definition of “normal” and “destroyed or abnormal” wall structures [6]. The normal anatomical wall structures consist of two mucosal layers (echorich and echopoor), an echorich submucosal layer and an echopoor muscle layer. Sometimes the echorich adventitial layer can be visualized (Fig. 4.2 a,b). Malignant T1 or T2 tumors appear as echopoor lesions within the normal mucosal layer leaving the submucosal and/or muscle layers intact. Once the echopoor lesion extends through the muscle layer the tumor

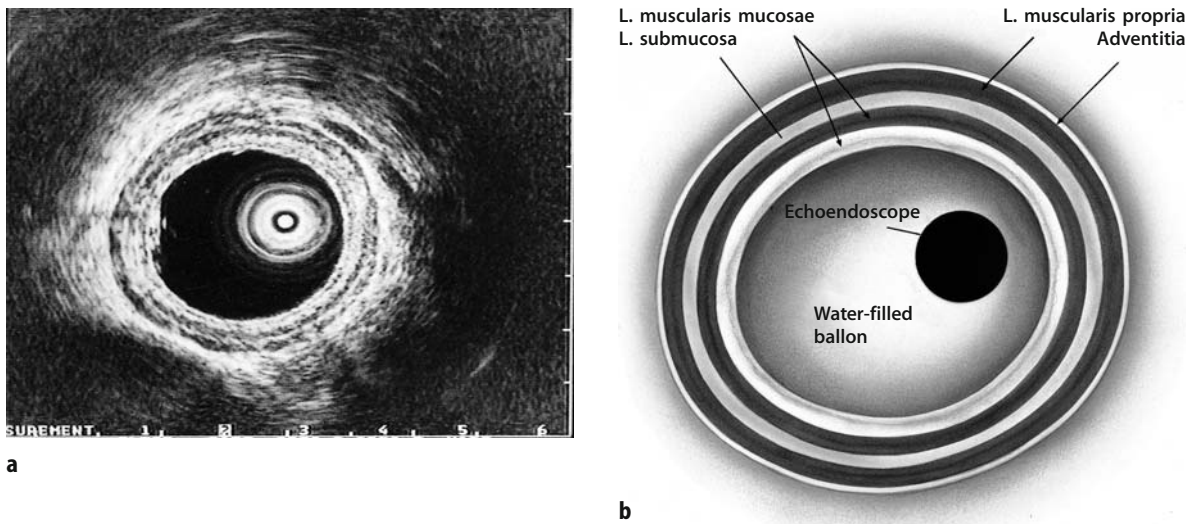
**Table 4.1.** TNM classification and stage grouping of esophageal carcinoma

■ Tx	– Primary tumor cannot be assessed
■ T0	– No evidence of primary tumor
■ Tis	– Carcinoma in situ
■ T1	– Tumor invades lamina propria or submucosa
■ T2	– Tumor invades muscularis propria
■ T3	– Tumor invades adventitia
■ T4	– Tumor invades adjacent structures





**Fig. 4.1.** a T1 sm; b T2; c T3; d T4.



**Fig. 4.2.** a Echo rich submucosal layer and echo poor muscle layer; b configuration of the layers.

is defined as T3 (Fig. 4.1). If there is invasion of adjacent organs, such as the trachea or diaphragm, it is defined as T4.

Although usually well visualized these tumors can be difficult to stage correctly. There is often edema around the lesion, which has similar echogenicity as the tumor itself and can lead to overstaging. Tumor understaging with endoscopic ultrasound is rather rare [7, 8].

Endoscopic ultrasound can penetrate about 5–7 cm, allowing visualization of the posterior mediastinum, celiac axis, part of the liver, the spleen and the body of the pancreas. Consequently in addition to T-staging it is possible to stage local nodes larger than 3–5 mm (N-staging) [9, 10] as well as some distant metastatic nodes (M-staging), in particular celiac axis nodes. Assessment of these distant nodes is most important if primary surgery with curative intent has been planned.

Tytgat and Tio [11] attempted to define EUS criteria for “normal” and “metastatic” lymph nodes in the presence of malignant disease. Criteria such as size, echogenicity, round shape, and smooth borders were used to classify nodes. Published data show an accuracy of up to 80% using this classification. However, this does not allow reliable differentiation of benign and malignant involvement [12, 13], and CT or EUS guided needle aspiration of detected nodes is required if these would change the treatment plan. This applies particularly to celiac axis nodes.

### Examination technique and instrumentation

Esophageal cancers are generally examined with mechanical or electronic radial echoendoscopes with shaft diameter of 11.5–13 mm and probes switchable from 5 to 10 MHz (Fig. 4.3, left). The mechanical echoendoscopes are side-viewing and have a 360° ultrasound image (Olympus Optical Inc, Tokyo, Japan). Newer electronic radial echoendoscopes are forward viewing and have color Doppler ultrasound.

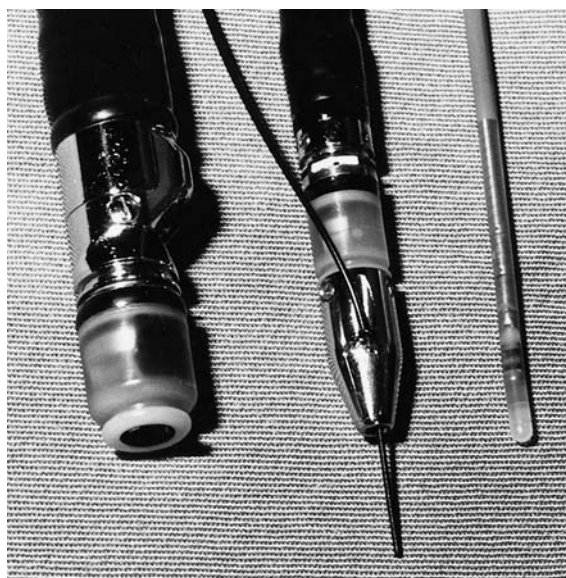
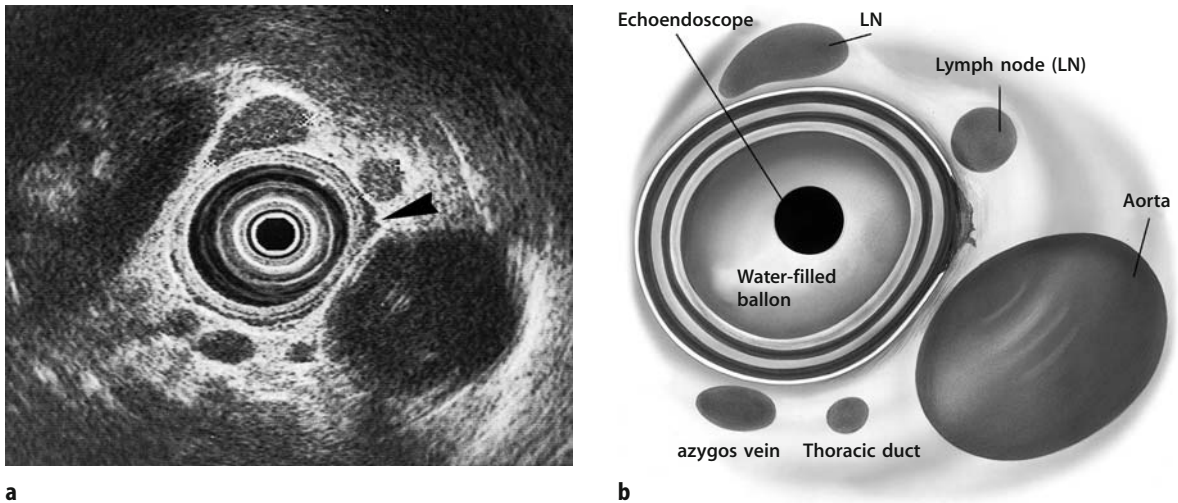


Fig. 4.3. Echoendoscopes.

A water filled balloon is mounted on the tip of the scope for better acoustic coupling to the bowel wall, which is sometimes needed to obtain optimal ultrasound images. Radial echoendoscopes have a scanning plane perpendicular to the endoscope and create images of the esophagus and surrounding structures in the same projection as axial CT. As a consequence the structures seen on EUS are moderately easy to recognize even for examiners not experienced in interpretation of ultrasound images. Consequently, evaluation and interpretation of pathologies is quite easily learnt (Fig. 4.4).

Unfortunately at the time of presentation many esophageal tumors are already quite advanced in the lumen, preventing passage of the main echoendoscopes. A special tapered echoendoscope, “the esophagoprobe”, with a shaft diameter of only 7.9 mm has been developed for these patients (GF MH 908, Olympus Optical Co., Tokyo, Japan) (Fig. 4.3, centre) [14, 15].

For very small and superficial or highly stenotic tumors, miniprobes are available. These are mechanical catheter-like 2.4 mm probes with a 360° view. They cannot be used independently but are operated through the accessory channel of a gastroscope (Fig. 4.3, right). The depth of penetration of these catheter probes varies from a maximum of 1.8 cm for




**Fig. 4.4.** **a** Evaluation of pathologies and structures; **b** interpretation of pathologies and structures.

the 20 MHz probe (UM 3R, Olympus Optical Co., Tokyo, Japan) to 2.9 cm for the 12 MHz probe (UM 2R, Olympus Optical Co., Tokyo, Japan). If necessary an additional water filled catheter sleeve can be used for better acoustic coupling. The higher resolution of these high frequency probes allows up to 7–9 layers to be seen in the wall of the bowel [16]. For endoscopic ultrasound guided fine needle aspiration (EUS-FNA) electronic linear array echoendoscopes with a 100–180 degree sector parallel to the long axis of the endoscope are available (Pentax GmbH, Hamburg, Germany; Olympus Optical Co., Tokyo, Japan; Toshiba, Tokyo, Japan) (Fig. 4.5).

The anatomical views seen with linear endoscopic ultrasound are quite different to those with radial echoendoscopes. Reliable identification of anatomical landmarks and pathology takes some time, and there is a rather longer learning curve [17]. A major advantage of the linear system over the radial is the ability to visualize the entire length of a biopsy needle advanced through the accessory channel. The needle can be seen endoscopically as it emerges from the channel and can then be followed on ultrasound in real time as it is pushed through the bowel wall into the target tissue. The needle can be advanced and retracted under direct ultrasound visual control.

For fine needle aspiration 170 cm long 19–22 gauge needle systems are commercially



**Fig. 4.5.** EUS-FNA echoendoscopes.

available. These can be securely screwed onto the accessory channel of the endoscope [18]. Color Doppler ultrasound can be used to identify and avoid vessels in the path of the needle. With this technique it is possible to sample nodes as small as 5 mm adjacent to large vessels or the heart. The fine needle aspiration is performed through the esophageal or gastric wall and does not leave any visible mark in the gut wall. Generally 22 gauge needles are used to obtain cytology. If histology is necessary, particularly for suspected GIST tumors or non-Hodgkin's lymphoma, a 19 gauge needle is available. These are similar to the smaller needles but are more rigid and slightly more difficult to handle, so they should be reserved for cases where cytology might not be sufficient.

The complication rate with these larger needles has not been established but is likely to be higher [19].

### EUS compared to other imaging techniques

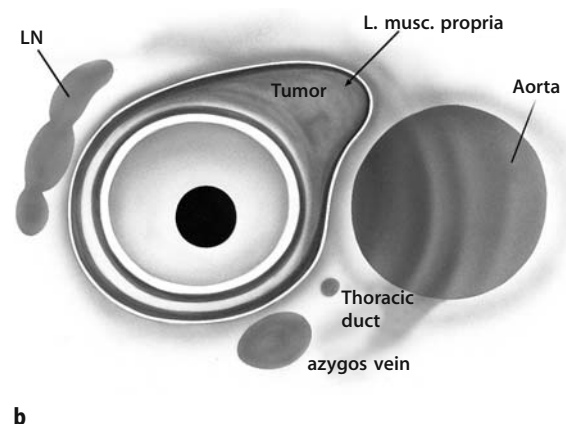
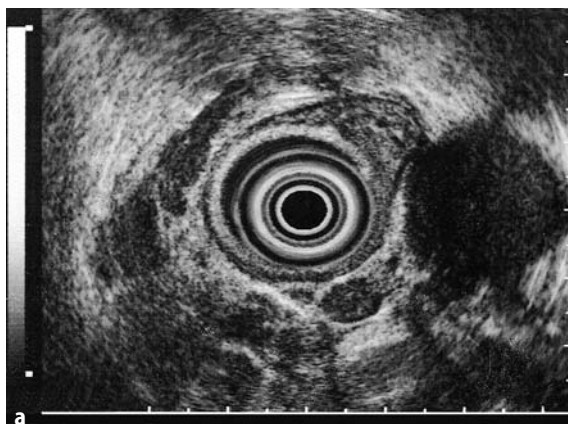
Several earlier studies compared the accuracy of CT and EUS in the staging of esophageal cancer. EUS correctly staged the primary tumor in 76–88% and nodes in 70–86%. CT in the same patients was significantly less accurate correctly staging the primary tumor and nodes in 43–59% and 46–58% respectively [2, 8, 20, 24, 26, 27].

Newer studies using helical or multi-slice CT showed slightly improved results. Of 60 patients with esophageal cancer who underwent pre-operative CT and EUS, sensitivities for T and N staging were 58% and 79% for CT and 72% and 91% for EUS, respectively (Figs. 4.6, 4.7). Specificity for both T and N stages was 80% and 84% for CT and 85% and 68% for EUS, respectively [28]. The impact of the tumor stage on final therapy was assessed in 125 patients. CT was less accurate (51%) than EUS (74%) for nodal staging. EUS-FNA further improved these results [29].

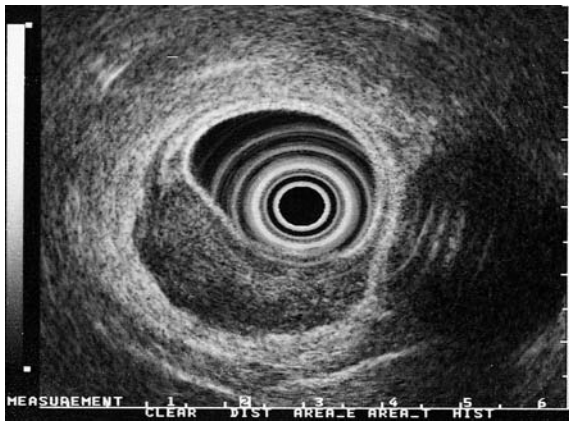In recent years Positron Emission Tomography (PET), a new imaging technique, has been introduced to overcome some of the shortcomings of CT for staging. This technique relies on increased uptake of the positron emitting glucose analogue by neoplastic tissue and has the

advantage over conventional imaging of not relying only on anatomic imaging. Recent studies comparing CT, PET and EUS showed sensitivity for T staging of 83–95% for PET, which was similar to EUS but higher than for CT (67%). Sensitivity for local N staging was 33–37–55% for PET compared to 69–81–89% for EUS. However the specificity for local node involvement was 89–100% with PET and only 54–67% for EUS, while accuracy was 63% for PET, 66% for CT and 75% for EUS [30–32]. These data clearly suggest EUS is superior to PET for staging local nodes. The relatively low specificity of EUS imaging alone can be improved by performing FNA during the procedure. PET detected distant metastases in 47% and CT in 33%, while EUS cannot be used for distant disease other than celiac nodes [30].

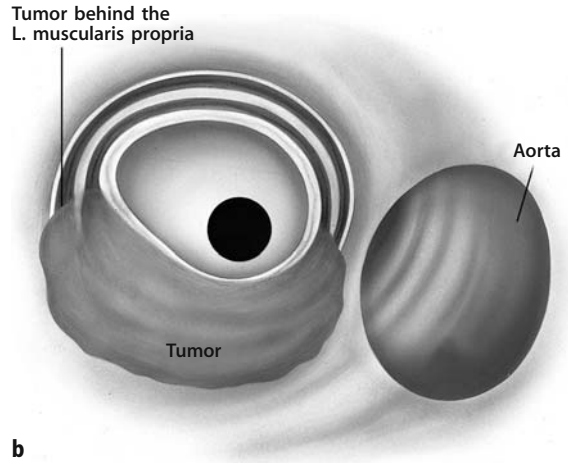
CT and PET add important information about possible distant metastases, and particularly CT remains an important imaging technique for the staging of esophageal cancer. It is readily available, relatively inexpensive, and fees are usually reimbursed. PET has a high specificity for nodal involvement and therefore may be indicated in selected cases. Wallace et al. compared the health care cost and effectiveness of all three imaging techniques for staging esophageal cancer in the USA. CT and EUS-FNA was the most inexpensive strategy and offered more quality-adjusted life-years than other strategies. PET+EUS-FNA were slightly more effective but also more expensive [33]. All in all CT and EUS are complimentary techniques for the staging of esophageal tumors,



**Fig. 4.6.** **a** T2-tumor, N1-status; **b** schematic demonstration of the pathologies and structures.



a



b

Fig. 4.7. a T3-tumor; b schematic demonstration.

and PET may add additional useful information in certain cases where there is uncertainty about nodal involvement.

### EUS and tumor stenosis

A prerequisite of a complete EUS examination is that the esophageal tumor allows the scope to pass into the stomach. If there is a tight malignant stenosis it may be impossible to pass the echoendoscope. Stenoses are present in 25–36% of tumors at the time of diagnosis [2, 34–36], and in most of these cases EUS evaluation is limited and incomplete. Images exclusively obtained from the proximal part of the tumor are not representative of the entire tumor, and correct T staging is possible in only 32% compared to 81% if the scope can pass (34%).

In general patients with tight strictures due to esophageal cancer have a higher tumor stage (T3–T4) and a less favorable prognosis. To be able to identify at EUS those strictures with a lower T stage suitable for curative surgery, endoscopic dilatation would be required. Despite controversial results such dilatation is not recommended only for imaging as the risk of perforation is as high as up to 25% [35, 36].

To reduce the risk of perforation in tight strictures a small calibre tapered echoendo-

scope has been developed, the esophagoprobe, which has a shaft of only 7.9 mm and a slippery tapered metal tip (Fig. 4.3, middle) [14, 15, 37]. As it has no optics it has to be introduced over a guide wire, which is advanced into the stomach via a small calibre gastro-scope prior to the EUS examination. Guided by the wire the echoendoscope can pass blindly through even the narrowest stenosis as the tapered tip serves as a dilator. A minor endoscopic dilatation is only rarely necessary [15]. Using this probe correct T staging is possible in up to 89% and N staging in 79%. The evaluation of nodes at the celiac axis can be achieved in 91%. There have been no reported complications using this scope [14, 15, 37].

In addition to the esophagoprobe ultra-thin miniprbes with 12, 20 and 30 MHz are available, which can be advanced via the accessory channel of a standard gastro-scope through tight strictures. With these catheters T staging is possible in 87–90% of cases [38, 39] although evaluation of celiac nodes is more difficult because of the limited depth of penetration.

Results using either the esophagoprobe or the miniprbes for evaluation of strictures due to esophageal cancer show that 12–19% of these patients have T2 stage disease and may be eligible for surgery [15, 37]. In these cases EUS can significantly change further management of these patients.

## EUS and re-staging of esophageal cancer

For patients with advanced tumors not suitable for surgery, combined chemoradiotherapy is an option. Post therapy follow-up and re-staging is necessary, at least in patients receiving neoadjuvant therapy, to evaluate whether the patient has become eligible for surgery. Imaging techniques used for this purpose include EUS.

Extent of the tumor, wall thickness, and number and size of locoregional nodes are used to evaluate therapeutic response. A number of studies have shown that EUS is not able to differentiate true extent of residual tumor from fibrosis and peripheral edema following therapy. These appear hypoechoic similar to the tumor and may result in over-staging. As a result T staging correlates with surgical staging in only 27–43% following neoadjuvant chemoradiotherapy [41–47]. This is also true if the patient receives radiotherapy alone [48].

Patients who have had an R<sub>0</sub> resection require regular follow-up. Nearly 50% of patients develop local recurrence or distant metastases. In these cases EUS can help detect irregularities of the wall and echopoor areas [49, 50]. The sensitivity is over 75% [49, 50]. However because of the surgery the normal wall layers are destroyed in the area of the anastomosis and early recurrence might be missed. False positive results also occur so special care has to be taken not to over-interpret the altered anatomy.

However in the presence of focal wall thickening or tumor near the esophageal or gastric wall EUS achieved a positive predictive value of 100% for recurrence.

EUS may provide satisfactory results for the detection of involved local nodes, but echogenicity and altered node shape and size alone does not prove malignancy as the specificity of EUS is low [13]. In these cases EUS-FNA is necessary for definitive tissue diagnosis.

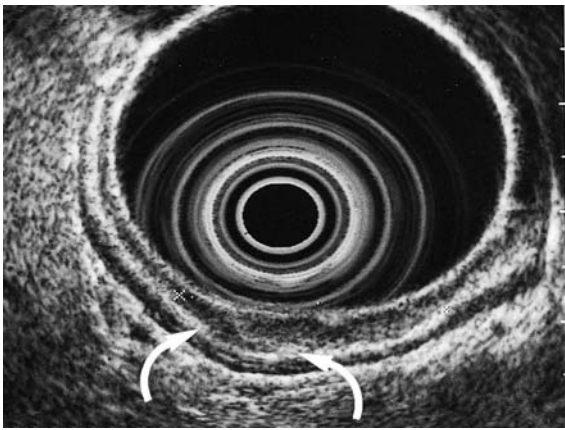
## Endoscopic ultrasound in early tumor stages

Since endoscopic mucosal resection (EMR) and other endoscopic methods such as photodynamic therapy and argon plasma therapy were introduced for the treatment of early esophageal cancer, accurate staging of these cancers has become even more important [52].

Early esophageal cancer can only be detected endoscopically as most imaging techniques are not sensitive enough to detect these subtle changes. Once proven histologically, accurate selection of patients for mucosectomy is vital. This includes the ability to differentiate T1m (tumors which are limited to the mucosa) from T1sm tumors (those which invade the submucosa). T1m tumors metastasise rarely to lymph nodes (<5%) and EMR may be curative. T1sm tumors behave like more advanced tumors and node metastases are more likely. Therefore these may better be treated with surgery, depending on the general condition of the patient [53–55].

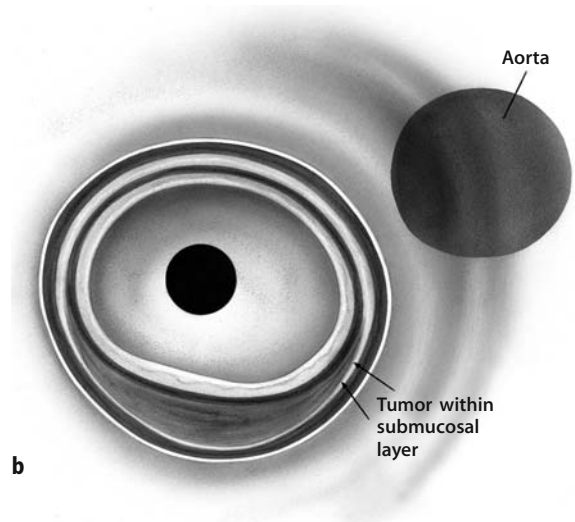
Although EUS performed with 5–10 MHz probes can differentiate between T1 and T2 malignancies, their resolution is not sufficient to reliably diagnose and differentiate between T1m and T1sm tumors. Although correct diagnosis may be possible in up to 71% (Fig. 4.8 a, b) the evaluation of these lesions is best performed with miniprobes at 12–30 MHz. These probes enable up to nine wall layers to be visualized resulting in easier differentiation between mucosal and submucosal spread. This differential diagnosis is possible in up to 86% of cases (Fig. 4.9) [56]. Failure to correctly stage these tumors is mainly due to the known surrounding edema, resulting in overstaging of a mucosal lesion into a T1sm or T2 stage tumor [57]. 30 MHz probes provide the best resolution but have poor penetration. Recently three dimensional probes have been developed, which transform two dimensional images into virtual three dimensional images and allow measurement of tumor volume [58].

With T1 tumors intended for endoscopic therapy it is especially important to evaluate lymph node status. In general local lymph nodes are correctly described in 67–91% with EUS [28, 30–32, 56, 59].

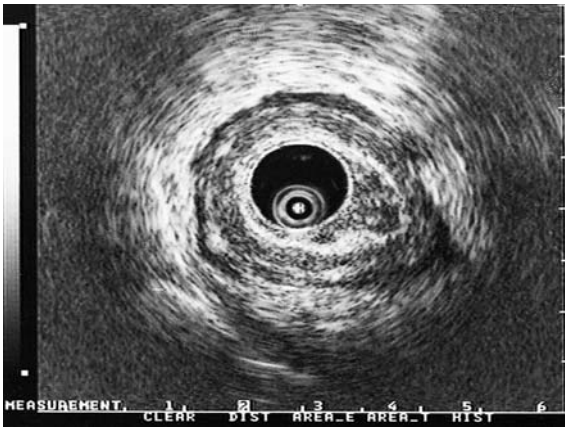


a

**Fig. 4.8. a** T1 sm-tumor; **b** schematic demonstration.

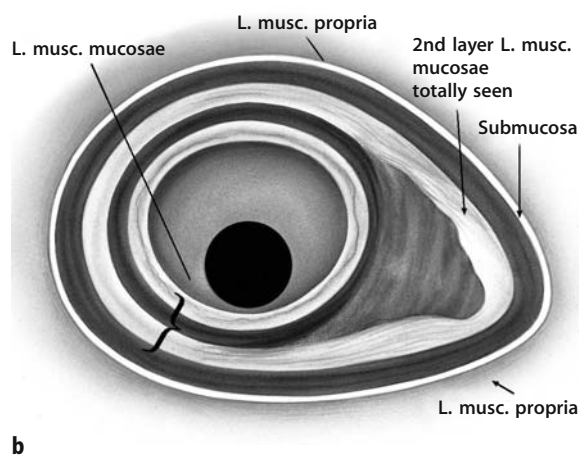


b



a

**Fig. 4.9. a** T1 m-tumor; **b** schematic demonstration.



b

Miniprobe have limited depth of penetration and therefore limited potential for the examination of local nodes. This is reflected by the lower accuracy of only 56% for N staging T1 tumors using miniprobe [56].

In general lymph node metastases are only to be expected with T1sm tumors. If fit enough, those patients with T1m tumor would undergo surgery, and it is hardly ever necessary to exchange a miniprobe for an echoendoscope to complete nodal staging in these cases. There may be some critical cases where therapy would be altered, in which case staging with both EUS probes is required. If nodes are

detected tissue proof is necessary to confirm metastatic involvement, as specificity of EUS alone is not sufficient for final diagnosis.

### Endoscopic ultrasound guided fine needle aspiration

CT evaluation of mediastinal and celiac nodes and their differentiation into benign and metastatic lacks precision [61, 62]. EUS is able to detect up to 90% of involved nodes, but the imaging alone using criteria such as echogeni-

city, clear margins and small size (>1 cm) is not able to define their aetiology with sufficient specificity [2, 7, 8, 12, 13, 20, 25, 28, 30–32, 63].

The required tissue diagnosis of detected nodes can be provided by EUS guided fine needle aspiration (EUS-FNA) of the mediastinum, performed at the same time as the EUS staging. Potentially this method is comparable to CT guided transthoracic biopsy, but this is burdened with a complication rate of 9%; 7.7% pneumothorax, which needs drainage in 1.6%; 1.3% bleeding [65–67]. In addition the accuracy of transthoracic needle biopsy of nodes smaller than 1 cm is low and cannot be performed in close proximity to large vessels. EUS-FNA represents a fairly new and alternative modality for tissue diagnosis. This can be used for all nodes within 5 cm of the GI tract as long as vision is not inhibited by air (Fig. 4.10). For esophageal cancer all lesions located within the posterior mediastinum 3 mm or larger, as well as celiac nodes can be visualized and punctured in real time under direct vision [10].

The pretracheal area and the anterior mediastinum are not accessible due to interfering air from the trachea. Nodes proximal or distal to the tumor are easily accessible. Nodes visible directly behind the primary tumor mass, which can only be approached through the tumor are to be avoided. The needle may be contaminated by malignant cells from the primary tumor giving rise to a false positive node cytology (68%). Around 20% of patients with esophageal cancer have celiac metastases, which are easily assessed (Fig. 4.11).

Technically EUS-FNA of mediastinal and celiac nodes is not demanding, especially when compared with fine needle aspiration of pancreatic masses or peri-pancreatic lymph nodes. The echoendoscope is straight, and the nodes are in close proximity to the gastrointestinal wall. Color Doppler allows the identification of nearby or interfering vessels allowing safer puncture. Advancement of the needle can be seen endoscopically as well as on ultrasound in real time. Complications of EUS-FNA for lymph node puncture are extremely rare. One esophageal perforation was reported when the echoendoscope was forced to pass a malignant esophageal stricture [62]. In general EUS-FNA

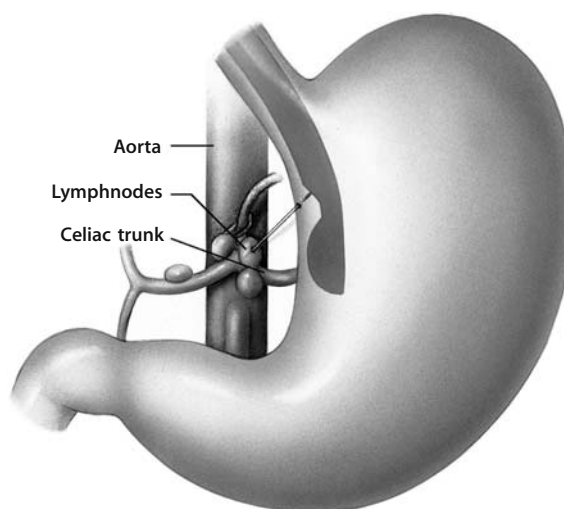


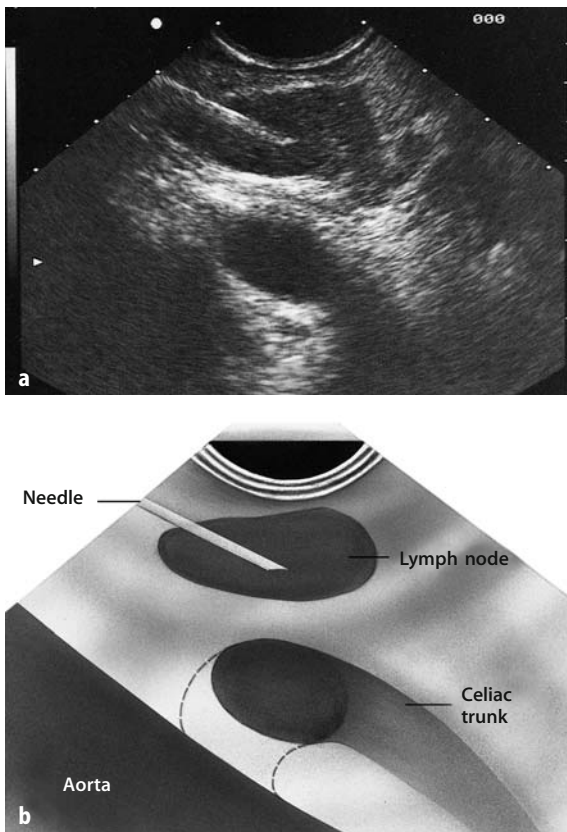
Fig. 4.10. Scheme of EUS-FNA.

provides cytology. It is able to verify the etiology of the tumor as well as metastases from other primaries such as breast, kidney, or lung cancer. False positive results are rare [69].

The technical success rate of EUS-FNA for mediastinal nodes is 89–96% [70–74] and is in the same range for the staging of lymph nodes in esophageal cancer [29, 75–78]. In a large prospective study of 125 patients EUS-FNA with lymph node involvement was significantly more sensitive (83% vs 29%) and more accurate (87% vs 51%) than CT, and also more accurate than EUS alone (87% vs 74%), resulting in a change in management in 77% of patients [29].

EUS and EUS-FNA of celiac nodes may require esophageal dilatation because stenosis may be seen in patients with advanced disease. No complications were observed from esophageal dilatation in a study using EUS. 18 (90%) of 20 nodes biopsied were positive for malignancy. CT detected only 6 (30%) of 20 cases of suspicious celiac lymph nodes, of which 83% were positive for malignancy by FNA [79]. In another study helical CT achieved a sensitivity and specificity for celiac nodes of 53%, and 86% of those nodes were detected and proven to contain malignancy by EUS-FNA [80]. Another group performed EUS-FNA in 94% [51, 54] of patients with celiac lymph nodes. The accuracy of EUS-FNA in detecting malignant nodes was 98% [78].





**Fig. 4.11 a,b.** Schematic demonstration of EUS-FNA at the celiac trunk.

In recent studies comparing the health care cost and effectiveness of multiple staging strategies EUS-FNA and/or CT + EUS-FNA were the most inexpensive options and offered the most quality-adjusted life-years. EUS-FNA ± CT can therefore be considered the preferred strategy [33, 81].

## Conclusion

EUS represents a highly sensitive and accurate method for the staging of esophageal cancer, which is not achieved by any other imaging modality to date. Simultaneously performed EUS guided FNA adds cytology for regional and celiac node staging, thus providing valuable information for the management of esophageal cancer patients.

## References

1. Moss A, Schnyder P, Thoeni RF et al (1981) Esophageal carcinoma: pretherapy staging by computed tomography. *AJR* 136:1051–1056
2. Tio TL, Cohen P, Coene PP et al (1989) Endosonography and computed tomography of esophageal carcinoma: preoperative classification compared to the new 1987 TNM staging system. *Gastroenterology* 96: 1478–1486
3. Halvorsen RA, Magruder-Habib K, Foster WL et al (1986) Esophageal cancer staging by CT: Long term follow up study. *Radiology* 161:17–151
4. Hutter VP (1987) At last – worldwide agreement on the staging of cancer. *Arch Surg* 122:1235–1239
5. Hermanek P, Sobin LH (eds) (1987) TNM classification of malignant tumors, 4<sup>th</sup> ed. Springer, Berlin
6. Kimmey MB, Martin RW, Haggitt RC et al (1989) Histologic correlations of gastrointestinal ultrasound images. *Gastroenterology* 96:433–441
7. Nattermann CH, Dancygier H (1993) Endoscopic ultrasound in the preoperative TN-staging of esophageal carcinoma. A comparative study between endosonography and computed tomography. *Ultraschall in Med* 14:100–105
8. Grimm H, Binmöller KF, Hamper K et al (1993) Endosonography for preoperative locoregional staging of esophageal and gastric cancer. *Endoscopy* 25:224–230
9. Tio TL, Coene PP, den Hartog Jager et al (1990) Preoperative TNM classification of esophageal carcinoma by endosonography. *Hepatogastroenterology* 37:376–381
10. Vilmann P (1996) Endoscopic ultrasonography-guided fine-needle aspiration biopsy of lymph nodes. *Gastrointest Endosc* 43:24–29
11. Tio T, Tytgat GNJ (1986) Endoscopic ultrasonography in analyzing peri-intestinal lymph node abnormality. Preliminary results of studies in vitro and in vivo. *Scand J Gastroenterol* 21 (suppl 123): 158–163
12. Catalano MF, Sivak MV, Rice TW et al (1994) Endosonographic features predictive of lymph node metastasis. *Gastrointest Endosc* 40:442–446
13. Bhutani MS, Hawes RH, Hoffmann BJ (1997) A comparison of the accuracy of echo features during endoscopic ultrasound (EUS) and EUS-guided fine-needle aspiration for diagnosis of malignant lymph node invasion. *Gastrointest Endosc* 45:474–479
14. Grimm H, Binmöller KF, Soehendra N (1992) Ultrasonic esophagoprobe (prototype I). *Gastrointest Endosc* 38:490–493
15. Binmöller KF, Seifert H, Seitz U et al (1995) Ultrasonic esophagoprobe for TNM staging of highly stenosing esophageal carcinoma. *Gastrointest Endosc* 41:547–552
16. Takemoto T, Yanai H, Hada M (1992) Application of ultrasonic probes prior to endoscopic resection of early gastric cancer. *Endosc* 24(suppl 1):329–333

17. Consensus conference (1993) Clinical applications of endoscopic ultrasonography in gastroenterology – State of the art 1993. *Endosc* 25:358–366
18. Vilman P, Hancke S (1996) A new biopsy handle instrument for endoscopic ultrasound guided fine-needle aspiration biopsy. *Gastrointest Endosc* 43: 238–243
19. Fritscher-Ravens A, Brand B, Bohnacker S, Sri Ram PVJ, Soehendra N (2000) Techniques in EUS-guided FNA of lymph nodes. *Techniques in Endoscopy* 2:142–248
20. Rösch T (1995) Endosonographic staging of esophageal cancer. A review of literature results. *Gastrointest Endosc Clin North Am* 5:537–547
21. Chak A, Canto M, Gerdes H et al (1995) Prognosis of esophageal cancers preoperatively staged to be locally invasive (T4) by endoscopic ultrasound (EUS): a multicenter retrospective cohort study. *Gastrointest Endosc* 42:501–506
22. Gertsch P, Vauthey JN, Lustenberger AA et al (1993) Long-term results of transhiatal esophagectomy for esophageal carcinoma. *Cancer* 72:231–239
23. Müller JM, Erasmí H, Stelner M (1990) Surgical therapy of esophageal carcinoma. *Br J Surg* 77: 845–857
24. Rösch T, Classen M (1992) Gastroenterologic endosonography. Thieme, Stuttgart
25. Dittler HJ, Siewert RJ (1993) Role of endoscopic ultrasonography in esophageal carcinoma. *Endosc* 25:156–161
26. Hordijk ML, Zander H, Van Blankenstein M et al (1993) Influence of tumor stenosis on the accuracy of endosonography in preoperative T-staging of esophageal cancer. *Endosc* 25:171–175
27. Souquet JC, Napoleon B, Pujol B et al (1992) Endosonography guided treatment of esophageal carcinoma. *Endosc* 24 (suppl 1):324–328
28. Weaver SR, Blackshaw GR, Lewis WG, Edwards P, Roberts SA, Thomas GV, Allison MC (2004) Comparison of special interest computed tomography, endosonography and histopathological stage of oesophageal cancer. *Clin Radiol* 59:499–504
29. Vazquez-Sequeiros E, Wiersema MJ, Clain JE, Norton ID, Levy MJ, Romero Y, Salomao D, Dierkhsing R, Zinsmeister AR (2003) Impact of lymph node staging on therapy of esophageal carcinoma. *Gastroenterology* 125:1626–1635
30. Rasanen JV, Sihvo EL, Knuuti MJ, Minn HR, Luostarinen ME, Laippala P, Viljanen T, Salo JA (2003) Prospective analysis of accuracy of positron emission tomography, computed tomography, and endoscopic ultrasonography in staging of adenocarcinoma of the esophagus and the esophagogastric junction. *Ann Surg Oncol* 10:954–960
31. Flamen P, Lerut A, Van Cutsem E, De Wever W, Peeters M, Stroobants S, Dupont P, Bormans G, Hiele M, De Leyn P, Van Raemdonck D, Coosemans W, Ectors N, Haustermans K, Mortelmans L (2000) Utility of positron emission tomography for the staging of patients with potentially operable esophageal carcinoma. *J Clin Oncol* 18:3199–3201
32. Heeren PA, Jager PL, Bongaerts F, van Dullemen H, Sluiter W, Plukker JT (2004) Detection of distant metastases in esophageal cancer with (18)F-FDG PET. *J Nucl Med* 45:980–987
33. Wallace MB, Nietert PJ, Earle C, Krasna MJ, Hawes RH, Hoffman BJ, Reed CE (2002) An analysis of multiple staging management strategies for carcinoma of the esophagus: computed tomography, endoscopic ultrasound, positron emission tomography, and thoracoscopy/laparoscopy. *Ann Thorac Surg* 74:1026–1032
34. Catalano MF, Van Dam J, Sivak MV (1995) Malignant esophageal strictures. Staging accuracy of endoscopic ultrasonography. *Gastrointest Endosc* 41:535–539
35. Van Dam J, Rice TW, Catalano MF et al (1993) High grade malignant stricture is predictive of esophageal tumor stage. Risks of endosonographic evaluation. *Cancer* 71:2910–2917
36. Kallimanis GE, Gupta PK, Al-Kawas FH et al (1996) Endoscopic ultrasound for staging esophageal cancer, with or without dilatation, is clinically important and safe. *Gastrointest Endosc* 41:540–546
37. Mallery S, Van Dam J (1999) Increased rate of complete EUS staging of patients with esophageal cancer using the nonoptical, wire-guided echoendoscope. *Gastrointest Endosc* 50:53–57
38. Menzel J, Höpfner N, Nottberg H et al (1999) Preoperative staging of esophageal carcinoma: Miniprobe sonography versus conventional endoscopic ultrasound in a prospective histopathologically verified study. *Endoscopy* 31:291–297
39. Hünerbein M, Ghadimi BM, Hänsch W et al (1998) Transendoscopic ultrasound of esophageal and gastric cancer using miniaturized ultrasound catheter probes. *Gastrointest Endosc* 48:371–375
40. Chak A, Canto M, Stevens PD et al (1997) Clinical applications of a new through the scope ultrasound probe. Prospective comparison with an ultrasound endoscope. *Gastrointest Endosc* 45:291–295
41. Isenberg G, Chak A, Canto MI et al (1998) Endoscopic ultrasound in restaging of esophageal cancer after neoadjuvant chemoradiation. *Gastrointest Endosc* 48:158–163
42. Hordijk ML, Kok TC, Wilson JH et al (1993) Assessment of response of esophageal carcinoma to induction chemotherapy. *Endosc* 25:592–596
43. Dittler HJ, Fink U, Siewert GR (1994) Response to chemotherapy in esophageal cancer. *Endoscopy* 26:769–771
44. Zuccaro G, Rice TW, Goldblum J et al (1999) Endoscopic ultrasound cannot determine suitability for esophagectomy after aggressive chemoradiotherapy for esophageal cancer. *Am J Gastroenterol* 94:906–912
45. Laterza E, Manzoni G, Guglielmi A et al (1999) Endoscopic ultrasonography in the staging of esophageal carcinoma after preoperative radiotherapy and chemotherapy. *Ann Thorac Surg* 67:1466–1469
46. Kalha I, Kaw M, Fukami N, Patel M, Singh S, Gagneja H, Cohen D, Morris J (2004) The accuracy of

- endoscopic ultrasound for restaging esophageal carcinoma after chemoradiation therapy. *Cancer* 101:940–947
47. Beseth BD, Bedford R, Isacoff WH, Holmes EC, Cameron RB (2000) Endoscopic ultrasound does not accurately assess pathologic stage of esophageal cancer after neoadjuvant chemoradiotherapy. *Am Surg* 66:827–831
  48. Tio LT, Blank LEC, Wijers OB et al (1994) Staging and prognosis using endosonography in patients with inoperable esophageal carcinoma treated with combined intraluminal and external irradiation. *Gastrointest Endosc* 40:304–310
  49. Lightdale CJ, Botet JF, Kelsen DP et al (1989) Diagnosis of recurrent upper gastrointestinal cancer at the surgical anastomosis by endoscopic ultrasound. *Gastrointest Endosc* 35:407–412
  50. Catalano MF, Sivak MV, Rice TW et al (1995) Post-operative screening for anastomotic recurrence of esophageal carcinoma by endoscopic endosonography. *Gastrointest Endosc* 42:540–544
  51. Fockens P, Manshanden CG, van Landschot JB et al (1997) Prospective study on the value of endosonographic follow-up after surgery for esophageal carcinoma. *Gastrointest Endosc* 46:487–491
  52. Soehendra N, Binmöller KF, Bohnacker S et al (1997) Endoscopic snare mucosectomy in the esophagus without any additional equipment: A simple technique for resection of flat early cancer. *Endosc* 29:380–383
  53. Goseki N, Koike M, Yoshida M (1992) Histopathologic characteristics of early stage esophageal carcinoma. A comparative study with gastric carcinoma. *Cancer* 69:1088–1093
  54. Bogomoletz WV, Molas G, Gayet B et al (1989) Superficial squamous cell carcinoma of the esophagus. *Am J Pathol* 13:535–546
  55. Tio TL (1998) Diagnosis and staging of esophageal carcinoma by endoscopic ultrasonography. *Endoscopy* 30 (suppl 1):A33–A40
  56. Hasegawa N, Niwa Y, Arisawa T et al (1996) Preoperative staging of superficial esophageal carcinoma: comparison of an ultrasound probe and standard endoscopic ultrasonography. *Gastrointest Endosc* 44:388–393
  57. Yanai H, Yoshida T, Harada T et al (1996) Endoscopic ultrasonography of superficial esophageal cancers using a thin ultrasound probe system equipped with switchable radial and linear scanning modes. *Gastrointest Endosc* 44:578–582
  58. Yasuda K, Kamaguchi M, Morikawa J, Honda M, Nakajima M (2005) Role of endoscopic ultrasonography in the diagnosis of early esophageal cancer. *Gastrointest Endosc Clin N Am* 15:93–99
  59. Natsugoe S, Yoshinaka H, Morinaga T et al (1996) Ultrasonographic detection of lymph node metastases in superficial carcinoma of the esophagus. *Endoscopy* 28:674–679
  60. McLoud TC, Bourgooin PM, Greenberg RW (1992) Bronchogenic carcinoma: Analysis of staging in the mediastinum with CT by correlative lymph-node mapping and sampling. *Radiology* 182:319–323
  62. Izbicki JR, Thetter O, Karg et al (1992) Accuracy of computed tomographic scan and surgical assessment for staging of bronchial carcinoma. *J Thor Cardiovasc Surg* 104:413–420
  63. Kondo D, Imaizumi M, Abe T et al (1990) Endoscopic ultrasound examination for mediastinal lymph node metastases of lung cancer. *Chest* 98: 586–593
  64. Ikenberry S, Bilderback S, Hawes R (1997) Endoscopic ultrasonography, fine-needle aspiration biopsy guided by endoscopic ultrasonography, and computed tomography in the preoperative staging of non-small-cell lung cancer: A comparison study. *Ann Int Med* 127:604–612
  65. Salazar AM, Westcott JL (1993) The role of transthoracic needle biopsy for the diagnosis and staging of lung cancer. *Clin Chest Med* 14:99–110
  66. Belfiore G, Camera L, Vetrani A, Fraioli G, Salvatore M (1997) Middle mediastinum lesions: Preliminary experience with CT guided fine-needle aspiration biopsy with a suprasternal approach. *Radiology* 202:870–873
  67. Schneider CP, Pröschild A, Mäder I et al (1999) CT-guided transthoracic biopsy of intrapulmonary and mediastinal lesions. A retrospective study in 300 patients. *Pneumologie* 53:71–76
  68. Ciccia D (1999) Endoscopic ultrasound-fine needle aspiration in esophageal cancer. *Techniques in Gastrointest Endosc* 1:60–62
  69. Fritscher-Ravens A, SriRam PVJ, Schröder S, Topalidis T, Bohnacker S, Soehendra N (2000) Stromal tumor as a pitfall in endosonography-guided fine-needle aspiration cytology. *Gastrointest Endosc* 51: 746–749
  70. Silvestri GA, Hoffmann BJ, Bhutani MS et al (1996) Endoscopic ultrasound with fine needle aspiration in the diagnosis and staging of lung cancer. *Ann Thorac Surg* 61:1441–1446
  71. Gress F, Savides T, Sandler A et al (1997) Endoscopic ultrasonography, fine-needle aspiration biopsy guided by endoscopic ultrasonography, and computed tomography in the preoperative staging of non small-cell lung cancer: A comparison study. *Ann Int Med* 127:604–612
  72. Fritscher-Ravens A, SriRam PVJ, Bobrowski B, Pforte A, Topalidis T, Thonke F, Jäckle S, Soehendra N (2000) Mediastinal lymphadenopathy in patients with and without previous malignancy – EUS-FNA based cytodagnosis in 153 patients. *Am J Gastroenterol* 95:2278–2284
  73. Wiersema MJ, Vilmann P, Giovannini M et al (1997) Endosonography guided fine-needle aspiration biopsy: diagnostic accuracy and complication assessment. *Gastroenterology* 112:1087–1095
  74. Williams DB, Sahai AV, Aabakken L et al (1999) Endoscopic ultrasound guided fine-needle aspiration biopsy: a large single center experience. *GUT* 44:720–726
  75. Giovannini M, Monges G, Seitz JF et al (1999) Distant lymph node metastases in esophageal cancer. Impact of endoscopic ultrasound-guided biopsy. *Endosc* 31:536–540

76. Reed CE, Mishra G, Sahai A (1999) Esophageal cancer staging: Improved accuracy by endoscopic ultrasound of celiac lymph nodes. *Ann Thorac Surg* 67:319–322
77. Chang KJ, Soetikno RM, Bastas D, Tu C, Nguyen PT (2003) Impact of endoscopic ultrasound combined with fine-needle aspiration biopsy in the management of esophageal cancer. *Endosc* 35:962–966
78. Eloubeidi MA, Wallace MB, Reed CE, Hadzijahic N, Lewin DN, Van Velse A, Leveen MB, Etemad B, Matsuda K, Patel RS, Hawes RH, Hoffman BJ (2001) The utility of EUS and EUS-guided fine needle aspiration in detecting celiac lymph node metastasis in patients with esophageal cancer: a single-center experience. *Gastrointest Endosc* 54(6): 714–719
79. Parmar KS, Zwischenberger JB, Reeves AL, Waxman I (2002) Clinical impact of endoscopic ultrasound-guided fine needle aspiration of celiac axis lymph nodes (M1a disease) in esophageal cancer. *Ann Thorac Surg* 73(3):916–920, discussion 920–921
80. Romagnuolo J, Scott J, Hawes RH, Hoffman BJ, Reed CE, Aithal GP, Breslin NP, Chen RY, Gumustop B, Hennessey W, Van Velse A, Wallace MB (2002) Helical CT versus EUS with fine needle aspiration for celiac nodal assessment in patients with esophageal cancer. *Gastrointest Endosc* 55: 648–654
81. Harewood GC, Wiersema MJ (2002) A cost analysis of endoscopic ultrasound in the evaluation of esophageal. *Am J Gastroenterol* 97(2):452–458
82. Greene FL, Page DL, Fleming ID et al (eds) (2002) TNM classification and stage grouping of esophageal carcinoma. American joint committee on cancer. *Cancer staging manual*, 6<sup>th</sup> edn. Springer, New York, pp 91–98

# Preoperative Evaluation of the Operative Risk Profile

K. A. GAWAD, C. BUSCH, D. C. BROERING, E. F. YEKEBAS

## Introduction

The primary goal of a preoperative risk analysis is the reduction of perioperative morbidity and mortality. The latter is still ranging up to 10% for esophageal cancer despite all progress in intensive care therapy and the refinement of surgical technique. The morbidity, in particular the incidence of pulmonary complications, is by far higher and amounts to approximately 50%.

To reduce this high morbidity, insufficient organ systems are to be recognized and their function should be improved by suitable means, preoperatively.

## Definition of "risk"

Mortality and morbidity are affected by *tumor-related* and *patient-related* factors, which have to be differentiated.

Tumor-related factors of risk such as tumor size, infiltration of neighboring organs, lymphatic spread, or possible distant metastasis are evaluated by preoperative staging.

The patient-related risk is characterized by pre-existing diseases leading to dysfunctions of certain organ systems not related to the malignant disease, thus accounting for the individual risk of the patient.

Methods for the ascertainment and objectification of this risk will be described in the following.

## Methods of risk ascertainment

Traditionally risk assessment is a subjective appraisal of the patient by the surgeon supported by objective findings such as routine blood chemistry, chest x-ray, and ECG. By questions evaluating physical performance such as "How many floors can you walk up without shortness of breath or chest pain?", the surgeon tries to objectify his appraisal.

This procedure assumes extensive clinical experience and is not suitable for a standardized, objective patient evaluation and selection.

Different instruments for the objective estimation of the risk are established. The ASA classification predominantly applied in anesthesia. It combines objective findings, the subjective impression, and the clinical findings of the examiner into a 5-step classification. It is designed, however, for the application to a broad spectrum of surgical patients and is not suitable for the individual risk assessment before esophagectomy.

Different analyses described in the literature could isolate a multiplicity of independent risk factors, which significantly affect postoperative mortality and the incidence of postoperative complications. However, none of these investigations lead to the establishment of a simple, practicable scoring system allowing a general evaluation.

**Table 5.1.** Classification of organ dysfunction

■ <b>Pulmonary function</b>	1 – normal	VC > 90% and PaO <sub>2</sub> > 70 mmHg
	2 – restricted	VC < 90% or PaO <sub>2</sub> < 70 mmHg
	3 – highly restricted	VC < 90% and PaO <sub>2</sub> < 70 mmHg
■ <b>Hepatic function</b>	1 – normal	ABT > 0.4
	2 – restricted	ABT < 0.4; cirrhosis
	3 – highly restricted	cirrhosis
■ <b>Cardiac function (cardiological appraisal)</b>	1 – normal	normal risk
	2 – restricted	increased risk
	3 – highly restricted	high risk
■ <b>General status</b>	1 – normal	Karnofsky Index > 80% and good cooperation
	2 – restricted	Karnofsky Index ≤ 80% or bad cooperation
	3 – highly restricted	Karnofsky Index ≤ 80% and bad cooperation

ABT: Aminopyrine breath test; VC: vital capacity; PaO<sub>2</sub>: arterial O<sub>2</sub> partial pressure; *Karnofsky Index*, see Table 5.2

**Table 5.2.** Karnofsky Index

100%	Normal activity, no complaints
90%	Marginally reduced activity and capacity
80%	Normal activity only with exertion, clearly reduced activity
70%	Unable for normal activity, autonomous maintenance
60%	Occasional help, largely autonomous maintenance
50%	Continuous support and care, regular medical help needed
40%	Mostly bedridden, professional nurse needed
30%	Continuously bedridden, professional nurse needed
20%	Badly ill, hospitalized, active supportive therapy
10%	Moribund

An instrument for preoperative risk analysis, particularly in esophageal cancer patients, was recently established on the basis of an analysis of 553 patients [1]. It seems to allow the identification of patients with a clearly increased risk who may have to be admitted to a non-surgical treatment. The factors shown in Table 1 are multiplied with a priority factor (general state × 4, cardiac function × 3, hepatic function × 2 and respiratory function × 2), and a total score is calculated allowing the assignment to

one of a total of 3 risk groups (small risk (11–15 points), moderate risk (16–21 points), high risk (22–33 points)).

In our own patient collective the use of scores established in thoracic surgery [2] has been shown to be effective for the assessment of pulmonary and cardiac risk. Based on our experience, these are the limiting factors that substantially affect postoperative morbidity and mortality. In particular a preoperative optimization of the patient condition can be achieved in a suitable manner. The function of other organ systems is assessed by means of laboratory analyses and, if necessary, function tests.

### Measures for preoperative risk minimization

We are in favor of an interdisciplinary approach with participation of surgeons, cardiologists, and pulmonologists. Patients in whom a restriction of the pulmonary or cardiac function is evitable by the preoperative analysis can possibly be brought into a lower risk group by suitable measures. To achieve an improvement of cardiac function above all, the optimization of the medication for hypertension, cardiac insufficiency or arrhythmia is mandatory. In coronary obstruction, stenting

or even bypass procedures should be performed to improve the cardiac risk of the patient. To improve pulmonary function the sensible use of mucolytic agents, bronchodilators as well as effective respiratory therapy (drainage, percussion, vibration, and breathing exercises) under physiotherapeutic guidance or machine measures (incentive spirometry, “Continuous positive airway pressure” (CPAP), “intermittent positive pressure breathing” (IPPB)) have to be considered. In patients with cachexia, a high caloric enteral nutrition should be supported by infusion therapy.

Patients with esophageal cancer represent a difficult patient group, usually afflicted with multiple pre-existing diseases. An exact history provides initial information on possible risk factors. It is especially necessary to ask about active alcoholism or other intoxicant consumption. For the minimization of the perioperative morbidity and mortality, an exact analysis of the organ systems is necessary by appropriate function tests. These should cover an examination of the cardiac function by means of echocardiography and ergometry. If necessary, further investigations have to be conducted after cardiological evaluation. If an improvement of function by respective treatment is possible, this has to be documented by repeat assessment after an appropriate interval. Pulmonary function testing should include plethysmography and ar-

terial blood gas analysis. Following appropriate pretreatment, a new analysis is also necessary.

In patients with pathological creatinin values, a determination of the creatinin clearance is mandatory.

After the execution of the investigations specified above, the operative risk for the patient can be objectified by assigning the findings into a scoring system. The following patients should be excluded from an operation: patients assigned to a high risk group according to the scoring system previously described, patients with a severe dysfunction of individual organ systems, or those with an accumulation of less severe but still serious dysfunctions. However, surgery can be indicated as an individual approach and only after an intensive consent discussion.

---

## References

1. Bartels H, Stein HJ, Siewert JR (1998) Preoperative risk analysis and postoperative mortality of oesophagectomy for resectable oesophageal cancer. *Br J Surg* 85(6):840–844
2. Izbicki JR, Knöfel WT, Passlick B, Habekost M, Karg O, Thetter O (1995) Risk analysis and long-term survival in patients undergoing extended resection of locally advanced lung cancer. *J Thorac Cardiovasc Surg* 110(2):386–395

Developments in surgical as well as anesthetic management have meant that the morbidity and the mortality of esophageal surgery have substantially reduced during the last decade. Modern anesthetic management allows targeted risk stratification, especially of cardiac and pulmonary risk factors, thus providing a rationale for intraoperative monitoring and choice of anesthetic technique as well as postoperative pain and intensive care therapy. It is essential for the attending anesthesiologist to understand the underlying principles of the pathophysiology and surgery of esophageal diseases and to cooperate closely with the surgeon in order to provide the best care possible for the patient.

## Preoperative evaluation

Depending on the pathologic condition of the esophagus, chronic, subacute or acute aspiration may occur. Aspiration often results in a poor preoperative respiratory status with recurring pneumonia. Furthermore, during induction of anesthesia the risk of regurgitation and aspiration is increased [1]. Patients with malignancies of the esophagus often present a history of smoking with resulting complications of chronic obstructive lung diseases.

Treatment of malignant esophageal tumors with bleomycin may cause further deterioration in the respiratory status especially after periods of ventilation with high oxygen tension [2]. Dyspnea due to obstruction of the airways by large mediastinal masses is a rare finding.

Initial screening of the severity of esophageal diseases with respect to tumor mass, occurrence of dysselectasis or atelectasis and

pleural effusions may be achieved by basic clinical techniques such as inspection, palpation, auscultation, and percussion. The preoperative chest X-ray in anterior-posterior and lateral position allows diagnosis of emphysema, pneumonia or intrapulmonary metastases. Displacements or obstructions of the trachea may indicate a difficult endotracheal intubation. The computed tomogram of the lung allows an even more detailed analysis of pulmonary and mediastinal pathologies. Forced expired volume in one second (FEV1) and functional vital capacity are the most important parameters determined by specialized lung function tests indicating obstructive or restrictive lung disease often accompanied by an increased risk of postoperative morbidity and mortality. Preoperative hypoxia and/or hypercapnia may indicate a postoperative need for mechanical ventilation as well as difficult weaning phase with a prolonged stay on the intensive care unit (ICU) [3].

Patients with obstructive diseases of the esophagus often have a poor nutritional status. Depending on the severity of the dysphagia solids and sometimes even fluids cannot pass the esophagus. Improving the nutritional status prior to surgery can lead to lowered morbidity and mortality. If the intake of fluids is restricted thus leading to hypovolemia, fluids need to be replaced by parenteral therapy. Many patients with malignancies of the esophagus are older than 40 years and have a history of hypertension, smoking, diabetes mellitus, claudication, and hyperlipoproteinemia. Further evaluation is necessary if history and examination reveal symptoms of coronary artery disease, a previous myocardial infarction, or congestive heart failure. The routine preoperative ECG does not exhibit signs of myocardial ischemia in 15–50% of patients with coro-



nary artery disease. Another 25% of the patients present with dysrhythmias that prohibit the use of ECG as a marker for myocardial ischemia. In addition to routine testing, examinations such as a stress ECG, echocardiography with and without stress, pharmacological stress tests, or diagnostic coronary angiography may reveal evidence of the severity of cardiac disease [4]. Depending on the results of the preoperative evaluation, a cardiologic or cardio-surgical intervention may be necessary before the planned operation. Chemotherapeutic agents such as daunorubicin and adriamycin as well as chronic alcohol abuse, which are often present in these patients, may also lead to cardiomyopathies.

The extent of preoperative laboratory testing depends on the history and physical examination of the patient. Basic testing includes hematologic parameters, electrolytes, glucose, serum creatinine, blood urea nitrogen, transaminases, alkaline phosphatases, and serum albumin. If the coagulation status exhibits abnormalities, factors and platelets should be administered as needed. A preoperative autologous blood donation should be considered if the underlying disease is not of malign nature, hemoglobin concentration is in the normal range, and the planned operation is not urgent.

The goal of premedication is sedation, anxiolysis and amnesia. This profile is best achieved by administration of short acting benzodiazepines. Additionally, if the patient is in pain or if preemptive analgesia is desired an opioid can be given. If signs of gastric reflux are present, H<sub>2</sub>-receptor antagonists may reduce gastric secretions and gastric pH. However, these agents require a sufficient interval between administration and anesthesia in order to provide adequate effects. Cimetidine and the more potent ranitidine are currently the preferred agents. Administration is usually orally. However in the presence of severe dysphagia they may be given carefully intravenously. Increased rates of bacterial pneumonia have been reported after administration of H<sub>2</sub>-antagonists. However, the significance of these findings is still being discussed. Metoclopramide increases the lower esophageal sphincter pressure and may thus reduce the risk of aspiration. In contrast, anticholinergic drugs may reduce the lower esophageal sphincter tone (Table 6.1).

In addition to routine monitoring, a central venous line and an arterial catheter are necessary to continuously monitor hemodynamics and to perform frequent analyses of the blood gas status. The intraoperative manipulation of the mediastinum and the accompanying compression of the heart or major vessels as well as the induction of cardiac arrhythmias together with massive blood loss often lead to severe intraoperative cardiocirculatory depression that makes continuous online monitoring of arterial and venous blood pressure mandatory. Depending on the preoperative status of the patient, the use of a pulmonary artery catheter should be considered [5]. Pulse oximetry is imperative for monitoring of oxygen delivery, especially during one-lung ventilation.

Anesthesia in esophageal surgery is performed as balanced anesthesia or as a total intravenous anesthesia (TIVA). Additionally a thoracic epidural catheter may be applied for intra- and postoperative pain therapy. Epidural analgesia has been demonstrated to provide better postoperative lung function, better spontaneous ventilation, and higher arterial oxygen tensions than systemic administration of analgesics [6]. In patients with coronary artery disease and myocardial infarction epidural analgesia has been demonstrated to be beneficial. Due to a favorable effect on the ratio between oxygen demand and oxygen delivery sympatholysis may improve stress-induced left ventricular function [7]. Placement of the epi-

**Table 6.1.** Preoperative minimal diagnostic requirements for patients undergoing major esophageal surgery

Laboratory tests	Apparative tests
■ Hemoglobin, hematocrit	■ plain chest x-ray
■ Serum electrolytes (sodium, potassium)	■ electrocardiogram (ECG)
■ Serum creatinine and urea	■ pulmonary function test
■ Blood glucose	
■ Liver enzymes	
■ Blood group	
■ Coagulation status	
Further investigations might be necessary depending on test results	

**Table 6.2.** Influence of various drugs on pressure of the lower esophageal sphincter

Reduction	Increase	No change
■ Atropine	■ Metoclopramide	■ Propranolol
■ Glycopyrrolate	■ Droperidol	■ Cimetidine
■ Dopamine	■ Edrophonium	■ Ranitidine
■ Nitroprusside	■ Neostigmine	■ Atracurium
■ Ganglionic blocking agent	■ Histamine	
■ Thiopentone	■ Succinylcholine	
■ Tricyclic antidepressant	■ Pancuronium	
■ Beta-adrenoceptor agonist	■ Metoprolol	
■ Volatile anesthetics	■ Alpha-adrenoceptor agonist	
■ Opioids	■ Antacida	

dural catheter is best performed before induction of general anesthesia because of the better positioning of the patient, early detection of complications such as hematoma or neural injuries, and more rapid detection of catheter displacements [8]. The injection of local anesthetics via an epidural catheter under general anesthesia is currently under discussion. Although analgesia, good surgical exposure due to a small and contracted gastrointestinal tract, and muscle relaxation are benefits of this approach, one has to consider increased risk of intraoperative hypotension and blood loss due to peripheral vasodilatation.

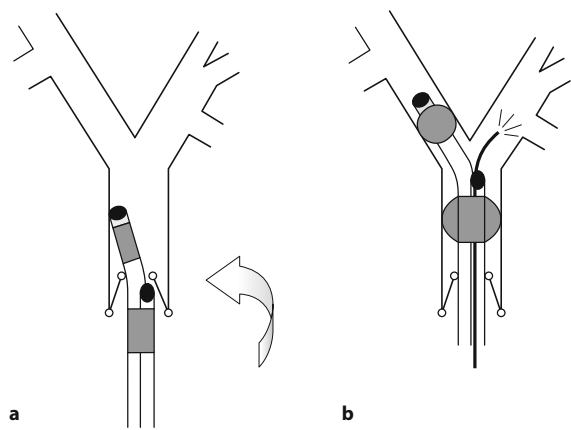
The role of the new volatile anesthetics sevoflurane and desflurane in anesthesia for esophageal surgery has not yet been determined. The rapid pharmacokinetics of these agents allows achievement of spontaneous ventilation and extubation of the patient shortly after skin closure. However, the use of TIVA may improve outcome with respect to postoperative shivering as well as nausea and vomiting. The opioid remifentanyl possesses an extremely short context-sensitive half-time, thus allowing a better adaptation to surgical stress. Nitrous oxide may diffuse into preformed gaseous bubbles, for example in the gastrointestinal tract, thus leading to bowel distention. Furthermore, one-lung ventilation requires the administration of high fractions of oxygen ( $FiO_2$ ), thus prohibiting the use of nitrous oxide.

Aspiration during induction of anesthesia is a frequent complication in patients with esophageal diseases.

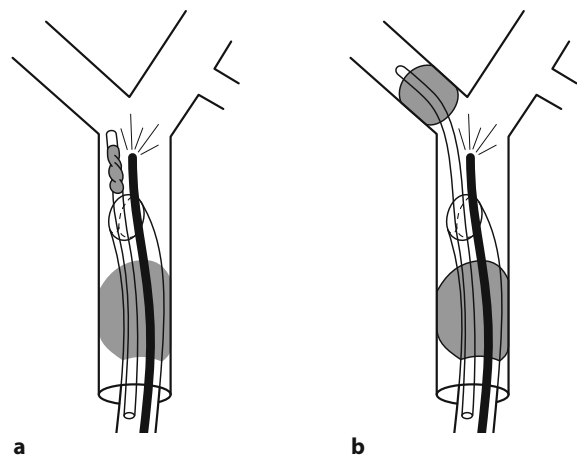
Therefore the trachea should be intubated after rapid-sequence induction with cricoid pressure. The introduction of rocuronium as a muscle relaxant allows performing a modified rapid-sequence induction without using succinyl choline and may thus reduce the risk of a massive release of potassium or the triggering of a malignant hyperthermia (MH) episode. Tumors of the esophagus or mediastinal lymph nodes may lead to a complete collapse and obstruction of the upper airways after loss of muscle tone due to administration of muscle relaxants [9]. Ventilation of the patient may be impossible unless an endotracheal tube is placed distally to the obstruction. However, placement of an endotracheal tube may be extremely difficult leading to a “cannot ventilate, cannot intubate” situation. If a difficult intubation is expected preoperatively, a fiberoptic intubation is performed in the awake, spontaneously breathing patient. In order to facilitate intubation, lidocaine is administered topically in nose and larynx. Additionally, parasympatholytics, sedatives, and analgesics may be administered systemically. Transcricoid administration of lidocaine is often useful to suppress coughing, thus aiding endotracheal intubation. After identification of the trachea, the endotracheal tube, which is placed on the fiberscope prior to starting the procedure, is pushed forward. Before securing the tube, a final fiberoptic check of placement is performed. An awake nasal intubation should only be performed in emergency situations.

If preoperative hypovolemia is not treated accordingly, hypotension is a common finding after induction of anesthesia. Thus adequate fluid therapy is mandatory before induction of anesthesia. Administration of anesthetics for induction is dependent on their effect. Etomidate has been demonstrated to exert the least cardiocirculatory depression and is thus the preferred induction agent at many hospitals.

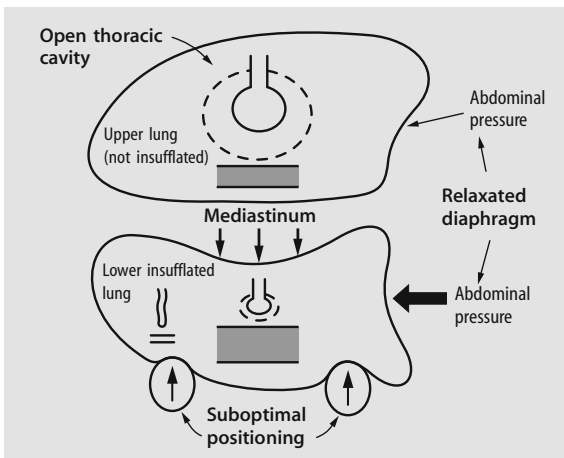
During surgery of the lower esophagus via a left thoraco-abdominal incision or during blunt esophagectomy, it is not necessary to collapse one lung using a double lumen endotracheal tube. A single lumen endotracheal tube can be placed, and surgical exposure may be obtained by retraction of the left lung. For esophageal surgery via a thoracotomy, it is usually necessary to place a double lumen endobronchial tube to collapse the ipsilateral lung. Double lumen tubes allow selective intubation of the right or left main stem bronchus (Fig. 6.1). Although some investigators have advocated the placement of a double lumen tube according to the side of surgery, a right-sided double lumen tube carries the risk of a collapse of the right upper lobe due to obstruction of the upper right bronchus. Thus left side double lumen tubes have been demonstrated to be more beneficial, independent of the side of operation if the operation does not involve the left main bronchus [10]. However, a right-sided double lumen tube is technically easier to place in the correct bronchus because of the steep angle between trachea and left main bronchus. Placement of a double lumen tube is checked by clamping and auscultation. However, additional fiberoptic control is indispensable [11] (Fig. 6.1). As an alternative to the double lumen tube a Univent tube may be placed (Fig. 6.2). This endotracheal tube consists of a one-lumen tube with a small lumen for insertion of a bronchus blocker. The patient is intubated in the usual fashion following in which a cuffed catheter is introduced under fiberoptic surveillance. Collapse of the lung is achieved via deflation through a small lumen in the bronchus blocker. The disadvantages of the Univent tube comprise frequently inadequate differential ventilation, especially if blocking the right lung, the lack of suction through the blocker lumen, and the often insufficient inflation and deflation of the lungs.



**Fig. 6.1.** Schematic depiction of placement of a left-sided double-lumen tube in a patient in the supine position. **a** Initially the tube is inserted by holding its end to one side. After passage of the laryngeal cords the tube is rotated by 90° to the left while it is gently pushed forward into the left main bronchus. **b** After placement of the tube positioning is checked by clamping and auscultation. However, fiberoptic control of the tube position is mandatory. Modified from Benumof and Alfery [11].



**Fig. 6.2.** Schematic depiction of a Univent tube. The patient's trachea is intubated in the usual fashion as for a single-lumen tube. Under fiberoptic surveillance the bronchus blocker is promoted through a thin working channel. The blocker is positioned by turning the attached catheter until the chosen left or right main stem bronchus is clearly shut off. Care has to be taken that the right upper lobe bronchus, which is close to the carina, is not obstructed by the cuff of the blocker. Modified from Benumof and Alfery [11].



**Fig. 6.3.** Schematic depiction of the relation between ventilation and perfusion during operations in a lateral position. The upper lung is well ventilated until clamped. However due to gravitation, perfusion is preferentially directed towards the dependent lung. Ventilation of the dependent lung is reduced because of suboptimal positioning, high abdominal pressure, and surgical manipulation. Some parts of the lung may even be atelectatic. However, oxygenation of the blood is improved by hypoxic pulmonary vasoconstriction (HPV), leading to a reduced perfusion of non-ventilated parts of the lung by reflex mechanism. Examples of factors reducing the positive influence of HPV are high pressures in pulmonary artery, hyperventilation, vasodilators, and volatile anesthetics. Modified from Benumof and Alfery [11].

If the trachea is injured during the course of operation, only the endobronchial lung should be ventilated until definite repair is achieved. If the patient has been intubated with a one lumen tube, the tube is advanced until an endobronchial position is obtained. During one-lung ventilation for esophageal surgery hypoxia may occur more often than during one-lung-ventilation for lung surgery (Fig. 6.3). This is because the patient presenting for lung surgery may already have limitations of blood flow to the diseased lung and, thus, less ventilation/perfusion mismatching during one-lung anesthesia. Frequently, parts of the pulmonary vessels are ligated during lung surgery, thus decreasing the shunt.

Should hypoxia occur during one-lung ventilation, the  $\text{FiO}_2$  is increased to 1.0 and the position of the double-lumen tube should be checked using a fiberoptic bronchoscope. Thus, the immediate availability of a fiberoptic bronchoscope is mandatory during one lung

ventilation. Another method to increase the arterial oxygen saturation is the administration of positive endexpiratory pressure (PEEP) to the ventilated lung [12]. However, because PEEP increases the pulmonary vascular resistance, perfusion of the unventilated lung may increase, thus increasing the shunt volume and increasing the ventilation/perfusion mismatch. Administration of a continuous positive airway pressure (CPAP) to the unventilated lung potentially increases arterial oxygenation, in this case. Finally, clamping of the pulmonary artery to reduce the shunt volume may be considered as a last resort. If none of these measures is successful in restoring oxygenation, conventional ventilation of both lungs has to be reinstated [10].

Patients who require postoperative ventilation on the intensive care unit should have the double-lumen tube replaced by a single-lumen endotracheal tube. However, an inadvertent intubation of the esophagus must be strictly avoided not only because of the catastrophic consequences of the hypoxia, but because the distension by ventilated air may lead to an insufficiency of the anastomosis. If a Univent tube has been used, simple retraction of the bronchus blocker allows this tube to be used as a single-lumen tube.

In patients who do not present with esophageal perforation, a nasogastric tube is placed by the anesthesiologist preoperatively. This tube will be accurately positioned by the surgeon intraoperatively. In some cases the distal end of the tube is placed close to the anastomosis in order to test for leaks by administration of methylene blue. After esophagectomy and gastric or colon replacement, the tube is needed to remove secretions. In order to avoid an accidental removal of the nasogastric tube securing by a suture has been suggested.

The patient is positioned intraoperatively by the surgeon. Especially in a lateral position care has to be taken to support the patient without exerting too much pressure and to cushion exposed body parts. At risk are especially the brachialis plexus, peroneal nerves, as well as soft tissues such as ears, eyes, and genitals. Peripheral pulses have to be checked in order to prevent obstruction of the arterial blood supply. The intraoperative control of body temperature is mandatory because it has

been demonstrated that even mild hypothermia results in an increased frequency of wound infections and prolonged hospital stay [13]. Effective measures of temperature maintenance are increase of room temperature, warm water blankets, convective warming devices, wrapping of exposed extremities in metallic foil, warming of fluids, as well as warming of ventilated air.

The decision to extubate the patient at the end of the surgical procedure depends on the preoperative status, the cardiac status, the temperature, and the extent of surgery. Weaning from mechanical ventilation should begin when the patient is awake and cooperative, able to protect the airway, have adequate return of pulmonary function, and when the patient is hemodynamically stable. Muscle relaxation should have faded or been antagonized. Usually this condition will only be achieved in the intensive care unit. Basically the patient should be weaned and extubated as soon as possible to reduce the risks due to prolonged mechanical ventilation. The use of a thoracic epidural catheter may facilitate this goal. However, patients with esophageal perforation often develop mediastinal infection and should be ventilated during the immediate postoperative period.

---

### Postoperative phase

Only after short surgical procedures on the esophagus (such as esophageal dilatation in achalasia) will postoperative care in the recovery room and consecutive transfer to the ward be possible. In all other cases a transfer to the intensive care unit offering the option of mechanical ventilation is necessary. Complications in the postoperative period comprise: first immediate problems such as pain, respiratory insufficiency and blood loss, second problems due to preexisting conditions, and third problems caused by insufficiencies of anastomoses and consequent infection.

Postoperative hypotension is most likely due to hypovolemia caused by hemorrhage or fluid imbalances. In case of hemorrhage, the sur-

geon should be notified immediately and a surgical revision be performed. The coagulation status should be optimized by substitution of coagulation factors or platelet concentrates.

Respiratory insufficiency is frequent after esophageal surgery especially if the patient is obese or presents with lung disease [14]. Pain due to the surgical incision leads to hypoventilation and that is often complicated by retention of secretions and dystelectasis. Pneumonia is a frequent complication under these circumstances. Postoperative pain therapy via a thoracic epidural catheter can reduce these complications and may facilitate postoperative mobilization of the patient. The prophylactic use of broad spectrum antibiotics is still a matter of discussion. A pneumothorax may lead to deterioration of the respiratory function of the patient. An immediate diagnosis by chest X-ray is necessary unless the patient is hypoxic and requires urgent chest decompression. Therapeutically an additional chest drainage is inserted. Care has to be taken that the laryngeal nerves on both sides are not injured during surgery. However, if the patient develops inspiratory stridor after extubation this possibility has to be considered. A reintubation and then tracheotomy is necessary in such circumstances.

Depending on the existence and the nature of preexisting diseases, a rapid or prolonged postoperative course can be expected. Cardiac and pulmonary diseases may exacerbate problems and lead to decompensation after the surgical procedure. In patients with malignant diseases of the esophagus pulmonary complications including the adult respiratory distress syndrome (ARDS) have been reported after a preoperative combination of chemotherapy and radiation [15]. Furthermore patients with malignancies frequently have a history of alcohol abuse. These patients often develop a delirium due to withdrawal that can considerably influence the postoperative course. Recently the administration of  $\alpha_2$ -adrenergic agonists has shown to be successful in the therapy of these conditions [16]. In rare cases the administration of alcohol cannot be avoided in order to keep the patient cooperative.

Leakage from anastomoses can occur from the third to the twelfth postoperative day. The diagnosis is confirmed if acidic fluids ( $\text{pH} < 6$ ) with a high concentration of amylase issue

from a thoracic drain. Endoscopy, X-ray (possibly with contrast medium) and computed tomography will further confirm the diagnosis. Consequences are mediastinitis and sepsis with a high rate of mortality. The therapy includes the administration of broad spectrum antibiotics and surgical revision with additional placement of drainage tubes.

## References

- Greenhow D (1988) Esophageal surgery. In: Marshall B, Longnecker D, Fairley H (eds) *Anesthesia for thoracic procedures*. Blackwell Scientific Publications, Boston
- Allen S, Riddell G, Butchart E (1981) Bleomycin therapy and anesthesia: the possible hazards of oxygen administration to patients after treatment with bleomycin. *Anaesthesia* 36:60–63
- Hickling K (1990) Ventilatory management of ARDS. Can it affect the outcome? *Intensive Care Med* 16:219–226
- Tonner PH, Scholz J, Schulte am Esch J (1996) Anesthesia for non-cardiac surgery in patients at high cardiac risk. *Anaesthesiol Intensivmed* 37:373–385
- Izbicki JR, Knöfel WT, Passlick B, Habekost M, Karg O, Thetter O (1995) Risk analysis and longterm survival in patients undergoing extended resection of locally advanced lung cancer. *J Thorac Cardiovasc Surg* 110:386–395
- Connors A, Speroff T, Dawson N, Thomas C, Harrell F, Wagner D, Desbiens N, Goldman L, Wu A, Califf R, Fulkerson W, Vidaillet H, Broste S, Bellamy P, Lynn J, Knaus W for the SUPPORT investigators (1996) The effectiveness of right heart catheterization in the initial care of critically ill patients. *JAMA* 276:889–897
- Fratacci M, Kimball W, Wain J et al (1993) Diaphragmatic shortening after thoracic surgery in humans: effects of mechanical ventilation and thoracic epidural anesthesia. *Anesthesiology* 79:654–665
- Blomberg S, Emanuelsson H, Kvist H et al (1990) Effects of thoracic epidural anesthesia on coronary artery disease. *Anesthesiology* 73:840–847
- Norlander O (1988) Combined epidural and general anesthesia for abdominal operations – a good technique. *Acta Anaesth Belg* 39:203–208
- Mackie A, Watson C (1984) Anaesthesia and mediastinal masses. *Anaesthesia* 39:899–903
- Benumof J, Alfery D (1995) Anesthesia for thoracic surgery. In: Miller R (ed) *Anesthesia*. Churchill Livingstone, New York
- Smith G, Hirsch N, Ehrenwerth J (1986) Sight and sound. Can double-lumen endotracheal tubes be placed accurately without fiberoptic bronchoscopy? *Anesth Analg* 65:S1
- Campos JH, Reasoner DK, Moyers JR (1996) Comparison of a modified double-lumen endotracheal tube with a single-lumen tube with enclosed bronchial blocker. *Anesth Analg* 83:1268–1272
- Hedenstierna G, Baehrendtz S, Klingstedt C, Santesson J, Söderborg B, Dahlborn M, Bindsvlev L (1984) Ventilation and perfusion of each lung during differential ventilation with selective PEEP. *Anesthesiology* 61:369–376
- Kurz A, Sessler D, Lenhardt R for the Study of Wound Infection and Temperature Group (1996) Perioperative normothermia to reduce the incidence of surgical wound infection and shorten hospitalization. *N Engl J Med* 334:1209–1215
- Kido Y, Ogawa Y, Kawasaki K, Shiozaki H, Morimoto S, Mori T (1988) Pulmonary complications following surgery for esophageal cancer. In: Siewert H, Hölscher A (eds) *Diseases of the esophagus*. Springer, Berlin Heidelberg New York

# Pathophysiology of Gastroesophageal Reflux Disease and Indication for Surgical Therapy

K.-H. FUCHS

## Introduction

Gastroesophageal reflux disease is one of the most common diseases in western societies. The prevalence is estimated to be around 10% in those populations, if the presence of the disease is based on weekly or daily reflux symptoms [1–3]. The disease has been diagnosed more often due to increased and improved diagnostic activities, but there is also a true increase in incidence of the problem. Since it is related to western lifestyle, eating habits and environmental factors are discussed. In addition in recent years, detection of extraesophageal problems, especially respiratory symptoms and problems, is increasing, often related to reflux [4, 5]. A special interest in this disorder has emerged in the past 15 years since studies have shown the possible connection between reflux, the development of intestinal metaplasia in the esophagus, and the increase in the incidence of adenocarcinoma in Barrett's esophagus [6–10].

The pathophysiologic background of the disease is multifactorial, as has been shown in recent years [11, 16]. The main reason for pathologic reflux is a malfunction of the antireflux barrier at the level of the gastroesophageal junction. This antireflux barrier consists of the high pressure zone of the lower esophageal sphincter as well as the hiatus or the phrenico-esophageal ligament, also causing a pinching effect at the level of the lower esophageal sphincter [13, 14]. The lower esophageal sphincter has been assessed quantitatively by mechanical parameters such as the lower esophageal sphincter pressure, the overall length, and the intraabdominal length. On the other hand, a functional description of transient lower esophageal sphincter relaxations described

by many gastroenterologists brings up more dynamic facts on the antireflux barrier [13, 16].

## Definition

An important issue when discussing pathophysiology is the appropriate definition of the disease. Several definitions have been discussed in the past decades. Currently, the definition of the GENVAL-consensus conference is being widely used [1]. Based on the latter, gastroesophageal reflux disease is present when the person/patient has a risk of complications due to excessive reflux and/or a significant reduction of her/his quality of life and well-being. Of course, the definition of gastroesophageal reflux disease can be discussed controversially since there is no diagnostic test that proves the presence of this disease in all cases and is able to exclude the disease at the same time [11, 12]. Endoscopy has a high specificity and can show the presence of esophagitis. However, its sensitivity is not sufficient since only about 60% of patients with gastroesophageal reflux disease have developed an endoscopically-visible esophagitis at the time of the initial investigation. Similar circumstances can be discussed for 24-hour-esophageal pH monitoring, which is often called the gold standard in the objective assessment of gastroesophageal reflux disease [13]. It quantitatively measures gastroesophageal acid exposure in the esophageal lumen. Negative results may be caused by technical failures, a “good day” in borderline reflux cases, the combination of mixed reflux with high proportion of duodenal juice, or a non-acidic stomach under PPI therapy. More-

over, typical symptoms such as heartburn and regurgitation are of course present in many but not in all reflux patients. As a consequence, symptoms cannot be a reliable guide for a definitive diagnosis. Therefore the detection of the disease must be based on a spectrum of diagnostic investigations in order to prove its presence [14].

The most accurate definition for the disease is a pathophysiologic explanation: The disease is present when pathologic exposure of the esophageal lumen to gastric juice occurs, and this can be a pathologic amount of acid and/or a pathologic amount of duodenal components such as bile [12]. The most frequent condition in gastroesophageal reflux disease is pathologic acid exposure, and therefore this is often used synonymously. Nevertheless, the role of duodenogastroesophageal reflux has been investigated recently, and its importance in complications of the disease such as Barrett's esophagus has been shown [15].

In order to obtain more information about the definition of gastroesophageal reflux disease used in clinical practice, the definitions of the disease used in randomized trials for anti-reflux therapy can be reviewed. It is surprising what a variety of definitions have been used for the disease by several authors performing randomized trials in the past decades. In 25 randomized trials focusing on surgical therapy of the disease, the definition used by the majority of the studies was the presence of symptoms and esophagitis [17–40]. Only in about one-third of the studies was positive pH-monitoring as a more specific tool to verify pathological esophageal acid exposure used as the definition. Only a few studies relied on symptoms only, since symptoms can be an unreliable guide for the presence of gastroesophageal reflux disease.

It must be emphasized that the presence of typical symptoms such as heartburn and acid or fluid regurgitation have been shown to be very specific symptoms with a positive predictive value for therapeutic success [41]. The authors of this study have shown that a good result of laparoscopic antireflux surgery is more probable in patients with preoperative presence of typical symptoms of reflux such as heartburn and regurgitation, a preoperative positive test in 24-hour-esophageal pH moni-

toring showing a pathological acid exposure in the esophagus, and a positive response to proton-pump inhibitors, indicating that medical acid reduction will also reduce at least some of the heartburn of the patient.

Regarding the diagnostic requirements, pH monitoring and endoscopy are necessary for the objective documentation of the disease [11–13]. With manometry other esophageal functional disorders can be excluded, which potentially cause a postoperative failure, especially spastic disorders [11]. Since a weak lower esophageal sphincter has been shown to be a poor prognostic sign regarding the future prognosis of GERD, one could use this criterion for the indication [42]. In addition, selection of patients with preoperative normal lower esophageal sphincter parameters can be indicative for worse postoperative results [43]. However, several studies have shown that its predictive value for the postoperative results remains controversial and is therefore not recommended by gastroenterologists [44, 45].

Currently gastroesophageal reflux disease has been redefined in three subgroups [1]. These subgroups are nonerosive reflux disease, erosive reflux disease, and Barrett's esophagus. This is a reasonable division. However, it must be kept in mind that there is some overlapping especially between patients with Barrett's esophagus and erosive gastroesophageal reflux disease, since it has been shown that this overlapping is present in at least 30% of the Barrett's patients in several series [11, 12, 15, 46, 47].

---

### The antireflux barrier

The lower esophageal sphincter has been assessed quantitatively by mechanical parameters such as the lower esophageal sphincter pressure, the overall length, and the intraabdominal length [11, 13]. Since reflux can be caused by different factors such as elevation of intragastric pressure, elevation of intraabdominal pressure and loss of gravity when persons lay down. In persons in a supine position, the sphincter system must prevent reflux in several ways. The intraabdominal portion of the lower esophageal sphincter is involved in preventing



reflux during the swallowing of the patient. Both the intraabdominal sphincter length and the pinching effect of the diaphragm help to close the sphincter during elevation of intraabdominal pressure. The high pressure zone on itself at rest prevents reflux in a person's supine position. Transient sphincter relaxation has been described by many gastroenterologists as the most important causes of reflux disease [13, 16]. This is supported by a number of studies showing abnormal acid exposure in the esophagus correlating with sphincter relaxation on simultaneous pH and motility recordings. In healthy volunteers the majority of reflux episodes occur during transient sphincter relaxations [1]. In reflux patients, especially in the postprandial phase, these relaxations occur more often. However, it is somewhat controversial that in patients with severe reflux disease, reflux episodes occur also without transient sphincter relaxations.

The mechanical incompetence of the lower esophageal sphincter has been described by DeMeester, using the overall length of the sphincter which is in the physiologic situation 3–4 cm long at the distal end of the esophagus as relevant criteria [11]. The resting tone of the sphincter characterized by the lower esophageal sphincter pressure varies in healthy volunteers in relation to the intragastric pressure between 10 and 30 mmHg. There are circadian changes with a low level in the postprandial phase and a high level at night. The sphincter tone is regulated by intrinsic and external factors and is influenced by intraabdominal pressure changes, gastric dilatation as well as composition of food and medication. As mentioned above, the intraabdominal length of the sphincter characterizing the segment of the sphincter which is exposed to the intraabdominal pressure is important for the optimal functioning of the antireflux barrier. Stress reflux occurs if an elevation of the intraabdominal pressure causes an overriding of the pressure level of the lower esophageal sphincter. Free reflux occurs without any changes of intragastric pressure and the pressure of the sphincter. Quantification of the lower esophageal sphincter and its mechanical components is expressed by manometric assessment of sphincter length, the intraabdominal length, and the sphincter pressure.

The role of a hiatal hernia has been interpreted controversially over the years [13, 48]. In the past decades hiatal hernia often observed with the presence of the reflux disease. Currently it has been shown that 80% of patients with GERD have a hiatal hernia, thus loosening the pinching effect of the diaphragm. It is also true that hiatal hernia is a promoter of gastroesophageal reflux. In the physiologic situation a substantial part of the lower esophageal sphincter is kept tight in the abdominal cavity and to the hiatal crura by a narrow fixation of the phrenico-esophageal ligament. The area of the lower esophageal sphincter is integrated in the architecture of the hiatus and the hiatal crura, causing the pinching effect mentioned above. In case of a hiatal hernia which usually develops in a person older than 50 years, the loosening of the phrenico-esophageal ligament fixation and the tissue of the GE junction allows gliding and causes temporary to permanent incompetence of the lower esophageal sphincter system.

### Esophageal peristalsis

Esophageal clearance and peristaltic function of the esophageal body is also involved in producing increased esophageal exposure to gastric juice [11, 12]. The physiologic swallowing function is involved in neutralizing the reflux of gastric acid through the swallowing of saliva. Another reason is impaired esophageal peristalsis either by a pre-existing motility disorder resulting often in simultaneous and interrupted contractions or weak peristalsis due to inflammation of the esophageal wall caused by esophagitis. Impaired esophageal peristalsis can be defined as more than 30% of non-effective contractions such as weak amplitude lower than 30 mmHg or non-propulsive peristalsis. Impaired esophageal peristalsis can lead to increased exposure of gastric juice to the esophageal mucosa by delayed esophageal emptying. This can cause a vicious cycle, since pre-existing esophageal motility disorders will cause an increase in acid exposure which again will cause inflammation and further loss of peristaltic activity. This, in turn, causes more esophageal

phagitis. So far it is not exactly known which level of physiological motor activity is necessary to keep a sufficient peristalsis for sufficient esophageal emptying. In healthy volunteer studies up to 30% of peristaltic action is non-effective. Severe motility disorders become clinically relevant probably only when 70–80% of the peristaltic actions are non-effective, since gravity compensates a lot [43–45, 49]. Recent studies with impedance manometry have provided more insights [50].

### Mucosal resistance

Mucosal resistance is not investigated on a routine basis in patients with the disease. It is, however, an important factor in assessing the ability of gastric juice to cause toxic effects in the esophageal wall [51, 52]. Few investigations have been reported to describe this process. It has been shown that toxic activity of gastric juice containing acid and bile as well as pancreatic components is a major factor in esophageal injury.

### Duodeno-gastroesophageal reflux

Gastroduodenal dysfunctions in reflux disease have been neglected for decades [11, 12]. Ever since new pathophysiologic understandings emerged that Barrett's esophagus is significantly associated with duodeno-gastroesophageal reflux, more attention and research activities have been focussed on this matter [15, 46]. It has been shown that acid production can be elevated in Barrett's esophagus. It has also been shown duodeno-gastroesophageal reflux can be detected in 10–15% of patients with reflux disease. Only recently it has been proven by many centers that Barrett's esophagus is associated with an increased exposure to bile and pancreatic components. Even though duodeno-gastric reflux is a physiologic phenomenon, once present it is obviously involved in the development of more serious esophageal mucosal injury together with acid.

### Gastroduodenal disorders

The backup of gastric contents in the intraduodenal segment due to delayed gastric emptying can cause pathologic acid reflux and bile reflux into the esophagus. In some patients delayed gastric emptying can be the only cause of pathologic reflux through a normal physiologic sphincter mechanism [53]. Transient sphincter relaxations are very important in these patients for deflation of the stomach. This is of major importance in patients who are candidates for antireflux surgery since after a fundoplication this deflation mechanism is not possible anymore and can cause severe gas bloat syndrome if the stomach cannot deflate air neither in a proximal direction nor in the distal direction.

### Indication for surgery

There is very little evidence-based information to justify certain factors for the indication of antireflux surgery. With the introduction of minimal invasive technique, antireflux surgery has boomed in the past ten years. In most western countries the number of antireflux operations have more than tripled as compared with the time before the introduction of minimal access techniques. This happened at a time when the most potent antisecretory drugs were on the market, which stimulates the controversial discussion between gastroenterologists and surgeons regarding the indication for surgery.

The presence of severe esophagitis was for many surgeons an indication for surgery. Today many authors are convinced that the only criteria for therapeutic success is the removal of symptoms, may it occur by healing of esophagitis or not [1]. In surgical literature, both removal of symptoms and healing of esophagitis are necessary to determine a successful surgical therapy [54, 55].

In summary, for the establishment of the indication of a surgical procedure, gastroenterologists and surgeons should use more than one criteria for the definition and the verification of gastroesophageal reflux disease. In several consensus projects it was documented that endoscopic signs of esophagitis should have been

documented at present or in the past at least once. In addition, a positive 24-hour pH monitoring together with typical symptoms of the disease such as heartburn and/or regurgitation are important criteria for the presence of disease, which are needed for indication.

## Conclusions

Gastroesophageal reflux disease is a multifactorial process. The most frequent pathophysiologic cause is a functional incompetence of the gastroesophageal junction as antireflux barrier. In a substantial part of patients other factors are also involved isolated or in combination which usually aggravate the disease and also implicate a special therapeutic consideration. Prior to any decision for a long term therapeutic management or especially prior to anti-reflux surgery these pathologic components should be assessed and documented. The indication for antireflux surgery, which should be performed by minimal access technique, must be based on multiple factors such as severe symptoms for a long time, documented presence of the disease and documented morphologic and functional defects.

## References

- Dent J, Brun J, Fendrick AM, Fennery MB, Janssens J et al (1999) Genval Workshop Group: An evidence-based appraisal of reflux disease management. *Gut* 44:S1–16
- Locke G, Talley NJ, Fett SL (1997) Prevalence and clinical spectrum of gastroesophageal reflux: a population based study in Olmsted-County, Minnesota. *Gastroenterology* 112:1448–1456
- Louis E, DeLooze D, Deprez P (2002) Heartburn in Belgium: prevalence, impact on daily life, and utilization of medical resources. *Eur J Gastroenterol Hepatol* 14:279–284
- Jaspersen D, Weber R, Hammer LH (1996) Effect of omeprazole on the course of associated esophagitis and laryngitis. *J Gastroenterol* 31:765–767
- Micklefield GH, Radu HJ, Grewing I (1998) Acid esophago-pharyngeal reflux as etiology of hoarseness. *Laryngorhinootologie* 77:496–499
- Haggit RC, Tryzelaar J, Ellis FH, Colcher H (1978) Adenocarcinoma complicating columnar-epithelium-lined (Barrett's) esophagus. *Am J Clin Pathol* 70:1
- Hameeteman W, Tytgat GNJ, Houthoff HJ, Van den Tweel JG (1989) Barrett's esophagus: development of dysplasia and adenocarcinoma. *Gastroenterology* 96:1249–1256
- Pera M, Cameron AJ, Trastek VF, Carpenter HA, Zinsmeister AR (1993) Increasing incidence of adenocarcinoma of the esophagus and esophago-gastric junction. *Gastroenterology* 104:510–513
- Lagergren J, Bergström R, Lindgren A, Nyrén O (1999) Symptomatic gastroesophageal reflux as a risk factor for esophageal adenocarcinoma. *New Engl J Med* 340:825–831
- DeMeester SR, DeMeester TR (2000) Columnar mucosa and intestinal metaplasia of the esophagus: fifty year controversy. *Ann Surg* 231(2):303–321
- DeMeester TR (1987) Definition, detection and pathophysiology of gastroesophageal reflux disease. In: DeMeester TR, Matthews HR (eds) *International trends in general thoracic surgery*, vol 3. Benign esophageal disease. Mosby, St. Louis, pp 99–127
- Fuchs KH, Freys SM, Heimbucher J, Fein M, Thiede A (1995) Pathophysiologic spectrum in patients with gastroesophageal reflux disease in a surgical GI function laboratory. *Diseases of the Esophagus* 8:211–217
- Zaninotto G, DeMeester TR, Schwizer W, Johanson KE, Cheng SC (1988) The lower esophageal sphincter in health and disease. *Am J Surg* 155:104–111
- Costantini M, Crookes PF, Bremner RM, Hoeft SF, Ehsan A, Peters JH, Bremner CG, DeMeester TR (1993) Value of physiologic assessment of foregut symptoms in a surgical practice. *Surgery* 114(4):780–786
- Fein M, Ireland AP, Ritter MP, Peters JH, Hagen JA, Bremner CG, DeMeester TR (1997) Duodenogastric reflux potentiates the injurious effects of gastroesophageal reflux. *J Gastrointest Surg* 1:27–33
- Mittal RK, Holloway RH, Penagini R, Blackshaw A, Dent J (1995) Transient lower esophageal sphincter relaxation. *Gastroenterology* 109:601–610
- Behar J, Sheahan DG, Biancani P, Spiro HM, Storer EH (1975) Medical and surgical management of reflux esophagitis. *N Engl J Med* 293(6):263–268
- Thor KBA, Silander T (1989) A long-term randomized prospective trial of the Nissen procedure versus a modified Toupet technique. *Ann Surg* 210:719–724
- Kmiot WA, Kirby RM, Akinola D, Temple JG (1991) Prospective randomized trial of Nissen fundoplication and Angelchik prosthesis in the surgical treatment of medically refractory gastro-oesophageal reflux disease. *Br J Surg* 78:1181–1184
- Lundell L, Abrahamsson H, Ruth M, Sandberg L, Olbe L (1991) Lower esophageal sphincter characteristics and esophageal acid exposure following partial or 360° fundoplication: Results of a prospective, randomized, clinical study. *World J Surg* 15:115–121

21. Spechler SJ and the Department of Veterans Affairs Gastroesophageal Reflux Disease Study Group (1992) Comparison of medical and surgical therapy for complicated gastroesophageal reflux disease in veterans. *N Engl J of Med* 12:786–792
22. Eyre-Brook IA, Codling BW, Gear MWL (1993) Results of a prospective randomized trial of the Angelchik prosthesis and of a consecutive series of 119 patients. *Br J Surg* 80:602–604
23. Janssen IMC, Gouma DJ, Klementsich P, van der Heyde MN, Obertop H (1993) Prospective randomized comparison of teres cardiopexy and Nissen fundoplication in the surgical therapy of gastro-oesophageal reflux disease. *Br J Surg* 80:875–878
24. Hill ADK, Walsh TN, Bolger CM, Byrne PJ, Hennessy TPJ (1994) Randomized controlled trial comparing Nissen fundoplication and the Angelchik prosthesis. *Br J Surg* 81:72–74
25. Ortiz EA, Martinez de Haro LF, Parrilla P, Morales G, Molina J, Bermejo J, Liron R, Aguilar J (1996) Conservative treatment versus antireflux surgery in Barrett's oesophagus: long-term results of a prospective study. *Br J Surg* 83(2):274–278
26. Lundell L, Abrahamsson H, Ruth M, Rydberg L, Lonroth H, Olbe L (1996) Long-term results of a prospective randomized comparison of total fundic wrap (Nissen-Rossetti) or semifundoplication (Toupet) for gastro-oesophageal reflux. *Br J Surg* 83(6):830–835
27. Rydberg L, Ruth M, Lundell L (1997) Does oesophageal motor function improve with time after successful antireflux surgery? Results of a prospective, randomized clinical study. *Gut* 41:82–86
28. Watson DI, Pike GK, Baigrie RJ, Mathew G, Devitt PG, Britten-Jones R, Jamieson GG (1997) Prospective double-blind randomized trial of laparoscopic Nissen fundoplication with division and without division of short gastric vessels. *Ann Surg* 226(5):642–652
29. Laws HL, Clements RH, Swillie CM (1997) A randomized, prospective comparison of the Nissen fundoplication versus the Toupet fundoplication for gastroesophageal reflux disease. *Ann Surg* 225(6):647–653, discussion 654
30. Anderson JA, Myers JC, Watson DI, Gabb M, Mathew G, Jamieson GG (1998) Concurrent fluoroscopy and manometry reveal differences in laparoscopic Nissen and anterior fundoplication. *Dig Dis Sci* 43(4):847–853
31. Lundell L, Dalenbäck J, Hattlebakk J et al (1998) Outcome of open antireflux surgery as assessed in a nordic multicentre, prospective clinical trial. *Eur J Surg* 164:751–757
32. Rydberg L, Ruth M, Abrahamsson H, Lundell L (1999) Tailoring antireflux surgery: a randomized clinical trial. *World J Surg* 23:612–618
33. Watson DI, Jamieson GG, Pike GK, Davies N, Richardson M, Devitt PG (1999) Prospective randomized double-blind trial between laparoscopic Nissen fundoplication and anterior partial fundoplication. *Br J Surg* 86:123–130
34. Luostarinen MES, Isolauri JO (1999) Randomized trial to study the effect of fundic mobilization on long-term results of Nissen fundoplication. *Br J Surg* 86:614–618
35. Csendes A, Burdiles P, Korn O, Braghetto I, Huer-tas C, Rojas J (2000) Late results of a randomized clinical trial comparing total fundoplication versus calibration of the cardia with posterior gastropexy. *Br J Surg* 87:289–297
36. Bais JE, Bartelsman JF, Bonjer HJ, Cuesta MA, Go PM, Klinkenberg-Knol EC, van Lanschot JJB, Nadorp JH, Smout AJ, van der Graaf Y (The Netherlands Antireflux Surgery Study Group) (2000) Laparoscopic or conventional Nissen fundoplication for gastroesophageal reflux disease: randomized clinical trial. *Lancet* 355:170–174
37. Nilsson G, Larsson S, Johnsson F (2000) Randomized clinical trial of laparoscopic versus open fundoplication: blind evaluation of recovery and discharge period. *Br J Surg* 87:873–878
38. Lundell L, Miettinen P, Myrvold HE, Pedersen SA, Liedman B, Hatlebakk JG, Julkonen R, Levander K, Carlsson J, Lamm M, Wiklund I (2001) Continued (5-year) followup of a randomized clinical study comparing antireflux surgery and omeprazole in gastroesophageal reflux disease. *J Am Coll Surg* 192(2):172–179, discussion 179–181
39. Luostarinen M, Virtanen J, Koskinen M, Matikainen M, Isolauri J (2001) Dysphagia and oesophageal clearance after laparoscopic versus open Nissen fundoplication. A randomized, prospective trial. *Scand J Gastroenterol* 6:565–571
40. Spechler SJ, Lee E, Ahnen D, Goyal RK, Hirano I, Williford WO (2001) Long-term outcome of medical and surgical therapies for gastroesophageal reflux disease. *JAMA* 285:2331–2338
41. Campos GM, Peters JH, DeMeester TR, Oberg S, Crookes PF, Tan S, DeMeester SR, Hagen JA, Bremner CG (1999) Multivariate analysis of factors predicting outcome after laparoscopic Nissen fundoplication. *J Gastrointest Surg* 3(3):292–300
42. Kuster E, Ros E, Toledo-Pimentel V, Pujol A, Bordas JM, Grande IC (1994) Predictive factors of the long term outcome in gastro-oesophageal reflux disease: six year follow up of 107 patients. *Gut* 35(1):8–14
43. Blom D, Peters JH, DeMeester TR, Crookes P, Hagen JA, DeMeester SR, Bremner CG (2002) Physiologic mechanism and preoperative prediction of new-onset dysphagia after laparoscopic Nissen fundoplication. *J Gastrointest Surg* 6(1):22–27
44. Fang J, Bjorkman D (2002) Prefundoplication testing: is manometry needed? *Am J Gastroenterol* 97(4):1056–1058
45. Fibbe C, Layer P, Keller J et al (2001) Esophageal motility in reflux disease before and after fundoplication: a prospective, randomized, clinical and manometric study. *Gastroenterology* 121:5–14
46. Vaezi ME, Richter JE (1995) Synergism of acid and duodeno-gastro-esophageal reflux in complicated Barrett's esophagus. *Surgery* 117:699–704

47. Tack J, Koek G, Demedts I, Sifrim D, Janssens J (2004) Gastroesophageal Reflux Disease Poorly Responsive to Single-Dose Proton Pump Inhibitors in Patients without Barrett's Esophagus: Acid Reflux, Bile Reflux, or Both? *Am J Gastroenterol* 99:981–988
48. Fein M, Ritter MP, DeMeester TR, Oberg S, Peters JH, Hagen JA, Bremner CG (1999) Role of the lower esophageal sphincter and hiatal hernia in the pathogenesis of gastroesophageal reflux disease. *J Gastrointest Surg* 3(4):405–410
49. Timmer R, Breumelhof R, Nadorp JH, Smout AJ (1994) Oesophageal motility and gastro-oesophageal reflux before and after healing of reflux oesophagitis. A study using 24 hour ambulatory pH and pressure monitoring. *Gut* 35:1519–1522
50. Sifrim D, Castell D, Dent J, Kahrilas PJ (2004) Gastro-oesophageal reflux monitoring: review and consensus report on detection and definitions of acid, non-acid and gas reflux. *Gut* 53(7):1024–1031
51. Orlando RC (1996) Why is the high grade inhibition of gastric acid secretion afforded by proton pump inhibitors often required for healing of reflux esophagitis? An epithelial perspective. *Am J Gastroenterol* 91:1692–1696
52. Orlando RC (2000) Pathophysiology of gastroesophageal reflux disease: offensive factors and tissue resistance. In: Orlando RC (eds) *Gastroesophageal reflux disease*. Dekker, New York, pp 164–192
53. Schwizer W, Hinder RA, DeMeester TR (1989) Does delayed gastric emptying contribute to gastroesophageal reflux disease? *Am J Surg* 157:74–81
54. Eypasch E, Neugebauer E, Fischer F, Troidl H (1997) Laparoscopic antireflux surgery for gastroesophageal reflux disease (GERD). Results of a consensus development conference. *Surg Endoscopy* 11:413–426
55. Fuchs KH, Feussner H, Bonavina L, Collard JM, Coosemans W for the European Study Group for Antireflux Surgery (1997) Current status and trends in laparoscopic antireflux surgery: results of a consensus meeting. *Endoscopy* 29:298–308

# Gastroesophageal Reflux and its Surgical Management

G.G. JAMIESON, D.I. WATSON

## Introduction

In Western societies, gastroesophageal reflux has assumed importance for two reasons. First it is a common disorder with as many as 40% of the adult population having heartburn at least once a month and 7% experiencing it daily. Secondly, it is associated with adenocarcinoma of the cardia. Because the incidence of this is rising at a considerable rate (particularly in white Western males), cure of reflux may assume an important role in preventing this cancer in the future.

In the past, surgical treatment of gastroesophageal reflux disease has tended to be limited to those patients with complicated reflux disease or those with very severe symptoms of reflux. Recently the surgical role has changed somewhat, and although varying from country to country, there is now an increasing tendency to utilize surgery at earlier stages in the course of reflux disease. This is because of changes in surgical technique (most notably the introduction of laparoscopic surgery), the previously mentioned rising incidence of adenocarcinoma of the cardia associated with uncontrolled reflux disease and, paradoxically, because of improvements in medical therapy (see later).

## Which patients should be considered for antireflux surgery?

Patients with gastroesophageal reflux disease can be divided broadly into 2 groups:

- first are patients who have complicated reflux disease, and
- second are patients who have straight forward symptoms without complications.

## ■ Patients with complicated reflux disease

■ **Reflux with stricture formation.** With extremely dense and undilatable fibrotic strictures, resection is the only effective treatment, but fortunately it is unusual today to see patients with such advanced strictures. Dilatable strictures in young and fit patients are best treated by fundoplication and dilatation [2]. However, many patients who develop strictures are elderly or infirm and the use of proton pump inhibitors with dilatation has proven very effective treatment and thus has lessened the need for operation in high risk patients [3].

■ **Reflux with respiratory complications.** When gastro-esophageal regurgitation leads to spill-over into the respiratory tree, this can cause chronic respiratory illness, such as recurrent pneumonia and asthma [4]. This is a firm indication for antireflux surgery, as proton pump inhibitors' predominant action is to block acid secretion rather than alter gastroesophageal regurgitation.

Such problems as halitosis, acid taste in the mouth, chronic laryngitis, chronic pharyngitis, and loss of enamel on teeth are sometimes attributed to gastroesophageal reflux. There is a little doubt that on occasions such problems do arise in refluxing patients, but acid is usually the damaging agent in these situations, and antireflux surgery should not be considered unless proton pump inhibition has shown unequivocally that it ameliorates the problem.

■ **Reflux with columnar lined esophagus (Barrett's esophagus).** At the present time it remains an open question whether Barrett's esophagus per se is an indication for antireflux surgery. There is experimental evidence to suggest that con-

tinuing reflux may be deleterious in regard to malignant change in esophagus mucosa [5], and one prospective randomized trial has suggested that antireflux surgery gives superior results to drug therapy [6]. However proton pump inhibitors were only introduced into the medical arm of that trial in its later years.

Therefore, one recommendation which might be given at present is that the indications for surgery are related to the reflux symptoms and not to the presence of columnar lined esophagus per se. However, as most observers regard columnar lined esophagus as being at the severe end of the reflux spectrum, it seems reasonable to factor it in as a further reason for giving strong consideration to antireflux surgery. One must also keep an open mind in regard to the link between reflux and intestinal metaplasia at the lower end of the esophagus. If this link and the progression to adenocarcinoma become firmly established, then the role of antireflux surgery will almost certainly be expanded.

### ■ Patients with uncomplicated reflux disease

In the past, it was easy to make the recommendation for antireflux surgery on the basis when the disorder was spoiling the patients' enjoyment of living, in spite of the best that medical therapy has to offer. This indication remains valid, but medical therapy in the form of proton pump inhibitors is so effective today that it is only a small minority of patients who do not get substantial or complete relief to their symptoms with the use of such agents [7]. Why then does there appear to be a trend for patients to present for antireflux surgery in greater numbers than ever? There are several reasons for this.

First, if patients will stop taking their proton pump inhibitors, symptoms of reflux recur very rapidly, and sometimes the symptoms are worse than they were prior to taking proton pump inhibitors. This may relate to parietal cell hyperplasia which has been reported in patients taking proton pump inhibitors [8]. The importance of this finding remains to be elucidated. Regardless, many patients do not like to be dependent on drugs to be symptom free. Thus, the second and related reason is that many patients with reflux potentially have

years of life remaining, and they do not wish to take drugs in the long term when the drugs have not been established as safe if taken for many years. It must be said, however, that there is no particular reason to think they will not establish such a record of safety.

The cost of proton pump inhibitors to the patients varies from country to country, but it is an additional factor, as is the cost of the drugs to society as a whole.

An additional factor, already mentioned, is the rising incidence of adenocarcinoma of the cardia associated with gastroesophageal reflux disease [9, 10]. However, whether antireflux surgery is more effective at preventing the development of columnar lined esophagus and carcinoma of the cardia than long term proton pump inhibition remains a controversial issue.

But perhaps none of these reasons, even taken together, would have convinced patients to take the operative alternative, if open surgery had remained the standard. There seems little doubt that the advent of laparoscopic fundoplication [11, 12] with its greatly reduced morbidity has also been a major factor in the swing to operation in the treatment to reflux.

## What are the advantages and disadvantages of antireflux surgery?

### ■ Advantages

The advantages are fairly clear. The operation is the only treatment which actually cures the problem, i.e. stops gastric contents from refluxing into the esophagus. So in terms of their reflux, patients can eat whatever foods they choose, they can lie down flat, bend over etc., without reflux occurring; importantly, they do not have to take any tablets.

### ■ Disadvantages

The first disadvantage is the morbidity associated with the operation (see later in regard to complications). It is true that the advent of laparoscopic surgery has meant that the pain of the open operation has abolished. Neverthe-

less, most patients have some difficulty in swallowing in the immediate postoperative period. Fortunately, in the great majority of cases this is only a temporary problem, but the time it takes to get better is widely variable and occasionally takes several months [12].

Furthermore, the great majority of patients feel very full after eating even small meals, which often leads to some postoperative weight loss. In the patients who are overweight at the time of surgery (the majority!) this is sometimes seen as an advantage of the operation, rather than a disadvantage. This restriction on meal size also usually disappears over a few months. Because fundoplication, along with all other effective antireflux operations, produces a one way valve, swallowed air, which has passed into the stomach, usually cannot pass back through the valve. Thus, patients have to be forewarned that they will not be able to belch effectively after the operation and so should be cautious about taking gassy drinks. As swallowed gas cannot be belched either, the great majority of patients are aware of increased flatulence with increased borborygmi and increased passage of wind after the procedure. For similar reasons, patients will be unable to vomit after the procedure, and should be informed of this. This is not of importance with such conditions as gastroenteritis, when patients will dry retch only. In fact, it only assumes importance if the patient should develop gastrointestinal obstruction. As vomiting cannot occur in such circumstance, the patient has a unique, large, closed loop obstruction (which can be decompressed by passing a nasogastric tube).

An overwhelming majority of patients state that the disadvantage of the procedure is far outweighed by the advantages of the operation, but occasionally this is not the case. Perhaps it may prove possible, by the use of preoperative psychological questioning, to predict those patients who will be troubled by what to the majority of patients are minor nuisances, although this remains to be proven [13].

## Operations available

There is no doubt that the fundoplication introduced by Rudolf Nissen in 1956, or some variant of it, is overwhelmingly the most popular operation in the world today. Total fundoplications such as the Nissen or partial fundoplications, whether anterior or posterior, probably all work in similar fashion. And the fashion may be as much mechanical as physiological, as it has been demonstrated that these procedures are effective, not only when placed in the chest in vivo [14] but also on the benchtop, i.e. *ex vivo* [15].

The principles of fundoplication are to mobilize the lower esophagus and to wrap the fundus of the stomach, either partially or totally, around the esophagus. When the esophageal hiatus is enlarged, it is narrowed by sutures to prevent paraesophageal herniation postoperatively, and also prevent the wrap being pulled up into the chest (although the fundoplication will work in the chest, other complications such as gastric ulceration sometimes occur in this situation).

These operations can be undertaken either transthoracically or transabdominally. Although the latter seems a simpler approach, the choice tends to depend on whether the surgeon is predominantly a thoracic or predominantly an abdominal surgeon.

Operations which are limited to one or the other approach (e.g. thoracic-Belsey and abdominal-Hill) have never gained the widespread popularity of the Nissen fundoplication operation.

## Traditional open fundoplication

Fundoplication was first described by Nissen 1956 [16] following the serendipitous discovery that a fundal patch, used to reinforce an esophageal suture line, also prevented gastroesophageal reflux. Whilst achieving good control of pathological reflux in the majority of patients [17], an incidence of adverse sequelae has led to the subsequent modification of Nissen's original technique. Shortening the fundoplication



plication length to 1 to 2 cm, dividing the short gastric vessels to achieve full mobilization of the gastric fundus, calibration of a loose fundoplication over a large intra-esophageal bougie, and modification of the complete fundoplication to one of a number of partial fundoplication variants, have all been advocated. Few of these modifications, however, have been evaluated within the context of prospective randomized trials.

Following four decades of experience with antireflux procedures, long term outcomes following open surgery have been well described. The postoperative hospital stay following open surgery ranges from 7 to 14 days, and short term morbidity is acceptable. Long-term success is achieved in the majority of patients [18, 19].

Adverse outcomes following open Nissen fundoplication include persistent dysphagia and the gas bloat symptoms. Although less common in late follow-up, many patients report troublesome early dysphagia [21]. The assessment of dysphagia symptoms, however, can be difficult because variable methods of clinical assessment and scoring are used in the various reported studies. There is also the potential for the introduction of assessment bias by clinician investigators, particularly if follow-up is performed by the operating surgeon. Despite these difficulties, it is likely that the incidence of persistent long-term troublesome dysphagia is less than 5% following Nissen fundoplication. Uncontrolled reports suggest that the performance of a partial fundoplication variant may reduce this incidence [22]. However, to date, this proposal has not been proven by randomized trials.

Despite the large number of publications describing fundoplication outcomes in the era of open surgery, few randomized trials have been conducted. Three trials have compared a Nissen fundoplication with a posterior partial fundoplication [23, 24], and one has compared a Nissen fundoplication with a Hill and a Belsey procedure [25]. None of these studies describe any significant increase in the likelihood or severity of dysphagia following Nissen fundoplication, compared to a posterior partial fundoplication procedure. However, with the exception of the study reported by Lundell et al. [21] which enrolled 137 patients, all of the

studies assessing the partial fundoplication variants enrolled small numbers of patients, which were inadequate to allow one to draw statistically valid conclusions. Other small studies have compared Nissen fundoplication with the Angelchik prosthesis and with the Ligamentum teres cardiopexy, demonstrating advantages for Nissen fundoplication [26, 27]. Another compared the Nissen procedure with and without division of short gastric vessels showing no difference [28], and a recent larger study compared medication with surgical treatment therapy [29]. Although findings were in favor of operation, neither the medical nor the surgical therapy used would now be regarded as optimal.

---

### Laparoscopic fundoplication

Initial reports of small case series of laparoscopic Nissen fundoplication with follow-up of 3 months or less first appeared in the published literature in 1991 [11, 30]. Although these studies confirmed the technical feasibility of laparoscopic antireflux surgery, the lack of adequate follow-up data and the small patient numbers precluded any adequate assessment of the merits of the procedures described. The first large study was published by Cuschieri et al. in 1993, who reported promising results from a multicenter series of 116 patients [31]. Further large single center experiences describing series of more than 100 patients have been published since, with follow-up intervals of 2 to 3 years described in some later studies [32]. Mean or median operating times vary from 30 to 185 minutes in these studies. Some of the reported variation in operating may be due to differences in laparoscopic technique, as well as possible increased operation times in some centers involved in teaching surgical trainees [33, 34]. Reported complication rates range from 2 to 26%, and surgical revision has been needed in a small group of patients in most series. Variation in these rates may be influenced by the effect of the institutional learning curve, technical factors associated with the choice of surgical technique, and different criteria used for the recognition and classification of com-

plications in different reports. For example dysphagia rates may depend on the choice of clinical measure used to determine post-operative dysphagia, and who applies the measure chosen. The operating surgeon may elicit a different response from an independent investigator.

Laparoscopic Nissen fundoplication is reported to control reflux symptoms in 91 to 100% of patients followed for up to two years, results which mirror previous experience with open antireflux surgery. Post-operative hospital stays have been short in all published reports, with mean/median stays ranging from 2 to 5 days. Overall results from these initial case series suggest that laparoscopic antireflux surgery is effective, and that it results in an overall reduction in the short term morbidity associated with surgery for reflux. However, several complications, some of which may be unique to the laparoscopic approach, have now been described.

■ **Pneumothorax.** This and accompanying pneumomediastinum is not an infrequent occurrence in more difficult cases, such as reoperative surgery. However, they are of no particular concern, and the CO<sub>2</sub> is rapidly absorbed.

■ **Vascular injury.** Vascular injury to the inferior vena cava, the left hepatic vein, the abdominal aorta, and the inferior phrenic vessels has all been reported [35]. It is possible that this complication is associated with a combination of aberrant anatomy, inexperience, and the excessive use of monopolar diathermy dissection. Intraoperative bleeding more commonly follows inadvertent laceration of the left lobe of the liver by a laparoscopic liver retractor or other instrument, or hemorrhage from short gastric vessels during fundal mobilization. A rare complication is cardiac tamponade due to laceration of the right ventricle by a liver retractor [36].

The overall risk of perioperative hemorrhage associated with antireflux surgery, however, may well be reduced by the laparoscopic approach. The risk of splenectomy due to inadvertent splenic injury during Nissen fundoplication is dramatically reduced by the laparoscopic approach [37]. Whilst splenectomy rates of 1 to 3% have been reported in association

with open fundoplication, splenectomy is a rare event following laparoscopic fundal mobilization. It is likely that the more precise dissection and better anatomical exposure afforded by the laparoscopic approach minimizes the likelihood of inadvertent splenic trauma.

■ **Para-esophageal hiatus herniation.** Although para-esophagus hiatus herniation may occasionally present in the late follow-up period following open fundoplication, most large case series of the laparoscopic procedure report an incidence of paraesophagus herniation, particularly in the immediate post-operative period. The incidence of this has ranged up to 7% in published reports [38]. This problem may be more likely following laparoscopic surgery for several reasons. First is the tendency to extend laparoscopic esophagus dissection well into the thorax, second is the increased risk of breaching the left pleural membrane, and third is the effect of reduced post-operative pain. Reduced pain may permit more abdominal force to be transmitted to the hiatal area during coughing, vomiting or other forms of early exertion, thereby pushing the stomach into the thorax. It is likely routine hiatal repair will reduce the risk of this problem [38, 39]. It is also possible that some of the apparent variation in the incidence of this problem reflects the steps taken to actively look for this complication. Also, the incidence following open fundoplication may be greater than previously recognized [21].

■ **Dysphagia.** Early severe dysphagia requiring surgical revision has been reported in a number of series. Conversion of a Nissen fundoplication to a posterior partial fundoplication has been performed for troublesome dysphagia by both open and laparoscopic techniques, usually with success. Over narrowing of the esophagus hiatus, another potential cause of early dysphagia may be difficult to assess intraoperatively because of reduced tactile feedback during laparoscopic surgery. This can be corrected by early laparoscopic re-intervention to release one or two hiatal sutures. Late narrowing of the esophagus hiatus due to the post-operative scarring, even in patient's not undergoing hiatal repair, has also been reported [40]. It is possible that this complication is due to an

idiosyncratic response to dissection which occurs in certain patients. Correction requires widening of the diaphragmatic hiatus by either open surgical or laparoscopic techniques.

■ **Pulmonary embolism.** Pulmonary embolism has been reported following laparoscopic antireflux surgery. This is likely to result from a combination of primarily mechanical factors. The combination of head up tilt of the operating table, intraabdominal insufflation of gas under pressure, and placement of the legs of patients in stirrups may greatly reduce venous flow in leg veins [41]. Coagulation changes associated with surgery are not altered by the application of laparoscopic techniques [42]. To prevent this problem it is mandatory that anti-thromboembolism prophylaxis is routinely applied.

■ **Perforation of the gastrointestinal tract.** Perforation of the esophagus, stomach, duodenum, or bowel has all been described following laparoscopic antireflux surgery. Whilst perforation of the small bowel and the colon may be related to laparoscopic access in general, esophagus and gastric perforations are specific risks of laparoscopic antireflux surgery, with an incidence of approximately 1% reported by most series. Perforation of the back wall of the esophagus can occur when dissecting the posterior aspect of the esophagus with laparoscopic instruments. The anterior esophagus wall is at risk when a bougie is passed to calibrate the tightness of the Nissen wrap. Gastric perforation is usually an avulsion injury of the gastric cardia due to rough handling by the surgical assistant, or the use of inappropriate grasping instruments to retract the stomach. These injuries can be repaired by sutures, applied either laparoscopically or by an open technique. Awareness of the potential for these injuries is likely to reduce their occurrence [43].

■ **Mortality.** Three deaths have been described following laparoscopic antireflux procedures [33, 44, 45]. The first was a patient who died secondary to peritonitis and sepsis from a duodenal perforation, presumably due to an instrumental injury occurring outside of the restricted field of view provided by the lapar-

scope [43]. Another was an instance of thrombosis of both the superior mesenteric artery and the coeliac axis [44]. This rare complication has also been seen following laparoscopic cholecystectomy, suggesting that it may be related to the use of positive pressure insufflation. A third was a case of infarction of the liver following laparoscopic fundoplication [45].

---

### Laparoscopic versus open surgery

Although laparoscopic approaches may reduce short term surgical morbidity, on a priori ground, it does not seem likely that long-term outcomes will be different from equivalent open procedures. It is even possible that technical modifications introduced to facilitate various laparoscopic approaches will result in poorer long term outcomes. Equally the superior view of the operative field in laparoscopic surgery might lead to better outcomes. Until the results of long term studies are available the true outcome of laparoscopic antireflux surgery, and its status as compared with open antireflux surgery will remain unknown.

Few direct comparisons of clinical outcome, surgical morbidity, and cost effectiveness have been attempted between early series of laparoscopic Nissen fundoplication and open surgical experience (historical or otherwise) within single institutions. Of the cost comparisons attempted, all are within the context of the American health system. Given the constraints of the non-randomized research methodology for almost all of these studies, and the different cost structure of the American health care, a fair comparison of laparoscopic and open techniques is difficult. All published studies report that laparoscopic antireflux surgery reduces hospital treatment costs and early surgical morbidity. Similar advantages were identified by non-randomized studies which compared laparoscopic inguinal hernia repair, appendectomy, and cholecystectomy with their equivalent open procedures. However, these advantages have not always been supported when prospective randomized trials were reported subsequently. Three randomized controlled trials which compare a laparoscopic Nissen

fundoplication with its open surgical equivalent have been reported [46–48], two in abstract only. Nevertheless, the results of all of these early trials confirm advantages for the laparoscopic approach, albeit less dramatic than the advantages expected from the results of non-randomized studies.

### Randomized trials of laparoscopic antireflux surgery

Apart from the above three randomized trials, which compare laparoscopic with open Nissen fundoplication, five other randomized trials examining laparoscopic antireflux surgery have been reported. Two of these studies compared different techniques for dividing the short gastric vessels during laparoscopic Nissen fundoplication. Laycock et al. [49] randomized 20 patients to have these vessels divided between metal clips or by the Ultracision Ultrasonic Shears (Ultracision, Smithfield, Rhode Island, USA). A time saving was demonstrated for the Ultrasonic Shears. Swanstrom and Pennings [50] randomized 31 patients in a similar study which also demonstrated a time saving of 10 minutes for the Ultrasonic Shear technique. Neither of these studies enrolled a large group of patients, or attempted to assess outcome differences between different antireflux procedures.

A third study, reported by Laws et al. [51], randomized 39 patients to undergo either a laparoscopic Nissen fundoplication or a laparoscopic Toupet fundoplication. No significant short term outcome differences were demonstrated between the two procedures.

The first of our own studies enrolled 103 patients to undergo either a total fundoplication without division of short gastrics vs a total fundoplication with division of short gastric vessels. At six months there were no significant or indeed appreciable differences between the two operations with regard to dysphagia, recurrent reflux, gas bloat, or patient satisfaction [52]. The second of our studies randomized 105 patients to undergo either a total fundoplication or an anterior fundoplication both without division of short gastric vessels. At six

months significant differences had emerged between the groups with the anterior group having less dysphagia, gas bloat, and a higher patient satisfaction rate [53]. Both of these trials are continuing in order to look at the important question of rates of recurrent reflux.

### Controversies and questions in regard to laparoscopic antireflux surgery

The advent of laparoscopic antireflux surgery has focused debate between protagonists of various antireflux surgical techniques. Whilst the Nissen fundoplication remains the technique advocated by the majority of surgeons, a number of variants such as posterior fundoplication, anterior partial fundoplication, and other techniques have been advocated to reduce the likelihood of post-operative dysphagia and gas bloat. Some surgeons advocate selective use of partial fundoplication variants for patients with esophagus dysmotility. Others advocate routine application of a particular partial fundoplication variant. Surgeons have not reached agreement on these questions which still require randomized studies for their resolution.

Even the incidence of disease induced by fibrotic shortening of the esophagus remains in doubt. Most surgeons report a very low incidence of shortened esophagus during laparoscopic antireflux surgery, with the incidence of conversion to an open procedure of this problem being less than 1% [54]. Although this suggests that the problem is infrequent, the ability of surgeons to determine adequate esophagus length at the time of laparoscopic antireflux surgery has been questioned with the suggestion that the problem is more common than usually appreciated [55, 56]. Because of this Kauer et al. [55] have advocated an open transthoracic approach to perform a Collis gastroplasty in patients with a hiatal hernia length of more than 5 cm. Swanstrom et al. [56] have described a method for the laparoscopic construction of a Collis gastroplasty if the surgeon considers the gastroesophageal junction cannot be brought down beyond the narrowed hiatus.

## Why do antireflux operations sometimes fail

■ **Inappropriate surgery.** If a patient does not have reflux, operation will cure whatever is causing the patient's symptoms. Perhaps the single most common non-reflux disorder, sometimes treated as reflux, is achalasia. In a collective review, the incidence of this occurring was 8% of cases presenting for re-operation [57].

The situation with adynamic (scleroderma) esophagus is not quite so clear cut although in the collective review was seen as the reason for reoperative surgery in 8% of cases also. There is little doubt that the potential for creating a *relatively* tight wrap in a patient with adynamic esophagus is quite high. Nevertheless, authorities are divided as to whether the preoperative demonstration of an adynamic esophagus should preclude the construction of a total wrap. It seems not unreasonable to accept that a very floppy complete wrap as advocated by Siewert [53] should not prove obstructive, although Skinner has stated that a partial fundoplication is preferred in these circumstances [58]. Duranceau et al. have demonstrated that a loose, short fundoplication can be constructed in patients with scleroderma esophagus, but significant acid exposure persisted in 50% of 12 patients [60]. Our own preference when an adynamic esophagus has been demonstrated on manometry is to carry out an anterior fundoplication.

As a general rule, it can be stated that if reflux cannot be demonstrated then antireflux surgery should not be undertaken.

■ **Obstructive problems.** The usual problem is the construction of wrap which is too tight and therefore produces obstruction even to a normally contracting esophagus. As mentioned above, if the esophagus is adynamic, this problem is potentially more likely to occur. Shirazi et al. compared 250 patients who had a short total fundoplication carried out around a 60 Fr bougie with 200 patients who had a long total fundoplication carried out around a bougie of < 40 Fr, and found the incidence of dysphagia in the latter group to be approximately double that in the former group [61].

In the collective review about 12% of patients had this indication for their reoperation [57].

Extrinsic obstruction can also occur by three other means. First is when the esophagus hiatus is narrowed too much in the placement of crural sutures, and second is when an Angelchik prosthesis is inserted. Although this device is effective in preventing reflux, it can cause severe dysphagia, leading to a need for early removal of the device in up to 20% of patients [62]. The third mechanism has only been described after laparoscopic fundoplication and consists of an excessive fibrous tissue reaction in the hiatus leading to extrinsic obstruction [40].

## ■ Gastric pullthrough (slipped Nissen)

In the presence of a shortened esophagus and fixed sliding hiatus hernia, it is sometimes difficult to be certain where the stomach finishes and the esophagus begins, when operating from the abdomen, or vice versa, when operating from the chest. Under these circumstances, it is possible that the inexperienced surgeon may mobilize the herniated stomach, believing it to be esophagus and then wrap the more distal stomach around this mobilized stomach – a so called gastric Nissen fundoplication. It is impossible to glean from the literature how often this occurs, as the end result is similar to the gastric pullthrough problem. The gastric pullthrough (slipped Nissen) is a moderately common form of failure reported. It is usually impossible to know if a gastric Nissen was fashioned in the first place, or if the fundoplication has slipped down from around the esophagus to lie around the stomach (which is probably unlikely), or if the longitudinal muscle of the esophagus has pulled the distal stomach through the fundoplication, which, a priori, seems inherently the most likely cause. This problem accounted for 29% of cases undergoing re-operative surgery in the collective review [57].

## ■ Breakdown of the repair

All patients who present with recurrent reflux probably have breakdown of their repair to some degree. Anatomical breakdown of the repair is the most common cause for re-operation (46% in the collective review [57]). The reasons why a repair should break down with time are conjectural. It might be expected that a loose wrap would be less likely to break down than a wrap constructed under some tension. There is no doubt that a floppy Nissen is associated with almost no tension, and a Nissen Rossetti repair (where only the anterior wall of the stomach is used) is often under quite a degree of tension. However, there is no evidence from the literature that the one type of repair is more likely to break down than the other. The fact that many of the repairs seem to break down early in the post-operative course suggests that precipitating factors such as straining coming out of anaesthesia, post-operative vomiting, or just post-operative gastric distension, may play a role. In the longer term it is not difficult to imagine gastric distension with eating chipping away at the repair, a factor which may explain why delayed gastric emptying seems to have a strong association with recurrent reflux [63].

### When do antireflux operations fail?

■ **Open operations.** If an inappropriate operation has been carried out, or if a total wrap has been constructed too tightly, either in relative or absolute terms, or if the hiatus has been made too narrow, or if an Angelchik prosthesis is going to cause problems, then the failure of the surgery should be evident from the outset. The fact that, often, problems only become apparent some months after the surgery probably relates to the fact that many patients will take liquid diets initially and only slowly progress to solid food. It may also relate to the strong placebo effect of a major abdominal operation. However, it is surprising that many repairs break down early after surgery, as mentioned previously, with some even appearing to break down in the immediate post-operative period.

Leonardi et al. found that the mean time to reflux recurrence was 19 months [64], and a similar finding was reported in 29 children [65]. Furthermore, Varron et al. stated that 19 of their 37 patients who came to re-operation developed recurrent reflux within 12 months of their surgery [66]. Collected data from some older series similarly showed that the majority of reflux recurrences occurred within the first 2 years after surgery [67].

■ **Laparoscopic operations.** Most large series of laparoscopic antireflux surgery describe an incidence of adverse outcomes requiring subsequent surgical revision [32, 65]. The incidence varies with the length of post-operative follow-up and the criteria used for reporting. An incidence of 2 to 6% at short term follow-up is usual with many of the reoperations required to correct unique complications of the laparoscopic approach. Early identification of these problems may facilitate early laparoscopic repair. However, later identification, beyond the first post-operative week, often necessitates a more difficult open surgical procedure due to adhesion formation and fibrosis rendering the laparoscopic option in many instances more difficult.

Laparoscopic revision procedures performed more than 3 months after the original fundoplication have also been described [37, 68]. However, these are often technically demanding operations. On the other hand, laparoscopic revision within a few days of the original procedure for complications such as post-operative paraesophagus herniation or early severe dysphagia are technically less demanding, and may not add greatly to the overall morbidity of the laparoscopic approach [33, 37]. To facilitate this, we recommend routine early post-operative barium swallow x-rays to enable early identification of problems and laparoscopic correction.

### Re-operative surgery for failed antireflux procedures

In general terms, the indications for second time around surgery are similar to indications for primary surgery, i.e. intractability of symp-

toms in spite of the best that conservative measures have to offer. However, it must be remembered that operative mortality has to be considered here (unlike with primary surgery). For this reason it seems prudent to resort only when symptoms are making a patient's life miserable.

It is extremely difficult to determine from the literature what proportion of patients with recurrent (or new) symptoms come to re-operative surgery. In O'Hanrahan et al.'s series the number was 7 of 12 patients, with demonstrated recurrent reflux [69]. However, whatever the proportion has been in the past, it is reasonable to expect that, for recurrent reflux at least, the figure will be somewhat less in the future, since the introduction of proton pump inhibitors.

The incidence of patients overall who come to re-operation is also not known for certain, as no series has achieved 100% follow-up of their patients. Nevertheless, the figure is probably of the order of 4–6%.

As the esophagus hiatus can be approached either from the thorax or from the abdomen, theoretically it seems attractive to advocate an approach for reoperative surgery via the previously unoperated route. In practice, however, it seems that surgeons operate through the route with which they are most familiar. Some form of total fundoplication remains the most popular re-operation, but equally a fundoplication constructed around an esophagus extension procedure may need to be performed.

Perhaps somewhat surprisingly, the results of re-do antireflux surgery are not that much different from the primary surgery [57], with the one important exception being operative mortality. Most series of patients having primary antireflux surgery show no or very low mortality rates. Thus, Siewert et al. report a collected series of 1240 patients with a 0.34% mortality rate [70]. However, series of re-do cases show operative mortality rates which vary from 0 to 18%, underlining the fact that this surgery can be technically extremely challenging [57].

The results of surgery worsen with the number of previous operations a patient has undergone for the problem. For example, Little et al. found that 85% of 34 patients who had undergone one previous operation had a good result,

66% of 19 who had undergone two previous operations obtained a good result, and only 42% of 8 patients who had undergone three or more operations had a good result [71].

## References

1. Nebel OT, Fornes MF, Castell DO (1976) Symptomatic gastro esophageal reflux: incidence and precipitating factors. *Am J Dig Dis* 21:953–956
2. Condon RE (1988) Intraoperative dilatation and fundoplication for benign peptic oesophageal stricture. In: Jamieson GG (ed) *Surgery of the Oesophagus*. Churchill Livingstone, London
3. Smith PM, Kerr CD, Cockel R et al (1994) A comparison of omeprazole and ranitidine in the prevention of recurrence of benign oesophageal stricture. *Gastroenterology* 107:1312–1318
4. Allen CJ, Newhouse MT (1984) Gastroesophageal reflux and chronic respiratory disease. *Am Rev Respir Dis* 129:646–647
5. Attwood SE, Smyrk TC, DeMeester TR et al (1992) Duodenoesophageal reflux and the development of adenocarcinoma in rats. *Surgery* 111:503–510
6. Ortiz A, Martinex LF, Parrilla P et al (1996) Conservative treatment vs antireflux surgery in Barrett's oesophagus: long term results of a prospective study. *Br J Surg* 83:274–278
7. Hardhan KD (1995) The role of the proton pump inhibitors in the treatment of gastroesophageal reflux disease. *Aliment Pharmacol Ther* 9(suppl): 15–25
8. Druman D, Wright C, Tougas C et al (1995) Omeprazole produces parietal cell hypertrophy and hyperplasia in humans. *Gastroenterology* 108(suppl): A85
9. Pera AM, Cameron AJ, Trastec VF (1993) Increasing incidence in adenocarcinoma of the oesophagus and esophagastric junction. *Gastroenterology* 104:510–513
10. Peters JH, Clarke GWV, DeMeester TR (1994) Do all adenocarcinomas of the esophagus arise in Barrett's mucosa. In: Giuli RR, Tytgat GNJ, DeMeester TR, Calmiech E (eds) *The esophageal mucosa*. Elsevier, Amsterdam, pp 1009–1115
11. Dallemagne B, Weerts JN, Jehaes C et al (1992) Laparoscopic Nissen fundoplication: preliminary report. *Surg Laparosc Endosc* 1:138–143
12. Jamieson GG, Watson DJ, Britten-Jones R et al (1994) Laparoscopic Nissen fundoplication. *Ann Surg* 220:137–145
13. Watson DJ, Chan ASL, Myers JC et al (1997) Illness behaviour influences the outcome of laparoscopic antireflux surgery. *J Am Coll Surg* 184:44–48
14. Maher JW, Hocking MP, Woodward ER (1981) Long term follow-up of the combined fundoplication for treatment of longitudinal peptic strictures of the oesophagus. *Ann Surg* 194:64–69

15. Watson DI, Mathew G, Pike GK et al (1997) Comparison of anterior, posterior and total fundoplication using a viscera model. *Dis Esophagus* 10:110-114
16. Nissen R (1956) Eine einfache Operation zur Beeinflussung der Refluxoesophagitis. *Schweiz Med Wochenschr* 86:590-592
17. Rossetti M, Hell K (1997) Fundoplication for the treatment of gastroesophageal reflux in hiatal hernia. *World J Surg* 1:439-444
18. DeMeester TR, Bonavina L, Albertucci M (1986) Nissen fundoplication for gastroesophageal reflux disease. Evaluation of primary repair in 100 consecutive patients. *Ann Surg* 204:9-20
19. Luostarinen M, Isolauri J, Laitinen J, Koskinen M, Keyrilainen O, Markkula H, Lehtinen E, Uusitalo A (1993) Fate of Nissen fundoplication after 20 years. A clinical endoscopic and functional analysis. *Gut* 34:1015-1020
20. Pope CE (1992) The quality of life following anti-reflux surgery. *World J Surg* 16:355-358
21. Lundell L, Abrahamsson H, Ruth M, Rydberg L, Lonroth H, Olbe L (1991) Long-term results of a prospective randomized comparison of total fundic wrap (Nissen-Rossetti) or semifundoplication (Toupet) for gastro-oesophageal reflux. *Br J Surg* 78:1088-1094
22. Watson A, Jenkinson LR, Ball CS, Norris TL (1991) A more physiological alternative to total fundoplication for the surgical correction of resistant gastro-oesophageal reflux. *Br J Surg* 78:1088-1094
23. Thor KBA, Silander T (1989) A long-term randomized prospective trial of the Nissen procedure versus a modified Toupet technique. *Ann Surg* 210:719-724
24. Walker SJ, Holt S, Sanderson CJ, Stoddard CJ (1992) Comparison of Nissen total and Lind partial trans-abdominal fundoplication in the treatment of gastroesophageal reflux. *Br J Surg* 79: 410-414
25. DeMeester TR, Johnson LF, Kent AH (1974) Evaluation of current operations for the prevention of gastroesophageal reflux. *Ann Surg* 180:511-525
26. Hill ADK, Walsh TN, Bolger CM, Byrne PJ, Hennesy TPJ (1994) Randomized controlled trial comparing Nissen fundoplication and the Angelchik prosthesis. *Br J Surg* 81:72-74
27. Janssen IM, Gouma DJ, Klementschtch P, van der Heyde MN, Obertop H (1993) Prospective randomised comparison of teres cardiopexy and Nissen fundoplication in the surgical therapy of gastro-oesophageal reflux disease. *Br J Surg* 80:875-878
28. Luostarinen MES, Koskinen MO, Isolauri JO (1996) Effect of fundal mobilisation in Nissen-Rossetti fundoplication on oesophageal transit and dysphagia. *Eur J Surg* 162:37-42
29. Spechler SJ (1992) Comparison of medical and surgical therapy for complicated gastroesophageal reflux disease in veterans. *NEJM* 326:786-792
30. Geagea T (1991) Laparoscopic Nissen's fundoplication: preliminary report on ten cases. *Surg Endosc* 5:170-173
31. Cuschieri A, Hunter J, Wolfe B, Swanström LL, Hutson W (1993) Multicentre evaluation of laparoscopic antireflux surgery. Preliminary report. *Surg Endosc* 7:505-510
32. Watson DI, Jamieson GG (2008) Antireflux surgery in the laparoscopic era. *Br J Surg* (in press)
33. Hinder RA, Filipi CJ, Wetscher G, Neary P, DeMeester TR, Perdakis G (1994) Laparoscopic Nissen fundoplication is an effective treatment for gastroesophageal reflux disease. *Ann Surg* 220: 472-483
34. Watson DI, Baigrie RJ, Jamieson GG (1996) A learning curve for laparoscopic fundoplication. Definable, avoidable, or a waste of time? *Ann Surg* 224:198-203
35. Baigrie RJ, Watson DI, Game PA, Jamieson GG (1997) Vascular perils during laparoscopic dissection of the oesophageal hiatus. *Br J Surg* 84:556-557
36. Firoozmand E, Ritter M, Cohen R, Peters J (1996) Ventricular laceration and cardiac tamponade during laparoscopic Nissen fundoplication. *Surg Lapar Endosc* 6:394-397
37. Watson DI, Jamieson GG, Devitt PG, Mathew G, Britten-Jones RE, Game PA, Williams RS (1995) Changing strategies in the performance of laparoscopic Nissen fundoplication as a result of experience with 230 operations. *Surg Endosc* 9:962-966
38. Watson DI, Jamieson GG, Devitt PG, Mitchell PC, Game PA (1995) Paraoesophageal hiatus hernia; an important complication of laparoscopic Nissen fundoplication. *Br J Surg* 82:521-523
39. Gotley DC, Smithers BM, Rhodes M, Menzies B, Branicki FJ, Nathanson L (1996) Laparoscopic Nissen fundoplication 200 consecutive cases. *Gut* 38: 487-491
40. Watson DI, Jamieson GG, Mitchell PC, Devitt PG, Britten-Jones R (1995) Stenosis of the oesophageal hiatus following laparoscopic fundoplication. *Arch Surg* 130:1014-1016
41. Jorgensen JO, Gilles RB, Lalak NJ, Hunt DR (1994) Lower limb venous hemodynamics during laparoscopy: An animal study. *Surg Lapar Endosc* 4:32-35
42. Pike GK, Bessell JR, Mathew G, Watson DI, Mitchell PC, Jamieson GG (1996) Changes in fibrinogen levels in patients undergoing open and laparoscopic Nissen fundoplication. *Aust NZ J Surg* 66:94-96
43. Cadriere GB, Himpens J, Bruyts J (1995) How to avoid esophageal perforation while performing laparoscopic dissection of the hiatus. *Surg Endosc* 9:450-452
44. Mitchell PC, Jamieson GG (1994) Coeliac axis and mesenteric arterial thrombosis following laparoscopic Nissen fundoplication. *Aust NZ J Surg* 64: 728-730
45. Medina LT, Vientimilla R, Williams MD, Fenoglio E (1996) Laparoscopic fundoplication. *J Laparosc Surg* 6:219-226
46. Franzen T, Anderberg B, Tibbling L, Johansson KE (1996) A report from a randomized study of open and laparoscopic 360 fundoplication. *Surg Endosc* 10:582 (Abstract)



47. Laine S, Rantala A, Gullichsen R, Ovaska J (1997) Laparoscopic vs conventional Nissen fundoplication. A prospective randomized study. *Surg Endosc* 11:441–444
48. Watson DI, Gourlay R, Globe J, Reed MWR, Johnson AG, Stoddard CJ (1994) Prospective randomised trial of laparoscopic versus open Nissen fundoplication. *Gut* 35(suppl 2):15 (Abstract)
49. Laycock WS, Trus TL, Hunter JG (1996) New technology for the division of short gastric vessels during laparoscopic Nissen fundoplication. *Surg Endosc* 10:71–73
50. Swanström LL, Pennings JL (1995) Laparoscopic control of short gastric vessels. *J Am Coll Surg* 181:347–351
51. Laws HL, Clements RH, Swillies CM (1997) A randomized, prospective comparison of the Nissen versus the Toupet fundoplication for gastroesophageal reflux disease. *Ann Surg* 225:647–654
52. Watson DI, Pike GK, Baigrie RJ, Mathew G, Devitt PG, Britten-Jones R, Jamieson GG (1997) Prospective double blind randomized trial of laparoscopic Nissen fundoplication with division and without division of short gastric vessels. *Ann Surg* 226:642–652
53. Watson DI, Pike GK, Davies N, Mathew G, Devitt PG, Britten-Jones R, Jamieson GG (2008) Prospective double blind randomized trial of laparoscopic Nissen fundoplication versus an anterior partial fundoplication. *Br J Surg* (in press)
54. Jamieson GG, Watson DI, Britten-Jones R, Mitchell PC, Anvari M (1994) Laparoscopic Nissen fundoplication. *Ann Surg* 220:137–145
55. Kauer WKH, Peters JH, DeMeester TR, Heimbucher J, Ireland AP, Brenner CG (1995) A tailored approach to antireflux surgery. *J Thorac Cardiovasc Surg* 110:141–147
56. Swanstrom LL, Marcus DR, Galloway GQ (1996) Laparoscopic Collis gastroplasty is the treatment of choice for the shortened esophagus. *Am J Surg* 171:477–481
57. Jamieson GG (1993) The results of antireflux surgery and reoperative antireflux surgery. *Gullett* 3:41–45
58. Siewert JR, Feussner J (1988) Collagen diseases, Chapter 54. In: Jamieson GG (ed) *Surgery of the oesophagus*. Churchill Livingstone, Edinburgh
59. Skinner DB (1992) Surgical management after failed antireflux operations. *World J Surg* 16:359–363
60. Durancequ A, Topart P, Deschamps C (1992) Tailorfer reflux control in operated scleroderma patients. Abstract SP-080, 5th World Congress of International Society of Diseases of the Esophagus
61. Stirling MC, Orringer MB (1989) Continued assessment of the Collis-Nissen operation. *Ann Thorac Surg* 47:224–230
62. Maddern GJ, Myers J, McIntosh N, Bridgewater F, Jamieson GG (1992) The effect of the Angelchick prosthesis on oesophageal and gastric function. *Arch Surg* 126:14–17
63. Maddern GJ, Jamieson GG, Chatterton BE, Collins PJ (1985) Is there an association between failed antireflux procedures and delayed gastric emptying? *Ann Surg* 202:162–165
64. Leonard HK, Crozier RE, Ellis FH (1989) Reoperation for complications of the Nissen fundoplication. *J Thorac Cardiovasc Surg* 81:50–56
65. Dedinsky GK, Vane DE, Black CT, Turner MK, West KW, Grosfeld JL (1987) Complications and reoperation after Nissen fundoplication in childhood. *Am J Surg* 153:177–183
66. Varron F, Siksik JM, Turet E, Parc R (1989) Reoperation for oesophagitis following failed antireflux procedure. Abstract 156, European Digestive Diseases Week, Amsterdam
67. Jamieson GG, Durandequ A, Deschamps C (1988) Surgical treatment of gastroesophageal reflux disease. In: Jamieson GG, Durandequ A (eds) *Gastroesophageal reflux*, chap 10. WB Saunders, Philadelphia
68. Depaula AL, Hashiba K, Bafutto M, Machado CA (1995) Laparoscopic reoperations after failed and complicated antireflux operations. *Surg Endosc* 9:681–686
69. O’Hanrahan T, Marples M, Bancewicz J (1990) Recurrent reflux and wrap disruption after Nissen fundoplication: detection incidence and timing. *Br J Surg* 77:545–547
70. Siewert JR, Feussner H, Walker SJ (1992) Fundoplication: how to do it? Periesophageal wrapping as a therapeutic principle in gastro esophageal reflux prevention. *World J Surg* 16:326–334
71. Little AG, Ferguson MK, Skinner DB (1986) Reoperation for failed antireflux operations. *J Thorac Cardiovasc Surg* 91:511–517

# Pathologic Classification of the Esophageal Carcinoma

P. HERMANEK

In esophageal carcinoma as well as in other malignant tumors, present-day oncology requires a standardized classification for

- planning treatment procedures,
- estimation of prognosis and
- evaluation of treatment results and, thus, quality assurance.

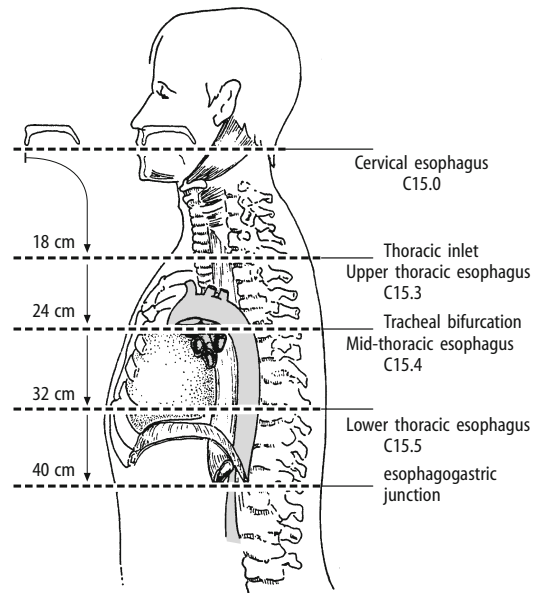
As in other malignant tumors the tumor classification of esophageal carcinoma is based on four pillars and follows uniform international recommendations by the World Health Organization (WHO) [4] and the International Union Against Cancer (UICC) (2002, 2005) [16, 18].

## Tumor classification

- |  |      |
|--|------|
| 1. Tumor site  | UICC |
| 2. Histomorphology   |      |
| – Typing   | WHO  |
| – Grading  |      |
| 3. Anatomical extent before treatment = TNM/pTNM                         | UICC |
| 4. Anatomical extent after treatment = Residual tumor (R) classification | UICC |

## Tumor site

The esophagus commences at the lower border of the cricoid cartilage. The UICC (2002, 2005) distinguishes between the cervical and the intrathoracic esophagus. The latter is subdivided into the upper thoracic, mid-thoracic, and lower thoracic portion (including the abdominal esophagus) (Fig. 9.1). The upper thoracic portion extends from the thoracic inlet to the level



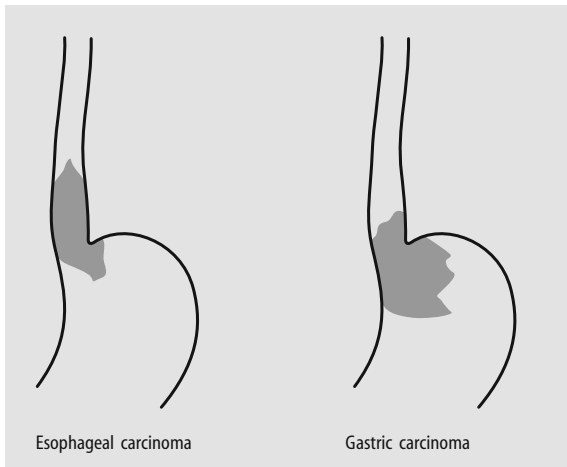
**Fig. 9.1.** Anatomic subdivision of the esophagus. Modified from UICC 2005.

of the tracheal bifurcation. The mid-thoracic portion is the proximal half, the lower thoracic portion the distal half of the esophagus between the tracheal bifurcation and the esophagogastric junction.

From a clinical point of view subdivision into an infrabifurcational portion (=mid-thoracic and lower thoracic), a suprabifurcational portion (including the region at the tracheal bifurcation) (=upper thoracic portion) and a cervical portion is important.

For the classification of tumors involving the distal esophagus as well as the cardiac area of the stomach the following rules of the UICC (2003) [17] should be applied (Fig 9.2):

- If more than 50% of the tumor involves the esophagus, the tumor is classified as esophageal, if less than 50%, as gastric;



**Fig. 9.2.** Distal esophageal carcinoma versus proximal gastric carcinoma/adenocarcinoma of the gastroesophageal junction.

- if the tumor is equally located above and below the esophagogastric junction or is designated as being at the junction, squamous cell, small cell and undifferentiated carcinomas are classified as esophageal, adenocarcinoma and signet ring cell carcinoma as gastric.

### Typing

The main histological types are the squamous cell carcinoma and the adenocarcinoma. In statistics from the 1980s from Western countries about 85–90% squamous cell carcinomas and 5–19% adenocarcinomas are reported. In the Erlangen Cancer Registry 1978–1991 (n=581) 83.3% squamous cell carcinomas, 10.2% adenocarcinomas and 6.5% other or unclassified carcinomas were observed. While adenocarcinomas in Japan are very uncommon, in the Western countries a considerable increase of adenocarcinomas during the last 10–20 years was registered: National Cancer Data base of USA: 1988: 33.2%, 1993: 43.1% adenocarcinomas [21]. However sometimes in such statistics carcinomas of the cardia are included, and in these cases the proportion of adenocarcinomas is considerably higher than in statistics of carcinomas of the esophagus only.

- **Squamous cell carcinomas** show intercellular bridges and variable amounts of keratin. Variants are:

- the verrucous carcinoma with papillary pattern and well differentiated,
- the spindle cell (pseudosarcomatous) carcinoma, a poorly differentiated carcinoma that may be misinterpreted as sarcoma or carcinosarcoma,
- the basaloid squamous cell carcinoma, in prognosis similar to the common squamous cell carcinoma, with difficulties in differential diagnosis to small cell and adenoid cystic carcinoma.

- **The adenocarcinoma** of the esophagus arises as a rule from a Barrett syndrome (endobrachyoesophagus, columnar epithelial-lined lower esophagus, CELLO). Very uncommon are adenocarcinomas arising from congenital foci of heterotopic gastric mucosa, mostly in the upper thoracic portion, or from esophageal glands. Adenocarcinoma show papillary, tubular, or tubulo-papillary pattern and may include circumscribed areas with squamous metaplasia.

- **Uncommon carcinomas** (less than 5%) include

- mucinous adenocarcinoma
- adenosquamous carcinoma
- mucoepidermoid carcinoma
- adenoid cystic carcinoma
- lymphoepithelioma-like carcinoma
- small cell carcinoma (to be distinguished from extension of a primary small cell carcinoma of the lung)
- undifferentiated carcinoma
- choriocarcinoma.

### Grading

Squamous cell carcinomas and adenocarcinomas are graded by considering the degree of cytological and architectural similarity to the tissue of origin as well as nuclear abnormalities and mitotic activity:

- |                                |                          |
|--------------------------------|--------------------------|
| ■ G1 Well differentiated       | Low grade of malignancy  |
| ■ G2 Moderately differentiated | Low grade of malignancy  |
| ■ G3 Poorly differentiated     | High grade of malignancy |

The small cell and the undifferentiated carcinomas are always G4 (Undifferentiated) and high grade.

An independent prognostic influence of the grade of differentiation could not be shown in most multivariate analyses. Recently, for squamous cell carcinoma a grading system (prognostic score) considering only the pattern of invasion and the inflammatory response was proposed by [14]:

**■ Pattern of invasion**

- Pushing well-delineated tumor margins 1 point
- Infiltrating, solid cords and bands 2 points
- Small groups of dissociated cells (n > 15) 3 points
- Marked cellular dissociation 4 points

**■ Inflammatory response**

- Marked 1 point
  - Moderate 2 points
  - Slight 3 points
  - None 4 points
- |                 |                  |                     |
|-----------------|------------------|---------------------|
| - Sum of points | Prognostic group |                     |
| 2.3             | 1                | Favorable prognosis |
| 4               | 2                | Favorable prognosis |
| 5.6             | 3                | Favorable prognosis |
| 7.8             | 4                | Poor prognosis      |

**TNM/pTNM classification**

The anatomic extent of esophageal carcinoma is classified according to the TNM/pTNM classification of UICC (2002, 2005). It is applied to the squamous cell carcinoma as well as to adenocarcinoma and other uncommon carcinomas.

The clinical TNM Classification is based on evidence from pre-therapeutic clinical examination, endoscopy, imaging, and from surgical exploration. The pathological pTNM classification entails relevant histopathological examination.

**Requirement for pTNM classification of esophageal carcinoma (UICC 2002, 2003)**

- pT1-3 Pathological examination of the primary carcinoma with no gross tumor at the deep (radial, lateral), proximal and distal margins of the resection (with or without microscopic involvement)
- pT4 Microscopic confirmation of invasion of adjacent structures
- pN0 Histological examination of a mediastinal lymphadenectomy specimen which will ordinarily include 6 or more lymph nodes
- pN1 Microscopic confirmation of at least one regional lymph node metastasis
- pM1 Microscopic (histologic or cytologic) confirmation of distant metastasis

**■ Primary tumor: T/pT classification.** The decisive parameter for the classification of the primary tumor is the depth of invasion (Fig. 9.3). In addition to the categories presented in Fig. 9.3 the categories T/pTX: Primary tumor cannot be assessed and T/pT0: No evidence of primary tumor is available.

In Japan, frequently the term “superficial esophageal carcinoma” is used to summarize Tis and T1 tumors [11]. In contrast, in Japan the term “early carcinoma of the esophagus” characterizes a pT1 carcinoma without metastasis in most publications.

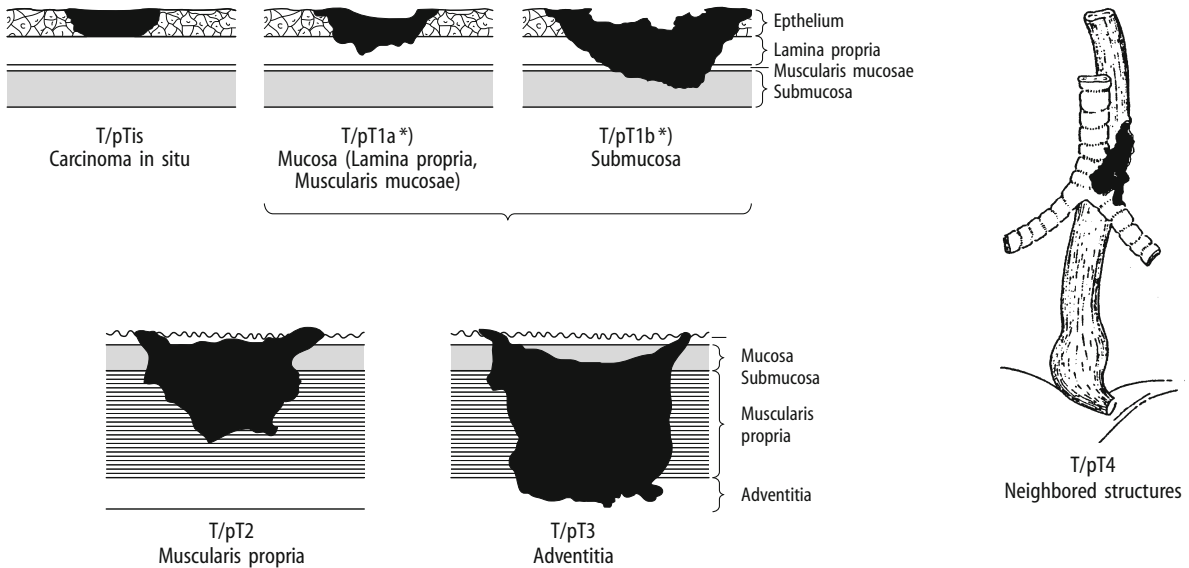
**■ Regional lymph nodes.** According to the UICC rules the regional lymph nodes for the cervical and the intrathoracic esophagus are different:

**■ Cervical esophagus.** Cervical lymph nodes including supraclavicular lymph nodes

**■ Intrathoracic esophagus**

- Mediastinal lymph nodes
- Perigastric lymph nodes along the lesser and greater curvatures (including right and left cardiac, supra- and infrapyloric nodes) and along the left gastric artery

(Attention: The celiac lymph nodes are non-regional, involvement is classified as distant metastasis!)



\*) Facultative classification: TNM Supplement (UICC 2001)

**Fig. 9.3.** T/pT classification (UICC 2002). Modified from UICC 2005.

From surgical point of view and for describing the extent of lymphadenectomy, the regional lymph nodes are subdivided into compartments or fields (cervical, mediastinal, and perigastric).

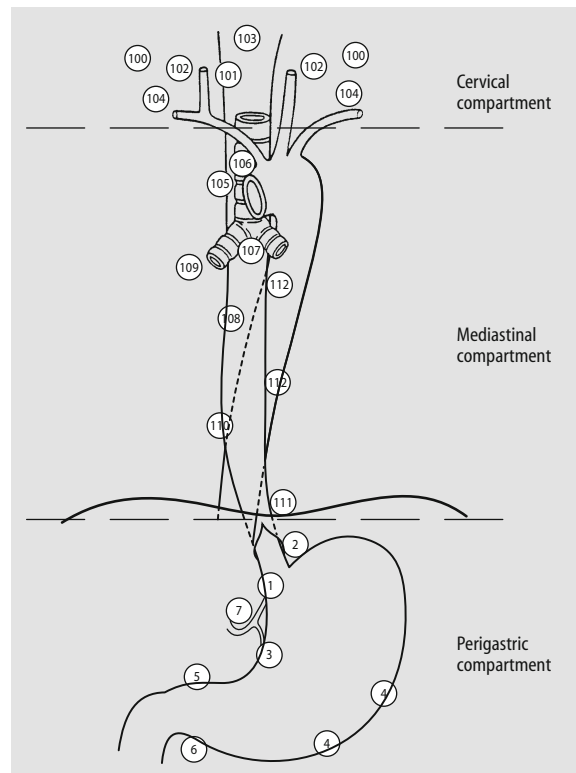
Thus, a two field and three field lymphadenectomy can be distinguished:

- |                           |                                  |
|---------------------------|----------------------------------|
| ■ Cervical compartment    | } Three field (all compartments) |
| ■ Mediastinal compartment |                                  |
| ■ Perigastric compartment |                                  |
|                           | } Two field                      |

Within the 3 compartments various lymph nodes stations are included and numbered by the Japanese Society for Esophageal Diseases [8] (Fig. 9.4).

#### ■ Regional lymph nodes for the cervical esophagus (cervical compartment)

- (100) Lateral cervical nodes bilateral
- (101) Cervical paraesophageal nodes
- (102) Deep cervical nodes (bilateral)
- (103) Retropharyngeal nodes
- (104) Supraclavicular nodes (bilateral), including the so-called scalenus nodes



**Fig. 9.4.** Regional lymph nodes of the esophagus. Subdivision into lymph node compartments and stations according to the Japanese Society for Esophageal Diseases (1992).

**■ Regional lymph nodes for the intrathoracic esophagus**

*Mediastinal compartment*

(105) Upper thoracic paraesophageal nodes	Upper region
(106) Thoracic paratracheal nodes (bilateral)	
(107) Nodes at the tracheal bifurcation	Middle region
(108) Middle thoracic paraesophageal nodes	
(109) Pulmonal hilar nodes (bilateral)	
(110) Lower thoracic paraesophageal nodes	Lower region
(111) Diaphragmatic nodes	
(112) Posterior mediastinal nodes	Middle and lower region

*Perigastric compartment*

- (1) Right cardiac nodes
- (2) Left cardiac nodes
- (3) Nodes along the lesser curvature
- (4) Nodes along the greater curvature
- (5) Suprapyloric nodes
- (6) Infrapyloric nodes
- (7) Nodes along the left gastric artery

The number of regional lymph nodes removed by a systemic two-field lymphadenectomy is 25 to 40 nodes in the Western countries [3, 7]. With increasing number of nodes histologically examined the number of node-positive cases is increasing [3].

Number of nodes examined per tumors resection specimen	Frequency of node positive resection specimen
1-5	1/10 = 10%
6-20	15/53 = 28%
> 20	55/93 = 59%

**■ N/pN classification.** The obligatory categories of the UICC classification are:

- N/pNX Regional lymph nodes cannot be assessed
- N/pN0 No regional lymph node metastasis
- N/pN1 Regional lymph node metastasis

Cases with micrometastasis only, i.e., no metastasis larger than 2 mm, can be identified by the addition of “(mi)”, e.g., pN1(mi) (UICC 2002).

In the TNM Supplement (UICC 2003) an optional ramification of N/pN1 is proposed:

- N/pN1a 1 to 3 regional lymph nodes involved
- N/pN1b 4 to 7 regional lymph nodes involved
- N/pN1c More than 7 lymph nodes involved

Because the tumor length appears to be an independent indicator of mortality [2], in the last edition of the TNM Supplement (UICC 2003) an additional optional ramification of the T categories according to the tumor length is proposed:

- T1a-T1b Tumor length < 3 cm
- T1b-T4b Tumor length > 3 cm

**■ Classification of isolated tumor cells in the regional lymph nodes** [6] (UICC 2002, 2003)

Isolated tumor cells (ITC) are single tumor cells or small clusters of cell not more than 0.2 mm in greatest dimension that are usually detected by immunocytochemistry or molecular methods (flow cytometry, DNA analysis), but which may be verified H and E stains. Their classification is as follows:

- pN0 (i-) No regional lymph node metastasis histologically, negative morphological findings for ITC
- pN0 (i+) No regional lymph node metastasis histologically, positive morphological findings for ITC
- pN0 (mol-) No regional lymph node metastasis histologically, negative non-morphological findings for ITC
- pN0 (mol+) No regional lymph node metastasis histologically, positive non-morphological findings for ITC

- **Distant metastasis: M/pM.** The categories are:
- M/pMX Distant metastasis cannot be assessed
- M/pM0 No distant metastasis
- M/pM1 Distant metastasis

For carcinomas of the intrathoracic esophagus the category M/pM1 is subdivided into M/pM1a and M/pM1b:

- Tumors of the upper intrathoracic esophagus
- M/pM1a Metastasis in cervical lymph nodes
- M/pM1b Other distant metastasis

Tumors of the mid-thoracic esophagus

All distant metastasis (including those in non-regional lymph nodes) are classified as M/pM1b

- Tumors of the lower intrathoracic esophagus
- M/pM1a Metastasis in celiac lymph nodes
- M/pM1b Other distant metastasis

The not uncommon so-called skip metastasis (intramural metastasis, predominant in the mucosa and submucosa) should not be classified as distant metastasis, their occurrence is not considered in the present TNM system.

If all distant metastases are not larger than 2 mm in dimension, i.e. micrometastasis, this may be indicated by the suffix “(mi)”, e.g. pM1b(mi).

■ **Classification of isolated tumor cells in non-regional lymph nodes or bone marrow.** Such findings are classified according to the same schema as for regional lymph nodes (see above), e.g., isolated tumor cells identified by morphologic techniques M0(i+) and non-morphologic findings as M0(mol+).

For specification of the site of distant metastasis the following notations may be used:

- PUL Lung(s)
- OSS Bone(s)
- HEP Liver
- BRA Brain
- LYM Lymph node(s) (non-regional)
- MAR Bone marrow
- PLE Pleura

- PER Peritoneum
- ADR Adrenals
- SKI Skin
- OTH Others
- GEN Generalized metastasis

### ■ Stage grouping

By considering of T, N and M and pT, pN and pM categories respectively so-called stages may be defined:

Stage 0	Tis	N0	M0
Stage I	T1	N0	M0
Stage IIA	T2,3	N0	M0
Stage IIB	T1,2	N1	M0
Stage III	T3	N1	M0
Stage IV	Any T	Any N	Any M

### Additional descriptors and optional categories of the TNM system

For identification of special cases in the TNM or pTNM classification, the following symbols are used:

■ **m symbol.** Addition to T and pT to indicate the presence of multiple synchronous primary tumors in the esophagus. In this case, the tumor with the highest T category should be classified and the multiplicity or the number of tumors should be indicated in parentheses.

Example: The pathological examination shows a pT2 tumor and an additional primary pT1 carcinoma. The classification is pT2(m) or pT2 [2].

■ **y symbol.** In those cases in which classification is performed following preoperative chemo- and/or radiotherapy, the TNM or pTNM categories are identified by the y prefix, e.g. yT2N0M0 or ypT2pN1M0.

■ **r symbol.** Recurrent tumors, when staged after a disease-free interval, are identified by the prefix r, e.g. rT2N0M0.

■ **a symbol.** The prefix “a” indicates that classification is first determined at autopsy.

■ **Lymphatic invasion.** For description of lymphatic invasion the following categories are used:

- LX Lymphatic invasion cannot be assessed
- L0 No lymphatic invasion
- L1 Lymphatic invasion

■ **The C-factor** (certainly factor) reflects the validity of clinical classification according to the diagnostic methods employed. The C-factor is added to the T, N, and M categories, e.g. T2C2 N1C3 M0C1. The definitions for the esophagus [19] are:

■ **Primary tumor**

- C1 Physical examination, esophagogastroduodenoscopy, esophagography, bronchoscopy
- C2 Chromoendoscopy, radiographs with special projections, endoluminal ultrasonography, CT, MRI, laparoscopy, biopsy, cytology
- C3 Surgical exploration including biopsy and cytology

■ **Regional lymph nodes**

- C1 Physical examination (cervical lymph nodes)
- C2 Endoluminal ultrasonography, CT, MRI, PET, laparoscopy
- C3 Surgical exploration including biopsy and cytology

■ **Distant metastasis**

- C1 Physical examination, standard radiography
- C2 Tomography, CT, external ultrasonography, MRI, scintigraphy, laparoscopy, biopsy, cytology
- C3 Surgical exploration including biopsy and cytology

For pTNM the C-factor is not important and may be omitted because the requirements for pT, pN, and pM are defined in the general rules of the TNM system and in the TNM Supplement (UICC 2003).

## Residual tumor (R) classification

While TNM and pTNM describe the anatomic extent of tumor before treatment, the R classification deals with tumor status after treatment. It reflects the effects of therapy, influences further therapeutic procedures, and is the strongest predictor of prognosis.

The categories of the R classification are:

- RX Presence of residual tumor cannot be assessed
- R0 No residual tumor
- R1 Microscopic residual tumor
- R2 Macroscopic residual tumor

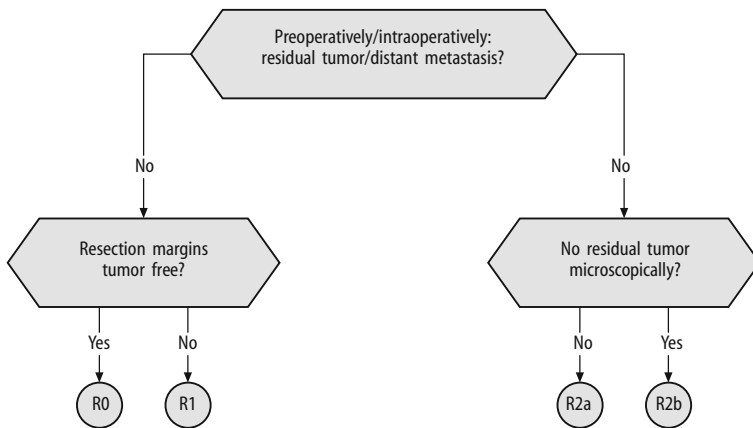
The Working Group of German Cancer Centers [1] proposed a subdivision of the R2 category:

- R2a Macroscopic residual tumor without microscopic confirmation
- R2b Macroscopic residual tumor with microscopic confirmation

In the R classification the loco-regional tumor status (primary tumor and regional lymph drainage area) as well as distant residual tumor in the form of remaining distant metastasis are taken into consideration. Thus the R classification following surgical treatment requires the co-operation of the surgeon and the pathologist (Fig. 9.5).

In esophageal carcinoma loco-regional residual tumor is found most frequently in the mediastinal (circumferential, lateral, radial) resection margins, more rarely on the oral, and very seldom on the aboral margin: In 107 locally-regionally incomplete esophageal resections the mediastinal margin was tumor positive in 82%, the oral margin in 15%, and the aboral margin in 3% [20]. Thus, the histological examination has to focus on the mediastinal resection margins in the region of the deepest invasion of the primary carcinoma. Transverse sections are taken for histology after marking the margin with India ink or white latex-emulsion (Tipp-Ex). Because of the relatively frequent histologic tumor extension beyond the gross tumor margins and microscopic skip metastasis, the additional histologic examination of the oral and aboral resection margin is obligatory [5].





**Fig. 9.5** Assessment of the residual tumor (R) classification. From Wagner and Hermanek 1995 [19].

### Grading of histological regression after neoadjuvant treatment

Following preoperative radio- and/or chemotherapy, a variable histologic regression of tumor tissue is seen. For grading these changes, two methods may be used [9].

■ Assessment of “effectivity” (Ef) according to the proposals of the Japanese Society for Esophageal Diseases [8]:

- Ef1 (no slight regression)  
vital tumor cells with absent or slight degenerative changes in more than 1/3 of the tumor
- Ef2 (moderate regression)  
neither Ef1 nor Ef3
- Ef3 (severe regression)  
no vital tumor cells

■ Assessment of tumor regression grade (TRG) according to Mandard et al. [10];

- TRG1 No identifiable residual cancer, only fibrosis with or without granulomas (complete regression)
- TRG2 Rare residual cancer cells scattered through fibrosis
- TRG3 Increased number of residual cancer cells, fibrosis still predominant
- TRG4 Residual cancer outgrowing fibrosis
- TRG5 No regressive changes

■ **Further prognostic factors** (for more information and references see Roder et al. [12] and Stein et al. [5]).

The anatomic extent of tumor, assessed by the TNM defined stage and after treatment, by the R classification are the most important indicators of outcome. For all other possible tumor-, patient- and treatment-related prognostic factors is the independent significance by multivariate analysis not yet proven and only for some patient subgroups probable [13]. This applies to the histologic type which influences prognosis probably only in pT1 tumors. An independent prognostic influence has been shown for the so-called lymph node ratio, i.e. the ratio of involved and removed nodes, by a single study from Munich [12]. This ratio reflects the extent of lymphatic metastasis as well as the extent of lymphadenectomy. Following neoadjuvant therapy the grade of histological tumor regression is of prognostic importance [10]. For all biological and molecular markers, it has to be stated that their significance for treatment decisions as well as for prognosis remains to be proven.

### Preconditions for adequate histopathological tumor classification

An optimal histopathological tumor classification requires the close co-operation between clinicians and pathologists. Optimal methods in the histopathological laboratories must be supplemented by three preconditions to be met by clinicians:

- Adequate sampling for pretherapeutic diagnostics,
- careful handling of specimen during the transport into the histopathological laboratories,
- sufficient information on the clinical situation for the pathologist.

■ **Sampling for pre-therapeutic diagnostics.** From any grossly recognizable lesion multiple biopsies (at least 5 particles) have to be taken. In ulcerous lesions, not only the ulceration itself but also the margins should be biopsied. Polypoid lesions up to 1 cm in dimension should be completely removed by diathermy snare as primary diagnostic step (total biopsy). Diagnostic difficulties arise in case of tumor stenosis and oral submucous extension. If stenosis cannot be passed by a baby endoscope, biopsies may be possible after dilatation. In such cases, material for cytological examination may be obtained by washing, brushing or balloon sampling. The assessment requires special experiences with esophageal cytology. During esophagoscopy, biopsies should be taken not only from the visible tumor, but also from the adjacent grossly normal mucosa to detect an associated in situ component. Synchronous multiple primary tumors of the category Tis and T1 sometimes can be detected only by chromoendoscopy (with lugol solution).

■ **Handling of specimens during the transport to the histological laboratories.** *Biopsies and ectomized polyps* should be immersed in fixative as soon as possible. The type of fixative should be chosen in agreement with the pathologist. Mucosal resection specimens should be mounted on cardboard or corkboard, mucosal side up, and attached to it with pins (avoid stretching!). If possible, *esophagectomy specimens* should be transported to the pathologist

immediately after resection. Areas suspicious of locally incomplete resection should be marked by the surgeon. In addition the level of tracheal bifurcation should be marked to enable a topographic assignment of the paraesophageal lymph nodes. All lymph nodes separately removed should be carefully labelled indicating their localisation. If resection specimens have to be sent to the pathologist by mail, the specimens have to be opened longitudinally, trying to cut on the side opposite to the tumor, in circular tumors on the anterior site and along the greater curvature of the stomach. The specimens are pinned up on styropore or corkboards (avoid stretching!) and then immersed in sufficient fixative (according to agreement with the pathologist).

■ **Information for the pathologist.** An optimal histological examination of incision and total biopsies and resection specimens requires adequate information for the pathologist on the clinical situation including history.

### References

1. Dudeck J, Wagner G, Grundmann E, Hermanek P (eds) (1994) Basisdokumentation für Tumorkranke, 4. Aufl. Springer, Berlin Heidelberg New York Tokyo
2. Eloubeidi MA, Desmond R, Arguedas MR et al. (2002) Prognostic factors in the survival of patients with esophageal carcinoma in the US. *Cancer* 95:1434–1444
3. Fraunberger L, Kraus B, Dworak O (1996) Verteilung von Lymphknoten und Lymphknotenmetastasen beim Ösophaguskarzinom. *Zbl Chir* 121:102–105
4. Hamilton SR, Aaltonen LA (eds) (2000) Pathology and genetics of tumors of the digestive system. World Health Organisation Classification of tumors. IARC Press, Lyon
5. Hermanek P, Wittekind Ch (1994) Diagnostic seminar: The pathologist and the residual tumor (R) classification. *Path Pract Res* 190:115–123
6. Hermanek P, Hutter RVP, Sobin LH, Wittekind Ch (1999) Classification of isolated tumor cells and micrometastasis. *Cancer* 86:2668–2673
7. Jacobi CA, Zieren HU, Müller JM, Pichlmaier H (1996) Systematische Lymphadenektomie beim Ösophaguskarzinom – Vorläufige Ergebnisse einer prospektiven randomisierten Studie. *Zbl Chir* 121:110–115
8. Japanese Society for Esophageal Diseases (1990) Guidelines for the clinical pathologic studies on carcinoma of the esophagus, 8th ed. Kanehara, Tokyo

9. Junginger T, Hermanek P, Klimpfinger M (2002) Klassifikation maligner Tumoren des Gastrointestinaltraktes I. Springer, Berlin Heidelberg New York
10. Mandard A-M, Dalibard F, Mandard J-C, Marnay J, Henry-Amar M, Petiot J-F, Roussel A et al. (1994) Pathologic assessment of tumor regression after preoperative chemoradiotherapy of esophageal carcinoma. *Cancer* 73:2680–2686
11. Nagawa H, Kaizaki S, Seto Y, Tominaga O, Muto T (1995) The relationship of macroscopic shape of superficial esophageal carcinoma to depth of invasion and regional lymph node metastasis. *Cancer* 75:1061–1064
12. Roder JD, Busch R, Stein HJ, Fink U, Siewert JR (1994) Ratio of invaded and removed lymph nodes as a predictor of survival in squamous cell carcinoma of the esophagus. *Br J Surg* 81:410–413
13. Roder JD, Stein HJ, Siewert JR (1995) Esophageal carcinoma. In: Hermanek P, Gospodarowicz MK, Henson DE, Hutter RVP, Sobin LH (eds) UICC Prognostic factors in cancer. Springer, Berlin Heidelberg New York Tokyo
14. Sarbia M, Bittinger F, Porschen R, Dutkowski P, Willers R, Gabbert HE (1995) Prognostic value of histopathologic parameters of esophageal squamous cell carcinoma. *Cancer* 76:922–927
15. Stein HJ, Feith M (2001) Prognostic factors in the cancer of the esophagus. In: Gospodarowicz MK, Henson DE, Hutter RVP, O'Sullivan B, Sobin LH, Wittekind Ch (eds) Prognostic factors in cancer, 2nd ed. Wiley-liss, New York
16. UICC (2002) TNM Classification of malignant tumours, 6th ed (Sobin LH, Wittekind Ch, eds). Wiley-Liss, New York
17. UICC (2003) TNM Supplement. A commentary on the uniform use, 3rd ed (Wittekind Ch, Greene FL, Henson DE, Hutter RVP, Sobin LH, eds). Wiley, New York
18. UICC (2005) TNM Atlas. Illustrated guide to the TNM/pTNM classification of malignant tumours, 5th ed (Wittekind Ch, Greene FL, Hutter RVP, Klimpfinger M, Sobin LH, eds). Springer, Berlin Heidelberg New York
19. Wagner G, Hermanek P (1995) Organspezifische Tumordokumentation. Springer, Berlin Heidelberg New York Tokyo
20. Wittekind Ch (1993) Bedeutung von Tumorwachstum und -ausbreitung für die chirurgische Radikalität. *Zbl Chir* 1118:500–597
21. Daly JM, Karnell LH, Menck HR (1996) National Cancer Data Base report on esophageal carcinoma. *Cancer* 78(8):1820–1828

# Lymphatic Dissemination and Principles of Lymph Node Dissection

J. R. IZBICKI, A. REHDEERS, A. KUTUP, C. BUSCH

Throughout the last decades the results of surgical treatment on esophageal cancer have improved continuously. Before 1980 Isono [1] reported a 5-year survival rate of 12.4%. In this study he describes the mode of recurrence after esophagectomy: 13.0% of patients had local recurrence, 8.7% had recurrence in the residual esophagus, 43.5% had evidence of lymph node metastasis, 28.3% had recurrence in other organs, and 6.5% had pleural or peritoneal tumor dissemination. The relapse pattern in lymph nodes showed recurrence in cervical nodes in 21.7%, mediastinal nodes in 19.6%, and abdominal nodes in 2.2%. These results suggest that extensive surgery with radical lymph node dissection could bear a chance of cure for these patients.

Meanwhile the more radical en bloc esophagectomy has found widespread approval. In Japan three field lymph node dissection, including systematic lymphadenectomy of cervical, mediastinal, and abdominal nodes has been proposed to improve survival rates. However, there is evidence that significantly improved 5-year survival rates can not be achieved as compared with two-field dissection [3, 27, 28].

The overall frequency of positive lymph nodes according to all tumor sites is shown in Table 10.1. Improvements in preoperative staging, with the introduction of CT, EUS, and EUS plus FNA (fine needle aspiration) have contributed to an improved treatment of patients with esophageal cancer. EUS has an overall staging accuracy for N-status of about 60–70% [34], and CT is the appropriate means to detect distant metastasis in secondary organs such as liver or lung. An improvement of staging accuracy may be achieved by complementarily supplementing FNA to EUS because FNA improves N-stage accuracy, but has no bearing on T-stage accuracy [35]. Thus, unre-

sectable cases can be excluded in most cases preoperatively and can be treated with palliative modalities. This better selection of patients could amount for the improved survival rates observed over the decades, rather than the introduction of lymphadenectomy. The issue of radical lymphadenectomy is discussed very controversially in surgical oncology. After initial enthusiasm a more realistic approach to this issue has now been advocated, for example in gastric cancer [4, 5, 29] and non small cell lung cancer [6, 30]. It seems that only a limited number of patients will experience a benefit from this procedure. Patients with advanced tumors (T4) and lymph node involvement should undergo preoperative radiochemotherapy and should only be operated in case of response [7]. This better selection of patients could account for the improved survival rates observed over the decades, rather than the introduction of lymphadenectomy.

Thus, prognosis of patients with esophageal cancer still remains unsatisfying. Tumor recurrence occurs frequently even despite the absence of residual tumor detectable at primary

**Table 10.1.** Frequency of lymph node metastasis

Author	Number of patients	Overall rate of lymph node metastasis
Akiyama 1991	236	73.7%
Isono 1991	4590	72.9%
Ide 1994	403	58.0%
Nishihira 1995	171	58.5%
Izbicki 1995	67	55.2%
Altorki 2002	80	69.0%
Lerut 2004	174	70.1%

surgery and by current clinico-pathological staging procedures. This observation suggests that a substantial fraction of these patients present initially with occult micrometastases. This is confirmed by our own results, with 50% of patients with tumor stage pT1 having immunohistochemically detected individual tumor cells in their lymph nodes. Histopathologically proven lymph node metastases are evident in about 30% of patients with small tumors (pT1), which also underlines the early metastatic potential of esophageal cancer [26]. This is of great clinical importance as lymph node involvement is regarded as one of the strongest prognostic factors for tumor recurrence [9–15]. Therefore, extensive lymph node sampling is essential to facilitate correct post-operative staging. Hence patients with an increased risk for tumor recurrence may be selected for adjuvant multimodal treatment.

### Anatomy of the lymphatic system

Lymph nodes draining the esophagus are widely distributed due to two different embryologic origins of the esophagus. Throughout embryologic development the branchial arches and the yolk sac grow together in the area of the tracheal bifurcation, forming the origin of the esophagus. Thus, the organ has two main lymphatic collection areas, in the abdomen around the celiac trunk and at the neck. Pioneering work on the lymphatics of the esophagus was done in 1903 by Sakata, who revealed that the submucosal lymphatics do not drain segmentally, but in a longitudinal fashion. The lymphatic pathway of the middle and superior esophagus goes to the neck before passing through the muscular layer to finally reach the deep cervical nodes and the nodes located along the recurrent laryngeal nerve. The lymphatics of the lower esophagus drain downwards to the cardiac nodes and the nodes around the celiac trunk. These results are also reflected by the frequency of lymph node metastasis according to tumor location (Table 10.2). To assess which lymph nodes have to be dissected for correct staging, analysis of data concerning the frequency of lymph node involvement is necessary.

**Table 10.2.** Frequency of involvement of lymph node groups assessed by three-field lymphadenectomy

Author	No. of patients	Cervical nodes	Mediastinal nodes	Abdominal nodes
Akiyama 1991	236	33.1%	58.1%	49.2%
Isono 1991	1740	27.4%	55.8%	49.2%
Kato 1991	79	36.7%	59.5%	41.8%
Altorki 2002	80	36.25%	–	–
Lerut 2004	174	23.6%	–	–

### ■ Cervical nodes

The deep cervical node group is often affected by metastasis, while superficial nodes usually are not involved except in very advanced primaries. The deep nodes consist of the deep lateral nodes or “the accessory nerve chain group” in the lateral part of the neck. The deep external nodes include those of the internal jugular chain and the supraclavicular nodes, and the deep internal nodes are located medial to the jugular chain. The lower part of the deep internal nodes is also known as the “recurrent laryngeal nerve chain”. However, the deep internal nodes bear a very high risk of metastasis (Table 10.3).

### ■ Superior mediastinal nodes

At the right side of the superior mediastinum, the lymph node chain along the right recurrent nerve winds around the subclavian artery. On the left side of the superior mediastinum, some smaller nodes are located along the left recurrent laryngeal nerve. Since these nodes lie along the left laryngeal border, they are also called the “left paratracheal nodes”. Both right and left laryngeal nerve chain groups bear a high risk of metastasis.

### ■ Middle mediastinal nodes

The nodes located at the tracheal bifurcation are also known as the carinal nodes. They are located closely to the mid-esophagus and are a

**Table 10.3.** Lymph node metastases mapping and localization of the primary tumor

Lymph node field	Lymph nodes	Kato 1991	Akiyama 1991	Nishira 1995
		Rate of involvement	Rate of involvement	Rate of involvement
■ Cervical	Accessory nerve chain (right/left)	∅	5%	∅
	Cervical paraesophageal	21.5%	∅	21.9%
	Supraclavicular right	6.3%	∅	9.4%
	Supraclavicular left	6.3%	∅	6.3%
	Deep cervical nodes right	15.2%	10.6%	9.4%
	Deep cervical nodes left	21.5%	8.9%	3.1%
■ Superior mediastinal	Right recurrent nerve	34.2%	37.3%	17.5%
	Paratracheal (right/left)	38.0%	21.2%	12.3%
	Brachiocephalic	∅	6.8%	∅
	Upper periesophageal	19.0%	9.8%	8.8%
■ Middle mediastinal	Infraaortic arch	2.5%	6.8%	1.8%
	Tracheobronchial	∅	∅	0.6%
	Pulmonary	∅	14.8%	4.6%
	Hilar (right/left) infracarinal	17.7%	14.8%	12.3%
	Middle periesophageal	20.3%	25.4%	12.2%
	Posterior mediastinal	∅	∅	9.4%
■ Lower mediastinal	Lower mediastinal	∅	25.8%	∅
	Lower periesophageal	13.9%	∅	9.4%
	Diaphragmatic (hiatal region)	∅	2.1%	0.6%
■ Superior gastric	Paracardiac (right/left)	38.0%	32.6%	25.2%
	Left gastric artery	21.5%	23.7%	10.5%
	Lesser curvature	11.4%	18.2%	8.2%
■ Distant abdominal	Celiac trunk	8.9%	16.1%	3.5%
	Splenic artery	∅	∅	4.7%
	Common hepatic artery	2.5%	5.1%	1.2%

frequent site of metastasis. The posterior mediastinal nodes, paraaortic nodes, and nodes along the thoracic duct can also be grouped together as “paraesophageal nodes”. Because of their vicinity to the esophagus, they are particularly often involved in tumors located at the level of the tracheal bifurcation, which is the most frequent site of tumor occurrence.

### ■ Lower mediastinal nodes

The description of the paraesophageal nodes of the mid-esophagus also applies here.

### ■ Superior gastric nodes

The paracardiac nodes are essential, as they are frequently involved in esophageal cancer, regardless of tumor location. They are located along the highest branch of the left gastric artery. The nodes of the lesser gastric curvature are an important route for tumor spread from the esophagus to the celiac trunk. The majority of the nodes affected by tumor dissemination are situated along the upper half of the lesser curvature in the left gastric area. As a matter of fact, positive nodes hardly ever occur along the fifth branch of the left gastric artery. Nevertheless, the lesser curvature should be removed. The left gastric artery nodes are inter-

posed between the route of the artery and lesser gastric curvature. This is one of the main routes of lymphatic spread from the primary tumor.

### ■ Distant abdominal nodes

The nodes along the short trunk of the celiac artery, the root of the left gastric, the common hepatic, and the splenic artery belong to the group of the celiac nodes. Lymph node metastasis occurring at this point indicates systemic dissemination of the tumor. The common hepatic artery nodes lie along the course of the common hepatic artery, and metastasis in this area also indicates distant tumor spread. Nodes of the hepatoduodenal ligament, distal splenic artery, or splenic hilum are very rare sites of lymphatic tumor spread. Therefore these groups are not discussed here.

The frequency of metastasis in certain lymph node groups is influenced by the location of the primary tumor. Akiyama published data on 236 patients about this aspect of metastatic spread [31]. All patients underwent cervico-thoraco-abdominal lymph node dissection. Patients with carcinoma of the upper esophagus had metastasis in the neck lymph nodes in 44.1%, upper mediastinum in 50.0%, middle mediastinum in 20.6%, and lower mediastinum in 5.9%. Remarkably 14.7% of the cases presented with metastasis in the upper gastric area.

Carcinoma of the mid-esophagus was associated with metastasis in 32.9% in the neck, 38.1% in the upper mediastinum, 41.0% in the mid-mediastinum, 20.2% in the lower mediastinum, and 42.5% in the upper gastric region. Carcinoma of the lower esophagus was associated with 29.4% positive lymph nodes in the neck and 30.9% in the upper mediastinum, 48.5% bad metastasis in the middle mediastinum, 35.3% in the lower mediastinum, and 69.1% in the upper gastric area.

In summary the incidence of metastases in the superior mediastinum and the neck is high, even in patients with primary tumors located in the lower esophagus. These data underline the importance of extensive lymph node sampling for correct staging.

**Table 10.4.** Frequency and location of lymph node groups affected by micrometastasis\*

Lymph node field	Lymph nodes	Rate of involvement (%)
■ Superior mediastinal	periesophageal	3.0
	paratracheal	4.5
■ Middle and lower mediastinal	carinal	8.9
	tracheobronchial	3.0
■ Abdominal	paracardiac	7.5
	hepatic artery	7.5
	celiac trunk	14.9
■ Periesophageal nodes next to primary lesion		8.9

\* Data from micrometastasis in 393 lymph nodes of 67 patients with esophageal cancer [26]

Since the present 5-year survival rates of radical three-field lymph node dissection do not seem to improve 5-year survival rates significantly, a minimal tumor spread in seemingly localized disease has to be assumed [26], which is confirmed by our own data. 50% of our pN0 patients had single immuno-stained tumor cells in their lymph nodes (Table 10.4). The presence of these cells was an independent factor for a significantly reduced relapse-free survival. The demonstrated prevalence for developing distant metastases in our patients with tumor cells in lymph nodes suggests that the presence of these cells is an expression of a generalized tumor disease rather than an indicator of the site of subsequent metastasis. Thus the majority of patients with esophageal cancer cannot be cured by surgery alone. Therefore, the benefit of radical systematic three-field lymphadenectomy on relapse-free survival, and overall survival, remains unclear. Therefore, we recommend extensive lymph node sampling for correct pathological staging to identify the group of patients who may benefit from adjuvant therapeutic regimes because of a minimal residual tumor load.

Since lymph node spread remains an extremely rare event in patients with early cancer confined to the lamina propria (Tis), new therapeutic concepts of local treatment have been advocated as an adequate therapy. Strip biopsy of the mucosa and photodynamic therapy or

laser therapy for local intraluminal treatment, and minimally invasive surgery for resection of the esophagus are applied to patients, in whom endoluminal ultrasound suggests a limitation of the tumor to the mucosa.

## Operative procedure

### ■ Abdomino-thoracic en bloc esophagectomy

The operation starts with the patient in a left sided position with the thorax slightly angulated, opening the right sided intercostal spaces and a right anterolateral thoracotomy in the fifth intercostal space is performed. After thoracotomy, a rib retractor is inserted, and decompression of the right lung is commenced. Incision of the mediastinal pleura starts by dividing the hilum of the right lung along the right pulmonary ligament, and then proceeds at the back of the lateral side of the trachea and the V. cava superior up to the thoracic aperture. At this point the incision turns lateral to the V. azygos and descends at its lateral side down to the diaphragm and then medial to complete the pleural incision. Care must be taken not to compromise the phrenic nerve.

The azygos vein is now divided between ligatures at the confluens to the V. cava superior. Lymphadenectomy starts along the vena cava superior up to the laryngeal nerve, which is identified properly. Lymphadenectomy extends now along the dorsal wall of the vena cava to the pre- and paratracheal lymph nodes, including the tracheobronchial, upper paraesophageal, and retrotracheal node groups. The vagus nerve is divided caudal to the laryngeal nerve.

The intercostal branches of the azygos vein are ligated and divided. Lymph node dissection is carried out along the dorsal pericardium extending from the main carina down to the vein of the right lower lobe including dissection along the bronchus intermedius and the bronchus of the right lower lobe paraaortal to the left hilum. Lymphadenectomy continues along the ascending aorta including the paraaortal node groups, the subcarinal nodes, and the lymph nodes of the left hilum.

Dissection continues at the anterior wall of the descending thoracic aorta to the anterior ligament of the spine up to the right brachiocephalic vein and the confluence of the anonymous veins, turning then to the left side of the aorta.

While dissecting along the aortic arch, branches supplying the esophagus are divided and ligated. Lymphadenectomy now is directed versus caudal on the adventitia of the aorta descendens. At the tracheal bifurcation, the thoracic duct is ligated cranially.

Dissection is completed down to the aortal and esophageal hiatus where the thoracic duct is ligated caudally.

The abdominal part of the lymphadenectomy starts after changing the patient to the supine position, with a bilateral subcostal incision combined with an upper median laparotomy.

Lymphadenectomy starts at the hepatoduodenal ligament. The right gastric artery is divided at the bifurcation from the gastroduodenal artery. Lymphadenectomy continues along the common hepatic artery up to the celiac trunk.

Next, the left gastric artery is divided at the celiac trunk and lymphadenectomy is performed along the upper margin of the pancreas along the splenic artery and down to the origin of the celiac trunk at the aorta. From there lymphadenectomy is performed along the aorta up to the aortic hiatus of the diaphragm. Abdominal lymphadenectomy is completed by lifting up the lesser curvature and dissecting the node groups at the cardia after incision of the esophageal hiatus.

### ■ Lymphadenectomy in transhiatal esophagectomy

Operation starts in supine position with a bilateral subcostal incision combined with an upper median laparotomy, as it is done in the abdominal part of the radical en bloc esophagectomy.

Abdominal lymphadenectomy is performed exactly as described for the abdominal part of the en bloc esophagectomy.

After incision of the esophageal hiatus, lymphadenectomy is performed along the ventral



side of the aorta up to the carina including the paraaortal and paraesophageal lymph node groups under direct vision. Both pulmonary ligaments are divided and the lymph nodes removed.

Starting at the level of the pulmonary hilum or the main carina, the dissection plane approaches the esophageal wall.

### ■ Three-field lymphadenectomy

Two-field lymphadenectomy is conducted as described earlier, except for the lymph node dissection of the anterior mediastinum. Incision of the median laparotomy is now extended up to the neck, and a Kocher's collar incision is made subsequently.

After partial or complete sternotomy is performed, cervico-mediastinal lymphadenectomy begins with dissection of the paratracheal node groups on both sides in the upper anterior and upper posterior mediastinum. It starts from the carina up to the node groups between anonymous vein and clavícula, dissecting the right and left laryngeal nerves from the origin to the larynx. Lymph node dissection also includes the thymus in the anterior mediastinum.

Lymphadenectomy goes up to the central cervical compartment between the carotid arteries including the paratracheal, infra- and suprathyroidal and submandibular node groups.

Three-field lymphadenectomy ends with dissection of the lateral cervical compartments including lymph nodes between the carotid artery and the trapezius muscle starting from the subclavian vein up to the hypoglossus nerve on the ventral and dorsal side of the cervical plexus.

Sometimes the term three-field lymphadenectomy applies just to the combination of the two-field lymphadenectomy with a bilateral modified neck-dissection encompassing cervical thymectomy without using a median sternotomy.

## References

1. Isono K, Onoda S, Ishikawa T, Sato H, Nakayama K (1982) Studies on the causes of deaths from esophageal carcinoma. *Cancer* 49:2173–2179
2. Byrne J, Waldron R, McAvinchey D, Dervan P (1987) The use of monoclonal antibodies for the histopathological detection of mammary axillary micrometastases. *J Surg Oncol* 13:409–411
3. Watanabe H (1992) Plattenepithelcarcinom des Oesophagus. *Chirurg* 63:689–692
4. Van de Velde CJH, Bohnenkamp HJ, Sasako M (1995) The value of extended lymphadenectomy for gastric cancer will become clear in a prospective randomized trial in the Netherlands. *Int J Surg Sci* 2:11–16
5. Siewert JR, Böttcher K, Roder JD, Busch R, Hermanek P, Meyer HJ (1993) Prognostic relevance of systematic lymph node dissection in gastric carcinoma. *Br J Surg* 80:1015–1018
6. Izbicki JR, Thetter O, Habekost M et al (1994) Radical systematic mediastinal lymphadenectomy in non-small cell lung cancer: a randomized controlled trial. *Br J Surg* 81:229–235
7. Shields TW (1990) The significance of ipsilateral mediastinal lymph node metastasis (N2 disease) in non-small cell carcinoma of the lung. A commentary. *J Thorac Cardiovasc Surg* 99:48–53
8. Watanabe Y, Shimizu J, Tsubota M, Iwa T (1990) Mediastinal spread of metastatic lymph nodes in bronchogenic carcinoma. Mediastinal nodal metastases in lung cancer. *Chest* 97:1059–1065
9. Siewert JR, Bartels H, Bollschweiler E et al (1992) Plattenepithelcarzinom des Ösophagus. *Chirurg* 63:693–700
10. Vogel SB, Mendenhall WM, Sombeck MD, Marsh R, Woodward ER (1995) Downstaging of esophageal cancer after preoperative radiation and chemotherapy. *Ann Surg* 221:685–695
11. Becker HD (1994) Esophageal cancer, early disease: diagnosis and current treatment. *World J Surg* 18:331–338
12. Hennessy TPJ (1994) Lymph node dissection. *World J Surg* 18:367–372
13. Lerut T, de Leyn P, Coosemans W, van Raemdonck D, Cuypers P, Van Cleynenbreughel B (1994) Advanced esophageal carcinoma. *World J Surg* 18:379–387
14. Scholz J, Steinhöfel U, Dürig M et al (1993) Postoperative pulmonary complications in patients with esophageal cancer. *Clin Investig* 71:294–298
15. Martini N, Flehinger BJ (1987) The role of surgery in N2 lung cancer. *Surg Clin North Am* 67:1037–1049
16. Izbicki JR, Passlick B, Karg O et al (1995) Impact of radical systematic mediastinal lymphadenectomy on tumor staging in lung cancer. *Ann Thorac Surg* 59:209–214

17. Shields TW, Yee J, Conn JH, Robinette CD (1975) Relationship of cell type and lymph node metastasis to survival after resection of bronchial carcinoma. *Ann Thorac Surg* 20:501–510
18. Pearson FG, DeLarne NC, Ilves R, Todd TR, Cooper JD (1982) Significance of positive superior mediastinal nodes identified at mediastinoscopy in patients with resectable cancer of the lung. *J Thorac Cardiovasc Surg* 83:1–11
19. The Lung Cancer Study Group (1988) Should subcarinal lymph nodes be routinely examined in patients with non-small cell lung cancer? *J Thorac Cardiovasc Surg* 95:883–887
20. Raymond WA, Leong AS (1989) Immunoperoxidase staining in the detection of lymph node metastases in stage I breast cancer. *Pathology* 21: 11–15
21. Martini N, Flehinger BJ, Zaman MB, Beattie EJ Jr (1983) Results of resection in non-oat cell carcinoma of the lung with mediastinal lymph node metastases. *Ann Surg* 198:386–397
22. Naruke T, Suemasu K, Ishikawa S (1978) Lymph node mapping and curability at various levels of metastasis in resected lung cancer. *J Thorac Cardiovasc Surg* 76:832–839
23. Lerut T, DeLeyn P, Coosemans W, van Raemdonck D, Schers I, LeSaffre E (1992) Surgical strategies in esophageal carcinoma with emphasis on radical lymphadenectomy. *Ann Surg* 216:583–590
24. Siewert JR, Dittler H-J (1993) Esophageal carcinoma: impact of staging on treatment. *Endoscopy* 25:28–32
25. Marcon NE (1994) The endoscopic management of esophageal cancer. *Acta Gastro-Enterol Belg* 57: 143–154
26. Izbicki JR, Hosch SB, Pichlmeier U, Rehders A, Busch C, Niendorf A, Passlick B, Broelsch CE, Pantel K (1997) Prognostic value of immunohistochemically identifiable tumor cells in lymph nodes of patients with completely resected esophageal cancer. *New Engl J Med* 337:1188–1194
27. Law S, Wong J (2007) Lymph node dissection in surgical treatment of esophageal neoplasms. *Surg Oncol Clin N Am* 16 (1):115–131
28. Nozoe T, Kakeji Y, Bab H, Maehara Y (2007) Two-field lymph-node dissection may be enough to treat patients with submucosal squamous cell carcinoma of the thoracic esophagus. *Dis Esophagus* 18(4):226–229
29. Danielson H, Kokkola A, Kiviluoto T, Siren J, Louhimo J, Kivilaakso E, Puolakkainen P (2007) Clinical outcome after D1 vs D2-3 gastrectomy for treatment of gastric cancer. *Scand J Surg* 96(1):35–40
30. Doddoli C, Aragon A, Barlesi F, Chetaille B, Robitail S, Giudicelli R, Fuentes P, Thomas P (2005) Does the extent of lymph node dissection influence outcome in patients with stage I non-small-cell lung cancer? *Eur J Cardiothorac Surg* 27(4):680–685
31. Akiyama H, Tsurumaru M, Udagawa H, Kajiyama Y (1994) Radical lymph node dissection for cancer of the thoracic esophagus. *Ann Surg* 220(3):364–372, discussion 372–373
32. Lerut T, Nafteux P, Moons J et al (2004) Three-field lymphadenectomy for carcinoma of the esophagus and gastroesophageal junction in 174 R0 resections: impact on staging, disease-free survival, and outcome. *Ann Surg* 240(6):962–974
33. Altorki N, Kent M, Ferrara C, Port J (2002) Three-field lymph node dissection for squamous cell and adenocarcinoma of the esophagus. *Ann Surg* 236(2):177–183
34. Kutup A, Link BC, Schurr PG et al (2007) Quality control of endoscopic ultrasound in preoperative staging of oesophageal cancer. *Endoscopy* 39(8): 715–719
35. Vazquez-Sequeiros E, Wiersema MJ, Clain JE et al (2003) Impact of lymph node staging on therapy of esophageal carcinoma. *Gastroenterology* 125(6): 1626–1635

# Rationale for Type of Resection in Cancer of the Esophagus and Gastroesophageal Junction

W. T. KNOEFEL, I. ALLDINGER, J. R. IZBICKI

Despite new insights into its molecular basis and various treatment options evaluated in numerous trials, therapy of esophageal cancer remains a challenge. In the past, surgery was the only treatment option. A patient qualified for surgery when he presented in stable condition and when the tumor was believed to be resectable. Today a vast number of treatment strategies, including induction chemotherapy, radiochemotherapy with or without combination with surgery, administered in an adjuvant or a neoadjuvant setting, are added to the traditional therapy of surgery alone. Even the question, whether surgery after effective chemoradiation does have any impact on prognosis at all or is no more than a “big biopsy” is discussed today. There is increasing evidence that patients may benefit from induction chemotherapy.

However, on the basis of the results of the trials performed, complete resection of the tumor currently remains the gold standard of therapy and surgery by far offers the best chance for cure. Ongoing trials concentrate on an improvement of the chemotherapy and radiotherapy regimens as well as on an improvement of the drugs used.

Adequate treatment for patients with esophageal carcinoma and carcinoma of the cardia is based on tumor typing, anatomic location, and tumor staging.

Resection usually entails subtotal esophagectomy and radical lymphadenectomy. In some cases, as discussed below, gastrectomy or extended resections may be necessary. However, in order to give the patient the chance to be cured, an R0 resection is imperative.

Esophageal carcinoma, if untreated, leads to death after diagnosis within 3–6 months. Radiotherapy alone can achieve two-year survival rates with a maximum of 20%. Results for che-

motherapy alone are even worse. The value of chemotherapy lies in neoadjuvant protocols or in combination with radiation, especially in adenocarcinomas.

## Tumor typing

In the past the majority of malignant esophageal tumors were squamous cell carcinomas. However, the frequency of adenocarcinomas is rising, accounting for up to 60% of all malignant esophageal tumors.

Due to the high potential of squamous cell carcinomas to metastasize into the peri-esophageal lymphatics, radical removal without residual disease will usually require transthoracic en bloc esophagectomy. This includes removal of the lymph nodes of the lower and upper mediastinum, and the abdominal lymph nodes. The value of removal of unsuspected cervical lymph nodes is still discussed controversially. So far this three-field lymphadenectomy has not been evaluated in a prospective randomized fashion. Retrospective data collections of personal experiences favor three-field lymphadenectomy over two-field lymphadenectomy with comparable morbidity and mortality, while other large personal data collections advocate transhiatal esophagectomy. The transhiatal approach enables removal of the lymph nodes of the entire lower mediastinum dorsal to the pericardium. However, lymphatic clearance around and above the main carina is dangerous and unreliable.

In contrast, adenocarcinomas, if localized at the cardia (type II according to Siewert's classification), metastasize mainly to the abdominal or inferior mediastinal lymph nodes. Since

these fields can be reached via a transhiatal approach, this procedure is warranted, especially in patients who are not fit for a transthoracic procedure. On the one hand some favor the transthoracic procedure in case of T2 tumors because of the probability of a high incidence of positive lymph nodes in the upper mediastinum. On the other hand, there are some who favor the extended gastrectomy for the true cardia carcinoma. According to Siewert's classification, for type III carcinoma the extended gastrectomy is the standard procedure.

Adenocarcinomas that arise more than 1 cm proximal to the muscular border between esophagus and stomach (type I according to Siewert's classification) may metastasize like squamous cell carcinomas. The value of lymphadenectomy of the upper mediastinum in these patients, however, is under discussion. Positive upper mediastinal lymph nodes are found in approximately 20% of patients with early adenocarcinomas (T1b), and lymph node recurrence of adenocarcinoma above the carina has been reported in over 20% of patients after lymph node clearance of the inferior mediastinum only. Lymph node metastases in the upper mediastinum are mainly present in T2 and T3. Therefore transthoracic resection with radical lymph node clearance of the lower and upper mediastinum is indicated.

If all histological typings, including adenocarcinomas and squamous cell carcinomas, are grouped together, a survival benefit has been shown for transthoracic en bloc esophagectomy. Consequently, if in doubt, this operation should be performed if the patient is deemed fit for the procedure.

### Anatomic location

The esophagus can be divided into 4 regions:

- The cervical esophagus extends from the upper esophageal sphincter to the entrance of the esophagus into the thorax. This corresponds to a distance between approximately 15 and 20 cm from the incisors.
- The upper thoracic part of the esophagus extends down to the bifurcation of the tra-

chea. This anatomical structure is best visualized on a barium swallow.

- The lower thoracic esophagus extends from the main carina down to the hiatus of the esophagus which corresponds to approximately 38–44 cm from the incisors.
- The gastroesophageal junction comprises the area of the esophagus 5 cm proximal to 5 cm distal to the anatomical cardia. Since the epithelial border moves during the individual's life and especially in disease, it cannot be used as a landmark for location.

### Cervical esophagus

Tumors of the cervical esophagus have their lymphatic drainage mainly to the neck and into the thoracic duct. These tumors usually arise from squamous epithelium. Due to their close anatomic relationship to the larynx and upper trachea these tumors are often primarily irresectable. Therefore large T3 and especially T4 tumors may benefit from preoperative combined radiochemotherapy to downstage the tumor. This enables transthoracic en bloc esophagectomy, bilateral modified neck dissection, and a reconstruction either with a gastric tube or colon interposition. Occasionally a local resection with free jejunal interposition may be indicated. However, even in these cervical lesions, lymphatic metastases to the mediastinum are frequent. These very high lesions are rare and account for only about 5% of esophageal cancers.

### Upper thoracic esophagus

The majority of tumors of the upper esophagus are squamous cell carcinomas with a tremendous increase in the proportion of adenocarcinomas over the last years.

Lymphatic drainage of squamous cell carcinomas of the upper thoracic esophagus is mainly towards the neck with 15–30% positive lymph nodes in surgical specimens. If these tu-

mors metastasize to the lymph nodes below the carina, the location of these metastases is infracarinal (15%), in the lower mediastinum (15%), or directly adjacent to the cardia (23%). The comparable data for adenocarcinomas are not yet available, but there is no reason to believe they would be different. Accordingly radical removal of the tumor entails thoraco-abdominal en bloc esophagectomy and resection of the corresponding lymph node regions [39].

These tumors are more likely to be resectable than tumors of the cervical esophagus. However, infiltration of the aorta, trachea, and the main bronchi should be ruled out before proceeding to surgery. If there is a strong suspicion of a T4 tumor involving the above mentioned structures, a preoperative radiochemotherapy might help to downstage the tumor and enable radical resection.

Unfortunately, the randomized studies performed included both adenocarcinomas and squamous cell carcinomas, although epidemiology, etiology, biology of metastases, and prognosis differ markedly [23]. Available data indicate that neoadjuvant chemoradiation is most effective in patients with advanced squamous cell carcinomas with a close topographical relationship to the tracheo-bronchial system [32]. The most effective adjuvant therapy in advanced adenocarcinomas is preoperative chemotherapy [32]. However, due to the weak evidence provided in the trials performed, a prospective randomized trial to assess the optimal subgroups of patients that benefit from this strategy is badly needed.

thoracic lymphatic metastases are frequent also in patients with adenocarcinomas [21]. The best chance for cure therefore lies in a thoraco-abdominal en bloc esophagectomy with radical systematic lymph node clearance in the thorax and the abdomen [31]. These tumors are more frequently initially resectable without residual tumor than those of the higher esophagus. Only T4 tumors with infiltration of the heart, the aortic wall, or vertebrae are generally considered non-resectable. Neoadjuvant therapy is recommended according to the criteria for the upper thoracic esophagus. T4 extension into the lung or the diaphragm is not a contraindication for surgery since prognosis of these tumors does not so much depend on T stage, but on N stage [33]. Unfortunately, these tumors metastasize in about 20% to the lymph nodes in the celiac trunk (M1 lymph). These M1 stages are currently considered a contraindication for radical surgery, although, for many surgeons, the difference between a lymph node at the left gastric artery or one at the celiac trunk is not striking. Convincing data to support a nihilistic approach for M1 (lymph) stages at the celiac trunk in comparison to N1 stages at the left gastric artery are lacking. However, detection of this stage by preoperative imaging is unreliable. Also, during the course of a routine thoraco-abdominal esophagectomy the thoracic part is already completed when the M1 stage is surprisingly detected. Hence, occasionally in these tumors a 'palliative' thoraco-abdominal esophagectomy ensues.

### Lower thoracic esophagus

Tumors of the esophagus below the carina occur in an approximately equivalent frequency as adenocarcinomas and as squamous cell carcinomas [8, 9]. Squamous cell carcinomas of this location metastasize in about 15% [10] to the lymph nodes above the carina and also in more than 10% to the lymph nodes in the hepato-duodenal ligament. Again, these data are not available for adenocarcinomas, but upper

### Tumors of the gastroesophageal junction

Most tumors that are summarized under this definition are adenocarcinomas. In fact they are defined as adenocarcinomas in the region 5 cm proximal to 5 cm distal of the muscular limit between esophagus and stomach. The mucosal limit is unreliable since it moves due to disease and age of the patient. Three tumor entities are summarized under this definition and require specific treatment.

■ The first entity, type I according to Siewert's classification [38], is a distal esophageal adenocarcinoma in the region between 5 cm proximal to 1 cm proximal of the muscular limit between esophagus and stomach. They account for 30–35% of the tumors of the gastroesophageal junction [35].

These tumors tend to spread longitudinally in the submucosal lymphatic vessels of the esophageal wall. Data about the ideal surgical approach are inconsistent. It is obvious that radical lymphadenectomy of the lower mediastinum is compulsory. No confident data are available to decide whether this procedure should be combined with thoraco-abdominal esophagectomy or if transhiatal esophagectomy with lymphadenectomy of the lower mediastinum and the periaortic compartment only is sufficient or should be reserved for high risk patients. The potentially higher oncological safety of the extended operation comes with an increased morbidity and mortality. Removal of all lymph nodes in the area of the lesser curvature, and especially around the celiac trunk and probably also in the hepatoduodenal ligament, remains advisable. After wide excision of the diaphragm, the lower mediastinum up to the carina can be cleared satisfactorily by this route. Aortic branches to the esophagus endanger the route above the carina during blunt dissection. Therefore the esophageal wall is reached at this level during dissection.

■ Type II of these entities is the so-called carcinoma of the cardia. It is defined as an adenocarcinoma between 1 cm proximal to 2 cm distal of the muscular border between esophagus and stomach. Although most of these tumors are truly adenocarcinomas, a certain percentage of up to 15% can occur as adeno-squamous carcinomas. It is speculated that this is due to an instable differentiation of these tumor cell lines [36]. These tumors should be treated just like the true adenocarcinomas.

For type II carcinomas of the gastroesophageal junction staging becomes important to select adequate treatment. All of these tumors except T1 N0 carcinomas will require total gastrectomy with lymphadenectomy as performed

in patients with gastric carcinoma. In patients with stage I or II carcinomas of the cardia, total gastrectomy with distal esophageal resection and transmediastinal reconstruction with a jejunal loop is sufficient. General experience not based on large studies so far is that the lymphatic spread into the periesophageal lymph nodes as well as in the esophageal wall is not extensive enough to justify an esophagogastrectomy. However, perigastric and lower periesophageal lymphatic clearance is important. It is also imperative to obtain negative resection margins on frozen section. In contrast patients with stage III and IV carcinoma of the cardia may benefit from esophagogastrectomy with consecutive colon interposition. No randomized prospective studies have shown a benefit for this procedure so far. Therefore this approach should be limited to low operative risk patients with a high risk of recurrence, to prospective studies, and eventually to patients with a simultaneously occurring very long Barrett's segment in the thoracic esophagus. In these tumors a transhiatal approach with removal of the lymph nodes in the lower mediastinum is preferred to avoid excessive morbidity and since no data exist so far showing a predominance for lymphatic relapse in the upper thorax.

■ Type III carcinoma of the gastroesophageal junction is defined as a tumor between 2 cm below the muscular gastroesophageal limit and 5 cm below this limit. These tumors account for 40–45% of all tumors of the gastroesophageal junction. Treatment of these tumors is similar to early type II carcinomas with abdominal transhiatal total gastrectomy including distal esophagectomy. However, since these tumors have not reached the longitudinal lymphatic vessels of the esophageal wall, subtotal esophagectomy is not necessary unless negative margins on frozen section cannot be reached. A subtotal proximal gastric resection is, however, not recommended. Functional results are, due to a high incidence of alkaline reflux, poor [37], and lymphatic clearance is less sufficient than with total gastrectomy.

## Limited resections

Limited resection of the gastroesophageal junction with reconstruction by jejunal interposition (Merendino procedure) between distal esophagus and gastric fundus seems to be sufficient in early stages of tumors of the gastroesophageal junction. A short Barrett's segment, ending below the carina and a T1a (T1b) N0 stage has to be confirmed before embarking on this less invasive procedure.

## Palliative esophageal resection

Palliative esophageal resection for esophageal carcinoma is extremely rare. It can be indicated if the palliative character becomes obvious only after the point of no return has been reached in the course of the operation. For example, after completion of the thoracic part of a thoraco-abdominal esophageal resection, a liver metastasis that eluded preoperative staging is detected after opening the abdomen. Another example is the postoperative detection of tumor spread in a celiac trunk lymph node. These palliative resections are incidental and cannot be compared to intended palliative resections. In extremely rare cases a palliative esophagectomy may be planned ahead as an individualized intent to treat or palliate. It is still unclear whether the patient will gain something in terms of quality of life or even in survival in comparison to palliative radiochemotherapy and stent placement [38]. Morbidity and mortality, however, are high in these patients. Palliative resections should ideally be limited resections, like cervical resection or a Merendino operation.

So far, reliable assessment of quality of life in these two patient groups is imperfect but is becoming standardized [39]. It will deliver guidelines for the treatment of this desperate group of patients. So far, valuable data comparing stent placement with surgical removal of the esophagus are not yet available. An individualized decision, based on the general and tumor specific condition of the patient as well as on the experience of the surgeon, is so far the only option.

## Recurrences

Distant relapse of esophageal cancer such as liver metastases, pulmonary metastases, etc. are usually no indication for operative treatment. In contrast, a localized relapse such as a relapse after transhiatal gastrectomy for an early type II carcinoma of the cardia may require surgery. The success depends very much on the early diagnosis of this recurrence. If the tumor has not spread to vital structures a radical surgical approach with consecutive colon-interposition or free jejunal interposition may be promising. For these recurrences, however, an individualized approach is necessary.

## Summary

Since current medical treatment has no other promising therapeutic alternative to an R0 resection, an aggressive surgical approach seems to be warranted. Subgroups of patients might qualify for different therapeutic approaches, but definition of these subgroups remains uncertain. Available data show that the parameters histology, tumor location, and tumor stage are not sufficient to define a tailored therapeutic concept. The goal for the next years lies in the development of tools to define these subgroups in order to avoid overtreatment and undertreatment. Gene expression and genomic profiling might help in the individualization of therapy.

## References

1. Munro AJ (2004) Oesophageal cancer: a view over overviews. *Lancet* 364:566–568
2. Bedenne L, Michel P, Bouche O et al (2002) Randomized phase III trial in locally advanced esophageal cancer: radiochemotherapy followed by surgery versus radiochemotherapy alone (FFCD 9102). *Am Soc Clin Oncol Proc*, p 519 (abstract)
3. Medical Research Council Oesophageal Cancer Working Group (2002) Surgical resection with or without preoperative chemotherapy in oesophageal cancer: a randomised controlled trial. *Lancet* 359:1727–1733

4. Stein HJ, Feith M, Müller J, Werner M, Siewert JR (2000) Limited resection for early adenocarcinoma in Barrett's esophagus. *Ann Surg* 232(6):733-742
5. Beatty JD, DeBoer G, Rider WD (1979) Carcinoma of the esophagus: pretreatment assessment, correlation of radiation treatment parameters with survival, and identification and management of radiation treatment failure. *Cancer* 43:2254-2267
6. Earlam R, Cunha-Melo JR (1980) Oesophageal squamous cell carcinoma: I. A critical review of surgery. *Br J Surgery* 67:381-390
7. Newaishy GA, Read GA, Duncan W, Kerr GR (1982) Results of radical radiotherapy of squamous cell carcinoma of the oesophagus. *Clin Radiol* 33:347-352
8. Lund O, Hasenkam JM, Aagaard MT, Kimose HH (1989) Time-related changes in characteristics of prognostic significance in carcinomas of the oesophagus and cardia. *Br J Surg* 76:1301-1307
9. Blot WJ, Devesa SS, Kneller RW, Fraumeni JF Jr (1991) Rising incidence of adenocarcinoma of the esophagus and gastric cardia. *JAMA* 265:1287-1289
10. Akiyama H (1980) Surgery for carcinoma of the esophagus. *Curr Probl Surg* 17:53-120
11. Baba M, Aikou T, Yoshinaka H, Natsugoe S, Fukumoto T, Shimazu H, Akazawa K (1994) Long-term results of subtotal esophagectomy with three-field lymphadenectomy for carcinoma of the thoracic esophagus. *Ann Surg* 219:310-316
12. Hennessy TP (1994) Lymph node dissection. *World J Surg* 18:367-372
13. Lerut TE, de Leyn P, Coosemans W, Van Raemdonck D, Cuypers P, Van Cleynenbreughel B (1994) Advanced esophageal carcinoma. *World J Surg* 18:379-387
14. Akiyama H, Tsurumaru M, Udagawa H, Kajiyama Y (1994) Radical lymph node dissection for cancer of the thoracic esophagus. *Ann Surg* 220:364-373
15. Fujita H, Kakegawa T, Yamana H, Shima I, Toh Y, Tomita Y, Fujii T, Yamasaki K, Higaki K, Noake T et al (1995) Mortality and morbidity rates, postoperative course, quality of life, and prognosis after extended radical lymphadenectomy for esophageal cancer. Comparison of three-field lymphadenectomy with two-field lymphadenectomy. *Ann Surg* 222:654-662
16. Kato H, Tachimori Y, Watanabe H, Igaki H, Nakanishi Y, Ochiai A (1996) Recurrent esophageal carcinoma after esophagectomy with three-field lymph node dissection. *J Surg Oncol* 61:267-272
17. Altorki NK, Skinner DB (1997) Occult cervical nodal metastasis in esophageal cancer: preliminary results of three-field lymphadenectomy. *J Thorac Cardiovasc Surg* 113:540-544
18. Lerut T, Naftoux P, Moons J, Coosemans W, Decker G, De Leyn P, Van Raemdonck D, Ectors N (2004) Three-field lymphadenectomy for carcinoma of the esophagus and gastroesophageal junction in 174 R0 resections: impact on staging, disease-free survival, and outcome: a plea for adaptation of TNM classification in upper-half esophageal carcinoma. *Ann Surg* 240:962-974
19. Orringer MB, Marshall B, Iannettoni MD (1999) Transhiatal esophagectomy: clinical experience and refinements. *Ann Surg* 230:392-403
20. Tachimori Y, Kato H, Watanabe H, Sasako M, Kinoshita T, Maruyama K (1996) Difference between carcinoma of the lower esophagus and the cardia. *World J Surg* 20:507-511
21. Hoelscher AH, Bollschweiler E, Bumm R, Bartels H, Hoefler H, Siewert JR (1995) Prognostic factors of resected adenocarcinoma of the esophagus. *Surgery* 118:845-855
22. Clark GW, Peters JH, Ireland AP, Ehsan A, Hagen JA, Kiyabu MT, Bremner CG, DeMeester TR (1994) Nodal metastasis and sites of recurrence after en bloc esophagectomy for adenocarcinoma. *Ann Thorac Surg* 58:646-653
23. Siewert JR, Stein HJ, Feith M (2003) Surgical approach to invasive adenocarcinoma of the distal esophagus (Barrett's cancer). *World J Surg* 27(9):1058-1061
24. Skinner DB, Little AG, Ferguson MK, Soriano A, Staszak VM (1986) Selection of operation for esophageal cancer based on staging. *Ann Surg* 204:391-401
25. Lerut T, De Leyn P, Coosemans W, Van Raemdonck D, Scheys I, LeSaffre E (1992) Surgical strategies in esophageal carcinoma with emphasis on radical lymphadenectomy. *Ann Surg* 216:583-590
26. Hagen JA, Peters JH, DeMeester TR (1993) Superiority of extended en bloc esophagogastrectomy for carcinoma of the lower esophagus and cardia. *J Thorac Cardiovasc Surg* 106:850-859
27. Junginger T, Dutkowski P (1996) Selective approach to the treatment of oesophageal cancer. *Br J Surg* 83:1473-1477
28. Doggett RLS, Guernsey JM, Bagshaw MA (1970) Combined radiation and surgical treatment of carcinoma of the thoracic esophagus. *Front Radiat Ther Oncol* 5:147-154
29. Parker EF, Gregorie HB (1976) Carcinoma of the esophagus. Long-term results. *JAMA* 235:1018-1020
30. Siewert JR, Hölscher AH (eds) *Diseases of the Esophagus*. Springer, Berlin Heidelberg New York Tokyo
31. Hulscher JB, van Sandick JW, de Boer AG, Wijnhoven BP, Tijssen JG, Fockens P, Stalmeier PF, ten Kate FJ, van Dekken H, Obertop H, Tilanus HW, van Lanschot JJ (2002) Extended transthoracic resection compared with limited transhiatal resection for adenocarcinoma of the esophagus. *N Engl J Med* 347(21):1662-1669
32. Lordick F, Stein HJ, Peschel C, Siewert JR (2004) Neoadjuvant therapy for oesophagogastric cancer. *Br J Surg* 91(5):540-551
33. Izbicki JR, Hosch SB, Pichlmeier U, Rehders A, Busch C, Niendorf A, Passlick B, Broelsch CE, Pantel K (1997) Prognostic value of immunohistochemically identifiable tumor cells in lymph nodes



- of patients with completely resected esophageal cancer. *New Engl J Med* 337:1188–1194
34. Siewert JR, Stein HJ (1998) Classification of adenocarcinoma of the oesophagogastric junction. *Br J Surg* 85(11):1457–1459
  35. Siewert JR, Hoelscher AH, Becker K, Goessner W (1987) Kardiocarcinom: Versuch einer therapeutisch relevanten Klassifikation (Cardia cancer: attempt at a therapeutically relevant classification). *Chirurg* 58:25–32
  36. Steele VE, Nettesheim P (1981) Unstable cellular differentiation in adenosquamous cell carcinoma. *JNCI* 67:149–154
  37. Hsu CP, Chen CY, Hsieh YH, Hsia JY, Shai SE, Kao CH (1997) Esophageal reflux after total or proximal gastrectomy in patients with adenocarcinoma of the gastric cardia. *Am J Gastroenterol* 92:1347–1350
  38. Wang LS, Chi KH, Hu MH, Fahn HJ, Huang MH (1996) Management for patients with advanced T4 epidermoid carcinoma of the esophagus. *J Surg Oncol* 62:22–29
  39. Blazeby JM, Williams MH, Brookes ST, Alderson D, Farndon JR (1995) Quality of life measurement in patients with oesophageal cancer. *Gut* 37:505–508

## Results of Extended en bloc Esophagectomy in Treatment of Patients with Esophageal Cancer

D. I. WATSON, G. G. JAMIESON

### Rationale for extended en bloc esophagectomy

Unlike some other malignancies, such as colon and breast carcinoma, recent progress in the management of esophageal carcinoma has been limited. The overall prognosis for this disease remains dismal, having improved only marginally over recent decades. Because most patients present with advanced stage carcinomas, treatment is usually palliative, and only a minority of patients are cured by surgery. Even when the disease is confined to the esophagus, there is only about a 50% chance of 5-year survival after surgical resection.

Opinions are divided as to the way forward. Many Western surgeons believe that increasingly radical surgical approaches are unlikely to improve long-term outcomes, and indeed could create further problems due to additional complications which follow radical resection. This body of opinion has supported the evaluation of adjuvant treatment strategies, with evidence now emerging that combined treatment with synchronous chemotherapy and radiotherapy improves overall survival [25]. On the other hand, an opposing body of opinion, led principally by the Japanese surgical community, has advocated more radical lymph node resection as the way forward, citing improved outcomes in uncontrolled studies to support this approach.

The concept of extensive lymph node resection combination with esophagectomy, i.e. en bloc esophagectomy, was proposed by Logan in 1963 [17]. Originally this entailed the removal of abdominal and thoracic lymph nodes up to level of the aortic arch. A more extensive resection which included lymph nodes in the superior mediastinum was the next step, whilst

recently the concept of 3 field (extended) lymph node dissection has emerged. This incorporates the additional removal of lymph nodes from both sides of the neck, as well as mediastinal and upper abdominal lymph nodes. This radical approach was devised following analysis of Japanese data which documented that recurrence of squamous cell carcinoma (SCC) can occur initially in the cervical lymph nodes. Therefore it was proposed that removing the cervical lymph nodes might improve the overall success rate following esophagectomy.

The procedure of extended (3 field) esophagectomy has been applied in Japan principally in patients with potentially curable, i.e. earlier stage SCC of the esophagus. Few Western studies have been reported, in part due to the lack of enthusiasm for this approach, and also because of a lower incidence of *curable* esophageal cancer. There has also been a general skepticism that extensive lymph node resection will achieve better surgical outcomes. In part a surgeon's acceptance of the concept of patterns of metastatic spread of esophageal cancer. Support for extended resection depends on the hypothesis that esophageal cancer spreads sequentially from the esophageal wall to local lymph nodes initially, and that metastases are arrested at this stage for a period of time before metastasis by hematogenous spread finally occurs to distant organs. This concept of tumor spread is often held to be correct for colonic malignancy although even here there is no universal acceptance of the concept, and anyway it is unlikely to be applicable to all malignancies. For example, radical lymph node resection was proposed by Halsted for carcinoma of the breast, and it was universally accepted as correct treatment until approximately 20 years ago. Breast carcinoma, however, ap-

pears to metastasize via both lymphatic and hematogenous routes at the same stage in the tumor development cycle. The understanding of this process has led to the development of conservative surgical approaches to breast cancer, and a greater emphasis on the role of systemic management therapies. It was not until the results of randomized trials of radical mastectomy versus less radical surgery were reported and their results widely disseminated that it was agreed that survival following surgery was not improved by radical lymph node resection.

As current opinion about the role of lymph node resection during esophagectomy is divided, it is likely that only well conducted prospective randomized trials will resolve the current controversy surrounding this question. However, as trials have not yet provided adequate information which can resolve this, it is important to closely examine outcomes following esophageal resection with and without extended lymph node resection to determine the level of support for radical lymph node resection during esophagectomy for cancer.

### **Proposed advantages and disadvantages for extended en bloc esophagectomy**

The proponents of 3 field lymph node resection claim improved survival following this procedure, as well as improved local disease control and reduced local recurrence rates, particularly in the neck. In addition, staging is facilitated by more accurate assessment of lymph node status because more lymph nodes are removed for pathological examination, thereby providing information which may help some surgeons to tailor post-operative adjuvant therapies. These advantages may be offset by disadvantages associated with more extensive dissection. The upper mediastinal and neck dissection requires the identification and removal of nodes around both recurrent laryngeal nerves, maneuvers which increase the risk of transient or permanent damage to these nerves. Of particular concern is the potential for bilateral nerve palsies which can compromise airway protection mechanisms and the

ability to cough, as well as cause breathing difficulties if both vocal cords cannot be abducted. This might be expected to lead to prolonged assisted ventilation following surgery in some patients, and possibly an increased requirement for tracheostomy. In addition, there is the potential for a higher rate of post-operative pneumonia and adult respiratory distress syndrome associated with this procedure.

Operating times are lengthened significantly due to the increased complexity of the surgery, and the suitability of the approach in Western patients who are often larger and heavier than Japanese patients has been questioned. The latter issue, however, has been partly resolved by Altorki and Skinner [4], who reported an experience with 30 American patients who underwent extended en bloc esophagectomy with acceptable results, thus confirming its feasibility in the non-Japanese.

### **Results of standard esophagectomy**

Before considering the possible advantages for extended lymphadenectomy during esophagectomy, it is necessary to review outcomes following esophagectomy using less radical techniques. Standard esophagectomy involves esophageal resection without formal en bloc lymph node dissection. Variants of this approach are commonly performed worldwide. In our own experience the majority of patients die from disseminated disease following esophagectomy, rather than lymph node recurrence. Hence, we have applied neoadjuvant preoperative combination chemotherapy/radiotherapy with the less radical surgical approach (usually a standard Ivor-Lewis procedure). The results of this approach for SCC of the esophagus at our hospital have been recently reported [5]. Despite a liberal selection policy, in which advanced preoperative stage alone was rarely considered to be a contraindication to resection, an overall 7-year survival of 27% was achieved from an experience of 53 patients. In addition, a subgroup of 14 patients who were down staged to T0 N0 by neo-adjuvant preoperative treatment achieved a 69% 7-year survival rate. These long term results

compare favorably with outcomes following extended lymphadenectomy.

Good outcomes have also been achieved by other surgeons. Bolten et al. [8] reported a 37% year survival rate following transhiatal blunt esophagectomy and an associated low perioperative mortality rate of 0% in the latter half of their experience. Similarly Orringer [20] described a mortality rate of approximately 1% with acceptable survival outcomes from a series of more than 1000 patients. Ellis et al. [9] highlighted the influence of tumor stage at the time of presentation on the subsequent outcome of surgery. Using a liberal selection policy for esophagectomy, a 19% overall 5-year survival was achieved. However, this improved significantly to 37% in patients with stage I disease. A similar outcome was reported by Watson [26] who described a 23% 5-year overall survival following Ivor Lewis esophagectomy. However, survival was much better for patients without cancer in lymph nodes (47% alive at 5 years) and even better if the tumor was confined to the esophageal wall muscle layer (71% alive at 5 years).

A much poorer outcome has been reported from South Africa by Mannell and Becker [18]. They described a 13% 5-year survival following 108 esophagectomies. However, in their series, 82% of patients undergoing surgery had advanced (T3) tumors, again highlighting the fact that overall outcome varies widely between different centers, depending on whether patients tend to present with early or late stage esophageal cancer. This must be constantly kept in mind when comparing outcomes from uncontrolled series of patients who have undergone esophagectomy for cancer.

### Results of 2 field (en bloc) esophagectomy

The techniques of 2 field (en bloc) esophagectomy has been advocated as a more applicable operation for esophageal cancer, as it entails the removal of the esophagus in continuity with a margin of surrounding tissues including draining thoracic and abdominal lymph nodes. The proponents of the 3 field technique, how-

ever, argue that this procedure is not oncologically adequate, as it fails to address cervical node metastases. Nevertheless it is important to consider the results for this procedure as Japanese surgeons who advocate the 3 field technique invariably compare their results with historical controls who underwent the extended 2 field lymphadenectomy technique.

Wong et al. described their experience with this technique in two publications [16, 24]. In their experience, 52% of patients developed recurrent cancer at a median follow-up interval of 20 months. 26% developed recurrence in systemic organs, 25% within the thoracic cavity, and 11% in cervical lymph nodes. In addition, cervical node recurrence tended to occur concurrently with recurrence elsewhere, and it did not precede systemic recurrence, i.e. the pattern of recurrence did not support the concept of more radical surgery which includes resection of cervical lymph nodes. Overall 5-year survival was 32%.

Skinner's experience with en bloc esophagectomy confirmed its relative safety. His initial report in 1983 [23] was associated with a 30 day operative mortality of 11%. Subsequent experience [3] described a 30 day mortality of 8%. Initial experience [23] resulted in an 18% 5-year survival rate, although only 44% of the overall esophageal cancer group underwent radical surgery. Subsequent experience [3] was associated with a 50% surgical exploration rate, and 33% resection rate. This highlights the possibility of selection bias which must be considered when evaluating outcomes following more radical esophagectomy procedures. Unlike the standard esophagectomy experience where the majority of patients underwent a standard surgical approach, less than half of patients presenting with esophageal cancer are likely to be offered en bloc esophagectomy, with patients with more advanced stage disease more likely to be excluded. This will improve the outcome following the more radical procedure due to the effect of selecting better prognosis patients only for this option.

Experience with 186 patients from Roder et al. [22] who all underwent en bloc resection was associated with a 30 day mortality of 12.4%. 61% of patients had stage T3 or T4 lesions, and 61% also had tumor in the lymph nodes. The most important prognostic variable

in their experience was not lymph node involvement, but presence of residual tumor at the completion of surgery. An overall 5-year survival rate of 31% was achieved, although this was better in patients with early stage tumors. Analysis of lymph node involvement versus survival suggested that lymph node dissection might improve prognosis if less than 20% of the nodes removed contained tumor. More extensive disease did not benefit.

Horstmann et al. [12] compared transhiatal with en bloc transthoracic esophagectomy in a non-randomized study of 87 patients. Hospital mortality, as well as the incidence of post-operative pulmonary and cardiac complications were similar for the two groups. Anastomotic leakage was more common following transhiatal esophagectomy (50 vs 24%). However, survival similar following the two procedures at 1, 2, and 3 follow-up, demonstrating no overall advantage for more radical lymph node dissection, perhaps with the exception of an improved ability to accurately stage the disease. Hagen et al. [11] compared two groups of patients, one group of 30 patients undergoing a radical lymphadenectomy below the carina and the other group of 16 patients undergoing a transhiatal esophagectomy (because they were deemed medically unfit to undergo the more radical procedure). Although both groups had similar numbers of equivalent stage disease, survival was greater at 5 years in the group undergoing en bloc lymphadenectomy (41 vs 14%). However, apart from the non-randomized nature of the study, the possible, and even likely, influence of comorbidity on the cancer was not addressed by the authors.

### Results of extended 3 field esophagectomy

Three field lymphadenectomy results have been reported predominantly by Japanese surgical groups, with Western surgeons who support the concept of radical lymph node dissection usually confining lymph node dissection to the thorax and abdomen. However, Skinner and his colleagues have recently decided to follow the Japanese lead (see later). Consequently the results for this procedure are heavily

weighted by Japanese practice, which because of endoscopic screening programs have a greater proportion of patients presenting with early stage disease. Western experience is characterized by late stage presentation, which makes direct comparison with the Japanese experience difficult.

### Case selection and peri-operative outcomes for 3 field esophagectomy

Most advocates of 3 field lymph node dissection recommend the application of this procedure wherever possible. However, it is not appropriate for advanced tumors in which residual tumor is likely to be left behind despite extensive lymph node resection. Furthermore, analysis of patterns of metastasis to cervical lymph nodes suggests that lymph node metastasis to the neck is less likely in patients with tumors involving the lowermost esophagus, in particular the abdominal esophagus [2]. In addition, superficial tumors confined to the mucosa and submucosa have a low risk of lymphatic metastases. Therefore, selection of cases best suited to 3 field lymphadenectomy has been recommended [2].

Short term outcomes may be affected by more extensive lymph node dissection. Operating times are generally prolonged. Kato et al. [14] describe a mean operating time of 484 minutes for 3 field dissection compared to 331 minutes for the two field procedure, i.e. operating time was prolonged by approximately 2.5 hours. Similar outcomes were reported by Nishihira et al. [19], 487 versus 396 minutes. Hospital stays of approximately 3 months are usual for these procedures in Japan [15]. However, this is influenced by the Japanese health system which encourages patients to remain in hospital for all preoperative work up and postoperative adjuvant treatment, rather than only for the time required to safely recover from surgery. No data for post-operative stay following this procedure are available from Western hospitals. Nevertheless, it is unlikely to be shorter than conventional experience of 2 to 3 weeks, and it may be prolonged if complications occur more often than following standard procedures.

### Complications following 3 field esophagectomy

Isono et al. [13] collected outcome data for esophageal resections performed between 1983 and 1989 in 96 Japanese institutions, 35 which performed 3 field and 61 performed 2 field dissections. Whilst this is the largest overview of outcomes following extended lymphadenectomy, the data must be interpreted cautiously as the authors obtained their results from a postal survey of Japanese hospitals, and the response rate was only 45%. Whilst post-operative pneumonia was equally common following 3 field esophagectomy compared to two field dissection (18.1 vs 16.6 %), the incidence of recurrent laryngeal nerve injury was increased by 3 field dissection; 20.3 versus 14.0%. This should also be compared to the standard Ivor Lewis technique during which the risk of this injury is nearly 0% [10]. Additional morbidity can occur due to phrenic nerve injury and a high requirement for tracheostomy. A 13% incidence of phrenic nerve injury, 56% incidence of recurrent laryngeal nerve injury, and 53% requirement for tracheostomy was recently reported by Nishihira et al. [19]. Similarly Bhanjali and Fujita et al. [6] describe an incidence of recurrent laryngeal nerve injury of 74% (of which 34% of patients overall had a permanent paresis), an anastomotic leak rate of 34%, and a 33% incidence of pneumonia.

Perioperative mortality in the Japanese experience with 3 field esophagectomy is probably similar to other esophagectomy techniques. Isono et al. [13] described a 30 day mortality rate of 2.8% from data collected by postal survey from 1,791 3 field esophagectomy procedures. Akiyama et al. [1] report a 2.2% 30 day mortality rate. Importantly, the hospital death rate was 2.5 times higher than this (5.2%), demonstrating how 30 day mortality rates can provide misleading information about the real mortality risk patients face when they undergo esophagectomy. Initial results have been reported from North America by Altorki and Skinner [3] who describe a 30 day mortality rate of 3.3%. This suggests that the relative safety of extended lymphadenectomy demonstrated by Japanese experience can

be replicated in selected Western patients, but of course the experience does not establish the necessity for the radicality.

### Lymph node metastases to the cervical nodes found by 3 field lymphadenectomy

Isono et al. [13] reported an incidence of cervical nodal metastases following cervical node dissection of 42% for upper thoracic esophageal cancer, 28% for middle thoracic esophageal cancer, and 11% when the tumor was located in the abdominal esophagus. Metastases were more likely as the T stage of the esophageal tumor advanced. Similar outcomes were described by Akiyama et al. [1], with cervical lymph node metastases present in 46% of patients with upper esophageal cancer, 29% with middle esophageal cancer, and 27% for lower esophageal cancer. Altorki and Skinner [3] report single field involvement for the cervical lymph nodes alone in 7% of procedures. Whilst the incidence of cervical node metastases is unequivocal, the important questions to be answered are: does removal of cervical nodes improve prognosis, and is involvement of cervical nodes really just a marker for 'incurable' disease?

### Survival following esophagectomy

Survival data for 3 field esophagectomy has been drawn principally from uncontrolled data. This data must be treated with caution as survival can be influenced by tumor stage differences between different series, and possible selection bias due to selection of potentially curable patients for the extended lymphadenectomy procedure. These factors may contribute to some of the good survival data reported in various case series. In addition it is difficult to directly compare series of different procedures as staging is more accurate following 3-field dissection, up-staging patients with lymph node metastases which would not have

been detected if a less radical lymph node dissection had been performed. This phenomenon can lead to improved outcomes following 3 field dissection in both early and late stage groups. The outcome of the early stage group is improved by removing patients' otherwise occult lymph node metastases from the group, and the outcome of the late stage group is improved by the addition of the patients with the occult lymph node metastases. Late stage groups of patients having less radical procedures will contain a larger proportion of patients with gross macroscopic nodal disease. The sub-group with occult lymph node metastases may have a better survival outcome than patients with gross lymph node involvement. It is possible that this effect accounts for at least part of the survival improvement seen in each stage following extended lymph node resection. In the group, as a whole however, overall prognosis should not be altered by the effect of restaging, unless different selection criteria for surgery are applied for the different operative procedures.

Isono et al. [13] describe a 34% year survival rate following extended lymph node dissection. Similarly Bhansali and Fujita [6] described 39% survival at 5 years following extended lymphadenectomy in 90 patients. These survival figures are reasonably consistent. The survival data should also be considered alongside good results reported by surgeons performing less radical procedures. For example Orringer et al. [21] reported a 27% 5-year survival following transhiatal esophagectomy without radical lymph node dissection, and our own experience with less radical surgery combined with adjuvant preoperative chemotherapy and radiotherapy was associated with an overall 27% 7-year survival [5]. These results might appear to be associated with a 10% reduction in survival. However, they were achieved following surgery in patients having advanced disease. When one compares outcome following extended lymphadenectomy with 2 field esophagectomy, most surgeons have relied on historical controls to provide comparative data. Isono et al. [13] describe an improvement in 5-year survival from 27 to 35%. Akiyama et al. [1] reported an even greater improvement from 38.3 to 55%. Interestingly Akiyama et al. achieved a better 5-year

survival following 2 field esophagectomy than the survival following extended 3 field lymphadenectomy reported by Isono et al., suggesting that the two groups of patients were different.

### Randomized trials of extended 3 field esophagectomy versus 2 field en bloc esophagectomy

Comparison of new procedures with historical experience can result in significant bias in favor of newer techniques. This issue has been elegantly highlighted by Bhansali and Patil et al. [6], who compared outcomes for esophageal carcinoma following adjuvant chemotherapy. They demonstrated that the benefits of adjuvant chemotherapy demonstrated in studies which used historical controls disappeared when data was re-analyzed after correcting for the year of entry into their study. They concluded that historical controls are unreliable for studies that seek to detect modest treatment benefits. Potential advantages for 3 field lymph node dissection are of a similar order of magnitude to those advocated for adjuvant chemotherapy, highlighting the importance of randomized trials to assess extended lymph node dissection.

Two *randomized* trials have been reported. Kato et al. [15] entered 150 patients with thoracic esophageal carcinoma into a comparative study of esophagectomy with 2 field versus 3 field lymph node resection. This group represented less than half of the patients presenting to their institution with esophageal carcinoma, and approximately 60% of all esophagectomies. Only patients with "good surgical status", i.e. predominantly earlier stage tumors, were entered. Patients were randomly allocated to one of two groups of surgeons. One group performed a 2 field procedure for the duration of the trial, and the other a 3 field procedure. This trial should be commended for enrolling an appropriate number of patients to enable a valid comparison between the two techniques. However, because different surgeons performed the different procedures, two variables were compared, i.e. the type of procedure and the skill of the surgeon. The study groups were

generally comparable, although the average age of patients undergoing 3 field resection was 4 years less than for the 2 field procedure (60.5 vs 64.5 years). The number of lymph nodes dissected was greater in the extended lymph node dissection group (69 vs 36), and 26% of patients had tumors in the cervical lymph nodes when these were dissected. Operating time was prolonged from 379 to 483 minutes by cervical lymph node dissection, and post-operative hospital stay was approximately 3 months for both groups.

No significant differences in the incidence of complications were demonstrated between the 2 groups, with vocal cord paralysis occurring in 11 (14%) of patients undergoing extended lymph node dissection versus 15 (21%) following 2 field dissection. Anastomotic leakage was higher in the 3 field group: 34% versus 23%. Hospital mortality was 2.6% (1 patient) in the 3 field group as compared with 12.3% (9 patients) in the 2 field group. This difference was highly significant ( $P=0.008$ , Fisher's exact test) and raised the problem of the study design of this trial as clearly there is no a priori reason why the 3 field lymphadenectomy should be safer than the 2 field techniques. Post-operative survival rates favored 3 field extended lymph node resection, with 49% of patients alive 5 years after 3 field resection versus 34% following 2 field resection. These survival rates, when compared with Western series indicate the early pathological stage in the Japanese series. The authors concluded that extended 3 field dissection resulted in improved 5-year survival following esophagectomy of thoracic esophageal carcinoma. However, the 13% survival advantage for the extended lymph node dissection was largely due to the 10% differences in the operative mortality rates. When patients who survived surgery are considered, then the survival advantage is no longer significant.

More recently Nishihira et al. [19] reported the outcome of a smaller randomized trial of 3 field versus 2 field lymphadenectomy during esophagectomy. 73 patients, 28% of the overall esophageal cancer caseload were entered into the trial and 11 (15%) were withdrawn after being randomized, leaving the study with groups of 32 and 30 patients. Whilst not specifically stated in their paper, one can probably

assume that the same surgeons performed surgery in both study groups. Post-operatively most patients received either adjuvant radiotherapy or combination treatment with chemotherapy and radiotherapy. Both groups were demographically similar, and most patients had middle third SCC's. The vast majority were T2 stage lesions, with more advanced cancers comprising only a small part of the trial.

Mean operating times were 487 versus 396 minutes, and the mean number of lymph nodes resected was 82 versus 43. Interestingly in this study only one patient in the 3 field lymphadenectomy group actually had metastases to the cervical nodes. Pathological examination in all other patients demonstrated no cervical lymph node involvement. Postoperative pulmonary complications were similar for the 2 procedures, although recurrent laryngeal nerve palsy (56 vs 30%), phrenic nerve palsy (13 vs 0%) and the need for tracheostomy (53 vs 10%) all occurred more frequently following 3 field lymphadenectomy. Anastomotic leakage, however, was less common following the more extensive procedure (6 vs 20%). In hospital mortality was 3% (1 patient) following 3 field dissection and 7% (2 patients) following 2 field dissection. There was a trend to improved survival following 3 field lymphadenectomy, although the survival difference was not significant ( $P=0.19$ ). At 5 years, the survival was 66% following 3 field lymphadenectomy as compared with 48% following 2 field lymphadenectomy. However, it is unclear from the report whether follow-up was complete for all patients, or whether the survival data was calculated by actuarial analysis.

The results of these trials allow us to conclude that 3 field lymphadenectomy is associated with a higher risk of complications such as injury to the recurrent laryngeal nerves, and phrenic nerve, and operation times are significantly lengthened. However, peri-operative mortality is not increased when this procedure is performed by experienced Japanese surgeons. The trials have only addressed this procedure for patients with early stage squamous cell carcinomas (i.e. not invading through the full thickness of the esophageal wall muscle), and a significant improvement in long term survival has yet to be demonstrated.



However, it is unlikely that the results of these studies can be extrapolated to Western experience, as the majority of patients undergoing surgery outside Japan have advanced tumors which penetrate the full thickness of the esophageal wall. In recent years the majority of patients presenting with esophageal carcinoma in the West have an adenocarcinoma involving the lower third of the esophagus and/or the gastroesophageal junction. Extended lymphadenectomy in the latter group of patients has been largely untested.

### Use of 3 field en bloc esophagectomy for adenocarcinoma of the esophagus

The application of this procedure for adenocarcinoma has only been reported in the study of Altorki and Skinner [3] of 30 patients undergoing 3 field lymphadenectomy. Fifteen of their patients had adenocarcinoma of the distal esophagus. Interestingly, 4 of these patients had cervical nodal metastases, although each of these 4 patients also had metastases in other nodal groups. The number of patients in this study is not sufficient to allow us to draw conclusions about the role of 3 field lymphadenectomy for adenocarcinoma of the distal esophagus.

### Conclusions

The role of 3 field lymphadenectomy remains controversial outside of Japan. Whilst good results have been reported from many Japanese institutions, data has been largely uncontrolled or compared to historical controls limiting the conclusions which can be drawn from these studies. Nevertheless, the relative safety of the procedure has now been demonstrated in both Japanese and Western experience. However, the procedure is associated with significant morbidity, including a high incidence of permanent recurrent laryngeal nerve and phrenic nerve injury, as well as possibly higher anastomotic leakage rates and a greater requirement

for assisted ventilation and tracheostomy following the more radical procedure. These problems may be acceptable if a long term outcome benefit can be demonstrated. For now, however, only data from well conducted prospective randomized trials is likely to convince the majority of surgeons that extended lymphadenectomy is beneficial. The 2 trials reported to date either had numbers too small to draw significant conclusions or were difficult to interpret because of potential problems associated with the randomization process used during the trial.

So far there is a lack of comparative data between 3 field lymphadenectomy and conventional resection combined with adjuvant chemotherapy and radiotherapy. These adjuvant approaches have achieved similar outcomes to radical surgery in uncontrolled trials. As patients usually die with distant metastases following esophagectomy, in the future it seems more likely that improvements in outcome for esophageal cancer will be achieved by improvements in systemic therapies rather than through the development of progressively more radical surgical techniques.

### References

1. Akiyama H, Tsurumaru M, Udgawa H, Kajiyama Y (1994) Radical lymph node dissection for cancer of the thoracic esophagus. *Ann Surg* 220:364-373
2. Akiyama H, Tsurumaru M, Udgawa H, Kajiyama Y (1997) Esophageal cancer. *Curr Probs in Surg* 10: 765-834
3. Altorki NK, Girardi L, Skinner DB (1994) Squamous cell carcinoma of the esophagus: therapeutic dilemma. *World J Surg* 18:308-311
4. Altorki NK, Skinner DB (1997) Occult cervical nodal metastases in esophageal cancer: preliminary results of 3-field lymphadenectomy. *J Thorac Cardiovasc Surg* 113:540-544
5. Bessell JR, Devitt PG, Gill PG, Goyal S, Jamieson GG (1996) Prolonged survival follows resection of esophageal SCC downstaged by prior chemoradiotherapy. *Aust NZ J Surg* 66:214-217
6. Bhansali MS, Fujita H, Kakegawa T, Yamana H, Ono T, Hikita S, Toh Y, Fujii T, Tou U, Shirouzu K (1997) Pattern of recurrence after extended radical esophagectomy with 3-field lymph node dissection for squamous cell carcinoma in the thoracic esophagus. *World J Surg* 21:275-281

7. Bhansali MS, Patil PK, Badwe RA, Havaladar R, Desai PB (1997) Historical control bias: adjuvant chemotherapy in esophageal cancer. *Dis Esoph* 10:51–54
8. Bolton JS, Ochsner JL, Abdoh AA (1994) Surgical management of esophageal cancer. A decade of change. *Ann Surg* 219:475–480
9. Ellis FH, Gibb SP, Watkins E (1985) Overview of the current management of carcinoma of the esophagus and cardia. *Can J Surg* 28:493–496
10. Goldmine M, Maddern GJ, LePrise W, Meunier B, Campion JP, Launois B (1993) Esophagectomy by a transhiatal approach or thoracotomy: a prospective randomised trial. *Br J Surg* 80:367–370
11. Hagen JA, Peters JH, DeMeester TR (1993) Superiority of extended en bloc esophagectomy for carcinoma of the lower esophagus and cardia. *J Thor Cardiovasc Surg* 106:850–859
12. Horstmann O, Verreet PR, Becker H, Ohmann C, Roher H-D (1995) Transhiatal esophagectomy compared with transthoracic resection and systemic lymphadenectomy for the treatment of esophageal cancer. *Eur J Surg* 161:557–567
13. Isono K, Sato H, Nakayama K (1991) Results of a nationwide study on the 3-field lymph node dissection of esophageal cancer. *Oncology* 48:411–420
14. Kato H, Tachimori Y, Watanabe H, Kikuchi S, Umemura A (1996) Recurrent disease after esophagectomy with 3-field lymph node dissection for thoracic esophageal carcinoma. In: Peraccia A, Rosati R, Bonavina L, Bona S, Chella B (eds) *Recent Advances in Diseases of the Esophagus*. Monduzzi Editore, Bologna, Italy, pp 405–410
15. Kato H, Watanabe H, Tachimori Y, Iizuka T (1991) Evaluation of neck lymph node dissection for thoracic esophageal carcinoma. *Ann Thor Surg* 51: 931–935
16. Law SYK, Fok M, Wong J (1996) Pattern of recurrence after resection for cancer: clinical implications. *Br J Surg* 83:107–111
17. Logan A (1963) The surgical treatment of carcinoma of the esophagus and cardia. *J Cardiovasc Surg* 46:150–163
18. Mannell A, Becker PJ (1991) Evaluation of the results of esophagectomy for esophageal cancer. *Br J Surg* 78:36–40
19. Nishihira T, Hirayama K, Mori S (1998) A prospective randomized trial of extended cervical and superior mediastinal lymphadenectomy for carcinoma of the thoracic esophagus. *Am J Surg* 175: 47–51
20. Orringer MB (1997) Editorial on Occult cervical nodal metastases in esophageal cancer: preliminary results of 3-field lymphadenectomy. *J Thorac Cardiovasc Surg* 113:538–539
21. Orringer MB, Marshall B, Stirling MC (1993) Transhiatal esophagectomy for benign and malignant disease. *J Thorac Cardiovasc Surg* 105:265–276
22. Roder JD, Busch R, Stein HJ, Fink U, Siewert JR (1994) Ratio of invaded to removed lymph nodes as a predictor of survival in squamous cell carcinoma of the esophagus. *Br J Surg* 81:410–413
23. Skinner DB (1983) En bloc resection for neoplasms of the esophagus and cardia. *J Cardiovasc Surg* 85:59–71
24. Tam PC, Cheung HC, Ma L, Siu KF, Wong J (1987) Local recurrences after subtotal esophagectomy for squamous cell carcinoma. *Ann Surg* 205:189–194
25. Walsh TN, Noonan N, Hollywood D, Kelly A, Keeling, Hennessy TP (1996) A comparison of multimodal therapy and surgery for esophageal adenocarcinoma. *N Engl J Med* 335:462–467
26. Watson A (1994) Operable esophageal cancer: Results from the West. *World J Surg* 18:361–366

# **Surgical Techniques**

---

# Blunt Transhiatal Subtotal Esophagectomy with Gastroplasty and Cervical Anastomosis

E. F. YEKEBAS, A. F. CHERNOUSOV, D. C. BROERING, P. M. BOGOPOLSKI, C. F. EISENBERGER, A. KUTUP, J. R. IZBICKI

## Blunt transhiatal esophagectomy and substitution by gastric tube

### ■ Indications

- Adenocarcinoma localized distal to the tracheal bifurcation
- Squamous cell carcinoma or severe dysplasia localized distal to the tracheal bifurcation
- Primarily palliative resection
- Extensive stricture\* (stenosis) due to erosion (chemical burns) unresponsive to nonsurgical treatment including bougienage
- Extensive peptic stricture\* (stenosis)
- Relapse of megaesophagus\* after surgical repair of cardiospasm combined with peptic strictures and failure of dilatation
- Extensive benign esophageal tumors\*
- Extensive intraluminal injury with perforation\* (one- or two-stage procedure)

### ■ Contraindications

- Florid duodenal ulcer
- Gastric stricture due to erosion (chemical burns)
- Status post distal gastrectomy or other operations in the epigastric region with incomplete gastroepiploic vascular anatomy
- Irreversible cardio-respiratory disorders

### ■ Operative risk and patient information

- High morbidity (~40%) and mortality (~5%)
- Prolonged monitoring in intensive care unit due to pulmonary complications
- Pulmonary complications (ARDS, pneumonia)
- Injury to recurrent laryngeal nerve uni- or bilateral
- Horner's syndrome
- Injury to phrenic nerve with diaphragmatic paralysis
- Necrosis of the gastric tube
- Injury to arteries of the gastric tube intraoperatively followed by immediate colon interposition
- Dehiscence of cervical suture line
- Mediastinitis
- Pancreatitis
- Peritonitis
- Pleural empyema
- Intraoperative emergency thoracotomy
- Tracheobronchial fistula

\* These indications do not need a lymphadenectomy (see chapter 10)

## ■ Specific preoperative management

Preoperative investigations (staging) include:

- Esophagogastroduodenoscopy incl. histologic diagnosis
- CT scanning of the thorax and abdomen
- Abdominal sonography
- Esophageal endosonography
- Bronchoscopy if the tumor is localized in the mid-third
- Pulmonary function tests and blood gas analysis
- Echocardiography
- Ergometry and other cardiac investigations if necessary

One day prior to the operation the esophagus and intestinal washout should be performed by means of orthograde irrigations with e.g. 3–4 liters cleansing solutions. Electrolyte, clotting, and hemoglobin imbalances (depletion) should be corrected preoperatively. Breathing exercises and physiotherapy must be explained and should be started preoperatively.

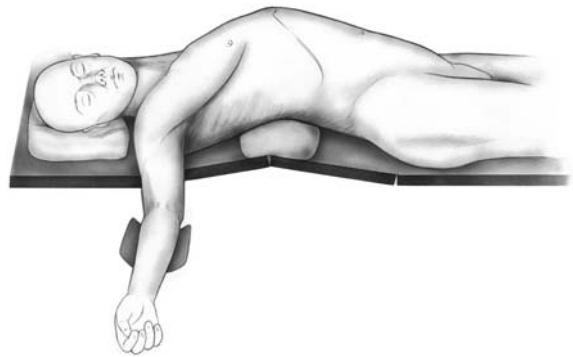
■ **Anesthesia.** Endotracheal intubation. Postoperatively, thoracic-epidural anesthesia is appropriate. Perioperative antibiotic therapy 30 min prior to operation.

## ■ Technique

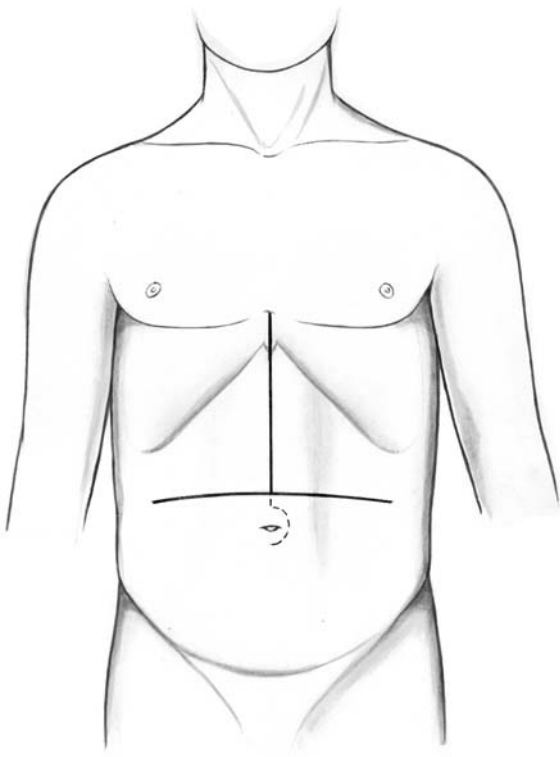
■ **Positioning.** Supine position with hyperlordosis and bending of the lower thoracic spine.

Abduction of the right arm. Adduction of the left arm. The head is turned to the right and slightly extended. This results in exposure of the cervical esophagus for performing the neck anastomosis.

■ **Approach.** Upper transverse incision with median T-shaped extension (inverted T-incision) for best overall view of the epigastric region, especially the diaphragmatic esophageal hiatus. Alternatively upper midline laparotomy with left periumbilical incision.



**Fig. 13.1.** Approach and positioning. The patient is placed in supine position with spinal hyperlordosis for better exposure of the epigastric region.



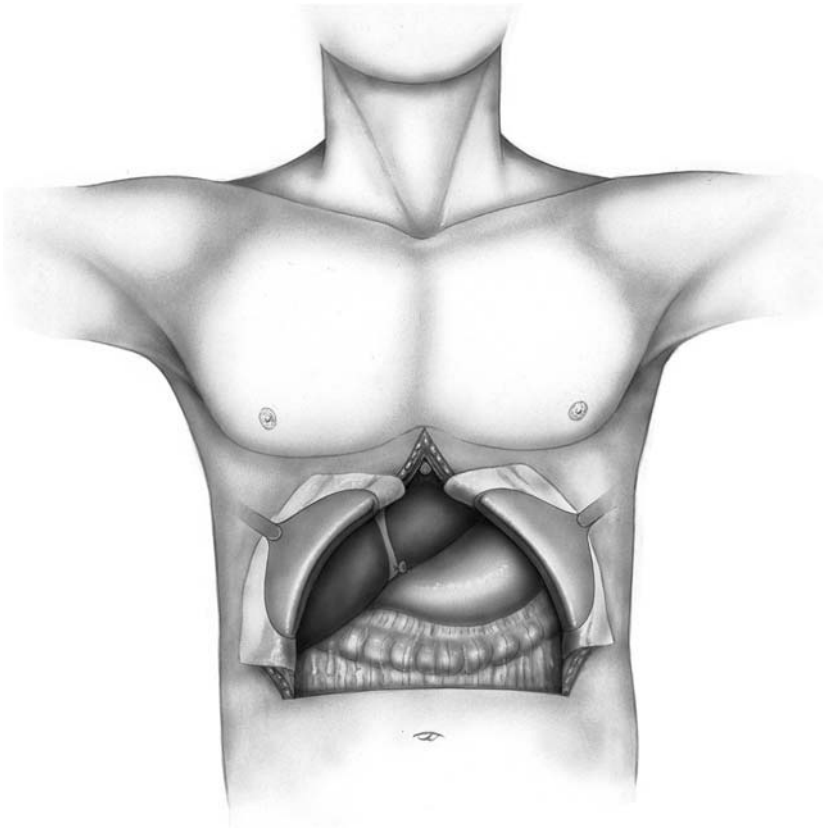
**Fig. 13.2.** Upper transverse laparotomy with median extension (inverted T-shaped incision).

### ■ Operative procedure

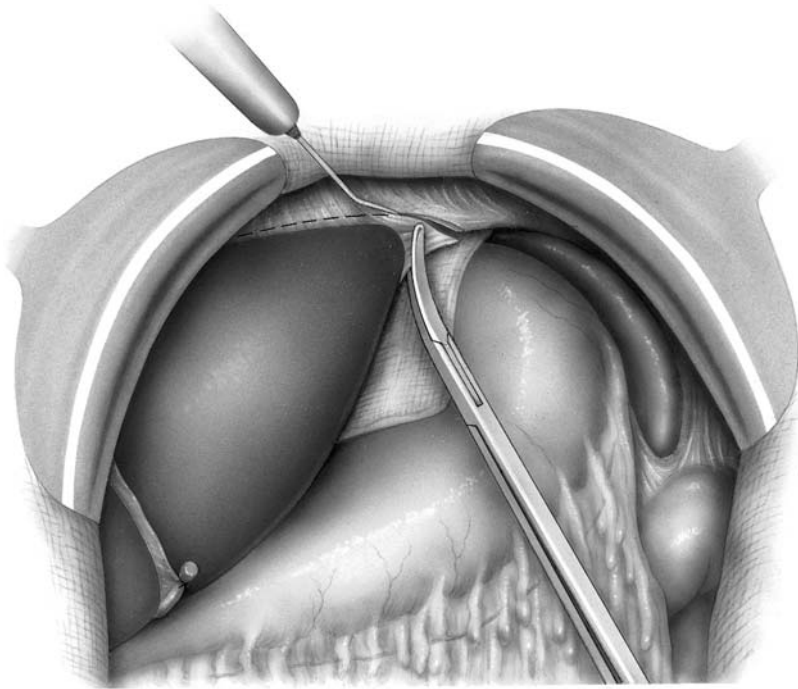
- Laparotomy and inspection of the stomach, distal esophagus, liver, and regional lymph nodes. Mobilization of left lateral lobe of the liver.
- Preparation and mobilization of the stomach with epigastric lymphadenectomy including paraaortic lymphatic tissue.
- Mobilization of abdominal portion of the esophagus and sagittal incision of the esophageal hiatus.
- Transhiatal esophageal dissection in the posterior mediastinum including paraaortic lymphadenectomy.
- Construction of a gastric tube.
- Mobilization and dissection of cervical esophagus. Resection of the esophagus.
- Transposition of the gastric tube through the anterior/posterior mediastinal tunnel after mobilization of the duodenum (extensive Kocher maneuver) and performing the cervical anastomosis.

■ **Special instruments.** Performing the inverted T-shape incision, insertion of Rochard retractors is useful to elevate the costal margin. During mobilization of the esophagus in the posterior mediastinum the use of very long Mikulicz retractors has been proved to be very worthwhile.

■ **Special technique.** Example: Resection of carcinoma of distal third of the thoracic esophagus.

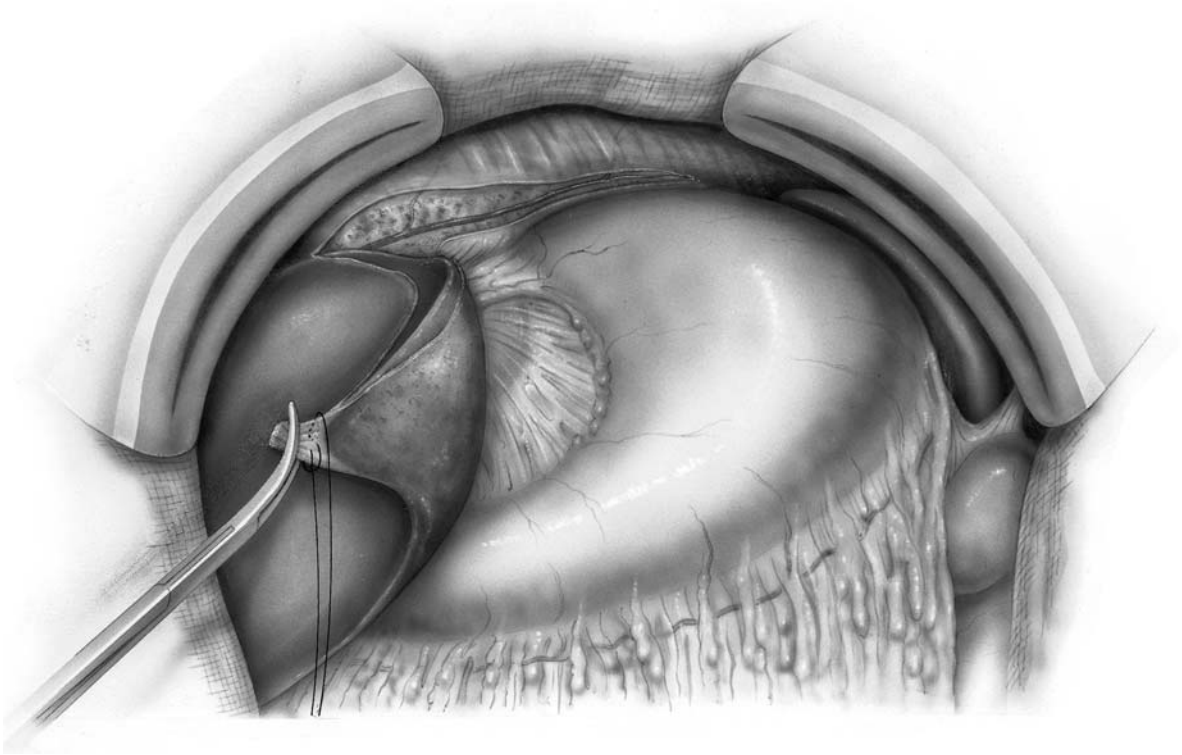


**Fig. 13.3.** Placement of Rochard self-retaining retractor system for exposure of the epigastric region. Alternatively use of the Sial retraction system.



**Fig. 13.4.** Mobilization of the left lateral liver lobe for optimal visualization of the diaphragmatic esophageal hiatus. Transection of the left triangular ligament with diathermy. To

prevent injury of adjacent structures, a pack is placed over the stomach.

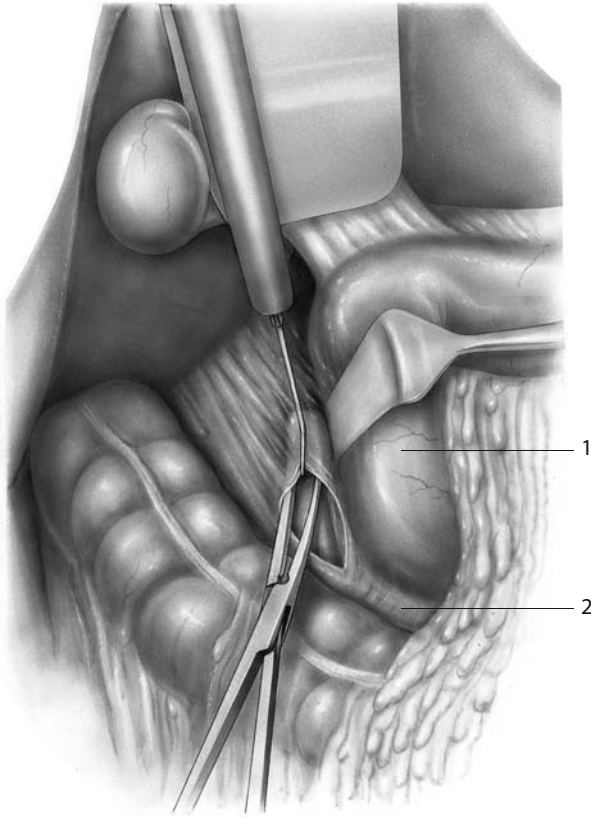


**Fig. 13.5.** To prevent the risk of a bile leak from an irregular bile duct, the tip of the left triangular ligament must be oversewn with a suture ligation.

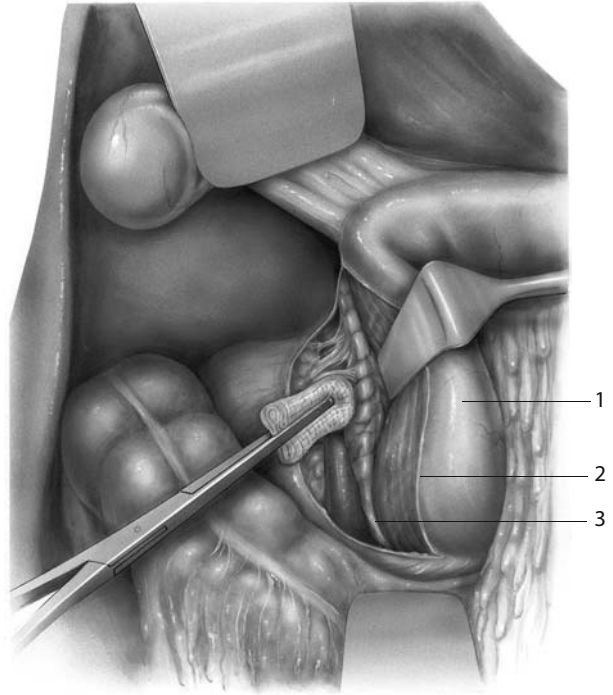


■ **Mobilization of the duodenum by an extensive Kocher maneuver.** This maneuver is always necessary in case of a very small stomach to allow a tension free gastric tube transposition to the

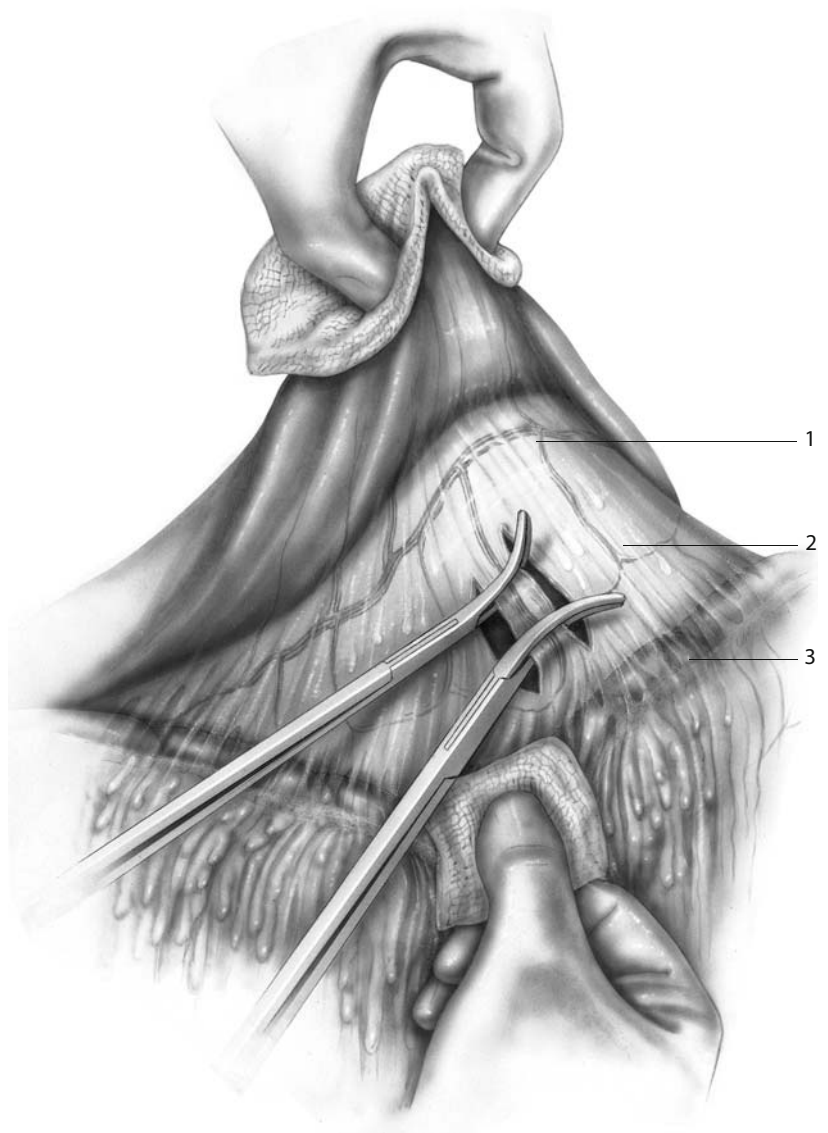
neck. In the situation of a normal anatomy, a tension free gastric tube transposition to the neck is also possible without mobilization of the duodenum.



**Fig. 13.6.** Mobilization of the duodenum by the Kocher maneuver. While the duodenum is being retracted medially, the peritoneum is incised close to the border of the duodenum. 1 Duodenum; 2 Peritoneum.

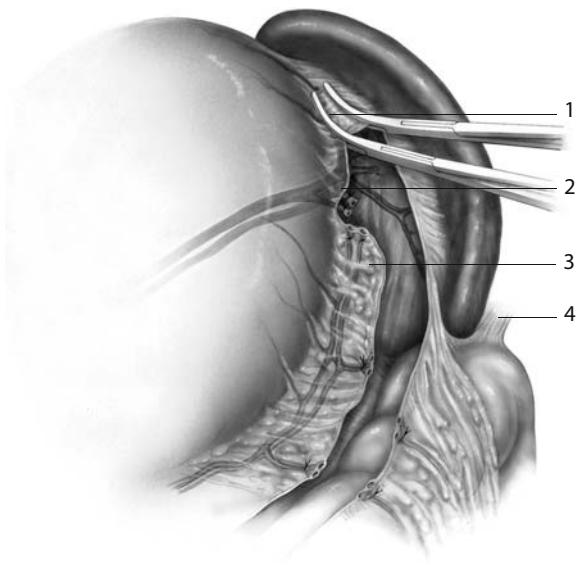


**Fig. 13.7.** Blunt dissection of the avascular plane between the duodenum, the head of the pancreas, and the retroperitoneal vessels until the anterior wall of the inferior vena cava is exposed. 1 Duodenum; 2 Peritoneum; 3 retroperitoneal vessels.

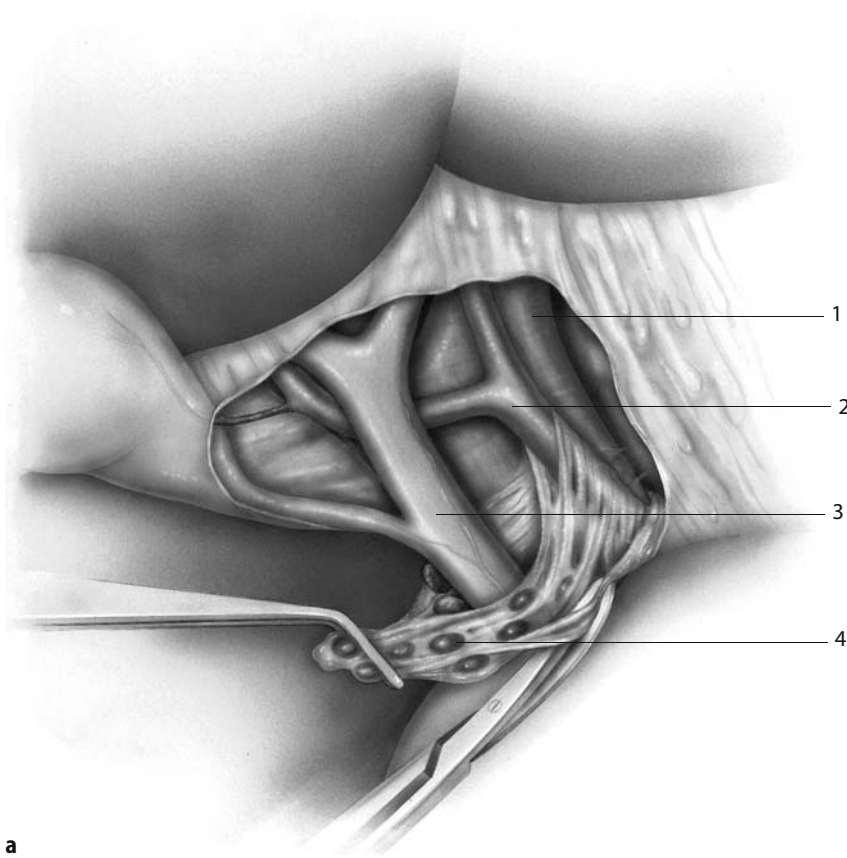


**Fig. 13.8.** Skeletonization of the greater curvature is commenced from below, care being taken to spare the left and right gastro-epiploic vessels up to the level of the splenic hilum. Moderate traction on the transverse colon and countertraction at the stomach results in proper exposure of the gastrocolic ligament. The skeletonization of the gastrocolic ligament should be performed away from the greater curva-

ture, thus avoiding any possible damage to the gastroepiploic vessels. **1** A. and V. gastroepiploica dextra; **2** Lig. gastrocolicum; **3** Colon transversum. Alternatively the skeletonization of the gastric tube can be performed using an automatic clip-applicator and cutter (multifire). Direction right to left and afterwards left to right.

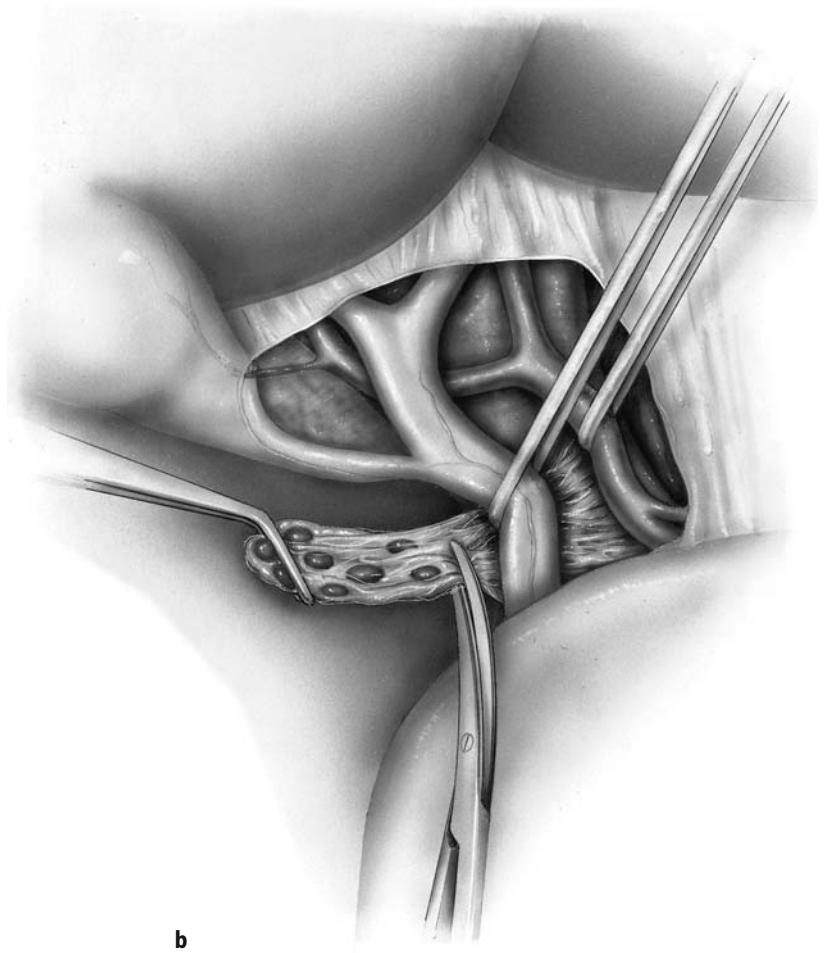


**Fig. 13.9.** Skeletonization of the greater curvature is continued towards the spleen. For preservation of the blood supply, the dissection must be performed well away from the stomach wall. Next the left gastroepiploic artery is transected directly at its origin at the splenic artery. In this way, an existing anastomosis between the left and right gastroepiploic arteries will be preserved, thus ensuring that the blood supply of the upper part of the gastric tube is maintained. **1** Gastrosplenic lig.; **2** splenic artery; **3** left gastroepiploic vessels; **4** phrenicocolic lig.

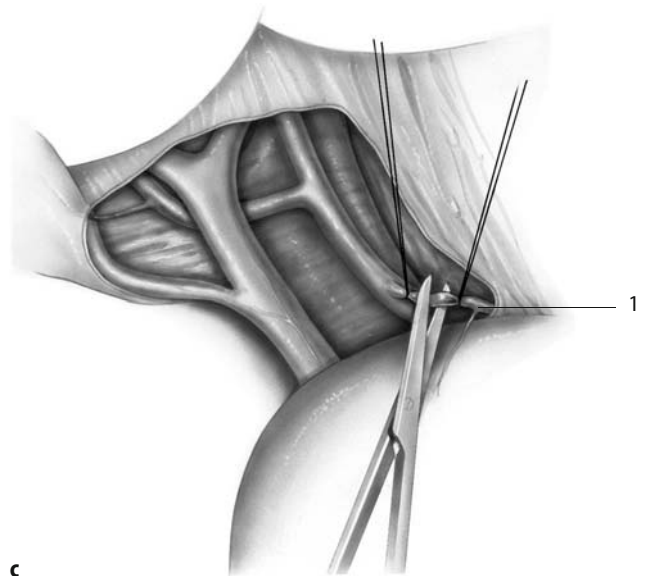


**a**

**Fig. 13.10. a** Lymphadenectomy in the area of the hepatoduodenal ligament. **1** Portal vein; **2** A. hepatica propria; **3** bile duct; **4** Lymphatic tissue.

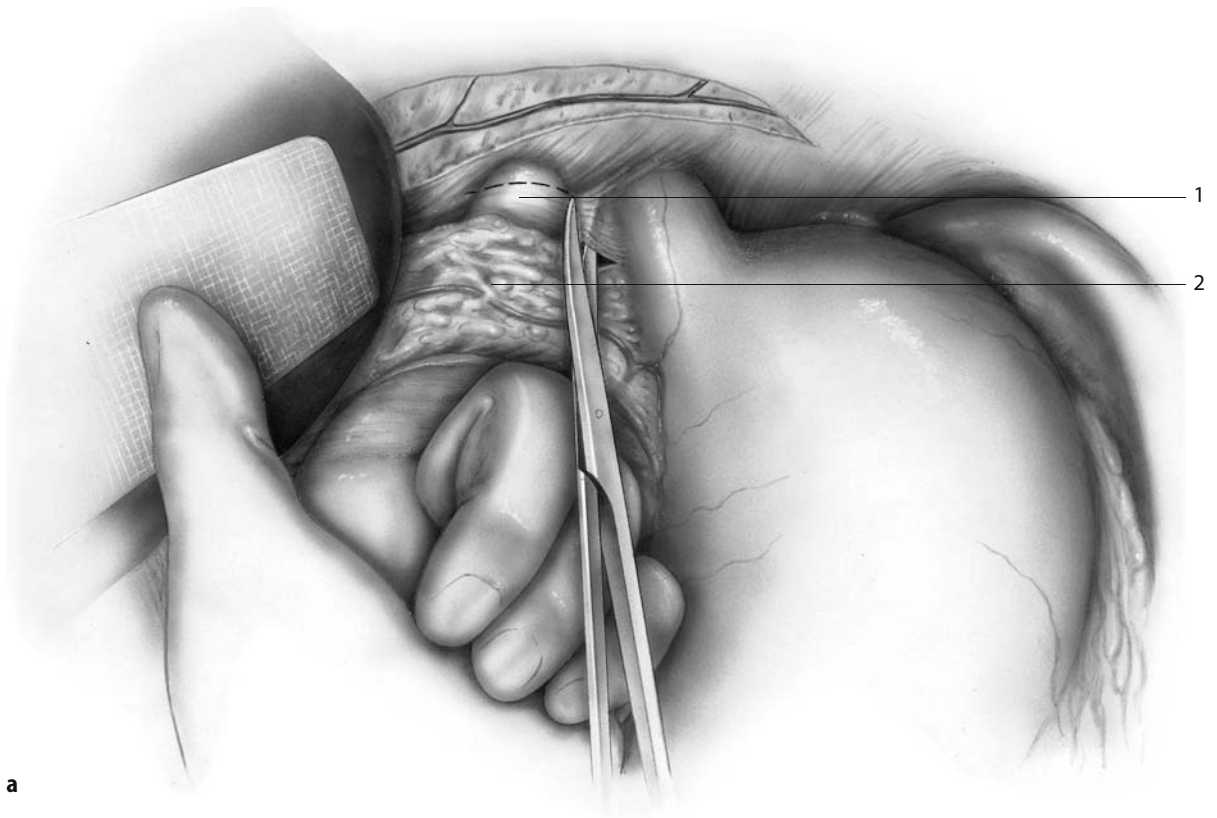


b



c

**Fig. 13.10.** **b** Dissection of the lymph nodes of the hepatic artery up to the celiac trunk, of the portal vein as well as the lymphatic tissue around the common bile duct is removed. **c** Division of the gastroduodenal artery. **1** A. gastrica dextra.



**Fig. 13.11 a–c.** Dissection of flaccidal part of the lesser omentum. The cranial part of the hepatogastric ligament (hepatoesophageal lig.) is tunneled with the finger and dissected from the diaphragm with electrocautery. Check for an

existing relevant accessory left hepatic liver artery which should be preserved. **1** Hepatooesophageal lig.; **2** accessory left hepatic artery.

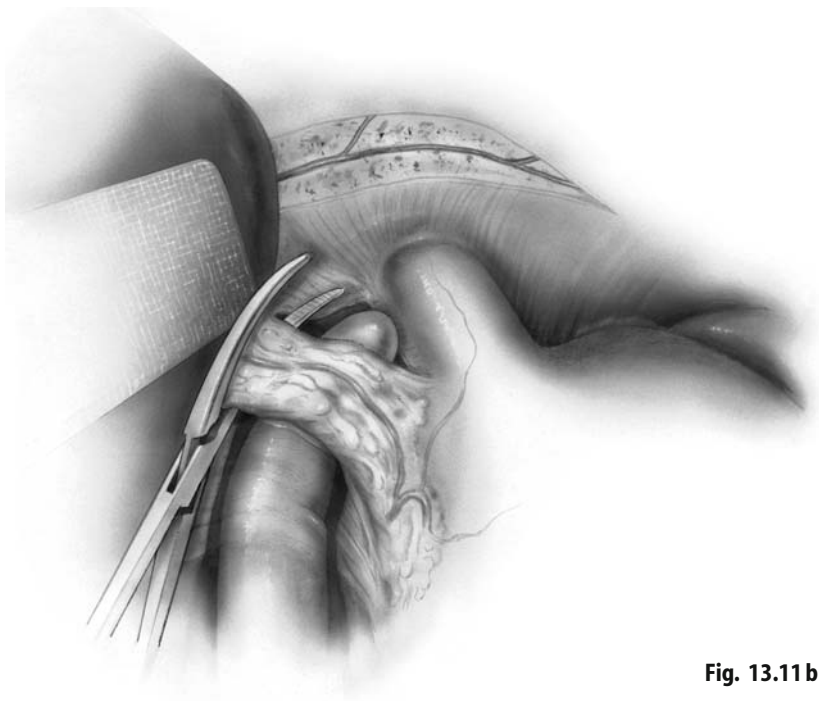


Fig. 13.11 b

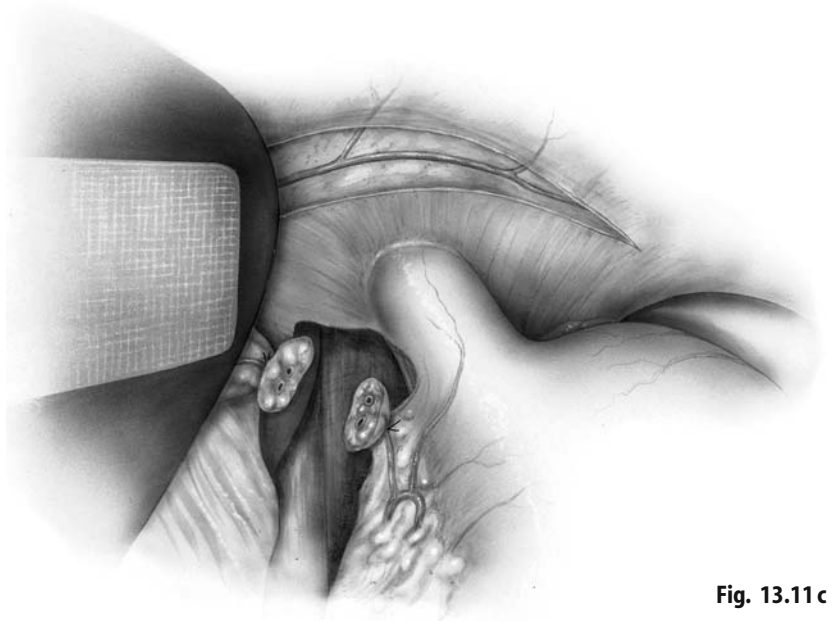
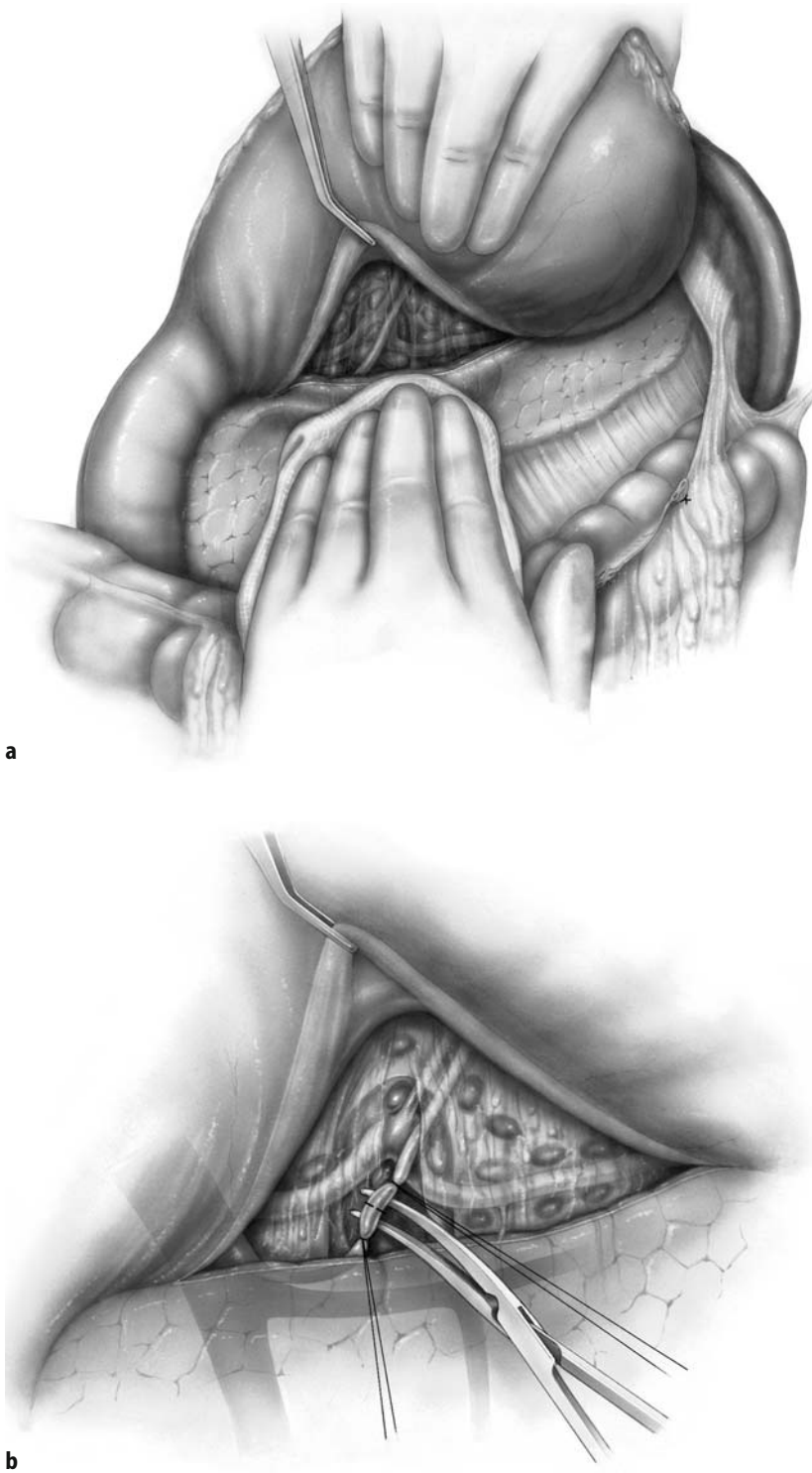


Fig. 13.11 c



**Fig. 13.12.** **a** After transection and ligation of short gastric vessels, the greater curvature can be positioned cranially and anteriorly, the parietal peritoneum is incised at the upper pancreatic margin. **b** Transection of left gastric vein is done between suture ligations. **c, d** In case the left gastric vein runs behind the left gastric artery, attention is focused

not to ensure this structure during the dissection of the left gastric artery.

All lymph nodes along the left gastric artery, the splenic artery, the common hepatic artery, the celiac trunk, and para-aortic lymph nodes are removed. This phase of the operation ends with the ligation of the left gastric artery.

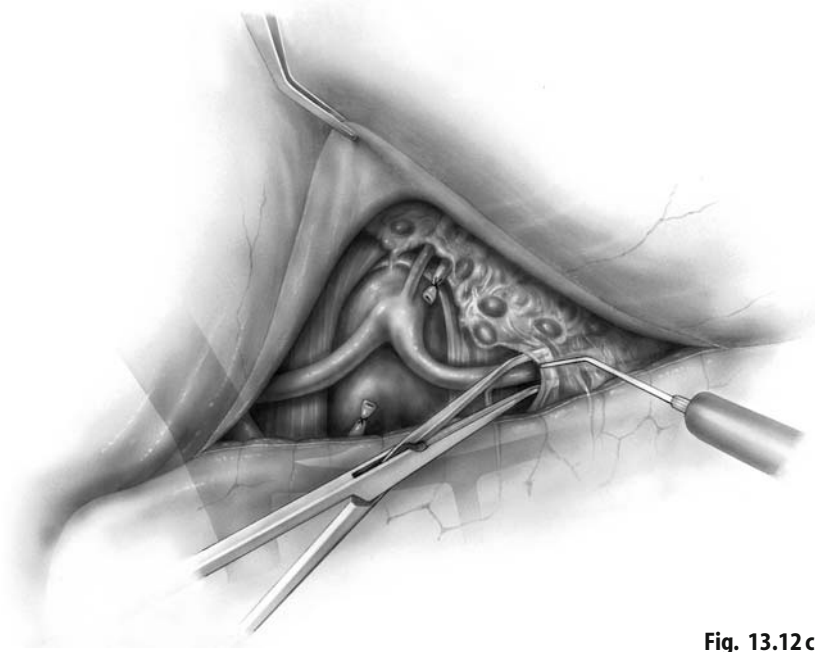


Fig. 13.12c

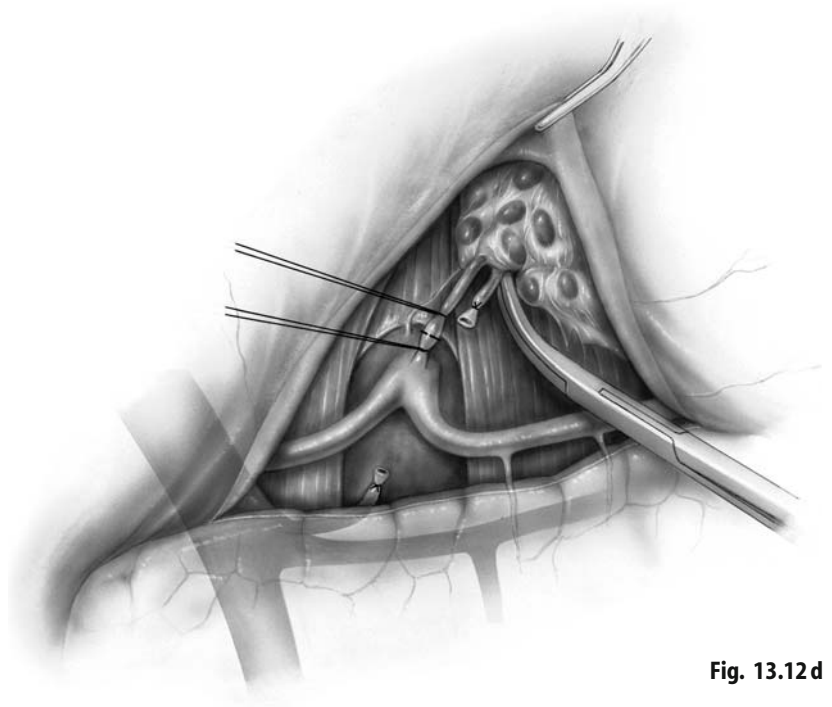
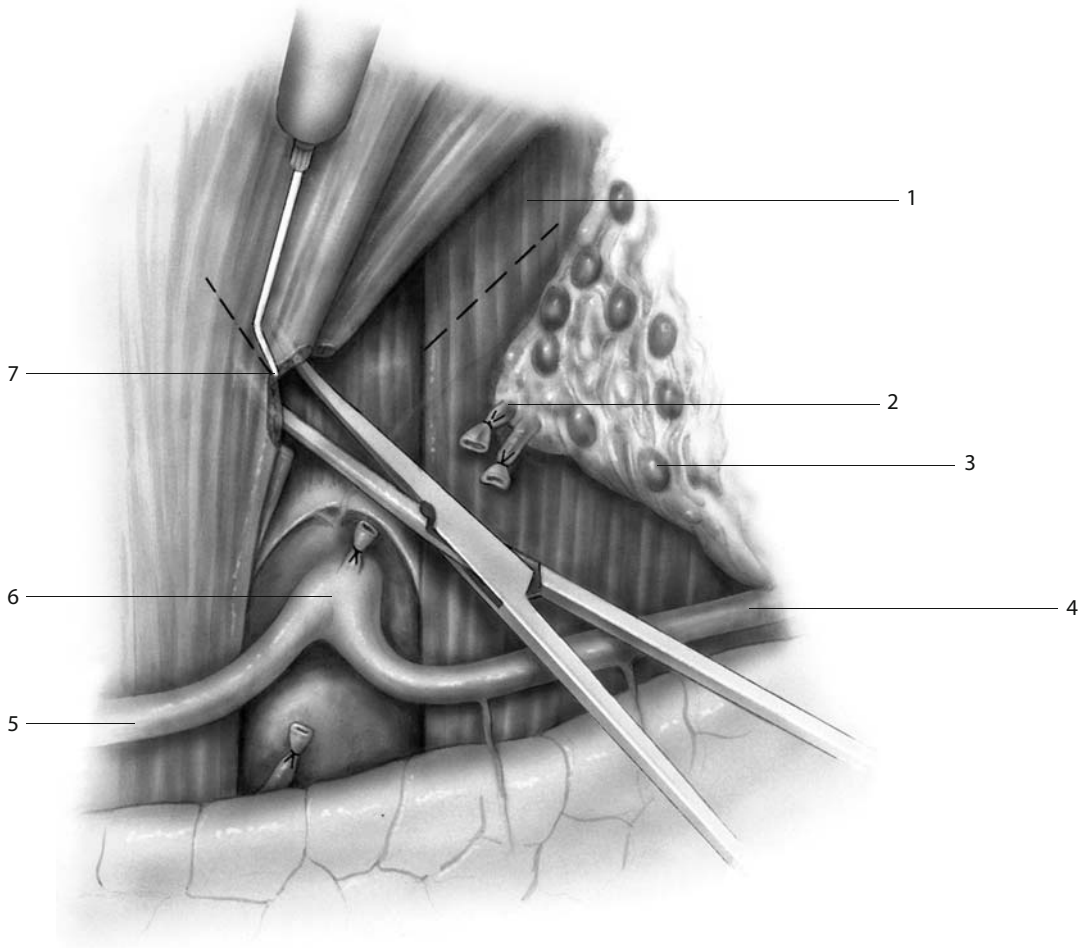


Fig. 13.12d

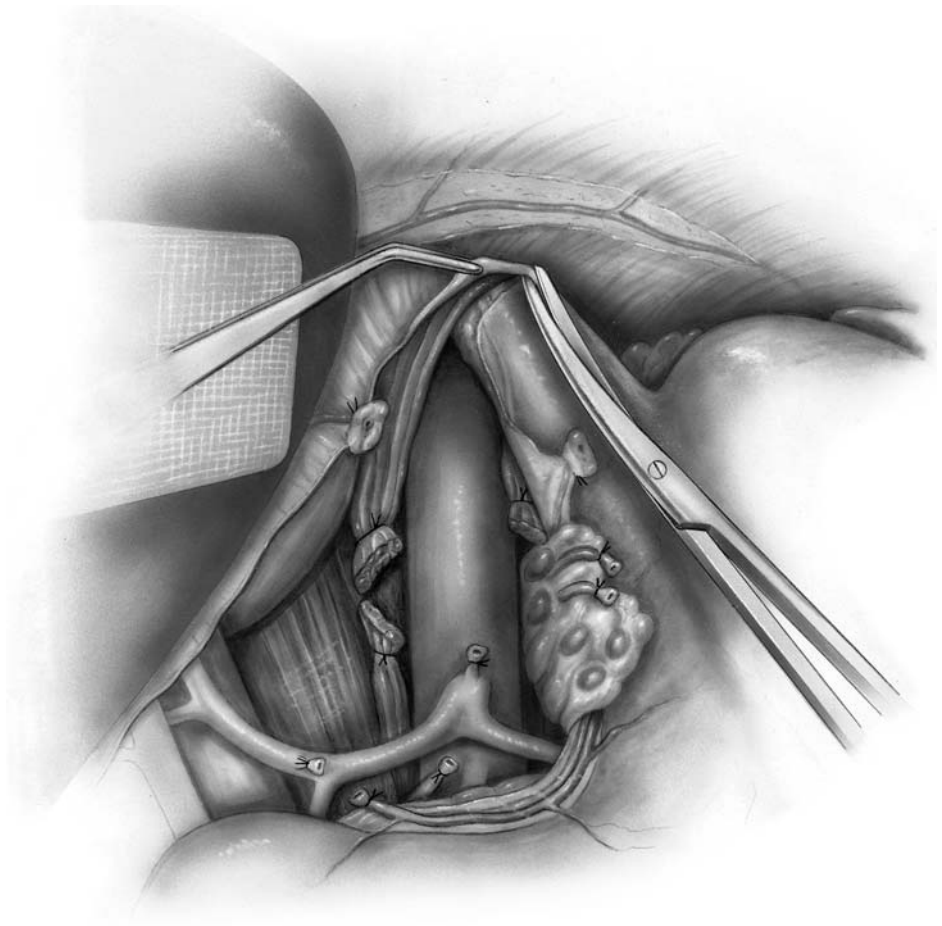


In case of a blunt transhiatal esophageal dissection for benign reasons, lymphadenectomy should be omitted.



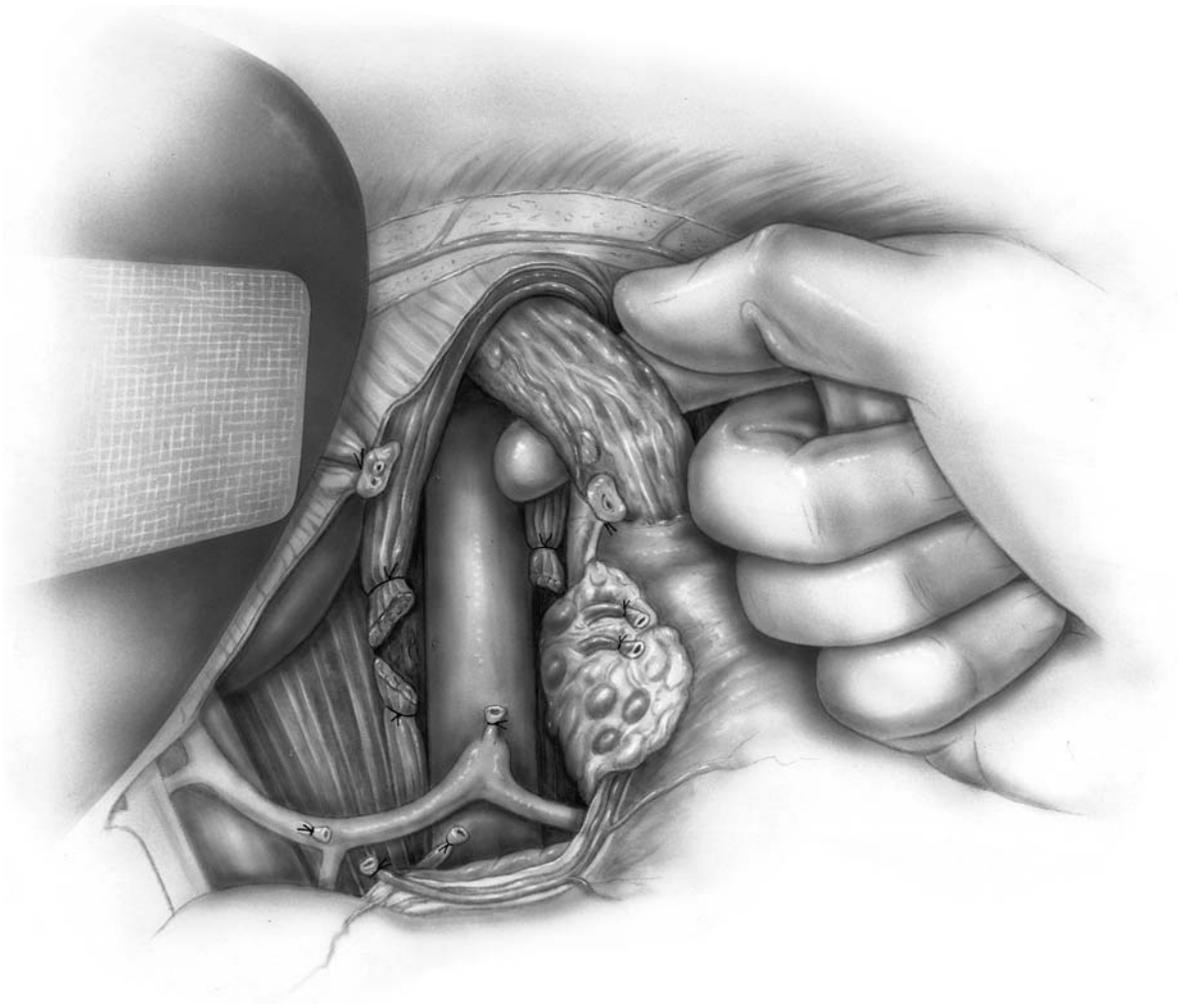
**Fig. 13.13.** After lymphadenectomy of the celiac trunk, splenic artery, and common hepatic artery, the lymphatic dissection is continued along the celiac trunk to the paraaortic region. Lymphatic tissue thus remains adherent en bloc with the lesser curvature and is later resected en bloc with the tumor. For better exposure of the esophageal hiatus and the

paraaortic region, the diaphragmatic crura are incised with diathermia and the stumps are ligated (see below Fig. 13.15). **1** Left diaphragmatic crus; **2** Left gastric artery; **3** Lymph nodes; **4** Splenic artery; **5** Hepatic artery; **6** Celiac trunk; **7** Incision of the right diaphragmatic crus (interrupted line on both sides).

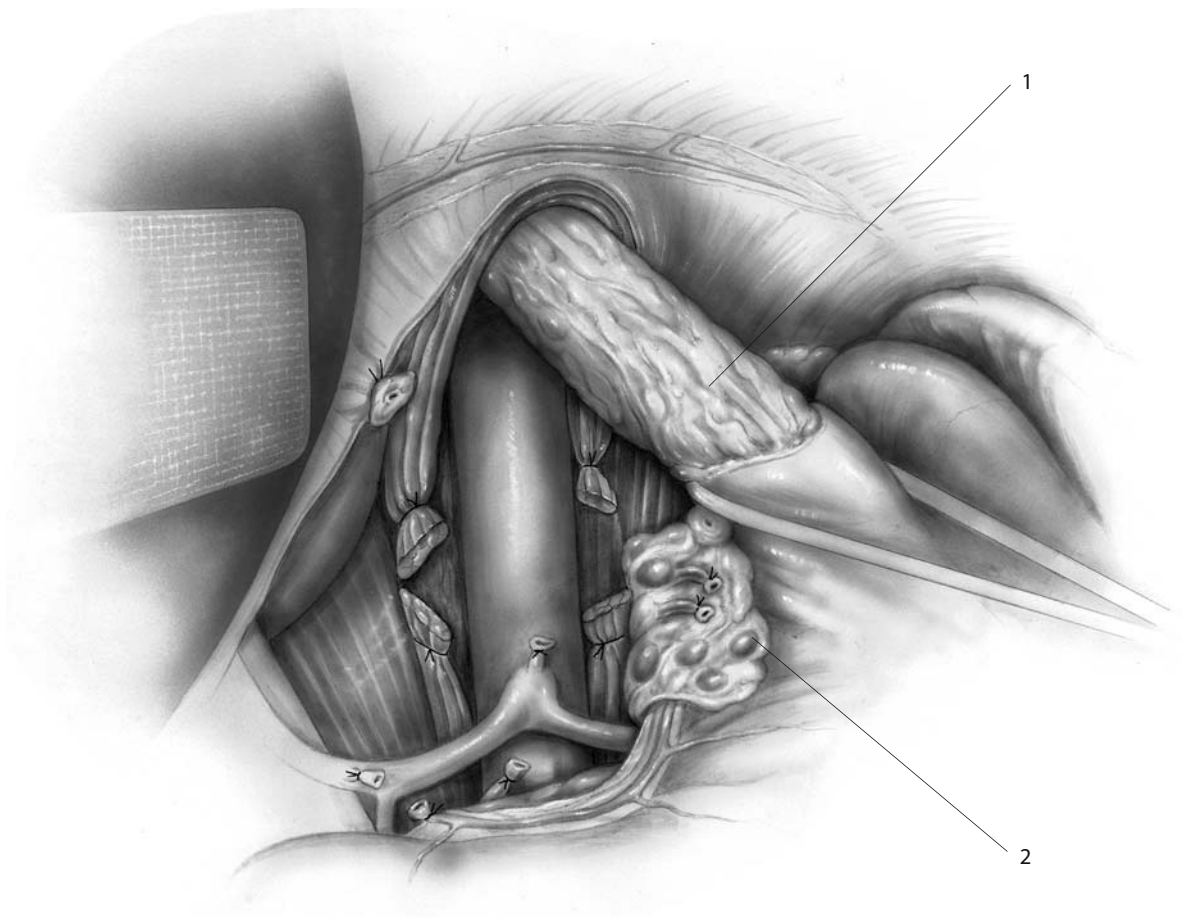


**Fig. 13.14.** Sharp transection of the phrenicoesophageal ligament at the margin of the esophageal hiatus. This step is facilitated by transection to the cardia caudally with an abdominal pad. Thus the diaphragmatic crura become exposed

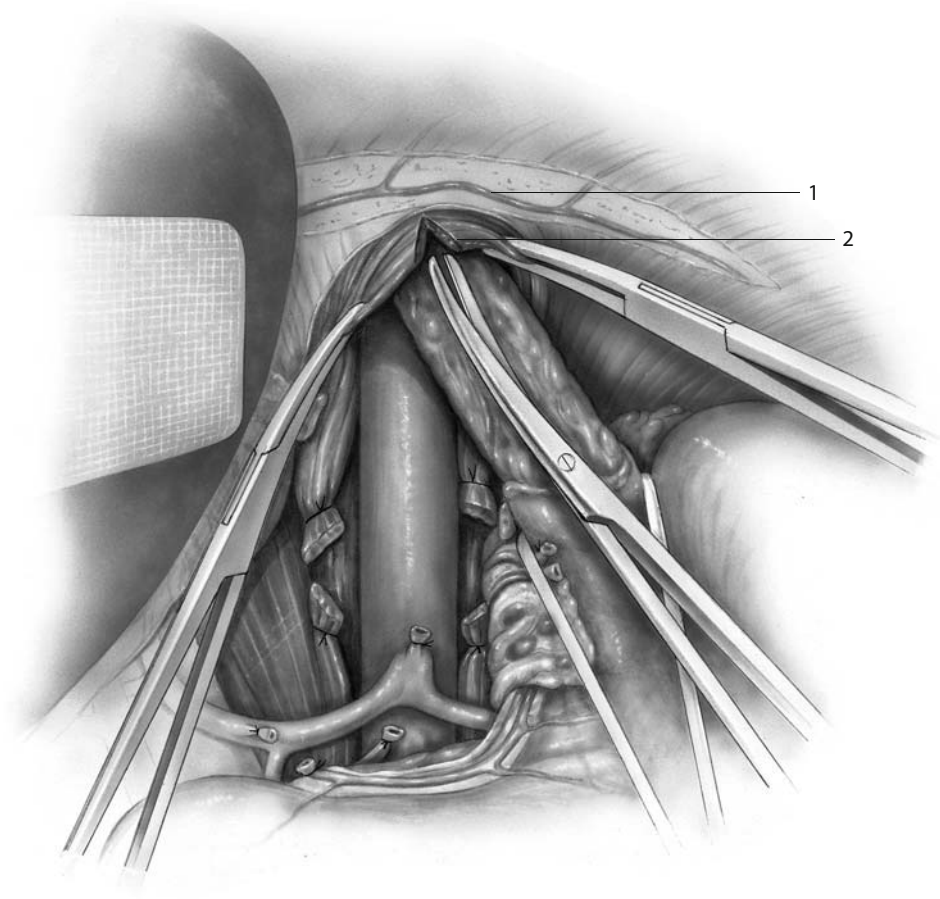
to the left and right side of the esophagus. Next, transection and ligation of the gastrophrenic ligament between clamps at the esophagogastric angle of His is undertaken.



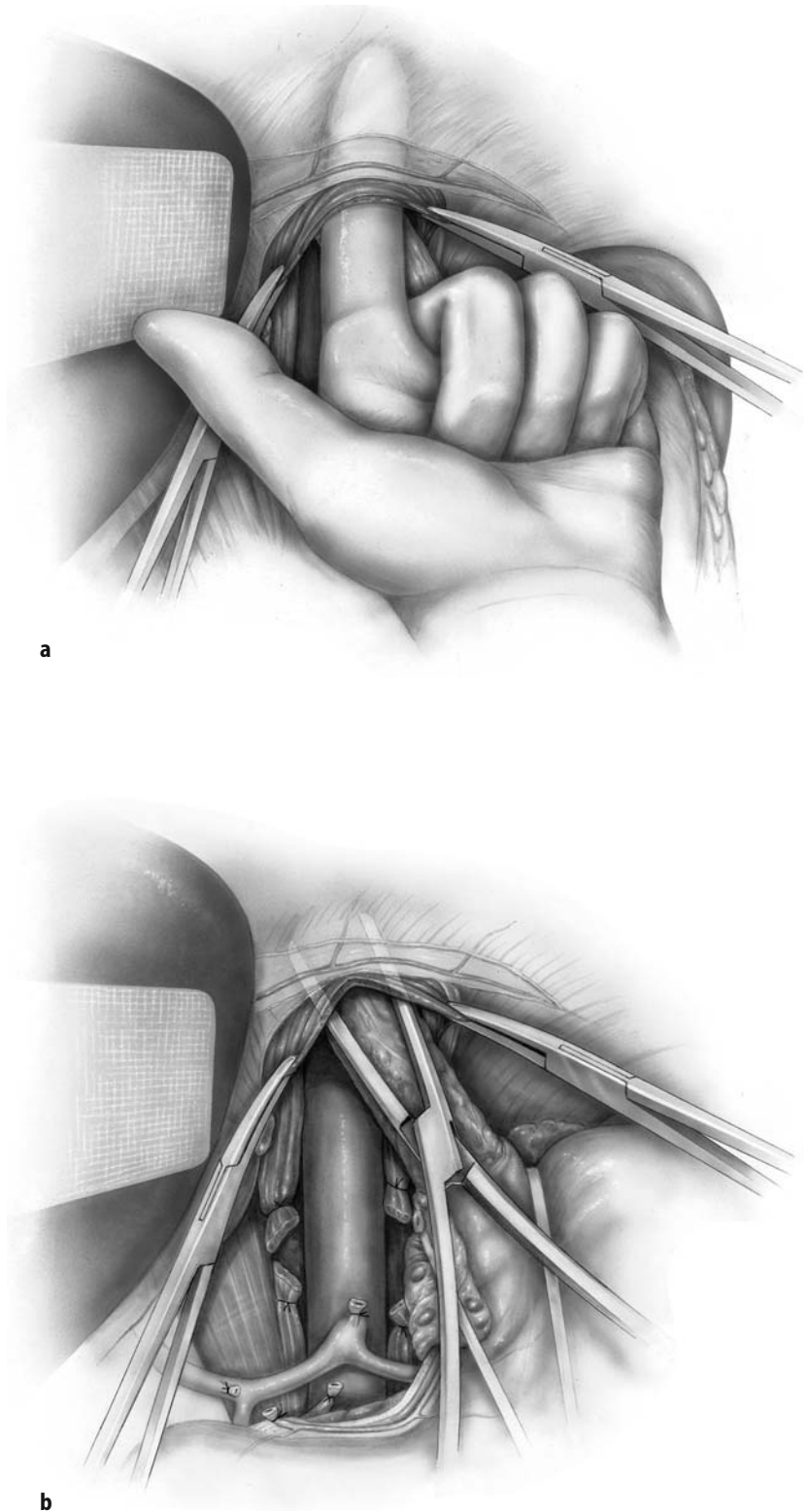
**Fig. 13.15.** Blunt mobilization of the esophagus with the index finger. During this maneuver connective tissue fibers between esophagus, diaphragmatic crus, and abdominal aorta must be removed carefully. The esophagus is armed with a rubber tube using a curved clamp.



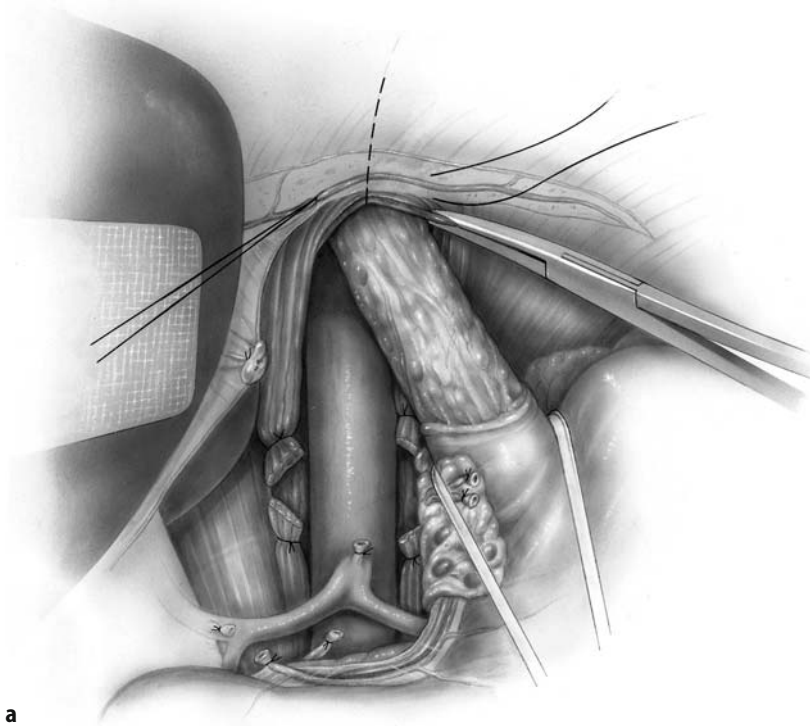
**Fig. 13.16.** The abdominal esophagus is mobilized and caudal traction is applied with the rubber tube. Identification of anterior and posterior vagus nerve. **1** Vagus nerve with branches; **2** paraaortic and paraceliac lymphatic tissue.



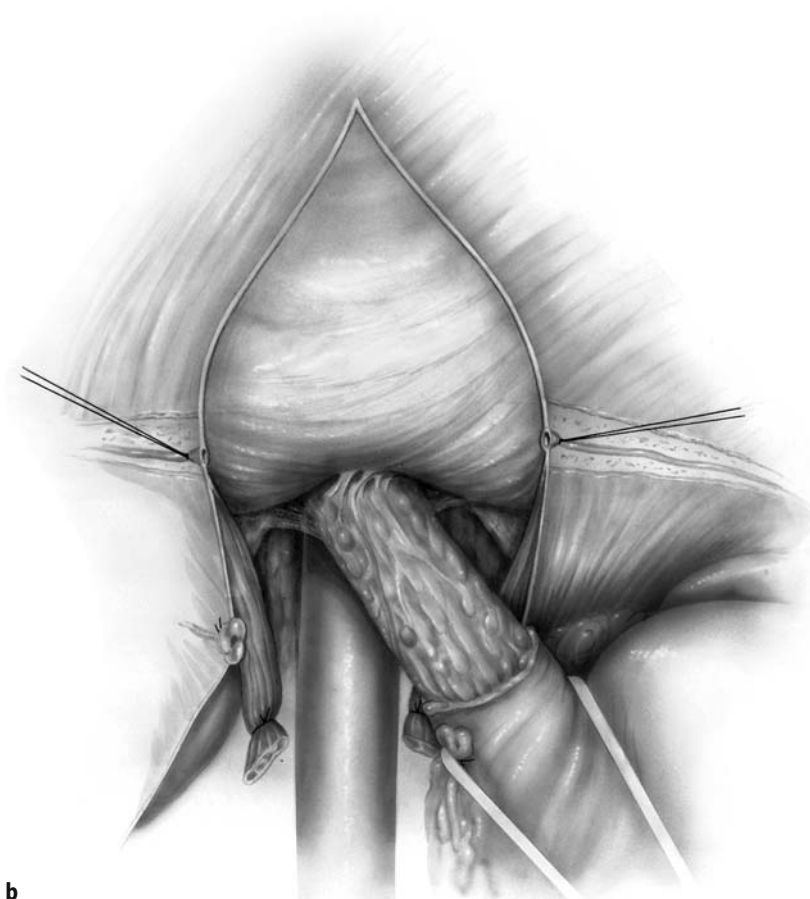
**Fig. 13.17.** For a better exposure of the distal esophagus, it is incised up to the inferior left phrenic vein with scissors or diathermy. Continuous traction should be applied during this part of the procedure. **1** Phrenic vein; **2** Diaphragm.



**Fig. 13.18a,b.** The esophagus is mobilized anteriorly by blunt dissection of the plane. The fingers are used to separate the diaphragm and pericardium from the esophagus.

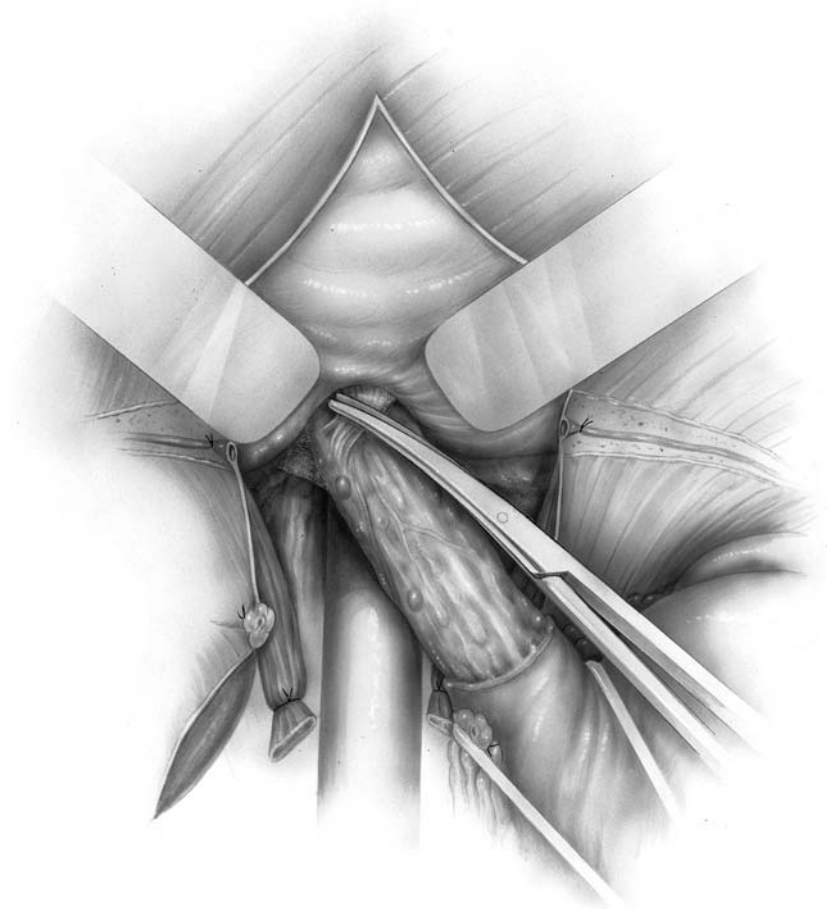


a



b

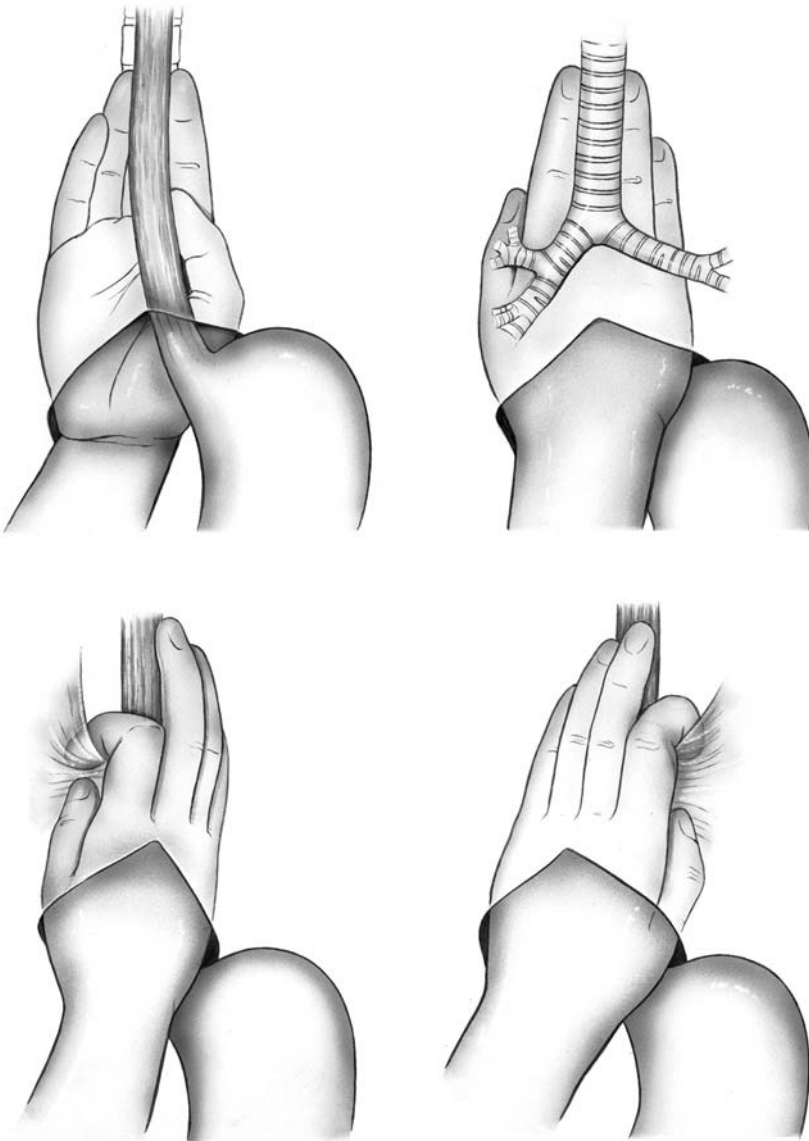
**Fig. 13.19 a,b.** Transection of the left inferior phrenic vein is suture ligated and transected and the diaphragm is incised up to the central portion. Exposure of the pericardium. Insertion of Mikulicz retractors, which are pulled upward to the left and to the right.



**Fig. 13.20.** Dissection of the distal esophagus starts with sharp dissection of the anteriorly esophageal surface from the pericardium. As a rule the dissection can be continued anteriorly under vision up to the tracheal bifurcation with two fingers initially and finally using the whole hand.

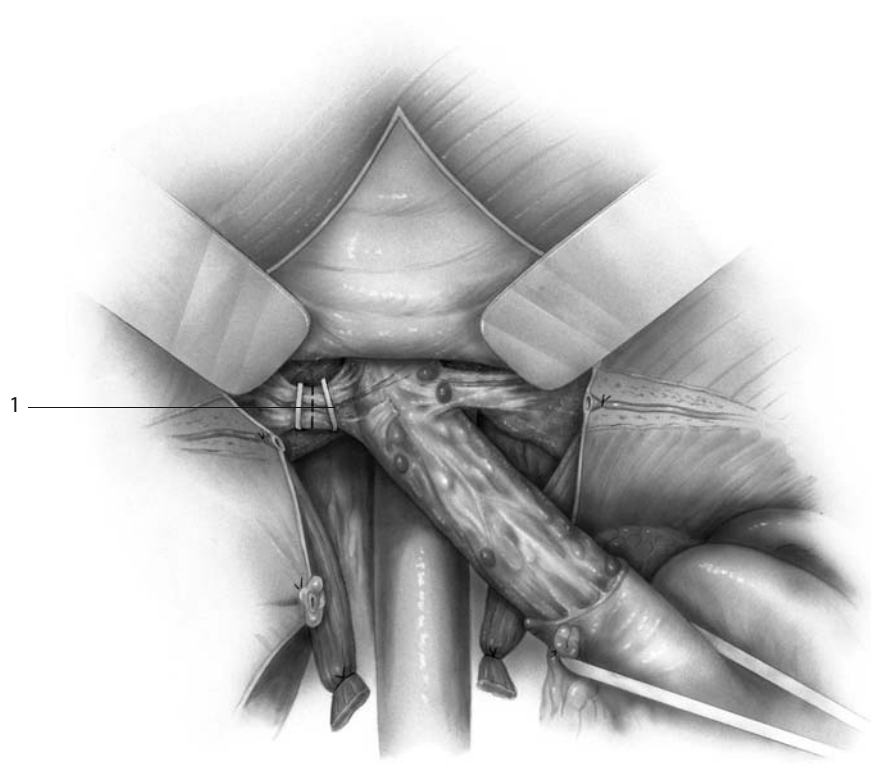
Injury to the pleural cavity should be avoided. Above the tracheal bifurcation the dissection is done bluntly with two fingers, with the dissection plane directly along the esophagus. The trachea and the brachiocephalic trunk are palpable anteriorly.





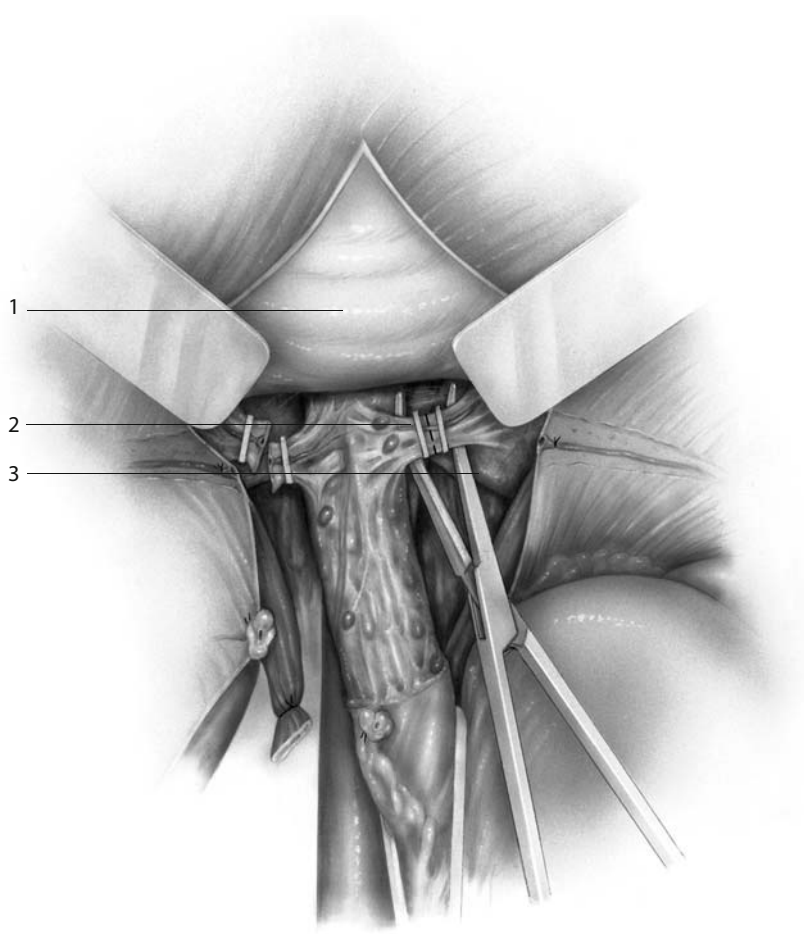
**Fig. 13.21.** Now we have reached the most critical stage of the procedure where complications can be lethal. If extensive local tumor growth has not been recognized during preoperative investigations, serious damage of the pars membranacea of the trachea, the azygos vein, the pulmonary vessels, or the aorta is possible. Extensive involvement of lymphatic tissue makes the blunt dissection more difficult, and also

makes complications more likely. In the same way mobilization of the region posterior to the esophagus including parasophageal lymphatic tissue from aorta and prevertebral fascia up to the tracheal bifurcation is done sharply and under vision. Above the tracheal bifurcation the dissection is continued bluntly using digital dissection and staying close to the esophageal wall.



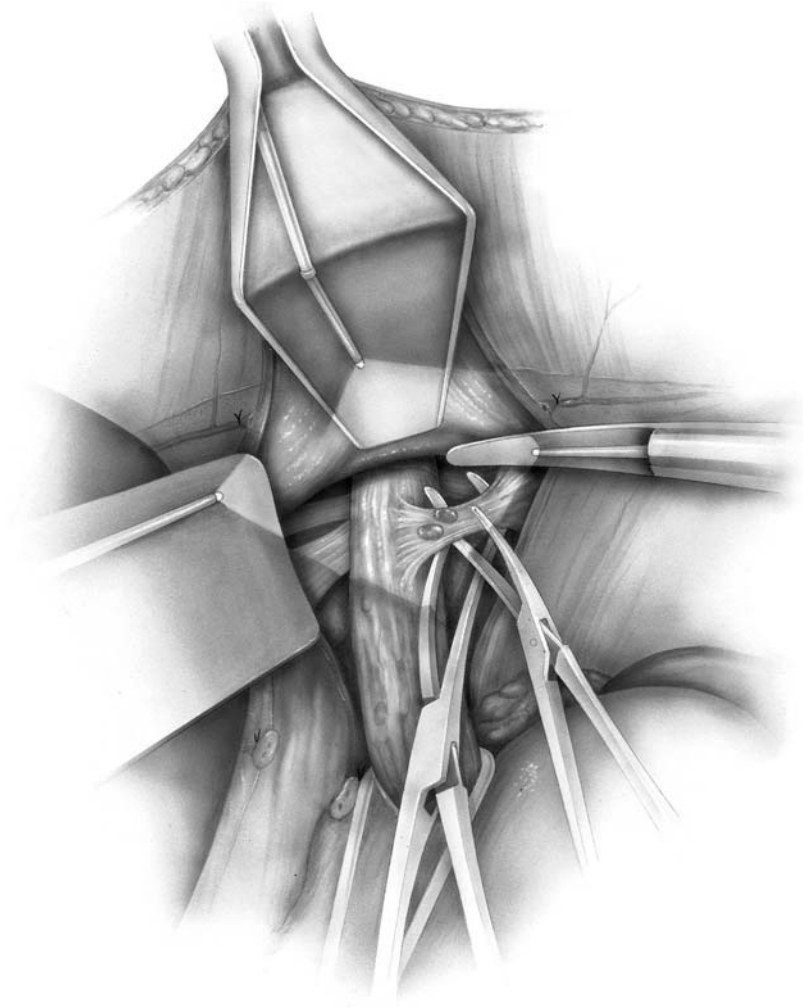
**Fig. 13.22.** Great care must be taken to avoid damage to the lateral esophageal wall and the parietal pleura. After complete anterior and posterior mobilization, the esophagus is pulled caudally. This causes the lateral ligament like structures to tighten. These so called lateral esophageal ligaments consisting of branches of the vagal nerves, pulmonary liga-

ments and esophageal branches should be transected sharply between clamps. Alternatively clips can be used for this step. The left lobe of the liver is moved to the right using Mikulicz retractors. Strong retraction of the esophagus to the left using a rubber tape facilitates transection of the right lateral esophageal ligament. **1** Right lateral esophageal ligament.

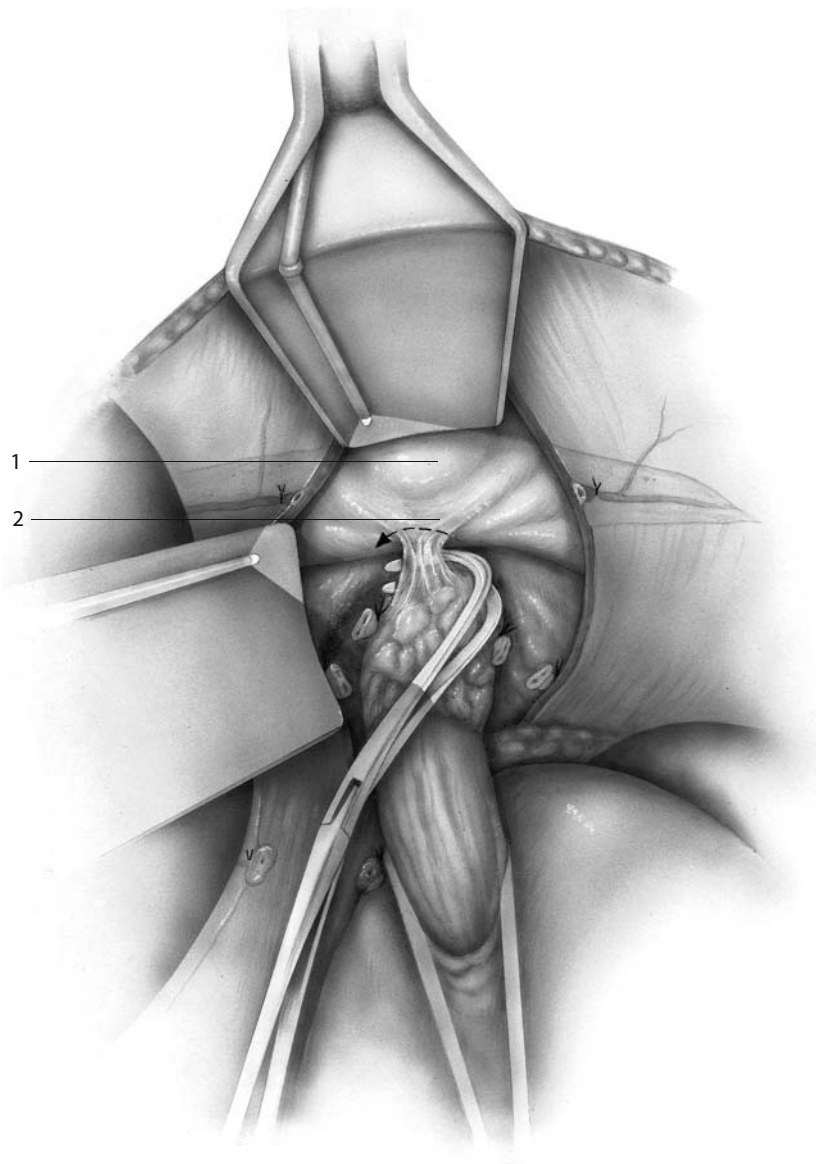


**Fig. 13.23. a** Dissection of the left lateral esophageal wall including all lymph nodes and surrounding tissue is carried out under direct vision. This step should be performed using mediastinal retractors. For better exposure optimal light from ceiling lights or from lights directly attached to the mediastinal retractors should be used. **b** The left lateral esophageal ligament should be ligated carefully. During this step it is important to proceed close to the aorta and under direct division. This ensures that all esophageal branches from the des-

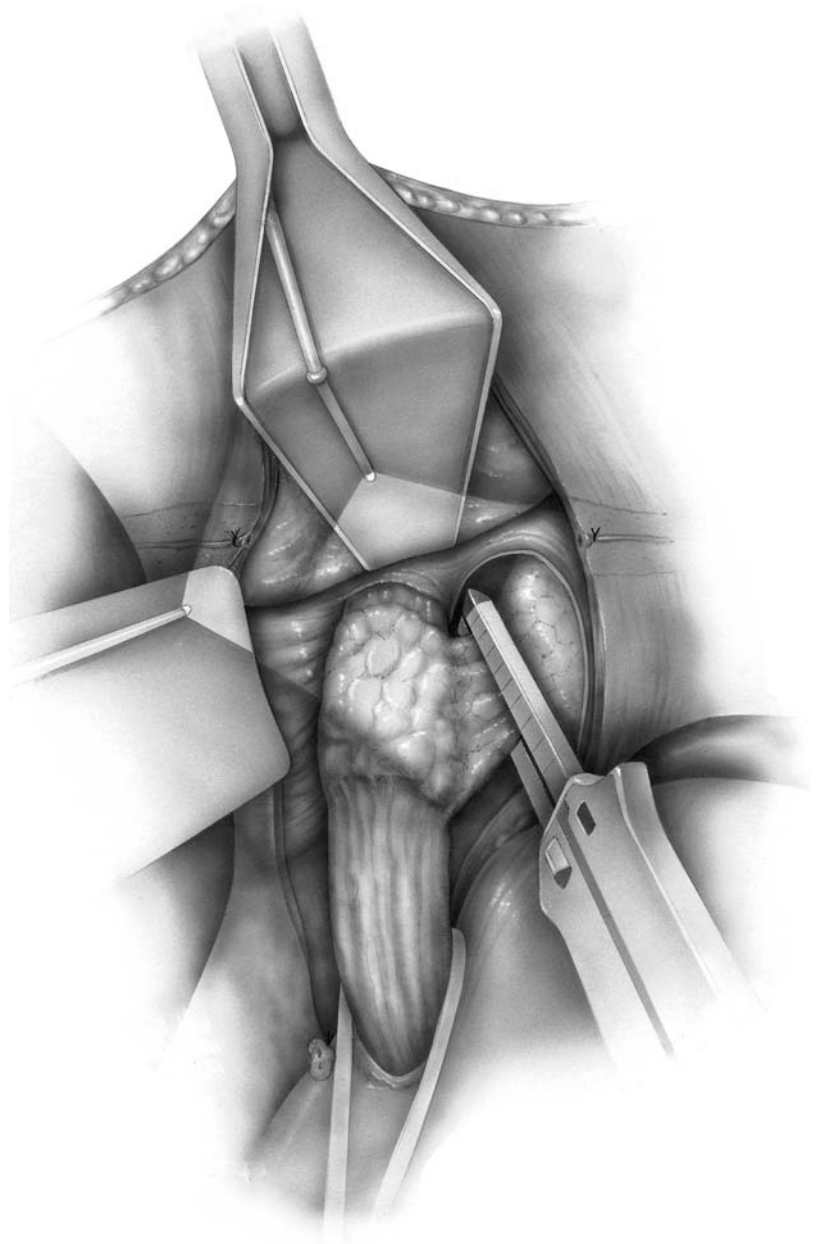
cending aorta are divided without bleeding. It is important to ligate the left lateral esophageal ligament very carefully at the level of the eighth vertebral body (T8), since the largest esophageal branches of the aorta originate from there. Any bleeding from esophageal branches is controlled by suture ligation close to the aorta using resorbable or nonresorbable monofilament suture. **1** Pericardium; **2** left esophageal ligament; **3** mediastinal pleura.



**Fig. 13.23b**

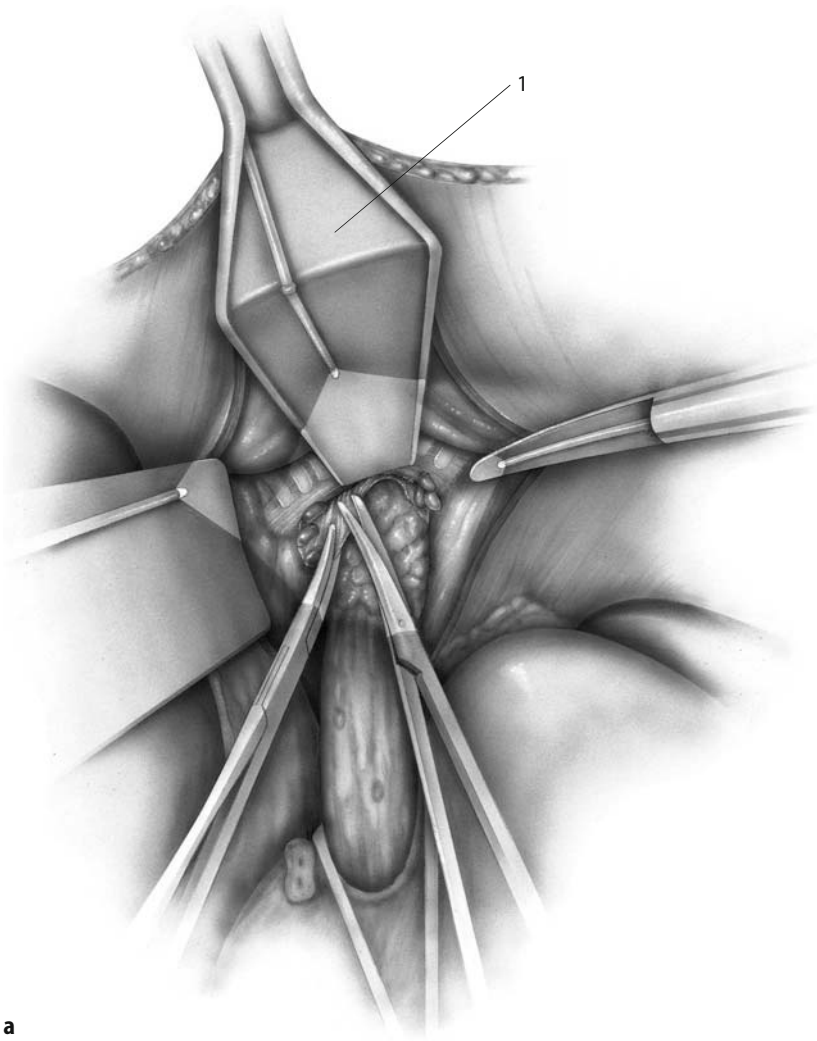


**Fig. 13.24.** In case of suspected pericardial infiltration, the adherent portion of the pericardium should be resected en bloc. **1** Pericardium; **2** pericardial resection margin.



**Fig. 13.25.** In case of tumor infiltration of the parietal pleura, the adherent part should be excised with a clear margin. The same applies for tumor infiltration of the mediastinal pleura

and lung. The diaphragmatic incision is enlarged and an en-bloc resection of the adherent lung segment using either a clamp resection or a linear stapler is performed.



**a**

**Fig. 13.26 a, b.** Ligation and dissection of the lateral ligament under direct vision up to a point directly proximal to the tracheal bifurcation. This step includes lymphadenectomy of the posterior mediastinum. **1** Light retractor; **2** Lymph nodes.

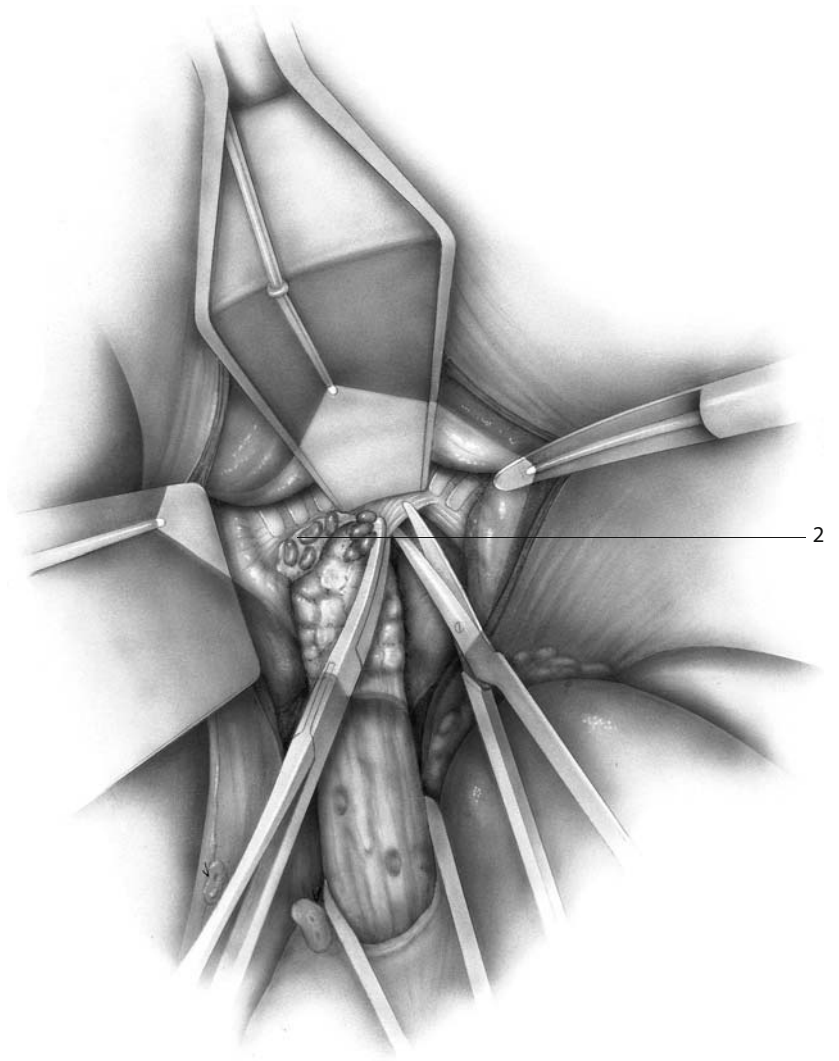
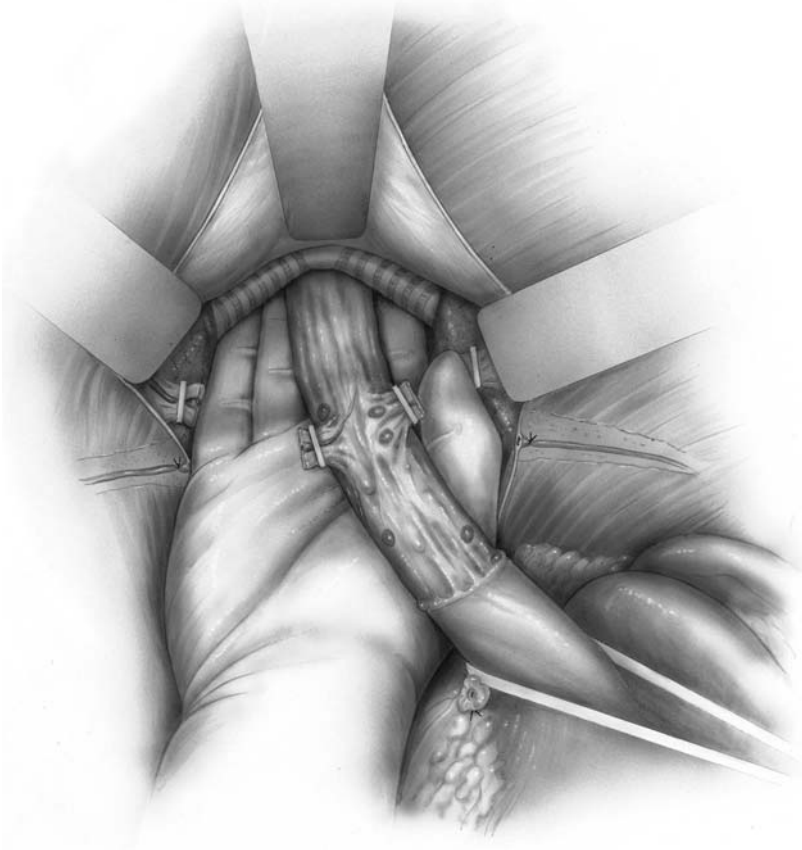


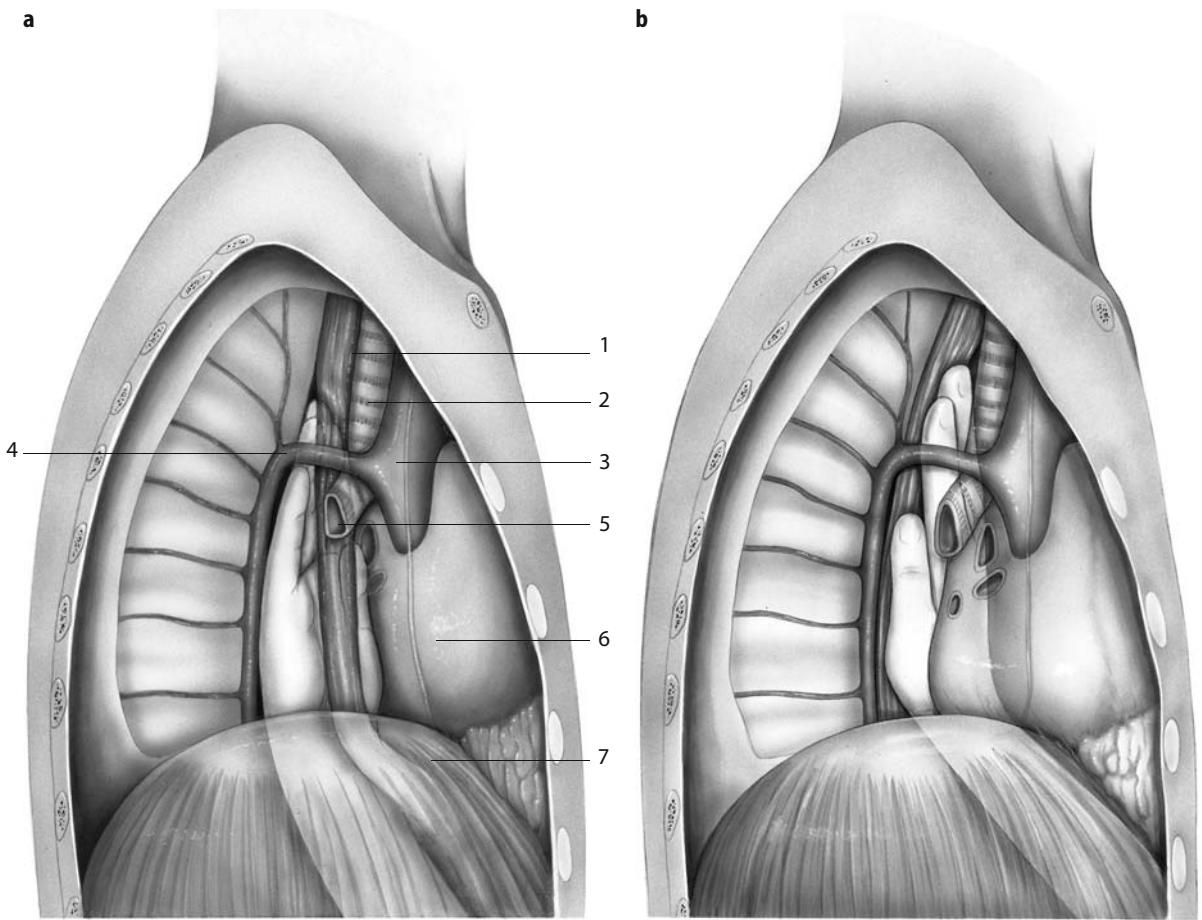
Fig. 13.26b





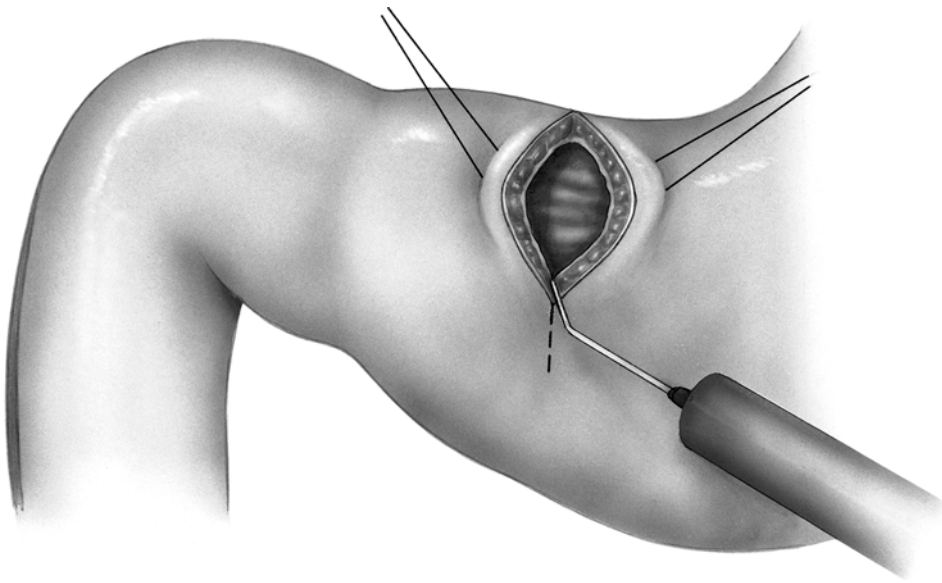
**Fig. 13.27.** After blunt dissection of the esophagus up to the thoracic inlet, pack gauze into the posterior mediastinum. This provides excellent hemostasis. In cases of scarring resulting from caustic burns, when multiple dilations with a bougie or even perforation may have occurred, the blunt dis-

section of the esophagus may prove impossible. In these cases sharp dissection of the esophagus under direct vision should be performed. Preparation close to the esophageal wall is mandatory to avoid injury of the adjacent structures.



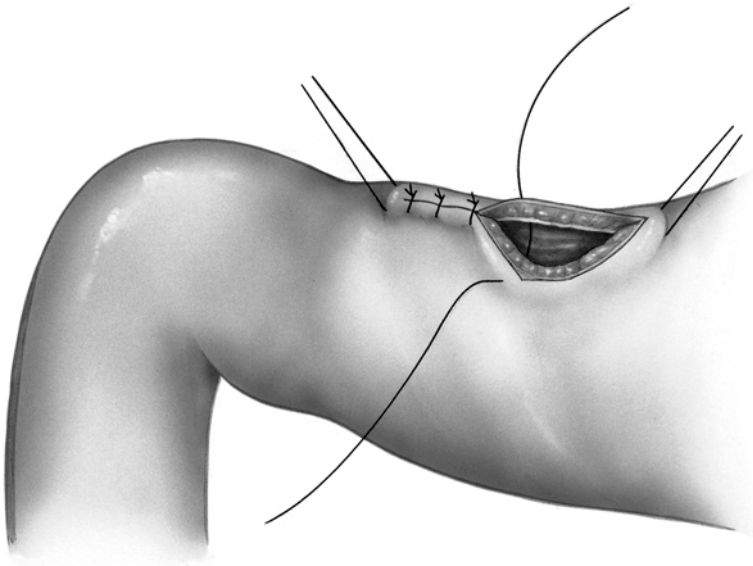
**Fig. 13.28 a, b.** There is no special order for the gastric ligature – starting with the left gastric artery is possible. The blood supply of the gastric tube after preparation is exclu-

sively provided by the right gastroepiploic artery. **1** Esophagus; **2** trachea; **3** superior vena cava; **4** azygos vein; **5** right bronchus; **6** pericardium; **7** diaphragm.



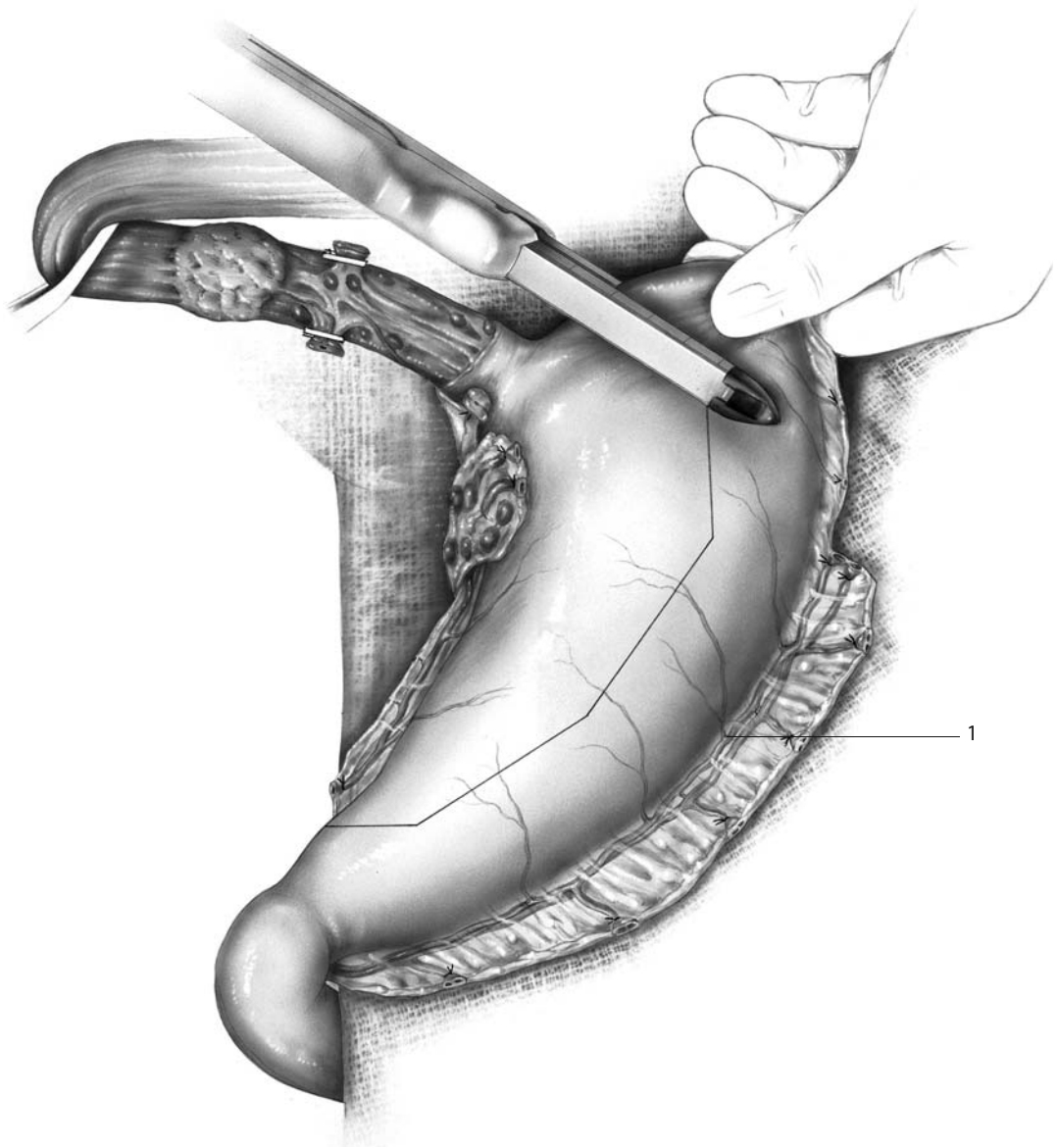
**Fig. 13.29.** Insert alternative: Transhiatal blunt esophageal dissection. Formation of the gastric tube. In case of a small stomach the first step in constructing an isoperistaltic gastric tube is to perform a transverse incision of the antrum 2.5–3.5 cm proximal to the pylorus. The incision starts at the

lesser curvature and is made for a distance of about half of the antral diameter. By doing the incision longitudinally a 3–4 cm elongation of gastric tube, which sometimes has a poor blood supply, can be resected if necessary during the performance of the cervical anastomosis.



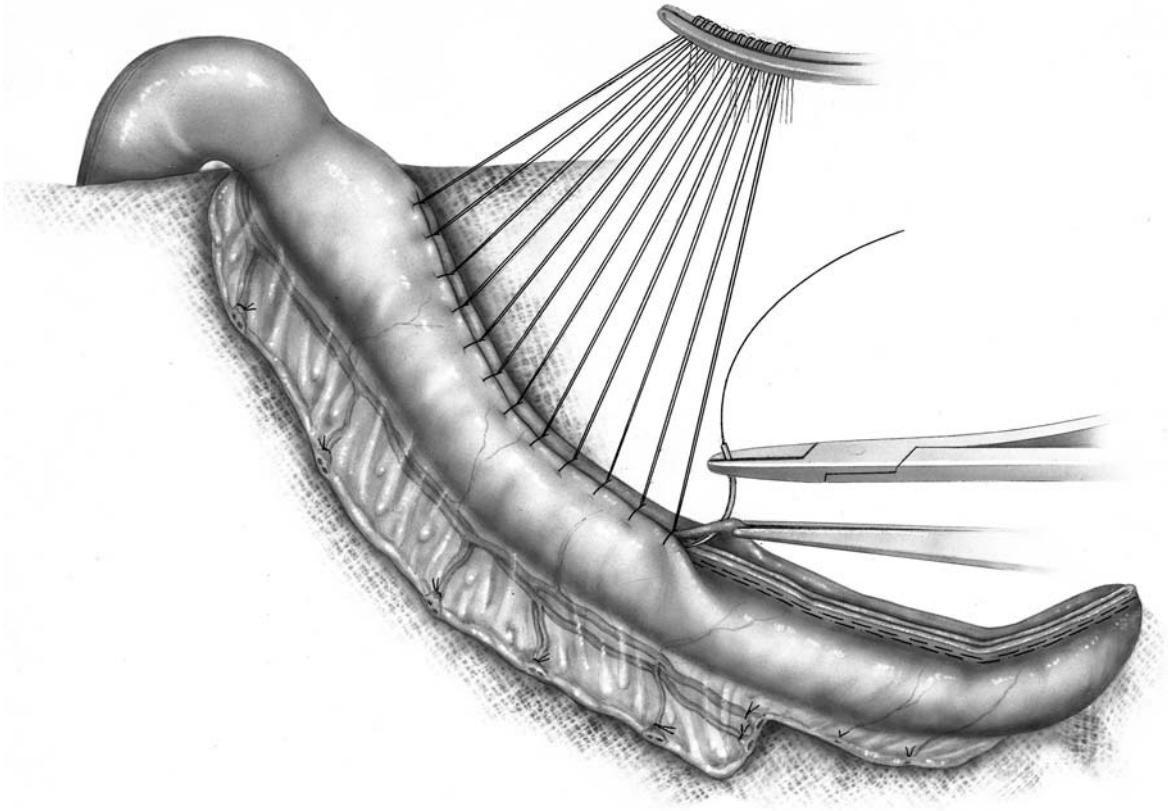
**Fig. 13.30.** Insert alternative: Transhiatal blunt esophageal dissection. Formation of a gastric tube. Stretch the transverse antrotomy and close longitudinally using a two-layer inter-

rupted suture. The optimal diameter of the gastric tube is 2.5–3 cm. Gastric tubes with a greater or lesser diameter may be associated with ischemia of the gastric wall.



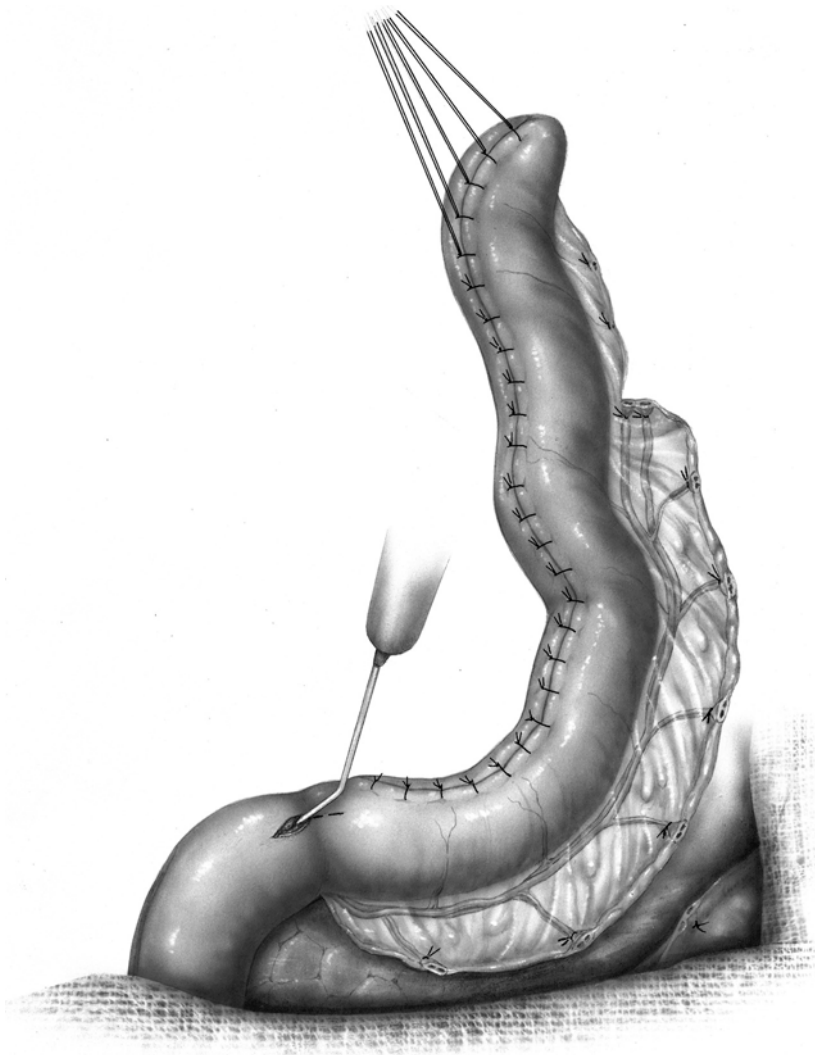
**Fig. 13.31.** Formation of an isoperistaltic gastric tube starts at the fundus. It follows the direction of the pylorus and is most easily performed with a stapler. The longer the stapler the less steps are needed. During the use of the stapler it is important to stretch the stomach longitudinally to avoid

shortening of the gastric tube caused by the stapler. To avoid gaps between the staple lines place the next stapler exactly behind the previous row of staples. **1** Gastroepiploic vessels.

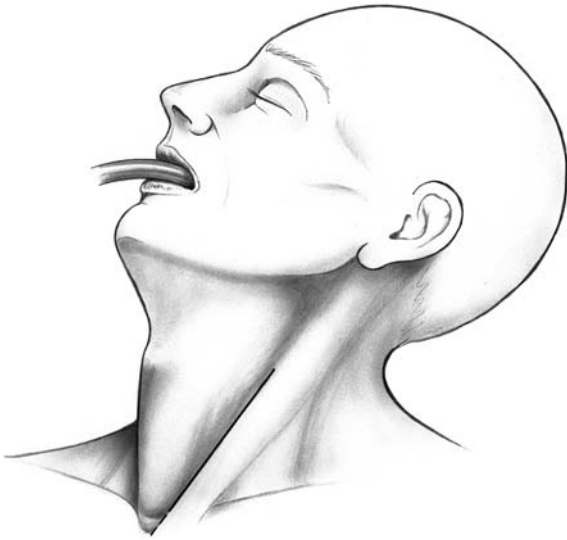

**Fig. 13.32.** A seromuscular suture is placed between two rows of staples to avoid leakage. Leave sutures long to keep the gastric tube stretched. Invert the stapled sutures by using seromuscular interrupted sutures. As mentioned above,

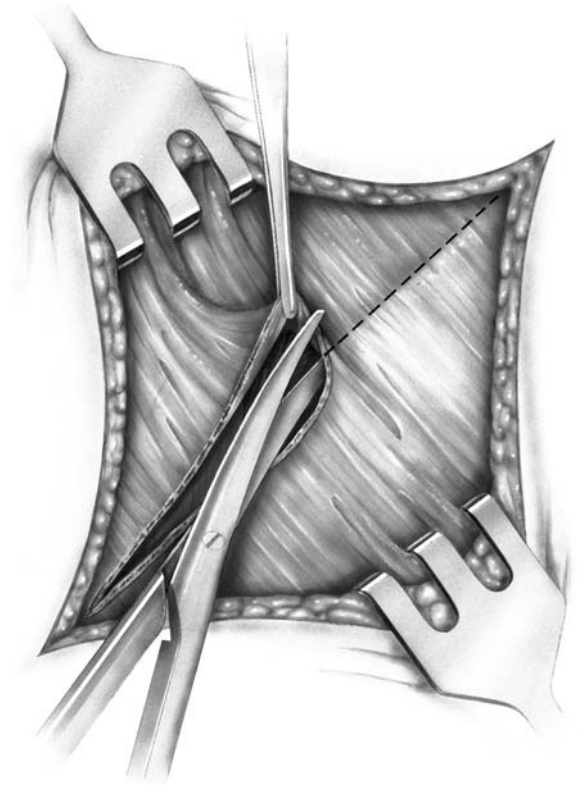
the diameter of the gastric tube should be 2.5–3 cm after inversion of the stapled sutures. The sutures at the top of the gastric tube are left long for the transthoracic transposition performed later on.



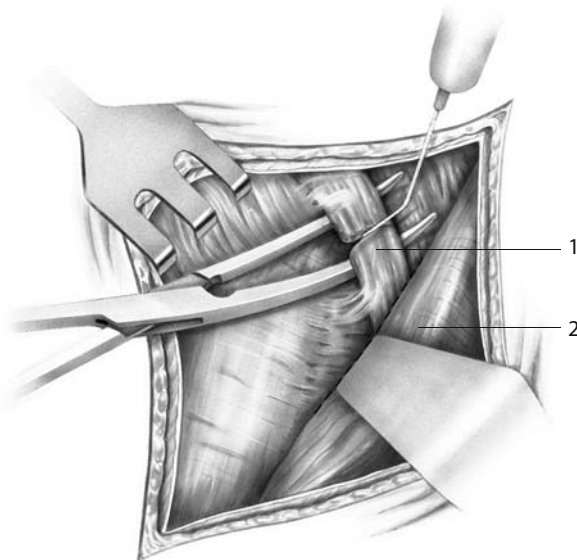
**Fig. 13.33.** A pylorotomy is necessary only when the whole stomach is used to avoid gastric outlet obstruction. By using the described procedure resulting in a gastric tube, a pylorotomy is not necessary.




**Fig. 13.34.** Cervical stage. For better exposition of the operative field, the patient is placed with an extended neck and head turned to the right. Oblique incision of the skin extending from the jugular notch to the level of the thyroid cartilage along the anterior rim of the sternocleidomastoid muscle.



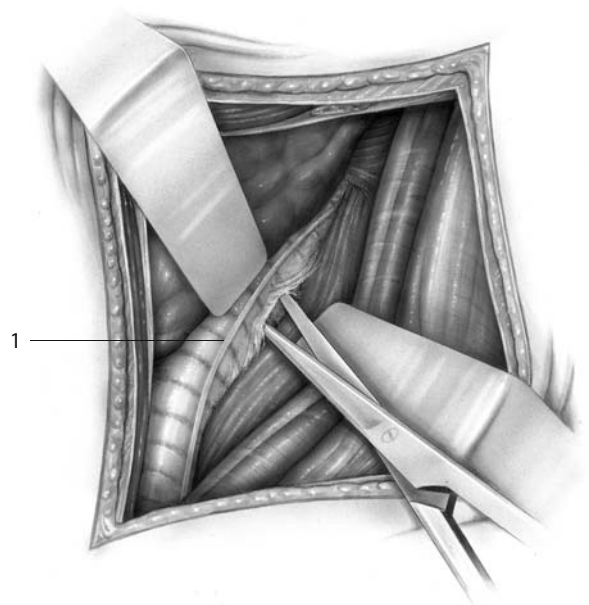
**Fig. 13.35.** Cervical stage. Sharp dissection of the subcutaneous fatty tissue and the platysma muscle along the anterior rim of the sternocleidomastoid muscle.



**Fig. 13.36.** Cervical stage. Blunt dissection of the space between the straight muscles and the sternocleidomastoid muscle. Retract the sternocleidomastoid muscle laterally. Sharp transection of the omohyoid muscle exposes the lateral edge of the thyroid, the jugular vein, and the carotid artery, when the straight muscles are pulled medially. The straight muscles may be transected in case of insufficient exposure of the esophagus. **1** Omohyoid muscle; **2** sternocleidomastoid muscle.

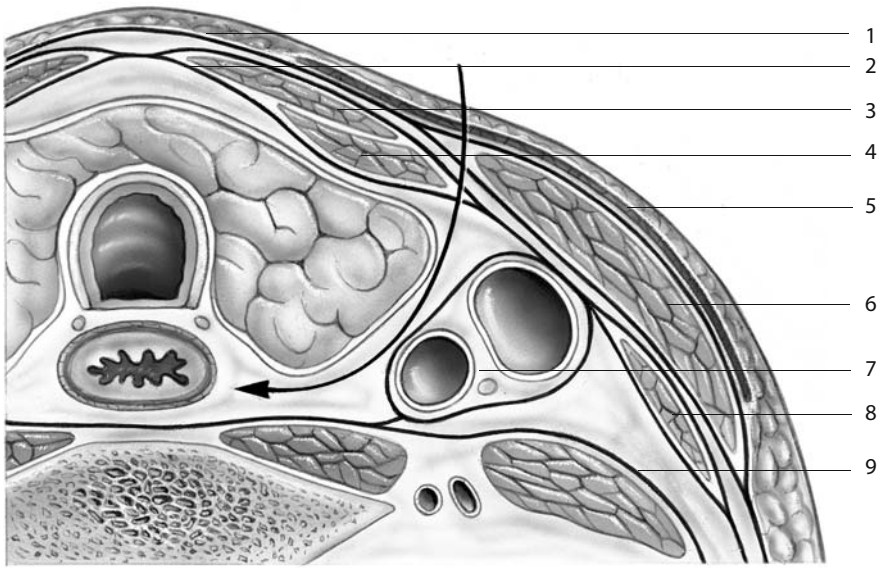


**Fig. 13.37.** Transection of the median venter of the sternocleidomastoid muscle near the clavicle with electrocautery for a better exposure.

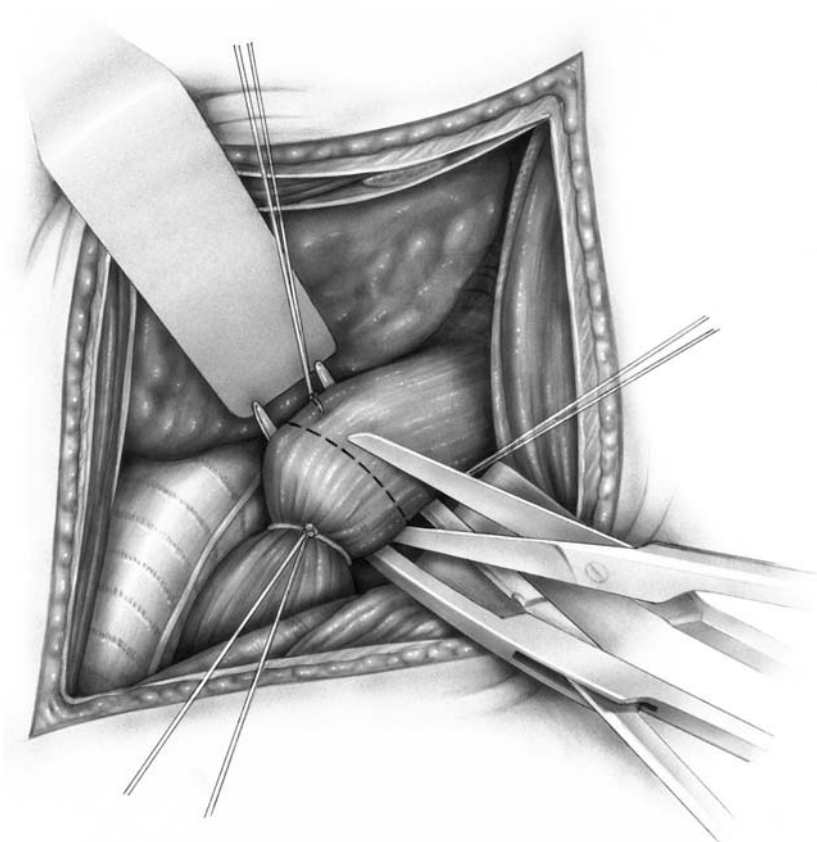


**Fig. 13.38.** Blunt dissection of the layer between the thyroid and the carotid sheath. Insertion of retractors for exposure of the left recurrent laryngeal nerve and inferior thyroid artery by retracting the thyroid medially and the neurovascular bundle laterally. Identification of the left laryngeal recurrent nerve in the tracheoesophageal groove. Medial retraction of the trachea together with the recurrent laryngeal nerve and partial blunt and sharp dissection of the cervical esophagus. **1** Recurrent laryngeal nerve.





**Fig. 13.39.** 1 Superficial fascia of the neck; 2 prevertebral fascia; 3 pretracheal fascia; 4 omohyoid muscle; 5 sternocleidomastoid muscle; 6 platysma muscle; 7 neurovascular bundle; 8 sternohyoid muscle; 9 sternothyroid muscle.



**Fig. 13.40 a**

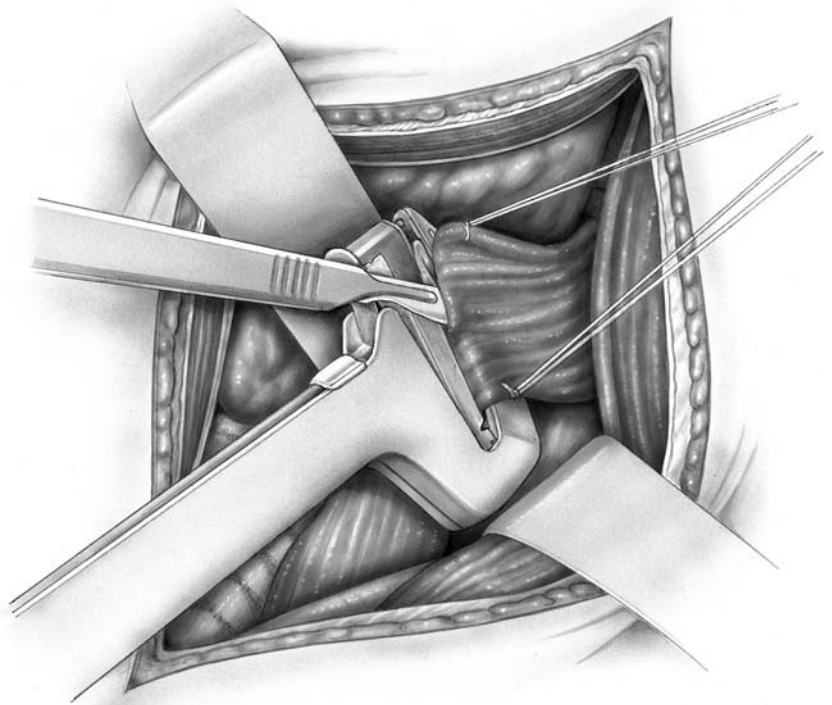


Fig. 13.40b

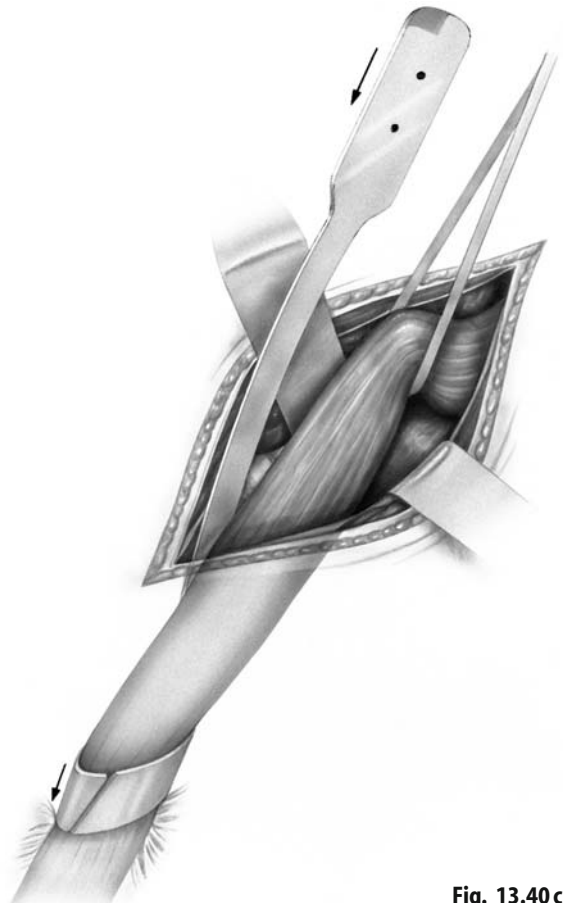
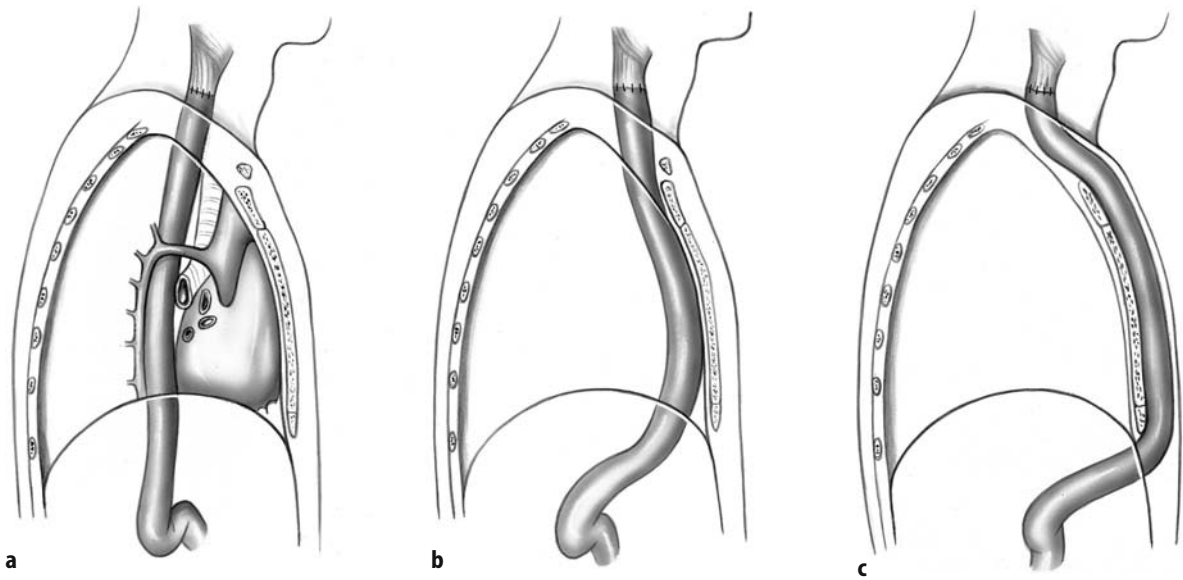


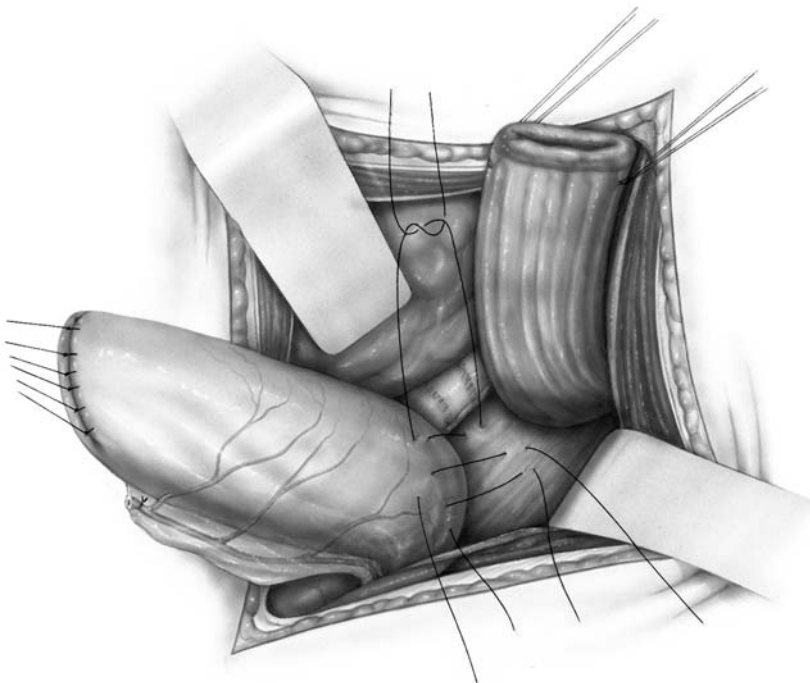
Fig. 13.40c

**Fig. 13.40a–c.** The cervical esophagus is dissected with curved instrument (right angle clamp) and armed with a rubber tube. Completion of the dissection of the cervical esophagus and upper thoracic esophagus by blunt dissection with the finger or dissector (c). Careful protection of the recurrent laryngeal nerve is mandatory. After removal of the naso-gastric tube, the esophagus is divided with a stapler (b) or with scissors (a), after ligation of the aboral part of the esophagus has been ligated (a). A strong thread or a rubber band is fixed to the aboral stump of the esophagus before the esophagus is transposed into the abdominal cavity. This facilitates easy transposition of the gastric tube to the neck later on.



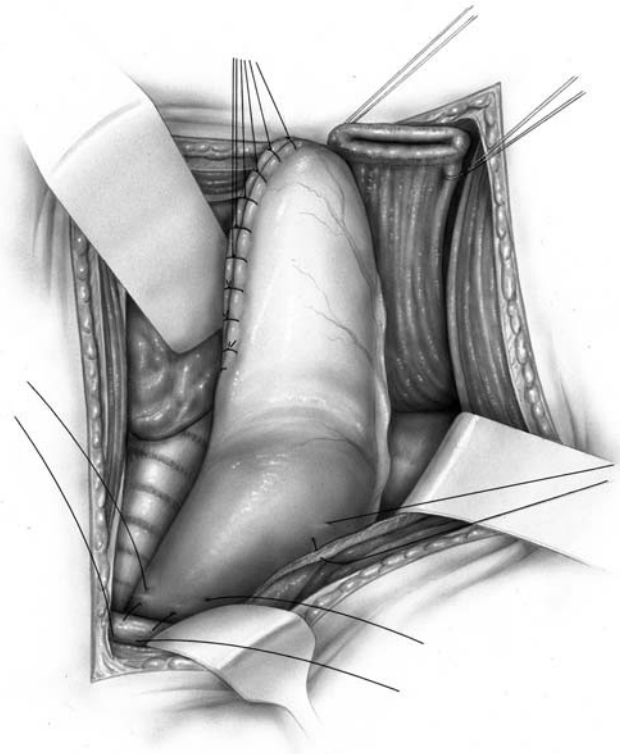
**Fig. 13.41 a–c.** Options for a gastric pull-up. The above mentioned formation of the gastric tube is useful for all forms of reconstruction because it provides sufficient length of the tube.

**a** Gastric tube pull-up in the original esophageal bed. **b** Retrosternal gastric tube pull-up. **c** Presternal gastric pull-up.

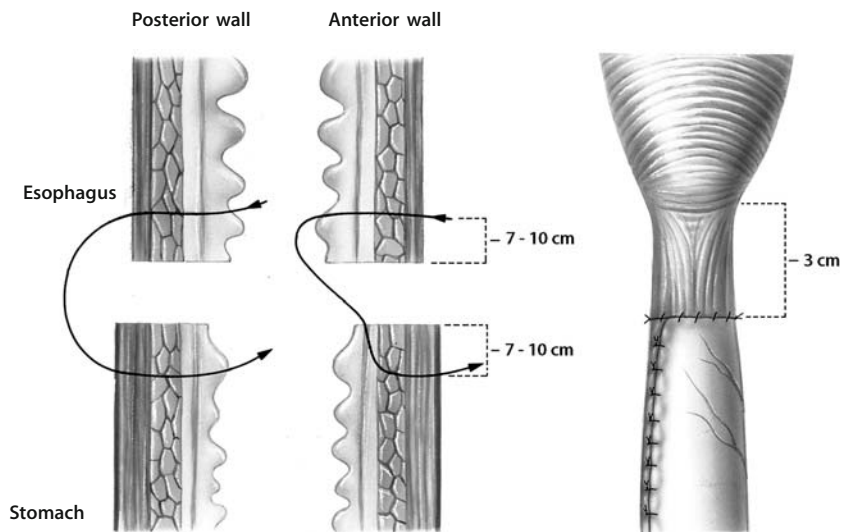


**Fig. 13.42.** The gastric tube is pulled up in the original esophageal bed into the cervical position and is fixed to the adjacent cervical tissue by 6 interrupted sutures. In this way the anastomosis is walled off from the posterior mediastinum

in order to prevent mediastinitis. Dislocation of the anastomosis into an intrathoracic position is prevented. The first stitches are placed in the prevertebral fascia.

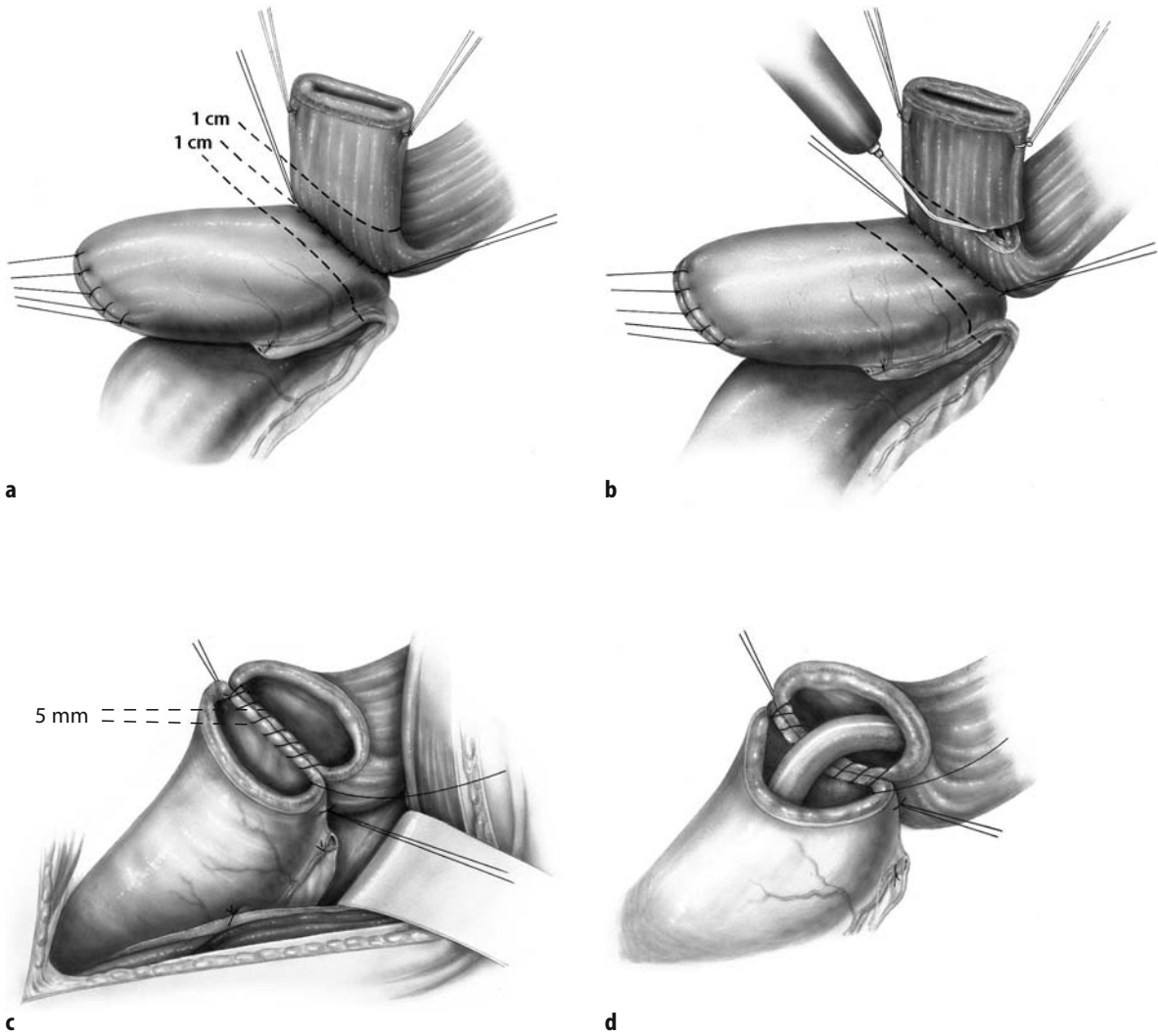


**Fig. 13.43.** Finally the gastric tube is fixed to the fascia and to the muscles of the caudal part of the wound.



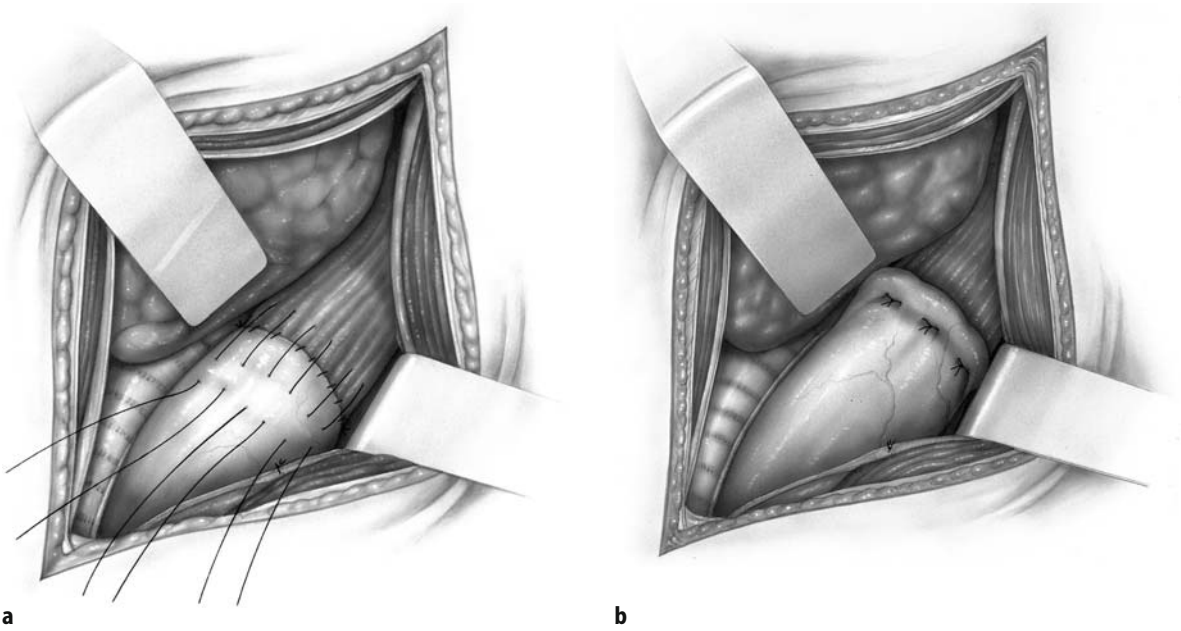
**Fig. 13.44.** Esophagogastrostomy can be performed as a one-layer or two-layer anastomosis. Two seromuscular sutures are placed, and the protruding parts of the gastric tube and the esophagus are resected. We prefer a full thickness extramucosal interrupted suture technique. The stitches should be 9–10 mm from the edge of the esophagus and the gastric tube, respectively. The knots should be just tight enough to bring them snugly into contact with the tissue. The sutures

always tighten later from the postoperative edema which occurs in the area of the anastomosis. After completion of the posterior wall a naso-gastric tube is inserted through the anastomosis and into the duodenum. The esophageal stump should not be longer than 2.0–2.5 cm. Thus, blood supply is improved reducing the probability of anastomotic leakage. In addition this means that the operation is more radical in cases of malignancy.



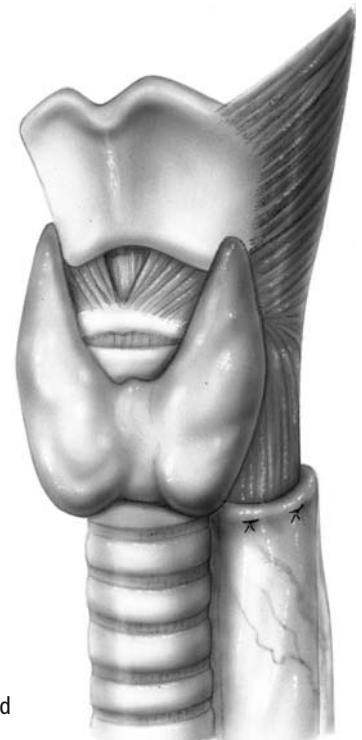**Fig. 13.45 a–d.** Technique of the two-layer anastomosis of the gastric tube and the esophageal stump. The first sero-muscular suture-line is performed in an interrupted fashion (a). Resection of the protruding parts of the esophagus and the gastric tube using electrocautery (b). The second inner suture of the posterior wall has to be done strictly extra-

mucosally and can be performed as an interrupted or a running suture (c). Having finished the posterior wall a naso-gastric tube is inserted over the anastomosis and into the duodenum (d). The naso-gastric feeding tube should not be removed before the 5th postoperative day.

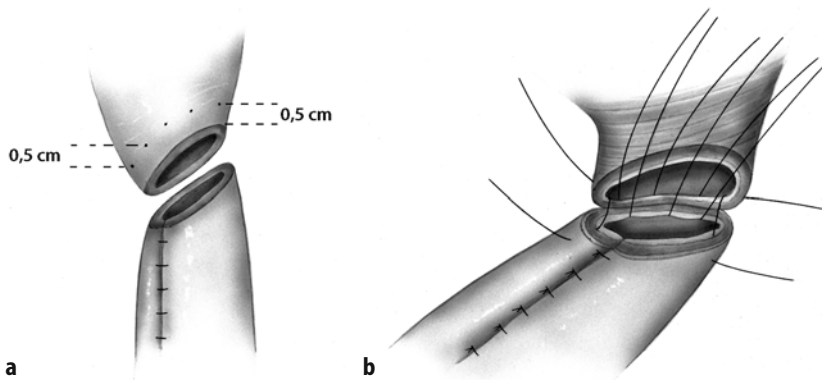


**Fig. 13.46 a, b.** Two-layer technique of the neck anastomosis between the gastric tube and the esophageal stump. The inner suture of the anterior wall is performed using interrupted sutures to prevent postoperative stenosis. The second suture of the anterior wall is performed in a U-shaped fash-

ion (a). The transverse suture is done at the esophagus. Tying of the knots after all three U-shaped sutures are placed. This guarantees an inversion of the anastomosis into the gastric tube (b).

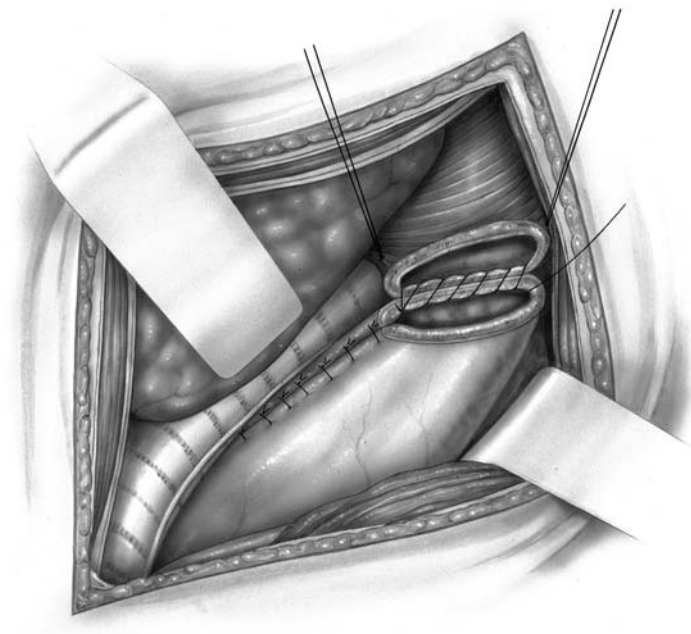


**Fig. 13.47.** Figure of the completed esophagogastrostomy.

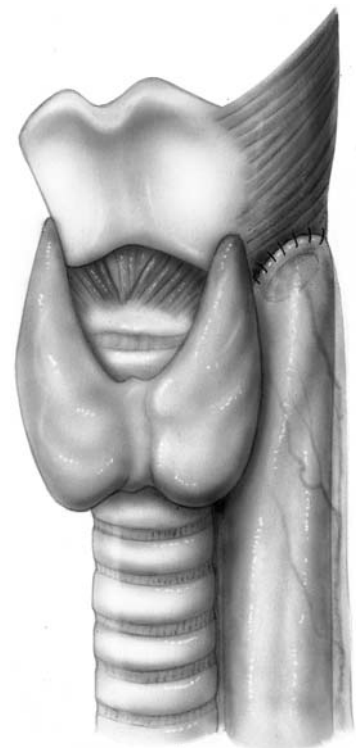


**Fig. 13.48 a, b.** Technique of pharyngogastrostomy in case of complete extirpation of the esophagus. The pharynx is trimmed diagonally through the piriform fossa (**a**). A one-layer anastomosis should be performed. All interrupted su-

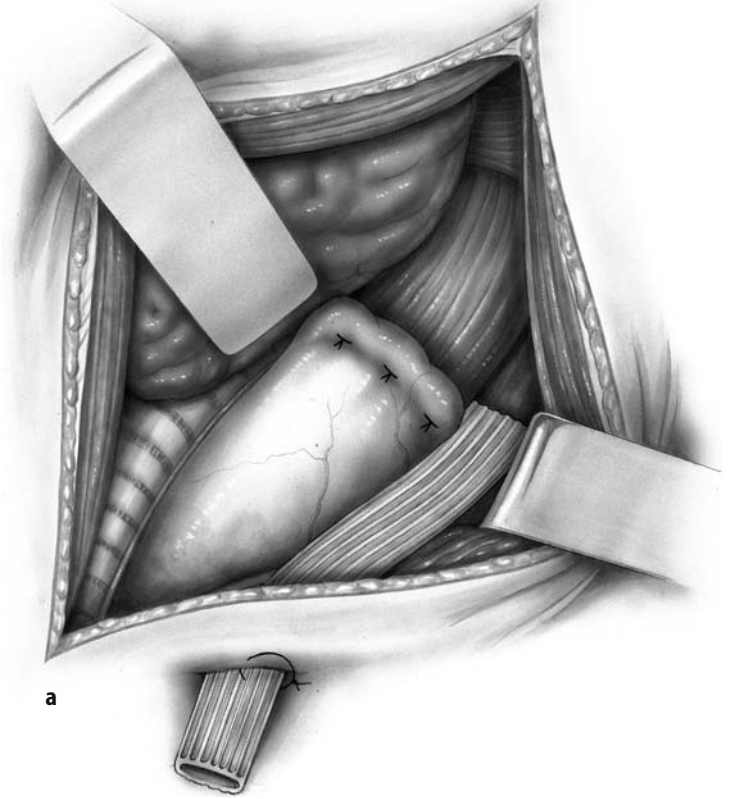
tures at the posterior wall are first placed and then tied consecutively (**b**). After insertion of the naso-gastric tube completion of the anastomosis of the anteriorly wall is undertaken using the same technique.



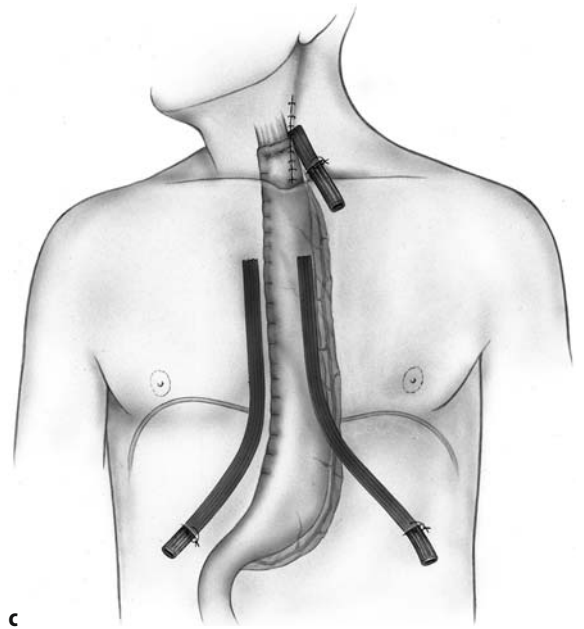
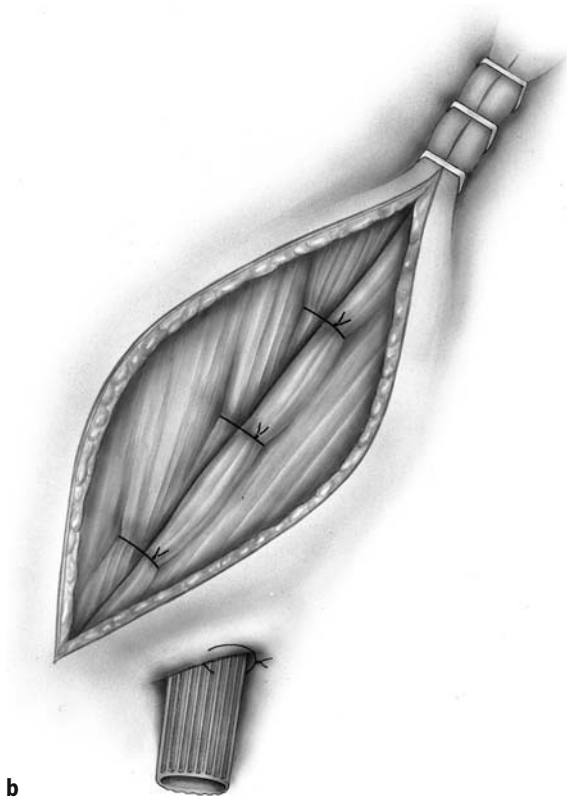
**Fig. 13.49.** Alternative methods of neck anastomosis between the gastric tube and the esophagus. Anastomosis using an end to end stapler.



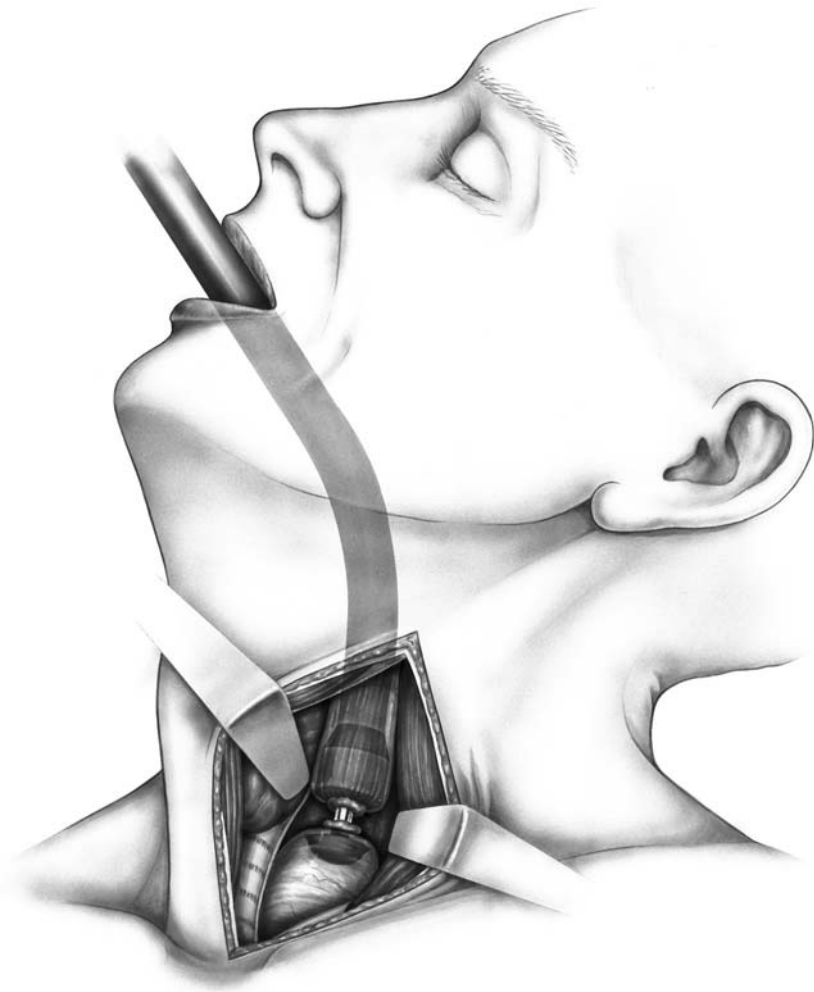
**Fig. 13.50.** Situation after having completed pharyngogastrostomy.



**Fig. 13.51.** One penrose drain is placed beside the cervical anastomosis (a). The wound is closed with cursory platysma sutures and skin closure (b). The mediastinum is drained transabdominally with two drains (c), additionally drains are placed in the right and left subphrenic space. A chest tube is used if the pleural cavity has been opened accidentally.







**Fig. 13.52.** Alternative methods of neck anastomosis between the gastric tube and the esophagus. Anastomosis using an end-to-side stapler.

## Complications of transhiatal blunt esophageal dissection and gastric pull-up

### ■ Intraoperative complications

■ **Injury of mediastinal visceral pleura.** During blunt esophageal dissection injury of the mediastinal visceral pleura with opening of the pleural cavity is a frequent event. In these cases posterior basal drainage with chest tube is necessary to prevent a pneumothorax or pleural effusion arising which might lead to postponing early extubation.

■ **Hemorrhage from esophageal branches of the aorta.** Slipped ligatures or retracted vessel stumps are the main causes of mediastinal hemorrhage from esophageal branches of the aorta. Bleeding from these branches can be resolved with sutures using a non-absorbable monofilament suture. If exact localization of the bleeding is not possible tamponade of the mediastinum with dry sponges or gauze is indicated. If the bleeding continues, a right thoracotomy has to be performed to stop the hemorrhage.

■ **Laceration of the thoracic duct.** If the thoracic duct has been damaged then ligation should be performed both above and below the damaged area. To avoid this complication, preparation and ligation of the lateral esophageal ligaments should be performed under direct vision.

■ **Injury of the azygos vein.** During blunt dissection of the esophagus injury of this vein is possible. If sudden hypotension caused by loss

of intravascular volume occurs during this operative step this complication has to be kept in mind. Mostly the blood loss is realized first by the anesthesiologist, because a considerable bleeding into the right thoracic cavity is possible before bleeding is recognized by the surgeon in the mediastinum. Injury to the azygos vein should be anticipated when the tumor is located in the middle third of the esophagus and with locally advanced and/or metastatic lymph node involvement close to the azygos vein. Transmediastinal dissection of the vein followed for ligation under direct vision should be undertaken to stop the bleeding. Time consuming trials of direct transhiatal dissection should be avoided if direct access cannot be achieved. In these cases tamponade of the posterior mediastinum is indicated and hemostasis is then achieved via a right anterolateral thoracotomy through the 5th intercostal space.

To avoid hemorrhage in cases of a close relation between the tumor and the azygos vein, ligation of the azygos vein should be performed before blunt dissection is carried out. If not possible then a thoracic approach should be undertaken.

■ **Injury of the aorta.** This severe complication usually is only a potential problem in cases where there is a tumor infiltration of the aorta. If there is a suspicion that tumor infiltration of the aorta has occurred, then a right thoracotomy is performed and the tumor is excised en bloc with an aortic cuff. Transhiatal sharp dissection of the esophagus from the esophageal bed is undertaken in cases where the tumor growth has occurred adjacent to the aorta.

# 14 Partial Abdominothoracic Resection of the Esophagus with Gastroplasty and Intrathoracic Anastomosis

A. F. CHERNOUSOV, A. KUTUB, P. M. BOGOPOLSKI, D. C. BROERING

## Indications

- Short distance peptic stenosis of the distal esophagus
- Boerhaave syndrome
- Short distance ruptures of the distal esophagus
- Carcinoma of the esophageal-gastric junction with tumor extension above the diaphragm
- Squamous cell carcinoma of the distal esophagus.

## ■ Contraindications, operative risks and patient information

See chapter 13.

## ■ Specific preoperative management

■ **Anesthesia.** Orotracheal intubation with a double-lumen tube for single lung ventilation.

## ■ Patient's position

- Supine position with intraoperative rearrangement on the left side
- Alternatively 45° spiral-positioning is possible, in this case intraoperative changes of the position are not necessary.

■ **Surgical approach.** Upper transverse incision with median T-shaped extension for the abdominal part.

Anterolateral thoracotomy through 5th ICR for the thoracic part.

## ■ Operative procedure

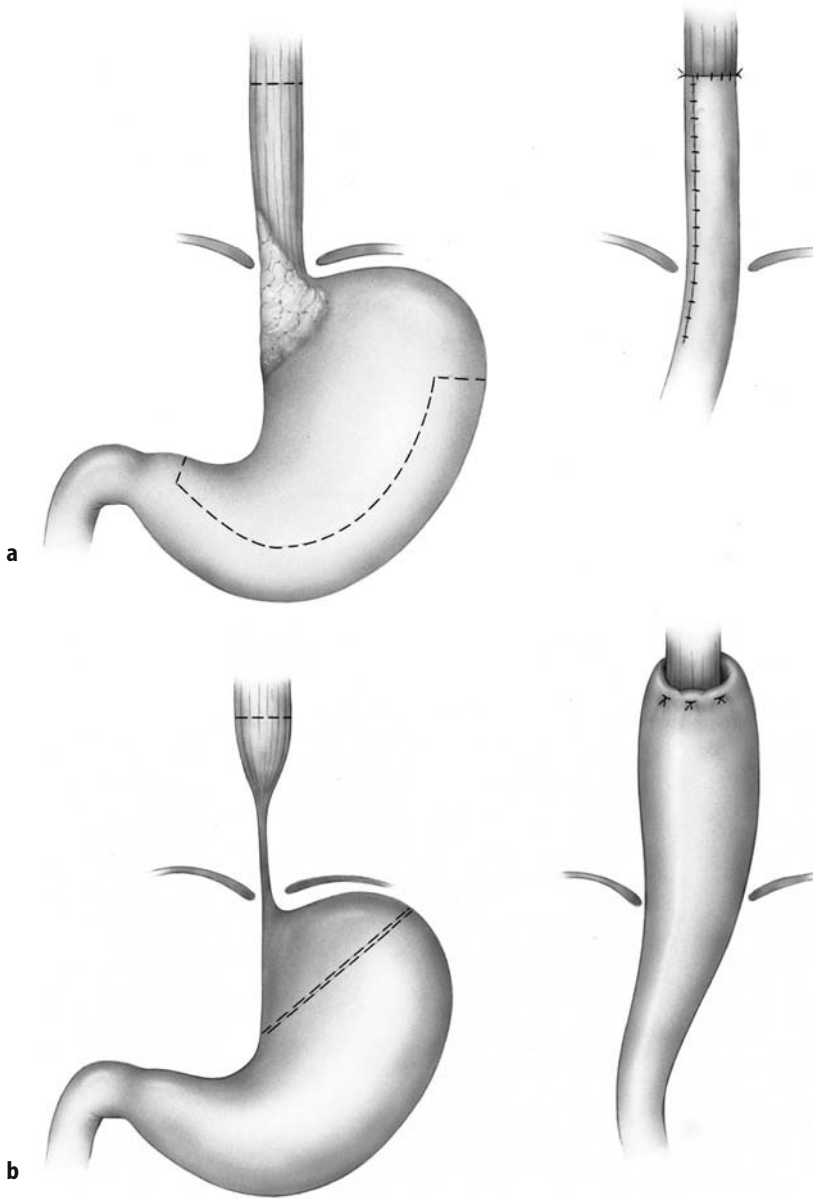
The most frequent techniques of reconstruction after partial abdominothoracic esophagectomy with intrathoracic anastomosis by gastric pull-up. For carcinoma of the esophageal junction, preparation and construction of the gastric tube should be performed following the oncological radical excision (Fig. 14.1 a). In case of benign diseases, e.g. strictures, a radical oncological construction of the gastric tube should be avoided (Fig. 14.1 b).

In benign disease the abdominal and distal-thoracic esophagus is mobilized after diaphragmotomy. Then transection of the esophagus above the tumor in the pericardial area using a surgical stapler. The oral end is fixated and marked using strong sutures (Fig. 14.2 a, b).

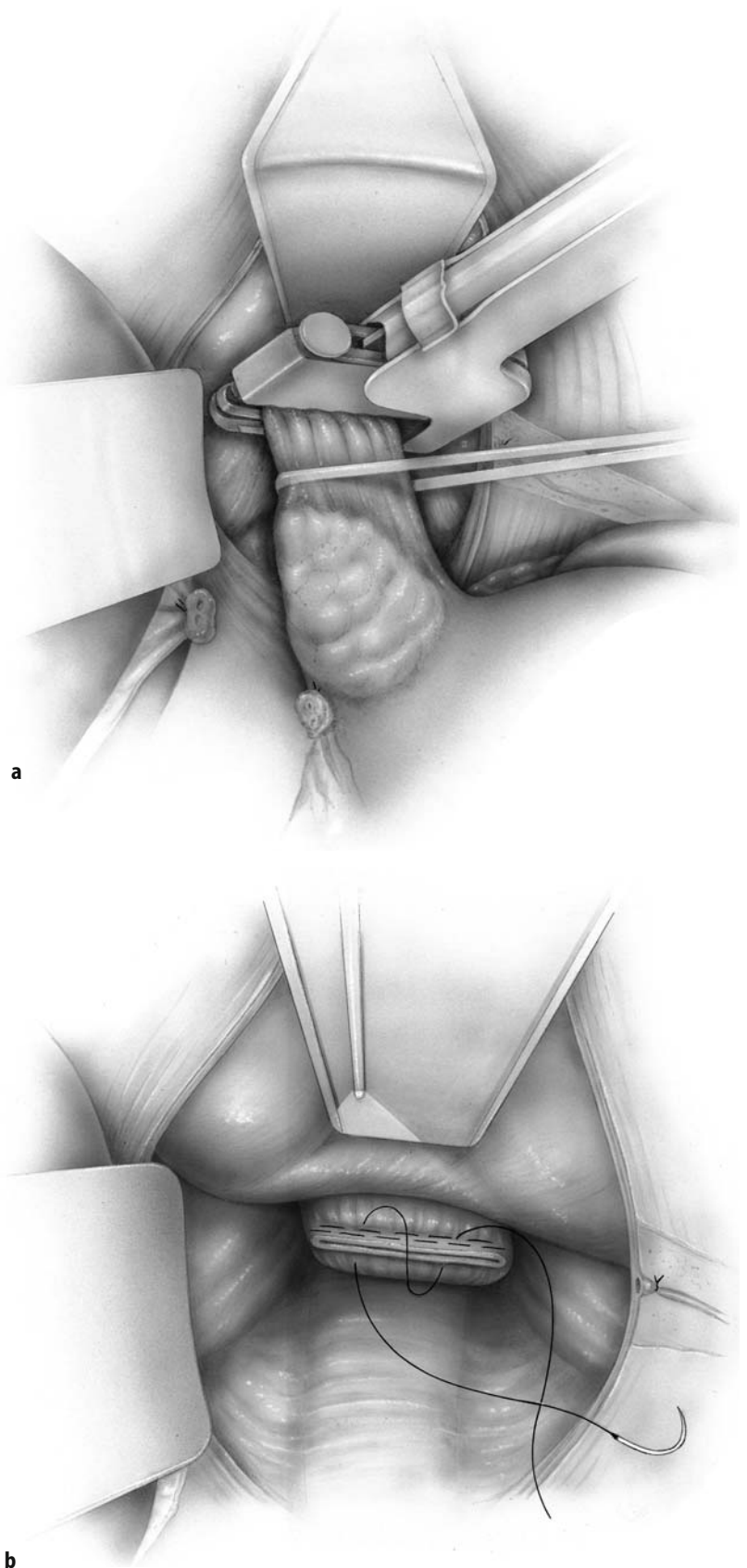
The greater omentum is divided along the great curvature of the stomach respecting the right gastroepiploic artery and vein. The stomach is mobilized gradually. According to the required length of the gastric tube and dignity of the lesion, transection of the left gastric artery and the short gastric veins is necessary. The required length of the gastric tube is significantly shorter for an intrathoracic anastomosis than for cervical anastomosis. There usually is no need for Kocher's maneuver.

After completion of the lymphadenectomy in carcinomatous disease, the sutures which were left long for serosa suture of the surgical staples at the proximal end of the gastric tube will be tied with the long suture at the distal esophageal end (Fig. 14.5).

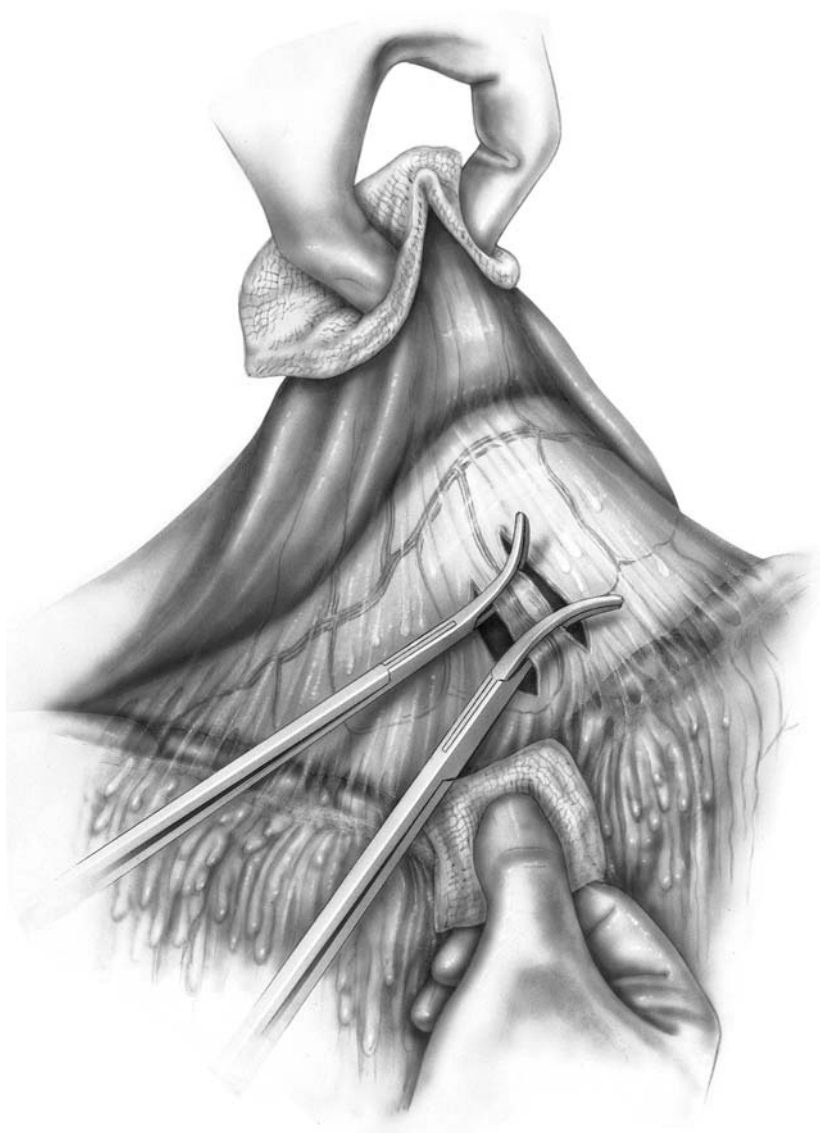After drainage of the left subphrenic area and epigastric region, which is the major location of lymphadenectomy, the abdomen is closed.



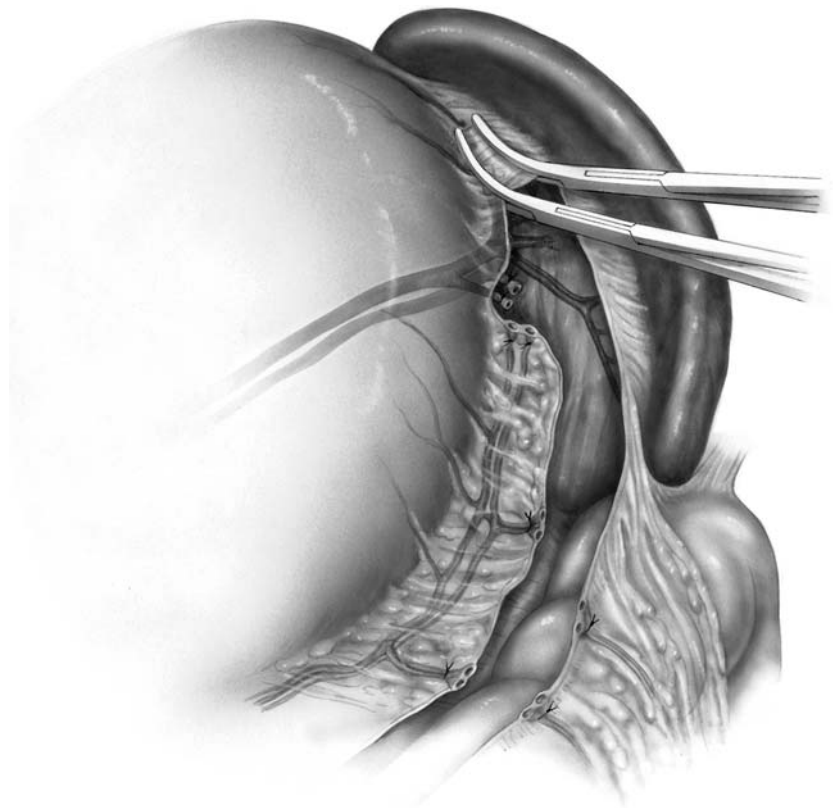
**Fig. 14.1.** **a** Oncological extent; **b** extent in benign diseases.



**Fig. 14.2.** **a** Transection of the esophagus with a stapler device; **b** fixation of the oral and of the esophagus with strong sutures.



**Fig. 14.3.** Skeletonization of the greater curvature (see Fig. 13.8).



**Fig. 14.4.** Skeletonization of the greater curvature (see Fig. 13.9).

The patient is positioned to the left for the thoracic part of surgery by turning the table (initially helical-positioning of the patient with 45° elevation of the right thorax and elevated arm).

The optimal access regarding the overall view is the right anterolateral thoracotomy in the fifth intercostal space. The gastric tube will be placed into the pleural cavity by traction on the distal esophagus. It follows the en bloc-resection of the thoracic esophagus including mediastinal pleura, the periesophageal fat tissue, and the mediastinal lymph nodes. It is recommended to ligate all adhesions with the surrounding tissue. The esophagus will be divided as cranial as possible (interrupted line) (Fig. 14.6).

The diameter of the esophagus is clearly smaller than that of the gastric tube if not prestenotically dilated. This incongruence of the

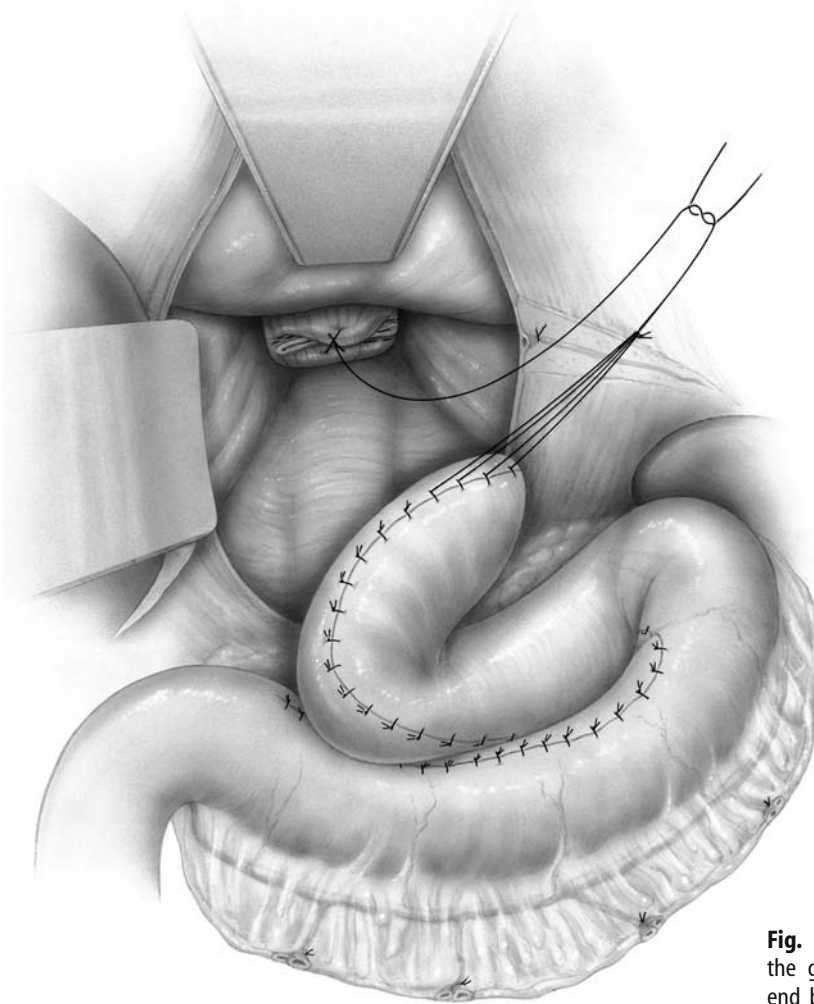
lumens can be equalized using a conic reduction plastic of the proximal gastric tube (Fig. 14.7).

After incomplete transverse incision and diagonally aboral completion of division of the gastric tube at the oral end, the 2.5–3 cm long diagonal incision will be closed using extramucous simple interrupted stitches (Vicryl/Dexon/PDS 3/0). Length and angle of the diagonal incision determine the resulting diameter of the lumen (Figs. 14.8, 14.9).

This procedure simplifies the inserting of the esophageal end into the gastric tube and creates a staple-free zone for anastomosis.

If the intestinal walls of the esophagus and gastric tube are strong, a double rowed anastomosis should be performed.

In case of a very thin esophageal wall, a single rowed all-layer anastomosis of esophagus with the gastric tube is favored.



**Fig. 14.5.** Connecting the proximal end of the gastric tube with the distal esophageal end before closure the abdomen.

Extramucous placed simple interrupted sutures should be laid out loosely in the posterior anastomotic area. The risk of anastomotic stenosis is higher in the running suture technique. If all posterior wall sutures are placed, they are tied gradually avoiding strong tissue tension. A slightly adaptation should be achieved, squeezing should be avoided.

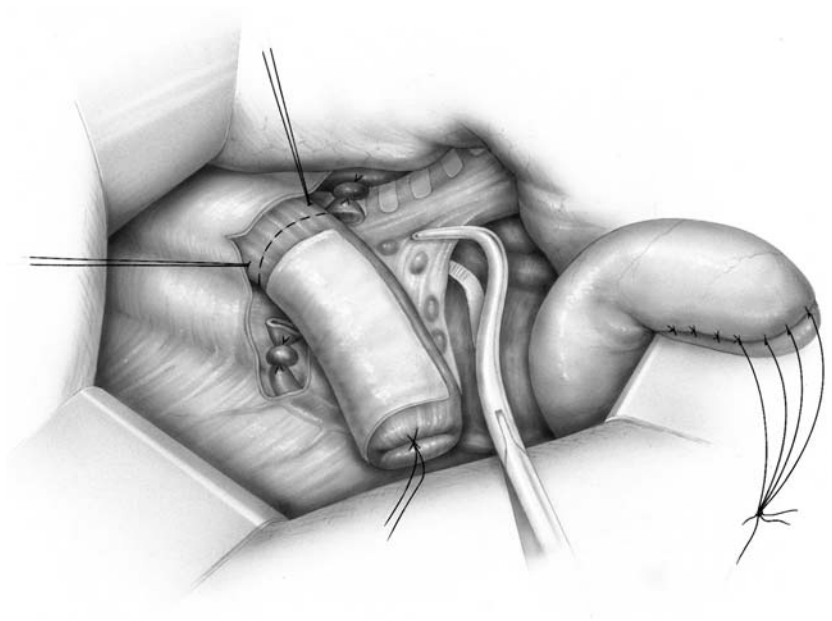
The single rowed anastomosis is covered with mediastinal pleura to secure the sutures and lessen the tension at the esophagogastrotomy, and consecutively the rate of insufficiency (Fig. 14.10).

The lesser curvature of the stomach will be not resected if there are strictures of the distal esophagus or the esophagogastric region. Therefore, the entire stomach can be used for

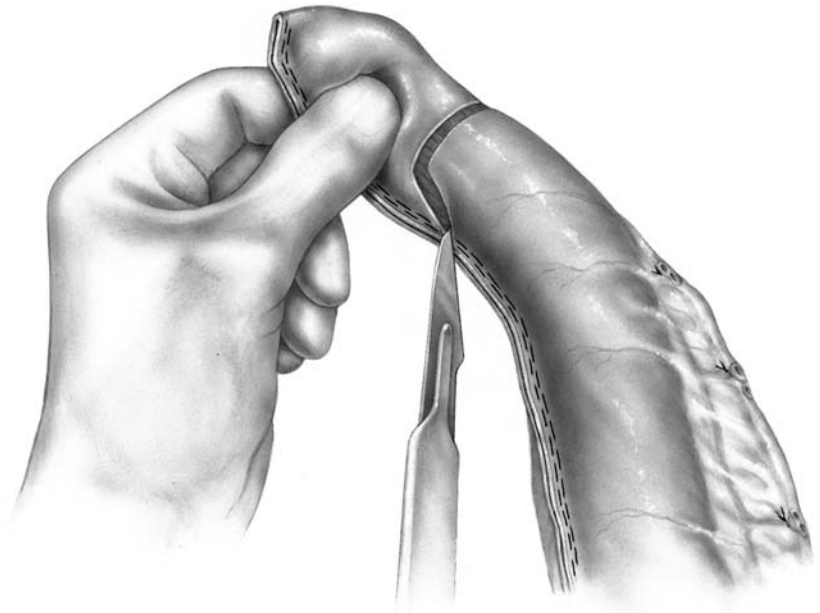
pull-up. As blood supply of cardia and distal parts of the fundus are insecure, both should be resected (Fig. 14.11 a, b).

The esophagus is being anastomosed with the anterior stomach wall in double row suture technique. The esophagus is fixated initially with the gastric tube using six seromuscular sutures. After incision of the gastric tube with the electrocautery the posterior wall is anastomosed with extramucous all-layer sutures in simple interrupted stitching technique. The distance between the sutures should be 5 mm (Fig. 14.12 a, b). A naso-gastric feeding tube is generally inserted over the anastomosis and placed into the duodenum for decompression and postoperative enteral feeding.

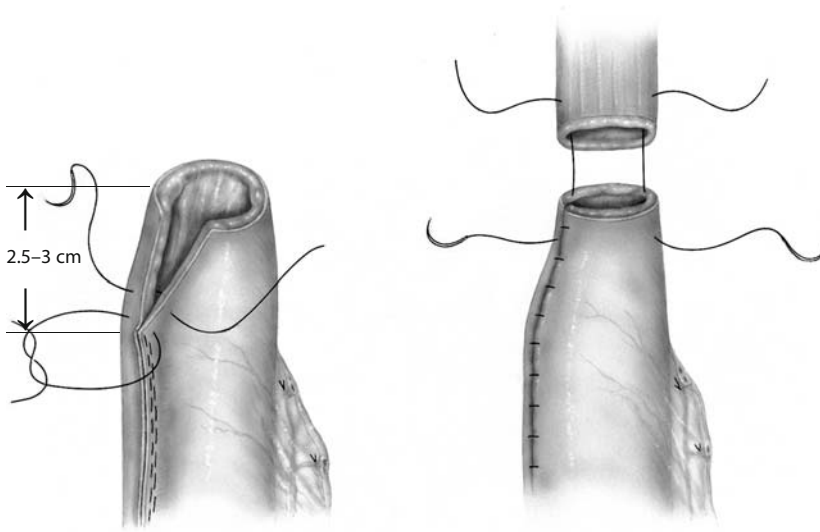




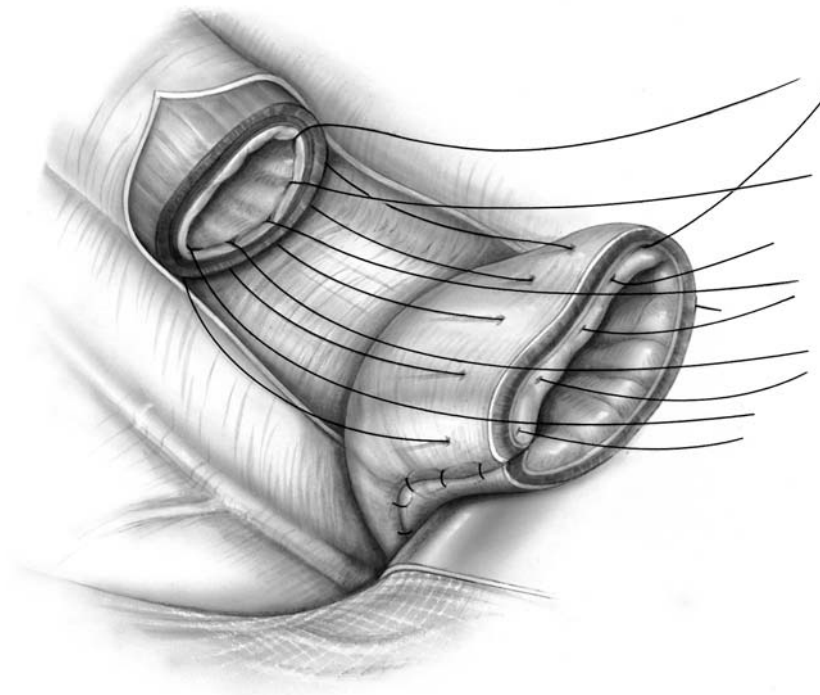
**Fig. 14.6.** Transection of the esophagus as cranial as possible (interrupted line).



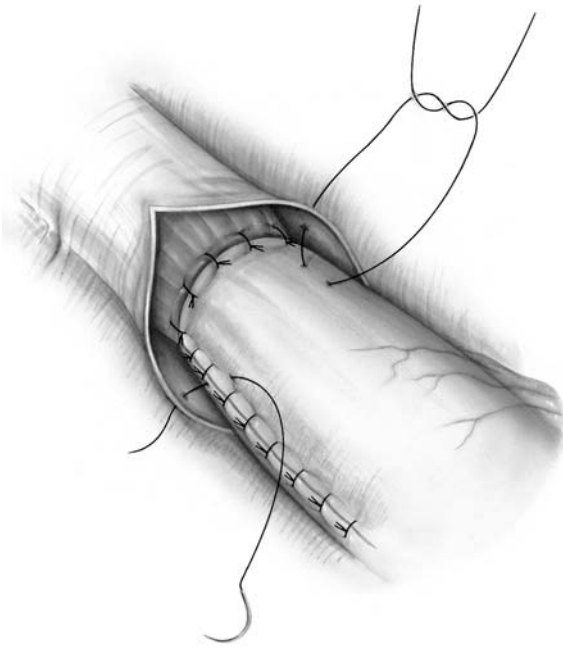
**Fig. 14.7.** Conic reduction plastic of the proximal gastric tube to equalize incongruences.



**Fig. 14.8.** Length and angle of the diagonal incision determine the diameter of the lumen.



**Fig. 14.9.** Extramucous placed simple interrupted sutures.



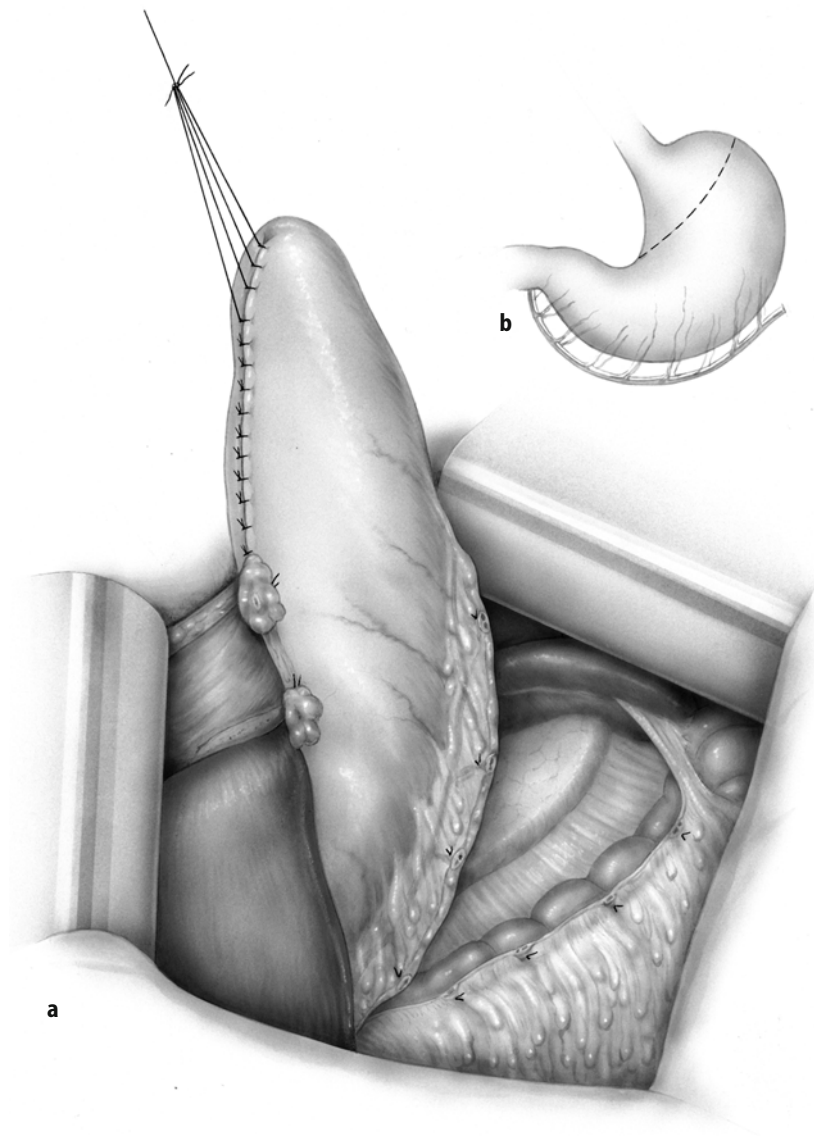
**Fig. 14.10.** Mediastinal pleura to secure the anastomosis.

After completion of the anterior wall anastomosis using the same technique as for the posterior wall, the anastomosis should be inverted telescopically by placing seromuscular U-sutures grasping the mediastinal pleura (Fig. 14.13 a). The tie of the U-suture should come to lie in the area of the gastric tube, as the serosa of the stomach gives the knots more strength. The base of the U-suture should be positioned 1.5 cm proximal to the anastomosis (Fig. 14.13 b). The distance between the sutures should be 6 mm (Fig. 14.13 a).

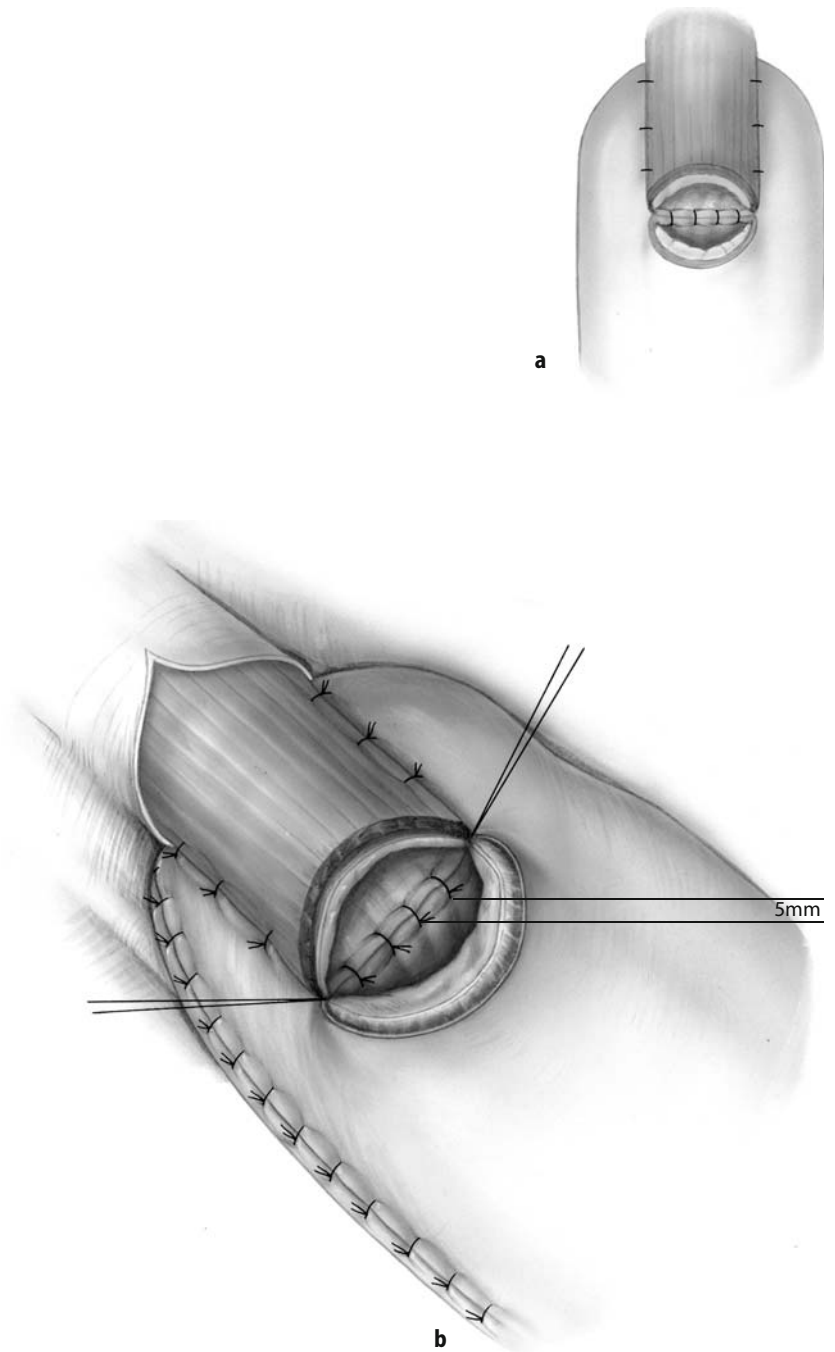
After completion of the esophagogastrostomy, the anastomosis is inserted into the stomach telescopically (Fig. 14.14). Drainage tubes are placed into the mediastinum. The supraphrenic region is drained by a further drainage tube.

Alternatively the anastomosis can be made transthoracically or transhiatally using a circular stapler.

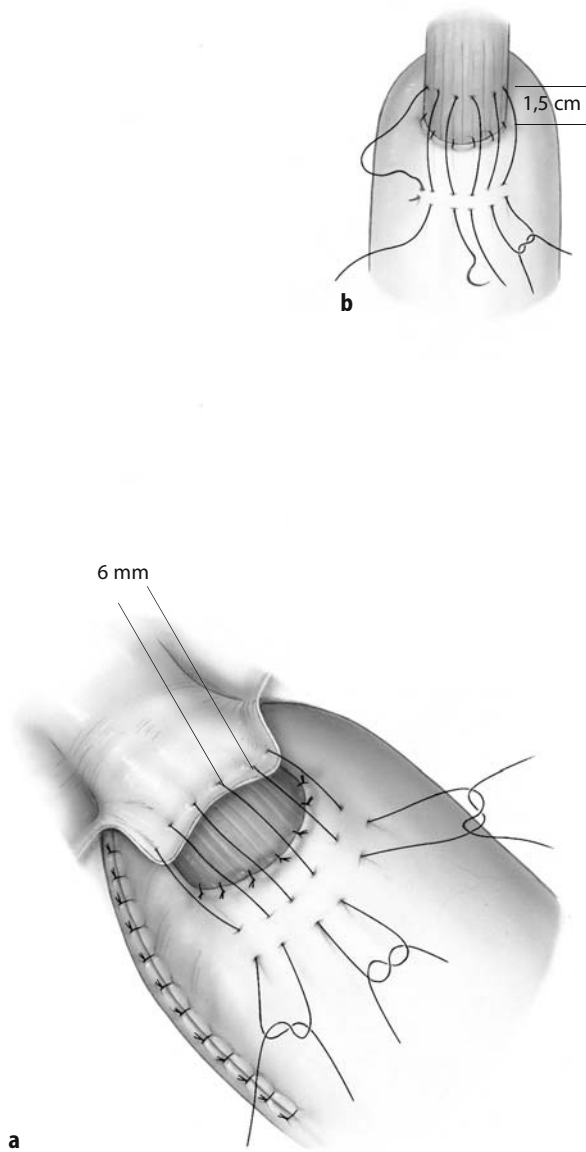
Introduction of the stapler into the gastric tube and perforation of the wall at the prospective site of the anastomosis with the pike. Removal of the pike and connection with the anvil. Firing of the instrument. Check for completeness of the anastomotic rings. Removal of the stapler and closure of the gastric tube with extramucous all-layer sutures (Fig. 14.15).



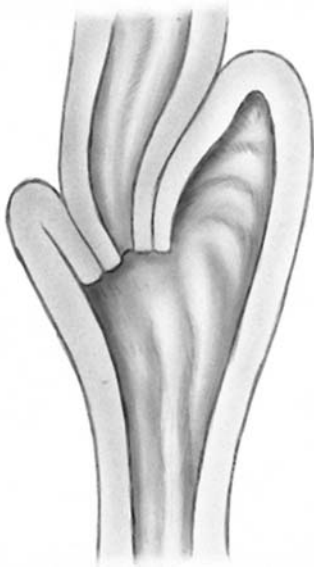
**Fig. 14.11. a** The entire stomach is used for pull-up.  
**b** Extent of the resection (interrupted line).



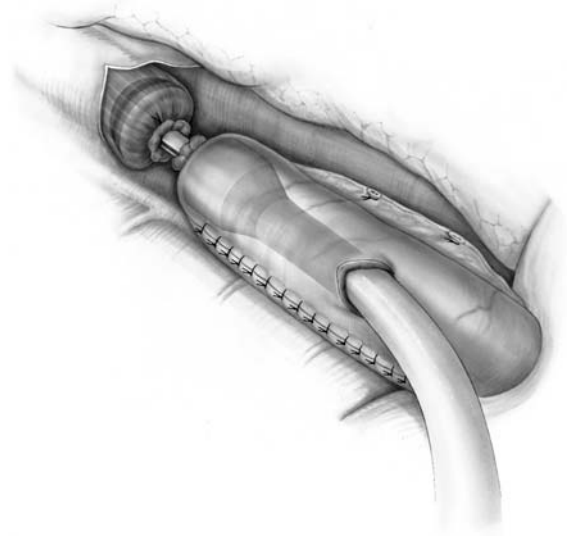
**Fig. 14.12.** **a** Fixation of the gastric tube with six seromuscular sutures; **b** the posterior wall is anastomosed. The distance between the sutures should be 5 mm.



**Fig. 14.13.** **a** Inversion of the anastomosis with mediastinal pleura (U-sutures) (distance 6 mm); **b** Positioning of the U-sutures (1,5 cm proximal to the anastomosis).



**Fig. 14.14.** Telescopically inserted esophagogastrostomy.



**Fig. 14.15.** Introduction of the stapler.  
Final situation before fixing.

# Abdominothoracic Subtotal en bloc Esophagectomy and Reconstruction with Gastric Tube Transposition

J. R. IZBICKI, D. C. BROERING, P. KAUDEL, A. KUTUP, E. F. YEKEBAS

## ■ Indication

- Mid thoracic esophageal carcinoma
- Esophageal squamous-cell carcinoma in the lower third of the esophagus
- Long peptic stricture, if transhiatal resection is not possible.

## ■ Contraindication

- Severe cardio-pulmonary insufficiency.

## ■ Risks and patient's informed consent

- Refer to chapter 13 blunt dissection. Additionally, the patient should be informed about bilateral pareses of the recurrent laryngeal nerve, pareses of the phrenic nerve, and chylothorax.

## ■ Special preoperative preparations

Anesthesia: Orotracheal intubation with a double-lumen tube for single lung ventilation.

## ■ Patient's position

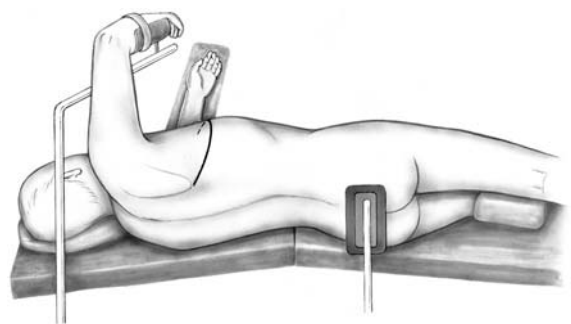
- Position of the patient on his left side for the thoracic part of surgery
- Supine position, comparable to blunt transhiatal dissection
- Alternatively 45° positioning is possible, in this case intraoperative changes of the position are not necessary.

## ■ Surgical approach

- Anterolateral thoracotomy through 5th ICR
- Transverse laparotomy with cranial median enlargement (inversed T-incision).

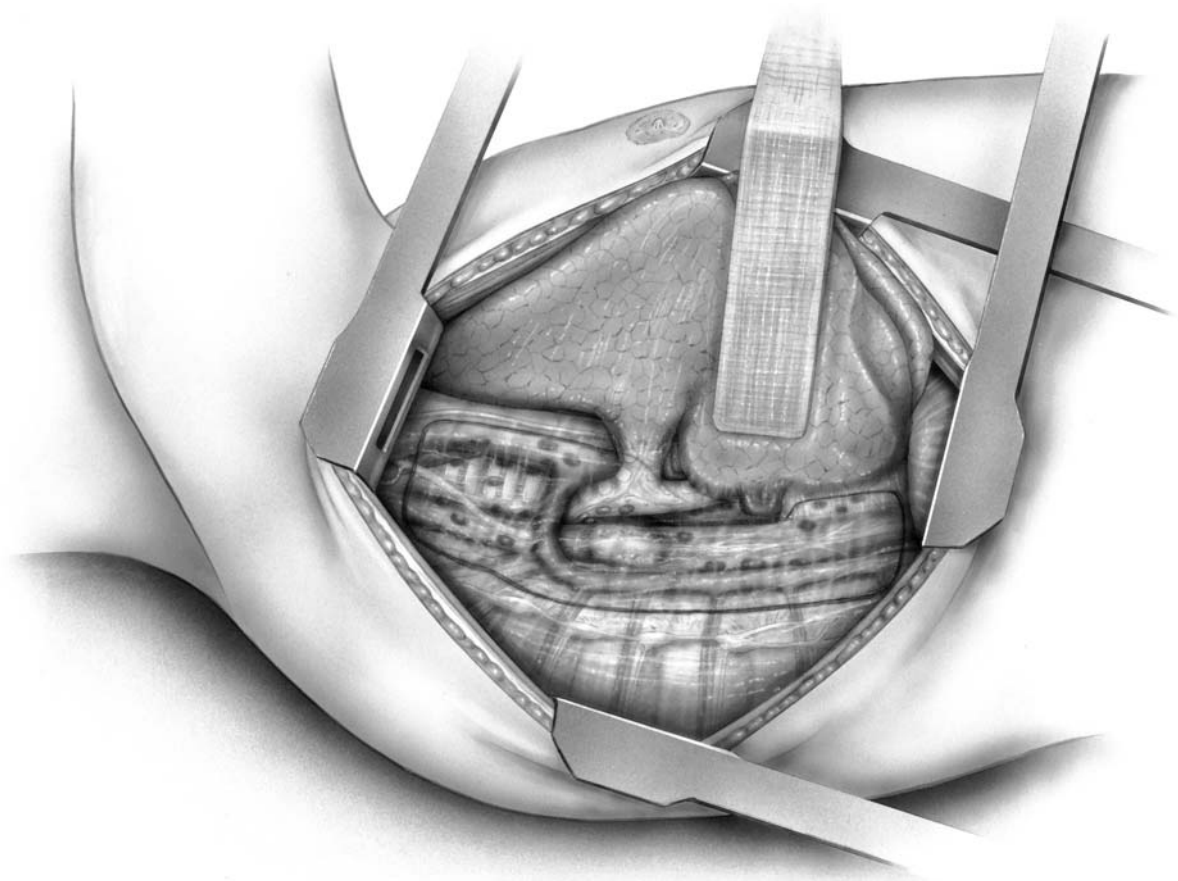
## ■ Operative procedure

1. Right-sided anterolateral thoracotomy through 5th ICR
2. Incision of the mediastinal pleura along the hilum of the right lung and the superior caval vein
3. Dissection and ligation of the azygos vein
4. Preparation of the vena cava by resection of the accompanying adipose and lymphatic tissue
5. Dissection of the vagus nerve distal to the recurrent laryngeal nerve
6. Dissection of intercostal veins, sparing the arteries
7. Dissection between esophagus, aorta, and trachea and resection of paratracheal, parabrachial, paracarinal, and infracarinal lymph nodes
8. Thoracic drainage and closure of the thoracotomy
9. Abdominal and cervical part (see chapter 13).



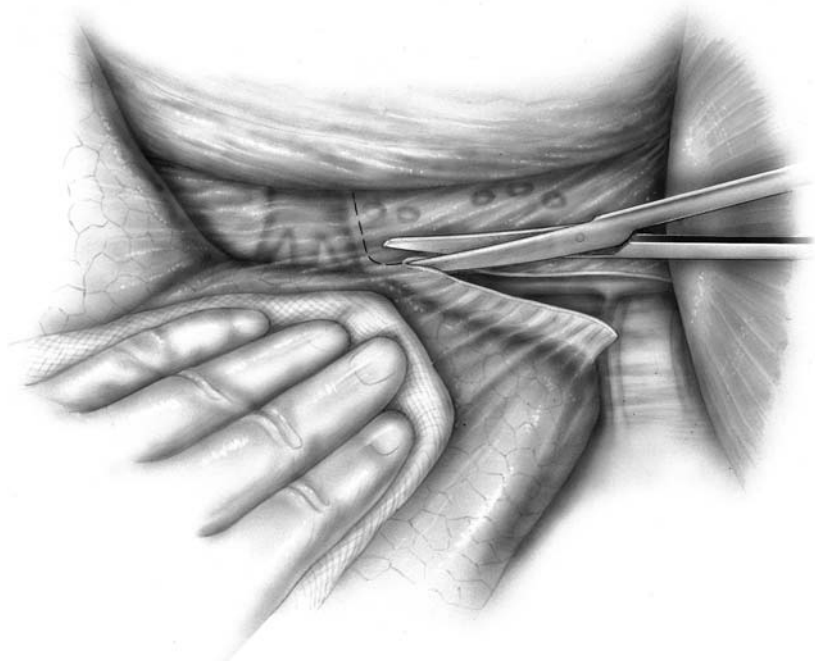
**Fig. 15.1.** Left-sided positioning of the patient with thoracic kinking. Skin incision from the apex of the scapula in the submammary fold in the 5th ICR.





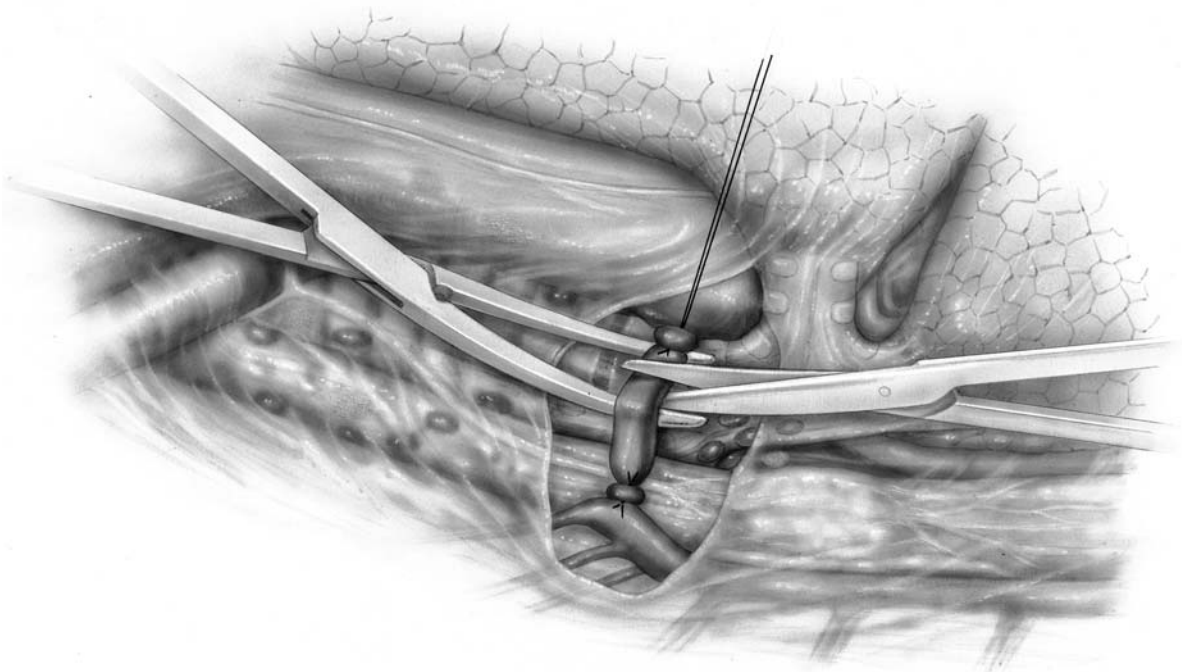
**Fig. 15.2.** After thoracotomy in 5th ICR, two retractors are placed to spread the incision and to retract the ribs. Single left lung ventilation. Incision of the mediastinal pleura along the marked line for the en bloc esophagectomy. It starts from the pulmonary ligament, runs along the dorsal part of the right hilum of the lung to the lateral margin of the

superior caval vein up to the upper thoracic aperture. Incision direction is changed to the right lateral margin of the spine, down to the diaphragm along the azygos vein. The most important part of this step is the recognition of the right recurrent laryngeal nerve and the right phrenic nerve.

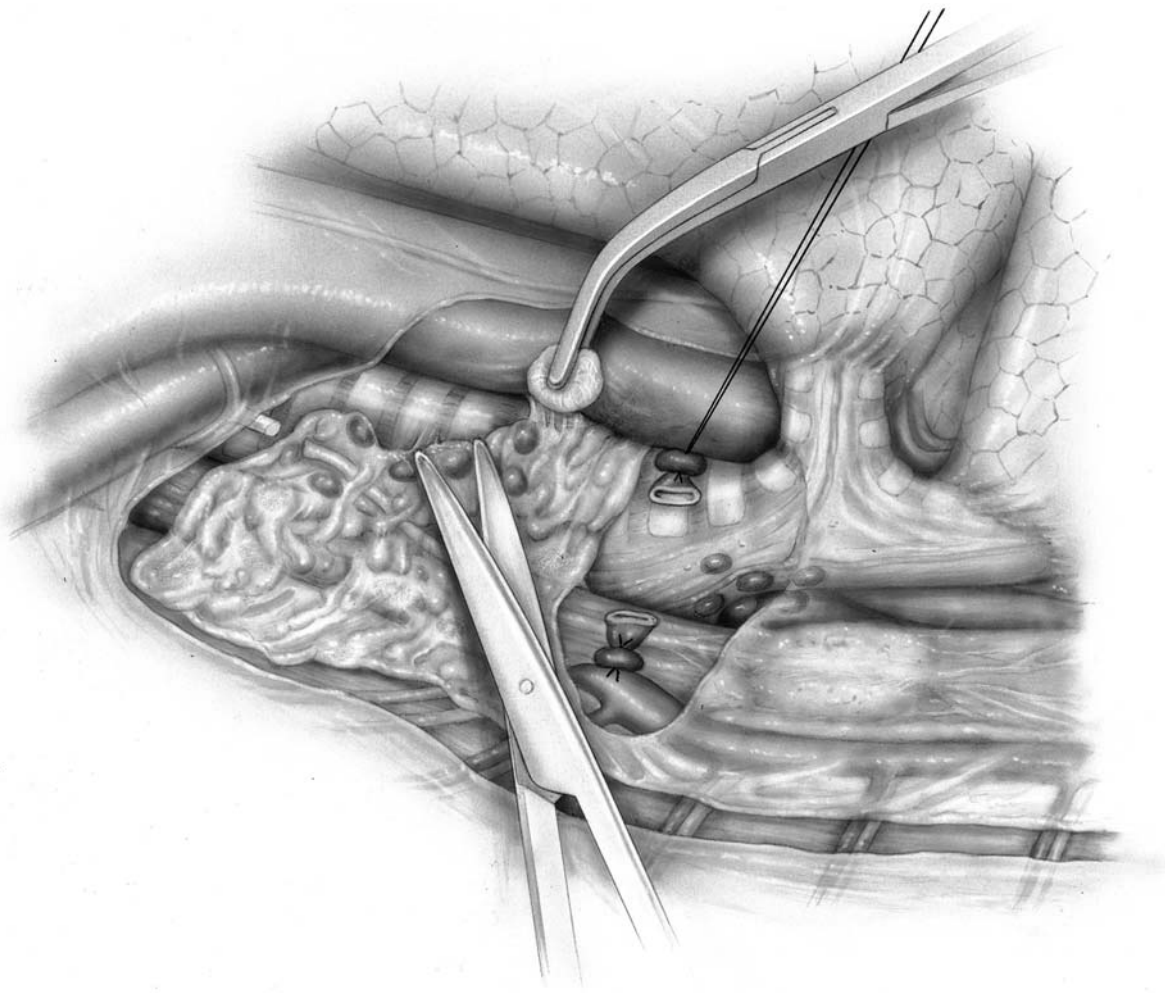


**Fig. 15.3.** The first step is the incision of the pulmonary ligament. For exposition of the pulmonary ligament the surgeon's left hand pushes the lung cranially and laterally. The lymphatic tissue of the pulmonary ligament should be dis-

sected towards the esophagus. The cranial margin of the pulmonary ligament – the veins of the lower lobe of the right lung – should not be injured during this procedure.

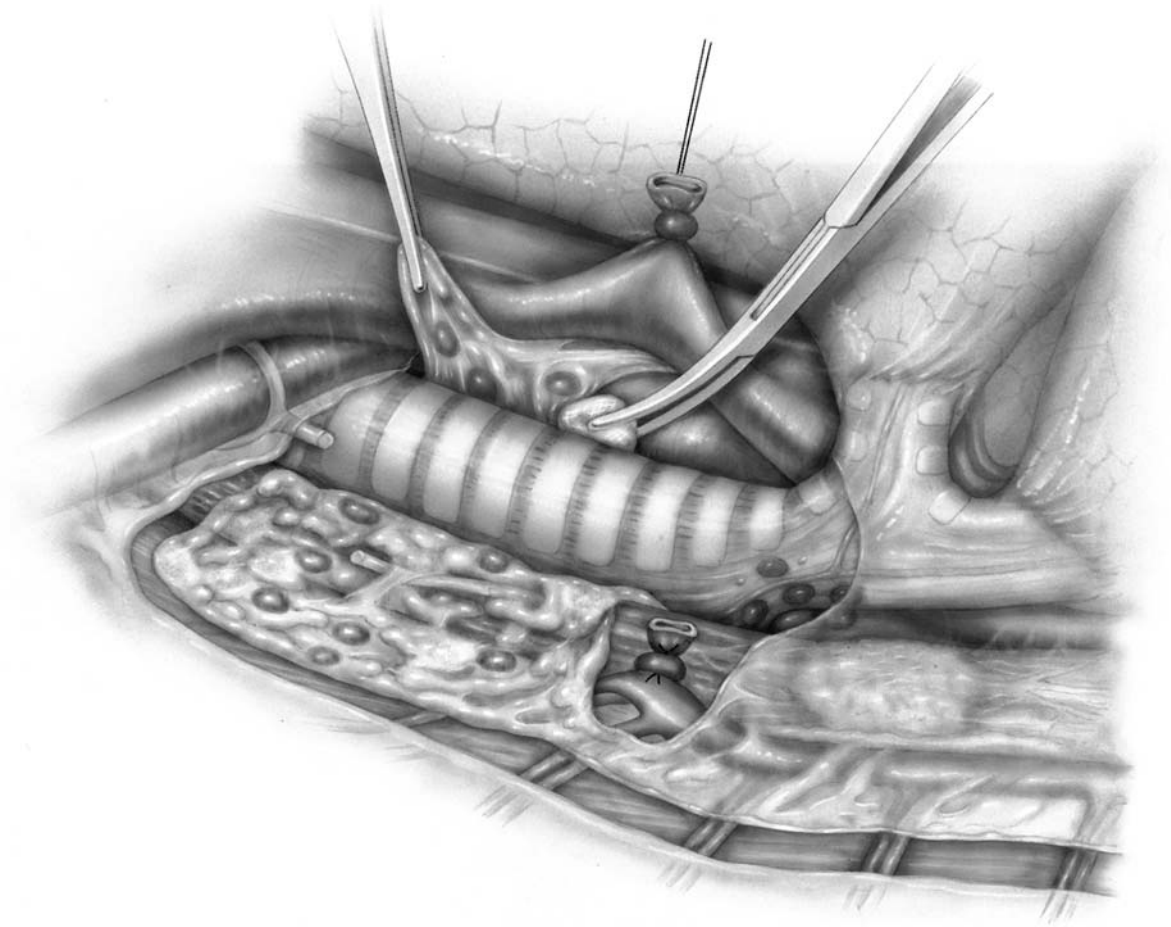


**Fig. 15.4.** Dissection of the junction of the azygos vein and superior caval vein with a right angle clamp. Double suture ligation of the vein adjacent to the caval vein.



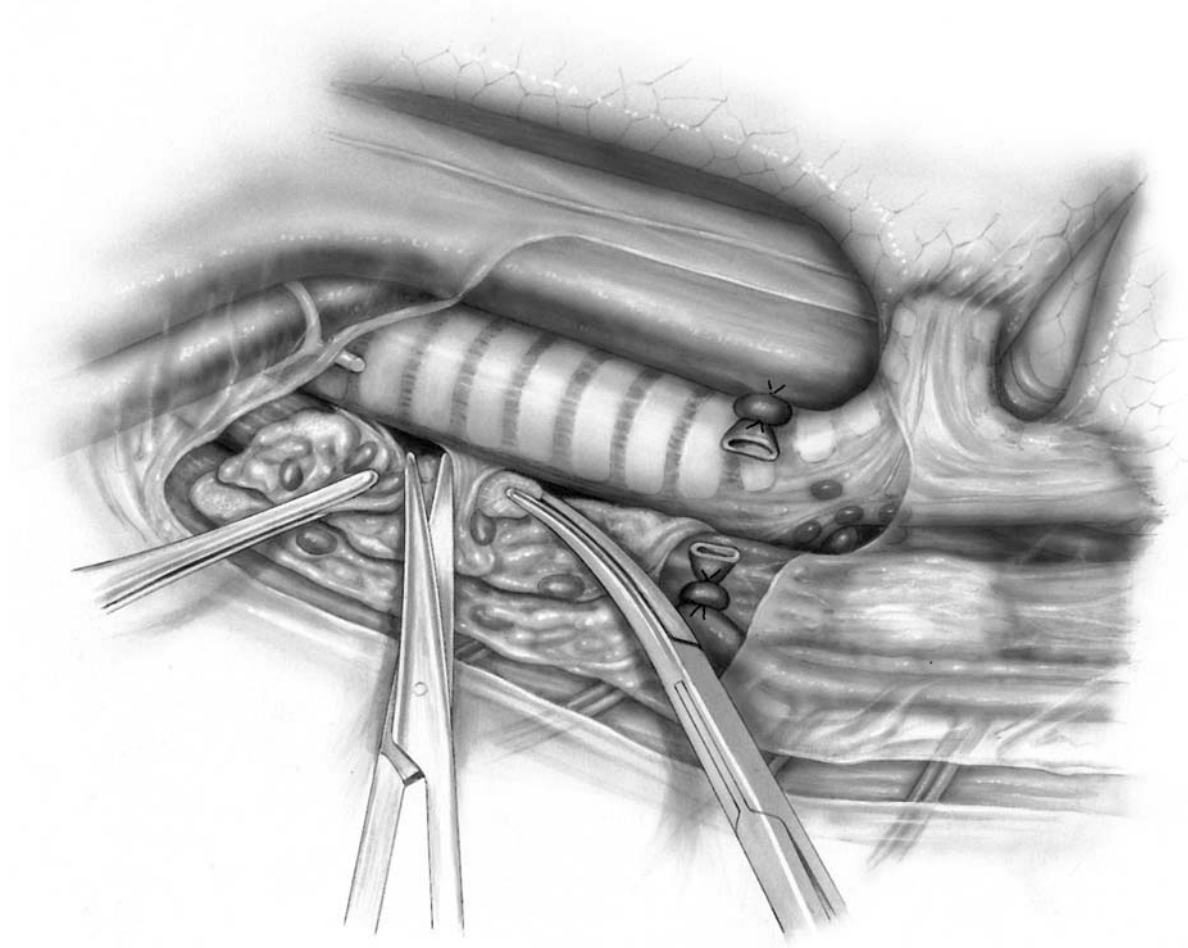
**Fig. 15.5.** The lymphadenectomy starts from the superior vena cava upwards to the confluence of the two V. anonyma. Preparation of the origin of the recurrent laryngeal nerve from the vagus nerve. Caudal to its origin the vagus

nerve is severed and pushed towards the en bloc specimen. The lymphadenectomy is performed along the dorsal wall of the superior caval vein.

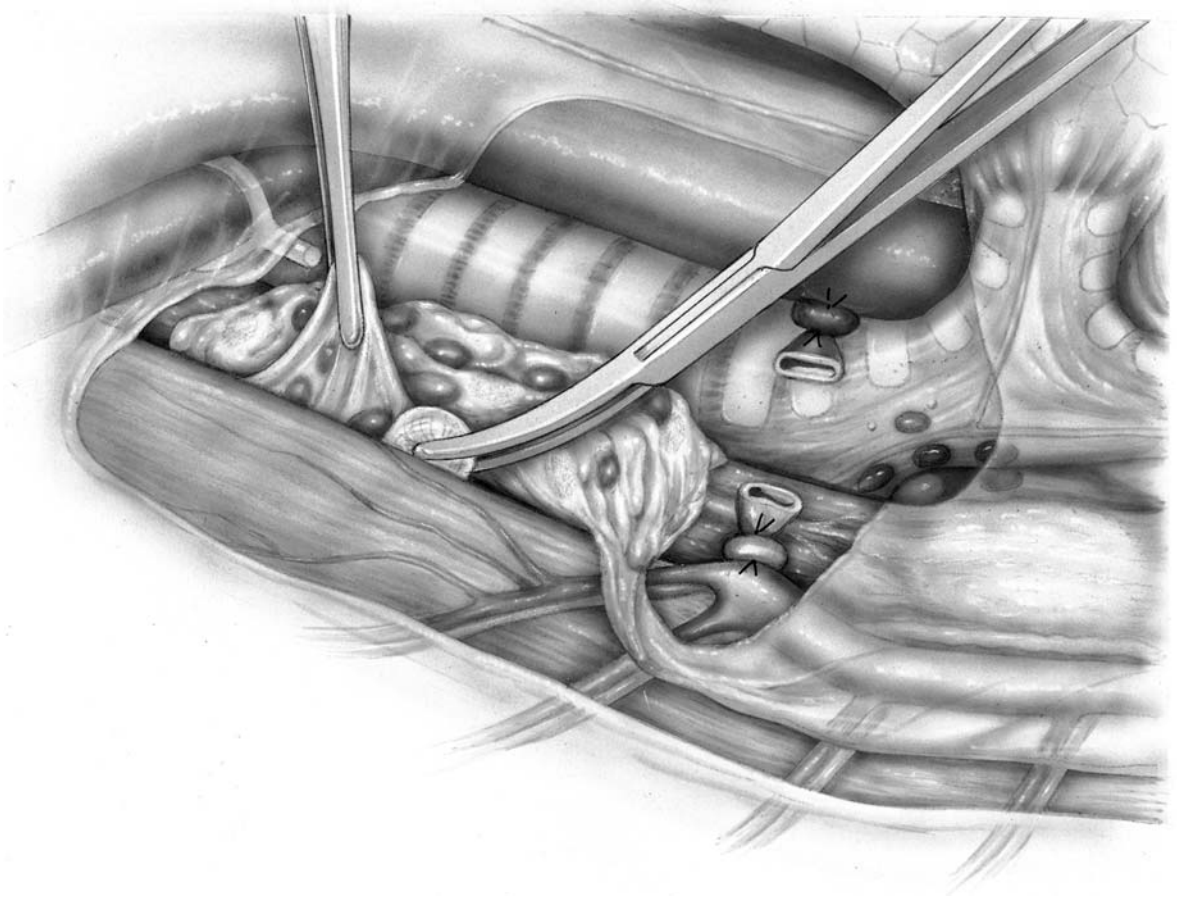


**Fig. 15.6.** After complete preparation of the superior caval vein, the trachea and the right- and left-sided main bronchus should be exposed from lymphatic tissue. The paratracheally

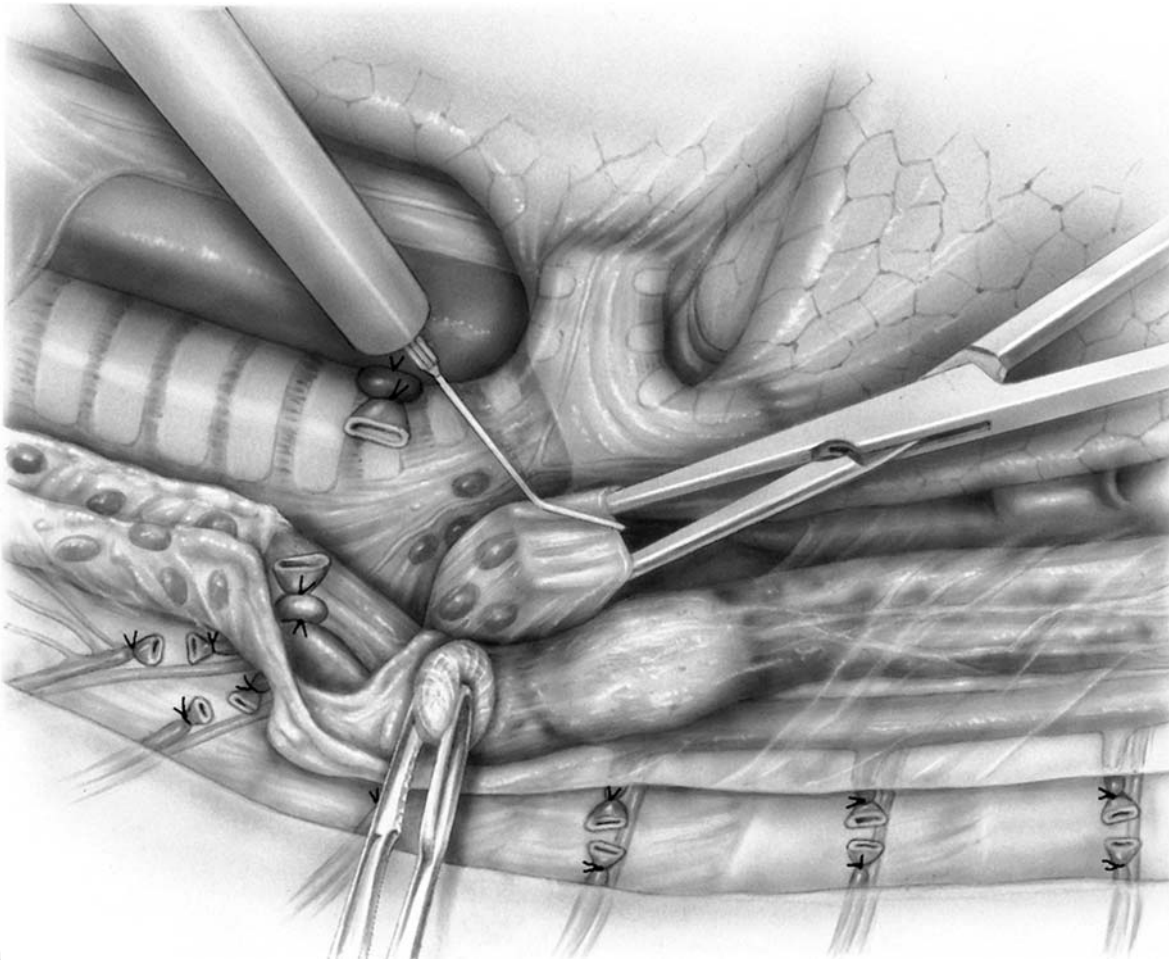
situated fat and lymphatic tissue is dissected towards the esophagus by sharp dissection or electrocautery and later resected en bloc with the esophagus.



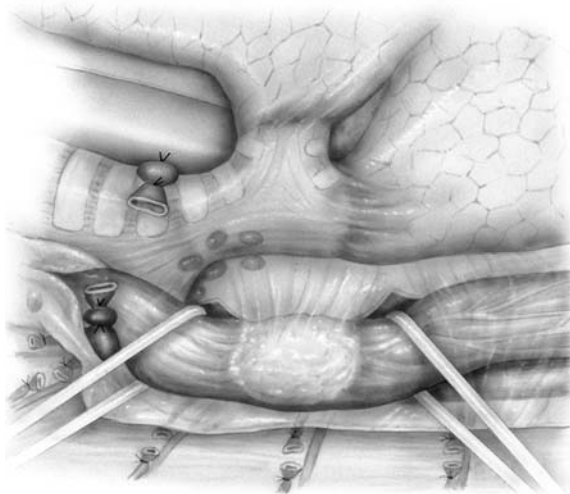
**Fig. 15.7.** Dissection of the retrotracheal lymph nodes. They should be dissected towards the esophagus. Care has to be taken to avoid injury to the membranaceous part of the trachea.



**Fig. 15.8.** Dissection of the cranial paraesophageal lymph nodes.

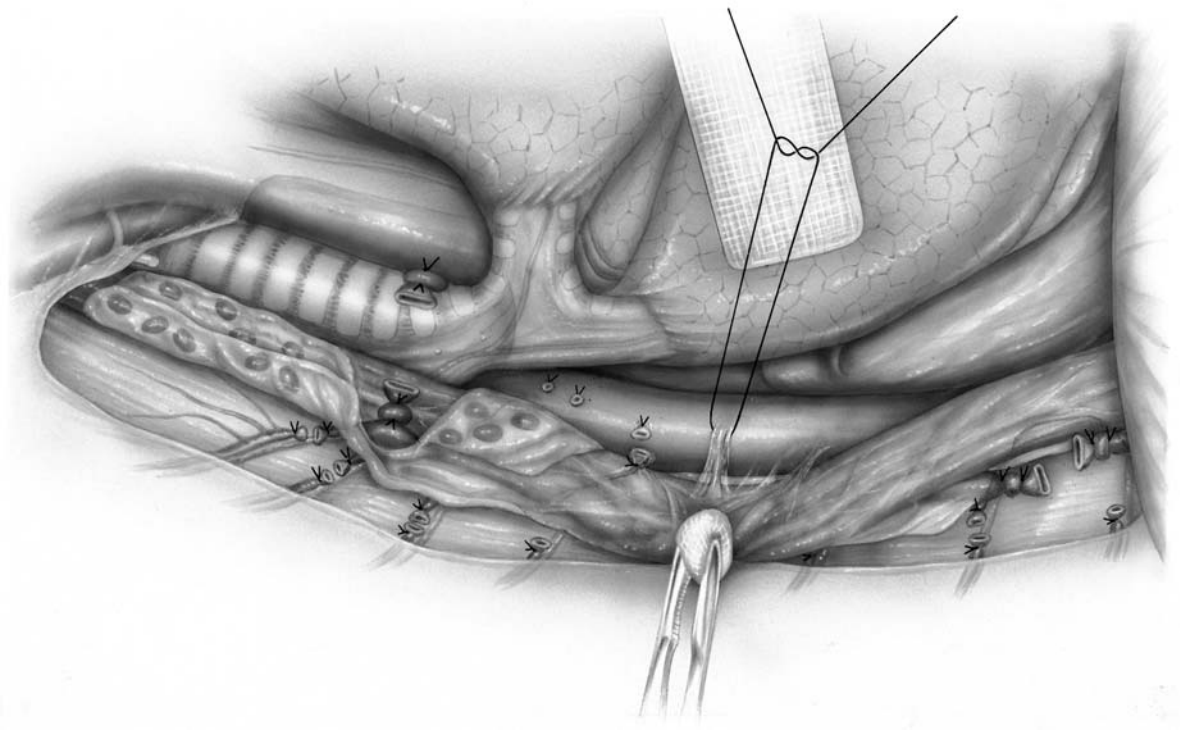


a



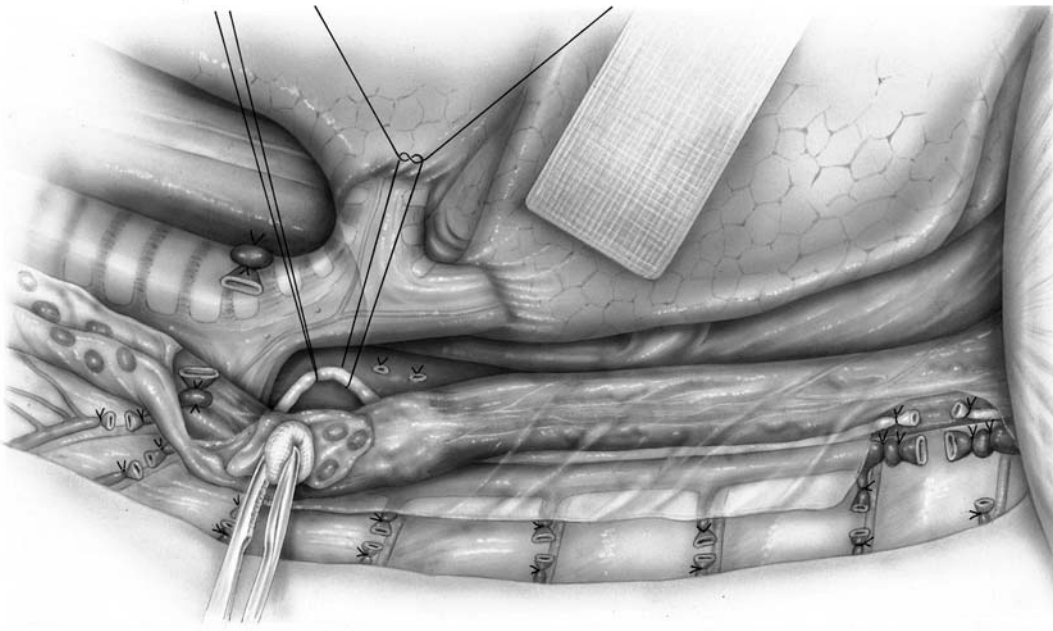
b

**Fig. 15.9a,b.** Dissection and ligation of all intercostal veins, which drain into the azygos vein for en bloc resection with the azygos vein. Lymphadenectomy of the subcarinal lymph nodes (a): For a better exposition of this area the esophagus should be held aside with a sponge (b): Alternatively the esophagus can be held with rubber bands.

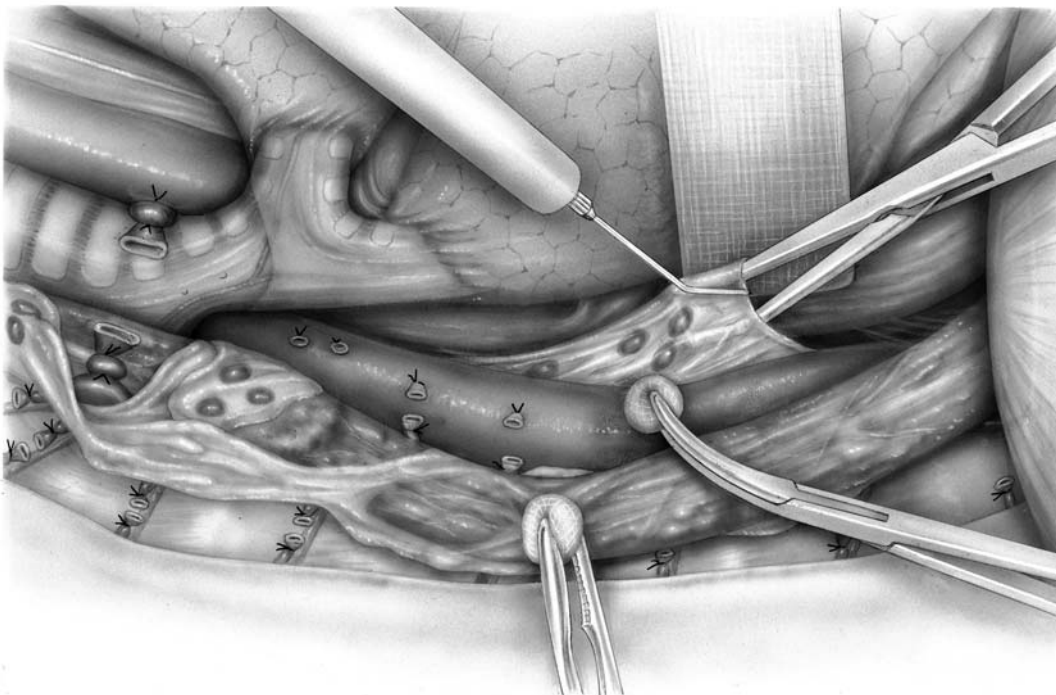


**Fig. 15.10.** Paraaortic lymphadenectomy. With continuous traction on the esophagus the paraaortic lymphadenectomy can be performed. The esophageal branches of the thoracic aorta have to be dissected very carefully and should be ligated with suture ligation.





**Fig. 15.11.** Transection of the thoracic duct with double ligations caudal to the tracheal bifurcation and directly above the diaphragm.



**Fig. 15.12.** Completion of the mediastinal lymphadenectomy with removal of the left sided paraaortic and retropericardial lymph nodes down to the esophageal hiatus. After completed mobilization of the en bloc esophageal specimen, thoracic

drains are placed in the right thoracic cavity. The thoracic incision is closed and the patient's position is changed for the abdominal part to a supine position.

## 16 Fundus Rotation Gastroplasty

M.K. SCHILLING, M.W. BUECHLER

The use of the stomach is still the preferred substitute for the esophagus requiring only the anastomosis to reestablish food passage. Furthermore the gastric substitute acquires spontaneous propulsive contractility and is associated with good long-term functional results. In Western populations, tubular transformation of the stomach following lesser curvature resection, as described by Akiyama occasionally results in a short gastric tube with perfusion deficiencies at the cranial part of the tube.

Gastric tube formation utilizing the gastric fundus and maintaining the arterial arcade along the lesser gastric curvature results in a longer and better perfused gastric tube.

■ **Anesthesia.** A combination between regional anesthesia and balanced intravenous and inhalation anesthesia is used. Epidural anesthesia at the level of TH 5–7 reduces perioperative opioid application and postoperative pain.

■ **Positioning.** For transhiatal esophagectomies, the patient is placed in a supine position with an 80° abduction of both arms. The head is flexed to the right side, to gain access to the cervical esophagus.

For a thoraco-abdominal approach, patients are placed in a spiral position with rotation of the torso to the left and abduction of the right arm. The head is flexed to the right side to gain access to the cervical esophagus.

■ **Incision.** An upper median laparotomy with extension to the left of the xyphoid is used to gain access to the abdominal portion of the esophagus and the stomach (Fig. 16.1). The abdominal cavity is kept open by two retractors (three in obese patients) (Fig. 16.2).

■ **Gastric mobilization.** The first step in gastric mobilization is dissection of the greater omentum. The dissection is performed at a 3–4 cm distance from the greater curvature to avoid injury to the gastroepiploic arteries and the extramural connections between the right and left gastroepiploic arteries.

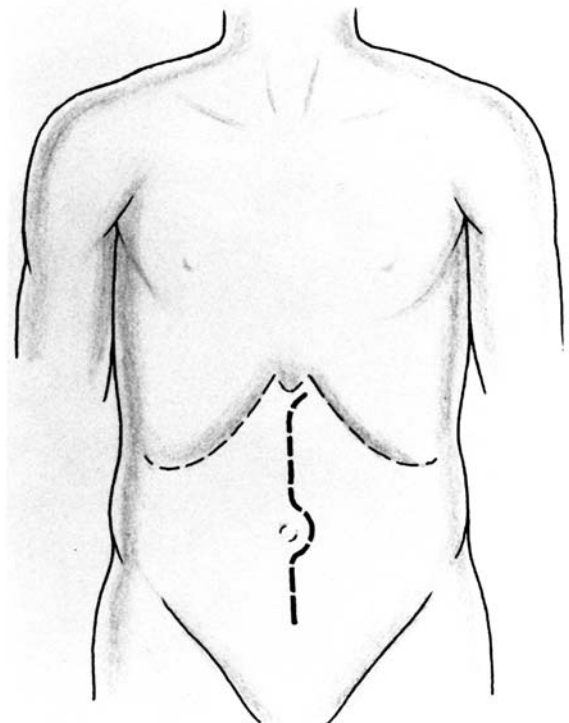
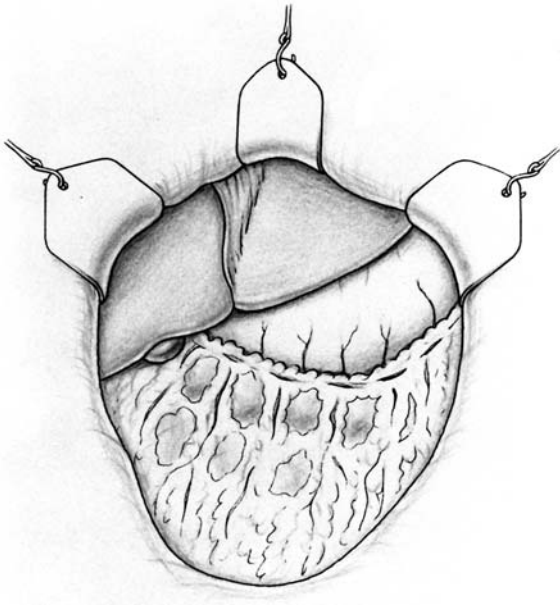
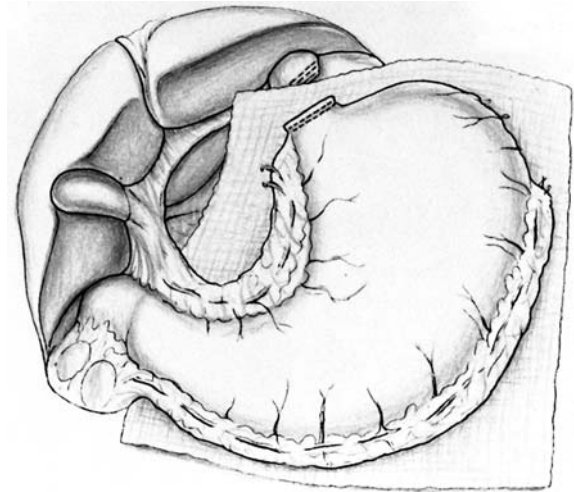


Fig. 16.1. Approach; upper mid-line incision.



**Fig. 16.2.** Open cavity with inserted retractors.



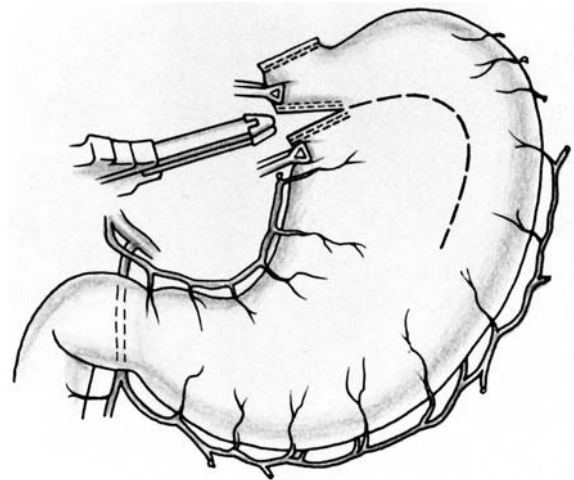
**Fig. 16.3.** Mobilized stomach on warm packs.

The short gastric arteries are divided close to the spleen to avoid injury to the gastric wall.

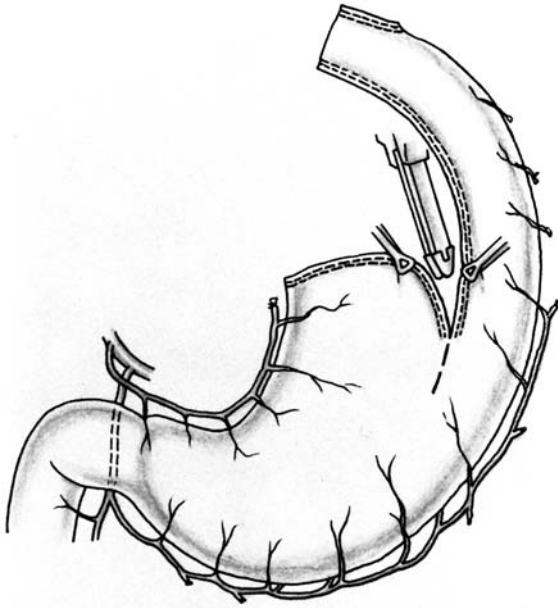
In a second step the lesser omentum is dissected close to the liver. Care is taken not to sever accessory left hepatic arteries from the celiac trunk or the left gastric artery. The stomach is dissected and the gastroesophageal junction is divided with a TA stapler.

After gastric mobilization, the stomach is placed on warm packs (Fig. 16.3).

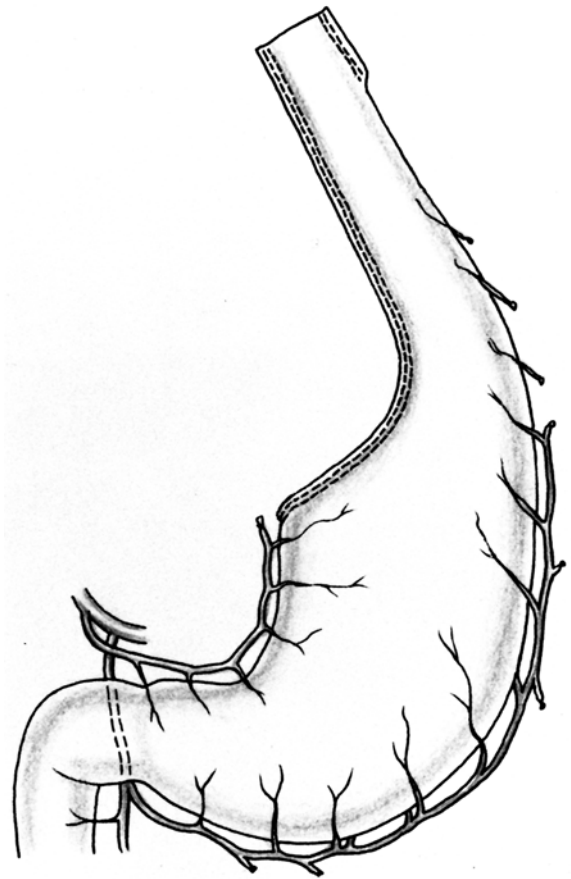
■ **Fundus rotation gastroplasty.** For oncological procedures, all connective, adipose, and lymphoid tissue is carefully dissected from the left gastric artery. The left gastric artery and the concomitant vein are ligated close to the stomach.



**Fig. 16.4.** Skeletonization starting at the proximal small curvature.



**Fig. 16.5.** Last steps of the fundus rotation gastroplasty.



**Fig. 16.6.** Completed fundus rotation gastroplasty.

The gastric tube is formed by stepwise stapling along the gastric fundus with a linear stapler as depicted in Figures 16.4 and 16.5. Careful traction is applied to the edges with Allis clamps (Fig. 16.6). The stapler line is inverted with 4/0 interrupted absorbable sutures.

Gastric tube formed by the fundus rotation gastroplasty technique are usually long enough

to perform tension-free anastomosis even with the mid pharynx.

The vascular supply of the tube in its distal part consists of direct vessels running from the left gastroepiploic artery, and the more oral part of the tube is supplied by an intramural vascular plexus, fed by the gastric and gastroepiploic arterial arcade.

# 17 Proximal Gastrectomy with Distal Esophagectomy (Proximal Resection)

A. F. CHERNOUSOV, O. ZEHLER, P. M. BOGOPOLSKI, D. C. BROERING, H. W. SCHREIBER†

## ■ Indications

Indications for this surgical procedure are rare.

- Carcinoma of the cardia in the abdominal esophagus (below the diaphragm) in patients with high comorbidity
- Long strictures of the abdominal esophagus.

## ■ Contraindication

Severe cardiopulmonary insufficiency.

## ■ Risks and patient's informed consent

See chapter 13.

## ■ Special preoperative preparation

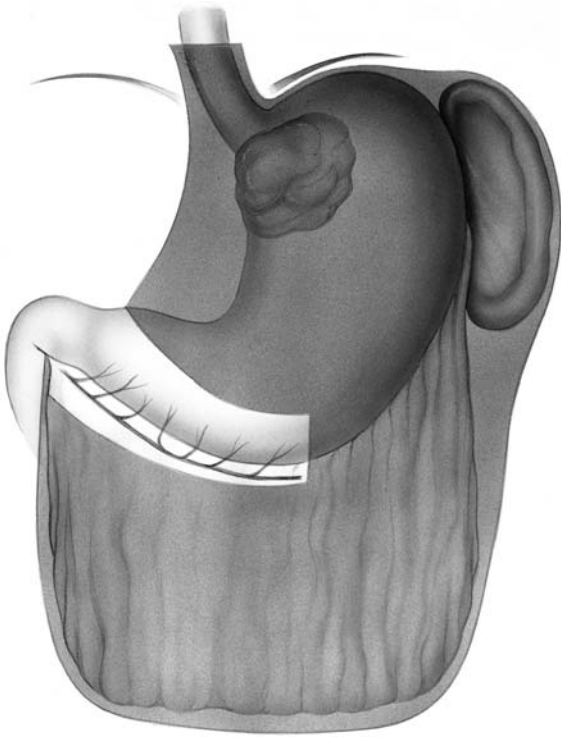
See chapter 13.

## ■ Patient position and surgical incision

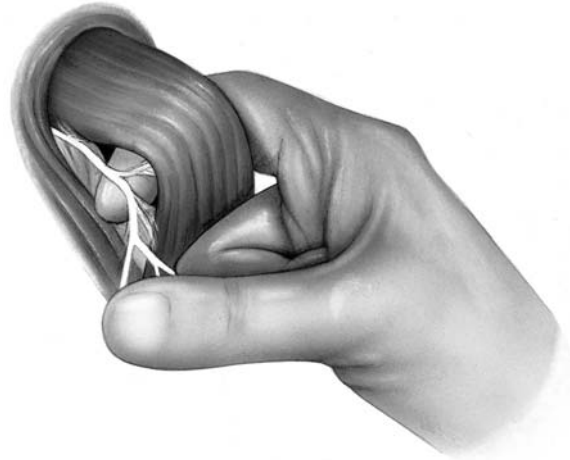
See chapter 13.

## ■ Operative procedure

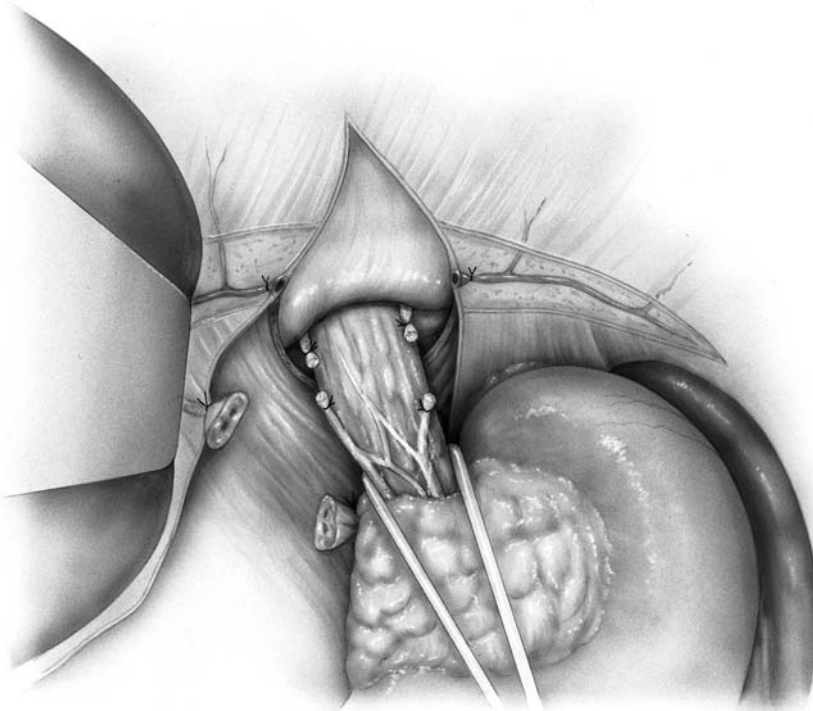
1. Mobilization of the abdominal part of the esophagus
2. Sagittal diaphragmotomy
3. Truncal vagotomy
4. Mobilization of the stomach with preservation of the right gastric omental vein and artery
5. Extensive lymphadenectomy in the area of the hepatic artery, splenic artery, celiac trunk, and paraaortal
6. Optional: splenectomy in patients with suspicious lymph nodes
7. Tube reconstruction using the distal stomach
8. Intrathoracic esophagogastrostomy.



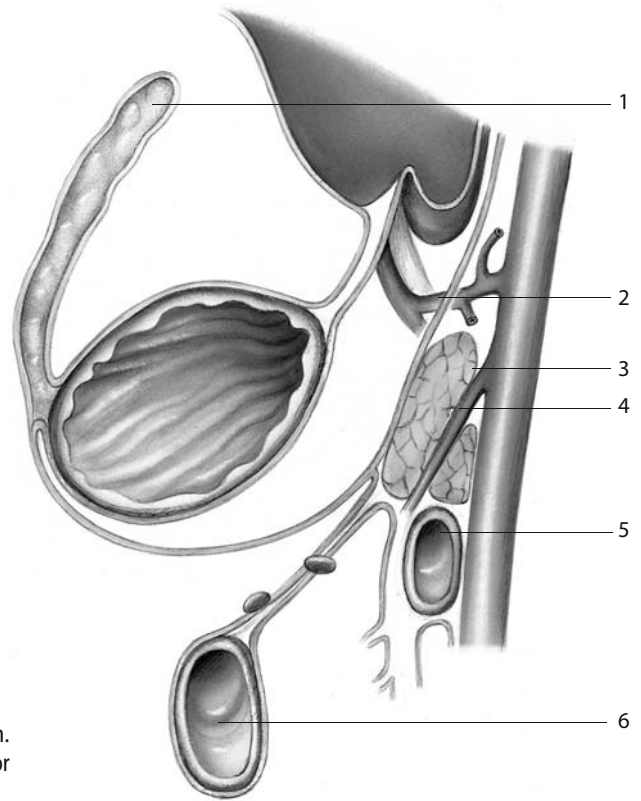
**Fig. 17.1.** Mobilization of the stomach and the distal esophagus, resection lines during the procedure of proximal gastrectomy, and distal esophagectomy.



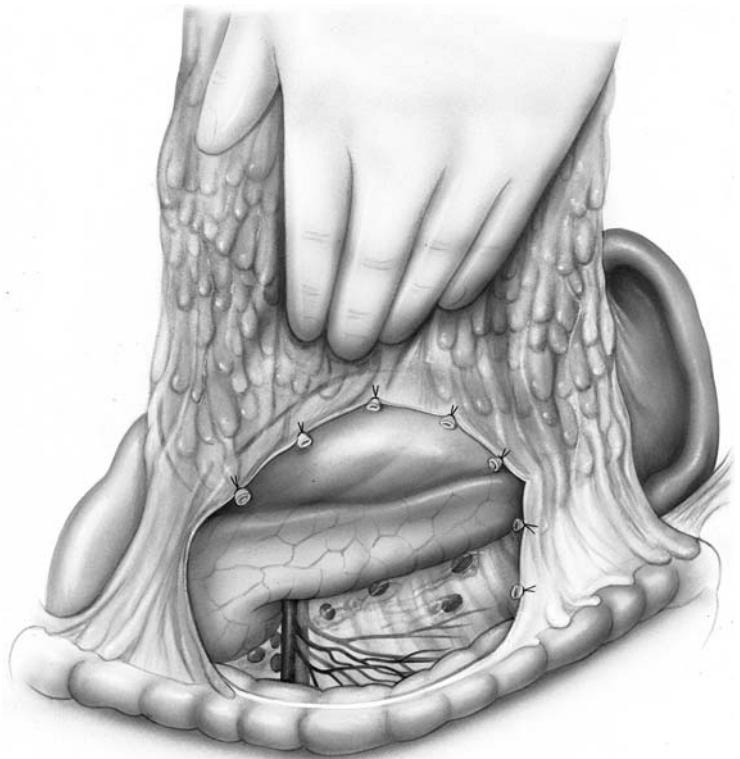
**Fig. 17.2.** Technique of blunt dissection of the esophagus at the diaphragm. After incision of the peritoneum on both sides of the esophagus, the forefinger of the right hand is bluntly inserted behind the esophagus. The esophagus and the vagal nerves are mobilized stepwise.



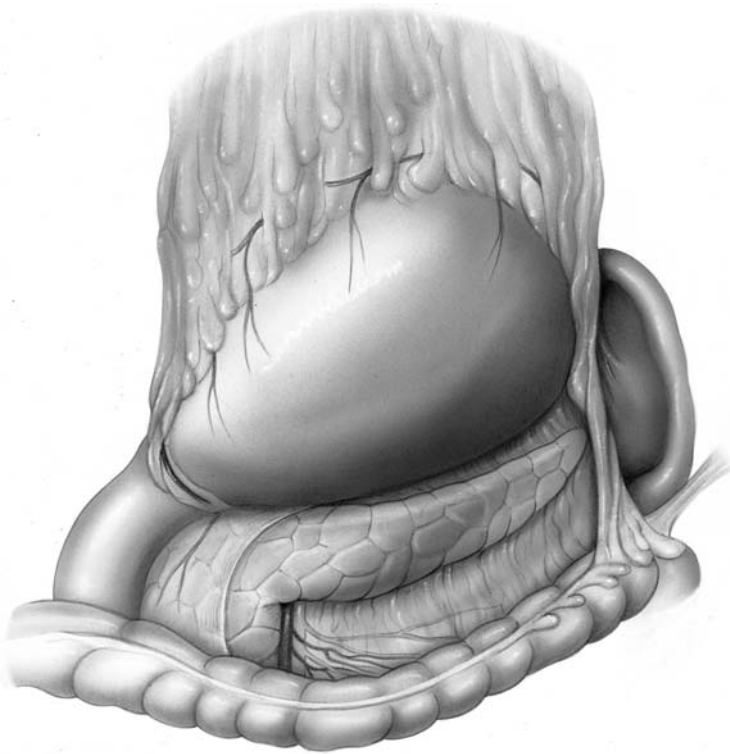
**Fig. 17.3.** The left lobe of the liver is dissected by the incision of the left triangular ligament. The diaphragm is retracted to the right side. Sagittal incision of the diaphragm is performed after suture ligation of the diaphragmatic vein. The retropericardial and intra-abdominal esophagus is mobilized. Slight traction is applied to the esophagus to the left and caudally. The vagal nerves are transected.



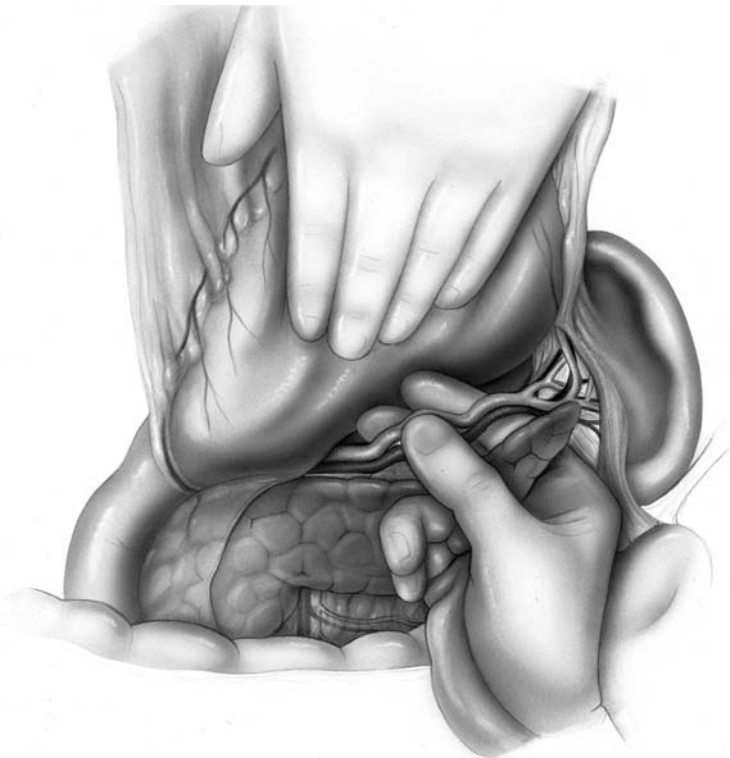
**Fig. 17.4.** Anatomy of the lesser omentum in cross-section. 1 Greater omentum; 2 celiac trunk; 3 pancreas; 4 superior mesenteric artery; 5 duodenum; 6 transverse colon.



**Fig. 17.5.** During the mobilization of the greater curvature, the greater omentum with the anterior peritoneal aspect of the colon is dissected. Lymphadenectomy in the area of the middle colic vessels.

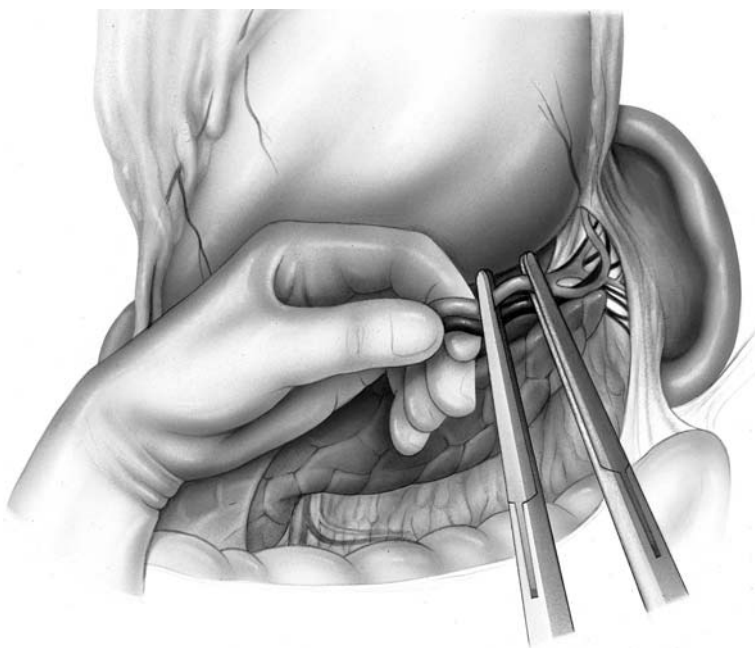


**Fig. 17.6.** The fat and lymphatic tissue along the lower pancreatic edge is removed. The peritoneum covering the body and the tail of the pancreas is dissected. The peritoneum of the frontal surface of the pancreas is preserved.

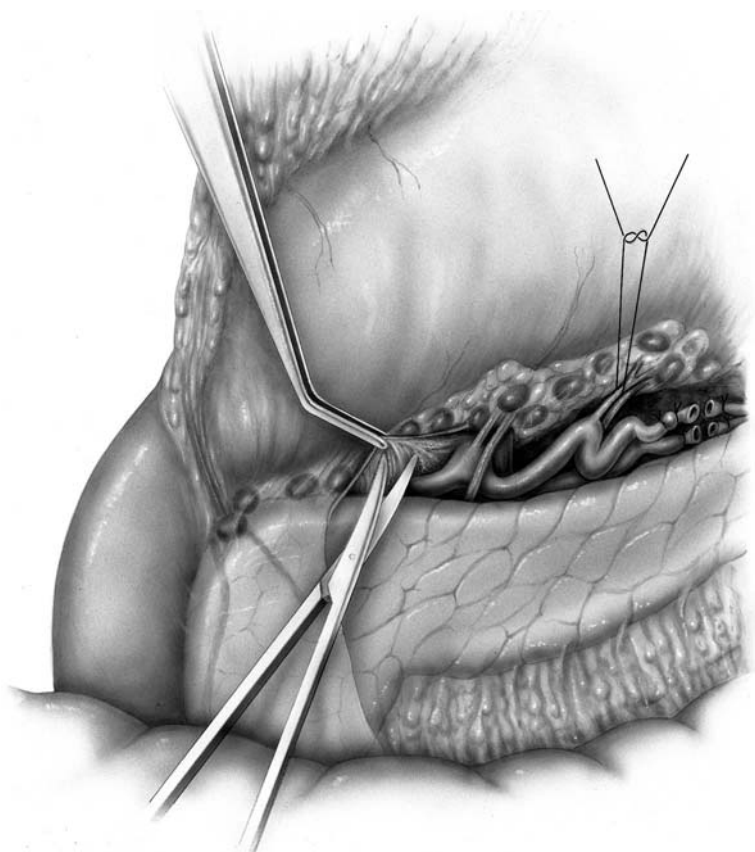


**Fig. 17.7.** In cases with enlarged pathologic lymph nodes at the hilar region of the spleen, en bloc splenectomy is indicated. Care should be taken to avoid any damage to the pancreatic tail. Dissection of the splenic artery and vein.

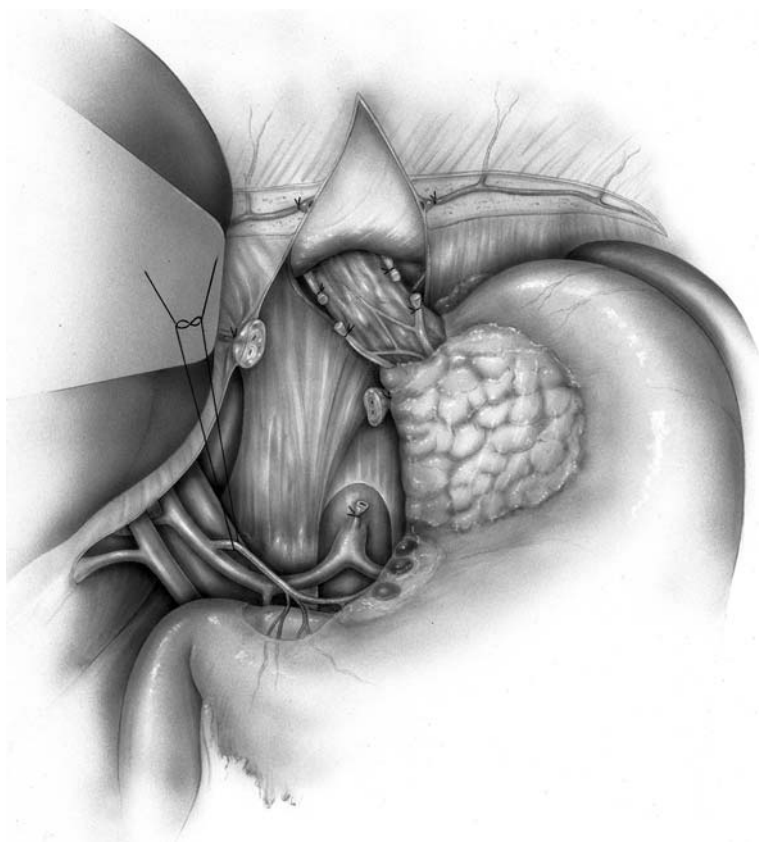




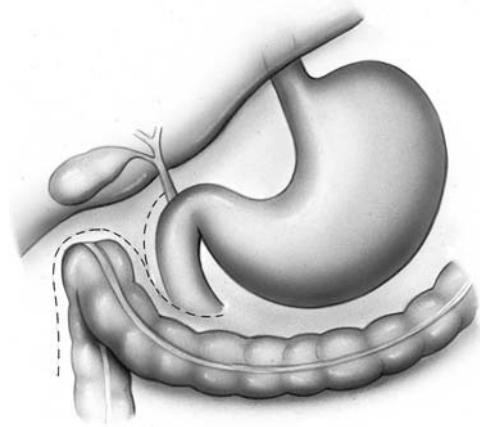
**Fig. 17.8.** Transection of the splenic vessels between clamps. The vessels are suture-ligated separately. The fatty tissue around the pancreatic tail is resected with the spleen.



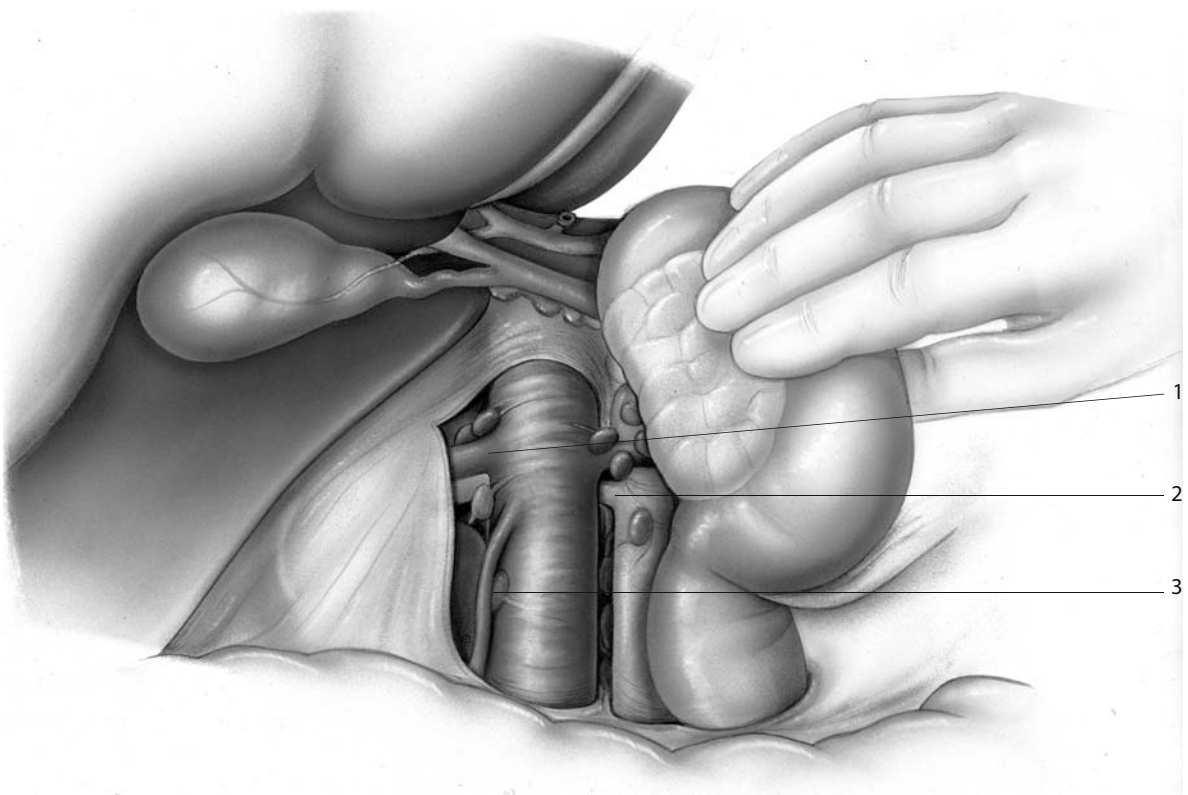
**Fig. 17.9.** The splenic artery is freed from the surrounding lymphatic tissue to the pancreatic head. Lymphadenectomy is completed along the left gastric artery, celiac trunk, and in the paraaortic area.



**Fig. 17.10.** Fat tissue and lymph nodes along the common hepatic artery, hepatic artery, portal vein, and the bile duct is resected. The right gastric artery is dissected and ligated close to the hepatic artery.

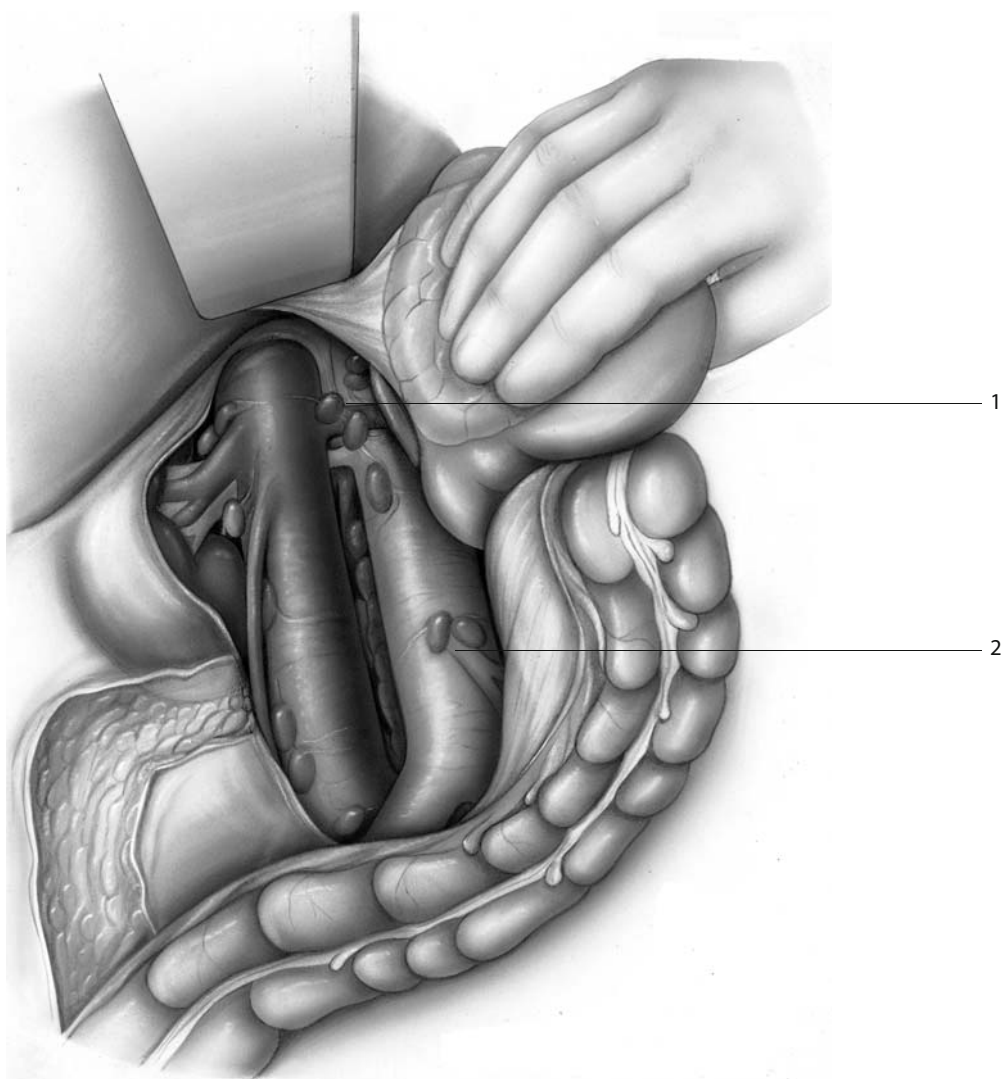


**Fig. 17.11.** Peritoneal incision line for the Kocher maneuver.



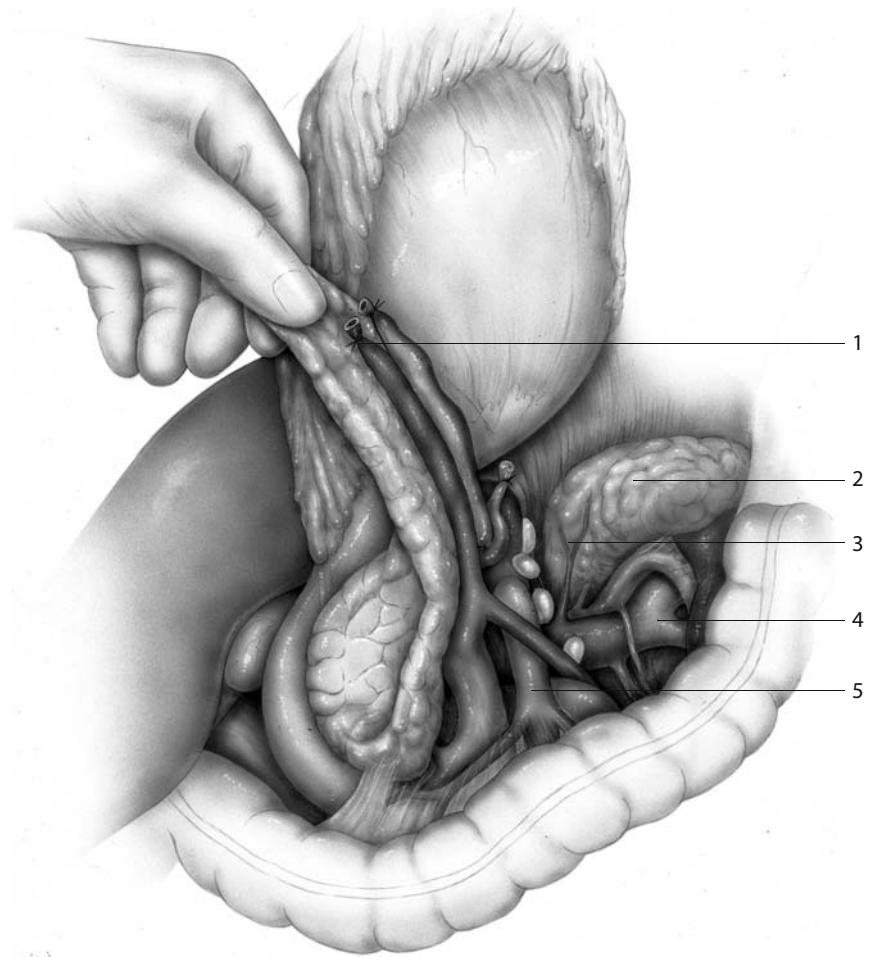
**Fig. 17.12.** After completion of the Kocher maneuver the retropancreatic, paracaval, and right paraaortic lymphadenectomy may be performed. The dorsal surface of the pan-

creatic head, the caval vein, the renal vein and the aorta are completely dissected. **1** Right renal vein; **2** right renal artery; **3** right ovarian or spermatic vein.



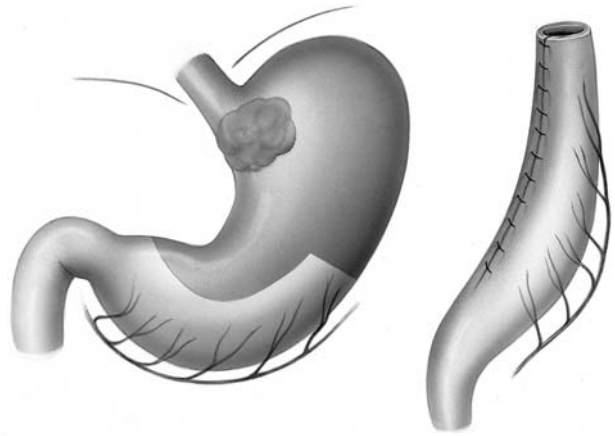
**Fig. 17.13.** A supracaval lymphadenectomy encompasses the continuation of the paracaval and paraaortal lymphadenectomy caudally to the bifurcation of the aorta. All lymph

nodes along the caval vein, the aorta, and the renal vein are removed (compartment-3 resection). **1** Superior mesenteric artery; **2** inferior mesenteric artery.

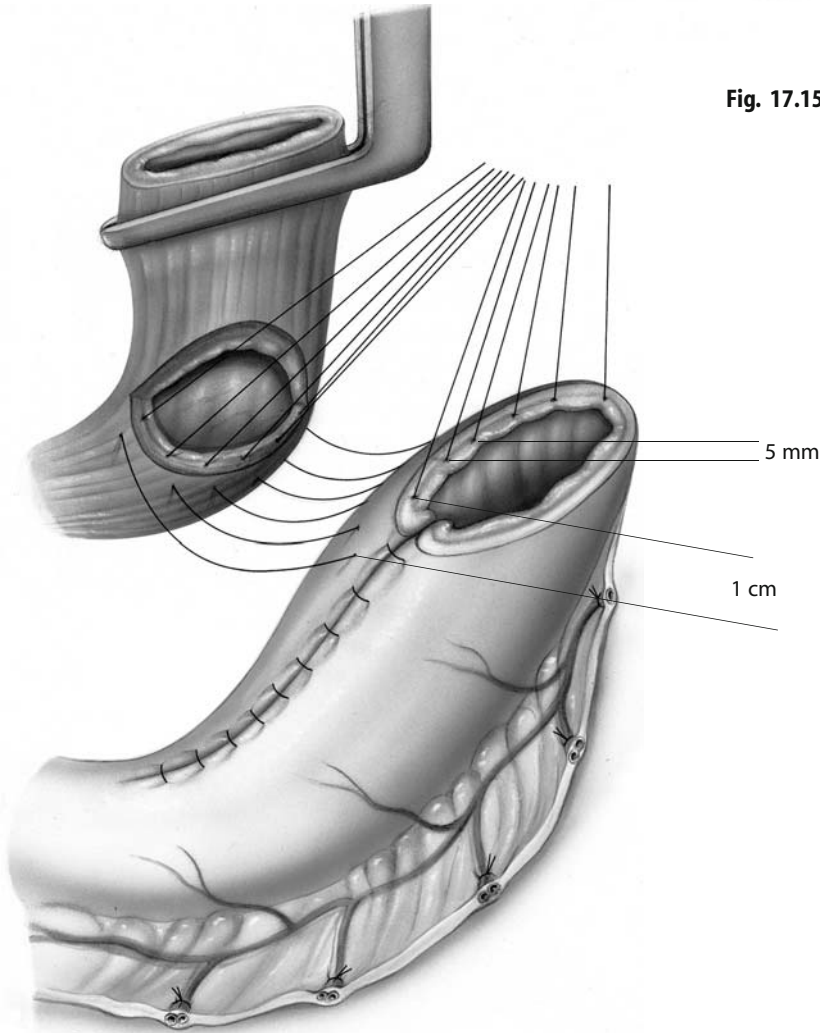


**Fig. 17.14.** Completion of the extensive lymphadenectomy in compartment 3. Dissection of the pancreatic corpus and tail. The remaining fatty tissue and lymph nodes along the superior mesenteric artery, the abdominal aorta, the left

renal artery, and suprarenal arteries are removed. **1** Splenic vein; **2** left suprarenal gland; **3** left suprarenal vein; **4** left renal vein; **5** superior mesenteric artery.

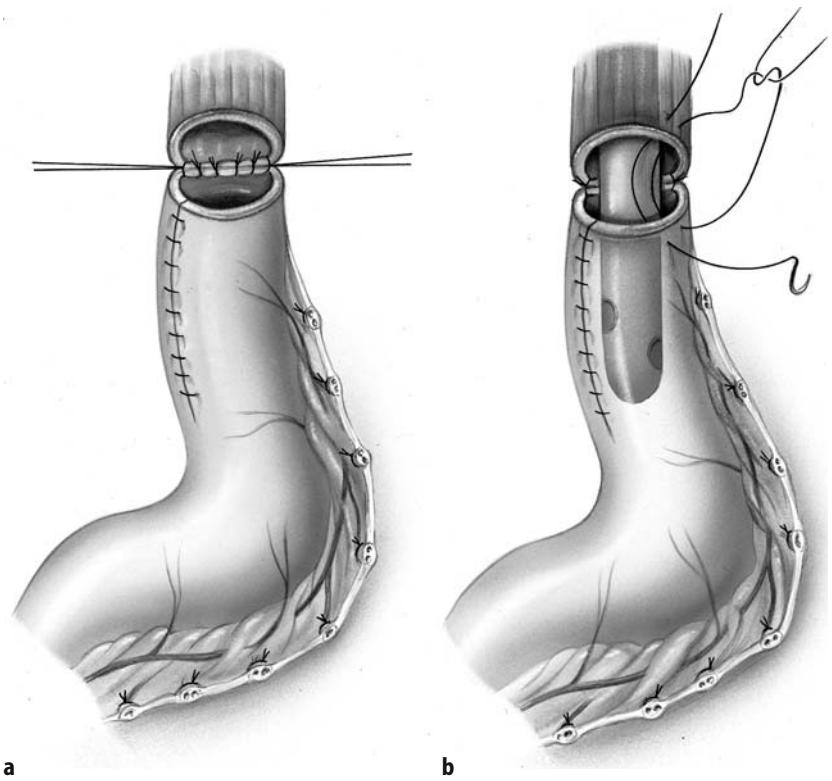


**Fig. 17.15.** Preparation of a distal stomach tube.

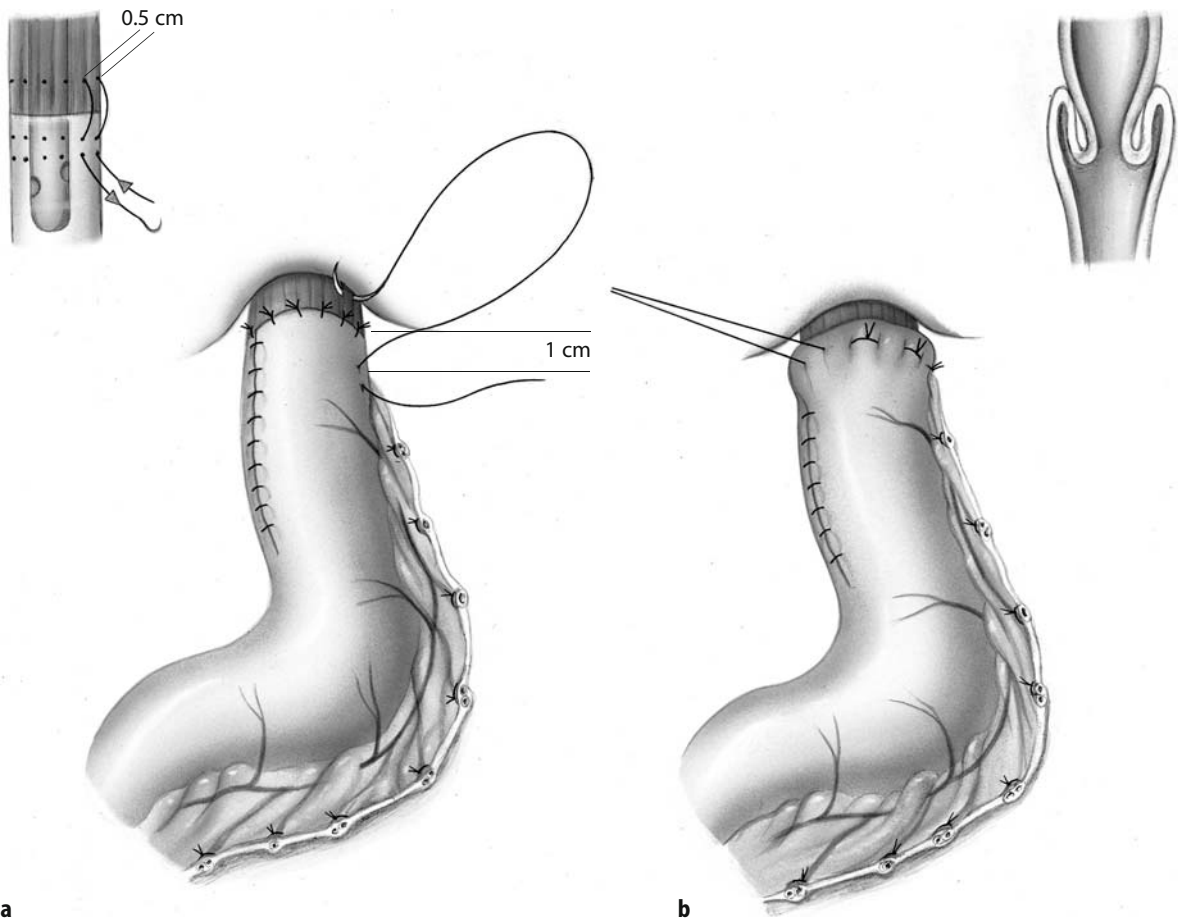


**Fig. 17.16.** Preparation of the distal stomach tube is performed in the same way as in the description of the blunt dissection excluding the transverse antotomy. The esophagus has to be resected with at least 5 cm tumor-free esophageal margin. After resection of the stomach including the tumor, a right-angle clamp is placed at the esophagus. The esophagus is incised. The anastomosis starts at the backside of termino-terminal esophagogastrostomy with extramucosal

all layer stitches in a single stitch technique. First, all stitches are armed with clamps and are then tied after completion of the dorsal wall. The distance between the single stitches is 5 mm. The external stitch is performed 1 cm from the edge of the anastomosis. After tying the sutures are cut. The corner stitches are not cut and ventral wall of the anastomosis is sewn in the same way.



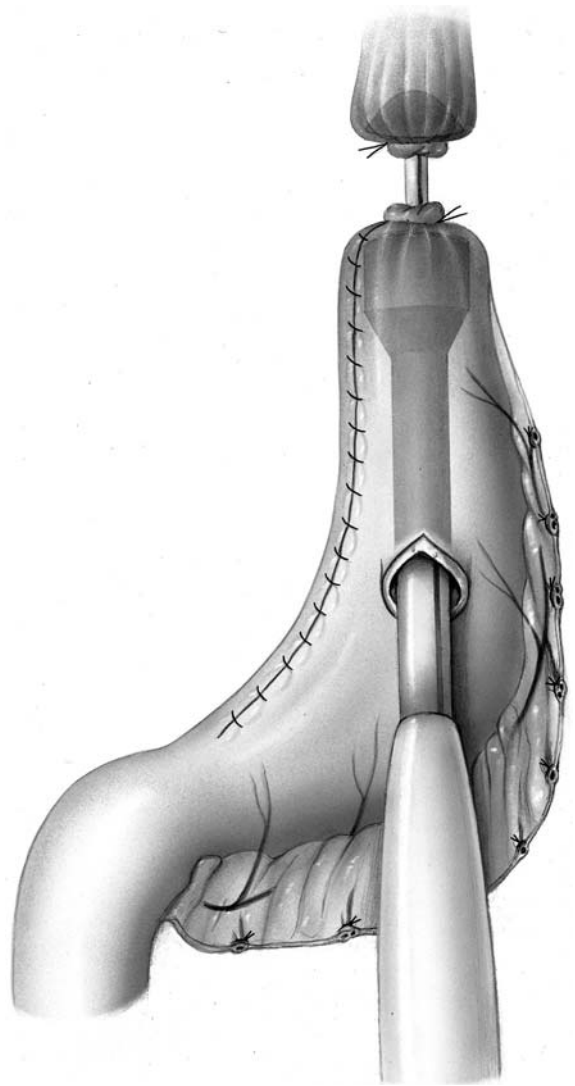
**Fig. 17.17.** The sutures of the dorsal wall are finished and tied (**a**). A naso-gastric tube is to be placed beyond the anastomosis (**b**). Finally, the ventral part of the anastomosis is performed.



**Fig. 17.18.** The dorsal and ventral suture line is doubled by using sero-muscular U-stitches. The distance between these stitches is 5 mm. The sutures should be 1 cm from the anastomosis (a). During tying of the knots, the index finger may

be helpful inverting the anastomosis. Principle of the anti-refluxive esophagogastrostomy (b). If the esophageal wall is very thin, the esophagogastrostomy should be performed in a single row anastomosis.





**Fig. 17.19.** Alternatively, the esophagogastrostomy may be performed using a circular stapler. The transverse gastrotomy for the introduction of the stapler is closed using all layer sutures. The stapled anastomosis is inverted as described above.

# 18 Transhiatal Esophagogastrectomy

J. R. IZBICKI, D. C. BROERING, A. KUTUP, E. F. YEKEBAS

## ■ Indications

- Adenocarcinoma of the distal esophagus with involvement of the proximal stomach
- Locally advanced carcinoma of the cardia
- Adenocarcinoma of the proximal stomach with infiltration of the distal esophagus.

## ■ Contraindications

- Active duodenal ulcer
- Severe cardiopulmonary insufficiency.

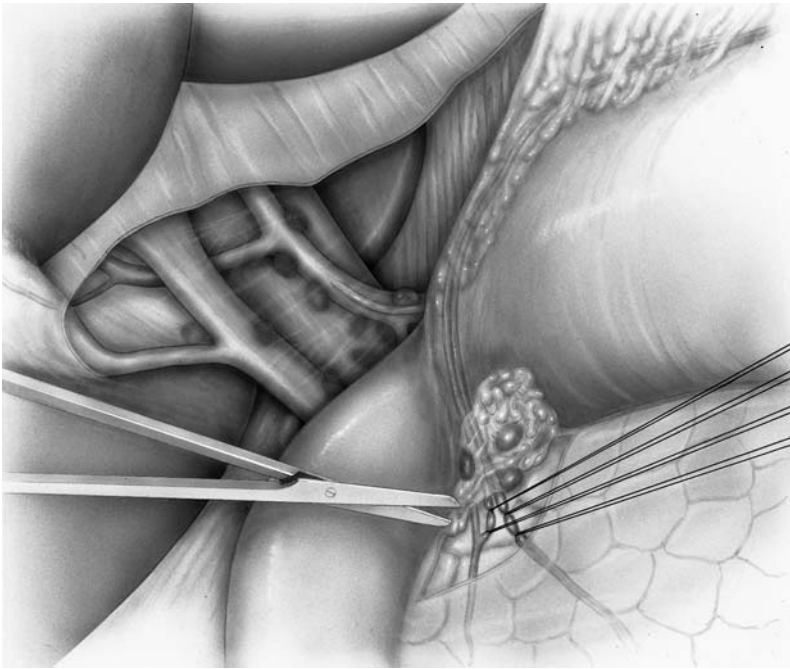
## ■ Risks and informed consent

- See chapter 13
- Necrosis of the colon
- Risk of pancreatitis and injury of the spleen.

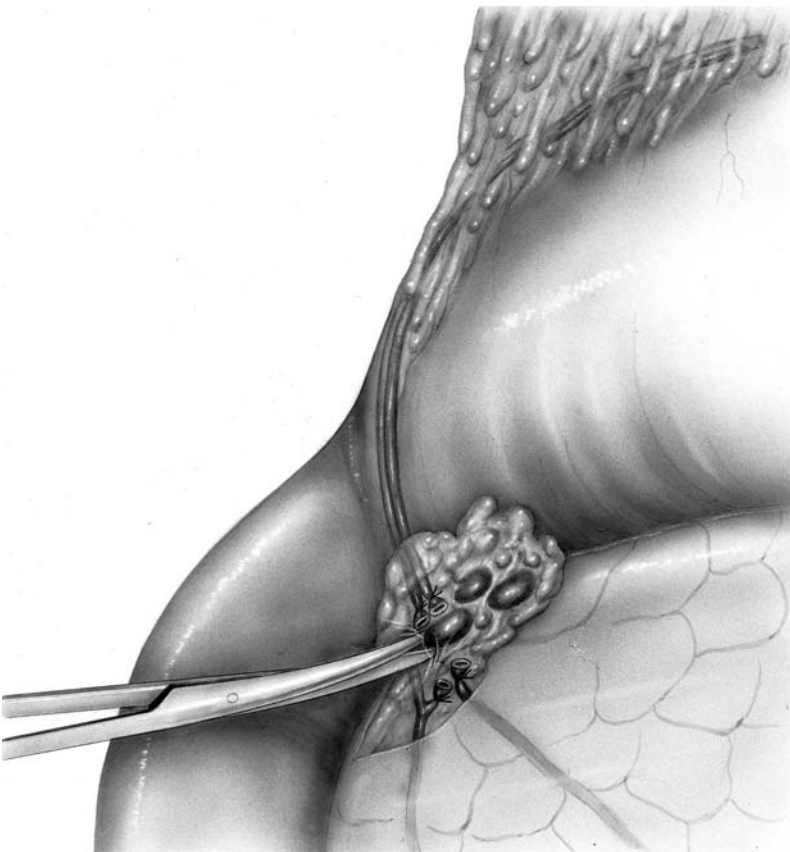
## ■ Special preoperative preparations

### ■ Anesthesia, patient position and surgical incision. See chapter 13.

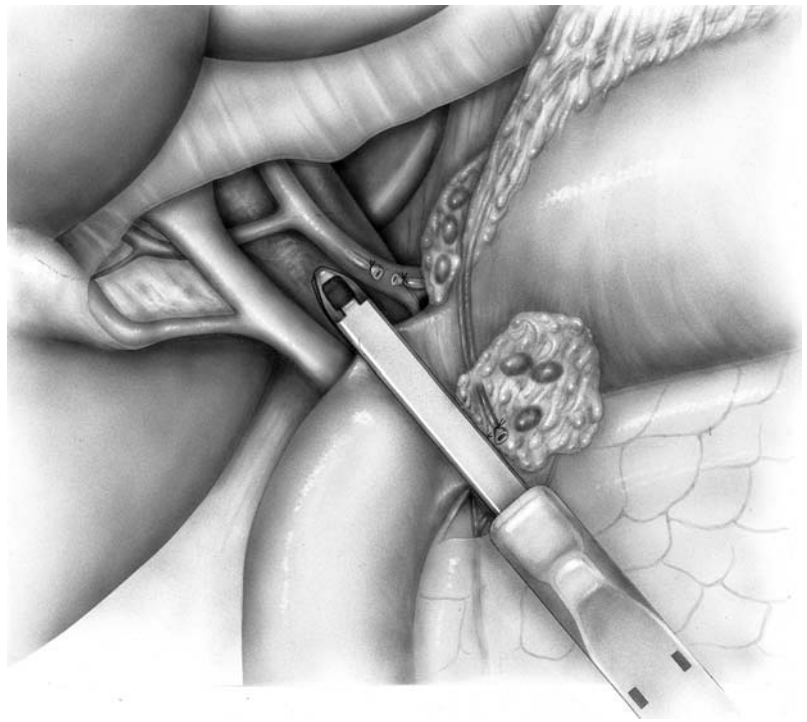
Laparotomy is performed as demonstrated in chapter 13 by transverse abdominal incision extended by an upper abdominal midline incision (inverse T-incision). After mobilization of the left lateral liver lobe and dissection of the lesser sac close to the liver, the greater omentum is detached from the transverse colon. Lymphadenectomy begins at the basis of the right gastroepiploic vessels.



**Fig. 18.1.** Incision of the peritoneal sheath above the right gastroepiploic vessels. The right epiploic vessels are suture ligated as close as possible to the pancreas without injuring the pancreatic capsule.

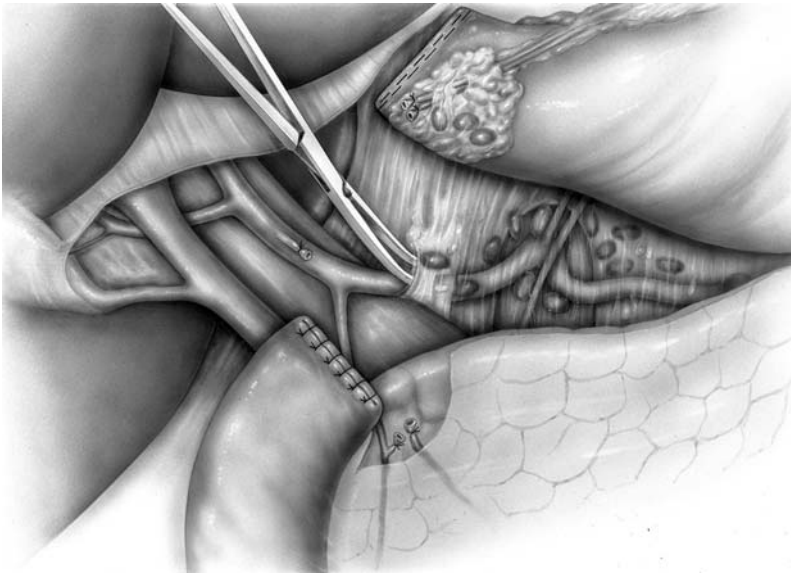


**Fig. 18.2.** Dissection of the surrounding lymph nodes is performed. For better exposure of these nodes, the stomach is held upwards using ventral traction. The lymph nodes at the upper margin of the pancreas are dissected towards the duodenum to facilitate the en bloc resection later. Injury of the serosa of the duodenum and of the capsule of the pancreas has to be avoided.



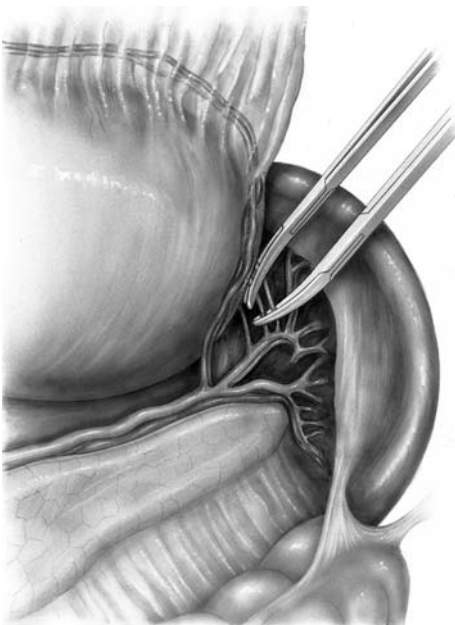
**Fig. 18.3.** The lymphadenectomy of the hepatoduodenal ligament is performed as described in chapter 13. In addition, the lymph nodes around the origin of the right gastric artery are dissected towards the stomach. The right gastric artery is

then ligated at its origin. After circular dissection of the gastroduodenal junction, the duodenum is transected 2–3 cm behind the pylorus with a linear stapler device, and the stapler suture line is inverted with single sutures.



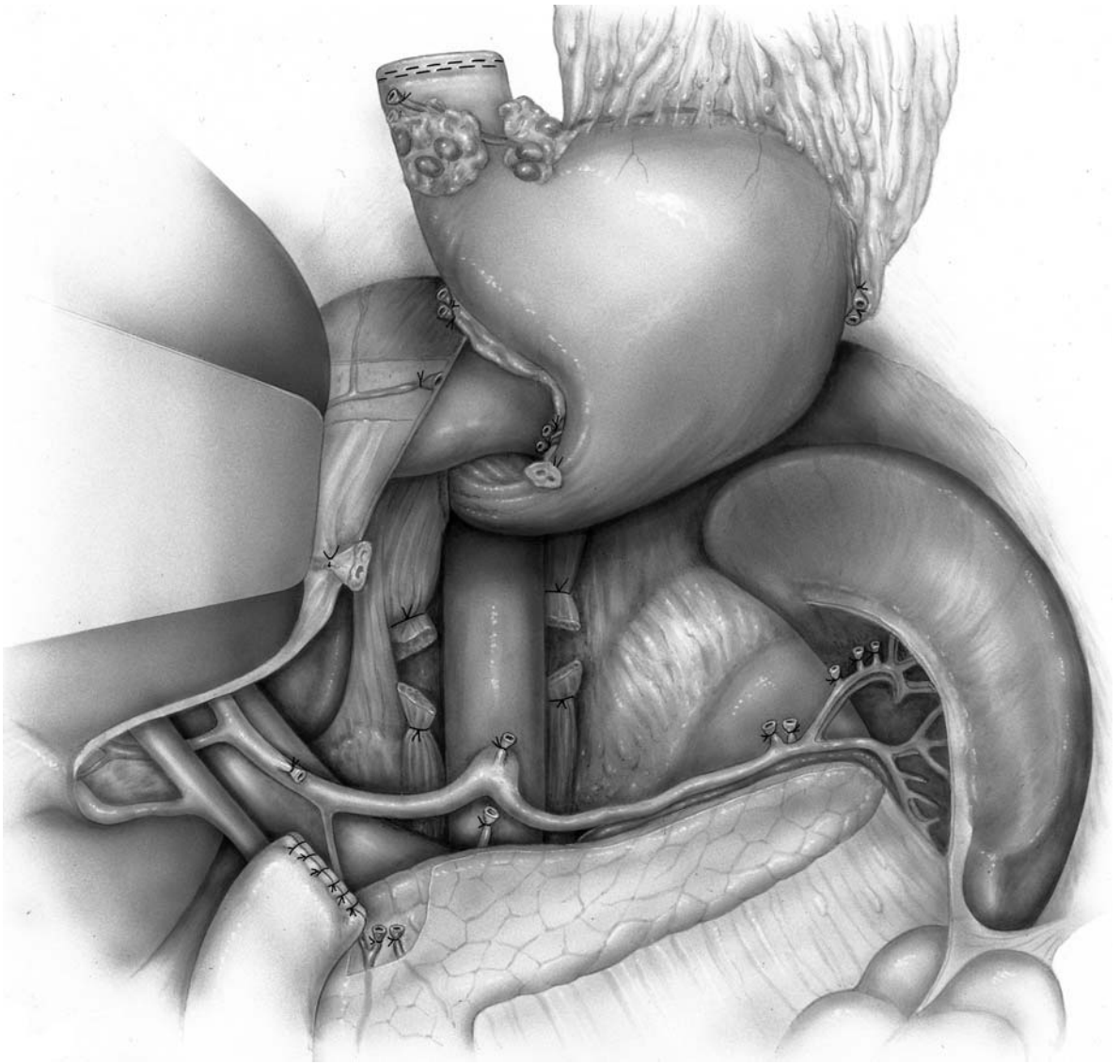
**Fig. 18.4.** The upper margin of the pancreas is now exposed by applying traction upwards to the distal stomach. Lymphadenectomy continues from the hepatoduodenal ligament

along the common hepatic artery down to the celiac trunk. Lymphadenectomy at the splenic artery, the celiac trunk, and the paraaortal space is performed as described in chapter 13.



**Fig. 18.5.** Traction is applied to the stomach towards the right upper abdomen to expose the origin of the left gastroepiploic artery and the short gastric vessels. These vessels are transected and ligated between clamps. Mobilization of

the greater curvature of the stomach is performed up to the gastroesophageal junction. During this step the phrenicogastric ligament has to be transected with electrocautery.



**Fig. 18.6.** Operative site after dissection of the stomach with completed lymphadenectomy at the hepatoduodenal ligament with exposure of the hepatic artery, the splenic artery, the celiac trunk, and the paraaortal region. The stapled suture line of the duodenal stump is oversewn. Median inci-

sion of the diaphragm in combination with incision of both diaphragmatic crura allows exposure of the esophageal hiatus. This is the first step of the transhiatal dissection of the esophagus.

# Colon Interposition after Total and Subtotal Esophagectomy

J. R. IZBICKI, K. STEFFANI, A. F. CHERNOUSOV, P. M. BOGOPOLSKI,  
D. C. BROERING, H. W. SCHREIBER †

## ■ Indications

- Patients with esophageal carcinoma after subtotal gastrectomy
- Locally advanced carcinoma of the cardia with infiltration of the lower esophagus
- Peptic stricture of the total esophagus, including strictures with extension to pharynx or stomach
- Long peptic stricture of the esophagus with severe esophagitis and esophageal fistula
- Extensive peptic stricture of the esophagus in patients after subtotal gastrectomy
- Any affection of the “neo-esophagus” after transpleural esophagectomy, gastric tube reconstruction with cervical esophagostomy (secondary reconstruction after gastric tube necrosis)
- Necrosis or inadequate length of the gastric or jejunal interposition for reconstruction.

## ■ Contraindications

- Severe cardiopulmonary insufficiency
- Pathology of the colon (e.g. carcinomas, adenomas, inflammatory bowel disease, strictures).

## ■ Risks and informed consent

- See chapter 13
- Insufficiency of the colo-colonic anastomosis with subsequent peritonitis
- Local ischemia with subsequent total or subtotal necrosis of the colon, leading to total or subtotal colon resection.

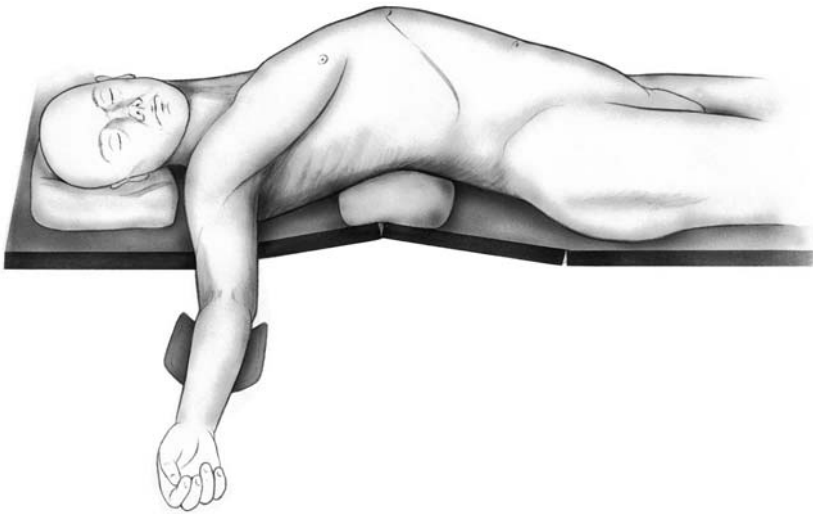
## ■ Special preoperative preparations

- See chapter 13
- Total colonoscopy
- Entire orthograde bowel preparation with hyperosmolar solution. In case of dysphagia, application through a stomach tube is recommended. Retrograde bowel lavage or application through a gastrostomy should be performed in patients with total esophageal stenosis. Patients suffering from catabolic metabolism are to be supported by hyperalimentation (parenteral or enteral) for several days prior to operation.

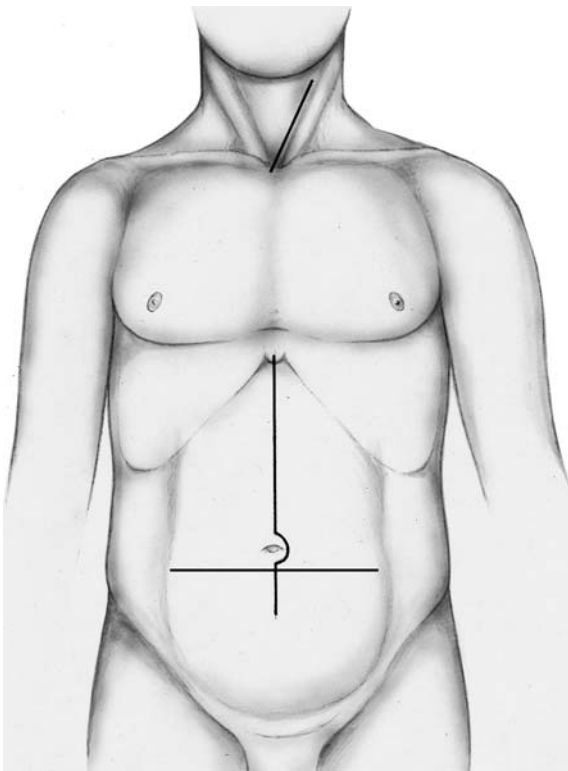
## ■ Anesthesia. See chapter 13.

■ **Position.** The patient should be in the supine position with hyperlordosis in the lower thoracic spine. The left arm is fixed to the body allowing better access to perform the collar anastomosis. The patients head is reclined and turned to the right (Fig. 19.1).

■ **Surgical approach.** Transverse lower abdominal laparotomy below the umbilicus with extension as midline upper laparotomy (low inverted T-incision). Alternatively a median laparotomy from symphysis up to the xiphoid process can be performed (Fig. 19.2).



**Fig. 19.1.** Perioperative positioning.

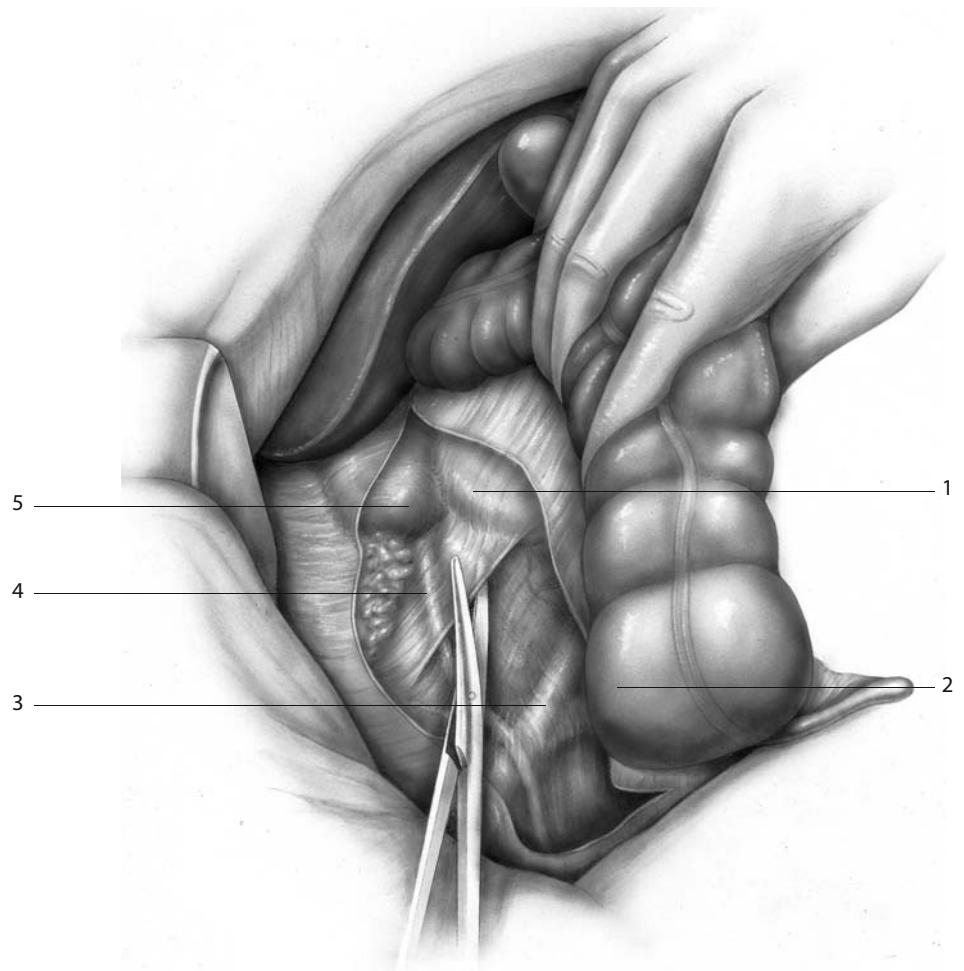


**Fig. 19.2.** Low inverted T-incision, or alternatively median laparotomy.

### ■ Operative procedure

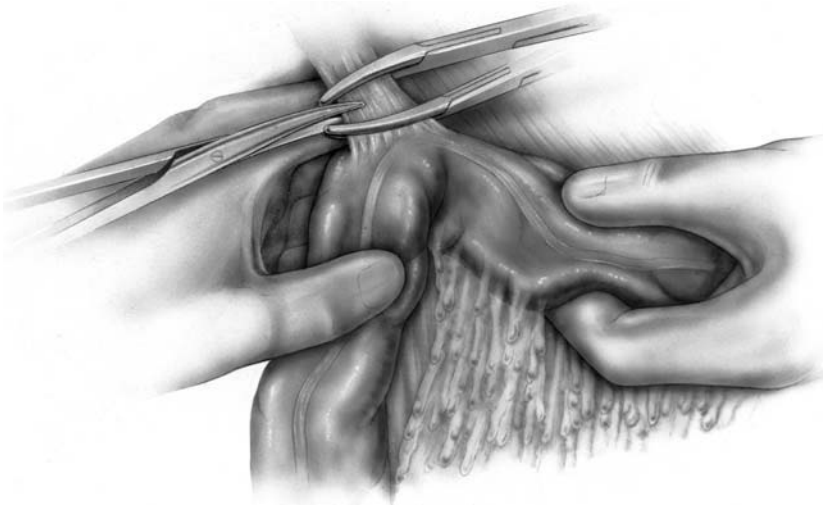
1. Mobilization of the large bowel beginning at the cecum up to the sigmoid colon
2. Gross examination of the vascular supply of the colon
3. Examination of the colonic segment, intended for interposition for adequate length and vascular supply by intermittent clamping
4. Preparation of the colonic segment, which is suitable for interposition
5. Establishment of a substernal tunnel (for retrosternal reconstruction route). Alternatively the posterior mediastinal route for orthotopic reconstruction is used
6. Exposure of the cervical esophagus or pharynx, transposition of colon interponate and performance of the esophago-colic or pharyngo-colic anastomosis
7. Performance of the cologastrostomy, alternatively anastomosis to the duodenum or jejunum
8. Colonic anastomosis for reconstruction of the lower gastrointestinal tract
9. Drainage of the mediastinum, abdomen, and neck.



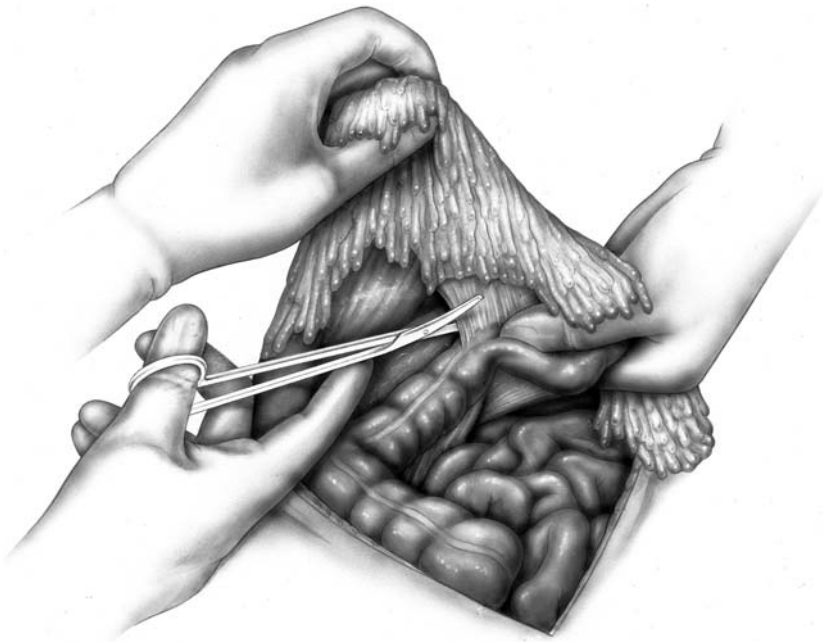


**Fig. 19.3.** Incision of the peritoneum using electrocautery or fine scissors and mobilization of the ascending colon and the right colonic flexure beginning at the cecum. The right ureter and the kidney should be preserved carefully. Care has to be taken not to injure the duodenum accidentally.

**1** Duodenum; **2** cecum; **3** right iliac vessels; **4** right ureter; **5** right kidney.

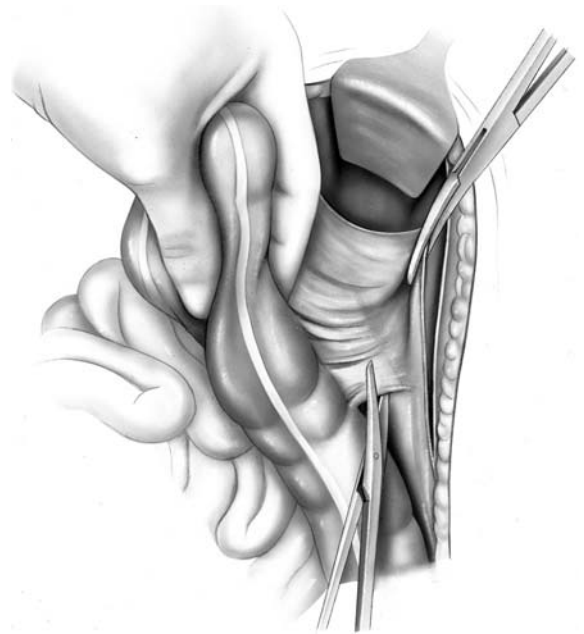


**Fig. 19.4.** For mobilization of the right colonic flexure, the right phrenico-colic ligament has to be divided and suture ligated.

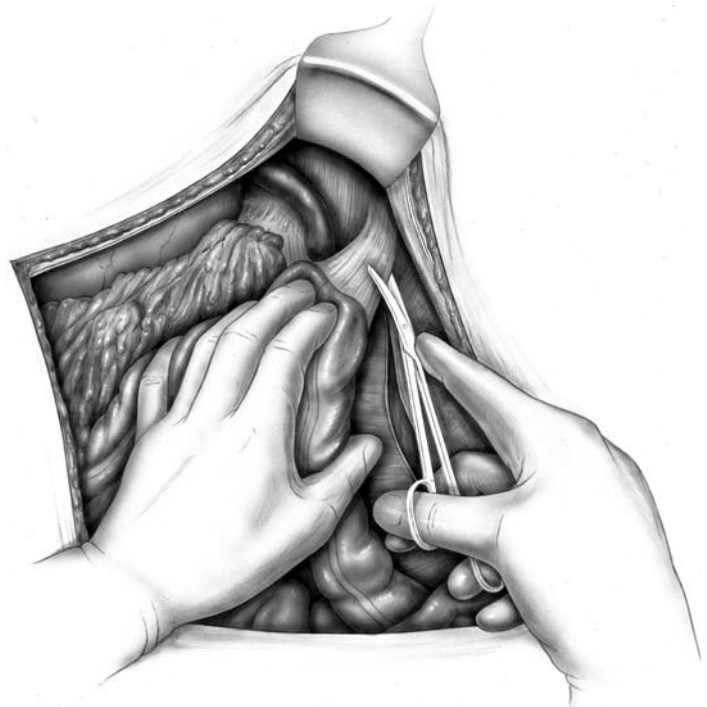


**Fig. 19.5.** Mobilization of the transverse colon by sharp dissection of the greater omentum. Preparation of the avascular tissue plane, assisted by antero-caudal traction of the trans-

verse colon (assistant) and ventro-cranial traction of the omentum and stomach, thus leaving the greater omentum at the stomach.



**Fig. 19.6.** Mobilization of the sigmoid colon, which is facilitated by performing medio-cranial traction to expose the embryonic adhesions between the colon and retroperitoneum. Further dissection between mesosigmoid and retroperitoneal fat, taking care of the left ureter and gonadal vessels.



**Fig. 19.7.** The left lateral peritoneal reflection is finally mobilized by dissection of the peritoneum in cranial direction. The colico-splenic ligament and the phrenico-colic ligament are ligated and divided using cautery or scissors. Thus, the

whole splenic flexure of the colon is mobilized. A prophylactic appendectomy after total mobilization of the colon is recommended.

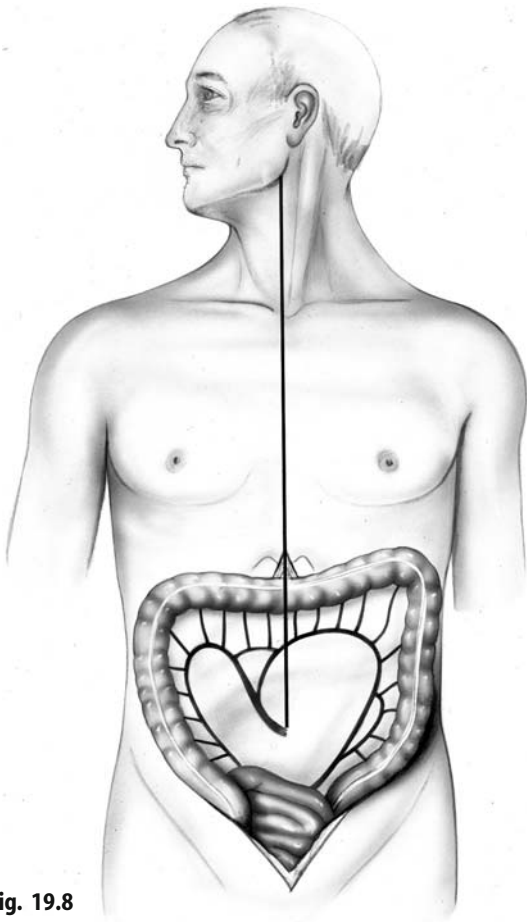


Fig. 19.8

**Fig. 19.8 and 19.9.** Selection of a colonic segment suitable for interposition. Determination of the essential length by the following procedure: Elevation of the colon in front of the abdominal wall, measurement of the distance between the abdomen and the angle of the mandible by a suture, fixed at the root of the strongest vessel of the colonic mesentery (see Fig. 19.9: middle colic artery). The length of the suture is finally transferred to the colon and the resection margin is marked.

**1** Anastomosis between the left and the middle colonic artery (Riolan); **2** left colonic artery; **3** root of the middle colonic artery.

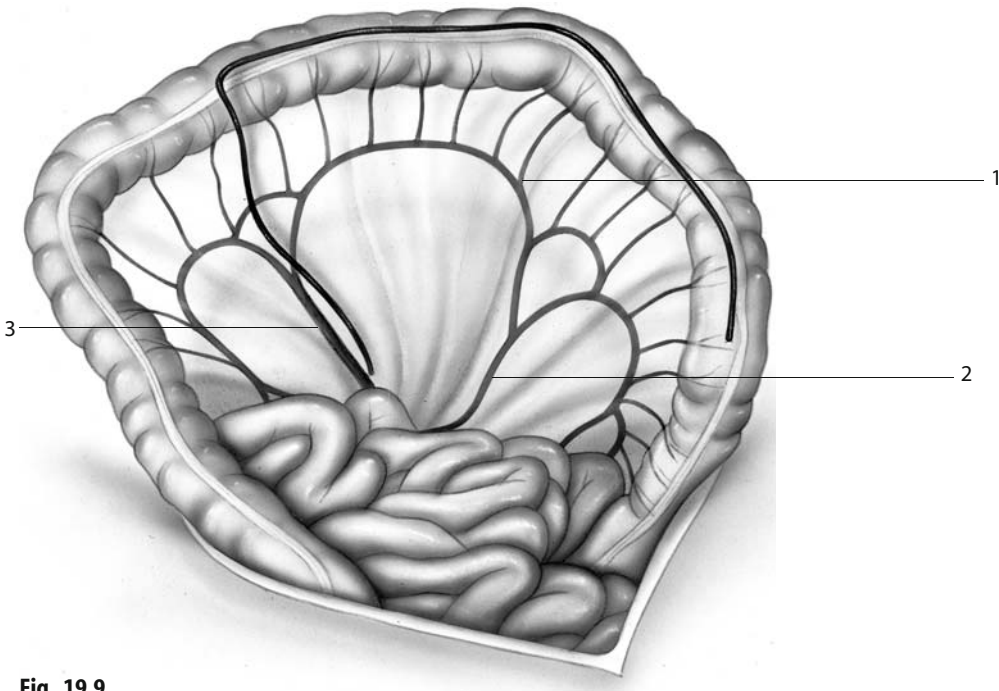
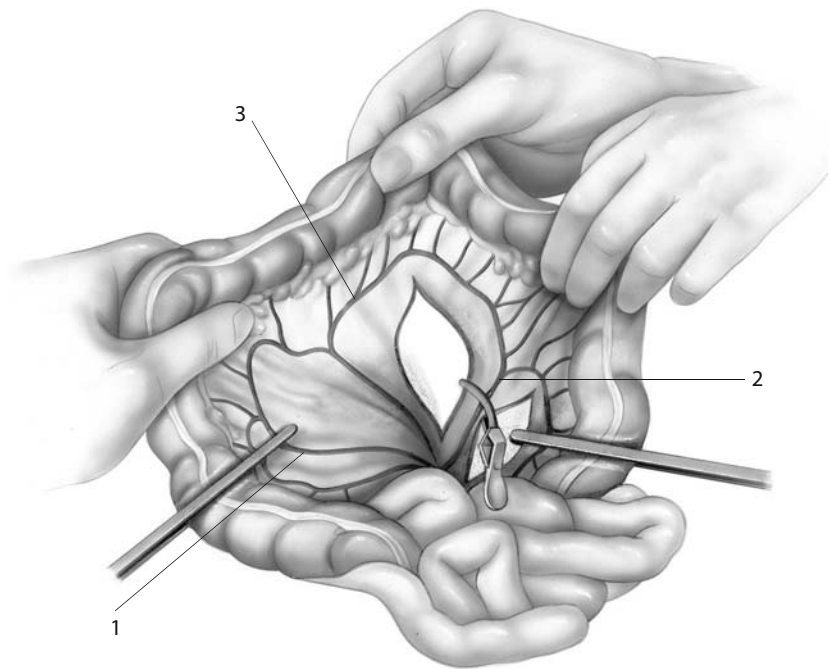


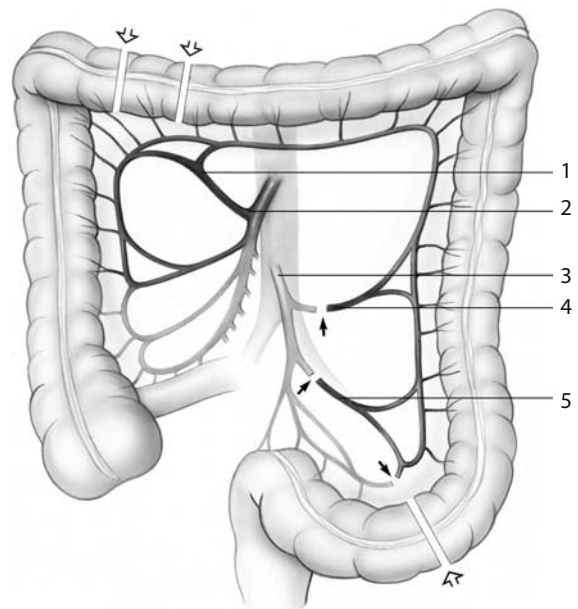
Fig. 19.9



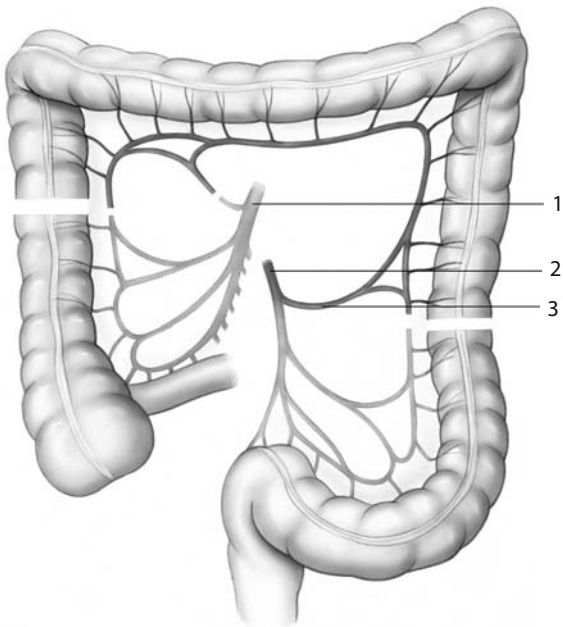
**Fig. 19.10.** Preparation of an anisoperistaltic colonic segment begins with incision of the peritoneum far from the colon and stepwise preparation of the mesocolon maintaining the paracolic arcades and the middle and left colic vessels. A vascular clamp is provisionally applied across the left colic artery and the sigmoid artery across the provisional co-

lonic transection plane to prove a sufficient arcade of Riolan. If no ischemia occurs after 3 minutes, the colon interposition can be performed.

**1** Middle colic artery; **2** left colic artery; **3** paracolic anastomosis between left colic artery and sigmoid artery.



**Fig. 19.11.** Construction of an anisoperistaltic colon interposition. **1** Middle colonic artery; **2** superior mesenteric artery; **3** inferior mesenteric artery; **4** left colonic artery; **5** sigmoid artery.



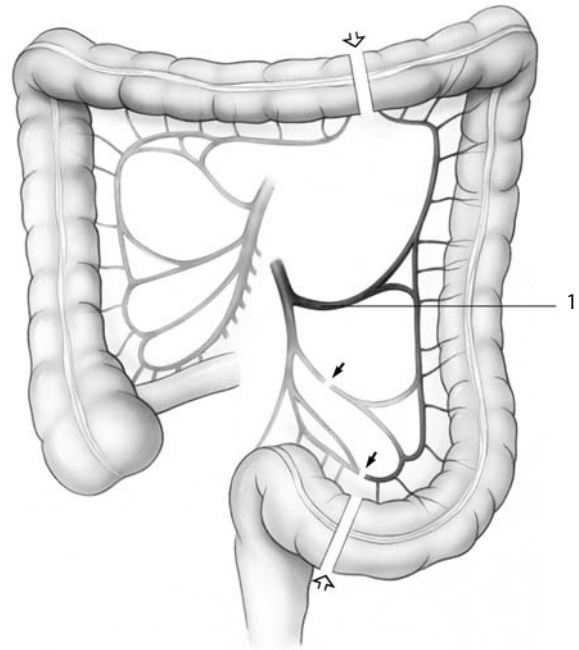
**Fig. 19.12.** A frequently employed alternative is a left-sided isoperistaltic colonic interposition.

The middle colonic artery is divided and the vascular supply is through the left colonic artery, if a sufficient Riolan's arcade exists.

**1** Superior mesenteric artery; **2** inferior mesenteric artery; **3** left colonic artery.

This approach ensures an isoperistaltic reconstruction. Care has to be taken not to injure the left colic vessels. Therefore, transection of the descending colon is always done without extensive dissection of the colon using a linear stapler device.

The transparent arrows show alternative lines for transection of the colon. Resection of bluish margins on the right flexure of the transverse colon between the middle and the right colic artery should be performed under preservation of the paracolic arcades. Following this procedure a better mobilization of the colonic segment can be obtained. To perform the pharyngo-colostomy in carcinomas of the upper third of the esophagus, a fairly long colonic segment is required. Therefore, parts of the sigmoid colon have to be used and the first (and probably the second) sigmoid artery has to be ligated close to the inferior mesenteric artery. Prior to dissection of the vessels, a clamp is provisionally applied to prove the sufficiency of the vascular supply. Dark arrows point to the vascular resection margins. The anastomosis between the right and middle co-



**Fig. 19.13.** An anisoperistaltic colon interposition supplied by the left colonic artery can be performed, if the Riolan's anastomosis is either not present or insufficient due to former surgical procedures.

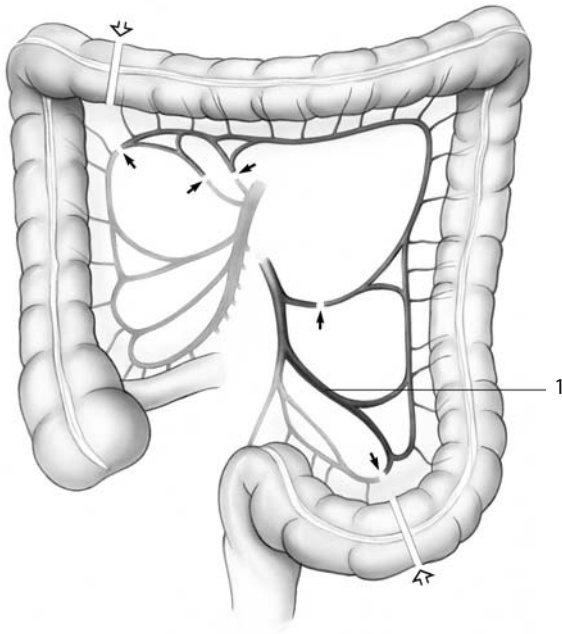
**1** Left colonic artery.

lonic artery should be preserved for a better vascular supply of the colonic segment chosen for interposition.

Advantages of using the left colonic segment are the following:

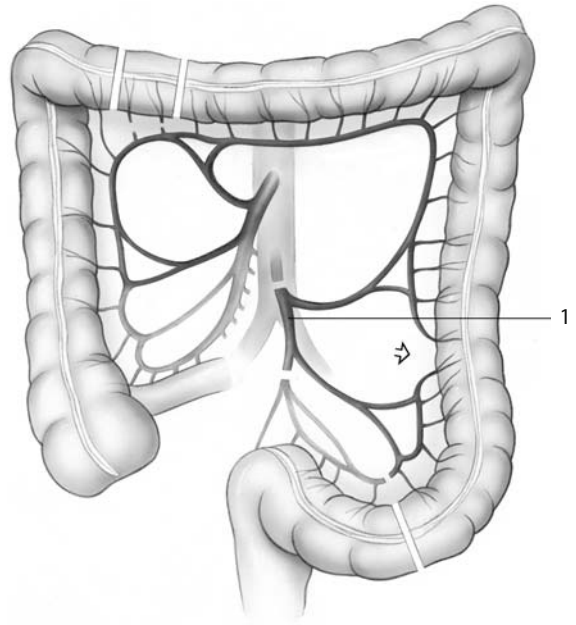
- the more predictably longer length and the smaller diameter of the left colon
- adequacy of the vascular pattern due to arteries with bigger diameter, instead of vascular supply via several arcades like in the right colon
- using an anisoperistaltic colonic segment has no clinical relevance, because the nutritional transport follows gravity.

The essential advantage of the left colon is the opportunity to obtain a longer colonic segment.



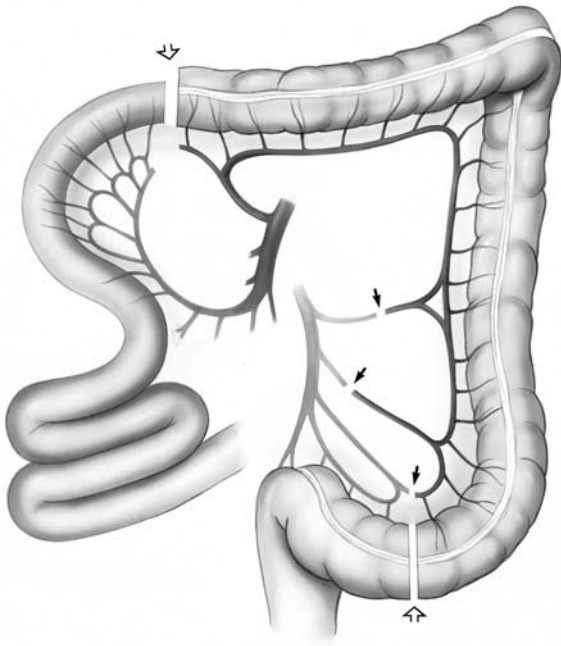
**Fig. 19.14.** In case of an inadequate vascular supply by the left and middle colonic artery, reconstruction of an isoperistaltic colon interposition supplied by the sigmoid artery is possible.

**1** First sigmoid artery.

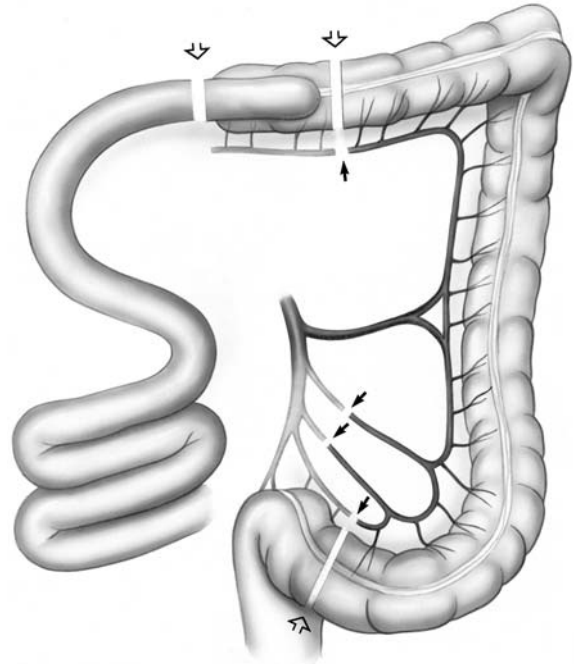


**Fig. 19.15.** In very rare cases no anastomosis is found between the left colonic artery and the first sigmoid artery. In those cases the main branch of the inferior mesenteric artery can be used as an anastomosis between the two areas of blood supply. This can only be accomplished when the distal parts of the sigmoid colon are adequately perfused by the medial and inferior rectal artery. This has to be checked by temporary clamping.

**1** Isolated segment of the inferior mesenteric artery with the branches of the left colic artery and the sigmoid artery.

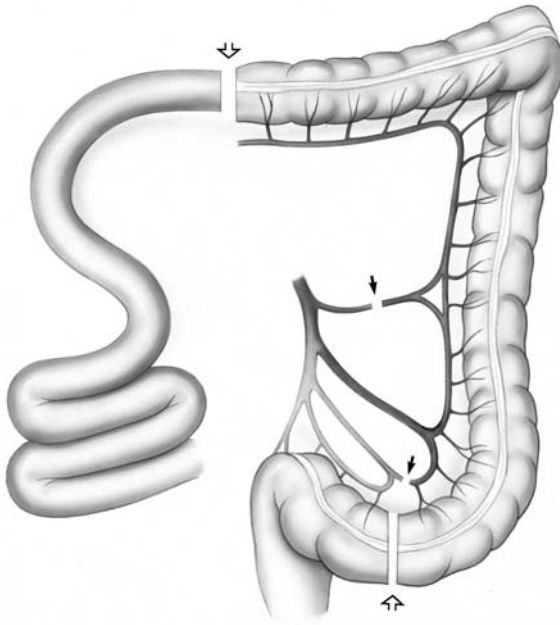


**Fig. 19.16.** Even after right hemicolectomy (e.g. following complicated right colonic interposition) construction of an anisoperistaltic interposition is possible, if the middle colonic artery has been spared during the first operation. The left colonic artery and the first sigmoid artery are dissected. Vascular supply of the interposition comes from the middle colonic artery. Reconstruction is performed with an ileo-sigmoidostomy.

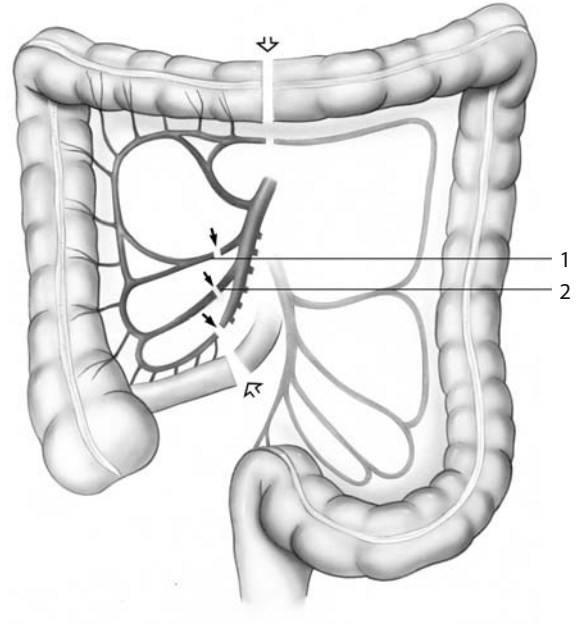


**Fig. 19.17.** Alternatively, an interposition after right hemicolectomy and after former transection of the middle colonic artery can be performed using the left colon. The blood supply comes from the left colonic artery. The entire sigmoid colon is needed for the purpose of receiving sufficient length for the interposition and all sigmoid arteries have to be dissected. The proximal colon segment with poor vascular supply is resected.





**Fig. 19.18.** After former surgical procedures (e.g. right colectomy) with transection of the middle colonic artery and presence of a small left colonic artery, a strong arcade between the left colonic artery and the first sigmoid artery is necessary to perform an isoperistaltic transplant, only supported by the first sigmoid artery. For that procedure, the left colonic artery has to be dissected.

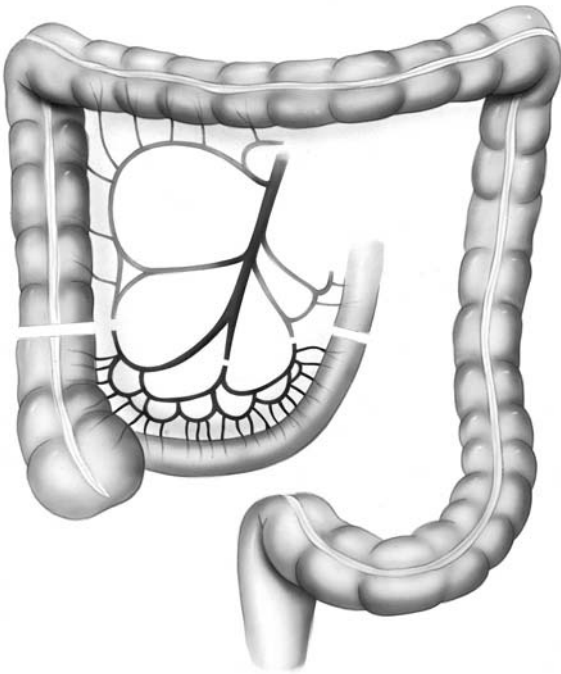


**Fig. 19.19.** If it is impossible to use the left hemicolon for interposition, the right hemicolon can be used to perform the transposition graft.

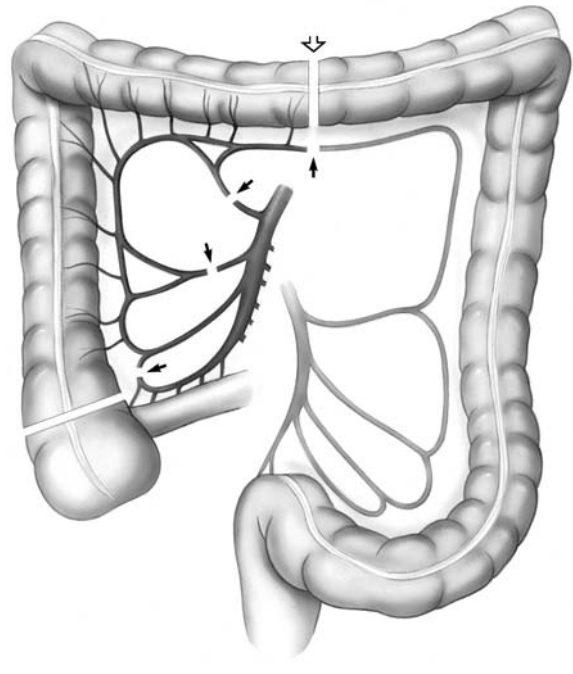
Scheme of construction of an isoperistaltic colonic interposition using the right hemicolon and the terminal part of the ileum. The vascular supply comes from the middle colonic artery.

**1** Right colonic artery; **2** ileocolic artery.

Using the right hemicolon for interposition is burdened by frequent complications leading to poorer postoperative functional results.

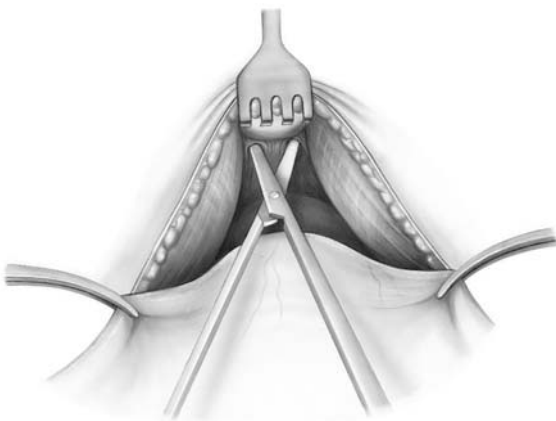


**Fig. 19.20.** Preparation of an anisoperistaltic colonic interposition using the right hemocolon, with vascular supply from the ileocolic artery.



**Fig. 19.21.** Adequate length of the right hemocolon enables construction of an isoperistaltic interposition without using the ileocolic portion of the intestine. This technique offers several advantages:

- omittance of the terminal ileum, which is prone to necrosis
- omittance of the ileocecal region which is prone for poor functional results.



**Fig. 19.22.** Preparation of a substernal tunnel. Blunt opening of the substernal cavity by spreading the scissars, while pulling the xiphoid ventrally with a sharp retractor.

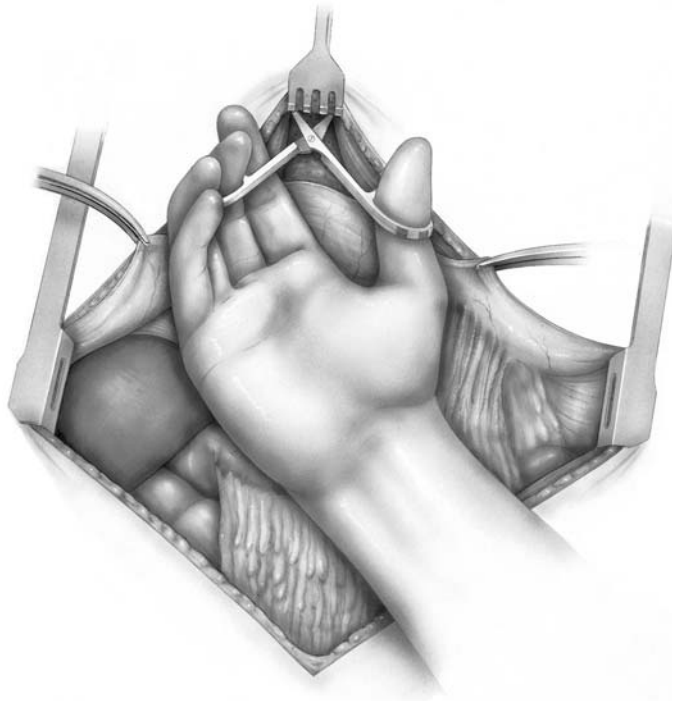


Fig. 19.23

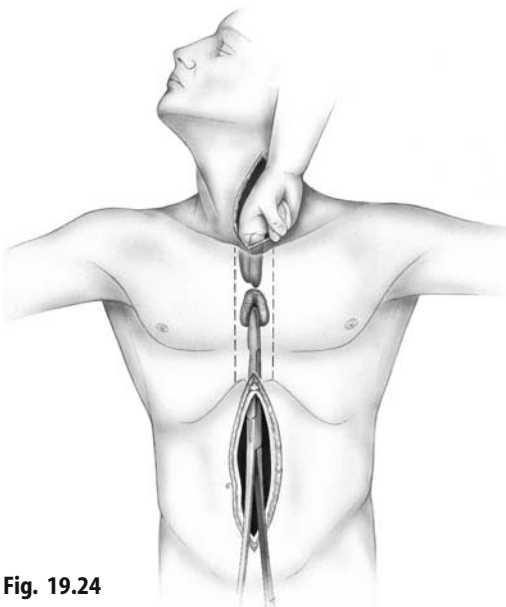


Fig. 19.24

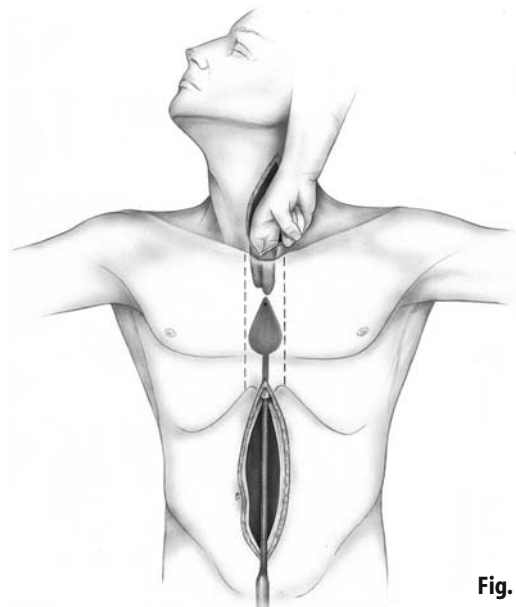
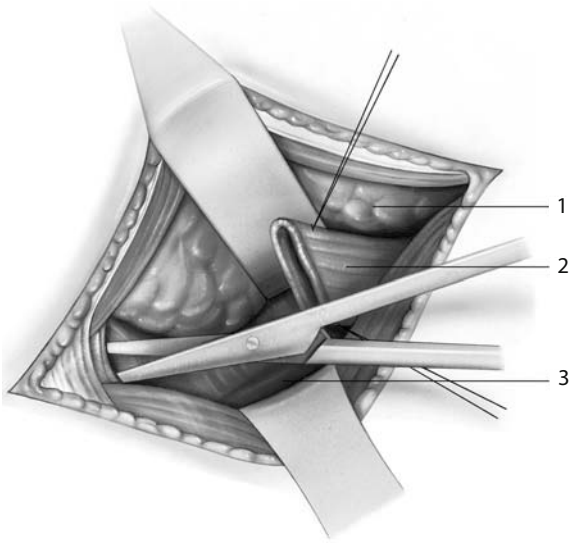


Fig. 19.25

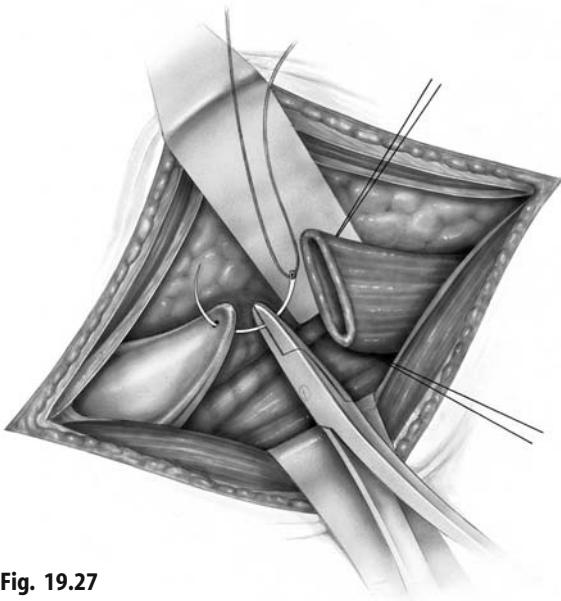
**Fig. 19.23–19.25.** After opening the substernal cavity, a substernal tunnel is constructed with an atraumatic clamp. The sternum has to be pulled continuously and the endothoracic membrane is to be separated from the sternum. A longitudinal incision along the anterior border of the left

sternocleidomastoid muscle is made to expose the cervical esophagus. Blunt preparation with the hand through the substernal tunnel usually leads to rupture of the mediastinal pleura.

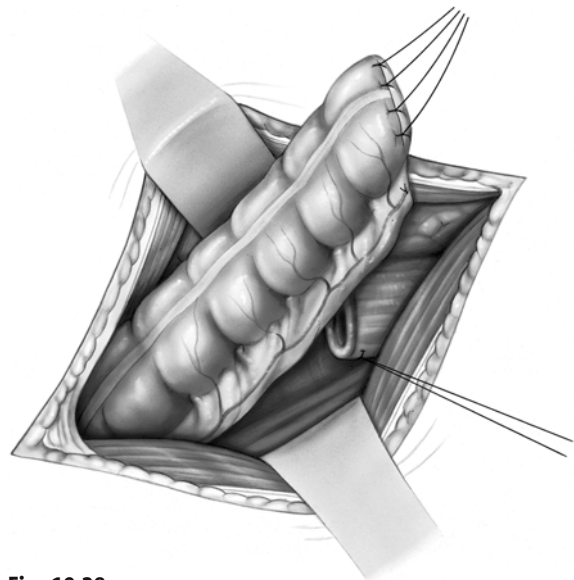


**Fig. 19.26.** Completed preparation of the retrosternal tunnel. In case of tight adhesions to the sternum, these adhesions are dissected sharply by scissors.  
**1** Thyroid gland; **2** esophagus; **3** trachea.  
 Between corpus and manubrium sterni the substernal fascia is very tightly connected to the sternum. Furthermore, the

visceral and parietal pleura are tightly connected in this region. For this reason, very careful, stepwise preparation with a long atraumatic clamp has to be performed and the preparation has to be manually controlled by the substernally introduced finger of the surgeon.



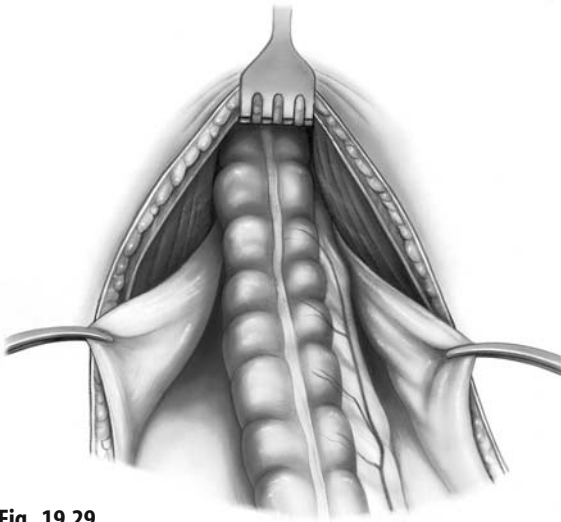
**Fig. 19.27**



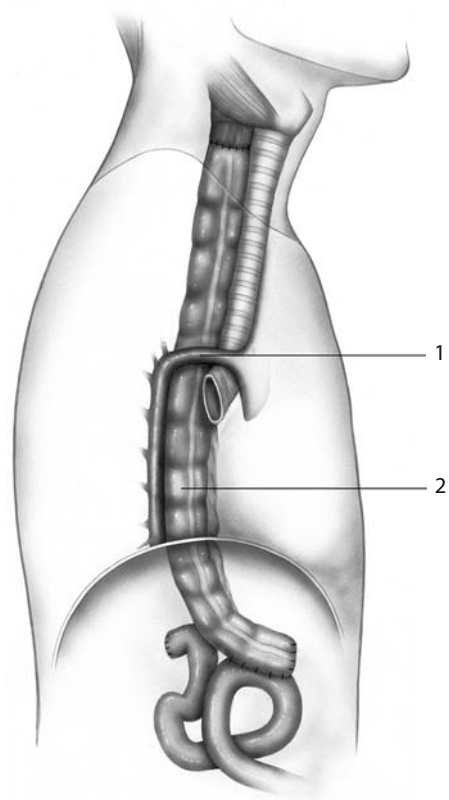
**Fig. 19.28**

**Fig. 19.27–19.29.** For the substernal reconstruction a long strong suture fixed to a drainage tube can be used for the pull-through procedure. The suture is tied to the oral end of the colonic interposition. The colon is transposed in the sub-

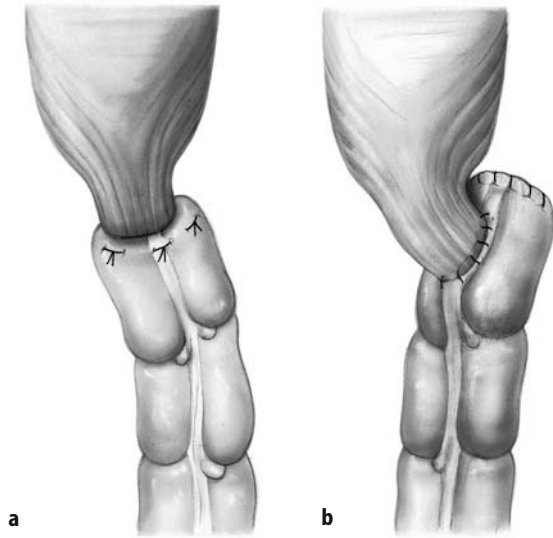
sternal tunnel to the cervical incision under continuous and gentle pull, and the sternum is to be pulled upwards with a sharp retractor during the procedure.



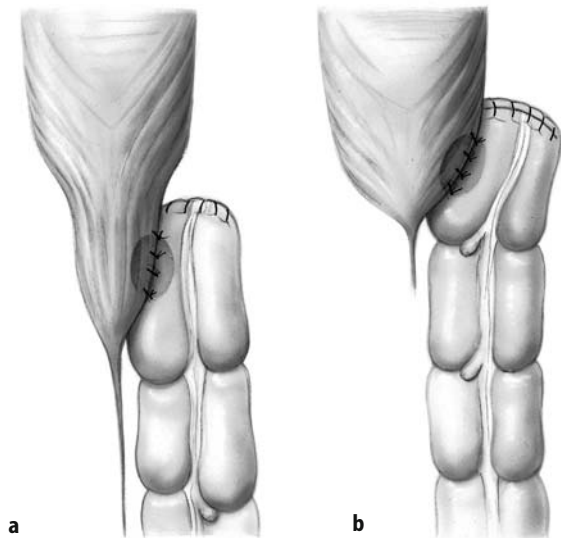
**Fig. 19.29**



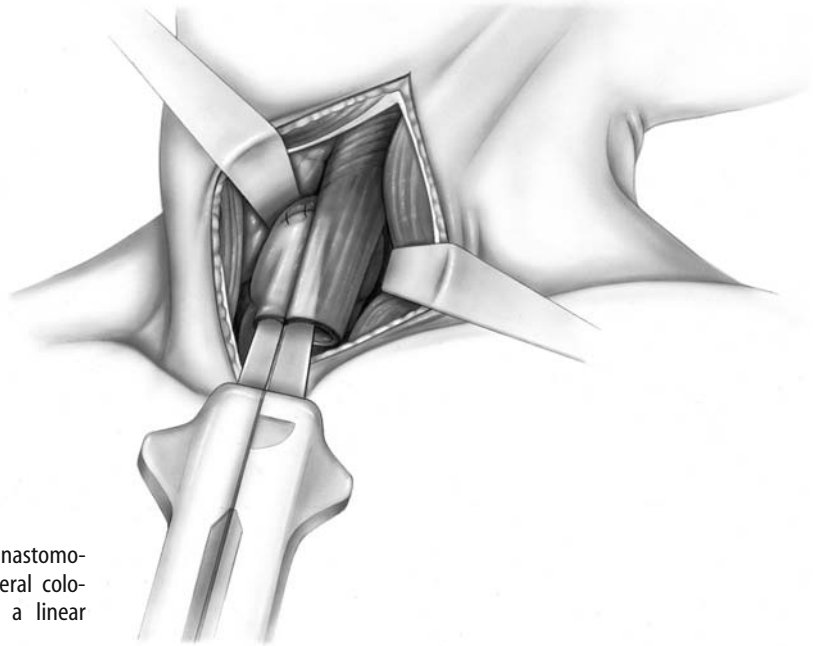
**Fig. 19.30.** Interposition of the colon through the posterior mediastinum, in the bed of the removed esophagus. The posterior mediastinal route of the interposed colon is favorable to the substernal or presternal position, because of the shorter distance to the neck. In addition, the posterior mediastinal route prevents kinking of the colon. The interposed colon causes hemostasis in the operation field.  
**1** Azygos vein; **2** colonic interposition.



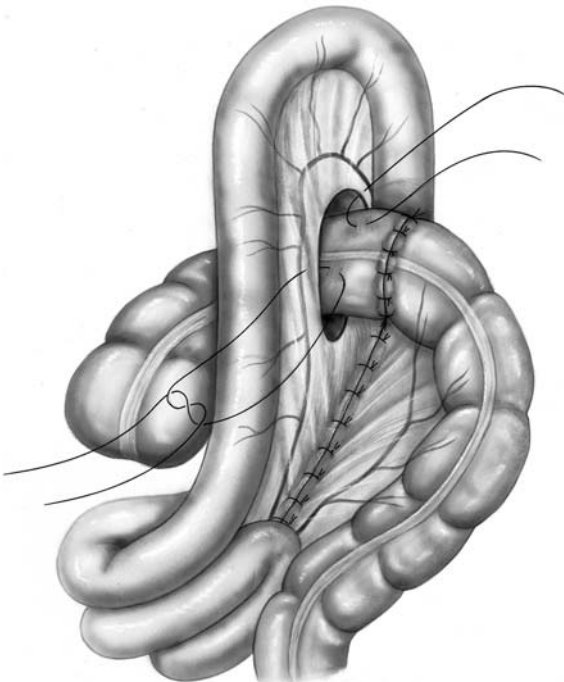
**Fig. 19.31.** **a** If possible, the termino-terminal anastomosis should be performed in a double row suture technique. **b** In case of different lumen diameter, single stitches and a termino-lateral anastomosis can be performed close to the taenia libera.



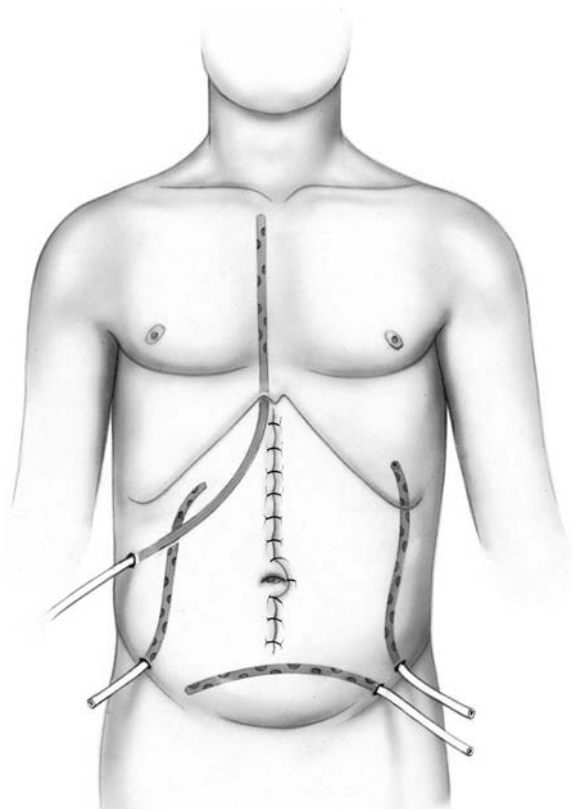
**Fig. 19.32 a, b.** After total esophageal resection in patients with carcinomas of the upper third of the esophagus or after corrosive injuries of the esophagus followed by cicatricial strictures, a latero-lateral pharyngo-colostomy close to the left recessus piriformis has to be performed in a double row suture technique.



**Fig. 19.33.** Alternative technique for anastomosis after colonic interposition: Latero-lateral colo-esophageal anastomosis performed by a linear stapler.



**Fig. 19.34.** Operative site after transposition of the colon into the upper abdomen and after the transverso-sigmoidotomy has been performed. The mesenteric incision has been closed. To avoid tension to the mesocolon, the mesenteric incision has to be placed dorsally.



**Fig. 19.35.** Drainage of the substernal tunnel, the lateral colonic segments, and the colonic anastomosis.

## Complications after subtotal or total esophagectomy with colonic interposition

### ■ Intraoperative complications

- *Wrong selection of the transposed colonic segment with insufficient length.*  
Most likely the vessels are not clamped prior to dissection, so that the vascular supply of the oral part of the colonic segment can not be visualized and the total length of the colon is not sufficient, causing necrosis of the interpositional graft. To avoid this complication, the entire dissection and mobilization as well as screening of the vascular supply of the colonic segment is done prior to the choice of the interpositional graft.
- *Wrong selection of the way to the neck.*  
The subcutaneous way is much longer, but in special cases of a short interposition or an interposition with insufficient vascular supply, the colon should be placed subcutaneously to have a simple access in case of necrosis.
- *Destruction of the main vessels of the interposed colon.*  
This complication is mostly due to traumatic surgical technique or enhanced tension to the vascular trunk, often due to inadequate length of the chosen interposition.
- *Opening of the pleura during preparation of the substernal tunnel.*  
This can be followed by pleural hernias with decreased circulation of the interposition. Therefore the mediastinal pleura should be incised widely in case of localized defects.
- *Paresis of the recurrent laryngeal nerve.*  
Gentle surgical technique and clear identification of the nerve prevents paresis.

### ■ Complications during early postoperative course

- *Pulmonary infections: Tracheobronchitis and pneumonia*
- *Septic complications:* Subphrenic or intraabdominal abscess; cervical wound infection (depending on contamination during surgery). Prevention: Aseptic surgical technique, sufficient drainage and antibiotic prophylaxis.
- *Cervical anastomotic leak.*
- *Reasons for necrosis of the interposition:* Decrease of circulation due to kinking or compression of the main vessels, hypovolemia, hypercoagulability. Avoidance by interposition of a long colonic segment without tension. Optimizing of the postoperative hemodynamic and rheologic parameters is necessary.

### ■ Complications during the late postoperative course

- *Cicatricial strictures of the cervical esophago- or pharyngeocolostomy:* Mostly due to anastomotic leak. Treatment of the stenosis is performed by bougienage or balloon dilatation. Only in single cases surgical intervention is indicated.
- *Kinking of the interposition:* Rare but dangerous complication, which often requires surgical intervention due to clinical symptomatic disturbance of the gastrointestinal passage by elongation of the interposition. Surgical intervention is performed by shortening of the graft.
- *Mechanical trauma to a subcutaneous graft,* which often needs surgical intervention.
- *Polyposis of the interposition:* No specific treatment, regular screening for dysplasias and subsequent resection.
- *Carcinoma of esophageal strictures after corrosive injury.*



# 20 Intrathoracic Esophagoplasty by Colon Interposition

A. F. CHERNOUSOV, P. M. BOGOPOLSKI, H. W. SCHREIBER†, D. C. BROERING

## ■ Indications

- Benign esophageal stricture in the middle or distal esophageal third
- Giant irresectable benign tumor of the distal esophageal third
- Irresectable carcinoma of the lower esophageal third

All mentioned indications are given only in very few cases and should only be used, if stomach or jejunum can not serve as interposition/bridging graft. A total or subtotal esophageal resection and interposition to the neck with a cervical anastomosis should be preferred.

## ■ Contraindications

- Severe cardiopulmonary insufficiency.

## ■ Risks and informed consent

- See chapter 13
- High risk of anastomosis insufficiency with following mediastinitis and pleural empyema.

## ■ Special preoperative measures and anesthesia

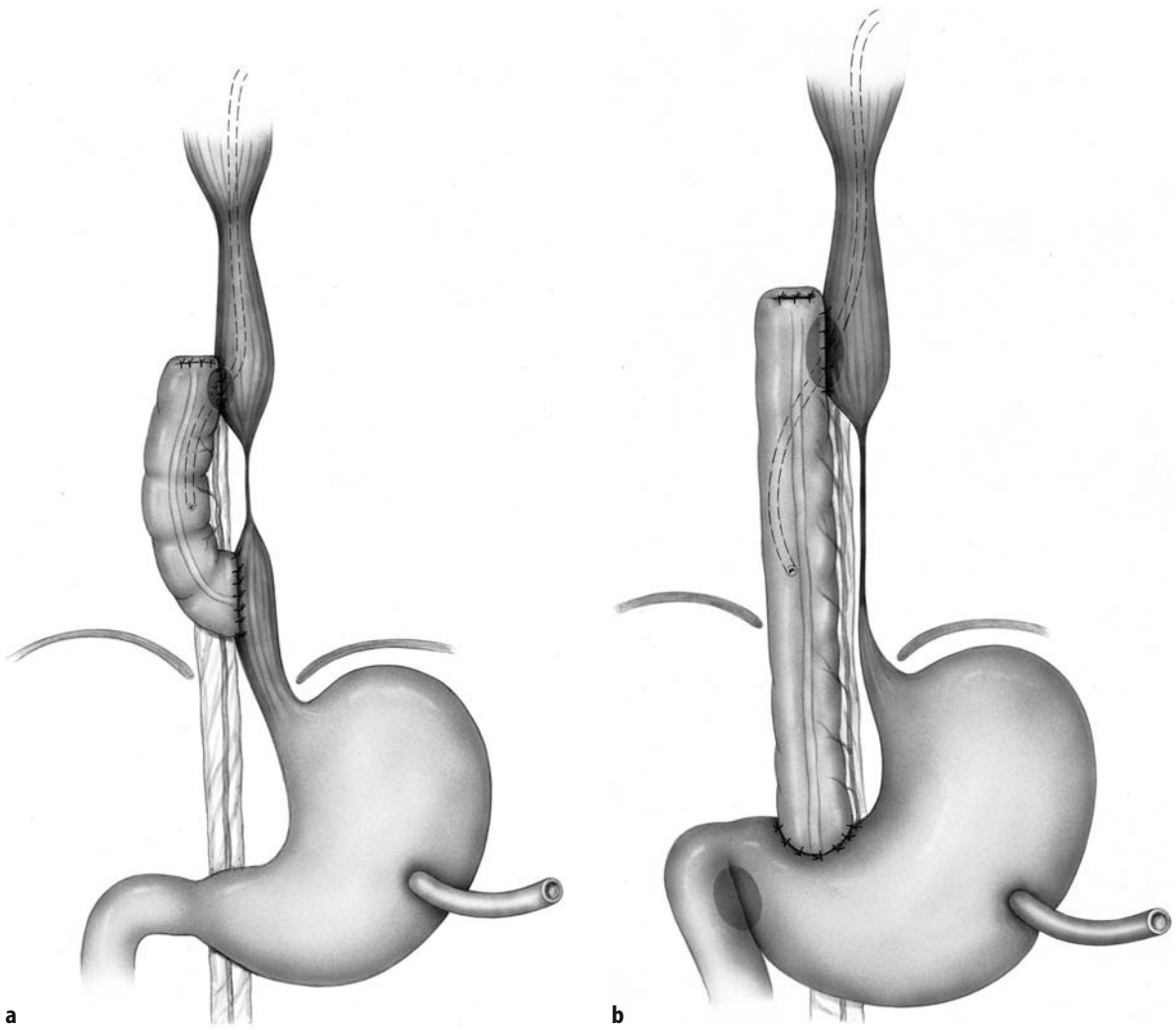
- The same as for total and subtotal esophageal reconstruction/substitute by means of colon.

■ **Positioning.** 45 degree right elevated position or intraoperative repositioning from the supine position to the left-sided position.

■ **Access/approach.** Median epigastric laparotomy below the navel/umbilicus, right anterolateral thoracotomy in the 4.-5. intercostal spaces.

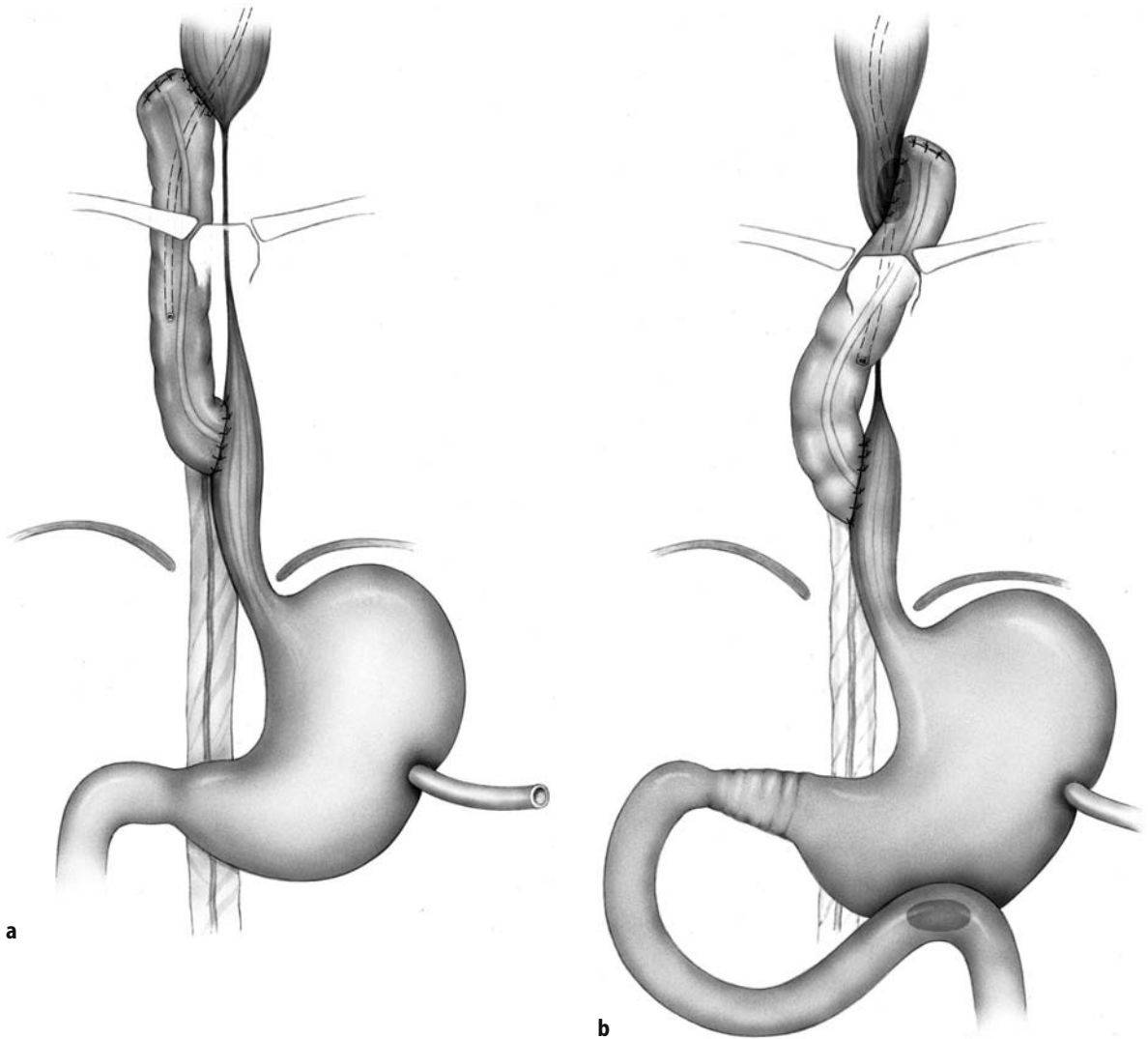
## ■ Operative procedure

1. Laparotomy and exploration of the abdomen
2. Establishing of an interposition, reconstruct the colon continuity via colo-colostomy, anastomosing the colon-interposition with the stomach
3. Incise the diaphragm and resect the crura of the diaphragm (lateral hiatusotomy)
4. Thoracotomy and preparation of the esophagus
5. Closure of the abdomen
6. Esophageal resection and esophago-colostomy, in case of a bypass operation esophago-colostomy
7. Drainage of the thorax and closure of the thoracotomy.



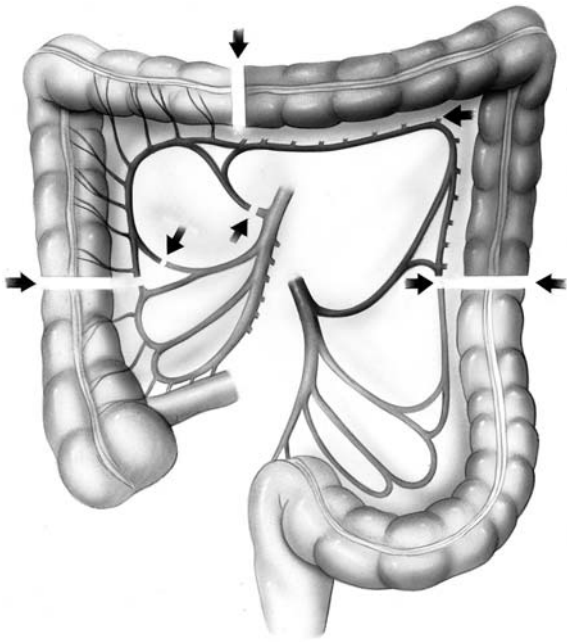
**Fig. 20.1 a, b.** Principle variations of intrathoracic bypass forms by means of colon-interposition for long benign esophageal strictures. **a** Bypass (Korbhenkel type) with upper latero-lateral anastomosis and lower termino-lateral anastomosis.

**b** Alternative bypass-variant with upper intrathoracic latero-lateral colo-esophagostomy and intraabdominal termino-lateral colo-gastrostomy in the region of the antrum.

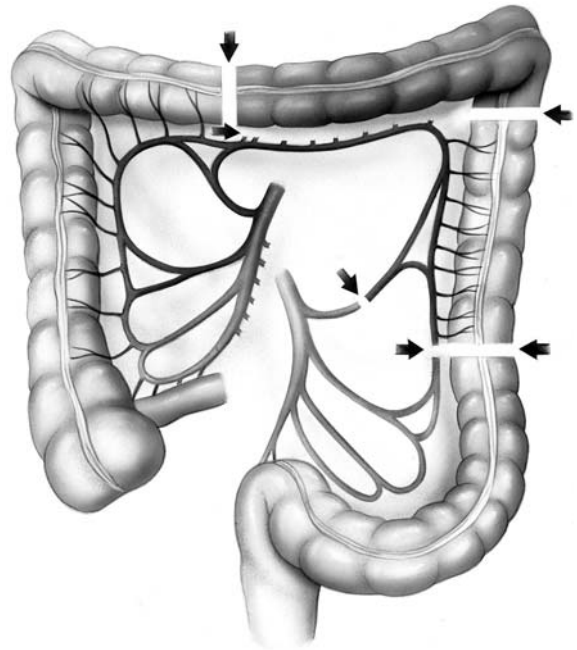


**Fig. 20.2a,b.** Rare variations of an intrathoracic bypass by means of colon-interposition for long strictures in the upper thoracic or cervical part of esophagus (an additional left or right cervical incision of the sternocleidomastoid muscle is required). **a** The lower anastomosis as termino-lateral anastomosis in the pleural cavity. The upper anastomosis as latero-lateral between colon-interposition and the right piriform recess.

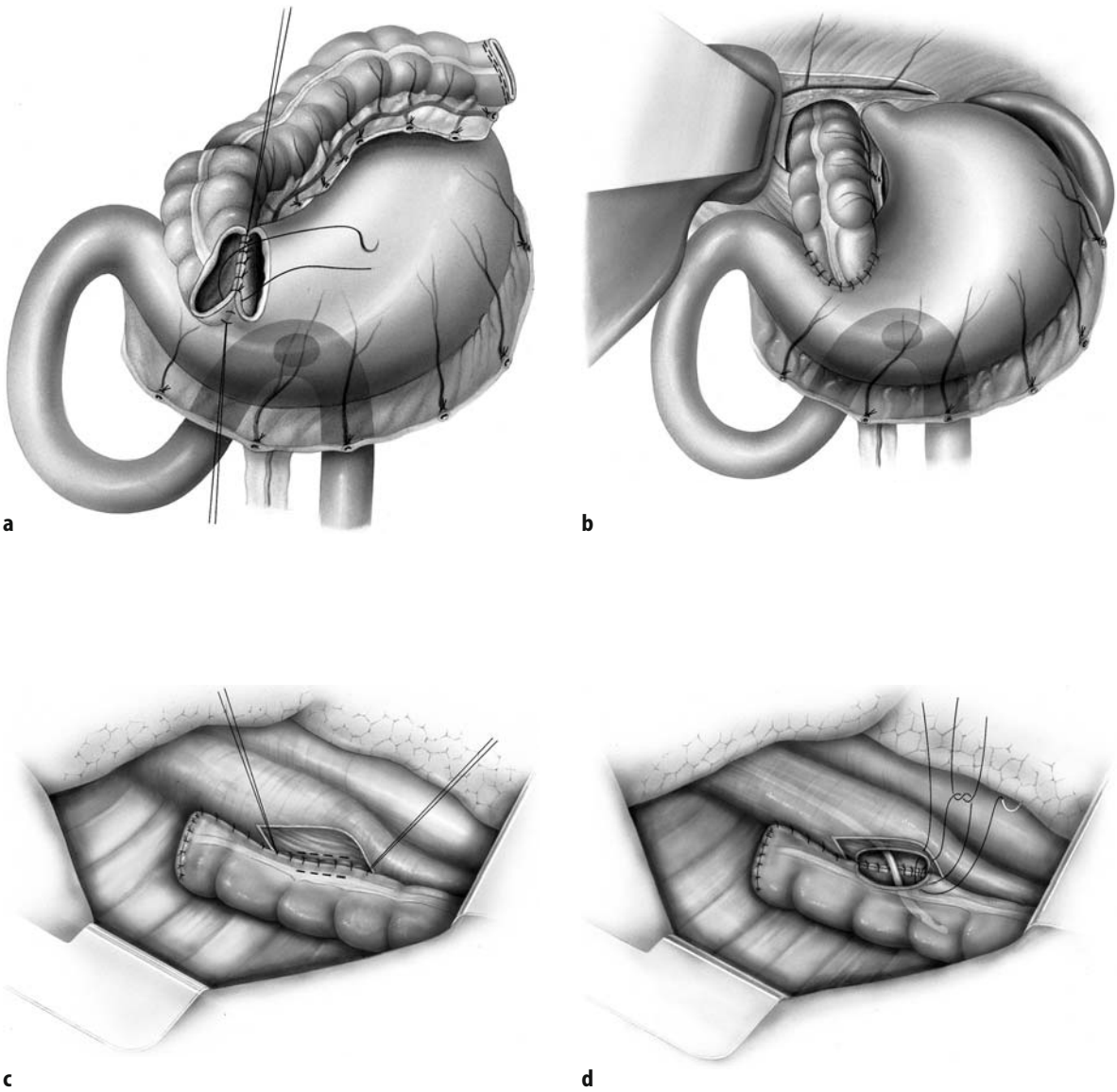
**b** The lower anastomosis also as termino-lateral anastomosis with the esophagus distal to the stricture in the right pleural cavity. The upper anastomosis will be made with the left piriform recess also as latero-lateral anastomosis. The preparation of a colon segment with a special long vascular pedicle is required for these variations of thoracic esophageal bypass.



**Fig. 20.3.** Preparation of an isoperistaltic colon-interposition from parts of the transverse colon and the ascending colon with a long vascular pedicle. The feeding vessel will be the left colic artery. The parts of colon which are colored as dark-grey will be rejected. The light-grey colored part of colon serves as interposition.

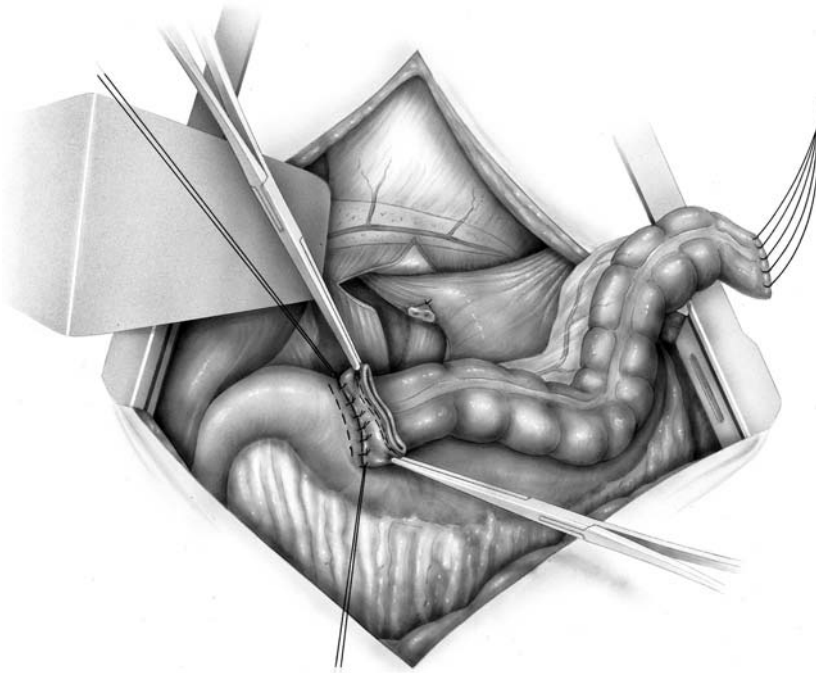


**Fig. 20.4.** Preparation of an isoperistaltic colon-interposition from parts of the descending colon with a long vascular pedicle. The feeding vessel will be the middle colic artery. The dark-grey colored parts of colon will be rejected. The choice of both described methods to construct a short colonic interposition with a long vascular pedicle depends on the individual vascular anatomy. Adequate blood supply is checked by intermittent clamping of each vessel which has to be transected (black arrows).

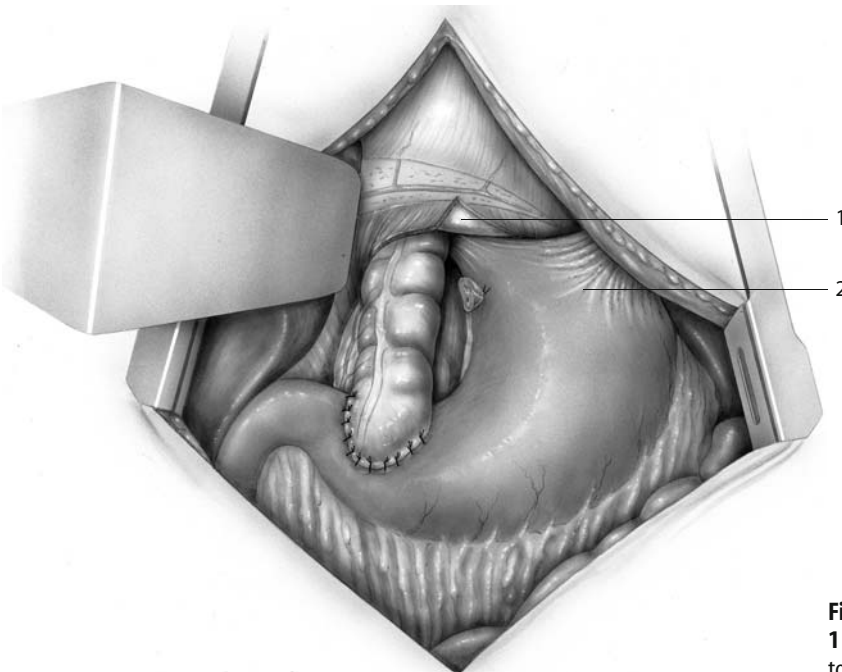


**Fig. 20.5a–d.** Important steps to create an intrathoracic bypass in the region of the distal esophagus. **a** The colon-interposition is transposed in a cranial direction in a retrogastral position. The termino-lateral anastomosis between colon and gastric antrum will be established by means of interrupted sutures (vicryl 3/0) in two rows with a distance of 0.5 cm.

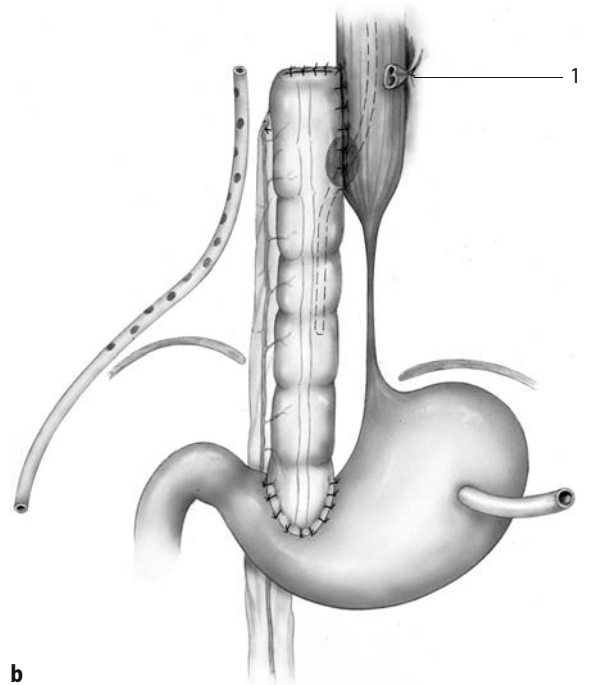
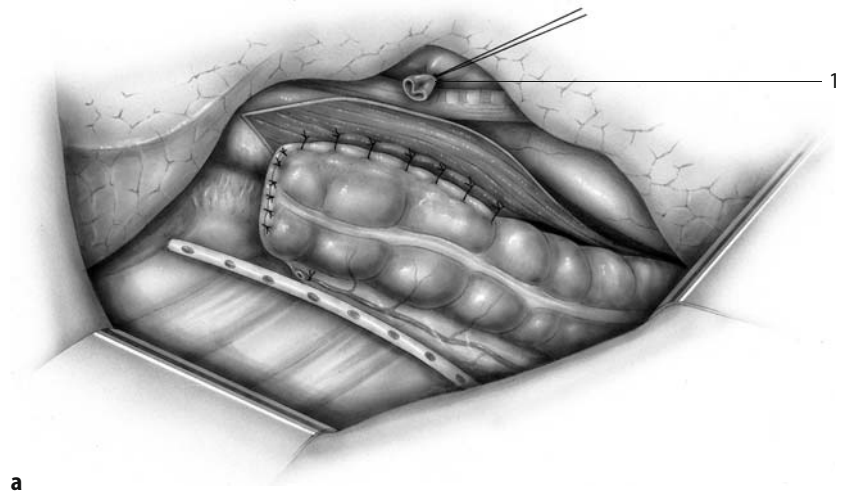
**b** The esophageal hiatus is now opened after longitudinal median incision of the diaphragm and its right crus. The interposition is transposed to the right pleural cavity. **c, d** The latero-lateral colo-esophagostomy will be established straight above the esophageal stricture. A transnasal tube will be inserted for decompression.



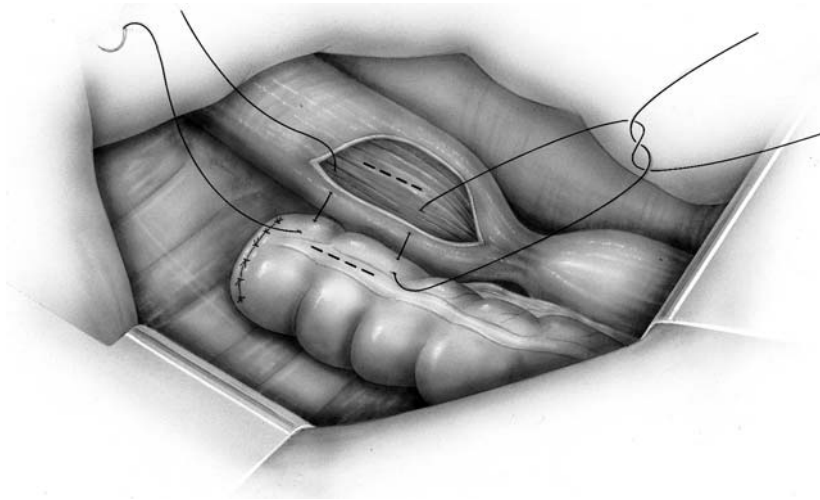
**Fig. 20.6.** Transverse colo-gastrostomy in the region of the antrum. The vascular pedicle of the colon-interposition is now located behind the stomach. The line of incision of the antrum is marked where the anastomosis between antrum and colonic interposition is done.



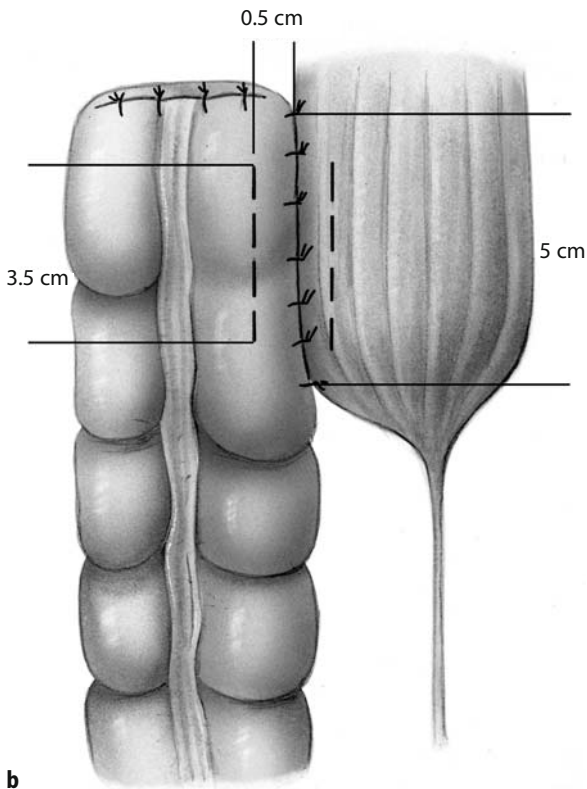
**Fig. 20.7.** Colo-gastrostomy is finished. **1** Diaphragm crurotomy; **2** gastrostomy.



**Fig. 20.8 a, b.** Operative site after finishing the right intrathoracic colo-esophagostomy. **1** Stump of ligated azygos vein. A transnasal tube is inserted into the interposition for decompression. The pleural cavity is drained by thoracic drainage, which will be placed near the anastomosis.



**a**

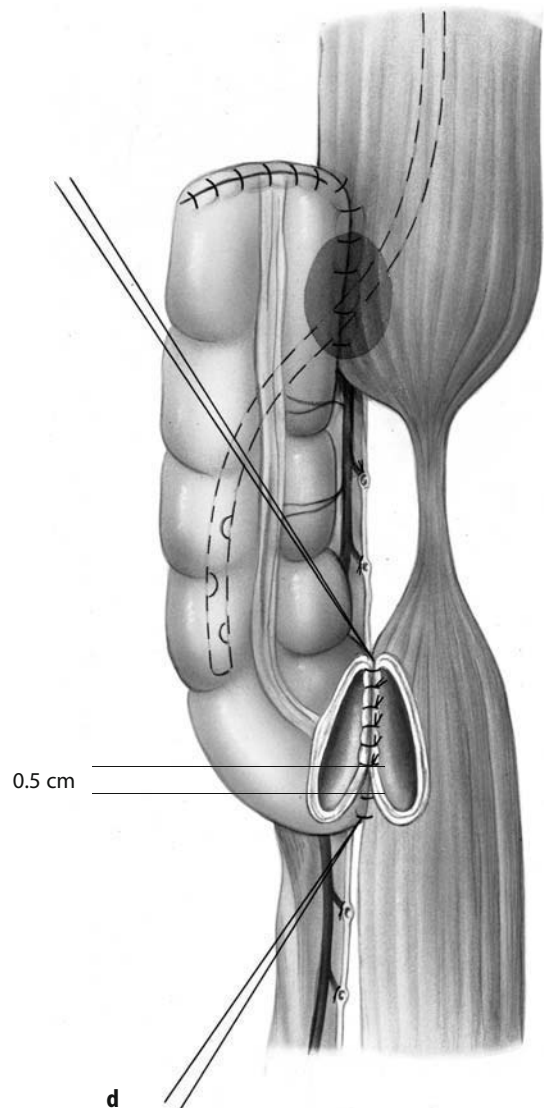
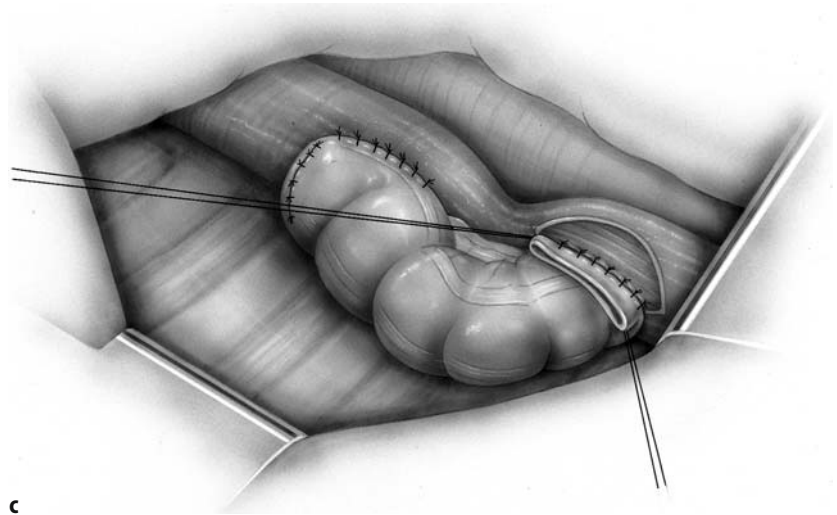


**b**

**Fig. 20.9 a–d.** Establishment of a Korbhenkel-type bypass to bridge a short distance benign esophageal stricture by means of a colon interposition. **a, b** Upper anastomosis: Longitudinal incision of the lamina muscularis of the esophagus of about 5 cm. Sero-muscular adaptation of colon to

esophagus will be established by vicryl 3/0 single sutures with a distance about 0.5 cm. Afterwards longitudinal incision of the esophageal mucosa and the colon in the region of the colonic taenia of about 3.5 cm. The interior row of sutures will be also made by single sutures.





**Fig. 20.9c,d.** Performance of the lower anastomosis and decompression of the interposition.

# 21 Reconstruction of Gastrointestinal Continuity by Jejunal Interposition following Total and Subtotal Esophagectomy

A. F. CHERNOUSOV, P. SCHURR, P. M. BOGOPOLSKI, D. C. BROERING, H. W. SCHREIBER†

## ■ Indications

Benign strictures and malignant tumors of the esophagus, when the stomach or colon cannot be used as a substitute.

The peculiarity of blood supply and conduct of vessels of the jejunum carries notable disadvantages in using it as a substitute for the esophagus. The anatomy of the jejunal vessels rarely allows for preparing a jejunal graft of sufficient length.

## ■ Contraindications

- Previous partial resections of the jejunum
- Billroth II anastomosis.

## ■ Risks and informed consent

See chapter 13.

Moreover the patient has to be informed of the fact that often the jejunal bridging graft does not have sufficient length, which might require a temporary stoma and a multi-stage procedure.

## ■ Special preoperative measures

See chapter 13.

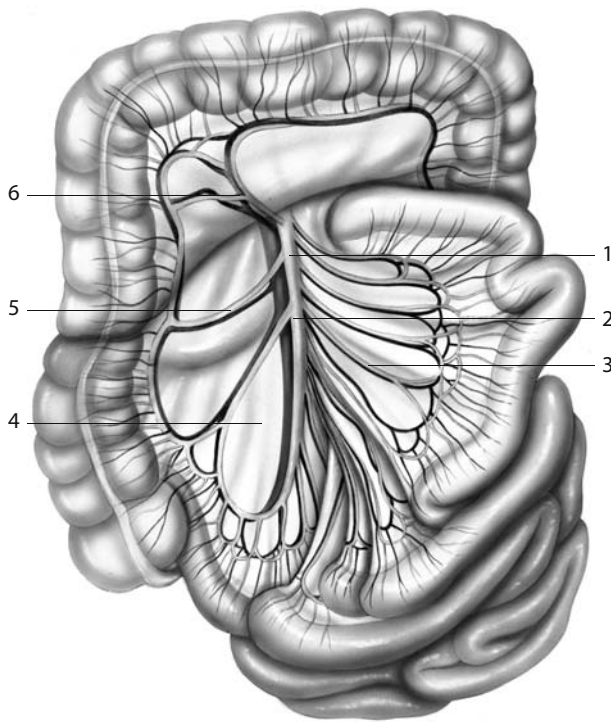
■ **Anesthesia.** General anesthesia; when thoracotomy is required: use of a double lumen tube.

■ **Positioning.** See chapter 13.

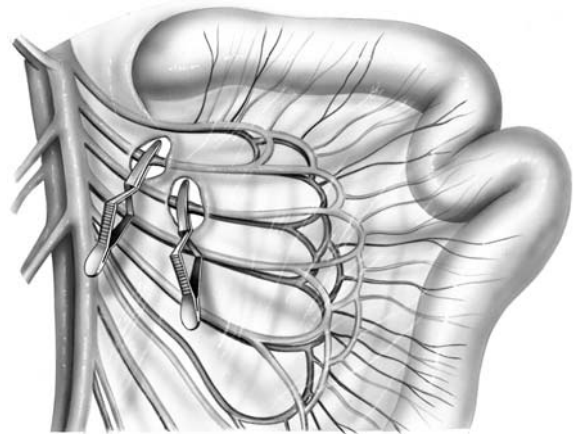
■ **Approach.** See chapter 13.

## ■ Operative procedure

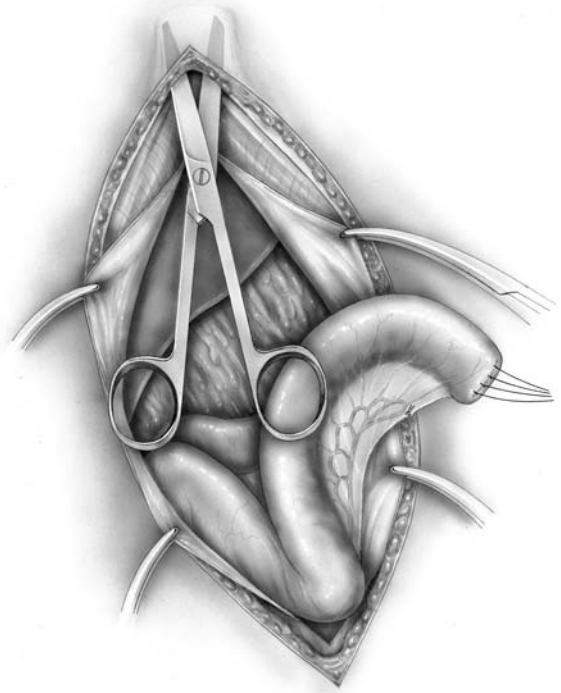
1. Laparotomy and inspection of the jejunal vascular architecture with particular attention to the anastomoses between the jejunal arteries
2. Temporary clamping of the jejunal arteries of the first loop starting with the second radial artery and vein
3. Provided a sufficient blood flow to the proximal jejunum, an isoperistaltic jejunal bridging graft can be fashioned that is supplied by the third or fourth jejunal radial artery.
4. Establishing esophagojejunostomy. In case the jejunal bridge is not long enough, the jejunum is transposed to the anterior chest wall via a subcutaneous tunnel and a jejunal stoma is constructed.
5. Jejunojejunostomy
6. If the upper thoracic esophagus can be preserved alternatively, continuity can be re-established by an intrathoracic esophagojejunostomy.



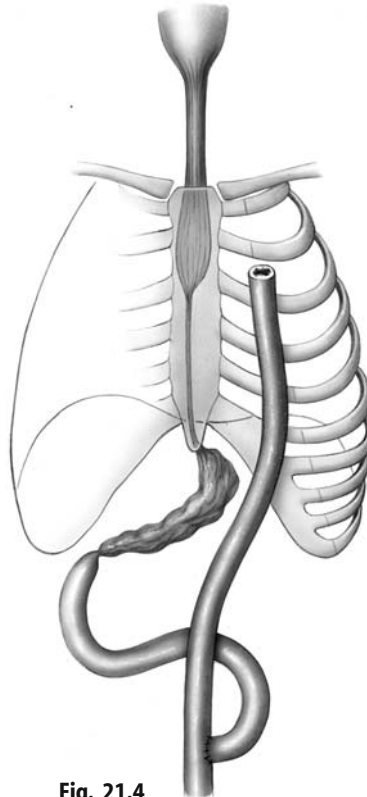
**Fig. 21.1.** Gross anatomy of the jejunal arteries and veins. **1** Superior mesenteric artery; **2** superior mesenteric vein; **3** fourth jejunal artery and vein; **4** ileocolic artery and vein; **5** right colic artery and vein; **6** middle colic artery and vein.



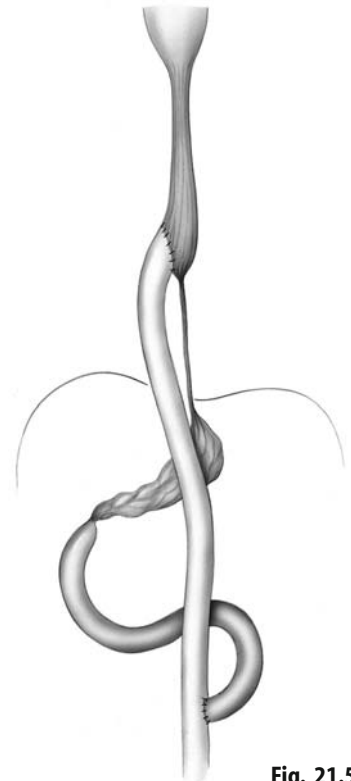
**Fig. 21.2.** Temporary clamping of the second and third jejunal artery and vein.



**Fig. 21.3.** In a combined stricture of esophagus and stomach after caustic injury and in the event that colon cannot be used as a bridging graft, interposition of jejunum must be established by several steps. The jejunal bridge, which is too short, is brought to the anterior chest wall via a subcutaneous tunnel and a jejunal stoma is positioned as high as possible.



**Fig. 21.4**



**Fig. 21.5**

**Fig. 21.4 and 21.5.** Transposition of the subcutaneously placed jejunal bridging graft through the hiatus into the right thoracic cavity and intrathoracic anastomosis of esophagus and jejunum.

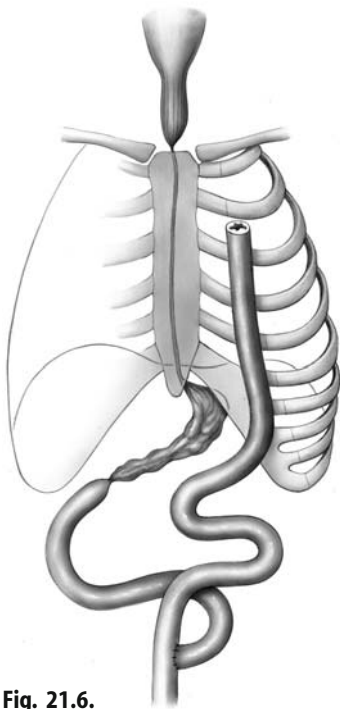


Fig. 21.6.

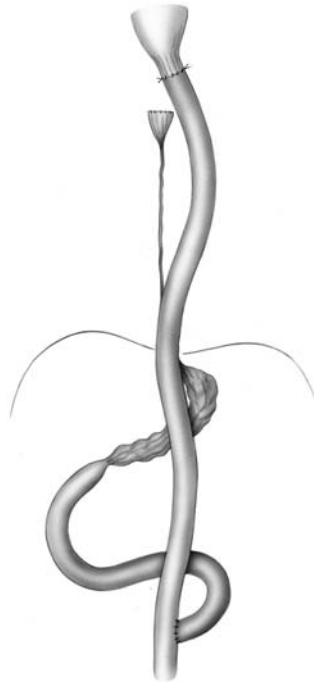


Fig. 21.7

**Fig. 21.6 and 21.7.** Remobilization of the subcutaneous jejunal segment and lengthening of the bridging graft subcutaneously to the neck with collar anastomosis of esophagus and jejunum.

■ **Combined stricture of esophagus and stomach: different variations of reconstruction (jejunum interposition)**

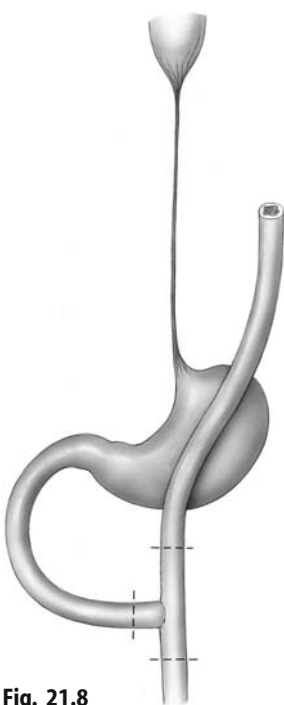

Fig. 21.8

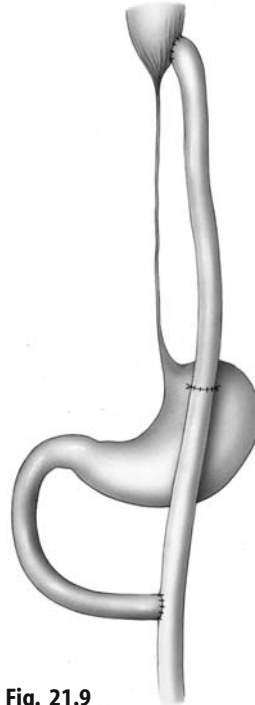
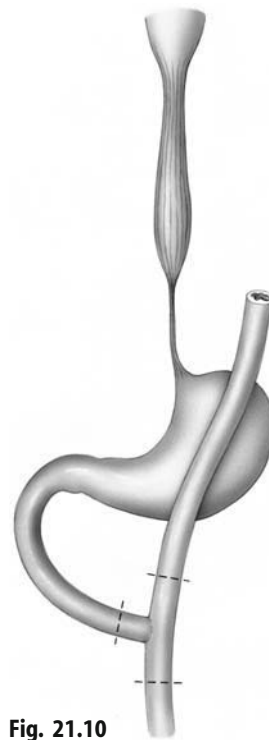

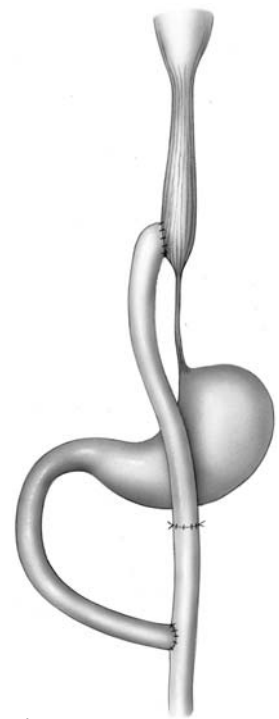
Fig. 21.9

**Fig. 21.8 and 21.9.** Resection of the jejunojejunostomy that was positioned too high and re-establishment of the continuity of the distal jejunal branch by a termino-terminal jejunojunction. Mobilization of the distal jejunal branch and pull-up to the neck for esophagojejunostomy. Again a termino-lateral Roux-en-Y jejunostomy is performed.

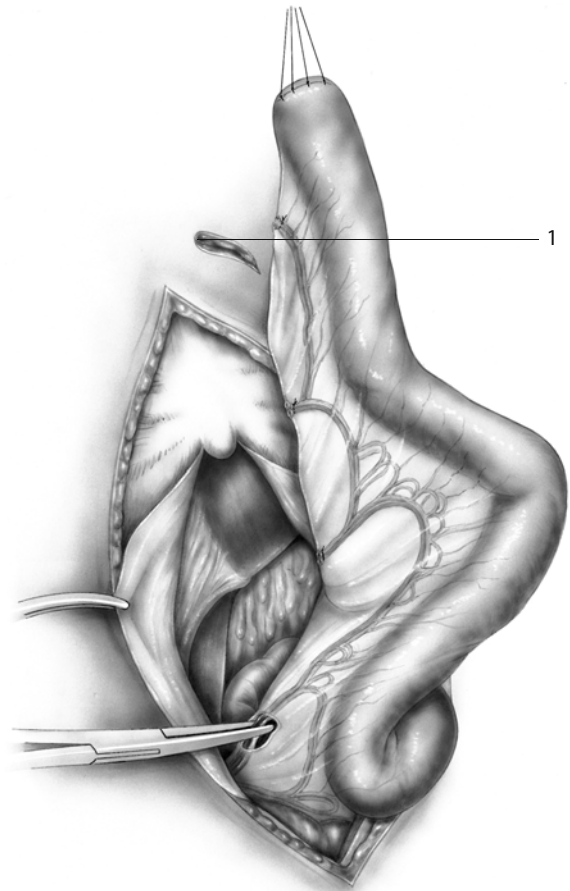
**Fig. 21.10** and **21.11.** Resection of the Roux-en-Y jejunojejunostomy that was positioned too high and reconstruction of the continuity of the jejunum. Transposition of the distal jejunal branch through the hiatus to the right thoracic cavity and establishment of an intrathoracic termino-lateral esophago-jejunosomy.



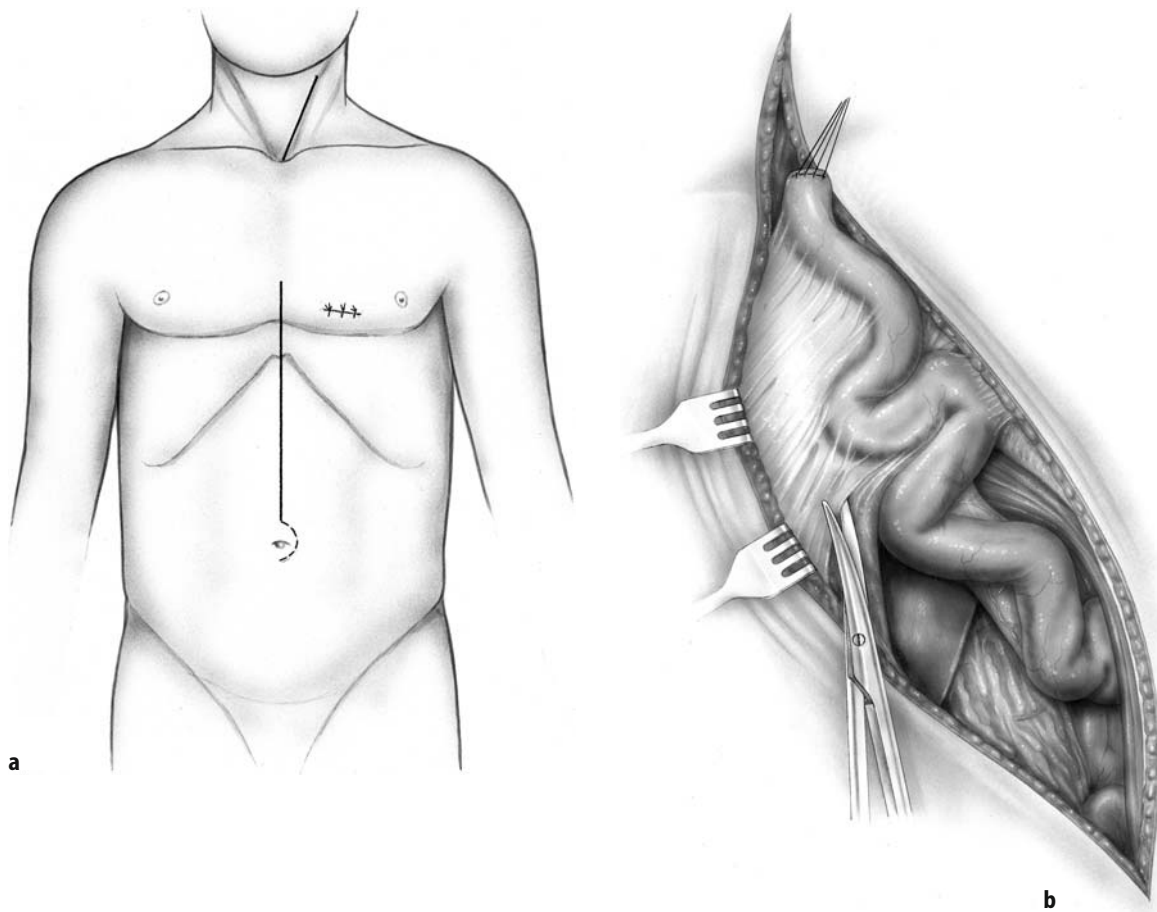
**Fig. 21.10**



**Fig. 21.11**



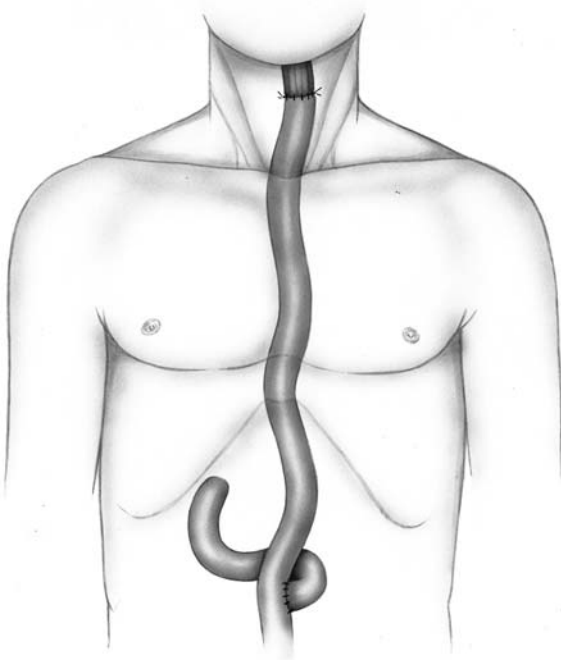
**Fig. 21.12.** Technique of remobilization of the subcutaneously placed jejunal branch including the jejunal stoma. If the subcutaneously located jejunal segment after freeing from the subcutaneous presternal tunnel is not long enough, one further radial artery and vein has to be cut and ligated after probatory clamping. **1** Skin defect after detached jejunostomy.



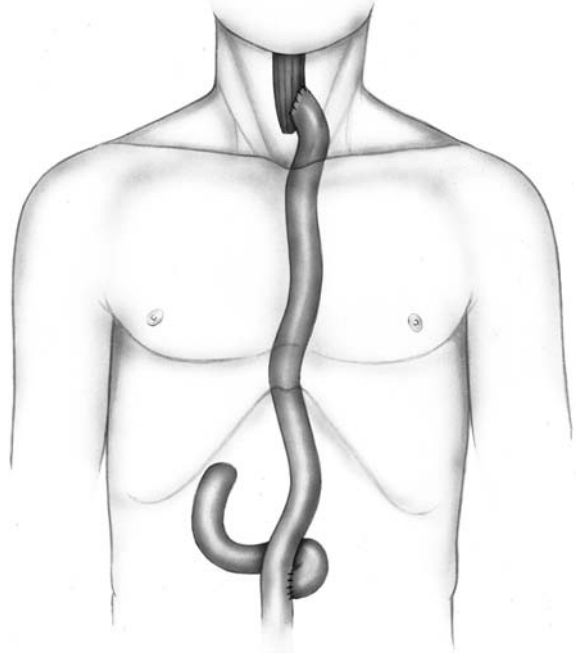
**Fig. 21.13. a** Incision for mobilization of the jejunal bridge located presternally. **b** Remobilization of the jejunal bridging graft that has been placed presternally earlier in this multi-stage procedure, by an incision from the left side of the neck towards the middle near, the jugulum, and another one

along the midline going beyond the umbilicus. The jejunum and the depending mesentery are freed from the surrounding tissue. The procedure is carried out 3–6 months after the first attempt to transpose the jejunum to the neck. By this time approximately 10 cm can be usually gained.

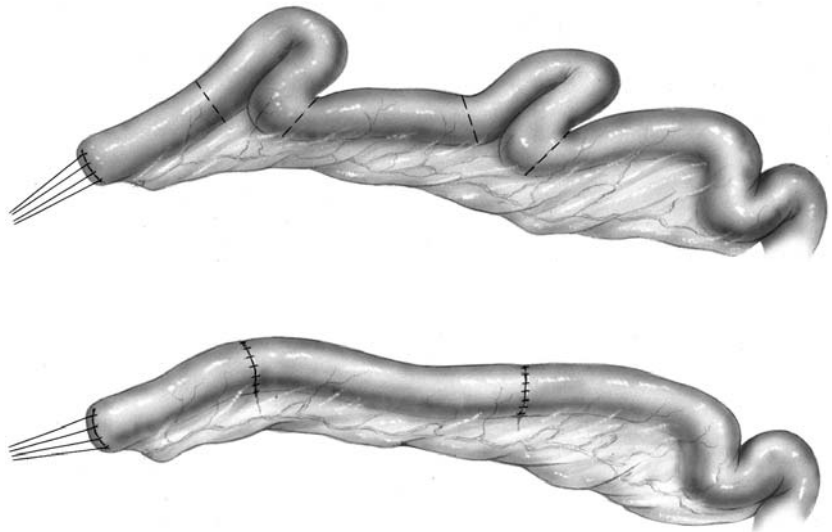
■ **Alternative operations for collar esophagojejunal anastomosis**



**Fig. 21.14.** Termino-terminal esophagojejunosomy.

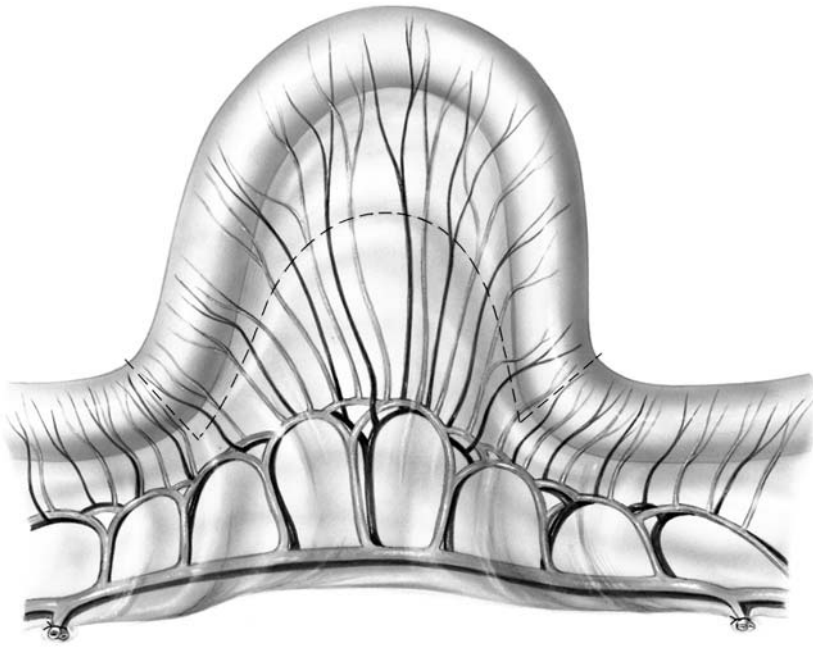


**Fig. 21.15.** Termino-lateral esophagojejunosomy.



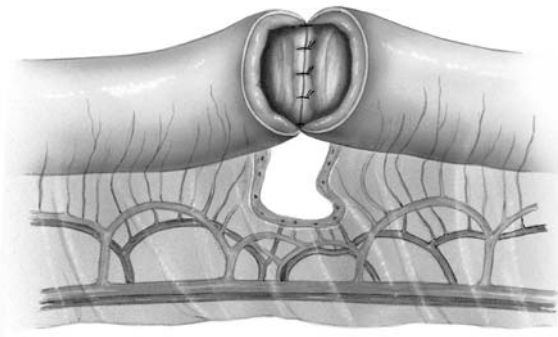
**Fig. 21.16.** Resection of an abundant bowel loop in order to straighten the graft and re-establishment of the continuity by termino-terminal jejunojunosomy.



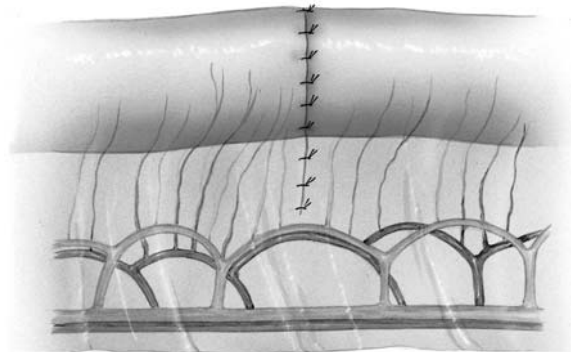


**Fig. 21.17.** Resection of the abundant loops of the bridging graft has to be done without compromising the parajunal vessel arcade. Therefore skeletonization must be carried out

very closely to the wall of the bowel loop that is about to be removed (dotted line).

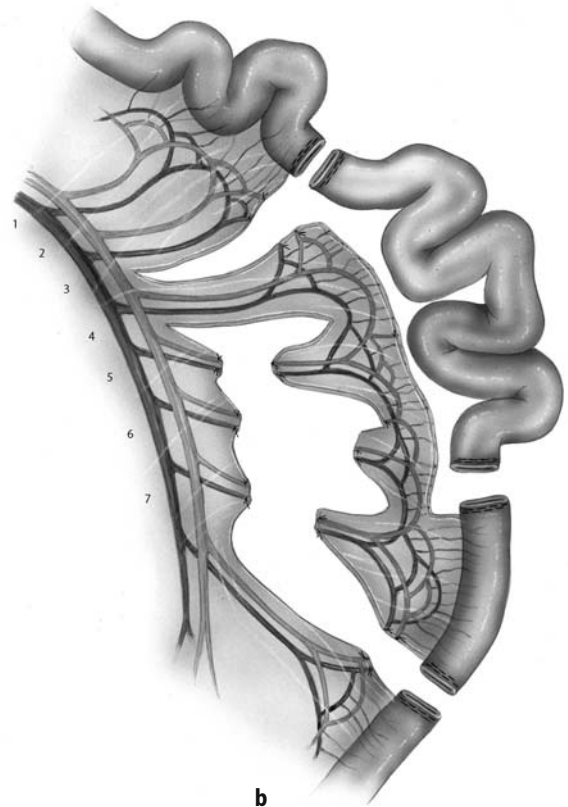
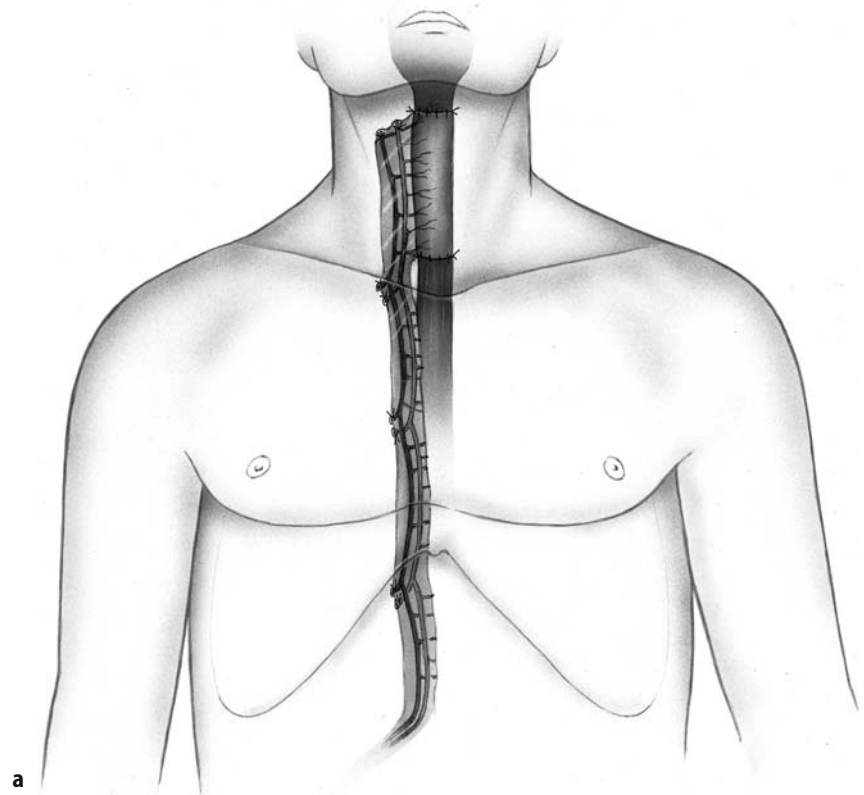


**Fig. 21.18**



**Fig. 21.19**

**Fig. 21.18 and 21.19.** Termino-terminal jejunostomy for reconstructing the jejunal continuity carefully sparing the vessel arcades.



**Fig. 21.20 a,b.** Fashioning of a short jejunal bridging graft with a long vascular pedicle to serve as a substitute for the cervical esophagus. Blood supply is provided by the third radial jejunal artery. The clamped-off jejunal segment is discarded.

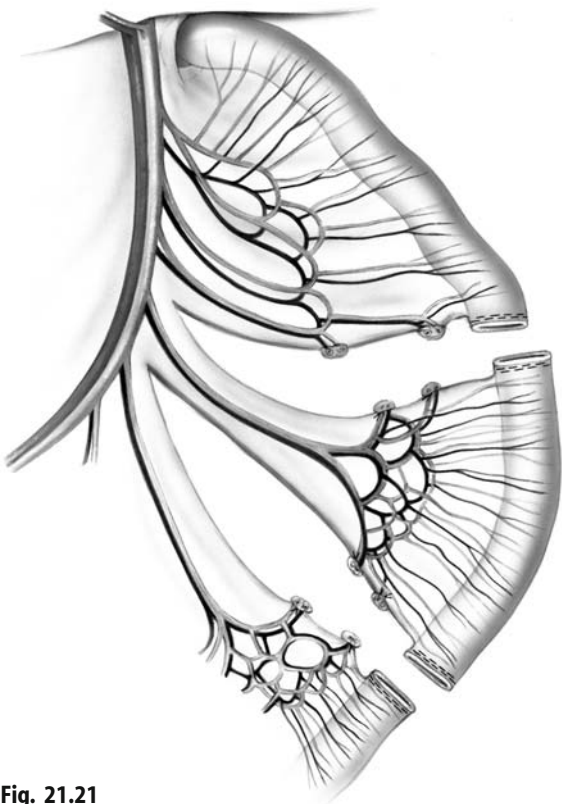


Fig. 21.21

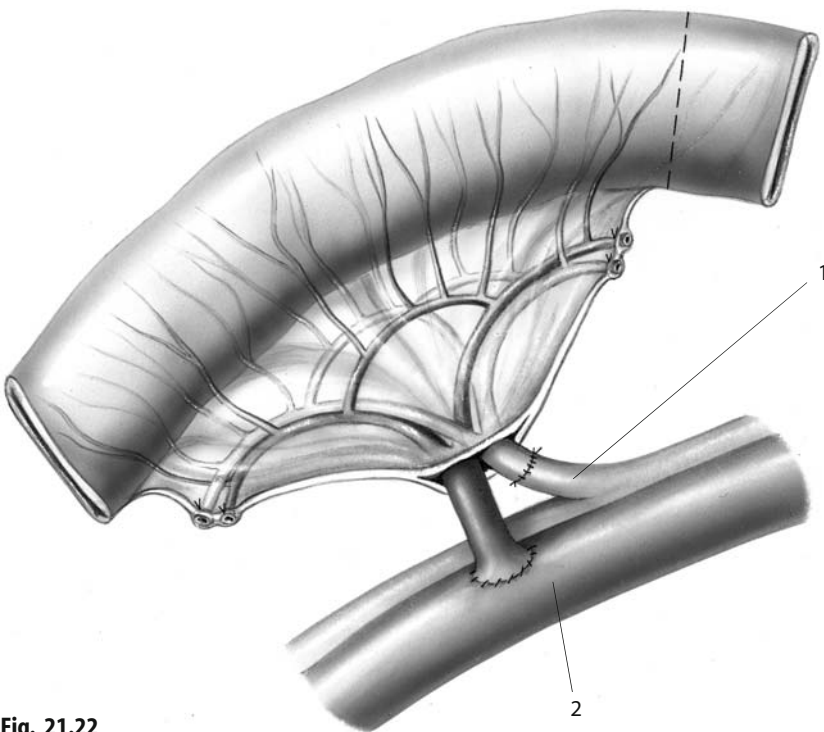
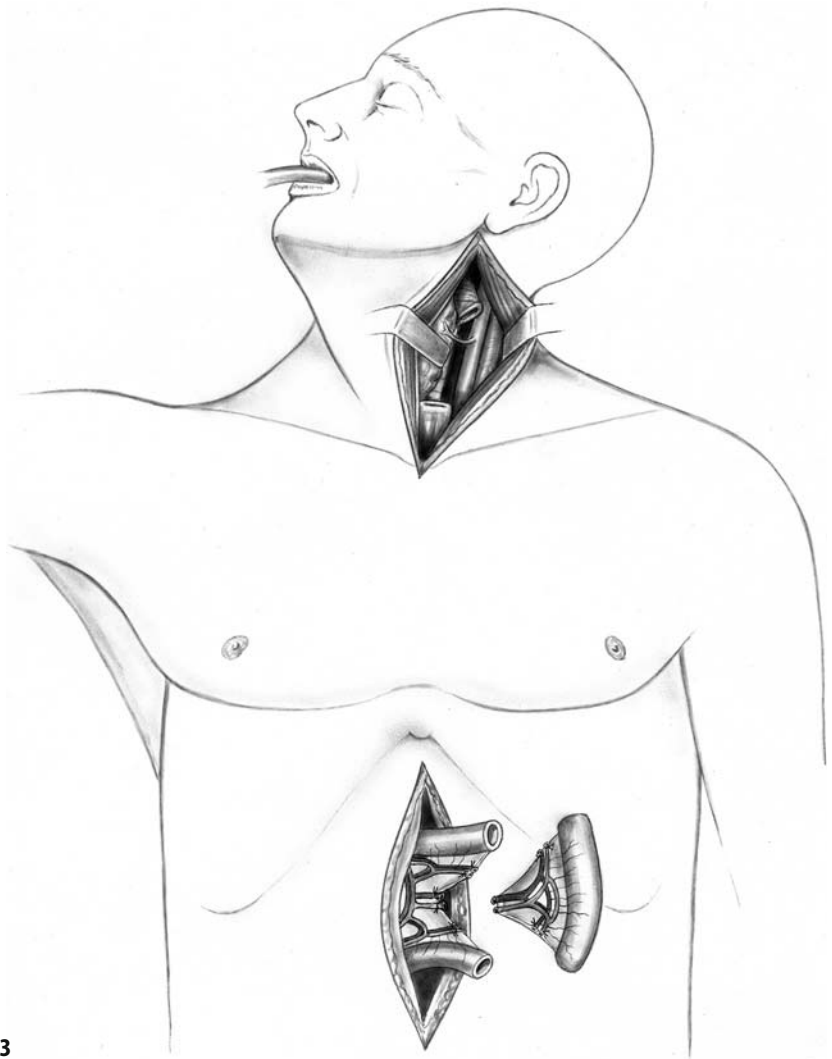


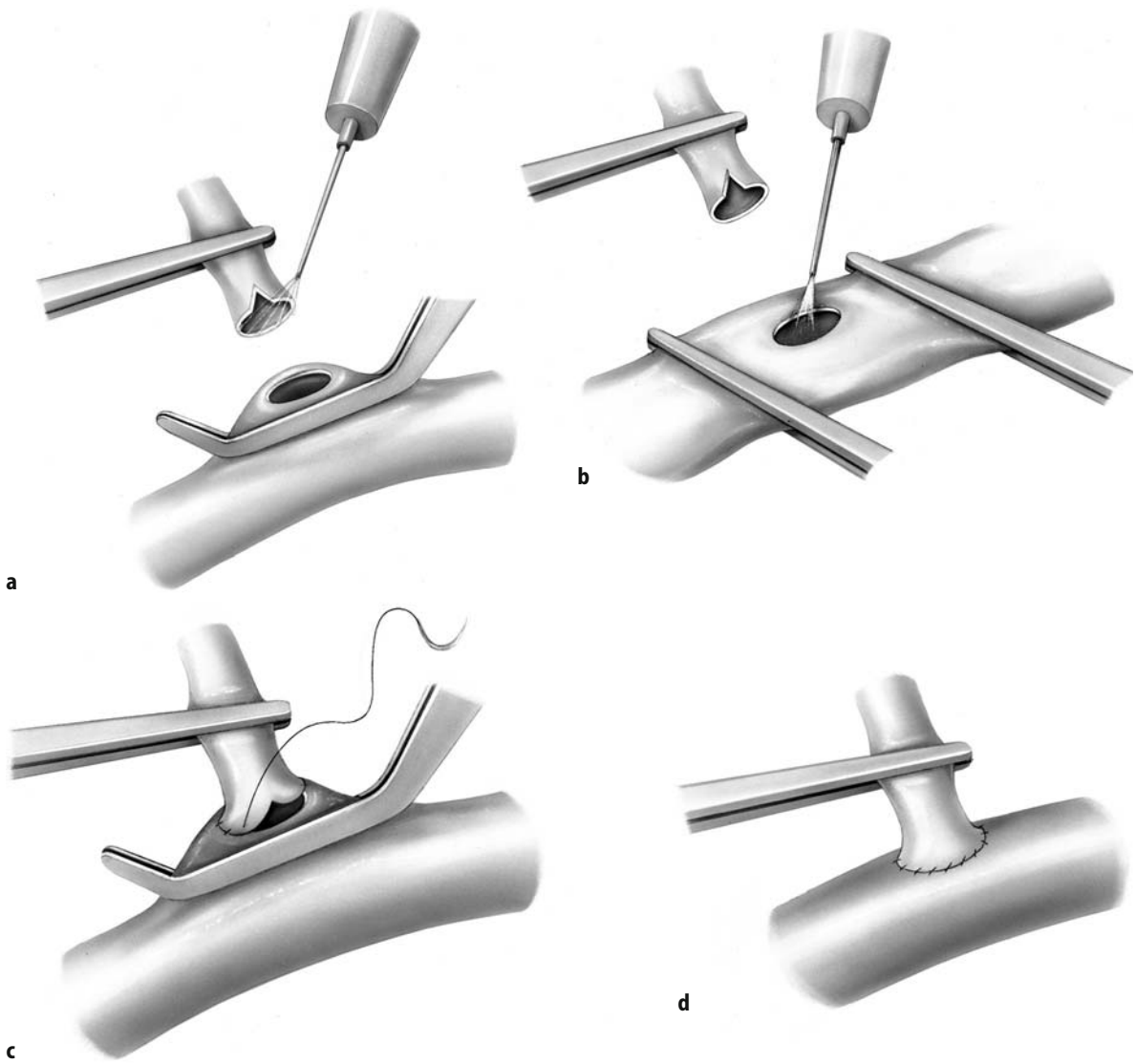
Fig. 21.22



**Fig. 21.23**

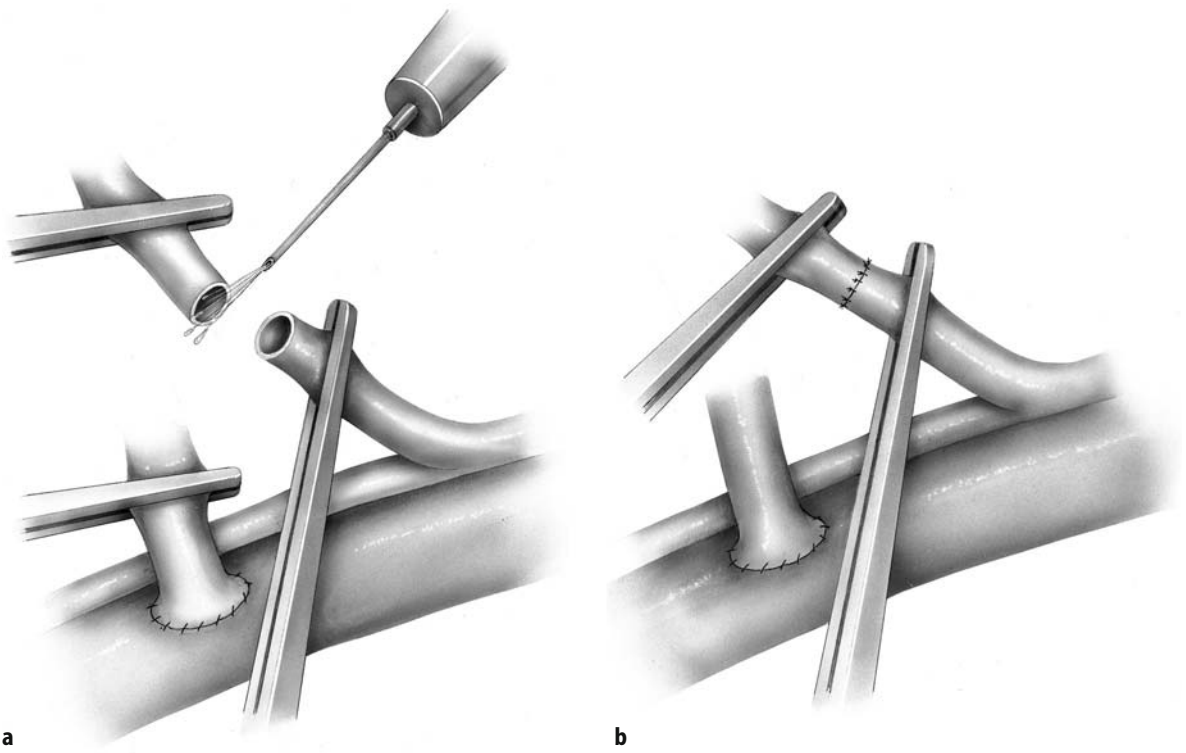
**Fig. 21.21–21.23.** The free jejunal graft replacing the cervical esophagus (Fig. 21.21). A jejunal segment that has a length of 18–20 cm and that is supplied via the fourth jejunal radial arterial branch is freed including the fourth radial vein (Fig. 21.22). After collection the graft is immediately

perfused with heparinized saline solution until it pours out clear from the venous branch. The collar vascular connection is performed on the thyroid artery and vein (Fig. 21.23). 1 Superior thyroid artery; 2 jugular vein.



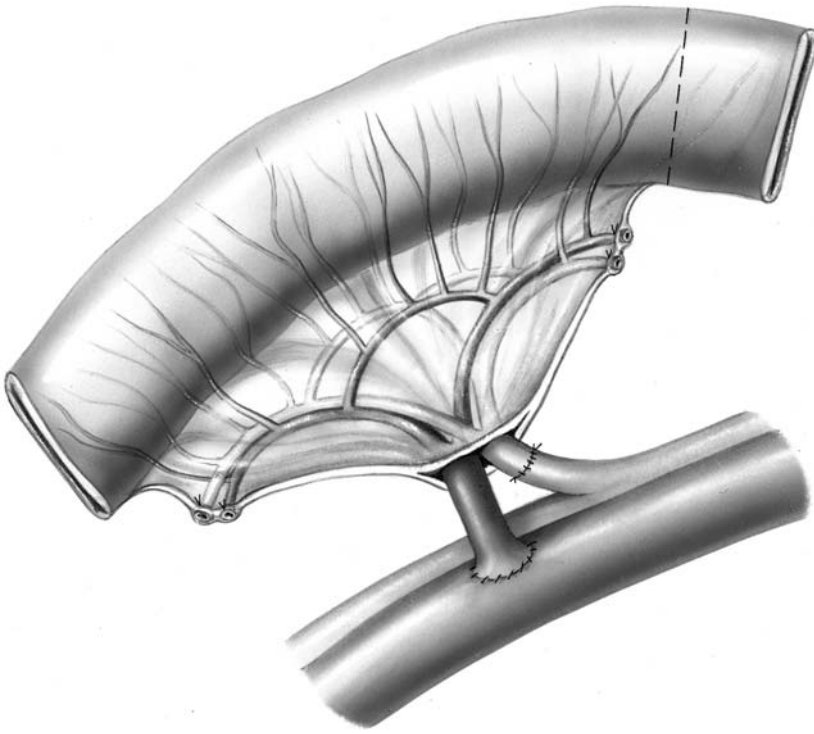
**Fig. 21.24 a–d.** The free jejunal graft replacing the cervical esophagus. The jugular vein is opened after tangential clamping (a) or clamping distally from the anastomosis (b). The tip of the jejunal vein is incised on a length of 2–3 mm

for distension of the lumen preventing later stenosis (a, b). Before being anastomosed both veins are flushed with heparine solution (a, b). The end to side anastomosis is done with a running suture using a non-absorbable 7-0 material (c, d).

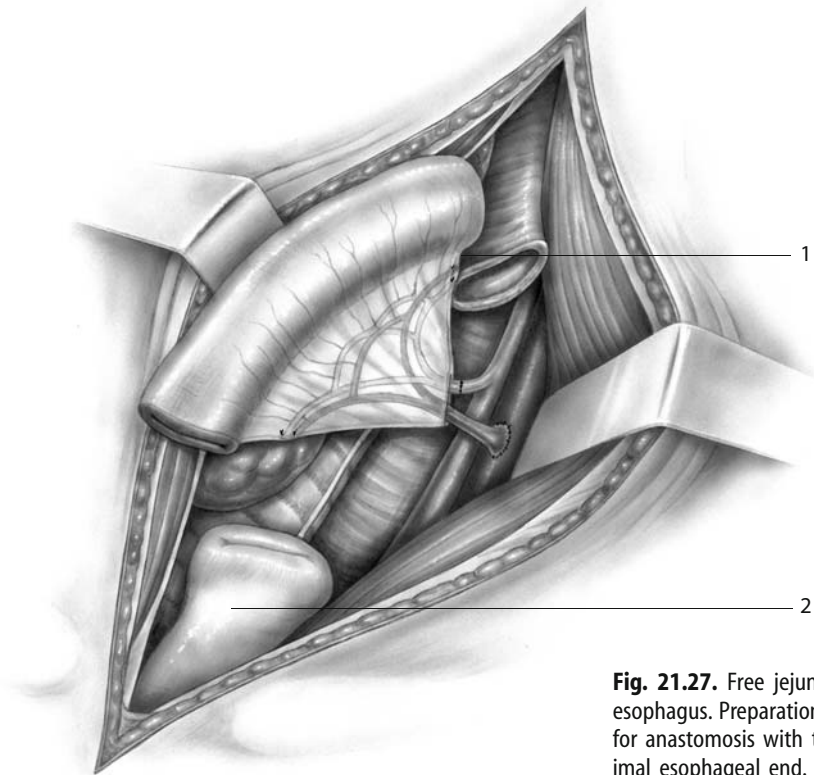


**Fig. 21.25 a, b.** The free jejunal graft as a substitute to the cervical esophagus. Dissection of the superior thyroid artery and transection between clamps. Ligation of the peripheral branch. Flushing of the proximal stump of the superior thyroid artery and of the jejunal artery with heparin solution. Establishment of an end-to-end anastomosis under the microscope or at least at 4-fold optical magnification with a running suture using monofile nonabsorbable 7.0 material.

The jejunal artery can also be connected to the external carotid artery, the lingual or facial artery. Care has to be taken that the vascular pedicle and particularly the vein is not kinked nor compressed when the jejunal graft is brought to its place of destination in the former esophageal bed. Thrombosis of the connected vein is always associated with necrosis of the graft.



**Fig. 21.26.** The graft is shortened to the matching length (interrupted line).



**Fig. 21.27.** Free jejunal graft as a substitute for the cervical esophagus. Preparation of the hypopharynx and the esophagus for anastomosis with the graft. **1** Open hypopharynx; **2** proximal esophageal end.

# Limited en bloc Resection of the Gastroesophageal Junction with Isoperistaltic Jejunal Interposition

J. R. IZBICKI, W. T. KNOEFEL, D. C. BROERING

## ■ Indications

- Severe dysplasia in the distal esophagus (Barrett's esophagus)
- distal adenocarcinoma of the esophagus stage pT1a and pT1b (UICC 2005).

## ■ Contraindications

- Advanced adenocarcinoma of the esophagus (stage pT2 and above)
- Long Barrett's segment above the carina.

## ■ Risks and informed consent

- Insufficiency of the esophagojejunostomy or the intraabdominal anastomosis
- Mediastinitis
- Pancreatitis
- Peritonitis
- Pleural empyema
- Emergency thoracotomy
- Necrosis of the jejunal interposition
- Postoperative reflux
- Postoperative delayed gastric emptying
- Possible extension of the operation including transhiatal esophagectomy or esophagogastrectomy in case an advanced tumor stage is encountered.

## ■ Particular preoperative measures

- Esophagogastrosopy with extensive biopsies
- Computed tomography of the chest and abdomen
- Abdominal ultrasound
- Endosonography of the esophagus
- Pulmonary function test

■ **Anesthesia.** Postoperative analgesia may be improved by implantation of a thoracic peridural catheter.

■ **Positioning of the patient.** See chapter 13.

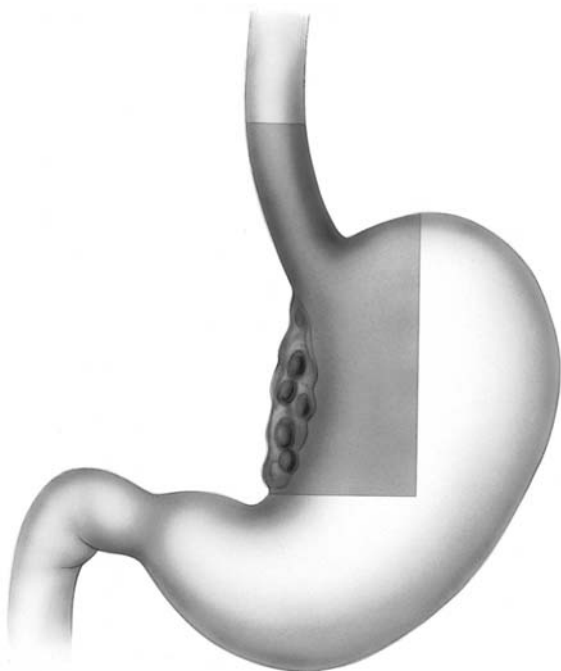
■ **Access.** See chapter 13.

## ■ Operative procedure

1. Inversed T-shaped upper abdominal incision
2. Mobilization of the left liver lobe
3. Division of the lesser omentum and identification of the diaphragmatic limbs and of the vagal nerves
4. Median longitudinal incision of the diaphragm
5. Intraoperative esophagoscopy and marking of the proximal limit of resection by diaphanoscopy
6. Lymphadenectomy of the inferior mediastinum and the upper abdomen
7. Positioning of a purse string clamp just cranial to the proximal resection limit and division of the esophagus
8. Resection of the lesser curvature including the distal esophagus, formation of a neo fundus
9. Isolation of a proximal jejunal segment of 15 cm in length and retrocolic transposition to the subdiaphragmatic region
10. Termino-lateral esophago-jejunostomy with a circular stapler
11. Latero-lateral or termino-lateral jejunogastrostomy and termino-terminal jejunostomy.

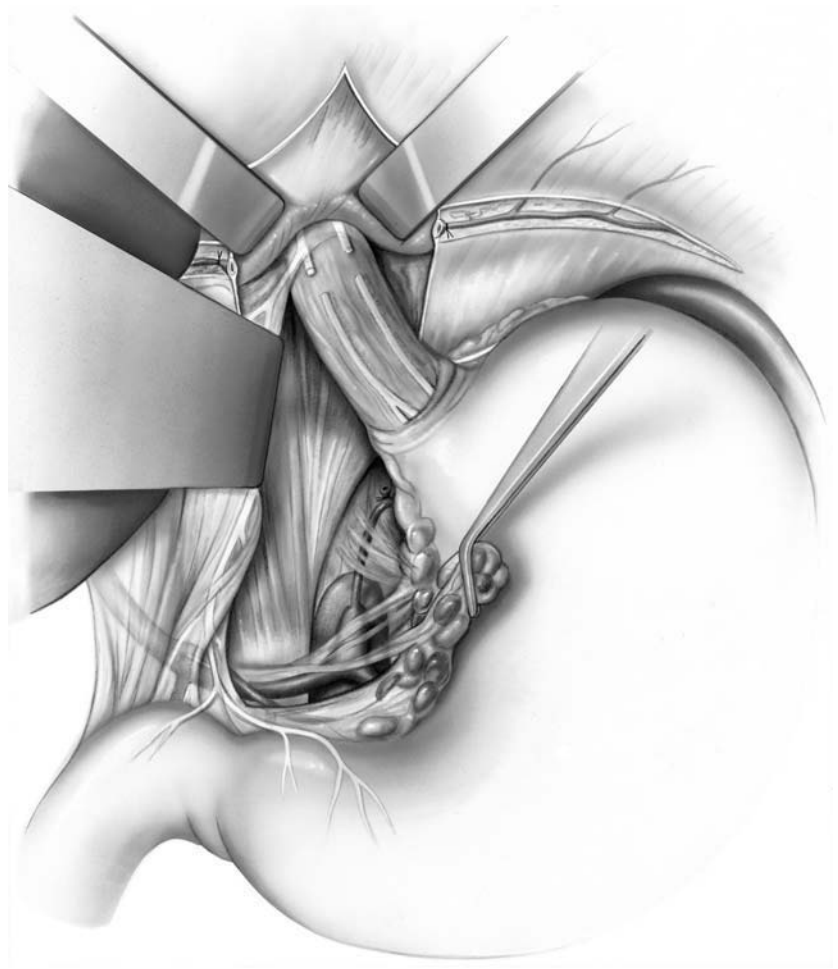
■ **Particular instruments.** Intraoperative esophagoscopy.





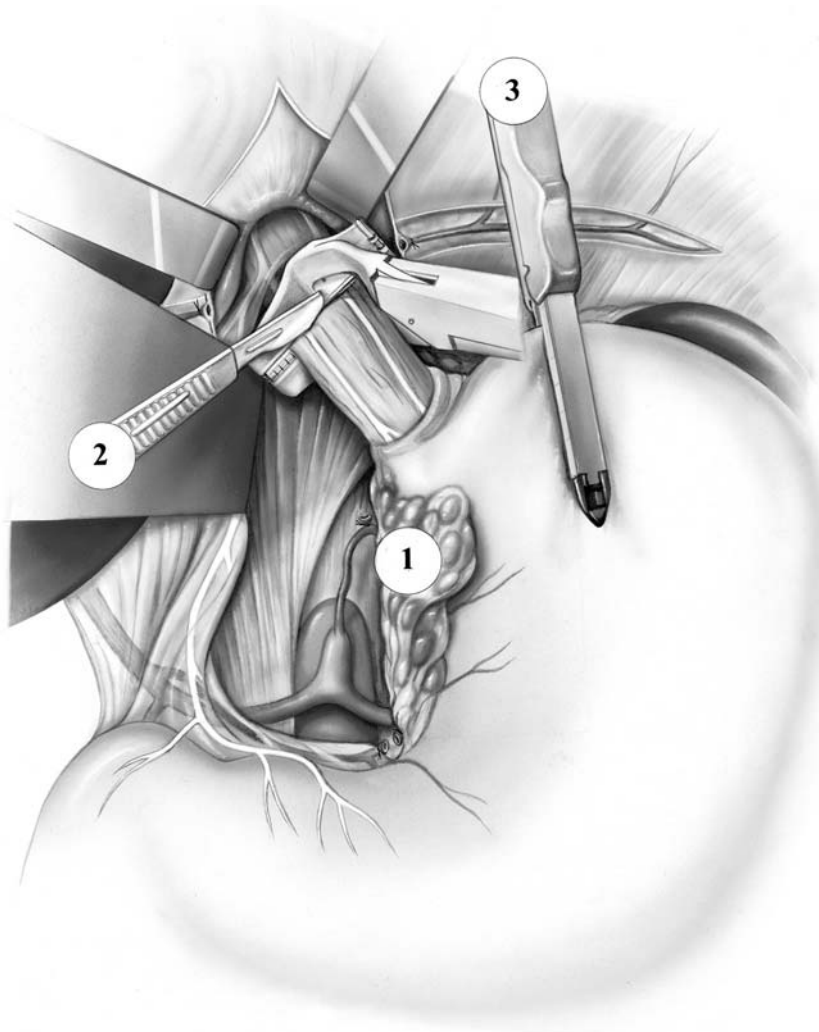
**Fig. 22.1.** Limited en bloc resection of the gastroesophageal junction includes complete removal of the esophageal segment with metaplastic mucosa, the lower esophageal sphincter and a part of the lesser gastric curvature, and formation of a neo-fundus. Since even early adenocarcinomas of the

distal esophagus (T1b) seed lymph node metastases in up to 20% of the patients, removal of the lymph nodes of the lesser curvature, of the hepatic and splenic arteries, the celiac trunk, the paraaortal region and the inferior mediastinum is an essential part of the operation.



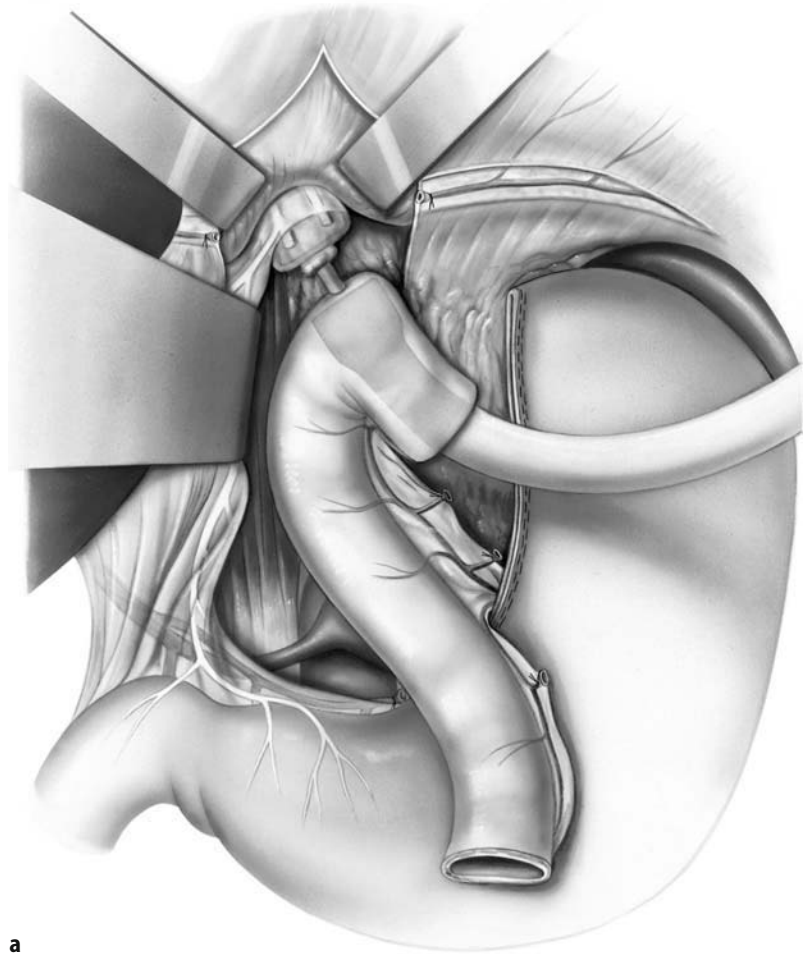
**Fig. 22.2.** The left liver lobe is completely mobilized, and the lesser omentum is incised just medial to the anterior and posterior gastric vagal branches. A longitudinal median diaphragmal incision enables exposure of the inferior posterior mediastinum. The distal esophagus is then mobilized including the paraesophageal tissue. The vagal nerves are divided. Intraoperative esophagoscopy identifies the cranial

limit of the Barrett's segment by diaphanoscopy. This also marks the proximal limit of resection. A lymphadenectomy around the splenic and hepatic artery is performed, the left gastric vein is divided, and the left gastric artery divided at the celiac trunk. Then the celiac trunk and the paraaortic region above the celiac trunk are cleared from lymphatic tissue.

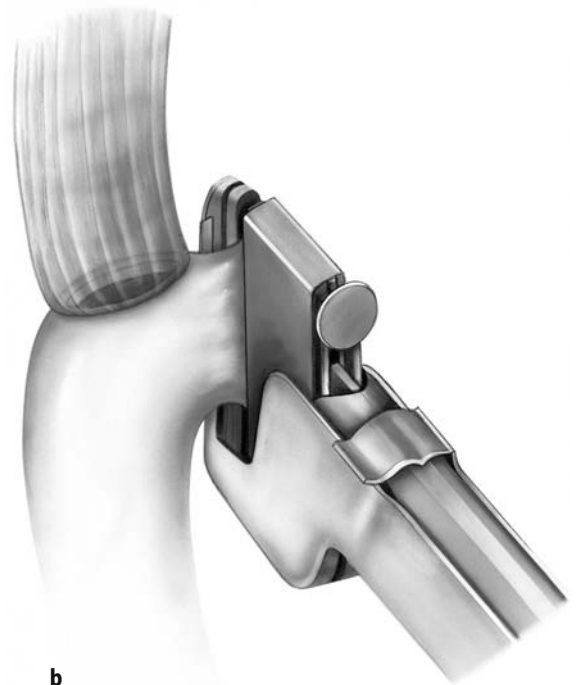


**Fig. 22.3.** Approximately 1 cm proximal to the cranial limit of the Barrett's segment, a purse string clamp is placed and the esophagus is divided. Removal of the cardia and lesser curvature is performed by placing multiple linear staplers down to the border between antrum and body. Thus, a

neo-fundus is formed. As an exception, the short gastric vessels have to be divided in order to allow for a sufficient mobilization of the gastric fundus. However, in most cases the gastric fundus is not mobilized. **1** Lesser curvature; **2** Division of the esophagus; **3** Linear stapler.

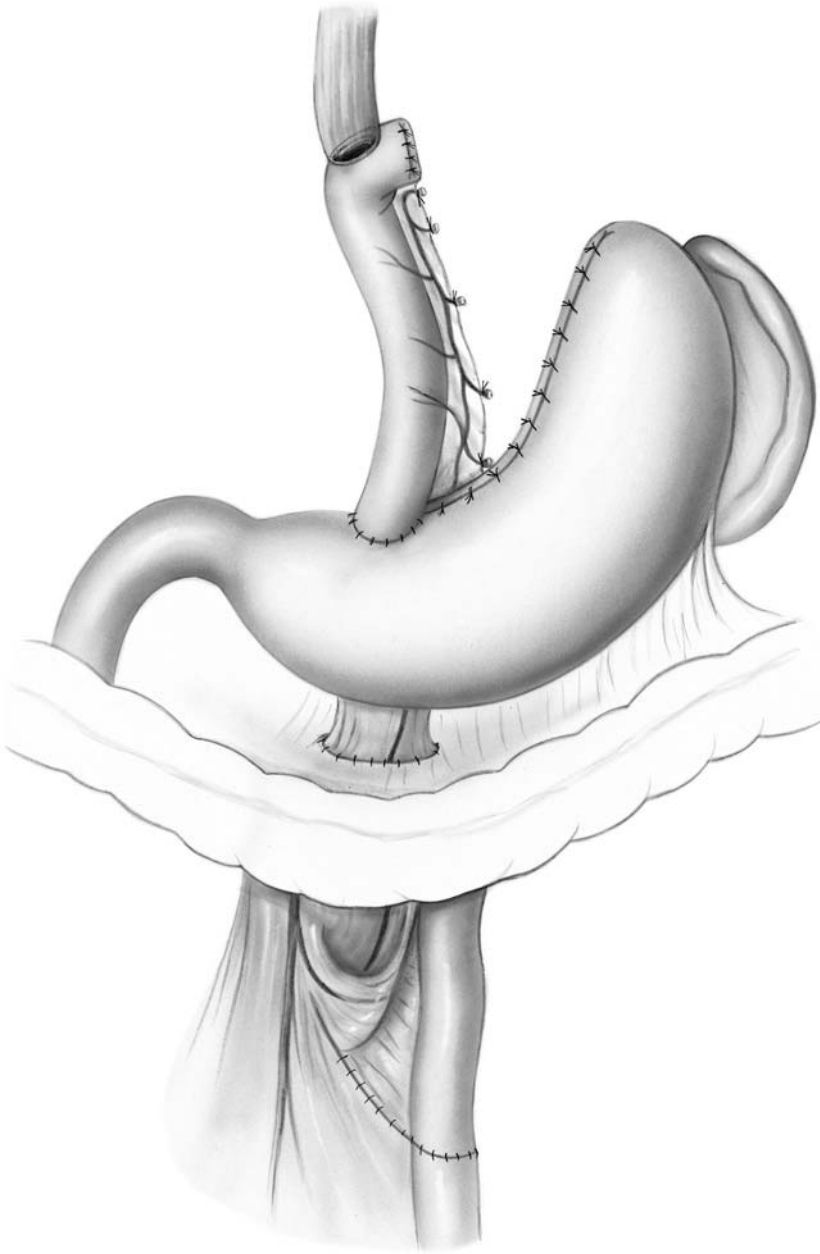


a



b

**Fig. 22.4a,b.** A 15 to 20 cm long segment of the proximal jejunum is isolated and transposed with its mesenteric root to the diaphragmatic region through the mesocolon and behind the stomach. Care has to be taken to dissect the vascular pedicle of this jejunal interposition carefully to provide adequate length. It is imperative to form an isoperistaltic jejunal interposition. The proximal anastomosis is then performed by a circular stapling device as a termino-lateral esophagojejunostomy (a). The stapler is introduced into the end of the jejunal interponate. After firing of the anastomosis, the blind end of the loop is then resected and closed by a suture or with a linear stapler and then oversewn (b).



**Fig. 22.5.** Close to the base of the neo-fundus, the gastric stapler line is removed over a distance of 3–4 cm, and a termino-lateral or latero-lateral jejunogastrostomy is performed. The remaining gastric suture line is oversewn. A termino-terminal jejunogastrostomy reconstructs the enteric passage. Finally an anterior and/or posterior hiatal repair is performed

## ■ Introduction

Achalasia is characterized manometrically by an incomplete relaxation of the lower esophageal sphincter. This “outflow obstruction” results in a motility disorder of the tubular esophagus, in most cases aperistalsis. However, an appearance as seen in diffuse esophageal spasm can also occur. Medical therapy shows short-term benefit but no long-term solution. Endoscopic dilatation has been established as primary therapy. However usually repetitive dilatations even in short intervals are necessary. In comparison to surgery dilatation is a less controllable procedure. The risk of perforation is always given, especially in cases of recurrent application. Surgical therapy on the other hand provides the opportunity for a controlled myotomy followed by an antireflux procedure with a high rate of permanent success. Recent publications support an early surgical approach because cure can be provided and a partial remission of the motility disorder can be noticed.

## ■ Indication

- Minimally invasive procedure impossible (previous extended upper abdominal surgery)
- Early dysphagia recurrence after repetitive dilatation
- (Peptical) Stricture and scarring paraesophageal and paracardial tissue after failed previous surgery.

## ■ Contraindications

- General – severe cardiopulmonary insufficiency etc.
- Nondistinctive dignity of the cardioesophageal “tumor”.

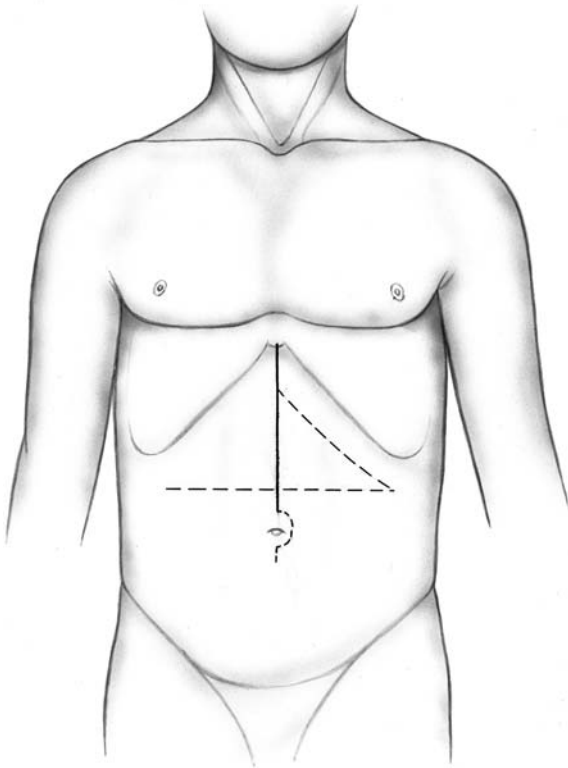
## ■ Special surgical preparation

- Parenteral nutrition or high caloric enteral nutrition in cachectic patients.

■ **Positioning on the operation table.** As for transhiatal blunt dissection (see chapter 13).

■ **Anesthesia.** General anesthesia.

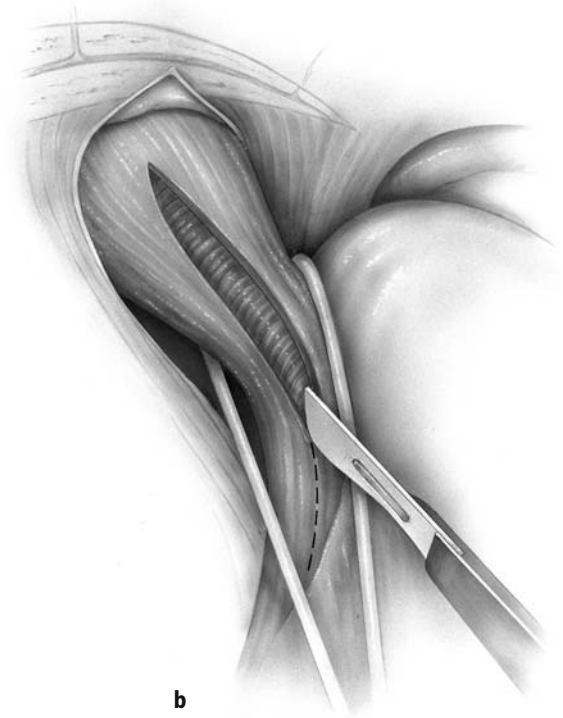
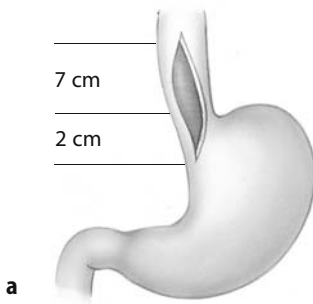
■ **Special instruments.** As for transhiatal blunt dissection.



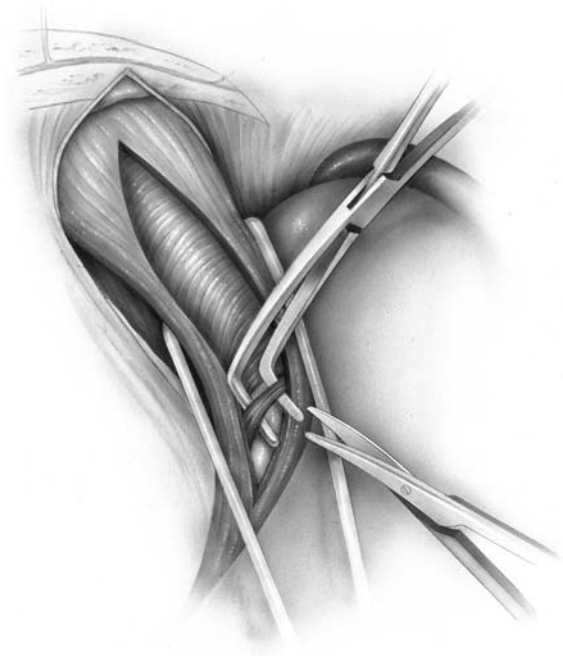
**Fig. 23.1.** Approach by upper midline incision. Alternatively the upper abdomen can be exposed by a left costal incision or an upper abdominal transverse incision.



**Fig. 23.2.** Cardia, distal esophagus, and gastric fundus are mobilized. The ventral branch of the vagus nerve is thoroughly preserved. For an extensive dissection of the esophagus, a long median incision of the diaphragm is helpful. Dissection of the scarred tissue around the esophagus.

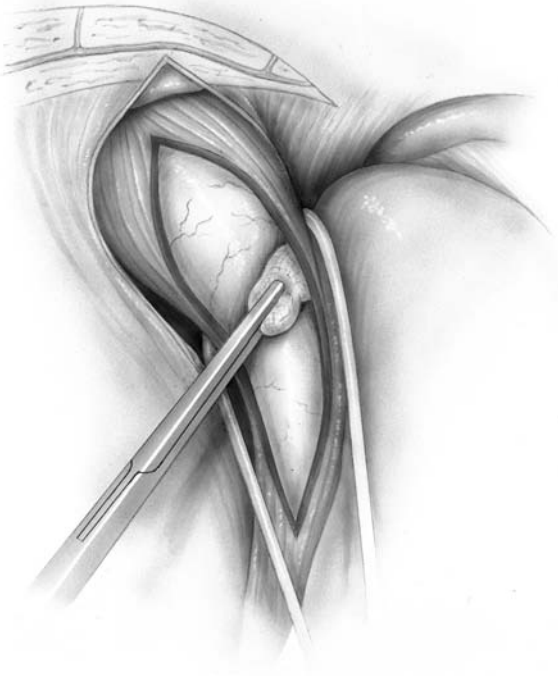


**Fig. 23.3 a, b.** Longitudinal myotomy along the left aspect of the anterior wall of the esophagus and cardia. The incision is extended over the entire length of the narrow segment, in total 7 cm upwards onto the esophagus and 2 cm downwards onto the cardia. At first only the longitudinal muscles of the esophageal wall is transected.

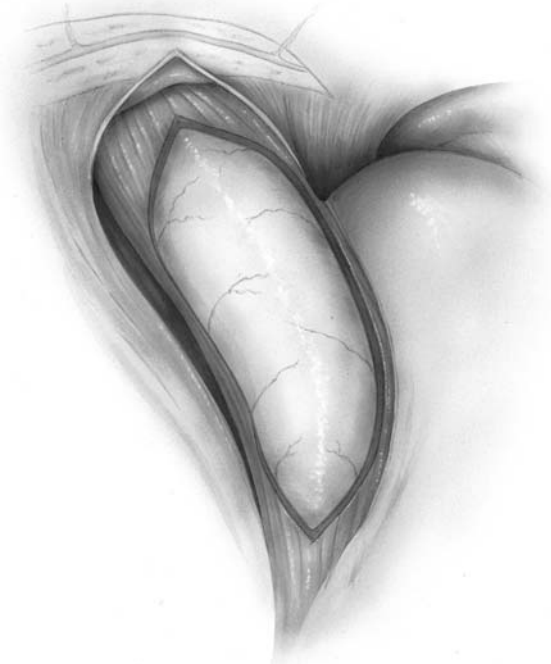


**Fig. 23.4.** Now the circular muscle layer is transected carefully undermining it with a clamp and dividing it with scissors or diathermy. It is mandatory that this division is complete because just a few remaining muscle fibers can result in recurrence.

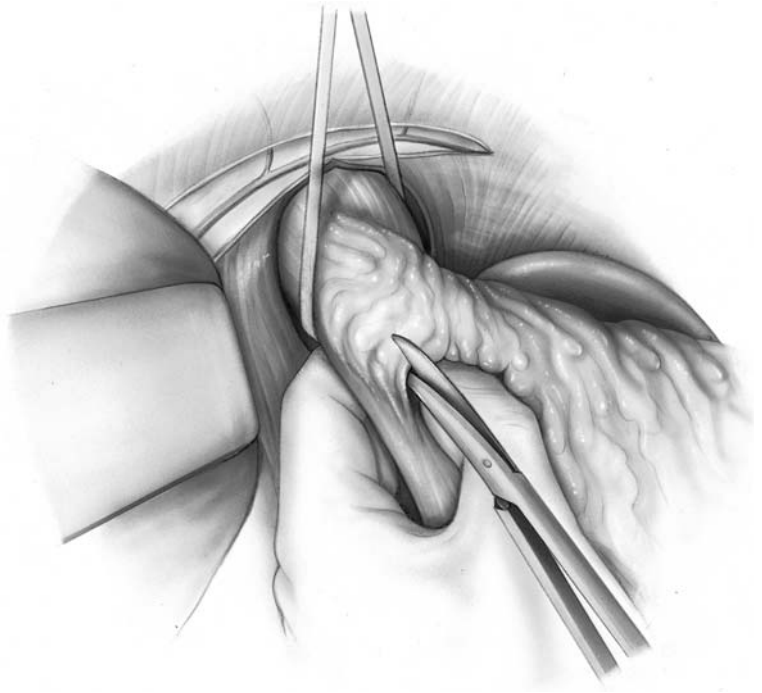




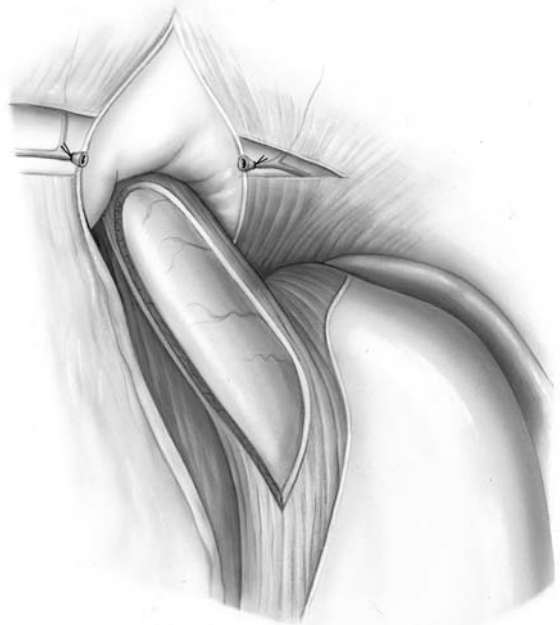
**Fig. 23.5.** The margins of the myotomy are bluntly dissected from mucosa and submucosa to at least half of the circumference.



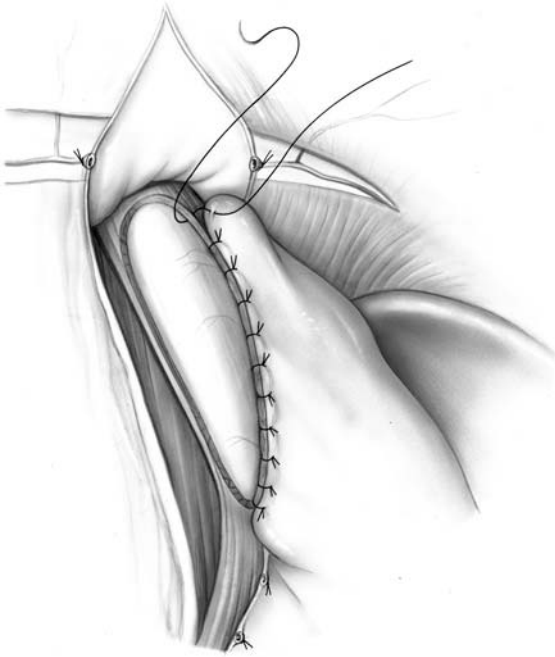
**Fig. 23.6.** At the end of the operation mucosa and submucosa must slightly prolapse through the myotomy. All steps of the operation are performed with a large gastric tube in place to arm the esophagus.



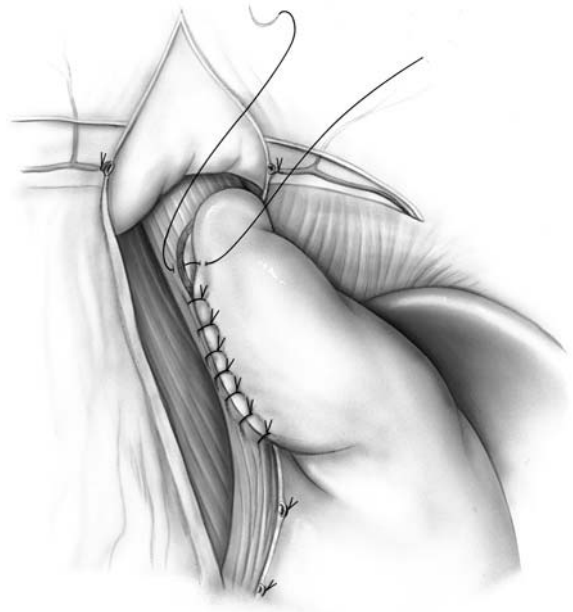
**Fig. 23.7.** The release of the esophagus from the surrounding tissue – as shown here from the omentum – can be very difficult. In these cases myotomy alone is ineffective because scarring prevents the blunt dissection in the layer between submucosa and musculature. In these cases a partial resection of the esophageal anterior-wall musculature will be necessary.



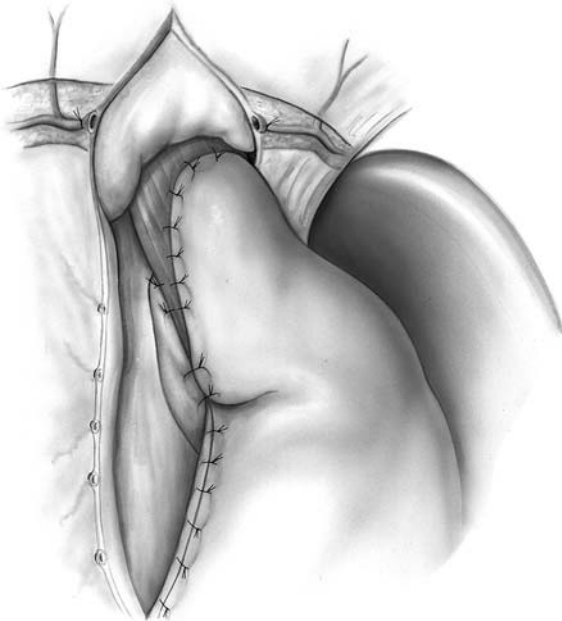
**Fig. 23.8.** After complete resection of the esophageal anterior wall, the esophagogastric junction is prepared for coverage.



**Fig. 23.9.** Partial fundoplication. The fundus wall is sewn to the left margin of the myotomy with interrupted sutures (Vicryl 3/0).



**Fig. 23.10.** Partial fundoplication. The fundus wall is finally fixed to the right margin of the myotomy for complete coverage, maintenance of tension, and spacing of the muscle defect.



**Fig. 23.11.** Partial fundoplication. The back wall of the fundus is slipped around the distal esophagus and fixed to the anterior wall in the region of the cardia with no more than two sutures. Cranially the fundus back wall is fixed to the esophageal wall resulting in an acute angle between fundus front and back wall. This type of fundoplication achieves optimal reflux prevention with minimal risk of dysphagia.

## 24 Surgical Technique in Gastroesophageal Reflux Disease – Conventional Approach

### Introduction and Techniques in gastroesophageal reflux

K. A. GAWAD, D. C. BROERING, C. BLOECHLE,  
C. BUSCH

Gastroesophageal reflux disease is characterized by unphysiologically long contact of gastric content with esophageal mucosa. This is caused by an insufficiency of the lower esophageal sphincter which can be verified by manometry and confirmed by 24-h pH metry.

The surgical therapy of gastroesophageal reflux disease (GERD) has changed many times during its development. In 1956 the first surgical procedure to treat reflux esophagitis was introduced by Rudolf Nissen. Around the same time, another technique was described in France by Lortat-Jacob (1957). During the following years further techniques had been developed and modified, demonstrating that there was no consensus on the optimal technique. Worldwide the most frequently used technique is the Nissen fundoplication enhanced by M. Rossetti. With this technique, in great series a good surgical long-term outcome could be achieved in 80–90% of all cases. By introduction of the proton-pump inhibitors a trend to conservative therapy was recognized. However, after the medication was discontinued the patients suffered from recurrence. Laparoscopic surgery has led to a revival of anti-reflux surgery (laparoscopic techniques are described in chapter 29), with most patients accessed that way. Although, care has to be taken in patients with recurrent disease or previous surgery, where the conventional approach still has its place.

Reflux disease is associated with sliding hiatal hernia in almost 90% of all cases. In cases of paraesophageal or combined hernias, indication for surgical therapy is always given.

Peptic stenosis is a complication of reflux disease. Here improvement can be achieved by anti-reflux surgery, especially in cases of “florid stenosis” by elimination of the noxa.

In addition an endoscopic dilatation can be performed. In the case of an irreversibly scarred stricture this single procedure can be insufficient, and further action as stricturoplasty, and/or the parietal cell vagotomy, or finally resection may become necessary.

Three basically different groups of surgical procedures have been established in the past as listed below:

#### I. Techniques aiming at an anatomical reconstruction of the gastroesophageal junction

##### 1. *Herniorrhaphia*

- 1.1 Classical column-suture according to Welch (1967)
- 1.2 Herniorrhaphy according to Harrington (1955) and Madden (1956)
- 1.3 Surgery according to Allison (1951)
- 1.4 Surgery according to Sweet (1948)

##### 2. *Gastropexia*

- 2.1 Gastropexia according to Nissen (1955)
- 2.2 Gastropexia anterior geniculata according to Boerema (1955)

##### 3. *Miscellaneous*

- 3.1 Ligamentum teres-plasty according to Rampil (1964), according to Narbona, Molina (1972), according to Mahmud, Ulrich, Kremer (1979)
- 3.2 Fundophrenicopexia and anterior hiatoplastic according to Höhle, Kümmerle (1972).

## II. Valvuloplasty

### 1. Total fundoplication

- 1.1 Fundoplication according to Nissen (1956)
- 1.2 Anterior wall fundoplication according to Nissen-Rossetti (1968)
2. *Partial Fundoplication:*
  - 2.1 Esophago-fundo-phrenicoplexia according to Lortat-Jacob (1957)
  - 2.2 Anterior hemifundoplication according to Dor (1957)
  - 2.3 Posterior hemifundoplication according to Toupet (1963)
  - 2.4 Fundoplasty according to Hill (1967)
  - 2.5 Mark IV operation according to Belsey (1967)

## III. Miscellaneous

1. Silicone antireflux prosthesis according to Angelchik (1979)
2. Vagotomy
3. Roux-Y anastomosis

The techniques aiming for anatomical reconstruction are always used when the hiatal hernia has to be treated. The Ligamentum teres-plasty has its constant indication in this instance. The lower esophageal sphincter is accepted to be the most important pathogenetic factor in the development of reflux disease. Thus the Nissen fundoplication and the modified Nissen-Rossetti procedure have become the standard surgical procedure par excellence. In the Anglo-American countries the Marc IV procedure is also widely accepted. Only in the laparoscopic era, partial fundoplications have been increasingly used.

## ■ Indications

### ■ Reflux disease

1. General indication for anti-reflux surgery (cp. chapter 7)
2. Minimally invasive procedure not possible (status post surgery in the upper abdomen)
3. Recurrent disease following previous anti-reflux surgery (laparoscopic or conventional).

### ■ Hiatal hernia

1. Sliding hernia: only with concurrent reflux disease

2. Paraesophageal and combined hernia: general indication for surgery, conventional procedure when a minimally invasive approach is not feasible.

### ■ Peptic stenosis

1. Failure of conservative therapy including dilatation
2. Nondistinctive dignity of the stenosis.

### ■ Contraindications

General – serious cardiopulmonary disorders etc.

### ■ Risks and considerations for informed consent

1. Cuff-rupture → recurrence
2. Cuff too tight → “Gas-bloat” syndrome
3. Stomach slips through the cuff = “Telescope-phenomenon”  
*Cave:* particularly following combined approach with vagotomy
4. Cuff primarily placed too low on the stomach → recurrence, gastric depletion disorder
5. Denervation syndrome → gastric depletion disorder, “Gas-bloat”.

■ **Positioning on the operation table.** As for transhiatal blunt dissection (cp. chapter 13).

■ **Anesthesia.** General.

■ **Special instruments.** As for transhiatal blunt dissection (cp. chapter 13).

## ■ Choice of the procedure

### ■ Simple reflux disease (esophagitis up to °III)

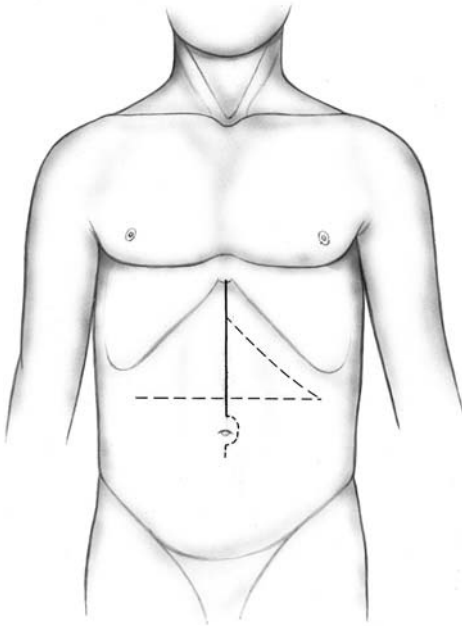
1. Fundoplication
2. Ligamentum teres plasty.

### ■ Complicated reflux disease (esophagitis °IV)

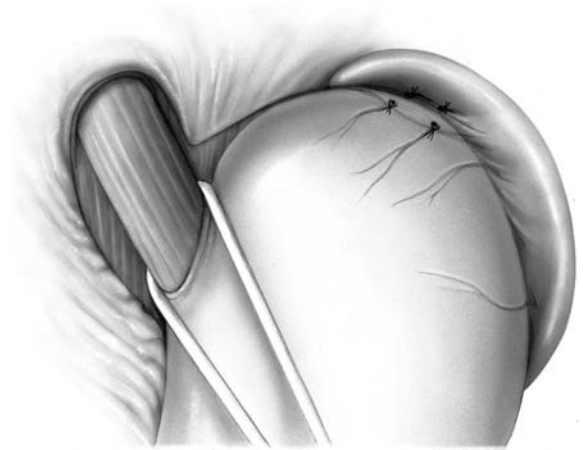
1. Fundoplication + dilatation (of floride esophagitis)
2. Fundoplication + parietal cell vagotomy (in gastric hyperacidity) + if necessary bougienage (of floride esophagitis)
3. Fundoplication + parietal cell vagotomy + stricturoplasty (of scarred strictures).

### ■ Paraesophageal hernia

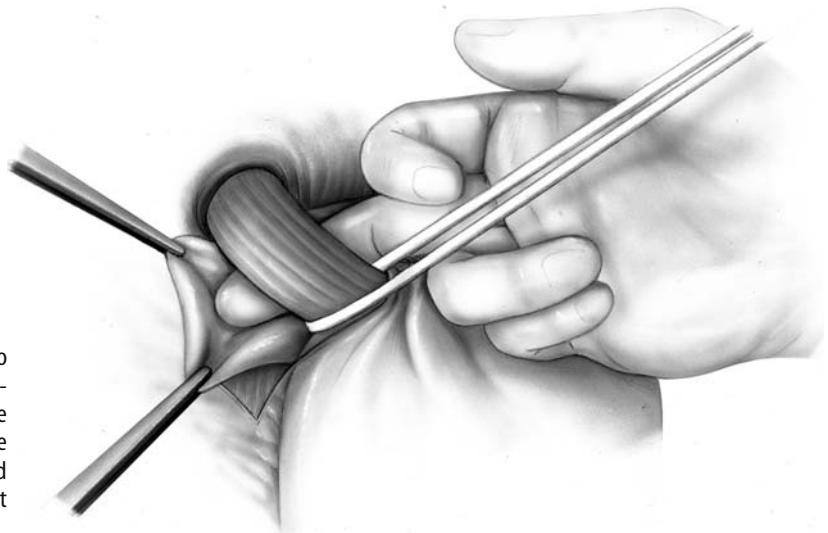
1. Reposition + hiatoplasty + fundophrenico- and if necessary anterior corporexia
2. Reposition + hiatoplasty + Lig. teres plasty
3. Reposition + hiatoplasty + fundoplication (in presence of concurrent reflux disease)



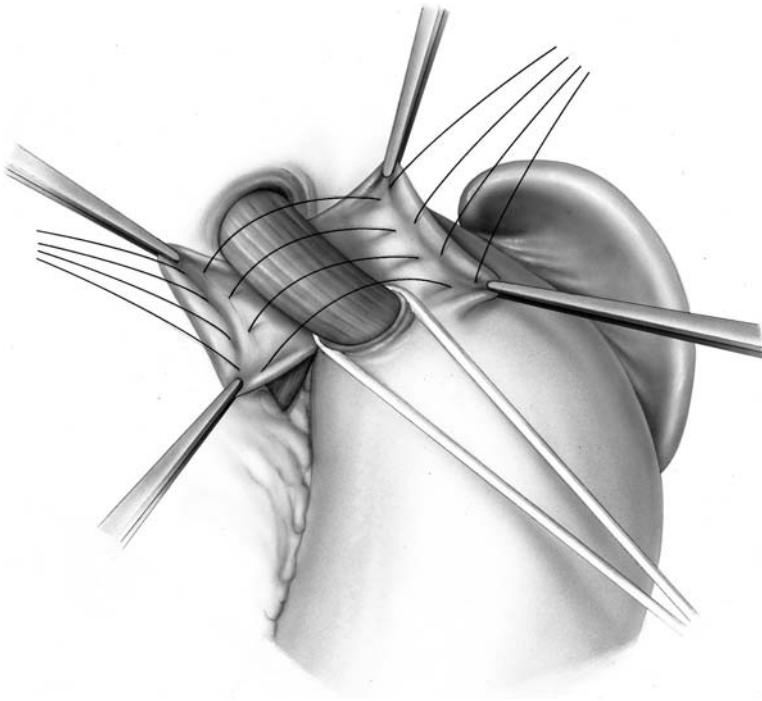
**Fig. 24.1.** Approach by median upper abdominal laparotomy. Alternatively the upper abdomen can be exposed by a left subcostal incision or an upper abdominal transverse incision. A *Rochard* retractor provides excellent exposure of the epigastrium.



**Fig. 24.2.** Fundoplication according to Nissen-Rossetti. The distal esophagus is enlarged. The cardia, the distal esophagus, and the gastric fundus are mobilized preserving the vagus nerve and the spleen. Dissection of the greater curvature is not mandatory, but can facilitate the easy formation of a loose, “floppy” fundoplication.

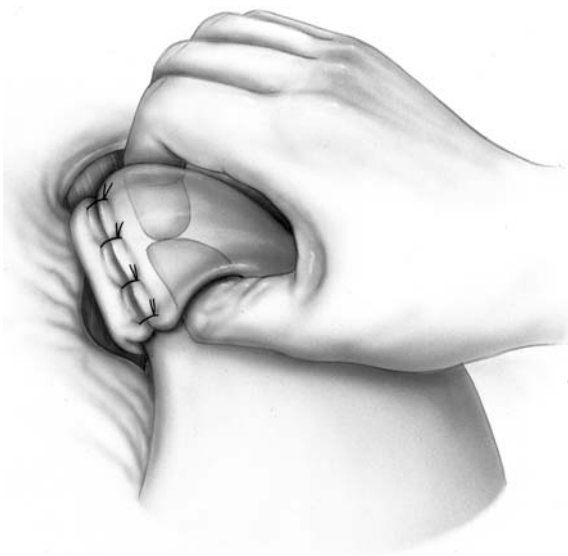


**Fig. 24.3.** Fundoplication according to Nissen-Rossetti. A retro-esophageal window is created to pass the fundus to the right side. It is transposed so far that the anterior wall can be wrapped around the distal esophagus loosely without any signs of tension.

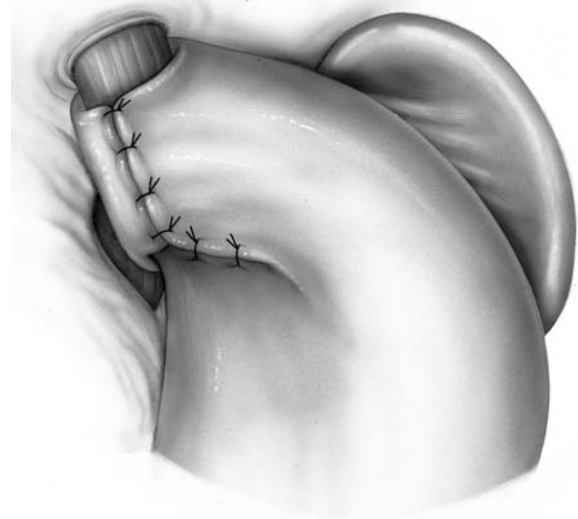


**Fig. 24.4.** Fundoplication according to Nissen-Rossetti. The fundoplication is formed by unifying the two cuff-folds of the anterior fundus wall and fixed by three, maximally four,

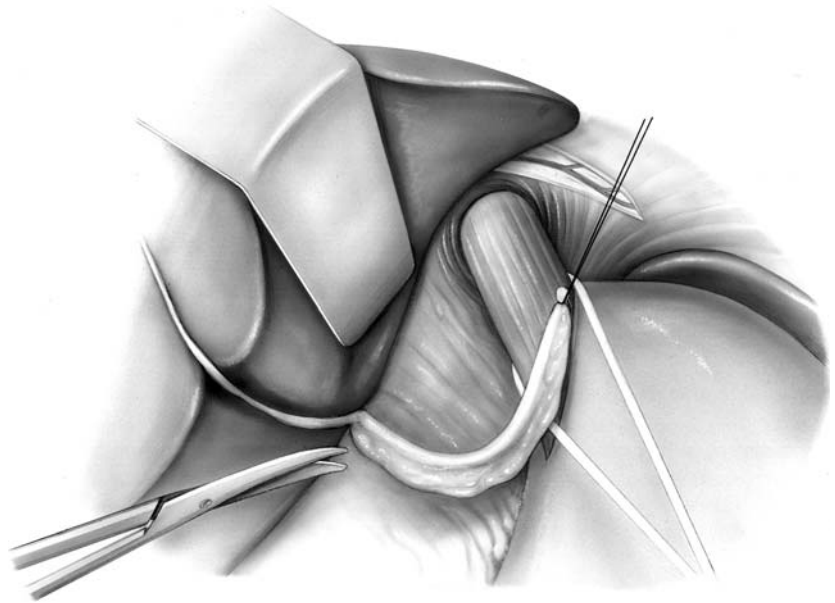
non-absorbable sutures. At least one suture should partially grab the esophageal wall to prevent a telescope phenomenon.



**Fig. 24.5.** The stomach encircles the distal esophagus building a loose cuff (“floppy-Nissen”) to avoid postoperative dysphagia.

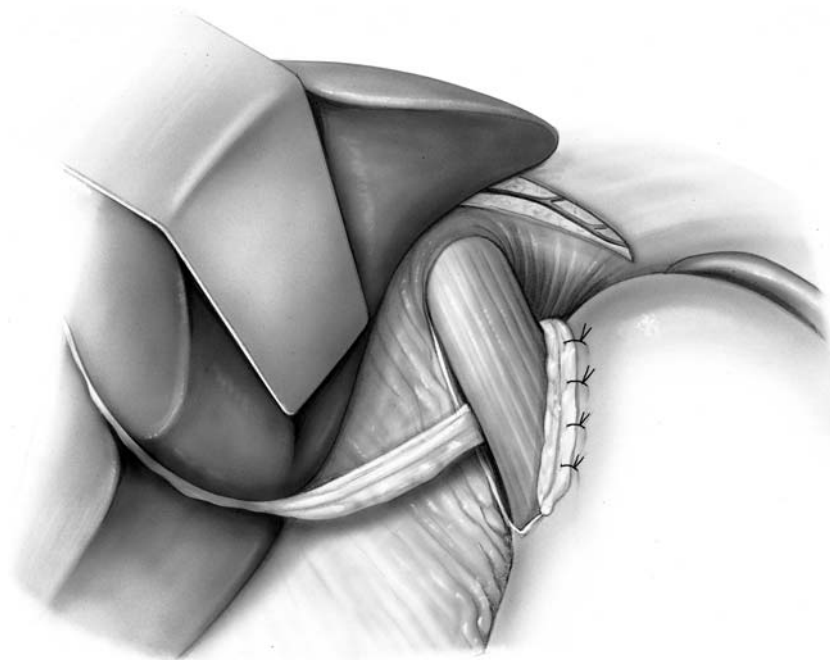


**Fig. 24.6.** Finally the anterior cuff-fold is secured with two sutures to the stomach to prevent slippage.



**Fig. 24.7.** Ligamentum teres (round ligament) plasty. After completion of the dissection of the esophagogastric junction and enlacement of the esophagus with a rubber band the round ligament is carefully dissected from the abdominal

wall and from the liver, respectively. Special attention has to be drawn to thoroughly preserving the ligament at laparotomy. The free end of the ligament is transposed dorsally around the esophagus coming from the right side.



**Fig. 24.8.** Ligamentum teres plasty. Finally the ligament is attached to the stomach anterior wall under relative tension using three or four non-absorbable sutures.



## Techniques in peptic stricture and hiatal hernia

A. F. CHERNOUSOV, P. M. BOGOPOLSKI, K. A. GAWAD

### Peptic stricture of the esophagus

#### ■ Indications

- Treatment failure of conservative therapy including endoscopic dilatation
- In the case of suspected carcinoma of the gastroesophageal junction
- Simultaneous occurrence with a disease of the upper gastro-intestinal tract as duodenal ulcer or cholecystolithiasis etc.
- Failed previous anti-reflux surgery or cardioplasty and in cases of poor outcome of conservative treatment.

#### ■ Contraindications

No special contraindications.

#### ■ Special surgical preparation

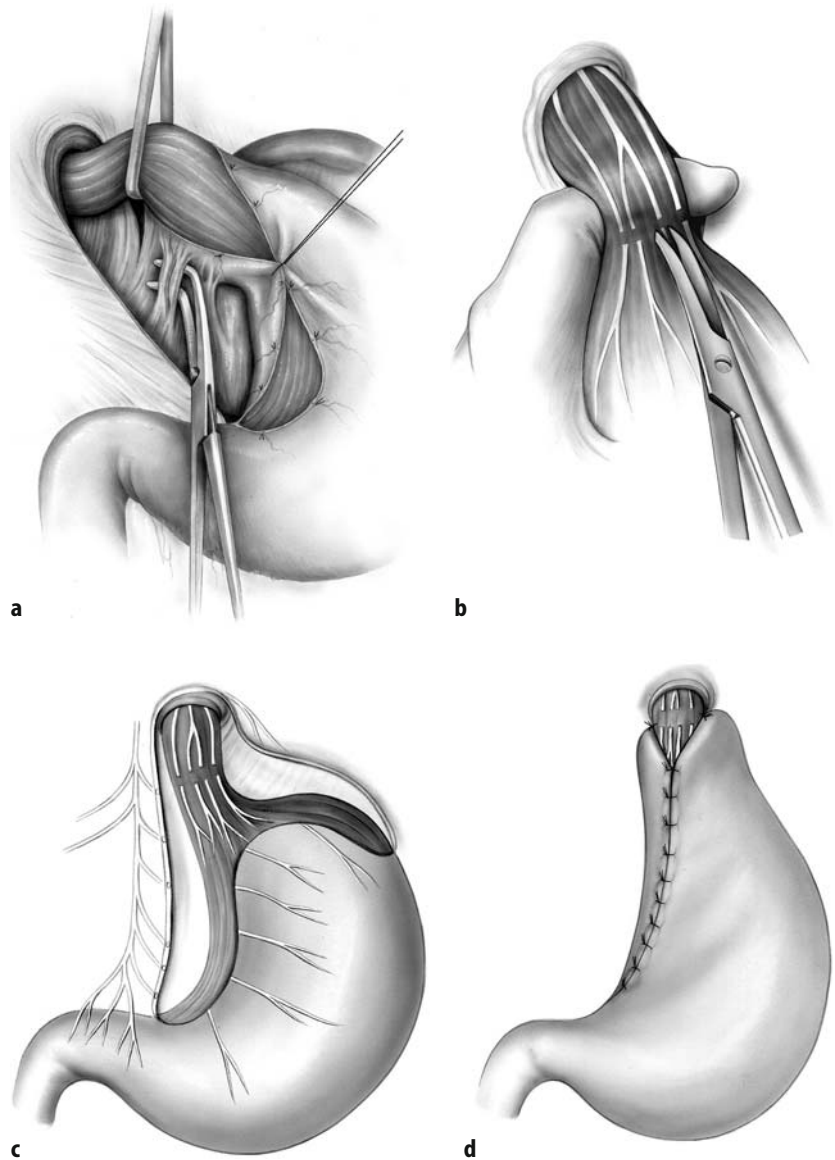
Endoscopic dilatation to achieve a transitory pre-operative remission of the complaints. Conservative anti-reflux therapy.

■ **Anesthesia.** General anesthesia.

■ **Positioning on the operation table.** See chapter 13.

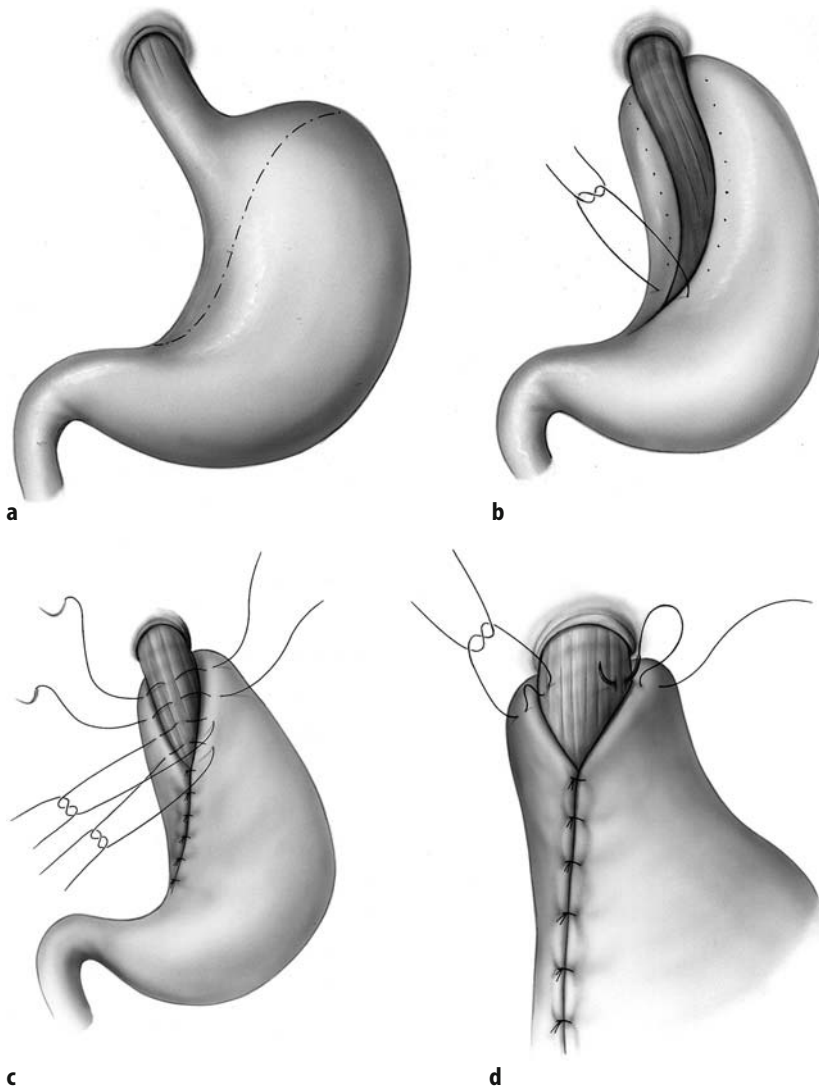
■ **Type of incision.** Median laparotomy.

■ **Special instruments.** See chapter 13.



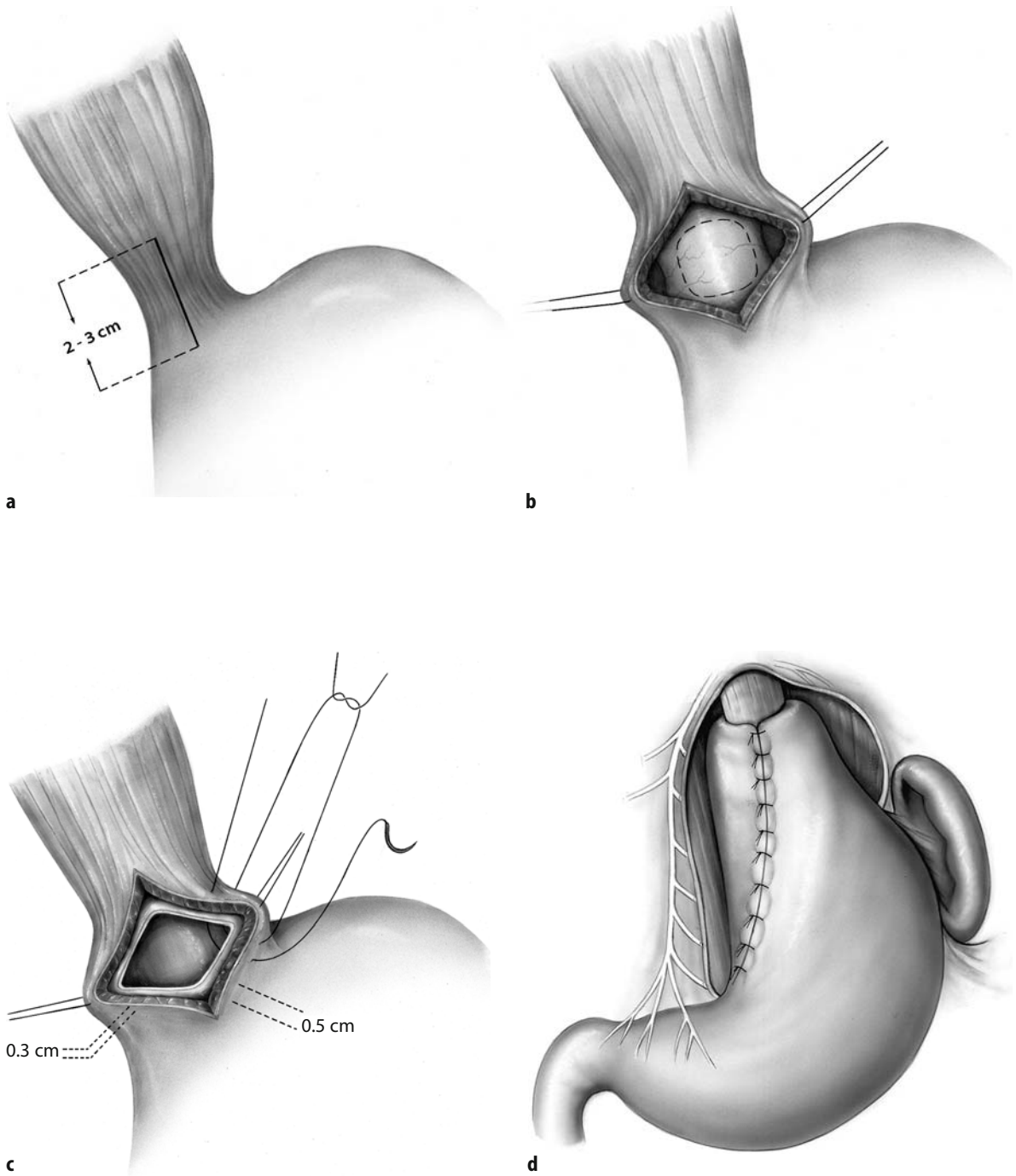
**Fig. 24.9a–d.** Peptic stricture of the esophagus. In cases of a peptic stricture with minor scarred alterations of the esophageal wall (“inflammatory stricture”) parietal cell vagotomy combined with a fundoplication is the approved method. **a** Dissection of the esophagogastric junction with mandatory transection of the A. polaris ascendens. The abdominal esophagus is exposed up to 6 cm cranial to the cardia. The

fundus is mobilized up to the short gastric vessels in the area of the hilum of the spleen. **b** A circular myotomy of the abdominal esophagus should be avoided to preserve the contractility of the esophagogastric junction. Only vagal branches which encircle the esophagus are dissected. **c, d** After completion of the parietal cell vagotomy, a modified fundoplication is performed.



**Fig. 24.10 a–d.** Peptic stricture of the esophagus. Performance of the modified fundoplication: During the creation of the cuff the esophagogastric junction should be armed with a large bore gastric tube to prevent the cuff from getting too tight. **a** Along the dashed line the gastric anterior and posterior wall are sewn together. **b** Beginning of the fundo-

plication at the antrum. The esophagus is drawn caudally into the cuff and will be covered by it. **c** The upper four sutures are anchored in the esophageal wall to prevent slipping of the esophagus within the cuff. **d** Two final sutures fix the neck of the cuff to the esophagus.



**Fig. 24.11 a–d.** Peptic strictures of the esophagus. Short stricture of the esophagogastric junction. **a** Longitudinal incision of the esophageal muscle (myotomy). **b** The ends of the incision are pulled aside with corner stitches. The strictured anterior wall is excised (dashed line). **c** The resulting

defect is closed with full thickness single stitches (Vicryl 3/0) in a single row. **d** Following parietal cell vagotomy, the suture line is covered again by a fundoplication as mentioned above.

## **Hiatal hernia**

### **■ Indications**

Cardiofundal and paraesophageal hernia because of the risk of incarceration, bleeding, or perforation of the hernia.

### **■ Contraindications**

No specific contraindications.

### **■ Special surgical preparation**

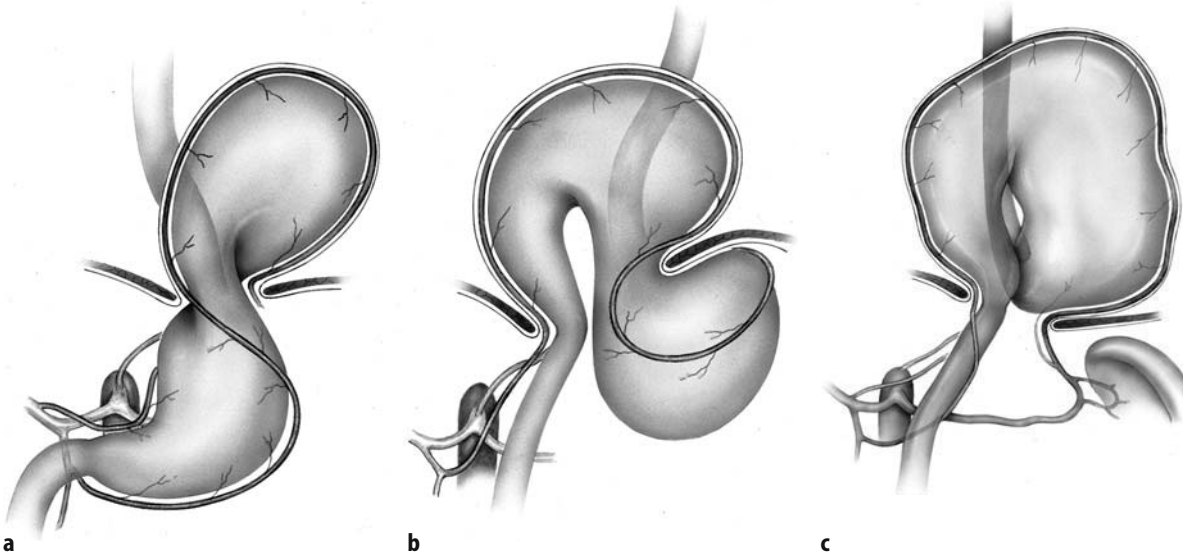
See chapter 14.

### **■ Anesthesia.** General anesthesia.

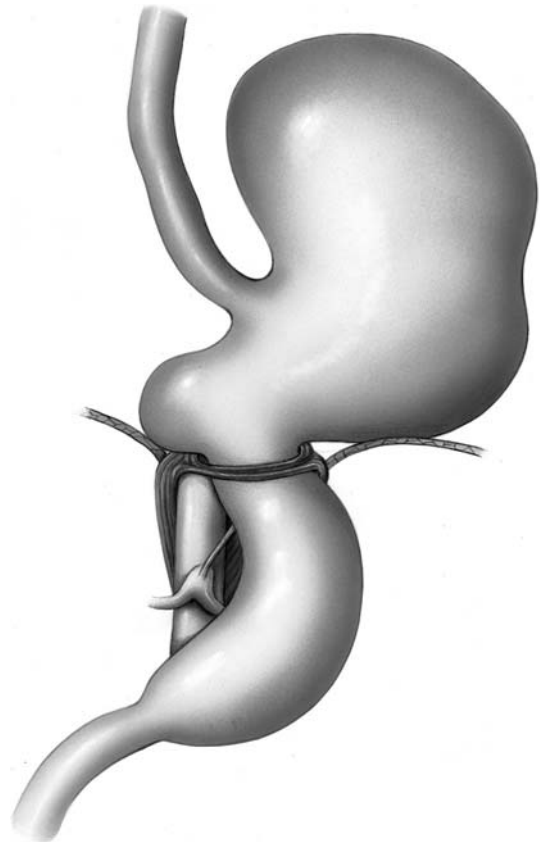
### **■ Positioning on the operation table.**

See chapter 14.

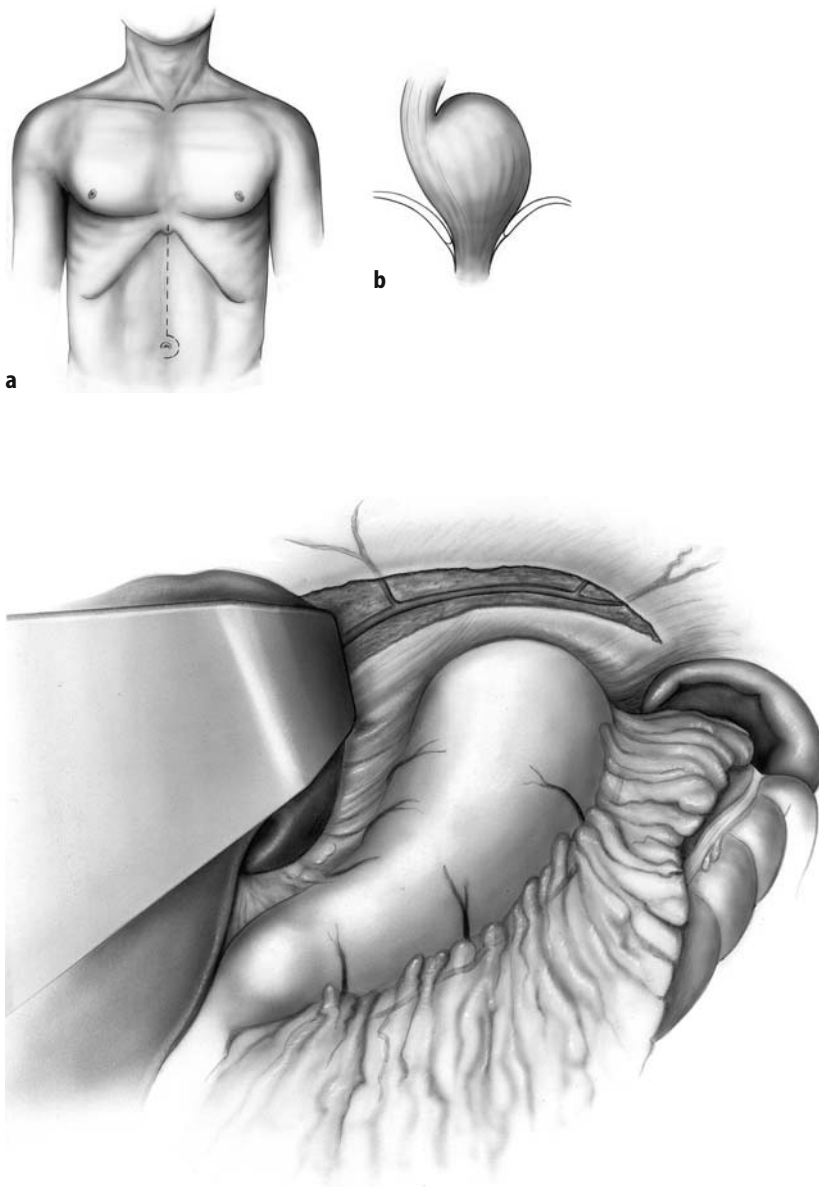
### **■ Type of incision.** Median laparotomy.



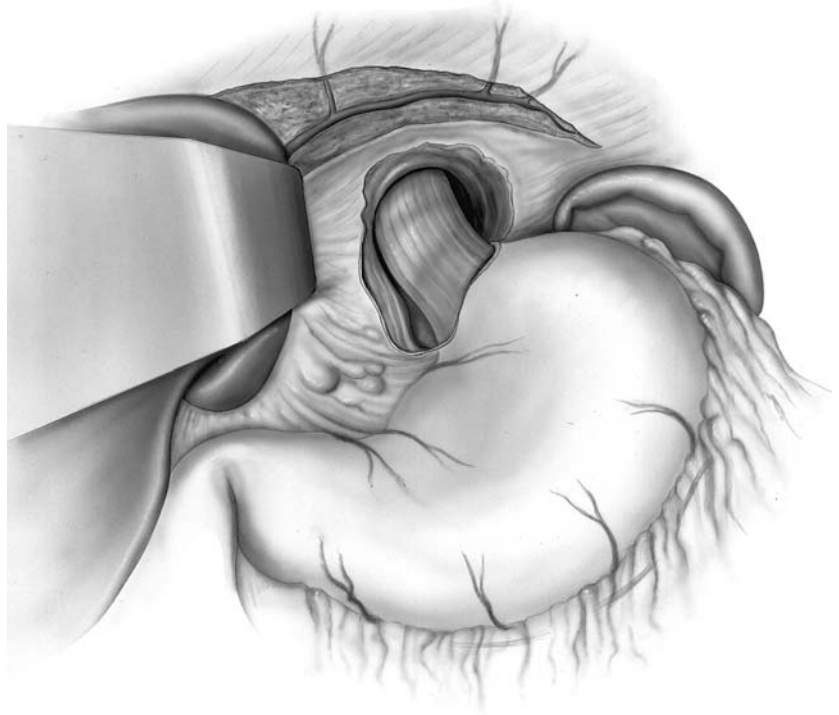
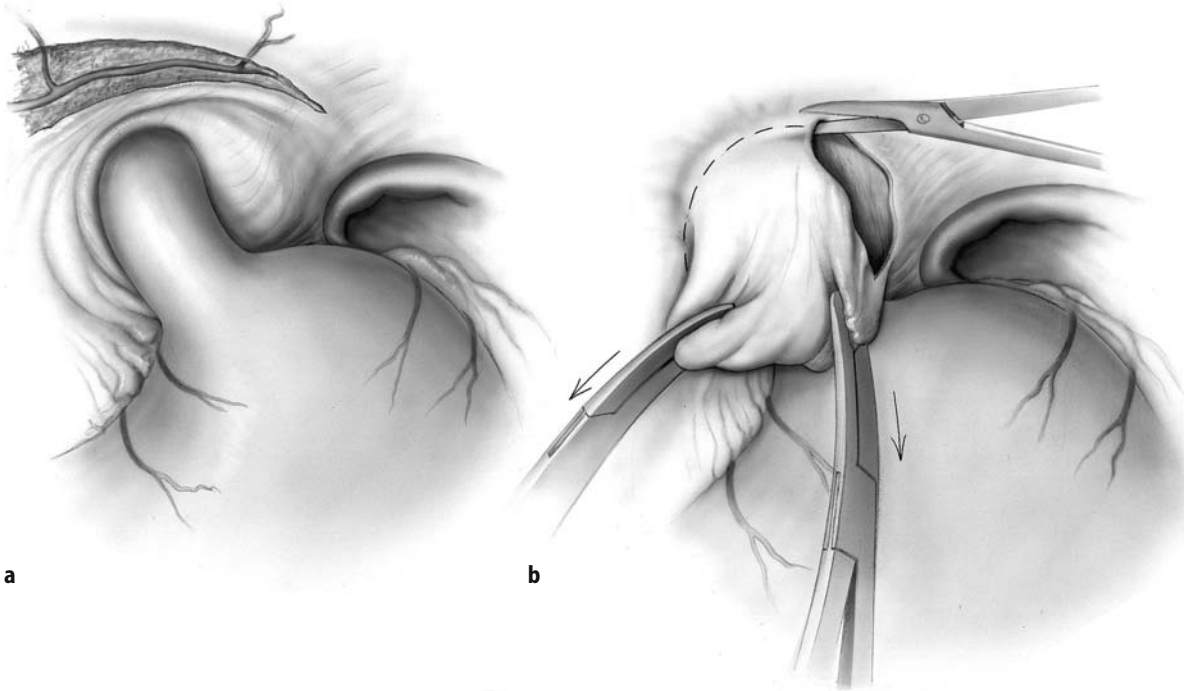
**Fig. 24.12a–c.** Paraesophageal hernia. Paraesophageal hernias lead to a partial or total gastric volvulus. **a** The most common type is the proximal partial gastric volvulus with rotation and prolapse of a proximal fundus; **b** rare type with rotation and prolapse of a distal gastric sector and generation of a functional gastric outlet obstruction; **c** upside-down stomach.



**Fig. 24.13.** Combined hernia. Combined hiatal hernia with axial sliding of the cardia and para-esophageal component. In both hernia types, a common hiatus is often seen.

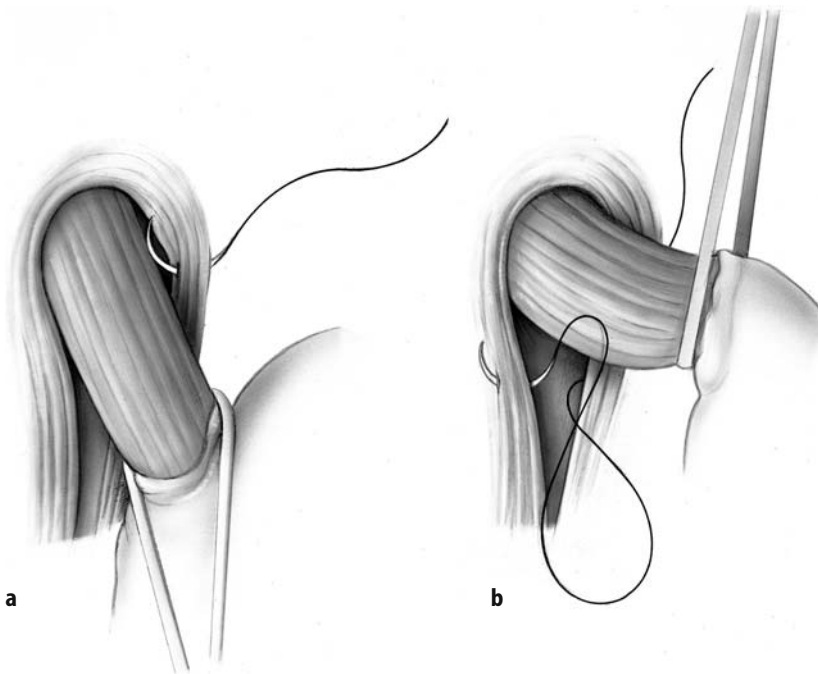


**Fig. 24.14 a,b.** Hiatal hernia. Field after mobilization of the left-lateral lobe of the liver with visible herniation of the gastric fundus into the esophageal hiatus. **a** Section line. **b** Scheme of cardio-fundal herniation.



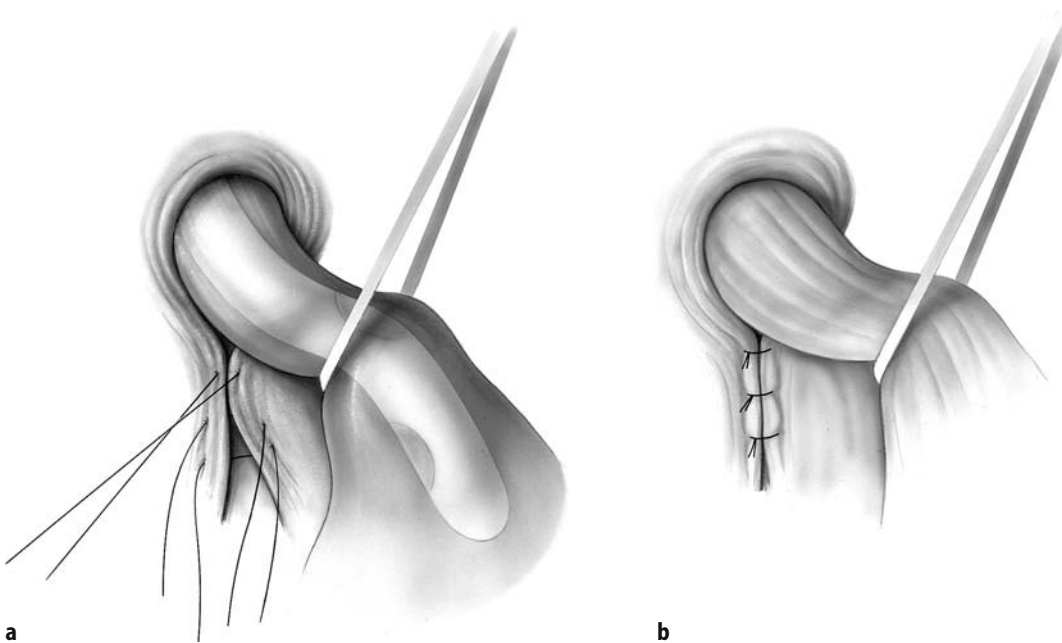
**Fig. 24.15 a, b.** Hiatal hernia. Stomach and esophagus after excision of the hernia sack. **a** The stomach is reduced from the hiatal hernia sack in the dorsal mediastinum. **b** The hernia sack is pulled caudally and excised.





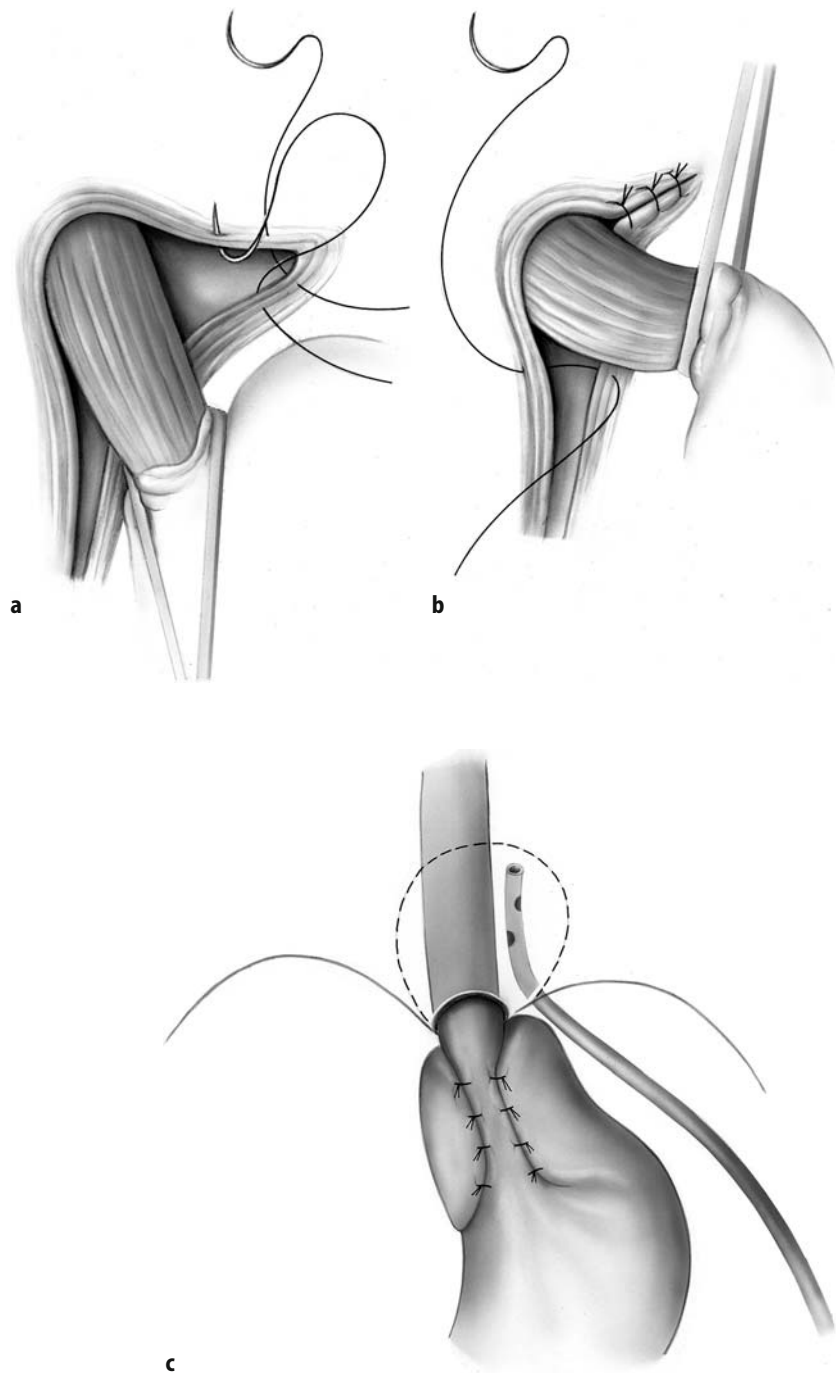
**Fig. 24.16 a, b.** Hiatal hernia. Closure of the hiatus behind the esophagus (posterior hiatoplasty). **a** The first stitch grabs the left crus; **b** the suture is then guided behind the esophagus

and the right crus is grabbed subsequently. When tying the sutures, the esophagus should be armed with a large tube to avoid a stenosis.



**Fig. 24.17 a, b.** Hiatal hernia. The phrenic crura are adapted with three non-absorbable sutures. **a** The large gastric tube is pushed forward into the stomach. The first suture is put

to tension to adjust the diameter of the hiatus. **b** Final view after tying all sutures.



**Fig. 24.18a–c.** Hiatal hernia, bilateral hiatoplasty for very large hernias. **a** If the esophageal hiatus is distinctively wide open after resection of the hernia sack, a hiatoplasty with two suture rows becomes necessary. The first row of sutures is placed to the left and ventral to the esophagus with 3 single sutures. **b** The second row of sutures is placed as mentioned for the posterior hiatoplasty. **c** Finally a partial

fundoplication is used to re-establish the angle of His. The former hernia cavity in the posterior mediastinum is drained. A further drainage can be placed subphrenically. A nasogastric tube should be left in place to decompress the stomach for the first postoperative days. During this operation neither the esophagus nor the gastric cuff should be fixed to the diaphragm.

Esophageal diverticula are rare. They can be either local or generalized, with local circumscript diverticula being the most common types. According to their location they are divided into: Cervical/pharyngoesophageal, para-bronchial/mid-thoracic, and epiphrenic diverticula.

Functional problems with regurgitation of meals and foetor ex ore are common in those patients. Dysphagia is the most common reason for surgical treatment. Endoscopic treatment might be possible for cervical diverticula (see chapter 30).

## ■ Indications

- Diverticulitis
- Dysphagia
- Regurgitation
- Perforation
- Mediastinitis
- Bronchial fistula.

## ■ Contraindications

General.

## ■ Special preoperative preparations

Gastric or duodenal nutrition tube for patients with large diverticula and severe dysphagia. Systemic intravenous antibiotic therapy for patients with complications as perforation, fistula, and mediastinitis.

## ■ Anesthesia

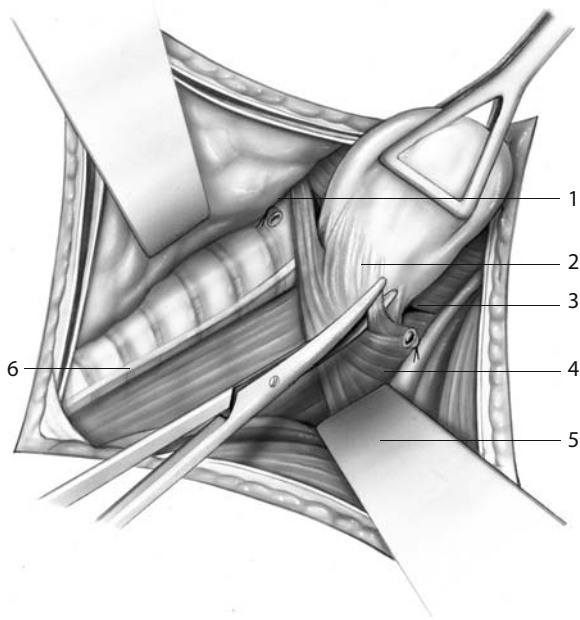
- Endotracheal intubation
- Perioperative antibiotic prophylaxis.

## ■ Positioning

- *Cervical diverticula*: Positioning of the patient on his back. The head of the patient is to be reclined and turned to the right side.
- *Mid-thoracic/mid-esophageal diverticula*: Positioning of the patient left sided, position for right anterolateral thoracotomy between the 4th and the 5th rib.
- *Epiphrenic diverticula*: Positioning of the patient in left-sided position for right anterolateral thoracotomy between the 5th and the 6th rib. If the diverticulum goes to the left side (very rare), the patient is to be positioned on the right side.

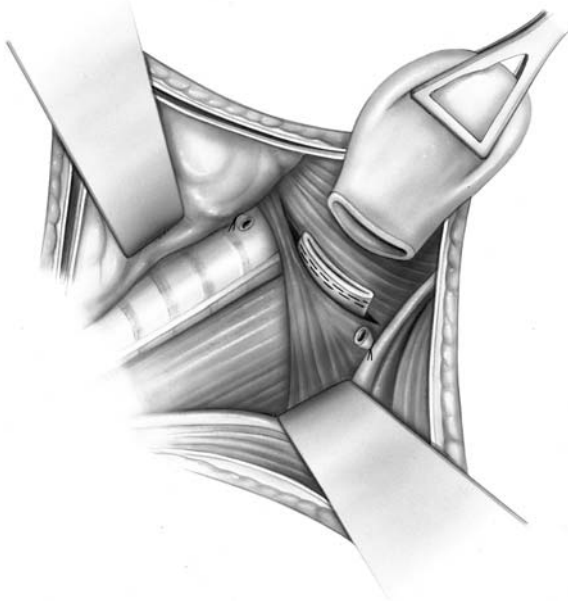
## ■ Zenker's/cervical diverticulum

The pharyngoesophageal diverticulum occurs in about 70% of all cases with esophageal diverticula (1:15000). It was first described by Ludlow and Zenker consecutively, initially defining and showing the correct anatomical position. The main localization is the Kilian triangle (first described in 1908 by Kilian and in 1950 by Negus), e.g. the weak muscular region above the cricopharyngeal muscle. The Laimer's triangle is a far less common anatomical localization of the diverticulum. The diverticula are mostly located on the left side of the patients' neck. Big diverticula appear to be in the midline. One of 60 patients with dysphagia might have a cervical esophageal diverticulum. Patients normally present in advanced age (male > female).

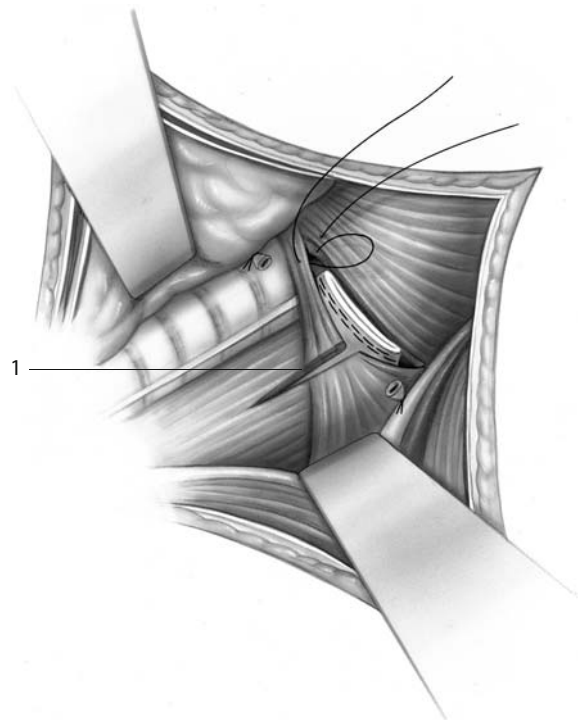


**Fig. 25.1.** Zenker's diverticulum. **1** Stump of the ligated upper thyroid artery; **2** diverticulum in the Kilian's triangle (between cricopharyngeal muscle and pharyngeal constrictor muscle); **3** pharyngeal constrictor; **4** horizontal part of the cricopharyngeal muscle; **5** Laimer's triangle (weak muscular portion underneath the cricopharyngeus muscle); **6** recurrent laryngeal nerve.

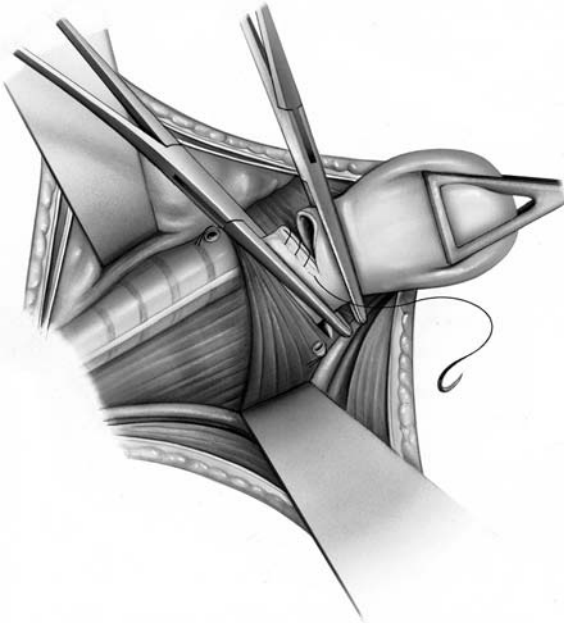
The access is through an incision along the anterior aspect of the sternocleidomastoid muscle. The left lateral wall of the esophagus and of the pharynx is dissected. The esophagus is intubated with a large gastric tube. Ligation of the upper thyroid vessels might be necessary, but this is not mandatory. Under continuous tension the diverticulum is dissected until the neck is exposed.



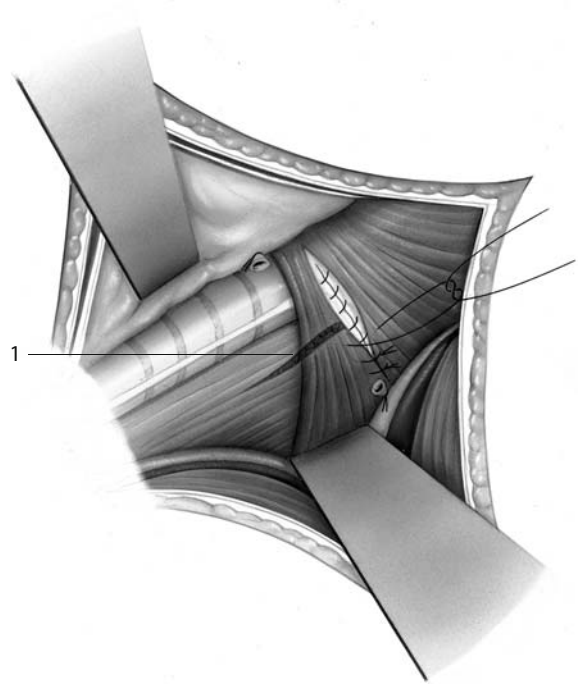
**Fig. 25.2.** Zenker's diverticulum. The diverticulum is transected with a linear stapler in a transverse direction. No tension is to be brought to the mucosa, otherwise stenosis might result after closing the muscular layer by sutures.



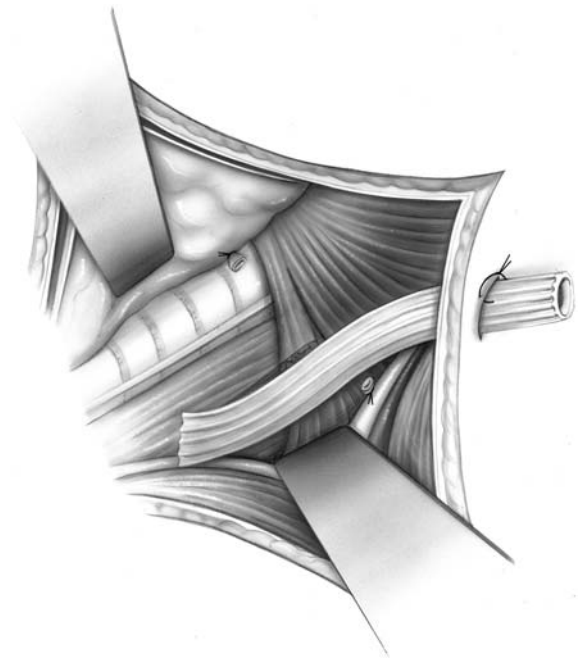
**Fig. 25.3.** Zenker's diverticulum. The pharyngoesophageal muscles are closed by interrupted sutures. Myotomy of the lower pharyngeal constrictor muscle over 2–3 cm is necessary in all cases. **1** Myotomy of the pharyngeal constrictor muscle.



**Fig. 25.4.** Zenker's diverticulum. Alternatively the diverticulum can also be resected between two clamps at its base. The base of the diverticulum should only be touched with a soft bowel clamp. The mucosa of the esophagus should be closed with a running suture above the clamp. The suture should be finished without tension to avoid stenosis of the esophagus.

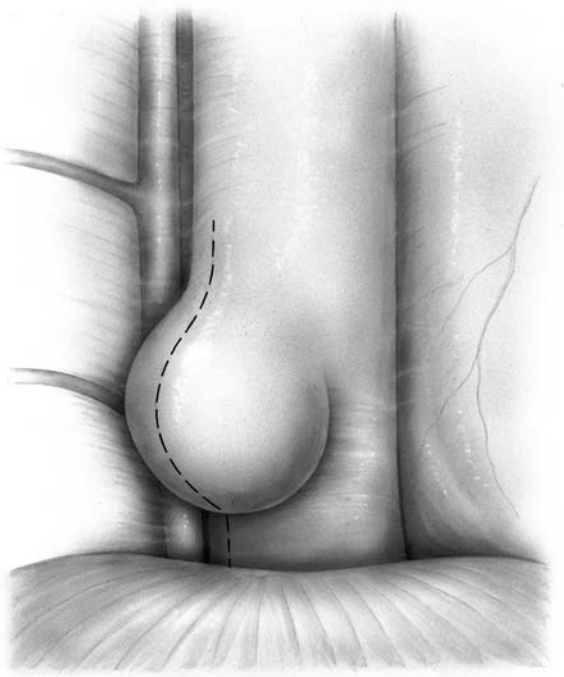


**Fig. 25.5.** Zenker's diverticulum. The pharyngoesophageal muscles is to be closed with single interrupted sutures. Myotomy over 2.3 cm is obligatory. **1** Myotomy of the pharyngeal constrictor muscle.

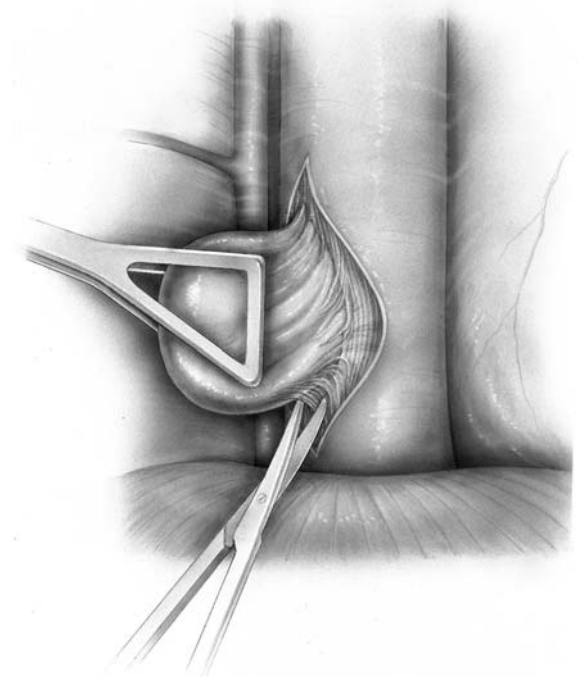


**Fig. 25.6.** Insertion of a soft drain and closure of the wound.

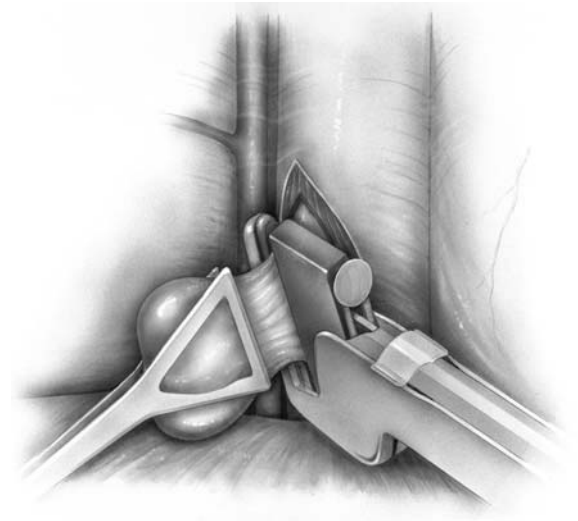
## Epiphrenic diverticulum



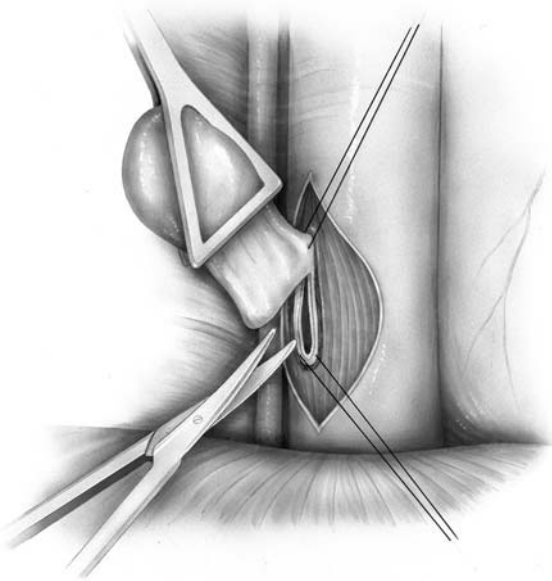
**Fig. 25.7.** Epiphrenic diverticulum. Line of incision of the mediastinal pleura.



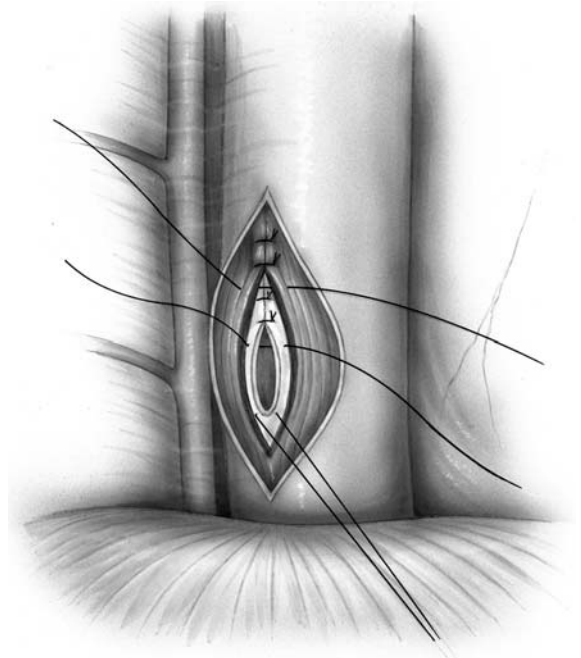
**Fig. 25.8.** Epiphrenic diverticulum. Dissected epiphrenic diverticulum.



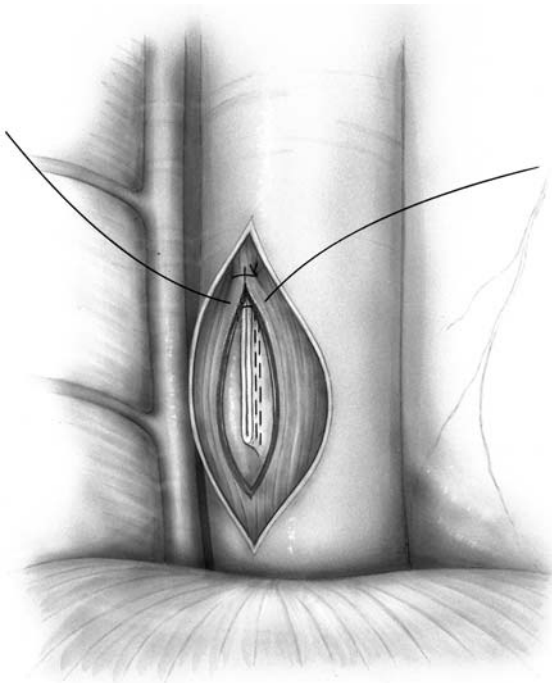
**Fig. 25.9.** Epiphrenic diverticulum. Transection of the diverticulum with a linear stapler. Only slight tension on the base is to be applied to avoid stenosis.



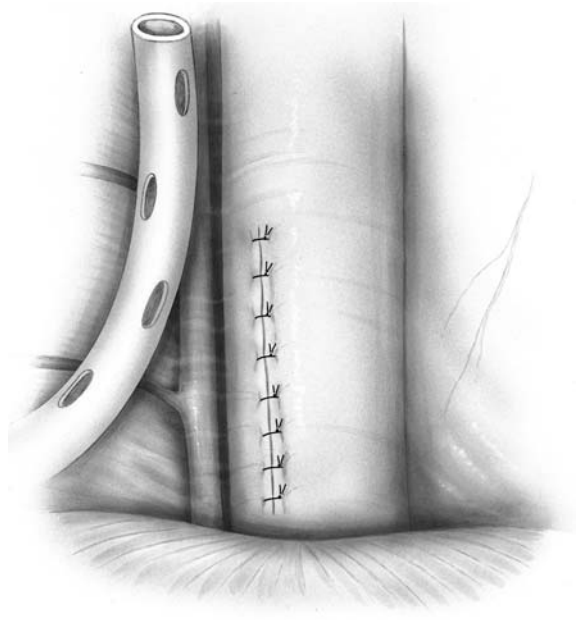
**Fig. 25.10.** Epiphrenic diverticulum. Alternatively, the diverticulum can be transected in an open fashion with scissors after applying stay sutures to both ends.



**Fig. 25.12.** Epiphrenic diverticulum. After the resection of the diverticulum with scissors, the mucosa and submucosa, and afterwards the muscular layer, is closed with interrupted sutures.

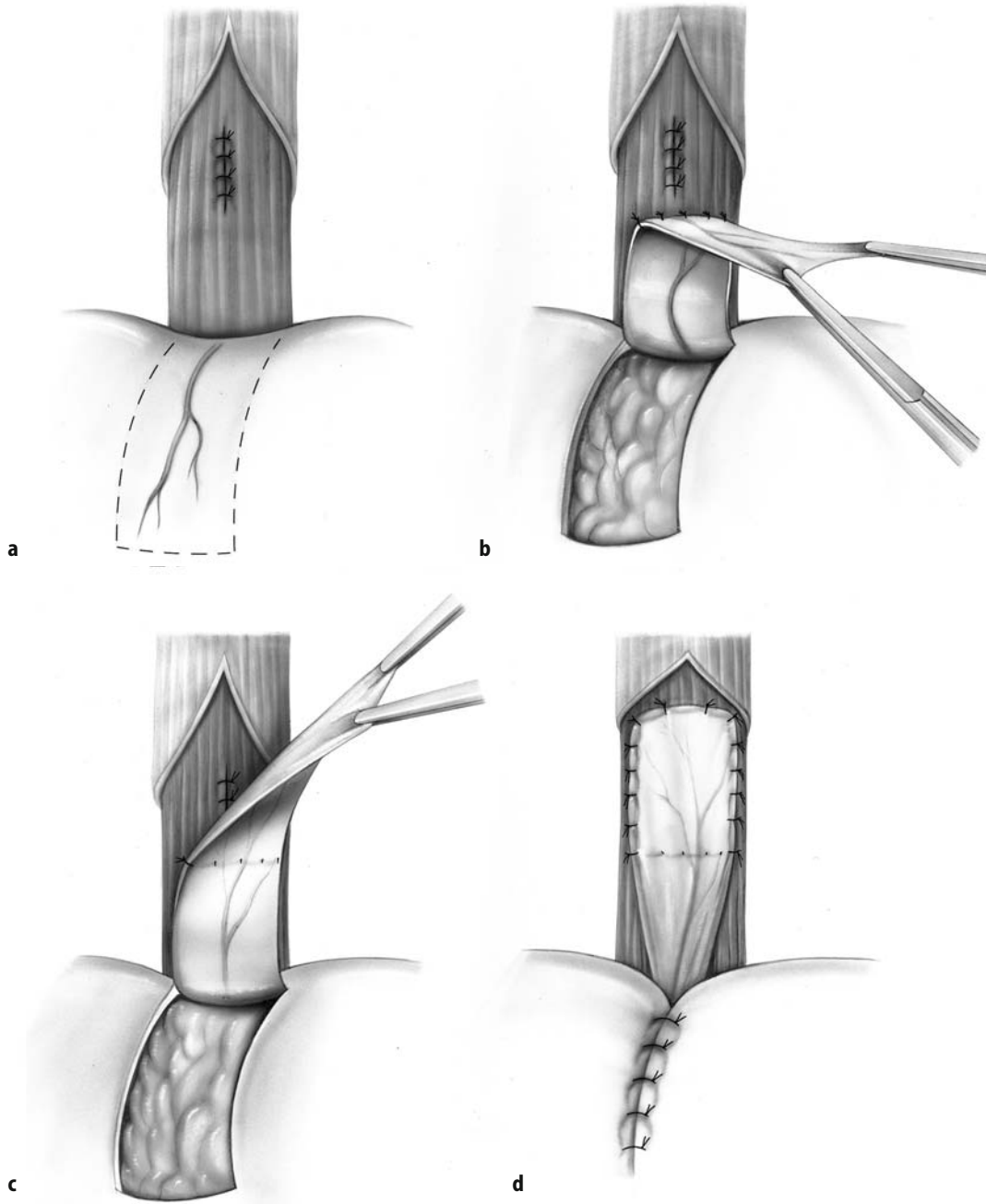


**Fig. 25.11.** Epiphrenic diverticulum. After the resection of the diverticulum with a stapler, the muscular layer is closed with interrupted sutures (Vicryl 3/0).



**Fig. 25.13.** Epiphrenic diverticulum. The sutures are covered with a pleural flap. The thoracic cavity is drained with a drainage.

### Preparation of a diaphragmatic flap for enforcement of the esophageal wall after resection of an epiphrenic diverticulum



**Fig. 25.14 a–d.** For sufficient viability the phrenic flap should have a vessel at the base of the graft (a). The graft is fixed circularly to the esophagus with interrupted sutures (b, c). View of the graft after fixation (d). The esophageal

wall is enforced by the diaphragmatic flap. The defect on the diaphragm is closed. Gastric decompression is necessary with a gastric tube as well as the drainage of the pleural cavity.



## ■ Indications

- Tumor of unclear dignity
- Risk of malignant potential
- Ulceration
- Dysphagia.

## ■ Contraindications

General.

## ■ Special preoperative preparations

- General
- An endoscopic biopsy of the tumor is not recommended because it prevents the tumor resection without incision of the esophageal lumen.

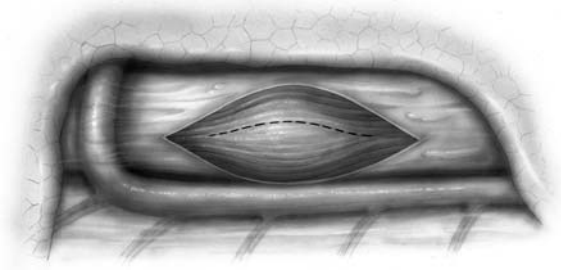
■ **Anesthesia.** Endotracheal intubation.

■ **Positioning and surgical approach.** It depends on the tumor's localization as described in chapter 25.

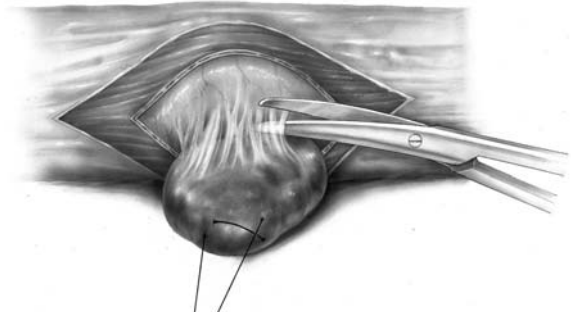
## ■ Leiomyoma of the thoracic esophagus

Leiomyomas localized at the abdominal esophagus were excised analogous to the approach described above.

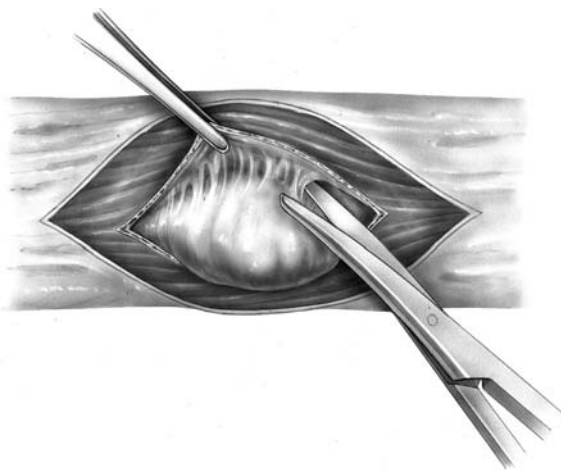
However, a subsequent fundoplication amplifies the esophageal sutures. Extremely rare large leiomyoma which seizes the whole circumference or ranges from the pharynx to the cardia requires a partial or complete resection of the esophagus.



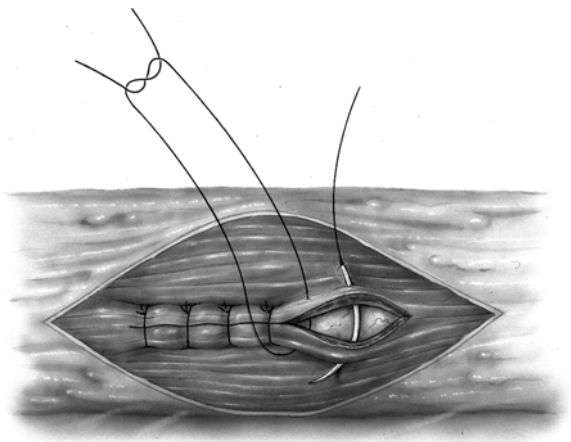
**Fig. 26.1.** Leiomyoma of the thoracic esophagus. Exposition of the thoracic esophagus over a right-sided anterolateral thoracotomy through the 5th ICR and incision of the mediastinal pleura and esophageal muscles above the tumor. Circular preparation is not necessary in most cases and should be avoided. In cases of rare circular tumor extension, complete mobilization of the esophagus has to be done.



**Fig. 26.3.** To perform an atraumatic pull on the tumor a stay suture is placed. Under pull at the stay suture preparation of the esophageal mucosa without injury should be performed.



**Fig. 26.2.** Different steps of tumor nucleation. The muscle layers are separated from the tumor.



**Fig. 26.4.** Occlusion of the muscle layer with button sutures (Vicryl 3/0). The gastric tube and the thoracic drainage should remain for at least two days.

## 27 Surgical Treatment of Esophageal Fistula and Perforation

A. F. CHERNOUSOV, N. ROCH, P. M. BOGOPOLSKI, D. C. BROERING, H. W. SCHREIBER †

Injuries of the esophagus may be caused by mechanical, chemical, and actinic damages. Usually, they are the consequence of a blunt trauma. The exceptions are perforations of the esophagus. Injuries of the esophagus by ingestion of a foreign body arise in physiologic narrow passages (pharyngoesophageal passage, in the middle third of the aortic arch, cardioesophageal passage). A decubitus of the esophagus can be seen if a foreign body remains longer in the esophagus. Diagnostic and therapeutic endoscopy measures may also lead to injuries of the esophagus. Esophagoscopy and bougienage of a cicatricial stricture, especially in an early phase after a corrosive injury, are the most frequent reasons for an iatrogenic perforation of the esophagus. Dilatation of the cardia with the Stark's instrument can cause a laceration and perforation. Complications for pneumatic or hydrostatic dilatation are rarely seen.

An injury of the esophagus is also possible through severe vomiting (spontaneous rupture, Boerrhaave's syndrome), blunt traumas of the neck, the thorax, or the abdomen. Radiation injury of the esophagus is a complication of radiation therapy of malignant tumors of the mediastinum and may lead to the development of esophageal fistulas. Chemical injuries of the esophagus are caused by swallowing acids or lyes. They are divided according to their seriousness:

- Grade 1: Exclusive destruction of the mucous coat.
- Grade 2: Destruction of the mucous coat, the submucosa, and parts of the muscularis.
- Grade 3: Destruction of the complete layers of the esophagus and of the surrounding fat tissue as well as related organs.

The grade of the corrosive injury depends on the quantity and ingredients of the swallowed

chemical substance. After swallowing an acid a coagulation necrosis results, which mostly is limited to the superficial layers of the esophagus. After swallowing lye, a dreaded colliquative necrosis develops, involving almost always all layers of the esophageal wall leading to a perforation. The most feared complication of the corrosive injury of the esophagus is the mediastinitis.

For grade 1-corrosive injury, a healing through epithelization without any consequences is expected. In cases of extended corrosive injuries, a perforation may occur one or two weeks after the ingestion; as late complications a shortening of the esophagus due to cicatricial contracture and ulcerations are described.

An iatrogenic injury of the esophagus is also possible during thoracic operations, for example during a pneumonectomy with a radical lymphadenectomy. In these cases, a perforation of the esophagus by devascularization and consecutive necrosis develops after a period of 1–2 weeks.

Superficial injuries of the esophagus manifest themselves in the form of an upper gastrointestinal bleeding. On the other hand, open or penetrating injuries of the esophagus become symptomatic by neck emphysema, mediastinitis, pleural empyema, or peritonitis. In case of an extensive, fresh injury of the esophagus, a transthoracic or transhiatal esophagectomy is the preferential method for surgical intervention. A direct suture of an intrathoracic injury of the esophagus with an additional augmentation of the suture through a pleural or diaphragmatic flap is not as safe as the esophagectomy. Furthermore, scarred strictures in the area of the direct suture of the esophagus are common late complications of this procedure.


The direct suture of injuries of the intra-abdominal part of the esophagus therefore is much safer to carry out since the suture can be covered and protected by a fundoplication. In the collar area of the esophagus, it is advisable to close the laceration immediately in order to prevent the development of fistulas. If they should form, they should be treated conservatively since they rarely lead to septic complications.

### Fistulas of the esophagus

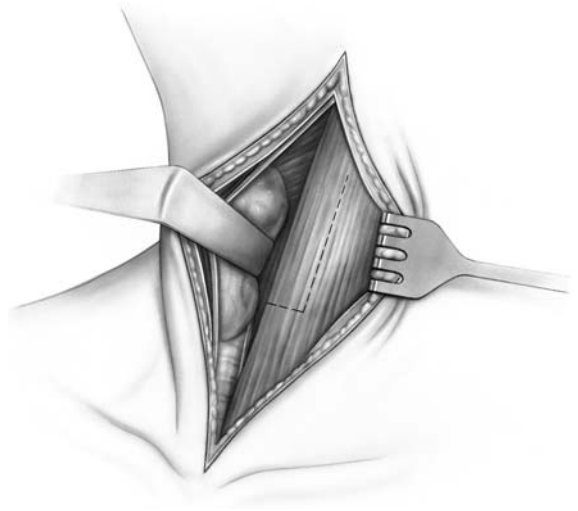
Acquired fistulas of the esophagus may be divided into internal and external fistulas. They can connect the esophagus with tracheobronchial structures, the pleural cavity, and the mediastinum. There is a principle that fistulas of the esophagus are the result of mechanical, chemical, and actinic injuries of the esophagus, of a decubitus caused by foreign bodies, of a perforation of an esophagus diverticulum, tumors, or ulcers. In rare cases fistulas of the esophagus may be healed by an adequate conservative therapy. Palliative operations (esophagostomy and gastrostomy) can also lead to satisfactory results in rare cases. Radical operations such as resection and occlusion of the fistulas mostly require an esophagectomy, a resection of parts of the lung, and decortication. Therefore, they are associated with a high postoperative morbidity.

The main principle of fistula surgery of the esophagus is the occlusion of the esophageal defect of the wall and isolation of surrounding tissue.

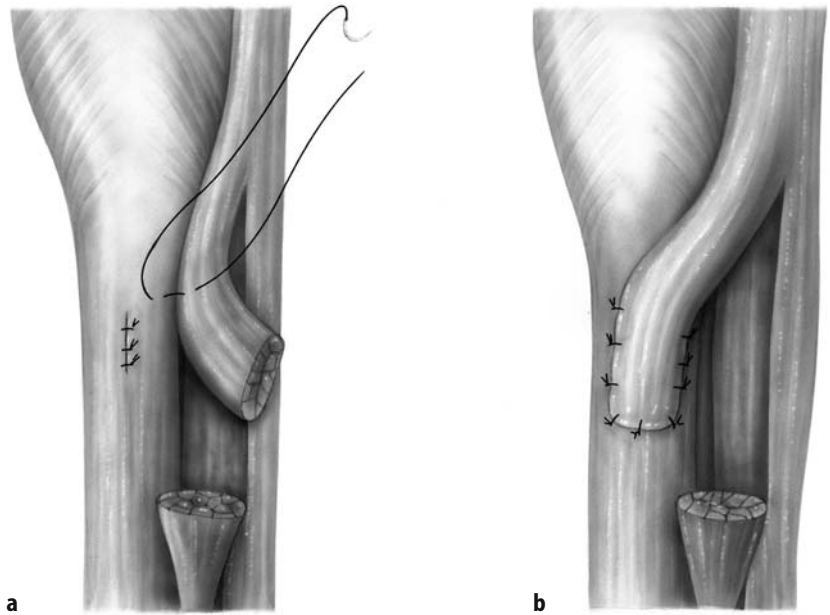
### Cervical fistulas of the esophagus



**Fig. 27.1.** Left-lateral approach to the cervical esophagus along the front edge of the sternocleidomastoid muscle. The fistula is excised and the resulting esophageal defect is closed with two rows of interrupted button-hole sutures.

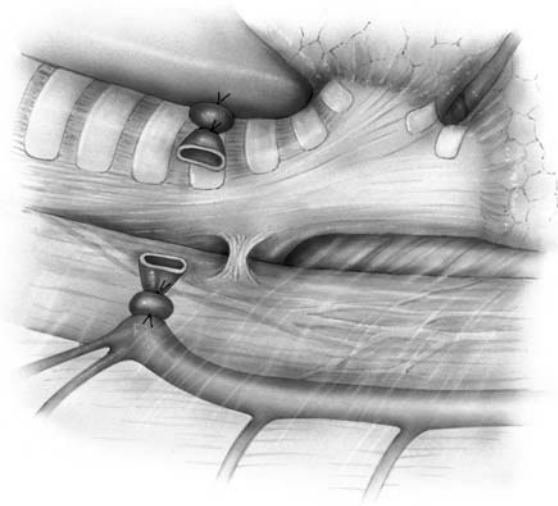


**Fig. 27.2.** To cover the suture of the esophagus, a muscle-flap of the sternocleidomastoid muscle will be prepared.

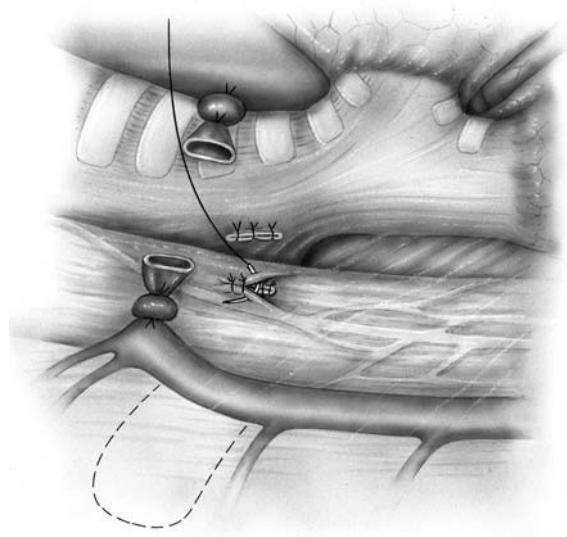


**Fig. 27.3 a, b.** The muscle-flap of the sternocleidomastoideus is fixed circumferentially to the closed fistula.

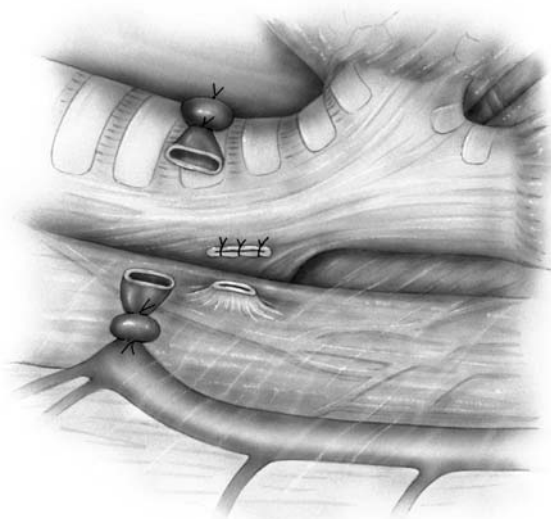
## Intrathoracic esophago-tracheal fistula



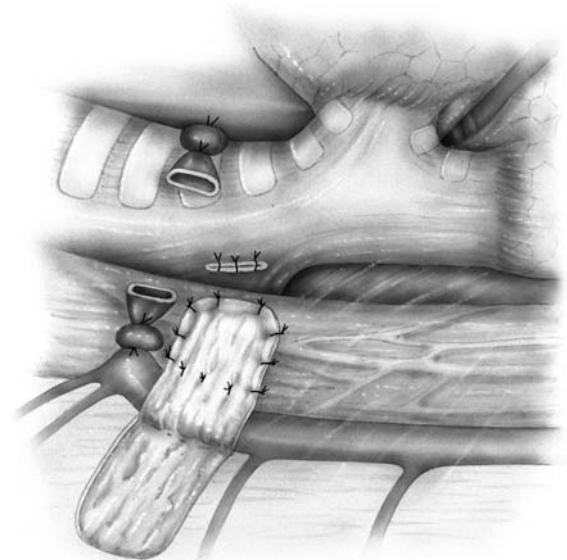
**Fig. 27.4.** Closure of an esophago-tracheal fistula. The fistula is exposed by right-lateral thoracotomy in the 4th or 5th intercostal space. The azygos vein is severed and the ends ligated with transfixing sutures. The fistula is excised.



**Fig. 27.6.** After the excision of the fistula the esophageal defect is closed with two rows of button-hole sutures (Vicryl 4/0).

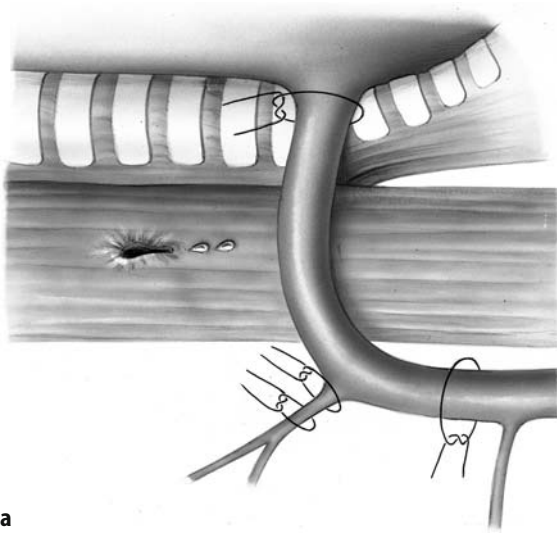


**Fig. 27.5.** Closure of the tracheal defect with one row of button-hole sutures (Vicryl 5/0). The stitches should be 2–3 mm apart.

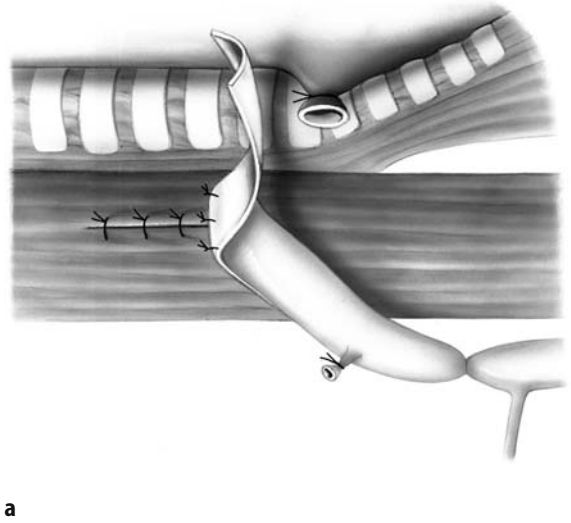


**Fig. 27.7.** The esophagus wall is reinforced by a pedicled flap from the pleura, and the fistula is simultaneously isolated. These operative steps should be carried out only in the presence of a wide lumen naso-gastric probe.

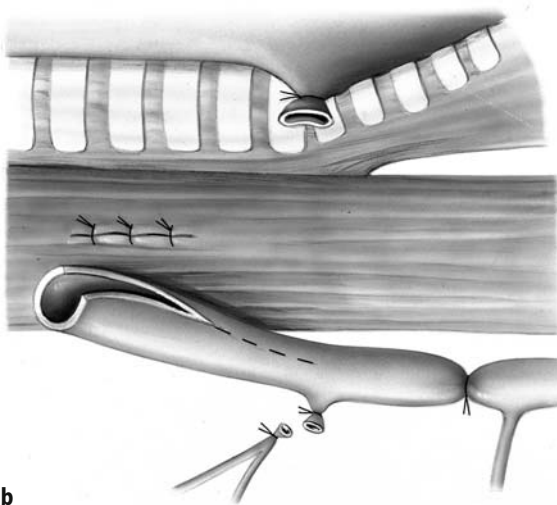
## Intrathoracic fistulas



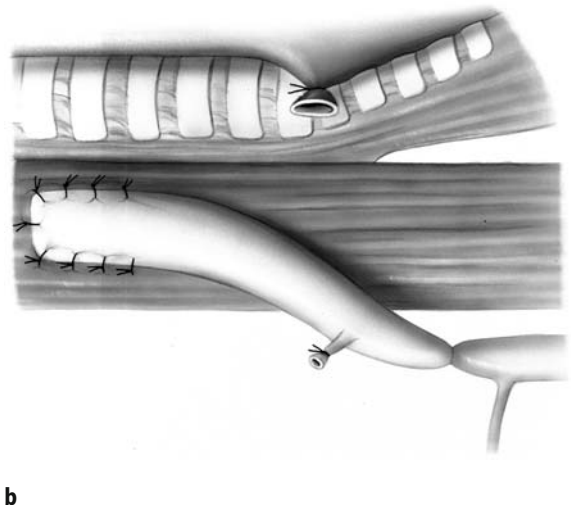
a



a



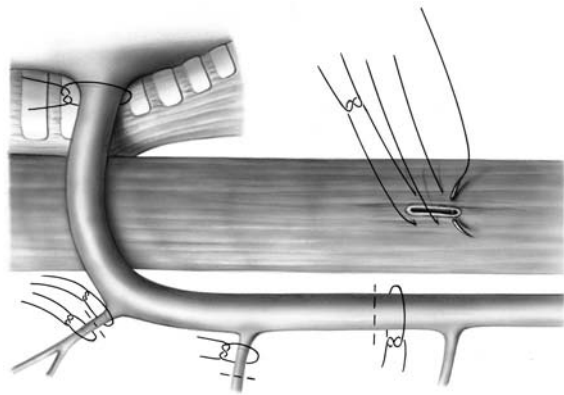
b




b

**Fig. 27.8 a, b.** Perforation in the middle third of the esophagus. Mobilization and dissection of the arch of the azygos vein. A patch is obtained by longitudinal incision of the vein. The esophageal perforation is closed with two rows of interrupted stitches (Vicryl 4/0).

**Fig. 27.9 a, b.** The vein is sutured on the esophageal wall circumferentially around the esophageal suture line. The azygos vein patch is also closed. It is obligatory to provide drainage of the pleural cavity and to ensure intraluminal decompression.



a

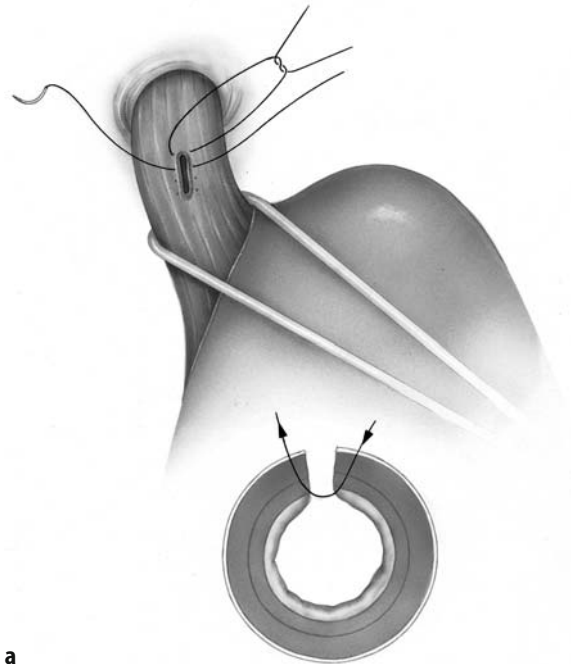


b

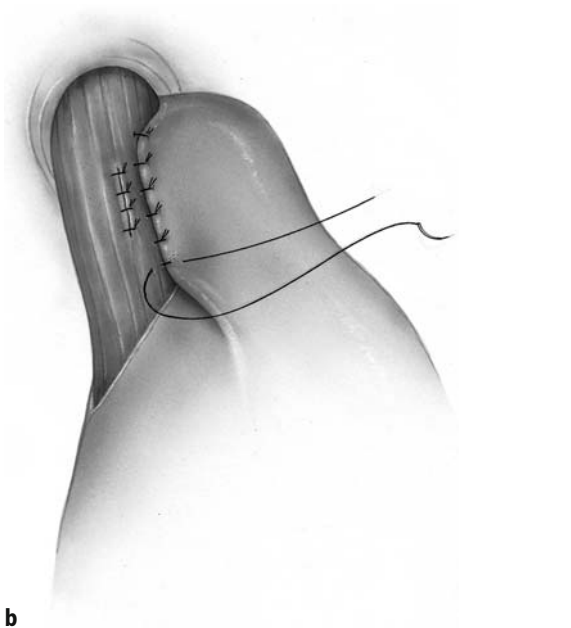
**Fig. 27.10 a,b.** The preparation of the venous patch depends on the location of the perforation. If the perforation is located in the lower segment of the thoracic esophagus, the venous patch must be prepared from the distal segments of the azygos vein. The azygos vein and its tributaries (broken line) are mobilized and dissected; the perforation is closed by suturing the venous patch.

**Fig. 27.11 a,b.** Closure of a perforation of the abdominal esophagus. The perforation is closed with interrupted sutures in two rows. The stitches should be 5 mm apart, and the stitches of the inner row are taken as plan-layer, extramucosal

## Intraabdominal fistulas of the esophagus



a



b

sal sutures. The 'in' and 'out' stitch should be approximately 3 mm away from the wound margin. The scheme also shows the start of the fundoplication for covering the esophageal suture line.



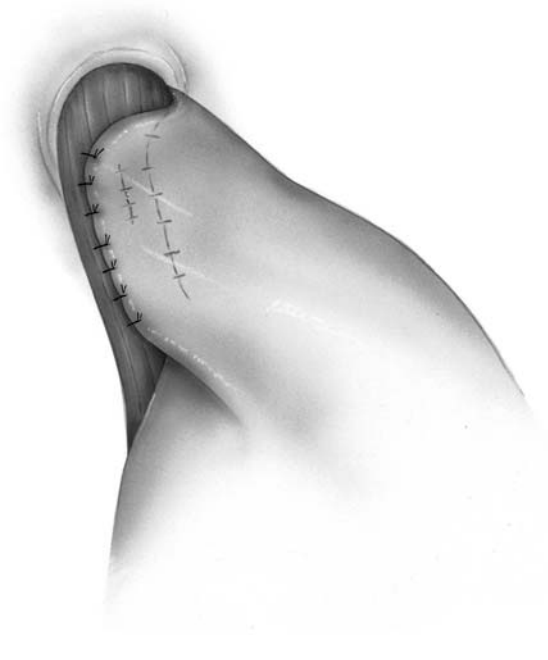

Fig. 27.12

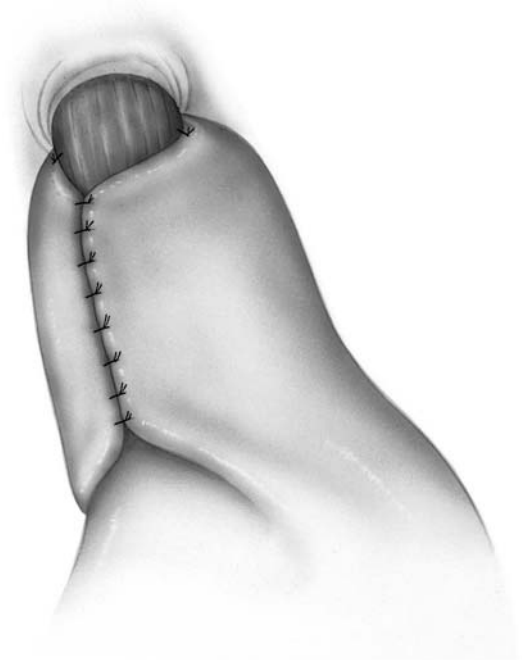


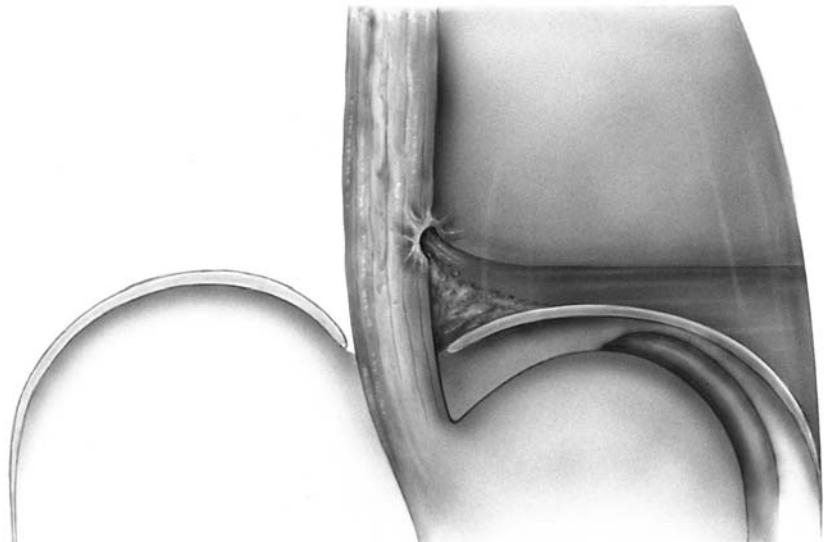
Fig. 27.13

**Fig. 27.12 and 27.13.** The suture line is covered by the anterior wall of the fundus. The suture is fixed in a circle around the perforation stitch (broken line). The posterior

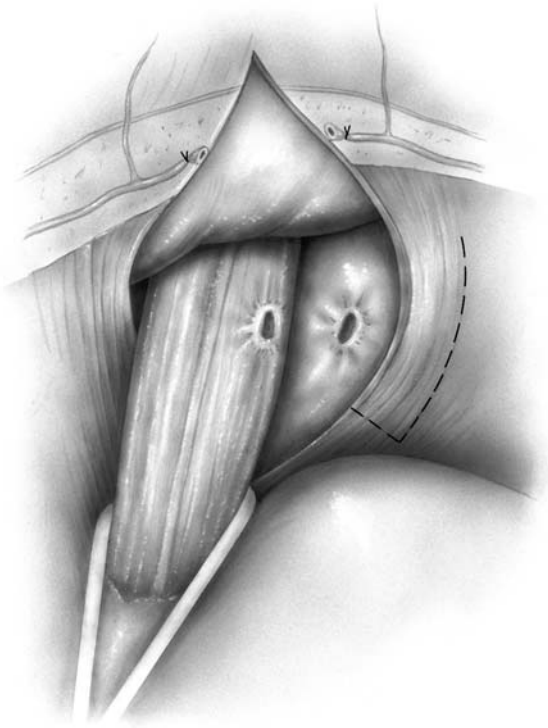
wall of the fundus is put behind the esophagus for plication and sutured ventrally to the esophagus with the pre-fixed anterior wall of the fundus.

## Esophagopleural fistulas

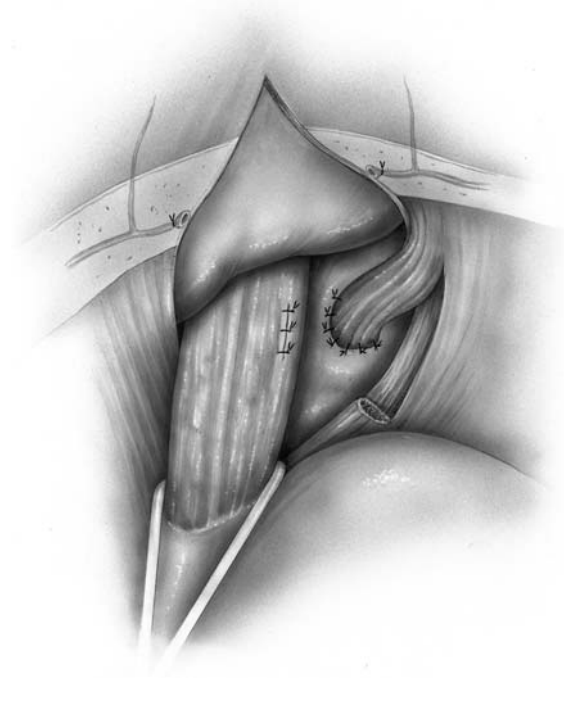
Transhiatal closure of an esophagopleural fistula (fistula of the lower esophageal third).



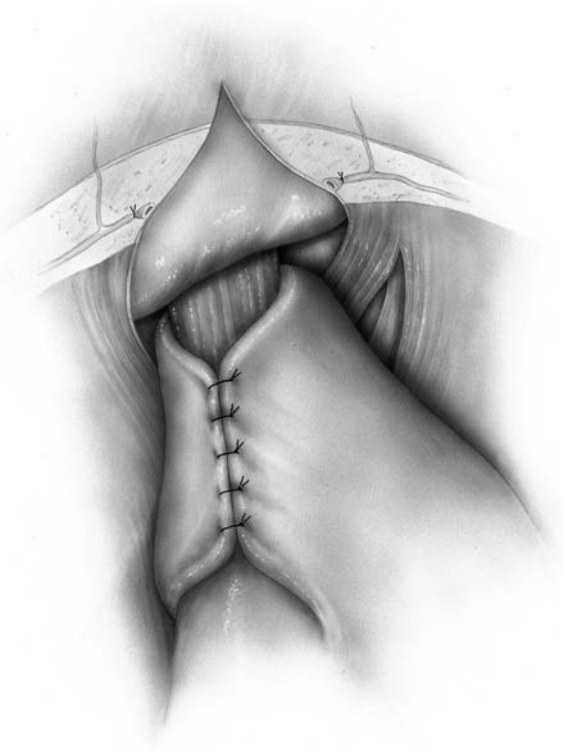
**Fig. 27.14.** Scheme of the esophagopleural fistula.



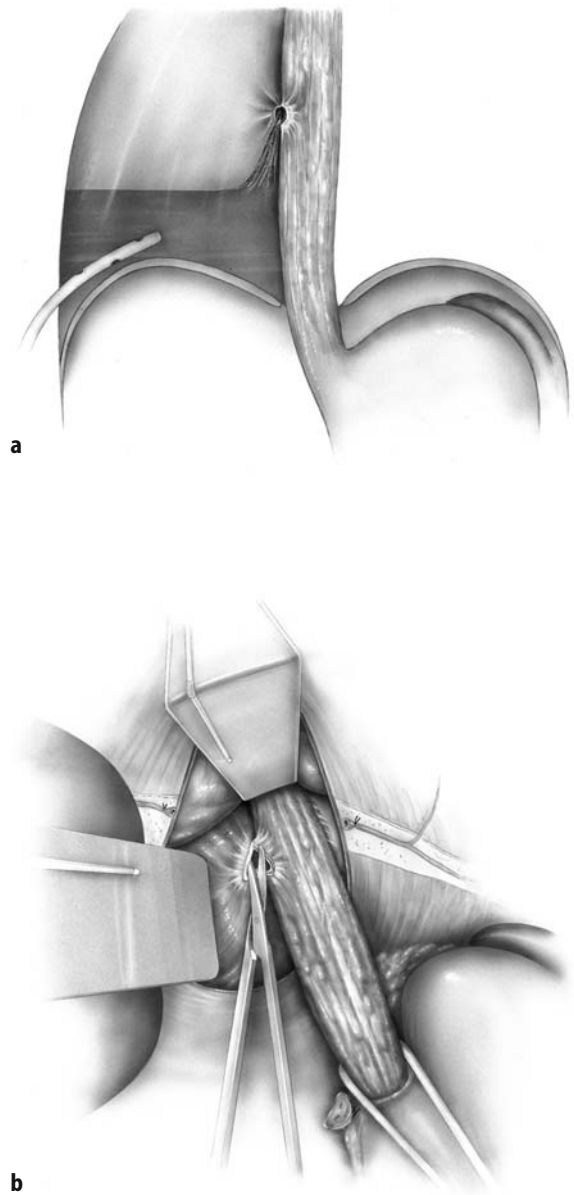
**Fig. 27.15.** Following sagittal diaphragmatomy and abdominal and distal thoracic mobilization, traction is applied to the esophagus in a caudal direction by a soft rubber tube. The fistula is excised.



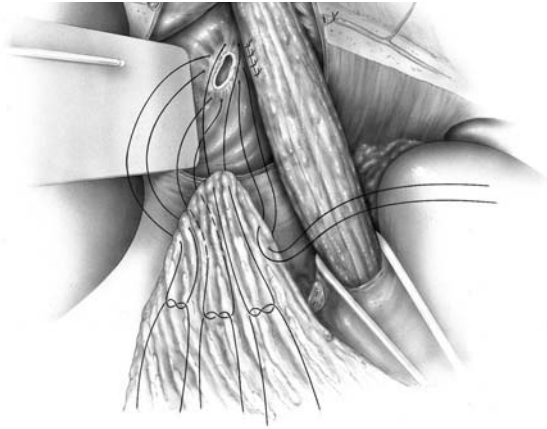
**Fig. 27.16.** The esophageal defect is closed with two rows of interrupted sutures. The defect in the mediastinal pleura is covered by a diaphragmatic pedicled flap.



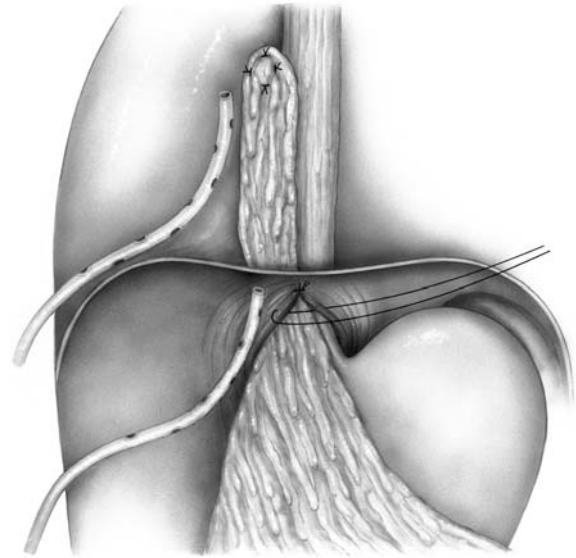
**Fig. 27.17.** As described earlier, the esophageal stitch is reinforced by 360° fundoplication. A drainage is provided for the pleural cavity and the abdomen.



**Fig. 27.18 a, b.** Transhiatal closure of a fistula located in the middle third of the esophagus. Diagram shows the localization of the fistula. The esophagus is mobilized along its right lateral wall, as described in the case of dissection of the transhiatal blunt dissection. Sharp excision of the fistula.



**Fig. 27.19.** The esophageal defect will be closed in two rows with button-hole sutures. The mobilized greater omentum will be fixed circumferentially around the defect in the mediastinal pleura with 4 mattress sutures. The sutures are first inserted and subsequently tied in succession. The pleural defect is separated from the esophageal suture line by the greater omentum flap.



**Fig. 27.20.** Anterior or posterior hiatoplasty.

## ■ Indications

After failure of endoscopic therapies including balloon dilatation and bougienage in cases of

- Short peptic stricture
- Short scarred stenosis.

## ■ Contraindications

- Suspicion of malignancy
- Severe cardiopulmonary insufficiency.

## ■ Risks and informed consent

See chapter 13.

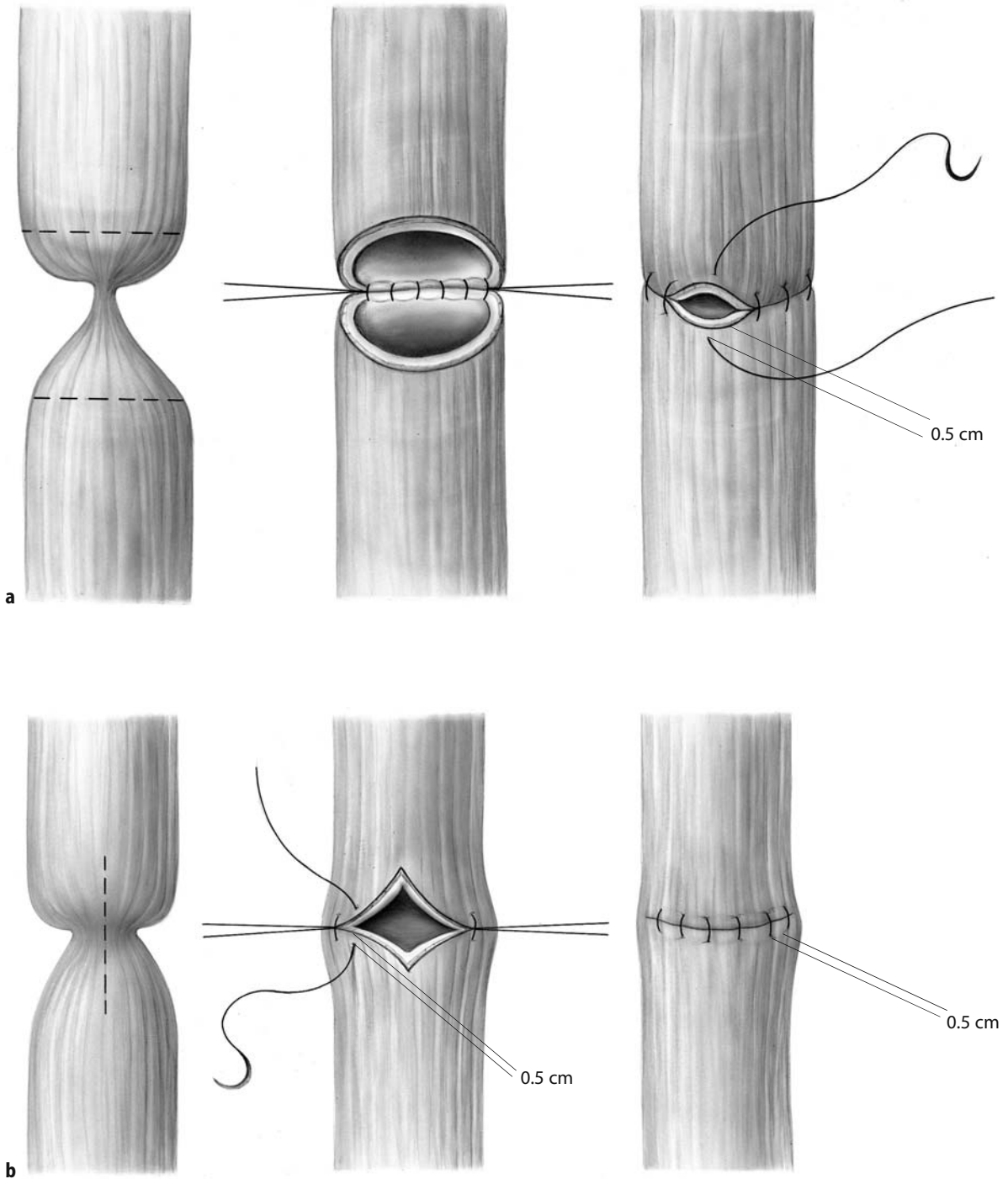
## ■ Special preparation

No peculiarities to the previously mentioned operations.

■ **Anesthesia.** Endotracheal anesthesia, in case of intrathoracic stenosis a tracheal tube with the possibility of separate ventilation should be used.

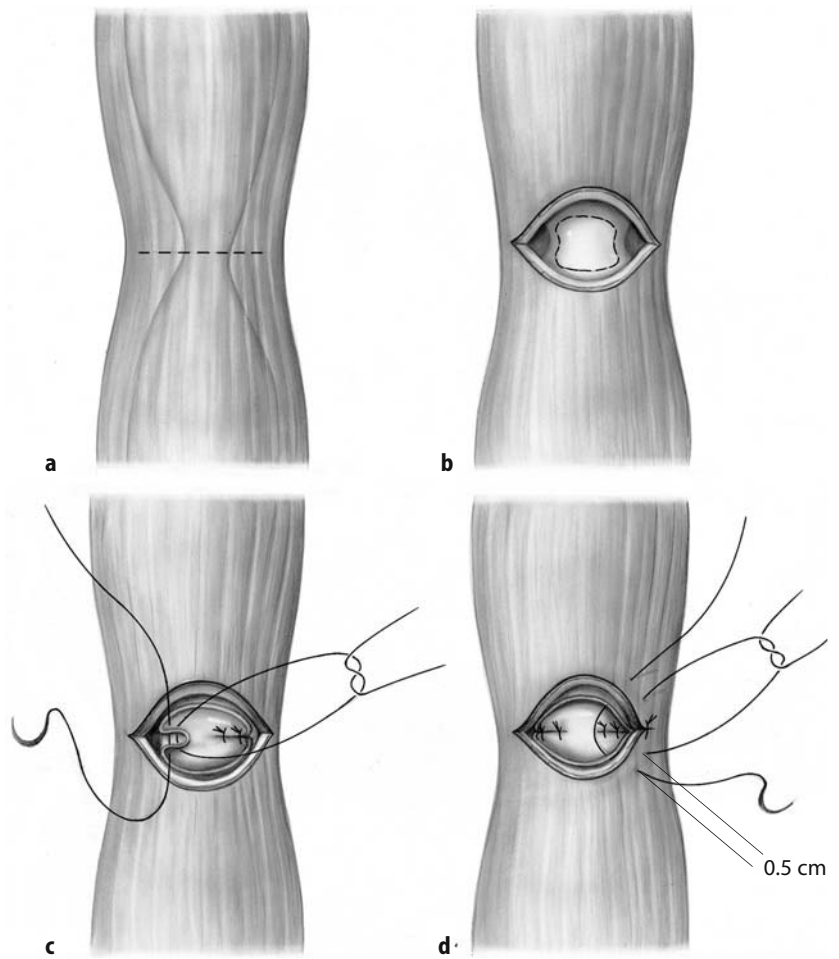
■ **Positioning and approach.** It depends on the location of the stenosis.

- Collar stenosis: Left cervical approach, supination
- Intrathoracic stenosis: Right antero-lateral thoracotomy 4–6 ICS
- Stenosis of the abdominal part of the esophagus: “inverted T-incision” or median laparotomy.



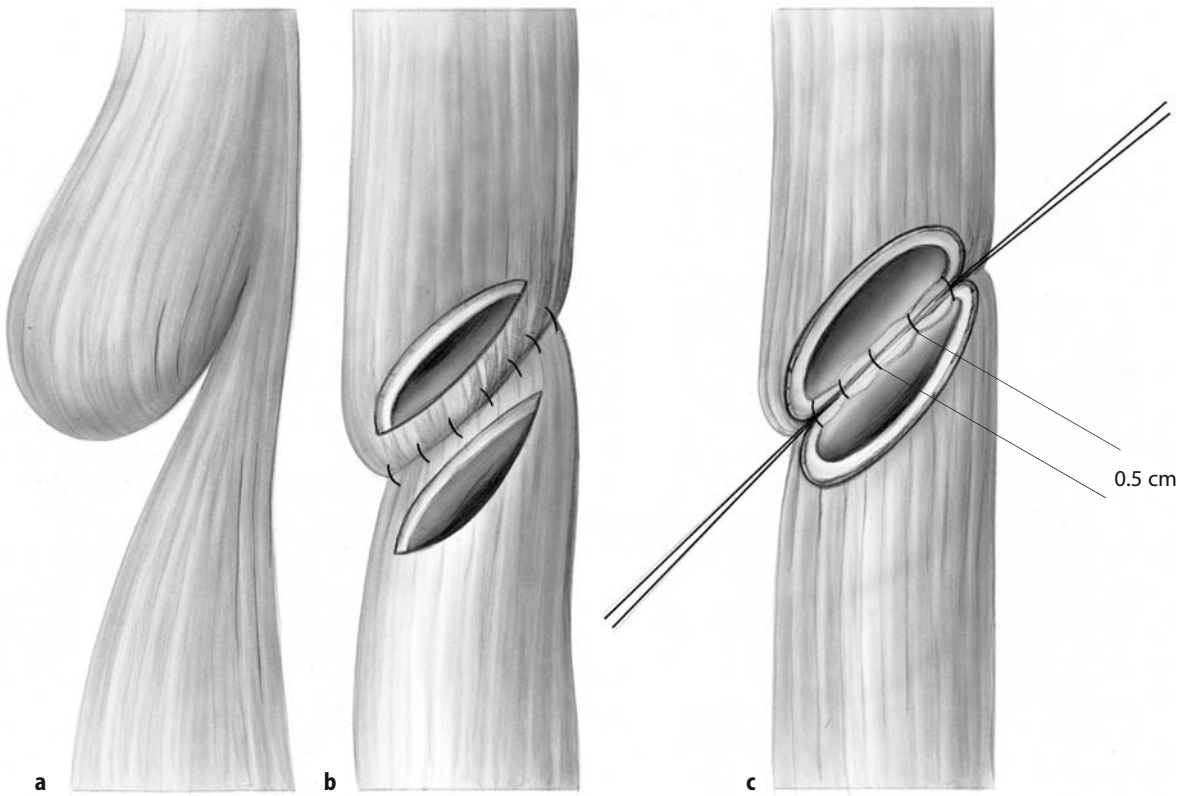
**Fig. 28.1 a, b.** Resection of a short stricture (length max. 1.5 cm). After resection of the stenotic segment, mobilization of the proximal and distal end of esophagus restores the basis for reconstruction of the continuity with single layer end-to-end anastomosis in single suture technique. The distance of each suture should be 5 mm. Each stitch should be placed

5 mm distant to the anastomosis. In stenosis shorter than 1 cm stricturoplasty according to Heineke Mikulicz should be performed. Therefore a longitudinal esophagectomy is performed and a single layer transverse closure with mattress sutures.



**Fig. 28.2 a–d.** In stenosis limited to mucosa and submucosa a transverse transection of the esophageal musculature over the stenosis suffices (a). The anterior part of the stricture is

resected (b). Reconstruction of the continuity of mucosa and submucosa in the posterior wall area (c). Transverse closure of the anterior wall with single layer mattress sutures (d).



**Fig. 28.3 a–c.** In case of a prestenotic dilatation of the esophagus a side-to-side esophagostomy of the pre- and post-stenotic esophageal segment should be performed. In all

local esophagoplasties an intraluminal placed tube (for example a large gastric tube) and an abundant external drainage is obligatory.



## Introduction

Minimal access surgery appears of particular value in the surgical treatment of esophageal diseases because of the disproportion between the access with its considerable invasiveness and morbidity and the surgical intervention per se which is, in the majority of cases, less severe. This obvious discrepancy makes a minimal-invasive approach an attractive alternative. The aim is to avoid a thoracotomy with its attendant morbidity and replace it with the smaller incisions used in MIC.

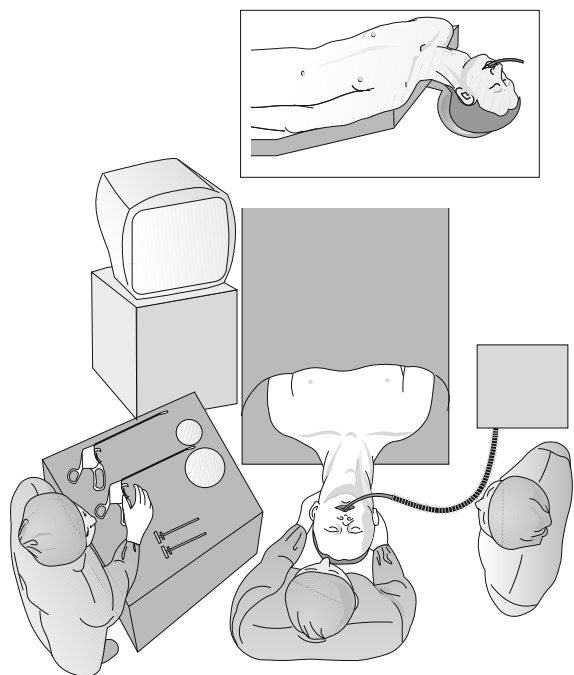
Meanwhile, MIC alternatives have been developed for all surgical interventions for benign diseases. MIC operations for malignancies are feasible as well – at least from the technical point of view. In the following, the details of clinically important esophageal interventions are demonstrated. Additionally, an evaluation of these techniques will be attempted in comparison to corresponding open procedures.

## Diverticula of the esophagus

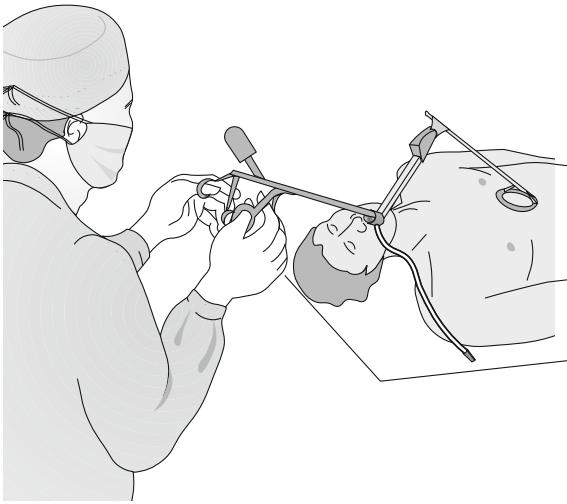
Diverticula of the esophagus may be found in the cervical part (Zenker's diverticulum), at the height of the bronchial bifurcation (para-bronchial) and above the esophagogastric junction (epiphrenic d.). In case of cervical and epiphrenic diverticula, we have to deal with so called "pulsion" diverticula which arise because of a malfunction of the correlated sphincter. Both of them need surgical intervention. Myotomy of the respective sphincter is an obligatory part of the operation.

## Endoscopic treatment of Zenker's diverticulum

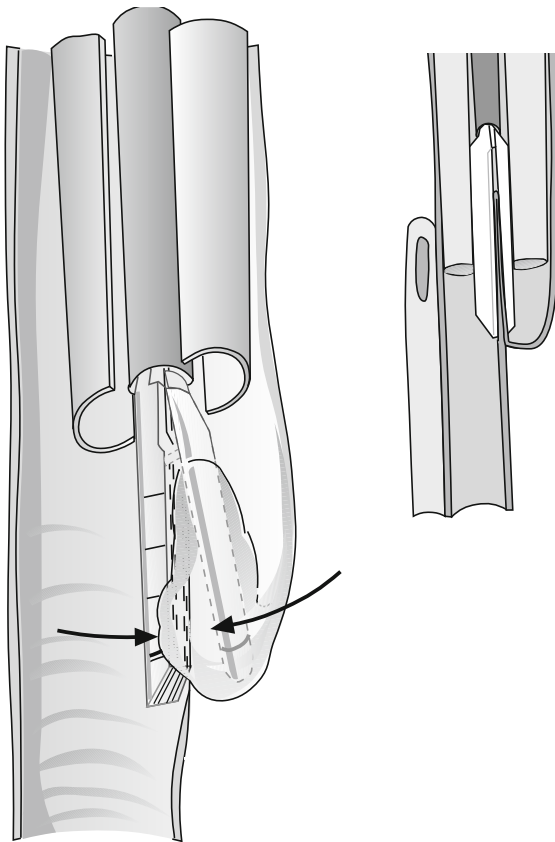
The decisive step in the surgical treatment is cricopharyngeal myotomy, i.e. a complete division of the upper esophageal sphincter. Incomplete opening is the cause for the development of a diverticulum. The classical surgical treatment is cricopharyngeal myotomy and an excision of the sac using a linear stapler. Many ENT surgeons, however, traditionally preferred transoral treatment (Mocher 1917). The therapeutic principle of severing the common wall between the esophageal lumen and the diver-



**Fig. 29.1.** Positioning of the patient for endoscopic treatment of Zenker's diverticulum. Extension of the head is essential. Woodbridge tube is required for intubation.



**Fig. 29.2.** Self-retaining laryngoscope. Sufficient exposure of the esophageal lumen may be difficult in some cases. The procedure can only be performed reliably with a self-retaining laryngoscope.



**Fig. 29.3.** Operative principle. The arm of the linear stapler containing the staples is introduced into the esophagus and the arm is placed into the diverticulum. Firing of the stapler creates a broad communication between the two lumens. The dissection line is secured by sutures.

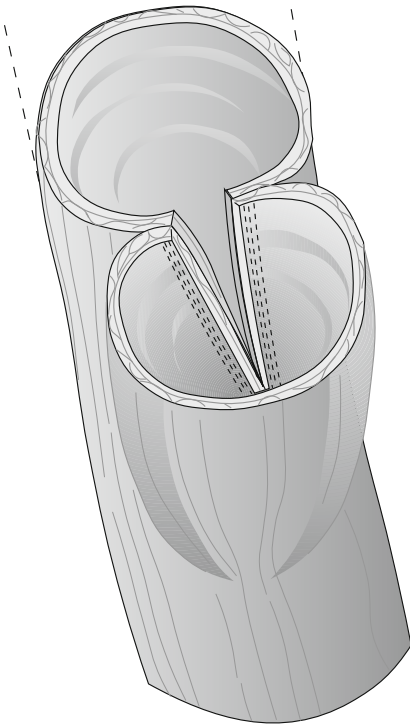
ticulum is a reasonable approach, since the upper esophageal sphincter is inevitably divided as well. Thus, the leading symptom – dysphagia – will be successfully treated. General surgeons, however, did not adapt this alternative technique, probably because a simple dissection of the sac without any securing of the line of dissection was considered too risky.

Today, linear cutting devices are available which seal the line of dissection by staples. Accordingly, this may now be used for the transoral treatment of cervical diverticulum. By one single movement of the handle, a broad communication between the esophagus is created including a complete myotomy of the upper esophageal sphincter.

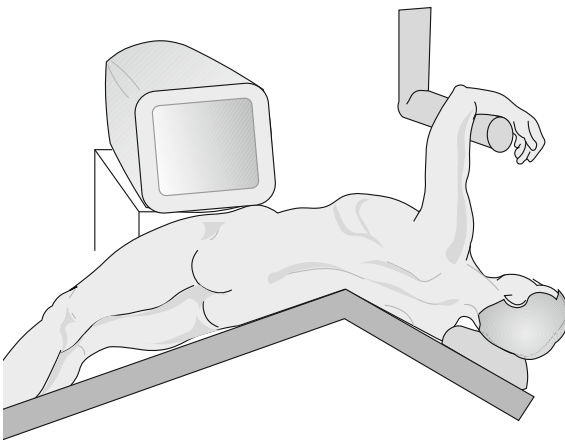
After the adequate exposure of the area by means of a laryngoscope (both the entrance of the esophagus and of the diverticulum must be clearly visible), the operation can be accomplished within a few minutes by the application of the linear cutter. Accordingly, it is minimally invasive. In comparison to the open procedure, the risk of a leakage (which may occur in open surgery not only in the area of the stapling line but as well in the region where the myotomy has been performed) should be lower as well as the risk of recurrent laryngeal nerve palsy.

### ■ Thoracoscopic extirpation of an epiphrenic diverticulum

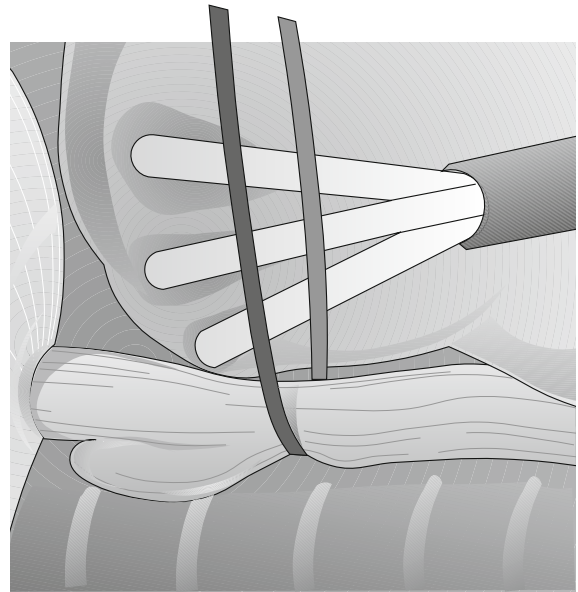
The pathogenesis of an epiphrenic diverticulum is identical to that of a cervical diverticulum. Due to the impaired opening (incomplete or uncoordinated relaxation) of the lower esophageal sphincter, the esophageal wall progressively bulges at a point of minor resistance. Myotomy of the lower esophageal sphincter is, therefore, an integral part of the operation as well as the extirpation of the diverticular sac. Extirpation of the diverticulum is only feasible by the transthoracic route. Correspondingly, the myotomy is performed by transthoracic access as well.



**Fig. 29.4.** After the application of the linear stapler, the lumen are in communication. The dissection lines are secured by clamps. Thus, a complete myotomy of the cervical sphincter is undertaken also and dysphagia is relieved.



**Fig. 29.5.** Positioning of the patient for the excision of an epiphrenic diverticulum and myotomy of the lower esophageal sphincter. A 90 degree lateral position is used. Double sided ventilation is required. The monitor is placed to the front of the patient and the operation is performed from the posterior side. The first trocar is inserted through the 5th or 6th intercostal space of the posterior axillary line. The other trocars are introduced posterior under direct vision.



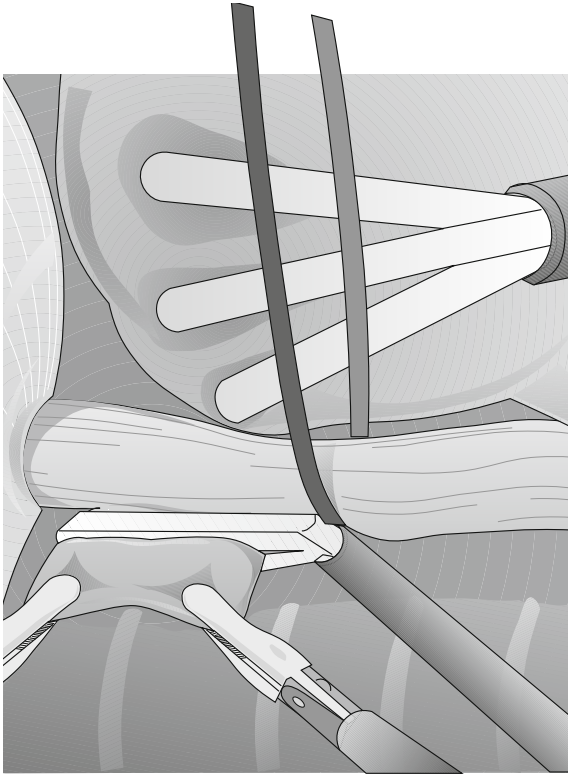
**Fig. 29.6.** The pleura is incised just proximal to the diverticulum and the esophagus is mobilized circumferentially. It is elevated by means of a rubber sling. A large gastric tube within the esophagus facilitates control. Next the diverticulum is circumferentially isolated.

### ■ Excision of a parabronchial diverticulum

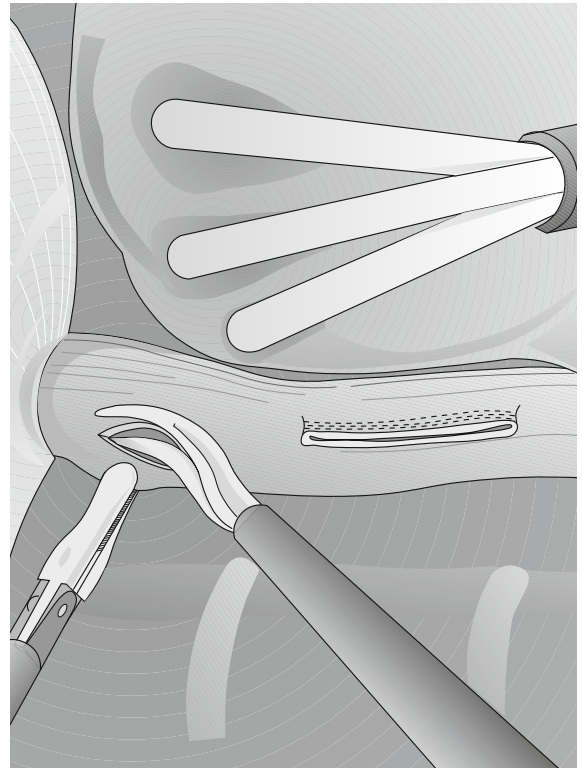
Surgical resection of a parabronchial diverticulum is required in a minority of cases only. If severe dysphagia is the leading symptom and can be explained by retention of food within the diverticulum, a resection may be justified. In any instance, a careful manometric evaluation of esophageal motility is mandatory. Eventually, the resection has been combined with myotomy.

### ■ Comment

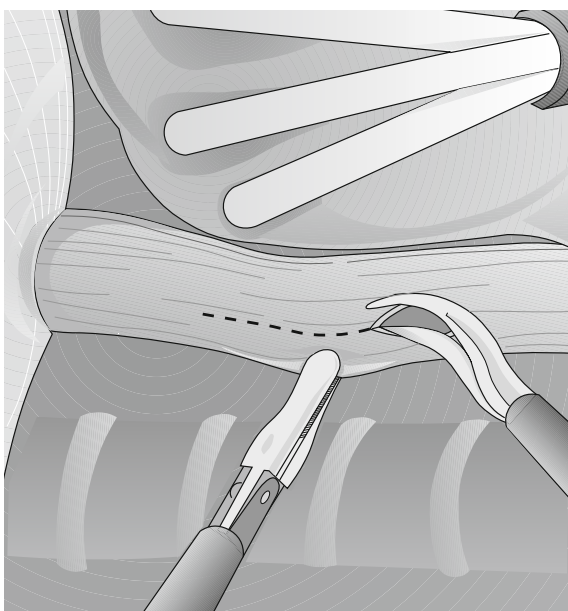
Since esophageal diverticula are comparatively rare, large series are rare even with conventional surgery. This is even more true for minimally invasive techniques which have been available for a few years only. An evaluation of their role is, therefore, still not possible. The conventional techniques are still the gold standard. However, MIC procedures may be acceptable, provided that informed consent is given by the patient. According to our preliminary experience, a growing popularity is probable, since the advantages of the minimal invasive approach become evident in clinical practice.



**Fig. 29.7.** The completely isolated sac of the diverticulum is now fixed with two clamps and put under light traction. The linear stapler (preferable with a flexible tip) is now applied. It is essential, during this step of the procedure, to have a large-bore bougie within the esophagus to avoid any narrowing of the lumen.



**Fig. 29.8.** Finally, the myotomy of the lower esophageal sphincter is performed through the thoracic approach. It should be extended sufficiently caudally to reach the stomach. The myotomized area can be covered by a mobilized patch of the gastric fundus.



**Fig. 29.9.** The long, extramucosal myotomy of the esophageal muscle layer is performed in a similar way to lower myotomy. With a large bore bougie in place, the esophagus can be easily palpated. Accordingly, circular mobilization is not required. The muscle layer, at the border between the upper and the middle third, is laterally elevated and incised. Any perforation of the mucosa is carefully avoided. The plane between the muscle layer and the mucosa is recognized easily at this level of the esophagus. The tip of a pair scissors is cautiously introduced into this plane. The muscle layer can now be lifted up and dissected safely. The myotomy is continued down the whole length of the esophagus. The mucosal layer is not covered by a flap of any sort.

## Minimal invasive treatment of esophageal motility disorders

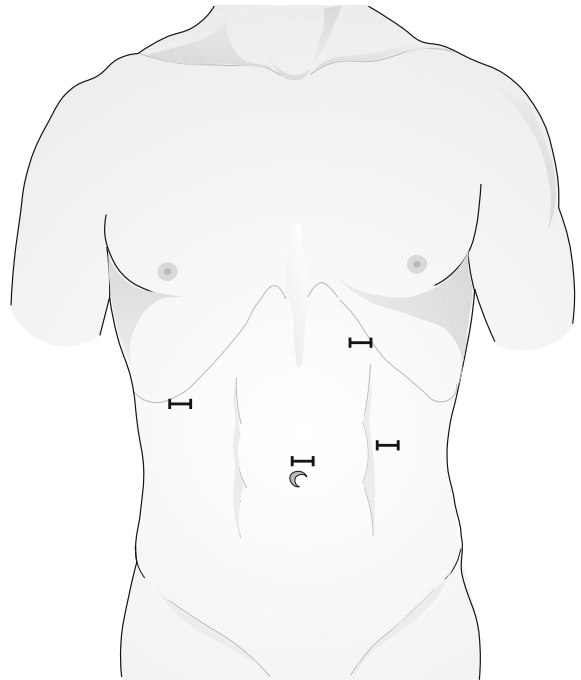
### ■ Long myotomy of the esophagus in diffuse esophageal spasm

The success of operation depends directly upon the selection of patients. The operative technique is less demanding. The approach is through the right thoracic wall, the layer between the muscle and the mucosa is identified. Then, the muscle layer has to be split completely over the whole length of the esophagus.

### ■ Cardiomyotomy with Thal (Dor) fundoplasty in achalasia

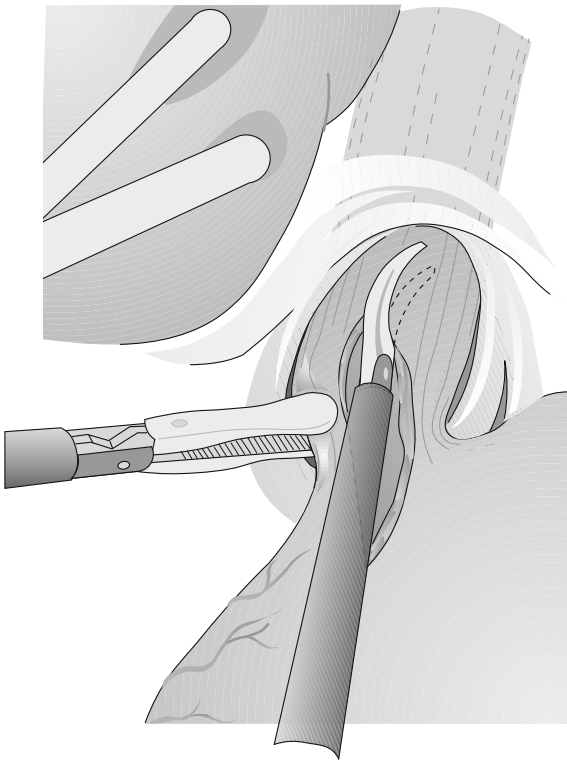
It is still a matter of debate whether surgical treatment of achalasia should be performed transthoracically or via the abdominal route. Either access is possible. Similarly, the necessity of an additional anti-reflux procedure is still in question. Currently, it appears most convincing that it may be superfluous if the transthoracic approach has been chosen but necessary if the transabdominal access is preferred. The port sites are demonstrated in Figure 29.10. Usually, 4 trocars are required. Most infrequently, a 5th trocar is advisable. The therapeutic aim is to relieve dysphagia. This can only be achieved by complete dissection of all muscle fibers within the esophagogastric junction. This means complete myotomy of not only the esophageal muscle layer but also of the proximal parts of the so called Willis loop of the gastric fornix.

The left lobe of the liver is a retractor for optimal exposure of the esophagogastric junction. Both pillars of the esophageal hiatus are important landmarks. The junction is covered by a fat pad of varying thickness which has to be split or resected. Damage to the vagus nerve has to be carefully avoided. Thus, the muscle layer can be exposed. Myotomy is initiated within the area of the proximal gastric wall. The muscle layer is thicker, and the plane between the musculature and the mucosal layer is identified more easily here than at the esophagus. Perforation of the mucosa can be closed here more safely. However there is greater vascularity in this area. Accordingly, a

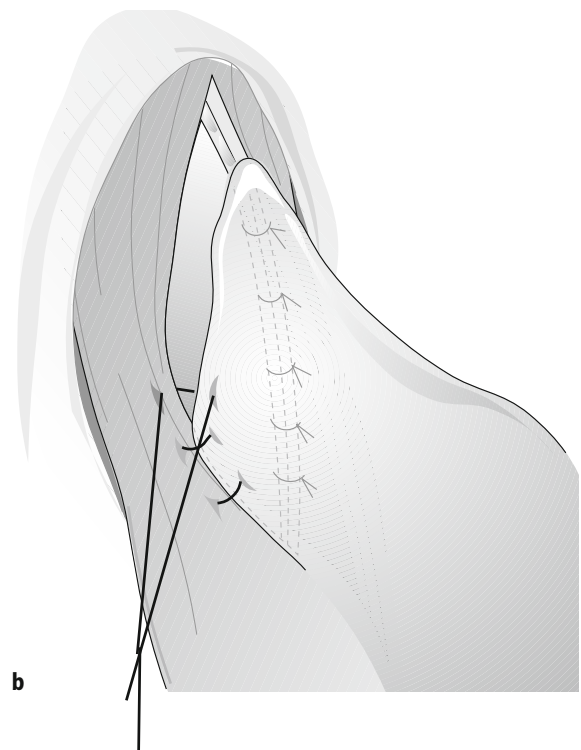
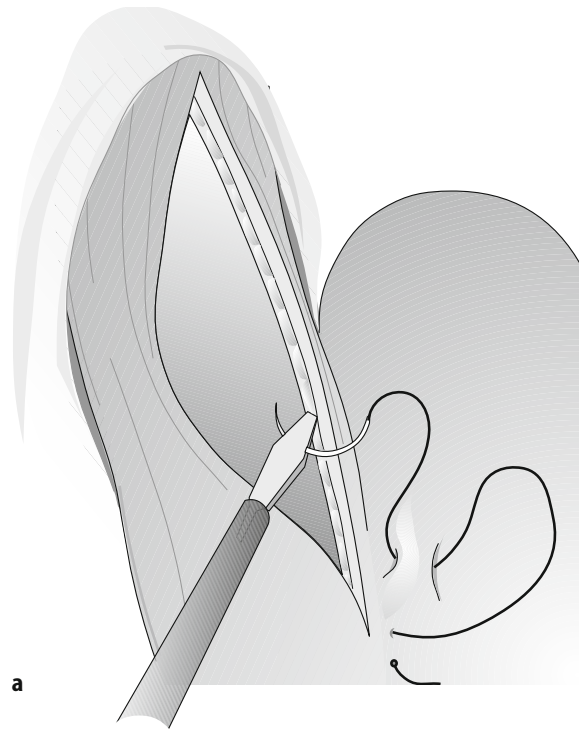


**Fig. 29.10.** Port sites for laparoscopic myotomy with fundoplasty. After having established the pneumoperitoneum, the first 10 mm trocar is inserted via a paraumbilical incision. Further trocars are introduced under direct vision. The 10 mm trocar for the telescope is positioned below the left costal margin medial to the midclavicular line. A trocar is placed below the right costal margin in order to elevate the left lobe of the liver. The fourth trocar is used for the insertion of the instruments of the right hand of the surgeon. The surgeon is positioned on the right side of the patient. As usual in all procedures in the upper abdomen, a 30 degree telescope is preferred.

few clips may have to be applied. As soon as the plane has been entered successfully, the remaining myotomy is usually possible without any difficulties. One further critical point has to be mentioned. At the transition between the thickened muscle layer of the lower esophageal sphincter and the thinner and dilated wall of the body of the esophagus, complete myotomy is of particular importance though the risk of perforation is slightly higher. Having performed the myotomy, it should be checked for completeness. The most reliable way to do this is to perform intraoperative endoscopy. Alternatively, a dilation tube can be inserted and in-



**Fig. 29.11.** Myotomy. The cardiomyotomy should extend about 2 cm onto the gastric fundus and about 4 cm of the distal esophagus. The plane between the mucosa and the muscle layer is best identified at the lowermost point of the myotomy on the anterior gastric wall. The muscle layer of the stomach is quite strong and well vascularized and the mucosa is somewhat thicker and stronger than the esophageal mucosa. Accordingly, the first critical step of the myotomy is performed more easily here than in the esophageal wall. As soon as the plane has been correctly identified, myotomy can now be continued cranially without any difficulties. If bleeding occurs from the muscle layer or mucosal vessels, they are usually meaningless. They should not be stopped by electrocautery to avoid mucosal lesions. Sometimes, swabs containing POR 8 may be used to stop the bleeding. At any rate, myotomy has to be accomplished completely. In case of doubt, intraoperative endoscopy may be helpful.



**Fig. 29.12.** Fundoplasty. Beginning from the lowermost point of myotomy, a patch of the gastric fundus is covered either with running or interrupted stitches onto the area of the myotomy. In the first step, the left edge of the muscle slit is sutured (**a**). Correspondingly, the right side will be fixed next. It is usually not required to mobilise the great curvature (**b**).

sufflated carefully. This makes muscle fibers visible if any remain intact.

The fundoplasty (Dor, Thal) is created next. First, the left muscle edge of the myotomy is sutured to a corresponding fundic fold. This is commenced from the lowermost point of myotomy using interrupted or continuous stitches. Then, another fold of the fundus, slightly to the left of the previous one, is taken and sutured to the right edge of the myotomy. In most cases, the gastric fundus does not need to be mobilized. Finally, a nasogastric tube is inserted for 1–2 days.

### ■ Comment

There is rarely a convincing indication for long myotomy, performed either open or thoracoscopically. Good results can be expected if the indication is very convincing. Accordingly, myotomy should be considered as an intervention which should be performed only in centers with particular expertise. Since the operation, per se, is simple to perform, the minimal access technique almost certainly will become the standard procedure.

This holds true for cardiomyotomy as well. The surgical option, being significantly less invasive now, has become very attractive in comparison to pneumatic dilation or alternative conservative treatment.

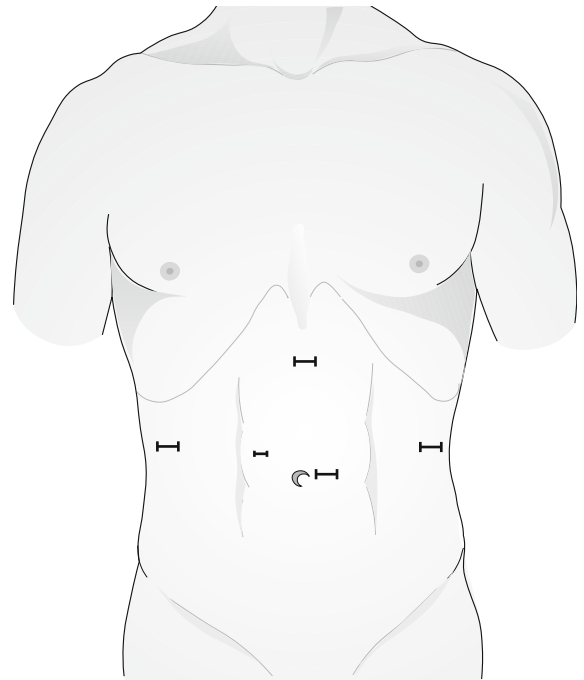
### Antireflux surgery

The positioning of the surgical team and of the equipment is identical to cardiomyotomy.

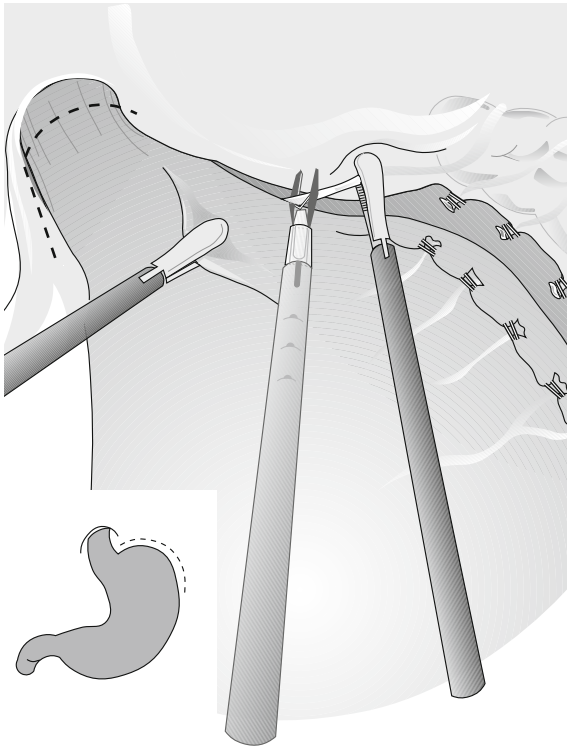
After elevation of the left liver lobe, the greater curvature of the stomach is mobilized. This mobilization also includes the dorsal adhesions of the stomach. This facilitates the dissection of the left pillar of the esophageal hiatus. Dissection is then continued from the right side. The part of the peritoneum which covers the right crus and the anterior aspect of the esophagogastric junction is split. The anterior branch of the vagus nerve has to be preserved carefully.

In the line between the right crus and the smaller curvature of the stomach, a retroesophageal tunnel is created. In most cases, this can be done bluntly with the use of a swap. Reduction of the hiatal hernia is achieved by pulling the stomach gently into the abdomen. The esophagocardiac junction is elevated by a hook or a rubber band. Thus, the posterior junction of the crura is exposed and may now be properly prepared for the posterior hiatoplasty.

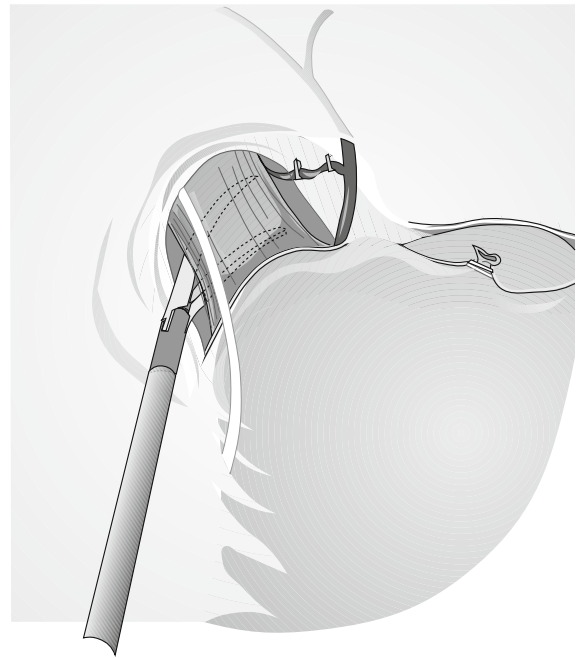
Prior to the shaping of the wrap, the gap in the hiatus is narrowed (posterior hiatoplasty). A large gastric tube is inserted into the stomach via the esophagus. The esophagogastric junction is elevated to get a good view of the posterior aspect of the hiatus. Depending upon the size of the hiatus, 1–3 non-absorbable su-



**Fig. 29.13.** Port sites for laparoscopic fundoplication. The first trocar is inserted via a paraumbilical incision. The 30 degree telescope will now be introduced to position the following ports under optical control. The second trocar which later on will be used for the telescope is inserted below the left rib arch between the medioclavicular line and the xyphoid. The third 10 mm trocar which is required for the elevation of the liver is localized in the medioclavicular line on the right side just below the rib arch. The fourth trocar is used within the left abdomen, laterally to the umbilical trocar. In most cases, another 5 mm port is helpful which should be inserted between the right and umbilical trocar.

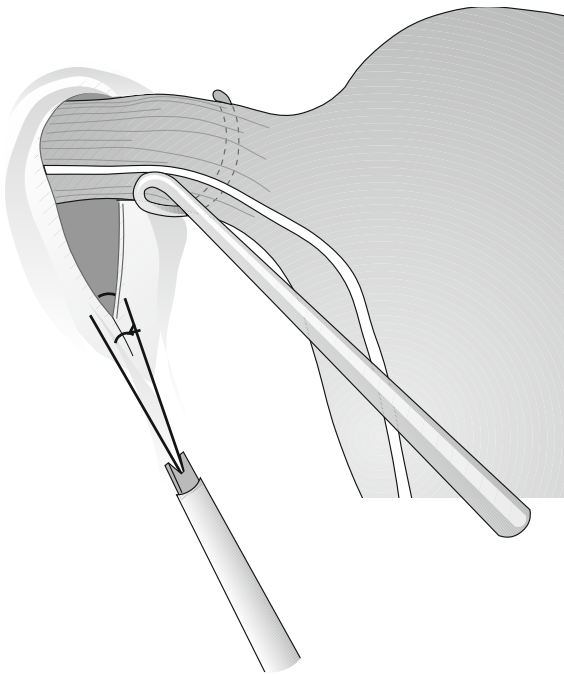


**Fig. 29.14.** Mobilization of the greater curvature. A really “floppy” tension free cuff can only be obtained if the greater curvature has been mobilized generously before. Accordingly, this has to be performed in open as well as in laparoscopic fundoplication. Beginning from the lowermost point (at the border between left and right gastroepiploic artery), the gastrosplenic ligament will be opened in an avascular area and dissected up to the fornix of the stomach. The short gastric vessels tend to bleedings which are difficult to control. Bilateral ligation with double clips is, therefore, recommended. Prior to the dissection, the vessel should be additionally coagulated. It is of particular importance to warrant the safe application of the clips, since these might easily slip off when the cuff is pulled through the retroesophageal tunnel later on. Alternatively, linear staplers (vascular magazine) or the ultrasound device can be used. Dissection in the upper part of the fundus has to be performed with particular caution, since branches of the splenic artery supplying the dorsal gastric wall may occur. Dissection of the left side is completed by the exposition of the whole left crus of the diaphragm including the posterior commissura.



**Fig. 29.15.** Exposition of the right crus of the diaphragm and retroesophageal mobilization. The right crus of the diaphragm is exposed by splitting peritoneal layer and by removing the paracardiac fat pad. The peritoneum is split in a curved line from the right crus to the left crus. Mobilization of the posterior esophageal wall is started from the right side bluntly by using the scissors. Care has to be taken to preserve the dorsal branch of the vagus which usually is left out of the wrap.

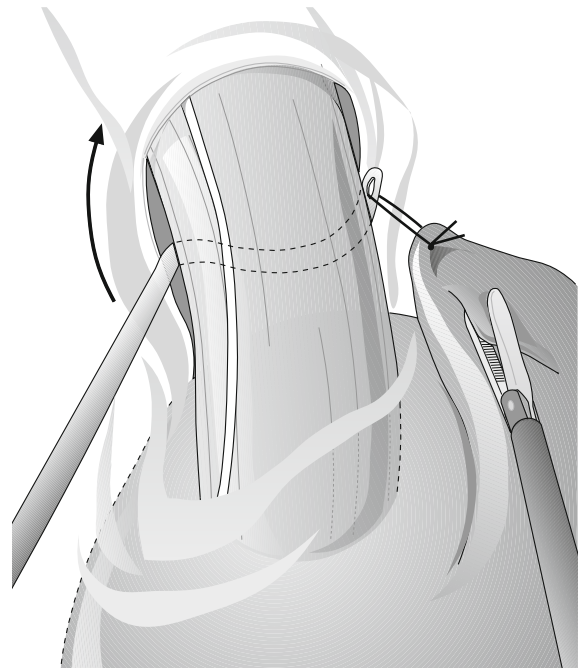




**Fig. 29.16.** Narrowing of the hiatus. With an additional hook or by the means of rubber band, the esophageal junction is elevated, which gives good exposure of the posterior crura of the diaphragm. The hiatus is now narrowed (posterior hiatoplasty), using several non-absorbable interrupted sutures which are knotted extracorporally. It is of utmost importance, to preserve sufficient width of the hiatus, which is achieved by a bougie of at least 50 French. In case of a too narrow hiatoplasty, severe dysphagia may be induced, even if the wrap has been shaped in a floppy way.

tures (2-0) are inserted. Any narrowing of the esophagus has to be strictly avoided. Otherwise, persistent dysphagia may occur even if the wrap is constructed in a “floppy” way.

The wrap is constructed using the anterior wall of the gastric fundus. From the right side, a suitable instrument is passed behind the esophagus to the left side. We use a hook or a grasping forceps with a flexible tip. The instrument is fixed to the anterior gastric wall about 2 cm to the right of the greater curvature. It is pulled back to the right side, thus moving the anterior fundic wall behind the esophagus to the other side of the esophagocardiac junction. This movement is supported by pushing the fold gently by a grasping forceps from the left side. As soon as the fundic fold appears on the right side of the esophagogastric junction, it



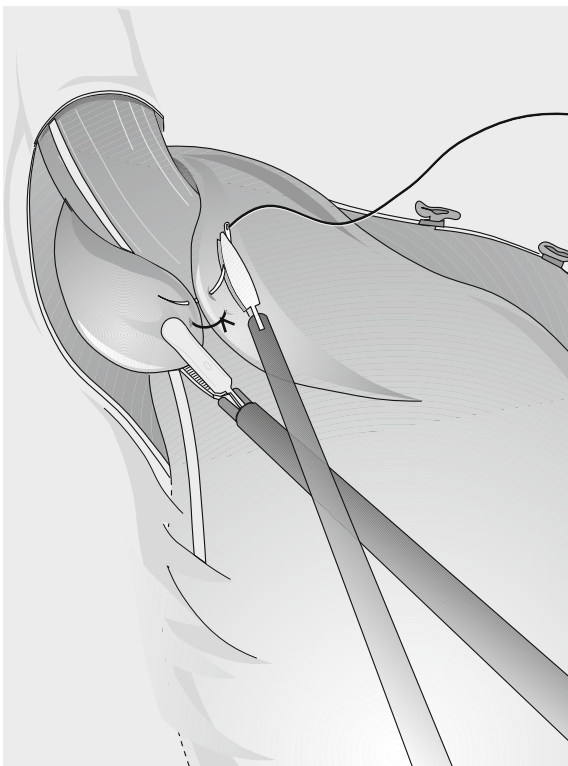
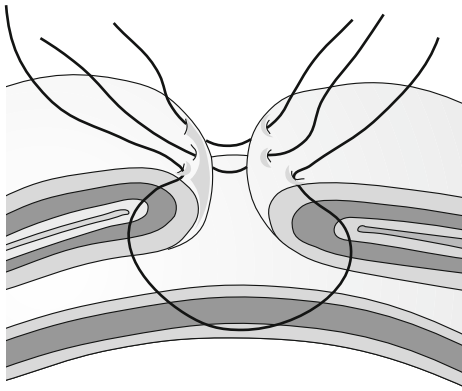
**Fig. 29.17.** Retroesophageal pull-through of the anterior gastric wall. The very point of the anterior wall of the gastric fundus, which will be pushed during the open operation with the middle finger to the right side, is now fixed to the tip of the hook. Alternatively it may be fixed by means of flexible grasping forceps. By gentle traction from the right side, and simultaneous support from the left side, the anterior gastric wall is passed through behind the esophagus.

should remain in position without fixation. If it tends to slip back, this suggests the previous mobilization of the fundus has been insufficient.

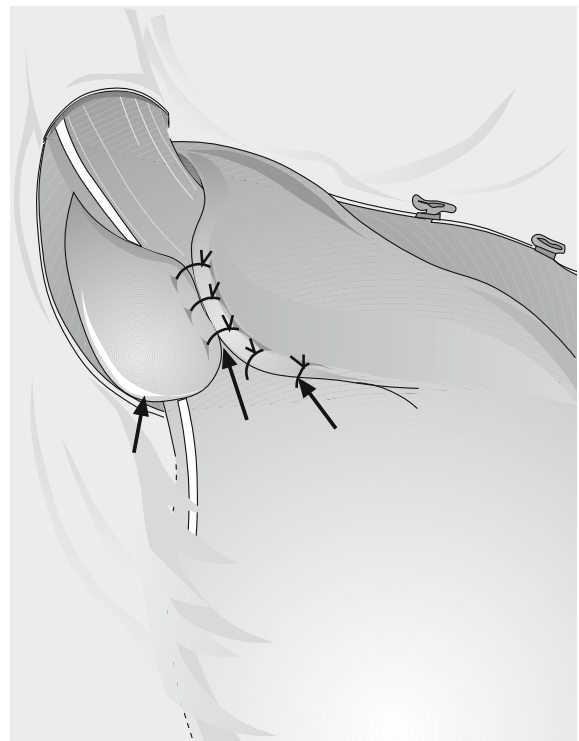
The wrap is sutured with three non-absorbable sutures. The lowermost stitch also incorporates the anterior gastric wall in order to prevent slippage of the wrap. Finally, the left edge is secured by two additional sutures. Thus, a so called 3-point support of the wrap is achieved which should prevent “slippage”.

### ■ Comment

Considerable data are available to judge the role of laparoscopic fundoplication. It has been clearly demonstrated that morbidity and mor-



**Fig. 29.18.** Closure of the cuff. The wrap is now made with three non-absorbable single sutures. The lowermost suture also incorporates the anterior gastric wall. Once the wrap has been made, it should be checked to see if it is loose enough using a 12 mm device (e.g. the hernia stapler). If the 12 mm device can be inserted without difficulties into the space between the wrap and the anterior gastric wall, it is regarded as floppy enough.



**Fig. 29.19.** Completed fundoplication. Finally, the left edge of the fundoplication is secured by two single sutures. Thus, the wrap is protected by a three-point support (lesser omentum on the right side, fixation to the anterior gastric wall in the middle, and the so-called "Flankennähte") on the left side against slippage. The large bougie is replaced by a normal naso-gastric tube, which should remain for one or two days. Optionally, abdominal drainage may be positioned for 24 h.

tality are not increased by the use of the new technique. On the basis of current follow-ups, the functional results are, at least, equal to those of open operations. Though controlled studies are not yet available to demonstrate a clear superiority, there is no doubt that laparoscopic fundoplication has become the treatment of choice in all major centers.

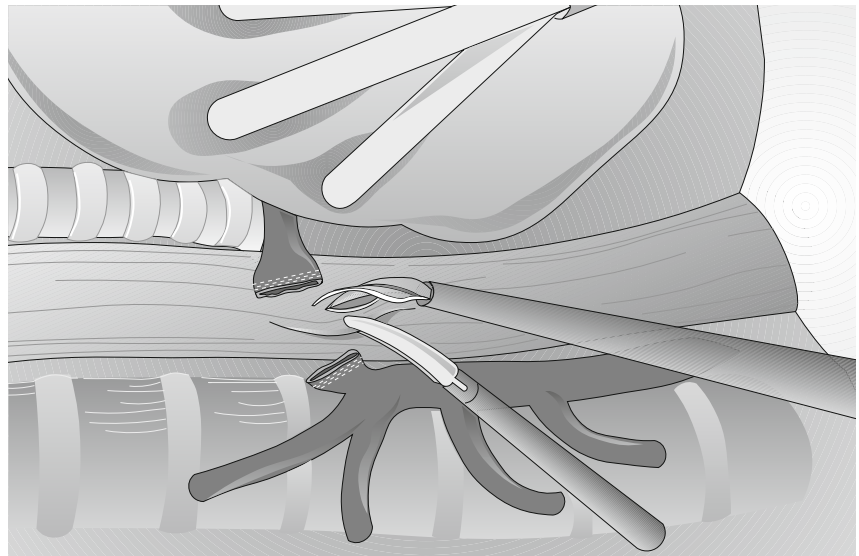
### Excision of benign tumors

Most benign tumors of the esophagus are leiomyomas. Provided that no preoperative endoscopic biopsy has been attempted, they can nearly also be removed easily without opening the esophageal mucosa. It is advisable to perform intraoperative endoscopy. This helps to identify the exact position of the tumor. The

access is identical to that for long myotomy. If the tumor is located anterior or on the right, it is sufficient just to split the covering muscle to expose the tumor and to dissect it by blunt or sharp dissection. If the tumor is localised posteriorly or on the left of the esophagus, the esophagus has to be mobilised before resection is undertaken. After the removal of the tumor, the muscle layer should be closed by interrupted sutures.

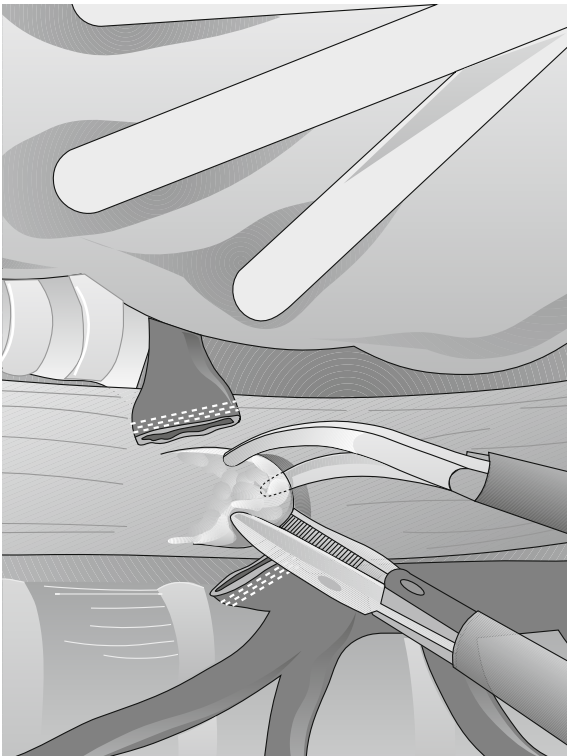
### ■ Comment

Thoracoscopic resection of small benign tumors of the esophagus seems to be advantageous, at least from the theoretical point of view. However, it is still too early to give a reliable statement about its true value.

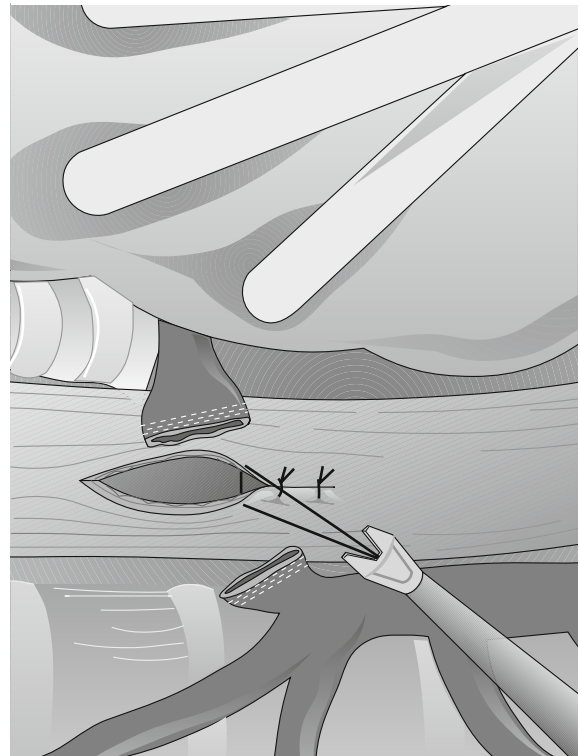


**Fig. 29.20.** Exposure of the esophageal tumor. The leiomyoma was localized by intra-operative endoscopy at the level of the azygos vein. After careful mobilization, the azygos

vein is divided using the vascular stapler. The esophageal muscle layer grasped directly above the tumor and is incised.



**Fig. 29.21.** Extirpation of the tumor. The anterior muscle layer is completely split. The lower edge of the tumor is elevated by grasping forceps, which allows us to divide it from the mucosal layer.



**Fig. 29.22.** After removal of the tumor, the muscle layer is closed, either with interrupted sutures or running sutures (3-0).

## Minimally invasive procedures in esophageal carcinoma

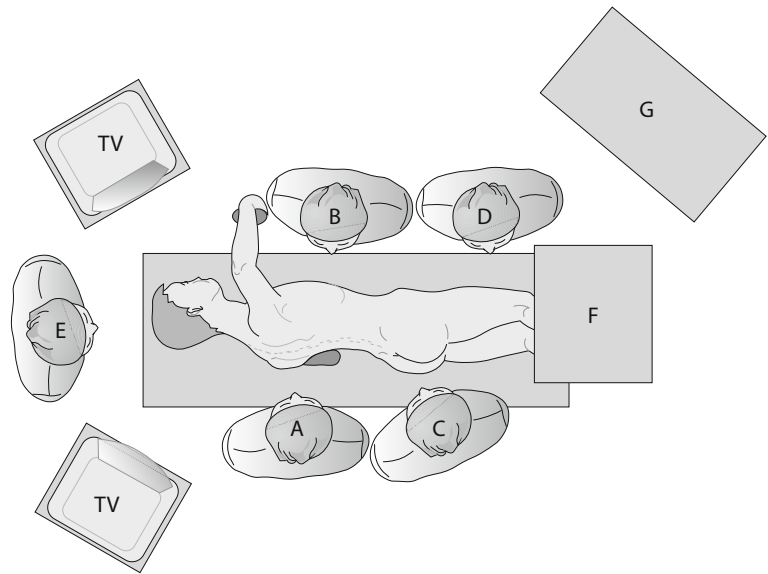
### ■ Thoracoscopic esophagectomy (squamous cell carcinoma)

This procedure should be carried out by a surgical team which is familiar with open thoracic and esophageal surgery. A complete set of instruments for the open approach should be ready for use. The patient is positioned in the left lateral position, more inclined to the position than is usual for right-sided thoracotomy. A precondition for successful thoracoscopy is ventilation with a double lumen insufflation tube. This allows the right lung to be collapsed and insufflation of CO<sub>2</sub> is not required. The first trocar is inserted below the shoulder blade through the 5th intercostal space of the posterior axillary line. Safer insertion is pro-

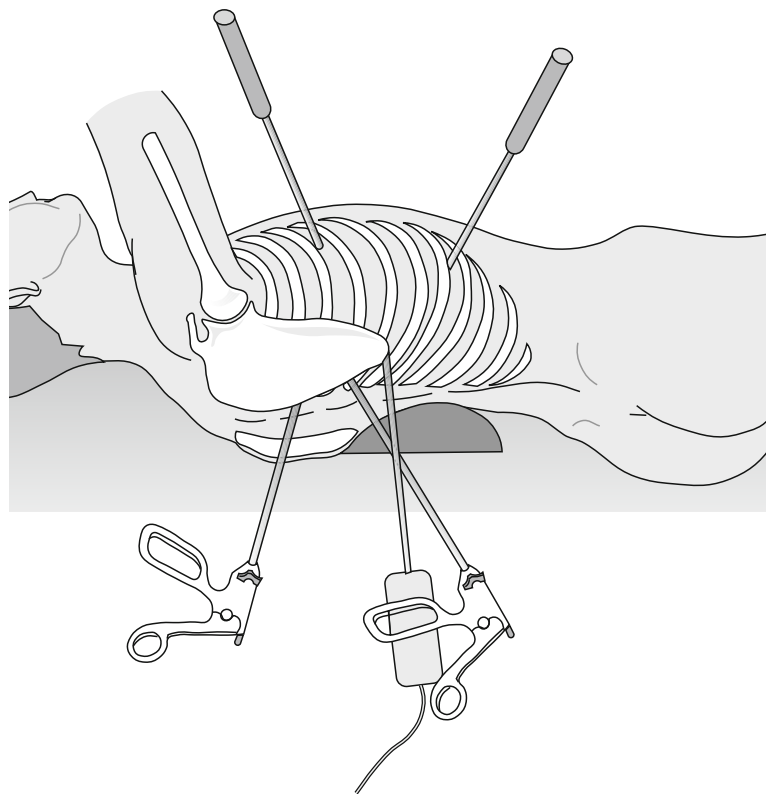
vided by using an optical trocar. The further trocars are then inserted under visual control. Usually, 5 trocars are required.

Adhesions of the pleura are dissected, followed by a meticulous exploration of the thoracic cavity. The lung is pushed aside by a suitable retractor, thus exposing the posterior mediastinum.

An incision in the mediastinal pleura is made parallel to the esophagus in two lines along the right edge of the trachea and the spine. The azygos vein is carefully mobilized and double-clipped on both sides and divided. However, it is possible to perform the division with a linear stapling device (vascular staples). Right-sided intercostal veins leading to the azygos vein and the thoracic duct are also divided between double clips. Careful preparation is of great importance, since bleeding from inadequately clipped veins is difficult to control. This makes further dissection more

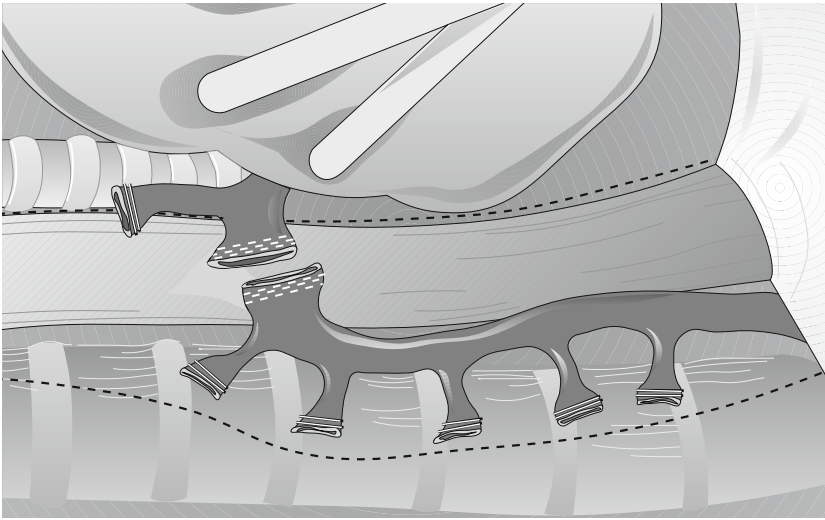


**Fig. 29.23.** Positioning of the surgical team of the equipment for thoracoscopic mobilization of the esophagus (A: surgeon, B: assistant, C: cameraman, D: scrubnurses, E: anaesthetist, F: instruments for the thoracoscopy, G: instruments for thoracotomy).

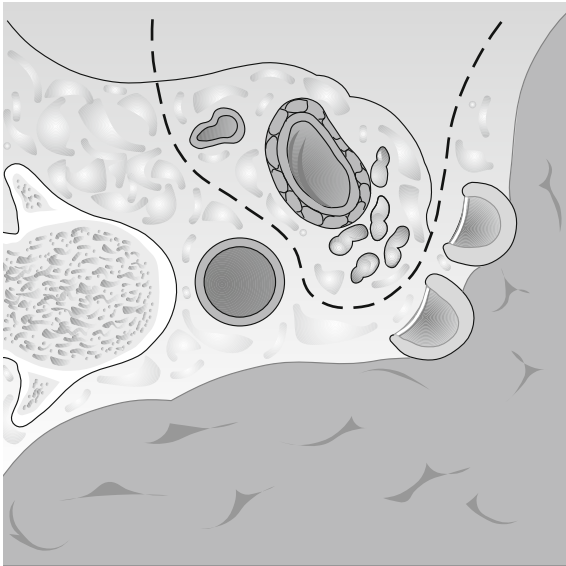


**Fig. 29.24.** Port sites for thoracoscopic mobilization of the esophagus. First trocar in the mid axillary line through the 5th intercostal space. A 30 degrees telescope is used. Lung retractors are inserted through the 3rd and 8th intercostal

spaces in the anterior axillary line using 5 mm trocars. Two 10 mm operating trocars are introduced through the 5th and 7th intercostal space in the posterior axillary line.



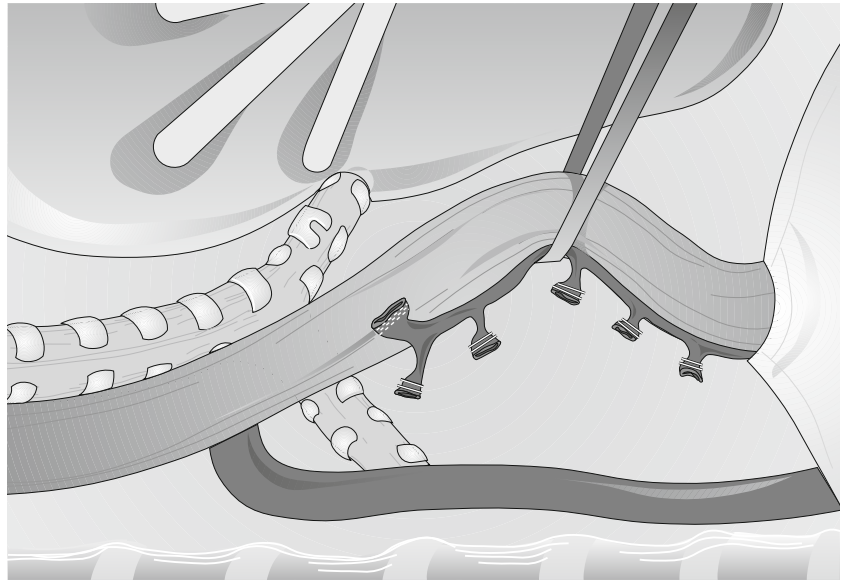**Fig. 29.25.** The mediastinal pleura is incised along the vertebrae, the trachea and the pericardium. The azygos vein is divided with a linear stapler. The right-sided intercostal veins are dissected near their junction with the azygos vein and divided between clips. In the phrenicocostal space, the thoracic duct is identified between the aorta and the azygos vein. After double clipping, it is severed as well.



**Fig. 29.26.** Dissection of the mediastinum inferior to the bifurcation of the trachea. The soft periesophageal connective tissue, fat and lymph nodes are removed en bloc.

difficult. The mobilisation of the esophagus is continued stepwise on the aortic aspect using another hook. Small tributaries to the esophagus are divided between clips. As far as possible from the tumor preferable immediately above the diaphragm, the esophagus is mobilized, and gentle traction is exerted using a rubber sling. After complete dissection from the aorta, the mobilisation is continued along the left side of the mediastinal pleura and the pericardium. Lymph nodes below the tracheal bifurcation are removed en bloc. The upper third of the esophagus is then mobilized parallel to the membranous part of the trachea. The left trunk of the vagus is preserved in its course until it reaches the left main bronchus. Thus, the whole intrathoracic segment of the esophagus is isolated including the adjacent tissue and lymph nodes. Thoracic drains are inserted through both of the lower trocar sites. Finally, the trocars are removed and the holes within the short wall are closed by sutures. The patient is repositioned and the esophagus is severed via a cervical incision. The specimen is then removed transabdominally. Esophago-intestinal continuity is restored by a gastric interposition and esophagogastrostomy.

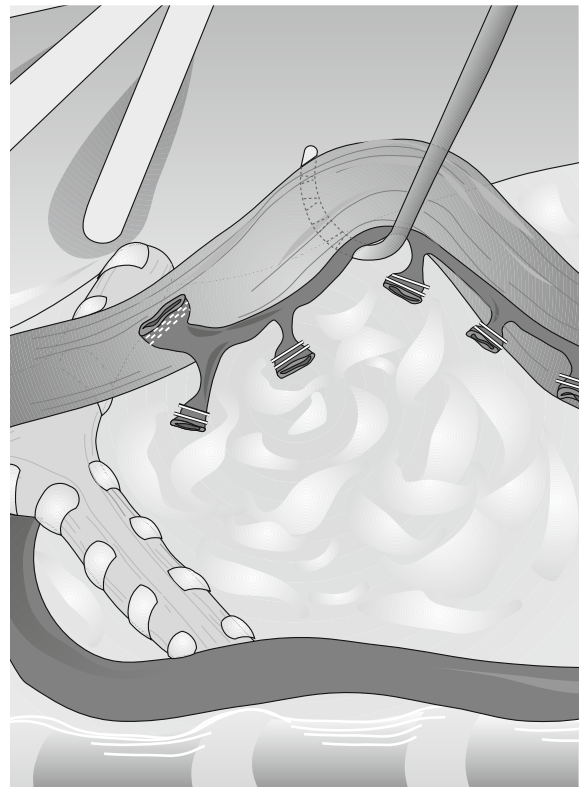
**Fig. 29.27.** After mobilization of a tumor-free segment of the esophagus, further mobilization is achieved using a flexible retractor. Careful preparation is essential in the region of the pulmonary vein and the left main bronchus. The membranous part of the main bronchus is often prominent due to the cuff of the endotracheal tube.



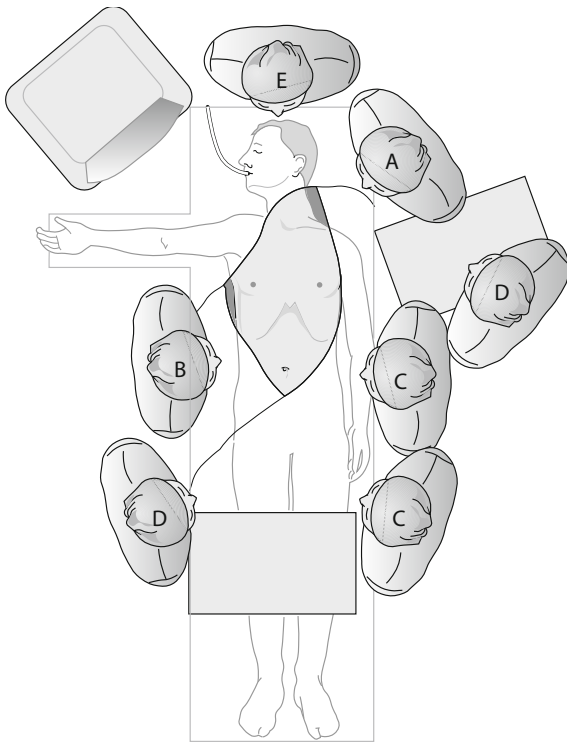
### ■ Endodissection of the esophagus (adenocarcinoma)

For this endodissection, the patient is positioned in the supine position. The head is turned to the right side and extended for 40 degrees. It is essential to have the patient's head positioned as much as possible to the left side to create sufficient space for the handling of the rigid endoscope. The abdominal part of the operation is performed from the right side of the patient. The surgeon performing endodissection is positioned behind the left shoulder of the patient.

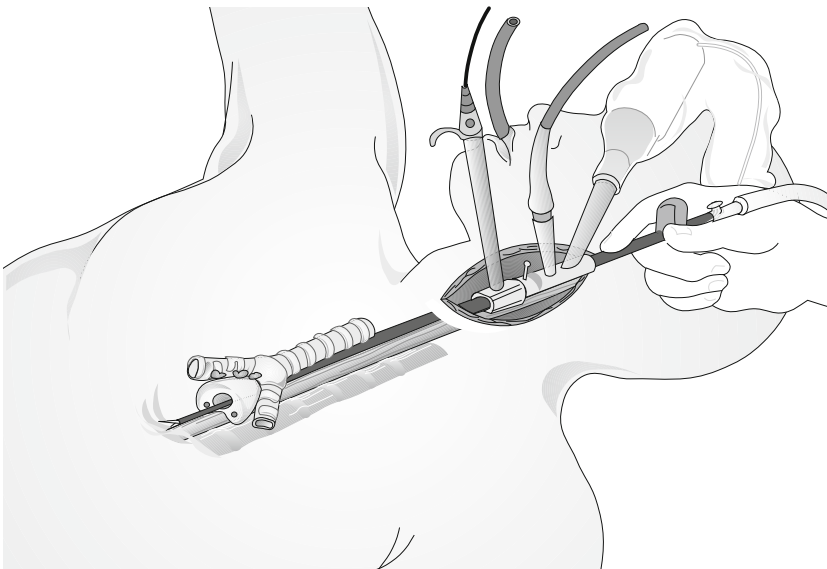
An oblique cervical incision parallel to the anterior edge of the sternocleidomastoid muscle is made and the omohyoid muscle is cut. After careful dissection of the left recurrent laryngeal nerve the cervical esophagus is exposed and held by a rubber sling. During this step of the operation, the esophagus is intubated with a large gastric tube. The posterior esophageal wall and the upper part of esophagus are dissected using a blunt technique. The tip of the endodissector is now introduced into the anterior mediastinum. The anterior esophageal wall is the anatomic landmark used



**Fig. 29.28.** After complete mobilization, all adjacent organs are easily seen.



**Fig. 29.29.** Positioning of the surgical team for endodissection of the esophagus. The surgical team for the abdominal part of the operation are positioned in the conventional way. The endoscopic surgeon stands at the level of the left shoulder of the patient; the screen is on the opposite side. Left – laterally to him – is his scrubnurse with the instruments for the endoscopic dissection (A: endoscopic surgeon, B: abdominal surgeon, C: assistants, D: scrub-nurses, E: anaesthetist).



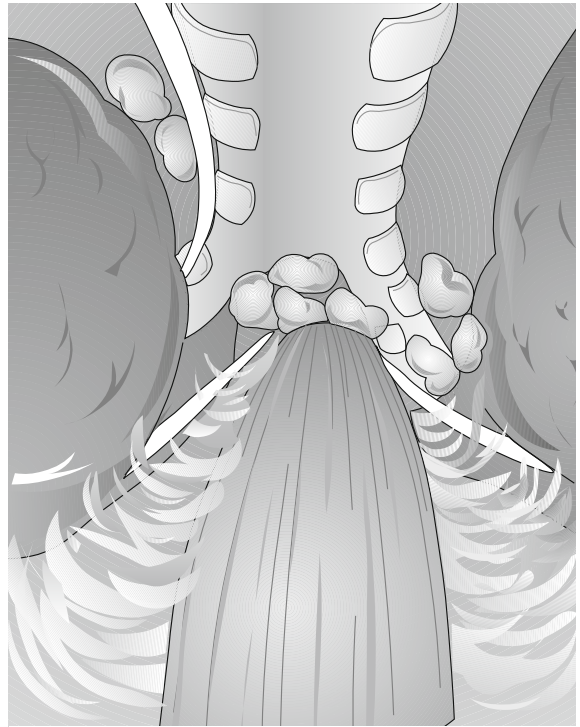
**Fig. 29.30.** Dissection of the anterior esophageal wall. The cervical esophagus is isolated through an oblique cervical incision, according to the conventional technique and controlled by a rubber sling. A modified mediastinoscope is introduced and placed anterior to the esophagus. Step by step

space between the posterior wall of the trachea and the esophagus is created by means of the tip of the instrument. Strands of connective tissue and small vessels are coagulated and dissected bluntly or using the scissors (Insert: tip of modified mediastinoscope, so called "bull's-head").

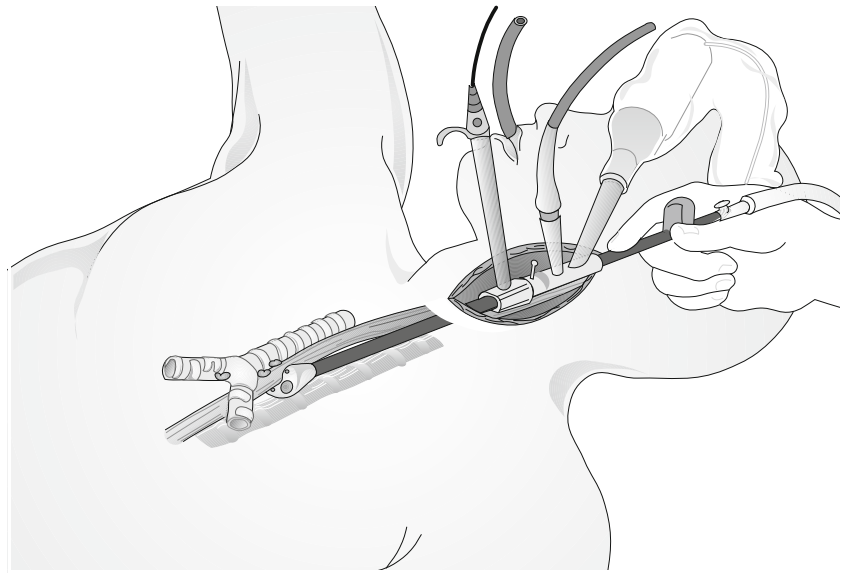


since it is identified more easily than adjacent structures. By the advancement of the thickened head of the instrument the paraesophageal tissue is put under traction which facilitates dissection using scissors or electrocautery. Proceeding step by step, the tracheal bifurcation is identified as another important anatomical landmark. Lymph nodes of this area as well as paratracheal lymph nodes are easily identified and removed.

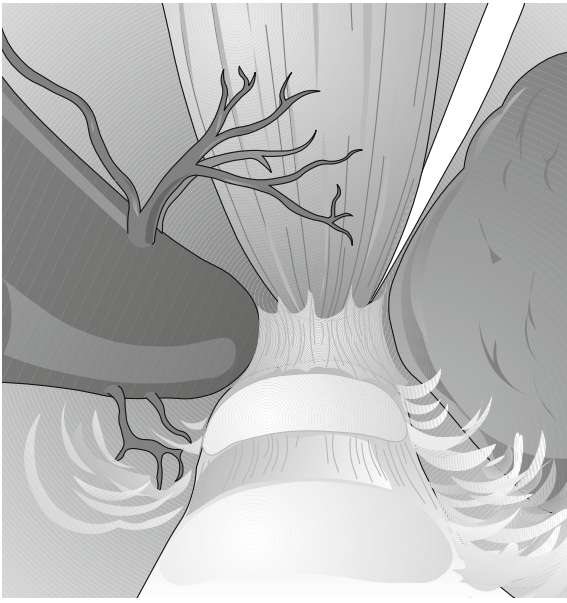The left recurrent nerve is easily recognized to the left of the trachea. Electrocautery should be avoided near the nerve to prevent thermal lesions of the nerve. After complete mobilization of the anterior aspect of the esophagus, the device is drawn back. The tip is rotated 180 degrees and inserted again into the mediastinum, now being positioned between the posterior esophageal aspect and the spine. Dissection of the posterior wall is easy. But dissection becomes more difficult on the left side, because of close adhesion to the left main bronchus which requires division as well as tissue bridges to the descending aorta. On the right side, the azygos vein has to be handled carefully. As on the anterior aspect, the poste-



**Fig. 29.31.** Dissection of the anterior esophageal wall. Lymph nodes below the tracheal bifurcation are exposed and excised.



**Fig. 29.32.** Dissection of the posterior esophageal wall. The tip of the modified mediastinoscope is rotated for 180° and is now advanced behind the esophagus.



**Fig. 29.33.** Dissection of the posterior esophagus wall.

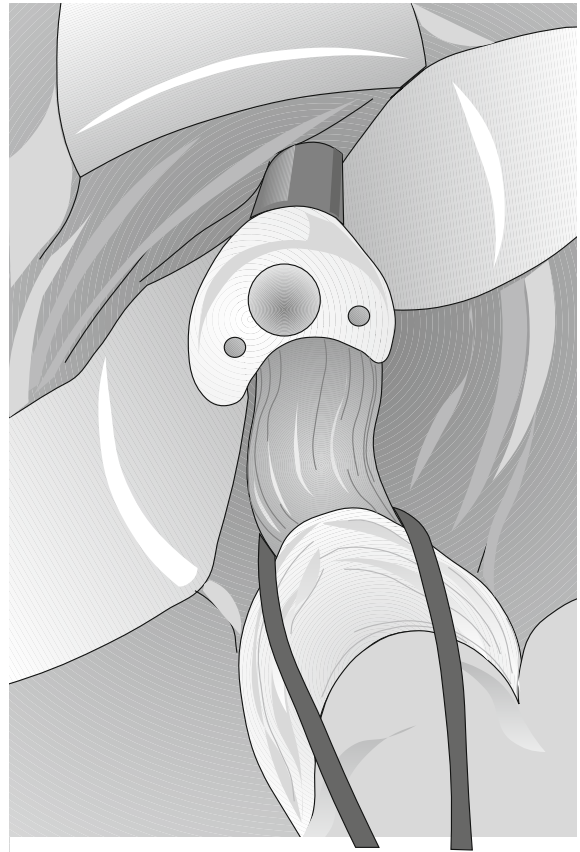
rior dissection is continued until the abdominal surgeon is met at the hiatus. Lesions to the visceral pleural are difficult to avoid. This is why we recommend placing thoracic drain at the end of the procedures.

Collection of fluid and blood in front of the endodissector requires continuous instillation of saline and aspiration.

Endodissection is particularly suitable for the mobilisation of the upper part of the esophagus. More distally, it is sometimes difficult to maintain the correct plane of dissection and perforations of the tumor of the esophagus may occur. Finally, the cervical esophagus is divided and removed in toto transabdominally. The esophagogastric anastomosis is performed in the usual way.

### ■ Comment

Thoracoscopic esophagectomy for squamous cell cancer of the esophagus – though being technically feasible – is still too time-consuming and too invasive to be considered acceptable as alternative to open transthoracic esophagectomy (Consensus Conference of the Internat. Soc. for Diseases of the Esophagus, Milan 1995). Further evaluation and technical im-



**Fig. 29.34.** Simultaneous abdominal procedure. Through a laparotomy, the hiatus is split, the esophagogastric junction including the crura of the diaphragm are mobilized, and the pericardial fat pad is resected. Complete mobilization of the distal esophagus is accomplished between the endoscopic and the abdominal surgeon. The cervical esophagus is divided and the esophagus is pulled down into the abdomen.

provements are required. For the time being, thoracoscopic esophagectomy should be confined to controlled clinical studies. Accordingly, adequate informed consent, documentation and scientific evaluation is necessary in each case. The situation is different for distal adenocarcinoma of the esophagus. Endodissection can be considered as a viable alternative to blunt transhiatal dissection, since the overall duration of the operation is shortened. The incidence of cardiopulmonary complications is reduced significantly. From the oncological point of view it is of interest that lymph node harvesting within the mediastinum is facilitated which has the potential to improve the survival rate.

# 30 Endoscopic Technique in the Treatment of Esophageal Diseases

Y.I. GALLINGER, M. REHNER, F.M. STEICHEN, N. SOEHENDRA

## Hemorrhage and esophageal varices

### ■ Introduction

Esophageal varices, ulcers due to reflux esophagitis, and Mallory Weiss lesions are the most common causes of esophageal hemorrhage. Less common causes include esophageal tumors (both benign and malignant) and iatrogenic lesions following endoscopic or surgical procedures. In all these cases, endoscopic management is the treatment of choice. To improve clinical outcome, a combination of various specialized endoscopic techniques may be required.

### ■ Indications

Endoscopic management is indicated in all instances of overt bleeding. In patients with hypovolemic shock, initial volume resuscitation is important. In order to temporarily stop massive variceal bleeding before endoscopy, pharmacotherapy and balloon tamponade using the Senkstacken Blakemore tube or the Minnesota tube may be needed.

### ■ Contraindications

In the context of emergencies like massive bleeding, time consuming diagnostic procedures are unnecessary and only serve to delay definitive treatment. However, it is necessary to obtain certain key information such as patient blood group and coagulation status. These can be evaluated simultaneously as the patient is being resuscitated.

### ■ Instruments

- Gastroscopes with a large working channel (3.7 or 6 mm) or with 2 channels for simultaneous suction and treatment
- Two powerful suction pumps with large containers
- Water pump for flushing to improve visibility
- Injection catheters for sclerotherapy
- Loaded clip applicator
- Over-tube and guide-wire in the context of single band ligation (Stiegman-Goff)
- Set for multi-band ligation (e.g. Six-shooter, Speedband)
- Injection solutions: epinephrine diluted with normal saline (1:20 000); N-butyl-2-cyanoacrylate mixed with lipiodol (0.5 ml:0.8 ml); polidocanol 1% or other sclerosants according to local preferences.

### ■ Patient position. Left lateral position.

### ■ Special techniques

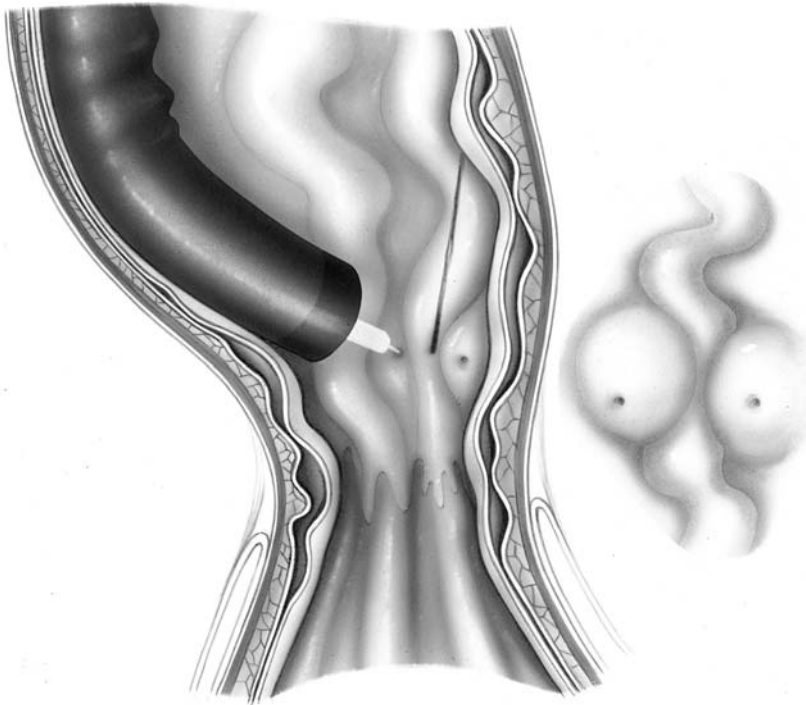
Identification of the actively bleeding site and source is crucial. With continued bleeding, sufficient volumes of washing solutions and adequate suction (2 pumps) are necessary to ensure adequate visibility.

#### 1. Stopping the hemorrhage

- Sclerotherapy (Fig. 30.1)
- Obliteration of bigger varices (Fig. 30.2)
- Clip application (Figs. 30.3–30.6)

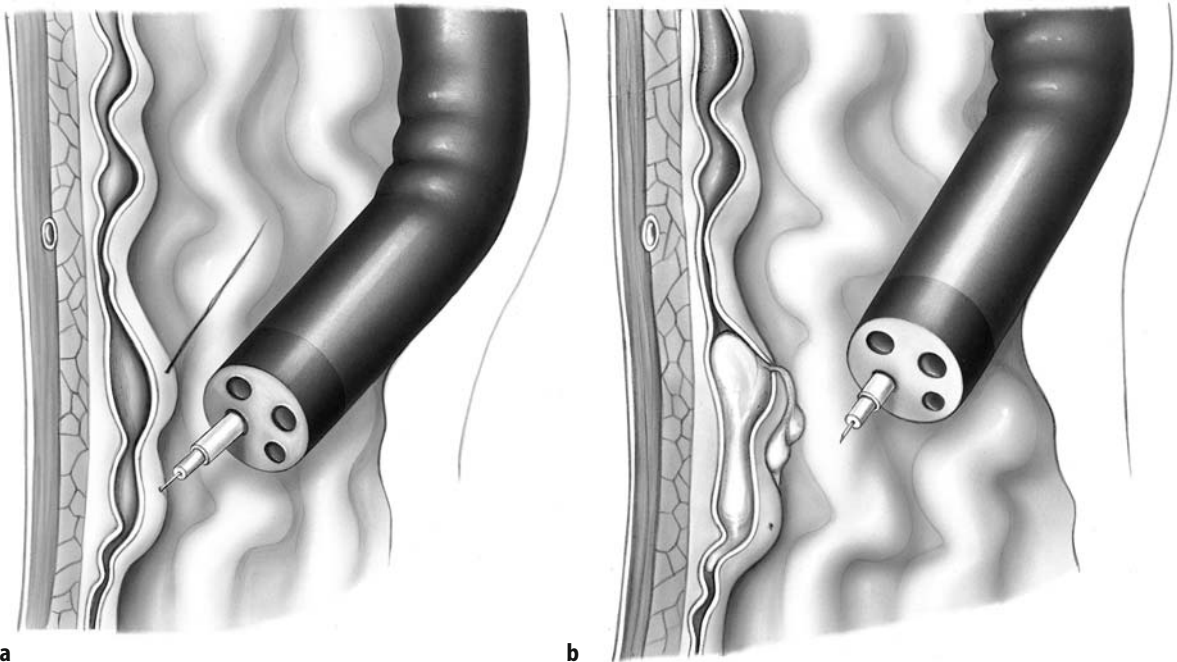
#### 2. Eradication of esophageal varices

- Perivascular injection of sclerosants (Figs. 30.7–30.9)
- Band ligation (Figs. 30.10–30.14).



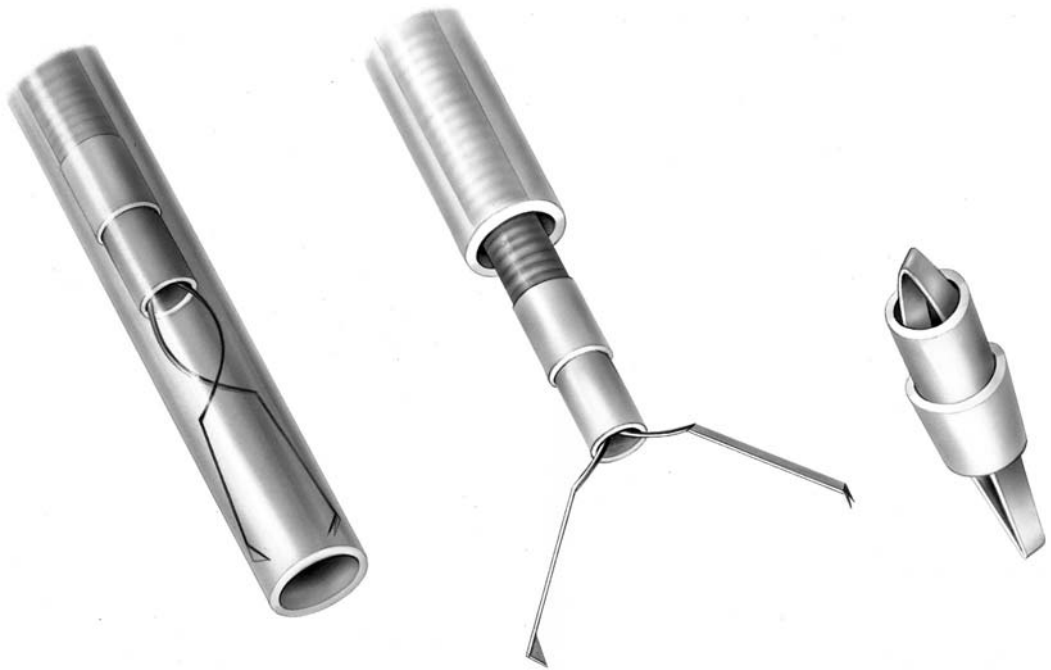
**Fig. 30.1.** Injection treatment for bleeding esophageal varices. This technique is also used for other types of hemorrhage. The injections are made around the lesions; the sequence of injection is from distal to proximal, so that one has better visibility. In non-variceal bleeding, 0.05% epinephrine solution alone can be injected around the lesion to

create a tamponade effect for initial hemostasis. If the tissue at the bleeding site is indurated due to scars or tumor infiltration, the injection technique might be more difficult or less effective; one should then try alternative techniques such as argon plasma coagulation or clipping.



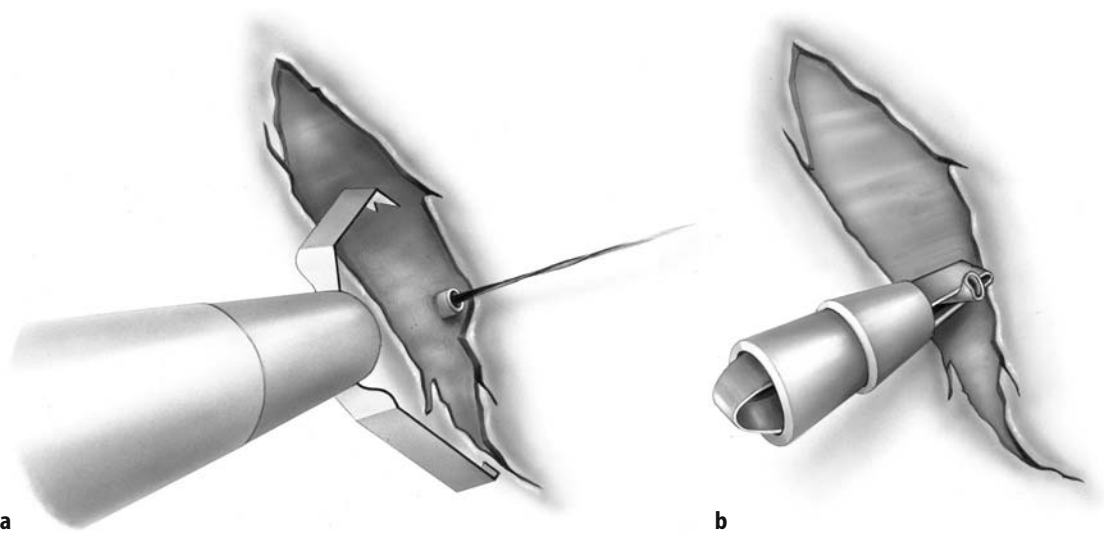
**Fig. 30.2 a, b.** Intravascular injection of a tissue adhesive is safer than sclerotherapy in the context of severe variceal bleeding. The volume injected each time should be limited

to 0.5 ml to reduce the risk of distal embolizations. An alternative technique is rubber band ligation.



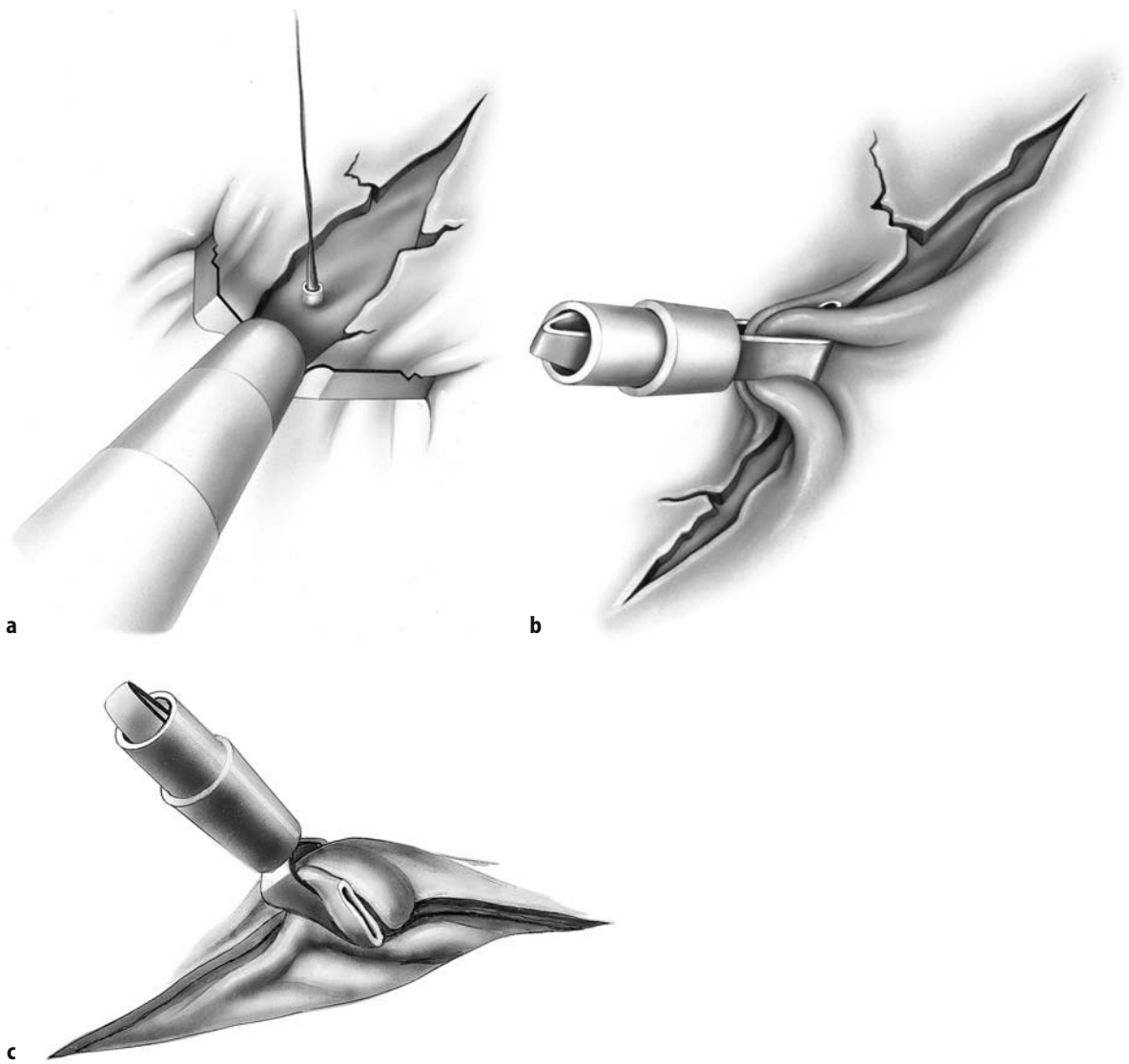
**Fig. 30.3.** Non variceal bleeding such as Mallory-Weiss lesions and ulcers due to reflux esophagitis can be reliably stopped by application of clips. This technique is performed with a special delivery system through the working channel

of the endoscope. If several clips are needed, several loaded applicators should be kept ready as a precaution. Left figure: system in position; right figure: the technique of correctly tightening the clip.



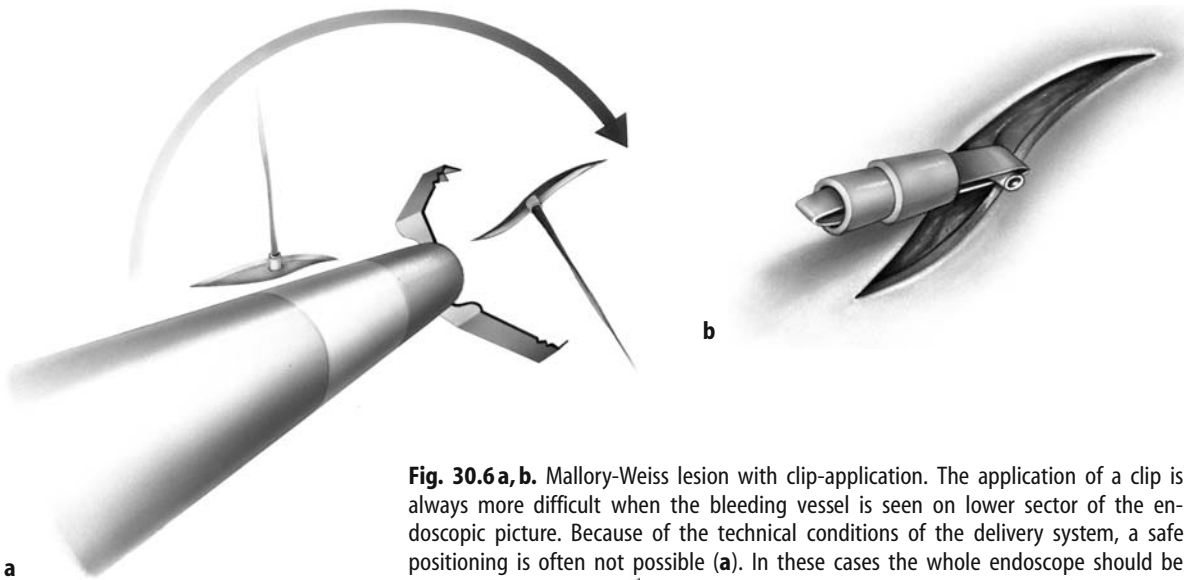
**Fig. 30.4a,b.** Mallory-Weiss lesion with clipping of a large artery. Sometimes the bleeding artery itself can be grasped with a clip (a) and the clip applied directly (b). The necessity

for more clips proximal or distal to the artery should be decided individually.

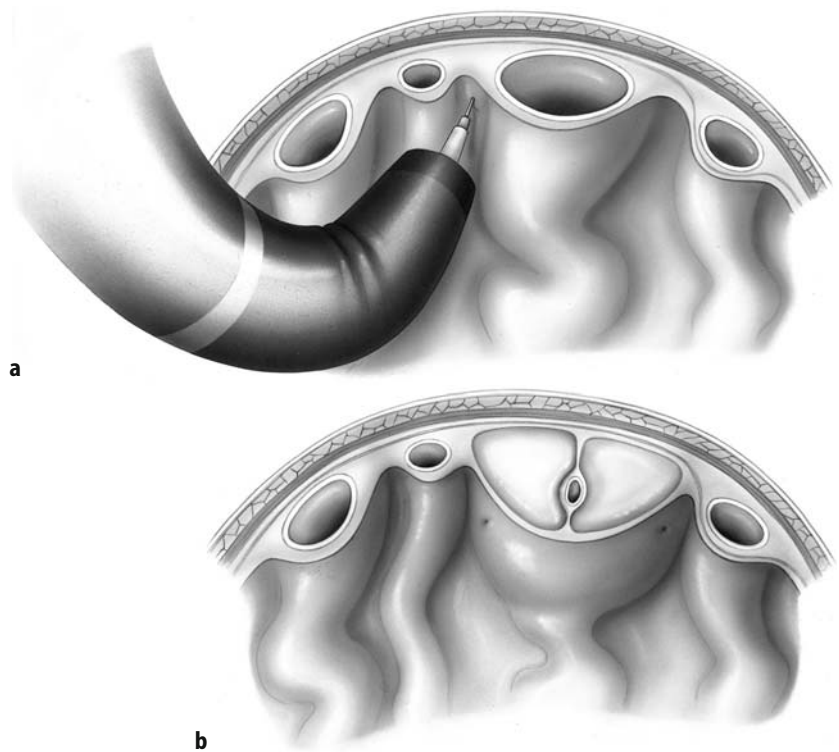


**Fig. 30.5 a–c.** Mallory-Weiss lesion with clip application. In most cases, direct occlusion of a bleeding artery is not possible. One could then grasp the mucosa on either sides of the lesion with the clip in order to occlude the vessel (a).

Whether one should grasp both sides of the adjacent mucosa (b) or only one side (c) depends on the individual situation. The important points are occlusion of the bleeding vessel and anchoring the clip securely in the tissue.

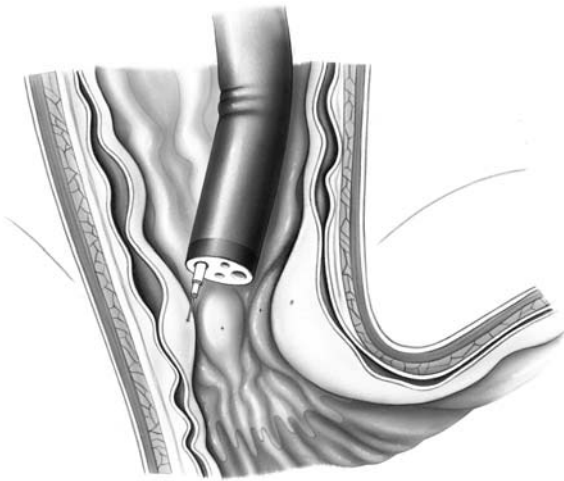


**Fig. 30.6 a, b.** Mallory-Weiss lesion with clip-application. The application of a clip is always more difficult when the bleeding vessel is seen on lower sector of the endoscopic picture. Because of the technical conditions of the delivery system, a safe positioning is often not possible (**a**). In these cases the whole endoscope should be rotated by  $190^\circ$  to get the bleeding lesion into the upper segment of the picture (**b**). Thereafter one can commence clip application.

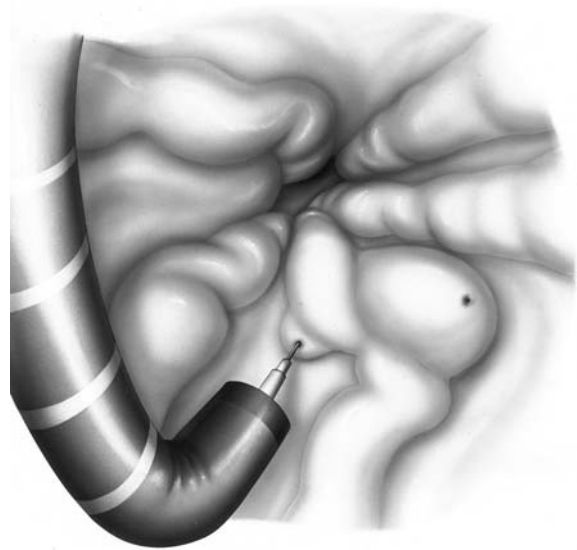


**Fig. 30.7 a, b.** Eradication of esophageal varices. The varices in the distal esophagus are at risk for hemorrhage because they run just beneath the epithelium (**a**). The aim of the treatment is to cause tissue fibrosis and perivascular induration using chemical solutions (e.g. polidocanol 1%). The concentration of

these solutions cannot be too high because otherwise tissue necrosis with perforation may occur. Injections are made on both sides of the vessel with volumes of 1–2 ml until tissue swelling is seen (**b**). The treatment must be repeated at weekly intervals until the varices are completely eradicated.

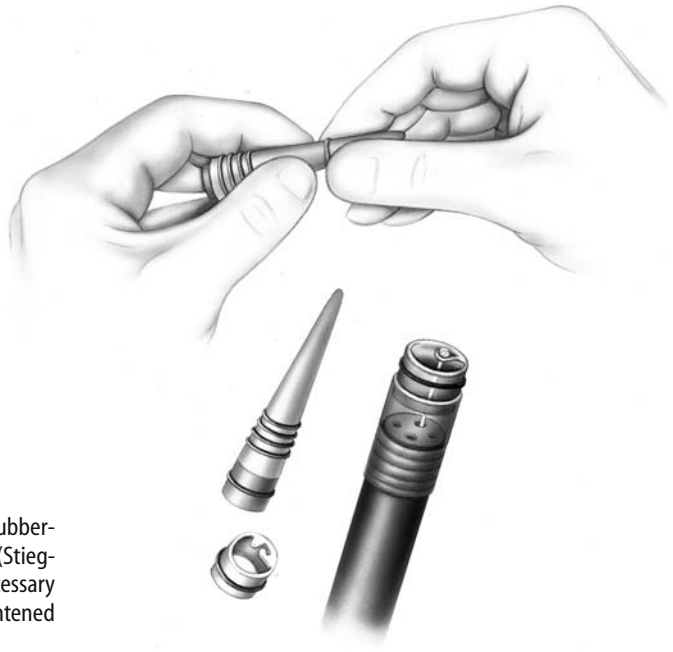


**Fig. 30.8.** Eradication of esophageal varices. The treatment starts at the distal part of a varix. Using this technique, minor bleeding after injections is common but does not affect the further treatment of the more proximal segments.




**Fig. 30.9.** Eradication of esophageal varices. One should ensure accurate perivascular and subepithelial injections. Intravascular injections are not effective because the sclerosant is diluted by the rapid blood flow and will also predispose to systemic side-effects. Deeper injections can cause necrosis of the wall with possible perforation; stenosis due to scars may develop later.



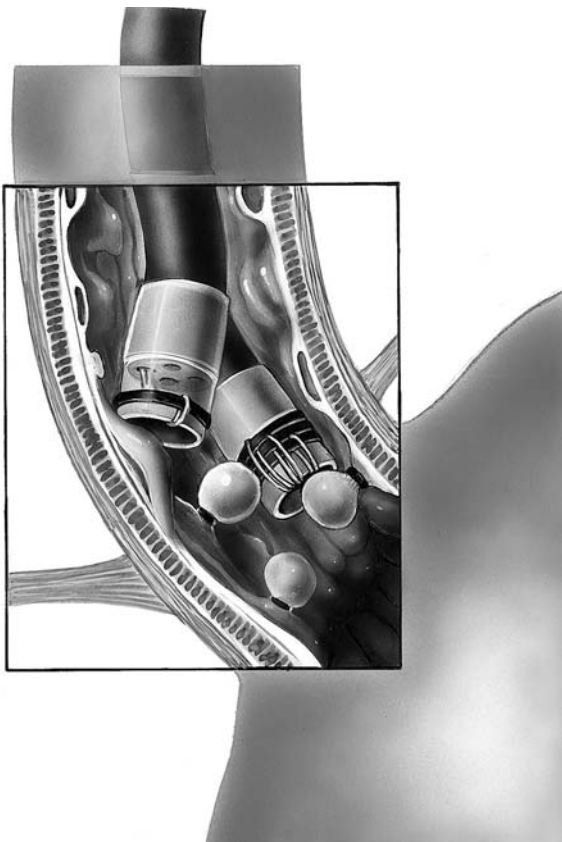


**Fig. 30.10 a, b.** Eradication of esophageal varices by rubber-band ligation. Instrument for single-band application (Stigman-Goff) (a). Using this technique, over-tubes are necessary because each rubber-band must be loaded and tightened separately before application (b).

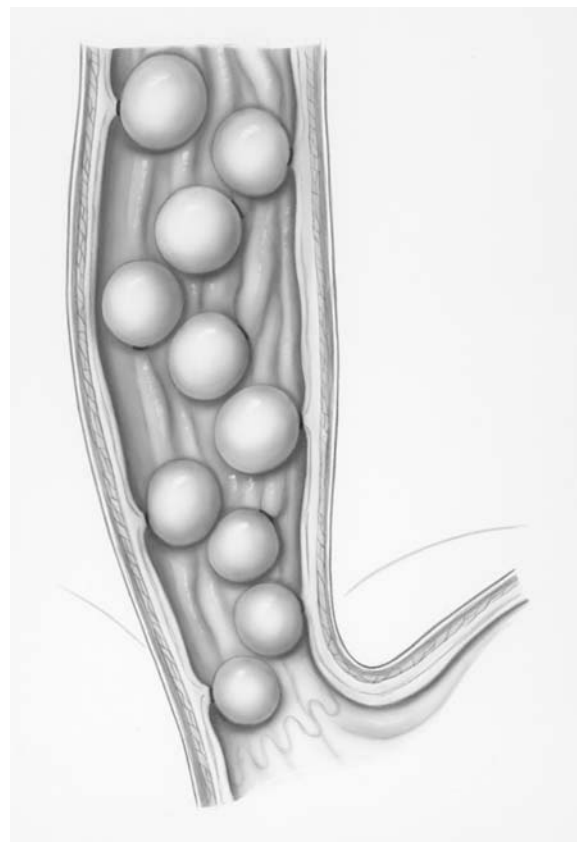


**Fig. 30.11 a–d.** Eradication of varices by rubber-band ligation using instruments for multiple-band applications (Six-shooter or Ten-shooter). The endoscope need not be withdrawn prior to each application and hence over-tubes are unnecessary (a, b). By the application of six or more bands

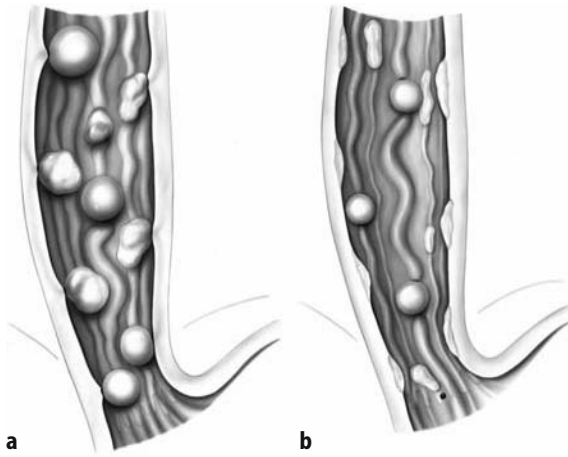
during one session, it is possible to ligate the varices adequately. The placement of the rubber-bands is managed by a special application set which is fixed to the working channel of the endoscope (c, d).



**Fig. 30.12.** Eradication of esophageal varices by rubber-band ligation. The ligations are performed from distal to proximal, starting with the biggest vessel. Ligations are made in spiral fashion to avoid later strictures.



**Fig. 30.13.** Eradication of varices by rubber-band ligations. The appearance after treatment.



**Fig. 30.14 a, b.** Eradication of esophageal varices by rubber-band ligations. After a couple of days, thrombosis and shrinking of the varix occurs. Demarcation of the tissue begins after 1–2 weeks, leaving flat lesions (**a**). A new layer of epithelium then forms (**b**). If necessary, additional treatments can be started after 4 days. Further sessions of variceal ligation may be continued at weekly intervals until the eradication is achieved. For many patients additional treatment with sclerotherapy may be necessary to obtain adequate fibrosis of the esophageal wall.

### ■ Complications

■ **Intractable hemorrhage.** Management: surgical treatment. This is associated with high morbidity and mortality.

■ **Recurrent bleeding.** Recurrent bleeding occurs mainly during the first 3 to 5 days after initial successful hemostasis. It is usually observed after sclerotherapy of varices. In this case, endoscopic obliteration of the varices

using tissue adhesive (e.g. N-butyl-2-cyanoacrylate 0.5 ml with lipiodol 0.8 ml) is useful in preventing further recurrences.

In Mallory-Weiss lesions, recurrent bleeding may occur with deeper tears. Application of clips should be used after initial injections of epinephrine (1:20 000 dilution).

■ **Perforations.** Prevention: Injections should be limited to the submucosa by selecting the correct needle length and controlling the depth of needle insertion. The volume per injection should be limited to 1–2 ml.

Treatment: Close clinical monitoring is necessary for early detection of mediastinitis. If in doubt, fluoroscopic examination with water-soluble contrast may be used. Conservative treatment with antibiotics and parenteral nutrition may be successful. If necessary, surgical treatment should be carried out. As an alternative to surgery, stenting has been used successfully in selected cases.

■ **Strictures.** Strictures may occur in a small number of cases after sclerotherapy. They result from deep tissue necrosis of the esophageal wall due to incorrect injection techniques.

Treatment: Endoscopic dilatation.

■ **Emboic complications.** They may occur after injections of excessively large volumes of N-butyl-2-cyanoacrylate during obliteration of varices. Prevention: Injection of smaller volumes (per injection: maximum volume of 0.5 ml for esophageal varices and 1 ml for gastric varices).

## Foreign bodies and bolus obstruction

### ■ Introduction

This problem arises mainly in children who swallow toys and other objects. In adults, bone fragments, fish-bones, parts of prostheses, or needles kept between the lips by tailors may be found. Bigger and bulkier foreign bodies are observed in psychiatric patients and in the context of self-destructive manipulations (e.g. in prisoners). These foreign bodies can be found in the stomach or impacted in the esophagus, such as coins in smaller children. Bolus obstruction may be a consequence of asymptomatic disturbances of the esophageal motility. Bolus obstruction may also occur in deep reflux-related esophageal ulcers or in stenotic scars. The occlusion of the esophageal lumen is very often followed by painful spasms that cannot be stopped with medications. Endoscopic removal of foreign bodies is the treatment of choice. If this is not available, fluoroscopy guided removal of foreign bodies using catheters (e.g. Foley catheters) can be tried. Open or minimally invasive surgery is limited to rare situations.

### ■ Indications

Every obstructing foreign body should be removed as soon as possible. Sometimes it is possible to push it into the stomach, as in the case of meatballs. However, it is absolutely necessary to extract all objects that might damage the intestinal wall or block the passage at areas with a narrow lumen (e.g. pylorus and ileocecal valve). Mini-batteries should be removed because of possible poisoning.

### ■ Contraindications

Small, non dangerous foreign bodies which are expected to pass out spontaneously do not need further treatment. The passage of these foreign bodies may be monitored using fluoroscopy if they are radio-opaque.

### ■ Preliminary procedures

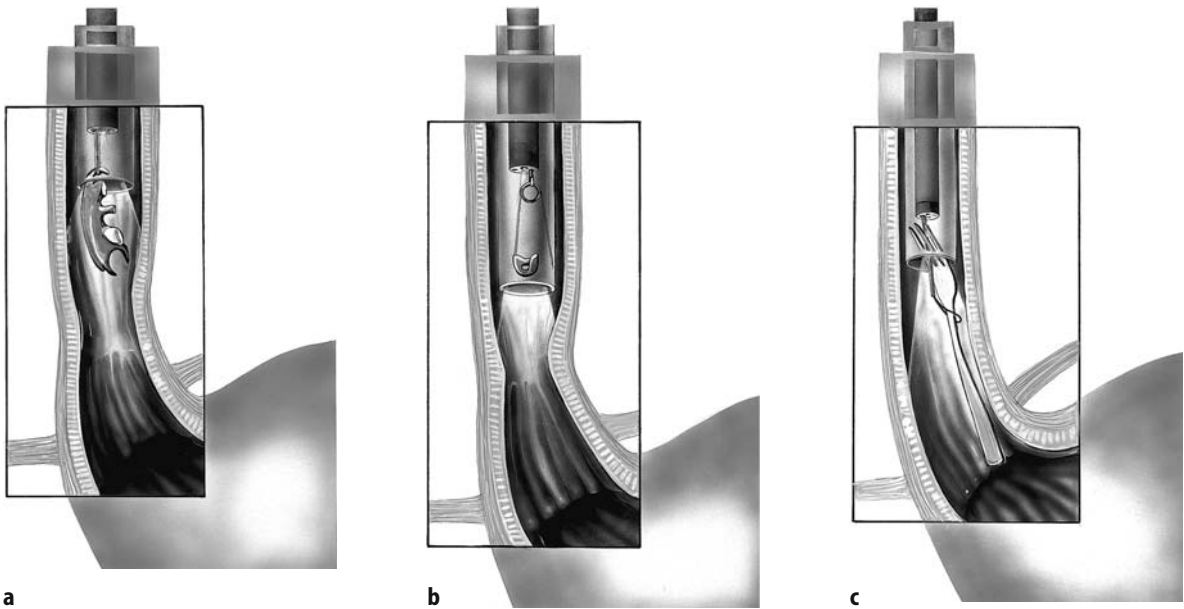
- Fluoroscopy is used to identify the diameter and configuration of the foreign body in order to guide the choice of instruments. During fluoroscopy of the thorax, the cervical esophagus must be observed carefully. The use of contrast such as gastrografin may be helpful in finding non radio-opaque objects.
- Premedication: Analgesia-sedation; for children and non co-operative patients, general anesthesia.
- Position: Left lateral.
- Monitoring and instrument-check.

### ■ Instruments

Gastrosopes with large working channels should be favored. Additional equipment: overtube; collecting sacs or umbrellas to protect the esophageal wall from injuries; different types of forceps and loops; Dormia basket; accessories to cut or break bigger boluses or bezoars.

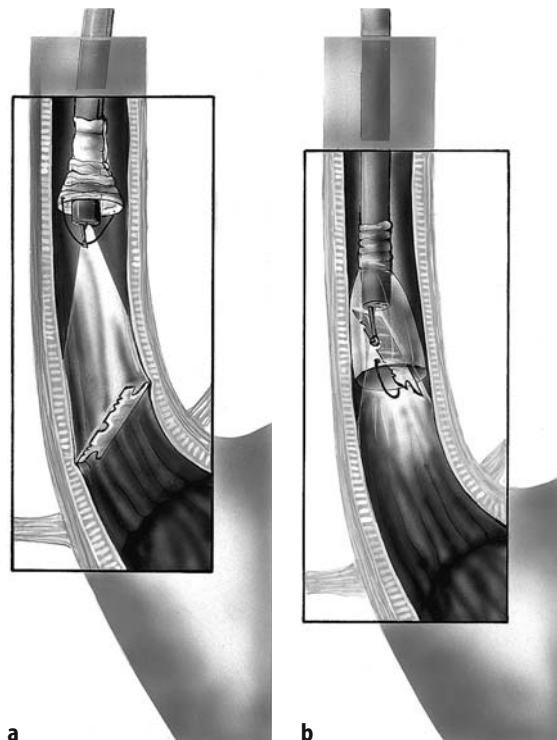
### ■ Special technique

- Extraction with forceps, loop, and Dormia basket (Fig. 30.15)
- Extraction with protection by cap and umbrella (Figs. 30.16–30.18).

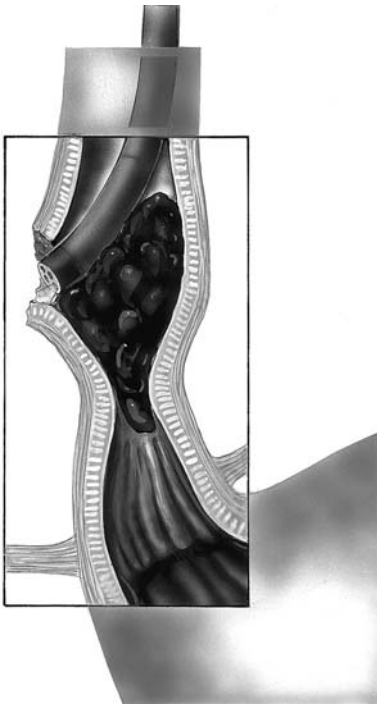


**Fig. 30.15 a–c.** Only smooth foreign bodies that do not injure the esophageal wall should be extracted without protective accessories. For this purpose a cap fixed to the tip of the endoscope is normally sufficient. An over-tube is used with protective accessories; the diameter of the protective

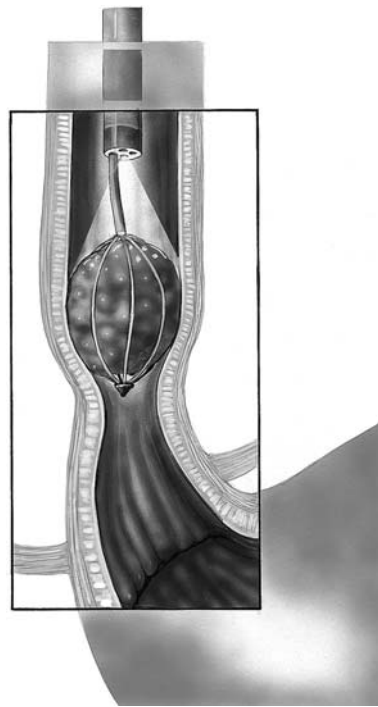
accessory is much larger than the foreign body and can help to extract foreign bodies like prostheses, safety-pins, or forks (a–c) without injuring the proximal parts of the esophagus. Extraction of the foreign body can be performed using forceps or snares.



**Fig. 30.16 a, b.** An umbrella fixed to the tip of the endoscope is a different type of protector. During the insertion of the instrument, the umbrella is still folded. After positioning the instrument in front of the foreign body, the umbrella is moved forward by grasping a fixed bow (a). The different umbrella diameters allow the safe extraction of even larger and dangerous foreign bodies (b).



**Fig. 30.17.** For bolus obstructions that are already present for a couple of days, one must avoid pushing the bolus distally with the endoscope. There may already be early necrosis of the esophageal wall, with an attendant risk for perforation if the bolus is pushed distally without visualizing the lumen.



**Fig. 30.18.** Hard meatballs or phytobezoars can often be grasped and extracted with a Dormia basket or with a snare. Rat-tooth forceps or nets are adequate to extract foreign bodies such as coins, mini-batteries, or small toys in children. Soft meatballs sometimes can be removed with suction using a cap. Very hard big balls or bezoars should be macerated with special instruments under endoscopic control (e.g. Bezotome, Bezotriptor).

## ■ Complications

■ **Perforation.** Injury of the esophageal wall with perforation is the most serious complication.

**Prevention:** In all cases with possible injuries and a need for repeated intubations, overtubes should be used.

**Treatment:** Superficial mucosal injuries do not require any active treatment. When deep tears occur, perforation with its attendant risk of mediastinitis should be checked for by radiography using water soluble contrast. However, CT is a much more sensitive method for detecting free air. Most of the smaller perforations can be treated conservatively by clips, parenteral nutrition, and antibiotics. Larger perforations will need surgery.

■ **Aspiration.** To prevent aspiration of foreign bodies during endoscopic extraction, overtubes and/ or net retriever baskets are used. In cases of high risk for aspiration, especially in children, general anesthesia should be used.

## ■ Follow-up

In uncomplicated cases, normal diet can be started early and no further follow-up is necessary.

## Resection of tumors

### ■ Introduction

The majority of benign tumors arise from the submucosal layer. Tumors arising from the epithelium (e.g. adenoma, papilloma) are not frequent. They are mainly located in the distal esophagus. Smaller submucosal tumors can be resected endoscopically, if the location is confirmed by endosonography (EUS). One must consider the risk of perforation. The endoscopic resection of malignant tumors of the mucosa (EMR or Endoscopic Mucosal Resection) is gaining popularity. Long-term results are comparable with surgery. Prior to EMR, precise staging using EUS is necessary. Besides EMR, different techniques of thermoablation are used (eg. electrocautery, laser ablation, and photodynamic therapy).

### ■ Indications

- Flat and elevated malignant tumors in all parts of the esophagus limited to the mucosa [stage T1m, N0, M0]
- Benign mucosal tumors
- Selected cases of benign tumors arising from the submucosa or from the muscularis mucosa.

### ■ Contraindications

Endoscopic resection should be avoided in all tumors arising or infiltrating beyond the submucosa. Large tumors (diameter greater than 3–5 cm) have a higher risk of perforation after endoscopic resection and should be managed individually.

### ■ Preliminary examinations

Endoscopy with sufficient number of biopsies; EUS for accurate staging and, if necessary, EUS guided fine needle aspiration biopsy (FNA); coagulation tests.

### ■ Pretreatment preparations

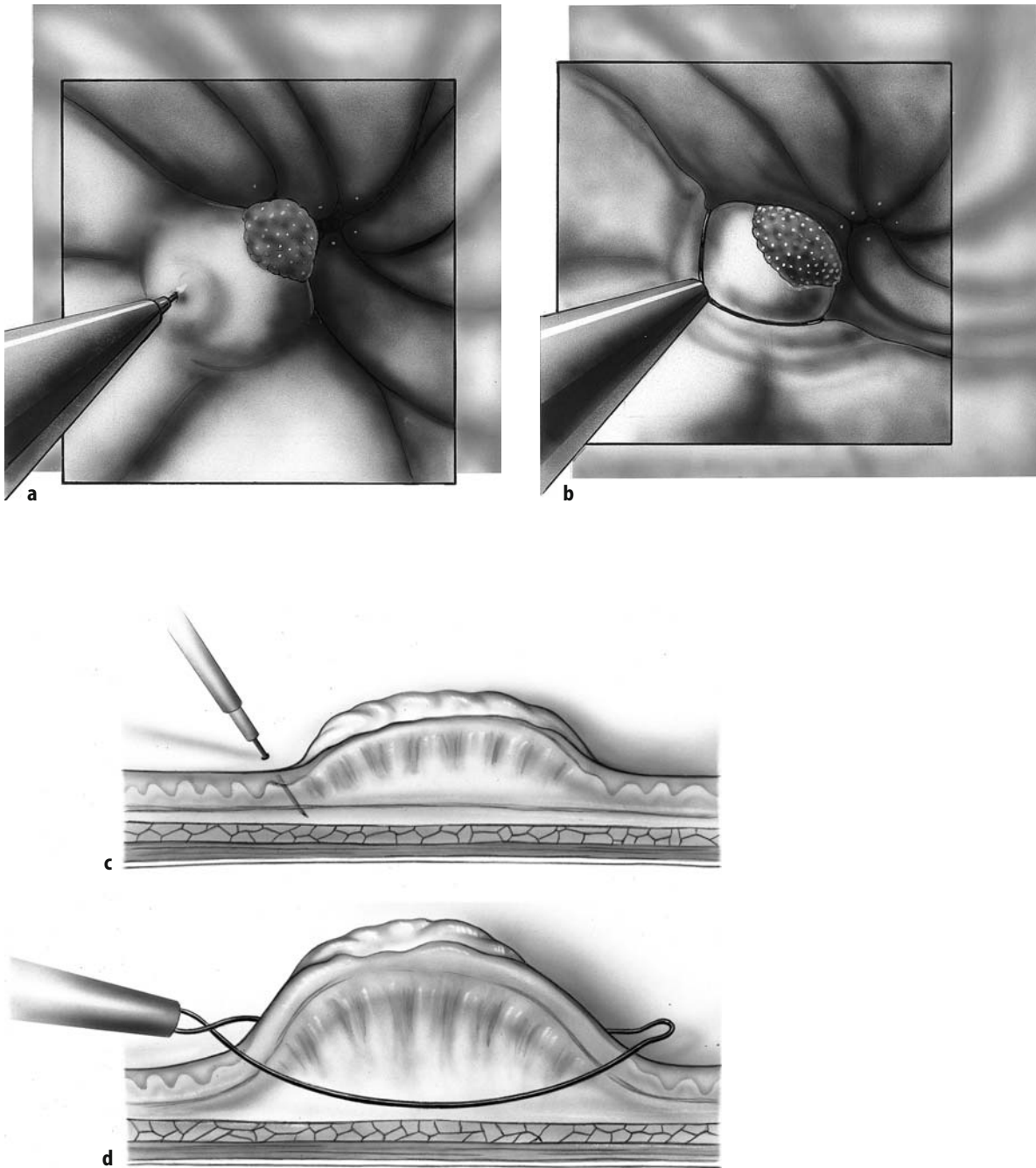
- Monitoring and instrument check
- Premedication: Analgesia-sedation
- Position: Left lateral.

### ■ Instruments

Gastrosopes with large or dual working channels are helpful; HF generator for electrocautery; injection needles with solutions for mucosal elevation and treatment of hemorrhage (epinephrine 1:20 000); band ligator and transparent cap for suction of the mucosa to the instrument tip; snares for cutting; forceps; needle knife for 2-channel technique; chromoendoscopy using solutions such as lugol iodine, indigo carmine and methylene blue to stain the tumor may be needed.

### ■ Special technique

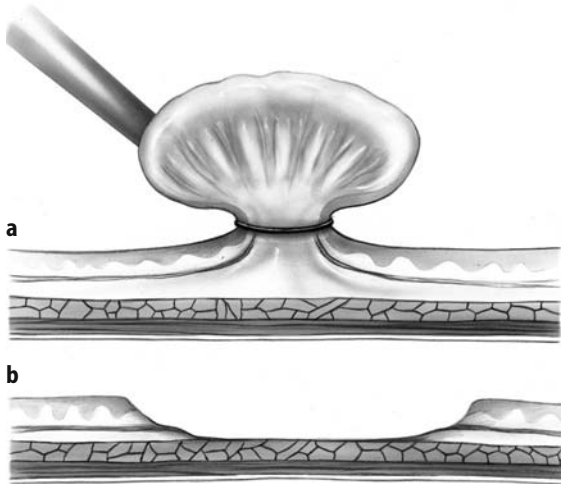
- Tumor resection with submucosal injection and loop; mucosa aspiration with cap (Figs. 30.19–30.22)
- Tumor resection with band ligation (Fig. 30.23)
- Tumor coagulation with argon plasma coagulation, laser ablation, or PDT.



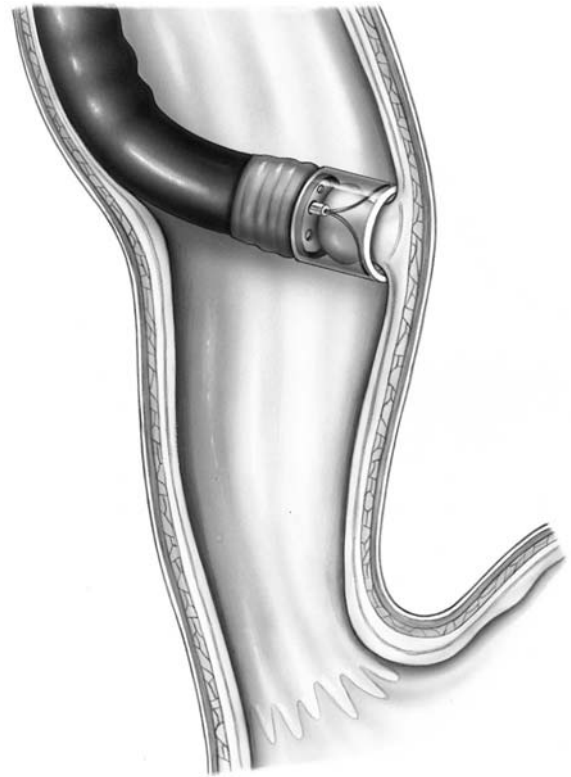**Fig. 30.19 a, b.** Endoscopic mucosal resection (EMR). The mucosa containing the tumor is elevated by injection of the submucosa with 0.05% epinephrine solution. This elevation of the tissue makes it easier to grasp the entire tumor with a snare (**a**). Simultaneously, the liquid cushion protects the wall from thermal injuries. If needed, the tumor margins can be demarcated using chromoendoscopy. Lugol's solution is

used for squamous cell tumors, while an adenocarcinoma is stained with methylene blue or indigocarmine (**c**). EMR can also be performed without preliminary injections; with this technique, it is helpful to let the wall collapse while sucking the air, with the intention to grasp a larger area of the mucosa within the snare (**b**). For resections, snares with stiff monofilament wires should be used (**d**).

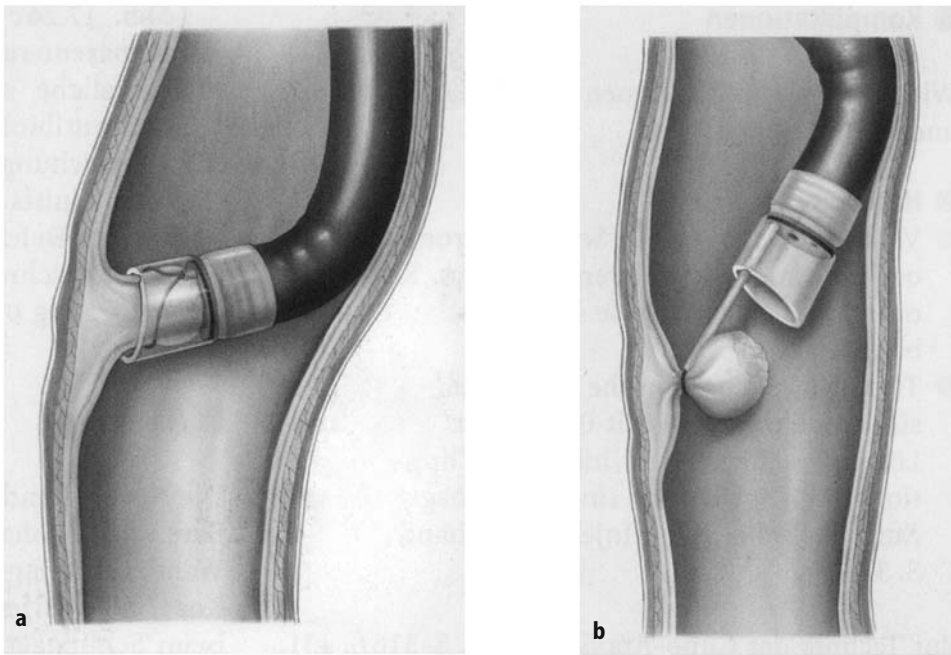




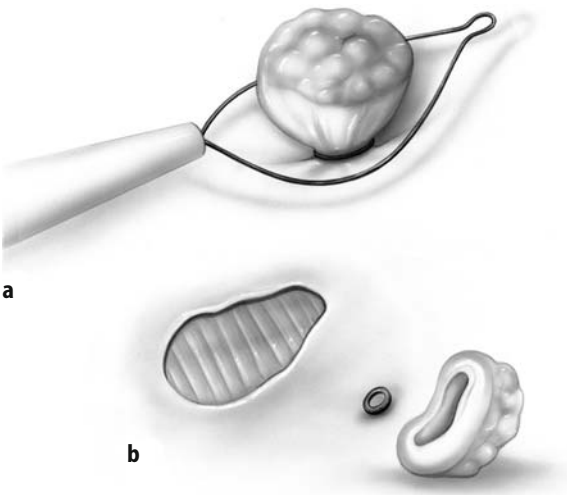
**Fig. 30.20 a, b.** Endoscopic mucosal resection (EMR). To prevent perforation, the correct technique for cautery should be observed. The snare must grasp only the mucosal and submucosal layers. The submucosa is expanded by preliminary infiltration (**a**). After resection the muscularis propria may be exposed (**b**). It should remain unscathed.



**Fig. 30.21.** Endoscopic mucosal resection (EMR). Another technique to ensure safe resection is the suction of the tissue using a cap. An asymmetrical snare made of braided wire is preloaded in the inner gutter of the cap and grasps the tissue layer after suction. For resection pure coagulation current with 60 W power is used.



**Fig. 30.22 a, b.** Endoscopic mucosal resection (EMR). Submucosal infiltration and suction can be combined (**a, b**). This technique is an additional safety step to prevent perforations (Inoue technique).



**Fig. 30.23 a, b.** Endoscopic mucosal resection (EMR). Rubber-band ligation can be used as an alternative technique to elevate the tumor from the surrounding tissue (**a**). The cut is performed above the rubber-band. The rubber-band then slips off, leaving behind an ulcer (**b**).

## ■ Complications

The most important complications are hemorrhage and perforation.

■ **Hemorrhage.** Prevention: Resect slowly step by step, preferably using coagulation setting; preliminary band ligation of the tumor-bearing mucosa may be performed if feasible.

Treatment: Injection of 0.05% epinephrine-saline solution and clip application. Using coagulation to stop the hemorrhage should be avoided.

Technique of sclerotherapy, see p. 316.

Technique of clip application, see p. 317.

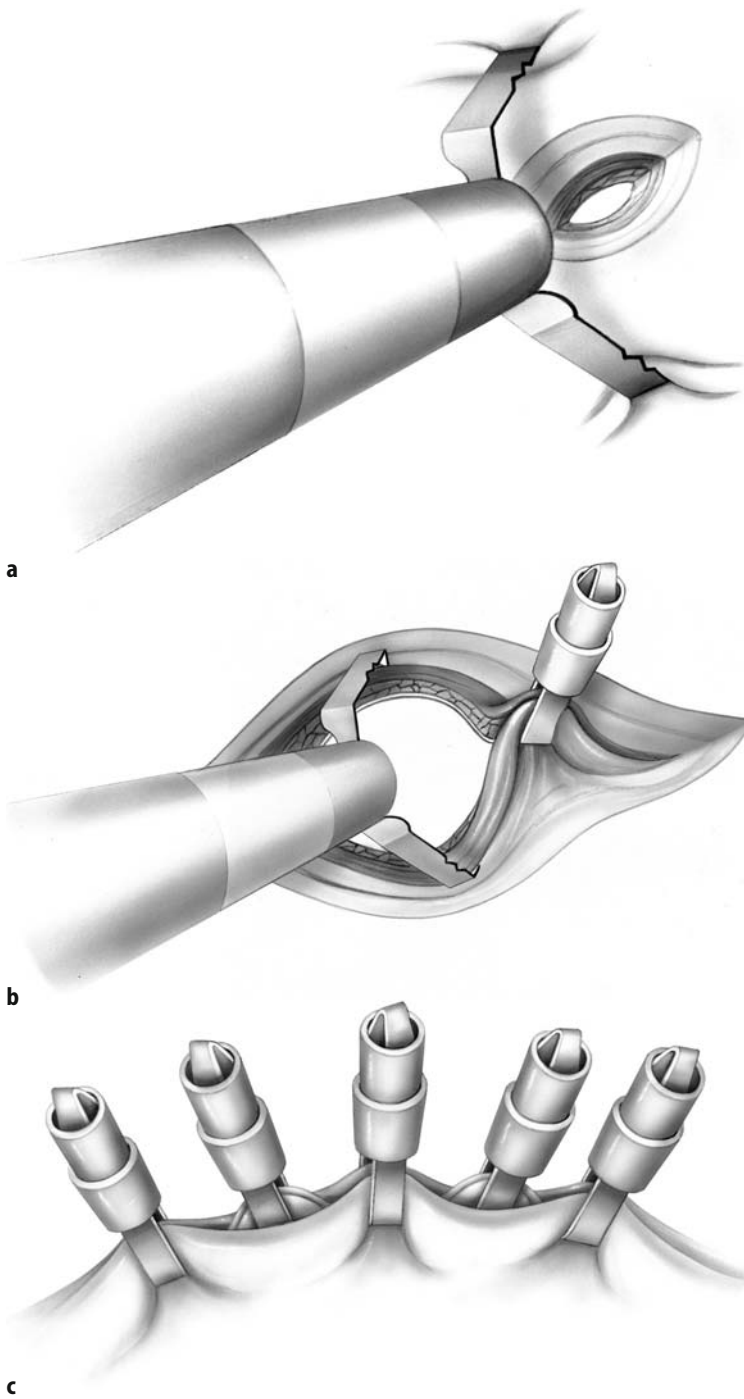
■ **Perforation.** Prevention: Infiltration of the submucosal layer with isotonic saline solution and strictly limiting the resection to the submucosa. When resecting benign submucosal tumors, the needle knife can be used to incise the mucosa, followed by enucleation of the tumor.

Treatment: Smaller lesions can be treated with endo-clips (Fig. 30.24), parenteral nutrition and antibiotics. Close monitoring is crucial for the early detection of mediastinitis and pneumothorax. In the case of larger perforations or suspected mediastinitis, open or minimally invasive surgery would be required.

## ■ Follow-up

After EMR of larger mucosal lesions, the patient may need to be kept fasted for a few days, depending on the size of the lesion and the clinical situation.

Surveillance with biopsies of the scar and surrounding areas should start 3 months later in all cases of malignant tumors with R-0 resections. Standards for further management and the value of additional tests such as EUS have not yet been established. In the case of thermoablation of tumors, surveillance with biopsies is mandatory after a shorter interval to confirm complete removal.



**Fig. 30.24 a–c.** Endoscopic mucosal resection (EMR). Perforation due to snaring of the muscle layer is a rare complication. If the injury is small and the edges smooth, it can be closed immediately using clips. In very small lesions which are not completely transmural, one can grasp the edges of the mucosa or mucosa plus muscle layer using just one or

two clips (a). For larger lesions a row of clips is first applied to the muscle layer (b). In between these clips a second row is added joining the mucosa and submucosa (c). Careful follow-up after endoscopic treatment of perforations is necessary to detect early signs of mediastinitis.

## Photodynamic therapy of tumors (PDT)

### ■ Introduction

Photodynamic therapy is based on the interaction of light with a photosensitizer that is retained, preferentially and for longer periods of time, by cancerous tissue compared with normal tissue. This interaction generates cytotoxic molecular reactions that result in tissue necrosis. The photosensitizer is first injected intravenously, followed 48 hours later by photoactivation with use of light that is transmitted through an optical fiber coupled to a cylindrical light diffuser. The light diffuser is introduced directly into the esophagus and positioned according to the measurements of the length of the lesion as determined during endoscopy. This technique has been used in selected patients for the past couple of years. Exact indications and contraindications have not been fully evaluated. Small case series have reported an acceptable efficacy when PDT is used as palliation for advanced tumors. Compared to other forms of thermoablative treatment, there are no significant advantages. A major adverse effect is the problem of skin photosensitivity which lasts for several weeks after the PDT session.

### ■ Indications

There is still a lack of data for appropriate patient selection for PDT. Only preliminary recommendations can be made. There is clinical experience with the following situations:

- Superficial spreading tumors of the mucosa [stage T1m]
- High grade dysplasia in Barrett's esophagus, especially for patients at high surgical risk
- Palliation of advanced non-resectable carcinoma.

### ■ Contraindications

- Resectable tumors arising from the submucosa or those with deeper infiltration (stage T1sm and higher)
- Suspicious involvement of regional lymph nodes in tumors of operable patients.

### ■ Preliminary examinations

Exact diagnosis of the tumor with endoscopic biopsy; EUS ± FNA for T and N staging.

### ■ Special preparations

Injection of the sensitizer (e.g. Porfimer-Sodium 2 mg/kg i.v.) 48 hours before treatment; patient should be fasted for 12 hours before treatment; premedication and safety procedures according to standard recommendations.

### ■ Instruments

A gastroscope with a large working channel, light generator, argon laser (630 nm wavelength), and an optical fiber coupled to a cylindrical light diffuser that is adapted to the extent of the tumor, monitoring unit. A dye solution to mark the borders of a spreading tumor (e.g. lugol iodine, indigo carmine, and methylene blue) may be required.

### ■ Special technique

The tumor is identified at endoscopy. If it is necessary to demarcate the tumor margins, chromoendoscopy is used. The light source is positioned over the tumor and photoradiation performed.

## ■ Complications

■ **Strictures** have been reported to occur in around 30%.

Treatment: Endoscopic dilatation.

■ **Perforations** are very uncommon.

■ **The ineffectiveness of the treatment** must be taken into account.

Due to the limited experience in small patient populations, the extent of the risk for complications cannot be accurately determined.

## ■ Alternative therapies in advanced tumors

- Chemical destruction of the tumor by injection of concentrated alcohol or other chemicals
- Laser ablation
- Electro-thermocoagulation
- Stenting.

## ■ Alternative therapies for elective tumor eradications

- In high grade dysplasia of Barrett's esophagus, an extended local eradication by argon plasma coagulation or Nd-YAG laser may be performed; this should be followed by long-term treatment with proton-pump inhibitors (PPI).
- Focal high grade dysplastic areas can be completely resected by EMR
- Extensive areas of multifocal high grade dysplasia may occasionally require surgery.

## ■ Follow-up

There should be protection from light exposure for 2 weeks. Surveillance biopsies should be performed after 4 weeks and then at regular intervals.

## Obstructions by malignant tumors

### ■ Introduction

Endoscopic management is the treatment of choice in malignant tumors causing esophageal obstruction. For inoperable patients or unresectable tumors, endoscopic techniques are often the definitive treatment. Alternatives for enteral feeding in these situations are percutaneous endoscopic gastrostomy (PEG) or -jejunostomy (PEJ). Relief of obstruction can be achieved by different endoscopic techniques such as bougienage and placement of an endoprosthesis, induction of tissue necrosis by the injection of solutions such as alcohol, and thermoablation. These techniques are commonly combined. We prefer the use of bougienage with subsequent stent placement. For obstructive tumors of the cervical esophagus, there is an additional risk of fistulae formation (tracheo-esophageal fistula, esophago-mediastinal fistula). If fistulae occur, modified stents are necessary in order to seal the fistulae. Injection and thermoablative techniques are mainly used for exophytic tumors prior to stent placement.

### ■ Indications

All patients with stenotic tumors of the esophagus can be treated. The treatment may be definitive or may serve as a temporary measure before surgery.

### ■ Contraindications

The presence of severe cardiac or respiratory decompensation which precludes the use of endoscopic procedures and premedication.

Advanced tumors without significant stenosis.

### ■ Preliminary examinations

- Endoscopy is used to determine the extent of the tumor and degree of stenosis. Biopsy is taken for tumor-typing.

- Screening for fistulae may be required (e.g. with bronchoscopy or radiography with water soluble contrast).
- Tumor staging by EUS.

### ■ Special preparations

- Premedication: Analgesia-sedation
- Monitoring: Based on recommended standards
- Prophylactic antibiotics (e.g. single dose prior to PEG)
- Positioning: left sided.

### ■ Instruments

- Gastroscopes, guidewires, bougies, and balloon dilators as per management of benign strictures.
- Injection techniques: the use of needles similar to that in the treatment of hemorrhage; solutions for tissue ablation e.g. absolute alcohol.
- Laser treatment: Nd-YAG laser; gastro-scope with a large working channel or 2-channel endoscopes to allow suctioning of the fumes generated during laser ablation.
- Stenting: Celestin-tubes of standard diameter (13 mm) or Baby-Celestin tube (11 mm); self expanding metal stents (Fig. 30.34). For proximal cervical stenoses with fistulae, the use of modified shortened Baby-Celestin tubes (Fig. 30.35).

### ■ Special techniques

- Dilatation (using guidewires and bougienage): Figs. 30.25–30.41
- Stenting (Figs. 30.30 a–c, 30.31 a–d, 30.37–30.40)
- Injection treatment
- Laser application

Injections of chemical solutions or laser application generate tissue necrosis after a few days, thus widening the lumen. For injections var-

ious solutions are used, but there is greater experience with the use of absolute ethanol, isopropanol, 3% povidocanol, and hypertonic saline (10–20%). These solutions are injected as multiple small deposits (0.5–1 ml) within the tumors. These treatments only have a temporary effect and should be repeated on demand or at short intervals. They are also often used as preliminary treatment prior to bougienage and stenting. In the palliation of stenotic tumors, stenting should be added in order to relieve obstruction for a longer time. Various techniques in stent placement are available, similar to those used in the treatment of fistulae.

### ■ Complications

■ **Hemorrhage.** It can occur during dilatations. Generally it stops spontaneously, but it can be treated by sclerotherapy if necessary.

■ **Perforation.** If perforation is suspected, fluoroscopic examination using water-soluble contrast should be performed immediately. Small lesions can be treated conservatively with parenteral nutrition, antibiotics and, in certain cases, placement of a stent. For larger lesions, surgery is safer.

■ **Stent migration.** Stent migrations are treated by endoscopic repositioning. For plastic stents it is sometimes more effective to place a new stent with a larger diameter (possibly one with a larger funnel and an additional distal stopper).

■ **Tumor overgrowth.** This can occur at both the proximal and distal ends of the stent. The tumor overgrowth can be treated by thermoablation or sclerotherapy. The treatment may need to be repeated depending on the clinical effect. Stent exchange is often more appropriate.

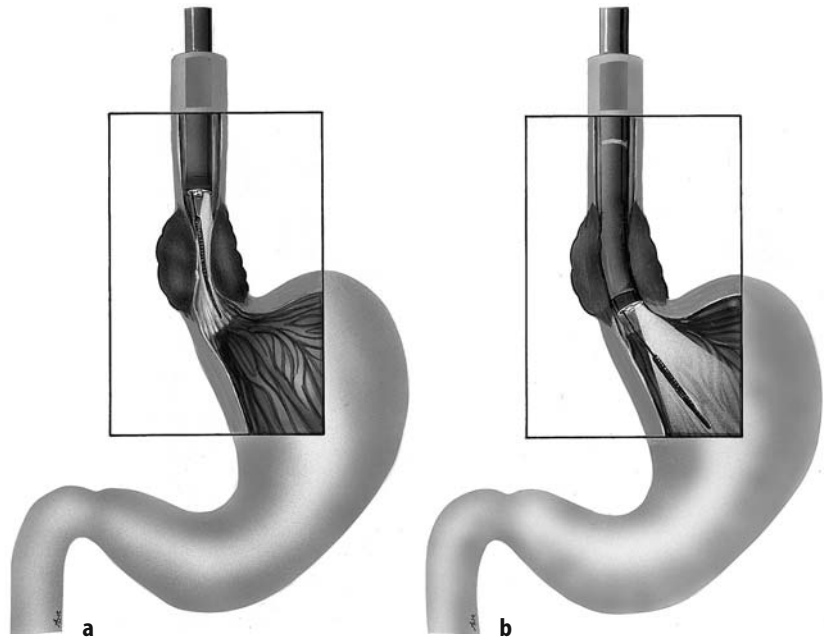
■ **Stent intolerance.** It is mainly observed after stenting of the cervical esophagus. Sometimes stent removal cannot be avoided. In that case, it has to be replaced by a nasogastric tube or PEG/PEJ. For uncovered metal stents, removal may not be easy. The use of removable covered stent is therefore recommended.

■ **Bolus obstructions.** Bolus obstruction is possible after stent placement. The treatment is similar to other forms of bolus obstruction. It may be prevented by allowing only a liquid or pureed diet.

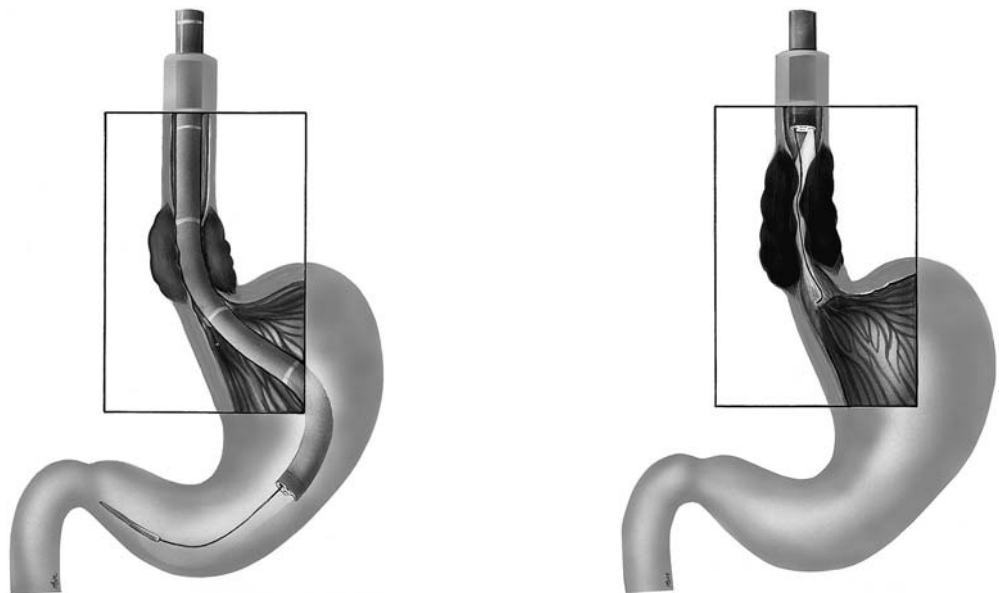
### ■ Follow-up

After an uncomplicated stent placement, liquid food is allowed after a few hours. This can then be followed by pasty and then normal soft diet. The correct position of stents should be monitored routinely during the first few days because most migrations occur early. Tumor overgrowth occurs only after a few months. Analgesics may need to be given during the first few days.



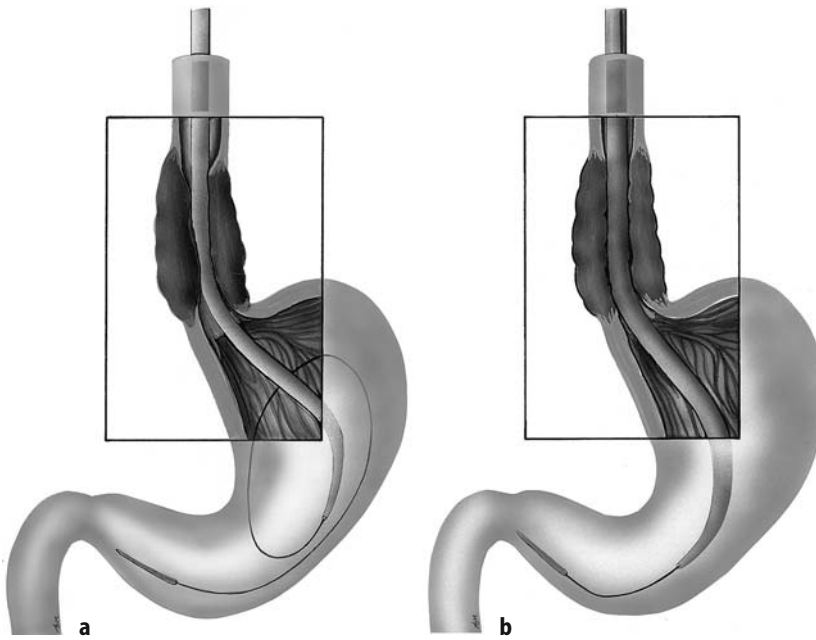


**Fig. 30.25 a, b.** For dilatations, a guidewire should be routinely inserted under endoscopic control (a). It is usually possible to insert a pediatric endoscope (7.9 mm diameter) or one with an even smaller diameter (5.3 mm) (b).



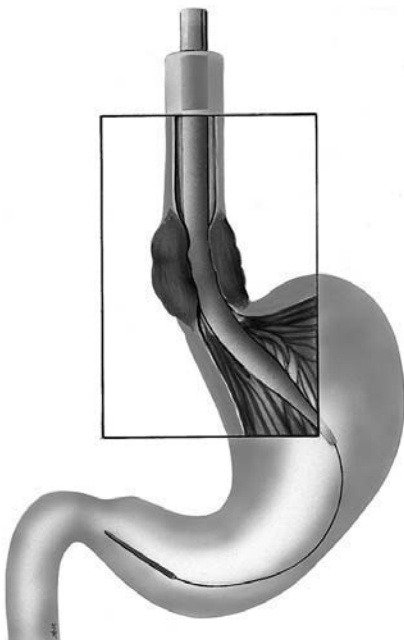
**Fig. 30.26.** To push the instrument through a longer stenosis, the guidewire should be positioned far into the stomach along the greater curve. This ensures an additional stiffening of the flexible tip of the endoscope.

**Fig. 30.27.** In very narrow stenoses which cannot be passed with the endoscope, a hydrophilic biliary guidewire with flexible tip should be tried first. This technique permits tracing of complicated stenoses under fluoroscopic control.

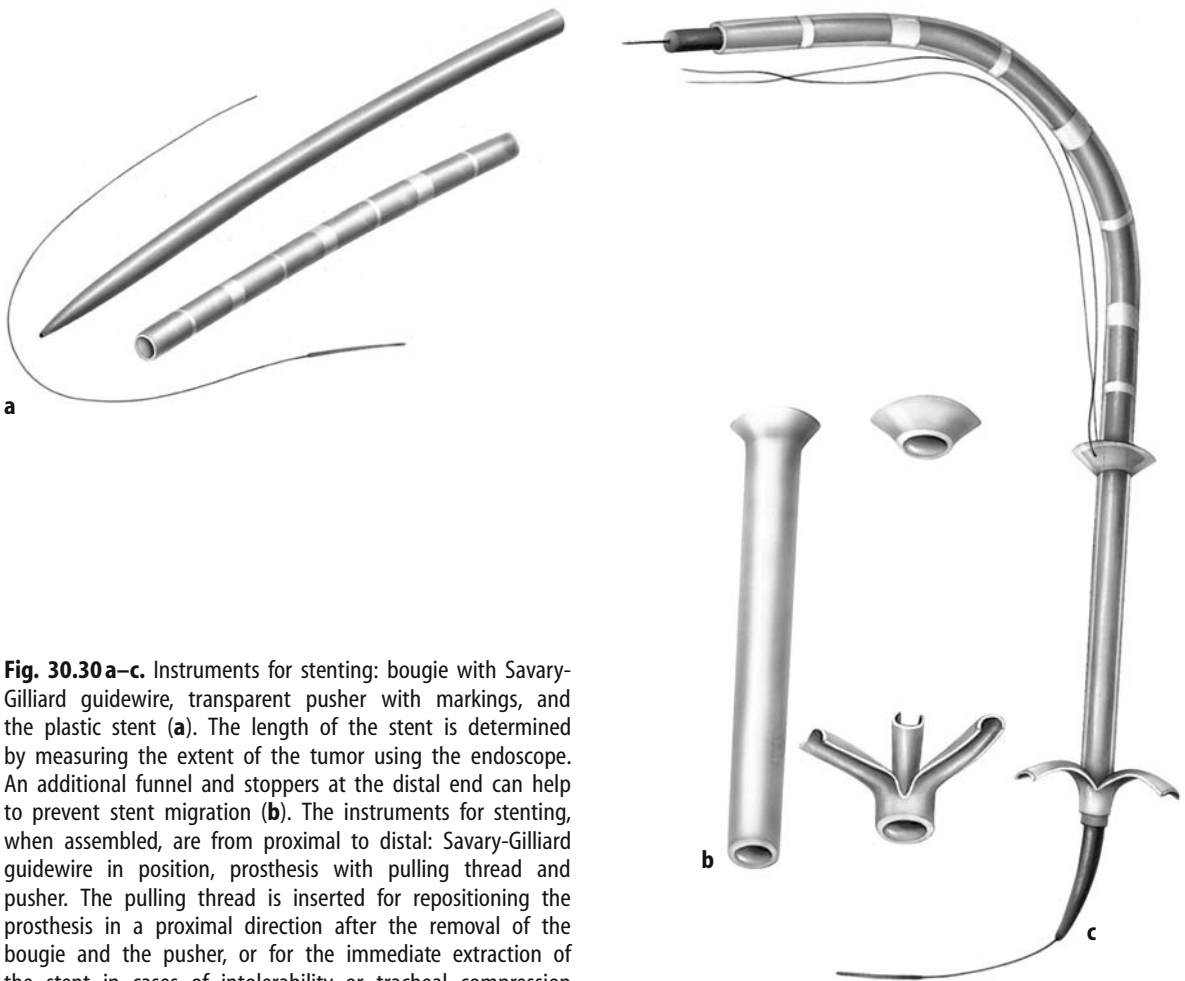


**Fig. 30.28 a,b.** In very tight stenoses bougienage over a biliary guidewire can be difficult. In these cases a radioopaque 9 Fr. catheter is first inserted. Then, under fluoroscopic control, a stiff Savary-Gilliard guidewire is inserted (**a**). Over this guidewire the bougienage is performed. One must avoid ex-

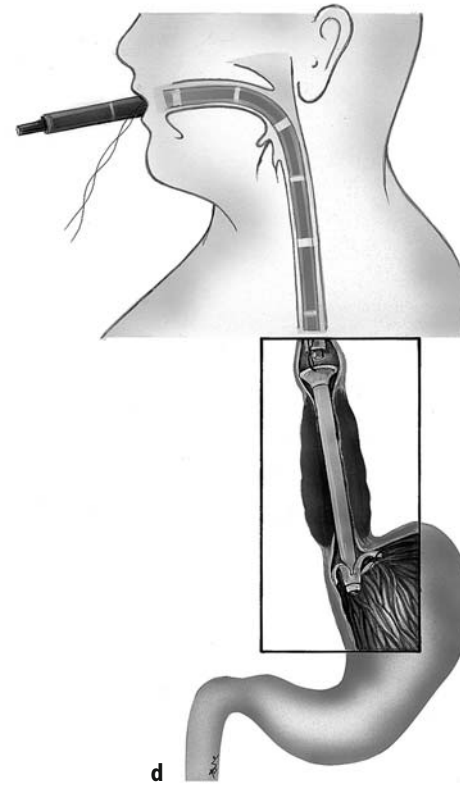
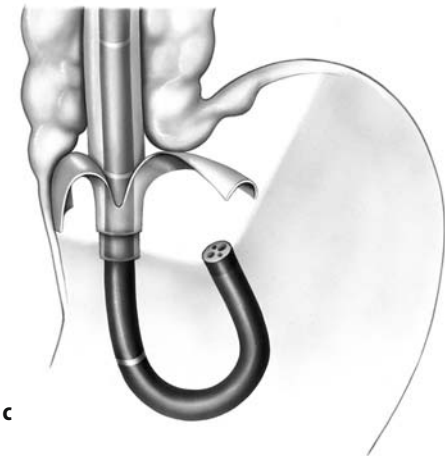
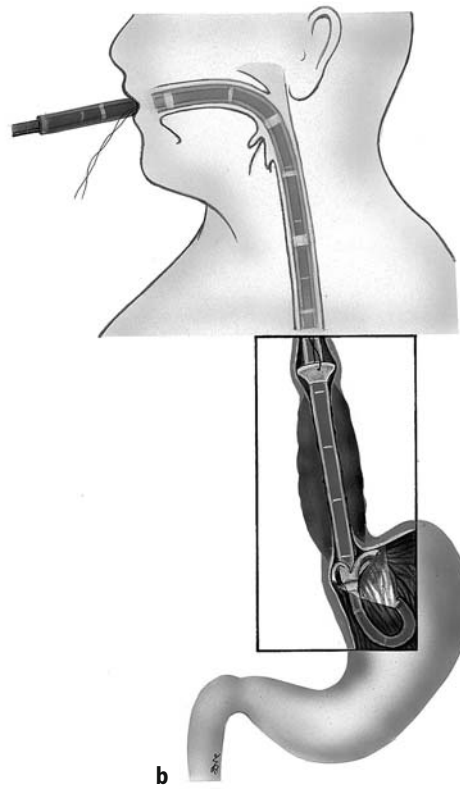
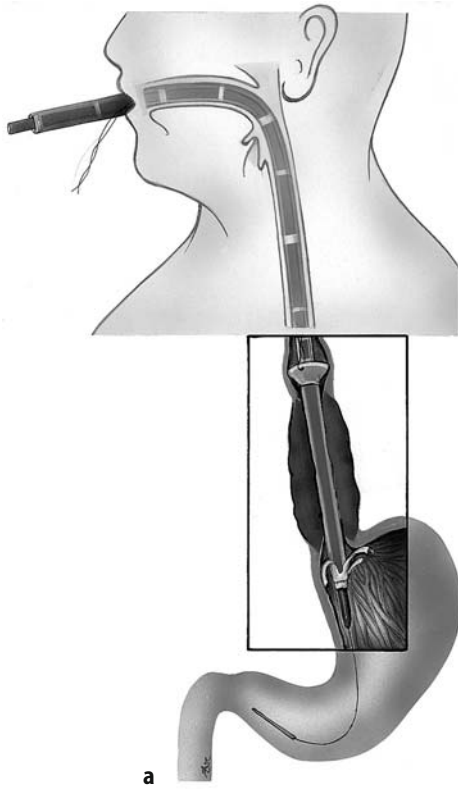
cessive pressure to reduce the risk for perforation. For repeated treatment, bougienage over the Savary-Gilliard guidewire can be performed without further fluoroscopic or endoscopic controls (**b**).



**Fig. 30.29.** If the stenosis can be passed with a 7.9 mm pediatric endoscope the treatment can be started using a bougie of 10 mm diameter. Dilatations should only be performed with increments of 2 mm. After each dilatation the wall must be checked carefully for deep ulcers.



**Fig. 30.30 a–c.** Instruments for stenting: bougie with Savary-Gilliard guidewire, transparent pusher with markings, and the plastic stent (a). The length of the stent is determined by measuring the extent of the tumor using the endoscope. An additional funnel and stoppers at the distal end can help to prevent stent migration (b). The instruments for stenting, when assembled, are from proximal to distal: Savary-Gilliard guidewire in position, prosthesis with pulling thread and pusher. The pulling thread is inserted for repositioning the prosthesis in a proximal direction after the removal of the bougie and the pusher, or for the immediate extraction of the stent in cases of intolerability or tracheal compression (c).



## Esophageal fistula

### ■ Introduction

The majority of fistulae arise from the sites of fresh anastomoses after esophagectomy. Spontaneous fistulae that arise from tumor infiltrations or after endoscopic procedures are not that common. In all these situations, traditional open surgery entails a high risk with unclear efficacy. Endoscopic procedures, of which several technical modifications have been developed, are now the treatment of choice.

### ■ Indications

All fistulae to the tracheobronchial system and the mediastinum should be treated. Esophago-bronchial fistulae need urgent management.

### ■ Contraindications

Very large lesions of the wall that cannot be sealed by endoscopic means should not be treated endoscopically.

### ■ Preliminary examinations

Radiographic identification of the fistula and its extent is achieved using water-soluble contrast and/or bronchoscopy.

### ■ Instruments

Pediatric endoscope (diameter 7.9 mm or smaller); bougienage for tumor dilatation (e.g. Savary-Gilliard dilators); plastic prostheses with various diameters; covered metal stents; 7 Fr catheter; hydrophilic guidewires; for esophago-mediastinal fistulae: fibrin glue; fluoroscopy.

### ■ Special preparation

The patient should be fasted for at least 12 hours.

Premedication and monitoring according to the recommended standard.

### ■ Special technique

1. Fibrin glue sealing (Fig. 30.31 a–c)
2. Sealing with stents (Figs. 30.32–30.35).

### ■ Complications

**■ Non healing fistulae.** Endoscopic and fluoroscopic monitoring should be planned 2 to 3 weeks after initial fibrin application in order to detect persistent fistulae.

**Treatment:** The whole system or cavity should be washed out and the surface of the wall curetted before a new series of fibrin application is started.

**■ Stent migration.** Stent migrations are possible both proximally and distally because of the absence of stenosis, and may occur with both plastic as well as metal stents.

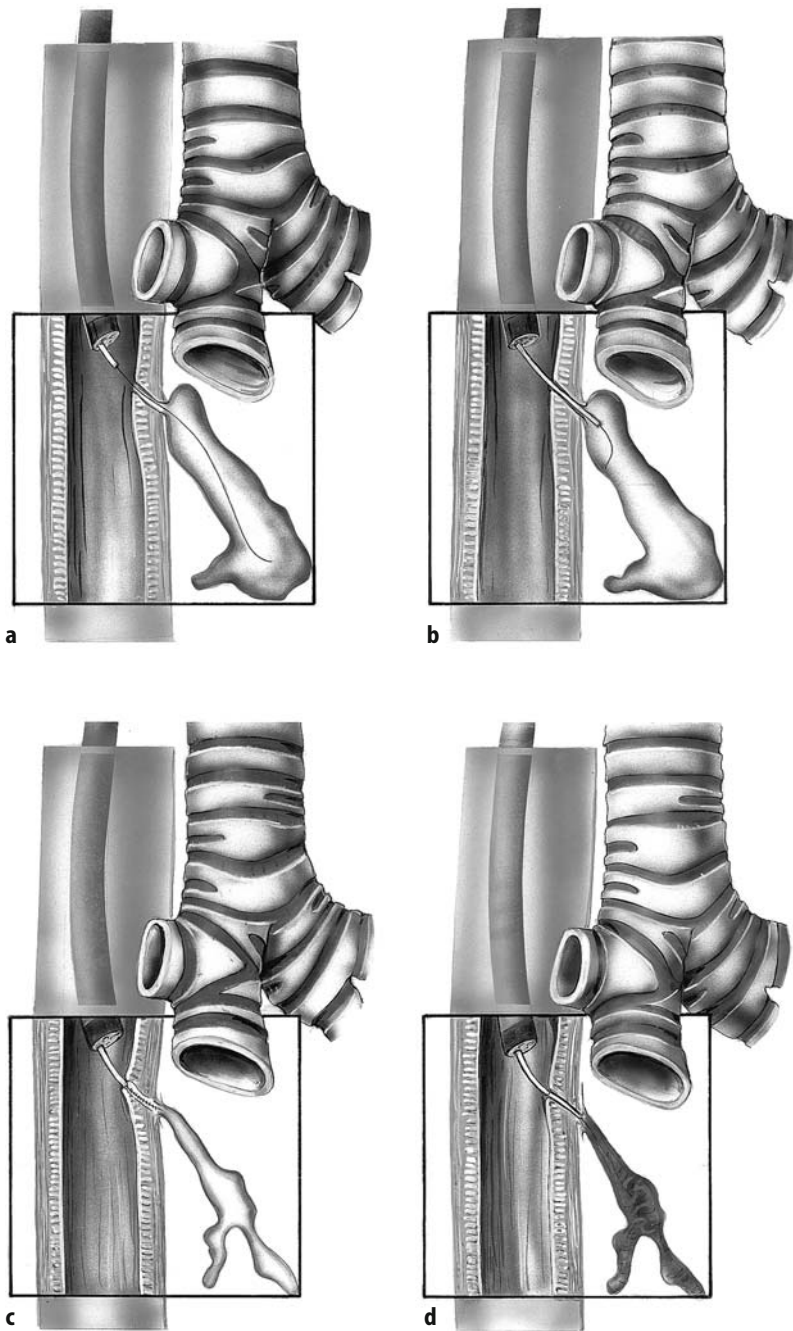
**Treatment:** In general, endoscopic repositioning is effective and sufficient. Sometimes a new stent with a larger diameter may be required. In the absence of esophageal stenosis, such as after anastomotic leakage, a plastic prosthesis can be fixed using a transnasal 7 Fr catheter; alternatively the fistula can be sealed with fibrin glue.

**■ Tumor overgrowth.** Treatment: Electrocautery or laser ablation of the tumor tissue. For cases of proximal overgrowth, an additional stent inserted up to the level of the first stent may be possible. Alternatively, the old stent is extracted and a new stent which is longer is then inserted.



**Fig. 30.31 a–d.** Positioning of the prosthesis. When the bougienage is finished, the assembled instruments are inserted as a unit. A pulling thread is present which is long enough for correction of the stent proximally (**a**). After preliminary positioning of the entire set, the bougie and guidewire are removed and a pediatric endoscope is inserted through the remaining pusher and stent. By retroflexion of the endo-

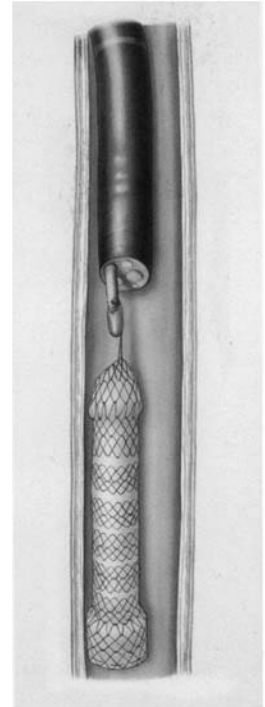
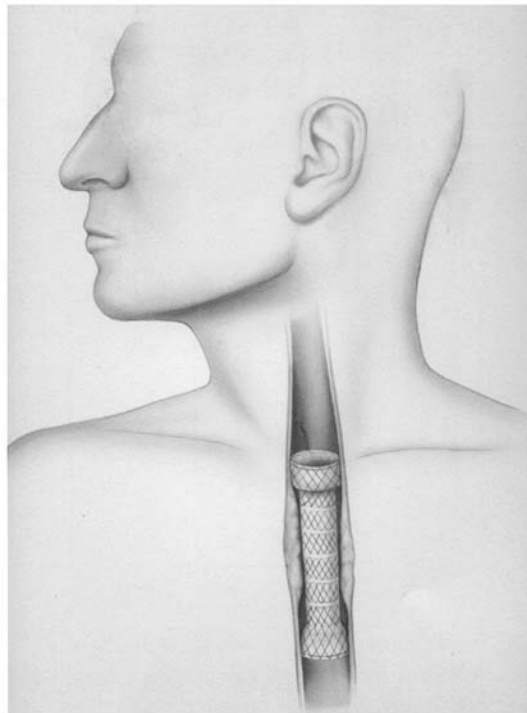

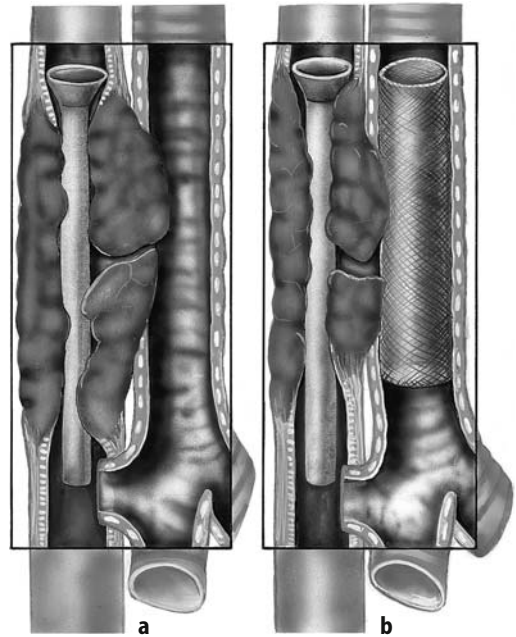
scope-tip in the stomach, the correct position and length of the stent can be confirmed (**b, c**). As the last step, the pusher and endoscope are removed simultaneously. The pulling thread is used for immediate removal of the stent in case of stent intolerance or tracheal compression. Dislocations can be safely prevented by using an additional funnel and distal stoppers (**d**).



**Fig. 30.32 a–d.** Esophagogastric fistula with fibrin sealing. After successful search for the entrance of the fistula an atraumatic hydrophilic guidewire is inserted (a). This guidewire is necessary for the insertion of a catheter (b). Afterwards the guidewire is removed. If there is a larger cavity at the end of the fistula, flushing can be tried. In narrow fistulas there is often only a small amount of exudates and necrotic material. Sometimes it is reasonable to curettage

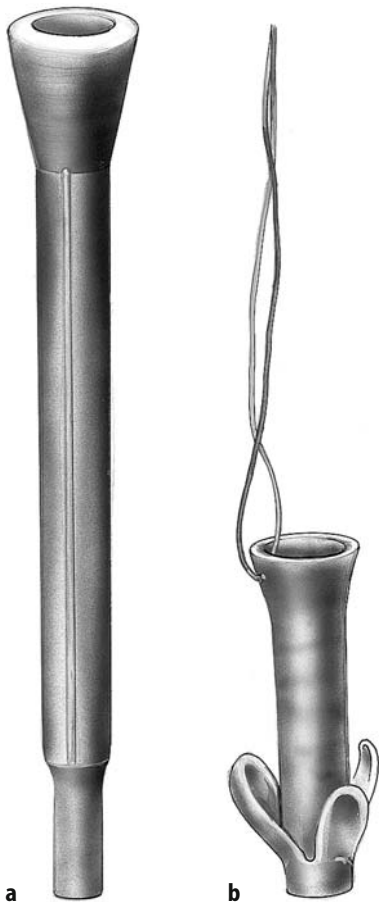
the inner surface of the fistula by means of a cytology brush (c). It is inserted with the catheter in place. After these procedures the components of the fibrin glue are instilled into the fistula and the cavity until one can see the material flowing out (d). In most cases repeated applications are necessary after short intervals of a couple of days. Most fistulas can be treated successfully in benign diseases.

**Fig. 30.33 a, b.** Esophagoatracheal fistula and endoscopic occlusion. In carcinomas of the upper cervical esophagus, combinations of stenoses and fistulas are common. Generally the occlusion of the fistula is possible by positioning a well fitting plastic stent (Celestin) which simultaneously keeps the passage free (a). According to the topographic position, modifications of the stent design might become necessary, e.g. shortening of the funnel. Only in some cases is the additional stenting of the trachea necessary (b). With one or two proximal correction threads, repositioning of the stent is possible later. In very high cervical fistulas, these proximal corrections are not possible because of patient intolerance.



**Fig. 30.34.** Esophagoatracheal fistula following infiltration of carcinoma with endoscopic occlusion. In addition to the cheaper plastic prostheses (e.g. Celestin), self expanding metal stents are commonly used in developed countries. For this purpose silicon- or polyurethane-coated stents are available

(Strecker-, Gianturco- or Wall-stents). The Choo-stent (Korean stent) has certain advantages for occlusion treatment. Its configuration prevents migration and a special traction loop facilitates extraction of the stent.



**Fig. 30.35 a, b.** Very proximal cervical esophagotracheal fistulas require special modifications of the plastic stent used, e.g. Celestin or Baby-Celestin (a). Patient intolerance is a major problem. In this position, smaller tubes with 9 or 12 mm diameter and shortened funnel are necessary (b). Additional distal stoppers to prevent proximal dislocations are not necessary.



## Dilatation of benign stenoses

### ■ Introduction

The majority of benign esophageal stenoses are the result of corrosive injuries due to caustic ingestion, reflux esophagitis, and radiotherapy. The historic blind methods of dilatation have been replaced by endoscopy-based techniques. In addition, for very short stenotic segments, local injections of steroids or incision with electrocautery can be attempted.

### ■ Indications

All benign stenoses resulting in dysphagia should be treated.

### ■ Contraindications

Dilatation is contraindicated in the setting of acute tissue necrosis after caustic ingestion. It should be delayed in the context of other acute medical illnesses such as myocardial infarction or cerebral infarction. If possible, enteral feeding should be secured by placing a thin soft nasogastric tube. In patients with concomitant esophagomediastinal or esophagotracheal fistulae, the dilatation treatment must be completed by sealing the fistula with an appropriate stent.

### ■ Special preparation

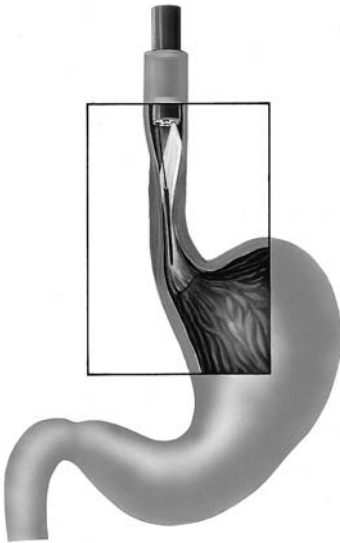
- Liquid food should be given for a couple of days before treatment. Endoscopy-guided lavage of the prestenotic esophagus may be necessary prior to treatment.
- Other preparations are made in accordance to the standards of safety and monitoring in endoscopic treatment.
- Antibiotic prophylaxis may be needed.
- Position: Left lateral.

### ■ Instruments

Gastrosopes with different diameters (including pediatric endoscopes) and large working channels (6.0 mm); Savary-Gilliard dilators with 12–42 Fr diameters; double-channel balloon catheters with diameter up to 30 mm and balloon length of 4–10 cm; guidewires with flexible tips. For stenoses that cannot be traversed even with a pediatric endoscope, additional 0.032–0.035 inch hydrophilic guidewires.

### ■ Special techniques

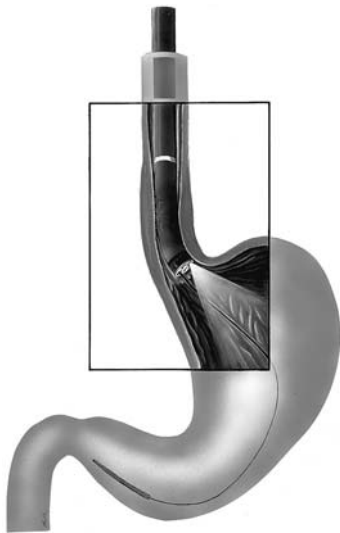
- Positioning of guidewires in very narrow stenoses (Figs. 30.36–30.39); bougienage (Fig. 30.40)
- Balloon dilatation (Fig. 30.41).



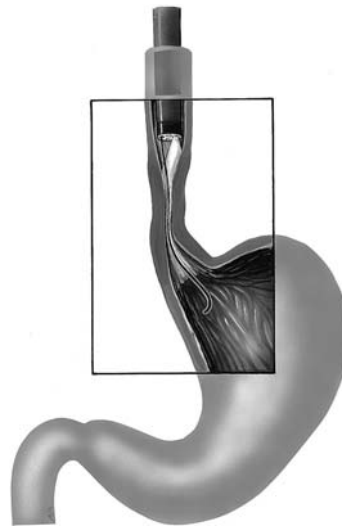
**Fig. 30.36.** Dilatation of benign stenoses. As first step a guidewire (Savary-Gilliard) is inserted through the stenosis. Under endoscopic control the flexible tip passes through the small luminal opening. In short stenoses this technique is not difficult.



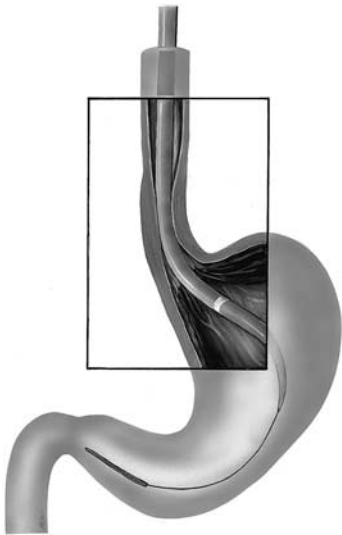
**Fig. 30.38.** The endoscope, assisted by the guidewire, has passed through the stenosis. The distal esophagus, the esophagogastric junction and stomach can then be examined.



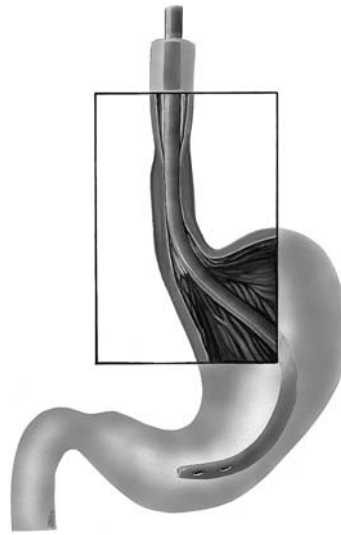
**Fig. 30.37.** The guidewire is pushed forward into the stomach and fluoroscopic monitoring can be helpful. In very narrow and tortuous stenoses which are difficult to pass, biliary guidewires should be used first (Terumo, Tracer). With this assistance a pediatric endoscope (7.9 or 5.3 mm diameter) can usually pass through the narrow segments. The wire helps to stiffen the flexible tip of the endoscope, facilitating its passage through the tight stenosis.



**Fig. 30.39.** Longer and very narrow stenoses are usually tortuous and cannot be passed with standard Savary-Gilliard guidewires. To manage these cases, hydrophilic atraumatic biliary guidewires are essential, which should be inserted under fluoroscopic monitoring. Using its flexible tip, tortuous parts of the stenosis can be passed by twisting the wire. After successful passage, the thin guidewire is replaced by a standard Savary-Gilliard wire with the assistance of a 9 Fr catheter.



**Fig. 30.40.** The bougie is pushed over the guidewire whose tip is situated in the distal stomach. The bougienage is performed step by step and care is taken to avoid excessive force. For each treatment session, the increase in diameter should be limited to 2 mm diameter in order to reduce the risk of perforation. It is safer to split the whole procedure to several sessions once or twice a week.



**Fig. 30.41.** In some situations, such as in the presence of pre-existing ulcers or inflammation of the esophageal wall, bougienage should be avoided due to an increased risk of perforation. In this scenario, a temporary gastric feeding tube can be used to start enteral feeding. After the inflammation has resolved in a couple of weeks, the dilatation can be re-attempted.

## ■ Complications

*Perforation* is the most important complication. It can be caused by inserting either the guidewire or dilator too forcefully or with excessive balloon dilatation.

**Prevention:** Use of guidewires with flexible tips; insertion of guidewires with endoscopic or fluoroscopic control; use of an atraumatic hydrophilic biliary guidewire in very narrow, tortuous stenoses; bougienage in small steps, with not more than 3 attempts per session.

**Attention:** The risk of perforation is always higher if one does not insert guidewires!

If the diameter of the dilator exceeds 42 Fr, the risk of perforation increases significantly.

**Treatment:** If perforation has happened or is suspected, fluoroscopic examination with water-soluble contrast should be carried out immedi-

ately. In small lesions, endoscopic clipping and conservative treatment with parenteral nutrition and antibiotics is justifiable. The insertion of a stent to seal the perforation may be helpful in borderline cases. For all major perforations, open or minimally invasive surgery is indicated.

## ■ Follow-up

In all uncomplicated cases, liquid food can be started after a few hours, progressing to pasty food the next day. In stenoses related to reflux esophagitis, long-term treatment with proton pump inhibitors (PPI) is required. Many stenoses require repeated sessions of dilatation. This should be continued in weekly or fortnightly intervals up to a diameter of 13–14 mm.

## Stenotic esophageal anastomoses and membranes (webs)

### ■ Introduction

Stenoses as a result of scar formation can be observed after esophagectomies or resection of the gastric cardia. In the treatment of these cases, conventional surgery has largely been replaced by endoscopic techniques. Congenital webs needing treatment are rare. Endoscopic procedures used include the following: bougienage, balloon dilation, incisions using electrocautery or laser, injection of steroids. The latter has been specially approved for children. Very often, a combination of techniques is used.

### ■ Indications

All clinically apparent stenoses caused by scars or webs.

### ■ Contraindications

Endoscopic treatment is contraindicated in the setting of fresh anastomoses with visible signs of inflammation or in the presence of fistulae. In these situations spontaneous recovery is still possible and temporary treatment with feeding tubes can be used to obtain enteral access. In all cases of recurrent tumors, dilatation per se would be inadequate; the treatment of choice would be stent placement or surgery.

### ■ Preliminary examinations

Endoscopy with biopsy in the case of previous tumor resection in order to detect recurrences; EUS±FNA; fluoroscopic examination to detect fistulae; coagulation status.

### ■ Special preparation


Liquid food for a couple of days. If necessary, lavage of the prestenotic area just before endoscopic treatment. Adherence to conventional standards of quality and safety in endoscopic procedures.

### ■ Instruments

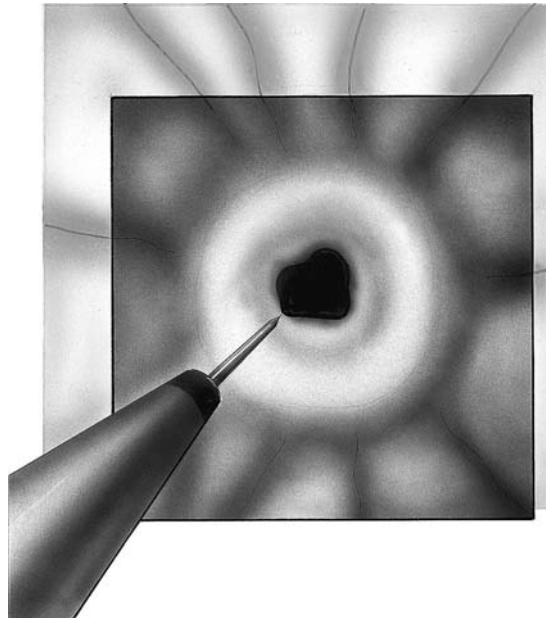
Small caliber or standard gastroscopes; Savary-Gilliard dilators; balloon catheters with fixed final diameters; standard guidewires; flexible atraumatic biliary guidewires for very narrow stenoses; needle papillotome for stricturotomy or partial resection of a scar; argon plasma; injection needles for local application of steroid solutions.

### ■ Special techniques


- Bougienage over a guidewire (Figs. 30.42, 30.43)
- Thermal treatment by cutting or excision (Fig. 30.44–30.46).



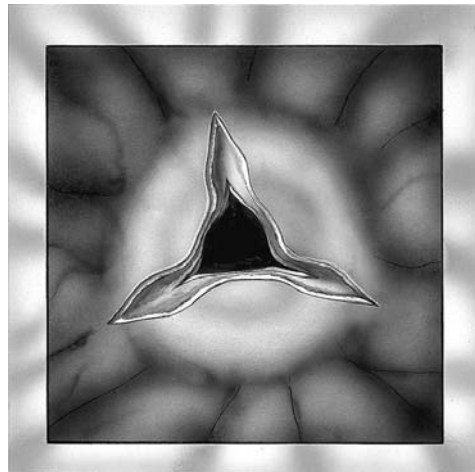
**Fig. 30.42.** Scars or webs. Bougienage with endoscopic inspection of the lesion. If the lumen is very narrow, a guide-wire should be inserted to assist the bougie. The dilatation is performed with limited pressure and repeated using dilators of different diameters. This technique is adequate mainly for webs and very short elastic strictures caused by scars.




**Fig. 30.44.** In very hard scars with granular tissue reaction the dilatation treatment should be supplemented by endoscopy-controlled incisions. They are performed with a needle-knife papillotome or with the tip of a snare.



**Fig. 30.43.** The result of the bougienage can be observed immediately through the endoscope. If a pediatric gastro-scope cannot pass through, the dilatation is usually still inadequate.



**Fig. 30.45.** Usually 3–6 radial cuts are necessary. The fibrosis of the surrounding tissue protects against perforation. Bougienage or balloon-dilatation follows the incisions immediately or after an interval of a few days.



**Fig. 30.46.** Strictureotomy can also be performed with argon plasma coagulation. There are no perceptible advantages as compared with electrocautery. Personal preferences seem to be of major importance. Using this technique, the cuts are also performed by multiple radial incisions, followed by bougienage or balloon dilatation.

## ■ Complications

- *Rupture* of the esophageal wall is very rare. The inner layer of the wall should be carefully inspected after every dilatation.
- *Hemorrhage* after incision is generally minor. If necessary, it can be stopped by sclerotherapy or endoscopic clip application.
- In many cases, the *first treatment is not fully sufficient*. If this is the case, the treatment should be repeated at weekly intervals until adequate.

## ■ Follow-up

In uncomplicated cases liquid food is permitted 3–4 hours after treatment. Normal soft diet is allowed after a couple of days.

The effect of treatment should be monitored after one week by endoscopy. If necessary, the next session can start immediately. A normal or near normal diameter of the lumen is the aim of treatment.

Re-stenoses are not very common after successful dilations. Therefore endoscopic monitoring is necessary only with recurrence of clinical symptoms, except for patients with previous tumor resections.

After injection of steroid solutions, follow-up endoscopy should be performed after 2 weeks and later on recurrence of symptoms, with repeated injections if needed.

## Achalasia

### ■ Introduction

There is a general consensus that endoscopic treatment should be tried before surgery in all patients with achalasia. Two endoscopic techniques are used: Endoscopy or fluoroscopy guided balloon dilatation and injection of botulinum toxin into the muscle layer. The clinical experience with the use of dilatation for treatment is over 2 decades, while that for botulinum toxin injection spans several years. The clinical outcome after botulinum injection is more variable. The effects of other forms of injection treatment are under clinical review.

### ■ Indications

Balloon dilatation can be used as the initial treatment. It can also be used after unsuccessful botulinum toxin injection or surgery. There are 2 technical modifications: high compliance balloons (HCB) and low compliance balloons (LCB), each with different pressures and final diameters. Injection with botulinum toxin may also be used as initial therapy, but one must bear in mind the poorer long-term outcome and higher costs.

### ■ Contraindications

Treatment is contraindicated in the presence of severe medical comorbidities such as acute myocardial infarction, strokes, and respiratory insufficiency. One must exclude the possibility of malignant tumors of the gastroesophageal junction mimicking achalasia. In the context of concomitant epiphrenic diverticula, it is difficult to estimate the risk of complications, and hence the treatment options must be carefully reviewed.

### ■ Preliminary examinations

Complete diagnostic testing including radiography, endoscopy with biopsies and manometry are done prior to treatment. If there is a suspicion of infiltrative tumors, biopsies of the deeper layers and EUS are imperative.

### ■ Special preparations

- In very narrow stenoses, liquid food should be started several days before treatment. If necessary, a lavage under endoscopic control should be performed before commencement of endoscopic treatment.
- Other preparations according to the standards for safe endoscopic treatment should be adhered to.
- Prophylactic antibiotics may be needed.
- Premedication: Analgesia-sedation.

### ■ Instruments

For injection treatment endoscopes with large working channels (3.7 mm) or a double channel are preferred in order to facilitate simultaneous suction. For pre-treatment lavage, endoscopes with 6 mm working channels are helpful.

For balloon dilatation, endoscopes with a smaller diameter are more appropriate for easier insertion into the stomach.

Important accessories: balloon dilators of different diameters with manometric control; injection catheters with predetermined needle length to allow safe infiltration of the muscularis propria (EUS may be used, if necessary, to guide the exact position of the botulinum deposits); guidewires for very tight stenoses; botulinum toxin (about 5 ml per session, equivalent to 80–100 U).

### ■ Special techniques

- Injection treatment (Figs. 30.47, 30.48)
- Balloon dilatation (Fig. 30.49)
- Endoscopy controlled balloon dilatation over a guidewire (Fig. 30.50).

### ■ Complications

Tears of the esophageal wall, with or without perforation, are the most common complications. If only the mucosal layer is involved, no specific treatment is necessary. Bleeding can be arrested by local infiltration with 0.05% epinephrine. In the case of deeper tears, an immediate fluoroscopic examination with water-soluble contrast should be performed. Small transmural tears can be treated with endo-

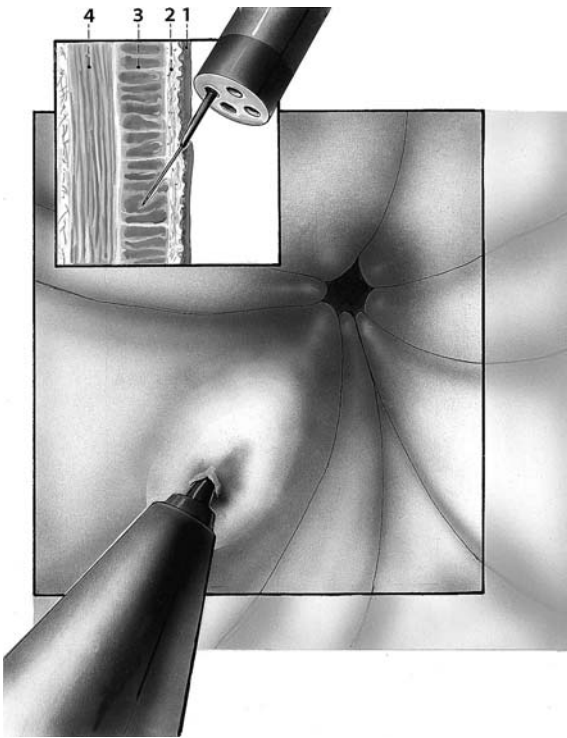
scopic clipping, parenteral nutrition, and antibiotics. However, if mediastinitis or peritonitis develops, conventional open or minimally invasive surgery is indicated.

Botulinum toxin injections may lead to retrosternal pain or a burning sensation; spontaneous relief can be expected within a few days.

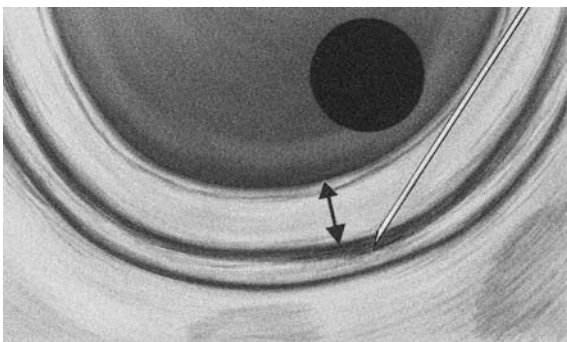
### ■ Follow-up

In uncomplicated cases liquid food can be permitted 2–3 hours after treatment, followed subsequently by normal diet. Treatment may be repeated upon recurrence of symptoms, which is not uncommon. Based on our experience, the effect of treatment lasts for several months. If the overall outcome is unsatisfactory, surgery may be indicated.

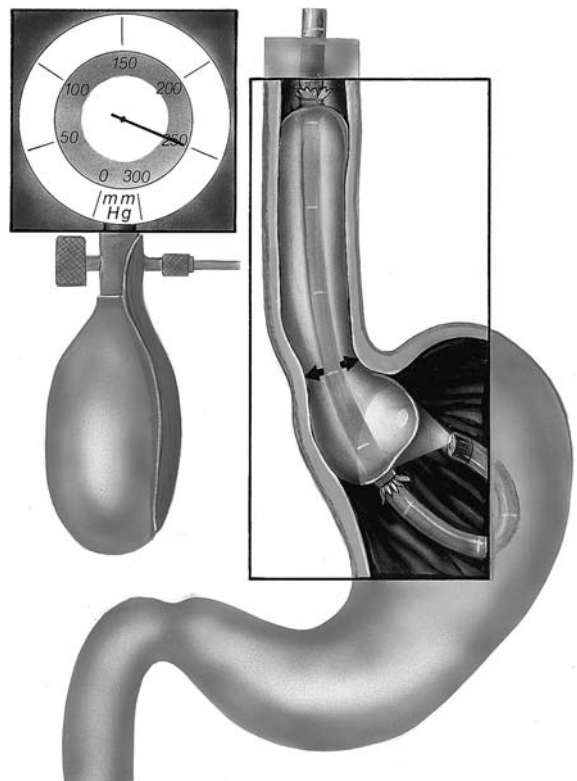




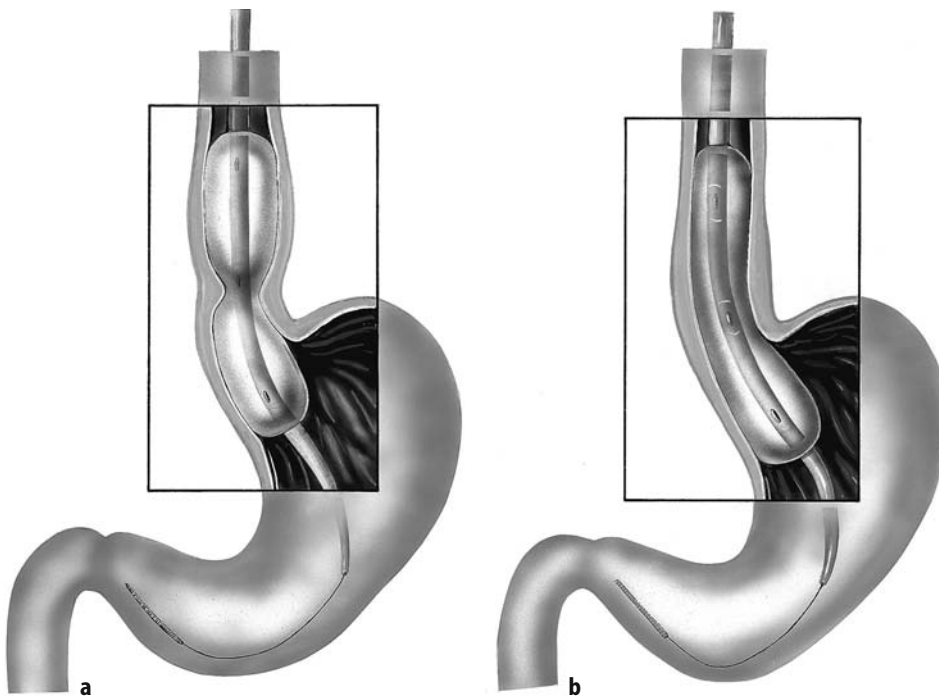
**Fig. 30.47.** Injection treatment for achalasia. The injection needle is placed exactly into the area of the lower esophageal sphincter. The tip is pushed forward just to the muscular layer (insert, 3). For each treatment session about 5 ml of botulinum toxin is injected in 4–6 deposits (1 mucosae, 2 submucosae, 3 muscularis propria, 4 surrounding tissue).



**Fig. 30.48.** Injection treatment of achalasia. The exact position of the needle can be identified using endosonographic examination. The intended muscularis propria is the echo-poor layer just beyond the echo-rich submucosa (double-arrow). During the injection a widening of the narrow echo-poor muscular layer can be observed.



**Fig. 30.49.** Achalasia with dilatation treatment. The balloon dilator is attached to the distal end of the endoscope next to the flexible distal end. The major advantage of this technique is that direct observation of the treatment result by retroflexion of the endoscope is possible.



**Fig. 30.50 a, b.** Achalasia with dilatation treatment. In very narrow stenoses of the lower esophageal sphincter, a guide-wire is inserted first. Over it, the balloon is pushed until the narrow segment is just in the middle of the balloon. Fluoroscopic monitoring is used (**a**). The markings of the catheter

permit a reliable estimation of the position. Then the pressure is slowly increased with manometric control. The selection of an adequate balloon diameter is essential. During fluoroscopy one sees the waist of the balloon slowly disappearing (**b**).

## Diverticula

### ■ Introduction

Diverticula of the esophagus are herniations of the mucosal layer through a gap of the muscularis propria (i.e. false diverticula). They are mainly found in the hypopharynx (Zenker's diverticulum) or near the diaphragm. Diverticula become clinically important when they impede the normal passage of solid food. Traditionally the treatment is surgical. The first non-surgical procedures for Zenker's diverticulum were performed by ENT surgeons through laryngoscopes (Dohlman and Mattson 1960). The principle of endoscopic treatment is the incision of the septum between the esophageal wall and the diverticulum, thus preventing the retention of food particles.

### ■ Indications

All patients with symptomatic Zenker's diverticula with clinical symptoms can be treated. In high risk patients, endoscopic treatment can replace conventional surgery.

### ■ Contraindications

Treatment is contraindicated in the presence of inflammation of the diverticular wall.

### ■ Preliminary examinations

Endoscopy and radiography to determine the anatomy of the diverticulum and septum, and to assess the presence of inflammation; coagulation status.

### ■ Special preparations

- Liquid food for a few days
- Monitoring and safety procedures as per recommended standards
- Premedication: Analgesia-sedation
- Position: Left lateral.

### ■ Instruments

Therapeutic gastroscopes with either a large working channel or dual channel.

Accessories: Needle knife. Alternative: Argon plasma coagulation.

### ■ Special technique

Cutting the septum with the assistance of a nasogastric tube (Figs. 30.51–30.54).

### ■ Complications

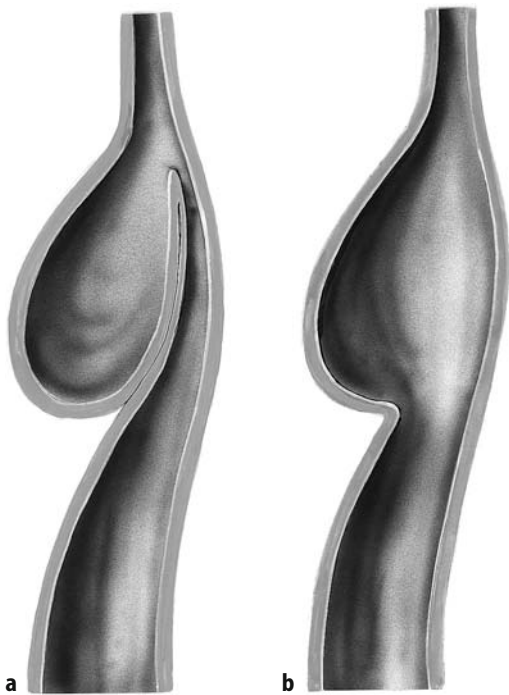- *Hemorrhages* are generally minor; if needed, they can be stopped by injections.
- *Perforation* with pneumomediastinum and mediastinitis are very rare complications.

Treatment of perforation in Zenker's diverticulum is mainly conservative with parenteral nutrition and antibiotics. Small perforations may be closed by endoscopic clipping.

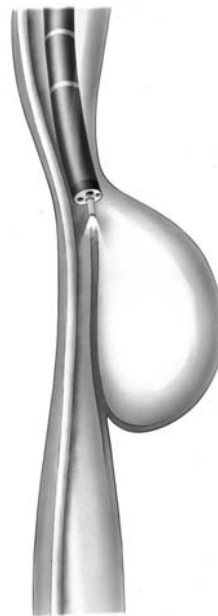
If the clinical response is inadequate, treatment sessions can be repeated at 3 weeks.

### ■ Follow-up

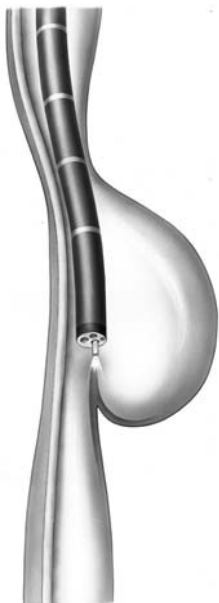Intravenous fluids should be maintained for a few days, followed by gradual introduction of pasty and then solid food. When the treatment is completed, the results should be documented by radiography.




**Fig. 30.51 a, b.** Endoscopic treatment of Zenker's diverticulum basically means the destruction of the septum between the esophagus and the diverticulum to achieve symptomatic relief from retentions of food (a). The result is a broad connection between the diverticulum and esophageal lumen and a flat diverticular cavity (b).



**Fig. 30.52.** The incision of the septum between the diverticulum and the esophageal lumen can be performed using pure cutting current or argon plasma coagulation. In some cases with larger diverticula, the treatment may need to be repeated at 3 week intervals.



**Fig. 30.53.** A complete destruction of the septum is not necessary. Sometimes it is safer to leave a small residual septum in place. It is more important to achieve functional results than perfect anatomy.



**Fig. 30.54.** A nasogastric tube is inserted to allow correct orientation of the location of the diverticulum. For both the needle knife and argon plasma coagulation techniques, the incision should not exceed 20 mm in one treatment session to avoid perforation. It can be continued at 3 week intervals.

## References

- Axelrad AM, Fleischer DE, Gomes M (1996) Nitinol coil esophageal prosthesis: advantages of removable self-expanding metallic stents. *Gastrointest Endosc* 43:155-160
- Annese V, Basciani M, Lombardi G, Caruso N, Perri F, Simone P, Andriulli A (1996) Perendoscopic injection of botulinum toxin is effective in achalasia after failure of myotomy or pneumatic dilation. *Gastrointest Endosc* 44:461-465
- Berggren PJ, Harrison ME, Sanowski RA, Ingebo K, Noland B, Zierer S (1993) Techniques and complications of esophageal foreign body extraction in children and adults. *Gastrointest Endosc* 39:626-630
- Bertoni G, Sassatelli R, Conigliaro R, Bedogni G (1996) A simple latex protector hood for safe endoscopic removal of sharp-pointed gastroesophageal foreign bodies. *Gastrointest Endosc* 44:458-461
- Bethge N, v Kleist D, Vakil N (1996) Treatment of esophageal perforation with a covered expandable metal stent. *Gastrointest Endosc* 43:161-163
- Bethge N, Somma A, Vakil N (1997) A prospective trial of self-expanding metal stents in the palliation of malignant esophageal strictures near the upper esophageal sphincter. *Gastrointest Endosc* 45:300-303
- Bigler PC (1966) The use of a Foley catheter for removal of blunt foreign bodies from the esophagus. *J Thorac Cardiovasc Surg* 51:477-479
- Binmoeller KF, Grimm H, Soehendra N (1993) Endoscopic closure of a perforation using metallic clips after snare excision of a gastric leiomyoma. *Gastrointest Endosc* 39:172-174
- Binmoeller KF, Thonke F, Soehendra N (1993) Endoscopic hemoclip treatment for gastrointestinal bleeding. *Endoscopy* 25:167-170
- Binmoeller KF, Krug Ch, Rehner M, Seifert H, Soehendra N (1997) Endoscopic implantation of endoprosthesis for the palliative treatment of stenoses and fistulas of the proximal cervical esophagus. *Zbl Chir* 122:44-48
- Blackard WG, Marks RD, Baron TH (1996) Suction sclerotherapy for the treatment of esophageal varices. *Gastrointest Endosc* 44:725-728
- Boerke JM, Hope RL, Chu G, Gillespie PE, Bull C, O'Rourke I, Williams SJ (1996) Laser palliation of inoperable malignant dysphagia: initial and death. *Gastrointest Endosc* 43:29-32
- Brayko CM, Kozarek RA, Sanowski RA (1985) Bacteremia during esophageal variceal sclerotherapy: its cause and prevention. *Gastrointest Endosc* 31:10-12
- Broor SL, Lahoti D, Bose PP, Ramsh GN, Raju GS, Kumar A (1996) Benign esophageal strictures in children and adolescents: etiology, clinical profile, and results of endoscopic dilation. *Gastrointest Endosc* 43:474-477
- Burdick JS, Venu RP, Hogan WJ (1993) Cutting the defiant lower esophageal ring. *Gastrointest Endosc* 39:616-619
- Celestin LR, Campell WB (1981) A new and safe system for esophageal dilation. *Lancet* 1:74-75
- Cellier C, Landi B, Faye A, Wind P, Frileux P, Cugnenc PN, Barbier JP (1996) Upper gastrointestinal tract fistulae: endoscopic obliteration with fibrin sealing. *Gastrointest Endosc* 44:731-733
- Chung SCS, Leong HA, Choi CYC (1994) Palliation of malignant esophageal obstruction by endoscopic alcohol injection. *Endoscopy* 26:275-277
- Cotton PB (1983) Overtubes (fleeves) for upper gastrointestinal endoscopy. *Gut* 24:863-866
- Cox J, Buckton GK, Bennett JR (1986) Balloon dilation in achalasia: a new dilator. *Gut* 27:986-989
- De Boer WA, Van Haren F, Driessen WMM (1995) Marking clips for the accurate positioning of self-expandable esophageal stents. *Gastrointest Endosc* 42:73-76
- Den Hartog Jager FCA, Bartelsman JFWM, Tytgat GNJ (1979) Palliative treatment of obstructing esophago-gastric malignancy by endoscopic positioning of a plastic prosthesis. *Gastroenterology* 77:1008-1014
- DePalma GD, DiMatteo E, Romano G, Fimmano A, Rondinone G, Catanzano C (1996) Plastic prosthesis versus expandable metal stents for palliation of inoperable esophageal thoracic carcinoma: a controlled prospective study. *Gastrointest Endosc* 43:478-482
- Deviere J, Quarre DP, Love J, Cremer M (1994) Self-expandable stent and injection of tissue adhesive for malignant broncho-esophageal fistula. *Gastrointest Endosc* 40:508-510
- D'Imperio N, Piemontese A, Baroncini D, Billi P, Borioni D, Dalmonte PP, Borello P (1996) Evaluation of undiluted N-butyl-2-cyanoacrylate in the endoscopic treatment of upper gastrointestinal tract varices. *Endoscopy* 28:239-243
- Domschke W, Foerster EC, Matek W, Rödl W (1990) Self-expanding mesh stents for esophageal stenosis. *Endoscopy* 22:134-136
- Dumont JF, Meric B, Sivak MV, Fleischer DE (1995) A new method of esophageal dilation using Savary-Gilliard bougies. *Gastrointest Endosc* 31:379-382
- Ell C, Riemann JF, Demling L (1986) Endoscopic occlusion of a neoplastic esophagomediastinal fistula by a fast-hardening aminoacid solution. *Gastrointest Endosc* 32:287-288
- Engel JJ, Panje WR (1995) Endoscopic laser Zenker's diverticulotomy. *Gastrointest Endosc* 42:368-370
- Fan Z, Dai N, Chen L (1997) Expandable thermal-shaped memory metal esophageal stent: experiences with a new nitinol stent in 129 patients. *Gastrointest Endosc* 46:352-357
- Fleischer DE, Sivak MV (1985) Endoscopic Nd-YAG laser therapy as palliation for esophagogastric carcinoma. *Gastroenterology* 89:827-831
- Fleischer DE, Bull-Henry K (1992) A new coated self-expanding metal stent for malignant esophageal strictures. *Gastrointest Endosc* 38:494-496
- Fleischer DE, Wang GQ, Dawsey S, Tio TL, Newsome J, Kidwell J, Prifti S (1996) Tissue band ligation followed by snare resection (band and snare): a new technique for tissue acquisition in the esophagus. *Gastrointest Endosc* 44:68-72

- Fiorini AB, Goldin E, Valero JL, Bloom A, Beyar M, Pfeffer RP, Goberman O (1995) Expandable metal coil stent for treatment of broncho-esophageal fistula. *Gastrointest Endosc* 42:81–83
- Goldin E, Beyar M, Safra T, Gliberman O, Craciun I, Wengrover D, Fich A (1994) A new self-expandable nickel-titanium coil stent for esophageal obstruction: a preliminary report. *Gastrointest Endosc* 40: 64–68
- Goldman JH, Goldberg RI (1994) Balloon removal of an impacted esophageal meat bolus. *Gastrointest Endosc* 40:391
- Goldschmiedt M, Haber G, Kandel G, Kortan P, Marcon N (1992) A safety maneuver for placing overtube during endoscopic variceal ligation. *Gastrointest Endosc* 38:399–400
- Gossner L, Sroka R, Hahn EG, Ell C (1995) Photodynamic therapy: successful destruction of gastrointestinal cancer after oral administration of aminolevulinic acid. *Gastrointest Endosc* 41:55–58
- Graham DY, Tabibian N, Schwartz JT, Smith JL (1987) Evaluation of the effectiveness of through-the-scope balloons as dilators of benign and malignant gastrointestinal strictures. *Gastrointest Endosc* 33:432–436
- Graham DY (1990) Treatment of benign and malignant strictures of the esophagus. In: Silvwis SE (ed) *Therapeutic gastrointestinal endoscopy*. Igaku-Shoin New York, pp 1–41
- Graham DY (1996) Fluoroscopy or no for esophageal dilation: the passing of an era (Editorial). *Gastrointest Endosc* 43:171–173
- Hachisu T, Miyazaki S, Hamaguchi K (1989) Endoscopic clip-marking of lesions using the newly developed HX-3L clip. *Surg Endosc* 3:142–147
- Hashizume M, Sugimachi K, Kishihara F, Kawanaka H, Ohta M, Tomikawa M, Tanoue K, Yamaga H, Higashi H (1995) A serial transparent endoscopic elastic band ligator. *Gastrointest Endosc* 42:169–170
- Healy GB (1988) Removal of esophageal foreign bodies with a Foley catheter under fluoroscopic control. *Can Med Assoc J* 138:490–491
- Hoffman RJ, Knapple WL, Bhutani MS, Verne GN, Hawes RH (1997) Treatment of achalasia by injection of botulinum toxin under endoscopic ultrasound guidance. *Gastrointest Endosc* 45:77–79
- Hordijk JL, Dees J, van Blankenstein M (1990) The management of malignant esophago-respiratory fistulas with a cuffed prosthesis. *Endoscopy* 22:214–244
- Inoue H, Takeshita K, Hori H, Muraoka Y, Yoneshima H, Endo M (1993) Endoscopic mucosal resection with a cap-fitted panendoscope for esophagus, stomach and colon mucosal lesions. *Gastrointest Endosc* 39:58–62
- Inoue H, Endo M, Takeshita K, Kawano T, Yoshino K (1991) Endoscopic resection of early-stage esophageal cancer. *Surg Endosc* 5:59–62
- Ishioka S, Sakai P, Maluf Filho F, Melo JM (1995) Endoscopic incision of Zenker's diverticula. *Endoscopy* 27:433–437
- Jankovic J, Brin MF (1991) Therapeutic use of botulinum toxin. *N Engl J Med* 324:1186–1194
- Johlin FC, Griglione G (1989) A new technique using injectable collagen to promote sealing of an esophago-respiratory fistula. *Gastrointest Endosc* 35: 220–225
- Jung M, Manegold BC, Brands W (1989) Endoscopic therapy of gastrointestinal fistulae with fibrin tissue sealant. In: Waclaviczek HW (ed) *Progress in fibrin sealing* 45–59. Springer, Berlin Heidelberg New York
- Kadakia SC, Wang RK (1993) Graded pneumatic dilation using Rigiflex achalasia dilators in patients with primary esophageal achalasia. *Am J Gastroenterol* 88:34–38
- Kirsch M, Blue M, Desai RK, Sivak MV (1991) Intraleisional steroid injections for peptic esophageal strictures. *Gastrointest Endosc* 37:189–192
- Kodali VF, Petersen BT, Miller CA, Gostout CJ (1997) A new jumbo-channel therapeutic gastroscope for acute upper gastrointestinal bleeding. *Gastrointest Endosc* 45:409–411
- Kozarek RA, Ball TJ, Brandabur JJ, Patterson DJ, Low D, Hill L, Raltz S (1996) Expandable versus conventional esophageal prostheses: easier insertion may not preclude subsequent stent-related problems. *Gastrointest Endosc* 43:204–208
- Lahoti D, Broor SL, Basu PP, Gupta H, Sharma R, Pant CS (1995) Corrosive esophageal strictures: predictors of response to endoscopic dilation. *Gastrointest Endosc* 41:196–200
- Lightdale CJ, Heier SK, Marcon NE, McCaughan JS, Gerdes H, Overholt BF, Sivak MV (1995) Photodynamic therapy with porfimer sodium versus thermal ablation therapy with Nd:YAG laser for palliation of esophageal cancer: a multicenter randomized trial. *Gastrointest Endosc* 42:507–512
- Likier HM, Levine JG, Lightdale C (1991) Photodynamic therapy for completely obstructing esophageal carcinoma. *Gastrointest Endosc* 37:75–78
- Lo GH, Lai KH, Shen MT, Chang CF (1994) A comparison of the incidence of transient bacteremia and infectious sequelae after sclerotherapy and rubber band ligation of bleeding esophageal varices. *Gastrointest Endosc* 40:675–679
- Lux G, Wilson D, Wilson L, Demling L (1987) A cuffed tube for the treatment of esophagobronchial fistula. *Endoscopy* 19:28–30
- Macken E, Gevers A, Hiele M, Rutgeerts P (1996) Treatment of esophago-respiratory fistulas with polyurethane-covered self-expanding metallic mesh stent. *Gastrointest Endosc* 44:324–326
- Malik A, Chitnavis V, Epstein A (1994) Use of a hydrophilic wire for esophageal intubation in Zenker's diverticulum. *Gastrointest Endosc* 40:523–524
- Mamel JJ, Weiss D, Pouagare M, Nord HJ (1995) Endoscopic suction removal of food bolus from the upper gastrointestinal tract using Stiegmann-Goff friction-fit adapter: an improved method for removal of food impaction. *Gastrointest Endosc* 41:593–596
- Mearin F, Armengol JR, Chicharro L, Papo M, Balboa A, Malagelada JR (1994) Forceful dilation under endoscopic control in the treatment of achalasia: a randomised trial of pneumatic versus metallic dilator. *Gut* 35:1360–1362
- McClave SA, Brady PG, Wright RA, Goldschmid S, Minocha A (1996) Does fluoroscopic guidance for Malo-

- ney esophageal dilation impact on the clinical endpoint of therapy: relief of dysphagia and achievement of luminal patency. *Gastrointest Endosc* 43:93-97
- McCoughan JS, Nims TA, Guy JT, Hicks WJ, Williams TE, Laufman LR (1989) Photodynamic therapy for esophageal tumors. *Arch Surg* 124:74-80
- Moreto M, Ojembarrena A, Rodriguez ML (1996) Endoscopic injection of ethanolamine as a treatment for achalasia: a first report. *Endoscopy* 28:539-545
- Mühdorfer SM, Hahn EG, Ell C (1996) High- and low-compliance balloon dilators in patients with achalasia: a randomized prospective comparative trial. *Gastrointest Endosc* 44:398-403
- Neu HC (1989) Recommendations for antibiotic prophylaxis before endoscopy. *Am J Gastroenterol* 84:1488-1489
- Neuhaus H, Hoffmann W, Dittler HJ, Niedermeyer HP, Classen M (1992) Implantation of self-expanding esophageal metal stents for palliation of malignant dysphagia. *Endoscopy* 24:405-410
- Neustater B, Barkin JS (1996) Extraction of an esophageal food impaction with a Roth retrieval net. *Gastrointest Endosc* 43:66-67
- Ng TM, Spencer GM, Sargeant IR, Thorpe SM, Brown SG (1996) Management of strictures after radiotherapy for esophageal cancer. *Gastrointest Endosc* 43:584-590
- Overholt BF, Panjehpour M, Tefftellar E, Rose M (1993) Photodynamic therapy for treatment of early adenocarcinoma in Barrett's esophagus. *Gastrointest Endosc* 39:73-76
- Overholt BF, Panjehpour M (1995) Barrett's esophagus: photodynamic therapy for ablation of dysplastic, reduction of specialized mucosa, and treatment of superficial esophageal cancer. *Gastrointest Endosc* 42:64-70
- Paquet KJ (1983) Endoscopic paravariceal injection sclerotherapy of the esophagus - indications, technique, complications: results of a period of 14 years. *Gastrointest Endosc* 29:310-315
- Pasricha PJ, Ravich WJ, Kalloo AN (1993) Botulinum toxin for achalasia. *Lancet* 341:244-245
- Payne-James JJ, Spiller RC, Misiewicz JJ, Silk DB (1990) Use of ethanol-induced tumor necrosis to palliate dysphagia in patients with esophagogastric cancer. *Gastrointest Endosc* 36:75-78
- Perez-Arroyo H, Hunter J, Waring JP (1997) Botulinum toxin for an esophageal muscular A-Ring. *Gastrointest Endosc* 45:193-195
- Raijman I, Walden D, Kortan P, Haber GB, Fuchs E, Siemens M, Kandel G, Marcon NE (1994) Expandable esophageal stents: Initial experience with a new nitinol stent. *Gastrointest Endosc* 40:614-621
- Ramirez FC, Dennert B, Zierer ST, Sanowski RA (1997) Esophageal self-expandable metallic stents - indications, practice, technique, and complications: results of a national survey. *Gastrointest Endosc* 45:360-364
- Saeed ZA, Winchester CB, Ferro PS, Michaletz PA, Schwartz JT, Graham DY (1995) Prospective randomized comparison of polyvinyl bougies and through-the-scope balloons for dilation of peptic strictures of the esophagus. *Gastrointest Endosc* 41:189-195
- Saeed ZA, Ramirez FC, Hepps KS, Cole RA, Schneider FE, Ferro PS, Graham DY (1997) An objective endpoint for dilation improves outcome of peptic esophageal strictures: a prospective randomized trial. *Gastrointest Endosc* 45:354-359
- Sakai P, Filho FM, Iryia K, Moura EGH, Tomishigue T, Scabbia A, Ishioka S (1996) An endoscopic technique for resection of small gastrointestinal carcinomas. *Gastrointest Endosc* 44:65-68
- Sanowski R (1987) Foreign body extraction in the gastrointestinal tract. In: Sivak MV (ed) *Gastroenterologic endoscopy*, 321-331. Saunders, Philadelphia
- Sass NL, Hagenmüller F (1992) First endoscopic implantation of memory metal stents in the esophagus. *Endoscopy* 24:622A
- Schulze S, Fischerman K (1990) Palliation of esophagogastric neoplasms with a Nd-YAG laser treatment. *Scand J Gastroenterol* 25:1024-1027
- Schuman MD, Beckman JW, Tedesco FJ, Griffin JW, Assad RT (1987) Complications of endoscopic injection sclerotherapy: a review. *Am J Gastroenterol* 82:823-830
- Smith JL, Michaletz PE, Tabibian N, Schwartz JT, Graham DY (1987) Improved palliation of a respiratory-esophageal fistula with a cuffed esophageal prosthesis. *Am J Gastroenterol* 82:1175-1176
- Soehendra N, Binmoeller KF, Seifert H, Schreiber HW (1997) *Praxis der therapeutischen Endoskopie*. Thieme, Stuttgart New York
- Stiegmann GV, Cambre T, Sun JH (1986) A new endoscopic elastic band ligating device. *Gastrointest Endosc* 32:230-233
- Stiegmann GV, Goff JS (1989) Endoscopic esophageal varix ligation: preliminary clinical experience. *Gastrointest Endosc* 34:113-117
- Tajiri H, Daikuzono N, Joffe SN, Oguro Y (1987) Photoradiation therapy in early gastrointestinal cancer. *Gastrointest Endosc* 33:88-90
- Tsang TK, Buto SK (1992) Catheter guided endoscopic intubation: a new technique for intubating a difficult esophagus. *Gastrointest Endosc* 38:49-51
- Tuan HA, Lam ECS, Fan ST (1989) Endoscopic retrieval of ingested broken glass in the esophagus and stomach by end-hood and suction technique. *Gastrointest Endosc* 35:357-358
- Tytgat GNJ, Huibregtse K, Bartelsman JWM, Den Hartog Jager FCA (1986) Endoscopic palliative therapy of gastrointestinal and biliary tumors with prosthesis. *Clin Gastroenterol* 15:249-271
- Tytgat GNJ (1989) Dilation therapy of benign esophageal stenosis. *World J Surg* 13:142-148
- Tytgat GNJ (1990) Endoscopic therapy of esophageal cancer: possibilities and limitations. *Endoscopy* 22:263-267
- Tytgat GNJ, Classen M (1994) *Practice of therapeutic endoscopy*. Churchill-Livingstone, Edinburgh
- Urita Y, Kondo E, Muto M, Yamada S, Hachiya A, Ishihara M, Ozaki M, Nishimo M, Naruki Y, Otsuka S (1996) Combined endoscopic clipping and injection

- sclerotherapy for esophageal varices. *Gastrointest Endosc* 43:140–143
- Utts SJ, DiPalma JA, Wytock DH (1995) Tracheobronchial obstruction complicating peroral prosthesis insertion. *Gastrointest Endosc* 31:383–384
- Van den Berg H (1998) On the evolution of some endoscopic light delivery systems for photodynamic therapy. *Endoscopy* 30:392–407
- Vargas-Tank L, Ovalle L, Fernandez C, Mella B, Estay R, De Solar MP, Soto JR (1995) Use of a very flexible guide wire to permit dilation of complex malignant strictures of the esophagus. *Gastrointest Endosc* 41:8–10
- Wang YG, Seitz U, Li ZL, Soehendra N, Qiao XA (1998) Endoscopic management of huge bezoars. *Endoscopy* 30:371–374
- Webb WA (1995) Management of foreign bodies of the upper gastrointestinal tract: update. *Gastrointest Endosc* 41:39–51
- Wehrmann T, Jacobi V, Jung M, Lembcke B, Caspary WF (1995) Pneumatic dilation in achalasia with a low-compliance balloon: results of a 5-year prospective evaluation. *Gastrointest Endosc* 42:31–36
- Weigert N, Neuhaus H, Rösch T, Hoffmann W, Dittler HJ, Classen M (1995) Treatment of esophagorespiratory fistulas with silicon-coated self-expanding metal stents. *Gastrointest Endosc* 41:490–496
- Wu WC, Katon RM, Saxon RR, Barton RE, Uchida BT, Keller FS, Rösch J (1994) Silicon-covered self-expanding metallic stents for the palliation of malignant esophageal obstruction and esophagorespiratory fistulas: experience in 32 patients and a review of the literature. *Gastrointest Endosc* 40:22–23
- Zein NN, Gresetz JM, Perrault J (1995) Endoscopic intralesional steroid injections in the management of refractory esophageal strictures. *Gastrointest Endosc* 41:596–598



# 31 Post-operative Complications of the Esophagus and Esophagus Bridge Graft

D. C. BROERING, J. R. IZBICKI, Y. VASHIST, A. F. CHERNOUSOV,  
P. M. BOGOPOLSKI, E. F. YEKEBAS

Due to the grave risk of insufficiency of the esophageal anastomosis and considering the severe operative trauma that is involved, surgery of the esophagus is one of the most dreaded operations in visceral surgery even today.

The post-operative complications could occur in the early or in the late post-operative period.

The residual stomach is left behind for as long as possible in order to ensure a good length of the residual stomach for secondary reconstruction. The proximal esophageal stump is not shortened for the same reason.

## Early post-operative complications

### ■ Necrosis of the gastric tube

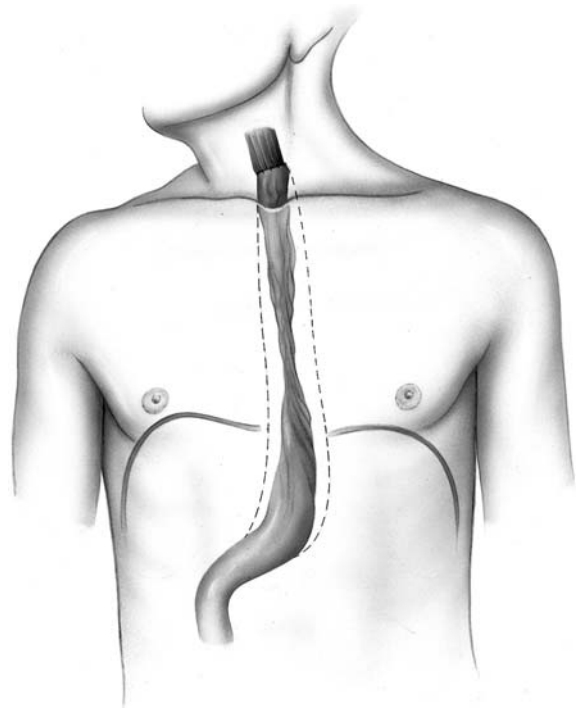
The first manifestation of gastric tube necrosis is the insufficiency of collar anastomosis, which presents clinically either as salivary fistula with fever as reddening of the skin, or results in a rise in amylase content of the drainage secretions.

In some cases, the first and only manifestation of gastric tube necrosis is the development of cardiac arrhythmias with subsequent mediastinitis.

Therefore, as soon as the symptoms occur, an endoscopy may be performed to assess the blood circulation.

If a necrosis of the gastric tube is demonstrated by endoscopy, the collar anastomosis is promptly released, and the necrotic segment of the bridging graft is resected.

The operation is concluded by providing mediastinal drainage, collar esophagostomy, and gastrostomy with the residual stomach.

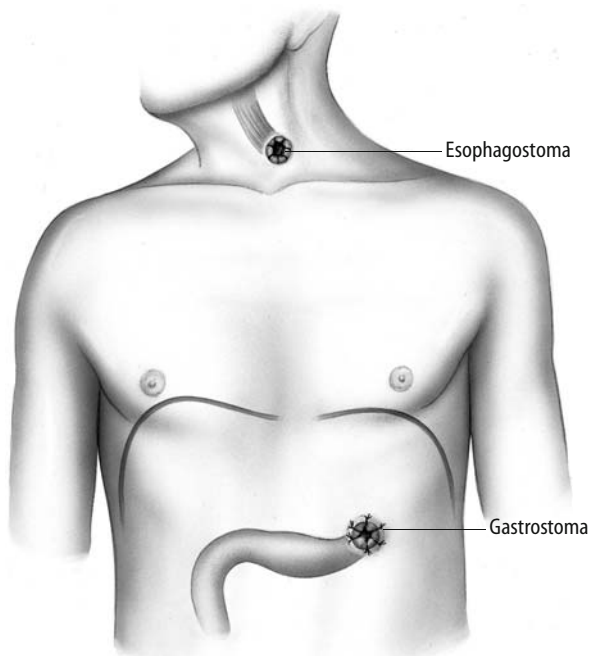


**Fig. 31.1.** Necrosis of the gastric tube after esophageal resection and transposition of the stomach in the former esophageal bed of the collar anastomosis.

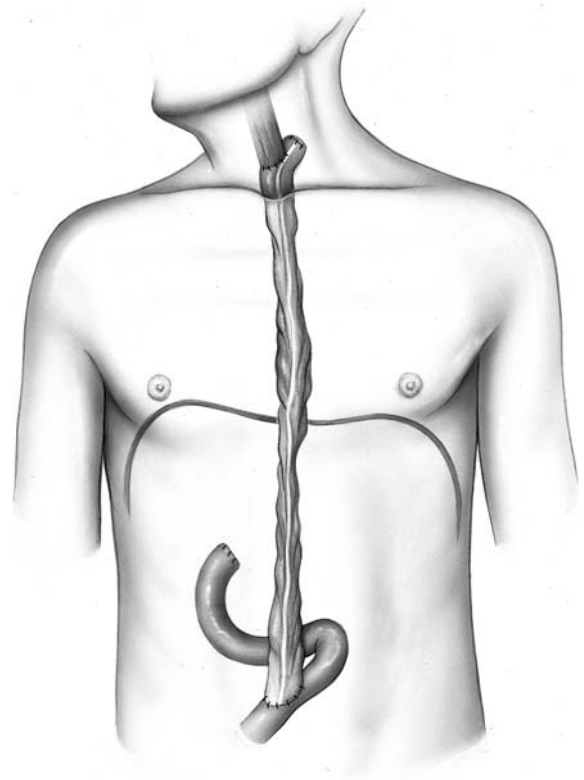
### ■ Necrosis of the colonic bridging graft

After interposition of the colon, the bridging graft can likewise undergo necrosis. A necrosis of the colonic graft is clinically not different from a necrosis of the stomach graft.

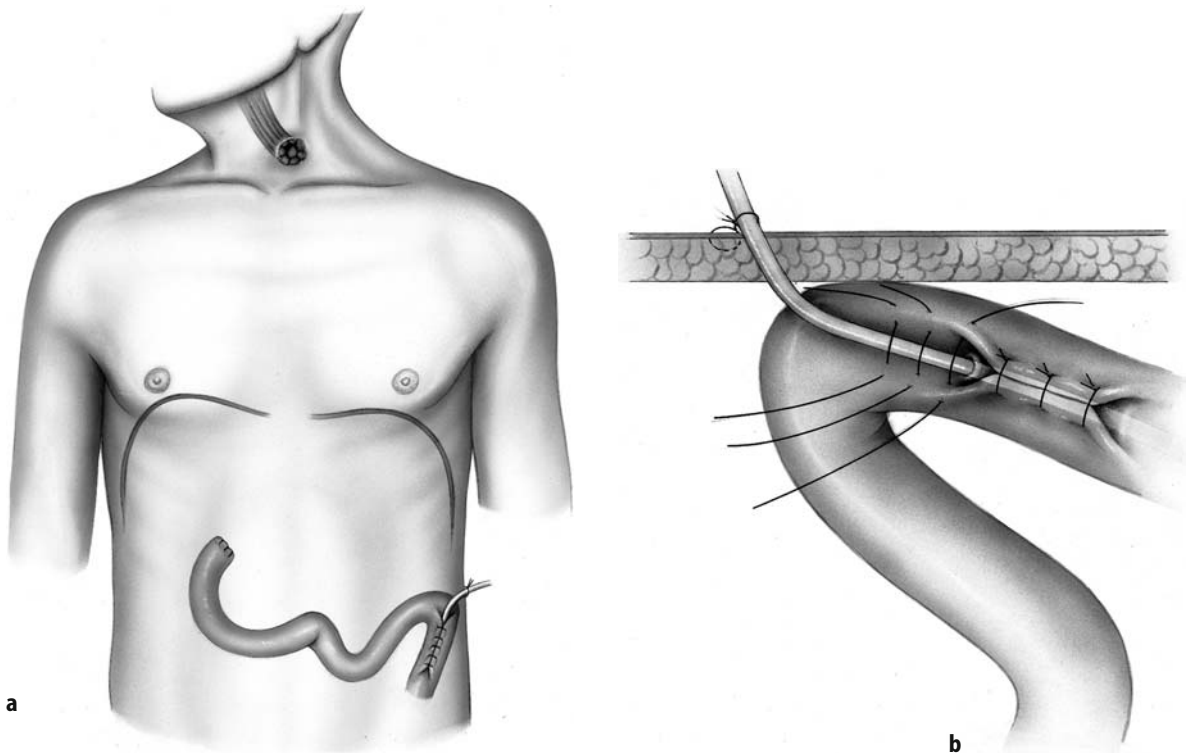
An immediate discontinuity resection with intensive drainage of the mediastinum is the preferred treatment in this case as well. Besides collar esophagostomy, a catheter jejunostomy is also necessary.



**Fig. 31.2.** Situation after discontinuity resection of the gastric tube.



**Fig. 31.3.** Site after esophago-gastrectomy and necrosis of the colonic bridging graft.

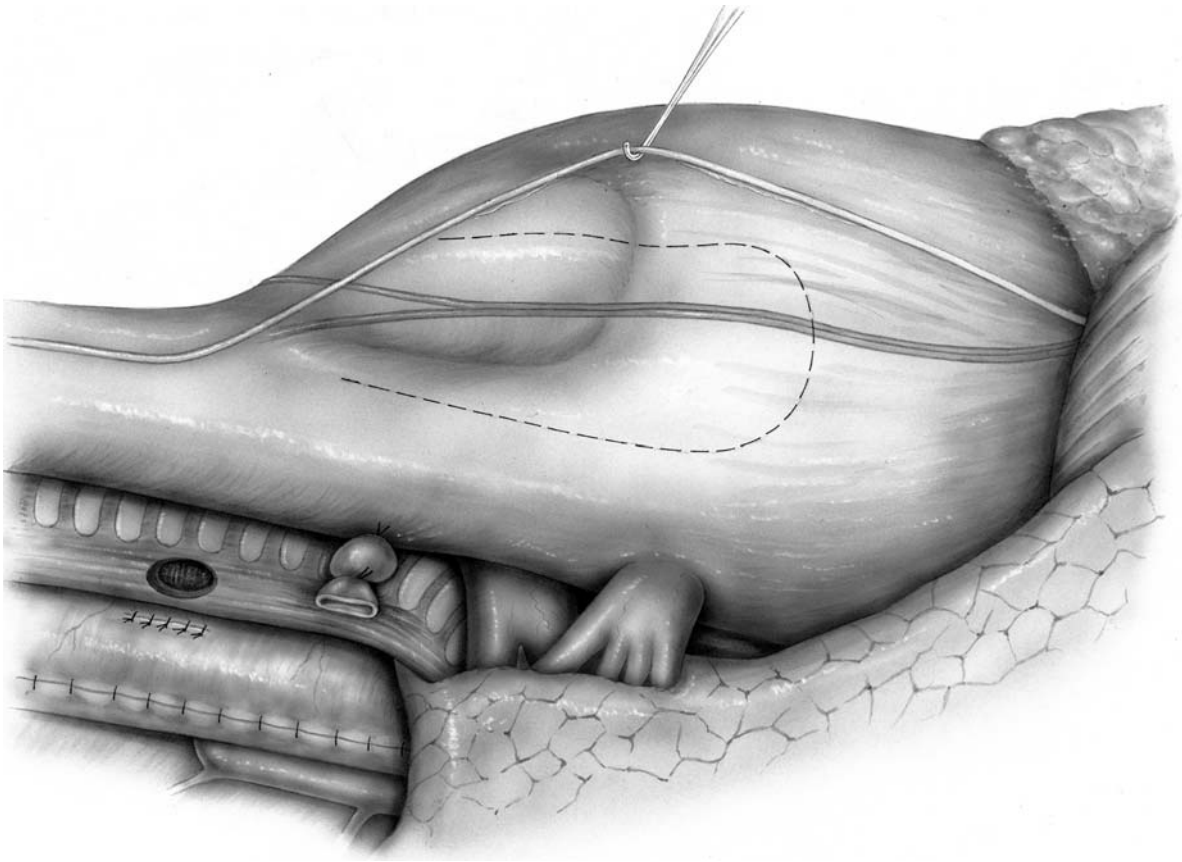


**Fig. 31.4a,b.** Situation after discontinuity resection of the colonic bridging graft, collar esophagostomy, and catheter jejunostomy. For catheter jejunostomy, the jejunum is punctured, and a nutrient catheter pushed deep into the proxi-

mal jejunum. The site of insertion of the catheter into the small intestine is closed with a purse-string suture and additionally reinforced by invaginating sero-muscular sutures.

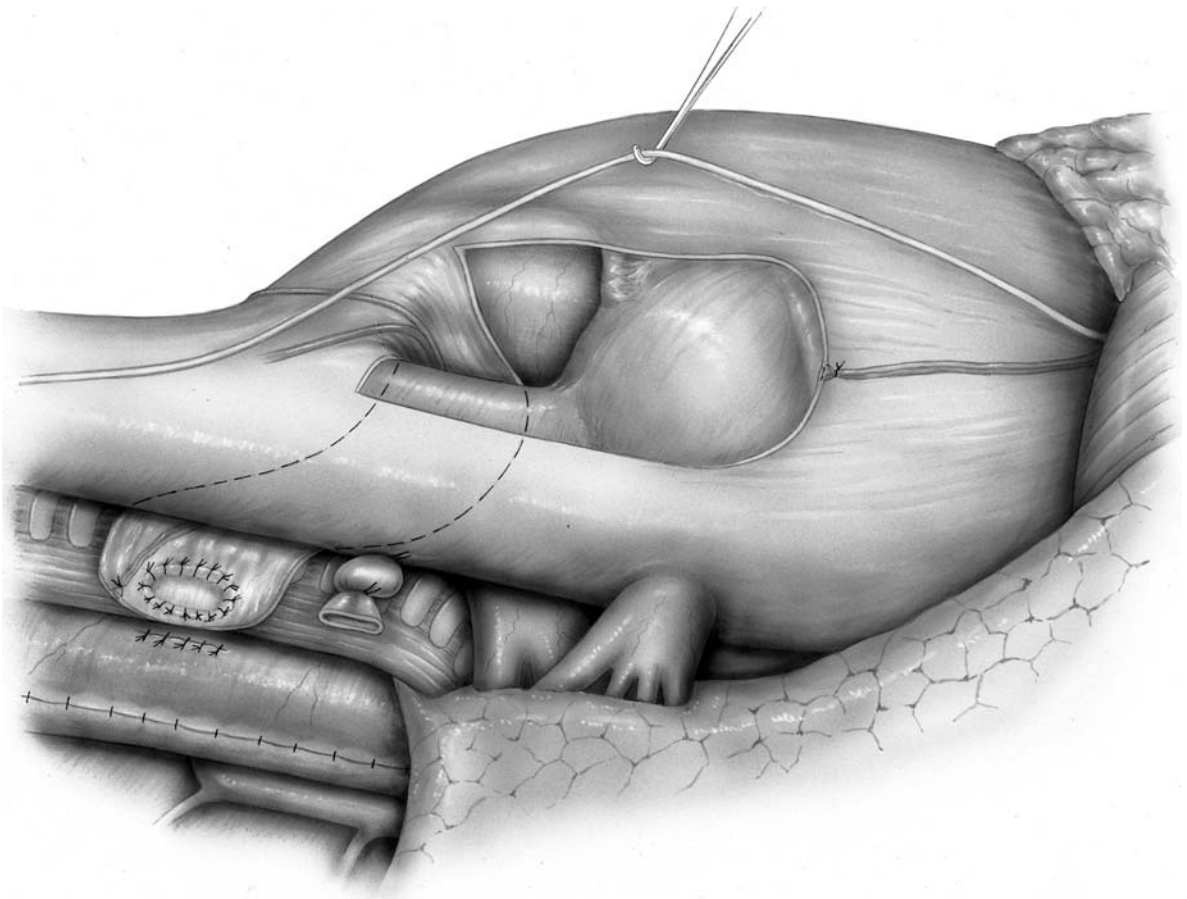
### ■ Fistula between the bridging graft (colon, stomach) and the trachea

The development of a fistula between the bridging graft and the trachea is one of the most dreaded complications. The fistula can be located in any part of the trachea, the most commonly affected region being the portion of the trachea above the tracheal bifurcation. The development of a fistula is an indication for surgery.



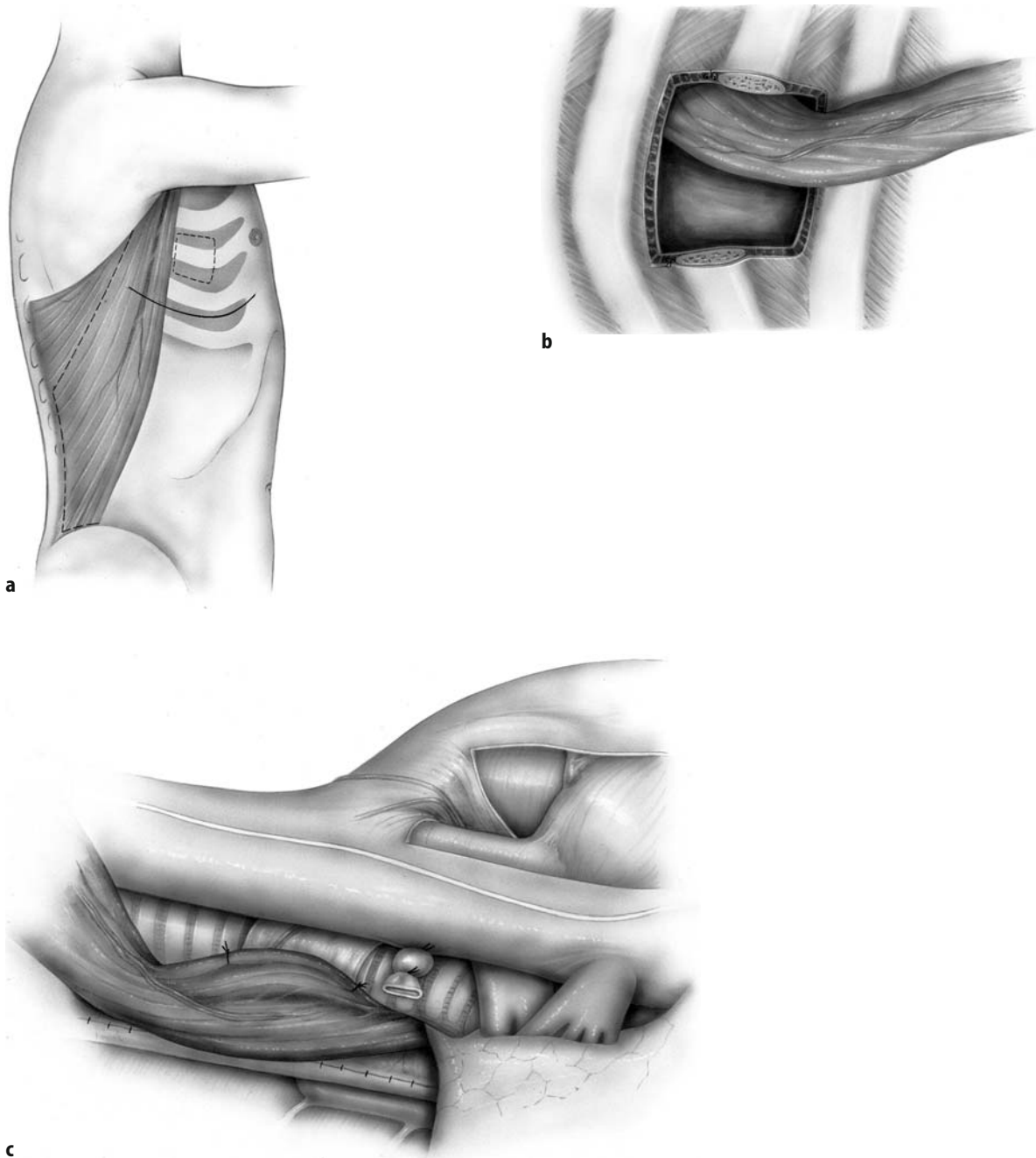
**Fig. 31.5.** Pedicle pericardial flaps for closing a fistula between the esophageal bridge graft and the trachea. The approach is via thoracotomy in the right 5th intercostal space. The latissimus dorsi muscle should never be incised. The fistula between the esophageal bridge graft (e.g. gastric tube) and the supra-bifurcational trachea is excised and the defect in the gastric tube is closed with button-hole sutures. The excision of the fistula leaves a defect in the region of

the pars membranacea of the trachea which can be sealed air-tight by a pedicle flap of the pericardium. The phrenic nerve is separated from the pericardium and held ventrally by using a nerve hook. The pericardiac-phrenic artery and vein form the vascular pedicle of the pericardial flap. To prevent necrosis of the flap, it is necessary that the length of the pericardial flap does not exceed three times the flap base.



**Fig. 31.6.** Pedicle flap of the pericardium for closing a fistula between the esophageal bridge graft and the trachea. The pericardial flap is transposed below the pulmonary artery between the pulmonary vein and the pulmonary artery to the

pars membranacea of the supra-bifurcational trachea and sutured circularly with button-hole sutures (Vicryl 4/0) into the defect in the pars membranacea. The suture should be as air-tight as possible.



**Fig. 31.7 a–c.** Flap of the latissimus dorsi muscle for muscular covering of a tracheal fistula. Keeping the muscle fascia intact, the latissimus dorsi muscle is mobilized subcutaneously up to the iliac crest. Similarly, keeping the vascular bundle intact, the lower surface of the latissimus dorsi muscle is also mobilized. The muscle is lifted from the iliac crest (a). After resection of the 4th rib from behind the anterior

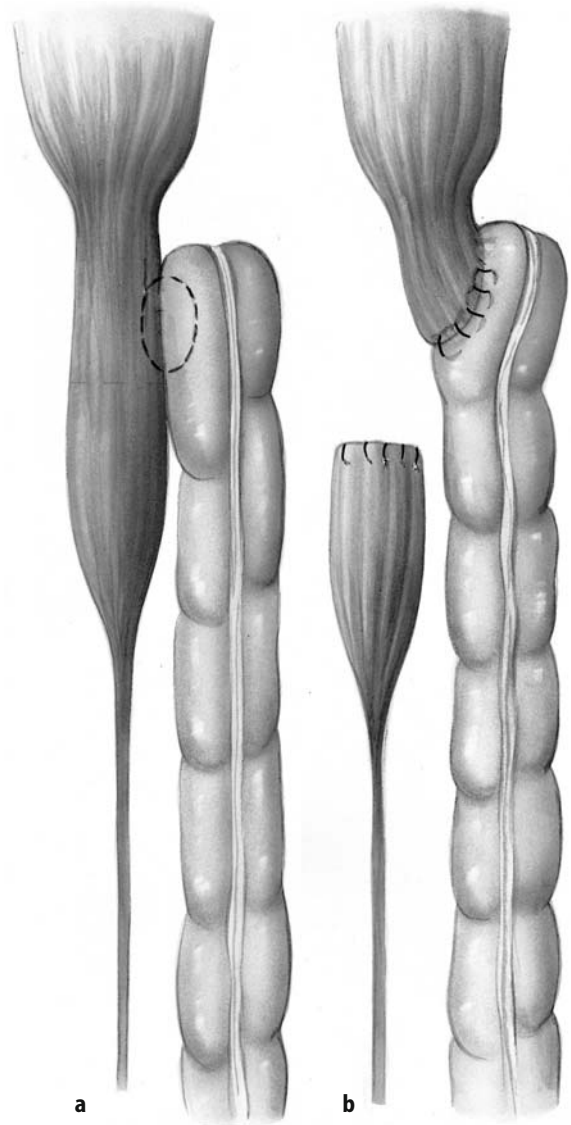
axillary line, the muscle is transposed into the thoracic cavity through the window thus formed in the thoracic wall (b). The muscle is elevated and placed loosely between the trachea and the esophageal bridge graft. The muscle is fixed to the cartilaginous part of the trachea with a few sutures (c). The muscle should not be fixed to the pars membranacea.

### Late post-operative complications

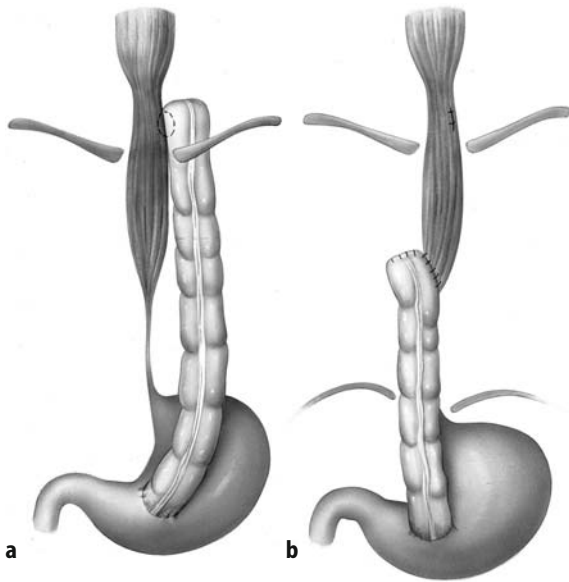
■ **Esophageal cul-de-sac** is a typical change observed after shunting operations of the esophagus.

The following are the indications for corrective surgical intervention in cul-de-sac syndrome:

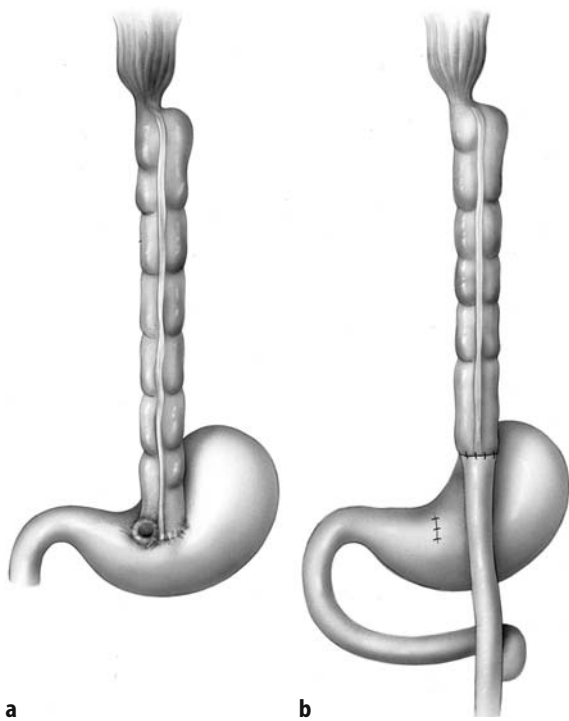
- Retention of food in the cul-de-sac
- Regurgitation of food
- Severe esophagitis.



**Fig. 31.8 a, b.** Dissection of the esophagus below the cervical anastomosis and blind closure of the aboral end of the esophagus. This corrective surgery can be performed only if a minimum length of the stricture is still patent; otherwise, there could be a risk of retention of the secretions, leading to bacterial growth. If there is no minimum passage in the stricture, an esophagectomy must be performed right after thoracotomy.

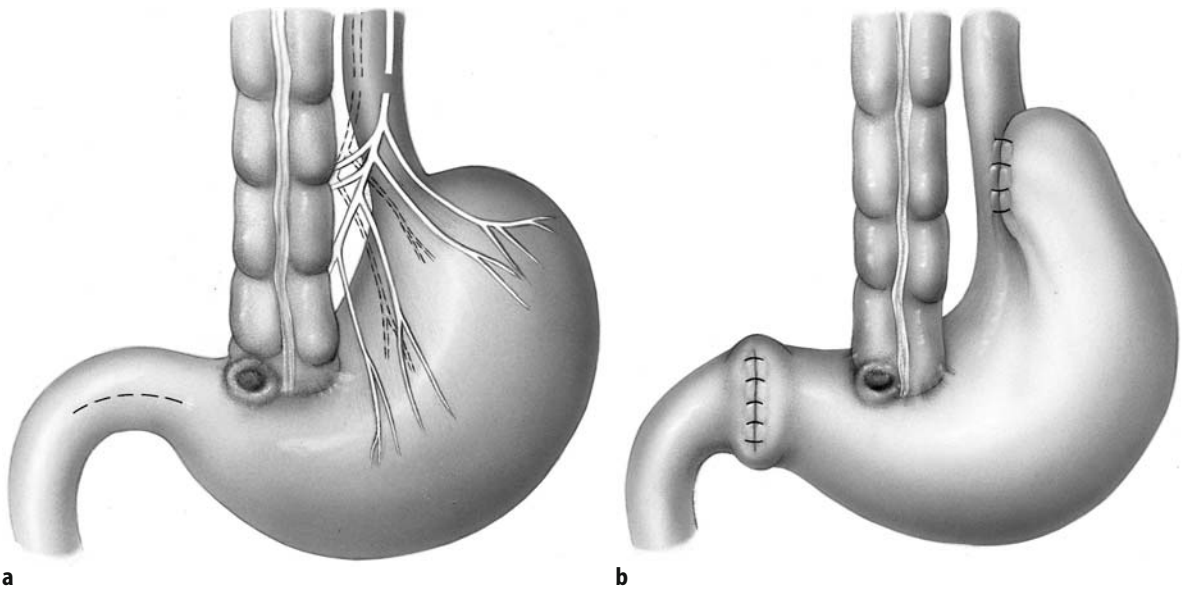


**Fig. 31.9 a, b.** A second alternative is to separate the colonic bridge graft from the cervical esophagus and to transpose it into the right thoracic cavity. Intrathoracic anastomosis of the esophagus with the colonic bridge graft directly above the stricture. The access is gained via a cervical incision extending below up to the abdomen. Intrathoracic transposition and anastomosis via a right thoracotomy.

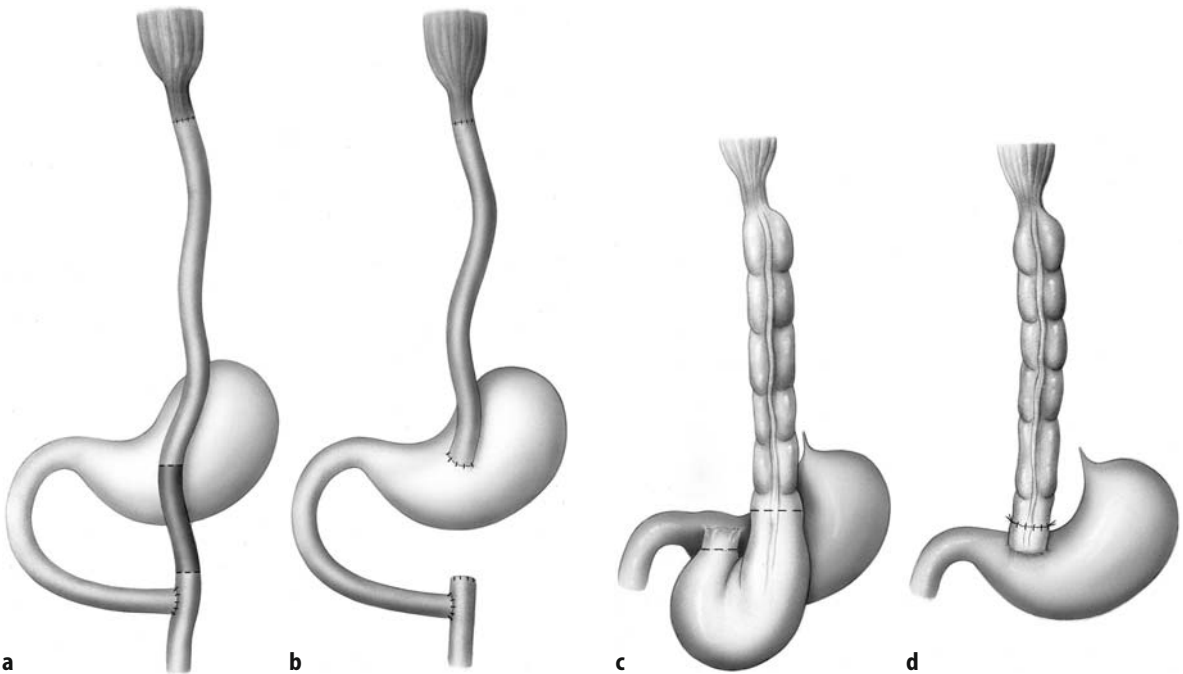


**Fig. 31.10 a, b.** The simplest corrective surgery is a closure of the colon-gastrostomy and anastomosis of the distal end of the colonic bridge graft with a Roux-y loop of the jejunum.



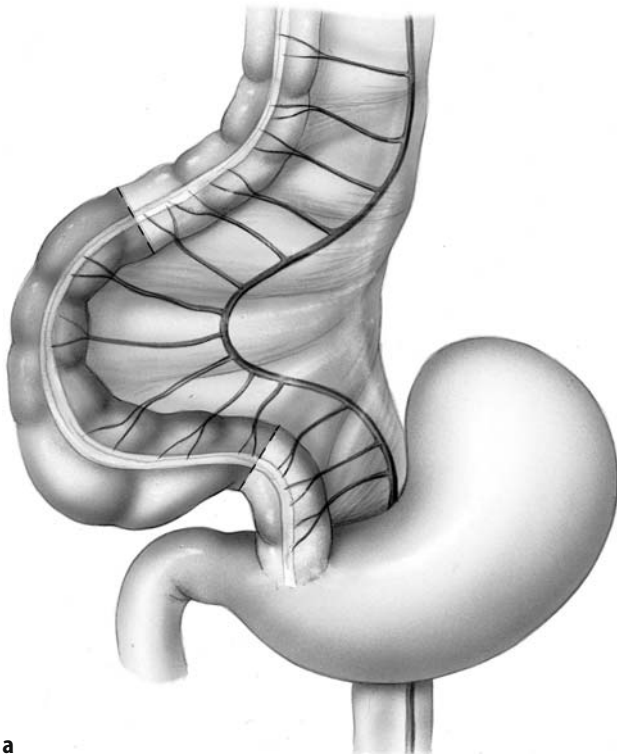


**Fig. 31.11 a, b.** A trunk vagotomy with pyloroplasty may be performed as an alternative.

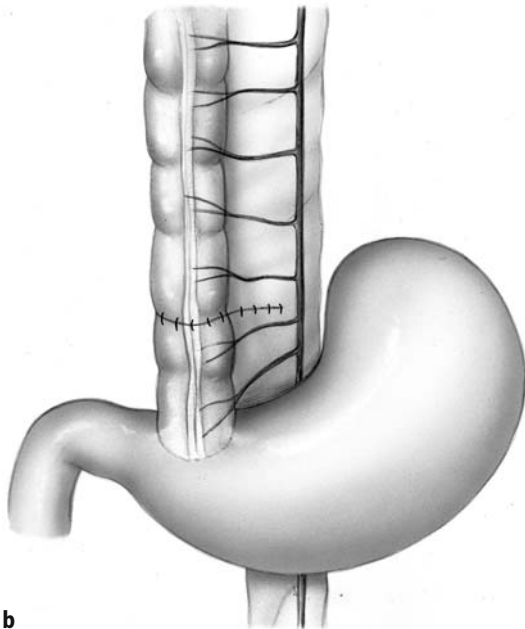


**Fig. 31.12 a-d.** A classical esophageal bridge graft of the jejunum (Roux-Hertzen – Yudin) can lead to severe intestinal disturbances. A majority of the symptoms can be eliminated by resection of a jejunum segment directly above the jejuno-jejunosomy, taking care to avoid trauma to the jejunal vascular arcade and to the anastomosis of the jejunum with the stomach.

The late post-operative complications of a colonic bridge graft include an undesirable lengthening of the colon with difficulty in passage. The preferred corrective surgery in this case is a resection of the excessively long colonic segment and end-to-end anastomosis of the ends of the colon. A trauma to the colonic vessels can be avoided by skeletonizing the intestine very close to the intestinal wall.



**a**

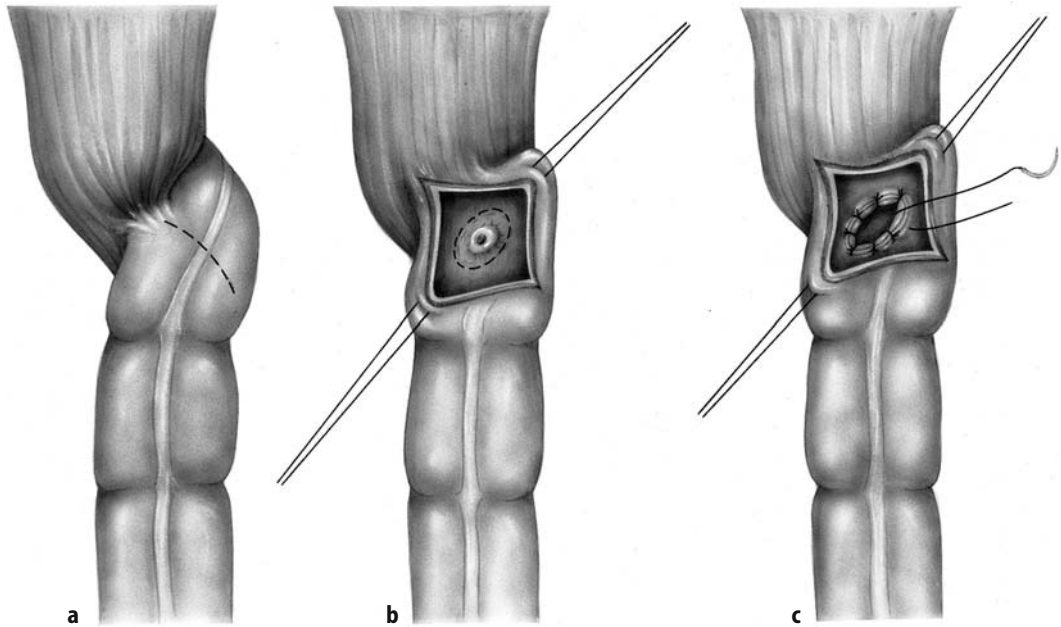


**b**

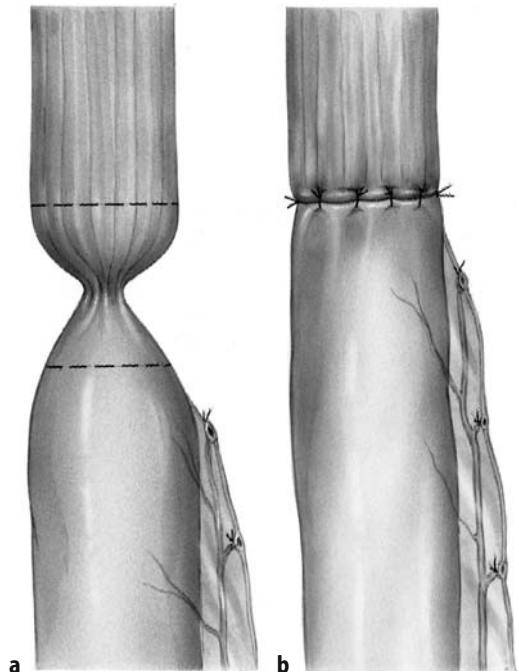
**Fig. 31.13 a, b.** Resection of an excessively long colonic bridge graft. In principle, the vessels draining the colonic bridge graft should not be traumatized during resection of a colonic segment.

### ■ Cicatrized stenosis of an esophago-gastrostomy or esophago-colostomy (pharyngo-gastrostomy or pharyngo-colostomy)

Surgery is indicated only if conservative therapy fails.



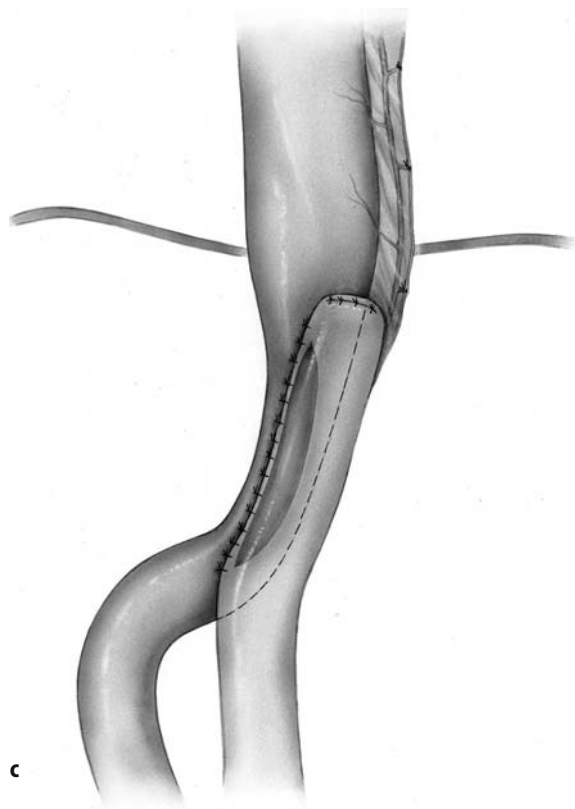
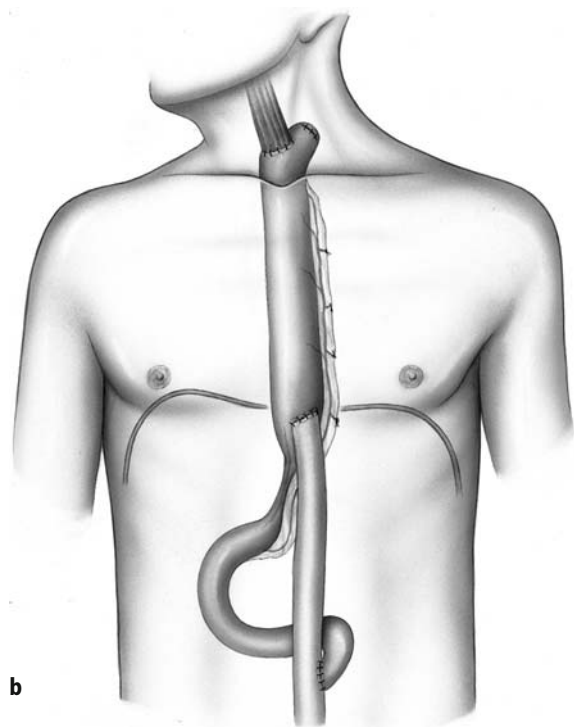
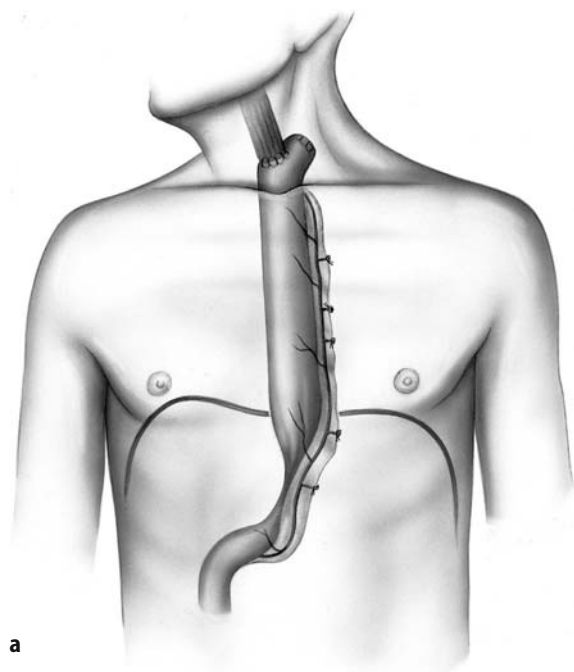
**Fig. 31.14 a–c.** Transverse incision of the colon above the strictured anastomosis. Circular excision of the stricture and adaptation of the mucosal border with interrupted sutures 5 mm apart (Vicryl 4/0). The intrathoracic and intraabdominal strictures can be managed similarly.



**Fig. 31.15 a,b.** In some cases, a complete excision of the strictured segment with end-to-end anastomosis is necessary. Surgery must always be followed by intraluminal decompression and external drainage of the operative area.

### ■ Cicatrization and deformation of the pyloric region

The pyloric region can undergo deformation and stenosis many months and even years after esophageal resection with interposition of the stomach, causing severe dysphagia.



**Fig. 31.16.** Cicatrization and deformation of the pylorus after interposition of the stomach (a). The cicatrized stenosis can be by-passed by gastro-jejunostomy with a Roux-Y loop (b). Alternatively, the stenosis can be subjected to stricturoplasty by a side-to-side jejunostomy with a Roux-Y jejunal loop (c).

# Subject Index

## A

- abdomen, drainage 291, 306
- abdominal esophagus, stenosis 293
- abdominal lymphadenectomy 85
- abdominal segment 4
- abdominal ultrasound 247
- abdomino-thoracic en bloc esophagectomy 85
- accessory left hepatic liver artery 118
- achalasia 12
  - cardiomyotomy 253
  - - with Thal (Dor) fundoplasty 301
  - dilatation treatment 353
  - endoscopic treatment 351
  - endoscopy 23
  - injection treatment 353
- additional stent, proximal overgrowth 341
- adenocarcinoma 20, 72, 89, 91, 109
  - advanced 247
  - Barrett's esophagus 22
  - distal 247
  - early (T1b) 90, 248
  - 3 field en bloc esophagectomy 104
  - mucinous 72
  - mucoepidermoid 72
- adenoid cystic carcinoma 72
- adenosquamous carcinoma 72, 92
- adult respiratory distress syndrome (ARDS) 48, 98
- advanced carcinoma
  - chemical destruction 334
  - distant residual 77
  - electro-thermocoagulation 334
  - esophageal, see esophageal tumor
  - exophytic, thermoablative technique 335
  - laser ablation 334
  - - stenting 334
  - loco-regional residual 77
  - mimicking achalasia 351
  - obstruction
    - - bougienage 335
    - - stent placement 335
    - overgrowth 336, 341
    - - sclerotherapy 336
    - - stent exchange 336
    - - stenting 336
    - recurrent 348
  - resection, endoscopic techniques 327
  - staging, EUS 335
  - stenosis, EUS 30
  - unresectable 335
- aminopyrine breath test 40
- anastomosis
  - Billroth II 233
  - cervical 111, 140, 153
  - collar
    - - esophagojejunal 239
    - - insufficiency 361
  - colo-colonic, insufficiency 205
  - colo-esophageal, latero-lateral 221
  - insufficiency 223
  - 2-layer esophagogastronomy 150
  - portocaval 5
  - postoperative edema 149
  - Roux-Y 260
- anastomotic leak rate 101
- anastomotic leakage 100, 103, 104, 149
- anastomotic stenosis, risk 162
- Angelchik prosthesis 62, 67, 260
- angle of His 123, 273
- anisoperistaltic colonic interposition 216
- anterior hiatoplastic 259
- antibiotic prophylaxis 335, 345, 351
  - perioperative 275
- antireflux barrier 51, 52
- anti-reflux surgery 264
  - advantages 60
  - breakdown of the repair 67
  - disadvantages 60
  - failures 67, 264
  - Gastric pull through 66
  - inappropriate surgery 66
  - MIC 303
  - obstructions 66
  - re-operative surgery 67
  - therapy, conservative 264
- aorta 191, 310
  - abdominal 193
  - bifurcation 192
  - descending 132
  - injury 155
  - thoracic 4
  - tumor infiltration 155
- aortic arch 4
- aortic cuff 155
- appendectomy, prophylactic 209
- arcade
  - of Riolan 211, 212
  - paracolic 211, 212
- argon laser 333
- argon plasma coagulation 316, 327, 334, 348, 350, 355, 356, 357

arterial blood gas analysis 41  
arterial blood supply 4  
arterial catheter 44  
arterial O<sub>2</sub> partial pressure (PeO<sub>2</sub>) 40  
artery  
– accessory left hepatic 182  
– carotid 86, 144  
– – common 3  
– – external 245  
– celiac 248  
– colic left 226  
– colon, middle 226  
– colonic 214, 216  
– – left 213, 214, 215  
– – middle 212, 213, 214, 215  
– facial 245  
– gastric 182, 189  
– – left 5, 85, 120, 139, 157, 182, 249  
– – right 190, 201  
– gastroepiploic 182, 304  
– – left 116, 183, 202  
– – right 116, 139, 157  
– hepatic 185, 190, 203, 248  
– – common 120, 122, 190, 202  
– – lymphadenectomy 249  
– jejunal 234, 245  
– lingual 245  
– longitudinal network 5  
– mesenteric  
– – inferior 212, 213  
– – superior 193  
– – pericardiac-phrenic 364  
– phrenic 5  
– pulmonary 4, 365  
– rectal inferior 213  
– renal, left 193  
– sigmoid 211, 212, 213, 214  
– – first 213, 215  
– splenic 5, 85, 120, 122, 185, 188, 189, 203, 248  
– lymphadenectomy 249  
– subclavian 4, 5  
– suprarenal 193  
– thyroid 243  
– – inferior 4, 145  
– – superior 5, 245  
ASA classification 39  
ascending colon 207  
aspiration 43, 45  
atraumatic hydrophilic guide-wire 342

Auerbach plexus 23  
axial sliding hernia 21

## B

Baby-Celestin-tubes 335, 344  
balloon dilatation 222, 293, 335, 345, 348, 349, 350, 351, 352  
– over a guidewire 352  
balloon tamponade 315  
band ligation 315  
band ligator 327  
Barrett's  
– esophagus 21, 22, 54, 247  
– – high grade dysplasia 334  
– segment 249  
– – long 247  
– epithelium 20  
basaloid squamous cell carcinoma 72  
Belsey procedure 62  
benign stenoses, dilatation 345, 346  
benign tumor  
– endoscopy 20  
– esophageal 109  
– excision 307  
– irresectable 223  
– leiomyomas 307  
– thoroscopic resection 307  
Bezotome 326  
Bezotripter 326  
big biopsy 89  
Billroth II anastomosis 233  
biopsy  
– diagnostic accuracy 20  
– endoscopic 20, 333, 348, 351  
– multiple, pre-therapeutic diagnostic 79  
bleeding, upper gastrointestinal 22  
– non-variceal 316, 317  
blood group 315  
body temperature, intraoperative control 47  
Boerhaave's syndrome 22, 157, 283  
bolus obstruction 324, 326, 336  
botulinum toxin 351, 352  
bougienage 293, 335, 338, 341, 347, 348, 349, 350  
– dilatation 222

– perforation 347  
– scars or webs 349  
bougies 335  
bowel preparation 205  
brachial fistula 275  
brachiocephalic trunk 129  
bronchial bifurcation 297  
– diverticula 297  
bronchography 11  
bronchoscopy 335, 341  
bronchus, main 175, 311

## C

candida 21  
carcinoma  
– adenocarcinoma, see adenocarcinoma  
– adenoid cystic 72  
– adenosquamous 72  
– cardia 89, 92, 185, 205  
– – advanced 199  
– choriocarcinoma 72  
– early carcinoma of the esophagus 73  
– esophageal, see esophageal carcinoma  
– esophageal-gastric junction 89, 157  
– esophagus  
– – early 20, 73  
– – N/pN classification 75  
– – regional lymph nodes 73, 84  
– gastric, see gastric carcinoma  
– gastroesophageal junction 92, 264  
– lymphoepithelioma-like 72  
– mucoepidermoid 72  
– scirrhous 14  
– small cell 72  
– spindle cell 72  
– squamous cell, see squamous cell carcinoma (SCC)  
– total gastrectomy with lymphadenectomy, T1 N0 92  
– uncommon 72  
– undifferentiated 72  
– verrucous 72  
cardiac arrhythmia 361  
cardiac risk 41  
cardiocirculatory depression 46  
cardiomyopathy 44, 302

- achalasia 253
  - cardiopulmonary complications 260, 314
  - cardiopulmonary insufficiency 171, 185, 199, 205, 223, 253, 293
  - catheter jejunostomy 362, 363
  - caustic ingestion 345
  - caustic injury 235
  - cecum 207
  - Celestin -tubes 335
  - celiac trunk 85, 92, 120, 122, 182, 185, 189, 202, 203, 249
  - dissection of the lymph nodes 117
  - lymph nodes 91, 93
  - central venous line 44
  - cervical anastomosis 111, 140, 153
  - cervical anastomotic leak 222
  - cervical approach, left 293
  - cervical diverticula 11, 275
  - endoscopic treatment 275
  - transoral treatment 298
  - cervical esophago-colostomy, strictures 222
  - cervical esophagus 3, 90, 217, 284, 336
  - cervical incision 225, 310
  - oblique 311
  - cervical lymph nodes 5, 73, 82, 97, 100
  - cervical pharyngeo-colostomy, strictures 222
  - cervical plexus 86
  - cervical sphincter, complete myotomy 99
  - cervical stage, transhiatal subtotal esophagectomy 144
  - cervico-mediastinal lymphadenectomy 86
  - C-factor 77
  - chemoradiation, neoadjuvant 91
  - chemoradiotherapy 31
  - adjuvant 102, 104
  - adjuvant preoperative 102
  - induction 89
  - chemotherapy/radiotherapy, neoadjuvant preoperative 98
  - chest drainage 48
  - chest tube 155
  - cholecystolithiasis 264
  - choriocarcinoma 72
  - chromoendoscopy 327, 328, 333
  - chromoscopy 20
  - chylothorax 171
  - cicatrized stenoses
  - esophago-gastrostomy 371
  - pharyngeo-colostomy 371
  - pharyngeo-gastrostomy 371
  - circular myotomy, abdominal esophagus 265
  - circular stapler 165
  - clamp resection 135
  - clipping 317
  - clips, application 315, 317, 318, 319, 331
  - coagulation status 315, 355
  - coagulation, argon plasma 316
  - collar anastomosis, insufficiency 361
  - collar esophagostomy 361, 362, 363
  - collar stenosis 293
  - collar vascular connection 243
  - collecting sacs 324
  - Collis gastroplasty 65
  - colo-colonic anastomosis, insufficiency 205
  - colo-esophageal anastomosis, latero-lateral 221
  - colo-esophagostomy
  - intrathoracic, right 229
  - latero-lateral 227
  - - left 224
  - colo-gastrostomy 206
  - intraabdominal termino-lateral 224
  - transverse 228
  - colon interposition 90, 92, 93, 205, 223, 230
  - anisoperistaltic 211
  - intrathoracic esophageoplasty 223
  - Korbhenkel bypass 224
  - left-sided isoperistaltic 212
  - posterior mediastinum 219
  - short 226
  - colon
  - flexure, splenic 209
  - kinking 219
  - necrosis 205
  - colonic bridge graft 367, 369
  - necrosis 362
  - colonic flexure, right 207, 208
  - colonic interposition, complications 222
  - colonic segment
  - anisoperistaltic 211
  - selection 210
  - colon-interposition 224, 227, 228
  - intrathoracic bypass 225
  - isoperistaltic 226
  - colonoscopy, total 205
  - color Doppler ultrasound 28, 33
  - columnar epithelial-lined lower esophagus (CELLO) 72
  - common bile duct 117
  - compartment -3 resection 192
  - complicated reflux disease 260
  - computed tomography (CT) 16, 247, 326
  - accuracy 25
  - distant metastasis 81
  - guided transthoracic biopsy 33
  - multislice 16
  - conic reduction plastic 161, 163
  - continuous positive airway (CDPA) 47
  - contrast esophagographie 11
  - contrast, water soluble 326
  - coronary angiography 44
  - coronary artery disease 44
  - creatinin clearance 41
  - cuff-folds 262
  - cuff-rupture 260
  - cul-de-sac- syndrome 367
  - cytomegalovirus (CMV) 21
- D**
- denervation syndrome 260
  - diagnostic accuracy, biopsy 20
  - diaphanoscopy 247, 249
  - diaphragm
  - incision 186
  - - median 254
  - posterior crura 305
  - right crus 304
  - diaphragmatic flap 283
  - preparation 280
  - diaphragmatic pericled flap 290
  - diaphragmotomy 157
  - diffuse esophagospasm 24, 253

- dilatation 337
    - achalasia 354, 535
    - endoscopic 253, 264, 323
    - fluoroscopic monitoring 354
    - hemorrhage 336
    - re-stenoses 350
  - dilation tube 301
  - discontinuity resection 36, 3632
  - dislocation, stents 341
  - dissection of the lymph nodes, hepatic artery 117
  - disseminated disease 98
  - distal stopper, stent 341, 344
  - distant abdominal lymph nodes 84
  - distant metastases, esophageal cancer 31
  - distant metastasis, CT 81
  - distant residual tumor 77
  - diverticula 11
    - cervical 11, 75, 275
    - – endoscopic treatment 275, 355
    - – transoral treatment 298
    - endoscopy 23
    - epiphrenic 12, 23, 275, 278, 279, 351
    - epiphrenic thoracoscopic extirpation 298
    - false 355
    - incision of the septum 355
    - MIC 297
    - mid-esophageal 275
    - parabronchial, excision 299
    - posterior pharyngeal 11
    - pulsion 297
    - resection 274
    - tracheobronchial 4
    - traction 12
    - Zenker 23, 355
    - – endoscopic treatment 356
  - diverticulitis 275
  - DNA analysis 75
  - Dormia basket 324, 326
  - double lumen endotracheal tube 46
  - double lumen insufflations tube 308
  - down-hill varices 23
  - duodenal ulcer 199, 264
  - duodenogastroesophageal reflux 52
  - dye solution 333
  - dysphagia 11, 12, 15, 258, 275, 299, 301, 305
    - postoperative 262
- E**
- early adenocarcinoma (T1b) 90, 248
  - early cancer, lymph node spread 84
  - early carcinoma of the esophagus 73
    - classification 20
  - early metastatic potential, esophageal cancer 82
  - early tumor staging, endoscopic ultrasound 31
  - echocardiography 41, 44
  - echoendoscopy 19
  - electrocautery 327, 348, 350
    - short stenoses 345
  - electronic radial echoendoscopes 27
  - embolic complications, N-butyl-2-cyanoacrylate 323
  - emergency thoracotomy 247
  - en bloc transthoracic esophagectomy 100
  - endobrachyoesophagus 72
  - endo-clips 331
    - perforation 331
  - endodissection 314
    - of the esophagus 311, 312
  - endoprosthesis 335
  - endoscopic biopsy 20, 333, 348, 351
  - endoscopic clipping 352, 357
    - perforation 347
  - endoscopic dilatation 253, 264, 323
    - tumor stenosis 30
  - endoscopic examination 19
  - endoscopic hemostasis 23
  - endoscopic mucosal resection (EMR) 327, 328, 329, 330, 334
    - cap 329
    - hemorrhage 331
    - perforation 332
    - surveillance 331
  - endoscopic occlusion, esophago-tracheal fistula 343
  - endoscopic removal, foreign bodies 324
  - endoscopic techniques, esophageal diseases 315f.
  - endoscopic therapy, strictures 293
  - endoscopic ultrasound (EUS) 19, 21, 25, 27, 351
    - accuracy 29
    - examination technique 27
    - re-staging of esophageal cancer 31
    - tumor staging 25, 31, 327
    - tumor stenosis 3
    - guided fine needle aspiration (EUS ± FNA) 28, 29, 32, 33, 81, 327, 333, 348
    - – accuracy 33
    - – complications 33
  - endoscopy 355, 361
    - intraoperative 301, 302, 307
  - endoscopy-controlled incision, hard scars 349
  - endosonographic examination, injection treatment 353
  - endosonography 18, 247
  - endothoracic membrane 217
  - end-to-end stapler 152
  - end-to-side stapler 154
  - epidural catheter 45
  - epigastric lymphadenectomy 111
  - epinephrine solution 328, 331
  - epiphrenic diverticula 23, 275, 278, 279, 299, 351
    - thoracoscopic extirpation 298
  - eradication, esophageal varices 319, 320
  - ergometry 41
  - erosive reflux disease 52
  - esophageal anterior-wall musculature, resection 257
  - esophageal bridge graft 364, 366
    - of the jejunum 369
  - esophageal carcinoma
    - diagnosis 14
    - distant metastasis (M/pM) 76
    - early metastatic potential 82
    - grading 72
    - indicator of outcome 78
    - lymphatic invasion 77
    - MIC 308
    - stage grouping 76



- staging 25
  - subtotal gastrectomy 205
  - superficial 73
  - tumor classification 71
  - typing 72
  - esophageal cul-de-sac 367
  - esophageal diseases, endoscopic technique 315 f.
  - esophageal diverticula, resection 274
  - esophageal fistula 205
    - perforation 283
    - surgical treatment 283
  - esophageal hiatus 270, 273
  - esophageal motility 299
  - esophageal peristalsis, GERD 53
  - esophageal resection, total 220
  - esophageal spasm, diffuse, long myotomy 302
  - esophageal sphincter
    - lower 3, 51, 52, 248, 259, 298, 353
    - - myotomy 299, 300
    - - pressure 45
    - upper 3
    - - complete myotomy 298
  - esophageal stricture
    - benign 230
    - carcinoma 222
    - distal esophageal third 223
  - esophageal stump 149
  - esophageal superficial carcinoma 73
  - esophageal tumor, benign, local excision 281
  - esophageal tumors 14
    - benign 15
    - diagnosis 14
  - esophageal varices 13
    - eradication 315, 319, 320
  - esophageal wall
    - anterior, dissection 312, 313
    - structure 9
  - esophageal-gastric junction, carcinoma 157
  - esophagectomy
    - abdomino-thoracic en bloc 85
    - abdominothoracic subtotal en bloc 171
    - en bloc transthoracic 100
    - extended
      - - 3 field 97
      - - - en bloc 97
      - - - - adaenocarcinoma 104
      - - - - advantages 98
      - - - - complications 101
      - - - - disadvantages 98
      - - - - results 100
      - - 2 field (en bloc)
        - - - results 99
    - esophagectomy
      - radical en bloc 81
      - randomized trials 102
      - subtotal 89
      - - jejunal interposition 233
      - survival 101
      - thoracoscopic 314
      - thransthoracic
        - - en bloc 89, 90
        - - open 314
        - total, jejunal interposition 233
      - transhiatal 92, 100, 274
      - - subtotal 109
        - - - operative risk 109
      - transhiatal blunt 109
  - esophagitis 21
    - complications 22
    - viral 21
  - esophago-colostomy 223
    - cicatrized stenoses 371
  - esophago-fundo-phrenicoplexia 260
  - esophagogastrectomy 247
    - transhiatal 199
  - esophagogastric junction 257, 301
    - diverticula 297
  - esophagogastroscope 149, 247
    - cicatrized stenoses 371
    - circular stapler 197
  - esophagogastrostomy
    - antirefluxive 196
    - complete 151
    - intrathoracic 185
    - telescopically 169
    - termino-terminal 194
  - esophagojejunostomy 233, 236
    - insufficiency 247
    - intrathoracic 233
    - termino-lateral 237, 239, 247, 251
  - esophagoplasty, local 293
  - esophagoprobe 30
  - esophagoscopy, intraoperative 247, 249
  - esophagospasm, diffuse 24
  - esophagostomy, side-to-side 296
  - esophago-tracheal fistula 20
    - EUS 27
  - esophagus bridge graft, post-operative complications 361
  - esophagus carcinoma
    - early 73
    - N/pN classification 75
    - regional lymph nodes 73
  - esophagus
    - anatomic subdivision 71
    - cervical, exposure 206
    - development 4
    - diagnostic methods 11
    - distal
      - - adenocarcinoma 199
      - - peptic stenosis 157
      - - ruptures 157
      - - squamous cell carcinoma 157
    - examination 11
    - fistula 284
    - intraabdominal fistula 288
    - long strictures 185
    - short 13
    - topography 3
    - transhiatal dissection 203
  - esophagogastrostomy 310
  - examination technique, EUS 27
  - extended lymph node dissection 97, 102
  - extensive stricture 109
  - extubation 48
- F**
- feeding tube 348
  - fiberoptic bronchoscope 47
  - fibrin glue sealing 341, 342
  - 2-fields lymphadenectomy 89
  - 3-fields lymph node dissection 84, 102
    - extended 97
  - 3-fields lymphadenectomy 86, 89, 98
  - 3-fields esophagectomy, case selection 100
  - fine needle aspiration 28
  - fistula 364

- cervical esophagotra-  
cheal 344
  - conservative therapy 284
  - curettage 342
  - esophageal 205
  - esophageal, endoscopic tech-  
niques 341
  - esophago-bronchial 341
  - esophago-mediastinal 335,  
342
  - esophagopleural, transhiatal  
closure 289
  - esophago-tracheal 11, 20,  
286, 335
  - external 284
  - graft metal 364
  - internal 284
  - intraabdominal 288
  - intrathoracic 287
  - non healing 341
  - palliative operation 283
  - radical operation 284
  - salivary 361
  - tracheobronchial 4
  - transhiatal closure 291
  - Flankennähte 306
  - flexible retractor 311
  - floppy, fundoplication 261
  - floppy-Nissen 67, 262
  - flow cytometry 75
  - fluoroscopic examination 352
    - perforation 336
  - fluoroscopic monitoring, dilata-  
tion 354
  - Foley catheters 324
  - foreign bodies 14, 324
    - aspiration 326
    - endoscopic removal 324
    - extraction, perforation 326
    - fluoroscopy guided removal  
324
  - free jejunal interposition 90,  
93
  - fundal varices 13
  - fundophrenicoplexia 259
  - fundoplasty (Dor, Thal) 260,  
302, 303
  - fundoplication 61, 262, 267,  
288, 291
    - 3-fields 306
    - floppy 261
    - laparoscopic 62
      - - complication rate 62
      - - modified 266
  - - Nissen 61
  - - partial 65, 66, 260, 273
  - - posterior 65
  - - total 260
  - fundus rotation gastro-  
plasty 181, 182
- G**
- Gadolinium DTPA 16
  - gas-bloat syndrome 260
  - gastrectomy 89
  - gastric carcinoma 92
  - gastric decompression 280
  - gastric depletion disorder 260
  - gastric feeding tube, temporary  
347
  - gastric interposition 310
  - gastric mobilization 182
  - gastric outlet obstruction 143,  
269
  - gastric patch 300
  - gastric pull-up 148
    - presternal 148
  - gastric tube 90, 256, 266, 272,  
280, 282, 296, 299, 303, 311
    - construction 111
    - diameter 142
    - fixation 167
    - formation 140, 181
    - isoperistaltic 141
    - length 157
    - necrosis 109, 205, 357
    - pull-up, retrosternal 148
    - transposition 114, 147, 171
  - gastric vagal branches 249
  - gastric vessels, short 250
  - gastric volvulus 269
  - gastric wall
    - ischemia 140
    - retroesophageal pull-  
through 305
  - gastrocolic ligament 115
  - gastroepiploic vessels 115
    - right 199, 200
  - gastroesophageal (GE) junc-  
tion 23
    - anatomical reconstruc-  
tion 259
    - carcinoma 89, 92, 264
    - en bloc resection 248
    - isoperistaltic jejunal interposi-  
tion 247
    - tumors 91
  - gastroesophageal reflux 13, 52
  - gastroesophageal reflux disease  
(GERD) 21, 51, 259
    - Barrett's syndrome 59
    - columnar lined esopha-  
gus 59
    - definition 51
    - diagnostic test 51
    - duodeno-gastroesophageal re-  
flux 54
    - esophageal peristalsis 53
    - gastroduodenal disorders 54
    - hiatal hernia 53
    - incident of adenocarcino-  
ma 60
    - indication for surgery 54
    - intestinal metaplasia 51
    - intraabdominal pressure 53
    - laparoscopy 259
    - manometry 52
    - mucosal resistance 54
    - prevalence 51
    - proton pump inhibitors 59
    - respiratory complications  
59
    - stricture formation 59
    - surgical management 59
    - symptoms 52
  - gastrointestinal bleeding,  
upper 22
  - gastrointestinal tract, lower,  
reconstruction 206
  - gastro-jejunosomy, with Roux-Y  
loop 372
  - gastropexia 259
  - gastroplasty 157
    - fundus rotation 181, 182
  - gastrosopes
    - large working channels 324,  
355
    - with dual channel 355
  - gastrostomy 361
  - GENEVAL-consensus confer-  
ence 51
  - GIST 27
  - glycogenic acanthosis 19
  - grater omentum 157, 187, 199,  
208
  - grater omentum flap 292
  - greater curvature
    - mobilization 304
    - skeletonization 115, 116, 160
  - guidewire 335, 337, 351
    - biliary 346

- flexible atraumatic biliary 348
- hydrophilic 342, 345
- hydrophilic biliary 346
- atraumatic 342, 346, 347
- - with flexible tip 337
- standard 348

**H**

- Heineke Mikulicz, stricturoplasty 294
- hemangiomas 20
- hematogenous spread, metastasis 97
- hemicolectomy, interposition 214
- hemicolon, right, isoperistaltic interposition 216
- hemifundoplication
  - anterior 260
  - posterior 260
- hemorrhage 48, 155, 331
- hemorrhagic esophagitis 22
- hepatic artery 85
- hepatoduodenal ligament 85, 91, 92
  - lymphadenectomy 116
- hepatogastric ligament 118
- hernia
  - axial sliding 21
  - cardiofundal 268
  - combined 259
  - hiatal 260, 268
    - - combined 269
    - - reduction 303
    - - repair 252
    - - sack 271
    - - sliding 259
    - - techniques 264
    - - GERD 53
  - hiatus 13
    - - sliding 13
  - paraesophageal 21, 259, 261, 268, 269
- herniorrhaphia 259
- herpes simplex virus (HSV) 21
- heterotopic gastric (columnar) mucosa 19
- HF generator 327
- hiatoplasty
  - anterior 292
  - bilateral 273

- posterior 272, 273, 292, 303, 305
- hiatotomy, lateral 223
- high compliance balloons 351
- Hill procedure 62
- histoacryl 23
- histological regression, neoadjuvant treatment 78
- Horner's syndrome 109
- hydrophilic guidewire 341
- hyperalimantation 205
- hypertonic saline 336
- hypoglossus nerve 86
- hypovolemic shock 315
- hypoxia 47

**I**

- iatrogenic lesions 315
- ileo-sigmoid ostomy 214
- iliac crest 366
- immunocytochemistry 75
- incision
  - left costal 254
  - subcostal 261
  - upper abdominal transverse 254, 261
  - upper midline 181, 254
  - upper transverse 157
- indigo carmine 327, 328, 333
- induction chemotherapy 89
- induction radiochemotherapy 89
- injection catheter 351
- injection of steroid 345, 348
  - stenoses, follow-up 350
- injection treatment 316, 352
  - achalasia 353
  - endosonographic examination 353
- injury
  - direct suture 284
  - corrosive, grading 283
  - foreign body 283
  - grade 1-corrosive 283
  - penetrating 283
  - radiation 283
  - superficial 283
- innervation, esophagus 8
- inoperable patients 335
- Inoue technique 330
- insufficient length, colonic segment 222
- intermittent clamping 206

- intestinal metaplasia 22
- intraluminal decompression 371, 287
- intraluminal injury 109
- intraluminal tube 296
- intrathoracic anastomosis 157
- intrathoracic bypass 224
  - colon-interposition 225
  - distal esophagus 227
- intrathoracic esophagoplasty, colon interposition 223
- intrathoracic stenosis 293
- intravenous antibiotic therapy 275
- irresectable benign tumor 223
- irresectable carcinoma, lower esophageal third 223
- isolated tumor cells (ITC) 75
  - bone marrow 76
  - non-regional lymph nodes 76
  - regional lymph nodes 75
- isoperistaltic colonic interposition, right hemicolon 215
- Ivor-Lewis esophagectomy 98, 99, 101

**J**

- jejunal bridging graft 241
- jejunal graft, free 243, 244, 245, 246
- jejunal interposition 93
  - isoperistaltic 251
  - necrosis 247
  - total esophagectomy 233
- jejunal interposition, subtotal esophagectomy 233
- jejunal loop 92
- jejunal stoma 235
- jejunal vascular arcade 369
- jejunogastrostomy 233, 247
  - latero-lateral 252
  - termino-lateral 252
- jejuno-jejunostomy 369
  - terminoterminal 236, 239, 252
- jejunostomy 362, 363
  - catheter 362, 363
  - Roux-en-Y 236, 237
  - side-to-side, with Roux-Y jejunal loop 372
  - termino-terminal 240, 247

**K**

- Killian's triangle 11, 23, 275, 276
- kinking of the colon 219
- kinking of the interposition 222
- Kocher maneuver 111, 114, 157, 191
- Kocher's collar incision 86
- Korshenkel type bypass 230

**L**

- Laimer's triangle 275, 276
- lamina epithelialis 9
- lamina muscularis mucosae 9
- lamina propria mucosae 9
- laparoscopic antireflux surgery, controversies 65
- laparoscopic fundoplication 62, 305
  - complication rate 62, 63
  - dysphagia 63
  - mortality 64
  - para-esophageal hiatus herniation 63
  - perforation of the gastrointestinal tract 64
  - port sites 303
  - pulmonary embolism 64
  - splenic injury 63
  - vascular injury 63
- laparoscopic Nissen fundoplication 65
- laparoscopic operations, failures 67
- laparoscopic Toupet fundoplication 65
- laparoscopy, GERD 259
- laparotomy
  - median 205, 264, 268
  - - epigastric 223
  - upper 182
  - upper abdominal 261
  - upper midline 110
  - transverse lower abdominal 205
- large bowel mobilization 206
- large working channels, gastroscopes 324
- large-bore bougie 300
- laryngeal nerve 85
  - recurrent, paresis 222

- laryngoscope, self-retraining 298
- laser ablation 327
- laser treatment 335
- 2-layer anastomosis, esophago-gastrostomy 150
- leakage from anastomoses 48
- left triangle ligament 113, 186
- left-sided double lumen tube 46
- leiomyoma 15, 20
  - EUS 21
  - nucleation 282
  - thoracic esophagus 281, 282
- leiomyosarcoma, EUS 21
- ligament
  - colico-phrenic 209
  - esophageal
    - - lateral 131, 155
    - - - right 131
    - - - left 132
  - gastrophrenic 123
  - gastrosplenic 304
  - hepatoduodenal 202
  - - lymphadenectomy 201, 203
  - phrenico-colic 209
  - - right ligament 208
  - phrenicoesophageal 123
  - phrenicogastric 202
  - pulmonary 131, 172, 173
- ligamentum teres cardio-pexy 62
- ligamentum teres-plasty 259, 263
- light diffuser 333
- limited resections 93
- linear stapler 135, 182, 201, 212, 221, 251, 276, 278, 297, 298, 299, 300
- lipomas, EUS 21
- liver cirrhosis 23
- liver metastasis 93
- liver, left lobe 186, 249, 301
  - lateral 270
- local intraluminal treatment, laser 85
- local recurrence, esophageal cancer 31
- loco-regional residual tumor 77
- long Barrett's segment 92, 247
- long colonic bridge graft, resection 370
- longitudinal myotomy 255

- Lugol's solution 20, 327, 328, 333
- lung function tests 43
- lung retractors 309
- lymphadenectomy 85
  - abdominal 85
  - abdominothoracic subtotal en bloc esophagectomy 174
  - celiac trunk 202
  - epigastric 111
  - 2 field 89, 103
  - - extended 99
  - 3 field 86, 89, 103
  - hepatic artery 249
  - mediastinal 180
  - - paraaortic 180
  - - retropericardial lymph nodes 180
  - middle colic vessels 187
  - paraaortal 179, 192, 202
  - paraaortic, right 191
  - paracaval 191, 192
  - posterior mediastinum 136
  - retropancreatic 191
  - splenic artery 249
  - supraradically 192
  - transhiatal esophagectomy 85
- lymphatic system, anatomy 82
- lymphatic vessels 5
  - submucous layer 10
- lymph-node 8
  - affected by micrometastasis 84
  - anatomical nomenclature 8
  - bronchopulmonary 8
  - celiac trunk 9, 73, 91, 93
  - cervical 5, 73, 74, 82, 97, 100
  - - dissection 103
  - - esophagus 111
  - - metastases 101
  - - recurrence 99
  - - unsuspecting 89
  - clearance 91
  - coeliacal 8
  - cranial paraesophageal 177
  - diaphragmatic 8
  - dissection 117
  - - 3-fields 84
  - - hepatic artery 117
  - - mortality 103
  - - principles 81
  - - radical 100
  - - survival rates 103

- distant abdominal 84
- gastric 8
- gastric superior 83
- mediastinal 8, 16, 73, 75, 161
- - middle 82
- - superior 82
- metastasis
- - frequency 81
- - mapping 83
- paraaortic 120
- paraesophageal 5, 16
- perigastric 8, 73
- prevertebral 5, 8
- recurrence 98
- regional 5, 73, 74, 75
- - compartments 74
- - intrathoracic esophagus 75
- - mediastinal compartment 75
- - perigastric compartment 75
- resection, radical 97
- retrotracheal 176
- subcarinal, lymphadenectomy 178
- supraclavicular 16
- tracheal bifurcation 310
- lymphoepithelioma-like carcinoma 72

**M**

- malignancy, early, classification 20
- malignant hyperthermia 45
- Mallory Weiss lesions 315, 317, 318, 319
- recurrent bleeding 323
- Mallory-Weiss tear 22
- manometry 24, 259, 351
- dilatation 354
- manubrium sterni 218
- Mark IV operation 260
- meatballs, obstruction 326
- mechanical echoendoscopes 27
- mediastinum, dorsal 271
- median epigastric laparotomy 223
- mediastinal drainage 361
- mediastinal lymph nodes, lower 83
- mediastinal pleura 165, 278, 310
- rupture 217

- mediastinal visceral pleura, injury 155
- mediastinitis 109, 223, 247, 275, 283, 323, 326, 331, 332, 352, 361
- mediastinoscope, modified 312
- mediastinum
- drainage 153, 165
- posterior 273
- - colon interposition 219
- - inferior 249
- - lymphadenectomy 136
- - tamponade 155
- superior 4
- medullary carcinoma 14
- megaesophagus 109
- megaesophagus congenitus 12
- membranes (webs) 348
- Merendino procedure 93
- mesocolon 251
- mesosigmoid 209
- metaplastic mucosa 248
- metastatic potential, early esophageal cancer 82
- methylene blue 20, 22, 327, 328, 333
- MIC 297
- micrometastasis 75
- lymph node groups 84
- occult 82
- microscopic skip metastasis 77
- Mikulicz retractor 111, 128, 131
- miniprobes 19, 30, 31
- EUS 27
- N-staging 32
- Minnesota tube 315
- mortality rate 101
- motility disorders, MIC 301
- MRI 16
- MRI probes, intraluminal 18
- M-staging, EUS 27
- mucinous adenocarcinoma 72
- mucoepidermoid carcinoma 72
- multifocal high grade dysplasia 334
- multiple linear stapler 250
- multiple-band application 320
- multi-slice CT accuracy 29
- imaging 16
- multi-stage procedure 233
- muscle
- cricopharyngeal 11, 275, 276
- latissimus dorsi 364

- - flap 366
- longissimus cervicis 3
- lower pharyngeal constrictor, myotomy 276
- omohyoid 144, 311
- pharyngeal constrictor 276
- - myotomy 277
- sternocleidomastoid 144, 145, 217, 225, 276, 284, 285, 311
- trapezius 86
- muscle-flap 285
- myocardial infarction 44
- myotomy
- circular, abdominal esophagus 265
- cricopharyngeal 297
- extramucosal 300
- laparoscopic with fundoplasty, port side 301
- long 307
- longitudinal 255
- lower esophageal sphincter 299
- margins 256
- risk of perforation 301

**N**

- narrow stenoses 337, 346
- nasal intubation 45
- naso-gastric probe 286
- naso-gastric feeding tube 162
- naso-gastric tube 47, 150, 152, 195, 273, 303, 306, 336, 355, 357
- enteral feeding 345
- postoperative edema 149
- N-butyl-2-cyanoacrylate 323
- Nd-YAG laser 334, 335
- neck anastomosis, alternative methods 154
- neck dissection 86, 90, 98
- neck emphysema 283
- necrosis of the colon 199, 205
- necrosis of the interposition 222
- needle knife 327, 331, 357
- needle-knife papillotome 348, 349
- neoadjuvant chemoradiation 91
- neoadjuvant preoperative chemotherapy/radiotherapy 98

neoadjuvant treatment, effectiveness (Ef) 78  
 neoadjuvant treatment, histological regression 78  
 neoadjuvant treatment, tumor regression grade (TRG) 78  
 neo-esophagus, affection 205  
 neo-fundus 247, 248, 250, 252  
 nerve supply, esophagus 10  
 nerve  
 - esophageal plexus 9  
 - laryngeal nerves 86  
 - parasympathetic 8  
 - phrenic 85, 364  
 - - right 172  
 - - injury 101, 104, 109  
 - - palsy 103  
 - - pareses 171  
 - recurrent 4  
 - - laryngeal 98, 145, 147, 171, 174  
 - - - injury 101, 104, 109  
 - - - palsy 10  
 - - - pareses 171  
 - - - right 172  
 - - left 313  
 - sympathetic nerve 8  
 - vagus 9,10,125,131,171, 174, 186, 247, 249, 254, 301,303, 304  
 - - dorsal branch 304  
 net retriever basket 326  
 Nissen fundoplication 61, 259, 260  
 - laparoscopic 65  
 - outcomes 62  
 Nissen  
 - floppy 67  
 - slipped 66  
 Nissen-Rossetti procedure 67, 260  
 nitrous oxide 45  
 nocturnal heartburn 12  
 nonerosive reflux disease 52  
 non-Hodgkin's lymphoma 28  
 N-staging  
 - CT 17  
 - EUS 27  
 nutcracker esophagus 24  
 nutrition tube 275  
 nutritional status 43

**O**

obliteration, esophageal varices 315  
 obstructions, malignant tumors 335  
 occult micrometastasis 82  
 omentum, lesser 249  
 one-lung ventilation 47  
 operating times 103  
 operation, exclusion 41  
 operative mortality 99  
 operative risk profile, evaluation 39  
 optional categories, TNM system 76  
 outflow obstruction 253  
 over-tube 320, 324, 325, 326

**P**

pain therapy, postoperative 48  
 palliative esophageal resection 93  
 palliative radiochemotherapy 93  
 palliative resection 109  
 pancreas 188, 200  
 pancreatic capsule 200  
 pancreatic corpus, dissection 193  
 pancreatic head 189  
 pancreatic tail 188, 189  
 pancreatitis 109, 199, 247  
 paraaortic region 203  
 parabronchial diverticulum excision 299  
 paravariceal sclerotherapy 23  
 parental nutrition 253, 336, 347, 352  
 parietal pleura, tumor infiltration 135  
 partial abdominothoracic resection 157  
 - parietal cell vagotomy 259, 265, 267  
 partial fundoplication 65, 66, 258  
 pathologic classification, esophageal carcinoma 71  
 pediatric endoscope 20, 337, 338, 341, 349  
 penrose drain 153  
 peptic stenosis 13, 260  
 peptic stricture 22, 109, 266, 267  
 - techniques 264  
 - total esophagus 205  
 percutaneous endoscopic gastrostomy (PEG) 336  
 percutaneous endoscopic jejunostomy (PEJ) 335, 336  
 perforation 11, 275  
 - clipping 332  
 - fluoroscopic examination 336, 347  
 - foreign bodies extraction 326  
 - mediastinitis 357  
 - pneumomediastinum 357  
 - sclerotherapy 323  
 - stenting 323  
 pericardial flaps 364, 365  
 pericardial infiltration 134  
 perioperative antibiotic therapy 110  
 perioperative ECG 43  
 perioperative opioid application 181  
 peritonitis 109, 247, 352  
 perivascular injection 320  
 pH manometry 21  
 pH metry-24-hours 259  
 pharmacotherapy, variceal bleeding 315  
 pharyngo-colostomy 212  
 - cicatrized stenoses 371  
 - latero-lateral 220  
 pharyngo-gastrostomy 152  
 - cicatrized stenoses 371  
 photodynamic therapy 84, 327  
 photodynamic therapy of tumors (PDT) 327, 333  
 - efficacy 333  
 - high grade dysplasia, Barrett 333  
 - ineffectiveness 334  
 - non-resectable carcinoma 333  
 - photosensitivity 333  
 - strictures 334  
 - superficial spreading tumor 333  
 - surveillance biopsy 334  
 photosensitizer 333  
 phrenic crura 272  
 phytobezoar 326  
 piriform fossa 152

- plastic stent 339, 341  
 pletyhsomography 41  
 pleura  
   – empyema 109, 223, 247, 283  
   – flap 279, 286  
   – parietal 218  
   – visceral 218  
 pleural cavity, drainage 280, 287, 291  
 pneumatic dilation 303  
 pneumonia 109  
   – post-operative 101  
 pneumothorax 48, 155, 331  
   – laparoscopic fundoplication 63  
 3-point support, fundoplication 306  
 polidocanol 319, 336  
 polyposis of the interposition 222  
 poor nutritional status 43  
 Porfimer-Sodium 333  
 portal hypertension 22, 23  
 portocaval anastomose 5  
 positive endexpiratory pressure (PEP) 47  
 positron emission tomography (PET) 18, 29  
   – accuracy 29  
 post operative adjuvant therapies 98  
 posterior fundoplication 65  
 postoperative hemodynamic 222  
 postoperative hypotension 48  
 postoperative management 43  
 postoperative pain 181  
 postoperative pain therapy 48  
 postoperative parameter 222  
 postoperative pneumonia 98, 101  
 postoperative reflux 247  
 postoperative stenosis, prevention 151  
 postoperative suture dehiscence 11  
 postoperative ventilation 47  
 pre treatment lavage 351  
 preliminary treatment  
   – ethanol 336  
   – hypertonic saline 336  
   – isopropanol 336  
   – polidocanol 336  
 premedication 44  
 preoperative autologous blood donation 44  
 preoperative chest X-ray 43  
 preoperative evaluation, risk 43  
 preoperative imaging 91  
 preoperative irradiation 16  
 preoperative laboratory testing 44  
 preoperative management 43, 110  
 preoperative radiochemotherapy 81, 91  
   – combined 90  
 preoperative respiratory status 43  
 pressure, lower esophageal sphincter 45  
 prestenotic dilatation 296  
 prestenotic esophagus, lavage 345, 348  
 pre-therapeutic diagnostics 79  
   – chromoendoscopy 79  
   – cytological examination 79  
   – multiple biopsies 79  
   – total biopsies 79  
 prophylactic antibiotics 335, 351  
 prosthesis, positioning 341  
 protective accessories 325  
 proton pump inhibitors (PPI) 59, 60, 259, 334, 347  
 proximal dislocation, stents 344  
 proximal jejunum 251  
 proximal resection 185  
 proximal stomach, adenocarcinoma 199  
 pseudodiverticula 23  
 pulling thread 341  
 pull-through procedure 218  
 pulmonary artery catheter 44  
 pulmonary complications 103, 109  
 pulmonary function 41  
 pulmonary function test 247  
 pulmonary infections 222  
 pulmonary ligament 86  
 purse string clamp 250  
 pusher 341  
 pyloric region  
   – cicatrization 372  
   – deformation 372  
 pylorotomy 143
- R**
- R2category, subdivision 77  
 radical en bloc esophagectomy 81  
 radical lymph node resection 97, 100  
 radiochemotherapy  
   – adjuvant 104  
   – adjuvant preoperative 102  
   – induction 89  
   – preoperative 81, 91  
   – – combined 90  
 radiography 335, 341, 351, 355  
 rat-tooth forceps 326  
 recess  
   – left piriform 225  
   – right piriform 225  
 recessus piriformis 220  
 reconstruction, transmediastinal 92  
 recurrence rate, en bloc esophagectomy 98  
 recurrences 93  
   – carcinoma of the gastroesophageal junction 93  
 recurrent laryngeal nerve 311  
 recurrent laryngeal nerve palsy 298  
 red color signs 23  
 reflux disease 260, 315, 317, 345  
   – erosive 52  
   – nonerosive 52  
 reflux prevention 258  
 reflux-related esophageal ulcers 324  
 regurgitation 275  
 re-operative surgery  
   – antireflux operation 67  
   – approach 68  
   – mortality rates 68  
 resection rate, esophageal carcinoma 99  
 residual tumor (R), classification 77  
 respiratory insufficiency 48  
 respiratory therapy 41  
 re-staging of esophageal cancer, EUS 31  
 retractors, mediastinal 132  
 retroesophageal mobilization 303  
 retroesophageal tunnel 303

- retroesophageal window 261
  - retrosternal tunnel 218
  - Riffini bodies 10
  - risk ascertainment, methods 39
  - risk minimization, preoperative 40
  - risk of bleeding, varices 23
  - risk of recurrence, carcinoma of the cardiac 92
  - risk, definition 39
  - Rochard retractor 111, 112, 261
  - Roux-Y anastomosis 260
  - Roux-Y loop 368
  - rubber band ligation 23, 316, 321, 322, 323
    - EMR 330
- S**
- sagittal diaphragmatomy 185, 290
  - Savary Miller
    - classification 21
    - dilator 341, 345, 348
    - guidewire 338, 339, 346
  - scirrhous carcinoma 14
  - scleroderma esophagus 24, 66
  - sclerotherapy 315, 336
    - additional treatment 323
    - intravascular injection 316
    - of varices, recurrent bleeding 323
    - perforation 323
    - stricture 323
  - self expanding metal stents 335
  - Senkstaken-Blakemore tube 315
  - septic complications 222
  - sero-muscular U-stitches 196
  - short Barrett's segment 93
  - short esophagus 13
  - short gastric vessels 120, 202, 304
  - short peptic stricture 293
  - short scarred stenosis 293
  - Sial retractor system 112
  - Siewert's classification 90, 92
  - sigmoid colon, mobilization 209
  - silicone antireflux prosthesis 260
  - simple reflux disease 260
  - single lung ventilation 157, 171
  - single-band application 320
  - six-shooter 320
  - slippage, prevention 305
  - slipped Nissen 66
  - small cell carcinoma 72
  - spindle cell carcinoma 72
  - spleen, injury 199
  - splenectomy 185, 188
  - splenic transection 189
  - squamocolumnar junction (Z-line) 22
  - squamous cell carcinoma(SCC) 20, 72, 73, 89, 90, 91, 109
    - prognostic score 73
    - recurrence 97
  - staging of esophageal cancer 25
  - standard esophagectomy, results 98
  - stapler 141
    - introduction 169
  - stenotic esophageal anastomoses 348
  - stenotic scars 324
  - stent
    - Choo-stent (Korean) 343
    - covered 336
    - covered metal 341
    - exchange 336
    - Gianturco-stent 343
    - insertion 347
    - instruments 339
    - intolerance 336, 341, 344
    - migration 339, 341, 343
    - placement 93, 335
    - plastic stent (Celestin) 343
    - proximal correction 343
    - sealing 341
    - self expanding metal stent 343
    - Strecker-stent 343
    - trachea 343
    - uncovered metal 336
    - Wall-stent 343
  - sternotomy 86
  - sternum 217
  - Stiegman-Goff 321
  - stomach tube, distal 194
  - stress ECG 44
  - stricture
    - cicatricial 220
    - endoscopic dilatation 259
    - injection needles 348
    - intraabdominal 371
    - intrathoracic 371
    - of the esophagogastric junction 267
    - sclerotherapy 323
  - stricturoplasty 259, 294, 372
  - stricturotomy 350
  - subcutaneous tunnel 235
  - submucosal layer 9
  - submucosal lymphatic vessels 10, 92
  - subphrenic area, drainage 153, 157
  - substernal fascia 218
  - substernal tunnel 206, 216, 217
    - drainage 221
    - opening of the pleura 222
  - subtotal esophagectomy 89
  - subtotal proximal gastric resection 92
  - supra-bifurcational trachea 364, 365
  - supraphrenic region, drainage 165
  - symbol descriptors TNM system
    - a symbol, TNM system 76
    - m symbol, TNM system 76
    - r symbol, TNM system 76
    - y symbol, TNM system 76
  - sympathic nervous system 10
  - synchronous chemotherapy 97
  - systemic dissemination, esophageal carcinoma 84
  - systemic recurrence, esophageal carcinoma 99
- T**
- T/pT classification 73
  - T1m tumors 31
  - T1N0 carcinomas, total gastrectomy with lymphadenectomy 92
  - T1sm tumors 31
  - TA stapler 182
  - telescophenomenon 260, 262
  - temporary clamping 234
  - temporary stoma 233
  - ten-shooter 320
  - terminal ileum 216



- Terumo 346  
 thermal treatment 348  
 thermoablation 327, 336  
   – surveillance 331  
 thoracic aorta 4  
 thoracic drainage 171, 181,  
   229, 279, 282, 310, 314  
 thoracic duct 3, 9, 85, 90, 180,  
   308, 310  
   – laceration 155  
 thoracic epidural catheter 44,  
   48  
 thoracic esophageal by-  
   pass 225  
 thoracic esophagus  
   – en bloc-resection 161  
   – leiomyoma 281, 282  
   – lower, 91  
   – upper 90  
 thoracic peridural catheter  
   247  
 thoraco-abdominal  
   – en bloc esophagectomy 91  
   – esophagectomy 92  
 thoracoscopic mobilization  
   of the esophagus, port sites  
   309  
 thoracotomy  
   – anterolateral 85, 157, 171  
   – – right 161, 223, 275, 282,  
     293  
   – emergency 247  
   – right 155  
   – right-lateral 286  
 thymectomy 86  
 thyroid cartilage 144  
 thyroid gland 3  
 T-incision, inverted 110, 111,  
   171, 199, 293  
   – low 205, 206  
 tissue necrosis 335  
 TMN supplement  
   (UICC 2003) 75  
 TNM classification, C-factor  
   (certainly factor) 77  
 TNM/pTNM classification  
   73  
 TNM system, symbols  
   – a symbol 76  
   – m symbol 76  
   – r symbol 76  
   – y symbol 76  
 toluidine blue 22  
 topography 3  
 total gastrectomy with lymphadenectomy, T1 N0 carcinomas 92  
 total intravenous anesthesia (TIVA) 44  
 Toupet fundoplication, laparoscopic 65  
 trachea 175, 310  
   – membranaceous part 130,  
     176  
   – supra bifurcation 364, 365  
 tracheal bifurcation 4, 85, 129,  
   136, 180, 313, 364  
   – lymph nodes 310  
 tracheal compression 339, 341  
 tracheobronchial diverticula 4  
 tracheobronchial fistula 109  
 tracheostomy 101, 103, 104  
 traction diverticula 12  
 transhiatal blunt esophageal dissection, complications 155  
 transhiatal closure, esophago-pleural fistula 289  
 transhiatal esophageal dissection 111, 121  
 transhiatal esophagectomy 92,  
   100  
   – lymphadenectomy 85  
 transit time, esophagus 3  
 transnasal tube 227, 229  
 transthoracic en bloc esophagectomy 89, 90  
 transthoracic resection 90  
 transverse colon 199  
   – mobilization 208  
 transverse-sigmoidostomy 221  
 treacheoesophageal septum 4  
 truncal vagotomy 185  
   – with pyloroplasty 369  
 T-shaped, inversed incision 247  
 T-staging  
   – CT 17  
   – EUS 25
- U**
- UICC TNM classification 25  
 umbrella 324  
   – protector 325  
 uncommon carcinomas 72  
 undifferentiated carcinoma 72  
 univent tube 46  
 unsuspecting cervical lymph nodes 89  
 up-side-down stomach 21, 269  
 ureter, left 209  
 U-shaped sutures 151, 168
- V**
- vagal plexus 4, 310  
 vagal trunk  
   – anterior 4  
   – posterior 4  
 vagotomy 260  
   – partial cell 259, 265, 267  
   – truncal 185  
   – truncal with pyloroplasty 185  
 valsalva maneuver 13  
 valvuloplasty 260  
 variceal eradication 23  
 varices 13, 22  
   – bleeding, risk 23  
   – down hill 23  
   – esophageal 13  
   – – eradication 319, 320  
   – – obliteration 315  
   – fundal 13  
 vascular pedicle, long 226  
 vascular stapler 307, 308  
 vein  
   – azygos 5, 85, 130, 172, 173,  
     178, 229, 286, 287, 288, 307,  
     308, 310, 313  
   – hemiazygos 5  
   – – injury 155  
   – – patch 287  
   – caval 191, 192  
   – – superior 85, 171, 172, 173,  
     174, 175  
   – coronary 5  
   – gastric  
   – – left 120  
   – – omental 185  
   – – short 157  
   – intercostals 178  
   – jejunal 244  
   – jugular 5, 144  
   – – internal 3  
   – phrenic 126  
   – – inferior 128  
   – portal 117, 190  
   – pulmonary 311, 365  
   – renal 191, 192  
   – splenic 188

- thyroid 243  
- - inferior 5  
vena anonyma 174  
venous drainage 5  
venous patch 288  
verrucous carcinoma 72  
videoendoscopes 19  
viral esophagitis 21  
vital capacity (VC)40

**W**

webs, congenital 348  
Willis loop 301

**X**

xiphoid 216

**Z**

Zenker's diverticulum 11, 23,  
275, 276, 277, 297