

Marc Sindou  
*Editor*

# Practical Handbook of Neurosurgery

From Leading Neurosurgeons



Volume 1

Cranial Approaches, Vascular,  
Traumas, Cerebrospinal Fluid, Infections

 SpringerWienNewYork

 SpringerWienNewYork

Marc Sindou  
*Editor*

Practical Handbook of Neurosurgery  
From Leading Neurosurgeons

*Volume 1*  
Cranial Approaches, Vascular,  
Traumas, Cerebrospinal Fluid, Infections

SpringerWienNewYork

Marc Sindou  
*Editor*

Practical Handbook of Neurosurgery  
From Leading Neurosurgeons

*Volume 2*  
Intracranial Tumors, Intraoperative  
Explorations, Pediatrics

SpringerWienNewYork

Marc Sindou  
*Editor*

Practical Handbook of Neurosurgery  
From Leading Neurosurgeons

*Volume 3*  
Spine, Functional, Peripheral Nerves,  
Education

SpringerWienNewYork

**Prof. Dr. Marc Sindou**

Department of Neurosurgery, Hôpital Neurologique P. Wertheimer, University of Lyon,  
Lyon, France

This work (3 Volumes) is subject to copyright.

All rights are reserved, whether the whole or part of the material is concerned, specifically those of translation, reprinting, re-use of illustrations, broadcasting, reproduction by photocopying machines or similar means, and storage in data banks.

Product Liability: The publisher can give no guarantee for all the information contained in this book. This does also refer to information about drug dosage and application thereof. In every individual case the respective user must check its accuracy by consulting other pharmaceutical literature. The use of registered names, trademarks, etc. in this publication does not imply, even in the absence of a specific statement, that such names are exempt from the relevant protective laws and regulations and therefore free for general use.

© 2009 Springer-Verlag/Wien

Printed in Germany

SpringerWienNewYork is part of  
Springer Science+Business Media  
springer.at

Cover Illustrations: Stefan Kindel  
Typesetting: Thomson Press (India) Ltd., Chennai, India  
Printing: Strauss GmbH, 69509 Mörlenbach, Germany

Printed on acid-free and chlorine-free bleached paper  
SPIN: 12186914

With 184 (partly coloured) Figures

Library of Congress Control Number: 2009927205

ISBN 978-3-211-84819-7 (3 Volumes) SpringerWienNewYork

**Prof. Dr. Marc Sindou**

Department of Neurosurgery, Hôpital Neurologique P. Wertheimer, University of Lyon,  
Lyon, France

This work (3 Volumes) is subject to copyright.

All rights are reserved, whether the whole or part of the material is concerned, specifically those of translation, reprinting, re-use of illustrations, broadcasting, reproduction by photocopying machines or similar means, and storage in data banks.

Product Liability: The publisher can give no guarantee for all the information contained in this book. This does also refer to information about drug dosage and application thereof. In every individual case the respective user must check its accuracy by consulting other pharmaceutical literature. The use of registered names, trademarks, etc. in this publication does not imply, even in the absence of a specific statement, that such names are exempt from the relevant protective laws and regulations and therefore free for general use.

© 2009 Springer-Verlag/Wien

Printed in Germany

SpringerWienNewYork is part of  
Springer Science+Business Media  
springer.at

Cover Illustrations: Stefan Kindel

Typesetting: Thomson Press (India) Ltd., Chennai, India

Printing: Strauss GmbH, 69509 Mörlenbach, Germany

Printed on acid-free and chlorine-free bleached paper

SPIN: 12186914

With 232 (partly coloured) Figures

Library of Congress Control Number: 2009927205

ISBN 978-3-211-84819-7 (3 Volumes) SpringerWienNewYork

**Prof. Dr. Marc Sindou**

Department of Neurosurgery, Hôpital Neurologique P. Wertheimer, University of Lyon,  
Lyon, France

This work (3 Volumes) is subject to copyright.

All rights are reserved, whether the whole or part of the material is concerned, specifically those of translation, reprinting, re-use of illustrations, broadcasting, reproduction by photocopying machines or similar means, and storage in data banks.

Product Liability: The publisher can give no guarantee for all the information contained in this book. This does also refer to information about drug dosage and application thereof. In every individual case the respective user must check its accuracy by consulting other pharmaceutical literature. The use of registered names, trademarks, etc. in this publication does not imply, even in the absence of a specific statement, that such names are exempt from the relevant protective laws and regulations and therefore free for general use.

© 2009 Springer-Verlag/Wien

Printed in Germany

SpringerWienNewYork is part of  
Springer Science+Business Media  
springer.at

Cover Illustrations: Stefan Kindel

Typesetting: Thomson Press (India) Ltd., Chennai, India

Printing: Strauss GmbH, 69509 Mörlenbach, Germany

Printed on acid-free and chlorine-free bleached paper

SPIN: 12186914

With 184 (partly coloured) Figures

Library of Congress Control Number: 2009927205

ISBN 978-3-211-84819-7 (3 Volumes) SpringerWienNewYork



---

## PREFACE



*“Practical Handbook of Neurosurgery”* invites readers to take part in a journey through the vast field of neurosurgery, in the company of internationally renowned experts. At a time when the discipline is experiencing a (detrimental) tendency to segment into various subfields and scatter in the process, it can be worthwhile to collect a number of practical lessons gleaned from experienced and leading neurosurgeons.

The book also aims to present numerous important figures in the neurosurgical community, with a brief overview of the vitae and main contributions for each. We must confess that we were sad that some of the most active members were unable to participate, likely due to time constraints. We are however fortunate that the majority were able to take part. As such, though not exhaustive, the book does represent an anthology of contemporary neurosurgeons.

At the very beginning of the project, our intention was to make a “pocketbook”. But month after month it became obvious that the work would be much more expansive; ultimately we produced three volumes. Nevertheless we hope that all the three volumes together will remain easily accessible and a daily companion. The pocket has to be more like a travel bag!

We would like to thank all of the contributors; they have sacrificed their valuable time to deliver sound and critical views, and above all useful guidelines. We would also like to acknowledge the hard and rigorous edition work of Mrs. Silvia Schilgerius at Springer-Verlag Vienna. Finally, we would like to wish you the reader an exciting journey, one we hope you will both enjoy and learn from.

---

## CONTENTS

### **Volume 1: Cranial Approaches, Vascular, Traumas, Cerebrospinal Fluid, Infections**

<b>Cranial Approaches</b>		<b>1</b>
M. G. YAŞARGIL	Microneurosurgery: principles, applications, and training	3
E. DE DIVITIIS	Endoscopy: principles and techniques	31
L. D. LUNSFORD	Image-guided radiosurgery using the Gamma knife	49
P. M. BLACK	How to perform surgery for intracranial (convexity) meningiomas	63
M. SINDOU	The “dangerous” intracranial veins	71
F. X. ROUX	How to perform subfronto-orbito-nasal approach for anterior cranial base surgery	85
O. AL-MEFTY	How to perform cranio-orbital zygomatic approaches	99
F. UMANSKY	How to perform middle fossa/sphenoid wing approaches	115
L. N. SEKHAR	How to perform central skull base approaches	135
Y. YONEKAWA	How to perform selective extradural anterior clinoidectomy	155
J. C. MARCHAL	How to perform approaches of the orbit	167
A. J. BASSO	How to perform transsphenoidal approaches	183
A. CROCKARD	How to perform transoral approaches	203
J. J. A. MOOIJ	How to perform posterior fossa approaches	213
T. KAWASE	How to perform transpetrosal approaches	233

<b>Vascular Lesions</b>		<b>243</b>
J. HERNESNIEMI	Principles of microneurosurgery for safe and fast surgery	245
C. RAFTOPOULOS	Surgical management of intracranial aneurysms of the anterior circulation	257
K. LINDSAY	Intracranial aneurysms in the posterior circulation	271
S. KOBAYASHI	Giant aneurysms	287
R. C. HEROS	Arteriovenous malformations of the brain	303
H. BERTALANFFY	Intracranial cavernomas	325
V. BENEŠ	Carotid endarterectomy	337
Y. YONEKAWA	Brain revascularization by extracranial-intracranial arterial bypasses	355
J. D. PICKARD	Management of intracranial venous pathologies – potential role of venous stenting	383
<b>Traumas, Cerebrospinal Fluid, Infections</b>		<b>393</b>
G. M. TEASDALE	The Glasgow Coma and Outcome Scales: practical questions and answers	395
P. J. A. HUTCHINSON	Cranial trauma in adults	411
T. TROJANOWSKI	Hydrocephalus in adults (including normal pressure hydrocephalus syndrome)	429
H. W. S. SCHROEDER	Arachnoid cysts	441
R. D. LOBATO	Brain infections	455
B. ABDENNEBI	Parasitoses of the central nervous system: hydatidosis	469
P. P. DIAZ-VASQUEZ	Parasitoses of the central nervous system: cysticercosis	485

---

# CONTENTS

## Volume 2: Intracranial Tumors, Intraoperative Explorations, Pediatrics

<b>Intracranial Tumors</b>		<b>1</b>
M. WESTPHAL	Classification of brain tumors and corresponding treatments	3
D. G. T. THOMAS	Stereotactic biopsies for tumors: indications, limits, diagnosis with histopathology and other laboratory techniques	29
E. R. LAWS	Management of (malignant) intracranial gliomas	49
H. LOISEAU	Management of lymphomas	59
E. KNOSP	Management of anterior fossa lesions	79
R. DELFINI	Management of tumors of middle fossa	99
B. K. MISRA	Management of central skull base tumors	115
T. FUKUSHIMA	Management of cavernous sinus lesions	129
E. SAMAHA	Management of convexity meningiomas	155
M. SINDOU	Meningiomas involving the major dural sinuses: management of the sinus invasion	169
A. H. KAYE	Posterior fossa meningiomas	181
A. B. KASSAM	Endoscopic surgery for skull base meningiomas	201
J. D'HAENS	Management of pituitary adenomas	217
J. ŠTEŇO	Craniopharyngiomas	235
J. LOBO ANTUNES	Management of tumors of the anterior third and lateral ventricles	255
P. DECQ	Endoscopic management of colloid cysts	275
N. DE TRIBOLET	Management of pineal region tumors	287
T. P. DÓCZI	Epidermoid/dermoid cysts	301
M. N. PAMIR	Tumors of the fourth ventricle and cerebellum in adults	319
M. SAMII	Vestibular schwannomas	333
A. BRICOLO	Brainstem tumors	349
B. GEORGE	Management of Foramen Magnum tumors	373
J. RÉGIS	Radiosurgery for intracranial tumors	385

<b>Intraoperative Explorations</b>		<b>405</b>
G. UNSGÅRD	Ultrasound-guided neurosurgery	407
T. HORI	Brain neuronavigation for deep-seated targets	427
J.-C. TONN	Brain mapping	449
V. DELETIS	Intraoperative neurophysiology in neurosurgery	461
<b>Pediatrics</b>		<b>483</b>
M. CHOUX	Specificities of, and changes in, pediatric neurosurgery	485
A. V. CIUREA	Cranial traumas in children	497
J. CHAZAL	Management of hydrocephalus in childhood	525
N. AKALAN	Intracranial tumors in childhood	543
C. DI ROCCO	Nonsyndromic craniosynostoses	561
A. PIERRE-KAHN	Management of lumbosacral lipomas	585
K. K. N. KALANGU	Management of encephaloceles	601
O. DELALANDE	Epilepsy surgery in children	609

---

# CONTENTS

## Volume 3: Spine, Functional, Peripheral Nerves, Education

<b>Spine</b>		<b>1</b>
R. ROBERT	Management of spine traumas and spinal cord injury	3
G. MATGÉ	Approaches to cervical spine	25
J. BRUNON	Management of degenerative disease of the cervical spine	45
A. K. MSADDI	Management of lumbar disc herniations and degenerative diseases of lumbar spine	61
R. G. FESSLER	Management of lumbar spondylolisthesis	79
F. LAPIERRE	Non-traumatic extra-medullary spinal cord compression	93
J. BROTCHE	Intramedullary tumors	115
J. A. GROTENHUIS	Chiari malformation	131
J. KLEKAMP	Syringomyelia	145
A. EL KHAMLICHI	Infections in spine	163
<b>Functional Neurosurgery</b>		<b>181</b>
D. A. BOSCH	Stereotactic techniques	183
C. OHYE	Selective thalamotomy	195
F. VELASCO-CAMPOS	Targets for electrical stimulation in functional neurosurgery	215
A. L. BENABID	Functional neurosurgery for Parkinson's disease	235
M. I. HARIZ	Functional neurosurgery for dystonias	255
Y. KANPOLAT	Neurosurgical management of cancer pain	273
M. SINDOU	Neurosurgery for neuropathic pain	293
M. SINDOU	Microvascular decompression for hemifacial spasm	317
M. SINDOU	Microvascular decompression for trigeminal neuralgia	333

K. J. BURCHIEL	Neurosurgery for trigeminal neuralgia	349
P. MERTENS	Neurosurgery for spasticity	365
R. ABBOTT	Selective dorsal rhizotomy for the treatment of childhood spasticity	387
A. M. LOZANO	State-of-the-art of surgical therapies for psychiatric disorders: depression	399
V. STURM	Neurosurgery for psychiatric disorders: obsessive-compulsive disorder	407
B. C. DEVAUX	Neurosurgical management of epilepsy in adults	419
F. MAUGUIÈRE	Neurophysiology applied to neurosurgery	441
J. P. NGUYEN	Neuronal transplantation: a review	461
<b>Peripheral Nerves</b>		<b>473</b>
D. G. KLINE	Management of nerve injuries (with emphasis on nerve action potential (NAP) recordings)	475
J. HAASE	Tunnel compression syndromes of median and ulnar nerves	497
F. LAPIERRE	Tumors of the peripheral nerves	519
<b>Education</b>		<b>531</b>
A. A. DE SOUSA	Message from the chairman of the education and training committee of the WFNS	533
Y. KERAVEL	What do young neurosurgeons really need	539
G. L. ROSSEAU	The role of the World Federation of Neurosurgical Societies in the development of world neurosurgery	545
M. SINDOU	Epilogue	551
List of Contributors		553
Author Index		563



# **CRANIAL APPROACHES**

---

# MICRONEUROSURGERY: PRINCIPLES, APPLICATIONS, AND TRAINING

M. G. YAŞARGIL

## THE IMPACT OF MICROTECHNIQUES ON THE DEVELOPMENT OF NEUROSURGERY

To fully discern and accept the significance of microneurosurgery a clear interpretation and grasp of its components is essential (see Table 1).

The history surrounding the evolution of the operating microscope, microvascular surgical techniques, rediscovery of the cisternal, vascular and parenchymal compartments of the CNS, as well as documentation of the surgical outcome and clinical results in the treatment of saccular aneurysms, various types of cranio-spinal lesions: AVMs, cavernomas, extrinsic and intrinsic tumors, occlusive cerebrovascular diseases, intractable temporal seizures and spinal disc-herniation, have been presented in numerous publications within the past 50 years [15, 19, 22, 26, 44, 46, 53, 65, 69, 78, 107, 116, 118]. A brief summary of these processes and developments follows.

## HISTORY OF MICROSCOPES AND OPERATING MICROSCOPES

The history of microscopes has been presented in many previous publications (34, 74, 99, 119, 149). Ernst Abbe, physicist, mathematician and astronomer at the Friedrich Schiller University Jena, Germany, was able to perfect the development of the microscope while working with his friends, Carl Zeiss, founder of the company of the same name, and Otto Schott, a chemist and founder of the famous glass company of the same name, which produced high quality glass for lenses. During the 1870s, while experimenting with water emission objective lenses, Abbe devised the equation of “angular aperture”. This accomplishment brought Zeiss to the forefront of microscope technology. By the 1880s, using oil immersion objective lenses, a numerical aperture of 11.4 was finally reached, allowing light microscopes to resolve two points only 0.2  $\mu\text{m}$  apart. With the exception of some very unusual immersion fluids or ultraviolet light, the above remains the limit today [1]. The electron microscope (1932) and scanning tunneling technology (1981) finally revealed the nanometric dimensions of intra- and intercellular structures.

---

*Keywords:* microneurosurgery, surgical techniques

**Table 1.** Microsurgical axioms summarizing personal experience

1. Microneurosurgery encompasses a cogent, cohesive concept comprising noninvasive approaches along the natural pathways of the cisternal systems, to reach the lesions of the central nervous system and to completely and skillfully eliminate them, the goal being to achieve, a "pure lesionectomy".
2. Microneurosurgery requires intensive, long-term training of one to two years (or preferably, longer) in the cadaver- and/or animal-laboratory, mastering the details of specific surgical neuroanatomy, acquiring proficiency using bipolar coagulation and the high-speed drill, learning the microtechniques of dissection and repair of extra- and intracranial vessels and nerves, as well as dura, arachnoidea, and pia, and practicing the art of surgical approaches and techniques, the ultimate goal being to optimize the reciprocal balance between the "mental eye", vestibulo-visual system, and manual dexterity of the surgeon.
3. Microtechniques present a significant and unequivocal advance in neurosurgery.
4. Microneurosurgery is superior to all other contending specialties in neurotherapy. It offers to patients a proven and more effective therapy, and shields them from academic discussion.

**Table 2.** Development of optical instruments for surgery from a personal view

Magnifying loupe		Operating microscope	
1823	Binocular opera glass	1921	Brinel-Leitz Monocular
1876	Saemisch	1921	Nylen-Person Monocular
c. 1880	E. Abbe/Zeiss	1922	Holmgren-Zeiss/Jena Binocular
1886	Westien and Schulze	1925	Hinselmann-Zeiss/Jena Binocular, colposcope
1886	Westien and von Zehender	1938	Tullio-Zeiss/Jena Binocular, floorstand
1899	Axenfeld	1953	OPMI 1 Binocular, floorstand
1910	Telescopic binocular loupe/Zeiss		Littman (Zeiss/Oberkochen): (later ceiling mounted changeable magnification)
1911	von Hess		stereoscopic vision in sharp
1913	von Rohr and Stock		focus through narrow surgical corridors;
1948	Riechert		coaxial light; beam-splitter: observer tube, cameras
1951	Guiot	1960	Littmann (Zeiss/Oberkochen) Binocular diploscope
1965	Drake	1972	Heller-Schattmaier-Yaşargil Binocular, floorstand
			(Contraves): counterbalanced stand; floating movements; mouth switch to release the brake system; electrical eyepiece warmer
		1992	Hensler-Yaşargil (modified Zeiss Contraves floorstand stand attached to an OPMI F1, Zeiss microscope optic)

Good illumination, stereoscopic vision, magnification changer, and good mobility of the stand are valuable requisites of an operating microscope for the neurosurgeon. Various types of magnifying spectacles were introduced by otologists, ophthalmologists and neurosurgeons (see Table 2) [67, 70]. All these spectacles permit free movement of the head but they fail to provide stereoscopic vision in the depths of a narrow neurosurgical approach. Furthermore, adequate illumination in the depths of a neurosurgical field is lacking.

A monocular monoscope was applied to surgery in 1921 by otologist Carl Olof Nylen in Stockholm, Sweden. Together with his teacher Holmgren he envisioned and pioneered micro oto-surgery and published the developmental process in his 1954 paper [59]. The monocular microscope had to be fixed to the patients' head. In 1922, Gunnar Holmgren used a binocular microscope, attached to the operating table. Another pioneer of otologic surgery, George Shambaugh Jr. was the first to use the microscope routinely for the one stage Lempert fenestration operation, beginning as early as 1939 [81].

L.H. Wullstein, another pioneer of otosclerosis surgery, arranged the construction of an easily movable microscope consisting of a 10× Leitz magnifier mounted on the stand swivelarm of a dental engine. Using this particular microscope, Wullstein carried out more than 1000 operations from 1949 to 1953. Perritt [63], Harms [28], Barraquer [8] pioneered microtechniques for operations on the eye [8, 28, 63, 104].

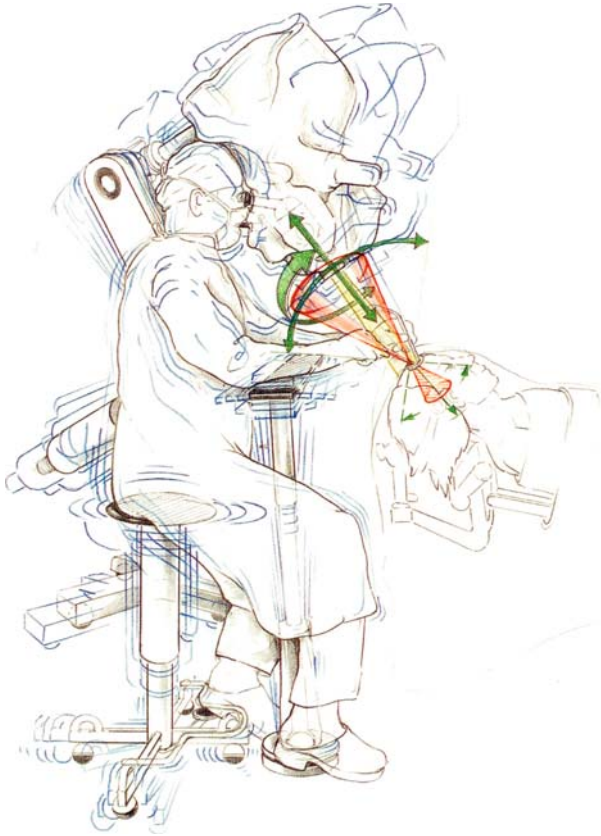
Under the guidance of H.L. Littmann, Zeiss engineers finally succeeded to construct a versatile binocular operating microscope, OPMI-1, which was introduced in 1953 [48]. This achievement was welcomed by otologists, ophthalmologists, vascular, plastic, reconstructive surgeons and neurosurgeons.

## **1. FLOATING OPERATING MICROSCOPE [116]**

After extensive research, a completely balanced floating microscope with adjustable counterweights mounted on the microscope stand was developed at the Department of Neurosurgery, University Hospital Zurich, Switzerland with the assistance of Contraves Company. This ingenious and sophisticated system allows the operating microscope to be easily and quickly brought into any desired position during neurosurgical procedures. The addition of a mouth switch permits horizontal and vertical movements, thus the surgeon can move the microscope around the operating field, and remains well in focus then continues the flow of the procedure. The prime aim of the neurosurgeon is to concentrate on dissection and elimination of the lesion and not to battle with the microscope (Fig. 1).

## **2. ACCESSORIES TO THE MICROSCOPE [54, 116]**

For assisting and education purposes co-observation equipment, such as a binocular tube and closed circuit television, can be attached to a beam splitter



**Fig. 1.** Artist's impression of the combined range of mobility between the hydraulic chair, arm rest, and microscope, with mouth switch, for the seated surgeon. These can all be adjusted in unison. Taken from [88]; illustration by P. Roth

between microscope body and binocular tube. An operation can be recorded and still camera photographs taken for documentation. Recordings and photographs are instructive supplements for teaching purposes. Prior to a re-operation (for recurrent tumor for instance), it is of great value to have the opportunity to study the previous recorded surgical procedure.

### 3. APPLICATION OF MICROTECHNIQUES TO CLINICAL NEUROSURGERY

W. House was a pioneer of microtechniques in his exploration of the internal auditory canal and removal of acoustic neurinomas (1961). His success stimulated and challenged neurosurgeons [29, 30]. Kurze and Doyle [45], Jacobson et al. [32], Kurze [44], Rand and Kurze [66], Loughheed and Tom [50], Pool and Colton [64], Jannetta and Rand [35], all reported on the application of the

microscope in neurosurgery. The operating microscope proved to be of particular value for operations on avascular or poorly vascularized organs such as the middle ear, and on the cornea and the lens of the eye. However, the availability of the microscope for surgery on the brain, a complex and highly vascular organ, provided the means and the stimulus to develop new approaches and atraumatic techniques to ensure preservation of normal vital structures and vessels.

The cerebral vascular procedure of thrombectomy for an occluded MCA has been performed without an operating microscope by Driesen, Scheibert, Schillito, Welch, Chou (see [115]), and the procedure of bypass graft of a saphenous vein between the extra- and intracranial carotid arteries has been performed by Woringer and Kunlin [103]. Technically, all procedures were successfully accomplished, but surgical outcomes were not satisfactory.

In 1960, Jacobson and Suarez, using an OPMI operating microscope (Zeiss), achieved convincing progress in suturing of the common carotid artery in mongrel dogs, with good surgical results [31]. Six years later in the same laboratory at the University of Vermont, Burlington, microvascular techniques were developed that could be applied to brain arteries embedded within their cisternal-arachnoidal network [20]. The first successful anastomosis between the superficial temporal artery and anterior temporal cortical artery was performed on a mongrel dog on March 30, 1966. During the ensuing 7 months, 34 bypass procedures on dogs were successful and remained patent [20]. These new and evolving surgical techniques led to the design of appropriate instrumentation, and especially of microsuture material. Bipolar coagulation technology allowed coagulation of fine caliber vessels, and therefore precise hemostasis was assured. Surgical tactics, the planning of a procedure, the concepts of operating were influenced by all these developments, and evolved accordingly.

## **MICROSURGICAL INSTRUMENTS [112, 116 VOL. IV B, 119]**

### **1. BIPOLAR COAGULATION-TECHNOLOGY**

In 1940, Greenwood introduced the use of two point coagulation to neurosurgery [23]. This concept was later perfected by Malis and is known as bipolar coagulation, which causes no current spread or radiation of heat to surrounding tissue [55]. Bipolar coagulation is crucial to accomplishing successful neurosurgery, and has been instrumental in promoting new concepts. Without bipolar coagulation the microsurgical approaches, tactics and concepts we currently apply, would be impossible [20, 114, 115, 118]. Less familiar are the bipolar coagulation ball electrodes, also developed by Malis. These can be used effectively to shrink vascular lesions such as hemangioblastomas, meningiomas, and cavernomas by very gently stroking the surface of these tumors with the ball, at a bipolar setting appropriate to the size, vascularization and location of the lesion [25–60]. Cold water irrigation during and following coagulation is recommended [53, 55].

The size, shape, weight, balance and spring of the bipolar coagulation forceps are important features of their design. Bayonet shaped bipolar forceps are available in many different lengths from 2 cm to 13.5 cm working length (2 cm and 3.5 cm for surface work, and longer forceps as dissection progresses deeper). A bayonet shape avoids the surgeon's hand blocking the field of vision. A moderate degree of spring aids in tissue dissection with the forceps. All forceps are insulated to prevent short circuit of current into tissue that may come into contact with the shaft of the forceps. The tips of bipolar forceps are available in various widths, 0.4 mm, 0.7 mm, 1 mm, and 1.3 mm. When applying coagulation, the vessel should not be tightly squeezed between the tips. When coagulating a larger diameter vessel, using brief bursts of current, along a short length of the vessel at a power of 15–25 Malis units is recommended. This usually prevents the tips from “sticking”. Bipolar forceps are in constant use for dissection, and coagulation, therefore it is advisable to prepare

**Table 3.** Instrument innovations in microneurosurgery

---

Counter balanced operating microscope stand can be attached to a binocular microscope, diploscope, triploscope, 2-D or 3-D videoscope monitor
Bipolar coagulation
Electrically powered perforator and craniotome and drill bits
Double-pronged spring hook for scalp and muscle flap
Flexible dura dissector
Self-retaining brain protection with malleable spatula
Ultrasound suction apparatus
Ultrasound detector
Brain and nerve stimulator, and monitoring
Microinstruments
Spring loaded bayonet bipolar coagulation forceps in seven different lengths (20–135 mm working length) and four different tip sizes (0.4–1.3 mm)
Ring tipped tumor or aneurysm grasping forceps with and without teeth
Bayonet-shaped scissors in four different lengths (50–135 mm working length) with straight and curved blunt tips
Biopsy rongeurs in two different lengths and six different jaw sizes
Micro-Rongeur with malleable shaft
Tumor-grasping forks in four different tip sizes and forked forceps
Suction tips: four lengths (50–150 mm) and five diameters (1.5–4.5 mm)
Regulator for suction pressure
Dissectors: 20 various shapes and sizes
Clips: 180 aneurysm clips, various shapes and sizes, hemoclips, temporary clips, microclips
Microsuture
Mobile tip mirror (5.0–7.0 mm), endoscopes
High quality cotton pledgets
Hydraulic surgeon's stool
Hydraulic arm support
Hydraulic instrument table for scrub nurse
Neuronavigation (not used by the author)

---

a whole series for each surgery. Forceps can then be cleaned frequently, and the tips cooled in a solution, which helps to prevent their “sticking”.

Basic microneurosurgical instruments are summarized in Table 3.

## 2. SUCTION SYSTEM

A suction pump with a pressure-regulating mechanism can be adjusted according to the intraoperative situation, for instance high for tumor suction and for hemorrhage, low when opening the sylvian fissure, and when dissecting vessels and aneurysms and nerves. A round, smooth, atraumatic surface of the suction tip prevents injury to the brain and vasculature. Suction tubes are available in various lengths and diameters, which can be interchanged depending on the depth of the surgical field, the nature of the dissection and consistency of the tissue and the fluids to be eliminated. Equally important, the suction tube functions as a retractor at low pressure, drawing tissue, tumor, a vessel, or a nerve to one side during dissection. On many occasions this dispenses with the need to apply the self retaining brain retractor. Coordinated with the bipolar forceps, the suction tube can act as a blunt dissector [116].

For the debulking or enucleation of tumors the suction apparatus is very effective for soft tumors. Tough, hard tumors can be excised with a knife, scissors, or bipolar cutting loop. The ultrasonic aspirator (CUSA) system supplies continuous irrigation and suction to aspirate emulsified tissue 1–2 mm from the tip, and is most efficient for all types of tumors.

Frequent irrigation of the operative field with fluid at 37°C minimizes tissue adhesion to instruments, removes blood and tissue debris, and maintains a clear operative field. Irrigation delivery systems have been developed, to attach to the various instruments (suction tube, bipolar forceps). A presoaked sponge affords a form of continuous irrigation.

## 3. PROTECTIVE RETRACTION DEVICES [116, VOL. IV B]

Ideally, retraction devices should not compress the brain, but provide a shield of protection. As discussed previously, the suction tube can be used to retract tissue: the area of the suction tube is narrow and the period of retraction is brief, due to the fact that dissection is continuously moving around the lesion, therefore the risk of damage to normal tissue is reduced. A cotton ball saturated with fluid constitutes a simple, non-injurious retractor, positioned, for instance, between tumor capsule and normal tissue. During dissection of the Sylvian fissure, interhemispheric fissure, cerebral sulci, cerebellopontine cistern for example, moistened cotton balls are placed, one at each end of the fissure, sulcus, etc., in increasing sizes, as dissection progresses, maintaining a delicate retraction. Sponges with strings attached have many applications: (1) protection of normal, exposed tissue, (2) retraction, (3) absorb fluids (CSF or blood), (4) fluid can be gently aspirated without damage to tissue beneath the



sponge (when opening the dura, a sponge can be placed over the brain and suction applied to absorb CSF), (5) when profuse bleeding occurs, the same method of sponge beneath suction tube can be applied, (6) dissection (a sponge held in the bipolar forceps, and using stroking motions, tumor is coaxed from a vessel wall), (7) once the tumor has been debulked, 2 or 3 sponges are placed inside the tumor sac to give it substance, during dissection of the sac from surrounding tissue. The sac is thus easier to grasp and manipulate, (8) a sponge can be positioned to temporarily displace tumor or normal tissue a little, during dissection, (9) to press and spread bone wax over bony hemorrhage, (10) placed over hemostatic agent (surgical, gelfoam) to firm the position.

#### **4. VESSEL AND ANEURYSM CLIPS [116, VOL. I]**

Temporary vascular clips differ from permanent aneurysm clips. They have a lower closing pressure to prevent damage to the vessel wall and endothelial lining. Temporary clips are golden in color to distinguish them from permanent clips, as they should not be implanted to permanently occlude an aneurysm or vessel. A selection of temporary clips with their applicators are available on the field, at every surgical procedure in preparation for any unanticipated hemorrhage that may occur. Should the wall of a small arterial vessel be injured, 2 small golden clips can be applied, one distal and one proximal to the injury. The previous oozing of blood can be cleaned by suction placed over a sponge for protection of the vessel. The injured wall is then clearly visible, can be closed by bipolar coagulation at Malis setting 15 or 20, and the clips removed. If the injury is on the posterior surface, the vessel can be rotated to reveal the hole by placing a flat sponge over the vessel and using the suction tube at low pressure to rotate.

Aneurysm clips are available in many sizes and in a variety of curved and angled shapes, to accommodate the diverse anatomic configurations and sometimes uncommon situations presented in patients. Unnecessary, repetitive opening of the aneurysm clips' blades is to be avoided as this reduces the

**Table 4.** Microneurosurgical concepts

---

1. Rediscovery of cisternal anatomy, which allows exploration of all the lesions of the CNS through subarachnoid pathways: "cisternal navigation"
  2. Recognition of the compartmental anatomy of the CNS and the related predilection sites of the lesions (neoplastic, vascular, infectious, toxic, degenerative, congenital)
  3. Complete elimination of the lesion: "pure lesionectomy"
  4. Meticulous hemostasis (bipolar coagulation technology)
  5. Exploration without rigid brain retraction but applying protective dynamic retraction
  6. Reconstruction and repair of central and peripheral nerves
  7. Reconstruction and repair of extra- and intracranial arteries and veins, pia and arachnoidea
  8. Creation of specific transosseous windows to the skull
-

closing pressure. The technique of stepwise obliteration of an aneurysm is described in detail in ref. 116, vol. I (see Table 6).

## 5. NEURO-NAVIGATION

With the emergence of high-quality intraoperative imaging using computed tomography and/or magnetic resonance imaging, the first integrated microscope navigation systems were developed which can be used effectively in cases of skull base tumors. The concept of microscope-based neuronavigation consists of superimposing the localization and extension of a lesion on to the microscope field of view through contours. The integration of preoperative functional data from magnetoencephalography and functional MRI, resulting in so-called “functional neuronavigation” can lead the way towards future improvements in the field of microneurosurgery. Other advances of note such as the use of tumor fluorescence, using 5-aminolevulinic acid or autofluorescence, show promising results [88]. Brain shift and spatial resolution of the implemented techniques should not be underestimated, and therefore applying this technology may give a false sense of surgical security and confidence. Personally I prefer to use the ultrasound detector to check for residual tumor.

The most relevant and reliable method for evaluating the location of a lesion and devising a surgical strategy, remains the thoroughly trained, multi-dimensional “mental eye” of the surgeon, which has acquired proficiency related to laboratory training and clinical knowledge and experience, combined with the accomplished evaluation of visualization technology. This is currently the most reliable guide and qualified method to determine a diagnosis and define a concept of treatment and design a surgical strategy.

## 6. MICRONEUROSURGICAL CONCEPTS

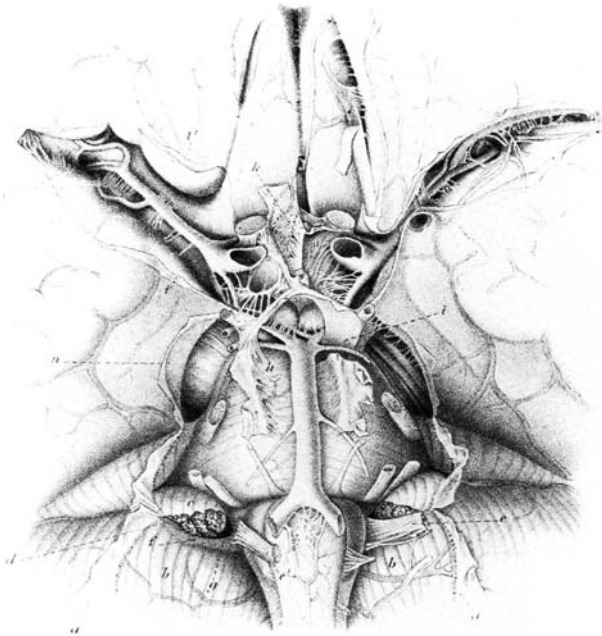
To master the techniques of microneurosurgery, it is necessary to become familiar with the detailed surgical and radiological anatomy of the cisternal, vascular and parenchymal systems, the course and variation of arteries and veins, and the distinct architecture of gyral segments and connective fibers in neopallial, archi-, paleopallial, and central areas of white matter, lentiform nucleus and brain stem [96, 97, 116, 120]. Altogether there are at least 50 compartments in each cerebral hemisphere, 8 compartments in each of the cerebellar hemispheres and 9 compartments of spinal cord, which provide natural pathways to approach the lesions, to achieve accurate exploration and dissection of adjacent vasculature, and to preserve the hemodynamics and homeostasis of the brain.

## 7. CISTERNAL ANATOMY REVIVED

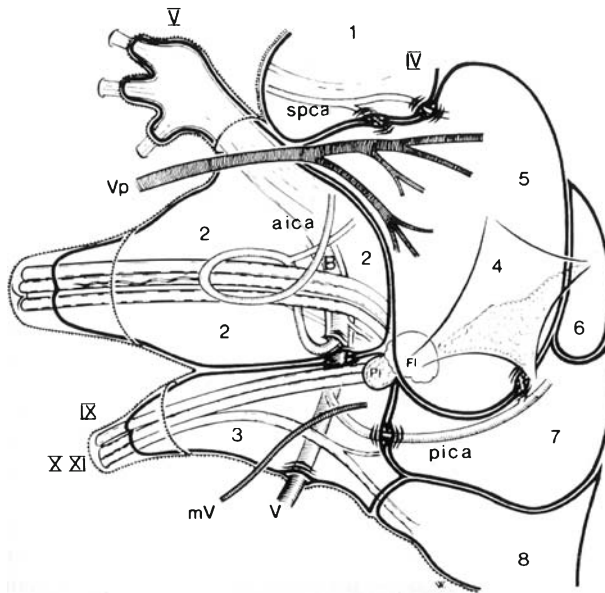
Key and Retzius [38], by injecting the subarachnoid space with blue dye, were able to demonstrate the cisternal anatomy of the brain, and confirmed

that the cisterns intercommunicate and are compartmentalized. They showed the relationship of the cerebral vessels to the arachnoid and to the numerous trabeculae which suspend these vessels from the walls of the cisterns. Their findings remain valid today, although appreciation of the importance of cisternal anatomy for neurosurgery had to await the introduction of the operating microscope. Performing procedures under the operating microscope has contributed to progress in understanding anatomy, and has defined the importance of precise dissection of the subarachnoid cisterns in the exposure of cerebral aneurysms, arteriovenous malformations, and extrinsic and intrinsic tumors.

The traditional definition of the subarachnoid space as consisting of a freely communicating channel for the flow of CSF is an inadequate explanation, and fails to correspond to the findings at operation under the microscope. The arachnoid partitions the subarachnoid space into relatively discrete chambers, possibly retarding and directing the flow of CSF. These barriers to CSF are seen in numerous locations, providing a rationale for naming them as individual subarachnoid cisterns (Figs. 2 and 3). Microneurosurgical procedures presented us with the opportunity to revise our knowledge of compartmentalization of the subarachnoid cisterns, because we are able to view them



**Fig. 2.** Original figure from Ref. [38], showing a dissection of the basal cisternal compartments (olfactory, chiasmatic, Sylvian, carotid, interpeduncular, crural, prepontine, cerebellopontine, and anterior spinal cisterns)



**Fig. 3.** Artist's impression of the left-sided infratentorial cisterns with the structures they encase (1 junction between cisterna ambiens and quadrigemina, 2 cerebellopontine cistern, 3 lateral cerebellomedullary cistern, 4 4th ventricle, 5 superior cerebellar cistern, 6 superior vermian cistern, 7 cisterna magna, and 8 cervical subarachnoid space). Taken from [88]; illustration by P. Roth

in their natural physiological state, fully distended with CSF. Knowledge of the cisternal anatomy allows precise exploration of intra- and extra-axial intracranial lesions along the “cisternal pathways”. The lesion can be circumferentially dissected, observing cisternal anatomy, and the parent arteries and main draining veins can be secured, thereby achieving control of cerebral hemodynamics.

In chapter 1 of “Microneurosurgery, volume I” cisternal anatomy and compartmentalization is reviewed in detail [60, 116]. A concept of the subarachnoid space is presented that attempts to describe the actual observations at operation as accurately as possible. In current neurosurgical nomenclature, these terms are commonly used, and continue to be relevant when describing dissection and exposure of intracranial and arachnoidal lesions and their accompanying cranial nerves and vasculature. The predilection sites of vascular, neoplastic, malformative, and degenerative lesions in these compartments can be defined precisely. Further advances in radiological imaging, and developmental and functional anatomy will give more detailed insight into the cisternal anatomy and physiology of arachnoid fibers and trabeculae [124].

## SEGMENTAL AND COMPARTMENTAL OCCURRENCE OF LESIONS [116 VOL. IV B, 118]

Diseases of various etiologies rarely involve an entire organ or the entire body. A disease occurs in segments or compartments of organs, sometimes entirely isolated, even encapsulated, sometimes without any symptoms and unnoticed by the patient. Central nervous system diseases follow a regular pattern, each individual lesion seemingly occurring in a distinct segment or compartment (Table 5).

**Table 5.** Predilection sites of primary brain tumors

---

1. Neopallial
    - a. Gyral segments of frontal (F1–F3), parietal (P1–P3), occipital (O1–O3), and temporal (T1–T4) lobes and cerebellar lobules (anterior and posterior quadrangular lobules, superior and inferior semilunar lobules, biventral lobule, tonsil, and superior and inferior vermis)
    - b. Gliomas have a tendency to extend, in pyramidal shape, toward the ventricle
    - c. Gliomas of neopallial, archi- and paleopallial, intraventricular, white matter, basal ganglia and central nuclei remain in their compartments; however, in high grade gliomas after radiotherapy and incomplete surgical removal, they may disseminate
  2. Archi- and paleopallial (limbic, paralimbic)
    - a. Mesiobasal temporal (temporal pole, amygdala-hippo- and parahippocampus)
    - b. Insular (anterior, posterior, entire)
    - c. Cingulate gyrus (anterior, middle, posterior)
    - d. Posterior frontoorbital gyri and septal region
    - e. Combined a–d
  3. Midline
    - a. Only caudate head (rare), never body or tail of caudate nucleus
    - b. Lentiform nucleus (extremely rare)
    - c. Corpus callosum (anterior, middle, posterior part)
    - d. Pre- and retrolentiform region of the white matter
    - e. Diencephalon (hypothalamus infero-anterior or supero-posterior; thalamus anterior or posterior [pulvinar]); only malignant gliomas in late phase transgress the borderline between hypothalamus and thalamus
    - f. Mesencephalon (dorsal, ventral, lateral, central)
    - g. Pons-medulla oblongata (dorsal, ventral, central)
  4. Intraventricular
    - a. Lateral ventricles (anterior horn, cella media, or atrium)
    - b. Third ventricle
    - c. Aqueduct
    - d. Fourth ventricle
  5. Cervical, thoracic, and lumbar spinal cord (dorsal, lateral, central)
-

The occurrence of extrinsic cranio-spinal tumors (meningiomas, neurinomas, craniopharyngiomas, adenomas, chordomas, chondrosarcomas and epidermoids) in specific cisternal compartments had already been clearly understood by the founding generation of neurosurgeons. The predilection sites of brain lesions such as AVMs, cavernomas, and the various types of intrinsic tumors can now be demonstrated with modern neurovisualization technology, coordinating three planar or three dimensional studies with all modalities. Despite these advances, the topographic description of intrinsic lesions of the brain continues to be the traditional terminology related to the “lobar” concept. This is by no means wrong, but imparts insufficient data and fails to define comprehensively the accurate location of a lesion in a particular parenchymal compartment(s) of the CNS. Intrinsic lesions occur in compartments of the neopallial, archi-pallial and paleo-pallial (limbic-paralimbic) systems, in the basal ganglia, in compartments of the white matter of the dien-, and mesen-, metencephalon, in the cerebellum, spinal cord and in the 4 compartments of the ventricular system [116 IV B, 120, 121, 122].

The generally accepted concept that gliomas grow in an infiltrative manner is not a convincing hypothesis. Glial tumors compress and displace but do not infiltrate into or follow connective fibers, and they do not transgress connective fibers until a very late phase of grade IV tumors. This segmental/compartmental concept has been reinforced by recent studies with diffusion tensor imaging and 3 planar MRI. Gliomas within neopallial, archi- and paleopallial, white matter, basal ganglion, diencephalon, brainstem and intraventricular compartments usually exhibit a sharp borderline to neighboring compartments. Nevertheless, as the limbic system encircles the brainstem and the telencephalon, topographically the appearance of limbic gliomas on MRI can be fairly confusing, because they may simulate a multi-lobar tumor, particularly in cases in which the gliomas involve the mesiotemporal, posterior frontoorbital, septal and insular compartments of the limbic system all at once. This segmental and compartmental occurrence of diseases, with different vascularization patterns of each compartment, creates for the surgeon and radiation-therapist the opportunity to offer a favorable form of therapy and pursue an efficient treatment regime to a successful and beneficial conclusion. Recurrence of low-grade gliomas always occurs in the same location even after decades. In approximately 95% of high-grade gliomas recurrence occurs in the same place; in 1–2%, dissemination is observed, and in about 2–3%, the recurrence is multicentric.

## 1. CRANIOTOMIES

Each craniotomy requires thorough studies of the architecture of the bone in the intended surgical region (CT) and the course and variation of arteries and veins and venous sinuses (CTA, MRA, MRV). The optimal size of craniotomy is chosen to improve the operating field of vision, minimize brain

retraction, and provide multiple surgical angles for dissection. Various approaches have been devised and described [3–5, 9, 16, 25, 27, 33, 36, 37, 62, 71, 72, 78, 80, 89, 94, 116, 120–122]. Sustained application of endeavors resulted in mastering of combined approaches, for instance, transsphenoidal-transSylvian, transSylvian-transcallosal, and supracerebellar-transtentorial explorations in one session. The use of the power drill is indispensable for precise achievement of these approaches. Perfection of drilling-skills and learning the complex anatomy of the skull base and the arachnoid space in the laboratory is strongly recommended.

## **2. THE CAVERNOUS SINUS**

The final hurdle in skull base surgery has finally been surmounted. Due to the vital structures passing through, the internal carotid artery, the cranial nerve of oculomotion, and the trigeminal nerve, the cavernous sinus has long been approached with the appropriate respect, and was not entered surgically because continued oozing of venous blood obstructed the surgical view. In the 1980s Vinko Dolenc was the first to enter the cavernous sinus for the purpose of treating internal carotid artery aneurysms and carotid cavernous fistulas, controlling venous bleeding with Surgicel and compression [17, 18]. His technique has been refined (in part with the advent of fibrin glue) and, for those who have trained long and extensively, the cavernous sinus is on the verge of being tamed [40]. The combined pterional pretemporal transcavernous approach achieves a wide exposure and is currently employed to treat saccular aneurysms in the cavernous sinus and at the level of the upper third of the basilar artery, including the basilar tip [41–43]. The treatment of cavernous tumors (meningiomas, chordomas) has become possible and total resection is possible, in cases without severe adhesions.

## **3. CISTERNAL APPROACHES**

Due to the limited space of this chapter a detailed presentation of the cisternal approaches cannot be given. The exploration and elimination of the various intracranial and intraspinal, extrinsic and intrinsic lesions has been described in extenso in former publications [108, 111, 116 vol. I, III B, IV B, 111, 120, 122].

## **4. CEREBROVASCULAR MICROSURGERY**

Alexis Carrel pioneered the basic vascular surgical techniques in the animal laboratory (1902–1940) [10, 75]. In 1953 Michael E. DeBakey began routine clinical application of vascular surgery. Concomitant advances in the diagnosis of arterial disease with improved angiography, followed by Duplex ultrasonography, CTA, MRA, and the availability of anticoagulants, contributed

to improvements [49]. The application of extracranial vascular surgical techniques to intracranial arteries necessitated the recognition of the distinct relationship of the cerebral vasculature to the cisterns and the necessity of maintaining a constantly bloodless surgical field. This became possible with the combined application of the operating microscope, bipolar coagulation, microinstruments and microsutures, later complemented by ultrasound flowmetry and fluoroscopy. Microneurosurgical techniques ultimately permitted preservation of arteries and veins down to 0.5 mm in size by meticulous dissection, repair and reconstruction within the cisternal-arachnoidal system. Exploration and elimination of saccular aneurysms, AVMs, cavernomas, hemangioblastomas also became possible [9, 18, 24, 43, 52, 92, 93].

Surgical concepts, techniques, tactics and results have been published in six volumes of “Microneurosurgery” [116]. In Table 6, surgical concepts are summarized.

Although impressive improvement of endovascular techniques has been documented, current neurosurgery needs to develop confidence and dexterity

**Table 6.** Microsurgery of intracranial saccular aneurysms, AVMs and cavernomas

*Aneurysms* (see Microneurosurgery, vols. I and II)

Transcisternal exploration of the proximal and distal segments of the parent artery(ies)

Recognition of the geometry and wall-condition of the aneurysms

Control of hemodynamics in parent arteries using proximal and distal temporary clips (maximum 3 minutes)

Taming, shaping, shrinkage, deflation and neck creation of dysmorphic saccular aneurysms using bipolar coagulation techniques, temporary and pilot clips (see Figure 208A-B in Microneurosurgery, vol. I, pp 253-254)

Complete elimination of aneurysm, particularly the inferiorly bulging parts and, if necessary, graft/bypass in case of large or giant aneurysms.

*Arteriovenous malformations* (see Microneurosurgery, vol. IIIA, B)

Perilesional helical exploration, identification and elimination of the feeding arteries

Temporary microclips of the small periventricular perforating arteries, bipolar coagulation

Consideration of specific hemodynamics in a given case related to the venous drainage, particularly the condition of the straight sinus (stenosis or occlusion)

Creation of new venous drainage

*Cavernomas*

The introduction of MRI technology markedly facilitated the diagnosis of cavernomas in CNS. Symptomatic cavernomas causing hemorrhages or seizures or neurologic and mental deficits should always be operated. Applying microtechniques they can be precisely explored and removed, saving adjacent venous anomalies (see Microneurosurgery, vols. IIIB and IVB).



in cerebrovascular microsurgery and advance techniques, because ultimately, surgical therapy provides the most definitive solution to cerebrovascular lesions.

## **5. REVASCULARIZATION OF THE BRAIN**

Reconstructive surgery of extracranial brain arteries has become, in the second half of the 20th century, a routine procedure involving vascular surgeons, neurosurgeons and interventional radiologists who aimed to create new ideas to attain the best and most effective treatment.

Extra-intracranial bypass and intracranial bypass procedures have been well established since 1967, and are an integral part of neurosurgery in the treatment of giant aneurysms, skull base tumors and reconstruction of the venous sinuses [6, 11, 12, 21, 24, 61, 68, 73, 77, 79, 84, 86, 91, 92, 102, 115]. In cerebrovascular occlusive disease, indications for EC-IC bypass requires careful evaluation and assessment [7]. However, a certain group of patients with compromised hemodynamics due to an insufficient collateral system, can be relieved from their burden of cerebrovascular ischemic events by this procedure.

The advent of quantitative MRI angiography as well as SPECT and PET promises to be of great value in determining those patients who may benefit [12, 96]. The excimer laser-assisted non-occlusive anastomosis (ELANA) technique is proving to be a successful alternative surgical technique to the classical procedure of suturing the vessels [95].

## **6. EPILEPSY SURGERY**

Anterior transSylvian selective amygdalohippocampectomy, introduced in 1973, is performed in patients with medically intractable mesiotemporal seizures, as indicated by an epileptologist [100, 113, 117]. This alternative to standard temporal lobectomy provides outstanding outcomes for seizure control. Microneurosurgical dissection achieves atraumatic opening of the anterior Sylvian fissure and the amygdalohippocampectomy can be accomplished without injuring the surrounding cerebrovascular system and neopallial and related white matter [88].

## **7. SPINE SURGERY**

Microsurgical techniques are applied to spinal surgery for disc disease, as well as for extrinsic and intrinsic extra- and intramedullary tumors, AVMs, cavernomas, and hemangioblastomas. Quadrilaminectomy has proven a practical and suitable method to approach and completely remove these lesions [39, 51, 52, 57, 105, 108–111]. Hemilaminotomy and microdiscectomy for lumbar disc surgery have advantages over open surgery as no spinal fixation is necessary

[2, 101, 106]. The spinal arachnoid cisternal space is also compartmentalized. A fenestrated arachnoidal septum exists between the dorsal median sulcus of the spinal cord and dura from C2 through Th10–11 and divides the dorsal spinal cistern into two compartments [57]. Meticulous manipulation to preserve the arachnoid aids in identifying the dorsal median sulcus. Precise closure of the pia, arachnoidea, and dura hinders dural-pial adhesions.

## **8. TRAUMA**

Having vivid memories of personal experiences treating the open wounds of cranio-spinal injuries (1967–1970), the application of microtechniques seemed, initially, to be superfluous to others and was therefore opposed. Soon, however, after observing the effectiveness of meticulous exploration and removal of debris and hematomas, repair of vessels, precise hemostasis and exact closure of wounds, microtechniques became accepted.

## **9. CADAVER AND ANIMAL LABORATORY TRAINING**

Theoretical learning methods are provided in abundance, whereas the technical, surgical aspects in the field of neurosurgery seem to be underappreciated.

Practical learning in well-equipped microneurosurgical laboratories provides a means to broaden knowledge of anatomy and acquire dexterity in microsurgical techniques, such as the appropriate use of the operating microscope, microsurgical instruments, drilling and dissection skills. Furthermore, microsurgical training will further enhance the capabilities of the “mental eye” of the surgeon.

## **DISCUSSION**

The components of microneurosurgical concepts can be defined as follows: availability of appropriate tools, instruments, and equipment, thorough training in a laboratory dedicated to microneurosurgery to acquire broader neuroanatomical perspectives, and to adapt to the operating microscope while perfecting microsurgical techniques and improving skills with tools, instruments, and equipment; finally, establishing teamwork and interactive dialog with neuroradiologists, neuroanesthesiologists, neuropathologists and neurosurgical nurses in the OR, ICU and ward to promote optimal care of patients.

Considering these challenging developments, young colleagues are encouraged and advised of the absolute necessity, to spend at least one year in a laboratory setting, training in surgical neuroanatomy and microsurgical technique. The employment of advanced robotic technology in neurosurgery will require us to be far more accurate and knowledgeable in neuroanatomy and neuro-

physiology and will demand confidence and precision in surgical maneuvers, methods and manipulations [87]. Aboud et al. [3] introduced an innovative lifelike model emulating the normal human anatomy and dynamic vascular filling found in real surgery. This model gives us the unique opportunity to develop and practice a wide range of skills, for example opening the Sylvian fissure, suturing microanastomoses, dissecting and clipping artificial aneurysms, and practicing neurosurgical approaches in general.

The most effective surgery is always that administered by the trained “mental eye” and hands of a surgeon. I am convinced the coming generation will participate with zeal, in advancing, developing and improving the field of neurosurgery, and in creating innovative ideas and initiating sound concepts for the benefit of our patients.

Ongoing laboratory experience throughout a neurosurgeon’s career is critical for the microsurgeon to learn new techniques and procedures and to refresh and refine a knowledge of anatomy. Hands-on laboratory dissection courses and individualized cadaver dissection opportunities are excellent means for fine tuning seldom-used techniques [3, 114, 123].

## **FUTURE**

In the information era, for the modern neurosurgeon, it is of importance to understand and master the interpretation of the many radiological imaging techniques, to implement neuronavigation in surgery and teaching, and to assist in developing even more advanced microscopes (such as with oscillating objectives to improve depth perception), microsurgical instruments, and 3D-television cameras with fluctuating objectives. In the field of neuroradiological imaging, diffusion tensor imaging and white matter tractography, although in their preliminary clinical phase, seem very promising techniques [47, 76, 83, 98]. They open exciting new possibilities for exploring features of the central nervous system anatomy that are invisible in vivo. These techniques have already expanded our current neuroanatomical knowledge, for example, the anatomic connectivity of cortical and subcortical structures, the somatotopical anatomic connectivity of cortical and subcortical structures, and the somatotopical organization of white matter tracts such as the pyramidal tract and medial lemniscus system [14, 58]. There is a parallel revival of interest in the anatomy and dissection of white matter tracts [76, 98, 121]. More recent studies have shown the relationship between intra-axial lesions, (gliomas, arteriovenous malformations, and cavernomas) to the adjacent white matter tracts. Preoperative neurosurgical planning and postoperative assessment of lesionectomy are defined according to the relationship of fiber systems to the lesion and whether they are impaired, displaced or intact [13, 83]. Optimally, intraoperative navigation with real-time information from ultrasound (parenchymography), MRI and CT, as well as tractography would be ideal to direct the process of dissection and serve as a pilot, guiding the

procedure to accomplish a pure lesionectomy. Five categories of tract alteration in relation to a lesion have been described by Lazar et al., namely: normal, deviated, interrupted, infiltrated, or degenerated [47]. Interestingly, they also showed that after lesion resection, the white matter tracts appeared more similar to normal anatomy, compared to the contralateral side. Tract alteration had disappeared which correlated with improvement or preservation of motor function, when lesions were associated with the pyramidal tract. Their findings corroborate well with the concept that “glial tumors grow initially from a focus of abnormal cells in the white matter, in specific architectonic areas that are phylogenetically more recently evolved” [116]. As stated previously, these tumors, in the early and intermediate phase of their existence, as they grow, remain primarily restricted to their sectors of origin and split the surrounding white matter fibers. It is important to remember that the white matter consists not only of myelinated and unmyelinated fibers, but also of migrating stem cells, microglia, a specialized capillary and arachnoidal system, CSF channels, and a cellular and fluidal immune system.

## CONCLUSIONS

The fundamental concepts of microneurosurgery are based on control of cerebral vasculature and hemodynamics, which includes exploration of main cerebral vasculature, also sulcal arteries and the arteries and veins surrounding cerebral lesions. As summarized in Table 1, successful fulfillment of these concepts is dependent on: (1) a clear understanding and recognition of the compartmental anatomy of the cisternal and parenchymal (neo-, paleo-, and archipalleal) and ventricular systems, (2) knowledge of the compartmental and segmental occurrence of gliomas and cerebral vascular lesions such as AVMs and cavernomas, (3) being well acquainted with instruments, bipolar coagulation, suction (regulation and CUSA), pledgets and sponges, (4) skilled reconstruction of arteries and veins using microsurgical techniques.

## Acknowledgements

I wish to convey my sincere thanks and appreciation to Ruben Dammers, MD for his dedicated and enthusiastic assistance and to Dianne C. H. Yaşargil, RN for reviewing the text.

## References

- [1] Abbe E (1886) The new microscope. *S Ber Jena Ges Med* 2: 107-108
- [2] Abernathey CD, Yaşargil MG (1990) Technique of microsurgery. In: Williams RW, McCulloch JA, Young PH (eds) *Principles and techniques in spine surgery*. Aspen Publishers Inc., Rockville, pp 271

- [3] Aboud E, Al-Mefty O, Yaşargil MG (2002) New laboratory model for neurosurgical training that simulates live surgery. *J Neurosurg* 97: 1367-1372
- [4] Al-Mefty O, Ayoubi S, Smith RR (1991) The petrosal approach: indications, technique, and results. *Acta Neurochir Suppl (Wien)* 53: 166-170
- [5] Apuzzo ML, Heifetz MD, Weiss MH, et al. (1977) Neurosurgical endoscopy using side-viewing telescope. *J Neurosurg* 46: 398-400
- [6] Ausman JI, Moore J, Chou SN (1976) Spontaneous cerebral revascularization in a patient with STA-MCA anastomosis. *J Neurosurg* 44: 84-87
- [7] Barnett HJ, Peerless SJ (1985) Failure of extracranial-intracranial arterial bypass to reduce the risk of ischemic stroke. Results of an international randomized trial. The EC/IC Bypass Study Group. *N Engl J Med* 313: 1191-1200
- [8] Barraquer JI (1956) The microscope in ocular surgery. *Am J Ophthalmol* 42: 916-918
- [9] Bertalanffy H, Seeger W (1991) The dorsolateral, suboccipital, trancondylar approach to the lower clivus and anterior portion of craniocervical junction. *Neurosurgery* 29: 815-821
- [10] Carrel A, Guthrie CC (1906) Uniterminal and biterminal venous transplantations. *Surg Gynecol Obstet* 2: 266
- [11] Charbel FT, Meglio G, Amin-Hanjani S (2005) Superficial temporal artery – MCA bypass. *Neurosurgery* 56(Suppl 1): 186-190
- [12] Chater N, Spetzler R, Tonnemacher K, Wilson CB (1976) Microvascular bypass surgery. Part 1: Anatomical studies. *J Neurosurg* 44: 712-714
- [13] Chen X, Weigel D, Ganslandt O, Buchfelder M, Nimsky C (2007) Diffusion tensor imaging and white matter tractography in patients with brainstem lesions. *Acta Neurochir* 149: 1117-1131
- [14] Concha L, Gross DW, Beaulieu C (2005) Diffusion tensor tractography of the limbic system. *Am J Neuroradiol* 26: 2267-2274
- [15] Conforti P, Tomasello T, Albanese V (1984) Cerebral revascularization. *Nuova Libreria, Padua, Picifi*
- [16] Derome PJ (1985) Surgical management of tumors invading the skull base. *Can J Neurol Sci* 12: 345-347
- [17] Dolenc V (1983) Direct microsurgical repair of intracavernous vascular lesions. *J Neurosurg* 58: 824-831
- [18] Dolenc VV, Skrap M, Sustersic J, Skrbec M, Morina A (1987) A transcavernous-transsellar approach to the basilar tip aneurysms. *Br J Neurosurg* 1: 251-259

- [19] Donaghy RM (1996) History of microneurosurgery. In: Wilkins RH, Rengachary SS (eds) *Neurosurgery*, 2nd edn, vol I. McGraw-Hill, New York, pp 37-42
- [20] Donaghy RMP, Yaşargil MG (eds) (1967) *Micro-vascular surgery: Report of first conference, October 6-7, 1966, Mary Fletcher Hospital, Burlington, Vermont.* Georg Thieme, Stuttgart
- [21] Ferguson GG, Drake CG, Peerless SS (1977) Extracranial-intracranial arterial bypass in the treatment of giant intracranial aneurysm. *Stroke* 8: 11
- [22] Flamm ES (1997) History of neurovascular surgery. In: Greenblatt SH (ed) *History of neurosurgery.* AANS, Park Ridge, pp 259-288
- [23] Greenwood J Jr (1940) Two point coagulation. A new principle and instrument for applying coagulation current in neurosurgery. *Am J Surg* 50: 267-270
- [24] Hakuba A (ed) (1996) *Surgery of the intracranial venous system.* Springer, Tokyo
- [25] Hakuba A, Liu S, Nishimura S (1986) The orbitozygomatic infratemporal approach: a new surgical technique. *Surg Neurol* 26: 271-276
- [26] Handa H (ed) (1973) *Microneurosurgery.* Gaku Shoin Ltd., Tokyo
- [27] Hardy J (1969) Transsphenoidal microsurgery of the normal and pathological pituitary. *Clin Neurosurg* 16: 185-216
- [28] Harms H (1953) Augenoperationen unter dem binocularen Mikroskop. *Ber Dtsch Ophthalmol Ges* 58: 119-122
- [29] House HP, House WF (1964) Historical review and problem of acoustic neuroma. *Arch Otolaryngol* 80: 599-604
- [30] House WF (1961) Surgical exposure of the internal auditory canal. *Laryngoscope* 71: 1363-1385
- [31] Jacobson JH II, Suarez EI (1960) Microsurgery in anastomosis of small vessels. *Surg Forum* 11: 243-245
- [32] Jacobson JH II, Wallman LJ, Schumacher GA, Flanagan M, Suarez EL, Donaghy RM (1962) Microsurgery as an aid to middle cerebral artery endarterectomy. *J Neurosurg* 19: 108-115
- [33] Jannetta PJ (1967) Arterial compression of the trigeminal nerve at the pons in patients with trigeminal neuralgia. *J Neurosurg* 26(Suppl): 159-162
- [34] Jannetta PJ (1968) The surgical binocular microscope in neurological surgery. *Am Surg* 34: 31
- [35] Jannetta PJ, Rand RW (1966) Trigeminal neuralgia. Microsurgical technique. *Bull Los Angeles Neurol Soc* 31: 93-99

- [36] Kawase T, Toya S, Shiobara R, Mine T (1985) Transpetrosal approach for aneurysms of the lower basilar artery. *J Neurosurg* 63: 857-861
- [37] Kelly PJ, Alker GJ Jr, Goerss S (1982) Computer-assisted stereotactic microsurgery for the treatment of intracranial neoplasms. *Neurosurgery* 10: 324-331
- [38] Key A, Retzius G (1875–1876) Studien in der Anatomie des Nervensystems und des Bindegewebes, vols I & II. Norstad, Stockholm
- [39] Klekamp J, Samii M (2007) Surgery of spinal tumors. Springer, Berlin
- [40] Krayenbuhl N, Hafez A, Hernesniemi JA, Krisht AF (2007) Taming the cavernous sinus: technique of hemostasis using fibrin glue. *Neurosurgery* 61: E52; discussion E52
- [41] Krisht AF, Kadri PAS (2003) Microsurgical anatomy of the cavernous sinus. *Tech Neurosurg* 8: 199-203
- [42] Krisht AF (2005) Transcavernous approach to diseases of the anterior upper third of the posterior fossa. *Neurosurg Focus* 19(2): E2
- [43] Krisht AF, Krayenbuhl N, Sercl D, Bikmaz K, Kadri PA (2007) Results of microsurgical clipping of 50 high complexity basilar apex aneurysms. *Neurosurgery* 60: 242-250; discussion 250-242
- [44] Kurze T (1964) Microtechniques in neurological surgery. *Clin Neurosurg* 11: 128-137
- [45] Kurze T, Doyle JB (1962) Extradural intracranial (middle fossa) approach to the internal auditory canal. *J Neurosurg* 19: 1033-1037
- [46] Lang WH, Muchel F (1981) Zeiss microscopes for microsurgery. Springer, Berlin, Heidelberg, New York
- [47] Lazar M, Alexander AL, Thottakara PJ, Badie B, Field AS (2006) White matter reorganization after surgical resection of brain tumors and vascular malformations. *Am J Neuroradiol* 27: 1258-1271
- [48] Littmann H (1954) Ein neues Operations-Mikroskop. *Klin Monatsbl Augenheilkd Augenärztl Fortbild* 124: 473-476
- [49] Loftus CM, Kresowif TF (2000) Carotid artery surgery. Thieme, New York, Stuttgart
- [50] Loughheed WM, Tom M (1961) A method of introducing blood into the subarachnoid space in the region of the circle of Willis in dogs. *Can J Surg* 4: 329-337
- [51] Malis LI (1978) Intramedullary spinal cord tumors. *Clin Neurosurg* 25: 512-539
- [52] Malis LI (1979) Microsurgery for spinal cord arteriovenous malformation. *Clin Neurosurg* 26: 543-555

- [53] Malis LI (1979) Instrumentation and techniques in microsurgery. *Clin Neurosurg* 26: 626-636
- [54] Malis LI (1981) Neurosurgical photography through the microscope. *Clin Neurosurg* 28: 233-245
- [55] Malis LI (1996) Electrosurgery. Technical note. *J Neurosurg* 85: 970-975
- [56] Malpighi M (1661) *Duae epistole de pulmonibus*. Florence
- [57] Nauta HJ, Dolan E, Yaşargil MG (1983) Microsurgical anatomy of spinal subarachnoid space. *Surg Neurol* 19: 431-437
- [58] Nucifora PG, Verma R, Lee SK, Melhem ER (2007) Diffusion-tensor MR imaging and tractography: exploring brain microstructure and connectivity. *Radiology* 245: 367-384
- [59] Nysten CO (1954) The microscope in aural surgery, its first use and later development. *Acta Otolaryngol* 116(Suppl): 226-240
- [60] Ono M, Kubik S, Abernathy CD (1990) *Atlas of the cerebral sulci*. Thieme, Stuttgart
- [61] Peerless SJ (1976) Techniques of cerebral revascularization. *Clin Neurosurg* 23: 258-269
- [62] Perneczky A, Tschabitscher N, Resch KDM (1993) *Endoscopic anatomy for neurosurgery*. Thieme, Stuttgart
- [63] Perritt RA (1958) *Micro-ophthalmic surgery*. XVIII. Belgica, Concil Ophthal
- [64] Pool JL, Colton RP (1966) The dissecting microscope for intracranial vascular surgery. *J Neurosurg* 25: 315-318
- [65] Rand RW (1969) *Micro-neurosurgery*. CV Mosby, St. Louis
- [66] Rand RW, Kurze T (1965) Micro-neurosurgical resection of acoustic tumors by a transmeatal posterior fossa approach. *Bull Los Angel Neuro Soc* 30: 17-20
- [67] Riechert T (1948) Die Operationen an der WS und am Rückenmark. In: Bier A, Braun H, Kümmel H (eds) *Chirurgische Operationslehre*, vol 2. JA Barth, Leipzig, p 753
- [68] Reichman OH (1971) Experimental lingual-basilar arterial microanastomosis. *J Neurosurg* 34: 500-505
- [69] Rhoton AL Jr (1979) Microsurgical anatomy of the posterior fossa cranial nerves. *Clin Neurosurg* 26L: 398-462
- [70] Rohr M, Stock W (1913) Über eine achromatische Brillenlupe schwacher Vergrößerung. *Klin Monatsbl Augenheilkd* 51: 206-210



- [71] Samii M, Ammirati M, Walter GF (1992) *Surgery of skull base meningiomas*. Springer, Berlin
- [72] Samii M, Mathies C (1997) Management of 1000 vestibular schwannomas (acoustic neuromas): Hearing function in 1000 tumor resections. *Neurosurgery* 40: 248-262
- [73] Samson DS, Boones L (1998) Extra-intracranial arterial bypass; past performance and current concepts. *Neurosurgery* 3: 79-86
- [74] Schierbeek A (1959) *Measuring the invisible world. The life and works of Antoni van Leeuwenhoek FRS. With a biographical chapter by Maria Rooseboom. Abelard-Schuman, New York*
- [75] Schlich T (2007) Nobel Prizes for surgeons: In recognition of the surgical healing strategy. *Int J Surg* 5: 129-133
- [76] Schmahmann JD, Pandya DN (2007) Cerebral white matter – historical evolution of facts and notions concerning the organization of the fiber pathways of the brain. *J Hist Neurosci* 16: 237-267
- [77] Schmiedek P, Gratzl O, Spetzler R, Steinhoff H, Enzenbach R, Brendel W, Marguth F (1976) Selection of patients for extra-intracranial arterial bypass surgery based on rCBF measurements. *J Neurosurg* 44: 303-312
- [78] Seeger W (1978) *Atlas of topographical anatomy of the brain and surrounding structures*. Springer, Wien
- [79] Sekhar LN, Bucur SD, Bank WO, Wright DC (1999) Venous and arterial bypass grafts for difficult tumors, aneurysms, and occlusive vascular lesions: evolution of surgical treatment and improved graft results. *Neurosurgery* 44: 1207-1223; discussion 1223-1204
- [80] Sekhar LN, de Oliveira E (1999) *Cranial neurosurgery*. Thieme, Stuttgart
- [81] Shambaugh GE (1939) Surgery for otosclerosis. Indications, techniques and results. *Fortschr Hals-Nas-Ohrenheilkd* 8: 367-428
- [82] Shillito J (1967) Intracranial arteriotomy in three children and three adults. In: Donaghy RMP, Yaşargil MG (eds) *Micro-vascular surgery*. Georg Thieme, Stuttgart, pp 138-142
- [83] Smits M, Vernooij MW, Wielopolski PA, Vincent AJ, Houston GC, van der Lugt A (2007) Incorporating functional MR imaging into diffusion tensor tractography in the preoperative assessment of the corticospinal tract in patients with brain tumors. *Am J Neuroradiol* 28: 1354-1361
- [84] Spetzler RF, Carter LP, Selman WR, Martin NA (1985) *Cerebral revascularization for stroke*. Thieme-Stratton, New York Stuttgart
- [85] Spetzler RF, Chater N (1976) Occipital artery-middle cerebral anastomosis for cerebral artery occlusive disease. *Surg Neurol* 2: 235-238

- [86] Spetzler RF, Chater NL (1980) Microvascular bypass surgery. Part 2: Physiological studies. *J Neurosurg* 53: 22-70
- [87] Spicer MA, van Velsen M, Caffrey JP, Apuzzo ML (2004) Virtual reality neurosurgery: a simulator blueprint. *Neurosurgery* 54: 783-797; discussion 797-788
- [88] Stummer W, Pichlmeier U, Meinel T, Wiestler OD, Zanella F, Reulen HJ (2006) Fluorescence-guided surgery with 5-aminolevulinic acid for resection of malignant glioma: a randomised controlled multicentre phase III trial. *Lancet Oncol* 7: 392-401
- [89] Sugita K (1985) *Microneurosurgical atlas*. Thieme, Stuttgart
- [90] Sundt TM Jr (1979) Neurovascular microsurgery. *World J Surg* 3: 53-65, 127
- [91] Sundt TM Jr, Fode NC, Jack CR Jr (1988) The past, present, and future to extracranial bypass surgery. *Clin Neurosurg* 34: 134-153
- [92] Sundt TM Jr, Piepgras DG (1979) Surgical approach to giant intracranial aneurysms. Operative experience with 80 cases. *J Neurosurg* 51: 731-742
- [93] Sundt TM Jr, Piepgras DG, Stevens LN (1991) Surgery for supratentorial arteriovenous malformations. *Clin Neurosurg* 37: 49-115
- [94] Tew JR, van Loveren HR (1994) *Atlas of operative microneurosurgery*. WB Saunders, Philadelphia
- [95] Tulleken CA, Verdaasdonk RM, Berendsen W, Mali WP (1993) Use of the excimer laser in high-flow bypass surgery of the brain. *J Neurosurg* 78: 477-480
- [96] Türe U, Yaşargil MG, Krisht AF (1996) The arteries of the corpus callosum: a microsurgical anatomic study. *Neurosurgery* 39: 1075-1084; discussion 1084-1075
- [97] Türe U, Yaşargil MG, Al-Mefty O, Yaşargil DCH (2000) Arteries of the insula. *J Neurosurg* 92: 676-687
- [98] Türe U, Yaşargil MG, Friedman AH, Al-Mefty O (2000) Fiber dissection technique: lateral aspect of the brain. *Neurosurgery* 47: 417-426; discussion 426-427
- [99] Turner GLE (1972) The study of the history of the microscope. *Proc R Microsc Soc* 7(2): 121-149
- [100] Wieser HG, Yaşargil MG (1982) Selective amygdalohippocampectomy as a surgical treatment of mesiobasal limbic epilepsy. *Surg Neurol* 17: 445-457
- [101] Williams RW (1978) Microlumbar discectomy. A conservative surgical approach to the virgin herniated disc. *Spine* 3: 175-182
- [102] Wolfe SQ, Tummala RP, Morcos JJ (2005) Cerebral revascularization in skull base tumors. *Skull Base* 15: 71-82

- [103] Woringer E, Kunlin J (1963) Anastomose entre le carotide primitive et la carotide intra-craniennet ou la sylvienne par greffon selon la technique da la suture suspendue. *Neurochirurgie* 9: 181-188
- [104] Wullstein H (1953) Technik und bisherige Ergebnisse de Tympanoplastik 87: 308
- [105] Yaşargil MG (1969) Surgery of vascular malformations of the spinal cord with the microsurgical technique. *Clin Neurosurg* 18: 257-265
- [106] Yaşargil MG (1977) Microsurgical operation for herniated lumbar disc. In: *Advances in Neurosurgery*, vol 4. Springer, Berlin, pp 81
- [107] Yaşargil MG (1985) History of microneurosurgery. In: Spetzler RF, Carter LP, et al. (eds) *Cerebral revascularization*. Thieme, Stuttgart, pp 28-33
- [108] Yaşargil MG, Antic J, Laciga R, de Preux J, Fideler RW, Boone SC (1976) The microsurgical removal of intramedullary spinal hemangioblastomas. Report of twelve cases and a review of the literature. *Surg Neurol* 1976: 141-148
- [109] Yaşargil MG, Perneczky A (1976) Operative Behandlung der intramedullaren spinalen Tumoren. In: Schiefer W, Wieck HH (eds) *Spinale raumfordernde Prozesse*. Verlag Peri Med, Erlangen, pp 299-312
- [110] Yaşargil MG, Symon L, Teddy P (1984) Arteriovenous malformations of the spinal cord. *Adv Tech Stand Neurosurg* 11: 61-102
- [111] Yaşargil MG, Tranmer BI, Adamson TE, Roth P (1991) Unilateral partial hemilaminectomy for the removal of extra- and intramedullary tumors and AVMs. *Adv Tech Stand Neurosurg* 18: 113-132
- [112] Yaşargil MG, Vise WM, Bader DC (1977) Technical adjuncts in neurosurgery. *Surg Neurol* 8: 331-336
- [113] Yaşargil MG, Wieser HG, Valavanis A, von Ammon K, Roth P (1993) Surgery and results of selective amygdala-hippocampectomy in one hundred patients with nonlesional limbic epilepsy. *Neurosurg Clin N Am* 4: 243-261
- [114] Yaşargil MG (2005) From the microsurgical laboratory to the operating theatre. *Acta Neurochir (Wien)* 147: 465-468
- [115] Yaşargil MG, Donaghy RMP, Fisch UP, Hardy J, Malis LI, Peerless SJ, Zingg M, Borer WJ, Littmann H, Voellmy HR (1969) *Microsurgery applied to neurosurgery*. Georg Thieme, Stuttgart
- [116] Yaşargil MG (1984–1996) *Microneurosurgery in 6 volumes*. Georg Thieme, Stuttgart
- [117] Yaşargil MG, Teddy PS, Roth P (1985) Selective amygdalo-hippocampectomy. Operative anatomy and surgical technique. *Adv Tech Stand Neurosurg* 12: 93-123

- [118] Yaşargil MG (1999) A legacy of microneurosurgery: memoirs, lessons, and axioms. *Neurosurgery* 45: 1025-1092
- [119] Yaşargil MG (2000) The history of optical instruments and microneurosurgery. In: Barrow DL, Kondziolka D, Laws ER, Traynelis VC (eds) *Fifty years of neurosurgery*. Lippincott, Williams & Wilkins, Philadelphia, pp 105-142
- [120] Yaşargil MG, Krisht AF, Türe U, Al-Mefty O, Yaşargil DCH (2002) Microsurgery of insular gliomas, Part I: Surgical anatomy of the Sylvian cistern. *Contemp Neurosurg* 24: 1-8
- [121] Yaşargil MG, Türe U, Yaşargil DCH (2004) Impact of temporal lobe surgery. *J Neurosurg* 101: 725-738
- [122] Yaşargil MG, Türe U, Yaşargil DCH (2005) Surgical anatomy of supratentorial midline lesions. *Neurosurg Focus* 18(6): E1
- [123] Yonekawa Y, et al. (1999) Laboratory training in microsurgical technique and microvascular anastomosis. *Oper Tech Neurosurg* 2: 149-158
- [124] Zhang M, An PC (2000) Lilliequist's membrane is a fold of the arachnoid mater: study using sheet plastination and scanning electron microscopy. *Neurosurgery* 47: 902-908; discussion 908-909
- [125] Zollner F (1949) *Mikroskopstativ fuer Operation*. *Laryngol Rhinol Otol* 28L209



### **Mahmut Gazi Yaşargil**

In 1994, Professor Yaşargil accepted an appointment as professor of neurosurgery at the University of Arkansas for Medical Sciences in Little Rock, where he is still active in microneurosurgical practice, research, and teaching. Professor M. Gazi Yaşargil was born on July 6, 1925, in Lice, Turkey. In 1953, he began his neurosurgical residency at the University of Zürich, under Professor Hugo Kraysenbühl. From 1965 to 1967 he was a research-fellow in microvascular surgery at the University of Vermont, Burlington, under Professor R.M. Peardon Donaghy, where he learned microsurgical techniques, which were then applied to the cerebral arteries in the animal laboratory. After returning to Zürich, he performed the first cerebral vascular bypass surgery using the surgical microscope on October 30, 1967. Since then, he shaped microneurosurgery with innovative instrumentation, such as the floating microscope, microsurgical instruments, and ergonomic aneurysm clips and appliers. The emergence of microneurosurgery and the consequences hereof for his patients have been summarized in his 6-volume monograph.

**Contact:** M. Gazi Yaşargil, Department of Neurosurgery, University of Arkansas for Medical Sciences, 4301 W. Markham Street #507, 72205 Little Rock, AR, USA  
E-mail: williamsronaldae@uams.edu

---

# ENDOSCOPY: PRINCIPLES AND TECHNIQUES

E. DE DIVITIIS

## INTRODUCTION

Neurosurgery, compared to other medical and surgical specialties, is a relatively recent one. Indeed, it is considered as one of the most rapidly evolving and flourishing. During the second half of the last century and the past few years, this field has made a well noticed advance in evolving ideas and surgical tools in the attempt to attain the lowest rates of morbidity and mortality in a safe, feasible, limited, yet practical way. Among those tools has been the endoscope. It first emerged as a diagnostic tool, shifted with time to become a surgical one, passed through an era of struggle to survive among other practical tools, and lastly has strongly re-emerged and gained popularity as the sole visualizing tool in more neurosurgical approaches.

Aiming to clarify the evolving role of the endoscope in neurosurgery, the historical background of neuroendoscopy, its past and recent applications in the field of brain surgery, the milestones of its technological advancements will be reviewed.

Minimal invasiveness is a surgical approach modality designed to minimize trauma, maximize outcomes and enable patients to quickly return to their normal life.

The goal for using endoscopes for surgery is to reduce the tissue trauma when compared with traditional “open surgery”. In addition, the use of side-viewing capability and better lighting produces much better viewing inside the operative field than traditional surgery. However, minimally invasive endoscopic surgery is certainly not a minor surgery. As a matter of fact, despite several advantages for the patient, such as reduced blood loss, shorter hospital stay, decreased postoperative pain and quicker return to normal activities, some complications must be taken into account. The procedure is not completely risk-free and can produce complications ranging from infection to death. Risks and complications include the following: bleeding, infection, blood vessel injury, CSF leak. Some disadvantages for the surgeon also exist: difficult handling of the instruments, restricted maneuverability, difficult eye-hand coordination, learning curve. Despite these problems, it is certainly

---

*Keywords:* neuro-endoscopy, approaches, techniques, skull base

true that the advent of the endoscope has produced ripples of enthusiasm and progress in the field of modern neurosurgery.

## **HISTORICAL BACKGROUND**

The development of endoscopic neurosurgical applications can be traced back to the XIXth century and continues in the present awaiting the next coming revolution that will change the view to this era to be an intermediate one, while shifting to the really new era from the perspective of that revolution. As a matter of fact, Philipp Bozzini is considered the spiritual father of the endoscope [10]. He invented the first simple model, the “Lichtleiter”, an eye piece and a mirror reflecting a candle light, which he demonstrated in the year 1806. Limited illumination and visualization together with painful application, yet it is always considered a breakthrough. More than 70 years later, around 1877, Max Nitze revolutionized the field [15], using an optical system consisting of a train of lenses and a glowing platinum wire as a source of illumination [14]. He has been also the first to consider the documentation ability of the endoscope via photography and the first to apply cutting loops during endoscopic procedures, changing the view from diagnosis to intervention [15]. It has not been until the year 1910 for the endoscope to be applied in a neurosurgical procedure by Lespinasse [12], who operated upon two hydrocephalic infants applying a cystoscope for endoscopic choroid plectomy [18]. Yet, Dandy is considered the father of neuroendoscopy. Concerning endoscopic third ventriculostomy, Mixer has been the first to report such a procedure in 1923 [18]. In 1935, Scarff performed the procedure with novel instruments: he used an endoscope with irrigation system, advanceable cauterization and ventriculostomy tips. Ventricular endoscopy started to gain land among few neurosurgeons who started to realize its benefits, considering the available facilities at that time.

It seems that the field of endoscopy and particularly that of neuroendoscopy entered then a stage of hibernation for more than two decades for many reasons, among them: inadequate illumination, poor image quality, advent of ventricular CSF shunting, last but not least, the birth of microneurosurgery in the early sixties of the last century offering more practical solutions for the endoscopic drawbacks, together with feasibility of approaching brain and skull base lesions through different novel trajectories.

Hopkins and Storz are credited for the renaissance of endoscopy [5]. Many technical advances lead to their innovative endoscope, “a Hopkins rod lens system with an external light source transmitted through incoherent glass fibers attached to the telescope”, that has been shown for the first time in 1967. It is worth clarifying that Hopkins invented his rod lens system in 1959. Compared to the previous train of lenses system of Nitze, this system offered greater light transmission, a wider view, better image quality, and a smaller diameter for the system [5]. Two years earlier to Hopkins’s invention,

Hirschowitz, in 1957, developed the fiberscope. Karl Storz inspired these two main ideas. We have come finally to the modern form of the endoscope that has been applied since then with little if any new advances.

Technical advances in image capturing and processing also took part in the field of endoscopy. Among them are the CCDs (charge-coupled devices), which have been incorporated in the endoscopic systems, resulting in improved image quality and decrease in size.

The modern era of neuroendoscopy can be identified with the role of T. Fukushima, who in 1973 reported the use of a ventriculofiberscope as a new technique for endoscopic diagnosis and operation [11]. He was followed in 1974 by Olinger and Ohlhaber, who used an eighteen-gauge microscopic-telescopic needle endoscope. Yet, it has not been until 1977, when Apuzzo et al. started to apply the concept of adjunctive endoscopy during the conventional microneurosurgical procedures. They reported the use of a side-viewing endoscope to control the angles hidden from the prospect of a microsurgical approach [1]. Again, due to the inferior image quality of the endoscopes compared to that of the surgical microscopes, this technique was not very popular. In the neurosurgical historic perspective, Apuzzo et al. [1] are credited for the concept of adjunctive endoscopy. During the eighties, neurosurgeons started to explore the extra capabilities of ventriculoscopy, both in diagnosis and interventions.

## ENDOSCOPES

The endoscope offers three main advantages: (i) improvement of the illumination because of a light source that brings the light in the surgical field; (ii) better definition of the anatomical details because of the use of high-definition lenses and the closer view of the scope that allows an augmented definition of the details at the tumor–tissue interface; (iii) marked increase of the angles of visualization with the use of angled lenses, allowing to see in areas otherwise hidden to the microsurgical vision and giving a different perception of the anatomy. Thus, the endoscope can increase the precision of the surgery and permit the surgeon to differentiate different tissues, so that a selective removal of the lesion can be achieved. However, one of the current limitations of the modern endoscopes is that they provide a bidimensional image. The lack of stereoscopy can be overcome with training, though, with the multiangled vision, with the fine understanding of all the lights and shadows of the image, with fixing the multiple landmarks during the operation and, in one word, with the knowledge of the surgical anatomy that the endoscope has pushed again.

Currently, different types of endoscopes exist and are classified either as fiber-optic endoscopes (fiberscopes) or rod lens endoscopes. The endoscopes specifically designed for neuroendoscopy can be classified into four types: (i) rigid fiberscopes, (ii) rigid rod lens endoscopes, (iii) flexible fiberscopes,





**Fig. 1.** Example of flexible endoscope

(iv) steerable fiberscopes. These different endoscopes have different diameters, lengths, optical quality, number and diameter of working channels, all of which vary with size. The choice between them should be made on the basis of the surgical indication and personal preference of the surgeon.

## 1. FLEXIBLE (STEERABLE) ENDOSCOPES

The properties of optic fibers permit the steerable fiberscopes to orient the tip up and downwards (Fig. 1) [4]. The angle of bending varies in the different models. Modifying the orientation of the optical fibers, the surgeon can orientate the instruments to reach all of the structures to visualize. This system makes looking and working around corners. The rigid part of the scope is attached to a mechanical or pneumatic holder. The diameter of the scope is usually between 2.3 and 4.6 mm, depending upon the number of optic fibers. The number of operative channels varies from one to three; the best device is the three-channel endoscope (one working channel for introduction of instruments and two independent channels for irrigation and aspiration). The diameter of the working channel is usually approximately 1.0 mm, allowing the introduction of 3-French (1 mm) different flexible miniaturized instruments, such as scissors, grasping and biopsy forceps, monopolar electrodes and Fogarty balloon. A dedicated peel-away sheath is essential to introduce the endoscope to reach the target.

## 2. RIGID ROD LENS SCOPES

Rod lens endoscopes consist of three main parts: a mechanical shaft, glass fiber bundles for light illumination, and optics (objective, eyepiece, relay system).

The angle of view of rod lens endoscopes ranges from  $0^\circ$  to  $120^\circ$ , according to the objective, but objectives with an angle greater than  $30^\circ$ – $45^\circ$  are not



**Fig. 2.** Example of rigid rod-lens endoscope, zero-degree and angled lenses

very useful in neuroendoscopy. The  $0^\circ$  scope provides a frontal view of the surgical field and minimizes the risk of disorientation [17] and is generally used during the majority of the operation. The angled objectives offer additional advantages, allowing to look around the corners.

The rod lens rigid endoscope is commonly used through a sheath, connected to a cleaning-irrigation system which permits cleaning and defogging of the distal lens, thus avoiding repeated entrances and exits from the surgical field. Preferably, the scopes used are without any working channel (diagnostic endoscopes) and the other instruments are inserted sliding alongside the sheath and using the latter as a guide for the correct direction. The diameter of rod lens endoscope varies between 1.9 and 10 mm, but for endoneurosurgery usually endoscopes with a diameter of 2.7–4 mm are used. It is not advisable to use smaller endoscopes because the smaller the diameter of the lens, the less light it can transport. It has been estimated that for each 10% of increase of diameter there is a 46% percent increase in light transmitted, but endoscopes larger than 2.7 mm can be too bulky and requiring larger approaches.

### 3. ENDOSCOPIC INSTRUMENTATION

#### 3.1 Video camera and monitor

In order to properly maneuver the instruments under fine control, the endoscope is connected to a dedicated video camera and the endoscopic images are projected onto a monitor placed in front of the surgeon. Additional monitors can be placed in varying locations in the operating room, as well as outside in the hallways or adjacent rooms, to permit other members of the team to watch the surgery.

Several types of endoscopic video cameras are available, the most common of which utilize a 3-CCD sensor which provides a better color separation, more brilliant colors and a sharper image with higher contrast than the 1-CCD cameras, which process all three fundamental colors in one chip. Most modern endoscopic cameras are analog.

A further improvement of the resolution of both the video cameras and the monitors is represented by the high-definition (HD) technology, which

is ready for the future 3-D endoscopes. The continuous improvements in endoscopic image quality offer tremendous visualization of the operative field, of the lesion and its relationships with the surrounding anatomical structures. A full HD 16:9 flat monitor (1080p, 60 Hz) needs to be coupled with the HD camera in order to visualize the HD images.

### 3.2 Light source

The endoscope transmits the cold light which arises from a source inside the surgical field through a connecting cable made of glass fibers. Currently, in endoscopic surgery xenon light sources are used. They have spectral characteristics similar to those of the sunlight, with a color temperature of approximately 6000 K, which is “whiter” than the classic halogen light (3400 K). The power of the unit is commonly 300 W. The flexible connecting cable is made of a bundle of glass fibers that brings the light to the endoscope, virtually without dispersion of visible light [14]. Furthermore, the heat (composed by infrared light) is poorly transmitted by the glass fibers, thus reducing the risk of burning the tissues.

### 3.3 Surgical instruments

For the endoscopic approach, the instruments need to be inserted along the same axis as the endoscope and need to maintain the same position with respect to the endoscope for their entire length. For this reason they need to be straight and not bayoneted. This is mainly due to two peculiarities of the endoscopic approach: (i) the visibility of only that which is beyond the distal lens of the scope and (ii) the panoramic and multian-gled view afforded by the endoscope. With regard to the first point, while the microscope produces magnification from a distant lens, and light is transmitted from the lamp of the microscope to the surgical field, so that the surgeon can follow the entrance of the instruments from the outside, the vision provided by the endoscope is maintained completely inside the surgical field. The instruments are inserted blind in the surgical field with the concomitant risk to injure the anatomical structures until the tip of the instrument becomes visible once it has passed beyond the distal lens, unless the endoscope is removed and inserted every time a different instrument is used.

Since the introduction of the endoscopic approaches, new instruments have been designed that meet the following criteria [2, 3, 14]:

- move easily and safely in a limited surgical corridor;
- be well-balanced and ergonomic for safe handling, while avoiding any conflict between the surgeon’s hands, the endoscope and other instruments that may be present in the same corridor;
- allow the surgeon to work in every visible zone of the surgical field provided by the endoscope.

### 3.4 Bleeding control

One of the most difficult and common problems of endoscopic surgery is the control of bleeding.

Monopolar coagulation is usually easy to obtain. However, bipolar coagulation is preferable, either alone or in association with hemostatic agents. Consequently, different dedicated bipolar forceps have been designed, with various diameters and lengths, which have proven to be quite effective in bleeding control.

Recently, the radiofrequency technology for either monopolar and bipolar coagulation has been introduced. Radiofrequency instruments have two main advantages over the electric ones: the spatial energy dispersion with radiofrequency is minimal, with concomitant minimal risk of injury to the surrounding anatomical structures; radiofrequency bipolar forceps do not need to be used with irrigation or to be cleaned every time.

### 3.5 Video documentation

Documentation and storage of intraoperative images and movie clips is of increasing importance for education and documentation. Although video recording is not mandatory, having the possibility to document either still images or video clips of the surgical procedure is quite important for a series of reasons. It is possible to review the operation and, if any mistakes are made, learn and know how to avoid them in future; to obtain pictures for publication or produce video clips to teach residents, course attendees, etc.; to store the material in an electronic library; to use the material for legal purposes.

### 3.6 Other instruments

Modern neurosurgery, no matter if with microsurgical and/or endoscopic technique, uses special instruments and devices that are quite helpful even if not absolutely needed [4].

Image-guided neuronavigation systems are very useful for intraoperative identification of the anatomic structures involved in the procedure. This is specially true in case of distorted anatomy due to a particular growth pattern of the lesion which causes the classic landmarks being not easily identifiable. In such cases, neuronavigation can help to maintain the surgeon's orientation.

Prior to performing sharp dissections or incisions and whenever the surgeon thinks it is appropriate (especially while working very close to vascular structures), it is of utmost importance to use the microDoppler probe to insonate the major arteries. The use of this device, frequently used in endoscopic skull base surgery, should be recommended every time a sharp dissection is made, to minimize the risk of injury to major arteries.

### 3.7 Preoperative planning

Preoperative radiological investigations are the same as for the microsurgical approaches. They include magnetic resonance imaging (MRI), computed tomography (CT), angiography, etc. These exams provide the neurosurgeon information about the peculiar anatomical conditions concerning the tumor itself and the bone and anatomical structures involved in the approach.

Such studies are important for the planning of the approach and the removal strategy and to be used with the image-guided surgery systems (namely, the neuronavigator).

## ENDOSCOPIC TECHNIQUES AND INDICATIONS

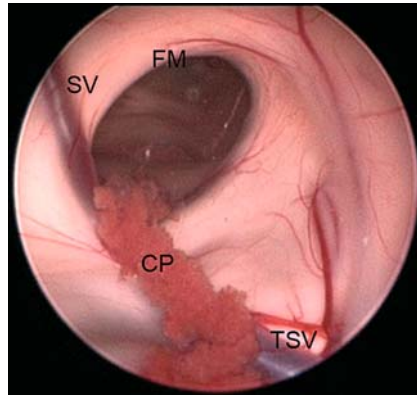
Neuroendoscopy can be used to treat a variety of pathologies [3, 4]. The more frequent indications are obstructive hydrocephalus, intra-paraventricular lesions, intraneural cysts, multiloculated hydrocephalus marsupialization, colloid cysts, pituitary adenomas and skull base approach.

In most of the neurosurgical cases treated with neuroendoscopic technique, a single drill hole is need for the approach. The hole site and the path that the neuroendoscope follows through the cerebral parenchyma to reach the target vary in relation to the type of surgery and the location of the lesion. The preoperative magnetic resonance multiplanar images permit to set the exact position of the drill hole and the more convenient path.

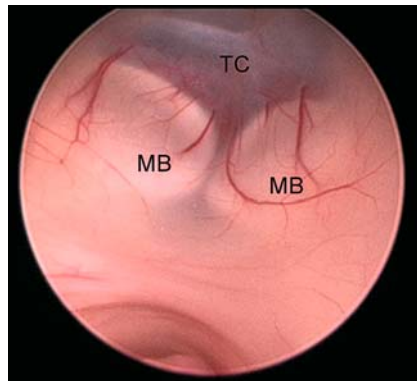
### 1. ENDOSCOPIC THIRD VENTRICULOSTOMY

Endoscopic third ventriculostomy is the most used procedure in neuroendoscopy [3, 4, 13]. By this technique, a communication between the anterior part of the third ventricle and the interpeduncular cistern is accomplished. Generally, the procedure is performed under general anesthesia; the endoscope is entered through a burr hole placed in front of the coronal suture, 2 cm away from the midline. The foramen of Monro is identified with its anatomical landmarks (choroid plexus, fornix, venous corner) (Fig. 3). Once the third ventricle is entered, through the foramen of Monro, the anatomical landmarks of the floor are recognizable: mammillary bodies, infundibular recess and the tuber cinereum (Fig. 4). The floor is perforated between the infundibular recess in front and the mammillary bodies behind. Then, the perforation is dilated by a Fogarty catheter. The interpeduncular cistern is entered with the endoscope to ascertain the existence of a good communication and the tip of the basilar artery comes under vision (Fig. 5). In case of some bleeding, bipolar coagulation, irrigation and balloon dilatation can be used.

This technique is the method of choice in treating occlusive hydrocephalus due do stenosis of the aqueduct (Fig. 6). A prerequisite of a successful endoscopic third ventriculostomy is the patency of the distal liquoral pathways.



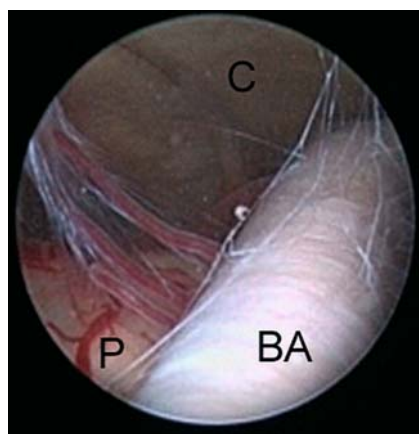
**Fig. 3.** Endoscopic view of the right foramen of Monro. The choroid plexus and the venous corner (septal vein and thalamo-striate vein) are recognizable. *FM* Foramen of Monro; *CP* choroid plexus; *SV* septal vein; *TSV* thalamo-striate vein



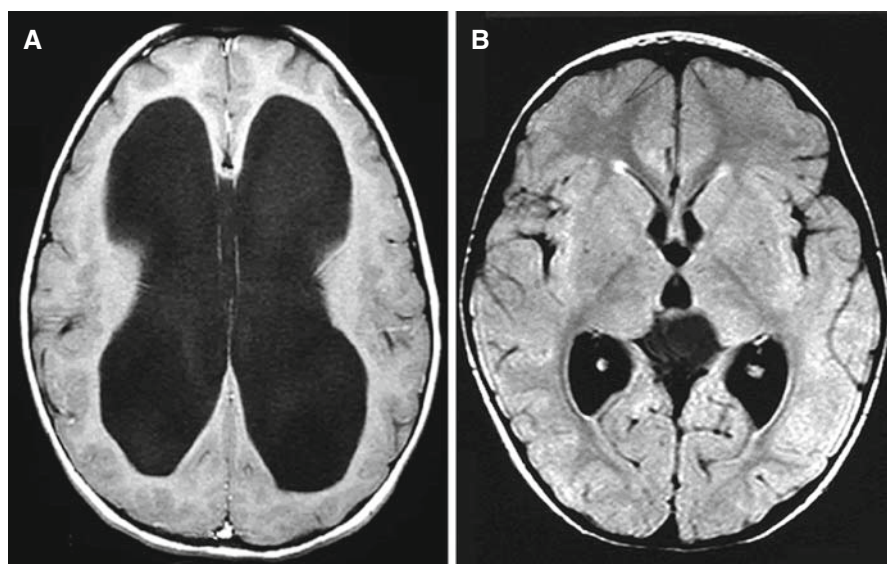
**Fig. 4.** Endoscopic view of floor of the third ventricle seen as soon as the foramen of Monro is entered. The landmarks formed by the mammillary bodies (*MB*) and the tuber cinereum (*TC*) are recognizable

## 2. COLLOID CYSTS

The choice of endoscopy as treatment modality depends on the adequacy of the surgeon experience and skill and the adequacy of the endoscopic equipment. The surgical technique is briefly reported [3, 4, 9]. The endoscope is inserted in the lateral ventricle of the non-dominant hemisphere through a burr hole in front of the coronal suture. The colloid cyst is usually identified filling the foramen of Monro (Fig. 7); the cyst wall is coagulated, punctured and opened as widely as possible in order to aspirate the colloid material. The capsule of the cyst is elevated from the fornix, coagulated and removed.



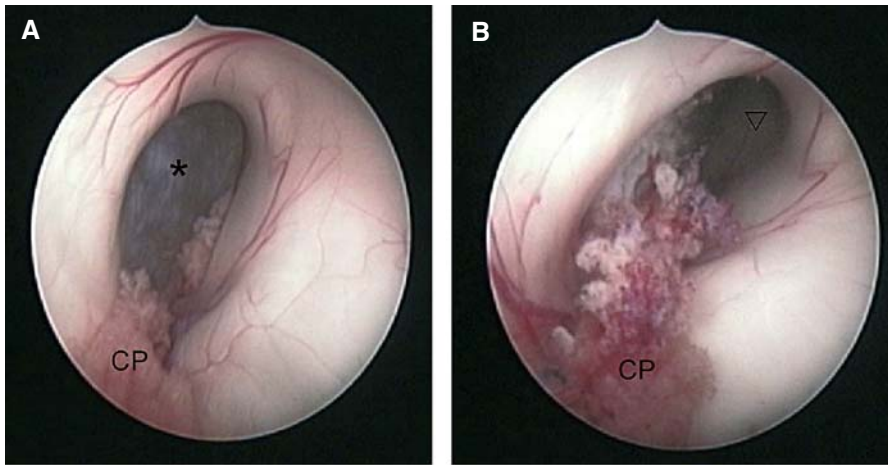
**Fig. 5.** Endoscopic view of the interpeduncular cistern after the endoscopic third ventriculostomy has been performed. The basilar artery (*BA*) and the anterior surface of the pons (*P*), together with the clivus (*C*) are recognizable



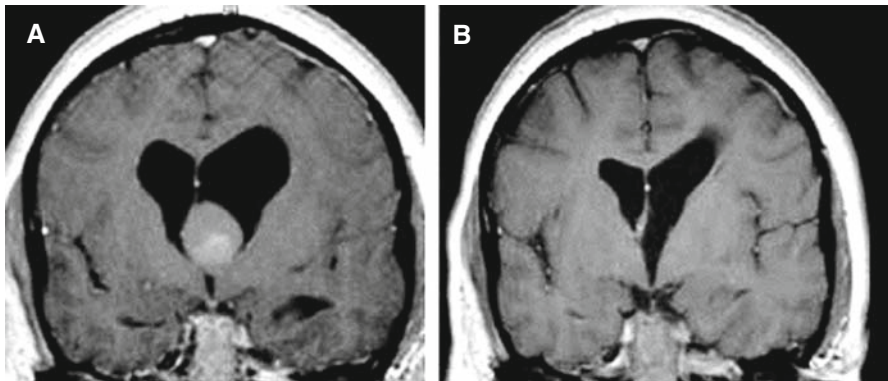
**Fig. 6.** Pre-operative (**A**) and post-operative (**B**) axial MRI of a case of a supratentorial hydrocephalus treated by endoscopic third ventriculostomy

In case it is strictly adherent to the surrounding vital structures, the remnant must be left in place to avoid complications.

The treatment is successful in 60–90% of cases treated by endoscopy (Fig. 8). The unsuccessful cases can be retreated by neuroendoscopy or by a transcranial approach.



**Fig. 7.** **A** Endoscopic view of a colloid cyst of the third ventricle protruding through the foramen of Monro. **B** The same case after the cyst emptying and capsule resection. *Asterisk*: cyst capsule; *arrowhead*: third ventricle seen through the foramen of Monro after the removal of the cyst

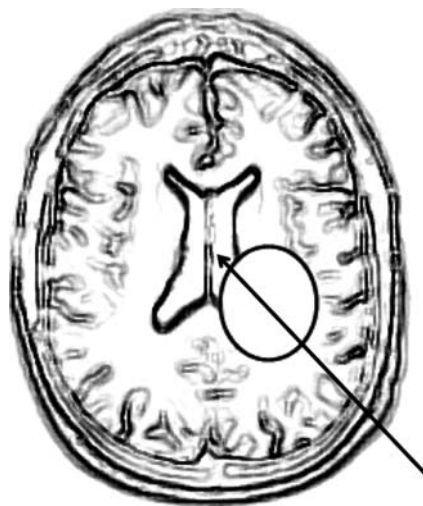


**Fig. 8.** Pre-operative (**A**) and post-operative (**B**) axial MRI of a case of a colloid cyst of the III ventricle

### 3. ARACHNOID CYSTS

Endoscopy is one of the multiple surgical strategies in the management of symptomatic arachnoid cysts. It aims for neuroendoscopic reduction of the cyst by establishing a communication between the cyst and the CSF pathway (Fig. 9). To avoid the closure of the stomy following the procedure, a large opening and the removal of fragments of the cyst wall as widely as possible are absolutely required. In order to improve the results, particularly when the cyst is associated with hydrocephalus, an association between fenestration





**Fig. 9.** Schematic drawing of the technique of fenestration of a paraventricular arachnoid cyst

of the cyst into the ventricle and opening of the ventricle into the cistern has been proposed.

Control of the cyst size and clinical symptoms are usually obtained, using this procedure, in 71–81% of cases [3, 4].

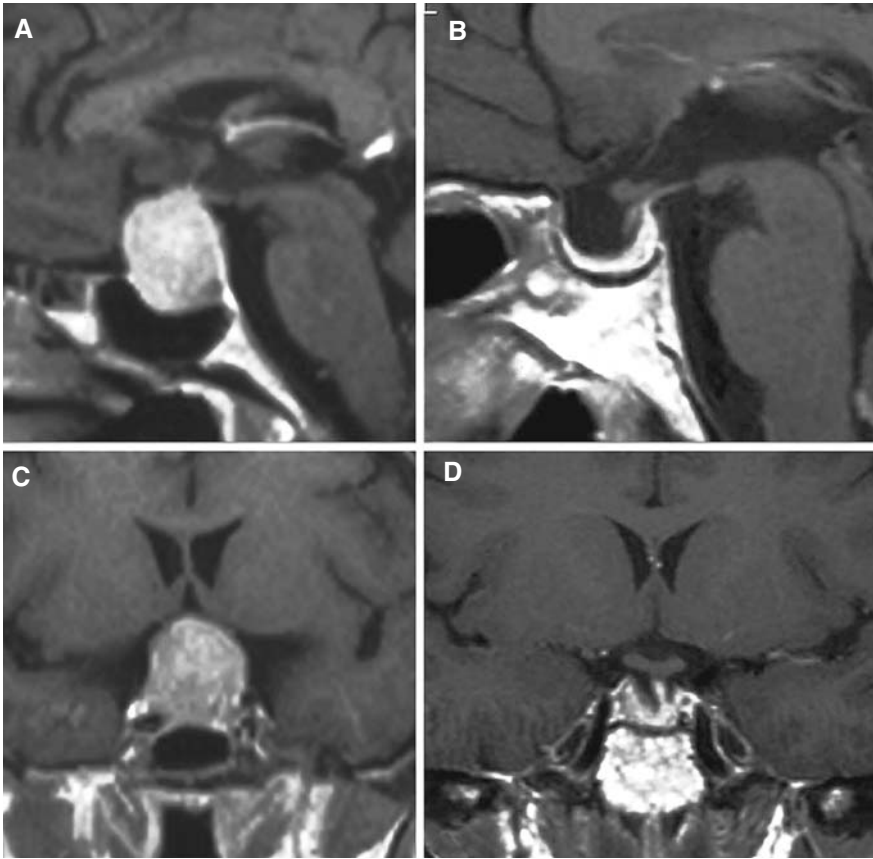
#### 4. ENDOSCOPIC ENDONASAL TECHNIQUE

The endoscopic endonasal approach to the sellar region is a recent evolution of the conventional transsphenoidal technique performed with the operating microscope. This method can be designated as “pure” pituitary endoscopy and not only as a complement to the microscopic intervention – the term “pure” being applied to a surgical procedure in which the endoscope is the only optical device being used.

The endoscopic endonasal transsphenoidal approach to the sella is performed via an anterior sphenoidotomy, through the enlargement of the natural sphenoid ostium, with a rigid diagnostic endoscope, and without the use of a transsphenoidal retractor. Three main steps make up this surgical procedure: nasal, sphenoidal and sellar [7].

During the nasal step the endoscope (18 cm in length, 4 mm in diameter) is inserted in the chosen nostril up to the middle turbinate. The endoscope is then advanced inside the nasal cavity up to the choana and along its roof, in the sphenoethmoid recess, until the natural sphenoid ostium is reached.

The sphenoid step starts with the coagulation of the sphenoethmoid recess and the detachment of the nasal septum from the sphenoid prow using a

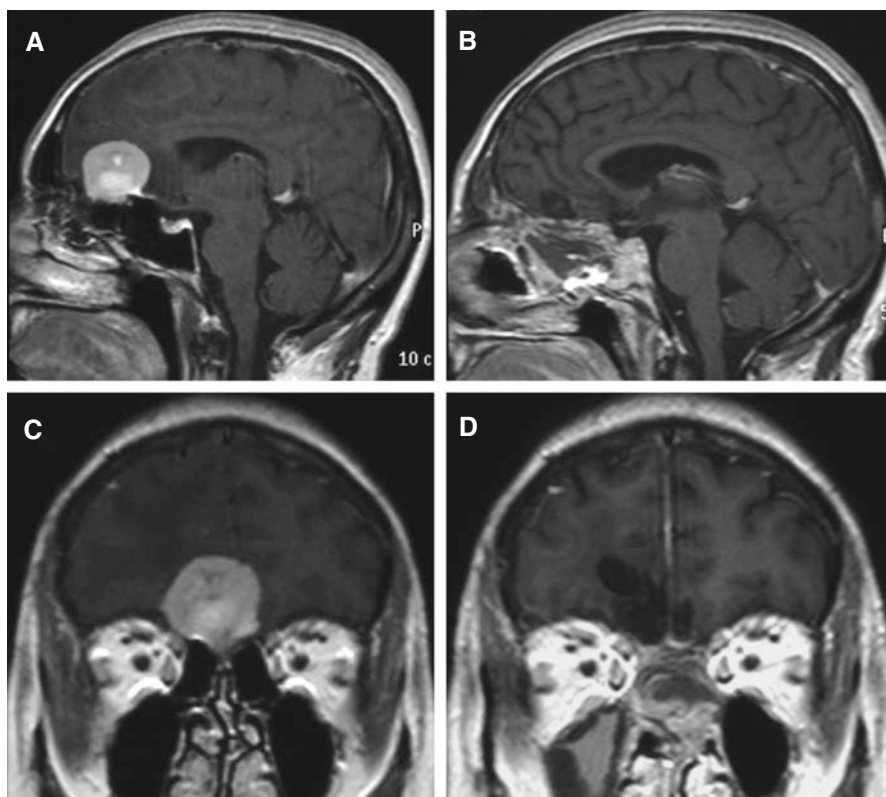


**Fig. 10.** Pre-operative (A, C) and post-operative (B, D) contrast-enhanced sellar MRI of a case of intra-suprasellar pituitary macroadenoma

microdrill. Once the anterior wall of the sphenoid sinus is exposed on both sides, it is removed all around with different bone punches.

During the sellar step, the endoscope can be held by a second surgeon in order to free both the surgeon's hands. Alternatively a longer scope (30 cm in length, 4 mm in diameter) can be used and fixed to an autostatic holder. The sellar floor is opened and the dura incised with a telescopic blade. The sellar lesion is then removed with different curettes depending on the size and position of the pituitary tumor (Fig. 10). After lesion removal the sellar floor is repaired, when necessary, with different autologous or heterologous or synthetic materials, according to the common guidelines.

The main advantages of the endoscopic procedure arise from the absence of the nasal speculum and from the use of the endoscope that discloses its bet-



**Fig. 11.** Pre-operative (A, C) and post-operative (B, D) contrast-enhanced sellar MRI of a case of suprasellar (tuberculum sellae) meningioma

ter properties, permitting a wider vision of the surgical field, with a close-up “look” inside the anatomy. The whole procedure is less traumatic. No post-operative nasal packing is necessary thus improving significantly the patient’s compliance [6].

With this standard transsphenoidal approach, however, it is difficult to provide complete visualization of the extrasellar lesions. To overcome this limitation, modifications of the approach have been developed for the removal of such lesions. The so-called extended transsphenoidal approach is a modification of the standard one, allowing for additional bone resection of cranial base to reach several areas from the “crista galli” to the craniocervical junction. This approach has become an alternative to transcranial surgery for several skull base tumors, such as suprasellar meningiomas (Fig. 11), cranio-pharyngiomas, clival chordomas, etc. [8].

## ADVANTAGES AND RESTRICTIONS

The endoscope in neurosurgery is increasingly used as a minimally invasive treatment of a wide spectrum of intracranial pathologies [3, 4]. That reflects the current tendency of modern neurosurgery to aim towards minimalism, allowing for a less invasive treatment of neurosurgical pathologies. Endoscopic procedures encourage excellent compliance on the part of the patients, particularly those already operated on by a transcranial approach, who can compare the two experiences and appreciate the reduced postoperative discomfort. Often, through a single burr hole it is possible to manage several lesions through anatomical cavities. In such a way, obstructive hydrocephalus, intracranial cysts and some small intraventricular tumors can be easily removed. Concerning the use of the endoscope in transsphenoidal surgery, the wider vision offered by this device, not only of the sellar cavity but of the whole sellar and parasellar areas (clivus, planum, sphenoidale) and also around the sphenoid sinus (pterygo-maxillary fossa and cervico-medullary junction) caused an enlargement of the indications and of the extension of this approach, thus demanding new and more effective and sophisticated instruments to safer manage new situations [8].

Beside the many advantages provided by the use of the endoscope in neurosurgery, there are several limitations which should be not underestimated: (i) there is a steep learning curve before becoming confident with the peculiar neuroendoscopic anatomy; (ii) the initially reduced ability makes operative times longer (several hours during the first attempts); (iii) the endoscope provides bidimensional, flat images that are inferior to the three-dimensional images provided by the microscope; (iv) the endoscope offers vision on the video-monitor without the sense of deepness that can be gained with the surgeon's experience, executing in-and-out movements; (v) dedicated instruments, such as microforceps, microscissors, mono- and bipolar coagulation, ad hoc designed are absolutely essential; (vi) the bleeding control, either venous and arterial, may be difficult to obtain.

## HOW TO AVOID COMPLICATIONS

Reducing the complication rate to 0% is a goal that is most of the times quite difficult to obtain. More realistic are the efforts towards minimizing the complications, specially the major ones, to an acceptable rate. In order to accomplish such task, several tips can be used and several tricks can be avoided.

1. The first important recommendation is to dedicate time and efforts to perform anatomical dissections and attend hands-on workshops to become confident with the surgical anatomy, fix the landmarks, learn how to handle the instruments and the endoscope, etc.

2. Play video games. In fact, it has been demonstrated that playing video games improves the eye–hand coordination, which is basic in endoscopic surgery.
3. Learn from the others' experience and try to avoid the complications already described.
4. Avoid quick movements in proximity to the surgical target.
5. The correct function of each component must be always checked before surgery.
6. Two complete sets of each endoscopic component should be available for each operation.
7. Work bimanually during the crucial steps of the endonasal procedure.

## CONCLUSIONS

It is certainly true that the advent of endoscopy has produced ripples of enthusiasm and progress similar to those seen when a sizable stone is thrown into a relatively quiescent pond [6]. It is imperative that young neurosurgeons and residents become familiar and comfortable with the endoscopic techniques and hopefully they can contribute to the evolution and development of these surgical methods which are currently on their way. Despite the many advantages which have been clearly outlined previously, the endoscope has also many features that are currently suboptimal because of the cumbersome nature of the endoscopes themselves and of the lack of intelligently designed appropriately miniaturized instruments to complete the use of this wonderful viewing tool.

## References

- [1] Apuzzo ML, Heifetz MD, Weiss MH, Kurze T (1977) Neurosurgical endoscopy using the side-viewing telescope. *J Neurosurg* 46: 398-400
- [2] Cappabianca P, Alfieri A, Thermes S, Buonamassa S, de Divitiis E (1999) Instruments for endoscopic endonasal transsphenoidal surgery. *Neurosurgery* 45: 392-395; discussion 395-396
- [3] Cappabianca P, Cinalli G, Gangemi M, et al. (2008) Application of neuroendoscopy to intraventricular lesions. *Neurosurgery* 62(Suppl 2): SHC575-SHC598
- [4] Cinalli G, Cappabianca P, de Falco R, Spennato P, Cianciulli E, Cavallo LM, Esposito F, Ruggiero C, Maggi G, de Divitiis E (2005) Current state and future development of intracranial neuroendoscopic surgery. *Expert Rev Med Devices* 2: 351-373
- [5] Cockett WS, Cockett AT (1998) The Hopkins rod-lens system and the Storz cold light illumination system. *Urology* 51: 1-2

- [6] de Divitiis E (2006) Endoscopic transsphenoidal surgery: stone-in-the-pond effect. *Neurosurgery* 59: 512-520
- [7] de Divitiis E, Cappabianca P, Cavallo LM (2003) Endoscopic endonasal transsphenoidal approach to the sellar region. In: de Divitiis E, Cappabianca P (eds) *Endoscopic endonasal transsphenoidal surgery*. Springer, Wien New York, pp 91-130
- [8] de Divitiis E, Cavallo LM, Cappabianca P, Esposito F (2007) Extended endoscopic endonasal transsphenoidal approach for the removal of suprasellar tumors: Part 2. *Neurosurgery* 60: 46-58; discussion 58-49
- [9] Decq P, Le Guerinel C, Brugieres P, Djindjian M, Silva D, Keravel Y, Melon E, Nguyen JP (1998) Endoscopic management of colloid cysts. *Neurosurgery* 42: 1288-1294; discussion 1294-1286
- [10] Engel RM (2003) Philipp Bozzini – the father of endoscopy. *J Endourol* 17: 859-862
- [11] Fukushima T, Ishijima B, Hirakawa K, Nakamura N, Sano K (1973) Ventriculofiberscope: a new technique for endoscopic diagnosis and operation. Technical note. *J Neurosurg* 38: 251-256
- [12] Grant JA (1996) Victor Darwin Lespinasse: a biographical sketch. *Neurosurgery* 39: 1232-1233
- [13] Hellwig D, Grotenhuis JA, Tirakotai W, Riegel T, Schulte DM, Bauer BL, Bertalanffy H (2005) Endoscopic third ventriculostomy for obstructive hydrocephalus. *Neurosurg Rev* 28: 1-34; discussion 35-38
- [14] Leonhard M, Cappabianca P, de Divitiis E (2003) The endoscope, endoscopic equipment and instrumentation. In: de Divitiis E, Cappabianca P (eds) *Endoscopic endonasal transsphenoidal surgery*. Springer, Wien New York, pp 9-19
- [15] Mouton WG, Bessell JR, Maddern GJ (1998) Looking back to the advent of modern endoscopy: 150th birthday of Maximilian Nitze. *World J Surg* 22: 1256-1258
- [16] Powell MP, Torrens MJ, Thomson JL, Horgan JG (1983) Isodense colloid cysts of the third ventricle: a diagnostic and therapeutic problem resolved by ventriculostomy. *Neurosurgery* 13: 234-237
- [17] Siomin V, Constantini S (2004) Basic principles and equipment in neuroendoscopy. *Neurosurg Clin N Am* 15: 19-31
- [18] Walker ML (2001) History of ventriculostomy. *Neurosurg Clin N Am* 12: 101-110, viii



### **Enrico de Divitiis**

Enrico de Divitiis is Professor and Chairman of Neurosurgery at the Università degli Studi di Napoli Federico II of Naples. He is chairman of the Italian Board of Neurosurgery Professors.

He is former president of the Italian Society of Neurosurgery (SINch) and member of many international scientific societies (American Association of Neurological Surgeons – AANS, Congress of Neurological Surgeons – CNS, Société de Neurochirurgie de Langue Française – SNLF, European Society for Stereotactic and Functional Neurosurgery – ESSFN). He is member of the editorial board of Neurosurgery, member of the advisory board of Operative Neurosurgery and of Journal of Neurosurgical Sciences and president of Italian College of University Neurosurgery Professors. He was organizer of twenty national and international congresses. He participated with personal communications in more than 420 national and international congresses, and has been invited speaker more than 200 times. He is author of more than 300 publications of neurosurgical interest, most of them reported in the Index Medicus/Current Contents/Journal of Citation Reports, and of 18 books or book chapters.

**Contact:** Enrico de Divitiis, Department of Neurological Sciences, Division of Neurosurgery, Università degli Studi di Napoli Federico II, Via Sergio Pansini 5, 80131 Napoli, Italy  
E-mail: dediviti@unina.it

---

# IMAGE-GUIDED RADIOSURGERY USING THE GAMMA KNIFE

L. D. LUNSFORD

## INTRODUCTION

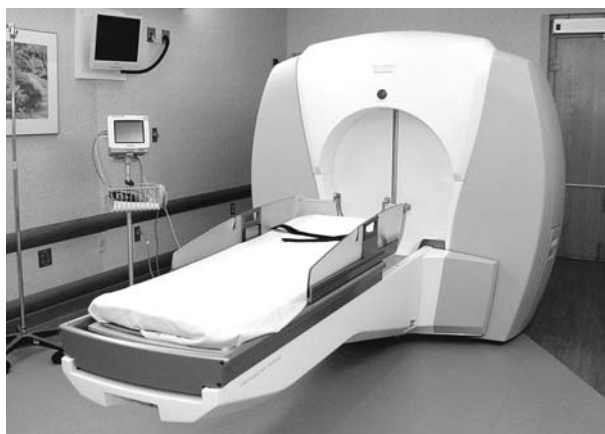Image guided brain surgery became a reality in the mid-1970s after the introduction of the first methods to obtain axial imaging using computed tomography (CT) [9]. The recognition of cranial disease much earlier in its clinical course prompted the need for concomitant minimally invasive technologies to both diagnose and to treat the newly recognized brain tumors and vascular malformations. Subsequently, the development of magnetic resonance imaging (MRI) spurred further interest in accurate, safe, and effective guided brain surgery. Stereotactic radiosurgery (SRS) was the brain child of the pioneering brain surgeons, Lars Leksell and Erik-Olof Backlund at the Karolinska Institute [4, 5]. Stereotactic guiding devices were adapted to newly evolving imaging techniques, ranging from encephalography to angiography, CT, and MRI. These new techniques prompted further evaluation of stereotactic radiosurgery, a field envisioned by Leksell in 1951. His concept that ionizing radiation could be cross fired to destroy or inactivate deep brain targets without a surgical opening proved to be an enormous step forward in minimally invasive surgery. Under the watchful eye of Leksell, Gamma knife technologies gradually expanded their role and their usage exploded across the field of neurosurgery [1–3, 6–13].

Our efforts at the University of Pittsburgh began in 1987 with the introduction of the first 201 source Cobalt-60 Gamma knife, which was the fifth unit manufactured worldwide [7]. Since that time, more than 9000 patients have undergone Gamma knife radiosurgery at the University of Pittsburgh Medical Center. Our efforts first began with usage of the original U unit. Since 1987 we have introduced each successive generation of the Gamma knife, starting with the B unit, the robotic assisted C unit, the 4C unit which advanced software capabilities, and the next generation and fully robotic Perflexion® Gamma knife (Fig. 1). Continuing incorporation of new imaging techniques, advanced long-term outcome studies, and multi-disciplinary care have facilitated the incorporation of Gamma knife radiosurgery into its application to more than 10% of patients undergoing neurosurgical cranial procedures at our center. Radiosurgery has refined the role of more invasive surgical tech-

---

*Keywords:* radiosurgery, Gamma knife, image guided radiosurgery





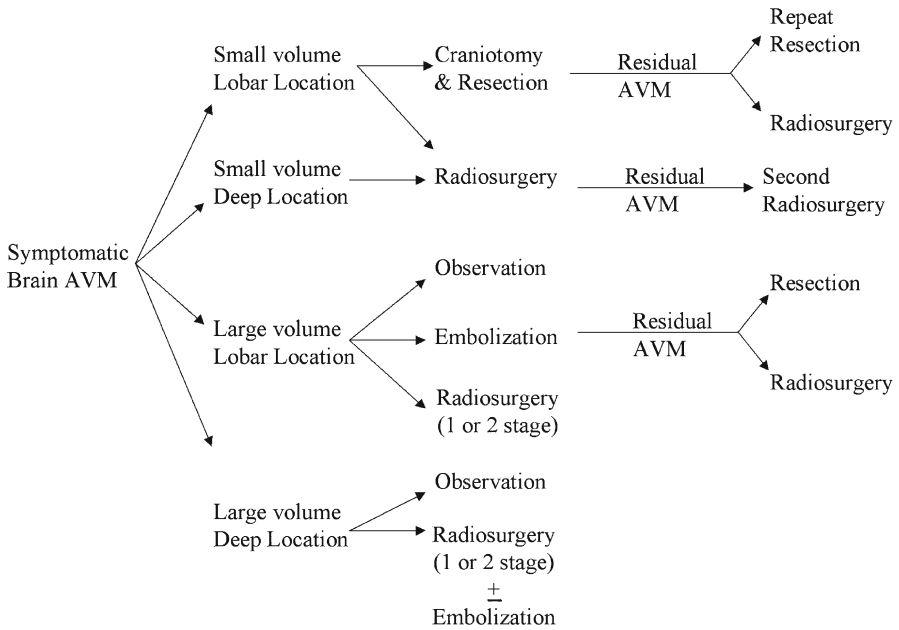
**Fig. 1.** The Leksell Perfexion Gamma Knife

niques and promoted better patient outcomes. When microsurgical brain surgery is incomplete because of the location or nature of the tumor, subsequent radiosurgery facilitates the ultimate goal: reduced morbidity, better clinical outcomes associated with long-term prevention of tumor growth, obliteration of vascular malformations, or non-invasive lesion creation in patients with movement disorders, chronic pain, or epilepsy.

## **RATIONALE**

Stereotactic radiosurgery represents the penultimate model of image-guided and minimally invasive brain surgery. Using stereotactic guiding devices coupled with high resolution CT, MRI, positron emission tomography (PET) or magnetic source imaging, we can target critical brain structures. Decision making related to the role of radiosurgery has expanded during the more than 20 years of experience since its potential was first tested. Long-term outcome studies have confirmed the benefits of radiosurgery as a primary therapeutic option for many primary brain tumors, especially those of the skull base, and brain metastases, as well as various functional neurosurgery indications such as trigeminal neuralgia, essential tremor, obsessive compulsive disorders, and mesial temporal lobe epilepsy. SRS has a major role in the adjuvant treatment of subtotally removed tumors of the skull base, selected glial neoplasms, and residual or recurrent pituitary tumors. For surgeons involved in the use of SRS, a different goal of patient management was needed: tumor control as opposed to tumor elimination *plus* patients with a stable or improved neurological examination.

Extensive studies at our center and many others have confirmed the role of Gamma knife radiosurgery in the management of many benign skull base tu-



**Fig. 2.** A decision tree for selection of management options for patients with arteriovenous malformations. Similar decision tree analyses that can be used for skull base tumors, brain metastasis, and trigeminal neuralgia are available via the internet on the National Guidelines Clearinghouse

mors such as acoustic and other non acoustic neuromas, meningiomas, and pituitary tumors. Its use in the primary cost effective care of patients with metastatic cancer to brain is now well established [1, 13]. SRS is successful in the care of the majority of patients with brain metastases that are not associated with extensive mass effect at the time of clinical recognition. Finally, emerging indications for radiosurgery include management of epilepsy, a resurgence of interest in medically refractory behavioral disorders, and even in the potential treatment of patients with obesity. All discussions related to the role of radiosurgery are based on an analysis of the risks or benefits of observation, alternative surgical techniques, the potential role of fractionated radiation therapy and chemotherapy (for malignant tumors) in comparison to what defined benefits of SRS are feasible. A typical decision making analysis is shown in Fig. 2 relative to the management of arteriovenous malformations.

### 1. THE TECHNIQUE OF GAMMA KNIFE STEREOTACTIC RADIOSURGERY

Patients are evaluated during clinical consultation, at which time we review all pertinent imaging studies. Such studies generally include high resolution MRI for tumors or in preparation for functional procedures. For patients with vas-

cular lesions, angiographic studies are critical as well. The patient is screened for the appropriate management for radiosurgery relative to other therapeutic options, and the risk–benefit ratio of radiosurgery is explained. Patients with benign brain tumors are evaluated by watchful waiting if they are asymptomatic, but indications for radiosurgery are clear when either documented tumor growth or new neurological symptoms or signs develop. However in certain cases the natural history of a particular disorder is clear enough to warrant intervention. For example, patients with small incidentally found arteriovenous malformations have a reasonably well defined natural history of bleeding over many years. In such cases SRS has a high success rate over several years as determined by obliteration potential and risk avoidance [2, 10, 11].

The risk of SRS for most AVMs can be projected as significantly lower than the natural history risk; such risks can be related to the location, AVM volume, and the dose delivered (which helps in turn to predict the adverse radiation effect risk in individual patients). For patients with suspected benign tumors with typical imaging characteristics such as meningiomas or acoustic neuromas, histological diagnosis is not necessary. For patients with atypical imaging defined characteristics, such as a pineal region tumor, histological diagnosis is often critical to recommend an appropriate treatment option. In such cases stereotactic biopsy may be the ideal method to determine the histology. Since we use the same stereotactic system for both open stereotactic surgery as we do in radiosurgical cases, in selected cases a patient may undergo diagnosis and treatment in the same sitting. This requires excellent neuropathological expertise to confirm the clinical suspicion during the procedure itself.

Radiosurgery has primary indications in the management of arteriovenous malformations unsuitable for microsurgical intervention, a primary management role in the care of skull base tumors such as acoustic neuromas and meningiomas, an adjuvant role in the management of most patients with pituitary tumors, and a primary role in the management of metastatic cancer to the brain. Additional adjuvant roles include boost radiosurgery in patients who have malignant glial neoplasms that have progressed despite prior management.

## **DECISION-MAKING**

Indications and results are briefly summarized below.

### **1. ARTERIOVENOUS MALFORMATIONS**

At our center, 1300 patients with vascular malformations of the brain have undergone radiosurgery in a 21 year interval. In properly selected patients, the goal of obliteration can be achieved in between 70–95% of patients, depending on the volume and the dose that can be delivered safely. Radiosur-

gery is especially valuable for deep-seated AVMs for which there is no other microsurgical option. At the present time, embolization strategies as part of the spectrum of options for arteriovenous malformations facilitates flow reduction but not volume reduction. Because of this, its role in preparation for conventional stereotactic radiosurgery has remained controversial. In the future, embolization strategies that facilitate the radiobiological response of subsequent radiosurgery may be more beneficial. For dural vascular malformations, radiosurgery followed immediately by embolization of the fistulous connections is a better staged strategy that provides both short term (early embolization benefit) and long-term response (as the radiosurgical oblitative response develops). SRS needs to precede the embolization so that the entire target can be visualized.

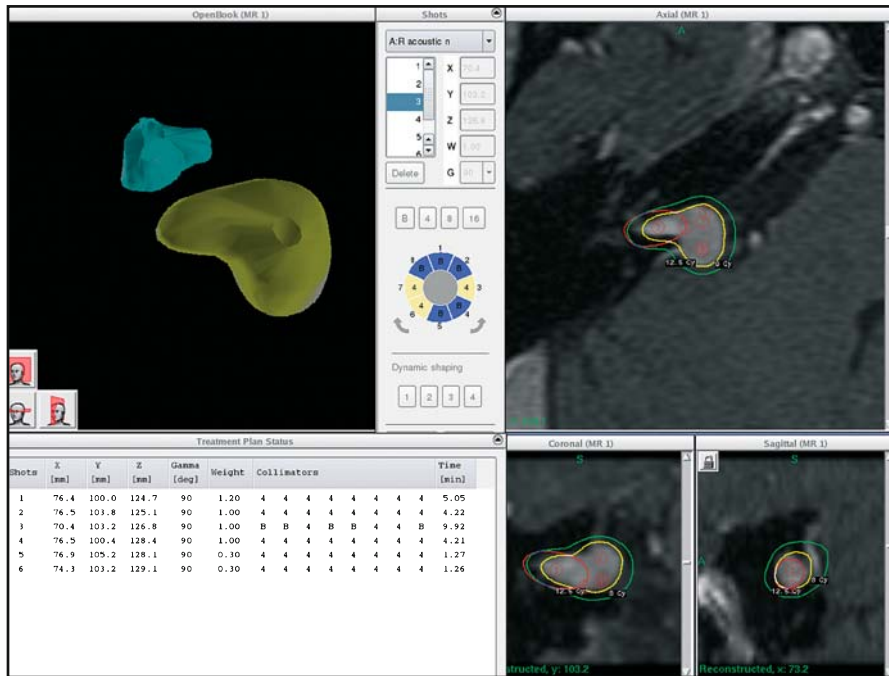
At our center we preferentially place the stereotactic frame, target the dural AVM using MRI and angiography, perform SRS, and immediately return the patient to the interventional suite with a femoral sheath in place to complete the embolization procedure.

Cavernous malformations that have bled twice and are located in deep seated brain locations respond to radiosurgery with a slow reduction in their subsequent bleeding rate, within a latency interval generally of approximately two years. Our studies have confirmed that once a patient has bled twice from a cavernous malformation, the annual rate of a third or additional bleeds may be as high as 33% per year. After two years, the annual bleed risk diminishes to less than 1% per year. Developmental venous anomalies, which are often seen adjacent to cavernous malformations are never treated by SRS. Occlusion of these aberrant venous drainage channels runs the risk of venous infarction.

## 2. SKULL BASE TUMORS

More than 1300 acoustic neuromas have undergone radiosurgery at our center. Over the course of the last 20 years, radiosurgery has become a primary management strategy for small to medium sized acoustic neuromas, achieving facial nerve preservation rates in virtually all patients, a 50–70% chance of preservation of hearing levels, and a rapid return to pre-radiosurgical employment and lifestyle. The long-term tumor control rate is 98% in patients who undergo radiosurgery with doses of 12–13 Gy at the tumor margin [12]. Highly conformal and selective radiosurgery is possible using the Gamma knife which allows this procedure to be done in a single session with precise intracranial guidance and stereotactic head frame fixation (Fig. 3).

Skull base meningiomas similarly can be treated, and have responded well. In a series of more than 1000 meningiomas treated over the last 21 years long-term tumor growth control rates are achieved in more than 95% of patients with low grade meningiomas [3]. Radiosurgery is an adjuvant management strategy for patients with more aggressive Grade II or malignant Grade III men-



**Fig. 3.** Dose plan for an acoustic neuroma

ingiomas, but such tumors require multimodality management. Outcomes may require multiple surgical procedures, SRS, and fractionated radiation therapy.

Pituitary adenomas are generally managed first by transsphenoidal resection. However, for tumors that are recurrent or residual after surgery, or located primarily de novo in the cavernous sinus, Gamma knife radiosurgery may be a primary option. It is very effective in preventing tumor growth control, but higher doses are necessary to achieve endocrine relapse for patients who have endocrine active tumors such as growth hormone or ACTH secreting tumors. With current highly conformal and selective dose planning techniques, pituitary radiosurgery is possible immediately adjacent to the optic chiasm – as long as the dose to the optic apparatus is kept below 8–10 Gy in a single procedure. SRS also has a very important role in the management of other lower skull base tumors, especially tumors involving the jugular bulb, the trigeminal nerve, and as an adjuvant management in the treatment of aggressive chondrosarcomas or chordomas of the skull base.

### 3. METASTATIC CANCER

In 2500 patients who have undergone radiosurgery for metastatic cancer, we have found that long-term tumor growth control rate can be achieved in most

patients without the need for invasive brain surgery. Depending on the tumor primary, long-term tumor control rates are achieved between 67 and 95% of patients [1]. Most patients now die of systemic disease rather than intracranial progression, a major shift in the paradigm of management of metastatic cancer affecting the brain. SRS has additional major benefits in comparison to other conventional therapies. As a single day procedure, during which multiple brain metastases can be treated, it does not delay the concomitant use of chemotherapy or radiation techniques that are needed to improve control of the systemic cancer.

We have not detected major differences in survivals in patients with one to four brain metastases. Long-term survivals have been confirmed in breast, lung, renal, and melanoma metastatic disease, especially when control of systemic disease is obtained. For patients with non small cell lung cancer with a solitary brain metastasis, median survivals often exceed two years. We cannot confirm that additional fractionated external beam radiation therapy improves survival, because repeat SRS is used for salvage management if new brain disease develops. For patients with long-term survival potential, elimination of the late cognitive disorders after whole brain radiation therapy is highly desirable.

Surgical removal is necessary for patients with large metastatic tumors who have symptomatic mass effect at the time of presentation. Tumor bed radiosurgery can be used to treat the peritumoral cavity in order to reduce the risk of delayed local recurrence as well as to avoid the long-term risks of whole brain radiation therapy. The new Perfexion model Gamma knife is an ideal tool for the treatment of multiple brain metastases scattered in widely different areas of the brain.

#### **4. GLIAL NEOPLASMS**

At our center more than 700 patients have been treated for brain gliomas ranging from Grade I to Grade IV. SRS can be considered as a primary management strategy for residual or recurrent primarily solid pilocytic astrocytomas. It is especially valuable for patients without cystic changes and achieves local control in more than 85% of patients. SRS is an alternative option for the management of small volume, sharply bordered Grade II tumors (astrocytomas and oligodendrogliomas). Such tumors are defined with high definition MRI using both contrast enhanced T1 and T2 studies. SRS is considered as an adjuvant strategy to provide boost radiation in patients with malignant gliomas, generally those patients who have failed conventional management with surgery, radiation and chemotherapy.

#### **5. FUNCTIONAL NEUROSURGERY**

Gamma knife SRS, which facilitates application of small volume, very precise lesions within the brain, has been used effectively in more than 800

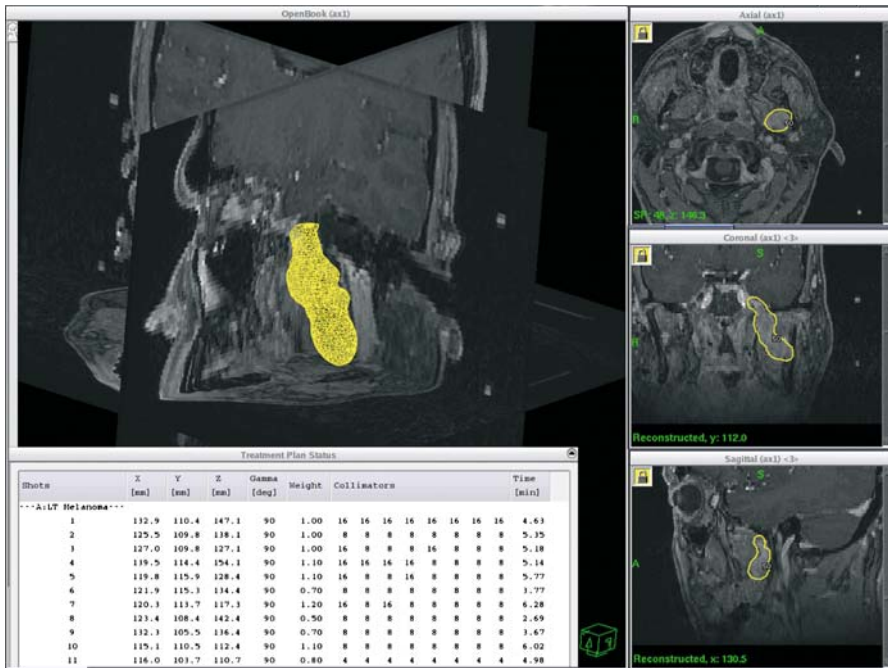
patients with trigeminal neuralgia at our center. Long-term results indicate that 70–90% of patients achieve pain control. Results are best for patients who have failed medical management for typical trigeminal neuralgia, but who have not failed a prior surgical procedure. The typical dose is 80 Gy using a 4 mm collimator to focus the beams at the root entry zone of the trigeminal nerve as defined by volumetric MRI, including 1 mm T2 volume slices to define the nerve. In selected cases CT imaging is used to define the nerve if the patient cannot have an MRI because of prior surgery or other medical issues such as a prior pacemaker placement. The latency until pain relief is between a few days and several months, during which time medicines are slowly tapered as pain control is achieved. SRS can be repeated for patients who develop a relapse. Trigeminal radiosurgery is most often used for patients with typical trigeminal neuralgia who are elderly or have medical co-morbidities that make them poor candidates for microvascular decompression. We prefer SRS to percutaneous pain management strategies as an initial treatment for appropriate patients because it has a high success rate and a low risk of delayed trigeminal sensory loss (less than 10% of patients develop changes in facial sensation).

Since its first development of radiosurgery in 1967, the Gamma knife has been used to create selective deep seated brain lesions for advanced movement disorders, especially essential tremor. Typically a radiosurgical dose of 120–140 Gy is delivered to the ventrolateral nucleus of the thalamus as identified by high resolution MRI. As a closed skull procedure physiological confirmation of the anatomically defined target is not possible. If bilateral symptoms are noted, we typically wait at least one year before proceeding with a contralateral thalamic lesion. Since the procedure does not require reversal of anticoagulants or antiplatelet agents, GK SRS is especially valuable for patients not eligible for deep brain stimulator implantation. The interval for full lesion development is typically 3–6 months.

Leksell originally proposed development of the Gamma knife in order to create 4–6 mm lesions in the anterior internal capsule in patients with advanced medically refractory behavioral disorders such as severe anxiety neuroses and obsessive-compulsive disorders. New investigative techniques are under evaluation for the possible role of radiosurgery for temporal lobe epilepsy and for chronic obesity (ventrolateral hypothalamotomy). At present both animal models and patient experience indicate that radiosurgery for medial temporal lobe epilepsy achieves comparable Engel class I results to microsurgical hippocampectomy, with a latency of about one year until the full effect occurs.

## **SURGICAL TECHNIQUE**

The patient is brought into the hospital as an outpatient and given mild intravenous conscious sedation using Medazepam and Fentanyl. Under



**Fig. 4.** Patient with metastatic melanoma tracking via the trigeminal nerve from the maxillary sinus region to the cavernous sinus. This patient had already failed local radiation and immune therapy

local anesthesia (a mixture of marcaine and xylocaine), the Leksell Model G stereotactic head frame is attached to the head using titanium pins. Appropriate frame shifting is based on the location of the target. Frame shifting is less important using the new Perfexion Gamma Knife which facilitates treatment of patients with lesions scattered throughout the brain or even in the inferior skull base and paranasal sinuses. We currently use both the Leksell 4-C and Leksell Gamma Knife Perfexion Units, which maximizes the precision and appropriate robotic positioning. Patients subsequently undergo high resolution imaging, most commonly MRI or CT for patients ineligible to have an MRI scan. Lower skull base lesions have generally both MRI and CT imaging performed (Fig. 4). Image fusion is used frequently for enhanced recognition of selective targets. Using the new Perfexion unit, extracranial disease can be treated effectively. Dose planning is performed using high speed workstations, and final treatment decisions are made by an experienced medical team including neurological surgery, radiation oncology and medical physics. Extracranial disease may also require consultation with appropriate colleagues in otolaryngology or head and neck surgery.



Dose selection is based on extensive experience published throughout the world's literature. The maximal dose, marginal dose, and isodose selected to cover the margin are based and modified by the histological diagnosis, the expected radiobiological response, the volume, and the location of the target.

## HOW TO AVOID COMPLICATIONS

After undergoing Gamma knife radiosurgery, patients are discharged on the day of the procedure. Other than mild headache after stereotactic frame removal, patients are able to resume their regular activities immediately. The risk of long-term adverse radiation effects (ARE) are related to lesion type, location, volume and dose. The development of intra- or perilesional reactive changes vary in individual patients, but may take 3 to 18 months to be detected. For AVMs we have found that the risk of MRI signal changes with or without associated neurological signs can be predicted on the volume of brain receiving 12 Gy or more, a volume outside of the isodose volume that conforms to the AVM target. This volume typically receives a dose of 18–23 Gy. The risk of ARE are directly related to this volume and the location of the AVM. As expected, AVMs located in the brainstem or basal ganglia (adjacent to the internal capsule) are more likely to have either temporary or permanent new neurological symptoms. Prior exposure to radiation may also increase the chance of subsequent ARE after radiosurgery. It is also estimated that 4% of the normal population may have special sensitivity to radiation, and are therefore more likely to suffer ARE. Typical imaging sequences performed on most patients include scans at six months, one year, two years and four years for assessment of response. Both tumor growth control is assessed as well as the risk of developing peritumoral reactive changes. Such changes may have minimal contrast enhancement but prolonged T2 signal changes compatible with edema formation. Such patients are treated with a brief course of corticosteroids.

Long-term risks of radiation necrosis are detected by serial imaging. To date, no additional imaging technologies including PET or SPECT has been particularly useful in sorting out tumor response versus radiation injury. For patients who have long-term effects suggestive of radiation injury after a corticosteroid trial of approximately two weeks, we try to switch patients to a combination of oral vitamin E and Trental. This is continued for approximately three months. Long-term risks published in our experience suggests that the risk of adverse radiation effects range from 3–10%. We have found that certain indications have a higher risk of ARE. For example, cavernous malformations have a higher risk of ARE at doses that do not have such risks when an AVM is treated. We suspect that chronic iron deposition in the gliotic brain surrounding the cavernous malformation may serve as a radiation

sensitizer. When a dose reduction was instituted for cavernous malformations, the ARE risk declined substantially.

The ability to minimize risks can best be enhanced by highly conformal and highly selective treatment plans and selection of the appropriate dose, modified by the volume and the radiobiological response. Fortunately, multiple outcome studies have now confirmed the necessary doses that are required to achieve the overall radiobiological goal. Over the course of 20 years, a gradual dose de-escalation strategy has significantly reduced complications. It is likely that further dose de-escalation will have an adverse effect in terms of long-term tumor growth control, and therefore it is likely that in the future, to enhance tumor response for more aggressive tumors, a gradual dose escalation study will be necessary.

## CONCLUSIONS

Stereotactic Gamma knife radiosurgery based on a discussion of comprehensive selection options and precise high resolution intraoperative management, is a critical component of modern neurosurgery. It is estimated that 10% of all neurosurgery, and as much as 15–20% of all intracranial brain surgery can be most safely and best performed using stereotactic radiosurgical techniques. The Gamma knife represents a technology which has been applied in more than 500,000 patients worldwide, with more than 400 outcome studies presented from our center alone over the last 20 years. Proper patient selection, review of appropriate treatment options, and a risk–benefit analysis are critical in the selection of any neurosurgical procedure. Radiosurgery using the Gamma knife represents an important technology that is now firmly established in the field of contemporary brain surgery.

## References

- [1] Bhatnagar AK, Flickinger JC, Kondziolka D, Lunsford LD (2006) Stereotactic radiosurgery for four or more intracranial metastases. *Int J Radiat Oncol Biol Phys* 64: 898–903
- [2] Flickinger JC, Kondziolka D, Lunsford LD, Pollock BE, Yamamoto M, Gorman DA, et al. (1999) A multi-institutional analysis of complication outcomes after arteriovenous malformation radiosurgery. *Int J Radiat Oncol Biol Phys* 44: 67–74
- [3] Kondziolka D, Mathieu D, Lunsford LD, Martin JJ, Madhok R, Niranjan A, et al. (2008) Radiosurgery as definitive management of intracranial meningiomas. *Neurosurgery* 62: 53–58; discussion 58–60
- [4] Lunsford LD (1996) Lars Leksell. Notes at the side of a raconteur. *Stereotact Funct Neurosurg* 67: 153–168

- [5] Lunsford LD (1993) Stereotactic radiosurgery: at the threshold or at the crossroads? *Neurosurgery* 32: 799-804
- [6] Lunsford LD, Flickinger J, Coffey RJ (1990) Stereotactic Gamma knife radiosurgery. Initial North American experience in 207 patients. *Arch Neurol* 47: 169-175
- [7] Lunsford LD, Flickinger J, Lindner G, Maitz A (1989) Stereotactic radiosurgery of the brain using the first United States 201 cobalt-60 source Gamma knife. *Neurosurgery* 24: 151-159
- [8] Lunsford LD, Kondziolka D, Bissonette DJ, Maitz AH, Flickinger JC (1992) Stereotactic radiosurgery of brain vascular malformations. *Neurosurg Clin N Am* 3: 79-98
- [9] Lunsford LD, Martinez AJ (1984) Stereotactic exploration of the brain in the era of computed tomography. *Surg Neurol* 22: 222-230
- [10] Pollock BE, Flickinger JC, Lunsford LD, Bissonette DJ, Kondziolka D (1996) Factors that predict the bleeding risk of cerebral arteriovenous malformations. *Stroke* 27: 1-6
- [11] Pollock BE, Flickinger JC, Lunsford LD, Bissonette DJ, Kondziolka D (1996) Hemorrhage risk after stereotactic radiosurgery of cerebral arteriovenous malformations. *Neurosurgery* 38: 652-659; discussion 659-661
- [12] Pollock BE, Lunsford LD, Kondziolka D, Flickinger JC, Bissonette DJ, Kelsey SF, et al. (1995) Outcome analysis of acoustic neuroma management: a comparison of microsurgery and stereotactic radiosurgery. *Neurosurgery* 36: 215-224; discussion 224-219
- [13] Rutigliano MJ, Lunsford LD, Kondziolka D, Strauss MJ, Khanna V, Green M (1995) The cost effectiveness of stereotactic radiosurgery versus surgical resection in the treatment of solitary metastatic brain tumors. *Neurosurgery* 37: 445-453; discussion 453-445



**L. Dade Lunsford**

L. Dade Lunsford, MD, FACS, is Lars Leksell Professor of Neurological Surgery, Distinguished Professor University of Pittsburgh, Director of the Center for Image Guided Neurosurgery, and Director of the Neurosurgery Residency Program at the University of Pennsylvania at Pittsburgh. He completed medical school at Columbia University College of Physicians and Surgeons, residency training in neurosurgery at the University of Pittsburgh, and fellowship training in stereotactic technologies and radiosurgery at the Karolinska Institute. Dr. Lunsford's primary interests are related to image-guided surgery, innovation in brain tumor management, stereotactic radiosurgery, and patient long-term outcome studies related to the use of modern minimally invasive technologies. His basic science and clinical studies have helped to substantiate the role of radiosurgery and other minimally invasive techniques in the armamentarium of modern neurosurgery.

**Contact:** L. Dade Lunsford, University of Pittsburgh Medical Center, Presbyterian B400, 200 Lothrop Street, Pittsburgh, PA 15213, USA  
E-mail: [lunsfordld@upmc.edu](mailto:lunsfordld@upmc.edu)

---

# HOW TO PERFORM SURGERY FOR INTRACRANIAL (CONVEXITY) MENINGIOMAS

P. M. BLACK

## INTRODUCTION

Convexity meningiomas are important tumors historically and in contemporary neurosurgery. Felix Plater provided their first recognizable description in 1614 and the first successful surgical removal was by Pecchioli in Siena in 1847 [10]. It was Cushing in 1922 who decided to group many previous meningeal tumors under the general name “meningioma”. In the 1920s, Cushing also established techniques for their removal that became the standard for these tumors. Walter Dandy, Leo Davidoff, Colin McCarty, Lindsay Simon, Jacques Philippon, Giovanni Broggi, Charles Wilson, Ossama Al-Mefty, Robert Ojemann, and many others are among the surgeons who have carried forward the understanding of their optimum care in the twentieth century [1]. In the last decade, improved imaging, navigation, and concepts of minimally invasive surgery have begun to create a quiet revolution in the management of these tumors [2].

## RATIONALE

1. *Goal of management.* The goal of management is to relieve brain compression without damaging cortical veins or compressed cortex and to prevent recurrence of tumor.

2. *Location and anatomy.* Convexity meningiomas originate in the meninges of the cerebral hemispheres; they constituted 51% of the author’s series of 807 meningiomas [1]. It is historically believed that they arise from arachnoid cap cells. The arachnoid layer is often intact, making their removal from eloquent cortex possible without deficit; however, for large meningiomas or for atypical and anaplastic meningiomas, there may be significant disruption of the arachnoid and adherence or invasion to the brain tissue. These tumors may often be very large before they are detected. They produce symptoms by compression of the brain under them – if above motor cortex, contralateral weakness; for vision, visual field loss; for frontal or temporal speech areas, aphasia. They also may cause seizures.

---

*Keywords:* intracranial tumors, meningiomas, convexity meningiomas, microsurgery

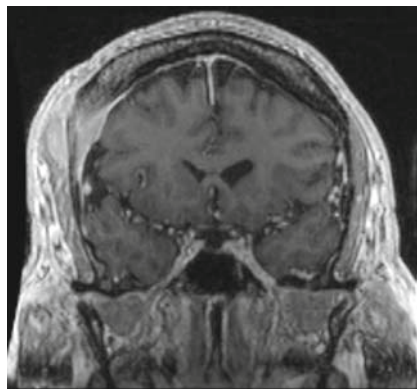
## DECISION-MAKING

### 1. DIAGNOSIS

The diagnosis of a convexity meningioma is usually made by CT or MRI scanning. Contrast material is necessary to see the tumor appropriately – without contrast, it may be almost invisible as its signal characteristics are very similar to those of the brain. Meningiomas are dural-based lesions with well-circumscribed margins that indent the brain but do not invade it. They are very characteristic but may occasionally be mimicked by a dural-based metastasis or even inflammation such as sarcoidosis. They may cause significant hyperostosis of overlying bone, a feature that confirms meningioma as the diagnosis (Fig. 1). Other imaging modalities do not contribute significantly to the routine diagnosis. If there is an important differential with metastasis, however, PET scanning with somatostatin receptors can establish the diagnosis definitively.

### 2. INDICATIONS FOR SURGERY

The major therapeutic options for convexity meningiomas are to observe or remove them. Unlike some skull base meningiomas, radiation including radiosurgery is not usually considered an option in the primary care of these tumors. An exception may be in an elderly patient with severe medical problems contraindicating surgery. Many convexity meningiomas, especially in patients over the age of 65, can simply be observed. There is about a 35% chance that they will grow over a five-year period [13]. Our general approach is to observe many convexity meningiomas as the first treatment; however,



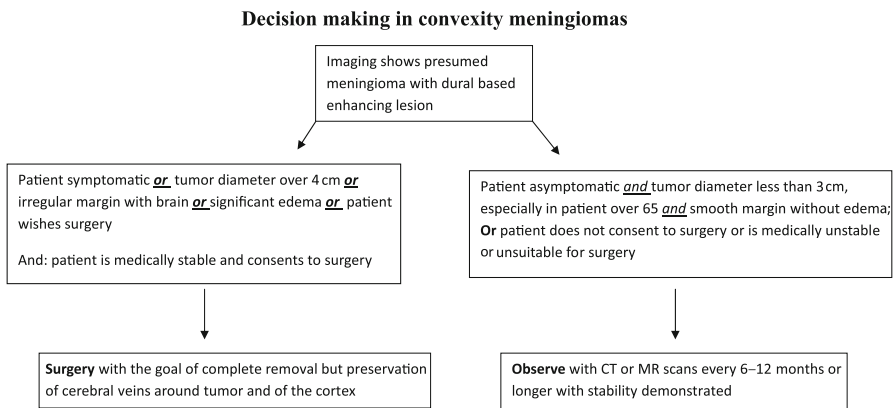
**Fig. 1.** Convexity meningioma which has also eroded through bone

there are certain conditions which indicate that surgery should be done as the initial step.

Indications for surgery at our center are as follows:

1. Symptoms attributable to tumor compression
2. Demonstrated growth with sequential scans
3. Size over 4 cm diameter
4. Apparent invasion of brain
5. Significant peritumoral edema
6. Patient preference
7. Need for diagnosis

Our decision-making algorithm is as follows:



### 3. PREOPERATIVELY, THERE ARE SEVERAL TESTS THAT SHOULD BE DONE AND QUESTIONS THAT SHOULD BE ANSWERED

1. Do I have the imaging I need? Can I see the veins around the tumor on the MRI? Is the MRI an appropriate scan for navigation? (We have found that a navigation system is extremely helpful for minimally invasive resection of these lesions including bone flap planning and identification of veins.)
2. Should embolization be carried out preoperatively? (In general, we embolize only very large or apparently very vascular tumors, fewer than 5% of our convexity meningiomas.)
3. Is the patient medically stable and are the patient's blood tests including coagulation studies acceptable?
4. Has appropriate surgical consent been obtained?

## **SURGERY**

### **1. PREPARATION**

Most of our convexity meningiomas are now done with the help of a navigation system that assures accurate localization of the tumor. Preoperatively, it is important to assure the proper scan sequences are done and they have been loaded into the system satisfactorily.

For the removal, an ultrasonic aspirator is usually helpful and loop cautery may be useful. For very vascular tumors, the contact YAG laser can help resect with hemostasis. The operating microscope is helpful for relation to the brain.

In our experience, embolization has only been needed in tumors over 5 cm that appear hypervascular on preoperative MR. Sometimes the vascular supply of a convexity meningioma comes from the contralateral middle meningeal artery that may be hard to identify at surgery.

### **2. OPERATIVE TECHNIQUE**

The patient is positioned with the tumor uppermost in the field and that position is maintained with three-point skull fixation. The tumor location and extent are marked out using the navigation system and the hair is shaved just at the site of the tumor. Usually a linear scalp incision is used directly over the center of the tumor; if the tumor is very large, a u-shaped flap based on the vascular supply is preferred. The bone can usually be removed with one burr hole and dural stripping from that; if tumor has invaded bone centrally, rongeurs or a drill are used to remove the bone rather than tearing tumor with the bone flap removal. Convexity tumors close to the sinus may require more careful stripping of dura from bone.

We take care not to open the dura initially much beyond the tumor margin to prevent venous congestion and infarction. It is extremely important to watch for cortical veins as the dura is opened; a cottonoid patty placed over the brain surface as the dura is opened is a useful technique. The dura is the origin of the tumor, so it is removed with the lesion. After the tumor is removed, it may be possible to get a wider excision margin, and we aim for a 1 cm margin if possible, taking all the dural tail seen on preoperative imaging.

Before removing a large tumor from the brain surface, it is important to internally core out the tumor with a loop cautery or cavitron; this allows internal decompression and gradual dissection from even eloquent cortex rather than trying to mobilize a large mass. Great care should be taken to avoid veins surrounding the tumor and to be as gentle as possible with the brain surface. Lifting up on the tumor as you dissect it from brain is potentially dangerous because deep white matter tends to come with it.



For dural closure, we replace the dura with pericranium or Alloderm (LifeCell, Branchburg, NJ), making a watertight closure. We avoid cadaver or bovine tissue because of the potential problem of slow viral infection.

We replace the bone flap with a plating system to hold it in place. If it is extensively involved with tumor, we will use a methylmethacrylate cranioplasty; if there is partial involvement, we will drill out the area that is hyperostotic. Postoperatively the patient is cared for in the neurosurgical ICU for an average of one night before returning to the ward. The average length of hospital stay is 3 days.

### 3. LONG-TERM RESULTS

Most convexity meningiomas can be completely removed; occasionally because of their proximity to the sagittal sinus or to cerebral veins they cannot be resected completely. We achieved a Simpson Grade I removal in more than 95% of convexity meningiomas, a finding similar to others [3, 4, 6, 11].

*Recurrence.* Several studies have evaluated the effect of tumor removal on recurrence – the most comprehensive is that of Jaaskelainen et al., who found a recurrence rate of 3% at 5 years for benign tumors completely removed, 9% at 10 years and 21% at 25 years [3].

Since most convexity tumors can have a Simpson Grade I removal, they provide an important test of the role of histological grade in recurrence. We noted that 88.3% of our convexity tumors were grade 1, 9.8% grade 2, and 1.8% grade 3. If the benign tumors in our series were separated into those that were completely benign and those that had some atypical features, the recurrence rate for the benign group was zero, whereas the “borderline atypical” group had a 5-year recurrence rate of 33%, which is in the same range as the atypical tumors. Grade 3 tumors had a recurrence rate of 78% at five years. Thus for convexity tumors the biology of the tumor is the most important criterion for recurrence [9].

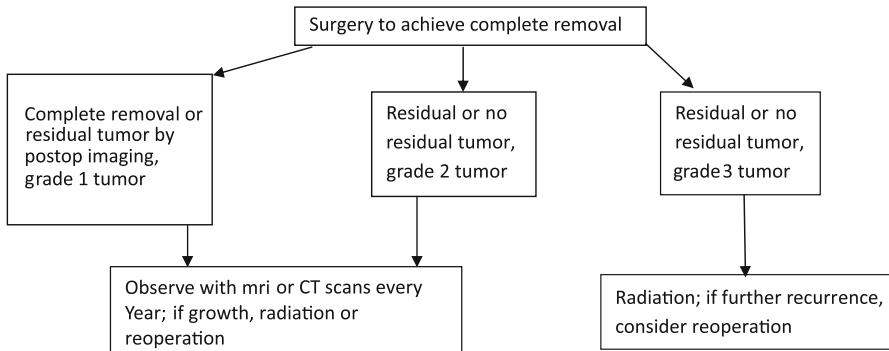
Several authors have reviewed histological features that predict recurrence; chief among them is the MIB-1 or other proliferative index [5, 7, 12].

*Adjunctive therapy.* Radiation may be a useful adjunctive therapy for grade 2 and 3 meningiomas of the convexity. Our approach is to irradiate all grade 3 meningiomas after the first operation but for other histological grades to select cases on an individual basis depending on the decision of our tumor board.

In our series, 3 of 16 patients with grade 2 meningiomas (18%) received adjuvant radiation following initial surgery. These tumors did not recur within the time period of our study, whereas 4 patients who did not receive initial adjuvant radiation after the initial operation later required radiation for recurrent tumors.

There is controversy about postoperative radiation therapy. Modha and Gutin suggest that all grade 3 tumors, and grade 2 tumors subtotally excised, with brain invasion or with an MIB-1 index of  $\geq 4.2\%$  should be treated with fractionated radiotherapy [8].

**Algorithm for adjunctive therapy after convexity meningioma removal**



**4. COMPLICATIONS**

In our series, there was no surgical mortality. The overall surgical morbidity was 5.2%: Complications included new neurological deficit in 1.7% of patients, a 0.6% incidence of postoperative hematoma and an infection rate of 2.9%. There were two cardiac complications, which occurred in the 65 years or older group. There was no significant difference in morbidity between patients under and over age 65.

These are similar to other reports. Yanno et al. reported a 4.4% morbidity rate in patients under age 70 and 9.4% in patients over age 70 [13].

**HOW TO AVOID COMPLICATIONS**

An important initial step in avoiding complications is to be sure the tumor is localized correctly and that cardiac and other conditions have been carefully evaluated preoperatively. During the surgery itself, there are two major potential problems to avoid: injury to cerebral veins and injury to the cortex and white matter as the tumor is removed. Although we did not have venous infarction in our series, it can be a devastating problem that gives new neurological deficit and problematic seizures. The veins must be preserved, if necessary by sharp dissection from the tumor; and if there is very dense adherence, a small amount of tumor can be left on them. When dissecting the tumor off the cortex and white matter, it is important to avoid coagulating vessels that may supply adjacent cortex and not to pull up on the white matter.

**CONCLUSIONS**

Convexity meningiomas are among the most satisfying tumors a neurosurgeon can treat. The major issue is often when to remove them, but there is a

tendency to have earlier surgery as our surgery becomes less invasive using navigation techniques. Moreover, early surgery removes the worry that tumor may grow or change, and has an acceptable morbidity of 5.5%. The tumor grade is particularly important in the long-term outcome of patients.

## References

- [1] Al-Mefty O (1995) Meningiomas. WB Saunders, Philadelphia
- [2] Black P, Morokoff A, Zauberman J (2008) Surgery for extra-axial tumors of the cerebral convexity and midline. *Neurosurgery* 63: 427-433; discussion
- [3] Jaaskelainen J, Haltia M, Servo A (1986) Atypical and anaplastic meningiomas: radiology, surgery, radiotherapy, and outcome. *Surg Neurol* 25: 233-242
- [4] Kamitani H, Masuzawa H, Kanazawa I, Kubo T (2001) Recurrence of convexity meningiomas: tumor cells in the arachnoid membrane. *Surg Neurol* 56: 228-235
- [5] Kim YJ, Ketter R, Henn W, Zang KD, Steudel WI, Feiden W (2006) Histopathologic indicators of recurrence in meningiomas: correlation with clinical and genetic parameters. *Virchows Arch* 449: 529-538
- [6] Kinjo T, Al-Mefty O, Kanaan I (1993) Grade zero removal of supratentorial convexity meningiomas. *Neurosurgery* 33: 394-399; discussion 399
- [7] Maiuri F, De Caro MB, Esposito F, Cappabianca P, Strazzullo V, Pettinato G, de Divitiis E (2007) Recurrences of meningiomas: predictive value of pathological features and hormonal and growth factors. *Neurooncology* 82: 63-68
- [8] Modha A, Gutin PH (2005) Diagnosis and treatment of atypical and anaplastic meningiomas: a review. *Neurosurgery* 57: 538-550; discussion 538-550
- [9] Morokoff AP, Zauberman J, Black PM (2008) Surgery for convexity meningiomas. *Neurosurgery* 63: 427-433
- [10] Patil DG, Laws ER Jr, Meningioma. history of the tumor and its management. In: Pamir N, Black P, Fahlbusch R (eds) *Meningiomas: a comprehensive text*. Elsevier, Philadelphia (in press)
- [11] Simpson D (1957) The recurrence of intracranial meningiomas after surgical treatment. *J Neurol Neurosurg Psychiatry* 20: 22-39
- [12] Yamasaki F, Yoshioka H, Hama S, Sugiyama K, Arita K, Kurisu K (2000) Recurrence of meningiomas. *Cancer* 89: 1102-1110
- [13] Yano S, Kuratsu J (2006) Indications for surgery in patients with asymptomatic meningiomas based on an extensive experience. *J Neurosurg* 105: 538-543



**Peter M. Black**

Peter Black is Franc D. Ingraham Professor of Neurosurgery at Harvard Medical School, Founding Chair of the Departments of Neurosurgery at Brigham and Women's Hospital, and Chair emeritus of the Department of Neurosurgery at Children's Hospital. He has had a long interest in meningiomas, working with Mr. Steven Haley to create the Meningioma Project. He is Chair of the Editorial Board of Neurosurgery and sits on numerous foundations and editorial boards. He has received many awards including the Charles Wilson award, Rofeh award, the Pioneer award of the Children's Brain Tumor Foundation, and the distinguished service award from the Section on Tumors. Dr. Black directs a molecular biology laboratory that investigates growth and invasion in meningiomas. His bibliography includes 13 books and five hundred papers. He is president-elect of the World Federation of Neurosurgical Societies. He has mentored over a hundred trainees and is very proud of the productivity of his former trainees, many holding prominent academic positions.

**Contact:** Peter M. Black, Department of Neurosurgery, Brigham & Women's Hospital, 75 Francis St, Boston, MA 02115, USA  
E-mail: [pblack@partners.org](mailto:pblack@partners.org)

---

# THE “DANGEROUS” INTRACRANIAL VEINS

M. SINDOU

## INTRODUCTION

No doubt that number of so-called unpredictable post-operative complications are likely to be related to iatrogenic venous damages. They manifest as locally developed edema, regional or diffuse brain swelling, some being fatal because of uncontrollable intracranial hypertension, and/or hemorrhagic infarcts, sometimes devastating and erroneously attributed to default in hemostasis. Ignoring the venous structures during surgery would lead to such disastrous consequences.

The main “dangerous” veins are classically the major dural sinuses, the deep cerebral veins and some of the dominant superficial veins like the vein of Labbé. A complete and detailed pre-operative setting including venous angio-MR, and if necessary digital subtraction angiography with late venous phases, helps to determine optimal surgical strategy. A sustained effort during surgery to always respect and sometimes reconstruct the venous system is an obligation for the surgeon.

## RATIONALE

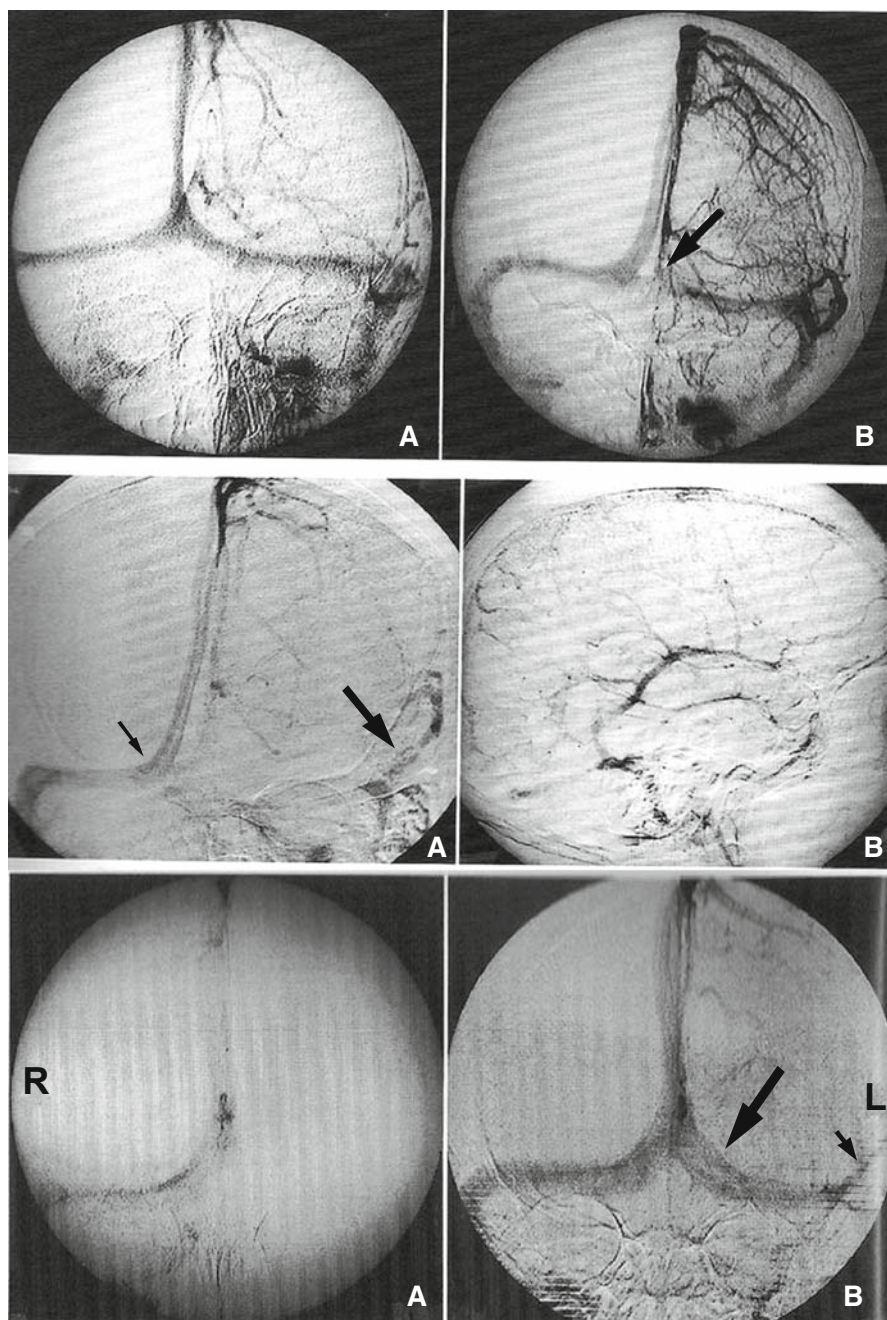
Good knowledge on the surgical anatomy and physiology of the intracranial venous system is of prime importance [3, 5, 9–11, 14].

### 1. THE DURAL SINUSES (Fig. 1)

The major dural sinuses – foremost the superior sagittal sinus (SSS) – carry a considerable amount of blood. The anterior third of SSS receives the prefrontal afferent veins; its posterior radiological landmark is the coronal suture. It is generally admitted that its sacrifice is well tolerated. Actually mental disorders, personality changes, loss of recent memory with a general slowing of thought processes and activity, or even akinetic mutism, may occur if sacrificed or if frontal veins are compromised. The midthird receives the numerous and voluminous cortical veins of the central group. Interruption of this portion entails high risks of bilateral hemiplegia and akinesia. The posterior third, as well as the torcular Herophili, which receives the straight sinus, drains a considerable amount of blood. Interruption would inevitably provoke potentially fatal intracranial hypertension.

---

*Keywords:* intracranial veins, major dural sinuses, brain, anatomy, vascular



The lateral sinuses (LS) ensure a symmetric drainage in only 20% of the cases; in the extreme one LS may drain the SSS in totality, most often the right one, and the other the straight sinus.

The transverse sinus (TS) may be atretic on one side, the sigmoid sinus segment draining the inferior cerebral veins (i.e. the Labbé system).

The sigmoid sinus (SS) drains the posterior fossa. It receives the superior and the inferior petrosal sinuses and also unconstant veins coming from the lateral aspect of pons and medulla. It has frequent anastomoses with the cutaneous venous network through the mastoid emissary vein. When the sigmoid segment of the lateral sinus is atretic, the transverse sinus with its affluents drains toward the opposite side.

All these anatomical configurations have surgical implications and must be taken into account before considering interrupting a sinus (Fig. 2).

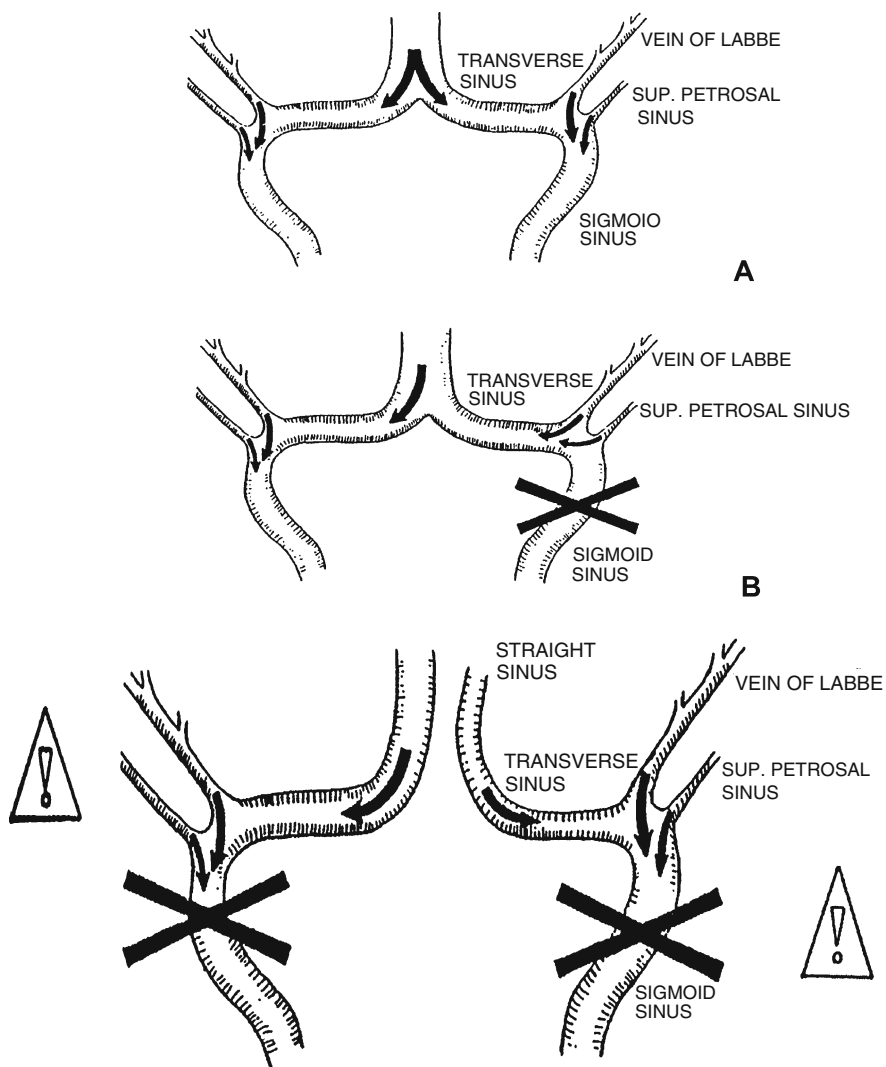
## 2. THE SUPERFICIAL CEREBRAL VEINS

Any of the superficial cerebral veins of a certain calibre has presumably a functional role. However, as shown by experience, some of them are more "dangerous" to sacrifice than others. The superficial veins belong to three "systems": the midline afferents to the SSS, the inferior cerebral afferents to the TS and the superficial sylvian afferents to the cavernous sinus. These three systems are strongly interconnected, but in very variable ways from one individual to another.

Midline afferent veins enter into the SSS. They are met during interhemispheric approaches. Seventy percent of sagittal venous drainage is evident within the sector four centimeters posterior to the coronal suture; it corresponds to the central group. Sacrifice of the midline central group is risky. The sacrifice of the other midline veins, unless they are of large calibre, does not appear so hazardous. The vein of Trolard, or superior anastomotic vein, links the superficial sylvian system to the SSS. It usually penetrates the SSS in the post-central region.

Inferior cerebral veins are cortical bridging veins that channel into the basal sinuses and/or into the deep venous system. They are met in the skull base approaches. Juxta-basal veins may be sacrificed only if they are small and do not contribute predominantly to the system of Labbé. The vein of Labbé, or inferior anastomotic vein, creates an anastomosis between the superficial sylvian vein and the TS before its junction with the SS. Necessity of the respect

←  
**Fig. 1.** *Upper row:* **A** Left carotid angiogram, AP projection. The SSS is drained equally by both lateral sinuses (LS). **B** Left carotid angiogram, AP projection. The right LS drains totally the SSS, the left one drains the straight sinus (arrow). *Middle row:* Left carotid angiogram; AP (**A**) and lateral (**B**) projections. The SSS exclusively drains into the right LS (small arrow). The left transverse sinus is atretic; the remaining sigmoid sinus drains the vein of Labbé (large arrow). *Lower row:* **A** Right carotid angiogram, AP projection; **B** left carotid angiogram, AP projection. The sigmoid sinus is absent on left side so that the left transverse sinus (large arrow) and its tributaries, especially vein of Labbé (small arrow), are drained toward the contralateral side

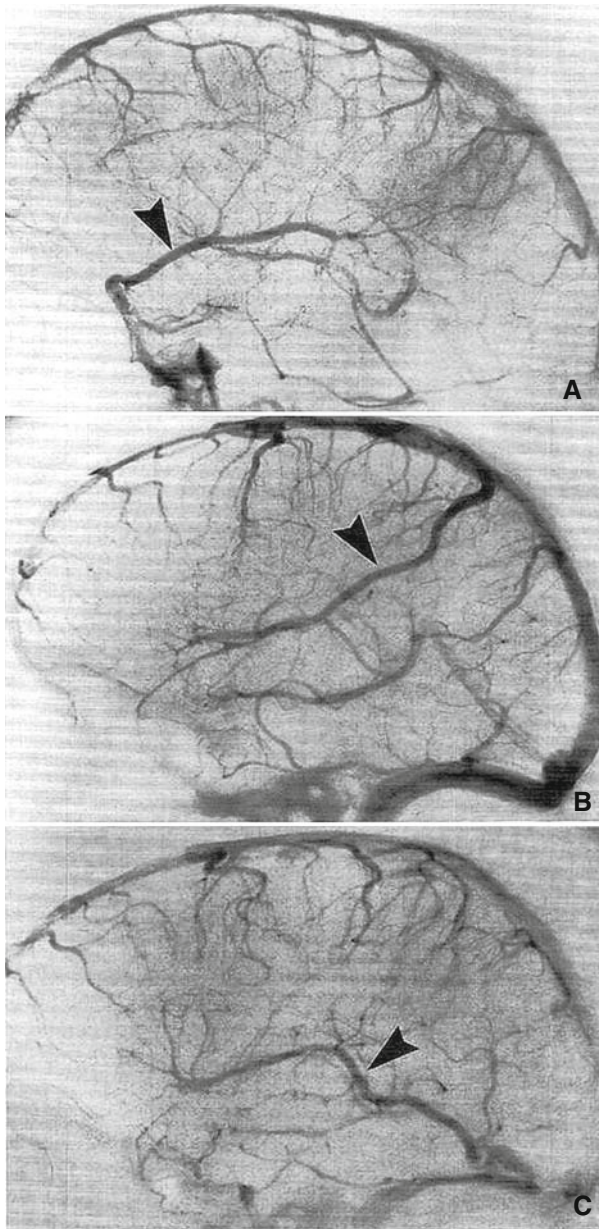


**Fig. 2.** Upper and middle rows: When both lateral sinuses (LS) are well-developed (upper row), interruption of one LS (middle row) may theoretically be tolerated. Lower row: When one LS drains exclusively the SSS and the other one the straight sinus (a frequent configuration), interruption of either one entails high risks for hemispheres, deep cerebral structures and Labbé vein(s)

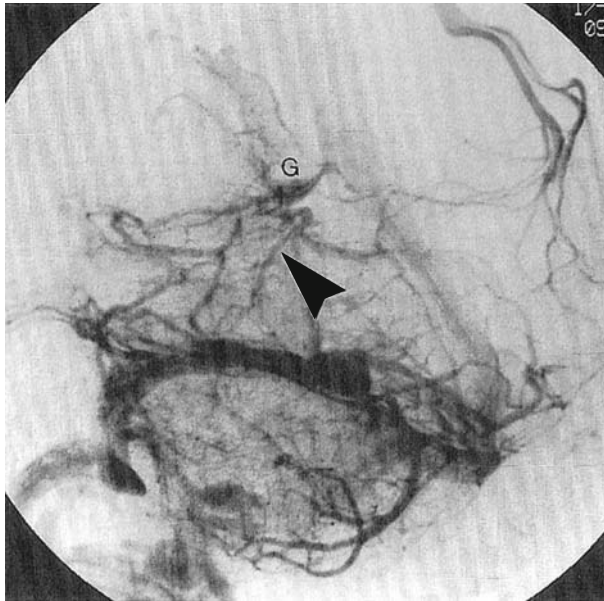
of vein of Labbé, especially in the dominant hemisphere, is mandatory to avoid posterior hemispheric infarction.

The superficial sylvian vein is formed by anastomosis of the temporo-sylvian veins; these veins are connected with the midline veins upward and





**Fig. 3.** Variations of superficial venous system. **A** The anterior drainage by the superficial sylvian vein is predominant. **B** The sss is predominant; the post-central vein drains the bigger part of the superficial sylvian vein territory (through Trolard anastomotic vein). **C** The lateral sinus is predominant; it drains almost all the superficial sylvian vein territory (through Labbé vein)



**Fig. 4.** Posterior fossa venous system by vertebral injection. Vein of Galen (G), precentral vermian vein (arrowhead)

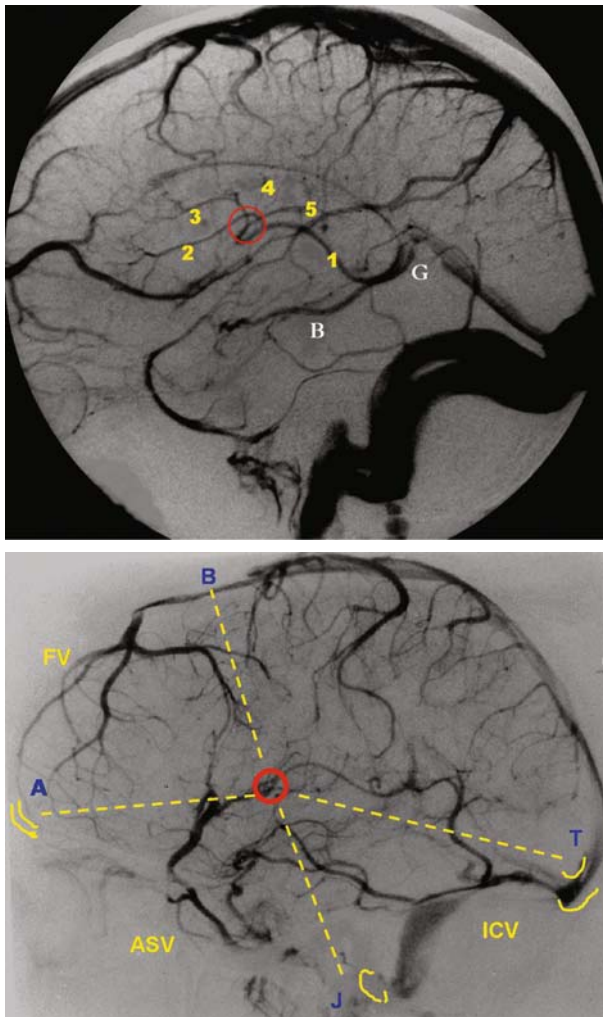
the juxtbasal temporal veins downward. It enters predominantly the cavernous sinus, either directly or through the sphenoparietal sinus. Many variations are possible. Sacrificing the superficial sylvian vein is risky when it is of large calibre and poorly anastomosed.

Skull base approaches must be prepared taking into account the anatomical organization of the superficial venous system (see details and literature quotations in references [3, 10, 11]) (Fig. 3, 5, bottom).

**Fig. 5.** *Top:* Deep cerebral veins and landmark of the interventricular venous confluence. DSA by carotid injection, venous phase, lateral view. The interventricular venous confluence (circle) is formed by confluence of the septal veins (2), caudate veins (3, 4), and thalamo-striate veins (5). Confluence gives rise to the internal cerebral vein (1). On lateral view, this confluence has an almost constant situation and corresponds to the interventricular foramen of Monro. This point may contribute a useful anatomical imaging reference. (Confluence of internal cerebral veins and basilar veins [B] gives Galen vein [G]. *Bottom:* Superficial veins involved in (supratentorial) skull base approaches. Three groups of veins can be distinguished: the middle afferent frontal veins, the inferior cerebral veins (i.e. the Labbé system) and the sylvian veins. These three groups can be delimited by three "triangles". (1) The triangle corresponding to the frontal group of veins (FV) is delimited by the three following landmarks: interventricular venous confluence (circle), bregma (B) and the anterior limit of anterior cranial fossa (A). (2) The triangle corresponding to the inferior group (ICV) is delimited by the interventricular confluence (circle), torcular (T) and jugular foramen (J). (3) The triangle corresponding to the anterior sylvian group (ASV) is delimited by the interventricular confluence (circle), anterior limit of anterior cranial fossa (A) and jugular foramen (J) landmarks. Skull base approaches must be designed so that the prominent venous drainage(s) be respected

### 3. THE DEEP VEINS OF THE BRAIN

The deep cerebral veins are the ones which drain toward the deep venous confluent of Galen (Fig. 5, top). The denomination of venous confluent is appropriate since – in addition to the two internal cerebral veins – the Galenic system receives the two basilar veins, and also veins from the corpus callosum, the cerebellum (mainly through the vermician precentral vein) and the occipital cortex. A good knowledge of the deep veins is important for surgery in the lateral ventricles and of course in the third ventricle and pineal region [2].



There is a general agreement that the sacrifice of the vein of Galen or of one of its main tributaries should be considered as a high risk, although animal experiments and a few reported clinical observations showed otherwise.

The thalamostriate vein represents an important anatomic landmark when accessing the third ventricle through the lateral ventricle by the interthalamo-trigonal approach. It drains the deep white matter of the hemisphere, the internal capsule and the caudate nucleus. This vein has to be sometimes sacrificed in this approach. Consequences vary depending on the authors: from little or none to venous infarction of basal ganglia. Because consequences can be severe, sacrificing the thalamostriate vein is justified only if widening the exposure of the third ventricle is absolutely necessary [4].

#### **4. VEINS OF THE POSTERIOR FOSSA**

It is important to consider venous anatomy when dealing with posterior fossa surgery (Fig. 4) [7]. The sitting position entails the risk of air embolism from sinus and/or vein opening. The cerebellum is at risk of swelling and infarction in the eventuality of venous interruption.

The sacrifice of the precentral vermian vein in order to approach the pineal region from posterior, is generally considered not dangerous.

The classical statement that the superior petrosal vein can be interrupted without danger needs to be reconsidered. Swelling of the cerebellar hemisphere after sacrificing a (voluminous) petrosal vein is not unfrequently observed and venous infarction may occur.

## **SURGERY**

### **1. AVOIDANCE OF VENOUS OCCLUSIONS DURING SURGERY**

The role played by venous occlusions occurring during surgery in post-operative hemorrhagic infarcts is undeniable. Important, the association of venous sacrifice to brain retraction entails significantly higher risk of brain damage than retraction alone. It has been experimentally shown that parenchymal retraction of one hour duration, in opposition to retraction combined to venous sacrifice, produces a subcortical infarct in 13% and 60% of animals, respectively [6]. Retraction of the brain provokes a local congestion by compressing the cortical venous network, reduction in venous flow by stretching the bridging veins, and thrombosis of veins if compression of the retractor or a cottonoid is prolonged.

Excessive brain retraction can be avoided by specially designed approaches obeying two principles: the one of minimally invasive opening: the “key-hole” approaches, and the one of bone removal: “osteotomies” associated with craniotomy at the base of the skull. Bone removal associated to

craniotomies for skull base approaches by increasing the field-view angle and the working-cone [1, 12] protect from important retraction and consequently avulsing veins. Extended approaches (as fronto-basal, orbital, zygomatic, orbito-zygomatic, at the level of the roof of the external auditory meatus, transpetrosal or extreme lateral of the foramen magnum) have become classical. Limited opening of the dura mater to the minimum required is most effective to avoid excessive retraction by the self-retractor. In the eventuality of necessary prolonged retraction, releasing the retractor from time to time decreases damaging phenomena. Removing the blade for approximately five minutes every fifteen minutes is considered beneficial.

It may happen that a bridging vein acts as a limitation. To be preserved, the vein has to be dissected free from arachnoid and cortex at a length of 10–20 mm [13]. It also may happen that a big vein inside a fissure or a sulcus performs as an obstacle. Because interruption would entail the risk to provoke "a cascade" of intraluminal coagulation of the neighbouring pial veins it is justified to attempt its preservation. If conservation seems difficult, before deciding sacrifice a gentle temporary clamping for a few minutes with a microforceps or a small temporary clip may be useful to test the absence of consecutive regional congestion.

## 2. REPAIR

When an important vein has been ruptured, its reconstruction may be considered. For this purpose the silicone tubing technique has been developed. "A silicone tube that is most suitable to the size of the vein origin is selected and inserted into the distal segment of the vein and fixed with a 10-0 monofilament nylon circumferential tie. The other end of the silicone tube is then inserted into the proximal end of the vein and tied [8]."

Frequent is the circumstance in which a wound is made in a vein wall during dissection. Rather than to coagulate the vein, hemostasis can be attempted by simply wrapping the wall with a small piece of Surgicel. If this is not sufficient, obliteration of the wound can be made by a very localized microcoagulation with a sharp bipolar forceps or by placing a single suture with a 10-0 nylon thread. But in all cases, whatever the technique used, quality of hemostasis has to be checked by jugular compression at the neck or with local patency test using two forceps, as classical in microvascular surgery.

When a major dural sinus has been injured or needs to be occluded, its repair is advocated [3, 10, 11].

## CONCLUSIONS

Respect of the intracranial venous system results from a constant belief of the importance of preserving veins and a sustained effort to do it during the whole operation.

Surgery on the intracranial venous system requires good neuro-images to work on. Venous angio-MR, as a complement of conventional MRI is mandatory. In supplement, digital subtraction angiography with late venous phases can be of prime importance to determine surgical strategy especially in “difficult tumors”. For these reasons neurosurgeons must incite neuro-imaging colleagues to be full-partners in the neurosurgical management.

## References

- [1] Alaywan M, Sindou M (1990) Fronto-temporal approach with orbito-zygomatic removal. *Surgical anatomy. Acta Neurochir (Wien)* 104: 79-83
- [2] Apuzzo ML (1977) *Surgery of the third ventricle*. Williams & Wilkins, Baltimore
- [3] Auque J (1996) Le sacrifice veineux en neurochirurgie. Evaluation et gestion du risque. *Neurochirurgie* 42(Suppl 1): 32-38
- [4] Delandsheer JM, Guyot JF, Jomin M, Scherpereel B, Laine E (1978) Accès au troisième ventricule par voie interthalamo-trigonale. *Neurochirurgie* 24: 419-422
- [5] Hakuba A (ed) (1996) *Surgery of the intracranial venous system. Embryology, anatomy, pathophysiology, neuroradiology, diagnosis, treatment*. First international workshop on surgery of the intracranial venous system at Osaka September 1994. Springer, Tokyo
- [6] Kanno T, Kasama A, Shoda M, Yamaguchi C, Kato Y (1989) A pitfall in the interhemispheric translamina terminalis approach for the removal of a craniopharyngioma. Significance of preserving draining veins. Part I. Clinical study. Part II. Experimental study. *Surg Neurol* 32: 111-115, 116-120.
- [7] Matsushima T, Rhoton AL Jr, de Oliveira E, Peace D (1983) Microsurgical anatomy of the veins of the posterior fossa. *J Neurosurg* 59: 63-105
- [8] Sakaki T, Morimoto T, Takemura K, Miyamoto S, Kyoï K, Utsumi S (1987) Reconstruction of cerebral cortical veins using silicone tubing. Technical note. *J Neurosurg* 66: 471-473
- [9] Schmidek HH, Auer LM, Kapp JP (1985) The cerebral venous system. Review. *Neurosurgery* 17: 663-678
- [10] Sindou M, Auque J (2000) The intracranial venous system as a neurosurgeon’s perspective. Review. *Adv Tech Stand Neurosurg* 26: 131-216
- [11] Sindou M, Auque J, Jouanneau E (2005) Neurosurgery and the intracranial venous system. *Acta Neurochir Suppl* 94: 167-175
- [12] Sindou M, Emery E, Acevedo G, Ben-David U (2001) Respective indications for orbital rim, zygomatic arch and orbito-zygomatic osteotomies in the surgical

approach to central skull base lesions. Critical, retrospective review in 146 cases. *Acta Neurochir (Wien)* 143: 967-975

- [13] Sugita K, Kobayashi S, Yokoo A (1982) Preservation of large bridging veins during brain retraction. Technical note. *J Neurosurg* 57: 856-858
- [14] Yaşargil MG (1984) *Microneurosurgery. Microsurgical anatomy of the basal cisterns and vessels of the brain, diagnostic and studies, vol 1.* Thieme, Stuttgart



**Marc Sindou**

Marc Sindou is Professor of Neurosurgery and Chairman of the Department of Neurosurgery at the Hôpital Neurologique P. Wertheimer, Lyon. Born in 1943 in Limoges, he completed in parallel his medical and scientific studies, at the Universities of Limoges, Bordeaux and Paris. Then he applied for residency in neurosurgery in 1969 at the University of Lyon, where a new Institute for Neurosciences had just been created by Pierre Wertheimer, one of the pioneers of French neurosurgery. The institute had 180 beds for neurology and 140 beds for neurosurgery and was served by ten operating rooms, with around 3800 surgical operations per year.

Marc Sindou obtained his M.D. degree in 1972 with the thesis “Anatomical study of spinal dorsal root entry zone. Applications for pain surgery”, and same year his Doctorat in Sciences (D.Sc.) with the thesis “Cerebral cortex electrogenesis in humans”. After a five-year training in Lyon, he benefited from two fellowships: the first with Professor William Sweet at the Massachusetts General Hospital in Boston, especially for pain surgery, the second with Professor Gazi Yaşargil at Kantonspital in Zurich for training in micro-neurosurgery. He was appointed associate professor in 1982 and became full professor in neurosurgery and chairman of department in 1986.

His research was directed to two different fields. On the basis of his M.D. thesis he developed neurophysiological investigations and surgery in the dorsal root entry zone



target for spinal deafferentation pain and focalized spasticity. In the fields of vascular surgery he worked in the laboratory on intracranial venous reconstruction which was then applied to patients harbouring meningiomas.

His main neurosurgical interests, with his large and outstanding team, were (1) functional neurosurgery, including pain, spasticity, epilepsy, trigeminal neuralgia; (2) microsurgery for intracranial aneurysms; (3) skull base meningiomas and meningiomas invading venous sinuses; (4) cranial nerve vascular compression syndromes, and (5) neurophysiology applied to neurosurgery. Surgical personal experience amounts to more than 20000 operations, which gave source to 549 publications.

Marc Sindou has been Founding-member of the International Association for the Study of Pain (IASP) in 1975, President (1998–2001) and Past-president (2001–2005) of the World Society for Stereotactic and Functional Neurosurgery (WSSFN), Vice-President of the European Association of Neurosurgical Societies (EANS) (1999–2003). He is presently President of the Société de Neuro-Chirurgie de Langue Française (SNCLF) (2007–2009). He is member of the editorial boards of a number of prestigious international journals, and has 135 editorials or comments published. He is a teacher in the EANS Training program and was awarded the prestigious “European Lecture” in 2007. He has been honoured by 16 visiting professorships and by 196 invited lectures in 49 different countries.

Main hobbies are: Mountaineering, with a number of summits in the french Alps, but with help of solid guides!, and also playing the piano, preferably when alone! Woody Allen and Umberto Eco are very much appreciated, and (only time to time) Mister Bean. “Resisting-administration” – of course not a hobby – takes part of his daily life.

Last but not least, he is supported by a nice and devoted wife, with whom he has three wonderful children and nine charming but turbulent grand-children.

Above all, Marc Sindou is indebted to all his masters, colleagues, staffs and pupils, from whom he learned so much through professional contacts and personal relationships.

**Contact:** Marc Sindou, Hôpital Neurologique P. Wertheimer, University of Lyon,  
59 Bd Pinel, 69003 Lyon, France  
E-mail: marc.sindou@chu-lyon.fr

---

# HOW TO PERFORM SUBFRONTO-ORBITO-NASAL APPROACH FOR ANTERIOR CRANIAL BASE SURGERY

F.-X. ROUX

## INTRODUCTION

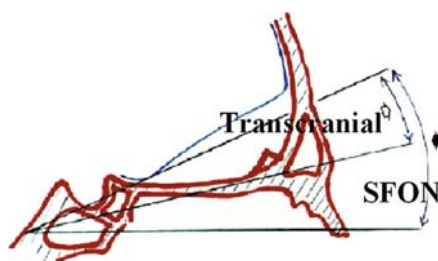
Subfrontal approaches were first proposed and described by Horsley and Cushing in the early beginning of neurosurgery. These approaches were mostly bifrontal flaps for skull base surgery. First combined craniofacial approaches were described by Dandy [1] in 1941 and by Ray and McLean [6] in 1943 for orbital tumors removal. Principles of transcranial and transfacial surgery were then precised by Smith et al. [8], Ketcham et al. [3] and Derome [2]. Later, enlarged approaches with mobilization of orbital rims and nasal pyramid were proposed. Subfronto-orbito-nasal (SFON) approach was first described in 1978 by Raveh as “anterior extended subcranial approach” for anterior skull base fractures [4, 5]. He extended the indications in 1980 for benign and malignant tumor resection [4, 5]. This approach allows performing a mediofrontonasal monobloc flap including nasal pyramid and orbital rims. We first used it for removal of ethmoidal tumors such as adenocarcinomas but we rapidly discovered the large field of vision given by this approach for anterior cranial fossa, ethmoidal, sphenoidal and maxillary sinuses, internal part of the orbit and clivus as well [7].

## RATIONALE

Main goal of this approach is to minimize brain retraction (Fig. 1) during anterior skull base surgery. Other goals are to reach some areas with respect of vasculonervous structures encountered. The SFON flap allows reaching extradural and intradural structures. Extradural structures include anterior skull base, ethmoidal, sphenoidal and even maxillary sinuses with access to clivus, mediosuperior part of orbital contents. Intradural structures include anterobasal part of both frontal lobes with olfactive tracts, jugum with optochiasmatic area, anterior part of the Willis circle and sellar area. Main advantage for intradural access is the minimal frontal lobe retraction. It allows early control of basal vessels such as ethmoidal arteries especially for tumors inserted on the anterior part of the skull. Moreover, this approach is widely modulable and can

---

*Keywords:* skull base approaches, fronto-orbital-nasal approach, anterior fossa



**Fig. 1.** Compared angles of access for classical subfrontal transcranial and SFON approaches showing minimal retraction and larger view for the latter

be adapted and extended as function of the areas to reach, laterally, upwards or downwards. This highly adaptable approach can be qualified of “swiss-knife” for craniofacial access.

## DECISION-MAKING

Basically, the SFON approach allows to reach lesions of the anterior skull-base, of the midline such as sellar, suprasellar or clivus masses, of the supero-internal part of the orbit, of sinuses of the face (ethmoidal, sphenoidal, maxillary sinuses) and anterior Willis circle as well. Thus, careful review of preoperative imaging is required to determine precisely if SFON approach is appropriate and to preview the anteroposterior and lateral extension of the approach. Both preoperative CT scan and MRI are mandatory to check bone and cerebral extensions of the lesion to be reached, and study angles between it and the skullbase plane in order to minimize retractions. Frontal sinus extension is not crucial since it is deliberately opened and cranialized. Other important information to check for intradural approach near the sellar area is the prefixed location of the chiasma which may limit dramatically the access to the concerned lesion.

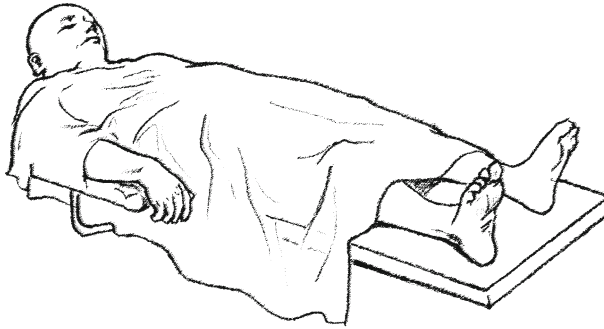
## SURGERY

### 1. POSITIONING

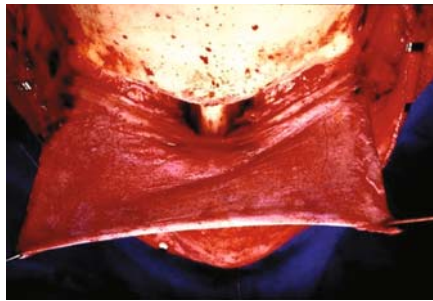
Patient is placed supine, the head fixed in median position and the neck slightly flexed to elevate the head (Fig. 2).

### 2. INCISION

After minimal shaving, bicoronal skin incision is performed from ear to ear. Care must be taken not to cut the galea which will be dissected and separated



**Fig. 2.** Operative supine position with the head fixed in median position and the neck flexed slightly to elevate the head (drawing by Marc Harislur)



**Fig. 3.** Pedicled pericranial flap

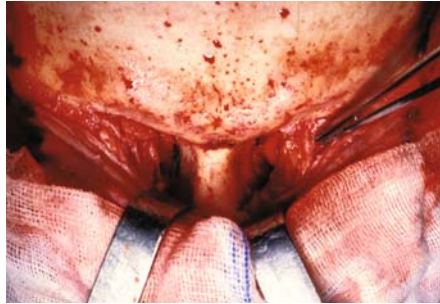from the skin starting 3 cm behind the orbital rims, thus sparing both supraorbital nerves.

### 3. GALEA FLAP

An anterior pediculated galea and pericranial flap is liberated and raised. Its limits are posteriorly the skin incision, and laterally both superior temporal lines. It must be as large as possible, about 8–10 cm laterally and 10–12 cm anteroposteriorly (Fig. 3).

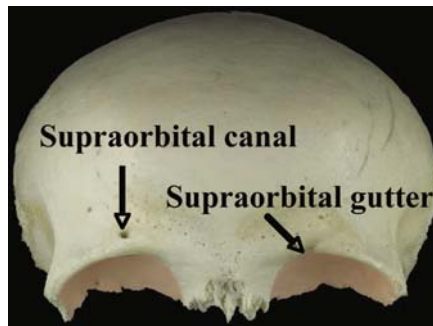
### 4. SUPRAORBITAL AND PERIORBITAL DISSECTION

Desinsertion of the galea is pursued to the orbital rims and nasal pyramid (Fig. 4). If the bone flap is extended downwards to the lachrymal crests, it may be necessary to cut the lacrymal ducts. To avoid secondary retraction and stenosis of them and consequent post-operative eye watering, lacrymal ducts should be cut obliquely. Then the priorbit is cautiously separated from

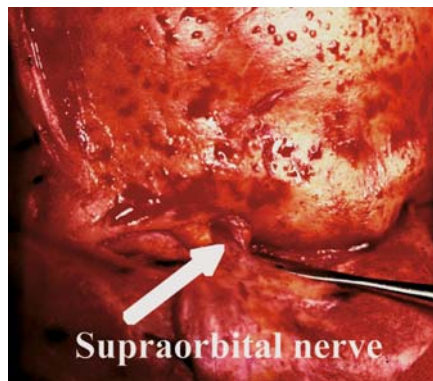


**Fig. 4.** Desinsertion of nasal pyramid with exposition of orbital rims and supraorbital grooves

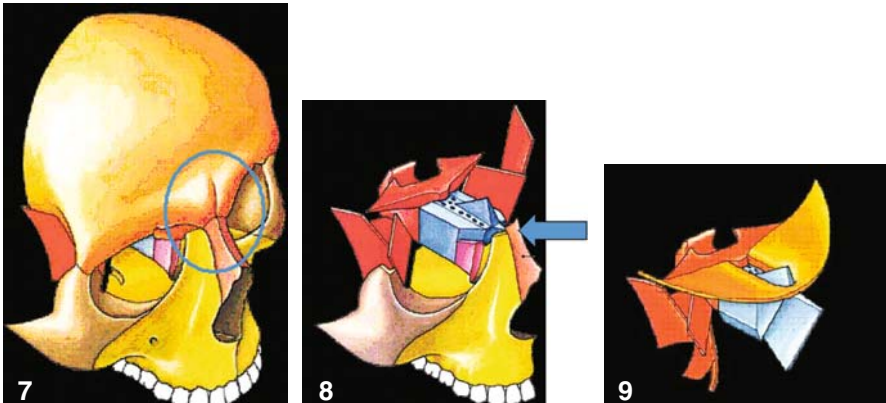
the medial wall of the orbit which should not be opened so as avoiding both risks of injury of intraconic structures and herniation of orbital fat in the operative field. Supraorbital pedicles are gently detached from both supraorbital



**Fig. 5.** Frontal bone anatomical piece showing: a supraorbital groove (left) and a closed groove as a supraorbital canal (right)



**Fig. 6.** Desinsertion of supraorbital pedicle within the supraorbital groove



**Figs. 7–9.** Scheme of craniofacial junction showing the location of the bone flap

grooves (Figs. 5, 6). Sometimes supraorbital gutters appear as canals and will have to be opened with scissors so as to preserve supraorbital nerves.

## 5. BONE FLAP

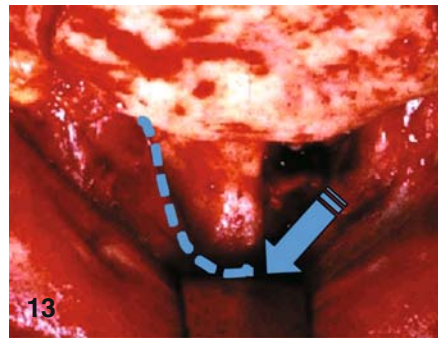
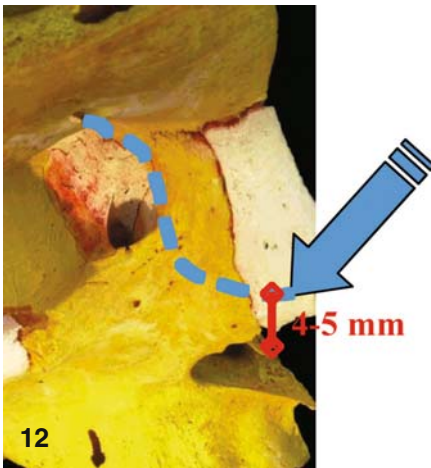
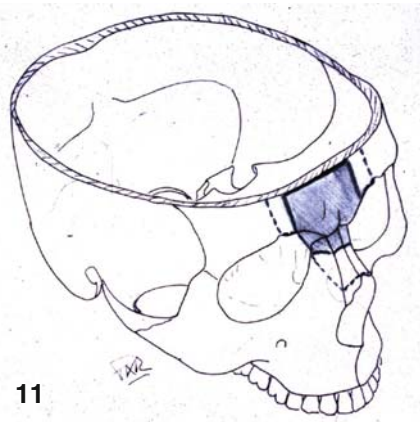
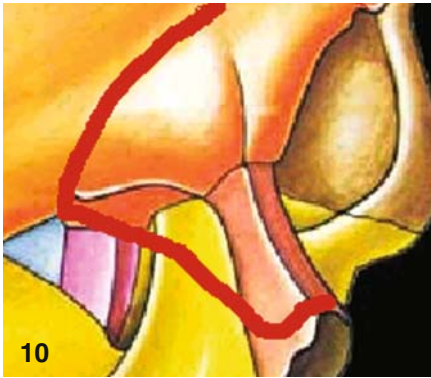
Only one burr hole is drilled on the median line facing the superior sagittal sinus in its anterior third. The dura is detached from the bone with a spatula, away in the sagittal sinus, in order to control it and avoid injuring it with the craniotome. The mediofrontal osteotomy is performed so as to raise a monobloc nasofrontal flap (Figs. 7–9). Upper part of the flap is performed with the craniotome starting from the burr hole towards both orbital rims. A flexible retractor is carefully placed in the orbit for retracting the eyeball while cutting, with an oscillant saw, the nasal pyramid and medial and superior walls of the orbits (Figs. 10, 11). Bradycardia may be noted if the eyeball retraction is too important. Then the bone flap is slightly elevated with two periosteal elevators and a vertical osteotomy is performed in front of the crista galli process. At last, the subfronto-orbito-nasal flap is raised in one bloc. Precise location of each lines of cut are shown on Figs. 12–16.

## 6. FRONTAL SINUS CRANIALIZATION

Frontal sinus is inevitably opened with this flap and it is thus mandatory to cranialize it. All frontal mucosa must be removed and both nasofrontal ducts will be obturated with bone powder, galea and eventually pieces of Surgicel.

## 7. EXPOSITION OF THE CRIBRIFORM PLATE OF THE ETHMOID

For ethmoidal tumor removal, the superior part of the ethmoid sinuses and the cribriform plates will be exposed. The approach being epidural, conse-

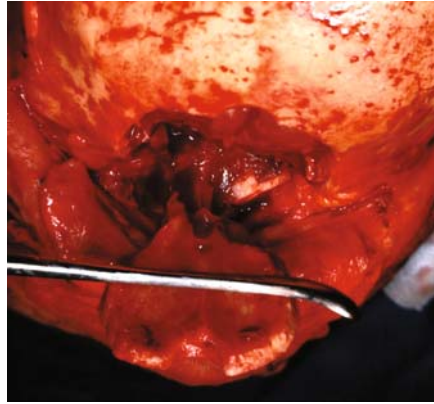


**Figs. 10-13.** Line of section of the frontal bone (mediofrontal osteotomy) and the nasal pyramid

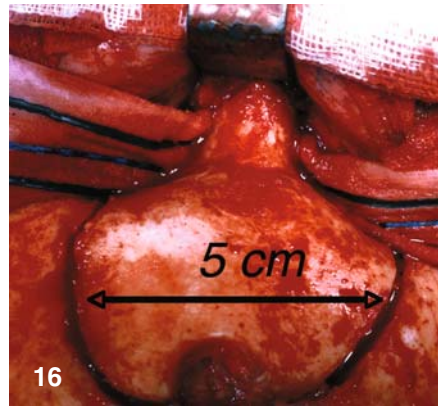
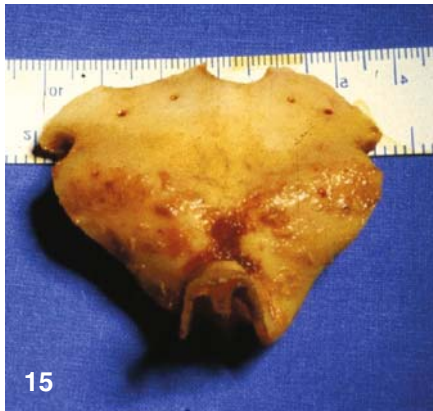quently the basifrontal dura will be desinserted from the front to the rear, the posterior limit being the jugum. During this surgical step both olfactive tracts will be coagulated and cut with the bipolar coagulator. This approach allows reaching both ethmoidal and sphenoidal sinuses as well as the maxillar sinuses which have to be controlled in case of wide ethmoidal tumor extending downwards. Opening the posterior part of the sphenoidal sinus allows an approach to the clivus itself, except the upper dead angle of the dorsum sellae.

## 8. DURA OPENING

The dura opening is performed transversally, entailing cutting the anterior insertion of the superior sagittal sinus (Fig. 17). It can be useful when beginning the procedure to suspend it peripherally on Halsted forceps.



**Fig. 14.** Detachment of the frontonasal flap after section of the crista galli process

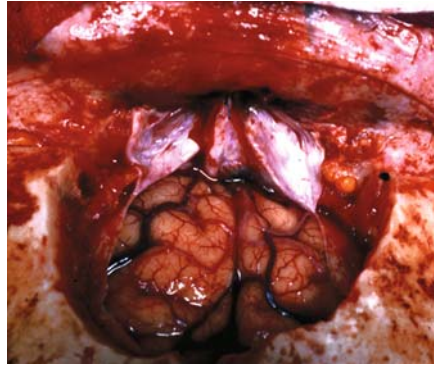


**Figs. 15, 16.** Frontonasal flap before and after removal

## 9. DISSECTION OF THE OLFACTORY TRACTS

For an intradural procedure, the dura has not to be detached from the cranial base. It is possible to spare olfactory tracts (at least one in order to preserve as much as possible the olfactory function) by a gentle arachnoidal dissection under smooth retraction of frontal lobes with an autostatic retractor. Biological glue is applied on both tracts to protect them and avoid ischemia or rupture during further dissection and retraction of the frontal lobe. This intradural approach allows exposing all the anterior cranial base, reaching easily the optochiasmatic tracts, the sellar and suprasellar region including the anterior part of the Willis circle. Approach can be lateral in its



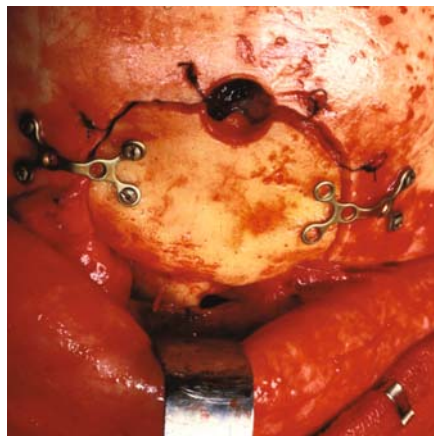


**Fig. 17.** Dura opening leading to basal access

anterior part and becomes more medial on its posterior part. All along the operation, retraction of frontal lobes will be minimalized due to the basal access.

#### **10. DURA CLOSURE, SUSPENSION AND TENTING**

Closure of the dura is performed after releasing transient suspensions and must be totally waterproof in order to avoid cerebrospinal fluid leakage and rhinorrhea. Then peripheral suspension and tenting of the dura is performed. This closure is doubled with the pediculated galea flap which is reclined on the base and the cranialized frontal sinuses and pasted to the dura with fibrin glue and a few stitches.



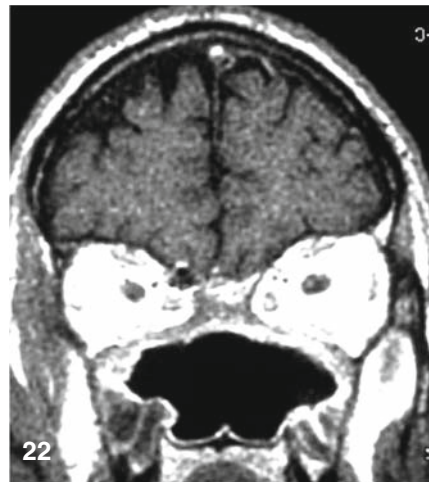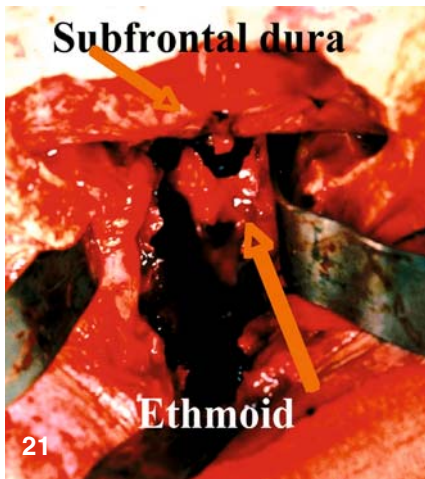
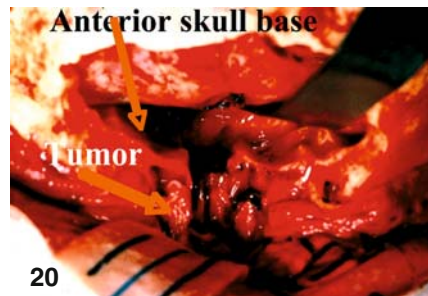
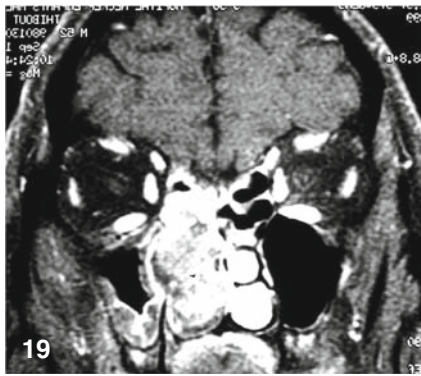
**Fig. 18.** Fixation of the flap with titanium miniplates (or stitches)

## 11. BONE FLAP REPOSITIONING

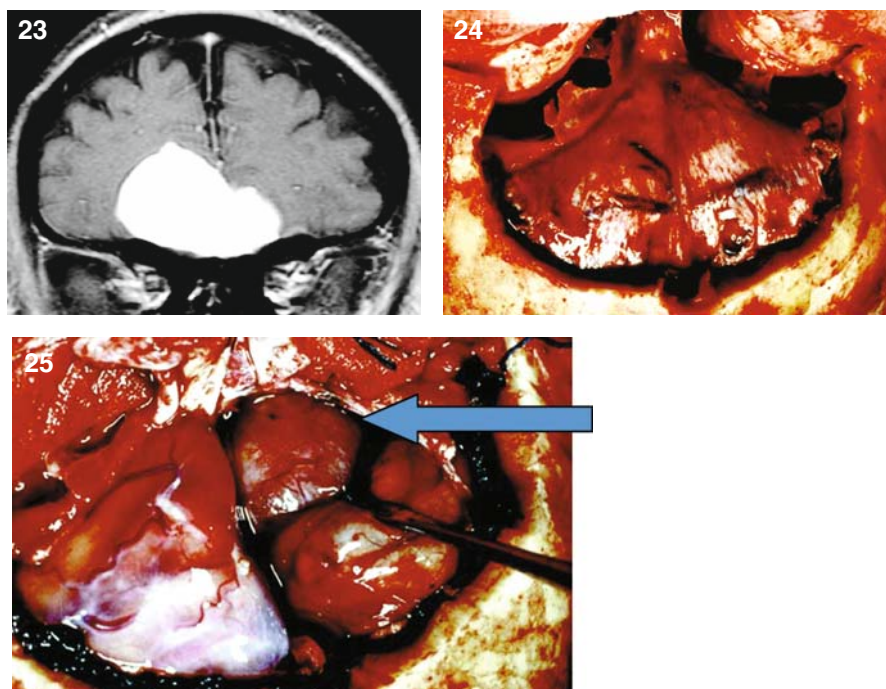
Bone flap is then repositioned and secured with transosseal sutures or titanium miniplates (Fig. 18). We avoid miniplates when the patient is planned for further radiotherapy because of a thinning of the skin with a bad cosmetic result and a higher risk of local infection.

## 12. SCALP CLOSURE

Scalp is then closed with both subcutaneous and cutaneous sutures with skin clips or stitches.



**Figs. 19–22.** Case 1: Ethmoidal carcinoma. **Fig. 19.** Preoperative MRI showing a T3 tumor invading cribriform plate. **Figs. 20, 21.** SFON approach. **Fig. 22.** Postoperative MRI showing complete removal



**Figs. 23–25.** Case 2: Olfactory meningioma. **Fig. 23.** Preoperative MRI. **Fig. 24.** View of the operative field before opening dura. **Fig. 25.** Meningioma inserted on the anterior skull base with direct access to its insertion

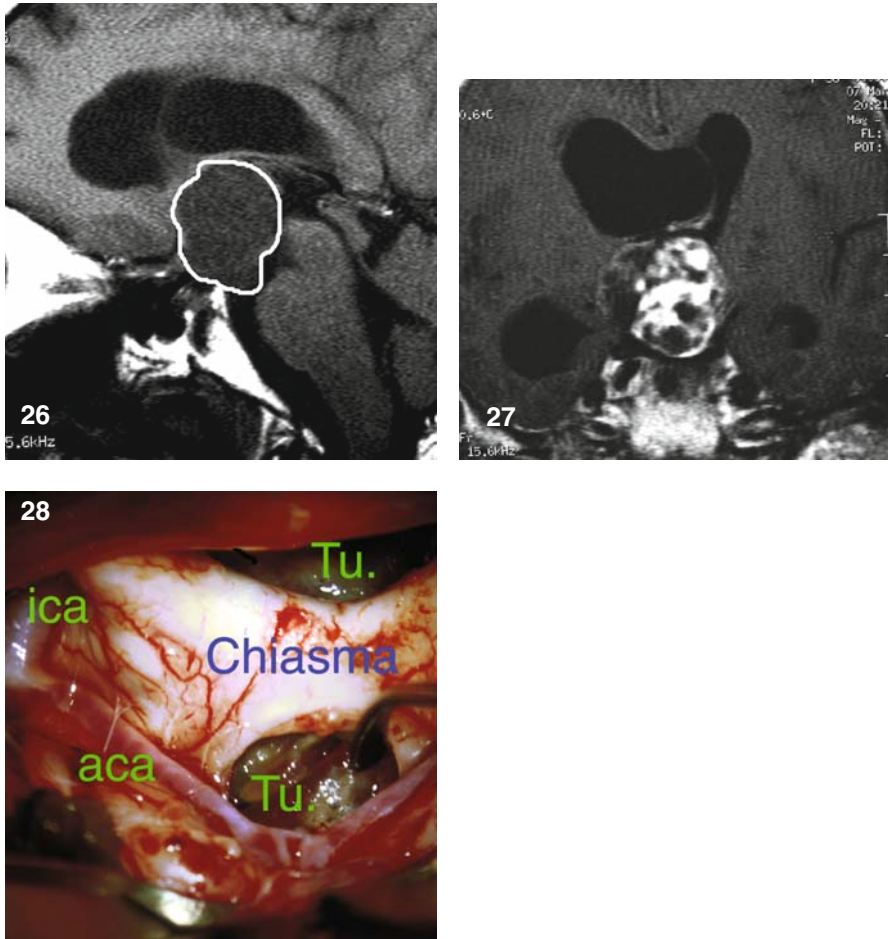
## HOW TO AVOID COMPLICATIONS

### 1. GENERAL COMPLICATIONS

General complications such as postoperative hematoma, infection (4.5%), thromboembolism will not be discussed here since they do not differ from those observed in other neurosurgical procedures. Preventive dose of low-molecular-weight heparin is usually administrated early after surgery (first postoperative day).

### 2. CSF LEAKAGE (3.3%)

One of the most important parts of the procedure to be stressed is a perfect waterproof dural closure. Indeed a possible complication to be avoided is CSF leakage responsible for either rhinorrhea or subcutaneous CSF collection. Therefore a very good and waterproof dural closure is necessary; we use the double galea flap which is reclined onto the cranial base (especially the dura of the base which can be dehiscent) and secured to the dura with fibrin



**Figs. 26–28.** Case 3: Craniopharyngioma. **Figs. 26, 27.** Preoperative MRI. **Fig. 28.** Intra-dural approach with both vasculonervous structures and tumor (*aca* anterior carotid artery; *ica* internal carotid artery; *Tu* tumor)

glue. In some cases, transient lumbar drainage could be discussed; but we never propose systematically such a drainage considering that the quality of the dural closure should sufficient.

### 3. NEUROLOGICAL COMPLICATIONS

#### 3.1 Anosmia

Anosmia is unavoidable in ethmoid tumor as well as olfactory meningioma removal since the approach of the cribriform plate requires section of both

olfactory tracts. Otherwise, if section of olfactory tracts is not compulsory, anosmia may be avoided when proceeding to intradural approaches with a careful dissection of the arachnoid surrounding the olfactory nerves and strengthening them with fibrin glue. If necessary, sacrifice of one olfactory tract could possibly preserve unilateral olfaction.

### 3.2 Confusion

Confusion may result from frontal retraction as well as venous or arterial ischemia (3.3%). Main goal of SFON approach is precisely to avoid such retraction. Nevertheless gentle frontal lobe retraction may be mandatory in some instances. CSF drainage in basal cisterns as well as mannitol perfusion may help to decrease this retraction. It must be released periodically during the procedure, and used only if it is really necessary. Great care must be given in avoiding vascular injury or coagulation, especially concerning large anterior frontal veins. If these veins are spared, anterior part of the superior sagittal sinus may be occluded without any consequences.

### 3.3 Ocular motor palsies, diplopia

Transient oculomotor palsies may often occur because of edema of intraorbital structures. This occurs more likely when the periorbit is opened which should be avoided. Permanent rate of transient postoperative diplopia is about 6.6% in our series.

### 3.4 Frontal branch of facial nerve injury

Injury of the frontal branch of the facial nerve should never happen. The bicoronal incision must be stopped at least 1 cm above the zygoma process.

### 3.5 Supraorbital nerve injury

Supraorbital injury may induce hypoesthesia or anesthesia of eyebrow and supraorbital area. It can be avoided by performing a careful subperiosteal dissection of the galea, and releasing the nerves in the supraorbital gutters or canals.

## 4. WATERING EYES

It can be seen postoperatively (9.9%) if lacrymal ducts are retracted and obstructed. That is why they should be cut obliquely when the approach is extended downwards.

## 5. MUCOCELE

Late occurrence of a mucocele can be avoided by careful cranialization of the frontal sinus and obstruction of the nasofrontal ducts.

## 6. ESTHETIC CONSIDERATIONS

Bicoronal scalp incision decreases the risk of an inesthetic visible scar. Frontal median burr hole may sometimes be visible especially after radiotherapy since the skin may become thinner. For same reasons, miniplates used for fixation of the bone flap must be avoided if external radiotherapy is scheduled after surgical procedure.

## CONCLUSIONS

SFON approach is a relatively simple approach. It has the advantage of being adjustable depending on the areas and structures to reach. It allows treating a wide field of craniofacial lesions with a limited retraction of cerebral structures. Great care must be taken to perform a perfect and waterproof closure of the dura.

### Acknowledgements

I want to thank very much Dr. François Nataf, neurosurgeon in my department, for his great help in the redaction of this paper.

### References

- [1] Dandy WE (1941) Orbital tumors. Results following the transcranial operative attack. Oskar Piest Publications, New York
- [2] Derome P (1972) Les tumeurs sphéno-orbitaires. Possibilités d'exérèse et de réparations chirurgicales. *Neurochirurgie* 18(Suppl 1): 164
- [3] Ketcham AS, Wilkins RH, Van Buren JM (1963) A combined intra-cranial facial approach to the paranasal sinuses. *Am J Surg* 103: 698-703
- [4] Raveh J, Laedrach K, Speiser M, Chen J, Vuillemin T, Seiler R, Ebeling U, Leibinger K (1993) The subcranial approach for fronto-orbital and anterioposterior skull-base tumors. *Arch Otolaryngol Head Neck Surg* 119: 385-393
- [5] Raveh J, Turk J, Ladrach K, Seiler R, Godoy N, Chen J, Paladino J, Virag M, Leibinger K (1995) Extended anterior subcranial approach for skull base tumors: long-term results. *J Neurosurg* 82: 1002-1010
- [6] Ray BS, McLean JM (1943) Combined intracranial and orbital operation for retinoblastoma. *Arch Ophthalmol* 30: 437-445
- [7] Roux FX, Moussa R, Devaux B, Nataf F, Page P, Laccourreya O, Schwaab G, Brasnu D, Lacau Saint-Guilj J (1999) Subcranial fronto-orbito-nasal approach for ethmoidal cancers. *Surg Neurol* 52: 501-510
- [8] Smith KR, Klopp CT, Williams JM (1954) Surgical treatment of cancer of the frontal sinus and adjacent areas. *Cancer* 7: 991-994



**François-Xavier Roux**

François-Xavier Roux is Head of the Department of Neurosurgery at Hopital Sainte-Anne, Paris, France.

He was nominated as associate professor in 1985, professor in 1998 and head of department in 2001. He was President of the French Neurosurgical Society from 1998 to 2000. He is well-known for his historical and actual expertise in stereotactic and epileptic surgeries. During the past 25 years, he developed anterior cranial base surgery which is now one of the main activities of the department. His experience concerns particularly ethmoid cancers, olfactory tract meningiomas as well as pituitary and supra sellar tumors. It is in this context that he proposed different techniques and approaches applied to this type of surgery, especially the SFON approach published in 1998, in *Surgical Neurology*.

He is also very much concerned by cerebral gliomas, particularly oligodendrogliomas, and vascular neurosurgery (aneurysms and AVM's). At last he developed laser neurosurgery since the early 1980s and is the author of 2 books treating this topic.

**Contact:** François-Xavier Roux, Hôpital Sainte-Anne, 1 rue Cabanis, 75014 Paris, France

E-mail: [fx.roux@ch-sainte-anne.fr](mailto:fx.roux@ch-sainte-anne.fr)

---

# HOW TO PERFORM CRANIO-ORBITAL ZYGOMATIC APPROACHES

O. AL-MEFTY

## INTRODUCTION

The cranio-orbital zygomatic approach has been in evolution since the frontal approach was first introduced. The addition of both the orbital and zygomatic osteotomies has expanded the limits of neurosurgery to include orbital, craniofacial, and infratemporal pathology. The goal of any skull base approach is to shorten the operative working distance and reduce retraction of the brain while improving exposure. Utilizing the benefits afforded by the cranio-orbital zygomatic approach requires a thorough understanding of the extradural anatomy of the anterior and middle fossae, including the temporal bone, the craniofacial skeleton, and the cavernous sinus.

McArthur and then Frazier were the earliest to incorporate the orbital rim osteotomy with the craniotomy to provide a low frontal approach to the pituitary [11, 17]. Yaşargil in 1969 introduced the pterional approach describing the extradural removal of the sphenoid wing and anterior clinoidal process [23]. Jane et al. resurrected the use of the orbital osteotomy for approaching orbital tumors [15]. Pellerin et al., Hakuba, and Al-Mefty expanded this approach by adding a fronto-orbito-malar osteotomy [6, 13, 20]. Al-Mefty went on to define the cranio-orbital zygomatic approach by combining each of these separate techniques to provide the approach as it is described today [3, 6, 8]. Since then, many authors have described their experiences and modification to this technique [1, 4, 5, 7, 9, 12–14, 18, 20, 21].

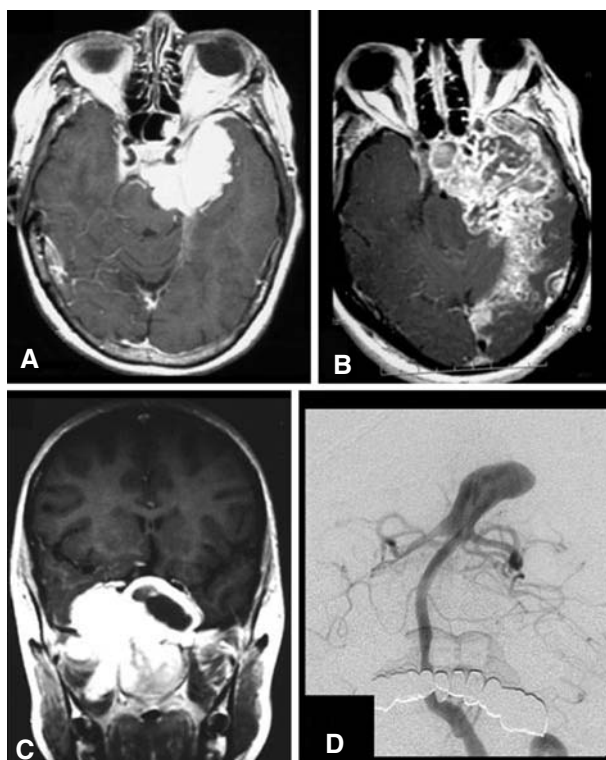
## RATIONALE

The cranio-orbital zygomatic approach provides the surgeon with a basal exposure of the anterior, middle, and upper ventral middle fossa without retraction of the brain. This approach provides extradural access to the craniofacial skeleton, infratemporal fossa, and paranasal sinuses: frontal, ethmoid, and sphenoid. The internal carotid artery (ICA) can be visualized from its entrance at the skull base through the cavernous sinus extradurally and beyond its bifurcation intradurally as well as the intrapeduncular fossa and the upper

---

*Keywords:* cranio-orbital zygomatic approach, skull base surgery, neurosurgical technique, craniotomy





**Fig. 1.** Example cases that benefit from the utilization of the cranio-orbital zygomatic approach. **A** Sphenocavernous meningioma. **B** Chordoma with extra- and intradural extension with involvement of the cavernous sinus. **C** Juvenile angiofibroma with involvement of the middle fossa and infratemporal fossa. **D** Basilar tip aneurysm

basilar artery complex. Access to the cavernous sinus can be achieved through both intradural and extradural routes. The optic apparatus can be visualized from the optic tracts through the entrance of the optic nerve into the apex of the orbit, as well as provide access to the entire orbit and orbital contents. Additionally, visualization of cranial nerves I through VIII as well as access to the petrous apex is available using this approach. This wide and basal exposure is paramount for the safe treatment for a variety of lesions (Fig. 1) [2, 19, 22].

## DECISION-MAKING

Tailored to the nature and extent of lesions in the anterior and middle cranial fossae, variations of cranio-orbital exposures can be used. Each patient should be evaluated individually to determine the most appropriate version [8]. Crucial variables relate to the lesion (pathology, size, and relation to neuro-

**Table 1.** Tailoring of the cranio-orbital approach

Location of the lesion		Extent of osteotomy
Suprasellar lesions	—>	Superior orbital rim
Parasellar lesions, cavernous sinus	—>	Superior lateral orbital rim and zygoma
Cavernous sinus, upper clivus	—>	Petrous apex
Retropharyngeal, infratemporal	—>	Floor of middle fossa
Sphenoid sinus, anterior clivus	—>	Frontal sinus, planum sphenoidale

vascular structures) and the patient (age, condition, and anatomy). Detailed radiological studies, including CT scans, MRI, MRA, and MRV are indispensable when selecting the most suitable surgical approach, delineating the tumor relation to surrounding structures and tumor extension. Tailoring of the cranio-orbital approaches is summarized in Table 1.

## SURGERY

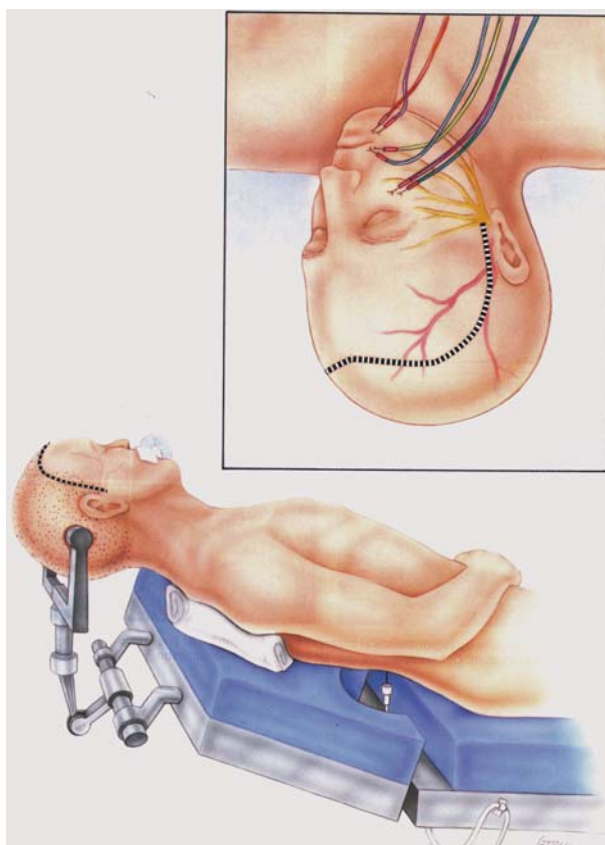
### 1. POSITIONING AND PREPARATION

The patient is placed supine. In patients with a small or medium sized tumor, a spinal needle is inserted through a split mattress. Controlled cerebrospinal fluid CSF removal relaxes the brain avoiding brain retraction during the extradural dissection. Approximately 25 ml of CSF is gradually drained with the aid of flow control clamp. The patient's trunk and head are elevated 20°. The head is hyperextended, rotated 20–30° away from the side of the lesion, and tilted slightly. The head is fixed in three point Mayfield head rest. The axis of visualization can be changed by turning the table from side to side. One of the patient's legs is also prepped should a graft of fascia lata, subcutaneous fat, or saphenous vein be needed for reconstruction. Electrodes are inserted for intraoperative monitoring of brain stem auditory evoked responses, and somatosensory evoked potentials, EEG (Fig. 2).

### 2. SOFT TISSUE DISSECTION

The skin incision is begun 1 cm anterior to the tragus at the level of the zygomatic arch and extended behind the hairline toward the contralateral superior temporal line. Care is taken to cut only through the galea sparing the pericranium. The scalp flap is turned with care to preserve the superficial temporal artery that remains on the temporal muscle. The scalp flap is reflected anteriorly with sharp dissection against the galea, rather than pushing it with a swap, this technique will maintain thick areolar tissue with the pericranium which will be used for reconstruction of the base if needed.

The superficial and deep fasciae of the temporalis muscle are cut 1 cm posterior and parallel to the course of the frontal branches of the facial nerve and

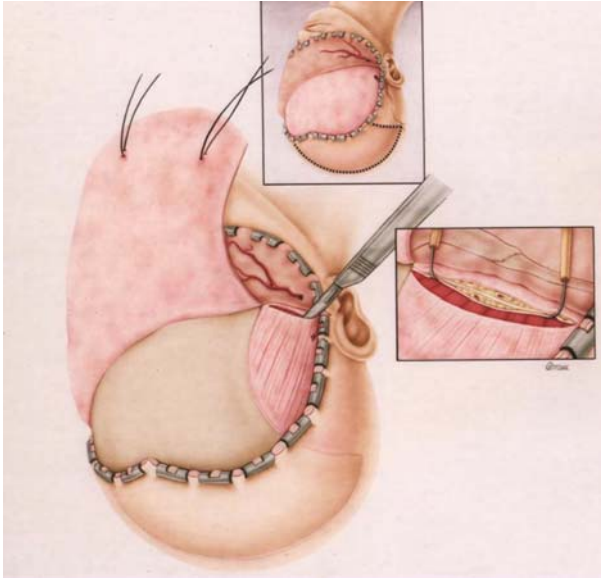


**Fig. 2.** Position of the patient on the operating table. A lumbar drain has been placed in the lumbar region. The Mayfield headframe is positioned to avoid obstruction to the surgeon. The head is slightly extended and rotation 20° to 30° away from the side of interest. **Inset** The skin incision, represented by the dotted lines, is shown as it relates to the external anatomy, the course of the STA, and the facial nerve, specifically the frontalis branch as it crosses over the zygoma. Needle electrodes have been placed for cranial nerve monitoring

dissected from the muscle fiber, the superficial fascia, fat pad along with the deep fascia are retracted with the skin flap anteriorly (Fig. 3).

### 3. THE PERICRANIUM

The pericranium is then dissected behind to the skin flap and incised as far posteriorly as needed. The large pericranium flap is reflected forward over the scalp flap. Its intact and vascularized base is dissected free from the roof and the lateral wall of the orbit. This vascularized pericranial flap is crucial for



**Fig. 3. Top inset** The skin flap is dissected sharply from the underlying pericranium and reflected forward. The anterior branch of the STA is transected to avoid retraction injury to the main trunk and posterior branch. The dotted lines represent the posterior extent of pericranium dissection. **Main panel** The pericranial flap is reflected forward maintaining a wide anterior base, which preserves its vascular supply. An incision is made through the superficial and deep temporalis fascial layers. **Right inset** The completed subfascial incision showing preservation of the frontalis branch within the fat pad

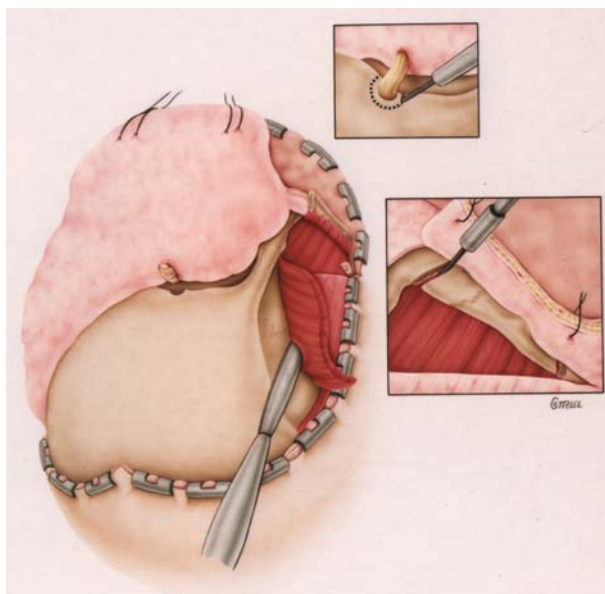
repairing the floor of the skull base and covering the frontal and ethmoid sinuses at closure to avoid CSF leak. As the intact base of the pericranial flap is dissected free from the orbital rim, the supraorbital nerve is released. If a foramen rather than a notch is present, high speed drill is used to make an osteotomy around this foramen. A collar of bone protects the nerve (Fig. 4).

#### 4. THE ZYGOMA

The temporal fascia is dissected off the zygomatic arch in subperiosteal fashion. The zygomatic arch is incised obliquely at the most anterior and posterior ends. The cuts are made obliquely so that the arch can be anchored during reattachment. The zygoma is then displaced downward with its masseter attachment (Fig. 4).

#### 5. THE TEMPORALIS MUSCLE

The temporalis muscle is incised posterior to the superficial temporal artery course and lifted in subperiosteal fashion from the temporal fossa in its en-



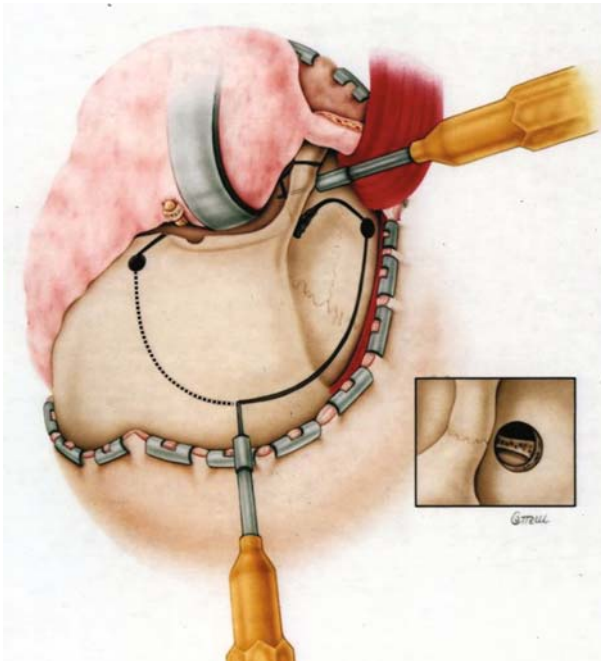
**Fig. 4.** **Top inset** When the supraorbital nerve exits a true foramen, an osteotomy is performed to prevent injury to the nerve. **Right inset** A subperiosteal dissection of the lateral orbital rim and zygoma is performed to avoid injury to the frontalis nerve. Oblique cuts are made in the zygoma flush with the malar eminence anteriorly and at the root of the arch posterior. **Main panel** The temporalis muscle is reflected inferiorly with the zygoma

tirety to preserve the deep temporal arteries and its nerve supply from the third division of the trigeminal nerves (Fig. 4).

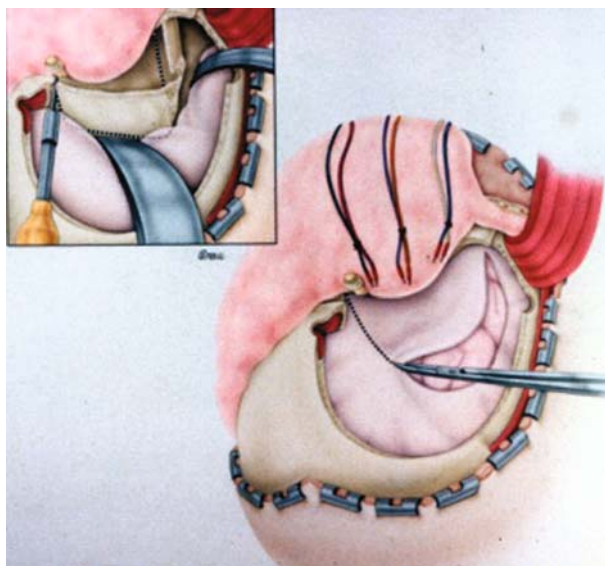
## 6. CRANIOTOMY

A burr hole is placed in the anatomic keyhole located in the depression just behind the suture between the frontal bone and the frontal process of the zygomatic bone. This provides access to the anterior fossa dura and periorbita, separated by the bone of the orbital roof. Burr holes are then placed along the floor of the middle fossa just superior to the root of the zygoma and along the superior temporal line. If necessary a fourth burr hole can be placed posterior to the superior orbital rim and medial to the supraorbital foramen; however, in most instances this hole will enter the frontal sinus. Starting at the burr hole located along the middle fossa floor, the craniotome is directed superiorly and then anteriorly toward the medial aspect of the superior orbital rim. The roof of the orbit will stop the craniotomy. A second cut is made anteriorly along the floor of the middle fossa to the sphenoid wing; the remainder of the cut across the sphenoid wing is made with the Midas Rex B1 attachment. Using a small dissector, the periorbita is dissected from the walls

of the orbit. The dissection should begin away from the area of the lacrimal gland as this is typically the thinnest area of the periorbita and therefore prone to laceration. Once the periorbita has been dissected from the bone, a brain spatula should be placed between the periorbita and the bone to protect it from laceration during the orbital osteotomy, carefully avoiding any pressure on the orbital contents. Using a Midas Rex B1 attachment, a cut is made through the inferior aspect of the lateral orbital rim flush with the malar eminence, then directed superiorly to the keyhole burr hole. A second cut is made through the superior orbital rim medially where the craniotome stopped. Only the thin bone of the orbital roof now attaches the bone flap. Although this can be cracked, we strongly recommend against this practice because the fracture line is inconsistent and may involve the superior orbital fissure or optic canal. Instead, we place a small V-shaped osteotome against the roof of the orbit, visualized in the anatomic keyhole site and direct it to-



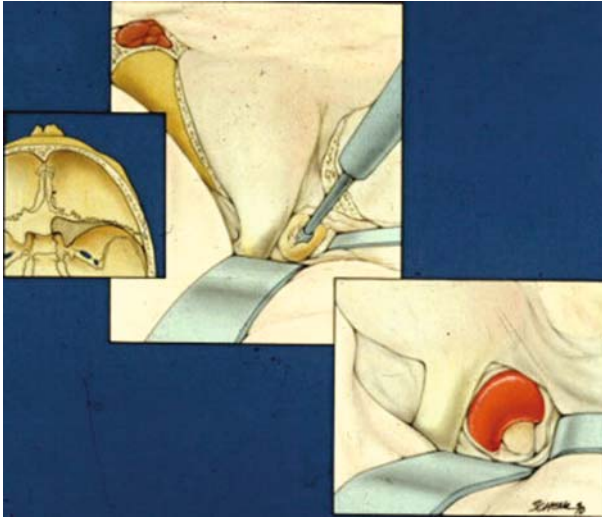
**Fig. 5. Right inset** A burr hole placed at the anatomic keyhole exposes the anterior fossa dura and the periorbita separated by bone of the orbital roof. **Main panel** Additional burr holes are placed along the floor of the middle fossa, posteriorly along the superior temporal line, and if necessary, medial to the superior orbital rim. The craniotomy is performed by a high-speed drill with a foot attachment. Osteotomies of the super and lateral orbital rims and across the lateral sphenoid wing are made by a high-speed drill without a foot attachment, carefully avoiding laceration to the dura or periorbita. The orbital roof osteotomy is performed using an osteotome placed at the anatomic keyhole



**Fig. 6. Inset** After dissecting the dura and periorbita, an osteotomy of the superior and lateral orbital walls is performed. The orbital osteotomy is reattached to the craniotomy flap to prevent enophthalmos. Care must be taken to avoid injury to the superior orbital fissure. **Main panel** Needle electrodes are placed through the periorbita directly into the medial and lateral rectus and superior oblique muscles allowing intraoperative monitoring of CNs III, VI, IV, respectively. The dura is opened in a curvilinear fashion and reflected anteriorly

ward the osteotomy site located medially along the superior orbital rim under direct observation, taking care to avoid laceration of the periorbita or dura. The bone flap, including the lateral and superior orbital rims, is now removed as a single piece (Fig. 5).

After the dura and periorbita have been dissected from the bone, the lateral wall and roof of the orbit are then removed in a separate osteotomy (Fig. 6). Using the Midas Rex B1, taking care to protect the periorbita and dura, an anterioposterior cut is made at the medial aspect of the orbital roof under direct visualization. This cut is lateral to the ethmoid sinus taking care to avoid injury to the trochlear insertion of the superior oblique muscle. A second anterioposterior cut is made at the inferior aspect of the lateral orbital wall. These cuts are connected posteriorly, taking care to avoid the superior orbital fissure (SOF). The remaining bone around the SOF, located at the intersection of the lateral wall and roof of the orbit, is removed using a small rongeur or high-speed drill. The optic canal, located at the apex of the orbit, medial to the SOF, is then opened extradurally, and the optic strut is drilled to allow the removal of the anterior clinoid process, exposing the subclinoid portion of the ICA (Fig. 7).



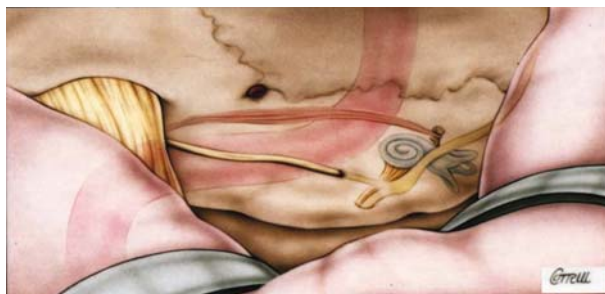**Fig. 7. Main panel** The remaining bone of the superior and lateral orbital walls is removed exposing the orbital apex and superior orbital fissure. **Right inset** Drilling of the optic strut allows removal of the anterior clinoid process, exposing the subclinoid portion of the internal carotid artery. **Left inset** Shaded region depicts area of sphenoid bone to be removed extradurally. Reprinted with permission from Al-Mefty O: The cranio-orbital zygomatic approach for intracranial lesions. *Contemporary Neurosurgery* 14(9): 1-6, 1992

## 7. EXPOSURE OF THE PETROUS ICA

Starting posteriorly and working anteriorly, the dura along the floor of the middle fossa is elevated. By following the middle meningeal artery, the foramen spinosum is identified and the middle meningeal artery is cut as it exits the foramen. Just medial to the foramen spinosum, the greater and lesser superficial petrosal nerves are identified (GSPN, LSPN) as they exit from the geniculate ganglion through the facial hiatus and run anteriorly in the sphenopetrosal groove. In some cases, the bony covering over the geniculate ganglion may be absent. Retraction of the GSPN can cause facial nerve injury and therefore must be avoided. Additionally, we have abandoned and do not recommend transecting the GSPN because it can cause ocular anhydrosis.

Dissection anterior to the foramen spinosum exposes the foramen ovale (V3), foramen rotundum (V2), and superior orbital fissure (III, IV, V-1, and VI). The horizontal portion of the petrous (ICA) lies deep and parallel to the GSPN and posteromedial to the foramen ovale and mandibular branch of the trigeminal nerve. The carotid artery can be unroofed using a diamond drill; however, it is not uncommon for the bony covering of the petrous carotid to be absent. The Eustachian tube is located lateral to the petrous





**Fig. 8.** The dura along the middle fossa is elevated exposing the middle meningeal artery (MMA). The MMA is coagulated and cut at the foramen spinosum exposing the GSPN as it exits the geniculate ganglion via the facial hiatus. The foramen ovale and mandibular branch of CN V are identified medially and anteriorly to the foramen spinosum. The course of the petrous ICA and inner ear structures (cochlea and semicircular canals) are shown in relationship to these structures. Figures 2, 3, 4, 5, 6, 8 are reprinted with permission from Al-Mefty O: Operative Atlas of Meningiomas. Philadelphia, Lippincott-Raven Press, 1998

carotid artery. Exposing the ICA within the petrous bone provides access to the ICA in the event that proximal control and/or a vascular bypass become necessary (Fig. 8).

Sharp dissection of the dural covering over the branches of the trigeminal nerve relaxes the dura for further medial dissection along the middle fossa floor and also exposes the lateral wall of the cavernous sinus. Elevation of the dura further medially and posteriorly along the middle fossa floor allows identification of the arcuate eminence, which is the landmark of the superior semicircular canal (SSC). Unfortunately, the precise position of the SSC can be difficult to appreciate. The SSC lies perpendicular to the petrous bone and about  $120^\circ$  to the course of the GSPN. The internal auditory canal lies at a  $45^\circ$  to  $60^\circ$  with the SSC. Further elevation along the floor will allow identification of the petrous apex. At this point the anterior petrosectomy is performed. The area to be drilled is limited by the trigeminal impression anteriorly, the petrous ICA laterally, the cochlea and facial hiatus posteriorly, and the internal auditory canal inferiorly (allowing access to cranial nerve VII and VII). The cochlea is surrounded by hard compact bone, unlike the bone of the petrous apex, and therefore can be differentiated during drilling of this area. With removal of the petrous apex, the posterior fossa, specifically the petroclival region, is visualized. Removal of the floor of the middle fossa between the foramina ovale and rotundum provides a route of access to the sphenoid sinus. Further removal of the middle fossa floor allows access to the infratemporal fossa through which the posterior wall of the maxillary sinus and nasopharynx can be accessed.

Needle electrodes are placed through the periorbita for intraoperative monitoring of the CNs III, IV, and VI. The dura is opened in a curvilinear fashion and reflected anteriorly.

## 8. CLOSURE

At the conclusion of the case, the dura must be closed in a watertight fashion using a patch graft as necessary to avoid tension on the brain and to allow tenting to the bone flap to occlude dead space, thereby avoiding epidural fluid collection. In cases where the sphenoid, ethmoid, or maxillary sinuses have been entered, we pack these areas with autologous fat and carefully identify and repair any associated dural openings. Exposure of the frontal sinus is commonly encountered. When exposed, the mucosa is exenterated, the frontal wall is drilled, and the sinus is cranialized by removing the posterior wall. The nasal frontal ducts are occluded with muscle, and the vascularized pericranial flap is placed between the dura and the exposed sinus. We recommend against packing the sinus with foreign material (i.e., bone wax, methylmethacrylate, or hydroxy-apatite) because it can provide a nidus for infection.

The orbital wall osteotomy is reconstructed to the bone flap using craniofacial miniplates. Reconstruction of the orbit reduces long-term enophthalmos. The bone flap is replaced with miniplates, carefully reconstructing the orbital rim to ensure a good cosmetic result. Finally the zygomatic arch is reconstructed using miniplates, and the temporalis muscle is reapproximated.

## HOW TO AVOID COMPLICATIONS

Because of the extensive blood supply to the skin flap, necrosis resulting from vascular insufficiency is rare; however, aggressive coagulation of superficial vessels, the application of strong hemostatic clips to the skin edge, or acute folding of the skin flap can interfere with the blood supply and subsequently cause flap complications [7]. The use of thermal coagulation along the temporalis fascia and during the elevation of the temporalis muscle can cause injury to the frontalis branch of the facial nerve and the trigeminal branch to the temporal muscle contributes to the postoperative atrophy of the temporalis muscle [9, 16]. Additionally, we recommend preservation of the STA, not only for its potential use as a vascular bypass, but also for its preserved vascular supply to the temporalis muscle [9]. Postoperative periorbital swelling is common but usually resolves quickly without functional or cosmetic deficits [9, 15].

Entrance into the frontal or other paranasal sinuses is a source of potential complications, including infection, CSF leaks, mucocelles, or pneumocephalus [9, 10]. However, with meticulous dural closure, packing of the exposed sinuses, exenteration of the frontal sinus, and disposal of the instruments from the surgical field after use in the sinus, we have experienced few complications specifically related to these maneuvers [2, 9].

Dissection of the middle fossa floor presents a specific group of complications. We use the operative microscope to aid in this dissection as it provides both improved illumination and better visualization of the structures. As stat-

ed earlier preservation and careful dissection of the GSPN are necessary. Additionally, dissection of the branches of the trigeminal nerve can cause post-operative pain, dysesthesia, or masticatory weakness; however, these complications have seldom been encountered in our experience. Careful dissection of the petrous ICA does not need elaboration; however, injury to the Eustachian tube should be avoided because it can cause chronic serous otitis media necessitating the placement of tympanostomy tubes. Finally, bleeding can be encountered during the dissection of the cavernous sinus. It can be brisk but usually is controllable by gently packing the sinus with hemostatic materials.

## CONCLUSIONS

The cranio-orbital zygomatic approach is a versatile approach, which can be custom-tailored to the patient's pathology. Its ability to maintain cosmetically appealing results with extensive exposure of the anterior fossa, middle fossa, and petroclival regions with minimal morbidity makes this approach a mainstay in skull base surgery.

## References

- [1] Alaywan M, Sindou M (1990) Fronto-temporal approach with orbito-zygomatic removal surgical anatomy. *Acta Neurochir* 104: 79-83
- [2] Al-Mefty O (1969) *Surgery of the cranial base*. Kluwer Academic Publishers, Boston
- [3] Al-Mefty O (1987) Supraorbital-pterial approach to skull base lesions. *Neurosurgery* 21: 474-477
- [4] Al-Mefty O, Anand VK (1990) Zygomatic approach to skull-base lesions. *J Neurosurg* 73: 668-673
- [5] Al-Mefty O, Ayoubi S, Schenk MP (1991) Unlocking and entering the cavernous sinus. *Perspect Neurol Surg* 2: 49-53
- [6] Al-Mefty O, Fox JL (1985) Supralateral orbital exposure and reconstruction. *Surg Neurol* 23: 609-613
- [7] Al-Mefty O, Smith RR (1988) Surgery of the tumors invading the cavernous sinus. *Surg Neurol* 30: 370-381
- [8] Al-Mefty O, Smith RR (1990) Tailoring the cranio-orbital approach. *Keio J Med* 39: 217-224
- [9] Al-Mefty O, Smith RR (1993) Combined approaches in the management of brain lesions. In: Apuzzo MLJ (ed) *Brain surgery: complication avoidance and management*. Churchill Livingstone, New York

- [10] Dandy WE (1966) *The brain*. WF Prior, Hagerstown
- [11] Frazier CH (1913) An approach to the hypophysis through the anterior cranial fossa. *Ann Surg* 57: 145-150
- [12] Fujitsu K, Kuwarabara T (1985) Zygomatic approach for lesions in the interpeduncular cistern. *J Neurosurg* 62: 340-343
- [13] Hakuba A, Liu S, Nishimura S (1986) The orbitozygomatic infratemporal approach. A new surgical technique. *Surg Neurol* 26: 271-276
- [14] Hakuba A, Tanaka K, Suziki T, et al. (1989) A combined orbitozygomatic infratemporal epidural and subdural approach for lesions involving the entire cavernous sinus. *J Neurosurg* 71: 559-704
- [15] Jane JA, Park TS, Pobereskin LH, et al. (1982) The supraorbital approach. Technical note. *Neurosurgery* 11: 537-542
- [16] Kadri P, Al-Mefty O (2004) The anatomic basis for surgical preservation of the temporal muscle. *J Neurosurg* 100: 517-522
- [17] McArthur LL (1912) An aseptic surgical access to the pituitary body and its neighborhood. *JAMA* 58: 2009-2011
- [18] Mann WJ, Gilsbach J, Seeger W, et al. (1985) Use of malar bone graft to augment skull base access. *Arch Otolaryngol* 111: 30-33
- [19] Origitano TC, Anderson DE, Tarassoli Y, Reichman OH, Al-Mefty O (1993) Skull base approaches to complex cerebral aneurysms. *Surg Neurol* 40: 339-346
- [20] Pellerin P, Lesoin F, Dhellemmes P, et al. (1984) Usefulness of the orbitofrontomalar approach associated with bone reconstruction for frontotemporosphenoid meningioma. *Neurosurgery* 15: 715-718
- [21] Sekhar LN, Schramm VL Jr, Jones NF (1987) Subtemporal-preauricular infratemporal fossa approach to large lateral and posterior cranial base neoplasms. *J Neurosurg* 67: 488-499
- [22] Smith RR, Al-Mefty O, Middleton T (1989) An orbitocranial approach to complex aneurysms of the anterior circulation. *Neurosurgery* 24: 385-391
- [23] Yaşargil MG (1969) *Microsurgery applied to neurosurgery*. Georg Thieme, Stuttgart, pp 119-143



**Ossama Al-Mefty**

Ossama Al-Mefty is Professor and Chairman of the Department of Neurosurgery at the University of Arkansas for Medical Sciences, a position he has held since 1993. He graduated from Damascus University Medical School in 1972 and underwent neurosurgical residency training at West Virginia Medical Center. It was during his position as a staff neurosurgeon at King Faisal Specialist Hospital in the early 1980s when he developed his abiding interest with skull base surgery. Upon his return to the United States in 1985, he joined the Department of Neurosurgery at the University of Mississippi, where he became professor, and then served as professor of neurosurgery at Loyola University of Chicago prior to his current position as the Robert Watson Endowed Chair in Neurosurgery at the University of Arkansas.

Dr. Al-Mefty is a pioneer in the field of skull base surgery and his expertise is well recognized and highly sought-after throughout the world. He has authored 189 peer-reviewed papers, 74 chapters and 8 books including the seminal textbook *Meningiomas*. He has given over 700 presentations and has had over 320 invited lectures at meetings and courses around the globe and has been honored with 67 visiting professorships. He is a dedicated teacher and has been faculty and director of well over 50 workshops and hand-on courses. He is on the editorial boards of numerous prestigious journals including *Neurosurgery*, *Contemporary Neurosurgery*, *Skull Base Surgery*, *Critical*

Reviews in Neurosurgery and Neurosurgical Review. He has received numerous honors including being named the Penfield Lecturer, the first Sugita Memorial Lecturer, the Hakuba Memorial Lecturer, the Dr. Khalifa Bo Rashid Memorial Lecturer, John L. Kemink, M.D. Memorial Lecturer, the First Annual Linda Wolfe Memorial Meningioma Lecturer, Sally Harrington Goldwater Visiting Professors, and the Milam E. Leavens Distinguished Lecturer.

Dr. Al-Mefty is a member of the Society of Neurological Surgeons, the American Association of Neurological Surgeons, the Congress of Neurological Surgeons, and the American College of Surgeons among others. He is President and founding member of the World Academy of Neurological Surgeons, Past President and founding member of the North American Skull Base Society. He is an honorary member of several societies internationally including Skull Base Society of Brazil, Canadian Neuroscience Society, Brazilian Neurosurgical Society, Georgia Neurosurgical Society, Portugal Neurosurgical Society, Turkish Neurosurgical Society, Mexican Society of Neurological Surgery, Japanese Neurosurgical Society, Syrian Society of Neurosciences, and the Chile Neurosurgical Society.

**Contact:** Ossama Al-Mefty, University of Arkansas for Medical Sciences,  
Department of Neurosurgery, 4301 W. Markham, #507 Little Rock, AR 72205, USA  
E-mail: keelandamye@uams.edu

---

# HOW TO PERFORM MIDDLE FOSSA/SPHENOID WING APPROACHES

F. UMANSKY

## INTRODUCTION

The skull base is a very complex anatomical region with an irregular bony architecture, which is classically divided into anterior, middle, and posterior compartments called fossae. The presence of dural folds, blood vessels, and cranial nerves provides a surgical challenge for even the most experienced neurosurgeon. Several approaches have been described to reach different parts of the middle fossa. These skull base approaches usually require bony drilling for exposure, to control the tumor blood supply, and to minimize brain retraction. Knowledge of anatomy acquired in the laboratory, as well as learning to handle relevant microinstrumentation, including microdrills, is of paramount importance for the young neurosurgeon who is interested in the difficult field of skull base surgery.

In this chapter we will discuss the tumoral pathology of the middle cranial fossa, with an emphasis on intracranial, intradural extra-axial lesions. Special consideration will be given to the most common tumors in this category, sphenoid wing meningiomas. We will discuss surgical approaches, techniques, and complications related to the surgical removal of these challenging lesions.

## RATIONALE

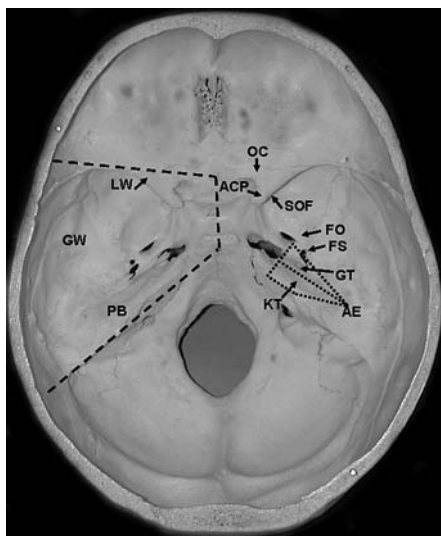
### 1. ANATOMY OF THE MIDDLE FOSSA

The middle cranial fossa is deeper than the anterior fossa, and its lateral parts are larger than its central part. The anterior limit is bounded by the posterior borders of the lesser wings of the sphenoid bone, the anterior clinoid processes (ACP), and the anterior margin of the chiasmatic sulcus. The middle fossa is limited posteriorly by the superior borders of the petrous bones and the dorsum sellae, and laterally by the temporal squamae, the frontal angles of the parietal bones, and the greater wings of the sphenoid (Fig. 1).

The central part of the middle cranial fossa is formed by the body of the sphenoid bone and includes the tuberculum sellae, the sella turcica, middle and posterior clinoid processes, the carotid sulcus, and the dorsum sellae. On

---

*Keywords:* skull base approach, middle fossa region, lateral approaches



**Fig. 1.** Endocranial surface of the skull base. The dashed lines on the left side represent the limits of the middle fossa. *ACP* Anterior clinoid process; *AE* arcuate eminence; *FO* foramen ovale; *FS* foramen spinosum; *GT* Glasscock's triangle; *GW* greater wing of the sphenoid bone; *KT* Kawase's triangle; *LW* lesser wing of the sphenoid bone; *OC* optic canal; *PB* petrous bone; *SOF* superior orbital fissure

each side of its central part, the cavernous sinus extends from the medial end of the superior orbital fissure to the apex of the petrous bone.

In the endocranial surface of the middle cranial fossa, there are several bony canals and foramina containing vessels and nerves that are important anatomical landmarks:

1. Optic canal – formed by the anterior and posterior root (optic strut) of the lesser wing. The optic strut separates the optic canal from the superior orbital fissure. The optic nerve (ON) (CN II) and the ophthalmic artery course through the canal.
2. Superior orbital fissure (SOF) – located between the lesser and greater sphenoid wings. The SOF contains the oculomotor (CN III), trochlear (CN IV), ophthalmic (CN V, V1), and abducens (CN VI) nerves, as well as a recurrent meningeal artery and the superior and inferior ophthalmic veins.
3. Foramen rotundum – located in the greater wing of the sphenoid, contains the maxillary (CN V, V2) and ovale for the mandibular (CN V, V3) nerves.
4. Foramen spinosum – posterior and lateral to the foramen ovale, contains the middle meningeal artery.
5. Trigeminal impression – located in the petrous apex, contains Meckel's cave and the semilunar ganglion (trigeminal or gasserian ganglion).



6. Upper surface of the petrous bone – presents two grooves for the greater (GSPN) and lesser (LSPN) superficial petrosal nerves. These nerves can be confused with dural strands of the middle fossa floor and are difficult to dissect.
7. Carotid window – the most anterior segment of the intrapetrous carotid artery, covered by a thin bony plate in 75% of our specimens, and by the periosteum only in the remaining 25%.
8. Tensor tympani and eustachian tube – located medial to the foramen spinosum and lateral to the horizontal segment of the petrous carotid.
9. Arcuate eminence – situated posteriorly in the upper surface of the petrous bone, marks the location of the superior semicircular canal.
10. Kawase's triangle (posteromedial middle fossa triangle) [8, 9] – the anterior limit is defined by the lateral border of V3 and the gasserian ganglion. Posteriorly, it is defined by a line parallel, and 13 mm posterior, to the anterior border. The medial limit corresponds to the superior petrosal sinus and the lateral limit is marked by the horizontal segment of the intrapetrous carotid and overlying GSPN.
11. Glasscock's triangle (posterolateral middle fossa triangle) [4] – located lateral to Kawase's triangle, is bounded laterally by a line drawn from the foramen spinosum toward the arcuate eminence, ending at the facial hiatus; medially by the GSPN; and anteriorly by the mandibular division of the trigeminal nerve (V3).

The exocranial surface of the middle fossa includes the infratemporal fossa, the pterygopalatine fossa, and the parapharyngeal and infrapetrosal spaces.

## 2. CLASSIFICATION OF THE MIDDLE FOSSA TUMORS

Tumors of the middle cranial fossa can be classified in accordance with their anatomical origin from intracranial or extracranial surfaces. By bony erosion, or growth through natural openings/canals, foramina, or fissures of the floor of the middle fossa, tumors can extend from one compartment to another.

### 2.1 Intracranial tumors

1. Intradural – meningiomas, schwannomas, epidermoids, dermoids
2. Extradural – chordomas, chondrosarcomas, metastases

### 2.2 Extracranial tumors

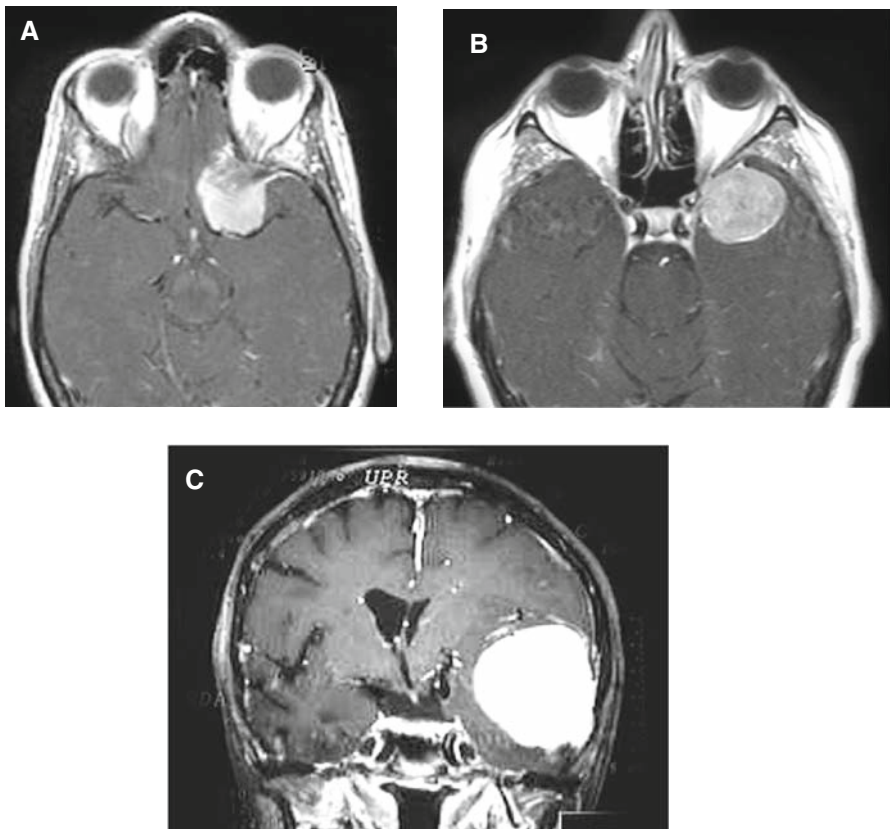
1. Infratemporal fossa – juvenile angiofibromas, fibrous dysplasias
2. Pterygopalatine fossa – juvenile angiofibromas
3. Parapharyngeal space – carcinomas

- 4. Orbital cavity - ON sheath meningiomas, schwannomas, lymphomas, cavernous hemangiomas, ON gliomas, bone lesions (osteomas, dysplasias, aneurysmal bone cysts, metastases, etc.)

### 3. SPECIAL FEATURES OF MENINGIOMAS, SCHWANNOMAS AND EPIDERMOID/DERMOID CYSTS

#### 3.1 Meningiomas

Meningiomas of the sphenoid wing and middle cranial fossa represent approximately 17–25% of all intracranial meningiomas. This is the third most common site of origin for meningiomas, after the convexity and parasagittal areas.



**Fig. 2.** T1-weighted+Gd MR images of meningiomas in the sphenoid wing. **A** Meningioma in the inner third of the sphenoid wing with optic nerve involvement. **B** Meningioma originating from and confined to the middle third of the sphenoid wing. **C** Pterional global meningioma in the outer third of the sphenoid wing

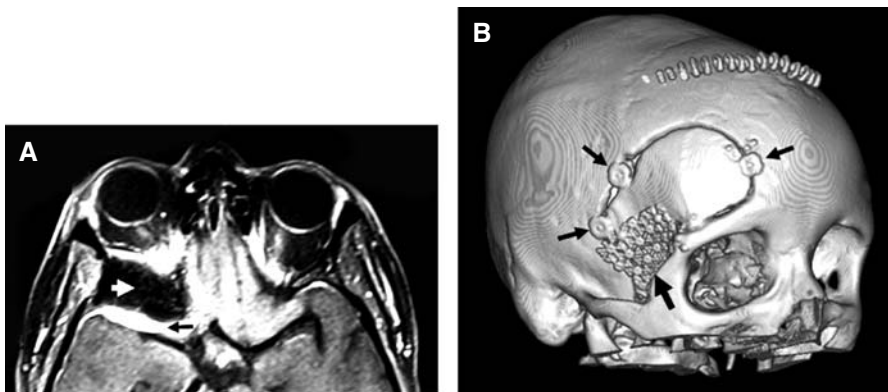
Cushing and Eisenhardt divided the sphenoid ridge into three approximately equal sections: deep, inner, or clinoidal; middle or alar; and outer or pterional [3]. They described two types of pterional lesions: meningiomas en plaque, which provoke hyperostosis of the greater wing; and global meningiomas, which expand within the crotch of the Sylvian fissure.

Inner third sphenoid wing- or clinoidal meningiomas (Fig. 2A) are characterized by involvement of the optic nerve (ON) early in their growth. Hyperostosis of the ACP is usually present, and there is partial or total encasement of the internal carotid artery and its branches. The tumor may also attach to the lateral wall of the cavernous sinus (CS) and/or invade it. Involvement of the CS may cause diplopia and facial hypoesthesia. Venous congestion, hyperostosis, and orbital extension may lead to exophthalmos.

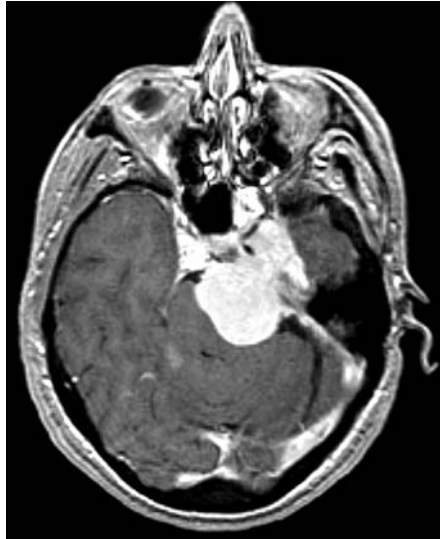
Meningiomas confined to the middle third of the sphenoid ridge are rare (Fig. 2B), and usually represent extension of a clinoid or pterional lesion.

Meningiomas of the outer third or pterional section may be either global or en plaque. Pterional-global lesions behave as convexity meningiomas (Fig. 2C), which can become large and cause seizures, mass effect, and focal neurological deficits, with or without signs of intracranial hypertension. The en plaque lesions (Fig. 3), also known as spheno-orbital meningiomas, are characterized by hyperostosis of the sphenoid wing and orbital bone, causing exophthalmos. Tumor can also infiltrate the orbit, optic canal, CS, and base of the middle fossa. Visual deficits are not infrequent.

Petrous apex meningiomas (Fig. 4) can be considered as a type of petroclival meningioma originating in the anterior aspect of the petrous bone, me-

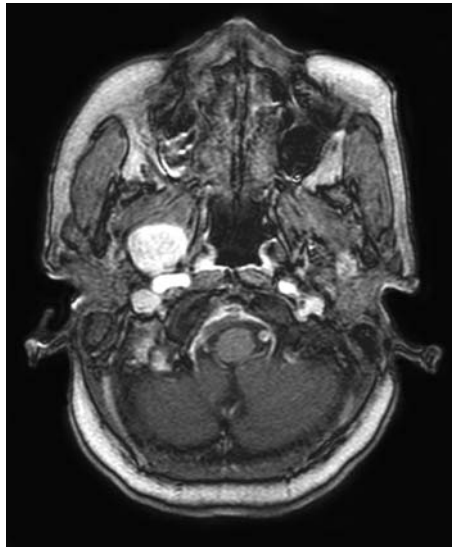

**Fig. 3.** **A** T1-weighted Gd-enhanced MR image of a spheno-orbital or en plaque meningioma. Note extensive bony hyperostosis (white arrow) and the enhanced plaque of the lesion (black arrow). **B** 3-D reconstruction of the craniotomy site showing closure using the Craniofix titanium clip (3 small arrows) (CF: Aesculap AG, Tuttlingen, Germany) and titanium mesh (large arrow)



**Fig. 4.** T1-weighted Gd-enhanced MR image of a petrous apex meningioma

dial to the internal auditory canal. These tumors can be resected by an extended middle fossa approach with anterior petrosectomy and opening of the tentorium, as described by Kawase in 1991 [9].



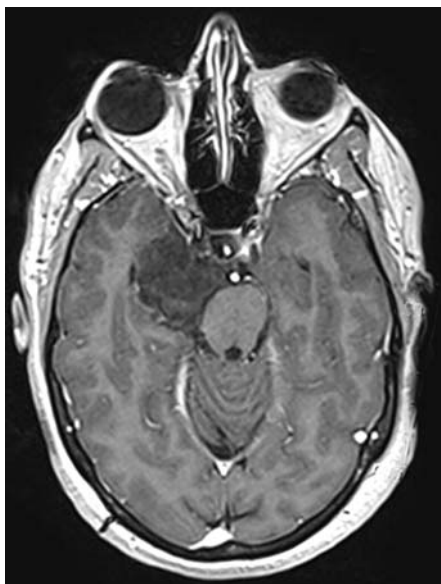
**Fig. 5.** T1-weighted Gd-enhanced MR image of a right trigeminal schwannoma arising from V3

### 3.2 Schwannomas

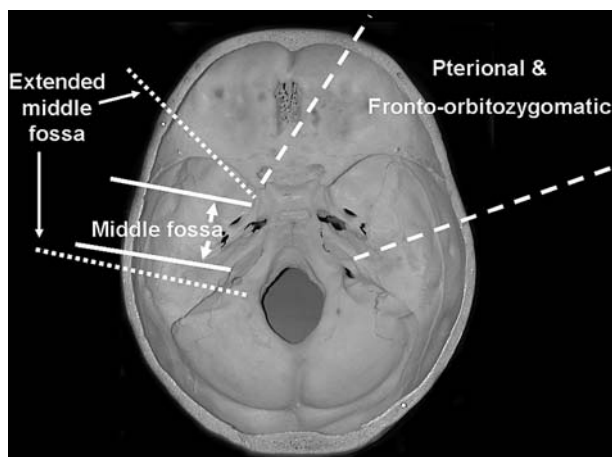
The schwannomas are benign tumors composed entirely of Schwann cells. They are the second most common extra-axial intracranial tumor, preceded by meningiomas. They constitute 5–10% of all intracranial neoplasms, and have a predilection for sensory nerves. The vestibular division of the eighth cranial nerve is the most common site of origin, followed by the trigeminal nerve. Schwannomas of the jugular foramen and the facial nerve are less frequent. Trigeminal schwannomas (Fig. 5) can originate from the cisternal segment of the nerve, from Meckel's cave, in the CS, and in the superior orbital fissure. The tumor can extend below the skull base through the foramen ovale. A dumbbell configuration with supratentorial (Meckel's cave) and infratentorial (cerebellopontine angle) components is not unusual.

### 3.3 Epidermoid and dermoid cysts

Intradural epidermoid and dermoid cysts are congenital developmental lesions composed of a layer of stratified squamous epithelium covered by an external fibrous capsule. Mesoderm elements (hair, sebaceous, and sweat glands) can be found inside the dermoid cysts. Epidermoid cysts, frequently called “pearly tumors” because of their gross external appearance, represent approximately 1.5% of all intracranial tumors. They grow slowly by desquamation of the epithelial cells and conversion to keratin and cholesterol crystals. They are usually located



**Fig. 6.** T1-weighted Gd-enhanced MR image of an epidermoid in the parasellar region compressing the brainstem



**Fig. 7.** Frequently used approaches for tumors of the middle fossa drawn on the skull base

in the cisterns of the cerebellopontine angle, supra- and parasellar regions, or the middle cranial fossa (Fig. 6). They can be differentiated radiologically from arachnoid cysts using MRI diffusion-weighted imaging. On T1-weighted MRI, epidermoid cysts demonstrate mild hypointensity, while dermoid cysts show marked hyperintensity. Dermoid cysts are less frequent than epidermoid cysts (0.3–0.6% of intracranial tumors) and located mostly in the posterior fossa. They can rupture into the subarachnoid space or inside the ventricles.

## DECISION-MAKING

In order to obtain a successful outcome in the treatment of neurosurgical diseases, the decision-making process is based on indications for surgery and its timing. Choosing the best operative approach for a particular situation is as important as the choice of specific instrumentation and updated technology. Surgical approaches to deal with middle fossa tumors (Fig. 7) are chosen based in the location and size of the lesions. Other considerations will be the neurosurgeon's experience, the extent of resection sought, and the patient's expectations.

## SURGERY

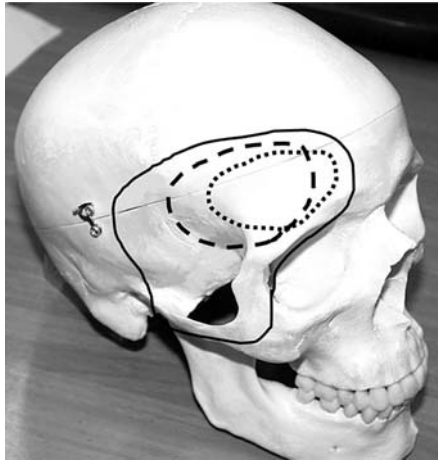### 1. PTERIONAL APPROACH

#### 1.1 Superficial planes

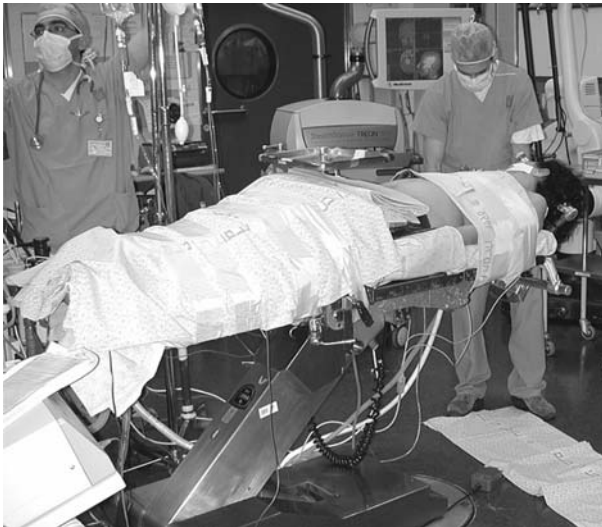The pterional-transylvian approach is the most common and useful approach to deal with a wide range of lesions in the anterior, middle, and posterior cra-

nial fossa. It is a classic approach, which was popularized by Yaşargil et al. [12], and can be modified according to the pathology into frontolateral or fronto-orbitozygomatic (FOZ) craniotomies (Fig. 8).

The patient is positioned supine with the head turned about 40° to the opposite side, and slightly extended. After positioning, the patient is securely



**Fig. 8.** The pterional approach (dashed line) and its frontolateral (dotted line) and fronto-orbital zygomatic (solid line) variants drawn on the skull surface



**Fig. 9.** The patient is firmly attached to the table with hip supports and plastic tape to enable tilting in the desired direction

attached to the table with plaster tape so that the table may be rotated in any direction (Fig. 9). For the frontolateral approach, the head is turned only about 20°. For expanded exposure, an orbitozygomatic osteotomy can be added.

The head is fixed to the operating table with the Mayfield three-pin headrest. The scalp incision starts inferiorly, just anterior to the tragus and behind the superficial temporal artery (STA). From here it runs superiorly behind the hairline towards the midline. In cases where the FOZ approach is to be used, the incision is extended towards the contralateral superior temporal line (STL). The subgaleal scalp flap elevation is sharply begun at the frontal convexity down to the ipsilateral STL level. At this point an interfascial dissection is started in order to preserve the frontal branch of the facial nerve. The pericranium is transected along the temporal line and elevated separately, preparing it for later use as a pericranial flap to cover the frontal sinus.

Next, with the cutting current of the diathermy, the posterior belly of the temporal muscle and its aponeurosis is cut down to the periosteum and parallel to the skin incision. A retrograde subperiosteal elevation of the temporal muscle from the STL is performed with the aid of a periosteal elevator, without any cauterization. Thus, the full bulk of the muscle is atraumatically elevated and its neurovasculature is nicely preserved.

## 1.2 Craniotomy

Two small diameter burr holes, just large enough to admit the craniotome footplate, are usually used to develop the bone flap. The first burr hole is the MacCarty keyhole [11], located behind the frontozygomatic suture, and the second is placed above the posterior part of the zygoma at the temporal fossa floor. A third burr hole may occasionally be necessary, and is located beneath the temporal line. No burr hole is placed in the forehead. The bone flap cut is made with the fluted router of a pediatric craniotome to minimize bone loss. From the temporal burr hole, the bone cut is directed across the temporal squama and the frontal bone to the keyhole. The lower part of the bone flap is cut using the same fluted pediatric router. The footplate is inserted into the temporal burr hole and the osteotomy is performed across the base of the bone flap towards the keyhole with the fluted router drill tilted as low as possible beneath the reflected temporal muscle, towards the floor of the middle cranial fossa. This usually eliminates the need for extra bone removal with the rongeurs upon completion of the craniotomy. The osteotomy is continued until the footplate is stuck at the lateral part of the sphenoid wing. Here, the last bone bridge is finally transected with a drill, and the free bone flap is elevated.

## 1.3 Frontolateral approach

The field of vision achieved with a more medially placed craniotomy, such as in the frontolateral approach, described by Brock and Dietz [1], can also be



achieved with the pterional approach, by tilting the operating table in the desired direction.

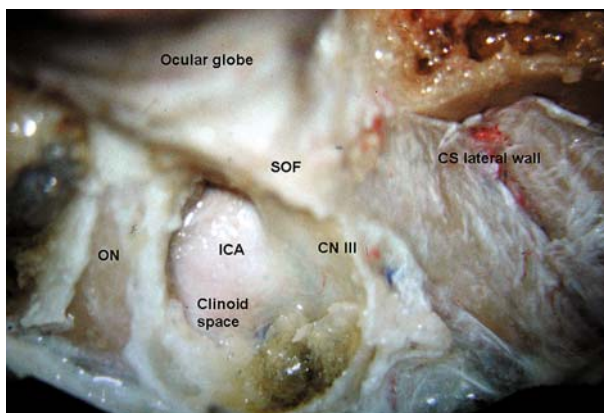
#### 1.4 Fronto-orbitozygomatic approach

Although variations of the orbitozygomatic approach have been used since the 1970s, it was popularized a decade later by Jane et al. [7] for the exposure of tumors of the lateral anterior cranial fossa and those in the orbit and retro-orbital regions.

The pterional approach will be used for the vast majority of tumors located in the anterior two thirds of the middle cranial fossa. In some circumstances, when a more basal approach is needed, an orbitozygomatic craniotomy may be necessary. We prefer to utilize the so called “two piece” orbitozygomatic craniotomy, which means that the pterional bone flap is elevated first, and then as a second, distinct step, the orbitozygomatic osteotomy is performed. This osteotomy will include the supraorbital rim, part of the roof and lateral wall of the orbit, and a portion of the zygoma.

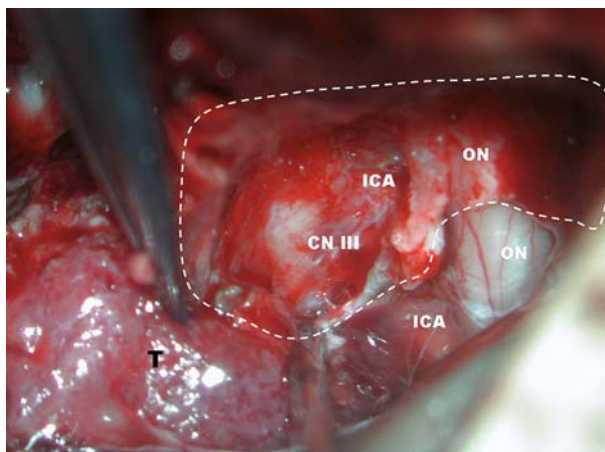
#### 1.5 Extradural stage

Meningiomas of the inner third of the sphenoid ridge, including clinoid meningiomas, frequently involve the ON, causing visual deterioration. They may also encase the internal carotid artery (ICA) and its branches, and induce hyperostotic thickening of the ACP. In many cases we prefer to begin with extradural drilling of the skull base to diminish tumor vascularization, to obtain early decompression of the optic nerve by opening its canal,

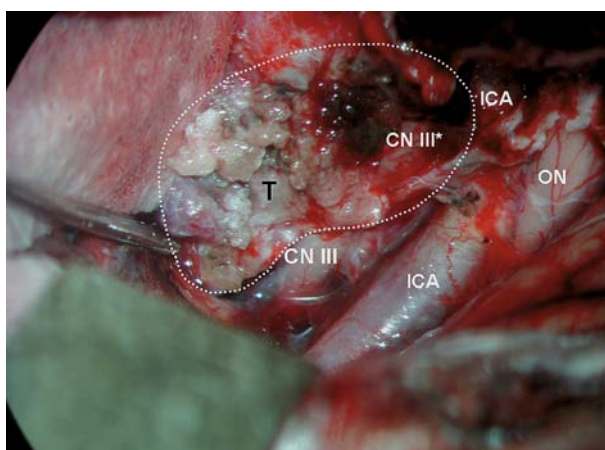


**Fig. 10.** Right side anatomical specimen after extradural drilling of the anterior clinoid process and opening of the optic canal and superior orbital fissure (SOF). The optic nerve sheath has been opened revealing the nerve (ON). Note the proximity of CN III to the internal carotid artery (ICA) in the clinoid space. The lateral wall of the cavernous sinus (CS) is clearly seen

and to identify the ICA in the clinoid space proximal to its encasement by the tumor. After the pterional bone flap is elevated, the microscope is brought to the surgical field. The dura mater covering the anterior and mid-



**Fig. 11.** Intraoperative view of a left inner third sphenoid wing meningioma after opening the dura mater. The area of extradural drilling is delineated by the broken line, showing the optic nerve (ON) after opening the canal, the ICA within the clinoid space, and CN III by transparency in the most medial aspect of the superior orbital fissure. Outside the broken line, the intradural portion of the ICA and ON are also seen, already dissected free from the tumor (T)



**Fig. 12.** Removal of the tumor has progressed toward the cavernous sinus (CS) with peeling of the outer layer of its lateral wall. The last piece of the tumor (T) is seen still attached to this layer. CN III is shown entering the CS, and then by transparency embedded in the deep layer of the lateral wall (CN III\*). The area of the CS is delimited by the dotted line

dle cranial fossa is elevated from the orbital roof and the lesser- and greater sphenoid ridges, under magnification. The meningo-orbital band is cut to facilitate further retraction of the dura mater, and the superior orbital fissure is exposed. An extradural clinoidectomy is performed, and the optic canal unroofed to expose the extradural ON (Figs. 10–12). Cutting and diamond drills accompanied by copious irrigation are used for this extensive drilling.

In cases of spheno-orbital meningiomas or meningiomas en plaque, there is a lot of hyperostotic bone that needs to be drilled away. The drilling includes the lesser sphenoid wing, the roof and lateral wall of the orbit, the edges of the superior orbital fissure down to the foramen rotundum, and the beginning of the superior orbital fissure. A partial clinoidectomy and unroofing of the optic canal are also performed. The intra-orbital extension of the tumor is removed, avoiding injury to the ocular muscles.

### 1.6 Dural opening and tumor removal

The dura mater is opened low and parallel to the skull base. An additional perpendicular cut is placed, following the Sylvian fissure. The fissure is opened, and CSF is released, exposing the tumor. Internal debulking will facilitate the dissection of the tumor from the vascular structures and optic apparatus. The falciform ligament is cut to complete exposure of the tumor and decompression of the ON. Meningiomas of the middle third of the sphenoid ridge will be managed in a similar manner, except that there is no need for either clinoidectomy or unroofing of the optic canal.

If the tumor is adherent to the lateral wall of the cavernous sinus, the outer layer of this wall can be peeled out together with the tumor, starting the cleavage plane anteriorly at the level of the superior orbital fissure, and advancing posteriorly.

## 2. SUBTEMPORAL APPROACHES

In this category can be included the classic middle cranial fossa approach and the transpetro-apical or extended middle cranial fossa approach.

### 2.1 Middle fossa approach

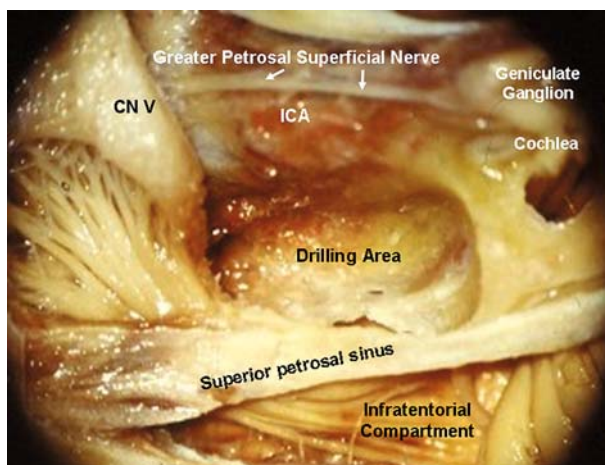
Hartley in 1892 [5], and Krause in the same year [10], independently described an anterior temporal craniotomy with extradural approach to the trigeminal roots and the gasserian ganglion for treatment of trigeminal neuralgia (TN). In 1900, Cushing [2] described total gasserian ganglionectomy for TN. House, in 1961, developed the middle fossa approach to reach the internal auditory canal (IAC) for the treatment of labyrinthine otosclerosis [6]. The approach is used for hearing preservation in cases of small vestibular schwannomas, and for removal of trigeminal and facial schwannomas.

The patient is positioned supine with the head turned towards the side opposite the tumor. A linear skin incision is performed anterior to the ear, extending from the zygoma to the parietal suture. The temporal muscle is cut and laterally retracted, and a temporal craniotomy flap reaching the skull base is tailored. Under the operating microscopy, the dura mater is elevated from the floor of the middle fossa in a posterior to anterior direction, with efforts to preserve the GSPN. The middle meningeal artery is cut at the level of the foramen spinosum. The arcuate eminence is identified, and lateral to it the tegmen tympani. In cases of vestibular schwannoma, the location of the IAC can be delineated with image-guided neuronavigation, and drilling can be started. In cases of trigeminal neurinoma, the tumor can be seen bulging through the dura, overlying Meckel's cave.

## 2.2 Transpetro-apical approach (extended middle fossa approach)

This approach, which consists of an anterior petrosectomy and tentorial incision, allows the removal of lesions that extend from the middle- to the posterior fossa, including the area of the petrous apex and superior clivus, to the level of the IAC. These lesions include meningiomas, chordomas, schwannomas, cholesterol granulomas, cholesteatomas.

The patient is positioned supine with the head rotated 60° to the side opposite the tumor, and extended. The skin incision is similar to that used for the pterional approach, but extended posteriorly to include more temporal bone in the craniotomy. This type of bone flap allows for extradural subtemporal drilling, as well as splitting of the Sylvian fissure for a better mobiliza-



**Fig. 13.** Right-side anatomical specimen showing the area of drilling in Kawase's triangle for an extended middle fossa approach. The tentorium has been cut, revealing the infratentorial compartment

tion of the temporal lobe when needed. Sometimes a zygomatic osteotomy can be added. Drilling in the area of Kawase's triangle (see the anatomic description) (Fig. 13) and cutting of the tentorium provide access to the upper petroclival region.

## HOW TO AVOID COMPLICATIONS

Despite many advances in surgery of the skull base, complications still occur. While mortality has been substantially reduced, morbidity remains significant. Some important considerations are worth noting here. Even experienced surgeons have complications; only those who do not operate have none. Be open minded, listen to your colleagues, and learn from their and your mistakes. Don't forget to put your ego to sleep when operating. Work in a team. Practice techniques in the anatomical laboratory.

As a first step in complication avoidance, the indications for surgery should be carefully analyzed, taking into consideration the patient's age and expectations; presumptive pathology; size, location, and natural history of the tumor; the extent of resection that may be achieved; and possibilities for adjuvant therapy. Although ideally the goal of surgery is gross total removal at the first attempt, in many patients this goal will not be achievable due to a high risk of morbidity. In these cases, leaving a small residual for imaging followup or radiotherapy may be the best option.

### 1. PLANNING

Resecting tumors of the central nervous system is based on the principle of atraumatic surgery. To achieve this goal, the surgeon must have a well-developed operative plan to optimize the use of the working corridors offered by the special anatomy of the brain and its surroundings. Although the best possible strategy is selected during preoperative planning, we must be prepared to deal with the unexpected. The choice of a surgical approach must accommodate the possibility of adverse situations, unforeseen difficulties, and related complications. Modern neurosurgery demands profound knowledge of anatomy, surgical skill, meticulous work, and honesty. The concept of minimally invasive surgery refers not only to a small skin incision and cranial opening, but to the use of basic principles of microneurosurgery in order to limit the damage to perilesional tissue.

The introduction of image-guidance to the neurosurgical armamentarium has provided a valuable tool for planning and performing neurosurgical procedures, allowing us to localize the anatomical boundaries of the tumor and recognize the neurovascular structures related to it. Since tumors of the skull base are attached to the dura mater and the bone, volumetric changes and shifting that occur while carrying out the surgical dissection are minimal when compared to those seen during the resection of intra-axial lesions.

## 2. POSITIONING, SKIN INCISION, AND CRANIOTOMY

Most middle fossa tumors are removed with the patient in a supine position, with the table slightly flexed and the head turned to the opposite side and extended. Care should be taken with fixation devices for the head. The homolateral shoulder should be elevated to avoid kinking of the neck veins and strain on the cervical muscles. Eyelids should be taped after protecting the eyes with lubricants, and bony prominences must be well padded. Pneumatic devices are applied to the lower extremities to avoid venous thrombosis, and the patient is securely attached to the table with several plaster tapes to allow for lateral tilting.

The skin incision should take into consideration the scalp vascularization and preserve the superficial temporal artery. Branches of the facial nerve crossing the zygoma to reach the frontalis muscle should not be injured. The temporal muscle is superiorly elevated without using cautery, to help maintain muscle trophism and improve the cosmetic outcome. A frontal pericranial flap is elevated separately and prepared for possible use during closure of the frontal sinus whenever it is transversed. In cases of a subtemporal approach, a temporal muscle flap is used to cover possible sources of CSF leak in the middle fossa floor. Reconstruction with vascularized pediculated flaps reinforced by application of fibrous glue is the best method to avoid leaking. If, despite these measures, there is a postoperative CSF leak, it usually will be controlled with a short period of spinal drainage.

To avoid the deleterious effects of excessive brain retraction, craniotomies are made low enough to reach the skull base, and bone drilling is frequently added. High speed drills are used with cutting and diamond burrs of different sizes. The skill to use these powerful instruments is developed in the laboratory during long hours of training. Overheating may damage cranial nerves, especially the optic nerve, and constant copious irrigation is needed.

## 3. INTRADURAL DISSECTION

After completing the extradural drilling, the dura mater is opened, and the intradural stage of the operation begins, usually with the splitting of the Sylvian fissure. CSF is released and sharp dissection of the middle cerebral artery and its branches is performed. The arachnoid of the Sylvian fissure should be opened in the frontal side, medial to the temporal veins. The ICA is dissected in the carotid cistern, and when necessary in the clinoid space. In cases of arterial encasement, angiography and balloon test occlusion will provide valuable information. Injury of the vessels during surgery may result in intra- or postoperative bleeding or infarction.

During resection of inner-third sphenoid wing meningiomas, the olfactory tract and optic and oculomotor nerves can be injured. Special attention is required when unroofing the optic canal and opening the superior orbital fissure.

In cases of a middle fossa approach (classical or extended), the dura elevation from the floor of the fossa may result in injury to the GSPN, resulting in loss of lacrimation. Traction of the geniculate ganglion or its injury during drilling will cause facial paralysis. Difficulties in closing the eye together with the absence of lacrimation result in severe keratitis and visual deterioration.

Drilling of the petrous apex can injure the petrous ICA, and result in profuse bleeding. Special care should be taken not to damage the cochlea.

The trigeminal ganglion and its branches are at risk in surgeries of the floor of the middle fossa and petrous apex, resulting in variable degrees of facial hypoesthesia, including loss of sensation in the cornea.

## CONCLUSIONS

Neurosurgeons frequently deal with tumors of the middle fossa, of which meningiomas are the most common. Several surgical approaches may be used; the pterional approach and its variants are the mainstays in this anatomically complex area. Careful consideration of tumor characteristics, patient preferences, and personal experience are essential while planning surgical strategy in order to achieve a good outcome. Efforts should be made to achieve a complete removal at the first surgery when possible. A thorough knowledge of skull base anatomy and experience acquired in laboratories are prerequisites in order to minimize complications and limit surgical morbidity.

## References

- [1] Brock M, Dietz H (1978) The small frontolateral approach for the microsurgical treatment of intracranial aneurysms. *Neurochirurgia (Stuttg)* 21(6): 185-191
- [2] Cushing H (1900) A method of total extirpation of the Gasserian ganglion for trigeminal neuralgia. *J Am Med Assoc* 34: 1035-1041
- [3] Cushing H, Eisenhardt I (1938) Meningiomas: their classification, regional behavior, life history, and surgical end results. Charles C Thomas, Springfield, Ill
- [4] Glasscock ME 3rd (1969) Middle fossa approach to the temporal bone. An otologic frontier. *Arch Otolaryngol* 90: 15-27
- [5] Hartley F (1892) Intracranial neurectomy of the second and third divisions of the fifth nerve. *NY State J Med* 55: 317-319
- [6] House WF (1961) Surgical exposure of the internal auditory canal and its contents through the middle, cranial fossa. *Laryngoscope* 71: 363-385
- [7] Jane JA, Park TS, Pobereskin LH, Winn HR, Butler AB (1982) The supraorbital approach: technical note. *Neurosurgery* 11: 537-542

- [8] Kawase T, Toya S, Shiobara R, Mine T (1985) Transpetrosal approach for aneurysms of the lower basilar artery. *J Neurosurg* 63: 857-861
- [9] Kawase T, Shiobara R, Toya S (1991) Anterior transpetrosal-transtentorial approach for sphenopetroclival meningiomas: surgical method and results in 10 patients. *Neurosurgery* 28: 869-875; discussion 875-876
- [10] Krause F (1892) Resection des Trigemini innerhalb der Schädelhöhle. *Arch Klin Chir* 44: 821-832
- [11] MacCarty CS (1959) Surgical techniques for removal of intracranial meningiomas. *Clin Neurosurg* 7: 100-111
- [12] Yaşargil MG, Fox JL, Ray MW (1975) The operative approach to aneurysms of the anterior communicating artery. *Adv Tech Stand Neurosurg* 2: 113-170





### **Felix Umansky**

Felix Umansky is chairman of the Department of Neurosurgery at the Hadassah–Hebrew University Medical Center in Jerusalem. He completed his medical training at the Universidad Nacional de Rosario in his native Argentina, and his neurosurgical residency at the Beilinson Hospital in Tel Aviv, Israel, where he did joint research with world renowned anatomist and anthropologist Prof. Nathan Hillel. Their work in the neuroanatomy of the lateral wall of the cavernous sinus made a significant contribution to surgical approaches involving structures in this region.

Prof. Umansky completed fellowships at Massachusetts General Hospital under Prof. William H. Sweet, and at Henry Ford Hospital in Detroit, Michigan, U.S.A. under Prof. James Ausman.

In 1984, Prof. Umansky joined the Department of Neurosurgery at the Hadassah–Hebrew University Medical Center in Jerusalem. In 1993, he was named Chairman, and later Professor of Neurosurgery at the Hebrew University – Hadassah Medical School. Under his leadership, Hadassah has established the leading skull base practice in Israel, where meningioma incidence is among the highest worldwide, and participates in the care of over 1500 neurosurgical patients annually.

From 2005, Prof. Umansky has also been appointed as a staff neurosurgeon in the Department of Neurosurgery of Henry Ford Hospital.

Prof. Umansky is an active member of the World Federation of Neurosurgical Societies (WFNS), where he presently serves as Chairman of the Ethics and Medico-Legal Affairs, as well as a member of the Education and Training, and Skull Base Surgery Committees. Prof. Umansky's seminal research in neuro-anatomy and clinical experience has been widely published in the literature, and he frequently lectures in international meetings.

**Contact:** Felix Umansky, Department of Neurosurgery, Hadassah-Hebrew University Medical Center, P. O. Box 12000, 91120 Jerusalem, Israel  
E-mail: [umansky@hadassah.org.il](mailto:umansky@hadassah.org.il)

---

# HOW TO PERFORM CENTRAL SKULL BASE APPROACHES

L. N. SEKHAR

## INTRODUCTION

The central skull base may be defined as the spheno-clival and clival areas. Lesions involving this region may be intradural or extradural. Intradural lesions may be petroclival or lower clival/foramen magnum meningiomas, trigeminal or jugular foramen/hypoglossal schwannomas, or other benign tumors. Lesions involving the extradural area are predominantly chordomas, chondrosarcomas, cholesterol granulomas, adenoid cystic carcinomas, and some invasive pituitary tumors. Many specialized skull base approaches have been developed to deal with these lesions.

In this chapter, different approaches will be described. Approaches described in detail in other sections of the book will only be mentioned briefly. In general, the approaches may be divided into anterior approaches (transsphenoidal, transnasal endoscopic, transmaxillary, and transoral), antero-lateral approaches (fronto-temporal orbito-zygomatic, subtemporal transzygomatic with petrous apex resection, subtemporal infratemporal), and postero-lateral approaches (transpetrosal, and extreme lateral transcondylar).

## DECISION-MAKING

*Preoperative Studies.* In addition to a neurological examination and a comprehensive physical examination, an audiogram is indicated whenever an approach through the temporal bone is contemplated. Most of the patients undergo an MRI examination, but a bone windowed CT scan will demonstrate the bony anatomy to help the surgeon. Whenever major arteries are affected by the tumor, a cerebral angiogram with demonstration of the collateral blood supply is performed. If the internal carotid artery is at risk, then an angiogram with ipsilateral carotid compression is performed with injection into the contralateral carotid artery, and the vertebral artery to demonstrate the collateral flow. This is adequate as long as the surgeon plans only a temporary occlusion, and a vascular repair or a bypass is performed in the event of a major arterial injury. When major venous sinuses are at risk, the venous phase of the angiogram must be carefully evaluated to examine the major venous sinuses, and their collateral circulation.

---

*Keywords:* skull base, central skull base approaches, microsurgery

*Team Planning.* Often, multiple approaches are possible to a lesion. The surgeon must be familiar with all of them. The final selection will be based on the location of the tumor, the areas of invasion, major arteries involved, the physical characteristics of the tumor (soft vs. hard), and the extent of resection (total, subtotal, or partial) planned. In some cases, the initial approach may not be adequate, and another approach may need to be performed in a different stage. In many cases, the services of a surgeon from another specialty (such as ENT or plastic surgery) may be needed in order to perform an approach, or the reconstruction. In addition, the patients will need to be under the care of a neuro intensivist postoperatively in a neurosurgical intensive care unit, with well trained neurosurgical nurses. Rehabilitation may be important for some patients after they leave the hospital.

*Anesthesia and neuro-monitoring planning.* In all patients, the anesthesiologist must strive to maintain an adequate blood volume and oxygenation during the case. The brain needs to be slack during the operation, and both diuretics and moderate hyperventilation may be used at the start of the operation. For extradural operations, this may be achieved by means of a lumbar drain (if the cisterns are open), or a ventriculostomy (if obstructive hydrocephalus is present). For intradural operations, cisternal drainage may be adequate, after the standard measures. For most procedures, total intravenous anesthesia using intravenous propofol is employed, to allow the monitoring of Motor Evoked Potentials (MEP). In addition to MEPs, the electroencephalogram, and SSEP (somatosensory evoked potentials) are monitored. The function of cranial nerves 5, 7, 8, 10, 11, and 12 are monitored as needed, when these nerves are involved by the tumor.

## **SURGERY**

### **1. ANTERIOR APPROACHES**

#### **1.1 Transsphenoidal approach**

The transsphenoidal approach is predominantly used for pituitary adenomas, which are intrasellar and suprasellar. The use of the endoscope (either primarily or as an assistive device) allows larger intracranial extensions to be resected. However, the purely endoscopic approach takes longer to perform, and is more difficult to learn. If excessive bleeding occurs, this can be a problem in the endoscopic approach, which may require a conversion to a microsurgical approach. The “extended transsphenoidal approach” allows the removal of tuberculum sellae meningiomas, which are encasing the carotid arteries.

For the microsurgical approach, the patients are placed supine and the head slightly tilted away from the surgeon (to the left for a right handed surgeon) with the neck in a slightly extended and in a pin-holder. We prefer to use intraoperative navigation, rather than the C arm fluoroscope in order to

localize the anatomy. A sublabial approach is useful for very large tumors which have a considerable suprasellar extension, and may also be used in the “extended transsphenoidal approach” for meningiomas of the planum sphenoidale. If a sublabial approach is used, the upper lip is retracted and a transverse incision is made in the upper gingival mucosa after infiltration of the soft tissue with local anesthetic. Dissection is continued with a dissector to expose the cartilaginous nasal septum. The septal mucosa is separated from the septum. The nasal septum is then fractured from the bony septum (perpendicular plate of the ethmoid), and a nasal speculum inserted and opened exposing the anterior wall of the sphenoid. Under the microscope, the sphenoid sinus is then opened at the ostia with a Kerrison rongeur, or a high speed drill and widened laterally until the floor of the sella turcica is completely visualized. The floor of the sella is removed exposing the overlying dura, from one cavernous sinus to the other, and from the palnum to the dorsum sellae. For the removal of tuberculum sellae meningiomas, the planum sphenoidale must be removed with a high speed drill, in addition to the sellar floor.

The transnasal transsphenoidal approach is preferred for most pituitary tumors. The nasal mucosa is treated with cocaine pledgets to reduce the vascular congestion. A speculum is placed on one side of the nasal cavity, and under the microscope, the postero superior wall of the septum and the anterior wall of the sphenoid are reached, using the middle turbinate as the landmark. A small incision is made in the nasal mucosa and careful dissection of mucosa free from the cartilaginous nasal septum and then fractured laterally. A microdebrider may be used here to partially remove the middle turbinate to enlarge the access to ostia. From here on the sphenoidectomy proceeds as in the sublabial approach, exposing the sella and the dura. During the resection, endoscopic assistance may be used for the removal of laterally placed, and suprasellar tumor.

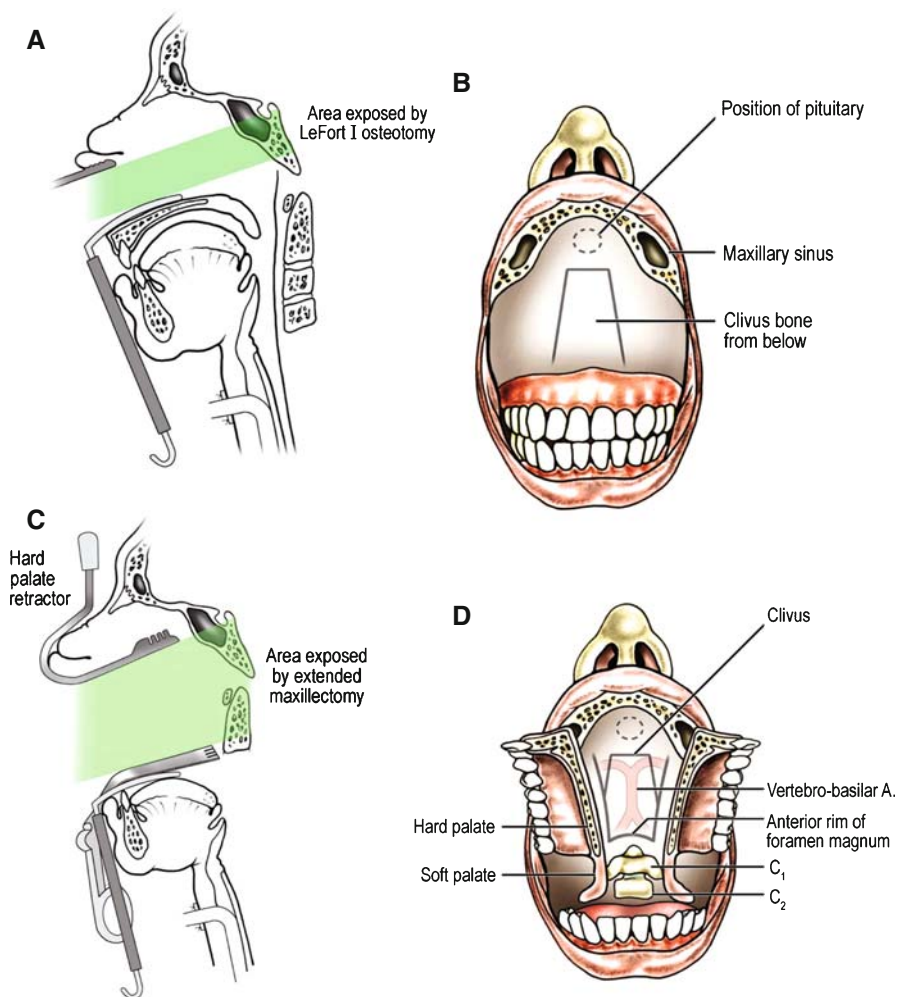
For closure, Duragen and alloderm are laid in the defect, tucked under the residual bone edges with a final layer of Bioglue. We then augment the closure with Nasopore packing. If an obvious CSF leak is encountered, a lumbar drain is placed in the operating room. If a large dura defect is created, an abdominal fat graft is harvested and placed within the sphenoid to augment the layer closure. A Foley catheter may be left inflated inside the sphenoid sinus, to keep the packing in place.

Currently, we often use an endoscopic transsphenoidal approach for pituitary tumors. However, for invasive tumors which involve the clivus extensively, a transmaxillary approach is preferred, because of the shorter, and wider exposure.

## 1.2 Transmaxillary/transfacial approach

This is an approach which is very good for extradural lesions in the midclivus, with slight extension to the upper clivus. Moderate extensions into the cavernous sinus and the pterygoid space can be easily dealt with. But this approach is not preferred when there is extensive invasion beyond these limits,

or when there is extensive intradural invasion. The patient is positioned supine with the neck slight extended and head held in a Mayfield pin-holder. A sublabial incision is made preferred for this approach to maximize cosmesis, however a Weber-Fergusson incision can also be employed to approach this region. A sublabial incision is made in the upper gingival mucosa and subperiosteal dissection is carried forward superiorly towards the frontal-nasal suture and laterally towards pterygoid plates to expose the nasomaxillary region. Additional dissection of the periorbita of the inferior and medial orbit



**Fig. 1.** **A** and **B** Transmaxillary approach. Upper and middle third of the clivus exposed with Lefort I osteotomy. **A** Lateral view. **B** AP view. **C** and **D** Extended maxillectomy. **C** Lateral diagram. **D** AP view

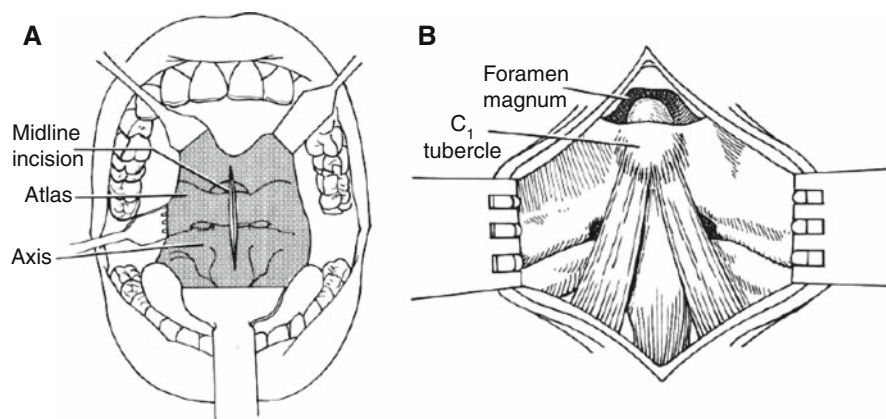
allows for further exposure of the nasomaxillary region. The lateral exposure is partially limited by the infraorbital foramen containing the nerve and blood vessels. A Lefort I osteotomy can be then performed to detach the maxillary bone flap to expose the necessary regions of the clivus and the infratemporal fossa (Fig. 1A, B). Titanium plates are placed before the osteotomy to secure a good alignment post operatively.

Once the lesion has been removed, if a dural defect is present, the defect is closed with an abdominal fascial graft and augmented with Duraseal, or bioglue. This is reinforced with a layer of abdominal fat graft followed by Duragen. This entire repair is held in place by Titanium mesh which is attached to the surrounding bone with titanium screws. The maxillary bone flap is reattached to the face with plates and screws. A lumbar drain is placed before the operation and used post-operatively for 3–5 days to prevent CSF leak.

For good accessibility to both clivus and craniocervical junction an extended maxillectomy approach can be used. This combines the Lefort I osteotomy with a midline incision of hard and soft palate (Fig. 1C, D). The initial incision is made like the transmaxillary approach; along the alveolar margin, extending to the molars on both sides and titanium plates placed in position similarly. Then a midline incision is made in the hard and soft palate and saw cut applied to hard palate between the upper incisors to allow flaps to wing laterally. A transpharyngeal retractor is applied to hold the palatal flaps along with the transoral retractors for adequate exposure to clivus and region below. This is particularly useful for extensive tumors and congenital anomalies producing basilar invagination. Closure is done as mentioned above for transmaxillary approach, but needs to be more meticulous to effect proper occlusion and functioning of the palate, making the surgery long and intricate.

### 1.3 Transoral approach

We rarely use this approach for tumors, since it becomes very limited in its lateral reach, which prevents the complete removal of tumors. It is a preferred approach for the resection of developmental and rheumatoid lesions of the C1 and lower clival area. The patient is positioned supine and the neck extended. The region of interest along the clivus will dictate the amount of extension of the neck (Fig. 2A, B). Once the oral retractor is placed, a longitudinal incision is placed in the posterior pharyngeal wall. The soft tissues are then retracted laterally to expose the nasopharynx and the adenoid pad. The mucosa of the nasopharynx is then open in the midline and elevated off the clivus. Superiorly, the dissection can be stopped at the junction of the hard and soft palate, however if needed the hard palate can be partially resected to transverse palatine suture. This will expose the posterior portion of the bony septum. Once the mucosa has been removed, the bony septum can then be resected to gain more exposure. Inferiorly, the anterior ring of C1 and C2 and also be easily exposed. Frequently, after the abnormal bone is resected, there



**Fig. 2.** Transoral approach. **A** Midline vertical incision with soft palate elevated to expose the posterior pharynx. **B** Exposed C<sub>1</sub> tubercle with muscle and ligament attachment through the incision (courtesy Raven Press, from "Surgery of cranial base tumors" L. Sekhar, I.P. Janecka)

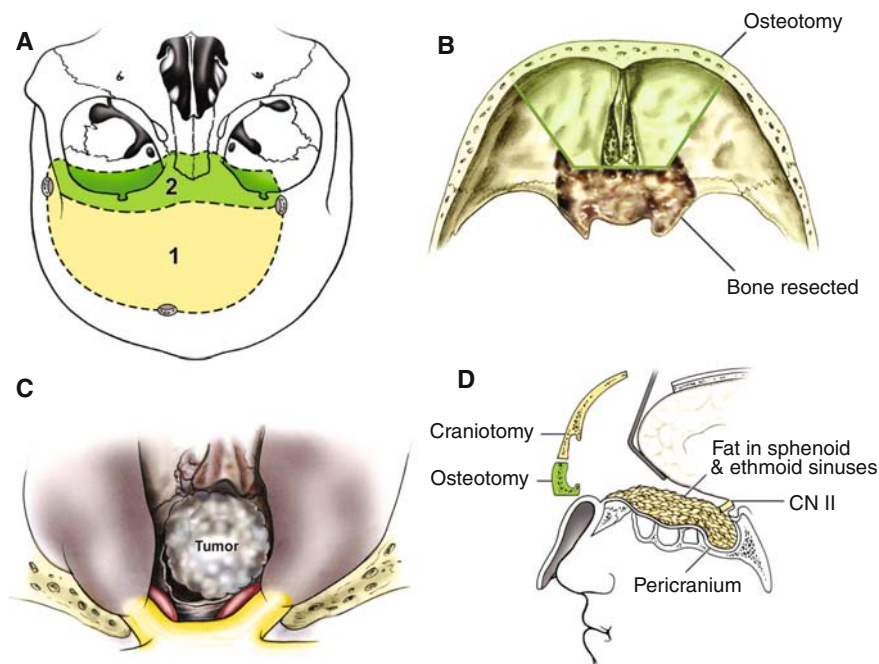
are hypertrophied soft tissues which have to be removed all the way to the dura mater. If there is entry into the dura, it must be repaired as previously outlined in the transmaxillary approach. The mucosa and the palate are closed in layers, and the patient is fed through a nasogastric tube until the mucosal layers are healed.

#### 1.4 Extended subfrontal approach

The extended subfrontal approach (Fig. 3A–D) is used for lesions in the same areas as the transmaxillary approach. However, a much wider exposure is obtained, with the ability to remove intradural and cavernous sinus lesions and even repair the ICA in the event of an injury. The patient is in the supine position without a head turn, and the surgeon frequently rolls the patient from side to side, in order to visualize the opposite corner. This is thus referred to as an X shaped approach, and the decompression of the orbits is needed for this as well as to enhance the midline exposure, and to reduce the brain retraction.

A bicoronal incision is made well behind the hair line, and a pericranial flap is dissected, starting behind the incision. As one approaches the nasion, care must be taken to preserve the supraorbital and supratrochlear arteries, which is best done by getting into the galeal–frontalis layer. The supraorbital nerves are notched out and freed, if they lie inside a foramen. Dissection is done just inferior to the frontonasal suture and the periorbita is dissected bilaterally for a distance of approximately 3 cm. A low bifrontal craniotomy is then performed, without dural tears. The subfrontal dura is dissected from the roofs of the orbit bilaterally and if possible from the





**Fig. 3.** Extended frontal transbasal approach. **A** Craniotomy. **B** Osteotomy. **C** Optic nerves unroofed and planum sphenoidale removed. Cavernous carotid artery unroofed and tumor resection begins. **D** Reconstruction of cranial base with free fat grafts and a pericranial graft

planum area, sparing the ethmoidal regions, under the microscope. CSF drainage from the lumbar drain is useful in this stage. In order to preserve olfaction, the entire cribriform ethmoidal plate is drilled away, preserving the dural sheath around the olfactory nerves. A bilateral orbitofrontal osteotomy is performed in a bat wing shaped fashion, encircling the olfactory dural sheath. The olfactory mucosa is then divided inside the nasal cavity, preserving it along with the olfactory dural sheath. This entire complex can then be retracted superiorly.

The next step is to decompress both optic nerves in their dural sheath, and removing the bone of the planum sphenoidale, and the sella turcica. The removal of the anterior clinoid process and the optic struts may be done if necessary. The bone is then removed from the body of the sphenoid, forming the medial wall of the cavernous sinus. Some of the petrous apex may also be removed in this fashion. The intracavernous ICA will be exposed extradurally at the posterior bend, horizontal segment, and the anterior bend. If the periosteum overlying the cavernous sinus or the intercavernous sinuses is open, profuse venous bleeding may occur. This is controlled by gently pack-

ing with oxidized cellulose and then injecting fibrin glue, which will stop the bleeding.

Any midline clival tumor can now be removed all the way down to the foramen magnum. The lateral limits are the petrous apices, and the hypoglossal nerves. The superior limit is the dorsum sellae, although if it is not considerably enlarged, this can be removed by traction. If there is intradural extension, it is dealt with similar to the transmaxillary approach, but a titanium mesh closure may not be possible, because of extensive bone resection.

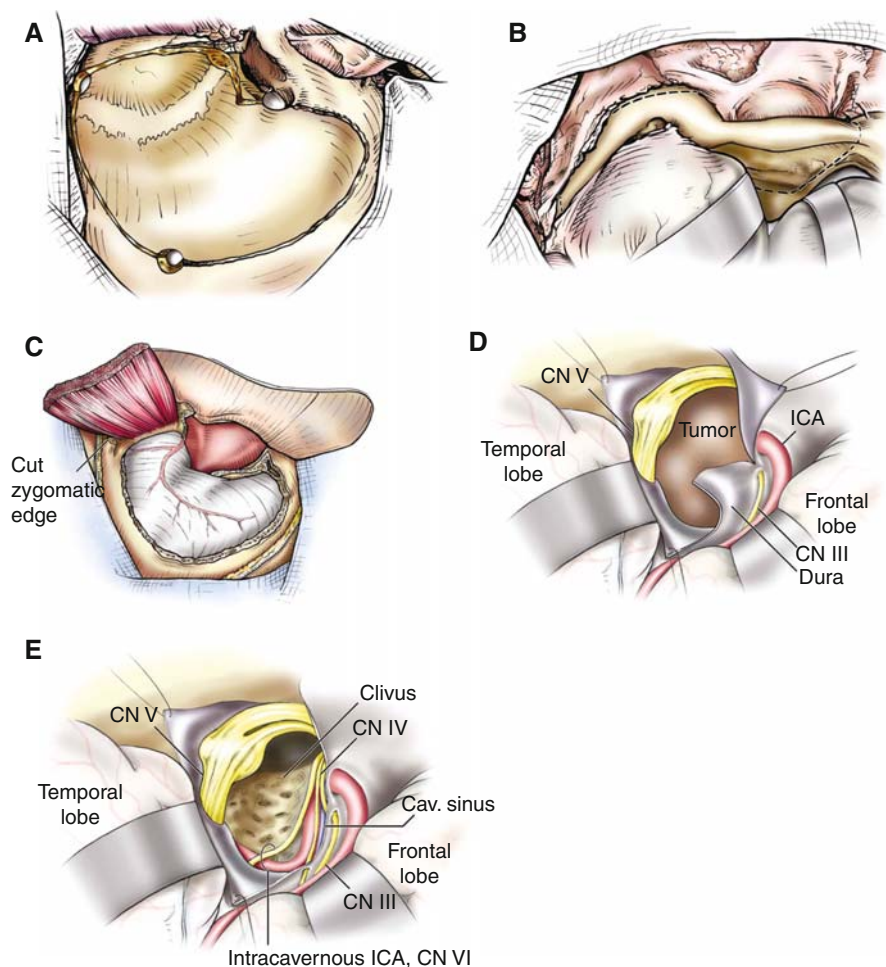
Closure involves the reconstruction of any dural defect with fascia, a vascularized pericranial flap lining the entire space, and abdominal fat graft to fill the dead space. A hole is made in the pericranial flap for the olfactory nerve dural sheath, which is attached to it with a few sutures. Thor orbitotomy is reattached in such a way that the pericranial flap vascularity is not compromised. The medial canthal ligaments of the eyeball may need to be attached to each other with a single suture, if they were splayed by the lesion. A lumbar drain is rarely needed.

## **2. ANTERO-LATERAL APPROACHES**

### **2.1 Fronto-temporal, orbito-zygomatic approach**

This approach is useful when there is significant lateral extension, and when the cavernous sinuses are involved in a significant way. The patient is positioned supine and the head turned 45° to the contralateral side with slight extension of the neck, malar eminence at the highest point (Fig. 4A–C), and fixed. An area in the abdomen or lateral thigh needs to be prepared for an autologous fat graft. Either a bicoronal or a pterional incision crossing midline is made behind the patient's hairline. The inferior portion of the incision lies in the skin crease anterior to tragus of the ear. Dissection to elevate the skin flap is carefully carried-out preserving the pericranium for repair of dura and/or frontal sinus. The dissection is carried anteriorly until the supraorbital nerve is encountered paramedially. Laterally, along the dissection of temporalis muscle occurs until the superficial temporal fat pad is encountered, and then an interfascial dissection would be required to elevate the skin flap anteriorly to preserve the frontotemporal branch of the facial nerve (Fig. 4C). A subperiosteal dissection is required along lateral orbit to expose the lateral orbit and inferiorly along the entire course of the zygoma. After the temporalis muscle is carefully elevated subfascially to preserve the underside, thin fascial layer of the temporalis muscle. The muscle is then retracted laterally. The craniotomy is done separately from the orbital osteotomy. A frontal-temporal craniotomy is then fashioned to include the ipsilateral anterior and middle fossa extending medially to the supraorbital notch.

The periorbita and the dura are then carefully dissected off the orbital roof and walls. Dissection of the frontal dura extends posteriorly to the superior



**Fig. 4.** **A** Frontotemporal transcavernous approach – osteotomy cuts for a standard OZO (orbitozygomatic osteotomy). **B** Osteotomy cuts in the orbital roof. **C** Final appearance after craniotomy and OZO. **D** Intradural exposure of tumor in the cavernous sinus. The sylvian fissure is split and lateral dural wall over tumor incised. **E** After removal of intracavernous tumor – cavernous sinus and clivus exposed. *ICA* Internal carotid artery

orbital fissure. Retractors are then placed to gently retract and protect the brain during the orbitozygomatic osteotomy. The medial cut is made lateral to supraorbital notch. Posteriorly the orbital osteotomy is made to preserve at least 2/3rds of the orbital roof to prevent enophthalmos, and anterior to the superior orbital fissure. Laterally, the osteotomy is made beginning of the inferior orbital fissure to the level of the zygomaticofacial foramen. A second lateral cut is made from the anterior, inferior edge of the zygoma to connect

with the malar eminence, creating a “V” cut centered on the zygomaticofacial foramen. The final cut is made across the root of the zygoma at the junction with the squamosal temporal bone (Fig. 4B).

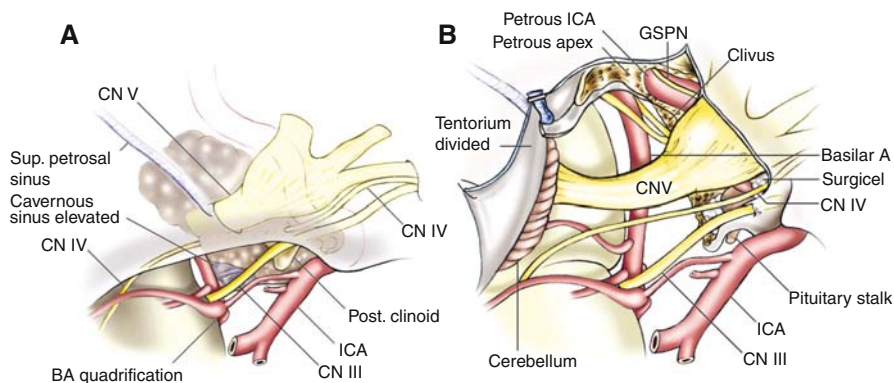
The remainder of the superior orbital fissure must be unroofed, and the anterior clinoid process removed using the operating microscope. The optic nerve is also decompressed with the removal of the anterior clinoid process (Fig. 4D, E). If the ACP is very long, then intradural resection may be needed.

The petrous ICA may be exposed extradurally if necessary. The lateral wall of the cavernous sinus is peeled away from the cranial nerves extradurally to remove the tumor. If there is extensive invasion, this is often performed intradurally, which allows the cranial nerve dissection to be more limited.

## 2.2 Subtemporal transzygomatic with petrous apex resection

This approach is preferred when the lesion involves the petrous apex, upper clivus and the posterior cavernous sinus. The patient is positioned supine with the head turned 70° to the contralateral side with slight extension of the neck. Excessive head turn is avoided by checking the jugular venous pressure. A frontotemporal incision is made, but extended inferiorly just anterior to the tragus of the ear. Dissection to elevate the skin flap is carefully carried-out preserving the pericranium for repair of dura and/or frontal sinus. Laterally, along the dissection of temporalis muscle occurs until the superficial temporal fat pad is encountered, and then an interfascial dissection would be required to elevate the skin flap anteriorly to preserve the frontotemporal branch of the facial nerve. A subperiosteal dissection is required along lateral orbit to expose the lateral orbit and inferiorly along the entire course of the zygoma. The temporalis muscle is carefully elevated subfascially, preserving the deep temporal fascia, in order to reduce the risk of temporalis atrophy. The muscle is then retracted laterally. A predominantly temporal craniotomy is performed, after some lumbar fluid drainage. The zygomatic osteotomy may be done with or without the inclusion of the condylar fossa, as dictated by the need for posterior exposure. If done without the condylar fossa, then the posterior cuts are made just anterior to the temporomandibular joint, and the anterior cuts lateral to the lateral wall of the orbit.

Any additional squamous temporal bone is resected piecemeal or as a single piece. Under the microscope, the middle fossa dura is elevated to expose the middle meningeal artery, greater superficial petrosal nerve (GSPN), V3, and arcuate eminence of the petrous bone are identified. The middle meningeal artery and GSPN are cauterized and divided. From here the greater wing of the sphenoid is drilled to expose foramen ovale (lateral) and foramen rotundum (anterior). The dura overlying V2 and V3 can be cut and elevated for added exposure medially along the petrous apex. Venous bleeding from the pterygoid plexus or the cavernous sinus is handled in the usual way, by gentle packing, and fibrin glue injection.



**Fig. 5.** **A** Subtemporal transzygomatic petrous apex resection with tumor lying in the cavernous sinus and extends to the level of the horizontal petrous internal carotid artery (ICA). **B** Exposed anatomy after tumor resection with this approach. BA Basilar artery; GSPN greater superficial petrosal nerve

From the exposure of the petrous apex, the petrous portion of the internal carotid artery (ICA) is identified at the junction of GSPN and V3 (Fig. 5A, B). The ICA is then unroofed anterior to the genu of the petrous ICA, which is medial to Eustachian tube. Once the carotid artery is identified, it can be skeletonized and freed from the surrounding bone. Mobilization of the carotid artery allows for further exposure of the apex. The petrous apex is removed with a high speed drill or the ultrasonic bone curette.

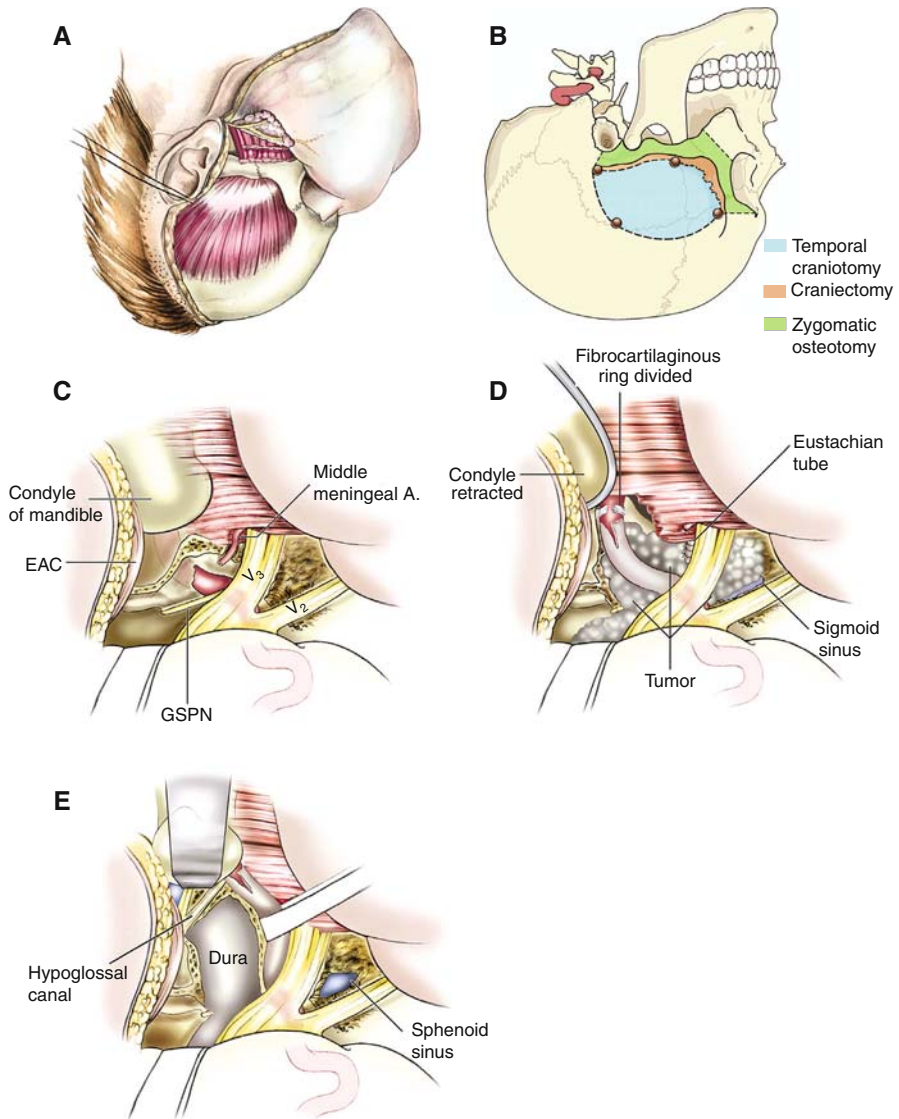
Once the bone is removed, the petroclival dura will be exposed. In order to expose the posterior cavernous sinus or the upper clivus, it is essential to open the dura mater, and to work between the fascicles of the trigeminal root inside the Meckel's cave, or by dividing the trigeminal ganglion between V2 and V3 (trans trigeminal approach).

Opening the dura of the medial wall of the cavernous sinus then exposes the dorsum sellae and the posterior cavernous sinus.

### 2.3 Subtemporal-infratemporal approach

The subtemporal-infratemporal approach is an inferior extension of the subtemporal transzygomatic with petroclival bone. A more extensive exposure of the mid and lower clivus is obtained, especially on the ipsilateral side. This is an ideal approach for some petroclival chondrosarcomas and cholesterol granulomas. The difference lies in performing an osteotomy of the zygoma with the condylar fossa, removing the Eustachian tube, and exposing and displacing the entire petrous ICA anteriorly.

The details of the approach are similar to the previous one until the zygomatic osteotomy (Fig. 6A, B). The dura mater is elevated over the condylar fossa extradurally. The temporomandibular joint capsule is opened and the



**Fig. 6.** Subtemporal infratemporal approach. **A** Incision. **B** Craniotomy and osteotomies. **C** After elevation of temporal lobe dura and division of middle meningeal artery and greater superficial petrosal nerve (*GSPN*) and partially exposed horizontal portion of the internal carotid artery (**D**). After incising the dura propria over the semilunar ganglion and V2 and V3. The sphenoid sinus is seen between V2 and V3. **E** Mobilization of petrous ICA from the ICA from the carotid canal

meniscus of the joint is depressed inferiorly. The middle fossa dura is elevated to expose the middle meningeal artery, greater superficial petrosal nerve (GSPN), V3, and arcuate eminence of the petrous bone are indentified (Fig. 6C–E). The middle meningeal artery is cauterized and divided and foramen spinosum is packed with bone wax. The condylar fossa then is transilluminated to outline the entire fossa and the two cuts are made to include the entire fossa medial to the foramen of spinosum and the root of the zygoma. Care must be taken not to make the cuts too medially, to avoid damaging the facial nerve or the ICA.

After the horizontal segment of the petrous ICA is exposed by extradural dissection, the dissection is extended inferiorly by removing the tensor tympani muscle, the Eustachian tube, and the tympanic bone, unroofing the genu and the vertical segment of the petrous ICA. The ICA is dissected from the bony canal extraperiosteally. At the entrance to the carotid canal, there is a thick fibrocartilaginous ligament which has to be divided, and partially excised. Superiorly, the bone is removed medial to V3, and lateral to the petrous ICA. This will allow the complete mobilization of the petrous and upper cervical ICA (Fig. 6E).

Critical structures lie medially and posteriorly. The middle ear and the genu of the facial nerve lie superiorly and posteriorly, whereas the jugular bulb and the lower cranial nerves lie posteriorly and inferiorly to the petroclival region. Entry into the jugular bulb is dealt with in the usual manner with gentle packing, and if necessary by fibrin glue injection. Both ends of the Eustachian tube must be closed, the anterior end by packing oxidized cellulose and a suture, and the posterior end with a small fat graft.

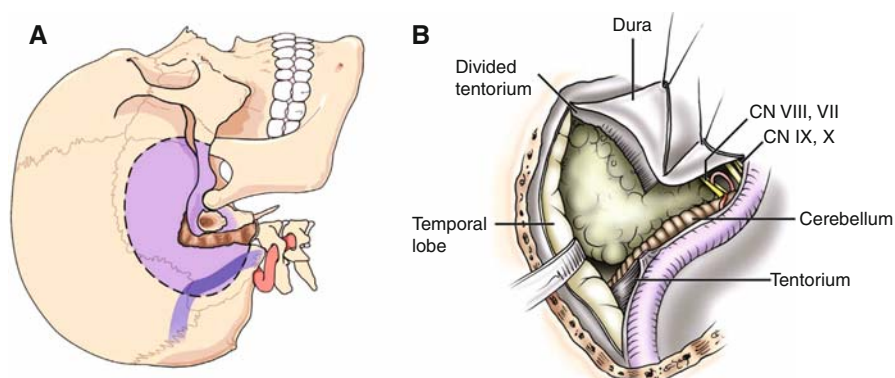
If there is a dural defect, it is closed in the usual fashion with fascia and Duraseal, augmented with abdominal fat graft. Flow through the petrous ICA must be confirmed by Doppler flowmetry.

### 3. POSTERO-LATERAL APPROACHES

#### 3.1 Transpetrosal (retrolabyrinthine, partial labyrinthectomy/petrocus apicotomy (PLPA), translabyrinthine, and total petrosectomy)

This approach is used predominantly for intradural tumors such as petroclival meningiomas. However, when an extradural lesions such as a chordoma has an extensive intradural invasion, marked compression of the brain stem and encasement of the basilar artery, this approach would be preferred, since it allows these structures to be removed under direct vision.

A lumbar drain is in place. The preoperative angiogram must be carefully inspected to observe the venous sinuses and the vein(s) of Labbe. The patient is placed in a supine position with the head turned 70° to the contralateral side or in a park bench position if a limited mobility of the patient's neck is observed preoperatively. A U-shaped incision starting in the preauricular area (1 cm anterior to the root of the zygoma), curving up into the temporal re-



**Fig. 7. A** Lateral approach with PLPA (for trigeminal schwannoma). Temporal craniotomy zygomatic osteotomy and transpetrosal approach. **B** Tumor exposure after cutting the tentorium

gion, and extending retro auricularly to just below the mastoid tip is used (Fig. 7A). The posterior half to third of the temporalis muscle and some of the pericranium in the frontal region (temporofascial flap) is elevated separately and reflected inferiorly. The retrosigmoid muscles are reflected inferiorly. After draining some fluid from the lumbar drain, a mid and posterior temporal craniotomy is performed, extending at least 2 cm posterior to the projected transverse sigmoid junction. Following this, a retrosigmoid craniotomy is performed (if necessary) across the transverse sinus, down to the floor of the posterior fossa. Depending on the petrosal approach chosen to expose the presigmoid space; a radical mastoidectomy is required to expose the sigmoid sinus, superior, lateral, and posterior semicircular canal, the vestibular aqueduct, jugular bulb, and the facial nerve canal (Fig. 7B). In the PLPA approach, the posterior and superior semicircular canals are opened and waxed to prevent the loss of endolymph and hearing loss. They are then removed. A petrous apicectomy is then performed, working through this space. This provides more room than a standard retrolabyrinthine approach, particularly on the right side, where the sinus is often larger. In the translabyrinthine approach, the entire labyrinthine bone is removed to the level of vestibule along with the bone to the IAC.

A total petrosectomy approach is rarely used in order to gain a much better exposure of the brain stem. Here, the facial nerve is completely skeletonized from the cisternal segment to the stylomastoid foramen, and after dividing the GSPN, displaced postero inferiorly. The petrous ICA is displaced anteriorly, similar to the subtemporal-infratemporal approach. The remaining temporal bone is drilled away, sacrificing ipsilateral hearing. The jugular bulb and the lower cranial nerves are carefully protected.

Once the bony work is completed the dura opening starts with an incision in the presigmoid area beginning anterior and parallel to the sigmoid sinus



and superior to the jugular bulb. This incision is then extended anteriorly until the superior petrosal sinus. A second dura opening occurs on the temporal side over the inferior temporal gyrus towards the superior petrosal sinus. The superior petrosal sinus is ligated and divided and the tentorium is then incised. Care must be taken to avoid the fourth nerve and superior cerebellar artery. Meckel's cave is then opened, with the control of the bleeding from the cavernous sinus as needed. The operation then proceeds with minimal brain retraction, working between cranial nerves 3–9.

For the closure of the transpetrosal approach, the mastoid air cells and the entrance into the middle ear are carefully closed with bone wax. Any dural defect is closed with pericranium or Duragen. The temporofascial flap is then rotated over the mastoidal area. Abdominal fat graft is used to fill any remaining defect posterior to the temporofascial flap. If the bone over the mastoid area has been removed by drilling, it must be replaced with titanium mesh, in order to prevent a depression in the area when it heals.

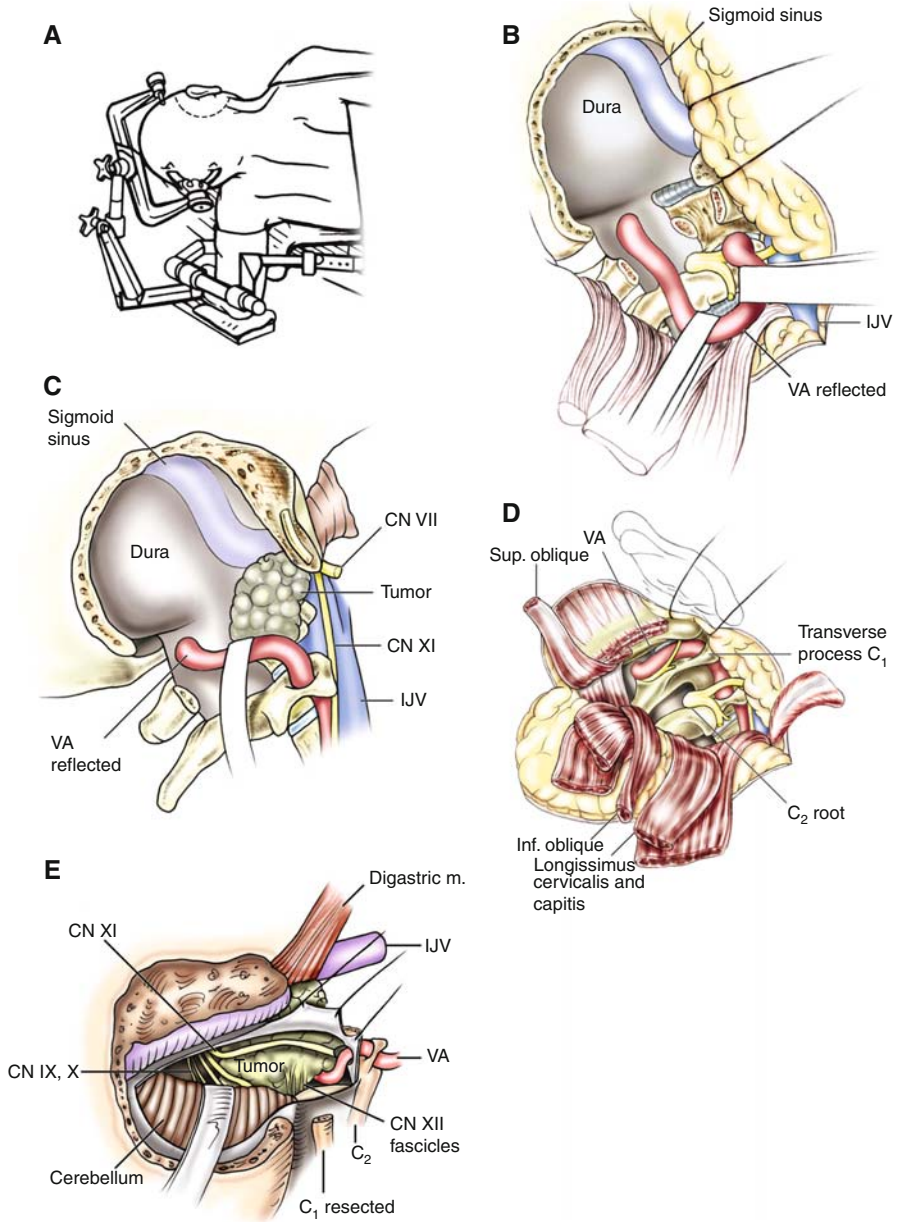
### 3.2 Extreme lateral transcondylar approach

This is the best approach for tumors in the foramen magnum upper cervical area which are anterior to the spinomedullar junction. The extreme lateral approach has 6 variations, which are useful for neoplastic and vascular lesions of this area. We will only describe the partial transcondylar (used for foramen magnum meningiomas), and the complete transcondylar (used for extradural lesions such as chordomas) approaches.

The patient is placed in a lateral, park bench position with the lower arm placed in a cloth sling and the upper arm padded around a pillow. The head is held in a Mayfield pin holder with the head rotated slightly towards the surgeon, and neck flexed and extended laterally (Fig. 8A). A C-shaped incision extending from the superior temporal line posteriorly into the retroauricular region and into the lateral neck is used. The inferior extent of the incision will depend on the need to expose C2. The skin flap is reflected forward with the sternomastoid muscle, and the remaining muscles are elevated in layers. The next layer consists of the Splenius capitis, the next layer has the semispinalis capitis, the longissimus capitis and cervicalis, and the oblique and recti muscles. The occipital artery lies between the second and third layers (Fig. 8B).

A key step is to identify the vertebral artery (the second and third segments) from C2 to the foramen magnum. This is done under the microscope. It may be identified in the suboccipital triangle, between C2 and C1. The C1 lamina, the perivertebral venous plexus, and the C2 nerve are useful landmarks in its identification. Any bleeding from the venous plexus is handled by bipolar cautery, and fibrin glue injection. The foramen transversarium of C1 is completely unroofed, and the lateral third of the C1 lamina is removed. The VA can then be displaced medially.

A small retrosigmoid craniotomy is performed extending through the foramen magnum. A low mastoidectomy just posterior to the facial nerve is



performed to expose the posterior edge of the sigmoid sinus, and to access the occipital condyle. Any bleeding from the condylar emissary vein is stopped with oxidized cellulose, and bone wax (Fig. 8C). This venous canal is also a marker to the hypoglossal canal which lies just inferior to it.

The posterior half of the occipital condyle, and the lateral mass of C1 including portions of the jugular tubercle are removed with a drill or ultrasonic aspiration which will expose the hypoglossal canal (Fig. 8E). For intradural tumors, removal of enough bone should be performed in order to have about 1 cm of dura exposed lateral to the entrance of the VA into the dura mater. The dural opening then is performed encircling the artery (Fig. 8C, D). The first dentate ligament and the C1 rootlets are divided, and tumor resection proceeds with no brain stem retraction. During closure, the resection bed is gently packed with autologous fat and dura primarily sutured if violated. Primary dural closure is usually impossible; a fascial or pericranial graft is used and supplemented with tissue glue, followed by autologous fat.

For extradural tumors, the entire occipital condyle and lateral mass of C1 are removed. Complete unroofing of the jugular bulb may also be helpful. Further inferior exposure can be achieved by unroofing the VA in the C2 foramen, and removing the lateral mass of C2. When a complete condylar resection is performed, a fusion procedure is needed. We prefer to delay this by about a week from the tumor removal. If possible, a bone graft may be placed from C2 to the clivus. The actual fusion is from the occiput to C2–3, using a preshaped titanium ring, screws into the occipital bone, and the lateral masses.

#### 4. USE OF COMBINED/ALTERNATIVE APPROACHES

Extensive tumors may require the use of combined approaches in stages, usually in 2 and rarely in 3 stages.

### HOW TO AVOID COMPLICATIONS

The key to complication avoidance is the use of the correct operative approach, anatomical knowledge, and expertise, which is gained by learning from one's and others' experience. Common complications include CSF

←  
**Fig. 8.** **A** Patient positioning and incision for a complete transcondylar extreme lateral approach. If combined with petrosal approach, then the patient is placed supine with head turned 45°. **B** Retrosigmoid craniotomy and C1 laminectomy have been performed. The VA (vertebral artery) has been mobilized medially. The occipital condyle can now be resected as needed for complete tumor removal. **C** Tumor resection commenced. **D** Relationship among the VA (vertebral artery), C2 dorsal root, C1 lamina and occipital condyle. **E** Extreme lateral partial transcondylar approach for a hypoglossal schwannoma. Intradural exposure shows the location of hypoglossal schwannoma. *IJV* Internal jugular vein

leaks, cranial nerve palsies, infection, hematomas, vascular injuries, and rarely brain or brain stem injuries. Management of complications addresses recognition of the cause of the problem, and appropriate treatment.

#### **Acknowledgement**

Doctors Chong C. Lee, MD, PhD, and Dinesh Ramanathan, MD, TNS, are acknowledged as co-authors.



**Laligam N. Sekhar**

Laligam Sekhar is Professor and Vice-chairman at the Department of Neurosurgery, University of Washington, Seattle. He received his degrees in biology from the Loyola College (1967) and Vivekanada College (1968) of Madras University in India and obtained his M.B.B.S. in Medicine from Madras University in 1973.

He then pursued his training in neurology and neurosurgery at Cook County Hospital (Chicago, IL), the University of Cincinnati (OH) and then at University of Pittsburgh (PA). He trained briefly with Prof. M. Gazi Yaşargil and Prof. Majid Samii in neurosurgery.

Dr. Sekhar completed his residency in 1982 and after that he worked extensively in skull base surgery and pioneered numerous new techniques. He was appointed as Assistant Professor in the Department of Neurological Surgery at the University of Pittsburgh. In 1993 he became chairman of the Department of Neurological Surgery at George Washington University in Washington, DC. Dr. Sekhar has published, more than 200 peer-reviewed papers, 100 book chapters and 4 books.

**Contact:** Laligam N. Sekhar, Department of Neurosurgery, University of Washington, Harborview Medical Center, 325 Ninth Ave., Box 359924, Seattle, WA 98104-2499, USA  
E-mail: lsekhar@u.washington.edu

---

# HOW TO PERFORM SELECTIVE EXTRADURAL ANTERIOR CLINOIDECTOMY

Y. YONEKAWA

## INTRODUCTION

The anterior clinoid process is a part of the sphenoid bone overlying the optic nerve and the carotid artery taking a veer medially to the planum sphenoidale, anterolaterally to the sphenoid ridge and caudally to the optic strut. Partial removal of the process has been recommended for the surgical management of aneurysms of the internal carotid artery (ICA) at its proximal intradural part, already as early as in 1972 [11, 12, 19]. It was however only in 1993 that the method of systematic en bloc removal of the bone fragment including the whole anterior clinoid process (ACP), namely, selective extradural anterior clinoidectomy (SEAC) was carried out, which then was reported in 1997 [22]. With this method one may obviate the more invasive and time consuming technique of extensive orbital roof removal together with anterior clinoidectomy which had been applied in surgical treatment for parasellar and cavernous pathologies pioneered by Dolenc [2, 3]. In this chapter, advantages, indications, technical details and complications are clarified.

## RATIONALE

The ACP is located at the medial end of the ala minor of the sphenoid bone and forms the lateral wall of the optic canal and the medial wall of the superior orbital fissure. The space gained by removal of the ACP by SEAC is called the clinoid space. Its floor makes the superior wall of the cavernous sinus. Removal of the ACP makes the operative field more spacious, which facilitates the handling of microsurgical instruments in the depth and allows to obtain much more illumination of the operating microscope. Incision of the lateral wall of the optic nerve sheath and partial or circumferential dissection of the distal dural ring of the internal carotid artery (ICA) after the SEAC enable easier further mobilization of the optic nerve and the ICA. This increased mobility of both structures enables radicality of procedures in the vicinity such as tumor removal or aneurysmal clipping with much more security. Opening of the cavernous sinus after the procedure enables surgical treatment of intracavernous pathology with complicated anatomy [7].

---

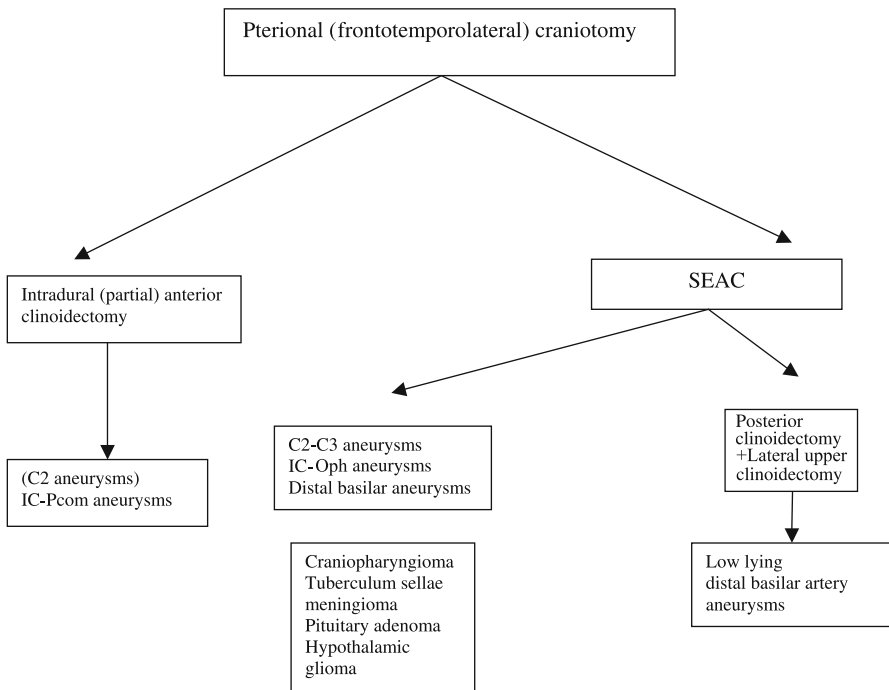
*Keywords:* skull base approaches, anterior clinoidectomy, microsurgery

Drilling away the posterior clinoid process and the upper clivus is helpful for clipping of lower lying distal basilar aneurysms [13, 18, 20, 21].

### DECISION-MAKING

Indications of SEAC are as follows (Fig. 1): aneurysms at C2 portion, especially proximal C2, and at C3 portion, meningioma of the tuberculum sellae, pituitary adenoma, craniopharyngioma, aneurysms of the distal basilar artery with or without combination of extensive posterior clinoidectomy by opening the cavernous sinus at its postero-superior corner [22]. A high-flow bypass between the C4 and the C2 portion can be performed in combination with the anterior petrosectomy [6].

Furthermore, aneurysm surgery in the acute stage for the distal basilar artery can be better performed even in the presence of brain swelling by pterional approach combined with SEAC than by subtemporal approach, by gaining the clinoid space and by better CSF drainage via third ventriculostomy by opening the lamina terminalis [20, 21].



**Fig. 1.** Decision algorithm for anterior clinoidectomy. Although internal carotid-ophthalmic artery aneurysms are to be included with paraclinoid aneurysms (C2-C3), they are classified here separately in the traditional way

## SURGERY

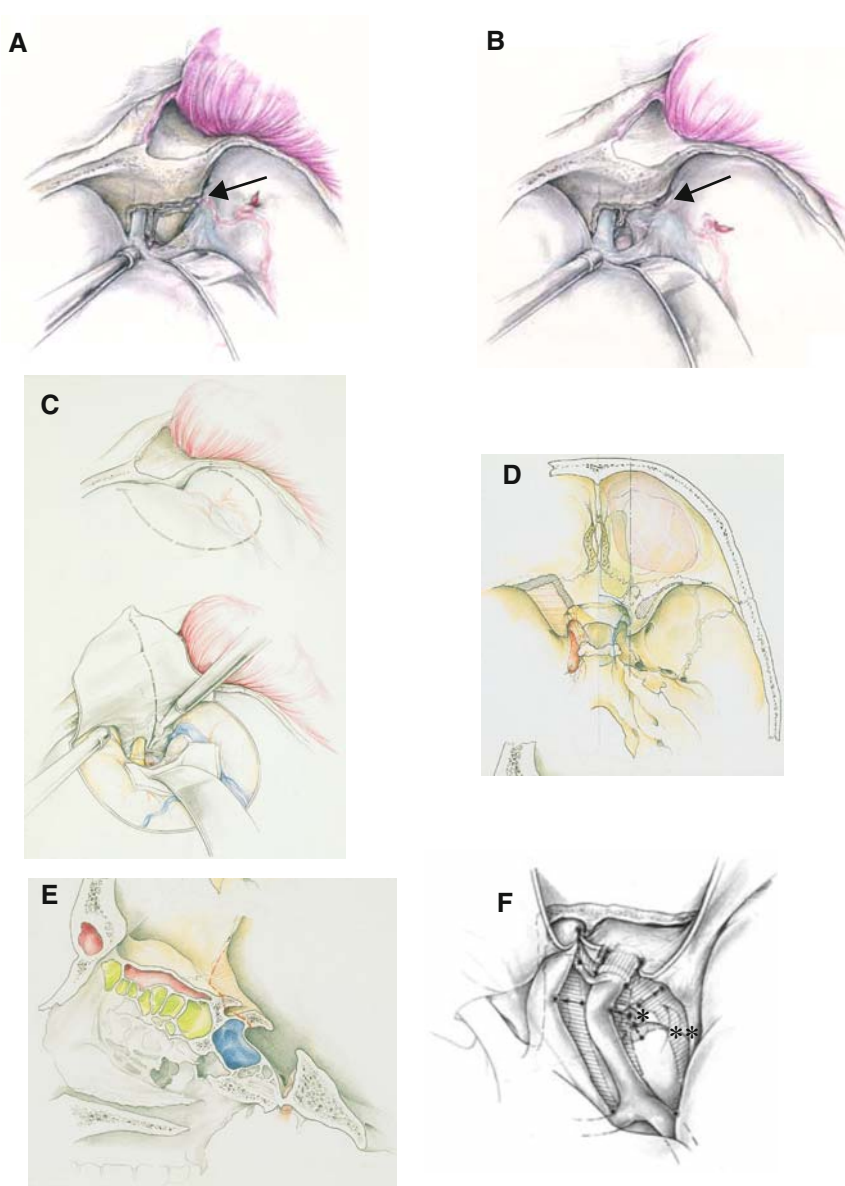
### 1. SELECTIVE EXTRADURAL ANTERIOR CLINOIDECTOMY (Fig. 2)

After having completed a pterional craniotomy, the sphenoid ridge is drilled away up to the lateral corner, the so-called frontotemporal dural fold (FTDF) (or orbitotemporal periosteal fold) [2, 5] of the superior orbital fissure (SOF), which might contain the lacrimal branch of the middle meningeal artery. Far medially extradurally towards the midline, one may reach the falciform fold of the optic nerve, which in our experience can be noticed in more than 80% of cases, so that one may postulate the course of the optic canal. Otherwise, this has to be checked after opening the dura by confirming the optic nerve. Careful drilling away with cutting burr of 2–3 mm is begun from the crossing point of the above mentioned FTDF of the SOF medioanteriorly so that the cutting or drilling line can cross over with that of the roof of the optic canal. With these two drilling procedures one may luxate the ACP and remove it en bloc. At that time, one has to pay attention to the following three points. (1) Compression or contusion to the optic nerve should be avoided. (2) The anesthesiologist should be informed and prepared for arrhythmia or even for cardiac arrest for a while due to trigeminal nerve stimuli. We are doing topical application of procaine in order to alleviate the reaction. (3) There is profuse bleeding from the clinoid space. This bleeding is no direct bleeding from the cavernous sinus and can be controlled effectively with oxycellulose immersed in fibrin glue and a sponge for compression with slight head elevation.

If the en bloc removal is difficult, as in our experience it appears in around 30–40% of cases mostly due to a strong optic strut, the part of the strut should be drilled away carefully and once more the en bloc removal should be tried. If the process still cannot be removed, one has to doubt and check the bony connection of the ACP to the posterior clinoid process, although such situation is rare. The connection is to be cut by drilling away to complete the SEAC procedure. Sometimes the strategy of en bloc removal might have to be abandoned in case of more difficulty and the remaining part of the ACP has to be removed only by drilling away. After the removal, the optic strut can be still so strong that a considerable part remains between the optic nerve and the ICA. One has to drill away the part in order to get a spacious clinoid space for performance of further surgical procedures.

During this procedure one may encounter two paranasal sinuses. One are the ethmoid cells at the time of drilling away of the roof of the optic canal at its medial corner, so that one should remain just at the most medial corner of the canal and not exceed the limit. The other sinus, the sphenoid sinus, can extend into the ACP, around 8–10% after previous reports [10] and our experience, so that its mucous membrane can be exposed on ACP removal. In both cases, the mucous membrane is pushed back with Betadine-immersed oxycellulose and is treated afterwards with fatty tissue or muscle piece and





**Fig. 2.** Artist drawing of SEAC procedure. **A** Drilling lines of SEAC showing over the optic canal and over the FTDF (arrow). **B** Clinoid space obtained by en bloc removal of the ACP. **C** Additional dural incision for preparation of the clinoid space. **D** Axial view of the skull base showing the extent of SEAC and paranasal sinuses. **E** Paramedian sagittal view of the skull showing paranasal sinuses. **F** Overview after dural opening and dissection of the optic nerve and the carotid artery as described in the text. Note the posterior clinoid process and the distal basilar artery (\*) in the depth medial to the oculomotor nerve (\*\*)

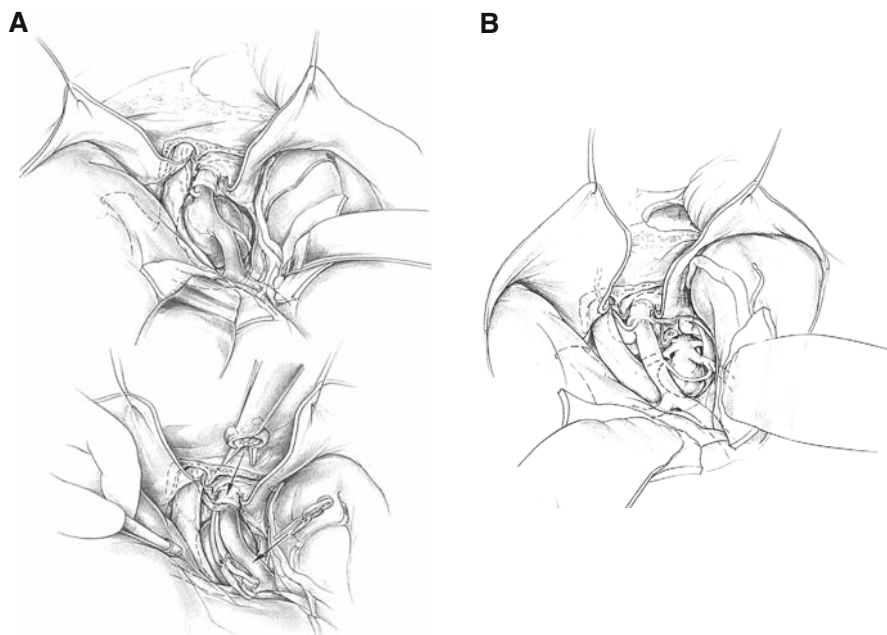
fibrin glue. Contents of the superior orbital fissure (the ophthalmic nerve, oculomotor nerve, nasociliary nerve, abducens, trochlear nerve, superior ophthalmic vein, recurrent branch of the ophthalmic artery and lacrimal branch of the middle meningeal artery) are not exposed during the SEAC procedure. Lesions of the cavernous sinus can be accessed by opening the anteromedial triangle after Dolenc, but this is beyond the scope of this chapter so that the other chapter about this should be referred.

After dural opening in a curvilinear fashion, the proximal dural flap is cut again to the direction of the clinoid space. After having reached the distal dural ring of the ICA, one may extend the cutting line to the falciform fold over the optic nerve. Longitudinal incision on the optic nerve sheath at the lateral corner about 5 mm anteriorly makes mobilization of the optic nerve easier, so that the ophthalmic artery origin located at the mediosuperior corner of the ICA comes into view in case of usual intradural origin (around 85%). This procedure can be done only after the unroofing of the optic canal is done following the original SEAC method. The distal dural ring of the ICA is incised according to the need of ICA mobilization. This might have to be combined with opening of the cavernous sinus so that the bleeding from the opened sinus has to be filled with oxycellulose together with fibrin glue successively. By this increased mobilization of the optic nerve and the ICA, aneurysms of the C2–C3 segment can be managed successfully with a conventional clipping method, also those of the distal basilar artery with or without combination of an extensive posterior clinoidectomy (Figs. 3 and 4). Radicality of tumor removal of the parasellar and hypothalamic region is accomplished by this increased mobility of the structures [1, 15, 22].

In cases with potential risk of aneurysmal rupture at the time of clinoidectomy [9] even in SEAC, it is recommended to perform dissection of the cervical carotid artery beforehand for eventual temporary carotid ligation for its management.

## 2. INTRADURAL ANTERIOR CLINOIDECTOMY

Anterior clinoidectomy can be carried out after dural opening especially for the treatment of aneurysms of the internal carotid–ophthalmic or the internal carotid–posterior communicating artery, whose neck locates very near to or under the clinoid process [11, 19]. Intradural en bloc removal has been also reported [17]. Precise neuroradiological evaluation has been reported to enable prediction of the necessity of clinoidectomy, for example, in cases with the distance between the proximal aneurysmal neck and the carotid knee C3 being less than 1 cm in the lateral view of angiography [14]. One has to be careful only with slipping off the drilling burr onto the carotid and neighboring optic nerve, as they are without dural covering, which is not the case for SEAC.



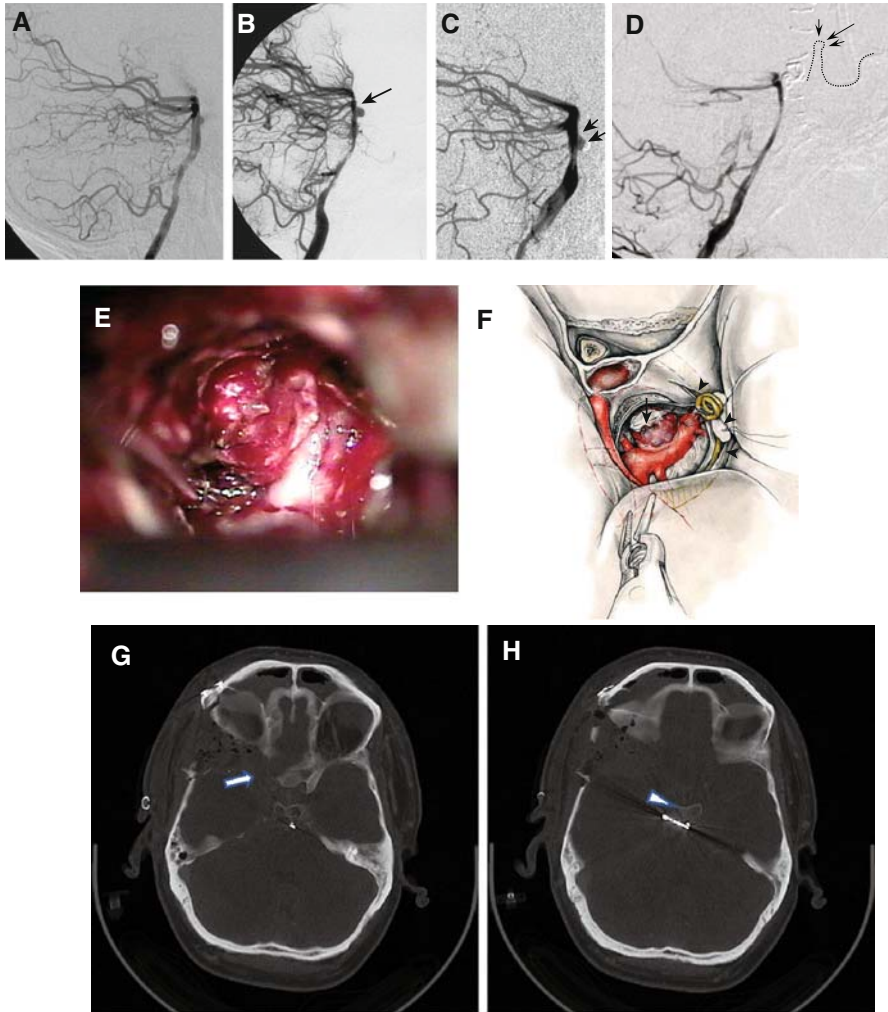
**Fig. 3.** Artist drawing of aneurysm neck clipping after SEAC procedure. **A** Large posterior wall aneurysm of the ICA-C2 portion. **B** Basilar bifurcation aneurysm.

### 3. POSTERIOR CLINOIDECTOMY

Combination of extensive posterior clinoidectomy with SEAC is effective for the surgical treatment of low lying distal basilar artery aneurysms; aneurysms of the basilar bifurcation, basilar SCA aneurysms and even upper basilar trunk aneurysms (Fig. 4) lying lower than the level of the posterior clinoid process at the lateral view of the angiogram [4, 13, 16, 18, 20, 21]. After the procedure of SEAC and partial or complete circumferential dissection of the carotid dural ring for mobilization of the ICA, the dural canal of the oculomotor nerve is opened by cutting the dural sheath towards the proximal dural ring. This enables mobilization of the oculomotor nerve, so that the procedures for the extensive posterior clinoidectomy can be carried out smoothly and safely due to a widened working space. The dura over the posterior clinoid process and that over the posterosuperior cavernous sinus are incised to enable the procedure. Bleeding from the cavernous sinus is managed with fibrin glue-immersed oxycellulose. Drilling away of the clinoid and lateral part of the upper clivus can be done thus more safely with a burr drilling equipped with a diamond head and irrigation.

### 4. CLINICAL RESULTS AND COMPLICATIONS

SEAC was carried out in 214 cases during the period between September 1993 and May 2007 as are shown in Table 1. SEAC-related complications are



**Fig. 4.** A case of basilar trunk dissection aneurysm located lower than the level of the posterior clinoid process. **A** This small outpouching at the anterior wall of the distal basilar trunk was overlooked on day 0 digital subtraction angiography (DSA) after subarachnoid hemorrhage. **B** Repeated DSA 5 days later revealed growth of the dissecting aneurysm (arrow), so that this was successfully coiled. **C** Coil compaction (double arrows) on the repeated DSA on day 17 after a rebleeding. **D** Follow-up angiography after the complete neck clipping. Notice the height of the posterior clinoid process and sellar (triple arrows) drawn additionally. **E** Exposure of the dissecting aneurysm after SEAC and extended posterior clinoidectomy. **F** Artist drawing of the situation of **E**. Notice the drilled upper lateral clivus on the left side (arrow) and opened oculomotor nerve canal on the right (arrowheads). **G** This bone window CT indicates status after SEAC right (arrow) following a standard pterional craniotomy. **H** This slice CT shows the status after the posterior clinoidectomy and the lateral clivectomy (arrowhead). Notice the aneurysm clip to the dissecting aneurysm. The compacted coil can be seen between the clivus and the tip of aneurysm clip

**Table 1.** Cases underwent SEAC (N=214)

Aneurysms	
ICA	
Paraclinoid (C2+C3)	25
IC-Oph	24
IC-Pcom	6
Distal basilar artery	
BA-bifur	44
BA-SCA	17
others (e.g. P1, basilar trunk)	4
Others (for ligation or trapping)	6
Meningioma	
Tuberculum sellae meningioma	18
Sphenoid ridge meningioma	10
Ant. clinoid process meningioma	10
Others (e.g. petroclival, sinus cavernosus)	8
Craniopharyngioma	18
Pituitary adenoma	13
Others (e.g. cavernous sinus angioma, intraorbital tumor)	9
Hypothalamic glioma	2

visual disturbances in 3 cases. One of them presented postoperatively with amaurosis which did not improve. Postoperative CT scan showed a small hematoma in the clinoid space. Persistent rhinorrhea was complicated in 4 cases; one was treated with transnasal repair plus V-P shunting and the other three with transcranial repair by recraniotomy.

## HOW TO AVOID COMPLICATIONS

Major complications are, as before mentioned, compromise of the optic nerve and CSF rhinorrhea. For prevention of these complications, on the one hand it is important to have appropriate preprocedural expectation of the anatomical relationship of the optic nerve and the carotid artery by correct interpretation of findings of neuroimaging including status of pneumatization of paranasal sinuses. One should be familiar with their topographical anatomy along with their pathological deviation, as one is requested to work correctly very closely to these important structures. Opening of sinuses should be noticed without oversight and treated as mentioned above. On the other hand microsurgical training with cadaver dissection is therefore mandatory and it cannot be over-emphasized to carry out the procedure very carefully avoiding direct mechanical injury and heat transmission of drilling by continuous saline irrigation. By trained hands, the procedure can be completed within 15–20 min.

Another thing to be cared is strong dural adhesion to the clinoid process in aged patients at the time of en bloc removal. In order to avoid inadvertent

injury to the neighboring structures in such situation, the removal should be carried out with great care.

## CONCLUSIONS

The anterior clinoid process covers part of the optic nerve and the internal carotid artery. On its removal, parasellar pathological processes such as tuberculum sellae meningiomas, craniopharyngiomas, paraclinoid aneurysms and upper basilar aneurysms can be managed surgically with more radicality and security. The removal can be done ideally by SEAC, which has some potential risk of injury to important structures so that it should be performed with good knowledge of topographical anatomy and by trained hands.


## Acknowledgment

I am indebted to P. Roth for the work of illustrations.

## References

- [1] Andaluz N, Beretta F, Bernucci C, Keller JT, Zuccarello M (2006) Evidence for the improved exposure of the ophthalmic segment of the internal carotid artery after anterior clinoidectomy: morphometric analysis. *Acta Neurochir (Wien)* 148: 971-976
- [2] Coscarella E, Baskaya MK, Morcos JJ (2003) An alternative extradural exposure to the anterior clinoid process: the superior orbital fissure as a surgical corridor. *Neurosurgery* 53: 162-167
- [3] Dolenc VV (1985) A combined epi- and subdural direct approach to carotid-ophthalmic artery aneurysms. *J Neurosurg* 62: 667-672
- [4] Dolenc VV, Skrap M, Sustersic J, Skrbec M, Morina A (1987) A transcavernous-transsellar approach to the basilar tip aneurysms. *Br J Neurosurg* 1: 251-259
- [5] Froelich S, Aziz KMA, Levine NB, Theodosopoulos PV, van Loveren HR, Keller JT (2007) Refinement of the extradural anterior clinoidectomy: surgical anatomy of the orbitotemporal periosteal fold. *Neurosurgery* 61(5 Suppl 2): 179-186
- [6] Fukushima T (1992) Operative technique of the skull base bypass. *Jpn J Neurosurg* 1: 41-47
- [7] Inoue T, Rhoton AL Jr, Theele D, Barry ME (1990) Surgical approaches to the cavernous sinus: a microsurgical study. *Neurosurgery* 26: 903-932
- [8] Khan N, Yoshimura S, Roth P, Cesnulis E, Koenue-Leblebicioglu D, Curcic M, Imhof HG, Yonekawa Y (2005) Conventional microsurgical treatment of paraclinoid aneurysms: state of the art with the use of the selective extradural anterior clinoidectomy SEAC. *Acta Neurochir Suppl* 94: 23-29

- [9] Korosue K, Heros RC (1992) "Subclinoid" carotid aneurysm with erosion of the anterior clinoid process and fatal intraoperative rupture. *Neurosurgery* 31: 356-360
- [10] Mikami T, Minamida Y, Koyanagi I, Baba T, Houkin M (2007) Anatomical variations in pneumatization of the anterior clinoid process. *J Neurosurg* 106: 170-174
- [11] Morgan F (1972) Removal of anterior clinoid process in the surgery of carotid aneurysm, with some notes on recurrent subarachnoid haemorrhage during craniotomy. *Schweiz Arch Neurol Neurochir Psychiatr* 111: 363-368
- [12] Nutik SL (1988) Removal of the anterior clinoid process for exposure of the proximal intracranial carotid artery. *J Neurosurg* 69: 529-534
- [13] Nutik SL (1998) Pterional craniotomy via a transcavernous approach for the treatment of low-lying distal basilar artery aneurysms. *J Neurosurg* 89: 921-926
- [14] Ochiai C, Wakai S, Inou S, Nagai M (1989) Preoperative angiographical prediction of the necessity to removal of the anterior clinoid process in internal carotid-posterior communicating artery aneurysm surgery. *Acta Neurochir (Wien)* 99: 117-121
- [15] Otani N, Muroi C, Yano H, Khan N, Pangalu A, Yonekawa Y (2006) Surgical management of tuberculum sellae meningioma: role of selective extradural anterior clinoidectomy. *Br J Neurosurg* 20: 129-138
- [16] Seoane E, Tedeschi H, de Oliveira E, Wen HT, Rohton AL Jr (2000) The pretemporal transcavernous approach to the interpeduncular and prepontine cisterns: microsurgical anatomy and technique application. *Neurosurgery* 46: 891-899
- [17] Takahashi JA, Kawarazaki A, Hashimoto N (2004) Intradural en-bloc removal of the anterior clinoid process. *Acta Neurochir (Wien)* 146: 505-509
- [18] Yaşargil MG, Antic J, Laciga R, Jain KK, Hodosh RM, Smith RD (1976) Microsurgical pterional approach to aneurysms of the basilar bifurcation. *Surg Neurol* 6: 83-91
- [19] Yaşargil MG, Gasser JC, Hodosh RM, et al. (1977) Carotid-ophthalmic aneurysms: direct microsurgical approach. *Surg Neurol* 8: 155-165
- [20] Yonekawa Y, Khan N, Imhof HG, Roth P (2005) Basilar bifurcation aneurysms. Lessons learnt from 40 consecutive cases. *Acta Neurochir Suppl* 94: 39-44
- [21] Yonekawa Y, Kaku Y, Imhof HG, Kiss M, Curcic M, Taub E, Roth P (1999) Posterior circulation aneurysms. Technical strategies based on angiographic anatomical findings and the results of 60 recent consecutive cases. *Acta Neurochir Suppl* 72: 123-140
- [22] Yonekawa Y, Ogata N, Imhof HG, Olivecrona M, Strommer K, Kwak TE, Roth P, Groscurth P (1997) Selective extradural anterior clinoidectomy for supra- and parasellar processes. Technical note. *J Neurosurg* 87: 636-642



**Yasuhiro Yonekawa**

Yasuhiro Yonekawa is consultant neurosurgeon at the Klinik im Park, Zurich, and at the Kantonsspital Aarau

1939: Born in Tsu, Mie, Japan

1964: Graduation, School of Medicine, Kyoto University, Kyoto, Japan

1970: Resident, Department of Neurosurgery, University Hospital Zurich, Zurich, Switzerland

1973: Chief Resident, Department of Neurosurgery, University Hospital Zurich, Zurich, Switzerland

1981: Associate Professor, Department of Neurosurgery, Kyoto University Hospital, Kyoto, Japan

1986: Director, Department of Neurosurgery, National Cardiovascular Center, Suita, Osaka, Japan

1993: Director, Department of Neurosurgery, University Hospital Zurich, Zurich, Switzerland

2007: Emeritation, Department of Neurosurgery, University Hospital Zurich, Zurich, Switzerland



Executive committee, International cooperative study of EC-IC Bypass (1978–1985  
NIH, USA)

Principal Investigator, National research committee of Moyamoya disease, Japan  
(1988–1992)

**Contact:** Yasuhiro Yonekawa, University of Zurich, Haldenbachstrasse 18, 8091  
Zurich, Switzerland

E-mail: [yasuhiro.yonekawa@usz.ch](mailto:yasuhiro.yonekawa@usz.ch)

---

# HOW TO PERFORM APPROACHES OF THE ORBIT

J. C. MARCHAL

## INTRODUCTION

There are several types of tumorous or pseudo-tumorous lesions affecting the orbit. The first historical stage was to make a coherent nosological approach of it. Often confused with the diagnosis and the treatment of tumorous proptosis, the first descriptions of tumors of the optical pathways and the optic nerve sheath are due to Antonio Scarpa (1816), who described a tumor of the optic nerve. Similarly, Jean Cruveilhier (1835) considered that meningiomas are tumors which do not belong to the central nervous system itself and must be distinguished from it. Albrecht von Graefe applied the same principle to tumors of the optic nerve. A. C. Hudson (1912) considered meningiomas of the optic nerve sheath as being separate from tumors of the optic nerve itself. However, it was Harvey Cushing [4], who provided the first accurate description of meningiomas as he distinguished meningiomas according to their origin from the arachnoid mater. He therefore dissociated orbito-sphenoidal meningiomas spreading the orbital content from meningiomas affecting the optic nerve sheath.

We can therefore understand why the neurosurgical approach to the orbit appeared only recently in the history of orbital surgery. The concept of the neurosurgical approach is directly linked to surgery of the craniofacial boundaries, and in this respect it should always be preceded by a multidisciplinary discussion. The concept of an endocranial approach was described and implemented by Durante (1887). Since then, retraction of the frontal lobe has been identified as the main obstacle to using this approach. Frazier (1913) partially resolved this technical difficulty when he suggested removing the superior orbital rim. Then came the work of Naffziger (1948), who established the specifically neurosurgical principles of the orbital approach, followed by Hamby (1964), who proposed the pterional approach for some of these lesions. In the 1960s and 1970s, plastic surgeons such as Converse, Mustarde, Stricker, and Tessier showed particular interest in craniofacial malformations, which gave new force to the aforementioned neurosurgical approaches as they added the notions of reconstruction and of volumetric reduction of the orbit to the existing notions of exocranial

---

*Keywords:* orbit, orbital approaches, tumor, pediatric neurosurgery

**Table 1.** Main orbital tumors in childhood in terms of histology and management<sup>a</sup>

Disease	Follow-up only	Biopsy	Chemo- or radiation therapy	Surgery
Optic nerve glioma	1 – clinical and MR imaging		2 – clinical worsening, avoid radiation therapy (NF1)	3 – resistant to chemotherapy, tumor spreading backwards
Plexiform neurofibroma	1 – clinical and MR imaging			2 – oculomotor and cosmetic considerations
Rhabdomyosarcoma		1	2 – after biopsy (bone marrow and/or tumor)	3 – checking MR findings at the end of treatment
Fibrosarcoma		1		2 – radical excision
Metastasis (neuroblastoma, Ewing's)			1 – according to histology	1 – primitive cancer unknown
Leukemia		1 – leukemia not diagnosed (chloroma)	1	
Teratoma				1 – radical excision
Dermoid cyst				1 – radical excision
Capillary hemangioma	1 – disappears spontaneously			
Lymphangioma	1 – clinical and MR imaging			2 – partial excision of cysts when growth spurts
Cavernous angioma				1 – radical excision
Fibrous dysplasia	1 – clinical and MR imaging			2 – oculomotor palsy, threatens optic nerves

<sup>a</sup> 1–3, steps in management

and endocranial approaches, and excision. These findings paved the way for surgical treatment of more complex lesions such as fibrous dysplasia and plexiform neurofibroma.

The history of neurosurgery reflects the difficulty of establishing a logical classification of the nature and origin of orbital tumors. These issues are still of concern today as specialists continue to face difficulties at the diagnosis stage [5], which can then lead to problems in choosing an appropriate strategy for treatment (Tables 1 and 2).

**Table 2.** Main orbital tumors in adulthood in terms of histology and management<sup>a</sup>

Disease	Follow-up only	Biopsy	Chemo- or radiation therapy	Surgery
Metastasis			According to histology	1 – primitive cancer unknown 2 – resistant to chemotherapy
Primitive lymphoma		1	2	
Optic sheath meningioma	1 – clinical and MR imaging			2 – if blindness of the eye
Spheno-orbital meningioma			2 – conformational radiation therapy following incomplete surgery	1 – excision (as complete as possible)
Schwannoma				1 – radical excision
Cavernous angioma				1 – radical excision

<sup>a</sup> 1–3, steps in management

## RATIONALE

The traditional anatomy of the orbital content is extremely complex as it describes numerous muscular, nervous and vascular structures within a small volume. Although anatomy books cover the elementary physiology of vision and of oculomotricity, the complexity of these books is not sufficient when dealing with the more pragmatic requirements of microneurosurgery. Furthermore, orbital fat is an anatomical factor of even greater importance than blood as it impedes navigation as well as surgical positioning in the orbit. As a result of these two considerations, traditional anatomical description should be considered as a concept rather than as a surgical model. It is equally important, when considering the neurosurgical approach of the orbit, to keep in mind a certain number of key anatomical references.

### 1. DEFINITION OF “NEUROSURGICAL ORBIT”

Tumorous or pseudo-tumorous lesions of the neurosurgical orbit are those which concern the two posterior thirds of the orbit [2]. Tumors of the eyeball should therefore be excluded. The choice of an approach depends on several topographical factors: the position of the tumor in the coronal plane of the orbit; monitoring of the orbital content, and, in the event of a tumor of the bone cavity or muscular cavity; monitoring of the epidural space, monitoring the optic nerve (ON) in the orbit, in the optic canal, and in the subarachnoid

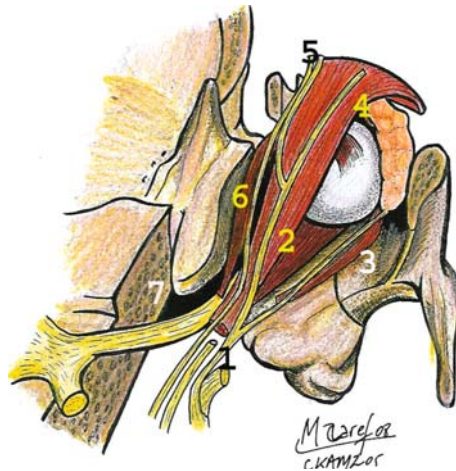
spaces; an approach which allows excisions of possible extension to the temporal fossa, the maxilla, zygomatic, and the nasal region.

## **2. LATERAL ORBITAL RIM: ACCESSING THE TWO POSTERIOR THIRDS OF THE ORBIT**

The anatomy of the anterior region of the orbit is formed by the suture of the zygomatic process of the frontal bone and the frontal process of the zygomatic bone. These two processes join backwards with the greater wing of the sphenoid bone. The frontal crest extends towards the rear on the parietal bone and bounds the lateral temporal fossa superiorly. By separating the periorbit from the medial aspect of the lateral wall of the orbit, and detaching the insertions of the temporal muscle at the anterosuperior region of the lateral temporal fossa, the surgeon can easily perform an orbitotomy which will remove the entire lateral wall of the orbit (in other words, the zygomatic process of the frontal bone and the frontal process of the zygomatic bone). From there the greater wing of the sphenoid bone is easily reached, and by removing the greater wing, the surgeon can access the superolateral region of the superior orbital fissure. Opening the periorbit superiorly towards the front provides access to the lachrymal nerve and to the lachrymal artery, running above the lateral rectus muscle and up to the lachrymal gland situated in the superolateral quarter of the orbit. The inferior oblique muscle is situated underneath the lateral rectus muscle. At the posterior part on the eyeball, the ON can be seen with the artery and the ciliary nerve. The ophthalmic veins can be seen at the rear of the eyeball.

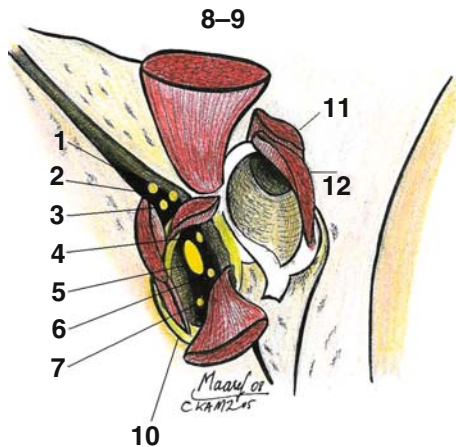
## **3. ORBITAL ROOF: ACCESSING THE SUPERIOR PART OF THE ORBIT AND THE EXOCRANIAL AND ENDOCRANIAL OPTIC CANAL**

The orbital roof can be easily separated from the dura of the inferior surface of the frontal lobe upwards and from the periorbit underneath. Once the orbital roof has been removed, it is possible to see, laterally across the periorbit in a posteroanterior direction, the frontal nerve, then the supra orbital nerve with the superior ophthalmic veins (Fig. 1). Medially from the frontal nerve, showing through an equally posteroanterior and medial direction, the trochlear nerve can be seen. These nerves are embedded in a substantial amount of periorbital fat, making dissection very delicate (Fig. 1). The incision of the periorbit can be made on either side of the frontal nerve, which rises above the levator palpebrae muscle–superior rectus muscle (LPM–SRM) complex. The retrobulbar part of the ON can either be exposed laterally or medially from the LPM–SRM. In order to reveal the ON, an incision should be made laterally on the periorbit, between the LPM–SRM and the LRM. At this point it is possible to see the lateral part of the ON [7], crossed over by the ophthalmic artery and the nasociliary nerve. The LRM is moved aside laterally with the abducens nerve, which penetrates into it at its me-



**Fig. 1.** Superior aspect of the right unroofed orbit. 1 Ophthalmic nerve (V), 2 frontal nerve (V), 3 lachrymal nerve (V), 4 supraorbital nerve (V), 5 supratrochlear nerve (V), 6 trochlear nerve (IV), 7 optic nerve (II)

dial aspect. Medially, by making an incision of the periorbit between the LPM–SRM and the medial surface of the superior oblique muscle, the entire intraorbital course of the ON is exposed and it is possible to make an incision into the common tendinous ring between the tendon of the SRM and the medial surface of the superior oblique muscle and to extend the visible part of the nerve towards the orbital apex (Fig. 2). The trochlear nerve must



**Fig. 2.** Coronal section of the right orbital apex. 1 Lachrymal nerve (V), 2 frontal nerve (V), 3 trochlear nerve (IV), 4 abducens nerve (VI), 5 oculomotor nerve (III), 6 sympathetic root of the ciliary ganglion, 7 nasociliary nerve (III), 8 and 9 levator palpebrae-superior rectus muscles, 10 common tendinous ring, 11 superior oblique muscle, 12 medial rectus muscle

therefore be protected at the point where it enters the oblique superior muscle. This area is easy to access since it has no nervous or vascular structure (except for the anterior section of the ophthalmic artery and the part of the trochlear nerve which crosses the LPM at its extraconical section). The central approach, which is performed between the levator palpebrae superioris muscle (LPSM) and the SRM, should be avoided as there is a risk to injure the nerve of the LPM (issuing from the oculomotor nerve) on the inferior surface of this muscle.

#### **4. OPTIC CANAL AND OPTIC NERVE**

The orbital apex is a complex anatomical area (Fig. 2) which, in order to be approached safely, requires endocranial monitoring of the ON and endo-orbital monitoring. This is why monitoring the ON involves opening the dura and the optic canal superiorly. In this way the nerve is easily identified at its endocranial exit of the optic canal in the optochiasmatic cistern. After drilling the roof of the optic canal, the superior surface of the ON up to the optic canal is situated between the LPM–SRM medially and the superior oblique muscle–medial rectus muscles superiorly and laterally. Laterally from the common tendinous ring, the lachrymal, frontal, and trochlear nerves are visible (Fig. 2).

### **DECISION-MAKING**

In terms of histology and management, main orbital tumors in childhood (Table 1) differ from those in adulthood (Table 2). There are 4 indications for surgery depending upon the knowledge of the diagnosis and the course of the disease [5]: biopsy, partial removal (in addition with chemotherapy and/or radiation therapy), total removal, checking a residual image after chemotherapy (for example, rhabdomyosarcoma).

### **SURGERY**

Choosing a neurosurgical approach to an orbital tumor depends on the location of the lesion in the orbit, extension to the bony structures, and extension to the dura and to the ON. Intraorbital lesions and intraconical and extraconical lesions of the two posterior thirds of the orbit which do not spread beyond the superior orbital fissure towards the rear, and which are situated in the superior and inferior quadrants, may be approached via a lateral orbital approach (schwannoma, cavernous angioma, and dermoid cyst, etc.) [1]. Lesions affecting the two posterior thirds in the medial quadrants with access to the orbital roof and to the dura require a frontal extradural approach. The subfrontal approach can be completed by opening

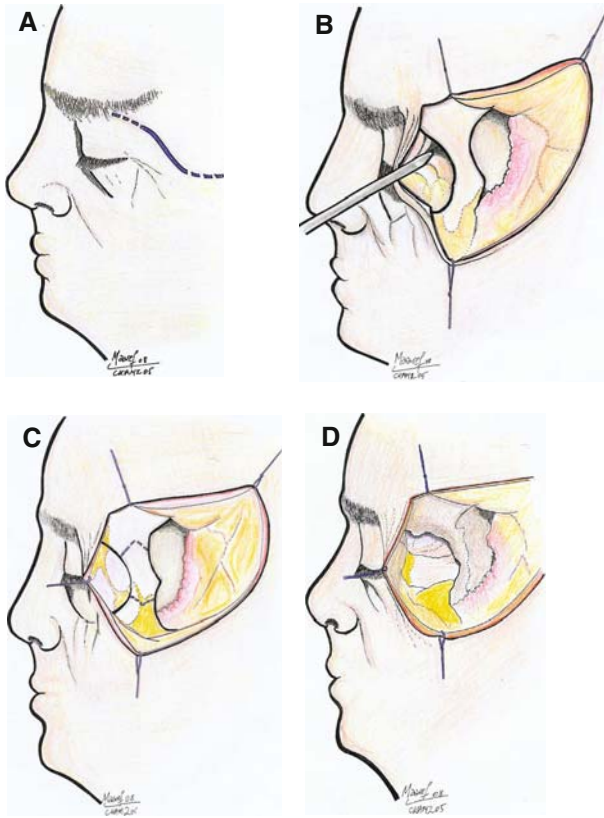
the dura in order to gain access to the ON from its extracranial entrance into the optic canal up to its endocranial exit in the optochiasmatic cistern (optic nerve glioma, optic sheath meningioma). If approaching via the temporal maxilla-zygomatic area, a pterional approach is recommended (orbittosphenoïdal meningioma, fibrous dysplasia). This pterional approach, although it does offer an excellent approach of the lateral rim and of the lateral walls of the orbit, will not be covered in this chapter as it is frequently performed as a preliminary to the lateral approach of the skull base for numerous pathologies.

## 1. LATERAL APPROACH

By this approach it is possible to avoid retraction of the frontal lobe [1]. The patient is in the supine position, with the head turned 30 to 40° on a head holder. The eyebrow should not be shaved off. The cutaneous incision follows the external orbital rim from the extremity of the eyebrow which stems from the zygomatic process (Fig. 3A). It is continued medially, either in the eyebrow or in a fold of the upper eyelid, thereby giving access to the superior orbital rim, and then continued in an S shape laterally and towards the rear in order to extend the zygomatic process. The incision is made right to the bone of the superior external orbital rim. The periosteum that lines the bony orbit is continuous with the periosteum of the skull's outer surface. The periosteum is detached upwards whilst the periorbit is carefully dissected from the medial surface of the lateral orbital wall downwards. Depending on requirements, the temporal muscle is detached from the anterior section of the temporal crest and the lateral orbital rim (Fig. 3B). The periorbit and the temporal muscle are protected on both sides of the lateral orbital rim with cottonoids. An osteotomy of the lateral orbital rim is performed using an oscillating saw. It is detached from the lateral orbital wall with a chisel (Fig. 3C). Excision of the lateral wall may be carried out using rongeurs or a drill. During this part of the operation, care must be taken to protect the periorbit, as any rupture into the operating field can hinder excision. If dealing with an intraconical lesion, the periorbit is opened above the raised area of the LRM, which is lowered carefully. The posterior part of the orbital globe is then accessible, as is the intraorbital section of the optic nerve because there are no important anatomical elements in the way. The only hindrance is the periorbital fat as it could block the surgical approach. It must be pushed aside and separated, and care must be taken not to remove it as this would cause bleeding.

By extending the incision outwards and backwards along the length of the zygomatic process, the surgeon gains easy access to both the lateral temporal fossa and the greater wing of the sphenoid bone (Fig. 3D). Extending the incision along the eyebrow or in an inward fold of the eyelid facilitates a small frontal craniotomy if the anatomy of the frontal sinus allows this. When the incision is extended inwards, care must be taken to avoid the supraorbital





**Fig. 3.** **A** Cutaneous incision follows the external orbital rim from the extremity of the eyebrow. It is continued medially, either in the eyebrow or in a fold of the upper eyelid. **B** Periorbit is dissected from the medial surface of the lateral orbital wall downwards. Depending on requirements, the temporal muscle is detached from the anterior section of the temporal crest and the lateral orbital rim. **C** Osteotomy of the lateral orbital rim. **D** Access to the lateral temporal fossa and the greater wing of the sphenoid bone

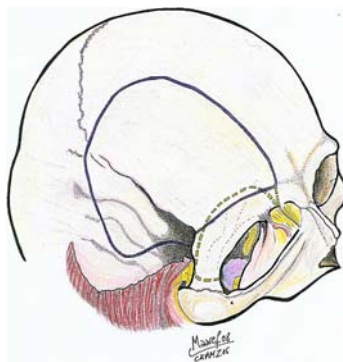
nerve, which penetrates the orbit via the supraorbital notch at the junction between the first medial third and the two lateral thirds of the superior orbital rim; it is perpendicular to the surgical approach and must be opened up and pushed inwards. It is important to remember that there is a possibility of extension of the frontal sinus from the superior orbital rim or from the orbital roof. If only an orbitotomy of the lateral rim is performed, there is no risk of this. However, if one wishes to perform a medial extension and small frontal craniotomy (in order to reveal the dura and remove the orbital roof, for example), there is a risk. If extension occurs, it must be treated, as failure to do so may cause postoperative infection, which is often difficult to treat. The simplest solution is to fill the gap with fat or with muscle that is stuck

with biological glue. The lateral orbital rim is laid down and osteosynthesis is performed using steel wires or screwed microplates.

## 2. SUBFRONTAL AND INTRACONICAL APPROACH OF THE ORBIT

### 2.1 Cutaneous incision, frontal craniotomy, and superior orbitotomy

The patient is in the supine position, with the head slightly extended and turned 10° opposite the side of the orbit to be explored. The bicoronal incision, skin flap and homolateral temporal muscle are bent back en bloc by detaching the periosteum directly from the bone situated on the pathological side. The superior insertions of the frontal muscle are progressively detached from the lateral temporal fossa, starting at the temporal crest during the folding of the skin flap towards the face. This detachment runs directly from the maxillary process of the frontal bone and the nasal bones medially and, laterally towards the zygomatic process of the frontal bone. Care must be taken to detach the anterior muscular insertions of the temporal muscle slightly towards the rear of the zygomatic process of the frontal bone, and to detach the latter as low as it is necessary to reveal the fronto-zygomatic suture. The supraorbital nerve is freed from its foramen or supraorbital notch: the nerve is accompanying its bony foramen, which is detached with a chisel and folded over downwards with the skin flap. Then, the periorbit is carefully dissected away from the inferior surface of the orbital roof, up to 2 cm. On the unaffected side, care must be taken to avoid injury to the temporal aponeurosis. A subcutaneous dissection can provoke paralysis of the frontal branch of the facial nerve. The frontal craniotomy can be confined to the vertical part of the frontal bone with or without the superior orbital rim. Removing the superior orbital rim can be carried out en bloc with the frontal craniotomy (Fig. 4), or in a second step, after lifting the frontal craniotomy (which is easier to perform on adults). A burr hole is made backwards from the zygomatic process



**Fig. 4.** Frontal craniotomy is confined to the vertical part of the frontal bone with (dotted line) or without (continuous line) the superior orbital rim

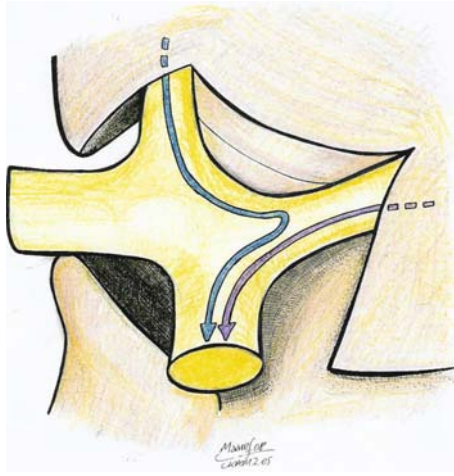
of the frontal bone, just under the crest of the insertion of the temporal muscle. After dissecting the dura, a rotative saw is used to cut the craniotomy along the lines (previously drawn on). The osteotomy of the superior orbital rim runs from the junction between the zygomatic process of the frontal bone and the frontal process of the zygomatic bone laterally and the medial third of the orbital roof. There is a risk, at this point, of entering the frontal sinus. Careful reading of the preoperative scan should prevent this to happen. If entering of the frontal sinus mucosa occurs, it must be sealed off in the manner described for the lateral approach. If the superior orbital rim is dissected en bloc with the frontal craniotomy, it is often necessary to end the craniotomy by separating the external orbitotomy with a chisel.

## 2.2 Unroofing the orbit

When the orbital rim has been pulled out, it is possible to remove the orbital roof [3] with a chisel, following a triangle at the anterior base. If the decision is made to leave the superior orbital rim in place, which is usual procedure when the frontal sinus spreads laterally, an orbitotomy is performed by perforating the roof with a perforator, then detaching it like a postage stamp. It is advisable to put it back at the end of the operation. This prevents the forming of a late post-operative meningocele and makes reoperation easier. It can be simply placed and fastened onto the periorbit in the final stages of the treatment.

## 2.3 Exposing the ON in the optic canal

When removing a tumor from the optic canal, from the sheath or the ON itself, it is necessary to expose not only the intraorbital part of the ON but also its course through the optic canal and the optochiasmatic cistern, as far as to the optic chiasm. This explains why the removal of the orbital roof must be completed by drilling the roof of the optic canal and opening the optochiasmatic cistern. Opening the cistern is preceded by the opening of the dura of the frontal lobe. The frontal lobe is carefully retracted following a midway axis between a pterional approach and a subfrontal approach. The optocrotid and optochiasmatic cisterns are opened according to microsurgical procedures. The dura of the orbital roof is coagulated, and then an incision is made on the superior surface of the optic canal, running parallel to the nerve and then joining with the exposed part of the ablation of the orbital roof. The superior surface of the optic canal is drilled [6] using a diamond ball which is carefully dampened so as to join the unroofed orbit. The surgeon must remember that the ON is vascularised from its sheath in a centripetal way so that the opening of the optic canal must be carried out minutely and the ON mobilized and dissected as minimally as possible. By carefully reclining the ON sheath laterally in the optic canal, the ophthalmic artery is exposed medially as it crosses the ON inferiorly. When it is necessary to cut the optic nerve, it is advisable to do so within the optic canal or at the point where it



**Fig. 5.** Contralateral nasal fibers cross over at the optic chiasm and pursue a recurring course in the ON

exits the canal. In fact, the contralateral nasal fibers cross over at the optic chiasm and pursue a recurring course in the ON, so if cutting is desired, this contralateral nasal contingent must be spared to avoid the risk of contralateral hemianopia on the unaffected side (Fig. 5). In the event of an optic nerve glioma, there is no need to open the roof of the optic canal. Cutting the ON in the orbit, working backwards from the tumor and level with the endocranial opening of the optic canal, is quite sufficient. The residual part of the optic nerve situated in the canal is emptied on either side, using the cavitron ultrasonic surgical aspirator. Access to the superior orbital fissure completes this approach by drilling the anterior clinoid process laterally from the ON.

#### 2.4 Intraconical exploration of the orbit

When the orbital roof is removed, the frontal nerve becomes visible in an anteroposterior axis through the orbit: this is the point at which to open the periorbit. An incision is made forwards, towards the rear from the orbital insertion of the LPM. Two further anterior and posterior incisions can be made perpendicularly to the first. There is a risk to injure the trochlear nerve on the posterior part of the incision of the periorbit, forwards from the optic canal, because from this angle the nerve is situated just inside the frontal nerve. Orbital fat, although it is considered as a predominant factor for the mobility of the oculomotor muscles, is in the way of all the intraconical approaches. However, its coagulation and retraction are essential to obtain a satisfactory view of the intraconical anatomical elements (Figs. 1 and 2). There are two ways of approaching the intraconical part of the orbit on either side from the LPM: the lateral approach and the medial approach.

The most frequently used is the lateral approach, which allows access to lateral lesions of the ON, the superior orbital fissure and the orbital apex. The LPM–SRM complex is mobilized en bloc by passing a silicone surgical loop underneath. This loop must be placed as far forwards as possible, under the muscles. By reclining medially the superior ophthalmic veins, the lateral surface of the ON becomes visible. The ophthalmic artery and the nasociliary nerve must be identified. They cross over the superior side of the ON laterally to medially. At its medial curvature the ophthalmic artery branches out into the ciliary arteries and the lachrymal artery, which are laterally reclined. Laterally to this entrance into the orbit, the abducens nerve runs along the medial side of the lateral rectus muscle. The branch of division of the oculomotor nerve destined for the inferior oblique muscle is situated at the level of the ON. Running backwards, an opening of the superior orbital fissure is feasible by dividing the annular tendon between the SRM medially and the lateral rectus muscle laterally. At this superior level of the superior orbital fissure the superior branches of division of the oculomotor nerve, the nasociliary nerve, and the abducens nerve are visible.

The medial approach runs between the oblique superior muscle medially and the LPM–SRM laterally. The ON is thus exposed across its entire length. The ophthalmic artery appears at the medial side of the ON after crossing it. An incision may be made to the common tendinous ring towards the rear, between the LPM and the SRM in such a way to expose the ON at the level of the apex. During the incision, care must be taken to protect the trochlear nerve because it is in an extraconical position.

The central approach should be avoided, except for limited and superficial surgery. As the LPSM overlaps the medial side of the SRM it is theoretically feasible to recline the LPSM medially and the SRM laterally. The frontal nerve is pulled away either medially with the LPSM or laterally with the SRM. The surgeon must remember that the trochlear nerve is in an extraconical position at this level; medial to the frontal nerve and in front of the ON sheath. This approach can be deleterious for the branch of division of the oculomotor nerve that innervates the LPSM and should therefore be undertaken with extreme care.

## **HOW TO AVOID COMPLICATIONS**

### **1. AMAUROSIS**

Worsening of preoperative visual deficiencies in the affected eye is a potential consequence of excessively brutal manipulation of the ON, of dissection which strips the ON sheath across its entire circumference, or of heating up of the ON during drilling of the optic canal. The nerve must therefore be handled very gently, and dissection of any tumor adjacent to the ON should not be carried out beyond its sheath. A diamond ball must be used for drilling the optic canal, and it should be abundantly dampened. Impairment of the visual field of the

unaffected eye may be the result of either accidental injury of the optic chiasm or of the recurrent contralateral nasal contingent during cutting of the ON.

## **2. MOST COMMON POSTOPERATIVE OCULOMOTOR NERVE PALSIES**

### **2.1 Postoperative ptosis of the upper eyelid**

Postoperative ptosis of the upper eyelid is frequent when the LPM–SRM complex is mobilized. Normally any paralysis will improve within a few days or a few months, but may be permanent if the LPM has been separated from the SRM as a result of dissecting them too far posteriorly.

### **2.2 Postoperative diplopia**

Injury to the abducens nerve may occur during dissection of the medial surface of the lateral rectus muscle. This may improve if it is followed up and given ophthalmic treatment, but sometimes it may require a further ophthalmic operation in order to restore tension of the LRM. The surgeon should therefore try to work above the superior rim of the LRM and avoid dissecting the medial surface too far forwards. Injury to the trochlear nerve can occur during incision of the periorbit as the nerve is in an extraconical position. As a result, it is particularly vulnerable during the medial intraorbital approach. The surgeon must therefore take great care when identifying these key anatomical points prior to making an incision on the periorbit. With this in mind, the frontal nerve is the most visible marker.

### **2.3 Other nerve injuries**

Palsy of the frontal branch of the facial nerve can occur when dissection of the skin flap is performed subcutaneously instead of under the periosteum.

Anaesthesia in the supraorbital area can occur if the supraorbital nerve has not been freed from the supraorbital notch or foramen during dissection of the superior orbital rim. To resolve this, the nerve must be pulled with the skin flap.

### **2.4 Opening the frontal sinus: postoperative infections, cerebrospinal fluid leak**

In patients less than ten years old, the frontal sinus is little developed, if at all; and in adults, it can pneumatize the entire superior orbital rim. Opening the frontal sinus is a major concern and can lead to severe postoperative infections: meningitis, epidural abscess, and osteitis of the bone flap. The best way to anticipate this complication is to know the particular anatomy of the patient's frontal sinuses. A preoperative CT scan will provide details on this anatomy better than those by MRI. An anti-pneumococcus vaccination should be performed prior to the surgical procedure. When a postoperative infection occurs, the surgeon

should always keep this hypothesis in mind even when there is no evidence of frontal sinus entering during the craniotomy. A reoperation is required for these infected patients, in order to plug the frontal sinus. Antibiotics are required in case of meningitis or general infection prior to reoperation. If the patient has a local infection, surgery must be performed prior to administering antibiotics, in order to take a sample of pus or infected tissue for bacteriological culture.

## CONCLUSIONS

The orbit is a narrow anatomical space which contains many highly functional anatomical elements. Tumors of the orbit are extremely varied in nature and require a multidisciplinary approach to treatment. Furthermore, etiologies in children are different from those in adults. Not all of them require surgery. This is why the patient's medical history, clinical tests, and preoperative imaging must be comprehensive. Neurosurgeons are primarily concerned with tumors affecting the two posterior thirds of the orbit, the ON, and those of the ON sheath. Tumors of the bony structures may require reconstruction, in which case it is often necessary to collaborate with a plastic surgeon during the procedure.

### Acknowledgement

I thank Dr. Maaref of the Henri Poincare University in Nancy (France) for the realisation of the illustrations displayed in this chapter.

### References

- [1] Al Mefty O, Fox JL (1985) Superolateral orbital exposure and reconstruction. *Surg Neurol* 23: 609-613
- [2] Benedict WL (1950) Diseases of the orbit. *Am J Ophthalmol* 33: 1-10
- [3] Blinkov SM, Gabibov GA, Tcherekayev VA (1986) Transcranial surgical approaches to the orbital part of the optic nerve: an anatomical study. *J Neurosurg* 65: 44-47
- [4] Cushing H, Eisenhardt TL (1938) Meningiomas: their classification, regional behaviour, life history and surgical end results. Charles C Thomas, Springfield, Ill, pp 250-282
- [5] Marchal JC, Civit T (2006) Neurosurgical concepts and approaches for orbital tumors. *Adv Tech Stand Neurosurg* 31: 73-117
- [6] Newman SA, Jane JA (1991) Meningiomas of the optic nerve, orbit, and anterior visual pathways. In: Al Mefty O (ed) *Meningiomas*. Raven, New York, pp 461-494
- [7] Rhoton AL, Natori Y (1996) The orbit and sellar region: microsurgical anatomy and operative approaches. Thieme, Stuttgart, pp 208-236



### **Jean Claude Marchal**

Jean Claude Marchal is professor and head of the Unit of Pediatric Surgery at the Institute of Neurological Sciences in Nancy, France. He was born on 30 September 1950 in Nancy and there he began studying medicine in 1968. He wrote his PhD thesis on the subject of traumatic injuries of the craniofacial boundaries. He continued his career in Nancy, working in both the Adult Neurosurgical Department and as clinic manager at the Henri Poincare University. Having obtained his certificate in general surgery in 1982, he was appointed as professor of neurosurgery in 1986. From 1990 onwards he began to specialize in paediatrics as manager of the Pediatric Neurosurgical Unit in Nancy. From 1999 to 2000 he was visiting professor at Sainte-Justine Hospital at the University of Montreal. Jean Claude Marchal is also a passionate piano player with a keen interest in chamber music and abstains from partaking in any sporting activities whatsoever.

**Contact:** Jean Claude Marchal, Chirurgie Pédiatrique (Pôle Neuro. Tête et Cou),  
Bâtiment des Neurosciences, Hôpital Central, 54035 Nancy Cedex, France  
E-mail: [jc.marchal@chu-nancy.fr](mailto:jc.marchal@chu-nancy.fr)



---

# HOW TO PERFORM TRANSSPHEOIDAL APPROACHES

A. J. BASSO

## INTRODUCTION

1. *The introduction of the surgical microscope* for the excision of pituitary adenomas by Jules Hardy in 1966 marked a new era in the treatment of hyperfunction clinical syndromes (namely, acromegaly, amenorrhea-galactorrhea or sexual impotence in men).

Considering that in most cases these syndromes are produced by a pituitary adenoma (sometimes a very small 0- or 1-grade intraglandular *microadenoma*), the contribution of neurosurgeons was essential for the understanding of their pathophysiology, which had historically been difficult to characterize.

During the 1970s, radioimmunoassay and immunohistochemistry were critical to accurately establish the type of pathological secretion of the anterior pituitary gland. CT scan and MRI in the 1980s led to in-depth anatomical knowledge of the lesion, its extension, and its relationships.

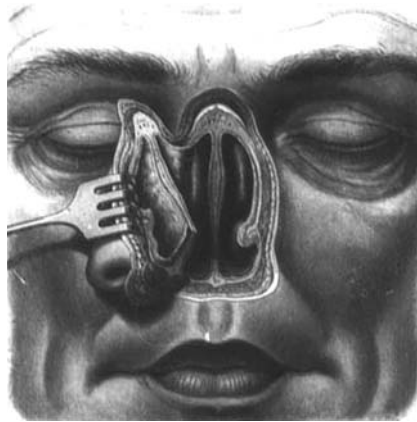Determining adenoma aggressiveness, invasive ability and recurrence potential is a function of molecular biology, a specialty which over the last 10 years has provided pertinent, albeit insufficient information, through tumor marker examination. Nevertheless, thirty-five years of continuous progress translate into an almost complete control of the disease.

International experience over the last 30 years has proved that the transsphenoidal approach is the procedure of choice for the treatment of most pituitary adenomas. This surgical choice has become widespread basically because it constitutes a low-risk highly efficient procedure. Favorably enough, complications are relatively uncommon, averaging approximately 4% in institutions largely conducting pituitary procedures [32].

2. Late in the eighteenth century and early in the nineteenth century, *transcranial approaches for the treatment of pituitary tumors* were associated with a high mortality rate. Horsley's reported 20% mortality rate in a series of 10 patients was significantly better than the 50–80% mortality rate range reported by his colleagues. As a result of these high rates, surgeons believed that a transfacial approach to the sella turcica would be safer [28]. Thus, based on Giordano's experience with cadavers [28], Hermann Schloffer (Fig. 1) performed in Austria the first transsphenoidal pituitary tumor resection in 1907;

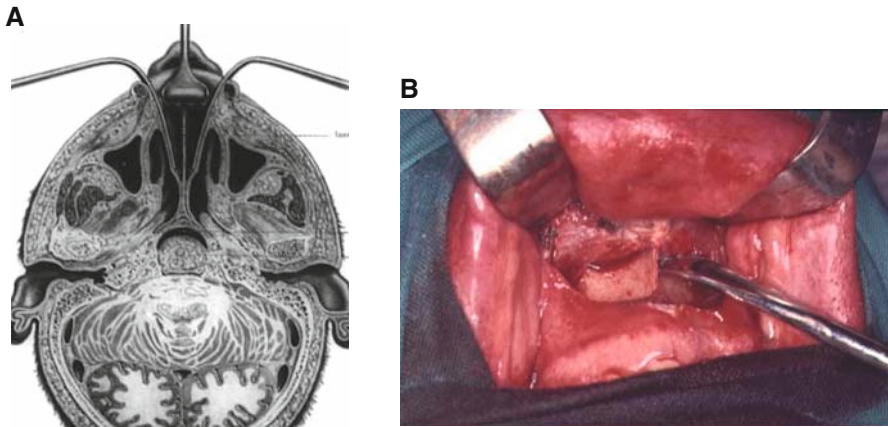
---

*Keywords:* pituitary adenoma, transsphenoidal approach, sella turcica, endoscopic surgery



**Fig. 1.** Schloffer's first transsphenoidal approach

his technique involved first moving the nose en bloc to the right, then removing the nasal turbinates and septum, accessing and opening the anterior wall of the sphenoid bone and, lastly, once within the sphenoidal sinus, opening the floor of the sella turcica [33]. This technique was applied by other general surgeons, with many patients dying intraoperatively or postoperatively owing to meningitis [34]. For this reason, new techniques were subsequently developed. In 1909, Theodor Kocher, in Switzerland, proposed a submucous dissection and resection of the septum, sparing the nasal cavity; for this procedure, a complex nasal incision was required [25]. Submucous septal dissection and resection marked the beginning of lower extracranial approaches to the pituitary gland, since it afforded a reduced risk of infection and an easier midline orientation [27]. In 1910, Oskar Hirsch, an otorhinolaryngologist from Austria, described the endonasal transseptal-transsphenoidal approach [22]. Also in 1910, Albert Halstead, in Chicago, described the sublabial-gingival approach [14]. Harvey Cushing initially used the transcranial approach (8 subtemporal and 5 subfrontal approaches); however, since he achieved poor results, he adopted the transsphenoidal route [28], thereby becoming the first surgeon to perform a sublabial-gingival transsphenoidal approach to the pituitary gland [34]. He used the transsphenoidal approach between 1910 and 1925, operating on 231 patients with pituitary tumors, with a mortality rate of 5.6% (Fig. 2A, B) [20]. From 1929 onwards, however, Cushing abandoned the transsphenoidal route and came to favor the transcranial route. Norman Dott, a disciple of Cushing's, continued to perform the transsphenoidal approach in Scotland [27] and eventually introduced a speculum with a built-in light [32]. Gerard Guiot, from France, visited Dott in 1956 and learned the transsphenoidal technique from him [27]. That year, Dott performed 80 consecutive operations with the transsphenoidal approach, with no deaths [34]. In subsequent years, Guiot started to refine the transsphenoi-



**Fig. 2A, B.** Cushing's sublaminar rhinoseptal transsphenoidal approach

dal approach by introducing intraoperative radiofluoroscopy [16]. Driven by his pioneering spirit, Guiot applied the transsphenoidal approach to the treatment of craniopharyngiomas, clivus chordomas and parasellar lesions [28]. Jules Hardy, from Canada, learned this procedure from Guiot. In 1967, Hardy adopted the surgical microscope for this procedure [18], and in 1968, he introduced the concept of microadenoma (a patient with endocrine disorders with no enlargement of the sella turcica) [19].

The many years' of experience we gained next to Guiot and Hardy provided us with extensive practice in terms of these modern techniques. In 1969, we performed the first microsurgical transsphenoidal approach in South America [2].

Technological advances in endoscopy, neuronavigation and intraoperative MRI have been applied to transsphenoidal surgery in an effort to further lower the morbidity and mortality rates associated with the classic procedure [28].

## RATIONALE

Rationale is based on surgical anatomy.

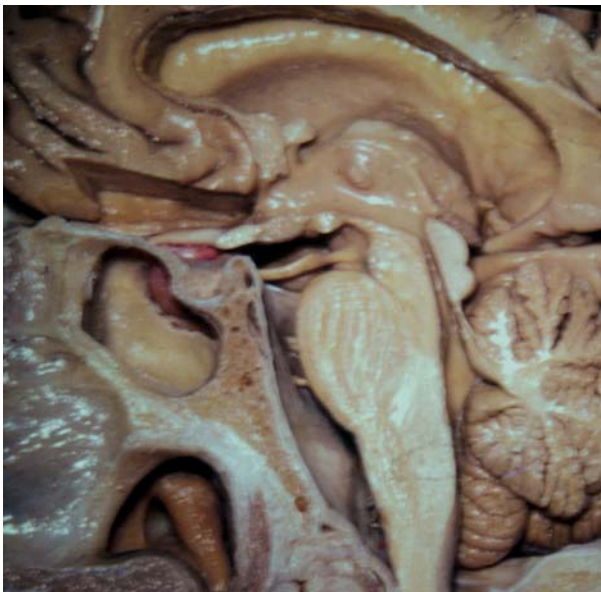### 1. NASAL CAVITY

The nasal cavity, which comprises the first upper respiratory tract, is limited by the anterior cranial fossa superiorly, by the orbits and the maxillary sinuses laterally, and by the palate inferiorly. The nasal cavity is divided into two halves, left and right, by the nasal septum, which has a sagittal and middle location, and an anterior cartilaginous part and a posterior osseous part (perpendicular plate of ethmoid bone superiorly and vomer inferiorly). The lateral wall exhibits a superior part formed, from anteriorly to posteriorly, by the

frontal process of maxilla, the lacrimal bone and the ethmoidal labyrinth, and an inferior part formed, from anteriorly to posteriorly, by the maxilla, the perpendicular plate of the palatine and the pterygoid process. The superior, middle and inferior nasal turbinates are located on the lateral wall, underneath which the superior, middle and inferior meatuses are found. The lower part of the cavity is comparatively wider than its upper part, and it communicates with the frontal, ethmoidal, maxillary, and sphenoidal sinuses.

## 2. SPHENOID BONE AND SPHENOIDAL SINUS

The sphenoid bone is found at the skull base, anterior to the temporal bones and the basilar part of occipital bone. Given the close contact of the body of the sphenoid bone with the nasal cavity inferiorly and the pituitary gland superiorly, the transsphenoidal route is the surgical approach of choice in most sellar tumors (Fig. 3) [30]. The body of the sphenoid bone is more or less cube-shaped and contains two large air sinuses that are separated by one or several septa; as a whole, this cavity is commonly called sphenoidal sinus. Form, size, degree of pneumatization, and number and location of septa in the sphenoidal sinus are highly variable. At birth, the sphenoidal sinus is a small cavity, which becomes pneumatized after puberty. With advancing age, the sphenoidal sinus enlarges as a result of bone wall resorption [30]. Therefore, depending on the level of pneumatization the sphenoidal sinus presents

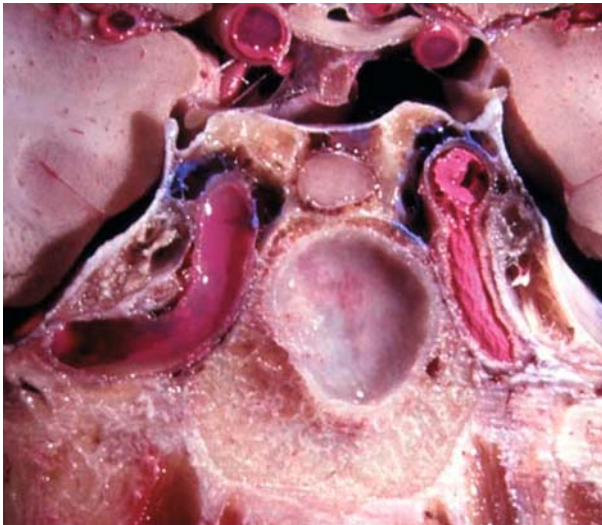

**Fig. 3.** Sellar-type sphenoidal sinus and sella turcica

one of three different patterns: conchal (absent sinus pneumatization), pre-sellar (pneumatization is restricted to a vertical line parallel to the anterior border of the sella turcica) and sellar (pneumatization reaches the clivus). The sellar sphenoidal sinus is the most common pattern. The internal carotid artery abuts the lateral surface of the body of the sphenoid bone, and its course creates a channel on the bone, known as the carotid groove. The carotid groove produces lateral protrusions within the sinus at either side and below the sella turcica.

### 3. CAVERNOUS SINUS

The cavernous sinus is a paired structure placed on either side of the pituitary gland (Fig. 4). Each cavernous sinus has four walls formed by dura matter. The lateral, superior and posterior walls consist of two layers, the external layer, the so-called dura propria, and the internal layer, also known as periosteal dura. Through the internal layer of the lateral wall course the oculomotor and trochlear nerves, and the ophthalmic division of the trigeminal nerve. The cavernous sinus medial wall comprises two segments. One is superior to the pituitary gland and the other is inferior to the lateral wall of the body of the sphenoid bone; different from the other walls, the medial wall has a unique, very thin dural layer, which could account for the lateral expansion of a pituitary adenoma. These four dural walls lodge venous blood contained in plexi, the internal carotid artery and its intracavernous branches, the abducent nerve, the sympathetic plexus, and fatty tissue. Both superior walls continue



**Fig. 4.** Cavernous sinus

medially to form the diaphragm sellae. The diaphragm sellae is the roof of the sella turcica and wholly covers the pituitary gland but for a central opening through which the pituitary stalk courses. Occasionally, it may be a very thin structure, and thus proves not enough of a protective barrier for suprasellar structures during transsphenoidal surgery [30].

#### **4. PITUITARY GLAND**

The pituitary gland is a grayish-red body with transverse and anterior posterior diameters of 12 mm and 8 mm, respectively. The pituitary gland is formed by two different embryological and functional regions, i.e. anterior (adenohypophysis) and posterior (neurohypophysis) pituitary glands. The anterior pituitary gland comprises the anterior (glandular part or anterior lobe) and the intermediate part, and the posterior pituitary includes the posterior part (neural part or posterior lobe), the stalk and the median eminence [31]. The lower surface of the gland usually takes the shape of the sellar floor, whereas the lateral and superior margins have variable shapes since those walls are composed of soft tissue but no bone [30].

### **SURGICAL APPROACHES**

#### **1. TRANSEPTAL-TRANSSPHEOIDAL APPROACH**

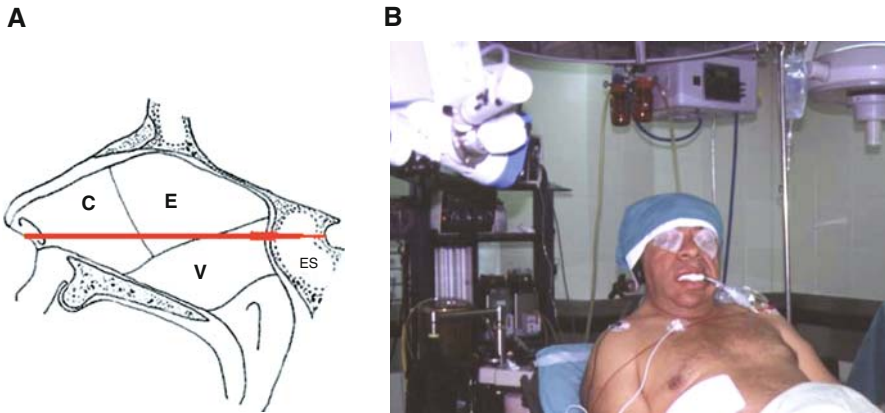
Mainly indicated for sellar tumors (including adenomas, craneopharyngiomas, granulomas, metastatic tumors), the classical or extended transeptal-transsphenoidal approach is currently used for other types of tumors arising centrally at the skull base, such as clivus chordomas or chondrosarcomas, tuberculum sellae meningiomas, among others.

For nearly twenty years, i.e. since 1969, we have been using the transeptal-transsphenoidal approach through a sublabial incision from incisor to incisor, exactly as first described by Harvey Cushing. Postoperative rhinological, respiratory or cosmetic complications associated with this technique, which are minor indeed, prompted our abandonment at the end of the 1980s and replacement with the (modified) technique described by Oskar Hirsch, which we call lateral transeptal approach and describe below.

#### **2. LATERAL TRANSEPTAL APPROACH**

##### **2.1 Patient positioning**

The patient is placed in a half-seated position (Fig. 5A, B), with the head resting on a horseshoe head-holder. The left shoulder lifted on a pillow, the head and neck are rotated approximately 45° to the right. The head is positioned with the nose in the “sniffing position”, so that the zygomatic arch stays



**Fig. 5A, B.** Patient placed in a half-seated position

flexed approximately  $20^\circ$  relative to the floor. Importantly, the head should be well fixed to the head-holder with adhesive tape in order to prevent any intraoperative movements. One major advantage of the half-seated position is that it frees the surgical field from blood, since any kind of potential bleeding falls on account of gravity and does not interfere with the surgeon's view. The patient is given general anesthesia with endotracheal intubation, and to prevent blood ingestion, a pharyngeal packing is used.

## 2.2 Preparation

After occluding the eyes with adhesive tape, the nose, the nasal area and the gingival mucosa are prepped with antiseptic solution (Pervinox solution). When the tumor has a suprasellar extension, the lower right quadrant of the abdomen is also prepped to harvest a fat graft to pack the sella turcica after tumor excision in order to prevent the potential development of a cerebrospinal fluid (CSF) fistula.

Surgical drapes are then placed and the surgical microscope is positioned.

## 2.3 Surgical technique

As the surgical assistant (standing to the left of the surgeon) separates the lateral border of the right naris, the surgeon infiltrates the septal mucosa with 1% xylocain containing epinephrine and then performs a 1.5 cm long vertical incision through the septal mucosa. The septal mucosa is then separated from the nasal septum with the help of a dissector. This is an easily performed maneuver since the mucosa has been partially detached from the nasal septum with the aid of a previous xylocain infiltration. The dissection is continued deeply until reaching the proximity of the attachment of the perpendicular plate of the ethmoid bone and the vomer with the sphenoid body; at that point, the bone sep-

tum is broken and moved from the midline (this maneuver is performed by opening and rotating the manual speculum to the right). Once reaching the midline, an autostatic speculum is placed and fully opened to maintain retraction of the nasal mucosa outside the field of view. The following step involves identifying both sphenoidal sinus foramina and removing symmetrically the anterior wall of the sphenoid bone. This leads us inside the sphenoidal sinus; the thin sinus mucosa is wholly removed when there is evidence of inflammatory or infectious changes. Otherwise, removal is only partial.

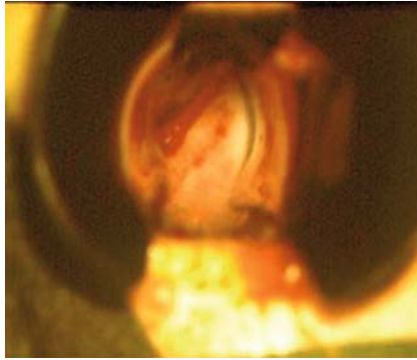
When one or more bone septa hinder the exposure of the sellar floor, removal of these septa is required to fully expose the posterior aspect of the sinus and the floor of the sella turcica. Wherever possible it is advisable to obtain a small piece of bone (from the vomer or bone septum), measuring approximately 1 by 1 cm, to repair the floor of the sella turcica. With the microscope pointing directly to the anterior lower surface of the sella turcica, and with the help of a small chisel, the sellar floor is opened from midline to lateral, creating a 1.5 cm wide, 1 cm long window. When the lesion is a macroadenoma with sella turcica enlargement, the sellar floor will be extremely thinned or partially absent. Sellar dura mater may also be thinned owing to tumor growth. The next step involves a cruciate incision of the sellar dura up to the margins of the bone opening; this is done with a bayonet-shaped knife holder. In most cases, after opening the dura and as a consequence of intrasellar pressure, grayish tumor tissue is expressed and should be removed with punch forceps for pathology examination. The remaining adenoma is dissected with differently angled curettes, directed in all orientations, plus a surgical aspirator. As soon as the sellar cavity has been emptied, the suprasellar extension of the tumor will move downward spontaneously towards the sella turcica and as a result of normal intracranial pressure. If this does not happen, intracranial pressure may be increased by applying compression to both internal jugular veins. At the end of the tumor excision procedure, the surgeon should perform a thorough exploration of the whole cavity to check for complete removal of the lesion and preservation of the normal gland. It is at this point that endoscopic assistance becomes highly useful, using a 30°- or 60°-angulated view endoscope.

After correct hemostasis is achieved, the piece of bone previously taken from the vomer is used to cover the sellar bone defect and fixed with methylmethacrylate. Finally, the nasal septum is moved back to its normal position and both nares are packed.

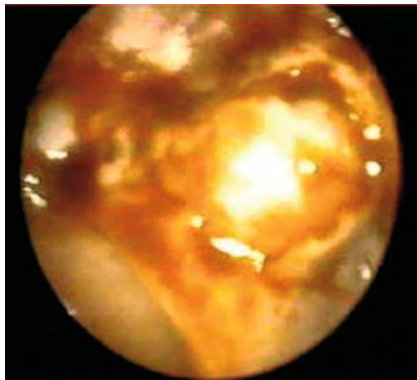
### **3. ENDOSCOPICALLY ASSISTED MICROSURGICAL TRANSNASAL APPROACH**

Endoscopic surgery, a minimally invasive and maximally effective procedure so defined after a modern conception of surgery, has also become widespread practice in neurosurgery in general and in pituitary surgery, in particular.

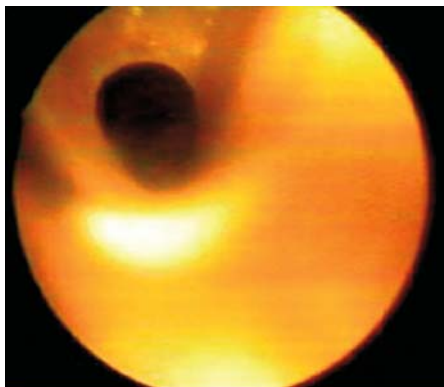




**Fig. 6.** Transnasal microsurgical approach



**Fig. 7.** Inspection of the sphenoidal sinus



**Fig. 8.** Control of the intrasellar residual cavity

In fact, during the 1990s, several authors started to show interest in the possibility of exploiting the benefits of endoscopic viewing, i.e. lateral views and excellent lighting [3, 23], for transsphenoidal surgery.

The aid of an endoscope can prove very useful if added to classic transsphenoidal microneurosurgery (Figs. 6–8).

In these cases, the microsurgical approach can be directly transnasal, i.e. right-handed surgeons access the mucosa directly through the right naris to perform an incision anteriorly to and along the sphenoid ostium, at the level of the middle nasal turbinate. After locating the anterior aspect of the sphenoid bone body, the vomer attachment is broken and the septum displaced towards the contralateral side, in order to get a better view of the area with a surgical microscope. At that point, the endoscope is angled at 30° or 60° into the cavity for inspection of the sphenoidal sinus and recognition of bone indentations corresponding to the carotid arteries or optical nerves.

When this mixed approach is applied, at this point it is advisable to switch to the ordinary microsurgical technique and subsequently open the sellar floor and the dura and, then, excise the tumor. When adenomas are large in size it is important that the endoscope be relocated at the end of the procedure in order to observe the residual cavity for any tumor remnant, which should be completely excised, or openings that might lead to the development of a CSF fistula.

Finally, closure should be performed with an appropriate technique, in order to prevent complications, especially CSF fistula.

#### **4. ENDOSCOPIC TRANSSPHENOIDAL APPROACH – SURGICAL TECHNIQUE**

The endoscopic technique is also used for the surgical treatment of sellar lesions, as it precludes the use of intranasal specula while offering a 360° panoramic view of the area, thereby assisting in the recognition of all anatomic structures at nasal, intrasphenoidal, sellar and suprasellar levels [33].

Endoscopic equipment includes a telescope, optical fiber, a light source, a digital videocamera, a monitor and a video-recording system. Telescopes used in these cases are usually rigid, 4 mm in diameter, 180 mm long and offer angles of vision of 0°, 30° and 45° to suit the different surgical requirements. The telescope is inserted into a rigid sheath which provides protection to the unit and allows the user to handle it appropriately. The sheath is connected to an irrigation system which enables a clean vision through the whole procedure, as the lens is cleansed in a controlled manner and the endoscope does not need to be repeatedly removed for cleaning. The telescope is connected to optical fiber for optimum transfer of the quality lighting generated by means of the xenon cold light source. The digital video camera, preferably a three-chip unit, is adjusted to the telescope and connected to a high-resolution monitor for superb quality imaging. A digital video-recording system is used for surgery documentation.

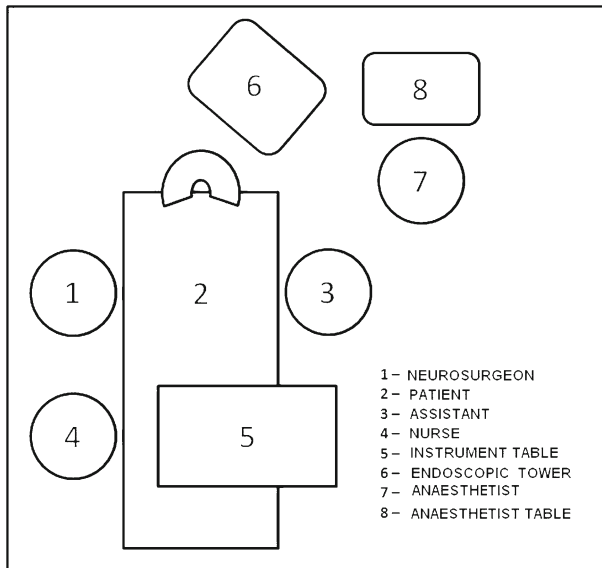
The endoscopic and microsurgical approaches use surgical instruments of similar features, the only exception being that the endoscopic approach uses straight instruments rather than the bayonet-shaped instruments preferred in microsurgery [9].

During the sellar phase of the procedure, the endoscope can be immobilized by means of a mechanic fitting which is attached to the bed. This helps to get a stable picture of the surgical field and allows the surgeon to use both hands concurrently.

The monitor, the light source, the digital video camera and the video-recording system are placed behind the patient's head, all together as a full block, on a straight vision line towards the neurosurgeon, who stands to the right of the patient. The surgeon's assistant stands to the left of the patient, whereas the surgical nurse stays at the level of the patient's feet. Finally, the anaesthetist remains to the left of the patient's head (Fig. 9).

Under general anaesthetic, the patient's trunk is positioned at  $15^\circ$ , the head fixed to the head-holder and  $10^\circ$  lateralized to the right towards the neurosurgeon. Whether the head is flexed or extended will depend on the suprasellar extension of the lesion, though excessive flexion should be avoided in order to prevent the thorax from hindering suitable handling of the endoscope.

Five percent chlorhexidine is used for face and nasal cavity asepsis. Surgical drapes are then positioned leaving only the nose exposed. Epinephrine



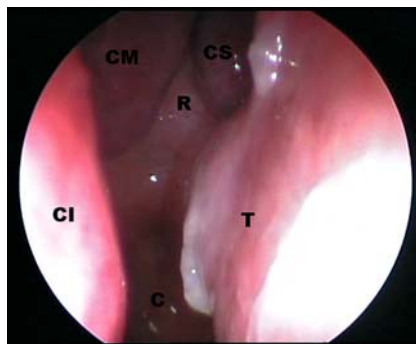
**Fig. 9.** Endoscopical team placement

solution (1:100000) is used for intranasal topicalization to assist in mucous decongestion for ease of procedure.

In this case, as in the microsurgical approach, three surgical phases are recognized: the nasal phase, the sphenoidal phase and the sellar phase [1, 6, 8, 13, 14, 24].

#### 4.1 Nasal phase

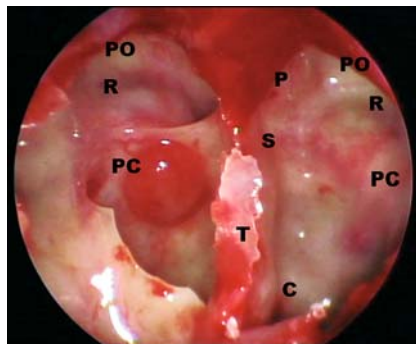
This phase starts by angling the endoscope at 0° through the right naris. The anatomic structures in the nasal cavity are recognized, firstly by identifying the lower nasal turbinate laterally and the nasal septum medially. The middle nasal turbinate is the closest to the nasal septum. As the endoscope penetrates deeply along the floor of the nasal cavity, we reach the choana, which is bounded superiorly by the sphenoidal sinus, inferiorly by the soft palate, laterally by the lower nasal turbinate and medially by the vomer in the septum. At a rhinopharyngeal level, the Eustachian tube can be recognized. The endoscope must be then moved on superiorly between the middle nasal turbinate and the nasal septum towards the sphenoethmoidal recess. This can be quite difficult owing to the close proximity between the middle nasal turbinate and the septum, as already explained. Once at the level of the sphenoethmoidal recess, the sphenoid ostium can be identified, as it is the entry towards the sphenoidal sinus. When pneumatization of the sphenoidal sinus is significant, the ostium can be found more laterally behind the upper nasal turbinate and be thus difficult to identify. In these cases, partial removal of the upper nasal turbinate may be required for a proper visualization of the ostium, carefully ensuring that the cribriform plate is not damaged, to minimize the risk of CSF fistula [10]. Where the sphenoid ostium cannot be properly identified, the access to the sphenoid cavity may be inferred at a point placed at approximately 15 mm from the choana's upper boundary, over the sphenoethmoidal recess (Fig. 10).



**Fig. 10.** Endoscopic view of the right nasal cavity

## 4.2 Sphenoidal phase

This phase is initiated by coagulating the mucosa in the sphenothmoidal recess around the sphenoid ostium. This prevents insidious bleeding of the septal branches of the sphenopalatine artery. After coagulation, a longitudinal incision is made along the mucosa and up to the bone plane. The nasal bone septum, which is composed of the vomer inferiorly and the perpendicular plate of the ethmoid bone superiorly, is drilled apart from the anterior aspect of the sphenoid bone with a 4 mm drill, thereby exposing the complete rostrum of the sphenoid bone – and its typical keel-like shape – submucosally and bilaterally. Removal of the sphenoid rostrum is done by drilling or with rongeurs. The procedure starts at the level of the sphenoid ostia, which are taken as the upper boundary of the bone opening. Rostrum osteotomy must be widely performed inferiorly to allow enough room for the instruments required later for the sellar phase to slide through. The mucosa of the sphenoidal sinus can be partially excised to avoid impairing endoscopic view. As the endoscope descends deeply into the sphenoidal sinus, it should be possible to recognize the bone septa, and there should exist a correlation between endoscopic anatomy and imaging studies (MRI and CT scan). By removing the septa in the sphenoidal sinus, the endoscopically anatomical bone recesses of the posterior and lateral walls of the sinus will be largely exposed, especially in the case of sphenoidal sinuses with good pneumatization. The sellar floor can be recognized centrally, with the planum sphenoidale above and the clivus underneath. The carotid protuberance, the optic nerve protuberance and the optic-carotid recess in between the two protuberances can be recognized on each side of the sellar floor. All together, bone endoscopic anatomy resembles embryological anatomy of the fetal face, where the forehead corresponds with the planum sphenoidale, the eyes with the optic-carotid recesses, the eyebrows with the optic prominences, the cheeks with the carotid prominences, the sellar floor with the nose and the clivus with the mouth. When pneumatization of the sinus



**Fig. 11.** Endoscopic view of the sphenoidal sinus

is not well developed, all these anatomic recesses may be absent. If this is the case, identification of the planum sphenoidale, the clivus and the carotid prominences should be enough to accurately establish the position of the sellar floor (Fig. 11).

### 4.3 Sellar phase

Once the sellar floor has been correctly identified, the endoscope is immobilized by means of a mechanic fitting. The sellar floor is drilled open or cut open with the aid of rongeurs, the extent of the opening depending on the type of lesion requiring treatment. After dural coagulation, whose purpose is to prevent potential bleeding of the (coronal) intercavernous venous sinuses, the dura is cut open in a linear or cruciate pattern to expose the sellar lesion.

After complete resection of pituitary microadenomas, there is no need to explore the sellar cavity with an endoscope, so hemostasis and reconstruction of the sellar floor can be initiated straightforwardly.

Resection of pituitary macroadenoma starts at the lower portion and proceeds on to the lateral extension of the adenoma to conclude on its upper portion. If resection would be initiated at the upper portion of the macroadenoma, the diaphragm sellae might descend prematurely and visually obstruct resection of the rest of the adenoma. A Valsalva maneuver (usually by bilateral jugular compression) can be useful to allow the diaphragm sellae to go down, where spontaneous descent does not occur. This assists in the resection of any adenoma remnant that might have been left adjacent to the diaphragm.

Telescopes with 30° and 45° angulations prove very useful to explore the sellar cavity, especially because they enable recognition of the lateral and suprasellar extension of macroadenomas and their resection, when the diaphragm sellae has not descended adequately. They also assist in recognizing the pituitary gland more clearly, as this is usually thinned on the superior and/or posterior sectors of the sellar cavity. Where the diaphragm sellae is large or practically inexistent, the suprasellar cistern can be recognized as a thin arachnoid membrane with CSF content and must be taken as the resection limit. To avoid the risk of CSF fistula, the suprasellar cistern must not be damaged.

Hemostasis of the sellar cavity is performed in a manner like the microsurgical technique is carried out, applying hemostatic agents, coagulation or cotton compression for some minutes.

Reconstruction of the sellar floor in this situation does not differ from the microsurgical technique and must be carried out in a watertight manner where occurrence of CSF fistula is confirmed, in which case external postoperative lumbar drainage is also performed [7].

Once the procedure has been completed, the endoscope is slowly removed and the nasal septum replaced in the midline, avoiding contact with the middle nasal turbinate and the consequent risk of postsurgical synechiae. Nasal tamponade is not regularly applied, except when insidious bleeding of the nasal mucosa is confirmed.

## HOW TO AVOID COMPLICATIONS

In general terms, the transsphenoidal approach is a safe procedure offering a low rate of complications when conducted by a well-trained team.

Interdisciplinary work is an important concept to be observed during perioperative care: the neurosurgeon, the anesthetist, the endocrinologist and the intensive care specialist must work closely to identify and prevent complications.

These can be classified as follows:

- a) Surgery-related complications
- b) Sodium and fluid balance disorders
- c) Hormone hypersecretion or hyposecretion disorders

### *Surgery-related complications*

Complications occur in <1% of the cases and are associated with anatomical manipulation during surgery [24, 25]. They can be immediate or mediate complications:

### *Immediate complications*

- a) Worsening of visual symptoms: Secondary to compression of the optical nerves during surgery or owing to the postoperative development of hematoma.
- b) Injury of the intracavernous carotid artery.
- c) Intracranial hematoma: Subdural, extradural or intraparenchymal.
- d) Brain ischemia: Secondary to vascular injury.
- e) CSF fistula.

### *Mediate complications*

- a) CSF fistula
- b) Postoperative meningitis

We will focus exclusively on the diagnosis and management of CSF fistula because we have practically never encountered the above mentioned complications throughout our experience.

In patients who were treated with a transsphenoidal approach, CSF fistula diagnosis is established mainly when tamponades are removed. It is commonly confirmed by evaluating nasal secretion with blood glucose-measuring test strips. Once a fistula has been clinically diagnosed, prophylactic antibiotics should be avoided to prevent meningitis: this generates a selection of nosocomial bacteria which require broader-spectrum and longer-lasting therapies with antibiotics. These fistulae tend to close spontaneously in the course of 48–72 hours. If closure does not occur, however, a

continuous lumbar drainage for 48–72 hours can be attempted. Radioisotope cisternography, metrizamide-enhanced CT scanning, intravenous gadolinium-enhanced MRI or even intrathecal gadolinium-enhanced MRI can be performed to confirm fistula closure. Surgical repair will be considered on the basis of the results obtained with these imaging methods.

## CONCLUSIONS

Historically, the transsphenoidal approach to intracranial structures was applied to corpses in ancient Egypt for ceremonial reasons, as it was considered to be the best solution to extract encephalic remnants without aesthetically altering the skull or the face of the deceased who would be mummified.

Early in the twentieth century, truly pioneering otorhinolaryngologists and neurosurgeons ventured to approach sellar disease through the body of the sphenoid bone.

Advances in imaging (CT scan and MRI) coupled with the evident improvement achieved with the introduction of the surgical microscope, T.V. fluoroscopic control, neuronavigators and, lately, the endoscope and intraoperative MRI have granted the adequately trained surgeon such safety that morbidity and mortality rates in this respect stand practically at zero.

Our own series of transsphenoidal approaches over the last 35 years has comprised more than three thousand cases covering the intrasellar benign tumors (96% of pituitary adenomas, the remaining 4% being hypophysectomies, Rathke's pouch cysts, craniopharyngiomas, pituitary granulomas, clivus chondrosarcomas and chordomas, metastatic tumors, small meningiomas of the tuberculum sellae, etc.).

We have used alternative pterional or subfrontal approaches only in the event of tumors with lateral intracranial extension.

## Acknowledgments

The author acknowledges his collaborators Santiago Gonzalez Abbati, MD, and Alvaro Campero, MD, for their support in the preparation of this chapter.

## References

- [1] Apuzzo MLJ, Heifetz M, Weiss MH, Kurze T (1977) Neurosurgical endoscopy using the side-viewing telescope: technical note. *J Neurosurg* 16: 398-400
- [2] Basso A, Amezúa L, Guitelman A, Ghersi J, Molocznic I (1973) Síndrome acromegalique: choix de la technique chirurgicale. *Neurochirurgie* 19: 537-544
- [3] Cappabianca P, Alfieri A, Colao A, et al. (2000) Endoscopic endonasal transsphenoidal surgery in recurrent and residual pituitary adenomas: technical note. *Minim Invasive Neurosurg* 43: 38-43



- [4] Cappabianca P, Cavallo LM, de Divitiis E (2004) Endoscopic endonasal transsphenoidal surgery. *Neurosurgery* 55: 933-934
- [5] Cappabianca P, Alfieri A, Thermes S, Buonamassa S, de Divitiis E (1999) Instruments for endoscopic endonasal transsphenoidal surgery. *Neurosurgery* 45: 392
- [6] Cappabianca P, de Divitiis E (2004) Endoscopy and transsphenoidal surgery. *Neurosurgery* 54: 1043-1050
- [7] Cappabianca P, Cavallo LM, Esposito F, Valente V, de Divitiis E (2002) Sellar repair in endoscopic endonasal transsphenoidal surgery: results of 170 cases. *Neurosurgery* 51: 1365-1372
- [8] Carrau Ricardo L, Jho H-D, Ko Y (1996) Transnasal-transsphenoidal endoscopic surgery of the pituitary gland. *Laryngoscope* 106: 914-918
- [9] Caton R, Paul FT (1893) Notes of a case of acromegaly treated by operation. *BMJ* 2: 1421-1423
- [10] Ciric I, Ragin A, Baumgartner C, Pierce D (1997) Complications of transsphenoidal surgery: results of a national survey, review of the literature, and personal experience. *Neurosurgery* 40: 225-237
- [11] Cushing H (1914) The Weir Mitchell lecture. Surgical experiences with pituitary disorders. *JAMA* 63: 1515-1525
- [12] de Divitiis E, Cappabianca P, Cavallo LM (2002) Endoscopic transsphenoidal approach: adaptability of the procedure to different sellar lesions. *Neurosurgery* 51: 699-707
- [13] de Divitiis E, Cappabianca P, Cavallo LM (2003) Endoscopic endonasal transsphenoidal approach to the sellar region. In: de Divitiis E, Cappabianca P (eds) *Endoscopic endonasal transsphenoidal surgery*. Springer, Wien New York, pp 91-130
- [14] de Divitiis E, Cappabianca P (2002) Endoscopic endonasal transsphenoidal surgery. *Adv Tech Stand Neurosurg* 27: 137-177
- [15] Frazier CH (1913) An approach to the hypophysis through the anterior cranial fossa. *Ann Surg* 57: 145-150
- [16] Guiot G (1973) Transsphenoidal approach in surgical treatment of pituitary adenomas: general principles and indications in nonfunctioning adenomas. In: En Kohler PO, Ross GT (eds) *Diagnosis and treatment of pituitary tumors*. American Elsevier, New York, pp 159-178
- [17] Halstead AE (1910) Remarks on the operative treatment of tumors of the hypophysis. With the report of two cases operated on by an oro-nasal method. *Surg Gynecol Obstet* 10: 494-502

- [18] Hardy J (1967) Surgery of the pituitary gland, using the trans-sphenoidal approach. Comparative study of 2 technical methods. *Union Med Can* 96: 702-712
- [19] Hardy J (1969) Transsphenoidal microsurgery of the normal and pathological pituitary. *Clin Neurosurg* 16: 185-217
- [20] Henderson WR (1939) The pituitary adenomata. A follow-up study of the surgical results in 338 cases (Dr. Harvey Cushing's series). *Br J Surg* 26: 811-921
- [21] Heuer GJ (1931) The surgical approach and the treatment of tumors and other lesions about the optic chiasm. *Surg Gynecol Obstet* 53: 489-518
- [22] Hirsch O (1910) Endonasal method of removal of hypophyseal tumors. With a report of two successful cases. *JAMA* 55: 772-774
- [23] Jho HD, Carrau RL, Ko Y, et al. (1997) Endoscopic pituitary surgery: an early experience. *Surg Neurol* 47: 213-222
- [24] Jho HD, Carrau RL, Ko Y (1996) Endoscopic pituitary surgery. In: Wilkins RH, Rengachary SS (eds) *Neurosurgical operative atlas*. AANS, Park Ridge, pp 1-12
- [25] Kocher T (1909) Ein Fall von Hypophysis-Tumor mit operativer Heilung. *Dtsch Z Chir* 100: 13-37
- [26] Krause F (1905) Hirnchirurgie. *Dtsch Klin* 8: 953-1024
- [27] Lanzino G, Laws ER (2001) Pioneers in the development of transsphenoidal surgery: Theodor Kocher, Oskar Hirsch, and Norman Dott. *J Neurosurg* 95: 1097-1103
- [28] Liu JK, Das K, Weiss MH, Laws ER Jr, Couldwell WT (2001) The history and evolution of transsphenoidal surgery. *J Neurosurg* 95: 1083-1096
- [29] McArthur LL (1912) An aseptic surgical access to the pituitary body and its neighborhood. *JAMA* 58: 2009-2011
- [30] Rhoton AL Jr (2002) The sellar region. *Neurosurgery* 51(Suppl 1): 335-374
- [31] Williams PL, Warwick R (1992) *Gray anatomía, tomo II*. Churchill Livingstone, Edinburgh
- [32] Rosegay H (1981) Cushing's legacy to transsphenoidal surgery. *J Neurosurg* 54: 448-454
- [33] Schloffer H (1907) Erfolgreiche Operation eines Hypophysentumors auf nasalem Wege. *Wien Klin Wochenschr* 20: 621-624
- [34] Welbourn RB (1986) The evolution of transsphenoidal pituitary microsurgery. *Surgery* 100: 1185-1190



**Armando J. Basso**

Armando J. Basso is Director of the Neuroscience Institute and Professor emeritus of the Department of Neurosurgery at Buenos Aires University. Born in Buenos Aires, Argentine, married to Milva Peca, three daughters, Dana, Carla and Daniela, seven grandchildren. Doctor in Medicine and Diplome d'études approfondies (Ph.D.) in Neurophysiology, Université d'Orsay, France, 1968, Director of the Neuroscience Institute University of Buenos Aires, Clinical Research Director of the Consejo Nacional de Investigaciones Científicas y Técnicas (CONICET), Argentine, President of the World Federation of Neurosurgical Societies Foundation (WFNSF), Past President of the World Federation of Neurosurgical Societies (WFNS) 1993–1997, Honorary President of the World Federation of Neurosurgical Societies (WFNS), Chairman of the WHO (World Health Organization) Working Group on Neurosurgery, Past-President of the Latin American Federation of Neurosurgical Societies (FLANC), Past-President of the Asociación Argentina de Neuro-Cirugía. Past-President of the World Federation of Skull Base Societies (President of the III International Skull Base Congress), President of the Argentine Stroke Society, eleven granted prizes in Argentine and Foreign Scientific Societies, Argentine National Academy of Medicine Award. Member of International Academies: Honorary Member of the National Academy of Medicine of

Belgium, Honorary Member of the National Academy of Medicine of Brazil, Honorary Member of the National Academy of Surgery of Perú, Honorary Member of the National Academy of Surgery of México. Societies: Honorary and Active Member of many national and international scientific societies: Honorary National Member of the Argentine Medical Association, Honorary Member of the Asociacion Argentina de Neurocirugia, Honorary Member of the American Association of Neurological Surgeons (AANS), Honorary Member of the Society of Neurological Surgeons. Honorary Member of the American Academy of Neurological Surgery, Honorary Member of the Japanese Society of Neurosurgery, Honorary Member of the German Society of Neurosurgery, Honorary Member of the Italian Society of Neurosurgery, Honorary Member of the Brazilian Neurosurgical Society, Honorary Member of the Academia Brasileira de Neurocirurgia, Honorary Member of the Sociedad Chilena de Cirugia, Honorary Member of the Sociedad de Neurocirugia del Peru, Honorary Member of the Sociedad Brasileira de Cirugia de Base do Craneo. Honorary Member of the Sociedad Boliviana de Neurocirugia, Member of the Congress of Neurological Surgeons, Member of the International Society of Pituitary Surgeons, Founder Member of the International Skull Base Study Group, Active Member of the Societe de Neurochirurgie de Langue Francaise, Active Member of the Sociedad de Neurocirugia del Uruguay, Active Member of the Colegio Argentino de Neurocirujanos, Active Member of Sociedad Argentina de Electro-encefalografía y Neuro-Fisiología Clínica, Active Member of the Sociedad Argentina de Biología, Active Member of the Sociedad Argentina de Neurociencias, Founder Member of the Argentine Society of Neuroendocrinology, Founder and Active Member of the Argentine Neurosurgical Forum. Author of more than 140 papers of his specialty.

**Contact:** Armando J. Basso, MD, PhD, President of the WFNS Foundation, Director of Neurosciences Institute, Buenos Aires University, Ayacucho 1342, Buenos Aires 1111, Argentina  
E-mail: armandobasso@aol.com

---

# HOW TO PERFORM TRANSORAL APPROACHES

A. CROCKARD

## INTRODUCTION

While transsphenoidal surgery was developed almost a century ago, it was the detailed anatomical studies, procedure, specific instrumentation and masterful teaching of Jules Hardy in Montreal in the 1960s that finally launched it as a standard neurosurgical procedure. Strange then, that an approach through an adjacent orifice met such (emotional) resistance, with fears of infection, bleeding and wound complications deterring many neurosurgeons. There had been isolated reports of removal of a bullet (Kanaval 1917) and tumors, but the technique did not come of age until ready access to neuroimaging defined clearly the anatomy and pathology of the ventral craniovertebral junction [5]. Again it has been the development of appropriate retractors and specific instruments which has allowed the procedure to be within the standard armamentarium of skull base and high cervical spinal surgeons. Pioneers in the field have been Arnold Menezes (Iowa), who put his early ENT training to good effect, and Hiroshi Abe (Sapporo). In the UK, it was a far-sighted orthopaedic surgeon, George Bonney, who successfully decompressed posttraumatic deformities at the atlantoaxial joint.

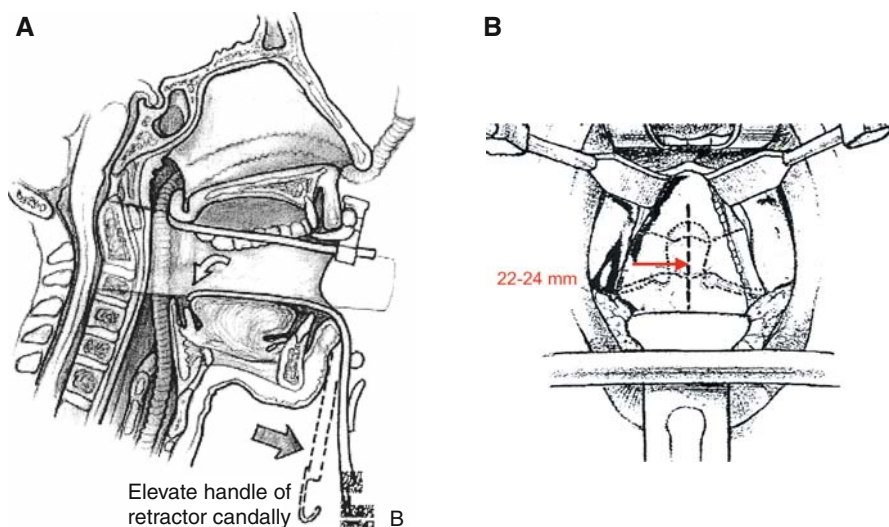
The term “transoral” covers a suite of surgical procedures in which the surgical instruments are passed between the lips to gain access to the clivus [5], ventral craniovertebral junction and the upper two or three cervical vertebrae. No single procedure will be suitable for all pathology; also the more extensive procedures such as the “open-door” maxillotomy [6] or “transmandibular transglottic” approach are best served by a team approach combining their individual skills. Their development is an important message to the modern surgeon, a move from the individual “surgical master” to the “premier league surgical team”.

## RATIONALE

The transoral family of surgical procedures are particularly indicated for ventral, midline, extradural pathology. They are contraindicated in lateral extra-

---

*Keywords:* skull base, posterior fossa tumors, microsurgery



**Fig. 1.** The standard transoral approach. **A** Exposure of the arch of C1 and odontoid peg by elevation of the soft palate using the Crockard retractor. **B** A vertical incision in the mucosa over the anterior tubercles will expose C1 and C2

dural pathology and entirely intradural tumors and vascular abnormalities. However, small intradural extensions or a dural tear can be accommodated with careful preplanning (see below) [1, 5, 9].

Understanding the complex three-dimensional anatomy in the area is essential for positioning, surgical approach and complication avoidance. The normal clivodental angle is about  $140^\circ$  and with head on neck extension this can be increased. In basilar invagination, the angle may be  $90^\circ$  or less, and, without temporary mobilisation of the teeth and alveolar margins, will render the craniovertebral junction surgically inaccessible. There are no extradural arteries at risk in the “transoral” target area, which measures 22 mm between the vertebral arteries at the clivus and at the body of axis and below. At the level of the atlas, this bony area is double the distance (22–24 mm on each side of the midline, i.e., 48 mm in total).

The surgical key to the area is the anterior tubercle on the arch of C1; this is the anatomical and embryological midline and to this are attached the longus coli muscles (and between these muscles is the subaxial midline). Below the craniovertebral junction the mucosa and muscle layer slide over each other due to an alveolar layer and permit a 2 layer closure (see below). Surgical closure above the ventral foramen magnum is more difficult as the pharyngeal lining is osteomucosal with Sharpey’s fibres firmly binding it to the bone underneath. There are also numerous venous intercommunications between the dural sinuses, the bone and the submucosal venous

plexus. (The best way to control such bleeding is by elevation of the head above heart level and gentle prolonged pressure. Bipolar coagulation does not work.)

The craniovertebral junction's movements and stability depend on strong ligaments, the alar apical complex, the transverse ligaments of the occipito-atlantal and atlantoaxial joints. Surgical removal of any of these will demand that stability is carefully tested after a transoral procedure. In some conditions, e.g., rheumatoid atlantoaxial subluxations, the neuraxial compression exists because of instability and thus a planned stabilisation must be part of the surgical solution. Careful detailed three-dimensional imaging of the bone and soft tissue is essential in surgical planning (for example, 1 in 11 people have a very large vertebral artery which may "interfere" with a planned screw trajectory).

Image guidance surgery and endoscopic techniques will facilitate greatly all surgery in this area.

Brainstem monitoring (SSEP and MEP) before and during surgery will alert the surgical team as to impending problems during the procedure. However, patients with severe deformity with neuraxial compression of more than 30% will not have preoperative SSEP waveforms and thus preoperative monitoring of this will be fruitless [8].

## DECISION-MAKING

Transoral surgery should be considered for midline ventral extradural pathology at the craniovertebral junction that is deforming or compressing the neuraxis and which cannot be alleviated by skull traction and realignment of the atlantoaxial joint.

Plain radiographs are insufficient and detailed CT and MR scanning essential; functional studies in flexion and extension are required. In advance of surgery there should be detailed knowledge of the pathology. If it is a "bony" problem such as the presence of translocation of the odontoid, any rotational element in the deformity and the quality of the bone of the lateral masses of the atlas and axis, then this information is essential. The vertebral foramina will alert the clinician to the path and size of the vessel which may be damaged by screw placement.

Image guidance is a great help but no substitute for rigorous preoperative investigations.

Vascular imaging is necessary for tumors, and tumor embolisation in some cases. A decision to remove a vertebral artery as part of the tumor surgery should not be made without first establishing that the patient has a complete circle of Willis. In some, a trial temporary balloon occlusion of the vessel in the conscious patient may be required (Table 1 and Fig. 2).

**Table 1.** Management of “transoral” patients

Pre op	Per op	Post op
Mouth opens more than 3 cm		
Bacteriology mouth swab		Repeat if wound inflamed
SSEP (MEP)		Repeat if deteriorate
Plain lateral radiograph of CCJ		To check for soft tissue swelling
Plain lateral radiograph of chest		To check for airway problem
Venous support stockings	Mechanical anti embolism	Venous support stockings
	Broad-spectrum antibiotic	Continue 24 hours
	Antiemetic	Continue 48 hours
	Hydrocortisone ointment	Continue 6 hourly 48 hours
	Nasotracheal tube*	Continue 24 hours
	Nasogastric tube*	Continue 5 days
		Nil orally 5 days
If a chance of a CSF leak	CSF lumbar drain (in position not opened unless a leak)	Remove if no leak 10–15 ml/hr for 5 days if leak Check CCJ instability
Open-door maxillotomy and transmandibular approach	Tracheostomy Percutaneous gastrostomy	As long as necessary

\*Used only if swallowing intact – otherwise tracheostomy etc.

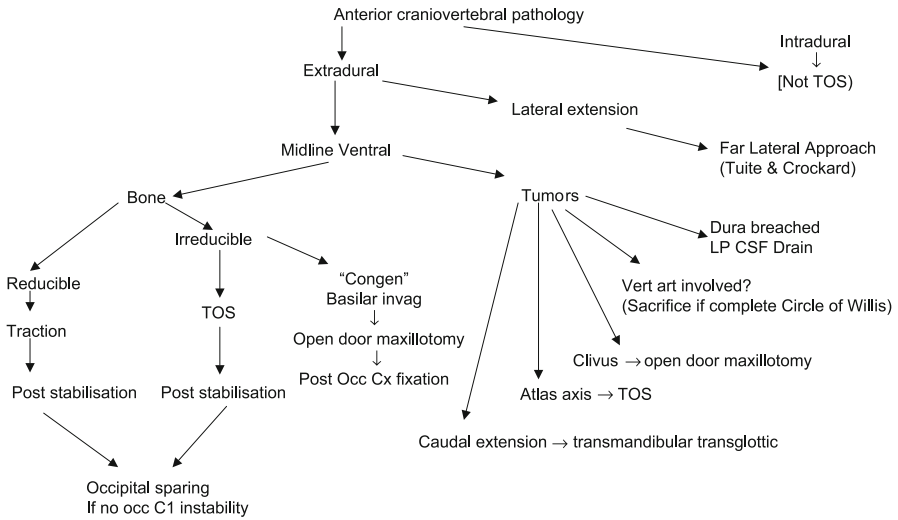
## 1. PATIENT MANAGEMENT

I bring this point up prior to description of surgery to emphasise the importance of a team approach in a Specialist Unit. While the surgical technique can and should be learnt in the laboratory, it is only a part in the management of these complicated patients. Timing of surgical intervention is critical and can only be carried out in a team used to long-term evaluation of these patients. For surgery, the anaesthetic team must be familiar with the management of the difficult airway and nasotracheal intubation [2, 3]; very few patients should require an elective tracheostomy. Intraoperative electrical monitoring and image guidance need to be used regularly in a variety of surgical procedures to acquaint all the team for them to be of value in transoral surgery. A postoperative intensive care team well versed in the care of these patients is essential.

## 2. WHICH OPERATION FOR WHICH PATIENT?

There is a wide range of pathology which may be amenable, but surgical team's may use a variety of skull base procedures. Set out in Fig. 2 is the decision-making pathway for transoral surgery in anterior craniovertebral pathology.





**Fig. 2.** Decision-making for transoral surgery for anterior craniocervical junction pathology

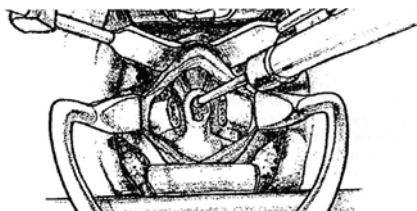
## SURGERY

### 1. A STANDARD “TRANSORAL”

The anaesthetised patient is secured supine on the table with head held in 3-pin head holder. The whole table is tilted 15–20° towards the surgeon; the head end of the table is tilted 20° upwards. Image guidance is positioned and registered. The operating microscope provides best illumination and magnification for the procedure, although specific portions of the operations may be carried out with a flexible endoscope.

The transoral retractor (Coolman, Raynham, MD) is carefully positioned (after application of hydrocortisone ointment to the mucosal surfaces, lips and tongue). Great care is necessary to avoid “nipping” a portion of the tongue or lips between teeth and retractor. Meticulous attention to this will very significantly reduce postoperative swelling. All the instruments in the transoral set are sufficiently long and bayoneted to allow access to the depths of the wound. A long angled high-speed air drill is necessary.

The soft palate and the nasogastric and nasotracheal tubes are retracted to expose the posterior pharynx [1]. The anterior tubercle on the arch of C1 is identified by instrumental palpation. A 4 cm vertical incision over this will expose the atlantoaxial area after the pharyngeal wall has been infiltrated with lignocaine and adrenaline to reduce cut edge bleeding. Separate this layer off the prevertebral fascia and the longus coli muscles and bones.



**Fig. 3.** Drilling out odontoid peg. The soft palate has been retracted to expose area. The pharyngeal retractor holds the pharyngeal incision apart

The cutting diathermy will separate these muscles off the area of the atlas laterally to the lateral masses. The pharyngeal retractor holds these muscles and the incised pharynx apart converting the vertical incision into a hexagon containing the arch of C1, the odontoid behind it, the vertebral body of the atlas below and the ventral rim of the foramen magnum cephalad.

The air drill will remove the arch of the atlas between the lateral masses to expose the odontoid, which in turn is hollowed out. During this manoeuvre the relative angle of the peg and the drill mean that the proximal position of the peg just below the transverse ligament may be the site of an unplanned penetration of the cortical bone and even the dura (Fig. 3). When the peg is thinned to a cortical shell, the latter is removed with the long 1 mm and 2 mm Kerrison upcuts along with the attached alar apical ligaments.

The transverse ligament is incised and removed to expose the cruciate ligament and any pannus in rheumatoid or pseudotumor of the elderly. The angled bayonnetted blunt hook will separate these structures and the underlying dura which has usually a greyish blue colour. Adequate decompression can be verified by image guidance and prominent dural pulsations [1].

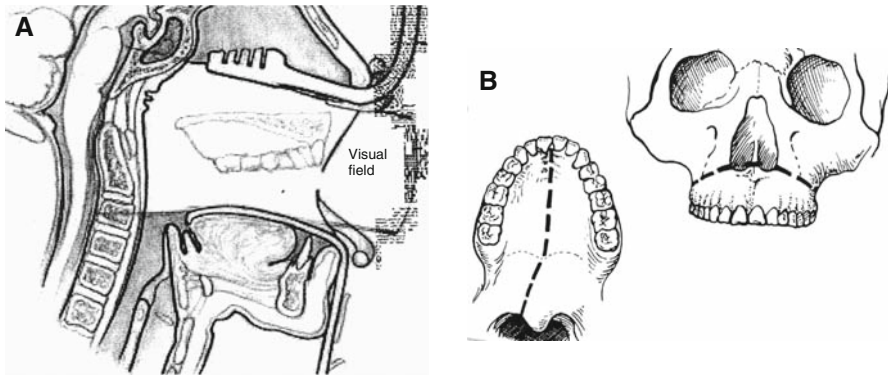
Wound closure is by 3/0 Vicryl on a round bodied needle angulated to convert the "C" to a "J" shape; two sutures to the muscles and four separate sutures to the pharyngeal wall. After the layered closure, fibrin thrombin "glue" is injected into the bony defect to fill the void and act as a haemostat.

## 2. "OPEN-DOOR" MAXILLOTOMY

This procedure was developed to gain access to the clivus in severe basilar invagination, e.g., osteogenesis imperfecta, or for a clival chordoma. It allows midline access from the pituitary fossa down to the base of the atlas; lateral extension is limited to the width of the clivus to prevent damage to the vertebral and carotid arteries and the lower cranial nerves.

Prior to this surgery, a percutaneous epigastric gastrostomy and a tracheostomy are necessary.

The superior alveolar bone above the level of the dental roots is exposed under the upper lip. Titanium miniplates are positioned in the nasal and pterygoid buttresses for postoperative fixations of the upper jaw. (To leave it till after



**Fig. 4.** The open door maxillotomy. **A** Area exposed. **B** Sawcuts for exposure

the maxillotomy will mean that the teeth are not in their exact preoperative position.) The plates are removed and carefully preserved till the end of the procedure. A LeFort III maxillotomy is effected using the reciprocating saw and the upper jaw down fractured into the mouth. A midline incision between the incisors across the alveolar margin, the hard palate and then the soft palate, will create the “open door” (Fig. 4). Both segments of the jaw depend on the blood supply from the vessels coming in from the pterygoid muscles. The front two teeth on each side may be denervated, but the author, in 20 years, has not seen major problems in these patients very ill with their presenting pathology.

### 3. TRANSMANDIBULAR TRANSGLOTTIC

In this procedure, a midline excision of the tongue back as far as the epiglottis and the mandible, coupled with a careful cosmetic incision across the lower lip will allow midline exposure caudad to C5. This is particularly useful in the staged excision of an extensive chordoma.

## LONG-TERM RESULTS

Since 1983, I have been involved in over 560 cases for a wide variety of pathology. Over this period there have been changes in pathology. For instance, with the change in treatment of rheumatoid arthritis and particularly no steroids, the extreme odontoid translocations with and without pannus have become a thing of the past [4]. On the other hand more and more tumors in the area have been referred and this has resulted in more “open door” procedures (476 transorals, 74 open door, 20 transglottic and other).

The acute complications are listed in Table 2.

There are long-term problems associated with these procedures, the chief of which is nasal regurgitation especially of fluids and altered “nasal” speech.

Reoperation in the area can pose considerable difficulties in terms of mobilisations of the pharyngeal wall. All such procedures should involve specialist head and neck or maxillofacial surgeons.

## HOW TO AVOID COMPLICATIONS

The major acute complications arise from confusion about the local anatomy and in particular the midline, and lack of meticulous care of the pharyngeal tissues. They are listed in Table 2.

Bleeding can be a surgeon's nightmare particularly if it is arterial, usually the vertebral within its bony canal. Immediate packing with Surgicel and bone wax will save the patient's life. It is virtually impossible to repair the vessel transorally, so control bleeding and request the interventional radiologists occlude the bleeding point. Following this it is most important to maintain good brain perfusion by keeping the systemic blood pressure normal or higher than normal.

Cerebrospinal fluid (CSF) leaks can lead to meningitis and a fatal outcome, so careful management is essential. The main preventative manoeuvre is to anticipate the possibility and have a lumbar drain in situ in those at risk (after the loss of a considerable amount of CSF it is practically impossible to establish a patient CSF line).

**Table 2.** Complication avoidance

Problem	Resolution
Access difficult	Pre-op mouth opening <3 cm. Increase head on neck extension
Irregular dentition	Pre-op manufacture "gum guard" to fit retractor
Where is midline?	Careful positioning, per-op X-ray, image guidance
Arterial bleeding	Surgeon not in midline
Venous bleeding	Surgical pack, "Head up" tilt table
Adequate decompression?	Image guidance
Possibility CSF leak	Lumbar CSF drain, Inserted during anaesthesia
"Accidental"	Lumbar CSF drain (after op) Multilayer closure, Surgicel, Fibrin glue Dural sutures will not work
Wound problems	Careful 2-layer closure, nil orally 5 days
Mouth and facial swelling	"Head up" position. Hydrocortisone ointment to mucosa (no systemic steroids)
Post-op swallowing	Re-intubate or change to tracheostomy If prolonged, tracheostomy or percutaneous gastrostomy
CVJ instability	Will require posterior fixation
Vertebral artery injury	Pack on op table → radiology → balloon occlusion (do not attempt transoral vascular repair)

In combination with lowering CSF pressure with regular lumbar drainage the wound should be closed very carefully and if necessary a rotation mucosal flap be used. Surgicel and fibrin thrombin glue injected into the space between the dura and soft tissue closure. It will be impossible to effect a watertight dural closure with dural sutures.

## CONCLUSIONS

Transoral surgery provides a further weapon in the armamentarium of the skull base and upper cervical spine surgeon. It requires detailed anatomical knowledge and time spent in the surgical laboratory. It is not a procedure of the occasional operator.

That said it can produce an extremely satisfying clinical result for patient and surgeon.

## References

- [1] Bouramas D, Crockard A (2003) Anterior odontoid resection. In: Hafer T, Merola A (eds) *Surgical techniques of the spine*. Thieme, New York, pp 10-15
- [2] Calder I, Calder J, Crockard HA (1995) Difficult direct laryngoscopy in patients with cervical spine disease. *Anaesthesia* 50: 756-763
- [3] Calder I. Anaesthesia and cervical spine disease. *Anaesth Intens Care Med* (in press)
- [4] Casey ATH, Crockard HA, Bland JM, Stevens J, Moskovich R, Ransford AO (1996) Surgery on the rheumatoid cervical spine for the non-ambulant myelopathic patient – too much, too late? *Lancet* 347: 1004-1007
- [5] Crockard HA, Johnston F (1993) Development of transoral approaches to lesions of the skull base and craniocervical junction. *Neurosurg Q* 3: 61-82
- [6] Harkey HL, Crockard HA (1998) Transoral-extended maxillotomy. In: Dickman CA, Spetzler RF, Sonntag VFH (eds) *Surgery of the craniovertebral junction*. Thieme Medical Publishers, New York, pp 371-380
- [7] James D, Crockard HA (1991) Surgical access to the base of skull and upper cervical spine by extended maxillotomy. *Neurosurgery* 29: 411-416
- [8] May DM, Jones SJ, Crockard HA (1996) Somatosensory evoked potential monitoring in cervical surgery: identification of pre- and intraoperative risk factors associated with neurological deterioration. *J Neurosurg* 85: 566-573
- [9] Tuite GF, Crockard HA (1997) Far lateral approach to the foramen magnum. In: Torrens M, Al-Mefty O, Kobayashi S (eds) *Operative skull base surgery*. Churchill Livingstone, New York, pp 333



**Alan Crockard**

Alan Crockard is head of spinal surgery research unit, at the National Hospital for Neurology and Neurosurgery, London. He entered neurosurgical training in Belfast just as the civil disturbances began in 1969. He quickly became proficient in triage and haemostasis of gunshot injuries and was first to show the beneficial effects of controlled ventilation in head injuries. After research in London and Chicago, he was appointed to the National Hospital at Queen Square and there established a skull base and spinal referral practice. He carried out anatomical studies to establish new surgical access to these difficult areas and developed transoral instruments in 1983. Laterally he has devoted himself to teaching and anatomical masterclasses.

**Contact:** Alan Crockard, Victor Horsley Department of Neurosurgery, The National Hospital for Neurology and Neurosurgery, Queen Square, London WC1N 3BG, UK  
E-mail: [alan.crockard@uclh.nhs.uk](mailto:alan.crockard@uclh.nhs.uk)

---

# HOW TO PERFORM POSTERIOR FOSSA APPROACHES

J. J. A. MOOLJ

## INTRODUCTION

The posterior fossa of the skull has always been considered a particular entity, from the beginning of the development of neurosurgery. This has to do with specific anatomical features, like the attachment of various muscle layers, the related irregular bony rims, the protuberantia externa (Inion), the mastoids, and within the skull barriers within the dura mater: the transverse and sigmoid sinuses. Inside the dural coverings, delicate structures of the central nervous system are hidden: the cerebellum, the brainstem, most of the cranial nerves, the vertebral arteries, the basilar arteries, their important branches, and the venous outflow system.

Surgery for pathologies in the posterior fossa started already in the 1890s, with Victor Horsley. All major founding fathers of neurosurgery have contributed to the development of surgery in this area: Cushing, Smith, Frazier, Krause, and De Martel, to mention the most important. In the beginning, surgery was done with the patient in a lateral position. A prone position became more popular with the development of a good head rest, the horse shoe type, by Frazier, and further developed by Cushing and Smith. Specific problems were immediately recognised, like abdominal pressure raise and concomitant haemorrhage risk. In 1905 Frazier performed the first operation with the patient in sitting position. De Martel propagated the sitting position and developed a special chair (1916). The risks for serious sequelae in the sitting position were recognised very soon, with pulmonary air embolism, syncope and shock. Therefore, the sitting position was not popularized in every centre. Instead, stepwise improvements in technique for other positions were developed. Generally four types of positioning have remained today: the prone position with variations; the lateral decubitus position with variations; the supine position with tilt and head rotation; and the sitting or semi-sitting position. Each has advantages and disadvantages, and certain preferences related to specific pathology and its localization within the posterior fossa. This will be dealt with in the next paragraphs of this chapter.

As is also true for neurosurgery in general, improvements in diagnostics, treatment techniques and operative results in posterior fossa surgery arose from the development of imaging (CT, MRI), the operative microscope,

---

*Keywords:* posterior fossa approaches, microsurgery, skull base

bipolar coagulation, CUSA, neuronavigation, and of course by improvement in anesthesiological and postoperative care.

Therefore, today surgery on pathologies in the posterior fossa can be as straightforward and safe as procedures in other places in the skull. There are, however, enough special aspects that warrant dealing with these in a separate chapter like this.

## **RATIONALE**

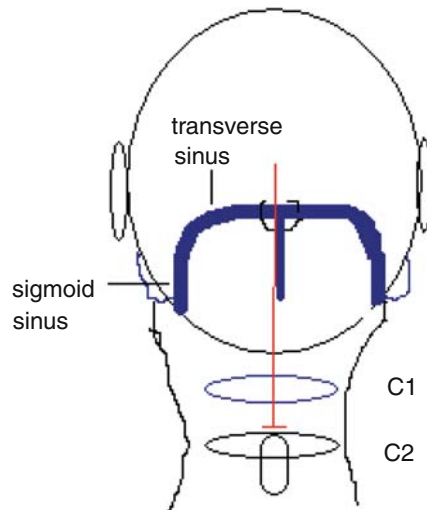
### **1. SURGICAL ANATOMY OF THE POSTERIOR FOSSA**

By “posterior fossa” is generally meant the most occipital and lower part of the skull. It is a compartment with a bony confinement consisting of the occipital and most caudal part of the cranial vault, extending from the midline to the mastoid processes on both sides. From there, bony thickenings, the pyramids containing the inner ear, converge medially to end in a basic bony structure, medially anteriorly located and called the clivus. The “roof” is formed by the tentorium, a dural double layer within the bony skull. Several openings in this rather closed compartment allow the content of the posterior fossa to be connected with other parts of the central and peripheral nervous system, and the body: (1) the opening in the tentorium, the hiatus tentorii, through which the upper brainstem and both fourth cranial nerves run; (2) the foramen magnum, an opening at the most basal side of the bony skull, allowing for the connection of the lower brain stem (medulla oblongata) with the spinal cord; and (3) numerous openings, foramina, for the cranial nerves, and the vessels that come in and go out [6]. On both sides of the foramen magnum, bony thickenings, called condyles, connect in a joint like fashion with the atlas, and thereby connect the skull as a whole with the vertebral column. Strong bands and ligaments, as well as many muscles, connect the lower part of the skull with the vertebral column and thorax, in a safe but flexible way. The attachment of the strongest muscles, the trapezius, the semispinalis, the splenius capitis and the sternocleidomastoid, lead to a curved ring that forms the upper border of the outside of the posterior fossa skull.

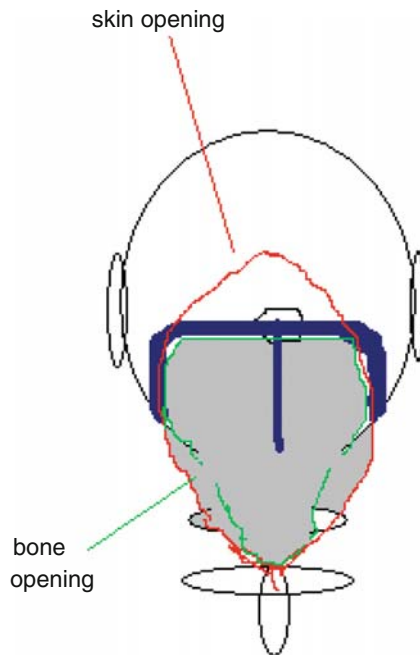
It is relevant to know that the suture between the occipital bone and the parietal bones, the lambda suture, reaches way above the borders of the posterior fossa.

On the inside, a dural layer is found, like in the rest of the skull. It covers the content of the posterior fossa, and folds within the skull to a double layer that covers the cerebellum, called the tentorium. In the middle part of this tentorium runs the straight sinus: a conduit connecting the vein of Galen to the connection of both transverse sinuses, the “confluens”. The transverse sinuses are conduits within the dural layer following and forming the attachment of the tentorium to the inner skull. From their confluens, also called “Torcular”, the sinuses run laterally to the petrous bone and bend caudally to

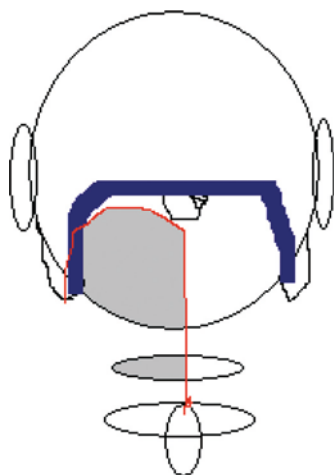




**Fig. 1.** Midline incision (red line) from above torcular (external protuberance) to upper rim of C2. In many cases an occipital sinus runs in the middle line from the confluence sinuum caudally



**Fig. 2.** Oval skin opening, bony opening up to transverse sinus, and showing beginning of sigmoid sinus. Middle part of atlas (C1) removed



**Fig. 3.** Far lateral approach: less high up, but more caudally aimed at occipital atlantoid junction, laterally

form the sigmoid sinus on both sides. They end through the jugular foramina in the jugular veins in the neck. At the site of transition from the transverse into the sigmoid sinus (left and right), a third conduit arises following the tentorial attachment on the petrous bone, the superior petrosal sinus. These sinuses run towards the cavernous sinus just below and laterally from the opening in the tentorium, the hiatus. The transverse and sigmoid sinuses form the upper and lateral borders of the generally accessible dura of the posterior fossa. For some situations these borders can be trespassed by special techniques: anterior sigmoid, translabyrinthine and/or transtentorial approaches, beyond the scope of this chapter.

Inside the dura of the posterior fossa the arachnoid layer is found. It contains the CSF spaces, which in this area enlarge into several cisterns:

- the cisterna magna, in the posterior caudal midline where between the two cerebellar hemispheres the vermis ends and the medulla oblongata transforms into the spinal cord;
- the lateral cerebello-medullary cisterns;
- the pontine and prepontine cisterns;
- the ambient cisterns connecting dorsally to form the quadrigeminal cistern, again between the two cerebellar hemispheres at the upper end of the vermis at the lamina quadrigemina.

The cerebellum consists of two hemispheres and the central connecting structure, the vermis. Detailed anatomical features can be found in neuroanatomical textbooks.

For the neurosurgeon a few aspects are specifically important: (1) The caudal part of both cerebellar hemispheres forms an appendage like extension, the tonsil. As a result of mass lesions, shifts may occur resulting in herniation of these tonsils into the foramen magnum with concomitant compression of the medulla oblongata and the spinal cord. (2) Laterally and more anteriorly, each hemisphere has an appendage near the lateral recess (opening) of the fourth ventricle, Luschka's foramen. This is called the flocculus, rather firmly attached to the dorsal and proximal part of the eighth nerve.

The cerebellum is connected to the brainstem by three major tracks on both sides, called brachium conjunctivum, brachium pontis and corpus restiforme. The most caudal part of the brain stem, the medulla oblongata, is reached directly caudally from the vermis. Between vermis and medulla opens the fourth ventricle through the foramen of Magendie. A thin covering form the velum medullare, and middle choroids plexus, is seen here. The anterior ("bottom") of the fourth ventricle is the pons, with some detailed elevations related to cranial nerve nuclei.

Seen from lateral or anterior, the pons is separated from the medulla by a sulcus, a helpful surgical landmark.

The cranial nerves XII–IV arise from the brainstem in the posterior fossa, at distinct and different places. They run through the arachnoid space to their specific foramina, which again are landmarks in surgical procedures. Again, detailed anatomical descriptions are beyond the scope of this chapter.

The most important veins to be considered in surgical approaches to the posterior fossa are, besides the already mentioned dural sinuses:

- the petrosal vein or veins, also called Dandy's vein, in the lateral pontine angle;
- the superior vermian veins, running dorsally from the upper vermis to the tentorium;
- the precentral cerebellar vein.

The arteries in the posterior fossa are:

- the vertebral arteries (VA) entering the posterior fossa through the dura on both sides of the foramen magnum, and joining into the basilar artery (BA) in front of the pons; before that, they give branches that form the anterior spinal artery;
- the posterior inferior cerebellar arteries (PICA), originating from the intradural vertebral arteries, looping around the XI–IXth nerves, the tonsils, and then branching to the choroid plexus and the medial cerebellar hemispheres;
- the anterior inferior cerebellar arteries (AICA), coming from the mid-basilar artery, running laterally and looping around the VII–VIIIth nerves before going to the middle portion of the cerebellar hemispheres;

- the superior cerebellar arteries (SCA), originating from the BA just caudally from the basilar bifurcation; the latter is lying just beyond the “borders” of the posterior fossa; the SCAs run on both sides over the upper pons, to the most cranial parts of the cerebellar hemispheres, and have a close relationship to the trigeminal and the trochlear nerves.

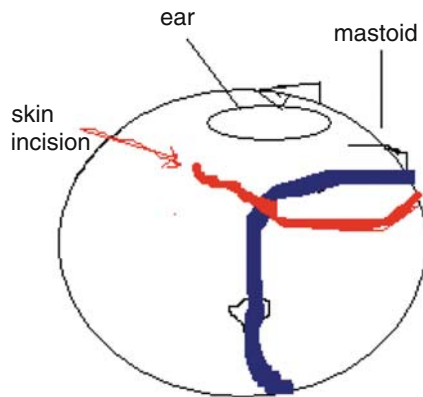
## 2. GENERAL ASPECTS OF PATHOLOGY AND PATHOPHYSIOLOGY IN THE POSTERIOR FOSSA

Surgical approaches to the posterior fossa are done for a variety of pathologies, details of which are found elsewhere in this book.

In general, surgery is done for:

- *tumors*
  - intrinsic tumors of the cerebellum
  - intrinsic tumors of the brain stem
  - tumors in the fourth ventricle
  - intrinsic tumors of the pineal gland/region
  - tumors of the cranial nerves (mostly vestibular schwannomas)
  - cerebellar metastases
  - extra axial tumors: meningiomas
    - superficial
    - petroclival
    - tentorial
    - foraminal
- *vascular lesions/problems*
  - aneurysms
  - arteriovenous malformations
  - fistulas
  - haemorrhage
- *neurovascular compression syndromes*
  - trigeminal neuralgia
  - hemifacial spasm
  - glossopharyngeal neuralgia
  - tinnitus-vertigo syndrome
- *infections (abscess, empyema)*
- *trauma (isolated posterior fossa trauma is seldom!)*

Symptomatology of these lesions is of course related to their localization, with or without impact on neurological function: it varies from cranial nerve dysfunction (deafness/dizziness in vestibular Schwannomas) to brainstem or cerebellar dysfunction, by distortion, compression or destruction.



**Fig. 4.** Lateral position, retromastoid approach. Skin incision starts behind and a little above the ear, curving towards some crease in the skin of the neck

Besides local (intrinsic) neurological dysfunction, a general problem may arise which is pertinent to the posterior fossa: the relatively small and confined space leads easily to a rise in intracranial pressure with brainstem compression and dysfunction. This can result in loss of consciousness, disturbance of gaze and other oculomotor symptoms, and ventilation problems. Such a mechanism is seen especially in acute mass lesions like in cerebellar haemorrhage.

A separate and often concomitant mechanism is the interference of pathology in the posterior fossa with the circulation of the cerebrospinal fluid (CSF), resulting in acute hydrocephalus. It can be difficult to unravel the pathophysiological mechanism in a certain situation and to decide whether treatment of the hydrocephalus or of the mass lesion itself is preferable.

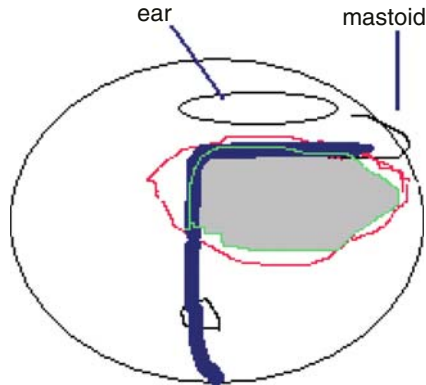
## SURGERY

### 1. POSITIONING IN POSTERIOR FOSSA APPROACHES

It is well known that positioning of the patient for neurosurgical procedures is of paramount importance and may be decisive for the success of the surgery. This holds especially true for approaches to the posterior fossa.

There are four main positions to be considered [2, 4, 7, 8]:

- *Prone/Concorde*
- *Lateral decubitus/park-bench*
- *Supine with rotation of the head*
- *Sitting position*



**Fig. 5.** Same as Fig. 4; oval skin opening (red line) bone opening reaching transverse and sigmoid sinus

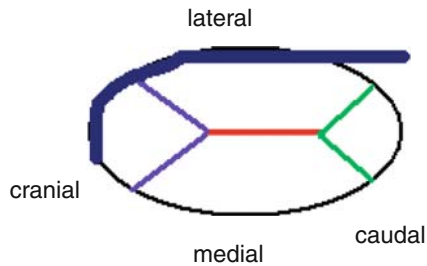
### 1.1 Prone and Concorde position

These positions are predominantly used for pathologies where a midline approach is necessary. But also for a so-called far lateral approach, this position has some advantages above a lateral positioning (see next paragraphs). In the prone position, the patient is lying prone on the table with support to thorax, pelvis and legs. This support should leave the belly free. Therefore, a U-shaped cushion may be used under the thorax. The head is either supported by a horse-shoe cushion, or fixed in a Mayfield clamp. The latter is my favourite, and gives more freedom for flexion of the head with concomitant better exposure of the lower occiput and neck. Such exposure can be even more exaggerated by lifting the upper thorax and shoulders, and bending and lowering the head to a maximal flexion. That is what is called the “Concorde” position, a self-explaining name!

In such a position, the surgeon may stand from one side of the body looking from below towards the occipital region. Therefore, the head can even be angulated and tilted a little, according to the surgeon’s preference. But, especially in the Concorde hyperflexion, the surgeon may work “upside down”, standing and even sitting with the patient’s head “in his/her lap”. This is my favourite position for surgery on midline posterior fossa pathology in infants and young children.

### 1.2 Lateral decubitus and “park-bench” position

This approach is primarily used for unilateral entering of the posterior fossa: a paramedian approach for a cerebellar hemisphere lesion, or a retromastoid opening for pontine angle pathology, including VA and PICA aneurysms. Careful support for the thorax is necessary leaving some space for the



**Fig. 6.** See Figs. 4 and 5, concentrating on dural opening. This starts with a linear incision (red), followed by two caudal incisions (green), for a basal dural flap; now CSF can be drained, underneath the cerebellum. Last incisions are cranial (blue), making a triangular dural flap based on the transverse sinus. The lateral trapezoid flap (blue-red-green lines) is based on the sigmoid sinus and allows for maximal lateral approach along the cerebellum

underlying upper arm, with some flexion for the lower arm. Also the hips must be well-supported and fixed in this position, in order to avoid inadvertent sliding or rotation. Again, the head is held by a Mayfield clamp, the neck can be flexed as far as necessary and appropriate. The major advance is that rotation of the neck, with risks for kinking of the VA, and postoperative cervical vertebral and muscle pain, is avoided. The problem is primarily the underlying arm, with risks for compression of the brachial plexus. Another problem and risk may be some hypoventilation of the lower lung and postoperative atelectasis. This needs special attention, especially at the end of the surgery. After closing up, the patient should be rotated first to the supine position, ventilated well, and only extubated thereafter.

However, with some routine the lateral decubitus position can be fine and stable, especially for long lasting procedures in elderly patients.

The arm problem can be mitigated by letting the arm hang in a sling past the end of the table, with still good support for the thorax. Moreover, some rotation of the patient towards a more prone position is then easy and may be preferable. That is the “park bench” position.

### 1.3 Supine position with rotation of the head

For lateral pathology in the posterior fossa, a supine position with the head fixed in a Mayfield clamp and rotated to one side is sufficient. It is easier and much faster than the lateral (or park bench) position. Many patients can rotate the head far enough, but this should be tested in the awake situation preoperatively. In order to avoid too much rotation, and subsequent kinking of the VA, the thorax should be supported by an extra cushion on one side, thus rotating the body already quite a bit. Some flexion in the neck can be added, for better accessibility of the lower lateral part of the posterior fossa. The most important to avoid in this position, besides the already mentioned interference with the VA, is compression of the underlying jugular vein,

which may be the major venous outflow of the brain. Venous congestion should be avoided at all costs, and can be diminished remarkably by lifting the head or the whole upper part of the table just a few degrees. This position is extremely well suited for surgery in the pontine angle (including petroclival meningiomas), on cranial nerves, on the lower lateral brain stem, and the cerebellum or the tentorium on one side.

#### 1.4 Sitting position

As already mentioned in the first paragraph, in the beginning of posterior fossa surgery the sitting position became very popular. With table tilt and more bending in the hips, one can even lower the whole position towards a so-called semi-sitting position. Head fixation has been improved remarkably thanks to the Mayfield clamp, which can be mounted in front of the head with a U-shaped device fixed on the side bars of the operation table.

The advantages in this position are:

- Best overview for the upper cerebellum, the midline tentorium area, and consequently ideal for the supracerebellar infratentorial approach to the tectal and pineal area;
- CSF and blood drain outwardly, resulting in less need for (time consuming) suction compared to the other position;

The disadvantages are, however:

- risk for pulmonary air embolism: given the 10% chance for unknown patency of the cardiac oval foramen, there is even risk for air embolism in the cerebral circulation;
- sagging of the cerebellum, which needs retractor support;
- risk for cardiovascular instability during positioning; transverse cord lesions have been described;
- need for postoperative sitting position in the ICU for the first hours, with slow adaptation towards a more supine nursing position;
- fatigue for the surgeon in long lasting procedures, with his/her arms more stretched due to the longer working distance, depending on the building of the microscope (less angulation of the oculars on the microscope body).

The disadvantages can be overcome, when there is a strong preference for this position, related to the pathology to be treated. The following measures should be taken [1, 3, 4]:

- stockings or even G-suit for the legs;
- preoperative work-up to exclude a patent oval foramen;



- precardiac transthoracic Doppler probe, or, even better, transoesophageal cardiac Doppler equipment in place;
- intra-atrial catheter for immediate suction when air embolism is detected;
- pCO<sub>2</sub> measurement in the outflow channel of the ventilation tube is standard for anesthesia, but should get extra attention;
- good access to cervical area, in order to allow for jugular vein compression when air embolism occurs;
- alertness of the surgeon for any suspicion of air embolism, especially during the opening and closure: active communication with the anaesthetist, extensive and continuous irrigation of the surgical field, careful coagulation, and excessive waxing of all bony structures and rims.

It is clear that the sitting procedure adds risks to the surgery in the posterior fossa. Therefore, this position should only be used by an experienced team, that performs surgery in this position on a regular basis. It is only justified when the advantage outweighs the risks, as for example in the supracerebellar infratentorial approach to the pineal or tectal area.

## 2. STEPWISE PROCEDURES [5, 6, 8]

### 2.1 Midline approach

This procedure can be performed in the prone and in the sitting position.

Procedure after positioning, fixation, mounting electrodes for monitoring, and draping:

- Midline skin incision, from 2 cm above the external protuberance, to the palpable spinous process of C2.
- Loosening the skin from the underlying periost and muscle fascia for about 0.5 cm, important for easy closure.
- Continuation of midline incision with monopolar cutting and coagulation needle device; in the sitting position even more care is taken to coagulate any little vessel, under lots of irrigation and with regular jugular compression in the neck, see paragraph on sitting position. In the upper and lower part of the incision, the midline can be found and followed very easily, which helps in finding the right place in and underneath the fascia to separate the muscle bundles on both sides of the midline.
- The periost of the occipital bone is scraped to both sides, with the muscles attached. For a very large opening to both sides, it may be preferable to cut the muscles horizontally on both sides (0.5 cm caudally from their attachment, for better closure), but in my experience

this is hardly ever necessary with a fine linear midline incision that goes up highly enough.

- The extra cranial muscle work is finalized by freeing the upper part of the C2 spinous process, then coming to the atlas, from below and from above, and subsequently scraping the periosteum from the back of the atlas to both sides, beginning in the midline. This last part is done with knife and scissors, followed by sharp small dissector, in order to avoid inadvertent damage to dura and/or vertebral artery so easily done with the cutting needle!
- Once enough of the occipital bone and the atlas is freed, visible and accessible, definite retractors are placed. However, during the microsurgical part of the surgery these retractors may form obstacles for smoothly bringing in and out microsurgical instruments. Therefore, we prefer to retract the muscles with sutures connected to rubber bands, or any type of fish hooks. So, the operation field is as flat as possible, making the surgery easier.
- The next step is the bone work. Decision on which technique to use is determined by age and local anatomical features. In children, and adults with a rather flat occipital bone, we make two burr holes on either side of the midline, just under the presumed position of the underlying transverse sinus. The holes are connected by drilling with a small burr head, and then the bone is cut from the burr holes caudally in a curved way using the craniotome. This is an osteoplastic technique, allowing for replacement of the bone at the end of surgery.
- In adults with thick bone, and/or irregularities, as well as in cases where the above technique encounters some (adhesion) problems, we use again the two burr holes, but continue with the Leksell rongeur. A piecemeal (osteoclastic) removal of the occipital bone results, more time consuming but sometimes safer than the method described before.
- Once the dura has been freed, one has to decide whether the opening is wide enough: for high located lesions it is mandatory to remove the bone until the first 3–5 mm of the transverse sinus are visible, allowing for better dural retraction upwards. In cases with significant mass lesions, and subsequent chance of already existing tonsillar herniation, the atlas should be removed in its middle 2–2.5 cm, upfront, before the dura is opened.
- Classically, one might prepare for a supratentorial burr hole, in order to have access to the ventricle for tapping CSF. In my experience I have hardly ever needed such an access: either the patient had already some CSF diversion because of a clinical emergency situation preoperatively, or the intraoperative situation could be easily handled by some table tilt or anaesthesiological measures, followed by rapid opening of one of the suboccipital cisterns as soon as the dura was opened.

- The next step is dural opening. The classical Y opening over both hemispheres, with the “long leg” of the Y in the midline as far down as necessary (so even to the upper rim of C2), is still my favourite. However, in some 10% of the cases, the midline dura contains (“hides”) a sinusoidal remnant, the occipital sinus. The surgeon should be prepared to encounter this venous conduit. There are several methods to solve the problem: the incision can be made more lateral, parallel, with a straight crossing at the higher point of the sinus and suturing it at both sides of the cut; or stepwise opening and suturing – or clipping with hemoclips – can be performed, with some additional bipolar coagulation. The latter method is especially preferable when that sinus is rather wide, which is sometimes the case.
- Adjuvant dural incisions towards the lateral side, more caudally starting from the Y’s long leg, may be helpful for a maximal overview.
- Since this approach is primarily chosen for midline or near midline pathology, the next step is to identify the fourth ventricle. The classical splitting of the vermis is not necessary in most cases: careful preparation (from now on under microscopic magnification) of the arachnoid, in particular between cerebellar hemisphere and vermis, allows lifting of the caudal end of the vermis. When more space is wanted, a subtle splitting of the velum medullare posterius on one side is sufficient in most cases. For further details of handling the intradural pathology one should read the chapters dedicated to these.
- Closure is done very carefully. The arachnoid cannot always be closed separately, which is less important here than for example in the spinal cord region. But the dura should be closed as watertight as possible, without causing compression. The latter might be the case when there is swelling of the cerebellum after removal of only relatively small pathology. In such a situation, a duroplasty should be performed, preferably with natural material: fascia from within the operative field, or even fascia lata, for which access should have been prepared in the draping procedure. There are many commercial products now for dural replacement, which may work fine. In our experience, body’s own material still works best! Of course such closure may be supported by fibrin glue sealing. The latter never resists a real CSF outflow under a certain pressure, though!
- Replacement of bone, over an epidural gelatine layer or other haemostatic material, may be helpful in controlling haemostasis, but is not absolutely necessary. We never fixate the bone, but use it only as a support between the layers.
- The deep and superficial muscles can be approximated in two layers, over which the fascia should be closed separately in a tight fashion. Here the advantage of the subcutaneous loosening at the beginning becomes obvious, resulting in more freedom for handling this closure.

- Next, subcutis and skin are closed, with interrupted and a running suture, respectively. A drain is placed only rarely, and should never replace careful haemostasis!
- A tight (compressing) bandage is hardly possible in this area, and actually not necessary.
- It should be stressed once more that in the sitting position the closure can be more time consuming, with again attention for any kind of venous openings (jugular compression, waxing the bone etc.).
- When surgery was performed in the prone position, the patient is turned supine while still intubated, well ventilated in this new position and only extubated thereafter. After a sitting position procedure, the patient should be awakened and extubated in the sitting position. Then, postoperative surveillance in the ICU should be with the patient sitting, slowly (over many hours) changing towards a supine situation.

## 2.2 Variants of the midline approach

For a so-called far lateral approach, we use also the prone position. After full exposure, the table (with the patient well fixated to it) may be tilted and/or turned as far as necessary and acceptable.

- The procedure starts as the standard midline opening, but the skin incision turns to one side at its upper extension, bending just behind the mastoid process, and ending there. This is called a hockey-stick incision.
- After undermining the skin a little, the muscle layers are cut with the diathermic needle, at the upper rim just under the attachment to the nuchal line on one side. Skin and muscles are detached from the bone in one layer, with a sharp dissector and diathermia.
- Retraction is done again with fish hooks and/or sutures with rubber bands.
- Now the occipital bone should be visible from a little over the midline, to one side with exposure of the lateral mastoid. Caudally the rim of the foramen is exposed, low laterally the digastric groove and the occipital part of the condyle. The atlas is freed as was described before, but more to one side, where it forms the atlanto-occipital joint.
- The resulting working space allows for more bone removal laterally, as far as is found necessary for the specific surgery at hand.
- Bone work is done as described before; special handling of the vertebral artery, freeing it from C2 and C1, can be part of this procedure.
- The dural incision is now over one cerebellar hemisphere ending in the cervical area just above C2; a separate incision reaches as far later-

ally as possible, allowing for triangular dural flaps and a wide opening over the lateral medulla.

- Closure is straightforward and follows the same principles as described before.

### 2.3 Retromastoid craniotomy/craniectomy

With a well performed retromastoid approach one can access the whole lateral part of the posterior fossa, from the foramen magnum caudally to the hiatus tentorii cranially. We use it for all pontine angle tumors, petroclival tumors, neurovascular compression syndromes, lateral pontine pathologies, and VA and PICA pathology (f.e. aneurysms).

We position the patients mostly supine with shoulder support and rotation of the head fixed in a Mayfield clamp (see before).

Stepwise procedure for retromastoid approach:

- After positioning and mounting of electrodes for monitoring (when appropriate), shaving, prepping and draping, an incision is made, starting 1.5 cm above and behind the upper ear, following the curvature of the ear and ending some 2 cm under and behind the palpable mastoid process.
- The skin is undermined in its upper part (for easy closure), then fascia-periost and muscles are cut by monopolar needle diathermia. The occipital artery is always encountered and needs careful coagulation and cutting.
- Sharp dissection of the muscles from the bone – with some emissaria veins to be controlled with bone wax – results in a bony area of 4×4 cm, which of course can be modified and enlarged in one direction or the other.
- Laterally, the first cm of the mastoid should be visible, as well the digastric groove behind and caudally to it. We free the bone till it shows the horizontal (= vertical in this position!) plane, the lowest part of the lateral occipital bone.
- Retraction is done with fish hooks and sutures with rubber bands, resulting in a flat operation field.
- We generally start with one burr hole in the upper part of the bone exposure, which is always near or on the transverse sinus. We never feel the necessity for neuronavigation at this stage.
- Depending on the thickness of the bone, we now make a flap with two curved lines, using the craniotome and starting from the burr hole. If that is awkward and difficult, we drill part of the outer layer of the bone and use rongeurs, turning a planned craniotomy into a craniectomy; bone pieces and bone dust are saved in order to be used at closure.
- The bone opening is widened with some drilling or rongeurs to such an extent that the transverse and sigmoid sinuses are visible for at least

3 mm at the edges of the craniotomy. This allows for better retraction of the dura.

- Two problems are always encountered, but can be handled easily: the major emissaria vein in this area comes from the upper sigmoid sinus; it can be coagulated, but sometimes a small tear is unavoidable which can be covered by some haemostatic agent (surgicel, gelfoam). Furthermore, some mastoid air cells are almost always opened when adequate bony exposure is pursued. These air cells should be covered and closed very carefully with bone wax. We do it always before opening of the dura, and again after its closure.
- Because of the drilling, the operative field may have become quite dusty by now! Irrigation and additional draping is very adequate for providing a nice surgical field.
- The dura is opened. For most pathologies we do this with a standard order of incisions: first, a straight incision in the middle of the exposed dura, parallel to the mastoid. From there a triangular flap is prepared caudally, by two cuts.
- At this time, the smallest retractor or dissector is used to lift the caudal cerebellum and reach for the lateral cerebellomedullary cistern. Optimal access is obtained when the bony opening has indeed reached the flat part of the occipital bone. CSF comes out, sometimes after some minimal arachnoid perforation with a forceps. Waiting and draining carefully allows the cerebellum to sink adequately, after which no retractor is needed anymore for the rest of the procedure.
- Now the last dural opening is made with two cuts to the upper part, resulting in an upper dural triangle, based on the transverse sinus. The trapezoidal dural flap that is based on the sigmoid sinus is now tagged with two sutures as far laterally as possible; the triangular flaps may be tagged as well.
- The more medial part of the dura, as well as the cerebellum, are covered with thin gelfoam.
- The microsurgical part of the procedure should start now: lateral from the already fallen down cerebellum the arachnoid cisterns are reached. They are opened on purpose, after which more CSF can be drained and adequate exposure of the pathology at hand is obtained. See again the dedicated chapters.
- Closure starts with running sutures for dural closure; many times this seems inadequate in the beginning, but after a first run, additional suturing will bring the dural rims together in most cases.
- Pieces of muscle or gelfoam in fibrin glue may help finalize a watertight closure.
- The bony rims and opened mastoid cells are waxed again. The epidural surface is covered by thin layers of gelfoam, on which the bone, bony pieces and/or bone dust is applied.

- Muscle layer are adapted, after which a tight closure of the fascia takes place. Here, especially at the upper part of the incision, the subcutaneous preparation payes off, enabling a watertight closure of the fascia.
- The subcutaneous tissue is adapted with 3–4 stitches, and the skin is closed with a running suture.
- No drains are necessary, a simple skin drape is used, over which a compressive bandage is applied for 3 days.

#### 2.4 Variation: the paramedian approach

For some pathologies that are located strictly in one cerebellar hemisphere, the surgeon might want to use an “intermediate approach”, which is between the midline and the retromastoid (lateral) approach. The difference with the retromastoid is a more straight incision, parallel to it and halfway the midline and the mastoid area. There is no necessity to go so caudally in that approach, and the procedure is literally straight forward, allowing for an adequate opening of just a part of the lateral half of the occipital bone. It is not felt necessary to analyse such an approach again in a stepwise fashion.

## HOW TO AVOID COMPLICATIONS

The most frequent complications of the approaches to the posterior fossa as such are:

- infection
- haematoma
- CSF leakage subcutaneously
- CSF leakage to oropharynx through mastoid and middle ear
- air embolism.

*Infection prevention* is pursued by meticulous sterility, avoiding necrosis by too heavy coagulation, and perioperative broad spectrum antibiotics (cephalosporine), a bolus before skin incision, and at 3 and 6 hours, when surgery takes that long.

*Haematomas* should be prevented by careful haemostasis, blood pressure control, and awareness of preoperative coagulation status of the patient (history, medication).

*CSF leakage* can occur intradurally, through the internal meatus when this is drilled open (in acoustic neuroma surgery); but more frequently, and related to any posterior fossa approach, by a not watertight dural closure. CSF can leak to the subcutaneous area only, or even come out through the skin. Or it can find its way through the opened and insufficiently waxed mastoid cells, given rise to rhinorrhoea.


As said before, avoidance is by optimal closure of dura and mastoid cells; or by plugging the internal meatus. In some 10% of cases even in the most experienced hands some CSF leakage occurs. Prompt treatment by a lumbar external CSF drain for some 3–5 days is generally adequate, and in case of significant subcutaneous CSF collections, by concomitant puncture of that and installment of a blood patch. We have used the latter only very seldom, though.

The problem of *air embolism* is already discussed before, in the paragraph on the sitting position. By adequate preparation of the patient, the installation of the right equipment (catheters, Doppler probes), and awareness of the risks by surgeon, anaesthetist and personnel, air embolism cannot be prevented in every case, but the sequaelae can and should be reduced to a safe minimum.

## References

- [1] Cucchiara RF, Black S (1993) Anesthetic considerations. In: Apuzzo MLJ (ed) Brain surgery: complication avoidance and management. Churchill Livingstone, New York, pp 1597-1608
- [2] Goodkin R, Mesiwala A (2004) General principles of operative positioning. In: Winn HR (ed) Youmans neurological surgery, 5th edn, vol I. Saunders, Philadelphia, pp 595-621
- [3] Hodge CJ, Primrose D (1993) Physiological considerations. In: Apuzzo MLJ (ed) Brain surgery: complication avoidance and management. Churchill Livingstone, New York, pp 1569-1596
- [4] Leonard IE, Cunningham AJ (2002) The sitting position in neurosurgery – not yet obsolete! Editorial. BJA 88: 1-4
- [5] Mohsenipour I, Goldhahn W-E, Fischer J, Platzer W, Pomaroli A (1994) Approaches in neurosurgery. Georg Thieme, Stuttgart, pp 107-125
- [6] Seeger W (1978) Atlas of topographical anatomy of the brain and surrounding structures. Springer, Wien New York, pp 428-435, figs 205-258
- [7] Tew JM, Scodary J (1993) Surgical positioning. In: Apuzzo MLJ (ed) Brain surgery: complication avoidance and management. Churchill Livingstone, New York, pp 1609-1620
- [8] Yaşargil MG (1996) Microneurosurgery, IVB microneurosurgery of CNS tumors. Georg Thieme, Stuttgart, pp 58-65





### **Jan Jakob A. Mooij**

Jan Jakob A. Mooij is Professor and Chairman at the Department of Neurosurgery, University Hospital, UMCG Groningen. Born in 1945. After his medical education at the State University of Groningen, PhD programme in Neuropharmacology, thesis in 1976. Training in Neurosurgery, at Groningen University, Dept. of Neurosurgery (with Prof. Dr. J. W. F. Beks). Assistance residency training at the Department of Neurosurgery in Zürich with Prof Dr. G. Yaşargil (1982). Junior staff neurosurgeon at Dept. of Neurosurgery, University of Amsterdam, 1982. Returning to Groningen end of 1982. Assistant Professor from 1987 onwards. Neurosurgical observer and research fellow at Barrow Neurological Institute, Phoenix (AZ), U.S.A. (Prof. Dr. R.F. Spetzler) 1992. Chairman of Dept. of Neurosurgery, University Hospital Groningen, since 1993. Training Committee EANS, member 1997–2003, chairman 2003–2007, vice-president 2007–. Main interests: aneurysm surgery, neuro-oncology, neurovascular compression syndromes, training and education in neurosurgery.

**Contact:** Jan Jakob A. Mooij, Department of Neurosurgery, University Hospital UMCG Groningen, Hanzeplein 1, 9713 GZ Groningen, The Netherlands  
E-mail: [j.j.a.mooij@nchir.umcg.nl](mailto:j.j.a.mooij@nchir.umcg.nl)

---

# HOW TO PERFORM TRANSPETROSAL APPROACHES

T. KAWASE

## INTRODUCTION

The middle fossa transpetrosal approach was originally developed by King in 1970, and so-called “extended middle fossa approach”, which was combined with middle fossa craniotomy and translabyrinthine approach [6]. The method was mainly applied to acoustic tumors, but it was indicated to clival lesions by Hakuba et al. [2].

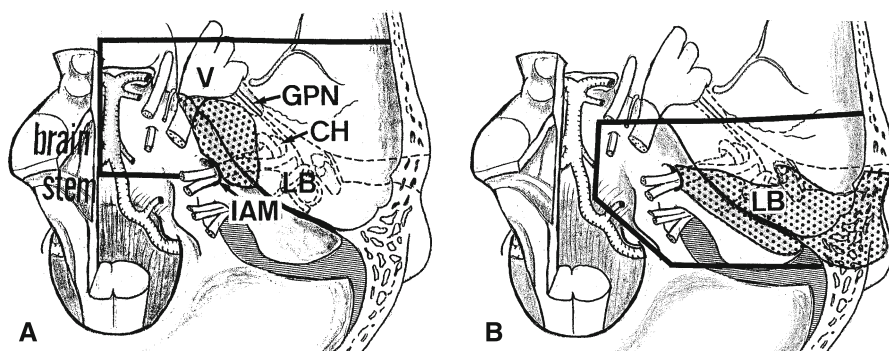
An advantage of this approach is low risk of cerebellar damage to access more laterally to the brain stem. The disadvantages were sacrifice of hearing and venous complication (venous thrombosis of vein of Labbe and sigmoid sinus). Al-Mefty used this approach for more number of the petroclival meningiomas, by preservation of acoustic structures (posterior transpetrosal approach) [1]. In 1985 and 1994, Kawase reported the anterior transpetrosal approach for basilar trunk aneurysms and petroclival meningiomas by selected resection of petrous apex [3–5]. The clival lesions were accessed by the shortest way to the area anterior to the internal auditory meatus (IAM) without sacrifice their hearing. In this chapter the anterior and posterior transpetrosal approaches are described.

## DECISION-MAKING

The anterior transpetrosal approach (ATP) is indicated for petroclival or prepontine lesions, such as meningiomas, chordomas or epidermoids. It is absolutely indicated for petroclival tumors showing extension into the middle fossa and Meckel’s cave, such as dumbbell type trigeminal neurinomas, or petroclival meningiomas showing middle fossa extension. Prepontine epidermoids over the midline or with supratentorial extension are indicated for this approach. Basilar trunk aneurysms or low positioned basilar top aneurysms are indicated for clipping by this approach. The maximal surgical field is limited in the area of foramen ovale anteriorly, oculomotor nerve superiorly, mid clivus inferiorly, internal auditory meatus posteriorly and contralateral abducens nerve medially (Fig. 1A).

---

*Keywords:* skull base tumors, transpetrosal approaches, minimal-invasive neurosurgery



**Fig. 1.** **A** Anterior transpetrosal approach. **B** Posterior transpetrosal approach. Site of pyramid resection (dotted) and the surgical field (broad line). *GPN* Greater petrosal nerve, *CH* cochlea, *LB* labyrinth, *IAM* internal auditory meatus, *V* trigeminal nerve

The posterior transpetrosal approach (PTP) is indicated for large cerebellopontine angle (CPA) tumors such as meningiomas, or vestibular schwannomas (Fig. 1B). By combination with the ATP (combined petrosal approach), it can be indicated for large petroclival meningiomas extending posterior to the internal auditory meatus.

Patient's hearing can be preserved in the patient whose semicircular canals be preserved by otological technique.

Compared to the lateral suboccipital approach, the benefits are as follows: (a) No retraction damage to the cerebellum and cranial nerves from VII to XI, (b) easy access to the tumor extended into the middle fossa and Meckel cave, (c) dried surgical field during tumor removal by devascularization of tumor feeders of middle meningeal and tentorial arteries, (d) no surgical blindness to anterior brain stem and basilar artery. The disadvantage is a surgical limitation to the lower clivus and jugular area.

Compared to the subtemporal-transtentorial approach, the benefits are as follows: (a) lower risk of injury to the temporal bridging veins by the epidural access, (b) deeper observation below the trigeminal nerve. The disadvantage is longer operation time for resection of the pyramid.

## SURGERY

### 1. SURGICAL INSTRUMENTS AND PREOPERATIVE PREPARATION

Sugita's hooked retractors and tumor retractors (Mizuho-Ika Co., Tokyo, Japan), surgical drill with twist tips of 5 and 3 mm in diameter and with a diamond tip of 2 mm, ultrasonic aspirator and evoked-potential monitoring system.

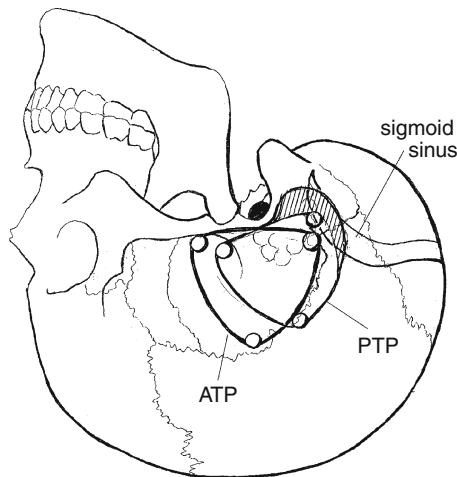
A spinal drainage tube is inserted before surgery. For large tumors with presumed risk of herniation, a ventricular drainage tube is inserted in the trigone, instead of the spinal drain.

## 2. OPERATIVE TECHNIQUES AND HOW TO AVOID COMPLICATIONS

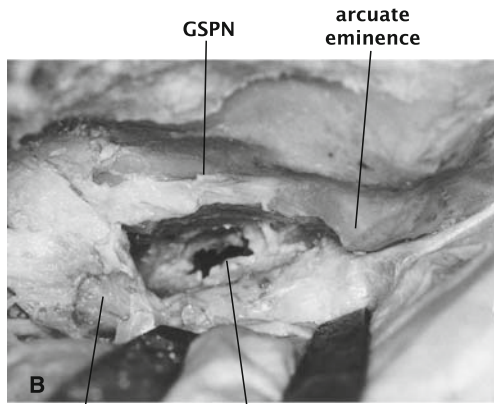
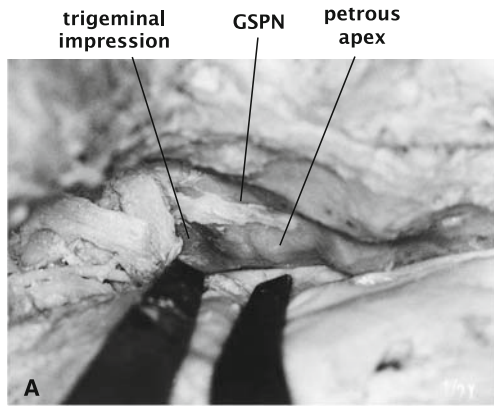
### 2.1 Anterior transpetrosal approach

The patient is positioned in supine with a shoulder pillow, and the head is fixed completely laterally with slight vertex down.

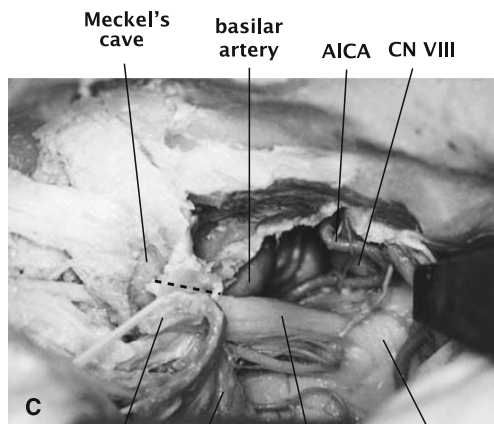
- 1) Craniotomy. After scalp incision above the auricle, the temporalis fascia, which is used for closure, is dissected from the muscle with its pedicle inferiorly. The temporalis muscle is reflected anteriorly. Root of zygoma, external auditory meatus, and squamous suture are confirmed for orientation of the craniotomy site. The craniotomy is made along the squamous suture with 3 burr holes (Fig. 2). The inferior margin is drilled until the bone window is flushed to the floor of the middle fossa.
- 2) Exposure and resection of petrous apex. Dura mater is dissected and elevated from the temporal bone, using hooked retractors after drainage of cerebrospinal fluid. Anatomically important points, such as arcuate eminence, petrous ridge, foramen spinosum are confirmed. The middle meningeal artery (MMA) is coagulated and cut. The periosteal dura, adhesive to the greater superficial petrosal nerve (GSPN), is cut to preserve the nerve (Fig. 3A). Epidural venous bleeding around



**Fig. 2.** Craniotomy site. *ATP* Anterior transpetrosal approach, *PTP* posterior transpetrosal approach, with partial mastoidectomy (shaded)



Meckel's cave      post. fossa dura

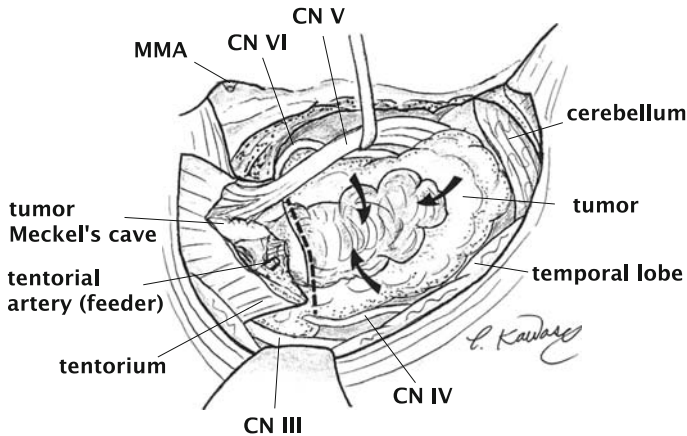


- MMA is controlled by head up position and insertion of surgical balls.
- 3) Lateral margin of the drilling is delineated medial to the GSPN and arcuate eminence. The triangular bone is resected until the posterior fossa dura is confirmed (Fig. 3B). The carotid artery and auditory structures are not exposed within the space. Take care not to break dural bulging of the internal auditory meatus (IAM) located postero-inferior margin of the triangle, and not to resect the bone above the geniculate ganglion of the facial nerve, located superficially on an extension line of the GSPN, to spare injury of the facial nerve. Overdrilling toward clivus may injure the abducens nerve in Dorello's canal.
  - 4) Dural incision. Incision of the middle fossa dura is started from 2 cm lateral to the superior petrosal sinus (SPS), and extended in T shape along the SPS. After incision of the dura on the posterior fossa, the SPS is ligated with suture twice and incised. Incision of the tentorium is extended until the tentorium is cut completely. Take care not to injure the trochlear nerve at the tentorial notch. Both sides of the tentorial leaflets are reflected and retracted with tapered retractor, then the tumor and root of the trigeminal nerve are exposed (Fig. 3C). The course of the trigeminal nerve varies depending to the tumor origin.
  - 5) Opening Meckel's cave and detachment of feeders from the Orifice of Meckel's cave, where the trigeminal nerve enters, is confirmed and incised anteriorly for 1cm along the superior margin of the nerve, then the trigeminal nerve can be mobilized. The tumor in Meckel's cave is removed. The main tumor feeders originated from the tentorial artery are commonly located medial to the orifice of Meckel's cave. They are coagulated after the trigeminal nerve is mobilized inferiorly.
  - 6) Removal of the tumor. Internal tumor decompression can be made using ultrasonic aspirator, without active bleeding from the tumor. The tumor attachment is gradually detached from the duramater. Margin of the tumor is retracted toward the tumor base with a tumor retractor, then the cranial nerves and arteries engulfed in the tumor appear in the surgical field. The tumor retraction makes dissection of cranial nerves and vessels easier, by increasing the peritumoral space and decreasing their overstretching. Possibility of the retraction technique may be one of the advantages of this approach (Fig. 4). Even if the tumor bulk is larger than the surgical field, it can be removed safely by this technique.

The abducens nerve, courses medial to the tumor, must be cared and separated from the tumor.

←

**Fig. 3. A** Right pyramid is exposed epidurally (cadaver). Greater superficial petrosal nerve (GSPN) is preserved by periosteal dura remaining on it. Trigeminal nerve is exposed for anatomical understanding. **B** Resection of petrous apex is medial to GSPN and arcuate eminence. **C** After incision of the dura and tentorium. The basilar trunk is seen. Trigeminal nerve can be mobilized by cutting the dura on the cave (dotted)



**Fig. 4.** Surgical illustration of right ATP. The tumor feeder (tentorial artery) is cut and trigeminal nerve is mobilized from the tumor. The tumor is decompressed and retracted toward the tumor attachment

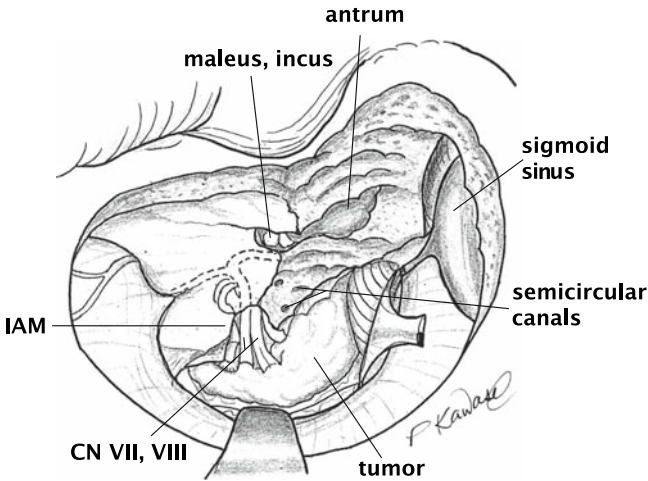
Presence or absence of encased brain stem perforators and tumor invasion into the cavernous sinus may influence on the tumor radicality. In case of perforator encasement, the tumor surface must be remained in 2–3 mm thickness. Amputation of the tentorial leaflets may increase the tumor radicality.

- 7) Closure of the dura is not possible, and CSF leakage is prevented by following double barrier technique:
  - (a) A piece of abdominal fat is transplanted on the exposed air cells of the pyramid and craniotomy and fixed with fibrin glue.
  - (b) The fat is wrapped with a pedicled temporalis fascia and the fascia is sutured with dura mater. Accumulated subdural air is removed to prevent pneumocephalus. The bone flap is replaced and fixed with titanium plates. Artificial bone is not necessary. A subcutaneous drain is inserted. The spinal drain tube is kept for a few days for emergency drainage in a case of CSF rhinorrhea.

## 2.2 Posterior transpetrosal approach

The patient is positioned laterally with the head rotated 20° prone. The upper body is elevated 20° to decrease venous congestion.

- 1) Craniotomy. A U-shaped scalp incision is made around auricle preserving a perocranial flap underneath. The craniotomy is made more posterior to that of the ATP, and partial mastoidectomy is made by drill thereafter until the sigmoid sinus is exposed (Fig. 5).
- 2) Petrosectomy. Mastoid air cells are drilled out until the antrum is opened. By further bone resection antero-medially the surgeon will



**Fig. 5.** Surgical illustration of cerebello-pontine angle tumor operated by PTP

meet a consistent bone which contains auricular organs, semicircular canal and labyrinth. Hearing preservation is depending on the resection of the organic bone or not. Location of the IAM is suspected medial to the anterior semicircular canal. It is safer to open the posterior wall and superior wall second to spare injury to the facial nerve. Never open the funds of IAM because the facial nerve courses superficially at this point. It is medial to the maleus, and the tympanic cavity can be opened to find the maleus.

- 3) Dural incision and tumor exposure. Method of the dural incision is similar to that of the ATP. The tentorial incision is made on the IAM, after double ligation of the superior petrosal sinus.

In the vestibular neurinomas, the facial nerve is widened and stretched. It commonly course on the anterior surface of the tumor being identified by the facila monitoring. In the case of CPA meningiomas, it is not rare to preserve hearing, and the auditory monitoring (ABR) should be prepared.

- 4) Closure. Even by using two layers, abdominal fat and pericranial flap, complete closure of CSF leakage cannot be achieved, and a small piece of fat is inserted in the orifice of Eustachian tube, located anterior to the maleus.

## CONCLUSIONS

By the two types of the transpetrosal approach, petroclival and CPA tumors can be removed without over retraction of the cerebellum, brain stem and



cranial nerves. However, those approaches need precise anatomical knowledge of the temporal bone, and operative training on cadaver is requested to the surgeon before operation.

## References

- [1] Al-Mefty O, Fox JL, Smith RR (1988) Petrosal approach for petroclival meningiomas. *Neurosurgery* 22: 510-517
- [2] Hakuba A, Nishimura S, Tanaka K, Kishi H, Nakamura T (1977) Clivus meningioma: six cases of total removal. *Neurol Med Chir* 17: 63-77 (in Japanese)
- [3] Kawase T, Shiobara R, Toya S (1991) Anterior transpetrosal-transtentorial approach for sphenopetro-clival meningiomas: surgical method and results in 10 patients. *Neurosurgery* 2: 869-876
- [4] Kawase T, Toya S, Shiobara R, Mine S (1985) Transpetrosal approach for aneurysms of the lower basilar artery. *J Neurosurg* 63: 857-867
- [5] Kawase T, Shiobara R, Ohira T, Kanzaki J, Toya S (1996) Developmental patterns and symptoms of petroclival meningiomas. *Neurol Med Chir* 36: 1-6
- [6] Shiobara R, Ohira T, Kanzaki J, Toya S (1989) A modified extended middle cranial fossa approach for acoustic nerve tumors. *J Neurosurg* 68: 358-365



**Takeshi Kawase**

Takeshi Kawase is Professor and Chairman of the Department of Neurosurgery, School of Medicine, Keio University, Tokyo, Japan. He was born in Tokyo in 1944, is married and has two sons. 1970, graduate Keio University, Tokyo; 1977, neurosurgical board; 1978, oriented to cerebrovascular diseases at Mihara Memorial Hospital; 1983, oriented to skull base surgery at Keio University; 1990, assistant professor, Keio University; 1996, professor and chairman, Keio University; 2001–2003, vice president of Keio University Hospital; 2002, chairman of the WFNS Committee of Skull Base Surgery; 2005, president of the 64th Annual JNS Congress. His hobbies are drawing and outdoor sports such as mountaineering, skiing, sailing, driving, and golf.

**Contact:** Takeshi Kawase, Department of Neurosurgery, School of Medicine, Keio University, 35 Shinanomachi, Shinjuku-ku, Tokyo 160-8582, Japan  
E-mail: kawase@sc.itc.keio.ac.jp

## **VASCULAR LESIONS**

---

# PRINCIPLES OF MICRONEUROSURGERY FOR SAFE AND FAST SURGERY

J. HERNESNIEMI

## INTRODUCTION

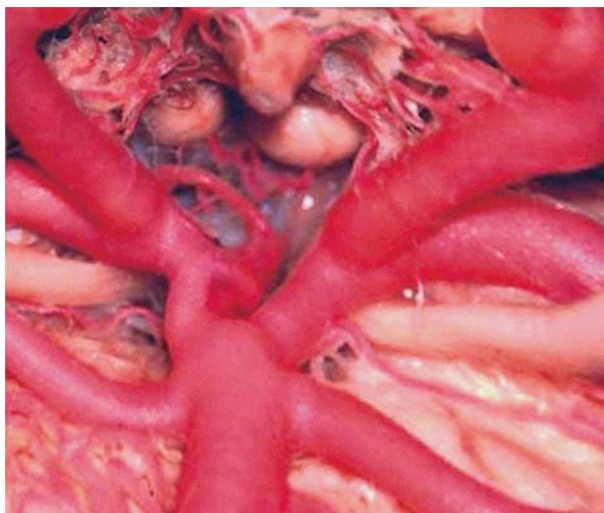
Microneurosurgical anatomy and principles of microneurosurgery are the essence of neurosurgical training. Apart from basic theoretical knowledge, a competent neurosurgeon should be trained to be capable of operating in small and often narrow and deep gaps. Their aim should be to perform minimally invasive procedures in almost bloodless fields. Prof. Yaşargil emphasized that profound knowledge of the microneurosurgical anatomy is acquired in cadaveric laboratories, and gentle handling of cerebral arteries and veins is acquired by performing microvascular anastomoses in rats and mice [11]. Both training facilities could be – admittedly with considerable effort – installed in many hospitals to support a variety of microsurgeons. However, cadaveric dissections may be deemed impossible for cultural, religious, economical, or other reasons (Fig. 1).

The training of residents is inevitably at odds with the precious operation room (OR) time better spent by senior neurosurgeons. Some senior neurosurgeons may wish to begin the operation, whereas in other practices, the residents routinely open under supervision. One learns to play violin only by playing. Watching the mentor's performance helps to create one's own mental framework on what is reasonable in the microneurosurgical anatomy of the skull and brain. The more one knows, the more one sees old and true wisdom. When one's own proprioception is forming, exchanging ideas and experience with others during training courses and visits is important – discussing and observing one's own videos are fruitful. Scrutinizing videos of experienced microsurgeons is extremely helpful; like a present to the younger generation [2]. And with recent technological advances it is even easier to obtain these multimedia training means online, when one is thousands of kilometers away.

This review of the basics is distilled from the Helsinki and Kuopio Neurosurgery practices in Finland, as well as from the author's experience of approximately 10,000 operations, and to encourage young neurosurgeons of the world – most of them working with limited resources – to continue to improve their microneurosurgical skills to best serve their patients.

---

*Keywords:* microneurosurgery, vascular malformations, aneurysms



**Fig. 1.** A beautiful cadaveric microdissection view from the posterior part of Circle of Willis

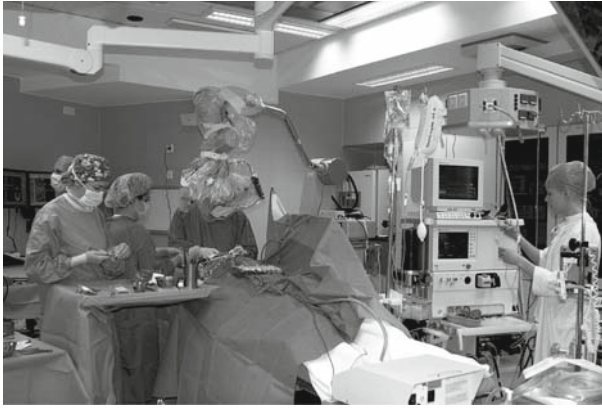## **OPERATION ROOM**

Professional team work is an essential part of microneurosurgical operations. All the members of the operating team should be well-trained and able to work in harmony. The architecture and design of the OR should be based on maximum usage of space despite the technical equipment. Real-time images from the microscope, endoscope, and operation light camera in properly placed monitors allow the staff, residents, medical students, and visitors to appreciate the teamwork and follow the steps of the surgery. The atmosphere of the OR should support the conduct of the surgery. Traffic in and out, irrelevant talking, and unnecessary noises must be avoided. The neurosurgeons in action may prefer minimal talking, just exchanging a few words on the anatomy in hand, and encouraging words when difficulties are anticipated. Intraoperative music should suit the entire team (Fig. 2).

In the event of an emergency, such as aneurysm rupture, all action in the OR should calm down to support the neurosurgeons.

### **1. POSITIONING**

Positioning is the first, and one of most important, steps in neurosurgical operations. Positioning of the patient should be planned by the surgeon, together with the other members of the team. Creating a comfortable and practical working positions for the neurosurgeons, anesthesiologist, and scrub nurse is of great importance. However, maximal moving ability for the oper-



**Fig. 2.** General view of an operation room in the newly renovated operation theatre in Helsinki with more than 3000 yearly operations

ating neurosurgeon should always be kept in mind. Protection of the eyes, nose, ears, skin, extremities, nerves, blood vessels, and airways must be routine. All pressure areas and vulnerable nerve compression points should be protected with cushions and pads. To facilitate venous outflow and reduce venous blood pressure and, obviously, to prevent venous oozing, the author recommends the patient's head be elevated approximately 20cm above the cardiac level. This principle is valid for most craniotomies, and is an effective way to have a clean and bloodless field. Accurately securing the patient's body and head provides the ability to quickly and safely tilt and/or rotate the operating table according to the surgeon's needs. The main principle in positioning of the head and body is to create a comfortable working angle (usually downward and somewhat forward) for the neurosurgeon. The head should be positioned so that gravitation helps to pull brain tissue away from the trajectory.

Positions used routinely in the practice of neurosurgery include supine, prone, semi-sitting, sitting, and lateral (park bench). However, these positions may be tailored and individualized for each patient, and according to localization and extent of the lesion and patient's medical status and general condition.

In the park-bench position for lateral posterior supratentorial and infratentorial approaches (used frequently by Dr. Drake), the upper shoulder is pulled away with strong adhesives to gain area, and spinal drainage (used routinely) helps produce a slack brain.

In the sitting position (e.g., in the supracerebellar infratentorial approach to the pineal region), the patient is secured by various cushions, the upper body by a vacuum cushion, and two fingers should fit between the manubrium and jaw to avoid too much flexion of the head. To prevent air embo-

lism, the patient should wear a G suit at a pressure of 30–40 cm H<sub>2</sub>O. Starting from the skin incision, all the veins should be coagulated meticulously and compression on the neck (jugular compression) may be a good way to demonstrate an open vein. Monitoring of the end-tidal CO<sub>2</sub> and Doppler is essential.

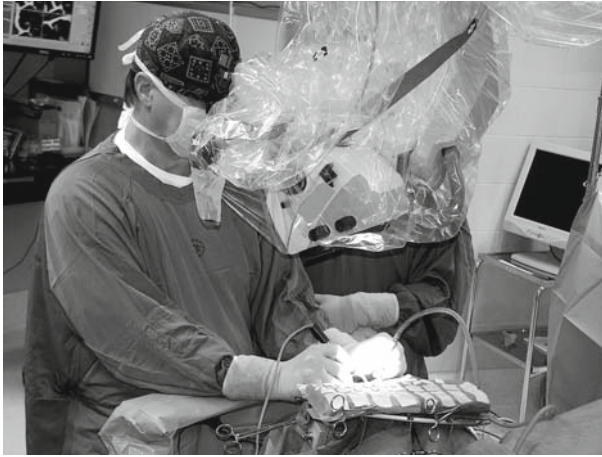
## 2. HEAD FIXATION

The patient's head should be fixed with three or four pins in a head frame. A Sugita head-fixation device is based on a four-pin fixation. It has the advantages of good skin and a muscle-flap-retraction system, as well as a system for brain retractors. This device is preferred in instances when a strong retraction of the skin-galea-muscle flap is needed or brain retractors are to be used. The Mayfield-Kees three-pin-head frame is more flexible with its one additional joint. This device is considered in the sitting, park-bench, and prone positions when linear skin incisions are used; here, a curved skin retractor is extremely useful.

No instruments or retractors should be constantly fixed immediately above the craniotomy, as they may accidentally cause injuries. Pin-fixation sites of the frames, as well as the arch and counter arch of the Sugita frame, should allow total access to the operative field and not prevent free movements of the neurosurgeon's hands, instruments, or the operating microscope. The position of the head should not compromise the arterial and venous flow in the neck. The head should not be turned too much, the cervical spine not positioned in extreme in any direction, and the trachea not overstretched or twisted. In temporal, parietal, and lateral occipital approaches, the park-bench position helps to avoid compression of the jugular veins. Fixation of the endotracheal tube by adhesives instead of a tape around the neck provides more safety during the positioning. After head fixation, further adjustments of the patient's position should be performed en bloc with the operation table.

## 3. NEUROSURGEON'S POSITION

After the patient is positioned and head and body fixed perfectly, the neurosurgeon should adjust his/her position continuously. To perform microneurosurgical operations in so-called "deep and narrow gaps," of vital importance is to have a good angle of vision. To have the maximum ability of being mobile around the operative field, the standing position is preferred by the author in majority of operations. The capability to use the mouthpiece effectively to focus and move the operation microscope to different directions should always be emphasized. Lifting or lowering and tilting of the operation table can provide further visual access to the operative field (Fig. 3). The neurosurgeon also may adjust the height by 3–4 cm by high-heeled clogs (by wearing them or not). Platforms are seldom necessary. Sitting might be more comfortable,



**Fig. 3.** Operating position preferred by the author. Using the mouthpiece to move the operating microscope, T-shape forearm support device and simultaneous performance of so-called “multifunctional right and left hands of the surgeon” are demonstrated

but reduces mobility. Sitting is preferable in certain instances; e.g., during the extracranial-intracranial bypass operations when the operative area is small and angle of vision does not have to be changed.

## **SURGERY**

### **1. NAVIGATION**

Preoperative planning and mental conduction of the entire procedure also should include ideas on unforeseen findings and occurrences – the art of dealing with them is achieved by experience. Cranial openings should be exactly placed and not larger than necessary, but sufficiently large to not endanger the safety of the operation. Neuronavigation is routine in many practices, and intraoperative imaging may become so in the future. However, it could be helpful to study the neuro-images carefully to identify landmarks such as the earlobes, coronal and lambdoid sutures,inion, sylvian fissure, central sulcus by the inverted omega hand area, confluens sinuum, straight and transverse sinuses, and others. However, neuro-navigators may not be available because they are too expensive for the institution. Quite frankly, to know neuro-anatomy well is by far more important than to own and use a navigator. Careful measurements among the landmarks, the lesion and intended trajectory can usually be transferred to the scalp with acceptable accuracy. Many approaches, such as the opening to the cerebral aneurysms and most extra-parenchymal brain tumors, are so dense with anatomical landmarks that no



neuronavigation is needed, just operative experience. With experience, the surgeon can go directly to the cerebral aneurysm without widely opening the sylvian fissure or other structures [3, 7, 10].

## **2. CRANIOTOMY**

The author's preference is to shave the scalp minimally and then wash and prepare it carefully. To reduce bleeding, infiltration of the incision line by a mixture of local anesthetic and vasoconstrictive agents is recommended. For more than 20 years, a single-layer flap is considered to be the most appropriate, especially for approaches to frontal and middle cranial fossae. This makes the procedure safe and fast, and results in no risks of temporal muscle atrophy or injury to the upper branch of the facial nerve. Furthermore, a good retraction system, such as Sugita frame fish hooks, provides a wide exposure of the sylvian fissure and skull base without large skull-base resections and, simultaneously, controls the scalp and muscle bleedings, which are swiftly dealt with by bipolar coagulation [3, 4].

It is possible to perform many craniotomies by only one burr hole and then to cut the bone flap with a craniotome. However, an additional burr hole may be necessary in the elderly in whom the dura can be adherent to the bone. A special curved dissector designed by our technician is useful for adequate dissection of dura. Detachment of the major dural sinuses can be achieved by placing the burr holes over them rather than laterally.

The author prefers high-speed electric microdrills because they are light, easy to use, fast, and safe. High-speed drilling is performed under the operating microscope. The burr is moved exactly by the right hand – some prefer both hands to avoid slipping – while controlled by proprioception, vision, and the right foot pedal. This interplay should be trained at cadaveric work. Important is to remove all coverings and cottonoids in and around the drilling area, as they can be caught by the drill and damage surrounding structures by windmill action. Only diamond-tipped burrs are used near eloquent structures. A bone-biting ultrasound aspirator is excellent for delicate removal of the skull base, and is safer than drilling.

Bleeding from the bone may be a problem while drilling. Drilling with diamond burrs without irrigation (hot drilling) controls such bleeding efficiently, but copious irrigation between drillings is necessary to avoid heat injury. Injection of fibrin glue or gelatin matrix–thrombin sealant also stops oozing. Injection of glue is the best and fastest way to stop some bleedings in the skull base or the cavernous sinus.

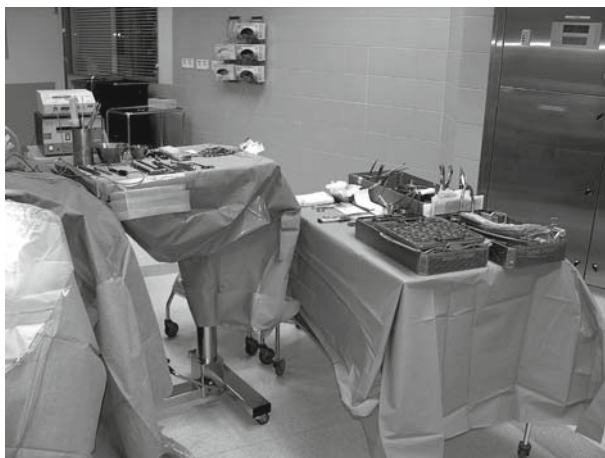## **3. OPERATING MICROSCOPE**

Stereoscopic vision, magnification, improved illumination, and counterweighted balance that allows the mouthpiece control constitute the es-

sential assets of the present operating microscope. The neurosurgeon also should be familiar with the common types of mechanical and electrical failures of his/her preferred microscope. Counter-weighting provides an essentially weightless optic unit of the microscope that can be effortlessly, continuously, and quickly moved, adjusted, and focused with the mouthpiece, as was originally designed by Prof. Yaşargil. Mouthpiece control efficiently eliminates interruptions and liberates both hands for continuous operative work, which results in smoother conduct of surgery and reduced operation time (see Fig. 3). Insulated, electrical-heating cables around the oculars prevent fogging of the oculars – a truly helpful device. After removal of the bone flap, everything should be performed under the operation microscope, from the high-speed drilling of the bone to the last stitch of the skin. For the residents-in-training, closing the entire craniotomy under the operation microscope is the most efficient way to become familiar with the microscope. Several supporting features can be added to the present microscopes such as the image guidance and display over the operative field, or the fluorescence-based angiography and resection control. These costly additions, however, also increasingly require special technical skills in the OR to adjust and maintain the machinery.

#### 4. MICROSURGICAL INSTRUMENTS

It should be emphasized again that a minimal array of microinstruments may reduce the number of instrument changes and operation time (Fig. 4). Some microinstruments have a single shaft (e.g., suction, dissectors), and others two



**Fig. 4.** Minimal array of microneurosurgical instruments reduces the number of changes and operation time

shafts (bipolar forceps and scissors), and also combined (Pernecky microinstruments). The bipolar forceps, suction, and dissector are the instruments used most frequently by most of the surgeons. The handle is designed to provide a steady and balanced grip. The two-shaft instruments, such as bipolar forceps and microscissors, are provided by a definite area to hold the instruments and control the opening and closure of the tips. The array of microinstruments should allow this hand position by various lengths such as very short, medium, long, and very long – more so with the two-shaft instruments. Fingertips should not obstruct the visual working channel. To minimize the fatigue and prevent the physiological tremor of the hands, use of mobile, bendable, and adjustable T-shaped forearm support designed by Prof. Yaşargil is highly recommended.

The bipolar forceps and suction are the multifunctional right and left hands of a right-handed neurosurgeon, respectively. The bipolar forceps can be used to dissect arachnoid planes, separate membranes, macerate tumor tissue inside solid tumors for suction, and even sharply cut glioma tissue when coagulation is applied. Malis forceps series are preferred by the author. These forceps are available in three to four different lengths, with two types of tips: sharp for delicate coagulation (Malis 20 or lower); and dissection and blunt for most of the work, stronger coagulation, manipulation of tumors, and coagulation of the aneurysm wall (Malis 25). Curved or angled-tip forceps are of assistance in awkward areas, such as the olfactory groove, or in cutting the tentorium or the falx. When coagulating small central nervous system vessels, it is important not to pinch them but to apply a delicate open-close and to-and-fro movement on the vessel trunk. This technique, together with the lowest effective coagulation power, copious irrigation, and careful cleaning of the tips by the scrub nurse, helps to prevent sticking of the tips. Swabbing the tips with glycerol when encountering small vessels in arteriovenous malformations may be helpful, and what is called “dirty coagulation” by using some brain tissue [8].

The suction is used for suction, retraction, and dissection. The distal shaft may gently retract the brain, cranial nerves, vessels, and aneurysms much more quickly than by adjusting self-retaining retractors. The strength of suction is controlled by sliding the thumb over the three holes in the handle. Mrs Dianne Yaşargil has introduced a suction tube pinch screw controlled by the scrub nurse. The OR staff also should be prepared to quickly adjust the strength of suction or run the second suction when needed. The suction tube should be of good-quality silicon rubber, light, and flexible so as not to disturb free movement of the left hand. Preferably, a set of suctions of three to four different lengths, each with two to three diameters, should be used. The tips of the suction should be checked regularly because drilling may cause sharp edges. The author’s usual saying is: “irrigation clears not only the operative area but also the operator’s mind.”

## 5. COTTONOIDS

Cottonoids – or superior future materials – are used to protect the cortex and brain tissue, cranial nerves, arteries, and veins, in particular, when suction is applied. The dura is opened under the operating microscope with a cottonoid between the cortex and short scissors. Cottonoids can be used as soft expanders of the sylvian fissure or the interhemispheric space, or between the cortex and dura. Small ones serve as dissectors to separate small arteries from adjoining structures (e.g., in aneurysm, cavernoma, or meningioma surgery).

During tumor debulking, large ones support the walls of tumor cavity while preventing venous oozing by compression. To control bleeding from small arteries or veins, a cottonoid is placed over the vessel under the suction tip, which clears the field for coagulation by bipolar forceps tips. The author prefers those without identification threads, which require careful removal before closure. A cottonoid left unnoticed between the cortex and dura may cause reactive masses that resemble meningioma in neuroimaging.

## 6. OPENING OF THE ARACHNOID AND BRAIN RETRACTION

Much of microneurosurgical dissection is performed sharply. A circular, semi-sharp arachnoid blade, such as that introduced by Prof. Yaşargil, is used by many neurosurgeons. In our hands, a pair of short jeweler's forceps has proved to be efficient in opening the most superficial arachnoid membrane around a tumor or over the sylvian fissure. Dissection of the arachnoid cannot be performed without a perfect knowledge of cisternal anatomy [11].

Water-jet dissection, as first introduced by Dr. Toth in Budapest [9], is less known, but is the most elegant and inexpensive technique in microneurosurgery. First, the arachnoid is penetrated while viewing the venous anatomy. Then saline is injected repeatedly into the subarachnoid space of the fissural anatomy by a hand-held syringe to expand it more widely. Water dissection has been used safely and routinely in the opening of the sylvian fissure and interhemispheric space, as well as in dissection of meningiomas, cavernomas, metastases, abscess walls, and large and giant aneurysms in thousands of patients.

When the neurosurgeon is well-trained to use the suction and bipolar forceps for gentle retraction of the brain, no other retractors are needed. First, the bipolar forceps is retracting for the suction to release cerebrospinal fluid, and then the suction tip is mainly retracting to make space for the bipolar forceps and other instruments. In experienced hands, left- and right-hand instruments constantly and unconsciously change roles as microretractors, according to the demands of the microneurosurgical anatomy in the hand. By changing the

retracting force between suction and forceps, one is going step-by-step (crawling), for example, under the frontal lobe. The bipolar forceps, when opened, can be used as a self-retaining retractor on the cortex protected by a cottonoid. Notably, the subtemporal approach toward a basilar tip aneurysm, for example, cannot be performed without self-retaining retractors and broad Aesculap-type retractors instead of the narrower Sugita-type retractors – the latter are preferred in other circumstances [4]. Brain injury caused by any retraction depends on the force, area of pressure, and time of exposure.

## CONCLUSIONS

While appreciating our own neurosurgical performance, the following questions may come in mind: Who are the most capable of clipping cerebral artery aneurysms of our wives or husbands, or of removing craniopharyngiomas of our children?

When unsure, you should go to the place where you want these operations to be done. Visiting other departments increases the collection of different techniques and tricks. Consider the population size that departments serve. Consider also the following questions: What happens in undeveloped countries where benign tumors may reach gargantuan sizes before diagnosis? What are the standards for outcome and acceptable risks of complications [5, 6]?

Microneurosurgery is indebted to those who are totally devoted to their work, but find time to share their experience with the next generation [1, 11]. modern microneurosurgery will increasingly cover huge populations, such as the mega-cities of China, and there will be considerable opportunities for experience in cases that Western departments encounter only a few times a year. A single idea to be adopted in the OR is worthy to bring one out of their world-wide, well-known center. Buy a flight ticket, west or east, to pick up good tricks from other places.

## Acknowledgments

The author thanks his own patients, staff, and the flow of critical fellows and visitors who have helped me to do better surgery with the rather moderate resources of a small country.

## References

- [1] Drake CG, Peerless SJ, Hernesniemi JA (1996) Surgery of vertebrobasilar aneurysms. London, Ontario experience on 1767 patients. Springer, Wien
- [2] Hernesniemi J (2001) Mechanisms to improve treatment standards in neurosurgery, cerebral aneurysm surgery as example. *Acta Neurochir Suppl* 78: 127-134

- [3] Hernesniemi J, Ishii K, Niemela M, et al. (2005) Lateral supraorbital approach as an alternative to the classical pterional approach. *Acta Neurochir Suppl* 94: 17-21
- [4] Hernesniemi J, Ishii K, Niemela M, et al. (2005) Subtemporal approach to basilar bifurcation aneurysms: advanced technique and clinical experience. *Acta Neurochir Suppl* 94: 31-38
- [5] Hernesniemi J, Koivisto T (2004) Comments on the impact of the International Subarachnoid Aneurysm Treatment Trial (ISAT) on neurosurgical practice. *Acta Neurochir (Wien)* 146: 203-208
- [6] Hernesniemi J, Niemelä M, Karataş A, et al. (2005) Some collected principles of microneurosurgery: simple and fast, while preserving normal anatomy: a review. *Surg Neurol* 64: 195-200
- [7] Kivisaari RP, Porras M, Öhman J, et al. (2004) Routine cerebral angiography after surgery for saccular aneurysms: is it worth it? *Neurosurgery* 55: 1015-1022
- [8] Kuhmonen J, Piippo A, Vaart K, et al. (2005) Early surgery for ruptured cerebral arteriovenous malformations. *Acta Neurochir Suppl* 94: 111-114
- [9] Nagy L, Ishii K, Karatas A, Shen H, Vajda J, Niemela M, Jaaskelainen J, Hernesniemi J, Toth S (2006) Water dissection technique of toth for opening neurosurgical cleavage planes. *Surg Neurol* 65: 38-41
- [10] Niemela M, Koivisto T, Kivipelto L, et al. (2005) Microsurgical clipping of cerebral aneurysms after the ISAT study. *Acta Neurochir (Suppl)* 94: 3-6
- [11] Yaşargil MG (1996) *Microneurosurgery*. Georg Thieme, Stuttgart



**Juha Hernesniemi**

Juha Hernesniemi is Professor and Chairman, Department of Neurosurgery, University Central Hospital of Helsinki, 1997–. He was born in a small village of Kannus, Finland, in 1947. High school in Ruovesi, Finland 1966, Medical school at the University of Zürich, Switzerland, Dr.med. Zürich 1973. Specialist in neurosurgery, Helsinki, 1979, Ph.D., Helsinki 1979. Associate Professor Kuopio 1987, Senior Physician and Co-Chairman Kuopio 1980–1997. Study periods at 20 foreign neurosurgical centers, including Profs. Yaşargil and Drake. Personal microsurgical experience: 10,000 operations including more than 3500 cerebral aneurysms and AVMS, more than 2500 brain tumors. Visiting Professor at many universities, more than 150 original articles, more than 100 reviews and text book chapters. Two short stories on childhood memories.

**Contact:** Juha Hernesniemi, Department of Neurosurgery, Helsinki University Central Hospital, Topeliuksenkatu 5, 00260 Helsinki, Finland  
E-mail: juha.hernesniemi@hus.fi

---

# SURGICAL MANAGEMENT OF INTRACRANIAL ANEURYSMS OF THE ANTERIOR CIRCULATION

C. RAFTOPOULOS

## INTRODUCTION

The international literature reports a prevalence of intracranial aneurysms (ICA) of around 1000 per 100,000 persons, with 85% of the ICA located on the anterior circulation around the circle of Willis, 45% of which are on the anterior communicating artery [3, 25]. The highest incidence of ICA in the population is at around 55–60 years of age.

The risk of an ICA rupturing is around 1% per year and so, ruptured intracranial aneurysms (RIA) have an incidence of around 10 per 100,000 population [9, 19]. The rupture rate increases from 0.05 to 10% depending on the size of the aneurysm, varies according to the location of the aneurysm with a higher risk for locations on the posterior communicating artery and the posterior circulation [25], increases in patients who have a history of smoking (relative risk: 1.5), and decreases with the patient's age. Active smoking seems to play even a more important role in the occurrence of RIA with an odds ratio of up to 5.0. RIA are 1.6 times more common in women than in men [9]. If not occluded, around 15% of these RIA will re-rupture within the first two weeks with 4% within the first 24 h leading to the patient's death in the majority of cases. Therefore, in case of rupture, an ICA should be occluded endovascularly or surgically within 72 h [5]. Despite improvement in all aspects of management, an RIA remains a "catastrophic" event with a poor outcome, i.e., death or significant neurological deficit, in about 75% of cases [5].

It is, therefore, important to be aware of the main risk factors for the presence of an unruptured intracranial aneurysm (UIA) [18]. Risk factors include: a positive family history (at least two first-degree relatives with a subarachnoid hemorrhage [SAH] gives a relative risk of 6.6); alcohol (relative risk of 300 g/week: 5.6); autosomal dominant polycystic kidney disease (relative risk: 4.4); hypertension (relative risk: 2.8); and smoking (relative risk: 1.5–5). In our unit, we suggest that all patients less than 65 years of age with a family history of RIA or autosomal dominant polycystic kidney disease should be screened for UIA. The alcoholic risk factor is much more difficult to evaluate and to apply.

---

*Keywords:* aneurysm, anterior circulation, microsurgery, vascular malformation



The physiopathology behind the formation of an ICA is complex but appears to be essentially acquired, with genetic and environmental factors [22]. ICAs are characterized anatomically by a partial or complete disappearance of the middle muscular layer. They often herniate into the subarachnoid spaces so that when they rupture they cause a subarachnoid hemorrhage (SAH). Sometimes ICAs are enclosed within the brain and will first be responsible for an intraparenchymal hematoma. Hemodynamic stresses play a particular role in the formation of ICAs especially at specific locations around the circle of Willis [22]: the anterior communicating artery accounting for 45% of all ICAs, the internal carotid artery 20%, and the middle cerebral artery 20%. ICAs can be associated with various diseases affecting tissue elasticity, including autosomal dominant polycystic kidney disease, fibromuscular dysplasia, Ehlers-Danlos syndrome type IV, and Marfan syndrome. Smoking also appears to be related to ICA occurrence and particularly to RIA occurrence in women. This associated risk seems to decrease rapidly with smoking cessation [2].

## **RATIONALE**

The history of the treatment of ICA, which now essentially comprises either coil embolization or surgical clipping, has been dominated by the work of just a few individuals. The major improvement in the surgical treatment of ICA came with introduction of the surgical microscope [5]. The first description of a microscope to help neurosurgeons in occluding ICA was made by Pool and Colton in 1966, but it was Yaşargil who really developed the technique providing exhaustive accounts of his experiences in a series of publications [7, 26–29]. Coil embolization with electrothombosis and coil electrolytic detachment was first reported by Guglielmi in 1991 and represented the second revolution [6] in the treatment of ICA but further discussion of this technique falls outside the scope of this chapter.

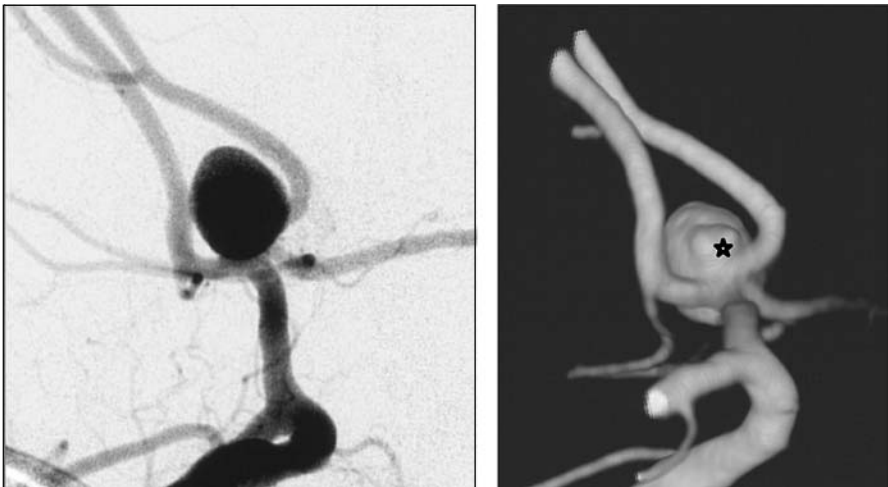
For optimal surgical management of ICA, three areas must be extensively studied and mastered. The first area is the surgical anatomy of the intracranial vessels and their surroundings, a good knowledge of which is an absolute prerequisite for managing ICA. Here, atlases of clinical brain-anatomy and, in particular, those written by Yaşargil or Lang focusing on the skull base and its related structures, provide a major source of information [8, 27]. The second area which must be watched and studied is the international literature focusing on the surgical treatment of ICA, in particular publications dealing with the surgical technique of ICA occlusion, wrapping or bypass [4, 7, 12, 21, 28, 29]. The third area is modern imaging techniques for ICA, in particular 3D rotational angiography and an original software with an adapted hardware, named Dextroscope (Volumes Interactions, Bracco, Singapore). The Dextroscope allows the user to see a 3D virtual reality multimodal head with its intracranial vessels, the brain and the skull base in whatever surgical position the

neurosurgeon chooses. This interactive technology enables neurosurgeons to perform as many virtual neurosurgical approaches as they want, thus preparing themselves for the different structures and particular orientation of these structures that may be met during the surgical procedure.

A good knowledge of various aspects of vascular-related neurophysiology is also required. One of the most important facets is a correct understanding of the literature dealing with the brain ischemia process so that the key technique of temporary clipping of a parent vessel can be used appropriately [12]. The vascular neurosurgeon should also be aware of the neurophysiology behind arterial vasomotor function and the inflammatory reaction involved in SAH vasospasm with its highest risk between the 3rd and 10th day post-rupture.

## DECISION-MAKING

The first step leading to diagnosis of an ICA is often clinical. For UIA, we distinguish three types of situation: incidental, symptomatic, or associated with a previous RIA. The discovery of incidental ICA is currently made by computed tomography (CT) or magnetic resonance (MR) angiography when investigating headaches, associated diseases or a positive family history of ICA. Symptomatic UIA can be associated either with a mass effect syndrome on a second or third cranial nerve or a transient ischemic stroke related to emboli originating from within the ICA. These symptoms support treatment of the related UIA. For RIA, the main symptom is an explosive – “as never

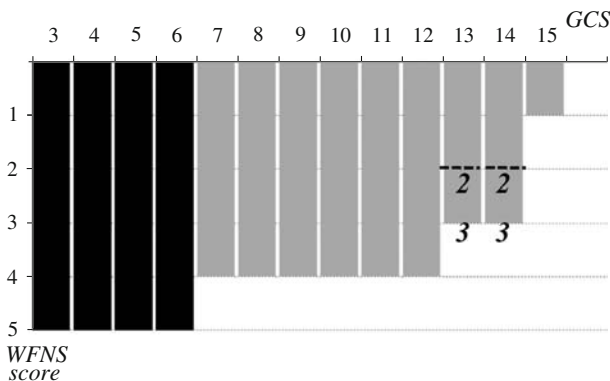


**Fig. 1.** Anterior communicating artery aneurysm showed by a catheter and a 3D angiograms. Note that the 3D angiogram shows additional details as the presence of two ecstasies (\*)

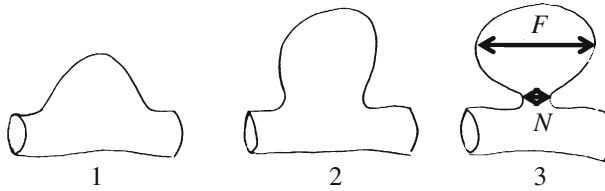
before” – headache often followed by a meningeal syndrome. When the first rupture remains minimal, it can go unrecognized and followed later by a massive catastrophic hemorrhage. This first minimal hemorrhage is appropriately called “warning leak” and must be early recognized [5]. For RIA, we use a clinical score, the World Federation of Neurological Surgeons (WFNS) score, which is based on the Glasgow Coma Scale score (Fig. 1).

When a SAH is suspected, a CT scan should be performed first and two features evaluated. The first feature is the quantity of blood in the subarachnoid spaces, associated or not with blood in the ventricular system or in the brain itself. The quantity of blood is scored according to the *Fisher scale*: Grade I, no blood; grade II, blood in the subarachnoid spaces with a thickness of less than 1 mm; grade III, blood thickness equal to or greater than 1 mm; grade IV, intraparenchymal clot or intraventricular clot without or with little blood in the subarachnoid spaces. The presence of blood in the lateral ventricles represents an additional risk for developing vasospasm with cerebral ischemia (odds ratio: 4.1). The second feature which must be evaluated is the presence of acute hydrocephalus which can be subtle in the first few hours and occurs in about 20% of RIA. Late identification of this complication can be fatal.

The next step in a patient with a SAH is to assess the underlying cause using one of the following three techniques: CT angiography, MRI angiography, or the gold standard, catheter angiography. Currently, all our patients undergo at least catheter angiography with 3D rotational angiography (Fig. 1), the results of which are introduced into the Dextroscope to give the neurosurgeon a 3D view of the aneurysm from different possible surgical positions. Preoperative assessment is based on clinical staging using the WFNS scale (Fig. 2) after a period of clinical stabilization, in particular after placement of ventricular drainage in cases of acute hydrocephalus.



**Fig. 2.** World Federation of Neurosurgical Societies (WFNS) score for subarachnoid hemorrhage (SAH). This score is based on the Glasgow Coma Scale (GCS, 15 to 3). There are 5 possible WFNS scores, five being the worst. The WFNS score is 3 when there is a motor deficit



**Fig. 3.** Fundus-to-neck (F/N) ratio. Coil embolization is recommended for case 3 with a  $F/N \geq 2.5$ . Surgical clipping is recommended for cases 1 and 2

In the 21st century, all ICAs should be managed in centers with a multidisciplinary team, including at least an interventional radiologist and a vascular neurosurgeon. For UIA, we inform the patient about the controversy surrounding whether or not to treat such aneurysms, particularly those smaller than 7 mm [1, 10, 24]. However, in my group, we recommend treatment in all patients less than 65 years of age or if there is an associated risk, such as a previous RIA, a family history, or an associated disease, such as autosomal polycystic kidney disease. For RIA, we nearly always recommend immediate treatment at least by coil embolization to occlude the aneurysm fundus. The treatment we recommend follows the following algorithm: coil embolization is considered first for all ICAs not associated with an intraparenchymal hematoma and with a fundus-neck (F/N) ratio equal to or greater than 2.5 (Fig. 3) or located on the posterior circulation or for a patient with a poor WFNS score of 4 or 5. If there is an intraparenchymal hematoma or if the endovascular approach is deemed too difficult by the interventional radiologist (tortuous vessels, atheromatosis or fibromuscular dysplasia), if the aneurysm neck is 4 mm or more and not controllable by a stent, or if the F/N ratio is  $<2.5$  for an anterior circulation aneurysm, surgical clipping is recommended. In patients with poor aneurysm geometry for embolization, especially in those with a poor clinical state (WFNS 4 or 5), we recommend at least a partial endovascular occlusion, followed by surgical clipping if necessary when the patient has recovered. Clip placement is also recommended where embolization has resulted in incomplete occlusion with increasing size of residual aneurysm six months or more after the endovascular procedure [17]. The residual aneurysm must be large enough to allow the placement of a clip.

## SURGERY

### 1. PREOPERATIVE CARE

The day before surgery, all patients have three shampoos with a 7.5% iodine solution, receive a laxative and start to wear Kendall socks (Tyco Healthcare Group). To reduce the risk of developing vasospasm, patients with SAH are

given nimodipine, a dihydropyridine calcium channel blocker, orally, if necessary through a nasogastric tube.

## 2. PROCEDURE

Our equipment for surgical clipping is essentially composed of a balanced microscope (OPMI Pentero, Zeiss), a high speed drill motor with curved tubes (Midas Rex, Medtronic), bipolar forceps with integrated water irrigation (Codman, Johnson and Johnson), Rhoton micro-instruments (Aesculap), and Perneczky clips, made initially by von Zeppelin and now by Adeor (Adeor Medical Technologies) [13]. The revolutionary design of these clips with the forceps passing inside the clip's posterior branches allows the surgeon to have a much better view of the aneurysm morphology and its surroundings and improved possibilities of using temporary clips and of removing the clips to relocate them in a better position.

For brain protection during surgery, all patients are kept normotensive, mildly hypothermic (32–33°C) and with a burst-suppression EEG. In a RIA, we also ask for cerebro-spinal fluid lumbar drainage and perfusion of an osmotic agent before opening the dura mater.

The majority of ICA of the anterior circulation are accessed by a pterional approach avoiding the fronto-temporal branch of the facial nerve [29]. The skull opening of 4–5 cm in diameter is perfectly centered on the sphenoid ridge for middle cerebral artery or internal carotid artery aneurysms. In anterior communicating artery aneurysms, the bone flap is extended slightly onto the frontal area just above the frontal crest. Using this approach, it is essential that the lateral part of the sphenoid ridge is completely removed to minimize brain retraction.

Once the dura mater is opened, we protect the cortex around the lateral fissure with an oxidized cellulose hemostat, such as Surgicel (Ethicon, Johnson and Johnson), and cottonoids and open the lateral fissure using a surgical blade to access the subarachnoid spaces. We then progress inside the lateral fissure separating the frontal lobe from the temporal lobe using forceps and micro-scissors to cut the arachnoid adhesions. A maximum of these arachnoid adhesions must be cut to allow gentle minimal retraction of the frontal and temporal lobes without impeding the brain microcirculation. Perfect hemostasis, in particular of venous origin, must be achieved and maintained.

Once the dissection approaches the ICA, the neurosurgeon will determine, depending on various factors, including experience, the type of ICA, and the existence of a SAH, whether or not to temporarily occlude the parent vessel(s). Our *protocol* for temporary occlusion is the following: less than 10 min for patients in mild hypothermia and with burst-suppression EEG; if any additional temporary occlusion is required, we always use a reperfusion period of at least 5 min between two temporary arterial occlusions of less than 10 min [14–17]. So far, using that protocol, no patient developed any perma-

nent deficit related to parent vessel temporary occlusion. In presence of an ICA impacted into the brain, we perform a delicate subpial dissection most of the time under temporary occlusion. To facilitate clip placement, we frequently reshape the aneurysm and its neck by using *mild electrocoagulation*, always under temporary parent vessel occlusion to avoid aneurysm rupture. Once the aneurysm neck is perfectly visible and separated from all surrounding vessels, the most suitable Perneczky clip is chosen.

In unclippable aneurysms, such as, for example, blister aneurysms, we try to use a *wrap-clip technique* consisting of a piece of knitted fabric (knitted polyester with bovine collagen, Hemashield, Boston Scientific, USA) wrapped around the aneurysm and its parent vessel and fixed tightly using a clip. If this technique is not possible because of efferent vessels or the depth of the operating field, we then use small elongated pieces of cotton placed around the aneurysm and the parent vessel. This last procedure should only be used in exceptional circumstances due to its undemonstrated efficacy.

Once the clip is placed on the aneurysm's neck, we check that no small vessels are compromised by the clip, that the aneurysm is completely occluded, and, finally, that the parent vessel retains a normal diameter. For this check, a small Zini mirror is sometimes used which allows the neurosurgeon to examine hidden aspects of the aneurysm's neck. For ICA with a large neck, for large or giant ICA, and for ICA located in the paracaloid area, somatosensory evoked potentials are used [17]. Stable somatosensory evoked potentials for more than 10 min are always used to check the adequate vascularization of the explored area. So far, we have never used intraoperatively Doppler, catheter angiography or indocyanine green video angiography.

In patients with an SAH, we remove as much blood as possible. To wash the subarachnoid spaces at the end of surgery we use at least one liter of physiologic solution. For about 10 years from 1996, we administered 2 mg tissue plasminogen activator (tPA) through a lumbar intrathecal catheter every 12 h, for a maximum of 4 days, and 4 mg into the peri-aneurysmal area just before wound closure. tPA was used only if there was no intraparenchymal hematoma or another unsecured UIA. Unfortunately, the price of this drug and the lack of incontrovertible data to support its use in such conditions led us to abandon it even though our positive experience favored another randomized controlled study.

Closure is an essential aspect of surgery, particularly from an esthetic point of view. Particular attention is taken to perfectly fix the bone flap and to replace all the bone that has been removed with a methyl-methacrylate cement and to perform a perfect muscle reinsertion.

### 3. POSTOPERATIVE CARE

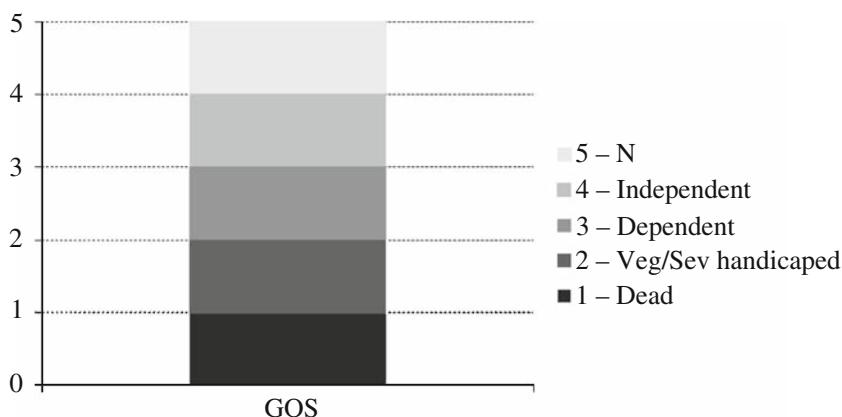
The postoperative care period is dominated by maintaining a normal circulating blood volume with a normal arterial blood pressure and by monitoring

for potential complications, such as vasospasm or chronic hydrocephalus. If the patient is receiving nimodipine, this can induce hypotension which must be corrected immediately. In the presence of clinical vasospasm confirmed by Doppler (positive predictive value: 63%) or perfusion CT with CT angiography (positive predictive value: 90%), triple-H therapy is implemented. If the clinical signs do not resolve with treatment, catheter angiography should be performed, followed by angioplasty if possible and by injection of papaverine when necessary.

In case of chronic hydrocephalus, we first try to control it by performing three lumbar punctures on consecutive days, removing 40 ml of cerebrospinal fluid each time. If this treatment is not sufficient, we place a ventriculo-peritoneal drainage under neuronavigation.

#### 4. RESULTS

The short-term results after surgical clipping of ICA are summarized in Fig. 5. Regarding UIA, we have just reported our experience (two centers: St-Luc, Brussels and Bicêtre, Paris) with 238 UIA in 176 patients (only one on the posterior circulation): all patients in this group achieved a good Glasgow Outcome Score (grade IV or V, Fig. 4) with only 1.7% having *slight* permanent morbidity and no mortalities. When considering permanent morbidity, Solomon reported a rate of 0% for small aneurysms and of 6% for large ones [20]. In our series, 25% of the 238 UIA were large or giant and their surgical treatment was not associated with permanent morbidity. For RIA, we published a preliminary personal series in 2000 of 26 consecutive RIA deemed not accessible to coil embolization: in 81% of the cases a good GOS was achieved and in 89% there was complete aneurysm occlu-



**Fig. 4.** Glasgow Outcome Scale. Outcome scale with five scores. A score of five corresponds to a normal clinical status. Score of two corresponds to severe (sev) handicap or a vegetative state

	UIA	RIA	
n	238 <sup>a</sup>	141 <sup>b</sup>	1055 <sup>c</sup>
Good GOS (%)	100	74.5	69
CO (%)	95	90.8	82
Near CO (%)	2.5	6.3	12

**Fig. 5.** Short-term results after surgical clipping. <sup>a</sup> 238 unruptured intracranial aneurysms (UIA) in 176 patients as reported by Aghakhani et al. in 2008. <sup>b</sup> Number of ruptured intracranial aneurysms (RIA) clipped between 1996 and 2007 in St-Luc University Hospital Brussels by myself or my senior collaborator, Dr G. Vaz. <sup>c</sup> Number of RIA surgically clipped and reported by the International Subarachnoid Trial (ISAT) in 2005. Good GOS: Glasgow Outcome Scale score of 5 or 4. CO Complete occlusion. Near CO Nearly complete occlusion, i.e., residue less than or equal to 5% of the initial aneurysm volume

sion [16]. This series has now expanded to include 141 RIA deemed not accessible to an endovascular procedure and thus surgically more difficult; our results (two neurosurgeons) show a good GOS in 74.5% with aneurysm complete occlusion in 90.8% and near complete occlusion in 6.3% (Fig. 5). We stress that the rate of good outcome for patients with a good pre-operative clinical grade (WFNS 1-3) was even better at 88%. In 2005, the International Subarachnoid Aneurysm Trial (ISAT) reported on the surgical treatment of 1555 RIA with 69% good GOS and a lower rate of complete aneurysm occlusion of 82% [11].

Considering the long-term results obtained with surgical clipping of ICA (Fig. 6), in 2001, Tsutsumi et al. reported on 112 clipped ICAs with a

	Tsutsumi et al. (2001)
n	112
If CO	2.4%
If NCO	7.1%
De novo	8%

**Fig. 6.** Long-term results after surgical clipping. Percentage of aneurysm regrowth at a mean interval of 9 years after surgery. In a series of 112 patients with a clipped aneurysm, the rate of regrowth depends on the quality of clipping occlusion. In complete occlusion (CO), the rate of regrowth was 2.4%. In nearly complete occlusion (NCO), the rate of regrowth was 7.1%



mean interval from surgery of nine years. These authors observed a 2.4% rate of regrowth for completely occluded ICA, 7.1% regrowth for nearly completely occluded ICA, and 8% de novo ICA [23].

## HOW TO AVOID COMPLICATIONS

The best way to avoid complications in the surgical treatment of ICA is first to acquire enough experience in brain surgery and particularly in vascular neurosurgery. In the 21st century, surgical ICA should only be treated by brain neurosurgeons with enough experience in vascular neurosurgery. The second essential requirement is the existence of a multidisciplinary group comprising an (preferably two) interventional radiologist(s) and a (preferably two) vascular neurosurgeon(s). Neuro-anesthesiologists, critical care physicians and nurses specially trained in the management of this very challenging pathology should also be involved.

## CONCLUSIONS

In 2008, we believe that surgical clipping remains the gold standard treatment for ICA of the anterior circulation with a F/N ratio <2.5, especially in young patients without SAH or with a good preoperative clinical grade.

## References

- [1] (1998) Unruptured intracranial aneurysms – risk of rupture and risks of surgical intervention. International study of unruptured intracranial aneurysms investigators. *N Engl J Med* 339: 1725-1733
- [2] Anderson CS, Feigin V, Bennett D, Lin RB, Hankey G, Jamrozik K (2004) Active and passive smoking and the risk of subarachnoid hemorrhage: an international population-based case-control study. *Stroke* 35: 633-637
- [3] Atkinson JL, Sundt TM Jr, Houser OW, Whisnant JP (1989) Angiographic frequency of anterior circulation intracranial aneurysms. *J Neurosurg* 70: 551-555
- [4] Deruty R, Dechaume JP, Lecuire J, Bret P, El OA (1976) Microsurgical treatment of a series of intracranial subtentorial arterial aneurysms. *Neurochirurgie* 22: 227-238
- [5] Drake CG (1981) Progress in cerebrovascular disease. Management of cerebral aneurysm. *Stroke* 12: 273-283

- [6] Guglielmi G, Vinuela F, Dion J, Duckwiler G (1991) Electrothrombosis of saccular aneurysms via endovascular approach. Part 2: Preliminary clinical experience. *J Neurosurg* 75: 8-14
- [7] Kraysenbuehl HA, Yaşargil MG, Flamm ES, Tew JM Jr (1972) Microsurgical treatment of intracranial saccular aneurysms. *J Neurosurg* 37: 678-686
- [8] Lang J (1995) Skull base and related structures. Schattauer, Stuttgart
- [9] Linn FH, Rinkel GJ, Algra A, van GJ (1996) Incidence of subarachnoid hemorrhage: role of region, year, and rate of computed tomography: a meta-analysis. *Stroke* 27: 625-629
- [10] Mitchell P, Gholkar A, Vindlacheruvu RR, Mendelow AD (2004) Unruptured intracranial aneurysms: benign curiosity or ticking bomb? *Lancet Neurol* 3: 85-92
- [11] Molyneux A, Kerr R, Stratton I, Sandercock P, Clarke M, Shrimpton J, Holman R (2002) International subarachnoid aneurysm trial (ISAT) of neurosurgical clipping versus endovascular coiling in 2143 patients with ruptured intracranial aneurysms: a randomised trial. *Lancet* 360: 1267-1274
- [12] Ogilvy CS, Carter BS, Kaplan S, Rich C, Crowell RM (1996) Temporary vessel occlusion for aneurysm surgery: risk factors for stroke in patients protected by induced hypothermia and hypertension and intravenous mannitol administration. *J Neurosurg* 84: 785-791
- [13] Perneczky A, Fries G (1995) Use of a new aneurysm clip with an inverted-spring mechanism to facilitate visual control during clip application. Technical note. *J Neurosurg* 82: 898-899
- [14] Raftopoulos C (2005) Is surgical clipping becoming underused? *Acta Neurochir (Wien)* 147: 117-123
- [15] Raftopoulos C, Goffette P, Vaz G, Ramzi N, Scholtes JL, Wittebole X, Mathurin P (2003) Surgical clipping may lead to better results than coil embolization: results from a series of 101 consecutive unruptured intracranial aneurysms. *Neurosurgery* 52: 1280-1287
- [16] Raftopoulos C, Mathurin P, Boscherini D, Billa RF, Van BM, Hantson P (2000) Prospective analysis of aneurysm treatment in a series of 103 consecutive patients when endovascular embolization is considered the first option. *J Neurosurg* 93: 175-182
- [17] Raftopoulos C, Vaz G, Docquier M, Goffette P (2007) Neurosurgical management of inadequately embolized intracranial aneurysms: a series of 17 consecutive cases. *Acta Neurochir (Wien)* 149: 11-19
- [18] Rinkel GJ (2005) Intracranial aneurysm screening: indications and advice for practice. *Lancet Neurol* 4: 122-128

- [19] Schievink WI (1997) Intracranial aneurysms. *N Engl J Med* 336: 28-40
- [20] Solomon RA, Fink ME, Pile-Spellman J (1994) Surgical management of unruptured intracranial aneurysms. *J Neurosurg* 80: 440-446
- [21] Spetzler RF, Carter LP (1985) Revascularization and aneurysm surgery: current status. *Neurosurgery* 16: 111-116
- [22] Stehbens WE (1989) Etiology of intracranial berry aneurysms. *J Neurosurg* 70: 823-831
- [23] Tsutsumi K, Ueki K, Morita A, Usui M, Kirino T (2001) Risk of aneurysm recurrence in patients with clipped cerebral aneurysms: results of long-term follow-up angiography. *Stroke* 32: 1191-1194
- [24] Weir B (2002) Unruptured intracranial aneurysms: a review. *J Neurosurg* 96: 3-42
- [25] Wiebers DO, Whisnant JP, Huston J III, Meissner I, Brown RD Jr, Piepgras DG, Forbes GS, Thielen K, Nichols D, O'Fallon WM, Peacock J, Jaeger L, Kassell NF, Kongable-Beckman GL, Torner JC (2003) Unruptured intracranial aneurysms: natural history, clinical outcome, and risks of surgical and endovascular treatment. *Lancet* 362: 103-110
- [26] Yaşargil MG (1996) Clinical considerations, surgery of the intracranial aneurysms and results. Georg Thieme, Stuttgart
- [27] Yaşargil MG (1996) Microsurgical anatomy of the basal cisterns and vessels of the brain. Georg Thieme, Stuttgart
- [28] Yaşargil MG, Fox JL (1975) The microsurgical approach to intracranial aneurysms. *Surg Neurol* 3: 7-14
- [29] Yaşargil MG, Reichman MV, Kubik S (1987) Preservation of the frontotemporal branch of the facial nerve using the interfascial temporalis flap for pterional craniotomy. Technical article. *J Neurosurg* 67: 463-466



### **Christian Raftopoulos**

Christian Raftopoulos is chairman of the new Department of Neurosurgery of University Hospital St-Luc in Brussels. Born in Africa (in former Belgian Congo) in 1958 (Belgium mother, Greek father). From 1978 to 1980, student-researcher in the neuroanatomy laboratory of Prof. M. Gerebtzoff (University of Liège, Belgium). 1983, diploma of medical doctor (University of Liège). 1989, diploma of neurosurgery (Free University of Brussels). 1994, Ph.D. in neurosurgery related to the normotensive hydrocephalus (Free University of Brussels). 1998, first implantation of a self-sizing cuff electrode around a human optic nerve. 1999, Mont Blanc summit climbing. 2000, full academic professor at the Université Catholique de Louvain. 2000 to 2006, General Secretary of the Société de Neurochirurgie de Langue Française. 2002, opening presentation at the American Association of Neurological Surgeons (Chicago, USA) about the surgical management of intracranial aneurysms. 2003, nominated as Master Neurosurgeon by the Congress of Neurological Surgeons (USA). 2005, co-director of the Center for Management of Pharmacological Refractory Epilepsy at the Université Catholique de Louvain. 2006, co-developer of a new operative suite with an intraoperative MRI at 3.0 T. 2007, creation of a surgical planning laboratory (Radionix, BrainLab, Dextroscope).

**Contact:** Christian Raftopoulos, Neurosurgical Department, Clinique Universitaire Saint Luc, Université Catholique de Louvain, Av. Hippocrate 10, 1200 Brussels, Belgium  
E-mail: christian.raftopoulos@uclouvain.be

---

# INTRACRANIAL ANEURYSMS IN THE POSTERIOR CIRCULATION

K. LINDSAY

## INTRODUCTION

Aneurysms of the posterior circulation have always proved a challenge to the neurosurgeon. In 1948, Schwartz reported a successful trapping of a large basilar artery aneurysm, but Drake, in 1961 was the first to report direct surgical repair of a ruptured basilar aneurysm in 4 patients [6]. He concluded that “direct surgical attack was feasible and worthwhile under exceptional circumstances, when life was threatened by repeated haemorrhages”. With the introduction of the operating microscope, improved micro-instruments and clips and advances in neuro intensive care, surgical repair of such aneurysms became the accepted norm, but outcome figures for repair of basilar tip and trunk aneurysms were always worse than for repair of aneurysms in the anterior circulation. As a result, with the introduction of coil embolisation in the 90s, early series of endovascular treatment always included a high proportion of posterior circulation aneurysms. In many centres (including Glasgow) an endovascular approach has become the first line of treatment for such aneurysms and standard coiling has been supplemented by the possibility of balloon remodelling or stenting. Despite this management approach, a proportion of the patients still require direct surgical repair due to technical failure or repeated coil impactions.

## RATIONALE

The International Study of Unruptured Intracranial Aneurysms (ISUIA) found that posterior circulation aneurysms are more likely to rupture than those in the anterior circulation [11]. Over a five year period, aneurysms over 6 mm diameter carry at least a 15% risk of rupture. This compares to 2.6% for those in the anterior circulation.

If rupture occurs, the chance of sudden death from a ruptured posterior circulation is double that of anterior circulation aneurysms and a smaller proportion of patients reach a neurosurgical unit. A community-based study reported that posterior circulation aneurysms constitute 18% of all docu-

---

*Keywords:* aneurysms, posterior circulation, vascular malformations, micro-surgery

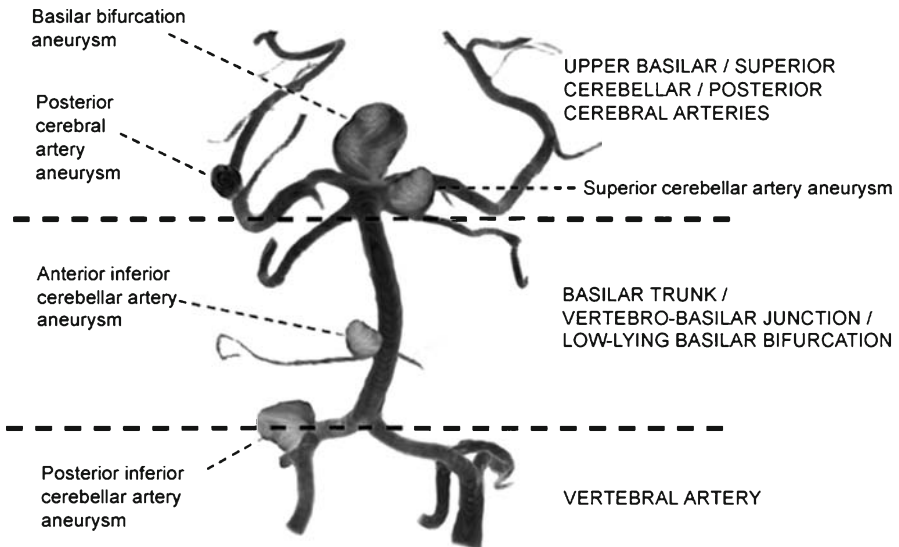
mented ruptured aneurysms, whereas in hospital based studies the instance of posterior circulation aneurysms varies from about 5 to 10% [9].

The goal of aneurysm repair, whether for ruptured or for unruptured aneurysms is to obliterate the aneurysm fundus and to preserve flow in adjacent vessels. For posterior circulation aneurysms, particularly those around the basilar tip, preservation of the thalamo-mesencephalic perforators is crucial.

## DECISION-MAKING

A wide variety of operative approaches exist and the surgeon must select the most appropriate for the aneurysm site and size. An angiogram combined with bone imaging reveals important anatomical features, of value not only in determining the optimal approach but also in indicating the operative risks. Note the height of the aneurysm neck in relation to the posterior clinoids and the size and direction of the aneurysm fundus. Rotation of a 3-D digital or CT angiographic image provides an ideal method of assessing the width of the aneurysm neck and the optimal direction of clip application. Selection of approach also depends on the preference and individual experience of the surgeon.

In considering the optimal approach it is convenient to subdivide posterior circulation aneurysms into three sites (Fig. 1).



**Fig. 1.** Sites of posterior circulation aneurysms: three levels for operative approach

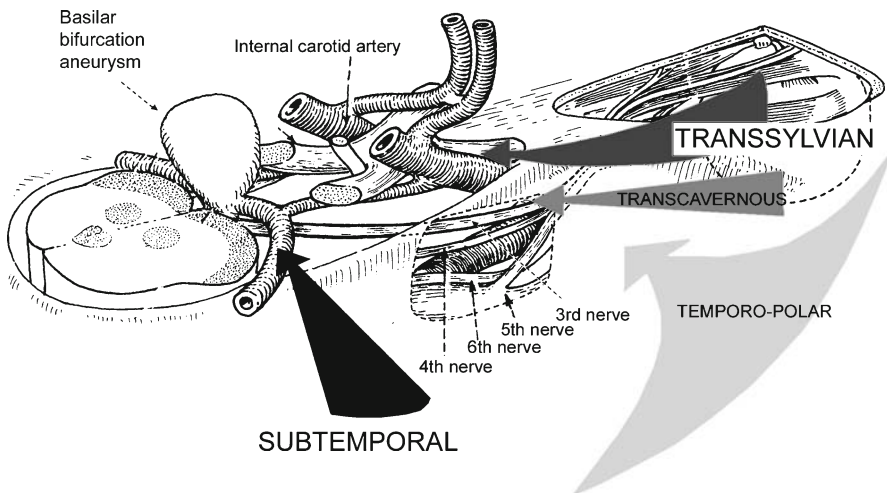
## 1. UPPER BASILAR/SUPERIOR CEREBELLAR/POSTERIOR CEREBRAL ARTERIES

### 1.1 Basilar bifurcation aneurysms

Operative repair at this site risks damage to perforators supplying the mid-brain and thalamus. These arise from  $P_1$ , a few millimetres from the bifurcation but some may arise directly from the basilar artery and adhere to the posterior surface of the fundus.

The *subtemporal approach* described by Drake [7] is particularly suited for posteriorly projecting or low lying basilar bifurcation aneurysms (Fig. 2). Posteriorly projecting aneurysms carry a greater risk of operative complications because of the direct relationship with the perforating vessels; for these aneurysms a subtemporal approach improves visualisation and provides the safest approach. The wider the aneurysm neck, the greater the need to clip the aneurysm parallel to the plane of the adjacent vessels, particularly if the neck engulfs part of the posterior cerebral artery. This is only feasible with the subtemporal approach. Note the height of the neck in relation to the posterior clinoid. The higher the basilar bifurcation, the greater the amount of temporal lobe retraction required if the subtemporal approach is used.

The *transylvian pterional approach* favoured by Yaşargil et al. [12] reduces such retraction, but access may still be difficult for aneurysms lying >10 mm above the posterior clinoids particularly if the internal carotid artery is also short (<10 mm) (Fig. 2). In such instances removal of the zygoma with



**Fig. 2.** Approaches to basilar bifurcation aneurysms (Adapted from Lindsay and Bone. *Neurology and Neurosurgery Illustrated*, 4th edn. Churchill Livingstone)

or without the lateral orbital margin may permit a steeper trajectory with less retraction. The transsylvian pterional approach also provides good exposure of both posterior cerebral vessels, but has the disadvantage of preventing direct visualisation of the perforators lying behind the aneurysm fundus. This route has the added advantage of permitting clipping of any anterior circulation aneurysms on the same side, but aneurysms arising at either the posterior communicating or anterior choroidal origins may hinder access to the basilar bifurcation.

The *temporo-polar approach* or “half and half” approach combines both routes. By changing the direction of temporal lobe retraction, the surgeon can approach from a more anterior or lateral direction as required (Fig. 2). Aneurysms lying *below* the posterior clinoids preclude a transsylvian pterional approach, unless this is combined with the trans-cavernous route described by Dolenc et al. [5]. Day et al. described an extradural trans-cavernous approach after removing the zygoma with or without the orbital rim [4]. This extradural technique preserves the temporal tip bridging veins and permits temporo-polar access to basilar apex aneurysms lying below the level of the posterior clinoids. The author has always favoured the subtemporal approach for low-lying aneurysms, believing this to be a simpler technique and allowing transtentorial extension if required (see below).

Basilar bifurcation aneurysms lying >10 mm below the posterior clinoids may require one of the approaches detailed in the next section.

Procedure selection for basilar bifurcation aneurysms

Favouring subtemporal approach:

- Fundus pointing posteriorly
- Low basilar bifurcation
- Wide neck
- Large right post. com. artery/ant. choroidal aneurysm

Favouring transsylvian pterional approach:

- High basilar bifurcation
- Narrow neck
- Other anterior circulation aneurysms on side of approach

## 1.2 Superior cerebellar aneurysms

These aneurysms usually project laterally and any of the above approaches apply. The subtemporal route demands an approach from the same side as the aneurysm, whereas the transsylvian route permits clipping of aneurysms on either side. With these aneurysms, perforators are less likely to involve the neck or the fundus, but the 3rd nerve is often closely adherent and must be dissected off the neck before clipping.



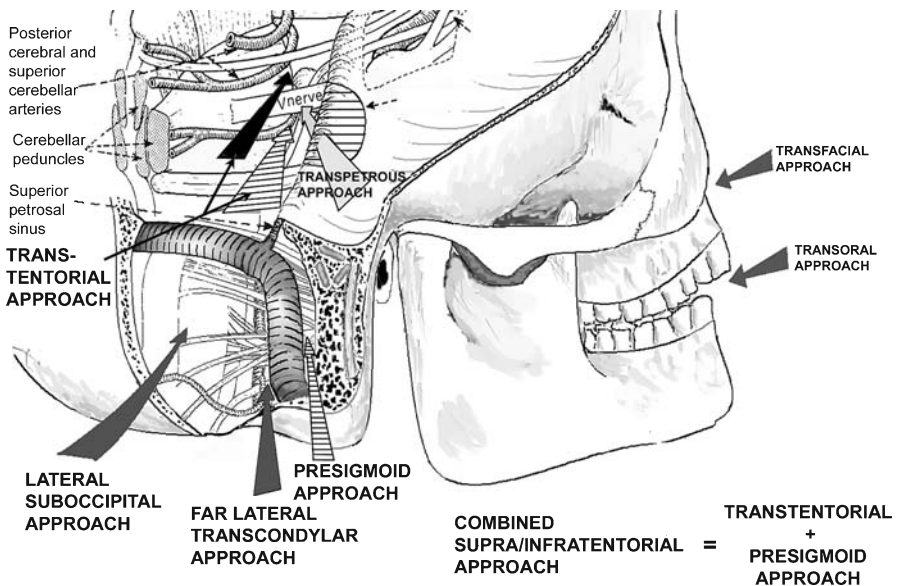
### 1.3 Posterior cerebral artery aneurysms

Aneurysms arising anterior to the midbrain (on either  $P_1$  or  $P_2$ ) can be approached either via the subtemporal, the trans-sylvian pterional or the temporo-polar route. Those lying in the ambient cistern arising from the  $P_2$  segment require a subtemporal approach. For aneurysms arising from the most distal  $P_3$  segment either an occipital interhemispheric approach or a posterior subtemporal approach will suffice. Occlusion of the distal posterior cerebral artery beyond the origin of the midbrain perforators or of the posterior choroidal artery seldom causes a permanent visual defect.

## 2. BASILAR TRUNK/VERTEBRO-BASILAR JUNCTION/LOW LYING BASILAR BIFURCATION

As with bifurcation aneurysms, the most important feature is the *height of the aneurysm neck* in relation to the posterior clinoid process and the clivus as seen on the lateral angiographic views.

The *subtemporal transtentorial approach* described by Drake [6] permits access to aneurysms extending down to 25 mm below the posterior clinoid process – in some as low as the vertebrobasilar junction (Fig. 3). Aziz et al. noted the variation in height of the posterior clinoids and suggested that the floor of the sella turcica provided a more accurate guide [2]. These authors recommended that approaches from above permitted access no lower than



**Fig. 3.** Diagrammatic view of approaches to the basilar trunk, vertebo-basilar junction and vertebral artery (tentorium cerebelli omitted)

18 mm from the sellar floor. This may or may not include aneurysms of the vertebrobasilar junction since this varies considerably from one patient to another. Kawase et al. described an extradural *transpetrosal approach* where the petrous edge is drilled off between the internal auditory meatus inferiorly, the cochlea postero-laterally and the trigeminal ganglion anteriorly, however the narrow bony opening restricts the operative field (Fig. 3, light grey arrow) [8]. The same technique can also be adopted during an intradural transtentorial approach if a more anterior trajectory is required.

Alternatively aneurysms at the vertebrobasilar junction and on the basilar trunk can be approached from below. The standard lateral suboccipital route would require considerable cerebellar and brainstem retraction to reach the midline and seldom affords sufficient exposure, particularly for large aneurysms. A *combined supra-infratentorial (petrosal) approach* provides a wide view of the basilar trunk and vertebrobasilar junction. This combined approach minimises the extent of pontine and cerebellar retraction and shortens the distance to the aneurysm.

The *transclival approach* either through a *transfacial* route or a *transoral* route avoids brain stem and cranial nerve retraction (Fig. 3). However such techniques present significant hazards – the operative corridor is long and narrow and the lateral exposure usually extends only 5 mm from the midline. Anteriorly pointing aneurysms could rupture when opening the dura and the problems of postoperative CSF leaks persist despite the availability of modern tissue glues.

The selected approach often depends on the surgeon's preference, but careful pre-operative angiographic assessment is required. Carefully determine the *relationship of the aneurysm neck to the midline*. Ectatic vessels may result in considerable deviation. Note the *size of the neck* and *direction of the fundus* and try to envisage the probable direction of clip application before deciding on the approach.

#### Procedure selection for basilar trunk/vertebro-basilar junction

Favouring subtemporal transtentorial approach:

- Aneurysms <18 mm below sellar floor
- Low lying basilar bifurcation aneurysms
- Small/medium sized basilar trunk aneurysms

Favouring *combined supra-infratentorial (petrosal)* approach:

- Large aneurysms of basilar trunk or vertebro-basilar junction
- Midline aneurysms lying >18 mm below sellar floor

Favouring *lateral suboccipital (or transcondylar)* approach:

- Small aneurysms of basilar trunk or vertebro-basilar junction
- Aneurysms lying >18 mm below sellar floor

- Anteriorly arising/tentorial origin of a dominant vein of Labbé on side of approach

### 3. VERTEBRAL ARTERY

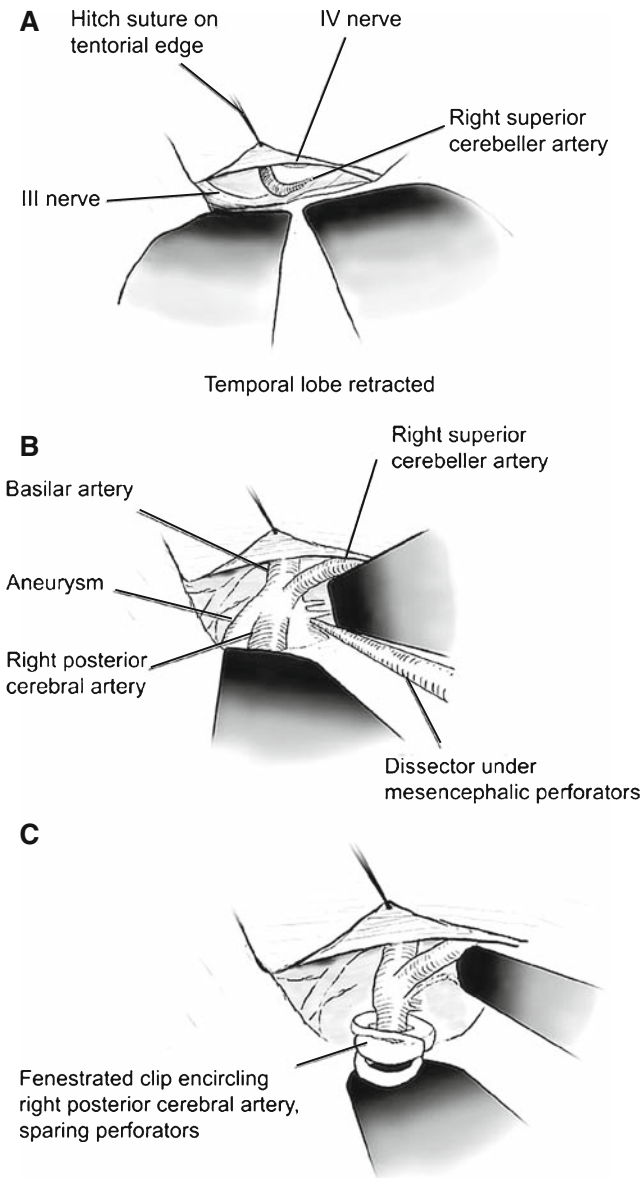
Most vertebral aneurysms arise at the origin of the posterior inferior cerebellar artery (PICA), but the height of this origin is variable ranging from the level of the foramen magnum to the vertebro-basilar junction. Rarely aneurysms lie extracranially – arising at the level of the anterior spinal artery or from a very low PICA origin. The height of the aneurysm to the midline should be determined from the lateral view of the angiogram and the distance from the midline from the AP/Towne's view. The standard *lateral suboccipital approach* usually provides sufficient access for most of these aneurysms, but for those lying more medially and nearer the vertebro-basilar junction a *far lateral transcondylar approach* may be required. This route improves access to the hyoglossal and jugular region and by creating a more caudal to rostral trajectory, provides a shorter route to the midline (Fig. 3).

## SURGERY

### 1. OPERATIVE TECHNIQUE

#### 1.1 Subtemporal approach

The patient is placed in the lateral position with the head slightly elevated and held horizontal in 3-pin fixation. A linear or curvilinear incision extends upwards from 1 cm anterior to the tragus. A 4 cm diameter bone flap is centred in line with the temporo-zygomatic junction, the surface landmark of the basilar artery. CSF drainage and mannitol aid retraction of the temporal lobe, but care is required to avoid damaging bridging veins, in particular the vein of Labbé. Access requires about one finger's breadth between the brain and the bone edge. Retraction of the retractor *tip* continues until the tentorial edge is identified. If venous bleeding occurs, temporarily ease retraction and if necessary, place some surgical over the site of bleeding. Stitching back the edge of the tentorium (avoiding damage to the 4th nerve which runs just under the tentorial edge) improves access to the interpeduncular fossa. Look for the 3rd nerve lying under the arachnoid and open the double layer of arachnoid between this and the 4th nerve (Fig. 4A). Following the superior cerebellar artery medially leads to the basilar artery, the bifurcation and posterior cerebral vessels (Fig. 4B). Usually the 3rd nerve is retracted superiorly, but when the bifurcation lies above the level of the posterior clinoid it may be necessary to open the arachnoid above the nerve. Before clipping, it is important to identify the



**Fig. 4.** Subtemporal approach to basilar bifurcation aneurysm

left posterior cerebral artery and the thalamo-mesencephalic perforators arising from  $P_1$  and from the posterior surface of the basilar artery and to separate these from the aneurysm neck and fundus. The disadvantage of the

subtemporal approach is the difficulty in visualising  $P_1$  and the associated perforators on the left side, particularly with large aneurysms. Changing the microscope angle, working in front of the aneurysm and if necessary compressing the fundus, help the surgeon identify these vessels. Application of a temporary clip makes manipulation of the aneurysm sac safer and easier. Anteriorly projecting aneurysms tend to lie free from perforators and carry least risk during clipping. Superiorly and posteriorly projecting aneurysms usually require a fenestrated clip to encircle the right posterior cerebral artery and occasionally the 3rd nerve (Fig. 4C). The clip length should only extend to the distal edge of the neck, otherwise it may occlude perforators arising from the left  $P_1$ . Again a temporary clip reduces the intraluminal pressure and the chance of the clip slipping down on to the bifurcation. If this occurs place a second clip above the first and then remove the first. Large aneurysms may require several clips to prevent the fundus refilling. After clipping it is essential to re-inspect the vessels on each side and ensure that none are included in the clip. When the basilar bifurcation lies below the level of the posterior clinoids, proximal control may be harder to achieve with temporary clips. Preoperative insertion of an inflatable balloon into the basilar artery provides an alternative method of temporary basilar occlusion.

## 1.2 Transsylvian pterional approach

First described by Yaşargil et al. [12]. The patient is positioned with the head in 3-pin fixation, slightly elevated and rotated at about  $45^\circ$ . Through a pterional craniotomy, the arachnoid overlying the optic nerve and Sylvian fissure is widely opened. By retracting the frontal lobe, internal carotid artery and middle cerebral vessels medially and the temporal lobe laterally, and following the posterior communicating artery posteriorly back to its junction with the posterior cerebral artery, the basilar artery and bifurcation is approached from an antero/lateral direction. In most instances the route extends between the internal carotid/middle cerebral arteries and the 3rd nerve. Thereafter dissection continues either lateral to the posterior communicating artery or medially between the branches of its perforators. Dividing the posterior communicating artery between lig clips may improve access; this carries little risk provided that this vessel is not the dominant source of filling of the right posterior cerebral artery. Yaşargil et al. originally described the option of a route between the optic nerve and the carotid artery, but this is rarely required. The advantage of this antero-lateral approach is the ease of identification of the left posterior cerebral artery. Perforators can be separated easily from the neck of small aneurysms before safely clipping the neck, but for larger aneurysms, retraction of the fundus may be required to identify perforators running from the posterior surface of the basilar artery. From this route, basilar aneurysms are normally clipped across the plane of the vessels without the

need of a fenestrated clip. As with the subtemporal approach temporary clipping can minimise dissection risks and reduce intraluminal pressure before clip application.

### 1.3 Subtemporal transtentorial approach

Position the patient as for a standard subtemporal approach. The temporal craniotomy is sited more posteriorly, centred above the mastoid. Considerable caution is required during retraction to avoid damaging the vein of Labbé. The tentorial edge is exposed and the tentorial layers are diathermied and divided parallel to the petrous ridge from near the junction of the petrosal and transverse sinus to the tentorial hiatus, to a point behind the dural entry of the 4th nerve. By stitching back the tentorial edge, the surgeon looks down the medial wall of the petrous bone. Aneurysms lying up to 20 mm below the posterior clinoids can be approached on the *medial* side of the trigeminal nerve (Fig. 3 black arrow); those lying more than 20 mm below require an approach *lateral* to the trigeminal nerve (Fig. 3, white striped arrow). Retraction of both the nerve and the pons may help identify the aneurysm neck. Rather than using a temporary clip, control may be achieved by inserting an indwelling non-detachable balloon catheter pre-operatively. If possible the aneurysm should be clipped in the plane of the vessels.

### 1.4 Combined supra-infratentorial (petrosal) approach

As described in detail by Al-Mefty et al., the patient is positioned in the lateral position with the head held horizontal in 3-pin fixation. In addition to a large temporo-occipital bone flap, a mastoidectomy permits a presigmoid retrolabyrinthine route to the posterior fossa [1, 3]. The temporal dura is opened and the superior petrosal sinus divided between clips just before its junction with the transverse sinus (Fig. 3). The dural opening is extended in front of the sigmoid sinus opening into the posterior fossa. Dividing the tentorium alongside the petrous ridge as described above and retracting the sigmoid sinus and cerebellum posteriorly and the temporal lobe superiorly, provides an extensive exposure. The 5th, 6th, 7th and 8th cranial nerves lie between the surgeon and the basilar artery/vertebro-basilar junction; all are at risk of damage during aneurysm dissection and clipping.

### 1.5 Lateral suboccipital approach

The patient is positioned semi-prone (or lateral), with the head held in 3-pin fixation and square to the shoulders and the chin tucked in to tighten the nuchal ligament. Through a paramedian excision the occiput and the atlas are exposed. The craniectomy extends from the midline to the edge of the transverse/sigmoid sinus and includes a rim of foramen magnum. For low-lying

aneurysms, to gain proximal control, the vertebral artery can be exposed extracranially in the sulcus arteriosis as it crosses the arch of C1, before penetrating the dura. On opening the dura, the cerebellar tonsil is retracted medially to expose the vertebral artery, bridged by the lower cranial nerves. After opening the arachnoid layer and taking care to minimise any retraction of the nerves, the vertebral artery is followed rostrally until the origin of the PICA. Alternatively PICA may be easily identified running around and under the tonsil and this can be followed down to its origin and the aneurysm. Large aneurysms, or aneurysms lying near the vertebrobasilar junction may require the additional access gained by extending the bone removal as described below.

### 1.6 Far lateral transcondylar approach

The craniectomy is extended laterally using a high speed drill around the rim of the foramen magnum, deroofing the sigmoid sinus and jugular bulb, and removing up to a third or even a half of the occipital condyle (Fig. 3). After opening the dura, division of the dentate ligament may improve exposure of a laterally situated aneurysm. As with the above approach, it is often necessary to work between the branches of the lower cranial nerves to reach the aneurysm neck; this requires extreme care to avoid permanent nerve damage. If a large jugular tubercle masks the aneurysm neck, this can be removed with the air drill. In general, the larger the aneurysm and the nearer to the midline, the greater the need to extend bone removal in a lateral direction. This minimises cerebellar/brainstem retraction, shortens the distance to the midline and allows clip application from a trajectory more in line with the vertebral artery.

## 2. RESULTS

For the last 10 years coil embolisation has been used as the first line approach for most aneurysms of the posterior circulation. To obtain data on surgical outcome uninfluenced by the introduction of endovascular techniques, I return to results of an audit from 1989 to 1993 showing 3 month outcome of 66 patients undergoing clipping of a posterior circulation aneurysm (Table 1). Even during this period, 6 patients were treated with interventional techniques and they have been excluded from the table. Of the 66 patients, 2 presented with 3rd nerve palsies and 4 had incidental aneurysms. The remainder all suffered a subarachnoid haemorrhage. Patients with post-operative cranial nerve palsies alone were not categorised as disabled. Although numbers at each site are small, it is evident that surgical repair of basilar bifurcation aneurysms carries the highest mortality and morbidity with 2 deaths and 3 patients with severe disability. Patients in the severe disability category all sustained perforator damage.

**Table 1.** Results of surgical repair of posterior circulation aneurysms 1989–1993

	Good recovery	Moderate disability	Severe disability	Death	Total
Basilar bifurcation	25	4	3	2	34
Superior cerebellar	10	3	0	0	13
Posterior cerebral	2	0	0	0	2
AICA	3	0	0	0	3
Vertebro-basilar junction	2	0	0	0	2
PICA	9	2	0	1	12
Total	51	9	3	3	66

AICA Anterior inferior cerebellar artery, PICA posterior inferior cerebellar artery

## HOW TO AVOID COMPLICATIONS

### 1. VENOUS INFARCTION

All subtemporal and petrosal (combined supra/infratentorial) approaches risk damage to the vein of Labbé. In about 50% of patients, occlusion will lead to venous infarction. If bleeding occurs, do not try to coagulate; ease back on retraction and pack with surgicel if necessary. A pre-operative CT venogram may help identify the relative importance of this draining vein and its position of entry into the transverse sinus. A dominant vein of Labbé entering the sinus immediately adjacent to the petrosal sinus or draining through a tentorial venous lake may be a reason to avoid the petrosal approach.

### 2. PER-OPERATIVE ANEURYSM RUPTURE

*Temporary clipping* of the proximal vessel (applied for 5 min, with 5 min reperfusion) may reduce the risk of aneurysm rupture during dissection and aid manipulation of the sac and identification of perforators and adjacent vessels, particularly with large aneurysms. The reduction in intraluminal pressure within the aneurysm sac allows optimal positioning of the aneurysm clip. For large basilar trunk or low lying bifurcation aneurysms, access to the proximal vessel may be difficult, if not impossible, particularly when approached from above. *Temporary endovascular occlusion* with a non-detachable silicone balloon inserted via a femoral catheter for 5-min periods provides a useful method of control. After clipping and deflating the balloon, the catheter permits intra-operative angiography to ensure accurate clip position with preservation of surrounding vessels. Over the last 30 years several authors have recorded the use of circulatory arrest in the treatment of giant intracranial aneurysms. These techniques permit up to



60 min of total circulatory arrest, thus helping both the dissection and clipping of such technically difficult aneurysms.

### 3. VESSEL OCCLUSION

It is essential to ensure that clip application does not constrict or occlude either proximal or distal vessels. A microdoppler probe can provide a guide to patency, but intraoperative angiography if available is a more certain method. Neither technique will show perforator occlusion. Only punctilious surgical technique can minimise this complication, particularly around the most vulnerable site at the basilar bifurcation.

### 4. CRANIAL NERVE DAMAGE

With the subtemporal approach to the basilar bifurcation about two thirds of patients sustain 3rd nerve damage. Most recover fully but in ¼ of those, some damage persists. The transtentorial approach to the basilar trunk risks damage to the 4th, 5th and 6th nerves and the combined petrosal approach also risks damage to the 7th and 8th nerves. Infratentorial approaches may damage the lower cranial nerves, particularly when dissecting and clipping PICA aneurysms. Great care and delicacy is required when retracting these nerves to gain access. Damage can lead to potentially fatal aspiration pneumonia.

## CONCLUSIONS

Most centres now use coil embolisation as the first line approach for the treatment of posterior circulation aneurysms. Despite major advances in endovascular techniques over the last decade including balloon remodelling and coiling combined with the insertion of horizontal and “y” stents, a proportion of patients still require direct operative repair. Before proceeding to operation, careful evaluation of the angiographic findings is essential to indicate the optimal approach. Individual surgical preference and experience with a particular route may be the ultimate deciding factor. Where possible the surgeon should avoid complex skull base approaches. Simplicity often provides the safest option.

### References

- [1] Al-Mefty O, Fox JC, Smith RR (1988) Petrosal approach for petroclival meningiomas. *Neurosurgery* 22: 510-517
- [2] Aziz KMA, van Loveran HR, Tew JM, Chicoine MR (1999) The Kawase approach to retrosellar and upper clival basilar aneurysms. *Neurosurgery* 44: 1225-1236

- [3] Bowles AP, Kinjo T, Al-Mefty O (1995) Skull base approaches for posterior circulation aneurysms. *Skull Base Surg* 5: 251-260
- [4] Day JD, Giannotta SL, Fukushima T (1994) Extradural temporopolar approach to lesions of the upper basilar artery and infrachiasmatic region. *J Neurosurg* 81: 230-235
- [5] Dolenc VV, Skrap M, Sustersic J, Skrbec M, Morina A (1987) A transcavernous-transsellar approach to the basilar tip aneurysms. *Br J Neurosurg* 1: 251-259
- [6] Drake CG (1965) Surgical treatment of ruptured aneurysms of the basilar artery. Experience with 14 cases. *J Neurosurg* 23: 457-473
- [7] Drake CG (1979) The treatment of aneurysms of the posterior circulation. *Clin Neurosurg* 26: 96-144
- [8] Kawase T, Toya S, Shiobara R, Mine T (1985) Transpetrosal approach for aneurysms of the lower basilar artery. *J Neurosurg* 63: 857-861
- [9] Schievink WI, Wijdicks EFM, Piepgras DG, Chu C-P, O'Fallon WM, Whisnant JP (1995) The poor prognosis of ruptured intracranial aneurysms of the posterior circulation. *J Neurosurg* 82: 791-795
- [10] Sugita K, Kobayashi S, Takemae T, Tada T, Tanaka Y (1987) Aneurysms of the basilar trunk. *J Neurosurg* 66: 500-505
- [11] Wiebers DO, Whisnant JP, Huston J 3rd, et al. (2003) Unruptured intracranial aneurysms: natural history, clinical outcome and risks of surgical and endovascular treatment. *Lancet* 360: 1267-1274
- [12] Yaşargil MG, Antic J, Laciga R, Jain KK, Hodosh RM, Smith RD (1976) Microsurgical pterional approach to aneurysm of the basilar artery. *Surg Neurol* 6: 83-91



**Ken Lindsay**

Ken Lindsay is Consultant Neurosurgeon at the Institute of Neurological Sciences, Glasgow. He completed a PhD in Neurophysiology in 1975 before training in Neurosurgery in Glasgow under Bryan Jennett and Graham Teasdale. In 1981 he was appointed to a consultant post at the Royal Free Hospital in London and moved to his present post in Glasgow in 1988. There he extended his clinical and research interests in cerebral aneurysms and became responsible for managing all patients with posterior circulation aneurysms in the West of Scotland.

He became Chairman of the Specialist Advisory Committee in Neurosurgery, the committee responsible for standards of training throughout the UK from 1996 to 1999. From 1999 to 2001 he was Vice President (Surgical) of the Royal College of Physicians and Surgeons of Glasgow. He chaired the European Association of Neurosurgical Societies (EANS) Training Committee from 1999 to 2003 and was President of the EANS from 2003 to 2007. He is currently Chairman of the Joint Residency Advisory and Accreditation Committee (JRAAC) of the EANS/UEMS.

**Contact:** Ken Lindsay, Department of Neurosurgery, Southern General Hospital,  
1345 Govan Road, Glasgow G51 4TF, UK  
E-mail: ken.lindsay@ggc.scot.nhs.uk

---

# GIANT ANEURYSMS

S. KOBAYASHI

This chapter has been written with collaboration of Prof. K. Hongo.

## INTRODUCTION

Giant intracranial aneurysms (GAs) are the most difficult kind of intracranial aneurysms to treat. They present with subarachnoid hemorrhage and/or space occupying signs; they can also produce thromboembolic phenomena manifested by transient ischemic attacks or remain asymptomatic for many years. Their surgical treatment has been attempted by various renowned surgeons including Drake [1], Yaşargil [15], Sundt [12], Sugita et al. [11] and Spetzler et al. [10], all of them using innovative microneurosurgical techniques, and all of them with successes and failures. Recent development of bypass surgery techniques [2, 4] and endovascular treatment [14] have increased treatment options and improved surgical outcome for patients harboring GAs. Management options for surgery including deep hypothermia and cardiac standstill [7] are often instrumental. This chapter deals with the goals of treatment, surgical considerations, standard surgical techniques and complication avoidance.

## RATIONALE

1. By definition, GA measures 25 mm or more in diameter and they represent approximately 3.5% of all intracranial aneurysms. It is known that the probability of rupture is higher than in smaller ones, and approximately 25% of GAs present with subarachnoid hemorrhage. The rate of rebleeding has been found as high as 18.4% at 14 days after admission [5]; observation after hemorrhage can lead to fatal outcome.
2. The goals of treatments of GAs are basically twofold; one is to prevent rupture and two to relieve the mass effect, if present. GAs are located either in the anterior or posterior circulation. In the anterior circulation, they are most common in the internal carotid artery followed by the middle cerebral artery, while in the posterior circulation the vertebral artery is most often involved. Occlusion of a GA is made by clipping with multiple clips or trapping the portion of

---

*Keywords:* vascular malformation, giant aneurysms, microsurgery

the parent artery harboring the aneurysm with or without bypass surgery. Decompression of the thrombotic bulk of a GA is effected as necessary. When occluding a GA, special care should be taken to preserve perforating arteries. Knowledge of collateral circulation is important when trapping the aneurysm.

3. It is of great importance to know the anatomy of the parent artery and its branching and/or perforating vessels, especially regarding to their relation to the local skull base. There are particular cases such as the proximal internal carotid, in which cavernous sinus anatomy must be taken into account. In GAs of the posterior circulation, it is mandatory to know the topographic brainstem anatomy in addition to the vascular anatomy.
4. Current endovascular therapies, when properly selected and applied, can provide a lower-risk therapeutic modality, but do not provide results that are as durable as current surgical techniques [13], and do not represent an ideal solution.

## **DECISION-MAKING**

### **1. DIAGNOSTIC STUDIES**

#### 1.1 Neurological symptoms and signs

- Asymptomatic GAs are incidentally found on brain CT or MRI taken for other purposes such as for headache, ischemic stroke or brain check-up screening.
- Subarachnoid hemorrhage causes symptoms ranging Hunt and Hess Grade 1.5. Often massive hemorrhage occurs with surrounding intracerebral hematoma.
- Mass signs are related to the location of GAs. For instance, a GA in the internal carotid artery can cause symptoms such as visual symptoms, cavernous sinus signs and hypopituitarism. GAs in the vertebral artery cause brainstem compression with long tract signs and lower cranial nerve symptoms such as dysphagia, dysarthria and hoarseness. GAs at the basilar artery bifurcation can cause bilateral oculomotor pareses and hydrocephalus [6].
- Thromboembolic phenomena commonly manifest as transient ischemic attacks or infarction with its corresponding neurological deficits.

#### 1.2 CT and MRI

- Location of the GA and its mass effect are well seen on the CT and MRI. MRA is obtained non-invasively and useful to see the aneu-

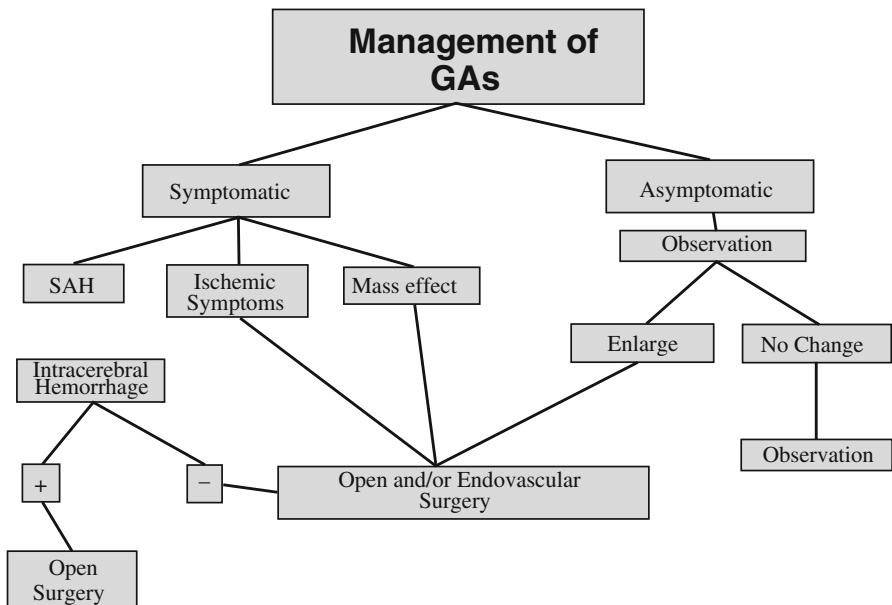
rysm and involved arteries. Post-contrast CT or MRI provides information regarding intra-aneurysmal thrombosis. 3-D CT is especially useful for observing the interrelation of the aneurysm and surrounding arteries from different perspectives, which is instrumental in designing the surgical approach.

### 1.3 Angiogram

- Despite recent refinement of CT and MRI technology, angiography still has an important place in studying perforating arteries and dynamic flow and collateral circulation.
- Balloon occlusion test is useful in determining safety of trapping procedure [13]. However, efficacy of the balloon occlusion test is not totally guaranteed.

## 2. INDICATIONS

Which patients should be candidates for surgical treatment of GAs (Fig. 1).



**Fig. 1.** Algorithm for the management of GAs. Asymptomatic patients should be followed by close observation until the presence of clinical symptoms or enlargement on radiological periodic examination; symptomatic patients must be treated via open surgery in case of rupture with the presence of intracerebral hemorrhage or via open surgery and/or endovascular treatment in case of other symptoms. SAH Subarachnoid hemorrhage

## **SURGERY**

### **1. CEREBRAL PROTECTION**

In GA surgery, temporary occlusion is usually required. Therefore, it is of vital importance to consider the neuroprotective measures such as intravenous infusion of mannitol and/or barbiturates (thiopental) with electroencephalographic burst suppression as a landmark; they are most effective when administered before periods of temporary occlusion. Patients can also be kept mildly hypertensive when a prolonged temporary clipping is expected [10].

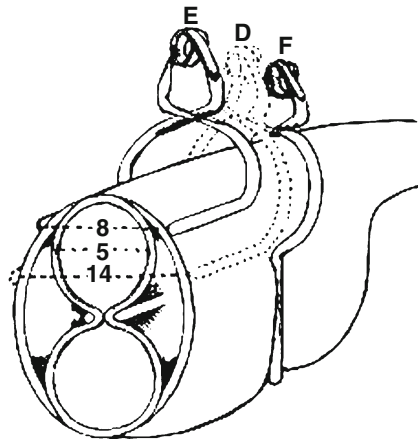
### **2. OPERATIVE TECHNIQUE**

The approaches for GAs are usually chosen under the same criteria as for non-GAs, considering always the need of proximal and distal control with minimal cerebral manipulation. For anterior circulation GAs, the pterional craniotomy with drilling of the lesser wing of the sphenoid bone and removal of the squamosal portion of the temporal bone, provides enough surgical working space. Some authors [10] prefer the orbitozygomatic approach with removal of the rim, roof and lateral wall of the orbit as well as the zygomatic arch. This approach provides additional access frontally, temporally and into the sylvian fissure, maximizing working room for clinoidectomy and exposure of the internal carotid artery. GAs of the distal anterior cerebral artery must be exposed by a wide middle-line based craniotomy with meticulous interhemispheric dissection. Posterior circulation GAs are approached by one of the following routes: (1) orbitozygomatic, (2) transpetrosal with its different variants and extensions, (3) extended far lateral approach and (4) combined approaches. To determine the appropriate approach, Spetzler et al. [10] has proposed the division of three distinct conceptual zones (upper, middle and low) according to the localization of the lesion in relation to the basilar artery.

Technical considerations:

1. Clipping with or without bypass and decompression
2. Trapping with or without bypass and decompression
3. Proximal occlusion of the parent artery
4. Under deep hypothermia
5. Under induced cardiac standstill
6. Under monitoring
7. Under temporary occlusion of the parent artery.

In order to occlude the aneurysm, clipping procedure is the most common and ideal, whereby long (ultra-long) clips or multiple clips are used. When



**Fig. 2.** Parent artery reconstruction with multiple clips. As the maximum opening distance of ring clip is not enough to prevent stenosis, it is recommended therefore to use first a straight ring clip to reduce the size of aneurysm and then one or two angled ring clips to completely close its neck. (The indicated distances are given in millimeters.) Modified from Sugita K (1985) *Microneurosurgical atlas*. Springer, Berlin Heidelberg, p 135

the aneurysmal neck of a GA is reconstructed, an ample volume of the neck portion of the aneurysm should be left on the side of the parent artery in order to avoid stenosis, because the neck is wide with thick wall. Special attention should be paid when using angled ring clips, because they do not open as wide as straight ones (Fig. 2).

There are several methods to occlude the neck with multiple clips and it is important to know them before undertaking surgery (Fig. 3).

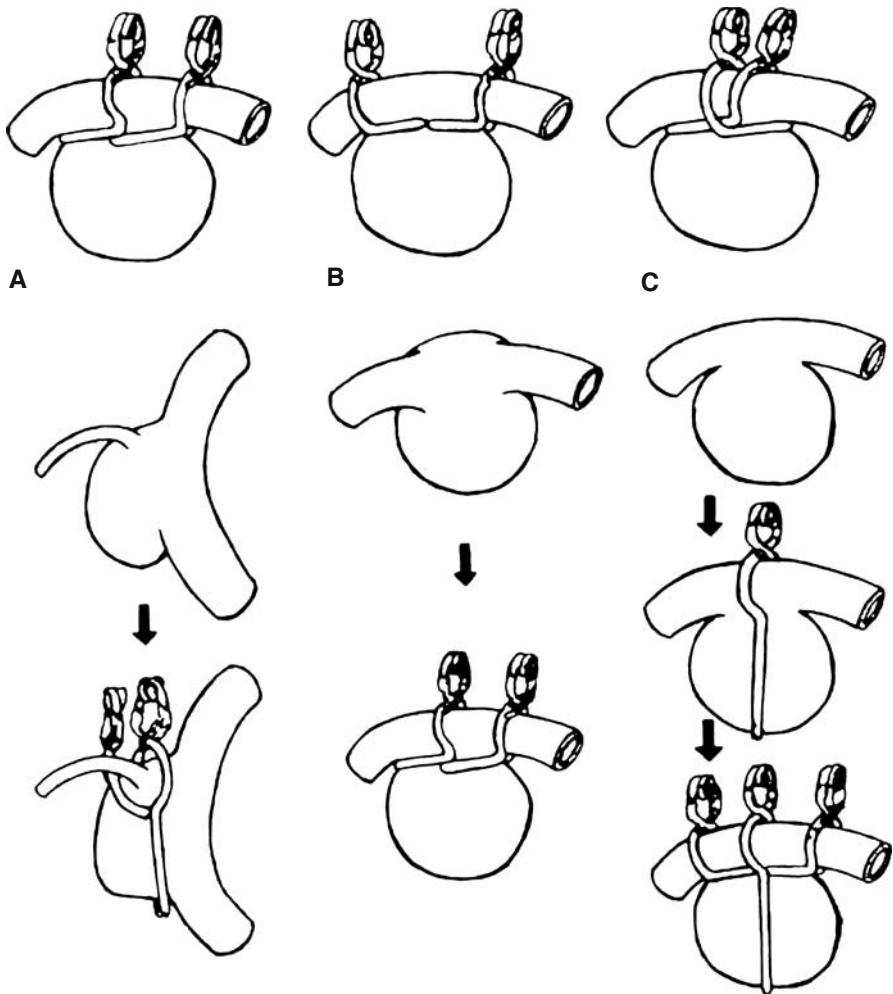
Trapping procedure is used often for GAs of the internal carotid and vertebral artery, and less frequently for those in the middle and anterior cerebral artery. In a rare special case of basilar GA, trapping can be performed combined with bypass, after meticulous preoperative hemodynamic analysis.

Bypass procedure has become a useful addition to either clipping or trapping of GAs. The superficial temporal artery (STA) has shown to provide a sufficient collateral flow and is best used for restoring the distal middle cerebral artery flow. For an internal carotid artery GA, high flow bypass using the radial artery is often necessary [4].

For GAs of the posterior circulation, it is mandatory to study angiographically the patency of the posterior communicating arteries, as well as the relation between the lesion and the anterior inferior cerebellar artery and/or posterior inferior cerebellar artery. All these measures are followed in order to prevent brainstem infarction and to plan an accurate revascularization procedure.

When a high flow bypass is necessary, radial artery graft is preferred, because its diameter fits better with the recipient vessel, and this avoids the

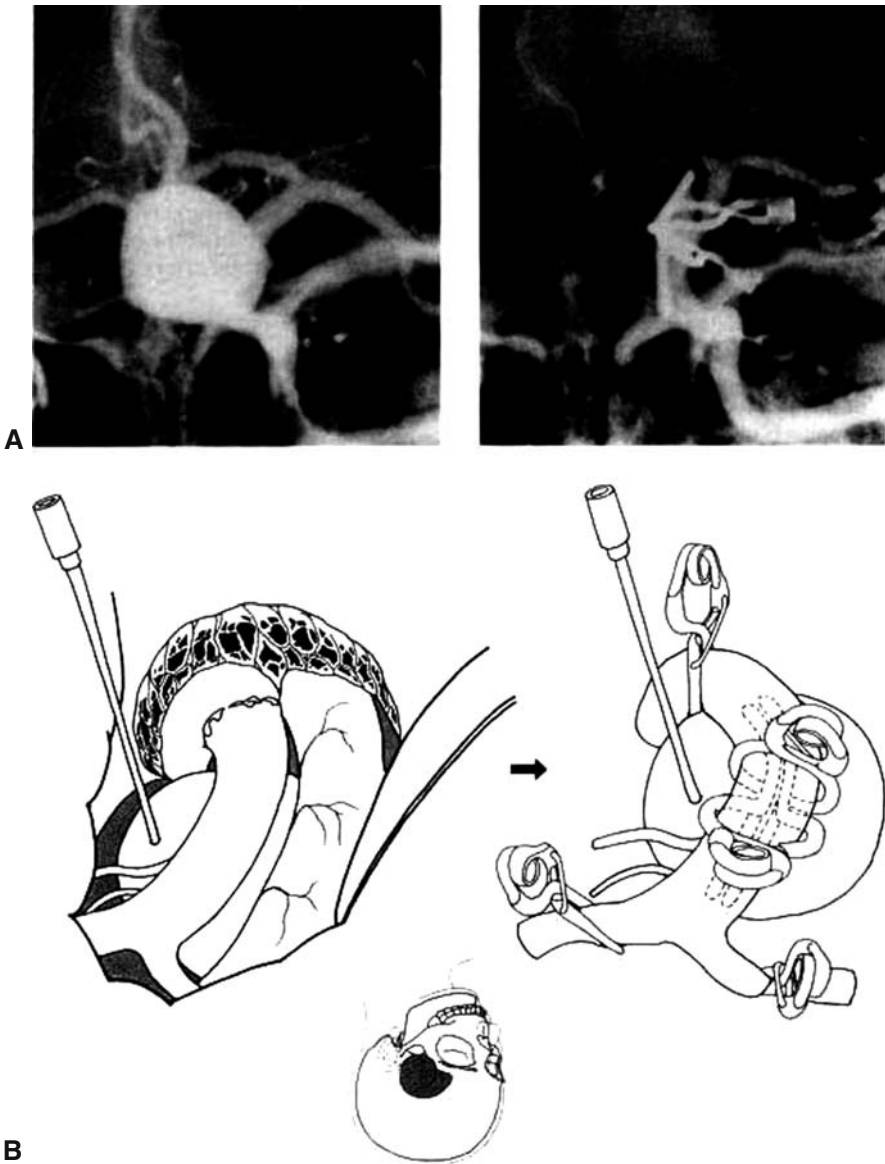




**Fig. 3.** *Top:* Multiple clipping, a method in which the aneurysm neck is occluded with more than two clips, includes many variations. Tandem clipping (A) and counterclipping (B, C) are commonly used for large or giant internal carotid aneurysms. Counterclipping can be carried out in facing (B) or crosswise fashion (C). *Middle and bottom:* Diagrammatic representation of formation clipping as branch artery formation (left), parent artery formation (middle) and aneurysm formation (right). (Modified from Kobayashi S, Tanaka Y, Apuzzo MLJ (1993) Brain surgery. Complication avoidance and management. Churchill Livingstone, New York, pp 833–843.)

presence of turbulent flow that has been observed with the saphenous vein grafts [4].

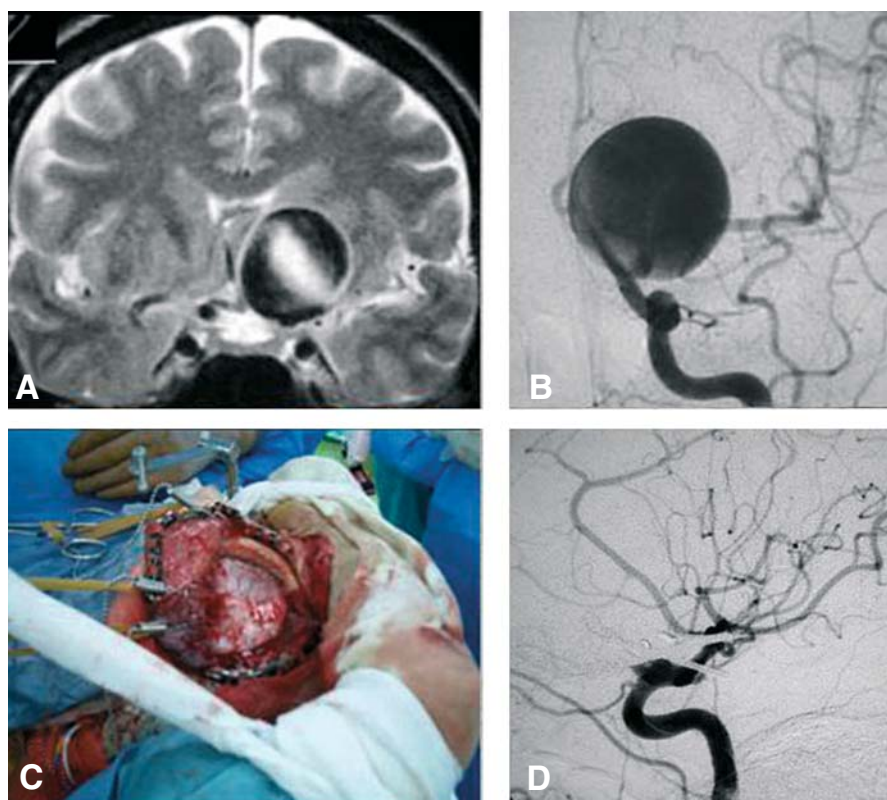
Despite the great importance of these revascularization procedures in the management of posterior circulation GAs, it is not to underestimate the



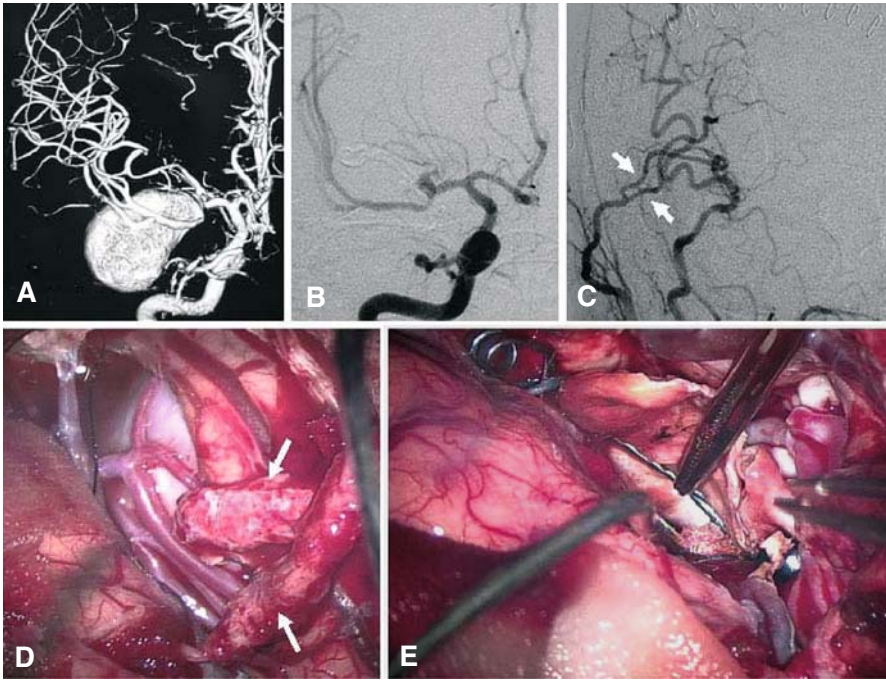
**Fig. 4.** ICA aneurysm clipped under temporary trapping without bypass. **A** Pre- and post-operative anteroposterior angiograms showing a giant aneurysm of the left internal carotid artery. A ring clip with blades bent to the left and a right-angled ring clip are applied with care to keep the original curve of the parent artery. **B** Schema of the operation in this case. Temporary clipping and suctioning of blood from the aneurysm reduce the aneurysm tension before application of permanent clips. (Modified from Kobayashi S, Tanaka Y, Apuzzo MLJ (1993) *Brain surgery. Complication avoidance and management*. Churchill Livingstone, New York, p 834.)

technical difficulties associated with its performance [2], and they must be taken into account in the preoperative plan. Even when considerable collateral flow is present, a bypass surgery can be used as an insurance procedure [3].

Decompression should be performed in thrombotic or sclerotic GAs causing mass signs. This is performed at the time of clipping or trapping. The aneurysm mass is debulked by internal decompression till the capsule gets thin enough to be soft (endoaneurysmectomy). The capsule should not be removed unnecessarily because surrounding arteries and perforators are often adherent to the outer surface of the capsule. Endoaneurysmectomy can be performed in the neck region only so as to facilitate clipping.



**Fig. 5.** ICA aneurysm clipped under temporary bypass with radial artery graft (**A** coronal MRI image; **B** preoperative anterior-posterior view of the left carotid angiogram). After exposure of M2, the patient's arm was raised (**C**) and a radial artery-M2 end to side anastomosis was made. The ICA was then trapped between the ophthalmic artery and the anterior choroidal artery, while the radial artery-M2 bypass was kept open. The aneurysm was then punctured and clipped with straight and ring clips (**D** postoperative lateral view of the left carotid angiogram). The bypass was closed: The radial artery was re-positioned to its original site at the wrist. Postoperative course was uneventful



**Fig. 6.** MCA aneurysm clipped under STA-MCA bypass. (A Preoperative 3-D angiogram.) Through a pterional approach, the sylvian fissure was widely opened and a double end-to-side STA-MCA bypasses (superior and inferior trunks) were performed. (D Intraoperative photograph, arrows indicating STAs). The aneurysm was temporarily trapped, dissected and opened to remove thrombus, and it was obliterated with two clips in counterclipping fashion (E). (B, C Postoperative angiograms, showing respectively the occluded aneurysm with intentionally left small neck and patent double bypasses.) The patient was discharged without neurological deficits

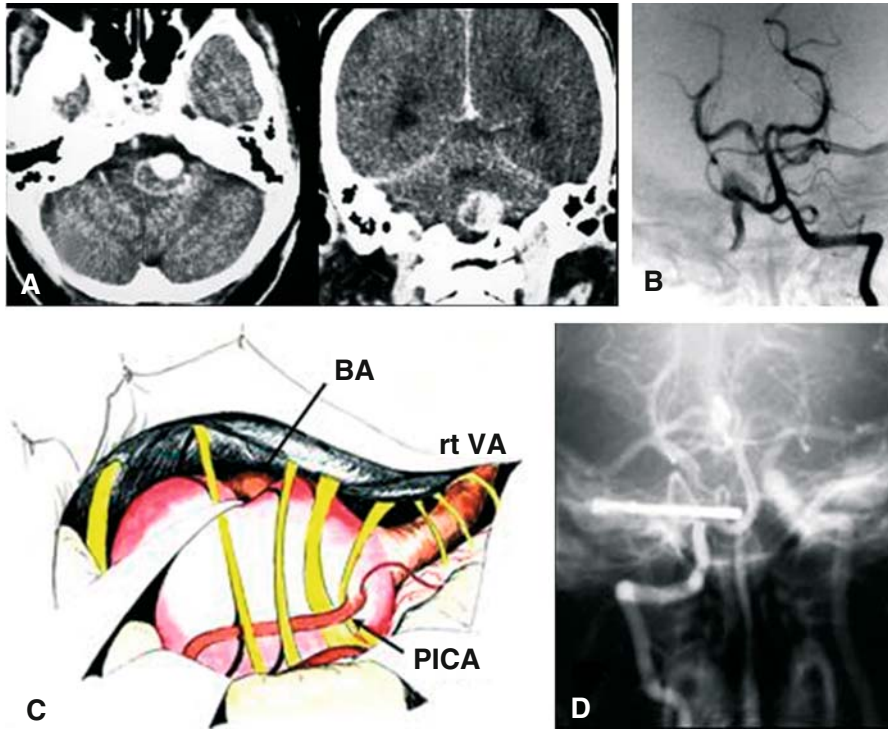
Coil embolization is being used more in recent years, however, its long-term results have not been proved better than clipping [14]. Especially, coil compaction and incomplete embolization seem to be problematic. It is often chosen for basilar bifurcation GAs because of the technical difficulties by open surgery.

Illustrative cases.

- Internal carotid artery GA (Figs. 4 and 5).
- Middle cerebral artery GA (Fig. 6).
- Vertebral artery GA (Fig. 7).

### 3. LONG-TERM RESULTS

Despite the complexity of its treatment, GAs have a poor prognosis if left untreated, because most of GAs continue to enlarge, regardless of the



**Fig. 7.** VA-PICA partially thrombosed aneurysm, clipped under temporary trapping. Preoperative CT (A) and angiogram (B) showing a 26 mm, partially thrombosed VA-PICA aneurysm. C Schematic view of the operative field. Under temporary trapping, partial clip thrombectomy was performed and the aneurysm was occluded with a single ultra-long clip. D Postoperative angiogram showing total occlusion

presence or absence of symptoms, and the risk of rupture increases during observation. Surgery reduces mortality from 31 to 4% compared with the conservatively treated patients [8].

## HOW TO AVOID COMPLICATIONS

### 1. INTRAOPERATIVE RUPTURE

Prevention of intraoperative rupture starts before surgery by obtaining a 3-D image of the lesion and its topographic anatomy, which helps designing the surgical approach and clipping the aneurysm.

During surgery, sharp arachnoidal dissection is mandatory to free uninvolved cerebral lobules, and to carefully access through the cisterns to the parent artery. Once the proximal artery is freed from all arachnoidal tension

points, dissection is followed proximally until the aneurysm neck is reached. In this point, it is of great importance to avoid tension to the aneurysm dome and to work as far as possible from the rupture point. There are some cases in which temporary clipping is needed, such as in some SAH cases, where arachnoidal plane is difficult to visualize because of thick hemorrhage, or in cases where the aneurysm is embedded in neural tissues, and its manipulation may cause tension with imminent rupture. In these cases one should strongly consider revascularization procedures, in order to maintain an adequate distal flow. This decision is made according to the preoperative analysis and intraoperative findings, depending on the expected time of ischemia and the possibility to restore flow through the parent artery after its occlusion.

## 2. CEREBRAL INFARCT

The complexity of these lesions provides a very high risk of postoperative cerebral infarction due to damage to perforators during dissection, inadvertent clipping of branches, failure to reconstruct properly the parent artery or prolonged temporary clipping without adequate alternative flow. Another possibilities leading to cerebral infarction are failure of bypass because of a tight anastomosis or because of the presence of thrombus inside the graft. Qualitative assessment of patency is easily made intraoperatively by micro-Doppler sonography. Exact confirmation by intraoperative angiography is of great value. A method gaining popularity in recent years is the Indocyanine Green Angiography (ICG) which is simple and provides real-time information on the patency of arterial and venous vessels, including small and perforating arteries (<0.5 mm) and the aneurysm sac [9].

## 3. CEREBRAL CONTUSION

In order to deal with GAs, a wide approach must be selected, one that permits clear visualization of proximal and distal vessels as much as surrounding venous and neural structures with minimal manipulation of nervous tissue [10]. Modern cranial base surgery techniques for approaches and proximal vascular control are invaluable tools to prevent excessive retraction and tension over brain tissue. When retracting the brain, it should be intermittently released as one practice for temporary arterial occlusion. Compromising veins should be avoided as much as possible, as venous congestion facilitate brain edema and contusion by retraction.

## CONCLUSIONS

Symptomatic GAs are surgically treated best by clipping or trapping with bypass as necessary. Other methods of treatment include intravascular

treatment. Asymptomatic GAs should carefully be observed and at a certain point, they should be treated as they would likely enlarge and eventually lead to rupture.

### Acknowledgement

We thank Drs. Tetsuyoshi Horiuchi and Francisco Hasslacher for their cooperation in preparing this paper.

### References

- [1] Drake CG (1979) Giant intracranial aneurysms: experience with surgical treatment in 174 patients. *Clin Neurosurg* 26: 12-95
- [2] Evans JJ, Sekhar LN, Rak R, Stimac D (2004) Bypass grafting and revascularization in the management of posterior circulation aneurysms. *Neurosurgery* 55: 1036-1049
- [3] Hongo K, Horiuchi T, Nita J, Tanaka Y, Tada T, Kobayashi S (2003) Double-insurance bypass for internal carotid artery aneurysm surgery. *Neurosurgery* 52: 597-602
- [4] Kamiyama H, Kazumata K, Kobayashi S (2005) *Neurosurgery of complex vascular lesions and tumors*. Thieme, New York, pp 338-345
- [5] Khurana VG, Piepgras DG, Whisnant JP (1998) Ruptured giant intracranial aneurysms. Part I: A study of rebleeding. *Neurosurg Focus* (4)1: E1
- [6] Kobayashi S (2005) *Neurosurgery of complex vascular lesions and tumors*. Thieme, New York, Chapters 3-7, 9-11, 14, 16, 19-21
- [7] Mack WJ, Ducruet AF, Angevine PD, Komotar RJ, Shrebnick DB, Edwards NM, Smith CR, Heyer EJ, Monyero L, Connolly ES Jr, Solomon RA (2007) Deep hypothermic circulatory arrest for complex cerebral aneurysms: lessons learned. *Neurosurgery* 60: 815-827
- [8] Nakase H, Shin Y, Kanemoto Y, Ohnishi H, Morimoto T, Sakaki T (2006) Long-term outcome of unruptured giant cerebral aneurysms. *Neurol Med Chir (Tokio)* 46: 379-384
- [9] Raabe A, Beck J, Gerlach R, Zimmermann M, Seifert V (2003) Near-infrared indocyanine green video angiography: a new method for intraoperative assessment of vascular flow. *Neurosurgery* 52: 132-139
- [10] Spetzler RF, Riina HA, Lemole GM Jr (2001) Giant aneurysms. *Neurosurgery* 49: 902-908
- [11] Sugita K, Kobayashi S, Tanaka Y, Okudera H, Ohsawa M (1988) Giant aneurysms of the vertebral artery. Report of five cases. *J Neurosurg* 68: 960-966

- [12] Sundt TM (1990) Surgical techniques for saccular and giant intracranial aneurysms. Williams & Wilkins, Baltimore
- [13] Van Rooij WJ, Sulzewski M, Metz N, Nijssen P, Wijnalda D, Rinkel G, Tulleken C (2000) Carotid balloon occlusion for large and giant aneurysms: evaluation of a new test protocol. *Neurosurgery* 47: 116-122
- [14] Wehman JCh, Hanel RA, Levy EI, Hopkins LN (2006) Cerebral aneurysms: endovascular challenges. *Neurosurgery* 59(Suppl 3): 125-138
- [15] Yaşargil MG (1984) *Microneurosurgery*, vols I and II. Thieme-Stratton, New York





**Shigeaki Kobayashi**

Shigeaki Kobayashi is Director of the Stroke and Brain Center and of the Medical Education and Research Center at the Aizawa Hospital, Matsumoto.

Education: Shinshu University School of Medicine, 1957–1963; Residency in Neurosurgery at Mayo Clinic, 1965–1971.

Degrees: M.D. from Shinshu University, 1963; Master of Science in Neurological Surgery, Mayo Graduate School of Medicine, 1971; Ph.D., Neurosurgery, Shinshu University Graduate School of Medicine 1977.

Certificate: American Board of Neurological Surgery, 1971; Japanese Board of Neurological Surgery, 1971; Board of the Japan Stroke Society, 2003.

Professional and academic appointments: Professor and Chairman, Department of Neurosurgery, Shinshu University, School of Medicine, 1988–2003; Professor Emeritus, Shinshu University, 2003; Director, Stroke and Brain Center & Director, Medical Education and Research Center, Aizawa Hospital, 2006; Mayo Clinic Alumni Association Professional Achievement Award, 2005.

Scientific Societies membership (main only): Japan Neurosurgical Society (president 2001–2002, honorary president 2003); Japanese Congress of Neurological Surgeons (president 1977–1988, honorary member 2003); Japanese Society on Surgery for Cerebral Stroke (president 1996); American Association of Neurological Surgeons (member since

1971); Congress of Neurological Surgeons (member, Executive Committee 1992–1994); International Society for Neurosurgical Instrument Inventors (founding president 1995); World Federation of Neurosurgical Societies (treasurer 1997–2001, 2nd vice president 2001–2005, honorary president 2005); American Academy of Neurological Surgeons (corresponding member 1998–); Society of Neurological Surgeons (honorary member 2001–); Japan Stroke Society (Executive Committee member 1997–2007); Japanese Society of Acoustic Neuroma (president 1995).

Honorary memberships and professorship: honorary member, Brazilian Society of Neurosurgery; honorary professor, Hebei Medical University, China; honorary member, Neurosurgical Society of Taiwan (R.O.C.); honorary member, Italian Neurosurgical Society; honorary member, Japan Neurosurgical Society; honorary member, Japanese Congress of Neurological Surgeons; honorary member, Japanese Society of Skull Base Surgery; honorary member, Japanese Society for Computer in Neurosurgery; honorary member, Japanese Society on Surgery for Cerebral Stroke; honorary member, Conference on Neurosurgical Tools and Techniques.

Co-editor for scientific journals (present and past): Journal of Clinical Neuroscience (co-editor), Neurosurgery (international advisory panel), Neurologia medico-chirurgica (Tokyo) (review board), Surgical Neurology (consulting editor 1996–), Neurological Research (international editorial board), Minimally Invasive Surgery (advisory board), Skull Base Surgery (editorial board), Neurological Surgery (Tokyo) (advisory board), Acta Neurochirurgica (panel of reviewers), Japanese Journal of Neurosurgery (panel of reviewers), Techniques in Neurosurgery (editorial board), Operative Techniques in Neurosurgery (editorial board), Contemporary Neurosurgery (editorial board), Turkish Neurosurgery (international board), Zentralblatt für Neurochirurgie (international advisory panel).

Medals and awards: HiVision Award '89, HDTV Promotion Society of Japan (for introducing HDTV in medicine), 1989; Kenneth Jamieson Lecture and Medal, Australasian Neurosurgical Society, 1994; Nikkei BS Prize of the Year 2000: Development of Minimally Invasive Surgery for Brain Tumors and other Lesions; Japan Society of Mechanical Engineers Award (for robotics and mechatronics) 2002; Kanto Neurosurgical Conference Annual Distinguished Service Award 2002; Japan Robotics Society Award (for developing neurosurgical robotics), 2003.

Fields of professional interests: cerebrovascular surgery, brain tumor surgery (especially meningioma, acoustic neurinoma, etc.), skull base surgery, general neurosurgery; developing neurosurgical instruments; image analysis and surgical simulation; robotics in neurosurgery; microsurgical anatomy, cerebral circulation research (cerebrovascular innervation and physiology).

**Contact:** Shigeaki Kobayashi, Medical Research and Education Center, Aizawa Hospital, Honjo 2-5-1, Matsumoto 390-8510, Japan  
E-mail: sub0305@wa2.so-net.ne.jp

---

# ARTERIOVENOUS MALFORMATIONS OF THE BRAIN

R. C. HEROS

## INTRODUCTION

Arteriovenous malformations (AVMs) are vascular abnormalities consisting of a number of direct connections of arteries and veins without a normal intervening capillary bed. AVMs are generally thought to be congenital, but they frequently grow during childhood, adolescence, and young adulthood. It is rare for them to grow significantly in the more mature adult. The most common presentation of intracranial AVMs is intracerebral hemorrhage closely followed by seizures. Other patients with AVMs present with headache and other signs of increased intracranial pressure and infrequently, with a progressive focal neurologic deficit which we generally attribute to a vascular steal, but which may well be due to venous hypertension in the territory of the veins draining the AVM.

Although the general orientation of this handbook is surgical, I will spend some time discussing issues relating to decision making which are extremely important and difficult with these lesions. I will also provide a short discussion of embolization and radiosurgery which are modalities of treatment that are frequently presented as “alternatives” to the patient but I will try to make the point that for each patient, there is only one best alternative and the different modalities of treatment should not be presented as interchangeable. Finally, I will discuss surgery, its results and its complications. While I will allude briefly to general surgical technique, most of the emphasis will be on the surgical approach to AVMs in different locations.

## DECISION-MAKING

### 1. NATURAL HISTORY

It is obvious that a good understanding of the natural history of a disease is essential in the process of decision making. Fortunately, we have several very good studies in the literature that give us robust data about the natural history of both AVMs that present with hemorrhage and those that have never

---

*Keywords:* cerebral arteriovenous malformation, surgery of cerebral AVMs, intracranial surgery

bled. One of the most important and earliest studies was reported by Graf et al. [4] who reported a 2–3% risk of hemorrhage in patients that had never bled from their AVM. In the group of patients that presented with hemorrhage, the risk of re-hemorrhage over the first year was 6% and subsequent to that, the risk was 2% per year. Brown et al. reported an annualized hemorrhage rate of 2.2% in patients that presented with hemorrhage [2]. Likewise, Crawford et al. reported a hemorrhage rate of 2% per year but in this particular series, the risk for those patients that presented with hemorrhage was 36% over a ten year period as compared to 17% in patients that had never bled [3]. In an excellent study with a 23.7 year average follow-up, Ondra et al. found that in patients that presented with hemorrhage, the annualized bleeding rate during follow-up was 3.9%; for patients that presented with seizures, the rate was 4.3% per year and for those that were asymptomatic or had other symptoms, the rate was 3.9% per year [14].

In summary, it appears that patients with cerebral AVMs bleed at a rate of approximately 2–4% per year and that rate of bleeding in most studies is similar whether the patient has ever bled or not although patients that present with hemorrhage have about twice the risk of re-bleeding during the first year. It appears clear then that unruptured cerebral AVMs have a much greater annual rate of bleeding than unruptured aneurysms although of course, the consequences of a hemorrhage from an aneurysm are worse than those of a hemorrhage from an AVM; the latter hemorrhages result in significant morbidity in approximately 25–30% of the patients and they result in death in approximately 10% of the patients [1].

## 2. THE PATIENT

Factors related to the patient are extremely important in the decision making process with cerebral AVMs. The most important of these factors is, of course, the age. Age is the most important determinant of the number of future years at risk for a hemorrhage and in addition, it is also a very important factor influencing the ability of the patient to tolerate a prolonged difficult operation and to achieve a satisfactory recovery from any neurologic deficit that may occur from surgery. For the same reasons, the patient's general medical condition must be taken into account. The clinical presentation of the patient and the neurologic condition at the time of presentation are also very important factors. For example, if a patient has a fixed neurologic deficit which would be the deficit expected from resection on an AVM in a particular region of the brain, the surgeon may be more inclined to recommend surgery. The occupation and lifestyle of the patient are also important considerations. Even a modest speech deficit may be intolerable to a teacher or a lawyer whereas a visual field cut that may be well tolerated by most patients may be intolerable to a pilot or a truck driver. The psychological reaction of the patient to the knowledge that he/she has an AVM must also be taken into consideration.

Some patients are simply devastated by the thought that they have a lesion that could bleed at any time whereas others can go on with a perfectly normal life in spite of that knowledge.

### 3. THE AVM

Clearly, the size, configuration, pattern of arterial feeding and venous drainage and location of the AVM are extremely important factors to consider in the decision making process. To help the neurosurgeon estimate the surgical risk, a number of classifications have been developed including the one we use most frequently today, which is the Spetzler-Martin Grading Scheme. This classification simplifies the estimation of the surgical risk by considering the size of the AVM, its location and the presence of deep venous drainage which is an objective indicator of whether the AVM extends to or involves deeper portions of the brain. Although these classifications are helpful, particularly in terms of reporting and comparing results, there is no classification that can take into account all the different variables that the experienced surgeon must consider in estimating surgical risk. Factors such as the presence of deep perforating arterial supply, the location of the venous drainage, the configuration of the nidus (compact vs. diffuse), etc. would be difficult to account for in any classification. It can truly be said that no AVM is exactly like any other which adds to the importance of a very individualized, patient by patient, decision making process.

### 4. THE SURGEON

Finally, it should be obvious with these difficult lesions that the surgeon's experience with AVMs is an extremely important factor. Furthermore, the availability of the different modalities of treatment at the center in question as well as the understanding by the surgeon of proper use of adjunctive or alternative treatments such as embolization and/or radiosurgery is of paramount importance. In my opinion, it should be an experienced neurosurgeon that gives the ultimate advice to patients with cerebral AVMs as to what treatment is best for them. The experience of that neurosurgeon should not be limited to surgical excision but should also include knowledge of the indications, efficacy and complications of embolization and radiosurgery as stated above. With this experience, the neurosurgeon is in the position to give to the patient proper advice as to what would be the optimal treatment for him which may be conservative therapy, radiosurgery, surgical excision with or without embolization, embolization alone or a combination of these modalities. It is my firm opinion that it is the ethical responsibility of that surgeon to give to the patient in a straight forward manner, his opinion as to what would be the best treatment for that particular patient with that particular AVM without any ambiguities or hesitation unless the surgeon really does not know, in which

case it may be prudent to refer the patient to a more experienced colleague. It does not seem fair to present the patient with a plethora of statistics and then tell the patient that it is “his decision” and that the surgeon will not make that decision for him. Of course, the patient will ultimately make the decision as to whether or not to accept the recommendation of the surgeon but he is entitled to have the benefit of the clear expert opinion that he is seeking.

## **TREATMENT MODALITIES**

### **1. RADIOSURGERY**

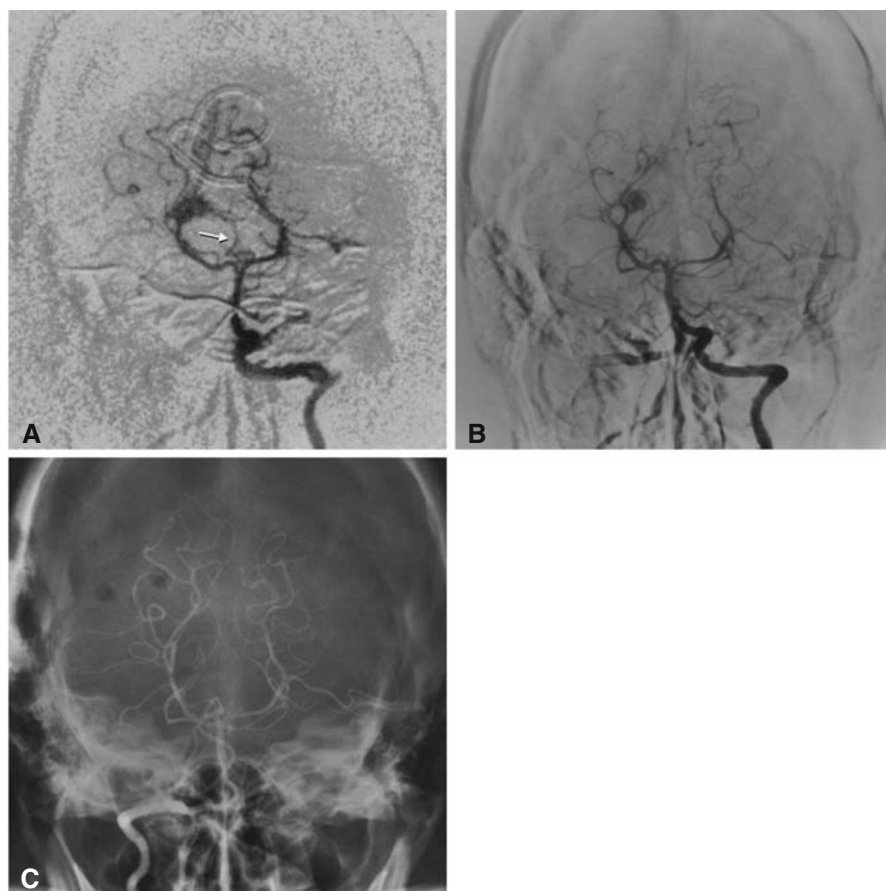
Unquestionably, radiosurgery, which was developed and is currently used mostly by neurosurgeons, has made a tremendous impact in the treatment of AVMs. It is clear that radiosurgery, as currently performed by a variety of techniques, is a very effective treatment for small AVMs, generally 3 cm or less in diameter. My colleagues and I have reviewed this topic in detail [1, 11] and have concluded that the average obliteration rate over a period of 2–3 years for AVMs treated with radiosurgery is somewhere between 60 and 80%. That rate appears to be closer to the higher figure for very small AVMs and decreases as we treat larger AVMs. The rate of clinically significant complications directly attributable to radiosurgery (radiation necrosis) is somewhere between 3 and 6% depending on whether the treated AVM involves an eloquent area of the brain or not. The morbidity of treating lesions in very critical regions such as the brainstem and the internal capsule may be substantially higher.

Obviously the great advantage of radiosurgery, in addition to its minimal invasiveness, is that it can be used for lesions that because of their deep and critical location would carry unacceptable surgical morbidity. The obvious disadvantage of radiosurgery, which is of course critical, is the uncertainty of cure (complete obliteration) and the fact that it generally takes between one and three or four years for complete obliteration to occur if it is going to occur at all. It has been clearly established that during this “latent” period of incomplete obliteration, the risk of hemorrhage is identical to the natural history of the disease [11]. In other words, the patient remains at the same risk that he was before treatment in terms of the probability of hemorrhage until the AVM is completely obliterated by radiosurgery. There are a few reports of late hemorrhage after angiographically proven complete obliteration and there are also reports of histologically proven patency of some of the components of the AVM after angiographic obliteration [8]; however, considering the very large number of patients that have been treated over the last 20 years with radiosurgery, it is fair to conclude that once angiographic obliteration has been demonstrated, the risk of a future hemorrhage after radiosurgery is extremely small and practically negligible.

## 2. EMBOLIZATION

Endovascular embolization of AVMs was also pioneered by a neurosurgeon, A. Luessenhop. Subsequently, many of our colleagues, particularly in neuro-radiology, have improved and continue to improve these techniques. Unquestionably, preoperative embolization has made it feasible to operate with considerable safety, cerebral AVMs that were clearly inoperable or at least not operable without substantial morbidity, in the days before embolization. The issue then is not whether preoperative embolization facilitates surgical excision, which unquestionably it does, but when it should be used. If embolization could be carried out without morbidity, every neurosurgeon would choose preoperative embolization for essentially all AVMs. However, it is clear from our recent review of the literature on embolization, that the morbidity of embolization is still substantial [1]. For example, Taylor et al. reported in 2004 a 6.5% permanent morbidity and a 1.2% mortality per embolization procedure [16]. Other modern series from excellent centers have reported similar morbidity rates. With these morbidity rates, it is clear that preoperative embolization should not be used only to facilitate the surgery but rather it should only be used when in the judgment of the experienced surgeon, the combined morbidity of the embolization plus the surgery after embolization would be less than what the expected morbidity of the surgery would be if it were carried out without embolization. Additionally, I strongly believe that preoperative embolization should be carried out under the direction of the operating surgeon in order to optimally facilitate surgery and reduce morbidity. For example, with a large temporal AVM, there is no need to embolize superficial middle cerebral feeders to which the surgeon would have ready access during the early operative stages. Rather, it would be much more important to embolize deep feeders from the posterior cerebral artery to which the surgeon may not have early access without significant retraction of the temporal lobe and risk of damage to bridging veins. Likewise, the difference between safe and unsafe surgical resection may be determined by the ability of the endovascular surgeon to occlude critical perforating vessels to which the surgeon would not have ready access (Fig. 1).

Another critical issue is whether and when to recommend embolization as the primary and only therapeutic modality. There is no question that in very competent hands, when the patients are properly selected by a very experienced endovascular surgeon, a relatively high rate of obliteration can be achieved; however, even in the best hands, that rate of complete obliteration does not seem to exceed 40% of those lesions where total obliteration was thought to be possible by the interventionist [17]. The rate of complete obliteration by embolization is much lower, generally between 5 and 15%, when considering all AVMs that are embolized rather than those that are specifically selected for embolization because complete obliteration was thought to be possible [1]. The real issue is whether obliteration by endovascular surgery



**Fig. 1.** Small thalamic AVM with large thalamoperforating feeder. **A** Anteroposterior (A-P) vertebral injection. Note large perforating feeder to the deep portion of the AVM (arrow). **B** A-P vertebral injection after successful embolization of large thalamoperforating feeder. **C** Postoperative A-P vertebral injection. The lesion was completely removed through a subtemporal approach

can be achieved with lower morbidity than the estimated surgical morbidity of microsurgical excision of those lesions, which are generally smaller AVMs with a limited number of arterial feeders.

When considering embolization as an “alternative” form of treatment, it should be kept in mind that, as our recent review has clearly indicated to us, the natural history in terms of risk of future hemorrhage is not changed at all for the better and may be changed for the worse (increased risk of hemorrhage) in those AVMs that are less than completely obliterated by embolization [1]. In other words, “palliative” embolization does not seem to improve the natural history of AVMs and it carries a significant morbidity;



therefore, it is only rarely, in my opinion, indicated. The exception is in cases that present with a progressive neurologic deficit due to steal, increased intracranial pressure from venous hypertension, intractable epilepsy which frequently can be improved by palliative embolization and intractable focal headaches that can be improved by obliteration of large dural feeders. It is also reasonable to consider palliative embolization in patients that present certain angiographic features such as stenosis of the main venous outlet, intranidal fistulas and aneurysms, aneurysms in feeding vessels, etc. who may be presumed to be at higher risk of hemorrhage and whose AVM cannot be removed completely or treated by radiosurgery because of its size, location, etc.

### **3. COMBINED MODALITIES**

I have discussed the usefulness of preoperative embolization to facilitate the surgical excision and have warned against its abuse. It is also frequent practice to use embolization before radiosurgery. The rationale for this has to be questioned. Frequently, embolization is used in large AVMs that normally would not be amenable to radiosurgery in order to make them “smaller” and therefore amenable to radiosurgery. This rationale is based on the assumption that areas of the AVM that do not fill angiographically immediately after embolization are indeed permanently occluded. However, we know that many of these portions of the AVM that appear to be completely occluded after embolization recanalize with time [15]. In fact, preoperative embolization has been one of the most important factors correlated with failure of radiosurgery [15]. Additionally, as we discussed above, there is no evidence that partial embolization reduces the risk of bleeding and in fact there is some weak evidence that it increases it [1]. Nevertheless, we do recommend embolization prior to radiosurgery for the occasional AVM that cannot be excised surgically without high morbidity and where the angiographic appearance of the AVM presents what we would consider significant risk factors for hemorrhage as listed above. In our opinion, pre-radiosurgery embolization simply to reduce the flow to the AVM or even to reduce its size, if such can really be accomplished, is not indicated and in fact, we feel, is contraindicated given the additional morbidity of embolization.

## **SURGICAL TREATMENT**

### **1. GENERAL COMMENTS**

I have written extensively about surgical techniques for AVMs [1, 9, 10] but I will reiterate here some points that I feel are important. I will begin by saying that AVM surgery generally should be elective surgery. There is the occasional

patient with a large intracerebral hemorrhage that requires surgical evacuation as a life saving operation. In these cases, I prefer to evacuate the hematoma very conservatively making every effort not to disturb the AVM which is left to be treated at a later time. Of course, there are those instances in which a very small superficial AVM is readily identifiable in relation to the hematoma and it can be removed safely but generally, we prefer to wait a few weeks, repeat the angiogram which sometimes would reveal a very different anatomy that what an emergency angiogram after the hemorrhage would indicate, and then operate electively.

For deep lesions, we have found frameless stereotactic guidance very helpful and tailor a relatively small craniotomy to get us to the lesion through the shortest trajectory through non-critical brain. For large superficial lesions, we use a larger-than-necessary craniotomy to be able to map the surface vascular anatomy including feeding arteries that sometimes can be identified on the surface before they plunge deeply into a sulcus as they approach the AVM. More importantly, the superficial draining venous anatomy sometime requires a large craniotomy to be able to be clearly understood. After the superficial anatomy is well defined, we proceed to systematically open under the microscope all the sulci around the AVM looking for superficial feeders which can be coagulated and divided as they approach the AVM. Sometimes, it is difficult to differentiate arterialized veins from feeding arteries and in these instances, if simple microsurgical observation under high power is not sufficient to differentiate them, we use a temporary clip which would show collapse of the vessel away from the AVM in the case of an arterialized vein. In critical areas of the brain, the surgeon must take feeding vessels only after he is absolutely sure the particular artery goes to the AVM and nowhere else. Arteries *en passage* that give small lateral branches to the AVM and go on to supply normal brain are a particular problem with AVMs in the Sylvian fissure and with pericallosal AVMs. In these cases, the artery needs to be meticulously "skeletonized" taking all the small side branches to the AVM and preserving the main trunk until the surgeon is sure that the artery goes on to normal brain without any further branches to the AVM. Of course, we try to preserve all arterialized veins but occasionally sacrifice one or more small superficial veins provided that there is ample venous drainage left intact. After we have identified all the superficial feeders to the AVM by opening all the adjacent sulci, we proceed with a circumferential corticectomy around the AVM. Empirically, we have found that if we carry that corticectomy to about 2.5–3 cm in depth, all the superficial arterial supply would be identified and occluded. After this is done, we proceed with a process of "spiraling" dissection around the AVM until we reach its deepest aspect. It is very important not to confuse loops of the AVM that project into normal brain with feeding arteries or draining veins. Coagulation and interruption of these loops could lead to significant bleeding from the AVM which is hard to control. As the deeper portion of the AVM is approached,

frequently the surgeon encounters significant bleeding which of course is the Achilles tendon of AVM surgery. In the case of AVMs that reach the ventricle, frequently the bleeding will not stop until the ependyma of the ventricle has been reached and small ependymal feeders to the AVM are controlled. These deep vessels are extremely difficult to coagulate or clip and we have found that the small micro clips designed by the late Dr. Sundt specifically for this purpose, are extremely useful for these tiny fragile vessels. At times, in spite of meticulous technique, the surgeon encounters significant bleeding from the AVM and when this is the case, it is frequently possible to place a small cottonoid patty over the point of bleeding, against the AVM, and if necessary, place gentle traction with a retractor on that area and proceed with dissection elsewhere. It is of course essential never to pack bleeding away from the AVM since this can result in significant parenchymal or intraventricular hemorrhage.

Bipolar coagulation is the mainstay of AVM surgery. I teach my residents that they must learn how to use bipolar coagulation properly with simpler cases only to have perfected the technique by the time they are ready to operate on AVMs. I prefer steady bursts of coagulation lasting one or two seconds without bringing the tip of the forceps together and under constant irrigation. It is essential for the scrub nurse to have the bipolar tips perfectly clean before returning them to the surgeon. As soon as the surgeon observes any "dirt" at the tip of bipolar forceps, he should have the nurse clean them and use a new perfectly clean bipolar forceps. Having one of these fragile deep AVM vessels "stick" to the bipolar tips is simply intolerable and can lead to major problems with avulsion of the vessel and retraction of the proximal end into the parenchyma with significant hemorrhage. Frequently I use bipolar coagulation to stroke the loops of the AVM in an effort to shrink it away from normal brain when the lesion is located in critical areas. However, this maneuver is only safe when a substantial amount of the arterial input to the lesion has been controlled and the AVM has become relatively "soft".

## 2. SPECIFIC LOCATIONS

I will proceed to discuss my preferred surgical approach to cerebral AVMs that do not have a convexity surface representation.

### 2.1 Medial temporal AVMs

The more anteriorly located of these lesions, in the region of the uncus, amygdala and the anterior hippocampal complex are approached through the medial aspect of the Sylvian fissure using a pterional craniotomy. As the Sylvian fissure is opened and the temporal lobe is retracted laterally, the feeding vessels to the AVM come nicely into view and can easily be identified. From superficial to deep, these branches are usually anterior temporal branches of the middle cerebral artery (MCA), the anterior choroidal artery and its

branches and branches of the posterior communicating artery as well as some early temporal branches of the posterior cerebral artery. All these feeders must be controlled and divided while preserving the draining veins which drain both anteriorly into the sphenoparietal sinus and medially into the basal vein. Once all the arterial supply is controlled, the lesion can be removed with little difficulty.

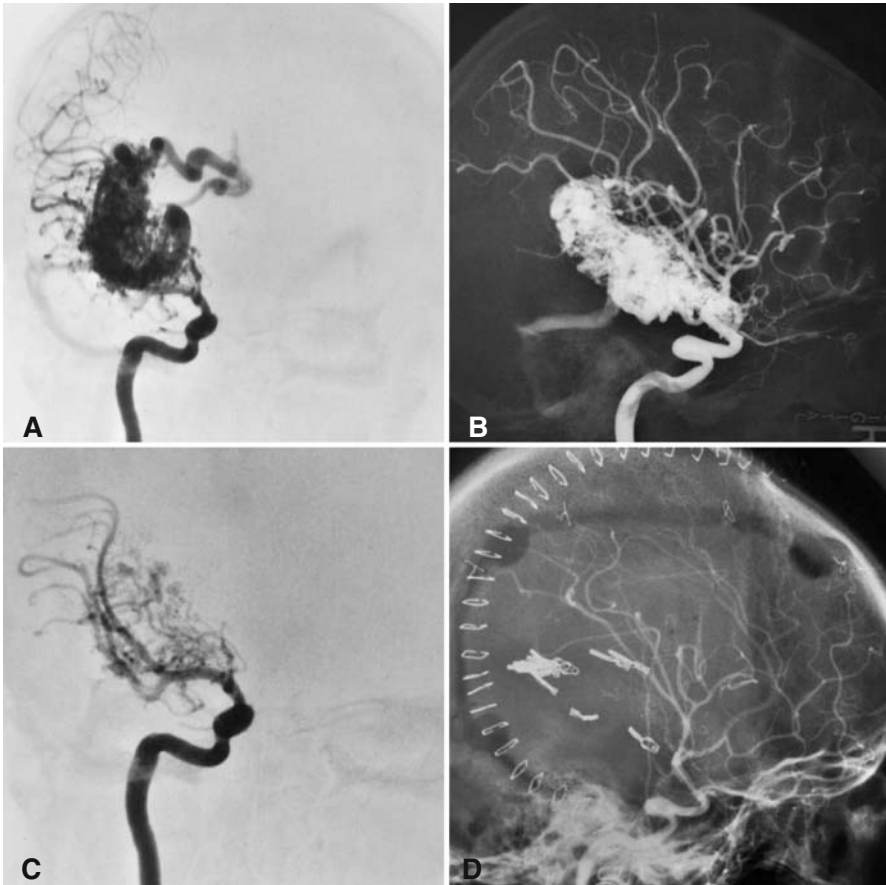
The more posteriorly located lesions of the medial temporal lobe involve the hippocampal and parahippocampal region as well as the fusiform gyrus and can extend back to the trigone. These lesions are approached through a temporal craniotomy working either subtemporally or through the inferior temporal gyrus as I described before [6]. The transtemporal approach has the advantage over a subtemporal approach of not stretching the vein of Labbe which may be arterialized. In either case, the direction is towards the temporal horn, which once identified, serves as a good anatomic landmark for orientation. The anterior choroidal artery, which invariably supplies these lesions, is identified at the choroidal fissure in the most anterior aspect of the temporal horn. A superior quadrantanopia has frequently resulted from using this approach, but this is well tolerated by most patients.

## 2.2 Insular AVMs

Those AVMs that involve the insula are approached through the Sylvian fissure with skeletonization of the MCA Sylvian branches to control the medially directed feeders to the AVM that sits just deep to the web of the Sylvian complex. Unfortunately, these lesions frequently have lenticular striate perforator supply which can be problematic at surgery (Fig. 2). If that supply is predominant, we may prefer to refer these lesions for radiosurgery if the size allows.

## 2.3 Trigonal AVMs

We use two different approaches for AVMs in this region. For those lesions located inferiorly involving the floor and lateral wall of the trigone, we prefer a transtemporal approach through the inferior temporal gyrus on the dominant side and either through the inferior temporal gyrus or the middle temporal gyrus on the non-dominant side. Again, a quadrantanopia may result from this approach. The lesions involving the medial aspect of the trigone and the parasplenic region which also frequently involve the roof of the trigone and at times even the dorsal surface of the pulvinar, are approached through a transcortical parieto-occipital approach that I have described before [7]. With this latter approach, which essentially is centered at a point 9 cm above theinion and 3.5–4 cm lateral to the midline, we are usually able to avoid significant motor sensory deficits as well as a significant visual field defect since the incision in the brain is between the parietal sensory association fibers and the occipital visual association fibers. Needless to say, frameless stereotaxis is extremely helpful to define the transcortical trajectory.



**Fig. 2.** Large left insular AVM. **A** A-P carotid injection. **B** Lateral carotid injection. **C** Early arterial phase of the A-P carotid injection demonstrating substantial lenticulostriate supply. **D** Postoperative lateral carotid injection. The lesion was successfully and completely removed by a trans-sylvian approach

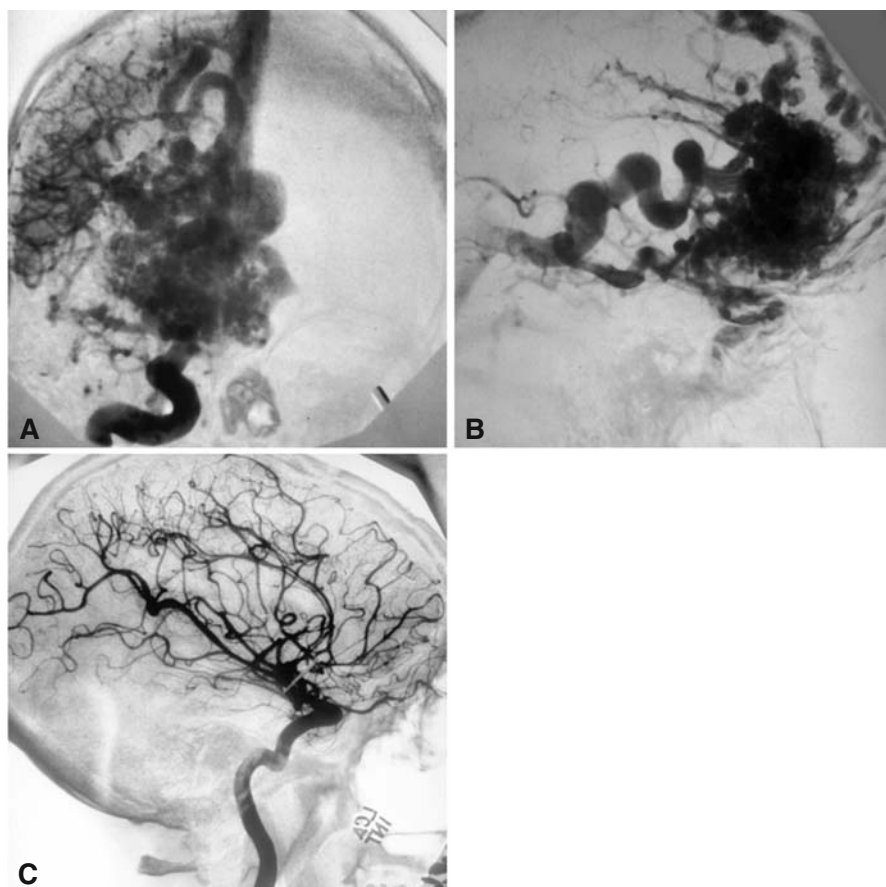
#### 2.4 Splenial-posterior third ventricular region

The difference between these AVMs and those that involve primarily the trigone is that the former are fed not only by posterolateral choroidal arteries coming from laterally into the trigone but also by posteromedial choroidal branches that come from medially. To control the latter, a parasagittal approach is preferable. For this approach, we prefer to use the lateral position with the ipsilateral side down and we have found that crossing veins are not a problem when a parieto-occipital trajectory is used. A lumbar drain is important in these cases to allow sufficient relaxation of the brain so as to not have

to retract the brain forcibly. The most difficult problem with these large splenial AVMs is the control of the posterolateral choroidal branches which usually come along the choroid plexus at the lateral extreme of the AVM which may be as far as 3.5 cm from the midline.

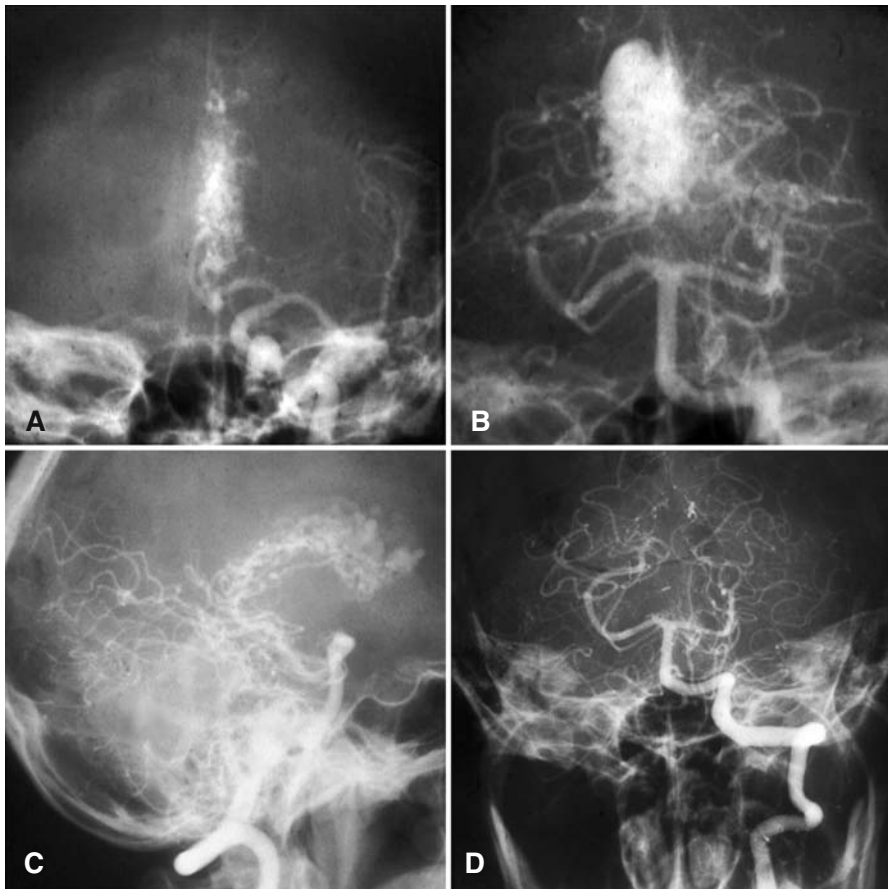
### 2.5 Callosal AVMs

These lesions are usually fed by anterior cerebral branches which are frequently *en passage*. This makes embolization of these branches difficult and control of the small side branches to the AVM tedious. The more anterior



**Fig. 3.** Large anterior callosal and left deep frontal basal AVM. **A** A-P carotid injection. **B** Lateral carotid injection. **C** Postoperative carotid injection. The lesion was successfully and completely removed through a combined pterional and superior interhemispheric approach

large lesions frequently involve the head of the caudate nucleus and may extend to the anterior limb of the interior capsule which invariably implies arterial supply by deep perforators from the medial portion of the MCA and from the recurrent artery of Heubner. Some of these lesions can be very large and involve the basal-medial aspect of the frontal lobe. We have had a couple of these large AVMs that required the sequential use of a basal pterional approach and then a superior parasagittal approach through a large combined craniotomy and a change in the position of the head (Fig. 3). When these lesions are very large and have exuberant lenticulostriate supply, the surgical morbidity is likely to be high and conservative treatment may be an option.



**Fig. 4.** Large intraventricular AVM occupying all the roof of the third ventricle. **A** A-P left carotid injection. **B** A-P vertebral injection. **C** Lateral vertebral injection; note predominant posteromedial choroidal supply without any thalamoperforating supply. **D** Postoperative A-P vertebral injection. The lesion was successfully and completely removed through a transcallosal approach with the craniotomy centered at the coronal suture

## 2.6 Intraventricular AVMs

In my opinion, these lesions have a rather bad natural history with repeated hemorrhages and I tend to be aggressive with them. Resectability is determined by the predominance of choroidal supply as opposed to deep perforating supply. When the latter predominates, which of course means that the lesions involve the parenchyma of the thalamus, conservative therapy may be preferable unless the lesion is small enough to be treated with radiosurgery. When the supply is exclusively or predominantly choroidal, the latter can be controlled readily in the ventricle even when the lesion extends along the entire length of the roof of the third ventricle (Fig. 4). The approach to these lesions is, of course, transcallosal and I prefer the lateral position with the ipsilateral side down. Perhaps the most difficult aspect of operating on these intraventricular AVMs is the preservation of the internal cerebral veins which are frequently intimately related to the lesion.

## 2.7 Striato-capsulo-thalamic region

When these lesions are large and have predominant perforator supply, we prefer to leave them alone unless the entire lesion can be covered with radiosurgery. Lesions lateral to the internal capsule involving the lateral basal ganglia and insula, as indicated before, can be operated upon with acceptable morbidity, but the perforator supply is a significant problem that makes me reluctant to operate in many of these lesions. Small lesions involving the posterolateral inferior aspect of the thalamus or the antero-medial ventricular surface of the thalamus can frequently be removed with safety, particularly if the lateral circumferential arterial supply that can be controlled in the ambient cistern in the former and the choroidal supply that can be controlled in the ventricle in the latter predominate over the deep perforator supply.

## 2.8 Cerebellar AVMs

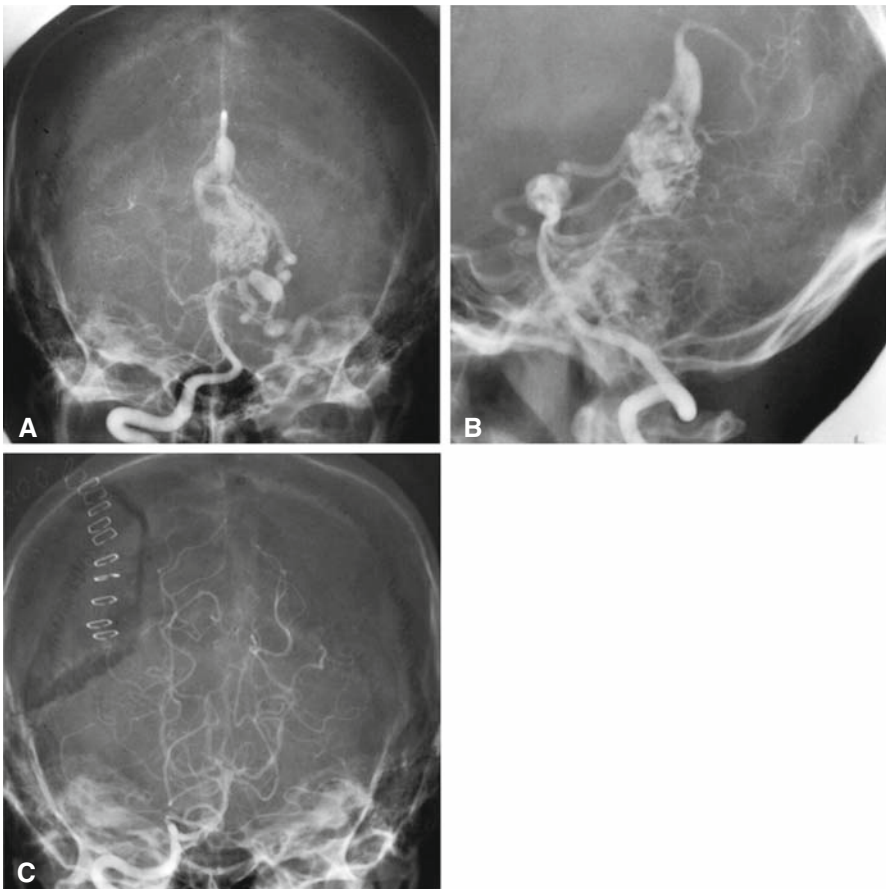
Superior vermian AVMs are invariably supplied by branches of the superior cerebellar arteries, most frequently bilaterally. To reach these branches safely, we prefer an infratentorial supracerebellar approach and we favor the sitting position in order to allow the cerebellum to fall down. One has to be particularly careful with arterialized veins that drain from the cerebellum to the tentorium. These arterialized veins should not be taken until at least most of the arterial supply is controlled which sometimes makes the exposure difficult by having to work around these veins and with minimal downward retraction of the cerebellum. Posterior and inferior vermian AVMs are approached suboccipitally in the prone or three quarters “park bench” position. These lesions are supplied predominantly by posterior inferior cerebellar (PICA) branches but they frequently get deep arterial supply from the superior cerebellar arteries. Frequently they reach the fourth ventricle and here they get small transependymal supply which is difficult to control. The more lateral hemispheric AVMs, which frequently can



be quite large, are generally approached on the lateral position through a retro-mastoid craniectomy which can be extended to the midline and supplemented by a far lateral suboccipital approach. In this fashion, the arterial supply from the PICA can be controlled infero-laterally, the anterior inferior cerebellar supply can be controlled at the cerebellopontine angle, and the superior cerebellar supply can be controlled superolaterally over the cerebellum.

### 2.9 Brainstem AVMs

I generally do not operate on AVMs located within the parenchyma of the brainstem. These lesions are generally fed by perforating arterial branches



**Fig. 5.** Moderate sized tectal AVM. **A** A-P vertebral injection. **B** Lateral vertebral injection. **C** Postoperative A-P vertebral injection. The lesion was successfully and completely removed using a posterior temporal transtentorial approach to gain early access to the superior cerebellar supply, which in this case was unilateral

which cannot be controlled early in the dissection and surgical morbidity is forbidding. I am not sure of whether these lesions should be treated with radiosurgery given the high morbidity from radionecrosis in this location. I generally recommend a conservative approach to patients with these lesions unless they have bled more than once or have progressive symptomatology. The few lesions in the brainstem that I have operated are mostly pial lesions with primarily circumferential arterial supply that can be controlled in one of the surgical surfaces of the brainstem. Some tectal lesions are also amenable to surgery, particularly if the patient already has a Parinaud's syndrome (Fig. 5).

## **HOW TO AVOID COMPLICATIONS**

We have categorized and discussed our complications with cerebral AVMs before [1, 9, 10]. Probably our most significant complications can be attributed to faulty surgical judgment; in other words, operating on patients that should not have been operated. This error was most commonly due to a misjudgment about the exact topographical localization of the AVM and the fact that it involved critical brain regions. These mistakes were more common before the days of MRI when we had to depend on a relatively crude CT scan and the angiographic anatomy to estimate whether a lesion, for example, was restricted to the cerebellar peduncle or it actually extended into the brainstem. With the advent of MRI and later functional MR, these mistakes are less common. Early in my experience, I adhered to the belief that there was no viable brain within the AVM and was overconfident in several cases in believing that I could resect a large or even a moderate sized AVM that involved critical areas of the brain without producing an unacceptable neurologic deficit. I have learned the lesson that it is best to expect the appropriate deficit from damage to an eloquent area of the brain when the AVM is located in that area. Even when the AVM does not involve a critical area of the brain such as the primary motor sensory region, primary speech areas and the primary visual cortex but it is immediately adjacent to these areas, the surgeon must be extremely careful in his judgment. I now prefer not to tackle these lesions unless they can be relatively well devascularized by early access to its arterial supply at surgery or by preoperative embolization. At times, I use preoperative embolization with high flow AVMs adjacent to a critical region and defer the decision to proceed with surgical excision until I can assess the result of embolization. If the lesion is markedly devascularized, I may proceed with surgical excision whereas if embolization was insufficient, I may refer the patient for radiosurgery or treat him conservatively. The reason that I fear operating on a turgent high flow AVM immediately adjacent to a critical area is that, in my opinion, the best way to remove these lesions is to gently stroke the loops of the AVM in the plane close to critical brain so as to shrink the AVM loops away from the brain and, as discussed earlier, it is too dangerous to do this when the lesion is still turgent and extensively arterialized.

Unnecessary parenchymal damage to normal brain can occur in a variety of ways. In my experience, this has occurred on a few occasions because I used an excessively generous margin of resection; in other words, as the AVM started bleeding, I moved the dissection to a “safer” plane around the AVM where there was no bleeding, thus injuring unnecessarily normal brain. Obviously, the way to avoid this is by staying right at the margin of the AVM and being patient with the bleeding which frequently can be controlled with relative ease by placing a patty and gentle retraction against the AVM. Another mistake that can result in unnecessary parenchymal damage is to take feeders at a distance from the AVM. Of course, there are areas where this can be done safely when the lesion is far away from critical areas, but generally it is best to follow each feeder until there is no question that the feeder goes exclusively to the AVM; most frequently this has to be done by a wide opening of the sulci around the AVM. Probably the most common cause of unnecessary parenchymal damage has been deep bleeding from the AVM and our efforts to control such bleeding by sometimes suctioning normal brain trying to get control of those feeders as they retract into normal brain parenchyma. As mentioned earlier, for the last several years I have depended very heavily on the Sundt AVM microclips to control these vessels as soon as they are identified rather than trying to follow them through normal white matter. I have commonly misjudged the significance of deep perforators which in the preoperative angiogram sometimes appear to be rather small and innocent. Deep bleeding from these perforators and the need to control them through important brain regions such as the brainstem, the basal ganglia and the thalamus has resulted in significant neurologic deficit. The lesson here is that when the AVM has significant deep perforating supply that is not amenable to preoperative embolization or to early surgical control, it may be best not to attempt surgical excision of the lesion. We commented before on vessels *en passage* which are a particular problem with Sylvian AVMs and with callosal AVMs and how their inadvertent occlusion can cause significant neurologic deficits.

Intraoperative hemorrhage into the brain parenchyma or the ventricle has resulted in several of the neurologic deficits that I have produced operating on some of the more difficult AVMs. I mentioned before the mistake of packing bleeding away from the AVM which should never be done. The surgeon should be doggedly persistent in stopping all bleeding from the “brain side” before moving to dissection in another plane. Intraventricular bleeding with lesions that reach the ventricle can be a significant problem because it is frequently not recognized immediately.

We have learned to minimize retraction damage by being more and more thoughtful about positioning the patient and using CSF drainage such as to insure that the brain “falls away”, for example, in parasagittal and subtemporal approaches. Retraction can not only damage the brain directly, but also can result in damage to bridging veins. To avoid this, we sometimes resect a

small portion of the brain in relatively silent areas such as the inferior temporal lobe to avoid injury to the vein of Labbe [7].

Even when the patient wakes up satisfactorily from surgery, there are a variety of causes of postoperative deterioration. The most dreadful, of course, is postoperative hemorrhage from retained AVM; with routine use of intraoperative angiography, this problem should not be seen. The problem of normal perfusion breakthrough which unquestionably was a significant one in the days before embolization, has practically been eliminated by preoperative embolization of the very high flow lesions that are likely to result in this problem.

Finally, there is of course, the problem of postoperative epilepsy. We have reviewed this topic in detail [13]. We observed new onset of seizures in 15% of the patients that did not have epilepsy before surgery. Most of these patients had only one or two seizures and only a handful had true epilepsy with repeated convulsions. We routinely use anti-convulsants after excision of supratentorial AVMs but generally discontinue these drugs after 3–6 months if the patients have had no seizures. Therefore, we do not know if the incidence of postoperative seizures would have been higher were it not for this policy.

## SURGICAL RESULTS

Table 1 summarizes my personal results with surgical excision of cerebral AVMs since 1981. Four of these patients required re-operation for residual AVM which in two cases resulted in postoperative hemorrhage and in the other two, it was detected by postoperative angiography in the days before routine use of intraoperative angiography. Intraoperative or postoperative angiography was performed in all of my patients with exception of a handful that had a very small AVM in a non-eloquent area of the brain and I was sure that the AVM was completely excised. In all the others, intraoperative or postoperative angiography showed complete excision of the AVM with exception of the two patients that needed to be re-operated for residual AVM in whom angiography

**Table 1.** Early surgical results (1981–2008)

Grade (S & M)	No. of patients	Good	Fair*	Poor	Dead	Major M & M
I	101	97	4	0	0	0%
II	172	160	10	2	0	1.1%
III	186	139	31	15	1**	8.6%
IV	113	72	25	15	1**	14.1%
V	45	15	10	19	1	44.4%
Total	617	483	80	51	3	8.7%

\*Minor or moderate neurologic deficit in immediate postop period not likely to result in permanent disability

\*\*These two patients died from complications related to preoperative embolization

subsequent to the second operation demonstrated complete excision. To my knowledge, none of these patients has re-bled except for the notable exception of a 15 year old boy who had the AVM completely resected as demonstrated by postoperative angiography. Two years later he died of an intraventricular hemorrhage due to a recurrent AVM.

A brief perusal through Table 1 indicates that Grades I and II AVMs can be operated upon with minimal morbidity and essentially no mortality. This has been demonstrated repeatedly in almost all of the large AVM series by experienced surgeons. On the other hand, the morbidity with Grade IV and especially with Grade V AVMs, has been unacceptably high in my hands as it has been demonstrated in most other large series. Almost all of the patients with Grade V AVMs in my series and many of the patients with Grade IV AVMs were operated upon before we did an extensive review of my early experience which was reported in 1990 [12]. At that time, I reported that the permanent (all patients had at least a six month follow-up and the average follow-up was three years) serious morbidity when Grade IV and Grade V AVMs were considered together was 17.7% and the mortality was 3.2%. These numbers were sobering enough that since then I have been much more conservative with these high grade lesions. I believe it is fair to say that this change to a very conservative surgical attitude in patients with Grade IV and Grade V AVMs is currently shared by the majority of experienced neurovascular surgeons including Dr. Spetzler and his group [5]. On the other hand, the excellent results with Grade I and II AVMs and with the majority of Grade III AVMs in most series confirms my strong bias towards surgical excision of these lesions. Clearly, there are some Grade III lesions, for example, a moderate sized AVM involving the primary motor sensory region that should not be operated.

## CONCLUSIONS


Cerebral AVMs are complicated neurovascular lesions that require decision making by a neurosurgeon with significant experience with these lesions. The natural history seems to be similar for AVMs that have bled as for unruptured AVMs with exception that the risk of hemorrhage is a bit higher during the first year after a hemorrhage. Thereafter, the annual rate of hemorrhage appears to be 3–4% annually with an approximate 30% morbidity and 10% mortality for both ruptured and unruptured AVMs. In my opinion, the neurosurgeon should recommend to the patient unambiguously what he feels is the best option for treatment of that particular patient with that particular AVM. Inferior options should not be presented as equivalent or alternatives to the “best option”. Radiosurgery is a great advance in the treatment of AVMs and is usually the best treatment option for patients with small AVMs that because of their location would present unacceptable surgical risk. I feel strongly that radiosurgery should not be presented as an acceptable alternative to open surgical excision in relatively young patients in good health with Grade I and Grade II AVMs.

Preoperative embolization can greatly facilitate surgical excision, but it should be used only when the combined risk of embolization plus surgical excision is lower than the estimated risk of surgical excision alone. In general, embolization should not be presented to the patient as an acceptable alternative to surgical excision in patients with Grade I or II AVMs which can be surgically excised with less morbidity than the morbidity of embolization as demonstrated by most modern surgical and embolization series. The indications for palliative or pre-radiosurgery embolization are very limited and generally restricted to lesions that cannot be excised surgically with acceptable morbidity and that present clinical or angiographic features suggestive of a considerably higher than average risk of hemorrhage. Finally, most Grade V AVMs and many Grade IV AVMs should be treated conservatively since they are generally too large for radiosurgery, present unacceptable surgical morbidity, can only rarely be completely occluded by embolization and incomplete embolization, which is risky, does not improve and may worsen the natural history.

## References

- [1] Baskaya MK, Jea A, Heros RC, Javahery R, Sultan A (2006) Cerebral arteriovenous malformations. *Clin Neurosurg* 53: 114-144
- [2] Brown RD Jr, Weiber DO, Torner JC, O'Fallon WM (1996) Incidence and prevalence of intracranial vascular malformations in Olmsted County, Minnesota, 1965-1992. *Neurology* 46: 949-952
- [3] Crawford PM, West CR, Chadwick DW, Shaw MDM (1986) Arteriovenous malformations of the brain: the natural history in unoperated patients. *J Neurol Neurosurg Psychiatry* 49: 1-10
- [4] Graf CJ, Perret GE, Torner JC (1983) Bleeding from cerebral arteriovenous malformations as part of their natural history. *J Neurosurg* 58: 331-337
- [5] Han PP, Ponce F, Spetzler RF (2003) Intention to treat analysis of Spetzler-Martin Grades IV and V arteriovenous malformations: natural history and treatment paradigm. *J Neurosurg* 98: 3-7
- [6] Heros RC (1982) Arteriovenous malformations of the medial temporal lobe: surgical approach and neuroradiological characterization. *J Neurosurg* 56: 44-52
- [7] Heros RC (1990) Brain resection for exposure of deep extra-cerebral and paraventricular lesions. *Surg Neurol* 34: 188-195
- [8] Heros RC (2005) Obliterated arteriovenous malformations. *J Neurosurg* 102: 829-831
- [9] Heros RC (1993) Parenchymal cerebral arteriovenous malformations. In: Apuzzo MLJ (ed) *Brain surgery - complication avoidance and management*, vol 2 (Part 3). Churchill Livingstone, Los Angeles, pp 1175-1193

- 
- [10] Heros RC (1995) Surgery for arteriovenous malformations of the brain (Chapter 27). In: Ojemann RG, Ogilvy CS, Crowell RM, Heros RC (eds) *Surgical management of neurovascular disease*, 3rd edn. Williams & Wilkins, Baltimore, pp 420-475
- [11] Heros RC, Korosue K (1990) Radiation treatment of cerebral arteriovenous malformations. *N Engl J Med* 323: 127-129
- [12] Heros RC, Korosue K, Diebold PM (1990) Surgical excision of cerebral arteriovenous malformations: late results. *Neurosurgery* 26: 570-577
- [13] Korosue K, Heros RC (1990) Complications of complete surgical resection of AVMs of the brain. In: Barrow DL (ed) *Intracranial vascular malformations. Neurosurgical topics*. American Association of Neurological Surgeons, Park Ridge, Ill, pp 157-168
- [14] Ondra SL, Troupp H, George ED, Schwab K (1990) The natural history of symptomatic arteriovenous malformations of the brain: a 24 year follow-up assessment. *J Neurosurg* 73: 387-391
- [15] Pollock BE, Kondzioka D, Lunsford LD, Bissonette D, Flickinger JC (1996) Repeat stereotactic radiosurgery of arteriovenous malformations: factors associated with incomplete obliteration. *Neurosurgery* 38: 318-324
- [16] Taylor CL, Dutton K, Rappard G, Pride GL, Reploge R, Purdy PD, White J, Giller C, Kopitnik TA, Samson DS (2004) Complication of preoperative embolization of cerebral arteriovenous malformations. *J Neurosurg* 100: 810-812
- [17] Valavanis A, Yaşargil MG (1998) The endovascular treatment of brain arteriovenous malformations. *Adv Tech Stand Neurosurg* 24: 131-214



**Roberto C. Heros**

Roberto C. Heros is Professor, Co-Chairman and Program Director of the Department of Neurosurgery at the University of Miami. Formerly, he was the Lyle A. French Professor and Chairman of the Department of Neurosurgery at the University of Minnesota and before that he was Professor of Neurosurgery and Director of Cerebrovascular Surgery at the Massachusetts General Hospital/Harvard Medical School. Dr. Heros is the President of the XIV World Congress of Neurological Surgery and he has been President of the American Association of Neurological Surgery and the American Academy of Neurological Surgeons. He is widely recognized as an expert in the treatment of cerebral arteriovenous malformations and he has written over 30 original articles, editorials and book chapters on this topic.

**Contact:** Roberto C. Heros, Department of Neurosurgery, University of Miami School of Medicine, 1095 NW 14th Terrace, Miami, FL 33136, USA  
E-mail: rheros@med.miami.edu



---

# INTRACRANIAL CAVERNOMAS

H. BERTALANFFY

## INTRODUCTION

Cavernous malformations form between 8 and 15% of all cerebral vascular malformations of the brain and constitute circumscribed benign vascular hamartomas. From the clinical point of view, these lesions show a great variability both morphologically and in terms of their behaviour. As the prevalence of cavernomas is rather low, it is sometimes quite challenging to decide whether an operation is indicated or not.

Many cavernomas are rather small in size (up to 20mm) and may be well accessible even if they are not readily visible on the surface of the brain. Deep-seated cavernomas, such as those located in the subinsular area or the basal ganglia, within the thalamus and particularly within the brainstem, form a special subgroup. Apparently, these deep-seated lesions more frequently tend to bleed, and because of their highly eloquent location, severe neurological symptoms are more likely to occur than in other locations.

## RATIONALE

When treating a cavernous malformation of the brain, a clear therapeutic goal has to be defined. Cavernomas may cause epilepsy in about 30% of cases, haemorrhage in about 15%, focal neurological deficit in 25%, headache in 6%. For clinicians it is important to know that cavernomas may appear as an asymptomatic (incidental) finding in up to 20% of cases. Treatment may either focus on avoiding or ameliorating epileptic fits in the future, on evacuating a large or compressing haematoma or, as a prophylactic measure, on avoiding future haemorrhages by completely eliminating the pathological lesion from the brain. The situation may be more complicated in the presence of multiple cavernous malformations within the brain, in lesions with high propensity for bleeding or in lesion that perhaps do not bleed but clearly increase in size over time. Estimating the risk of haemorrhage or re-haemorrhage in a certain specific case is one of the great challenges posed by these vascular malformations and needs many years of clinical experience. The coexistence of a venous and cavernous malformation may additionally complicate the clinical situation, particularly in the presence of a very large venous malformation. Moreover, these lesions may behave differently in the sporadic form of this disease where cavernomas

---

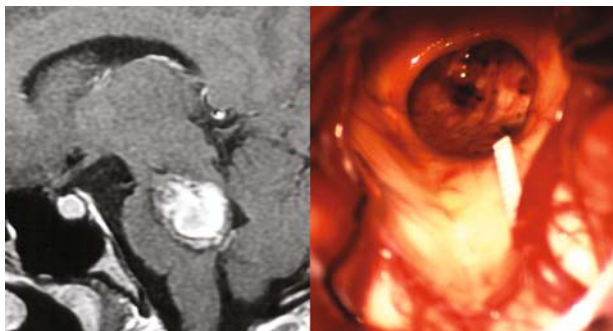
*Keywords:* brainstem, cavernoma, venous malformation, surgical technique

usually occur as a solitary lesion and in the hereditary form (found in up to 20% of cases) where multiple lesions and de novo formations may be observed more frequently than in the previous one. In such cases, several surgical procedures may be needed over time.

## DECISION-MAKING

Due to their specific appearance on MRI, cavernous malformations of the brain can be diagnosed in the vast majority of cases with high accuracy. Most of the lesions, albeit not all, may show a more or less evident surrounding zone of hemosiderin-loaded gliosis that can best be detected on gradient echo sequences; frequently this marginal zone can also be observed on T2-weighted MR images. In most cases we can estimate the amount of intralesional hematoma within the entire pathological mass and this information may be quite helpful for the surgeon.

At present, the only efficient treatment modality for cerebral cavernous malformations is total microsurgical removal. Epilepsy caused by a cavernoma may be treated medically; however, this may not influence the risk of a new or recurrent haemorrhage. Gamma knife radiation treatment has been applied and reduction of bleeding risk has been claimed by several authors who applied this treatment. However, according to the available data, gamma knife surgery by no means does completely eliminate the risk of re-haemorrhage. Additionally this technique, has its own complication rate. As I have

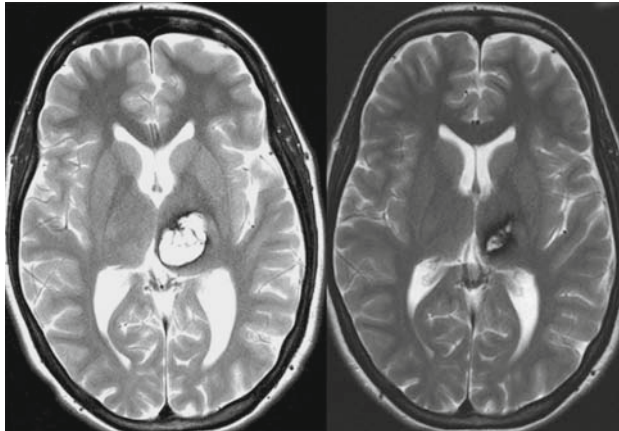


**Fig. 1.** Mid-sagittal T1-weighted contrast-enhanced MRI (*left*) showing a large dorsal pontine lesion composed to a great extent of intralesional hematoma. The cavernoma was located predominantly in the superior and anterior portion of the pathological mass. Part of the cavernoma is bulging dorsally towards the floor of the fourth ventricle. The lesion was excised through the rhomboid fossa using the supracollicular entry zone in the right paramedian region. The intraoperative photograph (*right*) shows the cavernoma cavity after complete removal and local haemostasis. During surgery the facial colliculus was identified and monitored by direct electrical stimulation. The location of the facial colliculus is inferior to the cavernoma cavity; the function of the nerve remained intact on both sides

observed in many cases, the pathological lesion may be formed of a high percentage of haematoma – sometimes over 90% – while the true cavernous malformation may be small and confined to a limited area of the lesion seen on MRI (Fig. 1). Applying radiation therapy to the entire pathological mass that is composed to a great extent by pure haematoma would require an inadequately high radiation dose that still may remain inefficient because the radiation may not be focused upon the malformation itself.

If the patient presents with acute neurological symptoms and in the early stage of bleeding, and if the images show a well-circumscribed and well-accessible lesion, surgery should be done in the acute stage because this will immediately eliminate the local pressure caused by the hematoma and allow for safe dissection of the malformation before significant scar formation has occurred. If the patient presents in the subacute or stable phase after a first haemorrhage, the size, location and particularly the morphologic aspect of the lesion are the most important criteria for decision making.

In some cases, an initial rather large haematoma may practically disappear by resorption without any treatment within two or three months, and MRI may only show residual hemosiderin or perhaps a small haemorrhage cavity but no more active cavernoma. In such cases surgical exploration is not indicated and a yearly MRI control is recommendable. I have observed many patients in whom one initial bleeding has not recurred over many years and the MRI aspect as described above has remained unchanged (Fig. 2).



**Fig. 2.** T2-weighted axial MRI (*left*) showing a significant hemorrhagic lesion most likely caused by a cavernous malformation within the left posterior thalamus that has caused a contralateral sensory disturbance. Six months later the symptoms had disappeared and control MRI (*right*) demonstrates that the haematoma had been completely resorbed. Apart from residual hemosiderin deposits, no active cavernous malformation can be detected; there is no indication for surgical exploration in this case

## SURGERY

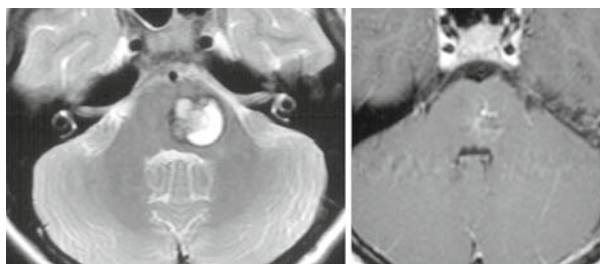
### 1. CHOICE OF THE SURGICAL APPROACH, POSITIONING OF THE PATIENT AND CRANIOTOMY

In many cases of intracranial cavernoma the surgeon may have more than one option for the surgical approach. Great experience is required to choose the optimal approach particularly in deep-seated lesions. An optimal approach is one that gives a straight-line access to the lesion with the least impact on the surrounding brain and also allows for a certain manipulation around the lesion in order to be able to completely resect the vascular malformation.

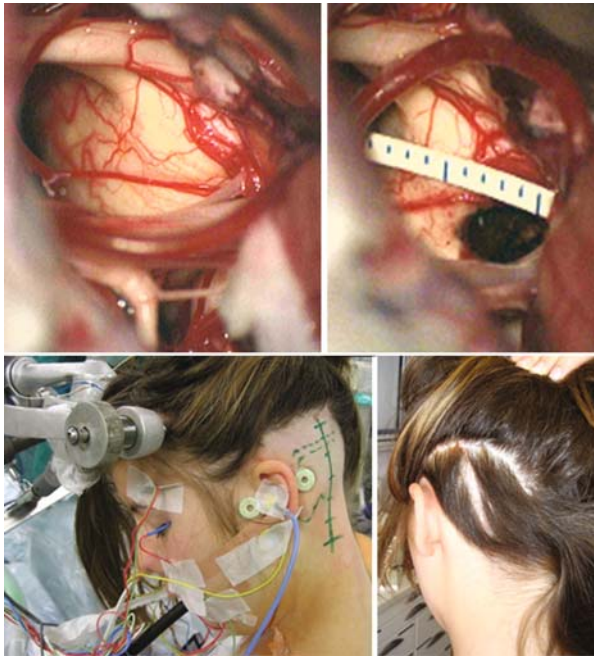As cavernomas may occur practically in all areas of the brain, they can be accessed in the same fashion as other lesions such as well-circumscribed tumors, etc. Neuronavigation and intraoperative ultrasound are of great help to precisely localize the lesion and adequately place the bone flap. We have previously described this technique for lesions located within the subinsular area or within the basal ganglia [1, 3]. Apart from the frontal, parietal, temporal or occipital access routes to various lesions of the hemispheres, the interhemispheric transcallosal approach was applied to expose intraventricular lesions, the pterional or, less frequently, the orbitozygomatic craniotomy have been used for hypothalamic or anterior midbrain lesions. Posterior thalamic and tectal cavernomas of the midbrain were accessed by the supracerebellar infratentorial approach. The patient was placed either in the sitting or in the lateral or prone (concorde) position. Lesions of the cerebellum, pons and medulla were frequently accessed by the midline or lateral suboccipital approach. Of particular importance for certain brainstem cavernomas were the subtemporal transtentorial and the suboccipital lateral transcondylar routes that give access to the lateral aspect of the brainstem (Figs. 3 and 4).

### 2. EXPOSURE OF THE LESION

Each of the mentioned approaches allows for visualizing a certain area of the brain including the brainstem. However, each specific surgical window ob-



**Fig. 3.** Preoperative (*left*) and postoperative MRI (*right*) of a 13 years-old female patient who presented with a double vision and gait ataxia. The cavernous malformation was removed by microsurgical resection via a left-sided infratentorial far lateral approach as shown in Fig. 4

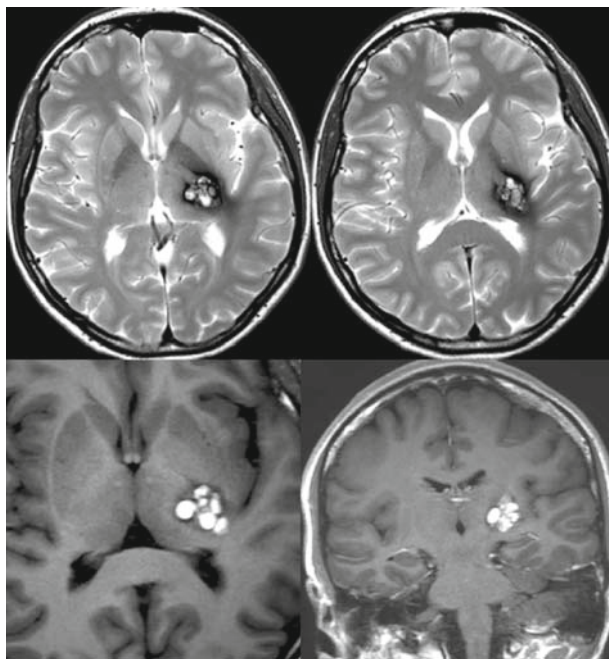


**Fig. 4.** Intraoperative images before (*upper left*) and during microsurgical resection (*upper right*) of the cavernous malformation located within the lower pons on the left side. Note that the malformation is not visible on the surface of the brainstem so that the exact entry point has to be defined by the surgeon. The region of the exit zones of cranial nerves seven, eight and nine was exposed from inferolaterally and the entry zone into the brainstem was chosen below the fibres of the facial nerve and superior to the exit zone of the ninth cranial nerve within the pontomedullary sulcus. Cavernous malformation and intralesional haematoma were removed through a small opening measuring not more than five millimetres in diameter. The patient was operated on in the sitting position (*lower left*); the postoperative course was uneventful with good cosmetic result (*lower right*) and without additional neurological deficits

tained with a certain approach has limits that should be well-known to the surgeon. Therefore, in case of a larger lesion, a combination of two different approaches can sometimes be useful as we have described at an earlier occasion [1]. Intraoperative guidance with navigation and ultrasound (or both in combination) may be most helpful. Nevertheless, these tools should never completely replace well-known anatomical landmarks, particularly when operating on a brainstem lesion. Such landmarks may be for instance the exit zones of various cranial nerves.

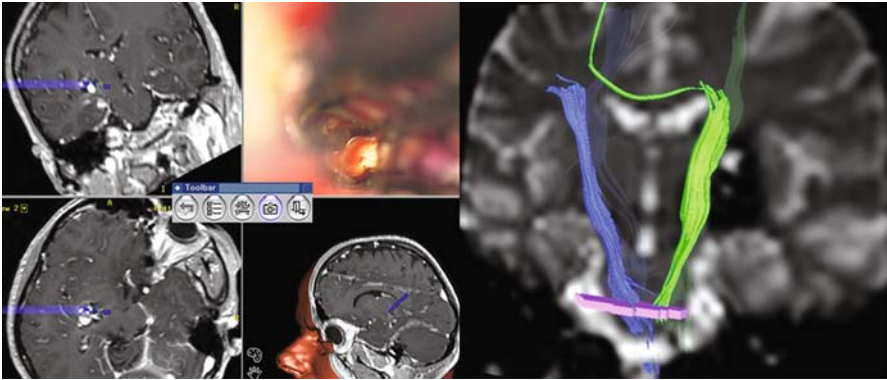
To access a cavernoma through the floor of the fourth ventricle requires bilateral sectioning of the tela choroidea and posterior medullary velum covering the inferior fourth ventricle. Sufficient exposure of the rhomboid fossa and visualization up to the aqueduct was always obtained with this technique. On the other hand, whenever possible, I avoided accessing the cavernoma via

the rhomboid fossa because this area is more sensitive than the lateral part of the brainstem. If the lesion could be approached equally well from laterally, this approach was my first preference as the brainstem tolerates surgical manipulation better in this area than within the floor of the fourth ventricle. Particularly facial and sixth nerve functions could better be preserved by using a lateral entry point. Figures 3 and 4 show the case of a 13-year-old female with a lower pontine cavernoma and intralesional hematoma. Although accessing the lesion through the rhomboid fossa seemed theoretically possible, I chose the lateral approach for the reasons mentioned above. Cavernoma and hematoma were located entirely intraaxially and were not visible on the surface of the brainstem, neither posteriorly nor laterally. I have found the pontomedullary sulcus to constitute an ideal access point into the brainstem, another “safe” lateral entry-zone in addition to those described by Recalde et al. [2]. In my experience, the small area between the exit zone of the facial glossopharyngeal nerves on the ventrolateral aspect of the pontomedullary region of the brainstem can obviously be incised over a few millimetres without causing any additional neurological deficits. One has to bear in mind, though, that an adequate viewing trajectory can only be ob-

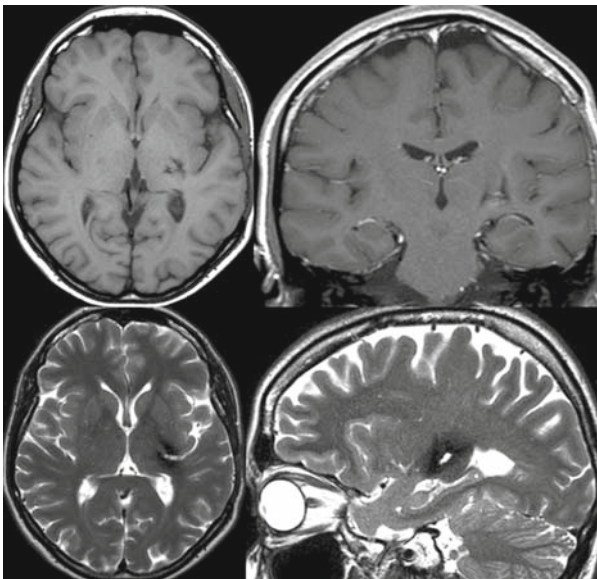


**Fig. 5.** Preoperative MRI of a 43-year-old female suffering from right-sided hemihypaesthesia. The lesion measuring 18 mm in diameter involved the posterior limb of the internal capsule and the left thalamus and did not reach the surface of the left insula

tained using the lateral suboccipital transcondylar approach. This special access route allows for sufficient manipulation in a lateral-to-medial and inferior-to-superior direction as shown in Figs. 4 and 5, so that the lesion can be



**Fig. 6.** Intraoperative screen shot from the neuronavigation monitor (*left*). Neuronavigation played an important role in determining the optimal trajectory through the posterior Sylvian fissure to reach the lesion in this specific case. The corticospinal tract is shown on preoperative MRI with fiber tracking to be located medial to the lesion with a slight lateral-to-medial shift



**Fig. 7.** Postoperative triplanar MRI of the same patient showing complete removal of the lesion. There is no reaction as consequence of microsurgical manipulation, neither by the transylvian approach nor within the perilesional area. Accordingly, there were no additional neurological deficits, and particularly no speech disturbance occurred postoperatively

completely excised under good visualization. I have used this exposure and entry zone into the brainstem successfully in a number of similar cases.

The true value of neuronavigation becomes obvious in cavernous malformation of the subinsular region as shown in Figs. 5–7. Our technique of intraoperative image guidance using a frameless stereotactic system has been described in detail [3].

### **3. MICROSURGICAL DISSECTION TECHNIQUE**

Once the lesion has been identified and visualized, the intralesional hematoma should be evacuated as the first surgical step. In some lesions, several separately encapsulated hematomas may be present; in others an intralesional hematoma may totally be absent. The next step should be identifying a clear dissection plane between lesion and surrounding brain parenchyma. This can sometimes be quite difficult as the lesion may be firmly adherent to the surrounding tissue due to scar formation following previous haemorrhages. These scars often show a yellowish discoloration and may occasionally be of extremely high consistency; in such cases precise severing with microscissors is required. The plane of dissection must be established in four directions; superior, inferior and bilateral. During the procedure, one must always be aware of and remain within this plane of dissection that can best be visualized with the aid of small cotton pledges. Tiny arteries supplying the malformation usually appear within this space; they must be coagulated and occasionally divided with microscissors. Tearing the lesion should be avoided as this manipulation may harm the surrounding tissue, particularly when working within a highly eloquent area. The surface of the dissected malformation should then gradually be coagulated and shrunk. Portions of the lesion that have already been separated from the surrounding parenchyma can be sharply excised; gradually, additional space is obtained allowing for safely continuing the dissection within a deeper area until the entire lesion is removed. In some cases the caverns of the lesion may lack a surrounding hemosiderin-loaded gliosis, and the caverns may be hidden within the parenchyma. These parts of the lesion deserve our particular attention in order to ensure their complete extirpation. At the end of this surgical step, the lesion cavity must be precisely examined under high magnification to ascertain the complete removal of the cavernoma and to obtain meticulous hemostasis by using direct bipolar coagulation at a low current intensity alternated by slight irrigation with saline solution.

### **HOW TO AVOID COMPLICATIONS**

Complications may be related either to the surgical approach, to the positioning of the patient, to anesthesia, to injury of surrounding vessels or brain tissue



or to inadequate surgical technique. Thus, a great variety of complications may theoretically occur. However, in our series of over 300 procedures performed for cavernous angiomas in practically all areas of the brain, the complication rate remained in a low range (less than 3%) while the surgical mortality was 0.3%. Minor complications were local wound infections or wound hematomas. An early intraaxial rebleeding occurred in one patient harbouring a pontine cavernoma. The hematoma was evacuated on the same day and the patient eventually had an uneventful postoperative course without additional neurological deficits. One patient experienced a hemorrhage within the temporal lobe on the left side due to compression of the vein of Labbé while using the subtemporal approach. An initial speech disturbance completely resolved within the next 14 days.

Generally, an accentuation of pre-existing neurological deficits or new deficits may occur postoperatively that may not necessarily be considered a complication, particularly when such deficits rapidly recover.

In order to avoid complications after surgery of a cavernoma, I have learned over the years to pay attention to a number of aspects:

- Carefully selecting the optimal surgical approach
- Anticipating the surgical window and trajectory obtained with a specific surgical approach and verify whether this surgical window is sufficient in a specific case.
- Applying intraoperative image guidance for rapid and precise localization of a deep-seated lesion.
- Dissecting and separating the vein of Labbé from the temporal lobe so that the brain retractor can be placed below the vein while the patency and integrity of the vein can be preserved despite slightly elevating the temporal lobe; generally, however, brain retraction should be completely avoided or at least minimized.
- Paying attention to an associated venous malformation that must not be coagulated except for small tributaries that drain the vascular malformation itself.
- Using minimal manipulation of the surrounding brain tissue.
- Establishing a clear plane of dissection between lesion and brain parenchyma at the very beginning of dissection.
- Favouring the lateral aspect of the brainstem as preferred entry zone whenever possible.
- Working under continuous electrophysiological monitoring (SEP, MEP, AEBP, direct cranial nerve EMG).
- Avoiding a midline incision in the central area of the rhomboid fossa where the posterior longitudinal fascicles decussate.
- Performing a meticulous hemostasis within the lesion cavity at the end of dissection with low intensity bipolar coagulation.
- Using a watertight dural closure in order to avoid CSF leakage.

## CONCLUSIONS

Complete microsurgical removal of a cerebral cavernoma presently constitutes the state-of-the art treatment of these heterogeneous vascular malformations. Generally, a symptomatic cavernoma should be treated surgically. Occasionally, small cavernous malformations can lead to a significant initial intracerebral haemorrhage with subsequent complete resorption of the hematoma. In such cases, the only finding on control MRI may be a hemosiderin spot without clear evidence of an active vascular malformation. Such lesions may remain silent over many years following the initial hemorrhage and do not require surgery or any other treatment.

Several relevant aspects of cavernoma treatment have been discussed in this chapter, emphasizing the importance of the surgical approach and microsurgical technique of cavernoma removal. Although modern technical tools such as navigation, ultrasound and electrophysiological monitoring play an important role in the management of these lesions, the surgeon's experience and anatomical knowledge remain important factors that influence the surgical result as well.

## References

- [1] Bertalanffy H, Benes L, Miyazawa T, Alberti O, Siegel AM, Sure U (2002) Cerebral cavernomas in the adult. Review of the literature and analysis of 72 surgically treated patients. *Neurosurg Rev* 25: 1-53
- [2] Recalde RJ, Figueiredo EG, de Oliveira E (2008) Microsurgical anatomy of the safe entry zones on the anterolateral brainstem related to surgical approaches to cavernous malformations. *Neurosurgery* 62(3 Suppl 1): 9-15
- [3] Tirakotai W, Sure U, Benes L, Aboul-Enein H, Schulte DM, Riegel T, Bertalanffy H (2003) Image guided transsylvian, transinsular approach for insular cavernous angiomas. *Neurosurgery* 53: 1299-1304



### **Helmut Bertalanffy**

Helmut Bertalanffy is Professor of Neurological Surgery and Chairman of the Department of Neurosurgery of the University of Zurich, Switzerland. He received his neurosurgical training from the Albert Ludwigs University of Freiburg im Breisgau, Germany, where he completed with honors a Medical Doctorate in 1986 and obtained the qualification as board certified neurosurgeon in 1990.

Dr. Bertalanffy spent more than 2 years from 1990 to 1992 at the Department of Neurosurgery of the Keio University, Tokyo, Japan, as a scientific fellow of the prestigious Alexander von Humboldt Foundation, Bonn, Germany, and the Japan Society for the Promotion of Science, Tokyo, Japan, working in the fields of cerebral and spinal microcirculation and skull base surgery.

He served as vice chairman of the Department of Neurosurgery of the Technical University of Aachen, Germany from 1992 to 1997. The Friedrich Wilhelm Foundation of the Technical University of Aachen honoured Dr. Bertalanffy with the “Friedrich Wilhelm” Prize in 1994 given annually for outstanding scientific work.

In 1997 Dr. Bertalanffy was appointed to Professor on a permanent basis by the State of Hessen, Germany, and served as Professor and Chairman of the Department of Neurosurgery of the Philipps University of Marburg for 10 years. In July 2007 he

accepted the position of Professor and Chairman of the prestigious Department of Neurosurgery of the University of Zurich, Switzerland, and moved from Marburg to Zurich.

He has been listed among the best doctors in Germany (Focus List 2001) and is frequently invited to meetings or congresses as guest speaker or to visiting professorships worldwide and has made significant contributions to developments in skull base surgery and microsurgery of vascular lesions of the brain and spinal cord.

Dr. Bertalanffy is a member of the German and Swiss Societies of Neurosurgery, the German Academy of Neurosurgery, the American Academy of Neurological Surgery (corresponding member), the World Academy of Neurosurgery, the Skull Base and the nominating committees of the World Federation of Neurological Surgeons (Chairman of the nominating committee), the International Advisory Board of the American Association of Neurological Surgeons, the Academia Eurasiana, and an honorary member of the Romanian Society of Neurosurgery.

He is the Editor-in-Chief of the scientific journal *Neurosurgical Review* and lends his expertise to the Editorial Boards of *Neurosurgery*, *Acta Neurochirurgica*, *Techniques in Neurosurgery*, *Neurologia Medico-chirurgica* and *Zentralblatt für Neurochirurgie*.

Dr. Bertalanffy has published 144 articles in peer reviewed journals, contributed over 50 book chapters or other articles to medical texts, and presented more than 300 lectures as visiting professor or at various congresses and symposia worldwide. He is married and has 2 daughters.

**Contact:** Helmut Bertalanffy, Professor and Chairman, Department of Neurosurgery, University Hospital of Zurich, Frauenklinikstrasse 10, 8091 Zurich, Switzerland  
E-mail: [helmut.bertalanffy@usz.ch](mailto:helmut.bertalanffy@usz.ch)

---

# CAROTID ENDARTERECTOMY

V. BENEŠ

## INTRODUCTION

Carotid endarterectomy (CEA) is a means for the secondary prevention of stroke that is caused by embolisation from carotid plaques. CEA is by far the most thoroughly studied surgical procedure as well as one of the most frequently used surgical techniques. Thrombendarterectomy was first performed by DeBakey in 1953. The number of surgeries increased steadily until the 1980s when, in the wake of extracranial-intracranial arterial bypass study, neurologists first questioned the rationale of CEA. The neurologists recognised that CEA was used to prevent stroke, but that stroke may happen during or after CEA as well. At that time the role of distal embolisation was not sufficiently understood and appreciated. The dangers of carotid stenosis were seen in terms of a reduction and interruption in blood flow. Only later was the embolic origin of the majority of strokes fully appreciated and antiaggregant treatment initiated. Such a treatment proved to be effective and thus the value of CEA was questioned even further.

Largely at the initiative of neurologists, randomised CEA versus the best medical treatment protocols were initiated. Altogether, four important studies (NAS-CET, ECST, ACAS, ACST [3–6]) led the American Heart Association (AHA) to postulate indication criteria for surgery. The latest guidelines were published in 2006 [11] and recent criteria for CEA are as follows: symptomatic stenosis >50%, provided the surgical morbidity/mortality (M/M) rate is <6% and in asymptomatic patients stenosis is >60%, provided M/M rate is <3%. Patient considered for CEA should have a 5-year life expectancy. This condition is difficult to establish precisely but should be kept in mind. Research indicates that the effect of CEA in women is lower than in men [2] and greater in older patients than in younger patients [1].

The trials proved CEA to be a very effective and safe procedure, which led to an increase in the number of procedures performed. In the USA, roughly 100,000 CEAs are performed each year, split nearly evenly between neuro- and vascular surgeons. In Europe, the majority of procedures are performed by vascular surgeons. It is my strong conviction that CEA could be useful to the neurosurgical armamentarium. The neurosurgeons are those with comprehensive experience and education in clinical neurology and neuroradiolo-

---

*Keywords:* brain, ischemia, endarterectomy, carotid artery, vertebro-basilar system

gy. Moreover, they possess the technical skills and necessary equipment. The target of CEA is the brain, not the vessel, and as such, the procedure is in the domain of neurosurgeons.

In general, the cerebral vasculature, including the magistral vessels, is very complex and the procedures to treat the lesions from aortic arch to distal branches of the middle cerebral artery are numerous. Another major impetus derives from the endovascular field and nowadays we hardly encounter stenotic lesions that are not amenable to some kind of correction. The description of various procedures is beyond the scope of this chapter. CEA is by far the most common vascular surgical procedure and the general rules of CEA are applicable to most of the other stenotic lesions. Neurosurgical involvement in the whole field of cerebral ischaemia is both exciting and rewarding.

CEA has not undergone so many technical changes: the basics involve longitudinal arteriotomy followed by plaque removal and vessel suture. Eversion endarterectomy technique was introduced, indwelling shunts and their use were discussed in the past and patching techniques are used by some surgeons on a regular basis. Numerous and long-lasting discussions exist between those advocating general anaesthesia and those operating in local and regional anaesthesia. Overall, it was demonstrated in several studies that the results of different anaesthesia techniques are not significantly different. Their use depends on institutional and individual experience and customs and is actually not that important.

The most important development came in the 1990s from the field of interventional neuroradiology, namely, the carotid stenting procedures (CAS), which are now being compared with CEA in several randomised studies. None of these randomised studies shows a superiority of CAS, some show non-inferiority of CAS as compared with CEA and the majority are not able to prove the non-inferiority of CAS. On the other hand, meta-analyses have indicated that CEA is superior to CAS in the majority of cases [7, 8].

## **RATIONALE**

The goal of surgery is to eliminate the source of emboli. Carotid bifurcation is a predominant location for atherosclerotic plaque formation. Such a plaque may be fragile, where the intraplaque material sometimes has a mudlike consistency. As soon as the intimal layer is disrupted, the debris may embolise distally into the brain circulation. The tighter the stenosis, the thicker the plaque and the higher is the likelihood of embolisation. Clinically, the consequence of embolisations is transient ischaemic attacks (TIAs), both ocular and hemispheric, or completed stroke. Not an uncommon finding in stroke patients is carotid stenosis and embolic occlusion of the M1 segment.

Alternatively, the carotid artery may thrombose, which causes stroke. Once occluded, the internal carotid artery (ICA) is seldom the target of ei-

ther emergency thrombendarterectomy or elective stumpectomy, which is to prevent embolisation via collaterals.

## 1. CLINICAL PRESENTATION

The patients considered for CEA are either asymptomatic or symptomatic. In asymptomatic patients the stenosis is diagnosed either accidentally or, more frequently, during the targeted evaluation of the patients at risk of atherosclerotic cerebral occlusive disease. Symptomatic patients present with the whole clinical spectrum, starting with TIAs, hemispheric or ocular, and ending with deep completed stroke. Patients with major ipsilateral completed stroke are considered for CEA with some reservations. The symptoms can be either relevant to the stenosis in question or relevant to a different territory (contralateral carotid, or vertebrobasilar territory). Clinical findings should always be evaluated carefully and individually.

## 2. RADIOLOGICAL WORK-UP

All patients must be subjected to basic radiological work-up, either brain CT or MR imaging. Any other than ischaemic lesion must be ruled out and the extent and “age” of eventual ischaemia must be clearly documented. In the past, digital subtraction angiography (DSA) was the most important and only reliable diagnostic procedure. Important randomised studies are based on DSA findings. However, DSA is an invasive mode of examination and the M/M rate of this procedure must be added to the surgical M/M. Recent M/M rates of diagnostic DSA do not exceed 1% (0.1% at the author’s institution). In the past decade, non-invasive modalities have gradually taken over. Duplex ultrasonography (US) is an excellent tool provided the procedure is performed by an experienced professional. US is now preferable in screening and post-operative follow-ups. MR and CT angiography are now frequently used techniques in diagnosing and evaluating carotid stenosis. Both these techniques have the advantage of displaying the whole vasculature. Actually, the correlation of diagnostic methods and actual stenosis as measured on a removed plaque is not good. We have studied this problem for several years (supported by grants of the Czech Ministry of Health, IGA NR 9435-3). Our findings show that both DSA and US significantly underestimate the actual stenosis. CT and MR angiography are now under investigation.

## DECISION-MAKING

The decision to treat carotid stenosis is based on AHA guidelines. AHA guidelines provide general recommendations based on firm scientific foundations. The presentation and discussion of AHA guidelines far exceeds the

format of this chapter and the reader is therefore recommended to check the guidelines directly at <http://stroke.ahajournals.org/cgi/content/full/37/2/577>. However, some patients do not fit the criteria but still CEA can and, in some instances, should be indicated. The most typical example is a stenosis below the set value of 50% that is ulcerated and where US shows fragile material and the patient suffers repeated TIAs despite the best medical treatment. Another condition is a floating thrombus. In such a case the stenosis is negative according to NASCET measurements. All indications that do not fit AHA criteria should be strictly individual and based on individual and institutional experience.

## 1. TIMING

Timing depends on several factors. One factor is the patient's condition. In patients with recent major stroke the procedure should be postponed for an arbitrarily set interval of 6 weeks. Another factor is the CT finding. In patients with recent ischaemia on the basis of CT images the surgery should be postponed for the risk of haemorrhagic conversion of the infarcted region. Again, an interval of 6 weeks is recommended. However, it seems the risk of haemorrhagic conversion is not that high and thus the interval of 6 weeks has recently been questioned. In patients with TIAs, CEA should be performed as soon as possible. One study showed that 23% of major strokes were preceded by TIAs, and 43% of these strokes appeared within 1 week after the initial TIA [10]. Recently, CEA has been recommended within a week after TIA: ideally, TIA should be handled as an emergency and consequently treated by CEA. Unfortunately, this policy exceeds the efficiency of any recent medical system. In asymptomatic patients the timing does not apply.

### 1.1 CEA versus CAS

The interventional neuroradiologists simply took over the CEA indication criteria and applied them to CAS. CAS procedures, especially after the introduction of distal protection, seemed very attractive and promising for both patients and physicians. Actually, the general impression a few years ago was that these techniques would likely replace CEA. Thus far, this does not seem to be the case and, quite surprisingly, randomised trials comparing both techniques have shown either similar results for both techniques or CAS' inferiority. The last major trial (EVA-3S) was prematurely terminated because of CEA's superiority [9]. The SPACE study could not confirm the non-inferiority of CAS versus CEA [12]. Recently, the M/M rate of endovascular techniques exceeded the requirements of AHA, i.e. 6% of the M/M rate in symptomatic patients and 3% in asymptomatic patients. The value and possible indications for CAS should be solved by major ongoing randomised trials (ICSS, CREST, ACST-2). At our institution, after the first wave of enthusiasm, CAS is currently reserved for patients for whom the general anaesthesia is too risky from a medical point of view, for patients with carotid restenosis and carotid



**Table 1.** CEA and CAS results at the author's institution

	CEA	CAS
Number of procedures	1335	363
Mean age (years)	64	72
30-day morbidity/mortality	2.00%	4.68%
TIA within 30 days after procedure	1.49%	7.43%
Minor complications	10.07%	17.63%

dissections, for patients with tandem lesions and for post-irradiation stenosis. In unfavourable anatomical situations, CAS is also preferred: in extremely obese patients and patients with carotid bifurcation above the C2 level. CAS is also used in patients with a contralateral cranial nerve lesion (VIIth, Xth, XIIth). These guidelines were set at the present author's institution after the EVA-3S publication; earlier, the choice of treatment modality was more liberal. From 1982 to 2007, 1335 CEAs were performed. From 2001 to 2007, 363 CAS interventions were performed. In our material CEA proved to be safer (Table 1). Apart from carotid stenosis, of which CEA seems to be superior, in all other locations endovascular techniques are preferred (vertebral artery origin stenosis, intracranial stenosis, etc.).

## SURGERY

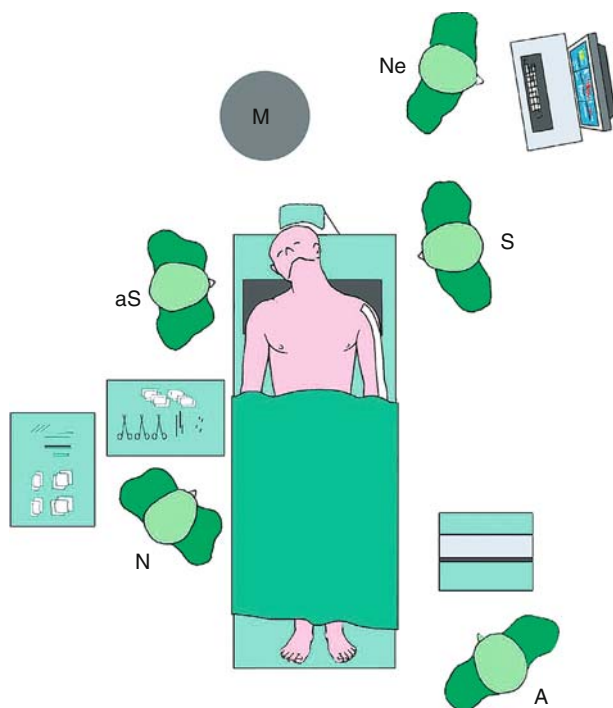
### 1. SURGICAL PROCEDURES

#### 1.1 Anaesthesia

All CEAs at the author's department are performed under general endotracheal anaesthesia with arterial line placement for continuous blood pressure monitoring. The controversy between general and local/regional anaesthesia is long-lasting and as of yet unresolved. The ongoing GALA trial, however, should shed some light on this issue. General anaesthesia has several advantages, including easier surgical manoeuvres, handling of complications and easier patient monitoring. On the other hand, clinical monitoring, which is allowed by local/regional anaesthesia, is unsurpassed by any other means. It seems that local/regional anaesthesia decreases the number of medical complications at the expense of neurological complications.

#### 1.2 Patient positioning

The patient is positioned supine and the head is slightly turned to the opposite side and extended. A small pad is placed under the ipsilateral shoulder and the arm is extended downwards. The entire operating table is slightly (10%) elevated head-wise.



**Fig. 1.** Operation room team position during CEA. *S* Surgeon, *aS* assisting surgeon, *Ne* neurophysiologist, *A* anaesthesiologist, *N* nurse, *M* microscope

At this point, the transcranial Doppler (TCD) probes are fixed in place. Somatosensory evoked potential (SSEP) needles are introduced into the scalp and electroencephalography (EEG) electrodes are fixed. Figure 1 shows the operation room team position during CEA. The procedure starts once it is ascertained that the monitoring system is functioning properly.

### 1.3 Carotid dissection

The incision runs along the anterior border of the sternocleidomastoid muscle (SCM), never above the angle of the jaw. Skin and platysma are incised and along the anterior border of the SCM the dissection proceeds deeper. The only traversing structure is the facial vein in the upper third of the approach. The vein is ligated and divided. The jugular vein is not dissected free; it is merely identified and left untouched. The common carotid artery (CCA) is gently palpated at the lower aspect of the wound and the carotid sheath exposed. Longitudinally, along the CCA runs the hypoglossal ansa, which is mobilised and moved anteriorly. The carotid sheath is then incised and the CCA exposed. The dissection proceeds cranially up to the carotid bifurcation and external carotid (ECA) and the superior thyroid arteries are

exposed to allow the application of the aneurysm clip. Only the self-retaining retractors are used throughout the procedure.

At this point, the microscope is introduced and the ICA is exposed as high up as needed using microsurgical techniques. Extreme care is taken not to harm the cranial nerves. The hypoglossal nerve is running immediately below the inferior head of the digastric muscle and its branch: the ansa cervicalis is running along the artery and at the level of the thyroid gland and curving anteriorly. The lower branch of the facial nerve runs transversally above the jaw angle in superficial layers. To protect this nerve in higher approaches the microscope is angled and higher up dissection runs only at and below the level of the digastric muscle. The lower head of this muscle may be transected, which would allow an even higher approach. The ICA is dissected well above the plaque, which is either seen at the vessel even from outside or can be gently palpated. The handheld retractors used by some surgeons to expose the distal ICA are never used for fear of injuring the peripheral nerves (VIIth and XIIth).

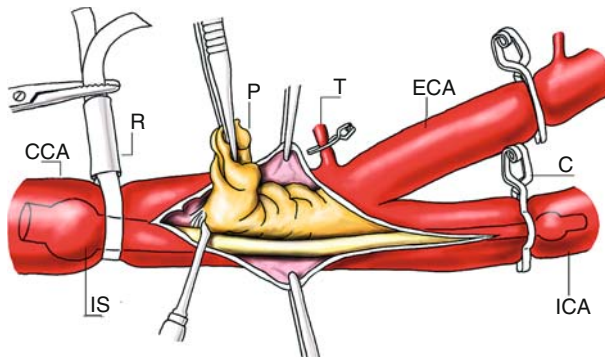
The ICA is usually positioned slightly lateral and posterior to the ECA. However, in some cases the ICA is hidden behind the ECA. The bifurcation complex is then dissected free from all the attachments and whole bifurcation is rotated using a sling around the ECA and eventual stitches in the adventitia are used to rotate the bifurcation.

Any manipulation of the vessels, especially at the level of stenosis, is strictly avoided. The arteries are not completely dissected from their attachment to the carotid sheath, i.e. they are dissected free only at points where clips are going to be placed. This procedure minimises the manipulation with the vessels and decreases the risk of embolisation.

If at this point in the procedure the SSEPs drop by 50% in three consecutive runs, the procedure is terminated. We have found this the hard way in the sense that neurological complications appeared always whenever the SSEPs dropped by more than 50% at the dissection phase. Such a decrease in SSEPs seems to indicate major distal embolisation. The significance of such an embolisation may not be sufficiently appreciated on TCD.

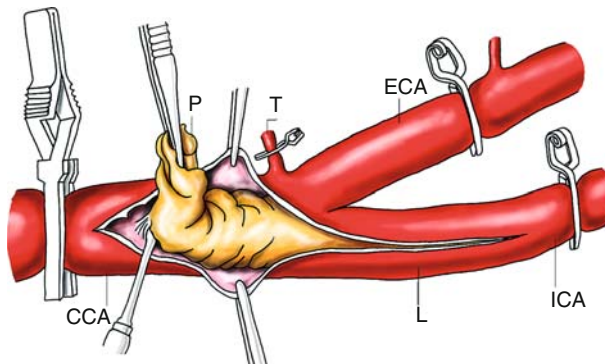
#### 1.4 Cross-clamping and endarterectomy

Dose of 5000 units of heparin (protocol at the author's institution) is administered before the clip application, a solution of local anaesthetics is applied to the region of glomus caroticum locally to block the carotid reflexes. The first clip is applied to the ICA, then one each to the ECA and the superior thyroid artery and finally to the CCA. The regular carotid clamp is used only for the CCA: all other clips are Yasargil aneurysm clips (slightly curved in order not to obscure the surgical field). The surgeon now waits about 1 minute for the electrophysiologist who closely monitors the SSEPs. Only if the SSEPs drop by more than 50% is longitudinal arteriotomy performed and the intraluminal shunt inserted (less than 3% in the last 500



**Fig. 2.** CEA technique with intraluminal shunt. *IS* Intraluminal shunt, *R* rubber band around the CCA, *C* window aneurysm clip at the ICA, *P* plaque, *T* superior thyroid artery

surgeries at our institution). If the shunt is used, it is kept in place by a rubber band around the CCA and by the window aneurysm clip at the ICA (Fig. 2). The appropriate aperture of the clip is chosen to hold the shunt and block any back bleeding from the ICA. If the shunt is not needed, the CCA is incised some 2 cm caudally from the bifurcation and the proper plane of dissection is found (colour of the vessel wall slightly deeper than the colour of the plaque, smooth surface). The plaque is transversally cut in the most caudal aspect of the arteriotomy. The plaque is then separated without cutting it longitudinally and the arteriotomy proceeds cranially stepwise always after the segment of the plaque is dissected free. The arteriotomy is slightly lateral to the midline (from the surgeon's point of vision); especially at the bifurcation it runs some 3 mm lateral from the upper aspect of the bifurcation (Fig. 3). When the cranial end of the plaque is reached, it is sharply divided. Lastly, the plaque is dissected from the ECA. Extreme care

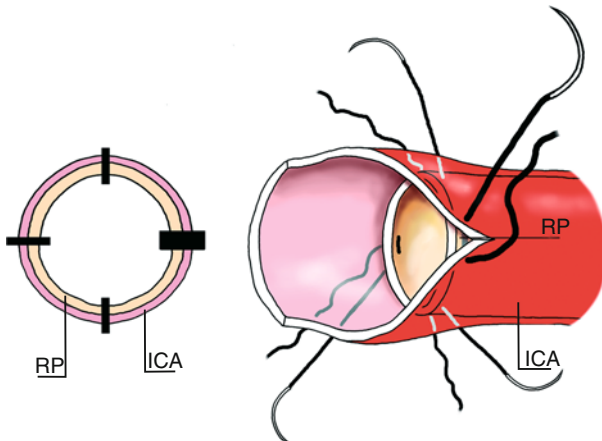


**Fig. 3.** Standard CEA technique. *P* Plaque, *T* superior thyroid artery, *L* longitudinal arteriotomy

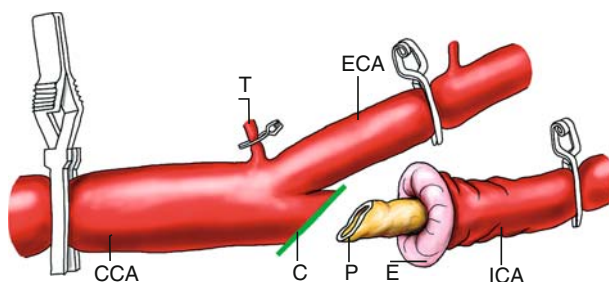
is necessary when dissecting hard, calcified plaques. In these cases the risk of injuring the thinned vessel wall is high and the calcified plaque always has firmer attachments to the outer vessel layers. Somewhat more comfortable is to cut through the plaque to the lumen, cutting it longitudinally until the healthy ICA is reached. Dissection then starts on the lateral aspect of the incision at the ICA origin where the proper plane is most easily encountered. At the author's institution, the uncut plaque is removed because it is used in a research protocol to compare the morphological stenosis with radiological findings. The whole plaque is fixed and cut transversally, where the slice with maximum stenosis is found and used for further studies.

After plaque removal, the whole arteriotomised segment is closely inspected and any loose material removed. The vessel wall is repeatedly flushed with a heparin solution to disclose any remnants. Extreme care is given to the distal end of the plaque. All flaps that are best seen under the jet of heparin solution are removed. In case this is not possible, two to four 8/0 tacking sutures are used. The stitches are positioned at 6, 9 and 12 hours "looking into ICA lumen" (Fig. 4). The 4th firm point is the first stitch starting the closure (at 3 hours on Fig. 4). If only two stitches are used, these are positioned at 7 and 11 o'clock. The stitches are introduced from outside of the vessel into the lumen and back outside again.

Eversion endarterectomy represents another technique of CEA when the ICA is transversally cut, plaque is removed after eversion of the ICA wall and the ICA is finally sutured to the CCA (Fig. 5). This technique is not performed at the author's institution.



**Fig. 4.** Technique to secure the distal end of the plaque. In case it is not possible to remove all remnants of plaque in the distal end of ICA and the intima is loose, tacking sutures are used. The stitches are positioned at 6, 9 and 12 hours "looking into ICA lumen". The 4th firm point is the first stitch starting the closure (at 3 hours). *RP* Residual plaque



**Fig. 5.** Eversion CEA technique. C Point where ICA is cut, E everted ICA wall, T superior thyroid artery

### 1.5 Arteriotomy suture

Arteriotomy is closed by the 6/0 running suture that starts at the cranial end. By using a microscope and microtechniques, we always have an abundance of the vessel wall, which obviates the need for patching. The first running suture is tight, short spaced. Before its completion, the ICA is shortly opened and flushed. Next, the artery is flushed with heparin solution. After completion of the first suture, the second suture, which is looser, is introduced, usually one stitch to each 2–3 of the first suture line. This is done because of the risk of suture material rupture. The second suture is for security. More knots are used – usually five – and the ends of the stitches are cut longer, some 5–6 mm from the knots. Again, this is for security purposes.

### 1.6 Clip removal and wound suture

After the arteriotomy is closed, the ICA clip is briefly (1 sec) opened. The clips are then removed from the ECA, the superior thyroid artery and the CCA. The last to remove is the clip from the ICA. This manoeuvre allows all the potential debris to be flushed into the ECA territory. If the surgeon is not fully satisfied with the procedure, direct dopplerometry is used to check the patency and disclose any irregularities in the vessels. The critical point is the cranial end of arteriotomy, where stenosis or the intimal flap may be found. In case of such an event (only twice in the last 500 surgeries at our institution), the clips are reapplied and the vessel reopened. The most frequent mistake is insufficient length of the arteriotomy and the ICA dissection is not sufficiently cranial, in which case the end of the plaque may not be reached properly and with the suture starting close to the clip the situation may not be sufficiently appreciated. To correct such a situation, further ICA dissection and a more cranial clip position are sufficient. The arteriotomy can then be sufficiently prolonged and any plaque remnants or intimal flaps can be handled.

In some cases, kink is appreciated at the end of the plaque and the ICA remains kinked even after the endarterectomy is completed. These

kinks are not excessive and usually simple caudal displacement of the bifurcation area suffices to straighten the kinks. Desired position is secured by 6/0 stitches between the CCA adventitia and the muscles (omohyoid, sternocleidomastoid).

The heparin is not reversed. Haemostasis is meticulous and any tiny bleeding points are coagulated by bipolar coagulation. The arteriotomy usually leaks a small amount and sometimes even a small jet of blood may be encountered. However, this event is not a reason to add extra stitches. Leaking arteriotomy is covered for some 3–5 min by muslin soaked in warm Ringer solution. Bleeding usually stops spontaneously. Finally, the arteriotomy is covered by a small strip of oxycellulose. The suction drain is positioned along the vessels and the wound is closed in two layers (platysma, skin).

After dressing the wound, the anaesthesia is terminated and the patient is awakened in the OR suite. The patient is then transferred to a semi-intensive care unit. Usually, 24 hours later the arterial line is removed and the patient is allowed to ambulate. The patient is usually dismissed on the 3rd or 4th post-operative day.

## 2. RESULTS

From a technical point of view, the results of CEA are very satisfactory. In the long run, restenosis appears in less than 5% of the procedures. There are two types of restenosis. First, is the recurrent atherosclerotic process, and second, the myointimal hyperplasia. It seems that recurrent stenosis is a far more benign process than primary stenosis and it is questionable whether some active means should be taken at all. Ultimately, the vessel becomes occluded without causing symptoms. However, because the patients are followed and restenosis diagnosed in time, the restenosis is usually treated according to the same criteria as those applied to primary stenosis. In the present author's series over the past 10 years all restenoses are treated by endovascular means, either by stenting or by percutaneous transluminal angioplasty.

From a clinical perspective, the results, i.e. a serious M/M rate, must be compared with the natural course of patients who are treated properly with antiaggregants. AHA allows for a 6% M/M rate in symptomatic stenosis and a 3% M/M rate in asymptomatic stenosis.

The number of patients needed to treat to prevent one stroke differ according to the degree of stenosis and the patients' symptomatology (Table 2).

**Table 2.** The number of patients needed to treat to prevent one stroke

Symptomatic stenosis (NASCET)		Asymptomatic stenosis (ACAS)
>70%	50–69%	>60%
<b>6</b>	<b>15</b>	<b>67</b>

In our material of 1335 consecutive CEAs, the overall serious M/M rate (death and completed stroke within 30 days after the CEA) was 2.02%. Minor complications constitute another 10%. These minor complications included TIAs, various minor medical complications, cranial nerve palsies, hyperperfusion syndromes, wound swelling and wound haematomas, infections, etc. For various reasons, 3% of our patients underwent revision surgeries.

### 3. COMPLICATIONS

#### 3.1 Medical

Medical complications depend on the patient population. We are treating seriously ill patients, usually in their 6th or 7th decennium. A typical patient is one that suffers from the combination of carotid occlusive disease (stenosis at relevant bifurcation only is very rare and other sclerotic findings are usually found elsewhere), ischaemic heart disease, arterial hypertension and diabetes mellitus. Consequently, the patients should be carefully selected and prepared for surgery. An experienced anaesthesiologist is far more important than the surgeon. He or she must collect all vital information about the patient, must be aware of all possible threats in the perioperative period and must be well prepared to deal with them effectively. The two possible serious complications likely to occur are myocardial infarction or cardiac failure during the perioperative period and a decrease in blood pressure during the perioperative period. A decrease in blood pressure, even a short and minor one (some 20 Torr), can cause stroke.

Another very dangerous condition in the immediate post-operative period is wound swelling and/or wound haematoma. Wound problems may cause breathing distress leading to myocardial infarction or failure with all possible consequences. As soon as the distress is noted after surgery, the patient should be taken back to the OR and the wound reopened, the haematoma removed and haemostasis achieved. If the haematoma is not present, the patient is intubated and ventilated for a few days. The sooner the action is taken, the better; in other words, the physician must “proact”, not react.

#### 3.2 Neurologic

The most frequent and unwelcome complication from surgery is exactly the disaster we want to prevent by surgery, namely, stroke. Stroke can be caused by a drop in blood pressure (see above), vessel thrombosis or by embolisation from the endarterectomised vessel. In case of stroke that is caused by thrombosis the patient must return to the OR and the vessel reopened. Any deep neurological deficit appearing in the immediate post-operative period is an indication for immediate investigation and revision in selected cases. This is an emergency and the success depends on timing. An immediate CT scan of the brain is indicated and CT angiography is very useful (if available).



TIAs, which appeared in 1.5% of our patients, should be treated as such (a single TIA can be considered inconsequential if CT and CT angiography is negative).

Hyperperfusion syndrome is characterised by unilateral headache and confusion. Close monitoring and maintaining the blood pressure within normal limits are manoeuvres to combat this condition.

In our series we have seen two typical hypertonic haematomas, both ipsilateral to the CEA and of grave consequences. To prevent intracerebral bleeding from reoccurring, close blood pressure monitoring and management are necessary.

### 3.3 Local complications

*Cranial nerve injury.* Nerve palsy appeared in 3.93% of our surgeries. The most frequently damaged nerve was the XIIth followed by the lower branch of the VIIth and recurrent nerve. In the majority of cases the palsy was caused by direct damage during surgery. Our experience shows that the function typically recovers within months. Inadvertent interruption of the nerve is a rare condition. If the surgeon is aware of the problem (in our material once in XIIth), the nerve should be sutured. We have encountered one permanent recurrent nerve palsy, two VIIth and four XIIth palsies.

*Wound.* As previously mentioned, wound haematoma and excessive wound swelling are potentially very dangerous. Haematoma should be removed and any swelling should be closely followed. Local infections are extremely rare (we encountered one early in the series).

## HOW TO AVOID COMPLICATIONS

### 1. PATIENT SELECTION

Patients scheduled for CEA are usually generally quite ill, having a combination of atherosclerotic changes in more than one system. It is therefore mandatory to perform an exhaustive pre-operative assessment (e.g., functional cardiac tests and full laboratory battery). It is also necessary to evaluate the whole cerebral vasculature in order to determine whether there are any other pathological findings. An experienced anaesthesiologist is a *conditio sine qua non*. The anaesthesiologist should see and evaluate the patients well prior to the procedure. The final indication should be set by the vascular panel composed of all involved specialists. This scheme is the best prevention of post-operative medical complications. However, in very few patients surgery is declined. The patients should be prepared for surgery and active treatment of any concurrent disease before surgery is mandatory. Since 1999, all those patients found unsuitable for surgery were treated by CAS (based on SAPHIRE study-13). In the past 2 years, CAS has been less frequently

used, however, and the patients are very thoroughly prepared for surgery in general anaesthesia.

## **2. ANAESTHESIA**

Very gentle and smooth anaesthesia is a must, where it is crucial that the anaesthesiologist keeps the patient's blood pressure some 20 Torr above his/her normal range. Any reduction in blood pressure is dangerous and hence should be strictly avoided. An arterial line for continuous blood pressure monitoring is mandatory throughout surgery and should continue another 24 hours post-surgery.

## **3. MONITORING**

Monitoring is essential for selective intraluminal shunting. A decrease in SSEP during the dissection phase of surgery should lead to immediate abandonment of the procedure, which, however, could be repeated in a week or CAS may be a sensible alternative. If changes in SSEP appear later in surgery, the surgeon should work faster and the anaesthesiologist should increase blood pressure. TCD backup is helpful but we do not rely on it as the only monitoring technique. PostCEA direct dopplerometry is useful in checking the endarterectomised segment. Whenever reopening of the vessel is considered, it should be done as it could be too late later.

## **4. DISSECTION AND ENDARTERECTOMY**

Sharp dissection with meticulous haemostasis throughout the whole procedure is required. Sufficient length of the vessels must be dissected free though the dissection should not reach caudally beyond the omohyoid muscle (recurrent nerve) and cranially above the angle of the jaw (facial nerve) above the lower head of the digastric muscle unless the hypoglossal nerve is dissected free. This strategy ensures good orientation within the surgical field and prevents peripheral nerve injury. After plaque removal, extreme care must be exercised on removal of all loose remnants. Otherwise, these loose remnants could embolise distally into the brain circulation after clip removal. The crucial point is the distal end of endarterectomy; the intima must be smooth and any flap either resected or fixed by stitch. This phase is the point where post-operative thrombosis can start. A meticulous surgical technique is the best prevention of post-operative thrombosis.

## **5. CROSS CLAMPING**

Proper sequence of clip application and removal decreases the risk of perioperative embolisation.

## 6. HAEMOSTASIS

Step-by-step meticulous haemostasis provides the best prevention of post-operative haematoma and swelling with all the concomitant consequences.

## 7. HEPARIN NON-REVERSAL

Non-reversal or partial reversal of heparin only diminishes the risk of post-operative thrombi formation.

## 8. POST-OPERATIVE CARE

Some 24 hours of close monitoring after surgery ensures early detection and proper handling of any possible complication.

## CONCLUSIONS

CEA is a rather safe and effective procedure. Its rationale has been proven by several major trials and its durability demonstrated over a long period. If indicated, and executed properly, it is a very effective method for the prevention of stroke. The risk of stroke, however, is not completely eliminated because only a tiny part of the vasculature is treated and the whole underlying process (atherosclerosis) remains unchanged. Thus, there is the need for lifelong medical treatment and regular exams.

CEAs should be performed only at institutions with a high volume of patients and a proven low M/M rate. Surgically, CEA in experienced hands is an easy and fast procedure. On the other hand, the patients are usually seriously ill with higher than usual surgical risks. Thus, to treat these patients effectively a dedicated team composed of neurologists, internists, anaesthesiologists, radiologists and neurosurgeons (vascular surgeons) is necessary.

The above described surgical techniques cannot be dogmatic. They work well at our institution, where they were developed and proven over the past 25 years (the author performed his first CEA in 1982). It has been shown that the same results were published with routine use of shunt, routine patching, eversion CEA, etc. Further, the monitoring system described here is not the only one providing the surgeon with relevant information. General versus local/regional anaesthesia is still under scrutiny. Concerning this matter, we are awaiting the GALA trial results. The important issues are not small differences in technique but final clinical results.

## Acknowledgements

J. Kacvinsky (for preparation of figures) and D. Netuka (for help with text preparation) are to be acknowledged.

## References

- [1] Alamowitch S, Eliasziw M, Algra A, Meldrum H, Barnett HJ; North American Symptomatic Carotid Endarterectomy Trial (NASCET) Group (2001) Risk, causes, and prevention of ischaemic stroke in elderly patients with symptomatic internal-carotid-artery stenosis. *Lancet* 357: 1154-1160
- [2] Alamowitch S, Eliasziw M, Barnett HJ; North American Symptomatic Carotid Endarterectomy Trial (NASCET); ASA Trial Group; Carotid Endarterectomy (ACE) Trial Group (2005) The risk and benefit of endarterectomy in women with symptomatic internal carotid artery disease. *Stroke* 36: 27-31
- [3] Asymptomatic Carotid Surgery Trial (ACST) Collaborative Group (2004) Prevention of disabling and fatal strokes by successful carotid endarterectomy in patients without recent neurological symptoms: randomised controlled trial. *Lancet* 363: 1491-1502
- [4] Barnett HJ, Taylor DW, Eliasziw M, Fox AJ, Ferguson GG, Haynes RB, Rankin RN, Clagett GP, Hachinski VC, Sackett DL, Thorpe KE, Meldrum HE, for the North American Symptomatic Carotid Endarterectomy Trial Collaborators (1998) Benefit of carotid endarterectomy in patients with symptomatic moderate or severe stenosis. *N Engl J Med* 339: 1415-1425
- [5] European Carotid Surgery Trialists' Collaborative Group (1998) Randomised trial of endarterectomy for recently symptomatic carotid stenosis: final results of the MRC European Carotid Surgery Trial (ECST). *Lancet* 351: 1379-1387
- [6] Executive Committee for the Asymptomatic Carotid Atherosclerosis Study (1995) Endarterectomy for asymptomatic carotid stenosis. *JAMA* 273: 1421-1428
- [7] Kastrup A, Gröschel K (2007) Carotid endarterectomy versus carotid stenting: an updated review of randomized trials and subgroup analyses. *Acta Chir Belg* 107(2): 119-128
- [8] Luebke T, Aleksic M, Brunkwall J (2007) Meta-analysis of randomized trials comparing carotid endarterectomy and endovascular treatment. *Eur J Vasc Endovasc Surg* 34: 470-479
- [9] Mas JL, Chatellier G, Beyssen B, Branchereau A, Moulin T, Becquemin JP, Larrue V, Lièvre M, Leys D, Bonneville JF, Watelet J, Pruvo JP, Albucher JF, Viguier A, Piquet P, Garnier P, Viader F, Touzé E, Giroud M, Hosseini H, Pillet JC, Favrole P, Neau JP, Ducrocq X, EVA-3S Investigators (2006) Endarterectomy versus stenting in patients with symptomatic severe carotid stenosis. *N Engl J Med* 355: 1660-1671
- [10] Rothwell PM, Warlow CP (2005) Timing of TIAs preceding stroke: time window for prevention is very short. *Neurology* 64: 817-820

- [11] Sacco RL, Adams R, Albers G, Alberts MJ, Benavente O, Furie K, Goldstein LB, Gorelick P, Halperin J, Harbaugh R, Johnston SC, Katzan I, Kelly-Hayes M, Kenton EJ, Marks M, Schwamm LH, Tomsick T (2006) Guidelines for prevention of stroke in patients with ischemic stroke or transient ischemic attack: a statement for healthcare professionals from the American Heart Association/American Stroke Association Council on Stroke: co-sponsored by the Council on Cardiovascular Radiology and Intervention: the American Academy of Neurology affirms the value of this guideline. *Stroke* 37: 577-617
- [12] SPACE Collaborative Group, Ringleb PA, Allenberg J, Brückmann H, Eckstein HH, Fraedrich G, Hartmann M, Hennerici M, Jansen O, Klein G, Kunze A, Marx P, Niederkorn K, Schmiedt W, Solymosi L, Stिंगele R, Zeumer H, Hacke W (2006) 30 day results from the SPACE trial of stent-protected angioplasty versus carotid endarterectomy in symptomatic patients: a randomised non-inferiority trial. *Lancet* 368: 1239-1247
- [13] Yadav JS, Wholey MH, Kuntz RE, Fayad P, Katzen BT, Mishkel GJ, Bajwa TK, Whitlow P, Strickman NE, Jaff MR, Popma JJ, Snead DB, Cutlip DE, Firth BG, Ouriel K (2004) Stenting and Angioplasty with Protection in Patients at High Risk for Endarterectomy Investigators. Protected carotid-artery stenting versus endarterectomy in high-risk patients. *N Engl J Med* 351: 1493-1501



**Vladimír Beneš**

Vladimír Beneš is Professor of Neurosurgery and Chief of Neurosurgery at the 1st Faculty of Medicine, Charles University, Prague, Central Military Hospital and Post-graduate School of Medicine. Vice-President EANS 2003–2007, Chairman of the EANS Training Committee 2007–, President of the European Skull Base Society 2007–, President of the Czech Neurosurgical Society 2002–. Special interest in cerebrovascular surgery, cerebral ischaemia, intracranial aneurysms, AVMs, cavernomas. Research of correlation of diagnostic methods (digital subtraction angiography, Doppler ultrasonography, MR angiography, CT angiography) and morphological findings in carotid stenosis. Clinical research in psychological sequelae of aneurysm treatment (clipping and coiling), clinical management of arteriovenous malformations. Involvement in neurooncology, meningiomas, pituitary adenomas and sellar lesions in general. Local principal investigator and coordinator in international studies: ACST, ISAT, Glioma ARC Study, STICH. 200 publications, eight books and book chapters.

**Contact:** Vladimír Beneš, Department of Neurosurgery, Charles University, 1st Faculty of Medicine, Central Military Hospital, U nemocnice 1200, 16902 Prague 6, Czech Republic  
E-mail: vladimir.benes@uvn.cz

---

# **BRAIN REVASCULARIZATION BY EXTRACRANIAL–INTRACRANIAL ARTERIAL BYPASSES**

Y. YONEKAWA

## **INTRODUCTION**

The therapeutic idea of anastomosis of the external carotid artery, or one of its branches, with the internal carotid artery above the area of narrowing was advocated by C. Miller Fisher in 1951. This was actually realized in another way than originally suggested at the cervical region, but in the form of superficial temporal artery–middle cerebral artery (STA-MCA) bypass using microsurgical technique by Donaghy and Yaşargil in 1967 [22]. Thereafter, applications of the revascularization technique have been reported for one cerebral vascular territory after the other. It was the international cooperative study of extracranial–intracranial (EC-IC) bypass, whose final results in 1985 called the role of the procedure in prevention of further recurrent stroke into question [5]. Most neurosurgeons were disappointed at the results then and apparently have lost interest in performing microvascular anastomosis. This tendency has been enhanced by the development of interventional neuroradiology represented by percutaneous an transluminal dilatation (PTA) pioneered by A. Grüntzig in 1979 and later with additional stenting procedure.

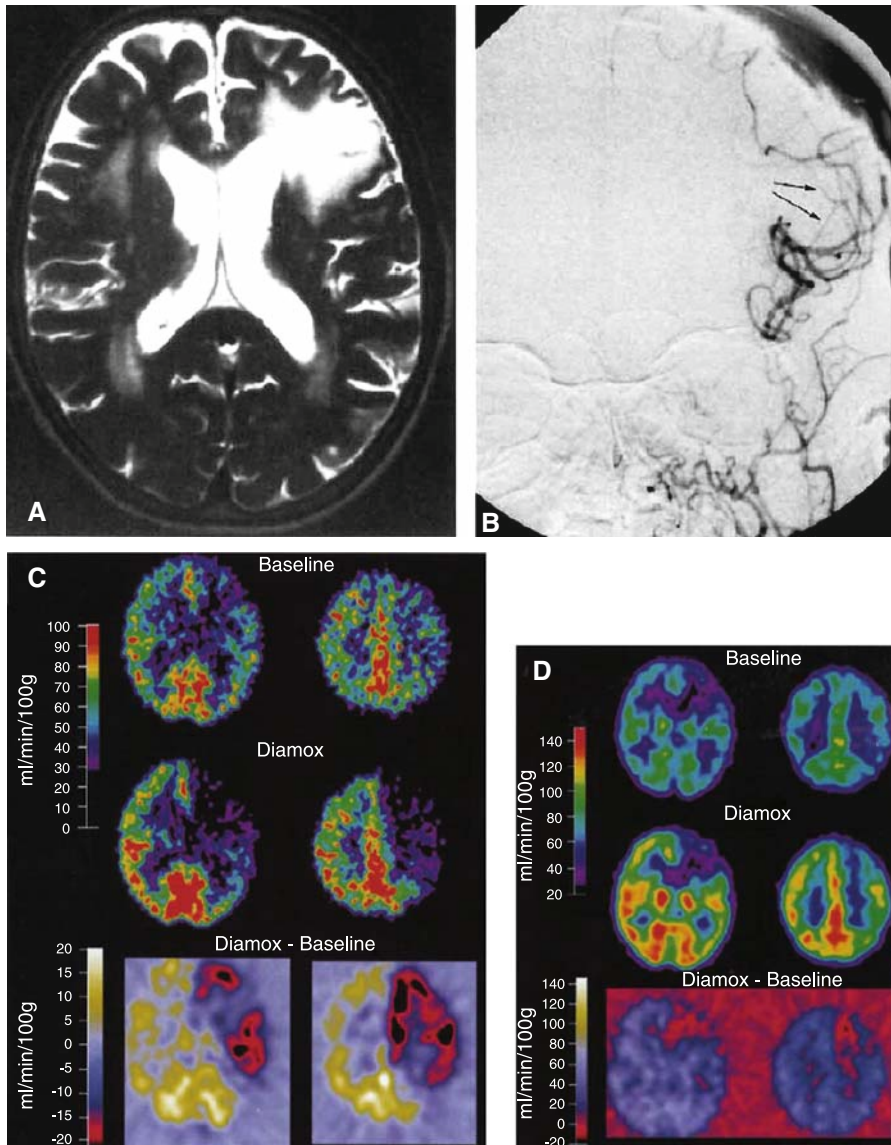
However, there are recently signs of a revival of interest in microsurgical revascularization, as some studies indicate the benefit of the bypass procedure in stroke prevention and also the limitation of the endovascular method has become gradually evident. In this chapter we present our method of revascularization, including indication, technique and results.

## **RATIONALE**

Occlusion or hemodynamically significant stenosis of cerebral arteries mostly due to atherosclerotic process cause symptomatic cerebral ischemia of varying severity: transient ischemic attacks (TIAs) or strokes, depending on the degree of reduced regional cerebral blood flow (rCBF). Clinical manifestation and pathophysiological changes are dependent on inherent collateral

---

*Keywords:* brain revascularization, ischemia, brain revascularization, extra-intracranial arterial bypasses



**Fig. 1.** 75-year-old female with completed stroke due to left ICA occlusion resulting in infarction in the frontal lobe (A). Despite antiplatelet therapy she had further TIAs presenting with aphasia and right hemiparesis. The preoperative PET scan revealed decrease of CBF in the left hemisphere along with decreased hemodynamic capacity on the Diamox test; there was even a steal phenomenon (C). Postoperative angiography showed an excellent filling of the MCA from the STA-MCA bypass (B). The patient was asymptomatic and free of TIAs after the bypass procedure. The 3-month follow-up postoperative PET scan showed increased CBF and normalized hemodynamic capacity except for the infarcted area (D)



circulation which brings various hemodynamic, physiologic and metabolic situation (Fig. 1). Hemodynamic compromise or hemodynamic failure in cases with occluded cerebral arteries is represented on the PET (positron emission tomography) images with reduced CBF unaccompanied by proportional reduction in cerebral metabolic rate of oxygen and increase of oxygen extraction fraction, namely, misery perfusion [3], or accompanied by reduced cerebrovascular reactivity CVR on Diamox loading (Fig. 1). These can be detected more or less also by single-photon-emission computed tomography (SPECT) [15, 25].

Recurrence of cerebral ischemia has been reported to be around 30–40% (this rate has been reported to be approximately halved by the administration of Aspirin or anticoagulants) in five years and to be more frequent in cases with reduced CBF or/and reduced hemodynamic reserve. Klijn and coworkers reported in 1997, in review of literature, that patients with symptomatic carotid occlusion and hemodynamic compromise have a higher risk of strokes: 12.5%/year for all strokes and 9.5%/year for ipsilateral stroke, as compared with 5.5% and 2.1%, respectively, in cases without hemodynamic compromise [30].

Augmentation of CBF by around 10% obtainable by bypass surgery is considered to prevent recurrence of cerebral ischemia in cases with hemodynamic failure, which could not be selected out as a group for the international EC-IC bypass study in the 1980s. At that time a subgroup of the Japanese-Asian group under study which mainly consisted of MCA occlusive lesions did however show less incidence of stroke recurrence in the surgical group, though of no decisive statistical significance [25]. Recently, the newly organized Japanese EC-IC trial study (JET) showed the role of bypass in stroke prevention in cases with compromised cerebral hemodynamics with CBF of <80% and regional cerebrovascular reactivity of <10%, namely, stage 2 after Powers [15], as inclusion criteria [7]. Better perfusion of the ischemic penumbra (16–20 ml/100 g/min) around an infarcted area by bypass surgery has been considered to contribute also to functional recovery, although there are still objections to this view representing the penumbra allegorically as “sleeping beauty” [1, 25].

*Moyamoya angiopathy (MMA)*, discovered in 1955, proved to occur not only in Japanese and Asian but also in Caucasian populations (USA, Europe) though with less incidence and is known to present mainly with ischemic cerebral symptomatology in accordance with a varying degree of hemodynamic disturbances [10, 27]. The revascularization procedure has been reported to prevent recurrent cerebral ischemia and neurological deterioration due to hypoperfusion or hemodynamic failure and also to prevent intracerebral hemorrhage due to rupture of the Moyamoya vasculature or related microaneurysms in the basal ganglia, which is another manifestation of MMA [8, 27]. The role of bypass surgery in prevention of bleeding has still to be defined systematically [27]. Indirect revascularization method, using burr

**Table 1.** Representative type of extracranial–intracranial bypass procedure

1. Anterior circulation	STA-MCA bypass, OA-MCA bypass, STA-ACA bypass, STA-M2-3 bypass
2. Posterior circulation	STA-SCA bypass, OA-PICA bypass, OA-AICA bypass, OA-SCA bypass, OA-PCA bypass
Interposition graft bypass	Subclavia (CCA, EA, C4)-C2 or M2 bypass (high flow), Bonnet bypass (low flow)

holes, dural reflection, putting arteries or omentum on the brain surface, ideas related with the concept of Henschen's encephalomyosynangiosis described in 1950, are not discussed in this chapter in detail though they are rather in prevalent use as surgical treatment of MMA. For these, the various relevant articles should be referred to [13, 27, 28].

*Reconstructive surgery of venous system* including venous sinus is beyond the scope of this chapter and hence relevant articles should be referred to [17].

*Revascularization using microvascular technique to be discussed in this chapter is represented with following bypasses (Table 1):* the superficial temporal artery STA or the occipital artery OA of around 1 mm in diameter is dissected in situ and anastomosed with a cortical branch of the middle cerebral artery (STA-MCA bypass or OA-MCA bypass), with the superior cerebellar artery (STA-SCA bypass) or with the posterior inferior cerebellar artery (OA-PICA bypass) in accordance with the location of the territory of hemodynamic failure. The STA- or OA-MCA bypass are considered to deliver 10–20 ml/min flow at the beginning of bypass construction and to deliver as much as 100 ml/min flow after several weeks to months according to the need of the ischemic brain territory in question, so that hemodynamically compromised brain can obtain around 10% increase of CBF [16, 25].

Pressure difference between the extracranial artery and the cortical arteries has been reported to be around 20% at normal condition without any occlusive lesion and much more consequently in an ischemic brain, so that a flow reversal from intracranial to extracranial direction cannot take place through the newly constructed bypass route [29].

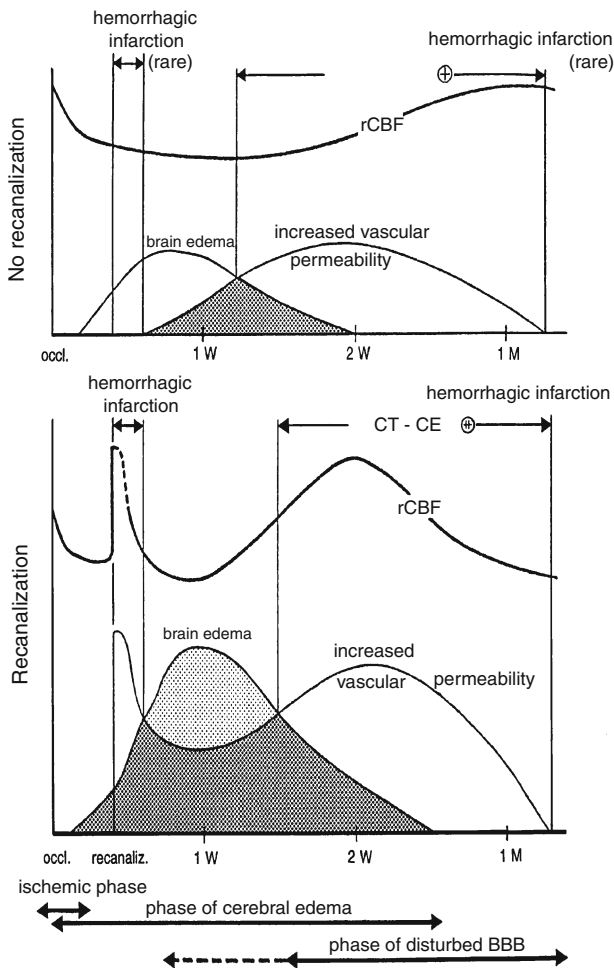
*Combination of bypass surgery with therapeutic occlusion of parent artery of aneurysms* is another indication of the revascularization procedure. A special type of revascularization high-flow bypass using saphenous vein graft or radial artery graft is also dealt with in this chapter.

## DECISION-MAKING

Candidates for surgery for prevention of recurrent cerebral ischemia (transient ischemic attack TIA or/and stroke) *must fulfil all three criteria* as shown in Table 2. (1) Symptomatology and neurological signs should cor-

**Table 2.** Indication criteria of the STA-MCA bypass for the anterior circulation (modified inclusion criteria of the international cooperative study [5] and those of JET study [7])

1. Clinically: TIA or minor stroke with no or minor neurological deficits (Rankin 1, 2, 3)
2. Angiographically:
  - a. MCA-M1 occlusion or stenosis (more than 50%)
  - b. ICA occlusion
  - c. ICA stenosis (more than 50%) above the mandibulomastoid line
3. Hemodynamic compromise (identified by PET scan or SPECT): CBF < 80%, Acetazolamide loading < 10%



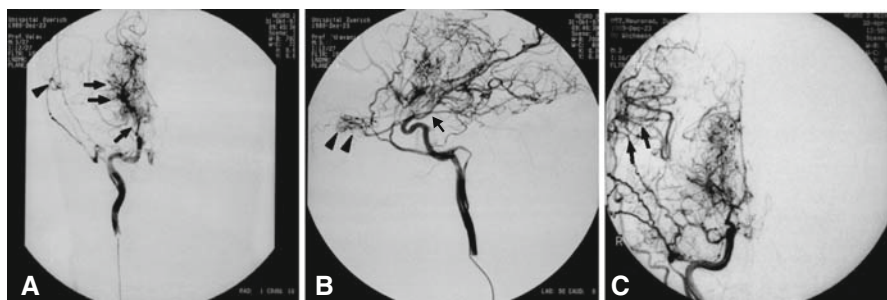
**Fig. 2.** Pathophysiological time course of an infarcted area after Mizukami [14]. With this diagram one can understand the pathophysiological process of an infarction is very dynamic and complicated within three weeks after the onset, especially at the time of recanalization or revascularization

respond with the lesion but the patients should not have severe neurological deficits (up to moderate disability of Rankin scale 3) due to the above mentioned lesion. (2) Selection criteria of angiographically identified occlusive lesions responsible for the ischemia are the same as those for international cooperative study for the ICA territory and these can be extended to the vertebrobasilar artery territory. (3) Hemodynamic compromise should be detected either by  $H_2^{15}O$  PET or SPECT (iodine-123-labeled amphetamine [IMP] or technetium-99m) with Diamox loading represented typically with decreased basal rCBF and reduced reactivity [7, 15, 25].

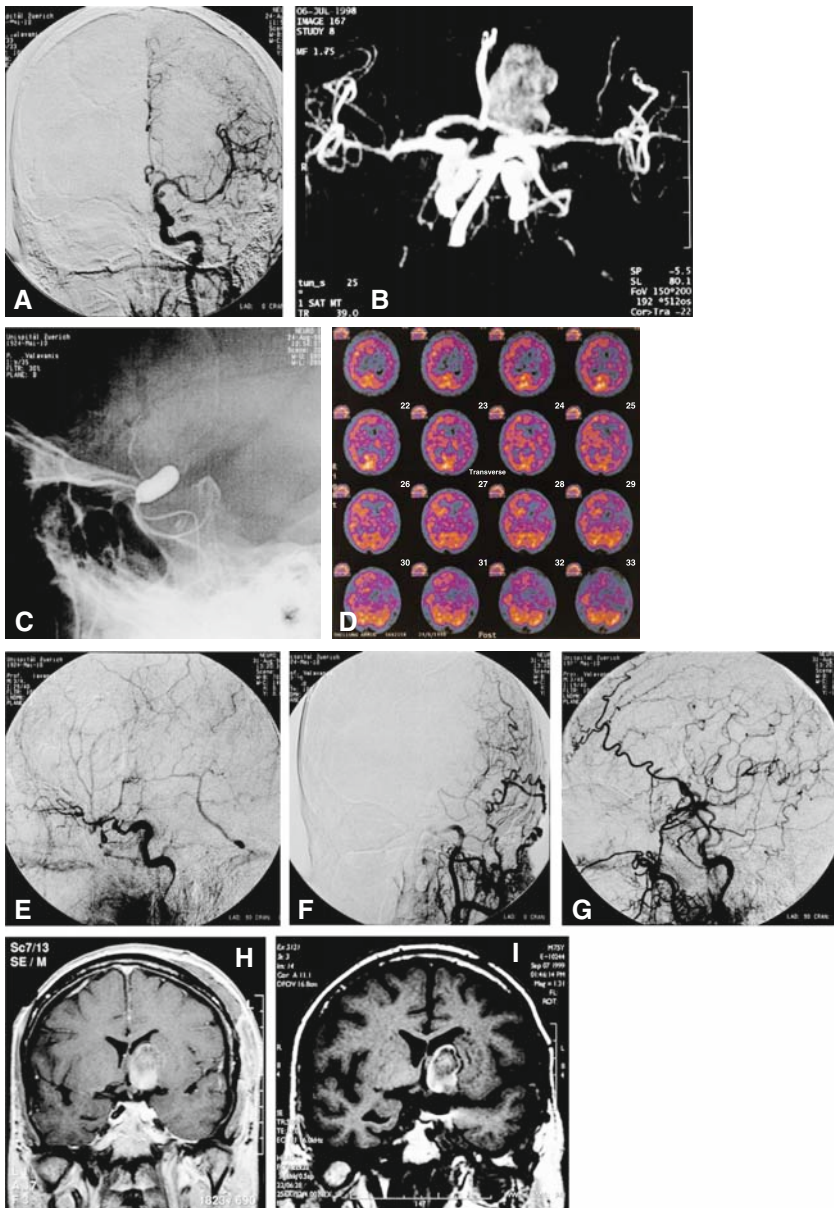
Revascularization surgery *should take place between 3 weeks and 3–6 months after a stroke*. Surgery before 3 weeks after a stroke has been reported to have a higher risk of bleeding on revascularization. Contrast enhancement of the infarcted area on CT scan during the period is considered to indicate impaired blood brain barrier (Fig. 2). The period within 3–6 months after a stroke is considered to be the one of frequent stroke recurrence.

For MMA patients the selection criteria are the same but the occlusive lesion lies typically at the carotid fork or C1 and usually the lesion is bilateral combined typically with Moyamoya vasculatures at the basal ganglia (Fig. 3) [27]. Hemodynamic compromise is to be detected on PET or SPECT examination. At a period or stage in which patients have repeated or frequent ischemic attacks, surgical intervention should not be performed. In our experience, revascularization surgery on patients should be postponed more than 48 hours after a Diamox loading test so that hemodynamic and metabolic stability can be more or less regained.

*Combination of bypass and Hunterian ligation* as treatment for intractable aneurysms (large and/or giant aneurysms especially at the cavernous portion of the ICA or dissecting aneurysms). I believe that the ligation



**Fig. 3.** 9-year-old girl with TIAs. AP view of digital subtraction angiography showing a stenosis at the carotid fork (arrow) with typical abnormal vasculature (Moyamoya) in the basal ganglia (double arrow). A vault Moyamoya (arrowhead) supplied by the middle meningeal artery is also seen (A). Lateral view showing typical stenosis at the carotid fork (arrow). Ethmoidal Moyamoya (double arrowhead) supplied by the ophthalmic artery is seen (B). AP view of the postoperative digital subtraction angiography showing a well functioning bypass supplying the MCA (double arrow) through the STA (C)

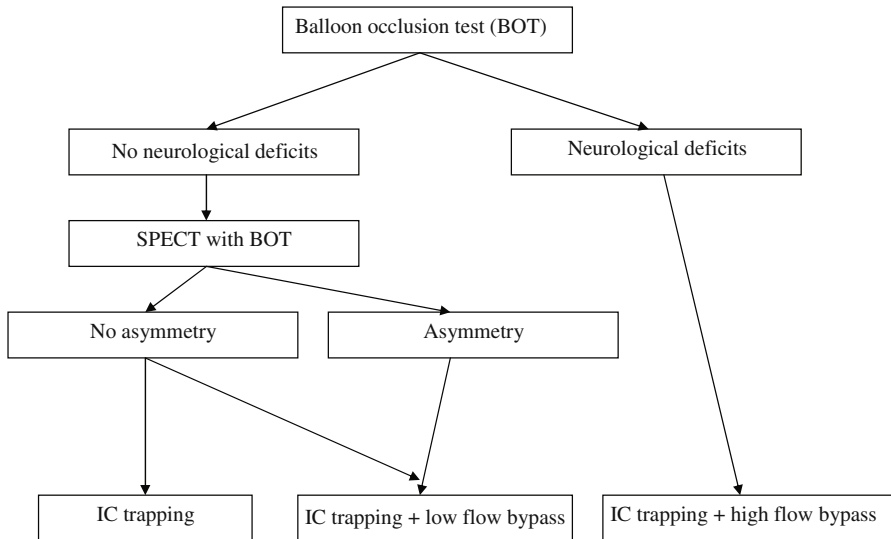


**Fig. 4.** 74-year-old male suffering from a growing mostly thrombosed giant aneurysm of the left ICA (A, B). He underwent the BOT (C), which was well tolerated but associated with asymmetry in SPECT (D). He underwent a standard STA-MCA bypass in combination with carotid occlusion just distal to the origin of the ophthalmic artery without any postoperative problems (E). The 3-month follow-up angiography showed an excellent filling of the MCA through the STA (F, G) and shrinkage of the thrombosed aneurysm (H, preoperative; I, one year postoperative)

should be replaced by a trapping procedure (distal occlusion site just proximal of a branching artery from the parent artery to be occluded) either by conventional surgery or by endovascular surgery in order to prevent distal propagation of thromboembolism or retrograde refilling of aneurysms [12, 32]. Candidates for the construction of a bypass are selected by the following criteria based on the endovascular balloon occlusion test (BOT), which has replaced formerly used Matas test and tournique test [30]:

- a) Presentation of ischemic symptomatology such as hemiparesis, speech and/or consciousness disturbance
- b) Tolerable BOT without neurological change but with
  - 1) Asymmetry of radionuclide uptake on SPECT study during BOT (Fig. 4)
  - 2) CBF measurement: less than 30 ml/100 g/min
  - 3) Transcranial Doppler sonography (TCD): less than 30% fall of mean flow velocity or less than 20 cm/s
  - 4) Changes of neurophysiological monitoring with EEG, SEP or near-infrared spectrophotometry

Hypotensive challenge at the time of BOT has been reported by some groups to be useful for selection of bypass candidates and type of bypasses (high flow or low flow). The treatment algorithm shown in Fig. 5, modified



**Fig. 5.** Treatment algorithm with the use of balloon occlusion test (BOT) (modified from those suggested by Kawano et al. [4] and Date et al. [9])

**Table 3.** Contraindications and/or conditions in which bypass surgery should not be performed

- 
- a. cancer other than skin cancer (including lymphoma, leukemia)
  - b. renal failure (BUN > 50 mg%)
  - c. congestive heart failure (past or present)
  - d. severe hepatic or pulmonary disease constituting anesthetic risk
  - e. stroke acute stage less than 3 weeks after the onset.

Furthermore

- f. blood sugar > 300 mg%
- g. diastolic pressure > 110 mmHg

These should be brought into the normal range and stabilized before surgery

---

from those proposed by Kawano et al. in 1991 and Date et al. in 2008, may also help to select patients and flow type of bypasses.

In bypass surgery for aneurysms indication has to be sometimes reviewed on individual basis in emergency settings of aneurysm surgery and in therapy-resistant vasospasm [12].

*Contraindications.* Most of the revascularization procedures are carried out for the prophylactic purpose, so that preoperative neurological and general physical status should not deteriorate after surgery. Items listed in Table 3 which were mostly exclusion criteria of the international EC-IC bypass study can be considered as contraindication.

## **SURGERY**

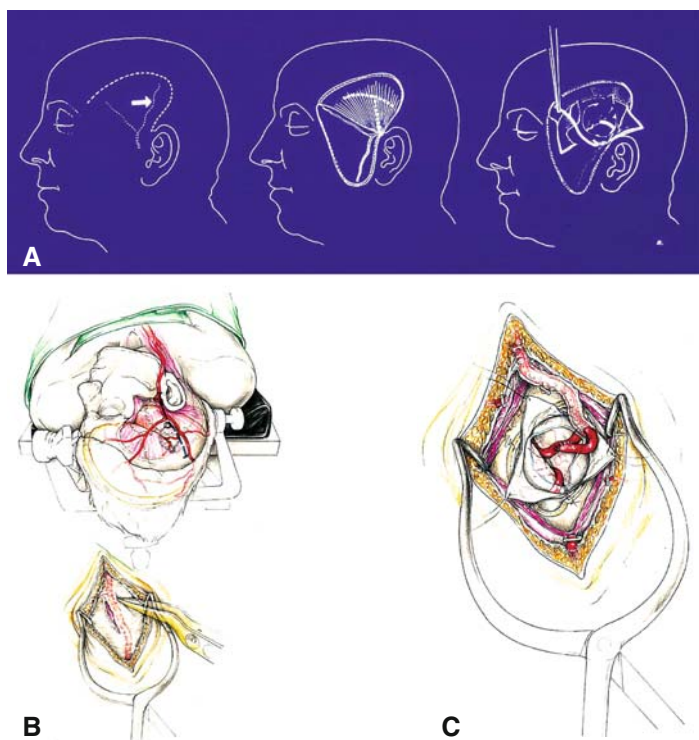
### **1. BYPASS SURGERY FOR ANTERIOR CIRCULATION**

#### **1.1 Operative technique of the standard the STA-MCA bypass (Fig. 6)**

Under general anaesthesia, the head is fixed with a Mayfield apparatus in supine position with slight elevation of the shoulder on the side of surgery with insertion of a cushion underneath, so that the plane of the squama temporalis as horizontal plane comes at the top of the operative field. To be cared for are the turning and flexion-deflexion of the head with due regard to cervical spondylosis, venous return and endotracheal tube. Arm rest is indispensable for performance of microvascular surgery.

#### *Dissection of the STA*

After the scalp to be operated has been shaved, one assesses, guided by Doppler sonography, the course of the STA parietal branch and also the frontal branch if necessary. One may dissect the STA with a diameter of around 1 mm in the skin flap after reflection of a question mark incision as originally described. The STA can be dissected also under a linear incision for a length



**Fig. 6.** Standard STA-MCA bypass. **A** Dissection of the STA from the skin flap. Frontal branch can be included also in the flap in case of necessity of its use [22, 29]. **B** Positioning of the head and dissection of the STA parietal branch by linear incision. **C** Completed STA-MCA bypass after a small craniotomy with its center placed 6cm cranial to the external acoustic porus.

of 8–10 cm. The arterial dissection is done including periadventitial tissues so that it can be performed quickly and atraumatically protecting arterial walls within it. After having cut the temporal musculature along its fibre direction, the squama temporalis is exposed by spreading the cut muscular line.

#### *Craniotomy*

The center of the craniotomy is placed at a point about 6 cm cranial to the porus acusticus externus. This point is supposed to correspond with the end of the Sylvian fissure, from which branches of the MCA with a diameter of about 1 mm emerge onto the cortical surface. These arteries are the angular artery, posterior parietal artery or posterior temporal artery and suitable as recipient artery for end-to-side microvascular anastomosis with the dissected parietal branch of the STA as donor.

An alternative method is to use 3-D CT angiography or MR angiography for navigation to the location of the target cortical artery and perform a crani-



otomy accordingly [11]. One burr hole is placed just caudal to the sutura squamosa and from this hole a small bone flap of around 3 cm is sawed out towards cranially so that the above mentioned cortical arteries can be dissected after dural opening [25, 29].

#### *End-to-side microvascular anastomosis*

After having opened the arachnoidea, one of the cortical arteries of around 1 mm in diameter in the operating field is dissected in a length of 1 cm, with several tiny branches of the artery being coagulated and cut. A rubber dam is inserted between the cortical surface and the dissected segment of the cortical artery for the isolation of the latter. After the segment has been closed with temporary mini-clip at its proximal and distal ends, a longitudinal arteriotomy or an elliptical arteriotomy for a length of 1.0–1.5 mm is done on the superior surface of this recipient artery.

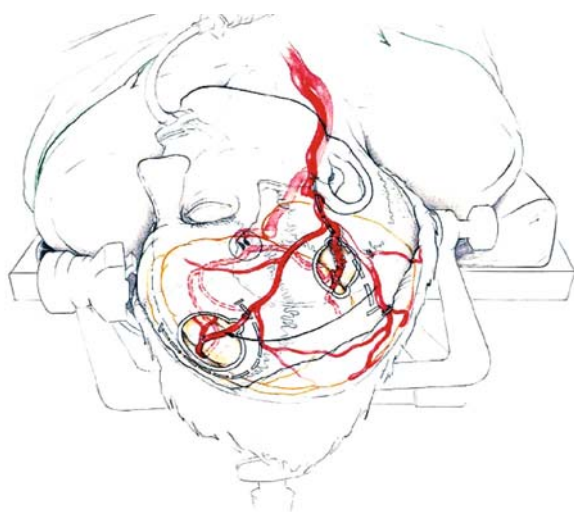
The cut end of the already dissected STA is brought over onto the recipient artery. The lengths should be optimally redundant to enable the whole anastomotic procedures and its torsion and strangulation should be avoided. After its temporary occlusion at the proximal part and irrigation of the lumen with heparin solution (1000–2500 IU/100 ml saline), the periadventitia is peeled off at its distal end and made ready for the anastomosing procedure. The end is cut so that the diagonal diameter corresponds with the opening of the recipient artery mentioned above. An end-to-side anastomosis is accomplished usually with 8 interrupted sutures with a 10-0 monofilament Nylon thread after the method described elsewhere for the laboratory training. This procedure needs around 20–30 minutes. This duration of blood flow interruption at the segment is considered acceptable and of no harm to the corresponding perfusion territory of the brain.

In MMA patients, especially in children, the cortical arteries are as small as 0.5 mm in diameter, so that around 6 sutures with a 11-0 monofilament are enough to complete an end-to-side bypass.

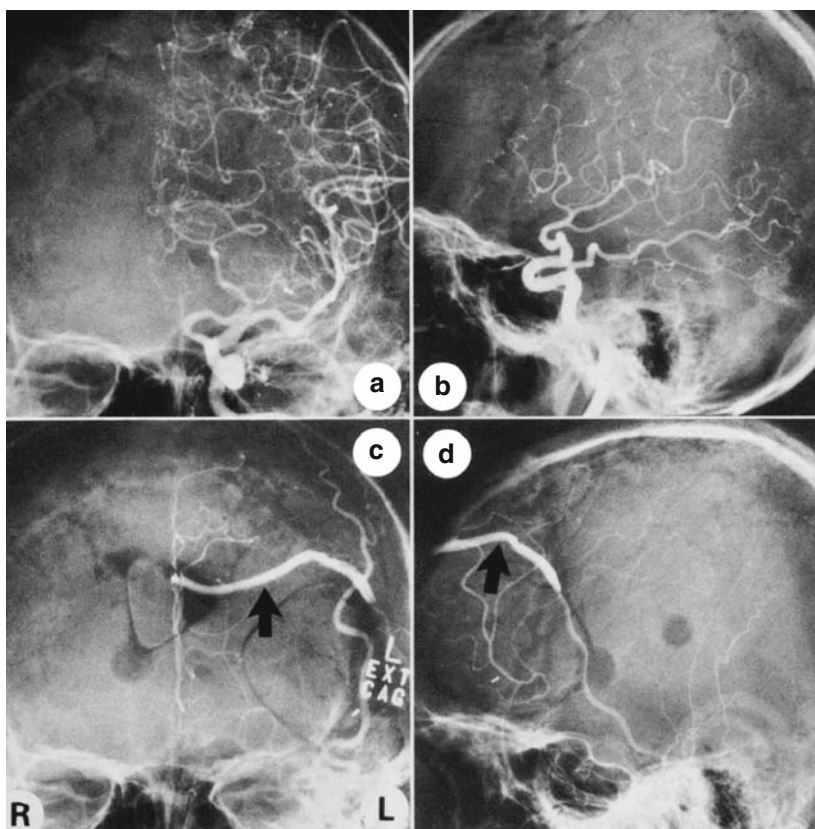
After the suture line has been checked, the temporary clips are transiently opened one by one, at first those applied to the cortical artery and then those at the STA. This procedure serves to check for the necessity of additional sutures around the anastomotic suture line and also to seal it. After completion of anastomosis by definite removal of the temporary clips and the rubber dam, the patency is checked representatively by micro-Doppler sonography or other methods such as fluorescence angiography, thermal clearance Peltier stack, or infrared probe, etc. We are using micro-Doppler sonography for its practical convenience and reliability.

#### *Closure of the craniotomy*

After oxycellulose has been applied around the suture line, the dura is approximated and closed not necessarily watertight but replacing the air with saline as much as possible. Strangulation of the donor STA is to be avoided at



A



the time of bone replacement and muscle fascia and skin closure. Neither epidural nor subgaleal drainage is necessary.

As a modified method, the STA can be anastomosed with M2 or M3 by opening the Sylvian fissure, for example, at the time of aneurysm surgery, so that the frontal branch of the STA should always be included and kept intact in the skin flap [12].

#### *Peri- and intraoperative management and follow-up*

Anticoagulant therapy and or Aspirin therapy should be discontinued prior to surgery, mostly 3 days before. We are doing surgery rather under some influence of such therapy in order to prevent thromboembolism cerebral as well as cardiopulmonary. Appropriate hydration is necessary and dehydration is contraindicated. In MMA patients, CBF measurement examination with Diamox loading should have been completed more than 48 hours before surgery. Period of instable cerebral hemodynamics manifested with frequent TIAs especially in MMA patients should be passed over by administration of Dexamethasone and surgery should be carried out in stable situation.

Under general anaesthesia the patient is put on controlled respiration.  $p\text{CO}_2$  is kept usually around 40 mmHg; both hypercapnea and hypocapnea should be avoided especially in MMA patients.

Postoperative blood pressure is kept in normal pressure range, especially systolic pressure is kept under 160 mmHg. Prophylactic antiepileptics is considered to be not necessary but prophylactic antibiotics is given intravenously only during surgery. Aspirin can be administered again after 24 hours postoperatively. Oral anticoagulant therapy can be resumed after a week. Patency of the bypass is followed up by Doppler sonography and whole postoperative follow-up hemodynamic check with angiography and water PET is done in 2–3 months postoperatively.

### 1.2 The STA-ACA bypass (Fig. 7)

As a special type of bypass procedure for the anterior circulation, the STA-ACA bypass is mentioned here. This bypass is indicated classically for MMA patients in which the ACA territory is hemodynamically compromised or for patients with large or giant aneurysms of the anterior communicating artery in which flow of the distal ACA is compromised by a clipping or coiling procedure. The frontal branch of the STA is anastomosed classically with the middle internal frontal artery (MIFA) at the medial corner of the frontal cortex located anterior to the coronal suture. Usually the end of the dissected frontal branch of the STA in its whole length at the frontal skin flap is long enough to reach the midline after stretching its curved and serpentine course



**Fig. 7.** STA-ACA bypass. **A** In MMA, the STA-ACA can be combined with STA-MCA bypass as illustrated. In this case, the interposition graft is taken from the distal STA (arrow). **Bc, Bd** Use of interposition saphenous vein graft in a patient with ACA occlusion (**Bab**)

and to anastomose with the MIFA. Otherwise, an interposition graft using a segment of the parietal branch of the STA, of the superficial temporal vein or of the distal saphenous vein is put between the MIFA and the end of the frontal branch [21].

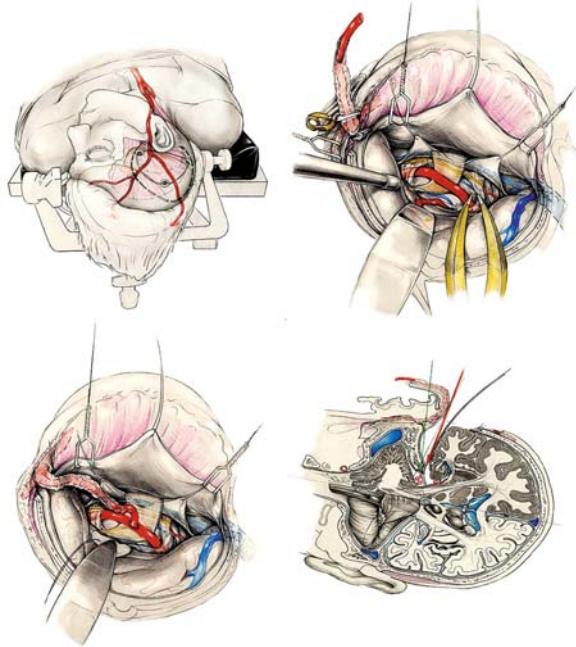
### 1.3 Bypass surgery for posterior circulation

Bypass surgery for the posterior circulation is indicated as in the anterior circulation: prevention of recurrent stroke in the vertebrobasilar territory in cases with atherosclerotic occlusive lesion with hemodynamic failure or major arteries in the territory being compromised at the time of surgical or endovascular management of large or giant aneurysms.

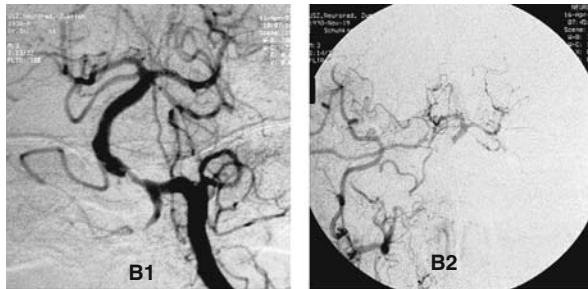
#### *The STA-SCA bypass (Fig. 8)*

STA-SCA bypass surgery was initiated by Ausman in 1978 [2]. The technical outline is as follows [24]: After induction of general anesthesia and intubation, spinal drainage is put in order to reduce the temporal lobe retraction. The head and body position is the same as described above for the standard STA-MCA bypass. The STA parietal branch is dissected by linear skin incision up to the periphery for more than 10 cm to enable the end to reach the SCA in the depth for the performance of anastomotic procedure. The skin incision is extended curvilinear posterocaudally down to the posterior part of the mastoid process. The temporal craniotomy should be larger than 4 cm in diameter: anterior to the origin of the zygomatic arch, posterior to the sigmoid transverse sinus junction, caudal just above the porus acusticus externus. Then the temporal base including the outer portion of the pyramid is drilled away caudally down to the very basis in order to get a wide enough operative field. The mastoid cells may be partly opened inbetween and these should be closed meticulously with bone wax and fascia at the time of craniotomy closure. This procedure together with the above mentioned spinal drainage enables to perform the bypass procedure in the depth without excessive retraction of the temporal lobe and to minimize injury to the vein of Labbé. A small incision is made to the tentorium about 1 cm medially from the transverse sigmoid junction so that the superior surface of the cerebellum is exposed. The incision is extended toward the tentorial edge just 1 cm posterior from its attachment to the pyramid tip and the cut end of the tentorium is reflected. This procedure together with opening of the primesencephalic cistern enables to expose the proximal part of the SCA

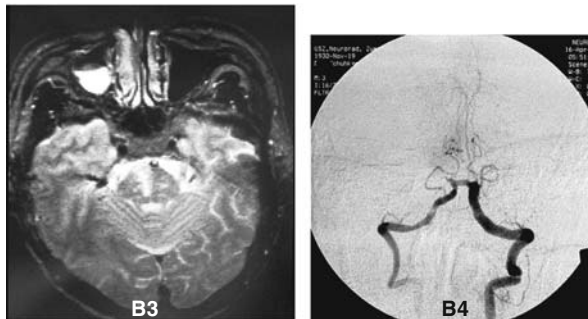
**Fig. 8.** STA-SCA bypass. **A** Illustration of the craniotomy and bypass procedure at the operating field by cutting the tentorium. **B** 56-year-old male underwent STA-SCA bypass due to basilar stenosis (**B1**) which turned out as occlusion on the 3-week follow-up angiography without any neurological deterioration. The bypass was patent (**B2**). The 3-month follow-up angiography on neurological deterioration showed patent bypass but propagation of thrombosis further distally up to the branching site of the anterior inferior cerebellar artery (**B4**). MRI showed pontine infarction (**B3**) but the patient could recover to Rankin 3



**A**



**B**

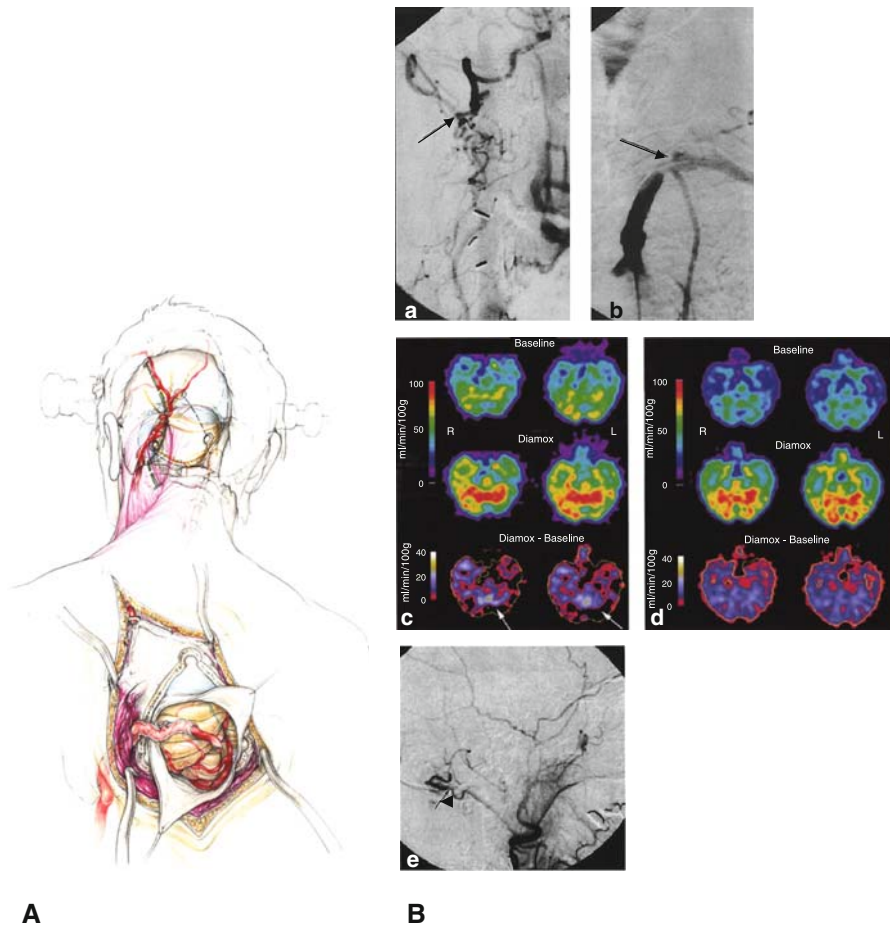


and its branches along with the trochlear nerve. There are practically no tiny branches to be sacrificed at the time of SCA dissection for the anastomosis. Further procedures are principally the same as for the above end-to-side anastomosis for a standard STA-MCA bypass. One has to be well trained to perform microvascular anastomosis in the narrow depth with longer micro-instruments. The technique can be learned and obtained only at the microsurgical laboratory and by cadaver dissection [23, 26].

*The OA-PICA bypass by paramedian transvertebralis ring approach (Fig. 9)*

OA-PICA bypass surgery was initiated by Khodadad in 1976 [2, 24]. Dissection of the OA usually of 1 mm in diameter is done, according to the early papers, from the curvilinear skin flap and on its reflection from the periphery towards the medial portion of the mastoid process and anastomosed with the caudal loop of the PICA after a unilateral suboccipital craniotomy. It is known that dissection of the OA is somewhat laborious and time consuming as compared with that of the STA. It has many tiny branches to be coagulated and cut, runs into the subcutaneous fatty tissue at the periphery and deep into the muscle layers proximally. Surgery in the sitting position has been recommended to be rather avoided for frequented complications according to Khodadad himself. Our experience, however, is different and we consider the position to be suitable for performing this revascularization surgery, as the operative field is clean without accumulation of CSF or blood. The difference might come from our routine use of the sitting position. In our department, the operating team and the anaesthesiologist know when to be careful and how to manage the problematic situations from an experience of more than 200 surgeries in the sitting position per year.

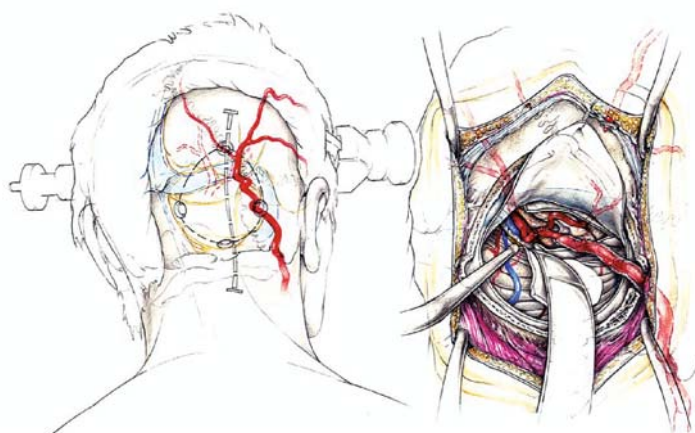
The head is fixed with Mayfield's three-point pin apparatus rotating ca. 30° turned to the operating side and flexed ca. 20° in the sitting position. After having checked the course of the OA with Doppler sonography, surgery is initiated by a linear skin incision over the OA followed by dissection of the OA down to the medial corner of the processus mastoideus. The squama occipitalis is exposed by splitting and spreading the nuchal muscles. After a paramedian suboccipital craniotomy with a diameter of 4–5 cm reaching down to the foramen magnum preferably followed by a partial condylectomy, the dura is opened longitudinally. The dural ring of the vertebral artery is thus exposed. Hemilaminectomy of C1 is not necessary. The arachnoidea of the cisterna magna is opened at its lateral corner. The PICA's caudal loop or lateral medullary segment of 1 mm in diameter comes directly into view after just elevating the cerebellar tonsil. The subsequent anastomosing procedure between the cut end of the OA and the PICA segment is the same as described above. Closure of the craniotomy should be done carefully to avoid strangulation of the donor OA, as muscle layers to be closed are thick to close after the bone replacement.



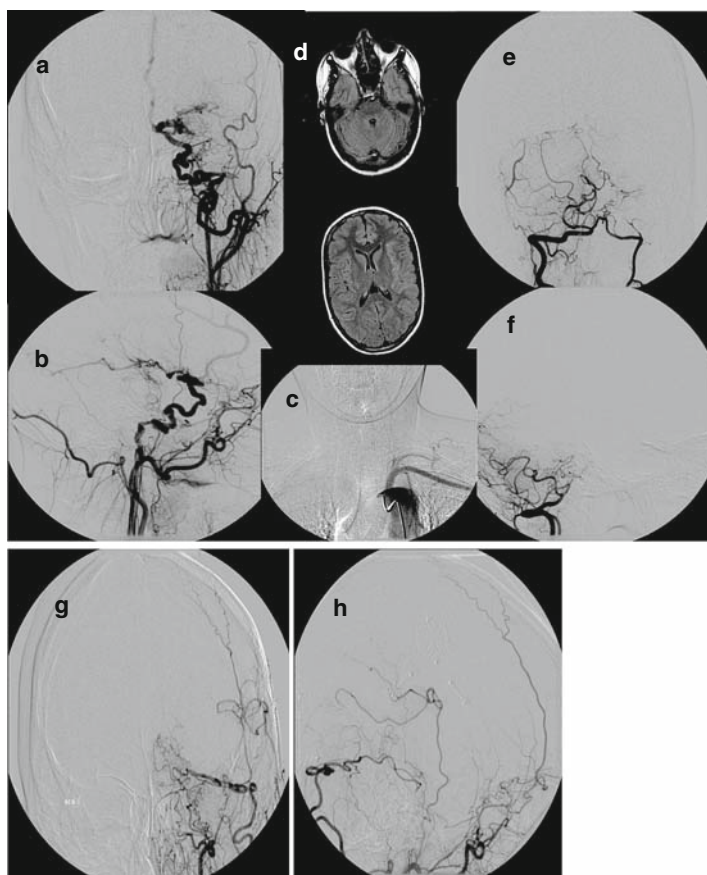
**Fig. 9.** OA-PICA bypass. **A** Illustration of the bypass by linear incision along the dotted line (see text). **B** 50-year-old male with both vertebral artery (VA) occlusion (**a** and **b**, arrow) and with hemodynamic compromise at the left PICA territory (**c**, arrows) underwent left OA-PICA bypass. The 3-month follow-up examination displayed a patent OA-PICA bypass (**e**, arrow) with improved hemodynamic capacity on the left cerebellar hemisphere (**d**)

*The OA-SCA and OA-PCA bypass by supracerebellar transtentorial approach (Fig. 9)*

The supracerebellar transtentorial approach in the sitting position has been reported by us in 2001 [31]. The OA is anastomosed either with the SCA or with the posterior temporal artery of the PCA. Dissection of the OA as long as possible is performed by linear incision in the same manner as described above. After a paramedian craniotomy, space between the tentorium and the cranial surface of the cerebellum is obtained by sacrificing one or two bridg-



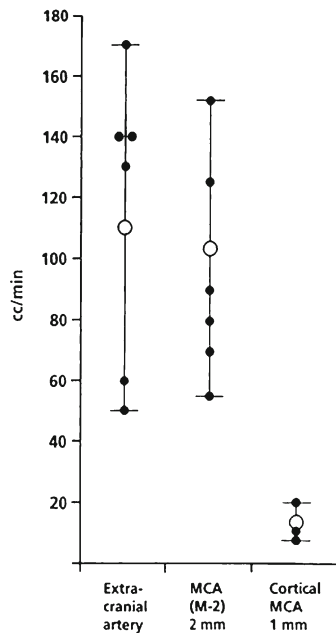
**A**



**B**



ing veins between them. The arachnoid of the cisterna magna is opened at its lateral corner for the purpose of CSF drainage beforehand, so that the mentioned space can increase. The tentorium is incised from the midway towards the tentorial notch. This procedure enables to obtain a spacious operative field and to obtain a cortical branch of the PCA as recipient artery around the corner of the parahippocampal gyrus and the lingual gyrus. The SCA marginal branch can be found together with the trochlear nerve at the cranio-anterior margin of the lobulus quadrangularis. The tentorial incision is done also for the OA-SCA bypass as this procedure brings about a more spacious and better illuminated operative field.



**Fig. 11.** Bypass flow vs. recipient diameter [30]

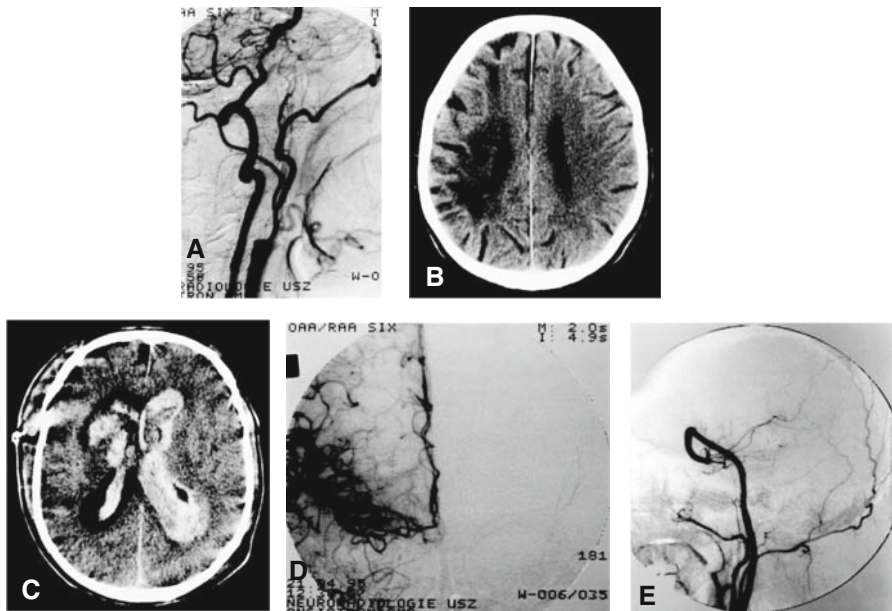
**Fig. 10.** OA-SCA and OA-PCA bypass. **A** Illustration of the bypass procedures via paramedian suboccipital craniotomy by linear incision. Note the tentorium is incised in both bypass procedures. The SCA and its branches are found just at the anterosuperior corner of the lobulus quadrangularis. The posterior temporal artery and its branches are found at the junction of the parahippocampal gyrus and lingual gyrus on the tentorial incision. **B** 21-year-old female with dysplastic ICA plus MCA occlusion on the left side (**a, b**) combined with aplasia of the left VA (**c**). The basilar artery was not opacified via the right VA. MRI did not show any abnormal findings. On the basis of PET findings the patient underwent STA-MCA and OA-SCA bypass. The 3-month follow-up examination demonstrated patency of both bypasses (**g, h**) with clinical improvement of cessation of vertigo attacks and hemodynamic improvement on PET scan

This type of bypass to the PCA does not need the use of the PCA trunk itself as in the STA-PCA interposition graft bypass [20], so that the possible complication of hemianopsia or hemiparesis can be avoided.

The end-to-side microvascular anastomosis is done in a similar fashion with long microinstruments as described above. The advantage of this procedure is again a clean operative field. The disadvantage of the sitting position, mainly the risk of air embolism, can be managed and overcome through experience of the anesthesiology team and operating team as mentioned above.

#### 1.4 High-flow bypasses

While a usual bypass, that is, a low-flow bypass, can carry 10–20 ml/min blood flow just after its construction, a high-flow bypass can carry around 100 ml/min. This volume depends not only on the calibre of the donor or interposition graft vessel but mostly on that of recipient vessel (Fig. 11). Large calibre of donor or interposition graft can be gained with a saphenous vein or



**Fig. 12.** High-flow venous graft bypass between the right common carotid artery and the MCA (M2). 58-year-old male with right ICA occlusion (A) with an extensive infarction on the right hemisphere (B) underwent this bypass surgery, as the STA as donor artery was not available. After an uneventful postoperative course, sudden neurological deterioration occurred on the 3rd postoperative day. The CT scan displayed bleeding into the infarcted area along with hemocephalus (C); and digital subtraction angiography, a patent high-flow bypass (D, E)

radial artery graft. One has to know that the length of a graft with blood flow would expand by around one-third as compared with an empty graft without blood flow.

*Saphenous vein graft and radial artery graft (Fig. 12)*

The saphenous vein is usually dissected at the medial side of the lower leg, beginning at the level of the maleolus medialis towards cranially up to the medial corner of the knee joint through a linear incision. We prefer harvesting this distal part of the saphenous vein to the proximal one of the upper thigh, as the calibre of the former is more suitable for anastomosis with intracranial arteries. For its dissection at a sufficient length, small tiny branches are coagulated and cut meticulously and the larger branches are closed with thread ligation or with metal clips. After blood remaining in the lumen of the harvested vein has been flushed, the segment is filled with heparin solution and preserved until its use slightly distended with temporary clips at both ends. Skin is closed in layers and then bandaged with slight compression. The graft may contain some venous valves which do not need to be removed as the graft is put according to the direction of the flow at the time of interposition. The proximal vessel to be anastomosed could be the subclavian artery, common carotid artery, proximal external carotid artery or C5 (after anterior persectomy) and the distal one C2 (after selective anterior clinoidectomy), M2 or M3 portion of the MCA by opening the Sylvian fissure. This venous graft is used also as low-flow bypass to cortical arteries with diameters of 1 mm in which some technical difficulties of microvascular anastomosis due to a difference in graft and recipient artery calibre have to be overcome.

The radial arterial graft has been used also for the purpose of high-flow graft. The size of the cut end is just that of the M2 portion (2–2.5 mm in diameter). After tolerated Allen test, a graft as long as 20 cm can be harvested without compromise of blood supply to the forearm and volar portion of the hand. In comparison with the saphenous vein graft, the following advantages and disadvantages can be pointed out for the radial artery graft.

1. Microvascular anastomosis on artery is easier to perform due to less distensibility and to more rigidity of the arterial wall than that of venous wall.
2. Torsion and kinking of the graft can easily be prevented.
3. Graft dissection is easier.
4. Length of the graft is rather limited.
5. Because of the graft's arterial nature, problem of atherosclerotic change is possible.

In spite of the advantages of the arterial graft over the venous graft, I prefer to use the venous graft from the practical point view of easier availability.

### *Use of high-flow graft in various bypass procedures*

A high-flow graft is used for the following bypasses:

1. Between extracranial supraaortic arteries such as common carotid and subclavian artery as in the subclavian steal syndrome
2. C5 to C2 bypass as in large and giant aneurysms in the ICA cavernous portion [6].
3. Subclavian artery, common carotid artery or external carotid artery to C2 or M2 as in intractable large or giant aneurysms in the ICA or MCA.

Although innovative techniques such as the use of excimer laser-assisted nonocclusive anastomosis for the construction of a high-flow bypass have been reported, in which no temporary occlusion of the recipient artery is necessary [19], the standard method with the use of microsutures of 8-0 to 10-0 monofilament under temporary occlusion of the recipient artery for around less than 30 min is still in wide practical use. Temporary occlusion of such duration is considered to be acceptable under general anesthesia with controlled hemodynamics and administration of neuroprotective drugs such as mannitol and barbiturate, and also with the use of mild hypothermia in extreme cases.

## **LONG-TERM RESULTS AND COMPLICATIONS**

Microsurgical revascularization procedures was performed as follows during the period from 1993 through 2007 at the department of neurosurgery, University Hospital Zürich: 203 patients underwent 277 microvascular revascularization procedures: atherosclerosis 93 cases, MMA 47 cases, aneurysms 57 cases (50% intractable large or giant aneurysms, 40% emergency bypass and 10% intractable vasospasm) and skull base tumors 6 cases. Most cases underwent revascularization to the territory of the MCA, 34 cases to the territory of the ACA and 13 cases to the territory of the posterior circulation. Multiple bypass procedures were necessary in most of the MMA patients followed by patients with atherosclerosis.

Bypass patency rate examined by follow-up angiography was 87%. Although the stroke recurrence rate in our recent series is still under investigation, the annual recurrence rate is expected to be around 2% (vs. 5% in conservative treatment) from our previous experience [25].

Major complications are listed in Table 4 and direct postoperative mortality was in 3 cases. Two cases of extensive ischemic swelling are cases of aneurysms: one is with symptomatic giant ICA aneurysm. ICA occlusion was interpreted as tolerable on BOT but with some asymmetry on SPECT, so that normal STA-MCA bypass was combined with therapeutic ICA occlusion.

**Table 4.** Complications<sup>a</sup>


---

Major complications (overlapped):

- Extensive infarction – insufficient flow 2 cases\*
  - Infarction – hemodynamic instability in 3 MMA cases
  - Infarction – conversion from stenosis to occlusion 1 case
  - Intracerebral hemorrhage into infarcted area 1 case
  - Epidural subdural, intracerebral hematoma 3 cases
  - Subdural hematoma-effusion 2 cases
  - Cardiopulmonary insufficiency 1 case\*
- 

<sup>a</sup>Asterisk indicates mortal cases (total, 3)

The patient died of extensive infarction in spite of subsequent decompressive craniotomy. The other patient was with ruptured giant anterior communicating aneurysm presenting with grade IV. One ACA had to be occluded at the time of radical clipping so that STA-ACA bypass was combined. The patient died of infarction and diffuse swelling due to SAH. The third case was a case of bonnet bypass [18] with the use of the brachio-cephalic vein as interposition graft. The patient expired 3 weeks after surgery due to cardiopulmonary failure. Postoperative ischemic complication in MMA patients was encountered in three cases. In another case of MCA stenosis of atherosclerosis, new ischemia was encountered at the basal ganglia originating in compromise of a lateral lenticulostriate artery due to conversion of MCA stenosis to occlusion after bypass procedure. Such conversion of stenosis into occlusion after bypass surgery with or without neurological deterioration has been infrequently reported also in the vertebrobasilar territory. These should be kept in mind. Other complications were related to hemorrhage. One was a case of infarction which changed into hemorrhage three days after the construction of a common carotid-M3 high-flow bypass using a long saphenous vein graft (Fig. 12). The other cases are more or less related with antiplatelet or anticoagulant therapy: epidural and subdural hematomas.

## HOW TO AVOID COMPLICATIONS

Complications can be classified into four groups:

1. ischemic complication
2. hemorrhagic complication
3. cardiopulmonary complication
4. minor complication such as wound healing problems, infection, CSF rhinorrhea, epileptic seizures, etc.

Strict attention should be paid to the following important items at perioperative care and management.

*Good hydration.* One of the most important things in the perioperative care is considered to be appropriate hydration. It is easy to understand that combination of hemoconcentration plus low perfusion can enhance the risk of rheological deterioration of the hemodynamic situation easily resulting in ischemia. This might be one of the reasons that cases with misery perfusion have also an elevated risk of ischemia.

*Normotension.* Excessive postoperative hypertension or hypotension should be avoided. We had some cases in the past in whom cerebellar hemorrhage complicated due to postoperative hypertension [25]. Hypotension would induce rheological deterioration and hence ischemic complication.

*Normocapnea.* Hypercapnea or hypocapnea must be avoided especially in MMA patients. Intraoperative regulation of pCO<sub>2</sub> around 40 mmHg is considered to be optimal in MMA patients and cases with atherosclerotic lesion. Diamox loading test is a good and simple procedure to find out hemodynamic failures but may induce metabolic acidosis and hypovolemia. Aggressive intervention of bypass surgery should be postponed until 48 hours after the test.

Complication of *subdural hematoma* has been observed in cases with infarction of considerable size and postoperative subdural air accumulation would turn to subdural effusion and then to hematoma under the necessary medication of antiplatelet agent [25]. Therefore, we are recommending to drive out subdural air by replacing it with saline as much as possible at the time of dural closure and bone replacement. Use of a linear incision for donor artery dissection instead of that in the skin flap seems to reduce the problem of *wound healing* and the method would reduce duration of surgery.

## CONCLUSIONS

State-of-the-art of microvascular intracranial revascularization procedures for both the anterior and the posterior circulation, indication, technique and results have been outlined. Negative results of international cooperative study of the procedure in stroke prevention would not justify to abandon the technique. We now are relatively sure that the procedure is effective in stroke recurrence prevention in the group of *hemodynamic compromise*. This procedure can be extended for the *treatment of MMA, aneurysms* and some *skull base tumors* in combination with other surgical or endovascular treatment.

Technique of revascularization microsurgery can be obtained only by microsurgical training in the laboratory [22, 23, 26]. Prerequisite for its clinical use is a 100% patency rate obtained at any performance of an end-to-end or end-to-side anastomosis of vessels with a diameter of 1 mm in the laboratory.

### Acknowledgement

I am indebted to P. Roth for the artist drawings.

## References

- [1] Astrup J, Siesjö BK, Symon L (1981) Thresholds in cerebral ischemia – the ischemic penumbra. *Stroke* 12: 723-725
- [2] Ausman JL, Diaz FG, De Los Reyes RA, Pearce JE, Schronitz CE, Pak H (1985) Microsurgery for atherosclerosis in the distal vertebral and basilar arteries. In: Rand RW (ed) *Microneurosurgery*. CV Mosby, St Louis, Mo, pp 497-510
- [3] Baron JC, Bousser MG, Rey A, et al. (1981) Reversal of focal “misery-perfusion syndrome” by extra-intracranial arterial bypass in hemodynamic cerebral ischemia: a case study with <sup>15</sup>O positron tomography. *Stroke* 12: 454-459
- [4] Date I, Tokunaga K, Sugiu K (2008) Multimodality therapy for large and giant intracavernous internal carotid artery aneurysms. *Surg Cereb Str (Jpn)* 36: 12-18
- [5] The EC/IC Bypass Study Group (1985) Failure of extracranial-intracranial arterial bypass to reduce the risk of ischemic stroke. Results of an international randomized trial. *N Engl J Med* 313: 1191-1200
- [6] Fukushima T (1992) Operative technique of the skull base bypass. *Jpn J Neurosurg* 1: 41-47
- [7] JET Study Group (2002) Japanese EC-IC Bypass Trial (JET Study): the second interim analysis. *Surg Cerebr Stroke (Jpn)* 30: 434-437
- [8] Karasawa J, Kikuchi H, Furuse S, Kanamura J, Sakaki T (1978) Treatment of Moyamoya disease with STA-MCA anastomosis. *J Neurosurg* 49: 679-688
- [9] Kawano T, Yonekawa Y, Miyake H, et al. (1991) Balloon occlusion test and Matas test – clinical efficacy, indication and practice. *Neurosurgeons (Jpn)* 10: 42-56
- [10] Khan N, Schuknecht B, Boltshauser E, Capone A, Buck A, Imhof HG, Yonekawa Y (2003) Moyamoya disease and Moyamoya syndrome: experience in Europe; choice of revascularisation procedures. *Acta Neurochir (Wien)* 145: 1061-1071
- [11] Kikuta K, Takagi Y, Fushimi Y, Ishizu K, Okada T, Hanakawa T, Miki Y, Fukuyama H, Nozaki K, Hashimoto N (2006) “Target bypass”: a method for preoperative targeting of a recipient artery in superficial temporal artery-to-middle cerebral artery anastomoses. *Neurosurgery* 59(4) (Suppl 2): ONS320-ONS327
- [12] Krayenbühl N, Khan N, Cesnulis E, Imhof HG, Yonekawa Y (2008) Emergency extra-intracranial bypass surgery in the treatment of cerebral aneurysms. *Acta Neurochir Suppl* 103: 93-101
- [13] Matsushima Y, Fukai N, Tanaka K, et al. (1981) A new surgical treatment of moyamoya disease in children: a preliminary report. *Surg Neurol* 15: 313-320

- [14] Mizukami K (1985) cited from Yonekawa Y: Cerebrovascular disease. In: Takakura K, Abe H (eds) (1996) *Neurosurgery*. Nankodo, Tokyo (Jpn), pp 239-291
- [15] Powers WJ (1991) Cerebral hemodynamics in ischemic cerebrovascular disease. *Ann Neurol* 29: 231-240
- [16] Schmiedek P, Piepgras A, Leinsinger G, Kirsch CM, Einhäupl K (1994) Improvement of cerebrovascular reserve capacity by EC-IC arterial bypass surgery in patients with ICA occlusion and hemodynamic cerebral ischemia. *J Neurosurg* 81: 236-244
- [17] Sindou M, Daher A (1987) Autogenous vein grafts for arterial and venous brain vascularization. *Neurosurgeons (Jpn)* 6: 231-239
- [18] Spetzler RF, Roski RA, Rhodes RS, Modic MT (1980) The “bonnet bypass”. Case report. *J Neurosurg* 53: 707-709
- [19] Streefkerk HJ, Bremmer JP, Tulleken CA (2005) The ELANA technique: high flow revascularization of the brain. *Acta Neurochir (Suppl)* 94: 143-148
- [20] Sundt TM, Piepgras DG, Houser OW, Campbell JK (1982) Interposition saphenous vein grafts for advanced occlusive disease and large aneurysms in the posterior circulation. *J Neurosurg* 56: 205-215
- [21] Tanaka K, Yonekawa Y, Satou K, Katagiri K, Kouno H (1992) STA-ACA anastomosis with interposed vein graft. A case report. *No Shinkei Geka* 20: 171-176
- [22] Yaşargil MG (1969) *Microsurgery: applied to neurosurgery*. Thieme, Stuttgart
- [23] Yaşargil MG (1967) Experimental small vascular surgery in the dog including patching and grafting of cerebral vessels and the formation of functional extra-intracranial shunts. In: Donaghy RMP, Yaşargil MG (eds) *Microvascular surgery*. Thieme, Stuttgart, pp 87-126
- [24] Yonekawa Y (1988) Posterior fossa revascularization – indication, technique and results. *The Mt. Fuji Workshop on CVD* 6: 71-76
- [25] Yonekawa Y (1988) Prevention of relapsing cerebral ischemia by the EC-IC bypass – Reevaluation of results of the EC-IC bypass international cooperative study and those of our cases. *Shinkei Shinpo (Jpn)* 32: 320-327
- [26] Yonekawa Y, Frick R, Roth P, Taub E, Imhof HG (1999) Laboratory training in microsurgical techniques and microvascular anastomosis. *Oper Tech Neurosurg* 2: 149-158
- [27] Yonekawa Y, Khan N (2003) Moyamoya disease. In: Barnett HJM, Bogousslavsky J, Meldrum H (eds) *Ischemic stroke. Advances in neurology*, vol 92. Lippincott Williams & Wilkins, Philadelphia, pp 113-118



- [28] Yonekawa Y, Yaşargil MG (1977) Brain vascularization by transplanted omentum. A possible treatment of cerebral ischemia. *Neurosurgery* 1: 256-259
- [29] Yonekawa Y, Yaşargil MG (1976) Extra-intracranial arterial anastomosis. Clinical and technical aspects. *Results. Adv Tech Stand Neurosurg* 3: 47-78
- [30] Yonekawa Y, Fandino J, Taub E (2001) Surgical therapy. In: Fisher M, Bogousslavsky J (eds) *Current review of cerebrovascular disease*. 4th edn. *Current Medicine*, Philadelphia, pp 219-232
- [31] Yonekawa Y, Imhof HG, Taub E, Curcic M, Kaku Y, Roth P, Wieser HG, Groscurth P (2001) Supracerebellar transtentorial approach to posterior temporo-medial structures. *J Neurosurg* 94: 339-345
- [32] Yonekawa Y, Zumofen D, Imhof HG, Roth P, Khan N (2008) Hemorrhagic cerebral dissecting aneurysms: surgical treatment and results. *Acta Neurochir Suppl* 103: 61-69

**Contact:** Yasuhiro Yonekawa, University of Zurich, Haldenbachstrasse 18,  
8091 Zurich, Switzerland  
E-mail: [yasuhiro.yonekawa@usz.ch](mailto:yasuhiro.yonekawa@usz.ch)

---

# MANAGEMENT OF INTRACRANIAL VENOUS PATHOLOGIES – POTENTIAL ROLE OF VENOUS STENTING

J. D. PICKARD

## INTRODUCTION

The anatomy and physiology of the cerebral venous system has received much attention. Through trial and error, the rules for safely dealing with the local venous drainage in various surgical approaches are well established. Many pathologies affect the cerebral venous system including

- Traumatic injury to the major dural sinuses
- Carotico-cavernous fistulae
- Dural arteriovenous fistulae
- Developmental venous anomalies
- Arterial venous malformations
- Meningiomas involving the dural sinuses
- Pineal and glomus tumors
- Cerebral venous thrombosis
- Pseudotumor cerebri syndrome (PTCS, benign intracranial hypertension (BIH), idiopathic intracranial hypertension (IIH))
- Giant arachnoid granulations.

Through study of PTCS, it is now becoming recognised that some patients have venous sinuses that reversibly collapse in the face of raised cerebrospinal fluid pressure. Venous stenting was recently developed by Higgins et al. in Cambridge to help some of these patients and has subsequently proven to be of value in managing challenging lesions within the venous sinuses presenting with raised CSF pressure such as meningiomas and giant arachnoid granulations.

This chapter will focus, firstly, on the general principles of protection of venous drainage during surgery for many different conditions and, secondly, on the potential of the recent advance of venous sinus stenting.

## RATIONALE

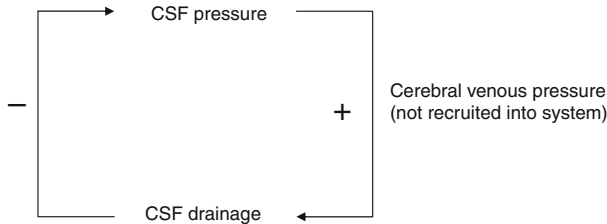
Careful consideration needs to be given to the local venous drainage when planning and executing most microsurgical approaches to the brain and base

---

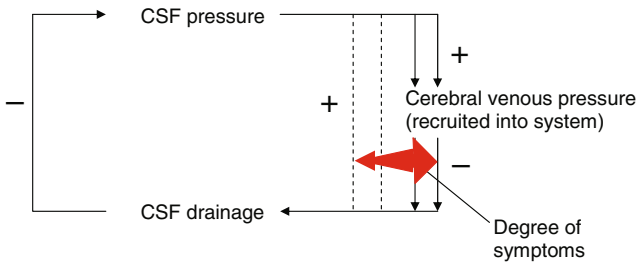
*Keywords:* intracranial venous pathologies, benign intracranial hypertension, venous shunting

of skull. Comprehensive accounts of the relevant anatomy and congenital variations are widely available. Sindou and Auque have provided a helpful account of which venous structures are “dangerous” to sacrifice including the mid third and posterior third of the superior sagittal sinus (SSS), the lateral sinus where it is dominant, the large calibre midline afferent veins to the SSS (including Trolard), interior cerebral veins (including Labbe), the large calibre superficial Sylvian veins and the deep cerebral veins including the vein of Galen, the thalamo-striate vein and the superior petrosal vein.

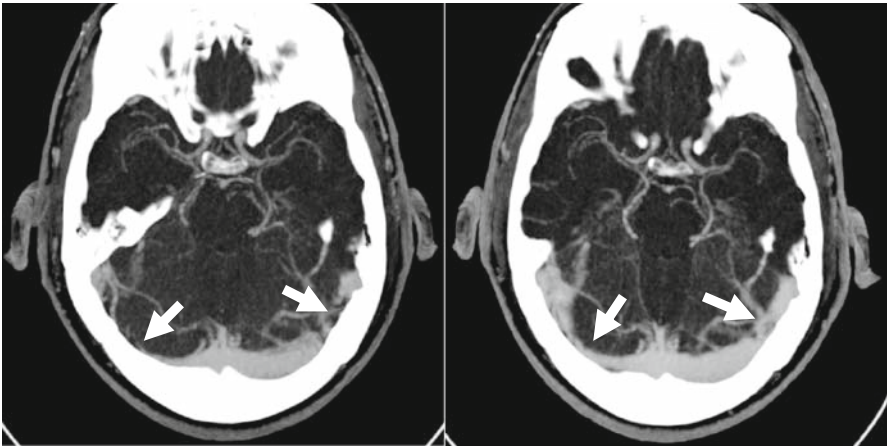
The experimental consequences of venous occlusion depend upon the species, acuity and method of occlusion presumably reflecting the ability of the venous collateral capacity to cope. In some studies, but not all, dural sinus occlusion leads to increased cerebral blood volume and cerebral water content resulting in raised intracranial pressure and reduced cerebral blood flow. Intraparenchymal haemorrhage and blood brain barrier disruption reflect the additional occlusion of cortical veins. Experimentally, chronic elevation of venous sinus pressure may induce either hydrocephalus or PTCS depending in part on whether the cranial sutures are open or closed. Venous sinuses that are compressed by raised CSF pressure may compound the increase in intracranial pressure (Figs. 1 and 2) [7].



**Fig. 1.** Normal negative feedback – Increases in CSF pressure are controlled by an increase in the rate of CSF absorption as it is a pressure dependent process



**Fig. 2.** Disordered positive feedback – Recruitment of the cerebral venous sinuses into the feedback loop due to venous sinus collapse, secondary to increased CSF pressure, causes venous sinus pressure (particularly SSS pressure) to increase. This inhibits CSF drainage and results in further increases in CSF pressure and so on



**Fig. 3.** CT venogram in a case of PTCS with compressible veins: immediate effects on the transverse sinuses of CSF withdrawal by lumbar puncture. Courtesy of Dr. N. Higgins

It is now clear that many sinus narrowings are not fixed obstructions but are reversible by lowering CSF pressure (Fig. 3).

## DECISION-MAKING

Magnetic resonance (MR), computerized tomography (CT), digital subtraction angiography (DSA) and direct retrograde cerebral venography (DRCV) all have their part to play in investigating the cerebral venous circulation. MR venography in its various forms including phase contrast or time of flight supplemented where appropriate with intravenous Gadolinium injection provides a comprehensive view of the intracranial venous circulation. CT venography with contrast is useful for examining the transverse sinuses. Conventional and digital subtraction angiography are useful particularly where there is a suspicion of a dural arteriovenous fistula.

Direct retrograde cerebral venography (DRCV) combined with manometry is the investigation of choice for venous sinus obstruction. It provides the most accurate information including the functional significance of any obstruction in terms of pressure gradient and clarification of whether MR appearances of sinus narrowing are genuine or the result of so-called “contrast streaming”. DRCV is invasive and carries a small risk of perforation of a vein or sinus by the guidewire and of thrombosis around the catheter. Temporary balloon occlusion of a sinus is occasionally used to assess whether it would be safe to sacrifice a lateral sinus during surgery.

## 1. SURGERY INCLUDING VENOUS STENTING

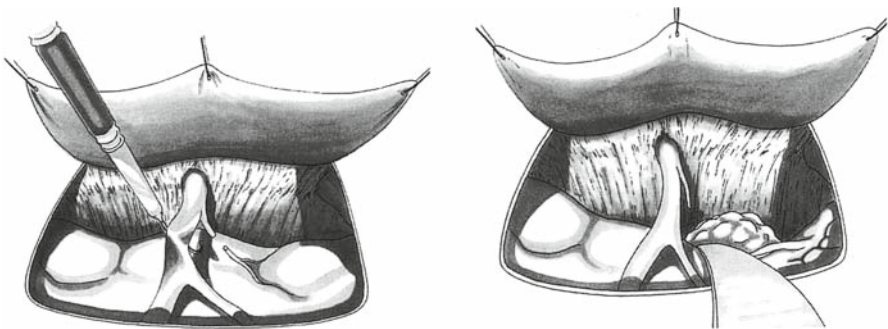
### 1.1 General measures to protect the venous drainage during surgical approaches

Obsessional care should be taken with the positioning of any patient in neurosurgery to minimize intracranial venous hypertension secondary to jugular compression caused by extreme neck positions or constricting bands around the neck. Modest head-up tilt is commonly used – when the torcula is about 15 cm higher than the right atrium, cranial venous pressure is slightly positive which prevents both air embolism and venous congestion of the brain. The sitting position is recommended by some but hated by other neurosurgeons because of the risk of air embolism. These risks may be minimized by obsessional neurosurgical/neuroanaesthetic team working (see Sindou and Auque).

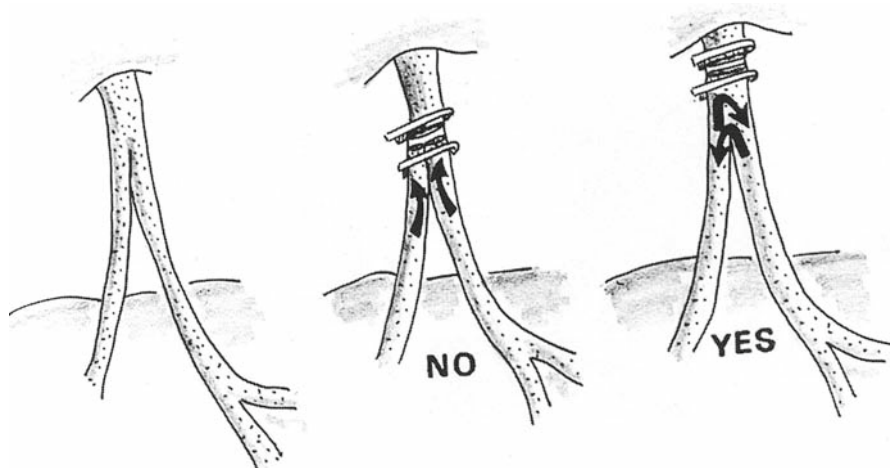
As always, excessive brain retraction must be avoided or venous drainage will be endangered. Unlike arterial bleeding, venous bleeding usually responds to gentle measures including gentle pressure and onlay of Surgicel or Spongistan, bone wax and disciplined use of bipolar diathermy. Small holes in veins including bridging veins may be controlled simply by wrapping with Surgicel or Spongistan. Veins that obstruct the surgical approach or are at risk during retraction should be sacrificed as little as possible. Sugita's technique for the dissection of bridging veins is helpful.

If a vein has to be sacrificed, it should be temporally occluded for a few minutes to see if the brain swells. Sindou's technique for dividing a bridging vein distal to its last bridging point is useful.

Various techniques have been described for the reconstruction of bridging veins by silicone tubes and vein grafts. Such techniques are not in common use and there is always the risk of unduly extending the duration of the operation.



**Fig. 4.** Sugita technique for dissection of bridging veins (Source: Sindou M and Auque J (2000) The intracranial venous system as a neurosurgeon's perspective. *Adv Techn Stand Neurosurg* 26, p 169, Fig. 22)



**Fig. 5.** The best way to *divide a bridging vein* (if necessary), according to the authors (Source: Sindou M and Auque J (2000) The intracranial venous system as a neurosurgeon's perspective. *Adv Techn Stand Neurosurg* 26, p 170, Fig. 23)

During closure, some surgeons wash the operative catheter with 10% papaverine in saline combined with Jugular compression to check that complete haemostasis has been secured.

Inadvertent tear of a dural sinus is best controlled by a skilled assistant gently applying a flat retractor whilst the surgeon stitches in a flap of dura or peracranium.

Where a meningioma involves the wall of a sinus, a similar technique may be used depending on the degree of invasion (see chapter by Sindou):

Type I: Excision of the outer layer, leaving a clean and glistening dural surface and coagulation of the dural attachment;

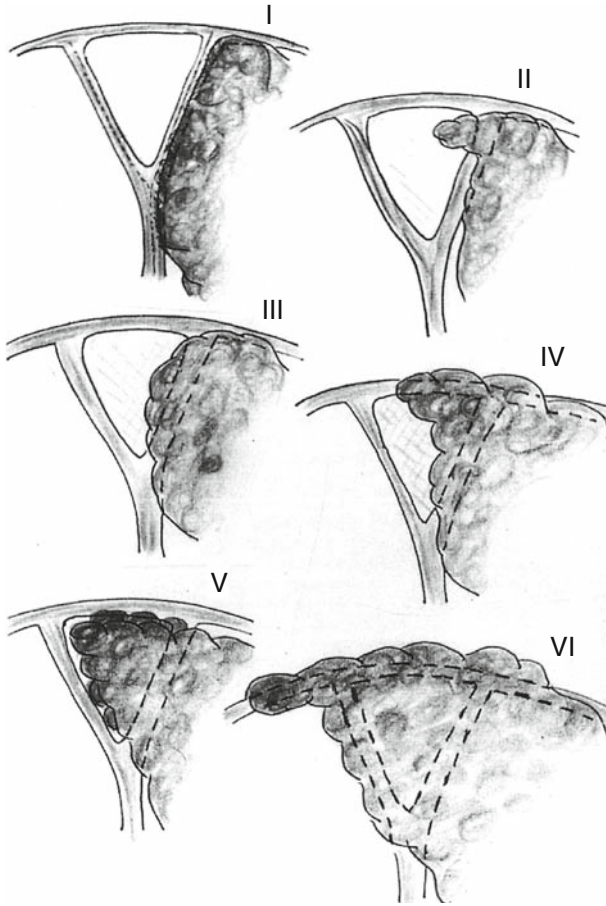
Type II: Removal of the intraluminal fragment through the recess and repair of the dural defect by re-suturing the recess or by closing it with a patch or sealing up the opening with aneurysm clips provided this does not cause stenosis;

Type III: Resection of the sinus wall and repair with a patch;

Type IV: Resection of both invaded walls and reconstruction of the two resected walls by patches;

Type V: This type can be distinguished from type VI only by direct surgical exploration of the sinus lumen. Where the opposite wall to the tumor side is free of tumor, Sindou prefers to reconstruct the invaded wall with a patch after resection rather than perform a bypass;

Type VI: Removal of the involved part of the sinus and restoration by venous bypass.



**Fig. 6.** Classification of meningiomas according to the degree of dural venous sinus involvement. *Type I:* meningioma attached to outer surface of the sinus wall; *Type II:* lateral recess invaded; *Type III:* lateral wall invaded; *Type IV:* entire lateral wall and roof of the sinus both invaded; *Types V and VI:* sinus totally occluded, one wall being free of tumor in type V. This classification is a simplified one from Krause F (1926) *Operative Freilegung der Vierhügel, nebst Beobachtungen über Hirndruck und Dekompression. Zentralbl Chir* 53: 2812-2819; Merrem G (1970) *Die parasagittalen Meningeome. Fedor Krause-Gedächtnisvorlesung. Acta Neurochir (Wien)* 23: 203-216 and Bonnal J, Brotchi J, Stevenaert A, Petrov VT, Mouchette R (1971) *Excision of the intrasinus portion of rolandic parasagittal meningiomas, followed by plastic surgery of the superior longitudinal sinus. Neurochirurgie* 17: 341-354 (Source: Sindou M and Auque J (2000) *The intracranial venous system as a neurosurgeon's perspective. Adv Techn Stand Neurosurg* 26, p 186, Fig. 29)

### 1.2 Venous bypass grafts

Sindou has pioneered the use of venous bypass autologous vein grafts for cases completely occluded by a tumor, venous thrombosis and jugular steno-

**Table 1.** Current published experience of stenting for PTCS ('IIH')

---

Higgins JN, Owler BK, Cousins C, Pickard JD (Cambridge; Lancet. 2002;359:228-230)	First case-report
Higgins JN, et al. (Cambridge; J Neurol Neurosurg Psychiatry 2003;74:1662-1666)	12 patients: 5 asymptomatic 2 improved 5 unchanged
Owler BK, et al. (Sydney; J Neurosurg 2003;98:1045-1055)	4 patients: headaches improved in all vision improved CSF leak resolved in one case
Ogunbo B, et al. (Newcastle; Br J Neurosurg 2003;17:565-568)	1 patient became asymptomatic
Rajpal S, et al. (Wisconsin, USA; J Neurosurg 2005; 102(3 Suppl): 342-346)	15 yr old boy; headache and papilloedema resolved
Donnet A, et al. (2008) (Marseille; Neurology 2008;70:641-647)	10 patients: papilloedema resolved in all; headache: 6 asymptomatic; 2 less; 2 no change
Thurtell M, et al. (2008)	27 patients – presented at INOS 2008

---

sis and bony obstruction of the venous system (Achondroplasia, complex craniostenoses). Long term patency is difficult to achieve but Sindou argues that even short term patency allows venous collaterals to develop. In contrast, some neurosurgeons prefer subtotal section of a sinus meningioma followed by radiotherapy or a staged approach. Intra-operative sinus pressure monitoring has been used to select those patients who really need sinus reconstruction with a bypass.

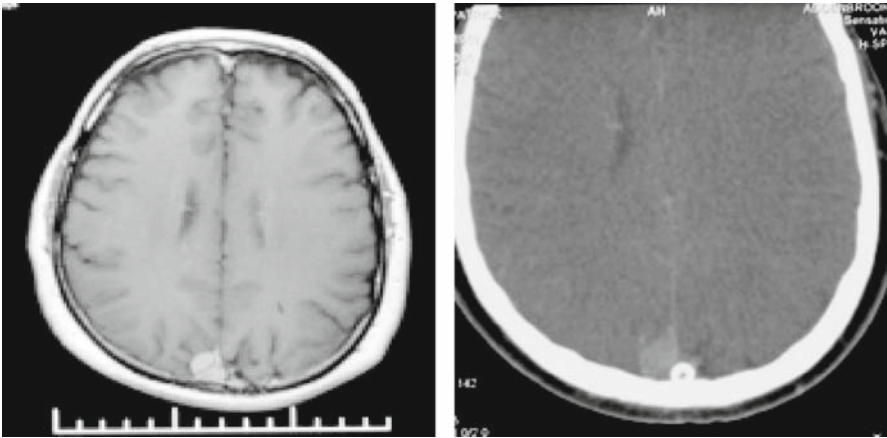
### 1.3 Venous stenting

A new approach to such a conundrum may be venous stenting. Venous stenting was introduced recently for venous thrombosis (2001) and by Higgins and colleagues for sinus stenosis causing or exacerbating PTCS (2002). The technique has now been extended by Higgins and colleagues for patients where raised intracranial pressure has been caused by sinus meningiomas (Fig. 7).

Raised intracranial pressure and vasogenic oedema have been successfully managed by stenting followed as appropriate by radiotherapy and/or surgery.

Venous sinus stenting is performed under general anaesthesia. The guide catheter is directed into the lateral sinus, usually from a percutaneous jugular puncture, and the stent deployed across the stenosis supported by a guidewire. In some patients overlapping stents have been deployed because of the length





**Fig. 7.** Tumor in sagittal sinus on axial T1 weighted MR after Gadolinium and the stent in the right side image

of the stenosis and development of “floppiness” either side of the initial stent. In the minority of patients, bilateral stents have been used for PTCS. Patients are heparinized during the procedure, subsequently converted to warfarin and then to low dose aspirin or clopidogrel after eight weeks. Follow upon venography and manometry is usually undertaken once anticoagulation has been discontinued.

## RESULTS

### 1. COMPLICATIONS OF VENOUS STENTING FOR PTCS

Probable intra-luminal thrombosis was observed in two patients which was successfully treated with thrombolytic therapy with resolution of symptoms. Ipsilateral headache over the side of the stent occurs in the minority of patients and resolves with time. Transient hearing loss ipsilateral to the side of stenting occurs in the minority but resolves within a few days as did unsteadiness in one patient. Anecdotally, acute subdural haematomas have been seen but not in the Cambridge series of over 50 cases.

## CONCLUSIONS

The rules for preserving the integrity of the venous circulation during surgical approaches to the brain skull base are well described. Considerable surgical ingenuity has been displayed in developing techniques to preserve

bridging veins and for reconstructing sinus obstruction caused by tumor, bony narrowing and thrombosis. Venous stenting has recently been introduced and has considerable potential as a way of re-establishing venous outflow in the face of thrombosis and intrasinus obstructing lesions.

## References

- [1] Auer LM, Loew F (eds) (1984) *The cerebral veins*. Springer, Wien New York
- [2] Ganesan D, Higgins JN, Harrower T, Burnet NG, Sarkies NJC, Manford M, Pickard JD (2008) Stent placement for management of a small parasagittal meningioma. *J Neurosurg* 108: 377-381
- [3] Higgins JN, Owler BK, Cousins C, Pickard JD (2002) Venous sinus stenting for refractory benign intracranial hypertension. *Lancet* 359: 228-230
- [4] Higgins JN, Burnet NG, Schwindack CF, Waters A (2008) Severe brain edema caused by a meningioma obstructing cerebral venous outflow and treated with venous sinus stenting. Case report. *J Neurosurg* 108: 372-376
- [5] Johnston I, Owler B, Pickard J (2007) *The pseudotumor cerebri syndrome*. Cambridge University Press, Cambridge
- [6] Kapp JP, Schmiedek HH (eds) (1984) *The cerebral venous system and its disorders*. Grune and Stratton, New York
- [7] Owler BK, Parker G, Halmagyi GM, Johnston I, Besser M, Pickard JD, Higgins JN (2005) Cranial venous outflow obstruction and pseudotumor cerebri syndrome. *Adv Tech Stand Neurosurg* 30: 107-174
- [8] Sindou M, Auque J (2000) The intracranial venous system as a neurosurgeon's perspective. *Adv Tech Stand Neurosurg* 26: 131-216
- [9] Sugita K, Kobayashi S, Yokoh A (1982) Preservation of large bridging veins during brain retraction. Technical note. *J Neurosurg* 57: 856-858



**John D. Pickard**

John D. Pickard is Professor of Neurosurgery in the University of Cambridge at Addenbrookes Hospital and Chairman of the Wolfson Brain Imaging Centre. He trained in Cambridge, London, Glasgow and Philadelphia and was Consultant Neurosurgeon (from 1979) and latterly Professor of Clinical Neurological Sciences in Southampton before moving in 1991 to the newly established Chair of Neurosurgery in Cambridge. His research interests include the pathophysiology and management of brain injury and disorders of the CSF circulation and impaired consciousness. He is the Immediate Past-President of the Society of British Neurological Surgeons.

**Contact:** John D. Pickard, Academic Neurosurgery Division, Box 167, Level A4, Addenbrooke's Hospital, Cambridge CB2 0QQ, UK  
E-mail: [prof.jdp@medschl.cam.ac.uk](mailto:prof.jdp@medschl.cam.ac.uk)

# **TRAUMAS, CEREBROSPINAL FLUID, INFECTIONS**

---

# THE GLASGOW COMA AND OUTCOME SCALES: PRACTICAL QUESTIONS AND ANSWERS

G. M. TEASDALE

## INTRODUCTION

Since they were described, the Glasgow Coma Scale [6] and Outcome Scale [1] have gained wide acceptance and are now in use throughout the world. Nevertheless, such commonplace use can engender a feeling of familiarity that can lead to them being used less effectively than ideal. Usually this is the result of some of the factors that were crucial in their development, and remain important in their day to day application, being overlooked. It is therefore appropriate to re-visit some of the features that are the basis of reliable, robust use of the scales and in the interpretation of their findings.

The reader of this handbook will already have, at the very least, an elementary knowledge of the make up and application of the scales. The approach adopted in this review is based around a series of questions that are often posed to the author by colleagues seeking guidance about aspects of practical use. An awareness of the answers to these queries ensures that the scales will continue to play their maximum part in benefiting the treatment of patients with acute brain damage.

**Why were the scales developed?** Assessment of the initial severity and late outcome play a key role in the management and understanding of a wide range of acute injuries and insults to the brain. Although their consequences can include focal neurological impairments, relating to the particular location of damage, the severity of the more generalised effects on the brain are usually much more important in acute management and ultimate outcome. Such effects are expressed in the acute stage as the depth and duration of impaired consciousness and at a later stage in impairments of lifestyle.

Since the scales were developed, the methodology of development of clinical assessments has advanced considerably and expanded into the science of 'clinimetrics'.

## THE GLASGOW COMA SCALE

**What were the main factors in the design of the scale?** We considered it to be important that the approach should be simple and practicable, useable

---

*Keywords:* comatous states, consciousness disorders, Glasgow Coma Scale

in a wide range of hospitals by staff without special training, reflecting the ubiquitous dispersion of head injured victims.

It is fundamentally unsound to expect clear watersheds in the continuous spectrum of states within the range of impaired consciousness and coma. We, therefore, did not seek to establish an overall classification with a series of arbitrary levels or steps. It is also important not to depend on only one type of response because this may, for various reason, becomes untestable and because different aspects of 'consciousness' such as arousal and awareness have different clinical expressions.

Eye opening was considered useful as a reflection of the intensity of impairment of activating functions. Verbal responses offer an index of higher cortical function. Motor responses are a way of investigating the integrity of the nervous system in patients who are not speaking. Subdivisions within the components reflected increasing degrees of impairment (Table 1).

**How are the responses assessed and interpreted?** The assessment had to have a high degree of consistency and be widely acceptable. The findings at any one point are less important than changes in the pattern over time and consistent communication about a patient is essential as responsibility for care is passed on between the staff of a unit or between units.

## 1. EYE OPENING

- *Spontaneous eye opening*, with sleep wake rhythms is the highest level. Although it indicates arousal mechanisms brain stems are active it should not be

**Table 1.** The Glasgow Coma Scale and Scores

<i>Eye opening</i>			
Spontaneous	4		
To pain	3		
To sound	2		
Absent	1		
<i>Verbal response</i>			
Orientated	5		
Confused	4		
Inappropriate	3		
Incomprehensible	2		
Absent	1		
<i>Best motor response</i>			
<i>Original scale</i>		<i>Expanded scale</i>	
Obey commands	5	Obey commands	6
Localise pain	4	Localise pain	5
Flexion	3	Normal flexion	4
Extension	2	Abnormal flexion	3
None	1	Extension	2
		None	1
Total Coma Score	14	Total Coma Score	15

taken to imply awareness. Indeed in the persistent vegetative or minimally conscious state, eye opening is characteristically dissociated from evidence of intellectual function.

- *Eye opening in response to speech* is sought by speaking or shouting at the patient. Any sufficiently loud sound can be used, not necessarily a command to open the eyes. This should be assessed before the patient is physically stimulated.
- *Eye opening response to pain* is assessed if the person is not opening their eyes to sound. It is essential that assessment is carried out using a consistent approach to stimulation, which does not give rise to ambiguous responses nor causes unnecessary injury to the patient. After extensive testing of various approaches, we recommended that the stimulus should be pressure on the bed of a fingernail. This gives a reproducible stimulation and also avoids the difficulty in interpretation that can arise if the person grimaces in response to a stimulus on the face. Options such as rubbing the sternum or pinching the chest or arm do not offer advantages.
- *An absence of eye opening* implies substantial impairment of brain stem arousal mechanisms. Before assigning this level of response, substantial effort should be made to ensure that this is not due to an inadequate stimulation. The key is that the examiner should be sure that if the patient would be examined subsequently by someone else, a higher level of response will not be elicited. It is also important to identify if a lack of eye opening is a consequence of local injury, for example fronto-basal fractures, or sedative and paralysing medication.

## 2. VERBAL RESPONSE

- *Orientation* is the highest level of response and implies awareness of self and environment. The person should be able to provide answers to at least three questions, who they are, where they are and the date – at least in terms of the year the month and day of the week. A person who can answer some but not all these questions can be subcategorised as partially orientated, either specifying what information that they are able to give or how many out of the three components they can provide.
- *Confused conversation* is recorded if the patient engages in conversation but is unable to provide any of the foregoing three points of information. The key factor is that the person can produce appropriate phrases or sentences.
- *Inappropriate speech* is assigned if the person produces only one or two words, in an exclamatory way, often swearing. It is commonly produced by stimulation and does not result in sustained conversation exchange.
- *Incomprehensible sounds* consist of moaning and groaning but without any recognisable words.

The verbal responses may be affected as a result of focal brain damage rather than a general impairment of function. For example, an impaired verbal response in an otherwise apparently alert person should raise the suspicion of dysphasia. The use of endotracheal intubation clearly precludes a verbal response.

### 3. MOTOR RESPONSES

The assessment of motor responsiveness becomes important in a person not conversing to at least a confused level.

- *Obedying commands* is the best response possible. It is important to be aware that motor responses can occur as a primitive grasp reflex or a startle response or a even simple posture adjustment and these should not be interpreted as a high level response. If in doubt, confirmation of the specificity of the response should be sought, for example by squeezing and releasing the fingers or holding up the arms or other movement elicited by verbal command.

If someone is not obeying commands, the pattern of motor responses to physical stimulation provides a very valuable method of assessing dysfunction. Stimulation should be applied in a standardised way and maintained until maximum response is obtained.

- Although stimulation of the fingernail will usually already have been applied to assess the level of eye opening, assessment for *localisation* should start with the application of pressure to a point in the head and neck – the supraorbital notch or styloid process behind the mandible. In order to be sure that the response is a specific motor response to a specific site of stimulation, localising should be recorded only if the person's hand reaches above the clavicle in an attempt to remove the stimulus. Stimulus to the trunk may result in the arms moving across the chest in a way that does not represent a specific localised response. If in doubt, stimulation can be applied to more than one site to ensure that the hand attempts to remove it.

- A *flexion response* is recorded if the elbow bends but the movement is not sufficient to achieve localisation whereas in *extension* the elbow only straightens. Before recording that someone has no motor response, vigorous and varied efforts should be made.

**What kind of flexion movements can be recognised?** A range of movements may be seen in patients with marked impairment of consciousness who do not localise painful stimulation. At one end it is often possible to recognise a relatively *normal flexion* movement characterised by rapid withdrawal, abduction of the shoulder, and external rotation which varies from stimulation to stimulation. At the other end, *abnormal flexion* is clearly present when the response is slow, stereotyped – that is repeated time after time – and results in the arm moving to an adducted internally rotated position, characteristic of the hemiplegic or so called decorticate posture. Nevertheless, between these



two clear patterns, varied patterns can be seen and some patients showing both types of movement at the same examination.

Experienced observers, particularly after careful training and discussion, can distinguish the two kinds of flexion response with an adequate degree of reliability. However, inexperienced staff, particularly working outside neurosurgical centres, find the distinction very difficult to make with consistency. For this reason, in the acute stage, it is sufficient in monitoring most patients to record simply that flexion is present.

The distinction is not crucial in the acute phase when deciding the need for action such as intubation to protect the airway or the performance of a CT scan – these will be indicated in any person not localising to a painful stimulus. Furthermore, transition between a normal and an abnormal flexion response is rarely sufficiently clear to signal deterioration or improvement in a way requiring alteration of management.

The distinction is useful prognostically and it is in this context that it is most relevant, for example when considering a likely outcome or in comparing series of patients.

**Why is it the best motor response?** The scale is based upon taking account of the best response of the better limb. Thus, during examination, a patient may show varying patterns with better responses occurring as the patient is more aroused. The highest level of response achieved provides the most consistent assessment of the patient's state and the best guide to the integrity of brain function remaining. A difference between the two sides may indicate focal brain damage. The worst or most abnormal response also should be noted in order to identify the site of focal damage, for the purpose of assessing the degree of impaired consciousness, it is the best response from the better limb that is relevant.

• *Absence of motor response.*

**What needs to be checked if there is apparently no response?** An absence of motor response clearly equates to a severe depression of function. Before ascribing this to structural damage it is important to exclude other causes – for example the effects of systemic insults such as hypoxia, hypotension or the use of drugs. Also, comparison should be made of the responses in the legs and arms with those in head and neck in order to alert the examiner to the possibility of spinal cord or brain stem injury. It is also important to ensure a stimulus of adequate intensity has been applied.

## DISCUSSION

**How consistent is the use of the scale?** The initial development of the scale was strongly influenced by the findings of studies in the Glasgow unit in which several observers were asked to examine patients and compare their

findings [8]. These guided the way that the scale could be used with equal consistency by nurses and non-specialist doctors, as well as by experienced neurosurgeons. Since these original studies, inter-observer consistency has been examined by many investigators and has been shown to be robust in a wide, relevant range of circumstances including emergency departments, intensive care units and in pre-hospital care. However, consistency cannot be assumed and should be confirmed and enhanced by training and communication between staff.

**How soon and how often should a patient be assessed?** Although these questions are frequent, common sense dictates that there are not simple single answers. The issue of when to commence observations reflects the need to distinguish between the use of the scale as a measure of early progress and as a predictor of ultimate outcome. Thus, when tracking the condition of a patient in the acute stage, the sooner an observation is made, the more useful it is as a guide to interpretation of later findings. Conversely, it is the very lability in the acute state that can make prognosis difficult so that most estimates of prognosis have been based upon an assessment after sufficient time has passed in order to ensure that the patient's state is not influenced by remedial disorders – for example hypoxia or hypotension or a developing intracranial haematoma. Later observations are often characterised as ‘post resuscitation GCS’ but it can sometimes be difficult to determine precisely when this is. Sometimes the ‘time after injury’ has been used, for example 6 hours, but this implies the time of injury is known, which is not always the case, and that emergency measures have been applied effectively.

Questions about the frequency of observations can likewise usually be resolved by common sense in relation to the likelihood that an influential change may take place. The shorter the time between an injury or other event and the assessment, the more the security about the stability of a patient's condition so that observations at frequent intervals are appropriate for example every few minutes and at least several times within an hour. As time passes the frequency can be reduced, and related to whether or not there are reasons for considering the patient needs continuing observation and care.

**How much change matters?** Questions are asked about the extent of change that should take place in order to trigger action. This may be simply to request assessment by another colleague or consultation with a more senior medical colleague. It may determine transfer to another unit e.g. from a general to a specialist neurosurgical department. Again, hard and fast rules are not appropriate.

The general guidance is that it depends upon where the patient is showing change from and the extent of the change. Thus, in a patient with no or mild impairment of responsiveness the certainty about a change may be less and the consequences of a small change also less so that a further period of observation and repeat assessments perhaps by a second colleague, can be appro-

priate. Conversely, the worse the patient's initial state, the more adverse the effect of a further deterioration and the greater the need for to avoid this. It is also the case that there is a greater degree of consistency in the assessment of the motor component of the scale than the verbal and eye features [8].

When in doubt, the safe thing is to consult and discuss, based upon a full description of all three aspects of the patient's condition and their changes over time and the time over which change has been taking place.

**What is the relationship between the scale and the score?** Our aim was for the approach to be useful both in practical day to day monitoring of patients with acute brain damage and in studies of prognosis, management and outcome. To enable the computerised analysis essential for such scientific studies, we assigned numbers to each response so that clinical recordings could be entered into a coding proforma [7].

For each of the three components of the scale, an absence of response was assigned the number 1 in order to make it clear that this was a positive identification of unresponsiveness. Increasingly high numbers were assigned to successively better responses and the three results entered separately. Inevitably, the temptation to sum together the three numbers into a total score became irresistible!

The total or sum score was initially used as a way of summarising information, in order to make it easier to present group data. However, the resulting score proved a useful and powerful summary of the extent of brain dysfunction and showed a strong relationship with prognosis [7]. The coma score has been the measure reported in most scientific papers and as a consequence as least as popular as the scale. It is, however, important to be aware of the pros and cons of the two approaches, how they are complementary and the circumstances in which one or other is more appropriate.

**What are the roles of the scale and the score?** When describing an individual patient, especially when communicating with colleagues, it is always preferable to refer to the responses observed and not to rely upon communication through the intermediary of numbers or a total score.

A major limitation of the total score is that it can be made up of a number of combinations of performance on the different components of the scale. This makes it difficult to translate the score into a clear picture of the patient's actual condition. This is particularly a risk in telephone exchanges.

Another problem with the total score is that if one component of the scale is untestable, this precludes allocation of a total score. Extrapolating and assigning an estimated score on the basis of the findings of only two components of the scale cannot be done reliably between the eye opening and the verbal responses nor between either the eye or verbal responses and the upper ranges of a motor response. Reporting what can be observed according to the framework of the subscales will convey whatever information can be reliably obtained.

**Is the total score 14 or 15?** Systems of numbering resulting in total scores of either 14 or 15 came about as a result of the differences in the approaches to assessment of flexion motor responses. In the simpler system, recommended for routine use in patient monitoring, no attempt is made to distinguish between normal and abnormal flexion. This results in a system summing to a total of 14. On the other hand, if the distinction between normal and abnormal flexion is considered to be reliable and to be useful, the total score possible becomes 15.

The approach giving a score of 15 has become most widely used, reflecting the way that the score was popularised through research papers. It is now not realistic to seek to establish one or other approach as the 'official' method. In order to avoid confusion if a patient is described by the total coma score, it should be made clear which system is being used by reporting the relevant total, i.e. a score out of 14 or 15.

**Does an early assessment of Coma Scale and Score relate to later events and outcome?** There are now many studies relating both the components of the scale [3] and the total score [7] to the occurrence of complications such as an intracranial haematoma in the acute stage and to late outcome after acute brain injuries. These provide a picture of a strong, close association. Moreover, where sufficient numbers have been studied, the relationship is both continuous (that is with each 'step' in the total score there is a change in outcome distribution) and almost quantitative (the extent of difference is similar across all steps). Although the way that the score came about was accidental, by good fortune it does provide a useful number!

## **THE GLASGOW OUTCOME SCALE**

**Why was an Outcome Scale needed?** An understanding of how outcome can be described after acute brain insult is as important as early assessment. Anxiety about the ultimate outcome is often foremost in the minds of patients and their families from the very moments after an acute insult. They need to be given a realistic and understandable account of the range of possibilities and kept informed as the prospects evolve as time passes and advised how to plan for the likely outcome.

Many decisions in the acute management of the patient depend crucially upon the outcome that it is expected will likely follow. Balancing the consequences of one option versus another, and how this is informed by the previous experience of the unit or in the literature, requires a succinct, relevant and readily comprehensible method of describing the different forms of outcome. There are, however, a number of challenges in assigning outcome to a brain damaged patient.

One challenge is that the consequences of brain injury can be expressed in such a wide variety of ways through disturbances in mental function, over and above any physical neurological defects or deficits. A thorough assess-

**Table 2.** Original and extended Glasgow Outcome Scale

Original	Symbol	Extended
Good recovery	GR	Upper good recovery Lower good recovery
Moderate disability	MD	Upper moderate disability Lower moderate disability
Severe disability	SD	Upper severe disability Lower severe disability
Vegetative state	PVS	
Dead	D	

ment from a multitude of perspectives may be necessary to fully understand the detailed picture in an individual but this does not yield the overall summation that can be used to encapsulate the extent of the impact on a patient's lifestyle. Moreover, the impact upon a person's lifestyle is often more determined by changes in emotional, behaviour and personality than in more specific aspects of neurological and neuropsychological function.

Another challenge is that the approach must be capable of integrating the perspectives of patient and family as well as clinicians. Finally, in view of the large number of patients with acute brain damage that need follow up, the approach must be capable of application without the need to spend time and resources on extensive testing.

**What factors influenced the design of the Glasgow Outcome Scale?** Unlike the Coma Scale, the Outcome Scale [1] was based upon an approach in which a number of features were integrated into a hierarchy of states, ranging from death to good recovery (Table 2). Assignment depended upon comparison between information about a patient and a description of the characteristics of each of the four categories of survival.

### How are the outcomes defined and assigned?

1) *Good recovery* is assigned if the patient is able to return to their previous level of lifestyle, including social and family activity as well as return to work – indeed it is the capacity to return to work rather than actually having done so that is relevant. Many people who otherwise clearly have made a good recovery do not return to work for a variety of reasons. Conversely, neurological, mild neuropsychological limitations or other deficits may be present without impairing the person's lifestyle.

2) *Mild disability* (also referred to as independent but disabled), refers to a patient who is able to look after themselves but has not regained their previous lifestyle in some significant way. If working, as some do, they have not attained their previous level, and there is substantial limitation of lifestyle and other social functions. Personality changes and memory and other cognitive problems are common but in some the restriction appears to reflect a failure to cope with residual deficits. The crucial factor is the person is able to care

for themselves for at least 24-hours in society, including an ability to shop and, if applicable, travel reliably by public transport.

3) In *severe disability* (also referred to as conscious but dependent) the person requires the support of some other person for some activities at least within every 24-hours. The worst affected have a combination of severe mental and physical disability but some are so seriously affected only mentally that they require support and supervision on a daily basis either by family or in residential care. This categorisation of severe disability is much broader than used for example by geriatricians or physicians in regard to aspects of daily living. For the latter, independence may indicate someone having no more than the ability to attend to their basic personal needs at home but be unable to be mobile outside their home or organise their living without assistance. Failure on either of these criteria would result in assignment to severe disability on the Glasgow Scale.

4) The *vegetative state* was defined by Jennett and Plum in 1972 as being survival with no evidence of psychologically meaningful activity as judged behaviourally. Their criteria included cycles of spontaneous eye closure and opening but a strict absence of obeying simple commands, expression of any words or evidence of appropriate responsiveness to the environment.

How long the vegetative state should be present before being referred to as *persistent* has usually been taken as at least 3 months but improvement can occur after this. For many purposes at least a year should elapse before it is considered *permanent*. Definition of this state has become more difficult leading to the additional concept of the minimally responsive state.

**Why is there an extended Glasgow Outcome Scale?** The categories in the original scale were considered by some to be too broad to be able to affect important differences between patients or in the evolution of the same patient with recovery over time. In 1981, the scale was extended by sub-division of the categories of conscious survival (severe and moderate disability and good recovery) into upper and lower bands. This produced an eight-point version (Table 2). Although this allowed greater discrimination, this was off-set by a much lesser degree of consistency of allocation.

**How was inconsistency dealt with?** The problem of variable assessment led to the development of a structured approach to the assignment of outcome on both the original and extended scales [11]. The questions reflected an emphasis on social disability and the multiple aspects of outcome in the original approach. Areas covered include consciousness, independence in the home and outside, work status, social and leisure activities, relationships with family and friends and a return to the lifestyle normal for that individual, always considering potential rather than actual achievement. No weighting is put on the different aspects but the relevance of the components varies across the spectrum of outcome.

The questionnaire also includes specific guidance about the outcome to which the patient would be allocated, depending upon the response obtained. The structured approach also made it possible to take into account previous

disabilities, which are found in a sizeable minority of patients with head injury and other intracranial insults.

The inter-observer reliability of the structured approach has been studied extensively. It shows a high degree of consistency when applied by the same observer on different occasions, by two observers on the same occasion, by comparison between face to face and telephone interview and also between assessments using self completed a postal questionnaire. Nevertheless, discrepancies are not entirely eliminated and can occur either in relation to the detailed information that is obtained or how this is translated into the overall score. Improvement can be obtained by training and by the use of a single central reviewer to allocate the scale on the basis of the detailed information.

### **What are the relationships between the Glasgow Outcome Scale and other indicators of outcome?**

Jennett and Bond's work [1] preceded many of the other approaches to assessing aspects of outcome after brain injury have been made, these support its validity and utility [9].

1) The *World Health Organisation* described a classification of impairments, disabilities and handicaps some years after the Glasgow Outcome Scale. It is important to appreciate that the term disability is used very differently in the two approaches. In the WHO system it rates much more closely to a specific deficit in functional activity whereas in the Glasgow system disability refers to the net effects, and corresponds more to the concept of handicap in the WHO system. Direct comparison is therefore not possible.

2) The relationships between *neuropsychological measures* of intellectual impairment and the Glasgow Outcome Scale have been extensively studied. Highly significant associations exist between the categories of both the original five point scale and the extended 8 point scale and a wide range of assessments. Nevertheless, these associations in group findings go along with substantial variability of performance among patients in a particular outcome category. It is difficult to predict from any one specific assessment how a person will be in terms of overall lifestyle and social reintegration.

3) The *Disability Rating Scale* is widely used in rehabilitation after brain damage. Although there are overall correlations between the two scales there are important differences. The disability rating scale has an emphasis on neurological limitations and activities of daily living and systematically under-reflects the disability or handicap shown in the Glasgow Outcome Scale. It was originally proposed as a method for tracking individuals through rehabilitation. In contrast, it is important to be aware that the degrees of disability on the Glasgow Outcome Scale cannot be assigned to a patient while they are still undergoing in patient care.

4) A number of '*quality of life*' assessments have been described, based upon summation of multi-item variables. One of the most widely advocated is the SF36. Comparison of assignments on the Glasgow Outcome Scale with

findings on each of the components of the SF36 showed a very significant relationship in each area with, reassuringly, with the greatest separation in the area of social handicap [9].

**What are the roles of the original and extended scales?** The two approaches to assignment of outcome have merits in different circumstances. In clinical care in the acute stage what is valuable is the predictability of outcome for an individual patient. Although there are clearly established correlations between initial clinical state as assessed by the coma scale and later outcome these correlations apply most clearly to the extremes of outcome, i.e. death or good recovery, and the extent of disability is very difficult to predict. For this reason, even the simpler original scale categories are often reduced to three: death or vegetative state versus severe disability, versus moderate disability or good recovery. There is little evidence of ability to discriminate between categories in the extended scale.

The value of the extended approach lies in the later stages after injury. It can be useful for tracking the progress of an individual patient and detect changes not evident in the original scale. It can also be useful in making more sensitive comparisons between groups of head injured patients. The distinction between upper and lower levels of severe disability is considered to have particular importance from an economic perspective – reflecting the much greater cost of care of the very severely disabled person. Conversely, the original scale performs well across the spectrum of head injuries and is sufficiently sensitive to detect the disability that commonly follows so-called mild injury [10].

**What is the utility of “dichotomous” division of outcome and how should it be done?** Division of outcome into only two options (dichotomisation) is common in research studies. The alternatives are referred to as favourable or unfavourable, worthwhile or not worthwhile, acceptable or unacceptable. Although these terms imply some value judgement, the approach initially was based more on the statistical merits in research of compressing even the five point scale into two different options. This maximises the numbers of people in the two categories rather than having them spread across five. This increases the statistical precision or confidence in the quoting of a percentage for either group and hence the greater reliability in comparing findings with another group. The division after a severe head injury is usually made between severe and moderate disability but other points can be appropriate, for example after less severe injury.

## **HOW SHOULD THE RESULTS OF THE GLASGOW COMA SCALE AND OUTCOME SCALE BE PRESENTED IN SCIENTIFIC REPORTS**

The use of the Coma Score is firmly established as a valid measure in the description of early severity. The issue is how the distribution of severity in a group of patients should be summarised. It is essential not to treat the findings as if the



score provided 'real' numbers – they are derived from rankings and the lowest score is not 0, nor even, 1 but 3! It is therefore completely invalid to summarise findings in a mean or average GCS – and even more to calculate this to a decimal point. Although quoting a median is more reasonable, the proper method is to present the distribution of the numbers of patients across the range of scores of interest. This may be by each step in the scale or in certain constellations, e.g. scores between 3 and 8 out of 15 are equated with a severe head injury, between 9 and 11 with a moderate injury and 12 to 15 as a mild injury. However, variations exist and the method used should always be specified.

In reporting outcome, there is no basis for referring to a Glasgow Outcome Score. It must be emphasised that the outcome assessment depends upon assignment to a scale. This simply presumes a hierarchy, with good recovery better than moderate disability, than severe disability, than vegetative state, than death. Numbers, or letters can be used only to indicate the rank order. What cannot be done is to assign a 'real' or cardinal value to any point. There is, therefore, no sensible way in which a numerical value can be assigned to any survival state as against another and even less sense in trying to decide how many times better than death is survival!

Recurring questions such as if death or good recovery should be given a score of one make no sense. It also is completely invalid to use summary statistics such as a mean or median to describe the findings of any numbers assigned to indicate order. Reports of outcome distribution should therefore provide the numbers of patients in each reported category, summarised if necessary in terms of proportion of the whole cohort studied.

## **CONCLUSIONS: DO THE GLASGOW SCALES REMAIN USEFUL TODAY**

Although initially described three decades ago, the Glasgow approaches to assessment of initial severity and outcome of brain damage have weathered the test of time.

The *Coma Scale* is widely employed throughout the world in its own right and also through incorporation into recommendations for clinical care. These include the Advanced, Trauma and Life Support system and guidelines for head injury management from organisations such as the National Institute for Clinical Excellence in the UK, the Brain Trauma Foundation and the World Federation of Neurosurgical Societies. It remains the standard for acute assessment [5].

The *Outcome Scale* is the most widely used approach in papers describing outcome after acute brain damage and its value is being enhanced by the increasing utilisation of the structured approach.

Alternatives to and adaptations of the Glasgow Scales have been described. Some of these have clear advantages, for example in relation to children.

Others find relevance to only very restricted groups of patients or in a particular clinical unit and have not been found to be useful replacements for the Glasgow Scales across the world.

It is, nevertheless, important to guard against this familiarity resulting in the scales being applied less rigorously and effectively than needed to ensure their value is used to the utmost. If issues arise about their application, relevance, reliability, interpretation or other aspects of their use and utility, these should be readily resolved by reference to the essential features of each of the two scales, to the factors underlying their application and the adoption of a common sense, flexible approach as set out in this account.

## References

- [1] Jennett B, Bond M (1975) Assessment of outcome after severe brain damage: a practical scale. *Lancet* 1: 480-484
- [2] Jennett B, Plum F (1972) Persistent vegetative state after brain damage: a syndrome in search of a name. *Lancet* 1: 480-484
- [3] Marmarou A, Lu J, Butcher I, Mc Hugh G, Murray GD, Steyerberg EW, Shkudiani NA, Choi S, Maas A (2007) Prognostic value of the Glasgow Coma Scale and pupil reactivity in traumatic brain injury assessed pre-hospital and on enrollment: an IMPACT analysis. *J Neurotrauma* 24: 270-280
- [4] Reilly PL, Simpson DA, Sprod R, Thomas L (1988) Assessing the conscious level in infants and children: a paediatric version of the Glasgow Coma Scale. *Child's Nerv Syst* 4: 30-33
- [5] Servadei F (2006) Coma Scales. *Lancet* 367: 548-549
- [6] Teasdale G, Jennett B (1974) Assessment of coma and impaired consciousness: a practical scale. *Lancet* 2: 81-84
- [7] Teasdale G, Jennett BJ (1976) Assessment and prognosis of coma after head injury. *Acta Neurochir* 34: 45-55
- [8] Teasdale G, Knill-Jones R, Van der Sande J (1978) Observer variability in assessing impaired consciousness and coma. *J Neurol Neurosurg Psychiatry* 41: 603-610
- [9] Teasdale GM, Pettigrew LEL, Wilson JTL, Murray G, Jennett B (1998) Analysing outcome of treatment of severe head injury: a review and update on advancing the use of the Glasgow Outcome Scale. *J Neurotrauma* 15: 587-597
- [10] Thornhill S, Teasdale G, Murray GM (2000) Disability in young people and adults one year after head injury. *Br Med J* 320: 1631-1635
- [11] Wilson JTL, Pettigrew LEL, Teasdale G (1998) Structured interviews for the Glasgow Outcome Scale and Extended Outcome Scale: guidelines for their use. *J Neurotrauma* 15: 573-585



**Graham M. Teasdale**

Graham M. Teasdale was Professor and Head of the Department of Neurosurgery, University of Glasgow (1981 to 2003). He qualified in medicine at the University of Durham. His career has been dedicated to improving the assessment, management and outcome of people suffering from acute brain damage from head injury and other causes. He is the author of more than 300 publications on topics including the Glasgow Coma Scale and the management of head injury. He was President of the Royal College of Physicians and Surgeons of Glasgow, Chairman of the European Brain Injury Consortium and of the International Neurotrauma Society. He is currently Editor in Chief of *Acta Neurochirurgica*, the *European Journal of Neurosurgery*, and Chairman of NHS Quality Improvement Scotland. He has received many awards and distinctions including the Medal of Honour of the World Federation of Neurosurgical Societies in 2005 and was made a Knight Bachelor in the 2006 New Year Honours list for services to Neurosurgery and victims of head injuries. He is FRCS Edinburgh; FRCPS Glasgow; FRCP London; FRCP Edinburgh; Honorary FRCS England, Ireland; MD Hon Causae Athens; Honorary International Fellow, American College of Surgeons; Fellow of the Academy of Medical Sciences; Fellow of the Royal Society of Edinburgh.

**Contact:** Graham M. Teasdale, The Royal College of Physicians and Surgeons  
Glasgow, 232-242 St. Vincent Street, Glasgow G25RJ, UK  
E-mail: [graham.teasdale@hotmail.co.uk](mailto:graham.teasdale@hotmail.co.uk)

---

# CRANIAL TRAUMA IN ADULTS

P. J. A. HUTCHINSON

Dr. Mathew R. Guilfoyle, Academic Clinical Fellow, University of Cambridge, is co-author of this chapter.

## INTRODUCTION

Cranial trauma and its sequelae present one of the most challenging areas of any healthcare system. Around 1% of all adult deaths annually result from head injury, with all age groups affected; in the young it accounts for up to a third of fatalities. Patients suffering trauma to multiple organ systems are up to ten times more likely to die if they have a concomitant brain injury. Moreover, those surviving severe brain injury have significant morbidity and disability with often devastating physical and psychological implications for the individual and, major economic burdens to society [4].

## RATIONALE

### 1. SKULL FRACTURE

Direct blows to the head can result in a variety of fractures to the cranial vault and skull base. Linear fractures of the vault usually result from diffuse low-energy trauma and, other than serving as a pointer to mechanism and severity of injury, are not of clinical significance unless associated with suture diastasis or an underlying extradural haematoma. Depressed fractures are caused by focal high-energy impacts, typically over the fronto-parietal convexities and vertex, which result in comminuted fragments of bone being displaced inwardly. Fragments that are significantly displaced – defined by depression equal or greater than the thickness of the vault – are elevated to help minimise complications such as post-traumatic epilepsy, and restore the normal contour of the head. Patients with scalp lacerations and compound vault fractures are at risk of developing infection involving the soft tissues, bone, meninges, CSF, or cerebrum, particularly if heavily contaminated (e.g. farmyard injuries). Similarly to other open fractures, early (<6 hours) debridement reduces this likelihood.

Linear fractures of the skull base are associated with a number of complications including cerebrospinal fluid fistula, cranial nerve palsies, and vascular

---

*Keywords:* cranial traumas, adults brain injury, cerebral oedema, intracranial pressure

injury. Fractures through the anterior fossa floor involving the orbital plate of the frontal bone present with “raccoon eyes” and with extension into the ethmoid bones there is often a dural tear causing CSF rhinorrhoea together with shearing of the olfactory nerves as they pass through their foramina in the cribriform plate resulting in anosmia.

Temporal bone fractures are classified into three types: (I) longitudinal fractures directed along the axis parallel to the petrous ridge, (II) transverse fractures oriented between foramen magnum and middle fossa, and (III) a mixed or oblique fracture pattern. Fractures that run through the mastoid typically manifest with mastoid ecchymosis (Battle’s sign) and CSF otorrhoea. The seventh nerve is vulnerable in its course through the temporal bone and is most often injured in transverse fractures. Complete facial palsy at presentation suggests nerve transection and has a poor prognosis whereas immediate but partial palsy may be recoverable with timely decompression of the nerve. Delayed facial palsy is caused by swelling around the fracture and in most cases resolves completely with conservative management. Hearing loss is a frequent complication of temporal bone fracture with a variable prognosis depending on whether there is a conductive deficit from disruption of the ossicular chain, which is potentially repairable with surgery, or a sensorineural deficit due to cochlear injury, which is less likely to recover. Fractures involving the foramen lacerum should raise the suspicion of carotid artery injury.

Linear fractures of the occipital bone can be associated with tears to the venous sinuses and posterior fossa extradural haematomas. Fractures running into the jugular foramen, hypoglossal canal, and occipital condyles can present with constellations of lower cranial nerve palsies. Three types of occipital condyle fractures are described: (I) impaction from axial loading, (II) extension of a linear fracture from the occipital bone, and (III) avulsion as a consequence of high velocity rotation. Only type III fractures result in potential instability of the cranio-cervical junction.

## 2. TRAUMATIC BRAIN INJURY

The primary brain injury sustained at the time of trauma remains the principal determinant of neurological outcome [7]. Severity is classified clinically on the basis of a patient’s initial (post-resuscitation) neurological status defined by the Glasgow Coma Scale (GCS; Table 1) and further by the appearance of computed-tomography imaging [3] (Table 2).

**Table 1.** Severity of traumatic brain injury

Minimal	GCS 15, no LOC or PTA
Mild	GCS 14–15 with brief LOC and PTA
Moderate	GCS 9–13 or LOC > 5 min or focal deficit
Severe	GCS 3–8
Critical	GCS 3–4

**Table 2.** CT classification

Diffuse I	No visible pathology on CT
Diffuse II	Basal cisterns present with MLS 0–5 mm and/or high or mixed density lesion density present <25 ml
Diffuse III	Basal cisterns compressed or absent with MLS 0–5 mm with no high or mixed density lesion density present >25 ml
Diffuse IV	MLS >5 mm high or mixed density lesion density present >25 ml
Evacuated mass lesion	Any lesions evacuated
Non-evacuated mass lesion	Any lesions of high or mixed density lesion density present >25 ml not evacuated

Epidural haematomas are caused by tearing of dural vessels, typically branches of the middle meningeal artery, and are associated with skull fracture in most cases. Subdural haematomas usually arise from disruption of bridging veins between cortex and the venous sinuses but can occasionally be due to arterial bleeding.

Injury to the brain parenchyma is classified as focal or diffuse. Cerebral contusions and haematomas characteristically occur in the frontal and temporal lobes as these are susceptible to impacting the skull following trauma. Diffuse axonal injury results from shearing of neurons at the neocortical-white matter junction during rapid deceleration. In high-energy trauma there is typically a combination of focal and diffuse parenchymal injury and, importantly, both are associated with delayed cerebral oedema and intracranial hypertension. Traumatic subarachnoid and intraventricular haemorrhage are both indicators of severe injury and poor prognosis.

Approximately 5% of traumatic intracranial haematomas occur in the posterior fossa with similar aetiologies as in the supratentorial compartment. Neurological impairment associated with posterior fossa lesions is due to a combination of direct pressure on the brainstem and obstructive hydrocephalus.

The degree of primary brain injury cannot be improved by current treatment modalities. Instead, the focus of management is averting secondary insults in the minutes, hours, and days following trauma that promote further derangement of glioneuronal metabolism and, ultimately, cell death. Fundamentally the aim is to prevent and aggressively treat cerebral ischaemia. Autoregulation of cerebral blood flow (CBF) is complex, but the principal modifiable factors are intracranial pressure (ICP), mean arterial pressure (MAP), arterial carbon dioxide tension, temperature, and serum osmolality. CBF is critically dependent on cerebral perfusion pressure  $CPP = MAP - ICP$  and is therefore reciprocally related to ICP. In addition, raised ICP causes secondary brain displacement and herniation through the fixed openings in the dura and skull resulting in brainstem ischaemia.

In the context of trauma, a rise in ICP is most often due to evolution of intra- or extra-axial haematomas, hydrocephalus, or cytotoxic/vasogenic

oedema. Left untreated, as ICP escalates and cerebral ischaemia ensues, energy failure results in cell breakdown and loss of blood–brain-barrier integrity with consequent increase in cytotoxic oedema. Compensatory mechanisms including cerebral vasodilatation further compound the cycle of worsening intracranial hypertension.

Medical control of ICP aims to lower cerebral metabolic demand with anaesthesia and hypothermia, counter oedema with administration of hypertonic solutions, and reduces cerebral blood volume by cautious application of moderate hyperventilation to induce controlled cerebral vasoconstriction whilst avoiding ischaemia. Ventriculostomy for external drainage of CSF can further significantly improve compliance. If ICP remains intractable despite these interventions then the only remaining option is to effectively increase the size of the cranial vault by decompressive craniectomy.

## **DECISION-MAKING**

### **1. DIAGNOSIS AND IMMEDIATE MANAGEMENT**

Improving neurological outcomes from TBI is critically dependent on instituting secondary prevention as early as possible. Detailed protocols exist for the prehospital and emergency department management of patients with (suspected) head injury with which all neurosurgeons should be familiar, particularly when advising referring physicians and transfer teams [1]. In short, patients should be managed in accordance with general advanced trauma and life support principles, and in particular resuscitated to a MAP of >90 mmHg, normoxia, normoglycaemia, and if signs of neurological deterioration (>2 GCS points) or herniation develop (uni- or bilateral pupillary dilatation) then hyperosmolar therapy with mannitol or hypertonic saline should be considered. A clear record of GCS at scene and initial hospital is invaluable in assessing severity of injury, prognosis, and making management decisions once the patient has been transferred to the neurosurgical centre.

Computed tomography (CT) is the investigation of choice to assess cranial trauma. Opinions on which patients should undergo CT vary widely; recent guidelines from the UK National Institute of Clinical Excellence are very helpful in this respect. In most circumstances a standard non-contrast scan with brain and bone windows is sufficient. Consideration should be given to performing any necessary spinal CT at the same time and if there is suspicion of vascular injury then a CT angiogram or venogram may be useful.

On the basis of the patient's neurological condition and CT findings a decision is made whether immediate surgery is necessary, guided by evidence-based criteria set out by the Brain Trauma Foundation [2] (Table 3). If a mass lesion requires evacuation this should be performed promptly – delays in surgery are well proven to have a major negative impact on outcome [11].

**Table 3.** Criteria for emergency surgery

<b>Extradural haematoma</b>				
Volume $\geq 30 \text{ cm}^3$	or	Volume $\leq 30 \text{ cm}^3$	and	<ul style="list-style-type: none"> <li>• Thickness <math>\geq 15 \text{ m}</math></li> <li>• MLS <math>\geq 5 \text{ mm}</math></li> <li>• GCS <math>\leq 8</math></li> <li>• Focal deficit</li> </ul>
<b>Subdural haematoma</b>				
Thickness $\geq 10 \text{ mm}$ MLS $\geq 5 \text{ mm}$	or	Thickness $\leq 10 \text{ mm}$ MLS $\leq 5 \text{ mm}$	and	<ul style="list-style-type: none"> <li>• Deterioration to GCS <math>\leq 8</math> since time of injury</li> <li>• Unequal pupils</li> <li>• Fixed and dilated pupil(s)</li> </ul>
<b>Parenchymal contusion/haematoma</b>				
Volume $\geq 50 \text{ cm}^3$	or	Volume $\geq 20 \text{ cm}^3$	and	<ul style="list-style-type: none"> <li>• GCS <math>\leq 8</math></li> <li>• MLS <math>\geq 5 \text{ mm}</math></li> <li>• Cisternal effacement</li> </ul>
<b>Posterior fossa</b>				
Any lesion causing mass effect (distortion or obliteration of fourth ventricle, effacement of basal cisterns, or obstructive hydrocephalus) or neurological impairment/deterioration				

If operation is not initially indicated the surgeon needs then to judge whether invasive ICP monitoring is required. Patients with post-resuscitation GCS of  $< 9$  without mass lesion needing evacuation should have an ICP monitor. Patients with a GCS of 8–14 present a difficult decision as often they are agitated and combative necessitating sedation, or require intubation for management of concomitant systemic injuries. Some have suggested that serial CT and assessment of basal cistern effacement is sufficient to monitoring in patients under 40 years, however given the low risk associated with modern ICP monitoring and the potentially devastating and irretrievable effect on outcome of undiagnosed intracranial hypertension we recommend that any patient with TBI who cannot be assessed neurologically at regular intervals with sedation breaks should have ICP monitoring. Adjunct multimodality monitoring varies between centres and includes microdialysis, brain tissue oxygen sensor, and thermodilution blood flow probes.

## 2. ICP CONTROL

Once invasive monitoring is instituted ICP should be managed aggressively with a standardised escalating protocol aimed at maintaining a target ICP of less than 25 mmHg and CPP of 60–70 mmHg [3]. An example from our Neurosciences Critical Care Unit is set out in Fig. 1. If medical therapy (including



## Addenbrooke's NCCU: ICP/ CPP management algorithm

All patients with or at risk of intracranial hypertension *must* have invasive arterial monitoring, CVP line, ICP monitor and Rt SjvO<sub>2</sub> catheter at admission to NCCU.

- This algorithm should be used in conjunction with the full protocols for patient management.
- Aim to establish multimodality monitoring within the first six hours of NCCU stay.
- Interventions in stage III to be targeted to clinical picture and multimodality monitoring.
- CPP 70 mmHg set as initial target, but CPP >> 60 mmHg is acceptable in most patients.
- If brain chemistry monitored, PtO<sub>2</sub> > 1 kPa & LPR < 25 are 2° targets (see full protocol)

**Evacuate significant SOLs & drain CSF before escalating medical Rx.**

**Rx in italics and Grades IV and V only after approval by NCCU Consultant.**

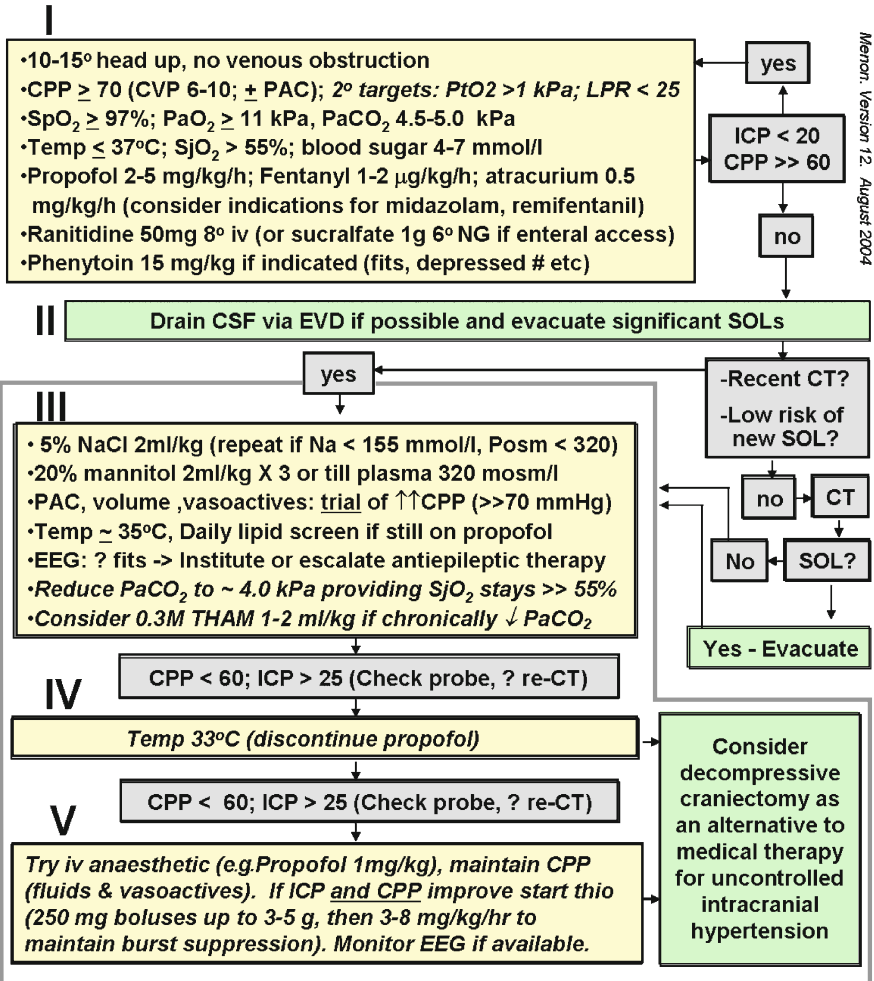


Fig. 1. Intracranial pressure management protocol

ventriculostomy and drainage of CSF) has been exhausted and refractory intracranial hypertension persists then craniectomy should be considered. The role of decompressive surgery is currently being evaluated in the RESCUE-icp randomised controlled trial ([www.rescueicp.com](http://www.rescueicp.com)).

### **3. DEPRESSED SKULL FRACTURES**

For closed injuries elevation is indicated if the fracture is depressed by more than the width of the skull. The same rule is applied to compound fractures but debridement, washout and closure of wounds may be necessary even if the fracture itself does not require elevating.

### **4. BASILAR SKULL FRACTURES**

Management is directed at preventing and treating complications. As a rule, traumatic CSF fistulae usually settle without intervention. Ongoing leak after seven days should prompt insertion of a lumbar drain to promote sealing off of the dural tear. Only a small minority of patients fail these measures and require operative repair either via sinus endoscopy or craniotomy. There is no evidence that antimicrobial prophylaxis reduces the risk of meningitis and such treatment should be reserved until there is indication of infection.

Temporal bone fractures with early facial palsy should be discussed with the ENT surgeons who may wish to undertake decompression of the nerve. Delayed palsy is managed expectantly. Steroid treatment remains controversial and of uncertain value in both settings. Hearing loss does not benefit from emergent investigation or intervention and should be assessed following the acute episode. If a fracture involves the carotid canal then angiography must be considered, particularly if there is atypical distribution of subarachnoid haemorrhage in the basal cisterns and sylvian fissure, or if there is otherwise unexplained poor GCS or lateralising neurological signs.

Potentially unstable occipital condyle fractures necessitate the hard cervical collar to be kept on and consideration of either internal fixation or conservative management with definitive immobilization in a halo vest.

### **5. SURGICAL APPROACH**

For the majority of lateralised supratentorial injuries the standard fronto-temporoparietal flap is the approach of choice. This craniotomy affords sufficient access to the structures most commonly injured in trauma – middle meningeal vessels, temporal and frontal poles, bridging veins to the sagittal sinus – and allows the surgeon to comfortably evacuate clot and obtain haemostasis. Furthermore, if at the end of surgery the brain is oedematous leaving the bone flap out provides a suitable decompressive craniectomy.

The craniectomy performed for decompression of predominantly diffuse injury is dictated by any signs suggesting more severe oedema in one hemisphere (e.g. midline shift, unilateral cisternal effacement) in which case a frontotemporoparietal flap is suitable. In generalised oedema a bifrontal craniectomy is the procedure of choice.

## **SURGERY**

### **1. OPERATIVE TECHNIQUES**

#### **1.1 General considerations**

Most procedures for trauma affecting the supratentorial compartment are performed with the patient supine and the head turned to the side contralateral to the lesion, with the exception of the bifrontal craniotomy which is performed with the head in a neutral position. A horseshoe headrest is sufficient for closing scalp lacerations and elevating uncomplicated depressed skull fractures, however procedures potentially involving craniotomy should be performed with the head secured in the three-pin Mayfield clamp. Jugular venous obstruction from excessive neck rotation is avoided by elevating the shoulder and hip ipsilateral to the operative side. If there is potential cervical spine instability instead of rotating the neck the patient is placed in the lateral position. If the thoracolumbar spine is not cleared then the procedure can still be carried out in the supine position but the whole spine should be maintained in neutral alignment by extensively padding the shoulders, back, hips, and knees.

For posterior fossa craniectomy the patient is turned prone with the head secured in the Mayfield clamp. Great care should be taken during positioning of a patient with cervical spine injury in a prone position as the immobilizing collar will need to be removed to allow for the approach.

Trauma procedures are often performed in patients who have multiple injuries, physiological derangements (including coagulopathy), and potential haemodynamic instability. Precautions such as large-bore venous access and readily available blood cross-matched products are mandatory. Close communication with the anaesthetist and theatre staff is essential in maintaining optimal cerebral physiology during surgery and in making procedures as uncomplicated as possible.

#### **1.2 Depressed skull fracture**

In a compound injury it is usually possible to incorporate the laceration in a linear or lazy-S incision to provide adequate exposure of the fracture. A caveat to this is in a fracture involving the frontal air sinus where, rather than extend lacerations on the forehead it is preferable to perform a bicoronal incision.

The bone fragments are often impacted. Elevation can be performed either via a burrhole sited alongside the fracture or by using a high-speed burr on the fragments to free them. Each piece of bone is removed, avoiding downward pressure, to reveal the dura and, following thorough inspection, any tears are washed out and closed in a watertight fashion. If the bone fragments are large enough they should be reconstructed using biplates and replaced to fill the defect. Otherwise, and only if there is no evidence of infection, a titanium mesh cranioplasty should be fashioned and the scalp closed in layers. If there is gross contamination of the wound the bone defect should be left and the scalp closed in a single layer with monofilament suture.

Fractures involving only the anterior wall of the frontal sinus may be fixed as described above or if the depression is not cosmetically significant then closure of any forehead lacerations is sufficient. When both the anterior and posterior walls are fractured the risk of infection and CSF leak is much higher and it is necessary to perform a bifrontal craniotomy (see below) to allow full inspection for dural tears and to repair the fracture. The pericranium is developed in a separate layer whilst reflecting the myocutaneous flap. Depressed fragments of the anterior wall are reconstructed and fragments of the posterior wall are removed – however, it is usually not necessary to formally remove the entire posterior wall (“cranialising” the sinus). The mucosa of the sinus is stripped and pushed down to occlude communication with the ethmoidal and nasal cavities and may be sealed with fibrin glue. Once any dural tears have been addressed the pericranial flap is laid over the frontal sinus. If there are associated fractures of the ethmoids or anterior cranial fossa floor these can be repaired with more fibrin glue or fascia lata graft if the pericranium is insufficient. A layered repair can be secured over the fracture with a small titanium mesh if necessary. The bone flap is replaced with four craniofix and the galea and skin are closed in the usual fashion over a suction drain. If the patient had a pre-operative CSF leak or is at high risk then a lumbar drain for 3–5 days post-operatively is prudent.

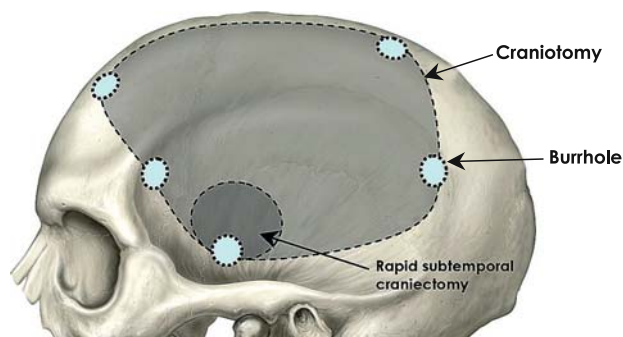
Elevation of fractures involving a venous sinus should be planned on the assumption of a bone fragment having perforated the sinus wall. Preparations for rapid haemorrhage should be in place and an assistant should be ready to manoeuvre the operating table at a moments notice. At surgery, decompression of the fragments may release any tamponade resulting in profuse bleeding and risk of air embolism. Continuous generous irrigation over the sinus during elevation reduces the chance of embolism and wet swabs should be at hand to immediately cover the sinus. Small holes or tears can be managed with surgicel or gelfoam and gentle pressure. Direct closure of tears can be performed if it does not result in sinus stenosis. For larger ruptures a patch repair using pericranium or fascia lata is required.

### 1.3 Frontotemporoparietal craniotomy

The “question-mark” incision begins 1cm anterior to the tragus and is first curved superioposteriorly over the ear, then superiomediaally to reach with-

in 1 cm of the midline and continued anteriorly ending just before the hair-line, or, optionally, curved 2–3 cm across the midline. Below the superior temporal line (STL) the incision is to the galea, above the incision is made directly on to bone. At 10 cm intervals bleeding from larger scalp vessels is controlled with bipolar diathermy and Raney clips are applied to the skin edges, and then the incision is continued. Once the incision is complete, temporalis fascia and muscle is divided in line with its fibers down to bone with cutting monopolar diathermy, half a centimetre from the skin margin. The myocutaneous flap is then reflected inferiorly elevating the periosteum from the frontal and parietal bones and temporalis off the temporal bone with a combination of sharp dissection and diathermy until the keyhole is exposed and the orbital rim palpable. The flap is retained by placing three or four sutures as low as possible in the undersurface of temporalis and securing these under tension to the drapes with artery or towel clips. It is important to control any bleeding from branches of the superior temporal artery now to avoid problematic haemostasis later in the operation.

Burrholes are placed at the inferior point of the temporal bone, the most anteromedial point of the frontal bone, the most posteromedial point on the parietal bone, the keyhole, and midway between temporal and parietal burrholes along the wound margin (Fig. 2). A free bone flap is completed with the craniotome extending medially to within 1–2 cm from the sagittal sinus cutting the section parallel to the sinus last. In patients precipitously deteriorating prior to induction or with escalating ICP the temporal burrhole should be made first and quickly extended circumferentially with Kerrison's rongeurs, (and the dura incised in cruciate fashion in the case of SDH) and clot suctioned as a temporising measure whilst the remainder of the craniotomy is completed. The sphenoid wing should then be nibbled down, any bleeding bone edges controlled with wax, and the edge of the craniotomy lined with surgicel.



**Fig. 2.** Frontotemporoparietal craniotomy

#### 1.4 Evacuation of extradural haematoma

Extradural haematoma is removed using suction and generous warm irrigation; clot can be gently stripped off the dura with forceps if necessary. As the evacuation proceeds bleeding points (usually from middle meningeal branches) should be controlled with bipolar diathermy. If bleeding continues despite cauterizing the visible branches of the middle meningeal then, with an assistant providing suction and irrigation, the temporal lobe is retracted to reveal the foramen spinosum and this is packed with a combination of bonewax and surgicel or gelfoam. Once any brisk haemorrhage has been stopped further haemostasis is best achieved by placing hitch stitches at 1–2 cm intervals along the dural margin to tamponade residual venous ooze and prevent recollection. These may be tethered to the periosteum and subgaleal tissue or oblique holes can be drilled in the bone edge. If there is suspicion of a concomitant subdural haematoma (either from preoperative imaging or at operation) a 5–10 mm incision can be made in the dura for inspection and closed if negative. To close, a sheet of surgical is laid on the dura and the bone flap is replaced with three craniofix. The central dura is hitched via two holes drilled in the centre of the bone flap. Galea and skin are closed over a suction drain.

#### 1.5 Evacuation of subdural haematoma

A frontotemporoparietal craniotomy is performed as described above. To access the subdural space a wide dural incision is made based on the sagittal sinus or inferior extent of the craniectomy. Subdural haematoma is removed with suction and warm irrigation, with particular care taken to not to unduly disrupt the arachnoid and pia. Bleeding points on the cortical surface are controlled as the evacuation progresses toward the part of the haematoma nearest the sagittal sinus. Great care is taken not to tear bridging veins whilst suctioning the haematoma, however, if one of the veins is bleeding or avulsed then it should be controlled with bipolar diathermy. A very proximal tear to a bridging vein or one that involves the sinus wall is better controlled with surgicel applied with gentle pressure using a patty, which is then left to tamponade whilst evacuation and haemostasis in other areas is attended to. Using a broad spatula the frontal, temporal, and parietal lobes are gently retracted in turn and the subdural space inspected for residual haematoma. Hitch stitches placed at 2–3 cm intervals are useful again as epidural oozing often begins following decompression of the SDH.

If the brain is slack following evacuation of the haematoma and the dura is easily approximated then it is closed in a watertight fashion with running 3-0 Vicryl. The bone flap is replaced with three craniofix and the frontal burrhole filled with bone dust.

If there is any concern regarding intracranial pressure from residual mass lesions such as parenchymal contusions (which may potentially evolve) or

from brain oedema then further releasing incisions are made in the dural edges and the dural flap is laid on the brain surface but not closed. A large sheet of surgicel is laid over the brain and dura, the bone flap is not replaced and the galea and skin are closed meticulously to avoid CSF leak.

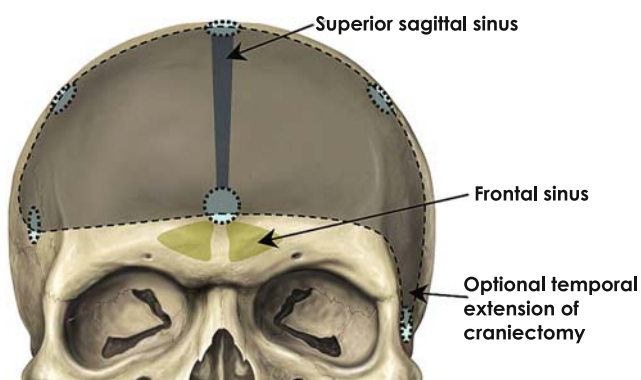
### 1.6 Evacuation of intracerebral haematoma and contusions

Following craniotomy, evacuation of an intracerebral haematoma proceeds as for spontaneous or aneurysmal haemorrhage. If the clot points to the cortical surface then it is entered through this point, otherwise a small corticotomy over the haematoma is made. The central bulk of the haematoma is removed with suction and irrigation and the cavity is then thoroughly inspected using the operating microscope. Once there has been satisfactory decompression haemostasis is achieved by lining the cavity with surgicel. As for SDH, a decision then has to be made whether to replace the bone flap.

Adequate surgical decompression in patients with diffuse injury and contusions depends on craniectomy. Contusions may be evacuated in the process of obtaining haemostasis and this is particularly true at the temporal tip where contusions frequently evolve and haemorrhage further. However, other than for these reasons, the additional benefits of debriding contusions is questionable as potentially eloquent or salvageable brain is removed together with haematoma and may negatively impact on outcome.

### 1.7 Bifrontal decompressive craniectomy

The patient is positioned as above with the head positioned neutrally and the neck slightly flexed. A bicoronal incision connecting the two points 1cm in front of the tragi is made behind the hairline. The scalp is reflected forward in the aponeurotic layer until the orbital rim is palpable. The temporalis muscle



**Fig. 3.** Bifrontal decompressive craniectomy

is divided along its fibers half a centimetre in front of the incision and reflected anteroinferiorly. Depending on the degree of injury to the temporal lobes the craniotomy can be taken to just below the superior temporal line or more inferiorly. Burrholes are placed in the temporal area and keyhole point bilaterally (Fig. 3). Two further burrholes are placed on the midline over the sagittal sinus at the anterior and posterior extents of the intended craniotomy, with the option for intermediate burrholes to free the dura from the bone. Anteriorly it is preferable to avoid entering the frontal sinus and the distance above the orbital rim at which the sinus ends should be gauged from the CT scan. Lateral to the frontal sinus the craniectomy is taken as close to the orbital rim as possible. Posteriorly the burrhole should be placed 1cm in front of the skin incision to facilitate future cranioplasty. Particular attention should be paid to stripping the dura around the midline burrholes and it is helpful to begin a channel for the craniotome with Kerrison's rongeurs to minimise the chance of injury to the sagittal sinus. The craniectomy is then completed on both sides cutting away from the sinus. Raising the bone flap presents the greatest risk of tearing the sinus and should be performed with great care. If there is a sinus injury then prevention of air embolism and repair are performed as described above. If the frontal air sinus has inadvertently been entered then it should be occluded as detailed above. Strips of surgical are placed along the sinus and around the margins of the craniotomy and bonewax applied liberally to the bone edges. Symmetrical U-shaped dural flaps are cut based on the sagittal sinus and further releasing cuts in the dural edges can be made if the brain is very tense. Lastly, the sagittal sinus is ligated no more than 1 cm from its most anterior point and then the frontal lobes are gently retracted to allow division of the insertion of the falx into the anterior fossa floor with scissors. The dural flaps are laid over the cortical surface and two large squares of surgical are placed over each hemisphere. The galea and skin are closed in the normal fashion.

### 1.8 Posterior fossa craniectomy

Post-traumatic haematomas in the posterior fossa are evacuated via bilateral suboccipital craniectomy. A linear midline incision is made from 1 to 2 cm superior to the external occipital protuberance to the level of C2–3. The paraspinal muscles are dissected in the avascular median raphe which is continued superiorly in a Y-shape parallel to the superior nuchal line to leave a cuff of tissue for closure. The muscles are dissected from the skull base with monopolar diathermy. For rapid decompression multiple burrholes can be made and the craniectomy completed with Kerrison's rongeurs. Alternatively burrholes are placed laterally over the transverse sinus and a bone flap can be completed using the craniotome. As in the supratentorial compartment extradural haematomas are removed with irrigation and suction with meticulous control of bleeding points with bipolar diathermy. Bleeding from the transverse sinus or, less commonly, the sigmoid sinus should be stopped with surgical applied with gentle pressure using a cottonoid patty. Larger tears



should be managed similarly to the sagittal sinus (above). Hitch stitches should be placed circumferentially before closing.

The durotomy to evacuate subdural haematoma is performed in a Y-shaped fashion taking care to ligate the occipital sinus if patent. Clot is then gently suctioned and a thorough inspection is undertaken to identify any bleeding from bridging veins or the sinuses. The dura is not closed primarily and is either left open or an expanding duraplasty can be performed with a suitable synthetic dural graft. Hitch sutures should be placed around the dural edges.

Traumatic cerebellar haematomas are evacuated via a small corticotomy made with the bipolar diathermy and using the operating microscope 0065. Once the bulk of haematoma is removed the cavity is lined with surgicel to obtain haemostasis. When substantial swelling is anticipated the posterior arch of the atlas can also be removed to make further room.

In all posterior fossa procedures meticulous closure of the fascia, subcutaneous layer and skin are paramount to prevent post-operative cerebrospinal fluid fistula.

## **2. PROGNOSIS AND OUTCOME**

The standard assessment of outcome following TBI is the Glasgow Outcome Score at six months post-injury. In clinical trials, the GOS is often dichotomised into favourable (GOS 4–5) and poor (GOS 1–3) outcomes. Recent studies have shown that TBI management in neurosurgical centres significantly improves outcome compared with non-specialist centres [10]. Implementing standardised ICP protocols and surgical interventions has significantly improved outcome compared to historical controls with yearly reductions in mortality. Despite this progress, mortality at 6 months in severe TBI remains approximately 30% [8]. A further 20% of patients are in the vegetative state or severely disabled leaving 50% with favourable outcome. Several models have been developed to help predict outcome for individual patients and in general concur that the principal factors are age, motor component of the initial GCS, and pupil reaction [6, 7, 9].

Data on long-term outcomes are lacking, particularly with respect to patient reported measures of quality of life. Nevertheless, it is clear that many survivors of TBI have problems with cognition, emotional difficulties, dependence for activities of daily living, and few return to their previous level of employment [12].

## **HOW TO AVOID COMPLICATIONS**

### **1. INEFFECTIVE OPERATION**

Management of raised ICP is inherently time critical, and inadequate decompression, whether evacuation of haematoma or craniectomy may drastically

change outcome for a patient. In contrast to current trends toward minimally invasive surgery, trauma procedures necessitate large craniotomies for evacuation of haematoma, thorough inspection, and haemostasis. Moreover when decompression is required if the craniectomy is too small the pressure against the brain at the bone edges may cause venous infarction and further oedema. Generally, in supratentorial compressive craniectomy a minimum bone flap size of 12 cm diameter is recommended.

## 2. RECOLLECTION OF HAEMATOMAS

Meticulous haemostasis is imperative intra-operatively and both anaesthetic and critical care teams should aggressively correct coagulopathy. Avoiding venous obstruction and dural hitch sutures are important in stopping ooze which develops when venous tamponade is released during haematoma evacuation and decompression. The operating microscope is invaluable to assist in obtaining haemostasis within haematoma cavities.

## CONCLUSIONS

Operative intervention in cranial trauma has an ancient history but until relatively recently a pessimistic view prevailed on the supposition that the severity of injury was the only real determinant of outcome, and subsequent treatment beyond supportive care did not change prognosis. However, in the latter half of the 20th century parallel advances in neuroimaging, anaesthesia, intracranial monitoring, and our knowledge of the basic pathophysiology underlying brain injury prompted a reappraisal of TBI management. There is now ample evidence to demonstrate that significant improvements in outcome can be gained by prompt institution of standardised care. Perhaps more than in any other aspect of neurosurgery a good working understanding of both medical and surgical treatment modalities is necessary to manage the individual patient and optimise their recovery.

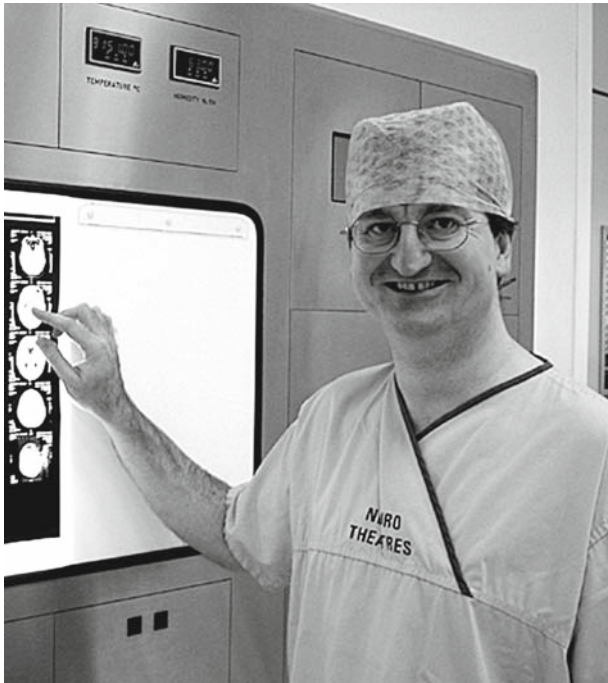### Acknowledgement

Original images were produced by Patrick J. Lynch.

### References

- [1] Badjatia N, Carney N, Crocco TJ, et al. (2008) Guidelines for prehospital management of traumatic brain injury, 2nd edn. *Prehosp Emerg Care* 12 Suppl 1: S1-S52
- [2] Brain Trauma Foundation (2006) Guidelines for the surgical management of traumatic brain injury. *Neurosurgery* 58: S1-S62

- [3] Brain Trauma Foundation (2007) Guidelines for the management of traumatic brain injury. *J Neurotrauma* 24: vii-viii
- [4] Maas A, Stocchetti N, Bullock R (2008) Moderate and severe traumatic brain injury in adults. *Lancet Neurol* 7: 728-741
- [5] Marshall L, Marshall S, Klauber M (1991) A new classification of head injury based on computerized tomography. *J Neurosurg* 75: S14-S20
- [6] MRC CRASH Trial Collaborators (2008) Predicting outcome after traumatic brain injury: practical prognostic models based on large cohort of international patients. *BMJ* 336: 425-429
- [7] Murray G, Butcher I, McHugh G, et al. (2007) Multivariable prognostic analysis in traumatic brain injury: results from the IMPACT study. *J Neurotrauma* 24: 329-337
- [8] Murray G, Teasdale G, Braakman R, et al. (1999) The European brain injury consortium survey of head injuries. *Acta Neurochir (Wien)* 141: 223-236
- [9] Mushkudiani N, Hukkelhoven C, Hernandez A, et al. (2008) A systematic review finds methodological improvements necessary for prognostic models in determining traumatic brain injury outcomes. *J Clin Epidemiol* 61: 331-343
- [10] Patel H, Bouamra O, Woodford M, et al. (2005) Trends in head injury outcome from 1989 to 2003 and the effect of neurosurgical care: an observational study. *Lancet* 366: 1538-1544
- [11] Seelig J, Becker D, Miller J, et al. (1981) Traumatic acute subdural hematoma: major mortality reduction in comatose patients treated within four hours. *N Engl J Med* 304: 1511-1518
- [12] Willemse-van Son AHP, Ribbers GM, Verhagen AP, et al. (2007) Prognostic factors of long-term functioning and productivity after traumatic brain injury: a systematic review of prospective cohort studies. *Clin Rehabil* 21: 1024-1037



**Peter J. A. Hutchinson**

Peter Hutchinson holds an Academy of Medical Sciences/Health Foundation Senior Surgical Scientist Fellowship within the Department of Clinical Neurosciences, University of Cambridge and Honorary Consultant Neurosurgeon post at Addenbrooke's Hospital. He has a general neurosurgical practice with subspecialist interest in the management of neurotrauma. He has a research interest in traumatic brain injury, multimodality monitoring in neuro-critical care and functional imaging. He is running the MRC funded RESCUEicp decompressive craniectomy study, [www.RESCUEicp.com](http://www.RESCUEicp.com), and is chairman of the EANS Research Committee.

**Contact:** Peter J. A. Hutchinson, Department of Clinical Neurosciences, Neurosurgery Unit, University of Cambridge, Cambridge CB2 3EB, UK  
E-mail: [pjah2@cam.ac.uk](mailto:pjah2@cam.ac.uk)

---

# **HYDROCEPHALUS IN ADULTS (INCLUDING NORMAL PRESSURE HYDROCEPHALUS SYNDROME)**

T. TROJANOWSKI

## **INTRODUCTION**

Hydrocephalus is defined as an increase of the amount of cerebrospinal fluid (CSF) within the cerebral ventricles and/or subarachnoid spaces of the brain which equals an enlargement of the intracranial spaces containing CSF.

It can result from loss of equilibrium between production (overproduction) and elimination (impaired absorption) of the CSF or an obstruction in its circulation.

Hydrocephalus was first described and named by Hippocrates (466-377 BC). Andreas Vesalius (1514–1564) presented the concept of hydrocephalus as accumulation of water inside the ventricles. In 1701 Pacchioni discovered arachnoid granulations but wrongly associated them with secretion of CSF. In the beginning of 20th century Walter Dandy and Kenneth Blackfan studied hydrocephalus in an animal model and showed that removal of the choroid plexus, before occlusion of aqueduct or of the foramina, prevented development of hydrocephalus. This showed that plexus is generating much of the CSF. It was only in the second half of the century when extensive research on hydrocephalus provided understanding of its pathophysiology and provided concepts for treatment. Removal of the choroid plexus proposed by Dandy was replaced by open third ventriculostomy performed in 1940 by White and Michelsen, Dandy and Stookey and an endoscopic method described by Mixer.

A major progress in the management of hydrocephalus came with introduction of a variety of shunting procedures, diverting excess of CSF into various body cavities or vessels.

In the recent years multiple studies searched for methods of selecting patients with NPH who would benefit from treatment by shunting. Progress in imaging and improvements in shunt technology, particularly introduction of an anti-siphon device, flow controlled valves and those with externally

---

*Keywords:* hydrocephalus, idiopathic normal pressure, shunt

adjustable opening pressure enhanced understanding and management of the condition.

## **RATIONALE**

Overproduction of CSF in excess of its absorption is rare and may occur in neoplasms of the choroid plexus: papillomas and choroid plexus carcinomas. Reduced absorption capacity of the CSF follows in some patients subarachnoid or ventricular haemorrhage, meningitis, or accompanies increased venous pressure in the superior sagittal sinus occurring in superior vena cava syndrome and in sinus thrombosis. Disturbed CSF circulation results from obstruction of the CSF pathways. This may occur in the ventricles, but can also take place in the subarachnoid space at the base of the brain or over the convexity. Tumors, haemorrhages, congenital malformations and infections can cause obstruction at any point in the pathways [7].

The intracranial pressure may increase under the influence of the mechanisms leading to hydrocephalus but it may also remain at the normal level.

Different forms of hydrocephalus are given specific names indicating basic differences between them.

*Communicating* hydrocephalus occurs when a patent communication between the ventricles is maintained and the flow is disturbed after CSF exits the ventricles into the subarachnoid space.

*Non-communicating* or *obstructive, occlusive* hydrocephalus develops when CSF flow is obstructed within the ventricular system leading to enlargement of the isolated parts of the ventricular system. *Normal pressure hydrocephalus* is recognized when cerebral ventricles are enlarged without increase in intracranial pressure and a characteristic set of neurological symptoms is presented. *Hydrocephalus ex vacuo* is a form of cerebrospinal spaces enlargement resulting from reduction of the volume of the brain damaged by ischemia, injury or degeneration. Intracranial pressure in those cases is normal. Enlargement of the cerebral ventricles is merely a replacement of lost cerebral tissue with CSF and no imbalance in fluid production and absorption exists. Some authors hesitate to diagnose this condition a hydrocephalus. *Arrested hydrocephalus* is a stable enlargement of the ventricles in patients whose neurological status do not change. It represents a condition persisting after a temporary enlargement of the ventricles triggered by a transitory cause.

Development of a hydrocephalus may be rapid in *acute hydrocephalus* or may take weeks to years in *chronic hydrocephalus*.

*Paediatric hydrocephalus* has its specific causes, course, pathology and treatment and is presented in another chapter. *Adult hydrocephalus* is of an acquired type, communicating or non-communicating. The main form is normal pressure hydrocephalus (NPH) which needs to be differentiated from hydrocephalus ex-vacuo.

## DECISION-MAKING

### 1. SYMPTOMS OF ADULT-ONSET HYDROCEPHALUS

Symptoms of adult-onset hydrocephalus vary depending on the ICP level associated with the condition.

In *occlusive hydrocephalus* with elevated ICP symptoms may include headache, nausea, vomiting and, sometimes, blurred vision. There may be problems with balance, walking and poor motor coordination. Irritability, fatigue, seizures, and personality changes, difficulties in concentration or memory deterioration may also develop. Drowsiness and double vision occur with higher ICP levels.

*Normal pressure hydrocephalus* (NPH) also called Hakim-Adams syndrome after the first authors who described it in 1965 presents in adults and is of a chronic, communicating type. A decrease in absorptive capacity of the arachnoid villi in the subachnoid space leads to increase of the CSF outflow pressure. This may result from a subarachnoid hemorrhage, head trauma, infection, neoplasm or complications of surgery. However, in many patients NPH occurs even when none of these conditions is present. It can occur at any age, but it is most common over the age of 50 with the mean age at onset close to 70. In cases with unknown aetiology it is called *idiopathic normal pressure hydrocephalus* (INPH). It has been shown, that in NPH and INPH there are periodical fluctuations of intracranial pressure with high level intervals, at least in the early stages of the disease. Therefore the name normal pressure may be misleading. Presence of intermittent elevation of ICP provides also a rationale for treatment by shunting, which cuts off the peaks of ICP waves, damaging the brain. NPH is caused by a blockage of the CSF draining pathways in the brain with increasing outflow or absorption pressure. Although the ventricles enlarge, the pressure of the CSF remains within normal range. The syndrome is important because it accounts for 5 to 6 percent of all cases of dementia, and occurs in 0.4% of the population [7].

NPH has a very distinct symptomatology. It is a triad of progressing symptoms consisting of gait disturbances, incontinence and cognitive decline eventually leading to dementia.

Walking disturbances are characterised by general slowing of movements. Gait is wide-based, steps are short, and shuffling. There are difficulties in going up and down stairs and over the curbs which may result in frequent falls. These disturbances range in severity from mild imbalance to the inability to stand or walk at all. Patients may have difficulty turning around. They turn very slowly with multiple steps. Gait disturbances are usually the first, most consistent and most pronounced symptom.

Impairment in bladder control in mild cases consists of urinary frequency and urgency whereas in more severe cases a urinary incontinence occurs.

Mental impairment and dementia presents as a loss of interest in daily activities, gradual loss of short-term memory, leading to difficulties in carrying routine tasks. In NPH those symptoms are often overlooked for years or accepted as an inevitable consequence of aging. The patients themselves may be less aware of their deficits because of the cognitive impairment. The symptoms get worse over time. Neuropsychological testing plays an important role in identifying intensity of mental impairment.

Because NPH symptoms may also be present in other disorders such as Alzheimer's disease, Parkinson's disease and Creutzfeldt-Jakob disease, correct diagnosis requires additional tests, including CT and MR brain scans, CSF dynamics, intracranial pressure monitoring and neuropsychological testing. Using MR it has been established that mean intracranial CSF volume in INPH is 280 ml compared to 195 ml in controls [9].

Differentiating NPH from ventricular enlargement in the course of brain atrophy and ageing is still difficult, despite a great variety of tests used to evaluate CSF flow dynamics, isotopic cisternography, MR flow studies, ICP monitoring, infusion test, CSF evacuation and neuropsychology [7].

*Syndrome of hydrocephalus in young and middle-aged adults* (SHYMA) is a recently described form of hydrocephalus. It is different from hydrocephalus diagnosed in infancy and early childhood as well as from adult-onset NPH. The syndrome name proposed by Dr. Michael Williams is described in the literature under a variety of self-explanatory terms like: late-onset idiopathic aqueductal stenosis, long-standing overt ventriculomegaly of the adult, and late-onset aqueductal stenosis. The cause of SHYMA may be congenital with a few or no symptoms in childhood, acquired after head injury, following meningitis or in the course of a brain tumor. It is idiopathic when no cause can be identified.

SHYMA is characterized by headache, subtle gait disturbance, urinary frequency, visual disturbances and some level of impaired cognitive skills. The job performance and personal relations of those patients can be affected at various degree. Early diagnosis is an important factor in obtaining resolution of symptoms.

In patients with disturbed gait, bladder control and mild dementia, SHYMA is diagnosed using a combination of CT and MR brain scans, intracranial pressure monitoring, lumbar puncture, ICP monitoring, measurement of CSF outflow resistance, isotopic cisternography and neuropsychological tests.

In properly diagnosed cases, treatment with shunting can reverse many of the symptoms, restoring much cognitive and physical functioning. In untreated patients symptoms can become disabling, leading to severe cognitive and physical decline [3].

## **2. ADULT HYDROCEPHALUS**

Adult hydrocephalus is treated in the ways appropriate to the type of hydrocephalus and its mechanism.



In occlusive hydrocephalus the cause of CSF pathways obstruction, usually a tumor, should be removed. If this is not possible a diversion of the fluid with endoscopic third ventriculostomy or a shunt is an option. Endoscopic third ventriculostomy is applicable when cerebrospinal pathways are obstructed beyond the third ventricle and absorptive capacity of the arachnoid remains adequate [4].

In most cases symptomatic non-communicating hydrocephalus needs to be treated before permanent neurologic deficits develop or neurologic deficits progress.

In urgent situation of rapid development of acute hydrocephalus it can be treated with temporary measures using ventricular drainage before the underlying condition, for example a posterior fossa tumor is removed, or intraventricular blood absorbed.

*CT and MR* scan delineates the degree of ventricular enlargement and in many cases discloses the causal aetiology. The degree of the ventricular enlargement can be evaluated by an Evan's index, which is a ratio of greatest width of the frontal horns of the lateral ventricles to the maximal internal diameter of the skull. An index exceeding 0.3 is indicative of a hydrocephalus. T2-weighted MR images can show transependymal flow of CSF and subependymal white matter damage. Widened temporal horns and flattened cortical sulci at the top of the brain are also found in NPH [2].

Differential diagnosis is based on a combination of clinical symptoms, imaging and tests predicting likelihood of improvement after shunting. All types of hydrocephalus may present with disturbed balance and gait, as well as cognition. It is important to identify patients with dementia in the course of subcortical or vascular dementia in Binswanger's or Alzheimer's disease and in Parkinson's disease in whom treatment with shunting is ineffective. Extensive leukoaraiosis is more common in vascular dementia than in ventricular dilation in INHP.

Predictive tests either measure CSF flow dynamics or simulate shunting by removal of the CSF.

*Isotopic cisternography* monitors absorption of CSF by tracing with gamma-camera a radioactive isotope injected into the lumbar subarachnoid space. Accumulation of isotope over the cortical surface indicates normal flow distribution. In NPH isotope enters the ventricular system. This method has not been proven to be reliable and was generally abandoned after 1992.

*Infusion tests* are based on recording of ICP during infusion of artificial CSF into the lumbar subarachnoid space or into the lateral ventricle. It allows calculation of CSF outflow resistance, compliance, CSF formation rate and dural venous pressure. Despite variations in the conduction and interpretation of the test the outflow resistance is regarded to be the most reliable predictor of effectiveness of shunting. Patients correctly selected for shunting based on elevated outflow resistance may not improve if the disease has reached an irreversible stage [8].

The flow within the CSF spaces can be studied non-invasively with MR. Increased velocity or volume of natural pulsatile flow in the aqueduct following blood pulsations predict favourable outcome of shunting.

*Draining* of 40–50 ml of CSF by lumbar puncture or continuous drainage of 150–250 ml a day in 2–4 days should temporarily relieve NPH symptoms, but not those related with other forms of dementia. The method has not proved to be particularly reliable with false positive and false negative results. Lumbar puncture can be simultaneously used to measure intracranial pressure, and provide samples of CSF for analysis. It should only be performed after imaging studies rule out an obstruction of the ventricular system and increased ICP [8].

*ICP monitoring* over a period of at least 24 hours with a pressure transducer inserted into the brain or cerebral ventricle permits detection of pressure waves that speaks for presence of NPH and indicates choice of treatment. Slow, rhythmic oscillations in pressure described as B-waves are regarded to be a good indicator of NPH likely to benefit from shunting, however evidence exists that only a weak correlation between ICP and surgical outcome exists [10].

*Biomarkers* offer some hope in enhancing diagnosis. Patterns of the concentration of neurofilament protein light (NFL), hyperphosphorylated tau (P-tau) and beta-amyloid (A $\beta$ 42) may help in differentiation of INPH from subcortical atherosclerotic encephalopathy [1].

Those supplemental tests can improve the accuracy of predicting a response to surgical treatment. CSF shunting provides significant symptom improvement in the majority of appropriately evaluated patients.

Patients with NPH who are considered for shunting should have gait disturbances and at least one of the two other elements of the triad: disturbances of urination and cognition. They should have dilatation of ventricles confirmed by imaging and an obstruction of the ventricular system excluded. Neuropsychological testing together with imaging help to exclude vascular dementia in Alzheimer's disease. At least one of the CSF dynamics tests should be indicative of a reduced compliance of the CSF flow. In our institution a lumbar infusion test with lumbar pressure measurement followed by evacuation of 50 ml of CSF and neurological and neuropsychological evaluation are done before decision making. In rare case ICP monitoring over 2 days is performed [6].

## **SURGERY**

### **1. OPERATION**

In the majority of NPH patients fulfilling above described criteria a ventriculo-peritoneal shunt is implanted.

Out of the great variety of shunting devices a variable opening pressure valves with an antisiphon are mostly used. It enables adjustment of opening pressure of the valve without operation. The initial opening pressure of the valve is set at the mean ICP level of the patient. This pressure is measured during pre-operative CSF-dynamic studies. The opening pressure is adjusted as necessary to counteract over- or under-drainage and resulting complications.

Shunt implantations are done in an operating theatre as the first procedure of the day, with additional restrictions in personnel circulation during the procedure to maintain highest level of asepsis. A single dose of prophylactic antibiotic approved for the whole hospital is used. The patient in general anaesthesia is placed supine on the operating table with the head resting on a horse-shoe support to allow repositioning during surgery, important at the stage of passing under the skin a guide from head to chest. The head is rotated to the left, hair shaved in the right frontal, temporal and retroauricular area. Upper part of the chest is elevated with a support across the shoulder blades to reduce curvature between the head, neck and chest to facilitate passage of the shunt passer without additional skin incisions between the head and abdomen. Incisions on the head and abdomen are marked and the skin in the area of shaved head, neck, chest and upper abdomen scrubbed with an antiseptic solution, covered with adhesive plastic and draped. A semicircular skin and periosteal incision is made immediately in front of the coronal suture and 2–3 cm to the right of the midline. It is slightly larger than the planned size of the burr hole. The skin flap with galea and pericranium is separated from the bone and retracted with a small self-retaining retractor. A burr hole is made with an electric drill. The diameter of the hole should be sufficient to accommodate the valve or a reservoir or provide space for the ventricular drain, depending on the construction of the shunt. The wound is temporarily covered with saline soaked gauze. A 4 cm long linear horizontal skin incision is made in the right upper quadrant of the abdomen. Appropriately moulded short passer is pushed under the skin from the frontal incision to the retroauricular area, where a secondary small straight skin incision is made. A long passer is guided under the skin between the abdominal and retroauricular incisions. Depending on the construction of the shunt modifications of this stage of operation may be necessary. We try to make as few secondary incisions as possible. In most cases one behind the earlobe is sufficient. Space in the subcutaneous tissue is prepared to accommodate valve and/or reservoir depending on the shunt type. In shunts without a tube shape passer pulling of the abdominal drain with a thread passed through the subcutaneous tunnel may facilitate the process. The peritoneal drain is passed from the frontal to the abdominal skin incisions. The dura and cortical arachnoidea are incised with No 11 blade and coagulated with a bipolar cautery. Making an incision prior to coagulation gives better control of the size of the dural opening and secure haemostasis. The size of the incision should be just large enough to allow passage of the ventricular drain. Larger opening increases the risk of

CSF subcutaneous leak along the drain. The ventricular drain of the length determined preoperatively on the MR is inserted perpendicularly to the bone into the lateral ventricle, anterior to the foramen of Monroe using a stylet. It is rarely necessary to use a ventriculoscope to confirm correct placement of the tip of the catheter, away from the choroid plexus. Proximity of ventricular catheter tip to the choroid plexus increases the risk of drain occlusion by adhesions with plexus. The usual length of the catheter is 5–6 cm. If shunt construction requires connecting ventricular and peritoneal catheters it is done at this stage. Drains are secured on the connector with a non-absorbable thread. Making a knot connecting both ligatures decreases the risk of disconnection. Free flow of the CSF from the peritoneal end of the shunt confirms patency of the system. Now abdominal straight muscle is split along its fibre lines, peritoneum elevated, opened with scissors and secured with clamps. The distal catheter of the shunt is introduced through the opening into the peritoneal cavity. It is suggested that a single-end hole catheters are more resistant to occlusion than those with multiple side holes or slits. A length of around 40 cm of catheter is left in the peritoneal cavity with a purse-string suture of the peritoneum tied around the entry point. Placing the drain over the liver is believed to reduce the risk of occlusion by peritoneal adhesions. Skin wounds are sutured in layers and dressing applied.

A lumboperitoneal shunt may be used as an alternative to the commonly used ventriculoperitoneal shunt. They are used if ventricles are small, like in pseudotumor cerebri. They tend to overdrain and cause headache, therefore a positional valve turning off the flow of CSF when the patient is upright is recommended.

Other types of shunts, like ventriculo-atrial or ventriculopleural are used very rarely in NPH and usually in special circumstances. Ventriculoatrial shunting is used in patients with contraindications for insertion of an abdominal catheter, which occurs after multiple abdominal operations, in extensive peritoneal adhesions, malabsorptive peritoneal cavity. Complications of the ventriculoatrial shunt include renal failure, great vein thrombosis, catheter thrombosis or cardiac arrhythmias. They are more common and severe than complications in ventriculoperitoneal shunts [5].

Shunting should not be performed in infected patients or those with high CSF protein level of >150 mg/dL.

## 2. POSTOPERATIVE CARE

Wounds are kept dry under sterile dressings. Skin sutures on the head are removed on the 5th postoperative day and those on the abdomen on the 7th day.

Plain radiographs of the implanted shunt provides control of the position of the shunt and connections as well as a good baseline for the future. In patients with variable pressure valve it confirms the setting of the opening pressure.

Postoperative CT scan is used to document ventricular size, although a scan performed shortly before the operation may suffice.

Patients with high brain compliance should be mobilized and brought to the upright position gradually to reduce the incidence of overdrainage and subdural haematoma formation.

### 3. COMPLICATIONS

Shunts are prone to complications. They include mechanical failure, infections and obstructions.

If the volume of drained CSF is inadequate the problem of overdraining or underdraining occurs. It results from an inappropriate opening pressure of the shunt system for the individual patient.

A shunt malfunction may be indicated by headaches, vision problems, irritability, fatigue, personality change, loss of coordination, difficulty in waking up or staying awake, a return of walking difficulties, mild dementia or incontinence.

Overdraining may lead to collapse of the ventricles and development of slit ventricle syndrome or to tearing of blood vessels resulting in formation of a subdural hematoma. The risk can be reduced by using antisiphon devices and avoiding selection of too low opening pressure of the valve. In adjustable pressure valves overdrainage can be overcome by increasing opening pressure.

Underdraining occurs when the volume of drained CSF is too low. In those cases the symptoms of hydrocephalus do not retreat or recur. It is managed by increasing opening pressure of the valve, but sometimes requires occlusion of the shunt system.

Collapse of the ventricular walls and occlusion of the ventricles lead to slit ventricle syndrome. It is rare condition occurring after ventriculitis or shunt infection. Usually high ICP develops. The slit ventricle syndrome does not imply overdrainage. It manifests with symptoms high intracranial pressure. Collapsed ventricle tends to block ventricular catheter, which may be resolved by a subtemporal decompression creating a pressure reservoir allowing expansion of the ventricle.

Infections of the shunt system are a serious and common complications of shunting. It is estimated that between 5 and 15% of the devices become infected, of which more than a half within the first month after surgery [5].

Eradication of the bacteria, commonly staphylococci, from the foreign body of the shunt is extremely difficult and usually is achieved only after removal of the system. Infection causes fever, symptoms of meningitis or encephalitis, swelling and tenderness along the shunt drains. Infection is usually combined with dysfunction of the valve and sometimes recurrence of the hydrocephalus symptoms.

Prognosis of the treatment of INPH with shunting is uncertain. It depends on the stage of the NPH and the level of brain damage before treat-

ment. Complications of shunts and their dysfunction further increase the failure rate. While the success of treatment with shunts varies, many patients, close to 80% of cases diagnosed early, treated in time with proper indications, recover almost completely and have a good quality of life.

## HOW TO AVOID COMPLICATIONS

Complications are unavoidable but we can reduce their frequency. To achieve this goal reliable diagnosis of NPH should be made, appropriate selection of patients with high likelihood of effectiveness of shunting. Meticulous execution of implantation plays an important role in complication avoidance. Too long or too short ventricular catheter, placed sub optimally in the ventricular system, mechanical damage of the shunt system by inadequate handling or bad instruments, too long operation time, violation of strictly aseptic technique increase the risk of shunt dysfunction or infection.

## CONCLUSIONS

Hydrocephalus in adults is different from that occurring in childhood. The most common and typical is normal pressure hydrocephalus, presenting a typical triad of symptoms. Treatment is basically implantation of a ventriculo-peritoneal shunt. Success of the treatment depends on the proper selection of candidates for shunting and exclusion of those with dementia in other brain conditions. Treatment is safe but not free of complications. Most of them can be avoided by using good clinical judgement and meticulous surgical technique. Bolus resistance testing and gait improvement immediately following shunting are the best prognostic indicators of a favourable outcome. It is common that gait and incontinence respond to shunting, but dementia responds less frequently.

## References

- [1] Ågren-Wilsson A, Lekman A, Sjöberg W, Rosengren L, Blennow K, Bergenheim AT, Malm A (2007) CSF biomarkers in the evaluation of idiopathic normal pressure hydrocephalus. *Acta Neurol Scand* 116: 333-339
- [2] Boon AJ, Tans JT, Delwel EJ, Egeler-Peerdeman SM, Hanlo PW, Wurzer HA, Hermans J (2000) The Dutch normal-pressure hydrocephalus study. How to select patients for shunting? An analysis of four diagnostic criteria. *Surg Neurol* 53: 201-207
- [3] Cowan JA, McGirt MJ, Woodworth G, Rigamonti D, Williams MA (2005) The syndrome of hydrocephalus in young and middle-aged adults (SHYMA). *Neurol Res* 27: 540-547

- [4] Dusick JR, McArthur DL, Bergsneider M (2008) Success and complication rates of endoscopic third ventriculostomy for adult hydrocephalus: a series of 108 patients. *Surg Neurol* 69: 5-15
- [5] Epstein MH, Duncan JA III (2000) Surgical management of hydrocephalus in adults. In: Schmidek HH, Sweet WH (eds) *Operative neurosurgical techniques. Indications, methods, and results*. W. B. Saunders, Philadelphia
- [6] Gallia GL, Rigamonti D, Williams MA (2006) The diagnosis and treatment of normal pressure hydrocephalus. *Nat Clin Pract Neurol* 2: 375-381
- [7] Malm J, Eklund A (2006) Idiopathic normal pressure hydrocephalus. *Pract Neurol* 6: 14-27
- [8] Marmarou A, Young HF, Aygok GA, Sawauchi S, Tsuji O, Yamamoto T, Dunbar J (2005) Diagnosis and management of idiopathic normal-pressure hydrocephalus: a prospective study in 151 patients. *J Neurosurg* 102: 987-997
- [9] Tsunoda A, Mitsuoka H, Bandai H, Endo T, Arai H, Sato K (2002) Intracranial cerebrospinal fluid measurement studies in suspected idiopathic normal pressure hydrocephalus, secondary normal pressure hydrocephalus, and brain atrophy. *J Neurol Neurosurg Psychiatry* 73: 552-555
- [10] Vanneste J, van Ecker R (1990) Normal pressure hydrocephalus: did publications alter management? *J Neurol Neurosurg Psychiatry* 53: 564-568



**Tomasz Trojanowski**

Tomasz Trojanowski is Chairman of the Department of Neurosurgery and Paediatric Neurosurgery at the Medical University in Lublin, Poland. Member of the Polish Academy of Sciences and of the Polish Academy of Arts and Sciences, born in 1947 in Lublin, Poland. Vice-President of the WFNS and of the EANS. Member of the Eurasian Academy of Neurosurgery, World Academy of Neurosurgery, German Academy of Neurosurgery, Turkish Academy of Neurological Surgery. Chairman of the JRAAC, Ethico-Legal Committee of EANS. President of the Section of Neurosurgery of UEMS. Honorary President of the Polish Society of Neurosurgeons, Honorary Member of the Polish Surgical Society, British Neurosurgical Society, Corresponding Member of the German Neurosurgical Society. Chairman of the Neuroscience Committee of the Polish Academy of Sciences. Main scientific interests: neurodiagnostics, vascular brain diseases, neurooncology, radiosurgery, neurosurgical technique, neuro-pathophysiology. Author of over 130 published papers, 180 congress presentations and chapters in 6 monographs.

**Contact:** Tomasz Trojanowski, Department of Neurosurgery and Paediatric Neurosurgery, Medical University in Lublin, Jaczewskiego 8, 20950 Lublin, Poland  
E-mail: [t.trojanowski@am.lublin.pl](mailto:t.trojanowski@am.lublin.pl)



---

# ARACHNOID CYSTS

H. W. S. SCHROEDER

## INTRODUCTION

Arachnoid cysts are congenital cerebrospinal fluid-filled lesions probably arising from anomalous splitting of the arachnoid during prenatal development [16]. In some cysts, a valve mechanism seems to play a major role in cyst enlargement [12, 13]. During life, these cysts may expand and cause symptoms by compressing the neighbouring brain structures or causing occlusive hydrocephalus. Therefore, they usually become symptomatic with signs of increased intracranial pressure. Furthermore, depending on their location, arachnoid cysts may cause seizures, hemisyndromes, increased head growth, ocular symptoms, cerebellar symptoms, endocrinological abnormalities, etc. Arachnoid cysts can be found anywhere in the brain, but are predominantly located in the Sylvian fissure [7]. With the increasing use of magnetic resonance (MR) imaging, arachnoid cysts are frequently discovered as an incidental finding. True congenital arachnoid cysts should be distinguished from acquired cysts which may occur after trauma, bleeding, or infection.

## RATIONALE

The goal of surgery in arachnoid cysts is simply the creation of a communication between the cyst and the normal cerebrospinal fluid (CSF) spaces, i.e. the ventricles and/or the cisterns (Fig. 1). This communication should be large to avoid reclosure of the opening by scarring [2, 14]. When a large opening cannot be performed for anatomical reasons, a silicon catheter can be placed between cyst and CSF space. However, foreign material should be avoided whenever possible. When all fenestration attempts fail, a cystoperitoneal shunt has to be inserted as the final treatment option (Fig. 2).

## DECISION-MAKING

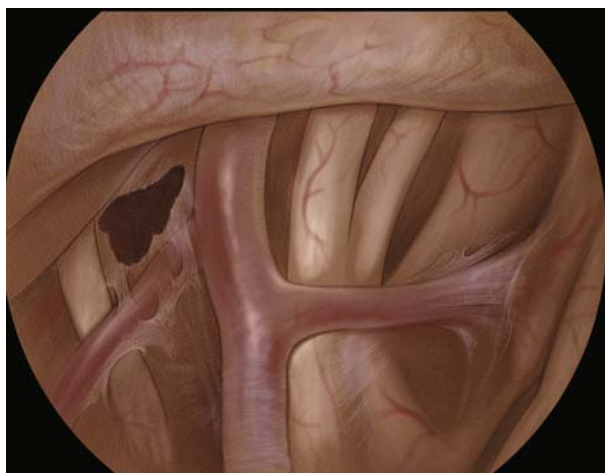### 1. DIAGNOSTIC CRITERIA

#### 1.1 Imaging

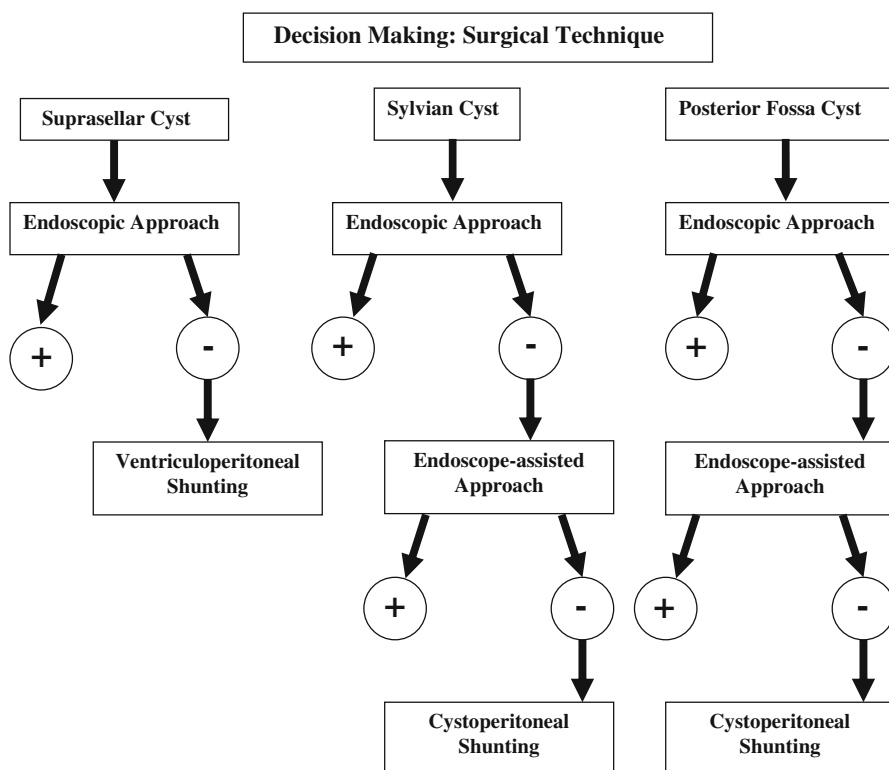
MR imaging is the imaging modality of choice. Our standard protocol for arachnoid cysts includes T1- and T2-weighted sequences in axial, coronar,

---

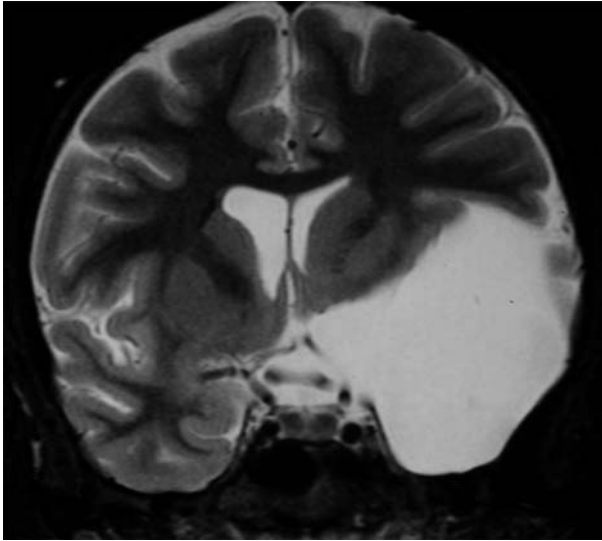
*Keywords:* arachnoid cyst, endoscopy, endoscopic fenestration



**Fig. 1.** Schematic drawing of a Sylvian arachnoid cyst showing the fenestration between carotid artery and oculomotor nerve which creates a communication to the prepontine cistern



**Fig. 2.** Decision making for surgical technique



**Fig. 3.** Coronal T2-weighted MR image showing a Sylvian arachnoid cyst with midline shift and ventricular compression

and sagittal plane, as well as high resolution CISS (constructive interference in steady state) and IRTSE (inversion recovery turbo spin echo) sequences (plane depending from the location of the cyst). Size, configuration, mass effect and width of the ventricles were evaluated (Fig. 3).

### 1.2 Clinical symptoms

Headaches are the most common complaint. Other symptoms depend from the location of the cyst. Sylvian cysts may cause seizures and hemi-syndromes. Suprasellar cysts usually lead to obstruction of the aqueduct resulting in occlusive hydrocephalus. Therefore, signs of acute or chronic hydrocephalus may occur. Sometimes endocrine dysfunction, such as precocious puberty, is the initial symptom. Arachnoid cysts in the pineal region may cause Parinaud syndrome or diplopia. Infratentorial cyst often present with dizziness, balance problems, or cranial nerve dysfunction.

## 2. INDICATIONS

Symptomatic arachnoid cysts are an indication for surgery if no contraindications exist. Symptomatic cysts usually show a mass effect on MR imaging with flattening of cerebral gyri, midline shift, and/or ventricular compression. The surgical indication for asymptomatic arachnoid cysts remains controversial [1, 3, 10]. In my opinion, surgery for asymptomatic arachnoid cysts in adults is not justified although the vulnerability of arachnoid cysts in mi-

nor head trauma is well known. In children however, asymptomatic cysts with a significant mass effect that may hinder the normal development of the adjacent brain tissue should be treated surgically [1, 4, 11].

## **SURGERY**

### **1. OPERATIVE TECHNIQUE**

In my experience, endoscopic or endoscope-assisted microsurgical cyst fenestration is the procedure of choice in most intracranial arachnoid cysts. Shunting should be avoided whenever possible and is considered to be the last-in-line treatment option although some reports favour shunting over cyst fenestration [1, 4].

The positioning of the patient on the operating table depends on the location of the cyst. The entry point should be the highest point to prevent excessive CSF loss. After general anesthesia has been induced, the head is placed in three-pin fixation. Single shot antibiotic prophylaxis (1.5 g cefuroxime) is administered intravenously. When required, computerized neuronavigation is installed and referenced. Neuronavigation is helpful in selecting the ideal entry point and the best trajectory [15]. In cystic cavities, lacking anatomical landmarks, neuronavigation is sometimes mandatory to stay oriented. When neuronavigation is not used, the entry point is determined according to the best trajectory obtained from MR imaging. Then the operating field is prepared and draped.

If an endoscopic procedure is performed, a 10-mm burr hole is made at the entry point. The endoscopic sheath with trocar inside is inserted free-hand or under navigational guidance into the cyst or ventricle and fixed with a self-retaining holding device. Care is taken to avoid significant CSF loss when directly approaching the cyst cavity. Therefore, the endoscopic sheath is inserted immediately after incising the cyst membrane and cottonoids are densely packed around the sheath at the level of the burr hole. Then the trocar is removed and the endoscope is inserted to inspect the cyst. We use a recently developed rigid multipurpose ventriculoscope which has a 6° Hopkins II rod lens optic, a 2.9 mm working channel, and two 1.6 mm irrigation channels (Karl Storz GmbH & Co. KG, Tuttlingen, Germany). The operations are performed under continuous irrigation with Ringer's solution at 36°C. Depending on the cyst location, cysto-cisternostomies, ventriculocystostomies, or ventriculocystocisternostomies are made. Once the endoscopic fenestration is accomplished, the cyst is inspected to make sure that a sufficient communication between cyst and cistern or ventricle has been created. Then the operating sheath is withdrawn with the endoscope inside to look for active bleeding in the puncture canal. Since suture of the dura in adults is not feasible, we pack the burr hole with a gelatin sponge and tightly suture the galea to prevent subgaleal CSF accumulation and fistula formation. In infants, we suture dura, periost (if possible), temporal fascia, and galea. The skin is closed with a running atraumatic suture.

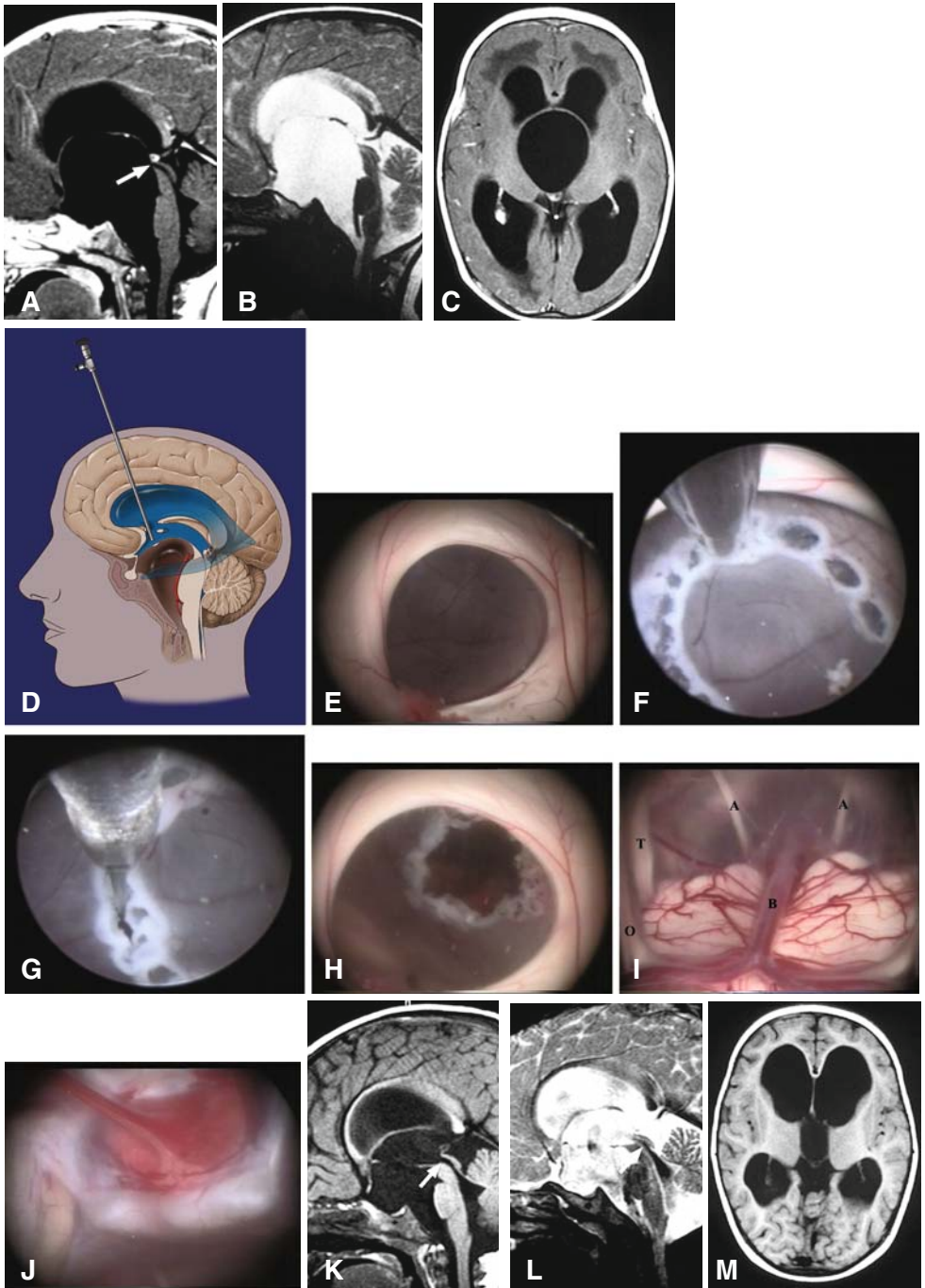
For endoscope-assisted microsurgical procedures, a mini-craniotomy (approx. 2 by 2 cm) is made and a fenestration or partial cyst resection performed under microscopic and endoscopic view. For endoscopic visualization, 2.7 mm Hopkins II rod lens optics (Karl Storz) with angulated eye piece and different angles of view are used. These endoscopes have no working channel. The instruments are guided around the endoscope. Because the endoscope is fixed with a self-retaining holding device, the surgeon has both hands free for bimanual dissection as he is used to do under the microscope.

## 2. SUPRASELLAR ARACHNOID CYSTS

Suprasellar arachnoid cysts are an ideal indication for an endoscopic approach. Usually large suprasellar arachnoid cyst cause occlusive hydrocephalus due to aqueductal obstruction (Fig. 4A and B). The ventricular dilation provides plenty of space for insertion of an endoscope. Because of their characteristic appearance on axial MR images these cysts are also referred to as Mickey Mouse cysts (Fig. 4C). The patient is placed supine with the head slightly anteflexed. A precoronal burr hole is made 2 cm paramedian on the right side. Thereafter, the endoscope is introduced into the right lateral ventricle (Fig. 4D). Usually the foramen of Monro is enlarged by the cyst (Fig. 4E). A large fenestration into the lateral ventricle (approx. 1 by 1 cm) is created in the cyst wall with the aid of bipolar coagulation and scissors (Fig. 4F and G). In cysts with a very thin cyst membrane, a bimanual technique is used to prevent collapse of the cyst. Via one irrigation channel a flexible forceps is introduced to hold the cyst membrane while scissors are used via the working channel to make the fenestration. Then the cyst membrane in front of the aqueduct is coagulated with a bipolar diathermy probe to shrink the collapsed cyst and restore CSF flow through the aqueduct. Once the fenestration has been accomplished (Fig. 4H), the inside of the cyst is inspected. The cranial nerves III to VII/VIII, basilar and vertebral arteries as well as pituitary gland can often be seen (Fig. 4I and J). If a valve mechanism is found around the basilar artery, this valve should be destroyed because a major pathogenic factor may be eliminated. If anatomically possible, a communication between the cyst and the basal cisterns is performed additionally to create a ventriculocystocisternostomy [5]. However, this step of the procedure seems to be not mandatory to be successful.

## 3. SYLVIAN ARACHNOID CYSTS

The optimal treatment for Sylvian arachnoid cysts is still under discussion. We prefer an endoscopic burr hole approach. However, when the cyst membrane turns out to be very tough or the windows between carotid artery, optic and oculomotor nerve are very narrow, we do not hesitate to switch to an endoscope-assisted microsurgical technique. Then, the burr hole is en-



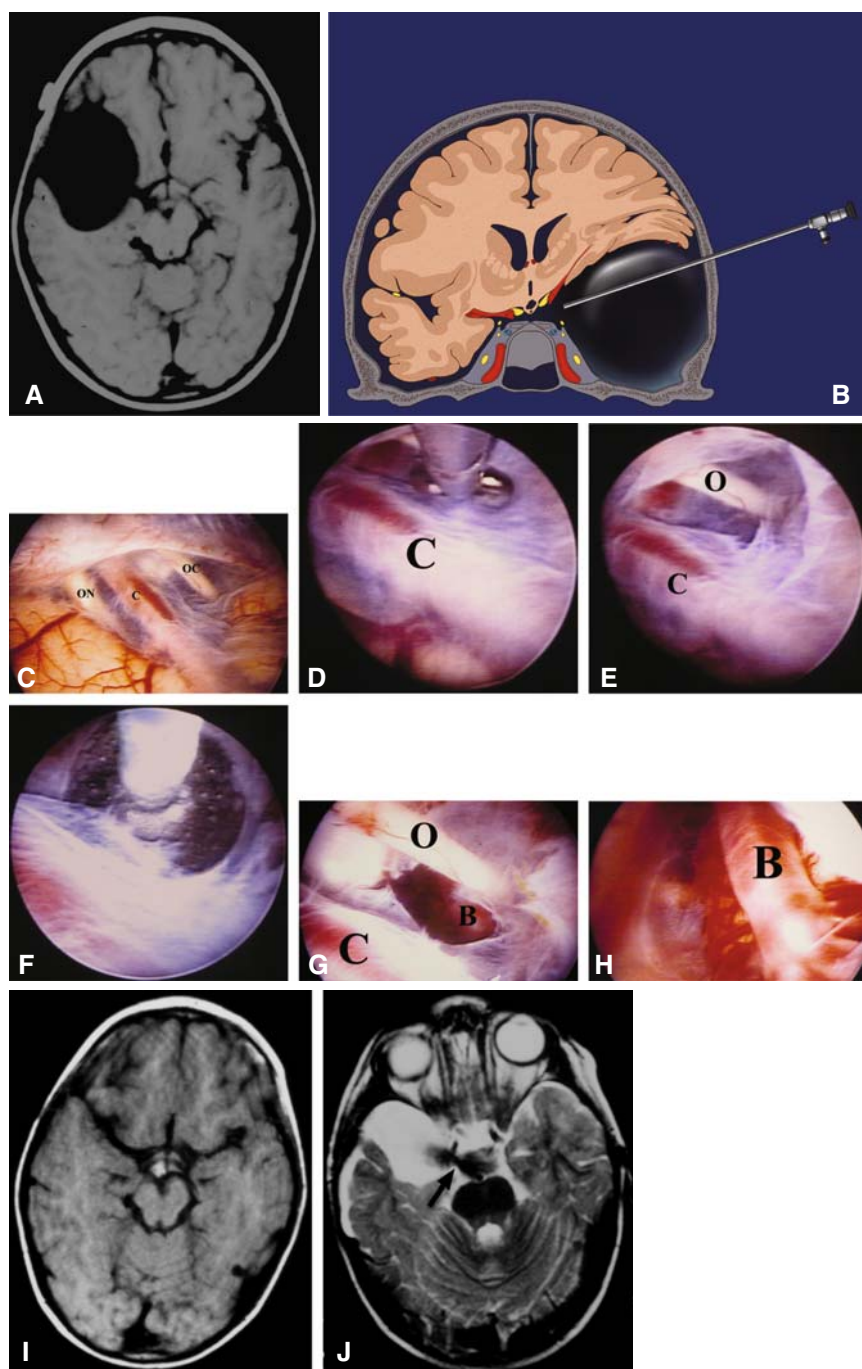
larged to a small craniotomy (2 by 2 cm), the CSF is sucked off, and the fenestration is performed under microscopic and/or endoscopic view. Since the approach goes through the cyst lumen, no higher rate of injury to brain tissue is caused with this approach compared with the pure endoscopic approach. However, the disadvantage of this technique is that the CSF has to be removed. That may result in cyst collapse and subdural effusions. Therefore, we start with the endoscopic inspection via a burr hole.

The patient is placed supine with the head turned to the contralateral side. Depending from the cyst size, the skin incision is placed more or less above the level of the zygomatic arch anterior to the ear. Neuronavigation is helpful to find the ideal entry point and the best trajectory to the basal cisterns without touching the brain. Care should be taken to spare the frontotemporal branch of the facial nerve. The temporal fascia and muscle are incised and the temporal muscle is dissected from the skull. A burr hole is made and a cross-shaped dura incision is performed. Then, the underlying cyst membrane is incised. It is of utmost importance to cauterize the fragile arachnoidal blood vessels in the entry zone to avoid bleeding induced by moving the endoscope. Outflow of CSF should be minimized and care has to be taken to prevent detaching the outer cyst membrane from the dura when inserting the operating sheath, which may result in cyst collapse and accumulation of CSF between the cyst membrane and dura which later may lead to subdural hematomas.

After insertion of the endoscope, the cyst is inspected (Fig. 5B). Usually orientation is easy because of the well known anatomical landmarks, such as the carotid and middle cerebral artery, optic nerves, and oculomotor nerve (Fig. 5C). In large cysts, even the frontal skullbase and olfactory tracts may be seen. In general, there is only a limited space for the fenestration of the cyst between carotid artery and oculomotor nerve or carotid artery and optic nerve. Rarely, the fenestration is performed lateral to the oculomotor nerve. Since blunt perforation of the cyst membrane is usually impossible, the membrane has to be cut with scissors. Sometimes parts of the cyst membrane can be removed with grasping forceps (Fig. 5D). After incision of the cyst wall, Lilliequist's membrane comes into view (Fig. 5E). This membrane has to be incised too to create a communication to the prepontine cistern. Thereafter, the opening is enlarged by inflating the balloon of a No. 3 French Fogarty



**Fig. 4.** Suprasellar cyst in a 1-year-old girl presenting with head growth and vomiting. **A** T1-weighted sagittal MR image showing a large suprasellar cyst with occlusion of the aqueduct (arrow). **B** T2-weighted MR image revealing no CSF flow through the aqueduct. **C** T1-weighted axial MR image showing the typical Mickey Mouse cyst. **D** Schematic drawing showing the approach trajectory. **E** Enlarged foramen of Monro. **F** Circular coagulation of the cyst wall. **G** Cutting of the cyst wall with scissors. **H** Collapse of the cyst after fenestration. **I** View into the prepontine cistern showing basilar artery (*B*), oculomotor (*O*), trigeminal (*T*), and abducens (*A*) nerve. **J** View to the sella with pituitary gland. **K** T1-weighted sagittal MR image obtained 3 months after surgery showing the collapse of the cyst with patent aqueduct (arrow). **L** T2-weighted MR image obtained 3 months after surgery demonstrating vigorous CSF flow through the aqueduct (arrow). **M** T1-weighted axial MR image obtained 3 months after surgery showing a marked decrease in cyst size





catheter (Fig. 5F) or with the aid of scissors and grasping forceps. Once the fenestration has been accomplished (Fig. 5G), the prepontine cistern with the basilar artery (Fig. 5H) has to be seen to make sure that a wide communication with the cistern has been created. Coagulation of the membrane should be avoided since the shrinking often leads to an even thougher membrane. If the created opening is too narrow and the risk of later occlusion by scarring is high, a fimbrial ventricular catheter may be inserted into the adjacent basal cisterns. Care must be taken not to injure the oculomotor nerve or branches of the carotid artery when advancing the catheter into the cistern.

When the endoscopic technique is not efficient because of anatomical conditions or a firm arachnoid membrane, we switch to an endoscope-assisted microsurgical technique [8].

#### 4. ARACHNOID CYSTS OF THE POSTERIOR CRANIAL FOSSA

For small arachnoid cysts which are covered by cerebellar tissue, an endoscope-assisted microsurgical approach is used. For large cysts reaching the dura in the area of a potential approach, an endoscopic approach is preferable.

Patients with cysts of the cerebellopontine angle are positioned supine with the head turned to the contralateral side. A retrosigmoid suboccipital craniotomy is performed or a burr hole is placed just over the cyst. After incision of the outer cyst membrane, a fenestration to the prepontine cistern is created between the cranial nerves. Care must be taken to avoid injury to the adjacent cranial nerves and vessels.

Patients with midline cysts are placed prone with the head anteflexed (Concorde position). If possible, the location of the burr hole should allow a straight approach to the cyst and adjacent cisterns. With the aid of scissors and grasping forceps, a large fenestration connecting cyst and cisterns is created.

#### 5. LONG-TERM RESULTS

According to the literature and my own experience the success rate of endoscopic cyst fenestration in suprasellar cysts is very high (90–100%) [2, 6, 10]. Only a few patients need to be shunted because of persistent or recurrent hy-

**Fig. 5.** Sylvian cyst in a 3-year-old boy presenting after a minor head injury. The cyst was an incidental finding. **A** T1-weighted axial MR image showing a large space-occupying Sylvian cyst. **B** Schematic drawing showing the trajectory of the approach. **C** Endoscopic view to the anterior clinoid with optic (*ON*) and oculomotor (*OC*) nerve as well as carotid artery (*C*). **D** Grasping of the thin arachnoid membrane between carotid artery (*C*) and oculomotor nerve. **E** After cyst fenestration, Lilliequist's membrane comes into view below the carotid artery (*C*) and oculomotor nerve (*O*). **F** Enlarging the fenestration with a Fogarty balloon catheter. **G** After completed fenestration the basilar artery (*B*) is visible below the carotid artery (*C*) and oculomotor nerve (*O*). **H** View into prepontine cistern showing the basilar artery (*B*). **I** T1-weighted axial MR image obtained 1 year after surgery showing a marked decrease in cyst size. **J** T2-weighted MR image shows a strong flow void signal at the site of the fenestration indicating its patency (arrow)

drocephalus although the cyst fenestration has been successful. The same is true for arachnoid cysts of the posterior fossa. The majority of patients (80–100%) improve after fenestration [8–10]. In Sylvian arachnoid cysts, the success rate seems to be less good (approx. 60–90%) [8, 10]. In my own series of 22 arachnoid cysts including 12 Sylvian, 5 suprasellar, 2 posterior fossa, 2 intraventricular, and 1 intrameatal cyst the overall success rate of endoscopic fenestration was 81% with a mean follow-up period of 6.3 years, ranging from 1.1 to 11.4 years. In children, the decrease in cyst size was more striking than in the adult patients.

## **6. COMPLICATIONS**

Severe complications resulting in mortality and permanent morbidity are fortunately very rare (0% in most reports in the literature). Subdural hematomas (10%), CSF leaks (5%), and meningitis (5%) were the most frequently reported complications [8, 10]. No permanent morbidity and mortality occurred in my own series. In one patient with a Sylvian cyst, a transient oculomotor palsy was observed which resolved completely within 2 months. In one boy, a subgaleal CSF accumulation occurred, but resolved spontaneously after 3 weeks. One patient had meningitis which responded quickly to antibiotic treatment. However, finally this patient needed to be shunted. Two patients presented with subdural collections on the routine postoperative imaging which did not require further surgical intervention.

## **HOW TO AVOID COMPLICATIONS**

### **1. HEMORRHAGE**

Before incising the arachnoid cyst membrane, care must be taken to coagulate all tiny arachnoidal vessels in the area of the approach. Oozing from these blood vessels may significantly blurr the endoscopic view. Furthermore, one must take care when incising and removing parts of the arachnoid membrane covering nerves and arteries when creating the fenestration to the cisterns.

### **2. SUBDURAL HYGROMA OR HEMATOMA**

It is of utmost importance to avoid detaching the arachnoid membrane from the dura when inserting the endoscopic sheath into the cyst. Sometimes it is advisable to suture the arachnoid to the dura to prevent detaching and collapse of the cyst. Furthermore, one should make sure that excessive loss of CSF is avoided which contributes to subdural collections.

### 3. NERVE INJURIES

Since the space between nerves and arteries in Sylvian cysts is mostly narrow, care must be taken to avoid injury to these structures. Sharp dissection is recommended when the arachnoid membrane is tough to prevent traction injury to the nerves.

### 4. CSF FISTULA

In adults, CSF leaks are usually not a problem although water-tight dural suturing is not performed. However, in children water-tight closure of the dura should be achieved. Because of the thin scalp, the risk of subgaleal CSF accumulations or fistulas is high.

## CONCLUSIONS

Endoscopic techniques are safe and effective options in the treatment of arachnoid cysts and should seriously be considered as the initial therapy. Should the endoscopic procedure fail, an endoscope-assisted microsurgical fenestration is the second line treatment. Shunting should be avoided whenever possible.

### References

- [1] Arai H, Sato K, Wachi A, Okuda O, Takeda N (1996) Arachnoid cysts of the middle cranial fossa: experience with 77 patients who were treated with cystoperitoneal shunting. *Neurosurgery* 39: 1108-1113
- [2] Caemaert J, Abdullah J, Calliauw L, Carton D, Dhooge C, van Coster R (1992) Endoscopic treatment of suprasellar arachnoid cysts. *Acta Neurochir (Wien)* 119: 68-73
- [3] Cincu R, Agrawal A, Eiras J (2007) Intracranial arachnoid cysts: current concepts and treatment alternatives. *Clin Neurol Neurosurg* 109: 837-843
- [4] Ciricillo SF, Cogen PH, Harsh GR, Edwards MSB (1991) Intracranial arachnoid cysts in children. A comparison of the effects of fenestration and shunting. *J Neurosurg* 74: 230-235
- [5] Decq P, Brugières P, Le Guerinel C, Djindjian M, Kéravel Y, Nguyen JP (1996) Percutaneous endoscopic treatment of suprasellar arachnoid cysts: ventriculocystostomy or ventriculocystocisternostomy? Technical note. *J Neurosurg* 84: 696-701
- [6] Gangemi M, Colella G, Magro F, Maiuri F (2007) Suprasellar arachnoid cysts: endoscopy versus microsurgical cyst excision and shunting. *Br J Neurosurg* 21: 276-280

- [7] Harsh GR IV, Edwards MSB, Wilson CB (1986) Intracranial arachnoid cysts in children. *J Neurosurg* 64: 835-842
- [8] Hopf NJ, Perneczky A (1998) Endoscopic neurosurgery and endoscope-assisted microneurosurgery for the treatment of intracranial cysts. *Neurosurgery* 43: 1330-1336
- [9] Jallo GI, Woo HH, Meshki C, Epstein FJ, Wisoff JH (1997) Arachnoid cysts of the cerebellopontine angle: diagnosis and surgery. *Neurosurgery* 40: 31-38
- [10] Karabatsou K, Hayhurst C, Buxton N, O'Brien DF, Mallucci CL (2007) Endoscopic management of arachnoid cysts: an advancing technique. *J Neurosurg* 106: 455-462
- [11] Okumura Y, Sakaki T, Hirabayashi H (1995) Middle cranial fossa arachnoid cyst developing in infancy: case report. *J Neurosurg* 82: 1075-1077
- [12] Santamarta D, Aguas J, Ferrer E (1995) The natural history of arachnoid cysts: endoscopic and cine-mode MRI evidence of a slit-valve mechanism. *Minim Invasive Neurosurg* 38: 133-137
- [13] Schroeder HWS, Gaab MR (1997) Endoscopic observation of a slit-valve mechanism in a suprasellar prepontine arachnoid cyst: case report. *Neurosurgery* 40: 198-200
- [14] Schroeder HWS, Gaab MR, Niendorf W-R (1996) Neuroendoscopic approach to arachnoid cysts. *J Neurosurg* 85: 293-298
- [15] Schroeder HWS, Wagner W, Tschiltshcke W, Gaab MR (2001) Frameless neuronavigation in intracranial endoscopic neurosurgery. *J Neurosurg* 94: 72-79
- [16] Starkman SP, Brown TC, Linell EA (1958) Cerebral arachnoid cysts. *J Neuro-pathol Exp Neurol* 17: 484-500



### **Henry W. S. Schroeder**

Henry W. S. Schroeder is Professor of Neurosurgery and Chairman of the Department of Neurosurgery at Greifswald University. He was born in 1963 in Prenzlau, Germany. He studied medicine at the Ernst Moritz Arndt University at Greifswald, where he was a resident at the Department of Neurosurgery, 1989–1996. 1990, M.D. graduation; 1996, board certification as neurosurgeon; 2001, Ph.D. graduation, associate professor of neurosurgery; 2003–2004, acting chairman of the Department of Neurosurgery at Greifswald University. He is a member of the German Society of Neurosurgery, Congress of Neurological Surgeons, and American Association of Neurological Surgeons. His main interests are in endoscopic neurosurgery and endoscope-assisted skull base surgery.

**Contact:** Henry W. S. Schroeder, Department of Neurosurgery, University of Greifswald, Ferdinand-Sauerbruch-Strasse, 17475 Greifswald, Germany  
E-mail: [henry.schroeder@uni-greifswald.de](mailto:henry.schroeder@uni-greifswald.de)

---

# BRAIN INFECTIONS

R. D. LOBATO

## INTRODUCTION

Brain infections can affect both its coverings and the brain parenchyma in either a diffuse or focal manner. Diffuse infections as meningitis and encephalitis are rarely subsidiary of surgical treatment. In contrast, intracranial focal purulent conditions are severe threatening pathologies in which surgery plays a keystone role. This chapter will focus on the latter i.e., brain abscess, subdural empyema and epidural abscess.

Before the 19th century, intracranial pyogenic infection was an almost uniformly fatal condition, rarely diagnosed before autopsy. The first surgical attempts to treat intracranial purulent collections are attributed to Galen, who as early as in the 2nd century used trepanation and trephination to drain pus underneath the skull. These procedures were also performed during the 17th and 18th centuries, and Morand is recognized to be the first in operating successfully an intracranial abscess of otic origin in 1752. In 1872 Weeds reported the successful drainage of a posttraumatic brain abscess. A few years later, Macewen published his monograph “Pyogenic infective diseases of the brain and spinal cord”, an unique text systematically describing “Surgical anatomy”, “Pathology of cerebral abscesses and meningitis”, “Symptoms of abscess of brain and meningitis”, “Thrombosis of intracranial sinuses”, “Treatment” and “Results”. He reported 25 brain abscesses 19 of which were operated on, with recovery in 18 cases [1]. Later on several techniques have been described to drain intracerebral abscess, including tube drainage, marsupialization, excision and tapping with aspiration. This last procedure was advocated by Dandy as a minimally invasive procedure, and has been refined in the modern era by using stereotactic techniques.

The other fundamental step in the treatment of intracranial pyogenic conditions was the development of antibiotic treatment introduced in the mid 20th century, with drugs such as penicillin or chloramphenicol. Currently new antimicrobials allow the treatment of almost every pathogen with reasonable risk of toxicity [4].

Finally, the development of neuroimaging techniques, namely the CT scan and MRI studies, have enormously improved not only initial diagnosis of these lesions by readily showing their number and location, but also the monitoring of treatment results.

---

*Keywords:* infectious diseases, brain infections, neurosurgery, antibiotics

## RATIONALE

Brain abscesses are focal intraparenchymal infections that cause neural tissue damage through inflammation, oedema and compression. Infective pathogens can reach brain parenchyma by one of the following mechanisms [2, 4, 7]:

- *Extension in contiguity*: Direct extension from infections affecting the paracranial sinuses or ear remains the main pathophysiologic mechanism in the formation of brain abscess. This occurs through the invasion and destruction of the skull and cerebral envelopes by pathogens, although it can also proceed through septic thrombophlebitis of intra-extracranial venous channels. These infections are frequently polymicrobial.
- *Hematogenous spread*: It is the result of bacteriemic episodes secondary to infectious pathologies in other organs (endocarditis), or breaches (i.e. dental extractions, or invasive diagnostic studies) bringing micro-organisms into the blood stream, and is favoured by underlying conditions shunting the pulmonary filter such as arteriovenous fistulas or persistent foramen ovale. This is a frequent source of brain abscesses that tend to be monomicrobial and multiple.
- *Direct inoculation by means of trauma or surgery*: The increment of neurosurgical procedures added to the relative decrease in other sources of infection resulting from improvement in their medical management (mainly of otic infections), has increased the relative incidence of this mechanism that nowadays equals that of contiguous extension in some series. Infections following open traumatic injuries are infrequent.
- Still, the origin of brain abscesses remains unknown in 20–30% of the cases (“cryptic” abscess without obvious source).

The above classification, based on the origin of the infection, correlates with its intracranial location, and helps to predicting the most frequent etiology and directing empirical treatment (Table 1). However, in some cases the source of infection is unknown, or no micro-organism has been isolated, precluding an optimal medical management. The absence of a microbiological specimen has been related to the need for broad-spectrum antibiotherapy which carries a higher risk of toxicity, higher costs, greater number of follow up studies and more prolonged treatment [4]. In these cases a surgical procedure can be indicated to obtain tissue sampling for microbiological study, whereas antibiotic treatment is readily instituted when the causative microorganism is identified. However, it should be noted that antibiotics alone can fail to cure the infection because the extent to which they cross the blood–brain barrier, permeate the abscess capsule and diffuse into devitalized purulent tissue is usually restricted, so they can be eventually unable to eradicate the infectious reservoir. Independently

**Table 1.** Characteristics of intracranial infections regarding location, the most common causative organism and the recommended empirical treatment. Most of the data can be applied to brain abscess, subdural empyema and epidural abscess

Source	Abscess location	Frequent organisms	Empiric treatment
Paranasal sinuses	Frontal	Streptococci (aerobic and anaerobic) <i>Haemophilus</i> sp. <i>Bacteroides</i> sp. <i>Fusobacterium</i> sp.	Ceftriaxone 3–4 g/d + Metronidazole 500 mg/8 h
Otic infections	Temporal Lobe Cerebellum	<i>Streptococcus</i> sp. <i>Enterobacteriaceae</i> <i>Bacteroides</i> sp. <i>Pseudomonas aeruginosa</i>	Ampicillin 2 g/8 h + Metronidazole 500 mg/8 h + Ceftazidime 2 g/8 h
Hematogenous spread/ cryptogenic	Mainly middle cerebral artery territory, but any region can be involved Multiple abscesses	<ul style="list-style-type: none"> <li>▪ Endocarditis <i>Staphylococcus aureus</i> <i>Streptococcus viridans</i></li> <li>▪ Urinary tract <i>Enterobacteriaceae pseudomonas</i></li> <li>▪ Intra-abdominal <i>Enterobacteriaceae Streptococcus</i> sp. <i>Anaerobes</i></li> <li>▪ Pulmonary abscess <i>Streptococcus</i> sp. <i>Actinomices</i> sp. <i>Fusobacterium</i> sp.</li> </ul>	Endocarditis: Benzolpenicillin 1.8–2.4 g/6 h Ceftriaxone 3–4 g/24 h + Metronidazole 500 mg/8 h
Trauma	Depends on site wound	<i>Staphylococcus aureus</i> Clostridium Enterobacteriaceae	Cloxacillin 2 g/4 h or Ceftriaxone 3–4 g/24 h
Neurosurgery	Depends on operated area	<i>Staphylococcus aureus</i> <i>Staphylococcus epidermidis</i> Enterobacteriaceae <i>Pseudomonas</i>	Vancomycin 1 g/12 h + Ceftazidime 1 g/8 h

of bacterial enzymes that can inactivate antibiotics, these drugs can be also neutralized by their binding to proteins present in pus fluid, or the pH of this material [6].

It has been found that patients with brain abscesses lesser than 2 cm in diameter have good outcomes with medical treatment alone, while sizes over this threshold increase the risk of treatment failure usually requiring surgical evacuation as an adjunctive therapy. It should be emphasized that in some instances the risk of neurological deterioration is very high with antibiotic treatment alone. Abscesses can reach a great volume causing significant mass effect and brain herniation prompting urgent surgical evacuation. In addition,



the periventricular location carries the risk of intraventricular rupture and ventriculitis, due to the relatively poorer vascularization and capsule development from the ependymal side. This event can precipitate abrupt neurological deterioration and carry a very poor prognosis, mortality rate reaching 80% of the cases. Thus, surgical evacuation of these abscesses and of those other unresponsive to antibiotherapy is strongly recommended.

Subdural empyema is a loculated collection of pus in the subdural space causing inflammation and oedema of the underlying brain, septic thrombophlebitis and venous infarction, which can rapidly extend along the subdural space because of the absence of tissue barriers. Most subdural empyemas (between 41 and 67%) develop as a complication of cranial sinus infection, and the second most common cause is infection following intracranial surgery. Hematogenous spreading from a distant infective focus occurs in some cases, and infection of subdural effusions in children with meningitis may also cause subdural empyema. In any case, subdural empyema is a condition that carries a very high risk of clinical deterioration and rapid surgical evacuation is mandatory to avoid death or irreversible neurological complications [5].

Epidural abscesses are pyogenic collections developing in the virtual space between the cranial dura and bone. The occurrence of osteomyelitis and bone erosion is usually required to strip the dura mater off the bone to which it is tightly adherent, a characteristic that usually contains the extension of these lesions. Direct extension from paracranial sites, or postoperative intracranial infection is the main cause of this condition. Due to the relative isolation of brain tissue and the insidious progression of this process, epidural abscess tend to reach a significant size at diagnosis. This fact, along with the usual involvement of the bone resulting in osteomyelitis and devitalized bone fragments, favours the indication of surgery to facilitate antibiotic activity and diminish the risk for intracranial complications.

## **DECISION-MAKING**

### **1. CLINICAL DIAGNOSIS**

Clinical presentation of a brain abscess depends on its size and location. Non-specific neurological manifestations such as headache, nausea, or vomiting depend on the presence of intracranial hypertension. Headache is the single most frequent symptom (49% of the cases), and alterations of the level of consciousness are present in many patients (51%). Focal neurological signs and symptoms depend on the involvement of eloquent areas by the lesion itself or surrounding oedema, and can occur in 25–50% of the patients. Meningeal symptoms or signs are present in about 25% of the cases, mainly when the lesion reaches the pial surface. However, the triad of headache, fever

and focal neurological symptoms is rare. In fact, fever is not a constant sign, and is present in less than half of the patients (43%). Seizures may occur in 25–50% of the cases. Infections of the craniofacial area can be a clue to diagnosis, and should be investigated in every patient with suspected or demonstrated pyogenic intracranial infection. The non-specific presentation and rarity of this pathology accounts for the frequent delays in diagnosis, so a high index of suspicion is necessary [2, 4].

Subdural empyema is usually a fulminant disease with a rapidly progressive clinic of headache, fever, meningismus, seizures and focal neurological deficit and this type of progression is a hallmark of this condition [6]. In contrast with brain abscesses, local signs reflecting the origin of the infection are present in 60–90% of patients in the form of an infective focus in the ENT field, or inflammatory changes over the skull.

Epidural abscesses tend to present in a more indolent fashion due to the relative isolation of the brain. Symptoms include fever, headache and findings referred to the primary source of infection.

Postoperative purulent intracranial complications tend to manifest by the development of new focal deficits or worsening of pre-existing ones, and are usually associated with inflammatory signs over the surgical wound.

## 2. LABORATORY TEST AND IMAGING STUDIES

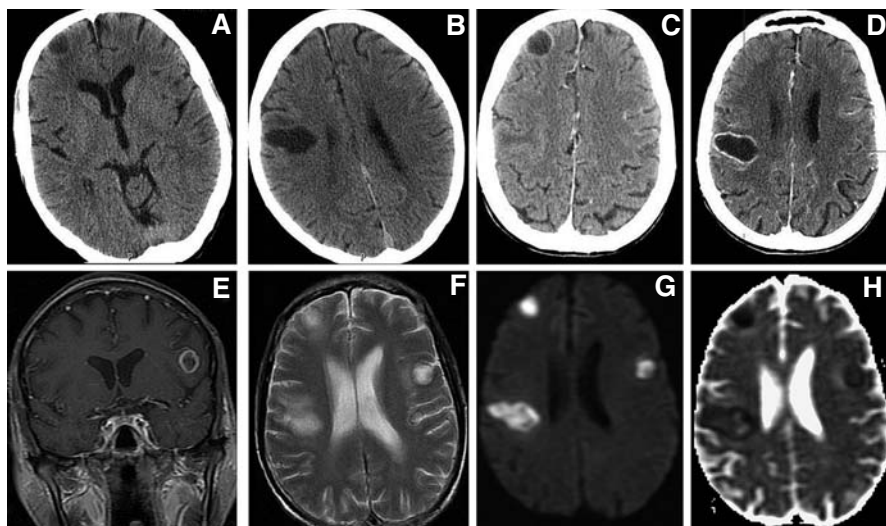
Blood test can sometimes show leucocytosis and abnormalities in certain inflammatory parameters (ESR, RCP). Blood cultures, which may be particularly useful when there is no available material from the pyogenic collection, are mandatory as they can identify the pathogen, orient to the systemic origin of infection, and initiate the most appropriate antibiotic therapy.

Lumbar puncture should be avoided in this clinical setting until the presence of intracranial mass effect has been ruled out, because the risk of brain herniation is very high (occurs in 15–33% of the cases).

Its widespread availability renders the CT scan the technique of choice for providing a rapid and precise diagnosis in patients with urgent pathologies such

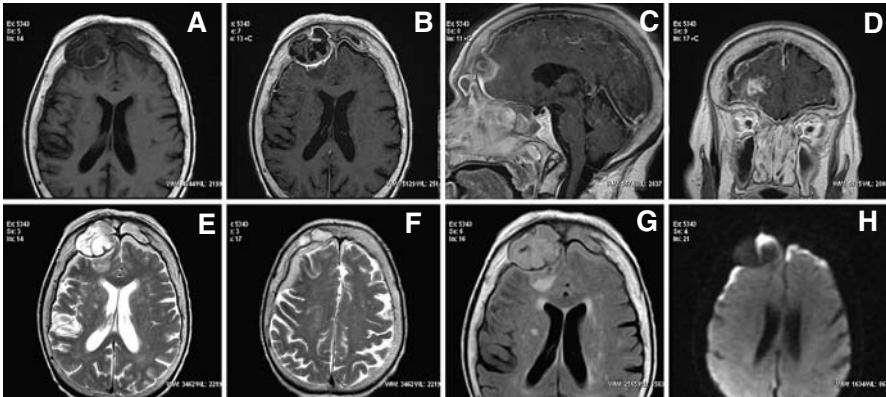
**Table 2.** Stages of brain abscess formation and correlative imaging features

Stage	Days	Histology	CT picture
	1–3	Early infection and inflammation, poorly demarcated from surrounding brain	Focal hypodense area with/without enhancement after contrast
Late cerebritis	4–9	Reticular matrix and developing necrotic center	Wider hypodense region with ring enhancement
Early capsule	10–14	Neovascularity, necrotic center, reticular network surrounds	Ring enhancing lesion
Late capsule	>14	Collagen capsule, necrotic center, gliosis around capsule	Ring enhancing lesion



**Fig. 1.** CT and MRI findings in a patient with multiple brain abscesses caused by haematogenous spread after superior digestive tract endoscopy (*Streptococcus milleri*). CT scan images (A–D) show hypodense lesions with fine ring enhancement. MRI shows them as hypointense lesions with peripheral enhancement on contrast-enhanced T1 weighted images (E). On T2 weighted images the lesions appear hyperintense with a hypointense halo (F). On diffusion weighted images the abscesses displayed a marked restricted diffusion (G) with very low ADC (H)

as purulent intracranial infections. The CT scan not only shows the location, size and number of lesions, but facilitates urgent treatment planning when necessary. MRI, which is better in terms of sensitivity and specificity, is not always available in emergency conditions. The appearance of a brain abscess in the CT scan correlates with its pathological stage (Table 2). The typical picture of a brain abscess is that of a hypodense ring enhancing lesion with extensive perifocal oedema (Fig. 1). On MRI abscesses are usually seen as hypointense lesions on T1 weighted images which enhance following intravenous contrast injection in the same way as they do in the CT scan study. On T2 sequences they are seen as hyperintense lesions, and a hypointense rim may be seen when a fibrous capsule is already formed. FLAIR images help to better delineate those lesions in the vicinity of CSF containing spaces, as it suppress the CSF hyperintense signal. The differential diagnosis with other ring enhancing lesions such as glioblastoma, lymphoma, or metastases, which may share a similar appearance, has been greatly improved with the introduction of more specific MRI sequences such as the diffusion ones as purulent collections typically show a restricted diffusion and a diminished ADC, in contrast with the above mentioned conditions. Diffusion studies also help in the evaluation of treatment response of brain abscesses, as low signal intensity at diffusion weighted imaging with high ADC correlates with a good therapeutic response.



**Fig. 2.** MRI study of a patient with frontal mucopyocele complicated with intracranial infection. T1 (A) and contrast-enhanced T1 weighted images (B–D) demonstrate a small subdural hypointense collection surrounded by fine contrast enhancement. This collection appears hyperintense on T2 weighted (E, F) and FLAIR images (G) and shows restricted diffusion (H). These findings were diagnostic of subdural empyema that was operated on with positive cultures for *Streptococcus milleri*

In the case of subdural empyema CT scan shows an extra-axial collection with variable degrees of accompanying brain oedema and mass effect. A fine enhancement can be seen in the pial side following intravenous contrast injection. However, a subdural empyema can be missed by the CT scan, and MRI has become the best technique to find and delineate the extension of the pathology (Fig. 2). Again, diffusion MRI sequences may result definitive for distinguishing this condition from other types of fluid collections. However, it should be noted that some infectious collections fail to show a restriction in MR diffusion sequences, a finding observed at our clinic and also reported by other authors. Sensitivity exceeds 95% in spontaneously developing (non postsurgical or posttraumatic) pyogenic collections, but false positive and false negative results are seen in up to 37% of postoperative infections [3].

Epidural abscesses tend to offer less diagnostic difficulties due to their usual biconvex appearance and bigger volume once they become clinically expressive, as well as for the frequently associated lesions involving the overlying bone or the paranasal sinuses. Attention should be paid to the possible imaging abnormalities in neighbouring structures such as the ear and the frontal sinuses, as well as to the presence of osteomyelitis or foreign bodies.

Once a cerebral abscess has been diagnosed the main question arising is whether surgery is indicated or not. The following are classical surgical indications: (a) abscess diameter of >2 cm; (b) intracranial hypertension; (c) risk of intraventricular rupture; (d) absence of response to medical treatment; and (e) mycotic infections.

In our opinion, only those lesions less than 2 cm in diameter occurring in clinically stable patients can be managed non-surgically. If they are diagnosed in

patients with a demonstrated infectious process and an identified causative organism, antibiotic treatment should be instituted or a microbiologic specimen taken from the original source. If no other infectious process is identified, basic investigation including urine analysis, body CT scan and an ENT examination should be performed, and when an etiologic diagnosis is not established following MRI and systemic studies, surgical aspiration and sampling is indicated.

Subdural empyema represents a neurosurgical emergency, as sudden and catastrophic neurological deterioration may occur, and once it has been diagnosed urgent evacuation should be performed.

Because of the anatomical peculiarities stated above epidural abscesses are less risky than their subdural counterparts. In fact the resistant duramater tightly adhered to inner table of the skull difficult spreading of infection and consequently decreases the risk for sudden neurological deterioration. In any case, the usually large volume of the collection along with the presence of bone erosion and fragments and the possibility of treating the underlying paracranial infection render surgery the most appropriate treatment.

## **SURGERY**

The need for interdisciplinary and cooperative management of patients with pyogenic intracranial infections by neurosurgeons, neurologists, neuroradiologists and infectious diseases specialists has been progressively recognized. While the main tool in the treatment of brain abscesses are antibiotics, their correct choice and dosage, the indication for adjunctive surgical treatment, and the radiological follow-up monitoring may exceed the scope of a single specialist.

Although open surgical evacuation was the main treatment used for many years, needle aspiration has progressively substituted this technique, diminishing the aggressiveness of surgical approaches. This improved management has been possible thanks to the marriage of neuroradiological and stereotactic techniques which allow the precise puncture of these lesions through burr holes with minimal brain damage. Although it might be argued that there is a higher risk of recurrence with tapping and aspiration as compared to abscess removal, similar results have been reported with both techniques. In any case, repeated aspiration still represents a low risk procedure with the higher probability of success. Although free hand puncture and aspiration has been used, it is based on surface anatomy references, and thus subjected to spatial imprecision and higher risk of complications (multiple tracks, non rigid needle handling). In contrast, stereotactic approaches optimize the choice of the trajectory and needle positioning for pus aspiration.

Frame based stereotaxy has been the traditional method used for tapping intracranial pyogenic collections. In this case the patient is taken to the operating room where the stereotactic frame is placed with the aid of mild sedation and local anesthesia; blockade of supraorbital and occipital nerves can be

performed 5 min before fixing the frame. Then the patient is moved to the CT scan/MR room for taking the integrated images showing both the lesion and frame marks. The coordinates of the target are calculated while the patient is returned to the operating room where puncture is planned through a safe trajectory avoiding eloquent areas, the ventricles and vessels. The patient is positioned either supine with the trunk slightly elevated and mild head flexion or semisitting. The frame is fixed to the operating table, the scalp is scrubbed, and the planned burr hole position marked over the skin. The coordinates are fixed in the frame and checked independently by the surgeon and an assistant. Draping the surgical field needs to allow the assemblage of the frame arch. A small longitudinal incision is made to the depth of the skull, a mastoid retractor is positioned and a burr hole is performed with an air driven craniotome. The dura is coagulated in a cross shape and then incised and coagulated to retract the small dural flaps. The arachnoid is open with diathermy coagulation and the needle is slowly advanced until reaching the target. Although the capsule can offer slight resistance in abscesses evolved to the late capsule stages, we have never found this to impede tapping. Then aspiration with a syringe is made without excessive suction until pus egress stops; thereafter slight irrigation of the abscess cavity can be performed. There is no scientific rationale for the instillation of antibiotics into the abscess cavity [7].

The introduction and development of frameless stereotactic systems has partly simplified this procedure, so we prefer to use neuronavigation. After initial diagnosis a contrast enhanced CT scan or MR is performed in adequate conditions for neuronavigation and the study is imported to the planning station where both the target and needle trajectory are calculated. In most patients we use general anesthesia for the sake of patient and surgeon comfort, although mild sedation and local anesthesia is preferably used in medically ill patients. In either case the patient's head is fixed in a Mayfield clamp, the neuronavigation system is prepared and the registration is performed. Patient's positioning is easier without the presence of the stereotactic frame, so lateral decubitus can also be used when dealing with temporal lesions. Registration is greatly aided with systems that allow face surface matching, although fiducial registration does not add significant difficulty. The rest of the procedure using a biopsy system adapted to the neuronavigation apparatus is identical to that explained above. When intraventricular rupture of the abscess does occur an external ventricular drainage can be inserted for the instillation of antibiotics.

There is still some controversy as to whether it is preferable to perform craniotomy or one/several burr-holes to drain a subdural empyema. Although good results have been reported using burr hole drainage, we prefer to perform a generous craniotomy covering as much as the affected brain surface as possible, crossing the midline when interhemispheric collections are present. Wide dural opening allows material sampling followed by drainage, debridement, and irrigation. The dura is closed when possible, without using allografts or any other foreign bodies. In cases without bone involvement this

should be replaced, but craniectomy and delayed cranioplasty is preferred when bone infection is present or suspected.

In the case of epidural abscess the frequent bone involvement makes craniectomy mandatory to eliminating any osteomyelitic component. The abscess is drained and infectious debris over the dura are carefully curetted. Given that paracranial sinuses are often affected craniectomy and sealing with a pericranial flap is also mandatory.

In patients with postoperative infectious complications we usually try antibiotic treatment when there are signs of cerebritis or surgical wound infection, but no collections are identified by MRI. When abscess or empyema are encountered surgical evacuation is indicated and allografts used to repair the dura or in cranioplasty, together with any devitalized tissue (bone flap, necrotic brain, etc.) should be removed because they act as a reservoir for infective organisms preventing antibiotic efficacy.

While antibiotic treatment can be directed in those cases with identified causative organisms, empirical treatment has to be instituted until cultures are available and when no germ is identified. The initial choice of antibiotics can be facilitated by patient pre-morbid conditions, the location of the abscess, the precipitating source of the infection (when identified) and Gram staining. Although available information is limited, Table 2 gives general treatment recommendations for covering a wide range of bacteria. The antibiotic treatment of postoperative infections should be tailored according to the pathogenic flora at each center. A high incidence in oxacillin resistant staphylococcus led us turn to vancomycin and ceftazidime (vancomycin + meropenem for patients with long stay in the ICU because of resistant acinetobacter).

Intravenous antibiotics should be administered for 2 weeks, and then they can be switched to an oral route if a good clinico-radiological evolution has been observed and the therapy regimen allows this change. Oral antibiotics will be taken during 4 additional weeks, although longer courses are sometimes necessary (it occurs in 50% of the patients in some series) as judged depending on the evolution [2].

The use of steroids is controversial, because they can diminish bacterial clearance, antibiotic diffusion into the abscess and delay capsule formation. However, they can be beneficial in patients with marked secondary brain oedema causing intracranial hypertension or focal neurological deficits. We recommend the use of dexamethasone up to 10 mg/6 h in these instances, dosage being tapered once the patient reaches clinical stability thus avoiding the long term use of these drugs.

Seizures can present in the acute stage and occur in up to 70% of the cases when long term course of the disease is considered [5]. In light of these data some authors recommend antiepileptic prophylaxis, which we consider indicated in patients with lesions close to the cortical surface. Seizures are even more frequent in patients with subdural empyema (25–80%), in whom prophylactic treatment is mandatory [5].

## HOW TO AVOID COMPLICATIONS

As the surgical technique does not carry great technical difficulty, the main way to achieve good results relays upon an appropriate overall management. Macewen stated that “One might almost conclude that in uncomplicated abscesses of the brain operated on at a fairly early period, recovery ought to be the rule” [1]. Certainly, and apart from the baseline patient characteristics, a good neurological status is the main prognostic factor and surgery, when indicated, should not be deferred based solely on clinical stability.

Although mortality rate in patients with intracranial pyogenic collections was reported to be as high as 50–70% in the past, it ranges from 2 to 10% in recent series [2].

## CONCLUSIONS

Purulent intracranial infections can pose an important diagnostic problem when signs and symptoms are non specific, so a high index of suspicion needs to be kept in mind, mainly in patients with immunodepression, a past history of otic, dental or nasosinusal pathologies, bacteriemic conditions or surgical or traumatic antecedents.

Surgical treatment is a fundamental tool in the management of brain abscesses as it permits to identify the microorganism, relieve mass effect, decrease the risk of complications and fasten clinico-radiological improvement. Surgical treatment of the primary focus (e.g. an otic infection) when present is essential. Some small abscesses with known causative organisms can be managed with antibiotics alone.

Surgical empyema represents a surgical emergency, so craniotomy and evacuation are mandatory as soon as it is diagnosed.

Epidural abscesses need to be evacuated to eradicate the infection. Treatment of the primary infection can also be performed in the same intervention in most cases.


Pyogenic infections following neurosurgical procedures need surgery when there exists a purulent collection. In these cases surgical removal of foreign bodies and wound debridement offers a faster and safer recovery.

## References

- [1] Canale DJ (1996) William Macewen and the treatment of brain abscesses: revisited after one hundred years. *J Neurosurg* 84: 133-142
- [2] Carpenter J, Stapleton S, Holliman R (2007) Retrospective analysis of 49 cases of brain abscess and review of the literature. *Eur J Clin Microbiol Infect Dis* 26: 1-11



- [3] Farrell CJ, Hoh BL, Pisculli ML, Henson JW, Barker FG, Curry WT Jr (2008) Limitations of diffusion-weighted imaging in the diagnosis of postoperative infections. *Neurosurgery* 62: 577-583
- [4] Mathisen GE, Johnson JP (1997) Brain abscess. *Clin Infect Dis* 25: 763-779
- [5] Osborn MK, Steinberg JP (2007) Subdural empyema and other suppurative complications of paranasal sinusitis. *Lancet Infect Dis* 7: 62-67
- [6] Wagner C, Sauermann R, Joukhadar C (2006) Principles of antibiotic penetration into abscess fluid. *Pharmacology* 78: 1-10
- [7] Working Party of the British Society for Antimicrobial Chemotherapy (2000) The rational use of antibiotics in the treatment of brain abscess. *Br J Neurosurg* 14: 525-530



**Ramiro D. Lobato**

Ramiro D. Lobato is Chief of the Neurosurgical Service at Hospital "12 de Octubre" and Professor of Neurosurgery and Vicedean of the Faculty of Medicine at the Universidad Complutense, Madrid. The areas of special interest in his neurosurgical work have been craniocerebral trauma, primary intracranial hemorrhage (vascular malformations and vasospasm following aneurismal SAH) and hydrocephalus. Currently his main interest is focussed on cranial base surgery. He has ruled the Editorial Committee of the Spanish neurosurgical journal *Neurocirugia* and has published over 300 papers in national and international journals.

At the present time he is involved in academic activity at both undergraduate and postgraduate levels paying especial attention to the reform of undergraduate curriculum at the Universidad Complutense in Madrid.

**Contact:** Ramiro D. Lobato, Service of Neurosurgery, Hospital "12 de Octubre",  
Avda Cordoba Km 6, 28041 Madrid, Spain  
E-mail: [rdiez.hdoc@salud.madrid.org](mailto:rdiez.hdoc@salud.madrid.org)

---

# PARASITOSSES OF THE CENTRAL NERVOUS SYSTEM: HYDATIDOSIS

B. ABDENNEBI

## INTRODUCTION

Parasitic zoonoses, transmittable from animals to humans, remain a serious and significant public health problem in developing countries [1, 13]. Twenty-five percent of the world's population could be suffering parasitic infestation. Among these parasitoses, neurocysticercosis, infection of the central nervous system by *Taenia solium* metacestodes, is the commonest encountered cerebral parasitic infection in the world. It is the first cause of epileptic seizures in developing countries. The other zoonosis with a world-wide distribution is the hydatid disease which will be the topic of this chapter.

Hydatid is a word derived from the Greek “ydatos” which means water. Hydatid disease is a parasitic infestation caused by a dog tapeworm larvae of *Echinococcus granulosus*, a helminth belonging to the cestod group.

It is common in sheep farming in underdeveloped countries such as those located in Asia, Africa, South and Central America or in the mediterranean area. “It follows the sheep as his shadow”. On the opposite, it is unusual in developed countries. Nevertheless, this notion should be attenuated by the movements of humans, especially migratory flows. Liver and lung, as big filters of the portal system, are the most infested organs, whereas involvement of brain, 2–3% of all body localisations, and spine, less than 1%, are rare. However, these spinal hydatid cysts (SHC) represent around 50% of the bone localisations.

Indeed, in Antiquity, according to Galen, Hippocrates (4th century AD) has evoked the disease and taught his students: “when liver is distended with water, it breaks in the epiploon, so the abdomen is full of water and the sick dies”. Arateus, Galen (first and 2nd century AD, respectively), Al Rhazes (860–932 AD) and Avicenna (980–1037) reported also on human involvement by hydatidosis. John Hunter in 1773 described the morphological picture and Goeze in 1782 the microscopic picture of the cyst. The first description of vertebral echinococcosis was by Chaussier in 1807 [5]. Reydellet is believed to have performed the first surgical intervention for spinal hydatidosis in 1819. Virchow, for the first time in 1855, established the helminthic nature of alveolar cysts. The life cycle of the parasite was first described in 1862. In 1890, Graham and Clubb were the first neurosurgeons to perform removal of a brain hydatid cyst. Since the last century, it is usual to associate the following names with improvement of the surgical procedures of brain hydatid cyst:

---

*Keywords:* parasitoses, hydatidosis, hydatid cyst, brain, spine

Dowling [7], Da Gamma Imaginario and Goinard, Descuns [9]. More recently Arana-Iniguez [2] perfected the procedure giving birth to an unbroken cyst by irrigating saline isotonic solution between cyst wall and brain.

## **RATIONALE**

The *Echinococcus granulosus* cycle requires two hosts: one intermediate, usually sheep, camel or swine, and the other final hosts represented by dog or fox. Dogs are infected by ingesting faeces or butchering infected animals containing cysts which develop into cestode, an adult tapeworm in their small intestine. Eggs included in some parts of the bowels pass out through faeces and contaminate pasture. When ingested by the sheep, the scolex or eggs become immediately infective by releasing larvae which cross the intestine wall. Then they are carried through the portal system to liver, where they develop into hydatid cysts. Occasionally humans can take the place of sheep as accidental intermediate hosts through contact with infected dogs or by oral ingestion of garden vegetables infected by the eggs of the parasite.

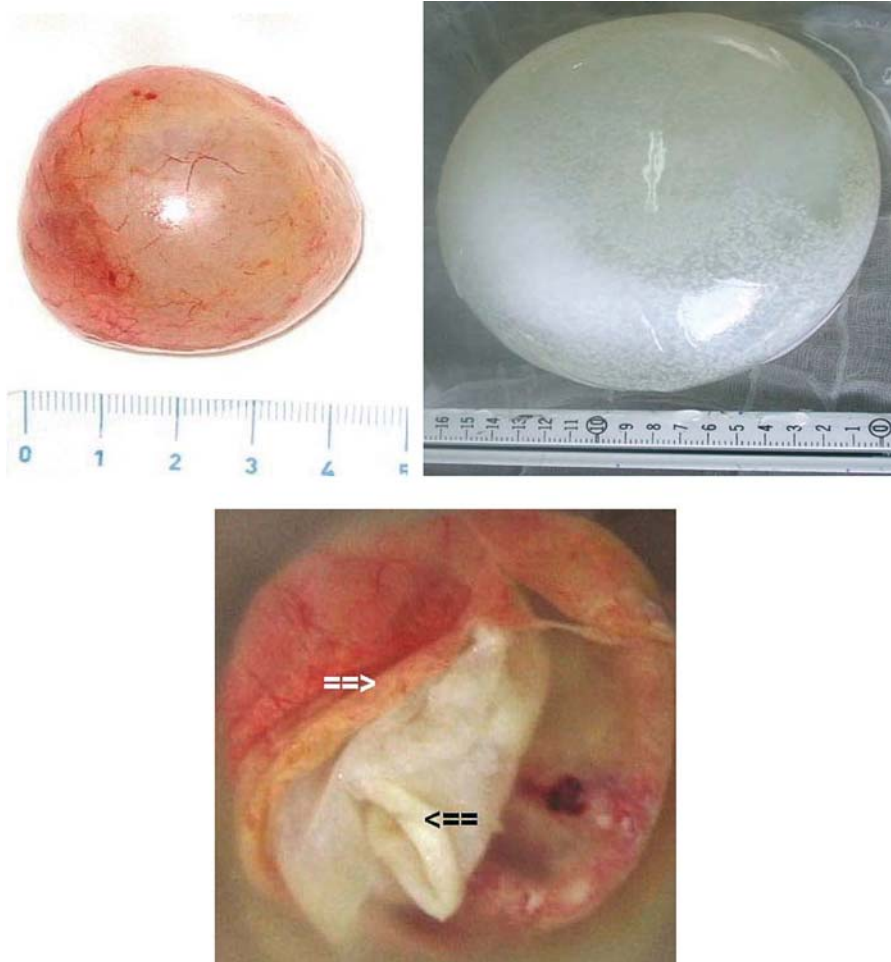If the daughter cyst crosses the hepatic filter; then it is spread through the bloodstream to other organs, i.e. lungs, and less frequently to brain. Usually, the infestation goes up the systemic circulation to the parietal lobe via the middle cerebral artery as in all embolic diseases. Brain hydatid cysts (BHC) are spherical, or balloon-shaped, and are characterized by slow growth. At diagnosis, their size varies from few centimetres to huge volume of 15 cm or more (Fig. 1). Ventricles, brainstem and orbit are other exceptional localisations. The solitary aspect of the BHC is the most observed (85%), remaining cases are multilocular or multiple. Growth rate is slow and controversial, ranging between 1 and 10cm per year. Rarely, BHC can be calcified, expression of their degeneration and death.

On the other hand, spinal involvement is possible, owing to direct portovertebral venous shunts. SHC is smaller either due to its growth inside the vertebra body or inside the spinal canal, being wedged by ligaments and disc. The thoracic spine is the most affected followed by the lumbar spine. Braithwaite and Lees [4] classified this spinal cord compression into five types: (1) primary intramedullary hydatid cyst; (2) intradural extramedullary hydatid cyst; (3) extradural intraspinal hydatid cyst; (4) hydatid disease of the vertebrae and (5) paravertebral hydatid disease. Involvement of the vertebra and extradural localisations are common. Although the supply is more favorable anteriorly, posterior arch involvement is most frequent. Contrary to the involvement of the spine, the skull is exceptionally affected, whereas the infection of the brain parenchyma is more frequent. Calcified SHC has never been reported.

Histologically, three membranes constitute the cyst wall (Fig. 1). From the outside:

- The external membrane or host derived adventitia is not easily defined in all cases.

- A thick acellular laminated layer, rich in amino carbohydrates, explains the Periodic Acid Schiff positivity. This nonnucleated membrane of parasitic origin surrounds also the daughter cysts.
- The inner germinal layer, composed of an alignment of nuclei which are cells of the parasite.



**Fig. 1.** *Top left:* Overall view showing the macroscopic aspect of the hydatid cyst covered with the host derived adventitia. *Top right:* Translucent cyst of 15 cm in diameter. We can distinguish many scolices and daughter vesicles arranged in bunch of grapes inside the cyst. *Bottom:* Gross pathology of the membranes of the open cyst demonstrating the adventitia externally (white arrow) and the thick acellular laminated layer intimately adherent to the inner germinal layer (black arrow)

The lumens of the cysts are filled with fluid, hydatid sand, daughter vesicles arranged in bunch of grapes, and protoscolices that have the capability to grow into adult worms if consumed by a definitive host.

## **DECISION-MAKING**

Patients living in endemic areas, possibly in contact with infected dogs or those who had previous surgery for hydatid cyst disease involving other organs are at high risk and the diagnosis should be kept in mind and evoked before imaging studies.

### **1. CLINICAL PRESENTATION**

#### **1.1 Brain hydatid cyst (BHC)**

BHC occurs more frequently in children than in adults. This data was confirmed in our 99 patients operated on between 2000 and 2007 in 4 departments of neurosurgery: 2 in Algiers (Ait Idir and Salim Zemirli), one in Annaba and one in Constantine. Among them, 59 (59.5%) were less than 15 years old. The probable reasons may be a ductus arteriosus, or their close contact with infected dogs. There is no appreciable difference between males and females affected: sex-ratio 46/53. In children, loss of balance and rapid growth of head circumference are suspicious for the parents. Headaches, blurred or decreased vision and vomiting are usual reasons for consultation. Signs of increased intracranial pressure are of paramount importance in the diagnosis of this space occupying lesion. Focal neurological deficit depends on the involved area and the size of the hydatid cyst. Nevertheless, some infants present with ataxia and or dysmetria when imaging features show huge parieto occipital hydatid cyst. This can be explained by the hypothesis of a pressure cone on cerebellum through the tentorium. Untreated, patient become lethargic, stuporous, eventually comatose. In our series, location of hydatid cyst in the supratentorial compartment was present in 92 cases, 4 cases were in the brainstem, one case was in the cerebellar hemisphere and two cases were in the orbit.

#### **1.2 Spinal hydatid cyst (SHC)**

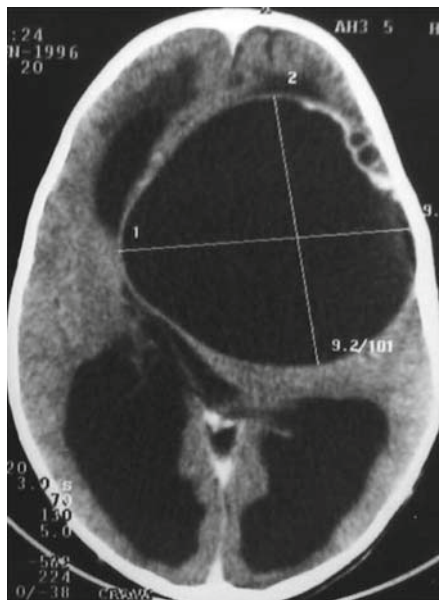
Spinal echinococcosis is a severe form of the disease and the most frequent bone location (50%). It occurs more in adults than in infants. It is well established that spinal echinococcosis remains asymptomatic for a long time due to its slow evolution. After this latent period, patients complain of thoracic radicular pain symptoms. These symptoms are tolerable and not sufficient for the patient to seek medical attention. As the pain increases, it becomes resistant to medication. Compression leads to other symptoms, i.e., sensory and motor signs, in particular, hypoesthesia of the lower limbs, weakness and sphincter disturbances. The initial nerve root or spinal cord injury rapidly

increases to paraplegia in few days to a few weeks. Paraplegia can sometimes occur acutely. Spinal cord compression is an emergency since it can lead to permanent paraplegia. Patient with physical examination of spinal cord compression, should undergo an adequate imaging check up and consequently an appropriate decompressive surgery as soon as possible.

## 2. DIAGNOSIS

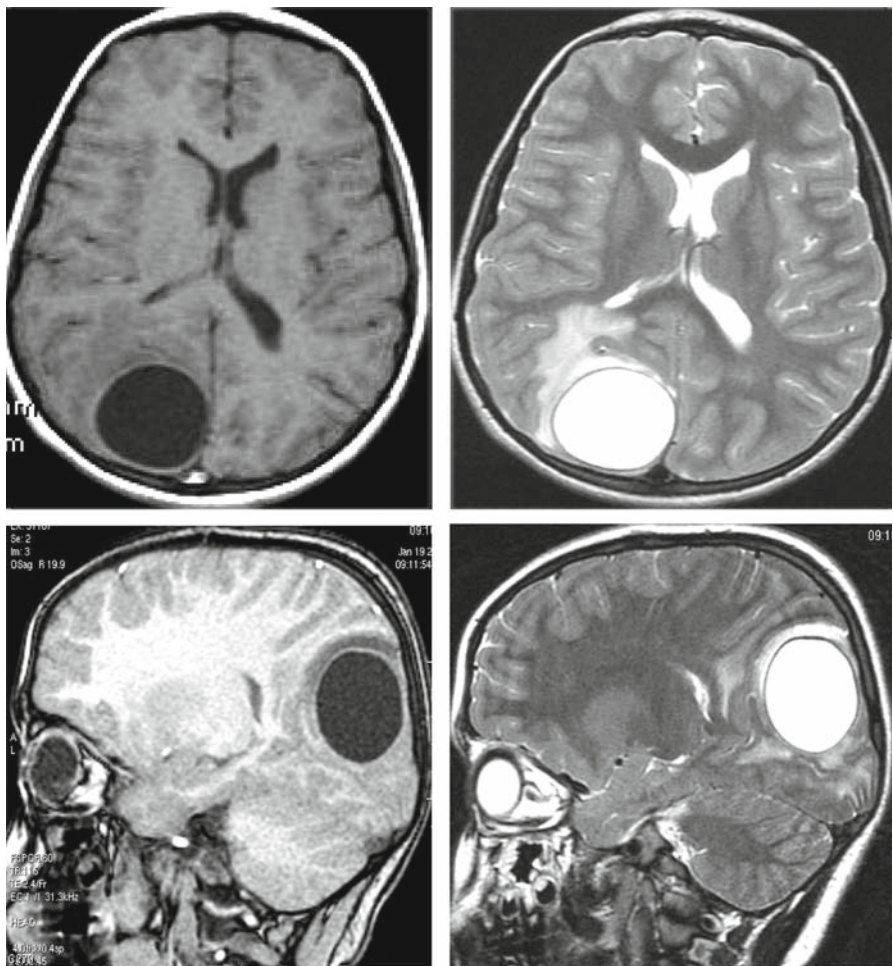
### 2.1 BHC

Children treated for head injury may sometimes show split sutures indicative of increased intracranial pressure, leading to the incidental discovery of intracranial mass lesion. Skull X-rays can be useful, showing signs of raised intracranial pressure as suture diastasis, unilateral enlargement or erosion of the inner table of the skull, or decalcification of the posterior clinoid process in older patients. CT scan demonstrates non contrast enhancing circular hypodense lesion [8, 12]; ipsilateral ventricles can be compressed, effaced with midline shift to the controlateral hemisphere (Fig. 2). Sometimes one large cystic lesion with internal septations evocative of daughter cysts can be seen. Absence of surrounding oedema is usual. In our series, a diameter of 5–10cm was the most frequent and was encountered in 56% of cases. In 51



**Fig. 2.** CT scan reveals giant fronto temporal cystic lesion with two daughter vesicles. Note the important midline shift, the effacement of the ipsilateral frontal horn and the massive hydrocephalus

cases (51%), BHC was single and multiple in 49 patients. Due to increased intracranial pressure and worsening of the patient condition, MRI was not performed on many patients and the decision was to operate as soon as possible. MRI, axial, sagittal and coronal views, reveal spherical or egg-shaped lesions with CSF-like signal intensity both in T1 and T2 sequences: hypointense in T1 and hyperintense in T2 (Fig. 3). On T1 weighted images, the thin capsule is iso- or slightly more hypointense than the fluid content; enhancing ring lesion is observed in case of infected cyst. T2W images show a low inten-



**Fig. 3.** *Upper and lower left:* MRI pictures depict on axial and sagittal T1-weighted images a hypointense occipital mass with no shift. *Upper and lower right:* Slices on T2-weighted images show a hyperintense occipital mass with hypointense capsule with slight surrounding oedema



sity rim which correlates to the external layer composed of fibrosis of surrounding brain tissue [11]. On the whole, image of BHC is a well recognized entity on CT scan, which is superior to MRI in depicting rare calcifications. On the other hand, MR imaging is more accurate in demonstrating the pericyst layer, which appears as a ring.

## 2.2 SHC

1. Antero posterior and lateral spine X-rays show multiple lytic lesions involving vertebral bodies and pedicles. It seems obvious that in the initial phase of the disease, especially in type 3, 4, and 5, the disc is spared which is explained by resistance of the anterior and posterior longitudinal ligaments.
2. Owing to its high bone resolution, CT scan demonstrates erosions of the posterior arch but also of the body of the vertebra in map shape configuration [4].
3. MRI is the best tool to illustrate spinal hydatid cysts: These lesions have a CSF-like intensity, i.e., isointense on T1 and hyperintense on T2 weighted images (Fig. 4). In intradural location SHC appears like a sausage, a date and in vertebral body as a green peas or grape bunch.

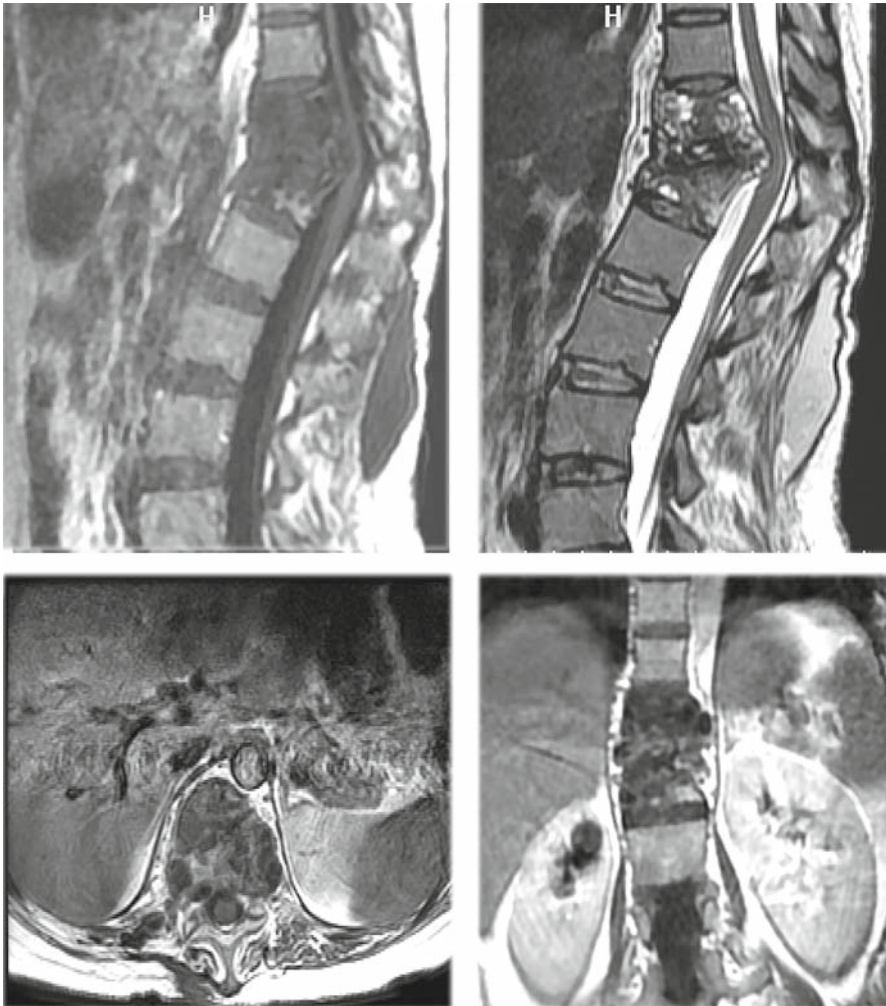
The growth of these cysts is surely limited by the osseous and ligamentous structures of the spine. Magnetic resonance imaging of the lumbar spine revealed: (a) one or numerous multiseptated cystic lesions inside the spinal canal, (b) cord compression, (c) possible intramedullary signal hyperintensity due to the pressure effect observed in case of chronic and severe compression, (d) contrast enhanced T1-weighted MR image shows thin walled cyst. Involvement of the vertebral bodies may not be obvious.

## 2.3 Serologic tests

The Casoni skin or intradermal test used to be the only test has now been replaced by hydatid serology which detects hydatid antibodies: hydatid immunoelectrophoresis, enzyme-linked immunosorbent assay (ELISA), latex agglutination (LA) and indirect haemagglutination (IHA) test. False results are possible. Tests can remain positive for a long time after surgery. Sensitivity varies with 4 parameters: the involved organ, intact or broken cyst, solitary or multiple cyst, and also the nature of test.

## 2.4 Differential diagnosis

- a) BHC: it should be anticipated with the following, slow-growing space occupying lesion, in particular arachnoid cyst, epidermoid cyst and cystic astrocytoma. But in case of ring enhancement and perilesional oedema one should suspect brain abscess.
- b) SHC: Pott disease and metastasis should be excluded.



**Fig. 4.** *Top:* Sagittal T1 and T2 weighted images of the thoracic spine demonstrating multilocular vertebral body lesions involving T9 and T10 with CSF-like signal intensities and mass effect on the spinal cord. The CSF spaces are totally obliterated. *Bottom:* Axial T1 and coronal T2 weighted images of the same pathology described above

## SURGERY

### 1. OPERATIVE TREATMENT

Multiple BHC is most likely secondary to locations in other organs. Hence, it is mandatory to look for the source in either the liver, lung or kidney. This

will prevent unexpected complications like bronchial cyst rupture which can happen during intubation leading to hydatid vomit and spillage into the airway. Usually, this type of surgery does not require intraoperative blood transfusion.

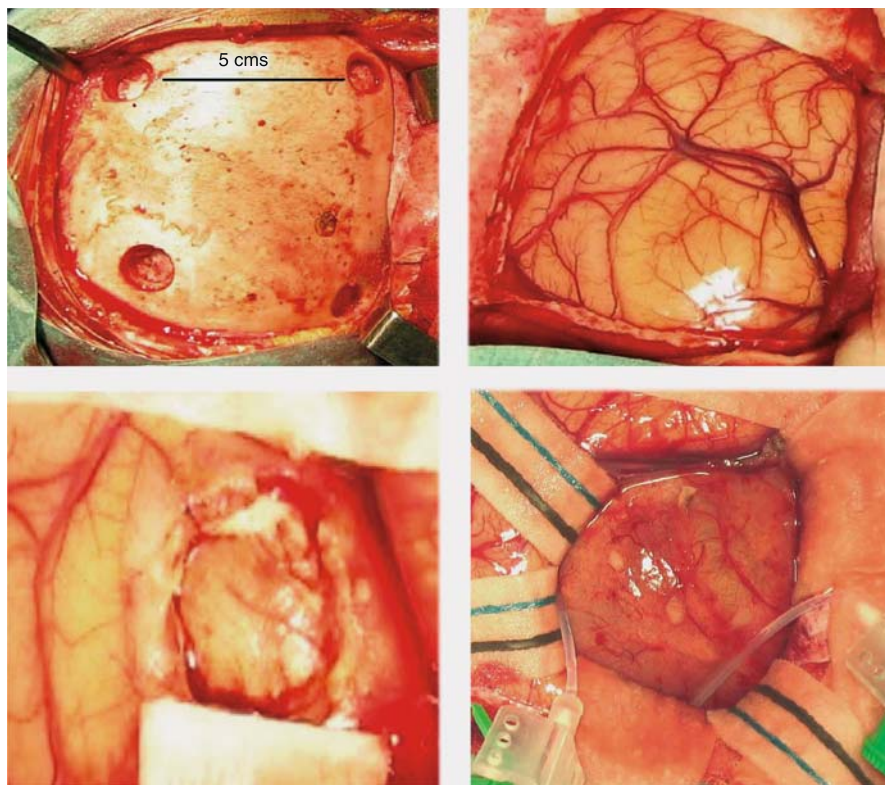
### 1.1 BHC

As for most of the space occupying lesions, total surgical excision remains the only treatment. Complete removal of an unruptured cyst with preservation of adjacent brain parenchyma leads to cure. It is absolutely contraindicated to place a ventricle-peritoneal shunt prior to the removal of the unruptured cyst. The use of monopolar cautery is dangerous and has to be avoided. Operative microscope is not necessary for intracranial localisations which are removed with protective eye shield. The microscope can be used with SHC.

Surgery is performed under general anesthesia, in the supine position except when dealing with posterior fossa or occipital lesions. The head is secured in a Mayfield head rest, slightly elevated and rotated to the contralateral side of the lesion. Scalp is shaved around the involved area.

The following principles should be respected:

1. The size of the bone flap is key to a successful extirpation. This should allow maximum space for maneuvering the cyst expulsion (Fig. 5).
2. The greatest care must be taken in performing this flap. The inner table of the skull may be eroded and thin in close proximity of the cyst. The surgeon should be extremely careful when performing the burr holes. Hand drill and Gigli saw are more advisable than pneumatic drill. The free bone flap is removed.
3. Dura is tense. Meningeal vessels must be coagulated. Dural opening is meticulous, since it may be in close proximity or adherent to the cyst. This dural flap is reflected and held by sutures.
4. The brain surface, under pressure, has lost its gyri and sulci (Fig. 5). The cyst may be visible. Usually a limited corticectomy is sufficient and performed precisely above the lesion. Finding the cyst wall is crucial. Gentle dissection of the cyst from the surrounding brain tissue is performed by spatula, cottonoid and saline irrigation. Soaked cotton patties are placed in the dissected plane between the brain surface and the cyst wall in leafs of daisy (Fig. 5). The brain parenchyma should be respected. For other locations, the approach will be similar to that practised in case of tumor.
5. Huge cysts are more translucent than smaller ones. Attention is focused on preserving the integrity of the cyst. Its intra-operative accidental rupture is devastating and leads first to dissemination and consequently to recurrences because each protoscolex released may grow and become a new cyst, second, anaphylactic shock may occur.



**Fig. 5.** Intraoperative photographs of the occipital hydatid cyst. *Upper left:* Position of burr holes: The bone flap is cut reaching the margins of sagittal and transverse sinuses. *Upper right:* In the lower right corner, the brain appears yellowish and less vascularized. *Lower left:* Corticectomy shows the cyst. *Lower right:* Dissection and hydropulsion of the hydatid cyst underway

6. Expulsion of the cyst is practised according to Dowling–Orlando technique [7] described in 1924, improved by Arana-Iniguez [2] based on water dissection. This technique is facilitated by the rarity of adhesions between the cyst wall and the brain surface. It is necessary to pass two catheters laterally and then under the cyst. This step must be undertaken with extreme care. Then, isotonic solution is injected under pressure by two syringes, to facilitate the cyst expulsion without rupture outside the operative field. The cyst can break and rupture. Its content should be immediately sucked and the cyst wall removed.
7. Hydrogen peroxide soaked cottonoids are placed inside the operative field for two minutes. Then, we irrigate with hypertonic saline solution for five minutes to kill any remaining eggs or larvae before

closing. Some authors advocate the use of 10% formaldehyde solution or cetrimide. Some deep seated cysts can be unrecognized and lead to recurrences.

8. At the end, inspect the cavity looking for small cysts, fill the cavity with isotonic saline solution in order to prevent pneumatocele or translation of the brain. Complete haemostasis is ensured.
9. Ensure watertight dural closure. The bone flap is repositioned. The wound is closed in the usual multilayered fashion
10. Atypical aspects according to:
  - a) Clinical status: In case of intracranial high pressure and eventually loss of consciousness, puncture aspiration of the cyst, easy to perform, is the adequate procedure realized in 16 patients (16%) of our series.
  - b) Numerous cysts:
    - In the same hemisphere: Extirpation through one approach of all cysts whenever possible
    - In both hemispheres: a staged removal is considered. The procedure is first performed on the most symptomatic cyst.

## 1.2 SHC

The goal of surgery is to decompress the spinal cord and nerve roots by removing hydatid cysts. To avoid mistakes, particularly in dorsal spine, the affected vertebra level is marked on the skin over the spinous process with metallic marker for preoperative X-rays. The procedure is performed under general anesthesia, in prone position with the head lower than the lower limbs so that the cerebrospinal fluid (CSF) loss from the intracranial compartment is minimized.

Laminectomy is the most appropriate approach. However, through this route, it is impossible to reach the vertebral body without cervical or thoracic spinal cord injury. Hence, it is necessary at times to perform a posterolateral approach, i.e., a costo-transversectomy at the thoracic level.

A single level laminectomy provides sufficient exposure in case of one intradural cyst. In most instances, a multilevel laminectomy is necessary. After a midline longitudinal skin and aponeurosis incision centered over the targeted spinal level, bilateral subperiosteal dissection and retraction of paraspinal muscles is realized. Spinous process and interspinous ligaments are undercut and the laminae are exposed.

Two possibilities:

1. *Vertebral body or spinal extradural HC*: Using Kerrison rongeurs, ligamentum flavum is removed piecemeal and the affected lamina is taken. Involved bone is of poor quality, usually friable. This laminectomy is started at the lower level in a rostro-caudal direction. The extension of surgery may

need to include posterior structures, i.e., lateral masses, facets or extend as lateral as the transverse processes. To disturb the adjacent facet joints in the thoracic spine is without consequences for spine stability. Contrarily, stabilization may be required for cervical or lumbar spine lesions.

Devices such as curettes and suction are indispensable for removing intraosseous cysts. Multiple pearly and translucent cysts of different size are observed. Operative microscope is useful. The real difficulty is how to totally extirpate the cysts, which may count in tens or more with a size of pin-head to chick-pea. Unfortunately, some cysts are ruptured by the suction tip or other tools. Severe spinal cord compression may be observed. It is well understood that complete removal of all cysts is illusive and their dissemination possible. For this, hydrogen peroxide sopped cottons are placed in the operative field for 2 minutes, after which the surgical area is irrigated with hypertonic saline solution.

Accidental durotomy in case of extradural compression is a serious complication and should be avoided.

Wide laminectomy with removal of the posterior or anterior parts of the vertebra can destabilize the spine and lead to kyphosis and or scoliosis. To preserve spinal stability, bone fusion with posterior or anterior instrumentation is useful and could be performed on the same day [3]. Fascia and skin are closed in layers.

Despite immediate and significant postoperative improvement of the neurological symptoms, surgery of spinal echinococcosis is deceptive. Recurrences remain the major worry of the neurosurgeon due to small daughter cysts that are left behind, despite microsurgical technique.

*2. Intradural localisation.* Here, the lamina is healthy, bone resection should be carefully adapted to size of the intradural cyst. Dura is opened and held to paravertebral muscles. Once the dural edges are retracted, hydatid cysts of different sizes are seen. Spinal cord compression and distortion may be visible. Cotton strips are rostrally and caudally slipped in subarachnoid spaces delineating the pathology. The cyst walls are dissected away from the spinal cord. Contrary to BHC, there is no adventitia around the cyst. Posteriorly located lesions are easier to remove than those anteriorly placed. If needed, division of the dentate ligament or posterior root is justified.

Following decompression, the spinal cord is now free of any tension.

In case of intradural location with normal vertebra, complete removal of cysts is feasible. The operative bed is filled with hydrogen peroxide soaked patties for a few minutes and then washed with hypertonic saline solution.

Closure is carried out in multiple layers.

## 2. MEDICAL TREATMENT

1. Is there a successful antiparasitic chemotherapy for hydatidosis of the central nervous system? The answer remains controversial. Neurosur-

geons agree on the possible benefit of albendazole, a broad-spectrum oral antihelminthic drug, used in cases of multiple BHC or SHC. For the majority of cases, a postoperative course is sufficient, whereas in others pre- and postoperative albendazole may be considered. The dosage is 400 mg twice a day for 4 weeks in 4 cycles separated by 2 weeks free of drugs.

2. Patients with preoperative seizures require long-term antiepileptic therapy.
3. Last but not least is an adequate rehabilitation, crucial for a successful management.

### 3. LONG-TERM RESULTS

According to our series and current literature [1, 6, 10], patients who undergo BHC or SHC surgery show immediate resolution of their symptoms in the postoperative follow-up. This affirmation excludes blindness, seizures or flaccid paraplegia. This appreciable improvement of neurological signs is detected in 80% of patients. Reexpansion of the brain is usually complete within few days. Sometimes it is difficult to distinguish on postoperative MRI or CT scan residual cyst from postoperative changes, hence the need to base evaluation and outcome on the clinical presentation rather than the imaging findings.

In BHC, long-term recurrences occur in 10–20% of cases, 12% in our series, and are more observed when cyst is multiple or ruptured preoperatively. In SHC, earlier clinical deterioration and recurrence within 2 years are the rule and happen in 40–100% of cases, particularly in the types 4 and 5 of Braithwaite and Lees classification.

### HOW TO AVOID COMPLICATIONS

Cyst rupture during dural opening or cyst dissection is redoubtable, providing ground for surinfection and what is more for recurrences. Hydrogen peroxide and hypertonic saline solution should be within hand-reach and used immediately. Anaphylactic shock can be observed when intraoperative spillage occurs. Antihistamines, hydrocortisone, crystalloids, adrenalin and high flow oxygen are administered according to the importance of the allergic reaction. Early postoperative complications include hematomas of the operative bed as well as epidural hematomas. Some of these may require repeated surgery if indicated by the neurological deterioration and the imaging findings.

This is avoided by ensuring of a perfect arterial and venous haemostasis of the operative field. Other complications are subcutaneous CSF collections, or leak which may be treated by repeated punctures or lumbar drainage.

In case of SHC, deep venous thrombosis are avoided with preventive measures such as intermittent calf pressure devices and if needed mild anticoagulation therapy.

Meningitis or abscess can occur. Postoperative spondilodiscitis can be observed in spinal surgery.

Kyphosis and other spinal deformities may be prevented by bone fusion. We deplore 5 deaths (5%). This concords with current literature.

## CONCLUSIONS

In summary, the most important requirement for a successful surgery is the extirpation of an intact cyst which remains technically feasible. Nevertheless, this lesion may recur, even after this meticulous surgery. Total recovery in case of BHC is possible and should be the rule. Concerning SHC, prognosis is bleak, better in intradural involvement where cure is possible. In case of vertebral body involvement, poor results are observed despite aggressive therapy. This is due to the difficulty to remove all the cysts without rupture, which explains the high rate of recurrences requiring several operations. This has been called “cancer blanc” or white malignancy by Dévé in 1948. Death may happen in a paraplegic patient due to complications of decubitus, mentioned above.

Like other parasitoses, regression of the disease is based on prophylaxis which includes improvement of sanitary services, elimination of carriers, i.e. dog, fox, and forbidding clandestine slaughtering of sheeps. This needs the collaboration between physicians, veterinarians and in particular full cooperation of the appropriate authorities. Public education includes preventive measures that break the infestation cycle and the hand–mouth contamination with the *Echinococcus granulosus*: meticulous hand washing before meals; fruits, vegetables and in particular salad cleaning prior to their consumption.

Due to globalisation, it is well understood that parasitoses of CNS are not a disease of the south hemisphere only but became a world-wide illness.

## References

- [1] Abada M, Galli L, Bousallah A, Lehmann G (1977) Kyste hydatique du cerveau, à propos de 100 cas. *Neurochirurgie* 23: 195-204
- [2] Arana-Iniguez R (1978) *Echinococcus*. Infection of the nervous system. In: Vinken PJ, Bruy GW (eds) *Infections of the nervous system, part III. Handbook of clinical neurology*, vol 35. Elsevier/North Holland Biomedical Press, Amsterdam, pp 175-208
- [3] Bozbuga M, Celikoglu E, Boran B (2005) Hydatid cyst of the craniocervical junction: case report. *Neurosurgery* 57(1): 193



- [4] Braithwaite PA, Lees RF (1981) Vertebral hydatid disease. Radiological assessment. *Radiology* 140: 763-766
- [5] Chaussier (1807) Un cas de paralysie des membres inferieurs. *J Med Chir Pharmacol* 14: 231-237
- [6] Ciurea AV, Fountas KN, Coman TC, et al. (2006) Long-term surgical outcome in patients with intracranial hydatid cyst. *Acta Neurochir (Wien)* 148: 421-426
- [7] Dowling E, Orlando R (1929) Quist hidatico del lobulo frontal derecho. *Rev Espec Assoc Med Argent* 4: 209-217
- [8] Draouat S, Filali N, Abdenabi B, et al. (1986) Apport de la scanographie dans la pathologie hydatique cérébrale de l'enfant. *J Radiol* 67: 179-184
- [9] Goinard P, Descuns P (1952) Les kystes hydatiques du nevraxe. *Rev Neurol* 86: 369-415
- [10] Onal C, Unal F, Barlas O, et al. (2001) Long-term follow-up and results of thirty pediatric intracranial hydatid cysts: half a century of experience in the Department of Neurosurgery of the School of Medicine at the University of Istanbul (1952–2001). *Pediatr Neurosurg* 35: 72-81
- [11] Ravalji M, Kumar S, Shah AK, et al. (2006) CT and MRI features of the typical and atypical intracranial hydatid cysts: report of five cases. *Neuroradiology* 16(4): 727-732
- [12] Rudwan MA, Khaffaji S (1988) CT of cerebral hydatid disease. *Neuroradiology* 30: 496-499
- [13] Vuitton DA (1997) The WHO Informal Working Group on Echinococcosis. Coordinating Board of the WHO-IWGE. *Parassitologia* 39: 349-353



**Benaissa Abdennebi**

Benaissa Abdennebi is head of the Department of Neurosurgery at Salim Zemirli Hospital in Algiers. Medical degree: University of Algiers, 1975. Neurosurgical residency: University of Algiers Medical Centers, 1975–1979. Fellowships: Hopital Neurologique de Lyon (France) – Prof. M. Sindou, 1983–1984; Kantonspital Zurich (Switzerland) – Prof. J. Siegfried, 1984–1985. President of the Algerian Training Committee of Neurosurgery, 1989–1994. Member of the Editorial Board of the Panarab Journal of Neurosurgery and the African Journal of Neurosciences. Reviewer: Acta Neurochirurgica, Journal of Pediatric Neurology. Member of the French Speaking Society of Neurosurgery (SNCLF), 1986–present; president elect of the Panarab Neurosurgical Society in 2008; member of the Panarab Society of Neurosurgery (PAANS), 1997–present; member of the Stereotactic and Functional Neurosurgical Committee of the WFNS, 1999–2002 and 2005–present.

**Contact:** Benaissa Abdennebi, Department of Neurosurgery, Salim Zemirli Hospital, University of Algiers, Route de Baraki, Algiers, Algeria  
E-mail: babdennebi@yahoo.fr

---

# PARASITOSSES OF THE CENTRAL NERVOUS SYSTEM: CYSTICERCOSIS

P. P. DIAZ VASQUEZ

## INTRODUCTION

Cysticercosis is a parasitic infection that results from ingestion of eggs from the adult tapeworm, *Taenia solium*. When cysticercosis involves the central nervous system, it is called neurocysticercosis (NCC). Historically, neurocysticercosis was endemic to only Latin America, Asia, and Africa, although it has become increasingly frequent in the United States since the 1980s. It is the most common parasitic infection of the central nervous system (CNS) [7].

## RATIONALE

### 1. LIFE CYCLE

*Taenia solium*, also called the pork tapeworm, is a cyclophyllid cestode in the family Taeniidae. It lives in the small intestine, adhered by the scolex (head). The scolex is provided with a rostellum, four suckers and a double-crown with 30 hooks. It can reach up to 5 m in length, and its scolex is followed by a neck and proglotids that contain a ramified uterus filled with ova.

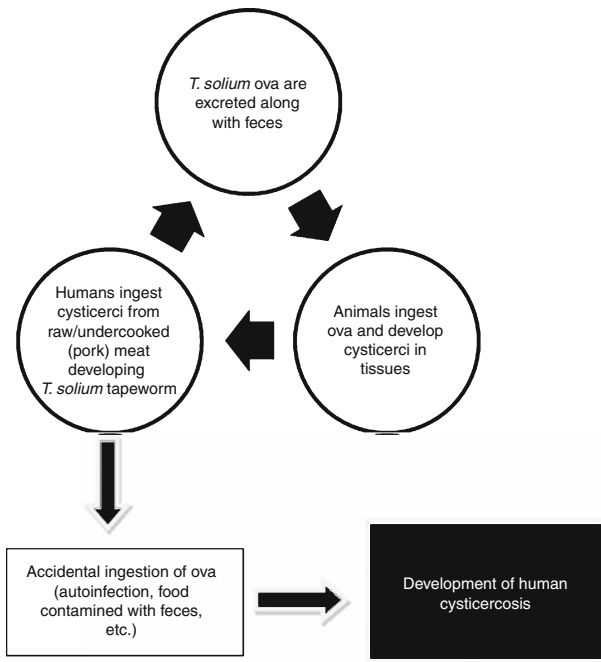
Humans are the only natural definitive hosts for the *Taenia solium*, which are acquired by the ingestion of undercooked or raw meat (most commonly pork) infested by larvae [9]. These larvae or cysticerci evaginate their scolex which adheres to the intestine and form proglotids, that develop into the adult form of the tapeworm. The proglotids eliminated along with feces free their eggs on the ground where they are ingested by the animals that will become the intermediate hosts. Humans may become accidental intermediate hosts by the ingestion of the parasite's ova, with development of cysticerci within organs. Cysticerci may be found in almost any tissue (Fig. 1). The most frequently reported locations are skin, skeletal muscle, heart, eye, and most importantly, the CNS.

### 2. PATHOLOGY

Cysticerci are vesicles consisting of two main parts, the vesicular wall and the scolex. The scolex has a similar structure to the adult *T. solium*, including a

---

*Keywords:* parasitoses, cysticercosis, brain, spine



**Fig. 1.** Diagram of *T. solium* life cycle

rostellum armed with suckers and hooks. In the CNS, cysticerci may lodge in the brain parenchyma (most frequently), subarachnoid space, ventricular system (most commonly the 4th ventricle), or spinal cord. Once the oncosphere has passed into the parenchyma, it grows and evolves through vesicular, colloidal, nodular-granular, and calcified stages. After entering the nervous system, cysticerci elicit a scarce inflammatory reaction in the surrounding tissues. In this stage parasites have a clear vesicular fluid and a normal scolex (vesicular stage). Cysticerci may remain viable for years or, as the result of a complex immunological attack from the host, enter into a process of degeneration that ends with its death. The first stage of involution of cysticerci is the colloidal stage, in which the vesicular fluid becomes turbid and the scolex shows signs of degeneration. Colloidal cysticerci are surrounded by a thick collagen capsule, and the surrounding brain parenchyma shows astrocytic gliosis and diffuse edema. Thereafter, the wall of the cyst thickens and the scolex is transformed into coarse mineralized granules; this is called the nodular-granular stage. Finally, in the calcified stage, the parasite remnants appear as a mineralized nodule. When parasites enter into the granular and calcified stages, the edema subsides but astrocytic changes in the vicinity of the lesions become more intense than in the preceding stages.

Meningeal cysticerci elicit intense inflammation in the subarachnoid space with formation of a dense exudate composed of collagen fibers, lymphocytes,

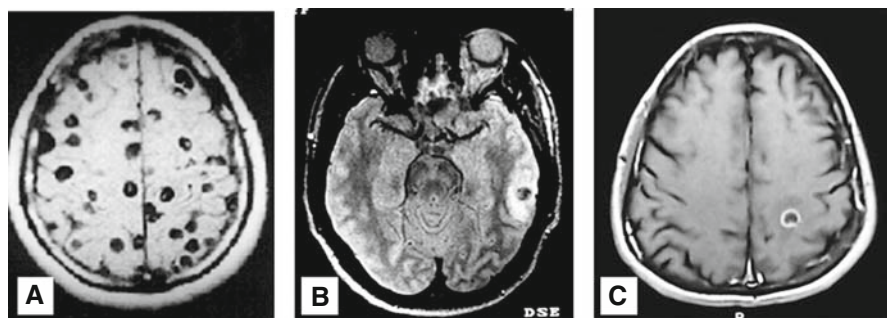
multinucleated giant cells, and hyalinized parasitic membranes, leading to abnormal leptomeningeal thickening. The optic chiasm and cranial nerves are encased in this exudate. The foramina of Luschka and Magendie may be occluded by the thickened leptomeninges with the subsequent development of hydrocephalus. Small penetrating arteries arising from the circle of Willis are also affected by this inflammatory reaction; this may cause occlusion of the lumen of the vessels and cerebral infarctions. Ventricular cysts also elicit an inflammatory reaction if they are attached to the choroid plexus or the ventricular wall. The ependymal lining is disrupted and ependymal cells are replaced by subependymal glial cells that protrude toward the ventricular cavities and block the transit of CSF, particularly when the site of protrusion is at the foramina of Monro or the cerebral aqueduct (most commonly the racemose form).

### 3. CLINICAL MANIFESTATIONS

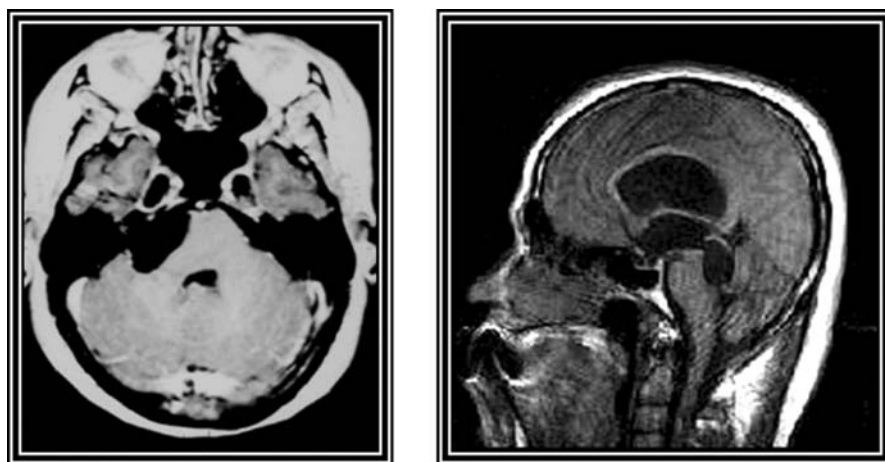
Clinical manifestations of NCC depend primarily on the number and location of cysticerci and the host's immune response to infection. Involvement of brain parenchyma is common and leads to the most frequent presentation of seizures (70–90% of acutely symptomatic patients) or headache [4]. Headache usually indicates the presence of hydrocephalus, meningitis, or increased intracranial pressure. Extraparenchymal ventricular and subarachnoid cysts are also found. These carry a worse prognosis and often lead to obstructing hydrocephalus requiring surgical intervention. Fourth ventricle cysts can create a subacute hydrocephalus via a valve-and-ball mechanism. However, head movement can suddenly increase the intracranial pressure (Brun's syndrome). Cysticerci within the basilar cisterns or Sylvian fissures may enlarge to 10–15 cm in diameter. Those within the cisterns may also cause serious vasculitis and stroke. The mortality rate of patients with hydrocephalus or increased intracranial pressure is higher than the mortality rate of patients with seizures. Patients with intrasellar cysticerci present with ophthalmological and endocrinologic disturbances similar to those produced by pituitary tumors. Spinal NCC is rare. It may present with root pain or motor and sensory deficits that vary according to the level of the lesion.

### 4. IMAGING STUDIES

Due to the poor sensitivity of MRI for the detection of calcifications, CT remains the best screening neuroimaging procedure for patients with suspected neurocysticercosis, and MRI is the imaging modality of choice for the evaluation of patients with intraventricular cysticercosis, brainstem cysts and small cysts located over the convexity of cerebral hemispheres. MRI is also superior to CT in the follow-up of the patients after therapy.

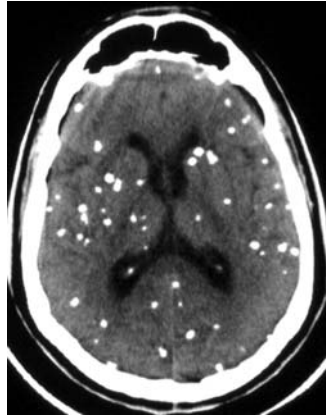


**Fig. 2.** Neurocysticercosis in its different stages of evolution. **A** Multiple viable cysts (vesicular stage). **B** Granular stage with abundant perilesional edema. **C** Single granular lesion with scarce edema



**Fig. 3.** *Left:* Vesicular cyst in posterior fossa. *Right:* Obstructive hydrocephalus secondary to aqueductal cysticercosis

CT and MRI findings in parenchymal neurocysticercosis depend on the stage of development of the parasites (Fig. 2). Vesicular (living) cysticerci appear on CT as small and rounded low-density areas without perilesional edema or enhancement after contrast medium administration (Fig. 3). On MRI, vesicular cysts appear with signal properties similar to those of CSF in both, T1 and T2-weighted images. The scolex is usually visualized within the cyst as a high intensity nodule giving the lesion a pathognomonic “hole-with-dot” imaging. Sometimes, these parasites are so numerous that the brain resembles a “swiss cheese”. On MRI, the wall of the colloidal cysticerci becomes thick and hypointense and there is marked perilesional edema, better visualized on T2-weighted images. Granular cysticerci appear on CT as nodular hyperdense lesions surrounded by edema after contrast administration. On MRI,



**Fig. 4.** Multiple calcificated cysts

granular cysticerci are visualized as areas of signal void on both T1 and T2-weighted images surrounded by edema or gliosis with hyperintense rims around the area of signal void. Calcified (dead) cysticerci normally appear on CT as small hyperdense nodules without perilesional edema or abnormal enhancement after contrast medium administration (Fig. 4).

Hydrocephalus, caused by inflammatory occlusion of the foramina of Luschka and Magendie, is the most common neuroimaging finding in patients with subarachnoid neurocysticercosis (Fig. 3). Acute hypertensive hydrocephalus is associated with periventricular lucencies representing interstitial edema due to transependymal migration of CSF. In contrast, chronic and relatively normotensive forms of hydrocephalus are not associated with this CT pattern. The fibrous arachnoiditis that is responsible for the development of hydrocephalus is seen on CT or MRI as areas of abnormal leptomeningeal enhancement at the base of the brain after contrast medium administration. Ischemic cerebrovascular complications of subarachnoid neurocysticercosis are well visualized with CT or MRI but these are nonspecific.

Ventricular cysticerci appear on CT as hypodense lesions that distort the ventricular system causing asymmetric or obstructive hydrocephalus. The administration of positive intraventricular contrast medium allows precise localization of intraventricular cysticerci by CT. The administration of contrast medium is usually performed by transcutaneous puncture of the antechamber of a ventricular shunt or through a ventriculostomy tube. Positive contrast medium may also be administered through a lumbar puncture; however, this procedure should be conducted cautiously since intracranial pressure may induce the development of brain herniation in patients with hydrocephalus or intraventricular masses. Most ventricular cysts are readily visualized on MRI. In some cases, the ventricular cyst is only visualized in the

proton density sequence or with FLAIR techniques, where they appear barely hyperintense with regard to the CSF. Cyst mobility within the ventricular cavities in response to movements of the patient's head, the "ventricular migration sign", is better observed with MRI than with CT. This finding facilitates the diagnosis of ventricular cysticercosis in some patients.

On MRI, intramedullary cysticerci appear as rounded or septated lesions that may have an eccentric hyperintense nodule representing the scolex. The periphery of the cyst usually enhances due to a breakdown of the blood-spinal barrier in the parenchyma of the spinal cord surrounding the cyst. The spinal cord is seen enlarged and if the scolex is not identified it is difficult to differentiate this condition from ependymomas, cystic astrocytomas, or primary syringomyelic cavities. Myelography is still of diagnostic value in patients with suspected spinal leptomeningeal cysticercosis. In this form of the disease, myelograms usually show multiple filling defects in the column of contrast material corresponding to the cysts. Leptomeningeal cysts may be freely mobile within the spinal subarachnoid space and may change their position during the exam according to movements of the patient in the exploration table.

## **DECISION-MAKING**

### **1. DIAGNOSTIC CRITERIA**

Del Brutto et al. provided diagnostic criteria for neurocysticercosis based on objective clinical, imaging, immunologic, and epidemiologic data [6]. These include four categories of criteria stratified on the basis of their diagnostic strength, including the following:

#### **1.1 Absolute**

- Histologic demonstration of the parasite from biopsy of a brain or spinal cord lesion.
- Cystic lesions showing the scolex on CT or MRI.
- Direct visualization of subretinal parasites by fundoscopic examination.

#### **1.2 Major**

- Lesions highly suggestive of neurocysticercosis on neuroimaging studies.
- Positive serum enzyme-linked immunoelectrodiffusion transfer blot (EITB) for the detection of anticysticercal antibodies.
- Resolution of intracranial cystic lesions after therapy with albendazole or praziquantel.
- Spontaneous resolution of small single enhancing lesions.



### 1.3 Minor

- Lesions compatible with neurocysticercosis on neuroimaging studies.
- Clinical manifestations suggestive of neurocysticercosis.
- Positive CSF enzyme-linked immunosorbent assay (ELISA) for detection of anticysticercal antibodies or cysticercal antigens.
- Cysticercosis outside the CNS.

### 1.4 Epidemiologic

- Evidence of a household contact with *Taenia solium* infection.
- Individuals coming from or living in an area where cysticercosis is endemic.
- History of frequent travel to disease-endemic areas.

Interpretation of these criteria permits two degrees of diagnostic certainty:

### 1.5 Definitive diagnosis

- One absolute criterion, or
- Two major plus one minor and one epidemiologic criterion.

### 1.6 Probable diagnosis

- One major plus two minor criteria, or
- One major plus one minor and one epidemiologic criterion, or
- Three minor plus one epidemiologic criterion.

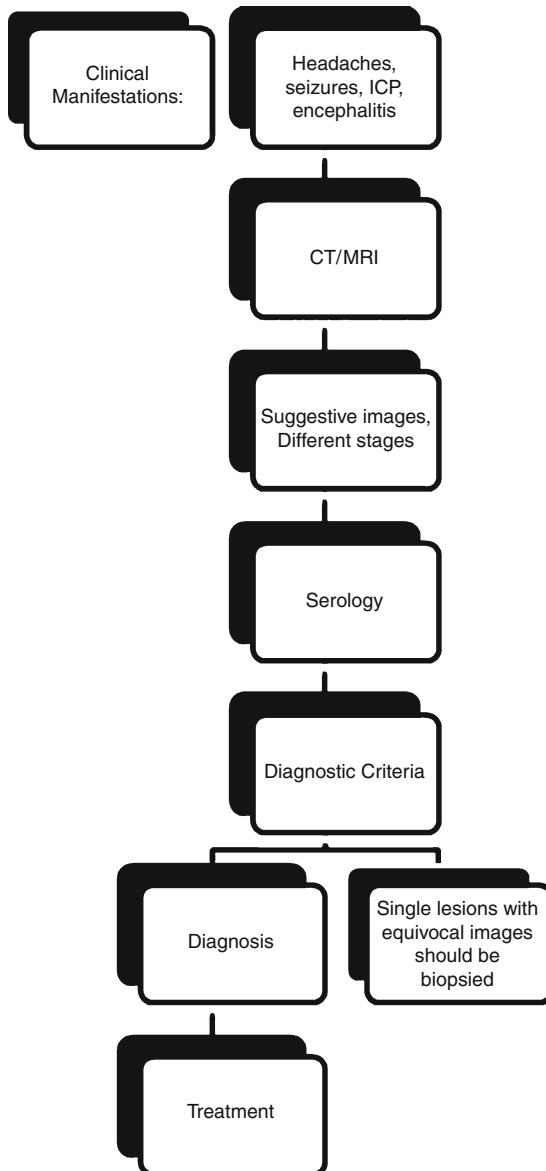
## 2. IMMUNOBLOT

The Western blot for cysticercosis or the EITB, which uses lentil lectin purified glycoprotein (LLGP) antigens extracted from the metacestode of *T. solium*, has been the “gold standard” serodiagnostic assay since it was first described in 1989. It gives close to 100% specificity and a sensitivity varying from 70 to 90%. This high sensitivity decreases when the number of cysticerci is low. The EITB is more efficient using serum instead of cerebrospinal fluid (CSF).

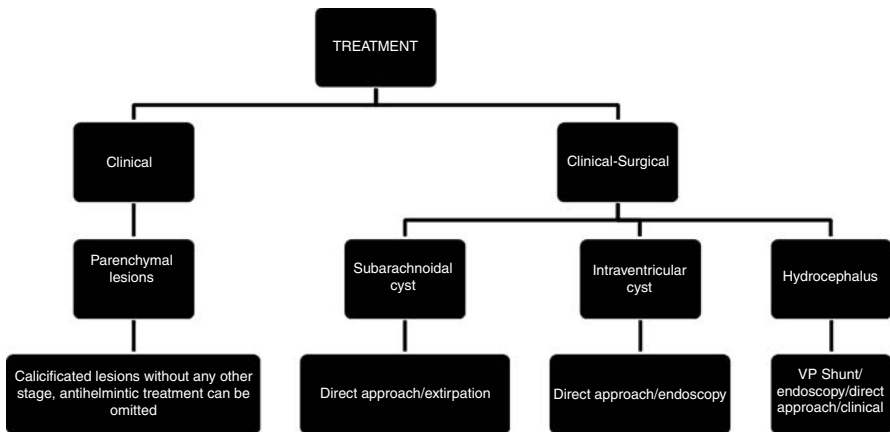
## 3. ELISA

ELISA, when used in serum, has 65% of sensitivity and 63% specificity. Sensitivity is higher with CSF. In developing countries ELISA is preferred because of its better availability, simplicity and lower cost compared to EITB. When used for detecting cysticerci antigens in CSF, ELISA gives close to 85% sensitivity and 100% specificity, with the advantage of identifying the active forms of the larvae.

I personally recommend to perform stereotactic biopsies when a doubtful single lesion shows no radiographic improvement with clinical treatment, even with a positive serology, because of the high incidence of gliomas (Fig. 5).



**Fig. 5.** Diagnostic approach to neurocysticercosis



**Fig. 6.** Decision-making for the treatment of neurocysticercosis

## TREATMENT

Cysts' number, location, stage and the hosts immune response are to take into consideration for a proper and individualized treatment that usually includes a combination of symptomatic drugs, cysticidal drugs, surgical resection of lesions, and placement of ventricular shunts (Fig. 6).

### 1. ANTIHELMINTICS

For intraparenchymal NCC with viable cysts, albendazole (ABZ) (15 mg/kg/day orally for seven days or longer) is associated with destruction of most cysts, and a decrease in seizures of at least 45% (higher in seizures with generalization). Praziquantel (PZQ) can be used orally in a single-day regimen of three doses of 25 mg/kg given at two-hour intervals, or the standard 15-day regimen of 50–100 mg/kg/day [3]. PZQ has a slightly lower cysticidal efficacy than ABZ. Steroids decrease serum levels of PZQ. Serum levels of phenytoin and carbamazepine may also be lowered as the result of simultaneous praziquantel administration [11].

Patients with single enhancing lesions may not need specific therapy as most of these lesions disappear spontaneously. Dead, calcified cysts do not need to be treated with anti-parasitic drugs. Steroids can shorten the duration of the edema but they might not affect the frequency of subsequent edema episodes.

For subarachnoid cysticercosis treatment with albendazole for 4 weeks is recommended, sometimes requiring more than one course. Cysticidal drugs must be used with caution in patients with giant subarachnoid cysts because the host's inflammatory reaction in response to the destruction of parasites may occlude leptomeningeal vessels surrounding the cyst.

In patients with ventricular cysts, the therapeutic approach with cysticidal drugs should be individualized. Although albendazole successfully destroys many ventricular cysts, the inflammatory reaction surrounding the cysts may cause acute hydrocephalus.

Patients with cysticercotic encephalitis should not be treated with cysticidal drugs because this may exacerbate the intracranial hypertension observed in this form of the disease. In patients with both hydrocephalic and intraparenchymal cysts, cysticidal drugs should be used only after a ventricular shunt has been placed to avoid further increases of intracranial pressure as a result of drug therapy.

## **2. ANTI-INFLAMMATORY TREATMENT**

Dexamethasone in doses between 4.5 and 12 mg/day. Prednisone at 1 mg/kg/day may replace dexamethasone when long-term steroid therapy is required [5].

Corticosteroids are the primary form of therapy for cysticercotic encephalitis, angiitis, and arachnoiditis causing progressive entrapment of cranial nerves. In such cases, up to 32 mg per day of dexamethasone may be needed for control of symptoms. In patients with cysticercotic encephalitis, corticosteroids may be used in association with mannitol at doses of 2 mg/kg per day [2].

Simultaneous administration of corticosteroids and cysticidal drugs ameliorate the secondary effects of headache and vomiting that may occur during cysticidal drug therapy. Headache and vomiting are not due to toxic effects of the drugs but rather to the destruction of parasites within the brain and are reliable indicators of drug efficacy. In patients with giant subarachnoid cysticerci, ventricular cysts, spinal cysts, and multiple parenchymal brain cysts, corticosteroids must be administered before, during, and even some days after the course of cysticidal drugs to avoid cerebral infarction, acute hydrocephalus, spinal cord swelling, and massive brain edema, respectively.

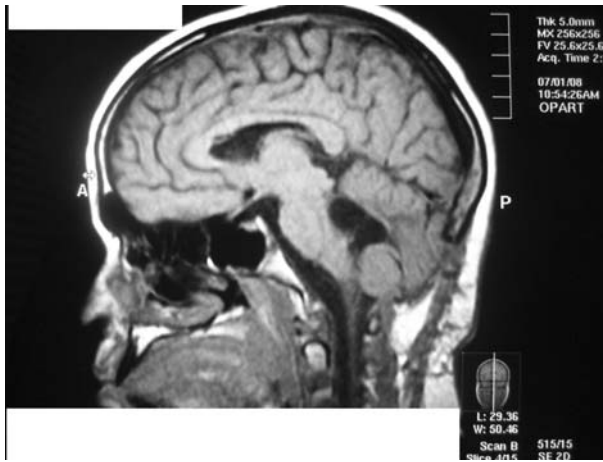
## **3. SURGICAL TREATMENT**

The main problem in ventricular shunt placement is the high prevalence of shunt dysfunction; indeed, it is common for patients with hydrocephalus secondary to neurocysticercosis to have two or three shunt revisions [8]. Maintenance steroid therapy and antihelminthic drugs may decrease the frequency of shunt blockages [10]. Neuroendoscopy can be used for resection of intraventricular cysts, with much less morbidity than with open surgery.

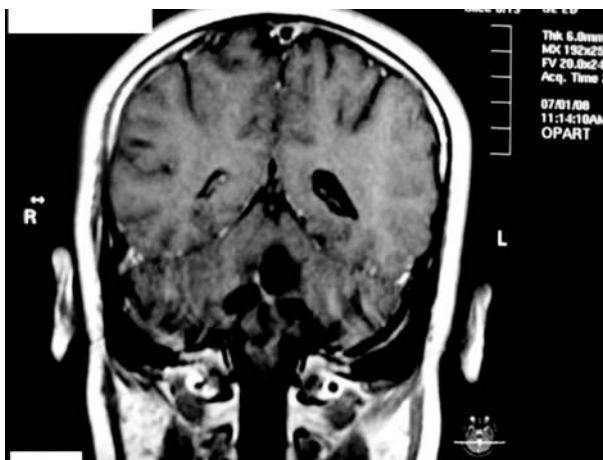
### **3.1 Surgical treatment basis**

Surgical treatment of NCC is an option when clinical treatment is not effective. Surgery should be the first choice of treatment in the presence of increased intracranial pressure secondary to giant cysts causing mass effect and hydrocephalus due to CSF circulation blockage.

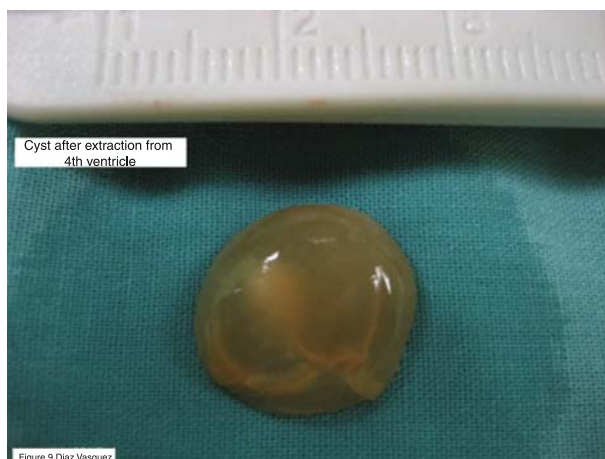The modality of the treatment is chosen according to the localization of cysticerci. The most common procedures are ventriculo-peritoneal shunting for treating hydrocephalus and neuroendoscopy for both cyst resection and extraction and management of hydrocephalus [1]. For those cysts localized in the 3rd and 4th ventricles, surgery is targeted to resection and extraction of the lesions, and resolution of the intracranial hypertension secondary to the hydrocephalus, all at the same time (Figs. 7–9). For cysts localized in the lateral ventricles, neuroendoscopic resection can be performed simultaneously with a ventriculocysternotomy for treating hydrocephalus.



**Fig. 7.** Residual cysts in 4th ventricle, after surgery



**Fig. 8.** Residual cysts after surgery in 4th ventricle



**Fig. 9.** Cyst after extraction from 4th ventricle

Intraparenchymal cysts will only be managed surgically, in the setting of severe intracranial hypertension.

Pseudotumors secondary to giant subarachnoid cysts, must be managed surgically whenever clinical treatment fails.

In spinal cord involvement, surgery is always mandatory in presence of medullary compression. Subarachnoid lesions are far more common than the intramedullaries. Resection should always be performed using a microscope. In the case of intramedullary cysts, resection constitutes an exceptional diagnosis without the evidence of a concomitant intracranial lesion.

Subarachnoid cysts are most commonly found in the racemous form. Surgery is considered when clinical treatment fails, and it consists in the resection under microscope of localized lesions.

### 3.2 Surgical techniques

The installation of a ventriculo-peritoneal shunt is performed in a classic manner, with the implantation of a mid-pressure valve, taking into consideration the side of the lesion. For the abdominal time, we prefer the transumbilical approach for aesthetic purposes, mainly in children and young women. We choose ventriculocysternostomy over shunting whenever possible. Shunt dysfunction due to obstruction of the catheter is one of the most common complications, which leads to a revision for its reinstallation.

Free-floating intraventricular cysts should be treated endoscopically. In many cases it may be necessary passing through the septum and performing a ventriculocysternostomy in the same intervention.

For cysts in the 4th ventricle, we choose a suboccipital classic approach, paying special attention to microsurgery, and a thorough irrigation with normal saline.

Lesions in the lateral ventricles are assessed through a frontal trepanus with the introduction of the neuroendoscope. The site and angle of entrance will vary depending on the number of vesicles. Sometimes it can be necessary an additional entry point in order to perform a simultaneous ventriculo-cysternoscopy. Septum pellucidum fenestration is a common procedure and carries no major consequences. The cyst may accidentally rupture without leading to complications.

In some subarachnoid cysts, stereotactic localization is needed: (1) giant cysts causing mass effect, (2) encephalitis secondary to cerebral edema (exceptionally).

## CONCLUSIONS

Neurocysticercosis is a parasitic infection that has become worldwide due to its easy spread through travelers. It has multiple forms of presentation like epilepsy, syndrome of intracranial hypertension, and hydrocephaly. Intraparenchymal neurocysticercosis has a favorable course and responds well to clinical treatment. Subarachnoid and intraventricular cysts have a greater morbi-mortality, since these can grow to the development of intracranial hypertension with mass effect. Hydrocephaly secondary to CSF obstruction and arachnoiditis require decompression surgery. A large number of patients treated with ventriculo-peritoneal shunts, need reintervention to release obstruction. The vast majority of patients need anticonvulsive therapy. True disease control is only achieved by avoiding transmission, with proper sanitary measures.

## References

- [1] Bergsneider M (1999) Endoscopic removal of cysticercal cysts within the fourth ventricle. *J Neurosurg* 91: 340-345
- [2] Carpio A, Santillan F, Leon P, Flores C, Hauser WA (1995) Is the course of neurocysticercosis modified by treatment with antihelminthic agents? *Arch Intern Med* 155: 1982-1988
- [3] Cruz M, Cruz I, Horton J (1991) Albendazole versus praziquantel in the treatment of cerebral cysticercosis: clinical evaluation. *Trans R Soc Trop Med Hyg* 85: 244-247
- [4] Del Brutto OH, Santibanez R, Noboa CA, Aguirre R, Diaz E, Alarcon TA (1992) Epilepsy due to neurocysticercosis: analysis of 203 patients. *Neurology* 42: 389-392

- [5] Del Brutto OH, Sotelo J, Roman GC (1993) Therapy for neurocysticercosis: a reappraisal. *Clin Infect Dis* 17: 730-735
- [6] Del Brutto OH, Wadia NH, Dumas M, Cruz M, Tsang VC, Schantz PM (1996) Proposal of diagnostic criteria for human cysticercosis and neurocysticercosis. *J Neurol Sci* 142: 1-6
- [7] Garcia HH, Gonzales AE, Evans CAW, Gilman RH (2003) *Taenia solium* cysticercosis. *Lancet* 362: 547-556
- [8] Madrazo I, Flisser A (1992) Cysticercosis. In: Apuzzo MLJ (ed) *Brain surgery: complication avoidance and management*. Churchill Livingstone, New York, pp 1419-1430
- [9] Roman G, Sotelo J, Del Brutto O, Flisser A, Dumas M, Wadia N, et al. (2000) A proposal to declare neurocysticercosis an international reportable disease. *Bull WHO* 78: 399-406
- [10] Suastegui Roman RA, Soto-Hernandez JL, Sotelo J (1996) Effects of prednisone on ventriculoperitoneal shunt function in hydrocephalus secondary to cysticercosis: a preliminary study. *J Neurosurg* 84: 629-633
- [11] Vazquez ML, Jung H, Sotelo J (1987) Plasma levels of praziquantel decrease when dexamethasone is given simultaneously. *Neurology* 37: 1561-1562





**Pedro Pablo Diaz Vasquez**

Pedro Pablo Diaz Vasquez is currently Professor of Neurosurgery and Neuroanatomy in the Universidad Autonoma de Santo Domingo and works as an adult and pediatric neurosurgeon in the Universidad Central del Este Medical Center, Santo Domingo.

He is president, founder and director of the French Hospital of Santo Domingo Foundation (Fundacion Hospital Frances de Santo Domingo), a non-profit, non-governmental institution dedicated specially to neurosciences. He was decorated as “Meritorious Gentleman” by the French Government.

He graduated as doctor in medicine from the Universidad Autonoma de Santo Domingo (Autonomous University of Santo Domingo). He completed his subspecialty training in neurosurgery, neuroradiology, anatomy of the central nervous system, microsurgery and fundamental and clinical neuropsychopharmacology at the University of Aix Marseille II, Marseille, France.

He was the President of the Dominican Society of Neurology and Neurosurgery and also President of the International Congress of Neurosurgery, Santo Domingo 1997 and of the 57th Congres de Neurochirurgie de Langue Francaise, Punta Cana, 2007.

**Contact:** Pedro Pablo Diaz Vasquez, Fundacion Hospital Frances de Santo Domingo, Calle Duarte #359, Zona Colonial, Santo Domingo  
E-mail: [ppdiazvasquez@hotmail.com](mailto:ppdiazvasquez@hotmail.com)

# **INTRACRANIAL TUMORS**

---

# CLASSIFICATION OF BRAIN TUMORS AND CORRESPONDING TREATMENTS

M. WESTPHAL

## INTRODUCTION

The first systematic classification system for brain tumors according to their presumed cells of origin was established by Cushing and Bailey in 1926. The World Health Organisation established an international tumor classification system in 1957 in order to initiate a classification and grading system with worldwide acceptance and usage since without such a system and the clearly defined histopathological and clinical diagnostic criteria it was not possible to conduct epidemiological studies and clinical trials beyond institutional and national boundaries. For brain tumors the initial classification was established in 1979 by Zülch and revised in 1993 by Kleihues with the introduction of immunohistochemistry. The third edition was published 2000, the so-called WHO blue book not only described and graded all brain tumors in precision, but also epidemiological, clinical, imaging and genetic information was presented in a structured fashion [3]. Currently the fourth edition of the WHO classification of tumors of the central nervous system, published in 2007 lists new entities and histological variants [4]. Despite of the WHO system brain tumors in general can be divided into axial and extra-axial lesions (i.e. meningioma vs. glioma) or into primary cerebral (gliomas) and secondary cerebral (metastases).

This chapter is a summarized overview of classification of brain tumors and their corresponding treatments, with additional materials by Oliver Heese, M.D.

## BRAIN TUMOR CLASSIFICATION

### 1. HISTOMORPHOLOGICAL CRITERIA

In order to grade and classify tumors of the brain, different histological criteria were defined based on conventional H+E stainings or immunohistochemistry of paraffin-embedded formalin-fixed tissue specimens. The criteria are listed in Table 1.

### 2. WHO GRADING SYSTEM

In the WHO classification brain tumors are differentiated into 4 grades according to their increasing malignancy from grade 1 to grade 4 based on his-

---

*Keywords:* neuro-oncology, brain tumor grading, brain tumor imaging

**Table 1.** Histological criteria for the WHO classification system

---

Grade 1:	Low cell density No nuclear atypies No mitotic figures No necrotic areas
Grade 2:	Moderate cell density Minor nuclear atypies Minor mitotic figures No necrotic areas
Grade 3:	High cell density Moderate nuclear atypies High rate of mitotic figures No necrotic areas Microvascular proliferations
Grade 4:	High cell density High rate of nuclear atypies High rate of mitotic figures High rate of necrotic areas Microvascular proliferations

---

tological criteria such as cellularity, nuclear atypia, vascularisation, necrosis or cell shape to mention just a few. This grading system correlates well with the clinical prognosis of the different tumor entities and has impact on therapy decision-making.

### 3. MOLECULAR DIAGNOSTICS

It has become accepted that histological criteria are neither sufficient for the unequivocal classification of brain tumors nor for a correlative analysis of treatment responses nor the prediction of progression, thus warranting the inclusion of information concerning molecular characteristics and genetic alterations. Despite a wealth of such information for various tumors these informations have not yet found sufficient appreciation in the WHO grading system.

So far only two molecular alterations play a significant clinical role, partially for making therapeutic decisions but mainly for estimating the prognosis of a patient. Prototypic is the functional 1p19q deletion in oligodendroglioma which appears to be the result of a chromosomal translocation. A loss of 1p19q suggests strongly a better prognosis and response to chemotherapy and radiation therapy in contrast to oligodendrogliomas of the same WHO grade but without the 1p19 deletion [6]. The other significant molecular determinant of therapeutic efficacy of alkylating agent chemotherapy is the methylation status of the MGMT (Methyl-Guanin-Methyl-Transferase) gene in glioblastomas (astrocytoma grade IV). MGMT is a DNA repairing enzyme and a methylation of the MGMT-promoter leads to a decreased amount of this enzyme in glioblastomas and therefore leads to a higher sus-

**Table 2.** The 2007 WHO classification of tumors of the central nervous system

---

<b>Tumors of neuroepithelial origin</b>
Astrocytic tumors
Diffuse astrocytoma
Fibrillary astrocytoma
Protoplasmic astrocytoma
Gemistocytic astrocytoma
Anaplastic astrocytoma
Glioblastoma
Variants
Pilocytic astrocytoma
Pleomorphic xanthoastrocytoma
Subependymal giant cell astrocytoma
Oligodendroglial tumors
Oligodendroglioma
Anaplastic oligodendroglioma
Mixed gliomas
Oligoastrocytoma
Anaplastic oligoastrocytoma
Ependymal tumors
Ependymoma
Cellular ependymoma
Papillar ependymoma
Clear cell ependymoma
Tanycytic ependymoma
Anaplastic ependymoma
Myxopapillary ependymoma
Subependymoma
Choroid plexus tumors
Choroid plexus papilloma
Choroid plexus carcinoma
Glial tumors of uncertain origin
Astroblastoma
Gliomatosis cerebri
Choroid glioma of the third ventricle
Neuronal and mixed neuronal-glial tumors
Dysplastic gangliocytoma of the cerebellum
Desmoplastic infantile astrocytoma/ganglioglioma
Dysembryoblastic neuroepithelial tumor
Ganglioglioma
Anaplastic ganglioglioma
Central neurocytoma
Cerebellar liponeurocytoma
Paraganglioma of the filum terminale
<b>Meningioma</b>
Meningothelial meningioma
Fibroblastic meningioma
Transitional meningioma
Psammomatous meningioma
Angiomatous meningioma
Microcystic meningioma
Secretory meningioma
Lymphoplasmacyte-rich meningioma
Metaplastic meningioma
<b>Neuroblastic tumors</b>
Olfactory neuroblastoma
Olfactory neuroepithelioma

---

**Table 2** (Continued)

---

- Pineal parenchymal tumors
    - Pineocytoma
    - Pineoblastoma
  - Embryonal tumors
    - Medulloepithelioma
    - Ependymoblastoma
    - Medulloblastoma
      - Desmoplastic medulloblastoma
      - Large cell medulloblastoma
      - Medullomyoblastoma
      - Melanotic medulloblastoma
  - Supratentorial primitive neuroectodermal tumor (PNET)
    - Neuroblastoma
    - Ganglioneuroblastoma
  - Atypical teratoid/rhabdoid tumor
  - Tumors of peripheral nerves
    - Schwannoma
      - Cellular schwannoma
      - Plexiform schwannoma
      - Melanocytic schwannoma
    - Neurofibroma
      - Plexiform neurofibroma
    - Perineurioma
      - Intraneural perineurioma
      - Soft-tissue perineurioma
  - Malignant peripheral nerve sheath tumor (MPNST)
    - Epithelioid MPNST
    - Glandular MPNST
    - Malignant triton tumor
    - Melanocytic MPNST
    - Melanocytic psammomatous MPNST
  - Primary melanocytic lesions
    - Diffuse melanocytosis
    - Melanocytoma
    - Malignant melanoma
    - Meningial melanomatosis
  - Tumors of uncertain histogenesis
    - Capillary hemangioblastoma
  - Lymphomas and hematopoietic tumors
    - Plasmocytoma
    - Granulocytic sarcoma (Chloroma)
  - Germ-cell tumors
    - Germinoma
    - Embryonal carcinoma
    - Yolk sac tumor
    - Choriocarcinoma
    - Teratoma
      - Mature teratoma
      - Immature teratoma
      - Teratoma with malignant transformation
  - Mixed germ cell tumors
  - Tumors of the sella region
    - Craniopharyngioma
      - Adamantinoid
      - Papillary
  - Granular cell tumors
  - Metastatic tumors
-

ceptibility for alkylating chemotherapeutic drugs (i.e., temozolomide). It was shown that glioblastoma patients with methylated MGMT-promoter had a better prognosis than patients where MGMT is unmethylated [2].

*The complete classification system* is listed in Table 2. For practical reasons this overview will focus on the most common brain tumor entities (astrocytomas, oligodendrogliomas, ependymomas, meningiomas, and metastases).

## **CLASSIFICATION OF BRAIN TUMOR TREATMENTS**

### **1. TREATMENTS**

#### **1.1 Surgery**

The surgical approach for brain tumors can be divided into two strategies. For extra-axial lesions the aim is a radical resection while preserving vital structures like cranial nerves, cerebral arteries or large draining veins (i.e. meningiomas, schwannomas). For intra-axial tumors of glial origin a radical resection with boundaries free of tumor-cells is not possible despite modern technologies like neuronavigation, intraoperative imaging or fluorescent-aided resections. But it has been shown that the amount of resected solid tumor has an impact on patient's prognosis and therefore the more tumor tissue resected the better for the patient [10]. This is broadly accepted not only for glioblastomas but also for low grade astrocytic tumors.

#### **1.2 Radiation therapy**

Radiation therapy is a major part in the treatment of malignant gliomas for many decades. Overall the principle of a conformal radiation including a 1.5–2 cm rim around the tumor has not changed [14]. Stereotactic radiation, either as a single dose (radiosurgery) or fractionated is an established option for non-resectable/residual extraaxial tumors (i.e. meningiomas, schwannomas), but has found limited acceptance for malignant gliomas in any situation. Interstitial radiation (brachytherapy) is only used in some centers and its value may be highest in low grade gliomas although this is still a matter of dispute.

#### **1.3 Systemic chemotherapy**

For a long time systemic chemotherapy was mainly used in recurrent malignant glioma with nitrosourea-based compounds being the major group of substances. But after a phase III trial proved the effectiveness of a combination of radiation and concomitant chemotherapy with temozolomide this regimen is a standard in the treatment also of newly diagnosed glioblastomas [11] where temozolamide has been considered to enhance the efficacy of ra-

diation. In what portion this therapeutic regimen is transferable onto the treatment of WHO grade III is not known so far. Systemic chemotherapy is also an established component in the treatment of oligodendroglioma. There is no established chemotherapy for meningiomas or the other more rare non-glial tumors. The efficacy of systemic chemotherapy is diminished in brain metastases except for small cell lung cancer.

## TUMOR ENTITIES

### 1. ASTROCYTIC TUMORS

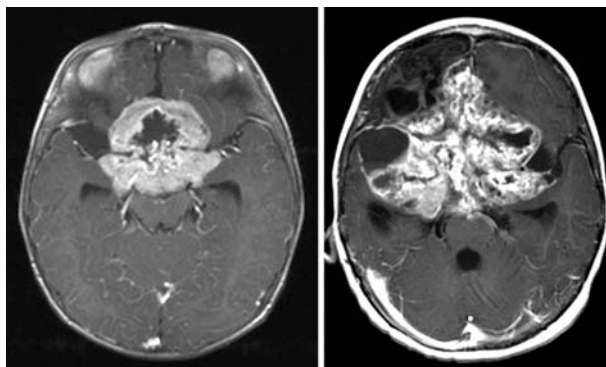
#### 1.1 Pilocytic astrocytomas (WHO grade I)

##### *Description*

This is a slow growing and mostly well circumscribed lesion of children and young adults accounting for 6% of all intracranial tumors. A preferred location is in the cerebellum. The other preferred region is the optic nerve or chiasm where tumors can become very large with brain stem compression but the tumors can well be hemispheric (Figs. 1 and 2). Histologically the most striking feature are so-called Rosenthal fibers, mitotic activity is low (MIB1 labeling <5%).

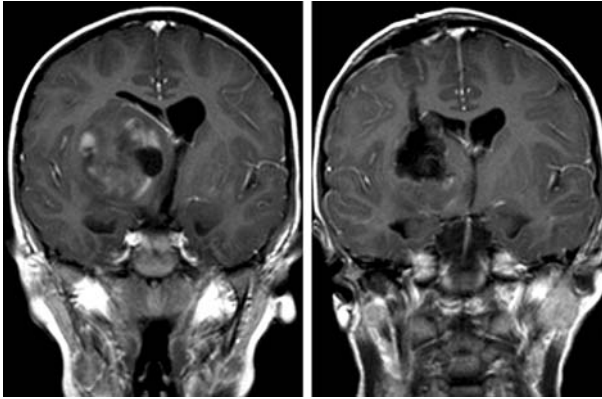
##### *Imaging*

On MRI imaging pilocytic astrocytomas tend to enhance after gadolinium and mostly a clear border to the surrounding brain tissue is seen, perifocal edema is rarely detectable. Cysts are a common feature. The variants of pilomyxoid astrocytoma or anaplastic pilocytic ependymoma show homogeneous contrast enhancement.



**Fig. 1.** Optic nerve glioma (pilocytic) diagnosed in the first years of life which was treated with chemotherapy and radiation with a long subsequent history of partial remissions and progression. The polycystic nature and the contrast enhancement are typical features





**Fig. 2.** Intrahemispheric pilocytic astrocytoma (*left*) which because of the well maintained borders was amenable to complete resection (*right*)

### *Treatment*

After complete resection the recurrence rate is low. These tumors defy the law of inevitable recurrence because they show almost no infiltration into the surrounding parenchyma. In case of tumor recurrence and subtotal resection or progression of inoperable tumors (Fig. 1) combined radiation/chemotherapy protocols for children exist and can be transferred for adults. Spontaneous regression of pilocytic astrocytomas has been observed.

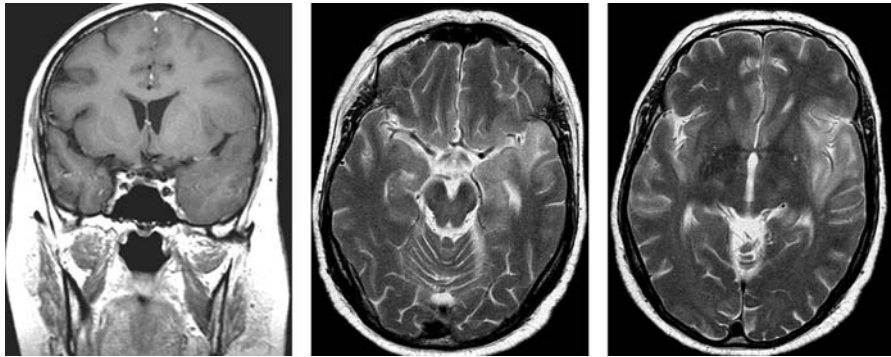
## 1.2 Diffuse astrocytoma (WHO grade II)

### *Description*

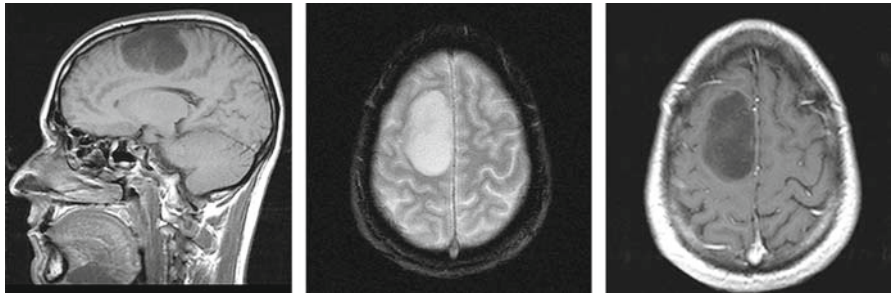
This entity is defined as a slow growing, well differentiated tumor with diffuse infiltration into the surrounding brain parenchyma. Five percent of CNS tumors are diffuse astrocytomas and the peak of the age distribution is between 30 and 40 years. Localized mainly in the cerebral hemispheres the predominant clinical signs are seizures. Histologically, the diffuse astrocytoma can be divided into a fibrillary type, a gemistocytic type and a protoplasmic type. Complete resection is by definition impossible due to the diffuse brain tissue invasion. Therefore the tumors tend to recur and have the potential for progression towards a more malignant grade during the clinical course. Progression is the cause of the only moderate prognosis of 5–7 years overall survival.

### *Imaging*

On MRI imaging no contrast enhancement is seen. There are two types of tumors which impress as a diffuse, poorly delineated change in intensity signal which is best seen in T2 weighted MRI or FLAIR images (Fig. 3) or lesion which in T1-weighted images are a mostly homogeneous hypointense mass,



**Fig. 3.** Very diffuse fronto-temporo-insular fibrillary astrocytoma with a history of intractable seizures. In T1 there is only a moderate mass effect in the left temporal lobe whereas the FLAIR images show the true extent of the tumor



**Fig. 4.** Right frontoprecentral lesion which was well delineated during surgery and could be removed en-bloc allowing complete histological workup resulting in the diagnosis of an astrocytoma WHO grade II

being hyperintense in T2 and FLAR-weighted images with apparently sharp borders (Fig. 4).

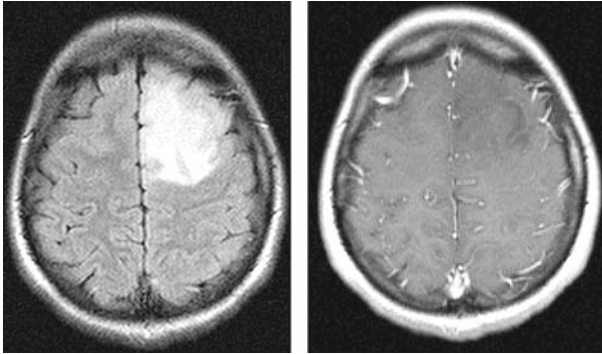
#### *Treatment*

Symptomatic and surgical accessible astrocytomas are resected as radically as possible and great efforts including intraoperative imaging, electrophysiological monitoring and awake craniotomies with functional mapping are made to increase the extent of resection which has been shown to be meaningful [9]. The value of adjuvant radiation therapy and chemotherapy is under debate.

### 1.3 Anaplastic astrocytoma (WHO grade III)

#### *Description*

Compared to grade II astrocytomas grade III tumors show a similarly diffuse infiltration of the surrounding tissue but with an increased cel-



**Fig. 5.** Left frontal anaplastic astrocytoma which has a strong signal intensity in the FLAIR (*left*) but has only very limited uptake of contrast in the T1 (*right*)

lularity, cellular atypia and a higher mitotic activity. Anaplastic astrocytomas account for 10 to 25% of all glial tumors with an incidence peak between 40 and 50 years. As with low grade astrocytomas the location is mainly in the cerebral hemispheres and clinical signs originate from the mass effect of the lesion depending on the proximity to eloquent areas or from seizures.

#### *Imaging*

On MRI imaging these tumors may show inhomogenities in native T1-weighted images and contrast enhancement after gadolinium application. Frequently however, these lesions are very similar to grade II astrocytomas in regular MRI (Fig. 5), are often found unsuspectedly postoperatively by histology and would only have been picked up with metabolic imaging, i.e. fluoro-ethyl tyrosine PET. Sometimes a pronounced edema can be detected in T2 and FLAIR weighted imaging and as such tumors show rapid recurrence, some of them are possibly already grade IV in regions not caught in the histological investigation. Histologically, the tumors show all signs of malignancy defined by the WHO (Table 1) like increased cellularity, nuclear atypia and a high mitotic activity but no microvascular proliferation and necrosis.

#### *Treatment*

The therapeutic approach is resection and radiation therapy often in combination with chemotherapy. Despite the absence of data from dedicated, randomized multicenter phase III trials anaplastic astrocytoma often are treated with a concomitant radiation therapy/chemotherapy protocol similar to glioblastomas [1]. The overall survival has been reported in the past to be between 2 and 3 years but with the survival times of glioblastoma extending, the new therapies will most likely lead to longer survival times

in the near future. There is an indication that for the initial adjuvant therapy one might select between chemotherapy and radiation with the same efficacy.

#### 1.4 Glioblastoma (WHO grade IV)

##### *Description*

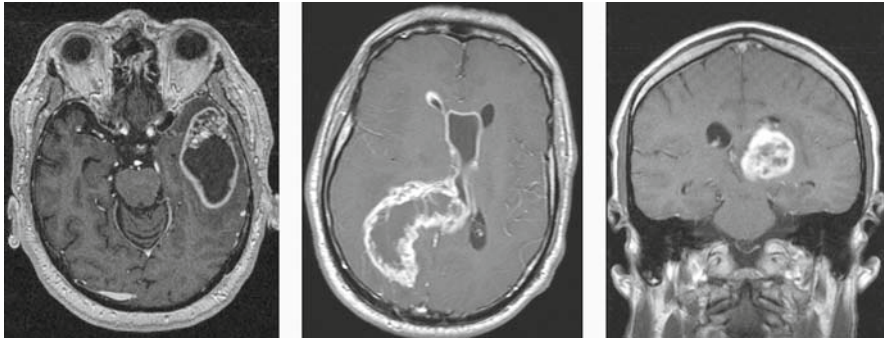
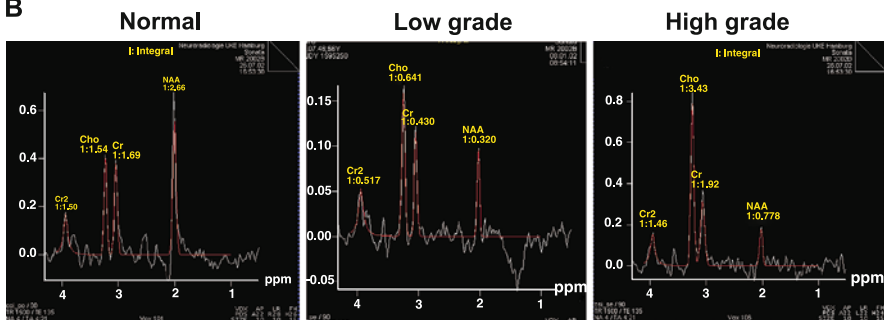
The glioblastoma is the most malignant glial tumor with an incidence of 10–15% of all intracranial masses and 50–60% of all glial tumors. The annual incidence is 5–7/100,000 population per year. Most glioblastomas develop de novo and are called primary glioblastoma. The development of a glioblastoma from an already existing astrocytoma is called secondary glioblastoma. Due to the fast growing tumor and the development of a profound perifocal edema often exceeding the tumor mass proper, the patient's history is short and clinical signs occur rapidly. The peak incidence lies between 50 and 70 years but glioblastoma can occur at any age. Macroscopically the tumors show areas of high cellularity and vascularisation and large necrotic areas giving the tumor the name glioblastoma multiforme. Histologically all characteristics of malignancy are found. A high mitotic activity, nuclear atypia and high cellularity are seen and per definition necrotic areas with pseudopalisading in close proximity to highly vascularised tissue areas are found.

##### *Imaging*

On MRI imaging typically for glioblastoma an irregular contrast enhancing rim surrounds a hypointense necrotic area on T1-weighted images. On T2- and FLAIR weighted images a perifocal edema can be seen often following white matter tracts and exceeding the tumor mass by size. Also in imaging the tumor is multiform (Fig. 6A). The malignant nature is reflected by the tumor's metabolism which can be characterised by MR spectroscopy and clearly shows the differences between low grade and high grade tumors (Fig. 6B).

##### *Treatment*

The therapeutic approach to glioblastoma should first be an attempt at macroscopical radical microsurgical resection [8]. If this cannot be accomplished due to the location of the tumor in close proximity to eloquent areas, a biopsy for histological diagnosis and confirmation is recommended, partial resections except when relieving immediately life threatening mass effect do not seem beneficial for patients. Only gross total resections seem to have an impact on overall survival. After surgery a combined radiation therapy/chemotherapy protocol has become the gold standard in the treatment of glioblastomas [11, 12]. Despite of this multidisciplinary treatment approach the overall prognosis of the patients remain poor with a median survival time of about 14 months.

**A****B**

**Fig. 6. A** Three images of glioblastoma with a large cyst mimicking abscess in the left temporal lobe (*left*), in the trigonal region with extensive subependymal spread (*middle*) and deep seated with no option for radical resection (*right*). The unifying characteristic is the rim of contrast enhancement. **B** Typical MR spectra from normal brain (*left*) a low grade glioma (*middle*) and a glioblastoma (*right*) showing the continuous diminishing of the NAA (N-acetyl aspartate) peak which is the indicator of neuronal integrity and the steady increase of the cholin peak as an indicator of increased membrane turnover (provided generously by Dr. Förster, Department of Neuroradiology, UKE)

## 2. OLIGODENDROGLIAL TUMORS

### 2.1 Oligodendroglioma (WHO grade II)

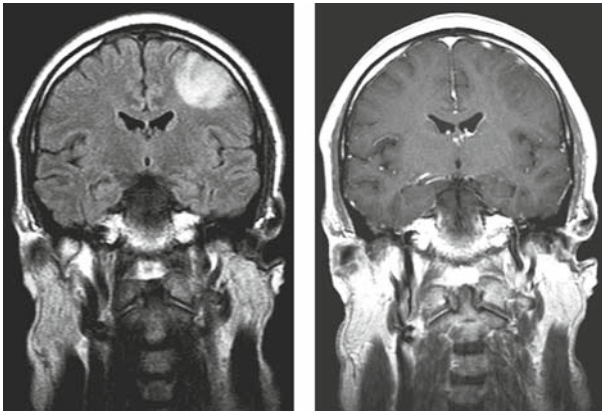
#### *Description*

Similar to low grade astrocytomas, oligodendrogliomas demonstrate a diffuse infiltration into the surrounding brain tissue. Localized mainly in the cerebral hemispheres with a predisposition for the frontal lobe the macroscopic appearance appears as a soft grayish-pink mass with occasional calcifications inside the tumor. 10–15% of all glial tumors are oligodendrogliomas with a peak incidence in the fifth decade. Two features are histologically typical for oligodendrogliomas, firstly microcalcifications can be found, secondly a so-called honey-

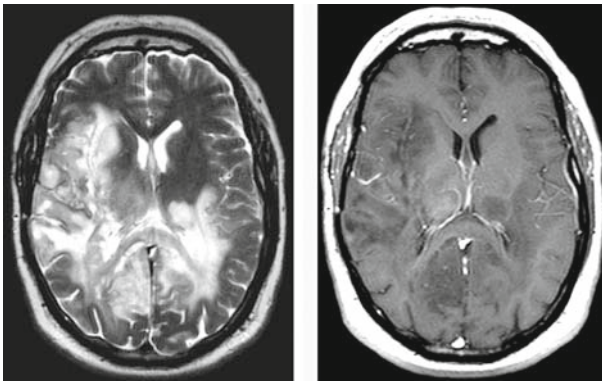
comb appearance is described. This phenomenon is an embedding and fixation artefact, as due to a swelling of the cells after formalin fixation this typical appearance occurs. The honeycomb feature is absent in frozen section specimens.

*Imaging*

Despite of the calcifications sometimes seen, oligodendrogliomas are in MRI imaging not distinguishable from astrocytic tumors and mimic low grade astrocytoma but can also have a very inhomogeneous appearance while invading throughout large parts of the brain (Figs. 7 and 8).



**Fig. 7.** Left frontal oligodendroglioma grade II which is undistinguishable from any other glioma by FLAIR or T1 weighted MR



**Fig. 8.** Histologically proven, extensively invasive oligodendroglioma with spread to the contralateral hemisphere and inhomogeneity due to the different brain region which are involved and also calcifications

### *Treatment*

Treatment of choice is surgical resection, the benefit of radiation therapy or chemotherapy is not clear so far although there are some reports that patients with low grade oligodendroglioma benefit from temozolamide. The true value of any therapy beyond resection will be resolved in trials which unfortunately will still need many more years before results are generated.

## 2.2 Anaplastic oligodendroglioma (WHO grade III)

### *Description*

About half of all oligodendrogliomas have either focal or diffuse signs of anaplasia and are graded as WHO III tumors. The incidence peak is between 45 and 50 years. Histologically the typical honeycomb appearance is maintained but anaplastic features intervene like necrosis, atypia and increased cellularity.

### *Imaging*

On MRI imaging differentiation between anaplastic astrocytoma and anaplastic oligodendroglioma is not reliably possible although there is a tendency for contrast enhancement. Again, as in the case of astrocytomas, MR spectroscopy or metabolic imaging has further discriminating capability.

### *Treatment*

After surgical resection anaplastic oligodendrogliomas are either treated by radiation therapy or chemotherapy, whereas chemotherapy is preferred in most centers (Procarbazine, CCNU and Vincristine (PCV) or temozolomide) [13].

- *Oligoastrocytomas and anaplastic Oligoastrocytomas also called mixed gliomas are treated like the astrocytic component*

## 3. EPENDYMAL TUMORS

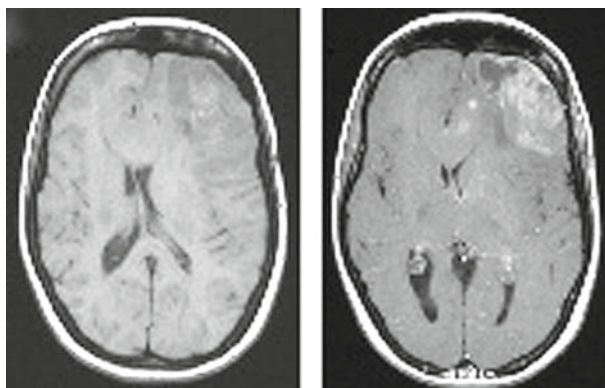
### 3.1 Subependymoma (WHO grade I)

#### *Description*

Subependymomas arise almost exclusively from the wall of the lateral ventricles in nodular shapes. They originate from the subependymal layer and might be considered a precursor cell type tumor. Histological features are a low cellular density and perivascular pseudorosettes. Mitosis and necrotic areas are per definition absent.

#### *Imaging*

These tumors are characterized on MRI imaging by a nodular appearance at the wall of the lateral ventricles with almost no contrast enhancement (Fig. 9).



**Fig. 9.** Left frontal anaplastic oligodendroglioma showing a pronounced mass effect and also diffuse contrast enhancement

Enlarged ventricles may occur due to occlusion of the CSF pathways, mostly due to occlusion of the foramen of Monro.

#### *Treatment*

In case of obstruction of CSF flow, resection of subependymomas is indicated. Resection of tumors in the lateral ventricles is performed either with microsurgical techniques via an anterior transcallosal or transcortical approach or endoscopically. There is no indication for any further therapy.

### 3.2 Myxopapillary Ependymoma (WHO grade I)

#### *Description*

This ependymoma subtype is usually located in the conus/cauda area, arises from the filum terminale and presents distinct histological characteristics like myxoid and pseudopapillary degeneration with deposition of mucinous extracellular material.

#### *Imaging*

On MRI imaging myxopapillary ependymomas are characterized by a homogeneous contrast enhancing mass in the conus/cauda area. For differential diagnosis schwannomas have to be considered.

#### *Treatment*

The treatment of choice is an attempt at a radical resection via a dorsal approach to the thoraco-lumbar or lumbar spine either by laminotomy or via a unilateral interlaminar window (spinal keyhole) depending on the size and lateralization of the ependymoma. Rarely the capsule cannot be resected completely due to adhesences to the fibers of the caudal nerve roots. In such cases recurrences may occur and adjuvant therapies such as radiation are advocated by some authors.



### 3.3 Ependymoma (WHO grade II)

#### *Description*

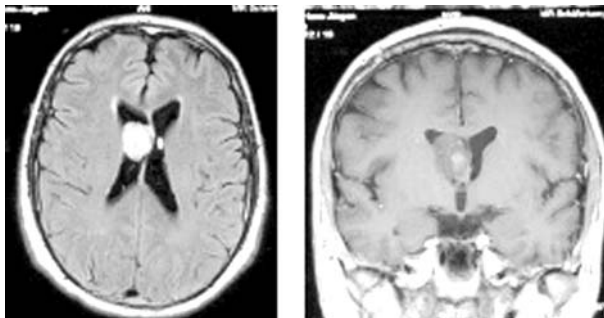
In general ependymomas arise typically along the ventricular system and the central canal. Every second tumor of the spinal cord is an ependymoma. In children most ependymomas arise infratentorially, in adults the infra- and supratentorial localisation are equally distributed. The histopathological hallmarks are so called pseudorosettes (perivascular tumor cells with extended fibrillary processes towards the vessel wall) and true ependymal rosettes consisting of a single layer of cuboidal tumor cells. According to the WHO classification four variants of grade II ependymoma exist: cellular ependymoma, papillary ependymoma, clear-cell ependymoma, tanyctic ependymoma but there does not seem a distinctive difference in the biology or clinical course.

#### *Imaging*

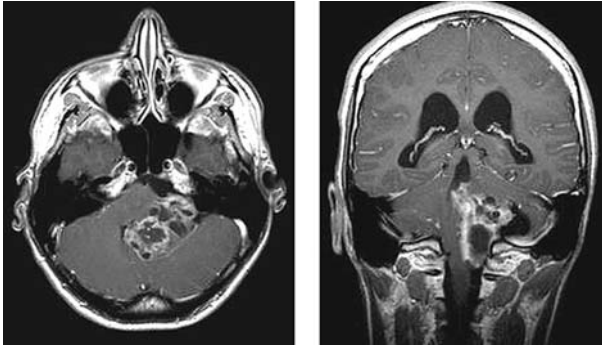
On MRI imaging these tumors demonstrate an inhomogeneous contrast enhancement and a well defined border to the adjacent brain tissue (Fig. 11). In the spinal cord, polar cysts are frequent and a syrinx far beyond the contrast enhancing tumor mass (Fig. 12). Ependymomas within the brain parenchyma are rare but even in these cases a relationship to the ventricular system can be suspected in most cases (Fig. 13). A perifocal edema around the tumor mass is not common.

#### *Treatment*

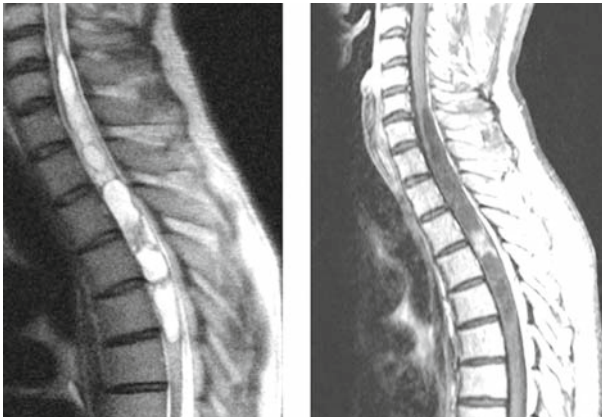
Treatment modality of choice is radical tumor resection. If substantial residual tumor is seen on post-op MRI and it appears resectable, a second operation has been advocated by some authors because the radicality of resection is the most relevant prognostic parameter. Any further therapies are undefined because there are no large series supporting a level 1 recommendation [7]. Radiation therapy is recommended in adults for recurrences with the evidence taken from inhomogeneous institutional series but not from any



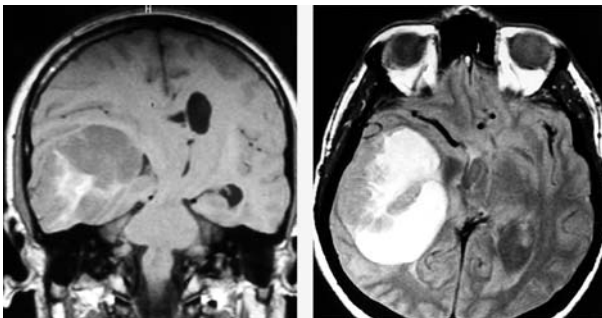
**Fig. 10.** Subependymoma of the right lateral ventricle arising from the septum pellucidum



**Fig. 11.** Typical extension of an ependymoma of the foramen of Luschke which has an inhomogeneous contrast enhancement but shows no signs of tissue reaction inside the fourth ventricle



**Fig. 12.** Typical intramedullary ependymoma with extensive involvement of the spinal cord but a rather circumscribed contrast enhancing portion representing the tumorous part



**Fig. 13.** Anaplastic ependymoma in an adult with intraparenchymal location but connection with the right temporal horn of the lateral ventricle

large scale randomised studies. Children are usually entered into protocols which are stratified by age and disease stage and may prescribe combination of radiation therapy and intense chemotherapy.

### 3.4 Anaplastic Ependymoma (WHO grade III)

#### *Description*

In anaplastic ependymomas the characteristic rosettes and pseudorosettes are often missing and the tumor shows a high mitotic activity, necrosis and microvascular proliferation.

#### *Imaging*

Differentiation between WHO grade II and grade III ependymomas on MRI imaging is not possible. Sometimes in grade III ependymomas the border towards the brain parenchyma is not well defined and perifocal edema is detectable on T2 and FLAIR sequences. In the supratentorial situation, the appearance may even be like a glioblastoma (Fig. 13).

#### *Treatment*

Similar to grade II ependymomas radical resection is the most crucial element of therapy. No standard protocols exist for adjuvant treatments in the adult population because of the complete absence of prospective, randomized studies. Mostly a combination of radiation therapy and chemotherapy is used by empirical rational. Radiation in newly diagnosed patients is restricted now to the local field and craniospinal radiation is reserved for patients with proven dissemination within the CSF space.

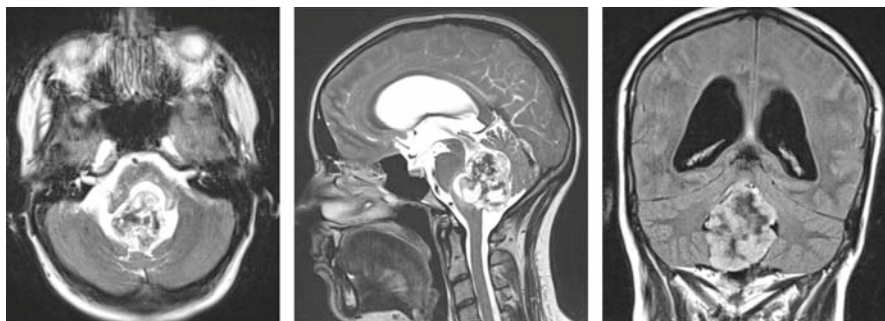## 4. TUMORS OF THE CHOROID PLEXUS

#### *Description*

Choroid plexus tumors arise inside the ventricles from the matrix of the choroid plexus. They are of neuroectodermal origin and are most frequent in children under 1 year of age where they account for over 10% of all intracranial tumors but in general account for less than 0.5% of all intracranial tumors. The majority of tumors are WHO grade I, the so called papillomas. In addition there are atypical plexus tumors (WHO grade II) and the very rare plexus carcinomas (WHO grade III).

#### *Imaging*

The regular plexus papillomas and also the atypical tumors are well circumscribed, occasionally “cauliflower” lesions within the ventricle, often in the fourth ventricle or around the trigonal region. Because of their slow growth and subsequent obstruction of CSF passage, either compartmental or triventricular, there may be pronounced accompanying hydrocephalus. Edema is uncommon as the displacement process is usually slow and the surrounding structures are not infiltrated (Fig. 14). The texture of the tumors is inhomogeneous.



**Fig. 14.** Large plexus papilloma of the fourth ventricle which became symptomatic during pregnancy but must have persisted for a long time as seen from the pronounced hydrocephalus

geneous, microcystic with regular contrast enhancement. As these tumors are frequently calcified, hyperdense structures may be seen in CT.

#### *Treatment*

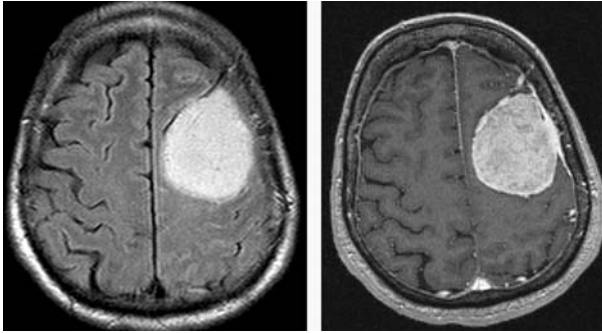
As most tumors are grade I and II they will be resected. Radical resection is usually possible but the patients still need to be followed for several years because recurrences are possible. For obstructive hydrocephalus there may be the necessity for a third ventriculostomy, and if the hydrocephalus has a malresorptive component due to long-standing protein secretion from the tumor and impaired CSF resorption, permanent shunting may be necessary. Also for plexus carcinoma the initial stage of treatment is resection with then added radiotherapy of which the efficacy is still a matter of debate. Follow-up is warranted in short intervals of six months at most and in cases of recurrence, resection is often the only option. Children are often treated more aggressively in multinational protocols.

## **5. MENINGIOMAS**

### **5.1 Benign meningioma (WHO grade I)**

#### *Description*

In general meningiomas are slow growing benign tumors arising from arachnoidal cap cells in the dura mater. The annual incidence of meningiomas is approximately 6/100,000 per year and the tumor develops preferentially in the elderly patient group between 50 and 70 years. Women are almost twice as often affected than men. Since meningiomas arise from the dura mater they are mostly seen over the cerebral convexity/falx, the skull base and in the spinal canal. Intraventricular meningiomas are rare and are supposed to arise from meningotheelial cells in the choroid plexus. Due to the slow growing biology of the tumor. Meningiomas can grow to enormous sizes before leading to clinical



**Fig. 15.** Large typical convexity meningeoma in the left fronto-precentral region. Presenting with only one initial seizure. There is no surrounding edema and a homogeneous contrast enhancement

symptoms even in eloquent areas (Fig. 15). Meningiomas at the skull base in contrast are often responsible for cranial nerve deficits even when small in size. Macroscopically meningeomas are of solid consistence with broad attachment to the dura and a border to the adjacent brain. Meningiomas tend to invade the dura and occasionally also the overlying skull, leading to thickening of the bone tissue. The border to the brain is sharp but in most cases, the arachnoid plane is not completely respected but infiltrated resulting in surface injury to the brain while dissecting the tumor out of its bed. Histopathologically benign meningeomas can be divided into 9 variants (meningothelial, fibrous, transitional, psammomatous, angiomatous, microcystic, secretory, lymphoplasmacyte-rich, metaplastic). They show low mitotic activity and a variable syncytial growth in sheets and lobules surrounded by stromal septation.

#### *Imaging*

On MRI imaging the striking feature of meningeomas are the homogeneous contrast enhancement after gadolinium injection except for cases with intense calcification. The dura adjacent to the meningeoma attachment enhances often up to a distance of 2 cm (“dura tail sign”), often not representing tumor but vascular proliferation as a direct response to the tumor. The surrounding brain parenchyma is displaced and when the arachnoid coverings are infiltrated there may be edema which can also be present due to venous compression and subsequent congestion. Sometimes, in particular in the secretory variant or due to significant venous obstruction, a profound perifocal edema visible in T2 and FLAIR sequences is present. On CT intratumoral calcifications and thickening of the adjacent skull is detectable.

#### *Treatment*

Treatment of choice for meningeomas is radical resection with excision of the origin resulting in tumor free dural edges. The extent of resection is

classified according to the Simpson grade I (complete) to IV (biopsy). Unfortunately radical resection is typical mostly for convexity meningiomas whereas in other locations it is more difficult and replaced by charring the origins. Often the dural attachment can only be treated by coagulation and in particular at the skull base meningioma remnants may have to be left due to attachment to cranial nerves and other vital structures. For residual tumor tissue or recurrent tumor radiosurgery (gamma knife, cyber knife, LINAC) is currently widely used especially when after an observation period, progression can be seen. There is however no class 1 evidence to support such strategy [5]. There does not seem to be any justification for medical therapies, especially as there are no proven effective agents.

## 5.2 Atypical meningioma (WHO grade II)

### *Description*

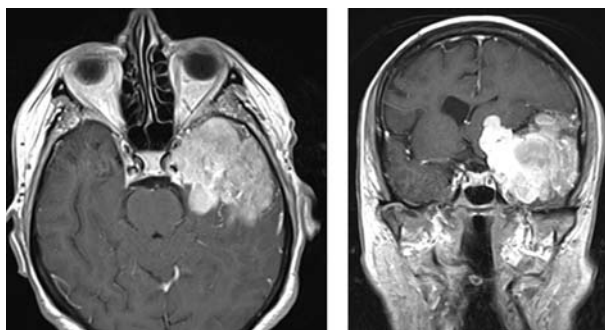
An atypical meningioma is defined using the following histological criteria: increased rate of mitosis, increased cellularity, prominent nucleoli, foci of necrosis. Clinically these tumors are associated with a higher rate of local recurrence.

### *Imaging*

With conventional MRI sequences without metabolic imaging it is not possible to distinguish between grade I and grade II meningiomas (Fig. 16).

### *Treatment*

The treatment regimen for grade II meningiomas basically does not differ from the treatment of grade I meningiomas. The initial treatment attempt has to be radical tumor resection. Since the recurrence rate, however, is higher than with grade I meningiomas the intervals for follow-up MRI scans are



**Fig. 16.** Left temporal meningioma with pronounced mass effect. This inhomogeneous tumor turned out to be an atypical meningioma

initially shorter (usually 3 to 6 months for the first two years). Recurrences are treated aggressively with repeated resections when possible and subsequent radiation therapy.

### 5.3 Malignant meningioma (WHO grade III)

#### *Description*

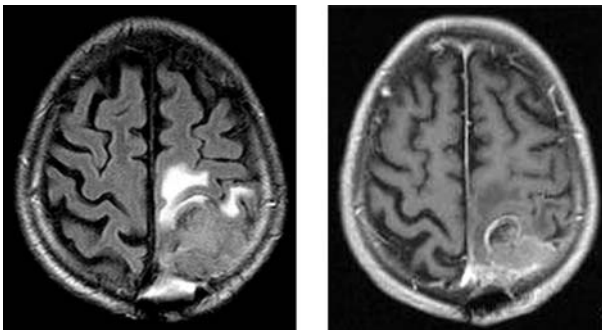
Primary anaplastic meningiomas are rare but with repeated recurrences, even well differentiated WHO grade I meningiomas can genetically progress to grade II and then III. Histologically the malignant meningiomas can be divided into three subtypes: anaplastic, rhabdoid and papillary. Clinically these tumors behave in an aggressive fashion with invasive and destructive growth towards neighbouring structures type and regular recurrence within a short time. They can metastasize, preferably to the lungs.

#### *Imaging*

On MRI and CT scan grade III meningiomas can show a destructive growth pattern with infiltration of the skull and sometimes the overlying soft tissue (temporal muscle, galea) leading to a profound contrast enhancement of this area. In addition, there is always a pronounced cerebral edema on T2 and FLAIR sequences (Fig. 17). As a rule there does not seem to be an arachnoidal cleavage plain so “fuzzy edges” are a neuroradiological characteristic.

#### *Treatment*

Despite radical surgical strategies a grade III meningioma is only rarely curable. In addition to aggressive surgery, radiation therapy is regularly used and then experimental therapy based on somatostatin receptors found on meningiomas, anti-progestins and any chemotherapy which is used for cancer and leukemias. Even with these adjuvant therapies the mean survival rates are similar to a glioblastoma.



**Fig. 17.** Recurrent anaplastic meningioma which evolved from an atypical meningioma after reoperation and radiation

## 6. METASTASES

### *Description*

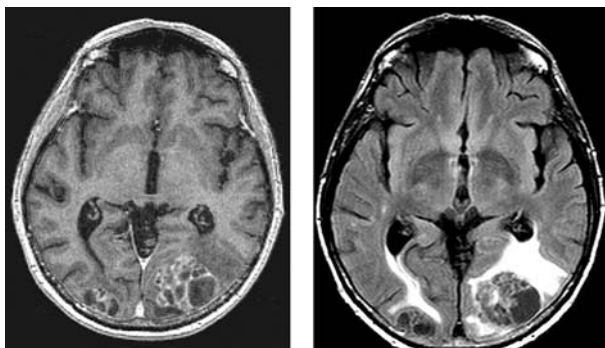
Overall metastases are the most common tumor of the central nervous system.

Metastatic spread of tumor cells detached from systemic tumors into the central nervous system occurs via the circulation. Little is known about the precise mechanisms of tumor cell attachment (seeding) in the brain and subsequent local progression of micrometastasis into clinically symptomatic tumors. Different tumor entities have a highly variable tendency to metastasize into the brain, independently of their incidence. Therefore the relative incidence of intracerebral metastases does not correlate with the systemic incidence of tumors. 25–30% of patients suffering from a metastatic cancer also develop cerebral metastasis. Most cerebral metastasis arise from lung cancer (approx. 40%) followed by breast cancer with 10–40% depending on the published series followed by malignant melanoma with 10–25% followed by tumors of gastro-intestinal tract and uro-genital tract except prostate cancer. In general every solid tumor is able to spread into the central nervous system. In 10–20% of patients no primary tumor is known at the time of diagnosis of a brain metastasis (metastasis of unknown primary).

In general no specific signs or symptoms of cerebral metastasis exist. The symptoms depend on size, location and degree of perifocal edema like in other benign or malignant intracranial tumors.

### *Imaging*

Sensitive sequences like FLAIR and T1 with contrast enhancement by gadolinium are mandatory to detect even small metastases or meningeal enhancement. CT is not enough and even when CT shows a clear lesion. An MRI is mandatory because multiplicity is common (Fig. 18) and small lesions may



**Fig. 18.** Bilateral occipital metastases of a colon carcinoma which could be removed without compromising the visual fields



not be picked up in CT while clearly impacting the clinical decision making. Even small metastases often produce a perifocal edema, therefore edema sensitive MRI sequences are often more helpful in small metastasis detection than T1-contrast enhanced sequences. The morphological appearance of brain metastasis is very heterogeneous. Even metastases with a diameter of 2–3 cm may be completely solid without signs of central necrosis, while on the other hand small metastasis may appear as a round structure with a gadolinium enhanced rim and central necrosis/low intensity reminiscent of brain abscess. In general, appearance of multiple lesions is highly suspicious of cerebral metastases, as differential diagnosis multifocal gliomas, multifocal lymphomas or abscesses have to be considered. For singular lesions differential diagnosis is malignant glioma or abscess.

### *Treatment*

The therapy of brain metastasis is complex and an interdisciplinary approach where a close cooperation between neurosurgeon, oncologist/neuro-oncologist and radiation oncologist is needed. Theoretically with a combined approach of surgery and radiation therapies, a tumor control over a prolonged time is possible, but due to systemic metastasis the major proportion of patients will die within one year from extracranial progression of their tumor. Therefore in order to begin with an aggressive therapy of cerebral metastasis the following criteria have to be taken into account: control of systemic tumor disease, life expectancy greater than 3 months in case of asymptomatic brain metastasis and a Karnofsky score higher than 60, in case of symptomatic brain metastases an expected improvement of the Karnofsky score up to 60 with a operation.

## **CONCLUSIONS**

Classification of brain tumors according to the WHO system has become accepted throughout the world. Despite of some incongruences the WHO grading system correlates well with the clinical situation and according to the system therapeutic decision are made and are generally accepted and can be systematically evaluated

The therapy of brain tumors is based onto three pillars, surgery, radiation therapy and systemic chemotherapy.

So far the role of local therapy options or targeted therapies according to the genetic make-up of a tumor have not been effective throughout the various histologies.

### **Acknowledgement**


This chapter owes much of its data assembly to Priv.-Doz. O. Heese who is an attending neurosurgeon in the Department of Neurosurgery in Hamburg

Eppendorf. He went to medical school in Lübeck where he also started his residency which was completed in Hamburg. His major research interest is in experimental neuro-oncology and clinical management of meningiomas.

## References

- [1] Chamberlain MC, Chowdhary SA, Glantz MJ (2008) Anaplastic astrocytomas: biology and treatment. *Expert Rev Neurother* 8: 575-586
- [2] Hegi ME, Diserens AC, Gorlia T, Hamou MF, de Tribolet N, Weller M, Kros JM, Hainfellner JA, Mason W, Mariani L, Bromberg JE, Hau P, Mirimanoff RO, Cairncross JG, Janzer RC, Stupp R (2005) MGMT gene silencing and benefit from temozolomide in glioblastoma. *N Engl J Med* 352: 997-1003
- [3] Kleihues P, Louis DN, Scheithauer BW, Rorke LB, Reifenberger G, Burger PC, Cavenee WK (2002) The WHO classification of tumors of the nervous system. *J Neuropathol Exp Neurol* 61: 215-225; discussion 226-219
- [4] Louis DN, Ohgaki H, Wiestler OD, Cavenee WK, Burger PC, Jouvet A, Scheithauer BW, Kleihues P (2007) The 2007 WHO classification of tumors of the central nervous system. *Acta Neuropathol* 114: 97-109
- [5] Marcus HJ, Price SJ, Wilby M, Santarius T, Kirillos RW (2008) Radiotherapy as an adjuvant in the management of intracranial meningiomas: are we practising evidence-based medicine? *Br J Neurosurg* 22: 520-528
- [6] Reifenberger G, Louis DN (2003) Oligodendroglioma: toward molecular definitions in diagnostic neuro-oncology. *J Neuropathol Exp Neurol* 62: 111-126
- [7] Reni M, Brandes AA (2002) Current management and prognostic factors for adult ependymoma. *Expert Rev Anticancer Ther* 2: 537-545
- [8] Ryken TC, Frankel B, Julien T, Olson JJ (2008) Surgical management of newly diagnosed glioblastoma in adults: role of cytoreductive surgery. *J Neurooncol* 89: 271-286
- [9] Smith JS, Chang EF, Lamborn KR, Chang SM, Prados MD, Cha S, Tihan T, Vandenberg S, McDermott MW, Berger MS (2008) Role of extent of resection in the long-term outcome of low-grade hemispheric gliomas. *J Clin Oncol* 26: 1338-1345
- [10] Stummer W, Reulen HJ, Meinel T, Pichlmeier U, Schumacher W, Tonn JC, Rohde V, Opper F, Turowski B, Woiciechowsky C, Franz K, Pietsch T (2008) Extent of resection and survival in glioblastoma multiforme: identification of and adjustment for bias. *Neurosurgery* 62: 564-576; discussion 564-576
- [11] Stupp R, Mason WP, van den Bent MJ, Weller M, Fisher B, Taphoorn MJ, Belanger K, Brandes AA, Marosi C, Bogdahn U, Curschmann J, Janzer RC, Ludwin SK,

- Gorlia T, Allgeier A, Lacombe D, Cairncross JG, Eisenhauer E, Mirimanoff RO (2005) Radiotherapy plus concomitant and adjuvant temozolomide for glioblastoma. *N Engl J Med* 352: 987-996
- [12] Stupp R, Roila F (2008) Malignant glioma: ESMO clinical recommendations for diagnosis, treatment and follow-up. *Ann Oncol* 19(Suppl 2): ii83-ii85
- [13] Van den Bent MJ, Reni M, Gatta G, Vecht C (2008) Oligodendroglioma. *Crit Rev Oncol Hematol* 66: 262-272
- [14] Walker MD, Alexander E Jr, Hunt WE, MacCarty CS, Mahaley MS Jr, Mealey J Jr, Norrell HA, Owens G, Ransohoff J, Wilson CB, Gehan EA, Strike TA (1978) Evaluation of BCNU and/or radiotherapy in the treatment of anaplastic gliomas. A cooperative clinical trial. *J Neurosurg* 49: 333-343



### **Manfred Westphal**

Manfred Westphal is Chair of Neurosurgery at the University Medical Center in Hamburg, Germany. He was born and raised in Hamburg. As a scholar of the German National Scholarship Foundation he went to medical school in Hamburg and Glasgow. And afterwards from 1982 to 1984 to San Francisco as a postdoctoral research fellow in the Hormone Research Laboratory (Choh Hao Li) at UCSF supported by a fellowship of the Deutsche Forschungsgemeinschaft (DFG). In 1984 he founded the Laboratory for Brain Tumor Biology in the Department of Neurosurgery at the University Medical School Hamburg Eppendorf, thereafter completed neurosurgical residency and became acting chairman in 1999. Revoking an offer to become chair of neurosurgery at the Medical University in Düsseldorf, he became permanent chair in Hamburg. He has served as the secretary of the EANS, two term chairman of the Committee for Neurooncology of the EANS, is a two term member of the neurosciences review panel of the DFG and presently the secretary general of the European Brain Council in Brussels.

**Contact:** Manfred Westphal, Department of Neurosurgery, University Medical Center Hamburg-Eppendorf, Martinistr. 52, 20246 Hamburg, Germany  
E-mail: westphal@uke.uni-hamburg.de

---

# **STEREOTACTIC BIOPSIES FOR TUMORS: INDICATIONS, LIMITS, DIAGNOSIS WITH HISTOPATHOLOGY AND OTHER LABORATORY TECHNIQUES**

D. G. T. THOMAS

## **INTRODUCTION**

The concept of stereotactic neurosurgery was introduced by Horsley and Clarke [4] on an experimental basis to explore the primate brain in 1905. This technology was adapted to the human brain by Spiegel and Wycis in 1947 [13] and subsequently stereotactic neurosurgical techniques have been applied not only for examination in the treatment for movement disorders and of chronic pain syndromes, but also in the management of brain tumors. With the development of CT scanning in the 1970s and of MRI scanning in the 1980s the use of stereotactic brain biopsy increasingly became widespread and was found to improve diagnostic yield of histological diagnosis with low morbidity and mortality, even in deep seated and highly eloquent areas.

## **RATIONALE**

The major indication for stereotactic biopsy of cerebral mass lesions, where the differential diagnosis is of brain tumor, is to obtain material for the purpose of pathological diagnosis, and on occasion additionally to aspirate fluid from a cyst or abscess cavity.

Improvements in stereotactic instrumentation have lead to a large number of satisfactory CT and MRI frame based systems being available commercially which provide accuracy of target localisation, with simplicity of use and versatility in performing biopsy within the intracranial volume.

Despite improvements in imaging techniques, including introduction of PET scanning as well as MR techniques including sophisticated imaging of diffusion as well as MR spectroscopy, there remains a need to achieve a tissue diagnosis to inform the neurosurgeon and oncologist as to what is the precise tumor type and grade in a particular case. Where the mass lesion is likely to be due to infection laboratory studies will inform the decisions made by the specialist in infectious diseases about choice of therapy.

---

*Keywords:* tumors, neurooncology, stereotactic biopsy, stereotaxy

Nevertheless, the relative indications for stereotactic biopsy do change over time. For example, in the author's experience increasingly more efforts are made to excise intrinsic brain tumors even in eloquent brain areas than before.

## **DECISION MAKING**

### **1. DIAGNOSTIC CRITERIA AND INDICATIONS**

#### **1.1 Adults**

Intrinsic brain tumors, either primary or secondary in adults may present with a wide range of symptoms, which however tend typically of one or more of: (i) epilepsy of late onset, (ii) focal neurological symptoms, for example hemiparesis or hemianopia, (iii) generalised neurological symptoms, for example personality change or intellectual failure or (iv) with raised intracranial pressure, involving headache, vomiting and papilloedema with visual failure.

Because of the relative abundance of CT and MRI scanning facilities in the developed world most patients with one or more of these features will have a brain scan and a lesion will be diagnosed. In some environments infective lesions, like tuberculoma, remain common, and often the differential diagnosis of tumor will remain even after scanning. In specific risk groups, for example chronic ear disease, valvular heart disease, immunosuppression, or HIV infection a predisposition to an infective brain lesion has to be considered.

In patients with a known primary malignant tumor not only single, but sometimes multiple, brain lesions may turn out not to be metastatic and brain biopsy has to be considered on an individual basis.

In general, if the patient's general condition permits, and where excision appears not to threaten eloquent brain areas an open operation with craniotomy and tumor resection will be the preferred recommendation, rather than biopsy. However, the prognostic value of histopathology from stereotactic biopsy is well established [10].

In other cases, for example with a single presumed fit associated with a low grade glioma the optimum management may require not only the most informed neurosurgical advice at a technical level about the degree of risk from surgery but also counselling of the patient about a "wait and see" management with appropriate serial brain scanning and follow up.

#### **1.2 Children**

Intrinsic brain tumors in children are most commonly found in the posterior fossa either in the cerebellum or brain stem. Generally, the neurosurgical treatment will involve resection, where possible totally. It is technically possible to biopsy brain stem lesions in infants and children and the diagnostic yield of altered diagnosis can be important [11]. In the relatively uncommon

supratentorial lesions in children stereotactic brain biopsy can be done; if necessary the infant skull can be reinforced with orthopaedic plaster if pin fixation of the stereotactic frame is required.

## 2. MULTIDISCIPLINARY NEUROONCOLOGY TEAM

It is good practice except in unusual circumstances – for example emergency deterioration, that not only the neurosurgeon but other specialist colleagues including the neuroradiologist, neuropathologist, neurologist and neuro-oncologist have discussed a management plan of the case before a stereotactic biopsy is performed. This may be done best in weekly planning meetings but where this is not possible standard local protocols for management should be formulated and agreed.

The purpose of this is to optimise the opinion about the most likely diagnosis prior to surgery, and to agree what will be the post-operative plan of management which may include adjuvant treatment. At a technical level neuroradiology and neuropathology input will generally help the surgeon to determine which specific areas of tumor are to be targeted.

## SURGERY

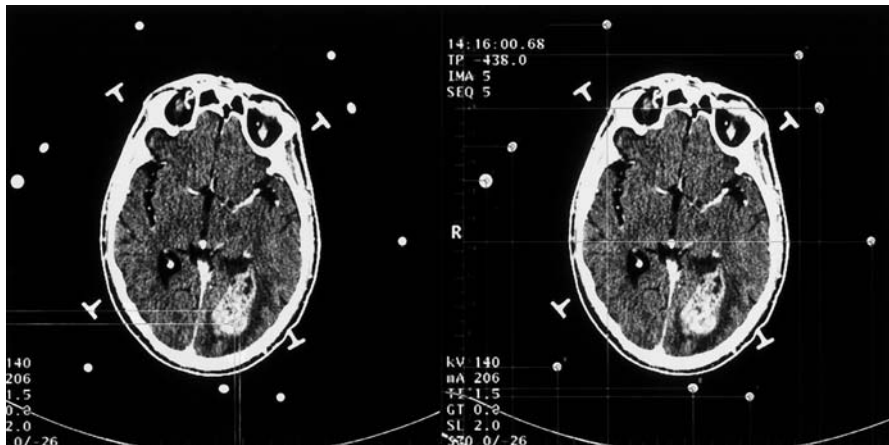
The author will describe and illustrate the stereotactic brain biopsy technique using the Cosman–Roberts–Wells (CRW) Stereotactic System [9]. Although there are several other excellent systems available his experience is with this frame and the previous Brown–Roberts–Wells (BRW) system.

The CRW is a target centred arc design based on the Cartesian (anteroposterior, lateral and vertical movement) principle. The arc-radius design has the advantage of allowing an infinite number of predetermined entry points, allowing for a given target. There is also the capacity to approach multiple targets through the same entry point. In general, with stereotactic biopsy it is possible to biopsy, for example, the periphery and the centre, through the same entry point. It is also possible to adjust to avoid known hazardous areas, like, for example, by avoiding the Sylvian fissure by a lateral approach through the temporal lobe rather than a transfrontal route for a medial temporal lesion.

### 1. INSTRUMENTATION

#### 1.1 Head ring assembly

- (1) The base ring consists of a base ring affixed to the skull at four points by four head ring posts through which, under local or general anaesthesia, are advanced four metal tipped head ring screws which are screwed in by hand with a screwdriver so as to pierce the scalp and fix firmly on the outer table of the skull.



**Fig. 1.** Axial CT brain scans with the CT localiser unit in place. On the right side the 9 carbon fibre rods, including the single large one, are visualised and digitised. On the left side two planned biopsy target sites in the occipital lesion have been digitised

- (2) An alternative, non-invasively relocatable head ring system is the G-T-C (Gill-Thomas-Cosman) unit, which is based for repeat location on a dental mould of the patient's upper teeth (or edentulous jaw). This permits accurate serial application of the head ring and can be employed for serial biopsy, if necessary with different imaging modalities.

### 1.2 CT localising unit

This consists of six vertical and three diagonal carbon fibre rods attached to two metal plates. Axial CT through the localising ring gives the two-dimensional position of the nine fiducial points which are used for calculation of an intracerebral target's position in that plane (Fig. 1).

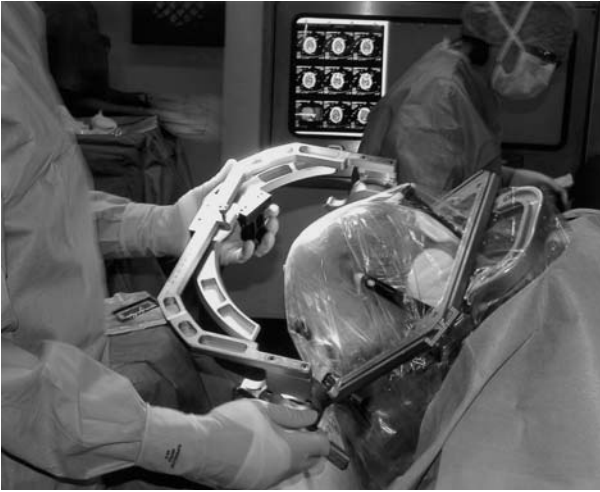### 1.3 MRI localising unit

A similar construct of carbon fibre rods, which generates fiducials in the axial plane, 6 in the sagittal plane and 7 in the coronal plane are used in MRI directed biopsy.

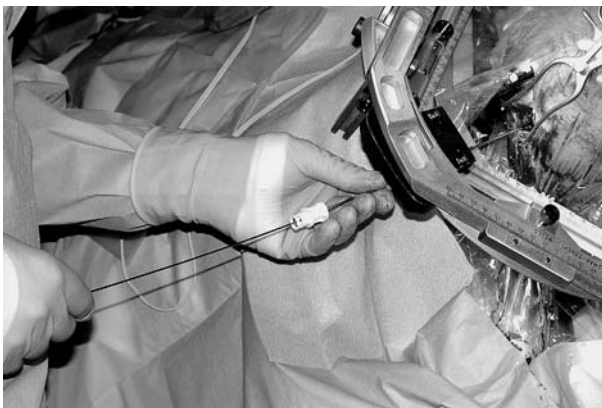
### 1.4 CRW arc system

This metal arc attaches to the base ring and anteroposterior, lateral and vertical co-ordinates are set, to a 0.1 mm precision. The distance from the upper surface of the guide block carrier to the centre of the arc is 160 mm so that a biopsy cannula set in the guideblock to this depth comes to the calculated target (Figs. 2, 3).





**Fig. 2.** The CRW arc has been applied to the head ring assembly, which is rigidly mounted on the head by fixation screws, which are visible under the sterile drapes



**Fig. 3.** A biopsy cannula is being advanced into the brain controlled by the guide block and through a twist drill opening in the skull

### 1.5 Phantom base

This consists of a phantom base ring with a movable phantom target (which can be sterilised), all fabricated of metal. This can be used to check the accuracy of the setting of the CRW arc before it is applied to the base ring during surgery.

## 1.6 CRW software

Specialist software is provided to calculate the three dimensional target co-ordinates from the two dimensional co-ordinates on the CT axial scan or from the axial, sagittal or coronal MRI Scans.

## 2. PATIENT PREPARATION

The procedure may be done under local anaesthetic, infiltrated into the scalp at the sites where the skull fixation and skull opening takes place, or alternatively under general anaesthetic. Either type of anaesthetic is satisfactory and the choice may often depend on patient preference, the neurosurgeon's normal practice as well as the organisation of the operating schedule. Even when local anaesthesia is used a neuroanaesthetist should be present to assist with sedation if necessary or, as rarely needed, conversion of the procedure to a general anaesthetic.

Frequently, pre-operatively patients with presumed brain tumors awaiting stereotactic brain biopsy will have been started on glucocorticoid steroids for cerebral oedema and also sometimes on anti-convulsant medication for epilepsy, and these drugs should be continued. If a brain abscess is suspected biopsy and aspiration before antibiotics have started probably increase the chances of identifying the causative organism in the laboratory. However, if the patient is in poor condition or there is to be any delay in operation it may be necessary to start antibiotics and steroids prior to biopsy.

## 3. APPLICATION OF BASE RING

Prior to application of the base ring it is essential to review the radiology and in particular to be sure that the base ring will lie below the lesion. However, it is also important not to overestimate and place the base ring so low that there is a risk of the arc snagging against the vault of the skull. It is also important at this stage to decide approximately where the entry point will be. Thus, for most frontal or parietal entry points a standard position of the head without rotation and with 15–20° of flexion is usually suitable, with the base ring applied with the AP centre line of the ring itself in line with the nose and occiput, without tilt. However, with a lateral approach, for example, a right temporal entry, may well require some tilt down on the right. An occipital entry may be done best with the patient prone on the operating table and the anterior part of the base ring lined up with the occiput.

Whatever the adjustments made usually the base ring can be applied with the patient supine. It is important that there is rigid fixation of the base ring to the skull and that is checked by the neurosurgeon lifting the head with one hand and with the other holding the base ring making sure there is no movement. In cases of MRI directed biopsy it is also wise to check with a hand held magnet that non-magnetic pins have been used for fixation. If the patient is under general anaesthetic the anaesthetist should be asked to confirm there is

not an armoured endotracheal tube in use, because the metal contained in such a tube can deform the MRI Scan linearity.

#### 4. DATA ACQUISITION

The patient is transferred to the CT or MRI scan, where the Localising Unit is attached to the base ring, and moved into position on the bed of the scanner. The localisers of the CRW stereotactic system have been designed to be scanner independent and it is not necessary to make a rigid connection between the base ring and the scanner. In discussion with the neuroradiologist it will be decided whether or not contrast enhancement is required to highlight features of the mass lesion to be biopsied as well as the position of blood vessels.

The accuracy of the localiser in determining target co-ordinates is directly related to scan slice thickness. Usually for CT directed biopsy slices of 1–5 mm thickness separated by 5 mm are adequate, but sometimes closer slice separation with reconstruction to help clarify lesion shape will be helpful.

In the case of MRI directed biopsy with this system scan data is usually obtained in the medium body mode, in axial, sagittal and coronal planes with T1 and T2 sequences. The scan points representing the fiducials are digitised in 2 dimensions using the CT or MRI can cursor. In the CT (Fig. 1) one of the 9 carbon fibre rods is larger than the other eight, and moving in a clockwise fashion the other rods are digitised. The biopsy target, or more frequently multiple (typically 2–5) targets are digitised in a similar way (Fig. 1). In the MRI localiser in each plane one of the localising rods has a dense centre and localisation is done in sequence for the remaining rods.

#### 5. DATA PROCESSING

The data entry of the CT or MRI Scan specified fiducials and target points, which is the form of 2 dimensional X and Y co-ordinates in the various scan planes, is entered into a pre-programmed computer (which may take the form of proprietary software in a laptop or PC, or a dedicated pre-programmed calculator): the calculations are made and a hard copy printed out.

#### 6. THE BIOPSY PROCEDURE

- i) The patient is transferred to the operating theatre and positioned as appropriate, usually supine with slight neck flexion and 15° head up tilt of the operating table. Alternatively, as discussed, it may be appropriate to position the patient in a lateral position or even prone, so that the biopsy entry site is uppermost.
- ii) The next essential step is to fix the stereotactic base ring by two tapered screws, which are part of the stereotactic system, to a standard Mayfield head holder adapter. Thus, the head can be fixed rigid-

ly in a comfortable position. In the prone position the two tapered screws are inserted on the anterior part of the base ring, and in the lateral position they are inserted into the appropriate lateral part of the base ring, on the side opposite to the proposed biopsy entry site. These arrangements permit rigid fixation of the head.

The patient's body, whether under local or general anaesthesia needs to be in a comfortable position on the operating theatre if necessary with knees and hips flexed to some degree.


- iii) The scalp is prepared and draped according to the usual method of the neurosurgeon. Also according to the practice of the surgeon hair may be shaved appropriately. The head and base ring may then be covered by a sterile transparent drape, supplemented by other surgical drapes as necessary to accommodate surgeon, assistant, scrub nurse as well as suction and diathermy, usually both bipolar and monopolar (Fig. 2).
- iv) Usually the neurosurgeon will have had in mind, before commencing the procedure, the probable route of the biopsy track. Thus, eloquent cortical areas such as the motor, speech, visual and sensory cortical areas should be avoided. It is also advisable to avoid crossing the Sylvian fissure with the biopsy track, because of the risk of bleeding. In general it is least invasive to stay within brain rather than crossing the deep sub-arachnoid spaces because of the risk of haemorrhage. Thus, the preferred route for the stereotactic biopsy of the brain stem is through an entry route just anterior to the coronal suture, close to the midline but not interfering with the sagittal sinus or large veins draining into it. The biopsy cannula can then pass along a trajectory entirely through the brain to the brain stem without crossing the sub-arachnoid space, and avoiding possible obstruction by the tentorium at the tentorial hiatus.

In general it is possible to avoid entry sites in the forehead which has a cosmetic benefit.

- v) The opening in the skull may be made with a 2.5 mm diameter twist drill, a 6 mm twist drill or by a conventional burr. Each has its advantages and disadvantages.

The first requires only a small scalp incision, however the dura is not visualised and occasionally significant bleeding from pial vessels can occur. It is also difficult to alter the angle trajectory of the biopsy through the 2.5 mm opening in the skull and sometimes extension of the scalp incision and widening of the bony opening with rongeurs to allow angulation is necessary.

The second requires a relatively small scalp incision and the bony opening is large enough to allow the dura to be opened under direct vision so that if necessary small veins or pial vessels may



**Fig. 4.** Detail of the inner tube of the biopsy cannula (Sedan-Nashold) from which a biopsy core has been extracted and placed on moistened card

be coagulated with bipolar diathermy. The bony opening is wide enough to allow angulation of the biopsy cannula to a moderate extent if necessary. It is also easier to use a rongeur, if required, to enlarge the 6 mm rather than the 2.5 mm bony opening.

The conventional burr hole requires a longer scalp incision but gives greater access to the dura and pial surface, as well as more flexibility of trajectory without the need to use bone rongeurs. However, it leaves a slightly larger wound.

Overall the 6 mm twist drill opening will be sufficient for most stereotactic biopsy procedures.

- vi) The author uses for stereotactic brain biopsy of tumor the Sedan-Nashold type of side-cutting biopsy needle (Fig. 4). This consists of two concentric metal tubes, closed at the distal end but with 10 mm long slots near the end. There is a Luer fitting into which to attach a syringe to exert suction. This causes tumor tissue to be drawn into the lumen of the inner tube. Rotation of the inner tube inside the outer then guillotines off a core of tissue which constitutes the biopsy specimen.

There are several alternative types of stereotactic biopsy cannulae which have been devised. These are advanced down a hollow open ended biopsy needle. They include small rongeurs (Gildenberg) or hemispherical cups to bite small pieces of the tumor, as well as a small spiral coil (Backlund) to enter the tumor rather like a corkscrew so that fragments can be withdrawn. There are also cannulae, typically with an outer diameter of 2.5 mm, with a blunt ended trocar inside and a Luer fitting at the proximal end to allow aspiration of cystic fluid or brain abscess. Individual neurosurgeons will have individual preferences amongst these biopsy needles.

Insulated cannulae, with an external diameter of 2 mm and an internal trocar which acts as an electrical conductor, are available for monopolar diathermy of the tumor if required.

In the case of the CRW system guide blocks which fit accurately the stereotactic arc and which are drilled out to the diameter of the varying biopsy cannulae are used to fix the depth always to 160 mm to the target from the upper surface of the guide block holder which is itself integral with the arc.

vii) *Biopsy samples*

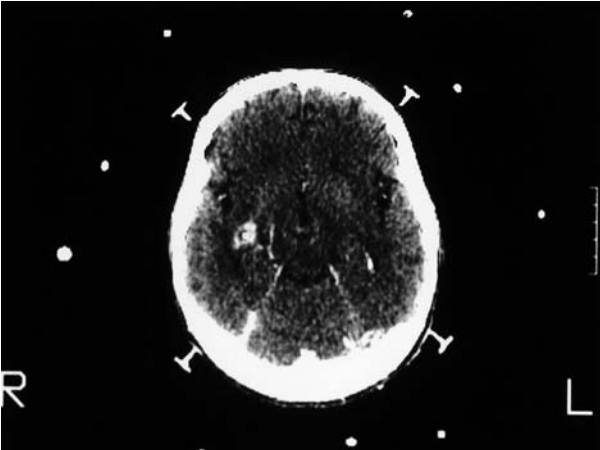
With the side cutting biopsy needle it is usually possible to obtain 4 cores of tissue approximately 10 mm long and 1 mm diameter (Fig. 4). This is done by leaving the outer cannula in position while withdrawing the inner cannula and teasing the core of tissue out onto a moistened card or glass slide with a fine needle and saline irrigation. The inner cannula can then be reinserted and the assembly of both cannulae rotated through 90° to obtain a second specimen at the same target in a similar way a third may be obtained at 180° and fourth at 270° rotation in respect of the first. This is the ideal situation, which is often achieved in firm tumors but in soft tumors the cores may be incomplete and maybe only one or two can be obtained at a given target site.

Usually, the experienced neurosurgeon will have a realistic opinion as to whether the sample will prove to be diagnostic or not. In most cases samples will be taken in more than one target site, often 3 to 4, seldom more than 7.

It is highly desirable that per-operative histopathological diagnosis by an experienced neuropathologist is available.

The samples are transferred immediately to the neuropathology department and processed immediately, often by smear or touch preparations, and with a report within 30 minutes. If the neuropathologist reports that the sample is diagnostic and there is sufficient material for definitive histology no more biopsies are needed for routine purposes. If the neuropathologist reports that the material is necrotic, or in some other way is unsatisfactory, and is not diagnostic further samples, usually from different targets, should be taken. If the neuropathologist finds definitely abnormal material, but without a definite diagnosis, usually the best course is to preserve the samples that have been taken and keep them for definitive histopathology and not take additional samples. In some cases the final histopathology is inconclusive and a further second stereotactic biopsy may be necessary.

If pus is encountered and aspirated during stereotactic biopsy for tumor, which turns out to be in fact a brain abscess, it is mandatory that samples should go as urgently as possible to the microbi-



**Fig. 5.** Detail of CT scan target of what proved to be an infective granuloma and not a suspected metastatic brain tumor

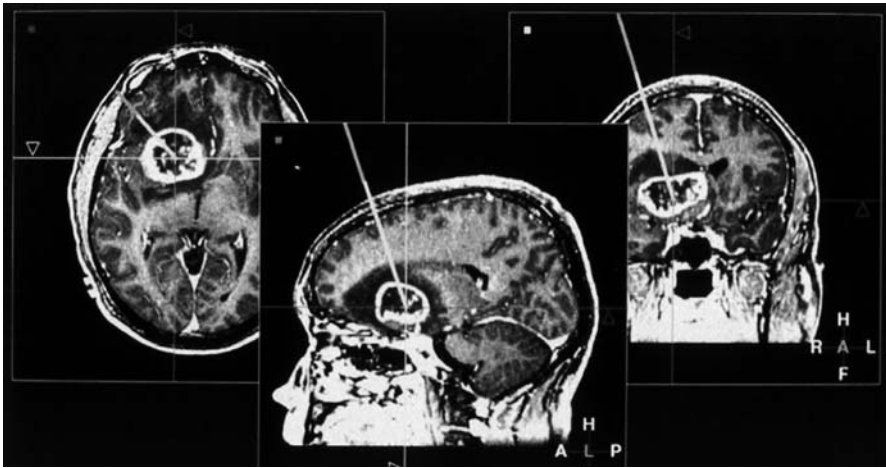
ology department so that there is the optimum chance of establishing culture and sensitivity (Fig. 5).

If clear or straw coloured cyst fluid is found samples should also be sent for laboratory examination. If a large cyst is encountered this will normally have been predicted from the pre-operative radiology and there will be a pre-planned neurosurgical strategy, for example to aspirate to the maximum extent, to implant a reservoir for future drainage, or alternatively to remove only diagnostic samples of cyst fluid.

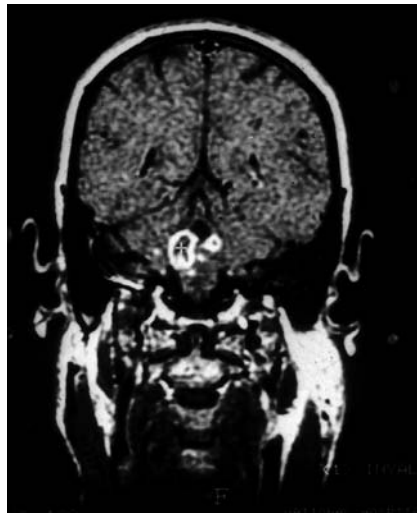
viii) Once the stereotactic biopsy samples have been taken and a per-operative histological diagnosis made the scalp wound is closed routinely. Alternatively it may be decided not to await per-operative diagnostic histology and to close the wound and await the definitive neuropathological result which is generally available within about 72 hours.

ix) *Frameless stereotaxy as an alternative to frame based stereotactic biopsy*

This is not strictly a stereotactic method in the classical sense and will be referred to only briefly. It employs modern neuronavigation systems and can achieve good results in suitable cases (Fig. 6). The method has the advantage that such procedures can save operative time because the required imaging does not require a stereotactic frame fixed to the head and may be done pre-operatively [2, 7]. However, in the author's opinion it is not as suitable for small deep lesions as are frame based methods using the MRI localiser (Fig. 7).



**Fig. 6.** Target planning in axial, sagittal and coronal planes from MRI scan using neuronavigation ("frameless stereotaxy"): the lesion was a glioblastoma



**Fig. 7.** Target planning in the MR scan coronal plane using the MRI localising unit by which the carbon fibre rods generate 7 external fiducials. The brainstem lesion was an abscess and not a tumor

x) *Post-operative care*

There is a small risk of serious complications following stereotactic brain biopsy. These are principally the risk of intracerebral haemorrhage, significant neurological deterioration as a result of the biopsy, and epileptic fits. In the early post-operative period the patient should



be closely monitored in a high dependency area where experienced nurses regularly observe and chart the patient's neurological responsiveness, as well as pulse, blood pressure and respiration. If the patient deteriorates a post-operative CT brain scan should be done to identify any haemorrhagic complication, which very rarely may require open neurosurgery for relief of a post-operative haematoma. Post-operative epilepsy may require additional medication, while increased cerebral oedema may require increased dexamethasone dosage or even elective ventilation with intracranial pressure monitoring.

Complications of stereotactic biopsy for brain tumor generally occur within 12–24 hours of surgery after which the patient should be stable.

## 7. HISTOPATHOLOGY METHODS

The biopsy samples are transferred directly to the Neuropathology Department, in a Petri dish to prevent drying out by evaporation. For intraoperative diagnosis small samples are selected from the stereotactic biopsy core and smears on a glass slide are made and stained with 1% toluidine blue and/or hematoxylin and eosin. Samples are also fixed in formalin and embedded in wax for conventional sectioning and usually are ready for definitive reporting in about 72 hours.

## 8. RESULTS

Clinical and neuropathological data from 419 stereotactic biopsies carried out from 1981 to 1989 at the National Hospitals were reviewed. There were 259 males and 160 females, with a mean age of 43.4 years (range 2–82 years). Three patients died in the first week (0.72%) and 24 (5.7%) within the first month after biopsy, most of the latter with very aggressive tumors [3].

A tumor was diagnosed in 326 (77.8%) of cases.

A glial tumor was diagnosed in 273 (65.1%) and this 65.1% was composed of Low grade astrocytoma 22.2%, Grade 3 astrocytoma (16.2%), Grade 4 (17.9%), Oligodendroglioma (5.7%), unclassified (3.1%).

A total of 53 non-glial primary tumors and secondary tumors (12.6%) were diagnosed. These included medulloblastoma/PNET, pineal tumors, lymphoma and metastatic carcinoma and melanoma.

A diagnosis of non-neoplastic lesions was made in 62 cases (14.8%), and no specific diagnosis was made in 31 cases (7.4%).

In these 31 cases follow up, further biopsy or post-mortem examination indicated the diagnosis of glioma in 15, carcinoma in 3, non-neoplastic disease in 4, with uncertain outcome in 9.

A potential criticism of grading based on small stereotactic biopsies may be unrepresentative of the whole tumor. However, subsequent follow up of

the glial tumors in this series indicated that grading resulting from the small stereotactic biopsies correlated well with the clinical outcome and survival.

A series of brain stem lesions in which brain biopsy was carried out, in some cases where the leading pre-operative diagnoses were sometimes of haematoma or abscess, has also been analysed.

In 72 cases of which 58 procedures were performed via a transcortical frontal trajectory and 14 via a transcerebellar sub-occipital route, and of which 61 were CT-guided and 11 MRI-guided adequate tissue for histological diagnosis was obtained in 70 [6].

In 42 cases tumor was diagnosed (33 glioma, 2 lymphoma, 1 PNET, 6 Metastatic carcinoma). Haematoma was found in 13 (3 with evidence of associated AVM/angioma), granuloma/abscess in 6, with other cases of demyelination (1), vasculitis (1), radiation necrosis (1), leuko-encephalopathy (1) and inconclusive findings in 2. Overall in 14 (19%) the result of biopsy was unexpected and in 9 (12%) subsequent management was changed as a result of biopsy.

## 9. OTHER LABORATORY TESTS

### 9.1 Tissue culture of stereotactic biopsy material

Typically stereotactic biopsy techniques provide only 10–15 mg of tumor tissue, compared with 100 mg plus from open biopsy samples [9]. It is essential to handle the samples aseptically and to transfer them as soon as possible to a tissue culture medium which contains nutrients as well as pH buffering agents and antibiotics to reduce the risk of bacterial overgrowth of the cell cultures. If the tissue cannot be processed immediately it is stored at 4°C in the culture medium; the success rate for cultures processed immediately is similar to cultures prepared within 24–48 hours. The cultures may be set up after enzymatic disaggregation or, by explant methods suitable for small biopsy samples [10]. Subsequently the cultures may be maintained or the cells may be frozen and then thawed for later studies.

Using contiguous stereotactic biopsies along a single stereotactic trajectory, employing the relocatable CRW system (4.1 A2), it was possible to correlate the standard histological appearance with expression of the proliferation associated antigen Ki-67 and to show that although there were often proliferating cells beyond the apparent edge on CT scan there were never any proliferating cells outside the PET scan apparent boundary [8]. Proliferating cell nuclear antigen (PCNA) can provide similar information in fixed paraffin embedded samples. Tissue culture techniques have also been applied to test the apparent chemosensitivity *in vitro* of individual gliomas [11].

### 9.2 Molecular neuropathology

Increasingly it has become clear that certain observed changes in the phenotype of individual gliomas are of prognostic importance. Thus, in the case of

oligodendroglioma the deletion of 1 p 19 q is a favourable prognostic sign, and probably indicates relative chemosensitivity of such tumors [5]. In grade 4 gliomas (glioblastoma) the silencing of the gene for MGPT also appears to be of prognostic importance in patients with glioblastoma treated after neurosurgery with concomitant temozolamide and radiation and subsequent continued adjuvant temozolamide [3].

Such laboratory tests have entered clinical practice in neurooncology and it is probable that further similar laboratory tests based on molecular changes within particular brain tumor types will become increasingly important as part of diagnostic neuropathology [12]. In the context of stereotactic tumor biopsy it is important that potentially they can be “miniaturised” to deal with small samples.

## HOW TO AVOID COMPLICATIONS

### 1. PROBLEMS WHICH MAY BE ENCOUNTERED WITH BIOPSY

- a) Sometimes there will be bleeding from the biopsy site coming up the cannula and visible at the proximal end. If this occurs it is best to leave the cannula in position for a few minutes to allow free drainage, until bleeding ceases. Then the cannula can be removed and further biopsies should not be taken at that same target site.

There may also sometimes be bleeding from the scalp when the fixation pins are removed and the base ring is removed from the head. When this occurs the bleeding can be controlled by one or more scalp sutures.

- b) Biopsy of wrong target can happen. Even though the stereotactic system has submillimetre accuracy it is possible by human error for mistakes about recording of the X and Y co-ordinates from the scan as well as to make wrong settings on the arc itself. The phantom is a check on such errors but the neurosurgeon in charge must double check each step of the procedure.
- c) Unnoticed movement of the head ring during the procedure, if it is not securely fixed has also the potential to cause errors in targeting.
- d) Brainshift, particularly if the procedure is long can occur, particularly if the patient has cerebral atrophy or ventricular dilatation, when undue CSF leakage may occur.
- e) The success rate of stereotactic brain biopsy is overall about 90–95% [10]. High grade malignant brain tumors are usually to achieve diagnosis unless there is widespread necrosis. Low grade brain tumors and non-neoplastic conditions may prove in some cases more difficult to verify. If the biopsy material on definitive neuropathological examination proves non-diagnostic the stereotactic procedure may be repeated at a later date.

## CONCLUSIONS

Stereotactic brain tumor biopsy has a high rate of diagnostic yield and, in lesions in which resection is not indicated because of the eloquence of the brain area involved or due to uncertainty of the differential diagnosis. It remains a flexible diagnostic method with generally low morbidity. With technical developments, many of which depend on molecular biology, new laboratory diagnostic methods are evolving in neuropathology.

## References

- [1] Darling JL (1993) Tissue culture of stereotactic biopsy material. In: Thomas DGT (ed) *Stereotactic and image directed surgery of brain tumors*. Churchill Livingstone, London, pp 29-37
- [2] Dorward NL, Paleologos TS, Alberti O, Thomas DGT (2002) The advantages of frameless stereotactic biopsy over frame-based biopsy. *Br J Neurosurg* 16(2): 110-118
- [3] Hegi ME, Diserens AC, Gorlia T, Hamou MF, de Tribolet N, Weller M, Kros JM, Hainfeller JA, Mason W, Mariani L, Bromberg JE, Hau P, Mirimanoff RO, Cairncross JG, Janzer RC, Stupp R (2005) MGMT gene silencing and benefit from temozolomide in glioblastoma. *N Engl J Med* 352: 997-1003
- [4] Horsley V, Clarke RH (1905) The structure and functions of the cerebellum examined by a new method. *Brain* 28(1): 1-98
- [5] Ino Y, Betensky RA, Zlatescu C, Sasaki H, Macdonald DR, Stemmer-Rachaminov AO, Ramsey DA, Cairncross JG, Louis DN (2001) Molecular subtypes of anaplastic oligodendroglioma: implications for patient management at diagnosis. *Clin Cancer Res* 7: 839-845
- [6] Kratimenos GP, Thomas DGT (1993) The role of image-directed biopsy in the diagnosis and management of brainstem lesions. *Br J Neurosurg* 7: 155-164
- [7] Paleologos TS, Dorward NL, Wadley JP, Thomas DGT (2001) Clinical validation of true frameless stereotactic biopsy: analysis of the first 125 consecutive cases. *Neurosurgery* 49(4): 830-835
- [8] Parkins CS, Darling JL, Gill SS, Wilson CB, Revesz T, Thomas DGT (1991) Cell proliferation in serial biopsies through human malignant brain tumors, measurement using Ki-67 antibody labelling. *Br J Neurosurg* 5: 289-298
- [9] Pell MF, Thomas DGT (1994) *Handbook of stereotaxy using the CRW apparatus*. Williams & Wilkins, Baltimore, pp 1-240
- [10] Revesz T, Scaravilli F (1993) Prognostic value of histopathology in stereotactic biopsy. In: Thomas DGT (ed) *Stereotactic and image directed surgery of brain Tumors*. Churchill Livingstone, London, pp 65-87

- [11] Roujeau T, Machado G, Garnett MR, Miquel C, Puget S, Georger B, Grill J, Boddaert N, Di Rocco F, Zerah M, Sainte-Rose C (2007-Jul) Stereotactic biopsy of diffuse pontine lesions in children. *J Neurosurg* 107(1 Suppl): 1-4
- [12] Scrideli CA, Carlotti CG Jr, Okamoto OK, Andrade VS, Cortez MAA, Motta FJN, Lucio-Eterovic AK, Neder L, Rosenberg S, Oba-Shinjo SM, Marie SKN, Tone LG (2008) Gene expression profile analysis of primary glioblastomas and non-neoplastic brain tissue: identification of potential target genes by oligonucleotide microarray and real-time quantitative PCR. *J Neurooncol* 88: 281-291
- [13] Spiegel EA, Wycis HT, Marks M, Lee AJ (1947) Stereotactic apparatus for operations on the human brain. *Science* 106: 349-350
- [14] Thomas DGT, Darling JL, Watkins BA, Hine MC (1984) A simple method for growth of cell culture from small biopsies of brain tumors taken during CT-directed stereotactic procedures. *Acta Neurochir (Suppl)* 33: 177-181



**David G. T. Thomas**

David G. T. Thomas was Head of the Division of Neurosurgery at the National Hospital for Neurology and Neurosurgery, London.

He was an undergraduate student at Cambridge University and at St Mary's Hospital Medical School, London. He qualified B.Chir, MRCS and LRCP in 1966. Following postgraduate training in general medicine and surgery he completed his neurosurgical training in the Institute of Neurological Sciences, Glasgow and was appointed in 1976 as Senior Lecturer and Consultant Neurosurgeon at the Institute of Neurology and National Hospital. He established a basic science and clinical research program in malignant brain tumors and also participated in the technical development and evaluation of both CT and MRI directed stereotactic surgery, as well as in the subsequent evolution and application methods of neuronavigation.

He is a member of the Society of British Neurological Surgeons (Honorary Secretary 1996–2000), of the Royal Society of Medicine (President, Clinical Neurosciences Section, 2001–2002), of the European Association of Neurosurgical Societies (Vice-President 1987–1991), of the World Federation of Neurosurgical Societies (First Vice-President, 2001–2005), and of the European Society for Stereotactic and Functional Neurosurgery (President, 1998–2002). He has also been the inaugural President of the British Neuro-oncology Society (2006–2007).

He has published widely on image directed neurosurgery, as well as in neurooncology and the field of functional neurosurgery.

**Contact:** David G. T. Thomas, The National Hospital for Neurology & Neurosurgery, Private Consulting Rooms, Box 147, Queen Square, London WC1N 3BG, UK  
E-mail: marcel.yazbeck@uclh.nhs.uk

---

# MANAGEMENT OF (MALIGNANT) INTRACRANIAL GLIOMAS

E. R. LAWS

## INTRODUCTION

Ever since removal of an intracranial astrocytoma diagnosed by neurologic localization in 1884, the management of malignant gliomas of the brain has represented a major challenge for neurosurgery. Malignant gliomas are the most common primary form of brain tumor. These difficult lesions account for a major problem and public health and in North America virtually everyone is acquainted with an individual or family member who has suffered from a primary brain tumor. New prevalence data indicate that the number of patients living with some form of brain tumor may be as high as 30 per 100,000 in the United States [5]. Among the malignant gliomas, approximately 30% are low grade, with the remainder being anaplastic lesions, the most common of which is the glioblastoma multiforme [6, 11].

Although surgery has traditionally been the mainstay of therapy for diagnosis and for treatment, the results have remained rather poor. Important advances in neurologic imaging including ventriculography, angiography, CT and MRI scanning, and more sophisticated metabolic imaging methods have added to the accuracy of diagnosis and localization (Fig. 1).

A significant advance occurred when it was recognized that radiation therapy improved the prognosis of patients operated on for these tumors, and radiation therapy has become a standard adjunct to treatment of malignant gliomas [3]. Many different strategies for utilizing chemotherapy in the adjunctive treatment of malignant gliomas have also been proposed, but few of these have led to major improvements in the outcome of our patients with this devastating disease [4, 8].

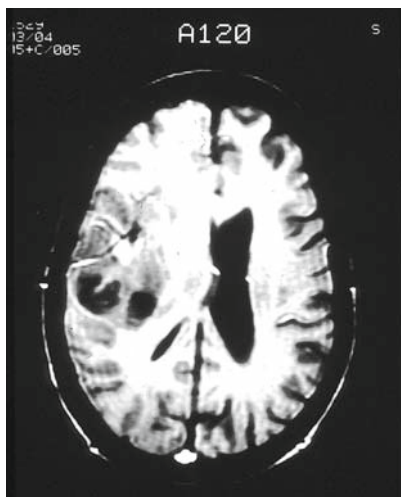
Research in the areas of molecular biology, stem cell biology, genomics, proteomics, and nanotechnology, all have provided hope that new therapies will be developed based on a clearer basic fund of knowledge regarding the pathogenesis of malignant gliomas. Translational research directed toward signal transduction and mechanisms of tumor cell invasion have also stimulated novel attempts at therapy [10].

Evidence that completeness of tumor resection and reduction in tumor cell burden can be accomplished using modern technology has encouraged strategies related to immunotherapy [9].

---

*Keywords:* neuro-oncology, gliomas, malignant gliomas





**Fig. 1.** Axial MRI – glioblastoma

## RATIONALE

It has become increasingly clear that accurate classification of gliomas of the brain is a major factor in determining prognosis and strategies for therapy [1, 11]. Histologic grading of these tumors has been accomplished in a systematic and widely accepted fashion resulting in the 2007 WHO guidelines [6]. The discussion will concentrate on the most common of these tumors: malignant astrocytomas of grade 3 and grade 4, the latter being recognized as glioblastoma. It has also been recognized that oligodendroglial component of high-grade gliomas can vary significantly and can also guide treatment and alter prognosis.

The less common grade 1 gliomas, extensively subclassified, ordinarily occur in children and young adults. The prognosis for these tumors is generally favorable and the treatment strategies reflect this fact and are quite different from those utilized in malignant gliomas. They will not be further discussed in this chapter.

It is important to recognize, however, that age of the patient is perhaps the most powerful indicator of prognosis, even in malignant gliomas [5]. Patients under 40 years of age generally have a more favorable prognosis than older patients even if they harbor lesions that are relatively high-grade. Conversely, patients over 65 years of age have a very poor prognosis even if they have tumors classified as grade 3 or anaplastic lesions [5].

The location of malignant gliomas in the supratentorial compartment generally follows the volume distribution of the different lobes of the brain. The majority of these lesions arise in the white matter of the frontal and temporal

lobes. A defining characteristic of the malignant glioma is its ability to infiltrate through the brain, preferentially utilizing white matter pathways. This infiltrative nature of most malignant gliomas makes total resection using standard surgical means a difficult goal to accomplish. This is particularly true in the so-called eloquent areas of the brain where radical resection may produce unacceptable postoperative neurologic deficits.

## DECISION-MAKING

The primary factors in decision-making with regard to recommendations for nature and aggressiveness of therapy depend in large part upon the clinical presentation of patients with malignant gliomas [4]. Some patients will present with seizures, some with incidentally discovered intracranial lesions, some with progressive neurologic deficit, and some with severe signs and symptoms of increasing intracranial pressure.

In most cases an important goal of surgical management is to obtain a representative tissue sample for accurate biopsy diagnosis and classification. In patients with relatively little in the way of symptoms and signs, and without increased intracranial pressure, this can be accomplished using stereotactic surgery with image guidance to direct the biopsy to the most likely area to provide such a diagnosis. Further therapy can then be directed based on the information from the biopsy.

In the majority of patients who present with progressive neurologic deficits or with signs and symptoms of increased intracranial pressure, a more extensive resection is usually recommended whenever this is possible. In addition to fulfilling the goal of establishing a clear histologic diagnosis, resective surgery decreases the tumor burden, decompresses the normal brain with the potential of restoring lost function, and may eliminate an irritative seizure focus. In patients where the diagnosis is a high grade tumor or glioblastoma, there is emerging evidence that completeness of resection leads to improved control of disease, delay in recurrence and better outcomes, including the quality of life [9].

Because surgery alone rarely results in the cure of a malignant glioma, once the histologic diagnosis is secure, plans need to be made for adjunctive therapy. Current consensus includes the use of postoperative fractionated radiation therapy to a total tumor dose of 58–60 Gray, with a focal boost to the resection cavity and a margin of at least 2 cm around the periphery. In 2008 there is no convincing evidence that brachytherapy for the implantation of radiation sources provides significant benefits either in survival or/and quality of life. It is fair to say that the use of stereotactic radiosurgery for patients with malignant gliomas remains controversial as well.

There have been significant advances in adjunctive therapy based upon advances in molecular biology. The well tolerated, orally administered, chemotherapeutic agent Temodar has become a standard adjunct to therapy for

glioblastomas, providing meaningful improvement in longevity and quality of life [10]. The recognition that methylation of MGMT, a DNA repair enzyme, potentiates the tumoricidal effect of Temodal has become important in determining strategies for the use of this agent. There is continuing enthusiasm regarding the use of anti-angiogenesis agents such as Avastin, particularly in the management of recurrent high-grade gliomas.

Molecular diagnosis has been applied to anaplastic oligodendrogliomas and to malignant gliomas with an oligo component. Analysis for deletions of 1p and 19q helps to guide chemotherapy strategies and significantly influences prognosis. Other commonly utilized molecular markers include determination of P53 tumor suppressor status and proliferation index as measured by Ki-67.

Once a malignant glioma has recurred or has failed standard therapy, there are a variety of clinical trials based on translational research which may lead to new directions in the successful management of malignant gliomas. These include efforts to utilize immunotherapy in the form of interleukins, interferons, and vaccination strategies. Gene therapy and stem cell based therapies are under continued investigation, as are strategies to interfere with the mechanisms of tumor cell invasion.

## **SURGERY**

In consideration of the initial surgical strategies, including those of obtaining a stereotactic biopsy, the basic principles are relatively clear. A variety of image-based computer technologies are available. Usually they are based on MRI findings, but can also be enhanced by using PET. The imaging characteristics of the lesion determine the target point of the biopsy, and the trajectory can be designed to avoid possible damage to important neural structures en passage.

The majority of operations for malignant glioma are done using a craniotomy approach. Whenever possible, the goal should be radical removal of the tumor. Careful assessment of the preoperative imaging studies is essential. If there is concern regarding proximity of the tumor to eloquent areas of cortex, then functional MRI imaging may be of great use in determining possible displacement of important areas of the brain. If there is concern about the inherent vascularity of the tumor or involvement by tumor of important blood vessels then cerebral angiography may be an important adjunct. Computer-based image guidance can be used to delineate an optimal trajectory for removal of lesion with preservation of normal brain. This technique may also help one determine the optimal size and position of the craniotomy. Standard equipment for craniotomy for malignant glioma is listed in Table 1.

A number of methods can be utilized in order to obtain a maximum tumor resection. These include electrophysiological monitoring for determination of motor and sensory cortex, the use of motor evoked potentials for the same purpose, and if language and speech are in jeopardy, the use of techniques

**Table 1.** Equipment for craniotomy for malignant glioma

---

Three-point fixation head holder
Computerized image-guidance (neuronavigation) system; ultrasonic imaging*
Operating microscope
Bipolar cautery
Ultrasonic aspirator*
Electrophysiological monitoring*
Intraoperative imaging; intraoperative MRI*

---

\*Desirable, but not essential in all cases

involving an awake craniotomy [7]. Because of the potential for brain shift once a craniotomy has been performed and resection has begun, the use of intraoperative MRI techniques may be helpful in obtaining a thorough resection and in the detection of areas of tumor that might have been missed using standard techniques.

In the relatively unusual situation of a pseudo-encapsulated malignant glioma, a careful microsurgical attempt at an extracapsular resection is an excellent strategy. In the more common situation of an invasive mass without distinct borders, a maximum debulking of obvious tumor should be accomplished, along with an attempt to remove the brain immediately adjacent to the tumor where infiltration by tumor cells can be assumed to be present. Using a trans-sulcal approach to expose the periphery of the tumor and to preserve adjacent normal brain may also increase the chances for a maximal resection, particularly in deep seated lesions. A safe biopsy of the margin of the tumor may be useful in assuring completeness of resection and in providing tissue for study of phenomenon of tumor cell infiltration. Once the resection is complete, immaculate hemostasis must be obtained, and a careful and watertight dural closure is desirable. Careful attention should also be directed to an anatomical reconstruction of the scalp, as the health and integrity of the scalp must be maintained during the anticipated postoperative radiation therapy.

It is customary to utilize dexamethasone in the perioperative period. This agent is usually given as a 10-mg loading dose and maintained at 4 mg every 6 h through the time needed for recovery from the craniotomy. It is also customary to utilize low dose Decadron therapy of during the course of radiation treatments, and whenever there is a significant amount of cerebral edema associated with the tumor. Ordinarily, broad-spectrum antibiotics are administered during the time of the operative procedure only. It is important to utilize precautions against deep venous thrombosis as this complication is relatively common in patients undergoing surgery for malignant gliomas. Rapid mobilization of the patient is desirable when appropriate. If the patient presented with seizures, then there is some rationale for the use of postoperative anticonvulsants. At the present time, however, the routine use of postoperative anticonvulsants in the absence of seizures is not recommended.

An analysis of the long-term results from the Glioma Outcome Study of more than 500 patients treated for malignant gliomas by surgery, usually followed by adjunctive therapy, revealed a median survival of 40.9 weeks for patients with glioblastomas [5]. The figures for survival in patients with grade 3 gliomas were much more favorable with a 58% survival rate at 104 weeks post-operatively. Survival at 24 months was 11% for glioblastomas. An attempt was made in the study to evaluate the quality of life, which remained quite satisfactory for the surviving fraction of patients up until a short period of time before their demise. It was noteworthy that there was a rather high incidence of depression among these patients which often was not specifically treated.

Complications encountered in surgery for gliomas are those of craniotomy in general. They include postoperative hematoma, intracerebral, subdural, and epidural; infection in the form of meningitis, cerebritis, subdural and epidural infection, and wound infection. Fortunately these complications are relatively rare, and they usually respond well to appropriate therapeutic correction. New neurological deficits as a result of surgical intervention occur rarely, in approximately 3% of patients. New-onset seizures are also an uncommon complication of resective surgery for malignant gliomas.

At the present time the major goals of surgery for malignant gliomas include the following: definitive histologic diagnosis and grading; maximal tumor resection, decreasing the tumor burden; reversal of progressive neurologic deficits; relief of increased intracranial pressure; reduction or elimination of the potential for seizures; and, the obtaining of tissue for scientific analysis resulting in new concepts of pathogenesis, therapy and optimal management.

## **HOW TO AVOID COMPLICATIONS**

A thorough preoperative assessment including a detailed neurologic examination and exhaustive imaging studies, anatomic, functional and metabolic, provide a sound basis for the indications for surgery, and also for the surgical strategies to be employed. The patient's general physical and neurological status should be optimized, including, if necessary, the management of increased intracranial pressure. The patient's coagulation status should be carefully assessed and use of aspirin-containing drugs discontinued prior to surgery if at all possible. Precautions should be taken against deep venous thrombosis. Intraoperative prophylactic broad-spectrum antibiotics should be given, and appropriate anticonvulsants should be given in those patients who present with a seizure disorder as part of their symptom complex.

Positioning of the patient during surgery can be extremely important. The head should be carefully fixed in a position that allows full access to the operative field. It is often useful to elevate the thorax 20–30° in order to decrease venous pressure. Careful padding of the extremities, avoidance of unnecessary rotation of the head on the neck, and the use of compression boots for the calves are important details.

With the assistance of the image guidance, careful attention should be given to the placement and the technical performance of the skin incision, done in a way to produce the best possible exposure of the surgical field and to assure the best possible postoperative healing of the wound. The elevation and replacement of the bone flap should be done with great care. The same is true of the dural opening and of a watertight dural closure. During the operative procedure every attempt should be made to preserve cortical veins draining toward the major sinuses, and to avoid inadvertent damage to the arterial circulation of the brain. During the course of the operation careful microsurgical technique should be employed, assuring maximal resection and perfect hemostasis.

## **CONCLUSIONS**

### **1. HIGH-GRADE GLIOMAS**

Successful management of malignant gliomas of the brain involves a concerted multidisciplinary effort. Careful consideration of the indications for surgery, for the selection of the surgical strategy in the technical approach, and philosophical considerations relative to the extent of resection all play a major role in the ultimate outcome for the patient. Surgery is essential for providing the correct diagnosis and for removing as much as possible of the offending lesion. Carefully designed and executed radiation therapy remains an integral part of the overall management of a patient with a malignant glioma. Scientifically designed adjunctive therapy using results of translational research studies is the best hope for a final solution to this challenging problem.

### **2. LOW-GRADE GLIOMAS**

Although the same basic principles utilized for the management of malignant gliomas apply to low-grade tumors as well, decision-making for low-grade gliomas can be problematic [2, 4]. Many patients with low-grade tumors present with little or no neurologic deficit, a mild seizure disorder, and no evidence of increased intracranial pressure. Also, most of these tumors are infiltrative, hypointense on imaging, and do not present a clear target either for stereotactic biopsy or for surgical resection. For those reasons, in some cases it may be acceptable to follow the patient carefully with repeated imaging studies and possibly with metabolic imaging as well. When a low-grade glioma is confirmed by biopsy or is resected because of its favorable position or its effect on the patient's neurologic status, the role of postoperative radiation therapy remains somewhat controversial. The best prospective studies would indicate that radiation therapy delays time to progression of the tumor from a low-grade lesion to a high-grade lesion, but does not provide a significant survival advantage of the patient.

## References

- [1] Daumas-Duport C, Scheithauer BW, O'Fallon J, Kelly P (1988) Grading of astrocytomas: a simple and reproducible method. *Cancer* 62: 2152-2165
- [2] Duffau H (2006) New concepts in surgery of WHO grade II gliomas: functional brain mapping, connectionism and plasticity – a review. *J Neurooncol* 79: 77-115
- [3] Jelsma R, Bucy PC (1969) Glioblastoma multiforme: its treatment and some factors affecting survival. *Arch Neurol* 20: 161-171
- [4] Kaye AH, Laws ER Jr (2001) *Brain tumors*, 2nd edn. Churchill Livingstone, London
- [5] Laws ER, Parney IF, Huang W, Anderson F, Morris A, Asher A, Lillehei K, Bernstein M, Brem H, Sloan A, Berger M, Chang S, et al. (2003) Survival following surgery and prognostic factors for recently diagnosed malignant glioma: data from the Glioma Outcome Project. *J Neurosurg* 99: 467-473
- [6] Louis DN, Ohgaki H, Wiestler OD, Cavenee WK (eds.) (2007) *WHO classification of tumors of the central nervous system*. WHO Press, Geneva
- [7] Meyer FB, Bates LM, Goerss SJ, et al. (2001) Awake craniotomy for aggressive resection of primary gliomas located in eloquent brain. *Mayo Clin Proc* 76: 677-687
- [8] Salzman M (1980) Survival in glioblastoma: historical perspective. *Neurosurgery* 7: 435-439
- [9] Stummer W, Reulen H-J, Meinel T, Pichlmeier U, Scumacher W, Tonn J-C, Rohde V, Opperl F, Turowski B, Woiciechowsky C, Franz K, Pietsch T (2008) Extent of resection and survival in glioblastoma multiforme: identification of and adjustment for bias. *Neurosurgery* 62: 564-576
- [10] Stupp R, Mason WP, van den Bent MJ, Weller M, Fisher B, Taphoorn MJ, et al. (2005) Radiotherapy plus concomitant and adjuvant temozolomide for glioblastoma. *New Engl J Med* 352(10): 987-996
- [11] Vandenberg SR (1992) Current diagnostic concepts of astrocytic tumors. *J Neuropath Exp Neurol* 51: 644-657



**Edward R. Laws**

Edward R. Laws is Director of the Pituitary Tumor Center at the Brigham & Women's Hospital in Boston.

He received his bachelor's degree from Princeton University with honors in Economics and Sociology in the Special Program in American Civilization, and then attended the Johns Hopkins University School of Medicine in Baltimore, Maryland, receiving the MD in 1963. He did his surgical internship and neurosurgical residency at Johns Hopkins under A. Earl Walker. After completing his residency, he joined the faculty at the Johns Hopkins Medical School with a primary appointment in pediatric neurosurgery. He subsequently joined the staff of the Mayo Clinic in Rochester, Minnesota, where ultimately he became Professor of Neurosurgery and developed major interests in pituitary surgery and epilepsy surgery along with a continuing interest in the metabolism and pathophysiology of primary brain tumors. In 1987 he became Professor and Chairman of the Department of Neurosurgery at the George Washington University in Washington, DC, and in 1992 joined the faculty of the University of Virginia as Professor of Neurosurgery and Professor of Medicine, establishing a Neuro-Endocrine Center there. He joined the faculty at Stanford University in 2007 where he served as Surgical Director of the Pituitary/Neuroendocrine Center there. During his surgical career he has operated upon more than 7500 brain tumors, of which 5000 have been pituitary lesions.



Dr. Laws completed his term as President of the American College of Surgeons, and has served as President of the World Federation of Neurosurgical Societies, President of the Congress of Neurological Surgeons, Editor of *Neurosurgery*, Chairman of the Board of Trustees of the Foundation for International Education in Neurosurgery, Director of the American Board of Neurological Surgery, President of the American Association of Neurological Surgeons, and President of the Pituitary Society. He has authored over 500 scientific papers and book chapters, and with Andrew Kaye is co-editor of the encyclopedic volume, "Brain Tumors".

In 2005 he was elected to membership in the Institute of Medicine of the National Academy of Science. He remains actively involved in surgery and in brain tumor and neuroendocrine research.

Dr. Laws and his wife Margaret (Peggy) have four daughters and six grandchildren.

**Contact:** Edward R. Laws, Department of Neurosurgery, Brigham and Women's Hospital, PBB3, Harvard University, 15 Francis St., Boston, MA 02115, USA  
E-mail: [elaws@partners.org](mailto:elaws@partners.org)

---

# MANAGEMENT OF LYMPHOMAS

H. LOISEAU

## INTRODUCTION

The central nervous system (CNS) may be affected by a lymphoma in many circumstances (Table 1). Lymphomas are divided into Hodgkin's lymphoma and non-Hodgkin's lymphoma (NHL) with a primary extranodal presentation in 5% and 30% of the cases. Extranodal NHL may develop in the gastrointestinal tract, skin, bone, upper respiratory tract, thyroid, breast, testis or CNS. Primary central nervous system lymphoma (PCNSL) is an extranodal lymphoma accounting for 1% to 2% of extranodal NHL, occurring in the brain, leptomeninges, spinal cord, or eyes and remaining confined to the CNS. Regardless of their origin, CNS lymphomas are no longer the curiosities they were in decades past and provide multiple challenges to physicians.

Virtually every type of lymphoma can be observed in two situations considering the immune status of patients (i.e. immuno-competent or immuno-suppressed) [3].

Immunodeficiency, either congenital or acquired (organ transplant-related, acquired immune deficiency syndrome-related or therapeutic), is the only established risk factor for PCNSL.

In immunosuppressed patients the role of the Epstein-Barr virus is commonly admitted. Pathogenesis of PCNSL is unclear and many hypotheses have been formulated. One of the most speculative is the ability for subependymal stem cells to rise in haematological cells. This theory can explain the frequent periventricular localisation of CNS lymphoma. However, substances leading to such a differentiation have to be identified.

The incidence rate of brain lymphoma has increased from 2.5 cases per 10 million habitants in 1973 to 30 per 10 million in 1992. This increasing frequency of PCNSL goes beyond what may be attributed to improvements in diagnostic tools, exceeds the increasing frequency of systemic NHL, cannot be explained by time trends in nosology, known high-risk groups, or the increasing incidence rate of brain tumors, and is independent of age and gender (review in [11]).

Since 10 years the annual incidence is quite stable. The advent of highly active antiretroviral therapy (HAART) is closely related to the stabilization of the annual incidence of PCNSL. Using specialized brain tumors registries, annual incidence of PCNSL is about 0.5 to 0.8 per 100,000 habitants.

---

*Keywords:* neuro-oncology, lymphoma, brain surgery

**Table 1.** Estimated frequency of CNS involvement according to lymphoma types and anato-mo-radiological forms

Lymphoma type	Associated anato-mo-radiological forms		Comments
	Intraparenchymal expansive mass	Lepto-Meningeal involvement	
Hodgkin's lymphoma			
Primary	<20 reported cases	1 reported case	Young adults or child
Secondary	0.02 to 0.5%	0.2 to 15%	Intraparenchymal Meningioma-like Meningeal
Non Hodgkin's lymphoma			
Primary	75 to 85%	<10%	Inaugural: 1%
Secondary	<10%	5 to 30%	CNS relapse 2 to 5%
Marginal zone lymphoma		Meningioma-like	Low-grade lymphoma
			Female predilection Staging procedure
Primitive Intra-Ocular Lymphoma		50 to 80%	20% asymptomatic lesion in PCNSL
Mycosis Fungoides	40 reported cases	10%	Occurring with advanced disease
Lymphomatoid granulomatosis	27% Few reported cases Multiple punctate enhancing foci	25%	Very rare disease 4th to 6th decade of age
Intravascular lymphoma			<0.1/100,000 sub-acute encephalopathy multifocal cerebrovascular events

## RATIONALE

### 1. PRIMARY CENTRAL NERVOUS SYSTEM LYMPHOMA (PCNSL) [2, 6, 8, 11]

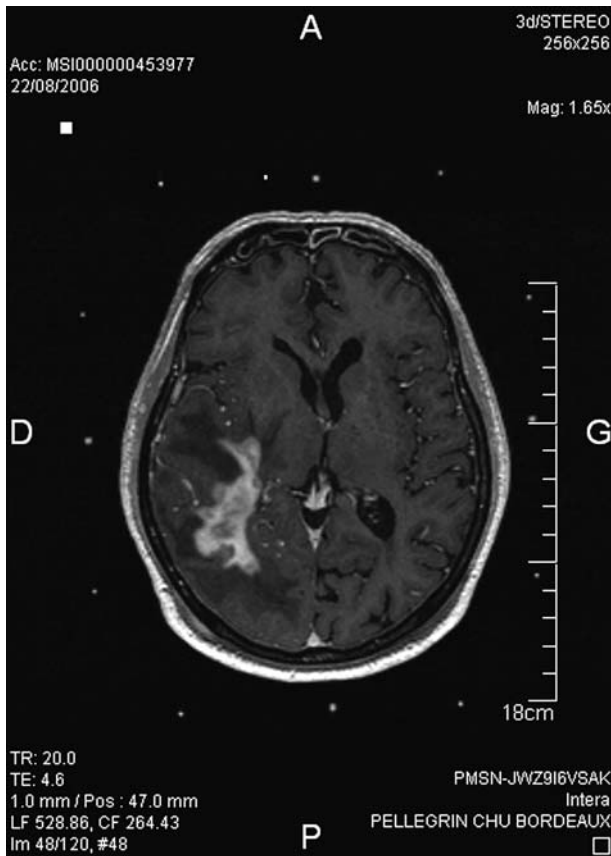
The first description of PCNSL was given by Bailey in 1929. These tumors were once assumed to arise from the reticuloendothelial system of the brain, namely from reticular or microglial cells. The presence of histiocytes, lymphocytes and plasma cells was regarded as a reactive phenomenon. In 1974, Henry and co-workers noted the resemblance with systemic lymphoma and proposed that the term 'primary central nervous system lymphoma' be used to replace all the existing synonyms. Subsequent studies have confirmed that PCNSL have morphological and immunophenotypic features similar to those observed in nodal and extranodal NHL. PCNSL are usually high grade, and

no correlation between histological types and clinical or radiological patterns has been demonstrated.

PCNSL arises within and is restricted to the CNS. Some authors believe that this definition should further include the qualification 'at presentation' and that there should be no evidence of disease elsewhere than in the CNS with the exception of the vitreous and retina. The latter proposals provide the basis for nosologic and therapeutic debates.

### 1.1 Clinical forms

PCNSL in immunocompetent patients usually arises during the sixth decade. Peak of incidence is between 60 and 70 years of age. A male:female ratio of approximately 1.5:1 is widely reported. The delay between onset of symptoms and diagnosis is around 2 or 3 months.

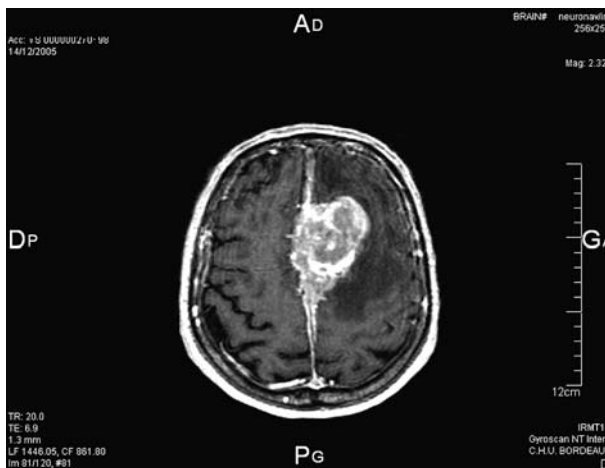


**Fig. 1.** Typical pattern: homogeneous periventricular enhancement on T1-weighted sequences after IV Gadolinium infusion

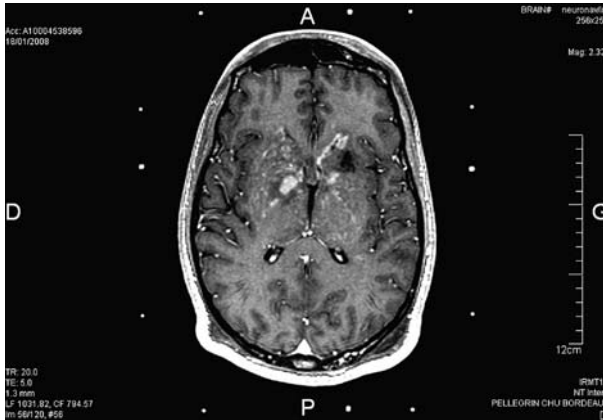
*Intracerebral parenchymal localization.* This is the most common picture, observed in more than 75% of cases. At the onset clinical signs are non-specific and evolution is consistent with an intracerebral expanding mass: neurological deficit more frequently than epileptic seizure or intracranial hypertension. Cases with exceptional clinical aspects have been published.

Both CT-scanning and MRI typically show solitary or multiple well-defined rounded lesions of large volume involving the corpus callosum and central grey nuclei. Roughly 90% of these lesions are spontaneously isodense or mildly hyperdense with homogeneous enhancement after contrast infusion (Fig. 1). In immunocompetent patients, a ring-enhanced aspect is observed in less than 10% of the cases and peritumoral oedema is mild. Frontal and parietal localizations are observed more frequently than other ones. Multiple localizations have been found in from none to half of cases. In less than 10% of cases a unique round lesion is observed which massively enhances after contrast infusion and which may be difficult to distinguish from a meningioma (Fig. 2).

*Meningo-encephalic form.* It is thought that, in this form, invasion of the brain occurs through the Virchow-Robin spaces (Fig. 3). Memory impairment, altered mental status, and personality changes are the most frequently observed symptoms. These nonspecific symptoms frequently have an acute onset. On radiological examinations, there is an aspect of subependymal infiltration with a small iso- or hypodense lining of the ventricular walls that is dramatically enhanced after contrast infusion. In most cases, parenchymal nodules adjacent to the ventricles are associated. Localizations of these tumoral nodules are closely similar to those observed in the intracerebral form



**Fig. 2.** Frontal homogeneous mass presenting as a meningioma (T1-weighted sequences after IV Gadolinium infusion)



**Fig. 3.** Diffuse periventricular enhancement on T1-weighted sequences after IV Gadolinium infusion

of the disease. Subependymal infiltrates are found in about one half or one third of the cases. Meningeal involvement is observed in less than 20% of the cases. Ventricular-wall lining associated with intraparenchymal nodules strongly suggests a lymphomatous origin, but these aspects may be observed in both primary and secondary lymphomas.

*Purely meningeal involvement.* Described in 1991, this entity accounts for less than 10% of PCNSL. Clinical signs are those of carcinomatous meningitis, associating headaches, meningismus, and involvement of cranial nerves or spinal roots. Clinically isolated spinal involvement such as paraplegia or radicular palsies may be observed. CT-scan and MRI are negative. Cerebrospinal fluid (CSF) examination shows malignant or monoclonal “normal” lymphocytes in half of the cases. A careful search must be conducted to rule out secondary lymphoma.

*Spinal lymphoma.* Spinal cord localizations of lymphomas are extremely rare, accounting for less than 1% of PCNSL. The lower cervical and upper thoracic segments of the cord are predominantly involved. Spinal cord localization is more common when lymphoma recurs, in which case it is usually associated with a meningeal extension. The primary spinal form must be distinguished from epidural localization with intradural extension of secondary lymphomas.

*Rare clinical forms.* Diffusely infiltrating hemispheric lymphoma without mass effect or contrast enhancement is observed in about 10% of PCNSL. It is considered as a differential diagnosis for infiltrating astrocytoma and progressive multifocal leuko-encephalopathy, among others.

At last, rare cases of gyriform enhancing lesion with extensive white matter edema have been described but in most cases they occurred in immunocompromised patients.

## 1.2 Prognostic factors

Identification of prognostic factors in PCNSL is difficult due to the rarity of this disease. Five prognostic factors are usually considered: age at diagnosis, performance status (using Karnofsky's index subdivided in two categories i.e.  $<60$  and  $\geq 60$ ), serum lactate dehydrogenase level, CSF protein concentration, and the involvement of deep structures of the brain (periventricular regions, basal ganglia, brainstem, and/or cerebellum). The combination of that prognostic factors has allowed to develop a prognostic scoring system that distinguishes three different risk group based on the presence of 0–1, 2–3, 4–5 unfavourable features [5]. The 2-year overall survival was respectively 80%, 48% and 15%.

The identification of biomarkers of prognosis remains a high priority in current PCNSL research. Overexpression of BCL-6 seems to be a promising one.

## 1.3 Histopathological data

The majority of PCNSL are high-grade B-cell tumors, low-grade B-cell varieties being relatively rare. Some of the high-grade B-cell PCNSL can be classified as immunoblastic, centroblastic or Burkitt-like, but the predominant type is a polymorphous high-grade B-cell lymphoma.

PCNSL with a T-cell origin are rare but are being recognized with increasing frequency. Incidence of T-cell lymphoma is higher in Japan and in Korea than in Western countries. Care should be taken to distinguish them from certain T-cell rich, B-cell lymphomas.

Under light microscopic examination, angiocentricity is a characteristic feature of PCNSL; it is associated with an infiltration of the vascular walls by lymphomatous cells, and with a laminar distribution of reticulin fibers. Single-cell necrosis or patchy necrosis is common. However, large areas of necrosis which is a conspicuous feature of AIDS-related PCNSL is uncommon in immunocompetent patients.

*Immunohistochemistry and molecular biology.* The B-cell origin of most PCNSL is confirmed by a positive immunohistochemical staining with pan-B markers such as CD19, CD20 and CD79a.

T-cell markers can confirm the T-cell origin of some PCNSL. Moreover, these T-cell markers may often show an admixed population of small reactive T cells within B-cell lymphomas. Proliferative activity in PCNSL is generally high with Ki-67/MIB-1 labelling indices of 50–70%.

Except in a few particular cases, ultrastructural study is not very informative in the diagnosis of PCNSL.

*Pitfalls.* The distinction between PCNSL and chronic inflammatory lesions may be difficult in certain cases of well-differentiated lymphoma or in cases of lymphomatous proliferation hidden by dense inflamma-

tory infiltrates composed of small mature lymphocytes, often of T-cell origin.

Genotypic analysis is useful in establishing the monoclonal nature of a B-cell proliferation by finding rearrangements of heavy and light chain immunoglobulin genes. Similarly, the monoclonal nature of a T-cell proliferation can be confirmed by T-cell receptor gene rearrangement.

## **2. CNS LYMPHOMA IN IMMUNOCOMPROMISED PATIENTS**

An association with congenital or iatrogenic immunosuppression and PCNSL has long been recognized. Extensive lists of predisposing diseases are provided in recent textbooks.

Among these situations, the most intriguing is that of AIDS patients. Histologically, these tumors are high-grade B-cell neoplasms. With the introduction of HAART, the proportion of AIDS-patients with CD4<sup>+</sup> cell counts less than 50/ $\mu$ L has drastically reduced as well as CNS lymphoma.

Median age at diagnosis is younger than in immunocompetent patients. Median diagnostic time is about 2 months. Clinical findings are unspecific, but B symptoms and seizures are observed more frequently than in immunocompetent patients. Clinical status is most frequently worse.

Comparing with immunocompetent patients, small lesions are seen more often, the corpus callosum is rarely involved, before contrast infusion, lesions are frequently hypodense and after contrast infusion, ring enhancement is observed in about 50% of the cases. Ill-defined edema associated with diffuse gyral enhancement is quite specific.

Prognosis is dismal and most patients survive less than 3 months. Infection rather than uncontrolled CNS lymphoma is the most common cause of death. One of the most important prognostic factors is a previous history of opportunistic infection.

Treatment schedules are tailored to the individual status. Chemotherapy is tolerated with difficulty. Radiation therapy alone is frequently the sole alternative.

## **DECISION-MAKING**

Diagnosis of CNS lymphoma is a stepwise process. Establishing an exact diagnosis is an absolute prerequisite before starting chemotherapy or radiation therapy.

### **1. DIAGNOSIS ASSESSMENT FIRST PART OR IT IS A LYMPHOMA?**

Differential diagnosis with other neurological diseases is very academic. Age at onset, clinical patterns and radiological findings are quite distinct. In



cases that raise a problem of differential diagnosis, histological analysis of a biopsy specimen reliably distinguishes among the alternatives. The principal speculations involve AIDS patients, steroid-sensitive diseases and difficulties in substantiating histologic diagnosis.

- **AIDS patients**  
Progressive multifocal leukoencephalopathy, fungal or bacterial abscess, infarction and haemorrhage can present as focal lesions in AIDS patients. However, the main differential diagnosis is toxoplasmosis. Cerebral biopsy is performed when empiric treatment for toxoplasmosis does not lead to clinical improvement.
- **Steroid-sensitive disease**  
*Sarcoidosis.* CNS involvement is observed in 5% of patients who have sarcoidosis. However, young patients of Afro-Caribbean origin are the exposed population. Radiological features include meningeal enhancing mass, involvement of the hypothalamic and hypophyseal regions, periventricular and multifocal white matter lesions. Intracranial and intraspinal sarcoid mass lesions are known to be sensitive to steroids. At last, less than 30 cases of neurosarcoidosis without evidence of systemic disease have been reported.  
*Acute disseminated encephalomyelitis.* This disease is monophasic with an acute onset and spontaneous improvement is the rule. MRI shows large enhancing periventricular lesions of heterogeneous aspect. Clinical improvement is associated with the disappearance of radiological enhancement that may confound the diagnosis when steroids are administered.  
*Multiple sclerosis.* This disease occurs earlier in life than CNS lymphoma. A waxing and waning course is the rule. Radiologically, lesions of different ages are observed in the white matter. In “large plaque” forms, the differential diagnosis with PCNSL may be considered because there is an obvious steroid sensitivity.
- **Difficulties in substantiating histologic diagnosis**  
*Subacute and chronic infections.* As a result of its protean clinical manifestations and abnormal CSF, CNS lymphoma must be differentiated from some infectious diseases as Lyme neuroborreliosis, tuberculosis or neurosyphilis. Serologies are helpful.  
*Others.* Biopsy is sometimes quite difficult to perform according to localisation (i.e. cavernous sinus, brain stem).

## 2. DIAGNOSIS ASSESSMENT SECOND PART OR HOW TO CONFIRM DIAGNOSIS?

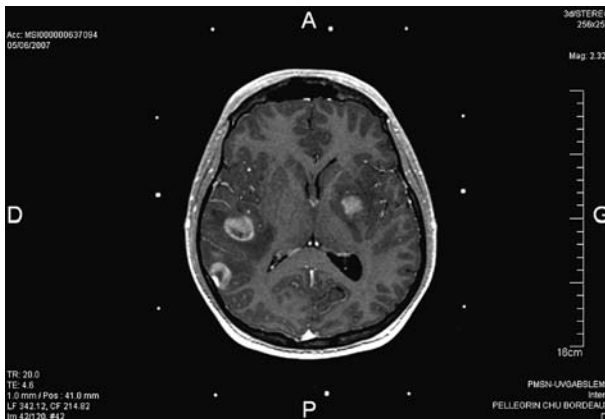
- **Cerebral biopsy**  
Sometimes obtained during surgical removal of a meningioma-like lymphoma, cerebral biopsies are mainly obtained using stereotaxic procedure. Histological assessment, immunophenotyping and classification are held to be highly reliable, even in small stereotaxic biopsies (correct diagnosis is

obtained in about 95.6% of cases). The mortality and morbidity of stereotaxic biopsy in CNS lymphoma is not known to differ from those observed in other brain tumors. If steroids have been administered, obtaining a CT-scan or MRI just before surgery may be useful.

- Cytology of the cerebral spinal fluid (CSF)  
Only abnormal monoclonal lymphocytic proliferation or activated lymphocytes have diagnostic value. Flow cytometry seems to be more sensitive than routine cytology to assay for occult leptomeningeal lymphoma. Increased cell count is observed in a wide range, from 0% to 70% of the cases and the required features were observed in highly variable rates, from 0% to 50% of the patients.
- Vitrectomy and retinal biopsy  
Vitrectomy and choroidal biopsy have been used for diagnosis in patients with ocular manifestations. In addition to vitrectomy, chorioretinal biopsy sampling or fine-needle aspiration of a subretinal lesion may be performed. Pathological examinations require special attention (contributory in only 20% to 50% of the patients who have ocular lymphoma).

### 3. DIAGNOSIS ASSESSMENT THIRD PART OR IT IS A PRIMARY CNS LYMPHOMA?

Differentiating primary and secondary lymphomas is of paramount importance in terms of prognosis and management. According to the admitted definition (i.e. PCNSL remains confined to the CNS) the discovery of extra-CNS localization indicates a systemic lymphoma with cerebral metastasis (i.e. systemic stage IV disease) and not a PCNSL with systemic metastasis.



**Fig. 4.** Secondary lymphoma: multiple deep-seated lesions (T1-weighted sequences after IV Gadolinium infusion) in a patient suffering extranodal lymphoma diagnosed 4 years ago

There is no pathognomonic radiological and/or pathological criterion that suggests the primary or secondary nature of lymphoma when the brain parenchyma is involved (Fig. 4). A careful and specific search must be conducted despite the low rate of positivity observed in several series and even totally negative results found in others [11]. These tests should target the main sites involved by other types of lymphomas.

- Clinical examination  
Complete and careful clinical examination is necessary with special attention to lymph nodes areas, the testes, skin and upper airways.
- Radiological examinations  
Thoraco-abdominal CT-scan should be requested to look for deep-seated lymph nodes, pulmonary nodules, and visceral abnormalities. Special attention must be given to facial sinuses.  
Ultrasound examination of the testes is warranted.  
PET-scan could be another useful tool.
- Others  
A complete battery of blood tests including viral serologies should be obtained.  
Myelogram and bone marrow examination are also justified.

#### **4. DIAGNOSIS ASSESSMENT FOURTH PART OR IF IT IS A PRIMARY CNS LYMPHOMA, WHAT MUST WE DO?**

This stage is important for at least two reasons [1]. The first one is to ensure that the patient will receive appropriate therapy. The second is to evaluate the efficacy of therapy as well as to monitor the side-effects of treatment.

- Clinical evaluation  
Age and performance status are the two most widely documented prognostic variables. Eastern Cooperative Oncology Group (ECOG) performance status is the accepted standard for the International Prognostic Index (IPI) in systemic NHL. Equivalent values for ECOG and Karnofsky performance status are available. Evaluation of cognitive index using, at least, Mini Mental status is recommended.
- Laboratory investigation  
Serum lactate dehydrogenase has been identified as an independent prognostic factor.  
Hepatic and renal function (creatinine clearance >50 to 60 mL/min) are important to determine especially in patients who will receive high-dose methotrexate (MTX).
- CSF examination  
CSF examination with biochemical and cytological analysis are necessary. CSF cell count,  $\beta_2$ -microglobulin and immunoglobulin H gene rearrangement are useful.

Repeated detailed lumbar puncture is required when initially positive. Evidence of abnormal lymphocytes corresponds to leptomeningeal involvement for which intrathecal chemotherapy must be considered. One must keep in mind that autopsy studies have found leptomeningeal involvement in 100% of subjects who had PCNSL.

- Ophthalmologic examination  
Ocular slit-lamp, funduscopy, fluorescein angiography and ultrasound examinations should be performed. Repeated detailed ophthalmologic examination is required when initially positive.
- Neuroradiological examinations  
Gadolinium-enhanced MRI of the brain (or contrast-enhanced CT-scan in patients in whom MRI is contraindicated) is the standard.  
Spinal MRI in patients with spinal symptoms is mandatory.

## **TREATMENTS OF PCNSL IN IMMUNOCOMPETENT PATIENTS [7, 9]**

PCNSL may be considered as a localized extranodal lymphoma (stage IE/ IIE). For a similar stage in other extranodal lymphomas, local control is obtained in 75% to 90% of cases with 25 to 50 Gy. Overall outcome of radiation therapy alone provides a 5-year survival rate of 40% to 75%. However, in PCNSL, results (in terms of both quality and duration) are clearly different, corresponding instead to those obtained in glioblastoma. Another working postulate is to consider the microscopic extension through the CNS, in which case PCNSL corresponds to stage-IV aggressive systemic disease. If this is admitted, (1) a 5-year survival rate of 18% is not surprising, and (2) the ineffectiveness of radiation therapy is to be expected. PCNSL, as the vast majority of other primary CNS neoplasms, cannot be staged.

The median survival of patients who have PCNSL is 1.5 months with conservative treatment, range from 0.9 to 5.5 months with surgery, from 15.2 to 39 months after radiation therapy alone and from 16.1 to 42 months after irradiation and chemotherapy.

*Surgery.* In 1974, JM Henry wrote: "Today, surgery is carried out (for PCNSL) only as a diagnostic procedure and/or to implant a system suitable for intrathecal delivery of chemotherapy". Surgical removal of cortical expanding masses might have been performed when the diagnosis was not suspected.

*Radiation therapy.* PCNSL are highly responsive to conventional radiotherapy. Median survival was increased three-fold when radiotherapy was associated with surgery. Whole-brain irradiation has been the standard treatment for PCNSL for years. However, optimal doses, fractionation and fields have never been clearly established. Response is known to be dose dependent and efficacy is observed for a dose of 50 Gy in whole-brain irradiation. The amount of radiation (from 30 to 59 Gy) delivered to the primary site had no

effect on duration of survival, whereas the dosage administered to the whole brain did.

The optimum modality appeared to be a whole-brain dose of 45 to 50 Gy with a boost on the tumor bed to achieve 55 Gy. Some authors did not use boost irradiation of the tumor site arguing that there were equal frequencies of recurrence both within and outside the boosted area. This last point provides the evidence that microscopical extension of lymphoma cannot be predicted from neuroradiologic features. Higher doses improve neither local control nor survival and saddle the patient with a very high risk of leukoencephalopathy.

In ocular PCNSL, the posterior two thirds of the globe must be irradiated (35 to 45 Gy).

Currently, systematic spinal cord irradiation is not indicated. Irradiating a substantial volume of bone marrow may limit subsequent administration of chemotherapy.

Analyzing results of exclusive radiotherapy 15 years ago, Andrés Ferreri and co-workers found a 1-year survival rate of 66%, a 2-year survival rate of 43% and a 5-year survival rate of 7%; the best median survival was 24 months. In other terms, long-term local control is rarely obtained with radiotherapy alone. Additionally, radiotherapy is associated with an increased likelihood of treatment-related neurotoxicity. These relatively poor results have prompted the search for new therapeutic approaches especially combined-modality therapy.

*Chemotherapy.* At first, chemotherapy was used only in cases of relapse. Progressively, it was used as an adjuvant to radiotherapy. From a review including 1100 patients, median survival was 16.6 months for patients treated with radiotherapy alone versus 29.1 months when chemotherapy was added. Despite a wide heterogeneity in protocols, median survival has been clearly improved, now reaching up to 24 months [6].

Scientific, empiric ideas and ideologies precluded the rationale for chemotherapy in PCNSL. Chemotherapy is the appropriate treatment in advanced systemic NHL. CHOP chemotherapy followed by locoregional irradiation in stage I or II aggressive NHL produced a complete remission rate of 98%. In view of this, it would not appear unreasonable to hope for similar results in PCNSL using the same effective drugs with the same effective protocols. Thus, steroids, MTX, nitrosoureas, alkylating agents, anthracyclines and other agents have been used alone or in association. Unfortunately, many results have been negative, notably with CHOP (i.e. the gold standard in systemic lymphomas). Transposition from systemic NHL to PCL cannot be achieved properly. Crossing the BBB is the first problem and its therapeutically induced restoration could cause intracerebral drug concentrations to decline hindering the subsequent efficacy of treatment.

The best results have been observed with chemotherapeutic regimens that include MTX. Efficacy of MTX was demonstrated 20 years ago both in CNS

localizations of systemic lymphoma or in recurrence of PCNSL. Responses were observed in 60% to 100% of the cases with an increased rate of survival at 12 and 24 months. Brain penetration of MTX is weak because of its low liposolubility. The intraarterial route was also tried with and without opening the blood-brain barrier but results on survival were quite similar. Increasing the dose of MTX was proposed twenty years ago. It is used in doses of 1 to 8 mg/m<sup>2</sup>. With a dose of 3 g/m<sup>2</sup> delivered continuously in three hours, MTX reaches micromolar levels in the CSF that are thought to be therapeutic, for 24 hours. With lower doses, adequate concentrations are not obtained in all patients (in only 22% when 1 g/m<sup>2</sup> is administered). However, neurologic and systemic complications of MTX are substantial. Administration of tetrahydrofolate derivatives limits the systemic toxicity of MTX, while urine alkalization and hyperhydration limits its renal toxicity. MTX-related leukoencephalopathy has been observed after isolated intravenous or intrathecal administration with or without combined radiotherapy. Other drugs such as arabinoside (Ara-C), nitrosourea have also been tested.

In theory, intrathecal or intraventricular drug administration is useful when lymphoma cells are present within the CSF. High intravenous doses of either MTX or Ara-C can yield therapeutic concentrations in the CSF and may represent an alternative to intrathecal therapy.

New active drugs and therapeutic options are currently under evaluation [11]. High-dose chemotherapy with autologous peripheral blood stem transplantation is an investigational therapeutic alternative. Temozolomide, rituximab (a chimeric monoclonal antibody directed against the B-cell specific antigen CD20), and topotecan are also tested.

Timing of chemotherapy, route of administration, use of a single agent or combination regimens, and manipulation of the blood-brain barrier offer many variations on the theme but many questions still remain to be answered. However, three points should be kept in mind.

1. Adverse effects of radiation therapy have been widely reported and imposed a firm limit on this treatment. Similarly, a high incidence of delayed neurotoxicity has been observed with MTX or polychemotherapy regimens. The rates of both immediate mortality and morbidity due to chemotherapy have been evaluated at around 10% each. In several series, an even larger percentage of patients (25% to 50%) did not receive full-dose chemotherapy due to early adverse effects. The very high percentage of immediate mortality must be taken into account when expressing results. Finally, only selected patients can be enrolled in polychemotherapy protocols due to the high acute toxicity or the modality of treatment.

2. Despite the widely used association of radiation therapy and chemotherapy, controlled trials designed to analyze the different arms of treatment have never been conducted. Is it appropriate to test so many drugs in so many ways despite the fact that a gold standard treatment of PCNSL has not yet been established? Is intrathecal administration mandatory in patients with

normal CSF? What are the optimum schedules in older patients in view of their higher sensitivity to both chemotherapy and radiation therapy? Considering that radiation therapy seems to be called for after upfront chemotherapy and that postirradiation chemotherapy is deleterious, what should one resort to in recurrences?

3. Results in terms of duration of survival cannot be transposed directly from a selected population of patients enrolled in a trial to the overall population of patients who have the same disorder. Improvement of results reported by controlled series can be in part due to the selection of patients. This aspect has been debated for gliomas. Overall survival has not improved consistently in the past three decades in studies on population-based cohort.

## HOW TO AVOID COMPLICATIONS

### 1. STEROID SENSITIVITY

When suspecting CNS lymphoma, avoiding corticosteroid before diagnosis is of paramount importance.

Glucocorticoids constitute a major therapy for a broad spectrum of haematological malignancies including CNS involvement. Cerebral and systemic lymphomas frequently respond to corticoid treatment to such an extent that clinical, radiological and pathological aspects disappear in a matter of days within administration.

In clinical series, disappearance of the lesion has been observed in 30% to 40% of patients with PCNSL. Complete remission can be obtained within a days. In such cases, microcystic cavitation, reactive gliosis and residual perivascular T-lymphocyte cuffing without lymphomatous proliferation are observed histologically. After discontinuation, the result can persist from weeks to years. In most cases, the sites involved at relapse differ from those initially affected.

The relative specificity of the cortico-induced remission has been used by some authors, either as a strong indicator of positive diagnosis or as sufficient in itself for diagnosis. For a large majority of authors, tumor shrinkage may interfere with confirmation of diagnosis and subsequent treatment. Vanishing lesion are lymphoma in only 50% of the cases.

Two pathophysiological mechanisms have been proposed to explain the disappearance of the lesion. The first is that corticoids are known to restore the normal BBB impermeability, limiting enhancement after contrast infusion. Glucocorticoids have a direct cytotoxic effect on lymphomatous cells *via* a specific membrane glucosteroid receptor involved in apoptotic phenomena. Extensive works have been done in order to clarify the precise nature of the receptor and the molecular mechanisms [7]. There are significantly more receptors on lymphomatous cells than on normal lymphocytes. There is a

**Table 2.** Ocular involvement and lymphoma type

	Primary Lymphoma		Secondary Lymphoma
Extraocular			
	Conjunctival, orbital, lacrimal		Conjunctival, orbital, lacrimal
Intraocular			
Choroid	Primary choroidal lymphoma		Secondary choroidal lymphoma
<i>Comments</i>			<i>Frequent disease, low-grade B cells</i>
Vitreous cavity Specific sites in the retina Not the choroid	Primary intraocular lymphoma (PIOL)	Intraocular PCNSL	Secondary lymphoma with vitreous and retinal involvement
<i>Comments</i>	<i>Precede CNS involvement in about 50% to 80% of the cases</i>	<i>Present in about 20% of the patients at time of diagnosis</i>	<i>Rare disease</i>

proportional relationship between the number of receptors and the intensity of the corticoid-induced response. However, this response cannot be predicted by histological assessment.

Not using the term “ghost-tumor” with corticoid-induced regression of CNS lymphoma is of paramount importance. The term “ghost-tumor” should be reserved for spontaneous disappearance of the lesion. This peculiar feature, in which apoptotic phenomena may be involved, has been reported in more than 20% of low-grade systemic NHL. Less than 20 cases of spontaneous regression of PCNSL have been reported (review in [11]).

## 2. WITH LYMPHOMA: THINK OCULAR [4]

There are many forms of ocular manifestations in lymphoma (Table 2). Extraocular lymphomas are beyond the scope of this chapter. Optic chiasm or nerve involvements have rarely been reported. They may be either the primary site of the disease or a metastasis from systemic, orbital or CNS localizations. Ocular involvement is more frequently observed in NHL than in Hodgkin’s lymphoma. The importance of intraocular lymphomas lies in the fact that, in more than 50% of cases, they herald the presence or the development of extraocular lymphoma. A number of studies have suggested that primary intraocular lymphoma (PIOL) is a subset of PCNSL. Patients who have PCNSL or PIOL have been found to be comparable in terms of demographic data. In about 20% of patients with PCNSL, ocular involvement is associated at the time of diagnosis. In about 50% to 80% of patients with PIOL, ocular



manifestations preceded CNS involvement with a median delay of 6 to 20 months. At last, in about 20% of patients with ocular lymphoma, systemic dissemination will occur during follow-up, and in additional 5% to 10%, both systemic and cerebral secondary localizations will occur.

In these diseases lymphoma predominantly involves the vitreous, sensory retina and subretinal pigment epithelial space explaining clinical complain and diagnostic difficulties. Clinically, the patients complained of floaters, blurred vision or decreased visual acuity. In most of these cases, nonspecific chronic uveitis or vitreitis was diagnosed initially. Steroid-sensitivity is usual, but the response is transient and the disease recurs. Unilateral symptoms were initially observed, but at time of diagnosis, the disease was bilateral in most of cases. Eye examination showed decreased visual acuity, mild anterior segment inflammation and subretinal yellow infiltrates. The results of slit-lamp examination and ocular ultrasound are very suggestive of the diagnosis. With normal CSF cytology, the diagnosis may be confirmed by vitrectomy or by choroidal/retinal biopsies (see diagnostic procedures).

Ocular lymphoma is hard to recognize due in part to its protean clinical manifestations and in part to the difficulties involved in sampling for pathology. When suspecting ocular lymphoma neurological work-up including clinical, neuro-radiological, and CSF examinations must be done. Conversely, when suspecting PCNSL ocular work-up must be done. Treatment of isolated ocular lymphoma is not standardized.

### **3. NEUROTOXICITY**

Neurotoxicity is a potential devastating complication that can occur in response to antineoplastic therapies [4]. For other brain tumors such as gliomas, this has been well documented and therapeutically induced late toxicity is clearly correlated with age, the association of radiation and chemotherapy, and the duration of survival and follow-up. This complication can manifest in a variety of ways, including impaired cognition, ataxia, and incontinence, and is associated with a significant decline in the quality of life. Patients affected by neurotoxicity often demonstrate MRI signal abnormalities in the periventricular white matter of both hemispheres. This leukoencephalopathy is not always correlated with cognitive impairment, especially in patients treated only with chemotherapy. Autopsy studies have suggested a vascular injury. Polymorphism of enzymes involved in the folate pathway, and hereditary defects leading to S-adenosylmethionine deficiency, and brain demyelination, could be strong indicators of risk.

Generally accepted risk factors for late neurotoxicity include age over 60, higher doses of radiation, higher daily fractions of radiation therapy, and chemotherapy such as MTX. Progressive cognitive dysfunction has been reported in 20% to 40% of patients treated with MTX and radiotherapy. Using multivariate analysis, a clear relationship has been demonstrated between

occurrence of late neurotoxicity and radiation therapy followed by chemotherapy. Cranial irradiation increases BBB permeability, an increase that can persist for weeks. Any water-soluble agent would have greater access to normal brain parenchyma if administered after whole-brain irradiation.

Series using upfront chemotherapy have reported not only a very high range of complete response, but also an improvement in cognitive functions. This point is of paramount importance because cognitive impairment has frequently been observed after, either whole-brain radiation therapy or combined-modality therapy especially in older patients. Upfront chemotherapy seems to be effective in older patients, in whom radiation therapy could salvage those who relapse after chemotherapy. Lastly, preirradiation chemotherapy could result in less neurotoxicity.

Potential candidates for experimentations on treatment of cognitive deficit are currently under investigation (among others donepezil, dextromethorphan, methylphenidate, aminophylline).

## CONCLUSIONS

CNS involvement is observed in several situations and the most challenging of them is represented by PCNSL. It remains a rare tumor limiting the experience of physicians managing this kind of problem. Similarities between systemic NHL and PCNSL are only apparent.

For several reasons, chemotherapy appears to be the most appropriate therapy. However, complete response to chemotherapy is not synonymous with microscopic ablation of lymphoma cells and does not obviate the necessity of irradiation. Moreover, specificities of the CNS limit the expected benefit of multimodality therapies. A gold standard treatment of PCNSL has not yet been established. CNS lymphomas remain in most cases aggressive malignancies requiring precise diagnosis and staging. Attention must be paid to the high level of steroid sensitivity of these lesions and to the high rate of ocular involvement. When managing PCNSL, the challenge is to associate prolonged survival and low rate of cognitive dysfunction.

## References

- [1] Abrey LE, Batchelor TT, Ferreri AJ, Gospodarowicz M, Pulczynski EJ, Zucca E, Smith JR, Korfel A, Soussain C, DeAngelis LM, Neuwelt EA, O'Neill BP, Thiel E, Shenkier T, Graus F, van den Bent M, Seymour JF, Poortmans P, Armitage JO, Cavalli F (2005) Report of an international workshop to standardize baseline evaluation and response criteria for primary CNS lymphoma. *J Clin Oncol* 23(22): 5034-5043
- [2] Bataille B, Delwail V, Menet E, Vandermarcq P, Ingrand P, Wager M, Guy G, Lapierre F (2000) Primary intracerebral malignant lymphoma: report of 248 cases. *J Neurosurg* 92(2): 261-266

- [3] Batchelor T, Loeffler JS (2006) Primary CNS lymphoma. *J Clin Oncol* 24(8): 1281-1288
- [4] Bessell EM, Hoang-Xuan K, Ferreri AJ, Reni M (2007) Primary central nervous system lymphoma: biological aspects and controversies in management. *Eur J Cancer* 43(7): 1141-1152
- [5] Ferreri AJ, Blay JY, Reni M, Pasini F, Spina M, Ambrosetti A, Calderoni A, Rossi A, Vavassori V, Conconi A, Devizzi L, Berger F, Ponzoni M, Borisch B, Tinguely M, Cerati M, Milani M, Orvieto E, Sanchez J, Chevreau C, Dell'Oro S, Zucca E, Cavalli F (2003) Prognostic scoring system for primary CNS lymphomas: the International Extranodal Lymphoma Study Group experience. *J Clin Oncol* 21(2): 266-272
- [6] Ferreri AJ, Reni M (2007) Primary central nervous system lymphoma. *Crit Rev Oncol Hematol* 63(3): 257-268
- [7] Frankfurt O, Rosen ST (2004) Mechanisms of glucocorticoid-induced apoptosis in hematologic malignancies: updates. *Curr Opin Oncol* 16(6): 553-563
- [8] Go JL, Lee SC, Kim PE (2006) Imaging of primary central nervous system lymphoma. *Neurosurg Focus* 21(5): E4
- [9] Gunduz K, Pulido JS, McCannel CA, O'Neill BP (2006) Ocular manifestations and treatment of central nervous system lymphomas. *Neurosurg Focus* 21(5): E9
- [10] Hoang-Xuan K, Camilleri-Broet S, Soussain C (2004) Recent advances in primary CNS lymphoma. *Curr Opin Oncol* 16(6): 601-606
- [11] Loiseau H, Cuny E, Vital A, Cohadon F (2000) Central nervous system lymphomas. *Adv Tech Stand Neurosurg* 26: 79-124
- [12] Omuro AM, Abrey LE (2006) Chemotherapy for primary central nervous system lymphoma. *Neurosurg Focus* 21(5): E12



**Hugues Loiseau**

Hugues Loiseau is Professor of Neurosurgery at the Hôpital Pellegrin Tripode, Bordeaux. Born in 1957, medical study at the University of Bordeaux, Professor of Neurosurgery since 1999. Main topic: neuro-oncology.

**Contact:** Hugues Loiseau, Department of Neurosurgery, University of Bordeaux 2, Hôpital Pellegrin Tripode, Place Amélie Raba Léon, 33076 Bordeaux, France  
E-mail: [hugues.loiseau@chu-bordeaux.fr](mailto:hugues.loiseau@chu-bordeaux.fr)

---

# MANAGEMENT OF ANTERIOR FOSSA LESIONS

E. KNOSP

## INTRODUCTION

The approach to the anterior cranial fossa, its development and modifications represent the history of neurosurgery itself. In the pioneering days of neurosurgery frontal approaches included a partial frontal lobe resection – the transfrontal approach by *Dandy* and also by *Cushing* to reach frontobasal tumors. Soon later F. Krause, W. Dandy and H. Olivecrona advocated a subfrontal instead of a transfrontal approach to resect lesions like tuberculum sellae meningioma, olfactory meningioma or pituitary adenomas [15, 19]. It is still advisable to read the classical monograph “Meningiomas” by Cushing and Eisenhardt to see their methods, their problems and concepts in these pathologies [7]. Light and magnification are combined in the operating microscope and were the most powerful factors of development and improvement. This big technological step leads to the era of modern microneurosurgery. Many large series of meningiomas of the skull base, including tumors of the anterior cranial fossa, were published in the following years [1, 2, 4, 10, 13, 29, 30]. Olfactory meningiomas and tuberculum sellae meningiomas are the key pathologies in surgery of the anterior cranial fossa.

## RATIONALE

The success of an operation depends on the appropriate approach. In this regard it is not at all true that all roads lead to Rome. This in mind the discussion on “approaches” became a fruitful soil over the decades for the benefit of patients. In this context I want to point out that not only the exact location of a lesion, but also the pathology is of importance. With these two fundamental prerequisites in mind I strongly recommend to have textbooks of neuroradiology and neuroanatomy, e.g. “Diagnostic imaging” by *A. Osborn* [20] or *A.L. Rhoton* and/or *J. Lang* [17, 24].

## DECISION-MAKING

The decision for an approach depends mainly on:

- location of the lesion
- presumed pathology

---

*Keywords:* skull base, anterior fossa lesions, tumors

- goals of surgery (biopsy, partial resection, radical resection)
- necessity of reconstruction
- experience and concepts of the surgeon

The size of the craniotomy should not be exaggerated, but should be decided in accordance with the above mentioned statements. I suggest to avoid “bomb crater surgery”, in other words I try to tailor the approach to the size of the lesion. This means e.g. to perform a large craniotomy with a much smaller dura opening without splitting of the Sylvian fissure to resect a small clinoidal meningioma. I suggest to think about the keyhole concept of surgery and to find your personal way to reach your goal. Another recommendation is to make the approach as simple as possible.

The discussion about the best approach to remove olfactory meningiomas – bifrontal or subfrontal – is an excellent example, because the subfrontal approach is simple, has less complications and provides the same results. A normal-sized subfrontal approach allows the removal of almost every olfactory meningioma. It is fast and usually avoids opening of the frontal sinuses. The splitting of the Sylvian fissure enables the surgeon to release CSF at an earlier stage than in the bifrontal approach. The main advantage, however, is that the landmarks and the most important structures in this approach, the ICA and the optic nerve, are detected and dissected early during the procedure. With these informations, devascularisation of the tumor is more effective and less dangerous. By extensive endocapsular tumor resection the tumor itself provides the approach for its own removal. In this stage neuronavigation is very helpful for the better estimation of the remaining capsule. Finally the dissection of the tumor surface is performed along the ICA, the anterior cerebral artery and the communicating complex with its perforators, the A2 segments and the frontopolar arteries of both sides.

Another argument for an unilateral approach is that you do not elevate or compress or retract both frontal lobes – at least in a much less extent. The discussions whether the subfrontal or the pterional approach would be superior to resect a tuberculum sellae meningioma are very long. In my experience, the more lateral (pterional) approach needs more manipulation on the ipsilateral optic nerve than a more medial (subfrontal) one. As soon as a tumor involves the anterior clinoid process, I prefer a pterional approach. I want to point out that the sphenoidal ridge and the clinoid process serve as a clear distinction for the indication to use a subfrontal or a pterional approach.

Indications are summarized in Table 1.

Table 1 shows the indications for the different approaches according their typical appearance and typical pathologies. The involvement of the sphenoid ridge and/or anterior clinoid process are an indication for a pterional approach. The presumed or proven diagnosis of malignancy in frontobasal tu-

**Table 1.** Indications for different approaches

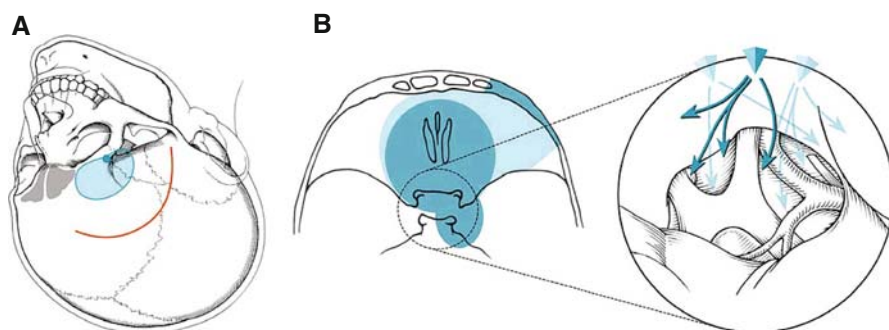
<p style="text-align: center;"><b>Subfrontal standard supraorbital eyebrow approach</b></p> <p>Meningiomas of the</p> <ul style="list-style-type: none"> <li>• olfactory groove</li> <li>• planum sphenoidale</li> <li>• tuberculum sellae</li> <li>• diaphragma sellae</li> </ul> <p>Aneurysms of the</p> <ul style="list-style-type: none"> <li>• anterior communicating complex</li> <li>• internal carotid artery (anterior wall)</li> <li>• ophthalmic artery (contralateral)</li> <li>• posterior communicating artery if projecting laterally</li> </ul>	<p><b>A N T E R I O R  C L I N O I D  P R O C E S S</b></p>	<p style="text-align: center;"><b>Pterional approach</b></p> <p>Meningiomas involving the sphenoid ridge</p> <ul style="list-style-type: none"> <li>• sphenoid ridge meningiomas</li> <li>• clinoidal meningiomas</li> <li>• optic sheath meningiomas</li> <li>• cavernous sinus meningioma (if surgery is indicated)</li> <li>• orbital meningiomas (superior and lateral quadrant)</li> </ul> <p>Aneurysms of the</p> <ul style="list-style-type: none"> <li>• posterior communicating artery</li> <li>• basilar tip</li> <li>• superior cerebellar artery</li> </ul>	
<b>MALIGNANCY</b>		<b>FUTURE APPLICATIONS?</b>	
<p style="text-align: center;"><b>Bifrontal approach</b></p> <p>Carcinomas of the</p> <ul style="list-style-type: none"> <li>• ethmoid</li> <li>• paranasal sinus</li> <li>• orbit</li> </ul> <p>Esthesioneuroblastomas</p> <p><b>2/3 unilateral variant of the approach</b></p> <p>Craniopharyngiomas Hypothalamic tumors Complex anterior communicating artery aneurysms</p>	<p><b>F U T U R E  I N D I C A T I O N</b></p>	<p style="text-align: center;"><b>Extended transsphenoidal approach</b> (Indications are still in discussion)</p> <p>Invasive pituitary adenomas Craniopharyngiomas Tuberculum sellae meningiomas Esthesioneuroblastomas</p>	

mors are a clear indication for a bifrontal approach, which allows adequate resection and reconstruction. The extended transsphenoidal approach may be an alternative for many above mentioned tumors, if the problem of closure is solved. But the indications are still discussed controversially.

## SURGERY

### 1. THE SUBFRONTAL APPROACH (Fig. 1)

The subfrontal approach is the prototype approach to resect intradural tumors of the anterior skull base, e.g. tuberculum sellae meningioma



**Fig. 1.** The subfrontal approach. **A** Head turning of 30° (i) interfascial dissection of the muscle with retraction of the temporalis muscle, (ii) frontal craniotomy beginning from the key borehole, (iii) the basal cutline must be at the level of the anterior fossa. **B** The area usually reached by this approach. The corridors which may be used to resect lesions beyond the anterior fossa between the optic nerves (see also Fig. 3) (i) the optic nerve and the carotid artery, (ii) the carotid artery and the oculomotor nerve

and olfactory meningioma, or to clip an anterior communicating artery aneurysm.

Surgical technique of the (standard) subfrontal approach:

In supine position the body is slightly elevated and the head is fixed by Mayfield clamp, slightly extended and turned approximately 30° to the left side, allowing the frontal lobe to fall slightly back by gravity. A turning of approximately 30° means that the external rim of the orbit is horizontal and the tuber maxillae is the highest point of the head.

We start with shaving of a 1–2 cm strip which allows cleaning and draping the skin. The skin incision starts preauricular and is continued usually to the midline. In patients with high hairline the incision sometimes crosses the midline. The scalp vessels are coagulated, no skin clips or clamps are used. After dissection of the periosteum, the scalp is retracted with hooks, and the incision of the periosteum is performed along the superior temporal line, starting at the supraorbital rim. Approximately 2–3 cm from the supraorbital rim an incision of the periosteum is performed towards the supraorbital incision, creating a “sharkfin” like periosteal flap. This flap is flected caudally and is also retracted together with the skin by hooks. In case of opening of the frontal sinus – intentionally or accidentally – this small flap provides as vascularised cover of the frontal sinus, preventing a CSF leak. The size of the sharkfin-like flap depends on pneumatization of the frontal sinus and can be tailored to the expected opening. If the frontal sinus is opened, the mucosa from the bone flap has to be removed precisely; the mucosa of the frontal sinus leaves untouched.

The superficial fascia of the temporalis muscle is incised and retracted as far to the sutura fronto-squamosa. The key borehole is drilled by high speed



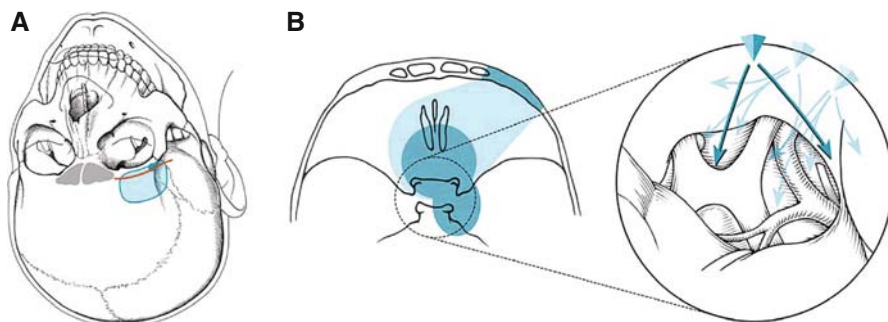
drill just anterior to the crest of the sphenoid wing. Starting from this bore-hole a 3–4 cm long and 2.5 cm high bone flap has to be removed. In a typical subfrontal approach, the lesser sphenoid wing is not exposed and removed (in contrary to the pterional approach). The critical point of a subfrontal craniotomy is not the size, but that the basal cutline. It should be as low as possible – ideally at the level of the anterior fossa. This should be accomplished – regardless of the pneumatization of the frontal sinus. Flattening the inner table of the skull with the diamond drill is mandatory and helps to reduce brain retraction. If necessary, juga cerebraia from the orbital roof have to be drilled too which helps to avoid compression of the frontal lobe.

The dura is fixed by tacking sutures through small bone holes at an early stage of the surgery, keeping the operation field as clear as possible. Dura incision follows the superior margin of the craniotomy and the dura is fixed caudally by staying sutures. The margins of the craniotomy are covered by cotton pads just before the microscope is introduced into the operation field.

The frontal lobe is gently retracted to identify the suprachiasmatic cistern which is opened by diamond knife. This incision is enlarged by scissors or the diamond knife to the opposite optic nerve and later into the medial third of the Sylvian fissure, usually from medial to lateral. At this stage of operation I advocate to take time to drain CSF until there is enough space for further dissection. This avoids retraction of the frontal lobe and provides workspace. Whenever possible, perform surgery without retractors (“retractorless surgery”). Now the olfactory tract can be identified and dissected if necessary. Depending on the approach, the intracranial pressure and the tumor location, the splitting of the Sylvian fissure can also be performed from lateral to medial. The advantage starting from lateral is that the Sylvian fissure is still full of CSF facilitating dissection between the superficial veins and the middle cerebral artery branches. As soon as the olfactory tract, the chiasm and the internal carotid artery with its major branches are identified, dissection of the tumor is started. The further dissection is performed along the arachnoid planes. If you stay within the arachnoid cleavage plane you can avoid damage of important structures best. In case of a meningioma the further step is to devascularise the tumor from the dura as early as possible and then to reduce the size of the tumor by endocapsular resection, using suction or CUSA. After these maneuvers dissection is much easier to accomplish.

## 2. THE SUPRAORBITAL EYEBROW APPROACH (Fig. 2)

The supraorbital eyebrow approach is the smallest variant of a subfrontal approach to anterior fossa and central skull base pathologies. This elegant small approach is an alternative to the standard subfrontal approach, mainly for small or medium sized intradural lesions.



**Fig. 2.** The supraorbital eyebrow approach: (i) this is a minimal invasive variant of the subfrontal approach, which requires slim instruments and surgical experience, (ii) it is somewhat limited towards lateral (temporal), (iii) preferably used in smaller tumors strictly limited to the anterior cranial fossa

In this approach the positioning of the head and the angle of the approach is of much more importance than in the subfrontal approaches described above.

The angle of view varies from 15 to 20° flexion for supra- or retrosellar lesions to 45–60° for lesions at the anterior part of anterior fossa floor.

The skin incision is within the eyebrow and starts from the supraorbital incisure sparing the frontal nerve and reaches to the lateral end of the eyebrow (in some cases a few millimeters laterally).

After incision of the frontalis and the orbicularis oculi muscles the temporal muscle is detached at the superior temporal line similar to the subfrontal approach. The skin and the muscles are retracted by strong (temporary) sutures. Self stretching retractors would hamper the surgeon and reduce the flexibility during the procedure.

Craniotomy starts from the borehole drilled behind the temporal line along the orbital rim to the supraorbital incision. A second cut is done in a C-shape fashion from the borehole to the supraorbital foramen. By precise retraction and protection of skin and muscles during craniotomy a 2.5 × 2 cm bone flap can be removed.

In this limited approach it is more important to drill the inner table at the frontal base than in the subfrontal approach. Although there are gained only a few millimeters, it is necessary to enlarge the approach by resecting the inner edge of the craniotomy.

The dura is opened in a usual way and fixed by sutures.

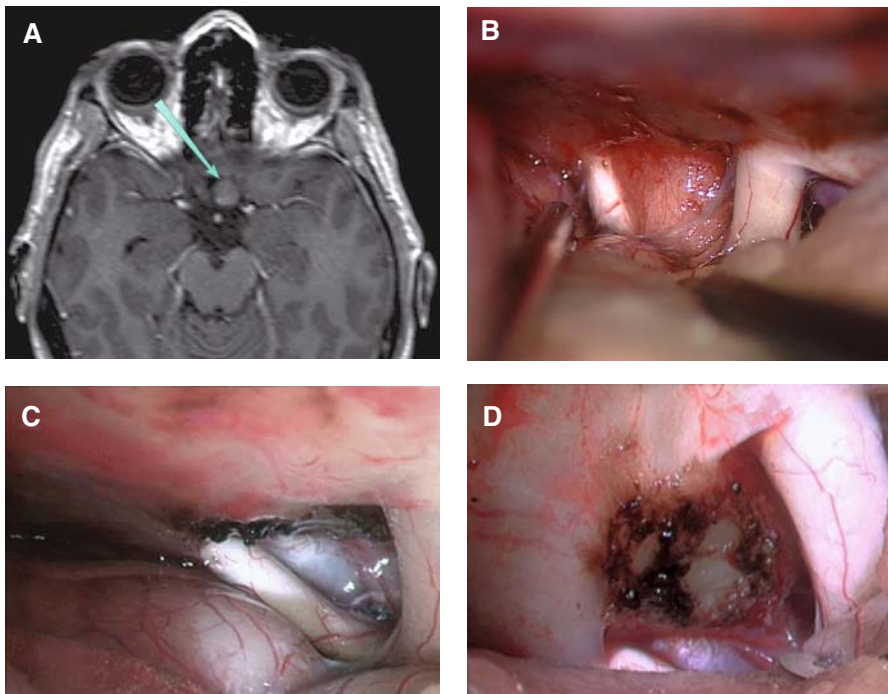
For using this approach slim instruments are necessary and the application of endoscopes to look around hidden corners is synergistic and is part of the concept of minimal invasive keyhole surgery as advocated by A. Perneczky [22, 23, 25].

### 3. THE CONTRALATERAL SUBFRONTAL APPROACH

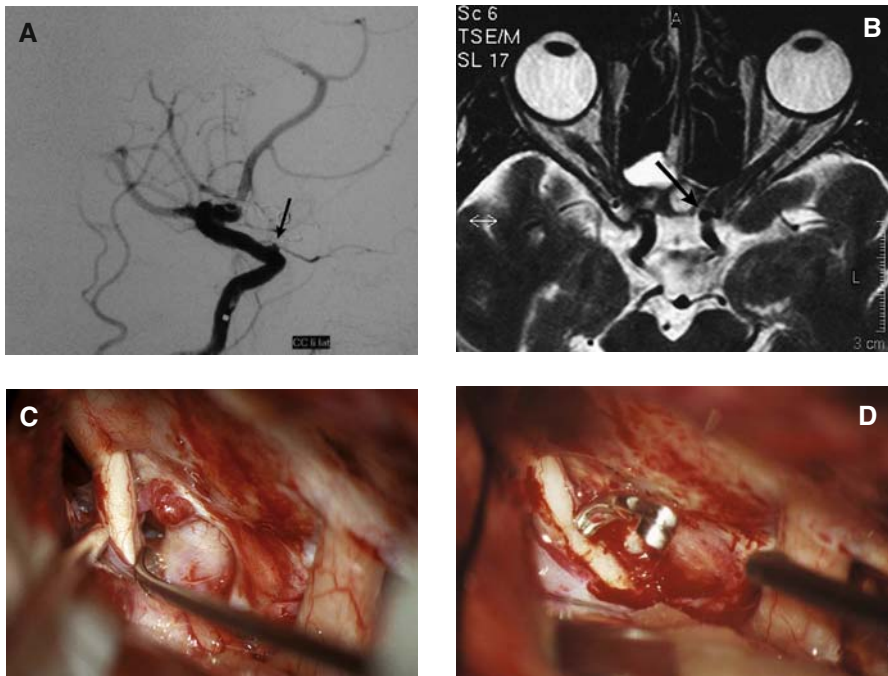
Small lesions medial to the optic nerve and at the medial circumference of the ICA are best approached by a contralateral one – either using a subfrontal or supraorbital approach. Tuberculum sellae meningiomas which are not strict in the midline, but a asymmetrical, represent an ideal indication for a contralateral approach (Fig. 3A). Detailed anatomical knowledge is important for clipping these aneurysms [21] and for removing tumors from the contralateral optic canal (Figs. 3, 4).

One has also to take account that there is a difference of the dura niveau (dural ring) between the lateral aspect of the ICA and its medial side. This difference results from the anterior clinoid process, which is approximately 5 mm.

Small medially projecting ophthalmic aneurysms and aneurysms arising from the superior hypophyseal artery – so called “carotid cave” aneurysms represent another ideal indication for this approach (Fig. 4).



**Fig. 3.** A small (asymmetrical) tuberculum sellae meningioma compressing the left side. Before (A) and after resection (B) by a right-contralateral approach. (C) Endoscopic visualisation of the hidden corner at the ipsilateral optic canal (30° straight endoscope).



**Fig. 4.** Small ophthalmic aneurysm on the left ICA (A, B). Contralateral (right) subfrontal approach before (C) and after (D) clipping

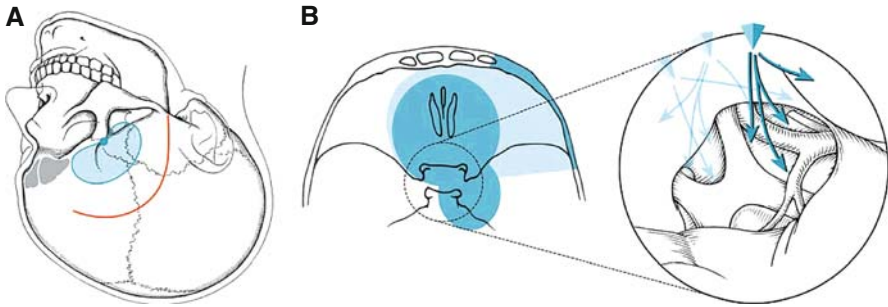
#### 4. THE PTERIONAL APPROACH (Fig. 5)

There are significant and important differences between the subfrontal and pterional approach:

The main preparation in a pterional approach is along the lesser sphenoid wing, that means that the rotation of the head is  $45^\circ$  from the median sagittal line.

The extradural resection of the sphenoidal wing together with the splitting of the Sylvian fissure are synergistic effects to gain space between the frontal and the temporal lobe.

The additional mild retroflexion of the head of  $10^\circ$  will create an ideal situation for retractorless surgery in which the frontal and temporal lobes were alternately pushed gently aside to reach the lesion. By doing so, this approach provides the shortest route to the supraclinoidal internal carotid artery and to its branches, but also to deep-seated areas of the retroclival and retrochiasmatic/supra/parasellar space.



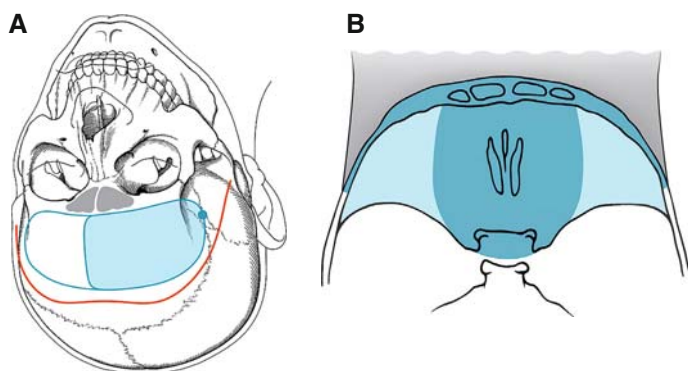
**Fig. 5.** The pterional approach. Head rotation  $45^\circ$  (i) interfascial dissection is more important, because the temporalis muscle has to be incised and released from the planum temporale, (ii) after frontal and temporal craniotomy extradural resection of the lesser sphenoid wing is necessary, (iii) splitting of the Sylvian fissure. These two manoeuvres provide the working space in this approach

But there are further differences to the subfrontal approach:

- An interfascial dissection between superficial and deep temporal fascia to protect the frontal branch of VII in order to avoid damage is more important than in the subfrontal approach.
- A longer posterior incision along the superior temporal line is necessary to detach the temporalis muscle.
- The incision of the temporalis muscle should be done along its oblique fibers and not perpendicular to them.
- The borehole is drilled exactly at the sphenoid wing, which allows opening the frontal and the temporal fossa with one borehole. The following craniotomy is centered to lesser sphenoid wing with equal size of the craniotomy above and below the sphenoid ridge.
- The extradural removal of sphenoid wing with diamond drill is performed until to reach the lateral aspect of the superior fissure. If necessary, the extradural bone resection can include the anterior clinoid process (*Dolenc* technique), but this manoeuvre is rarely necessary and needs a lot of experience.

## 5. THE BIFRONTAL APPROACH (Fig. 6)

In supine position the head is minimally reclined, without flexion. After shaving and draping a coronar incision is performed from one ear to the other well behind the hairline. In most cases a bifrontal approach is performed to have a big periosteum flap which allows a frontobasal reconstruction. Its size should be according to the expected defect at the anterior fossa. Because the flap is of paramount importance to avoid CSF leaks a pediculated, vascularised peri-



**Fig. 6.** The bifrontal approach. Rarely used for intradural benign lesions; (i) only used, if frontobasal reconstruction is required (malignant tumors or trauma); (ii) the size and the quality of the periosteal flap is the critical point to achieve a perfect "dura" closure; (i) a 2/3 bifrontal craniotomy may be indicated if interhemispheric dissection is necessary

steom is necessary. It is better to have an oversized flap to assert a perfect closure of the dura.

The temporalis muscle is incised at the linea temporalis and retracted posteriorly. A borehole trepanation is performed on each side, a further one is made at the midline directly over the superior sagittal sinus. Starting from the sagittal borehole the craniotomy is performed to the temporal boreholes and is then continued across the midline. The basal cutline opens the frontal sinuses and it may be difficult to perform near the midline.

The inner wall of the frontal sinus (or the inner table) can be removed in order to have better access to the anterior skull base and the olfactory groove as the deepest point of anterior skull base.

The dura incision is performed one centimeter parallel above to the basal cutline and the superior sagittal sinus is ligated (not clipped because it creates artefacts in MRI) and cut together with the falx.

Further steps depend on the nature of the lesion to treat. In most pathologies necessitating a bifrontal approach the olfactory function is already damaged, or in malignances is not relevant to preserve. In some cases however, dissection and preparation of the olfactory nerves are necessary to save olfaction [28].

For me there are rare indications for a bifrontal craniotomy, e.g. for some craniopharyngeomas or hypothalamic gliomas. In these cases in which I need a median anterior approach I prefer a 2/3 bifrontal approach usually on the right side – instead of the classical bifrontal one.

In this variant the bone flap is done on the right side – for a right handed surgeon and a right handed patient – crossing the midline only 1.5–2 cm. In this variant I open the dura unilaterally only. This approach allows to dissect the interhemispheric fissure as well as the anterior skull base. This is necessary

in complex anterior cerebral artery or anterior communicating aneurysms or hypothalamic lesions. The big advantage of this approach is that it avoids retraction on both frontal lobes because one frontal lobe is protected by dura and the falx during interhemispheric dissection. This slightly oblique approach also allows a reconstruction of skull base in small and middle sized defects with bone (e.g. split calvaria) as well as a watertight dura closure with a pediculated periosteal flap. In these cases it is mandatory to achieve the watertight closure with sutures.

In extended cases where it is necessary to resect tumors close to the optic canals, including the tuberculum sellae, it is advisable to prepare 4–6 staying sutures at the deepest points of the dura reconstruction and then to bring the periosteal flap “curtain like” into the depth. After that the sutures have to be knotted and secured by fibrin glue.

## 6. THE EXTENDED TRANSSPHENOIDAL APPROACH

With increased experience in endoscopic transsphenoidal surgery for pituitary adenomas, craniopharyngiomas and anterior skull base tumors like tuberculum sellae meningiomas or esthesioneuroblastomas are in the scope of extended transsphenoidal approaches. Anatomical studies and first surgical reports demonstrate that endoscopic transsphenoidal approaches to anterior skull base pathologies are feasible [6, 12, 14].

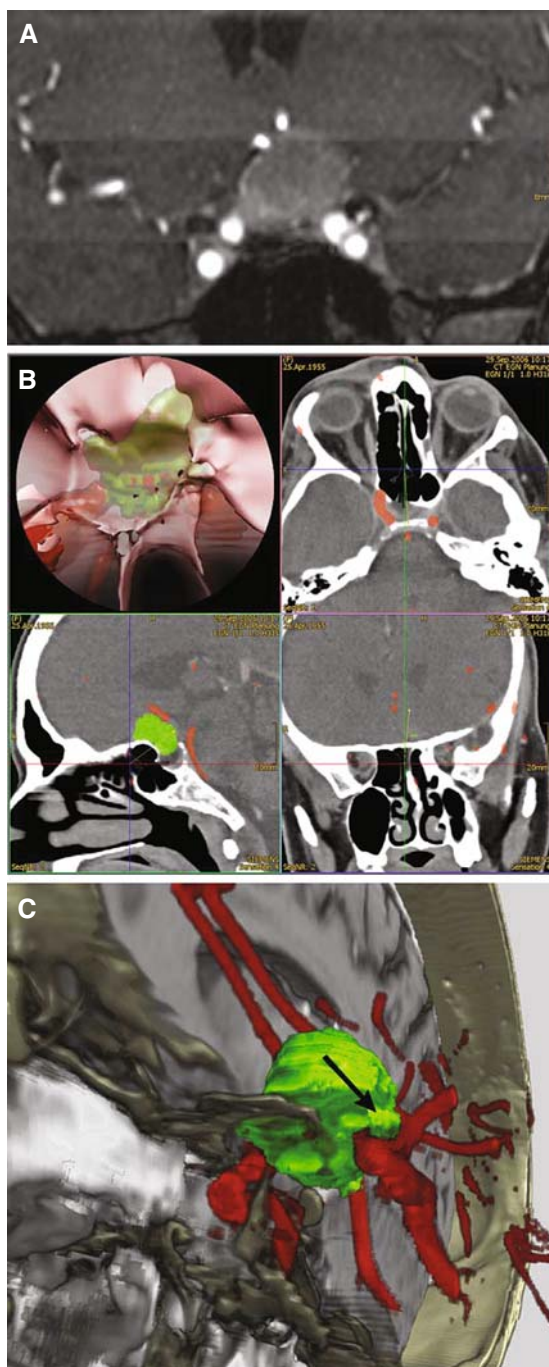
The biggest problem in these approaches is the postoperative CSF leak, which is not yet sufficiently solved. The excellent results with these subfrontal approaches for these lesions let me hesitate to advocate a transsphenoidal approach.

An other argument not to perform extended transsphenoidal surgery for tuberculum sellae meningiomas is the frequent growth into the optic canal (Fig. 7B). If the problem of a safe dura closure is solved, many tumors of the anterior skull base (and the clivus and posterior fossa) become resectable by extended transsphenoidal approaches.

Today the endoscopic techniques have been rapidly developed. Some decades ago we were in a very similar situation with the conventional transsphenoidal approach in pituitary adenomas, which became the standard approach today. I expect that the extended transsphenoidal approaches for meningiomas of the anterior fossa will be accepted in the future if we can solve the problem of closure.

## 7. THE ORBITOZYGOMATIC OR ZYGOMATIC APPROACHES

Orbitozygomatic or zygomatic approaches [2, 3, 13, 32] have their merits and may be necessary in complex central skull base tumors or complex aneurysms. For me these approaches are not necessary for lesion of the anterior skull base and are beyond the subject of this chapter.



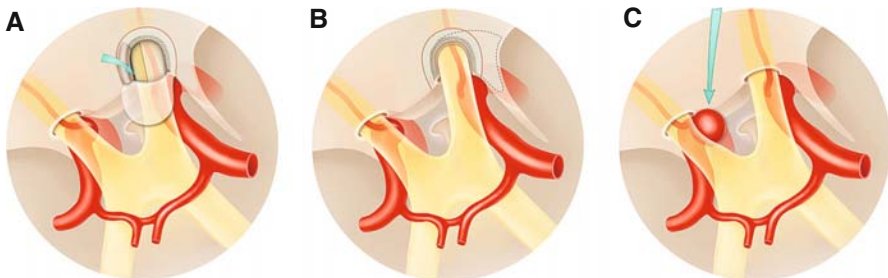


## 8. GENERAL PROBLEMS OF OPENING OF THE OPTIC CANAL (Fig. 8)

In tuberculum sellae, diaphragma sellae, large olfactory and many medial sphenoid ridge meningiomas the tumor extension into the optic canal is a rule and not an exception. Therefore an opening of the canal is a common demand – regardless of the used approach.

In large tuberculum sellae meningiomas, in which the optic nerve is kinked by the falciform ligament, it is necessary to start with incision of the ligament and sometimes this is enough to remove the tumor extensions from the optic canal. If there is any doubt of completeness of removal, the use of endoscopes is an advantage. It is possible to see the critical hidden corner on the medial aspect of the ipsilateral optic nerve as well as the origin of the ophthalmic artery and sometimes an additional opening of the bony optical canal is not necessary. The view into the contralateral optic canal is better and rarely needs endoscopic assistance (Fig. 3C).

In cases with significant growth into the optic canal, additionally the bone covering of the optic nerve has to be removed. In these cases I create a small C-like dura flap centered to the optic canal, which exposes the bone over the optic canal. Due to chronic pressure, the bone may be very thin and sometimes absent and surgery should be performed very carefully. The flap serves as a protection of the optic nerve during drilling. Drilling is performed with sufficient rinsing along the bony canal, leaving a very thin bony shell intact (“egg-shell technique”). At the end this shell will be removed by angulated microdissectors. The extent of bone resection depends on the tumor extension and/or the bone invasion and can easily be enlarged including the whole anterior clinoid process.



**Fig. 8.** Opening of the optic canal. A C-shape dura flap is created which covers and protects the optic nerve during drilling (A). After bone resection which may include also the anterior clinoid process, the flap is resected and the optic sheath incised (B) to remove tumor extensions into the optic canal. Illustration of a contralateral approach to a small ophthalmic aneurysm (C).

**Fig. 7.** Tuberculum sellae meningioma. A Conventional CT angiography. B, C The preoperative 3-D planning shows tumor growth into the optic canal (arrow)

The same procedure of clinectomy and opening of the optic canal is required to dissect the neck of ophthalmic aneurysms and to gain proximal vessel control in some carotid artery aneurysms.

Attention has to be paid in cases in which the anterior clinoid process is pneumatized because the risk of a CSF leak into the sphenoid sinus. In these cases it is enough to plug a small piece of muscle into the opening to prevent a leak.

In recent cases a pieco-resection technique is applied for the bone resection of the optic canal. This technique is promising for the removal of (thin) bone without having the hazard of drilling.

## **HOW TO AVOID COMPLICATIONS**

### **1. TAILOR THE APPROACH TO THE LESION**

General intentions in surgery should be to reduce the surgical trauma and to tailor the approach to the size of the lesion *and* the presumed pathology.

Although there is a correlation between size of the craniotomy and the complications, like subcutaneous and epidural hemorrhages, the size of the craniotomy should not be overemphasized. To use an unilateral subfrontal approach [9, 11] instead of a bifrontal one in an olfactory meningioma, would be a good example to reduce the morbidity: like CSF leaks and anosmia (2.6% in the supraorbital eyebrow approach [25] and 11, 18). Furthermore it reduces the surgical trauma and saves time of surgery.

### **2. THINK ABOUT THE KEYHOLE CONCEPT**

Try to avoid “bomb-crater” craniotomies! It is not necessary to perform a very large frontotemporal craniotomy with a considerable smaller dura opening for the resection of a small clinoidal meningioma. With a small craniotomy, either supraorbitally or subfrontally, together with splitting of the Sylvian fissure, you can achieve the same result.

### **3. CSF LEAKS**

Watertight dura closure has to be accomplished and special attention has to be paid, if paranasal sinuses are opened. A “sharklike” periosteal flap (see above) is very helpful to overcome this problem in small openings.

Autological material is the best for reconstruction – e.g. periosteum, harvested during the approach, is much better and cheaper than any dura substitute. This is specially true in reconstruction of the anterior cranial fossa which should be provided by a pediculated, vascularized flap (periosteum and/or galea).

Do not trust resorbable materials like fibrin glue or gelfoam without an adequate flap.

It is always better to sew than “glue”.

In case of a postoperative CSF leak, an external lumbar drainage is inserted for approximately five days; a reoperation however is necessary, if the leak persists.

#### 4. CRANIAL NERVE LESIONS

- Frontal branch of the facial nerve:

To avoid lesions of the frontal branch of the facial nerve I follow Yaşargil’s recommendation to perform an interfascial dissection [31].

Although most facial nerve lesions in a supraorbital approach are transient, special attention should be paid at the lateral corner of the eyebrow incision (5.5% transient weakness according to 25).

Finally I avoid extremely low and complex craniotomies, e.g. orbitozygomatic approach for lesions in the anterior cranial fossa, because there is a high risk to stretch the nerve at the level of the zygoma.

- Olfactory nerve

Any lifting of the frontal lobe carries the risk of olfactory nerve lesion – the closer the approach comes to the midline, the higher is the risk of damage. The highest risk of lesion carries the bifrontal approach in which dissection of the nerve is recommended [28] to save olfaction. A higher risk of anosmia may also be encountered in contralateral approaches.

- Optic nerve

Detailed knowledge of the anatomy of the optic system [17, 24] is a prerequisite of surgery and cannot be compensated by neuronavigation or neurophysiological monitoring. Meticulous and sharp dissection with diamond knife or scissors avoids traction and compression of the optic nerve. To save and to improve the function of the optic nerve and chiasm it is mandatory to preserve the ophthalmic artery, the superior hypophyseal artery and the perforators from the anterior communicating complex.

Furthermore, applying *Papaverin* on spastic vessels may prevent unexpected vision loss.

Deterioration of vision is the most critical complication in perisellar tumors. The risk of deterioration in tuberculum sellae and in olfactory meningiomas are reported to be from 5 to 25% [1–3, 9, 10, 18, 29, 30].

#### 5. ENDOCRINOLOGICAL COMPLICATIONS

In tumors of the anterior cranial fossa endocrinological deficits are rare [9]. In tuberculum sellae and diaphragma sellae meningiomas it is sometimes diffi-

cult to identify the pituitary stalk but high field MRI imaging helps to identify the stalk in most cases. In craniopharyngiomas however the preservation of the pituitary gland, the stalk and the hypothalamus is the most important issue during surgery.

## 6. NEUROPSYCHOLOGIC DISORDERS

Patients with large olfactory meningiomas usually have frontal lobe symptoms, but during surgery additional damage can happen. The absence of a dissectable arachnoid plane and the presence of a perifocal brain edema make the likelihood of mental deterioration higher and surgery more difficult.

## 7. CLOSURE

The bone flap is fixed by titanium plates (craniofix®) in most of our cases. Furthermore, I fill the gap at the cutlines with methyl-acrylate (Palacos®) to achieve an optimal cosmetic result. The patients – not only the ladies – will be grateful for that. Although the borehole is covered beneath the anterior part of the temporalis muscle, a mild overcorrection with palacos at this point is recommended. This counterbalances the atrophy of the temporalis muscle in slim patients.

## CONCLUSIONS

Anterior approaches to the frontobasis are the most utilized approaches in neurosurgery and are technically simple, provided that some precautions have been applied. But they may become increasingly difficult, if lesions involve the sella, the parasellar or retrosellar space. The problems inhering with these various pathologies are beyond this chapter and will be discussed in detail in the cited literature. I am sure, there will be ample space for discussions and suggestions for your own considerations. At the end I will add a very important fact which is not measurable: experience. Experience plays an important role in all of these considerations and a surgeon, who is able to reflect his decisions and analyses his operations, will find new concepts for the next (similar) case.

### References

- [1] Al-Mefty O, Holoubi A, Rifai A, Fox JL (1985) Microsurgical removal of supra-sellar meningiomas. *Neurosurgery* 16: 364-371
- [2] Al-Mefty O (1987) The supraorbital-pterional approach to skull base lesions. *Neurosurgery* 21: 474-477

- [3] Al-Mefty O (1991) Meningiomas. In: Al-Mefty O (ed) Meningiomas. Raven Press, New York, pp 427-443
- [4] Andrews BT, Wilson CB (1988) Suprasellar meningiomas: the effect of tumor location on postoperative visual outcome. *J Neurosurg* 69: 523-528
- [5] Benjamin V, McCormack B (1995) Surgical management of tuberculum sellae and sphenoid ridge meningiomas. In: Schmidek H, Sweet W (eds) Operative neurosurgical techniques. WB Saunders, Philadelphia, pp 403-413
- [6] Cappabianca P, Cavallo LM, Esposito F, de Divitiis O, Messina A, de Divitiis E (2008) Extended endoscopic endonasal approach to the midline skull base: the evolving role of transsphenoidal surgery. *Adv Tech Stand Neurosurg* 33: 151-199
- [7] Cushing H, Eisenhardt L (1938) Meningiomas: their classification, regional behavior, life history, and surgical end results. Charles C Thomas, Springfield, pp 298-319
- [8] Dolenc VV (2003) Microsurgical anatomy and surgery of the central skull base. Springer, Wien New York
- [9] Fahlbusch R, Schott W (2002) Pterional surgery of meningiomas of the tuberculum sellae and planum sphenoidale: surgical results with special consideration of ophthalmological and endocrinological outcomes. *J Neurosurg* 96(2): 235-243
- [10] Grisoli F, Diaz-Vasquez P, Riss M, et al. (1986) Microsurgical management of tuberculum sellae meningiomas: results in 28 consecutive cases. *Surg Neurol* 26: 37-44
- [11] Hassler W, Zentner J (1989) Pterional approach for the surgical treatment of olfactory groove meningiomas. *Neurosurgery* 25: 942-947
- [12] Honegger J, Fahlbusch R, Buchfelder M, Huk WJ, Thierauf P (1993) The role of transsphenoidal microsurgery in the management of sellar and parasellar meningioma. *Surg Neurol* 39(1): 18-24
- [13] Hakuba A, Liu SS, Nishimura S (1986) The orbitozygomatic infratemporal approach: a new surgical technique. *Surg Neurol* 26: 271-276
- [14] Kassam Ab, Thomas A, Carrau RL, Snyderman CH, Vescan A, Prevedello D, Mintz A, Gardner P (2008) Endoscopic reconstruction of the cranial base using a pedicled nasoseptal flap. *Neurosurgery* 63(1 Suppl 1): ONS44-ONS52; discussion ONS52-ONS53
- [15] Krause F (1941) *Chirurgie der Gehirnkrankheiten*. Verlag von Ferdinand Enke in Stuttgart, Band III
- [16] Koos WT, Spetzler RF, Pendl G, Perneczky A, Lang J (1985) *Color atlas of microsurgery*. Georg Thieme Verlag, New York, Stuttgart

- [17] Lang J (1995) Skull base and related structures. Atlas of clinical anatomy. Schattauer, New York, Stuttgart
- [18] Nakamura M, Struck M, Roser F, Vorkapic P, Samii M (2008) Olfactory groove meningiomas: clinical outcome and recurrence rates after tumor removal through the frontolateral and bifrontal approach. *Neurosurgery* 62(6 Suppl 3): 124-132
- [19] Olivecrona H (1967) The surgical treatment of intracranial tumors. In: Olivecrona H, Tonnis W (eds) *Handbuch der Neurochirurgie*. Springer, Berlin, pp 1-301
- [20] Osborn AG, Blaser SI, Salzman KL, Katzman GL, Provenzale J, Castillo M, Hedlund GL, Illner A, Harnsberger HR, Cooper JA, Jones BV, Hamilton BE (2004) *Diagnostic imaging: brain*. Amirsys Inc., Salt Lake City
- [21] Perneczky A, Knosp E, Vorkapic P, Czech TH (1985) Direct surgical approach to infraclinoid aneurysms. *Acta Neurochir (Wien)* 76: 36-44
- [22] Perneczky A, Fries G (1998) Endoscope-assisted brain surgery: Part 1 – Evolution, basic concept, and current technique. *Neurosurgery* 42: 219-225
- [23] Perneczky A, Müller-Forell W, van Lindert E, Fries G (1999) Keyhole concept in neurosurgery. Thieme Medical Publishers, Stuttgart
- [24] Reisch R, Perneczky A (2005) Ten-year experience with the supraorbital subfrontal approach through an eyebrow skin incision. *Neurosurgery* 57(4 Suppl): 242-255; discussion 242-255
- [25] Rhoton AL (2003) Rhoton's anatomy. *Neurosurgery* 53: 1-746
- [26] Samii M, Knosp E (1992) *Approaches to the clivus*. Springer, Berlin
- [27] Simpson D (1957) The recurrence of intracranial meningiomas after surgical treatment. *J Neurol Neurosurg Psychiatry* 20: 22-39
- [28] Spetzler RF, Herman JN, Beals S, et al. (1993) Preservation of olfaction in anterior craniofacial approaches. *J Neurosurg* 79: 48
- [29] Symon L (1977) Olfactory groove and suprasellar meningiomas. *Adv Tech Stand Neurosurg* 4: 67-91
- [30] Symon L, Rosenstein J (1984) Surgical management of suprasellar meningioma: Part 1. The influence of tumor size, duration of symptoms, and microsurgery on surgical outcome in 101 consecutive cases. *J Neurosurg* 61: 633-641
- [31] Yaşargil MG (1984) General operative techniques. In: Yaşargil MG (ed) *Microsurgery*, vol. 1. Thieme-Stratton, New York, pp 208-271
- [32] Zabramski JM, Kiris T, Sankhla SK, Caniol J, Spetzler RF (1998) Orbitozygomatic approach: technical note. *J Neurosurg* 89: 336-341



**Engelbert Knosp**

Engelbert Knosp is Professor and Chairman of the Department of Neurosurgery, Medical University, Vienna. 1953 born in Salzburg/Austria; 1979 graduated from Medical University of Vienna; 1979–86 Neurosurgical training at the University of Vienna – (Chairman Prof. W.Th. Koos); 1989–91 Associate professor at the Department of Neurosurgery, Vienna Medical School; 1991 Associate professor and Vice director at the Johannes Gutenberg University, Mainz, Germany (Prof. A. Perneczky); 1994 Director of the Department of Neurosurgery, Donauspital, Vienna; President of the Austrian Society for Neurosurgery; Delegate to the EANS and WFNS; Member of the World Academy on Neurosurgeons; Member of the German Academy of Neurosurgeons; Member of Int. Society of Pituitary Surgeons; Member of the European Skull Base Society; Honorary membership of the Japanese Society of Neurosurgeons; Honorary membership of the Brazilian Society of Neurosurgeons. Professional activities including membership on the Editorial Boards of national and international journals.

**Contact:** Engelbert Knosp, Department of Neurosurgery, Vienna Medical University, Währinger Gürtel 18-20, 1090 Vienna, Austria  
E-mail: engelbert.knosp@meduniwien.ac.at

---

# MANAGEMENT OF TUMORS OF MIDDLE FOSSA

R. DELFINI

Dr. Angelo Pichierri and Dr. Elena Davella are co-authors of this chapter.

## INTRODUCTION

The middle cranial fossa is the site of several tumors. These tumors may be primarily intracranial, arising from the meninges or cranial nerves, such as meningiomas or schwannomas. Other tumors, such as chordomas and chondrosarcomas, may arise from the bone and cartilage. Some tumors can originate from extracranial tissues and secondarily invade the middle cranial fossa structures, such as nasopharyngeal carcinoma, esthesioneuroblastoma, lymphoma and systemic metastasis. The majority of middle cranial fossa tumors are meningiomas; among them, sphenoid wing meningiomas are the most common.

These tumors are most often approached through the pterional or the subtemporal approach and their variants.

The first successful removal of a lateral sphenoid wing meningioma was described in 1774 by A. Louis. In 1918, G. J. Heuer pioneered the pterional approach as a surgical technique to approach lesions of the middle cranial fossa, although W. Dandy is frequently credited with inventing this operation. In the following years, many surgeons modified the pterional approach to gain a more direct working distance and to minimize brain retraction. The orbitozygomatic and supraorbital osteotomies have been proposed as extensions to the pterional approach to wider exposure of the middle cranial fossa and to enable entry to the neighbour compartments (orbit, posterior fossa, pterigopalatine space).

The first successful removal of a schwannoma of the Gasserian ganglion was described in 1918 by C. H. Frazier. Cushing's prediction in 1938 is fast approaching fulfillment: "It is possible of course that a method may some day be evolved whereby a Gasserian ganglion neuroma or meningioma may be safely approached and removed. Should this come to pass, it will be another conquest for neurosurgery". Olivecrona, in 1956, reported a one year mortality rate of 41% after trigeminal nerve schwannoma treatment. In recent years, various surgical approaches have been used for treatment of these tumors with almost no mortality. The subtemporal approach with its varia-

---

*Keywords:* meningiomas, neuromas, chordomas, chondrosarcomas, metastasis, pterional approach, fronto-temporo-orbito-zygomatic approach, subtemporal approach, middle fossa



tions, such as Kawase's approach, the zygomatic-temporal approach or the combined subtemporal-transtentorial approach, have been proposed as a safe surgical strategy for removing middle fossa trigeminal schwannomas.

To sum up, many advanced methods have been introduced to treat tumors of the middle fossa, based on the standard pterional and subtemporal surgical routes, resulting in better outcome.

## **RATIONALE**

### **1. SURGICAL ANATOMY OF THE MIDDLE CRANIAL FOSSA**

The middle cranial fossa is formed by the sphenoid and temporal bones. The anterior border of this fossa consists of the sphenoid wing and anterior clinoid process. Posteriorly, it is limited by the superior border of the petrous temporal bone and the dorsum sellae of the sphenoid bone. The floor is formed by the greater wing of the sphenoid anteriorly and the squamosal temporal bone posteriorly. The middle cranial fossa is divided into a medial portion and a lateral portion. The medial part is formed by the body of the sphenoid bone. The cavernous sinus occupies a significant portion of this region and its anatomy will be described elsewhere in this book. The lateral part is formed by the lesser and greater sphenoid wings, with the superior orbital fissure between them. The lesser wing is connected to the body of the sphenoid bone by an anterior root, which forms the roof of the optic canal, and by a posterior root, also called the optic strut, which forms the floor of the optic canal and separates the optic canal from the superior orbital fissure. The greater wing forms the largest part of the middle fossa, with the squamosal and the petrosal parts of the temporal bone completing this surface. The superior orbital fissure transmits the oculomotor, trochlear, ophthalmic, and abducens nerves, a recurrent meningeal artery, and the superior and inferior ophthalmic veins. The maxillary and mandibular nerves pass through the foramen rotundum and ovale, both located in the greater wing of the sphenoid. The upper surface of the petrous bone is grooved along the course of the greater and lesser petrosal nerves. The carotid canal extends upward and medially and provides passage to the internal carotid artery and carotid sympathetic nerves in their course to the cavernous sinus. The roof of the carotid canal is formed by the petrous bone. However, this bony roof is frequently dehiscent to a variable degree. In many cases, the internal carotid artery in the carotid canal is covered only by the dura of the middle cranial fossa. The posterior trigeminal root reaches the middle fossa and the impression on the upper surface of the petrous bone where Meckel's cave sits. The Meckel's cave is a cleft-like dural pocket that originates from the dura propria of the posterior fossa, between the periosteal and the meningeal layer of dura of the middle cranial fossa. The contents of the Meckel's cave are the sensory and motor root of the trigeminal nerve, Gasserian ganglion and arachnoid layer. The arcu-

ate eminence indicates the position of the superior semicircular canal. A thin lamina of bone, the tegmen tympani, roofs the area above the middle ear and auditory ossicles on the anterolateral side of the arcuate eminence. The internal auditory canal can be identified below the floor of the middle fossa by drilling along a line approximately 60° medial to the arcuate eminence, near the middle portion of the angle between the greater petrosal nerve and arcuate eminence. The petrous apex, anteromedial to the internal acoustic meatus, is free of important structures. The middle cranial fossa is covered by dura and is fed by the middle meningeal artery; and is innervated by the trigeminal nerve [8].

## 2. TYPES OF TUMORS

### 2.1 Meningiomas

Meningiomas are the most common extraaxial brain tumors. The middle cranial base is the site of several groups of meningiomas. These include: meningiomas of the lateral and middle sphenoid wing; meningiomas of the anterior clinoid; en plaque meningiomas of the sphenoid wing; meningioma of the lateral wall of the cavernous sinus; meningioma of Meckel's cave.

Meningiomas of the cavernous sinus are extensively described elsewhere in this book. Meningiomas of the lateral sphenoid wing arise from the pterion and grow along the Sylvian fissure, separating the frontal and the temporal lobes. Tumors of the middle sphenoid wing originate from the middle of the sphenoid ridge. They usually remain separated from the carotid and the optic structures. Through extensive extradural removal of the sphenoid ridge, tumors of the lateral and middle sphenoid wing can be transformed into convexity-like tumors. Clinoidal meningiomas are of three types. Type one originates from the inferior aspect of the anterior clinoidal process, adhering directly to the carotid artery's adventia, without an interfacing arachnoidal membrane. Type II originates from the superior or lateral aspect of the anterior clinoid process and is separated from the carotid artery by the arachnoid membrane, which has already invested the artery in the carotid cistern. Type III clinoidal meningiomas originate medially to the anterior clinoid, at the optic foramen where there is no arachnoid layer between the optic nerve and the tumor. En plaque meningiomas of the sphenoid wing invade the sphenoid bone and the orbital roof. The dural attachment is usually an en plaque spread along the sphenoid wing, the lateral wall of the cavernous sinus and the floor of the middle fossa. The optic canal and the superior orbital fissure are often compressed by the tumor or by the hyperostotic infiltrated bone which is often present. The involved bone must be totally removed to prevent recurrence. Meningiomas of the Meckel's cave originate within the cave itself, but are rarely confined to it. These meningiomas may grow and extend into the middle fossa, posteriorly into the petroclival area, or in both directions [1].

Meningiomas of the sphenoid wing may present with any of the signs or symptoms of intracranial disease, such as headaches, seizures, paresis, confu-

sion. Clinoidal meningiomas most often present with monocular visual loss. Meningiomas of the lateral wall of the cavernous sinus may result in diplopia, facial hypoesthesia or oculomotor dysfunction. Meckel's cave meningiomas may present with facial numbness or pain and diplopia secondary to a sixth nerve palsy. The mainstay of treatment of meningiomas remains surgical resection not only of the neoplasm but also of the infiltrated dura and bone to decrease the incidence of recurrence. Skull base meningiomas cannot be completely removed and stereotactic radiosurgery and radiotherapy may be used as an adjunct in residual tumors.

## 2.2 Neuromas of the trigeminal nerve

Neuromas or schwannomas arising from the trigeminal nerve are rare tumors, representing 0.07–0.36% of all intracranial tumors and 0.8–8% of all intracranial schwannomas. The trigeminal nerve is the second most frequent intracranial site of origin for neuromas, after the VIII nerve. They tend to occur during midlife with a peak incidence in the fourth and fifth decades. They are slightly more common in women. The clinical presentation of trigeminal schwannomas, as well as the surgical approach, depends on their intracranial location along the trigeminal nerve. Schwannomas may arise from the ganglion, the root or, more rarely, the divisions of the trigeminal nerve. Jefferson was the first to classify them according to location. Approximately 50% arise predominantly within the middle cranial fossa; 30% within the posterior fossa and 20% are dumbbell shaped with significant extension into both fossae. The most common complaint at the time of presentation is a sensory disturbance in the ipsilateral face. The disturbance is most often described as numbness but may include pain or paresthesia. Facial pain is more common in tumors involving the trigeminal ganglion from the trigeminal root. Objective findings are common and are usually attributable to the involved trigeminal nerve. Decreased sensation in one or more divisions along with a diminished or absent corneal reflex is seen in 80–90% of patients, while mild weakness in the masticatory muscles is found in 30–40%. Middle fossa tumors can produce a conductive hearing loss from Eustachian tube destruction and a facial palsy secondary to compression of the nerve in the Fallopian canal or stretching of the greater superficial petrosal nerve. The surgical approach must be tailored according to whether it is necessary to enter Meckel's cave alone or other surrounding compartments too. The subtemporal interdural approach is generally adequate for exposing these tumors and has the advantage of being convertible into an intradural approach, as required. The tumor is removed through an intracapsular debulking procedure generally using ultrasonic aspirator. The tumor tends to displace the parent nerve medially and/or the ganglion eccentrically and every effort must be made to avoid damaging them. After debulking the capsule must be carefully dissected away from the surrounding structures. In large dumbbell shaped tumors the trochlear nerve is usually found on the superior pole of the capsule and the auditory and

facial nerves along the inferior pole. The tumor does not generally invade the venous space of the cavernous sinus nor encase the carotid artery.

### 2.3 Chordomas and chondrosarcomas

Chordomas and chondrosarcomas are a rare group of tumors that together constitute less than 1% of intracranial tumors. Chordomas originate from embryonal notochord remnants along the midline skull base, while chondrosarcomas arise predominantly in lateral structures of the middle cranial fossa, the temporo occipital synchondrosis, the sphenocciput and the sphenothmoid complex being the most common sites of origin. Since the imaging characteristics of chordoma and chondrosarcomas are similar, the location of the tumor is often the best guide to differential diagnosis. These tumors cause pain from bony erosion and neurologic symptoms from compression of cranial nerves. Mesenchymal chondrosarcoma is the most common form of cranial base chondrosarcoma and is the most malignant subtype. The priority of complete tumor excision that is paramount in chordoma management, is less clear for chondrosarcomas; this is because the control rates for chondrosarcomas are very high with adequate radiation treatment [5].

### 2.4 Metastasis and other malignancies

Middle cranial fossa can be involved by metastatic tumors from systemic malignancies, such as lung cancer, breast cancer and melanoma, and from direct extension of neighbouring head and neck tumors, such as esthesioneuroblastoma, lymphoma, squamous cell carcinoma, nasopharyngeal carcinoma and adenoid cystic carcinoma. Metastasis to the middle cranial fossa become symptomatic by affecting the neurovascular structures exiting the foramina at the basicranium, most often causing ipsilateral facial numbness or pain and sixth cranial nerve palsy. Pain is caused by bone invasion. Modern surgical techniques permit biopsy for definitive diagnosis and debulking of these lesions. Radiation therapy is used for middle cranial fossa metastasis. Systematic chemotherapy has been ineffective in preventing skull base metastasis [6].

## DECISION-MAKING

Patients harbouring middle cranial fossa tumors should undergo scrupulous radiographic evaluation. On CT scans meningiomas are mostly hyperdense, eventually with calcification (25%), strong and homogenous enhancement, often associated with bony changes such as hyperostosis. On MRI these tumors appear isointense on T1 weighted-images (WI), isointense on T2 WI. Strong and homogenous contrast enhancement is seen and a dura tail can be identified. Trigeminal schwannomas appear as an iso-hyperdense mass on CT scan; they can be solid or solid-cystic, expand the Meckel's cave and enhance

uniformly. On MR scans, they appear iso-hypointense on T1 WI and hyperintense on T2 WI. MRI may show heterogeneous cystic components with a clear relation to the trigeminal nerve. These lesions enhance strongly after gadolinium administration. For chordomas, CT demonstrates a soft tissue density mass, isodense or hypodense to brain on non-enhanced images, that erodes the bone with nonsclerotic margins. The mass may enhance with intravenous contrast. On MRI the mass is typically isointense or hypointense to brain on non-enhanced T1 weighted images and hyperintense on T2 WI. Heterogeneous contrast enhancement may appear within the mass. Chondrosarcomas show similar radiographic characteristics to chordomas. CT demonstrates a soft tissue mass, hypodense to brain with an epicentre along one of the cranial base synchondroses. Lytic destruction of the bone is seen. More than half of chondrosarcomas have calcifications. MRI shows chondrosarcomas as enhancing soft tissue masses that are hypointense on T1 WI and hyperintense on T2 WI. MRI and CT are complementary modalities for evaluating middle cranial fossa metastasis. CT with bone window exposure of the skull base detects calcification and the effect of the metastases on the bone of the skull base. MRI demonstrates the relationship of a skull base mass to cranial nerves and vascular structures. MRI or CT demonstrate metastatic lesions in 77% of patients with metastasis of the middle cranial fossa; when skull base metastasis is suspected but unconfirmed by CT or MRI, Tc99m-SPECT appears to be an alternative for the diagnosis of middle cranial fossa metastasis. Magnetic resonance angiography has nowadays supplanted cerebral angiography for the determination of the relationship of the tumor to the major intracranial arteries and their branches and for preoperative evaluation of the vein of Labbé and venous sinus patency. However, for those few meningiomas that require endovascular embolization, cerebral angiography remains necessary to determine the feasibility and safety of the procedure.

## **SURGERY**

### **1. PREPARATION OF THE PATIENT**

#### **1.1 Middle cranial fossa surgery**

Middle cranial fossa surgery requires brain retraction. Although the best means of reducing brain retraction is to eliminate its need by using basal approaches, several methods can be used to minimize it: spinal drainage is of paramount importance for ensuring brain relaxation. Cerebrospinal fluid drainage is performed using a lumbar sub-arachnoid drain inserted after induction and intubation of the patient. Gradual withdrawal of fluid (about 25 ml) is carried out during the operation as required. A flow-control clamp is applied to the draining tube to prevent rapid loss of cerebrospinal fluid. Other techniques are: patient positioning to take advantage of the effects of

gravity, hyperventilation to a  $PCO_2$  of 25–30 and osmotic diuretics such as 20% solution of mannitol at the dosage of 0.25 g/kg [7].

### 1.2 Intraoperative electrophysiologic monitoring

Intraoperative electrophysiologic monitoring during middle cranial fossa surgery is based mainly on trigeminal and facial nerve monitoring. These monitoring systems will detect several types of physiological activity in the muscle, which are indicative of mechanical stimulation of the nerves or nerve trauma.

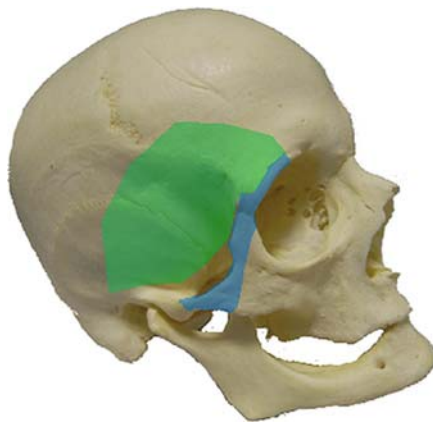## 2. OPERATIVE TECHNIQUE

Tumors of the middle cranial fossa can usually be approached through the pterional approach and the subtemporal approach. Both approaches can be further extended by means of additional osteotomies, such as the cranio-orbital zygomatic approach and the temporo-zygomatic approach.

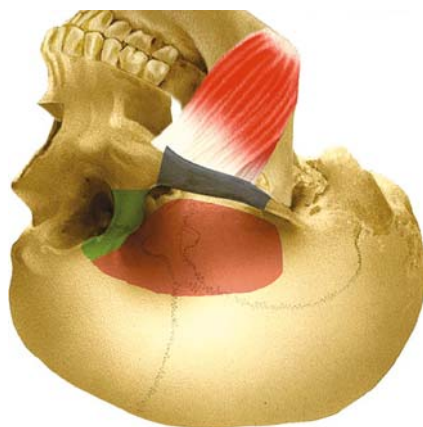
### 2.1 Pterional approach

The pterional approach (Fig. 1A) is indicated for tumors of the middle cranial fossa located at the sphenoid wings or at the anterior clinoid. We prefer the pterional approach to the pure temporal one when exposure of the temporal pole, the Sylvian fissure and the superior orbital fissure is required. In this way, the tumor can this way be approached from the transylvian or subtemporal surgical route.

The patient is placed supine with the ipsilateral shoulder elevated to reduce head rotation. The head is rotated  $45^\circ$  away from the side of the tumor, elevated  $15^\circ$  to the trunk to favour venous drainage and hyperextended for brain relaxing. The head is fixed in a three point Mayfield headrest.



**Fig. 1A.** The green area shows the pterional approach which may be extended with a orbitozygomatic craniotomy



**Fig. 1B.** The fronto-temporo-orbito-zygomatic approach performed with the three-steps technique (cf. Operative technique in the text)

The skin incision is begun 1 cm anterior to the tragus at the level of the zygomatic arch and extended behind the hairline, as far as 1–2 cm before the midline. Subcutaneous dissection is performed and the superficial layer of the temporal fascia and the temporal muscle are incised following the scalp incision. The frontal scalp remains attached to the superficial temporal fascia. Then a subfacial subperiosteal dissection of the temporal muscle is performed and the fronto-temporal bone is exposed to the pterion. The temporal muscle is carefully detached from the frontal process of the zygomatic bone. During exposure of the orbital roof care must be taken to avoid stretching the supraorbital nerve. The scalp is retracted together with the temporal muscle anteriorly and inferiorly. Craniotomy is centered on the pterion (McCarty point). Another burr-hole is made at the posterior limit of the zygomatic bone. The craniotomy is wider on the temporal side than on the frontal one. The lesser sphenoid wing makes it difficult to use the craniotome to connect the two burrholes and a drill or an oscillating saw can be used instead. The bone flap is removed and the remaining bone is drilled to expose the floor of the middle cranial fossa.

*Further step: anterior clinoidectomy.* The anterior clinoidectomy is indicated for clinoidal meningiomas, meningiomas of the lateral wall of the cavernous sinus and when the optic nerve has to be decompressed. Different techniques have been proposed for reducing the attachment of the clinoid to the sphenoid wing and its extent. The bony CUSA minimizes the heating of the bone and damage to neurovascular structures, such as the optic nerve and the internal carotid artery.

## 2.2 Fronto-temporo-orbito-zygomatic approach

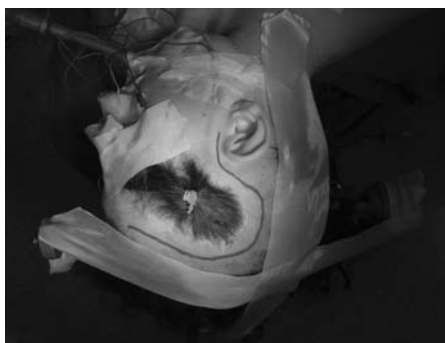The orbitozygomatic approach (Fig. 1B) is an extension of the pterional approach, mainly indicated for exposing the cavernous sinus.

During this approach subperiosteal dissection of the temporal muscle cannot be performed. With a subfacial dissection, the temporal fascias are dissected from the temporal muscle and remain attached to the frontal scalp. The periorbit must be exposed and care must be taken to preserve the supraorbital nerve. The nerve runs in a bone channel at the lateral third of the orbital roof. The bone channel can be inferiorly delimited by fibrous tissue, instead of bone. The supraorbital nerve must be freed from the channel and retracted inferiorly with the scalp. Dissection of the periorbit starts at the orbital roof and the thin capsule must be preserved. The subperiosteal dissection at the zygomatic arch preserves the facial nerve. The facial nerve runs superiorly to the zygomatic arch in a fat pad between the superficial temporal fascia at the zygomatic periosteum, anteriorly to the superficial temporal artery. At the superior end of the zygoma, the temporal fascia split into two layers (superior and inferior), which come together again at the superior orbital rim. The facial nerve runs in a fat pad in between the two temporal fascia layers. The subperiosteal dissection is continued to expose the zygomatic arch and the zygomatic protuberance of the frontal bone. Using an oscillating saw, the zygomatic arch is sectioned with oblique cuts in its most posterior end and anteriorly where the zygomatic arch meets the lateral wall of the orbit. Pre-plating is performed, then the zygoma is displaced inferiorly. The attachment of the masseter muscle on the inferior border of the zygomatic arch is preserved. The temporal muscle is dissected together with the deep temporal fascia and reflected inferiorly. A frontotemporal craniotomy is performed, obtaining the cranio-orbital flap via an osteotomy is performed between the inferior orbital fissure and the lateral wall of the orbit. Another osteotomy is performed to detach the orbital roof and the lateral two-thirds of the superior orbital rim. The entire orbital roof should be removed in one piece.

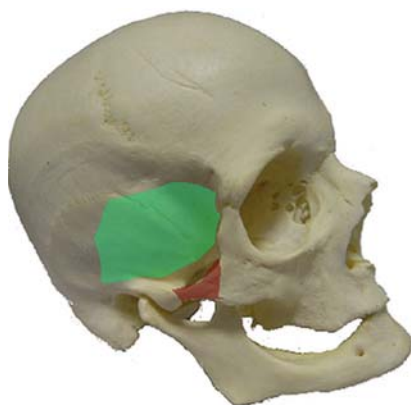### 2.3 Subtemporal approach

The subtemporal approach (Fig. 2) is indicated for Meckel's cave tumors and tumors that invade the petrous bone, such as chordomas and chondrosarcomas. The patient is placed supine with the shoulder on the same side as the tumor elevated. The head is rotated, so that the superior longitudinal suture is parallel to the floor, and elevated 15° to the trunk. The zygoma represents the vertex of the surgical field in order to favour temporal lobe retraction. The head is fixed in a three point Mayfield headrest. The skin incision depends on the desired extension of the surgical field. A skin incision in question mark fashion is indicated when the control of both the superior orbital fissure, temporal pole and petrous region are desired. The incision starts 1cm anteriorly to the tragus, curves posteriorly along the ear and ends anteriorly on the midpupil line. The need to perform a zygomatic osteotomy depends on the individual conformation of the middle cranial fossa. The variable concavity of the middle fossa can be calculated. We consider the distance between the deepest point in the middle fossa and a line passing from the lowest



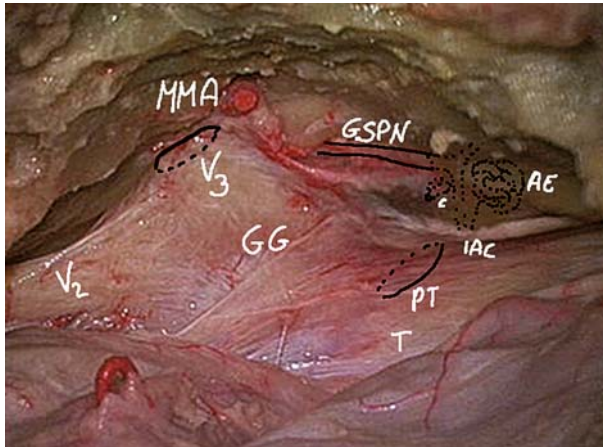


**Fig. 2A.** Temporal approach to the middle fossa. Patient is positioned supine; Mayfield pins must be inserted into frontal and occipital bones; gel pads are placed under the shoulder and under the bottom to rotate the head 90° (parallel to the floor). The vertex is tilted down 10°–20° so that the zygoma is the highest point: this provides a natural retraction of temporal lobe. The patient is monitored for motor trigeminal and ocular muscles functions when needed. Note the scalp incision for the temporo-zygomatic and the fronto-orbito-temporo-zygomatic approaches



**Fig. 2B.** The green area corresponds to the temporal craniotomy. In red, the entity of the zygomotomy

lateral point on the temporal lobe and the cerebro-mesencephalic sulcus. Patients require zygomatic osteotomy if the distance is more than 1.5 cm (Fig. 3). The removal of the zygomatic arch is also indicated for lesions that extend from the middle cranial fossa to the infratemporal cranial fossa. A subfascial dissection is performed and the temporal muscle is reversed inferiorly. The first hole is made on the McCarty point and the second just posterior to the external acoustic meatus. Craniotomy is then performed in order to obtain a flat working angle to the floor of middle cranial fossa thus minimizing temporal bone retraction. An extradural approach is indicated for pure osseous lesions. An interdural dissection is performed, between the dura



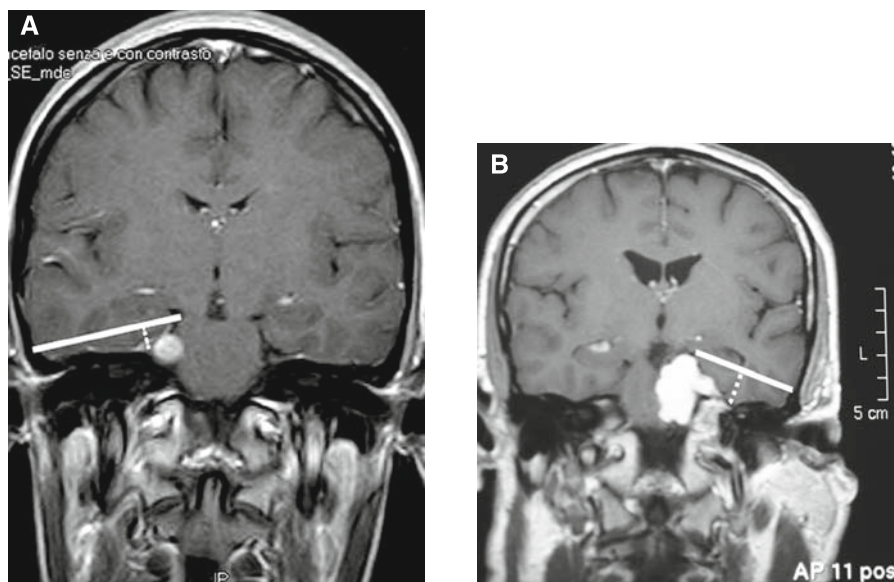
**Fig. 2C.** At the end of the subtemporal interdural approach, various anatomic landmarks can be recognized: the meningeal artery (MMA), the greater superior petrosal nerve (GSPN), arcuate eminence (AE), V3 and foramen ovale, V2 and foramen rotundum, Gasserian ganglion (GG), the porus trigeminalis (PT), the tentorium (T). Note the projection of the inner ear structures on the petrous bone: the labyrinth corresponds to the AE; the cochlea (C) lies just medially and posteriorly to the GSPN hiatus, the internal acoustic canal (IAC) bisects the angle between the GSPN and the AE. The Kawase's triangle is the area delimited by the lateral side of the Meckel's cave, the GSPN, the cochlea, the IAC and the PT. This area can be drilled to gain access to the posterior fossa. The Glasscock triangle is bound by a line from the MMA at its foramen spinosum to the facial hiatus, the greater superficial petrosal nerve and V3. This area surrounds the horizontal petrous IAC

propria of the middle fossa, that faces the brain surface, and the periosteal dura of the floor of the middle cranial fossa. The cleavage plane is easier to find at the foramen spinosum as the meningeal artery is contained between these dural layers. The meningeal artery at the foramen spinosum is exposed and cut. All the other anatomic landmarks are progressively exposed (greater superior petrosal nerve, arcuate eminence) and Meckel's cave is eventually exposed to the porus trigeminalis to the foramina ovale and rotundum. Attention must be paid not to push the interdural dissection too posteriorly toward the margin of the petrous bone in order to avoid opening of the superior petrosal sinus which forms the roof of the porus trigeminalis and flows between the dural layers we are dissecting.

### 3. LONG-TERM RESULTS AND COMPLICATIONS

The most frequent complications related to the surgical approach are: cerebrospinal fluid leakage, brain edema, temporal muscle atrophy, cranial nerve palsies, epidural haematoma.

The overall surgical mortality for meningiomas of the middle cranial fossa is 1%; the rate of neurological deficit depends on the tumor location, varying



**Fig. 3.** The need to add a zygomatic osteotomy to the approach can be predicted by the individual confirmation of the middle fossa: **A** a patient with a very flat middle fossa floor is showed; **B** a patient with a concave middle fossa

in published series from 9 to 11%. Total excision for middle cranial base meningiomas can be achieved at most locations with a recurrence rate of 0–5% if we exclude en plaque meningiomas which are burdened with a higher rate of recurrences. Surgical removal of the involved bone is necessary to reduce recurrence. Radiosurgery has proved to be an extremely important and a valuable adjunct to the treatment of meningiomas remnants or recurrences after surgery, with a very high rate of tumor control from 85 to 98% at 5 years [4]. Trigeminal schwannomas can be totally resected in most cases. After subtotal resection, many authors report a satisfactory clinical outcome with few symptomatic recurrences, usually within 3 years. Recurrences may be treated with radiosurgery. Many studies show a control rate of 100% over four years; however, the exact role of radiosurgery in the treatment of trigeminal neuromas has yet to be determined in large long-term studies [3]. Long-term outcome of chordoma treatment depends primarily on the degree of surgical excision, due to their ability to recur and to the relative radioresistance of chordoma cells. The extent of surgical removal is less important in chondrosarcomas because long-term local control can be obtained with adequate radiation therapy: approximately 97% after 20 years [5]. The prognosis of most patients with middle cranial fossa metastasis remains poor and the goal of surgery and radiotherapy is to maintain the quality of life and functional status while maximizing survival.

## HOW TO AVOID COMPLICATIONS

When performing the pterional approach care must be taken to avoid damaging the temporal branch of the facial nerve, which supplies the frontalis muscle and the mimic muscles of the orbit. The frontalis muscle raises the ipsilateral eyebrow and denervation produces an obvious cosmetic deformity. Skin incision begins 1cm anterior to the tragus to preserve the nerve. The subcutaneous flap is dissected no further than 3 cm from the eyebrow line. When a subfascial dissection is performed, the risk of damaging the nerve is maximum at the zygoma if the dissection of the arch is not subperiosteal. The nerve passes parallel and anteriorly to the superficial temporal artery which should be also preserved because it supplies the forehead and because it can be useful for low-flow extra intracranial bypass. Another complication that may occur during the pterional approach is atrophy of the temporal muscle, which would impair elevation of the mandible. A blunt subfacial dissection of the temporal muscle preserves the deep temporal fascia, which contains the vessels and nerves that supply the muscle. The use of electrocautery during temporal muscle dissection is indicated only to detach the muscle from the superficial temporal line. During closure, the temporal muscle is returned to its anatomic position and secured to the bone along its original insertion.

Cerebrospinal fluid leakage can occur if the frontal sinus or mastoid cells were entered during the pterional or subtemporal approach. If so, they must be plugged with fat or muscle from the patient and biological glue. During the subtemporal approach, the meningeal artery must be well cauterized at the foramen spinosus, to avoid epidural haematomas. Epidural haematomas can also be prevented by anchoring the dura peripherally at the bone or at the periosteum. Brain edema during pterional and subtemporal approach is mainly caused by venous drainage impairment. This is particularly true during the subtemporal approach as a result of obstruction of the venous flow in the Labbé vein during temporal lobe retraction. Brain edema can be, in part, prevented by reducing brain retraction through extensive osteotomy, cerebrospinal fluid drainage and a correct patient positioning. Facial nerve injury during the subtemporal approach can be caused by a traction on the geniculate ganglion during interdural dissection near the greater superficial nerve. To avoid this, dissection must be carried out in a posterior to anterior direction; at the most, the great superficial nerve may be cut sharply but dry eye syndrome is a frequent result of this sectioning.

## CONCLUSIONS

The middle cranial fossa is the site of different tumors, with various origins, pathological features, clinical presentation and outcomes. Nonetheless, these tumors constitute a continuum because the surgical avenues and techniques

used to approach them are similar. As Cushing observed about meningiomas: “all said and done, it is the final result that counts, and having been brought up to believe that convalescence is shortened by attention to the technical details while the patient is on the operating table, I have no dread of a long session”, the outcome of surgical treatment of middle cranial fossa tumors often depends on technical and time-consuming details. In the last two decades, a better understanding of microsurgical anatomy, refinements in imaging techniques and neuroanesthesia, and the development of innovative skull base approaches, have significantly improved the surgical management of middle cranial fossa tumors, resulting in a lower rate of mortality, morbidity and recurrence. In addition, stereotactic radiosurgical techniques may offer more modalities for treatment and for preventing recurrences.

## References

- [1] Al-Mefty O (1998) Meningiomas of the middle cranial base. In: Al-Mefty O (ed) *Operative atlas of meningiomas*. Lippincott-Raven Publishers, Philadelphia, pp 67-207
- [2] Ardeshiri A, Winkler PA (2006) Subtemporal approach to the tentorial incisura: normative morphometric data based on magnetic resonance imaging scans. *Neurosurgery* 58(1 Suppl): ONS22-ONS28
- [3] Day JD, Fukushima T (1998) The surgical management of trigeminal neuromas. *Neurosurgery* 42: 233-240
- [4] Dunn IF (2005) Meningioma: surgery. In: Black PM, Loeffler JS (eds) *Cancer of the nervous system*, 2nd edn. Lippincott Williams & Wilkins, Philadelphia, pp 315-327
- [5] Griffith R (2003) Surgery of cranial base tumors. In: Harsh G, Janecka IP, Mankin HJ, Ojemann RC, Suit H (eds) *Chordomas and chondrosarcomas of skull base and spine*. Thieme Medical Publishers, New York, pp 80-97
- [6] Hanbali F (2004) Metastatic tumor of the skull base. In: Sawaya R (ed) *Intracranial metastases: current management strategies*. Blackwell Publishing, Oxford, pp 415-429
- [7] Jellish WS, Murdoch J (2002) Perioperative management of complex skull base surgery: the anesthesiologist's point of view. *Neurosurg Focus* 12(5): 1-7
- [8] Rhoton AL (2002) The anterior and middle cranial base. *Neurosurgery* 51(Suppl 1): 273-302



**Roberto Delfini**

Roberto Delfini directs the I Chair of Neurosurgery of the University of Rome. He was born on January 5, 1948. He specialized in neurosurgery in 1976. In 1991, he became Director of the Division of Neurotraumatology of Policlinico Umberto I – “Sapienza” University of Rome. He is author of more than 200 scientific contributions on national and international journals, 15 chapters of books, 205 communications and 95 presentations in national and international meetings. He has been holding various duty offices in several national and international neurosurgical societies and, particularly, inside the Italian Society of Neurosurgery (SiNCH) since 1998. His surgical experience covers the entire neurosurgical practice: he performed more than 9000 surgical operations.

**Contact:** Roberto Delfini, Department of Neurological Sciences and Neurosurgery, University of Rome “Sapienza”, Policlinico Umberto I, Via del Policlinico 155, 00161 Rome, Italy  
E-mail: [delfiniroberto@gmail.com](mailto:delfiniroberto@gmail.com)

---

# MANAGEMENT OF CENTRAL SKULL BASE TUMORS

B. K. MISRA

## INTRODUCTION

The cranial base is conventionally classified into anterior, middle and posterior parts that correspond to the respective cranial fossa. However, many pathologies straddle the middle and posterior skull base and can be considered under the region of central skull base (CSB). Though sporadic attempts at skull base surgery were made in the early 20th century, it was only in the 1960s that serious efforts of interdisciplinary cooperation among neurosurgeons, otorhinolaryngologists and maxillofacial surgeons were made to tackle skull base lesions [7]. The CSB, especially the cavernous sinus (CS) region was the last to be tackled directly. While Parkinson's article describing the direct surgical attack on the cavernous sinus for the carotid-cavernous sinus fistula was the first of its kind, it was Dolenc's extensive experience and his description of the combined epidural and subdural approach to the CSB that led many neurosurgeons to venture into cavernous sinus surgery [2]. In spite of the many advances and large experiences, debate still continues as to the best approach to the parasellar region – microsurgery, radiosurgery, combined modality or observation.

## RATIONALE

### 1. SURGICAL ANATOMY

The CSB bony region includes the sella, the clinoid processes (anterior and posterior), the posterior portion of the planum sphenoidale, the tuberculum sellae, the dorsum sellae, the upper clivus, the parasellar regions including the cavernous sinus and the petroclival regions. The vascular structures in relation to this region are both internal carotid arteries (ICAs) from the petrous carotid to the supraclinoid, the circle of Willis, the cavernous sinuses, intercavernous sinuses and the venous connections of the cavernous sinus. Safe entry triangles to the parasellar and petroclival regions have been described between the cranial nerves II and VIII [3]. Though there is significant distortion of the various triangles in the parasellar area by tumors, the entry points of the cranial nerves, the bony structures and the dural folds remain more or

---

*Keywords:* skull base, central skull base, tumor, approaches, microsurgery

less constant, hence it is critical to have a 3D concept of this area in the mind of the surgeon supported by neuronavigation to have optimal results.

The CS is the parasellar epidural space on either side containing a plexus of veins. Its other contents are the internal carotid artery accompanied by the sympathetic plexus of nerves and the sixth cranial nerve lateral to the ICA. The CS is bounded medially and inferiorly by a periosteal layer of dura which in its superior and lateral wall is contiguous with the connective tissue sheaths of the III, IV and V cranial nerves and is the true cavernous membrane. The dura coursing on the undersurface of the temporal lobe is adherent to this true cavernous membrane, forming a double dural covering of the cavernous sinus. Superiorly and laterally, this sub-temporal dura can be elevated from the true cavernous membrane without significant bleeding in an extradural approach to the CSB and CS. The petrous carotid artery in the carotid canal is parallel to the greater superficial petrosal nerve (GSPN). It is surrounded by a dense fibrous ring, the first of three, at its entrance to the cavernous sinus. The ICA is covered by another two rings at its exit, the first being a membranous one just medial to cranial nerve III, and the second being a fibrous dural ring which it pierces to become intradural. The two distal rings are fused medially and are separated by the anterior clinoid laterally [3, 8]. The surgical anatomy of the petrous bone can be considered in relation to anterior and posterior approaches [7]. The anterior approach, also called the Kawase's approach or the middle fossa petrous apex approach, involves the extradural exposure of the superior surface of the petrous bone [5]. The key landmarks in this approach are the foramen spinosum, the middle meningeal artery (MMA), the foramen ovale, V3, GSPN, the arcuate eminence and the petrous ridge. Posterior approaches are not considered here.

**Table 1.** Mass lesions of the central skull base

Primary bony lesion	Intracranial origin	Extra cranial origin
Metastasis	Metastasis	Para pharyngeal malignancies
Chordoma	Meningioma	Angiofibroma
Chondrosarcoma	Pituitary tumors	Esthesioneuroblastoma
Fibrous dysplasia	Craniopharyngioma	Schwannoma
Dermoid	Epidermoid, dermoid	Nasal glioma
Giant cell tumor	Schwannoma of cranial nerves III to VII	Sphenoid sinus mucocele/pyocele
Rhabdomyosarcoma	Astrocytoma	
Osteogenic sarcoma	Germinoma	
	Rathke's Cleft Cyst	
	Hamartoma	
	Lymphoma	
	Granuloma	
	Teratoma	
	Histiocytosis	
	Cavernous angioma	
	Giant aneurysms	



## 2. PATHOLOGICAL LESIONS

Various pathological lesions (Table 1) are encountered in the region of CSB. A classification based on the pathological type and anatomical location is described here knowing fully well the considerable overlap.

The essentials of the surgical approaches to the CSB with special emphasis on the approaches to meningioma, chordoma, chondrosarcoma and trigeminal schwannoma will be dealt with in this chapter.

## DECISION-MAKING

The process of decision-making, whether and when to operate, what approach (subtotal or total) is most important yet difficult.

- It is important to understand that many tumors in the parasellar region are completely outside the cavernous sinus or only partially enter the cavernous sinus and their first line of treatment is microsurgical excision. It is also essential to remember that many of these tumors are slow-growing benign neoplasm and not life-threatening. Thus, the natural history of the disease and the expected post-operative quality of life should be discussed in detail with the patient before deciding on any treatment.
- **Preoperative assessment.** The clinical features are related to both tumor location and pathology. The symptoms and signs can be grouped under cranial nerve dysfunction, endocrinological dysfunction, long tract signs, cerebellar signs and raised intracranial pressure (ICP). The preferred imaging modality today is MRI of the brain with and without contrast. A high resolution CT scan with bone algorithms adds to the diagnostic accuracy. MR angiography and more recently 3D CT angio are routinely performed to study the vascular anatomy in detail. An invasive 4-vessel cerebral digital subtraction angiography (DSA) resorted to earlier in every case is not done any more by the author except for the purpose of pre-operative embolization or for balloon occlusion test while planning elective carotid sacrifice. Plain X-rays of the skull are no more routinely employed. A MRI/CT brain (with or without contrast) image guided protocol is a standard preoperative workup in the author's practice since 1998. Apart from the routine medical pre-anesthetic work up, all patients have endocrinological, neuro-ophthamological (Visual acuity, ventricular fibrillation, ocular motility and fundus evaluation), and neuro-otological evaluation (audiogram and brainstem evoked response audiometry [BERA]).
- The process of decision-making, whether and when to operate, what approach (subtotal or total) is most important yet difficult.
- **Surgical approach.** The surgical approach to a given patient of CSB is dictated by (i) patient factors, (ii) tumor factors, and (iii) surgeon

**Table 2.** Approaches used for tumor of the CSB

<b>Anterior approaches</b>	
<i>Primary approach</i>	<i>Modification</i>
Transbasal	Extended transbasal
Transsphenoidal	Extended transsphenoidal
Transmaxillary	
Transmandibular	
<b>Anterolateral approaches</b>	
<i>Primary approach</i>	<i>Modification</i>
Pterional	Fronto-temporo-orbito-zygomatic (FTOZ)
	Frontotemporal epidural and subdural
	Lateral Frontal
	Supraorbital
<b>Lateral approaches</b>	
<i>Primary approach</i>	<i>Modification</i>
Sub-temporal	MCF/Petrous apex approaches
<b>Posterolateral approaches</b>	
<i>Primary approach</i>	<i>Modification</i>
Retrosigmoid	Translabyrinthine
	Retrolabyrinthine
	Transcochlear

factors. The important patient factors to be considered are age, comorbidity and deficit at presentation. Tumor factors like consistency, adhesiveness, cavernous sinus occupation, invasion of carotid artery adventitia and en plaque morphology make complete excision difficult and often impossible without compromising quality of life. Last but not the least, is the surgeon factor. Surgery of meningiomas of the cavernous sinus and the petroclival region and chordomas and chondrosarcomas of the skull base requires special training, long hours of meticulous micro-dissection and excellent postoperative critical care facilities. Hence, before embarking on such an endeavor a thorough understanding of the magnitude of the problem is essential.

The various approaches used for tumor of the CSB are summarized in Table 2.

## **SURGERY**

### **1. PREOPERATIVE PREPARATION AND ANESTHESIA**

The patient is kept fasting overnight and a mild sedative/anxiolytic and laxative are prescribed the night before. A preoperative discussion is held with the

anesthetist about the expected length of the surgery, the need for temporary vascular occlusion, hypo/hypertensive measures, hypothermia, dehydration and the need for a lumbar CSF drain. Facial nerve monitoring, BERA (when functional hearing is preserved preoperatively) and more recently extraocular muscle monitoring are performed by the author, hence the need for discontinuing paralyzing drugs and nitrous oxide and maintaining the depth of anesthesia with propofol and sevoflurane.

It is critical to have a lax brain. For years now, we have not been using mannitol or furosemide routinely; instead, we use a lumbar subarachnoid drain (a ventricular drain in cases of raised ICP and hydrocephalus). Perioperative antibiotics in 4 doses starting with 2 g of Cefazolin just before the skin incision, followed by 1 g 6-hourly are routinely employed. A bolus dose of intravenous methyl prednisolone 15 mg/kg at the beginning followed by 7–10 mg/kg 12-hourly is given for two days. The patient is also loaded with parenteral phenytoin sodium or sodium valproate which is continued in the immediate post-operative period and normally 6 weeks postoperatively. All pressure points are adequately padded and pneumatic compression pumps are applied for deep vein thrombosis (DVT) prophylaxis.

The patient's head is fixed in the Mayfield clamp in the desired position and registration is done for image guidance. Appropriate planning is done based on the preoperative work-up and neuronavigation data. Hair shaving is restricted to the incision site and 2 cm on either side.

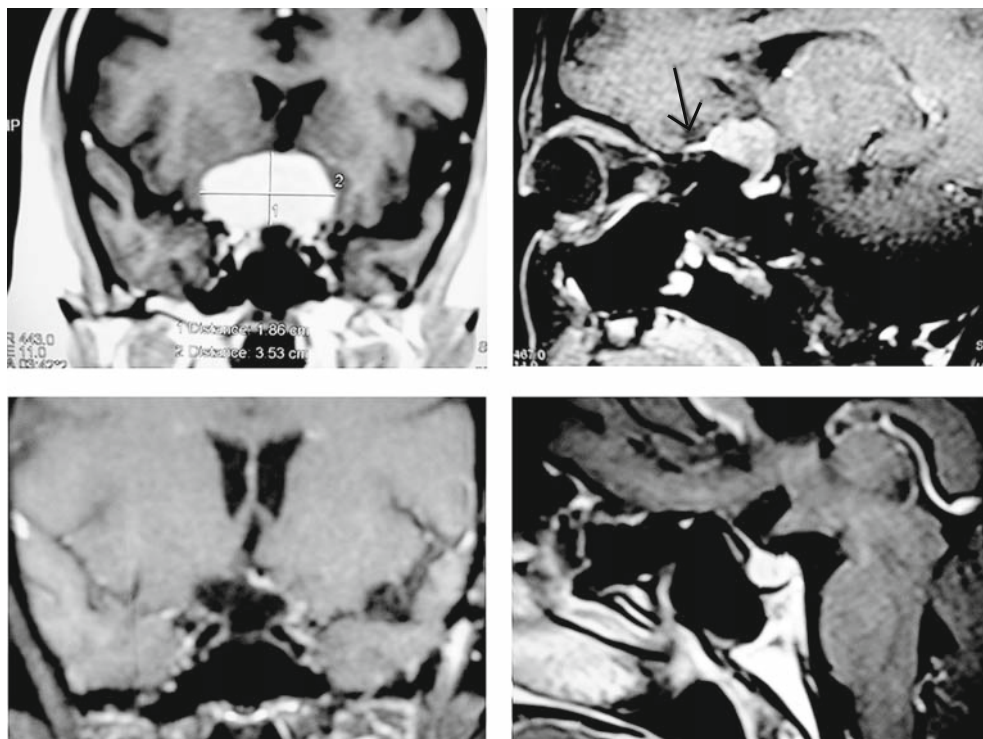
## 2. SURGICAL MANAGEMENT ACCORDING TO TYPES OF TUMORS

### 2.1 Meningiomas

CSB is a fertile ground for meningiomas because cell rests from which the tumor appears to take origin are clustered in this area as basilar cell clusters.

**Suprasellar Meningiomas:** Meningiomas arising from the planum, tuberculum, diaphragm, and dorsum sellae are grouped under suprasellar meningiomas. Both, the standard pterional and the supraorbital approach, are adequate for excision of this tumor. The author has, in the last 5 years, utilized the supraorbital approach in 31 cases, 25 of them basal meningiomas and 6 of them craniopharyngiomas. While we no longer prefer this for craniopharyngiomas, we utilize the supraorbital approach for suprasellar meningiomas without significant calcification and parasellar extension (Fig. 1). FTOZ is used for dorsum sellae meningiomas. The basic surgical principle in this group is, as in all meningiomas, devascularization of the tumor by taking care of the attachment, debulking, total excision by developing the tumor arachnoid plane, excision of the basal attached dura and drilling of the underlying involved bone.

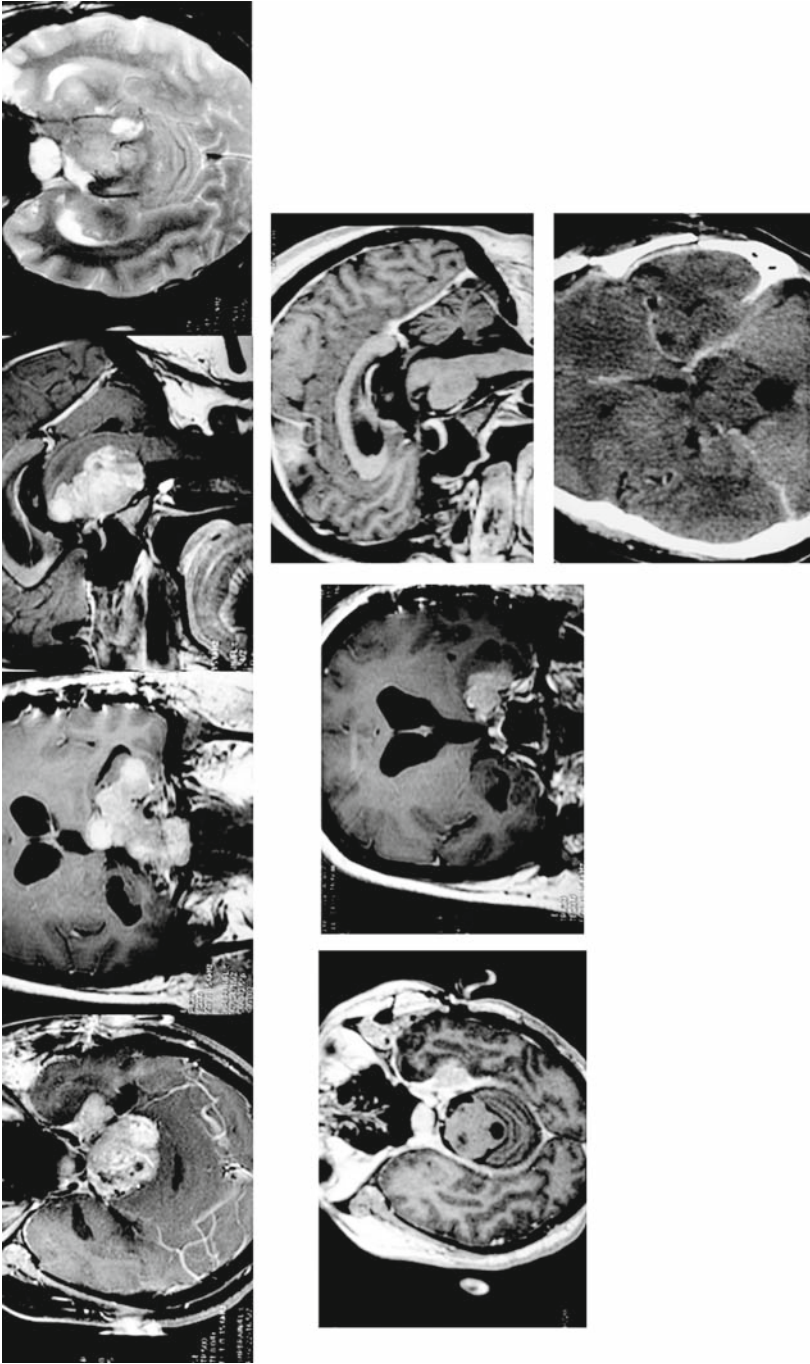
**Parasellar meningioma:** Tumors arising from the sphenoid wings medially, both the lesser and the greater, form the major bulk of this group. Cavernous sinus involvement in such cases, when present, is usually secondary. Primary cavernous sinus meningioma is rather uncommon. Extent of exposure



**Fig. 1.** Pre- and post-op CE MRI images in a case of tuberculum sellae meningioma operated through supra orbital approach

will vary depending on the size and extent of the tumor. Essentially after a frontotemporal craniotomy, sequential drilling of the sphenoid wing, the orbital roof and the optic canal and anterior clinoidectomy are performed. Complete separation of the two layers of the lateral wall of cavernous sinus, working between the safe triangles and drilling of the petrous apex to access any extension into the posterior fossa will access most of the tumor. While the aim of the surgery is total excision, it is in reality dictated by infiltration of the adventitia of the ICA and its branches by the tumor (Type I tumor of Al-Mefty) [1] or intracavernous occupation, in which case a subtotal excision is better. The residual tumor in the cavernous sinus has an indolent course and can be treated by adjunct radiosurgery either electively or on demonstrable growth [4, 6, 9].

**Petroclival meningiomas:** Meningiomas arising from the upper 2/3rd of the clivus (clival) or along the petroclival borderline where the sphenoid, petrous, and occipital bones meet (petroclival) and those petroclival meningiomas with significant middle fossa extension into the cavernous sinus (sphenopetroclival) are considered under petroclival meningiomas [6]. A clival meningioma (CM) and sphenopetroclival meningioma (SPCM) without posterolateral/inferior



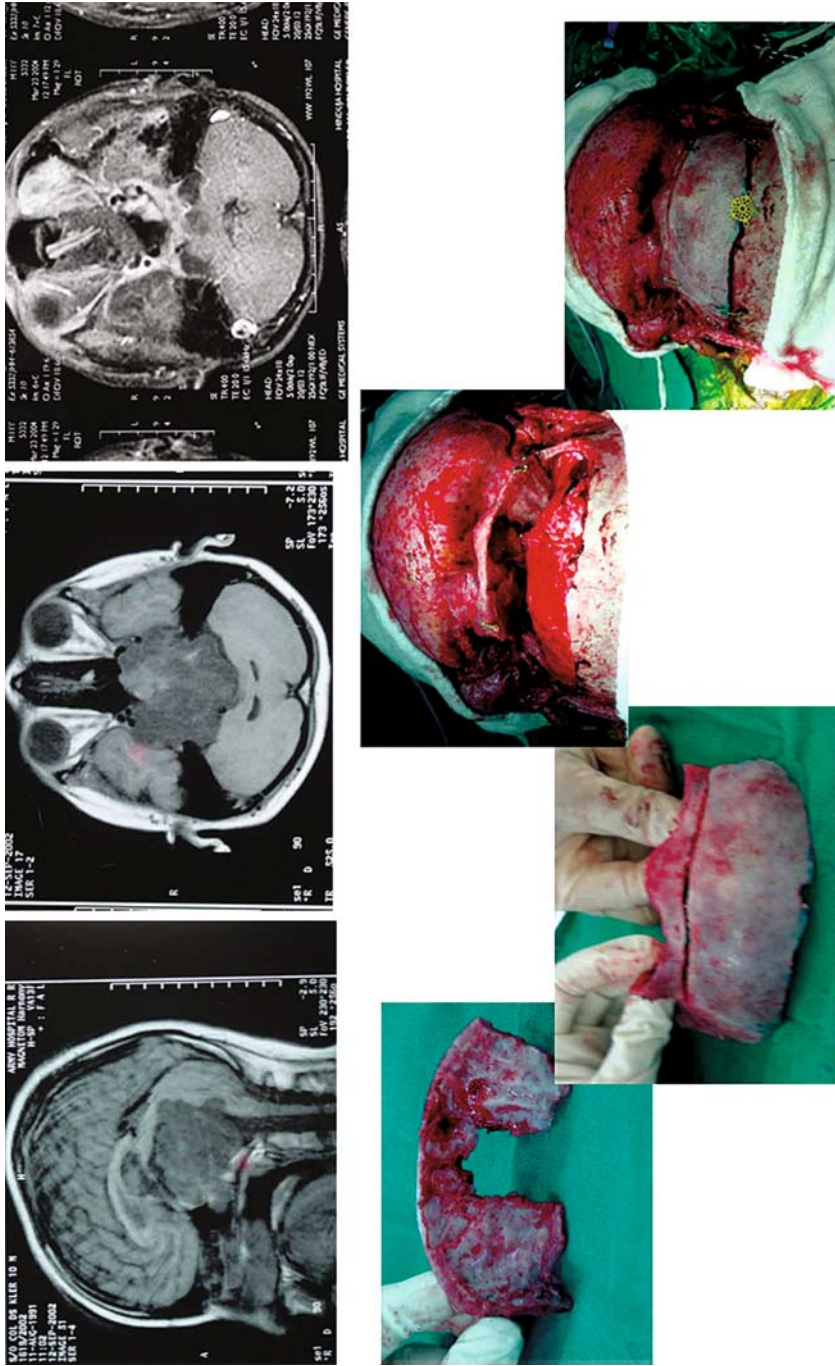
**Fig. 2.** Case of SPCM. Upper row – Pre-op MRI images. Second row – Post 1st stage retrosigmoid craniotomy and excision of post fossa component. MRI images. Third row – Post 2nd stage frontotemporal epidural subdural approach for excision of parasellar component CECT images

extension beyond the internal acoustic meatus (IAM) are best managed by middle cranial fossa/petrous apex approach. Additional orbitozygomatic craniotomy will facilitate excision of tumor extending high up in the dorsum and above. SPCM with significant inferolateral extension is best approached by a combined anterior petrosal and retrosigmoid approach. In such a scenario, the author presently uses a two-staged approach and usually the tumor inside the cavernous sinus is left behind for better functional outcome (Fig. 2). Petroclival meningiomas (PCM) without significant middle cranial fossa (MCF) extension are operated by a retrosigmoid approach or posterior petrosal approach. The author has in the last decade reverted back in most cases to a retrosigmoid craniotomy and a supraparacerebellar approach, as opposed to an earlier posterior petrosal approach.

The author has operated on 81 PCM, mostly large and giant, between 1988 and 2008. A study done in 2006 aimed at the changing trends in treatment strategy in the author's practice demonstrated that out of the 70 patients treated till 2006, 58 were microsurgically operated, of which 6 had adjunct Gamma knife radiosurgery (GKR), and 12 patients were managed by primary GKR. The various microsurgical approaches utilized were posterior petrosal in 26, retrosigmoid supraparacerebellar in 21 and MCF/anterior petrosal in 11. A comparison of the approach and results between patients treated earlier (1988–97) and those treated later (1998–2006) showed a preference towards retrosigmoid approach in the latter half. Though there was significant morbidity, especially with cranial nerve deficits, fortunately results were better in the latter half because of the learning curve and the change in strategy to safe excision as opposed to total excision.

## 2.2 Chordomas and chondrosarcomas

Situated extradurally, chordomas and chondrosarcomas constitute less than 1% of intracranial tumors. It is often difficult to distinguish chordoma from chondrosarcoma in view of the considerable overlap in their clinical, radiological and histological features. The two tumors however can be distinguished immunohistochemically; chordoma is positive for keratin and other epithelial markers with variable S–100 expressivity, while chondrosarcomas lack epithelial markers and are almost always S–100 positive. The peak incidence of chordomas and chondrosarcomas is in the fifth and sixth decade with a slight male preponderance. The clinical presentation is related to the predominant location of the tumor, higher up in the basisphenoid presenting with cranial nerve involvement of the 2nd through the 6th cranial nerves and occasional endocrinological dysfunction as opposed to tumor located lower down in the basiocciput which tends to present with lower cranial nerve involvement and long tract and cerebellar signs. Diplopia, commonly from 6th cranial nerve dysfunction, and headache are the most common features at presentation. Though usually extradural, occasional dural transgression can be appreciated on MRI. The mainstay of treatment in chordomas and chondro-



**Fig. 3.** Pre- and post-op CE MRI images in a case of extensive chordoma operated by two stages are (1) MCF petrous apex approach and (2) Extended transbasal approach. Operative pictures of transbasal approach

sarcomas is radical surgical excision. Reports of post-op heavy particle proton beam therapy and more recently Gamma knife radiosurgery (GKR) for residual tumor has shown promise. Though the natural history of these tumors is variable, these are essentially malignant tumors, and most chordoma patients ultimately succumb to the disease. Many surgical approaches have been used to eradicate the tumor, the main principle being an essentially extradural approach which is dictated by the tumor extent. The goal of surgery is radical excision without compromising quality of life. Adequate care at closure is necessary to prevent CSF leak in case of dural breach and appropriate adjunct procedure to prevent craniospinal instability. An analysis of the author's series between 1988 and 2006 demonstrated 41 cases of chordoma and chondrosarcoma of which 25 were males. Often staged and multiple surgery is necessary to achieve optimal outcome (Fig. 3). Complete eradication of tumor is often impossible and ultimately most tumors recur, chordomas earlier than chondrosarcoma.

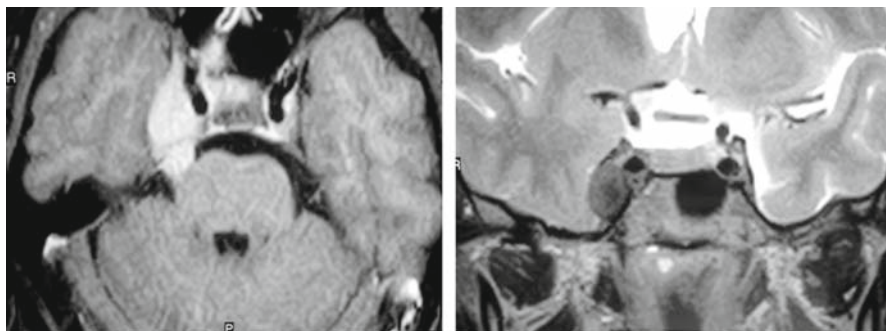
### 2.3 Trigeminal schwannomas

Trigeminal schwannomas (TS) are comparatively easier to operate, excise totally and achieve cure as opposed to meningiomas of CSB. The exact surgical approach is usually dictated by the extension of the tumor. Most tumors in the parasellar region, arising from Gasserian ganglion and the division, the commonest location, can be removed through an interdural sub-temporal approach. Well-encapsulated, the tumor is easily dissected from the adjacent neurovascular structures in the lateral wall of the cavernous sinus without the need of entering the cavernous sinus proper. Posterior fossa extensions of this tumor can often be removed through the eroded petrous apex. Additional drilling of petrous apex and cranial nerve exit foramina however is required in dumbbell tumors with a narrow waist and intact bone. No effort should be spared to preserve the GSPN while excising this tumor, so as to prevent dry eye in a hyposensitive cornea, a lethal combination. TS arising from roots and predominantly located in the posterior fossa with minimal MCF extension can be removed by a retrosigmoid craniotomy. Giant multicompartiment TS are best removed by a combined anterior petrosal+retrosigmoid approach. While most TS can be totally excised without significant morbidity, tumors in children and those associated with neurofibromatosis (NF) are more difficult because of the high vascularity in children and associated calcification and multiple tumors in NF.

### 2.4 Granulomas

Granulomas of the parasellar region can often be mistaken for meningiomas pre-operatively. Characteristically these are hypointense on T2W images, relatively avascular, with variable degree of bony erosion (Fig. 4). Typically the granulomas are firm (especially fungal) and have an en plaque occupa-





**Fig. 4.** T1W CE and T2W MRI images in a case of parasellar fungal granuloma

tion at surgery. Such cases should be as radically removed as possible without compromising neural function and followed up with prolonged pharmacotherapy.

## HOW TO AVOID COMPLICATIONS

There are two aspects of dealing with complications: (i) their prevention and management, and equally important (ii) their prior understanding and acceptance of the problem by the patient. Hence, the first step in the prevention of complications both for the patient and the surgeon is proper information to the patient about the magnitude of the problem, the natural history of the disease, alternative options and past experience of the surgeon, and proper information to the surgeon regarding the patient's general health and pre-morbidity. The next important step towards prevention of complications is adequate planning, e.g., detailed study of the intracranial vasculature, neuro-navigation and team discussion, both surgical and interdisciplinary, and proper execution. The general principles laid down above would go a long way in avoiding undesirable complications. Some of the steps to prevent complication in specific situations are enumerated below:

### *Before the operation starts:*

(i) proper positioning, adequate padding of pressure points, (ii) head fixation without compromising neck veins and generally with the head above the heart level, and (iii) pneumatic pump compression device for DVT prophylaxis

### *During Surgery:*

An optimally invasive approach, as big an approach as essential and as small an approach as adequate, is the best way to go.

(i) mild dehydration with reduced parenteral fluids, (ii) taking off bone at the base and remaining extradural as long as possible, (iii) lumbar drain in

small tumors and ventricular drain in large ones, (iv) wide opening of the Sylvian fissure and release of CSF from cisterns, (v) malleable retractors to support the brain and not retract, (vi) limit exposed brain to the minimum and kept covered with moist gelfoam, and (vii) respecting veins and all efforts to preserve the large ones, (ix) utilizing the safe corridors to the cavernous sinus while working extradurally and respecting the tumor-arachnoid plane during intradural dissection are the keys to successful surgery. It is vital to understand that most intradural benign tumors, especially meningiomas, are extra-arachnoidal and the plane of dissection is between the tumor and arachnoid and not in the subarachnoid space. (x) Interrupting tumor blood supply and leaving passage vessels intact. It is better to leave little bit of tumor attached to critical neurovascular structures in case of excessive adhesiveness and infiltration of the adventitia of the vessels rather than injure them. (xi) Copious irrigation while drilling near neurovascular structures to prevent thermal injury, using diamond drill in sensitive areas, leaving a thin shell of bone to be elevated at the end are other important steps in prevention of injury.

#### *Prevention of CSF leak:*


One of the commonest and irritating post-op complications in skull base surgery is post-op CSF leak. Recognition and obliteration of all opened sinuses, after exenterating of mucosa, with muscle, plugging of mastoid air cells with bone wax and watertight dura closure primarily or with fat graft or fascia lata are essential steps. Even when primary dura closure is done, it is a good practice to reinforce the dural closure, the sinuses and the mastoid air cells with fat graft and fibrin glue.

## **CONCLUSIONS**

A wide spectrum of pathologies affects the CSB posing varying degrees of difficulty. Hence, a proper appreciation of the magnitude of the problem is essential to set up realistic goals of surgery. Strict adherence to principles of tumor surgery, atraumatic brain retraction, pure tumorectomy, maintenance of tumor contours, elimination of tumor vasculature and preservation of passage vessels and a thorough knowledge of the anatomy are essential to success in surgery of the CSB [10]. Most benign CSB tumors have an indolent course and there are proven less invasive options for small volume tumors. Hence, the process of decision-making – whether and when to operate, what approach – subtotal or total, is most important yet difficult. Unfortunately, sound decision-making comes with experience and experience does not come without a price. Thus, an intelligent neurosurgeon would do well by learning from all the sources available and get a second opinion, when necessary, to reduce the pain of damaging a fellow human being.

## References

- [1] Al-Mefty O (1991) Clinoidal meningiomas: In: Al-Mefty O (ed) Meningiomas. Raven Press Ltd., New York, pp 427-443
- [2] Dolenc VV, Skull and skull base tumors: overview (2004) In: Richard Winn H (ed) Youman's neurological surgery 5th edn. Saunders, Pennsylvania, pp 1265-1281
- [3] Fukushima T, Day JD (1995) Surgical management of tumors involving the cavernous sinus. In: Schmidek HH, Sweet WH (eds.) Operative neurosurgical techniques, vol. 1, 3rd edn. W. B. Saunders, Philadelphia, pp 493-509
- [4] Hasegawa T, Kida Y, Yoshimoto M, Koike J, Lizuka H, Ishii D (2007) Long term outcomes of Gamma knife radiosurgery for cavernous sinus meningioma. *J Neurosurg* 107: 745-751
- [5] Kawase T, Shiobara R, Toya S (1991) Anterior transpetrosal – transtentorial approach for sphenopetroclival meningiomas: surgical method and results in 10 patients. *Neurosurgery* 28: 869-876
- [6] Misra BK (1999) Surgical approaches to petroclival region. *Prog Clin Neurosci* 14: 183-192
- [7] Samii M, Tatagiba M (2004) Basic principles of skull base surgery. In: Richard Winn H (ed.) Youman's neurological surgery, 5th edn. Saunders, Pennsylvania, pp 909-929
- [8] Sekhar LN, Ross DA, Sen CN (1993) Cavernous sinus and sphenocavernous neoplasms: anatomy and surgery. In: Sekhar LN, Janecka IP (eds.) Surgery of cranial base tumors. Raven Press Ltd., New York, pp 521-604
- [9] Sindou M, Wydh E, Jouanneau M, Nebbal M, Lieutared T (2007) Long term follow up of meningiomas of the cavernous sinus after surgical treatment alone. *J Neurosurg* 107: 937-944
- [10] Yaşargil MG (1996) Microneurosurgery of CNS tumors: microneurosurgery IV B. Thieme Medical Publishers, New York, pp 1-52



**Basant Kumar Misra**

Basant Kumar Misra is Visiting Consultant at the Breach Candy Hospital, Mumbai, India.

Previously, Professor (Additional) of Neurosurgery at Sree Chitra Tirunal Institute of Medical Sciences and Technology, Trivandrum.

*Membership:*

President, Neurological Society of India (LM), 2008

President, Asian Conference of Neurological Surgeons, 2004–06

President, Skull Base Surgery Society of India, 2002–04

World Academy of Neurosurgeons

Guest Member, Japan Neurosurgical Society

Corresponding Member, American Academy of Neurological Surgery

Executive Committee Member, Congress of Neurological Surgeons

**Contact:** Basant Kumar Misra, Consultant Neurosurgeon, Head, Dept. of Neurosurgery, P. D. Hinduja National Hospital & MRC, V. S. Marg, Mahim, Mumbai – 400 016, India

E-mail: basantkmisra@gmail.com

---

# MANAGEMENT OF CAVERNOUS SINUS LESIONS

T. FUKUSHIMA

## INTRODUCTION

Direct surgical management of the lesions in and around the cavernous sinus area is technically “the most difficult” in neurosurgery. The cavernous sinus region presents very complex microanatomy, which involves multiple cranial nerves, vital cerebral arteries, huge venous plexus and the brainstem. Before 1980, these lesions were nearly inoperable or with high risk of mortality and morbidity. Particularly, the cavernous sinus was designated as “No Man’s Land.” In the early 1980s, Hakuba [4] and Dolenc [1, 2] revitalized Parkinson’s direct operative method [5] introducing both the intradural and extradural direct micro-operative access to the cavernous sinus. Fukushima [3] elaborated on practical microsurgical anatomy around the cavernous sinus and established the concept of multiple triangular operative corridors to the cavernous sinus in 1986. Along with the new knowledge of the anatomy and micro-operative development, it has become feasible to perform direct surgical approach to the majority of vascular and neoplastic pathology or processes of the cavernous sinus. This article presents the summary of the author’s cavernous sinus surgical experience.

## RATIONALE

### 1. NOMENCLATURE OF THE CAROTID SEGMENTS AROUND THE CAVERNOUS SINUS

We have been using the system described by Fisher in 1938, which numbers the segments beginning from the petrous carotid segment. We make a small modification to the original system with regard to numbering the petrous carotid segment (Fig. 1).

### 2. THE CAVERNOUS SINUS TRIANGLES

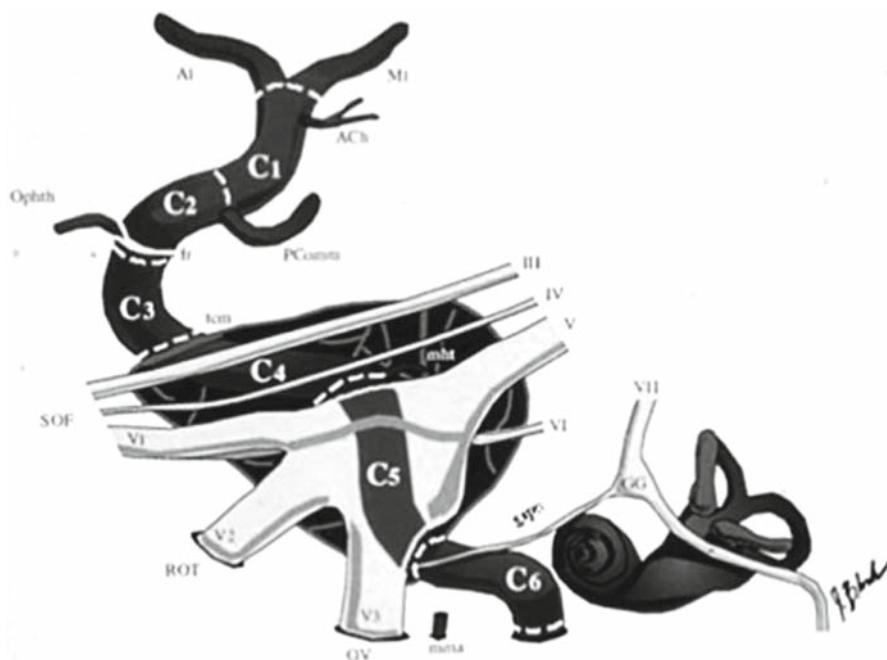
The following is the precise description of the definition and nomenclature of the cavernous sinus triangles (The Fukushima Scheme 1986) (Fig. 2).

#### 2.1 Anteromedial triangle of Dolenc

This area is exposed by careful removal of the anterior clinoid process. This triangular space, the so-called clinoidal triangle is defined laterally with the

---

*Keywords:* skull base lesions, tumor, aneurysm, cavernous sinus, microsurgery

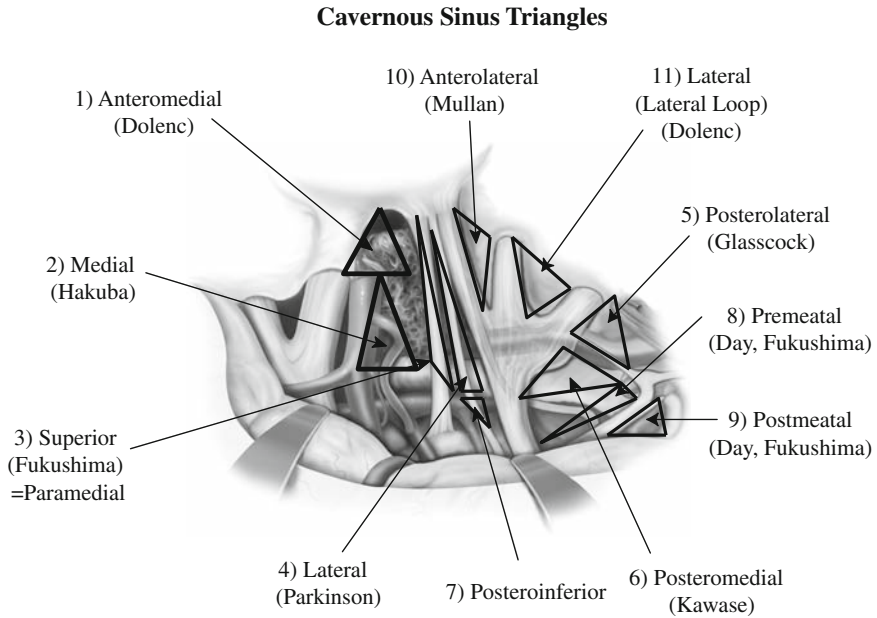


**Fig. 1.** The C1 segment is the intradural internal carotid artery between the posterior communicating artery and the carotid bifurcation. The C2 intradural segment is the area between the Pcom and the carotid fibrous ring. The C3 segment is the extradural clinoidal portion or siphon segment between the carotid fibrous ring and the true cavernous sinus membrane. The C4 segment is the horizontal intracavernous segment from the true anteromedial cavernous membrane to the genu of the cavernous carotid with the meningo-hypophyseal trunk. The C5 segment is the ascending portion of the intracavernous carotid artery from the posterolateral fibrous ring to this meningo-hypophyseal trunk. The C6 segment is the petrous carotid segment from the infratemporal carotid canal to the posterolateral fibrous ring. This segment is the one to be used for direct cavernous bypass anastomosis. The C7 segment is the infratemporal vertical carotid artery, which is often involved by the glomus jugulare or by glomus vagale tumors

oculomotor nerve medially along the lateral margin of the optic nerve and the fibrous ring and C3 carotid siphon segment. The space is essentially an epidural area and with the excision of the fibrous ring, dissection of the ophthalmic artery and hemostasis of the siphon angle as well as the medial cavernous sinus, most of the paraophthalmic and the paraclinoid carotid aneurysms can be treated safely through this clinoidal triangle.

## 2.2 Medial triangle of Hakuba

This triangle is defined by the oculomotor nerve, fibrous ring or siphon angle and the posterior clinoid process. Approach through this medial triangle will expose the medial cavernous sinus, pituitary gland and the C4 horizontal segment of the intracavernous carotid artery. Most aneurysms of the C4 seg-



**Fig. 2.** The full exposure of the extradural and intradural cavernous sinus regions with description of the 11 cavernous sinus triangles, each of which will provide the safe microsurgical access into the cavernous sinus

ment, carotid cavernous fistulae and medial intracavernous tumors can be treated through this route.

### 2.3 Superior triangle of Fukushima

This triangle is bound by the oculomotor nerve and the 4th cranial nerve and is most suitable for exposure of the C4 and C5 junction and the exposure of the meningo-hypophyseal trunk. Most of the meningo-hypophyseal aneurysms, primitive trigeminal aneurysms and cholecystocolocutaneous fistulas (CCFs) can be treated through this superior triangle.

### 2.4 Lateral triangle of Parkinson

This is a rather narrow space bound by the 4th cranial nerve and the trigeminal 1st division originally described by Parkinson for entry into the cavernous sinus. This area is most suitable for access to the C5 ascending segment of the cavernous carotid artery.

### 2.5 Posterolateral triangle of Glasscock

This is the lateral half of the posterior cavernous region defined by the middle meningeal artery, posterior border of the 3rd branch of the trigeminal nerve,

greater superficial petrosal nerve (GSPN) and the geniculate ganglion. This area is medial to the foramen ovale, foramen spinosum, and the lesser petrosal nerve. Through this triangle, the C6 segment of the petrous carotid artery can be exposed and has been used for the high flow saphenous bypass graft to this segment, either end-to-end or end-to-side originally described by Fukushima in 1986.

## 2.6 Posteromedial triangle of Kawase

This triangle is defined by the posterior border of the trigeminal 3rd branch, posterior margin of the trigeminal fibrous ring or petrous apex, petrous ridge, arcuate eminence or superior semicircular canal, geniculate ganglion and the greater superficial petrosal nerve (GSPN). This medial anterior portion of the middle fossa rhomboid area is named as the posteromedial triangle of Kawase by Fukushima in 1986. The posterior portion of the rhomboid is composed of the premeatal triangle (IAC) and the postmeatal triangle. Kawase's triangle is actually the anterior petrosectomy to the posterior fossa originally described by the House group in Los Angeles and further elaborated on the extended middle fossa approach by Kanzaki. The anterior petrosectomy approach was utilized for neurosurgical skull base procedure by Kawase. Most of the infracavernous chordomas, chondrosarcomas, small to medium size petroclival meningiomas can be exposed and excised through this extended middle fossa anterior petrosectomy posterior cavernous sinus approach.

## 2.7 Posteroinferior triangle of Fukushima

This area is the small triangular corridor between the 4th nerve and the anterior margin of the trigeminal fibrous ring which contains petroclinoid ligament and petrosphenoid ligament of Gruber. This area is the best approach to expose the abducens nerve at Dorello's canal or tube in the cavernous sinus.

## 2.8 Premeatal and postmeatal triangles of Fukushima

The posterior half of the middle fossa rhomboid region is defined by the geniculate ganglion, the cochlea and the internal auditory canal. The middle fossa approach to expose the internal auditory canal can be best performed by the drilling of the petrous ridge and medial portion of this rhomboid fossa. The internal auditory canal is well exposed with the use of a 3 mm coarse diamond drill. The anterior portion of the bone is premeatal triangle. The postmeatal triangle is defined between the superior semicircular canal and the internal auditory canal. There is no definitive key to identify the cochlea. I use two landmarks to define the cochlea; about 5 mm anteromedial from the center of the geniculate ganglion, 1 or 2 mm posterior from the genu of the C6 petrous carotid artery.



## 2.9 Anterolateral triangle of Mullan

This is the area between the trigeminal 1st branch (superior orbital fissure) and the foramen rotundum trigeminal second branch that contains the confluence of the superior and inferior ophthalmic veins. Also, this triangle can be used for the packing obliteration of the carotid cavernous fistula or for the exposure of the peripheral portion of the intracavernous abducens nerve.

## 2.10 Far lateral triangle

This is the area between the foramen rotundum and the foramen ovale between the peripheral portion of the trigeminal 2nd and 3rd branches. This triangle contains the lateral wing of the sphenoid sinus, vidian nerve and the pterygoid region. Far anterior-inferiorly the maxillary sinus can be exposed and posteriorly the infratemporal Eustachian tube can be exposed under the lateral and medial pterygoid muscle. This far lateral triangle is the corridor toward the anterior infratemporal fossa approach for any of the infraorbital, maxillary and pterygoid tumors and the exposure of the epi- and parapharyngeal wall.

## DECISION-MAKING

During the past three decades, from 1980 to 2007, I have operated on a total of 552 cases of cavernous sinus lesions, either vascular (258 cases) or tumors (294 cases), and 568 additional cases of petroclival tumors. Tables 1 and 2 show the pathological process of the cavernous sinus lesions. For the direct operative approach to the cavernous sinus, neurosurgeons should first learn to operate on pericavernous vascular lesions such as ophthalmic aneurysms or paraclinoid aneurysms. After acquiring sufficient experience of clinical micro-anatomical knowledge, exposure of the cavernous sinus triangles, and hemostasis technique with Surgicel and bipolar, then surgeons can proceed to the surgery of intracavernous aneurysms, CCF and cavernous sinus tumors.

The easiest of the cavernous sinus tumors to operate is the intracavernous extension of the pituitary adenoma or intracavernous neuromas because the

**Table 1.** Cavernous sinus aneurysms (1980–2007: 258 cases)

Cavernous giant aneurysms	77	C6-C3 Bypass	56
		EC-M2 Bypass	16
		Clipping	5
Siphon giant	5		
Clinoidal-paraclinoidal	49		
Ophthalmic	58		
Paraclinoid giant	51	Bypass	5
		Clipping	46
C4 and Meningohypophyseal	9		
Primitive trigeminal	3		
CCF Clipping, suture	6		

**Table 2.** Cavernous sinus tumors (1980–2007: 294 cases) (Benign 259, malignant 35 cases)

Meningiomas total 122:	
Spheno-orbital clinoidal cavernous	18
petroclival intracavernous	22
Purely intracavernous	82
Trigeminal neuromas (ganglion type)	24
Chordoma and chondrosarcomas	41
Pituitary adenomas (cavernous extension)	32
Cavernous sinus cavernous angiomas	17
Epidermoid	12
Dermoid	4
Colloid cyst	3
Benign teratoma	4
Malignant neuromas	4
Malignant meningiomas	12
Adenoid cystic carcinoma	6
Sarcomas	9
Malignant lymphoma	4

majority of pituitary adenomas and neuromas are soft and can be easily removed by suction and ring curettes, and the tumor capsule can be readily separable from the neurovascular structures. Then I recommend the surgeon to proceed to the surgery of chordomas, chondrosarcomas and other intracavernous tumors. The most difficult tumors to operate are meningiomas and cavernous angiomas. Meningiomas involving the cavernous sinus can be classified into three categories; (1) the extension of the cavernous sinus infiltration of the spheno-orbital and clinoidal meningioma; (2) extension and infiltration of the petroclival meningioma into the cavernous sinus and (3) purely intracavernous meningioma. In any category, cavernous sinus meningiomas tend to be fibrous, adherent and vascular and therefore, it is extremely difficult to achieve sufficient surgical resection. In my series of 122 cases of cavernous sinus meningiomas, gross total resection could be achieved in only 10% of small to medium size softer meningiomas.

Most of the cavernous sinus *pituitary adenomas* can be removed through the medial triangle and occasionally a technique pushing the adenoma tissue from the lateral side with cottonoids is useful so surgeons can remove tumor from the medial triangle, medial to the oculomotor nerve. Most of the *ganglion-type intracavernous trigeminal neuroma* can be approached through the extradural lateral approach between the trigeminal 2nd and 3rd branches. The surgeon has to be extremely careful not to damage the oculomotor and abducens nerve and the intracavernous deviated and compressed internal carotid artery. *Chordomas and chondromas* can also be approached through multiple cavernous triangles, but mostly from the lateral and posterior transcavernous approach in order to keep the oculomotor and the abducens nerves intact. The majority of chordomas or chondrosarcomas is soft and gelatinous and can be suctioned and removed in a radical fashion by various sizes of ring curettes. Approximately 10%

of chordomas are somewhat vascular, hard with multiple fibrous trabeculae that hampers radical resection. Complete total resection of chordomas is usually not feasible (most cases are near total or radical subtotal) and postoperative proton beam radiation is usually indicated to prevent recurrence. Other benign tumors such as *dermoid*, *epidermoid* and *colloid cyst* are usually technically not so difficult for the evacuation of these suckable tumors.

*Cavernous sinus cavernous angioma* is totally different from the cavernoma in the brain. Cavernous sinus cavernous angioma is more similar to orbital cavernous angioma or similar to more vascular tumors such as hemangioblastoma or hemangiopericytoma. Small to medium size cavernous sinus angioma in this region can be approached through the lateral or posterior transcavernous approach or medial approach (7 cases) or through the endonasal transsphenoidal route. Four cases of small cavernous angioma were radically resected through the transnasal transsphenoidal route. Large and giant angiomas (6 cases) are extremely difficult to eradicate. In these cases, postoperative cavernous sinus neuropathy is common and a large amount of blood loss will occur. Usually, I recommend that large and giant size cavernous sinus cavernous hemangiomas are best treated first by focused beam radiation with Cyberknife followed by surgical excision.

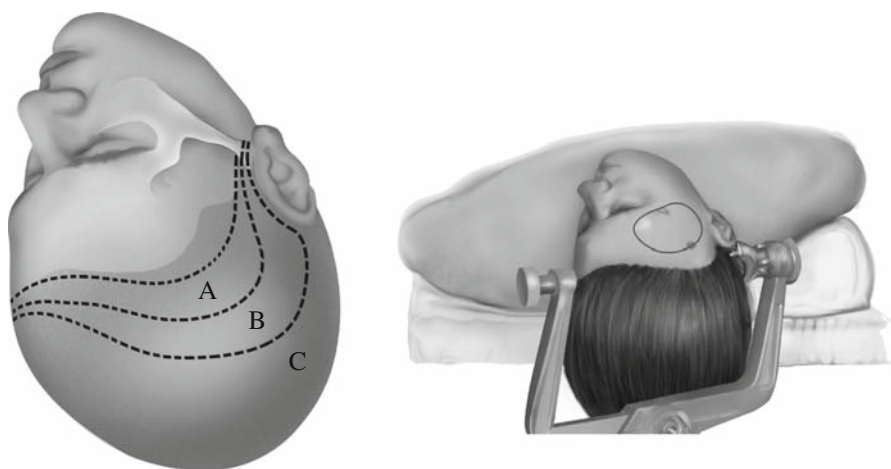
*Cavernous sinus meningiomas* are by far the most difficult to perform radical surgical intervention. Gross total resection can be achieved only for non-adherent soft type meningioma, which is only 10% of the cavernous sinus meningiomas. Subtotal or partial resection were performed in the other 90% of cavernous sinus meningiomas yet the postoperative cavernous sinus neuropathy with persistent double vision and trigeminal facial numbness are common; therefore, if the patient presents with small to medium size cavernous meningioma with minimal neurological deficit, usually observation is recommended. Most of these meningiomas do not grow for several years. Once the patient develops progressing neurological deficit or facial numbness, pain or diplopia and MRI evidence of growing cavernous sinus meningioma, neurosurgeons have the options of moderate surgical excision or focused beam radiation such as Cyberknife management. Radiation to benign tumors such as meningiomas or neuromas carry definitive risk of cranial nerve neuropathy, radiation induced angiopathy and possible aggressive or malignant changes in benign tumors; therefore, indication of surgery or focused beam radiation are different for tumor type, size, extension, patient age, occupational and social background and the most important is the patient's own choice of management.

## **SURGERY**

### **1. OPERATIVE TECHNIQUE FOR CAVERNOUS SINUS LESIONS**


Because the majority of intracavernous and pericavernous processes are in the frontotemporal skull base, and because the surgeon will make direct

### Head Positioning and Design of Skin Incision



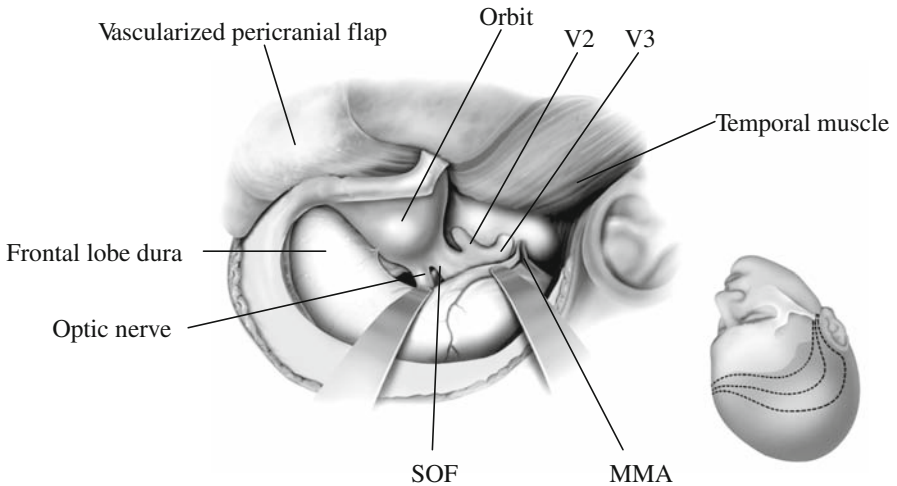
**Fig. 3.** **A** Routine pterional approach limited incision. **B** Incision for a larger frontotemporal exposure. **C** Extended incision for frontotemporal, orbitobasal and middle fossa exposure

operative access with the microscope in a *down-looking viewing angle*, *orbitozygomatic* or *transzygomatic technique* is rarely needed. Most of the trans-cavernous surgery can be performed through the standard frontotemporal and pterional approach. The head is rotated  $45^\circ$  with the vertex slightly down and with the neck in a moderately hyper-extended position. The Mayfield three-pin should be placed with two pins on the back side, with the upper pin to the mastoid body inside the hairline and the lower pin around the inion and the other one pin to the other side of the frontal inside the hairline in order to make cosmetic pin placement and to secure the head position. The skin incision is made from the preauricular zygomatic point, which is about 10mm in front of the tragus and coursing inside the *hairline* at the frontotemporal area slightly crossing over the midline (Fig. 3). The scalp is elevated usually in one layer for cosmesis of the frontotemporal area to protect the temporal muscle from surgical emaciation. Fukushima's wide dynamic range *retraction-holder system* (Integra) greatly facilitates the operative exposure without any eye-ear compression (Fig. 4). In selected cases, half one-layer scalp elevation or two-layer elevation can be performed making the temporal muscle reflected inferiorly and posteriorly and preparing the vascularized fasciopericranial flap separate from the galeocutaneous flap. After the scalp and temporal elevation, a standard frontotemporal osteoplastic craniotomy is performed with minimal bone loss. Usually it is recommended to use Anspach E-Max II electric power drill system with 5 and 4 mm extra-coarse burs making only one or two burr holes of 6 mm size and 4 mm groove detachment at the pterion, orbitotemporal junction and the anterior subtempo-



**Fig. 4.** Fukushima's wide dynamic range retraction-holder system (Integra)

### Extradural Drilling and Shaving of the Frontotemporal Base

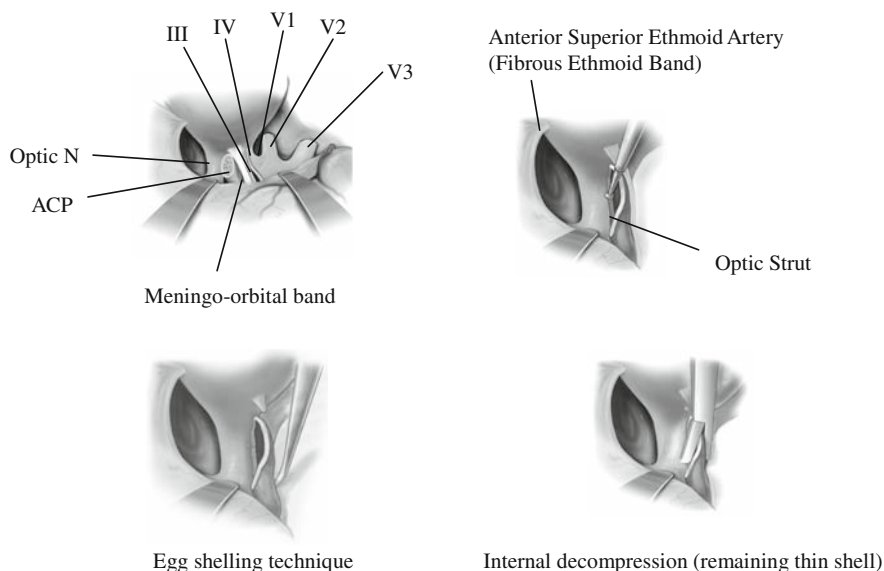


**Fig. 5.** The orbital roof of the orbit will be shaved down until there is only a thin depressible shell of bone remaining. Injury to the orbital fascia and damage to the periorbital soft tissue should be avoided. The temporal dura is elevated from the anterior temporal vase to the mid-subtemporal base

ral area. It is advised not to open the frontal sinus to avoid infection and CSF leak. After the elevation of the bone flap, we shave the orbital roof, lateral orbital wall and the sphenoid ridge. In the majority of cases, it is recommended to flatten and thin down the *orbital wall* and not to perform total orbital decompression (Fig. 5).

We then proceed to the drilling of the anterior clinoid process and *removal of the anterior clinoid process with or without optic canal unroofing*. This drill work is the most important skull base procedure in the cavernous sinus approach. Any diamond drill heat or damage of the dura may lead to visual disturbance and oculomotor weakness. Essentially, the anterior clinoid process starts from the end of the sphenoid ridge at the meningo-orbital band and usually I recommend using 4 or 3 mm coarse diamond burrs to make the inside of the anterior clinoid process to be halo and to shave off the medial half of the anterior clinoid process to detach from the optic strut (Fig. 6). In a majority of the cases, the sphenoid sinus medial to the optic nerve will not be opened. The ethmoid fibrous band will be maintained to secure the ethmoid artery intact. The optic canal unroofing should be performed under running water without heat and using the so-called egg shell-

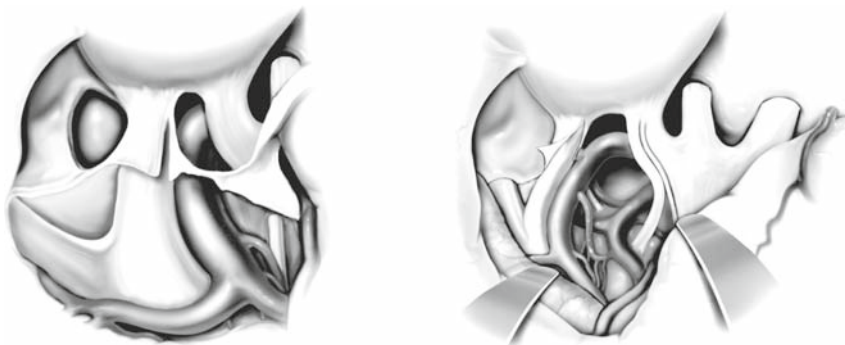
### Optic Canal Decompression- Removal of the Anterior Clinoid



**Fig. 6.** Removal of the anterior clinoid process (ACP) is accomplished by internal decompression with a high-speed drill, followed by dissection of the remaining thin shell. Removal of the anterior clinoid process provides exposure, to the anterior cavernous triangle and the internal carotid artery siphon. The medial limit of dural reflection defined by the anterosuperior ethmoidal artery as it pierces the bone, passing into the orbit

ing technique to protect the dura of the extradural optic nerve. The lateral half of the anterior clinoid process is then dissected using a sharp A or D rigid skull base dissector and to be removed gently twisting with alligator forceps. The tip of the anterior clinoid process has always fibrous adhesion at the bottom of the anteromedial cavernous sinus into the siphon angle and after the removal of the anterior clinoid process, two or three pieces of small moist Surgicel are necessary to pack into the siphon angle to stop the cavernous sinus venous bleed. The surgeon should keep in mind that the medial aspect of the anterior clinoid process is the optic nerve, the lateral aspect is the oculomotor nerve, and the bottom is the C-3 clinoidal segment of the cavernous carotid artery. After the secure and safe removal of the anterior clinoid process, then proceed to elevate the dura propria of the anterolateral cavernous sinus wall starting from the superior orbital fissure, foramen rotundum and toward the ovale. Using a semi-sharp 15 blade knife and A-dissector, the dura propria can be cut and elevated at the junction of the superior orbital fissure, rotundum and the temporal dura. One must be extremely careful to elevate this dura propria and not to enter into the intradural space. The inner half layer of this dura covers the trigeminal nerve and the lateral cavernous sinus wall. Any bleed should be controlled by placing 1 or 2 or 3 mm of small Surgicel as well as one or two seconds of short bipolar coagulating technique. With this extradural exposure of the lateral wall of the cavernous sinus, we can identify the oculomotor nerve, 4th nerve and the trigeminal 1st, 2nd and 3rd branch towards the Gasserian ganglion and to the cisterna trigeminalis. The fibrous ring around the junction of the internal carotid artery exists between the C2 and C3 carotid segments just around the

### Posterior Clinoid Process Removal for Basilar Artery Exposure

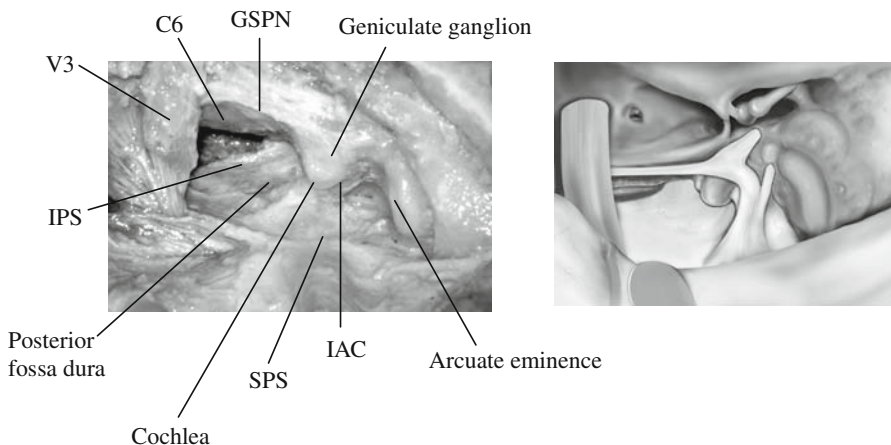


**Fig. 7.** The fibrous dural ring is dissected from the ICA to allow mobility of the vessel. To completely mobilize the medial temporal dura, the fibrous ring is freed, the porus oculomotorius is opened, and the tentorial edge between the carotid artery and third cranial nerve is retracted laterally. With the dura and the arachnoid planes opened, the ICA is visualized to its bifurcation. For added exposure of the basilar bifurcation, the posterior clinoid process is removed with a high-speed drill. Opening the membrane of Liliequist exposes the basilar artery

ophthalmic artery. The anterior to this carotid fibrous ring is the epidural space of the siphon called the C3 clinoidal segment. The majority of paraophthalmic aneurysms and paraclinoid aneurysms can be safely approached and clipped only by exposure of this *anteromedial cavernous sinus triangle*. For adding exposure of the interpeduncular space, the posterior clinoid process can be removed and the Lilliequist membrane opened (Fig. 7).

The space between the oculomotor nerve and the posterior clinoid process is named Hakuba's medial triangle, which is the access to the C4 horizontal segment of the cavernous carotid artery and medially to the pituitary area. The space between the oculomotor and the 4th cranial nerve is named Fukushima's superior triangle and this is the best approach to expose the C4 and C5 junction to the meningo-hypophyseal trunk. The space between the 4th cranial nerve and trigeminal first branch is the classical Parkinson's triangle which is the best corridor for exposure of the C5 ascending segment of the carotid artery. The space between the trigeminal 1st branch together with the abducens nerve and the 2nd branch that is between the superior orbital fissure and the foramen rotundum is named as the Mullan's triangle, which contains the venous confluence of the superior and inferior ophthalmic veins. The area between the trigeminal 2nd and 3rd branch was named as the lateral loop, which contains the lateral wing of the sphenoid sinus, Vidian nerve and the anterior infratemporal fossa towards the lateral epipharyngeal and parapharyngeal wall. The posterior cavernous sinus region is called the rhomboid area which is determined by the

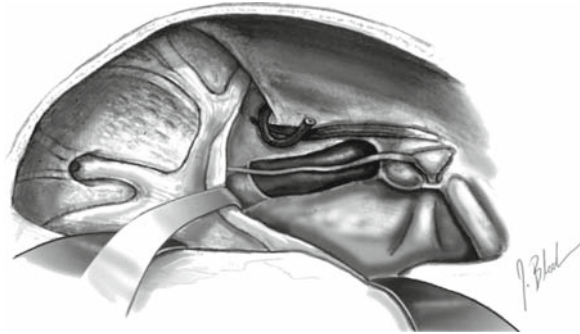
### Middle Fossa Rhomboid Exposure



**Fig. 8.** Bisect the angle between the lines projected along the axes of the greater superficial petrosal nerve and the arcuate eminence. Start drilling, with a medium diamond burr, along the midpoint of this bisection axis. The dura overlying the IAC will be identified once you have removed approximately 3–4 mm of bone. Continue to expose the dura overlying the medial IAC towards the petrous ridge



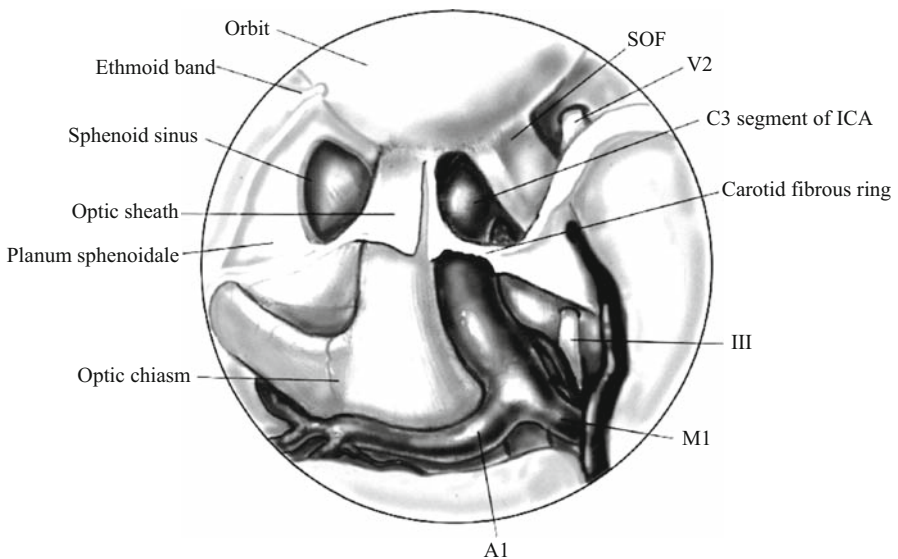
### Middle Fossa: V3 Anterior Translocation



**Fig. 9.** At the proximal genu of the C6 petrous carotid artery, the cochlea is extremely close, and drilling should be stopped without going further, to the proximal carotid canal. Exposure of the petrous carotid artery is facilitated by the skeletonization of the peripheral branch of the trigeminal third division and anterior translocation of the gasserian ganglion


posterior border of the trigeminal 3rd branch, greater superficial petrosal nerve (GSPN), geniculate ganglion and the arcuate eminence or superior semicircular canal, petrous ridge and the posterior point of the trigeminal fibrous ring.

### Antero-medial Approach



**Fig. 10.** The frontotemporal dural can be incised in an inverted T-fashion. The falciform ligament (porus opticus) is incised using a 15 or 11 blade knife at the lateral border of the optic nerve to decompress the optic nerve and to identify the ophthalmic artery

Ultrasonic surgical aspirator  
(SONOPET UST-2001)



Tokyo claw

**Fig. 11.** The intradural high speed drill carries some risks of catching patties, Surgical or Gelform and may cause damage. In recent years, we use mostly the Sonopet ultrasonic bone shaver which provides extremely safe and effective anterior clinoid process removal. The Sonopet is compatible with cottonoids and any material in the surgical field. The shaver will not snag patties. The best shaver tip is Tokyo tips (Tokyo claw)

The *drilling of the rhomboid area* while maintaining the C6 petrous carotid laterally, cochlea and the internal auditory canal posteriorly will expose the posterior transcavernous approach and the posterior fossa dura to the infracavernous lesions such as chordomas and chondrosarcomas (Fig. 8). The petrous apex (“the Big Shark Tooth”) bone is located just under the Gasserian ganglion. The *anterior translocation of the V3 root* (Fig. 9) greatly facilitates the removal of the petrous apex bone and the exposure of the inferior petrosal sinus, abducens nerve Dorello’s tube and the posterolateral fibrous ring of the C6–C5 junction. The Dorello’s tube is located just beneath the trigeminal fibrous ring at the floor of the inferior petrosal sinus. The petroclinoid ligament, the petrosphenoid ligament (Gruber’s) and the posterior cavernous abducens nerve are best exposed in the posteroinferior triangle. The intradural exposure can be started at the *internal carotid fibrous ring at C2–C3 junction* (Fig. 10). The carotid fibrous ring is better to be excised to mobilize the C2–C3 segments. When the surgeon performs intradural removal of the anterior clinoid process or the posteroclinoid-dorsum sellae removal, I recommend absolutely not to use any high speed drill, but to utilize the Japanese Sonopet *ultrasonic bone shaver for safety* (Fig. 11).

## 2. OPERATIVE TECHNIQUE FOR SKULL BASE BYPASSES

- For the management of giant intracavernous aneurysms or radical resection of tumors with sacrifice of involved cavernous carotid artery, the surgeon needs to perform a carotid artery replacement with a bypass graft.

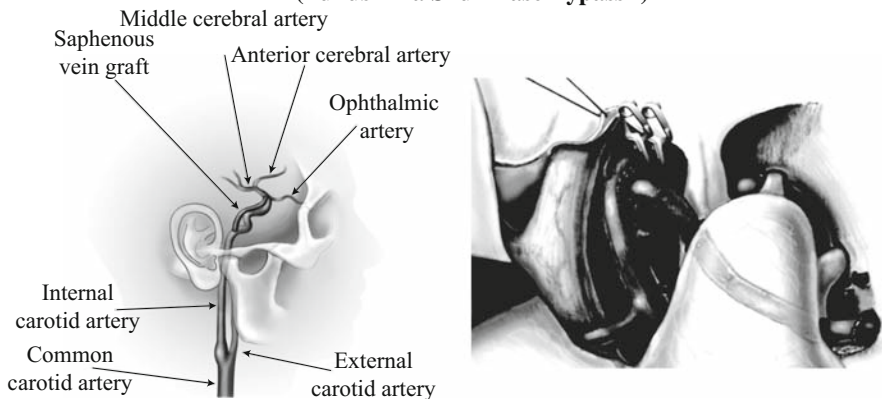
**Table 3.** Surgical approaches for petroclival meningioma (1980–2007: 310 cases)

1. Combined petrosal (with retrolabyrinthine, translabyrinthine, or transcochlear temporal exposure)	113 (36.5%)
2. Retromastoid (with or without combined transcondylar exposure)	110 (35.5%)
3. Frontotemporal (with transcavernous or pericavernous dissection)	35 (11.3%)
4. Middle fossa (preauricular subtemporal with anterior petrosectomy)	32 (10.3%)
5. Pre/Post-auricular with total petrosectomy (with translabyrinthine, transcochlear, or transotic)	9 (2.9%)
6. Transmastoid, extended translabyrinthine	11 (3.5%)

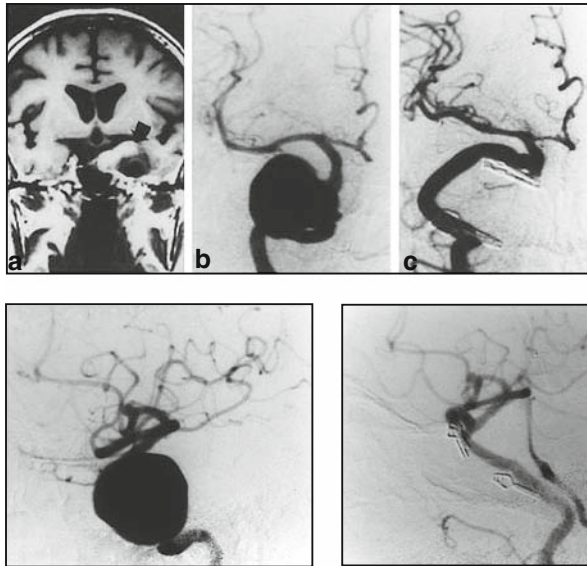
Since 1986, I have developed *three types of high-flow skull base bypass using saphenous vein interposition graft*. Over the two decades, I have performed high-flow saphenous bypass in 110 patients. Table 3 demonstrates the types of Fukushima skull base bypass and the number of operated patients.

The **skull base bypass I** is the saphenous vein interposition graft between the C6 petrous carotid to the paraophthalmic C2–3 segment of the internal carotid artery (Fig. 12A). This was mainly used for the jump bypass as trapping treatment of the cavernous giant aneurysm, or after the total resection of invasive cavernous sinus tumors to establish the internal carotid circulation. The surgery is performed through a routine frontotemporal pterional craniotomy. Then extradural temporopolar approach can be performed to expose the entire cavernous sinus with drilling of the middle fossa rhomboid to expose the C6

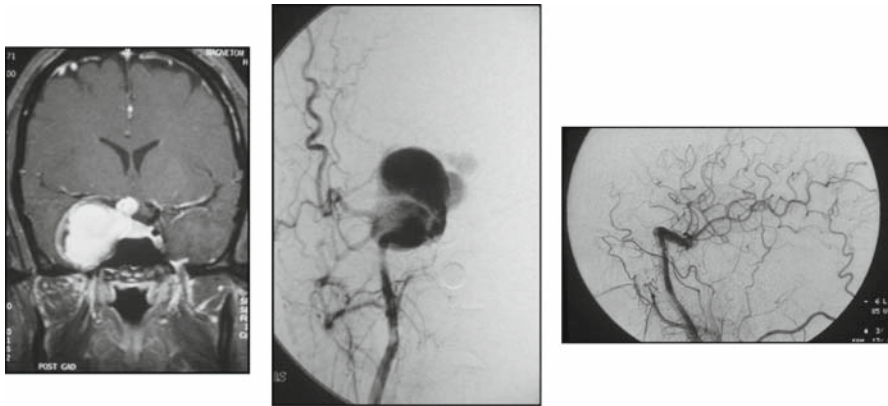
#### Operative Technique of C6-C3 Saphenous Vein Interposition Graft Bypass (Fukushima Skull Base Bypass I)



**Fig. 12A.** The saphenous vein is passed through a small dural incision from the subtemporal to the clinoidal area under the temporal lobe. After occluding the proximal carotid artery by packing a small cottonoid into the carotid canal, the carotid artery is ligated under the gasserian ganglion at the C6-C5 junction. Then, the petrous carotid is incised and end-to-end anastomosis is performed with the saphenous vein, using 8-0 monofilament nylon interrupted sutures



**Fig. 12B.** 85M The oldest patient in this series; patients with painful ophthalmoplegia. He was cured by bypass



**Fig. 12C.** 21F college student. Right: combined intracavernous giant aneurysm and paraclinoid large aneurysm. EC to M2 bypass with trapping procedure. She is cured and living well now nearly for 10 years

petrous carotid under the greater superficial petrosal nerve (GSPN) [6] and the anteromedial cavernous triangle after the removal of the anterior clinoid process and optic canal unroofing. In many cases, I perform minimally invasive approach without retracting the temporal lobe just by exposure of the anteromedial triangle and the petrous carotid exposure. The saphenous vein is then

passed through a small dural incision at the subtemporal base with mostly end-to-end anastomosis at the petrous carotid segment and end-to-side anastomosis to the paraophthalmic segment (Fig. 12B). After performing 56 cases of this bypass for giant aneurysms, I encountered 7% incidence (4 cases) of visual deficit due to the temporary clip to the ophthalmic artery during the paraophthalmic anastomosis. Therefore, the surgeon has to be extremely careful for the temporary clipping of the ophthalmic artery, which may cause ischemia of the central retinal artery. In my current practice, I prefer more the skull base bypass III using the external carotid to the M2 saphenous vein graft technique (Fig. 12C). The EC to M2 bypass through the submandibular, subzygomatic pterygoid to the anterior subtemporal fossa route is the shortest secure and safe technique to the Sylvian area.

**The skull base bypass II** is the external carotid to the submandibular pterygoid subzygomatic route to the C6 petrous carotid bypass. This infratemporal bypass can be used for the repair of high cervical and infratemporal aneurysms and radical resection of infratemporal tumors such as carotid body tumor or glomus vagale tumors.

**Table 4.** Mortality and post operative neurological deficits (1993–2007: 310 cases)

Mortality	1 (0.5%)
Bed Ridden	2 (both malignant)
Patients with any deficit	62 (20%)
Hemiparesis	17 (5.5%)
Unsteadiness	11 (3.5%)
III	14 (4.5%)
IV	12 (3.8%)
VI	18 (5.8%)
V (dysesthesia)	25 (8.0%)
VII	16 (5.1%)
VIII	21 (6.8%)
IX/X	18 (5.8%)
XII	2 (0.6%)

**Table 5.** “Fukushima bypass” 110 cases (1986–2007)

1. Fukushima bypass I (C6 to C3 saphenous bypass)	(70 cases)
cavernous giant aneurysms	56 cases
C3 siphon stenosis	1
tumor-meningioma	6
malignant tumor (chordoma, glioma)	7
2. Fukushima bypass II (EC to C6 infratemporal bypass)	(16 cases)
infratemporal high cervical aneurysms	6
glomus tumor-carotid body	4
glomus vagale	3
meningioma	3
3. EC to M2 saphenous bypass	(21 cases)
cavernous giant aneurysms	16
IC distal aneurysms	5
4. EC to P2 saphenous bypass	(3 cases)

**The skull base bypass III** is indicated for any cavernous sinus vascular or neoplastic lesions, if the lesion involves the petrous carotid artery. The saphenous vein is anastomosed to the external carotid artery end-to-side at the submandibular region and the saphenous vein can be passed through the submandibular through the pterygoid and subzygomatic route to the subtemporal area between the V2 foramen rotundum and V3 ovale with the chest tube. Distally, the saphenous vein is anastomosed end-to-side to the M2 segment usually posterolateral M2 trunk in the sylvian fissure. This bypass is technically much easier than any of the other skull base bypasses yet provides immediate high-flow and virtually no risks of visual deficit. Currently, this skull base bypass III EC to M2 saphenous vein graft is the major high-flow skull base bypass for the management of cavernous sinus pathology.

**How to avoid complications.** Operative results of 110 bypass cases over the past two decades were excellent. There were no mortality and the morbidity rate was 7% for visual deficit and 3.6% for hemiparesis. A 65-year-old female had a calcified paraophthalmic carotid artery and anastomosis after microendarterectomy resulted in occlusion and hemiplegia. If the surgeon observes thick atherosclerosis or calcified wall, never make anastomosis. One patient showed hemiparesis by sylvian clot, a 16-year-old girl had a very small M2 branch and the bypass occluded and the other 60-year-old man had a collision flow and congestive hyperperfusion by bypass, resulted in hemiplegia. If the recipient's vessel is smaller than one third of the saphenous vein, the surgeon should select a more proximal larger vessel. When the EC-M2 high-flow bypass is established, the surgeon must immediately occlude the internal carotid artery at the neck to avoid overflow phenomenon of the middle cerebral arterial territory. I use 1000–5000 units of Heparin IV during surgery and give patients Lovenox protocol and coated aspirin postoperatively.

### 3. OPERATIVE TECHNIQUE FOR PETROCLIVAL LESIONS

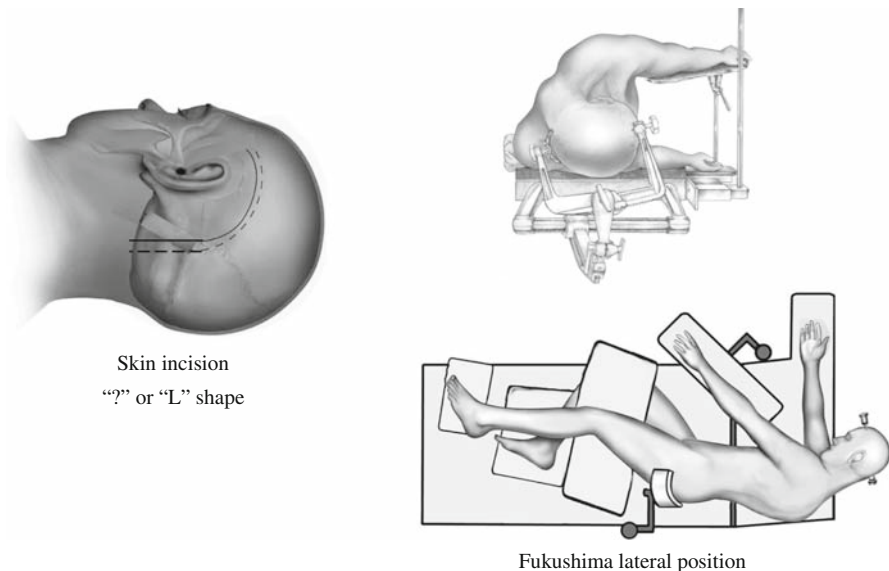
Skull base tumors arising from the petroclival area remain the most difficult and challenging surgical problem in neurosurgery due to the *involvement of multiple cranial nerves and vascular structures as well as adhesion to the brainstem.*

From 1980 to the end of 2007, I have operated upon a total of 568 cases of petroclival tumors (meningiomas 419, trigeminal neuromas, either root type or dumbbell type 72 cases, petroclival chordomas 65 cases and giant epidermoid tumor involving supra and infratentorial cerebellopontine angle 12 cases).

- **The combined petrosal approach** was developed and elaborated by Japanese neurosurgeons such as Hakuba and myself in the early 1980s. Professor Hakuba operated through a partial labyrinthectomy transpetrosal approach and I developed a retrolabyrinthine hearing preservation so-called para-petrosal approach around 1985. The surgeons who wish to operate on large petroclival meningiomas must have precise understanding of the con-

temporary skull base microanatomy, precise hemostasis technique and sufficient experience through the transtentorial exposure in order to eradicate the meningioma in a radical fashion. The majority of patients with petroclival meningiomas still have good hearing; therefore, the retrolabyrinthine combined supra- and infratranstentorial approach must be performed through the pre-sigmoid and subtemporal dural incision. Usually the patient is positioned in a Fukushima lateral position with the head supported with a three-pin head clamp with moderate flexion, vertex down and with sufficient space between the neck and the lower arm. The nose should be rotated slightly upward in order to avoid the shoulder obstructing the surgeon's left hand performance. Most of the time we use a large C or L shaped scalp incision and the galeal cutaneous flap is first elevated. The vascularized fascial pericranial graft usually is taken with the pedicle around the anterior subtemporal lesion. Then the suboccipital muscle is divided and the temporal muscle is reflected anterior inferiorly. I recommend first to identify the outer mastoid triangles from the posterior point of the route of zygoma, asterion, digastric groove and mastoid tip. The outer mastoid triangle surface mastoid bone is shaved using a 6 mm cutting burr with maximum thinning of the posterior wall of the external ear canal and skeletonization of the thick transverse sigmoid and jugular bulb. After the initial

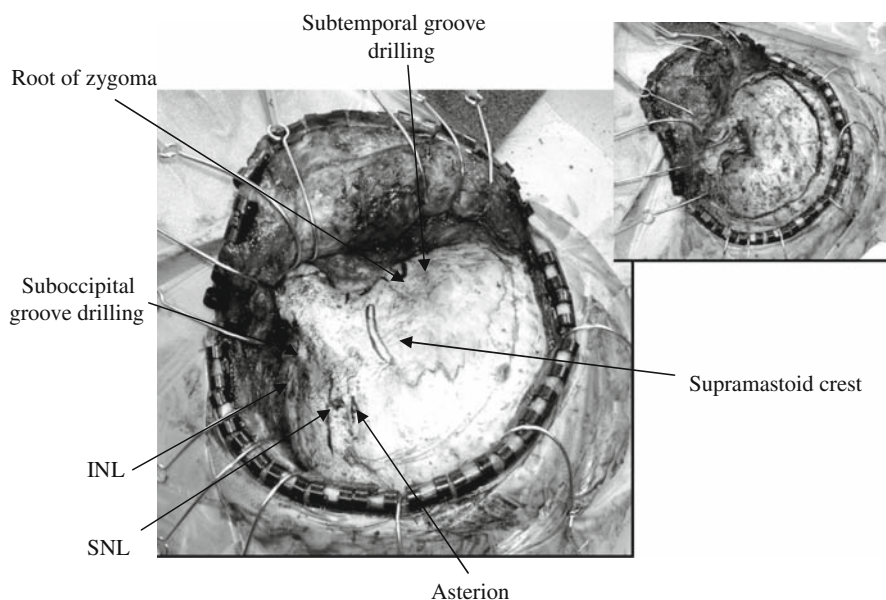
### Positioning and Skin Incision



**Fig. 13.** The head is then placed in three-point fixation and positioned in such a manner as to keep the nose parallel with the floor and the cranial vertex tilted slightly down towards the floor. This position of the head allows access to the middle fossa, the cerebello-pontine angle, the mastoid process, the petrous temporal bone, and the far lateral skull base extending down to the foramen magnum and upper cervical spine

bone removal, the surgeon should use 5 or 4 mm extra coarse diamond burr to further shave and decompress the sigmoid sinus and presigmoid dura. Then the surgeon should change to the 3 mm coarse burr. The mastoid antrum is shaved to identify the lateral semicircular canal, posterior semicircular canal and then the superior semicircular canal. The temporal tegmen must be entirely removed to identify and to dissect the soft posterior temporal dura from the sinal dural angle to the aditus. It is not necessary to skeletonize the facial nerve; however, one has to identify the pink line of the facial nerve fallopian canal, stylomastoid foramen and genu to protect the facial nerve and not to make any facial weakness postoperatively. After the skeletonization of the temporal tegmen, sinal dural angle, transverse sinus and presigmoid dura, then a large L shaped osteoplastic craniotomy should be performed from the anterior middle, posterior temporal, occipital and suboccipital craniotomy without dural rupture. You should then proceed to the subtemporal dural elevation to identify the middle

### Clinical Case: Bone Landmark and Craniotomy

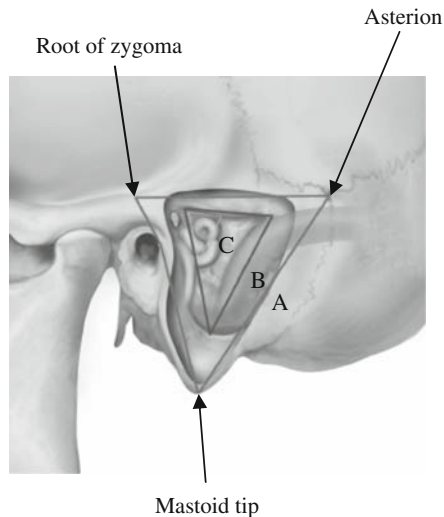


**Fig. 14.** Small burr holes (7 mm) are made using an ANSPACH extra coarse 5 mm diamond burr on the temporal squama in preparation for cutting the craniotomy. It is important to recognize the projection of the root of zygoma posteriorly, known as the supramastoid crest. An extension of this crest passes through the asterion toward theinion. This extension forms the superior nuchal line, which is a critical external landmark to define the temporal basal dura (temporal tegmen). Then, anterior temporal, subtemporal and inferior suboccipital grooves are drilled with a 4 mm diamond burr to detach the anterior-inferior and suboccipital inferior ends of the craniotomy flap (craniotomy cannot reach this area). Next, using the craniotome, an "L" shaped incision is made connection the superior end of the anterior temporal and the posterior end of the retrosigmoid grooves



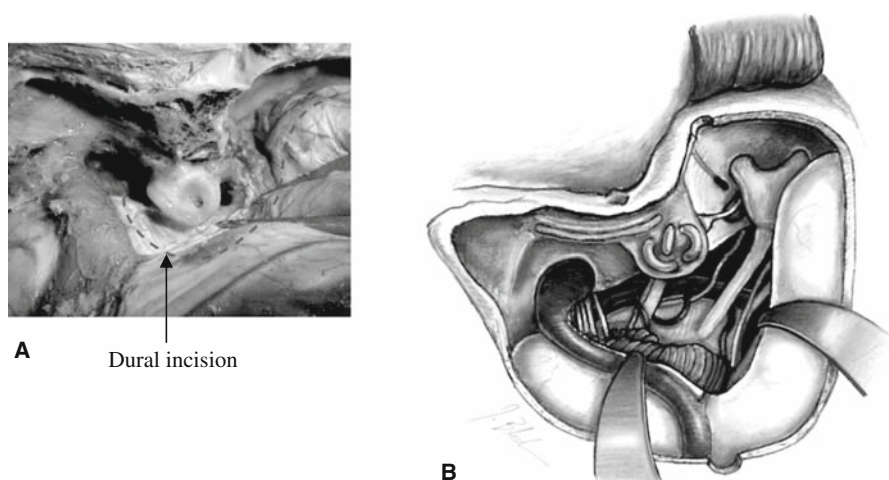
fossa rhomboid to remove the entire petrous ridge. Skeletonized the trigeminal third branch from the trigeminal fibrous ring to the foramen of ovale, identify the greater superficial petrosal nerve (GSPN) and the C6 petrous carotid and anterior petrosectomy to expose the posterior fossa dura and the inferior petrosal sinus. The key anatomical point is the superior semicircular canal, which must be skeletonized and the petrous ridge has to be shaved maximally to isolate the superior canal to the ampulla and then further drill off the postmeatal and premeatal triangle to skeletonize the internal auditory canal in the middle fossa yet preserving the geniculate ganglion and the cochlea. Figure 13 shows the positioning of the patient and design of the skin incision. Figure 14 shows the clinical example of the galeocutaneous flap, temporal muscle elevation and the bony landmark around the lateral skull base, posterior point of root of zygoma, squamosal point, supramastoid ridge, external auditory canal, digastric groove, asterion, superior nuchal line and the inferior nuchal line. Figure 15 shows the skull base drill procedures of the mastoid triangle skeletonizing the transverse, sigmoid sinus, jugular bulb, presigmoid dura and maximum skeletonization of the semicircular canal. Figures 8 and 9 demonstrate the extradural subtemporal exposure of the middle fossa rhomboid space and the anterior petrosectomy as well as the exposure of the internal auditory canal between the trigeminal third branch, GSPN, geniculate ganglion, cochlea, superior semicircular canal and the petrous ridge. After completing the mastoid drilling and

### Mastoid Triangles and Drilling



**Fig. 15.** **A** Outer mastoid triangle: Asterion – Root of zygoma posterior point – Mastoid tip. **B** Inner triangle: Sinodural angle – Aditus – Digastric ridge. **C** Macewen's triangle, suprimeatal triangle (Mastoid antrum)

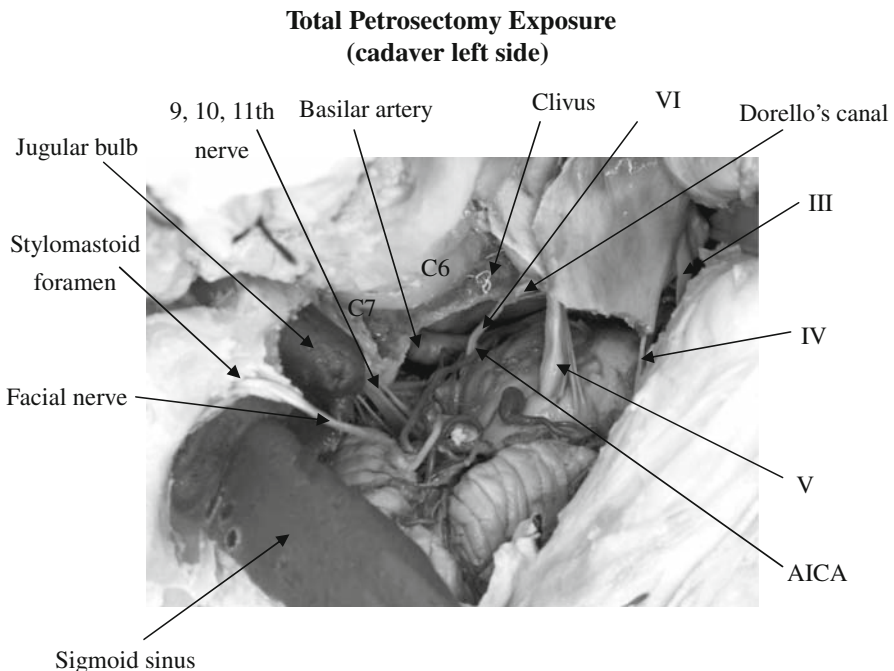
### Dural Incision, Transtentorial Exposure, and Intradural Dissection



**Fig. 16.** Left: retrolabyrinthine combined parapatrosal approach. Typical dural incision and exposure of the Fukushima para-petrosal approach (A). A picture after the resection of the petroclival meningioma (B)

middle fossa exposure, the dura must be incised in the middle of the presigmoid dura from the supra-jugular point passing the endolymphatic sac and then the surgeon ligates the superior petrosal sinus about 1 cm from the transverse and sigmoid sinus junction. A subtemporal dural incision is then continued along the tentorial attachment (Fig. 16A). In that way, the surgeon can protect the temporal lobe with dural coverage (Fig. 16B). The best protection of the cerebellum and the temporal lobe is the dura. This curvilinear incision is sufficient to have the operative space posterior to the semicircular canal. The incision along the transverse sinus must not be performed because such an incision will damage the vein of Labbe. The most important issue in surgery of petroclival meningiomas is the coagulation and detachment of the posterior tentorial edge from the superior petrosal sinus with 90° vertical deep towards the tentorial edge and thereby identifying and separating the 4th nerve. Then the tentorial edge is liberated from the arachnoid, 4th nerve, posterior cerebral artery and possibly the superior cerebellar artery. While making precise hemostasis, elevate the dura propria of the subtemporal outer layer from the foramen rotundum and foramen ovale to expose the trigeminal post ganglion rootlet and the Gasserian ganglion. Then excise the trigeminal fibrous ring from the lateral posterior corner to the medial corner. That is the junction of the tentorium to the posterior cavernous sinus. At this point, dissect the 4th nerve from the dural entrance about 7 mm using a 15 blade knife. From the intratentorial 4th nerve, the incision goes laterally to join the fibrous ring while making hemostasis of the tentorial feeders to the meningioma. With Surgicel packing towards

the superior petrosal sinus and the posterior cavernous sinus, this posterior cavernous sinus detachment of this tentorium and actual resection of this petroclival area of the tentorium will make significant devascularization to the petroclival meningioma. The trigeminal preganglionic root should be separated from the meningioma and further the posterior cavernous and petroclival devascularization and detachment of the meningioma is conducted. Further devascularize the meningioma. The surgeon must be very careful with the abducens nerve entrance which is right beneath the inferior trigeminal fibrous ring and at the level of the inferior petrosal sinus floor. Usually the meningioma should be decompressed with the Sonopet tumor remover and further devascularized. After sufficient multiple stage coring and debulking of the meningioma, then the meningioma capsule can be separated from the posterior temporal, from the cerebellum and then further from the brainstem. The facial nerve should be identified using the NIM facial nerve monitor and carefully observe the auditory brainstem response. At the caudal pole of the meningioma, the surgeon has to be very careful to separate the anterior inferior cerebral artery (AICA) branches and then further to identify the proximal portion of the abducens nerve. About 25% of petroclival meningiomas, particularly large



**Fig. 17.** At this moment, the petrous portion of ICA (C6–C7 segment), the basilar artery and lower cranial nerves can be seen. The Dorello's canal is composed of two ligaments: the petrosphenoid ligament and the Gruber's ligament in which the abducens nerve passes

and giant tumors have significant fibrous adhesion with the brainstem. If the adhesion is significant, I recommend leaving a thin capsule of the meningioma with the brainstem surface to avoid brainstem damage and particularly destruction of the pontomesencephalic basilar perforators. Any aggressive dissection will lead to hemiparesis and ataxia. Figure 17 demonstrates total petrosectomy exposing the C6 and C7 carotid artery with partial clivectomy and total skeletonization and rerouting of the entire facial nerve over the jugular bulb. The entire surgical procedure from the scalp incision, preparation of the vascularized fascial pericranial graft, craniotomy and mastoid middle fossa skull base procedure and resection of the meningioma in most cases takes 6–15 hours of surgical time. If the tumor is more vascular and fibrous with engulfment of the cranial nerves and vascular structures, surgery may take over 15 hours; therefore, large, large-giant and difficult petroclival meningiomas currently are performed using an extradural procedure of the mastoid and craniotomy the day before the operation with continuous lumbar spinal drainage. The second day a middle fossa procedure is performed with extradural temporal retraction. Then proceed to the meningioma resection in order to avoid surgeon fatigue.

• **How to avoid complications.** So far, for the past five years, with this two-staged combined petrosal approach, I have never seen any significant incidence of infection or meningitis. Infection, meningitis and cosmetic deformity occur solely due to the surgeon's inability to close the dura watertight. The technique of abdominal fat grafting and the use of vascularized pericranial grafting should be used. Always perform the harvest of the abdominal fascia and the abdominal fat. The abdominal fascia should be long and large to stitch to the temporal and presigmoid dura so with the jugular bulb, semicircular canal and middle fossa rhomboid there is no dura remaining. A long strip of micro-plate where the lateral edge of the fascial graft can be sutured should be used and then fixed this with two screws to the skull base bone. Then you should use Surgicel, fibrin glue and then abdominal fat grafting. At this point, use the vascularized pericranial graft. Over the vascularized pericranial graft, apply several pieces of abdominal fat graft. Then large Surgicel and fibrin glue are applied. With this triple watertight closure technique, it is extremely rare in my practice to see CSF leak, meningitis or any cosmetic deformities. Even though I operated on over 400 cases of petroclival meningioma, the risk is not zero. I had one case of mortality in a young 35-year-old patient on whom I separated the very adherent capsule from the basilar tip and the P1 P2 proximal segment. I had several perforators bleed. That was my inappropriate judgment to remove a non-separable capsule from the basilar tip area. The patient had a midbrain infarction. Both patients with malignant petroclival meningioma had unfavorable outcomes. About 5% of patients may have persisting hemiparesis, unsteadiness, or some cranial nerve deficit. I have 20% of cases with patients with some deficit; however, 80% of the patients had excellent outcomes.

## CONCLUSIONS

To conclude this chapter, I wish to stress the importance of continuous learning of skull base microanatomy and at least one or two cadaver dissection experience every year to refresh the surgeon's dissection technique and learn the refined and newer techniques and developments. Even as an expert, I am still involved in three or four cadaver dissection demonstrations every year. Every time I perform cadaver dissection and practice the skull base approaches and procedures, I still learn new things. The key issue, even with meningiomas, chordomas or other invasive tumors in the cavernous sinus or petroclival region, is the surgeon's experience and accurate decision as to how much can be removed for total resection, near total resection or radical total resection. With extreme care to preserve all neurovascular structures and the brainstem surface, the surgeon must know normal practical clinical microanatomy, variation of normal anatomy and abnormal displaced anatomy of the neurovascular structures by the tumors.

## References

- [1] Dolenc V (1983) Direct microsurgical repair of intracavernous vascular lesions. *J Neurosurg* 58: 824-831
- [2] Dolenc VV (1985) A combined epi- and subdural direct approach to carotid-ophthalmic artery aneurysms. *J Neurosurg* 62: 667-672
- [3] Fukushima T (1988) Direct operative approach to the vascular lesions in the cavernous sinus: summary of 27 cases. *Mt Fuji Workshop Cerebrovas Dis* 6: 169-189
- [4] Hakuba A, Nishimura S, Shirakata S, Tsukamoto M (1982) Surgical approaches to the cavernous sinus, report of 19 cases. *Neurol Med Chir (Tokyo)* 22: 295-308
- [5] Parkinson D (1965) A surgical approach to the cavernous portion of the carotid artery. *Anatomical studies and case report. J Neurosurg* 23: 474-483
- [6] Paullus WS, Pait TG, Rhoton AL Jr (1977) Microsurgical exposure of the petrous portion of the carotid artery. *J Neurosurg* 47: 713-726



**Takanori Fukushima**

Takanori Fukushima is Professor of Neurosurgery at the Duke University Medical Center and at the West Virginia University Medical Center. He is internationally renowned for his research and clinical work in the treatment of skull base tumors, pituitary tumors, cerebral aneurysms, arteriovenous malformations, trigeminal neuralgias and hemifacial spasms. He received his postgraduate training in neurosurgery at the University of Tokyo Hospital, Free University of Berlin and Mayo Clinic and Graduate School in Rochester, Minnesota. He received Japanese Board Certification in 1979. He is Director of both Carolina Neuroscience Institute and International Neurosurgery Education & Research Foundation.

**Contact:** Takanori Fukushima, Carolina Neuroscience Institute PC, 4030 Wake Forest Rd, Ste 115, Raleigh, NC 27609, USA  
E-mail: [fukushima@carolinaneuroscience.com](mailto:fukushima@carolinaneuroscience.com)

---

# MANAGEMENT OF CONVEXITY MENINGIOMAS

E. SAMAHA

## INTRODUCTION

Convexity meningioma over a nonfunctional area, is considered as the first intracranial tumor candidate to be a resident case. This chapter presents the details that could constitute the basis for the management of all intracranial meningiomas, whatever their locations. If I had to summarize this chapter in a sentence, I would say: Avoiding complications means paying consistent attention to details.

Historically, the first published case of a successfully operated meningioma was done by Pecchioli [12]. Cushing and Eisenhardt, who are considered the real pioneers in this field, introduced the electric coagulation in operating such tumors and published a series of 313 cases [4]. The diagnosis and the preoperative strategy have been greatly facilitated by the introduction of the computed tomography (CT) scan of the brain by Hounsfield in 1972 and of magnetic resonance imaging (MRI) in 1980, giving more confidence to neurosurgeons.

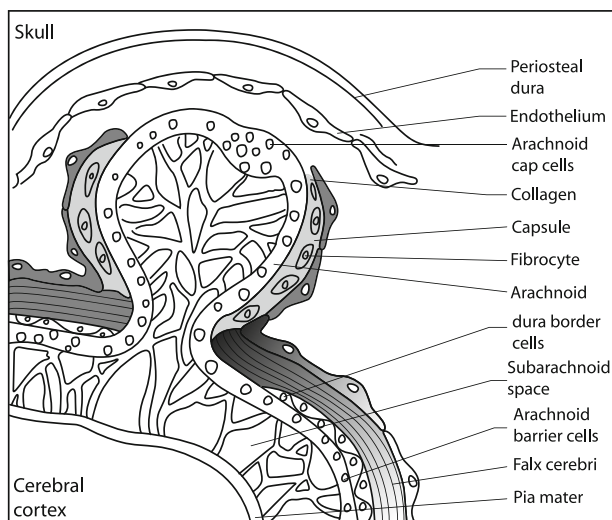
## RATIONALE

The genetic basis for the development of meningiomas was first revealed in 1967 by K. D. Zang, who demonstrated the loss of one copy of chromosome 22 in 50% of the patients with meningiomas [17]. Thereafter, other chromosomal abnormalities have also been detected in atypical and anaplastic meningiomas mainly in chromosomes 1, 10, and 14.

Meningiomas are benign tumors originating from the meninges. The latter are formed by three layers: the dura mater (i.e., pachymeninx), the arachnoid, and the pia mater (leptomeninges). Cerebrospinal fluid (CSF), circulating in the subarachnoid space, is absorbed mostly by the arachnoid villi, which protrude into the venous sinuses. Arachnoid granulations and Pacchionian bodies are larger and more pronounced versions of arachnoid villi. It was suggested that meningiomas may develop from the neural crest, the fibroblast of the dura, or the pial cells. But most authors found that meningiomas mainly originate from arachnoid cap cells, wherever they are located, especially the cells of arachnoid villi [8] (Fig. 1).

---

*Keywords:* convexity meningiomas, management of meningiomas



**Fig. 1.** Description of the arachnoid villi and the relationship of arachnoid cap cells (the origin of meningiomas) with neighboring structures

Regarding their epidemiology and genesis, meningiomas represent 15–20% of intracranial tumors. Their annual incidence is approximately 2 per 100,000 in the general population. They increase with age and commonly occur in the fourth to sixth decades of life. Females have meningiomas more often than males, at a ratio of 2:1. This sex distribution is not valid for the pediatric population [7]. The consistence of convexity meningiomas varies from soft to rock hard. They constitute 20–35% of all intracranial localizations. Donnell et al. were the first to describe the presence of female hormone receptors in meningioma cell membranes, thus probably explaining the higher incidence of these tumors in women [5]. In addition, the presence of progesterone receptors may explain the increase in growth of meningiomas during pregnancy and their high association with breast cancer. The etiology of meningiomas like that of other brain tumors is unknown. Virus and trauma have been suggested [1], without sufficient evidence. On the other hand, Umansky et al. published a review article confirming the causative role of low- and high-dose radiation in the development of meningiomas, especially during childhood [15].

Convexity meningiomas may arise from any part of the cranial convexities. The parasagittal region along the coronal suture and the frontotemporal junction are the sites of predilection of this localization. If located anteriorly, they may remain clinically silent while growing to large size, and then they manifest by signs of intracranial hypertension. Epilepsy and focal neurologic signs are common for the other locations.

Convexity meningiomas on CT scan and MRI manifest as enhanced extra-axial brain tumors, sharply limited, and based against the dura margin. MRI



**Table 1.** Classification of meningiomas grouped by likelihood of recurrence and grade

Grade I	Grade II
Meningothelial meningioma	Atypical meningioma
Fibrous (fibroblastic) meningioma	Clear cell meningioma
Transitional (mixed) meningioma	Chordoid meningioma
Psammomatous meningioma	Grade III
Angiomatous meningioma	Rhabdoid meningioma
Microcystic meningioma	Papillary meningioma
Secretory meningioma	Anaplastic (malignant) meningioma
Lymphoplasmacyte-rich meningioma	
Metaplastic meningioma	

is definitely more useful in demonstrating the surrounding edema, the aspect (cystic or lobulated), the tumor–cortex interface and its relationship to neural and vascular structures. Bone reacts to neighboring meningiomas or it may be invaded by it. The dura enhancement adjacent to the meningioma attachment is called “tail sign”; it is specific for meningiomas in 90% of cases. This part of the dura has been studied histologically and it seems not always specific for infiltration of the dura by meningioma cell nests.

According to the literature, there are several pathologies that can mimic convexity meningiomas on MRI, such as lymphomas, plasmocytomas, carcinoma tumor, solitary fibrous tumor, and dural metastasis [5]. Convexity hemangiopericytomas are undistinguished clinically, radiologically, and operatively from angiomatous meningiomas. The behavior of the latter tumors (aggressiveness), the prognosis, and the modalities of their treatment are completely different, rendering anatomopathological differentiations mandatory.

In 2000, the World Health Organization (WHO) classified meningiomas on the basis of microscopic aspects, their risk of recurrence, and aggressive growth [10] (Table 1), atypical and anaplastic meningiomas having a much higher tendency to recur.

## DECISION-MAKING

The management of asymptomatic convexity meningiomas essentially depends on their natural history, growth, and the assessment of the potential postoperative complications. These tumors appeared to show minimal (less than 1 cm<sup>3</sup>) or no growth over periods of time measured in years. Operative morbidity is about 6% for patients whose asymptomatic tumors were located at the convexity. Conservative treatment with close clinical and MRI follow-up may be a therapeutic strategy for asymptomatic convexity meningiomas [16]. The radical treatment of convexity meningiomas is complete resection. However, Kondziolka et al. propose radiosurgery as an effective treatment choice for symptomatic small- to medium-sized meningiomas [9]. In 1957, Simpson introduced a five-

**Table 2.** Simpson grade [13]

Grade I	Macroscopically complete tumor removal with excision of the tumor's attachment and any abnormal bone
Grade II	Macroscopically complete tumor removal with coagulation of its dural attachment
Grade III	Macroscopically complete removal of the intradural tumor without resection or coagulation of its dural attachment or extradural extensions
Grade IV	Subtotal removal of the tumor
Grade V	Simple decompression of the tumor

grade classification of the surgical removal of meningiomas [13] (Table 2), affecting the prognosis and the degree of recurrence. This grading system, among others more recent, remains the most applicable. Grade zero was added to the Simpson grades for a removal of additional 2 cm from the dural margin.

The surgical decision depends on the natural history of the convexity meningioma, general status of the patient, clinical picture, and size of the meningioma. The day before surgery, the operative procedure strategy is planned on the basis of details provided by MRI images. The inspection of these images is important and different from that by the radiologist. The latter essentially searches the diagnosis, the neurosurgeon the approach. The neurosurgeon examines the images for the following:

- location of the tumor (any effort must be made to localize the limits of the meningioma with respect to the anatomic landmarks like the coronal suture, the pinna of the ear, the midline, and the vertex);
- size and shape of the tumor and presence of abundant vascular structures inside it indicated by void signal (the thickened enhanced linear structure or "tail" seen in 60–70% is noted [6]);
- status of the normal vessels (sylvian branches, Trolard and Labbé veins) in the periphery of the meningioma and presence of other vessels on the surface of the cortex.

Study of the angiographic results is most useful to evaluate participation of the pia mater in the arterial supply and consequently the cleavability of the tumor [2, 14]. However, we do not believe that preoperative angiography may change the intraoperative techniques especially with the availability of recent noninvasive imaging techniques like MR angiography (arterial and venous time). In our department, we perform angiography only for huge tumors in consideration of eventual preoperative embolization. In such cases, surgery is usually done within 48 hours of the embolization. In the absence of contraindication and when cerebral edema is present in the periphery of the meningioma, steroids (methylprednisolone) are given 48 hours prior to surgery and continued for the perioperative period associated to antacid gastric protection. Administration of anticonvulsant drugs is initiated before surgery.

## SURGERY

### 1. PREOPERATIVE PREPARATION IN THE OPERATING ROOM

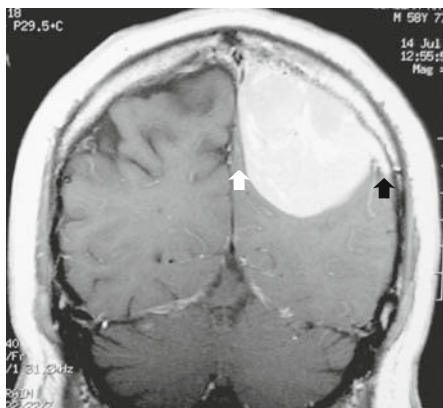
The preoperative antibiotic protocol is administered (Cefuroxime, 1.5 g) upon induction of anesthesia and half of the initial dose is given every four hours until the end of the intervention. A radial artery catheter and an in-dwelling Foley catheter are inserted. Compressing stocking or thigh-high alternating compression air boots are placed and started.

For convexity meningiomas, the neurosurgeon's aim is Simpson grade zero to one resection. A close coordination with the anesthesiologist concerning the particularities of the different steps, the risk of bleeding, and the desired systemic parameters is necessary.

### 2. OPERATIVE TECHNIQUE

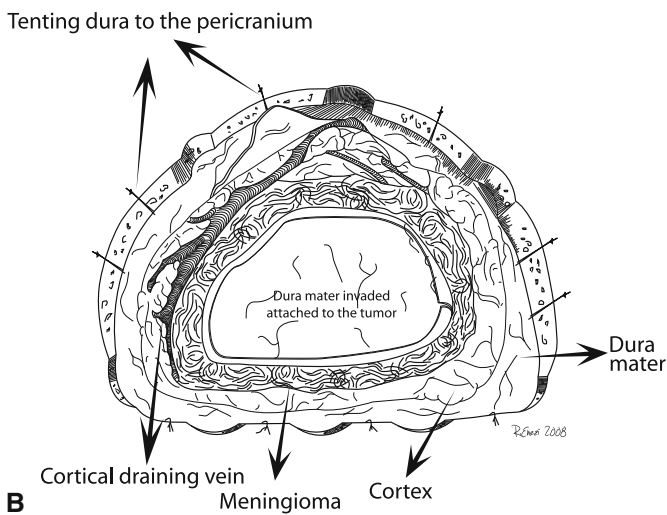
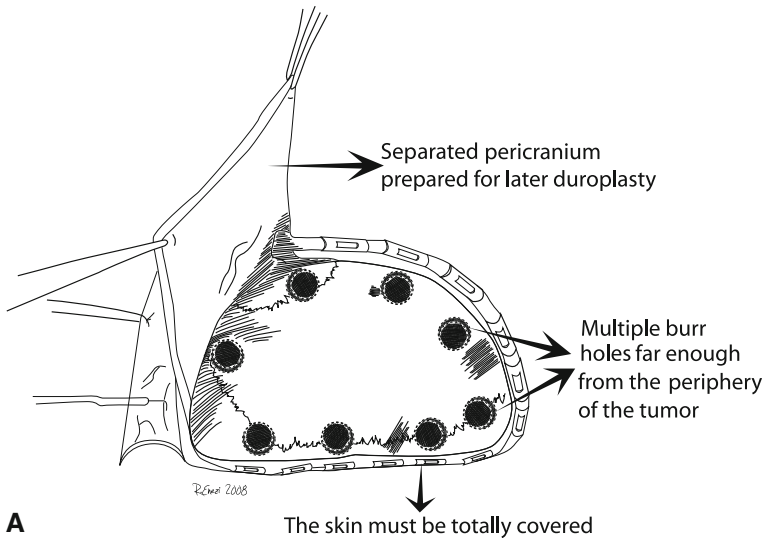
The patient's positioning aims at the presumed center of the convexity meningioma to be uppermost in order to avoid brain retraction. For tumors anterior to the coronal suture, the supine position is adopted with variable rotation of the head depending on its laterality. For tumors situated behind the coronal suture, the lateral position is chosen. The prone position is reserved for the occipital convexity meningiomas close to the midline. The head is fixed with a three-point skeletal fixation head rest (Mayfield) in a manner that the scalp over the center of the meningioma will be the highest point of the head.

The preparation of the scalp is done the day before and in the morning of the intervention by twice antiseptic shampooing, without any shaving; and



**Fig. 2.** Parietal left meningioma. The presence of cerebral parenchyma between the sagittal sinus and the falx on one side (white arrow) and the tumor on the other side, differentiates this convexity location from the parasagittal and the falcorial ones. Note the "tail sign" at the external edge of the tumor (black arrow)

then the scalp is covered with sterile dress. A horseshoe-shaped line surrounding the estimated location of the meningioma is drawn, with its base facing down to preserve vascularization of the cutaneous flap. The incision is

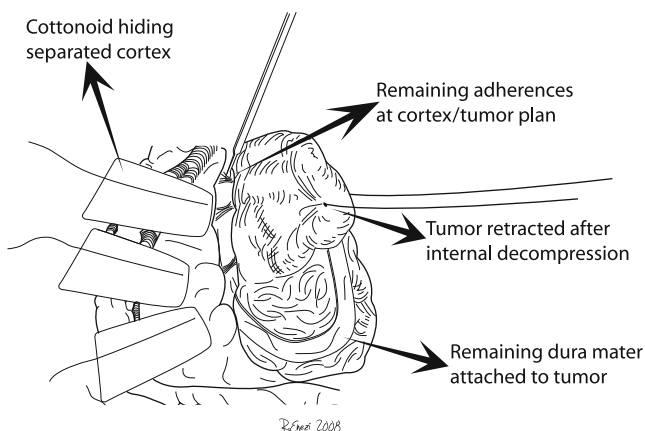


**Fig. 3. A** The pericranium is prepared at the beginning of the intervention; it later replaces the dura invaded by the meningioma. Multiple burr holes are made far enough from the estimated periphery of the meningioma. **B** The dura is opened around the meningioma. While opening, great care is taken to avoid injury to the veins draining the cerebral hemispheres. Dura is kept attached to the tumor for eventual further traction. Early tenting avoids epidural bleeding along the intervention

made in such a manner to allow a generous exposure of the tumor with the possibility to remove the surrounding dura at least for 2 cm of the border of the meningioma, when possible. Just the region of the skin incision is shaved, with a width of 2–3 cm. After scalp infiltration with a lidocaine-adrenaline mixture if there is no contraindication to adrenaline, the incision is made. The skin of the scalp is totally hidden by clips and the flap is retracted. The pericranial tissue is separated from the skull and prepared for the further replacement of the infiltrated dura. The bone bleeding over the meningioma is easily controlled with bone wax, and this bleeding is different from the one coming from the surrounding region.

In general, this step of craniotomy (Fig. 3A) is hemorrhagic, mostly for huge angioblastic convexity meningiomas. The burr holes are placed 1–2 cm around the periphery of the tumor (estimated before surgery in planning the incision according to the MRI) and are more numerous than for a classic bone flap craniotomy. The dura is separated from the overlying bone to join burr holes. The free bone flap is gently but quickly detached to avoid consistent loss of blood. Then, a particular bleeding from the underlying infiltrated dura is noted and the control of the major feeder vessels is done: Distal branches of dural vessels supplying the meningioma are controlled with bipolar coagulation or with hemoclips, in cases when preoperative embolization was not performed. Continuous normal saline irrigation with a syringe on the dura facilitates identification of the source of the bleeding to be coagulated. Gelfoam over a wet gauze applied for a few minutes on the dura stops the moderate oozing. If the tumor invades largely the inner and outer table, we advise to leave a part of the bone attached to the meningioma and to detach the bone flap around it. In elderly patients, the bone flap separation is more complicated due to the attachment of the dura to the inner table. In such cases, especially when the bone flap is involved by the tumor, it can be taken in more than one piece. The dura mater in convexity meningiomas is very well irrigated due to angiogenesis induced by the tumor and bleeding from the epidural space is particularly abundant. Thus, before its opening, the superficial layer of the dura must be held with tight sutures to pericranial tissue or to the bone at the craniotomy margin. In some rare cases of convexity meningiomas, the vascularization of the bone is exceptionally important. In such cases, a rapid craniectomy with progressive control by bone wax is mandatory to avoid massive bleeding. The anesthesia team must be informed and prepared to this hemorrhagic period. In such a case, the bone flap is replaced, at the end of the surgery, by a confection of a prosthetic cranioplasty. Just after the detachment of the bone flap and while performing hemostasis, the neurosurgeon assesses subjectively the intracranial pressure and the tension of the brain and evaluates the utility of a charge dose of mannitol and/or Pentothal.

Once there is a clean operative field, gentle palpation often gives an indication of the limits of the tumor and allows to evaluate the tension of the intracranial compartment. When this later becomes acceptable, the dura is opened

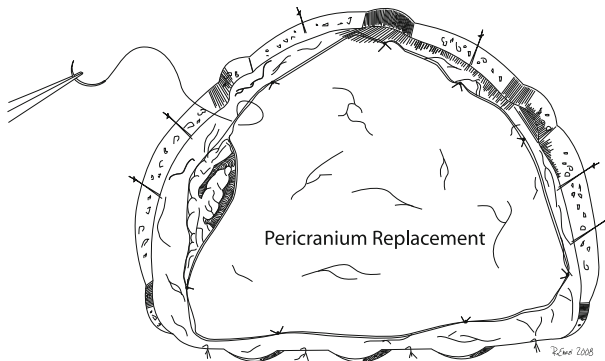


**Fig. 4.** After internal decompression, the capsule can be reflected away from the cortex more easily. Tight attachments mean important vascular adhesences; in such situations, we have to gently turn around, coagulate, and cut them

laterally to the meningioma and around it. While opening the dura, the several feeder vessels are coagulated before cut; sometimes, these vessels need to be controlled with hemoclips; great care is taken to avoid injury to the veins draining the cerebral hemispheres. The dura is left attached to the tumor, which helps, along the procedure, to apply a moderate outward traction.

For tumor resection (Fig. 4), the operating microscope is always used. Only small to medium convexity meningiomas with large attachment base may be removed in one piece. In most cases it is wise to adopt the internal decompression method. Autostatic retraction is not recommended; this might aggravate the situation of the brain already compressed and edematous. Alvernia and Sindou [2] attempted to describe the value of neuroimaging in predicting the surgical plane of cleavage and found that the possibility to achieve an extrapial resection in this extraparenchymal tumor was approximately 43% of cases. Under high magnification the surrounding normal cortical veins as well as the entries to the extrapial plane are identified. Mild pressure is made against the capsule and then the arachnoid and vascular attachments after coagulation are divided. This maneuver is done in a circumferential manner. Cerebral tissue is gently separated from the capsule by using bipolar forceps and fine aspiration over small cottonoids. Adhesences and tumor vessels encountered are coagulated with bipolar cautery and divided with microscissors. Every separated area is protected with a moistened cottonoid.

When the traction starts to be hard on the tumor, internal decompression is done with an ultrasonic aspirator or sometimes laser. Major bleeding identified inside the tumor should be coagulated. Then the capsule can be reflected away from the cortex easily, facilitating a forward separation deeply in the cortex–tumor plane. During dissection, tight attachments mean impor-



**Fig. 5.** The cut of the dura is enlarged 2 cm from the meningioma margin if possible and replaced by the pericranium initially prepared. Tenting is completed and hemostasis verified

tant vascular adherence. Any excessive traction to the capsule may avulse these vessels. These maneuvers are repeated enough times and circumferentially until complete resection of the meningioma is done. The cottonoids placed in the separation plane are then removed one by one and remaining bleeding is coagulated. Meanwhile the anesthesiologist is asked to raise the systolic blood pressure to 140 mmHg; when the systolic blood pressure reaches this level, good hemostasis is considered to be achieved. When convexity meningiomas are close to the base of the skull, the resection of the dura involved at the base must be done. In the low coronal convexity meningiomas, the middle cerebral artery branches may be adherent to the capsule; great care must be taken in the dissection in this particular area in order to avoid further deficit.

For closure (Fig. 5) the cut of the dura is enlarged 2 cm from the meningioma margin, if possible. The piece of pericranium prepared at the beginning of the intervention is tailored according to the surface of dura to be replaced. Then the graft is sutured tightly to the remaining dura. In some cases, when the pericranium is not sufficient, we can use a fascia lata graft from the thigh in order to substitute the missing dura. Suspending the dura of the periphery of the craniotomy margin is essential before fixing the bone flap. The inner table over the center of convexity meningioma must be drilled if there is any doubt of its involvement by the tumor. An acrylic cranioplasty material with antibiotic is used to replace the bone flap in case the two tables of the skull are involved by the meningioma.

### 3. POSTOPERATIVE CARE

The neurosurgeon can classically predict the complication because it is closely related to the intraoperative events. In general, there is no need for sedation and respiratory assistance at the postoperative period. A smooth awakening

and a permanent control of blood pressure, for at least 24 hours, are mandatory. The first night is spent in an intensive care unit or a recovery room for close observation. The patient is encouraged to walk the next day if possible. Steroids are continued for three weeks and tapered progressively in the last period. We always combine antacid gastric medication with steroids. For convexity meningiomas, seizures are more frequent than for meningiomas at other locations; therefore, anticonvulsant treatment is continued for at least four months and gradually tapered.

#### **4. LONG-TERM RESULTS AND MANAGEMENT OF RECURRENCE**

In the literature the operative mortality rate of convexity meningiomas is improving and is tending to zero percent in the hand of a most experienced neurosurgeon [11]. Even elderly patients (over 70 years old) have low perioperative morbidity and mortality [3].

Recurrence rate for meningiomas at the convexity is the lowest among the different locations and is evaluated to 5% [7]. The rate of recurrences depends on several risk factors such as WHO degrees II and III, resection of Simpson grade II or greater, high MIB-1 antibody labeling index, high vascular endothelial growth factor (VEGF), and negative progesteron-receptor status. MIB-1 was not a statistically significant predictor of survival time in totally excised WHO degree I meningiomas. Fractional radiotherapy and radiosurgery are used after surgery for malignant, multiple-recurrency, and incomplete-resection convexity meningiomas [1]. Chemotherapy with drugs such as hydroxyurea (HU) and the antiprogesterone mifepristone (RU486) has been applied also in such cases, but results have been disappointing.

#### **5. COMPLICATIONS**

The presence of an immediate postoperative deficit may be related to the effect of the anesthetic agents, especially in the case of a meningioma located in a functional area. If a neurological deficit does not improve quickly, an urgent control CT scan is necessary. The deficit may be due to a postoperative hematoma, infraclinical post-seizure palsy, venous or arterial ischemic lesions. If postoperative hematoma is found, its urgent or late evacuation depends on the clinical status, the hematoma's size, and its location. Moderate sedation, hyperventilation, osmotic diuresis, and increased steroid doses are needed in case of brain swelling. Delayed neurological deficit during the first week is usually due to cerebral edema. These symptoms usually respond to an increase of steroids.

Wound infection is managed according to its severity; a major one requires the removal of the bone flap. Meningitis is another serious complication. With respect to any such suspicion, lumbar puncture is done for CSF study and culture; only thereafter antibiotics are administered. Systemic infections are pos-



sible as postoperative urinary infections. Special aseptic care must be taken while putting the indwelling bladder catheter to minimize this risk.

Early spirometry can prevent pulmonary obstructions and pneumonia. Preventive protocols now exist in most departments to avoid postoperative deep thrombophlebitis and consequently pulmonary embolism. A high level of suspicion must always be maintained and immediate consequent therapy should be introduced in case of confirmed diagnosis.

## HOW TO AVOID COMPLICATIONS

The main precautions to be taken are listed in Table 3.

### 1. NEUROLOGICAL COMPLICATIONS

Once the operative decision is taken, the anticonvulsant therapy must be started. In the preoperative period, the neurosurgeon must spend enough time assessing MRI images searching for details which can facilitate strategy dissection and avoid impairing events. These details concern the location and shape of convexity meningiomas, intratumoral “void flow” signals, the interface between tumor and cortex, and the relationship with adjacent cortical vessels (mainly sylvian artery branches in frontotemporal location).

The neurosurgeon himself must control the positioning of the patient. The head must be positioned for the center of the tumor to be uppermost. The head must be tilted up to 15° and the internal jugular veins must be free from any distortion. The pressure points of the entire body must also be protected.

The preservation of all cortical draining veins represents the key for avoiding venous infarction and edema. Small pieces of tumor attached to normal vessels should be left if their dissection seems hazardous.

**Table 3.** Precaution details to avoid complications

---

In conservative treatment, first control MRI must be done 2–3 months later. Anticonvulsants should be administered early in preparation to surgery. Thorough assessment of MRI images has to be done for surgery planning. Position control, center of the tumor to be uppermost, avoiding brain retraction are essential. Extreme smooth dissection near the functional areas is crucial. Cortical vessels, especially venous, should be preserved. Blood systolic pressure should be at 140 mmHg when verifying the hemostasis. Good preoperative systemic medical preparation (collaboration with anesthesiologist) is imperative. The skin should be considered as an enemy and a source of infection; fight it by adequate preparation, protection, and frequent irrigation. Postoperative early ambulation and compression stocking are important details. Spirometry and antacid gastric protection (mainly by the use of corticosteroids) are primordial details.

---

The elevation of blood systolic pressure to 140 mmHg after resection of the meningioma should be checked. It is only after hemostasis has been attained, but not before, that the meningioma seat is finally covered by Surgicel.

Gentle irrigation with normal warm saline is mandatory at the end of the procedure, helping to verify hemostasis.

## 2. SYSTEMIC COMPLICATIONS

Complete work-up and preparation by the anesthesiologist and eventually other specialists (cardiologist and pneumologist, etc.) is an important step to limit systemic complications.

Since the skin is the major source of sepsis, special attention to skin preparation is essential. The hair shampooing the day before and just preoperatively, the septic and aseptic cleaning of the skin, and its covering after the incision are effective to separate from this contaminating source of infection. The assistant is liable to pay attention to all these details. Pre- and perioperative prophylactic antibiotics have proved their effectiveness. Asepsis in putting venous lines and Foley catheter is of prime importance; they have to be withdrawn as soon as possible.

To limit occurrence of thromboembolic complications, we usually introduce – twenty-four hours after the intervention – subcutaneous low-molecular-weight heparin. Other teams administer it sooner, without raising the postoperative hemorrhagic intracerebral rate. Whatever, we insist on early ambulation of the patient the day after surgery.

Other (minor) complications are avoided by an early postoperative respiratory reeducation and by the prescription of an antacid gastric protection (mainly if corticosteroids are administered).

## CONCLUSIONS

Surgical resection of the convexity meningioma is classified as a “simple” procedure in comparison to many other neurosurgical interventions; however, complications may happen if specific details are not respected. Complications can be avoided only if every detail is controlled.

## References

- [1] Al-Mefty O (ed) (1991) Meningiomas. Raven, New York
- [2] Alvernia J, Sindou M (2004) Preoperative neuroimaging findings as a predictor of the surgical plane of cleavage: prospective study of 100 consecutive cases of intracranial meningioma. *J Neurosurg* 100: 422-430
- [3] Caroli M, Locatelli M, Prada F, Beretta F, Martinelli-Boneschi F, Campanella R, Arienta C (2005) Surgery for intracranial meningiomas in the elderly: a clin-

- ical-radiological grading system as a predictor of outcome. *J Neurosurg* 102: 290-294
- [4] Cushing H, Eisenhardt L (1938) Meningiomas: their classification, regional behavior, life history and surgical end results. Charles C Thomas, Springfield
- [5] Donnell MS, Meyer GA, Donegan WI (1979) Estrogen-receptor protein in intracranial meningiomas. *J Neurosurg* 50: 499-502
- [6] Goldsher D, Litt AW, Pinto RS, Bannon KR, Kricheff II (1990) Dural "tail" associated with meningiomas on Gd-DTPA-enhanced MR images: characteristics, differential diagnostic value, and possible implications. *Radiology* 176: 447-450
- [7] Haddad G, Al-Mefty O, Abdulrauf S (2003) Meningiomas. In: Winn HR (ed) *Youmans neurological surgery*, Vol. 1, 5th edn. Saunders, Philadelphia, pp 1099-1131
- [8] Jan M, Velut S, Lefrancq T (1999) Méningiomes intracrâniens. *Traité Encyclop Médico-Chir Neurol* 17-251-A-10
- [9] Kondziolka D, Mathieu D, Lunsford LD, Martin JJ, Madhok R, Nirajan A, Flickinger JC (2008) Radiosurgery as definitive management of intracranial meningiomas. *Neurosurgery* 62: 53-58
- [10] Louis DN, Scheithauer BW, Budka H, von Deimling A, Kepes JJ (2000) Meningiomas. In: Kleihues P, Cavenee WK (eds) *Pathology and genetics of tumors of the nervous system*. IARC Press, Lyon, pp 176-180
- [11] Ojeman R, Ogilvy C (1993) Meningiomas. In: Apuzzo MLJ (ed) *Brain surgery*. Churchill Livingstone, New York, pp 187-265
- [12] Pecchioli Z (1838) Soria di un fungo della dura madre, operato coll'estirpazione dal Professor Zanobi Pecchioli. *Nuovo G Lett – Sci* 36: 39-44
- [13] Simpson D (1957) The recurrence of intracranial meningiomas after surgical treatment. *J Neurol Neurosurg PS* 20: 22-39
- [14] Sindou M, Alaywan M (1998) Most intracranial meningiomas are not cleavable tumors: anatomic-surgical evidence and angiographic predictability. *Neurosurgery* 42: 476-480
- [15] Umansky F, Shoshan Y, Rosenthal G, Fraifeld S, Spektor S (2008) Radiation-induced meningioma. *Neurosurg Focus* 24: E7



**ELIE SAMAHA**

Elie Samaha is Associate Professor at the Medical School of Saint Joseph University and Chairman of the Neurosurgical Department at the Hôtel-Dieu de France Hospital, Beirut; Ex-president of the Lebanese Society of Neurosurgery, president of local and international neurosurgical congresses, assistant and certificated in neurovascular diseases at the Medical School of Montpellier University, France.

**Contact:** Elie Samaha, Hôtel-Dieu de France Hospital, P.O. Box 16, 6830 Beyrouth, Liban  
E-mail: [elie.samaha@hdf.usj.edu.lb](mailto:elie.samaha@hdf.usj.edu.lb)

---

# MENINGIOMAS INVOLVING THE MAJOR DURAL SINUSES: MANAGEMENT OF THE SINUS INVASION

M. SINDOU

## INTRODUCTION

Surgery of meningiomas involving the major dural sinuses leaves the surgeon confronted with a dilemma: leave the invasive fragment and have a higher rate of recurrence, or attempt a total removal and have the venous circulation at risk. In meningiomas with the sinus remaining patent, current tendency is resection of the tumor mass outside the sinus wall(s) with surgical coagulation or adjuvant radiosurgery on the remnant. For meningiomas with complete sinus occlusion, most authors advocate “en-bloc” removal of the invaded portion [4]. Conventional knowledge states that complete removal of the invaded sinus is little dangerous because of the development of collateral venous pathways; this however may far from being true [2, 10]. Few authors favour total gross removal and, if so, reconstruction of the venous circulation [5–7, 11, 17]. The latter attitude is our preference. Literature review of the various policies has been done in references [8, 13].

## RATIONALE

### 1. PLEAD FOR COMPLETE TUMOR RESECTION

A commonly accepted belief is the decreased likelihood of a recurrence with less residual tumor. In fact Simpson reported that complete removal of a meningioma with excision of its dural attachment leads to a lower rate of recurrence (6%) compared with the rates following complete removal with coagulation (16%) or without treatment of the dural attachment (29%) [12].

In our series of 100 patients who underwent surgery between January 1980 and January 2001, the meningioma originated at the superior sagittal sinus in 92 patients (28 in the anterior, 48 in the middle and 16 in the posterior third), the transverse sinus in 5 and the torculae confluence in 3. Gross tumor removal was achieved in 93% of the cases, with the sinus reconstruction attempted in 45 (65%) of the 69 cases with wall(s) and lumen invasion. The overall recurrence rate was 4%, with a follow-up ranging from 3 to 23 years (mean: 8 years) [13].

---

*Keywords:* meningiomas, major dural sinuses, venous surgery, parasagittal meningiomas

## 2. PLEAD FOR SINUS RECONSTRUCTION

In our series the mortality rate was 3%. In all the 3 cases, the fatal evolution was due to brain swelling after a “en-bloc” resection of the meningioma which had totally occluded the sinus; none of the three had venous restoration. Eight patients who harbored a lesion in the mid-third portion of the superior sagittal sinus had permanent neurological aggravation, likely due to local venous infarction. Six of these patients had not undergone venous repair. On the other hand, venous reconstruction did not increase the morbi-mortality rate in our series. The subgroup of patients without venous reconstruction displayed statistically significant clinical deterioration after surgery compared with other subgroups ( $p = 0.02$ ). So venous flow restoration seems justified when not too risky.

In the event of sinus invasion with preserved sinus circulation, resection of the invaded wall(s) requires patching of the defect to maintain flow. In the event of a totally occluded sinus, the surgeon has the dilemma to decide whether to restore venous circulation by performing a bypass prior or once the occluded sinus is resected.

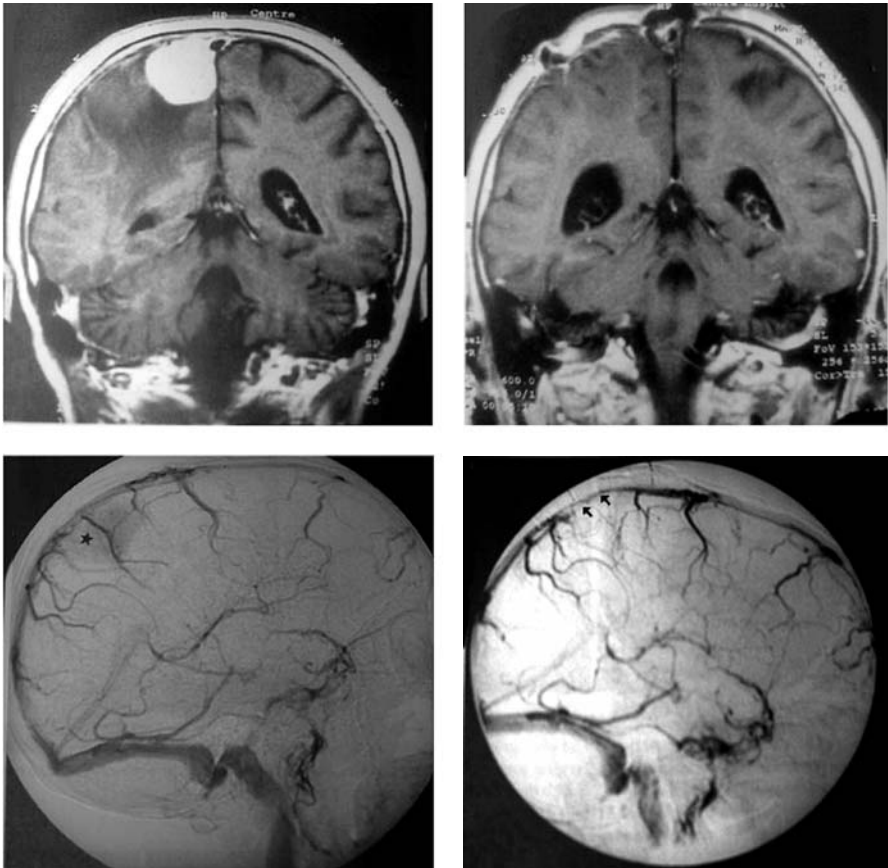
## DECISION-MAKING

### 1. PREOPERATIVE WORK-UP

Magnetic Resonance Imaging (MRI) with and without contrast medium are the key. MRI (T1-weighted sequences with and without gadolinium injection and T2 sequences) is effective in delineating the tumor (Fig. 1). Gadolinium enhancement of the dura may indicate actual tumor invasion or simply corresponds to hyperemia.

Venous MR offers additional useful information on venous system involvement (Fig. 2). MR angiography does not succeed in providing a reliable exploration of the tumor vascularization and hemodynamics. Therefore, angiography through the transfemoral route is of value prior to establishing the detailed surgical strategy. Selective bilateral internal and external carotid subtraction angiographies as well as vertebral angiography serve to determine the dural and cortical-pial supply (Fig. 3). The arterial phase is useful to predict the difficulty of dissection of the capsule from the cortex. As shown in prior publications dissection entails neurological risk when a pial vascular supply is identified [1]. When meningeal supply is important, preoperative embolization may be of value in producing tumor necrosis and diminishing the blood loss that may accompany resection of the tumor.

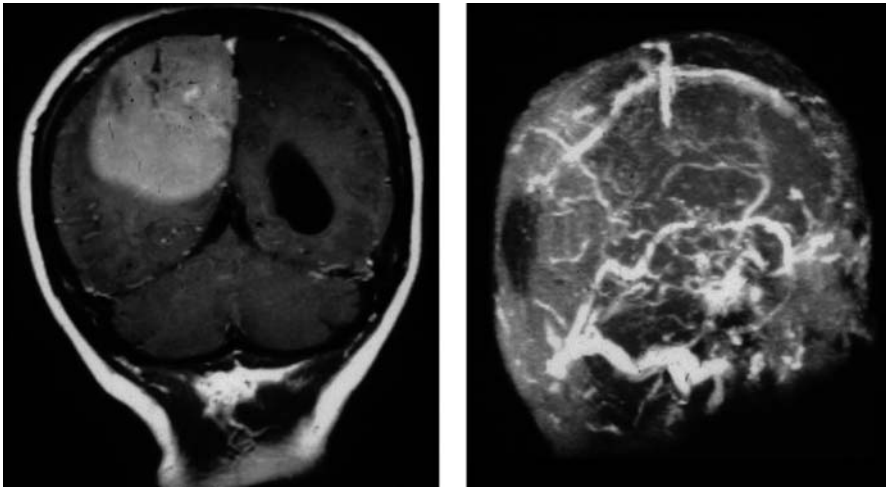
The late venous phases with bilateral filling of the sagittal sinus are required for an exact evaluation of sinus patency and collateral venous pathways. Oblique views well depict the Superior Sagittal Sinus (SSS) throughout its entire course. Various degrees of sinus occlusion can be observed, from simple



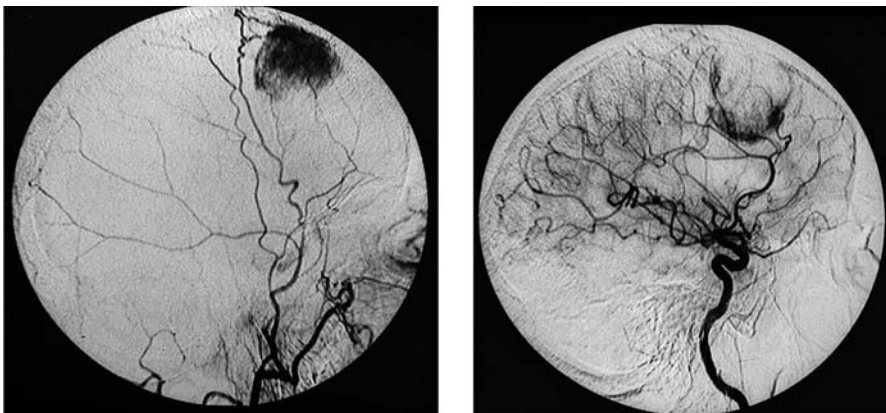
**Fig. 1.** Type III mid-third parasagittal meningioma. *Upper left:* preoperative coronal Gd-enhanced T<sub>1</sub>-weighted MR image showing a right parasagittal meningioma with Type III invasion of right wall of the sinus. *Upper right:* postoperative coronal Gd-enhanced T<sub>1</sub>-weighted MR image showing no evidence of tumor remnant. The lateral sinus wall was resected and patched. *Lower left:* preoperative venous-phase angiogram, lateral view, demonstrating a patent sinus and tumor blush (*star*). *Lower right:* postoperative venous-phase angiogram, lateral view, demonstrating sinus patency (*arrows*)

compression with narrowing of the sinus lumen, to intraluminal defect, to total occlusion. Complete occlusion may be assumed from no visualization of segments of the sinus and from collateral venous channel development. The pattern of venous drainage and venous collateral channels must be established preoperatively to determine the surgical approach.

Plain X-ray films may be most useful by showing intraosseous collateral venous channel(s), which must be taken into account before designing the borders of the craniotomy and turning the bone flap (Fig. 4).



**Fig. 2.** Posterior third, right, parasagittal Type VI meningioma. *Left:* Coronal MRI – T1 sequence after gadolinium. *Right:* pre-operative venous MR, lateral view, showing total occlusion of the sinus and compensatory drainages through intra-osseous emissary veins which communicate with extracranial circulation. Exposure may destroy these collateral drainages and lead to brain swelling

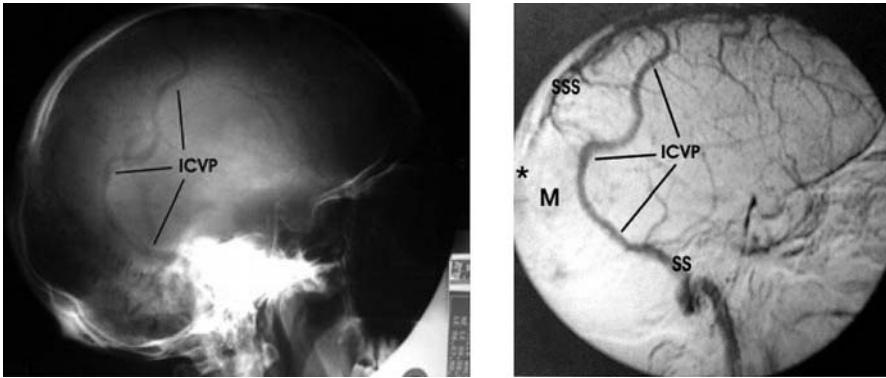


**Fig. 3.** Frontal parasagittal meningioma. Selective external (*left*) and internal (*right*) carotid artery angiograms illustrating a typical case of mixed arterial supply of the meningioma. Vascularization is supplied by branches of the ECA, namely the middle meningeal artery (*left*) and by cortico-pial branches of the anterior cerebral artery (*right*)

## 2. CLASSIFICATION OF MENINGIOMAS ACCORDING TO SINUS INVASION

A personal classification scheme based on the degree of dural sinus involvement was established to determine surgical strategy [14]. Type I: lesion





**Fig. 4.** Parasagittal meningioma with Type VI invasion in the posterior third of the sinus. *Left:* Plain X-ray, lateral view, showing a voluminous intraosseous collateral venous pathway (ICVP). *Right:* venous-phase DS angiogram, lateral view, demonstrating the collateral venous circulation from the Superior Sagittal Sinus (SSS) to the sigmoid sinus (SS). Note complete occlusion (*asterisk*) of the SSS by the meningioma (M)

attachment to the outer layer of the sinus wall, Type II: tumor fragment inside the lateral recess, Type III: invasion of the ipsilateral wall, Type IV: invasion of the lateral wall and roof, Types V and VI: complete sinus occlusion, with (Type V) or without (Type VI) the contralateral wall free (Fig. 5). This classification was based on a simplification of those described by Krause (as quoted in Merrem's article [9]) and by Bonnal and Brotchi [3].

The categories developed for the parasagittal location were also applied to the meningiomas involving the confluence of sinuses and the transverse sinus.

## SURGERY

The following surgical strategy has been established after having performed preliminary experimental and clinical works on the intracranial venous system [15, 16] and surgical attempts at gross total removal of meningiomas including their intrasinus portion, in a series of 100 patients long-term followed [13].

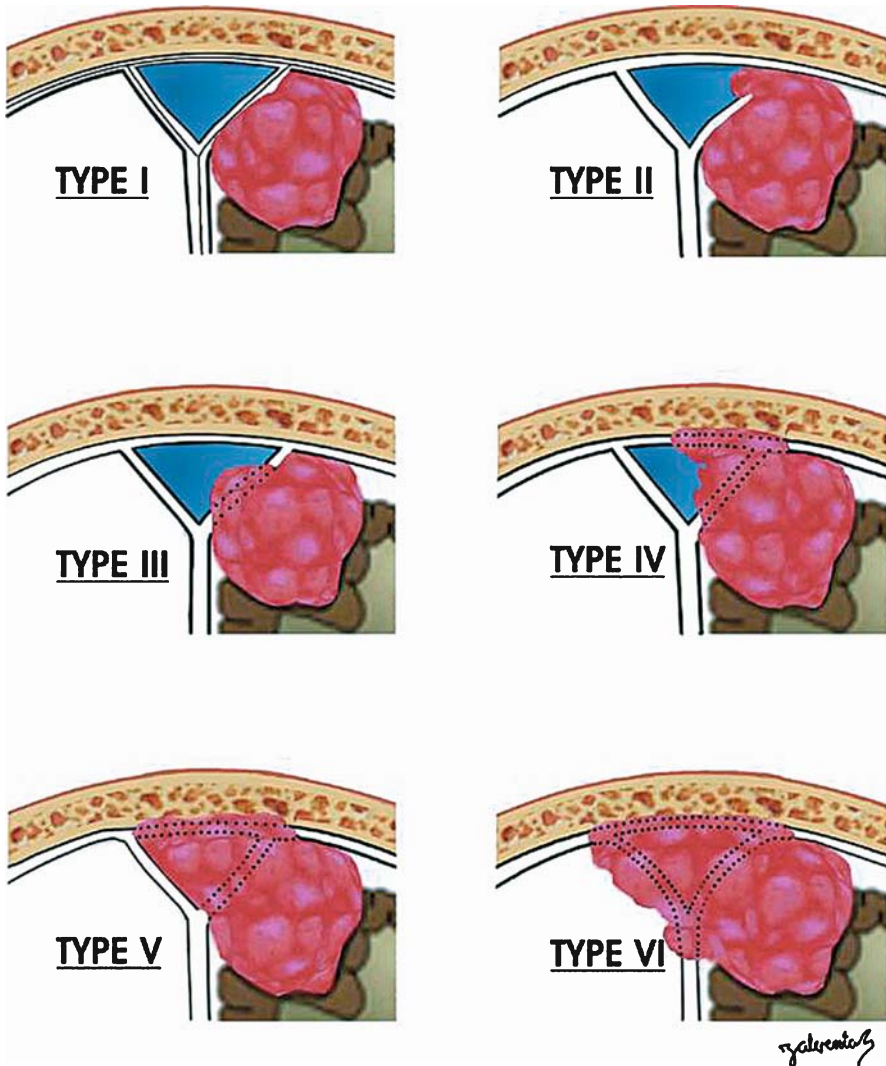
### 1. GENERAL PRINCIPLES

- Positioning the patient in the semisitting (lounging) position allows a good venous return without increased intracranial pressure. Although possible, there is no practical risk of air embolism because of the relatively high intracranial venous pressure in these patients.
- Operative exposure should be as extensive as necessary. The skin flap and craniotomy should extend across the midline to permit

visualization of both sides of the sinus and about 3 cm outside the margins of the occluded sinus. However such a large access should be reconsidered if there are scalp, pericranial or diploic collateral venous pathways, which might be impaired during approach. Dura is incised circumferentially around the margins of the tumor insertion on the dura of the convexity and along the border of the corresponding portion of the superior sagittal sinus, taking care not to compromise the adjacent afferent veins (= bridging veins) to the sinus.

- Tumor surgery starts as follows. Attachment of the meningioma to the lateral wall of the sinus and neighbouring falx is detached by using the cutting mode of the bipolar coagulation forceps, thus cutting off the tumor dural supply. Then intracapsular debulking is performed so that the remaining capsule of the tumor can be easily mobilized from the underlying cortex. Under the microscope an extra-arachnoidal plane of dissection must be carefully searched. When absent, the plan of dissection becomes subpial because of the pia-mater incorporation into the tumor capsule [1].
- Sinus surgery obeys the vascular microsurgery principles. Because there are frequent discrepancies between images and anatomical findings, the sinus should be explored through a short incision (around 5 to 10 mm linear opening) to disclose any intrasinus fragment. Temporary control of venous bleeding from the sinus and afferent veins can be easily obtained by packing small pledgets of hemostatic material (Surgicel, Johnson Medical, Viroflay, France) in the lumen and at the ostia of afferent veins. Balloons should not be used because they do not pass easily through the sinus septa and may injure the sinus endothelium. Vascular clamps as well as aneurysm clips should be avoided because they may injure the sinus walls and afferent veins. Bridging veins, especially in the rolandic outflow area, should be preserved by dissecting them free from adjacent brain and tumor. Venous construction is performed using patches or bypasses, with two hemirunning sutures (Prolene 8.0 Laboratoire ETHNOR, Neuilly/Seine, France). Although the autologous vein would appear the most suitable material for use as a patch, vein harvesting seems excessive for patching only. The locally situated dura mater, fascia temporalis or pericranium can be used. When possible we favor the use of fascia temporalis because it is both resistant and thin with a glossy-glistening surface. When a bypass is needed, autologous vein graft has to be harvested from the internal saphenous vein for long bypasses (that is longer than 6 cm) or from the external jugular vein for shorter bypasses.
- The graft should not be compressed by any surrounding structure.
- Postoperative cares are of prime importance. To facilitate venous patency after surgery, blood pressure, volume and viscosity must be carefully cared. Heparin therapy (two times control value) is

recommended for at least three weeks to prevent the reconstructed sinus from getting clotted and antiagregant for three months to allow sinus wall endothelialization.

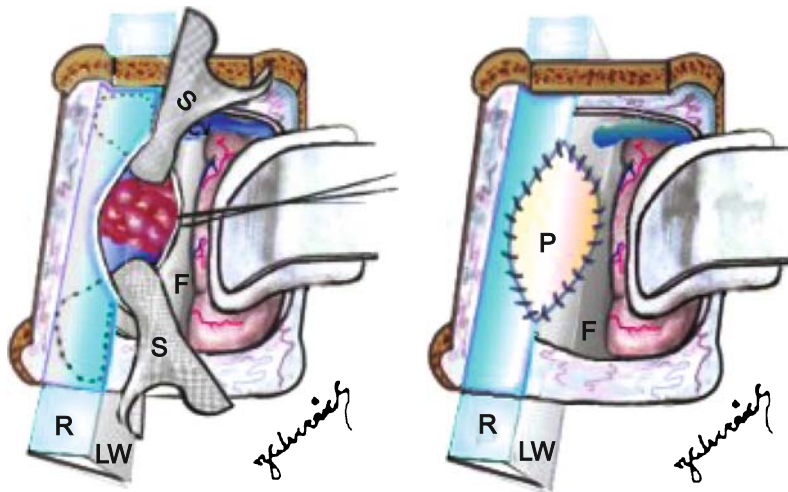


**Fig. 5.** Classification scheme of meningiomas according to the type of sinus invasion. *Type I*, meningioma attached to the outer surface of the sinus wall; *Type II*, lateral recess invaded; *Type III*, ipsilateral wall invaded; *Type IV*, ipsilateral wall and roof of the sinus both invaded; *Type V*, sinus totally occluded, but the contralateral wall free of invasion; and *Type VI*, sinus totally invaded with no walls free of invasion (Drawings by Doctor J. Alvernia)

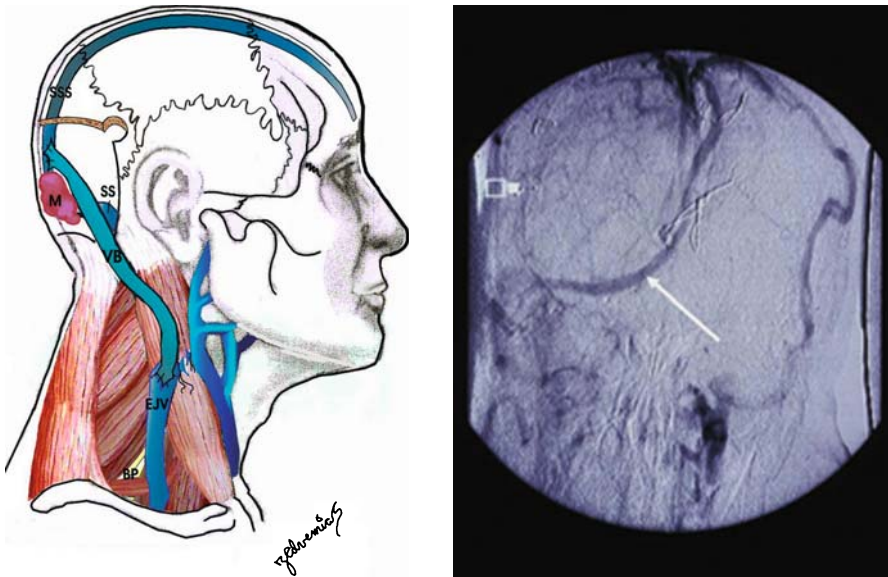
**2. SURGERY ACCORDING TO THE DEGREE OF SINUS INVASION (Fig. 5)**

Algorithm has been established as follows:

- Type I: Excision of the outer layer, leaving a clean and glistening dural surface, and coagulation of dural attachment.
- Type II: Removal of the intraluminal fragment through the recess, then repair of the dural defect by resuturing the recess or by closing it with a patch.
- Type III: Resection of the sinus wall and repair with a patch.
- Type IV: Resection of both invaded walls and reconstruction of the two resected walls with a patch.
- Type V: Because in the this type the opposite wall to the tumor side is free of tumor, it is possible and preferable to reconstruct the two invaded wall defects with a patch after their resection, rather than to perform a bypass. Important, this type can be distinguished from Type VI only by direct surgical exploration of the sinus lumen.
- Type VI: Removal of the involved portion of the sinus and restoration by venous bypass. The site of the bypass is: on the sagittal sinus for meningiomas involving the superior sagittal sinus (SSS), between the SSS and the external jugular vein for meningiomas totally occluding the posterior third and the torcular, between the transverse sinus (TS) and the external jugular vein for meningiomas involving the TS.



**Fig. 6.** Patching technique in a parasagittal meningioma with Type IV sinus invasion. *Left:* exploration of the sinus lumen through a 3 cm long opening, which allows identification of a intrasinusal tumor fragment. Control of the venous bleeding using pledgets of Surgicel on both extremities of the opening (i.e., proximal and distal). *Right:* venous reconstruction performed using an autologous patch (fascia temporalis). *F* falx cerebri; *LW* lateral wall of SSS; *P* patch; *R* roof of SSS; *S* Surgicel pledgets



**Fig. 7.** Meningioma of the posterior third and confluence of sinuses with Type VI invasion. Patient had severe intracranial hypertension syndrome with headaches, papilledema, and demential manifestations. Drawing (*left*) and postoperative angiogram (*right*) showing a surgical bypass (arrow) from the SSS to the external jugular vein (EJV) with an autologous saphenous vein. After surgery the patient experienced recovery. VB Venous bypass (saphenous vein). SS sigmoid sinus. M meningiomas. BP Brachial plexus

### 3. CLINICAL OUTCOME AND CONTROL OF PATENCY

- Clinical outcome in our series was extensively described in a recent publication [13]. Briefly, gross-total tumor removal was achieved in 93% of the cases, and sinus reconstruction was attempted in 45 (65%) of the 69 cases with wall and lumen invasion. The recurrence rate in the study was 4%, with a follow-up period from 3 to 23 years (mean: 8 years). The mortality rate was 3%, all cases due to brain swelling after en-bloc resection of a Type VI meningioma without venous restoration. Eight patients – seven of whom harbored a lesion in the mid-third portion of the superior sagittal sinus – had permanent neurological aggravation, likely due to local venous infarction. Six of these patients had not undergone a venous repair procedure. Overall, the mean preoperative Karnofsky score (KPS) was  $92.7 \pm 1.8$  and the mean postoperative KPS score was  $90.7 \pm 1.8$ , differences being not statistically significant ( $p=0.2$ , Student *t*-test).
- Concerning angiographic results, in our series only 40 of the 45 patients who underwent venous reconstruction had DS angiography control two weeks after surgery. All eight patients (100%) who had

undergone removal of a lesion fragment within the lateral recess together with simple resuture had sinus patency. Thirteen (87%) of the 15 patched cases with dura or fascia were patent. Harvesting autologous veins, seemed us too excessive for patching. According to our experience, the most appropriate material was fascia temporalis.

Eight (72.7%) of the 11 autologous bypasses controlled were patent. Important, six patients in whom a synthetic Gore-Tex tube graft had been used were found to have thrombosis in spite of anticoagulation. One of them suffered acute intracranial hypertension, which was successfully reversed after intensive care management; the other five had asymptomatic thrombosis. When a saphenous venous graft was used, seven (70%) of the 10 controlled bypasses were patent. The one with external jugular vein was patent as well. So, for performing bypasses, the internal saphenous vein (which has valvulas) or the external jugular vein (which does not have valvulas) are recommended for a long or a short graft, respectively.

## **HOW TO AVOID COMPLICATIONS**

### **1. BRAIN SWELLING**

Placing the patients in semisitting (= lounging) position for sagittal sinus meningiomas, and sitting position (or lateral position with the head elevated) for lesions in the confluence or the transverse sinuses, allows good venous return.

Care has to be taken to preserve the venous anastomatic pathways that developed throughout the scalp, pericranium and diploic venous channels.

If brain swelling occurs before undertaking surgery on the sinus, the surgeon should be prepared to stop, and decide to postpone removal to a more or less delayed (around one month) stage.

### **2. BLOOD LOSS**

Blood loss can be reduced by (1) head elevated to decrease intracranial venous pressure, (2) careful constant hemostasis, (3) affixing Surgicel on the vessel defects and slight compression rather than extensive use of the sucker, (4) use of cell-saver until tumor resection starts.

### **3. DIFFICULTIES FOR TEMPORARY OCCLUSION OF THE SINUS**

Inflated balloons should not be used, as they do not pass through the lumen because of septations, as well as vascular clamps or aneurysm clips because of their crushing effect on the sinus walls and/or afferent veins. Temporary occlusion of the sinus should be controlled by transiently inserting small pledgets of Surgicel within the sinus lumen, which makes venous surgery easy.

#### 4. RISKS OF THROMBOSIS

Microvascular surgical skill is mandatory; this needs training in the lab. The best material for reconstruction seems to be: a piece of dura or fascia temporalis for patching, and autologous vein graft for bypassing. Synthetic Gore-Tex prosthesis should be avoided because it always creates thromboses. Long-duration use of anticoagulants, then of antiagregants, is of prime importance until endothelialization of the graft.

#### CONCLUSIONS

The low recurrence rate observed in our study supports resecting not only the tumor portion outside the sinus but also the fragment invading the sinus. Ultimately, a decision must be made after weighing the benefits and risks. When attempt at radical removal is decided, venous reconstruction is mandatory when the sinus is incompletely occluded. In cases with total occlusion, complete resection with performing a bypass can be considered to restore the flow that might be compromised by impairment of the compensatory collateral channels. Post-operative use of anticoagulants/antiagregants is mandatory for at least 3 months, until re-endothelialization occurs; this strategy did not increase hemorrhagic complications in our series.

We do not pretend that all tumors invading the major dural sinuses must be radically resected and the sinus systematically repaired. Before deciding to perform such procedures, especially for the meningiomas located in the mid-third portion of the sinus, other alternatives should be discussed: (1) primary surgery to shave the tumor from the sinus and, if the tumor grows, adjuvant radiosurgery and (2) radiosurgery for a small meningioma, with secondary surgery if the tumor is not controlled.

#### References

- [1] Alvernia JE, Sindou M (2004) Pre-operative neuro-imaging findings as a predictor of the surgical plane of cleavage: prospective study of 100 consecutive cases of intracranial meningioma. *J Neurosurg* 100: 422-430
- [2] Auque J (1996) Le sacrifice veineux en neurochirurgie. Evaluation et gestion du risque. *Neurochirurgie* 42 (Suppl 1): 32-38
- [3] Bonnal J, Brotchi J (1978) Surgery of the superior sagittal sinus in parasagittal meningiomas. *J Neurosurg* 48: 935-945
- [4] Di Meco F, Li KW, Casali C, Ciceri E, Giombini S, Filippini G, Broggi G, Solero CL (2004) Meningiomas invading the superior sagittal sinus: surgical experience in 108 cases. *Neurosurgery* 55: 1263-1274

- [5] Donaghy RMP, Wallman LJ, Flanagan MJ, Numoto M (1973) Sagittal sinus repair. Technical note. *J Neurosurg* 38: 244-248
- [6] Hakuba A (1991) Reconstruction of dural sinus involved in meningiomas. In: Al-Mefty O (ed) *Meningiomas*. Raven Press, New York, pp 371-382
- [7] Hakuba A, Tsurund T, Ohata K, Nagai K, Matsuoka Y (1996) Microsurgical reconstruction of the intracranial venous system. In: Hakuba A (ed) *Surgery of the intracranial venous system*. Springer, Berlin Heidelberg New York, Tokyo, pp 220-225
- [8] Heros RC (2006) Meningiomas involving the sinus; editorial. *J Neurosurg* 105: 511-513
- [9] Merrem G (1970) Parasagittal meningiomas. Fedor Krause memorial lecture. *Acta Neurochir (Wien)* 23: 203-216
- [10] Oka K, Go Y, Kimura H, Tomonaga M (1994) Obstruction of the superior sagittal sinus caused by parasagittal meningiomas: the role of collateral venous pathways. *J Neurosurg* 81: 520-524
- [11] Sekhar LN, Tzortzidis FN, Bejjani GK, Schessel DA (1997) Saphenous vein graft bypass of the sigmoid sinus and jugular bulb during the removal of glomus jugular tumors. Report of two cases. *J Neurosurg* 86: 1036-1041
- [12] Simpson D (1957) The recurrence of intracranial meningiomas after surgical treatment. *J Neurol Neurosurg Psychiatry* 20: 22-39
- [13] Sindou M, Alvernia JE (2006) Results of attempted radical tumor removal and venous repair in 100 consecutive meningiomas involving the major dural sinuses. *J Neurosurg* 105: 514-525 (71 references)
- [14] Sindou M, Auque J (2000) The intracranial venous system as a neurosurgeon's perspective. *Adv Tech Stand Neurosurg* 26: 131-216 (148 references)
- [15] Sindou M, Mazoyer JF, Fischer G, Pialat J, Fourcade C (1976) Experimental bypass for sagittal sinus repair. Preliminary report. *J Neurosurg* 44: 325-330
- [16] Sindou M, Mercier P, Bokor J, Brunon J (1980) Bilateral thrombosis of the transverse sinuses: microsurgical revascularization with venous bypass. *Surg Neurol* 13: 215-220
- [17] Steiger HJ, Reulen HJ, Huber P, Boll J (1989) Radical resection of superior sagittal sinus meningioma with venous interposition graft and reimplantation of the rolandic veins. *Acta Neurochir* 100: 108-111

**Contact:** Marc Sindou, Hôpital Neurologique P. Wertheimer, University of Lyon, 59 Bd Pinel, 69003 Lyon, France  
E-mail: marc.sindou@chu-lyon.fr



---

# POSTERIOR FOSSA MENINGIOMAS

A. H. KAYE

Dr. Andrew Morokoff is co-author of this chapter

## INTRODUCTION

Harvey Cushing was the first to use the term “meningioma” in 1922, although the tumors were known under various other names since the 17th century. Meningiomas represent 20% of all intracranial tumors and predominantly affect those in the 5th to 7th decades of life with a 2.7:1 female to male ratio. According to the World Health Organisation scheme, meningiomas are graded as benign (WHO I), atypical (WHO II) and malignant (WHO III). There are various histological subtypes of benign meningiomas, but these generally do not correlate with the aggressiveness of the tumor. Ten percent of meningiomas occur in the posterior fossa; these tumors have presented a formidable challenge throughout the history of neurosurgery and many, especially those arising from the petro-clival region, were considered “inoperable” up until the 1970s. However, with the advent of the operating microscope, CT and MR imaging, microsurgical techniques and the development of various skull base approaches, it became possible to safely resect the majority of posterior fossa meningiomas.

The main surgical approaches can be categorised as either the standard retrosigmoid craniotomy or the various presigmoid exposures. The anterior transpetrosal approach was originally described by Bochenek and Kukwa [2] and further developed by Kawase et al. [5]. Posterior petrosal approaches, based around the translabyrinthine approach described by Morrison and King [10] were subsequently refined by Al-Mefty et al. [1]. Hakuba first described a combined anterior and posterior petrosal approach [3]. Other authors including Mayberg and Symon [8], Sekhar et al. [12], Samii and Tatagiba [11] and Spetzler et al. [14] published case series with mortality rates of under 10% and major morbidities ranging from 8 to 34%. Surgery, if possible, is still the accepted first line treatment option but the advent of stereotactic radiosurgery and fractionated and intensity-modulated radiotherapy has contributed to treatment decision algorithms. There is still no effective chemotherapy for aggressive meningiomas and the molecular biology, long-term behaviour, recurrence rates and optimal treatment algorithms of meningiomas, particularly those in difficult anatomical locations that limit complete resection, remain a topic of contention.

---

*Keywords:* Meningioma, posterior fossa, petroclival, transpetrosal approach, complications

## **RATIONALE**

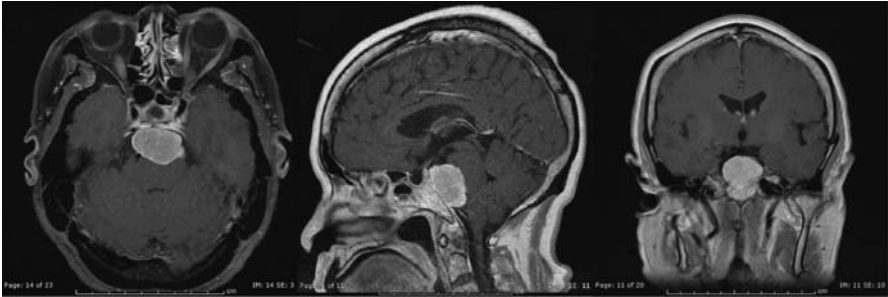
The rationale behind treatment of any meningioma is twofold: to relieve the patient's symptoms and to prevent the adverse consequences of tumor growth. Once the decision is made to operate, the goal of posterior fossa meningioma surgery varies with the extent and size of the tumor. With small to moderate sized tumors or those located peripherally at the cerebellar convexity or tentorial edge without sinus involvement, the goal is usually complete removal, whereas with large tumors this goal is much more difficult to achieve, particularly with those tumors that extend in front of the brain stem or have significant involvement of the skull base and venous sinuses. In these tumors, a subtotal resection is often all that can be achieved. The decision process following surgery includes the options of radiotherapy or careful observation, with further surgery and/or radiotherapy at the time of progression/recurrence.

## **DECISION-MAKING**

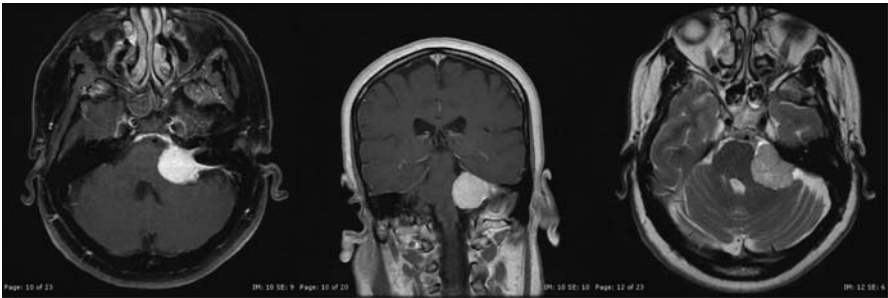
### **1. DIAGNOSTIC CRITERIA**

The diagnosis of posterior fossa meningiomas is made on clinical and radiological grounds. The vast majority of these tumors present with an insidious onset of symptoms, usually over 2 to 5 years, but an increasing number of asymptomatic tumors are discovered incidentally after brain imaging for other reasons. The most common symptoms associated with meningiomas of the posterior fossa are headache (70%), ataxia (60%), cranial nerve dysfunction and symptoms related to mass effect on the brainstem. Unlike supra-tentorial meningiomas, seizures are extremely uncommon. The pattern of cranial nerve involvement depends on the location of the tumor [4, 14]. Diplopia due to oculomotor nerve palsy commonly occurs with tumors of the upper clivus medial to the trigeminal nerve, particularly if there is suprasellar extension through the tentorial notch. Tumors involving the cavernous sinus typically present with 6th nerve palsies, related to the course of the nerve through the dura in Dorello's canal. Facial sensory disturbance due to trigeminal nerve involvement is frequent, especially with tumors located near Meckel's cave. Many petrous apex meningiomas present with hearing loss. Intracanalicular meningiomas may present with tinnitus, hyperacusis, vestibular symptoms or facial palsy and may mimic vestibular schwannomas. Larger tumors that compress the brain stem structures or the 4th ventricle may present with ataxia or hydrocephalus or multiple cranial nerve palsies.

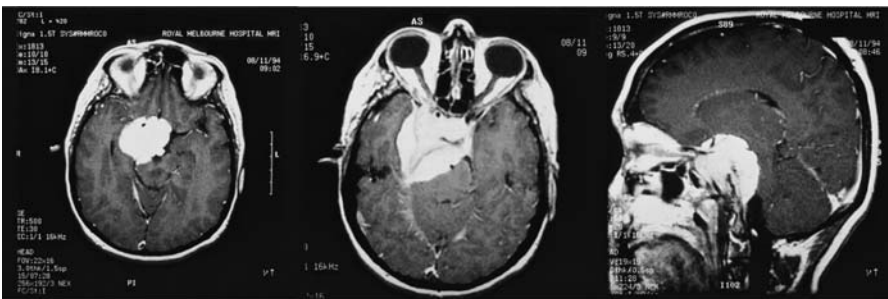MR imaging is the investigation of choice for diagnosis of a meningioma. Classical findings include iso-intensity with gray matter on non-enhanced scans, vivid homogeneous enhancement, CSF clefts and an enhancing dural tail (Figs. 1–3). This last feature, in particular, is helpful in differentiating a meningioma from a vestibular schwannoma, the latter typically having a more



**Fig. 1.** Clivus meningioma in an 84-year-old woman. A gadolinium-enhanced axial, sagittal and coronal MRI showing classic imaging features of a meningioma arising from the middle third of the clivus. Note the marked, homogeneous contrast enhancement and thickened dural enhancement inferior to the tumor along the lower clivus. The vertebrobasilar vessels are displaced to the right and the brainstem is markedly distorted



**Fig. 2.** Cerebellopontine angle meningioma in a 61-year-old woman. An axial T2 and gadolinium-enhanced coronal and axial T1 MRI scan, showing a meningioma based around the internal acoustic meatus. Note extension into the meatus but no expansion. Also note significant dural tail both anteriorly along the clivus and posteriorly along the petrous ridge and also attachment to the tent. This patient presented with facial numbness, ataxia and episodes of nausea



**Fig. 3.** Large petroclival-clinoidal meningioma in a 38-year-old female. This large tumor presented with facial parasthesia and visual loss. Note extensive involvement of the petroclival junction, Meckel's cave, sella region, anterior clinoid process and superior orbital fissure on the right

rounded appearance and expansion of the bony internal auditory canal (IAC). Meningiomas, however, may mimic other tumors including schwannomas, cysts or metastases. MR spectroscopy may also be helpful in making the diagnosis preoperatively. Meningiomas typically have a low creatinine peak, high choline and alanine, and a low inositol peak, which may help distinguish them from schwannomas.

## **2. INDICATIONS**

The natural history of most of posterior fossa meningiomas is usually relentless slow progression; therefore we would generally recommend surgery for those under the age of 70 years, particularly if the patient is already symptomatic. Once the adaptive limit of the brainstem structures is reached, then pial invasion and edema can lead to rapid clinical deterioration. Surgery allows confirmation of the pathology, and the potential for cure or at least long term control. Because it immediately reduces mass effect, surgery will also relieve symptoms associated with cerebellar, brainstem and cranial nerve compression.

Asymptomatic patients with small or moderate size tumors can be watched carefully in the first instance with repeat MR imaging. The first follow up imaging should be done within 3 months and then six months later to rule out rapid growth that would be expected if the lesion is atypical or malignant. If the tumor appears benign and continued observation is elected, patients will then need indefinite follow up with at least yearly MRI. If symptoms develop, or serial imaging demonstrates significant growth, then surgery is indicated.

If the tumor is large then the risks of surgery, given the patient's age and status, must be weighed against the risk of further deterioration over their lifespan. In cases where the patient is elderly or unfit for surgery, or prefers to avoid surgery, stereotactic radiotherapy or radiosurgery may be considered. This modality has demonstrated effectiveness both in long term control of the tumor, as well as relief of symptoms [6]. However, focused radiation is generally not possible for tumors greater than 3 cm in diameter.

## **3. PREOPERATIVE ASSESSMENT**

A careful history and neurological examination is the basis of preoperative assessment. Clinical risk factors to take into consideration in planning the procedure include patient age, significant medical disease, poor performance status and prior surgery and/or radiotherapy. A medical or anesthetic consultation may be warranted to optimise any co-morbidities before surgery. Audiometry evaluation is essential for any tumors that present with hearing loss, are adjacent to the internal acoustic meatus (IAM) or in which surgery has the potential for injury of the VIIIth nerve. A formal neuroophthalmologic assessment is relevant to identify any subtle extraocular neuropathies or visual field deficits in cases with suprasellar extension. Tumors with suprasellar extension

may also require testing of the pituitary axis preoperatively. For tumors where there is likelihood of lower cranial nerve palsies either pre- or postoperatively such as jugular foramen lesions, a formal swallow assessment is done and the patient is warned of the possible potential need for a tracheostomy and/or percutaneous feeding gastrostomy.

The MRI characteristics of the tumor are helpful in assessing the risks associated with surgery. Larger tumors are associated with an increased risk especially if the tumor extends anterior to the brainstem. Encasement of the vertebrobasilar arteries is a key factor that increases risk significantly; however, it is often possible to dissect the vessels out safely as there is usually, but not always, an arachnoid plane between the tumor and the vessels. If there is brainstem pial invasion, this may be indicated by the presence of T2 or FLAIR abnormality in the brainstem and this also represents a major risk factor. A preoperative CT with bone windows is helpful for showing the degree of bony remodelling and hyperostosis and planning the approach. Hyperostosis occurs in around a third of cases. Calcification within a tumor is strongly suggestive of a meningioma and if the tumor is heavily calcified is thought to have a much slower growth rate.

Angiography helps to demonstrate the blood supply of posterior fossa meningiomas, but is usually not necessary unless embolisation is contemplated. These tumors often have a combination of internal and external carotid supply via dural, tentorial or ascending pharyngeal vessels. Supply from the vertebrobasilar system via pial vessels is another sign that the tumor has invaded the pial layer of the brainstem. Pre-operative embolisation is indicated in cases where supplying vessels can be occluded practically and safely by an experienced neuroendovascular proceduralist. Great care must be taken following embolisation as swelling of the tumor within the posterior fossa can result in rapid neurological deterioration. The patency of the major sinuses and the anatomy of the draining veins of the temporal lobe and tentorium can also be assessed on the venous phase of the angiogram or on MR venography and this is critical in planning the operative approach. If the tumor has already invaded and occluded the adjacent sinus, then this can usually be taken safely during the procedure.

## **SURGERY**

### **1. OPERATIVE TECHNIQUE**

#### **1.1 Preoperative preparation and equipment**

Adequate preoperative informed consent is of particular importance for these patients, in whom major surgery with potentially significant complications is being proposed for a “benign” and sometimes asymptomatic tumor. Patients are given a general anesthetic and positioned on the operating table (see below).

All patients have an indwelling urinary catheter. In many patients, and in all being done in the sitting position, we insert a central venous catheter. Special care is taken during positioning to make sure that pressure areas are protected with gel pads. The eyes are protected with clear adhesive plastic film to prevent entry of alcoholic preparation fluid. A lumbar spinal drain is inserted and drainage of CSF is commenced at the start of the craniotomy in most cases undertaken in the lateral or parkbench position, especially if the tumor is large, to afford reduction of pressure in the posterior fossa upon opening the craniotomy. Registration of the frameless stereotactic navigation system is done at this stage if necessary; however we have not found neuronavigation to be of significant benefit for most posterior fossa meningiomas and generally do not use it. Facial and/or Cochlear nerve monitoring is placed for tumors in the vicinity of the cerebellopontine angle (CPA). The head is shaved in the appropriate area and the incision marked out before final preparation with alcoholic iodine. Equipment needed during the case such as the operating microscope, high speed drill, CUSA (ultra sonic tumor aspirator), irrigating bipolar system and nerve monitor are set up. All patients are given intravenous antibiotics (cefazolin), dexamethasone and mannitol. Patients undergoing exposure of the temporal lobe are loaded with anticonvulsant (phenytoin, 1 mg/kg).

## 1.2 Choice of approach

The anatomical location of the meningioma is a critical determinant of the operative approach that will be chosen. Posterior fossa meningiomas have been usefully classified by Sekhar et al. [13] into six groups as listed in Table 1. For cerebellar convexity, tentorial, transverse sinus-based and posterior petrous meningiomas (cerebellopontine angle) tumors we use a simple suboccipital craniotomy. Image-guided frameless stereotactic navigation is occasionally used to localise the craniotomy. If the tumor is located superiorly in the posterior fossa, we prefer to use the sitting position for ease of view and to allow gravity to assist in retracting the cerebellum. Particular care is taken with the torcular and sinuses upon opening the craniotomy. The diamond drill burr

**Table 1.** Classification of posterior fossa meningiomas [13]

Type	Location	Anatomical extension
I	Cerebellar convexity – lateral tentorial	Tentorium, transverse, sigmoid sinuses
II	Cerebellopontine angle	Petrous ridge, IAC
III	Jugular foramen	Cerebellomedullary angle, internal jugular vein, extracranial
IV	Petroclival	Upper 2/3 clivus, cavernous sinus, Meckel's cave, petrous ridge
V	Foramen magnum	Lower 1/3 clivus, C1–2 area
VI	Unclassified	Entire clivus, mid and lower clivus, other types

is useful for managing bone bleeding. For tumors located on the convexity, the craniotomy must be large enough to allow resection of the involved dura around the margins. For most cerebellopontine angle tumors, we use a retrosigmoid craniotomy, discussed below. A presigmoid approach, often combined with a middle fossa craniotomy is usually used for tumors located more anteriorly, especially petroclival tumors where the main tumor bulk lies anteromedial to the cranial nerves. Foramen magnum meningiomas are addressed in a separate chapter in this book and are therefore not included here.

### 1.3 Retrosigmoid approach

For cerebellopontine angle tumors where the main mass lies around, posterior or inferior to the IAC, a retrosigmoid (suboccipital) craniotomy is used. The advantages of this approach include familiarity to neurosurgeons and shorter time. The opening affords a good view of the petrous face and a large area of the lateral brainstem can be accessed through a relatively small opening. For tumors extending below the level of the lower cranial nerves, the opening can be extended and the foramen magnum, lateral C1 arch and posterior part of the condyle can be removed if necessary. The main disadvantage to the retrosigmoid approach is limited access anteriorly for tumors arising from the clivus or the Meckel's cave region and extending anterior to the brainstem. The lateral patient position is used for the vast majority of our retrosigmoid craniotomies. The lateral position can be difficult in obese patients or those with thick, short necks and in these circumstances we use the sitting or semi-sitting position. For lateral positioning, the patient is placed on the table with the operative side superiorly with a pad and axillary roll under the torso. Both legs are flexed and two pillows placed between them. The hips are taped for stability and an arm rest and back support are placed. The head is held in the 3-pin head holder and flexed and rotated 10–15° towards the floor. The ipsilateral shoulder is taped to hold it away from the surgeon's access to the craniotomy. A linear or slightly sigmoid-shaped incision is made one finger's breadth posterior to the transverse-sigmoid sinus junction. The muscles are divided and dissected off the bone using monopolar cautery until the root of the digastric groove is visible. Care must be taken to avoid diathermy injury to the extracranial facial nerve which exits the stylo-mastoid foramen anteriorly in the groove. Pericranium may be harvested at this stage for use in closure of the dura at the end. A burr hole is made near the asterion to expose the "corner" at the transverse-sigmoid sinus junction and the bone flap is lifted using the high speed drill. A large emissary vein often seen arising from the sigmoid sinus should be skeletonised with the drill, dissected free of the bone flap and coagulated before division. Small tears in the sinus should be covered with pieces of gelfoam and cottonoid patties. Further bone can be removed anteriorly over the edge of the sigmoid sinus to improve exposure, however this often necessitates opening the mastoid air cells, which must be waxed thoroughly.

The dura is then opened in an asymmetrical Y-shaped fashion, with the larger flap hinged anteriorly and a small flap hinged superiorly on the transverse sinus edge. A critical next step is to open the arachnoid membrane over the infero-lateral cerebellar cisterns and drain CSF to allow the cerebellum to relax. This process is made easier by the preoperative institution of lumbar drainage and this is essential in large tumors. The Greenberg retractor system is attached and a retractor blade is used to gently hold back the cerebellum. At this stage the operating microscope is brought in and the tumor is identified.

It is essential to identify the arachnoid plane around the tumor; this greatly facilitates dissection of the surrounding neurovascular structures, which must be preserved. Small vessels may be coagulated and divided if they are penetrating into the tumor but the surgeon must be sure that they are in fact supplying the tumor and are not “en passant”, being adherent to the capsule on their way to the brainstem or cranial nerves. It may be necessary to take the superior petrosal vein to improve access; it is far better to coagulate and divide this vein rather than inadvertently avulse it from the superior petrosal sinus. The facial nerve stimulator is a useful dissecting instrument when attempting to identify the course of the facial nerve around the tumor. The position of the nerve depends upon the point of origin of the tumor in relation to the IAC and the nerve may be thinned or splayed considerably as it courses over the tumor. Ideally, the dural base of the tumor may be coagulated with the bipolar diathermy to reduce the blood supply but this may be difficult especially if the tumor is large or centered around the IAC. It is important to realise that heat transmission from the bipolar can damage nerves, therefore the lowest effective wattage must be used and irrigating or non-stick “cool” bipolars are helpful, if available. The tumor should be debulked intra-capsularly using the ultrasonic aspirator following identification and dissection of the tumor-arachnoid-cerebellar plane. A combination of debulking, dissection of the capsule from the arachnoid plane and coagulation of the dural base is then used until the tumor is completely excised. Tumors that extend into the IAC require dura to be dissected off the bone and drilling of the posterior lip of the canal. Tumor can then be dissected out of the canal after identification of the VIIth and VIIIth nerves. In a small proportion of cases the tumor will engulf the cranial nerves or be inseparably adherent to the nerves; in this situation a subtotal resection may be required, leaving some small fragments of tumor attached to the nerves in order to preserve them.

Meticulous haemostasis is essential at the end of the procedure. We aim to achieve a watertight dural closure in all cases; in most cases this requires sewing in a dural patch either pericranium or artificial material. The bone flap is replaced, held in place by small titanium plates and any bone defects repaired using bone substitute. A complete bone repair may reduce the incidence of postoperative headache. The wound is closed in layers.



#### 1.4 Combined middle fossa transpetrosal approaches

For tumors situated more anteriorly (petroclival, clival, posterior clinoid, Meckel's cave) or transtentorially we generally use a middle fossa craniotomy, combined with one of the presigmoid transpetrosal approaches, either retrolabyrinthine, translabyrinthine or transcochlear. These are also known as anterior petrosal or "extended" middle fossa approaches and involve division of the superior petrosal sinus and tentorium down to the tentorial hiatus. The transpetrosal portion of the procedure is performed by one of our neuro-otological surgery colleagues; we have found that having two surgeons shortens operative time, reduces operator fatigue and improves overall results for these cases. The exact choice of transpetrosal approach depends on the anatomical location of the tumor. The retrolabyrinthine approach has the advantage of preserving hearing, but by itself is a very restricted approach and provides a view limited to the entry zone of nerves V, VII and VIII. However, it is very useful in combination with a middle fossa approach for transtentorial tumors in the petroclival region.

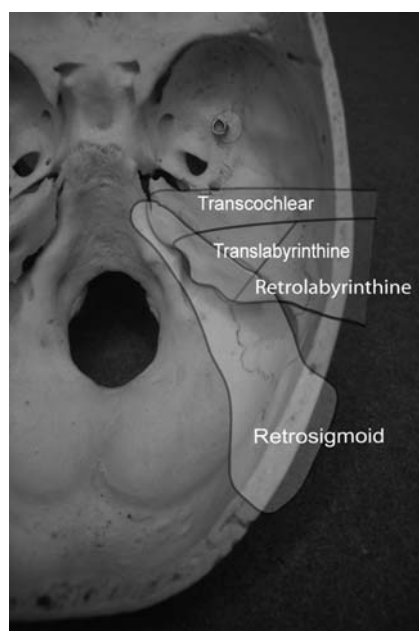
The translabyrinthine approach provides an excellent view of the CPA from the tentorium down to the level of the jugular foramen including nerves but is limited in its exposure of lesions below the lower cranial nerves. It affords a better view of tumors ventral to the midbrain or pons than the retrosigmoid approach. The translabyrinthine approach is less often used for meningiomas, unless the patient has already lost hearing. We routinely use the translabyrinthine approach alone for acoustic schwannomas of 3 cm or larger when hearing has been lost.

The transcochlear approach exposes the area from the pons down to the medulla including cranial nerves V to XI and the mid-basilar artery and is usually used in combination with a middle fossa craniotomy for lesions medial to the IAC and/or ventral to the brainstem. It requires rerouting of the facial nerve and therefore has a higher incidence of postoperative facial weakness.

For meningiomas situated lower in the posterior fossa below the IAC or CN IX, X and XI with preserved hearing, we would use the retrosigmoid approach. The proportion of approaches used in 324 cases over the last decade at our institution, and the corresponding chance of complete resection is shown in Table 2.

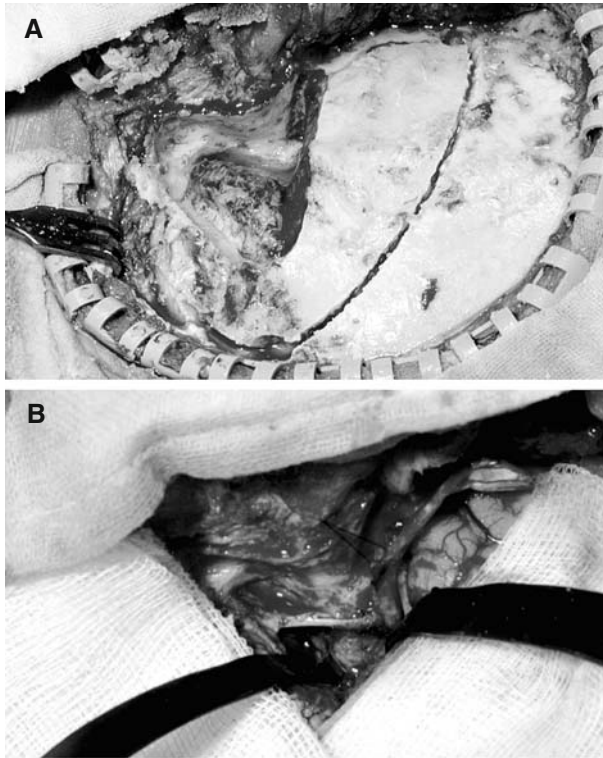
**Table 2.** Posterior fossa meningioma cases 1995–2006. Royal Melbourne Hospital

Approach	% of total cases	% achieving complete resection
Retrosigmoid	50	90
Middle fossa + retrolabyrinthine	35	50
Middle fossa + translabyrinthine	5	30
Middle fossa + transcochlear	10	35



**Fig. 4.** Approaches to posterior fossa meningiomas. Axial photograph of skull base showing bony area removed and operative exposure gained by various approaches to posterior fossa meningiomas. The transcochlear, translabyrinthine and retrolabyrinthine approaches are usually combined with a middle fossa craniotomy and a transtentorial approach. Note that the retrosigmoid approach requires retraction of the cerebellum and that anterior petroclival exposure is limited by the vestibulocochlear nerve complex and the working distance

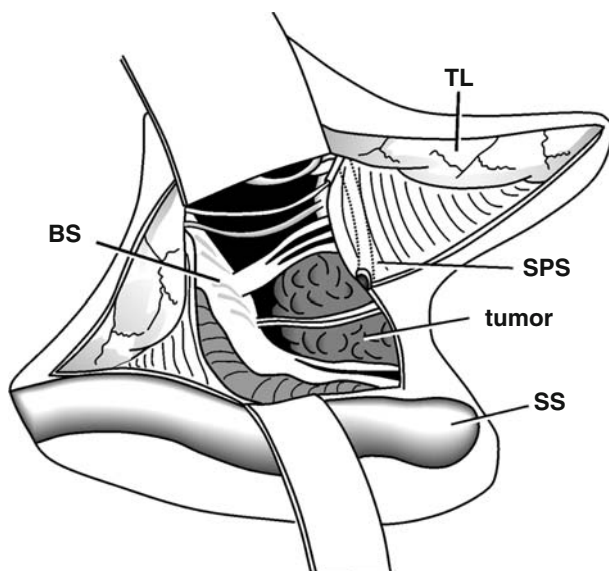
The combined middle fossa retrolabyrinthine approach is performed with the patient in the supine position with the head turned  $45^\circ$  towards the contralateral side. A spinal drain for CSF drainage is inserted preoperatively. A large C-shaped incision is made from above the tragus down to below the tip of the mastoid process at the posterior border of the sternocleidomastoid muscle and the skin and muscle flap is retracted antero-inferiorly. The petrous bone drilling is performed next exposing the sigmoid sinus posteriorly and down to the jugular bulb. The craniotomy is then performed, exposing the temporal lobe, the transverse-sigmoid junction and the posterior fossa just posterior to the sigmoid sinus. The dura of the posterior fossa is opened anterior to the sigmoid sinus and extended anteriorly across the middle cranial fossa. The superior petrosal sinus (SPS) is divided and occluded with 3-0 proline. The temporal lobe can be gently retracted superiorly. The tentorium is divided down to the tentorial hiatus, being careful to avoid the IVth nerve which runs just medial to its edge (Fig. 6). Division of the dura allows posterior mobilisation of the sigmoid sinus. If the vein of Labbé drains into the superior petrosal sinus (SPS) anteriorly, the division of the SPS and tentorial



**Fig. 5.** Combined retrolabyrinthine-middle fossa approach. Intra-operative photographs showing the incision, flap and bone work. **A** Note that the mastoidectomy and retrolabyrinthine drilling is performed first, exposing the sigmoid sinus and skeletonising the labyrinths. Then after making burr holes along the floor of the temporal fossa and on either side of the transverse sinus, the craniotomy is lifted, exposing the postero-inferior temporal lobe and attachment of the tent. **B** Dividing the superior petrosal sinus and cutting the tentorium. Care must be taken to avoid injuring the vein of Labbé and the IVth cranial nerve

incision to the incisura must be made more anteriorly than the entry point of the vein of Labbé. Great care must be taken in retracting the temporal lobe to avoid damaging or tearing the Inferior Anastomotic vein of Labbé.

After opening the dura the remainder of the operation follows the same principles as described above for the retrosigmoid approach. The margins of the tumor are dissected with care being taken to preserve the arachnoid that where present forms a layer between the tumor capsule and adjacent critical vascular and neural structures. The tumor is debulked with the ultrasonic aspirator allowing the capsule of the tumor to be dissected away from the brainstem and cranial nerves with minimal retraction. The tumor may extend medially to compress or engulf the major vessels including the vertebral, basilar superior cerebellar and posterior cerebral arteries. Critical attention must be



**Fig. 6.** Operative diagram. Diagram of exposure of tumor obtained after posterior petrosectomy and middle fossa craniotomy and division of the superior petrosal sinus and tentorium. A wide view of the anterior part of the brainstem from the 3rd nerve down to the lower cranial nerves can be achieved (SS Sigmoid sinus; SPS superior petrosal sinus; TL temporal lobe; BS brainstem)

given also to the perforating vessel arising from these arteries, in addition to the veins draining the brain stem. As maximal as possible resection is attempted, but this must not be at the expense of causing significant neurological morbidity. It is usually possible to resect virtually all the intracranial tumor, but the tumor extending through the cavernous sinus is not resected, as the potential benefit is not worth the risk of serious neurological deficit.

At the end of the procedure, we close the dura with the aid of a dural substitute. The bone flap is replaced with titanium plates and an abdominal fat graft is packed into the petrosal/mastoid space. The fascial layer is closed to help hold the fat in place. Meticulous closure of the wound in three layers is then done and a pressure head dressing applied.

The middle fossa approach can be extended anteriorly to include a pterional craniotomy if there is significant anterior extension of the tumor to the anterior clinoid, parasellar region or anterior cranial fossa. For large “dumb-bell” tumors with a major anterior extension, it is often preferable to plan a two-stage operation rather than attempt to resect the whole tumor with one protracted operation. For meningiomas in the very elderly or patients medically risky for protracted surgeries, the transpetrosal approaches may not be appropriate and a suboccipital/retrosigmoid craniotomy is the approach of choice. This allows access to most areas of the posterior fossa for debulking

of the tumor only, unless the tumor is placed centrally and/or very anteriorly along the clivus. In this case, radiotherapy may be the preferred first line option if the tumor was growing or symptomatic.

### 1.5 Jugular foramen meningiomas

For uncommon tumors located around the jugular foramen a petro-occipital trans-sigmoid (POTS) approach is useful [9]. This combines a retrosigmoid craniotomy and an infero-posterior petrosectomy with the addition of a translabyrinthine approach if hearing is lost with large tumors. This exposes the sigmoid sinus completely from the SPS down to the jugular bulb. The sigmoid sinus is sacrificed unless it is the lone sinus or on the dominant side.

### 1.6 Postoperative care

The patient is nursed in the high dependency neurosurgical care unit for the first 24–48 hours following the operation. Intravenous antibiotics are given for 24 hours. Particular attention is given to control of postoperative hypertension. We aim to minimise the use of postoperative steroids unless there is brainstem, temporal lobe or cerebellar edema. The patient is mobilised early and anti-thromboembolism management is instituted. A non-contrast CT scan is performed routinely on day 1 postoperatively to exclude hematoma and hydrocephalus. Delayed facial nerve palsy can occur up to 14 days after surgery. This is usually managed with a short course of oral steroids and frequently resolves.

## 2. LONG-TERM RESULTS

Complete resection can be achieved in 90% of tumors located posterior to the IAC i.e. those done mostly with the retrosigmoid approach. Meningiomas arising from the petro-clival region and involving the cavernous sinus requiring a presigmoid approach are usually more intimately involved with neurovascular structures and more difficult to access; in these the complete resection rate is only 30–50% (Table 2) as it is not our policy to attempt a radical complete resection of the tumor within the cavernous sinus. It is well recognised that recurrence rate depends on two major factors: the extent of surgical resection (Simpson grade) and the pathology of the tumor. The literature indicates a 5-year recurrence rate for all (benign) posterior fossa tumors of approximately 21% (range 7–42%) reflecting the fact that many cannot be completely excised. The recurrence rates for atypical and malignant meningiomas are much higher. In our series of over 300 cases, radiation therapy was utilised in 9% of cases undergoing subtotal resection. Second operation was performed in 14%.

The routine postoperative management involves a baseline MRI and then regular follow up scans, initially at 6 months and then at least at yearly

intervals. The management options for residual tumor include “observation” with regular follow up MRI, further surgery and/or radiation treatment. In the majority of our cases of typical “benign” tumors we have elected to follow residual tumor with regular MRI and institute active management only if there is radiological and/or clinical progression. Surgery may be considered if the residual/recurrent tumor is easily accessible. Otherwise radiation treatment is advised. In general we advocate post operative radiation treatment for residual tumor if the histology shows atypical or anaplastic features.

### 3. COMPLICATIONS

The large series published over the last decade of petroclival meningiomas show a mortality rate of 2% and morbidity rate of 23% (range 7–39%) [1, 5, 8, 11, 13]. Approximately 17% of patients are eventually disabled or have poor function. We have experienced no mortality in our series of 324 posterior fossa meningiomas operated between 1995 and 2006.

New onset cranial nerve injuries occur in up to 30% of cases and commonly involve the Vth, VIIth and VIIIth nerves. Facial numbness, or less commonly trigeminal neuralgia or deafferentation facial pain can occur following resection of tumors near Meckel’s cave. In our series, significant trigeminal nerve dysfunction occurred in around 7%. Facial nerve function is better preserved with more laterally and posteriorly placed tumors [15]. Our overall rate of facial nerve preservation is 95%. Hearing loss occurs in all cases following translabyrinthine or transcochlear petrosectomy but can also follow significant retraction or direct injury to CN VIII or traction on the GSPN during the middle fossa approach. However, hearing is much more likely to be preserved in meningioma surgery compared to vestibular schwannomas. There is a high incidence of lower cranial nerve palsies following resection of

**Table 3.** Complications in 324 posterior fossa meningioma cases.  
Royal Melbourne Hospital

Complication	Number (%)	Comments
Trigeminal nerve dysfunction	21 (6.5)	
Deep venous thrombosis	21 (6.5)	
Facial nerve palsy	14 (4.3)	2 severe and permanent
Pulmonary embolism	10 (3.1)	
Diplopia	6 (1.9)	
Hemiparesis	3 (1.0)	2 severe and permanent
Increased hydrocephalus	2 (0.6)	Both requiring shunting
Infection	2 (0.6)	
CSF leak	2 (0.6)	No reoperations required
Epilepsy	2 (0.6)	
Death	0 (0)	

jugular foramen meningiomas but can also occur as a result of injury to the nerves during dissection of the capsule of tumors arising in other locations. Venous injuries due to retraction or direct injury to the sigmoid sinus, or temporal lobe draining veins can lead to hemorrhage and venous infarction with hemiparesis or speech deficits. Arterial injuries are uncommon but perforators to the brainstem or pial vessels, if damaged, can lead to serious morbidity. Postoperative seizures are very unusual but can occur following injury to the temporal lobe in middle fossa approaches.

The incidence of CSF leak in the literature ranges from 2 to 29% (mean 10%). Most CSF leaks occur via the air cells and result in rhinorrhea rather than through the wound. The risk is certainly higher with the transpetrous approaches because of the difficulty in obtaining perfect closure of the dura. There were no CSF leaks in our recent series of 200 consecutive retrosigmoid craniotomies.

Deep venous thrombosis/pulmonary embolism is a serious concern with the long time required for many of these operations. Our rate of DVT/PE was high initially but this has reduced considerably since we instituted the routine use of postoperative low dose anticoagulants.

## **HOW TO AVOID COMPLICATIONS**

### **1. HEMORRHAGE AND VENOUS INJURY**

Preoperative planning, particularly careful assessment of the imaging is essential to plan the appropriate approach and to be aware of the relevant anatomy. The bony anatomy of the petrous bone, the IAC and the position of the sigmoid sinus and jugular bulb are noted. Cerebellar or brainstem injury can be due to retraction or from arterial or venous injury. This can be avoided in most cases by lumbar drainage, opening the cisterns carefully to relax the cerebellum at the start of the procedure and by minimising direct retraction. Similar principles apply to the temporal lobe when a middle fossa craniotomy is done as part of the procedure. Careful management of postoperative blood pressure is essential. We routinely perform a non-contrast CT scan on the first postoperative day to rule out the development of significant bleeding. Being aware of the venous anatomy and its potential variations is important. Operating on the side of a dominant or lone sigmoid sinus or non-communicating torcula increases the risk of venous hypertension if there is compromise of that sinus. Avoiding extreme flexion/rotation of the neck during positioning decreases potential compression of the ipsilateral jugular vein. The vein of Labbé and tentorial draining veins must be preserved when performing transtentorial approaches. The tentorial incision may need to be modified to avoid an anteriorly placed vein or anomalous venous anatomy in the region of the superior petrosal sinus. For sitting cases, careful monitoring

for CO<sub>2</sub> changes and regular neck vein compression to find potential venous bleeding points has helped minimise our rate of air embolism.

## **2. CRANIAL NERVE INJURY**

It is essential to have neurophysiological nerve monitoring in order to decrease the risk of facial nerve paresis. Finding and respecting the peri-tumoral arachnoid plane is a key concept. Near total resection is preferred over gross total resection when the tumor is adherent or engulfing the neurovascular structures. There is no significant difference in the recurrence/progression rates between near total and complete excision [7]. Care must be taken with microdissection around all other cranial nerves. Fourth nerve injury can be avoided by taking care during transtentorial procedures when dividing the medial edge of the tent and resecting the upper pole of the tumor.

## **3. CSF LEAK**

Prevention of CSF leak requires watertight closure of the dura where possible. In retrosigmoid craniotomies and the transpetrosal approaches, this usually requires sewing in a dural patch of either pericranium or artificial dura. The dura can be further repaired with collagen dural matrix e.g. Duragen® (Integra, Plainsboro, NJ) or dural substitute e.g. Durepair® (Medtronic, Minneapolis, MN) and reinforced with synthetic hydrogel sealant such as DuraSeal® (Confluent Surgical, Waltham, MA). In translabyrinthine approaches, we place a free abdominal fat graft and hold it in place by closing the fascia firmly over it (the fascia must be preserved during the opening of the incision). A compressive head dressing is then applied. Mastoid air cells must be waxed thoroughly and internal air cells exposed by opening the posterior wall of the IAC must be sealed at the end of the resection with a small piece of muscle and fibrin glue. Postoperative CSF leak can usually be controlled with lumbar puncture or drainage and antibiotic cover to prevent the small incidence of meningitis. To reduce postoperative headache, the craniotomy flap is fixed with titanium plates and defects are filled with calcium phosphate bone substitute.

## **CONCLUSIONS**

Posterior fossa meningiomas present insidiously with slowly progressive but eventually seriously disabling or life-threatening symptoms. Most posterior fossa meningiomas can be resected either completely or nearly completely with microneurosurgical techniques in order to minimize morbidity. The approach must be specifically tailored to the individual tumor, in terms of its



size, location and symptoms, particularly in relation to hearing loss. Surgery must aim to avoid cerebellar retraction, preserve arterial and venous structures and prevent injury to cranial nerves. The management of recurrent and residual tumors is still controversial in terms of the type and timing of radiotherapy and repeat operation.

## References

- [1] Al-Mefty O, Ayoubi S, Smith RR (1991) The petrosal approach: indications, technique, and results. *Acta Neurochir Suppl (Wien)* 53: 166-170
- [2] Bochenek Z, Kukwa A (1975) An extended approach through the middle cranial fossa to the internal auditory meatus and the cerebello-pontine angle. *Acta Otolaryngol* 80: 410-414
- [3] Hakuba A, Nishimura S, Jang BJ (1988) A combined retroauricular and preauricular transpetrosal-transtentorial approach to clivus meningiomas. *Surg Neurol* 30: 108-116
- [4] Kawase T, Shiobara R, Ohira T, Toya S (1996) Developmental patterns and characteristic symptoms of petroclival meningiomas. *Neurol Med Chir (Tokyo)* 36: 1-6
- [5] Kawase T, Shiobara R, Toya S (1991) Anterior transpetrosal-transtentorial approach for sphenopetroclival meningiomas: surgical method and results in 10 patients. *Neurosurgery* 28: 869-875; discussion 875-866
- [6] Kondziolka D, Mathieu D, Lunsford LD, Martin JJ, Madhok R, Niranjan A, Flickinger JC (2008) Radiosurgery as definitive management of intracranial meningiomas. *Neurosurgery* 62: 53-58; discussion 58-60
- [7] Little KM, Friedman AH, Sampson JH, Wanibuchi M, Fukushima T (2005) Surgical management of petroclival meningiomas: defining resection goals based on risk of neurological morbidity and tumor recurrence rates in 137 patients. *Neurosurgery* 56: 546-559; discussion 546-559
- [8] Mayberg MR, Symon L (1986) Meningiomas of the clivus and apical petrous bone. Report of 35 cases. *J Neurosurg* 65: 160-167
- [9] Mazzoni A, Sanna M (1995) A posterolateral approach to the skull base: the petro-occipital transsigmoid approach. *Skull Base Surg* 5: 157-167
- [10] Morrison AW, King TT (1973) Experiences with a translabyrinthine-transtentorial approach to the cerebellopontine angle. Technical note. *J Neurosurg* 38: 382-390
- [11] Samii M, Tatagiba M (1992) Experience with 36 surgical cases of petroclival meningiomas. *Acta Neurochir (Wien)* 118: 27-32

- [12] Sekhar LN, Jannetta PJ, Burkhart LE, Janosky JE (1990) Meningiomas involving the clivus: a six-year experience with 41 patients. *Neurosurgery* 27: 764-781; discussion 781
- [13] Sekhar LN, Wright DC, Richardson R, Monacci W (1996) Petroclival and foramen magnum meningiomas: surgical approaches and pitfalls. *J Neurooncol* 29: 249-259
- [14] Spetzler RF, Daspit CP, Pappas CT (1992) The combined supra- and infratentorial approach for lesions of the petrous and clival regions: experience with 46 cases. *J Neurosurg* 76: 588-599
- [15] Voss NF, Vrionis FD, Heilman CB, Robertson JH (2000) Meningiomas of the cerebellopontine angle. *Surg Neurol* 53: 439-446; discussion 446-437



**Andrew H. Kaye**

Andrew H. Kaye, MBBS, MD FRACS is the James Stewart Professor of Surgery and Head of the Department of Surgery, The Royal Melbourne Hospital. He is the Director of the Department of Neurosurgery at The Royal Melbourne Hospital, and the Director of the Melbourne Comprehensive Cancer Centre.

His main clinical interest involves neuro-oncology and cerebrovascular disease. He is the foundation Editor-in-Chief of the Journal of Clinical Neuroscience and he authored and co-authored numerous journal articles and book chapters, as well as five books including being the co-author of “Brain Tumors”, a text recognised as being the definitive work on the subject.

He was awarded the Commonwealth of Australia Centenary Medal in 2003 and the Order of Australia in 2004.

**Contact:** Andrew H. Kaye, Department of Neurosurgery, University of Melbourne, The Royal Melbourne Hospital, Parkville, Vic 3050, Australia  
E-mail: [a.kaye@unimelb.edu.au](mailto:a.kaye@unimelb.edu.au)

---

# ENDOSCOPIC SURGERY FOR SKULL BASE MENINGIOMAS

A. B. KASSAM

## INTRODUCTION

Endoscopic surgery within the paranasal sinuses began in the early 1900s, however Gerald Guiot was the first neurosurgeon to apply endoscopy during a transsphenoidal approach performed in 1963 [2, 10]. The development of rod lens systems by Harold Hopkins greatly accelerated the introduction of endoscopes into the operating room [8]. By the late 1970s, several neurosurgeons had reported on the endoscope as an adjunctive tool during microscopic resection of pituitary lesions with extrasellar extension [1, 4, 7, 9]. Yet, the endoscope did not outgrow its peripheral role in neurosurgery until the early 1990s when Jankowski and colleagues first described pure endoscopic transsphenoidal approaches to the sella [12]. More recently, Paulo Cappabianca and Luigi Cavallo have helped lead the popularization of a purely endoscopic transsphenoidal approach [3]. A critical point in the history of endonasal surgery has been the recent introduction of vascularized nasoseptal flaps for reconstruction. The nasoseptal flap has greatly reduced the morbidity of endoscopic skull base surgery and has made the endonasal resection of extrasellar skull base tumors, such as meningiomas, feasible [11, 16].

Since 1998, over 1000 patients have undergone endoscopic skull base surgery at the University of Pittsburgh. Working closely with our ENT colleagues, Dr. Carl Snyderman and Dr. Ricardo Carrau, we designed a series of modular expanded endonasal approaches (EEA), which are a completely transnasal endoscopic surgery providing access to the ventral skull base down to the C2 vertebrae. Only after many years of refining EEA for sellar pathology was this approach gradually applied to the skull base meningioma. In the last few years, EEA has proven to be a safe and effective corridor for over a hundred of these tumors at our institution. Nevertheless, EEA in our hands has not supplanted traditional skull base approaches for meningiomas but rather complemented it. We continue to feel strongly that the optimum surgical treatment for skull base meningiomas requires a 360° multicorridor strategy whereby trajectories are created to avoid crossing the plane of cranial nerves. Specifically, in our opinion, the primary morbidity sustained during removal of skull base tumors occurs from manipulating cranial nerves. Therefore, if a corridor is selected (endonasal or lateral) it should be done so to

---

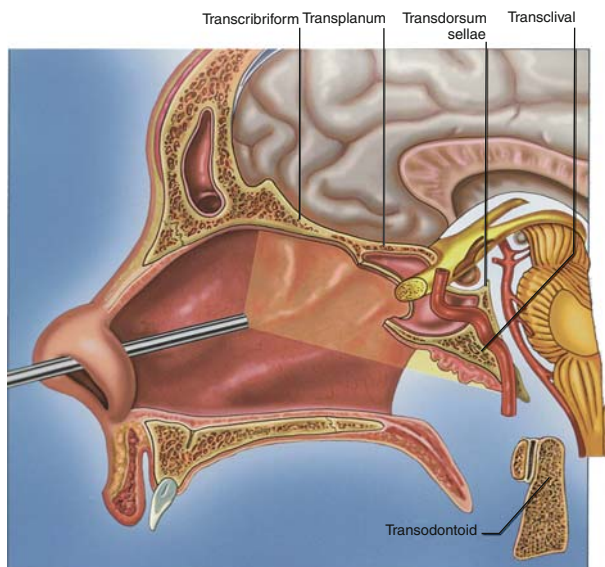
Keywords: endoscopy, skull base, meningioma, minimal-invasive neurosurgery

avoid crossing the plane of nerves. Occasionally this requires a multicorridor strategy thereby creating complementary roles for these approaches.

## RATIONALE

Endoscopic skull base surgery is founded on anatomical studies which have demonstrated that the transnasal corridor can provide access to the entire ventral skull base extending from the crista galli to the spinomedullary junction; all 12 cranial nerves along with the carotid and vertebrobasilar arterial systems can be well visualized through the nose [5]. Moreover, many skull base tumors, including meningiomas, often originate along the ventral skull base and have a tendency to grow and displace neurovascular structures laterally (along the perimeter), which makes an anteromedial transnasal approach an attractive natural corridor. Finally, besides sparing patients a skin incision and the associated wound healing issues, the endonasal route perhaps most importantly obviates the need for retracting the brain, which may result in consequent morbidity.

The expanded endonasal approach has been constructed as a series of modular approaches in the sagittal (midline) and coronal (paramedian – lateral to the carotid arteries) planes [14, 15]. The sagittal plane modules run

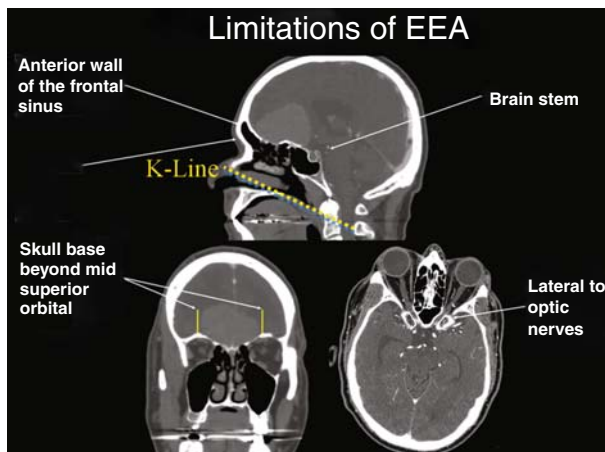


**Fig. 1.** Sagittal plane modules for endonasal skull base surgery. Reprinted with permission from Kassam AB, Snyderman CH, Carrau RL, Mintz AH, Gardner PA, Thomas AJ, Prevedello DM. Silver Book – The Expanded Endonasal Approach to the Ventral Skull Base: Sagittal Plane. Endo-Press™, Tuttlingen, Germany, 2007

between the internal carotid arteries as it courses along the ventral skull base. These median modules consist of the transcribriform, transplanum, transdorsum sellae, transclival, and transodontoid approaches (Fig. 1). The coronal plane paramedian modules are represented by approaches lateral to the internal carotid artery. Most ventral skull base meningiomas can be managed solely with the sagittal modules. It is infrequent that coronal EEA modules are used for the treatment of skull base meningiomas. Meningiomas located in Meckel's cave can be accessed endonasally through the quadrangular space and meningiomas involving the infratemporal fossa can be approached using the coronal transpterygoid corridor [15]. We have utilized this modular system to design an endonasal training scheme which requires that modules of increasing difficulty be mastered in stepwise fashion starting with the transsellar corridor. Many large skull base meningiomas require more than one EEA module for adequate resection. The anatomic "keyhole" of endonasal skull base surgery is the medial opticocarotid recess (OCR), which represents the ventral surface of the medial clinoid and lateral aspect of the tuberculum sellae and permits simultaneous entry into the carotid canal, optic canal, sella turcica, and medial cavernous sinus [15].

## DECISION-MAKING

The decision to approach a skull base meningioma via an endonasal approach rests primarily on anatomical principles. If neurovascular structures are ventral to a skull base tumor and will need to be manipulated in order to reach a tumor through the nose, then EEA should not be the preferred approach.



**Fig. 2.** Limitations of EEA. A line drawn in the sagittal plane from the anterior nasal septum to the posterior hard palate (K-line) defines the inferior limit of EEA. Moreover, tumors lateral to the optic nerve or lateral to the mid-superior orbit are best approached via craniotomy

Therefore, tumors lateral to the optic nerve are still best approached via a transcranial approach (Fig. 2A). Moreover, a line drawn in the sagittal plane from the anterior nasal septum to the posterior hard palate defines the inferior limit of an EEA – nasopalatine-line (Fig. 2B).

We also feel that endonasal surgery should only be offered to patients by neurosurgeons who have had substantial training in traditional skull base approaches and vascular neurosurgery. Neuronavigation has been critical to the advance of endoneurosurgery and all patients undergo preoperative imaging with fine-cut CT angiograms and brain MRI using image-guidance mask protocols. Patients with tumors surrounding or narrowing the internal carotid arteries on imaging are referred to a neurointerventionalist for diagnostic angiography and balloon test occlusion. We have only pursued preoperative endovascular embolization for skull base meningiomas that have a significant feeder off the external carotid system. Tumor size has not been a limiting factor for EEA. In fact, large tumors, for which a staged operative strategy may be chosen, are particularly well suited for EEA given that the vascularized nasoseptal flap preserves the approach and can be peeled away multiple times to facilitate staged surgery.

In the final analysis, the corridor selected is a function of: the goals of surgery, comorbidity of the patient, the surgeon's experience, and position of critical neurovascular structures. In particular the position of the cranial nerves determines the corridor if all other things are equal. Occasionally a multicorridor (combined EEA and open) may be the best approach.

## **SURGERY**

We highly recommend and have employed a two-surgeon four-hand technique for all endonasal approaches. The dual surgeon operation fosters a team approach which becomes increasingly important with complex cases and the human-manuevered endoscope affords one a real-time three-dimensional feedback which we feel is completely lost with the endoscope holders. The surgeons stand at the right side of the patient whose head is stabilized by Mayfield pin fixation after the induction of endotracheal anesthesia. The vertex of the patient's head is tilted to the left and the face is turned approximately 20° to the right side of the surgical bed. Somatosensory evoked potentials are monitored in all cases to assess cortical function and brainstem evoked responses and cranial nerve electromyography are performed if deemed prudent by tumor anatomy.

Pledgets soaked with 0.02% oxymetazoline are placed in the nose to decongest the mucosa and povidone antiseptic solution is applied over the nose and upper lip. The abdomen is prepped with povidone if the need for a fat graft for reconstruction is anticipated. A third or fourth generation cephalosporin (usually ceftriaxone or cefipime) is administered for antibiotic prophylaxis.

## 1. GENERAL PRINCIPLES

### 1.1 Exposure

We advocate a binasal approach for all endonasal approaches. The endoscope is introduced into the right nostril at the 12 o'clock position and retracts the nasal vestibule superiorly to elongate the nostril. A suction tip is positioned within the right nostril at the 6 o'clock position. The left naris is reserved for dissecting instruments. A suction irrigation sheath or continual irrigation by the co-surgeon allows the endoscope lens to be cleaned without removing the endoscope from the nose. EEA begins within the right naris with removal of the middle turbinate. The nasal corridor is further widened by out-fracture of both inferior turbinates. The contralateral middle turbinate is not removed but out-fractured. The critical step is to resect the posterior third of the nasal septum. This prevents contamination of the endoscope when the instruments are passed from the contralateral side. Finally, it is imperative that when the exposures are created they are done so to accommodate the endoscope which takes physical space within the sinuses. Therefore, all exposures need to be exceptionally wide and involve a cavity or a sinus and a half. The half is for allowing the endoscope to maneuver without competing for space, and the remaining cavity provides for unobtrusive movement of the bimanual instrumentation.

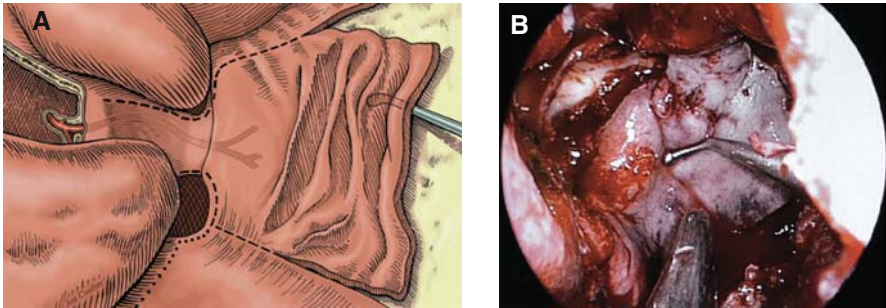
### 1.2 Resection

The principles of resection are the same as they are for microsurgical resection. Specifically, the tenants of microsurgery and cerebrovascular surgery form the foundation for all tumor removal. The underpinning of this is bimanual dissection, which if not possible, signals the end of the procedure. The technique is traditional: capsular coagulation, internal debulking, extracapsular sharp dissection, identification of critical neurovascular structures, and repeating the sequence. The degree of tumor removal is not contingent on the tool used for visualization (endoscope or microscope) but rather, the presence of arachnoid planes. The instruments used for endoscopic removal are identical to that of microscopic, i.e., suction and microscissors predominantly. There are no grasping forceps and no curettes used. Whenever possible, we favor a two suction technique for tumor debulking whereby one suction is used for debulking and the other provides gentle countertraction. For more firm tumors, a variety of instruments have been developed including an endonasal aspirator.

### 1.3 Reconstruction

The principles of reconstruction follow those of microsurgical repair. In conventional skull base surgery this has evolved to rely on the use of vascularized flaps, most commonly the pericranial flap. Similar evolution in endoscopic skull base surgery has yielded to the use of a vascularized nasoseptal flap that has proven to be robust and reliable.





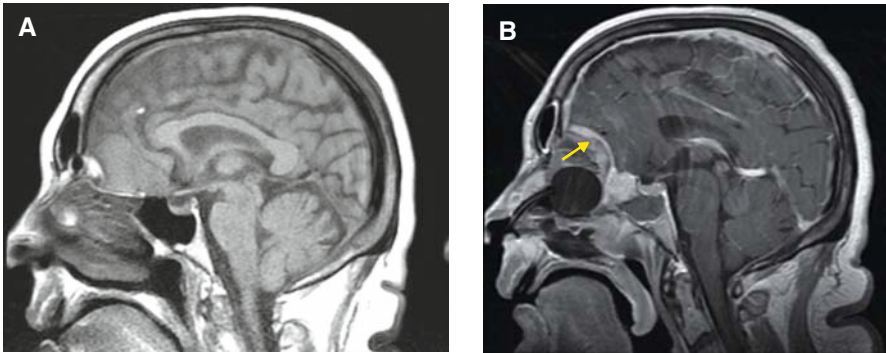
**Fig. 3.** Nasoseptal flap. The Hadad-Bassegasteguy flap shown in the diagram (A) and intraoperatively (B) has become the foundation of endonasal skull base reconstruction. Reprinted with permission from Kassam AB, Thomas A, Carrau RL, Snyderman CH, Vescan A, Prevedello D, Mintz A, Gardner P (2008) Endoscopic reconstruction of the cranial base using pedicled nasoseptal flap. *Neurosurgery* 63(1 Suppl 1): ONS44-ONS52

*The nasoseptal flap:* Currently, for all meningiomas treated with EEA, we reconstruct the skull base with a nasoseptal flap (Fig. 3). The nasoseptal flap is a pedicle flap of the nasal septum mucoperiosteum and mucoperichondrium which is based on the nasoseptal artery [16]. Radiographic studies have demonstrated that the nasal septum has the potential to yield a nasoseptal flap large enough to cover practically any defect engendered by a transcribriform, transplanum, transsellar, and transclival EEA [6]. The nasoseptal vascularized mucosal flap is elevated at the beginning of EEA using unipolar electrocautery with an insulated needle tip to incise the septal mucosa. Two parallel incisions are made in the septum which are joined anteriorly by a vertical incision which is usually placed just rostral to the anterior head of the inferior turbinate. The flap is elevated with Cottle dissection and is stored out of the way either in the nasopharynx (for transsellar approaches) or inside the maxillary sinus (for transclival and transodontoid approaches) until it is needed for reconstruction. The flap reconstruction is rarely augmented with abdominal fat grafts and is bolstered by an inflated intranasal Foley balloon. In addition to this onlay reconstruction, a single layer of Duragen (collagen Matrix, Integra Life Sciences, New Jersey) is used as a subdural inlay graft. Therefore, the collagen matrix recapitulates the arachnoid while the nasoseptal flap recapitulates the dura.

## 2. SPECIFIC MODULES

### 2.1 Transcribriform approach

The working “cavity and a half” for this module consists of bilateral anterior and posterior ethmoidectomies and the half is represented by frontal sinusotomy or Draf III procedure. This approach is defined by removal of the cribriform plate and anterior skull base and extends from the posterior ethmoidal

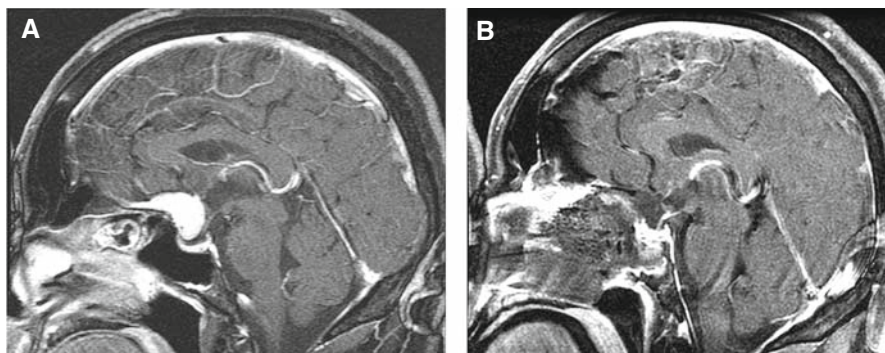


**Fig. 4.** Transcribriform approach for olfactory groove meningioma. Preoperative (A) and postoperative (B) brain MRI showing the complete resection of an olfactory groove meningioma with transcribriform EEA. This 59-year-old woman presented with neurocognitive decline. The nasal Foley is seen in the second image supporting the nasoseptal flap (arrow) reconstruction

artery to the crista galli and frontal sinuses. Transcribriform EEA is limited laterally by the lamina papyracea, anteriorly by the frontal sinuses, and posteriorly by the transition with the planum sphenoidale. The key anatomic structures for this approach include the anterior cerebral arteries (A2) and their branches (fronto-orbital and fronto-polar) as well as the orbits. This approach is used for olfactory groove meningiomas (Fig. 4). Sparing olfaction is usually not an option given that the first cranial nerves are commonly compromised by anterior skull base tumors. However, we have successfully performed olfactory-preserving unilateral transcribriform EEA for small lesions. Tumor devascularization via coagulation of the dura mater and ligation of the anterior and posterior ethmoidal arteries significantly aides in tumor resection. There are 3 primary feeders to meningiomas in this location: ethmoidal arteries, anterior falcine artery and parasitic supply from the anterior cerebrals. Ethmoidals are eliminated during the bony exposure. The anterior falcine becomes an important consideration during the dural opening. The dura must be opened paramedially and then the falx ligated in the midline once it can be dissected from both openings. This allows for not only control of the anterior falcine artery but also the inferior sagittal sinus. Therefore, the dura is never opened along the midline but rather, bilateral paramedian openings are created.

## 2.2 Transplanum approach

The working corridor for this module consists of a wide bilateral sphenoidotomy and the “half cavity” consists of the posterior ethmoids. In this approach, we remove the planum sphenoidale and tuberculum sellae. The anterior limit of bony resection is marked by the posterior ethmoidal arteries since further anterior bony removal would damage olfaction. This approach

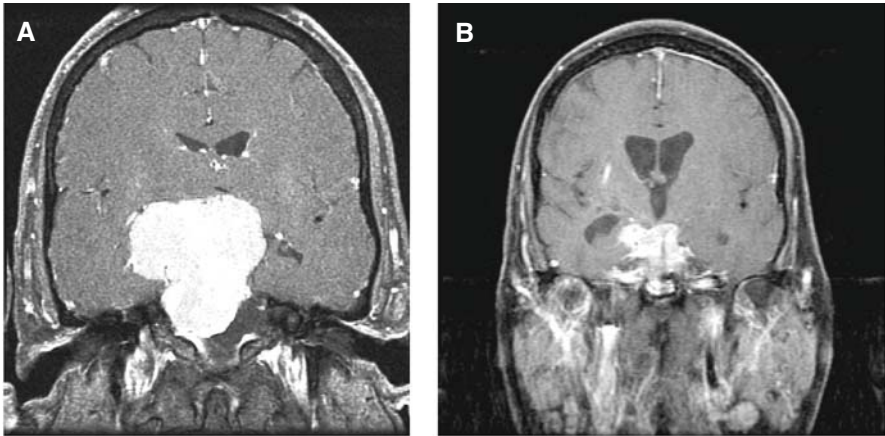


**Fig. 5.** Transplanum approach for tuberculum sellae meningioma. Preoperative (A) and postoperative (B) contrasted sagittal MRI of the brain showing the complete resection of a large tuberculum sellae meningioma

is ideal for meningiomas along the planum sphenoidale (Fig. 5), and the key anatomic landmark is the medial opticocarotid recess (OCR) which must be removed to allow access to the suprasellar region. Reaching the suprasellar extent of a skull base meningioma with this approach is greatly facilitated by resection of the tuberculum sellae. The planum is drilled from a rostral-to-caudal direction and fractured inferiorly with a Kerrison rongeur once it is thinned sufficiently. The dura can be safely opened from one internal carotid artery to the other after the medial OCRs have been resected. The most important anatomic structures related to this approach are the optic nerves, ophthalmic arteries, the internal carotid arteries, and the anterior cerebral arteries (A1, Heuber, anterior communicating arteries). It is imperative to identify and preserve the superior hypophyseal arteries as they can be the primary subchiasmatic blood supply. Therefore, the bipolar should be used sparingly and sharp dissection is mandatory for perforator preservation.

### 2.3 Transclival approach

The working corridor in this module consists of the bilateral sphenoidotomy and the nasopharyngeal space. EEA can provide an important ventral corridor for petroclival meningiomas. The ventral corridor allows for early devascularization and can be combined with other transcranial approaches to treat these complex lesions (Fig. 6). We divide the clivus into thirds (upper, middle, and lower). The transclival approach can be used to remove a single third of the clivus or a panclivectomy can be performed. The vidian nerve and artery are important landmarks in this module as they travel in the vidian canal to join the genu of the anterior internal carotid artery [17]. After the basopharyngeal fascia is completely removed from the floor of the sphenoid sinus and clival face, the clivus is drilled with a 3 mm coarse bit. After the clivus is removed, the dural mater and underlying basilar venous plexus are exposed.



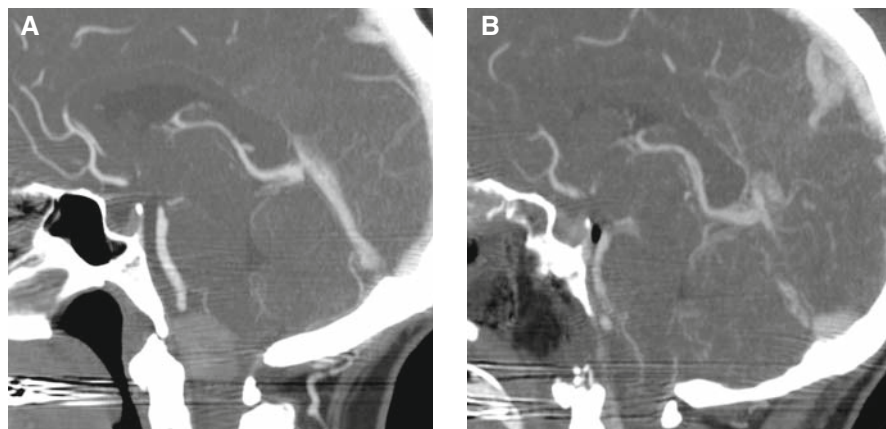
**Fig. 6.** Transclival approach for petroclival meningioma. Preoperative (A) and postoperative (B) MRI of the brain showing significant debulking of a large petroclival meningioma via EEA

Microfibrillar collagen “sandwiches” are used to control sinus bleeding which can be profuse. Once intradural, care must be taken to identify the abducens nerve which is always located at the vertebrobasilar junction. Access to the interpeduncular cistern is possible after dural opening and control of the basilar venous plexus. The key neurovascular structures exposed include the brainstem, cranial nerves II, III, and VI, the basilar and vertebral arteries, superior cerebellar arteries, and the posterior cerebral arteries.

It is important to note that sometimes lesions can extend behind the upper third of the clivus into the retrodorsal region encroaching upon the contents of the interpeduncular cistern. In these cases the meningioma will become very intimate with the posterior circulation and requires a direct approach. An endoscopic pituitary transposition followed by a dorsectomy and posterior clinoidectomy can provide for unprecedented exposure to this region. A direct view of the interpeduncular fossa allowing for cerebrovascular dissection of the posterior circulation can be achieved using this module [13].

#### 2.4 Transodontoid approach

Foramen magnum meningiomas situated anterior to the brainstem are well suited for this approach (Fig. 7). If performed independently of a transclival approach, a sphenoid opening is not necessary. The arch of the C1 vertebrae and the odontoid process are exposed and removed with a drill. The medial occipital condyle can be partially drilled and one alar ligament sacrificed without compromising stability. The critical anatomic structures in this module are the vertebral arteries, the posterior inferior cerebellar arteries (PICA), the brainstem, and the lower cranial nerves. Most important in this module is the position of the hypoglossal canal which emerges at the “10 and 2 o’clock”



**Fig. 7.** Transodontoid approach for foramen magnum meningioma. Preoperative (A) and postoperative. Reprinted with permission from Prevedello DM, Kassam AB, Snyderman C, Carrau RL, Mintz AH, Thomas A, Gardner P, Horowitz M. Endoscopic cranial base surgery: ready for prime time? *Clin Neurosurg* 2007 Oct; 54: 48–57. (B) CT angiogram of the head of a 46-year-old woman with an anteriorly-based foramen magnum meningioma who underwent two-stage transodontoid EEA

position at the foramen magnum. There, EEA is appropriate for lesions between the hypoglossal canals which displaces the nerve along the perimeter. If the lesion is lateral to the “10 and 2 o’clock” position then an external lateral paracondylar approach is preferred.

## HOW TO AVOID COMPLICATIONS

In our opinion, there are two primary sources of morbidity: neurovascular related (arterial and venous) and cranial nerve. Vascular morbidity can be minimized by ensuring the operating surgeon has a strong foundation in microsurgical techniques and cerebrovascular surgery. Furthermore, as discussed above, creating adequate exposure allowing for bimanual resection using the principles above is mandatory. Perforator preservation, particularly in the perichiasmatic space, is critical to ensure optimum visual outcomes. Several considerations on preoperative imaging should be observed that determine the degree of cerebrovascular dissection required. First, one should observe if there is a cortical cuff of brain tissue separating the tumor capsule from the Circle of Willis and its branches. If so, these are ideal endoscopic cases to begin and develop an intradural experience. Second, if there is no cuff, is the vessel adherent to the capsule or is it encased by the tumor. These represent progressively more complex situations that the surgeon must decide if his/her experience is adequate to deal with endoscopically. Finally, in the case of any vascular dissection, proximal control is a requirement.

With respect to cranial nerves, this really is the driving issue that determines the approach. The golden rule that is pursued is to avoid crossing the plane of a nerve. For example, in the anterior skull base if the lesion is lateral to the optic nerve, a lateral approach is selected whereas, if it is medial, an endonasal approach is used. On occasion, particularly for petroclival lesions, an EEA corridor is used until a nerve is reached and then a posterior lateral corridor is used. It should be noted that there are situations in which cyto-reductive surgery may be the desired goal depending on the patient's comorbidities, age, and symptoms.

With respect to reconstruction, we believe strongly in the use of vascularized reconstruction techniques. We have found the use of grafts and prostheses to be less reliable and more prone to delayed leaks. CSF diversion via lumbar drain is used only if: wide arachnoidal cisternodissection has been done, a ventricle has been opened, or significant spillage of subarachnoid blood has occurred creating risk of transient hydrocephalus. In the event a leak does occur (5–10% incidence) [11], we recommend immediate and early re-exploration rather than diversion with a lumbar drain. Early re-exploration will usually identify a small segment of the reconstruction that can easily be augmented with little difficulty. This prevents the formation of mucosalized fistulae which can prove very problematic to reconstruct and also minimizes the risk of infection. Using this strategy, our incidence of bacterial meningitis has been less than 2%.

## CONCLUSIONS

Meningiomas of the skull base are only “benign” through the eyes of a microscope and the morbidity and mortality of their natural history and treatment remains significant. On a foundation of traditional skull base approaches, we have, after years of accruing experience with endoscopic transsphenoidal approaches, began to use the endonasal corridor increasingly. Our preliminary experience has proved that EEA can be applied safely and successfully to skull base meningiomas from the cribriform plate to the foramen magnum. The visual and endocrine morbidity of EEA for skull base meningiomas has compared favorably with transcranial approaches, and I believe that this approach currently provides the most direct and least invasive neuroprotective strategy for many skull base meningiomas. We embrace the onus of long-term outcomes as we continue to disseminate these techniques and apply EEA patiently on a case-by-case basis in lieu of traditional operative approaches; however we still rely on external corridors. In the end, independent of the corridor used, the technique of microsurgery and cerebrovascular surgery are identical and the endoscope and microscope only provide visualization tools. Therefore, the endoscope is only a tool and outcomes are dependent upon the judgment with which the tool is selected and the technique by which it is applied.

## Acknowledgements

I would like to thank Dr. Daniel Prevedello and Dr. Nestor D. Tomycz for their help in preparing this chapter.

## References

- [1] Apuzzo ML, Heifetz MD, Weiss MH, Kurze T (2004) Neurosurgical endoscopy using the side-viewing telescope. *J Neurosurg* 46: 398-400
- [2] Cappabianca P, de Divitiis E (2004) Endoscopy and transsphenoidal surgery. *Neurosurgery* 54: 1043-1048; discussions 1048-1050
- [3] Cappabianca P, de Divitiis E (2007) Back to the Egyptians: neurosurgery via the nose: a five-thousand year history and the recent contribution of the endoscope. *Neurosurg Rev* 30: 1-7
- [4] Catapano D, Sloffer CA, Frank G, Pasquini E, D'Angelo VA, Lanzino G (2006) Comparison between the microscope and endoscope in the direct endonasal extended transsphenoidal approach: anatomical study. *J Neurosurg* 104: 419-425
- [5] Cavallo LM, Messina A, Cappabianca P, Esposito F, de Divitiis E, Gardner P, Tschabitscher M (2005) Endoscopic endonasal surgery of the midline skull base: anatomical study and clinical considerations. *Neurosurg Focus* 19(1): E2
- [6] Diogenes Pinheiro C, Prevedello DM, Carrau RL, Snyderman CH, Mintz A, Gardner P, Kassam A (2007) Improving the design of the pedicled nasoseptal flap for skull base reconstruction: a radioanatomic study. *Laryngoscope* 117(9): 1560-1569
- [7] de Divitiis E, Cappabianca P (2002) Microscopic and endoscopic transsphenoidal surgery. *Neurosurgery* 51: 1527-1529; author reply 1529-1530
- [8] Doglietto F, Prevedello DM, Jane JA Jr, Han J, Laws ER Jr (2005) Brief history of endoscopic transsphenoidal surgery – from Philipp Bozzini to the First World Congress of Endoscopic Skull Base Surgery. *Neurosurg Focus* 19: E3
- [9] Frank G, Pasquini E, Doglietto F, Mazzatenta D, Sciarretta V, Farneti G, Calbucci F (2006) The endoscopic extended transsphenoidal approach for craniopharyngiomas. *Neurosurgery* 59: ONS75-ONS83; discussion ONS75-ONS83
- [10] Griffith HB (1977) Endoneurosurgery: endoscopic intracranial surgery. *Proceedings of the Royal Society of London Series B, Containing papers of a Biological character* 195: 261-268
- [11] Hadad G, Bassagasteguy L, Carrau RL, Mataza JC, Kassam A, Snyderman CH, Mintz A (2006) A novel reconstructive technique after endoscopic expanded

- endonasal approaches: vascular pedicle nasoseptal flap. *Laryngoscope* 116(10): 1882-1886
- [12] Jankowski R, Auque J, Simon C, Marchal JC, Hepner H, Wayoff M (1992) Endoscopic pituitary tumor surgery. *Laryngoscope* 102: 198-202
- [13] Kassam AB, Prevedello DM, Thomas A, Gardner P, Mintz A, Snyderman C, Carrau R (2008) Endoscopic endonassal pituitary transposition for transdorsum sellae approach to the interpeduncular cistern. *Neurosurgery* 62(ONS Suppl 1): ONS57-ONS74
- [14] Kassam A, Snyderman CH, Mintz A, Gardner P, Carrau RL (2005) Expanded endonasal approach: the rostrocaudal axis. Part I. Crista galli to the sella turcica. *Neurosurg Focus* 19(1): E3
- [15] Kassam A, Snyderman CH, Mintz A, Gardner P, Carrau RL (2005) Expanded endonasal approach: the rostrocaudal axis. Part II. Posterior clinoids to the foramen magnum. *Neurosurg Focus* 19(1): E4
- [16] Kassam AB, Thomas A, Carrau RL, Snyderman CH, Vescan A, Prevedello D, Mintz A, Gardner P (2008) Endoscopic reconstruction of the cranial base using a pedicled nasoseptal flap. *Neurosurgery* 63(1 Suppl 1): ONS44-ONS52
- [17] Kassam AB, Vescan AD, Carrau RL, Prevedello DM, Gardner P, Mintz AH, Snyderman CH, Rhoton AL (2008) Expanded endonasal approach: vidian canal as a landmark to the petrous internal carotid artery. *J Neurosurg* 108(1): 177-183





**Amin Bardai Kassam**

Amin Bardai Kassam is Chairman of the Department of Neurological Surgery at the University of Pittsburgh, PA. He was born in Kampala, Uganda in 1967. He pursued his undergraduate studies in biochemistry from the University of Toronto where he stayed on to obtain his medical degree. Dr. Kassam completed his neurological surgery residency at the University of Ottawa where he also sought postgraduate training in epidemiology. Since joining the faculty of the Department of Neurological Surgery at the University of Pittsburgh in 1997, Dr. Kassam has focused his career on endoscopic skull base surgery, cerebrovascular disorders, brain tumors, and cranial nerve disorders. Together with colleagues in the department of otolaryngology, Dr. Kassam designed the multidisciplinary expanded endonasal approach (EEA), which has since been applied to well over 1000 patients – both adults and children – with skull base lesions. He was appointed chairman of neurological surgery at the University of Pittsburgh in 2007 and continues to actively train both residents and fellows in open and endoscopic intracranial surgery. Dr. Kassam has published and lectured extensively and has led the worldwide dissemination of endoscopic skull base surgery through frequent

intensive training courses. He lives with his wife, Greta, and two sons, Mikael and Armand.

**Contact:** Amin Bardai Kassam, Department of Neurological Surgery, University of Pittsburgh School of Medicine, Director Minimally Invasive endoNeurosurgery Center, University of Pittsburgh Medical Center, 200 Lothrop Street, Suite PUH B-400, Pittsburgh, PA 15213, USA  
E-mail: [kassamab@upmc.edu](mailto:kassamab@upmc.edu)

---

# MANAGEMENT OF PITUITARY ADENOMAS

J. D'HAENS

## INTRODUCTION

Pituitary disorders touch on many aspects of the medical field. Our understanding of the role of the pituitary gland continues to evolve. New endocrinologically active molecules which can modify or influence therapeutic approaches to pituitary disorders are being discovered. It is of prime importance that neurosurgeons involved with pituitary surgery be well informed about the most recent therapeutic advances available. Interdisciplinary debate with endocrinologists and radiologists is essential to make the best possible therapeutic decisions.

The role of the pituitary gland has intrigued scientists and doctors for many centuries. It was only in 1887 that its clinical role was discovered by Minkowski, one year after acromegaly was described by Pierre Marie. The first pituitary tumor operations were performed at the end of the 19th century. Transsphenoidal surgical techniques have been improving since 1907 when Schloffer performed the first successful transnasal operation in Vienna [7]. In the USA, Hirsch (1910) and Cushing (1912) contributed to the evolution of transsphenoidal surgery and had surgical mortality rates as low as 9.5 and 4.8% without the use of cortisone or antibiotics. Cushing initially used a head light and otologic mirrors but eventually discontinued transsphenoidal surgery because of insufficient vision on the surgical field. Later, Guiot and Derome (1967), in Paris, and Hardy (1969), in Montreal, again popularized the transsphenoidal approach by introducing the surgical microscope, intraoperative radiographs and image intensification. With further technical improvements in neurosurgery and the introduction of antibiotics and cortisone, surgical mortality dropped under 1%. The recent introduction of endoscopy has reduced nasal complications and improved patient comfort. The endoscope had already been used by G. Guiot during transsphenoidal surgery more than 40 years ago but the pure endoscopic approach to pituitary lesions was introduced by Jankowski and Jho in the mid 1990s.

Pituitary tumors can be approached using either a transcranial procedure from above or an inferior transsphenoidal route. The choice of the technique to be used will depend on the shape of the tumor and its extension. Most

---

*Keywords:* pituitary adenomas, transsphenoidal approach, endocrinology

cases can be approached by the transsphenoidal route except when the tumor has largely and diffusely invaded the intracranial space.

## **RATIONALE**

### **1. HISTOPATHOLOGY AND CLINICAL CONSIDERATIONS**

Pituitary adenomas arise from the anterior pituitary gland and account for about 10% of intracranial tumors.

Modern pathological classification of pituitary adenomas is based on immunohistochemistry and electron microscopy. From a clinical point of view these tumors are classified as either functioning or nonfunctioning adenomas depending on whether or not there are clinical and biological signs of hormonal hypersecretion.

Any anterior pituitary gland cell type can be at the origin of an adenoma: somatotroph cells, corticotroph cells, lactotroph cells, thyrotroph cells and gonadotroph cells. Functioning adenomas are characterized by clinical symptoms resulting from hormonal hypersecretion causing acromegaly, Cushing's disease, amenorrhea-galactorrhea or hyperthyroidism.

Gonadotrophinomas usually result in pituitary insufficiency and mass effect on surrounding structures. They very seldom cause hormonal hypersecretion syndrome.

Some adenomas, such as mixed GH-PRL cell adenomas, arise from two populations of cells. They cause acromegaly and are associated with varying levels of hyperprolactinemia. Other tumors derive from less differentiated progenitor cells that have the capability to produce both GH and PRL. They tend to follow a more aggressive clinical course.

Biologically nonfunctioning adenomas can be silent adenomas showing immunohistochemical features similar to biochemically active adenomas but producing hormones lacking bioreactivity, or they can be null-cell adenomas derived from incomplete differentiated adeno-hypophysial cells that are not actively engaged in hormone production. The latter are histochemically immunonegative, as are oncocytomas.

Clinically speaking, the revealing symptom of microadenomas is related to endocrine hypersecretion. These tumors are too small to provoke visual symptoms or pituitary insufficiency.

Nonfunctioning pituitary adenomas result in a clinical picture related to the compression of structures surrounding the sella turcica, such as the optic pathways, and cause a typical bi-temporal visual field defect, or the failure of one or several anterior pituitary secreting functions as a result of the compression of the residual pituitary gland.

Pituitary functions are under hypothalamic control. Most hypothalamic hormones have a stimulating effect on anterior pituitary cell secre-

tion. However, dopamine's PRL-inhibiting activity confers inhibitory control on prolactin secretion to the hypothalamus. This explains the slight increase in the serum prolactin level that can result from compression of the pituitary stalk (stalk effect). Somatostatin, another hypothalamic factor, inhibits secretion of growth hormone and TSH. Severe damage to the pituitary stalk will cause diabetes insipidus by interrupting the pathways carrying vasopressin from the hypothalamus to the posterior pituitary gland.

Malignant adenomas and pituitary carcinomas occur very infrequently.

Ninety percent of ACTH-secreting adenomas are microadenomas. Some are so small that even high-quality magnetic resonance imaging (MRI) is unable to visualize them. On the other hand, 70 to 90% of GH-secreting adenomas are macroadenomas showing invasiveness in about 30% of cases. PRL-secreting microadenomas are usually discovered in childbearing-aged women whereas in men, prolactinomas are nearly always diagnosed at the macroadenoma stage.

Pituitary apoplexy is a clinical syndrome related to hemorrhagic or necrotic changes occurring in pituitary adenomas. The patient experiences acute onset of severe headaches associated with visual disturbances and clinical signs of meningeal irritation. The treatment consists of high-dose corticosteroids and correction of blood electrolytes balance secondary to acute hypopituitarism. Early surgical decompression is warranted to relief visual disorders.

## 2. RADIOLOGICAL ASPECTS AND CLASSIFICATION

Tumors are classified according to size and invasiveness, which is predictive of surgical results. There is no consensus on the use of a universal classification but one which has stood the test of time was proposed by Hardy in 1976 [5]. This classification is based on modifications of the sella turcica on plain X-ray studies and is now adapted to MRI findings. The tumors are divided in four groups as follows.

Grade I tumors, or microadenomas, are lesions up to 10mm in diameter.

Grade II tumors are more than 1 cm in diameter and cause diffuse enlargement of the sella turcica with or without suprasellar extension. These non-invasive macroadenomas remain enclosed in the anatomical structures containing the pituitary gland (diaphragma sellae, medial wall of the cavernous sinus, dura of sellar floor and dorsum sellae) that can be displaced but not invaded.

Grade III tumors are adenomas which show signs of local invasion. Some of them can be smaller than 10 mm (invasive microadenomas) [8].

Grade IV tumors show extensive and diffuse invasion of the skull base and/or the intracranial space.

## DECISION-MAKING

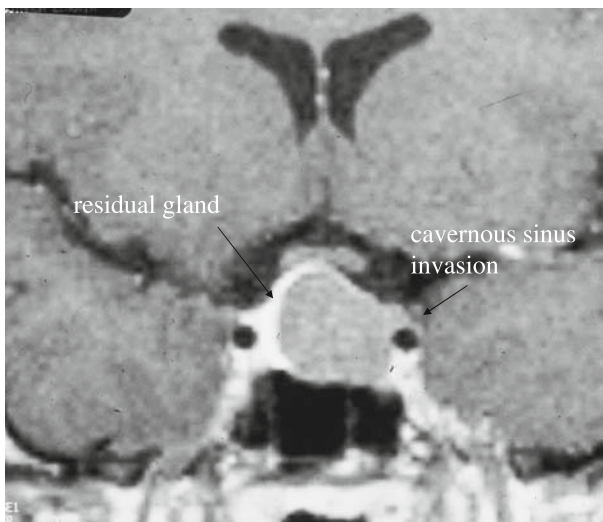
### 1. IMAGING

The role of MRI in microadenomas is to confirm the existence of clinically suspected tumors and to localize them in order to facilitate surgical removal. Microadenomas usually appear as a rounded or oval images which, after intravenous contrast medium injection, present hypointense signal intensity compared to the normal surrounding pituitary gland.

In macroadenomas, MRI is used to determine the extent of the tumor and its relationship with surrounding structures in order to orient the therapeutic choice and surgical approach. The normal compressed pituitary gland is reduced to a thin layer appearing as a contrast-enhanced crescent-shaped image close to the medial wall of the cavernous sinus or the diaphragma sellae, opposite the site of origin of the tumor where the cavernous sinus may be invaded (Fig. 1).

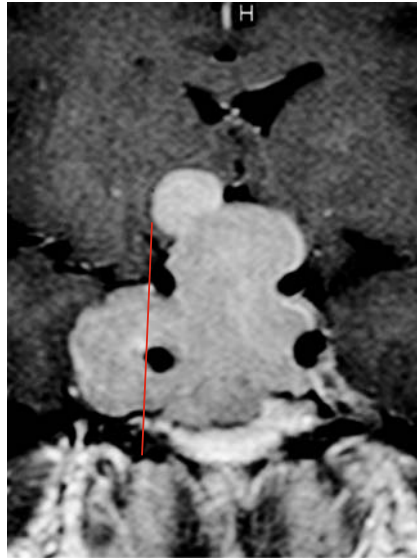
Upward extension of non-invasive tumors occurs through stretching of the diaphragma sellae or by extension through the natural aperture of the diaphragma, where the top of the tumor has a regular shape. Invasive tumors infiltrate the diaphragma in an asymmetric and irregular fashion.

Radiologic assessment of parasellar invasion presents the problem of distinguishing whether the inner wall of the cavernous sinus has been infiltrated or simply displaced [11]. Correlation between radiological and

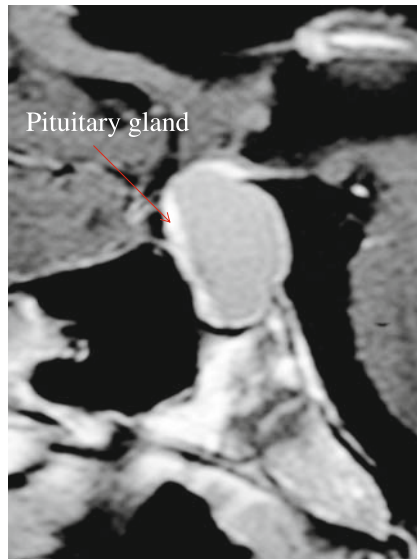


**Fig. 1.** Macroadenoma with residual pituitary gland and cavernous sinus invasion

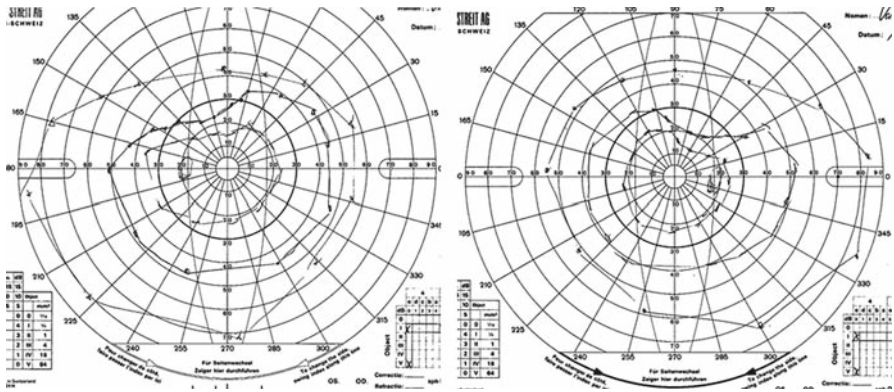
surgical findings has shown that tumor extension beyond the lateral tangent on the intra- and supracavernous segments of the internal carotid artery (ICA) strongly suggests invasion of the cavernous sinus space



**Fig. 2.** Lateral tangent to intra- and supracavernous ICA in invasive adenoma



**Fig. 3.** Pituitary gland anterior to the lesion (craniopharyngioma)



**Fig. 4.** Visual field defect in pituitary adenoma

(Fig. 2). Encasement of the intracavernous ICA greater than 45% of its circumference is another very specific and early sign of cavernous sinus invasion.

Visualization of a thin layer of residual normal pituitary gland anterior to the tumor suggests a lesion arising from posterior, such as a Rathke cleft cyst or a craniopharyngioma (Fig. 3).

## 2. PREOPERATIVE OPHTHALMOLOGIC EVALUATION

Visual field defect is the first anomaly to appear in the course of visual pathway compression. A peripheral field defect affecting the superior and temporal quadrants is observed in the early course of chiasmatic compression from below (Fig. 4). In a later stage, when the central visual field becomes affected, visual acuity drops dramatically. Optic atrophy at fundusoscopic examination appears after a long evolution of the disease and is predictive of a poor visual outcome after surgical decompression. Diplopia and ophthalmoplegia indicate compression or invasion of the cavernous sinus and can appear suddenly in the case of “pituitary apoplexy”.

## 3. PREOPERATIVE ENDOCRINOLOGICAL EVALUATION

Basal hormonal dosage values reveal gross pituitary insufficiency. Patients presenting hypopituitarism should be preoperatively treated to restore thyroid and corticotroph functions in order to avoid cardiac and blood pressure instabilities during anaesthesia. Correction of hypocortisolism can be started the day before surgery with intravenous administration of corticosteroids. Treatment of thyroid insufficiency should be started orally 10–14 days before surgery with gradually increasing doses of thyroid hormone replacement.



Other pituitary function disorders, such as gonadotroph or somatotroph insufficiencies are treated after postoperative hormonal re-evaluation. Diabetes insipidus, usually transitory when occurring after surgery, requires nasal administration of desmopressine.

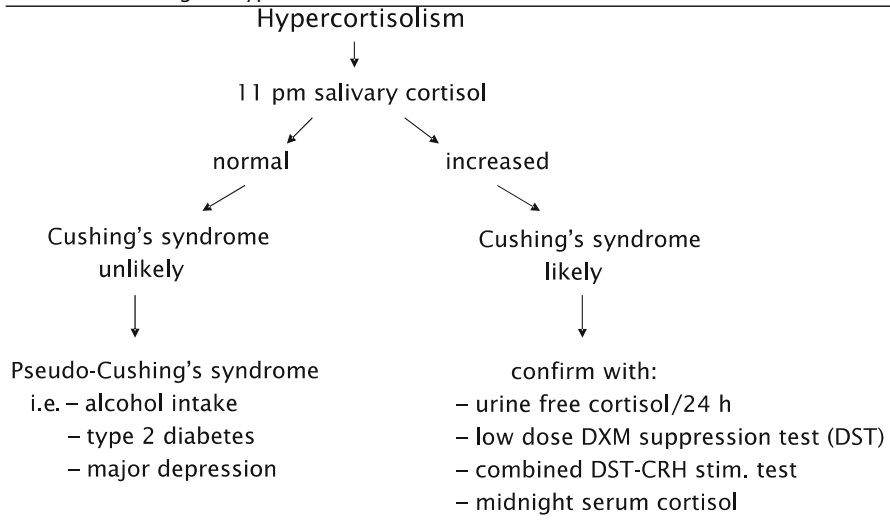
When dealing with clinical symptoms suggestive of pituitary hypersecretion, the preoperative endocrinological workup will require more extensive dynamic hormonal stimulation and/or suppression tests.

The biochemical criteria for *prolactinomas* include elevated basal plasma prolactin (PRL) levels and a blunted PRL response to intravenous thyrotropin-releasing hormone (TRH), in the absence of any medication influencing prolactin levels.

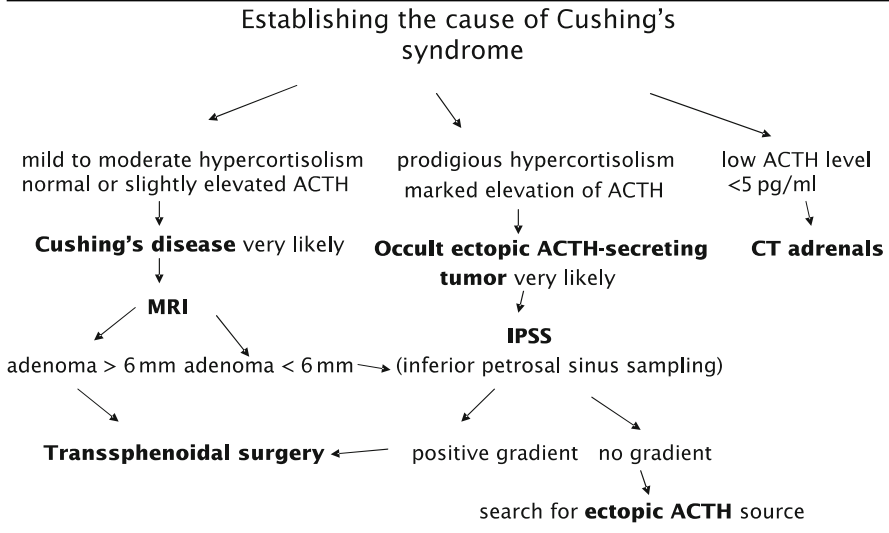
A diagnosis of *acromegaly* is based on elevated serum insulin-like growth factor I (IGF-I) levels and the inability to suppress serum growth hormone (GH) during an oral glucose tolerance test (OGTT).

*Cushing's disease* is confirmed by the presence of detectable plasma adrenocorticotropin hormone (ACTH) concentrations in patients with increased 24-hour urinary free cortisol excretion, loss of circadian plasma cortisol pattern and failure of low dose (1 mg) dexamethasone to suppress cortisol secretion (serum cortisol  $>1.8 \mu\text{g}/\text{dl}$  or  $50 \text{ nmol}/\text{l}$ ). In the event of a negative MRI, bilateral inferior petrosal sinus sampling (IPSS) is advocated to confirm the central origin of hypercortisolism [9] and to determine the lateralization of the lesion in the pituitary gland. This is to perform a hemi-hypophysectomy should there be no evidence of adenoma during surgical exploration. IPSS is also advocated in the presence of small ( $<6 \text{ mm}$ ) microadenomas on the MRI because of the high percentage (10%) of pituitary incidentalomas (Tables 1 and 2).

**Table 1.** Screening for hypercortisolism



**Table 2**



The measurement of detectable, inappropriately normal, or elevated serum thyroid-stimulating hormone (TSH) levels in the presence of clinical and biological hyperthyroidism with elevated peripheral thyroid hormones indicates inappropriate TSH secretion and is suggestive of the presence of a *thyrotropinoma*. A blunt TSH response to TRH stimulation supports the presence of a TSH-secreting tumor. Sex hormone-binding globulin (SHBG), a marker of peripheral hormone action, is elevated in more than 80% of patients with a TSH-secreting tumor. This is not the case in thyroid hormone resistance, another situation associated with elevated serum TSH.

## MANAGEMENT

### 1. TREATMENT OPTIONS

Surgery is required for the great majority of symptomatic pituitary adenomas except in the case of prolactinomas, for which a simple and particularly effective medical alternative to surgical treatment is available (Tables 3 and 4). Dopamine agonists (DA) are effective in suppressing hormonal hypersecretion and for tumor growth control in more than 90% of prolactinomas. However, DAs are not tumoricidal, and discontinuation of the medication can result in prompt re-expansion of the tumor.

Suppressive drugs are less effective in reducing the volume of the tumor in other secreting adenomas. They can sometimes be used as a first-line treat-

**Table 3.** Indications for surgery in pituitary adenomas

- 
- 1) Mass effect due to macroadenomas:
- On visual pathways with visual field defect
  - On cavernous sinus with oculomotor palsy
  - On residual healthy pituitary causing progressive hypopituitarism
- NB: start DA in macroprolactinomas
- 2) Functioning adenomas:
- Patient's preference in prolactinomas
  - Surgery in other functioning adenomas
- 

**Table 4.** Indications for surgery in prolactinomas

- 
- Tumor unresponsive to dopamine agonists
  - Intolerable side effects of dopamine agonists
  - Women with macroprolactinoma before attempting pregnancy
  - Young women with non-invasive adenomas who want to avoid long-term medical therapy
- 

ment but are usually prescribed after surgery when complete removal of the tumor was not possible.

Ketoconazole can usefully be used in the treatment of hypercortisolism to inhibit various steps of adrenal and testicular steroidogenesis but the long-term beneficial effect of this drug is somewhat variable. Medical treatment of hypercortisolism is usually prescribed to improve a patient's physical condition before surgery or after unsuccessful surgery and when waiting for radiotherapy to take effect in patients who have received this other treatment modality. Bilateral endoscopic adrenalectomy should be considered if there is persistent hypercortisolism after radiotherapy or if a pharmacological therapy has become ineffective.

In acromegaly, long-acting somatostatin analogs provide long-term control of hypersomatotrophism and normalization of IGF-I levels. They can be used preoperatively to shrink the pituitary adenoma but are more effective in the correction of hormonal hypersecretion after debulking of the tumor. The newly developed GH receptor antagonist pegvisomant may become another therapeutic option to normalize IGF-I levels. DA should be tried first in mixed PRL-GH-secreting adenomas.

Somatostatin analogs are very effective for the treatment of thyrotropinomas.

The place of radiation therapy in the treatment of pituitary adenomas remains controversial. Correction of hormonal hypersecretion can be achieved with radiosurgery in about 50% of cases after a delay varying from six months to two years. The best indication for radiosurgery is a localized residual

**Table 5.** Endocrinological criteria for remission in secreting pituitary adenomas

*Prolactinomas:* normalization of the postoperative serum prolactin level checked at least six weeks postoperatively and after withdrawal of any dopamine agonists within the same period

*Cushing's disease:* (highly variable criteria)

- undetectable post-operative serum cortisol levels (within 48–72 h)
- Normalization or suppressed serum ACTH and cortisol levels, and 24-h urinary free cortisol concentrations
- Overnight low-dose dexamethasone inhibition test (matinal serum cortisol level < 18 µg/l)

*Acromegaly:* (Conference of Cortina d'Ampezzo, 1999)

- normalization of the basal GH level below 2.5 µg/l
- IGF-I normal for age and gender
- Suppression of GH to < 1 µg/l during OGTT

*Thyrotropinomas:*

- normalization of plasma TSH and peripheral thyroid hormone levels
- normalization of dynamic responses to TRH or T3 are good predictor of long-term remission

adenoma in the cavernous sinus after transsphenoidal surgery. The main advantage of stereotactic radiosurgery is to focus the radiation on the target, preserving healthy surrounding tissue. When diffuse invasion is present, fractionated stereotactic radiotherapy is mandatory if no effective pharmacological therapy can be offered.

The choice of treatment, that is, surgical or medical, will be strongly influenced by its effectiveness and the clinical results that each therapeutic modality can provide in any given situation.

Remission of hormonal hypersecretion can be obtained with surgery alone in 75–85% of non-invasive adenomas [3]. This drops to barely 20% in invasive adenomas. Long-term recurrence rates of hormonal hypersecretion after surgical correction depend on the criteria for remission used (Table 5) and vary from 7 to 25%. On the other hand, recurrence of hyperprolactinemia after withdrawal of dopamine agonists in micro- and macroprolactinomas treated medically for decades with success occurs in 34 and 53 of cases, respectively.

## 2. SURGICAL APPROACH SELECTION: TRANSSPHEROIDAL VERSUS TRANSCRANIAL

A transsphenoidal approach can be used for about 95% of all pituitary adenomas. In tumors with significant anterior extension into the anterior cranial fossa or lateral extension into the middle fossa, either a transcranial approach consisting of a pterional or a subfrontal craniotomy, or a combina-

tion of both these approaches is required. In dumbbell-shaped tumors with both a significant intrasellar component and a suprasellar-intracranial extension separated by a narrow neck, transsphenoidal surgery can first be tried to decompress the visual pathways. Postoperative imaging will indicate if a subsequent transcranial approach will be required.

Since the mortality rate is very low when the transsphenoidal approach is used by experienced surgeons (less than 1%), priority must be given to this technique in difficult cases. The situation must be re-evaluated after this first surgical step. Repeated transsphenoidal resections can be proposed to decompress any residual mass. This is because intracranial pressure will cause the residual suprasellar tumor to progressively descend into the sella in the weeks following surgery.

Combined approaches and staged procedures have to be considered in difficult cases as do alternative treatment modalities such as tumor-suppressive drugs and radiation therapy. In the case of very fibrous adenomas that cannot be removed by the transsphenoidal approach, care should be taken to avoid worsening of visual function by manipulation of the optic nerves and optic chiasm during subsequent cranial surgery.

Mortality and morbidity related to hypothalamic ischemia, chiasmatic manipulations and uncontrollable bleeding during cranial surgery for large pituitary adenomas is mentioned in the literature.

As a corridor can be safely drilled into the sphenoid bone under navigation or fluoroscopic control during the endoscopic procedure, transsphenoidal surgery can be performed on young children ( $\geq 5$  years) or when the sphenoid sinus is poorly pneumatized [6].

A small-normal sized sella turcica in the presence of a macrotumor with suprasellar extension is not suited for transsphenoidal surgery and implies reconsidering the diagnosis of pituitary adenoma.

### 3. ENDOSCOPIC APPROACH

The fully endoscopic endonasal approach is becoming the “gold standard” in pituitary surgery. In our practice this approach has improved our ability to achieve complete resection of pituitary adenomas. It has resulted in fewer surgical complications and shorter hospitalization times.

The patient is installed in a semi-sitting position to minimize venous bleeding and to facilitate the prolapse of the suprasellar extension of the adenoma during tumor resection.

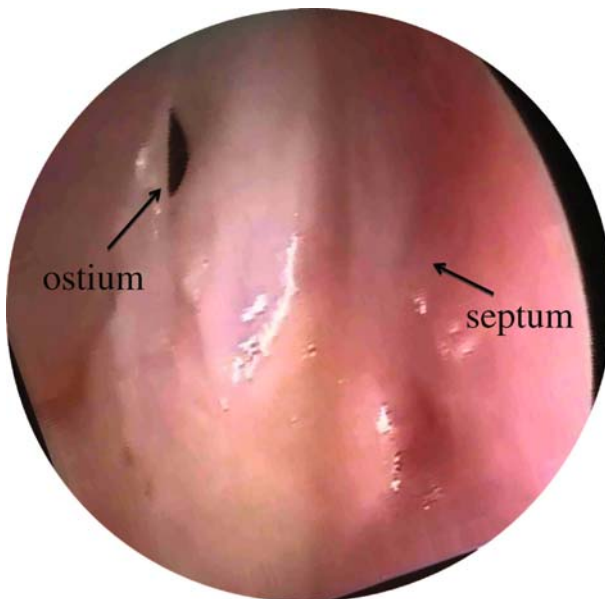
Antibiotic prophylaxis is given for 48 hours since the endonasal approach is a clean-contaminated procedure. Stress dose corticosteroids are started during surgery if no residual pituitary gland can be identified during tumor resection.

We use a 300 mm long by 4 mm diameter rigid-endoscope (Olympus, Germany) with angled lenses of 0°, 30° and 70°. The endoscope is fitted on a camera (Storz, Germany). An endoscope holder (Aesculap, Germany) with a

pneumatic system for locking and unlocking the instrument position enables fast displacements of the endoscope and provides surgeons with the possibility of using both hands to operate the surgical instruments. We do not use an irrigation sheath because it increases the endoscope diameter to more than 5 mm and a drop of washing fluid often remains hanging on the lens, creating visual distortion. We prefer to clean the lens and regularly wash the surgical field with a syringe fitted with a long blunt needle inserted into the nostril beside the endoscope. We still use the bayonet-shaped instruments used for the classic microscopic procedure in order to avoid contact between the surgeon's fingers and the endoscope.

We perform the entire single nostril approach ourselves using the side contralateral to the tumor's greatest extension. However, we recommend cooperation with an ENT surgeon for neurosurgeons who are not yet familiar with classic microscopic transsphenoidal surgery.

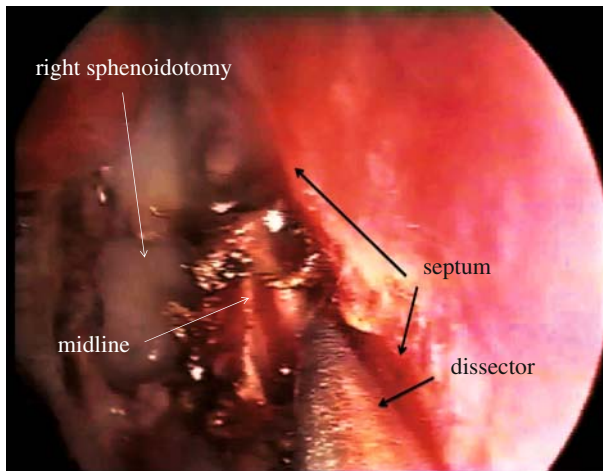
The narrow endonasal way between the middle turbinate and the nasal septum is widened by lateral luxation of the turbinate's head. After broad mucosal coagulation with a coated aspiration cannula or a specially designed coagulation ball (Storz, Germany), the posterior part of the nasal septum is disarticulated from the sphenoid rostrum. The temporary use of a Killian retractor can be useful to hold the narrow corridor open between the nasal septum and the middle turbinate. The sphenoid sinus ostium is a crucial landmark indicating the upper and lateral margin of the sphenoidotomy (Fig. 5).



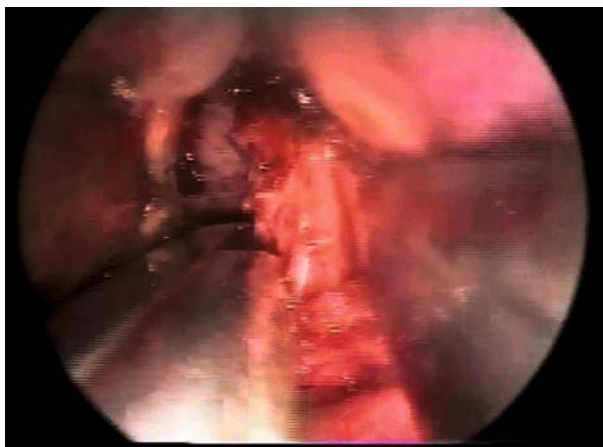
**Fig. 5.** Right nostril approach

We always use fluoroscopic guidance or a neuronavigation system to avoid misdirection toward the anterior cranial fossa and to check the bony landmarks at each step of the procedure. It is crucial to maintain a midline trajectory to avoid undesirable entrance into the cavernous sinus. Midline orientation can be determined with a navigation system but not with a C-arm fluoroscopy. The base of the rostrum is a good anatomical landmark to localize the midline (Fig. 6).

A wide bilateral anterior sphenoidotomy is mandatory in order to insert both the endoscope and other surgical instruments into the sphenoid sinus



**Fig. 6.** Midline exposure after right sphenoidotomy and septum luxation to the left side



**Fig. 7.** Anterior bilateral sphenoidotomy

without competition between them during the next steps of the procedure. This manoeuvre can be performed with a microchisel, a Kerrison-type punch (Fig. 7), or a high-speed drill under direct visual control [1].

A wide opening of the vertical portion of the sellar floor is necessary for correct exploration of the sellar content. Removal of the horizontal part of the sellar floor is not necessary and will make reconstruction and packing of the sella more difficult at the end of the operation. Dural opening must respect the upper part of the exposed dura, corresponding to the intercavernous sinus, to avoid bleeding and damage to the diaphragma sellae that can prolapse into the sella, especially in the case of small microadenomas. Lateral opening must be performed very cautiously to avoid damage to the carotid arteries. Exploration behind the dura with a blunt hook before making a lateral incision ensures safe exposure.

Macroadenomas are removed with ring curettes, avoiding any traction on the tumor. We recommend starting the resection by curetting inside of the tumor, avoiding extra capsular dissection that could damage the thin residual pituitary gland. This thin layer of pituitary tissue must be identified by pre-operative MRI (Fig. 1).

We first remove the inferior part of the adenoma and then proceed laterally along the wall of the cavernous sinuses in order to allow the spontaneous descent of the suprasellar extension of the tumor into the sella. Bilateral compression of the jugular veins is a safe, effective and simple way to facilitate prolapse of the diaphragma. If this prolapse cannot be obtained, the insertion into the sella of endoscopes with 30° or 70° angled lenses will allow visualization and further resection of any residual tumor. In some cases the diaphragma will remain in a high position adherent to the base of the brain, even after total removal of the tumor, and will progressively drop down later.

When cerebrospinal fluid (CSF) leaks occur, we take subcutaneous abdominal fat through a small curvilinear incision in the navel to avoid visible scars on the abdomen and plug it into the sella, avoiding over-packing. In this case we recommend placing a lumbar drainage at the end of the operation while the patient is still under anesthesia. This drainage should be maintained for several days.

We reconstruct the sellar floor with bone fragments from the rostrum and fix them with fibrin glue. If repeated surgery is indicated in the future, this will greatly facilitate new exploration by providing a clear anatomical landmark at the entrance of the sella.

The posterior nasal septum is repositioned on the midline and the middle turbinate is tilted back to its anatomical position in order to avoid post-operative synechia with the ostium of the maxillary sinus that could cause sinusitis or mucocoele formation. Postoperative nasal packing is not necessary.

Patients are discharged on postoperative day 1 or 2, except if an early extensive postoperative endocrinological workup is requested.



**Table 6.** Advantages of fully transnasal endoscopic surgery

- 
- Minimal septum manipulation (no perforation)
  - Minimal retraction (no post-op facial swelling)
  - No nasal packing
  - Less post-op pain
  - Panoramic view of the sphenoid sinus (more adequate opening of the sellar floor)
  - Better visualisation of the lateral wall of the cavernous sinus and the suprasellar area
  - Patient can be discharged home on postop day 1 or 2
  - Possibility to use high-speed drill or intrasellar ultrasonic aspirator under endoscopic visual control
  - Easy reoperation
- 

#### 4. ADVANTAGES AND DISADVANTAGES OF ENDOSCOPIC SURGERY

Advantages of endoscopy over the microscopic procedure are numerous and summarized in Table 6.

The main advantages of the fully endoscopic procedure are the less invasive character for the patient and the better view of the surgical field for the neurosurgeon, including the possibility of “looking around the corner” [2].

Disadvantages of endoscopy include the lack of binocular vision and the narrow surgical corridor that is partially occupied by the endoscope, leading to possible competition with the surgical instruments.

#### 5. RESULTS

Using the fully endoscopic transnasal approach, endocrinological remission rates in non-invasive functioning adenomas are about 75 to more than 80%. Results achieved in non-invasive grade 2 macroadenomas are similar to those obtained in microadenomas.

The invasive character of the tumor is a factor influencing the results negatively: correction of hormonal hypersecretion in parasellar invasive macroadenomas is only exceptionally observed.

Visual improvement is nearly always obtained after good decompression of the visual pathways from below, using a transsphenoidal approach, unless a long preoperative evolution has resulted in optic atrophy.

Careful tumor resection should avoid postoperative hypopituitarism; however, literature mentions new anterior pituitary insufficiency in up to 14% of the cases.

Postoperative transient diabetes insipidus is the most frequent complication and generally recovers in 48 hours.

Using endoscopy, postoperative CSF leakage rates vary from 1.2 to 6% [4].

**Table 7.** Complications in endoscopic transsphenoidal surgery

---

- Due to wrong track: damage to the optic nerves, cribriform plate, cavernous sinus contents (VIth nerve, carotid artery)
  - Due to too aggressive tumor resection: hypothalamic damage, CSF leak, diaphragmatic breach, hypopituitarism
  - Nasal complications
- 

## 6. MANAGEMENT OF POSTOPERATIVE RESIDUAL LESION

Nowadays, effective drugs on functioning pituitary adenomas are at our disposal. If they are not used in first-line therapy, they can prove to be very useful after incomplete surgical resection. Reoperation and radiation therapy must be considered individually.

### HOW TO AVOID COMPLICATIONS

Complications can be due to a wrong track causing damage to the optic nerves, perforating the cribriform plate or penetrating the cavernous sinus and damaging the VIth nerve or the carotid artery (Table 7). Frequent fluoroscopic or navigation controls to check the anatomical landmarks during the surgical approach are recommended.

Hypothalamic damage, CSF leak and diaphragmatic breach or hypopituitarism can result from too aggressive tumor resection. Gentle handling of smooth ring curettes and avoiding any traction on the tumor or the surrounding structures should prevent these complications.

Nasal and sinuses infectious complications will be avoided by repositioning the nasal septum and the middle turbinate at the end of surgery to ensure good ventilation. The use of prophylactic antibiotics for 48 hours is recommended.

### CONCLUSIONS

Pituitary adenomas represent more than 10% of intracranial tumors and are a frequent cause for neurosurgical consultation.

Pituitary diseases show multiple and different pathological and clinical aspects, requiring multidisciplinary diagnostic approaches and multimodality treatment options including endocrinology, surgery and radiotherapy [7].

Despite recent improvements in medical therapy, surgery still has an important place in the treatment of these lesions and requires well-trained pituitary surgeons. In experienced hands, pituitary surgery and especially endoscopic transsphenoidal surgery is safe with very low morbidity [1, 4, 7, 10].

Lifelong follow-up is needed because recurrent disease can occur, even after complete remission [7].

## References

- [1] Cappabianca P, Cavallo LM, de Divitiis E (2004) Endoscopic endonasal transsphenoidal surgery. *Neurosurgery* 55: 933-940; discussion 940-941
- [2] Cavallo LM, Dal Fabbro M, Jalalod'din H, Messina A, Esposito I, Esposito F, de Divitiis E, Cappabianca P (2007) Endoscopic endonasal transsphenoidal surgery. Before scrubbing in: tips and tricks. *Surg Neurol* 67: 342-347. Review
- [3] Fahlbusch R, Buchfelder M (1988) Transsphenoidal surgery of parasellar pituitary adenomas. *Acta Neurochir (Wien)* 92: 93-99
- [4] Frank G, Pasquini E, Farneti G, Mazzatenta D, Sciarretta V, Grasso V, Faustini Fustini M (2006) The endoscopic versus the traditional approach in pituitary surgery. *Neuroendocrinology* 83: 240-248
- [5] Hardy J, Vezina JL (1976) Transsphenoidal neurosurgery of intracranial neoplasm. *Adv Neurol* 15: 261-273
- [6] Kassam A, Thomas AJ, Snyderman C, Carrau R, Gardner P, Mintz A, Kanaan H, Horowitz M, Pollack IF (2007) Fully endoscopic expanded endonasal approach treating skull base lesions in pediatric patients. *J Neurosurg* 106: 75-86
- [7] Laws ER (2008) Surgery for acromegaly: evolution of the techniques and outcomes. *Rev Endocr Metab Disord* 9: 67-70
- [8] Ludecke DK, Abe T (2006) Transsphenoidal microsurgery for newly diagnosed acromegaly: a personal view after more than 1000 operations. *Neuroendocrinology* 83: 230-239
- [9] Nieman LK, Biller BM, Findling JW, Newell-Price J, Savage MO, Stewart PM, Montori VM (2008) The diagnosis of Cushing's syndrome: an Endocrine Society Clinical Practice Guideline. *J Clin Endocrinol Metab* 93: 1526-1540
- [10] Shahinian HK (2008) Endoscopic skull base surgery. Humana Press, Totowa
- [11] Vieira JO Jr, Cukiert A, Liberman B (2006) Evaluation of magnetic resonance imaging criteria for cavernous sinus invasion in patients with pituitary adenomas: logistic regression analysis and correlation with surgical findings. *Surg Neurol* 65: 130-135; discussion 135



**Jean D'Haens**

Jean D'Haens is Head of Neurosurgery at Vrije Universiteit Brussel. Born: June 28, 1949, Brussels, Belgium. Nationality: Belgian. Medical School: Free University of Brussels: 1967–1974. Neurosurgery Training (1974–1980): Free University of Brussels (Prof. J. Brihaye). This period included two years at the University of Lille, France (Prof. E. Laine) (1978–1979). Resident (1981–1985) and Assistant Clinical Professor (1985–1988): Department of Neurosurgery at the Erasme Hospital, Free University of Brussels (Prof. J. Brotchi). Professor and Chairman (October 1991–Present): Vrije Universiteit Brussel. Specialties: Endoscopic transnasal transsphenoidal surgery, Novalis radiosurgery.

**Contact:** Jean D'Haens, Neurochirurgie, UZ Brussel, Laarbeeklaan 101, 1090 Brussels, Belgium

E-mail: [jean.dhaens@uzbrussel.be](mailto:jean.dhaens@uzbrussel.be)

---

# CRANIOPHARYNGIOMAS

J. ŠTEŇO

## INTRODUCTION

Craniopharyngioma is a benign extra-axial epithelial tumor which often follows an aggressive clinical course resulting in significant morbidity and shortened life expectancy. Harvey Cushing (1932) considered it “the most baffling problem confronting the neurosurgeon” [9]. Mortality after radical tumor removal representing almost 100% lowered after availability of steroid replacement [9]. Further improvement of surgical treatment was brought by microsurgery [2, 5, 7, 12, 16]. Nevertheless, surgical treatment of craniopharyngiomas still remains a challenge. The difficulty of surgical treatment is caused by complex and intimate relationship of the tumor with adjacent nervous and vascular structures of utmost functional importance.

## RATIONALE

Controversy of a benign histological nature and malignant clinical course of craniopharyngioma together with difficult surgery led to two different attitudes to the management of this neoplasm: (a) radical surgical excision, (b) intentional incomplete (subtotal or partial) excision and radiotherapy.

The argument for radical surgery is a considerably lower recurrence rate after complete tumor removal comparing to subtotal or partial tumor resection reaching 0–36% and 40–64%, respectively and worse outcome of secondary surgery. Many neurosurgeons therefore advocate radical tumor removal [2, 4, 5, 10, 11, 14, 16, 17].

The authors advocating conservative surgery and radiotherapy stress lower incidence of endocrine deficit, hypothalamic insufficiency, major disability and even higher rate of local tumor control [6]. There is almost general agreement on decreasing the number of recurrences after radiotherapy. Choux et al. reported 56.6% recurrence rate after incomplete removal with lowering to 29.6% after radiotherapy [2]. Some other studies however found no relation between recurrence and adjuvant radiotherapy – neither globally nor in patients with incomplete resection [15]. Different modalities of irradiation (conventional external radiation therapy, gamma knife or linear accelerator radiosurgery, radioactive yttrium implantation) in our clinical series failed to prevent the recurrence or progression of the tumor in five of eleven patients followed from 6 to 60 months after irradiation.

---

*Keywords:* craniopharyngioma, neuro-oncology, intracranial tumor

Moreover the radiotherapy can also damage the pituitary, the hypothalamus, the visual structures, it may cause Moyamoya syndrome and malignant gliomas [4]. The rate of endocrinological deterioration can be the same for both modes of treatment [17]. In our morphological study of autopsy series of craniopharyngiomas [13] the occlusion of the supraclinoid internal carotid artery occurred in a 15 years boy six years after intracystic instillation of  $^{90}\text{Y}$  and two years after additional external radiotherapy.

The best management of craniopharyngiomas seems to be a radical tumor removal. Complete surgical eradication of the tumor tissue however may not be reachable in some instances because of: (a) complex relationship of the tumor with the structures of the chiasmatic-hypothalamic-pituitary region (difficult accessibility) and (b) its firm adherence to surrounding structures (problematic resectability). Sainte-Rose et al. [11] recommend radical removal for tumors not involving, or just compressing the hypothalamus and intentional subtotal/partial excision and radiotherapy for tumors involving hypothalamus. The problem is how to distinguish between these two conditions as our morphological and clinical studies showed that some craniopharyngiomas extending towards the third ventricle, even the tumors entirely occluding its cavity may just compress the hypothalamus and not invade it [13, 14].

## **DECISION-MAKING**

### **1. DIAGNOSTIC CRITERIA**

#### **1.1 Clinical presentation**

The most common signs and symptoms include visual disturbances observed in up to 82% of the patients, more frequent in adults, and endocrine deficiencies revealed in more than 90% of the patients, more frequent in children. Children rarely become aware of visual problems and often present after almost complete visual damage has taken place. Endocrine deficiencies include those for growth hormone (75%), gonadotropic (40%), thyrotropic (35%) and corticotropic (25%). Most young patients present with growth failure and delayed puberty, sometimes obesity. Adults complain of decreased sexual drive and almost 90% of men complain of impotence, while most women complain of amenorrhea. Diabetes insipidus is noted in up to 17% of children and up to 30% of adults. Signs of increased intracranial pressure from obstructive hydrocephalus are frequent in patients with the tumor invading the cavity of the third ventricle. Cognitive impairment and personal changes are observed in up to 50% of the patients.

#### **1.2 Neuroimaging**

Changes of the sella revealed by plain radiography may help to differentiate primarily intrasellar, i.e. infradiaphragmatic from primarily supradia-

phragmatic tumor growth. Originally infradiaphragmatic tumors, i.e. intrasellar or intrasellar and suprasellar craniopharyngiomas enlarge the sella similar to the pituitary adenomas. Such a ballooning sella differs from a shallow sella with depressed tuberculum and shortened dorsum acquiring a “J” or a “pear” form which can be found in supradiaphragmatic tumors displacing the diaphragm and the pituitary downwards. Calcifications are present in about 85% of children and in 40% of adult patients with craniopharyngiomas. They are more sensitively detected by computed tomography. Calcium deposits are present in most adamantinous tumors. In intraventricular and extraventricular craniopharyngiomas calcium deposits are located predominantly in basal, i.e. suprasellar part of the tumor. Egg-shell like calcification of the wall of a cystic tumor may occasionally delineate the entire lesion. Cyst fluid is usually of low density, however cystic portions may appear dense or solid if they contain a sufficient quantity of suspended calcium salts.

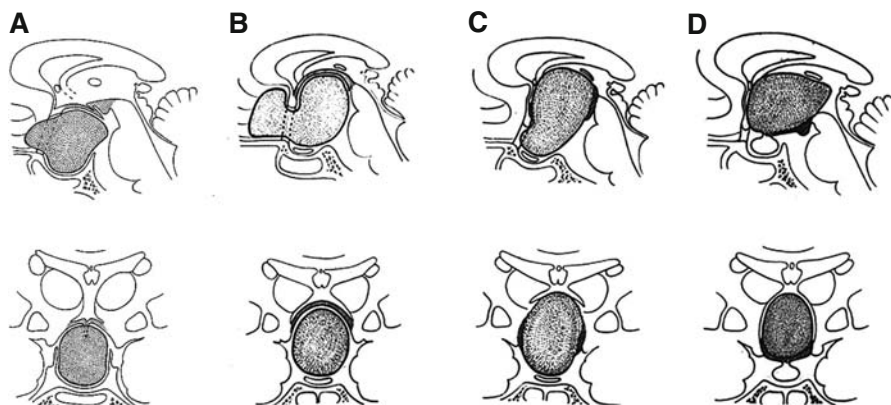
Heterogeneous nature of the craniopharyngiomas is best displayed by magnetic resonance imaging (MRI). Solid parts of the tumor are most often isointense on T1 images and show contrast enhancement. Hyperintense ring enhancement of the cyst wall is common. The high signal of the cyst fluid seen on T1 in some tumors is related to high protein content or blood breakdown products. MRI provides information on the topography essential for planning surgical approach and techniques.

## 2. INDICATIONS

The analysis of the clinical data and radiological findings showed no prognostic factors for the recurrence of craniopharyngioma except for the quality of the exeresis confirmed by the first postoperative MRI [8]. Optimum treatment according to the literature and our own experience is safe radical tumor removal whenever possible. The goal can be achieved if the chosen surgical approach allows sufficient exposure of the tumor. Direct visual control of the relations of the latter with adjacent structures helps the surgeon to decide for the optimum degree of the radicality of tumor removal. The adequacy of surgical approaches depends on the topographical relationship of the tumor with adjacent structures.

### 2.1 Topography of the tumor

The relationship of craniopharyngiomas with the structures of the sellar-suprasellar region depends first of all on the point of original growth of the tumor [3]. The craniopharyngiomas may start to grow within the sellar cavity below the diaphragm or above it. Enlargement of the *infradiaphragmatic*, i.e. *intrasellar craniopharyngiomas* causes upwards displacement of the sellar diaphragm and the arachnoid. Such an *intrasellar and suprasellar craniopharyngioma* grows below the chiasm and gradually compresses and displaces it upwards as well as the floor of the third ventricle similarly to pituitary adenomas (Fig. 1).



**Fig. 1.** Schematic representation of relationship of intrasellar and suprasellar (A), suprasellar extraventricular (B), intraventricular and extraventricular (C) and intraventricular (D) craniopharyngiomas with the optic chiasm and the floor of the third ventricle (dashed lines)

The point of original growth of *primarily supradiaphragmatic* tumors may be in the pituitary stalk or inside the infundibulum, i.e. in the most basal part of the floor of the third ventricle. Tumors starting to grow from the pituitary stalk are located in the subarachnoid space (intraarachnoidally) and grow below the chiasm and the floor of the third ventricle (*suprasellar extraventricular craniopharyngiomas*). A part of such a tumor almost always extends anteriorly in front of the chiasm between the optic nerves where it can be reached. Rarely we met a suprasellar extraventricular craniopharyngioma growing exclusively behind the chiasm [13, 14]. The cause of retrochiasmatic location of a suprasellar extraventricular tumor could be short optic nerves and premorbidly prefixed chiasm.

The tumors taking their origin from the infundibulum grow from the beginning behind the chiasm in the region of its posterior angle between the optic tracts. Growing tumor may disrupt the floor of the third ventricle at the beginning of its development. The lower part of the tumor then grows in the suprasellar space, the upper one extends into the cavity of the third ventricle and comes in direct contact not only with the atrophied remnants of the floor of the third ventricle but also with lateral ventricular walls. Such location of a craniopharyngioma, namely partially inside and partially outside the cavity of the third ventricle (*intraventricular and extraventricular craniopharyngiomas*) is the most common among all topographical types. Although these tumors are located behind the optic chiasm the most basal part of the tumor can rarely extend below the chiasm or even between the optic nerves but in much less extent than in extraventricular tumors. This happens in a patient with premorbidly long optic nerves and a postfixed chiasm. The final relation of all craniopharyngiomas with the chiasm is thus the consequence of two factors, the point of original

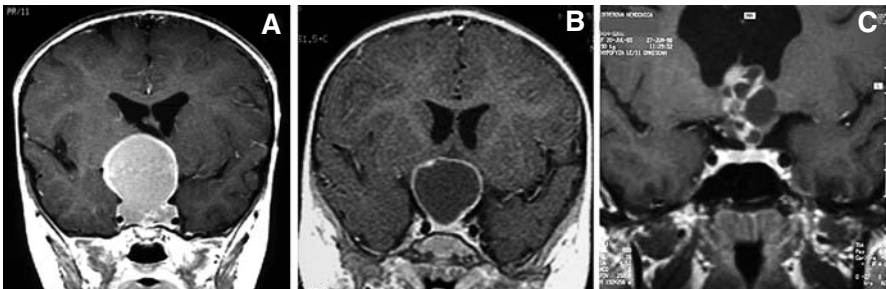

tumor growth and the premorbid topographical variation of the optic chiasm.

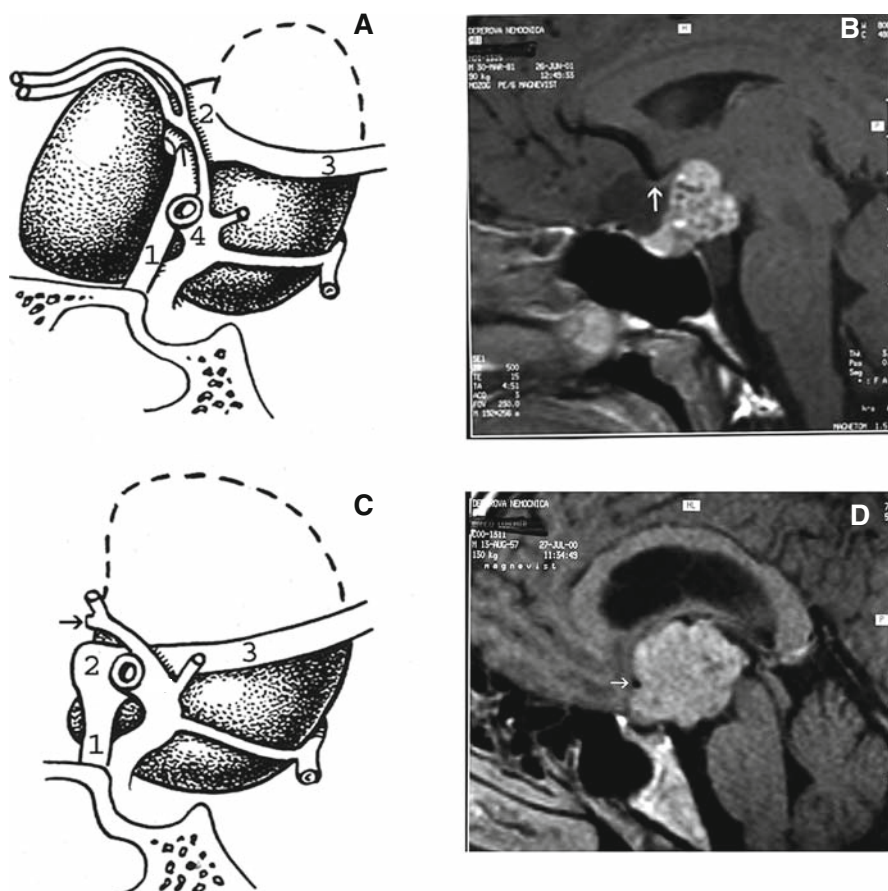
While the suprasellar extraventricular tumors grow in the subarachnoid space, extrapially, the intraventricular and extraventricular craniopharyngiomas, although extraaxial tumors, are in direct contact with the brain tissue since the beginning of their development and grow as intrapial lesions. Tumors growing from the infundibulum may rarely be localized completely within the third ventricle (*intraventricular craniopharyngiomas*).

## 2.2 MRI characteristics of the topographical relations

The changes of the sella as seen on sagittal MRI scans are similar to those described at plain radiography of the skull. Relation of the tumor to the sella and its diaphragm can be even more precisely assumed according to the appearance on the coronal scans (Fig. 2). Direct visualisation of the chiasm is a rule in small tumors. Also in cases with large intraventricular and extraventricular tumors located entirely behind the chiasm the latter may be clearly delineated at the anterior-inferior surface of the tumor on the midsagittal scans. The position of the chiasm can also be detected indirectly according to the location of the anterior communication artery (AcomA) on sagittal scans as the vessel lies immediately above the chiasm (Fig. 3). The relation of the tumor with the distorted floor of the third ventricle or with its atrophied remnants containing the hypothalamic structures can be assessed only indirectly. According to the results of our clinical and radiological study, MRI finding of a completely retrochiasmatic tumor accompanied by hydrocephalus is the evidence of intraventricular (at least partially) location of the tumor [14]. In cases with intraventricular and extraventricular craniopharyngiomas the remnants of the floor of the third ventricle are located around the “equator” of the tumor. On the contrary, supradiaphragmatic tumor apparently occupying the whole cavity of the 3rd ventricle which does not cause hydrocephalus and at the same time grows partially in front of the optic chiasm (as shown by the position of the AcomA), is located below the third ventricular floor, i.e. extraventricularly (Fig. 4).



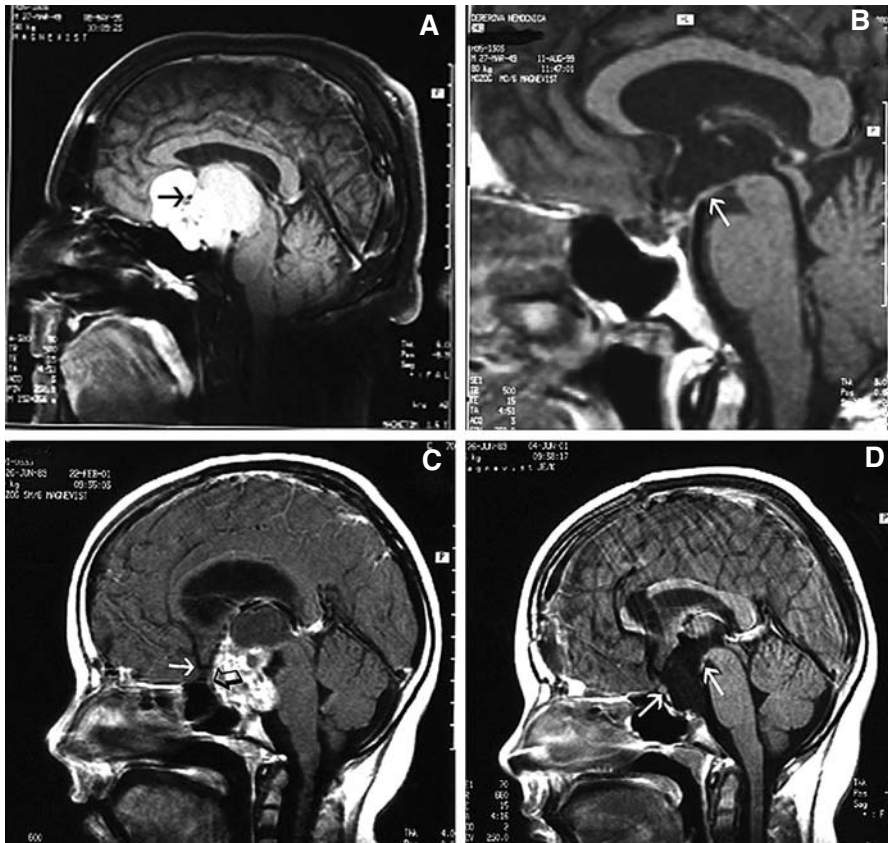
**Fig. 2.** Relationship of the craniopharyngiomas to the sella on coronal MRI scans. **A** Intrasellar and suprasellar, **B** suprasellar extraventricular, **C** intraventricular and extraventricular



**Fig. 3.** Relationship of suprasellar (A, B) and intraventricular and extraventricular (C, D) craniopharyngiomas with the structures of the optic pathway, anterior communicating artery (AcomA), and the third ventricle. A, C Schematic representation, 1 optic nerve, 2 chiasm, 3 optic tract, 4 internal carotid artery, arrow, AcomA. B, D MRI scans showing the position of the AcomA (arrow)

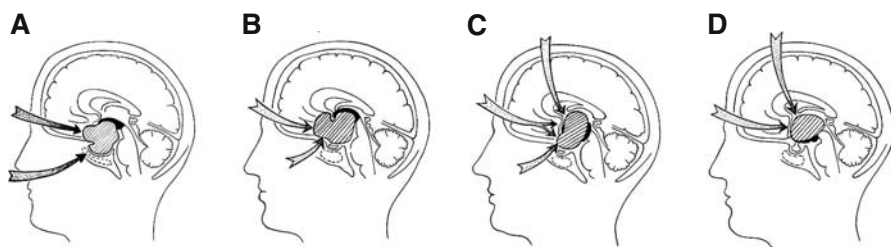
## SURGERY

Surgical strategy and tactics are based on the answers to two questions: Where to begin, and when to stop tumor removal? The topographical relationship of the tumor with the sella (infradiaphragmatic vs supradiaphragmatic location), with the optic chiasm (prechiasmatic or subchiasmatic vs exclusively retrochiasmatic location), and with the hypothalamic structures (extraventricular vs intraventricular and extraventricular or rare purely intraventricular location) have to be found out by preoperative neuroradiological



**Fig. 4.** Preoperative and postoperative MRI scans of suprasellar extraventricular (A, B) and intraventricular and extraventricular (C, D) craniopharyngiomas. A, C Arrow: AcomA, open arrow: chiasm. B Preserved floor of the third ventricle (arrow) after subfrontal tumor removal. D Remnants of the ventricular floor after combined transcallosal and trans-lamina terminalis tumor removal (arrows)

workup in order to choose appropriate surgical approach (Fig. 5). The neuro-radiological findings determine also planning of the surgical steps. However, there are some factors limiting the possibilities of revealing the topographical relationships by means of diagnostic imaging methods. Firstly, indirect signs of either extraventricular or intraventricular tumor location may not be expressed in a small retrochiasmatic supradiaphragmatic tumor not reaching the foramina of Monro and not causing hydrocephalus. Such a tumor may lie below the third ventricular floor or it may be embedded inside the infundibulum and the tuber cinereum. Secondly, besides the clear-cut topographical types of craniopharyngiomas there are rare cases of transitional types of tumors displaying the features of two topographical groups. For instance, in



**Fig. 5.** Diagram of surgical approaches to intrasellar and suprasellar (A), suprasellar extraventricular (B), intraventricular and extraventricular (C), and intraventricular (D) craniopharyngiomas avoiding hypothalamic structures of the floor of the third ventricle (black)

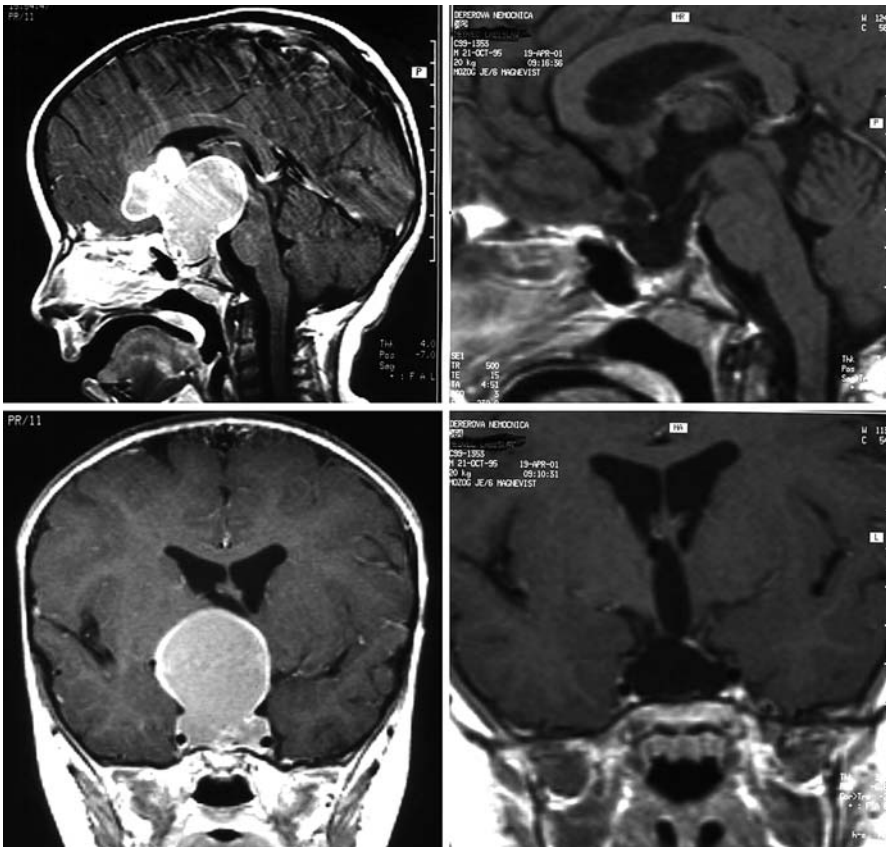
some cases of intrasellar and suprasellar craniopharyngioma which is usually extraarachnoidal, the upper part of the tumor may grow within the subarachnoid space having intimate relationship with the pial vessels of the floor of the third ventricle similar to suprasellar extraventricular tumors. This situation was observed in a dumbbell tumors. Still, the most important limitation is inability of MRI to reveal the intensity of the tumor adherence to surrounding neural and vascular structures. The final decision about the extent of tumor removal thus cannot be made before the operation.

## 1. THE CHOICE OF SURGICAL APPROACH AND THE EXTENT OF TUMOR REMOVAL

### 1.1 Intrasellar, and intrasellar and suprasellar craniopharyngiomas

For *intrasellar* craniopharyngiomas the only appropriate approach is the transsphenoidal route which exposes entire tumor and allows identification of the remnants of pituitary located in front of the tumor or behind it [5]. In majority of the cases in which compressed pituitary was found it could be detected at the sellar floor immediately after dural incision. Transsphenoidal approach is suitable also for the *intrasellar and suprasellar craniopharyngiomas* if the MRI suggests infradiaphragmatic location with the exception of the tumors of a dumbbell or multinodular shape which is rather rare in intrasellar and suprasellar craniopharyngiomas (Fig. 6). In our series of 40 infradiaphragmatic tumors four were intrasellar, the others extended above the sellar entrance. Some of them were of a large or even giant size.

To expose the tumor via transsphenoidal route we use unilateral paraseptal, usually sublabial approach performed under operative microscope from the first incision. In order to get sufficient exposure of intrasellar content a large opening of the sphenoid sinus and the sellar floor is mandatory [5]. The anterior wall of the sinus and the sellar floor is resected under neuronavigation guidance. The remnants of the pituitary were found in one third of the intrasellar and suprasellar tumors including a large one. The gland identified



**Fig. 6.** Intrasellar and suprasellar craniopharyngioma (*left*) removed via unilateral subfrontal approach (*right*)

at the bottom of the enlarged sella, was split in the midline and displaced to the sides so the tumor capsule could be identified. The capsule always adheres to surrounding dura covering the sellar cavity, nevertheless the tumor does not invade the cavernous sinus as it can be seen in pituitary adenomas. The capsule is detached from the dura by pulling it into the sellar cavity and by detaching by microdissector, sometimes sharp dissection is necessary. If the capsule is thin and fragile care must be taken not to lose its continuity as then it may not be identified and may be unintentionally left in place. On the other hand, a thick firmly adhering capsule may not be possible to dissect free and a part of it has to be left in place. The capsule may contain egg-shell like calcification which may be a blade like sharp so the maximum caution is necessary during its removal. Adherence of the capsule to the diaphragm is always extensive, its removal is sometimes not possible without resection of the

diaphragm and transection of the pituitary stalk. Preservation of the pituitary stalk necessitates leaving the piece of the capsule in some cases.

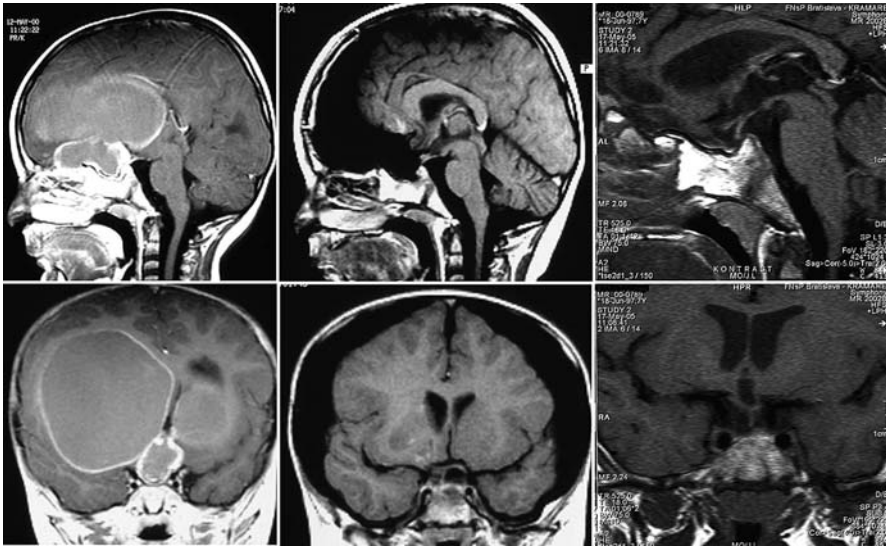
Even the tumors with a large suprasellar extension can be removed by transsphenoidal approach. Only the tumors with irregular shape, e.g. dumbbell lesions with narrow entrance to the sella or the tumors with multinodular suprasellar part we approached by unilateral frontal craniotomy (Fig. 6) which we also use in almost all suprasellar extraventricular craniopharyngiomas.

## 1.2 Suprasellar extraventricular craniopharyngiomas

Primarily *supradiaphragmatic tumors* we expose transcranially (Fig. 4). Partial prechiasmatic extension of a great majority of the *suprasellar extraventricular craniopharyngiomas* allows tumor removal through the prechiasmatic space between the optic nerves, anterior margin of the chiasm, and the sellar tubercle; through the optico-carotid triangle between the lateral margin of the optic nerve and chiasm, supraclinoid carotid artery, and the A1 segment of anterior cerebral artery; and laterally to the carotid. All these extracerebral routes to the tumor are accessible by unilateral subfrontal approach. Removal of an extraventricular tumor through the lamina terminalis would jeopardize hypothalamic structures of the floor of the third ventricle covering the upper surface of the tumor. Therefore a rare extraventricular tumor growing exclusively behind the optic chiasm we approach below and behind the chiasm through pterional craniotomy. Skull base approaches enabling to approach the tumor more from below like orbitozygomatic or transpetrosal approach may be of great help in these cases.

For both subfrontal and pterional approaches we perform frontotemporal skin incision just behind the hair line, beginning from the midline medially and continuing laterally to the zygoma, preferably on nondominant side. The extent of the bone flap in subfrontal approach includes the convexity of the frontal bone at its merges with the supraorbital rim at its middle and lateral portions. In cases of a large frontal sinus the latter may be opened and then closed by the periosteal flap before opening of the dura. After evacuation of the cerebro-spinal fluid (CSF) by lumbar drain and opening the dura, the sellar region is approached with the forceps in one hand and the sucker in the other without spatula. The carotid and chiasmatic cisterns are opened for more CSF evacuation, then the medial part of the Sylvian fissure is opened for relieving the pressure on the frontal lobe. Removal of the tumor starts by opening and evacuation of the cyst if visible. Subarachnoid space around exposed tumor is blocked by cottonoid pads before the opening of the cyst to prevent the leakage of the cyst content into the CSF space.

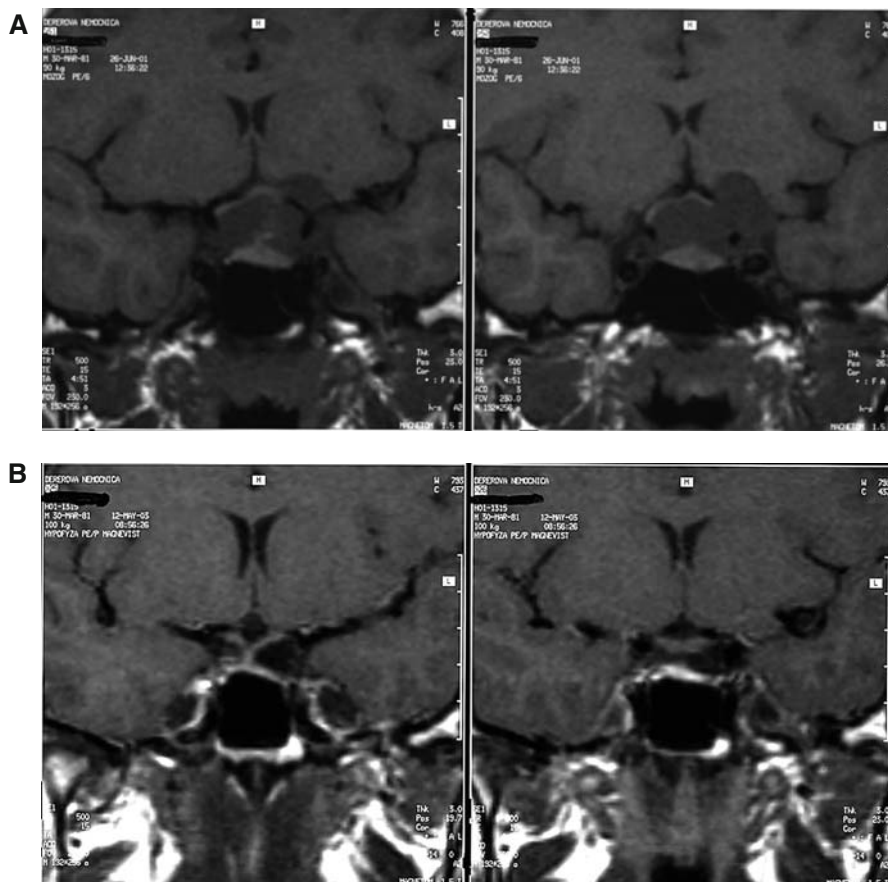
Solid parts of the tumor are removed piecemeally. The capsule is then detached from the optic nerves, the optic chiasm, the carotid arteries and their branches. At this stage the capsule may be dissected from the pituitary stalk which may be displaced by the tumor towards one side. In some cases



**Fig. 7.** Suprasellar extraventricular craniopharyngioma removed via bilateral subfrontal approach. *Center* – 2 days postoperatively, *right* – 5 years postoperatively. Note preserved pituitary stalk

the dissection of the tumor capsule from the pituitary stalk is relatively easy (Fig. 7) in others its lower part fades in the capsule and cannot be traced down to the sella.

The tumor may adhere to large blood vessels. Intraoperative damage to internal carotid artery has been reported. Especially removal of a calcified portion of the tumor from the wall of the carotid in children may be dangerous. Such an extensive calcification may be met more commonly in intraventricular and extraventricular tumors. In suprasellar extraventricular craniopharyngiomas the tumor could be dissected safely from the adventitia even if it completely enveloped the large arteries at the base of brain (Fig. 8). Extreme care must be taken to look for the minute perforating vessels, the branches of the supraclinoid carotid and the posterior communicating arteries supplying the visual pathways and the hypothalamus. The vessels are coagulated and cut only after it has been proven that they supply only the tumor. If the perforators adhere firmly and cannot be safely detached from the tumor surface we leave a part of the capsule harbouring the vessels. More common cause of an incomplete removal of the suprasellar extraventricular craniopharyngioma is the adherence of the upper pole of the tumor to pia mater of the superiorly displaced floor of the third ventricle. If the capsule cannot be dissected without disruption of the pial vascular network the part of it or even a small piece of a calcified tumor tissue has to be left in place. Removal of the posterior pole of the tumor usually does not pose a problem as the basilar artery, its branches and the brain



**Fig. 8.** Coronal MRI scans of suprasellar extraventricular craniopharyngioma encapsulating the bifurcation of the internal carotid artery before (A) and after (B) radical tumor removal

stem are protected by the Liliequist membrane covering the posterior border of the tumor. In a rare case where the posterior perforators adhere to the tumor capsule the attachment is rather loose, so we always could detach the tumor without damaging the vessels.

### 1.3 Intraventricular and extraventricular craniopharyngiomas

Displacement of the atrophied remnants of the floor of the third ventricle around the “equator” of the *intraventricular and extraventricular craniopharyngiomas* allows to approach the tumor through the cavity of the third ventricle as well as by extracerebral approaches. However, common low position of the chiasm and a slit-like optico-carotid triangle most often preclude



extracerebral tumor exposure. Opening of the lamina terminalis allows good exposure of the anterior and the basal parts of the intraventricular mass and of the entire extraventricular portion of the tumor. Basal part of the tumor is often calcified, sometimes it turns into a rock-like mass which has to be broken into pieces by CUSA. After piecemeal removal of the basal part of the tumor the pituitary stalk may be seen below the chiasm after pulling the latter upwards from the sellar tubercle. The chiasm quite often stays prefixed even after complete tumor removal. In some cases the pituitary stalk cannot be identified or just its lower part can be found at the entrance into the opening of the sellar diaphragm. The rest is destroyed by the tumor. After removal of the basal part of the tumor the brainstem comes into view, together with the basilar artery and its branches separated from the tumor by Lilliequist membrane. If the mammillary bodies are displaced predominantly basally, they can be seen in front of the brainstem. The remnants of the infundibulum and the tuber, if present, and their supplying blood vessels originating from the posterior communicating artery can be clearly seen and spared. This approach also provided good access to the postero-basal expansion of the tumor into the cerebellopontine angle seen in one patient. Majority of intraventricular and extraventricular craniopharyngiomas may be removed via trans-lamina terminalis approach. A disadvantage of this approach is insufficient exposure of the superior-posterior part of the third ventricular cavity. The most superior-posterior part of a large or giant intraventricular or intraventricular and extraventricular tumor reaching the roof of the 3rd ventricle can thus not be seen directly. The upper limit of the direct visual control of the ventricular cavity is represented by the line connecting the lower limit of the craniotomy and the AcomA. The upper part of the tumor hidden above this borderline can thus be seen only after pulling it down to the lower part of the ventricle or by opening the lamina terminalis also above the AcomA. We prefer to reach the tumor through the foramina of Monro using transcallosal approach. Another advantage of this approach is the possibility to start tumor removal at its upper pole where it only touches and not invades the walls of the third ventricle. More basally it merges with the hypothalamus and the plane of cleavage between the tumor and the remnants of the third ventricular floor sometimes cannot be found. Adhering portions of the tumor capsule or even its parenchyma should be left in place in such situations in order to avoid serious damage to hypothalamus.

We have abandoned the transfrontal transcortical approach. Our experience with the third ventricle tumors of other histological types than craniopharyngiomas confirmed the data from the literature concerning the incidence of seizure complications which is much higher than after transcallosal exposure. On the other hand our results confirmed the observation of the others that a short incision up to two centimeters in the anterior part of the corpus callosum behind its genu causes no clinically apparent neuropsychological deficit. We have observed severe though transitional short

memory disturbances in only one patient. The tumor, an intraventricular and extraventricular craniopharyngioma was removed through the lamina terminalis below and also above the AcomA. The cause of memory disturbances lasting for almost one year could be a bilateral manipulation of the columnae of the fornix and the anterior commissure. We avoid the manipulation of both parts of the fornix whenever possible. During transcallosal approach we try to remove the tumor through one foramen of Monro using the other one for assessing the completeness of tumor removal.

The transcallosal approach has also its limitation. The most inferior-anterior part of the tumor is not exposed sufficiently. Therefore a combined trans-lamina terminalis and transcallosal approach is necessary for the exposure of the entire tumor. According to our experience suitable approach to giant intraventricular and extraventricular craniopharyngiomas is combined one stage subfrontal and transcallosal approach through one large unilateral frontal craniotomy [14]. We perform a large unilateral bone flap beginning at the lateral and the middle thirds of the orbital rim anteriorly, crossing the midline by 1.5 cm medially, and reaching or exceeding by one centimeter the coronal suture posteriorly. An opening of the dura approximately 7 cm long (in anteroposterior diameter) enables combined one-stage transcallosal and subfrontal tumor exposure (Fig. 7). The indication for combined approach is a giant tumor located entirely behind the chiasm/AcomA reaching the roof of the third ventricle behind the foramina of Monro and causing hydrocephalus.

#### 1.4 Intraventricular craniopharyngiomas

Rare purely *intraventricular craniopharyngiomas* push the floor of the third ventricle downwards. Extracerebral approach would jeopardize the hypothalamic structures covering the basal part of the tumor. The tumor may be removed through the third ventricular cavity either by opening of the lamina terminalis or through the foramina of Monro. Adherence of the tumor to lateral walls of the third ventricle is less pronounced than in intraventricular and extraventricular craniopharyngiomas. The tumor is attached to partially atrophied floor of the ventricle. If the border and the plane of cleavage between the tumor and the hypothalamus can be found the tumor may be removed radically.

## 2. PERIOPERATIVE MANAGEMENT

Pituitary insufficiency is common before surgery. Appropriate perioperative hormonal replacement therapy therefore is necessary. The dose of hydrocortisone depends on the location and the extension of the tumor, and the radicality of surgery. In large or giant tumors involving hypothalamus 400 mg of hydrocortisone is administered during the day of surgery: 100 mg before

surgery, 100 mg during tumor removal and the rest after the operation. The dose is progressively diminishing during next days to approximately one fifth of the initial dose on the fifth postoperative day.

Severe acute hypothalamic failure may occur after removal of the tumor adherent to hypothalamus with subsequent life threatening metabolic disturbances. Careful monitoring and early correction of mineral and water balance disturbances presenting by diabetes insipidus, hypernatremia and hypokaliemia, is absolutely mandatory. The disturbance may be the consequence of a combination of disruption of pituitary stalk (lack of antidiuretic hormone) and damage of osmoreceptors in anterior hypothalamus (loss of thirst sensation). Disturbances of the fluid and electrolyte balance we treat at the intensive care unit. Detailed measurement of intake of fluid and output of urine, blood and urine level of sodium and potassium should start at the day of surgery continuing twice a day later on. Measurement of osmolality of serum and urine should also be performed twice a day in cases with severe metabolic disturbances. Antidiuretic hormone (ADH) is administered if the diuresis exceeds 1 liter in 6 hours and if there is tendency to hypernatremia and hyperosmolality. Hyponatremia and hypoosmolality may follow after the phase of central diabetes insipidus. It may be a part of different syndromes, inappropriate ADH secretion (SIADH), cerebral salt wasting syndrome (CSWS) and others. Management of the disturbance includes fluid restriction in transient or asymptomatic SIADH and aggressive replacement of urine water losses in CSWS. Sodium replacement is necessary in advanced stage. Treatment of these life threatening metabolic disturbances should be managed by anesthesiologist experienced in neurointensive care.

### 3. NONSURGICAL TREATMENT

Adjuvant therapy includes irradiation and chemotherapy with bleomycin. The latter may lead to shrinking of the cystic tumor and reinforcement of the capsule which is then less fragile and its complete removal is easier. However severe complications associated with intratumoral treatment with bleomycin have been reported.

Shrinking of cystic craniopharyngioma may also be achieved by means of instillation of the solution of beta-emitting radioactive isotopes of <sup>90</sup>yttrium, <sup>198</sup>gold or <sup>32</sup>phosphorus. Stereotactic radiosurgery may also be indicated. Close tumor relationship to visual pathways however is a limiting factor for the targeted single high dose irradiation by gamma knife or by linear accelerator dedicated to radiosurgery. Growth arrest or even tumor regression was reported also after conventional external radiotherapy. All kinds of radiation treatment we reserve for the tumors recurring after repeated surgery. We have recommended external radiotherapy of the first recurrence in a single case where the adhesions seen at primary surgery were extensive so a successful removal of the recurrent tumor seemed unlikely.

#### 4. LONG-TERM RESULTS

The outcome of surgery depends on the topographical type of the tumor, its size, and the extent of surgery. In a series comprising over 60% of large and giant tumors in which radical tumor removal was achieved in 90% of the cases, the mortality reached 16.7%. On the other hand the tumor recurred in only 7% [16]. In another large series there was no operative mortality after transsphenoidal surgery and 1.1% mortality after primary transcranial surgery with 45.7% radical removals. The recurrence-free survival rate in 10 years after total removal was 81.3%, after subtotal and partial removal it reached in 5 years only 48.8% and 41.5% respectively [5]. The difference in outcomes of transsphenoidal and transcranial surgery is most probably caused by different topography and the size of the tumors operated by either approach. In our consecutive series of 100 patients operated since 1991 there was no mortality in 40 infradiaphragmatic tumors (22 transsphenoidal, 18 transcranial) including a large and giant ones with 80% radical removals (90% in primary surgery). Out of 60 patients with supradiaphragmatic tumors (75% radical removals) four patients died after surgery (6.7%). During the follow up of 12–201 months, mean 91 months, the tumor recurred in 19 of 94 patients after primary surgery (20.2%), in 16% after radical and in 40% after incomplete removal. Although higher mortality in general is reported after secondary surgery we had no death after 37 operations in 25 patients with 59.5% radical removals of recurrent tumor. At the end of follow up 86 patients were alive. Two of them were partially and one was totally dependent because of bilateral blindness that had been present before surgery. Preoperative visual functions remained stable or improved in 79 patients and worsened in seven. Permanent diabetes insipidus was found in 69.8%, anterior pituitary hormonal replacement of at least one hormone was necessary in 91.2%. There were no postsurgical neuropsychological sequelae, except for a long lasting temporary memory deficit in 1 adult and episodes of emotional lability and aggressiveness in 1 child. Impaired cognitive functions present before surgery in 2 children improved.

#### HOW TO AVOID COMPLICATIONS

Hypopituitarism may be the consequence of the damage to anterior lobe of the pituitary, or to the tuber cinereum, or it may be caused by the interruption of the portal vessels within the pituitary stalk. The pituitary gland and the pituitary stalk are most easily preserved in cases with intrasellar or a small intrasellar and suprasellar craniopharyngiomas during transsphenoidal surgery. However, even preservation of the remnants of pituitary connected with the hypothalamus by preserved pituitary stalk does not secure appropriate anterior pituitary function.

Diabetes insipidus is another common consequence of craniopharyngioma removal. It has been documented that the disturbance can be reversible if the pituitary stalk is cut low just above the diaphragm.

Acute postoperative disturbances of water and electrolyte balance and chronic hypothalamic insufficiency with the weight gain or progression of preoperative obesity is the consequence of damage to hypothalamic structures, or to their blood supply, or both. In order to avoid serious damage to the hypothalamus one should choose surgical approach avoiding hypothalamic structures and dissect the tumor safely. A safe removal of a tumor which comes into direct contact with the neural tissue (intraventricular or intraventricular and extraventricular craniopharyngiomas) means finding the exact border between the tumor and the hypothalamus, a clear plane of cleavage and easy detachment of the tumor. The parts of the tumor which cannot be safely dissected free from the structures of the floor or from the lateral walls of the third ventricle should be left alone. In extraventricular tumors care should be taken to preserve the perforators adhering to the tumor capsule and all the pial vessels of the lower surface of the distended and distorted floor of the third ventricle.

The same is true for visual disturbances. Severe disorders may appear after interruption of the blood supply of the structures of visual pathways even without causing damage to nerve tissue. If the vessels cannot be dissected free a part of the capsule with adhering vessels should be left intact.

## CONCLUSIONS

Optimum treatment of craniopharyngiomas according to our experience is safe radical tumor removal whenever possible. Complex topographical relationship of craniopharyngiomas with surrounding structures (sella and pituitary, optic chiasm, third ventricular floor) predominantly depends on primary site of the growth of the tumor. Preoperative neuroimaging enables to disclose these anatomical relationships and to choose an appropriate surgical approach allowing sufficient exposure of the tumor while avoiding the hypothalamic structures. Reasonable extent of radicality of tumor removal however may be established only during the operation by assessing the degree of intensity of tumor adherence to important surrounding structures. Radical removal of originally infradiaphragmatic craniopharyngiomas is possible in approximately 90% (including large and giant tumors) and around 75% of primarily supradiaphragmatic tumors.

## References

- [1] Apuzzo MLJ, Levy ML, Tung H (1991) Surgical strategies and technical methodologies in optimal management of craniopharyngioma and masses affecting the third ventricular chamber. *Acta Neurochir Suppl (Wien)* 53: 77-88
- [2] Choux M, Lena G, Genitori L (1991) Craniopharyngioma in children. *Neurochirurgie* 37: 1-174
- [3] Ciric IS, Cozzens JW (1980) Craniopharyngiomas: transsphenoidal method of approach – for the virtuoso only? *Clin Neurosurg* 27: 169-187

- [4] Di Rocco C, Caldarelli M, Tamburrini G, Massini L (2006) Surgical management of craniopharyngiomas – experience with a pediatric series. *J Pediatr Endocrinol Metab* 19(Suppl 1): 355-366
- [5] Fahlbusch R, Honegger J, Paulus W, Buchfelder M (1999) Surgical treatment of craniopharyngiomas: experience with 168 patients. *J Neurosurg* 90: 237-250
- [6] Kalapurakal JA (2005) Radiation therapy in the management of pediatric craniopharyngiomas – a review. *Childs Nerv Syst* 21: 808-816
- [7] Konovalov AN (1981) Operative management of craniopharyngiomas. *Adv Tech Stand Neurosurg* 8: 281-318
- [8] Lena G, Paz Paredes A, Scavarda D, Guisiano B (2005) Craniopharyngioma in children: marseille experience. *Childs Nerv Syst* 21: 778-784
- [9] Matson DD, Crigler JF Jr (1969) Management of craniopharyngioma in childhood. *J Neurosurg* 30: 377-390
- [10] Minamida Y, Mikami T, Hashi K, Houkin K (2005) Surgical management of the recurrence and regrowth of craniocraniopharyngiomas. *J Neurosurg* 103: 224-232
- [11] Sainte-Rose C, Puget S, Wray A, Zerah M, Grill J, Brauner R, Boddaert N, Pierre-Kahn A (2005) Craniopharyngioma: the pendulum of surgical management. *Childs Nerv Syst* 21: 691-695
- [12] Samii M, Samii A (1995) Surgical management of craniopharyngiomas. In: Schmidek HH, Sweet WH (eds.) *Operative neurosurgical techniques: indications, methods, and results*, Vol. 1, 3rd edn. W.B. Saunders Co., Philadelphia, pp 357-370
- [13] Šteňo J (1985) Microsurgical topography of craniopharyngiomas. *Acta Neurochir Suppl (Wien)* 35: 94-100
- [14] Šteňo J, Maláček M, Bízík I (2004) Tumor-third ventricular relationships in supradiaphragmatic craniopharyngiomas: correlation of morphological, magnetic resonance imaging, and operative findings. *Neurosurgery* 54: 1051-1060
- [15] Tena-Suck ML, Salinas-Lara C, Arce-Arellano RI, Rembao-Bojourquez D, Morales-Espinosa D, Sotelo J, Arrieta O (2006) Clinico-pathological and immunohistological characteristics associated to recurrence/regrowth of craniopharyngiomas. *Clin Neurol Neurosurg* 22: 661-669
- [16] Yaşargil MG, Curcic M, Kis M, Siegenthaler G, Teddy PJ, Roth P (1990) Total removal of craniopharyngiomas. *J Neurosurg* 73: 3-11
- [17] Zuccaro G (2005) Radical resection of craniopharyngioma. *Child Nerv Syst* 21: 679-690



**Juraj Šteňo**

Juraj Šteňo is the Head of Department of Neurosurgery of Comenius University School of Medicine in Bratislava. He was born 1948 and has been graduated at Comenius University School of Medicine in 1972. After the training and board certification in general surgery (1977) he entered the training in neurosurgery in the Department of Neurosurgery of Comenius University School of Medicine in Bratislava, Slovakia headed by professor P. Nádvořník and passed the board certification in 1983. From 1975 to 1980 he prepared under Prof. A. N. Konovalov the Ph.D. theses on microsurgical topography of craniopharyngiomas in Burdenko Neurosurgical Institute in Moscow, Russia. Later on he studied in the Neurosurgical Departments in Erlangen, Germany (Prof. R. Fahlbusch), in 1985, in Zurich, Switzerland (Prof. M. G. Yaşargil) in 1992, in Hannover, Germany (Prof. M. Samii) in 1992, and in Little Rock, Arkansas (Prof. O. Al-Mefty) in 1999.

**Contact:** Juraj Šteňo, Department of Neurosurgery, Comenius University School of Medicine, Derer's Hospital, Limbova 5, 83305 Bratislava, Slovakia  
E-mail: juraj.steno@fmed.uniba.sk

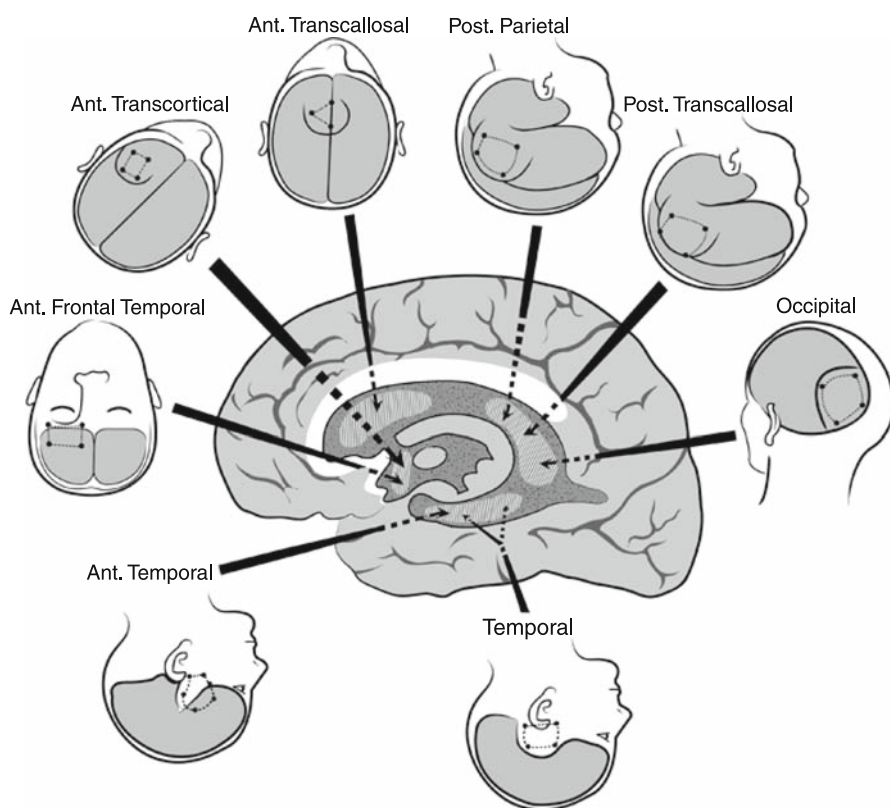
---

# MANAGEMENT OF TUMORS OF THE ANTERIOR THIRD AND LATERAL VENTRICLES

J. LOBO ANTUNES

## INTRODUCTION

Although in most series, tumors of the anterior third and lateral ventricles represent less than 3% of all intracranial tumors, they pose formidable tech-



**Fig. 1.** An outline of the main surgical approaches to intraventricular tumors (adapted from Piepmeier et al. [10] and Rhoton [11])

---

*Keywords:* surgical approaches to third ventricle, surgical approaches to the lateral ventricle, tumors, microsurgery



nical challenges, given its deep location and the need to go through normal brain, sometimes creating corridors close to important functional areas (Fig. 1). They are often histologically benign so if they are totally and safely removed, patients can be definitively cured. Like in several other areas, the principles of surgery for tumors of the third ventricle were established by Walter Dandy, who in 1936 published his monograph “Benign Tumors in the Third Ventricle of the Brain” [3].

Contemporary advances in the surgical treatment of these tumors were the result of better medical-endocrinological management, introduction of microsurgical techniques, improvement of image diagnostic techniques, particularly magnetic resonance, and, in recent years, neuro-navigation. Minimally invasive techniques, which are the object of separate chapters in this handbook, may play a role in specific lesions such as colloid cysts, and have constituted a major advance in the management of hydrocephalus due to obstruction of the distal outlet of the third ventricle.

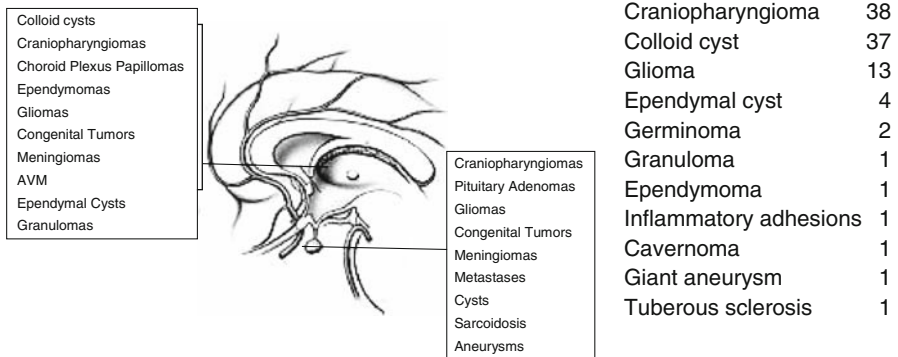
In this chapter, we will deal exclusively with lesions of the anterior third and lateral ventricles.

## **PART 1: TUMORS OF THE ANTERIOR THIRD VENTRICLES**

### **RATIONALE**

Tumors of the anterior third ventricle are certainly among the most difficult to treat, given their intimate relationships with the neural and vascular structures of the base of the brain, as well as with the hypothalamo-pituitary axis. Together with the pineal region, this region harbors the most wide variety of pathologies that can affect the neural axis [7].

Knowledge of the surgical anatomy of the third ventricle [11] is of utmost importance not only to decide the safest approach, but also to avoid complications that result from injury of functionally important structures like the hypothalamus or the fornices. The roof of the third ventricle which extends from the foramen of Monro to the suprapineal recess is a composite structure. Dorsally it is made up of the fornix, to which is attached the septum pellucidum. Underneath and lateral to the fornices lies the tela choroidea, made of two membranous pial layers and, between them, a vascular network including the internal cerebral veins, that often are not two single venous channels, and branches of the posterior and medial choroidal arteries. Below it, we find the choroid plexus. The lateral walls are made of the thalamus and hypothalamus. The anterior wall contains the optic chiasm and the lamina terminalis, which extends dorsally to the anterior commissure. The lamina terminalis is a neuroendocrine structure, and a safe door to enter the ventricle from one of the basal approaches. The floor of the third ventricle is made of the infundibu-



**Fig. 2.** Pathological diagnosis in a consecutive series of 100 lesions of the third ventricle. On the left side are represented the primary (*left*) and secondary (*right*) intraventricular lesions

lum, which extends caudally to the mammillary bodies, and has become the elected site to establish a communication with the basal cisterns in cases of obstructive hydrocephalus.

Topographically, tumors of the anterior third ventricle can be divided into two groups (Fig. 2). Primary lesions arise from the structures that make up the walls of the ventricle and therefore are attached to them by a pedicle of variable width, through which they receive their blood supply. The paradigmatical entity is the colloid cyst, which together with craniopharyngiomas, are the most common lesions in this area. Others include gliomas, choroid plexus papillomas, meningiomas, germinomas, other glial tumors and non-neoplastic lesions such as ependymal or parasitic cysts and cavernomas.

Secondary lesions arise outside the third ventricle in the sellar or parasellar areas, and impinge upon the ventricular wall or transgress it. The most common are pituitary adenomas, craniopharyngiomas, gliomas of the optic nerve or the hypothalamus, congenital tumors, meningiomas and secondary deposits of pineal germinomas. Among the non neoplastic lesions, we should mention arachnoid cysts, sarcoidosis and giant aneurysms.

## DECISION-MAKING

### 1. INDICATIONS

Except for the few tumors (mostly gliomas) that cause specific diencephalic-hypothalamic syndromes, which actually are not usually relieved by the surgical excision, most tumors of the third ventricle manifest by signs and symptoms of increased intracranial pressure, mostly due to the associated hydrocephalus, and often visual deficits. The indications for surgery are therefore mainly the relief of these symptoms, and the establishment of normal CSF flow.

## 2. PREOPERATIVE EVALUATION

A careful preoperative evaluation is mandatory, and is crucial for the selection of the appropriate surgical route. A careful clinical and endocrine assessment is, of course, indispensable, and close cooperation with an experienced neuroendocrinologist is mostly recommended. In cases which require dissection from the lateral wall of the hypothalamus, the patient may have a rather stormy post-operative course with severe hydroelectrolytic disturbances, agitation or sleepiness, and other manifestations of hypothalamic dysfunction.

The diagnosis depends, of course, on good imaging techniques. MRI is the method of choice, and in most cases the correct pathological diagnosis can be predicted. It is also relevant to determine accurately the site of origin of the tumor and whether or not hydrocephalus is present. Image protocols to exclude the presence of a vascular lesion may be needed, and may also be helpful to outline the venous anatomy, particularly of the parasagittal veins draining to the superior sinus. Digital angiography is rarely needed in these circumstances.

## 3. SURGICAL PLANNING

In this section we will outline the relevant steps.

### 3.1 What to do with hydrocephalus if it is present?

If patients do not present an acute hydrocephalus requiring immediate ventricular drainage – and this may occur in cases of colloid cysts – ventricular enlargement is advantageous for the surgical approach, particularly if one favors (and we do not) a transcortical approach. Intra-operatively, if the transcallosal route is chosen, one way is to implant a ventricular drain to avoid excessive retraction of the medial wall of the frontal lobe. Although this has occurred seldomly in our experience, we then tap the contralateral ventricle. We strongly believe that is safer, once the lesion is removed, to leave a ventricular drain for 24 a 48 hours, because the intraventricular pressure may remain temporarily high, and CSF flow may remain disturbed by blood or tumor debris. In fact, we have treated cases of colloid cysts with secondary aqueductal stenosis.

### 3.2 Which route to choose: dorsal or basal?

For tumors that arise within the third ventricle wall extending to the foramen of Monro or arising from the roof of the ventricle, superior approaches are usually more adequate. For lesions that grow extrinsically from the base and extend quite far dorsally, as it occurs often with large craniopharyngomas, these are also excellent options, and the basal cisterns can be approached through the lamina terminalis or the floor of the ventricle.

Basal approaches are ideally suited for lesions that arise from the sella and parasellar region that do not extend dorsally enough to allow a superior route. The inside of the ventricle can be reached through the lamina terminalis.

### 3.3 Open surgery vs. endoscopic approaches

In general endoscopic approaches with the goal of achieving a total removal are best suited for lesions not exceeding 2–3 cm in size and are not very vascular. Endoscopy is also useful for biopsy and opening of the floor of the ventricle. It is our belief that with good microsurgical techniques the morbidity/mortality of open surgery is not higher than the minimally invasive procedures.

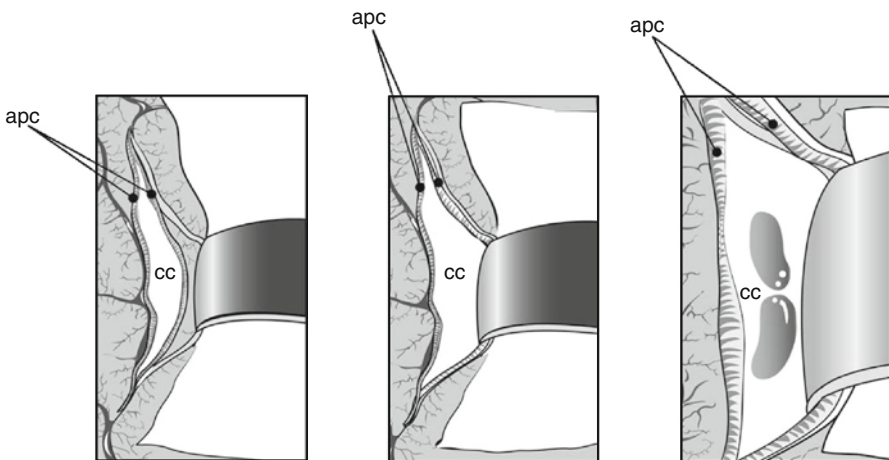
### 3.4 Transcallosal vs. transcortical approaches

Both approaches are effective and usually safe, although neither is without complications. The initial steps of the transcallosal are perhaps a bit more difficult and require meticulous microsurgical techniques. We do prefer it, however, and it is also the procedure of choice if ventricles are not enlarged. It allows a good visualization of both lateral ventricles and the infundibular recess of the third ventricle.

## 4. SURGERY

### 4.1 The transcallosal approach [7, 11, 12] (Fig. 3)

In this approach the third ventricle is entered through the lateral ventricle, in general the right, but in cases where the tumor presents through the left foramen of Monro, we go through the the ipsilateral side. Ideally no vein should be sacrificed, and meticulous dissection of the venous channels usually allows sufficient room to expose the medial wall of the hemisphere. A correct position of the patient is crucial. The head should be secured with a pin-holder and pointing in such a way that the sagittal and coronal sutures are horizon-

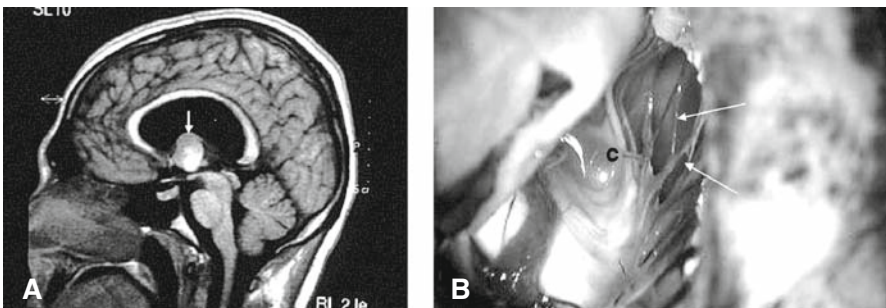


**Fig. 3.** Initial steps in the transcallosal approach (see text). *cc* corpus callosum *apc* pericallosal artery

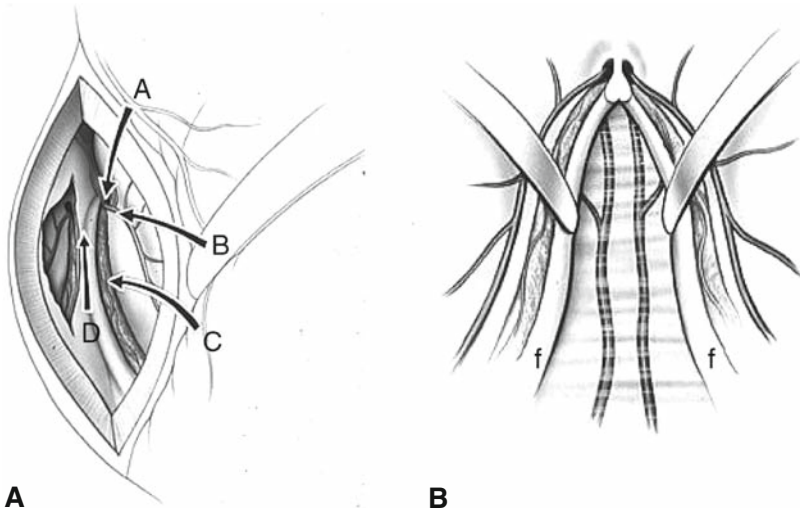
tally aligned. A triangular small bone flap extending two-thirds anteriorly to the coronal suture and to the midline (most surgeons prefer to expose the sinus) is raised, and the dura reflected medially. Dissection proceeds along the medial surface of the brain, with care not to injure the bridging veins or the pial surface. This is sometimes a rather tedious step, but avoiding a bloody field is of utmost importance. There may be defects in the falx and adhesions between both hemispheres at the level of the cingulate gyri, which may be taken wrongly by the corpus callosum. In fact this structure is easily recognizable by its smoother appearance and whitish color. The next step requires dissection of both pericallosal arteries and the opening of the corpus callosum should be made, whenever possible, between them. Once the corpus callosum is identified, a self retaining retractor is placed over the medial wall of the hemisphere. Retraction of the falx is usually not necessary. Two cotton pledgets can be placed anteriorly and posteriorly, so a small rectangle is defined. This also helps to stop the annoying venous oozing which often occurs, usually anteriorly. Perfect hemostasis should be achieved before the corpus callosum is opened. The incision of the corpus callosum does not have to exceed more than 2–2.5 cm. Once the lateral ventricle is entered, the retractor may be lowered, but care should be taken to not injure the head of the caudate nucleus or the genu of the internal capsule which lays very close underneath. The next step is to find the foramen of Monro and the safest way is to follow the choroid plexus anteriorly. The confluence of the septal, the caudate and the thalamostriate veins is also a useful landmark.

There are two possible sources of confusion: one is to enter the contralateral ventricle; the other is to fall within the two layers of a cavum septum pellucidum. Occasionally the septum pellucidum is found to be fenestrated. If not, we like to open it at this stage, while the contralateral ventricle is still bulging.

In most cases, the foramen of Monro is enlarged enough to allow removal of the various tumors. This is the case in most colloid cysts (Fig. 4) or cystic craniopharyngiomas. In the case of colloid cysts, the wall must be further



**Fig. 4.** **A** Colloid cyst (*arrow*), MRI sagittal cut. Note the heterogenous content and the dorsal extension. **B** Intraoperative view (left side approach). *c* colloid cyst. Note the spontaneous fenestration of the septum pellucidum (*arrows*)

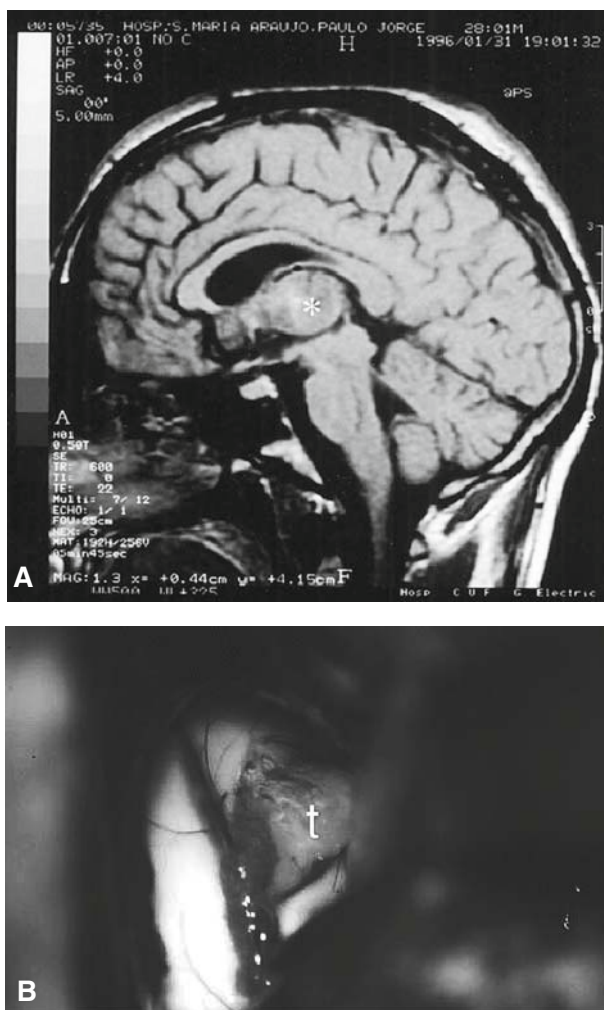

**Fig. 5. A** Approaches to the inside of the III ventricle. *A* Section of the fornix. *B* Coagulation of the thalamostriate vein. *C* Transchoroidal *D* Interforminal. **B** The interforminal approach. Retractors separate fornix. *f* Exposing tela choroidea

separated of the adjacent choroid plexus, and rather than enter the roof of ventricle it may be preferable to leave a tiny portion of the capsule attached to the choroid plexus. We avoid coagulating the plexus. The degree of aggressiveness depends obviously on the relationship of the various tumors with the wall of the ventricle and this is principally a matter of judgement, taking in consideration that injury of the walls may cause severe hypothalamic dysfunction, particularly with craniopharyngiomas. In these situation we try to tease them very gently from the wall.

At times, one has to enlarge the surgical “door”. Several options have been proposed: section of the fornix, coagulation of the thalamostriate vein, and enlarging the opening between the thalamus laterally and the choroid plexus and the internal cerebral vein medially (Fig. 5A). We prefer to use a transchoroidal route as outlined by Lobo-Antunes and others [7]. So once the choroid plexus is located, we can recognize two thin translucent membranes, the taenia fornicis, between the fornix and the plexus, and the taenia choroidea, between the plexus and the thalamus. In order not to injure branches of the medial posterior choroidal arteries and superior thalamic veins, it is preferable to approach the choroid fissure through the taenia fornicis, so to gain access to the tela choroidea of the third ventricle (Fig. 6). We then expose the contents of the velum interpositum, and we can work between both internal cerebral veins, opening, in sequence, the inferior membrane of the tela choroidea, and the midline, between the choroid plexus.

We favor this approach rather than opening the choroidal fissure along the tenia choroidea and retracting the choroid plexus and the body of the fornix



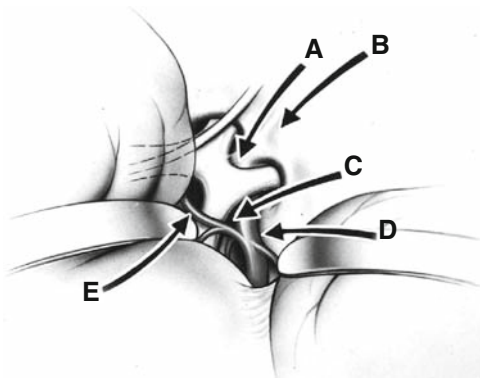
**Fig. 6.** Intraventricular glioma (A) MRI Sagittal cut (asterisk). B Intra-operative picture. The tumor (t) is visualized at the level of the foramen of Monro, but the exposure is limited. A choroidal route was chosen

in a lateral to medial direction. Another route to approach the roof of the ventricle is the interforaminal (Fig. 5B) route, first proposal by Busch and later advocated by Apuzzo and Giannotta [1]. In this approach the two leaves of the septum pellucidum are progressively and bluntly separated until the raphe fornicum is reached. The fornices are separated, for a distance of approximately 15 mm, and finally the velum interpositum is divided between the internal cerebral veins.

The third ventricle may also be approached through the middle frontal gyrus of the non dominant hemisphere. With neuronavigation techniques it is rather easy to gain precise access to the lateral ventricle, but this approach is better suitable when the ventricles are enlarged. It requires retraction of the brain parenchyma and does not allow adequate visualization of the contralateral foramen of Monro.

#### 4.2 Basal approaches

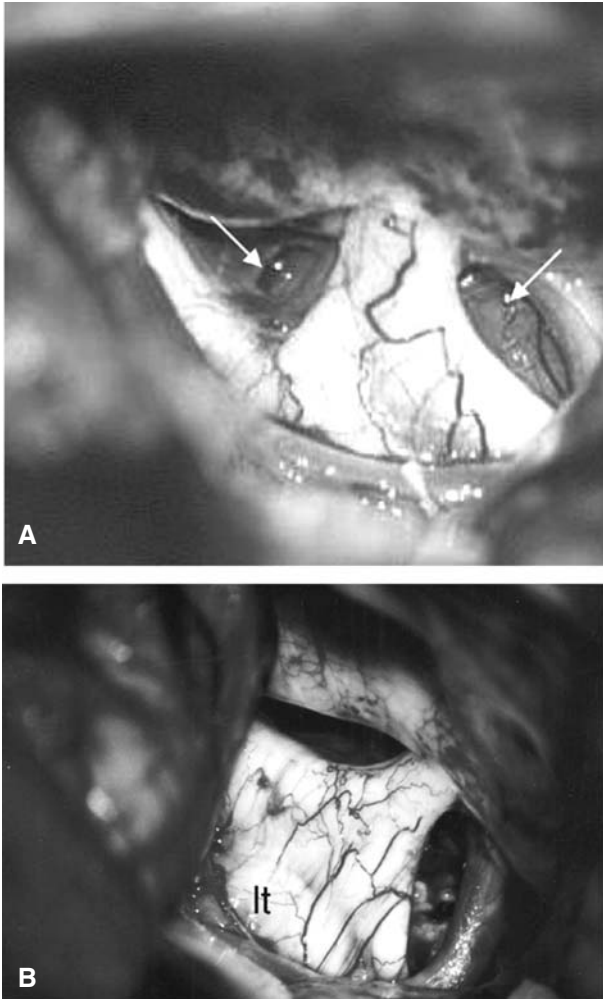
These are ideally suitable for extrinsic lesions that arise from the sellar or parasellar area and displace or invade the wall of the third ventricle, and occasionally for primary intraventricular tumors that do not expand dorsally enough to be approached through one of the superior routes. We have mostly used these for large craniopharyngiomas. It should be pointed out that these tumors can be completely extra-arachnoid, partially intra- and extra-arachnoid, completely intra-arachnoid and intrapial, interdigitating with the hypothalamic wall, or they can be totally intraventricular. Once the neurovascular structures of the base are exposed, dissection may take one of several different routes (Fig. 7). (1) Subchiasmatic, between the optic nerves and underneath the chiasm. (2) Opticocarotid, between the optic nerve medially, the carotid artery laterally and the A1 segment of the anterior cerebral artery posteriorly. (3) Lateral to the carotid artery. (4) Transfrontal – transphenoidal, drilling the tuberculum sellae and entering the sphenoid sinus. Once the tumor is exposed, the steps to be taken depend in the nature of the tumor, consistency and relationship with the neurovascular structures. In most cases one begins by working in the space between both optic nerves and the carotid artery and progressively reach beyond the sellar region to the interpeduncular cisterns, sometimes visualizing both the III nerves and the basilar artery and its branches. Occasionally, the chiasm presents a prefixed position, which



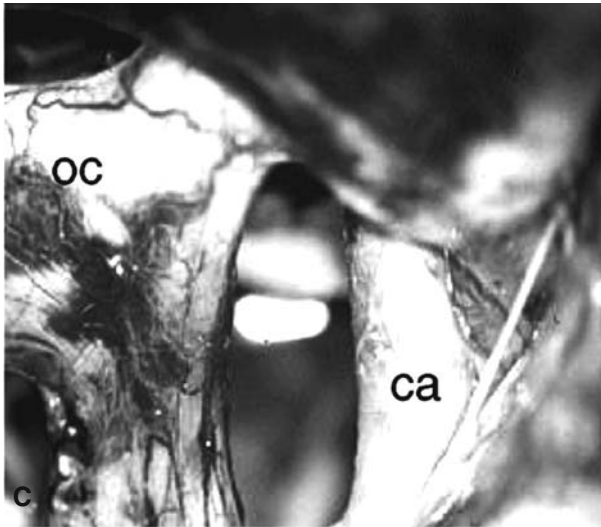
**Fig. 7.** Basal approaches. A prechiasmatic, B jugum splenoidale, C optico-carotid, D lateral carotid, E lamina terminalis



we believe is often due to the “pushing” effect of the tumor behind the chiasm, making it quite hard to reach underneath it. We have found that the best access is to work through the lamina terminalis [9] (Fig. 8), and as the tumor is removed this way, we gain increasing space in front of the chiasm. In most cases of intraventricular tumors, the lamina is often distended and bulging, so one has enough room to enter it without being encumbered by the anterior cerebral or anterior communicating arteries. It is crucial, however, to identify



**Fig. 8.** Craniopharyngioma approached through the lamina terminalis (lt). **A** Tumor is seen in front and lateral to the optic nerves (*arrows*). **B** Lamina terminalis is pushed. **C** After removal of tumor. *oc* chiasm *ca* carotid artery



**Fig. 8.** (Continued)

the chiasm and the medial border of the optic tracts. Care has to be taken to preserve as much as possible the vascular supply to the chiasm, so bipolar coagulation should be used sparingly. Internal decompression is achieved first by dissection, traction and piecemeal removal. One should remember that quite often craniopharyngiomas are attached to the dorsal and posterior part of the chiasm an area that cannot be visualized directly. An equally inaccessible (unless the endoscope or small mirrors are used) is the most dorsal part, underneath the anterior commissure, but quite often, with gentle traction, one may pull the remaining tumor through the initial opening.

#### 4.3 Minimally invasive procedures

Under these techniques we consider the endoscopic and endoscope-assisted keyhole approaches. Cystic tumors within the third ventricle, particularly colloid cysts, were sometimes treated in the past with simple stereotactic aspiration. It should be pointed out, however, that often the content is too thick and hard to aspirate [8] and, furthermore, part of the capsule was left behind, causing recurrence of the lesion in an unacceptably high rate. Subsequently, flexible endoscopes were used, introduced via a right frontal burr hole. Presently, rigid endoscopes with two working channels and different angles ( $0^\circ$ ,  $30^\circ$  or  $70^\circ$ ), assisted with neuronavigation, are reasonable alternatives, although the technique requires a fair amount of experience. In any case, in most instances, portions of the capsule are left behind so the risk of recurrence still remains. A dual-port endoscopic technique (through a frontopolar and precoronal holes)

was also proposed. This appears to allow a more direct visualization of the attachment of the capsule to the tela choroidea. It is questionable, however, whether or not this represents an advantage over a single port. Endoscopic techniques have also been used also for biopsy or excision of solid tumors which are less than 2 cm in size and relatively avascular. In these circumstances a third ventriculostomy, septostomy or placing a stent in the aqueduct can be performed at the same time.

The question still remains regarding the advantages of open versus endoscopic resection of colloid cysts. Horn et al. [5] comparing a series of a single institution, have concluded that the length of stay was slightly shorter in the endoscopic group, but the rate of residual or recurrent cysts was higher in the endoscopic group during the intermediate follow-up period (9 out of 21 cysts). They also underline the fact that despite being minimally invasive, severe complications such as hemiparesis and memory deficits can occur.

Another minimally invasive approach was proposed by Patrick Kelly, and consisted in placing stereotactically a tube retractor through a frontal burr hole. Synchronous endoscopy and microsurgical strategies have also been advocated recently by a very experienced group, but its advantages need to be established [2].

It is our opinion that endoscopic removal of colloid cysts is an acceptable alternative in experienced hands. It can also be used in patients without hydrocephalus but it is not without complications. It may also be difficult to accomplish when these lesions are attached more posteriorly. One has to accept that, in many cases, small portions of the capsule will be left behind, so the risk of recurrence still remains.

## **PART 2: TUMORS OF THE LATERAL VENTRICLES**

### **RATIONALE**

Tumors of the lateral ventricle can also be divided into primary and secondary according to its origin. They are relatively rare, usually reach large sizes before becoming symptomatic, are quite often benign (choroid plexus papillomas, meningiomas, epidermoid tumors, giant subependymal astrocytomas) and are more common in children.

*Anatomically* [7] the lateral ventricle is a C-shaped cavity with five components: the frontal horn, the body, the atrium, the occipital horn, and the temporal horn. The *frontal horn* is the part of the lateral ventricle anterior to the foramen of Monro. The roof and anterior wall are formed by the genu of the corpus callosum, the medial wall by the septum pellucidum and the lateral wall by the head of the caudate and the narrow floor by the rostrum of the corpus callosum. The *body* is located behind the foramen of Monro and is limited me-

dially by the septum pellucidum, laterally by the body of the caudate nucleus, superiorly by the corpus callosum, inferomedially by the body of the fornix and inferolaterally by the thalamus. The *atrium* and the *occipital* horn form a conic cavity with the apex at the occipital lobe and the base at the pulvinar. The *temporal horn* extends from the atrium into the medial part of the temporal lobe, ending just behind the amygdala. The floor is formed medially by the hippocampus and laterally by the collateral eminence. The lateral part of the roof is formed by the tapetum of the corpus callosum, which also sweeps inferiorly to form the lateral wall, separating the temporal horn from the optic radiations. In the *medial wall* there is the choroidal fissure between the thalamus and the fimbria of the fornix.

## DECISION-MAKING

### 1. INDICATIONS

Tumors of the lateral ventricle become symptomatically usually when they reach a size enough to cause obstruction of the ventricles, sometimes dilating one or more of its chambers. As mentioned, most are histologically benign so the goal of treatment is total removal.

### 2. PREOPERATIVE EVALUATION

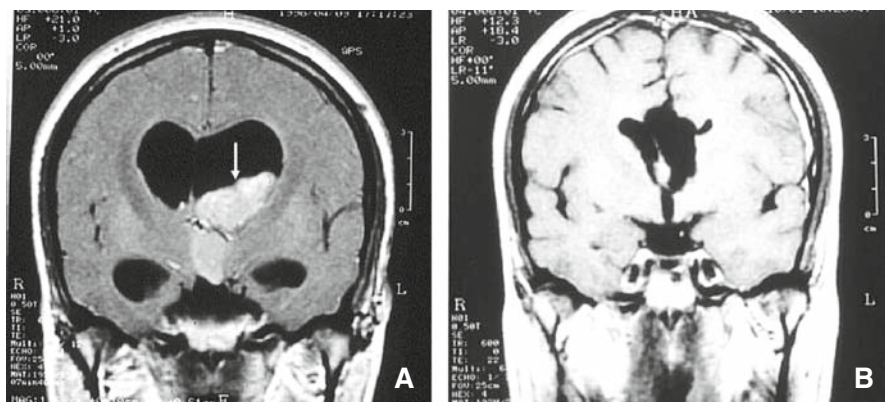
Image evaluation by CT and MRI is mandatory. If one suspects a very vascular tumor, digital subtraction angiography or MR angiography are most useful for adequate planning. They also supply relevant information concerning the histological type, size, site of attachment, pattern of growth, relationship with neural structures, presence of hydrocephalus, arterial supply and venous anatomy.

### 3. SURGICAL PLANNING

In rare instances ventricular drainage has to be placed prior to surgery. Enlarged ventricles are useful to approach the lesions.

The following general principles should be considered.

1. Bone flaps should be designed to minimize brain retraction.
2. The surgical approach should be the simplest and the safest, with minimal retraction.
3. The blood supply should be interrupted as soon as possible. However, in most cases, this can only be achieved after debulking of the tumor mass.
4. Interruption of venous channels should be kept at a minimum.
5. In most cases piecemeal removal is advisable.



**Fig. 9.** Neurocytoma (MRI) of the lateral ventricle extending to the III ventricle (*arrow*). **A** pre-operative. **B** post-operative

## **SURGERY** [4, 6, 10–12] (Fig. 1)

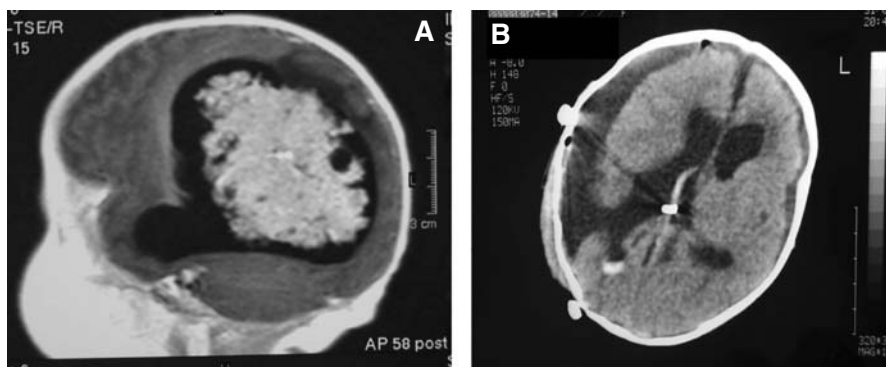
### **1. FRONTAL HORN AND BODY OF THE VENTRICLE**

Most lesions in this location can be approached through a transcallosal or transfrontal route (Fig. 9). Incision of the corpus callosum can be brought more posteriorly, and this allows to get close to the atrium. Once the tumor is exposed we begin by internal debulking, which in certain lesions, such as neurocytomas, can cause considerable, mostly venous, oozing, which can be controlled with cottonoids. The next step is to try to identify the floor of the ventricle and gently lift the tumor, trying to preserve the thalamostriate vein. Tumors may originate in the septum and we often end up with a wide communication with the contralateral ventricle. Care has to be taken dorsally not to disrupt the fornices. There is a somewhat “blind spot” underneath the corpus callosum laterally, close to the head of the caudate nucleus. It is advisable to keep the foramen of Monro occluded, so blood does not enter the third ventricle. A transfrontal route through the middle frontal gyrus may be suitable for the larger lesions.

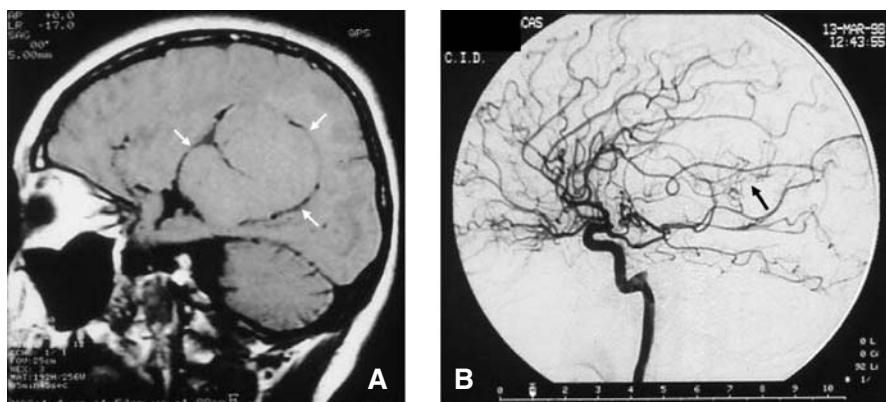
### **2. ATRIUM AND OCCIPITAL HORN**

The paradigmatic lesions in this location are choroid plexus papillomas (Figs. 10 and 11) and intraventricular meningiomas. Both neoplasms receive their supply from anterior and posterior choroidal arteries which are hidden from the surgeon and both may reach considerable size. There are two main choices:

- Transcortical using the superior parietal gyrus or a slightly more posterior occipital-parietal route. Neuronavigation is crucial in helping



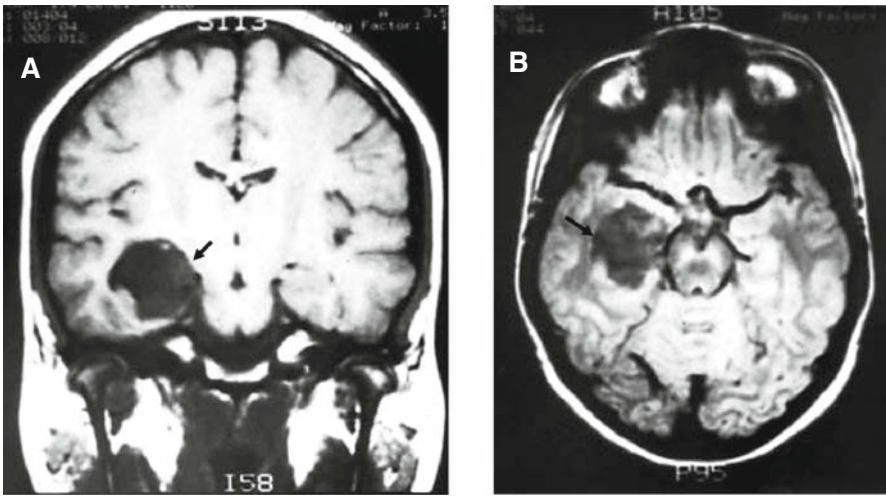
**Fig. 10.** Choroid plexus papilloma in 4 year old child. **A** Sagittal MRI. **B** Post-operative CT scan



**Fig. 11.** Meningioma of the atrium. **A** MRI showing a large tumor (arrows). **B** Carotid angiogram demonstrating feeding from the posterior choroidal arteries (arrow)

to delineate the route. Position of the patient may be semi-sitting or a three-quarter prone with the patient facing the floor and the exposed area in a uppermost position. With neuronavigation one may select to go through a sulcus, which often does not allow a wide enough exposure, or through a gyrus. Coming from behind allows a better control of the medial part of the tumor, where the blood supply and venous drainage is mostly located. Near the midline the tumor may come close or even transgress the velum interpositum and reach the major venous channels. There are other possible variations but we have found this to be the safest approach, particularly concerning the visual pathways.

The atrium may also be reached through a posterior temporal or temporo-parietal approach, which often interrupts Meyer's loop with



**Fig. 12.** Epidermoid of the temporal horn (*arrow*) removed through the middle temporal gyrus

consequent quadrantanopsia. Further neurological deficits may occur if the approach is carried in the dominant hemisphere.

- Posterior transcallosal, which may be of use in lesions that originate in the splenium or the roof. The semi-sitting, a three-quarter prone or even a lateral position, with the exposed hemisphere in an inferior position may be adopted. The route is posterior to the post-central vein and one may enter the splenium in the middle or direct the dissection more laterally. It should be reminded, however, that at this level, the lateral ventricle is already far from the midline. We have used this approach only for arteriovenous malformations in the splenial region.

### 3. TEMPORAL HORN

Tumors in this region are uncommon. They can be approached through an incision in the middle or inferior temporal gyrus. We found the approach through the collateral sulcus unnecessary (Fig. 12). Again, we use neuronavigation in most cases and fashion the bone flap and the size of the cortical incision accordingly. One may use the supine position with the head turned or, for the more posterior lesions, a lateral position. It is crucial to remove the bone necessary to reach the floor of the middle fossa. Dissection through the sulcus may be too limited. The vein of Labbé is an useful landmark posteriorly. Care should be taken as one gets close to the tentorial notch, where we can visualize the choroidal vessels and the posterior communicating and posterior cerebral arteries. These may send branches to the tumor, and one has to avoid to avulse them from the major trunks. For the more posteriorly located

tumors, which may reach the atrium, one can extend the incision posteriorly but the risk of causing a field defect increases exponentially. On the dominant hemisphere this maneuver is particularly dangerous, so a combined approach with a posterior parietal route may be advisable.

## **PART 3: HOW TO AVOID COMPLICATIONS**

### **COMPLICATIONS**

#### **1. COMPLICATIONS IN TUMORS OF ANTERIOR THIRD VENTRICLE**

Complications of the superior approaches are related to the initial surgical steps, and to the entrance into the ventricular system and the maneuvers required by the removal of the lesion itself. The neuropsychological complications of a limited callosal section are probably minimal or even impossible to document, unless sophisticated testing is applied. Focal symptoms resulting from occlusion of a cortical vein may occur. One rather unusual complication is related to damage of the supplementary motor area, causing diminution of speech outflow and soft pronunciation (aphemia). The main concern about the transcortical approach is the possible occurrence of seizures (about 7% in our series). One feared complication in any of these approaches, as well as in the minimally invasive ones, is transient or permanent memory deficits, which may be due to injury of the fornices or to the septal region.

Injury to the deep venous structures including the thalamostriate vein may cause an hemorrhagic infarction of the basal ganglia. Collapse of the ventricular system is a common occurrence and the subsequent hygroma may eventually require drainage. Preoperative hydrocephalus may not resolve with removal of the tumor by simply unblocking the foramen of Monro or the posterior third ventricle. Whenever feasible, the floor of the third ventricle should be opened as an alternative escape of the CSF. Finally, damage of the hypothalamus may have terrible consequences, but it can be avoided by a prudent assessment of the relationship between the tumor and the wall of the ventricle. It is important to emphasize that severe hypothalamic-pituitary dysfunction can manifest months after surgery and replacement therapy has to be carefully monitored.

Complications of the basal approaches are usually due to injury to the neurovascular structures of the base, and include transient or permanent visual deficits, and to the hypothalamus-pituitary axis, with diabetes insipidus and pituitary insufficiency.

#### **2. COMPLICATIONS IN TUMORS OF LATERAL VENTRICLES**

Complications of surgery of tumors of the lateral ventricle are related to the surgical route and the need to transgress the parenchyma and its retraction.



They include focal symptoms such as visual field defects, motor and cognitive deficits and seizures. Collapse of the cerebral mantle once the CSF pathways are unblocked may result in subdural effusions not always easy to deal with.

### **3. COMPLICATION AVOIDANCE**

We believe that the key to success in the treatment of supratentorial intraventricular tumors depends on the careful delineation of the surgical strategy, versatility in choosing the safer route, minimal retraction of the parenchyma, experience in working through relatively narrow corridors, meticulous technique, perfect hemostasis, patient step-by-step, piecemeal removal and, simply, experience. We believe that probably the biggest challenges are the neurocytomas, the large tumors of the atrium (meningiomas and papillomas), and the intraventricular craniopharyngiomas. In fact, each histological type (and they are most variable), has different topographical relationships, texture and vascularity, something akin we may say, to a specific personality. For instance, a colloid cyst may have a content of high consistency (may even be calcified), be almost hidden or largely adherent to the choroid plexus, and its removal without injuring the fornices becomes a fastidious exercise.

### **4. RESULTS**

In our experience results of surgery of tumors of the anterior third ventricle are, with good microsurgical technique, quite gratifying. We have had no operative mortality in colloid cysts or intraventricular craniopharyngiomas and an overall morbidity of about 5%.

Results of surgery of tumors of the lateral ventricle depend on the histology of the lesion. In the frontal horn and the body, neurocytomas are the most challenging and we had one post-operative death due to hemorrhage, probably from residual tumor. Recently, radiosurgery has been advocated when only a subtotal removal has been achieved. In older series, removal of intraventricular meningiomas had an unacceptably high mortality, which can be prevented with meticulous microsurgical technique. Choroid plexus papillomas are sometimes malignant, in which case and the prognosis is rather poor.


### **CONCLUSIONS**

As mentioned before, the goal of the surgical treatment of these tumors is, whenever possible, their total removal. In this chapter we addressed mainly the primary tumors, since the secondary lesions, such as hypothalamic or thalamic gliomas with an intraventricular exophytic component, pose different surgical and oncological challenges. We have found that modern image techniques and particularly neuronavigation most useful tools for the planning of the surgical approach. It is our belief that minimally inva-

sive techniques will play a major role in well selected cases, but should be performed only by experienced surgeons. There are certainly most challenging and demanding lesions which should not be dealt with by the novice neurosurgeon.

## References

- [1] Apuzzo MLJ, Giannotta SL (1987) Transcallosal interforaminal approach. In: Apuzzo MLJ (ed.) *Surgery of the third ventricle*. Williams & Wilkins, Baltimore
- [2] Charampaki P, Filippi R, Welschehold S, et al. (2005) Tumors of the lateral and third ventricle: removal under endoscope – assisted keyhole conditions. *Neurosurgery* 57 (ONS Suppl 4): ONS-302-ONS-311
- [3] Dandy WE (1933) *Benign tumors in the third ventricle of the brain: diagnosis and treatment*. Charles C. Thomas, Springfield
- [4] D'Angelo VA, Galarza M, Catapano D, et al. (2005) Lateral ventricle tumors: surgical strategies according to tumor origin and development. *Neurosurgery* 56 (ONS Suppl 1): ONS-36-ONS-45
- [5] Horn EM, Feiz-Erfan I, Bristol RE, et al. (2007) Treatment options for the third ventricular colloid cysts: comparison of open microsurgical versus endoscopic resection. *Neurosurgery* 60: 613-620
- [6] Lapras C, Deruty R, Bret PH (1984) Tumors of the lateral ventricles. *Adv Tech Stand Neurosurg* 11: 103-167
- [7] Lobo-Antunes J (1982) Surgical approaches to the anterior third ventricle. *Contemp Neurosurg* 4(25): 1-6
- [8] Lobo-Antunes J, Louis KM, Ganti SR (1980) Colloid cysts of the third ventricle. *Neurosurgery* 7: 450-455
- [9] Maira G, Anile C, Colosimo C, et al. (2000) Craniopharyngiomas of the third ventricle: trans-lamina terminalis approach. *Neurosurgery* 47: 857-865
- [10] Piepmeier J, Spencer D, Sassk K, et al. (1993) Lateral ventricular masses. In: Apuzzo MLJ (ed.) *Brain surgery: complications, avoidance and management*. Churchill Livingstone, New York, pp 581-600
- [11] Rhoton A (2002) The lateral and third ventricles. *Neurosurgery* SI (Suppl 1) 51: 207-271
- [12] Yaşargil MG (1996) Intraventricular tumors. In: *Microneurosurgery, Vol. IVB*. pp 313-330



### **João Lobo Antunes**

João Lobo Antunes is Professor of Neurosurgery at the Faculty of Medicine, University of Lisbon, and Director of the Department of Neurosurgery at Hospital de Santa Maria, Lisbon. He was born in Lisbon, Portugal, 1944. He graduated with honors at the University of Lisbon. He finished his residency in neurosurgery, as a Fulbright Fellow, at the Neurological Institute of New York, Columbia Presbyterian Medical Center in 1974. He was later appointed Associated Professor of Neurosurgery at Columbia University. In 1984 he returned to Portugal as Professor and Chairman of Neurosurgery at the University of Lisbon. He was Vice President for Europe of the World Federation of Neurosurgical Societies in 1990, and was elected President of European Association of Neurosurgical Societies in 1999, which awarded him its Medal of Honor in 2007.

His main research areas have been in the area of the physiopathology of the hypothalamus-pituitary axis and in the development of a visual prosthesis for the blind. He received the Neurobionik Award in 2004.

**Contact:** João Lobo Antunes, Hospital Universitario de Santa Maria, Av. Egaz Moniz, 1649-035 Lisbon, Portugal  
E-mail: [jlobo.antunes@mail.telepac.pt](mailto:jlobo.antunes@mail.telepac.pt)

---

# ENDOSCOPIC MANAGEMENT OF COLLOID CYSTS

P. DECO

## INTRODUCTION

Colloid cysts are histologically benign tumors that represent between 0.5 and 2% of all intracranial neoplasms. They are mostly located at the anterior part of the third ventricle and are able to produce occlusion of the foramina of Monro, resulting in biventricular hydrocephalus. Because of their obstructive nature, colloid cysts can cause rapid neurological deterioration and even sudden death. On the other hand, neurological and neuropsychological deficits can be observed in patients without increased intracranial pressure [15]. The vast majority of colloid cysts reported in the literature are symptomatic and were therefore treated. The treatment of asymptomatic colloid cysts depends on individual characteristics and is debatable [17, 18].

Since Dandy's first surgical approach to a colloid cyst in 1921 [6], several treatment modalities have been developed. Generally they are divided into two categories: open surgical removal and percutaneous aspiration procedures. Apart from these treatments, simple shunting of cerebrospinal fluid (CSF) without removal of the cyst has been described.

The microsurgical transcortical-transventricular and transcallosal approaches have been developed for a long time and are considered as gold standard. However, for several decades the endoscopic approach has been advanced and has gained acceptance as a true alternative to microsurgical techniques. As microsurgical approaches of ventricular lesions are presented in another chapter of the present book, I focus on the endoscopic management which for more than 10 years is our exclusive approach of colloid cysts. It still remains debatable if it can be considered as preferential and primary surgical modality. Nevertheless, in our hands, it is a real minimally invasive procedure which could be easily repeated if necessary and which has an acceptable success rate and a very low morbidity rate if several rules, outlined in this chapter, are strictly followed.

## RATIONALE

Colloid cysts are usually found attached to the roof of the anterior part of the third ventricle. It can also be placed more posterior in the third ventricle, only

---

*Keywords:* neuro-endoscopy, brain tumors, colloid cysts, intraventricular tumors

rarely other locations have been described: among others, the lateral ventricles, septum pellucidum, fourth ventricle, or prepontine region [3, 10]. Multiple-location, paired, or even triple cysts have been described [24]. The size of the cyst is reported to range from only several millimeters up to 9 cm in diameter.

Symptoms are related to enlargement of the cysts. When they occlude the foramina of Monro, obstructive hydrocephalus may result. Also compression of nearby structures like the fornix may give symptoms. Due to its swinging attachment to the tela choroidea, intermittent symptomatology might occur first postulated by Sjovald in 1910 [22]. The cyst may enlarge due to production of colloid material, and often signs of inflammation are found. Bleeding is another mechanism of cyst enlargement [2]. This sudden increase in size is related to serious neurological deficit; it is not known which cysts are more prone to bleed. For patients with colloid cysts sudden deterioration is rare; it is often precluded by intermittent, vague, or misdiagnosed symptoms [5]. This period rarely lasts less than 24 hours. The exact mechanism of rapid deterioration is not known. It can be related to the obstruction of CSF outflow mentioned above. It can also be the cause of venous infarction caused by (postural) kinking of the proximal internal cerebral veins. A third hypothesis suggests local compression of the wall of the third ventricle, thus compromising cardiovascular regulatory centers in the hypothalamus. As suggested by Hamlat et al. [10], the mechanism in such cases is a multifactorial and dynamic process in which increased sagittal sinus pressure might play a central role. Acute deterioration might be provoked by lumbar puncture [5].

Thus the rationale for surgery is to free the CSF pathway, to suppress any compression of the structures around the foramen of Monro, and to remove the entire cyst capsule to avoid any recurrence.

Endoscopic aspiration of a colloid cyst was first reported by Powell et al. in 1983 [19]. Since then numerous reports on endoscopic treatment appeared [1, 7, 11, 13, 14, 16, 20, 21, 23]. The advantages reported are shorter operating time, lower complication rate related to smaller cortical incision, and lower risk of a seizure disorder. However, several remarks have to be made. Endoscopic removal of colloid cysts requires a learning curve and should therefore be done by experienced neuroendoscopists [20]. The recurrence rate has been a matter of concern because total removal seems difficult but has been reported [23, 9]. With respect to a good equilibrium between a removal of the cyst capsule as total as possible and a low morbidity rate, some authors question whether the capsule should be removed completely [7, 20].

## **DECISION-MAKING**

The spectrum of symptomatology in patients with colloid cysts is large, and there are no pathognomic signs [24]. There are three categories of presentation: headache as the main problem in the first group, a progressive or fluctuating

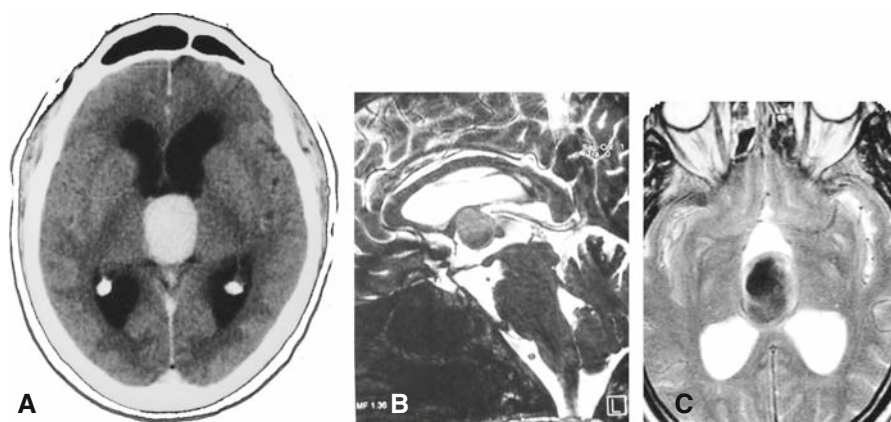
dementia with or without symptoms of raised intracranial pressure only, and paroxysmal attacks with complete freedom from all symptoms in between. Probably the distinction between the groups is not so strict, and combinations are possible. The occurrence of "classical" postural headache is probably overestimated. Other symptoms include nausea and vomiting, visual deficit, gait disturbances, seizures, short-term memory deficit, symptoms known as triad occurring in normal-pressure hydrocephalus, and psychiatric symptoms. Sudden death is rare and lumbar puncture might be a precipitating factor.

There is a large consensus to treat all the colloid cysts which are symptomatic or which induce progressive enlargement of the lateral ventricles. Rapidly progressive or paroxysmal headaches should be considered as a real emergency.

Neuropsychological assessment could be useful before surgery but is not easily performed in emergency cases. Neuroradiological assessment should include computed tomography (CT) and magnetic resonance imaging (MRI) scans.

CT imaging of colloid cysts mostly reveals a homogeneous well-defined rounded mass at the foramina of Monro which often is (slightly) hyperdense with respect to the brain, but may occasionally be hypodense or isodense to it, associated with hydrocephalus, sometimes in combination with periventricular hypodensities. A spontaneous hyperintensity may predict surgical difficulties.

In MR imaging, colloid cysts (Fig. 1) have a varied appearance but are usually homogeneously hyperintense on T1-weighted images and hypointense on T2-weighted images. The T2 signal intensity of the central portion of a colloid cyst can be low, probably related to cholesterol esters. The hypointensity on T2-weighted images may predict difficulty of aspiration during endoscopic procedures [8].



**Fig. 1.** **A** Noncontrast CT scan of hyperdense colloid cyst. **B** Sagittal MR T2 view of isointense colloid cyst. **C** Axial T2-weighted MRI of hypodense colloid cyst

## **SURGERY**

### **1. PREPARATION OF THE PATIENT**

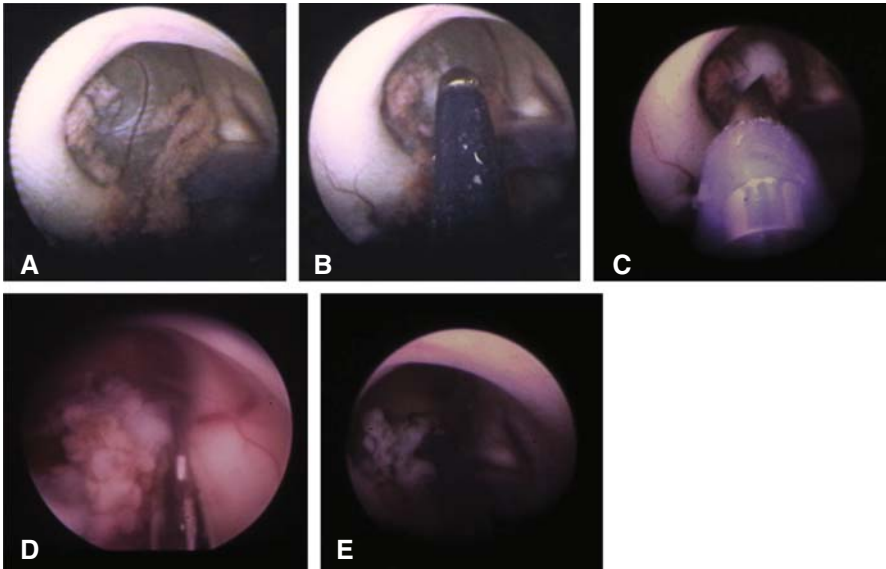
The procedure is performed under general anesthesia, the patient in decubitus with a slight head flexion of 20–30°. It is recommended to use an endoscope holder to secure the movement of the sheath. For that purpose, the head should be fixed in a Mayfield clamp to avoid any involuntary head movement (the alternative is to use curarization). Prophylactic antibiotics are recommended because it is a more than one hour procedure with the opening of the ventricular cavities. There is no need for anticonvulsant therapy as it is a percutaneous procedure.

### **2. EQUIPMENT**

The endoscope should have the possibility to be fixed in a holder arm and should have instrumental channels as large as possible (channels with a diameter of 3 mm allow the use of quite large instruments, mainly cannulas to aspirate the viscous cyst content). Both the telescope and the light source cable have to be controlled to ensure the optimum quality of vision. This point is very important because the procedure will take more than one hour and some blood and cyst debris and content may progressively obscure the field despite irrigation. The use of a 3-CCD (charge-coupled device) or better a high-definition camera also has to be considered for that purpose. The endoscopic instrumentation is not very developed. Nevertheless, for this indication, puncture needles are very useful with transparent aspiration cannula (inner diameter of more than 2 mm) to control cyst evacuation. Microscissors with only one mobile branch are much easier to control than conventional microscissors with two mobile branches. Conventional grasping and biopsy forceps as well as mono- and bipolar tools are always very useful. Neuronavigation has to be considered.

### **3. OPERATIVE TECHNIQUE**

A 4 cm linear skin incision is made parallel to the midline, 4 cm laterally and 4 cm in front of the coronal suture. After a 1 cm diameter burr hole has been drilled, the dura is incised and the endoscope introduced. If the ventricles are not large enough to allow safe freehand guided introduction of the neuroendoscope, stereotactic guidance or neuronavigation is recommended. The entrance side is chosen taking into account ventricular size and extension of the cyst. A right-sided approach is chosen unless the cyst is far more prominent through the left foramen of Monro or the right ventricle is too small. The cyst is immediately visible through the foramen of Monro, which is filled with the cyst. It is sometimes covered by some choroid plexus. It is important to mention that after identification of the foramen, the endoscopic sheath will re-



**Fig. 2.** **A** Third ventricular cyst obstructing the foramen of Monro. **B** Coagulation of the outer cyst wall. **C** Puncture of the cyst with subsequent aspiration of its contents. The transparent cannula permits control of aspiration. **D** Opening of the cyst wall with microscissors. **E** Coagulation and removal of remnants

main in the lateral ventricle all along the surgery, with the surrounds of the foramen of Monro always visible, to avoid any damage on these structures. The entire visible cyst wall is coagulated with a bipolar probe and then punctured and the cyst content is aspirated (Fig. 2). When the cyst content is too viscous, the opening of the capsule is enlarged with microscissors and aspirated with large cannulas. Smallest aspiration cannulas could be useful at this stage to slightly dissect the stiffest part of the content from the capsule. When a large part of the cyst content is aspirated, the capsule is caught by a grasping forceps and slowly pulled towards the lumen of the lateral ventricle. Without any adhesions and venous bleeding, the entire cyst capsule could be removed that way and a total removal is achieved. When the cyst appears to be strongly attached to the choroid plexus, it is recommended not to continue to pull, because bleeding may occur. The cyst capsule insertion is then coagulated and sectioned, with additional coagulation of its insertion site. This manoeuvre is not easy to perform, requiring bimanual instrumentation: one hand manipulates a grasping forceps pulling the cyst wall, the other hand manipulates the above described microscissors to cut the cyst insertion. The best is to dispose one large channel allowing the introduction of both instruments which could move one from the other. The microscissors could turn around the forceps by acting on its mobile branch to be placed on the exact position for the required



purpose. Finally, in some cases, the adhesions are very stiff and the cyst capsule is left in place. It is opened and coagulated as much as possible with an outside and inside coagulation.

In rare cases, the cyst develops posteriorly to the foramen, which appears to be closed without any visible cyst. In those cases, a posterior puncture could be done through the most prominent part of the deformation, as cranial as possible to avoid the fornix.

Additional procedures could be done during the same surgery, mainly a pellucidostomy or an endoscopic third ventriculostomy if needed.

#### 4. POSTOPERATIVE COMPLICATIONS

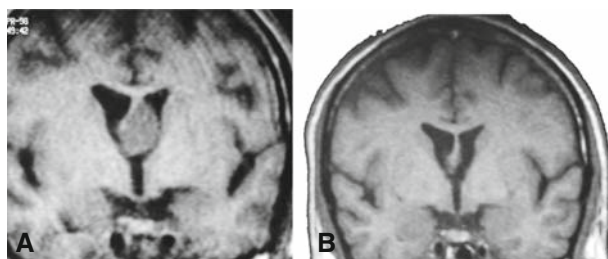
In a retrospective study of 90 patients who underwent an endoscopic resection of a colloid cyst from February 1994 to September 2007 at Radboud University Nijmegen, the Netherlands (41 cases) and Hôpital Henri Mondor, France (49 cases), the following complications have been observed [4].

Permanent morbidity occurred in 2 patients, 1 patient presented with memory deficit preoperatively which persisted postoperatively, and 1 patient died from unknown cause during hospitalization one week postoperatively the night before planned discharge: emergency external drainage revealed no high pressure, cardiovascular resuscitation was unsuccessful, postmortem examination was not allowed.

Transient morbidity was septic meningitis in 1 patient; aseptic meningitis in 10; transient memory deficit in 9; transient organic psychosyndrome in 2; transient hemiparesis in 1; transient visual deficit in 2, of whom 1 patient had a Terson syndrome; pulmonary embolism in 1; wound infection in 1; and CSF leak in 1. A single postoperative seizure occurred in 1 patient two weeks after surgery. No patient developed a persistent seizure disorder.

#### 5. LONG-TERM RESULTS

The appearances in postoperative MR imaging were divided into 3 groups: group A, no cyst or membrane visible; group B, free floating membrane, with



**Fig. 3.** **A** Preoperative coronal T1-weighted MRI. **B** Postoperative MRI (after 1.5 years) shows no remnant or obstruction of the foramen of Monro

**Table 1.** Results of endoscopic colloid cyst removal

Author(s)	Year of publication	Nr. of cases	Nr. of Clinically relevant complications	Nr. (%) of cases with initial total or nearly total endoscopic removal	Reoperation	Mean (range) follow-up <sup>a</sup>
Kehler et al.	1994	10	1 septic meningitis, 1 intraoperative bleeding, 1 stitch granuloma, 1 mispuncture of ventricle	3 (30)	1	19 mo (2–47 mo)
Lewis et al.	1994	7	right basal ganglia infarction, short-term memory loss	7 (100)	0	N.R. <sup>b</sup>
Abdou et al.	1998	13	3 transient memory deficit, 2 hydrocephalus requiring postoperative shunt placement	9 (69)	1	48 mo (6–84 mo)
King et al.	1999	14	1 transient memory deficit, transient hemiparesis	11 (78)	0	25 mo (3–38 mo)
Teo	1999	18	1 transient memory deficit, 2 aseptic meningitis	18 (100)	0	32 mo (8–52 mo)
Rodziewicz et al.	2000	12	1 transient memory deficit	N.R.	2	173 wk
Schroeder et al.	2002	12	1 transient memory deficit	8 (67)	0	56 mo (12–93 mo)
Hellwig et al.	2003	20	1 permanent memory deficit, 1 aseptic meningitis, third cranial nerve palsy, unconsciousness, psychosis, shunt infection; revision, salt wasting syndrome	17 (85)	1	64 mo (1–10 yr)
Longatti et al.	2006	61	1 septic meningitis, 1 temporary hemiparesis, 1 communicating hydrocephalus, 3 early intraventricular hemorrhages, 1 trajectory hematoma	23 (38)	3	32 mo (1–132 mo)
Boogaarts et al.	2007	90	1 death, 1 permanent memory deficit, 10 aseptic meningitis, 1 bacterial meningitis, 2 transient organic psychosyndrome, 2 transient visual deficit, 1 seizure, 1 pulmonary embolism, 1 superficial wound infection, 1 transient hemiparesis, 1 asymptomatic subdural hematoma	46 (51)	6	50 mo (70 d to 11.1 yr)

<sup>a</sup>d, days; wk, weeks; mo, months; yr, years. <sup>b</sup>N.R., not reported

content similar to CSF on MRI; group C, residual cyst with content different from CSF on MRI.

In the retrospective study mentioned above, MRI follow-up was available for 80 patients. Total cyst removal (group A) was possible in 41 patients (51.3%) (Fig. 3) and nearly total removal (group B) in 5 (6.3%). A residual cyst (group C) was present in 34 patients (42.5%). In group C, 6 patients required reoperation (7.5% of total and 17.6% of those in group C). Repeated endoscopy could be performed without difficulties in all 6 patients, of whom 1 required a third operation. For those 6 patients, postoperative MR imaging showed no residual cyst in 3 cases (group A), a membrane in 1 (group B) and a residual cyst in 1 (group C). A review of the literature regarding results and complications of endoscopic management of colloid cysts is summarized in Table 1.

## **HOW TO AVOID COMPLICATIONS**

Endoscopic treatment of a colloid cyst is not an easy procedure and should be done by an experienced endoscopist. As conventional microsurgery, it should be performed step by step under a good visual control. The use of an arm holder helps for that purpose, avoiding additional and involuntary movements of the endoscope and to perform safely all the steps. After frontal ventricular puncture and identification of the foramen, the endoscopic sheath has to remain in the lateral ventricle all along the surgery, with the surrounds of the foramen of Monro always visible, to avoid any damage on these structures. And as for all endoscopic procedures, the movements of the endoscope have to be as smooth as possible.

The main point is about the aim of the procedure: We have to keep in mind that a safe partial removal with coagulation of the remnant is mostly preferable to a “blind” and uncontrolled pulling of the cyst in case of strong adhesions, which could be followed by ventricular hemorrhage and damages of periventricular structures. A coagulated remnant does not lead to systematic recurrence. And an endoscopic procedure could be easily repeated, which is not the case with microsurgical approaches. Moreover, recurrences could always occur, even rarely after microsurgical removal.

## **CONCLUSIONS**

There is a consensus to state that symptomatic colloid cysts of the third ventricle should be treated. The immediate aim of surgery is to free the CSF pathways in order to prevent blockage of the ventricles which could lead to sudden death and to decompress the periventricular structures. Recurrences could appear after a long period of time and are ideally avoided by total removal of the colloid cyst capsule. Endoscopic treatment of colloid cysts offers a real mini-

mally invasive possibility to treat hydrocephalus and to remove totally the cyst in around two-thirds of the cases (on MRI control) with a low morbidity rate. Total removal can best be accomplished with the microsurgical approach but the morbidity is not neglectable. Because both treatment modalities have pros and cons, the ultimate choice is definitely related to the experience of the neurosurgeon. No doubt, with increased endoscopic experience over the world, more and more colloid cysts will be treated endoscopically.

## References

- [1] Abdou MS, Cohen AR (1998) Endoscopic treatment of colloid cysts of the third ventricle. Technical note and review of the literature. *J Neurosurg* 89: 1062-1068
- [2] Beems T, Menovsky T, Lammens M (2006) Hemorrhagic colloid cyst. Case report and review of the literature. *Surg Neurol* 65: 84-86
- [3] Bertalanffy H, Kretzschmar H, Gilsbach JM, Ott D, Mohadjer M (1990) Large colloid cyst in lateral ventricle simulating brain tumor. Case report. *Acta Neurochir (Wien)* 104: 151-155
- [4] Boogaarts HD, Decq P, Grotenhuis JA, Beems T, Le Guérinel C, Palfi S, Kéravel Y (2007) Traitement endoscopique des kystes colloïdes du troisième ventricule. Résultats en 2007. Société de Neurochirurgie de Langue Française, Paris
- [5] Buttner A, Winkler PA, Eisenmenger W, Weis W (1997) Colloid cyst of the third ventricle with fatal outcome: a report of two cases and review of the literature. *Int J Legal Med* 110: 260-266
- [6] Dandy WE (1933) Benign tumors in the third ventricle of the brain: diagnosis and treatment. Williams & Wilkins, Baltimore, pp 4-37
- [7] Decq P, Le Guérinel C, Brugières P, Djindjian M, Silva D, Kéravel Y, Melon E, Nguyen JP (1998) Endoscopic management of colloid cysts. *Neurosurgery* 42: 1288-1294
- [8] El Khoury C, Brugières P, Decq P, Cosson-Stanescu R, Combes C, Ricolfi F, Gaston A (2000) Colloid cyst of the third ventricle: are MR imaging patterns predictive of difficulty with percutaneous treatment? *Am J Neuroradiol* 21: 489-492
- [9] Gaab MR, Schroeder HWS (1998) Neuroendoscopic approach to intraventricular lesions. *J Neurosurg* 88: 496-505
- [10] Hamlat A, Pasqualini E, Askar B (2004) Hypothesis about the physiopathology of acute deterioration and sudden death caused by colloid cysts of the third ventricle. *Med Hypotheses* 63: 1014-1017
- [11] Hellwig D, Bauer BL, Schulte M, Gatscher S, Riegel T, Bertalanffy H (2003) Neuroendoscopic treatment for colloid cysts of the third ventricle: the experience of a decade. *Neurosurgery* 52: 525-533

- [12] Kehler U, Brunori A, Gliemroth J, Nowak G, Delitala A, Chiappetta F, Arnold H (2001) Twenty colloid cysts – comparison of endoscopic and microsurgical management. *Minim Invasive Neurosurg* 44: 121-127
- [13] King WA, Ullman JS, Frazee JG, Post KD, Bergsneider M (1999) Endoscopic resection of colloid cysts: surgical considerations using the rigid microscope. *Neurosurgery* 44: 1103-1111
- [14] Lewis AI, Crone KR, Taha J, Van Loveren HR, Yeh HS, Tew JM (1994) Surgical resection of third ventricle colloid cysts. Preliminary results comparing transcallosal microsurgery with endoscopy. *J Neurosurg* 81: 174-178
- [15] Lobosky JM, Vangilder JC, Damasio AR (1984) Behavioural manifestations of third ventricular colloid cysts. *J Neurol Neurosurg Psychiatry* 47: 1075-1080
- [16] Longatti P, Godano U, Gangemi M, Delitala A, Morace E, Genitori L, Alafaci C, Benvenuti L, Brunori A, Cereda C, Cipri S, Fiorindi A, Giordano F, Mascari C, Oppido PA, Perin A, Tripodi M (2006) Cooperative study by the Italian neuroendoscopy group on the treatment of 61 colloid cysts. *Childs Nerv Syst* 22: 1263-1267
- [17] Pollock BE, Huston J (1999) Natural history of asymptomatic colloid cysts of the third ventricle. *J Neurosurg* 91: 364-369
- [18] Pollock BE, Shreiner SA, Huston (2000) A theory on the natural history of colloid cysts of the third ventricle. *Neurosurgery* 46: 1077-1083
- [19] Powell MP, Torrens MJ, Thomson JLG, Horgan JG (1983) Isodense colloid cysts of the third ventricle: a diagnostic and therapeutic problem resolved by ventriculocopy. *Neurosurgery* 13: 234-237
- [20] Rodziewicz GS, Smith MV, Hodges CJ (2000) Endoscopic colloid cyst surgery. *Neurosurgery* 46: 655-662
- [21] Schroeder HWS, Gaab MR (2002) Endoscopic resection of colloid cysts. *Neurosurgery* 51: 1441-1445
- [22] Sjoval E (1910) Über eine Ependymcyste embryonalen Charakters (Paraphyse?) im dritten Hirnventrikel mit tödlichem Ausgang. Zugleich eine Beobachtung wahrer lipochromer Veränderungen mit Auftreten von Halbmondkörperchen. *Beitr Pathol Anat* 47: 248-269
- [23] Teo C (1999) Complete endoscopic removal of colloid cysts: issues of safety and efficacy. *Neurosurg Focus* 6(4): article 9
- [24] Witzig EP (1982) Etude statistique du kyste colloïde du troisième ventricule (pre-tendu kyste de la paraphyse). Serie anatomo-clinique de 75 cas. *Acta Neurol Belg* 82: 281-299



### **Philippe Decq**

Philippe Decq is Professor of Neurosurgery at the University of Paris XII and Neurosurgeon at the University Hospital Henri Mondor, Creteil, France. He is a member of the French Society of Neurosurgery, the French-speaking Society of Neurosurgery, the European and the World Societies of Neurosurgery, and the European and the World Societies of Stereotactic and Functional Neurosurgery; associated member of the Chilean Society of Neurosurgery; and honorary member of the German Society of Neurosurgery. He was president of the 2007 World Congress of Neuro-Endoscopy. His topics of interest are functional neurosurgery of spasticity, rehabilitation after stroke, and endoscopy of the brain and the skull base.

**Contact:** Philippe Decq, Université Paris XII, Department of Neurosurgery, Assistance Publique – Hôpitaux de Paris, Henri Mondor Hospital, 94040 Creteil Cedex, France  
E-mail: [philippe.decq@hmn.aphp.fr](mailto:philippe.decq@hmn.aphp.fr)

---

# MANAGEMENT OF PINEAL REGION TUMORS

N. DE TRIBOLET

## INTRODUCTION

Pineal region tumors include a variety of neoplasms of different histological origin growing from the pineal gland itself or from structures of the parapineal space. These tumors are rare and account for 0.4 to 1.0% of intracranial tumors in adults and 3.0–8% in children. The most common types are germ cell tumors, pineal parenchymal cell tumors and glial cell tumor. Other pineal region tumors such as meningiomas, PNET, neurocytomas, hemangioblastomas, cavernomas and metastasis are infrequent.

The treatment options for the different pineal region tumors vary according to their histological nature. However, with the exception of germinomas which can be nowadays cured by low-dose radiotherapy and chemotherapy and only require a biopsy for diagnosis, surgery still plays a central role in the management of most of the other pineal region tumors followed or not by adjuvant radiotherapy, chemotherapy or a combination of both.

The first successful removal of a pineal tumor was reported in 1913 by Oppenheim and Krause. In the following decades, several surgical approaches to the pineal gland have been described such as the parietal parasagittal transcallosal approach by Dandy in [2] or the transventricular approach by Van Wagenen in [12]. Krause was the first to describe and successfully use the infratentorial supracerebellar approach in three cases [4]. In the microsurgical era, Stein further developed and popularized this approach during the 1970s [11]. Finally the right suboccipital approach was described by Poppen and further modified by Jamieson in [3].

The infratentorial supracerebellar and the occipital transtentorial approaches are nowadays accepted as the main standard accesses to the pineal region.

## RATIONALE

For benign pineal tumors (pineocytoma, meningioma, neurocytomas, mature teratomas, hemangioblastomas, cavernous hemangiomas, gangliogliomas, and symptomatic pineal cysts) total surgical resection is a primary goal as surgery alone can be curative [1, 9]. For malignant tumors surgery is only a part of the treatment which will consist of adjuvant therapies and therefore radical surgical resection is not an objective [9, 10]. In all cases focus should

---

*Keywords:* neuro-oncology, pineal region, tumor, surgery, anatomy

be given to reduce post treatment morbidity. Pineal region tumors lie deep in the center of the cranium and are surrounded by critical anatomical structures that have to be respected at all costs. Therefore, a precise knowledge of the complex anatomy of the pineal region and the structures encountered approaching the pineal gland is of paramount importance [6, 7, 9].

The pineal gland is located on the midline and forms an appendix of the caudal end of the diencephalons embracing the pineal recess of IIIrd ventricle. The pineal stem is continuous with the habenular commissure dorsally and the posterior commissure ventrally. The pineal body projects posteriorly in the quadrigeminal cistern where it is flanked by the splenium of the corpus callosum superiorly and lies on the tectal quadrigeminal plate in-between the left and right superior colliculi. The velum interpositum covers the posterior aperture of the IIIrd ventricle over the habenular commissure and contains the internal cerebral veins as they exit the ventricle to join the Galenic venous system as well as the medial choroidal arteries. The pineal gland is mainly vascularized by the medial and lateral posterior choroidal arteries. The medial posterior choroidal arteries are branches of the peduncular segment of the posterior cerebral artery and in addition to the pineal body they supply the superior and inferior colliculi, and the choroidal plexus of the third ventricle. These arteries pass-by lateral to the pineal body and are displaced laterally by pineal tumors in the cistern and rostrally in the posterior part of the third ventricle together with the velum interpositum and internal cerebral veins. The posterior lateral choroidal artery supplies the pulvinar and is generally displaced laterally by pineal tumors. Other important arterial landmarks are the superior cerebellar arteries that can be displaced inferiorly by pineal tumors and the medial occipital artery branching from the posterior cerebral artery and giving the calcarine artery.

During surgical approaches to the pineal gland, the major anatomical obstacle is the venous system. The pineal region and the quadrigeminal cisterns are in close relation with the Galenic venous system. The vein of Galen has several tributaries: the superior vermian vein and the precentral cerebellar vein run in the midline and into the dorsocaudal part of the great vein. The internal cerebral veins and the pineal veins join ventrally. In pineal tumors, the posterior portion of the internal cerebral veins is always elevated rostrally, and the veins are occasionally separated from each other. On the lateral aspect of the great vein, the medial occipital veins, the third segment of the basal veins of Rosenthal, and the posterior mesencephalic veins join. The pineal veins are the draining veins of pineal tumors and drain into either the posterior portion of the internal cerebral veins or the vein of Galen. At this point pineal tumors are tightly adherent to the internal cerebral vein and/or the vein of Galen. The superior vermian vein, the precentral cerebellar vein, and the pineal veins can be sacrificed, but all the other veins must be preserved. An injury to the basal veins or the internal cerebral veins will yield major complications. And a transection of a major medial occipital vein may cause homonymous hemianopsia or visual seizures.



## DECISION-MAKING

### 1. DIAGNOSIS

#### 1.1 Clinical presentation

Symptomatic hydrocephalus or oculomotor signs are generally the first clinical manifestation of pineal region tumors. Hydrocephalus is triventricular by compression of the aqueduct of Sylvius and can be acute or chronic. Symptoms include headaches, gait problems and oculomotor signs such as Parinaud syndrome. In slow growing tumors, chronic hydrocephalus may develop and cause dementia. Oculomotor signs can also occur through direct compression of the superior colliculi or the posterior commissure [9].

#### 1.2 Radiology

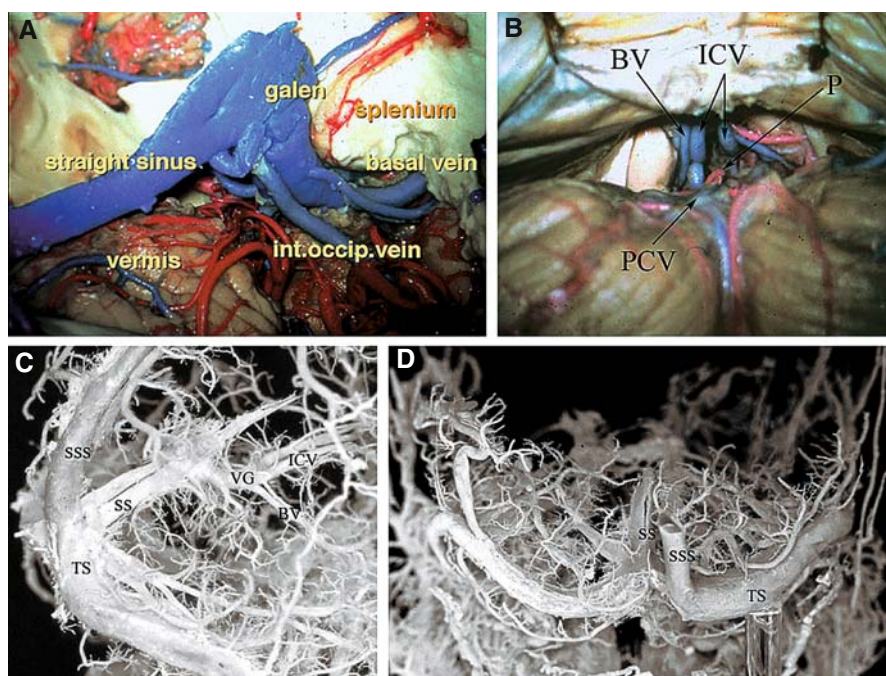
The radiological exam of choice is MRI which will reveal the tumor and its relations to adjacent anatomical structures. Particular attention has to be given to T1+ gadolinium sequences, high resolution T2 sequences for surrounding vessels (flow void) and cranial nerves, phlebo-MRI sequences for assessing the 3D anatomy of the deep venous system and its relation with the tumor. A CT is also useful to detect intratumoral calcifications or hemorrhage. Even if the many different pineal tumor types may have a preferential appearance on cranial imaging, no such characteristics are specific for one or another tumor type and do not preclude obtaining tissue for histological examination. An exception are benign pineal cysts which have a homogenous cyst content with a thin enhancing rim and have no or only mild mass effect on surrounding structures. Except for pineal region meningiomas or falcotentorial notch meningioma extending in the pineal region, angiography is usually not necessary [9].

#### 1.3 Markers

Serum and CSF markers contribute to the diagnosis of pineal parenchymal tumors and assessment of their malignancy. BHCG and  $\alpha$ -foetoprotein are found in germ cell tumors.  $\beta$ -HCG is mainly positive in choriocarcinomas, embryonal carcinomas and mixed germ cell tumors and AFP is expressed by yolk sac tumors (high levels), embryonic carcinomas, immature teratomas and mixed germ cell tumors.  $\beta$ -HCG is usually low in germinomas which are often positive for PLAP on immunohistochemistry [8].

#### 1.4 Biopsy

Histological diagnosis is obtained either by stereotactic or endoscopic transventricular biopsy or directly during open surgery. For large pineal tumors a stereotactic biopsy is a safe initial procedure to obtain diagnosis. For tumors

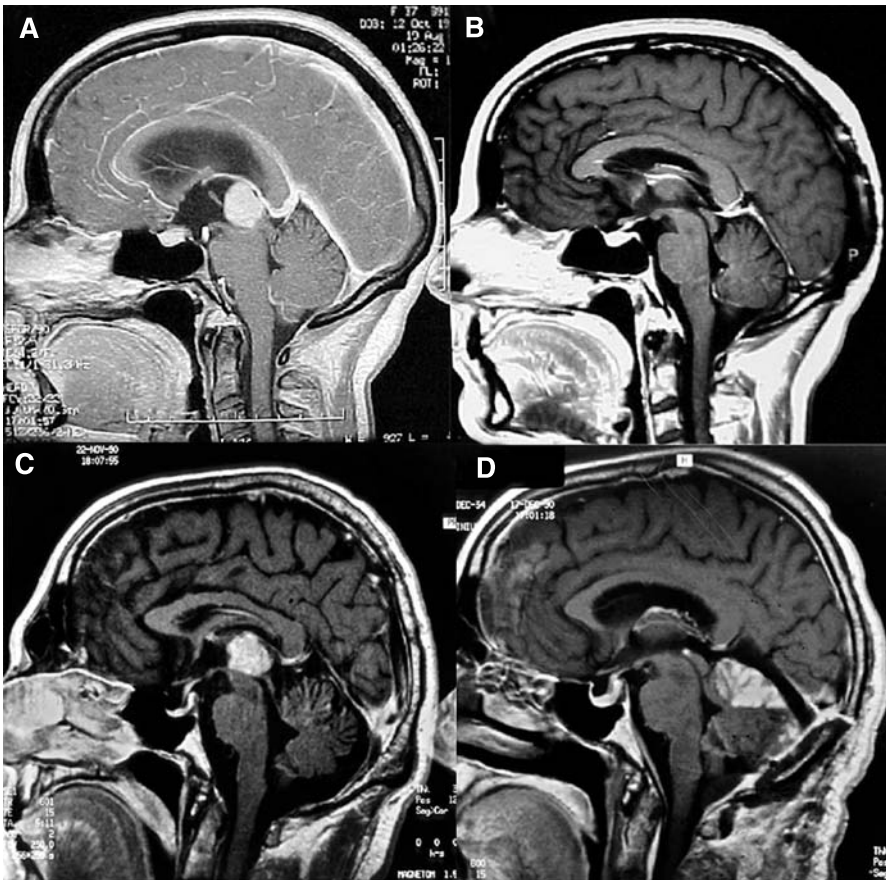


**Fig. 1.** **A** Anatomical view of the neurovascular structures as seen during a right occipital transtentorial approach (the right occipital lobe was removed). **B** Anatomical view of neurovascular structures as seen during the supracerebellar transtentorial approach. **C** and **D** Cast of the venous system showing the deep veins, the venous sinuses and the anastomotic collateral network as exposed during the occipital transtentorial (**C**) and infratentorial supracerebellar approach (**D**). *BV* Basal vein; *ICV* internal cerebral vein; *P* pineal body; *PCV* precentral cerebral vein; *SSS* superior sagittal sinus; *SS* straight sinus; *TS* transverse sinus; *VG* vein of Galen

extending into the posterior part of the third ventricle, endoscopic transventricular biopsy allows access to tumor tissue as well as third ventriculostomy to treat hydrocephalus [9].

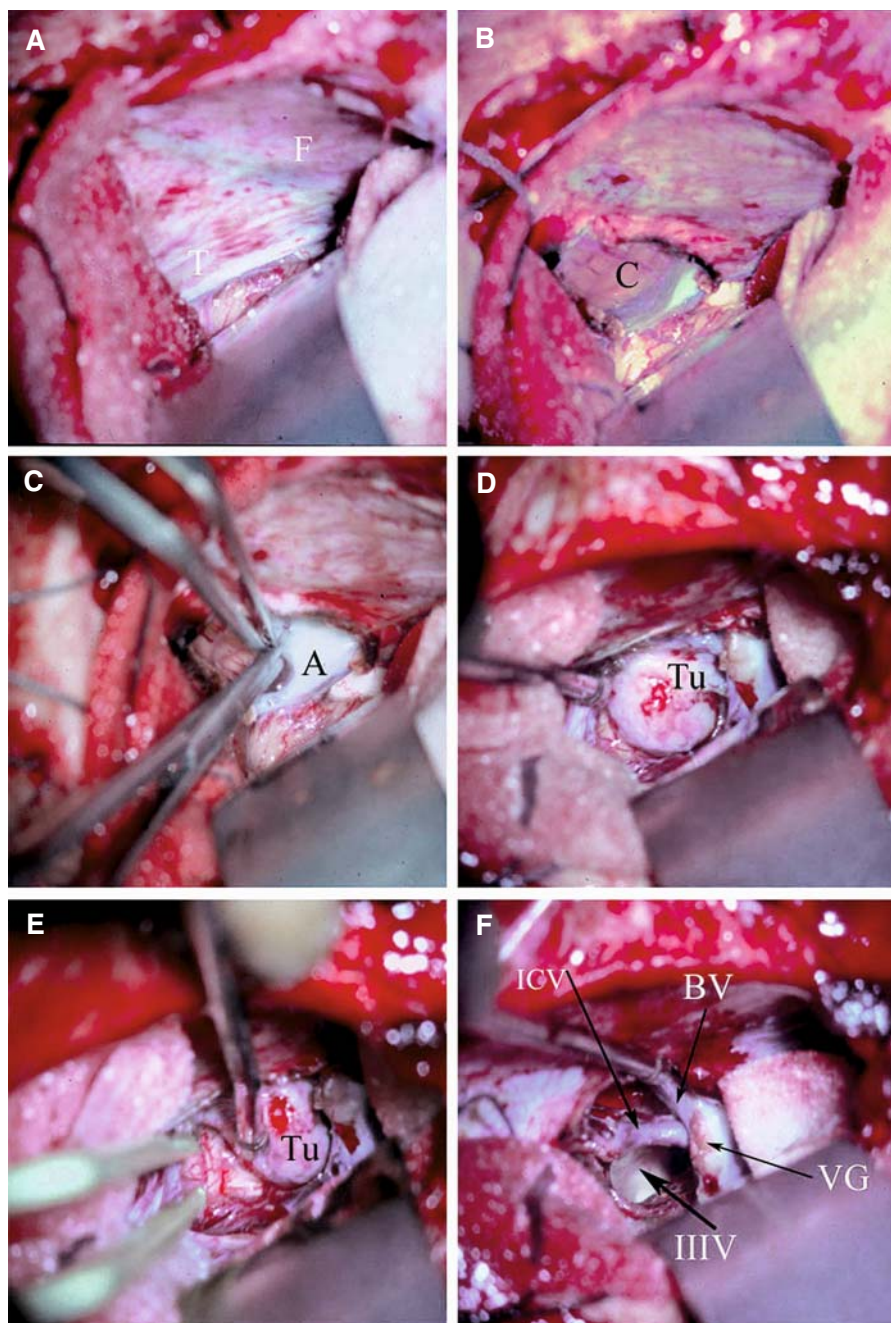
## 2. INDICATIONS

If a newly diagnosed pineal mass is accessible by stereotactic or endoscopic biopsy and the cranial MRI is compatible with a germinoma, a biopsy should first be done in order to avoid an unnecessary craniotomy in that case. If the radiological examination is compatible with an asymptomatic benign pineal cyst and the serum and CSF markers are negative, the patient can be followed up without treatment. The treatment of other pineal tumors requires surgery but the choice of radical or conservative resection will depend on the diagnosis of the pre-surgical biopsy or the intraoperative



**Fig. 2.** Two examples pineal region tumors. **A** Sagittal MRI section (T1+ gadolinium) of a pineal lesion removed by the occipital transtentorial approach. Note the steep angle of the straight sinus and the position of the lesion anteriorly to the quadrigeminal plate making a supracerebellar infratentorial approach difficult. **B** Postoperative MRI of the patient described in (**A**). **C** Sagittal MRI section (T1+ gadolinium) of a pineal region removed by the infratentorial supracerebellar approach. The lesion is above the quadrigeminal plate and although the angle of the straight sinus is somewhat steep as well, the infratentorial approach offers a direct access to this lesion. **D** Postoperative MRI of the patient described in (**C**)

frozen section. Benign tumors such as mature teratomas, pineocytomas or meningiomas require radical surgical resection when feasible without compromising surrounding neurovascular structures. More aggressive tumors, such as malignant teratomas, pinealoblastomas, embryonal carcinomas, choriocarcinomas and yolk sac tumors require a combination of surgery, radiation therapy and chemotherapy. In any case the prime goal of surgery should be avoiding surgical morbidity even at the cost of a less radical surgical resection.



The choice of approach is a matter of evaluating the anatomical relation of the tumor with the surrounding structures. A steep angle of the straight sinus makes the infratentorial supracerebellar approach difficult as an extensive retraction of the cerebellum is required to visualize and reach the pineal area. Moreover, in that case the lateral exposure of the surgical field is restricted and renders the resection of larger tumors more complicated. Evaluating the relationship of the tumor with the quadrigeminal plate is also important. For smaller midline tumors located in the posterior part of the third ventricle and displacing the quadrigeminal plate and the tegmentum of the midbrain caudally, the infratentorial supracerebellar approach is favored as it allows simple, direct and symmetrical exposure of the walls of the third ventricle and internal cerebral veins on both sides. In the case the tumor lies more caudally and extends in the upper portion of the aqueduct of sylvius, lying therefore cranially of the tectum, the infratentorial approach is inappropriate as the quadrigeminal plate obstructs the surgical exposure. Finally, the occipital transtentorial approach is preferred as well in big tumors with lateral extension in the pulvinar thalami as it gives a better lateral exposure of the walls of the third ventricle [9].

### 3. CHECKLIST FOR PREOPERATIVE ASSESSMENT

- Complete clinical and neurological examination
- Neuroophthalmological assessment
- MRI and CT scan, MRI of the brain and spinal cord
- Serum and CSF markers: BHCG, AFP, PLAP
- Angiography only in meningiomas

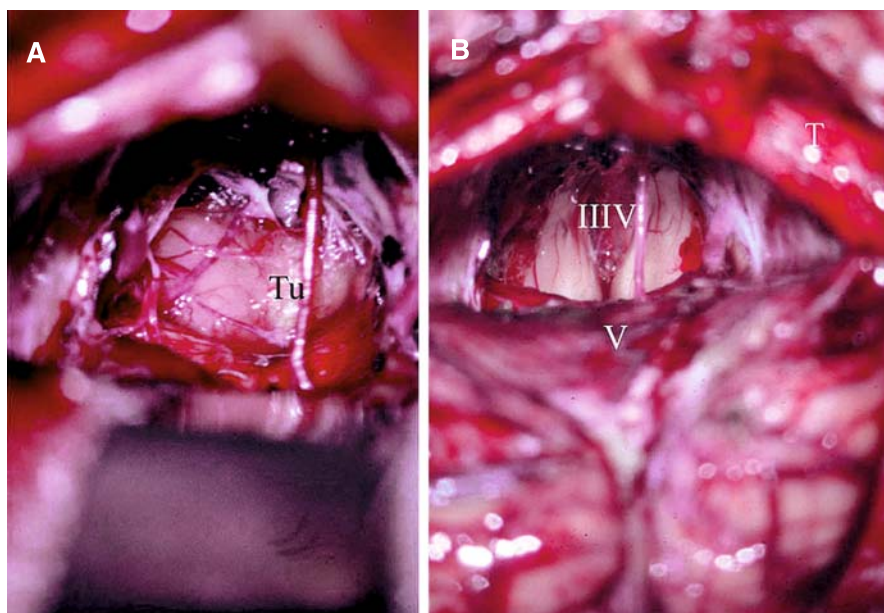
## SURGERY

### 1. THE OCCIPITAL TRANSTENTORIAL APPROACH

The occipital transtentorial approach can be performed with the patient installed in a prone, park-bench (semi prone) or sitting position. In the park-bench position, which we currently favour, the head is flexed forwards with the nose pointed down allowing the occipital lobe to fall aside with the aid of gravity.

←

**Fig. 3.** Surgical steps of a right occipital transtentorial approach. **A** Initial view of the falco-tentorial rige and the straight sinus. **B** Cutting of the tent along the straight sinus allows visualization of the cerebellum and opens the way to the quadrigeminal cistern. **C** Opening of the thick arachnoid layers of the arachnoid cisterns. **D** After dissecting the arachnoid, the tumor comes into full view. **E** Resection of the tumor with dissection of the capsule from surrounding structures. **F** Final view of the operative field after resection of the tumor, under the corpus callosum the posterior part of the third ventricle is visible. The great vein of Galen and the left basal vein are also visible. *F* Falx, *T* tent, *SS* straight sinus, *C* cerebellum, *A* arachnoid, *T* tumor, *VG* vein of Galen, *BV* Basal vein, *ICV* internal cerebral vein; *III/V* third ventricle



**Fig. 4.** Surgical view of the infratentorial supracerebellar approach. **A** initial midline view of the pineal region before tumor resection. **B** Final view after tumor resection, the lateral walls of the third ventricle are visible. Note one bridging vein in the middle of the field that was spared. *Tu* Tumor, *IIIIV* third ventricle, *T* tent

The side of the approach is chosen considering the direction of tumor extension, the shape of the *torcular*, and the location of major occipital bridging veins, although in general, large cortical bridging veins are rarely present in the occipital area. All this taken into consideration we usually prefer approaching from the right side whenever possible.

The skin incision is made in an inverted U-shape over the right occipital region starting 1.5 cm on the left of the occipital protuberance, extending upward parallel to the midline, next turning right and finally downward to reach the right mastoid. Alternatively, a linear occipital paramedian incision can be used. This should allow exposing the sagittal suture superiorly and the occipital protuberance inferiorly. Two burr holes on the midline, one over the torcular and another 4 to 6 cm apart and upward, allow detaching the dura from the superior sagittal sinus and the *torcular Herophili*. An occipital bone flap exposing 2 cm of the transverse sinus, the torcular and 4–6 cm of the superior sagittal sinus is elevated. The medial cut should extend 0.5 to 1 cm beyond the sagittal sinus to the left. The dura is opened in an inverted C-shape and turned over the superior sagittal sinus exposing the occipital lobe. The incision extends obliquely down to the torcular, leaving a sleeve of dura that will prevent the occipital pole bulging backwards. The dural flap is suspended toward the contralateral side with some traction on the sagittal sinus. The

occipital horn of the ipsilateral ventricle is taped to release CSF. The falx and tentorium are exposed and the tumor is visualized. As mentioned above no large occipital bridging veins are usually present, however when such veins are encountered, they could limit significantly the exposure. Nevertheless, they should be preserved as their sacrifice might cause a hemorrhagic infarction of the occipital lobe as we have encountered in one of our cases.

The surgeon then proceeds in the unilateral interhemispheric space between the falx and the medial side of the occipital lobe. When the patient is in the park-bench position, most of the time, the whole procedure can be done without placing any retractors on the occipital lobe which falls down with gravity and is deflated by CSF drainage. The straight sinus is followed until the incisura of the tentorium is exposed. The tentorial incision is made postero-anteriorly and begins 2 cm anterior to the torcular and 0.5 cm lateral to the straight sinus and proceeds parallel to the sinus until the falco-tentorial junction is reached. Great care should be taken not to injure the vein of Galen, which is sometimes adherent to or covered by the falco-tentorial dura.

After the tentorium has been divided, the dura reflected, one stay suture can be placed on the dura below the vein of Galen to increase the visibility superiorly and to the left. When the thick arachnoid covering the cistern of the great vein of Galen becomes visible, a retractor can be placed on the occipital lobe if necessary, avoiding an over-compression of the calcarine gyrus and an avulsion injury of the medial occipital veins. The dorsal aspect of the splenium comes then into sight. The arachnoid has to be cut first laterally and inferiorly on both sides avoiding injury to the deep venous system. The medial occipital vein is mobilized first allowing further release of the occipital lobe. An extensive dissection of the arachnoid tissue helps to expose the ipsilateral medial occipital vein, the pericallosal veins, the precentral cerebellar vein and the tributary veins. The superior vermian vein and the precentral vein can be coagulated and sectioned but in small tumors they can be preserved, this allows further dissection upwards and the identification of the great vein of Galen. If the tumor extends posteriorly, it will be apparent at this point. The dissection proceeds laterally towards the right ambient cistern to identify the P3 portion of posterior cerebral artery, the IVth cranial nerve emerging below the inferior colliculus, and the third segment of the basal vein. If the tumor is small, this can be done on both sides. If it is large, the contralateral side should be dissected after debulking of the tumor.

Inferiorly, the identification of the quadrigeminal plate will also depend on the position of the tumor. If the tumor is posterior, the quadrigeminal plate will be covered by it, whereas if it is more anterior, the quadrigeminal plate will be pushed backwards and downwards by the tumor making it easily identifiable after opening of the cistern. A careful inspection of the sagittal sections of the MRI will allow predicting these findings. The small arteries running in the arachnoid can be coagulated and divided; however, all the arteries vascularizing the quadrigeminal plate should be carefully preserved.

The dissection can proceed on both sides to separate the lateral aspect of the tumor from the pulvinar. The vascularization of the tumor usually comes from branches of the postero-median and postero-lateral choroidal arteries. During the dissection of the lateral part of the tumor, great care should be taken not to injure the basilar veins of Rosenthal. These veins will form an arch delimitating the supero-lateral borders of the operative field. In very large tumors, dissection can also proceed above these veins. The last part of the dissection enters the third ventricle and will handle the superior aspect of the tumor adherent to the velum interpositum, the internal cerebral veins, and the anterior aspect of the vein of Galen. One entry to the roof of the third ventricle is through the space between the vein of Galen and the splenium. It is usually not necessary to cut the splenium. Cutting the posterior pericallosal veins allows the splenium to be detached from the great vein. The bilateral internal cerebral veins will appear in the velum interpositum cistern. A dissection of the cistern will expose the anterior choroidal artery in the third ventricle as well as the ventral part of tumor. Another entry, which we actually favour, is below the vein of Galen and the internal cerebral veins. A subchoroidal trans-velum interpositum approach has also been described previously [5]. Very tough adherences may be encountered and it is wiser to leave some tumor behind rather than to damage the internal cerebral veins. If bleeding occurs, coagulation should be avoided and hemostasis achieved by packing surgical. After complete removal of the tumor, the surgeon will have a good view into the IIIrd ventricle and its left lateral wall. The right lateral wall however might be difficult to visualize. The view into the IIIrd ventricle can extend all the way to the foramina of Monroe and the lamina terminalis. Since an en-bloc removal of the tumor is rarely possible, all the different steps of this dissection should be preceded by a gentle and piece-meal intracapsular decompression of the tumor which will allow preparing excellent cleavage planes. This is particularly true for the separation of the tumor from the quadrigeminal plate and the periaqueductal tissue.

Care should be taken to “unplug” the aqueduct of Sylvius. When this is properly achieved, no postoperative drainage of CSF will be necessary.

Closure is done in the usual way with a running suture on the dura and the bone flap is fixed with titanium miniplates.

## **2. THE INFRATENTORIAL SUPRACEREBELLAR APPROACH**

After an endotracheal tube is placed under general anesthesia, the patient is installed in the sitting position. The standard preventive measures against air embolism including a central venous line, oesophageal Doppler and end-tidal CO<sub>2</sub> monitoring are mandatory and should be installed by an experienced neuro-anesthesiologist. The patient legs should be placed at the level of the heart to avoid excessive negative venous pressure in the operative field. Regularly, after each step of the procedure the surgeon has to remember



identifying and sealing any venous leak to avoid air embolism. A strait midline incision is made from 2 cm above theinion to the level of C2 or a couple of centimeters further down if the patient's neck is thick. Two paramedian burr holes are placed just below the torcular and the transverse sinus to facilitate cross cutting the midline crest of the suboccipital bone and sinus injury. A suboccipital craniotomy centered on the midline is made and the inferior edge of the transverse sinus and torcular are exposed by drilling. The foramen magnum does not need to be opened. The dura is incised in a dull U shape pediculated over the transverse sinus. If the patient does not have a ventricular drain, opening of the cisterna magna allows draining the CSF and relaxing the cerebellum which then shifts down with gravity and opens the supracerebellar access without considerable retraction. Under microscope magnification the superior surface of the cerebellum is carefully inspected and posterior bridging veins are cauterized and divided to access the thick arachnoid membranes covering the quadrigeminal cisterns. The superior verminan vein and the precentral vein need to be divided to open the field further to the quadrigeminal cistern. The arachnoid is sharply cut with microscissors taking great care not to injure the vein of Galen and the internal cerebral veins which lie posteriorly in the cistern. One good landmark is the straight sinus which can be followed on the midline of the tent to the vein of Galen. Once the several arachnoid layers are dissected and the vein of Galen and the internal cerebral veins are identified it is usually possible to visualize the basal veins joining the vein of Galen more laterally on each side. At this stage the Pineal tumor which usually lies in front of the veins and displace them laterally and posteriorly can be seen. A careful inspection of the tumor relations with surrounding structure should allow determining the plane of the tumor capsule. However, since the tumor might invade neural structures such as the thalamus, the midbrain or the anterior aspect of the tectal plate and adhere to vascular structures no attempt should be made to extirpate the tumor "en bloc". The tumor should be carefully resected intracapsularly in a piece-meal fashion or with ultrasonic aspiration always keeping in mind the tumor relations with surrounding structures in order to avoid breaking open the tumor limits. Once the tumor is debulked, the capsule, if there is one, could be mobilized and sharply dissected from the surrounding structures. After precise hemostasis, the jugular veins are compressed by the anaesthesiologist or the assistant to identify and seal any venous leak. The dura is then closed in a watertight fashion with a running suture and with the aid of fibrin glue, muscular patches or Tachosil. The bone flap is fixed with titanium miniplates and the muscles are closed tightly in several layers along the median raphe.

## HOW TO AVOID COMPLICATIONS

The first measure that has to be taken in order to avoid complications is a careful evaluation of the patient's anatomy and the location of the tumor in

order to choose the right approach as explained before. This will avoid confronting an unfavourable intraoperative situation due to poor visualization of the tumor limits and enhanced dead angles.

During the occipital transtentorial approach, hemianopsia and visual seizures are complications due to transient or permanent damage of the occipital lobe or more specifically the calcarine gyrus. Most often they are due to retraction of the occipital lobe and therefore care should be taken to minimize retraction by draining CSF through a ventricular tap. Also, the occipital craniotomy could be placed 2–3 cm higher than the transverse sinus allowing a more superior and oblique approach along the medial occipital cortex avoiding the exposure of the calcarine gyrus. We have not used this strategy in our series but it can theoretically represent a way to decrease the risk of visual complications. Usually no bridging veins are present in the occipital area however if such veins are present their sacrifice might lead to hemorrhagic infarction of the occipital lobe. One should therefore carefully check the angiographic sequences on the preoperative MRI and consider an alternative approach if this is the case.

In the infratentorial supracerebellar approach, air embolism should be avoided by proper positioning of the patient, employing meticulous surgical technique and continuous and vigilant monitoring as discussed above. Cerebellar vermian infarction could occur, leading to transient or permanent gait problems due to excessive down retraction of the cerebellum and sacrifice of bridging veins over the superior surface of the cerebellum. Even if the sacrifice of bridging veins is needed to approach the pineal area we try to spare lateral veins that do not significantly interfere with the approach.

In both approaches, compromise of the deep venous return by injuring the internal cerebral veins, the vein of Galen or the basal veins can lead to permanent neurological deficit or death by massive venous infarction of the diencephalons, internal capsule and/or corticospinal tract. Direct neurological injury during tumor resection can lead to oculomotor signs such as skew deviation or Parinaud sign. Therefore, meticulous and patient microsurgical technique should be employed in order to avoid trauma to the deep veins, the thalamus, midbrain and tectal plate. If the surgeon feels the tumor is adherent to neuro-vascular structures and even with his or her best efforts, the patient is at risk of neurological damage; we cannot insist more that it is far more acceptable to leave a tumor residue than disabling the patient.

Finally, in patients with massively dilated ventricles tension pneumocephalus can occur and should be avoided by abundant irrigation with saline solution before closing the dura.

## **CONCLUSIONS**

Contemporary management of pineal tumors requires a multidisciplinary cooperation where surgery represents only one aspect of the treatment plan. How-


ever, with the exception of germinoma where only a biopsy is needed, the role of the surgeons still remains prominent as resection of pineal tumors requires high technical skill and experience as well as precise clinical judgment. The infratentorial supracerebellar approach and the occipital transtentorial approach when used appropriately allow access to nearly every type of pineal neoplasms.

### Acknowledgments

I thank Ivan Radovanovic who helped preparing this manuscript and Yutaka Sawamura for providing anatomical illustrations.

### References

- [1] Bruce JN, Stein BM (1995) Surgical management of pineal region tumors. *Acta Neurochir (Wien)* 134: 130-135
- [2] Dandy WE (1921) An operation for the removal of pineal tumors. *Surg Gynecol Obstet* 33: 113-119
- [3] Jamieson KG (1971) Excision of pineal tumors. *J Neurosurg* 35: 550-553
- [4] Krause F (1926) Operative Freilegung der Vierhügel, nebst Beobachtungen über Hirndruck und Dekompression. *Zentralbl Chir* 53: 2812-2819
- [5] Lavyne MH Jr, PRH (1983) Subchoroidal trans-velum interpositum approach to mid-third ventricular tumors. *Neurosurgery* 12: 86-94
- [6] Matsuno H, Rhoton AL Jr, Peace D (1988) Microsurgical anatomy of the posterior fossa cisterns. *Neurosurgery* 23: 58-80
- [7] Ono M, Rhoton AL Jr, Peace D, Rodriguez RJ (1984) Microsurgical anatomy of the deep venous system of the brain. *Neurosurgery* 15: 621-657
- [8] Sawamura Y (1998) Overview for management. In: Sawamura YS, de Tribolet HN (eds.) *Intracranial germ cell tumors*. Springer, Wien New York, pp 169-191
- [9] Sawamura Y, de Tribolet N (2002) Neurosurgical management of pineal tumors. *Adv Tech Stand Neurosurg* 27: 217-244
- [10] Sawamura Y, de Tribolet N, Ishii N, Abe H (1997) Management of primary intracranial germinomas: diagnostic surgery or radical resection? *J Neurosurg* 87: 262-266
- [11] Stein BM (1971) The infratentorial supracerebellar approach to pineal lesions. *J Neurosurg* 35: 197-202
- [12] Wagenen WPV (1931) A surgical approach for the removal of certain pineal tumors. Report of a case. *Surg Gynecol Obstet* 53: 216-220



**Nicolas de Tribolet**

Nicolas de Tribolet is currently Professor emeritus at the University of Geneva. He was born in Switzerland in 1942. He completed medical school and his neurosurgical training in Lausanne. He completed a fellowship at the Massachusetts General Hospital where he started his research on brain tumors which in the following years developed into a major neuro-oncological laboratory. In 1980, he worked at UCSF as visiting neurosurgeon before being appointed Professor of Neurosurgery and Chairman of the Department of Neurosurgery of the University of Lausanne in 1984. In 1994 he directed the merge of the two University Departments of Neurosurgery of Geneva and Lausanne. He served as the chairman of the Division of Neurosurgery and as the Director of the Department of Clinical Neurosciences of the University Hospital of Geneva until 2007.

**Contact:** Nicolas de Tribolet, Division of Neurosurgery, Geneva University Hospitals and University of Geneva, 24 rue Micheli-du-Crest, 1211 Geneva, Switzerland  
E-mail: [nicolas.detribolet@unige.ch](mailto:nicolas.detribolet@unige.ch)

---

# EPIDERMOID/DERMOID CYSTS

T. P. DÓCZI

## INTRODUCTION

Intraspinal epidermoids were reported first in 1829. Epidermoids are rare tumors, amounting to 0.6% in the material of Cushing (1935), 0.66% in that of Foerster (1937), 1.8% in that of Tönnis' (1937) and 1.5% in that of Zülch (1939). The dermoids are even rarer, accounting for only 0.15% in the material of Cushing, and in that of Zülch [4]. Percival Baily was probably the first to publish an account of a successful operation for epidermoid (cholesteatoma, inclusion cyst, or pearly tumor) of the brain. Numerous reports on operations for epidermoid are to be found in the pre-CT/MR era, when it was generally agreed that, although complete extirpation of the tumor including the capsule was the ideal treatment, this was not often feasible, except in cholesteatomas of the calvarium. In intradural tumors it was rarely possible to remove the capsule completely because of its adherence to the blood vessels and sensitive nervous tissue [4]. With the advent of modern imaging and micro-neurosurgery, the proportions of epidermoids and dermoids identified within intracranial tumors have increased. However, they still account for fewer than 2% of intracranial tumors. The ratio of intracranial epidermoids to dermoids is 4:1, with epidermoid tumors typically becoming symptomatic during the third and fifth decades, whereas dermoids tend to occur in the paediatric age group. While the pioneers of macro-neurosurgery warned that complete extirpation of the capsule is practically never advisable or possible when the tumor was situated in brain areas adjacent to important blood vessels or cranial nerves, the goal of micro-neurosurgeons has been complete resection with as little morbidity as possible [10]. For Yaşargil, radical removal was possible in 47 patients with intracranial epidermoids, and 9 with dermoids, and the resection was subtotal due to involvement of the eloquent structures in only 1 infratentorial epidermoid and 1 dermoid tumor [10]. Samii achieved total resection in 30 (75%) of 40 patients with epidermoid cysts of the cerebellopontine angle (CPA); in 10 cases (25%), parts of the cyst capsule were left because they adhered to the brainstem and vascular structures of the CPA. One patient died of pulmonary aspiration and infection. At the follow-up examinations after a mean of 5.7 years, 93% of the patients were able to lead useful lives. Three cases of cyst regrowth were noted [6]. Yamakawa attained total resection in 47% of his patients with CPA masses, and subtotal resection in another 40% [5]. If the capsule is not removed,

---

*Keywords:* intracranial tumors, epidermoid cyst, dermoid cyst, tumor

recurrence is relatively frequent, but it is usually many years before a second operation is necessary. Modern imaging tools and microsurgery techniques have improved the completeness of cyst resection considerably and reduced the postoperative mortality and morbidity rates; however, there are still many cases in which complete resection is impossible without producing severe neurological deficits. In this chapter I attempt to answer the question of whether the management of epidermoid tumors has improved.

## **RATIONALE**

Epidermoids and dermoids are benign, congenital, true ectodermal inclusion cysts, lined by an epithelium, unlike teratomas, they are not true neoplasms. CPA epidermoids are often called congenital cholesteatomas because of their cholesterol content. However, they are quite distinct from the “acquired cholesteatomas”, which result from chronic middle ear infection that give rise to retraction pockets from the pars flaccida of the tympanic membrane. Epidermoids stem from ectopic multipotential ectodermal cells that are carried along with the internal migration of the otic capsule and retained within the neural groove at the time of closure at a gestational age of 3–5 week. They are well-demarcated, encapsulated lesions of varying size, often with a striking white capsule having a mother-of-pearl sheen (hence the synonym pearly tumor). The outer surface may be smooth, nodular or lobulated. The cut surface reveals an interior filled with soft, pasty to dry, flaky material. The contents may occasionally be brownish-grey and viscous. Calcification is rare. Histologically, similarly to “acquired cholesteatomas”, they appear as an internal layer of stratified squamous epithelium mounted on collagenous connective tissue forming a white fibrous capsule. This epithelial lining reproduces the normal layers of the epidermis, complete with keratohyalin granules. The progressive production and subsequent desquamation of keratin result in the formation of concentric lamellae that fill the interior of the cyst and cause a constant gradual expansion. Cholesterol crystals are usually present. Epidermoid tumors are soft and pliable, and tend to extend into adjacent spaces as they enlarge and fill the subarachnoid space of their original intracranial compartment. They also engulf cranial nerves and vessels, causing ischaemic injury and paresis. They practically “flow” into any available subarachnoid space, crossing cisternal and compartmental boundaries. They can insinuate themselves between cranial nerves and vascular structures.

They are extraaxial lesions, typically lateral in location, and most commonly found in the CPA (approximately 60% of all intracranial epidermoids). However, they may occur in a median position along the dorsal midline: in the suprasellar region, the floor of the 4th ventricle (5–18% of all intracranial epidermoids) and spinal cord, rarely in the brain stem, the corpus callosum and the pineal gland or quadrigeminal cisterns. Rare examples may be encountered within the cerebral parenchyma. Although the vast majority of epidermoids are intradural, they can be extradural. The diploic skull is also a common location.

In the cranial vault, the frontal and parietal bones are most often involved. Large intradiploic variants usually break through the inner table and may destroy the outer table to cause soft-tissue swelling under the scalp.

Their clinical features are extremely variable and depend on the localization of the tumor. As the growth is slow and the included elements are soft and pliable, they tend to conform to the shape of the cavities they enter, with symptoms resulting from compression, distortion, and/or obstruction occurring long after the mass has attained a very large size. Furthermore, the neurological symptoms may initially be vague and non-specific, with periods of waxing and waning similar to those described for demyelinating diseases. They generally cause focal and generalized symptoms and signs, the latter being those of an elevated intracranial pressure. The common CPA variety of epidermoids most often presents with involvement of the facial nerve, followed in frequency by a unilateral hearing loss, trigeminal neuralgia and other cranial nerve palsies. Headaches are commonly reported in many series. Some patients present with a history of recurrent aseptic meningitis, which can be severe and prolonged.

Spinal epidermoid cysts may be congenital or acquired. Acquired spinal epidermoid tumors are probably caused by skin fragments that have been transplanted by trauma or lumbar puncture. Spinal subdural epidermoid cysts should be distinguished from intramedullary cysts, as the total excision of subdural cysts is possible and the prognosis is better than for intramedullary cysts. They almost always occur in the region of the cauda equina.

The goal of treatment is complete resection. When incompletely removed, they tend to recur. It is usually many years before a second operation is necessary.

Dermoid cysts should be distinguished from epidermoids; they also result from ectodermal inclusions, but they have a lining that is further differentiated to include dermal appendage structures such as hair follicles, sebaceous glands and sweat glands. Central nervous system (CNS) dermoids are different from abdominal (ovarian) dermoids, which are well-differentiated teratomas. CNS dermoids almost always occur in a midline location, mostly in the posterior fossa attached to the dura or embedded in the vermis. They may also develop in 4th ventricle, the brain stem or at the base of the skull including the cavernous sinus. Supratentorial dermoids are uncommon and are frequently associated with an extracranial component or dermal sinus tract. In the spinal canal, they most often develop in the lumbosacral regions, they may be extramedullary or intramedullary.

## **DECISION-MAKING**

### **1. DIAGNOSIS**

Imaging studies are the key component in the diagnosis of epidermoid and dermoid tumors. Computed tomography (CT) and magnetic resonance imaging

(MRI) scans are used [8]. However, the agents usually applied to distinguish tumors from normal tissue in the background do not provide contrast in ectodermal inclusion cysts, and the tumors may therefore be indistinct.

Epidermoids have specific imaging characteristics. On CT, they present as low-density masses that do not enhance because of their low vascularity. These lesions with decreased attenuation are most often extradural, and usually have the same attenuation as that of the cerebrospinal fluid (CSF); this characteristic makes their differentiation from arachnoid cysts difficult. Enhancement is rare, but can sometimes be observed around the margin of the tumor. Calcification occurs in only 15–20% of the cases. CT is valuable in delineating the bone anatomy. MRI is the method of choice for establishment of the diagnosis. Their appearance on T1-weighted MR images is isointense relative to the grey matter or hypointense (Fig. 1A). More specifically, the T1-weighted signal intensity tends to vary with the lipid content, the signal intensity being increased in lesions with a high lipid content and decreased in those with a low lipid content. On T2-weighted images, they are slightly hyperintense or isointense relative to the CSF (Fig. 1B). This is similar to the MR appearance of arachnoid cysts. The centre of these lesions usually exhibits an internal architecture with areas of heterogeneity. Enhancement of portions of the rim may be seen after the administration of contrast material. The remainder of the lesion is not enhanced. On fluid-attenuated inversion recovery (FLAIR) images or on proton density-weighted images, arachnoid cysts tend to follow the CSF intensity, whereas epidermoids become hyperintense (Fig. 1C). Rarely, epidermoids may appear as low-intensity lesions on FLAIR sequences, in a manner resembling arachnoid cysts. This dilemma can be resolved by the bright appearance of epidermoid tumors on diffusion-weighted images, because epidermoids display markedly restricted diffusion and therefore high signal intensity on the diffusion-weighted trace images (Fig. 1D, E). Diffusion-weighted images are helpful in assessing residual epidermoid tumors after surgical resection.

Patients with asymptomatic recurrences may be followed up by comparing serial neuroimaging studies for a differential diagnosis between CSF cyst and tumor regrowth. However, both CT and MRI may be associated with doubts because the brain reexpansion is extremely slow and incomplete.

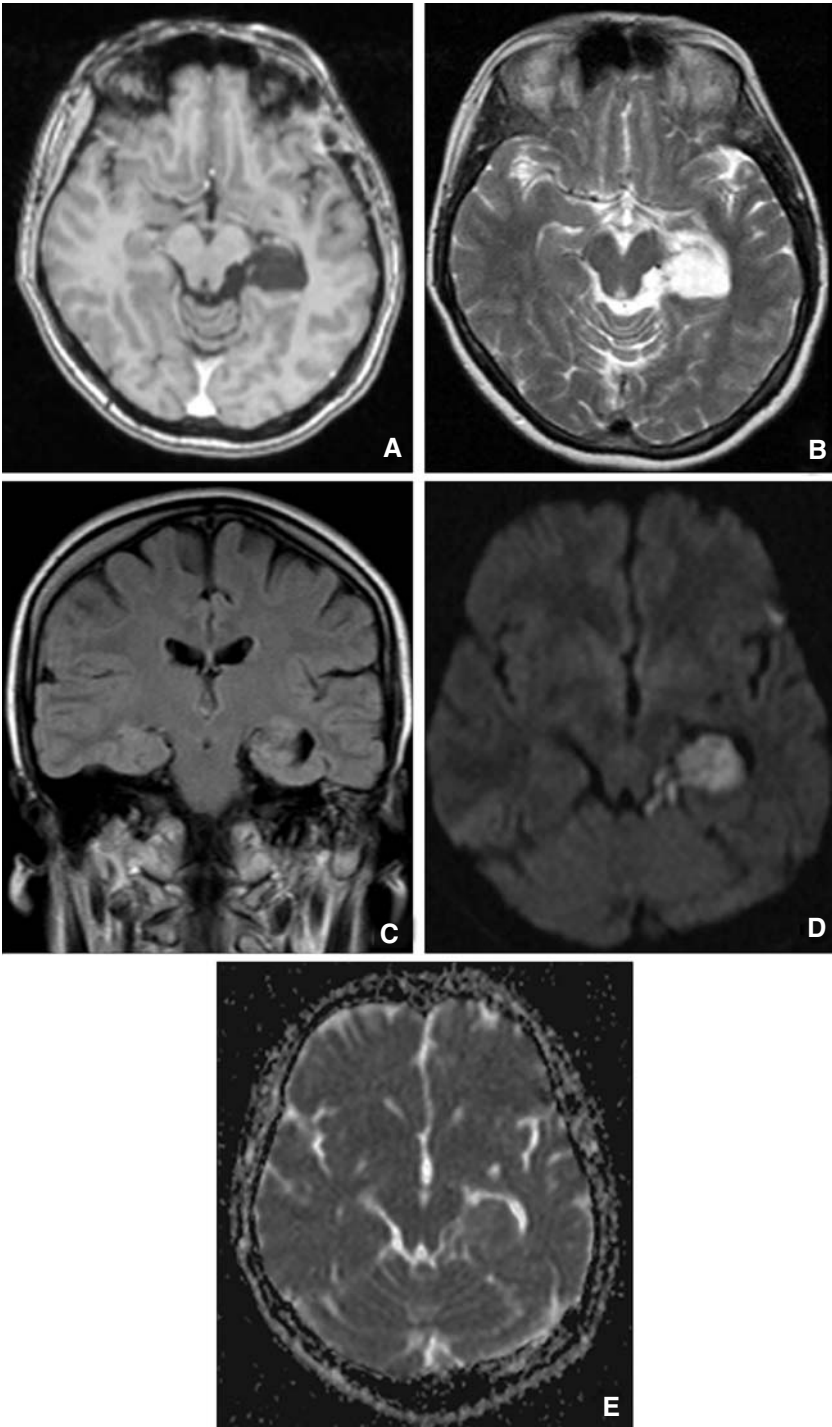
CT scan and MR images of dermoids reveal both the route of the dermal sinus and intradural lesions.

## 2. INDICATIONS

Ideal treatment of symptomatic ectodermal inclusion cysts is radical, single-staged microsurgical removal. It has been hypothesized that the rate of growth

**Fig. 1.** MRI scans of a patient suffering from a left medio-temporo-basal epidermoid tumor. **A** T1-weighted axial image, **B** T2-weighted axial image, **C** FLAIR coronal image, **D** Diffusion-weighted axial image, **E** ADC (apparent diffusion coefficient) map





of a congenital epidermoid tumor is one generation per month, which is equivalent to the turnover regeneration of skin. In primary cases with focal or generalized symptoms and signs, operation is indicated. If the tumor capsule is not removed completely, recurrence is comparatively frequent, but it is usually many years before symptoms and signs redevelop.

Accidentally discovered cases without symptomatology should be judged individually. It is generally agreed that the chances of radical removal are better at an early stage. However, the pros and cons of an early operation should be carefully considered in high-risk cardiac or other patients.

Late recurrence is quite common. It may be an asymptomatic re-growth discovered by follow-up imaging, or a symptomatic “clinical” recurrence. The timing of subsequent surgery is rather controversial. Because of the very low growth rate of some tumor recurrences, a wait-and-see attitude may be regarded as a reasonable option in asymptomatic cases. Progressive neurological deficits or progressive radiographic changes suggest a need for additional surgery.

I would probably not be inclined to perform subsequent surgery on a known residual or persistent tumor unless it was producing new symptoms and signs or was demonstrated by imaging studies to be undergoing enlargement.

It is often impossible to follow a schematic algorithm in order to establish the indication for surgery. It should be emphasized that, despite the giant size of the lesions, some patients can be followed up without a need for surgery if they are asymptomatic or if the symptoms are minimal.

In the event of lesions that are extensive, and that extend into adjacent multiple areas, we have used staged operations in an effort to remove the entire lesion. It is not unreasonable to leave fragments of tumors attached to vital neural and vascular structures if the risk involved in removing them completely is too high.

## **PREOPERATIVE ASSESSMENT**

A resection requires careful preoperative planning with the aid of modern imaging modalities. MRI findings allow a diagnosis with a high degree of confidence, and the performance of MRI is therefore mandatory. The extent of the disease is well depicted, which facilitates surgical planning.

The exact location of epidermoid tumors should be specified. Several classifications of epidermoids have been elaborated to assist the surgeon in the assessment, choice of treatment, and prognosis, but none of them have won general acceptance [9]. The following sites of occurrence are most typical.

Intracranial locations:

Intradural: Posterior fossa: CPA, petrous apex, 4th ventricle, cerebellum, brain stem.

Supratentorial: suprasellar region, corpus callosum, pineal gland (quadrigeminal cistern), cerebral parenchyma.

Extradural: Cranial vault: frontal and parietal bones, petrous region.

Extracranial locations:

Lumbosacral area: within spinal cord, extramedullary location.

Typical locations of dermoid tumors (often associated with an extracranial component or dermal sinus tract):

Posterior fossa: in the midline attached to the dura or embedded in the vermis cerebelli, 4th ventricle, brain stem.

Supratentorial: uncommon: skull base, including the cavernous sinus.

Definition of approach, patient positioning, and the need for image-guidance.

## **SURGERY**

### **1. PREPARATION OF THE PATIENT AND LIST OF NECESSARY EQUIPMENT**

After a thorough clinical assessment, stabilization is performed, if required. The reduction of parenchymal oedema is rarely needed. The preoperative use of steroids for resection of these lesions is reasonable as the occurrence of postoperative aseptic meningitis is well known. The necessity of the administration of perioperative antibiotics continues to be controversial in clean neurosurgical procedures. Antibiotics are probably justified in cases involving reoperation, when there has been a history of mastoid disease, or following radiation therapy. Anticonvulsant therapy may be required.

Meticulous preoperative planning of the surgical approach is mandatory. Involvement of vital structures by the epidermoid tumor is the norm and not the exception. The surgical approach should afford adequate exposure to allow aggressive dissection of the tumor mass from major vessels and nervous structures. The goal of the surgical approach is to provide maximum access to the tumor with as little destruction of the normal anatomy as possible. The surgical approach should be chosen on the basis of the location and extent of the tumor. The balance between total resection and safety can be achieved when the exposure is wide. Because of the growth characteristics and the consistency of these lesions, a single-staged operation is all that is required for resection. As the tumor forces the subarachnoid space to expand, a "channel" is created and, since the centre of the tumor has been removed, further exposure is allowed for additional resection in regions not routinely available via the selected approach. Accordingly, extensive skull base approaches, such as drilling of the petrous bone, can mostly be avoided.

These frequently large lesions should be approached via a number of single and seldom combined routes. For lesions in the CPA cisterns, the retromastoid lateral suboccipital approach is employed, whereas for 4th ventricular tumors the median suboccipital approach is preferred. A pterional transsylvian route is appropriate for tumors in the parachiasmatic cisterns, in

the Sylvian fissure or in the mediobasal temporal area. Dorsal mesencephalic tumors can be explored by a posterior interhemispheric-transtentorial, or suboccipital-supracerebellar approach. Although the operations are preferably performed in a single stage, with lesions that are bilateral and extensive, and that extend into multiple areas, we have also used staged operations to attempt remove the entire lesion.

The best positioning for the surgical procedure depends on the experience of the surgeon and anaesthesiologist, the location of the lesion, and the medical condition of the patient. I utilize the semi-sitting position for the resection of almost all posterior fossa lesions. This provides the best surgical access and drainage of the CSF and venous system. It offers a constant clean view, i.e. better visibility, and permits a permanent bimanual technique as the bleeding is cleared away by gravity, which obviates the need for regular suction, though the potential for venous air embolism should be considered. Accordingly, the prone and lateral positions are used very rarely. In the sitting position, it is important to apply a precordial Doppler monitor to detect venous air emboli and to have central venous access to aspirate such emboli. When lesions in proximity to the 7th nerve are resected, it may be useful to consider monitoring the 7th nerve function intraoperatively. Image guidance: trajectory planning and intraoperative neuronavigation may be useful in cases of the rare intracerebral epidermoid lesions.

## 2. MICROSURGICAL EQUIPMENT

As in conventional micro-neurosurgery, the operating microscope and the usual microsurgical armamentarium are necessary. Handling of a large epidermoid requires microsurgical expertise involving the ability to work through key-hole approaches, with procedures that are atraumatic and non-invasive to the CNS. Personally, I strongly adhere to the principles of microsurgical instrument usage as developed by Talacchi [10].

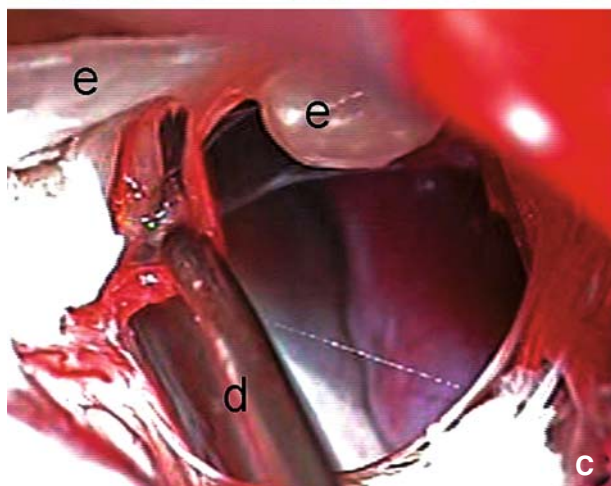
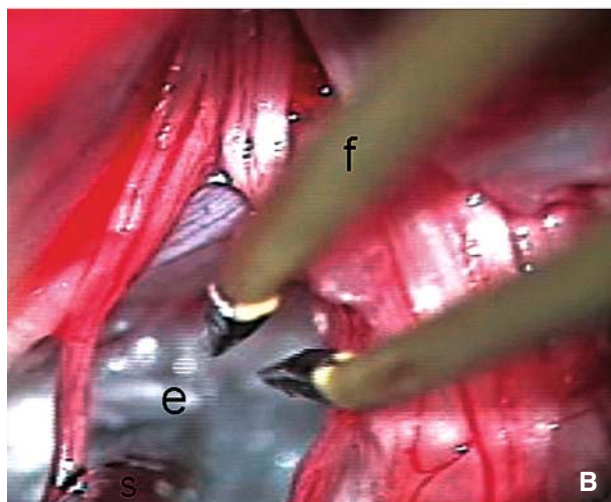
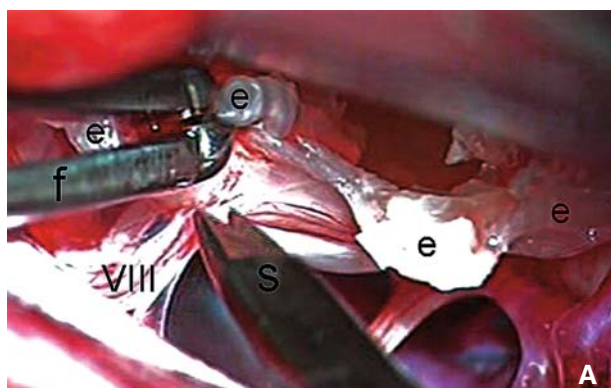
There is a current trend to reduce the invasiveness of classical microsurgical craniotomies, and endoscopic surgery has also gained wider application especially in skull base diseases [7]. Neuroendoscopy can be performed in various ways: [1] a coaxial (pure) endoscopic technique [2] endoscopic assistance: use of the endoscope in addition (and at certain stages of the surgery) to the microscope, and [3] endoscopy-controlled surgery: use of endoscopic visualization in an open (but small) approach, with the use of microsurgical dissection instruments and techniques. I regard the endoscope as a reliable tool for assessment of the extent of epidermoids, but it cannot be used efficiently for the removal of large tumors by means of a coaxial technique. It may be helpful in depicting epidermoid remnants in blind areas of the cisterns and in reducing the need for extensive cranial base approaches. Endoscopic assistance in posterior fossa surgery facilitates the minimally invasive classic retromastoid approach. Through a preformed (retroptrosal) fissure combined with the advantage of

the (30° and 45°) rigid scope, it furnishes an excellent image around the corner, e.g. supratentorial or along the trigeminal nerve, and allows a more radical, and atraumatic resection of recurrence-prone cysts in these spaces, which may be less clearly presented under the microscope. I have employed endoscopic assistance in some cases involving extension beyond the CPA.

### 3. OPERATIVE TECHNIQUES

The optimum management of epidermoid tumors (whether intracranial or spinal) is complete surgical removal. The more complete the resection, the less likely that the cyst will return. This is often difficult to achieve because of the intimate relation between the tumor capsule and vital structures. The technique of resection is somewhat different from that employed with other solid neoplasms. Epidermoids are avascular, and the best advice is to enter the lesion and to work slowly and steadily, removing the contents and lining, following the cisternal compartments.

**Specificities of epidermoid removal:** Atraumatic exploration: arachnoidal access is nearly always easy as the tumor fills in the cisterns. Minimal retraction and no lobulectomy or tissue removal should be employed. The special pre-removal tactic of CSF release to gain working space is seldom needed. The epidermoid capsule is opened once the tumor is accessed. As opposed to the rule of opening only one window when removing tumors of firm tissue, avascular epidermoids can be resected by opening parallel entrances on the cyst: the borderline between the pathological and normal tissues does not become spoiled, i.e. indistinct and lost, and the adjacent normal tissue normally does not bleed. The substance of an epidermoid is soft keratin debris that can be eliminated by means of gentle suction and piecemeal removal. This reduces the internal volume of the tumor and allows manipulation of the tumor capsule. A plane can often be created between the thin, shimmering capsule and the overlying arachnoid and vital structures. Suction may have an outstanding role in epidermoid removal rather than peeling away the layers of the tumor with the help of the bipolar forceps. It is the method of choice in our hands for the piecemeal removal of not only the central portion of the tumor. Since these lesions are avascular, the best technique for debulking is to keep the sucker within the lesion and to work slowly and steadily with suction to dispose of the contents and lining, following the CSF compartments and protecting the nervous structures and vessels with the bipolar forceps (Fig. 2B). Atraumatic brain retraction is mandatory and can often be performed with ease via the suction tip. The hole in the suction tip for the finger control of pressure helps the surgeon adjust it to an appropriate level. During this procedure, either the assistant or the nurse is assigned the task of regulating the force of the suction under the direction of the operator by holding a clamp on the suction tube. The assistant follows the removal carefully under the microscope and controls the suction pressure, raising, lower-



ing or interrupting it as dictated by the situation to avoid inadvertent injury to the surrounding structures. If this control function is assigned to the nurse, she can follow the operation via the TV screen. The CUSA is rarely used for fear of causing inadvertent injury to cranial nerves that have become involved in the tumor mass. It is important to identify the vascular and neural structures systematically as the removal progresses because of the tendency of these lesions to insinuate themselves among these elements, making their location unpredictable. The lesion is either gently pulled away or sharply incised from its attachments. Blunt dissection of the capsule from cranial nerves is strongly contraindicated; sharp dissection with scissors is advised (Fig. 2A). When the peripheral interface is dissected, the capsule is always pulled or sucked in a central direction (centripetally), i.e. towards the tumor hole, so as to leave the normal tissue unretracted. The tumor mass may be easily shelled out from adjacent structures or they may be firmly anchored as a result of local inflammation. As the mass becomes increasingly more mobile as the debulking process is performed, the critical structures are protected by laying Gelfoam and cottonoid onto them. With this special tumor, I do not use sponges to re-inflate the collapsed tumor in order to reconstitute the original shape of the wall. The maintenance of tumor contours does not facilitate the dissection of epidermoids. With epidermoids, application of the classical microsurgical rule for tumor removal (“from a large ball towards a small ball”) is not mandatory: one can progress along the shape of cisterns or fissures from a superficial starting point through to the end of the lesion. At the end of the dissection, it is rewarding to see the stretched but intact cranial nerves along the length of the cranial axis.

If the capsule has a granulomatous reaction with adherence to vital structures, parts of the tumor capsule should intentionally be left behind rather than risk injury (Fig. 2C). It must be emphasized that the literature does not afford a clear picture as to how much tumor or capsule removal is required to prevent the patient from suffering recurrent clinical problems. Consequently, aggressive dissection around the neural and vascular structures should be tempered by this fact.

CPA tumors: These lesions can be treated by neurosurgeons and/or neurotologists (ENT surgeons). There are multiple approaches to the resection of CPA lesions, such as retromastoid suboccipital, subtemporal, skull base approaches (transpetrosal), e.g. middle cranial fossa and translabyrinthine. The translabyrinthine approach is impractical if preservation of the hearing is desired. Additional tumor exposure can be achieved by extending it to a translab-

←  
**Fig. 2.** Removal of a left CPA epidermoid tumor. **A** Sharp dissection of the vestibulo-cochlear nerve from the capsule of the epidermoid (*e* epidermoid tumor, *f* tumor forceps, *s*: pair of scissors, *VIII* vestibulo-cochlear nerve). **B** Removal of the soft keratin debris by means of suction. CPA nerves are protected by the forceps (*e* epidermoid tumor; *f* bipolar forceps, *s*: tip of the suction tube). **C** If the capsule has an adherence to nerve roots, parts of the tumor capsule should intentionally be left behind rather than risk injury (*e* epidermoid, *d* dissector)

yrinthine-transcochlear approach. The transcochlear addition provides maximum control of the carotid artery and provides the most extensive surgical freedom of the petroclival region. Cases with extensive spread of the tumor are ideally suited for a team approach. In 3 patients where a significant portion of the mass was located anterior to the brain stem, we performed team operations. Additional pre-sigmoid transpetrosal exposure was performed.

In situations where a significant tumor mass extends through the tentorial incisura, the lesion can be readily dealt with by performing combined supra- and infratentorial craniotomies. The dural opening will include incisions into both the supra- and infratentorial spaces. Extreme care should be paid to the maintenance of venous drainage. In cases with dominant side lesions, I always make use of pre-operative MR-angiography so as to be familiar with the individual venous circulation.

In the majority of cases, I have performed lateral retromastoid suboccipital craniectomy. The technique of lateral retromastoid suboccipital craniectomy has been described in the chapters by Al-Mefty, Mooij, and Kawase. As epidermoids tend to compel the subarachnoid space to expand, they create “surgical channels”, which allow access from the posterior fossa into the middle cranial compartment. The tentorium can be split to gain access to the middle fossa and cavernous sinus when tumor dissection has begun in the posterior fossa. This can be achieved by identifying the 4th cranial nerve as it enters the incisura of the tentorium. The tentorium is incised posterior to the entrance of 4th cranial nerve. Occlusion of the superior petrosal sinus may also be necessary. Cavernous sinus bleeding is controlled with gentle Surgicel packing. Epidermoids may extend into the pons and into the 4th ventricle. The path of surgical dissection simply follows access to the pons and through the widened foramen of Luschka to the ventricle.

Petrous apex lesions may present a dilemma as concerns the surgical approach. The transcochlear approach could be appropriate if hearing is absent. If hearing is present, however, a middle cranial fossa approach could be chosen, but the cochlea and the internal carotid artery must be avoided.

Fourth ventricular tumors: The technique of midline suboccipital craniectomy has been presented in the chapter by Mooij (How to perform posterior fossa approaches). Instead of a craniectomy, a craniotomy can often be performed without difficulty especially in younger patients. For the vast majority of lesions situated superior to the foramen magnum, a C-1 laminectomy is not required. As for the route to the 4th ventricle, we prefer that via the tonsillar-uvula sulcus to the transvermian route.

**Specificities of dermoids removal:** Supratentorial dermoid cysts demonstrate a predilection for the cavernous sinus [4]. They are usually interdural. A granulomatous reaction is often present, which causes dense adherence between the capsule and adjacent structures. There is involvement of the arachnoid, and occasionally the pia mater. In these cases, careful and meticulous dissection is required. Complete microsurgical removal is generally possible,



but on rare occasions the infiltration is too extensive and affects vital structures. In this situation, it is better to leave small areas of capsular tissue attached, rather than risk damage to nerves and other structures.

A posterior fossa dermoid cyst should be considered in all children with an occipital dermal sinus. Cerebellar abscesses will arise once bacterial infection has occurred through the dermoid-associated dermal sinus. Early neurosurgical interventions, including external ventricular drainage, external abscess drainage and primary removal, should be planned as soon as possible in accordance with the child's condition.

The rupture of intracranial dermoid cysts is usually spontaneous and non-fatal. If the capsule is adherent to vital areas, incomplete removal is advised as recurrence and malignant transformation are unlikely to occur.

Spinal dermoid cysts are associated with a dermal sinus tract [3]. The clinical significance of the dermal sinus tract depends on whether its deep end with the dermoid cyst is extra- or intrathecal. If it lies outside the dural sac, the dermal sinus tract can be traced from the cutaneous opening (the pit) through the midline defects in the lumbosacral fascia, muscles and neural arches to the bone spur, and should be removed together with the dermoid cyst before the dura is ever opened. If the dermal sinus tract is intradural, its intrathecal part with the cyst is often densely adherent to the cord or cauda equina, and exerts a tethering effect. The dermoid cyst is often large enough to cause cord compression. The entire intradural sinus tract and cyst must be excised in order to eliminate the tethering effect and prevent recurrence. The cyst is first collapsed by intracapsular evacuation of its cheesy content, and the cyst wall is then carefully peeled off the pial surface of the cord. Its deep end should be removed with the fibrous median septum.

#### **4. POSTOPERATIVE CARE**

Chemical meningitis and communicating hydrocephalus may develop. Focal deficits due to over-aggressive dissection around the neural and vascular structures should also be dealt with in the intensive care unit. Postoperative hydrocortisone, a regular lumbar tap or insertion of an extraventricular drain may help to prevent or treat these postoperative problems. Insertion of a ventriculo-peritoneal shunt may afford a long-term solution of mal-resorptive hydrocephalus.

After removal of a dermoid, fat may persist asymptotically in the sub-arachnoid spaces for years. Surgery is the only way to deal with these benign lesions.

#### **5. LONG-TERM RESULTS AND COMPLICATIONS**

Since epidermoids are benign in nature, their long-term assessment is required, not only to determine the extent of surgical removal, but also to monitor tumor recurrence. During the initial follow-up period, the surgeon's

assessment of the extent of removal is more reliable than radiological information, because the immediate shrinkage of the hypointense area on MR images leaves open questions regarding residuals. However, the surgeon's intraoperative judgement may not prove so accurate in the later follow-up. Fukushima reported on 152 CPA epidermoid patients, the largest series involving this entity, 95% of whom underwent gross total resection of the lesion, including complete microsurgical dissection of the tumor capsule [2]. Three patients with extensive tumors participated in planned staged resection in two separate operations. Six cases were secondary resections of recurrent lesions after subtotal resection at other institutions. Twenty-three percent of these patients experienced new postoperative cranial neuropathies, but only 10% exhibited cranial nerve deficits at the 6-month follow-up, most of which were mild. Nine patients (6%) displayed postoperative cerebellar symptoms. There was only one case (0.7%) of disabling postoperative chemical meningitis. No mortality occurred in this series.

Talacchi and colleagues analysed the recurrence-free survival rate as a function of the extent of removal [9]. After subtotal removal, the curve gradually descended, starting at 5 years; after 13 years, 95% of the totally resected patients were recurrence-free, as compared with 65% of those who underwent subtotal removal. A lower rate of tumor regrowth was clearly demonstrated after total removal.

Complete removal of the tumor was achieved in 80% of the patients in the series of Kaylie and colleagues and the resection was close to total in the remainder [3]. Altschuler and colleagues reported a 54% total or near-total resection rate, and Yaşargil achieved "radical removal" in 97% of his patients [1, 10]. Yamakawa and colleagues attained total resection in 47% of their patients with CPA masses, and subtotal resection in another 40% [5]. Gross keratin debris was not left in any of the patients in these series. The Altschuler team discussed the reasons for tumor recurrence and surgical failure [1]. Failure primarily occurred when the original surgery did not pursue total removal sufficiently and the surgeon tried to reduce cranial nerve morbidity by not removing the tumor aggressively from sensitive areas. They concluded that ultimately these patients were not spared cranial nerve deficits. The subsequent surgery required was more difficult, which resulted in more extensive nerve injury than that which may have been caused by aggressive initial surgery. They postulated that a second reason for failure was "most likely the result of a limited initial exposure". Yaşargil reported similar arguments for near-total resection. I performed total resection in approximately 60% of the 28 patients operated on in the past 15 years, and left adherent capsule or portions of the tumor on the other side or with the vital neurovascular structures in 40% of the cases. The preoperative status improved in 70% of these patients, particularly as regards the function of cranial nerves (CN) V and VII. Only 3 patients had permanent cranial nerve deficits. The function of CN V and CN VII may recover after decompression, but the outcome of the symp-

toms related to CN VIII is less certain. All authors correctly emphasize the importance of a long-term follow-up, because late recurrence is frequent, especially in patients with subtotal removal of their tumors. In view of this, the goal of the initial surgery must be total removal, if at all possible. Talacchi and colleagues operated on 30% of their patients a second time for progressive neurological deterioration, mean interval of 8.1 years after tumor removal. It seems that the time-span of the follow-up exerts a major influence on the proportion of reoperations or even second reoperations. I recently treated a patient who required a second operation 20 years after the initial surgical procedure. In conclusion: among CPA epidermoids, higher rates of preoperative neurological disturbances and postoperative morbidity are observed in mesencephalic extended tumors. Fourth-ventricle tumors carry higher risks of surgical complications, whereas few clinical signs and a good outcome are more customary in posterior fossa basal epidermoids.

## HOW TO AVOID COMPLICATIONS

What are the main complications?

1. Radical removal can be associated with significant neurological morbidity, such as cranial nerve deficits, infarction due to damage to vessels, etc. It is important to utilize surgical judgement and avoid damage to vital structures through overly aggressive resection, but the long-term results are improved following a total resection.
2. Incomplete removal may leave tumor remnants that prevent relief from preoperative symptoms and signs.
3. Recurrence can ensue with progressive symptoms and signs.

How to deal with these complications: a balance between total (potentially over-aggressive) resection and safety (with poorer long-term results) can be achieved when the surgical planning is meticulous and wide exposure is attained. This highlights the concept of ensuring wide surgical exposure, with acceptable cranial nerve morbidity, so as to prevent incomplete resection and the need for revision surgery.

Chemical meningitis: Cysts in the ventricles or in the subarachnoid space are liable to rupture. Spillage of the keratin debris into the CSF at the time of surgery may lead not only to distant seeding, but also to aseptic meningitis. An inflammatory reaction develops between the capsule and the underlying structures, with consequent dense adherence between them. The neurosurgery literature refers to chemical meningitis as a frequent postoperative event, but none of the patients in our series developed this complication. Great care must be taken to avoid the spillage of tumor material. The routine use of prophylactic corticosteroids is suggested. A high

rate of total or near-total tumor removal is virtually a guarantee that very little keratin debris will be left in the subarachnoid space to cause an inflammatory reaction.

Malignant transformations are extremely rare.

## CONCLUSIONS

Epidermoid and dermoid cystic lesions are rare tumors. Their benign nature makes their total resection curative. However, their growth patterns and tendency to adhere densely to vital structures makes complete removal difficult at times. The dilemma in the management of these tumors is that they are often large or giant-sized, they extend into a number of regions, and the patients may experience only mild neurological symptoms. Some surgeons deal with such lesions by operating through a minimally invasive small craniotomy, and remove only the contents of the cyst, and not the tumor capsule. This is a good short-term strategy. Nonetheless, such tumors usually do recur, often within a few years but overall, on average after 8 years. The second operation on the patient poses various problems, including the serious scarring caused by previous chemical meningitis, severe adhesions to the blood vessels and the brain, and the inability to remove the lesion totally or nearly totally without considerable morbidity. It is my view, therefore, that, whenever these lesions are operated on, the surgeon should strive to remove the lesion totally, or nearly totally (leaving small remnants if the capsule is attached to critical structures). Meticulous preoperative planning and wide surgical exposure increase the rate of total removal and decrease the incidence of injury to important cranial structures. The key issue in the surgical technique is the sharp dissection of the tumor capsule from the nerves and the vessels. The use of a microsurgical endoscope may be helpful in depicting epidermoid remnants in blind areas of cisterns and in reducing the need for extensive cranial base approaches. I would like to stress that the development of complications is, in part, directly dependent on the surgeon's skill and experience. With lesions that are extensive, and that extend into several areas, operations can be staged in an effort to remove the entire lesion. It must be emphasized that, despite the giant size of the lesions, some elderly patients can be followed up without undergoing surgery if they have no or only minimal symptoms. Serial MRI studies are recommended for the management of recurrent posterior fossa epidermoids, beginning 2 years after the initial operation and repeated at 2-year intervals. This strategy allows a better assessment for subsequent surgery, before the tumor extends beyond the original location.

In conclusion: modern imaging tools and microsurgery techniques have considerably improved the completeness of cyst resection and reduced the rates of postoperative mortality and morbidity; however, there are still a significant number of cases in which complete resection is impossible without producing severe neurological deficits.

## References

- [1] Altschuler E, Jungreis C, Sekhar L (1990) Operative treatment of intracranial epidermoid cysts and cholesterol granulomas: report of 21 cases. *Neurosurgery* 26: 606-614
- [2] Grossi P, Sameshima T, Sampson J, Friedman A, Fukushima T (2005) Microsurgical management of cerebellopontine angle epidermoid tumors: operative technique and results in 152 cases. *Neurosurgery* 57: 411-412
- [3] Kaylie DM, Warren FM, Haynes DS, Jackson CG (2005) Neurologic management of intracranial epidermoid tumors. *Laryngoscope* 115: 1082-1086
- [4] Lunardi P, Missori P, Gagliardi FM (1989) Long term results of the surgical treatment of spinal dermoid and epidermoid tumors. *Neurosurgery* 25: 860-864
- [5] Olivecrona H (1967) The surgical treatment of intracranial tumors. In: Olivecrona H, Tönnis W (eds) *Handbuch der Neurochirurgie, Vierter Band, Vierter Teil. Klinik und Behandlung der raumbeengenden Intrakraniellen Prozesse IV*. Springer, Berlin Heidelberg New York, pp 279-287
- [6] Safavi-Abbasi S, Di Rocco F, Bambakidis N, Talley MC, Gharabaghi A, Luedemann W, Samii M, Samii A (2008) Has management of epidermoid tumors of the cerebello-pontine angle improved? A surgical synopsis of the past and present. *Skull Base – An Interdisciplinary Approach* 18: 85-98
- [7] Samii M, Tatagiba M, Piquer J, Carvalho G (1996) Surgical treatment of epidermoid cysts of the cerebellopontine angle. *J Neurosurg* 84: 14-19
- [8] Schroeder HWS, Oertel J, Gaab MR (2004) Endoscope-assisted microsurgical resection of epidermoid tumors of the cerebellopontine angle. *J Neurosurg* 101: 227-232
- [9] Sirin S, Gonul E, Kahraman S, Timurkaynak E (2005) Imaging of posterior fossa epidermoid tumors. *Clini Neurol Neurosur* 107: 461-467
- [10] Talacchi A, Sala F, Alessandrini F, Turazzi S, Bricolo A (1998) Assessment and surgical management of posterior fossa epidermoid tumors: report of 28 cases. *Neurosurgery* 42: 242-251
- [11] Yaşargil MG (1996) *Microneurosurgery IV B*. Georg Thieme Verlag, Stuttgart-New York, pp 192-200



**Tamás P. Dóczi**

Tamás P. Dóczi is Professor and Chairman of the Department of Neurosurgery at the University of Pécs, Hungary. He graduated from the Medical School at the University of Szeged in Hungary. He participated in neurosurgical training at the Department of Neurosurgery at the University of Szeged; at the National Hospital, Queen Square, London; and at the Department of Neurosurgery, University Hospital of Zürich, in Switzerland. He was awarded his Ph.D. degree for his work on “Central Neuroendocrine Regulation of Brain Volume”. For these studies, he was awarded the Upjohn Prize of the EANS in 1984. He has made original contributions to the role of the blood–brain barrier in aneurysmal subarachnoid haemorrhage and brain oedema. He has organized a regional university neurosurgical service with an integrated diagnostic centre in Pécs dedicated to image-guided minimal invasive neurosurgical techniques. He has served as Vice-President of EANS and is an elected member of the Hungarian Academy of Sciences.

**Contact:** Tamás P. Dóczi, Department of Neurosurgery, Medical School of University of Pécs, 2 Rét St., 7623 Pécs, Hungary  
E-mail: [tamas.doczi@aok.pte.hu](mailto:tamas.doczi@aok.pte.hu)

---

# TUMORS OF THE FOURTH VENTRICLE AND CEREBELLUM IN ADULTS

M. N. PAMIR

## INTRODUCTION

The posterior fossa can harbor a diverse pathological spectrum of lesions. The incidence of these lesions varies considerably with age. Intraaxial tumors in this region can originate from the fourth ventricle, cerebellum and/or brain stem. Although the vast majority of intra-axial posterior fossa tumors in adults are metastatic in origin, other tumors and tumor like lesions may be encountered in this region, especially in young adults. The management strategy depends on the nature and localization of the lesion and preoperative radiological diagnosis plays a very important role in choosing this strategy. When surgery is indicated, cerebellar tumors can be approached with a median suboccipital craniectomy, unilateral posterior fossa craniectomy or lateral suboccipital retromastoid approaches. The fourth ventricle tumors are also approached with a posterior median craniotomy/craniectomy. After dural opening, the fourth ventricle is exposed through the telovelotonsillar fissure by cutting the tela choroidea or with a midline approach with vermian splitting. The exposure of fourth ventricle tumors by splitting of the vermis was first described by Dandy, who indicated that this can be performed without serious complications. However, cerebellar mutism, as well as other neurological sequelae. As an alternative technique to avoid vermian splitting, Yaşargil described the median inferior suboccipital approach along the tonsilloveal sulcus to expose fourth ventricle lesions. Matsushima et al. reported the use of cerebellomedullary fissure for a similar approach.

## RATIONALE

The posterior fossa extends from the tentorium down to the foramen magnum and contains cerebellum, brainstem, fourth ventricle and the cranial nerves. Intraaxial tumors of the posterior fossa arise from the cerebellum, fourth ventricle or the brain stem.

The cerebellum makes up 10% of the total brain weight but contains more than 50% of all neurons. Functionally, it performs regulatory functions on different sets of input. The major function is adjustment of the output

---

*Keywords:* posterior fossa tumor, tumor in adults

for major descending pathways. Anatomically, the cerebellum has 3 surfaces and it can be divided into midline and hemispheric structures. Posterior approaches expose the posterior surfaces. Vermis is centrally located and neighbors the tonsils at its inferior opening which is termed the vallecula. Bilateral cerebellar cortices contain lobules and fissures, which correspond to gyri and sulci of the cerebrum. Cerebellar corticotomy is performed parallel to the folia and the shortest route to tumor is used to avoid injury to deep nuclei and minimize iatrogenic injury. The deep white mater contains 3 sets of nuclei: fastigial, interposed and dentate. The horizontal fissure provides the shortest route to the dentate nuclei and is used to evacuate hypertensive cerebellar hemorrhages, which are most commonly localized to the dentate nuclei. Lateral 1/2 cerebellar resection can be performed in emergency situations and this is usually well tolerated with transient hypotonia and ipsilateral disdiachokinesia. Iatrogenic injury to the dentate nucleus, however, results in more severe and commonly permanent limb ataxia, nystagmus, hypotonia and hyporeflexia. The fourth ventricle is located between cerebellum and the brain stem and has a rhomboid shape. The cerebral aqueduct is located in the most rostral point and in the most caudal point at the obex the ventricle connects to the central spinal canal. Lateral recesses harbor the foramina of Luschka, which are above the stria medullares and caudal to flocculi, which open to the cerebellopontine angle. The upper 2/3 of the rhomboid fossa is located in the pons, while the inferior 1/3 lies in medulla oblongata. Within the rhomboid fossa several surface landmarks can be differentiated such as the vertical central fissure, facial colliculi, stria medullares. These anatomical structures are used to define the hypoglossal and vagal triangles in planning of safe surgical entry zones to the brain stem. The posterior wall consists of the superior medullary velum rostrally and inferior medullary velum caudally, which are connected by the fastigium. Through a posterior approach the telovelotonsillar fissure can be exposed in the cerebellar vallecula and division of either the tela choroidea or the inferior medullary velum leads the surgeon into the ventricular cavity. The posterior inferior cerebellar artery (PICA) crosses through the telovelotonsillar fissure, is encountered and protected during surgical approaches.

## **DECISION-MAKING**

### **1. CLINICAL PRESENTATION**

Patients with posterior fossa tumors present to clinical attention either by direct neuronal dysfunction or signs and symptoms of obstructive hydrocephalus. Obstructive hydrocephalus will present with increased intracranial pressure (headache, nausea-vomiting, depression of mental status, and diplopia). Midline cerebellar masses present with truncal and gait ataxia and cerebellar hemispheric tumors result in limb ataxias, nystagmus, hypotonia and hypore-



flexia. Primary brain stem tumors or others that secondarily invade the brain stem structures result in direct cranial nerve involvement, usually involving multiple contiguous nerves. Upbeat nystagmus is also a classical manifestation of brain stem involvement. Laterally located tumors may present with disabling vertigo. Obstructive hydrocephalus can be seen in lesions located anywhere within the posterior fossa.

## 2. DIFFERENTIAL DIAGNOSIS

MRI is the gold standard in evaluating posterior fossa tumors. A correct preoperative diagnosis may be provided by MRI in more than 80% of the cases. Patient age and presenting symptoms provide extremely important clues and should be considered when evaluating the radiological findings.

The vast majority of cerebellar lesions in the adult are metastatic in origin. Metastases are reported to comprise 55–75% of cerebellar masses in adults and this incidence is known to increase with advancing age. The typical metastatic lesion in the posterior fossa is located at the grey-white matter interface of the cerebellar cortex, enhances homogeneously or in ring like pattern after contrast injection and present with marked peritumoral edema. Very rarely metastases can be encountered in the brain stem, pineal region, cerebellopontine angle. Carcinomatous meningitis is also more commonly seen with posterior fossa metastases than with supratentorial metastases. Multiplicity is highly suggestive of a metastatic origin, however may also be seen in hemangioblastomas, cerebellar abscesses or cavernomas.

Localization of a cerebellar-fourth ventricle mass may be suggestive of its diagnosis. Tumors that commonly arise in the midline structures are distinct from those that originate within the cerebellar hemispheres. Tumors commonly encountered in cerebellar hemispheres are hemangioblastomas and astrocytomas. In adult patients, a large cystic posterior fossa mass with a brightly enhancing mural nodule is suggestive of a hemangioblastoma. Hemangioblastomas most commonly present between the 3rd and 5th decades. They may occur sporadically or in 25% of the cases in association with other visceral tumors and cysts as component of the familial von Hippel-Lindau syndrome. Syndromic cases occur significantly earlier with a mean age of 29. In children, a cystic cerebellar lesion with a mural nodule is far more likely to be a pilocytic astrocytoma. Pilocytic astrocytomas can both be solid or cystic and the size of the cyst varies with some cases having intratumoral lacunae while others present with massive cysts and only small solid components in the form of mural nodules. The cyst wall is made up of the tumor. Pilocytic astrocytomas are more common in younger adults with only rare cases occurring after the 5th decade.

Brain stem gliomas may present as posterior fossa masses, but are very infrequently encountered in the adults. Other masses that may mimic cerebellar hemispheric tumors are abscesses and cerebellar hemorrhages. Cerebellar hemorrhage may mimic tumors or may be the initial manifestation of a posterior

fossa tumor. Extraaxial tumors that present as posterior fossa masses are most commonly located in the cerebellopontine angle and include vestibular schwannomas, meningiomas, epidermoid tumors and metastases. Both epidermoid tumors and arachnoid cysts may present as extraaxially located cystic masses which characteristically have no enhancing mural nodules.

Tumors that commonly arise in the midline are medulloblastoma, ependymoma, choroid plexus tumors, dermoid tumors and arachnoid cysts. In adults, 80% of medulloblastomas are seen in the second to fourth decades. Although most childhood medulloblastomas are located in the vermis, incidence of cerebellar involvement increases with age. Both medulloblastomas and ependymomas may present with calcifications. Calcifications are small punctate in ependymomas and in the form of large clumps in medulloblastomas. Tumors of the fourth ventricle may originate from within the ventricle (as in choroid plexus papillomas, subependymomas and ependymomas) or secondarily invade the ventricle (as in astrocytomas, gangliomas, medulloblastomas dermoid and epidermoids).

### **3. INDICATIONS (SCHEMATIC ALGORITHMS)**

The management of the posterior fossa tumor depends on the nature of the lesion, its localization and the medical status of the patient. Surgical resection of a cerebellar metastasis is a palliative or in some cases a diagnostic procedure. The surgical outcome is dependent on preoperative functional status, so that surgical resection is considered in functional and independent patients that present with posterior fossa mass effect or in those with solitary cerebellar metastases to obtain a tissue diagnosis. Chemo- or radio-sensitive primaries or carcinomatous meningitis as well as multiplicity are contraindications for surgical treatment. For most tumors of the cerebellum and fourth ventricle other than metastases, the surgery is performed with a curative intent, with the optimal goal being total surgical removal. Brain stem invasion carries a very high risk of operative morbidity and the benefits should be weighed against potential surgical risks in such patients. As an example, residual tumor in the brain stem or on cranial nerves is preferable to devastating neurological deficits in patients with medulloblastoma which is responsive to radiation and chemotherapy.

There is no clear consensus on how obstructive hydrocephalus should be managed in a patient with a posterior fossa tumor. Preoperative CSF-shunting or ventricular drainage is performed by some centers, however our preference is to primarily treat the underlying pathophysiology by removing the tumor mass and decompressing the posterior fossa.

### **4. PREOPERATIVE ASSESSMENT**

The spectrum of diseases encountered in the posterior fossa differs between age groups and certain symptoms and findings can lead the managing physician to

different diagnoses. Therefore a detailed history and neurological examination and the contrast enhanced MRI are mandatory to reach the most accurate diagnosis possible. As lung cancer is the forerunner among metastatic malignancies, chest X-ray will simply and quickly provide information about a possible malignancy. If the posterior fossa tumor is suggestive of a malignancy with CSF dissemination risk (medulloblastoma, ependymoma), preoperative MRI of the spinal axis is mandatory. Postoperative contrast enhancement makes the interpretation of these studies difficult and this leads to a delay of two weeks. It is convenient to perform these studies preoperatively.

## **SURGERY**

### **1. PREPARATION OF THE PATIENT AND LIST OF NECESSARY EQUIPMENT**

Preoperative workup of the patient for posterior fossa surgery does not differ significantly from other craniotomies. In patients with significant mass effect within the posterior fossa, close surveillance, preferably in the intensive care unit is justified. All tumor resections in the posterior fossa are performed using microsurgical technique. We prefer using the three pin-head fixation and a Gilsbach frame as a hand-rest and to fix the self retaining retractors. In certain cases the ultrasonic aspirator may be needed.

### **2. OPERATIVE TECHNIQUE**

Depending on the localization of the mass, different approaches can be used for intraaxial posterior fossa tumors. Midline tumors and fourth ventricle lesions are best approached with a midline suboccipital craniectomy. The fourth ventricle is exposed either through the telovelotonsillar fissure or by incision of the inferior vermis. Cerebellar hemispheric tumors can be exposed with the same midline approach or through a unilateral posterior fossa craniotomy. Tumors that are localized to the lateral surface of the cerebellum can be approached with a lateral suboccipital craniectomy.

Posterior midline lesions and medial cerebellar hemispheres are best approached with a *midline posterior suboccipital craniectomy*. On the vertical plane the midline approach provides an exposure from the superior aspect of the cerebellum, down to the foramen magnum. The patient is placed in the prone position and the head is fixed with a pin-headrest. The sitting position is not utilized at our institution due to the high incidence of complications, which is commonly cited in the literature. A slight reverse-Trendelenburg position facilitates venous return. The midline skin incision extends from theinion down to the cervical region. Dissection of the avascular median-raphé provides a convenient entry route. Occipital muscles are cut and the periosteum is dissected laterally. Bleeding from emissary veins can be controlled

with bone-wax. The occipital squama may be thinned with a pneumatic drill which shortens the opening duration. Craniectomy extends down to foramen magnum. Removal of the C1 arc may be performed in patients with tonsillar herniations to adequately decompress the bulbous and the upper cervical cord. While going laterally, the relation of the vertebral artery to Atlas and occipital bone should be kept in mind and great care should be given to its protection. The dura is opened in Y shaped fashion. Occipital and circular sinuses are ligated and divided. Entry to deep seated lesions can be performed with a small horizontal corticotomy parallel to cerebellar folia or as in the surgery of cerebellar hemorrhages in the dentate nucleus, through the horizontal fissure. Localization of a small tumor mass within the cerebellum and determination of the shortest route to the tumor may be accomplished using intraoperative ultrasonography. Navigation systems also will aid in correct localization. Tumor resection is followed by meticulous hemostasis and watertight closure of the posterior fossa dura. A generous duroplasty is usually performed using the patient's own tissue materials such as galeal or fascia-lata grafts. Removed bone is not replaced.

*Unilateral posterior fossa craniectomy* is performed in the lateral decubitus position and in many respects similar to midline posterior suboccipital craniectomy. Mastoid emissary veins and mastoid air cells are sealed with bone wax. Following a unilateral craniectomy, the rim of foramen magnum and the arch of Atlas are removed.

Lateral lesions can also be approached with a *lateral suboccipital craniectomy*. Lateral suboccipital craniectomy may be performed in the lateral, Jannetta or park Bench positions. The head is fixed with a pin-headrest and 15° lateral bending of the neck. Head may be slightly rotated depending on the localization of the target on cerebellar surface. A vertical incision from 3 cm posterior to the mastoid process down to the neck is followed by muscle dissection in the neck to expose the occipital bone. Mastoid air cells should be plugged with bone-wax to avoid CSF fistula and bleeding from mastoid emissary veins should be occluded with bone-wax. We thin the occipital bone with a pneumatic drill and perform an ovoid craniectomy below the transverse and posterior to sigmoid sinuses. With a "Y" shaped incision, dura is opened which exposes the cerebellum. Cisternal CSF drainage can be performed to gain extra space. As in midline approaches, localization of the tumor within cerebellum can be performed with intraoperative ultrasonography or navigation.

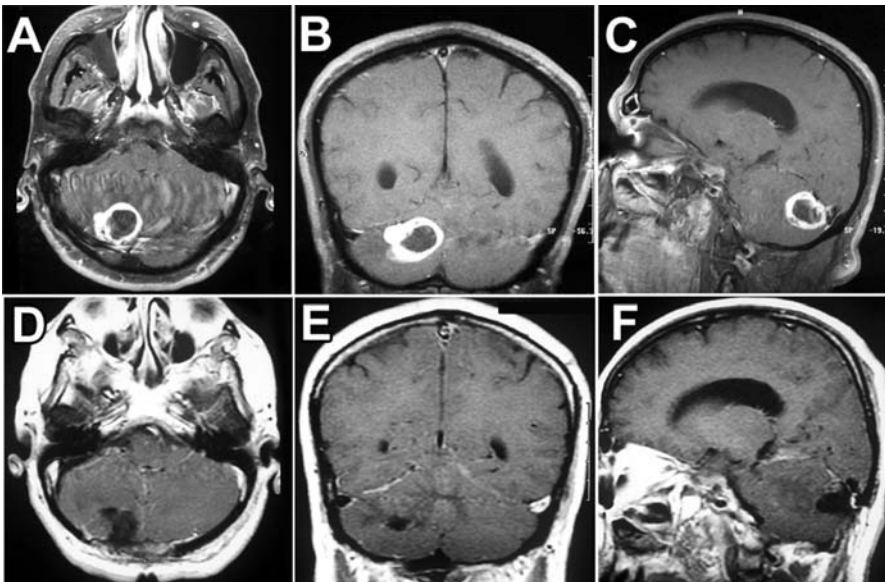
The fourth ventricle approached through the *telovelotonsillar fissure approaches* and *vermian splitting* is seldom required. The telovelar approach is directed through the cerebellomedullary fissure to the tela choroidea and the inferior medullary velum. Opening of the tela or splitting of the paper thin velum leads to the ventricular cavity. In large intraventricular tumors both structures may be stretched on the tumor pseudocapsule. Opening of these anatomical structures does not result in new neurological deficits. The rhom-

boid fossa, dentate nuclei that lie rostral to the tonsils, cerebellar peduncles and the PICA should be protected during surgery. These approaches provide a wide view of the ventricle, lateral to the foramen of Lushka. Vermian splitting involves a median suboccipital craniectomy, cerebellar exposure, incision of the inferior vermis and entry into the fourth ventricle between the laterally retracted cerebellar lobes.

### 3. SPECIAL CONSIDERATIONS IN INDIVIDUAL TUMOR TYPES

*Metastatic tumors* in cerebellar hemispheres make up 15–30% of patients with intracranial metastases. Complete surgical removal followed by postoperative whole brain irradiation provides symptomatic improvement and increased functionality. Posterior fossa metastases have a poorer prognosis when compared to their supratentorial counterparts. Local recurrence is similar to that of supratentorial metastasis surgery but leptonemingeal seeding is more commonly observed in cerebellar metastases.

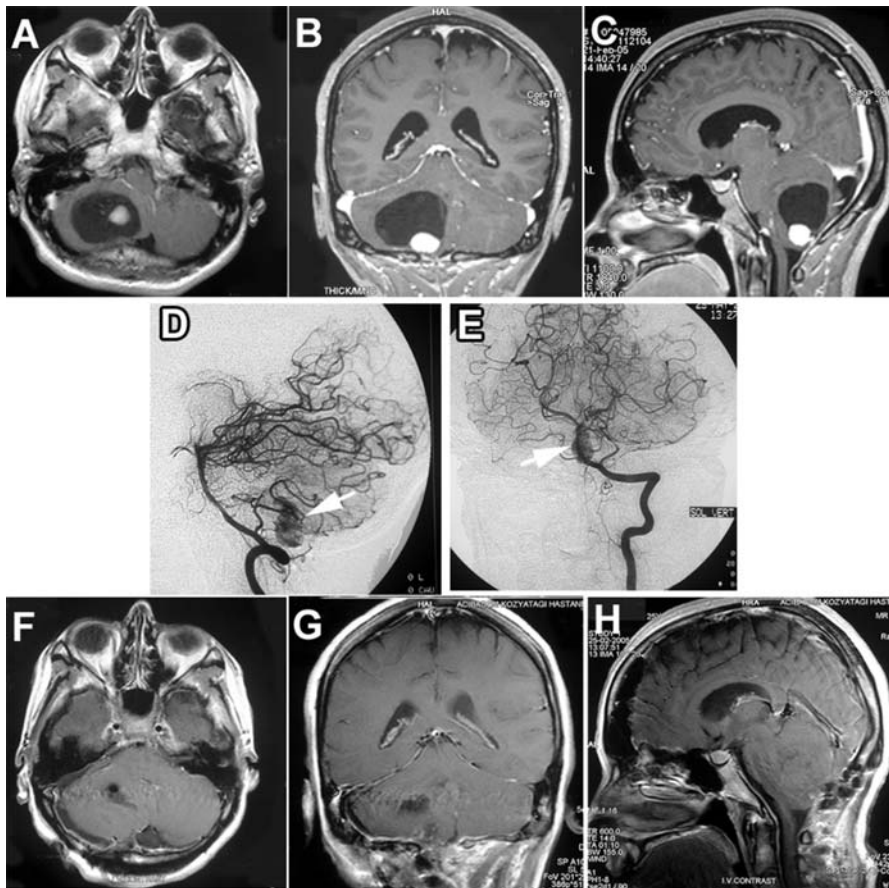
Total surgical resection is curative in cerebellar pilocytic astrocytomas so every attempt must be made to completely remove the tumor during initial surgery. These tumors are more commonly encountered in pediatric patients.



**Fig. 1.** Posterior fossa metastases are well demarcated from the surrounding cerebellar tissue. The tumor in the figure (A–C) was totally resected with a midline posterior suboccipital craniectomy (D–F). If the localization of the tumor is not evident on intraoperative imaging, intraoperative ultrasonography or navigation are helpful

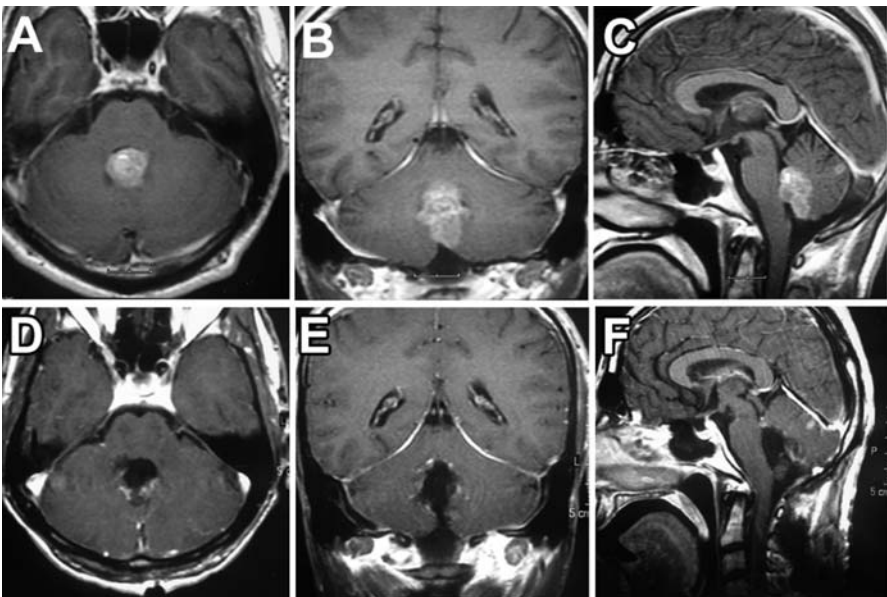
The tumor may be solid, microcystic or may harbor large cysts filled with a xanthochromic fluid. The cyst wall contains tumor cells, however in such cases the mural nodule is resected and the removal of the wall is not necessary. Solid tumors are first decompressed by internal debulking using ultrasonic aspirator.

*Capillary hemangioblastomas* are histologically benign and highly vascular tumors. Within the posterior fossa hemangioblastomas may present as cerebellar or brain stem masses. Especially those, that are associated with von Hippel-Lindau syndrome may present with multiple masses. The definitive



**Fig. 2.** Cerebellar hemangioblastomas can present in the posterior fossa as cerebellar, fourth ventricle or brain-stem lesions. The figure presents a cystic hemangioblastoma localized to the cerebellar hemisphere (A–C). Hemangioblastomas are highly vascular lesions as demonstrated on the cerebral angiogram (D, E). Therefore the tumor should be dissected and devascularized along the gliotic margin (F–H). Attempts at biopsy or subtotal resection may result in massive hemorrhage

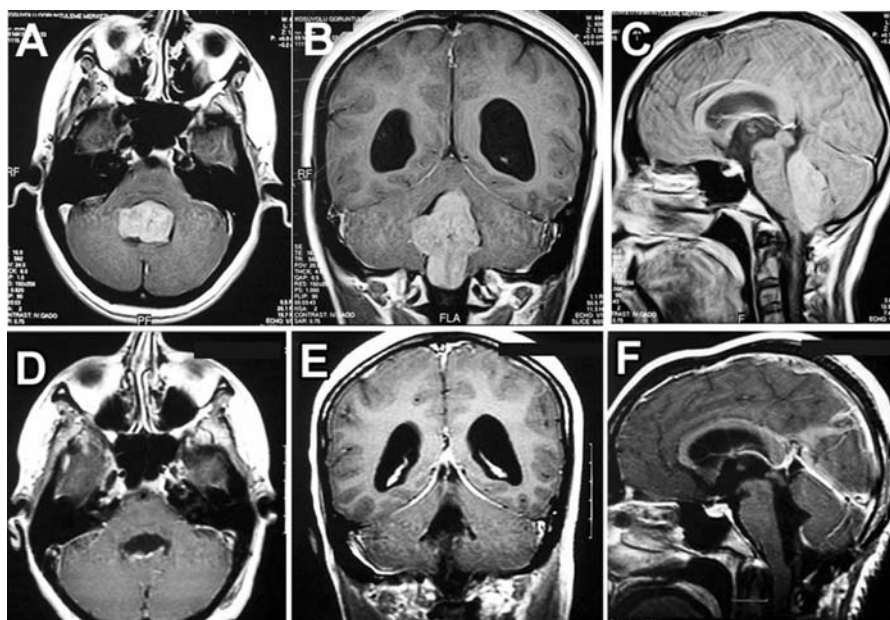
treatment is complete surgical excision and this is virtually curative. Three-fourths of cerebellar hemangioblastomas present as cystic tumors with a mural nodule and these can be resected with little difficulty. The cerebellar surface is exposed with a posterior median suboccipital craniectomy and the shortest route to the tumor is determined using intraoperative ultrasonography. Entry of the cyst cavity leads to the mural nodule. Among posterior fossa tumors, hemangioblastomas are the most vascular. Attempts at tumor biopsy or piecemeal removal will result in significant hemorrhage, therefore the tumor nodule is dissected along the gliotic margin and devascularized using bipolar coagulation. Associated cysts do not contain viable tumor tissue and therefore should not be resected. The decision making is more critical in brain-stem hemangioblastomas. Such tumors may arise within the fourth ventricle without brainstem involvement and such cases can be resected by transvermian splitting or the telovelar approaches with minimal morbidity. However, those that arise from the floor of the fourth ventricle have a subpial attachment and attempts at radical removal are associated with a significant risk of brainstem injury. Gamma-Knife radiosurgery may be an alternative means of treatment in these cases. Ten year tumor control rates in excess of 95% have been reported using radiosurgery.



**Fig. 3.** *Medulloblastomas* most commonly arise at the midline in the posterior fossa (A-C). The tumor most commonly has a suckable consistency. *Medulloblastomas* can invade the fourth ventricle floor, therefore the initial goal should be identification and protection of the fourth ventricular floor. Total resection should be possibly resected totally (D-F) but aggressive resection of parts that invade the brain stem or cranial nerves can result in serious morbidity

*Medulloblastomas* are most commonly midline tumors and usually dis-tend the vermis and protrude through the foramen of Magendie. They appear reddish-grey during surgery, are friable in nature but easily “suckable” in consistency. The tumor may invade the floor of the fourth ventricle both laterally and at the midline and attempts to resect this portion are associated with very high morbidity. Therefore the initial goal in surgery for medulloblastomas is to identify and protect the fourth ventricle floor. Due to the frequently large size, tumor resection starts with internal decompression using suction or ultrasonic aspirator followed by circumferential dissection. Medulloblastomas recur in the posterior fossa, therefore proper closure, respecting the anatomy, is of great importance.

*Ependymomas* most commonly arise at the obex and grow into the fourth ventricle. They conform to the shape of the anatomical compartment they grow in. Protrusion into the upper cervical spinal canal and extension to the cerebellopontine angle are very commonly encountered. Ependymomas are exposed with a telovelar approach or by vermian splitting to the fourth ventricle. The bulk of the tumor can easily be resected through a posterior mid-line approach. However, most commonly ependymomas attach with a broad



**Fig. 4.** *Choroid plexus papillomas* in the adults are commonly located within the fourth ventricle (A–C) and commonly causes hydrocephalus. During surgery the tumor will appear as a cauliflower-like mass that fills up the fourth ventricular space. Total resection can be easily achieved in most cases as the tumor is well demarcated from the surrounding tissues (D–F)



base to the fourth ventricle floor and in most cases this adherence precludes total resection.

*Choroid plexus papillomas and carcinomas* are cauliflower-like masses. They are usually well delineated from brain tissue but may adhere to the ventricular wall.

#### **4. POSTOPERATIVE CARE, ADJUVANT THERAPIES AND LONG-TERM RESULTS**

In our institution we use 3T-intraoperative MRI (ioMRI) to assess the extent of resection. If unexpected residual tumor is detected, further resection is performed. If no ioMRI is available, early postoperative MRI, within the first 24 hours gives an objective estimate of the resection and this will direct adjuvant treatment.

Surgical resection of a solitary cerebellar metastasis is a palliative procedure and should be followed by whole brain irradiation and treatment directed at the primary. Medulloblastomas are malignant tumors and invariably require adjuvant therapies. Radiation therapy, especially to the posterior fossa, has an important impact on survival. Radiotherapy to the rest of the neuraxis is also considered in case of CSF seeding. Chemotherapy is of greatest value for patients with large residuals and CSF metastasis. In most ependymomas residual tumor tissue attached to the fourth ventricle floor requires adjuvant treatments. Ependymomas are generally radioresistant tumors, results with radiosurgery are not significantly better. Chemotherapy can be considered in selected cases.

Gamma-Knife radiosurgery can be used as adjunct in the case of residual tumors or as a primary treatment for small metastases, small and solid hemangioblastomas. In our experience results are very satisfactory for metastases, hemangioblastomas, medulloblastomas, pilocytic astrocytomas; however significantly poorer in ependymomas and ependymoblastomas.

#### **HOW TO AVOID COMPLICATIONS**

Potential complications of the posterior fossa surgery are numerous and many can be disastrous. Hematoma in the surgical bed is a common surgical complication and can be avoided with meticulous hemostasis. Epidural hematomas may be seen with use of the pin-head rests. In patients with a posterior fossa hematoma may present without any warning and progress to respiratory depression due to brain stem compression. Hypertension should alert the managing team. Cerebellar swelling is also reported but is very rarely observed during surgery or postoperatively due to cerebellar venous injury in retrosigmoid approach. Our institutional routine is to close the posterior fossa dura in a watertight fashion, but CSF leak and pseudomeningoceles can still be encountered. In our experience surgical

glues have greatly increased the infection risk, therefore we prefer to use patients' own tissues such as muscle, fat and fascia lata for such repairs. Rhinorrhea may occur after posterior fossa surgery, due to CSF leak through mastoid air cells, therefore meticulous closure of air cells should be performed during surgery using bone-wax. Infection rate in posterior fossa surgery is not any higher than the rest of the brain. A disastrous complication in tumors that invade the brain stem is failure to wake up after surgery which may occur due to brain stem injury. Cranial nerve deficits may occur due to brain stem injury or due to direct manipulation in tumors that invade the anterior brain stem. Cerebellar mutism is reported to occur after vermian splitting and can be avoided by using the telovelar approach instead. Both cerebellar mutism and pseudobulbar palsy are peculiar clinical syndromes that may occur after posterior fossa surgery, mainly in pediatric patients and are usually self limiting. Air embolism and tension pneumocephalus are described during surgery in the sitting position. Some authors have indicated that the risk may be minimized with continuous monitoring for air embolus and atrial cardiac catheterization to aspirate the embolus when needed. In our practice we do not use the sitting position as the risks of surgery far outweigh its advantages.

## CONCLUSIONS

- The most common tumor in the posterior fossa of an adult is metastasis.
- A variety of other intraaxial posterior fossa lesions may also be seen. The pathological spectrum of these pathologies varies with patient age and tumor localization within the posterior fossa.
- Patient history, symptomatology, neurological findings and neuroradiological imaging can provide significant clues about the diagnosis.
- The management strategy depends on the nature and localization of the lesion, the functional status of the patient.
- Cerebellar lesions can be approached with median, unilateral or paramedian suboccipital craniectomies. Fourth ventricle can be exposed using the median suboccipital approach through the telovelotonsillary fissure or by vermian splitting.

## References

- [1] Dağçınar A, Özek MM, Karabağlı H, Kılıç T, Elmacı İ, Aydın Sav, Pamir MN (2002) Tumors of the choroid plexus. *Turkish Neurosurg* 12(1-2): 26-32
- [2] Kleihues P, Cavenee WK (2007) Pathology and genetics. Tumors of the nervous system. IARC, Lyon-France

- [3] Rhoton AL Jr (2000) Cerebellum and fourth ventricle. *Neurosurgery* 47(3 Suppl): S7-S27
- [4] Yaşargil MG (1994) *Microneurosurgery*, vol. 4a. Thieme Verlag, Stuttgart-New York
- [5] Yaşargil MG, Abdulrauf SI (2008) Surgery of intraventricular tumors. *Neurosurgery* 62(6)(Suppl): SHC1029-SHC1040



**M. Necmettin Pamir**

M. Necmettin Pamir is Chairman of the Department of Neurosurgery at Acibadem University School of Medicine in Istanbul, Turkey. He is a 1976 graduate of Istanbul University Cerrahpaşa School of Medicine. He completed his neurosurgical training at Hacettepe University and then became an Assistant Professor and Associate Professor in the same university. In 1986 he became the chairman in the Department of Neurosurgery in Marmara University School of Medicine. In 1991, he earned his Professor's degree in neurosurgery from Marmara University. He formed both the Neurosurgery department at Marmara University School of Medicine and the Marmara University Institute of Neurological Sciences. He currently holds also the positions of President of Acibadem University; Chairman of Medical Executive Committee, Acibadem Healthcare Group in Turkey; President of Academia Eurasiana Neurochirurgica (2007–present).

**Contact:** M. Necmettin Pamir, Acibadem University, School of Medicine, Department of Neurosurgery, Inonu cad., Okur sok. No. 20, Kozyatagi, 34742 Istanbul, Turkey  
E-mail: pamirmn@yahoo.com

---

# VESTIBULAR SCHWANNOMAS

M. SAMII

## INTRODUCTION

The first description of a vestibular schwannoma (VS) was done by Eduard Sandifort in 1777, while the first successful surgical removal of VS was reported in 1894 by Sir Charles Ballance. Major advancements were made later on by F. Krause, who introduced the retrosigmoid approach to the cerebellopontine angle (CPA), by V. Horsley, H. Cushing, W. Dandy, and H. Olivecrona. Dandy was the first to demonstrate that the complete removal of VS should be the goal of surgery in order to prevent recurrences and that – if the capsule is dissected meticulously – the mortality and morbidity could be reduced.

The translabyrinthine approach was developed by Panse in 1904 but was disfavoured in the following 60 years. W. House introduced the microscope and microsurgical techniques and repopularized this approach as a method not only of achieving tumor removal but also of preserving the facial nerve. He developed also the middle fossa approach to the CPA.

The further elaboration of the retrosigmoid approach and the introduction of the microsurgical principles in the VS surgery over the last 4 decades, transformed the surgery of VS. Nowadays it is a safe procedure; complete tumor removal has become the rule and functional preservation of all cranial nerves is achieved in exceeding numbers [1, 10, 12].

## RATIONALE

The CPA is a triangular space defined by the pyramid anterolaterally, the tentorium superior, the pons medially, and the cerebellum dorsomedially [6]. It is located between the superior and inferior limbs of the cerebellopontine fissure. The CPA cistern contains the trigeminal, abducent, facial, and vestibulocochlear nerves, the superior cerebellar and anterior inferior cerebellar arteries, the flocculus of Luschka, and the choroid plexus that protrudes through the foramen of Luschka. VS are heterogeneous tumors with varying extension pattern and unpredictable displacement of the cranial nerves in the CPA. A detailed knowledge of the complex relationship of the tumor to cranial nerves, cerebellar arteries, and brain structures to the VS is a prerequisite for optimizing the outcome of surgery. At the brain stem and in the internal auditory canal (IAC) the course of the nerves is relatively constant. The facial

---

*Keywords:* vestibular neuromas, microsurgery, cerebellopontine angle surgery

nerve exits the brain stem in the lateral part of the pontomedullary sulcus, 1–2 mm anterior to the entry zone of the vestibulocochlear nerve. The position of the nerves in the lateral portion of the IAC is also constant: the facial lies in the superior-anterior quadrant, the cochlear nerve – in the inferior-anterior quadrant, the superior vestibular nerve – in the superior-posterior quadrant, and the inferior vestibular nerve – in the posterior-inferior quadrant. In the CPA the facial nerve is found most frequently anterior to the tumor in the middle or upper third of the capsule [11]. The cochlear nerve has less anatomical variation and is usually found in the anterior-inferior portion of the tumor capsule. The ninth, tenth, and eleventh cranial nerves are located in the lower part of the cerebellopontine angle.

Tumors of the CPA account for 5 to 10% of all intracranial neoplasms. The most frequent are VS, followed by meningiomas and epidermoid tumors.

## **DECISION-MAKING**

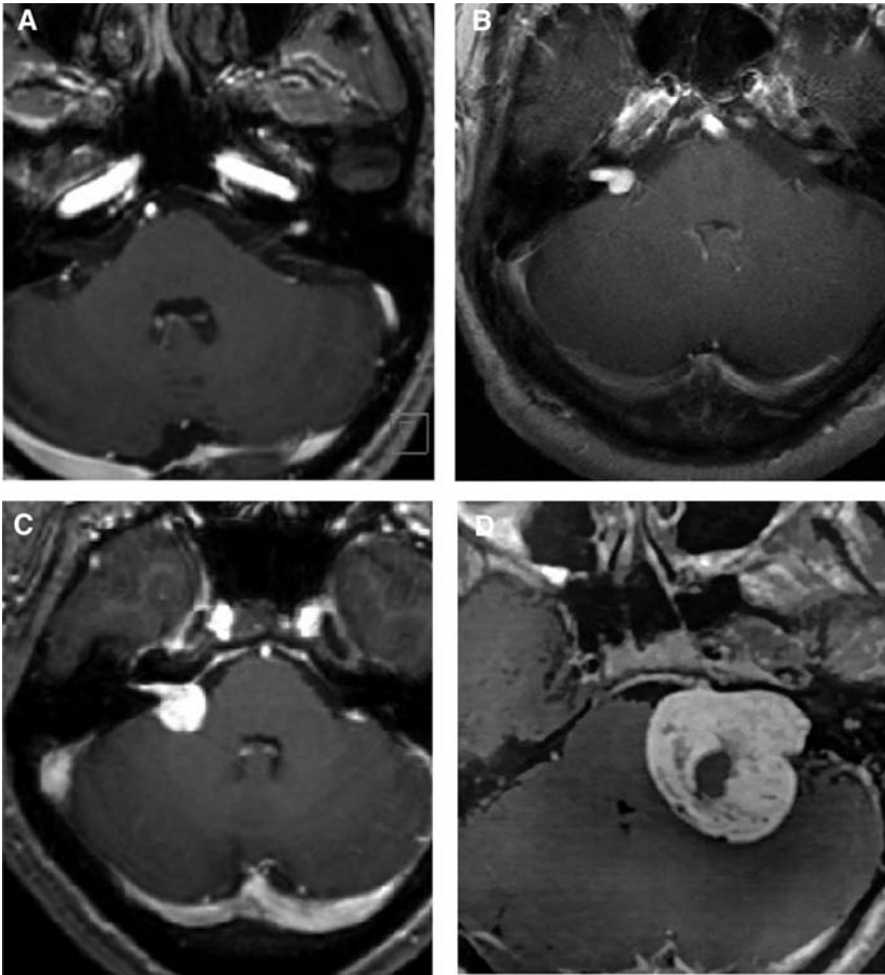
VS are histopathologically benign, typically slow-growing neoplasms and comprise 75–86% of CPA tumors [1, 3, 7]. VS originate most frequently from the intracanalicular part of the vestibular nerve in the region of the transition zone between central and peripheral myelin, generally in the medial part of the IAC. Their natural evolution is unpredictable, with an annual growth rate between 0.2 mm and 2 mm.

Four stages of VS growth have been described: intracanalicular, cisternal, brainstem compressive, and hydrocephalic. Each stage is characterized by specific neurological symptoms that are due to compression or displacement of cranial nerves, brain stem, and cerebellum, or to hydrocephalus.

VS are commonly classified according to their size or extension. However, the extension of the tumor in the CPA is more important than its diameter. A classification [7] based on the extent of tumor growth and the presence and severity of brain stem compression in its relation to the brain stem (Fig.1A–D) is presented below:

- T1 – purely intracanalicular VS
- T2 – intrameatal or extrameatal
- T3 A – filling the CPA cistern
- T3 B – reaching the brainstem
- T4 A – compressing the brainstem
- T4 B – severe compression and dislocation of the brainstem and the fourth ventricle

The diagnosis of VS relies on history, physical examination, and audiometry and is solidified by neuroradiologic examination. Audiograms generally reveal high frequency sensorineural hearing loss and speech discrimination is severely affected. High-resolution bone window CT is essential for visualizing



**Fig. 1.** T1-weighted MRI with contrast enhancement showing the 4 stages of VS growth (A–D)

bony changes and erosion of IAC, as well as for surgical planning. MRI is the diagnostic tool of choice for all CPA tumors. On T1-weighted MRI images VS are isointense or slightly hypointense to the normal brain and on T2-weighted images they are hyperintense. They show an intense and homogeneous contrast enhancement with the exception of cystic tumor parts.

Treatment options of VS include observation, radiosurgery, and microsurgical removal via one of several operative approaches. Another option – suggested for large VS – is the combined staged treatment. At the first stage the tumor is debulked and its mass effect and compression of the brainstem are

relieved. The residual tumor is treated radiosurgically at a second stage. In choosing the most appropriate treatment mode the preservation of neurological functions and quality of life are of paramount importance.

The number of asymptomatic incidentally discovered small VS is increasing due to the wide spread of MRI facilities. Some of them might not show further growth or might even undergo spontaneous regression. Based on this, the conservative approach – observation – is recommended. As the natural evolution of VS is still unpredictable, this strategy should be applied only in very carefully selected cases, with regular MRT follow-up – at 6 to 12-month intervals. It is indicated for old and/or somatically unstable patients with small asymptomatic tumors or tumors causing mild stable symptoms. However, long-term follow-up results indicate that majority of the tumors exhibit further growth and in case of larger tumors the chance of hearing preservation might be much lower.

An alternative to microsurgical tumor removal is the radiosurgery [4]. Its goal is to achieve tumor control and success rates of 93–98% have been reported. Further tumor growth, however, is observed in 2 to 7% of the cases. The risk of late facial neuropathy varies from 1 to 24%, the rate of trigeminal dysfunction is 2–27%, and hearing preservation is achieved in 40–74%.

The optimal therapy of VS is complete tumor removal with preservation of all neurological functions. This goal is achieved in ever increasing numbers in different highly specialized centers. The three most commonly used operative approaches are the translabyrinthine, the middle fossa and the retrosigmoid. The selection of the approach is related to factors such as tumor size, extension in the IAC, preoperative hearing level, and mostly – surgeon's experience, preferences, and institutional tradition. Excellent results have been achieved with each of these techniques: complete tumor removal is achieved in 80–99% [1, 3, 10, 12].

The benefits of the translabyrinthine approach [1–3] are shorter distance to the tumor, avoidance of cerebellar retraction, and early identification of the facial nerve at the lateral end of the IAC. Drawbacks are inevitable sacrifice to hearing, restricted access to the CPA, difficult dissection and hemostasis close to the brain stem, as well as poor visualization and access to the caudal cranial nerves.

The middle fossa approach [1, 12] is a hearing preserving option that allows direct access to the lateral end of the IAC and safe removal of the most lateral part of the tumor. The risk of CSF leaks is low. On the other hand, the approach is applicable for small tumors, necessitates temporal lobe retraction, endangers the vein of Labbé, and offers a restricted access to the CPA.

The retrosigmoid suboccipital approach is the most popular among neurosurgeons [1, 6–11]. It offers: an excellent panoramic visualization of the whole CPA; increased safety during dissection from the brain stem and lower cranial nerves; possibility to preserve hearing even in large VS; identification of the facial and cochlear cranial nerves both in their proximal (close to the



brain stem) and lateral part (in the IAC) thus increasing the chances for their preservation; and possibility to reconstruct the facial nerve in the CPA at the same surgery, if needed. Some drawbacks, traditionally ascribed to the approach – need of cerebellar retraction, difficult visualization of the most lateral part of the IAC without endangering the integrity of the inner ear; higher rate of postoperative headache – have been largely overcome with some modification of the original technique described below.

## **SURGERY**

### **1. POSITION OF THE PATIENT**

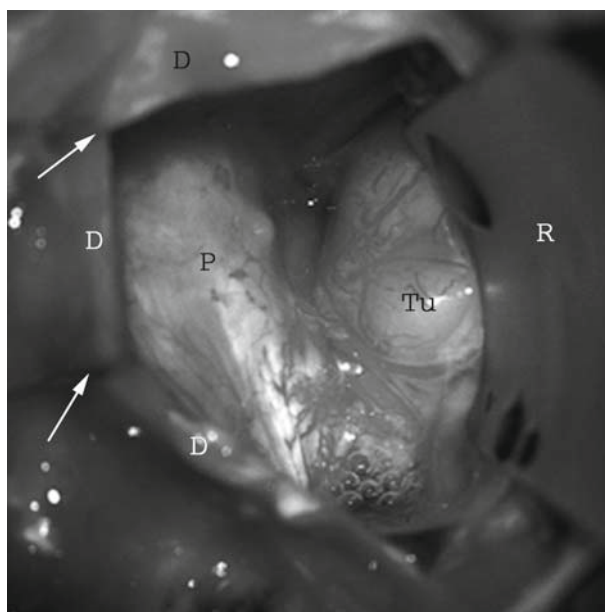
The semi-sitting position is preferred because it allows bimanual tumor dissection [7]. Further, the assistant performs continuous irrigation of the operative field and thus there is no need of constant suction and coagulation during tumor removal. The head of the patient is slightly flexed and rotated 30° to the involved side but the venous jugular outflow should not be occluded or the cervical spine hyperflexed or extended. This position of the patient is related to some risks, such as venous air embolism, paradoxical air embolism, tension pneumocephalus, or circulatory instability. The measurement of end-tidal carbon dioxide levels and the routine precordial Doppler echocardiography allow early detection of venous air embolism. The morbidity related to venous air embolism is insignificant if immediate and effective measures at the first sign of venous air embolism are undertaken.

### **2. MONITORING**

The continuous neurophysiological monitoring throughout the procedure is of utmost importance in every CPA surgery [5]. Monitoring of somatosensory evoked potentials is especially important during patient positioning in order to avoid spinal cord compression. The facial nerve is monitored continuously by EMG transferred by loudspeakers. Bipolar recording needle electrodes are fixed at the eyebrow for the orbicularis oculi muscle and at the mouth angle for the orbicularis oris muscle. Electrical activation is applied in case of difficult nerve identification or for testing the reactivity of the nerve. Monitoring of the auditory evoked potentials is a prerequisite for preserving hearing function.

### **3. INCISION AND EXPOSURE**

A slightly curved skin incision approximately 1 to 1.5 cm medial to the mastoid process is performed. The underlying fasciae and the suboccipital muscles are incised and separated from their bony attachments. The superior nuchal line overlies the transverse sinus and the sigmoid sinus descends along

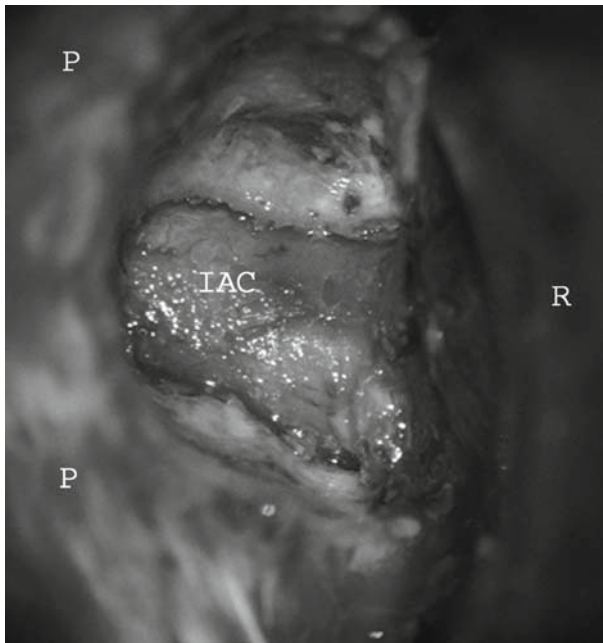


**Fig. 2.** The dura (D) has been incised circularly just inferior o the transverse sinus and medial to the sigmoid sinus and pulled out with 2 stitches (*arrows*). The tumor (Tu) and the posterior surface of the pyramid (P) are visible. The cerebellum is supported by a retractor (R)

the axis of the mastoid groove. A burr hole is made and the occipital bone is removed using bone rongeurs, thus exposing the borders of the sigmoid and transverse sinuses, as well as their junction. The craniotomy should extend to the floor of the posterior fossa. Because of the high risk of damaging the dura and/or the venous sinuses with the craniotome we do not recommend the one-piece craniotomy. The dura is incised in a circularly just 1.5–2 mm medial to the sigmoid and inferior to the transverse sinus (Fig. 2). The cerebellum is elevated slightly with a spatula, the lateral cerebellomedullary cistern is opened, and CSF is allowed to drain. Thus, the cerebellum relaxes away from the petrous bone and the self-retaining retractor just supports and protects the hemisphere, instead of compressing it.

#### 4. TUMOR REMOVAL

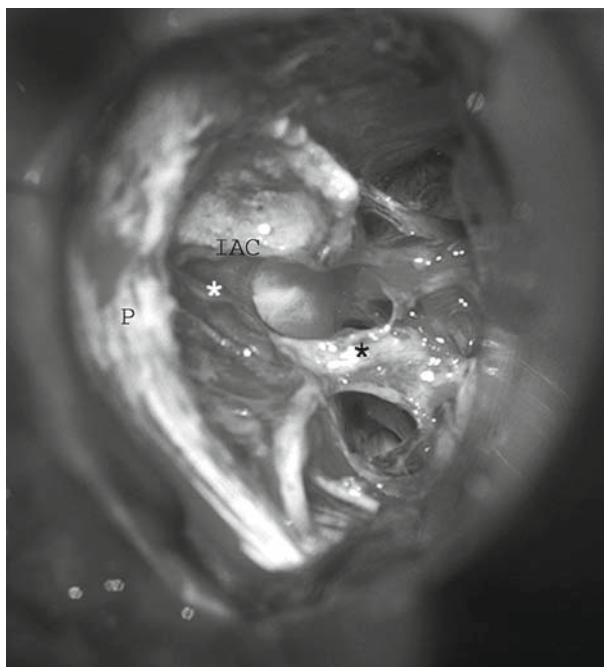
The intrameatal tumor portion is exposed initially with the exception of very large tumors which overlap the posterior pyramid. The preoperative high-resolution bone window CT scans with thin slices have to be studied and the position of inner ear and jugular bulb determined prior to opening of the IAC. The dura around the posterior lip of the IAC is removed widely. The posterior and superior walls of the IAC are drilled off with decreasing sizes of



**Fig. 3.** The IAC is widely opened and the tumor is still covered by the meatal dura

diamond drills (Fig. 3). It should be remembered that the posterior semicircular canal and its common crus with the superior canal are located lateral to the posterior meatal lip, while the vestibular duct is located inferolateral to the meatal lip. These structures should not be damaged if hearing is to be preserved [8]. The extent of IAC opening is tailored to the extent of lateral tumor extension. If drilling of IAC is limited by the inner ear structures, the region of the fundus could be inspected with the help of an angulated endoscope.

The meatal dura is then incised and the intrameatal tumor is exposed. The facial and vestibulocochlear nerves are identified due to their constant location in the IAC. Then, the most lateral tumor portion is carefully mobilized out of the IAC with a microdissector and the tumor is piecemeal removed. The extrameatal intracapsular tumor debulking is performed with the Cavitron ultrasonic aspirator. The dissection of the capsule should begin only after adequate internal decompression is achieved. It is performed by strictly gripping the tumor capsule and dissecting in the level of the arachnoid plane under continuous saline irrigation. As most of the microvascular blood supply to the nerves is in the subarachnoid space, it is important that dissection of the nerves from the capsule proceed in the correct plane [6, 11]. The tumor is dissected medially along the brain stem for identification of the medial part of the facial nerve [9]. Then, the nerve is dissected from the upper tumor portion. Pulling of the rest of the capsule medially and upward, allows visualisa-

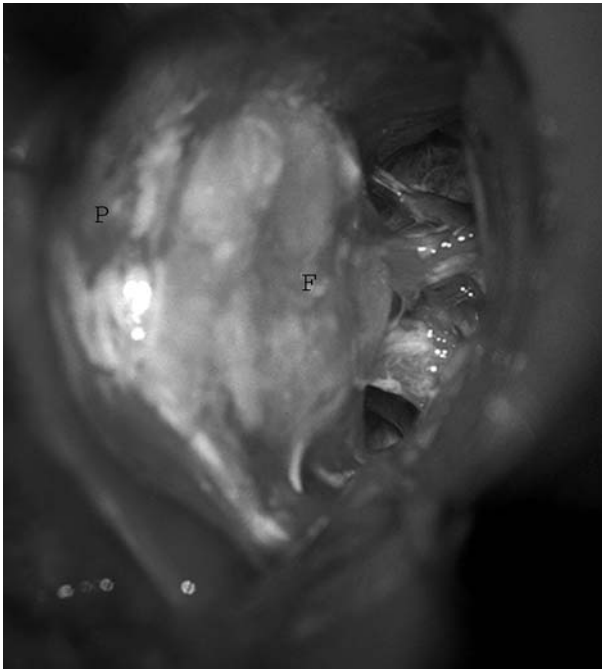


**Fig. 4.** Intraoperative view of the CPA after complete tumor removal. The 7th and 8th cranial nerves (\*) have been preserved

tion of the lowest and most lateral aspects of the facial nerve. The dissection is alternated from different directions. In order to avoid thermal injury to the vulnerable cranial nerves, bipolar coagulation is reduced to a minimum and left up to the end of surgery for final hemostasis. In the area just medial to and inside the porus the facial and cochlear nerves are generally extremely adherent to the tumor. This tumor part is dissected at the end (Fig. 4).

Once complete tumor removal is achieved, the continuity of the facial nerve can be confirmed by its electrical stimulation from the brain stem to the IAC. In case the nerve is interrupted, it could be reconstructed at the same operation [9]: directly end-to-end (which is rarely possible) or with a sural nerve graft attached with fibrin glue. If only the proximal nerve stump is available, the intracranial-intratemporal technique is recommended. In case the facial nerve is preserved anatomically but responds very poorly to electrostimulation, a “bypass” end-to-side anastomosis with sural nerve graft could be performed [10].

The opened IAC is occluded by placing pieces fat tissue fixed with fibrin glue over the drilled region (Fig. 5). The dura is closed watertight and the opened mastoid air cells are also occluded. Then, the posterior skull base is reconstructed with methyl methacrylate. With this cranioplasty technique



**Fig. 5.** The IAC is occluded with multiple small fat pieces (F) sealed with fibrin glue

better cosmetic result is achieved and the formation of pseudomeningocele or adhesions between the dura and neck muscles is prevented.

The recurrence rates after complete tumor removal in the largest series vary from 0.5 to 5% [1, 3, 10, 12]. Tumor size is the main predictive factor for the outcome. Therefore, follow-up MRI examinations at 1 year interval are required in order to detect early any possible recurrent tumor.

The personal experience of the author confirmed the existence of an operative learning curve. It is related initially to avoiding mortalities and reducing morbidity, and later – to increasing the rates of preservation of facial nerve function and hearing. Thus, in the last 2500 cases there were no mortalities; in the last 500 cases the rate of facial nerve preservation was 98% and in tumors, corresponding to grades T1–T3 of the Hannover classification (less than 3 cm) was 100%. At the last follow-up examination 81% of the patients had excellent or good facial nerve function and there were no patients with total facial palsy. Hearing preservation is strongly dependent on the level of preoperative hearing and the auditory brain stem response, and to a lesser extent on tumor size. If functional hearing was available preoperatively, the anatomical integrity of the cochlear nerve was preserved in 84% and the overall rate of hearing preservation after surgery was 51% [10].

## **BILATERAL VESTIBULAR SCHWANNOMAS**

Bilateral VS are characteristic for Neurofibromatosis Type 2 (NFII), a relatively rare autosomal dominant inherited disease. In patients with NFII a lifelong tendency to formation of new central nervous system tumors exists. Therefore, these patients cannot be cured and treatment is focused on life prolongation, maintenance of quality of life, preservation of cranial nerve function or auditory rehabilitation. Over a period of 4 decades the author has operated more than 170 patients with bilateral VS. The goal always has been complete tumor removal, as in case of unilateral VS, and has been achieved in 85% of the operated tumors. Deliberate subtotal resections have been performed in 15%: for brain stem decompression, for hearing preservation in the last hearing ear, or for facial nerve functional preservation. Facial nerve preservation was possible in 89% of the surgeries. In the rest the tumor (or tumors) originated from the facial nerve or no cleavage plane between the cranial nerves and the tumor could be found.

Some surgeons propose a more conservative approach in order to preserve hearing—follow up of the patient and subtotal intracapsular resection if the VS enlarges. Our treatment philosophy is based on the assumption that surgical removal of VS can preserve hearing. Therefore, if the chances of functional hearing preservation are realistic, our recommendation is for early surgery. Tumor extension, audiometry data, and auditory brainstem responses (ABR) determine which side should be operated initially. The side with best chances for hearing preservation is treated first. The main predictors of successful hearing preservation are tumor extension, preoperative hearing level and quality of ABR. We recommend initial treatment on the side with the smaller tumor or the side with better hearing level. If the hearing and the tumor size are similar on both sides, our decision is based on the preoperative ABR. Thus, we achieved bilateral hearing preservation in 23% of the patients. Preserved unilateral hearing after surgery had 65% of the patients with useful preoperative hearing level. For VS on the only hearing side we perform IAC decompression and complete or partial tumor removal, depending on the intraoperative ABR. If slight microsurgical actions are followed by severe deterioration in ABR, only partial resection is performed.

In some patients with NFII bilateral deafness is inevitable. The recent introduction of auditory brainstem implants that are designed to stimulate directly the second-order neurons might provide a solution in the near future.

## **HOW TO AVOID COMPLICATIONS**

### **1. PATIENT POSITIONING**

Preoperative functional X-rays of the cervical spine can help identify those patients that are at risk of complications due to positioning of the head. Its

flexion should be less in those with degenerative spine disease. The feedback information provided by the monitoring of the somatosensory evoked potentials guarantees its safety.

## **2. INJURY TO VENOUS SINUSES AND VEINS**

The burr hole should be positioned away from the sinuses, usually 2–2.5 cm below the superior nuchal line, two-thirds behind and one-third in front of the occipitomastoid suture. Excessive traction to the mastoid emissary vein could lead to sinus laceration and venous air embolism. In order to avoid that, the vein should be skeletonized with the diamond drill from its bony encasement, then coagulated and cut. The petrosal vein (or veins) should be preserved whenever possible, because its occlusion may cause hemorrhagic edema of the cerebellum and the brain stem.

## **3. INTRACRANIAL BLEEDING**

Since coagulation in the vicinity of the cranial nerves should be avoided, the achievement of hemostasis after tumor removal might be difficult. Tamponade with oxidized cellulose or gel sponges for several minutes might be beneficial. If bipolar coagulation is necessary, it should be performed at very low power. After tumor removal jugular venous compression is performed to make any opened or torn veins visible. It is applied twice: initially the CPA is inspected while the retractor is still in place. Then, the retractor is removed, the cerebellum reexpands, and the jugular veins are compressed again. The presence of any torn and bleeding supracerebellar bridging veins are thus detected.

## **4. CSF LEAK**

The occlusion of the opened IAC is more reliable if several pieces of fat tissue are applied and fixed with fibrin glue over the drilled region. Similarly, the risk of CSF is less if the opened mastoid air cells are occluded with pieces of fat tissue sealed with fibrin glue. Bone wax has to be avoided, except for hemostasis if there is significant bleeding from the bone edges. The dura should be sutured watertight. It might be even necessary to fix a piece of fat to the sutured dura.

## **5. POSTOPERATIVE HEADACHE**

The occurrence of postoperative headache might be a sequence of: adhesion of the dura to nuchal muscles or to subcutaneous tissues; dural tension in the case of direct dural closure; use of fibrin glue, and/or intradural drilling. The methyl methacrylat cranioplasty significantly decreases the risk of

this complication. The reason for the suboccipital headache might be the formation of scar tissue around the occipital nerves or of a posttraumatic scar neuroma. In such cases careful examination of the area around the operative incision usually reveals a small point, whose palpation triggers identical suboccipital pain. Infiltration with local anesthesia in this area usually ameliorates the symptoms. If the pain is lasting and resistant to medications, operative excision of the scar and/or the neuroma through a limited skin incision could be performed and leads to immediate amelioration of the pain.

## CONCLUSIONS

Nowadays several treatment options exist for managing patients with VS: radiosurgery; surgical removal via the middle fossa, translabyrinthine, or retrosigmoid approaches; or staged therapy. The optimal treatment – according to our experience – is their complete removal at one stage with preservation of neurological functions and of quality of life. If at least some hearing is available preoperatively an attempt should be made to preserve both the facial nerve and the cochlear nerve in every case, whatever the tumor's size. This can be safely and successfully achieved via the retrosigmoid suboccipital approach. Best outcome is achieved in highly specialised medical centers in which several VS are operated weekly by a single neurosurgeon.

## References

- [1] Briggs RJ, Fabinyi G, Kaye AH (2000) Current management of acoustic neuromas: review of surgical approaches and outcomes. *J Clin Neurosci* 7: 521-526
- [2] Day JD, Chen DA, Arriaga M (2004) Translabyrinthine approach for acoustic neuroma. *Neurosurgery* 54: 391-395
- [3] Lanman TH, Brackmann DE, Hitselberger WE, Subin B (1999) Report of 190 consecutive cases of large acoustic tumors (vestibular schwannoma) removed via the translabyrinthine approach. *J Neurosurg* 90: 617-623
- [4] Lunsford LD, Niranjan A, Flickinger JC, Maitz A, Kondziolka D (2005) Radiosurgery of vestibular schwannomas: summary of experience in 829 cases. *J Neurosurg* 102(Suppl): 195-199
- [5] Matthies C, Samii M (1997) Management of vestibular schwannomas (acoustic neuromas): the value of neurophysiology for intraoperative monitoring of auditory function in 200 cases. *Neurosurgery* 40: 459-466
- [6] Rhoton AL Jr (2000) The cerebellopontine angle and posterior fossa cranial nerves by the retrosigmoid approach. *Neurosurgery* 47: S93-S129



- [7] Samii M, Matthies C (1997) Management of 1000 vestibular schwannomas (acoustic neuromas): surgical management and results with an emphasis on complications and how to avoid them. *Neurosurgery* 40: 11-21
- [8] Samii M, Matthies C (1997) Management of 1000 vestibular schwannomas (acoustic neuromas): hearing function in 1000 tumor resections. *Neurosurgery* 40: 248-262
- [9] Samii M, Matthies C (1997) Management of 1000 vestibular schwannomas (acoustic neuromas): the facial nerve – preservation and restitution of function. *Neurosurgery* 40: 684-694
- [10] Samii M, Gerganov V, Samii A (2006) Improved preservation of hearing and facial nerve function in vestibular schwannoma surgery via the retrosigmoid approach in a series of 200 patients. *J Neurosurg* 105: 527-535
- [11] Sampath P, Rini D, Long DM (2000) Microanatomical variations in the cerebellopontine angle associated with vestibular schwannomas (acoustic neuromas): a retrospective study of 1006 consecutive cases. *J Neurosurg* 92: 70-78
- [12] Slattery WH III, Brackmann DE, Hitselberger W (1997) Middle fossa approach for hearing preservation with acoustic neuromas. *Am J Otol* 18: 596-601



### **Madjid Samii**

Madjid Samii is President of the International Neuroscience Institute (INI) at Otto-von-Guericke-University, President of China INI, Chairman (Retired) of Neurosurgical Departments, Hannover School of Medicine and Klinikum Hannover Nordstadt, Honorary President of the World Federation of Neurosurgical Societies. 1957–1963: Medical School University of Mainz, Germany, including second study of biology. 1970: Associate Professor and Vice Director of Neurosurgical Department, University of Mainz. 1971: Professor of Neurosurgery. 1977–2002: Director of Neurosurgical Department, Nordstadt Hospital, Hannover. 1996–2002: Director of the Neurosurgical Departments at Hannover School of Medicine and Klinikum Hannover Nordstadt. 1997–2001: President of the World Federation of Neurosurgical Societies (WFNS). 1998–2005: Founder and first President of WFNS Foundation. July 2000: President of the International Neuroscience Institute (INI), Inauguration on 21 July, 2000. Sept. 2001: Honorary President of WFNS. July 2004: Nomination as President of the China International Neuroscience Institute at the Capital University of Medical Sciences in Peking, China. Since 2005: Honorary President of WFNS Foundation. Honorary doctors and professors of 12 universities. Honorary and/or corresponding member of 64 national and international scientific societies. Editor of 15 neurosurgical books and more than 500 publications on peripheral nerves, spinal tumors and syringo-

myelia, skull base pathology, brain tumors, cranial nerve disorders, pain. More than 1000 lectures as invited and/or honoured guest of numerous national and international congresses.

**Contact:** Madjid Samii, International Neuroscience Institute, Rudolf Pilchmayr Str. 4, 30625 Hannover, Germany  
E-mail: [samii@ini-hannover.de](mailto:samii@ini-hannover.de)

---

# BRAINSTEM TUMORS

A. BRICOLA

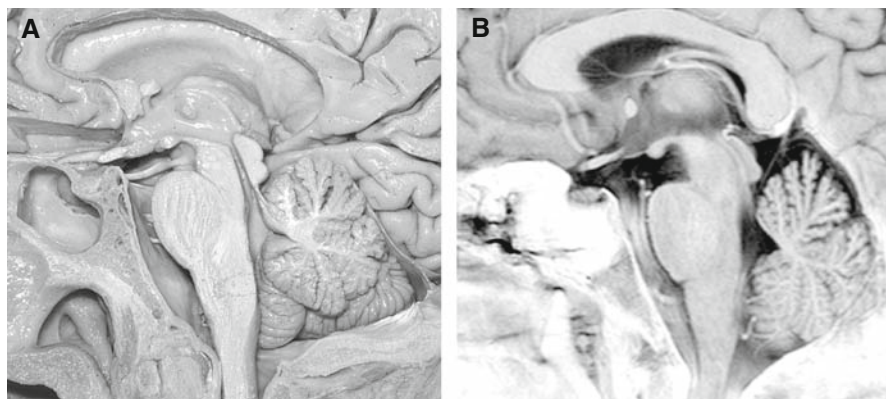
## INTRODUCTION

The stem of the brain, which comprises the mesencephalon, pons and medulla, is contained almost entirely in the posterior fossa where it lies protected by the clivus and the petrous pyramids shielded by cranial nerves and arteries and covered by the cerebellum (Fig. 1). This small part of the encephalon presents a highly complex neural structure both anatomically and functionally. It is crowded with cranial nerve nuclei and numerous fascicles and pathways as well as reticular formation – all playing important roles in securing normal central nervous function and regulation of bodily homeostasis [1]. Infants born without cerebral hemispheres yet with intact brainstem (anencephalic) as well as adults with extensive damage of the forebrain (vegetative state) can survive and exhibit complex behavioral and visceral regulation, clearly demonstrating the essential vital and vigilance mechanisms contained within the brainstem [19]. The brainstem has 3 general functions: first, it receives sensory information from cranial structures, and controls all the muscles governed by the cranial nerves – a function similar to that of the spinal cord; second, it contains neuro-circuits that transmit information from the spinal cord to the brain and back; and third, the integrated action of the medulla, pons, and midbrain regulate the level of arousal through the activity of the reticular formation which lies in the core of the brainstem. In addition, the medulla and pons participate in blood pressure and respiratory regulatory mechanisms. Severe damage to the brainstem is indeed devastating and almost always life threatening [2, 5].

Because of its difficult access and functional importance, in the past, the brainstem was seldom explored by neurosurgeons, with its injury often conducive to deep coma, decerebrate rigidity, cardio-respiratory failure, and other severe complications. For many years, a tumor growing inside the brainstem was considered malignant in itself and managed empirically as a homogeneous group with radiation therapy as well as adjunctive chemotherapy [17]. The neurological course generally progresses and after a relatively short remission the patient rarely survives more than one or two years after the primary diagnosis. Only in the last two decades, a series of favorable concomitant factors including advances in neuroimaging, microsurgical techniques and intraoperative electrophysiologic monitoring and mapping have materially changed this pessimistic attitude, making the brainstem and its pathology more accessible for direct surgery [2, 4, 10].

---

*Keywords:* brainstem, tumors, microsurgery, neuro-oncology

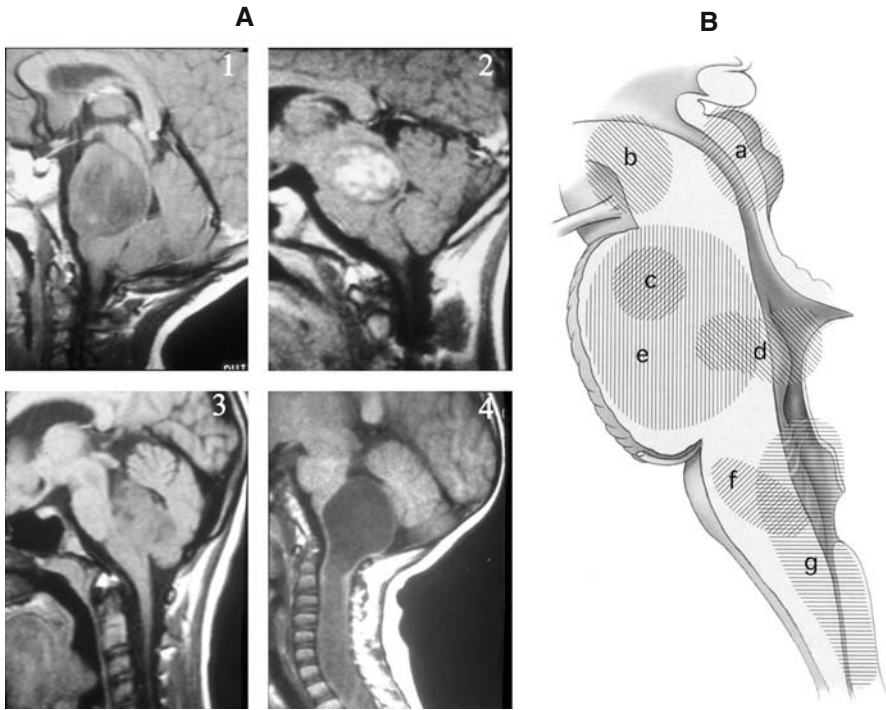


**Fig. 1.** Midline sagittal view of the brainstem in a cadaver (**A**, courtesy of Dr. A. Rhoton) and a comparable MR image of a live subject (**B**) that very clearly capture the brainstem. Only after the advent of MRI did the diagnosis of brainstem lesions become more precise and easier

## RATIONALE

For diagnosis and classification, the contribution of magnetic resonance imaging (MRI) was immeasurable because of the fundamental finding that not all the tumors in the brainstem are diffuse. Since its appearance, MRI has become the primary diagnostic modality for brainstem gliomas and for now is the unique examination that gives us the possibility of identifying whether a tumor has clear edges between it and normal tissue, and furthermore, understanding its growth pattern. Right from the first glance, it is possible to distinguish “diffuse” tumors, which do not present surgical indication, from all others, which are potentially surgically treatable. At present there is a general consensus to classify the brainstem gliomas into four subgroups on the basis of MRI, namely, *diffuse*, *focal*, *dorsally exophytic* and *cervico-medullary* (Fig. 2A). These subgroups, which reflect different growth patterns, not only assist the surgeon to identify tumor invasiveness but also aid in selecting those amenable for surgical treatment and determination of prognosis.

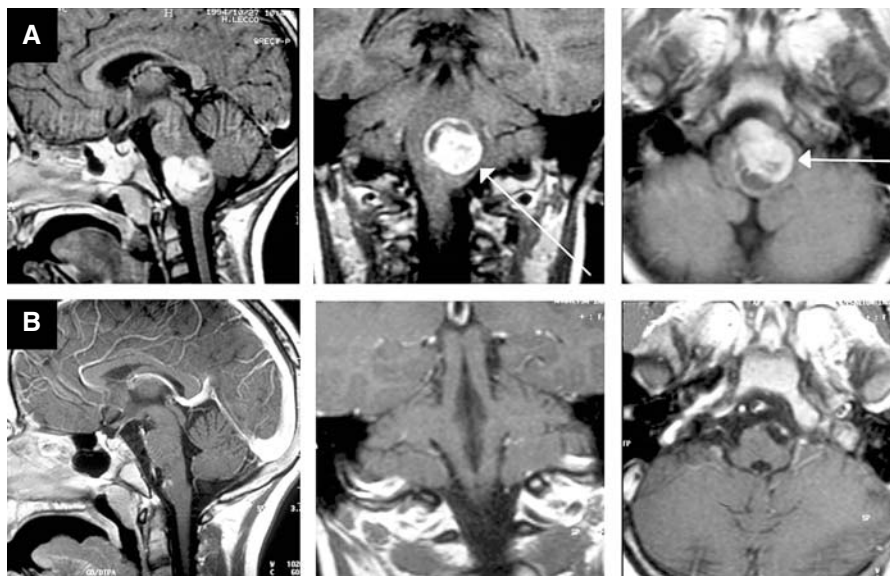
1. *Diffuse tumors.* In the end everyone agrees in considering these tumors as “malignant” glioma, which have a poor prognosis. In MRI they present as an enlargement, and sometimes deformation, of the brainstem at the pons without the chance of seeing any clear edges of the tumor. These tumors are characterized by a low or an isointense signal on T1-weighted images and an increased signal on T2-weighted images. The majority of them is centered in the pons and can extend up to the midbrain and/or down to the medulla. Not rarely during their growth do they engulf the basilar artery and at times they can show areas with contrast enhancement



**Fig. 2.** **A** Subgrouping of brainstem gliomas based on MRI patterns: (1) diffuse, (2) focal, (3) dorsally exophytic, (4) cervico-medullary. **B** A sketch pattern of brainstem gliomas in the author's series: (a) mesencephalic tectal, and (b) tegmental, (c) pontine focal, (d) dorsal exophytic, and (e) diffuse, (f) medullary focal, and (g) cervico-medullary (*Modified from 7*)

internally, which is a sign of malignant veering. One must remember, as stressed by Konovalov [15], that at the early stage of its growth even the classic diffuse glioma can present as a focal tumor. Unfortunately the diffuse group constitutes the majority of brainstem gliomas (more than 50%) and their therapy remains limited to radiation and/or chemotherapy. Surgery has no role in these cases and there is a general consensus that even a biopsy is no longer necessary.

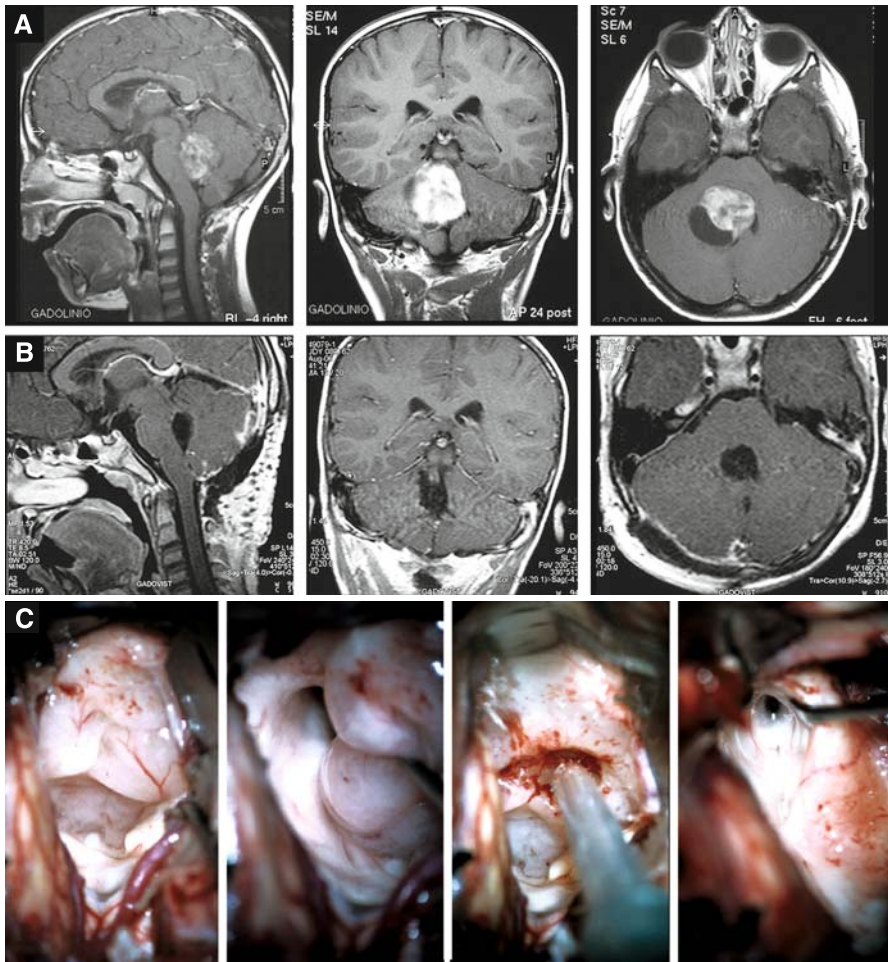
**2. Focal tumors.** These tumors (Fig. 3) are those that are seen on MRI with great clarity and a good demarcation from the surrounding tissue and that can arise in the midbrain, pons or medulla and that remain intrinsic in the brainstem. These lesions appear isodense or with a slightly lower signal on T1-weighted MRI, while the signal results as well increased in T2-weighted images. The contrast enhancement in these focal tumors, most of which are benign, is variable. A strong enhancement is typical of a pilocytic astrocytoma, but there can also be astrocytomas with a low or no enhancement. A number of these tumors



**Fig. 3.** Preoperative (**A**) and postoperative (**B**) contrast enhanced sagittal, coronal and axial MR images revealing a giant intra-axial intramedullary pilocytic astrocytoma totally removed (from ref. 7). The arrows indicate how the tumor is growing towards the brainstem surface facilitating its exposure. In fact the tumor was completely removed through a low mini retrosigmoid approach and a short lateral longitudinal myelotomy in the medulla just below the exit of the lower cranial nerves. **B** MR images obtained 5 years after surgery show no tumor regrowth and a return to a normal physiological anatomy of the medulla. The 3-year-old child presented with facial and hypoglossus initial palsies, right hemiparesis, ataxia, dysphagia and dysphonia. All the neurological deficits resolved in a few months after surgery and the child is now living a normal life

have intrinsic or satellite cysts. A small minority of focal intrinsic tumors is malignant and encompasses glioblastoma, anaplastic astrocytoma, metastasis, etc.

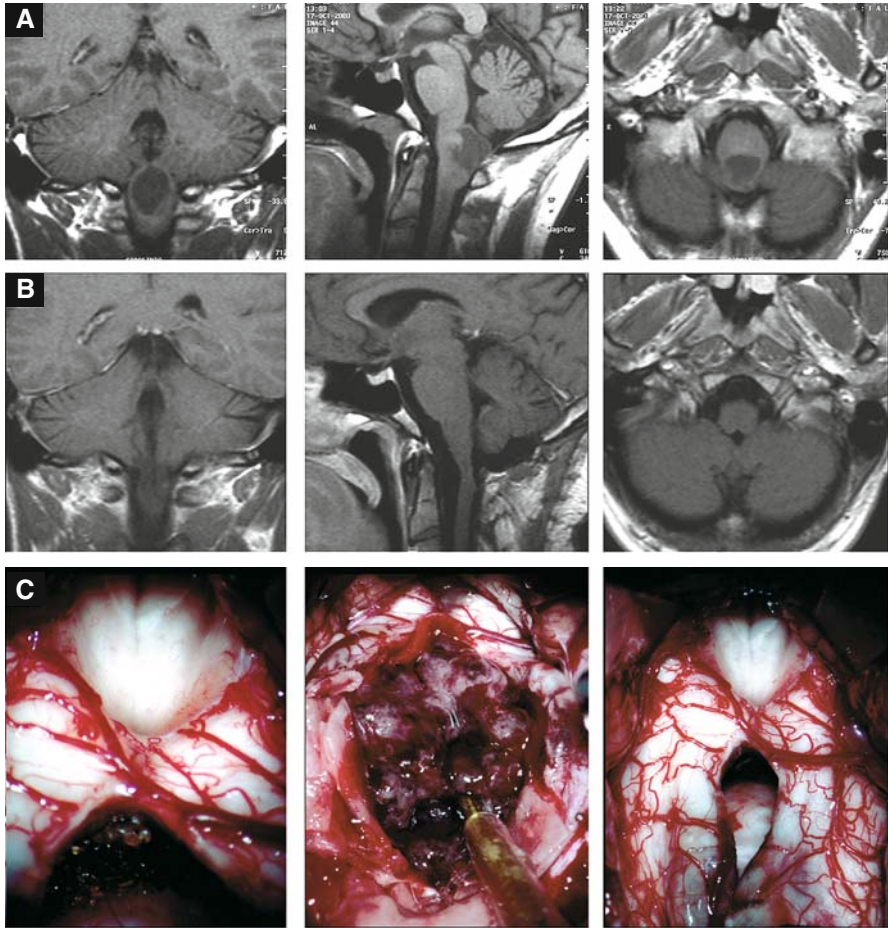
**3. Exophytic tumors.** Harold Hoffmann [13] was the first to describe this subgroup of tumors, which he named “dorsally exophytic”: they arise from subependymal tissue of the IVth ventricle floor and grow expanding into the IVth ventricle chamber (Fig. 4). More frequently these tumors are juvenile pilocytic astrocytomas or gangliogliomas; they are usually benign and well delineated and may be successfully and safely excised. In our experience a minority of exophytic tumors can protrude also from the lateral and ventral surfaces of the brainstem into the cerebello-pontine, pre-pontine and other cisterns. A number of patients harboring this kind of tumor may present with associate hydrocephalus due to the IVth ventricle obstruction made by the tumor mass. In this case, when possible, we prefer to go directly to the removal of the tumor avoiding, in many cases, prior shunting procedures and/or endoscopic 3rd-ventriculosomy.



**Fig. 4.** 4-year-old child presented with headache, vomiting, ataxia and diplopia. The preoperative contrast enhanced MR images (**A**) revealed a IV ventricle tumor which was completely removed (**B**) using a midline suboccipital craniotomy. The tumor resulted as a dorsally exophytic pilocytic astrocytoma originating from the right IVth ventricle floor (**C**). The complete exeresis was facilitated by the ultrasonic aspirator and at the end the IV ventricle was empty and clean, and the aqueduct opened. The preoperative symptoms reduced over time until finally disappearing completely

4. *Cervicomedullary tumors.* One must clarify that not all tumors developing at the highest cervical level also involve the low brainstem. Consequently, the subgroups of tumors, called cervicomedullary encompass only those gliomas which in their development involve both the medulla and the high cervical spine (Fig. 5). Some of these may protrude at the lowest part of the IVth ventricle at the obex and in the cisterna magna [12]. Cervicomedullary





**Fig. 5.** 44-year-old undergraduate of engineering presented with increasing dysphagia and dysarthria associated with paresthesia in the lower limbs and left arm with the sensation it was moving upwards. Preoperative MRI (A) show a non-enhanced intra-axial cervicomedullary tumor which was completely removed (B) through a midline suboccipital-C2 opening. Intraoperative mapping and monitoring of the IX and X cranial nerves as well as the motor and somatosensory potential of the four limbs suggested entering below the calamus scriptorius maintaining the longitudinal myelotomy below the obex (C). The tumor was exposed, debulked with an ultrasonic aspirator and then easily removed. The postoperative course was uneventful and the patient left the hospital with an added modest motor deficit in the extremities of the left hand. At the first follow-up – meantime the patient graduated – he was neurologically intact

tumors are usually low-grade astrocytomas, gangliogliomas and ependymomas; they are all well-delineated and benign tumors which can be removed with low risk, provided that all the appropriate microsurgical maneuvers are adopted.

## DECISION-MAKING

### 1. PATIENT SELECTION AND INDICATION FOR SURGERY

Criteria for selecting patients harboring brainstem gliomas for surgical treatment varies considerably among neurosurgeons and depends even more on personal experience. Therefore, nowadays the management is still a matter of debate with controversies in the indication for surgery. The risk tied to direct removal is considered high in terms of severe neurological complications that may follow surgery compared to that of the patient treated with non-invasive methods. Yet the author's large personal experience of direct surgery in brainstem gliomas treated with extensive and/or radical excision may indicate some feasible guidelines and help in choosing patients for surgery. Table 1 summarizes the relevant data of the personal caseload.

Figure 2B reports schematically the sites and patterns of brainstem gliomas found in our series. In the midbrain, both tectal and tegmental are almost always focal, benign and resectable. In the pons, there are 3 types of tumors: the focal are uncommon and only few are benign, whereas almost all those dorsally-exophytic are low-grade astrocytomas. Diffuse gliomas, typically centered in the pons, are malignant. Focal medullary and cervicomedullary tumors are mainly benign and resectable, although in the lower brainstem some anaplastic astrocytomas with a diffuse growth pattern may also be encountered. In our series, the majority (86%) of gliomas with a focal growth pattern on MRI are benign, whereas almost all diffuse (93%) are malignant. Also the location of the tumor within the brainstem appears to be an important factor. The extent of removal significantly relates to growth pattern and pathology: gross-total removal is achieved in 80% of focal low-grade astrocytomas, while it is less than 3% in malignant gliomas with the large majority demonstrating diffuse MRI patterns. The overall results are satisfactory considering the pathology being dealt with (Table 1).

This experience strongly confirms that brainstem gliomas no longer represent a homogeneous group amenable only to non-specific treatment. Instead, they differ in their MRI and histopathological patterns and, therefore, it is essential that they be regarded as distinct entities with their growth being infiltrative only in the group of diffuse tumors. A focal tumor is an expanding mass that frequently dislocates neighboring nervous structures without invading them and tends to move toward the surface of the brainstem, which makes tumor exposure and removal less risky (Fig. 3).

The fact that the majority of focal brainstem gliomas result as benign and resectable with good outcome suggests that they do not directly invade the nearby nuclear and fascicular structure, but rather they displace them. Together with other neurosurgeons [3, 6, 11, 14, 15], I believe that direct surgery should be advocated for all focal tumors, also because nowadays with

**Table 1.** Relevant data of the author's series of surgically treated brainstem gliomas<sup>a</sup>

	No. (%) of patients		
	Total	With focal tumors <sup>b</sup>	With diffuse tumors
MRI patterns	310	243 (48)	67 (21)
<b>Location</b>			
Midbrain	86 (29)	81 (33)	5 (8)
Pons	135 (43)	82 (34)	53 (79)
Cervicomedullary	89 (28)	80 (33)	9 (13)
<b>Pathology</b>			
Low grade	213 (69)	208 (86)	5 (7)
High grade	97 (31)	35 (14)	62 (93)
<b>Removal</b>			
Gross total	195 (63)	192 (79)	3 (4)
Subtotal/partial	115 (37)	51 (21)	64 (96)
<b>Outcome<sup>c</sup></b>			
Good	188 (61)	186 (77)	2 (3)
Fair	39 (12)	36 (15)	3 (4)
Death	83 (27)	21 (8)	62 (93)

<sup>a</sup>Modified and summarized from ref. 9

<sup>b</sup>Data include those for exophytic and cervico-medullary tumors, in addition to those for focal tumors

<sup>c</sup>Mean follow-up of 8.2 years

the advancement in skull base approaches to the posterior fossa there is no surface of the brainstem that cannot be exposed. In my opinion, also a subset of diffuse brainstem gliomas, namely, those protruding into the cerebellopontine angle or bulging at the external aspect in a relatively silent area, may be surgically debulked and then submitted to radiotherapy and chemotherapy with a more favorable clinical course.

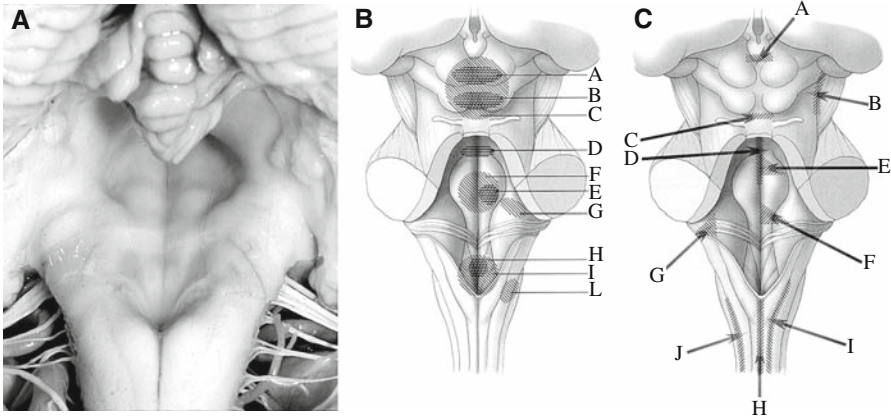
## 2. GENERAL PRINCIPLES OF BRAINSTEM SURGERY

The operative approach must be selected to optimize the exposure of the area of the brainstem surface through which we have chosen to enter because it is less risky and therefore safer. The choice of entry and the pathway inside the brainstem to reach the lesion is the most difficult mental process, which is at the total discretion of the surgeon. These two things, entry and pathway, are often neither the most direct nor the shortest nor the easiest. In this setting it is absolutely necessary to have a deep knowledge not only of the topographic microsurgical anatomy but also of the functions the nervous structures in which the lesion lies.

## 2.1 Anatomic-functional basis of microsurgical procedures for intra-axial brainstem tumors

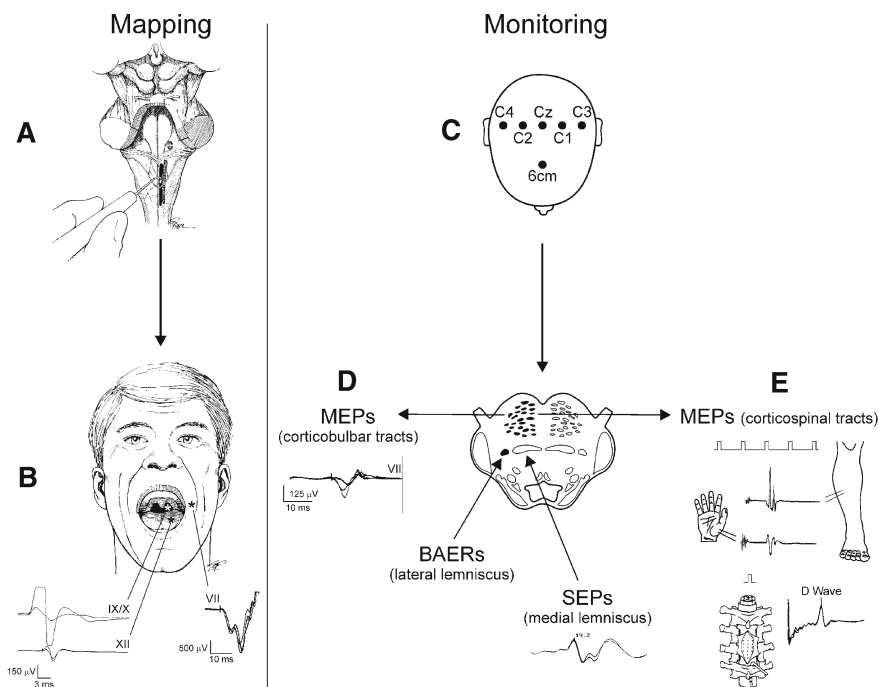
Tumors with no surface components – the pure intrinsic tumor – require a deep understanding of the involved regional anatomy and functions. With a clear mental image of the internal architecture of the brainstem and the possible deficits which may be incurred by its surgical injury, one chooses safer entry zones, avoiding those more dangerous, and keeps in mind that the most convenient route for the patient is not always the shortest or the easiest.

The floor of the IVth ventricle, through which a number of tumors are reached, may be compared to a minefield requiring a great understanding of the underlying structures and thus constitutes a good model for reasoning. In Fig. 6, the anatomical landmarks of the floor of the IVth ventricle and the most dangerous areas for injury are summarized and reported along



**Fig. 6.** **A** Photograph (courtesy of Dr. A. Rhoton) of the fourth ventricle floor – known as the rhomboid fossa – in a cadaveric brainstem clearly showing the most important anatomical landmarks that allow orientation for the surgeon when choosing the surgical strategy: the median sulcus, the sulcus limitans, facial colliculus, area acustica, lateral recess, striae medullares, trigonum hypoglossi, vagus nucleus, ala cinerea, obex and posterior median sulcus. The sulcus limitans is a very important groove because it represents the line of separation between the sensory areas laterally and the motor areas medially. **B** The risky areas for entering the dorsal brainstem are listed together with the neurological consequences. A=visual and oculomotor disturbances due to superior colliculi damage; B=auditory disturbances due to inferior colliculus damage; C=disturbances as in both A and B together; D=internuclear ophthalmoplegia due to lesion of medial longitudinal fascicles; E=facial and abducens palsy and internuclear ophthalmoplegia due to the damage to the facial colliculus; F=immobile eyes and bilateral facial and abducens palsy due to the damage of both facial colliculi; G=facial palsy due to facial nerve damage; H=dysphagia due to hypoglossi nucleus damage; I=dysphagia and cardiorespiratory disturbances due to the bilateral damage of the calamus scriptorius; L = ataxia due to somatosensory tract damage. **C** The relatively safe entry zones to dorsal brainstem are listed. A=supracollicular; B=infracollicular; C=lateral mesencephalic sulcus; D=median sulcus; E=suprafacial; F=infrafacial; G=area acustica; H=posterior median fissure; I=posterior intermediate sulcus; J=posterior lateral sulcus

with suggested alternative safer entry areas. The most important thing to keep in mind always is that all nuclei with motor function lie in the more medial columns, whereas those receiving afferent fibers are arranged more laterally [5].



**Fig. 7.** **A** Mapping of the floor of the fourth ventricle to identify the motor nuclei or intramedullary roots of motor cranial nerves VII, IX/X, XI and XII. A direct electrical stimulation through a hand-held monopolar probe is used to deliver single stimuli of 0.2 ms duration at a rate of 1–2 Hz and intensity up to 1.5–2 mA. **B** The recordings after direct stimulation of the brainstem are from Teflon-coated wire electrodes inserted pre-operatively and bilaterally into the superior rectus muscle for cranial nerve VII, the posterior wall of the pharynx for cranial nerves IX/X, and tongue muscles for the XII cranial nerve. During midbrain surgery, electrodes can also be placed in extraocular muscles (superior rectus for the III, and rectus lateralis for the VI cranial nerve) for mapping purposes (not shown). **C** Continuous monitoring of corticospinal and corticobulbar tracts obtained by transcranial electrical stimulation is performed using a short train of 4 stimuli (0.5 ms duration, intensity up to 100 mA, train repetition rate 1–2 Hz). **D** Corticobulbar muscle motor evoked potentials are recorded from the same electrodes used to record compound muscle action potentials after brainstem mapping and are of longer latency and smaller amplitude when compared to the response after direct mapping. **E** Corticospinal motor potentials are elicited through multipulse transcranial electrical stimulation and recorded from limb muscles and the corticospinal epidural potentials (D-wave) are elicited through single pulse and recorded epidurally (or subdurally) from the spinal cord. The intraoperative monitoring may be completed by brainstem auditory evoked responses (BAERs) and somatosensory evoked potentials (SEPs)

## 2.2 Intraoperative neurophysiological monitoring during brainstem surgery

During the last decade intraoperative neurophysiology has established itself as one of the paths by which modern neurosurgery can improve surgical results while minimizing morbidity [18, 20]. It consists of *monitoring* (the continuous “on-line” assessment of the functional integrity of neural pathways) and *mapping* (the functional identification and preservation of anatomically ambiguous nervous tissue) techniques. Mapping techniques can be used to identify – and therefore preserve– cranial nerve motor nuclei and corticospinal or corticobulbar pathways while entering the brainstem. Similarly, monitoring of motor evoked potentials can continuously assess the functional integrity of these pathways during surgery (Fig. 7).

Mapping of the corticospinal tract at the level of the cerebral peduncle as well as mapping of the VII, IX–X and XII cranial nerve motor nuclei on the floor of the fourth ventricle is of great value to identify “safe entry zones” into the brainstem (Fig. 6). Mapping techniques allow recognizing functional anatomical landmarks such as the facial colliculus or the hypoglossal and glossopharyngeal triangles on the floor of the fourth ventricle, even when anatomy is completely distorted by a tumor. However, brainstem mapping cannot detect injury to the supranuclear tracts originating in the motor cortex and ending on the cranial nerve motor nuclei.

Transcranial monitoring of motor evoked potentials is also currently used during brainstem surgery in order to assess the functional integrity of motor corticobulbar and corticospinal pathways. Recently, current concepts of muscle motor evoked potential monitoring during spinal cord surgery have been extended to the monitoring of motor cranial nerves. So-called “corticobulbar” motor evoked potentials can be used to monitor the functional integrity of corticobulbar pathways from the cortex through the cranial motor nuclei and to the muscle innervated by cranial nerves. Methodological aspects have appeared in the literature only recently and mostly with regards to the VII cranial nerve monitoring. Nevertheless, this technique has not yet been standardized and some limitations still exist [8].

In particular, with regards to the preservation of the swallowing and coughing reflexes, available intraoperative techniques are not always able to provide reliable prognostic data since only the efferent arc of the reflex can be tested. In our experience, the complete disappearance of a corticobulbar motor evoked potentials correlate with a severe, mostly irreversible, post-operative deficit. Conversely, when the corticobulbar motor evoked potentials are unchanged at the end of surgery, this may not prevent a transient deficit, but virtually all patients at the follow-up have recovered to their pre-operative status. One must remember that to have good intraoperative monitoring, the surgeon needs to collaborate with a ready and willing anesthetist. A special general anesthesia is required using Propofol 100–150 mg/kg/min and Fentanyl 1mg/kg/h. No Propofol or Fentanyl can be

used in bolus, and after intubation, halogenated agents or muscle relaxants are abandoned.

## SURGERY


### 1. SURGICAL TECHNIQUES AND APPROACHES

The best approach to brainstem tumors is that which allows exposure of the tumor with the least risk of injury to surrounding structures: in essence, the problem is how to reach the mass and remove it without adding new neurological deficits to the already existing ones. The brainstem, although a compact and delicate whole, is composed of highly critical places where damage may result in major neurological failure, whereas there are other places in which functional disruption is better tolerated, and knowing the position of these areas may assist in selecting a safe surgical entry (Fig. 6).

These two things, entry and pathway, are often neither the most direct nor the shortest nor the easiest. In this setting it is absolutely necessary to have a deep knowledge not only of the topographic microsurgical anatomy but also of the functions of the nervous structures in which the lesion lies.

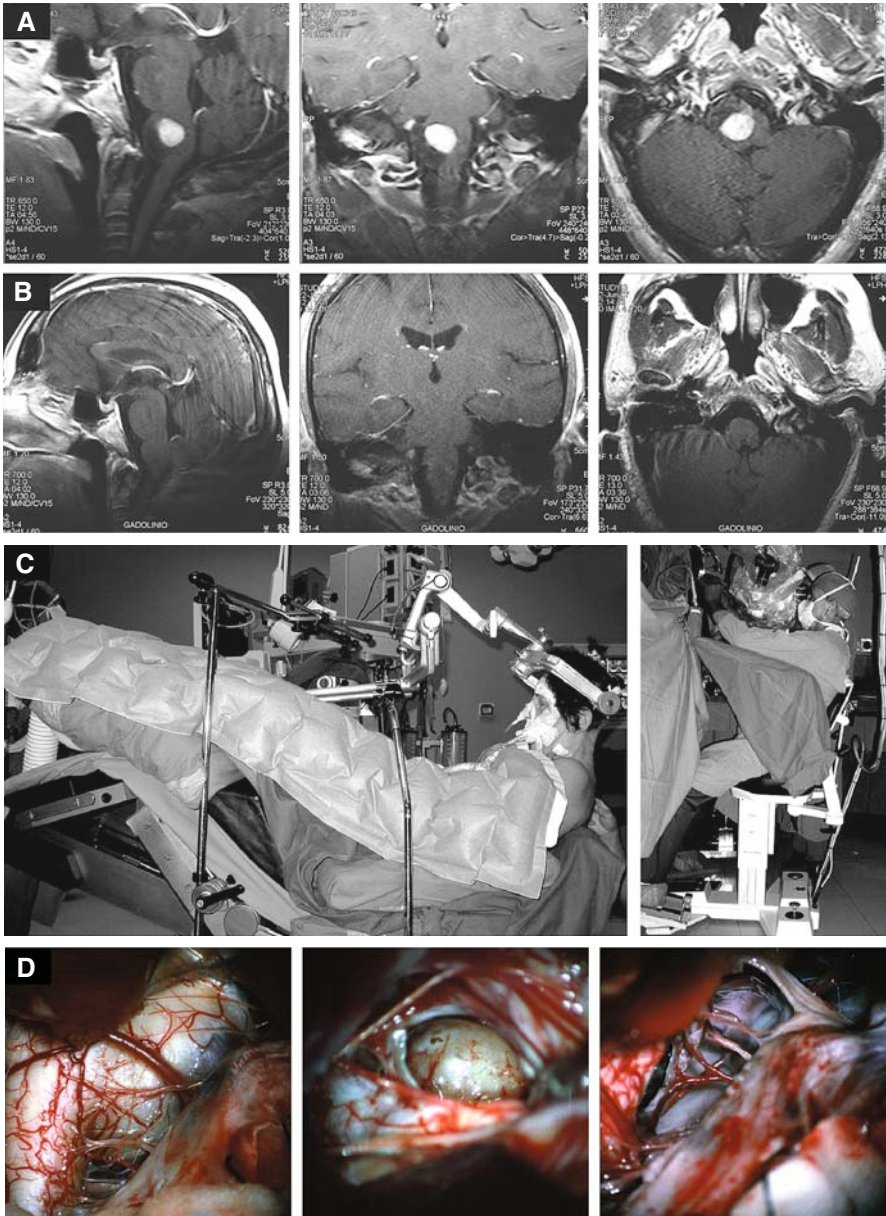
All patients treated for brainstem tumor through the posterior fossa are operated on in a semi-sitting position (Fig. 8). This position has demonstrated to be advantageous for the patient, surgeon and the anesthetist and, despite controversy, there has not yet been convincing evidence to prove that this position should be abandoned due to risks involved. The choice of approach and the path to follow for direct surgical removal of brainstem lesions must be based on neuro-anatomical and functional data, the tumor location and the expansion and the patient's neurological condition. The rationale behind the crucial preoperative choice of surgical strategy must take into account the functional ranking of the structures which confront us and of the consequence of a possible surgical injury to a tract, nucleus, nerve, artery or vein in the individual patient.

The excellent multiplanar capabilities of MRI permit accurate localization of the tumor and its relationship to brainstem structures, and consequently



**Fig. 8.** Intrinsic focal partially cystic pilocytic astrocytoma at the medulla in a 45-year-old woman presenting with worsening left hemiparesis with bilateral Babinski sign, ataxia and initial dysphagia. **A** and **B** Pre- and post-operative sagittal, coronal and axial MR images demonstrating total removal of the tumor. **C** Standard semi-sitting position of the patient and the surgeon sitting in a chair with all the commands at his feet for the control of the functions of ceiling microscope, cameras and ultrasonic aspirators. The foot commands control even the surgeon's own chair. **D** Intraoperative microphotographs showing the exposure obtained by a dorsal lateral approach, the tumor itself exposed and the lateral surface of the medulla area after complete removal of the lesion; lower cranial nerves and vascularization are preserved. The patient had an uneventful post-operative course and was discharged one week after surgery while showing neurological improvement

provide valuable information in selecting the most advantageous route that allows exposure of the target area. One must keep in mind that the brainstem is a small structure approximately 6 cm high and 3.5 cm wide at the pons, the





tumor we try to remove is therefore much smaller and the required opening into the brainstem even smaller. The surgical microscope often used at its highest magnification, fixed microretractors, ultrasonic aspirators and a few tiny instruments are the standard tools for this type of surgery.

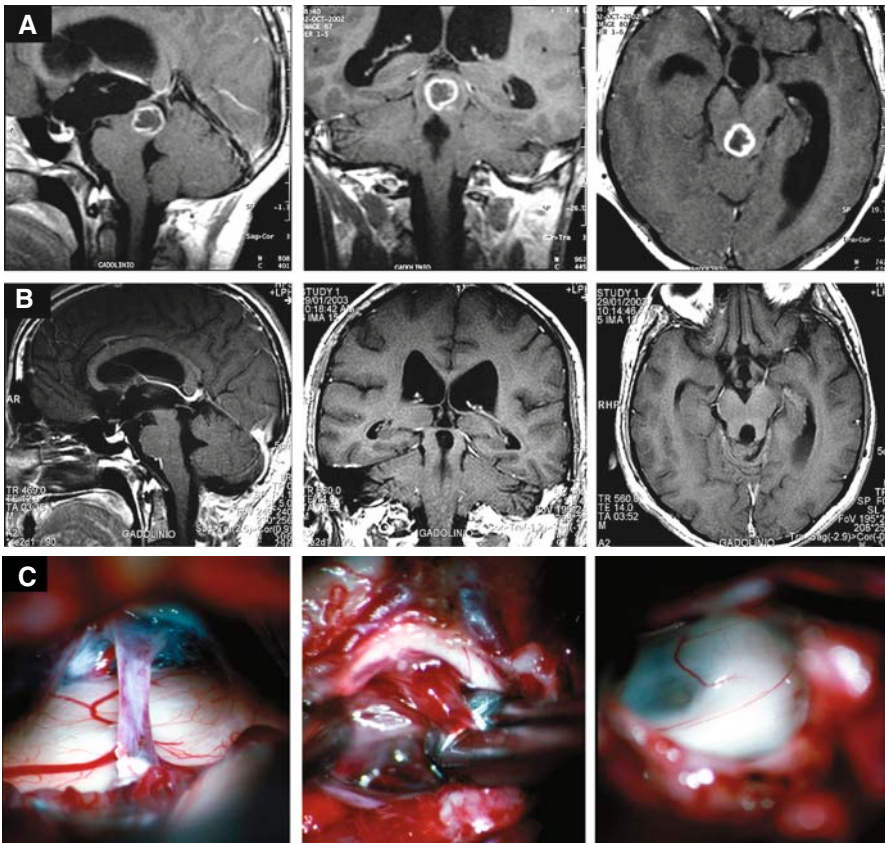
Once reached, the glial tumor is gently explored with blunt microdissectors in order to obtain an initial understanding of the tumor relationship with the surrounding structures and specimens of it are removed for immediate histological examination. The pathological information helps the surgeon in choosing his strategy accordingly and evaluates the possibility to obtain a complete removal mainly in benign tumor. The extent of tumor removal may change the outcome of the patient and so a gross-total removal represents the ideal goal for a benign focal astrocytoma because it results in a definite cure for the patient with no need of adjuvant therapy. However, of course, one must avoid obtaining total removal at all costs if in doing so, severe neurological deficits may be predicted. The tumor is removed in a piecemeal manner, depending on its consistency, cut with microscissors or reduced with ultrasonic aspiration, always remaining inside the tumor and never yielding to the temptation to attempt to remove, from the start, the tumor en bloc. Manipulating the tumor right from the start, if it is solid, in search of an eventual cleavage must be done with the utmost delicacy because otherwise it can induce retraction of healthy tissue, which in turn may result traumatic to the delicate and richly microvascularized structures involved, and conducive to “unexpected” postoperative deficits. Ultrasonic aspiration must be used with the utmost care at the lowest effective intensity and suction rate with a sufficiently small and finely balanced handpiece (Figs. 4 and 5). The instrument must be used in an angled direction so that its destructive action is constantly aimed inside the tumor mass to avoid injury to surrounding healthy structures. Tumor debulking must remain rigorously confined to inside the tumor and stopped whenever boundary with normal tissue becomes poorly defined. Only when the tumor is emptied, one may start to look for the cleavage plane: if this is clear, radical removal may be obtained without injuring the surrounding structures. What makes total removal difficult and, in fact not recommended, is primarily the lack of tumor demarcation; indeed and above all, when such a pattern is associated with a location near critical structures, no further removal should be attempted. I recognize that disregard of these principles may have contributed to the avoidable increase of postoperative morbidity in our series [9].

### 1.1 Midbrain

The midbrain, which occupies the notch of the tentorium, consists of a dorsal part, the corpora quadrigemina (or tectum), a large ventral portion, the tegmentum and the cerebral peduncles. Almost all midbrain gliomas are focal benign astrocytomas developing from either the tectal plate or tegmentum and may extend upward to the thalamus or rarely downward to the pons,

displacing but not infiltrating these structures. The planned goal of surgery in this setting should be the complete removal of the tumor, which will result in permanent cure of the patient [7, 16].

A large amount of neural structures of great functional importance are concentrated in the midbrain: superior colliculus, nuclei of the III and IV cranial nerves, medial longitudinal fascicles, red nucleus, medial geniculate body and pyramidal tract. The surgeon should therefore deal with an approach that is the most direct one to the tumor.



**Fig. 9.** 20-year-old man presenting with oculomotor disturbances, headache, ataxia and papilledema. The tectal benign astrocytoma shown on MR images (A) was radically removed (B) via an infratentorial supracerebellar approach. The intraoperative views (C) show the swollen quadrigeminal plate bulging ventrally to the cerebellum with its central vein, which was sacrificed. By entering below the plate, the dorsal aspect of the tumor is exposed, freed a little at a time, and then completely removed with consequent resolution of the hydrocephalus. The patient had a favorable course with disappearance of the neurological disturbances

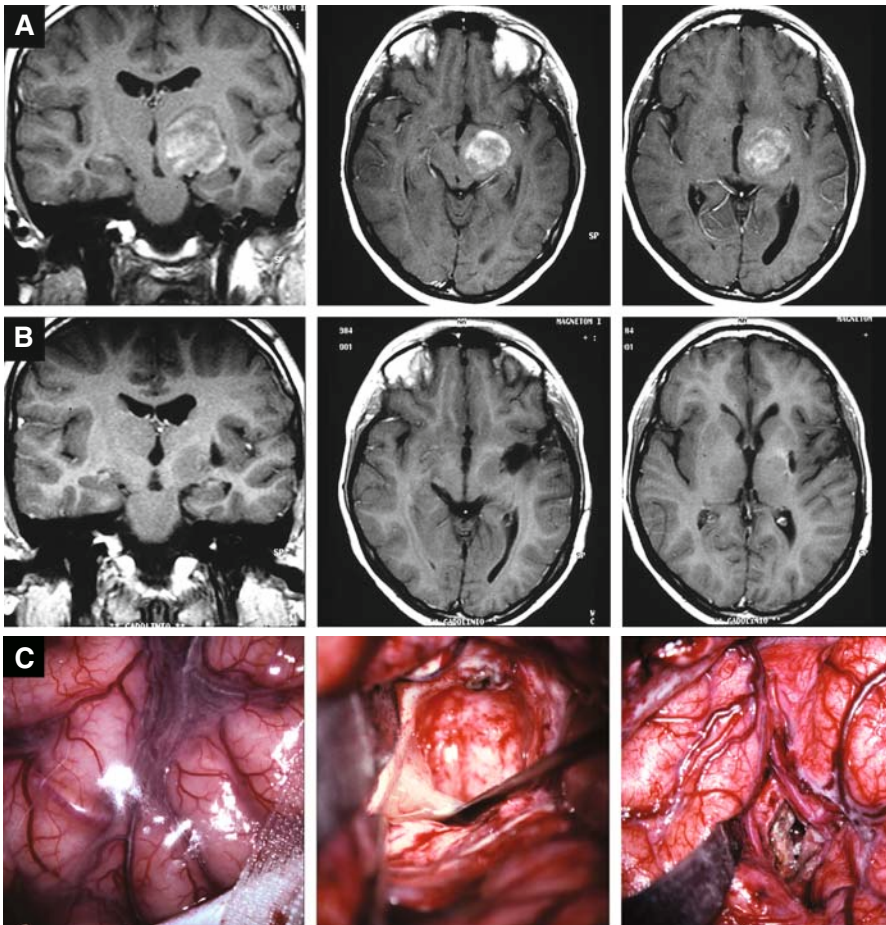
Tumors in the tectal area of the quadrigeminal plate are approached through a standard *infratentorial supracerebellar approach*, possibly with the patient in a semi-sitting position, which allows better exposure (Fig. 9). The same approach is even used on lower median tumors in the quadrigeminal region when an infracollicular entry is chosen. In this case it is not necessary to section the anterior vermis because with a meticulous opening of the cerebellomesencephalic fissure and a retractor resting on the vermis, exposure as far down as the inferior colliculi and the exit zone of the trochlear nerve may be obtained. The same infratentorial supracerebellar approach may result as successful even in the removal of lesions more ventrally placed in the tegmentum and peduncles [9]. If we extend the dura opening more laterally close to the lateral and sigmoid sinus on the side of the chosen pathways, a careful dissection of the arachnoid membranes allows a wide opening of the cerebellomesencephalic fissure. A retractor is then placed in order to slightly weigh down the anterior part of the tentorial surface of the cerebellum and, with this done, a full exposure of the lateral aspect of the midbrain is obtained. Here it is easy to identify the lateral mesencephalic vein, which courses into the lateral mesencephalic sulcus. The entry is posterior to this sulcus in order to avoid injury to the pyramidal tract in the peduncle [9].

Tumor of the midbrain located near its median ventral surface may be accessed through a *pterional transsylvian route*. Following a wide opening of the Sylvian fissure, the tentorial edge, III cranial nerve and interpeduncular cisterns are exposed. The anatomical landmark of the target area is the emergence of the III cranial nerve from the mesencephalon and the safe entry zone is the small rectangular area lateral to the exit of the III cranial nerve. This narrow but fairly safe window allows surgical access through the more medial part of the peduncle, sparing the motor tract, which occupies only the intermediate three-fifths or so of the peduncle [5]. Mesencephalo-thalamic tumor can be reached through a pterional approach via the anatomic posterior transsylvian corridor (Fig. 10).

Tumors involving the arterolateral aspect of the midbrain can be reached through a *subtemporal transtentorial approach*. The tentorial incisure is divided posteriorly to the entry of the IVth cranial nerve, allowing larger exposure of the anterolateral midbrain and upper pons. This seemingly attractive route, at least in my experience, is associated with some risk because sometimes it requires a risky temporal lobe retraction and thus a possible injury to the vein of Labbè.

## 1.2 Pons

Tumors which involve one side of the ventral pons and fungate into the area of the cerebellopontine angle are reached with a *standard retrosigmoid approach* through a lateral suboccipital retromastoid craniotomy as used in acoustic neuroma surgery. This applies also to some pontine centered diffuse gliomas that originate in the ventrolateral side of the pons and tend to grow



**Fig. 10.** 15-year-old female presenting with motor deficits in the right upper limb with worsening hand dystonia; even the leg on the same side showed vague, but similar symptoms. Pre- (A) and post-operative (B) gadolinium enhanced MR images show a focal mesencephalo-thalamic tumor that was totally removed through a pterional transsylvian approach (C). The patient showed a progressive improvement. She writes well despite a persistent slight dystonia of the hand

laterally bulging on the cerebellopontine angle. With the patient in a semi-sitting position with the head rotated toward the side of the expansion, the bulging pons is entered through the fissure between the stretched V and the VII–VIII cranial nerves and the diffuse tumor is then debulked [5].

The uncommon focal pontine tumor ventrolaterally placed requires a *combined petrosal approach* to create a subtemporal, transtentorial presigmoid avenue with the main advantage being the shorter distance and the direct line of light to the anterolateral brainstem.

For tumors located in the dorsal part of the pons (and the open portion of the medulla), access is by a *midline suboccipital craniotomy* and trans-IVth-ventricle route. With the patient in a semi-sitting position with the head fairly flexed, a wide exposure of the rhomboid fossa may be obtained through the cerebello-medullary fissure without sacrificing the vermis. Adverse effects of splitting the vermis may be body truncal ataxia, a wobbling gait, oculomotor disturbances and mutism.

By elevating and splitting the cerebellar tonsils and displacing the PICAs, which course into the fissure itself, one can expose the tela choroidea of the roof of the IVth ventricle, cut it at the taenia at both sides and then fold it back upward to expose both the lateral recesses, if necessary. Next, the tela choroidea can be divided longitudinally until the anterior medullary velum, to which it is attached along with the choroid plexus. At that point, two strategically positioned retractors will keep the access open and a suitable angulation of the surgical microscope will yield a complete view of the floor of the IVth ventricle from the obex to the cerebral aqueduct (Fig. 4). This route can be used also for some tumors of the dorsal mesencephalon which dip into the ventricular chamber, thereby avoiding possible injury to the colliculi.

### 1.3 Cervicomedullary junction

Tumors developing in the dorsal closed part of the medulla near its posterior aspect and in the cervicomedullary junction are usually approached through a low *midline suboccipital craniotomy* extended to the posterior arch of the atlas and to the necessary cervical laminotomies if the lesion extends further caudally (Fig. 5). When the tumor is medial, the surgical technique of removal is the same as that normally used for intramedullary spinal cord tumors – the tumor is accessed through a midline longitudinal myelotomy. For tumors laterally placed either the posterior intermediate or the posterior lateral sulcus is used for entrance.

When the tumor is more laterally and/or ventrally located, a *dorso-lateral approach* is used providing excellent exposure of the anterolateral aspect of the medulla, the cervicomedullary junction, cranial nerves IX–XII and vasculatures. For removal of intra-axial lesions which expand into the lower brainstem, it has not been found necessary to perform extensive bone removal of the occipital condyle and the lateral mass of C1. Adequate exposure is obtained by a restricted retrosigmoid craniotomy, a C1-hemilaminectomy and only when necessary drilling away of the posterior third of the occipital condyle (Fig. 8).

## 2. POSTOPERATIVE CARE

Surgery for brainstem tumors mainly if they are totally intrinsic carries the most potentially dangerous risks of an operative procedure in the posterior

fossa and despite advancement in this area resulting in greatly reduced mortality and morbidity, it is unrealistic to expect a patient, following removal of an intra-axial brainstem glioma, to awaken in a better condition than before, as in the majority of cases the opposite occurs. Fortunately most new or worsened neurological deficits will improve or disappear in the postoperative period, and at first follow-up the clinical conditions are much improved, or even returned to normal.

All patients and/or parents prior to surgery are informed that they may expect, early after surgery, a transient or permanent worsening of their condition, and will require a stay in an intensive care environment. As a rule, the patient immediately after surgery is taken to the neurosurgical intensive care unit for at least 24 hours. The oral or nasal tracheal tube is maintained with mechanical ventilation and necessary sedation; and a CT scan is taken in order to exclude any early blood clotting, pneumocephalus and hydrocephalus, although such complications are very uncommon. Having a "clean" early postoperative CT scan, the tracheal tube may be safely removed when the patient regains consciousness and normal ventilation parameters, and a positive testing of coughing and swallowing are registered. The removal of the tube must be done by expert doctors with great caution, particularly in such patients operated on for lower brainstem tumors in whom dysphagia, vocal cord paresis and loss of cough and gag reflex may be expected or anticipated. Also in patients presenting severe dysphagia, it has proven beneficial to delay tracheostomy because often with sedulous care and rehabilitation training, these disturbances will resolve and the patient regains swallowing.

Typically, patients regain vigilance, consciousness and cooperation with a tapering off of sedation, whereas a small group of patients operated on for a midbrain tumor may remain in a comatose state or more frequently in a stuporous condition similar to an akinetic mutism for periods even longer than one week before gaining awareness.

## HOW TO AVOID COMPLICATIONS

The operative approach must be selected so that the zone of entry and the pathway inside the brainstem to reach the lesion be the less risky. This needs a deep knowledge of the topographic anatomy of the brainstem. Sitting position has demonstrated to be advantageous for the patient, surgeon and the anesthetist, despite controversy. Anesthetists and neurosurgeons must be well-trained in such procedure.

Intraoperative neurophysiological monitoring is of prime importance to minimize morbidity.

Most patients may have, early after surgery, a transient or even permanent worsening of their condition. This will require a stay in an intensive care environment.

## CONCLUSIONS

Traditionally all tumors growing inside the brainstem are considered infiltrating with diffuse glial proliferation and treated with radiation therapy as well as with adjunctive chemotherapy with unsatisfactory results. Only in the last decades, advances in neuroimaging for diagnosis, improvements in surgical approaches and microsurgical techniques, better knowledge of functional anatomy and the more recent application of new advanced intraoperative electrophysiological monitoring and mapping have gradually helped in performing surgery more safely in such delicate structures as the brainstem.

Our experience demonstrates that today many lesions developing in this sensitive area may be successfully treated by direct surgery alone. The great majority of focal, dorsally exophytic and cervicomedullary gliomas can be safely removed and if the tumor is to be totally removed the patient results definitely cured.

Intraoperative neurophysiology during posterior brainstem surgery has dramatically evolved as compared to a decade ago when only somatosensory and auditory evoked potentials were monitored and peripheral cranial nerve mapping was available.

I would like to close by stressing the importance of the routine use of intraoperative electrophysiological monitoring. The first analysis in our series based on a historical control demonstrated a significant improvement in the outcome of the group of monitored patients. The monitoring system is best used at all times even if it might appear ineffective initially.

## Acknowledgement

The author is deeply grateful to his colleagues Sergio Baietta, Barbara Masotto and Francesco Sala for their help, understanding, time, support, encouragement and willingness to experiment in this challenging field.

I thank the neuro-anesthetists, nurses and rehabilitation staff of neuro-surgical intensive care for their sedulous care of the patients. I also thank Ms. Tracey Sinclair for her superb editorial assistance.

## References

- [1] Blessing WW (1997) *The lower brainstem and bodily homeostasis*. Oxford University Press, New York
- [2] Bricolo A, Turazzzi S (1987) Esperienza nella chirurgia dei gliomi del tronco cerebrale. In: *Attualità in neurochirurgia*. Moduzzi, Bologna, pp 45-50
- [3] Bricolo A, Turazzi S, Cristofori L, Talacchi A (1991) Direct surgery for brainstem tumors. *Acta Neurochir (Wien) (Suppl 53)*: 148-158

- [4] Bricolo A, Turazzi S, Cristofori L, Talacchi A (1993) Surgical treatment of brainstem tumors: experience in 75 patients. AANS 61st Annual Meeting, Boston, April 24-29 (abstr)
- [5] Bricolo A, Turazzi S (1995) Surgery for gliomas and other mass lesions of the brainstem. In: Symon L, et al. (eds) *Advances and technical standards in neurosurgery*, vol. 22. Springer, Wien New York,
- [6] Bricolo A (1999) Comment on Selvapandian S, Rajshekhar, Chandy MJ, Brainstem glioma: comparative study of clinic-radiological presentation, pathology and outcome in children and adults. *Acta Neurochir* 141: 721-727
- [7] Bricolo A (2000) Surgical management of intrinsic brain stem gliomas. *Oper Tech Neurosurg* 3: 137-154
- [8] Bricolo A, Sala F (2002) Surgery of brainstem lesions. In: Deletis V, Shies J (eds) *Neurophysiology in neurosurgery: a modern intraoperative approach*. Academic Press, London, pp 267-289
- [9] Bricolo A (2004) Brainstem tumors: direct surgical approach. Master operative colloquium, CNS 54th Annual Meeting, San Francisco, CA, USA
- [10] Epstein F, McCleary EL (1986) Intrinsic brain-stem tumors of childhood: surgical indications. *J Neurosurg* 64: 11-15
- [11] Epstein F, Wisoff JH (1990) Surgical management of brain stem tumors of childhood and adolescence. *Neurosurg Clin N Am* 1: 111-121
- [12] Epstein F, Farmer JP (1993) Brain-stem glioma growth patterns. *J Neurosurg* 78: 408-412
- [13] Hoffman HJ, Becker LE, Craven MA (1980) A clinically and pathologically distinct group of benign brain stem gliomas. *Neurosurgery* 7: 243-248
- [14] Jackowski A (1995) Brainstem surgery. *Br J Neurosurg* 9: 581-589 (editorial)
- [15] Konovalov AN, Gorelyshev SK, Khuhlaava EA (2006) Surgical management of brain stem, thalamic, and hypothalamic tumors. In: Schmidek H, Roberts D (eds) *Operative neurosurgical techniques*. Elsevier, New York, pp 821-856
- [16] Lapras C, Bogнар L, Turjman F, Villanyi E, Mottolese C, Fischer C, Jouviet A, Guyotat J (1994) Tectal plate gliomas: part 1. Microsurgery of tectal plate gliomas. *Acta Neurochir (Wien)* 126: 76-83
- [17] Matson DD (1969) *Neurosurgery of infancy and childhood*, 2nd edn. Charles C Thomas, Springfield, Ill
- [18] Morota N, Deletis V, Epstein FJ, Kofler M, Abbott R, Lee M, Ruskin K (1995) Brain stem mapping: Neurophysiological localization of motor nuclei on the floor of the fourth ventricle. *Neurosurgery* 37: 922-930



- [19] Neilsen JM, Sedgwick RP (1949) Instincts and emotions in an anencephalic monster. *J Nerv Mental Dis* 110: 387-394
- [20] Sala F, Lanteri P, Bricolo A (2004) Intraoperative neurophysiological monitoring of motor evoked potentials during brain stem and spinal cord surgery. *Adv Tech Stand Neurosurg* 29: 133-169



**Albino Bricolo**

Albino Bricolo is Consultant in the Neurosurgical Department of the University Hospital of Verona. Department as well as being a Vice-President and Member of the International Faculty of WFNS for which he teaches numerous education courses all over the world. After graduating in Medicine and Surgery, Dr. Albino Bricolo shortly became lecturer in Nervous and Mental Diseases and in Neurosurgery. Initially his main scientific interests were head and spine injuries and consciousness states. In these fields he produced much literature that it still consulted. He is one of the first to have inserted electrodes to stimulate deep brain structures in prolonged comatose states. Later on he dedicated himself to developing skull base surgery mainly for the treatment of the posterior fossa tumors and accumulated large experience in brainstem and intramedullary spinal cord tumors. Recently he introduced the intraoperative neurophysiological monitoring in the afore-mentioned surgeries. Apart from a two-year period spent as Full Professor at North Western University, Chicago, he followed his entire career within the Neurosurgical Department of the University Hospital of Verona, Italy, becoming Full Professor and Chairman and Director of the Department of Neurosurgery, which has seen great development. He is also Past President of WANS.

**Contact:** Albino Bricolo, Department of Neurosurgery, University Hospital, Piazzale Stefani 1, Verona 37126, Italy  
E-mail: albino.bricolo@univr.it

---

# MANAGEMENT OF FORAMEN MAGNUM TUMORS

B. GEORGE

## INTRODUCTION

### 1. DISTRIBUTION OF PATHOLOGIES

The Foramen Magnum area (F.M.) is a complex region with many different pathologies that may develop either intradurally or extradurally. The former mainly include meningiomas (M) and neurinomas (N), while the latter corresponds to chordomas (Ch) and bone tumors (BT). Altogether these pathologies are very rare. The most common type (M) accounts for less than 0.5% of the intracranial tumors and 2.5% of the intraspinal tumors. In Table 1 the distribution of F.M. tumors in our personal series is given. Meningiomas account for about 70% of the intradural tumors and for 40% of all F.M. tumors; they represent 6.5% of posterior fossa M, 1.5% of cranial M, 12% of spinal M and 42% of cervical M. Neurinomas include C1 and C2 spinal nerve roots N and XI and XII cranial nerve N. The C2 N is the most frequent and represents 5% of spinal N and 20% of cervical N. Chordomas are most frequently located in the sacrum (40%), at the skull base (38%) and along the spine (22%). In our series Ch at the cranio-cervical junction (CCJ) level are quite predominant among skull base (65%) and cervical (85%) locations. However, there is certainly a bias related to our referral process. In Wellinger series, F.M. Ch accounts for 30% of cervical Ch and 12% of all spinal Ch. Then bone tumors (BT) (16% of all F.M. tumors) includes metastases (35% of BT) and primary BT of many different types; the most frequent ones are osteoid osteoma, chondrosarcoma, aneurysmal cyst and plasmocytoma.

### 2. HISTORICAL BACKGROUND

Until recently there were very few reports on F.M. tumors. Since the first observation (post-mortem) of a F.M. M by Hallopeau in Lariboisiere Hospital in 1874 and the first successful removal of a F.M. M by Elsberg in 1925, only 3 large series had been published before 1995: one by the MayoClinic group (Dodge, then Yasuoka and finally Meyer in 1984), one by Guidetti and Spallone in 1988 and a French cooperative study in 1993. Until the end of the last century, most of F.M. tumors (especially M) were published among series of posterior fossa or cervical tumors.

---

*Keywords:* Foramen Magnum, meningiomas, chordomas, lateral approach, skull base

**Table 1.** Distribution of FM tumors (Lariboisière Hospital experience)

Extradural	N=74	Intradural	N=154
Meningioma	5	Meningiomas	104
Neurinoma	29	Neurinoma	31
Chordoma	53	Others	19
Sarcoma	23		
Metastasis	19	Pseudotumors	N=41
Osteoid osteoma	7		
Others	28		

### 3. DEFINITION

In the literature several different definitions of the limits of the F.M. area can be found. Then following the report of the French cooperative study, most people agree on the following limits: anteriorly from the junction of the middle and lower third of the clivus down to the body of C2; posteriorly from the occipital bone at the margin of the F.M. down to the superior edge of the laminae of C2; laterally from the jugular tubercle down to the C1–C2 joints thus including the occipital condyle and the lateral mass of atlas.

Intradurally these limits correspond on top to the junction between pons and medulla oblongata with the vertebro-basilar junction and on bottom to the C2 spinal nerve roots. The neighbour regions are the jugular foramen region superiorly and laterally, the cerebellar convexity posteriorly, the clival region superiorly and anteriorly, and the superior cervical regions inferiorly.

### RATIONALE

The F.M. region is limited by bony walls which are very strong and important for the CCJ stability; anteriorly with the tip of the clivus, the anterior arch of atlas and the odontoid process; laterally with the jugular tubercle, the occipital condyle, the lateral mass of atlas and the two C0–C1 and C1–C2 joints. On the contrary posteriorly no important bony structures (occipital bone, posterior arch of atlas) are found. However, they are covered by several layers of big muscles while the anterior wall is only covered by a thin layer of muscle and mucosa separating the bone from the mouth.

It must be noticed that the C0–C1 and C1–C2 joints are in fact located in front of the neuraxis as they are on both sides of the odontoid process. As a consequence there is no intervertebral foramen at these two levels and the C1 and the C2 spinal nerve roots are merging behind and not before the joints (as are doing the other spinal nerve roots). This gives the possibility of approaching the F.M. area behind these joints without compromising the stability of the CCJ. Therefore progressing just along the posterior aspect of these joints brings the surgeon in front of the neuraxis. Moreover this approach is gener-

ally realized to reach a tumor located in front of the neuraxis, therefore shifting the neuraxis more or less posteriorly and laterally, and enlarging the pre-axial space. As a matter of fact to work close to the C0–C1 and C1–C2 joints, it is necessary to control the Vertebral Artery (VA) which runs vertically along the C1–C2 joints between the transverse foramina of C2 and C1 and horizontally behind the C0–C1 joints in the groove of the posterior arch of atlas. Extraperiosteal control is mandatory to avoid any troublesome bleeding from the perivertebral venous plexus which is enclosed in the same periosteal sheath with the VA. One must be aware of the many variations in the diameter and course of the VA at this level. An angio CT or angio MR is generally sufficient to check all these VA variations.

Because the head rotation is mostly achieved by the atlas around the odontoid process, the anatomical relations between the different structures (especially neuraxis and VA) and the bone are changing. This must be clearly understood before positioning a patient for surgery. Looking from the side, rotating the head towards the opposite side brings the ipsilateral transverse process of atlas more superficial, the ipsilateral posterior arch directly onto view but the ipsilateral anterior arch far away from access; moreover this position stretches the C1–C2 and above C1 segments of the ipsilateral VA which become almost parallel on both sides of the posterior arch of atlas.

## **DECISION-MAKING**

### **1. DIAGNOSIS**

Nowadays diagnostic problems are generally easily solved by modern tools of imaging. MRI permits nice imaging studies of the soft tissues including the neuraxis, pharyngeal and retropharyngeal spaces, muscular elements and vascular structures (internal jugular vein, carotid arteries, VA). CT scanner is almost always useful even in case of intradural tumor to appreciate the shape of the bony structures. CT scanner is obviously necessary for bone tumors or bone infiltrating tumors. In Western countries most patients have today an easy access to these imaging modalities and therefore are referred with minimal symptoms. Most frequently patients present with posterior headache and nuchal pain with stiffness. Neurological deficits are often lacking or are very limited to paresthesiae or a mild sensory and/or motor deficit of one limb. The classical evolution of the motor deficit following a U shape (left arm, then left leg, right leg, right arm) is no longer observed. Similarly there is no more misdiagnosis of multiple sclerosis or of spondylotic myelopathy delaying the time of performing imaging studies. However, still many imaging studies start by a CT scanner and are then completed with an MRI, while the opposite would be more appropriate. Whatever both exams have generally to be carried on.

## 2. STRATEGY

Then 3 parameters must be analyzed so as to define the exact tumoral location and to apply the more adequate surgical strategy. First is the location in the horizontal plane; anterior if tumors extend on both sides of the anterior midline; lateral (uni or bilateral) if it develops between the midline and denticulate ligament and posterior behind the denticulate ligament. Second is the location regarding the dura: intra, extra, or intra-extradural. Third is the location regarding the VA: above, below or on both sides. The two first parameters (horizontal plane and dura mater) lead to the choice of the surgical approach, anterior (transoral), posterior (standard midline), posterolateral (far lateral) or anterolateral (extreme lateral) approach and corresponds to the extent of the opening in the horizontal plane. Basically the intradural location makes favor the posterolateral approach and the extradural location the anterolateral or the transoral approach (Table 2). Intra and extradural development generally leads to posterolateral approach if the main bulk of the tumor is intradural and to anterolateral approach if it is extradural. The location regarding the VA permits to adjust the extent of opening in the vertical plane: towards the occipital condyle for tumors above the VA and towards the lateral mass of atlas for tumors below the VA.

This strategy has two goals: (1) the best tumoral resection, (2) the preservation of the CCJ stability. Therefore every surgeon dealing with F.M. tumors must master all the surgical approaches around the F.M. As a consequence, instability related to the surgical approach should be exceptional (no case in our series); however in some cases, CCJ instability may be the consequence of the tumoral bone invasion and destruction. Therefore a complementary fusion procedure is decided only preoperatively because of the tumoral extent on the imaging work-up. For instance intradural F.M. meningiomas never require any drilling of the occipital condyle and/or the lateral mass of atlas. In our series a partial drilling of these bony structures was realized in only one case of the group of lesions not involving the bone. Obviously tumors invading the joints of the lateral wall need a more or less extensive bone drilling but without changing the patient's condition regarding stability. In case of instability, stabilization procedure is preferentially realized after tumor resection so that it does not impinge on the patient's positioning. Strategy defining the order of surgical steps is of utmost importance especially in case of chordomas for

**Table 2.** Surgical strategy following tumor location

	ID	ED	ID-ED
Anterior		Transoral	Transoral and/or posterolat.
Lateral	Posterolat.	Anterolat.	Posterolat and/or anterolat.
Bilateral	Posterolat bilat.	Anterolat bilat. or transoral	Posterolat bilat. and/or anterolat.
Posterior	Posterior	Posterior	Posterior

which surgical resection often requires two different surgical approaches and instability asks for a complementary procedure. Among extradural and bony lesions, non-tumoral processes may be observed. They include inflammatory, infectious, vascular, degenerative and malformative processes. They should not be misinterpreted as tumors since most of them need only decompression or even just a biopsy and a medical treatment (tuberculosis).

Very rarely an angiography is required before surgery. Analysis of the vascular relationships is almost always possible from an MRI and an angioMR. Moreover in many cases, most vascular feeders (from ECA and VA) can be controlled and suppressed in the surgical approach; therefore the need for preoperative embolization is very unusual. However, a balloon occlusion test, sometimes followed by a permanent occlusion of the VA may be necessary either for a safe exposure or for a more radical resection (malignant tumors).

## **SURGERY**

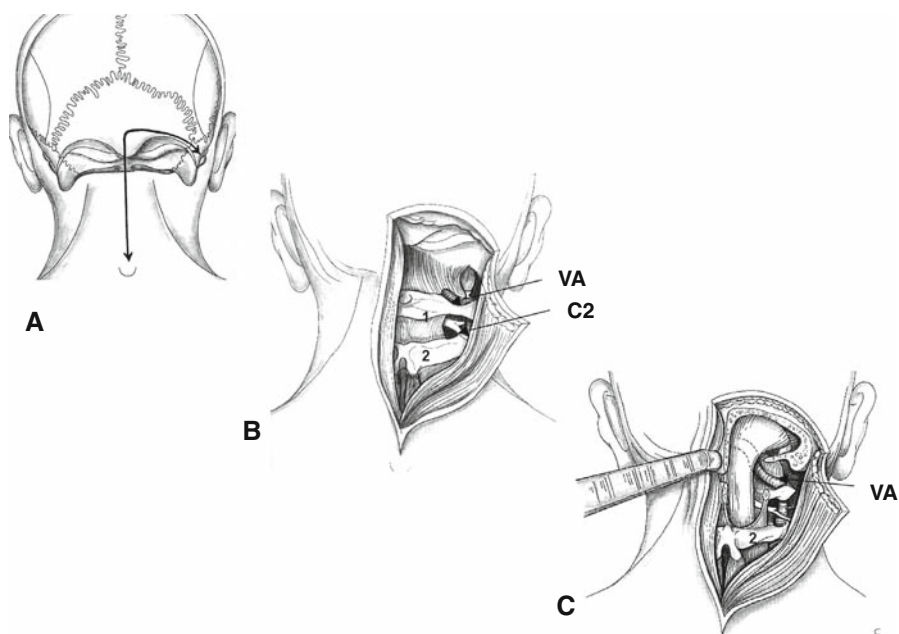
Dealing with a F.M. pathology one must be able to apply any of all the main surgical approaches leading to the F.M.

### **1. ANTERIOR APPROACHES**

The F.M. is made of an anterior wall which can be reached by the transoral approach. This approach with all its variations (upper extension with transpalatal splitting and transmaxillary combined Le Fort approach and lower extension with transglossal and transmandibular approach) is useful for any midline lesion located before or into this anterior bony wall. It is a straight forward approach, deep and therefore needing long instruments but without any structure on the way; only the mucosa and prevertebral muscles have to be divided and laterally retracted. It has lateral limitations with the two VAs and for upper opening the jugular veins and internal carotid arteries. It is certainly not indicated for lesions located behind the anterior bony wall and moreover for intradural lesions. In fact to reach these lesions through the transoral approach, it is necessary to destroy the anterior bony wall, so creating a previously non-existing instability. This problem can be avoided using lateral approaches. Then closure of the dura is often difficult to achieve with a high risk of CSF leak and meningitis.

### **2. POSTERIOR APPROACHES**

The posterior wall is rather weak as compared to the anterior and lateral ones. It has little importance in the F.M. instability. The direct route to this wall is the standard posterior midline approach, very well known by every neurosurgeon. It leads directly to the posterior midline of the F.M. area by splitting



**Fig. 1.** Posterolateral approach. **A** Skin incision. **B** Exposure of the posterior fossa, the posterior arch of Atlas 1 with the groove of the Vertebral Artery (VA). 2 lamina of C2. C2 C2 spinal nerve root. **C** Exposure after resection of the occipital bone and posterior arch of atlas up to the lateral mass. VA Vertebral Artery. 2 lamina of C2

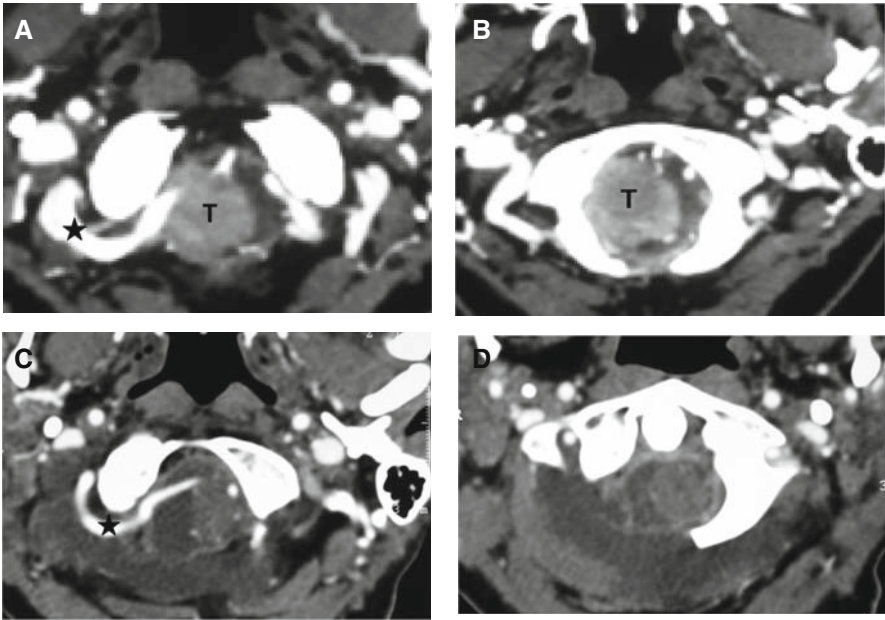
in between the two parts of the posterior cervical muscles dividing the avascular midline. It may be used for any midline posterior lesion extra or intradural. It is limited laterally by the end of the VA groove in the posterior arch of atlas and anteriorly by the neuraxis.

### 3. LATERAL APPROACHES

The lateral wall of the F.M. mainly includes the two joints C0–C1 and C1–C2. It is in fact an anterolateral wall since the line of these joints is at the level of C2 vertebral body. There is no pedicle and no intervertebral foramen at the F.M. level. So lateral approaches are directed to these joints either turning around the posterior aspect of them (the posterolateral approach) or going straight to them (the anterolateral approach).

The posterolateral approach (Fig. 1) is in fact the lateral extension of the midline posterior approach so that the VA groove is exposed and the resection of the occipital bone and posterior arch of atlas reaches the medial aspect of the occipital condyle and lateral mass of atlas. The patient's position can be sitting, prone or lateral; the skin incision is either vertical on the midline curved at the occipital protuberance down to the mastoid process or oblique



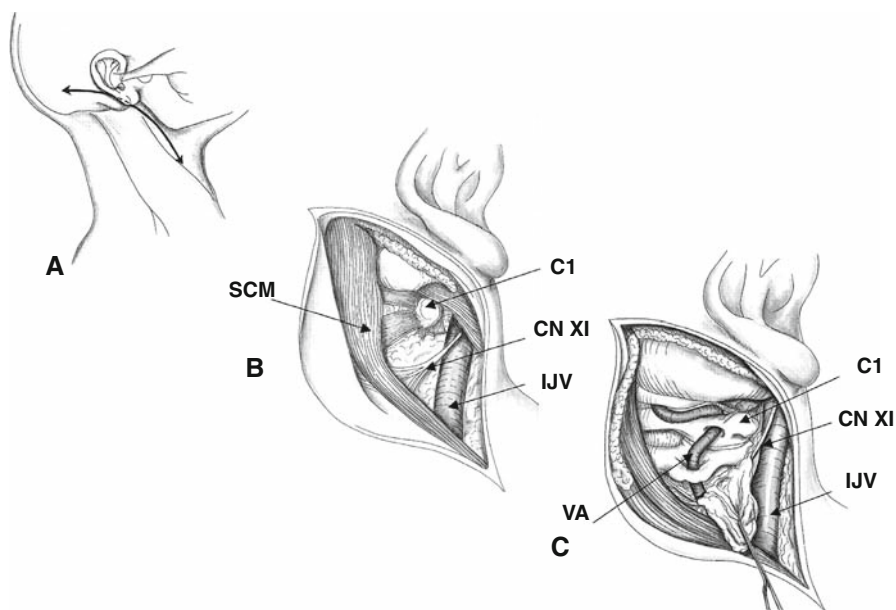


**Fig. 2.** Foramen Magnum Meningioma, lateral location below the Vertebral Artery. Pre- and post-operative axial views at the level of the occipital condyle (A–C) and lateral mass of Atlas (B–D). *Black star* Vertebral Artery. *T* tumor

vertical from the top of the ear towards the posterior midline at the C5–C6 level. The bone is exposed subperiosteally so as to keep intact the periosteal sheath surrounding the VA. Then the bone can be safely removed above and/or below the VA. Then following the course of the VA, one may penetrate into the foramen magnum subarachnoid space first along the lateral then the anterior aspect of the medulla oblongata (MO). These spaces lateral and anterior to the MO are generally enlarged by the tumoral development making still easier the access to them.

This posterolateral approach is therefore essentially designed for intradural tumors or for extradural pathologies developed behind the lateral wall of the F.M. The lateral opening is extended towards this lateral wall especially in case of lesions anterior to the neuraxis (Fig. 2).

The anterolateral approach (Fig. 3) is similar to the one used lower in the neck to expose the transverse processes and the VA. At the F.M. level, the anterolateral approach goes to the C1 and C2 transverse processes and to the suboccipital (V3) VA segment. The field is opened between the medial aspect of the Sternomastoid muscle (SM) and the lateral edge of the internal jugular vein. To get more space it is often useful to detach the SM and occasionally the posterior cervical muscles from the occipital bone. For this the patient is in the supine position with the head slightly extended and

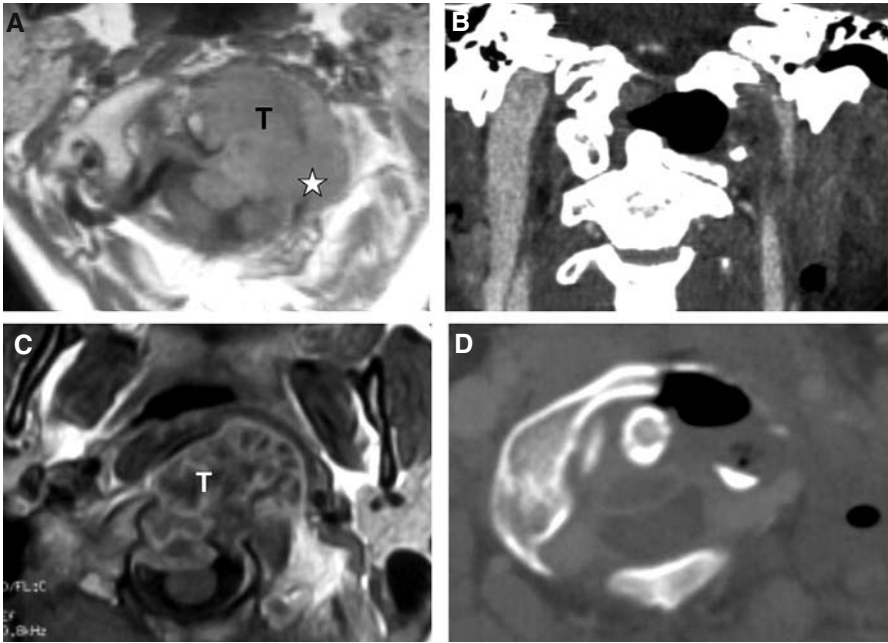


**Fig. 3.** Anterolateral approach. **A** Skin incision. **B** Opening of the field between the Sternomastoid Muscle (SCM) and the Internal Jugular Vein (IJV). **C** Expose of the V3 segment of the Vertebral Artery (VA) after dividing the muscles attached on the tip of the transverse process of C1 (C1). The Accessory Nerve (CN XI) is dissected and retracted inferiorly with the fat pad filling the depth of the field

rotated towards the opposite side. The skin incision follows the upper 10 cm of the medial limit of the SM up to the tip of the mastoid process then follows the mastoid process and the superior occipital crest towards the occipital protuberance. Once the field between the SM and the internal jugular vein is opened, the accessory nerve (CN XI) must be identified and dissected, then retracted inferiorly with the fat pad covering the depth of the field.

The transverse process of atlas can be palpated 15 mm below and before the tip of the mastoid process. It is freed from all the small muscles attached on it so giving view to the C1–C2 and above C1 segments of the VA with the posterior arch of atlas interposed in between them. Transposition of the VA out of the transverse foramen permits to expose the F.M. lateral wall with the two joints C0–C1 and C1–C2. More rotation of the head contralaterally brings the posterior part of atlas and F.M. into view while less rotation permits to run in front of the joints and to reach the anterior wall (anterior arch of atlas, vertebral body of C2 and odontoid process).

This approach can be extended as necessary inferiorly to lower levels in the neck since the same anterolateral approach permits to expose and control



**Fig. 4.** Chordomas. Pre-operative MRI axial view at the level of C1 (A) and of the occipital condyle (C). T tumor. White star Vertebral Artery. Post-operative coronal (B) and axial views (D) showing the tumoral resection through antero-lateral approach

the entire cervical spine. It can also be extended superiorly to the jugular foramen and the cerebellopontine angle region. In this case a complementary opening of the posterior fossa by a retrosigmoid approach is realized. The last possible extension is towards the petrous bone above the jugular foramen.

Most of time, the anterolateral approach is applied for tumors invading the bony elements of the anterior and lateral wall (Fig. 4). It means that F.M. stability is already compromised and will be still more impaired after surgery; therefore a stabilization procedure has generally to be considered in the management of these patients either in the same surgical stage or in a separate one. It must be quite exceptional to make unstable a patient which is preoperatively stable. It generally means that something was wrong in the strategy and the chosen surgical approach was not appropriate.

## RESULTS/HOW TO AVOID COMPLICATIONS

Results are very much related to a good surgical strategy choosing the most adequate approach(es). *Intradural lesions* (meningiomas, neurinomas) in

our series were totally resected in 98% at first presentation. Remnants are sometimes left around the VA where it pierces the dura or nearby the lower cranial nerves at the jugular foramen. A clear separation with the medulla could always be obtained. Conversely in case of recurrence, the scar tissues and adherences with the nerves and parenchyma generally make a partial resection a better option. Morbidity should be reduced substantially (4% in our series) related to transitory or permanent worsening of swallowing disturbances. Morbidity related to the surgical approach (posterolateral) is similar to that of midline posterior approach: muscular nuchal pain and stiffness for few days. There should be no instability and no VA lesion.

*Extradural lesions* included a variety of benign and malignant lesions for which complete resection is more difficult to achieve: 76% in our series using one or several (31%) surgical approaches. A complementary stabilization procedure was necessary in 64% of our cases mostly with occipito-cervical plating and bone grafting. Morbidity related to the tumoral resection was essentially due to lower cranial nerves (IX to XII) damages and to CSF leak. A tracheostomy must be anticipated soon after or even performed before the tumoral resection so as to avoid inhalation pneumonia. Indeed it is pre-operatively difficult to assess the level of compensation which may exist in case of IX and XI cranial nerves preoperative palsy. Dividing already invaded and paralysed nerves in fact is not always well tolerated and may need a tracheostomy and gastrostomy. Conversely preoperatively not infiltrated nerves either may be preserved or always lead to long lasting (weeks or months) swallowing disorders if they are sacrificed. In case of anterolateral approach, the extraperiosteal VA exposure and even transposition was always done safely. In 5 cases of malignant tumors, resection included the VA resection as well for radicality. In relation with the surgical approach, no VA lesion was observed. Stretching of the accessory nerve by overretraction of the SM muscle was observed in two cases inducing pain and neck stiffness for 2 weeks. Postoperative problems after transoral approach have been extensively reported in the treatment of bony malformations. Tumoral resection particularly brings a high rate of CSF leak which is reduced by lumbar drainage and careful closure. There was no reoperation for dural closure in our series including 12 transoral surgeries in spite of 5 leakages with meningitis in 3 cases. Dural closure must use several tissue layers with stitches and glue. In one chordoma patient with a large dural defect a forearm free flap was realized.


Then instability should not be considered as surgical morbidity but estimated from the preoperative tumoral extent. Stabilization procedure may induce its own morbidity; besides the limitation of head and neck movements which cannot be avoided, infection (2 cases out of 48 cases) is the main problem.

## CONCLUSIONS

The preoperative planning using CT scanner for the bone, MRI for the soft tissues and angio CT or angio MR for the vessels is fundamental precising the exact location in the horizontal plane and regarding the dura, the bone and the vessels and identifying as well as possible the type of tumor. It helps to define the best strategy using the most appropriate surgical approach(es) to get as complete as possible a resection without inducing instability if it does not exist yet. All the surgical approaches must be available in the surgical team so that the choice is not influenced by a favourite technique. A great variety of tumors can be observed at the Foramen Magnum level; each of them requires a different strategy aiming at complete resection preserving the quality of life.

## References

- [1] Bertalanffy H, Gilsbach JM, Mayfrank L, Klein HM, Kawase T, Seeger W (1996) Microsurgical management of ventral and ventrolateral foramen magnum meningiomas. *Acta Neurochir Suppl* 65: 82-85
- [2] Bruneau M, Cornelius JF, George B (2006) Antero-lateral approach to the V3 segment of the vertebral artery. *Neurosurgery* 58(Suppl I): ONS29-ONS35
- [3] Bruneau M, George B (2008) Foramen magnum meningiomas: detailed surgical approaches and technical aspects at Lariboisière Hospital and review of the literature. *Neurosurg Rev* 31: 19-33
- [4] Carpentier A, Polivka M, Blanquet A, George B (2002) Suboccipital and cervical chordomas. The value of aggressive treatment at first presentation of the disease. *J Neurosurg* 97: 1070-1077
- [5] Crockard HA, Steel T, Plowman N, Singh A, Crossman J, Revesz T, Holton JL, Cheeseman A (2001) A multidisciplinary team approach to skull base chordomas. *J Neurosurg* 95: 175-193
- [6] George B, Lot G (1995) Foramen magnum meningiomas. A review from personal experience of 37 cases and from a cooperative study of 106 cases. *Neurosurg Quat* 5: 149-167
- [7] George B, Blanquet A, Alves O (2002) The V3 segment of the vertebral artery. In: Spetzler RF (ed.) *Surgery around the craniocervical junction in operative techniques in neurosurgery*, Vol. 5(1). WB Saunders, Philadelphia, pp 50-74
- [8] Rhoton AL (2000) The far-lateral approach and its transcondylar, supracondylar, and paracondylar extensions. *Neurosurgery* 47(3): S195-S209



**Bernard George**

Bernard George is neurosurgeon at the Hôpital Lariboisière, Paris. Born in Paris September 14, 1948, Qualified Neurosurgeon 1977, Professor of Neurosurgery 1988, Head of Department of Neurosurgery Hopital Lariboisière Paris – France 1997, Vice-president of the French Society of Neurosurgery 1990–. Vice-president of the European Association of Neurosurgical Societies 1995–1999, Member of the board of the European Society of Skull Base Surgery 1993–1997, Member of the board of the French Speaking Society of Neurosurgery 2007, Member of the editorial boards of *Acta Neurochirurgica*, *Minimally Invasive Neurosurgery*, *Neurochirurgie*, *Neurosurgical review*, *Surgical Neurology*, and *Neurosurgery*. 300 publications in national and international journals. Member of the *Academia Eurasiana Neurochirurgica* 1992, Member of the *World Academy of Neurological Surgery* 2005. Fields of interest: Skull Base Surgery, Cervical Spine and Vertebral Artery Surgery.

**Contact:** Bernard George, Neurochirurgie, Hôpital Lariboisière, 2, rue Ambroise Paré, 75010 Paris, France

E-mail: [bernard.george@lrb.aphp.fr](mailto:bernard.george@lrb.aphp.fr)

---

# RADIOSURGERY FOR INTRACRANIAL TUMORS

J. RÉGIS

## INTRODUCTION

Radiosurgery has become a major neurosurgical tool for treatment of intracranial tumors [4, 40, 47]. The large clinical experience aggregated worldwide nowadays have allowed refinement of the technic and better understanding of radiobiological concepts [14, 16, 20, 32]. Proper selection of the indications, advances in MR technology, access to powerful computer based navigation systems have led to a very significant improvement in results. Radiosurgery has provided neurosurgeons with a novel approach allowing to treat efficiently small deeply seated lesions with high risk of functional deterioration in case of microsurgical attempt. This chapter will summarize present knowledge on applications of radiosurgery to intracranial tumors, and give a large literature review.

Historically radiosurgery was introduced by Leksell in the 50s and materialized by the first Gamma Knife in the 70s [34, 35, 36]. First applied to functional indications and arterio-venous malformations, radiosurgery revealed effective for skull base tumors. In the 80s vestibular schwannomas and meningiomas have become prominent indications for radiosurgery. Since 1960, roughly 400,000 patients have been treated worldwide using Gamma-Knife. Thus Gamma Knife surgery is no longer an experimental method and a sufficient evidence is available for drawing a quite precise picture of the potential role of radiosurgery in the neurosurgical management of intracranial tumors [48].

## RATIONALE

*Radiosurgery is defined* as “a neurosurgical procedure using convergent narrow ionizing beams, delivered in a single session, with a stereotaxic accuracy and precision, to destroy or modify biologically a predefined target without injuring the critical surrounding structures” [64]. Radiotherapy was already used for the treatment of tumors when Leksell developed the concept of radiosurgery in the 50s. If in both approaches ionizing radiation is used, physical conditions of this use are making the radiobiological effects of these two methods dramatically different. Thus, clinical effects, radiological effects, indications, risks, complications requirements for practice are very much different.

---

*Keywords:* intracranial tumors, radiosurgery, Gamma Knife, neuro-oncology

Theoretically radiotherapy is poorly adapted to the treatment of brain lesions due to the usually high level of radioresistance of these tumors and the high sensitivity to radiation of the precious neural structures. Radiotherapy is attempting to compensate this handicap by biological selectivity brought by fractionation and supposed to attenuate this bad safety efficacy balance. At the opposite the neurosurgeons in line with their philosophy which is to spare as much as possible the normal structures have developed with Gamma Knife radiosurgery a topological selectivity instrument, by delivering the huge majority to the target and very few energy to the surrounding structures [38].

With a single dose *the radiobiological effect* on the targeted structure is much more important than when the same total dose is spread in several fractions. The calculation, for a radiosurgical treatment, of the Biological Equivalent Dose (BED) in order figure what dose should be used with a fractionated treatment (e.g. 2 Gy per fraction) for the same radiobiological effect [33] requires to take into account the nature of the targeted tissue (linear quadratic formula). This calculation is indicating that there is in benign tumors (slow reacting tissue) a strong radiobiological benefit to use radiosurgery instead of radiotherapy [33].

*Topological differential effect* is the basic principle for safety in radiosurgery due to the delivery of a high dose in a single session. This requires high spatial accuracy both for imaging and doseplanning, peculiarly when there is a close relationship to highly functional and fragile surrounding structures. The Gamma-Knife with its fixed sources is providing with an excellent fall off of dose. However in order to achieve a precise radiosurgical treatment the accuracy of the radiosurgical instrument is crucial but not sufficient. Each step of the procedure needs to be secured in order to guarantee this safety and quality control plays a major role to ascertain this safety.

*Long-term complications of Radiosurgery.* The long-term potential carcinogenic risk of Stereotactic Radiosurgery (SRS) was not evaluated until recently. The definition of radio-induced tumors is based on the criteria by Cahan: the tumor must occur in a previously irradiated field, after a long time interval from irradiation, and must be pathologically different from the primary tumor and not present at the time of irradiation. In addition, the patient must not have a genetic predisposition for the tumor. A low dose of radiation, such as 1 Gy, has been associated with second tumor formation and a relative risk between 1.57 and 8.75. This relative risk increases to 18.4 for an interval time between 20 and 25 years. Radiation-associated tumor incidence is linked to different factors such as age and individual genetic susceptibility. At this time, three radiation-associated gliomas and five malignant vestibular schwannomas have been reported in the literature. Moreover, these second tumors do not meet all the Cahan criteria. We have reported two cases from our radiosurgical experience to discuss these points [45]. Long-term follow-up, ranging from 5 to 30 years, is needed to observe



the crude incidence of radiation-induced tumors. The relative risk is estimated less than 1 per 1000 and must be reported to each patient prior to any radiosurgical procedure.

Numerous intracranial tumors, specially when there are small, well-defined, and difficult to remove safely microsurgically, are potentially good indications for radiosurgery.

## **DECISION-MAKING, PROCEDURES, RESULTS ACCORDING TO PATHOLOGIES**

### **1. VESTIBULAR SCHWANNOMAS**

Gamma-Knife SRS was first used in 1969 by Lars Leksell to treat vestibular schwannomas (VS) [35]. No group has contributed more to the evaluation and administration of SRS in the management of VS than Drs. L. Dade Lunsford, Doug Kondziolka and John Flickinger from the University of Pittsburgh. This group has established optimal treatment parameters for tumor control of VSs in combination with hearing and facial nerve preservation [19]. Dr. Lunsford et al. have confirmed the importance of G. Noren's policy of "low irradiation doses which are therapeutically effective" [17]. Flickinger et al. recently reviewed their series of 313 patients presenting with previously untreated unilateral VS who underwent SRS (with 12–13 Gy margin) between 1991 and 2001 [18]. The actuarial six-year tumor control rate was 98.6%. The six-year actuarial rates for preserved facial nerve function, trigeminal nerve function, and hearing were 100%,  $95.6 \pm 1.8\%$ ,  $78.6 \pm 5.1\%$ , respectively. Dr. Lunsford's team was the first to prospectively demonstrate the advantage (in term of functional outcome) of SRS over microsurgery in the management of VS [52].

Between 1973 and 2004, a total of 2577 VSs have been surgically resected or treated by SRS in Marseille. Approximately 1500 patients were treated with SRS using Gamma Knife. All VS patients treated with SRS received a 12 Gy tumor marginal dose. Three major technical advances have clearly influenced our practice: the availability of high resolution stereotactic MRI [19], workstations to select the dose and treatment plan (Gamma Plan) [55], and the installation of the robotic APS system. The average number of isocenters used in 1992 was less than 5 and more than 15 in 2003 with the APS system [56]. Consequently, if we consider the first 100 patients of our experience representing our learning curve, 4 treatment periods can be defined. The rate of transient facial palsy and hemifacial spasm for VS patients treated by our group was 3 and 3% during the first phase (June 1992–December 1994; 100 pts), 1.4 and 2.8% during the second period (December 1994–July 1997; 212 pts), 0.55 and 0.83% during the third period (July 1997–May 2000; 360 pts), and 0 and 0% during the last period (May 2000–January 2002,

258 pts), respectively. Only patients with greater than 2 years of follow-up were included in our series [54].

*Comparison to microsurgery.* In a comparison of 110 VSs surgically resected and 97 treated by SRS, a lower rate of facial palsy and a higher probability of functional hearing preservation were both achieved after SRS [57]. All patients had Koos stage II–III tumors with a minimum follow-up of 4 years. Only three other studies have compared microsurgery to radiosurgery in term of safety efficacy and all these studies are confirming our results [46, 52, 57].

*Efficacy of radiosurgery.* In order to better define the accuracy and efficacy of SRS, the morphologic imaging changes of tumors treated between July 1992 and January 2002 were evaluated [11]. Systematic measurements were performed on all tumors treated before and after SRS (intervals of 6 months, 1, 2, 3, 5, 7, and 10 years). At the time of SRS, the median tumor volume was 732 mm<sup>3</sup> (mean 1346; range 20–14405). According to the Koos topographical classification, there were 80 stage I, 538 stage II, 322 stage III, and 56 stage IV cases. Loss of central enhancement was visible on postoperative MR imaging at 6 months and/or 1 year in 45.5% patients. In 64% of these patients, loss of the central contrast enhancement occurred. A significant increase in tumor size was recorded in 15% of the patients; in 3% of the patients, progression led to a second procedure, either resection or a second SRS procedure. Failure was defined as continuous tumor progression after 3 years from SRS treatment. Tumor control was achieved in 97% of the cases. Since the natural history of the VSs include growth of 2mm/year, our results confirm the efficacy of SRS.

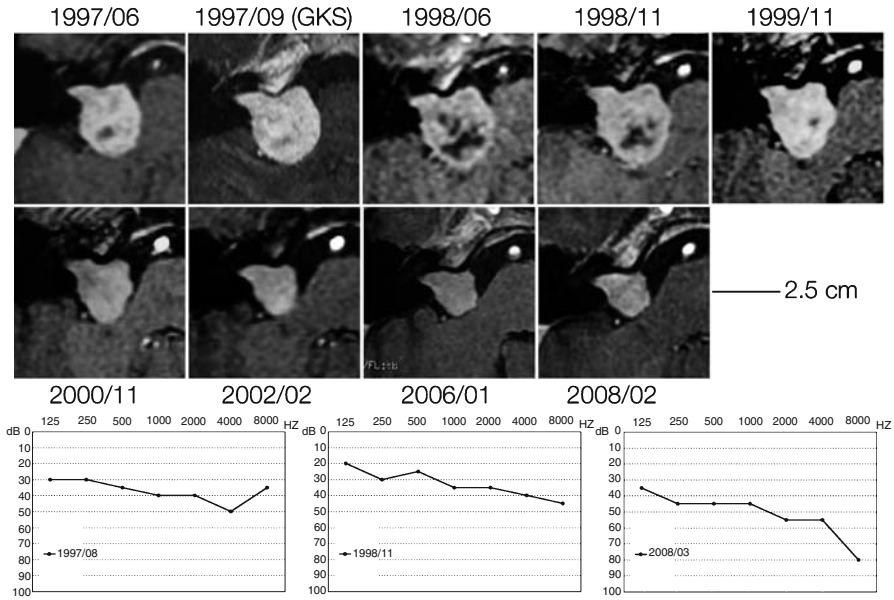
*Hearing preservation.* In our SRS experience, 175 patients with a VS and functional preoperative hearing (Gardner and Robertson 1 or 2) were initially treated with SRS. All these patients had a follow-up longer than 3 years [22]. Hearing preservation after SRS was 60% for all patients. Univariate and multivariate analysis have revealed parameters which influence the probability of functional hearing preservation at 3 years. These parameters include: a limited hearing loss (Gardner/Robertson stage 1), the presence of a tinnitus, younger age of the patient, and small lesion size. Functional hearing preservation at 3 years is 77.8% in patients with stage 1 hearing, 80% in patients with tinnitus as a first symptom, and 95% when the patient had both stage 1 hearing and tinnitus. In these patients, the probability of functional hearing preservation at 5 years is 84% [22].

*Facial nerve preservation.* Facial palsy was very rare (less than 1%) in our SRS management of VSs. Our results coincide with the Pittsburgh and Rhode Island experiences [54] (Table 1).

In summary in Marseille SRS experience, which includes 2000 patients, with more than 1000 patients with a follow-up longer than 3 years, has the following results: a long-term tumor control rate of 97%, transient facial palsy lower than 1%, and a probability of functional hearing preservation

**Table 1.** Table presenting the main features from 5 main Vestibular Schwannomas radiosurgical series. RS represent the kind of radiosurgical technic used: either Gamma Knife Surgery (GKS) or LINAC radiosurgery (LINAC); Dose is the median dose at the reference isodose line, FU is the median follow up in months, MS represent the % of patient already operated of the same lesion by microsurgical approach, Volume represent the total volume of the lesion on the treatment day in cubic centimeters, VIII indicate the % of patient preserving a functional hearing, VII indicate the percentage of patient experiencing a facial nerve neuropathy induced by radiosurgery, V indicate the percentage of patient presenting V nerve complication after radiosurgery

Authors	Year	No. of Patients	Sex M/F ratio	Median age (yrs)	Median Origin	RS	Dose (Gy)	FU (mo)	MS (%)	Failure (%)	Volume (cc)	Control rate (%)	VIII (%)	VII (%)	V (%)	Period
Chopra	2007	216	116/100	NA	PA/USA	GKS	12-13	68	0	1.7	1.3	98.3	74	0	6.8	1992-2000
Régis	2007	927	414/513	53.7	France	GKS	12.57	52	9	2.3	1.2	97.7	60	0.70	0.6	1992-2001
Pollock	2006	46	27/19	53.9	MI/USA	GKS	12.2	42	0	4.3	1.5	95.7	63	0	2.1	2000-2002
Lunsford	2005	829	411/418	?	PI/USA	GKS	13	72	19.9	3	2.5	97	70.3	1	3	1987-2002
Foote	2003	149	?	36	FI/USA	LINAC	14	36	NA	13	NA	87	42	11.8	9.5	1988-1998
Prasad	2000	153	80/73	60	VA/USA	GKS	13	51.24	37	7.2	2.8	92.8	60	1.3	3.2	1989-1999



**Fig. 1.** Vestibular Schwannomas Gamma Knife radiosurgery. In a 42 years old female, presenting with tinnitus on the right ear, with a Gardner Robertson class II residual hearing on the right side, is discovered a Koos III right Vestibular Schwannoma in June 1997. On the day of Gamma Knife Surgery (September 10th, 1997), the MR is demonstrating a dramatic increase of the tumor which have become a Koos IV tumor with a slight mass effect on the brainstem. Decision is taken with the patient to proceed with the treatment in spite of this tumor enlargement. Six months after the MR is displaying a loss of the central contrast enhancement. After a transient asymptomatic increase of the tumor subsequent images have demonstrated a dramatic reduction (from 5 cc to less than 1 cc) of the tumor volume. On the last MR in February 2008 the tumor have shrunk, there is no longer any mass effect on the brainstem. The patient have experienced no complication, side effect or discomfort since radiosurgery and have kept a functional hearing. Between the first audiometry in April 1997 and the treatment day (5 months) the patient have experienced an average loss of 10db. Since radiosurgery and after 11 years of follow up the average loss is only 15 db. The probability of preserving a normal facial function after a radical microsurgical removal should have been poor in this case of a large lesion and the probability to preserve a functional hearing close to zero

between 50 and 95% was achieved in this large series of patients treated by state-of-the-art SRS (Fig. 1).

*Small and middle sized VS in young patients with few symptoms* are the best candidates for radiosurgery. Patients with Koos stage II and III tumors are good candidates as well. Intracanalicular, cystic, previously resected, and Koos stage IV tumors may be candidates as well. Originally, Koos class I tumors, until 1999, were considered for radiosurgery only in cases of tumor progression at our institution. Our retrospective analysis of tumor growth rate, functional hearing preservation, and patients requesting radiosurgery have led us to modify our practice. Patients treated by SRS have a

higher probability of functional hearing preservation [58]. Consequently, patients presenting with a stage I lesion and functional hearing are now considered for radiosurgery at our institution even in the absence of tumor progression.

*Large vestibular schwannomas* can be effectively treated by deliberately adopting the strategy consisting in combining the surgical retrosigmoid approach, which is a relatively non-invasive approach, with Gamma Knife radiosurgery. This two-fold therapeutic method seems to give an excellent functional outcome and a high rate of tumoral control. Excellent facial nerve function (House and Brackmann Grade I or II) was preserved in our experience in 87.5% of the patients. Consequently, nowadays whatever the size of the tumor Gamma Knife surgery is a very important piece of the neurosurgical armamentarium in otoneurology.

## 2. MENINGIOMAS

In all the situations where radical removal seems achievable, there is few room for radiosurgery. When the complete resection of a large meningioma appears unachievable safely due to its topography and its close relationship to critical structures radiosurgery may be consider upfront as a combined treatment after a first stage of subtotal removal.

*For Cavernous sinus meningiomas* enclosed in the cavernous sinus, small enough and far enough from the optic pathways, a first line radiosurgery is recommended [61]. When the lesion is too big or too close to the optic pathways a combined approach (resection of the portion out of the cavernous sinus) or a conformal radiotherapy are advocated [13, 43].

*Petroclival meningiomas* specially when they are growing, inducing clinical signs but small enough may be indication with lower morbidity than microsurgery [60].

*Parasagittal meningiomas* have been demonstrated to correlate with a high rate of brain edema specially in patients previously operated and or presenting with a neurological deficit at time of radiosurgery [27].

*Malignant and anaplastic meningiomas* are clearly more likely to fail to respond to radiosurgery [28].

*Hemangiopericytomas* are frequently presenting similarly to meningiomas from a radiological point of view but are usually much more sensitive to radiosurgery [10, 12].

## 3. PITUITARY TUMORS

In acromegaly, Gamma-Knife radiosurgery has been used in our center since 1993. We prospectively evaluated the long-term results of this procedure in 82 patients, of whom 63 had previous transsphenoidal surgery [8]. Patients were considered as in remission when mean GH levels were less than 2ng/ml and

IGF-1 was normal for age off somatostatin agonists. With a mean follow-up of 49.5 months, 17% patients were considered as in remission. In addition, 23% considered as uncured had GH below 2 ng/ml and normal IGF-1 on somatostatin agonists, whereas they were not normalized on the same treatment before radiosurgery. Initial GH and IGF-1 levels off somatostatin agonists were significantly higher in the uncured than in the remission group. Withdrawal of somatostatin agonists at the time of radiosurgery had no incidence on the outcome. No significant difference was found in success rate whether Gamma-Knife radiosurgery was used as a primary or as an adjunctive treatment. There were only few long-term side effects, mainly complete ( $n=2$ ) or partial ( $n=12$ ) hypopituitarism. Radiosurgery thus represents a potential therapeutic approach for acromegaly, particularly in patients with moderate growth hormone hypersecretion previously refractory to other therapies [6].

*In Cushing's disease*, though transsphenoidal surgery remains the first-line treatment, recurrence occurs frequently. Conventional radiotherapy and anticortisolic drugs both have adverse-effects. Forty patients with Cushing disease treated by GK were prospectively studied over a decade, with a mean follow-up of 54.7 months in our department [7]. Eleven of them had Gamma-Knife as primary treatment. Median margin dose was 29.5 Gy. Patients were considered in remission if they had normalized 24h free urinary cortisol and suppression of plasma cortisol after low-dose dexamethasone suppression test. Seventeen patients (42.5%) were in remission after a mean of 22 months (range 12–48 months). The two groups did not differ in terms of initial hormonal levels. Target volume was significantly higher in uncured than in remission group (909.8 vs. 443 mm<sup>3</sup>,  $p=0.038$ ). We found a significant difference between patients who were on or off anticortisolic drugs at the time of GK (20% versus 48% patients in remission respectively,  $p=0.02$ ). With 42% of patients in remission after a median follow-up of 54 months, GK stereotactic radiosurgery, especially as an adjunctive treatment to surgery, may represent an alternative to other therapeutic options in view of their adverse effects.

*In non secreting tumors*, when a remnant is demonstrated to progress after microsurgical removal, radiosurgery can be performed safely if the target is small and not too close from the optic pathways [66]. It is of interest to note that the marginal doses required for high rate of control are quite low compared to those necessary for control of the endocrinological disease.

#### 4. CRANIOPHARYNGIOMAS

Craniopharyngiomas are among the tumors requiring traditionally high radiotherapy doses due to their well-known radioresistance. They are certainly the tumors the more radiosensitive to radiosurgery, which allows the very safe and effective radiosurgical treatment of small residual craniopharyngiomas even when there are very close to the optic pathways.

## 5. METASTASES

Classically solitary brain metastases are ideal candidates to be microsurgically resected with the addition of a whole brain radiotherapy (WBRT) in order to improve the local control [50], brain control [49] and survival [50]. This attitude is well demonstrated to be superior to surgery alone or WBRT alone [49, 50]. Therefore this attitude became the standard of care till the 90s. This well-established standard has to be rediscussed nowadays due to the introduction of radiosurgery in the modern management of brain metastases. Our initial radiosurgical experience have shown a quite high rate of local control with radiosurgery alone (86%). In spite of their well-known resistance to radiotherapy brain metastases from melanomas or renal cell cancers are turning out to be specially sensitive to radiosurgery than other and specially than lung cancer adenocarcinomas [23, 44]. Local control, median survival, Karnofsky performance status are demonstrated to be superior with radiosurgery plus WBRT compared to WBRT alone [1, 29]. Local control obtained with radiosurgery alone being demonstrated to be equivalent to the local control obtained with surgery plus radiotherapy our team have favor the strategy of radiosurgery alone repeated on demand, WBRT being proposed only for salvage therapy. Microsurgery is proposed in large or associated to extensive edema with impending herniation or cystic solitary lesions. WBRT is proposed upfront in small cell lung cancer (randomized trials show >50% of patients will develop brain mets and that WBRT improves survival) or in patients with too-numerous-to-count chemoresistant brain metastases. Radio-surgery alone in a large multicentric study show high local control (85%), few complications (1% radionecrosis), with a median survival of 11 months [15]. The advantages of this attitude are (1) a better local control than WBRT alone or MS alone equivalent to MS+WBRT (2) avoids WBRT toxicity, (3) is a one-day procedure, (4) chemotherapy delay is not necessary, (5) can be repeated on demand, (6) can be used after prior WBRT, (7) WBRT can be used in future if necessary, (8) toxicity is low. Its disadvantage is (for radiosensitive histologies like lung ADK) a higher probability of brain recurrence [2]. Aoyama et al in 2006 comparing SRS to SRS+WBRT have reported a median of new brain metastases of 64% and 42%, respectively [2]. However WBRT toxicity is more and more clearly reported. Slotman in 2007 reported in small-cell lung cancer patients without brain metastases treated with preventive WBRT show significant increase of fatigue, hair loss, appetite loss, nausea vomiting and leg weakness [68]. In patients with brain metastases Welzel et al. have found that WBRT was one cause of neurocognitive dysfunction immediately after the beginning of RT, and Xu et al. have shown an increase risk for radionecrosis for patients treated with WBRT before or at the same time of SRS (ASTRO 2007). Sneed et al have demonstrated, comparing SRS alone to SRS+WBRT, that the probability of being brain free from progression was no longer significant when allowing for salvage therapy [69]. Analyses of the

impact of salvage therapy in Aoyama et al. prospective study (SRS versus SRS+WBRT) shows that SRS alone followed by SRS on demand and eventually salvage WBRT when numerous lesions are appearing allows to reduce the use of WBRT (16% instead of 100%) with, as a price to pay, an increase of the number of additional SRS from 14 to 28%, but less chemo delay, less total number of procedure (95/125) less total treatment days (194/638), and less costs [2, 3]. Thus data clearly favor radiosurgery alone for 1–4 metastase patients due to significant fewer procedures, less chance of getting any WBRT toxicity, fewer days undergoing procedures, fewer possible chemo delays and less costs. When patient's initial number of brain metastases is >3 freedom from distant brain metastases at 12 months is 0% versus 46% for those presenting initially with less than 3 according to Sawrie et al [62]. However, the number of metastases (after controlling for KPS, age, primary cancer status, extracranial mets, total target volume, WBRT) is not influencing the survival [71].

Radiosurgery is representing a very appealing alternative to conventional management of brain metastases [15] specially if quality of the remaining life is the first concern.

## 6. GLIAL TUMORS

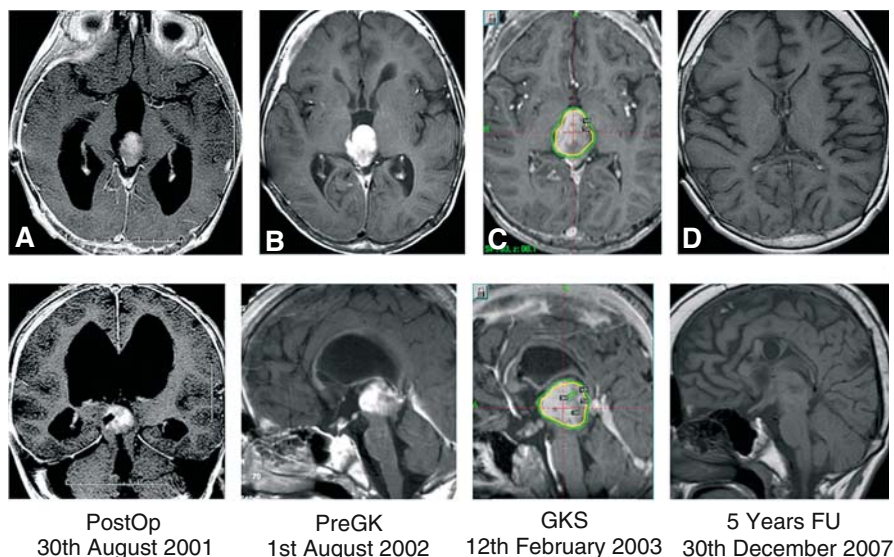
Glial tumors, even when they are at a radiological focal stage of expression, are obviously already a diffuse disease of the central nervous system poorly adapted to such a hyperfocal approach. In our team, the only cases in which radiosurgery can be discussed are small recurrences occurring at the limit of a first line large lobectom [67]. Consequently, that is not surprising to observe that in our overall activity of radiosurgery in Marseille among 7012 radiosurgical interventions only 16 have been done for patients presenting with a glioblastoma. First intention radiosurgery of small glioblastomas [31] seems well tolerated in spite of the use of high dosages with a rate of toxicity and reoperation lower than with brachytherapy [67]. Targetting of small recurring tumors based on spectroscopic MR or PET [37] is still a strategy under evaluation.

Second line radiosurgery in recurrent anaplastic ependymomas have been reported by the Pittsburgh team in a series of 22 patients with tumoral control in 68% of the patients actuarial 5 years local control rate and brain control (whatever the location) being respectively of 62.3 and 32.4%. No complication is reported by these authors. Radiosurgery appears as an interesting minimally invasive procedure in some of these patients [24].

Globally malignant gliomas are poor indication for radiosurgery due to their diffuse mode of invasion.

At the opposite, some pineal tumors [41, 53, 59], especially pilocytic astrocytomas, can be excellent indications of radiosurgery when they are small, well circumscribed, deeply seated and therefore not easy to remove safely [26, 63]. Pilocytic astrocytomas of the tectal plate are specially fitting to these





**Fig. 2.** Pilocytic astrocytoma radiosurgery in a pediatric case. In a 11 years old boy a microsurgical removal of a tectal tumor (in a foreign country) have left a voluminous residue (see postoperative MR August 30th, 2001). Gamma Knife surgery performed in February 12th 2003 have demonstrated an impressive efficacy with an important shrinkage of the tumor on follow up MR. At 5 years after radiosurgery (MR December 2007) the tumor is no longer visible on the images. The patient have experienced no side effect or complication related to radiosurgery

criterion [26] with in our experience and in the literature very few risks compared to microsurgical exereses (Fig. 2).

## 7. HEMANGIOBLASTOMAS

The interest of radiosurgery in the treatment of small hemangioblastomas, multiple or recurring or when patients are not good candidates for microsurgical resection is well established [9, 25, 51]. Jawahar et al. reported a series of 27 patients (29 lesions, mean follow up 4 years) with actuarial control rate of 84.5 and 75.2 at 2 and 5 years. Better results were noted in patients presenting with small lesions and with marginal doses superior to 18 Gray [25].

## 8. GLOMUS JUGULAR TUMORS

Few glomic tumors treated by radiosurgery have been reported in the literature. On the occasion of a European multicentric study, we have been able to aggregate 66 such cases. Radiosurgery was the primary treatment in 30 cases (45.5%), a previous microsurgical resection had been performed in 24 cases (36.4%), embolisation in 14 (21.2%) radiotherapy in 5 (7.6%). Fifty-two patients have been followed an average of 24 months (3–70). Clinical improve-

ment was observed in 15 patients (29%) and a worsening in 3 patients (5.8%). A clear radiological decrease of the tumor was reported in 19 patients (40%) and a stabilisation in the other 28 patients (60%). Due to the very slowly growing natural history of this kind of tumors these interesting results must be confirmed by further studies with longer follow-up [21, 39, 65].

## CONCLUSIONS

Radiosurgery has acquired – nowadays – a large place in the therapeutic armamentarium for the management of small deep-seated tumors. Radiosurgery allows to treat these lesions under local anesthesia, without mortality, and a very low morbidity rate.

One can separate four clinical situations:

1. Some lesions must be operated conventionally because of a more radical and fast efficacy, associated to few risks of complications. In this group, radiosurgery is discussed in second line when there is a remnant difficult to remove (e.g. residual secreting pituitary microadenomas invading the cavernous sinus).
2. Some lesions must be operated by radiosurgery in first intention due to a clear benefit in term of functional outcome and avoidance of surgical complications (e.g. small vestibular schwannomas of Koos stages I, II or III in young patients, small meningiomas enclosed in the cavernous sinus).
3. Some lesions can be approached deliberately with a combination of microsurgical reduction and radiosurgical treatment of the remnant close to the critical structures (e.g. foramen jugulare large schwannomas, Koos stage IV vestibular schwannomas).
4. Some lesions due to their biological behaviour are not good candidates to radiosurgery out of exceptional circumstances (e.g. glioblastomas).

## References

- [1] Andrews DW, Scott CB, Sperduto PW, Flanders AE, Gaspar LE, Schell MC, Werner-Wasik M, Demas W, Ryu J, Bahary J-P, Souhami L, Rotman M, Mehta MP, Curran WJJ (2004) Whole brain radiation therapy with or without stereotactic radiosurgery boost for patients with one to three brain metastases: phase III results of the RTOG 950 randomised trial. *Lancet* 363: 1665-1672
- [2] Aoyama H, Shirato H, Tago M, Nakagawa K, Toyoda T, Hatano K, Kenjyo M, Oya N, Hirota S, Shioura H, Kunieda E, Inomata T, Hayakawa K, Katoh N, Kobashi G (2006) Stereotactic radiosurgery plus whole-brain radiation therapy vs stereotactic radiosurgery alone for treatment of brain metastases: a randomized controlled trial. *JAMA* 295: 2483-2491

- [3] Aoyama H, Tago M, Kato N, Toyoda T, Kenjyo M, Hirota S, Shioura H, Inomata T, Kunieda E, Hayakawa K, Nakagawa K, Kobashi G, Shirato H (2007) Neurocognitive function of patients with brain metastasis who received either whole brain radiotherapy plus stereotactic radiosurgery or radiosurgery alone. *Int J Radiat Oncol Biol Phys* 68: 1388-1395
- [4] Apuzzo M (2000) Reinventing neurosurgery: entering the third millennium. *Neurosurgery* 46: 1-2
- [5] Attanasio R, Epaminonda P, Motti E, Giugni E, Ventrella L, Cozzi R, Farabola M, Loli P, Beck-Peccoz P, Arosio M (2003) Gamma-Knife radiosurgery in acromegaly: a 4-year follow-up study. *J Clin Endocrinol Metab* 88: 3105-3112
- [6] Castinetti F, Morange I, Dufour H, Régis J, Brue T (2009) Radiotherapy and radiosurgery in acromegaly. *Pituitary* 12: 3-10
- [7] Castinetti F, Nagai M, Dufour H, Kuhn JM, Morange I, Jaquet P, Conte-Devolx B, Régis J, Brue T (2007) Gamma Knife radiosurgery is a successful adjunctive treatment in Cushing's disease. *Eur J Endocrinol* 156: 91-98
- [8] Castinetti F, Taieb D, Kuhn JM, Chanson P, Tamura M, Jaquet P, Conte-Devolx B, Régis J, Dufour H, Brue T (2005) Outcome of Gamma Knife radiosurgery in 82 patients with acromegaly: correlation with initial hypersecretion. *J Clin Endocrinol Metab* 90: 4483-4488
- [9] Chandler HC Jr, Friedman WA (1994) Radiosurgical treatment of a hemangioblastoma: case report. *Neurosurgery* 34: 353-355; discussion 355
- [10] Coffey R, Cascino T, Shaw E (1993) Radiosurgical treatment of recurrent hemangiopericytomas of the meninges: preliminary results. *J Neurosurg* 78: 903-908
- [11] Delsanti C, Tamura M, Galanaud D, Régis J (2004) Changing radiological results, pitfalls and criteria of failure. *Neurochirurgie* 50: 312-319
- [12] Dufour H, Metellus P, Fuentes S, Murracchiole X, Régis J, Figarella-Branger D, Grisoli F (2001) Meningeal hemangiopericytoma: a retrospective study of 21 patients with special review of postoperative external radiotherapy. *Neurosurgery* 48: 756-762; discussion 762-753
- [13] Dufour H, Murracchiole X, Metellus P, Régis J, Chinot O, Grisoli F (2001) Long-term tumor control and functional outcome in patients with cavernous sinus meningiomas treated by radiotherapy with or without previous surgery: is there an alternative to aggressive tumor removal? *Neurosurgery* 48: 285-294; discussion 294-286
- [14] Flickinger J, Kondziolka D, Lunsford L (1999) Dose selection in stereotactic radiosurgery. *Neurosurg Clin N Am* 10: 271-280
- [15] Flickinger J, Kondziolka D, Lunsford L, Coffey R, Goodman M, Shaw E, Hudgins W, Weiner R, Harsh Gt, Sneed P (1994) A multi-institutional experience

- with stereotactic radiosurgery for solitary brain metastasis. *Int J Radiat Oncol Biol Phys* 28: 797-802
- [16] Flickinger J, Kondziolka D, Lunsford L, Kassam A, Phuong L, Liscak R, Pollock B (2000) Development of a model to predict permanent symptomatic post-radiosurgery injury for arteriovenous malformation patients. *Arteriovenous Malformation Radiosurgery Study Group. Int J Radiat Oncol Biol Phys* 46: 1143-1148
- [17] Flickinger JC, Kondziolka D, Lunsford LD (1996) Dose and diameter relationships for facial, trigeminal and acoustic neuropathies following acoustic neuroma radiosurgery. *Radiother Oncol* 41: 215-219
- [18] Flickinger JC, Kondziolka D, Niranjana A, Voynov G, Maitz A, Lunsford LD (2003) Acoustic neuroma radiosurgery with marginal tumor doses of 12 to 13 Gy. *Int J Radiat Oncol Biol Phys* 57: S325
- [19] Flickinger JC, Kondziolka D, Pollock BE, Lunsford LD (1996) Evolution in technique for vestibular schwannoma radiosurgery and effect on outcome. *Int J Radiat Oncol Biol Phys* 36: 275-280
- [20] Flickinger JC, Lunsford LD, Kondziolka D (1992) Dose prescription and dose-volume effects in radiosurgery. *Neurosurg Clin N Am* 3: 51-59
- [21] Foote R, Coffey R, Gorman D, Earle J, Schomberg P, Kline R, Schild S (1997) Stereotactic radiosurgery for glomus jugulare tumors: a preliminary report. *Int J Radiat Oncol Biol Phys* 38: 491-495
- [22] Gabert K, Régis J, Delsanti C, Roche PH, Facon F, Tamura M, Pellet W, Thomassin JM (2004) Preserving hearing function after Gamma Knife radiosurgery for unilateral vestibular schwannoma. *Neurochirurgie* 50: 350-357
- [23] Grob JJ, Régis J, Laurans R, Delaunay M, Wolkenstein P, Paul K, Souteyrand P, Koeppel MC, Murraciale X, Perragut JC, Bonerandi JJ (1998) Radiosurgery without whole brain radiotherapy in melanoma brain metastases. *Club de Cancerologie Cutanee. Eur J Cancer* 34: 1187-1192
- [24] Jawahar A, Kondziolka D, Flickinger J, Lunsford L (1999) Adjuvant stereotactic radiosurgery for anaplastic ependymoma. *Stereotact Funct Neurosurg* 73: 23-30
- [25] Jawahar A, Kondziolka D, Garces Y, Flickinger J, Pollock B, Lunsford L (2000) Stereotactic radiosurgery for hemangioblastomas of the brain. *Acta Neurochir (Wien)* 142: 641-644; discussion 644-645
- [26] Kihlström L, Lindquist C, Lindquist M, Karlsson B (1994) Stereotactic radiosurgery for tectal low-grade gliomas. *Acta Neurochir Suppl (Wien)* 62: 55-57
- [27] Kondziolka D, Flickinger J, Perez B (1998) Judicious resection and/or radiosurgery for parasagittal meningiomas: outcomes from a multicenter review. *Gamma Knife Meningioma Study Group. Neurosurgery* 43: 405-413; discussion 413-404


- [28] Kondziolka D, Mathieu D, Lunsford LD, Martin JJ, Madhok R, Niranjan A, Flickinger JC (2008) Radiosurgery as definitive management of intracranial meningiomas. *Neurosurgery* 62: 53-58; discussion 58-60
- [29] Kondziolka D, Patel A, Lunsford L, Kassam A, Flickinger J (1999) Stereotactic radiosurgery plus whole brain radiotherapy versus radiotherapy alone for patients with multiple brain metastases. *Int J Radiat Oncol Biol Phys* 45: 427-434
- [30] Landolt AM, Haller D, Lomax N, Scheib S, Schubiger O, Siegfried J, Wellis G (2000) Octreotide may act as a radioprotective agent in acromegaly. *J Clin Endocrinol Metab* 85: 1287-1289
- [31] Larson D, Gutin P, McDermott M, Lamborn K, Sneed P, Wara W, Flickinger J, Kondziolka D, Lunsford L, Hudgins W, Friehs G, Haselsberger K, Leber K, Pendl G, Chung S, Coffey R, Dinapoli R, Shaw E, Vermeulen S, Young R, Hirato M, Inoue H, Ohye C, Shibasaki T (1996) Gamma Knife for glioma: selection factors and survival [see comments]. *Int J Radiat Oncol Biol Phys* 36: 1045-1053
- [32] Larsson B (1992) Radiobiological fundamentals in radiosurgery. *Radiosurgery: Baseline and Trends* 3-14
- [33] Larsson D, Flickinger J, Loeffler J (1993) The radiobiology of radiosurgery. *Int J Radiat Oncol Biol Phys* 25: 557-561
- [34] Leksell L (1951) The stereotaxic method and radiosurgery of the brain. *Acta Chirurgica Scandinavica* 102: 316-319
- [35] Leksell L (1969) A note on the treatment of acoustic tumors. *Acta Chirurgica Scandinavica* 137: 763-765
- [36] Leksell L (1971) *Stereotaxis and radiosurgery: an operative system*. C. C. Thomas, Springfield
- [37] Levivier M, Wikier D, Goldman S, David P, Metens T, Massager N, Gerosa M, Devriendt D, Desmedt F, Simon S, Van HP, Brotchi J (2000) Integration of the metabolic data of positron emission tomography in the dosimetry planning of radiosurgery with the Gamma Knife: early experience with brain tumors. Technical note. *J Neurosurg* 93(Suppl 3): 233-238
- [38] Linskey ME (2000) Stereotactic radiosurgery versus stereotactic radiotherapy for patients with vestibular schwannoma: a Leksell Gamma Knife Society 2000 debate. *J Neurosurg* 93(Suppl 3): 90-95
- [39] Liscak R, Vladyka V, Wowra B, Kemeny A, Forster D, Burzaco J, Martinez R, Eustacchio S, Pendl G, Régis J, Pellet W (1999) Gamma Knife radiosurgery of the glomus jugulare tumor – early multicentre experience. *Acta Neurochir (Wien)* 141: 1141-1146

- [40] Lunsford L (1999) Radiosurgery as a future part of neurosurgery. *Mayo Clin Proc* 74: 101-103
- [41] Manera L, Régis J, Chinot O, Porcheron D, Levrier O, Farnarier P, Peragut J (1996) Pineal region tumors: the role of stereotactic radiosurgery. *Stereotac Funct Neurosurg* 66: 1-10
- [42] Mdarhri D, Touzani A, Tamura M, Régis J (2004) Gamma Knife surgery for VII nerve schwannomas. *Neurochirurgie* 50: 407-413
- [43] Metellus P, Régis J, Muracciole X, Fuentes S, Dufour H, Nanni I, Chinot O, Martin PM, Grisoli F (2005) Evaluation of fractionated radiotherapy and Gamma Knife radiosurgery in cavernous sinus meningiomas: treatment strategy. *Neurosurgery* 57: 873-886; discussion 873-886
- [44] Mori Y, Kondziolka D, Flickinger J, Logan T, Lunsford L (1998) Stereotactic radiosurgery for brain metastasis from renal cell carcinoma [see comments]. *Cancer* 83: 344-353
- [45] Muracciole X, Cowen D, Régis J (2004) Radiosurgery and brain radio-induced carcinogenesis: update. *Neurochirurgie* 50: 414-420
- [46] Myrseth E, Moller P, Pedersen PH, Vassbotn FS, Wentzel-Larsen T, Lund-Johansen M (2005) Vestibular schwannomas: clinical results and quality of life after microsurgery or Gamma Knife radiosurgery. *Neurosurgery* 56: 927-935; discussion 927-935
- [47] Niranjan A, Lunsford L (2000) Radiosurgery: where we were, are, and may be in the third millennium. *Neurosurgery* 46: 531-543
- [48] Niranjan A, Lunsford L, Gobbel G, Kondziolka D, Maitz A, Flickinger J (2000) Brain tumor radiosurgery: current status and strategies to enhance the effect of radiosurgery. *Brain Tumor Pathol* 17: 89-96
- [49] Patchell RA, Tibbs PA, Regine WF, Dempsey RJ, Mohiuddin M, Kryscio RJ, Markesbery WR, Foon KA, Young B (1998) Postoperative radiotherapy in the treatment of single metastases to the brain: a randomized trial. *JAMA* 280: 1485-1489
- [50] Patchell RA, Tibbs PA, Walsh JW, Dempsey RJ, Maruyama Y, Kryscio RJ, Markesbery WR, Macdonald JS, Young B (1990) A randomized trial of surgery in the treatment of single metastases to the brain. *N Engl J Med* 322: 494-500
- [51] Patrice S, Sneed P, Flickinger J, Shrieve D, Pollock B, Alexander Er, Larson D, Kondziolka D, Gutin P, Wara W, McDermott M, Lunsford L, Loeffler J (1996) Radiosurgery for hemangioblastoma: results of a multiinstitutional experience. *Int J Radiat Oncol Biol Phys* 35: 493-499
- [52] Pollock B, Lunsford L, Kondziolka D, Flickinger J, Bissonette D, Kelsey S, Jannetta P (1995) Outcome analysis of acoustic neuroma management: a comparison

- of microsurgery and stereotactic radiosurgery published erratum appears in *Neurosurgery* 36(2): 427. *Neurosurgery* 36: 215-224; discussion 224-219
- [53] Régis J, Chinot O, Manera L, Porcheron D, Muracciole X, Juin P, Dufour H, Peragut J (1995) Pineal region tumors management: role of stereotactic radiosurgery? Presented at 7th International Leksell Gamma Knife Society Meeting, Hawaii, 12–15 November
- [54] Régis J, Delsanti C, Roche PH, Thomassin JM, Pellet W (2004) Functional outcomes of radiosurgical treatment of vestibular schwannomas: 1000 successive cases and review of the literature. *Neurochirurgie* 50: 301-311
- [55] Régis J, Hayashi M, Porcheron D, Delsanti C, Muracciole X, Peragut JC (2002) Impact of the model C and Automatic Positioning System on Gamma Knife radiosurgery: an evaluation in vestibular schwannomas. *J Neurosurg* 97: 588-591
- [56] Régis J, Levivier M, Wikler D, Porcheron D (2004) Dosimetric planning for radiosurgical treatment of vestibular schwannomas. *Neurochirurgie* 50: 289-300
- [57] Régis J, Pellet W, Delsanti C, Dufour H, Roche PH, Thomassin JM, Zanaret M, Peragut JC (2002) Functional outcome after Gamma Knife surgery or microsurgery for vestibular schwannomas. *J Neurosurg* 97: 1091-1100
- [58] Régis J, Roche PH, Delsanti C, Soumare O, Thomassin JM, Pellet W (2002) Stereotactic radiosurgery for vestibular schwannoma. In: Pollock BE (ed) *Contemporary stereotactic radiosurgery: the technique and evaluation*. Futura Publishing Company, Armonk, New York, pp 181-212
- [59] Reyns N, Hayashi M, Chinot O, Manera L, Peragut JC, Blond S, Régis J (2006) The role of Gamma Knife radiosurgery in the treatment of pineal parenchymal tumors. *Acta Neurochir (Wien)* 148: 5-11; discussion 11
- [60] Roche PH, Pellet W, Fuentes S, Thomassin JM, Régis J (2003) Gamma Knife radiosurgical management of petroclival meningiomas results and indications. *Acta Neurochir (Wien)* 145: 883-888; discussion 888
- [61] Roche PH, Régis J, Dufour H, Fournier HD, Delsanti C, Pellet W, Grisoli F, Peragut JC (2000) Gamma Knife radiosurgery in the management of cavernous sinus meningiomas. *J Neurosurg* 93: 68-73
- [62] Sawrie SM, Guthrie BL, Spencer SA, Nordal RA, Meredith RF, Markert JM, Cloud GA, Fiveash JB (2008) Predictors of distant brain recurrence for patients with newly diagnosed brain metastases treated with stereotactic radiosurgery alone. *Int J Radiat Oncol Biol Phys* 70: 181-186
- [63] Shaw E (1992) Role of radiation therapy in the management of low-grade gliomas. *Ann Neurol* 32: 835

- [64] Shaw E, Kline R, Gillin M, Souhami L, Hirschfeld A, Dinapoli R, Martin L (1993) Radiation Therapy Oncology Group: radiosurgery quality assurance guidelines. *Int J Radiat Oncol Biol Phys* 27: 1231-1239
- [65] Sheehan J, Kondziolka D, Flickinger J, Lunsford LD (2005) Gamma Knife surgery for glomus jugulare tumors: an intermediate report on efficacy and safety. *J Neurosurg* 102(Suppl): 241-246
- [66] Sheehan JP, Jagannathan J, Pouratian N, Steiner L (2006) Stereotactic radiosurgery for pituitary adenomas: a review of the literature and our experience. *Front Horm Res* 34: 185-205
- [67] Shrieve D, Alexander E, Wen P, Fine H, Kooy H, Black P, Loeffler J (1995) Comparison of stereotactic radiosurgery and brachytherapy in the treatment of recurrent glioblastoma multiforme. *Neurosurgery* 36: 275-282; discussion 282-274
- [68] Slotman B, Faivre-Finn C, Kramer G, Rankin E, Snee M, Hatton M, Postmus P, Collette L, Musat E, Senan S (2007) Prophylactic cranial irradiation in extensive small-cell lung cancer. *N Engl J Med* 357: 664-672
- [69] Sneed PK, Lamborn KR, Forstner JM, McDermott MW, Chang S, Park E, Gutin PH, Phillips TL, Wara WM, Larson DA (1999) Radiosurgery for brain metastases: is whole brain radiotherapy necessary? *Int J Radiat Oncol Biol Phys* 43: 549-558
- [70] Stalla GK, Stalla J, Loeffler JP, von Werder K, Muller OA (1987) Pharmacological modulation of CRH-stimulated ACTH secretion by ketoconazole. *Horm Metab Res Suppl* 16: 31-36
- [71] Yan E, Sneed P, McDermott M, Kunwar S, Wara W, Larson D (2003) Number of brain metastases is not an important prognostic factor for survival following radiosurgery for newly-diagnosed nonmelanoma brain metastases. *Int J Radiat Oncol Biol Phys* 57: S131-S132





**Jean Régis**

Jean Régis is neurosurgeon at Hôpital d'adulte de la Timone, Marseille, France.

Birth April 12th, 1963 Marseille – France.

Research position INSERM U721.

Professor of Stereotactic and Functional Neurosurgery (2003).

Associated Professor in Japan at the TWMU, 2003.

Scientific Committee Chairman of the ISRS 2005.

Medical Director Marseille Neurosurgical Radiosurgery Department, 2006.

Chairman First European Radiosurgery Course (ESSFN), Marseille 2007.

Secretary Treasurer of the ISRS 2007.

Vice President of the EANS September 2007.

**Contact:** Jean Régis, Neurochirurgien des Hôpitaux, Professeur des Universités, U751-INSERM, Service de NeuroChirurgie Fonctionnelle et Stereotaxique, Hôpital d'adulte de la Timone, 264 bvd Saint Pierre, 13385 Marseille Cedex 05, France  
E-mail: jregis@ap-hm.fr

# **INTRAOPERATIVE EXPLORATIONS**

---

# ULTRASOUND-GUIDED NEUROSURGERY

G. UNSGÅRD

## INTRODUCTION

Intraoperative sonography has been used in neurosurgery since the 1950s. The first ultrasound (US) modality introduced was A-mode, which did not produce anatomical images, but detected highly reflective surfaces along the direction of the ultrasound beam. A-mode ultrasound could be used to localize intracerebral mass lesions and to detect midline shift.

In the 1960s, two-dimensional B-mode ultrasound became available. The technology was refined in the years to come and in the early 80s several reports on the intraoperative use of real time B-mode ultrasound were published. The technique was helpful for localizing small subcortical neoplasms, as well as delineating deeply located solid and cystic lesions and also for finding the best approach to the tumor. Eventually, probes more adapted to the requirements of intraoperative ultrasound in neurosurgery became available. The probes became smaller, enabling imaging through small craniotomies, laminectomies, and even burrholes. A variety of guidance systems for stereotactic real-time ultrasound guided biopsies were also developed allowing quick and precise placement of needles and catheters.

In the late 80s the computer technology had developed to a stage that made it possible to use preoperative image data to tell the position of a tool in the brain. The concept of neuronavigation was born, and during the next decade a lot of effort was put into technical development and clinical evaluation of neuronavigation systems. Eventually, neuronavigation became a standard tool for planning and guidance of brain surgery. However, conventional neuronavigation systems based on preoperative data have some important shortcomings. There are always some inaccuracies when the images are registered to the skull. Further, it was discovered that craniotomies led to a displacement or shift of intracranial structures. The main causes for brain-shift are removal of CSF and tumor tissue during brain tumor surgery.

The accuracy of conventional neuronavigation is impaired by brain shift. The brain-shift is nonuniform, being largest at the cortical surface and smaller in deeper structures of the brain. Furthermore, the shift is larger close to a tumor resection than far away. Calculations of the brain-shift by mathematical models have proven difficult.

The main solution to the brain-shift problem is to update the images during the operation. There are mainly two ways to obtain new images during

---

*Keywords:* ultrasound, ultrasound-guided neurosurgery, imaging

the operation, *Intraoperative MRI* or *Intraoperative Ultrasound*. Intraoperative ultrasound is a flexible technology that allows near real-time 3D image acquisitions of high quality with little or no interference to the surgeon's workflow. In addition, the cost associated with intraoperative ultrasound is considerably lower than for intraoperative MRI.

## RATIONALE AND METHODS

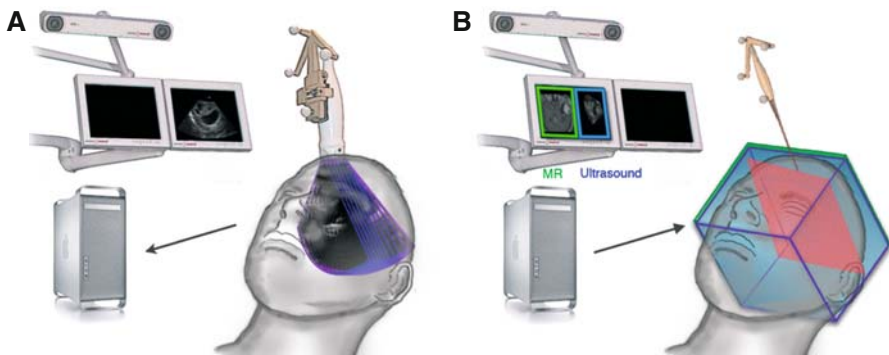
### 1. INTRAOPERATIVE 2D ULTRASOUND

The use of real time 2D US for different neurosurgical procedures may be cumbersome because the probe hampers the use of instruments. In order to see and guide the surgical instrument used in the ultrasound image, special attention must be taken for positioning the surgical instrument accurately in the real time 2D US scan plane. In addition, extra space is needed in the craniotomy for simultaneously placement of both the US probe and the instrument. Another problem with 2D US is the orientation. 2D US images have a different orientation compared to MR images and may cover only a small part of the area of interest.

Some articles have described the integration of real-time 2D US with navigation technology. This enables display of intra-operative 2D US with corresponding images of preoperative MRI, solving part of the orientation and brain-shift problem.

### 2. INTRAOPERATIVE 3D ULTRASOUND

The further development into 3D ultrasound systems is the optimal way of using intraoperative US [2]. By integrating neuronavigation and 2D ultrasound



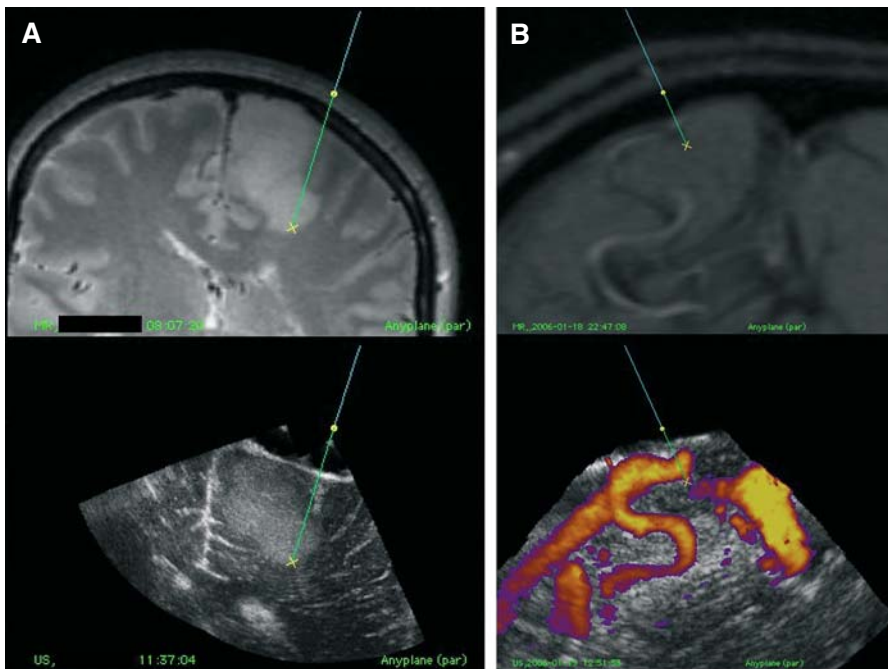
**Fig. 1.** **A** The probe is moved over the region of interest, while each of the 100–200 images is tagged with position data from the optical tracking camera and reconstructed into a regular 3D volume. **B** The pointer steers the display of the 3D volume

it is possible to create 3D US volumes and to navigate directly based on 3D US data. We have used a system (SonoWand®) where the 3D US volume is reconstructed from 100–200 2D images, created by making a move or tilt over the area of interest with a pre-calibrated and tracked US probe [1]. The optical tracking system reads the position of the patient reference frame and the US probe. It typically takes about 30 seconds to create a new 3D US volume (Fig. 1).

Intraoperative 3D US can be used alone for navigation, but it is often useful to register 3D MR volumes to the patient's head before start of the operation as in conventional navigation systems. This will make it easier to plan the approach and craniotomy, facilitate ultrasound image orientation, and help the less experienced US user to interpret the US images (Fig. 2A).

In addition to tissue images it is also possible to make images of vessels (US angiography) based on recordings of the power Doppler signals from the blood stream. In the intra-operative imaging system that we use, the vessels are presented as red overlay in the tissue images (Fig. 2B).

3D US volumes can be acquired many times during the operation, and the instruments can always be guided in an updated US image map. Furthermore, the probe is not in the operation field during the operation, except when new 3D US image acquisitions are done.



**Fig. 2.** **A** Corresponding cross sections of 3D MR (*upper row*) and 3D US (*lower row*) of a low grade astrocytoma. **B** Corresponding cross sections of 3D MRA and 3D US angiography (power Doppler) of an AVM showing a feeding vessel

### 3. NAVIGATION INACCURACY

The overall clinical inaccuracy is the difference between the position of an object in the true physical space and the position of the object as displayed in the image space. When using preoperative images (MR or CT) the overall clinical inaccuracy consists of both *registration inaccuracy*, describing the inaccuracy of the registration of the images to the head, *technical inaccuracy*, indicating the inaccuracy in the navigation system itself, and the inaccuracy due to *brain-shift*. The registration inaccuracy can be considerable (often more than 5 mm). For 3D US, the registration inaccuracy is eliminated because both US acquisition and navigation based on 3D ultrasound is done in the same reference system. The inaccuracy due to brain-shift can be abolished by repeated acquisitions of 3D US during the operation. The overall inaccuracy of the US based navigation system SonoWand® is  $1.40 \pm 0.45$  mm [4].

### 4. DISPLAY OF THE IMAGES

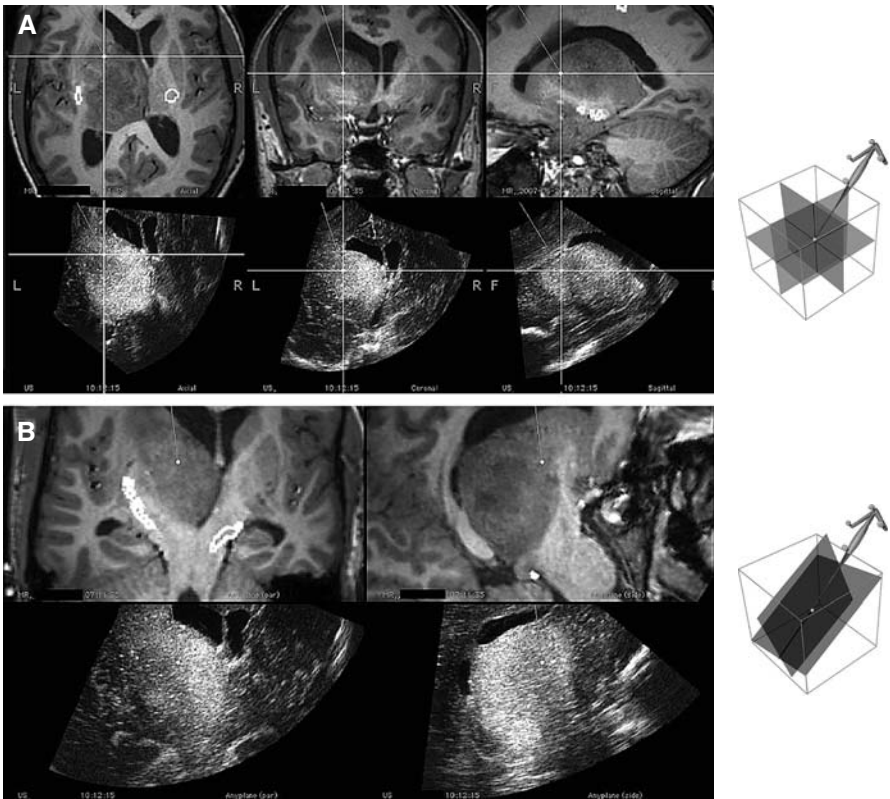
The display modalities offered by the ultrasound-based navigation system are *orthogonal slicing* (similar to conventional navigation systems, see Fig. 3A), *anyplane* (oblique slices defined by the direction and rotation of the pointer) *as well dual anyplane slicing* (anyplane + plane perpendicular to the anyplane, see Fig. 3B) and stereoscopic projections. This stereoscopic display has been used for visualizing vessels.

The slicing and display of the volumes on the monitor is steered by a pointer or another calibrated instrument like the CUSA, the biopsy forceps, an endoscope or a microscope.

### 5. IMAGE QUALITY

Image quality is of crucial importance in intraoperative imaging. The US image quality is related to the spatial resolution (the ability to resolve targets), which in the 2D US scan plane is mainly determined by the frequency of the probe used. Higher frequency means better resolution. The drawback is attenuation and thus loss of penetration in the tissue with higher frequency. Further, the size of the probe footprint, i.e. the aperture with number of probe elements is an important factor for image resolution. Generally, a larger probe footprint means higher resolution.

One of the reasons why US image quality has improved dramatically in recent years is that the probes can be electronically tuned for a range of frequencies. In this way optimal resolutions can be obtained simultaneously at multiple depths, resulting in high image quality at a broad range of depths. Most of the images shown in this chapter we have obtained by a 5 MHz (4–8 MHz) phased array probe. This probe gives optimal image quality at a



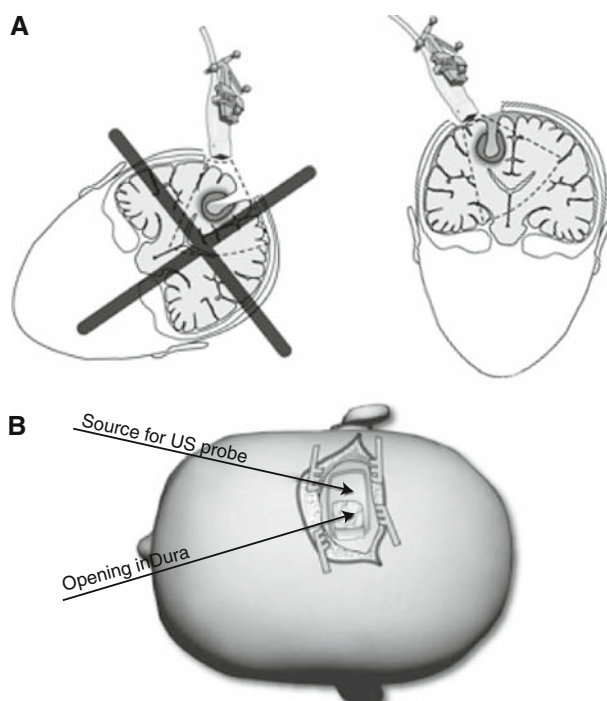
**Fig. 3.** Display modes. **A** Orthogonal display – axial, coronal and sagittal plane. **B** Dual anyplane – a plane defined by the direction and rotation of the pointer (anyplane) + a plane perpendicular to the anyplane. The tumor shown in all modes is a low grade glioma in thalamus with outline of inserted pyramidal tract as white lines. MR – upper row, US – lower row

distance of 2.5–6 cm from the probe. It is sometimes useful to apply a gelatine stand off on the brain. A plate of gelatine, about 1 cm thick, is formed and placed on the brain over the area of interest. Since gelatine does not give any echo at all, it only lifts the probe away from the lesion, optimizing the distance between a superficial lesion and the probe.

The images generated by a phased array probe spread out like a fan. It will cover a wide area at a distance from the probe, but close to the probe it has a small sector. Such a probe is suitable for deep-seated lesions. A drawback with phased array technology is the inability to display tissue adjacent to the probe, i.e. superficial to the probe's focal point. For lesions close to the surface a flat linear array probe will be more suitable. It covers only a rectangular area under the probe, but image quality can be extremely good depending on the aperture and frequency of the probe.

## 6. CLINICAL ARRANGEMENTS FOR OPTIMIZING IMAGE QUALITY

Less experienced users of US imaging technology have sometimes been unable to achieve good image quality throughout the operation because they have not paid enough attention to the nature of US penetration in tissue. Air located between the probe and the dura or in the operation channel will give acoustic shadows and bad image quality. Sterile gel may be put between the probe and the dura to give good beam penetration. If the images are acquired over bare brain, water will provide sufficient acoustical contact. Calcifications in the dura may also produce acoustic shadows and reduced image quality, which may be overcome by simply acquiring new US images after the dura is opened. Some probes may be sterilized, but still most probes need to be wrapped in sterile drapes before use. When packing the probe before the operation it is important to put gel on the probe head in the sterile plastic drape to remove air and thus obtaining optimal conditions for beam propagation.



**Fig. 4.** **A** The patient should be positioned to obtain a vertical access to the lesion. In that way it is possible to fill the operation cavity with water for renewed 3D US acquisition. **B** In deep-seated lesions a linear incision of the skin and an ellipsoid craniotomy is beneficial. Image at an angle to the operation access may be useful to reduce artefacts from the operation channel



To be able to record new US volumes with good image quality throughout the operation, the positioning of the patient is important [8]. The patient should be positioned so that the preferred operation channel becomes vertical (Fig. 4A). Thus air bubbles will rise to the surface when the operation cavity is filled with saline for 3D US acquisition, which is important in order to avoid air artefacts. Such a positioning is always possible (own experience). The only obvious exception is operations in sitting position. After registration of the 3D MR volume to the head of the patient, it is sometimes necessary to adjust the position of the head to obtain a vertical access to the lesion. This can be done without a new registration because the reference frame is fixed to the three-point head frame.

Even though only a small craniotomy is needed for 3D US guided surgery on deep-seated lesions, it is often useful to make an ellipsoidal craniotomy (Fig. 4B), to be able to acquire images at an angle to the surgical channel. This seems to reduce the artefacts from the operation channel.

A vertical access will also reduce the retraction on the normal tissue because the retractors do not have to work against gravity. Retractors in the surgical cavity should generally be removed before image acquisition to reduce artefacts and shadows. The image quality during the operation is also dependent on having a clean resection cavity. Blood clots, cottonoids etc. must be removed, and the cavity should be flushed with saline to remove air bubbles and tissue particles before 3D US acquisition.

## **SURGERY**

### **1. HOW TO USE 3D US IN DAILY NEUROSURGERY**

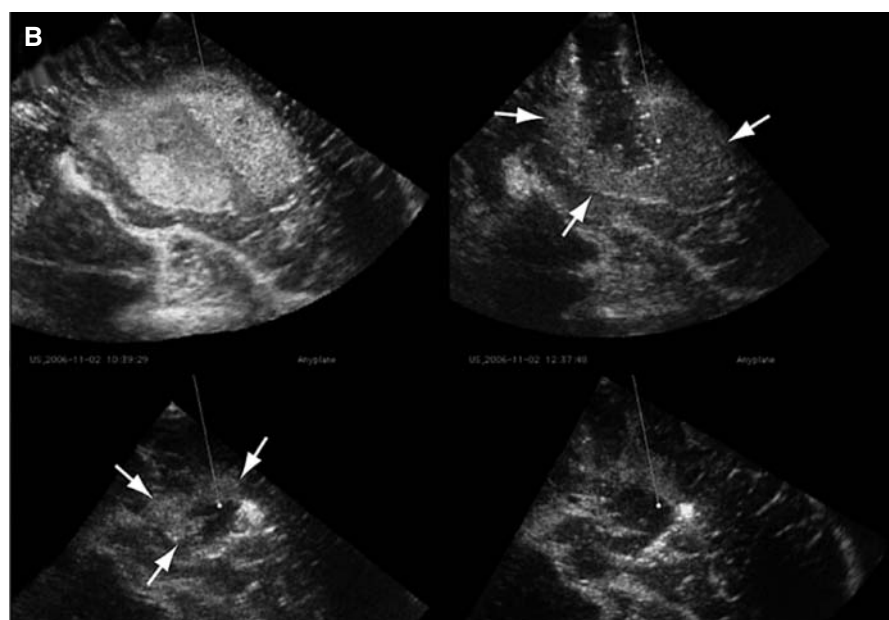
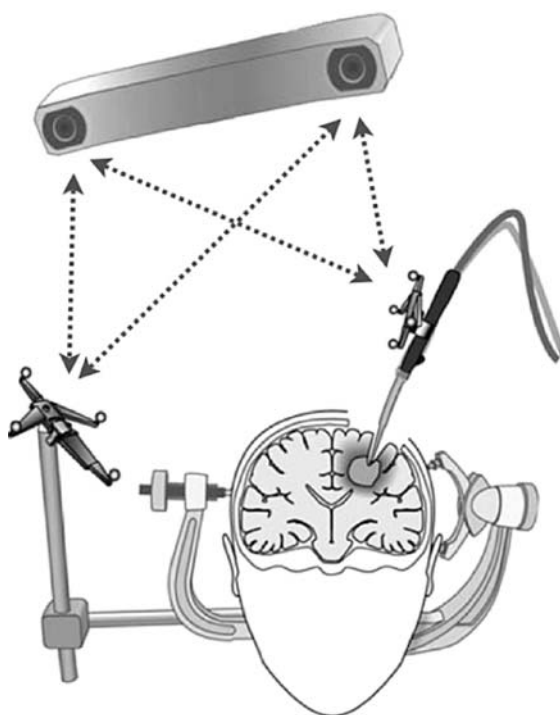
Intraoperative navigated 3D US has been used for a wide variety of applications. The extent of use may be different in different neurosurgical departments. At my department we use it for all intra axial brain tumors, for biopsies and for all cavernomas and AVMs. We also use it for most skull base cases, and sometimes to guide endoscopes as well as insertion of ventricle catheters [11].

#### **1.1 3D ultrasound guided tumor resection**

3D MR is useful for the planning of the operation, but according to our experience all operative decisions after the craniotomy should be based on the 3D US volume as it gives a more accurate picture of the intraoperative situation.

The information in the 3D US volume can be explored in a conventional way by using a pointer. The drawback is that the operation has to be stopped while pointing in the resection cavity. A more elegant and dynamic approach is to attach an optical tracking frame to the resection instrument (CUSA). In

A



that way it is possible to continuously follow the position of the resection instrument during the operation (Fig. 5A). While the conventional axial, sagittal and coronal display is frequently used for planning, our experience is that slicing controlled by the position and orientation of the operation instrument (anyplane) is more useful when guiding the resection. A plane perpendicular to this plane (dual anyplane) gives additional value especially when working close to tumor borders where one plane could be tangential to the tumor (Fig. 3B). Furthermore, the monitor has to be located so that the surgeon only needs to glance to the side of the microscope in order to see the navigation display.

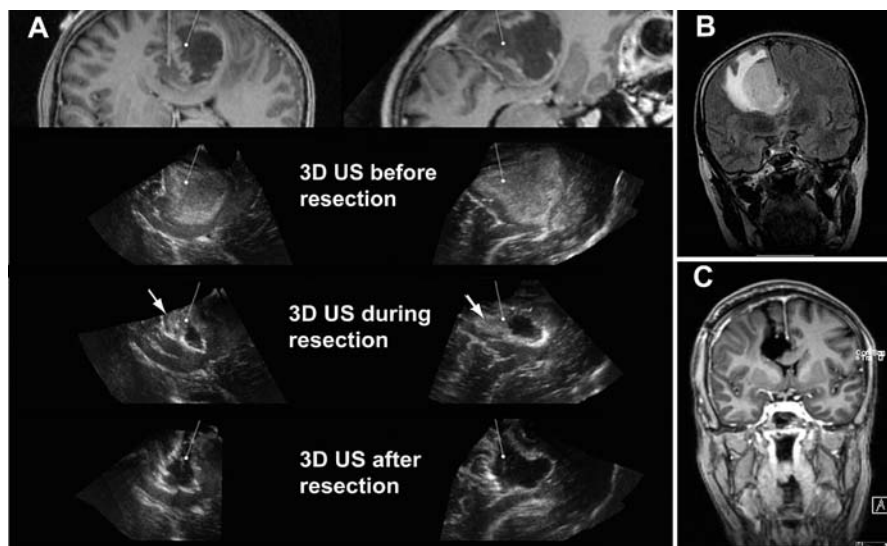
Many conventional navigation systems have an interface to the microscope instead of the tracked instrument interface. Both interfaces are useful and a microscope interface will also be available for the 3D US system that we are using. However, we think that the interface with continuous tracking of the operation instrument is far more dynamic than the microscope interface. With the microscope interface it is necessary to manually outline the tumor border. When using a calibrated operation instrument, a guided resection can be done immediately after the US acquisition. In deep-seated parenchyma tumors the resection can be done through a very small opening with visual information from the microscope and position information from the navigated 3D US volume. This will reduce the injury to normal tissue. The online information about the distance from the tip of the resection instrument to the tumor borders, or to important vessels, may speed up the resection and make the surgeon feel more confident in different phases of the operation.

## 1.2 Resection control

There is growing evidence for a beneficial effect of complete removal of gliomas on recurrent growth and patient survival. To obtain a total resection it is necessary to acquire images towards the end of the operation. Typically 3 to 5 new image volumes are acquired during an operation (Fig. 5B). Resection control is dependent on good image quality. To obtain good image quality during the resection, spatula and cottonoids should be removed, and there should be no blood in the operation cavity. The preoperative positioning of the patient is also important. The operation channel should be vertical. In that way it is possible to fill the cavity with water and the air



**Fig. 5. A** With tracking of the ultrasound aspirator, the position of the tip of the instrument can be continuously monitored in the 3D US volumes (dot at the end of the line). **B** Corresponding anyplane views of four ultrasound volumes of a patient with low grade glioma acquired at different phases in the operation (order of progression: upper left, upper right, lower left and lower right). The arrows indicate residual tumor. Notice the considerable shift of normal tissue towards the end of the operation. The position of the CUSA tip is close to the normal tissue in the forth US volume, while the same position is deep in the tumor in the second US volume



**Fig. 6.** **A** Snapshot from the navigation monitor showing a dual anyplane display of different phases of the operation of a glioblastoma. In the row of images named “during the resection”, no more tumor tissue could be detected by the microscope. The residual tumor tissue identified by the 3D US (white arrow) was readily localized and removed by the tracked CUSA. **B** MR before resection. **C** 1 day after the tumor resection. No additional morbidity was observed

bubbles in the cavity will surface. Even though the operation access turned out to be oblique, it is often possible to adjust the table to obtain vertical operation channel during image acquisition, and turn it back during operation. The preparation of the resection cavity for a new ultrasound acquisition may take a few minutes; depending on how clean the cavity is during the operation. The process of acquiring and processing new images takes less than one minute. Thus, several ultrasound acquisitions will not alter the workflow of the operation to any significant degree.

There might be a slight decline in US image quality during the operation. However, our experience is that residual tumor tissue missed during microsurgery can be detected and removed with 3D US [9] (Fig. 6).

## 2. APPLICATIONS

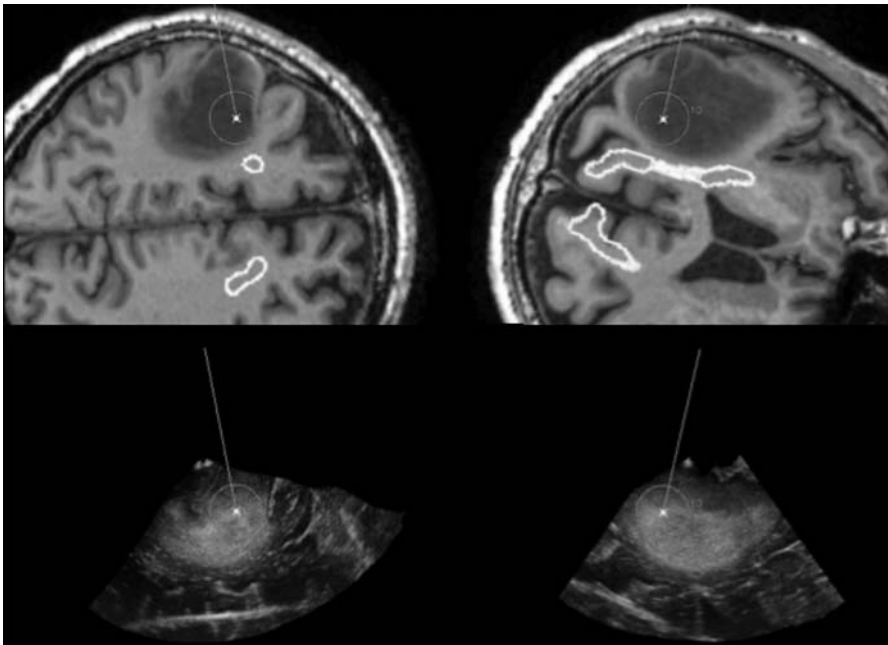
### 2.1 Low grade gliomas

US is an excellent imaging modality to depict low grade gliomas (Figs. 3 and 5). There is no oedema in low grade gliomas, so the lesion seen in the images is tumor tissue. A study where biopsies were collected inside and outside the

imaged tumor border with a navigated biopsy forceps revealed that US is just as precise as MR T2 in delineating the tumor border [12]. A few biopsies sampled between 2 and 7 mm outside the imaged border contained tumor cells (false negative), but no biopsies collected from 2 to 7 mm inside the imaged tumor border was normal (no false positive). Accordingly, navigated US depicts the borders of low grade gliomas in a very safe way.

**Resection of low grade gliomas in non-eloquent area.** A safe and efficient method for operating these tumors is to do 3D US guided resection in layers perpendicular to the access channel. In that way it is possible to do resection at the edge of the tumor with a minimum of brain shift. Towards the end of the operation new 3D US images are acquired and residual tumor tissue is resected until gross total resection is obtained.

**Resection of low grade gliomas in eloquent areas.** In addition to preoperative MR data (e.g. T1, T2, FLAIR, MRA) it is possible to import 3D func-



**Fig. 7.** Snapshot from the navigation monitor (low grade glioma). Dual anyplane display of 3D MRI (*upper row*) and 3D US (*lower row*). The pyramidal tractography is inserted in the 3D MRI volume, and the outline of the tract is displayed as a white line. The pointer shows a considerable shift between MRI and US. The tract is outside the tumor, as shown in MRI. The position of the tumor borders can be trusted on 3D US, even though it may look as if the 3D US borders of the tumor are inside the tract on MRI

tional MRI and 3D tractography into the intraoperative 3D US imaging system [5]. However, the location of the eloquent cortex and the tracts in the 3D MRI cannot be trusted due to brain-shift and registration inaccuracy. After acquiring 3D US images we will immediately see the shift by pointing with the virtual pointer at the border of the tumor or some other landmarks. Even though it takes some spatial thinking it is always possible to find out where the eloquent cortex or tracts are located compared to the tumor depicted in the 3D US image (Fig. 7). Several research groups are working on automatic methods for updating preoperative MR images using intraoperative 3D US. In most cases eloquent areas can be handled only with accurate 3D US, because both eloquent cortex and tracts with normal function seem to be located outside the depicted tumor. It is, however, important to be extremely conscious when operating close to eloquent areas.

**Very small low grade gliomas.** In some parts of the world a MRI investigation is done even on minor symptoms and always as part of work up after an epileptic seizure. Sometimes a very small lesion is discovered. Some years ago a lesion like that would not be operated, because it would be nearly impossible to find the lesion during the operation. With 3D US it is easy to locate and operate such a lesion. Whether removal of such tumors with good margin will eliminate recurrence and permanently cure the patients remains to be seen, but there are good reasons for expecting that.

## 2.2 High grade gliomas

Anaplastic gliomas and glioblastomas are easily depicted with US. Sometimes there is a considerable oedema around a high grade tumor. In most cases the tumor tissue can be differentiated easily using navigated ultrasound images. In a biopsy study where we compared image interpretation with navigated biopsies [12] we found very few biopsies in a 2–7 mm range inside the depicted tumor border that were normal tissue.

High grade gliomas both in eloquent and non-eloquent area can be operated in the same way as low grade gliomas.

With 3D US and image guided surgery it is possible to obtain gross total resection also in deep-seated lesions with a low risk of additional morbidity (Fig. 6).

## 2.3 Skull base tumors

Even in skull base tumors the MR volume may have a shift, mainly due to inaccurate registration of the 3D MR volume to the patient. 3D US support may therefore be useful also in skull base cases. In large skull base meningiomas or very large acoustic neurinomas 3D US guided resection can be used to do a safe and rapid subcapsular resection without having to do any dissection of the capsule. It is much easier to peel the capsule off the normal brain

or brain stem when most of the tumor is removed for two reasons: first, a lot of space in the operation field makes it easier to dissect and second, a thin, flexible capsule comes off more easily than a stiff capsule with some tumor tissue.

When important vessels are found inside the tumor, it is useful to have updated information of US angiography [7]. The display of the US angiography will show the distance between the instrument tip and the vessels. During resection there might be a shift of these vessels. Therefore it is important to acquire new 3D US volumes to have reliable images.

For large and difficult skull base tumors it may be useful to have an updated map of the progression of the tumor removal. It is not unusual to overestimate the amount of the tumor removed during different phases of the operation. A real time update can be useful, especially for the less experienced skull base surgeons.

#### 2.4 Free hand biopsy

Neuronavigation systems based on preoperative 3D MR images have been used for biopsies in many neurosurgical departments. The patient registration procedure and the brain shift caused by the positioning of the head and loss of CSF will introduce navigational inaccuracies. With intra-operative 3D US all these error sources are eliminated because the 3D US volume is created immediately before the collection of the biopsy. The images can be made with the 5 MHz phased array probe through a burr hole with diameter of 14 mm. The biopsies are collected with a navigated biopsy forceps.

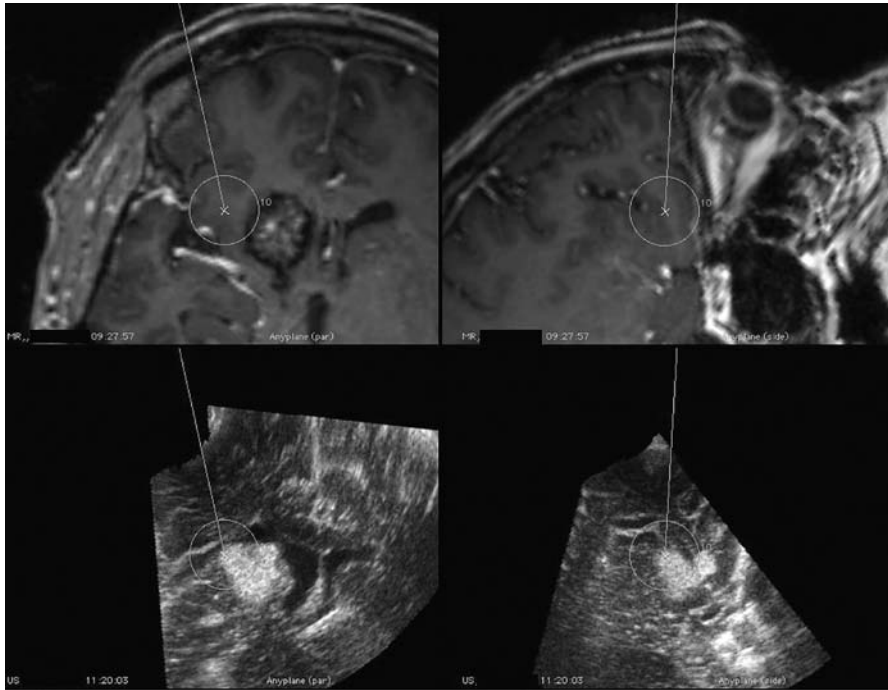
In vascular regions it can be useful to make 3D US angiography to avoid injuring vessels with the biopsy forceps. 3D US also make it possible to control the biopsy site by acquiring a 3D US volume after the biopsy sampling.

A disadvantage with the present equipment is that the reference frame must be attached to a head holder (Mayfield), and the patient therefore has to be in narcosis. With some small modifications of the equipment it should be possible to do 3D US biopsies also in local anaesthesia.

The success rate of 3D US guided biopsies compared to the approach based on a stereotactic frame and MR data has not been tested. In our experience we always get a valid biopsy with the 3D US system. That is not always so when we use the stereotactic frame system.

#### 2.5 Cavernous haemangiomas

3D US is useful for operation of deep-seated cavernous hemangiomas. Our experience is that cavernous haemangiomas both in brain parenchyma (Fig. 8) and in the brainstem are seen very well with 3D US. Especially in the brainstem we have experienced that the MR images often have a shift. This shift makes it dangerous to use only 3D MR to find a cavernous haemangioma in the brainstem that is not visible on the surface. However, the clinical accuracy



**Fig. 8.** A snapshot from the navigation monitor showing a cavernoma located in the right nucleus caudatus (MR – upper row, US – lower row). The pointer tip is located at the edge of the cavernoma. Notice a considerable inaccuracy in the 3D MRI

of navigation based on intraoperative 3D ultrasound will remain below 2 mm as acquisition and navigation is performed in the same coordinate system.

## 2.6 Endoscopy guidance

In endoscopic operations of complex pathological structures like multiple cysts, it is difficult to know the exact position of the endoscope. It may be helpful to calibrate the endoscope to conventional navigation systems based on preoperative CT and MRI. However, navigation of the endoscope based on intra-operative 3D US seems to be preferable for two reasons [6]. First, with 3D US an extra CT or MRI investigation can be avoided. This is especially desirable in paediatric neurosurgery. The other reason is that anatomy may change during the operation due to leakage of CSF from ventricles or fluid from cysts. 3D US offers a possibility to update the map during the operation. The only disadvantage is that a minicraniotomy is necessary for the probe instead of a burr hole. This can be done through a small incision, so the cosmetic result is very good, in fact often better than after a conventional burr



hole. For newborns the images can be acquired through the fontanel. It is also useful for the planning of the trajectory to display the US angiography.

## 2.7 Evacuation of haematomas

There are arguments for a beneficial effect of early and minimal invasive evacuation of spontaneous intracerebral haematomas, but there is no first grade evidence. Thus, the way of handling these lesions are very different in the various clinics. For those who want to do a rapid and minimal invasive evacuation, we have described a method using two minicraniotomies, one for the probe and one for the evacuation [8]. The evacuation through a small tube in the normal tissue either by suction or by ultrasound aspirator can occur very rapidly. A real time 2D surveillance picture is crucial to know the exact positioning of the tip of the suction or the CUSA, and to observe the rapid narrowing of the hematoma cavity during the evacuation. However, this is a technically challenging method. An easier method is to acquire 3D US through one minicraniotomy, and evacuate with guided CUSA. The haematoma is gradually removed by careful evacuation and repeated 3D US acquisitions.

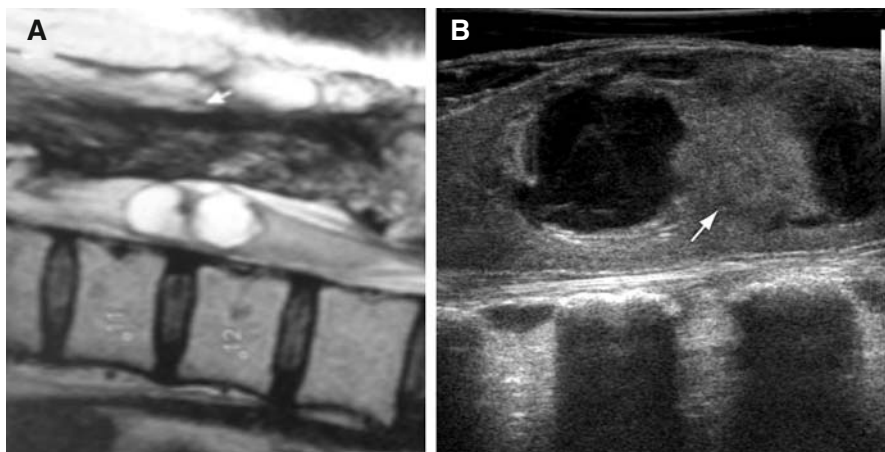
## 2.8 Vascular operations

3D volumes reconstructed from power Doppler data may be displayed either in red colour overlaying the tissue images, or it can be used to construct stereoscopic images of the vessels. In tumor operations where the objective of the angiography is to avoid harming vessels with the operation instruments, slicing the volume in different ways are usually sufficient, as already mentioned. Though this display technique is useful also for vascular operations, the vessels are usually showed in a more optimal way using 3D rendering techniques and stereoscopy.

**Aneurysm surgery.** In *aneurysm surgery* 2D US have been used to localize the aneurysm. We have found it helpful to use the anyplane display of 3D US to localize peripheral aneurysms.

The US angiography has so far not been very useful in evaluating the clipping of aneurysms because the power Doppler signal is too intense and smeared out (the blooming effect) to give a sharp delineation of the small vessels around the aneurysms.

**AVM.** 3D rendering techniques as well as stereoscopic visualization of the vessels may be helpful to understand the tortuous architecture of the feeding vessels of AVMs. Our experience is that the navigated stereoscopic display of 3D MR angiography can be used successfully to identify and clip the larger feeders of AVMs at the initial phase of the operation, thus making it easier to perform the extirpation of the nidus [10]. The stereoscopic display of US angiography is



**Fig. 9.** MRI (A) and US (B) of a medulla tumor with cysts

not of the same quality as the MR angiography. However, the US angiography adds value to the operation by making it possible to correct for the registration error as well as brain shift and to enable intra-operative resection control.

### 2.9 Intra-spinal pathology

One problem with 2D US in spinal surgery is that the probe obstructs the operation access and has to be removed before the image information can be used. Navigation in updated 3D US images eliminates that problem [3]. The linear array probes are well suited for medulla imaging and seem to give excellent image quality (Fig. 9). 3D US is useful for planning the surgical approach to intradural tumors through minimal dural openings. 3D US is also useful to ensure minimal invasiveness and preservation of normal tissue when collecting biopsies from or resecting deeper intramedullary tumors not visible on the surface of the spinal cord. When resecting tumor masses that may involve important vessels such as the vertebral arteries, 3D US angiography is helpful. In syrinx surgery 3D US has also been found valuable and time saving.

3D US used for intra-spinal pathology has the great advantage that no preoperative registration procedure is required. However, the potential benefits associated with this technology have still not been tested out in larger clinical series of medulla pathology.

## HOW TO AVOID COMPLICATIONS

No complications related to the use of 3D US have been described or observed.

*The Learning Curve:* Experienced neurosurgeons sometimes express that if you know the anatomy very well there is a limited need for intraoperative imaging. Indeed, decades of surgical experience may sometimes compensate for the lack of access to intraoperative navigation. However, experience requires practice, and most surgeons are exposed to a limited number of challenging neurosurgical cases. 3D US, especially in combination with 3D MRI based neuronavigation may help the less experienced surgeon to achieve great results with minimal risk. The ability to constantly navigate and confirm the position of the instruments in relation to anatomical structures will most likely make the surgical learning curve faster and safer for younger neurosurgeons. Even the most experienced neurosurgeon will benefit from using intraoperative 3D US in order to obtain resection control and to cope with complex anatomical settings. The only requirement is that the surgeon is willing to learn how to use 3D US. Our experience is that surgeons that start to use intraoperative 3D US learn very fast both to acquire and interpret images, and the 3D US system readily becomes part of their every day equipment.

## CONCLUSIONS

3D US is a very easy and flexible way to get intraoperative image data. It is also a much less expensive solution than intraoperative MR. A disadvantage with 3D US is that the acquired volume only covers the region of interest and do not provide a complete overview to the anatomy. This drawback is easily managed by either displaying corresponding preoperative MR/CT and US cross sections, or fusing the US volume into a CT or MR volume. Thus, the overview of the MR/CT is combined with the 3D US's accuracy and ability for intraoperative updates. Another problem is that many neurosurgeons are unfamiliar with US. Our experience is that surgeons in departments that have made 3D US part of their operative armamentarium learn very fast.

The main advantages with ultrasound-based neuronavigation are:

- 3D US depicts most brain tumors with very good image quality.
- Operation with image guided operation instruments enables the surgeon to work *safer*, some times *faster* and always with *more confidence*.
- 3D US is useful for resection control.
- An intraoperative 3D US navigation system with the combination of navigated MR and US enables resection of very small low grade tumors.
- US visible intra axial tumors in eloquent areas can be removed without permanent neurological deficit.
- In skull base surgery the system provides information about the location of important vessels, about tumor borders as well as information about the progression of the surgery that is useful, especially to less experienced surgeons.

- 3D US is very useful for localization and resection control of cavernomas.
- Guidance of endoscope with 3D ultrasound is useful, especially in pediatric neurosurgery. 3D US provides an updated overview of the volume of interest while the endoscope shows the surface details.
- The use of 3D angiography in vascular surgery is promising, but some more technological development is desirable.

These advantages make neuronavigation based on 3D ultrasound an excellent tool for everyday clinical use.

## References

- [1] Gronningsaeter A, Kleven A, Ommedal S, Aarseth TE, Lie T, Lindseth F, Langø T, Unsgård G (2000) SonoWand, an ultrasound-based neuronavigation system. *Neurosurgery* 47(6): 1373-1380
- [2] Jodicke A, et al. (1998) Intraoperative three-dimensional ultrasonography: an approach to register brain shift using multidimensional image processing. *Minim Invasive Neurosurg* 41(1): 13-19
- [3] Kolstad F, Rygh OM, Selbekk T, Unsgård G, Nygårds OP (2006) Three-dimensional ultrasonography navigation in spinal cord tumor surgery. Technical note. *J Neurosurg Spine* 5(3): 264-270
- [4] Lindseth F, et al. (2002) Accuracy evaluation of a 3D ultrasound-based neuronavigation system. *Comput Aided Surg* 7(4): 197-222
- [5] Rasmussen IA, Lindseth F, Rygh OM, Berntsen EM, Selbekk T, Xu J, Hernes TAN, Harg E, Håberg A, Unsgård G (2006) Functional neuronavigation combined with intra-operative 3D ultrasound: initial experiences during surgical resections close to eloquent brain areas and future directions in automatic brain shift compensation of preoperative data. *Acta Neurochir* 149: 365-378
- [6] Rygh OM, Cappelen J, Selbekk T, Lindseth F, Hernes TANH, Unsgård G (2006) Endoscopy guided by an intraoperative 3D ultrasound based neuronavigation system. *Minim Invasive Neurosurg* 49(1): 1-9
- [7] Rygh OM, Selbekk T, Lindseth F, Müller TB, Hernes TAN, Unsgård G (2006) Intraoperative navigated 3D ultrasound angiography in surgery. *Surg Neurol* 66: 581-592
- [8] Unsgård G, et al. (2002) Brain operations guided by real-time two-dimensional ultrasound: new possibilities as a result of improved image quality. *Neurosurgery* 51(2): 402-411; discussion 411-412

- [9] Unsgård G, et al. (2002) Neuronavigation by intraoperative three-dimensional ultrasound: initial experience during brain tumor resection. *Neurosurgery* 50(4): 804-812; discussion 812
- [10] Unsgård G, et al. (2005) Operation of arteriovenous malformations assisted by stereoscopic navigation-controlled display of preoperative magnetic resonance angiography and intraoperative ultrasound angiography. *Neurosurgery* 56(2 Suppl): 281-290
- [11] Unsgård G, Rygh OM, Selbekk T, Müller TB, Kolstad F, Lindseth F, Hernes TAN (2006) Intra-operative 3D ultrasound in neurosurgery. *Acta Neurochir* 148(3): 235-253
- [12] Unsgård G, Selbekk T, Müller TB, Ommedal S, Torp HS, Myhr G, Bang J, Nagelhus Hernes TA (2005) Ability of navigated 3D ultrasound to delineate gliomas and metastases – comparison of image interpretations with histopathology. *Acta Neurochir* 147(12): 1259-1269



**Geirmund Unsgård**

Geirmund Unsgård is head of the Neurosurgical Department at St. Olav University Hospital, Trondheim. M.D. (1974), Ph.D. (1979). Professor in Neurosurgery, NTNU (1989). Head of neuro-division (Neurosurgery and Neurology) St. Olav University Hospital (since 2003). Dean of Medical Faculty, NTNU (1993–1998). Entrusted different positions in National, Sandinavian and European Neurosurgical organizations. Entrusted different professional advisory positions by the National Government. Published 130 papers in peer review journals covering both cell biology and medical technology. Research profile: early-cell immunology and tumor immunology, later-MR technology, last 10 years- 3D ultrasound in neurosurgery.

**Contact:** Geirmund Unsgård, Department of Neurosurgery, St. Olav University Hospital, The Norwegian University of Science and Technology (NTNU), Olav Kyrres gate 17, 7005 Trondheim, Norway  
E-mail: [geirmund.unsgard@ntnu.no](mailto:geirmund.unsgard@ntnu.no)

---

# BRAIN NEURONAVIGATION FOR DEEP-SEATED TARGETS

T. HORI

## INTRODUCTION

Recent advances in computer technology have allowed the development and widespread use of intraoperative navigation systems for neurosurgical procedures. Many intraoperative navigation systems have been introduced in the field of neurosurgery [1, 3–6, 10]. In this chapter, augmented reality microscope and/or endoscope navigation system for transnasal transsphenoidal surgery and epilepsy surgery, and the use of semi-real time updated navigation system using intraoperative MRI (iMRI) for resection of glioma will be presented.

Especially for glioma removal, the contribution of intelligent operation room with permanent magnet (0.3 Tesla) MRI system and newly developed devices including coils and mapping apparatus for the improved resection rate and increase of survival rate in malignant gliomas will be presented.

## RATIONALE

With this system, surgical interventions can be performed more safely and accurately, the majority of reported systems indicate only the 3-D location of the surgical site. Most of the previously developed navigation systems provided information only on the location of ongoing surgery in 3-D MRI planes or overlaid simple virtual images of objects, including tumors, on microscopic real images in two-dimensional planes. We consider these not to be true 3-D image-guided navigation systems, although they use AR technology.

The modern available navigation system in our institute is AR navigation, and “realtime” (semireal) intraoperative MRI (iMRI) updated navigation. The limiting factor of using iMRI is the position of the patient. Under iMRI, the usable positioning is either supine or prone position; because the space available for taking MRI is only 43 cm, some complex patient’s position such as “Concorde Position” cannot be adopted. In such complex position AR navigation system is useful. In this chapter, AR navigation system for the endoscopic transnasal transsphenoidal removal of pituitary adenoma, and for subtemporal selective amygdalohippocampectomy to medically intractable temporal lobe epilepsy, and realtime iMRI updated navigation for corpus cal-

---

*Keywords:* brain, neuronavigation, deep-seated lesions, imaging

losotomy for intractable drop attack caused by Lennox-Gastaut syndrome, and finally realtime iMRI updated navigation for glioma resection, will be successively illustrated. The indication of iMRI for various intracranial lesions, resection rates, and complications are demonstrated.

## DECISION-MAKING, INDICATIONS AND SURGERY

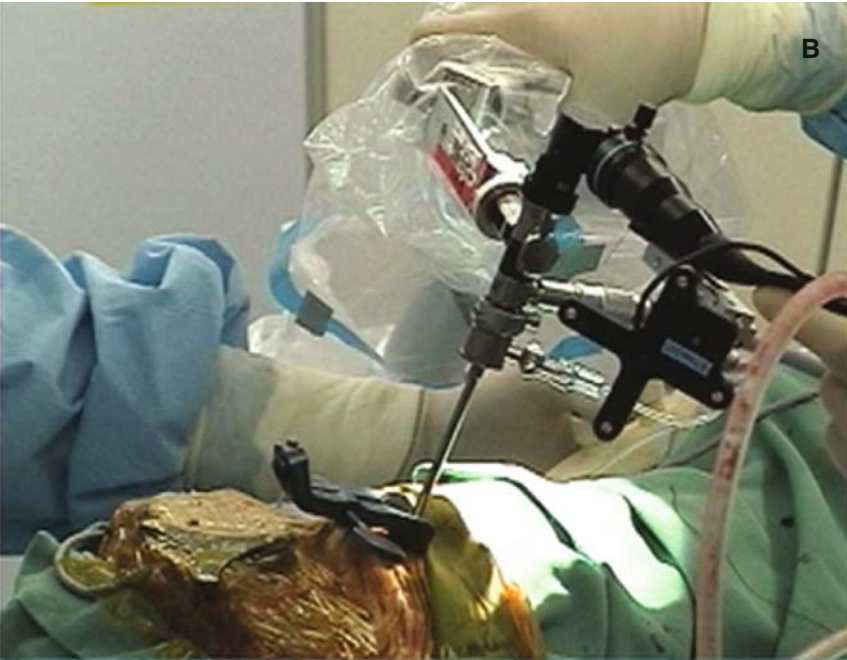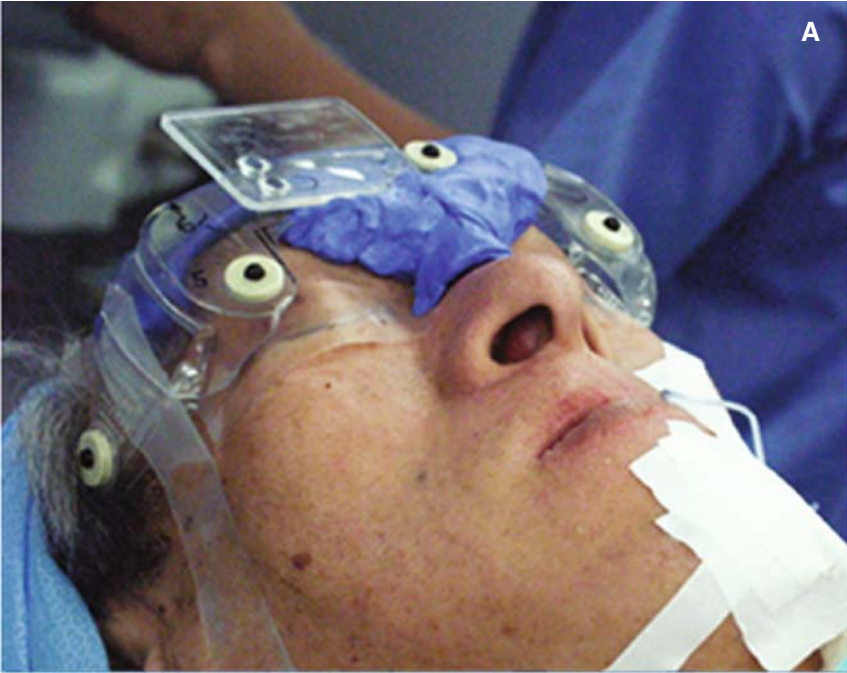### 1. AR-NAVIGATION SYSTEM FOR TRANSNASAL TRANSSPHENOIDAL SURGERY

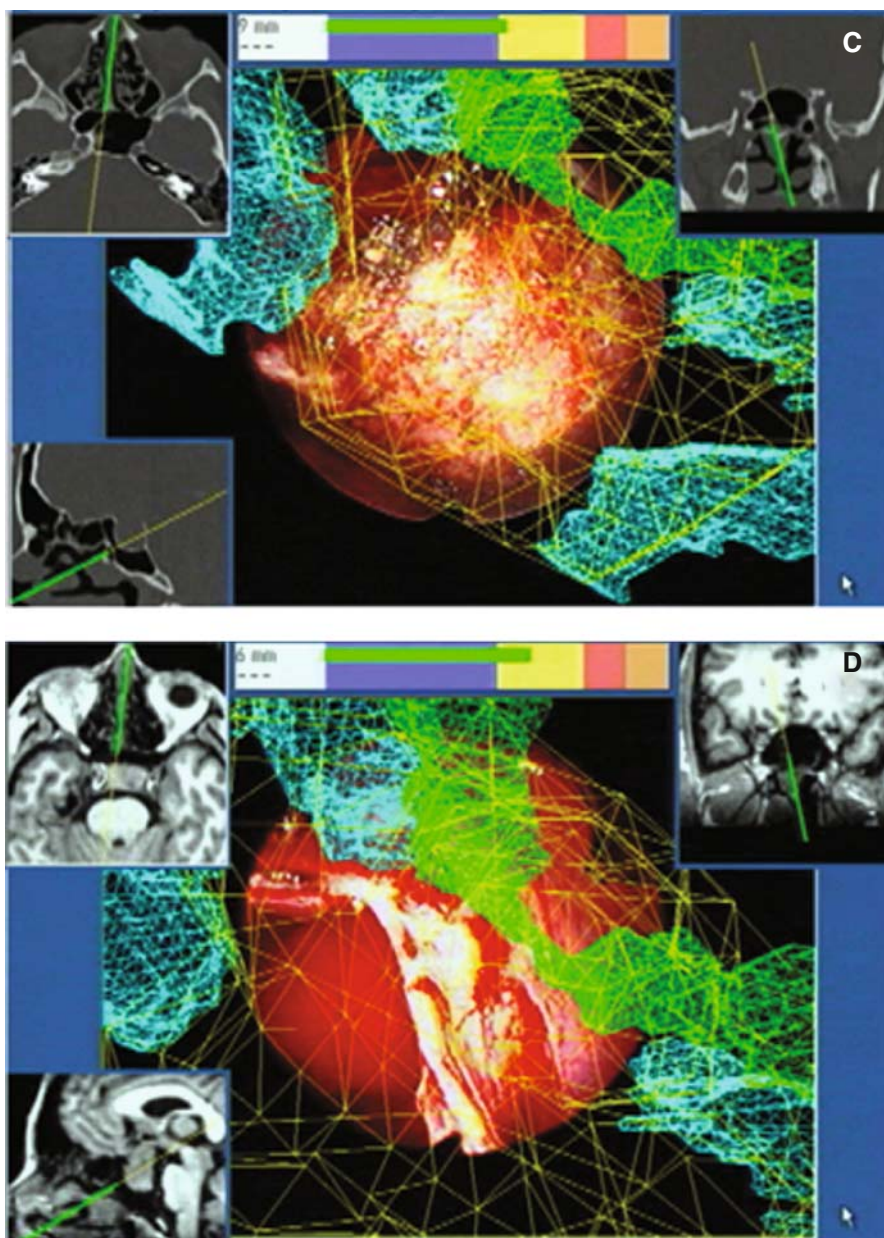
For endoscope-assisted, endonasal, transsphenoidal surgery to treat pituitary tumors, an endoscopic navigation system is even more necessary and useful for safe operations, because an endoscope permits much greater access to suprasellar and lateral surgical areas, where critical structures (including internal carotid arteries) are situated, as a result of the wider angle of view (compared with an operating microscope). Our present AR navigation system not only indicates the 3-D direction and position of the endoscope on axial, coronal, and sagittal MRI or CT scans, but also offers 3-D virtual images of the tumor and nearby anatomic structures superimposed on real-time endoscopic live images. With our navigation system, the virtual images are continuously presented three-dimensionally on the screen.

The system consists of a rigid endoscope, an optical tracking system, and a controller. We use endoscopes intermittently during pituitary surgery. For the AR navigation system, we usually used rigid endoscopes (2.7 mm in diameter, with viewing angles of 0 or 30 degrees) equipped with a lens-cleansing irrigation/suction system (Olympus Optical Co., Ltd., Tokyo, Japan). The endoscope was mounted in a self-retaining holder, to allow the surgeon to use both hands freely. The operation of the optical tracking system (Flashpoint 5000 3-D localizer; Image Guided Technologies, Inc., Boulder, CO) was based on two sets of infrared light-emitting diodes (LEDs), which measured the position and orientation of the endoscope in relation to the patient's head. The first set of LEDs was attached to the patient's head, to measure the position and orientation of the head relative to reference markers mounted on a goggle-type frame (Fig. 1A). The second set of LEDs was mounted on an endoscope and a probe (Fig. 1B), to measure the position and orientation of the endoscope and the probe relative to

**Fig. 1. A** Intraoperative photograph, showing the reference markers mounted on the goggle-type frame worn by the patient. A set of infrared LEDs will be attached to the flat plate, to measure the position and orientation of the patient's head relative to the reference markers mounted on the goggles. **B** Endoscope attached with fiducial marker LEDs is inserted to the nasal space with nasal speculum in the nasal cavity. **C, D** Endoscopic view during nasal procedures in an operation to treat a pituitary tumor, with superimposed wireless frame images. The sella floor is being approached (**C**), and dura is opened and tumor is now under removal (**D**). The three planes of CT scans (**C**) and MR images (**D**) (axial, coronal, and sagittal) are presented in the corners of the monitor, with indications of the directions of the endoscope and endoscopic beam (green line)







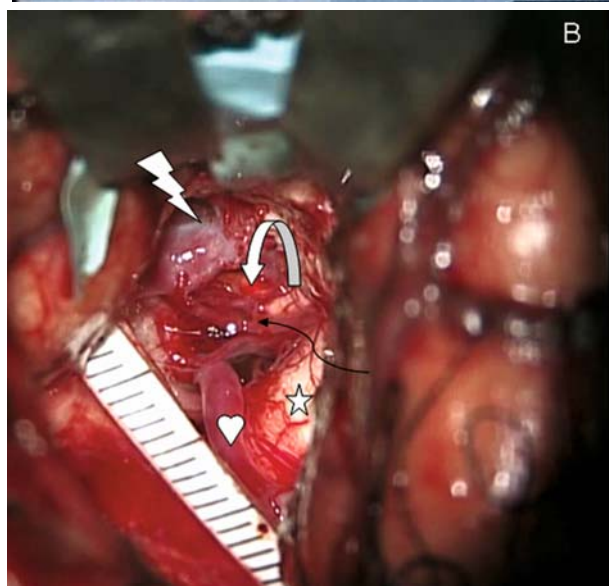
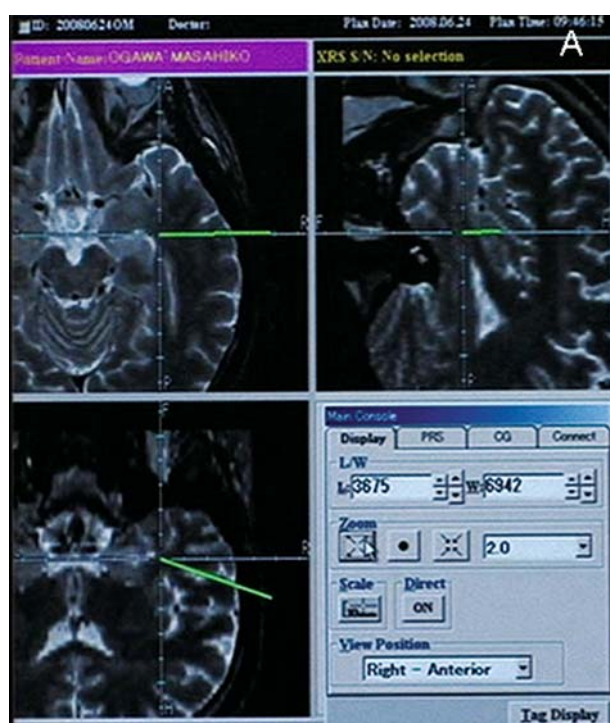
**Fig. 1.** (Continued)

the reference markers on the goggle-type frame. The system calculated the relative position and orientation of the patient's head and the endoscope in real time, permitting movement of the patient's head during surgery.

The controller (a Pentium III-based personal computer) generated 3-D wire-frame model images of the tumor and nearby anatomic landmarks (including the internal carotid arteries, sphenoid sinuses, and optic nerves), which were reconstructed on the basis of the preoperative MRI data for the patient. MRI or CT scans (slice thickness, 1 mm; without gaps) were obtained preoperatively, with the patient wearing the goggles with the reference markers (Fig. 1A). The procedures related to reconstruction of the wire-frame images are described below. The process was semiautomated. First, we applied a region-based segmentation algorithm to preoperative CT (Fig. 1C) and MRI scans (Fig. 1D), for the tumor and each anatomic structure. With the system, we specified subregions, which constituted the regions of interest, by clicking computer mouse. We were able to obtain a volumetric representation of the 3-D object in each region of interest. After the procedure, we confirmed and manually corrected the selected regions for tumors and nearby structures, on the basis of the CT and MRI scans. These procedures required approximately hours and were performed before the day of surgery. The 3-D wire-frame models were superimposed on the endoscopic live images on the basis of the actual position and orientation of the endoscope during surgery. The endoscopic AR navigation system we developed demonstrates the position and direction of the endoscope on 3-D MRI or CT scans (axial, coronal, and sagittal sections), together with anatomic 3-D virtual images superimposed on endoscopic live images.

Therefore, intraoperative lateral (C-arm) fluoroscopy was not necessary. The midline was always identified with the AR navigation system when we used an endoscope or the probe with LEDs (Fig. 1B). Furthermore, the location and orientation of the endoscope were indicated three-dimensionally on MRI or CT scans on the monitor in green, with the direction of the endoscopic beam in yellow. This was extremely useful, because surgeons often become confused regarding direction when using endoscopes with viewing angles of 30 or 70 degrees.

Another benefit was that the system took into account the lens distortion observed in endoscopic views. Our endoscopic AR navigation system provided 3-D information for surgery, with simultaneous display of superimposed, "real", 3-D, wire frame, virtual images of the tumor and nearby structures, color changes of the tumor according to the distance between the tip of the endoscope and the tumor, a bar graph of the distance, and indications of the location and direction of the endoscope and endoscopic beam in 3-D MRI or CT planes. These features are superior to those of conventional navigation systems, which are available only for operating microscopes, and they permit safe accurate endoscopic pituitary surgery. In particular, the AR navigation system proved efficient for reoperations, in which midline landmarks may be absent.



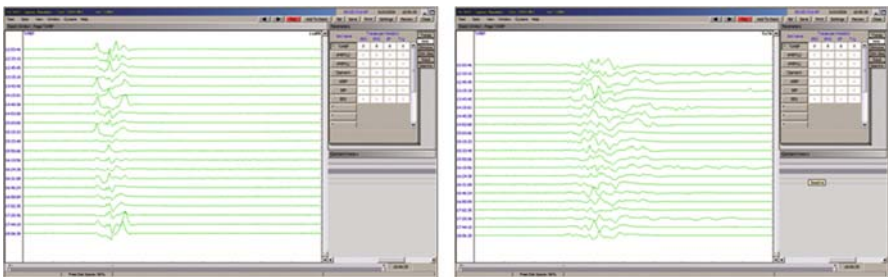
## 2. AR NAVIGATION USING FOR EPILEPSY SURGERY

This endoscopic augmented reality navigation system can be utilized to epilepsy surgery, replacing simply endoscope to operative instruments such as bipolar forceps. In a case of selective amygdalohippocampectomy [2] bipolar forceps AR navigation system was quite useful to detect the temporal horn and hippocampus (Fig. 2A, B). Motor evoked potential (MEP) monitoring [9] during removal of amygdala and hippocampus is useful not to have complication of hemiplegia related to the manipulation of anterior choroidal artery. Successive monitoring of MEP of EMG of upper extremity (Fig. 3, left) and lower extremity (Fig. 3, right) on the contralateral side to the operation are demonstrated.

The combined use of iMRI and AR navigation system was especially useful in case of subcortical small cavernous angioma resection and total corpus callosotomy for 8-year-old boy afflicted with drop attacks caused by Lennox-Gastaut syndrome (Fig. 4A, B). AR navigation indicated the tip of the bipolar forceps just on the lowest end of the corpus callosum, so that, the neurosurgeon is confident that total callosotomy has been well performed. Bilateral synchrony of spike and wave discharges on electrocorticographic recording before (Fig. 4C) callosotomy disappeared after total callosotomy (Fig. 4D).

## 3. REAL-TIME UPDATED IMRI NAVIGATION FOR REMOVAL OF MALIGNANT GLIOMAS

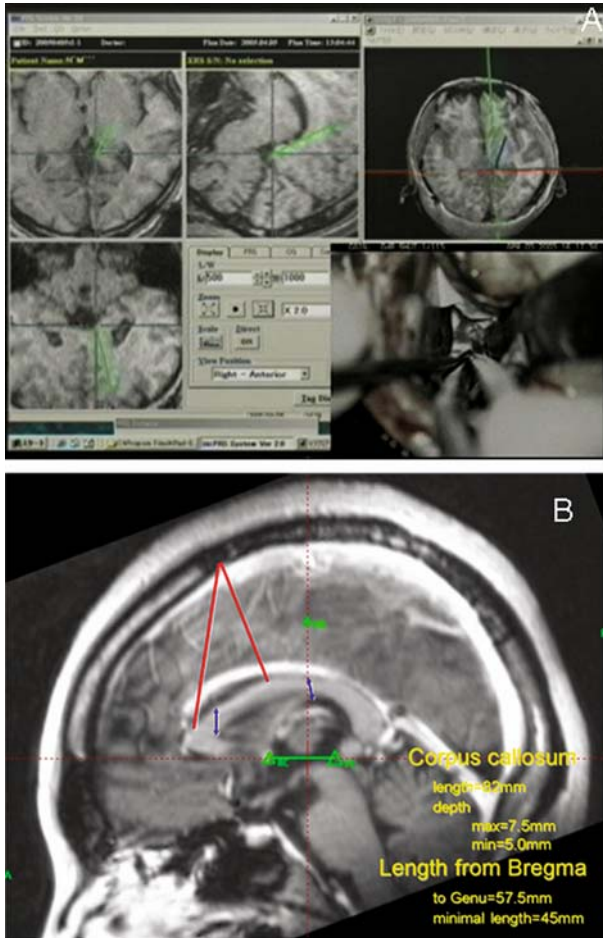
Since the first reports of the clinical feasibility of intraoperative MRI (iMRI) by Black [1] and Tronnier [10] independently in 1997, several groups have described their application and a variety of newly developed or modified systems, including C-shaped low-field systems, systems with a vertical gap,



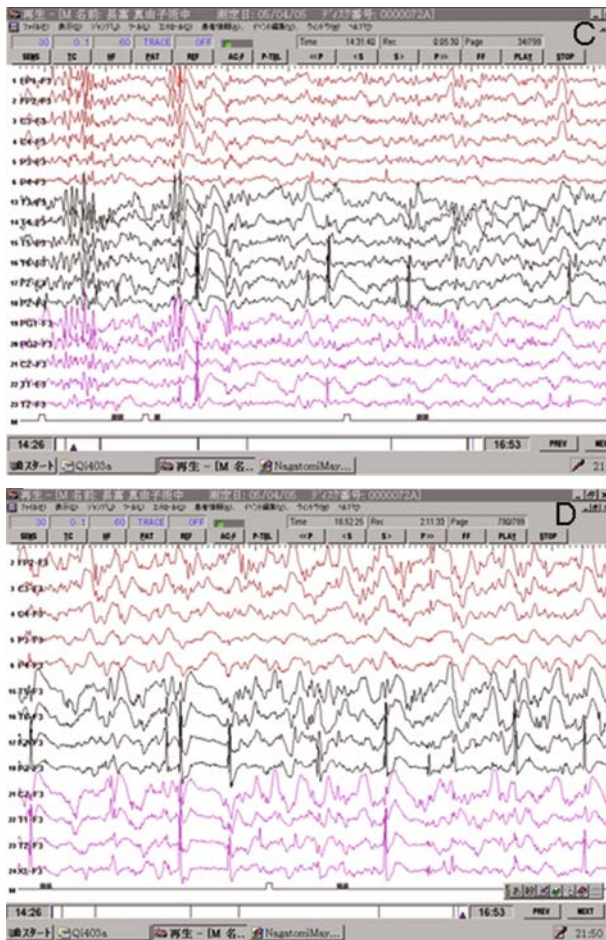
**Fig. 3.** During the selective amygdalohippocampectomy, upper (left panel) and lower extremity (right panel) motor evoked potentials are continuously monitored. In this case, there were no decline of MEP potential during surgery

**Fig. 2. A** Three intraoperative MRI planes demonstrating the direction of the bipolar forceps to the hippocampal head. **B** After selective amygdalohippocampectomy, midbrain (☆) internal carotid artery (♣) optic tract (♣), anterior choroidal artery (♣), and posterior cerebral artery (♣) are demonstrated

dedicated designs such as the “double donut” systems, a system with a cylindrical, ceiling-mounted, movable magnet. Despite the variety of systems available, the principle of (nearly) real-time imaging and the intention to maximize image guidance throughout each procedure are common to all of them.



**Fig. 4.** AR navigation in a case of 8-year-old boy afflicted with Lennox-Gastaut syndrome, whose drop attack was intractable and to be operated by total callosotomy. **A** Using updated realtime navigation system with iMRI, the tip of the bipolar forceps are just at the posterior end of the corpus callosum indicated by green lines on axial, coronal, and sagittal three planes on the left side, and the upper right is the tip of the bipolar forceps at the axial plane, and lower right is the operative microscope picture. **B** In sagittal plane, the directions and length from the bregma to corpus callosum are demonstrated by red lines. **C** ECoG of subdural recording of bilateral frontal lobes at the time of pre-callosotomy. Bilateral synchrony are demonstrated. **D** ECoG of subdural recording of bilateral frontal lobes after total callosotomy, Bilateral synchrony has disappeared



**Fig. 4.** (Continued)

Since the introduction of iMRI to the intelligent operating room in March 2000, 400 lesions were already operated in intelligent OR using with iMRI until June 2006. The lesion included 283 cases of glioma, 39 cases of parasellar tumor, 34 cases of angioma/AVM, and 10 patients of epilepsy surgery including a patient of Rasmussen encephalitis and 34 patients of other lesions. The improved resection rate and improved survival rate will be described.

### 3.1 Usefulness of iMRI for malignant glioma surgery in terms of established treatment algorithm and improved image quality

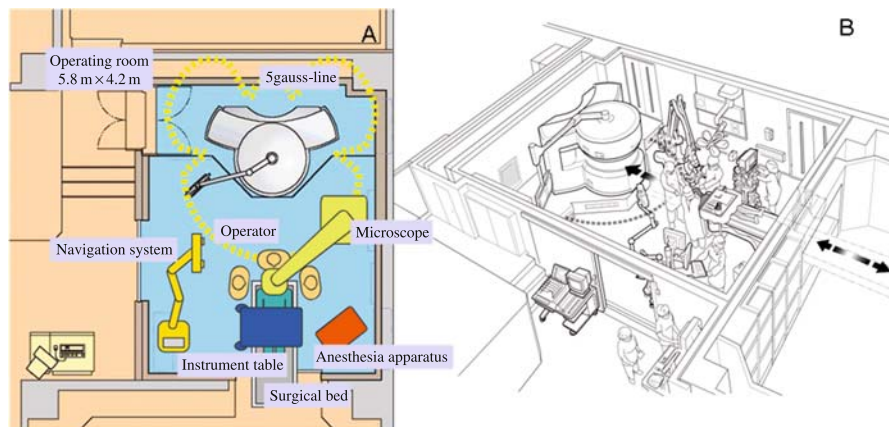
There is significant controversy with regard to the goals of surgical resection of malignant gliomas. Some believe that since the relationship between resec-

tion rate and patient prognosis has not yet been established, the possible benefit of radical removal of tumor is overshadowed by the relatively high risk of postoperative neurological morbidity. At the same time others argue that correlation between resection rate and prognosis has sufficiently been defined and that total tumor removal is the most effective treatment for malignant glioma [7, 8, 11]. Regardless of this controversy, most investigators agree that better demarcation of the tumor border in the eloquent areas of the brain would result in an increased resection rate with reduced risk of postoperative neurological deterioration. The objective of the present study is to evaluate the usefulness of low magnetic resonance (0.3 Tesla) iMRI imaging for complete resection of glioma with emphasis on functional outcome.

From 2000 to 2004, ninety-six patients had resection of intracranial glioma with the use of iMRI. The vast majority of procedures were performed by the same team (Chief TH). Informed consent was obtained before surgery from each patient and his/her nearest family member. Resection rate and postoperative neurological status were compared between control group (46 cases, operated on during initial period after installation of iMRI), and study group (50 most recent cases, in which surgery was done using established treatment algorithm and improved image quality).

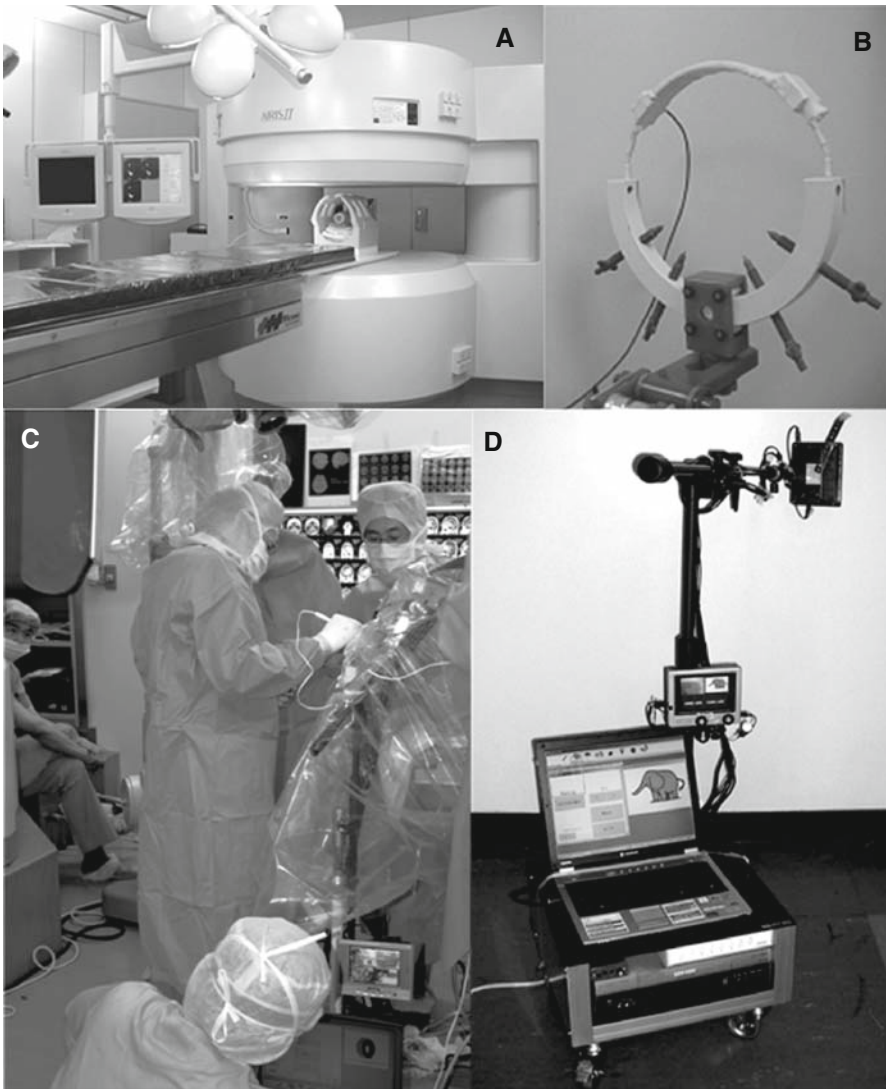
### 3.2 How to use intraoperative MRI and MR compatible operating devices

The internal organization of our “intelligent operating theatre” is presented on Fig. 5A,B. Intraoperative MRI scanner (AIRIS II, Hitachi Medical,



**Fig. 5. A and B** The internal organization of the “intelligent operating theatre” at the Tokyo Women’s Medical University Hospital: general schematic view A, the diagram of the intelligent OR with yellow dotted line indicating 5-gauss line. During the awake surgery with iMRI, the monitoring can be performed outside of this 5-gauss line, with newly designed language mapping kit. The images can be displayed at the same time for examiner and the patient with transparent vinyl covering for patient’s observation during the awake surgery





**Fig. 6.** **A** Intraoperative MR machine, **B** newly developed coil, **C** The patient is under language mapping during awake craniotomy, **D** The language mapping kits

Tokyo, Japan Fig. 6A), as available at Tokyo Women's Medical University, has a disc-shaped permanent magnet with a magnetic field strength of 0.3 Tesla and a gantry gap of 43 cm in width. Low magnetic field strength creates narrow 5-gauss line, and the patient can easily be moved outside of the field but still remaining in the operative theater (Fig. 5A) which permits to use some conventional surgical devices (for example, high speed drill). Neverthe-

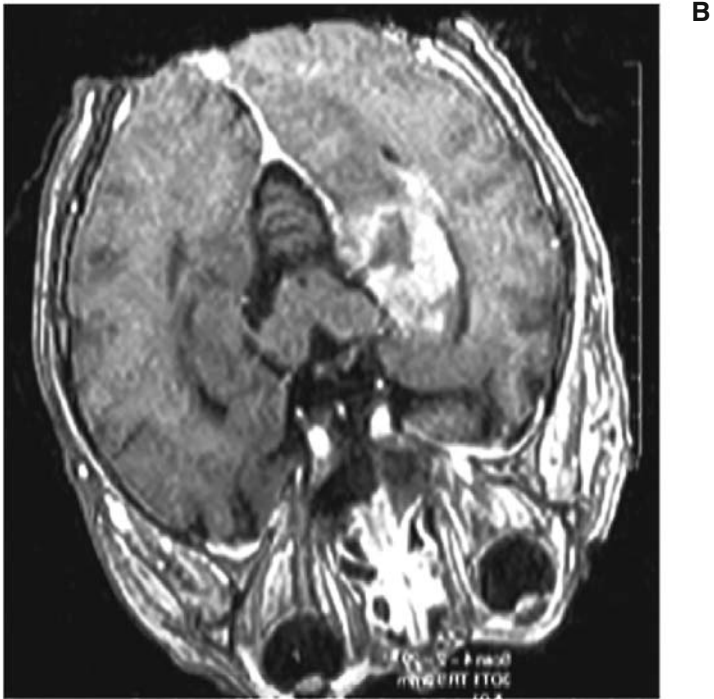
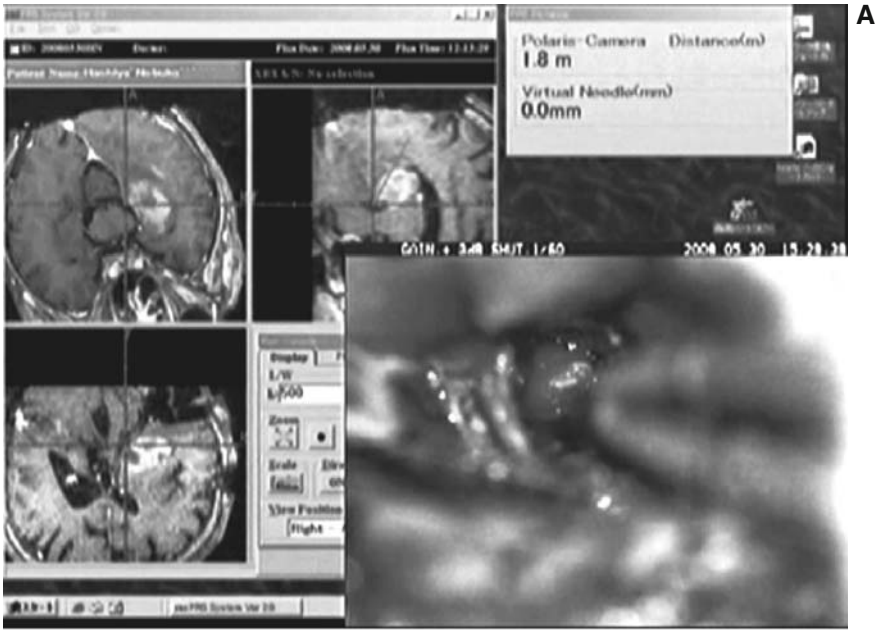
less, all surgical devices and instruments that are used within the 5-gauss line (Fig. 5A, yellow dotted line), such as operating table (MOT 2000-MRI, Mizuho Ikakogyo, Tokyo, Japan, Fig. 5A, B) and operating microscope (MRI-30, Mitaka Kohki, Tokyo, Japan, Fig. 5B), are constructed from non-ferromagnetic material to prevent accidents and avoid image artifacts. Body coils for the scanning of the abdominal region were used as receiver coil in the control group, while original coils for the scanning of open brain surgery with higher signal-to noise ratio were developed later on (Head Holder Coil., Hitachi Medical, Tokyo, Japan, Fig. 6B) and used in the study group. Although the field strength of this scanner is low, it can provide images of sufficient quality for identification of residual tumors, and allows generation of 3-D reconstruction images, magnetic resonance angiography (MRA), and cine-MRI.

During surgery MR images were obtained at 3-slice thickness (1.5-mm slice intervals, 100 slices) under the following conditions: field of view (FOV), 230×230 mm; TR, 27 msec; TE, 10 msec (for T1-weighted spin echo), and FOV, 230×230 mm; TR, 3000 msec, TE, 120 msec (for T2-weighted turbo). An MRI contrast agent (gadolinium diethylenetriamine pentaacetic acid) was administered intravenously at 0.2 ml/kg in the control group and at 0.4 ml/kg in the study group. Scanning duration was 3 min and 36 sec for T1 weighted images and 5 min for T2-weighted images. All MRI data were displayed on the in-room display screen. A surgical navigation system (PRS navigator, Toshiba, Tokyo, Japan, Fig. 5A, B) was used in 35 recent cases to facilitate tumor removal and detection of its remnants. The navigator was based on a conventional infrared location-identification device, which shows the location and position of the bipolar tip in 3 sectional planes. Navigation DICOM format files of MR images were transferred to a computer through a local area network. Images were available for use in less than 5 minutes after MR scanning.

### 3.3 Surgery (How I do it)

In 84 cases surgery was performed with patients in the supine position, whereas 12 patients were in prone position. After induction of anesthesia, the patient head was fixed in a four-point head holder coil (Fig. 6B). Craniotomy was performed in a usual manner, followed by opening of the dura mater and arachnoid. Thereafter, fiducial markers were fixed to the skull, the covering

**Fig. 7.** A case of glioblastoma of 56-year-old woman of left parahippocampal gyrus. The patient was put in prone position and posterior interhemispheric approach has been adopted. **A** Updated iMRI demonstrating the tip of the bipolar forceps in three dimensional images (axial, sagittal, and coronal). The lower right corner is the real-time microscopic picture. **B** Preremoval updated iMRI figure demonstrating the presence of GBM at the left parahippocampal gyrus. **C** After subtotal removal, there was a small remnant at the depth of the operative field which was well demonstrated by updated iMR images. **D** After final removal of the GBM by posterior interhemispheric approach, iMRI was taken and demonstrating the complete removal of the tumor



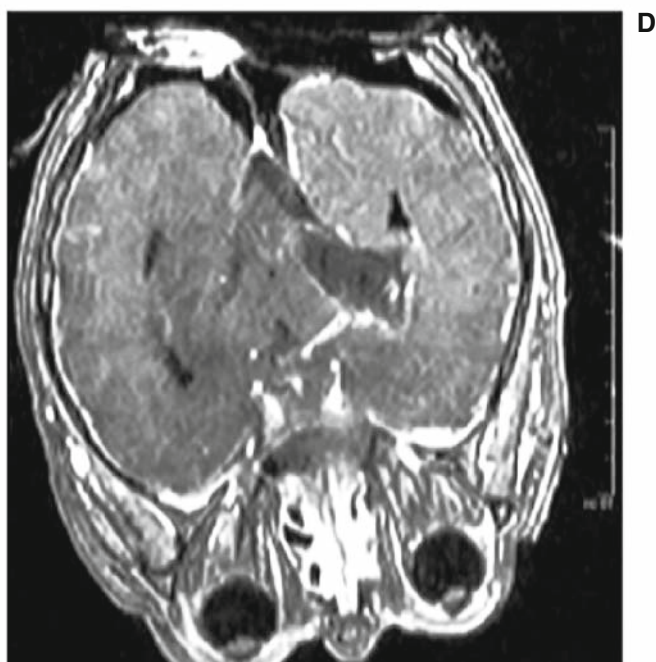
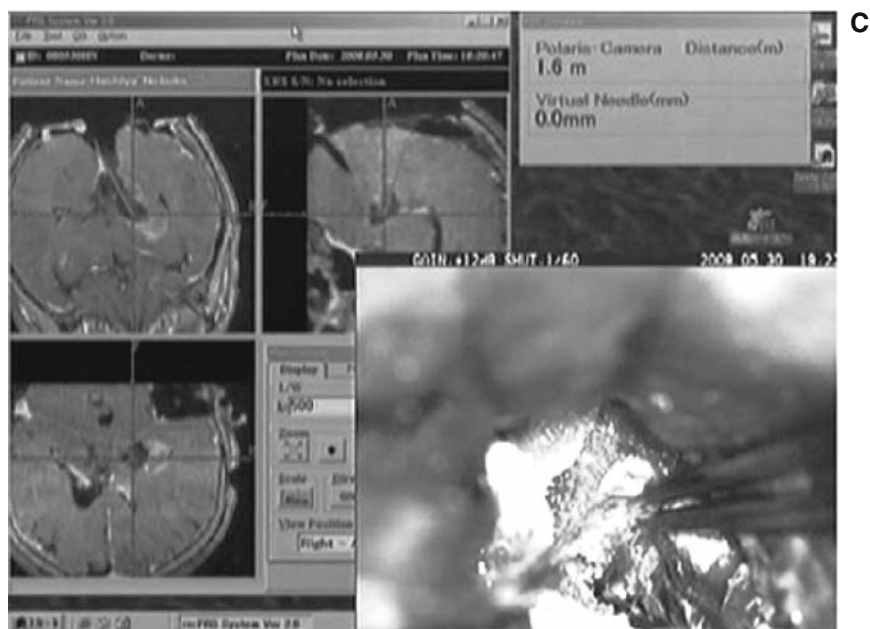


Fig. 7. (Continued)

coils was connected to the four-point head holder coil, and the operating table was covered with the second transparent drape (Fig. 6C). Patient's head was moved in the center of the MRI gantry by sliding the upper portion of the operating table. MR imaging was performed, and data were transferred onto a computer for further neuronal-navigation. The fiducial markers were registered in the computer, which permitted use of "real-time" update neuronavigation during tumor removal. If the tumor was located near or in eloquent brain areas, cortical mapping, neurophysiological monitoring, and/or stimulation of the cranial nerves were performed – as appropriate before resection of neoplasm- for identification of the motor area, speech area, cranial nerves and its nuclei. Somatosensory evoked potentials (SEP) and motor evoked potential (MEP) [9] were routinely monitored during surgery. If the tumor is in or around the language area, awake craniotomy with intraoperative language mapping is performed (Fig. 6C, D). After removal of the neoplasm, iMRI was performed again to assess the completeness of tumor resection, identification of the residual neoplasm or possible adverse effects such as hemorrhage. If residual tumor was identified and considered suitable for additional resection, the newly obtained MRI data were transferred to the navigation computer and further resection of the tumor was performed following this updated information. When resection of the tumor was completed, final iMRI was done to evaluate the resection rate. Such treatment algorithm permitted us a more precise orientation in the operative field compared to conventional neuronavigation systems, which are based on MR images obtained before surgery and constitute a risk for possible mislocalization errors due to brain shift after removal of CSF and the tumor itself.

### 3.4 Results

A comparison of the two groups of patients revealed their compatibility in clinical characteristics. At the same time, resection rate in the study group compared to control group was significantly higher (91% vs. 95%,  $P < 0.05$ ), whereas residual tumor volume was significantly smaller (1.7 ml vs. 0.025 ml;  $P < 0.01$ ). The number of cases with total removal was also higher in the study group as compared to the control group (52% vs. 39%), but this difference did not reach statistical significance. Further subgroup analysis showed that residual volume of WHO grade IV tumors (4.6 ml vs. 0.05 ml;  $P < 0.05$ ) and neoplasms of Sawaya functional grade III [8], located in the eloquent areas of the brain (3.8 ml vs. 0.23 ml,  $P < 0.05$ ), as well as resection rate of the latter (88% vs. 95%,  $P < 0.05$ ) were significantly improved in the study group compared to the control group.

#### Representative illustrative cases

1. First case: A case of glioblastoma of 56-year-old woman of left parahippocampal gyrus. The patient was put in prone position and posterior interhemispheric approach has been adopted. Fig. 7A: Updated iMRI

demonstrating the tip of the bipolar forceps at the edge of the tumor in three dimensional images (axial, sagittal, and coronal). The lower right corner is the real-time microscopic picture. Fig. 7B: Preremoval updated iMRI figure demonstrating the presence of GBM at the left parahippocampal gyrus. Fig. 7C: After subtotal removal, there was a small remnant at the depth of the operative field which was well demonstrated by updated iMR images. Fig. 7D: After final removal of the GBM, iMRI was taken and demonstrating complete removal of the tumor.

2. Second case: Another case of a recurrent left frontal GBM. The operation was performed under awake craniotomy. Fig. 8A: The patient's head with skin incision marking was fixed by 4 pins' head holder with special made coil. Fig. 8B: The first iMR image demonstrating the presence of a small recurrent tumor at the deep frontal lobe. Fig. 8C: The position of the tumor was well demonstrated by 3-dimensional updated MRI planes with intraoperative real-time operating microscopic picture. For the removal of this small recurrent tumor, the approach site has been selected on the basis of language mapping. Fig. 8D: During removal deep subcortical mapping was also performed with patient's cooperation by awake surgery.

### 3.5 Complications

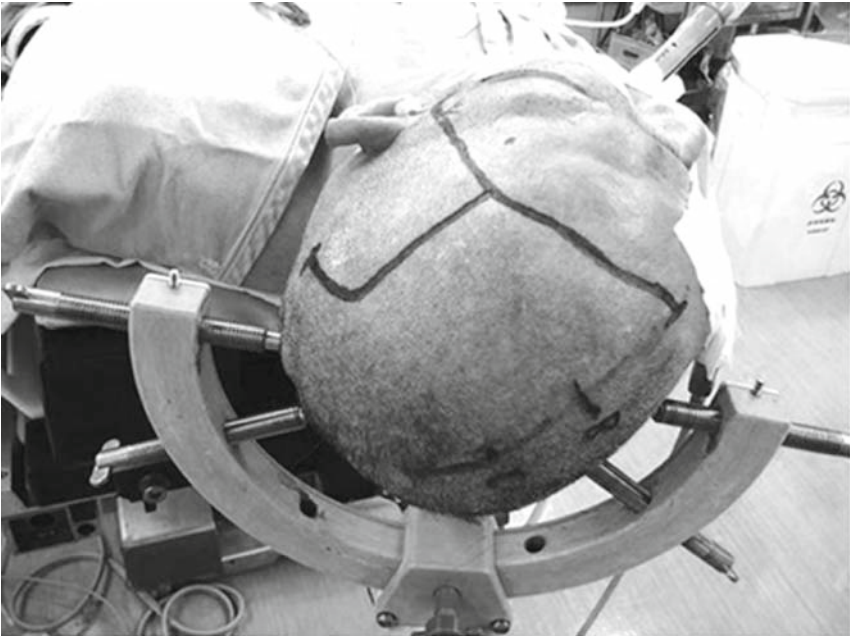
Nine patients in the control group (20%) and 24 in the study group (48%) experienced temporary postoperative neurological deterioration ( $P=0.01$ ). However, the rate of permanent morbidity, which was evaluated 3 months after surgery, did not differ significantly between the groups investigated. (13% vs. 14%) ( $P=0.89$ ).

### 3.6 Usefulness of diffusion tractography imaging (DTI)

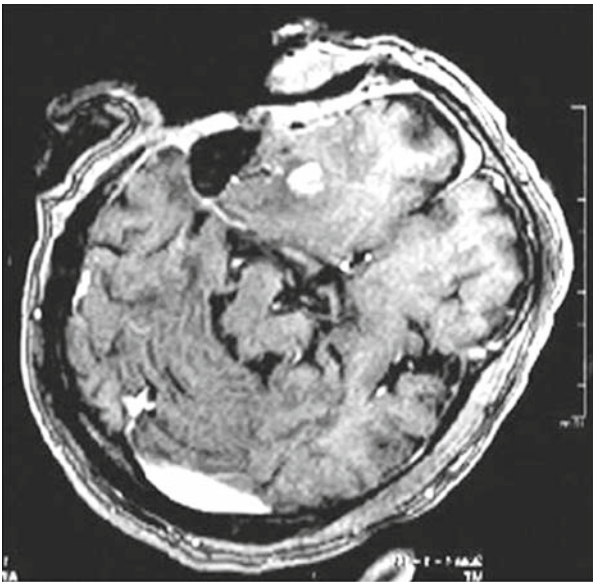
Recent progress of diffusion tractography imaging (DTI) is remarkable as demonstrated in Fig. 9A, B. In Fig. 9A, pyramidal tractography demonstrated medial shift of the right pyramidal tract by the tumor, and in Fig. 9B the arcuate fiber tract in the temporal lobe is touched by the temporal glioma. To avoid the permanent complications, intraoperative tractography is mandatory. Currently in Tokyo Women's Medical University low magnetic field strength (0.3 Tesla) open intraoperative magnetic resonance imaging (iMRI) is

---

**Fig. 8.** Another case of a recurrent left frontal GBM. The operation was performed under awake craniotomy. **A** The patient's head with skin incision marking was fixed by 4 pins' head holder with special made coil. **B** The first iMR image demonstrating the presence of a small recurrent tumor at the left deep frontal lobe. **C** The position of the tumor. was well demonstrated by 3-dimensional updated MRI planes with intraoperative real-time operating microscopic picture. **D** For the removal of this small recurrent tumor, the approach site has been selected on the basis of language mapping, and also during removal deep subcortical mapping was also performed with patient's cooperation in awake surgery



**A**



**B**

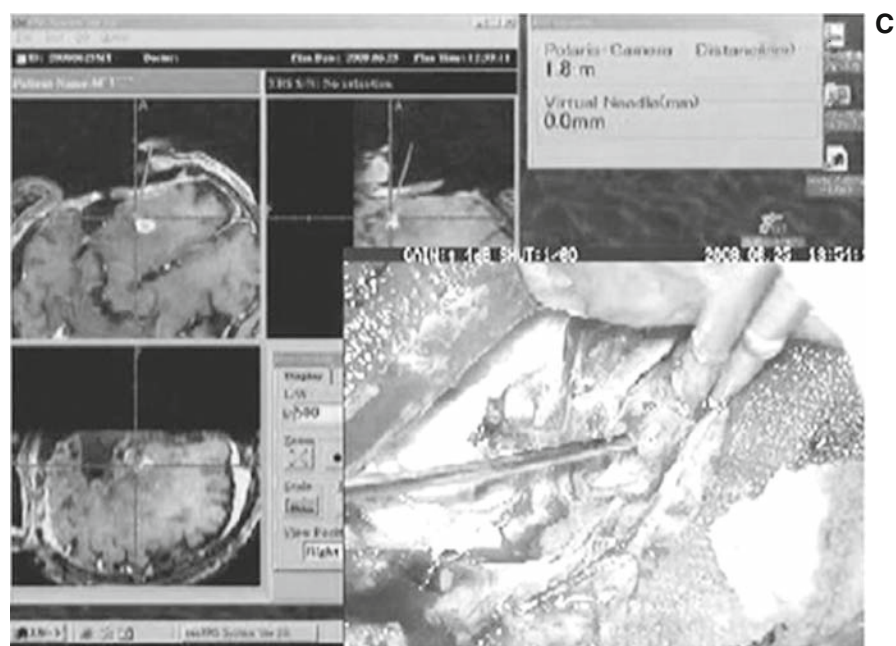
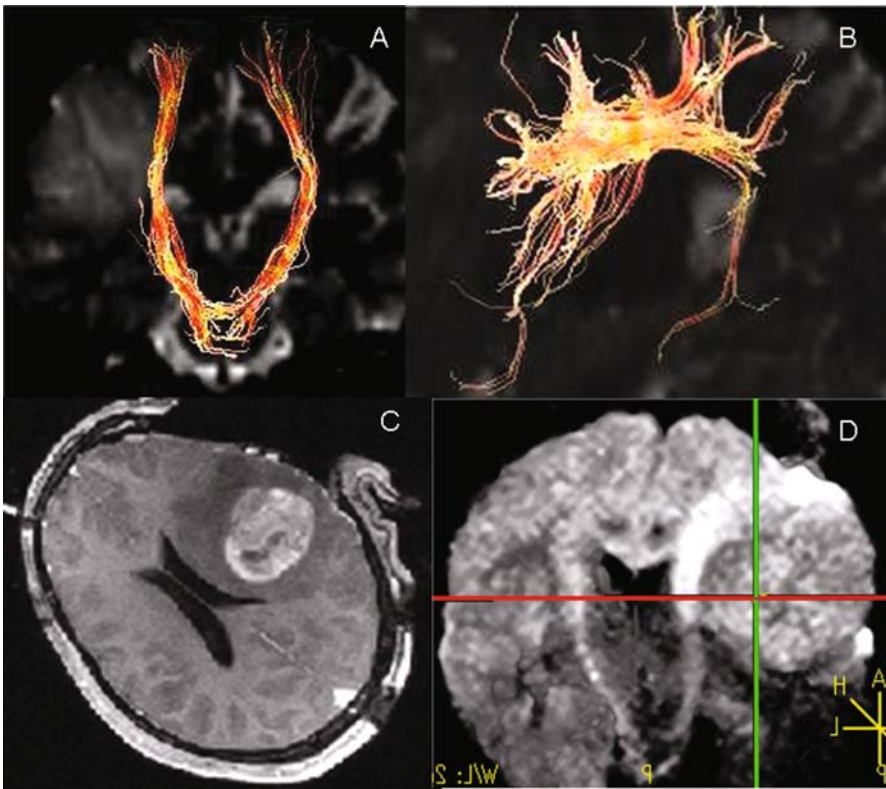


Fig. 8. (Continued)





**Fig. 9.** **A** Pyramidal tractography with right frontal glioma. The pyramidal tract was compressed by the tumor (T2WI HI lesion). **B** Arcuate fiber has been infiltrated by the tumor (T2WI deep temporal HI). **C** Left frontal glioblastoma (T1WI with Gd(+)), **D** Intraoperative pyramidal tractography demonstrating small shift of the tract superomedially by the tumor

used. As it is shown in the present study, such system is useful for the resection of intracranial glioma. Moreover, our recent experience shows that such MR scanner permits to obtain intraoperative diffusion-weighted images for the visualization of pyramidal tracts (Fig. 9C, D) as well as functional MR images for identification of the motor cortex. Using specially developed coils (Fig. 6B) for the scanning of open brain surgery that provide higher signal-to-noise ratio, represents significant improvement of image quality, especially of contrast-enhanced tumors, which was reflected in a higher resection rate of such neoplasms as reported in study group. Spatial separations of the operative table and MR gantry and removable head-holder coil provides freedom for any surgical manipulations, which can be done in both supine and prone position of the patient. Therefore, it seems that compared to other available systems our device has a very good cost-to-benefit ratio.

## CONCLUSIONS

Modern brain neuronavigation – using AR navigation and “realtime” intra-operative MRI updated navigation – allows to perform deep-seated operations more safely and accurately.

## Acknowledgement

The author acknowledges the cooperation of Dr. Michael Chernov, Department of Neurosurgery, Tokyo Women’s Medical University, Tokyo, Japan, Dr. Chie Shinohara, Department of Neurosurgery, Tokyo Women’s Medical University, Tokyo, Japan, Dr. Takemasa Kawamoto, Department of Neurosurgery, Tokyo Women’s Medical University, Tokyo, Japan, and Faculty of Advanced Technology, Department of Advanced Biomedical Engineering and Science, Graduate School of Medical Science, Tokyo Women’s Medical University, Tokyo, Japan, Dr. Takashi Maruyama, Department of Neurosurgery, Tokyo Women’s Medical University, Tokyo, Japan, Dr. Yoshihiro Muragaki, Department of Neurosurgery, Tokyo Women’s Medical University, Tokyo, Japan, and Faculty of Advanced Technology, Department of Advanced Biomedical Engineering and Science, Graduate School of Medical Science, Tokyo Women’s Medical University, Tokyo, Japan, Dr. Hiroshi Iseki, Faculty of Advanced Technology, Department of Advanced Biomedical Engineering and Science, Graduate School of Medical Science, Tokyo Women’s Medical University, Tokyo, Japan, Dr. Kintomo Takakura, Faculty of Advanced Technology, Department of Advanced Biomedical Engineering and Science, Graduate School of Medical Science, Tokyo Women’s Medical University, Tokyo, Japan.

## References

- [1] Black PM, Moriarty T, Alexander E 3rd, Stieg P, Woodard EJ, Gleason PL, Martin CH, Kikinis R, Schwartz RB, Jolesz FA (1997) Development and implementation intraoperative magnetic resonance imaging and its neurosurgical applications. *Neurosurgery* 41: 831-842
- [2] Hori T, Yamane F, Ochiai T, Kondo S, Shimizu S, Ishii K, Miyata H (2007) Selective subtemporal amygdalectomy for refractory temporal lobe epilepsy: operative and neuropsychological outcomes. *J Neurosurg* 106: 134-141
- [3] Kawamata T, Iseki H, Shibasaki T, Hori T (2002) Endoscopic augmented reality navigation system for endonasal transsphenoidal surgery to treat pituitary tumors: Technical note. *Neurosurgery* 50: 1393-1397
- [4] King AP, Edwards PJ, Maurer CR Jr, de Cunha DA, Strong AJ, Chandler CL, Richards A, Gleason MJ (1999) A system for microscope-assisted guided interventions. *Stereotact Funct Neurosurg* 72: 107-111

- [5] Muragaki Y, Maruyama T, Kawamata T, Yamane F, Nakamura R, Kubo O, Takakura K, Hori T (2006) Usefulness of intraoperative magnetic resonance imaging for glioma surgery. *Acta Neurochir* 98(Suppl): 67-75
- [6] Nimsky C, Ganslandt O, Von Keller B, Romstöck J, Fahlbusch R (2004) Intraoperative high-field-strength MR imaging: implementation and experience in 200 patients. *Radiology* 233: 67-78
- [7] Sanai N, Berger M (2008) Glioma extent of resection and its impact on patient outcome. *Neurosurgery* 62: 753-766
- [8] Sawaya R (1999) Extent of resection in malignant gliomas: a critical summary. *J Neurooncol* 42: 303-305
- [9] Tanaka S, Takanashi J, Fujii K, Ujiiie H, Hori T (2007) Motor-evoked potential mapping and monitoring by direct brainstem stimulation. *J Neurosurg* 107: 1053-1057
- [10] Tronnier VM, Wirtz CR, Knaauth M, Lenz G, Pastyr O, Bonsanto MM, Albert FK, Kuth R, Staubert A, Schlegel W, Sartor K, Kunze S (1997) Intraoperative diagnostic and interventional magnetic resonance imaging in neurosurgery. *Neurosurgery* 40: 891-902
- [11] Wirtz CR, Knauth M, Staubert A, Bonsanto MM, Sartor K, Kunze S, Tronnier M (2000) Clinical evaluation and follow-up results for intraoperative magnetic resonance imaging in neurosurgery. *Neurosurgery* 46: 1112-1122



**Tomokatsu Hori**

Tomokatsu Hori is Chairman of Neurological Center, Tokyo Women's Medical University. 1968: M.D., Tokyo University Faculty of Medicine. 1973: Research Fellow at Sainte Anne Hospital (Professor J. Talairach), 1973–1975. 1984: Professor, Department of Neurosurgery, Tottori University. 1995: Director, Institute of Neurological Sciences, Tottori University. 1998: Chairman and Professor, Department of Neurosurgery, Tokyo Women's Medical University. 2007: President of the 66th Japanese Neurosurgical Society (2007). WFNS: Educational committee, Executive Committee. WSSFN: Asia-Australasia Continental Vice-President (2002–2005). Neurosurgery International Advisory Board (1999–). Neurosurgical Review, Review Board. Acta Neurochirurgica Review Board. Stereotactic and Functional Neurosurgery Editorial Board (2007–).

**Contact:** Tomokatsu Hori, Department of Neurosurgery, Tokyo Women's Medical University, 8-1 Kawadacho, Shinjyuku, Tokyo 162-8666, Japan  
E-mail: [thori@nij.twmu.ac.jp](mailto:thori@nij.twmu.ac.jp)

---

# BRAIN MAPPING

J.-C. TONN

## INTRODUCTION

Brain mapping (BM), which nowadays is a distinct, inevitable surgical technique of intraoperative monitoring (IOM) within our specialty, had been a research tool for neurologists and neurosurgeons in the early days. Otfried Foerster (1873–1941) and Fedor Krause (1857–1937) used direct stimulation of the cortex to identify single functions like motor response or sensual perception and their location within the cortex. This was facilitated by the fact that surgery of the brain was performed under local anaesthesia at that time allowing monitoring of function during surgery. Wilder Penfield (1891–1976) and Walter Dandy (1886–1946) intensified these studies systematically, thus being able to describe the structural organization of motor function known as the “homunculus” which is the sketch of functions according to their localisation on the cortex [9]. These findings did not only encourage neurosurgeons to push the frontier of their surgical challenges further and further as they learned and understood to preserve function. They were also the basis of topologic diagnosis in neurology – neurologists had been most interested in the mapping results obtained by neurosurgeons in order to understand the functional organisation of the brain and to refine their diagnostic procedure due to the knowledge of the functional anatomy. Penfield and Rasmussen [10] modified the technique of direct brain stimulation for language monitoring thus widening the scope of mapping towards more complex functions.

Today, brain mapping is an elaborated technique which allows the neurosurgeon to identify functionally relevant areas in order to use the methods of modern microneurosurgery and image guidance without endangering the patient’s neurological integrity. This is increasingly important since patients more and more expect neurosurgery to be safe and not being associated with procedure-related morbidity even in face of more complex procedures than ever before. Preservation of function today is as important as radicality in order to achieve successful surgery.

## RATIONALE

IOM techniques are usually applied with the hope to reduce the frequency of postoperative deficits and to maximize at the same time the complexity of the

---

*Keywords:* brain mapping, surgery in eloquent areas

procedure or the extent of tumor resection. Numerous studies have reported the feasibility of intraoperative BM and its possibly positive influence on clinical outcome scores [2, 11, 14, 15]. Brain mapping is achieved by direct cortical stimulation with bipolar stimulation forceps or a bipolar stimulation electrode. Alternatively, electrodes embedded into silicone sleeves in form of stripes or grids may be used (details see below). During stimulation with defined parameters such as voltage, duration and intensity, either a function is elicited (such as motor response) or a function, asked for concomitantly, is suppressed (e.g. execution of language). Thus, function relevant sites are identified. In general, the same can be performed by stimulating white matter tracts [1].

Intraoperative mapping of language functions requires a most demanding cooperation of the neurosurgical, anaesthesiological, and neuropsychological team.

Functional MRI (fMRI) analysis has been hoped for to overcome the necessity for direct mapping with cortical stimulation by making function “visible”. However, this imaging technique, which traditionally exploits the oxygen saturation effects of hemoglobine for delineation of activated cortical regions during execution of specific tasks, has been shown to be strongly influenced by subject-specific parameters, cortical regions analyzed, and the statistical workup of the data (e.g. choice of threshold). Even more, only a moderate test-retest reliability of the fMRI mapping results has been observed so far [3, 13]. In addition, the congruence of fMRI and BM data remains unsatisfying: although very optimistic reports with sensitivity values up to 100% have been published for fMRI, the occurrence of misses (cortical sites found to be essential by BM but not being identified by preoperative imaging) precludes the use of imaging data for guiding resections up to now. Validation of fMRI (as compared to BM) still remains difficult: The transfer of preoperatively generated fMRI data into a neuronavigation system easily sums up multiple technology related errors (such as mathematical deviation of the imaging data), which might be further aggravated by brain-shift effects after opening of the dura [7, 12].

New fMRI approaches using water diffusion tensor imaging permit more direct exploration of tissue metabolism [6]. Additionally, white matter tracts can be visualized by radiological “tractography” obtained during diffusion tensor weighted MRI. However, these data have not been functionally validated yet with intraoperative mapping of fiber tract function [4, 5]. Thus, given these and other limitations, microsurgery in the vicinity of functionally relevant areas still should rely on the results of BM.

## **DECISION-MAKING**

**Candidates.** Patients with a lesion or in whom the planned approach to the lesion is close to functionally relevant areas such as the motor strip or sites

possibly related to language function have to be considered potential candidates for BM. Since due to modern neuro-anaesthesiological intraoperative management, patients in whom BM for identification of cortical motor function is considered need not necessarily be awake during the procedure. Thus, any patient, even children are eligible for intraoperative mapping of motor function under general anaesthesia without muscle relaxation.

Monitoring of language function, however, does require the patient to be awake during the procedure of testing. Moreover, patients who might be subject to mapping of language function must not have had severe aphasic disturbances preoperatively since these defects may be mistaken as deficits elicited by the stimulation. Hence, a clear distinction between BM related “positive sites” with aphasic disturbances and pre-procedural morbidity would be impossible, rendering these persons no candidates for reliable intraoperative BM for language.

For language monitoring during “awake” procedures, patients have to be made familiar with the stimulus material and thoroughly be trained to perform the tasks before. The necessity for the patient to comprehend and cooperate explains why non-cooperative or non-oriented as well as very labile patients and young children have to be excluded from mapping procedures requiring the patient to be awake.

Patients with a history of epileptic seizures have to be adequately covered with anticonvulsant drugs before surgery.

In the following the mapping procedures are described according to the technique performed at the author’s institution. Mapping of language function is dealt with separately from mapping of motor function since the latter does not require special elements of so-called “awake craniotomy” (i.e. craniotomy under local anaesthesia).

## **SURGERY**

### **1. LANGUAGE MONITORING (“AWAKE CRANIOTOMY”)**

#### **1.1 Patient information and preparatory training**

Confrontation naming (naming of pictures of objects) is of widespread use as a basic task in mapping procedures for language relevant areas. Naming is a core component in language abilities being a reliable and robust method of identifying essential language sites [8]. Within three days prior to surgery, patients are informed in detail about the IOM procedure by the neuropsychologist/neurolinguist who will also be responsible for the intra-operative testing. The patient is made familiar with the procedure, the stimulus material and trained to perform the naming task. If a patient has difficulties recognizing or naming certain objects, these items are to be removed from the stimulus pool.

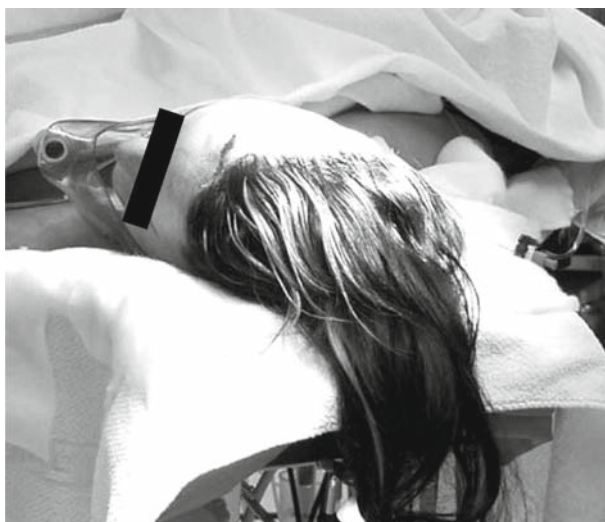## 1.2 Anaesthesiological monitoring and management

Spontaneous breathing is monitored by side-stream capnometry. In addition, continuous transcutaneous measurement of  $pO_2$  and  $pCO_2$  is installed. A flexible tube with a foam tip is placed in a nostril allowing  $CO_2$ -monitoring while the patient is breathing and speaking. Analgesia and sedation are induced and maintained by continuous infusion of propofol (0.5–1.2 mg/kg) and remifentanyl (0.05–0.01  $\mu\text{g}/\text{kg}/\text{min}$ ) with a dose titrated according to patients' requirements and guided by the parameters of ventilation and gas exchange. It is aimed to maintain an optimal and reproducible performance of the patient during each step of test procedure.

In patients not yet treated with anticonvulsant drugs, phenytoin is administered (750 mg i.v.) at the beginning of surgery and then weaned off during the next two post-operative days.

## 1.3 Patient positioning

The major goal of intraoperative patient positioning is to maximize the comfort of each patient (in order to reduce distress and anxiety), to allow proper visualization of the screen presenting the stimuli, and to comply with the requirements of the surgeon. On the OR table, the patient is bedded in a comfortable position supported by pillows. The head is elevated and turned about  $60^\circ$  to the side. Fixation of patient's head and neck is achieved by using a vacuum pillow (Schmidt GmbH, Garbsen, Germany) (comparable to those



**Fig. 1.** Positioning of the patient's head for awake craniotomy on a vacuum pillow



used for stabilization of trauma patients) to avoid the usual head clamp. Local anaesthesia is performed by infiltration of the planned skin incision with 60–80 ml bupivacain hydrochloride 0.25%.

Drapes are fixed by sutures surrounding the OR situs. After positioning the neuropsychological monitoring unit on the side contralateral to the patient's lesion, the drapes are arranged in a way that the patient is able to recognize the presented stimuli on an LCD monitor.

#### 1.4 Intraoperative cortical stimulation

Numbers, printed on sterilized paper (size 2 × 3 mm) are placed on the exposed cortical surface. Prior to stimulation the operative situs is documented by photograph. We use a Nicolet Viking IV P eight channel monitoring unit and bipolar stimulation forceps (Fischer Leibinger, Freiburg, Germany). Electrophysiological parameters are: square wave; 50/s; 0.2 ms; stimulation intensities at all sites starting with 8 mA and stepwise increments of 2 mA, if necessary up to 16 mA. A photograph of the cortical surface with the numbers in place is taken immediately after the stimulation to be able to identify sites of positive stimulation even later on. In case of seizures elicited during cortex stimulation, ice cold (4°C) saline solution (0.9%) is irrigated onto the cortex. After completion of the mapping procedure, the paper numbers are removed and the patient is sedated for the microsurgical resection procedure. When resection is directed close towards language relevant areas, sedation is reduced, and the mapping procedure is repeated [11]. Stimulation of subcortical pathways is performed accordingly once white matter adjacent to fiber tracts is exposed during dissection of the lesion.

#### 1.5 Intraoperative language testing

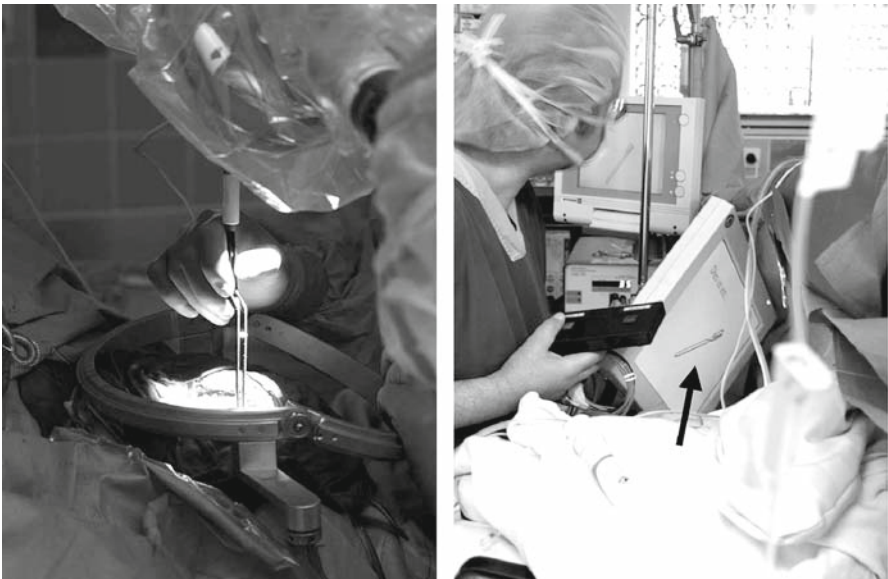
Stimulus presentations are performed by means of a computer system via an LCD screen. After placement of the stimulation forceps to a cortical site, the stimulus presentation is started, which triggers electrical stimulation. During each stimulation (4 seconds' duration), a line drawing of an object together with the carrier phrase "*Dies ist ...*" ("*This is ...*") is presented to the patient. The task is to produce the carrier phrase plus the name of the object. The use of a carrier phrase allows discriminating language and speech errors. If the carrier phrase is produced correctly, three types of errors are possible: an aphasic arrest (the object name is not produced at all), an aphasic disturbance (semantic or phonematic paraphasia instead of the object name) or a naming delay (the object name is produced only after a marked delay). Disorders of speech concern also the production of the carrier phrase. If no utterance is produced at all, this is classified as a speech arrest. If the utterance is dysarthric or marked by strain to speak, this is classified as a speech disturbance. After occurrence of an error, at least one stimulus presentation is performed without stimulation to make sure that the patient is able to perform the task correctly again.

### 1.6 Surgical strategy

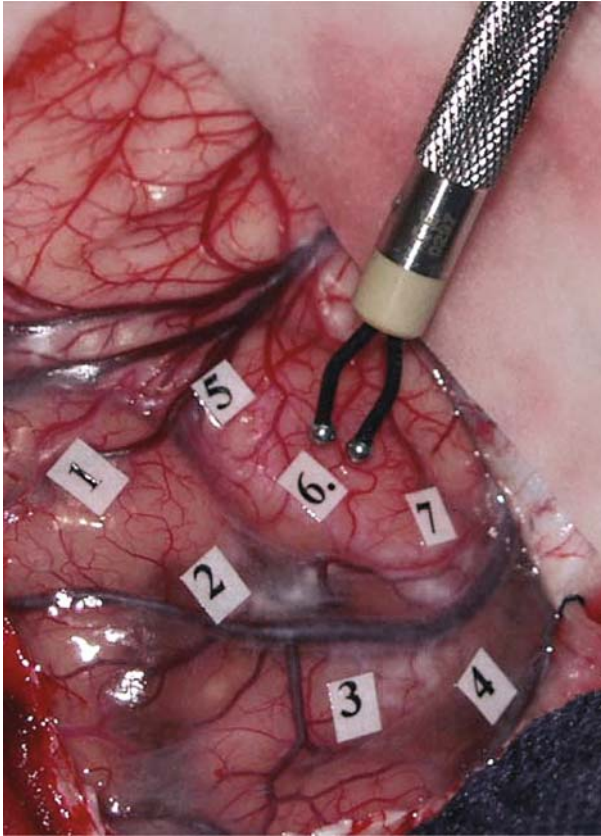
The site of corticotomy has to be tailored according to the results of the cortical mapping: To our experience, the distance of the cortical incision to areas of positive motor or language response should be 10 mm. Usually resection of tumor adjacent to eloquent regions is stopped when a safety distance of 5–10 mm is reached.

## 2. MAPPING OF MOTOR FUNCTION

For electrophysiological mapping of the cortex or white matter tracts to detect relevant sites for motor function, the patient may be operated under general anaesthesia. The patient needs not to be awake for this procedure. Care has to be taken, however, to avoid muscle relaxation since this would elicit false negative results of stimulation! Patient positioning as well as the surgical setup in the OR do not have to be changed for this procedure. In order to be able to detect motor response of facial muscles, hand/arm and foot/leg, these regions have to be exposed to inspection by medical assistants who have to report any motor response related to cortical stimulation. Since the technician operating the monitoring unit for electrophysiological monitoring has to concentrate completely on this task, usually an additional person is required for the period of patient's surveillance during stimulation.



**Fig. 2.** Language mapping: presentation of the drawings for the naming paradigm on a flat screen (arrow) for the patient (*right*) during cortical stimulation with forceps (*left*)



**Fig. 3.** Cortical stimulation at pre-marked sites (sterile numbers) in the vicinity of a low grade tumor

The parameters for electrophysiological stimulation and the surgical strategy are the same as for language monitoring as described above.

## HOW TO AVOID COMPLICATIONS

Possible major pitfalls to be avoided are (i) false/false negative results during the stimulation process (ii) adverse events of stimulation, i.e. epileptic seizures (iii) adverse events of the patient being awake for language mapping, i.e. panic or respiratory insufficiency.

- (i) The surgeon has always to make sure that the equipment is working properly. Online measurement of electrical impedance at the elec-

trode tip is standard on most equipment today; however, the technician using the setup has to be acquainted with and aware of this feature. Routine check-up of the conductive chain from electrical stimulator to stimulation electrode/forceps has to be conducted in each case. The stimulation parameters have to be checked regularly during the procedure, the technician and the neurosurgeon have to communicate this at the beginning of each series of mapping. An absolutely essential prerequisite for cortical mapping of motor function under general anaesthesia is to avoid any muscle relaxants! This has to be communicated extensively to the anaesthesiology team, each new anaesthetist stepping in during surgery has to be aware thereof!

- (ii) To prevent epileptic convulsions due to cortical mapping, in our practice every patient receives anticonvulsant drugs at the day of surgery. Those who have been under medication already before just continue on the day of surgery. Those patients with no history of seizures and thus not currently treated with anticonvulsants receive phenytoine (750 mg i.v.) after initiation of general anaesthesia. This will be weaned off during the following two days.
- (iii) Patients being awake during parts of intracranial surgery have to be familiar with as much details of the procedure and the atmosphere in the OR as possible. Aside of getting familiar with the paradigms to be tested, the patient is thoroughly informed about the positioning on the OR-table, the draping, any procedural steps of surgery as well as noises and actions that may come to his attention during the procedure. Positioning of the patient has to be as comfortable as possible on the OR-table. We allow enough time for the patient at the day of surgery to test and adjust himself to be as comfortable as possible to avoid any distraction of the patient due to pain or aching. During those phases of surgery where cooperation of the patient is not required, he might be mildly sedated to be drowsy or to sleep. However, the end-expiratory  $pO_2$  has to be monitored very carefully by capnometry to avoid any situation of uncontrolled brain swelling or respiratory insufficiency.

## CONCLUSIONS

Brain mapping is an easy to use, very reliable, cost-effective and validated method to detect functional areas for brain surgery. With appropriate experience it is safe and well tolerated both by the patient and the surgical team. It remains still the gold standard for localization of relevant functional regions during microsurgery even in times of functional imaging with MRI.

## References

- [1] Bello L, Gallucci M, Fava M, Carrabba G, Giussani C, Acerbi F, et al. (2007) Intraoperative subcortical language tract mapping guides removal of gliomas involving speech areas. *Neurosurgery* 60: 67-82
- [2] Duffau H, Lopes M, Arthuis F, Bitar A, Sichez J-P, Van Effenterre R, et al. (2005) Contribution of intraoperative electrical stimulations in surgery of low grade gliomas: a comparative study between two series without (1985-1996) and with (1996-2003) functional mapping in the same institution. *J Neurol Neurosurg Psychiatr* 76: 845-851
- [3] Havel P, Braun B, Rau S, Tonn J-C, Fesl G, Brückmann H, et al. (2006) Reproducibility of activation in four motor paradigms: an fMRI study. *J Neurol* 253: 471-476
- [4] Kamada K, Todo T, Masutani Y, Aoki S, Ino K, Takano T, et al. (2005) Combined use of tractography-integrated functional neuronavigation and direct fiber stimulation. *J Neurosurg* 102: 664-672
- [5] Kinoshita M, Yamada K, Hashimoto N, Kato A, Izumoto S, Baba T, et al. (2005) Fiber-tracking does not accurately estimate size of fiber bundle in pathological condition: initial neurosurgical experience using neuronavigation and subcortical white matter stimulation. *NeuroImage* 25: 424-428
- [6] Mori S, Zhang J (2006) Principles of diffusion tensor imaging and its applications to basic neuroscience research. *Neuron* 51: 527-539
- [7] Nimsky C, Ganslandt O, Cerny S, Hastreiter P, Greiner G, Fahlbusch R (2000) Quantification of, visualization of, and compensation for brain shift using intraoperative magnetic resonance imaging. *Neurosurgery* 47: 1070-1080
- [8] Ojemann G, Ojemann J, Lettich E, Berger M (1989) Cortical language localization in left, dominant hemisphere. *J Neurosurg* 71: 316-326
- [9] Penfield W, Boldrey E (1937) Somatic motor and sensory representation in the cerebral cortex of man as studied by electrical stimulation. *Brain* 60: 389-443
- [10] Penfield W, Rasmussen T (1950) *The cerebral cortex of man*. The MacMillan Company, New York
- [11] Peraud A, Ilmberger J, Reulen H-J (2004) Surgical resection of gliomas WHO grade II and III located in the opercular region. *Acta Neurochir (Wien)* 146: 9-18
- [12] Quinones-Hinojosa A, Ojemann SG, Sanai N, Dillon WP, Berger MS (2003) Preoperative correlation of intraoperative cortical mapping with magnetic resonance imaging landmarks to predict localization of the Broca area. *J Neurosurg* 99: 311-318

- [13] Rau S, Fesl G, Bruhns P, Havel P, Braun B, Tonn J-C, et al. (2007) Reproducibility of activations in Broca's area with two language tasks: a functional MR imaging study. *Am J Neuroradiol* 28: 1346-1353
- [14] Taylor MD, Bernstein M (1999) Awake craniotomy with brain mapping as the routine surgical approach to treating patients with supratentorial intraaxial tumors: a prospective trial of 200 cases. *J Neurosurg* 90: 35-41
- [15] Whittle IR, Borthwick S, Haq N (2003) Brain dysfunction following 'awake' craniotomy, brain mapping and resection of glioma. *Br J Neurosurg* 17: 130-137



### **Joerg-Christian Tonn**

Joerg-Christian Tonn is Director of the Department of Neurosurgery, University Hospital, Ludwig-Maximilians-University Munich. Born 1958 in Frankfurt/Main, Germany, married, two children. 1983 state exam at Justus-Liebig-Universität Gießen/Germany; neurosurgical training at the Department of Neurosurgery, University Hospital of Gießen/Germany; post doctoral lecturing qualification (Habilitation) 1993 at the University of Würzburg, Medical School, and 1997 appointment as C3 Professor for Neurosurgery at Julius-Maximilian-University Würzburg/Germany. As from 1996 Vice-Director of Department of Neurosurgery, University-Hospital Würzburg/Germany. Member of several national societies; member/chairman of several committees in national and international societies.

**Contact:** Joerg-Christian Tonn, Ludwig-Maximilians-University, Klinikum Grosshadern, Marchioninstr. 15, 81377 Munich, Germany  
E-mail: Joerg.Christian.Tonn@med.uni-muenchen.de

---

# **INTRAOPERATIVE NEUROPHYSIOLOGY IN NEUROSURGERY**

V. DELETIS

## **INTRODUCTION**

As a rule in any scientific discipline, especially in clinical neuroscience, a reliable and simple methodology is the ultimate goal. The same rule can be implemented in the field of intraoperative neurophysiology (ION), a sub-discipline in clinical neurophysiology.

At the very beginning of its development, the original idea for ION was to evaluate online the functional integrity of the nervous system intraoperatively. But the practicality of this idea and its realization faced many problems, which resulted in the neurosurgeons' lack of confidence that ION could help them reduce neurosurgical morbidity. Eventually, a development in neuroanesthesia and new reliable and specific methods in monitoring different parts and tracts of the nervous system slowly contributed to the confidence gained in using ION as an everyday practice.

In this chapter we will take a nonconventional approach to the present achievements and possibilities of ION as it continues to prevent and document intraoperatively induced injuries to the nervous system. In addition to these achievements, ION now serves as an excellent education tool for the young neurosurgeons.

## **METHODOLOGIES FOR MONITORING THE FUNCTIONAL INTEGRITY OF THE MOTOR PATHWAYS**

### **1. MOTOR EVOKED POTENTIALS - MONITORING AND MAPPING OF THE CORTICOSPINAL TRACT**

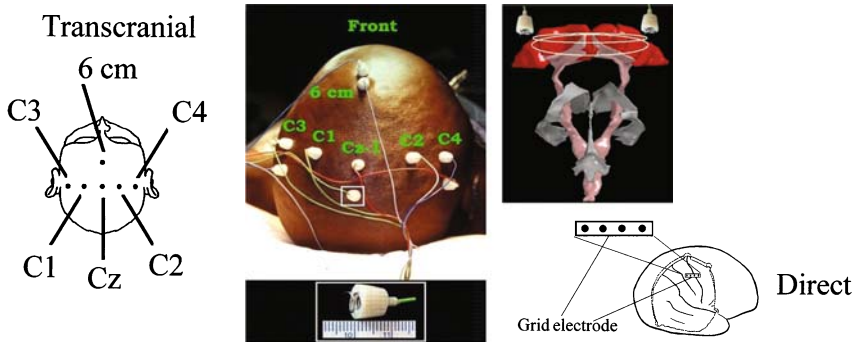
These methodologies are represented in Fig. 1 and they are (a) the monitoring of fast conducting neurons of the corticospinal tract (CT) in the form of D- and I-waves by means of epidural electrodes and (b) monitoring of muscle motor evoked potentials (mMEPs) from the limb muscles. Both methods require the use of transcranial electrical stimulation (TES).

One method can substitute the other except in monitoring surgeries for intramedullary spinal cord tumors, in which it is essential to use both methods [6, 7]. Another example in using a monitoring combination of MEPs with somatosensory evoked potentials (SEPs) is presented in Fig. 2. The disappearance of mMEPs can intraoperatively predict the motor outcome and

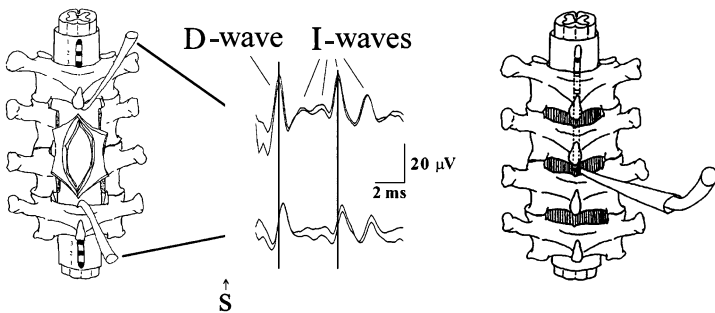


distinguish between permanent versus transient motor deficits. Furthermore, even in cases when mMEPs disappear, the D-wave presence encourages the surgeon to continue operating because, postoperatively, the patient will end up only with transient motor deficits (Fig. 3). This is an important part of the ION methodology, specifically in surgeries for intramedullary spinal cord tumors.

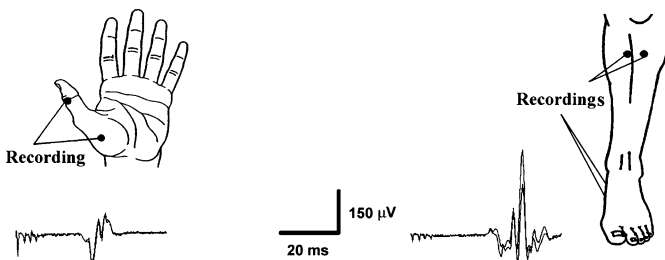
In supratentorial surgeries, using both methods of MEPs monitoring gives us the same predictable results as those in intramedullary spinal cord tumor



**Epidural Recording**



**Muscle Recording**



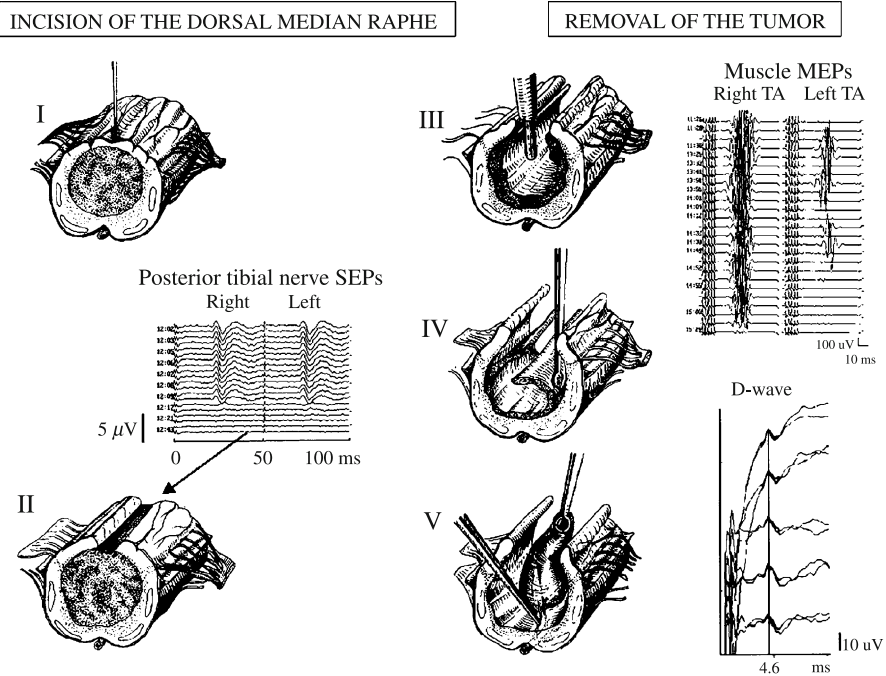
surgeries, i.e., they can predict early postoperative motor status that distinguishes between permanent and transient motor deficits (Fig. 4). Today, most of the neurosurgical centers use only mMEPs in supratentorial surgeries in combination with SEPs. The usefulness of mMEPs and SEPs combination is presented in Fig. 5, in which lesions of perforating branches to the internal capsula supplying the CT were damaged with consecutive mMEPs losses but with intact SEPs. This translates to what is referred to as “pure motor hemiplegia” in the postoperative clinical picture.

## 2. THE D-WAVE COLLISION TECHNIQUE WITH INTRAOPERATIVE CT MAPPING OF THE SPINAL CORD

Further methodological development of recording D-waves has brought new methods in intraoperatively mapping the CT within the spinal cord (collision of the D wave) [4]. This technique allowed us to intraoperatively map and find the anatomical position of the CT within the surgically exposed spinal cord. It involves simultaneous TES of the motor cortex with concurrent stimulation of the CT from the surgically exposed spinal cord (Fig. 6).

The D-wave is elicited by TES and recorded cranially and caudally to the spinal cord tumor. Simultaneous to TES, we stimulated the surgically exposed spinal cord (caudal to the tumor site) with a miniature bipolar hand-held probe (#5522.010, Inomed GmbH, Germany). The tips of the probe were 1 mm apart and were delivering a constant current stimulus up to 2.5 mA in intensity, with 0.5 ms in duration and a repetition rate of 1 Hz. Whenever the stimulating probe was in close proximity to the CT, the D-wave, elicited by TES, collided with the “anti D-wave” elicited by the spinal cord stimulation. The collision results in diminished amplitude of the D-wave recorded cranially to the lesion. This technique allows modifying the resection of spinal cord tumors (or other pathology) by helping the surgeon locate and “visualize” the CT tract position within the spinal cord.

**Fig. 1.** *Top:* Schematic (*left*) and actual illustration (*middle*) of electrode placement for transcranial electrical stimulation and direct stimulation of the motor cortex (*right*). C1, C3, Cz, C2 and C4 are the positions of the stimulating electrodes aligned over the projection of the motor strip to the head. Upper right is the schematic of the coronal posterior view to the motor cortex (in red) and corticospinal tracts (in pink) with an electrical field between the stimulating electrodes. Schematics of the grid electrode (*right*) overlying the exposed motor and sensory cortexes *Middle:* Schematic diagram of the positions of the catheter electrodes (each with three recording cylinders) placed cranially to the tumor (control electrode) and caudally to the tumor to monitor the descending signals after passing through the surgery site (*left*). In the middle are D- and I-waves recorded rostrally and caudally to the tumor site. On the right, the placement of an epidural electrode is depicted percutaneously or through a flavectomy/flavotomy or when the spinal cord is not exposed. *Bottom:* Recordings of MEPs from the thenar, tibial anterior and abductor hallucis muscles after eliciting them with a multipulse stimulus applied either transcranially or over the exposed motor cortex (Modified from ref. 2)



**Fig. 2.** Neurophysiological monitoring during surgery for ISCTs. Incision of the dorsal median raphe (*left panels*): myelotomy is carried out by using a fine blade or laser. In spite of any attempts to stay within the median raphe (*Panel I*) to avoid damage to the dorsal column, SEPs are frequently compromised or lost during this surgical step (*Panel II*). Although the drop in amplitude is usually reversible, SEPs may remain unmonitorable for several hours. Removal of the tumor (*right panels*): there is direct access to the tumor after dorsal columns are separated. If there is no adequate lateral visualization to safely remove the tumor without excessive retraction to normal neural tissues, ultrasonic aspiration can be used to debulk the central part of the tumor (*Panel III*). At this point it is possible to gently dissect the tumor from the neural tissue. In doing so, traction on the corticospinal and other descending motor tracts can occur (*Panel IV*). Accordingly, muscle MEPs as well as epidural MEPs (*D-wave*) should be strictly monitored during this surgical step. The upper right panel shows the disappearance of the left tibialis anterior MEP during tumor removal. The lower right panel illustrates a stable D wave, which warrants good long-term motor outcome (see text for more details). Finally, the ventral part of the tumor is detached from the anterior spinal cord where perforating vessels from the anterior spinal artery are located (*Panel V*). Here again it is critical to monitor motor pathways since a vascular injury to the cord may result in an irreversible severe motor deficit (From ref. 14)

Similar ways in CT-mapping, as the previously mentioned collision technique, have been used during cerebello-peduncular tumor surgeries, which are often burdened with a high incidence of CT-lesioning resulting in postoperative hemiplegia (Fig. 7). Usually, the initial incision to the cerebellar peduncle results in a lesion to the CT.

**Principles of MEP Interpretation  
(spinal cord surgery)**

D-wave	Muscle MEP	Motor Status
unchanged or 30-50 % decrease	preserved	unchanged
	lost uni-or bilaterally	temporary motor deficit
>50 % decrease	lost bilaterally	long term motor deficit

**Fig. 3.** Principles of MEPs interpretation during surgery for intramedullary spinal cord tumors (From ref. [2])

**Principles of MEP Interpretation  
(supratentorial surgery)**

D-wave	Muscle MEP	Motor Status
unchanged or <30 % decrease	preserved	unchanged
	diminished	temporary motor deficit
>30 % decrease	lost	long term motor deficit

**Fig. 4.** Principles of MEPs interpretation during supratentorial surgery (Modified from refs. [17] and [6])

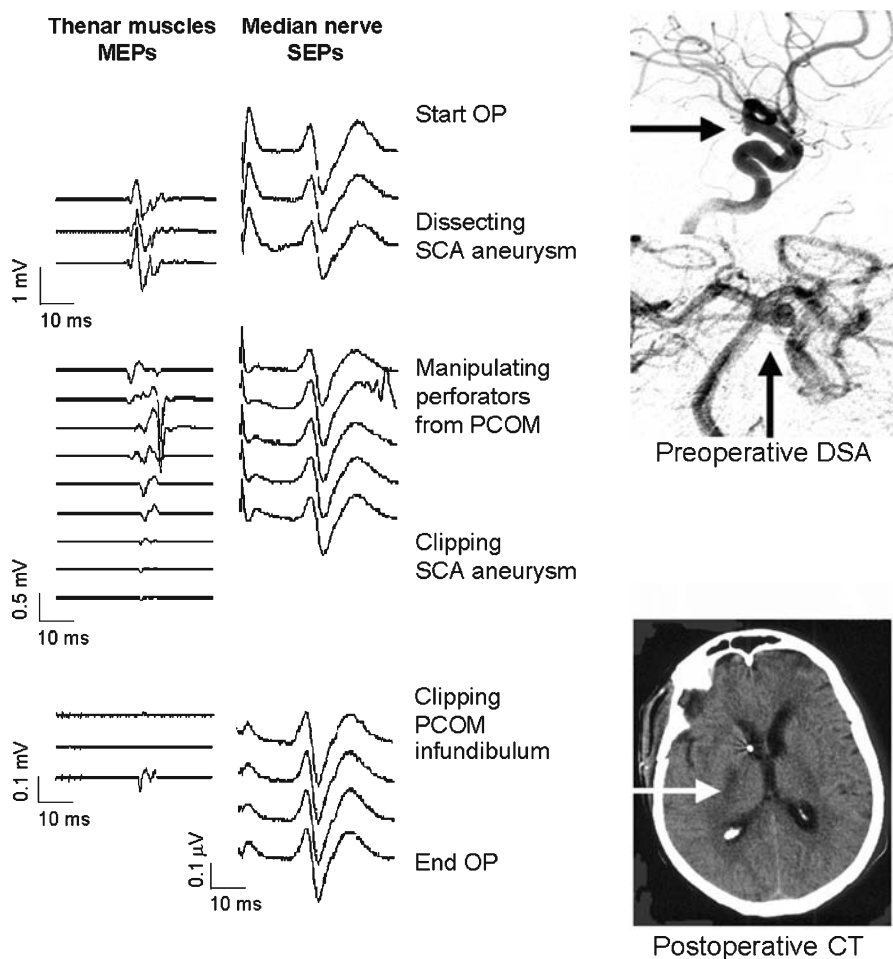
**3. MAPPING OF CRANIAL NERVES MOTOR NUCLEI AT THE FLOOR OF THE FOURTH VENTRICLE**

During surgery for cervicomedullary junction tumors, the medulla and brainstem have a high risk of lesioning to the cranial nerve motor nuclei in addition to other very important and condensed structures in these miniscule anatomical spaces. The main features of these methodologies are presented in Fig. 8. Figure 9 presents a typical case for monitoring this type of surgery and follows each of the main steps of this procedure.

Figure 10, taken from the work of Morota et al. [12], shows typical examples of anatomical displacement of upper and lower cranial nerve motor nuclei due to the growth pattern of the brainstem tumors as revealed by this method.

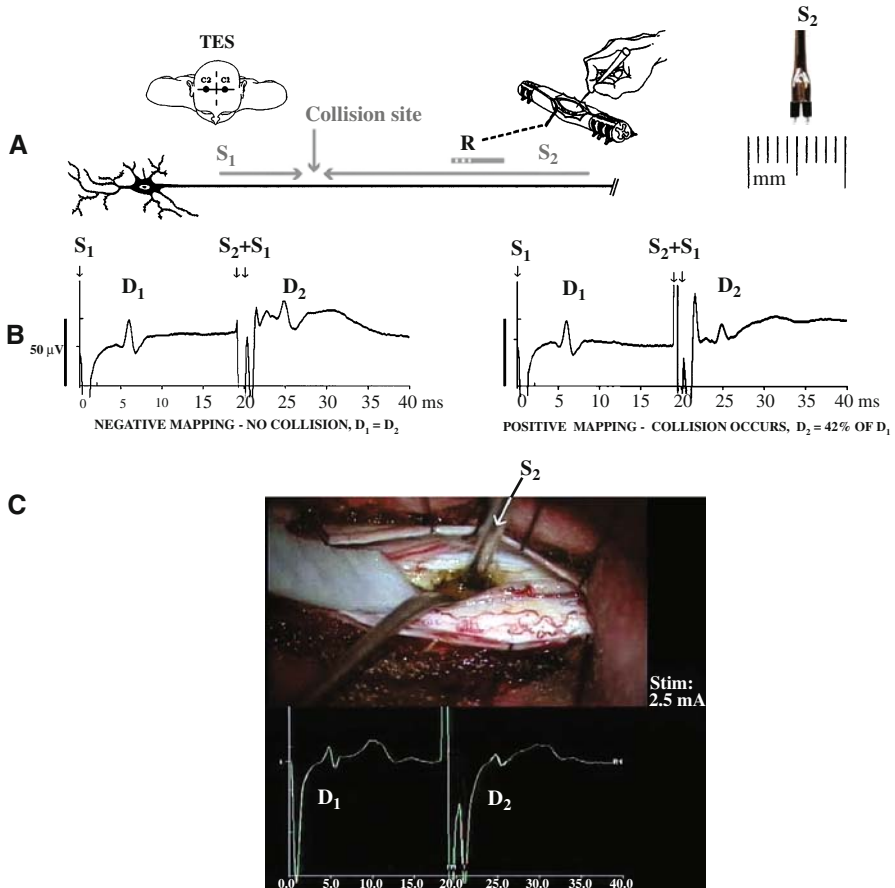
**4. MONITORING CORTICOBULBAR MOTOR EVOKED POTENTIALS**

In order to overcome the limitations of the cranial nerve motor nuclei mapping methods, a new method has been developed to continuously monitor its functional integrity. This method operates with TES of the motor cortex and subcortical motor pathways with recordings of corticobulbar MEPs



**Fig. 5.** A new motor deficit resulting from a subcortical stroke, following the perforating manipulation reflected by the loss of transient MEPs and the subsequent deterioration of MEPs despite stable SEPs. Thenar MEPs and median nerve SEPs were recorded during dissection and clipping of an aneurysm on the basilar artery, superior cerebellar artery and the posterior communicating artery (PCOM) infundibulum via right pterional approach. MEPs impairment with no changes in the parameters of SEPs occurred during the manipulation of perforators from the PCOM. Postoperatively, the patient experienced a new slight hemiparesis, and brain CT scans revealed a small basal ganglia infarction (From ref. 13)

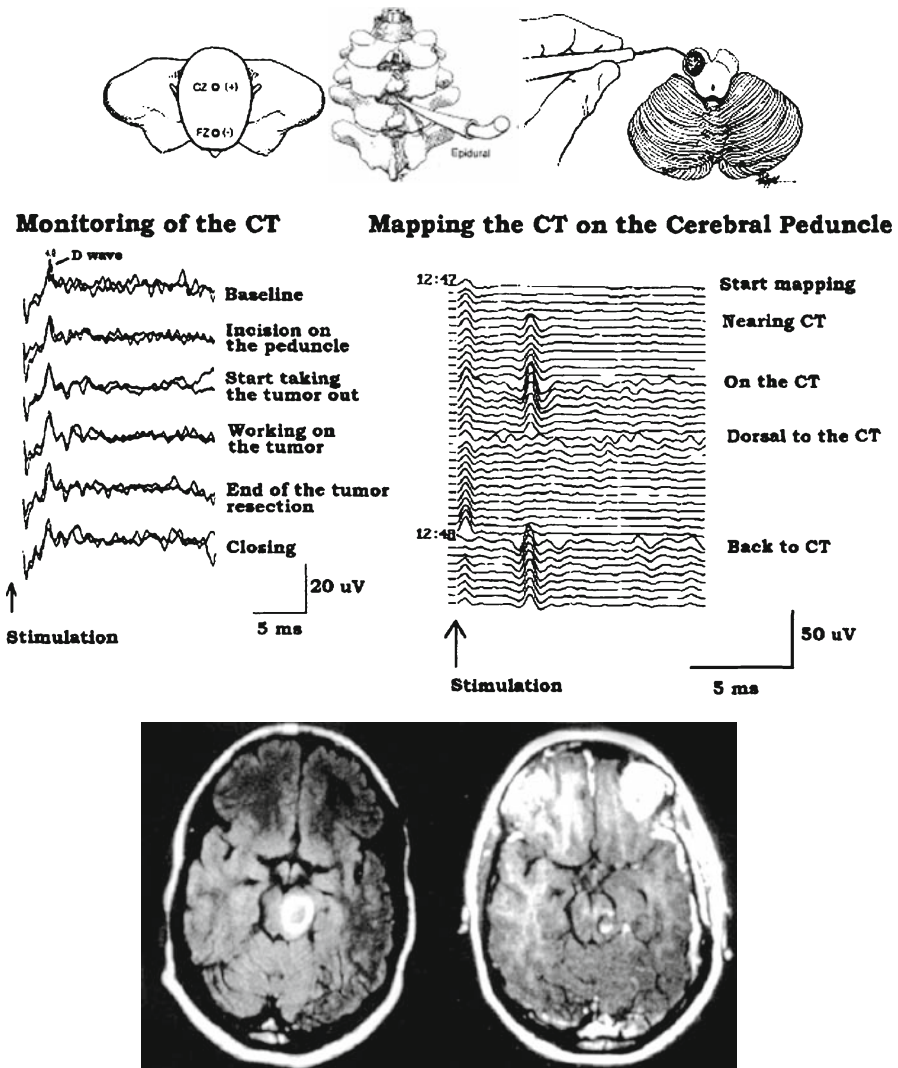
(CoMEPs) from the muscles innervated by motor cranial nerves (Fig. 11). Further refinement of this methodology is the monitoring of CoMEPs for vagal nucleus together with monitoring of the functional integrity of the vagal nerve. Details of placement of recording “hook-wire electrodes” in the vocal muscles, after patient was intubated, are presented in Fig. 12.



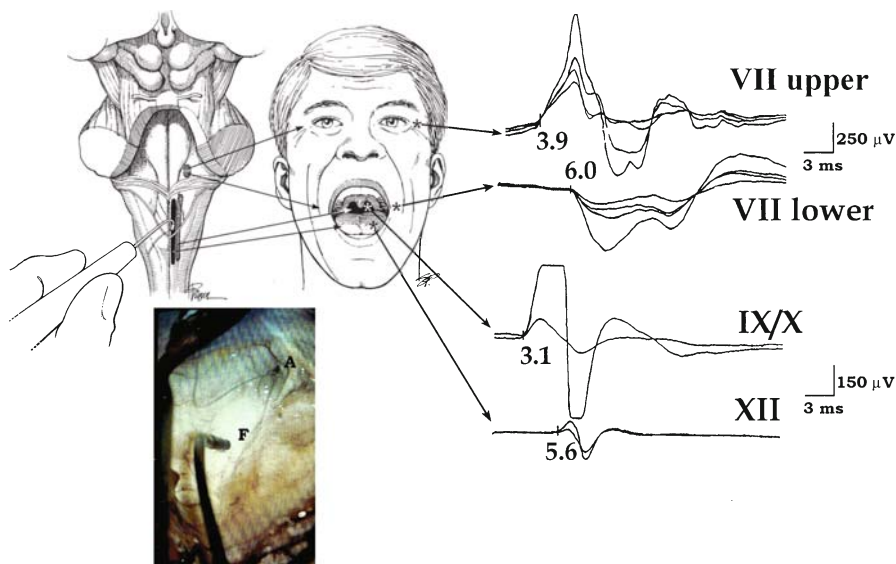
**Fig. 6.** Mapping of the CT using the D wave collision technique (see text for explanation). **A** S<sub>1</sub> = Transcranial Electrical Stimulation (TES). S<sub>2</sub> = Spinal Cord Electrical Stimulation. D<sub>1</sub> = Control D wave (TES only). D<sub>2</sub> = D wave after combined stimulation of the brain and spinal cord. R = The cranial electrode for recording the D wave in the spinal epidural space. *To the right:* A tip of the hand held stimulating probe with a scale in millimeters. **B** *Left:* Negative mapping results (D<sub>1</sub> = D<sub>2</sub>). *Right:* positive mapping results (D<sub>2</sub> wave amplitude significantly diminished after collision). **C** Intraoperative mapping of the CT within spinal cord in 44-year-old patient with intramedullary arterio-venous malformation at T3–T5 level. Stimulating probe delivering 2.5 mA current pulse in the close proximity with CT, revealed by a decrement of the D<sub>2</sub> wave in comparison with D<sub>1</sub> wave (control) (Modified from ref. 3)

## SOMATOSENSORY EVOKED POTENTIALS

Monitoring of somatosensory evoked potentials (SEPs) along with brainstem auditory evoked potentials (BAEPs) is one of the oldest ION-methods. After



**Fig. 7.** Mapping and monitoring of the corticospinal tract (CT) during surgery to remove a left cerebral peduncle tumor in a 27-year-old woman. *Bottom left:* Preoperative axial view of T1-weighted MR image with gadolinium documented complete removal of the tumor. The incision was placed in the area where no response to the stimulation of the cerebral pedunculus was recorded (see middle right panel). Postoperatively, the patient had preserved preoperative motor function. *Top right:* Mapping of the CT on the cerebral peduncle is shown schematically. The cerebral peduncle is being mapped by a hand-held monopolar probe. As the probe neared the CT, responses were recorded from epidural catheter (middle right). Responses were consistently repeatable. Stimulation intensity was 2 mA, stimulation rate was 4 Hz, and 4 responses were averaged. *Middle left:* Monitoring of the CT during tumor resection. After CT mapping, MEPs were continuously monitored by recording D waves epidurally after transcranial electrical stimulation. The D waves remained stable throughout the procedure (From ref. 1)



**Fig. 8.** Mapping of the brain stem cranial nerve motor nuclei. *Upper left:* Drawing of the exposed floor of the fourth ventricle with the surgeon's hand-held stimulating probe in view. *Upper middle:* Sites of insertion of wire hook electrodes for recording the muscle responses. *Upper right:* Compound muscle action potentials recorded from the orbicularis oculi and oris muscles after stimulation of the upper and lower facial nuclei (*upper two traces*) and from the pharyngeal wall and tongue muscles after stimulation of the motor nuclei of the operating microscope with hand stimulating a floor of the fourth ventricle (F) Caudal to aqueduct Silvii (A) (From ref. 1)

more than a half century of use and a tumultuous beginning of nonfulfilled expectations that they could predict injury to the motor system, SEPs have come ahead and established their value as (a) an excellent predictor of the cortical ischemia, (b) an intraoperatively finder of the central sulcus (Fig. 13) and (c) the guideline for shunt placement during carotid endarterectomy.

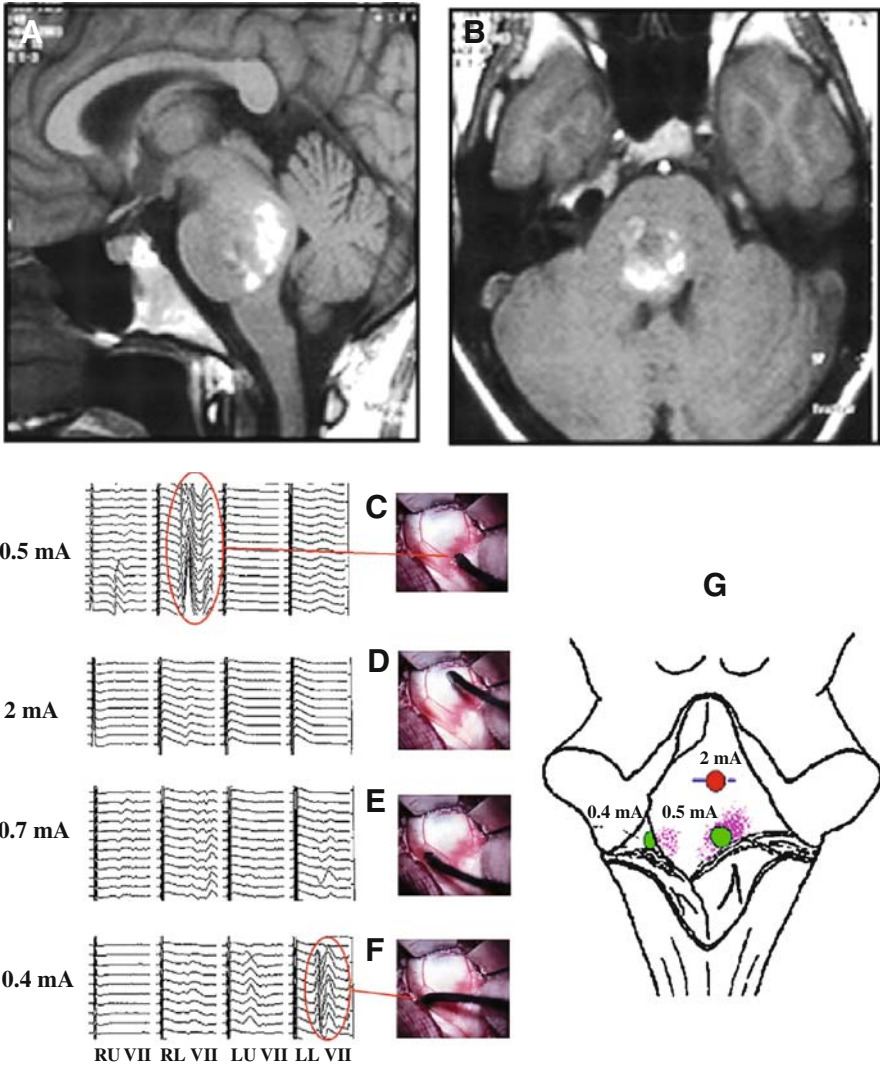
We should not underestimate the value of this method, but it should be restrained as the indicator of the functional integrity of the sensory and not of the motor system.

## INTRAOPERATIVE NEUROPHYSIOLOGICAL MAPPING OF THE DORSAL COLUMN OF THE SPINAL CORD

One of the interesting uses of SEPs is the dorsal column mapping method. This methodology can determine the anatomical position of the dorsal fissure and can correctly indicate a myelotomy, especially in surgeries for syringomyelic cyst and shunt placement (Fig. 14).



Dorsal column mapping (DCM) is based on two basic principles: first, evoked potentials that travel through the dorsal columns can be recorded. Second, the site of the recording electrode where the maximum amplitude is attained represents the point on the electrode in closest proximity to the dorsal columns. For recording these traveling waves, a miniature multi-electrode is placed over the surgically exposed dorsal columns of the spinal cord. This electrode consists of eight parallel wires, 76  $\mu\text{m}$  in diameter, 2 mm length, placed 1 mm apart and embedded in a 1  $\text{cm}^2$  (approximately) silicone plate. An



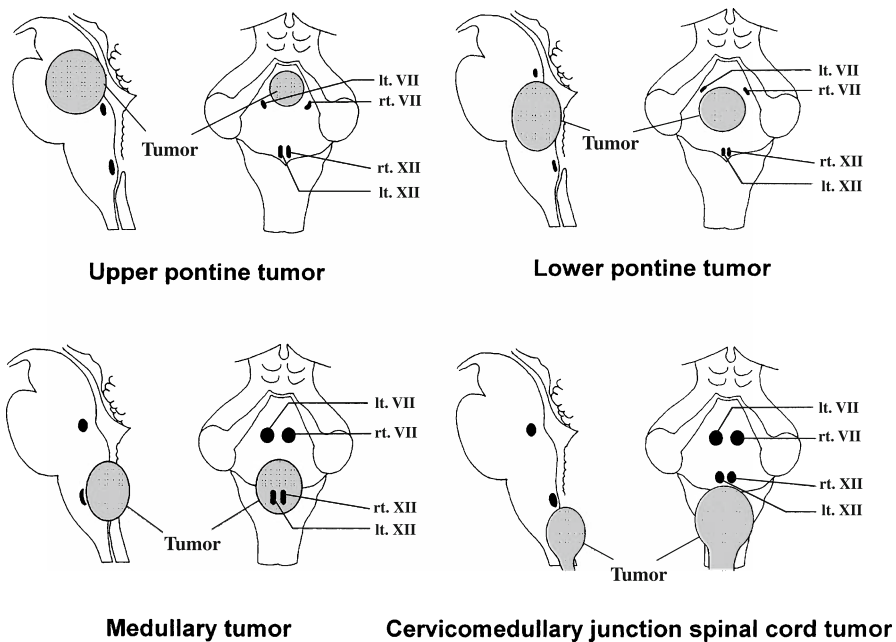
extremely precise amplitude gradient is observed as the conducted potentials pass beneath the electrodes after right and left tibial and median nerve stimulations. The amplitude gradient of the conducted potentials indicates the precise location of the functional midline corresponding to the dorsal fissure of the spinal cord (i.e., usually the optimal site for myelotomy). This data can be used by the neurosurgeon to prevent injury to the dorsal columns, which could occur through an imprecise midline myelotomy. Thus, it is especially useful during surgery for intramedullary spinal cord tumors or during spinal cord incision for the placement of a shunt to drain syringomyelic cysts. The use of an Nd:YAG hand-held laser (SLT, Montgomeryville, PA) with a 200  $\mu\text{m}$  tip for myelotomy is a prerequisite for optimal results and for avoiding collateral thermal and physical damage to the dorsal columns.

## INTRAOPERATIVE MONITORING OF THE SACRAL NERVOUS SYSTEM

A relatively high percentage of pediatric surgical pathologies is in the lumbosacral (LS) spinal cord and sacral roots within the cauda equina, where the LS nervous system can be damaged. In the last few years, effective methods for the intraoperative testing of the LS nervous system have been developed [16]. We have had much success with these and will describe each in detail. From a didactic standpoint, we have categorized these methods based on recordings of neurophysiological signals of sensory systems (“afferent events”) and record-



**Fig. 9.** Neurophysiological mapping of the floor of the fourth ventricle. **A** and **B** Sagittal and axial MR T1-weighted images of a 24-year-old female harboring a hemorrhagic pontine cavernoma. The patient underwent surgery in semi-sitting position. After opening of the dura, an extensive neurophysiological mapping of the floor of the fourth ventricle was performed. CMAPs were recorded from muscles innervated by the right (*R*) and left (*L*) facial nerves. *U* upper, i.e. orbicularis oculi; *L* lower, i.e. orbicularis oris. **C–F** Left to right: stimulation intensity thresholds, CMAPs and stimulation site on the floor of the fourth ventricle. Anatomy of the dorsal aspect of the brainstem is completely distorted by the cavernoma. Midline is shifted to the left and there are dyschromic areas on the ependyma. **C** When stimulating the dyschromic area in the lower pons, CMAPs are obtained from RU and RL at 0.5 mA. **D** This threshold significantly increases up to 2 mA when stimulation is moved upward, where one would expect facial motor nuclei according to normal anatomy. **E** moving stimulation downwards and to the left side, threshold drops again to 0.7 mA but still elicits CMAPs from right side muscles. Finally, moving the hand-held probe to the far left, CMAPs from left side muscles are elicited at a very low intensity (0.4 mA). **G** Schematic drawing summarizing mapping results. Facial nerve motor nuclei appeared to be significantly displaced caudally with respect to the location where they were expected, according to normal anatomy. Moreover, left nuclei were displaced very laterally and the physiologic midline was also moved to the left. The safest entry-point turned out to be located in the upper pons. It is noteworthy that, without mapping, the surgeon would have been tempted to enter the brainstem in the area with a more marked dyschromia of the ependyma, since one would expect this route to give the shortest access to the cavernoma/hematoma. Interestingly, as seen in **C**, this area corresponds to that with one of the lowest thresholds (0.5 mA) and entering the brainstem here would have likely resulted in postoperative facial palsy (From ref. 15)

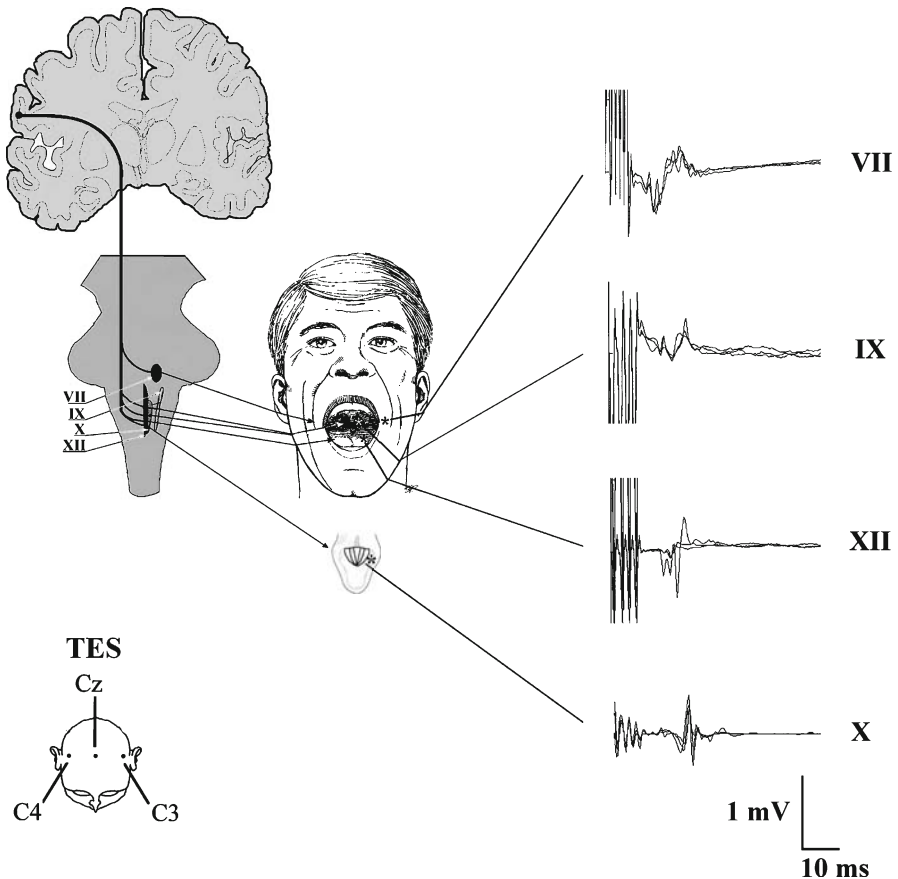


**Fig. 10.** Typical patterns of cranial nerve motor nuclei displacement by brain stem tumors in different locations. *Upper and lower pontine tumors:* Pontine tumors typically grow to push the facial nuclei around the edge of the tumor, suggesting that a precise localization of the facial nuclei before tumor resection is necessary to avoid their damage during surgery. *Medullary tumors:* Medullary tumors typically grow more exophytically and compress the lower cranial nerve motor nuclei ventrally; these nuclei may be located on the ventral edge of the tumor cavity. Because of the interposed tumor, in these cases mapping before tumor resection usually does not allow identification of cranial nerve IX/X and XII motor nuclei. Responses, however, could be obtained close to the end of the tumor resection when most of the tumoral tissue between the stimulating probe and the motor nuclei has been removed. At this point, repeated mapping is recommended because the risk of damaging motor nuclei is significantly higher than at the beginning of tumor debulking. *Cervicomedullary junction spinal cord tumors:* These tumors simply push the lower cranial nerve motor nuclei rostrally when extending into the fourth ventricle (From ref. 12)

ings of signals from motor systems (“efferent events”). In intraoperative monitoring practice, they have been incorporated in one set of monitoring protocols (Fig. 15).

## 1. AFFERENT EVENTS

After electrical stimulation of the dorsal penile or clitoral nerves, a variety of neurophysiological signals can be recorded along the sensory pathways conveying this information to the brain. Recording of cerebral SEPs from the scalp after such stimulation has been shown to be very useful in the testing of patients with sacral involvement. Unfortunately, due to its high sensitivity to anesthetics, it cannot be used intraoperatively.

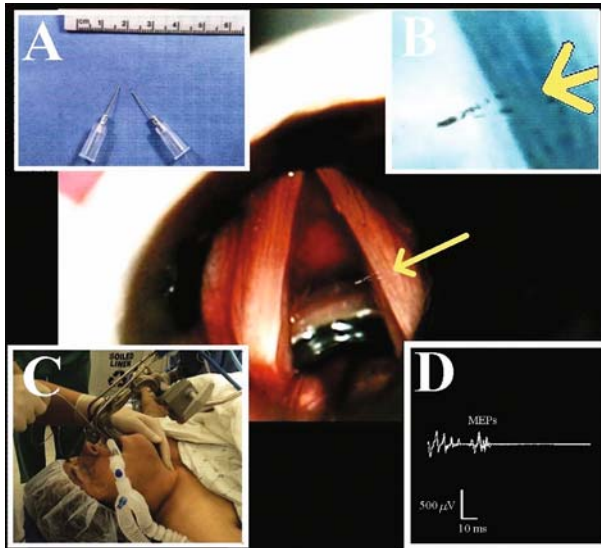


**Fig. 11.** Schematics in intraoperatively eliciting and recording of corticobulbar motor evoked potentials (MEPs from muscle innervated by motor cranial nerves). *Lower left:* Schematic of positioning stimulating electrodes over the scalp. *Upper left:* Schematic of corticobulbar pathways innervating motor cranial nerves nuclei (VII, IX, X, XII). *Middle:* Positioning of recording electrodes inserted in orbicularis oris (N VII), pharyngeal (N IX), tongue (N XII) and vocal muscles (N X) for monitoring corticobulbar MEPs. *Right:* Typical examples of CoMEPs recorded from cranial motor nerves innervated muscles

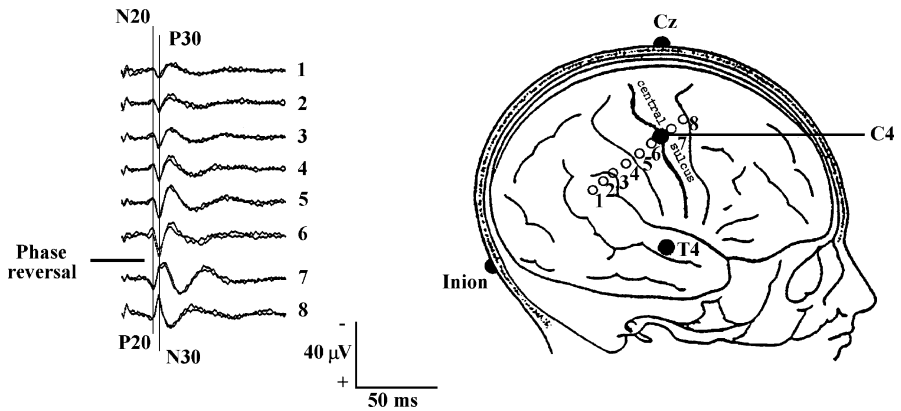
### 1.1 Dorsal root action potential (DRAP)

DRAP recording (Fig. 15, inset 2) in the pudendal nerve afferent fibers, or the “pudendal neurogram” (the more frequently used term), is the mapping method most frequently used for selective dorsal rhizotomy to relieve spasticity in children with cerebral palsy.

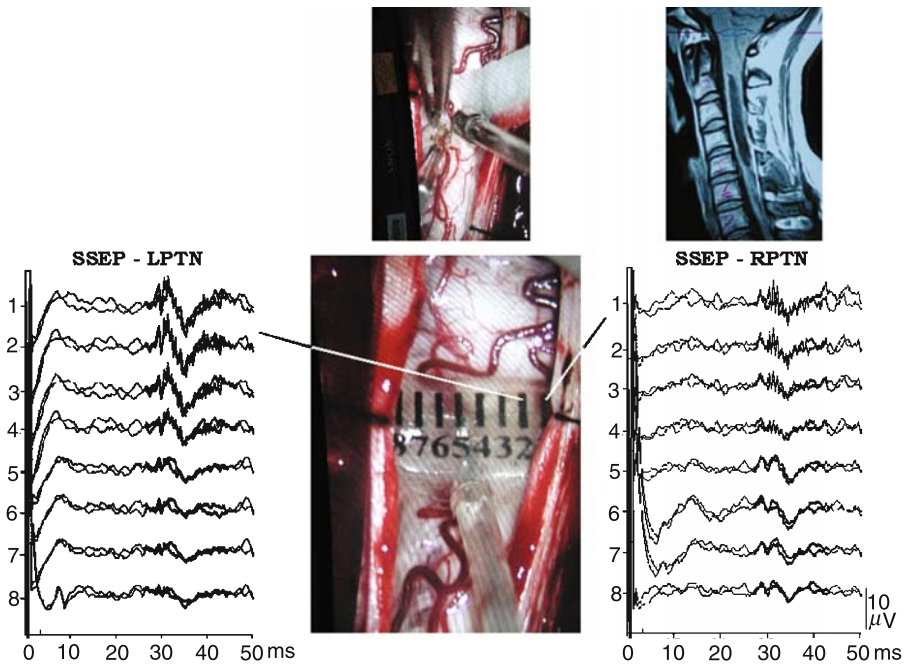
In this surgery, the DRAP is used to quantify the amount of pudendal afferent fibers coming from dorsal penile or clitoris nerves and entering the spinal cord via each of the S1, S2 and S3 dorsal roots. The DRAP is evoked by an electrical stimulation of the penis or clitoris via two cup electrodes fixed on



**Fig. 12.** Composed photograph of the larynx with the endotracheal tube (*middle*). **A** Needles with hook wire electrode. **B** Hook wire electrode placed in the right vocalis muscle. **C** Insertion of the electrode through the rigid laryngoscope. **D** Recording of the CoMEPs from vocalis muscle



**Fig. 13.** Identification of the central sulcus obtained by the phase reversal of the median nerve cortical somatosensory evoked potentials. *Right*: Schematic drawing of the exposed brain surface with a grid electrode position orthogonally to the central sulcus. *Left*: Recorded evoked potentials phase reversed between electrodes 6 and 7, showing a “mirror image” of the evoked potential between motor and sensory cortex, indicating the central sulcus lying between electrodes 6 and 7 (From ref. 2)

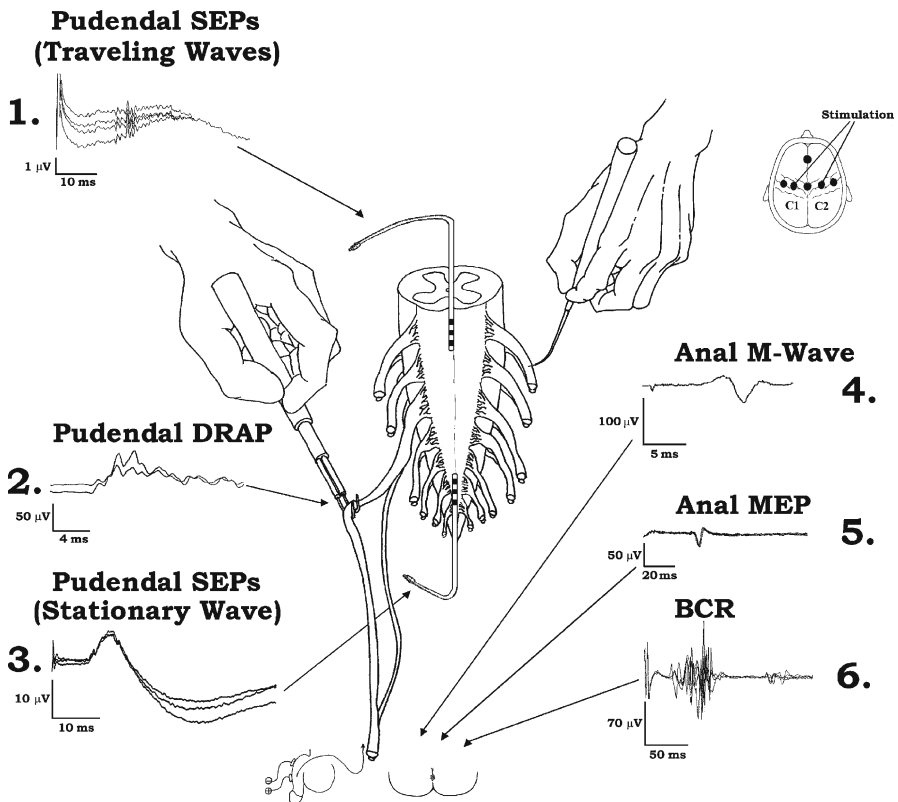


**Fig. 14.** Dorsal column mapping in an 18-year-old patient with a syringomyelic cyst between the C2 and C7 segments of the spinal cord. *Upper right:* MRI showing syrinx. *Lower middle:* Placement of miniature electrode over surgically exposed dorsal column; vertical bars on the electrode represent the location of the underlying exposed electrode surfaces. SEPs after stimulation of the left and right tibial nerves showing maximum amplitude between electrodes 1 and 2 (*lower left and right*). This data strongly indicates that both dorsal columns from the left and right lower extremities have been pushed to the extreme right side of the spinal cord. Using this data as a guideline, the surgeon performed the myelotomy using a YAG laser through the left side of the spinal cord and inserted the shunt to drain the cyst (*upper left*). The patient did not experience a postoperative sensory deficit (From ref. 8)

the dorsal surface of the penis or one on the clitoris and another on the adjacent labia. To record the DRAP, the surgeon frees a dorsal root and isolates it from its neighbors by lifting it outside the spinal canal using a hand-held bipolar hook electrode.

For the purpose of selective dorsal rhizotomy, an S2 root is spared if it carries pudendal afferents. If it is essential to cut the S2 root, it is best to divide it into rootlets and cut only those that do not carry pudendal afferent fibers.

A recent study in 105 cerebral palsy children, it was shown that the distribution of pudendal afferents in individual patients was highly asymmetrical (with respect to both side and sacral roots). One of the most striking aspects of this asymmetry was that 7.6% of patients in this series had all pudendal afferent fibers (from the right and left pudendal nerves) entering the spinal cord via the S2 roots only. These data can explain the significant urogenital and sexual dysfunction after a relatively restrained injury to the sacral roots. We

**AFFERENT EVENTS****EFFERENT EVENTS**

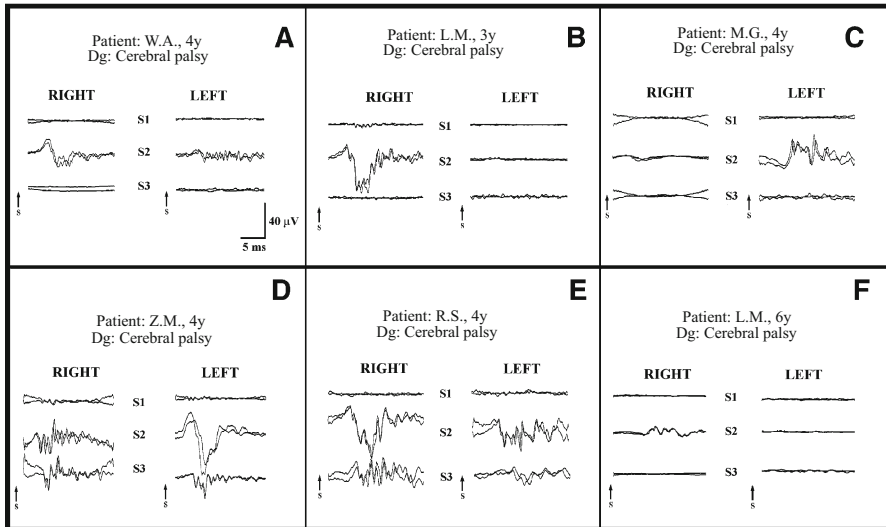
**Fig. 15.** Neurophysiological events used to intraoperatively monitor the sacral nervous system. *Left:* "Afferent" events after stimulation of the dorsal penile or clitoral nerves and recording over the spinal cord: (1) pudendal SEPs, traveling waves; (2) pudendal DRAPs; and (3) pudendal SEPs, stationary waves, recorded over the conus. *Right:* "Efferent" events: (4) anal M wave recorded from the anal sphincter after stimulation of the S1–S3 ventral roots, (5) anal motor-evoked potentials recorded from the anal sphincter after transcranial electrical stimulation of the motor cortex, and (6) bulbocavernosus reflex obtained from the anal sphincter muscle after electrical stimulation of the dorsal penile or clitoral nerves (From ref. 2)

suggest that mapping the DRAP during selective dorsal rhizotomy be mandatory if S2 roots are considered for lesioning. Furthermore, we suggest that this method should be used in any surgery where S2 roots can be damaged.

### 1.2 Pudendal SEP - stationary wave

This potential, obtained by electrically stimulating the dorsal penis or clitoris nerves (Fig. 15, inset 3), sometimes called spinal segmental response, can easily be recorded when the conus region and root entry zone from S2 to S4 roots are

### Mapping of Pudendal Afferents



**Fig. 16.** Six characteristic examples of DRAP showing the entry of a variety of pudendal nerve fibers to the spinal cord via S1–S3 sacral roots. Symmetrical distribution of DRAPs confined to one level, S2 (**A**) or three levels (**D**). Asymmetrical distribution of DRAPs confined to the side (**B**), only one root (**C** and **F**), or all roots except the right S1 (**E**). Recordings were obtained after electrical stimulation of bilateral penile/clitoral nerves (From ref. 16)

exposed. If an electrode is placed precisely over this anatomical structure, a high amplitude potential could be recorded, representing interneuron activity of the gray matter of the S2 to S4 spinal cord segment that is generated by sensory afferents from the bilateral dorsal penis/clitoris nerve.

#### 1.3 Pudendal SEP – traveling waves

This potential (Fig. 15, inset 1) is rarely recordable from the dorsal column of the spinal cord and has rather low amplitude (1–2 μV). Due to the rare recordability and low amplitude, we did not find this potential suitable for intraoperative monitoring of the sacral nervous system integrity.

## 2. EFFERENT EVENTS

Three kinds of motor events can be recorded intraoperatively from the motor part of the sacral nervous system: motor evoked potentials from the anal sphincter (anal MEP), the M wave after direct stimulation of motor roots of the cauda equina, and the bulbocavernosus reflex. Each of these events represents a different kind of activity that belongs to the motor part of the sacral nervous system.

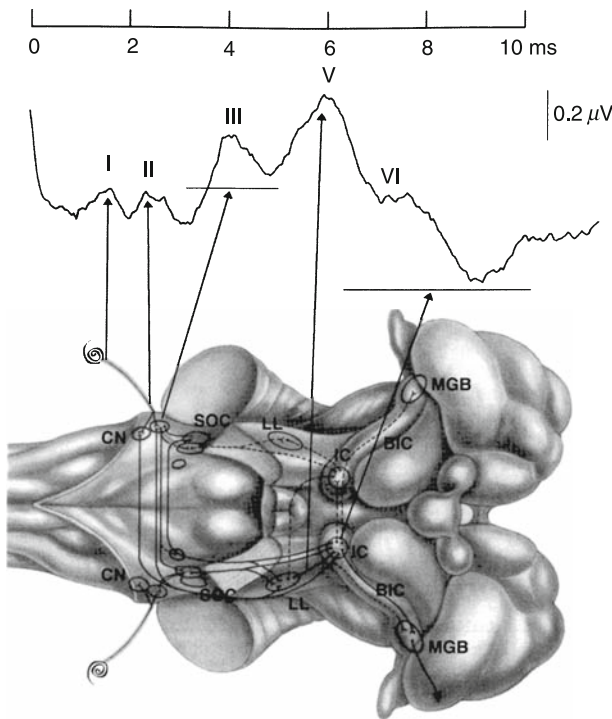


### 2.1 Anal sphincter M wave

Mapping of S1, S2 and S3 motor roots that contribute to the motor part of the pudendal nerves can easily be performed by directly stimulating the exposed cauda equina with a hand-held probe, and by recording the electrical activity from the anal sphincter muscle (anal M wave) through tiny wire hook electrodes inserted preoperatively in the right and left hemisphincter muscles (Fig. 15, inset 4). Mapping motor sacral roots within the cauda equina can be very useful in detecting a “hidden” root within the tumor or by testing the phylum terminale for adherent sacral roots during untethering of a tethered spinal cord.

### 2.2 Anal MEP (anal sphincter muscle MEP)

This efferent response from the anal sphincter can be elicited and monitored by transcranial electrical stimulation over the C1/C2 scalp points (Fig. 15, inset 5), in similar fashion as TES for eliciting MEPs from the limb muscles. The recorded response indicates the functional integrity of the descending pathways for suprasegmental volitional control to the anal sphincter, as well



**Fig. 17.** Auditory pathway drawing within the anatomy of the brain stem with BSAEP generators. *CN* Cochlear nuclei, *SOC* superior cochlear complex, *LL* lateral lemniscus, *IC* inferior colliculus. *MGB* medial geniculate body, *BIC* brachium of inferior colliculus (From ref. 10)

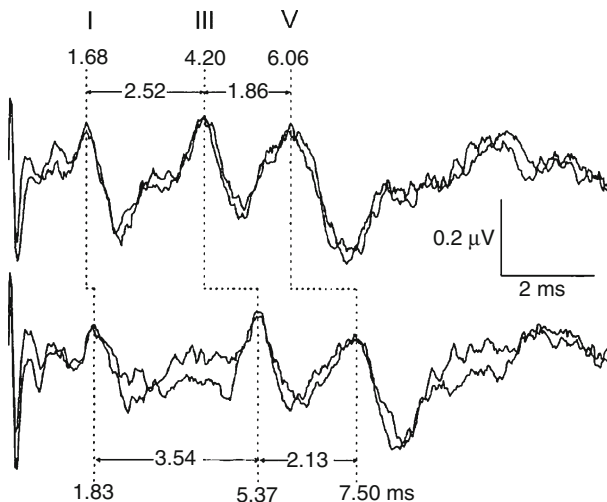
as the motor part of the pudendal nerves, from the anterior horn to anal muscle. Sometimes deep anesthesia can be an obstacle for eliciting anal MEP.

### 2.3 Bulbocavernosus reflex (BCR)

The BCR is an oligosynaptic reflex mediated through the S2–S4 spinal cord segments, elicited by electrical stimulation of the dorsal penis or clitoris nerves with the reflex response recorded from any pelvic floor muscle (Fig. 15, inset 6). The afferent paths of the BCR are the sensory fibers of the pudendal nerves; its reflex center is the S2–S4 spinal segment, the efferent paths are the motor fibers of the pudendal nerves and anal sphincter muscles. In neurophysiological labs, the BCR is usually recorded from the bulbocavernosus muscles, and this is where it gets its name. The advantage of BCR monitoring is that it tests the functional integrity of three different anatomical structures: sensory and motor fibers of the pudendal nerves and gray matter of the S2–S4 sacral segments. A preserved reflex indicates the preserved integrity of all of these structures. Also, this reflex can be recorded in babies as young as 24 days.

## 3. MAPPING AND MONITORING OTHER SENSORY AND MOTOR ROOTS WITHIN CAUDA EQUINA

Other motor roots of the cauda equina (L1 to S1) can be mapped by recording the M wave after electrical stimulation of the exposed cauda in a similar



**Fig. 18.** Intraoperative BSAEP to a right ear stimulation recorded during surgery for a right acoustic neuroma, shown before (*top*) and after (*bottom*) retraction of cerebellum. The most prominent change in BSAEP was an increase in the I to III waves interpeak interval of more than 1 ms, reflecting a stretching of the eighth nerve. The smaller change in the III to V interpeak interval may reflect an effect of the retraction on the brainstem (From ref. 9)

fashion as for the anal M wave. The electrical activity from the appropriate myotomes should be recorded.

By electrical stimulation of the tibial nerves at the ankle or popliteal fossa, recording of the stationary wave over conus can be achieved. Furthermore, the traveling waves can be recorded more proximal over the spinal cord. This can be done with the same electrodes as for pudendal SEPs. By using these methods, monitoring of the sensory roots of the cauda equina, dorsal horns, and dorsal columns can be achieved.

## **BRAINSTEM AUDITORY EVOKED POTENTIAL**

The brainstem auditory evoked potential (BSAEP) represents the far field electrical activity recorded from the auditory nerve and brain stem auditory nuclei and pathways. BSAEP consists of the seven waves generated in the auditory pathway and nuclei (Fig. 17), but for our practical use, only the first five are important. This definition encompasses only a short latency of BSEAP. Each of the main five waves in BSAEP is generated by one or more anatomical structures within the brainstem. Therefore, their latency and appearance can intraoperatively indicate the functional integrity of the dorsal part of the brainstem where these generators are located. The methodology to continuously monitor intraoperatively the BSEAP is mainly used during surgeries for acoustic neurinomas, posterior fossa surgeries and microvascular decompression in trigeminal neuralgias.

It has been accepted that the interpeak latency between waves I and III represents the functional status of the acoustic nerve, while the III to V wave interpeak latency for functional integrity of the dorsal part of the brainstem is from the striae medullares to the inferior coliculi (Fig. 18).

### **References**

- [1] Deletis V, Sala F, Morota N (2000) Intraoperative neurophysiological monitoring and mapping during brain stem surgery: a modern approach. *Oper Tech Neurosurg* 3: 109-113
- [2] Deletis V (2001) Neuromonitoring. In: MacLone D (ed) *Pediatric neurosurgery*, 4th edn. WB Saunders, Philadelphia, pp 1204-1213
- [3] Deletis V, de Camargo AB (2001) Interventional neurophysiological mapping during spinal cord procedures. *Stereotact Funct Neurosurg* 77: 25-28
- [4] Deletis V (2002) Intraoperative neurophysiology and methodology used to monitor the functional integrity of the motor system. In: Deletis V, Shils J (eds) *Neurophysiology in neurosurgery: a modern intraoperative approach*. Academic Press, Amsterdam, pp 25-51

- [5] Deletis V (2006) Intraoperative neurophysiology of the corticospinal tract of the spinal cord. *Suppl Clin Neurophysiol* 59: 107-112
- [6] Fujiki M, Furukawa Y, Kamida T, Anan M, Inoue R, Abe T, Kobayashi H (2006) Intraoperative corticomuscular motor evoked potentials for evaluation of motor function: a comparison with corticospinal D and I waves. *J Neurosurg* 104: 85-92
- [7] Kothbauer K, Deletis V, Epstein FJ (1998) Motor evoked potential monitoring for intramedullary spinal cord tumor surgery: correlation of clinical and neurophysiological data in a series of 100 consecutive procedures. *Neurosurg Focus* 4(5): E3
- [8] Kržan M (2002) Intraoperative neurophysiological mapping of the spinal cord's dorsal columns. In: Deletis V, Shils JL (eds) *Neurophysiology in neurosurgery: a modern intraoperative approach*. Academic Press, Amsterdam, pp 153-165
- [9] Legatt AD (2002) Mechanism of intraoperative brainstem auditory evoked potential changes. *J Clin Neurophysiol* 19: 396-408
- [10] Møller A (2006) *Intraoperative neurophysiological monitoring*. Humana Press, Totowa, NJ
- [11] Morota N, Deletis V, Epstein FJ, Kofler M, Abbott R, Lee M, Ruskin K (1995) Brainstem mapping – neurophysiological localization of motor nuclei on the floor of the fourth ventricle. *Neurosurgery* 37: 922-930
- [12] Morota N, Deletis V, Lee M, Epstein FJ (1996) Functional anatomical relationship between brainstem tumors and cranial motor nuclei. *Neurosurgery* 39: 787-794
- [13] Neuloh G, Schramm J (2002) Intraoperative neurophysiological mapping and monitoring for supratentorial procedures. In: Deletis V, Shils JL (eds) *Neurophysiology in neurosurgery: a modern intraoperative approach*. Academic Press, Amsterdam, pp 339-401
- [14] Sala F, Bricolo A, Faccioli F, Lanteri P, Gerosa M (2007) Surgery for intramedullary spinal cord tumors: the role of intraoperative (neurophysiological) monitoring. *Eur Spine J* 16(Suppl 2): S130-S139
- [15] Sala F, Lanteri P, Bricolo A (2004) Intraoperative neurophysiological monitoring of motor evoked potentials during brain stem and spinal cord surgery. *Adv Tech Stand Neurosurg* 29: 133-169
- [16] Vodušek VB, Deletis V (2002) Intraoperative neurophysiological monitoring of the sacral nervous system. In: Deletis V, Shils JL (eds) *Neurophysiology in neurosurgery. A modern intraoperative approach*. Academic Press, Amsterdam, pp 197-217
- [17] Yamamoto T, Katayama Y, Nagaoka T, Kobayashi K, Fukaya C (2004) Intraoperative monitoring of the corticospinal motor evoked potential (D-wave): clinical index for postoperative motor function and functional recovery. *Neurol Med Chir (Tokyo)* 44: 170-182



**Vedran Deletis**

Vedran Deletis is Director of the Intraoperative Neurophysiology Department in St. Luke's-Roosevelt Hospital and an Associate Professor at the Albert Einstein College of Medicine in New York. Dr. Deletis is the founder of the International Society for Intraoperative Neurophysiology (ISIN) and served as its first president. He completed his doctoral thesis in Clinical Neurophysiology and for the last 20 years he has dedicated his career to the field of intraoperative neurophysiology (ION). He established a fellowship program for ION in New York in which so far 18 fellows have participated, and have successfully implemented their acquired knowledge and experience in their respective countries. He has published numerous papers in the basic field of ION, especially on ION of the motor system. He is the editor of one of the leading books in the field of Intraoperative Neurophysiology in Neurosurgery.

**Contact:** Vedran Deletis, Albert Einstein College of Medicine, St Luke's-Roosevelt Hospital, 11C-08, 1000 Tenth Avenue, New York, N.Y. 10019, USA  
E-mail: [vdeletis@chpnet.org](mailto:vdeletis@chpnet.org)

## **PEDIATRICS**

---

# SPECIFICITIES OF, AND CHANGES IN, PEDIATRIC NEUROSURGERY

M. CHOUX

## INTRODUCTION

The very first text dealing exclusively with a pediatric neurosurgical subject, "Brain tumors in infancy and childhood", was published in 1936 by Dandy. The second major book dedicated to pediatric neurosurgery, "Neurosurgery of Infancy and Childhood", was written by Ingraham and Matson in 1954 [6]. Before the 70ies, Pediatric Neurosurgery (PN) was performed only by individuals and in a few centers. Between 1960 and 2000 several PN centers or departments were established, as well as national or international pediatric neurosurgical societies. The first independent PN department was founded in Toronto in 1964 by Bruce Hendrick; however, Raul Carrea was director of a pediatric neurosurgical unit in Buenos Aires as early as in 1956. The first international society, the European Society for Pediatric Neurosurgery (ESPN), was founded in Vienna in 1967, with an official journal entitled "Child's Nervous System". To date the ESPN organises regular post-graduate courses. The International Society for Pediatric Neurosurgery (ISPN) was founded in 1972 in Chicago by A. Raimondi, R. Carrea, S. Matsumoto, K. Till and myself, with an annual meeting.

Today, the discussion whether to consider PN a speciality or a subspeciality seems to be over. Pediatric neurosurgery, as C. Di Rocco pointed out in 1993, is neurosurgery applied to children [4], but it has its own criterias and specificities since children are more than young adults. It is more convenient and safe to have pediatric patients in a pediatric environment, with pediatric nurses, a pediatric operating theatre, pediatric anesthetists and a pediatric intensive unit.

Is it desirable for PN to exist worldwide as an independent speciality? In selected places, where neurosurgery is well established yet, the answer might be yes, but this does probably not apply to most of the developing countries where we rather need neurosurgeons interested and trained in PN instead of exclusive pediatric neurosurgeons. However, centers of reference may be suitable in some places, where difficult cases like those with craniopharyngiomas, pineal tumors or craniofacial abnormalities may be safely investigated, managed and followed.

In order to illustrate some radical changes that occurred in the last decades in pediatric practice, we have selected three main pediatric neurosurgical diseases as hydrocephalus, craniopharyngiomas, and craniosynostoses.

---

*Keywords:* cranial traumas, brain injury, craniopharyngiomas, hydrocephalus, craniosynostoses, childhood, pediatric neurosurgery

## MANAGEMENT OF HYDROCEPHALUS

The management of hydrocephalus has seen significant changes since the first implanted shunt in 1949. I remember the period in the sixties, when a hydrocephalic child was considered a potentially and inevitably handicapped patient. These children were unable to attend a normal school or even to have a proper social or family life and additionally had to cope with the various mechanical or infectious complications of an internal shunt. Thus, the families of such hydrocephalic patients knew that a complicated evolution was near to normal and considered a fatality.

Fortunately, since 1980, significant progresses were observed, not only in shunt complications, but also regarding the development of alternatives to shunt implantation, mainly endoscopic procedures. Complications, such as disconnection of catheters, subcutaneous effusion of liquid, exteriorisation of the valve, or malplacement of the ventricular catheter have nowadays become rare.

The main factor of progress was certainly the surgeons' rigour regarding the **surgical technique of shunt implantation**, as the future of the implanted shunt depends on what happens during the 30 min of the shunt implantation. The choice of the material and the etiology are of less importance for us. We could demonstrate these facts by changing our protocol of shunt implantation in order to approach an infection rate of 0%. Our change in 1983 was due to our infection rate of 9%, independently of age or etiology. This was published in 1992 in the *Journal of Neurosurgery* [2]. The new protocol, which started in 1983, included the following items. In our publication the importance of the technical details was emphasized, such as minimal cranial and abdominal incisions, with a maximum length of 3–4 cm, a narrowest bone trepanation, a careful pre-operative selection of the material, a simplest right angle ventricular catheter, without reservoir or connector, a correct ventricular catheter orientation from the occipital level to the frontal horn, a single ligature between the ventricular catheter and the valve (most of the peritoneal catheters being attached to the valve), an introduction of a long peritoneal catheter (30–40 cm) in order to avoid secondary lengthening of the catheter, and a careful skin closure. The duration of an operation remains an important factor; we think that the intervention should not exceed 30 min in experienced hands. In this protocol we did not deliver pre- or post-operative antibiotics. Only a per-operative intravenous injection of Kefandol was administered.

The choice of the valve always remains controversial since at the present time more than 130 different types of valves are available on the market. But what are the most important criteria for choosing a valve then? I remember the conclusion of the "Shunt Book" written by two experts in hydrocephalus, J. Drake and C. Sainte Rose in 1995: "At this time, there is no shunt system or device which has been scientifically proven to be superior to any other" [5].



Consistent with their conclusion, for me the most important criterion in the selection of a shunt remains its price, especially for developing countries. Therefore, the Foundation of the WFNS since 2007 sponsors the Chabra-Shunt, a cheap shunt produced by an Indian company at the price of 35 USD. A recent paper by B.C. Warf, published in 2005 in *Journal of Neurosurgery (Pediatrics)* on 195 children in Uganda, concluded that there were no statistically significant differences in any outcome category for patients receiving the Chabra compared to a Codman-Hakim shunt system [10]. Moreover, we have for many years been interested in the management of hydrocephalus in the developing world, considering that the incidence of hydrocephalus is increasing in developing countries according to the percentage of the pediatric population and the lack of prenatal diagnostics, whereas it is decreasing in developed countries due to the prenatal diagnostics.

Regardless of its short duration, a shunt implantation should be performed with an adequate care, as most of the patients with hydrocephalus are initially neurologically and intellectually intact. A correct treatment without complications should maintain the same normal conditions. Therefore, a shunt implantation should be given appropriate attention and not be considered a minor procedure, done by the youngest untrained resident at the end of the day, after the “major operations” have been done.

Alternatives to shunts represent other crucial changes in the approach of the management of hydrocephalus. We currently know that a definitive internal shunt may be avoided in more than 30% of the cases. If causal treatment options are available, for instance in cases with brain tumors or cysts, a shunt may become redundant. In cases with a posterior fossa tumor with symptomatic hydrocephalus, an **endoscopic third ventriculostomy** represents the first step and we do not insert an internal shunt routinely. Furthermore, in patients who had been provided with a shunt prior to the tumor removal, we try to withdraw it secondarily after a few weeks.

Another alternative to shunt are **external drainages**, for example in cases with tumors or hemorrhage or infection. Following the same protocol the infection rate is not higher for external drainage than for an internal shunt. Endoscopic approaches represent the main progress that we have observed in the treatment of hydrocephalus, not only as an initial procedure but also in case of revision. We know now that this technique may be used in patients younger than one year and that it can be repeated as well.

## MANAGEMENT OF CRANIOPHARYNGIOMAS

The second example which illustrates significant changes in the philosophy of pediatric neurosurgery is the management of craniopharyngiomas. Treatment still remains controversial; it must be carefully discussed since a wrong initial decision may have definitive and irreversible consequences. The eighties rep-

resent the decade of enthusiasm for craniopharyngioma surgery, and we, as well as H. Hoffman, F. Epstein, J.F. Hirsch or C. Di Rocco, were in favor of a radical removal. In 1991 we published a monograph that presented a collection of 474 pediatric cases studied by members of the ISPN [3]. We presented our personal experience of 108 cases of craniopharyngiomas in patients under the age of 16, managed since the MR era and with a minimal follow-up of 8 years. After this “gross total resection” period, a change occurred regarding the acceptance of the post-operative consequences, mainly endocrine disturbances. What was considered inevitable and acceptable complications for many years cannot be accepted anymore. Following the recent opinion of C. Sainte-Rose, just like a swinging pendulum, we moved from aggressive to conservative treatment.

- 1) **Surgical removal**, either total or subtotal, remains the first option in most cases. Prior to the intervention, the anatomical relationships of the tumor and the hypothalamus, the optic pathways, the pituitary stalk, the brainstem, the vessels and the dura must be carefully taken into consideration. The consequences of a large removal, mainly a severe post-operative endocrine deficit, eventually associated with hypothalamic dysfunction, are well-known. Obesity, growth retardation and diabetes insipidus remain major endocrinal problems after surgery. Moreover, all the preoperative endocrine symptoms are aggravated after surgery. According to our experience a total removal may be possible in 70% of the cases, but after a so-called radical removal the recurrence rate is between 15% and 38% in the recent literature, 20% in our series.

We agree with Tomita’s conclusion, who in 2005 stated that “because of the often unacceptably high complication rates and the lack of 100% prevention of recurrence following radical tumor resection, there has been a growing advocacy for a less invasive tumor resection followed by adjuvant therapy” [9]. Endoscopic approach now represents an interesting way in the management of this tumor. The majority (55%) of craniopharyngiomas represent a mixed type and 36% are cystic, allowing an initial endoscopic approach in order to empty the cyst and thus preparing for the surgical resection.

- 2) There is no indication for conventional irradiation at the pediatric age. 3D conformational irradiation may be an option after incomplete removal or in cases of recurrence. **Stereotactic radiosurgery** can also be useful for recurrent lesions or in cases of tumor. In a cooperative study achieved in the radiosurgical department by J. Régis, 44 cases of craniopharyngiomas were treated by radiosurgery, with a reduction in size in 21 patients, a stabilization in 16; 7 cases showed failure. Recently protontherapy has been promoted with promising results.

- 3) Another interesting alternative treatment is **stereotactic intracystic injection of radioactive agents**, such as Phosphorus 32, Rhenium 186, Yttrium 90, or Interferon.
- 4) **Chemotherapy with intracystic injection of Bleomycin** through a catheter has been used in our department since 1991 up to 2005, with positive results in nearly 40% of the cases.

**These different options may be used as isolated treatments or in combination.**

The selection of a therapeutical option must trade the clinical consequences of each option off against the risk of recurrence. Children without or with minimally significant ophthalmological deterioration, or without or with minimal endocrinological deficit, will be managed in a different way than children with more severe visual or endocrine symptoms. The quality of life should remain the goal of our decision.

## **MANAGEMENT OF CRANIOFACIAL ABNORMALITIES**

The surgical management of craniofacial anomalies in children is also an example of the extraordinary changes that occurred in the recent years. The first surgical approaches for craniosynostosis were described at the beginning of the last century, and at this time nearly all the cases were diagnosed as oxycephaly. A revolution started in 1967, when Paul Tessier, a plastic surgeon, published his famous article on "Total facial osteotomy: Crouzon's syndrome, Apert's Syndrome, oxycephaly, scaphocephaly, turriccephaly" in *Annales de Chirurgie Plastique* [8]. He was the first who pointed out the necessity to consider the skull and the face as an entity. He clearly described the selection criteria for craniofacial surgery: the type of malformation, its degree of monstrosity, the existence of a mental retardation, whether the child will enter a school, the family situation, the risks in vital functions, the functional risks, the severity of the operation, the resources of bone grafts and at last the experience acquired by a team working together.

The craniofacial team includes a neurosurgeon, a plastic surgeon, a neuroanesthetist, an intensive care unit, a pediatric neuroradiologist, an orthodontist and dentist, an otorhinolaryngologist, an ophthalmologist, a genetician, a pediatrician and a speech specialist. Such a group of specialists may be concentrated in the same place only in a few centers. The British Society of Neurosurgery in 1993 pointed out that the minimum population required for a major Cranio-Facial Unit should be around 8 million. The solution could be to have Centers of Excellence where all types of craniofacial diseases would be managed safely [7]. Expertise in craniofacial surgery implicates not only a team, but also the ability to perform a sufficient number of cases, with an estimated minimum of 30 cases of different types and ages per year.

For craniofacial abnormalities investigations include standard X-rays, bi-dimensional CT, MRI and 3D reconstruction (Shaded Surface Display and Volume Rendering). The surgical planning has to be supported by three dimensional computer aid. Furthermore, an increased intracranial pressure may exist in some types of craniosynostoses, for example brachycephaly, oxycephaly, Crouzon's disease or Apert Syndrome; therefore, ICP monitoring can be indicated in some cases. Genetic studies are indispensable in the initial investigations and are part of the routine investigation.

The main reasons for surgery are aesthetic factors, psychological and social factors and/or functional factors: raised intracranial pressure symptoms, ophthalmological manifestations, malocclusion of the mouth or nasopharyngeal obstruction.

Do all craniosynostoses require surgical treatment? The answer is, certainly not. In our series only 63% of scaphocephalies, 85% of plagiocephalies, 64% of trigonocephalies and 64% of oxycephalies were operated on. We know that in case of occipital asymmetrical deformation the cause is a positional molding in more than 80% of the cases. Consequently surgical indications should be exceptional, as the correction can be obtained in few months by wearing a helmet.

Furthermore, the timing for surgery is essential. We have seen an interesting historical evolution, with a surgical correction done generally after one year of age before 1965, an earlier surgery – i.e., before 6 months during the period of 1970–1980, whereas now we are waiting until the age of 6–8 months.

At present, anesthesiological problems are well-known and better controlled, namely positioning, blood loss, hypothermia, hypotension, air embolism, or brain edema. The reasons of possible complications are the duration of surgery and the low weight of most of the patients. Again we have to mention the importance of having anesthesiologists and intensive care familiar with this type of surgery.

Technically we have seen important improvements in the recent years, i.e. at the level of skin incisions, less blood loss, or different material for osteosynthesis, from silk, nylon or metallic ligatures to resorbable plates and screw or absorbable material with ultrasonic rivet. Minimally invasive endoscopic techniques have been introduced since 1995, especially for scaphocephaly. Two or four short incisions allow the removal of a sagittal piece of bone from the coronal level to the lambdoid level. The advantages are a possible shorter and safer operation, the reduction of associated costs, less blood loss and a shorter in-hospital time.

In Crouzon's disease the fronto-orbital advancement must be done in the first months after birth. The facial advancement (Lefort II or III) must be done ideally at the age of 10–12 years. Now, with distraction techniques introduced by Renier and Marchac in 1995, an earlier correction of the face is possible in the first years of life. This distraction may be external, or, preferably, internal.

**Table 1.** Outline of revised protocol for shunt implantation*preoperative period*

- assessment of patient
  - localized skin problem
  - general medical condition
- no shaving (except in older children undergoing revision)
- skin preparation (povidone iodine or chlorhexidine)
- no antibiotic medications

*shunt implantation*

- theater schedules/timing
  - shunts early in the morning, before other operations
  - neonates and infants before older children
  - no more than four shunt procedures per day
  - length of operation: 20–40 min
- theater staff
  - only four people in operating room (surgeon, assistant, anesthesiologist, circulating nurse)
  - no scrub nurse
  - experienced neurosurgeon
- shunt material
  - careful selection of shunt
  - opening sterile packaging at last moment
  - no testing of valve
- surgical technique
  - two skin incisions
  - meticulous hemostasis
  - careful siting of valve/reservoir
  - quality of skin closure
- antibiotic medications
  - prophylactic intravenous antibiotic 30 min before skin incision

*postoperative period*

- head position – avoid pressure on valve
- no antibiotic medications
- two shampoos
- approximate length of stay:
  - 4 days (first shunt)
  - 2 days (shunt revision)

The risks of complications in facial advancement with a distractor are much less important than they were at the time of complex surgical advancement type Lefort III. There is no doubt that we will see the development of distraction techniques for other types of craniosynostoses in a near future.

## CONCLUSIONS

Confronted with a neurosurgical disease in a child, the pediatric neurosurgeon is part of a trilogy, the two others being the patient and the parents. The

parents cannot be ignored at the time of the discussion preceding the surgical decision. We have to keep in mind that they usually do not have a medical background and therefore do not know the exact sense of medical terms. Sometimes they have performed some internet research and the information at their disposal might be rudimentary and incomplete, if not wrong. This discussion regarding the child's surgical treatment should take place in a quiet and undisturbed environment, the parents seated, without being interrupted by a mobile phone or other persons, allowing them to completely understand all options and to ask questions if necessary. Visualisation of the radiological exams or a simple drawing may be very useful as well. The parents have to actively participate in the decision-making. An appropriate preparation of the parents is generally followed by a better follow-up, especially in cases of severe or complicated diagnosis. This "complicity" between the patient, the parents and the pediatric neurosurgeon is one of the most the fascinating part of our job.

A pediatric neurosurgeon is finally a general neurosurgeon with a specific interest and expertise in pediatric neurosurgery. In a few places he will be dedicated to the treatment of children exclusively; in other places he will be dedicated to it partially.

The question what training pediatric neurosurgeons should go through remains crucial. All neurosurgeons in training should have experience of key pediatric neurosurgical problems, particularly those that may present as an emergency. All neurosurgeons in training need a minimum of 6 months of involvement in pediatric neurosurgical practice. On the other side, we have always emphasized the necessity of having a large neurosurgical experience before taking the decision to practice specifically pediatric neurosurgery; there would be a real danger to have an exclusively pediatric training.

## References

- [1] Arnaud E, Marchac D, Renier D (2001) Double internal distraction with monobloc advancement in infants. In: Proceeding of the 3rd International Congress on Cranial and Facial Bone Distraction Processes. Paris, France, June 14–16, pp 455–460
- [2] Choux M, Genitori L, Lang D, Lena G (1992) Shunt implantation: reducing the incidence of shunt infection. *J Neurosurg* 77: 875–880
- [3] Choux M, Lena G, Genitori L (1991) Le Craniopharyngiome de l'Enfant. *Neurochirurgie* 37(Suppl 1): 1–174
- [4] Di Rocco C (1993) The identification and the education of a pediatric neurosurgeon at an international level. *Child Nerv Syst* 9: 197–202
- [5] Drake JM, Sainte-Rose C (1995) *The shunt book*. Blackwell Science Inc., Cambridge, Mass.

- [6] Matson DD (1969) *Neurosurgery of infancy and childhood*, 2nd edn. Thomas, Springfield, Illinois
- [7] (1993) "Safe Neurosurgery". The maintenance and development of high standards. A Report from the Society of British Neurological Surgeons, London
- [8] Tessier P (1967) Osteotomies totales de la face. Syndrome de Crouzon, syndrome d'Apert, oxycephalies, scaphocephalies, turriccephalies. *Ann Chir Plast* 12: 273-286
- [9] Tomita T (2005) Editorial on current surgical management of craniopharyngiomas. *Child Nerv Syst* 21: 8-9
- [10] Warf BC (2005) Comparison of 1-year outcomes for the Chabra and Codman-Hakim Micro Precision shunt systems in Uganda: a prospective study in 195 children. *J Neurosurg (Pediatrics 4)* 102: 358-362



### **Maurice Choux**

Maurice Choux is Professor at the University of Marseille and consultant in the Department of Pediatric Neurosurgery.

Administrative Functions in Scientific Societies:

Founding-member of the International Society for Pediatric Neurosurgery (ISPN), in Chicago 1972; then Secretary (1976–1980) and President of ISPN (1980–1981). Président de la Société de Neurochirurgie de Langue Française (1994–1997). President of the European Society for Pediatric Neurosurgery (ESPN) (1996–1998). Secretary of the World Federation of Neurosurgical Societies (WFNS) (1997–2001). Chairman of the Training and Education Committee of the WFNS (2001–2005). Honorary President of the WFNS (2005). Member of the WFNS Foundation. Member of 41 International Scientific Societies.

- Editor of Scientific Publications: *Shunts and Problems in Shunts* (Karger – 1980), a volume, 228 pages. *Le Médulloblastome* (Masson – 1982), a volume, 229 pages. *Principles in Pediatric Neurosurgery* (Springer-Verlag), with A. Raimondi and C. Di Rocco (1985–1993). *Craniopharyngiome de l'Enfant* (Masson – 1991), a volume with G. Lena, L. Genitori (174 pages). *Medulloblastoma* (Pediatric Neurosurgery) 1993,



pp 285-335. Publisher: Springer-Verlag. *Pediatric Neurosurgery*, a volume with C. Di Rocco, A. Hockley, M. Walker (875 pages) Publisher: Churchill Livingstone, London, 2001.

- Editorial service in the following neurosurgical journals:  
Acta Neurochirurgica, Clinical Neuro-Science, Journal of Pediatric Neurosciences, Neurochirurgie, Neurological Research, Neurosurgery, Surgical Neurology, Journal of Clinical Neuroscience, Critical Reviews in Neurosurgery, Neurol. Med. Chir., Pan-Arab Journal of Neurosurgery, Operative Techniques in Neurosurgery.
- Present main interest is visiting-professorships and training of young neurosurgeons all around the world.

**Contact:** Maurice Choux, 14 Avenue Solvert, 13009 Marseille, France  
E-mail: mchoux4842@numericable.fr

---

# CRANIAL TRAUMAS IN CHILDREN

A. V. CIUREA

## INTRODUCTION

Head injury is the leading cause of death and disability in children.

Most common causes of head injury are falls, child abuse, sport accidents, assaults and motor vehicle accidents. According to age distribution of head injury, two risk groups are identified: 0–4 years old and 15–19 years old. Boys are affected by head traumas at twice the rate of girls.

## RATIONALE

Growing and development process from infant-toddler to teenager implies important, general and specific, anatomical and functional particularities of central nervous system (CNS). In each phase of development, there is a distinctive response to external damaging factors. Because of these age-related particularities, in children there is an immediate posttraumatic response completely different from that in adults.

Although children tolerate larger space-occupying, traumatic or nontraumatic, lesions than adults, consequences are similar.

Physical exam of a child with traumatic brain injury (TBI) must be quick and safe, and consists of several steps:

- Assessment of airway, breathing and circulation (ABC exam)
- Checking for signs of cervical spine cord injury (rare in young children), and cervical spinal immobilization
- Evaluation of level of consciousness, pupils' size, and their reaction to light
- Assessment of local traumatic injuries
- Neurological exam, calculating trauma scores, according to trauma scales used into respective neurosurgical department
- General physical exam, and for polytraumas, determination of MISS (Modified Injury Severity Scale)
- Establishment of useful paraclinical tests

Neurologic exam of the child must be individualized according to the age and level of consciousness.

---

*Keywords:* cranial trauma, brain injury, childhood

## DECISION-MAKING

### 1. PEDIATRIC COMA SCALE

For children we must use pediatric scales, according to age. The most important neurotrauma pediatric scale is the Pediatric Coma Scale (PCS) [9]. This scale evaluates eye opening response, verbal response and motor response to stimuli (Table 1). The aggregate score is the sum of the scores of the individual categories.

*Normal aggregate scores differ according to age:*

0–6 months	9
6–12 months	11
1–2 years	12
2–5 years	13
>5 years	14

PCS is used in evaluation of brain injury severity in preverbal children. Scores must be adjusted according to child's age:

*During the first 6 months*, best verbal response is crying, so normal verbal score expected is 2, and best motor response is usually flexion with a normal motor score expected of 3.

*Between 6 and 12 months*, a normal infant makes noises, so normal verbal score expected is 3, an infant will usually locate pain, and so normal motor score expected is 4.

**Table 1.** Pediatric Coma Scale [9]

Category	Score
Eye opening	
Spontaneously	4
To speech	3
To pain	2
None	1
Verbal response	
Oriented	5
Words	4
Vocal sounds	3
Cries	2
None	1
Motor response	
Obeyes command	5
Localizes pain	4
Flexion to pain	3
Extension to pain	2
None	1

*Between 12 months and 2 years*, recognizable words are expected, so normal verbal score expected is 4, and the infant will usually locate pain but not obey commands, so normal motor score expected is 4.

*Between 2 and 5 years*, recognizable words are expected with a normal verbal score expected of 4, and the infant will usually obey commands, so normal motor score expected is 5.

*Children older than 5 years* are oriented, aware of their location (home, hospital), so normal verbal score expected is 5.

In conclusion, PCS is extremely useful for all pediatric TBI, in perfectly connection with the age. Besides, this scale is very easy to work with.

## 2. GRADING OF TRAUMATIC BRAIN INJURY

Grading the severity of TBI in children should be done, as in adults, according to GCS (Glasgow Coma Score) in: *minor head injury* (HI) (GCS of 13–15), *moderate HI* (GCS of 9–12) and *severe HI* (GCS of 3–8). Each category has specific diagnosis, evaluation, management, different treatment strategies, complication, and particular outcome.

*Head Injury Severity Scale* (HISS) [10] introduces two new criteria:

- *Minimal TBI*: GCS of 15 points, no loss of consciousness (LOC), no posttraumatic amnesia (PTA)
- *Mild TBI*: GCS of 14 points, brief LOC for less than 5 min, PTA
- *Moderate TBI*: GCS of 9–13 points, LOC for more than 5 min, focal neurological deficit
- *Severe TBI*: GCS of 5–8 points
- *Critical TBI*: GCS of 3–4 points

More accurate grading of TBI must also take into consideration other important criteria, such as mechanism of injury (e.g. the fall off a swing is a more aggressive mechanism of trauma, than fall from the same level, etc.), LOC, PTA, vomiting, and posttraumatic seizures.

### 2.1 Minor head injury

Almost 90% of pediatric HIs are minor. The child which has sustained minor HI is alert, with a normal neurologic performance, and presenting inconstant vomiting. GCS is 13–15 points. Local exam may show scalp lesions: epicranial hematoma, skin abrasions or lacerations. Minor HI are graded as follows.

- Grade 0 minor HI – no LOC, impact-site-localized pain, bruises, scalp abrasions, epicranial hematoma; CT scan is not necessary, the patient is discharged home with instructions.

- Grade 0 with risk minor HI – no LOC, but the patient belongs to the following categories: extreme age, history of neurosurgery, ventriculoperitoneal shunt, seizures, anticoagulant therapy, drugs or alcohol abuse (very rare in children); CT scan is performed, and the patient is admitted for at least 24 hours.
- Grade 1 minor HI – LOC, PTA, persistent headache, vomiting, large scalp wounds; CT scan must be performed within the first 6 hours after trauma, and the patient requires hospitalization even if the CT scan, native and bone window, is normal.
- Grade 2 minor HI – GCS of 13–14 points, LOC maximum of 30 min, no focal deficits; the patient requires CT scan and hospitalization.

Skull X-ray positive for a skull fracture requires head CT scan, native and bone window, and admission for observation of the child. CT scan can show a small size focal lesion, located within a noneloquent area, lacking of neurological signs. In this case, HI is not considered minor anymore. In that condition, the classification of HI, according to the severity should be done only after craniocerebral diagnostic imagery scan.

The child is discharged home but only after informed consent of parents. Both the parents and child must be aware of persistent or increased headache, vomiting, changes within level of consciousness, drowsiness, seizures (single or multiple posttraumatic seizures lasting more than 2 min) – situations in which they must contact immediately a neurosurgeon. Occurrence of any of these signs requires immediate neurosurgical reexamination of the child. CT scan is mandatory for children with neurosurgical interventions and shunted patients. Also CT scan is mandatory in all road accidents, passenger or pedestrian, and in child abuse. In these two situations, CT scan will be extended to cervical spine.

## 2.2 Mild head injury

According to HISS, a child with mild HI has GCS of 14 points, brief LOC for less than 5 min, and PTA. Mild HI is of great importance in children because of the possibility of multiple posttraumatic neurobehaviour sequellae. Children presenting with mild HI may subsequently deteriorate and die from intracranial causes, situation known as “talk and die” syndrome.

## 2.3 Moderate head injury

In moderate HI there is a history of trauma with LOC, changes in mental status, repeated vomiting, and focal neurological deficit. The child may present, even during examination, LOC or seizures. Local exam may show scalp lesions: epicranial hematoma or, more frequently, skin abrasions or lacerations. GCS ranges between 9 and 12 points.

Immediate CT scan and admission into a pediatric neurosurgical department are mandatory. Therapy is individualized according to age, type of injury, PCS, Children Coma Score, Trauma Infant Neurological Score, and GCS, CT scan and evolution.

Children with favorable outcome, with normal neurological exam, and normal CT scan can be discharged after few days hospitalization and can be observed at home.

#### 2.4 Severe head injury

The child with a severe HI is unconscious, often immediately after the injury, and has a GCS between 3 and 8 points (comatose patient). Clinical exam of a posttraumatic unconscious child consists of assessment of vital signs, neurological exam, pupils' size their reaction to light, brainstem reflexes, checking for cervical spinal cord injuries, etc., and obtaining history of trauma.

A CT scan, native and bone window, is performed immediately, and according to the neuroimaging result the child is admitted into the pediatric intensive care unit (PICU) or is taken directly into the operating room, where specific treatment is initiated [2]. It is better to extend the CT scan to cervical spine and in road traffic accidents to thoracic and abdominal area [2]. All these patients with severe HI are in comatose status and must be admitted to a PICU with special facilities for infants, toddlers and children.

### 3. PARACLINICAL FINDINGS

Paraclinical examination in newborns and infants can be done by transfontanelle ultrasonography, but in general the investigation is unsatisfactory. Gold standard examination in TBI is native CT scan. In selected cases, MRI can be performed. CT scan examination can be repeated according to initial findings, lesion transforming risk, and clinical outcome. Also cervical spine investigation should be made.

Special indications for CT scan in children with TBI:

- Newborn and infants under 3 months
- Suspected child abuse or shaken baby syndrome
- Scalp lesion: bruise, swelling, wound over 5 cm in diameter, in children under 1 year old
- Trauma Infant Neurological Score greater than 2, in children under 2 years old
- Children Coma Score less than 14, in children over 2 years old
- GCS less than 15, persisting 2 hours after trauma
- Focal neurological deficits, LOC, abnormal mental status, drowsiness
- Antero- or retrograde PTA, lasting more than 5 min
- Persistent vomiting (in general, more than 3 times)
- Posttraumatic seizures, in children with no history of epilepsy

- Open skull fracture, depressed skull fracture, anterior tense fontanelle
- Signs for a skull base fracture: hemotympanum, “raccoon’s eyes”, Battle’s sign
- CSF leakage: rhinorhorrhea, otorrhea, otoliquorrhea
- Potential dangerous traumatic mechanism: high-speed road traffic accident, fall from height of greater than 3 m, etc.
- Coagulopathies, anticoagulant therapies
- History of neurosurgical operation or ventriculoperitoneal shunt

## **SURGERY**

### **1. SPECIFIC POSTTRAUMATIC PATHOLOGY IN CHILDREN**

The specific posttraumatic pathology in children depends on child’s age, and craniocerebral anatomical and functional particularities of the newborn and growing child. According to age, HI has several characteristics for newborn and infant, age less than 6 months; infant and toddler, age ranging from 6 months to 2 years; preschool child, aged from 2 to 5 years; school child, age between 6 and 12 years; and teenager, over 13 years.

#### **1.1 Caput succedaneum**

Caput succedaneum is encountered during the neonatal period, and it is a consequence of a prolonged labor or instrumented delivery. Caput succedaneum is a scalp swelling extending across the midline and over suture lines. It is usually of no clinical importance and spontaneously resolves within a couple of days after birth.

Puncture is indicated in large-volume caput succedaneum, together with prophylactic antibiotherapy, initiated for preventing the occurrence of infection.

#### **1.2 Subaponeurotic (subgaleal) hematoma**

Subaponeurotic hematoma is a collection of blood developing between the periosteum and galea aponeurotica. It is less common than the other extracranial injuries. It can be caused by a forceps delivery or vacuum extraction. It can contain a large amount of blood and crosses suture lines. Subgaleal hemorrhage is a potentially life-threatening complication of delivery, which can lead to hypovolemic shock in newborns, with pallor, hypovolemia, tachycardia, and hypotension. Differential diagnosis between epicranial collections is of great importance. Subaponeurotic hemorrhage requires immediate treatment consisting of blood transfusion (in order to maintain normovolemia) and repeated evacuation by thick needle.

### 1.3 Cephalhematoma

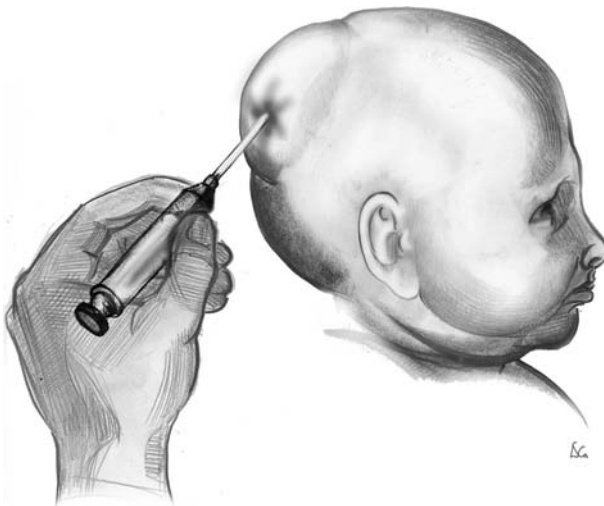Cephalhematoma (CPH) is a newborn-specific posttraumatic lesion. It is a subperiosteal hemorrhagic collection caused by rupture of blood vessels between skull and periosteum. Usually the CPH is unilateral and most commonly over the parietal bone. It is limited to one bone by the attachment of the periosteum to the sutures. An underlying linear skull fracture may also be present. CPH appears within hours of delivery as a soft, fluctuant swelling on the side of the head. CPH are usually small and require no treatment.

CPH spontaneously withdraw within the first three months, without any surgical treatment or tap. In cases with persistent collection or infection, CPH requires evacuation through incision or tap. Usually a simple puncturing with a thick needle evacuates the hemorrhagic collection (Fig. 1).

Surgical treatment is performed in calcified lesion (Fig. 2): Wide, arcuate incision of the skin in "horse shoe", generally in parietal area, on the border of CPH; large scalp dissection; exposure of calcified collection; step-by-step resection with continuous wax hemostasis; level adjustment in the parietal region; careful hemostasis; no external drainage is needed, compressive bandage.

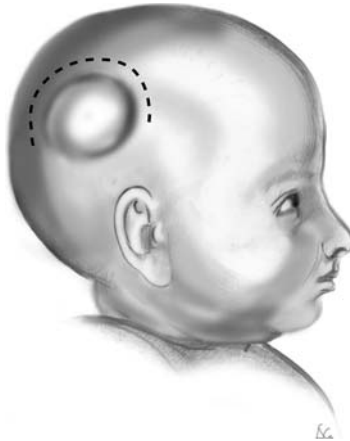
### 1.4 Posttraumatic subarachnoid hemorrhage

Posttraumatic subarachnoid hemorrhage (SAH) in newborn is a consequence of prolonged labor or forceps delivery. It is caused by rupture of small veins bridging the leptomeninges. Usually, if subarachnoid hemorrhage is minimal, it lacks clinical signs. Internal hydrocephalus occurs in a few weeks time



**Fig. 1.** Cephalhematoma. Evaluation by tapping





**Fig. 2.** Calcified cephalhematoma, surgical approach

if the quantity of blood is greater. The treatment of subarachnoid hemorrhage is symptomatic.

Posttraumatic SAH in childhood has the same clinical features like in adults. The clinical monitoring and CT scan are necessary to appreciate the outcome in this situation, also in pediatric minor head trauma. Generally, posttraumatic SAH is an important predictive factor of obstructive internal hydrocephalus.

### 1.5 Diffuse brain swelling

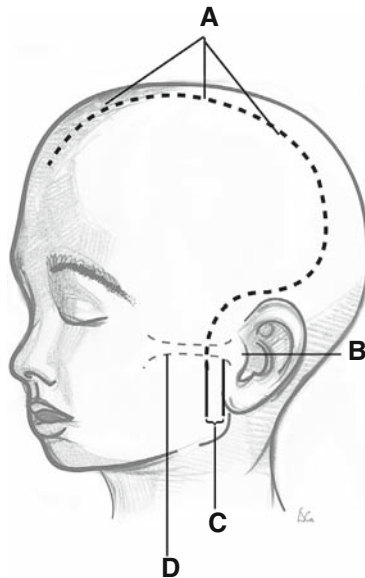
Diffuse brain swelling (DBS) in newborns is due to birth asphyxia and secondary reperfusion. DBS is mixed, by vasogenic and cytotoxic edema.

The diagnosis is established by CT scan and the treatment is specific, according to the clinical status. The particularity of DBS in children is represented by its early onset. It is very severe and often is followed by diffuse cerebral ischemia (“black brain”).

Posttraumatic DBS can accompany any cerebral lesion in children and it requires intracranial pressure (ICP) monitoring. After failure of conservative therapy, bilateral decompressive craniectomy may be needed as the last-resort treatment strategy. In children, bilateral decompressive craniectomy improves neurological outcome and diminishes death risk [5]. The necessity of decompressive craniectomy and duraplasty is especially important in children due to lack of response to usual therapies in the treatment of intracranial hypertension [6] (Fig. 3).

### 1.6 Skull fractures

Skull fractures in newborns are extremely rare. Following difficult labor, a depressed skull fracture may be encountered.



**Fig. 3.** Wide hemicraniectomy. Schematic of the skin incision and "trauma flap". (A) Wide skin incision for "trauma flap". (B) Tragus, (C) 1 cm in front of tragus, (D) zygomatic arch

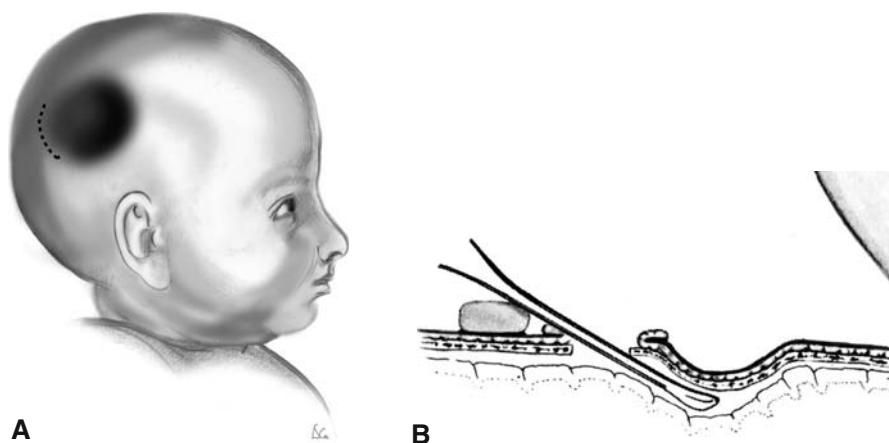
Linear skull fractures are usually of no clinical significance and require no specific treatment, only to be followed up for epidural hematoma. Diastatic fractures are traumatic disjunctions of suture lines and, usually, do not require surgery but will be followed up because of the risk of transforming into a growing skull fracture (GSF). In simple depressed skull fractures with or without focal neurological deficits or seizures, surgical elevation is indicated.

*Depressed skull fractures.* Depressed skull fractures are classified as closed (simple fracture) or open (compound fracture). Closed depressed skull fractures require surgical therapy according to the depth of deformity. A particularly type of newborn fracture is "ping-pong" fracture. It is usually encountered in parietal bone and requires surgery.

Surgical technique for "ping-pong" fractures (Fig. 4): Linear arcuate skin incision 4 cm long, posterior to the depressed skull fracture; burr hole in the middle of the incision; by means of a periosteal elevator, introduced through the burr hole, into the epidural space beneath the fracture, the depressed bone is elevated; wound closure.

Surgery for depressed fracture, closed or compound, situated over the superior sagittal sinus (SSS), is made after performing a CT scan with coronal and sagittal reconstruction or an angiography with venous phase, in order to evaluate the caliber and patency of the sinus beneath the impacted bone.

Surgical technique for fractures over the SSS (Fig. 5): Medial, rectangular free bone flap, centered over the SSS; elevation of the bone flap, with careful

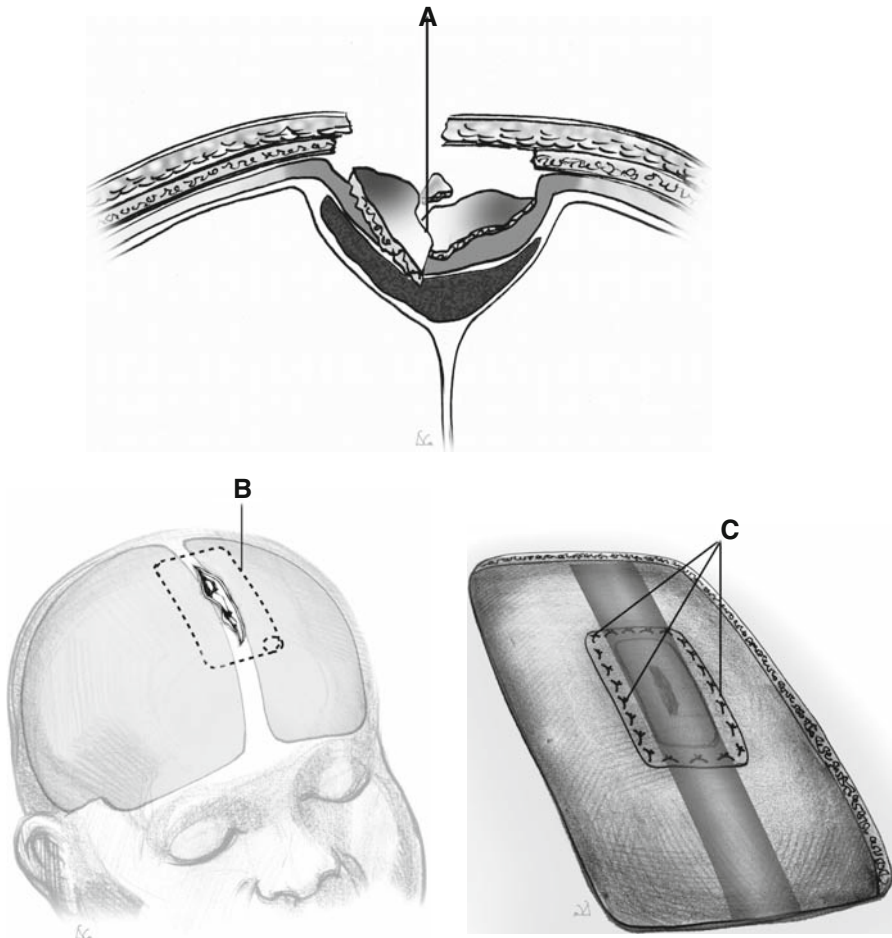


**Fig. 4.** Surgical technique for depressed "ping-pong" fracture. **A** Skin incision at the border fracture. **B** Periosteal elevator, introduced through the burr hole

removal of bone fragments; repairing of the SSS. Tachocomb is used to cover the rent within the sinus. A surgical strip is packed over, and periosteal graft is brought into the field and sewed over the surgical strip and over the sinus. Closure with periosteum or aponeurotic galea, in surget manner, in narrow step, after dural closure, covering with Tachocomb and surgical; dural repairing of SSS must be performed carefully, in order to not lose blood (in children there is a bigger risk for developing hemorrhagic shock); bone placement and wire fixation; wound closure; possible external drainage.

Compound fracture, containing bony fragments depressed or not with dural laceration represents an emergency for surgery. Also CT scan can show associated hemorrhagic subdural collection that needs mandatory surgical evacuation. Bone fragments must be elevated carefully, and lacerations of the dura will be treated by dural graft. Cortical laceration must be solved because it is an epileptic focus. Also, careful hemostasis must be performed. Cranioplasty with methylmethacrylate is performed if bone fragments could not be replaced. We recommend cranioplasty only in children older than 3 years (Fig. 6).

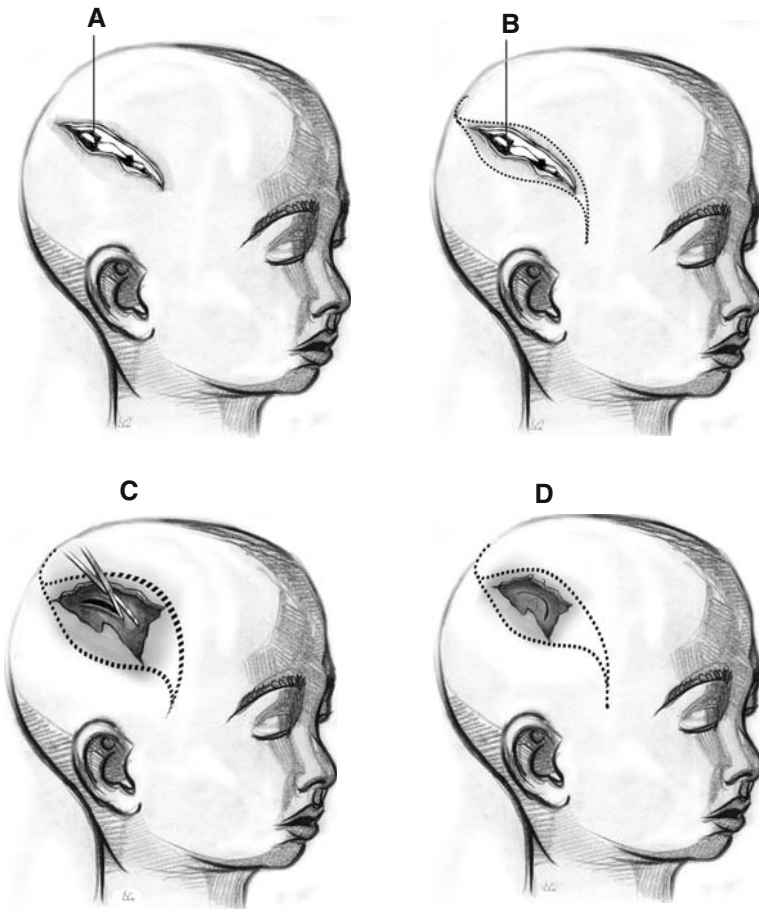
*Growing skull fracture.* Generally, growing skull fracture (GSF) is found in children under three years old. It is usually located in the parietal region, and the reported incidence is only 0.05 to 0.1% of skull fractures in childhood. Pathogenesis of GSF consists of three phases. First, a linear skull fracture with periosteum tear and dural laceration occurs, then healing of the fracture margins is hindered by the presence of an intracranial hypertension syndrome, with invagination and entrapment of arachnoids into a diastatic fracture. During the last phase, there is an important bone diastasis, associated with leptomeningeal herniation and elevated intracranial pressure [4].



**Fig. 5.** Surgical technique for fracture over the SSS. (A) Depressed skull fracture in the SSS area. (B) Surgical approach by craniotomy and removal the bone fragments. (C) Dural tight closure with periosteal graft or other materials

History of trauma, clinical aspects and CT scan establish the diagnosis. The treatment of GSF is exclusively surgical. Sometimes it requires bone defect grafting.

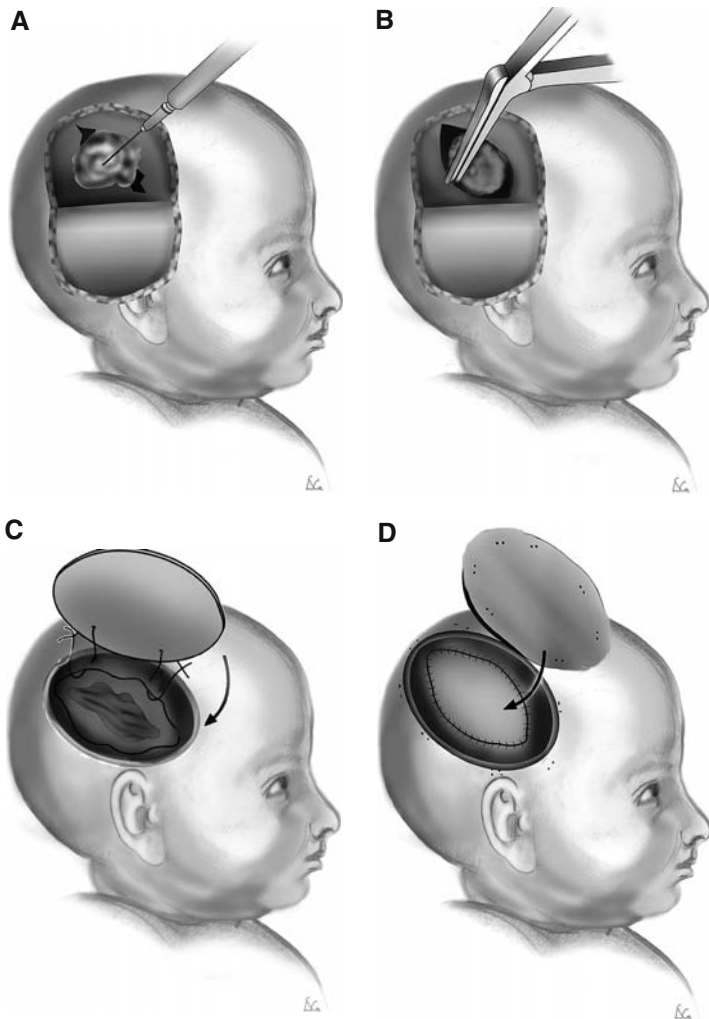
Surgical technique for GSF (Fig. 7): Skin flap in “horse shoe” with the fracture in the center; identification of the leptomeningeal cyst protruding through the skull fracture; opening the leptomeningeal cyst to evacuate its contents; the cyst is collapsed, revealing the borders of the fracture; extending the fracture to a craniectomy with the aid of a Kerrison until free bor-



**Fig. 6.** Surgical approach in compound depressed fracture with dural laceration. **A** General view of the depressed compound fracture. **B** Plastic skin incision in “S” shape and fracture fragments removal. **C** Arrangement of the dura mater rims and surgical approach of the brain laceration with large dural opening. **D** Tight dural suture in narrow step

ders of the dura on both sides of the fracture are exposed; once the borders of the dura have been found, duraplasty is performed by a patch formed of periosteum, lyophilized dura, temporal fascia, fascia lata, or artificial dura, tightly sutured to the borders of the dura; cranioplasty. We recommend cranioplasty in children older than 3 years old; Wound closure.

*Skull base fractures.* Skull base fracture are suspected in the presence of some characteristic signs, such as periorbital (“raccoon’s eyes”) or postauricular ecchymosis (Battle’s sign), epistaxis, otorrhagia, etc., and are diagnosed by CT scan. They require surgical treatment only in the presence of a CFS fistula, with



**Fig. 7.** Surgical technique for growing skull fracture. **A** Large "horse shoe" in the parietal area with the tap of the leptomeningeal cyst. **B** Bone fragments removal till normal dural rim. **C** Removal of the brain laceration and duraplasty with periosteal graft-tight suture. **D** Cranioplasty

rhinoliqorrhea or otoliqorrhea, in cases of failure of conservative therapy. Frontobasal fractures are a frequent pattern of injury in children less than 5 years of age.

Imaging studies assess the location of the dural tear in CSF leakage. Surgical treatment must close dural defect, and if possible bone defect as well.

Surgical approach can be classical, transcranial extra- or intradural, or transnasal transsphenoidal endoscopic in CSF leakage with rhinoliquorrhea, difficult in children. Rents in the cribriform plate, the region of the planum sphenoidale, the superomedial surface of the orbit, and the posterior surface of the petrous bone, may be closed through intradural or extradural approaches. Breaches in the medial region of the greater wing of sphenoid, along the arc extending from the foramen spinosum through the superior orbital fissure, and over the tip of the petrous bone, are properly approached intradurally [8]. Extradural approach allows the surgeon to plug the fracture line with bone fragments, bone dust, to cover bony repair with periosteum and to close dura mater. Indirect approach, performed by transsphenoidal route, consists of packing the sphenoidal sinus with fat tissue, a muscle graft, and a plug of bone, and antibiotherapy [8]. Generally, after complete clinical assessment and CT scan, a combined team with neurosurgeon, ophthalmologist, oromaxillofacial surgeon is needed for repairing dural defect and craniofacial skeleton.

*Brain concussion.* Brain concussion is a transient LOC or disorientation, as a result of a closed head trauma. Length of alteration of consciousness remains controversial, but it is accepted to last longer (even for a few hours), if after regaining consciousness the child has a normal clinical examination and a normal CT scan. Concussion is a diffuse posttraumatic lesion, due to a transient and completely reversible disturbance in neuronal function, a synaptic disconnection in glial-neuronal junctions, and glial-capillaries connection. Alteration of function of ion transmembranal channels and levels of neurotransmitters with a secondary functional reversible block occurs.

Neurological exam is normal, and the diagnosis is usually retrospective. The child presents with pallor, delayed verbal and motor responses, in the absence of any morphologic changes. Toddlers may present with drowsiness, vomiting and posttraumatic seizures, and older children may have antero- or retrograde PTA. CT scan shows no evidence of traumatic lesion. The treatment is exclusively symptomatic and observation of the child.

*Brain contusion.* Brain contusion is a focal posttraumatic lesion, secondary to external traumatic forces or it can arise in cerebral herniations. Contusions are well defined and induce neurological changes due to local parenchymatal changes, mass effect or cerebral herniation.

Traumatic forces induce vascular injuries, endothelial cell, basal lamina and glia lesions. Vascular disruption causes intraparenchymatal hemorrhagic foci. On the other hand, neurons lack the metabolic support. Leptomeningeal layer, pia mater and arachnoids are intact.

Size and number of contusions depend on previous conditions of the brain (blood supply, volume of intercellular space, etc.), intensity and direction of traumatic forces. The lesion has a progressive character, evolving either to limiting the hemorrhagic lesion and resolution, or to growing in size, number and extent of contusions.

Clinical findings depend on the location in an eloquent area, cortical or deep location, size, number and extend. Clinical pattern may be minor, moderate or severe TBI, intracranial hypertension, with or without focal neurological deficits. The diagnosis and follow-up are performed by CT scan.

Treatment is pathogenic and symptomatic. It is focused on impairment of contusion extension, prevention of secondary lesions, and improvement in clinical behavior. Surgery usually is not required in children but they will be under clinical and CT scan observation.

*Brain laceration.* Brain laceration is a focal posttraumatic lesion with a complete disruption of brain parenchyma, hemorrhage and tissue necrosis, and tearing of pia mater. It is found in 2–3% of children sustaining head injury.

Brain laceration can be:

- Direct brain laceration, without craniocerebral wound, located at the impact site, beneath the skull fracture, often a depressed skull fracture, and with craniocerebral wound, when all anatomical layers till the brain parenchyma are torn
- Indirect brain laceration, through a “contre coupe” mechanism

Besides, brain lacerations are grouped into:

- Pure traumatic cerebral lacerations, without other intracranial lesions (especially hematomas)
- Traumatic cerebral lacerations associated with subdural hematoma
- Traumatic cerebral lacerations associated with intracerebral hematoma
- Cerebral lacerations associated with a nontraumatic intracerebral hematoma

Clinical findings depend on location and size of the lesion and associated injuries (hematoma).

The diagnosis is made by CT scan. Usually is accompanied by a hemorrhagic collection, which differentiates it from contusion. The treatment depends on the type and size of lesion and the development of intracranial hypertension syndrome development.

Direct brain laceration with craniocerebral wound always requires surgical treatment.

Brain lacerations without craniocerebral wound are treated conservatively or surgically (rare in children), according to the clinical aspect. Focal neurological deficits or elevated intracranial pressure depend on the location, size and number of lesions, and associated injuries, such as secondary hematomas.

*Craniocerebral wounds in children and penetrating head injury.* Craniocerebral wounds and penetrating head injury are rare in children. In penetrating head injury, all anatomic structures, scalp, skull, dura mater, leptomeningeal layer and brain parenchyma are involved. Many bizarre injuries

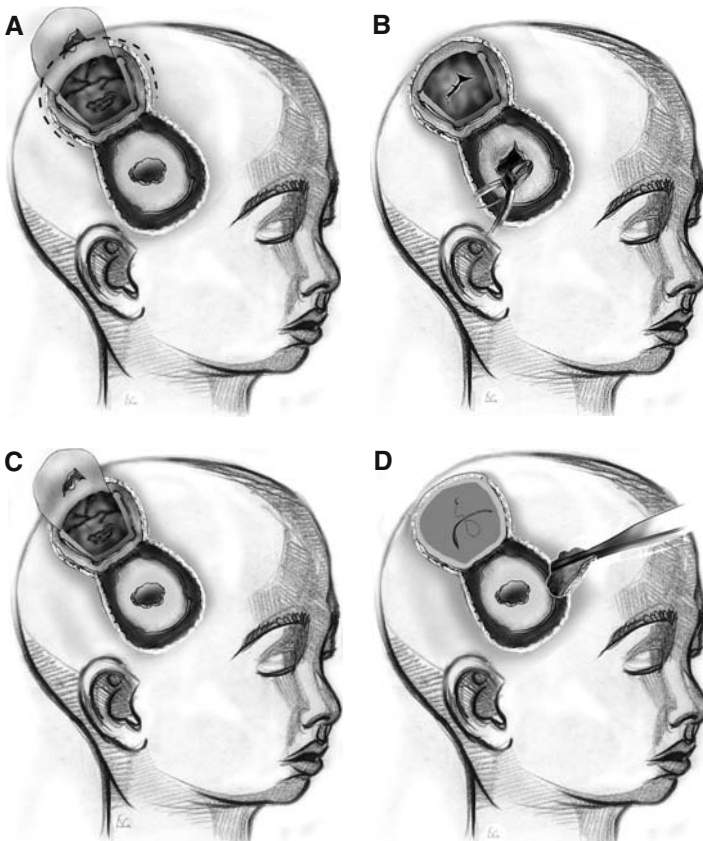


were reported caused by pencils, keys, power drills, glasses, chopsticks, animal claws and iron bars.

According to the nature of traumatic agent, two categories of craniocerebral wounds are distinguished: gunshot craniocerebral wounds and craniocerebral wounds produced by different agents other than gunshots.

Generally, gunshot craniocerebral wounds are encountered in children in war zones. Local exam shows traumatic mark and neurological exam evaluates the level of consciousness, focal neurological syndrome, and meningeal syndrome.

Classical skull X-ray and CT scan, showing the extent of the lesion and the presence of associated injury, complete the diagnosis.



**Fig. 8.** Surgical technique of the craniocerebral wound. **A** Large arcuate skin incision. **B** Craniectomy in normal bone with craniotome and bone fragments removal. **C** Removal of lacerated dura mater and brain laceration. **D** Tight dural closure and bone reposition

Urgent surgical treatment is mandatory, and its purpose is the removal of the bone fragments and cerebral detritus, reconstruction of anatomical layers, and antibiotherapy.

Surgical technique in craniocerebral wounds (Fig. 8): Skin incision, from the corners of the wound, with resection of contused borders of the wound; extraction of superficial foreign bodies; hemostasis; bone lesion evaluation: Craniectomy is performed if bone lesion is limited, and bone fragments are removed, if there is a large, compound fracture; removal of lacerated dura; removal of brain laceration. Clots and foreign bodies are removed by lavage with saline and mild suction. Excision of cerebral debris until healthy tissue is found; hemostasis; tight dural closure. Sometimes dural defect requires a duraplasty. For this can be used a patch of periosteum, lyophilized dura, temporal fascia, fascia lata or artificial dura sutured to the borders of the normal dura mater; dura mater suspension; bone reposition, and wire fixation; wound closure.

*Epidural hematoma.* Epidural hematoma (EDH) is a posttraumatic endocranial blood collection between the inner table of the skull and dura mater and results from tearing of dural blood vessels.

Epidural hematoma may be:

- *Convexital* supratentorial or cerebellar. The source of bleeding is usually arterial, meningeal middle artery, fracture, diastatic fracture (diploic veins).
- *Suprasinusal* (over the superior sagittal or transverse sinus). The source of bleeding is usually venous.

Usually EDH is unilateral and located most frequently in the temporoparietal region, followed by frontal and occipital regions, and less common vertex and posterior fossa. Pediatric acute EDHs are quite rare, with a frequency of occurrence around 3% of all head injury. The frequency rises with age, according to the increased severity of HI in older children. Diagnosis must be quick and urgent surgery is needed.

Generally in children below 3 years old, EDH is uncommon, because of endocranial adherences of dura mater to the inner table. In newborns, EDH is extremely rare and can occur in prolonged labor. Several cases with fetal EDH were recently reported, they were diagnosed by ultrasonography and MRI: fetal supratentorial EDH secondary to a maternal abdominal trauma, and fetal posterior fossa EDH without history of trauma. Unfortunately, there is no efficient therapy in these cases so far.

EDH is often associated with other posttraumatic lesions such as skull fracture, contusion, and subarachnoid hemorrhage.

Clinical feature of EDH include the following: immediate posttraumatic or delayed LOC, focal neurological deficits, intracranial hypertension, and progressive worsening in cerebral herniation. The clinical signs depend on the

source of bleeding, which assert the rapidity of progression (supraacute, acute, subacute hematoma), location of EDH and presence of associated lesions. In infants, epidural hematoma is large, due to the opened fontanelle and easily separating sutures, and up to 100 cm<sup>3</sup> of blood can collect in the epidural space before any neurologic signs occur. Infants with EDH may present with acute anemia, accompanied by hypotension, and hypovolemic shock. According to official data, at the age of 3 months the total blood volume is 550–600 ml; 1 year, 700–800 ml; 2 years, 850–950 ml; 5 years, 1300–1400 ml; 15 years, 3500–4000 ml.

According to the level of consciousness and presence of comatose status, clinical features may be:

- brief posttraumatic LOC, followed by lucid interval for several hours, and then progressive alteration of level of consciousness
- persistent posttraumatic coma
- posttraumatic coma, followed by regaining of consciousness
- posttraumatic conservation of consciousness without coma
- posttraumatic conservation of consciousness with delayed coma

The clinical features of EDH in newborns and infants are vague, consisting of hypothermia, seizures, and tense fontanelle.

A special situation is the occurrence of an EDH in a hydrocephalic shunted child, which represent a serious and urgent entity of pediatric pathology. Although after a mild TBI the hydrocephalic shunted child is usually initially asymptomatic, it will be in a coma. In this situation we deal with a giant EDH with a rapid onset. CT scan must be performed without delay. Often there is no lucid interval, with rapid alteration of level of consciousness immediately posttrauma and severe impairment of vegetative functions. In supratentorial EDH, focal neurological signs consist of motor deficits, jacksonian seizures, anisocoria, and comatose state [3].

Posterior fossa EDH blocks cistern magna and leads to brainstem compression and acute obstructive hydrocephalus with acute intracranial hypertension. Posterior fossa EDH occurs less frequently than supratentorial hematomas but it is the most common traumatic space-occupying lesion of the posterior fossa in children. It is often associated with an acute clinical deterioration without significant warning symptoms and may result in death.

Diagnosis, localization and size of EDH is made by CT scan. EDH may appear as an extraaxial lenticular-shaped mass situated between the brain and the skull, with density varying according to the age of the lesion. A normal CT scan performed immediately after trauma does not exclude the possibility of further development of an EDH.

A child harboring a skull fracture, usually within occipital bone, presenting vomiting, must be observed clinically and by CT scan for development of an EDH.

Surgical indications are established by clinical status and CT scan:

- Comatose patient with anisocoria and CT scan showing EDH require urgent surgery
- Coma and worsening of neurological state in case of EDH volume of >25 ml
- EDH volume of >30 ml, even in the absence of clinical signs
- EDH volume of >25 ml, if EDH is located within the posterior fossa or temporal region
- Midline shift of >4 mm, with worsening of neurological status
- Increase in volume of EDH

Surgery consists of evacuation of the hematoma through craniotomy. It is important to perform an initial blood replacement to the shocked child; this should be carried out within 20–30 min, before starting operatory procedures.

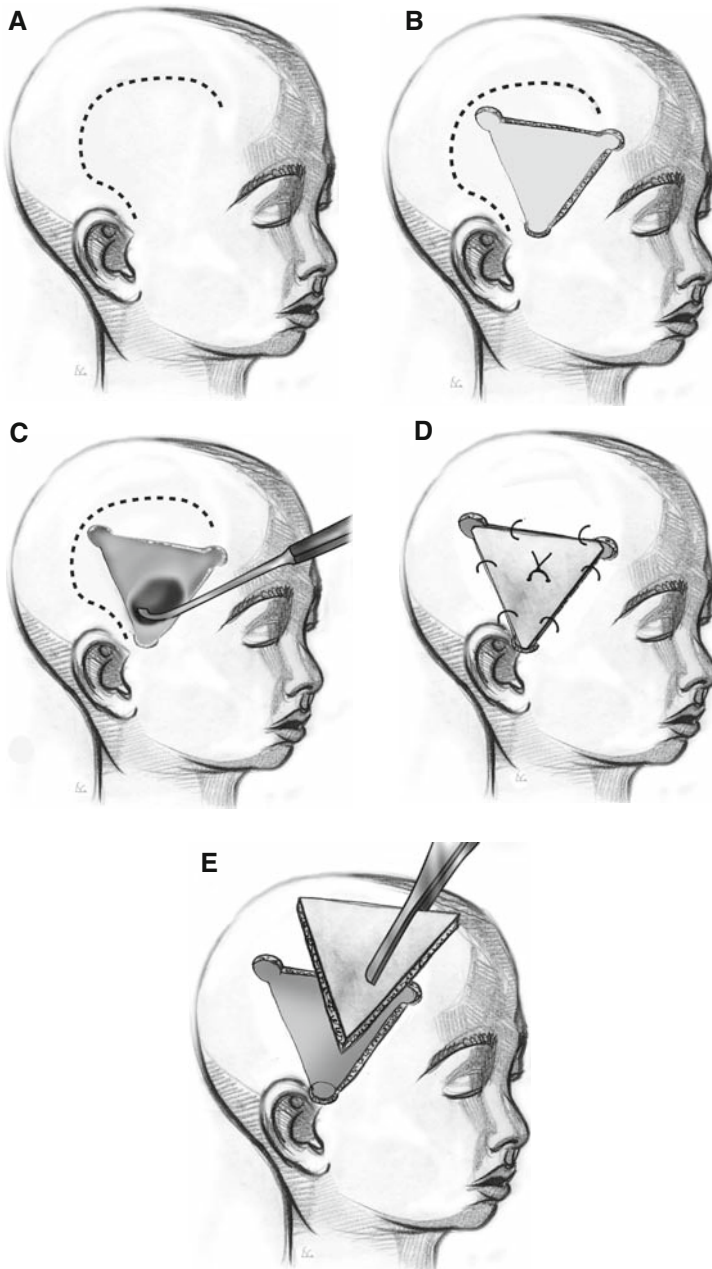
Conservative treatment is attempted in an alert child, without focal neurological deficits, in which CT scan showed an EDH with a volume of <25 ml, a thickness of <10 mm and midline shift of <4 mm, under attentive clinical observation and repeating of the CT scan in a neurosurgical center, where surgery can be performed if needed [1].

Surgical technique for convexity temporal EDH (Fig. 9): For trauma flap “question mark” scalp incision from the zygomatic arch, 1 cm anterior the tragus, in order to spare the facial nerve branch of the frontalis muscle and the anterior branch of the superficial temporal artery, curved posterior at the top of pinna, 4–5 cm behind the pinna, proceeded superiorly 1–2 cm ipsilateral to the midline, curved anteriorly and ended at the hairline. Incision of the temporal muscle with electrocoagulation. Frontotemporal craniotomy; evacuation of the hematoma step by step; hemostasis. Coagulation of the bleeding source. If the bleeding source is not found, it is assumed to be caused by bleeding from the inner surface of the skull. Usually, secondary to reexpansion of the brain rebleeding is hindered, but application of bone wax to the inner surface of the skull or reflection of a free bone flap along the limbus of the hematoma may be performed; dura mater anchoring with bone flap reposition; wound closure.

For posterior fossa EDH there is no special surgical technique: vertical median or paramedian skin incision, suboccipital craniectomy, evacuation of the hematoma, hemostasis, dura mater suspension and wound closure.

*Posttraumatic subdural hematoma.* Posttraumatic subdural hematoma (PTSDH) in children occurs with an overall frequency of 5%, less common before 3 years of age. The incidence increases with ageing, reaching in teenagers the frequency of young adults.

In infants and toddlers, PTSDH occurs in shaken baby syndrome and following head injury caused by accidental falling. In children aged between 5 and 6 years, acute PTSDH is generally produced by falls and motor vehicle



**Fig. 9.** Surgical technique for convexity temporal EDH. **A** "Question mark" scalp incision. **B** Triangular frontotemporal craniotomy. **C** Evacuation of the hematoma. **D** Dura mater anchoring. **E** Bone flap reposition

accidents. In older children, common causes are motor vehicle accidents, falls, and playing accidents, etc.

According to the clinical outcome and establishment of diagnosis, subdural hematomas are acute in the first two days, subacute within the next days until 3–4 weeks, and chronic after 4–6 weeks. Chronic PTSDH in children is considered to be a consequence of conservative treatment or misdiagnosis of an acute PTSDH.

According to the location and volume of the hematoma, clinical signs consist of alteration of level of consciousness, focal neurological signs, and intracranial hypertension, in various grades of intensity.

In acute PTSDH, clinical signs occur immediately and consist of coma with motor deficits and anisocoria, which requires urgent surgical exploration and therapy. In infants and toddlers, clinical findings associated with acute PTSDH may include the following: apathia, adynamia, vomiting, seizures, tense anterior fontanelle, alteration of consciousness and coma.

A child with a subacute PTSDH may experience a variable period of LOC after trauma, followed by clinical improvement (lucid interval varies from days to weeks), followed by subsequent clinical worsening, motor deficit, seizures, anisocoria and coma. Sometimes loss of consciousness can be absent, but the child may present totally unspecific symptoms and a progressive outcome. Focal neurological signs indicate the location of the lesion, and worsening in neurological status indicates increased intracranial pressure.

Deterioration can be rapid in children, with repeated generalized or jacksonian seizures, hemiplegia, decorticated or decerebrate rigidity, unilateral midriasis, and coma.

Chronic PTSDH in children is a consequence of a misdiagnosed PTSDH with minimal clinical findings. Chronic PTSDH can have a different etiology in toddlers: perinatal subarachnoid hemorrhage, prolonged, difficult labor, following meningitis, and coagulopathy.

Clinical features are unspecific: more commonly seizures are found, followed by irritability, delayed psychological and motor development. In infants and toddlers, tension of the anterior fontanelle and abnormal increase of the head circumference. Additionally, motor deficits and cranial nerve palsy may occur, and during the deterioration phase, lethargy and alteration of level of consciousness. Extremely rarely, the child is asymptomatic.

CT scan is mandatory for diagnostic and therapeutical management. Acute PTSDH appears on the noncontrast head CT scan as a crescent-shaped hyperdense area between the inner table of the skull and the surface of the cerebral hemisphere. Within time, the density appearance on CT scan of the collection modifies as follows: inhomogeneous, with hyper-, hypodense appearance in subacute PTSDH; in the chronic phase, PTSDH is iso-, hypodense to brain tissue. CT scan shows other posttraumatic lesions, such as contusion, subarachnoid hemorrhage, brain swelling, etc. Sometimes, the thickness of the subdural collection is not directly proportionate

to the compressive effect on brain parenchyma, manifested by increased brain swelling and subfalcian herniation. In children, clinical appearance can show a great discrepancy. Sometimes small PTSDH can have important mass effect or vice versa large subdural collection can have reduced clinical signs.

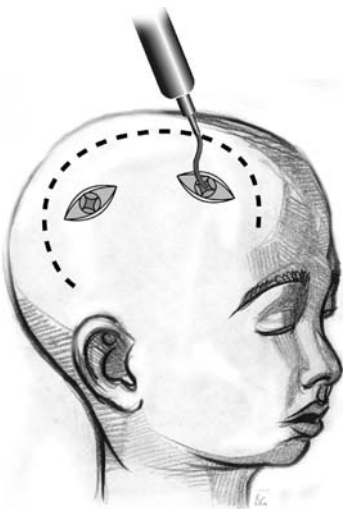
Treatment of PTSDH depends on the time of diagnosis, clinical findings, location and type of hematoma, and child's age, and it can be conservative or surgical.

Conservative treatment in acute PTSDH is indicated only when the child is alert, with minor symptoms, without focal neurological signs, without any signs of intracranial hypertension, and CT scan showing a subdural collection less than 3 mm thick, without midline shift or midline shift smaller than 3–4 mm. The child must be attentively clinical observed and CT scan must be repeated.

In cases when CT scan does not show surgical indications, but the general clinical condition is severe, with a GCS of <9, but without focal neurological or other intracranial hypertension signs, monitoring of the ICP will indicate the optimal therapy.

Acute PTSDH with focal signs or increased ICP requires urgent surgery. Surgical treatment consists of hematoma evacuation, hemostasis, and treatment of associated lesions.

Also in subacute and chronic PTSDH, treatment is always surgical. Many neurosurgical techniques were proposed: subdural tapping, drainage of hematoma through burr holes, drainage of the fluid into a closed external system, shunting the hematoma to the peritoneum or pleura, subgaleal shunt, evacuation of the hematoma and excision of the membranes by wide craniotomy.

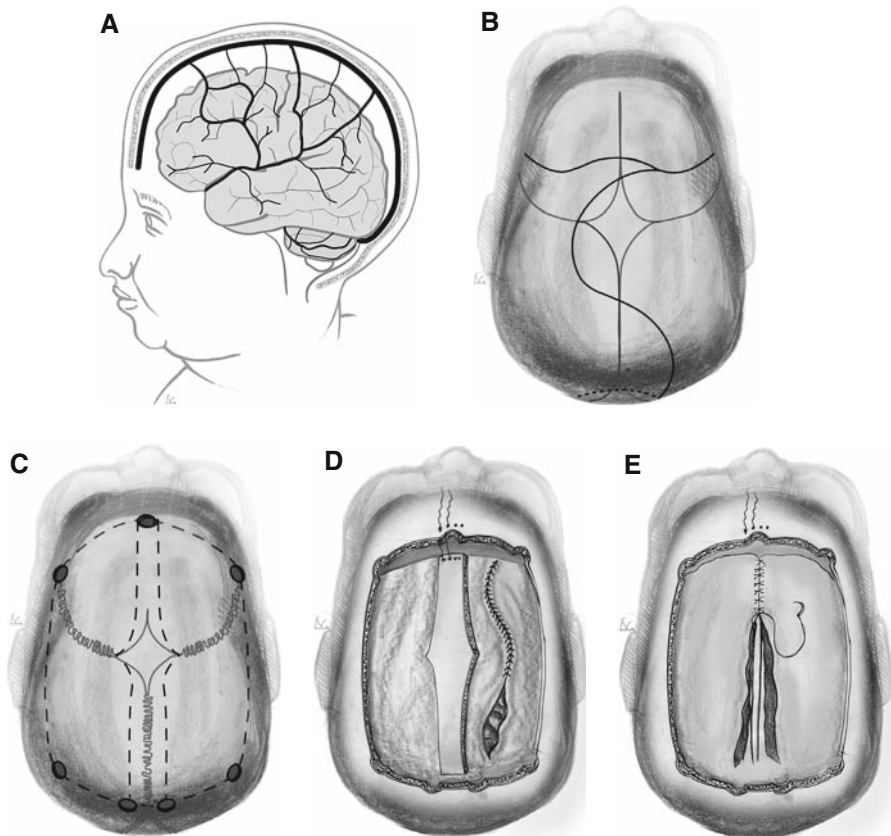


**Fig. 10.** Surgical technique for chronic PTSDH (two burr holes over the hematoma with lavage and external drainage). Arcuate scalp incision; two burr holes, frontal and parietal

In children over 3 years old there are two options in surgical treatment for chronic PTSDH: one is drainage, lavage of the PTSDH through one or two burr holes over the hematoma, and another one is the Raimondi technique [8]. Personally, I recommend the last surgical technique in PTSDH, but without frontoparietal bone reshaping.

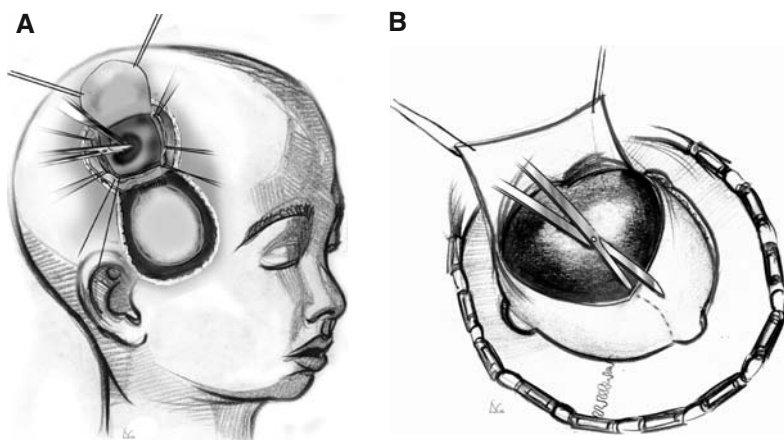
Surgical technique for chronic PTSDH (Fig. 10): Arcuate scalp incision; One or two burr holes over the hematoma (frontal and temporal, or frontal and parietal); drainage and lavage with saline of the hematoma; wound closure.

Raimondi technique for failure of other techniques in treatment of chronic PTSDH (Fig. 11) [8]: Frontoparietal craniotomy; dura opening. The dura is incised in a “Z” or “X” configuration bilaterally. PTSDH is evacuated. The dura is sutured back and the excess trimmed to diminish its surface. In this



**Fig. 11.** Raimondi technique in bilateral PTSDH. **A** Schematic view of bilateral PTSDH. **B** Possibilities of scalp incisions. **C** Frontoparietal craniotomy. **D** Dural closure. **E** Free borders of the dura may be sutured over the SSS. **F** Bone flaps are reshaped



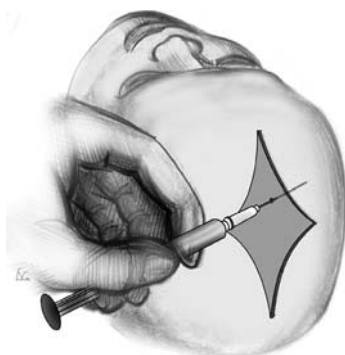

**Fig. 12.** Surgical technique for chronic PTSDH. **A** “Horse shoe” skin incision over the hematoma; osteoplastic bone flap by craniotome; opening the dura mater. **B** PTSDH evacuation

way, the superior longitudinal sinus is lowered. If craniofacial disproportion exists, the original bone bridge over the sinus is lowered also and the frontoparietal bone flaps are reshaped; wound closure.

The Raimondi technique is very aggressive for the children especially 0–3 years old. Our routine technique in chronic PTSDH (Fig. 12): “Horse shoe” incision; bone flap over the PTSDH, in three burr holes, with craniotome (general fronto-temporal). In cases with bilateral PTSDH, two bilateral bone flaps will be needed; hematoma evacuation, step by step; careful hemoastasis; dural anchoring; bone flap repositioning.

With this last technique is possible to achieve perfect evacuation of hematoma and efficient hemostasis. We do not encourage use of the old technique by temporal scalp incision and craniectomy.



**Fig. 13.** Subdural tap through the lateral part of the anterior fontanelle

Subdural punctures through the fontanelles are dangerous and are not performed for diagnostic or therapeutic procedures. This technique will be performed only in chronic hygroma and hematoma in infants (Fig. 13).

*Child abuse and shaken baby syndrome.* Child abuse is a posttraumatic syndrome presenting multiple injuries resulting from bad treatment or beating of the child. Almost all cases are found in children under 3 years old, with a maximum of incidence under 1 year.

Clinical findings include vomiting, pallor, irritability, overcrying, drowsiness, multiple bruises, respiratory disturbances, etc. Although there are no pathognomonic findings for child abuse, there are some characteristic factors which raise the index of suspicion: retinal hemorrhages, subdural hematoma, intraparenchymal hemorrhage, other cerebral hemorrhages, cerebral edema, and bone fractures (long bones, ribs). Intraocular hemorrhage findings are usual findings in child abuse, and when they are associated with a PTSDH, they strongly suggest shaken neglect [7]. The mechanism of trauma is shaking injury, with or without impact (shaken impact syndrome), and direct pure impact injury. Violent shaking of the child's head produces whiplash-like angular acceleration-deceleration of the head, sometimes with rapid onset of the symptoms. CT scan is mandatory at admission and the child requires PICU observation. The treatment depends on the multiple lesions including posttraumatic anemic syndrome or coagulopathy. Outcome is, generally, poor, having a higher mortality than accidental TBI, because of the multiple trauma complexes in a growing infant.

## CONCLUSIONS

1. TBI in infants, toddlers, preschool children and growing up children is completely different from that in adult; each age has its anatomical and etiologic particularities, specific type of lesions (e.g. GSF), clinical features with insufficient clinical signs.
2. Usually the signs and symptoms in infants, toddlers and preschool children at admission are transient or sustained LOC, vomiting, headache, irritability, pallor, PTA, seizures, visual disturbances.
3. CT scan is mandatory at admission and is necessary in follow-up in spite of danger of radiation.
4. Children must be addressed in a hospital with special neurosurgical pediatric facilities, including PICU.
5. Reactivity and outcome of a child are completely different from those of the adult. Special attention in children should be paid to "talk and die" syndrome that can occur in any moment following a TBI. For that reason careful observation is necessary.
6. Particularities in TBI in infants and toddlers are clinical features dominated by pallor and irritability, presence of seizures and difficulties of clinical examination. In this condition the diagnosis must be quick and efficient.

7. In all cases of TBI in children with or without intracranial hematoma or multiple associated traumas, we must take into consideration the possibility of hemorrhagic shock occurrence associated with a high mortality within the first few hours following trauma. An initial blood replacement to the shocked child is mandatory and will be carried out as an important therapeutical target. Pediatric neurointensive care specialist, pediatric neurosurgeon and general pediatric form the best team for complete diagnosis and therapy.
8. A child with multiple traumas must be treated by a multidisciplinary team; the possibility of abdominal, thoracic and leg injuries (specially in road accidents) must be take into consideration and the multidisciplinary team will be involved.
9. Early decompressive craniectomy with duraplasty must be performed in cases with intracranial hypertension (e.g. DBS) refractory to conservative therapy.

## References

- [1] Balmer B, Boltshauser E, Altermatt S, Gobet R (2006) Conservative management of significant epidural haematomas in children. *Childs Nerv Syst* 22: 363-367
- [2] Ciurea AV, Coman T, Rosu L, Ciurea J, Baiasu S (2005) Severe brain injuries in children. *Acta Neurochir Suppl* 93: 209-212
- [3] Ciurea AV, Kapsalaki EZ, Coman T, Roberts JL, Robinson JS 3rd, Tascu A, Brehar F, Fountas KN (2007) Supratentorial epidural hematoma of traumatic etiology in infants. *Childs Nerv Syst* 23: 335-341
- [4] Drapkin AJ (2006) Growing skull fracture: a posttraumatic neosuture. *Childs Nerv Syst* 22: 394-397
- [5] Figaji AA, Fieggen AG, Peter JC (2003) Early decompressive craniotomy in children with severe traumatic brain injury. *Childs Nerv Syst* 19: 666-673
- [6] Kan P, Amini A, Hansen K, White GL, Brockmeyer DL, Walker ML, Kestle JRW (2006) Outcomes after decompressive craniectomy for severe traumatic brain injury in children. *J Neurosurg (5 Suppl Pediatrics)* 105: 337-342
- [7] Pierre-Kahn V, Roche O, Dureau P, Uteza Y, Renier D, Pierre-Kahn A, Dufier JL (2003) Ophthalmologic findings in suspected child abuse victims with subdural hematomas. *Ophthalmology* 110: 1718-1723
- [8] Raimondi AJ (1998) *Pediatric neurosurgery*. Springer, Berlin Heidelberg New York, pp 343-377
- [9] Simpson D, Reilly P (1982) Paediatric coma scale. *Lancet* 2: 450
- [10] Stein SC, Spettell C (1995) The head injury severity scale (HISS): a practical classification of closed-head injury. *Brain Inj* 9: 437-444



### **Alexandru Vlad Ciurea**

Alexandru Vlad Ciurea is Head and Chairman of the First Department of Neurosurgery, Clinical Hospital Bagdasar-Arseni, Bucharest, Romania. Speciality: M.D., Ph.D., senior neurosurgeon. From 1972, he works directly in neurosurgical field (36 y), main interest: brain tumors, cerebrovascular diseases, intramedullary tumors, neurotrauma, and pediatric neurosurgery.

1976 – Confirmation as “*Doctor in Medical Sciences*” (Ph.D.), Neurosurgical speciality.

1989 – *Chief of 1st Neurosurgical Department*, Hospital “Dr. Gh. Marinesco”, Bucharest.

1997 – *Professor of Neurosurgery UMP* (University of Medicine and Pharmacy), “Carol Davila”, Bucharest, *Head & Chairman 1st Neurosurgical Clinic*, Hospital “Prof. Dr. D. Bagdasar” Hospital, Bucharest.

**Contact:** Alexandru Vlad Ciurea, Clinical Hospital Bagdasar-Arseni, First Department of Neurosurgery, 10–12 Bercent Street, Bucharest, Romania  
E-mail: rsneurosurgery@gmail.com

---

# MANAGEMENT OF HYDROCEPHALUS IN CHILDHOOD

J. CHAZAL

## INTRODUCTION

Hydrocephalus is defined as the enlargement of brain ventricles (internal hydrocephalus) and/or subarachnoid spaces (external hydrocephalus). The cause may be known (acquired or congenital) or unknown (apparently idiopathic). The incidence of congenital hydrocephalus ranges between 0.9 and 1.8/1000 live births. Hydrocephalus is the most common condition in pediatric neurosurgery, occurring as an isolated disorder or associated with other conditions.

From the historical point of view, diagnostics were transformed by the advent of modern neuroimaging (CT scan and MRI). The evolution of therapeutic implements can be divided into three periods. The first period was marked by the conception of the first valve in 1956 by Holter, the second by the advent of flow regulation, anti-siphon or programmable pressure devices. The third period followed the advent of endoscopic third ventriculostomy initially performed by W. Dandy in the USA and G. Guiot in France, which allowed avoiding external drainage and permanent shunts in obstructive hydrocephalus.

Since clinical data are not always sufficient for the diagnosis of hydrocephalus because symptoms are mixed with those of the etiological lesion, imaging is mandatory.

Surgical treatment should be undertaken without too much delay before irreversible damages and definitive neurological deterioration may occur.

## RATIONALE

### 1. THE CEREBROSPINAL FLUID (CSF) [2, 4, 5, 7]

1. *Cerebrospinal fluid (CSF) secretion* is an active process, stable under physiological conditions. Seventy percent are produced by ventricular choroid plexuses, 30% by extrachoroid sources (capillary ultrafiltrate, ependyma, and metabolic water production). In childhood and adult, the rate of production is about 0.35 ml/min or 500 ml/day.

2. *CSF drains* from the ventricular system into the subarachnoid space through the median foramen of the fourth ventricle. It is passively absorbed by

---

*Keywords:* hydrocephalus, childhood, CSF, shunt, ventriculocisternostomy

the blood stream through the arachnoid villi protruding into the intracranial venous dural sinuses and the spine venous plexuses. Cranial arachnoid villi, not mature at the time of birth, continue to develop until the 18th month. There are other possible pathways of absorption in this period: the choroid plexuses, the perivascular and the perineural sheaths. The absorption rate is a linear function of the CSF pressure, with a positive gradient from subarachnoid space to dural sinuses.

## 2. THE INTRACRANIAL PRESSURE

1. *The central nervous system* has three components: the parenchyma and the vascular and the fluid systems enclosed inside the skull and the spine. In the antenatal period and infancy, the skull is an osteo-membranous structure, expanding according to the intracranial pressure (ICP). In older children and adult, the bony structure is nonexpanding. The resistance to CSF flow in the fluid system generates a physiological pressure of about 5–12 cm H<sub>2</sub>O.

2. *Intracranial pressure or CSF pressure* ( $P_{\text{CSF}}$ ) is a combination of the CSF secretion rate (F) and of the resistance (R) to CSF flow and absorption:  $P_{\text{CSF}} = F \times R$ . Physiological ICP values range between 2 and 4 cm H<sub>2</sub>O in infancy, increase along skull growth and ossification process. In older children, normal values range between 10 and 12 cm H<sub>2</sub>O.

## 3. PATHOPHYSIOLOGY

1. *Hydrocephalus results from CSF pressure increase in relation to CSF overproduction and/or impairment of CSF circulation-absorption.*

- CSF overproduction: hypervitaminosis A, choroid plexus tumors... In the latter situation, an increase of resistance to CSF flow due to CSF protein hypersecretion and microhemorrhages is suspected.
- Obstruction to CSF flow: before the site of obstruction, CSF pressure increases and induces a pressure gradient from the ventricles to the parenchyma and the subarachnoid spaces. The ventricular dilatation generates mechanical damages to the parenchyma. The subarachnoid spaces shrink and the brain cortex, covered by the dura mater, comes into contact with the skull vault.
- Obstruction of CSF absorption sites: arachnoid villi or venous stream obstruction theoretically determines both internal and external hydrocephalus in “open skull” situation. In “closed skull”, venous pressure increase (venous obstruction, dural sinus thrombophlebitis) induces brain edema, which limits the CSF compartment expansion. Before the sutures and fontanelles close, ICP increase induces early macrocrania (head circumference greater than 98th percentile or more than  $3\sigma$ ).

2. *Two evolutions are possible.*

- Acute hydrocephalus: intracranial hypertension and brain perfusion pressure decrease lead to circulatory arrest.
- Chronic hydrocephalus: the ventricular dilatation stops when the pressures are balanced by adaptive mechanisms: decrease of CSF secretion and possible contribution of other absorption pathways such as the vascular and cranial nerves sheaths, the ependymal lining and the choroid plexuses. The pressure gradient decreases and the ventricular dilatation stabilizes. In fact, the situation worsens and CSF pressure remains abnormal: above a mean value relatively low, CSF pressure monitorings show pathological A and/or B waves [7]. A persistent transependymal gradient maintains the ventricular dilatation. This is probably favored by alterations of the mechanical properties of the parenchyma and a disturbance in the vasoregulation system.

3. *Specific situations of newborns and infants.* In external hydrocephalus (pericerebral hygroma), evolution is spontaneously favourable, shunting is not necessary in most cases. When the collection does not decrease (1–2%), there is a need for investigations (as an example: hemorrhages in shaken baby syndrome).

#### 4. ETIOLOGY [6, 10]

##### 4.1 Antenatal causes

1. *Obstructions of the aqueduct of Sylvius* represent 10% of hydrocephalus in newborns. They can be primary or secondary aqueductal stenosis (in utero infectious, hemorrhagic or neoplastic processes). Diagnosis is often made in older children or adulthood; CSF obstruction may be compensated for years with macrocrania and episodes of headaches.

2. *Dandy-Walker malformations* account for 2 to 4% of hydrocephalus in newborns. They are characterized by total or partial vermis agenesis, fourth ventricle expansion into the posterior fossa forming a cyst like expansion covered by a thin meningo-ependymal layer. They can be isolated or part of a polymalformative syndrome (corpus callosum agenesis, cleft palate, ocular and cardiac anomalies and facial angiomas). Hydrocephalus by CSF obstruction between the fourth ventricle and the subarachnoid space generally develops within the first three months.

3. *Arnold Chiari type II malformation* is defined by a small posterior fossa, enlarged foramen magnum, cerebellar hypoplasia, lengthening of cerebellar peduncles, Z-shape deviation of the medulla oblongata, caudal displacement of the tonsils through the foramen magnum. Hydrocephalus is due to CSF obstruction by the crowding of the hindbrain into the posterior fossa. Myelomeningocele is nearly always associated.

4. *Main venous causes* are vein of Galen malformations, superior vena cava obstruction.

5. *Intraventricular hemorrhages* are the predominant cause of hydrocephalus in premature infant. The brain parenchyma immaturity enables the development of considerable ventriculomegaly without proportional enlargement of the skull. Hydrocephalus generally develops within the month after hemorrhage.

6. *In utero infections* (toxoplasmosis, cytomegalovirus infection, etc.) are the cause of hydrocephalus by inflammation and sclerosis of the arachnoid spaces, and secondary aqueductal gliosis.

#### 4.2 Postnatal causes

1. *Hemorrhages* due to birth traumatism are present in roughly 25% of asymptomatic neonates, mostly located in the posterior fossa and more frequent in premature infants. Probability of hydrocephalus is correlated with the amount of bleeding. Hydrocephalus may be transitory.

2. *Infectious meningitis*: communicating hydrocephalus (especially purulent, tuberculosis). In neonates, Gram-negative infections lead to multiloculated hydrocephalus with extensive brain damages.

3. *Carcinomatous meningitis* blocks CSF outflow.

4. *Expansive processes* (tumors, abscesses, arachnoid cysts, hematomas). Tumors of lateral ventricles (gliomas, choroid plexuses, papillomas, and carcinomas), of the floor of the third ventricle (optic gliomas, craniopharyngiomas, pineal region tumors). Tumors of the posterior fossa, frequent in childhood (astrocytomas, medulloblastomas, ependymomas). Tumors of the spine (controversial, compression of CSF outflow, microhemorrhage, increase in protein secretion, and CSF viscosity).

5. *Head injury*: hemorrhages, role of the traumatism itself difficult to establish.

6. *Neurosurgical procedures* with hemorrhagic opening of CSF pathways, especially in the posterior fossa.

## DECISION-MAKING

### 1. CLINICAL PRESENTATION [2, 6, 10]

Clinical presentations vary according to the age of patients.

The cause of hydrocephalus may produce specific localizing symptoms.

*Signs of intracranial hypertension require urgent diagnosis and treatment.*

#### 1.1 Premature infants

The most important sign is the *rapid head growth* (head circumference increases of 1 cm/week in healthy premature infants). The head has a globoid shape. The anterior fontanel is tense, bulging (normally flat and concave): the



**Table 1.** Head circumference growth in infants

Premature infants	1 cm/week
Full-term infants	2 cm/month
0–3 months	1 cm/month
4–6 months	0.5 cm/month
7–12 months	

scalp vein distension, episodes of apnea and bradycardia indicate intracranial hypertension syndrome.

Some symptoms may remain unnoticed: poor feeding, vomiting.

*Abducent nerve palsy and papillary edema are commonly lacking at this age.*

### 1.2 Full-term infants

The most common sign is the bulging of the anterior fontanel, and the abnormally rapid head growth leading to *macrocrania* if hydrocephalus occurs before the age of 2 years. *Head circumference should be regularly measured* (Table 1). Other signs are present: irritability, vomiting, drowsiness, axial hypotonia, setting-sun sign (both eyes deviated downward, the upper lids retracted), distended scalp veins. Papilledema is uncommon but retinal hemorrhages may be present in severe intracranial hypertension.

### 1.3 Children

- *Signs of acute intracranial hypertension* are more frequent, because the skull vault is less distensible: headaches, vomiting (frequent in tumors of the posterior fossa, projectile vomiting is not specific of the syndrome), diplopia (abducent nerve palsy), Parinaud syndrome, blurred vision, visual acuity loss, papilledema (detected at least two weeks after the onset of intracranial hypertension). *The lack of papilledema does not rule out the diagnosis of early intracranial hypertension.* The persistence of hydrocephalus may lead to optic nerve atrophy and blindness. Abdominal pain, hyperthermia, alteration of consciousness may be misleading. Neck pain, stiff neck (possible without alteration of consciousness), opisthotonos, cardio-respiratory impairment, Cheyne-Stoke respiration, impaired consciousness are signs of *tonsillar herniation*.
- *Chronic hydrocephalus* is characterized by macrocrania if the disorder began in the first 2 years, mental deterioration (decrease in school performances, memory loss, behavior disturbance), anomalies of gait (walking retardation, repeated fallings), disturbances of micturition with delayed bladder control.

Seizures are uncommon in internal hydrocephalus (5% of patients only); they may indicate symptomatic pericerebral collections (external hydrocephalus or subdural posttraumatic hematomas).

## 2. DIAGNOSTIC STUDIES

1. *Ultrasonography* can be performed to detect and follow fetal hydrocephalus. In infants, transfontanellar ultrasonography is useful for serial evaluation of hydrocephalus because of its innocuousness, but it is not suitable to evaluate the fourth ventricle and the subarachnoid spaces.

2. *CT scan* before and after intravenous contrast medium injection is able to show the following features:

- Increased volume of lateral ventricles (temporal horns normally barely visible), ballooning of the frontal horns (“Mickey mouse ventricles”) and the third ventricle. Ventricular dilatation can be measured by: (i) Bifrontal ratio (largest width of the frontal horns to the internal skull diameter at the same level) favors the diagnosis of active hydrocephalus when greater than 0.50. (ii) Evan’s ratio (maximal frontal horns to the maximal biparietal diameter) suggests hydrocephalus when greater than 0.30. Those ratios that do not take into account the width of the pericerebral spaces are insufficient to rule out brain atrophy.
- Transependymal CSF absorption, as periventricular low density in active and acute hydrocephalus.
- Subarachnoid space modifications: either compressed in internal hydrocephalus or widened in external hydrocephalus. CT scan does not provide any reliable information in relation to the nature of the collection.
- Calcifications of arteriovenous malformations and oligodendrogliomas.
- After intravenous contrast agent injection: enhancement of underlying tumors or vascular abnormalities such as arteriovenous malformation, malformation of vein of Galen, dural sinus thrombosis.

Successive, frequent CT scans are noxious for the lens and the immature brain. In a survey, dosimetric data must be taken into account.

3. *MRI* may require short tranquilization or anesthesia in non-compliant patients. MRI is able to show:

- Internal hydrocephalus: enlargement of the ventricles proximal to the blockage. T2 weighted and flair images demonstrate transependymal CSF absorption as subependymal hyper-signals at frontal and occipital ventricular horns.
- External hydrocephalus, also known as “extra-axial fluid collection”: collection made of CSF, thickness more than 1 cm. More frequent in males, the disorder recovers spontaneously but favors the constitution of traumatic subdural collections over the frontal lobes and in interhemispheric fissure. The density depends on the age of the traumatic event. Posttraumatic subdural collections may exert a mass effect upon the convexity gyrus and compress the ventricular system, unlike external hydrocephalus.

MRI may identify the site and sometimes nature of obstruction: low-grade astrocytomas as heterogeneous signals, and aqueductal stenosis. In idiopathic stenosis no abnormality is detected in morphological sequences.

Cine-phase contrast sequence MRI allows to assess the CSF flow in the ventricles and the arachnoid spaces, through the interventricular foramina, the aqueduct of Sylvius or the fenestration after a third ventriculostomy.

Angiographic sequences may be informative for demonstrating vascular malformations, aneurysms or venous thromboses. A negative MRI, in cases with brain hematoma, needs to be repeated 3 to 6 months later. Arteriography is mandatory in case of subarachnoid hemorrhage.

4. *Conventional angiography* is less frequently performed since the advent of angiographic CT scans or MRI. It is part of the endovascular treatment of aneurysms and arteriovenous malformations.

5. *Continuous CSF pressure recording and hydrodynamic tests (CSF flow resistance and PVI measurements)* can be performed when the diagnosis is not made by imaging or when the underlying pathophysiologic process remains unclear. In infants, continuous pressure recording is performed through the anterior fontanel. In children, the procedure is performed with intraparenchymal pressure recorder or a manometer connected with a ventricular or lumbar catheter.

## MANAGEMENT

### 1. MEDICAL TREATMENT

Medical treatment can be undertaken to gain time before neurosurgery.

*Intravenous mannitol* may be given only in an emergency in acute hydrocephalus to prevent uncal or tonsillar herniation before specific treatment.

*Acetazolamide* limits CSF secretion by arachnoid plexus. The delay of action is not suitable for acute hydrocephalus. It is generally used in association with lumbar punctures.

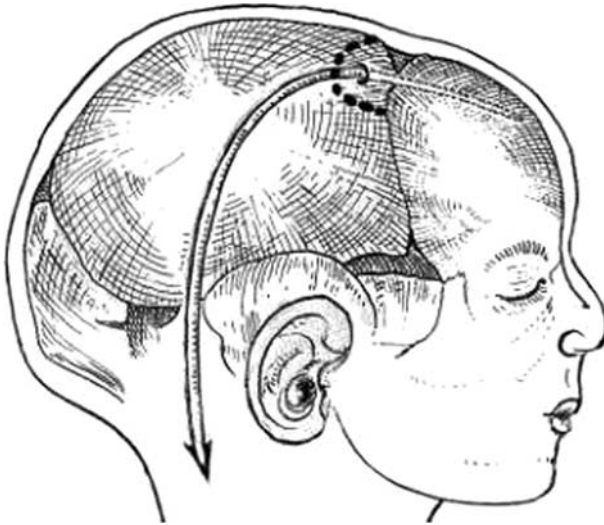
*Lumbar punctures* may be efficient in post-hemorrhagic hydrocephalus to avoid permanent shunt. Perforations of the spinal meningeal sheath probably generate CSF leak toward the epidural space.

### 2. SURGICAL TREATMENT

Etiological treatment is indicated when possible; otherwise CSF derivation shall be performed.

1) *Etiological treatment* does not require a shunt as primary treatment. Surgical treatment of the obstructive lesion cures hydrocephalus (as for instance in 90% of cases after tumor removal).

2) *Pericerebral drainage (symptomatic external hydrocephalus)* consists of a proximal catheter placed into the frontal subarachnoid spaces through a



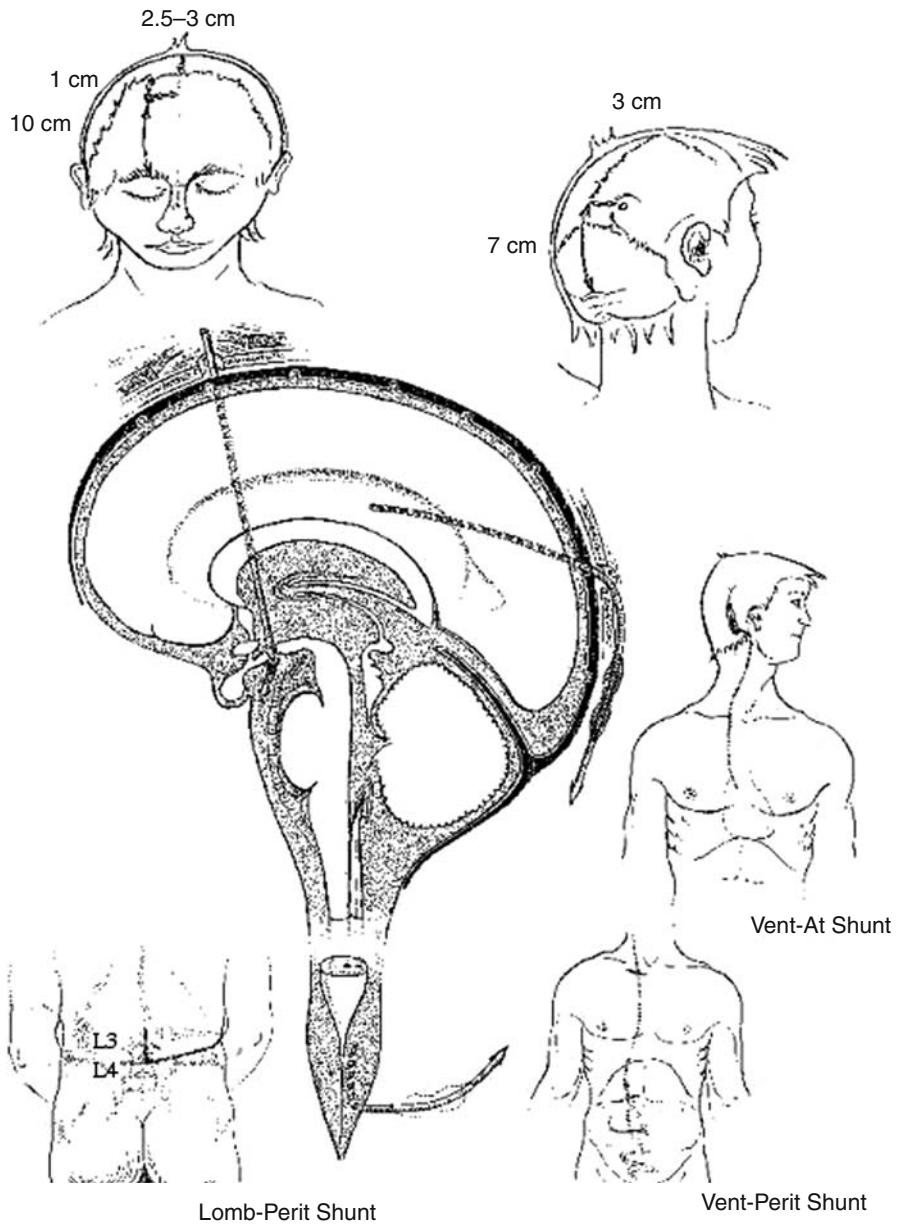
**Fig. 1.** Pericerebral drainage

burr hole drilled laterally from the anterior fontanel and 1 cm behind the coronal suture (Fig. 1). Valve is not necessary, slits at the distal end of the peritoneal catheter regulate the CSF flow. In most cases, it is possible to remove the shunt at the age of 2–3 years.

3) *External ventricular drainage* consists of a ventricular catheter placed into the frontal horn of the right lateral ventricle, under local or general anesthesia according to the age and the compliance of patients. Skin linear parasagittal incision is made at 2.5 cm from the sagittal plane, 10 cm behind the nasion. Burr hole is drilled 1 cm anterior to the coronal suture. A large burr hole (diameter, 1 cm) is necessary to allow modifications of trajectories of the catheter. The catheter is put into the ventricle after coagulation and incision of the dura mater. The depth is indicated by CSF draining at the distal end. The catheter is tunneled subcutaneously and connected with a closed drainage bag and a pressure transducer to record CSF pressure continuously.

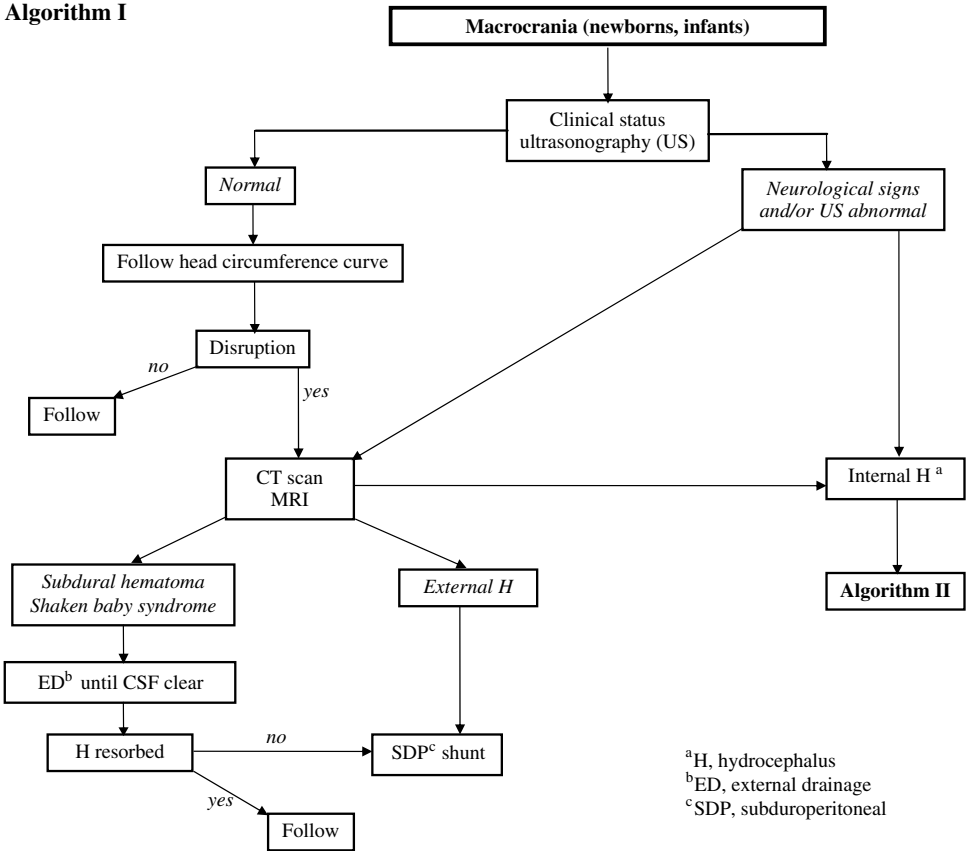
Amount of CSF drained daily is determined by the hydrostatic pressure given by the vertical distance between the drainage bag and the head of the patient. If CSF outflow were totally blocked, theoretical CSF volume drained would be about the CSF secretion: 500 ml/day. In fact, the volume is defined according to CSF pressure monitoring and clinical status.

External ventricular drainage is performed in emergency to alleviate intracranial hypertension in acute hydrocephalus before etiological treatment. Its placement, better achieved in the operating room, is possible in the intensive care unit. When hydrocephalus follows subarachnoid hemorrhage, each day, CSF is analyzed to follow CSF proteins and blood decrease and check the absence of



**Fig. 2.** Different types of shunts

**Algorithm I**



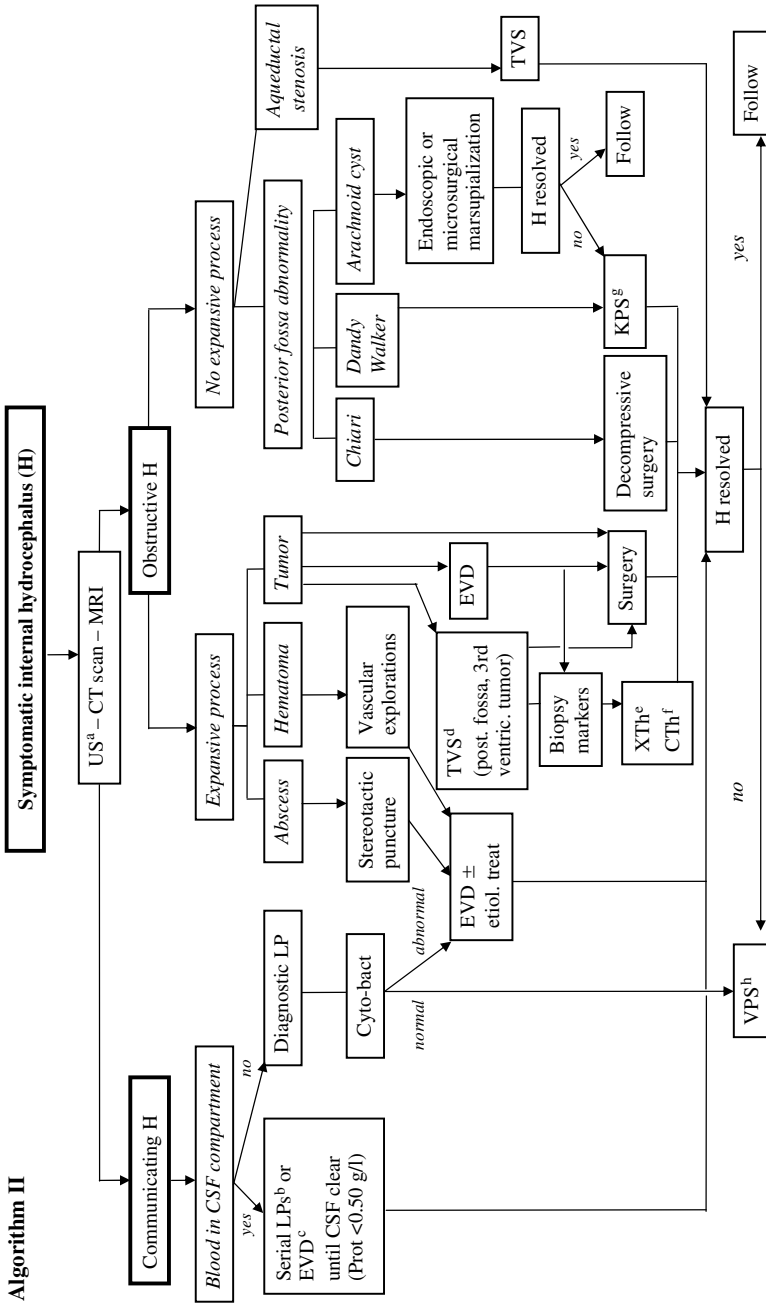
infection. When CSF protein concentration tends to normalize ( $\leq 0.5$  g/l), the drainage catheter is closed. If CSF pressure increases, hydrocephalus is not resolved or clinical status worsens, internal shunting is performed. If CSF pressure remains normal, external drainage is removed without shunting.

4) *CSF shunts* (Fig. 2) drain the CSF (from the ventricles or the lumbar subarachnoid spaces) into a site of absorption (peritoneal cavity or right atrium). Shunts are ventriculo-peritoneal, ventriculo-atrial and exceptionally lumbo-peritoneal. The procedure is performed under general anesthesia with the patient placed in recumbent position.

**4.1 Ventricular shunts**

The ventricular catheter: The hair is clipped over the skin incision. The ventricular catheter is placed proximally to the CSF obstruction, generally into the right occipital horn (in right-handed patients). The site of insertion is 7 cm from the inion and 3 cm from the sagittal plane. The distal part of the ventricular catheter is tunneled subcutaneously and connected to a valve.

Algorithm II



<sup>a</sup>US, ultrasonography  
<sup>b</sup>LP, lumbar puncture  
<sup>c</sup>EVD, extra ventricular drainage  
<sup>d</sup>TVS, third ventriculostomy  
<sup>e</sup>XTh, X ray therapy  
<sup>f</sup>CTh, chemotherapy  
<sup>g</sup>KPS, kystoperitoneal shunt  
<sup>h</sup>VPS, ventriculoperitoneal shunt

Insertion into the frontal horn is possible but increases the length of tunneled catheter. Two catheters may be placed into the frontal horns and interconnected in interventricular foramen obstructions.

The distal catheter:

- In ventriculoperitoneal shunt the distal catheter is inserted into the peritoneal cavity after a horizontal skin incision midway between the inferior boundary of the thoracic wall and the umbilicus or at the level of umbilicus. A short laparotomy avoids visceral injury. The length must be sufficient taking into account the potential growth of the child. Contraindications are extensive abdominal surgery, infectious and carcinomatous peritonitis. Intracranial malignant neoplasms are controversial; no metastatic spread into the peritoneal cavity has been reported in our institution.
- In ventriculoatrial shunt, insertion into the internal jugular vein is performed via the common facial vein (thyro-linguo-facial trunk) under intraoperative X-ray. The tip of the catheter is in the right cardiac atrium at the level of T6. Preoperative phlebography is helpful in patients with central venous site of injection. The procedure is less performed by most institutions and reserved to cases of peritoneal catheter infection or contraindication.

Different types of valves. Programmable pressure devices make possible to set the opening pressure according to clinical data, ventricular size and subarachnoid width at CT scan. Anti-siphon devices antagonize the increase of hydrostatic pressure when the patient is vertical. Flow regulating systems maintain a constant flow, whatever the pressure, by increasing its resistance when hydrostatic pressure increases.

#### 4.2 Lumboperitoneal shunt

This type of shunting is only for communicating hydrocephalus. The shunt is not always connected to a valve; the slits at the distal end of the peritoneal catheter regulate the CSF outflow. The absence of a valve renders the management of CSF flow impossible and increases the risk of tonsillar herniation (Chiari formation induced by lumboperitoneal shunt).

5) *Third ventriculostomy* [3, 9] creates a bypass to a ventricular obstruction in non-communicating hydrocephalus. It may be performed in emergency prior to the removal of the obstructive tumor. Description is as follows: Procedure under general anesthesia, patient positioned supine, with neck flexion of about 30°. Burr hole 1 cm before the coronal suture in the midpupillary line, 3 cm off the midline, position adjusted according to frontal and sagittal MRI. A large burr hole is made to have enough room to handle the endoscope. The ventricular cavity is continuously irrigated with saline or lactated Ringer solution. A rigid endoscope is introduced into the lateral ventricle: Landmarks are the medial septal vein, the thalamostriate vein and



the choroid plexus. The endoscope is introduced into the third ventricle through the interventricular foramen without stretching the column of fornix. Fenestration of the third ventricle floor made with a rigid probe in the mid-line, anterior to the basilar artery, between the mamillary bodies and the infundibulum. A dilating balloon is inserted to enlarge the hole: pulsatile movements of the fenestration margins indicate a CSF flow into the interpeduncular cistern. Basilar artery visualized in the interpeduncular cistern. A successful third ventriculostomy is indicated by early resolution of intracranial hypertension syndrome and CSF flow through the fenestration at cine-phase contrast MRI. Importantly, the clinical outcome is not correlated with ventricular size reduction.

A low success rate is reported in the following conditions: tumor, previous shunt, subarachnoid hemorrhage or whole brain irradiation.

Some surgeons use neuronavigation.

## HOW TO AVOID COMPLICATIONS [1, 6, 10]

### 1. PERICEREBRAL DRAINAGE

*Obstruction of the proximal catheter* is the most common complication; it is related to improper proximal catheter placement or increased CSF protein concentration. Temporary external drainage and/or catheter replacement is advised.

### 2. EXTERNAL VENTRICULAR DRAINAGE

*Obstruction* is frequent in hydrocephalus following subarachnoid hemorrhage or meningitis. The ventricular catheter is obstructed at its proximal end by blood clot or fibrin. If slow instillation of water does not restore the flow, the catheter should be removed and replaced.

*Infection* is the major risk after about 10 days of CSF drainage. Cutaneous infections are treated conservatively with local antiseptic agents. In CSF infection, clinical presentations range from asymptomatic meningitis to acute ventriculitis. Staphylococcus epidermidis infections account for 75% of shunt infections. Being a skin commensal of low virulence, CSF infection is often indolent, without fever, CSF protein or cell count increase. Primary antibiotic treatment may be administered intravenously or directly into the ventricles. If CSF remains infected after a few days, the entire shunt system should be removed and replaced.

*Overdrainage and subdural hematoma*: should not occur if the CSF flow is managed according to the intracranial pressure monitoring.

### 3. VENTRICULAR SHUNTS

*Hemorrhage* is the consequence of inappropriate ventricular catheter placement. Acute subdural hematoma occurs when a large amount of CSF is removed during the procedure.

*Overdrainage* appears when the differential pressure across the valve increases above its opening pressure (postural changes, physical effort inducing arterial pressure increase, ventricular drainage device unsuitable to the pathophysiological condition...).

*Slit ventricle syndrome* is manifested by headache (predominating in upright position), decrease of scholar efficiency, asthenia and lately altered state of consciousness. Pathophysiology is unclear; a decrease in CSF compartment compliance is suspected.

*Chronic subdural hematomas* are produced by the tearing of bridging veins stretched between the cortex and the dura mater.

*In both conditions* the patient should be installed in the recumbent position, the valve adjusted at a higher pressure with clinical monitoring and serial CT scans. If insufficient, for slit ventricle syndrome, solutions tend to restore a physiological compliance (mannitol IV, valve replacement, decompressive craniectomy). Extracerebral collections with symptomatic mass effect require drainage and transitory ligation of the shunt in some cases.

Underdrainage and shunt malfunction are manifested by the persistence or the recurrence of ventriculomegaly and clinical symptoms. Diagnosis is difficult; the ventricular size is not accurately correlated with the clinical improvement and the functionality of the system. *Twenty percent of drainage system dysfunction appear without modification of the ventricular size.* The valve pressure is adjusted according to clinical modifications. If the clinical status does not evolve, the system should be revised.

*Shunt disconnections, migrations and ruptures* have various causes: calcifications and/or fibrosis along the system impede the distal catheter to move under the skin during the growth of the patients and their movements. X-rays make the diagnosis.

*Peritoneal pseudocysts* constituted at the end of peritoneal catheter are responsible for abdominal pain and chronic shunt dysfunction. They may be secondary to indolent CSF infection. They are diagnosed on ultrasonography or CT scan.

*Sepsis* usually occurs in the first 2 months after surgery, sometimes until 6 months or more. The most common agent is staphylococcus epidermidis by contamination of the system at the time of surgery. Cutaneous and subcutaneous infections may be treated conservatively. Meningitis and ventriculitis require urgent removal of the system and placement of an external drainage. Abdominal pain, symptoms of shunt malfunction or seizures are possible. CT scan may show active hydrocephalus and contrast enhancement of ven-

tricular walls and subarachnoid spaces. Bacteriological exams of blood and CSF are mandatory. Primary intravenous probabilistic antibiotic is introduced until antibiogram results. The best prevention of sepsis relies on the choice of material and procedures well known in the department and performed by senior surgeons.

#### **4. LUMBOPERITONEAL SHUNTS**

Lumboperitoneal shunts leading to tonsillar herniations have been reported. The risk of overdrainage increases when the shunt does not include a valve.

#### **5. THIRD VENTRICULOSTOMY**

As regards third ventriculostomy, early failure is most often related to non-punctured arachnoid of the interpeduncular cistern. Large fenestration does not always prevent late hydrocephalus relapses. The most severe complication is basilar artery injury. Subdural hematomas are reported, possibly due to insufficient intraoperative solution irrigation. Transient symptoms suggesting hypothalamic disorders can occur, such as syndrome of inappropriate antidiuretic hormone and fever without infection.

### **CONCLUSIONS**

Shunting is one of the most common procedures in pediatric neurosurgery but complications are frequent: disconnections, infections, failures, hypodrainage, hyperdrainage. They are related to the heterogeneity of the pediatric population (growth and development) and the complexity of the hydrocephalus syndrome. Its pathophysiology remains often difficult to understand and the prognosis of the treatment uncertain. Endoscopic third ventriculostomy, performed in about 20% of hydrocephalus, does not solve all the problems of shunting procedures.

Clinical outcome is difficult to assess owing to the heterogeneity of patients and causal lesions. The risk of surgical revision after shunt placement in newborns and infants is almost 100%. In childhood, chronic shunt dysfunction may remain non-diagnosed because clinical presentation is often poor. Shunt revision may be beneficial. Overall, 80% of the pediatric population after shunting have normal intellectual evaluations. However, in chronic hydrocephalus, clinical improvement after shunt placement is difficult to assess.

#### **Acknowledgments**

I thank Laurent Sakka MD DVM for his contribution to this work.

## References

- [1] Blount JP, Haines SJ (1996) Infections in cerebrospinal shunts. In: Youmans JR (ed) Neurological surgery, 4th edn. Saunders, Philadelphia, PA, pp 945-966
- [2] Bret P, Guyotat J, Chazal J (2002) Is normal pressure hydrocephalus a valid concept in 2002? *J Neurol Neurosurg Psychiatry* 73: 9-12
- [3] Cohen AR, Perneckzy A (1998) Endoscopy and the management of third ventricular lesions. In: Apuzzo MLJ (ed) Surgery of the third ventricle, 2nd edn. Williams and Wilkins, Baltimore, Md, USA, pp 889-936
- [4] Cutler RW, Page L, Galich J, et al. (1968) Formation and absorption of cerebrospinal fluid in man. *Brain* 91: 707-720
- [5] Epstein CM (1974) The distribution of intracranial forces in acute and chronic hydrocephalus. *J Neurol Sci* 21: 171-180
- [6] Greenberg MS (1997) Handbook of neurosurgery, 4th edn. Greenberg Graphics Lakeland, FL
- [7] Hakim S, Venegas JG, Burton JD (1976) The physics of the cranial cavity, hydrocephalus, and normal pressure hydrocephalus: mechanical interpretation and mathematical model. *Surg Neurol* 5: 187-210
- [8] Kestle JR, Garton HJ, Whitehead WE, Drake JM, Kulkarni AV, Cochrane DD, Muszynski C, Walker ML (2006) Management of shunt infection: a multicenter pilot study. *J Neurosurg* 105(3 Suppl): 177-181
- [9] Sainte-Rose C (1992) Third ventriculostomy. In: Manwaring K, Crone K (eds) Neuroendoscopy. Mary Ann Liebert, New York, pp 47-62
- [10] Sainte-Rose C (1996) Hydrocephalus in childhood. In: Youmans JR (ed) Neurological surgery, 4th edn. Saunders, Philadelphia, PA, pp 890-926



**Jean Chazal**

Jean Chazal is the head of the Adult and Pediatric Neurosurgical Department of University Hospital of Clermont-Ferrand (France). He was trained by Pierre Janny, a pioneer in the study of intracranial pressure in Man. Professor of Anatomy at the Faculty of Medicine of Clermont-Ferrand, Jean Chazal is specialized in the study of the central nervous system fluid compartment, its pathophysiology and applications in clinical practice. The disorders of the CSF circulation-absorption system including hydrocephalus are one of the major topics of the department.

Jean Chazal was formerly President of the French Speaking Neurosurgical Society (2004–2006).

**Contact:** Jean Chazal, Service de Neurochirurgie A, Centre Hospitalier et Universitaire de Clermont-Ferrand, Université d'Auvergne, B.P. 69, 63003 Clermont-Ferrand Cedex 1, France  
E-mail: [jchazal@chu-clermontferrand.fr](mailto:jchazal@chu-clermontferrand.fr)

---

# INTRACRANIAL TUMORS IN CHILDHOOD

N. AKALAN

## INTRODUCTION

Compared with the adult counterparts, pediatric brain tumors have diverse properties in terms of incidence, histology, localization and responsiveness to therapy which eventually influence their treatment modality. Tumors of the nervous system are the most common form of childhood malignancy and the leading cause of cancer-related morbidity and mortality with a reported incidence of 2.5–4 per 100,000 children [9]. Despite the advancements in understanding tumor biology, diagnosis and patient care, surgery remains as the single most efficient modality in disease control. The role of surgery is further augmented with refined diagnostic technology; the availability of magnetic resonance imaging (MRI) has triggered dramatic changes in childhood tumor management. The first impact is the relative increase in the incidence of childhood tumors reported in the last two decades, due to rapid and early diagnosis. Second, comprehensive information on tumor morphology with postoperative imaging availability enforced refinement of surgical approach and techniques. Moreover, the high sensitivity enabled to appreciate the effectiveness of different treatment modalities where the surgical resection surpassed the other available adjuncts in treatment of childhood tumors.

The wide variety of histological types of tumors has predilections for different compartments of the central nervous system which makes it more practical to discuss their surgery according to localization rather than pathology. In the broadest manner, tumors are distributed almost evenly among infratentorial and supratentorial compartments with slight shifts from one to the other depending on age groups between new-born and adolescence [13].

## PART I: INFRATENTORIAL TUMORS

Infratentorial localization is a common site for tumors in children, and compared to adults, a much higher percentage of tumors arise at the posterior fossa. Medulloblastomas, ependymomas and astrocytomas together in this location constitute almost half of all brain tumors in children [7]. While they represent far ends of the spectrum in terms of malignancy and natural course, their tendency to arise at specific anatomic locations makes it possible to limit the access basically to posterior midline (and paramedian) approaches.

---

*Keywords:* childhood, brain neoplasm, infratentorial neoplasms, supratentorial neoplasms

## **RATIONALE**

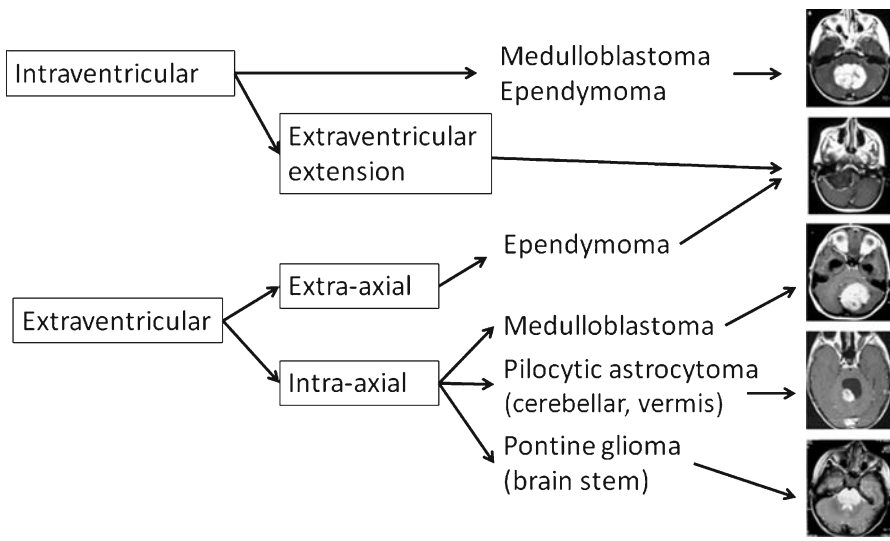
Medulloblastoma (or, primitive neuroectodermal tumor [PNET]) is the most common malignant brain tumor in children and accounts for 30% while cerebellar pilocytic astrocytomas represent 10% and ependymomas 8% of all pediatric brain tumors. All together, they are responsible for almost 90% of posterior fossa tumors. Medulloblastomas are classified as WHO grade IV and pilocytic astrocytomas, grade I, where ependymomas stand in between as grade II and occasionally grade III tumors [2]. The goal of surgery being to obtain a tissue diagnosis or to relieve increased intracranial pressure is not valid as whatever the pathology may be, the only variable for favorable outcome has been the amount of resection, for a posterior fossa tumor in a child. The effort should always be towards total resection without causing morbidity.

## **DECISION-MAKING**

1. Almost all infratentorial tumors in children come to attention with the symptoms and signs of increased intracranial pressure due to hydrocephalus. Exceptions would be pontine gliomas or ependymomas with extraventricular extension for which cranial nerve involvement might be the first sign [14]. The aim of treatment is to relieve the symptoms, to obtain a tissue diagnosis and provide best available outcome which can only be achieved by radical surgery.
2. MRI is the only modality which non-invasively provides diagnosis; related changes such as the severity of hydrocephalus, extent of the disease, best available approach and localization based pathological diagnosis at the same time.
3. Childhood medulloblastomas and ependymomas are typically confined to 4th ventricle, while astrocytomas are always extraventricular (Table 1). This makes it reasonable to approach most of the tumors through a midline suboccipital craniotomy. Retromastoid approach is reserved for pilocytic astrocytomas exclusively at cerebellar hemisphere or those rare tumors at the cerebellopontine angle.

## **SURGERY**

1. Owing to the general awareness and highly specific, non-invasive MRI technology, children with brain tumors are being diagnosed at a much earlier stage than before. This is especially true for posterior fossa tumors where children used to go through several diagnostic work-up before being referred to neurosurgery. Early diagnosis provides obvious advantages in planning the treatment; general physical condition, neurological status and the degree of hydrocephalus at

**Table 1.** Pre-operative differential diagnosis for major childhood infratentorial tumors based on magnetic resonance imaging

admission allow considering the patient as an elective case and not an emergency, as had been in the past. This in turn provides a detailed preoperative assessment of the child, minimizing potential risks of surgery. Moreover, early detection combined with improved anesthesiology management made it unnecessary to treat hydrocephalus by shunt or ventriculostomy prior to tumor resection.

2. MRI findings are of great value in both planning the most appropriate approach and estimating the pathology and disease state. Dissemination prior to surgery would strongly indicate a medulloblastoma at an advanced state, while extension of a fourth ventricular tumor out through foramen of Luschka suggests an ependymoma.
3. Corticosteroids are given as a loading dose of 8 mg and then 4–8 mg every 6 hours. There is no indication for prophylactic anticonvulsants for posterior fossa pathology. Pediatric cases with brain tumors, regardless of age, have major requirements different from those of adults in terms of anesthesiology and post-operative care. Besides the surgeon, the entire facility should be capable of handling all age groups.
4. Utilization of operative microscope and microsurgical techniques prove classical large bone and dural openings unnecessary, which saves time and minimizes blood loss and wound related complications. C1 posterior arch removal is almost never necessary unless there is a major tumor extension to the cervical canal. Those tumors at the mid-line arising from vermis are invariably pilocytic astrocytomas with

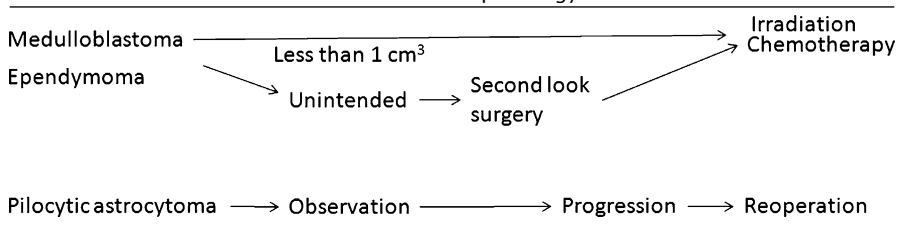


occasional cystic components; they can be reasonably distinguished from normal tissue and should be resected completely to provide surgical cure. Entrance to the fourth ventricle should be avoided, not to disturb the normal CSF floor. For tumors within the fourth ventricle, being either an ependymoma or medulloblastoma, microsurgical techniques allow resection through cisterna magna and very seldom cerebellar vermis incision is required. Creating a paravermian corridor through cerebellomedullary fissure by opening the tela choroidea should be preferred to vermis incision, if necessary [17].

5. As stated before, the aim should be total resection as it directly correlates with survival. It is more convenient to reach the superior surface of the tumor initially to visualize the tumor and brainstem interface. In medulloblastomas arising from the fourth ventricular roof, total tumor resection is possible without additional morbidity as fourth ventricular floor invasion is exceptional. Handling brainstem infiltration of some medulloblastoma cases and more frequently ependymomas is the most critical step of the posterior fossa tumor surgery. The surgeon is faced to decide between serious morbidity that might be caused by attempted total resection and leaving residuals which may directly contribute to overall survival. Besides the morbidity due to attempted resection of floor infiltration, another source for postoperative neurological deterioration is damage to posterior inferior cerebellar artery (PICA) and tributaries. Medulloblastomas and especially ependymomas that tend to grow outside fourth ventricle into cisterna magna not infrequently encase PICA and tributaries, and damage to those during tumor excision ends up with varying degree of postoperative deficits.
6. Postoperative early MRI within 24 hours is essential for future therapy planning and survival assessment. Unexpected residual astrocytomas can be followed with MRI to be resected in case of growth, while substantial amount of residual medulloblastomas and ependymomas require a second look surgery for prolonged survival (Table 2).

With appropriate surgical intervention, juvenile pilocytic astrocytomas as WHO grade I tumors can be cured without any further adjuvant therapy.

**Table 2.** Treatment algorithm for postoperative residual tumor in early MR of the major childhood infratentorial tumors based on tumor pathology



Those with residual disease, follow-up and reoperation are justified rather than radio- or chemotherapy which carries substantial late side-effects in children [4]. On the other end of the tumor spectrum, the WHO grade IV tumor, medulloblastoma requires full-scale treatment with radio- and chemotherapy following surgical resection. Unlike adult high grade tumors, five-year survival rates reach to 70% with total resection and appropriate adjuvant therapy. Posterior fossa ependymomas, although being WHO grade II tumors, have comparable survival rates close to medulloblastomas rather than astrocytomas. Radiotherapy and chemotherapy are not as effective as for medulloblastomas, leaving total resection as the most important determinant for survival [1]. Unfortunately, tendency of ependymomas to adhere the fourth ventricular floor and extension through the foramen of Luschka prevent total resection.

Besides above mentioned tumors, diffuse brainstem gliomas are almost exclusively pediatric tumors that make almost 10% of all posterior fossa tumors. They represent one of the very few childhood tumors for which surgery has not proved to play any role in treatment. Their radiological appearance in MRI is distinctive enough to initiate adjuvant therapy without biopsy. A very important detail is to differentiate focal pontine astrocytoma from diffuse form, which comprises 10% of brainstem tumors. Focal pontine astrocytoma is a typically surgical disease, for which total resection provides cure. Miscellaneous tumors like hemangioblastomas, gangliogliomas and cavernomas are intra-axial pathologies occasionally found in children as well as extra-axial schwannomas, meningiomas and chordomas. They are cared accordingly as in adults with respect to age related physiological distinctiveness of children.

## **PART II: SUPRATENTORIAL TUMORS**

In general neurosurgical practice, a childhood brain tumor traditionally implies infratentorial pathology, most often a medulloblastoma. This assumption is partly true as almost 25% of pediatric brain tumors are posterior fossa medulloblastomas. Recent studies demonstrate that almost half of all brain tumors are localized at the supratentorial compartment with a substantial percentage representing low-grade or benign tumors, unlike those of the posterior fossa [6]. This may explain the discrepancy between previous and recent tumor series, as these pathologies remain silent for prolonged periods while being diagnosed increasingly after utilization of MRI.

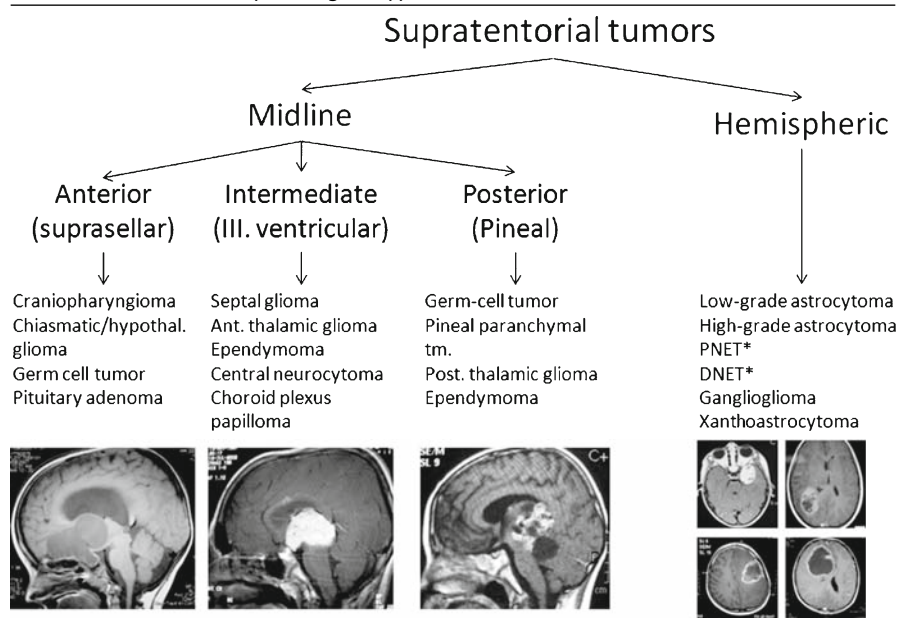
### **RATIONALE**

Supratentorial tumors in children demonstrate a diverse histological profile between almost hamartomatous benign lesions and aggressive malignant forms compatible to adult glioblastoma. Regardless of their pathology, child-

hood supratentorial neoplasms require different treatment algorithms depending on their localization and presentation [10]. The most important aspect to take into consideration is that a child's nervous system is still immature with ongoing differentiation and any insult either by the existing pathology or efforts for treatment including surgery interferes with normal neurocognitive development. Seizures, frequently the single symptom for certain benign neoplasms, may require more than tumor resection to eliminate and avoid detrimental effects of abnormal neuronal activity. On the other hand, most of the benign tumors, despite their indolent course in terms of histology, either originate from critical structures like optic pathways or pituitary stalk or reach critical sizes before coming to attention, complicating the treatment strategy. While surgical resection remains as the best available modality for survival, consequences of resection in terms of quality of life are the crucial issue in decision making. Malignant supratentorial tumors have a remarkably different response to conventional treatment modalities compared to that in adults. Whereas any treatment combination provides a modest survival benefit in adult patients, chemotherapy combined with aggressive surgery and radiotherapy is associated with prolonged survival in children.

Childhood brain tumors have predilection to specific localizations at the supratentorial area and can be classified as midline and hemispheric tumors (Table 3). Sellar/parasellar tumors, tumors growing from or into the third

**Table 3.** Practical classification of childhood supratentorial tumors based on localisation with most common histopathological types

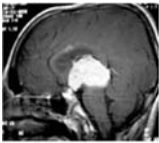
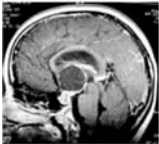
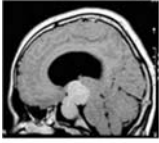
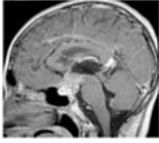


ventricle and pineal region tumors represent midline neoplasms, while low- and high-grade gliomas are predominant at the hemispheres. In pediatric brain tumors, the evolution of the disease process is important for timing and extent of surgery [19]. Signs and symptoms of pediatric supratentorial tumors are closely related to localization and growth rate of the neoplasm. Although they represent a very heterogeneous group, a significant percentage of supratentorial tumors fall into low-grade category [3]. This requires the tumor to grow to considerable size before coming to attention. Depending on the location, detection may be shorter due to tumor–brain interaction.

## DECISION-MAKING

1. For midline tumors, the proximity of the growing tumor to the ventricular system, in mainly the third ventricle, results in hydrocephalus.

**Table 4.** Differential diagnosis for suprasellar tumors, based on clinical and radiological findings

	Pathology	MR/CT			Supportive signs
		texture	contrast enhancement	calcification	
	chiasmatic-hypothalamic glioma	Solid, may extend along optic tracts	homogenous	no	Visual impairment, predominant
	craniopharyngioma	cystic and solid	heterogenous	yes	Visual impairment or hydrocephalus
	pituitary adenoma	solid	heterogenous	no	Endocrine involvement
	germ cell tumor	Solid, fills suprasellar cisterns	homogenous	no	DI*, additional pineal lesion

\*Diabetes insipidus

Sellar region tumors, depending on their direction of growth related to optic pathways and third ventricle, initial symptoms may be either visual impairment or hydrocephalus. Together with clinical signs and MR findings, it is usually possible to predict the histopathology and to tailor treatment, accordingly (Table 4). Tumors within or around third ventricle, growing either into the third ventricle from suprasellar area or from walls of the third ventricle, represent the intermediate group of tumors at the midline, between sellar and pineal region tumors [11, 15]. Posterior midline tumors arise from the pineal region and are represented mostly by germ-cell and pineal parenchymal tumors. When dealing with midline tumors, attention should be given to compromised anatomy and physiology as well as tumor resection.

2. Hemispheric tumors represent more than 25% of all intracranial tumors in children. Almost half of these are low-grade gliomas. In addition to high-grade gliomas, there are primitive neuroectodermal tumors of which a small percentage is high-grade; both gliomas and primitive neuroectodermal tumors behave like their adult counterparts; patients show signs raised intracranial pressure and mass effect and should be dealt accordingly [16]. Low-grade gliomas either reach a considerable size or present with raised intracranial pressure when originating at silent areas or initiate focal neurological deficits depending on the eloquent cortex they reside. Besides low-grade gliomas, specific tumor types like ganglioglioma, dysembryoplastic neuroepithelial tumor and xanthoastrocytoma represent lesions responsible for focal seizure activity and they are not infrequently discovered during work-up for childhood epilepsy. Therefore, management of pediatric hemispheric tumors may require more than standard tumor resection alone in terms of investigation and resection strategy [3].

## **SURGERY**

1. Several approaches are available for supratentorial midline tumors [12]. The choice depends on localization, origin of the tumor, co-existing hydrocephalus and neural tissue compromise (Table 5). Approaches can be reduced to three main categories based on tumor localization.

- a) Anterior midline tumors, composed of sellar/suprasellar tumors are exclusively extra-axial and can either threaten visual pathways and hypothalamo-pituitary axis or obstruct CSF flow due to third ventricular extension. Subfrontal and pterional approaches provide excellent exposure for craniopharyngiomas, optic/chiasmatic gliomas, pituitary adenomas and germ cell tumors arising at this localization. Pterional approach has the advantages of providing the shortest route to sellar area and familiarity due to being used very frequently in gen-

**Table 5.** Surgical approaches to supratentorial midline tumors and preferred route based on localisation and clinical features

Location and pathology	Approach	Major impairment	Consider
<b>Anterior (suprasellar) group</b>			
<i>Craniopharyngioma</i> <i>Hypothalamic/</i> <i>chiasmatic glioma</i> <i>Germ cell tumor</i> <i>Pituitary adenoma</i>	<ul style="list-style-type: none"> <li>• Subfrontal</li> <li>• Pterional</li> <li>• Anterior Interhemispheric</li> </ul>	Visual loss →  Hydrocephalus →	Subfrontal Pterional  Anterior Interhemispheric
<b>Middle (3.ventricular) group</b>			
<i>Thalamic/</i> <i>Hypothalamic glioma</i> <i>Ependymoma</i> <i>Septal glioma</i>	<ul style="list-style-type: none"> <li>• Transcortical-transventricular</li> <li>• Anterior Interhemispheric</li> </ul>	Hydrocephalus (-) →	Anterior Interhemispheric
<b>Posterior (pineal) group</b>			
<i>Germ-cell tumor Post.</i> <i>thalamic glioma</i> <i>Ependymoma</i>	<ul style="list-style-type: none"> <li>• Posterior interhemispheric</li> <li>• Suboccipital</li> <li>• Supracerebellar</li> </ul>	(+) tumor markers for germinoma →	Endoscopic biopsy?

eral neurosurgical practice. Once tumor is visualized, extent of surgery is decided according to pathology and extension; primary aim should be to decompress the visual pathways and restore CSF flow, if compromised. Except for germ cell tumors, almost all other tumors at this location are benign and curable with total resection. On the other hand, depending on the origin, resection carries devastating morbidity risk in children. Diabetes insipidus, growth retardation, obesity are hallmarks of pituitary dysfunction in spite of replacement therapy, especially after attempted radical resection of craniopharyngiomas. Visual compromise is a serious limiting issue for resection of optic pathway gliomas.

- b) Tumors within or around third ventricle, growing either into the third ventricle from suprasellar area or from walls of the third ventricle, represent the intermediate group of tumors at the midline, between sellar and pineal region tumors. A great variety of approaches have been described to reach the third ventricular region [8]. Main concern of all approaches is to reach this location with minimum normal tissue compromise and maximum exposure. No single approach works well for every portion of this area neither for any given type of tumor. Basic knowledge on the neurophysiology of the neighboring structures, as well as familiarity to surgical microanatomy, is mandatory for choosing and utilizing the appropriate approach. Lesions within or around the anterior portion of the third ventricle are most common-

ly reached by anterior transcallosal and transcortical approaches. The anterior transcallosal has the advantage of being the least destructive in terms of normal neural tissue incision. Furthermore, it does not require hydrocephalus unlike transcortical approach. The rationale is to approach the ventricles through interhemispheric fissure, a natural corridor between the falx and cerebral hemisphere without any cortical incision. The normal tissue incision is made to a small segment of corpus callosum. Optimal exposure is provided by a small frontal bone flap on the coronal suture with the patient in supine position. Key points are avoiding extensive retraction of the cerebral tissue, identification of pericallosal arteries and their branches and exposing enough length of corpus callosum for entrance. Splitting the corpus callosum at the midline, parallel to the pericallosal arteries provides access to both lateral ventricles. Complications particular to this approach and technique arise due to cortical bridging vein tears and coagulation, extensive brain tissue retraction, damage to pericallosal arteries and their branches and erroneous identification of cerebral tissue as corpus callosum. The main advantage of transcallosal approach is the less chance of having postoperative seizures, neurological deficits and subdural effusion, compared to transcortical route. Anterior transcortical approach has indications similar to those of the transcallosal approach in terms of localization of the lesion within or close to the lateral ventricle. The main disadvantage is that it requires dilated ventricles hence thinner cortical mantle for a shorter route to the ventricle. One limitation is the necessity to center the craniotomy flap on the middle frontal gyrus preferably at the non-dominant side to avoid the eloquent cortical areas like speech and supplementary motor areas and the precentral motor stripe. This approach is utilized through a frontal bone flap with the patient in supine position and the head slightly rotated to the opposite side. After dural opening, middle frontal gyrus is appreciated for the cortical incision. The frontal horn is reached through a cortical incision parallel to the middle frontal gyrus. Technical complications for this approach are brain injury due to extensive retraction, higher risk for postoperative seizures and subdural collection. Once the lateral ventricle is reached by either transcallosal or transcortical approach, it is mandatory to get familiar with the distorted anatomy in respect to certain landmarks of the intraventricular structures. Identification of the choroid plexus and following this structure anteriorly leads to the foramen of Monro. Veins of this part of the ventricle, thalamostriate, septal and caudal veins, are directed to foramen of Monro. Potential complications of intraventricular intervention include damage to draining veins or basal ganglia, which may result in hemiparesis; damage or traction to hippocampal structures resulting in memory disturbances

**Table 6.** Comparison of three different routes for third ventricular access through the lateral ventricle

Approach	Tumor localization	Advantages	Disadvantages
Transforaminal	Anterior/inferior	Natural entrance, no additional dissection needed, both foramina can be used	Requires enlarged foramina, difficult to expose middle and posterior parts
Interfornicial	Middle/posterior	Good exposure from the roof, no hydrocephalus required	Requires exact identification of the fornices, traction to fornix may be a problem
Subchoroidal	Middle/posterior	Good exposure from the roof	Requires familiarity with ventricular anatomy, meticulous dissection needed

and mutism. There are several routes leading to the third ventricle through the lateral ventricle and the choice depends on several factors (Table 6). Most of the lesions localized anterosuperiorly in the third ventricle cause hydrocephalus by blocking the foramina of Monro uni- or bilaterally. Enlarged foramen of Monro serves as an ideal entrance to the third ventricle [18]. Most of the lesions filling the anterosuperior and middle part of the ventricle can adequately be exposed through the enlarged foramen. Main limitation is a small foramina, posteriorly extended or posteriorly localized tumors; those require either enlargement of the foramen or using other routes. Foramen of Monro is delineated by the column of fornix medially and anteriorly, thalamostriate vein laterally and by thalamus and choroidal plexus posteriorly [12]. Many techniques are advocated for the least hazardous enlargement, including unilateral sacrifice of thalamostriate vein, incision of unilateral column of fornix or mobilization of choroid plexus with unpredictable consequence. Potential complications of the transforaminal approach are mutism, drowsiness, hemiplegia and memory deficits caused by traction or injury to periforaminal neural and vascular structures. For those tumors occupying the middle and posterior part of the third ventricle, interfornicial approach is an alternative. This approach uses the natural plane between the fornices at the roof of the third ventricle. It requires a midline transcalsal approach to access the roof through lateral ventricular bodies and septum pellicidum. It is important to be strictly at the midline and recognize both fornices before entering the third ventricle. Potential risks are memory loss due to bilateral damage or traction to fornices and more serious problems with damage to internal cerebral veins.

- c) Tumors occupying the posterior aspect of the third ventricle are most likely to be pineal region tumors or tectal neoplasms extending to



the postero-inferior ventricular space. A variety of posterior approaches has been described to access pineal region, each having certain advantages and disadvantages. These approaches are described in detail at the “pineal region tumors” section.

2. Surgical technique for a hemispheric tumor is no different from that for adult counterparts. Whether low- or high-grade, the extent of resection, rather than the indication or technique, is the challenging component in children. The extent of resection is the most important predictor of prolonged or permanent disease-free survival in low-grade tumors [20]. Compared to adults, children are extremely vulnerable to late effects of adjuvant therapy. The morbidity of aggressive excision should be weighed against the poor functional outcome caused by radio- or chemotherapy in case of residual disease [21]. In high-grade tumors, although aggressive resection can relieve symptoms and extend the survival, overall prognosis still depends on adjuvant therapy [16]. One important aspect of hemispheric low-grade tumors in children is the surgical planning for those with refractory epilepsy. Ganglioglioma, xanthoastrocytoma and dysembryoplastic neuroectodermal tumor have predilection to temporal lobe and are invariably diagnosed due to seizures rather than mass effect [5]. It must be kept in mind that seizure activity does not necessarily originate from the tumor but from the adjacent cortical tissue. This demands an appropriate work-up to tailor the resection area besides the tumor tissue for a seizure-free survival.

## **PART III: HOW TO AVOID COMPLICATIONS**

### **PREOPERATIVE MEASURES**

As in adults, measures to minimize the morbidity in pediatric tumor surgery begin with preoperative investigation. Due to their diverse physiology, there are different priorities and algorithms for pre-surgical preparation of children. Pre-operative chest X-ray, which is mandatory for adults, is questionable for children with normal physical findings unless a history for pulmonary disease, congenital heart disease or asthma is present. On the other hand, a full blood count with cross-matching is necessary to appreciate the necessity and quantity of blood transfusion. It must be kept in mind that critical level for anemia is markedly different in various childhood age groups and should be evaluated accordingly, at the given age. Status of liver and renal function as expressed by blood tests is important in children as they are easily and adversely affected by anesthetic agents in prolonged exposure.

Positioning of the patient aims to access the tumor along the shortest and safest route, minimizing the need for brain retraction. The ideal position sometimes interferes with patient safety, increasing morbidity other than those related to tumor excision. This is especially profound in children, where

**Table 7.** Disadvantages of main surgical positions

Position	Disadvantages
Supine	<ul style="list-style-type: none"> <li>• ICP ↑ with low head position</li> <li>• Air embolus and hypotension risk with high head position</li> <li>• ICP ↑ with neck flexion</li> <li>• Airway obstruction with tube kinking</li> </ul>
Lateral	<ul style="list-style-type: none"> <li>• Peripheral nerve compression plus above</li> </ul>
Prone	<ul style="list-style-type: none"> <li>• Pooling of CSF and blood at surgical area</li> <li>• Anesthesiologist distant to endotracheal tube and face</li> <li>• Aorto-caval compression causing hypotension</li> </ul>
Sitting	<ul style="list-style-type: none"> <li>• Risk of air embolism</li> <li>• Hypotension</li> <li>• Fatigue by working with elevated arms</li> <li>• Pneumocephalus</li> </ul>

the physiological limits are narrower and compensating mechanisms are less effective. This, in turn, brings more restrictions and requires more sacrifice in favor of metabolic and physiological homeostasis over the ease of access to a given location in pediatric tumor surgery. From surgical point of view, main consequence of a non-physiological position is increased intracranial pressure complicating dural opening and tumor access (Table 7). Among the four commonly employed ones, supine position is utilized for the majority of supratentorial tumors. Level of the head compared to body has several consequences in terms of circulation and intracranial pressure dynamics. Leveled or lower head position increases the intracranial pressure while extreme head-up tilt may initiate air embolism as well as hypotension hinder proper hemostasis. Studies have shown that a tilt of 15–30° to horizontal plane helps to maintain a low intracranial pressure. Most of the cases require neck flexion and rotation where kinking of endotracheal tube or jugular veins produce a predisposition to serious intracranial pressure elevation. Lateral position, preferred in temporal and certain posterior fossa tumors need the same safety measures as supine, except for extra attention for brachial plexus and peripheral nerve traction risk.

Sitting position for infratentorial approach has the advantage of better orientation as traditionally being used for adults for several decades. It provides a better control of the increased intracranial pressure and a clear field with CSF and blood swept away from the field by gravity. The disadvantages are risk of air embolism, hypotension, fatigue caused by working with elevated arms and pneumocephalus following surgery. Moreover, fixation of head depends on skull thickness and might be impossible in infants. The alternative is the prone position, which is also utilized for posteriorly located supratentorial tumors, where above mentioned risks are substantially decreased. The main disadvantage is pooling of CSF and blood at the op-

erative area and anesthesiologist being distant to endotracheal tube and face of the child. Aorto-caval compression in prone position may result in serious hypotension during surgery. Unless a three-pin holder is used, pressure to face and especially eyes should be thoroughly checked to avoid disastrous pressure sores. Nevertheless, the current technology and monitoring systems are able to overcome the inconveniences due to the position, so there is no scientific data proving one position to be superior to the other. Regardless of the position, special care must be given to neck flexion. Flexion facilitates a better exposure by distracting C1 and occiput but extreme flexion impedes venous drainage by occluding jugular veins while bending of the endotracheal tube impairs air flux and excess pressure may cause airway damage.

## **INTRAOPERATIVE ADVERSE EVENTS**

Tautness of the dura and stiff brain as a result of increased intracranial pressure is usually due to the tumor and corresponding oedema as well as the existing hydrocephalus. Still, it must be ensured that the child has the proper position with ideal tilt, no venous compromise due to neck flexion, no excess fluid introduction and proper ventilation parameters. Same situation during the later phases of tumor surgery but not at the beginning is most often due to the surgical manipulation such as excessive retraction, bleeding and venous infarction. Hypotension due to blood loss or fluid imbalance, or CO<sub>2</sub> retention due to airway obstruction also contributes to brain stiffness.

Other common intraoperative adverse events in children are hypotension, tachycardia and hypothermia, the consequences of which can be more serious than for adults. Blood loss, bradycardia, anesthesia level, fluid imbalance are the factors that contribute to tachycardia and hypotension. Hypothermia is also a serious intraoperative insult in children and may result from massive blood transfusion, exposure of relatively large surgical field and cold irrigation fluids. One of the most undesirable postoperative conditions following tumor surgery is not to recover from anesthesia. In children, besides the neurological insult directly from surgery itself, hypothermia, non-replaced blood or volume loss, administration of disproportionately high dose anesthetic drugs or insufficient reversal of neuromuscular blocking agents might be responsible and should be questioned.

Children, due to their physiological properties and immature compensation mechanisms, are more vulnerable to these pre- and intraoperative insults. Moreover, reversing the adverse effects of these insults due to the course of tumor surgery and homeostasis of the child is more difficult than for an adult patient. Therefore, special attention should be given to probable causes of these events and measures should be taken beforehand by both the surgeon and the anesthesiologist when dealing with pediatric brain tumors.

## CONCLUSIONS

Considerable advances have been made over the past decades in the treatment of childhood malignancies. Unfortunately, this progress has not been reflected to childhood brain tumors at the same extent and childhood brain tumors have remained as the leading cause of cancer-related morbidity and mortality. Surgery is still the best available therapeutic approach in providing disease control for a wide variety of histopathological types of childhood brain tumors which can originate in almost any region. Furthermore, advanced neuroimaging as well as improved technology at the operating theater have impacted greatly on the surgical treatment of brain tumors. These facts enhance the role and responsibility of the neurosurgeon on the treatment of brain tumors, especially in children. It must be kept in mind that, compared to adults, children have different response to an insult as well as the treatment modality. The nuances that comprise these diversities should be carefully weighed for each age group while planning a treatment algorithm for brain tumors.

## References

- [1] Albright AL (1999) Medulloblastomas. In: Albright AL, Pollack IF, Adelson PD (eds) Principles and practice of pediatric neurosurgery. Thieme, Stuttgart
- [2] Akyüz C, Emir S, Akalan N, Söylemezoğlu F, Kutluk T, Büyükpamukçu M (2000) Intracranial ependymomas in childhood – a retrospective review of sixty-two children. *Acta Oncol* 39: 97-100
- [3] Berger SM, Keles E, Geyer JR (1992) Cerebral hemispheric tumors of childhood. *Neurosurg Clin N Am* 3: 839-852
- [4] Büyükpamukçu M, Varan A, Yazici N, Akalan N, Söylemezoğlu F, Zorlu F, Akyüz C, Kutluk MT (2006) Second malignant neoplasms following the treatment of brain tumors in children. *J Child Neurol* 21: 433-436
- [5] Cataltepe O, Turanlı G, Yalnizoglu D, Topçu M, Akalan N (2005) Surgical management of temporal lobe tumor-related epilepsy in children. *J Neurosurg* 102(Suppl): 280-287
- [6] Hockley DA, Sgouros S (1999) Tumors of the cerebral hemispheres. In: Choux M, Di Rocco C, Hockley A, Walker M (eds) Pediatric neurosurgery. Churchill Livingstone, London
- [7] Maher CO, Raffel C (2004) Neurosurgical treatment of brain tumors in children. *Pediatr Clin N Am* 51: 327-357
- [8] Oi S, Samii A, Samii M (2003) Operative techniques for tumors in the third ventricle. *Oper Tech Neurosurg* 4: 205-214

- [9] Packer RJ (1999) Brain tumors in children. *Arch Neurol* 56: 421-425
- [10] Pollack IF (1999) Supratentorial hemispheric gliomas. In: Albright AL, Pollack IF, Adelson PD (eds) *Principles and practice of pediatric neurosurgery*. Thieme, Stuttgart
- [11] Puget S, Crimmins DW, Garnett MR, et al. (2007) Thalamic tumors in children: a reappraisal. *J Neurosurg (Pediatrics)* 106: 354-362
- [12] Rhoton AL Jr, Yamamoto I, Peace DA (1981) Microsurgery of the third ventricle: Part 2. Operative approaches. *Neurosurgery* 8: 357-373
- [13] Rorke LB (1999) Pathology of brain and spinal cord tumors. In: Choux M, Di Rocco C, Hockley A, Walker M (eds) *Pediatric neurosurgery*. Churchill Livingstone, London
- [14] Shu HK, Sall WF, Maity A, Tochner ZA, Janss AJ, Belasco JB, Rorke-Adams LB, Phillips PC, Sutton LN, Fisher MJ (2007) Childhood intracranial ependymoma: twenty-year experience from a single institution. *Cancer* 15: 432-441
- [15] Sutton LN, Phillips P, Lange B (1992) Midline supratentorial tumors. *Neurosurg Clin N Am* 3: 821-837
- [16] Tamber MS, Rutka JT (2003) Pediatric supratentorial high-grade gliomas. *Neurosurg Focus* 14(2): 1-8
- [17] Tanriover N, Ulm AJ, Rhoton AL Jr, Yasuda A (2004) Comparison of the transvermian and telovelar approaches to the fourth ventricle. *J Neurosurg* 101: 484-498
- [18] Ture U, Yasargil MG, Al-Mefty O (1997) The transcallosal-transforaminal approach to the third ventricle with regard to the venous variations in this region. *J Neurosurg* 87: 706-715
- [19] Turgut M, Akalan N, Ozgen T, Ruacan S, Erbenli A (1996) Subependymal giant cell astrocytoma associated with tuberous sclerosis: diagnostic and surgical characteristics of five cases with unusual features. *Clin Neurol Neurosurg* 98: 217-221
- [20] Varan A, Akyüz C, Akalan N, Atahan L, Söylemezoglu F, Selek U, Yalçın B, Kutluk T, Büyükpamukçu M (2007) Astrocytic tumors in children: treatment results from a single institution. *Childs Nerv Syst* 23: 315-319
- [21] Varan A, Akalan N, Söylemezoglu F, Zorlu F, Yalçın B, Akyüz C, Kutluk T, Büyükpamukçu M (2006) Central nervous system tumors in patients under three years of age: treatment results of a single institute. *Pediatr Neurosurg* 42: 89-94



**Nejat Akalan**

Nejat Akalan is Director of Pediatric Neurosurgery and Epilepsy Surgery at Hacettepe University School of Medicine, Ankara. Born: November 26, 1957, Ankara, Turkey. Medical education: Ankara University School of Medicine, 1974–1980. Neurosurgery Residency: Department of Neurosurgery, Hacettepe University School of Medicine, 1980–1986. Fellowship: Department of Neurosurgery, University of Washington, Seattle, USA, 1988–1989. Ph.D.: Neuroendocrine surgery, Institute of Neurological Sciences, Hacettepe University, 1989–1993. Assistant Professor: Department of Neurosurgery, Hacettepe University School of Medicine, 1992–1994. Associate Professor: Department of Neurosurgery, Hacettepe University School of Medicine, 1994–2000. Membership: Turkish Neurosurgical Society, EANS, AANS, ISPN, ESPN, Academia Eurasiana Neurochirurgica. Current affiliations: Treasurer, EANS Secretary, Academia Eurasiana Neurochirurgica Co-editor: *Advances and Technical Standards in Neurosurgery*. Regional Editor: *Child's Nervous System*, Editorial Board Member: *Neurosurgery*, Turkish.

**Contact:** Nejat Akalan, M.D., Ph.D., Department of Neurosurgery, Hacettepe University School of Medicine, Ankara 06100, Turkey  
E-mail: nakalan@hacettepe.edu.tr

---

# NONSYNDROMIC CRANIOSYNOSTOSES

C. DI ROCCO

## INTRODUCTION

Craniosynostoses and facio-craniosynostoses constitute an heterogeneous group of nosographic entities characterized by the premature fusion of one or more sutures of the skull. The phenomenon results in a variety of functional and morphological alterations of the craniofacial development and in different degrees of cranio-cerebral volumetric disproportion. Aims of the surgical correction of these conditions are to counteract the cosmetic and functional anomalies of the craniofacial skeleton, to restore the normal spatial relationship between the skull and the contained neural and vascular structures, to correct the possibly associated abnormalities of the cerebral blood flow and cerebrospinal fluid (CSF) circulation as well as to re-orientate the deviated growth vectors of the skull base and vault. Among the various forms of abnormal cranial and facial bone development, those collectively defined as *simple craniosynostoses* allow the neurosurgeon to achieve all the just mentioned therapeutic goals by means of relatively simple surgical procedures. The definition of simple craniosynostosis however implies further characteristics. Namely, the functional and anatomical anomalies should be easily identified on the base of the mere physical examination without the necessity of specific laboratory investigations. In other words, simple craniosynostoses tend to repeat their peculiar phenotype which allow their recognition already at the first inspection. Furthermore, their natural history and prognosis can be predicted with good reliability. Consequently, the family can be offered a definite surgical plan, an adequate information on the risks and the advantages of the surgical correction as well as on the long-term outcome.

*Facio-craniosynostoses* or *complex craniosynostoses* are completely different. The phenotypic recognition may remain uncertain in many cases, such as, for example, in Crouzon's, Jackson-Weiss and Pfeiffer syndromes, where the phenotypic appearance is just a continuum of apparently different clinical patterns actually depending on mutations of a single gene *FGFR2* (clinical variability). On the other hand, different genes may express similar clinical forms, such as the Saethre Chotzen syndrome which may depend on mutations of both *TWIST* and *FGFR3* genes (genetic heterogeneity).

Furthermore, in these malformations, the clinical phenotype can remain under-expressed in the first months of life, see, for example, the Crouzon's syndrome which may firstly present as the simple fusion of sagittal or coronal su-

---

*Keywords:* craniosynostoses, simple craniosynostoses, complex craniosynostoses, sagittal, metopic, coronal, lambdoid

tures to become clinically obvious only in later ages. In other terms, in complex craniosynostoses the individuation of the responsible genes is necessary to confirm the clinical diagnosis and to predict the natural history and the prognosis.

In these synostoses the understanding of the functional and anatomical anomalies as well as their variable interaction in the different subjects are particularly complex. Indeed, the clinical manifestations may depend on variable degree of cerebral and cerebellar compression and distortion, cerebral blood flow impairment, abnormalities in CSF circulation, and defective respiratory function. Each of these anomalies may require a specific and timely surgical correction. As a consequence, the surgical plan may be difficult to establish in several instances; furthermore, the surgical plan often requires adjustments in the course of time in relation to the response of the child and its clinical evolution. Because of this complex surgical management, there is nowadays a general consensus that the correction of complex craniosynostoses which nearly always requires multiple and repeated surgical procedures, some of them particularly severe, should be carried out by a team of specialized surgeons operating in selected clinical centers. These centers should be supra-regional in order to treat an adequate number of cases and able to adopt a multidisciplinary approach assured by the contemporary presence of at least five main surgical specialties: neurosurgery, maxillo-facial surgery, plastic surgery, ophthalmological and ear-nose and throat surgery. The surgical team should be assisted by several other specialists such as genetists, radiologists, orthodontists, psychologists, speech therapists, and specialized nurses.

## **RATIONALE**

The premature fusion of one or more cranial sutures occurs in about 2500 births. In 85–90% of the affected subjects the phenomenon is not associated to any specific syndrome whereas in the remaining cases the premature closure of the cranial sutures is part of complex syndromes such as Crouzon, Apert, Pfeiffer, Carpenter syndromes and many others.

In the past simple or single suture craniosynostoses have been often regarded as a purely cosmetic problem. Consequently, the surgical indication has been a subject for debate in front of a relatively high surgical risk due to the still insufficient anesthesiological and surgical techniques. In the last years, the refinements of these techniques have decreased the surgical mortality to less than 1%. Furthermore, several studies have pointed on the possible occurrence of functional problems mainly related to abnormalities of the intracranial pressure, vision and brain maturation [12]. Psychological investigation have also unequivocally demonstrated the negative impact of the cranial deformity on the self-esteem of many untreated children as well as the significant associated social stigma in most severe cases. As a consequence, nowadays, the discussion is no more centered of the possibility of avoiding the surgical correction rather



on the optimal timing of the operation and the choice of the most appropriate surgical technique. On the other hand, the indication for the surgical treatment of complex craniosynostoses has never be questioned even when the surgical mortality and the morbidity were considerably high. Indeed, the rapidly worsening of the clinical condition in the affected children related to the uncontrolled intracranial hypertension and severe respiratory problems prompted some kind of surgical correction to be carried out in practically all the cases. In many instances, however, the operations were inadequate or performed too late. In recent time advances in the physiopathogenetic interpretation of these conditions, progresses in surgical techniques as well as in perioperative and postoperative intensive care have allowed to modulate the timing and the modalities of the surgical correction on the needs of the single subject.

*Calvarial development.* Suture morphogenesis and cranial growth are controlled by a complex molecular network regulated by a large number of genes. These genes are being progressively identified; some of them are specific to a given cranial suture [2]. Hopefully, they will become candidates for targeted therapies besides being useful for screening the mutations which cause craniosynostoses.

The formation of the calvarial bones depend on the osteoblasts deriving from the proliferation and differentiation of multipotent mesenchimal cells. The process (intramembranous ossification) is distinct from that accounting for the development of most of the other bones in the body which derive from the ossification of a preexisting cartilagineous matrix (enchondral ossification). The calvarial bones originate first from the condensation of the mesenchyme into a primary center of ossification. Then, mesenchymal cell proliferation and differentiation into osteoblasts take place at the margins accounting for a radial growth of the bone until the osteogenic fronts of two calvarial bones approximate each other. Between these two osteogenic fronts fibrous structures (sutures) develop allowing flexibility and changes in shape of the skull during growth. The normal activity of the osteogenic fronts requires a balanced control between proliferation and osteoblast differentiation and apoptosis ensuring their separation. The premature fusion of the suture is the result of the disruption of any of these processes. The phenomenon may depend on a variety of causes: genetic mutations, haematologic abnormalities, nutritional deficiencies, exposure to teratogenic agents, endocrinological disorders. Mechanical stresses in utero may also induce craniosynostosis by affecting the expression of the transforming growth factor beta (TGE beta) which also has a role in suture formation as demonstrated experimentally by applying a constraining cerclage on the uterus of pregnant rats. On the other hand, the early fusion of the cranial suture may be caused by decreased mechanical forces acting of the calvarial bones and sutures in cases of insufficient brain growth (microcephaly) or chronic CSF hyperdrainage in children harboring extrathecal CSF shunt devices for hydrocephalus treatment (secondary craniosynostosis). This type of early suture fusion depends on the altered

tension of the dura mater underlying the suture as also the dura mater has a role in maintaining the suture patency. In fact, the direct contact with this structure is essential for the suture to remain open.

Non syndromic or simple craniosynostoses correspond to a sporadic suture fusion not associated to other developmental malformations. The phenomenon affects generally only one cranial suture and the sagittal one is the most commonly involved.

Syndromic craniosynostoses occur in the context of other developmental anomalies, in particular affecting the limbs. More than a hundred of syndromes with craniosynostosis have been described, most of them with recognizable genetic mutations. Crouzon's and Apert's syndromes are the most frequently encountered and the coronal suture the most frequently affected. Indeed this suture is specifically involved in *FGFR1*, *TWIST1* and *EFNB1* mutations and is the most frequent targeted by other genetic mutations such as the *FGFR2* mutations (which may, however, affect all the remaining sutures too), the *FGFR3* mutations (which may also affect the metopic suture), and the *MSX2* mutations (which may affect also the sagittal suture).

Recent studies indicate that genetic mutations affect each human calvarial suture differently, consequently postulating the existence of specific gene expression patterns for each of them. Similar conclusions could also be drawn on the grounds of previous reports describing different phenotypes induced by known mutations.

With the exception of the metopic suture which fuses within the first year of life, the cranial sutures remain patent for many years, although their role in the cranial growth become negligible after the fifth-sixth year of age.

## **DECISION-MAKING**

In the last decades the techniques for the correction of simple craniosynostoses have been refined considerably and new materials for skull reconstruction and bone regeneration have been introduced. These progresses together with the contemporary advancements in anesthesiological and intensive care have allowed neurosurgeons to abandon simple suturectomies in favor of extensive procedures for calvarial vault remodeling with the aim to obtain better cosmetic results and more rewarding functional outcomes. In the same time emphasis has been placed on early operations with the multiple purpose of utilizing the expansile forces of the developing brain in a period of maximal cerebral growth, obtaining a better reshaping of the still flexible calvarial bones and protecting the developing cerebral parenchyma from the increased intracranial pressure resulting from the impaired growth of the skull. As extensive cranial procedures carry an excessive surgical risk in the early months of life, it is not surprising if the introduction of the endoscopic techniques has

led to a revival of those operations based on strip craniectomies which had been previously criticized and abandoned. The introduction of remodeling helmet has been critical to the success of this type of procedures, which are undoubtedly associated with shorter operative time, minor surgical blood loss, and shorter stay in hospital [1].

Crucial for the surgeon's decision is then the understanding whether early operations are really more effective than late corrections. The proponents of late surgery emphasize the possibility of obtaining better calvarial reconstructions using more extensive and definite surgical procedures on a skull, the deformities of which have already stabilized and other advantages, besides the child's higher tolerance, such as the minor risk of recurrence. On the other hand, those surgeons favoring an early correction of the malformed skull stress that in general about one third of the affected infants show abnormally high intracranial pressure levels. However, the equation "craniosynostosis-reduced intracranial volume" is challenged by volumetric studies which have actually registered higher than normal intracranial volumes even in cases of complex craniosynostoses. Furthermore attempts to correlate intracranial pressure to the intracranial volume in craniosynostosis have failed to demonstrate any direct relationship.

As clinically intracranial hypertension in infants with craniosynostosis is difficult to evaluate without using invasive investigations, the timing of the surgical operation remains at the moment based on surgeon's conviction, the training he received as well as collegial interaction.

However, currently early operations appear to be the preferred option in the great majority of the cases. In the last years, protocols for blood sparing have been introduced at the light of the known infective and immunologic risks of allogenic blood transfusions. Preoperative acute normovolemic hemodilution, intraoperative and postoperative blood salvage have become integral steps of the surgical correction of craniosynostosis [7]. The ideal early timing for the surgical treatment with concern to blood loss has been established on physiological criteria around the fourth/fifth month of life taking into account that in the neonatal period human hemoglobin is present in both fetal (HbF) and adult (HbA) forms. Under standard conditions, HbF and HbA bind the same amount of oxygen. However, HbF releases only 25% of oxygen to the tissues whereas HbA releases 50%. The concentration of HbF fades during the first 6–7 months of life to be progressively substituted by the more efficient adult type. At age four months, HbF has already dropped at about 16% of the total hemoglobin [7].

## **SURGERY**

### **1. SCAPHOCEPHALY**

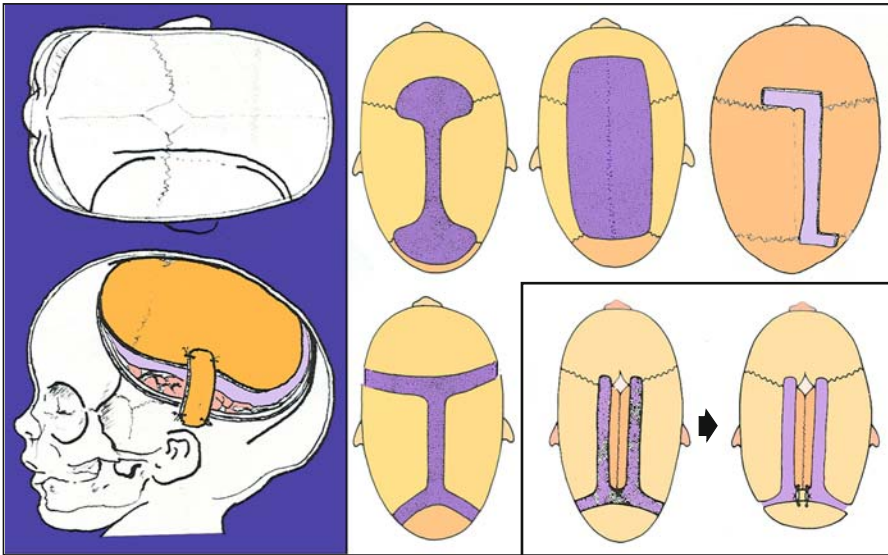
The premature fusion of the sagittal suture results in the characteristic elongated shape of the head described under the term of *scaphocephaly* (in Greek,

boat) due to the impaired transversal growth of the skull compensated for by the abnormal longitudinal development of its antero-posterior diameter. Males are more frequently affected than females. According to the severity of the process, the extent of the involvement of the suture and the age of the patient at diagnosis various morphological subtypes and additional compensatory changes of the skull can be observed. Among the latter, the frontal and, less frequently, the occipital bossing may be particularly obvious in infants in whom the surgical correction is excessively delayed. In some cases, especially when the compensation for the restricted growth of the skull occurs at the level of the still open anterior fontanel, the anterior region of the skull can maintain a nearly normal size in contrast with the severely reduced latero-lateral development of its posterior two thirds.

In some instances, a focal depression of the sagittal suture at the parietal level gives the skull a peculiar "saddle" shape. Nearly all the infants show a bone ridge along the affected suture which can be easily appreciated at the visual inspection or at the palpation. Consequently, the diagnosis is obtained by the mere physical examination. In a few cases, excessively dilated scalp veins may reveal an abnormally increased intracranial pressure. More frequently, however, infants with sagittal craniosynostosis present only transitory abnormal increases in intracranial pressure which can remain clinically silent and revealed only by prolonged recordings of intracranial pressure. These increases are related to an impaired ability of these subjects to compensate for abrupt increases in intracranial venous volume, such as those brought about by physiological events, namely crying, coughing, Valsalva's manoeuvres, REM sleep. The alterations in CSF dynamics are likely due to the lost ability of the superior sagittal sinus to dilate in order to rapidly dissipate the secondarily induced pressure waves in case where its walls are compressed within the osseous groove created by the premature ossification of the sagittal suture [2]. There is an apparently increasing age-related trend for the incidence of cases with abnormally high pressure with older children more involved than the younger ones. The phenomenon appears to bear clinical implications on psychomotor development as children operated on at an older age tend to present a lower IQ than children operated on in the first months of life [10].

Moderately enlarged lateral cerebral ventricles and CSF pooling at the frontal and/or occipital poles should also be regarded as sentinel signs for an impaired CSF dynamics on neuroimaging investigations.

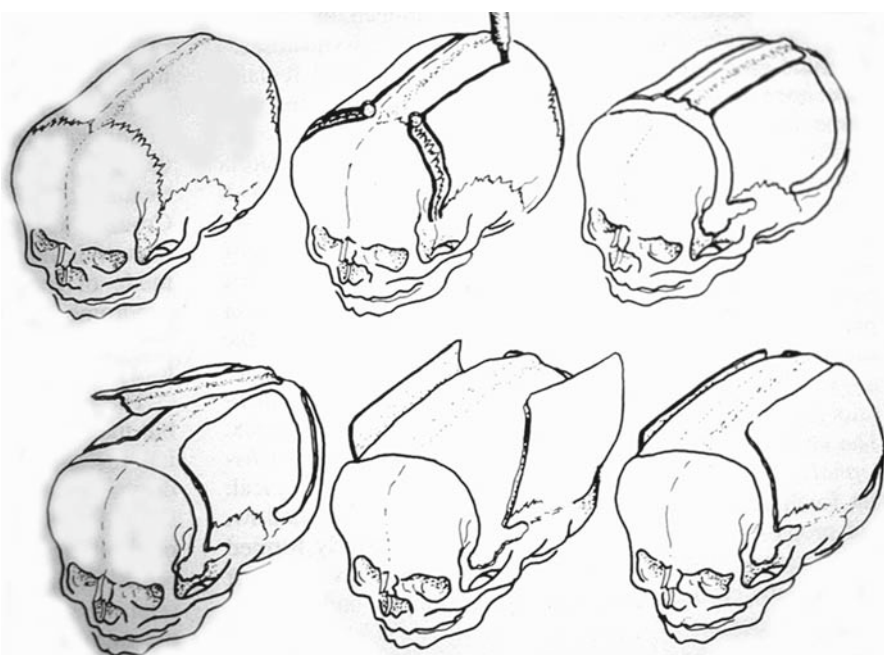
**Surgical considerations.** Scaphocephaly is the most common and most benign form of craniosynostosis. It accounts for half of the cases. The surgical indication is challenged by the lack of obvious neurological alterations in the great majority of cases and by the relatively good natural history in untreated subjects. However, the social stigmata associated to the cranial dysmorphism and the CSF dynamics abnormalities demonstrated by prolonged recordings of the intracranial pressure indicate the opportunity of a surgical correction



**Fig. 1.** Various techniques for correction of sagittal synostosis introduced in the course of the years. On the left, the technique utilized by Dandy

to be carried out in the first months of life. Late surgical corrections require in fact more severe surgical procedures than early operations. Several surgical procedures are available to the neurosurgeon, nearly all of them effective in achieving the main goals of the surgical correction: to reduce the cosmetic deformity, to counteract the abnormal cranial growth vectors, and to correct CSF dynamics abnormalities (Fig. 1).

The most utilized surgical procedure consists of multiple strip craniectomies along the fused sagittal suture and both coronal and lambdoid sutures. Its aims are to create two relatively mobile parietal bone flaps apt to accommodate the growing brain and to immediately relieve the pressure on the superior sagittal sinus. In order to diminish the surgical risk some surgeons prefer to perform two linear craniectomies parallel to the superior sagittal sinus and to leave in place, eventually in pieces, the bone segment including the prematurely closed sagittal suture. Other surgeons, however, prefer to remove such a bone segment entirely in order to better free the underlying venous channel which may be compressed within the bone groove resulting from the early ossification of the suture. Additional maneuvers include the prolongation of the lower end of the coronal and lambdoid strip craniectomies in the temporal bone, parallel to the skull base and the green-stick fracture of the base of the parietal flaps aimed at diminishing their mechanical resistance and barrel stave craniotomies on the parietal bone flaps, apt to favor the plastic reconstruction of the calvarial bones (Fig. 2). In the youngest infants an

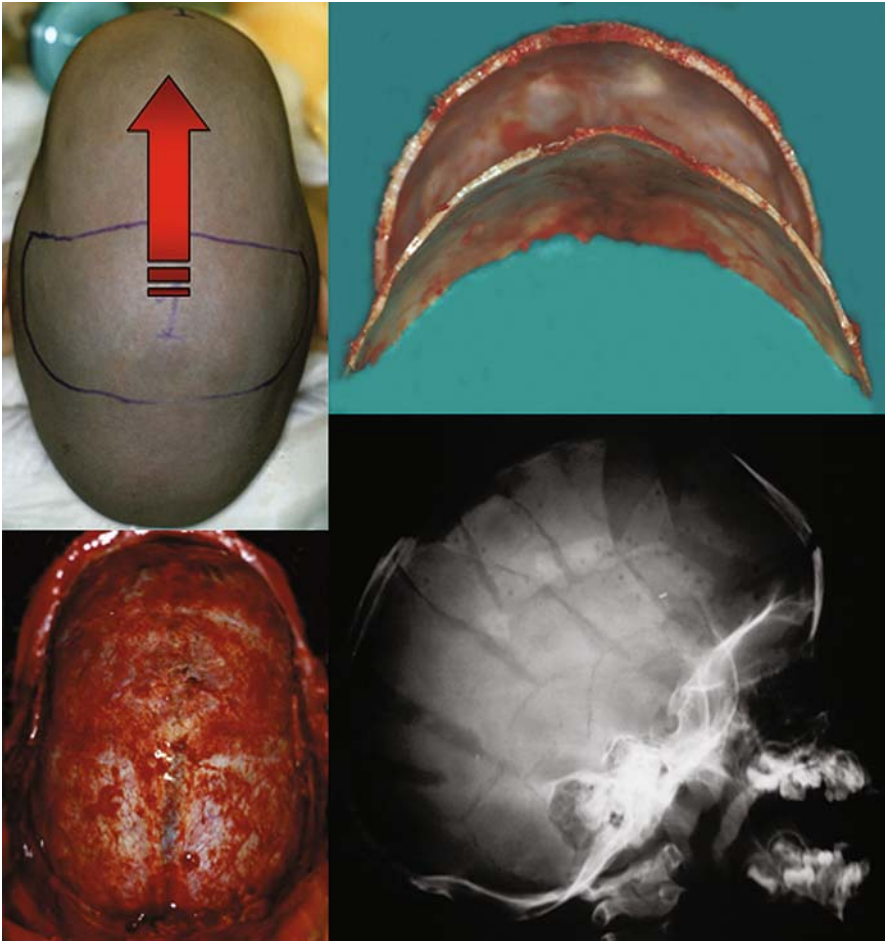


**Fig. 2.** One of the most widely utilized techniques for the correction of sagittal synostosis is based on the removal of the segment of the bone above the fused suture and the “opening” of the parietal bone flaps. Barrel-stave linear parietal osteotomies may be added to increase the plasticity of the parietal bones.

approximation of the frontal and occipital bones may be obtained by using stitches between the posterior frontal and anterior parietal borders as well as between the posterior parietal and the anterior occipital borders at the level of the coronal and lambdoid craniectomies (Fig. 1). Aim of this maneuver is to obtain an immediate reduction of the antero-posterior diameter of the skull.

After one year of age, the progression of the malformation, in particular, the frontal bossing and the occipital cupping and the excessive elongation of the skull base, the marked narrowing of the vault, the thick calvarial bone combined with a decelerated cerebral growth do not allow to rely on the expansile forces of the brain and the compliance of the skull. Then, the surgical correction requires more invasive procedure with displacement, dislocation and reconstruction of multiple free bone flaps in order to achieve the cranial expansion and in the same time an improved skull configuration (Fig. 3). However, as the abnormally long base can not be made shorter, the cosmetic outcome of children operated on too late may be only partially satisfactory.

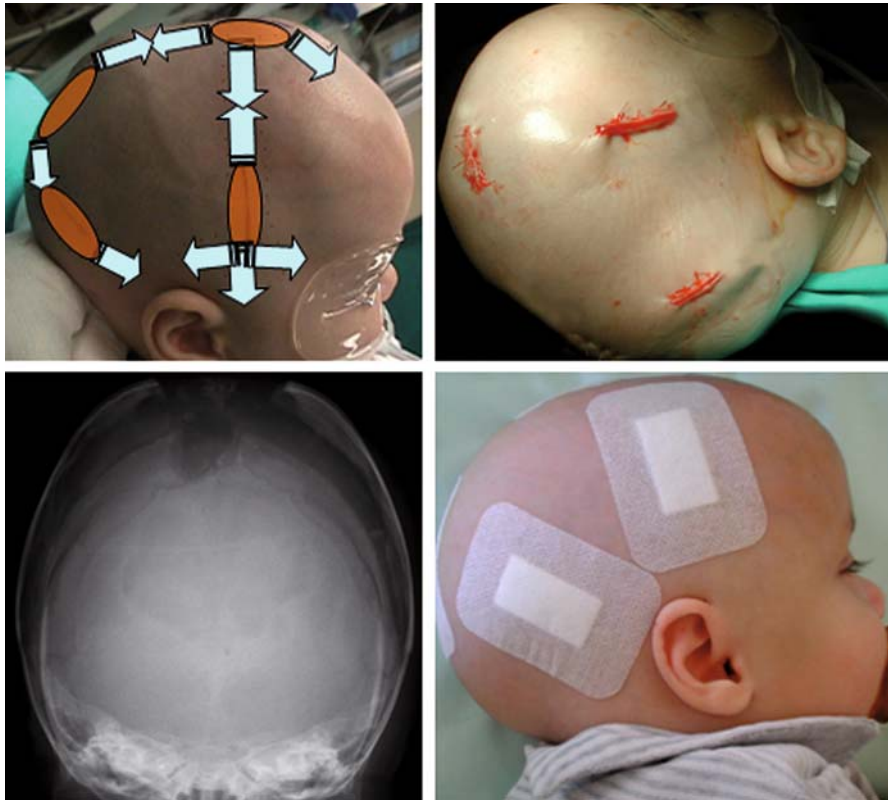Recently, interest has been arisen in the surgical treatment of non-synostotic forms of scaphocephaly, such as those observed in premature babies and in children shunted for hydrocephalus, based on the spring expansion of the



**Fig. 3.** Technique for the correction of sagittal synostosis in older children based on the creation and replacement in different location of multiple free bone flaps

sagittal suture without osteotomy [3]. The affected children present a reduction of the transverse and an elongation of the longitudinal diameter of the skull and look similar to those with synostotic scaphocephaly without however frontal or occipital bossing. It is still to be understood whether this kind of anomaly may jeopardize the psychomotor development. However, the minimal blood loss associated to the procedure and its good aesthetic outcome as well as the normalization in many cases of the Retzius cranial index may justify an operation carried out essentially for cosmetic reasons.

**Personal surgical technique.** We routinely use a minimal invasive technique apt to reduce the surgical stress, the postoperative discomfort of the



**Fig. 4.** Author's minimal invasive technique for the correction of sagittal synostosis (for further explanation, see text)

infant, the duration of the hospitalization, and the cosmetic disturbance created in most subjects by the stigma of the extended surgical scar which ensues standard operations [4]. The technique has the same advantages of the endoscopic procedure although it does not require special instruments and expertise in endoscopy (Fig. 4).

One of the most unpleasant side-effects of the standard operations for the correction of sagittal synostosis is the long visible scar of the biparietal incision, the inferior margins of which tend to enlarge under the action of the temporal muscles. Such a scar is not easy to conceal under the hair, even when *ad hoc* attempts are made such as avoiding skin incisions in front of the tragus, reflecting the inferior edge of the incision posteriorly above the ear, placing the incision in the posterior parietal or anterior occipital regions, or using a “zig-zag” type scalp incision. The procedure we devised utilize 4 to 6, two/three cm long, scalp incisions, critically placed according to the shape of the deformed skull (Fig. 4). The first two incisions are carried out on the midline,



the first of them just behind the anterior fontanel and the second in front of the posterior fontanel. The other incisions are made laterally above the mid-portion of the coronal and lambdoid sutures, respectively. The last two incisions are generally not necessary in the youngest infants, 3–4 month old.

These incisions are utilized to perform linear craniectomies along the fused sagittal suture firstly and along the coronal and the lambdoid sutures, subsequently. The craniectomies are carried out partly under direct visual control, partly under the intact scalp (Fig. 4). In such a way, two parietal bone flaps are created which can be mobilized just as with the standard operations. The mobilization of the parietal bone flaps may be facilitated by extending the inferior border of both lateral craniectomies in the temporal bone, parallel to the skull base.

The ideal candidates for this type of operations are infants 3–4 month old but the procedure can be successfully performed in nearly all the cases during the first year of life.

There are significant benefits from this minimal invasive operation besides the relatively small and scattered scars which can be easily concealed under the hair. The blood losses during the operation and the immediate postoperative period are consistently minor than in standard operations due to the limited extension of the surgical wound and galea detachment. For the same reason, the postoperative swelling of the skull covering tissues is minimal and the infant does not need a postoperative subgaleal drainage. The hospitalization period is shorter than that required by the standard operations.

Finally, surgical outcomes evaluated with cranial index (biparietal diameter/anteroposterior diameter  $\times 100$ ) are comparable with those ensuing more invasive and complex surgical procedures.

## 2. TRIGONOCEPHALY

The craniosynostosis resulting from the early closure of the metopic suture is the second commonest form of monosutural synostoses and the most frequently associated with other malformations, especially related to the body midline structures. Up to three fourths of the affected subjects are males. Due to the precocious ossification of the metopic suture, which takes place during the intrauterine life, the diagnosis is nearly always possible already at birth when the newborn shows the characteristic triangular shape of the forehead when viewed from above. A major awareness of the neonatologist may actually explain the apparently increasing incidence registered in the last decade in several referral centers. However, the increase may be real as this type of craniosynostosis has been recently related to environmental factors, as, for example, the maternal assumption of valproate [9].

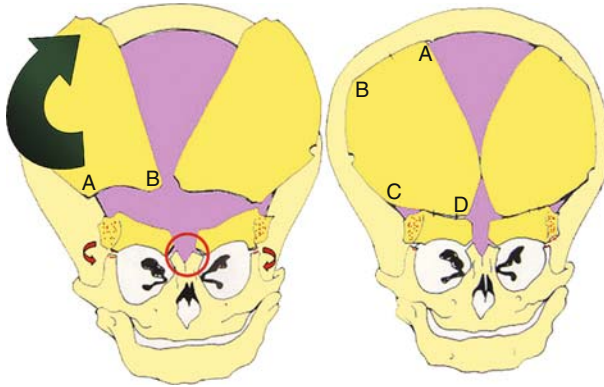
In mildest cases, which usually do not require surgical correction, the skull abnormalities are limited to a minimal triangular configuration of the forehead and to the presence of a midline bone ridge which tends to disappear

with the age. More commonly, the anterior part of the skull is considerably narrowed and assumes an obvious keel-shaped appearance, especially in cases where the longitudinal diameter of the anterior cranial fossa is elongated in the midline to compensate for the reduced widening of the same region due to the impaired function of the metopic suture. The keel-shaped deformity of the anterior skull results from the median prominence of the precociously fused metopic suture, the secondary hypotelorism, the recession of the lateral aspect of the orbital rims, and the diminished cranial transverse diameter at the level of the anterior temporal regions. The volumetric compensation to the restricted growth of the anterior third of the skull occurs at the parietal regions along either an horizontal axis, with a consequent enlargement of biparietal diameter, or a vertical axis, with a resulting abnormally increased height of the calvaria.

**Surgical considerations.** Several surgical procedures have been propounded to treat the condition, all of them aimed at increasing the volume of the anterior cranial fossa, at modifying the triangular shape of the skull, at correcting the hypotelorism and the recession of the lateral segment of the superior orbital ridges. By excepting the endoscopic technique, all these procedures are based on the following surgical steps: bifrontal craniotomy and creation of a frontal bone flap in one or two pieces, removal of the nasal processes of the frontal bone and the upper part of the nasal bones, lateral advancement of the superior orbital ridges by pivoting on their sectioned or green-stick fractured medial edges, replacement of the frontal flap(s) after having modified their shape, curvature and orientation. Variations include the creation of a free orbital bar and its replacement after opportune remodeling, the insertion of a bone graft in the midline gap resulting from the removal of the upper part of the nasal bones to correct the hypotelorism without merely relying on the natural plasticity of the skull base, and the enlargement of the temporal fossa by barrel stave osteotomies.

Nearly all the available surgical techniques allow to obtain good to excellent correction of the cranial deformities. Nevertheless, the neurocognitive outcome is not satisfactory in all the instances in spite of the mechanical relief obtained with the operation and the creation of an extra-space adequate to accommodate the growing brain. Still unidentified subtypes associating a primary cerebral dysfunction to the impaired skull development could be at the base of the phenomenon.

**Personal surgical technique.** The same considerations made for sagittal synostosis apply to trigoncephaly: it is a benign condition and untreated children can achieve a satisfactory psychomotor development, though weighted by the social handicap related to the cosmetic defect. Consequently, the treatment should be safe and essentially limited to providing additional room for the brain to expand and to correct the cosmetic defect and the secondary hypotelorism (Fig. 5). All these goals can be reached utilizing a procedure we have named "shell operation" because of the characteristic shape of the fron-

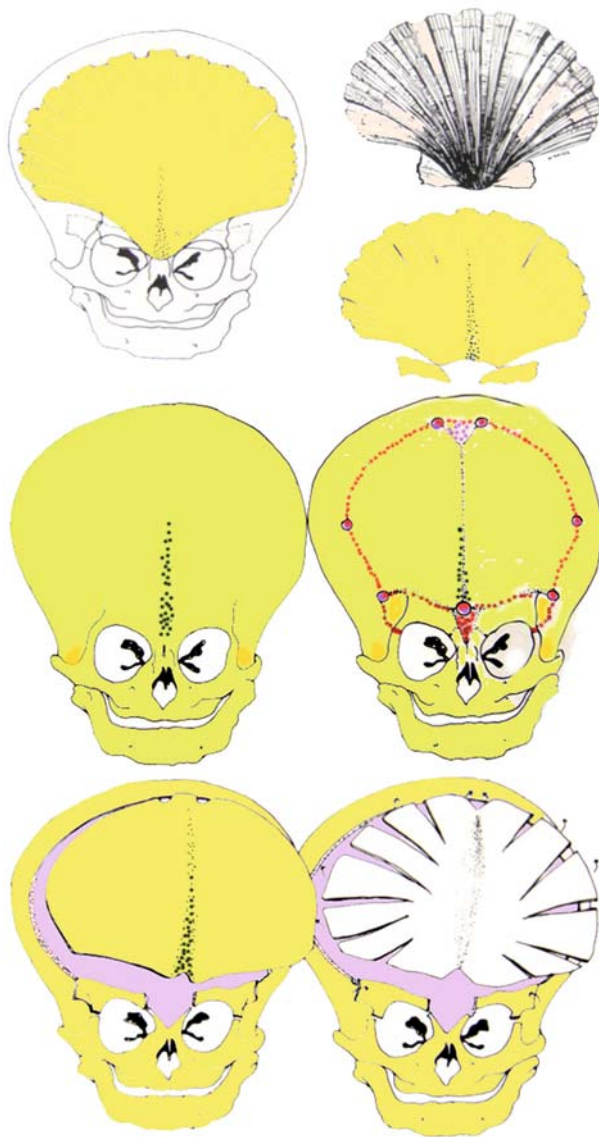


**Fig. 5.** One of the most widely utilized technique for the correction of metopic synostosis based on the creation and replacement after rotation of two free bone flaps, the opening of the orbital roof and lateral advancement superior orbital ridge after removal of the nasal process of the frontal bone and the upper part of the nasal bones

tal bone reminding the Saint Jacques shell [9]. Essentially the procedure consists of a frontal craniotomy allowing to remove the malformed frontal bone and part of the parietal bones from a line 1.5–2 cm above the orbital ridges to the anterior fontanel (Fig. 6). This flap is subsequently remodeled with the drilling of the thick ridge of the prematurely fused suture and the anterior displacement of its lateral aspects. Barrel stave linear osteotomies converging downwards and towards the midline (so mimicking the lines of the shell) (Fig. 6) diminish the resistance of the bone and allow to modify its curvature using a bone *bandeur*. The nasal processes of the frontal bone and the upper part of the nasal bones are removed. The roof and the lateral walls of the orbits are then sectioned and the lateral borders of superior orbital ridges pushed forwards in order to compensate for the hypoplastic orbital cavity. The pushing maneuver is made using the medial borders of the superior orbital ridges, cut only partially, as pivots. The advancement is maintained by replacing the remodeled frontal bone between on the advanced superior orbital rims and the anterior border of the parietal bones. Outcomes are quite satisfactory with the immediate and persistent correction of the forehead. The hypotelorism disappears progressively without the need of any interposing material to fill the interorbital bone gap created by the removal of the upper part of the nasal bone and the nasal process of the frontal bone.

### 3. ANTERIOR PLAGIOCEPHALY

The unilateral flattening of the frontal bone, nearly always associated to scoliosis of the face and commonly to torticollis is the result of the early fusion of one coronal suture.

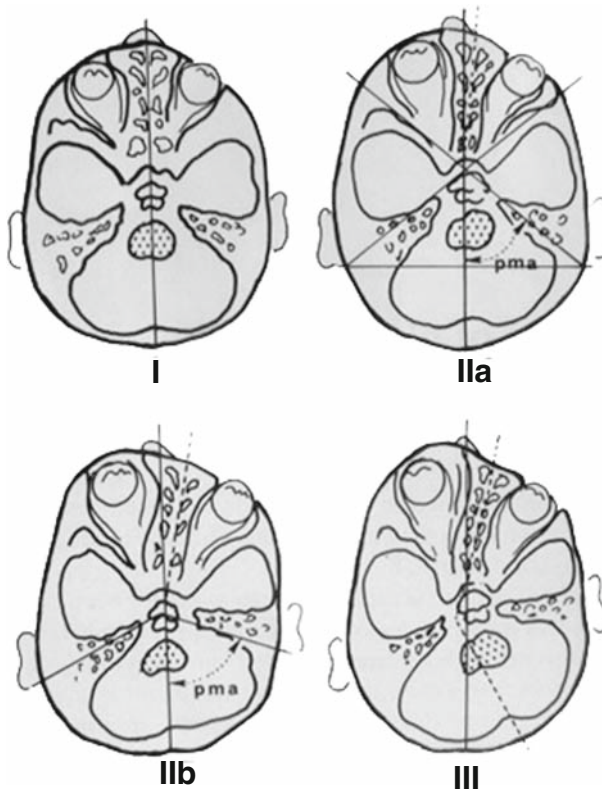


**Fig. 6.** The “shell” operation introduced by the author (for further explanation, see text)

It is relatively frequent, accounting for the third most common monosutural craniosynostosis and affects females more than males. Up to a tenth of the subjects present a familial inheritance; in such cases the molecular anomalies more often found involve the *FGFR2* and the *FGFR3* genes [8]. When

untreated, the condition rapidly evolves with the progressive involvement of the facial skeleton and the base of the skull.

The diagnosis can be easily obtained by visual inspection: the affected infants show an obvious unilateral flattening and recession of the frontal bone. The homolateral eye appears larger than the controlateral one, due to its protrusion secondary to the shallow orbit which results from the defective antero-posterior development of the anterior cranial fossa. The ocular protrusion is accentuated by the elevation of the superior orbital ridge and its lateral recession. A particular strabismus, more easily noticed in the upwards gaze, is often appreciable as the consequence of the abnormal insertion of the supero-oblique muscle within the deformed orbit. The vertical diameter of the orbit is increased as it is easy to notice also on the X-ray skull examination. In most cases the nasal pyramid is controlaterally deviated and, because of this deviation and that in the opposite direction of the chin, the face assumes a scoliotic configuration. The homolateral external ear is rotated and displaced



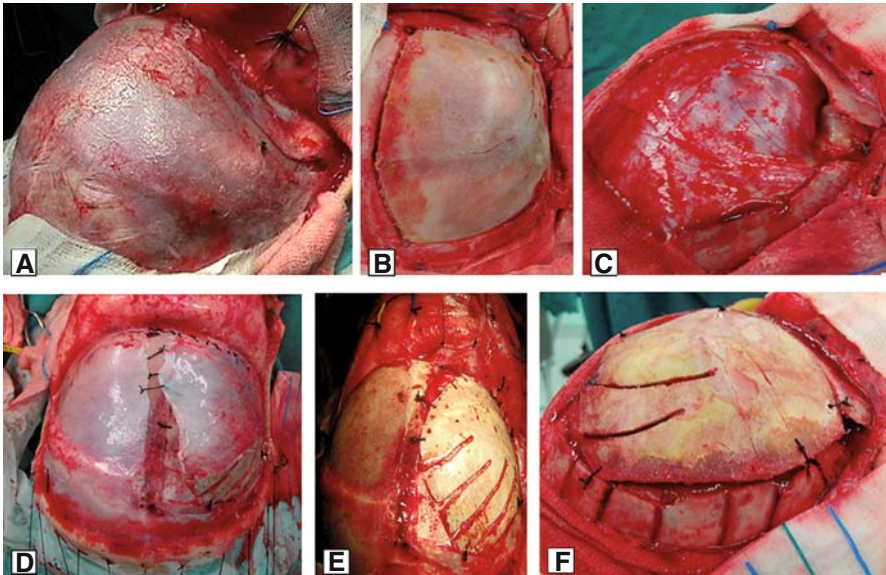
**Fig. 7.** Author's classification of anterior plagiocephaly based of the various degrees of facio-cranial bone anomalies

anteriorly with a diminished lateral canthus–tragus distance. A variable degree of temporal bulging is commonly observed. Most infants tend to keep their head twisted and lowered on the homolateral shoulder. The differential diagnosis includes postural and, more rarely, ocular plagiocephaly. Recently, a further specific nosographic entity has been described, namely the anterior plagiocephaly resulting from synostosis of the fronto-sphenoidal suture [13].

Even though the unilateral flattening of the frontal bone is the most obvious anomaly, different degrees of severity of the condition may be distinguished on the grounds of the secondary involvement of other cranial sutures as well as the morphological changes and deviation of the skull base bones. For this reason, a classification has been proposed which distinguishes 3 main types [5] (Fig. 7): Type I with a mere unilateral flattening of the frontal bone; Type II, which associates also the homolateral deviation towards the affected suture of the vomer bone and the contralateral deviation of the nasal pyramid, without (Type IIa) or with (Type IIb) anterior displacement and rotation of the homolateral petrous bone; Type III, which comprises also the homolateral deviation of the posterior third of the midline skull base and the hypoplasia of the occipital squama and the occipital condyle on the affected side. In the last type, the size of the corresponding lateral mass of the atlas vertebra exhibits a compensatory excessive growth. As a result, the rotation plane of the craniovertebral junction is oblique, consequently accounting for the obvious torticollis which infants with Type III anterior plagiocephaly exhibit. This classification is not a mere morphological distinction of different degrees of cosmetic and functional deformities; indeed, it bears a prognostic value as Type I patients are completely cured by the surgical treatment whereas Type III children will continue to suffer facial asymmetry and torticollis in many instances, with Type II having intermediate surgical outcomes.

The variable surgical results are explained by the fact that all the surgical techniques utilized, including the endoscopic procedures, are essentially directed at correcting the precociously closed coronal suture while the associated posterior skull bone abnormalities are not practically addressed.

**Surgical considerations.** The main goals of the surgical correction of anterior plagiocephaly are to enlarge the hypoplastic anterior cranial fossa and to remodel the abnormal orbit. They can be achieved by removing the flattened hemifrontal or the entire frontal bone, by opening the orbital roof and the lateral wall of the orbit in order to displace anteriorly and to lower the superior orbital ridge after having sectioned or green-stick fractured its medial aspect. The advancement of the orbit lateral canthus is maintained by using a graft taken from the parietal bone or reabsorbable plates and by replacing and adequately rotating the frontal bone flap, once corrected its shape. When necessary, multiple barrel stave osteotomies and modification in curvature of the resulting bone segments by bone *bandeur* can be carried out to reduce the associated temporal bulging (Fig. 8).



**Fig. 8.** Intraoperative images of the surgical steps for the correction of anterior plagiocephaly (A): removal of the flattened frontal bone (B); opening of the orbital roof and lateral advancement of the superior orbital ridge (C); the advancement of the superior orbital ridge is maintained by replacing the rotated frontal bone flap (D). Barrel stave linear osteotomies may be utilized when required to achieve a better shape of the skull on the frontal flap (E) as well as on the anterior border of the parietal bone (F)

Cosmetic outcomes range from excellent in Type I anterior plagiocephaly to good in Type II as the current surgical treatment is quite effective in resolving the frontal and orbital asymmetry while the facial abnormalities tend either to fade away spontaneously or, at least, remain stable after the operation. The surgical results are less rewarding in Type III infants with the frequent persistence or late recurrence of the head deviation. In this last evenience maxillo-facial surgical procedures may be required at an older age.

#### 4. BRACHICEPHALY

The early ossification of both coronal sutures impairs the longitudinal growth of the skull and results in a “short head” (in Greek, *Brachicephaly*). The ensuing transverse and vertical compensatory volumetric expansion of the skull contributes to give the affected subjects their peculiar appearance with the head becoming not only shorter but also higher and broader than normal. In most advanced cases the head assumes a characteristic tower-like shape (turriccephaly). The commonly present frontal bossing is accentuated by the concomitant retrusion of the lower part of the frontal bone, the nasal dorsum and

the superior orbital ridges. The last anomalies may account also for a certain degree of ocular proptosis. Differently from what occurs in faciocraniostenoses with early bicoronal fusion, the inferior orbital ridge is nearly always normal. In cases with associated prominent temporal bossing it is often found a genetic molecular mutation in FGFR3 P250 (Lajeunie-Muenke brachicephaly). The affected infants may also feature sensorineural hearing loss, psychomotor retardation, and abnormalities of the hands and feet. Increased intracranial pressure is often present, likely accounting for mental retardation which is also possible to observe in this type of craniosynostosis. However, other factors should play a role as psychomotor delay occurs most frequently in females than in males.

**Surgical considerations.** A significantly high percentage of infants with bicoronal synostosis present an abnormal elevated intracranial pressure which can remain undetected or heralded only by subtle clinical signs. Consequently, besides the cosmetic correction, it is necessary in these patients to resolve the craniocerebral disproportion in early age by enlarging the anterior third of the skull. The standard operation consists of a bifrontal craniotomy, the advancement of the supraorbital bar aimed at displacing the superior orbital rim anteriorly. The “tongue in groove” technique is generally utilized. In order to obtain a more physiological inclination for the remodeled frontal bone, the advanced orbital bandeau is replaced in a more oblique position to reorientate the growth vector anteriorly and counteract the tendency that the frontal bone has to develop more vertically and more posteriorly in bicoronal synostosis as compared to normal. A 180° rotation of the replaced frontal flap may provide further room for the growth of the frontal lobe by utilizing the large superior concavity of this bone. Additional maxillo-facial procedures are required in cases of too deep nasal root or associate hypertelorism.

## 5. OCCIPITAL PLAGIOCEPHALY

A bilateral or, more often, unilateral flattening of the occipital bone is commonly due to a postural preference in the first months of life (posterior head molding, non synostotic occipital plagiocephaly). Actually, the lambdoid suture does fuse in early life very rarely. As infants tend to remain in the same position when put in bed during their first four months, the posterior molding of the head has become a relatively frequent phenomenon after the pediatricians have started to advise the mothers the supine position to avoid infants' sudden death. Radiological studies are not indicated for the differential diagnosis as the ossification of the lambdoid suture is uncommon even in cases of true synostotic posterior plagiocephaly. On the other hand, sclerosis of the lambdoid suture, once regarded a reliable sign of synostosis characterizing a “lazy” suture, can be found also in positional posterior head molding. Furthermore, the positional flattening is easily recognizable at the physical



examination because of the typical parallelogram shape that the head assumes due to the compensatory advancement of the homolateral frontal bone and petrous pyramid. In most severe cases, the resulting frontal bossing may erroneously suggest an anterior plagiocephaly. In contrast with the dynamic changes induced by the posterior molding of the head, the true synostosis of the lambdoid suture tends to attract the petrous pyramid posteriorly and downwards so that the external ear moves in a more posterior and inferior position while in the postural plagiocephaly it remains on the same plane.

Positional molding only exceptionally requires a surgical correction and can be usually managed with physical therapy and by adopting a correct posture of the head, especially when the condition is recognized before 5–6 months of age. Similar good results can be obtained with the helmet therapy. Generally, however, this therapy proves to be very effective in the correction of the posterior cranial deformity but it is associated with a higher incidence of persistent asymmetry of the forehead and the face. After the first year of life, in cases where the posterior asymmetry is particularly disturbing it is possible either to reduce the cosmetic defect using subcutaneous implants or to perform a posterior skull expansion.

The surgical treatment is advised in infants with synostotic plagiocephaly, especially when the impaired development of the occipital squama results in a hemi-posterior fossa unable to accommodate the growing cerebellum. In such an evenience, in fact, it is not rare to observe a caudal migration of the homolateral cerebellar tonsil into the upper cervical canal. Linear craniectomies along the affected suture or the creation of free floating parieto-occipital bone flaps may suffice to allow the posterior skull to expand. However, more extended procedures with bone displacement, replacement and rotation have been proposed in order to achieve an immediate correction of the hypoplastic posterior fossa without relying of the plasticity of the underlying cerebral parenchyma merely. In more recent years, active techniques using various types of distractors and springs are increasingly utilized.

## HOW TO AVOID COMPLICATIONS

In spite of its more than a century long history, the surgical management of simple craniosynostoses is still in its young age. Indeed, the understanding of these conditions remains insufficient and the role of factors, e.g. genetic molecular anomalies, which can not be mechanically corrected, still unclear. It is likely that such factors might account for the unsatisfactory outcomes, which are still recorded after an apparently initially successful operations, more than inappropriate surgical procedures.

Insufficient physiopathogenetic interpretations continue to limit the surgical indication, especially in mild cases. As compared to the past times, nowadays the surgical decision is justified by the availability of more effective

surgical techniques and better anesthesiological care which have decreased the surgical mortality to less than 1 per cent of the cases. Severe complications such as those depending on the rupture of great vessels or cerebral contusions range on the same low level. Also wound and bone infection rate is currently very low, remaining between 0.5 and 1.5% in all the major series. Minor complications, such as dural tears or defective new bone formation, are still encountered. However, they rarely impact on the surgical outcome significantly. Recurrences, once the most feared complication, have become very uncommon at the level of the treated suture. More often, indeed, the term refers only to a progression of the disease, either because of further involvement of other cranial sutures besides the one operated on or because inadequate surgical modalities unable to arrest the natural history of the disease, e.g. the mere correction of the frontoorbital asymmetry in anterior plagiocephaly.

## CONCLUSIONS

Increased awareness, more refined surgical techniques, improved anesthesiological care and decreased risks associated to the operation justify the current increasing interest paid to the treatment of simple craniosynostosis and account for the proliferation of centers dealing with this type of malformations. In contrast, there has been a surprising little progress in developing tools apt to evaluate the surgical outcomes objectively. Most of the current grading systems are still based on subjective evaluation of the cosmetic results by the neurosurgeon, the family and, more rarely, the patient. Also of limited value are those systems which take into account other variables, such, for example, the number of reoperations judged to be necessary to reach a satisfactory correction. More objective criteria are provided by anthropometric analyses of which the cranial index is probably the best known. Although quite widely utilized and enough reliable for specific forms of craniosynostosis, namely sagittal synostosis, this index, however, cannot grade the persistence of focal abnormalities, e.g. an excessively flattened temporal fossa, which may impact on the cosmetic appearance unfavorably. Further objective evaluations such as neuroradiological studies imply the risk of radiations, which is not justified in this type of patients.

Probably the most disturbing consideration regards the limits in evaluating the cognitive outcome. Indeed, it would be extremely important for the neurosurgeon to know whether the increased surgical risk associated with an early operation is ever justified in terms of improved psychomotor development. Most of the published papers are biased by the still unproved believe that the surgical brain decompression obtained by the opening of the cranial results in eliminating the risk of mental developmental impairment. However, while the advantages of an early surgical treatment have

been unequivocally demonstrated in complex craniosynostoses through the obvious benefits of an early correction of the associated hydrocephalus and impairment in venous circulation, in monosutural synostoses such an evaluation is not possible. Most of these children develop normally and the psychomotor retardation shown by a minority of them should be blamed to the still insufficient ability to detect these cases who likely suffer from a primary cerebral dysfunction rather than to an insufficient or too late operation. At the moment, only a few studies are available with objective measures to evaluate the advantage of an early versus a late correction [11]. However, they are based on relatively crude indexes, e.g. the intelligence quotient and not on the evaluation of all the functions involved in psychomotor development.

Actually, very little is known about the natural history of untreated children. The historical evidence is biased by the inclusion in the reported clinical series of subjects with cerebral atrophy or other kind of cerebral anomalies which could not be detected with the diagnostic tools available at that time. Finally, most of the studies analyzing cognitive outcomes have been carried out in the very young population or at relatively short temporal distance from the surgical corrective procedure. Consequently, the cognitive outcomes of adolescents and young adults remain to a vast extent a field still open to further investigations.

## References

- [1] Clayman MA, Murad GJ, Steele MH, Seagle MB, Pincus DW (2007) History of craniosynostosis surgery and the evolution of minimally invasive endoscopic techniques. *Ann Plast Surg* 58: 285-287
- [2] Coussens A, Wilkinson CR, Hughes IP, Morris CP, van Daal A, Anderson PJ, Powell BC (2007) Unravelling the molecular control of calvarial suture fusion in children with craniosynostosis. *BMC Genomics* 8: 458-483
- [3] Davis C, Wickremesekera A, Mac Farlane M (2009) Correction of nonsynostotic scaphocephaly without cranial osteotomy: spring expansion of the sagittal suture. *Child's Nerv Syst* 25: 225-230
- [4] Di Rocco C (2003) How to decrease the impact of surgical scar in the correction of sagittal synostosis. *Child's Nerv Syst* 19: 42-45
- [5] Di Rocco C, Velardi F (1988) Nosographic identification and classification of plagiocephaly. *Child's Nerv Syst* 4: 9-15
- [6] Di Rocco C, Velardi F, Ferrario A, Marchese E (1996) Metopic synostosis: in favour of a "simplified" surgical treatment. *Child's Nerv Syst* 12: 654-663
- [7] Di Rocco C, Tamburrini G, Pietrini MD (2004) Blood sparing in craniosynostosis surgery. *Semin Ped Neurol* 11: 278-287

- [8] Lajeunie E, El Ghouzzi V, Le Merrer M, Munnich A, Bonaventure J, Renier D (1999) Sex-related expressivity of the phenotype in coronal craniosynostosis caused by the recurrent P250R FGFR3 mutation. *J Med Genet* 36: 9-13
- [9] Lajeunie E, Barcik U, Thorne JA, El Ghouzzi V, Bourgeois M, Renier D (2001) Craniosynostosis and fetal exposure to sodium valproate. *J Neurosurg* 95: 778-772
- [10] Renier D, Sainte-Rose C, Marchac D, Hirsch JF (1982) Intracranial pressure in craniostenosis. *J Neurosurg* 57: 370-377
- [11] Renier D, Arnaud E, Marchac D (2006) Le ressentissement fonctionel des cranios-tenoses. *Neurochirurgie* 52: 302-310
- [12] Tamburrini G, Caldarelli M, Massimi L, Santini P, Di Rocco C (2005) Intracranial pressure monitoring in children with single suture and complex craniosynostosis: a review. *Child's Nerv Syst* 21: 913-921
- [13] van Veelen-Vincent MLC, Mathijssen I, Arnaud E, Renier D (2009) Non-syndromic craniosynostosis. In: Lumenta C, Di Rocco C, Haase J, Mooij JJA (eds) *European manual of neurosurgery*. Springer, Heidelberg (in press)



### **Concezio Di Rocco**

Concezio Di Rocco is Head of Pediatric Neurosurgery at Policlinico Gemelli at the Catholic University Medical School in Rome. He graduated in Medicine at the Catholic University Medical School, in Rome. Subsequently, he specialized in neurosurgery, under the guidance of Prof. G.F. Rossi, a neurosurgeon well-known for his interest in neurophysiology and his experience in the surgical treatment of epilepsy. Prof. A.J. Raimondi was the one who aroused Prof. Di Rocco interest in pediatric neurosurgery, an emergent subspecialty at the time when he had completed his training in general surgery. Prof. Di Rocco then was trained by him at the Children's Memorial Hospital, Northwestern University, Chicago, a preferential center for all the international neurosurgeons who wanted to be acquainted with pediatric neurosurgery. Thus, Prof. Di Rocco had the possibility to meet a series of young colleagues who, in the future, would have maintained a strict cultural relationship with him in the frame of a new society, the International Society for Pediatric Neurosurgery (ISPN) aimed at expanding the knowledge in the field. A second person who influenced his cultural life deeply was Prof. M. Choux, Marseille, who also gave him the opportunity to further improve his training in pediatric neurosurgery in the center he had developed in Marseille. With him and Prof. Hovind (Oslo), Prof. Di Rocco established the first Postgraduate Course in

Pediatric Neurosurgery destined to European in training neurosurgeons which is still going more than 20 years after its establishment. In Rome Prof. Di Rocco has developed a center for pediatric neurosurgery with the cooperation of his co-workers Prof. Caldarelli and Dr. Tamburrini. This department is the reference center for pediatric neurosurgery in Italy and has justified the creation of the first Chair in Pediatric Neurosurgery in the country.

Prof. Di Rocco has held various position in international societies, in particular he has been Vice-President of the European Association of Neurosurgical Societies (EANS), President of the International Society for Pediatric Neurosurgery (ISPN), the European Society for Pediatric Neurosurgeon (ESPN), Chairman of the Pediatric Committee of the World Federation of Neurosurgical Societies (WFNS).

**Contact:** C. Di Rocco, Pediatric Neurosurgeon, Policlinico Gemelli, Catholic University Medical School, Largo Gemelli 8, 00168 Rome, Italy  
E-mail: cdirocco@rm.unicatt.it

---

# MANAGEMENT OF LUMBOSACRAL LIPOMAS

A. PIERRE-KAHN

## INTRODUCTION

Congenital lumbosacral lipomas are the most common form of occult spinal dysraphism. They are part of a loco-regional malformation involving almost always the skin, the spine and the nervous tissue. The most characteristic neural anomaly is a low-lying cord. These lipomas are diagnosed usually pre- or immediately post-natally. A few, however, are seen later on during childhood or adulthood, because of evolving sensory-motor, sphincterian or orthopedic deterioration. In 1950, Basset proposed [1] to operate on asymptomatic patients to prevent them from late deterioration. This concept of preventive surgery became the gold standard of treatment after the publications in 1981 of James and Lassman [5] and of Yamada [9] who demonstrated the development of neuronal dysfunction in response to acute stretching of the terminal cord on rats. Recently, however, prophylactic surgery was questioned [7] at least for lipomas of the conus and, now, a growing number of pediatric neurosurgeons would not operate any more on asymptomatic patients [2–4, 8, 10], estimating that surgery is risky and does not modify the natural history of the malformation.

## RATIONALE

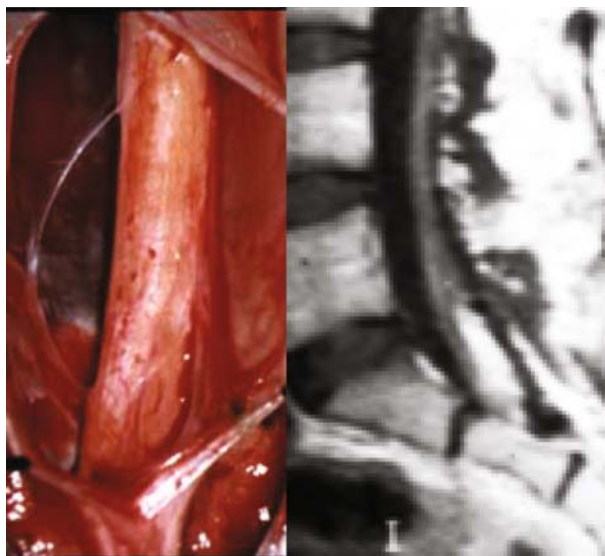
Lipomas of the filum must be distinguished from those of the conus, much more frequent and complex.

*Lipoma of the filum* (Fig. 1). The lipoma involves the whole length of the filum or only part of it. The dural sac is almost constantly normal and the lesion subarachnoid. Roots around are always normal, easy to recognize, only slightly adherent to the filum.

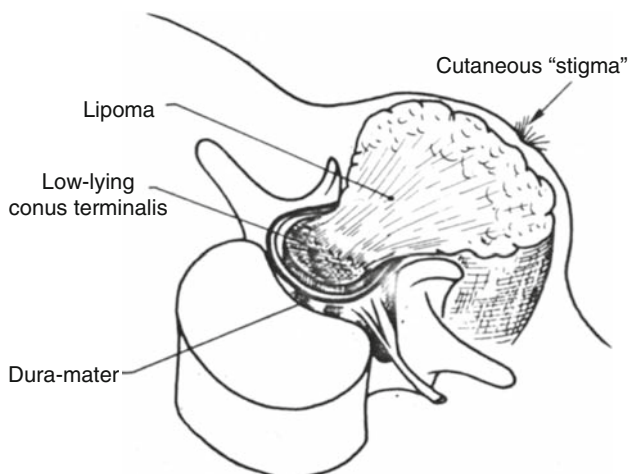
*Lipoma of the conus*. Typically, the lipoma develops both subcutaneously and intradurally (Fig. 2). The stalk joining these two components passes through a defect of a spina bifida and of the dura. The intradural lipoma is anchored to the conus. The interface between the two structures is usually resistant and whitish, extending in average from L4 to S3. The intradural lipoma may compress the cord. Recognition, dissection and preservation of the roots and of the interface may be compromised by (1) the density of the adhesences, (2) a posterolateral insertion of the lipoma on the cord (Fig. 3) with then intralipomatous roots (Fig. 4), (3) an extraspinal extension of the cord (Fig. 5). Strictly intradural lipomas are rare.

---

*Keywords:* lumbo-sacral lipomas, pediatric neurosurgery, spine



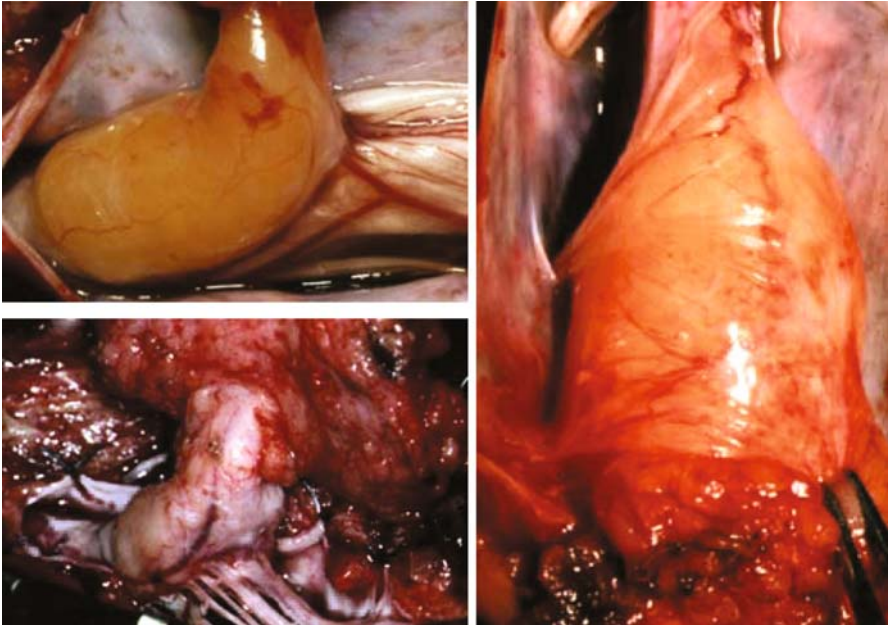
**Fig. 1.** Lipomas of the filum. *On the left*, operative view of a lipoma involving the whole filum. *On the right*, MRI, T1 sagittal view, showing in another case a lipoma of the filum



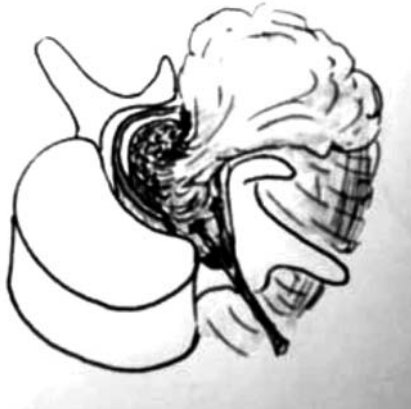**Fig. 2.** Schematic representation of a typical lipoma of the conus

The most common associated malformations are cutaneous and vertebral, (90% of the cases). *Cutaneous stigma* on the midline of the back have variable diagnostic values (Fig. 6): very high in the case of bump, deviation of the intergluteal fold, or coexistence of two or more lesions, whatever their type, low in the case of atypical dimple, aplasia cutis, dermal sinus, “queue de faune”, and very low in the case of hemangioma, port-wine stain, hypertri-



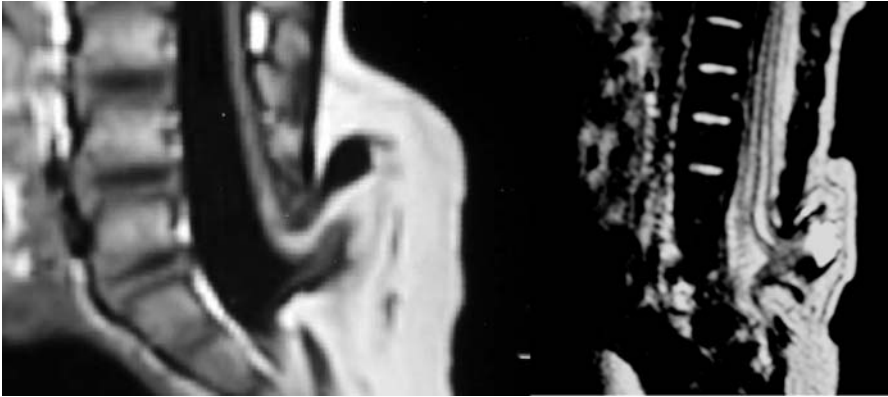

**Fig. 3.** Operative views of three different types of insertion of the lipoma on the cord. *Left up:* dorsal insertion; *left down:* caudal insertion; *right:* posterolateral insertion. In this last case, some of the roots emerge directly from the lipoma

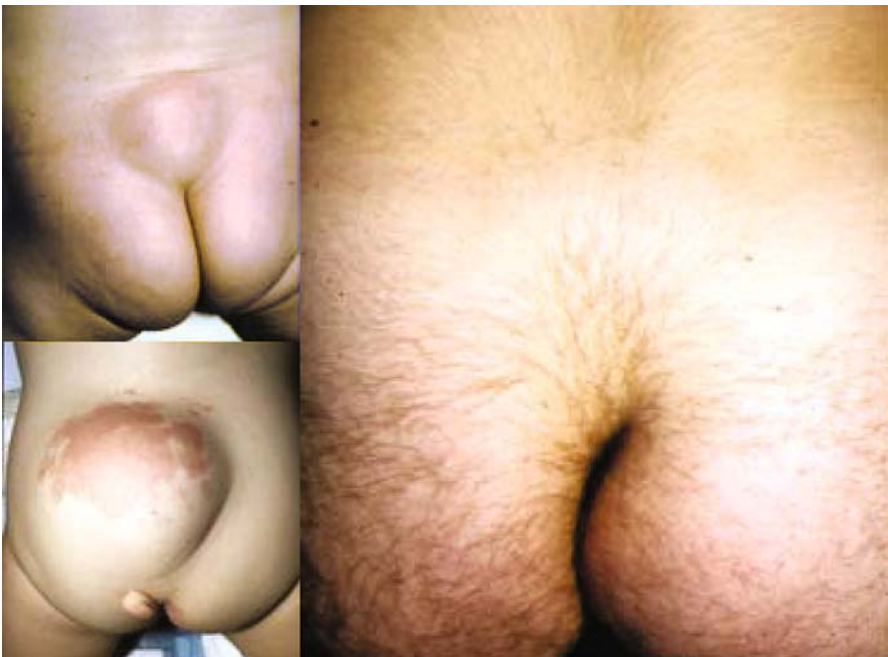

**Fig. 4.** Schematic representation of a lipoma inserted on the posterolateral aspect of the cord. Roots, on one side, are intermingled within the lipoma before emerging from its lateral aspect

chosis, fibroma pendulum, pigmentary noevus, coccygeal dimple. *The spina bifida* involves often the whole sacrum, extending frequently to L5-4. *Sacral agenesis* is rare, but almost constant in patients with urogenital or ano-rectal



**Fig. 5.** Sagittal view of MRIs in two different patients showing a meningo-myelocele in both cases. In each of them, the cord extends extra-spinally and is in close relationship with the subcutaneous lipoma. *On the left* (T1 sequence), the terminal cord ends within the lipoma and the interface is visible. *On the right* (T2 sequence), the malformation is more atypical since the herniated nervous tissue is not the tip of the terminal cord but the conus itself. Note the presence of an extensive syringomyelia in this case



**Fig. 6.** Cutaneous stigma. *Left:* two cases presenting a lumbosacral subcutaneous bump very suggestive of a lipoma. *Left down:* the bump is associated with other cutaneous anomalies that are frequently seen in any other types of occult dysraphism. *Right:* minor cutaneous anomaly (deviation of the intergluteal fold) remained undetected until adolescence and the insidious development of an urogenital bladder

anomalies. *Scoliosis* is generally related to vertebral bodies malformations or shortening of a leg. *Syringomyelia* is noted in ¼ of the patients essentially at the lower cord. Other intradural malformations are exceptional. *Brain anomalies* are extremely rare (3%). *Extra-axial malformations* are described in almost ¼ of the cases, essentially urogenital and ano-rectal.

## DECISION-MAKING

### 1. DIAGNOSIS

#### 1.1 Prenatal diagnosis

*Ultrasonography* may make the diagnosis from week 17 on the basis of a lumbosacral spina bifida, hyperechogenic skin, low-lying cord and normal intracranial anatomy. The presence of a meningocele may lead to erroneous diagnosis, the lipoma revealing only at birth or at the very end of the pregnancy. *Prenatal MRI* does not provide more information than echography.

#### 1.2 Perinatal diagnosis

*Cutaneous anomalies* are the key of the diagnosis. In their absence, or when the anomaly is minor (Fig. 6), the diagnosis is often delayed for years and has even the greatest chances to never be done if the patient remains asymptomatic.

*Congenital deficits* are rare (22% of our patients), resulting from root malformations. They are exceptionally obvious, and bilateral. Most often, they are extremely difficult to assess in neonates and infants. A thorough neurological examination including feet, toes and anus is mandatory. Voiding difficulties remain frequently unapparent in the absence of clear incontinence or repeated urinary infections. *Urodynamic studies* at birth and every 6 months until the age of two years, and at any age in case of doubt, are recommended. *MRI* is the first necessary investigation in the presence of a bump or of deficits to confirm the diagnosis. Sagittal and axial views in T1-T2 weighted images are necessary. Fat saturation and gadolinium may be useful. In our experience, dynamic MR has been always useless. *Ultrasonography* must be proposed first under the age of 2 months in asymptomatic babies with cutaneous anomalies of low or very low diagnostic value. Doing so, MRI can be avoided if ultrasonography is normal. *Brain MRI* is unnecessary.

#### 1.3 Diagnosis in children and adults

*Neurological symptoms* are predominant and cutaneous anomalies absent or minor (Fig. 6).

- *Sphincter disorders*, especially micturation difficulties, are the most common. Incontinence results mainly from dysuria, pollakiuria,

urgent micturation and incomplete voiding. Bladder infection or pyelonephritis is not rare, due to urinary retention. Constipation necessitating digital evacuation is not rare, but frequently concealed by a pseudo diarrhea. It is always associated with urinary disorders.

- *The neuro-orthopedic syndrome* is typically unilateral or asymmetrical (clubfoot, equino-varus deformation, clawing of the toes, hypotrophy of the leg) and affects 1/3 of the patients. At examination, one third have a motor neuron syndrome but hyperreflexia is usually associated with abolished reflexes. Hypoesthesia and trophic ulcerations are much more rare.
- *Sexual dysfunction* is almost constant in symptomatic adults.
- *The caudal syndrome* is exceptional (1.8–5.1%) and associates sacral agenesis, presacral mass and perineal malformation(s). Its diagnosis is usually made at birth on perineal malformations, but sometimes only in adulthood when symptoms are limited to moderate bowel dysfunction and unspecific neurological signs. A heterozygous point mutation of the coding sequence of HLXB9 gene on chromosome 7 (7q36) has been observed recently in these patients [6].

*Urodynamic studies* should be part of the decision-making work-up, even in the very young and in case of unsuspected urinary troubles. They may reveal a combination of hyperactive bladder and vesico-sphincter dyssynergia. *Spinal MRI* is necessary in all cases.

## 2. EVOLVING DEFICITS

It is frequently said from medical data that the older the patients, the worse their neurological condition. This is a misinterpretation, healthy carriers never appearing in medical statistics. It might simply signify that adults, when deteriorating, systematically require care and hospitalization. In our experience, deterioration affects a minority of patients (Fig. 8). *The diagnosis* of evolving deficits is often difficult to make early due to their usually slow progressiveness or even to assess. For example, evolving deformation of an already known clubfoot can simply result from growth. *Urodynamic studies and/or electromyography of the lower limbs* are therefore extremely useful at any doubt.

## 3. FUNCTIONING SCORING SYSTEM

To appreciate the functional and social repercussion of the malformation, it is useful to dispose of a specific scoring system as the one developed in our department (Table 1). This system takes into account the motor, sensory, vesical and anal handicaps. Normality is given a score of 5 for motor and urinary functions and of 4 for sensory and anal functions. Asymptomatic patients have a score of 18. A normal life is compatible with a score above 15.

**Table 1.** The modified Necker Enfants Malades (NEM) functional score. The scoring levels for children and adults are written in standard script, while the scoring levels for neonates and infants are written in *italics*. D&N: day and night

Score	Motor	Sensory	Bladder	Bowel
1	Wheelchair <i>Major deficit</i>	Skin ulceration Amputation	D&N Incontinence <i>Incontinence</i>	Incontinence
2	Major orthosis 2 crunches	Pain	Night Incontinence <i>Retention</i>	Painful constipation <i>Digital maneuvers</i>
3	Distal orthosis	Painless deficit	Intermittent catheterization	Constipation
4	Fatigue on walking	Normal	Dysuria, stress incontinence	Normal
5	Normal		Normal	

#### 4. SURGICAL INDICATIONS

- *In the presence of congenital deficits*, there is a general agreement in favor of systematic surgery, although such deficits will never regress.
- *In the presence of acquired or evolving deficits*, surgery is mandatory, as early as possible after the recognition of the deficits. It is the only way to improve the patient and probably the sooner the surgery, the better the results. The difficulty, however, is to recognize a deficit at its onset because of its usually insidious installation.
- *In the presence of postoperative evolving deficits*, a first redo surgery is mandatory despite its difficulty and risks. In the case of continuing, we would now not recommend further re-operations but exceptionally.
- *In the absence of deficits*, there is still no consensus.
  - *In asymptomatic lipomas of the filum*, prophylactic surgery is probably acceptable, the risk of surgery being quasi nil and the vast majority of the operated patients, if not all, remaining asymptomatic along with time. Does surgery have a truly preventive effect? None can answer for the moment, the natural history of this malformation remaining unknown.
  - *In asymptomatic lipomas of the conus* we consider that “preventive” surgery does not fulfill the ethical rules prevailing in other fields of the medical practice and cannot be advised any longer. On the basis of our non-randomized study, we can conclude indeed that (1) The treatment is not without risk (3.4% of neurological complications in our hand) and not always satisfactory (2) “Preventive” surgery is not preventive, the pattern of deterioration with or without surgery being at least similar (Fig. 8). (3) The pathology is far from being as

severe as previously described. (4) Finally and from a functional point of view, patients are better after surgery at first symptom than after routine and early surgery (Fig. 9).

Asymptomatic patients with a lumbosacral lipoma of the conus should be submitted to a strict protocol of surveillance and operated only at first symptom. The protocol should include, as it does in our daily practice, (1) thorough and multidisciplinary clinical examinations, at referral, every 6 months until the age of 2 years, then every year, (2) urodynamic studies at referral and every six month until the age of the continence (grossly two year of age) and later on at any doubt, (3) MRI at diagnosis, at one year to assure that the lipoma has not increased, and later on every five years until growth is finished. EMG of the legs and perineum was part of our protocol at the beginning. It ceased to be so because this investigation is both painful and difficult to interpret. It may be useful, however, if a new deficit is questionable.

## **SURGERY**

### **1. SURGICAL TREATMENT**

*Principles.* Surgery aims to untether the cord, decompress it if necessary, spare the functional nervous tissue and prevent from retethering. It must be conducted under optic magnification and micro-instruments. In the case of lipoma of the conus, ultrasonic aspiration and contact laser are extremely useful. Intra-operative neuro-physiological recording is theoretically useful to distinguish functional roots from fibrotic bands but, in our experience, it did not give the security expected because stimulations were not permanent and recording from sensory roots not totally reliable, in particular from sphincterian rootlets. For these reasons, we stopped using it since 1994.

#### **1.1 Surgery for lipoma of the filum**

It is a one-hour procedure. A small cutaneous incision is sufficient, vertical or horizontal to put a distance between it and the gluteal furrow. The dural sac is reached through an inter-spinous approach between L5 and S1. A one-centimeter incision allows recognition, isolation, division and resection of 1cm of filum. It is frequent that the filum retracts strikingly after its division.

#### **1.2 Surgery for lipoma of the conus**

- *The cutaneous incision* is vertical on the midline, or horizontal when the lipoma is sacral, to limit risks of postoperative infection.
- *The resection of the subcutaneous lipoma* is, in our opinion, better minimal than total or subtotal to prevent the creation of a dead space

in which the CSF could collect postoperatively. The residual subcutaneous lipoma is easy to remove later on by liposuction.

- *A laminectomy* of the lowest or the two lowest normal laminae is, in general, necessary to expose the normal dura and the upper part of the lipoma.
- *The dural incision* is made rostro-caudal, circumscribing the stalk of the lipoma.
- *The division of the subdural adhesions* is crucial both to expose the lateral aspects of the lipoma and the underlying roots and to free the cord. The severity of the adherences, a missing dura replaced by musculo-aponeurotic bundles, or shortness of roots may be such that freeing of the cord is impeded, at least partially.
- *The degree of removal of the intraspinal lipoma* varies, in the literature, from minimal to “total”. There is no doubt that “total” removal in an attempt to reach the fibrotic interface is doable, but carries the intrinsic risk of injuring the posterior columns, provoking severe and durable pain, trophic ulcers or bladder paralysis. For that reason, we no longer advocate as complete a resection as we did in the past, especially as we have not found any correlation between postoperative results and degree of removal. Removal of the lipoma must be cautious and necessarily limited in the case of a posterolateral insertion of the lipoma because of the presence of intra-lipomatous roots.
- *The closure of the placode* is not always possible, depending upon its shape and the volume of residual lipoma. In our experience, the closure edge to edge of the placode does not prevent from postoperative re-adhesion but facilitates an eventual second surgery.
- *The drainage of a terminal syrinx* by means of a myelotomy or a drain is not recommended, as we found no correlation between patient’s pre- and postoperative status, and the presence or the size of a syringomyelia. Many syrinx regress postoperatively.
- *The enlargement of the dural sac* has been recommended to prevent postoperative retethering. Many prosthetic materials have been proposed, including Gore-Tex® more recently, but none has proved to be better than the other. None prevents from postoperative adherences or reduces the risk of late postoperative deterioration. For these reasons, we ceased to systematically enlarge the dural sac. In our patients, re-adherences were constant whatever the technique used. Interestingly, of these patients, only a few developed further symptoms related to a tethered cord syndrome, illustrating the fact that fixed cord and tethered cord are different concepts [4].
- *The closure of the dura*, with or without enlargement, is never waterproof because of constant dural anomalies. It may also be difficult or impossible when the dura is largely missing, obliging

to fix the edges of the dura or of the duroplasty to the paraspinal muscles.

- *Postoperatively*, knowing the frequency of temporary mictional difficulties, we recommend leaving in place a urinary catheter for 2–3 days.

## 2. OUTCOME

### 2.1 Long-term postoperative outcome of symptomatic patients

It is frequently said that preoperative deficits rarely regress postoperatively. This is one of the main arguments in favor of preventive surgery. This is clearly not our experience where only clubfoot, scoliosis and congenital deficits never regressed. Pain usually totally disappears. For the rest, the long-term results depend upon the type of lipoma [7].

*In lipomas of the filum*, results are excellent. In our series, 41% of the patients were cured, 12% improved, and 47% stabilized.

*In lipomas of the conus*, results tended to erode with time. The percentage of patients worse than before surgery increased from 9% at one year to 29% at more than 5 years. We noticed that the outcome actually depended upon the immediate postoperative results and that the better they were, the better it was. Most of those who clearly improved at one year remained improved. Conversely, many of those who apparently stabilized or suffered from transient postoperative complications deteriorated with time. Nevertheless, 70% of the patients took advantage of the surgery being either improved or stabilized.

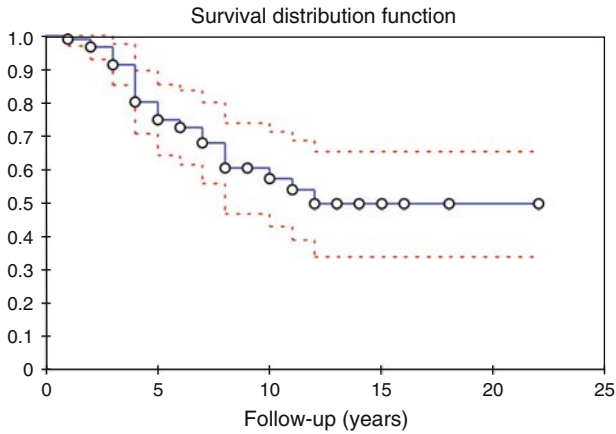
### 2.2 Long-term outcome of preventive surgery in asymptomatic patients

The outcome differs according to the type of lipoma [7].

*In lipomas of the filum*, results are as excellent as in symptomatic patients. In our series, only one patient slightly deteriorated with time.

*In lipomas of the conus*, results erode with time. This was clear in our series (Fig. 7) and has been confirmed by several others [2–4, 8]. Retethering is probably not the sole explanation. An underlying myelodysplasia could also play a great role in this decline, explaining why long-term deterioration is a problem in lipoma of the conus and in myelomeningocele but not in spinal cord tumor, arterio-venous malformation or lipoma of the filum, all situations where myelodysplasia is absent or minor. It could also explain the failure of some redo surgeries that do not avoid postoperative continuous deterioration. Patients with minor myelodysplasia and severe retethering have good chances to be improved or even cured surgically. Those, in contrast, with severe myelodysplasia, will probably not improve or even continue to worsen.

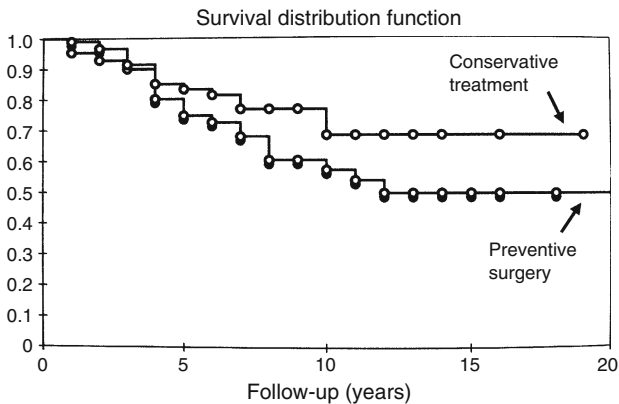




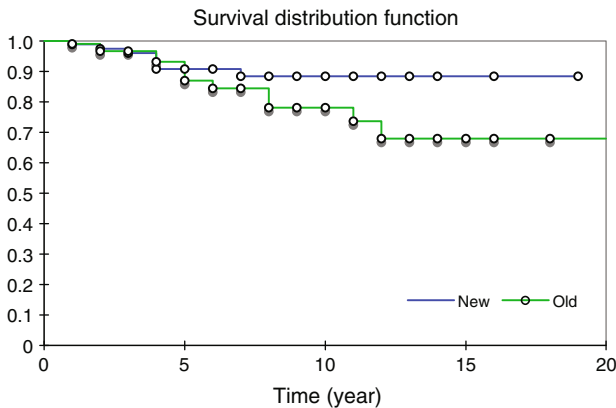
**Fig. 7.** Survival curve showing the deterioration-free survival following “preventive” surgery

### 2.3 Long-term outcome of conservative treatment in asymptomatic lipomas of the conus

The spontaneous long-term history of asymptomatic lipomas of the conus parallels the long-term outcome after “preventive” surgery [10]. In our series, 32% ( $n=33$ ) of the 106 asymptomatic patients treated conservatively developed symptoms in a 10 year follow-up. After surgery, 7 of these (51.5%) returned to normal (score=18), 2 improved (6%), 10 remained unchanged (30.3%), 2 were aggravated by surgery and 2 continued to deteriorate. At final follow-up, 82% of the 106 patients were strictly normal (score=18) and



**Fig. 8.** Survival curves comparing the deterioration-free survival in two groups of asymptomatic lipomas of the conus: group 1 retrospective, following preventive surgery; group 2 prospective, after conservative treatment. The difference is not statistically significant ( $p=0.8$ )



**Fig. 9.** Survival curves of patients following normal life (NEM score=16/17) in two groups of asymptomatic lipomas of the conus: group 1, retrospective following preventive surgery (green); group 2, prospective after conservative treatment and surgery at first symptom (blue). The difference is not statistically significant ( $p=0.26$ )

91% had minimal handicap (score=16/17), allowing normal life. These data were respectively 60% and 70% after “preventive” surgery but the difference is not statistically significant. The survival curves of both surgical retrospective and conservative prospective studies are presented in Fig. 8. At 10 years, the actuarial risk of deterioration, as determined by the Kaplan-Meier method, was 32% for the conservative treatment vs. 42% for the surgically treated patients, the difference not being significant.

## 2.4 Re-operations

Re-operations are always difficult and detethering often limited. Nevertheless, there is a consensus in favor of a first redo surgery in the case of spontaneous deterioration following a first surgery. Further re-operations are more difficult to indicate. Indeed, if a first reoperation is usually beneficial, the same cannot be said about further surgeries. In our series, a few children underwent 3 to 5 consecutive surgeries, all without profit. All of them are now more or less severely handicapped with self urinary catheterism, frequently severe constipation, sexual difficulties if adults, sensory-motor deficits with amyotrophy, walking difficulties and trophic complications in a few cases.

## HOW TO AVOID COMPLICATIONS

### 1. SURGICAL COMPLICATIONS

*In lipoma of the filum*, surgery is benign in nature and the patient discharged at day 3–5. The incidence of complication is quasi nil. However, it must be

reported that the only death among our 671 patients was for a filum surgery due to dramatically acute meningitis.

*In lipoma of the conus* surgery is much more risky.

- *Local complications* occur in an average 25% of the cases. The subcutaneous meningocele is the most frequent, often complicated by skin disunion, CSF leak and infection. Its treatment implies compressive bandages and repeated punctures to apply the skin to the underlying tissues. Reoperations to close the fistula were necessary in 3% of our patients.
- *Transient neurological complications* have been mentioned in the literature, but not their incidence. In our patients, urinary and motor deficits were the most common, noted in 7.5% of the cases. They generally cleared up in a few weeks as EMGs and urodynamic studies normalized. Pain rarely needed aggressive treatment.
- *Permanent neurological complications* occurred in 3.4% of our patients.
  - Sphincter-related complications were the most frequent. Urinary retention was much more common than incontinence.
  - Motor deficits were unilateral, distal and moderate in the vast majority of the cases. One patient, however, developed a dramatic paraplegia associated with an immediately postoperative encephalitis, pancreatic, kidney insufficiency and hemoglobinuria. The cause of this dramatic outcome is thought to have been the hemoglobinuria, itself supposed to be consecutive to a long-standing surgery. All the troubles regressed but the paraplegia.
  - Trophic ulcers are exceptional, probably consecutive to injury of the interface and the posterior columns.

## 2. PREVENTION OF POSTOPERATIVE COMPLICATIONS

A few rules or advices must be put forth: (1) to leave the largest possible volume of subcutaneous lipoma in order to prevent the subcutaneous meningocele, (2) to reduce the volume of the residual lipoma later on by lipo-aspiration, (3) to leave a few millimeters of lipoma over the interface in order to not injure the posterior columns, (4) to accept to not achieve a total untethering of the cord as soon as roots are unrecognizable among adhesences.

## CONCLUSIONS

Two conclusions must be drawn from our 35-year experience with lumbosacral lipomas. The first one is that any study on lipomas must distinguish lipo-

mas of the filum from those of the conus. These two lesions have almost nothing in common from both clinical and therapeutic aspects. To the simplicity and benignity of the first type, one must oppose the complexity and frequent severity of the second one. The second conclusion is that treatment of asymptomatic lipomas of the conus is no more acceptable, implying risks and not improving the natural prognosis of the pathology. "Preventive" surgery in this field remains a dream. The error has been to advocate this concept before knowing the natural history of lipomas and weighting operative advantages.

In addition to treatment recommendations, we should emphasize the fact that fixed cord does not mean tethered cord [4]. Following surgery, 100% of the patients develop new adherences tying up again the cord to the dura but, among them, only a few will deteriorate. The same reasoning should be held when a lipoma is diagnosed in absence of deficits. The presence of a cord attached to a lipoma and surrounding structures does not mean that the cord is necessarily tethered and at risk of dysfunction. We should also remind that tethering might not be the only factor causing neurological worsening since some patients aggravate ineluctably whatever has been done surgically. This certainly suggests that surgery does not ameliorate all of the relevant pathophysiological factors.

## References

- [1] Basset R (1950) The neurologic deficit associated with lipomas of the cauda equina. *Ann Surg* 131: 109-116
- [2] Chumas PD (2000) The role of surgery in asymptomatic lumbosacral spinal lipomas. *Br J Neurosurg* 14: 301-304
- [3] Colak A, Tahta K, Ozcan OE, Eryilmaz M (1992) Congenital lumbosacral lipomas presenting as a form of occult dysraphism. A report of 9 surgically treated cases. *Zentralbl Neurochir* 53: 15-19
- [4] Drake JM (2006) Occult tethered cord syndrome: not an indication for surgery. *J Neurosurg* (5 suppl Pediatrics) 104: 305-308
- [5] James CCM, Lassman LP (1981) *Spina bifida occulta. Orthopaedic, radiological and neurosurgical aspects.* Grune & Stratton, New York
- [6] Cretolle C, Zerah M, Jaubert F, Sarnacki S, Revillon Y, Lionnet S, Nihoul Fekete C (2006) New clinical and therapeutic perspectives in Currarino syndrome. *J Pediatr Surg* 41: 126-131
- [7] Pierre-Kahn A, Zerah M, Renier D, Cinalli G, Sainte-Rose C, Lelouche Tubiana A, Brunelle F, Le Merrer M, Giudicelli Y, Pichon J, Kleinknecht B, Nataf F (1997) Congenital lumbosacral lipomas. *Childs Nerv Syst* 13: 298-334; discussion 335

- [8] Steinbock P, Garton HJ, Gupta N (2006) Occult tethered cord syndrome: a survey of practice patterns. *J Neurosurg* 104: 309-313
- [9] Yamada S, Zinke DE, Sanders D (1981) Pathophysiology of “tethered cord syndrome”. *J Neurosurg* 54: 494-503
- [10] Zerah M, Roujeau T, Catala M, Pierre-Kahn A (2008) Spinal lipomas. In: Özek MM, Cinalli G, Maixner W (eds.) *Spina bifida. Management and outcome*. Springer-Verlag, Italia, pp 445-474



**Alain Pierre-Kahn**

Alain Pierre-Kahn is Professor in Neurosurgery at Hôpital Necker Enfants-Malades, Paris. He was Chairman of the Department of Pediatric Neurosurgery, Hôpital Necker Enfants-Malades, Paris, from 1993 to 2005. President of the French Society of Pediatric Neurosurgery (2002–2005), President of the International Society for Pediatric Neurosurgery (2001–2002), President of the 31st meeting of International Society for Pediatric Neurosurgery (Monaco 14/18 September 2003), Corresponding member of American Association of Neurological Surgeons (1991). Main subjects of interest: Dysraphism, Craniopharyngiomas, Ependymomas, Prenatal diagnosis, Intracranial cysts.

**Contact:** Alain Pierre-Kahn, Hôpital Necker-Enfants Malades, 149 rue de Sèvres,  
75743 Paris cedex 15, France  
E-mail: [alain.kahn@nck.aphp.fr](mailto:alain.kahn@nck.aphp.fr); [apk1@wanadoo.fr](mailto:apk1@wanadoo.fr)

---

# MANAGEMENT OF ENCEPHALOCELES

K. K. N. KALANGU

## INTRODUCTION

Cephalocele is a herniation of intracranial contents through a defect on the skull [4, 5] and according to the nature of the contents, they will be called meningoceles if they contain only meninges, encephaloceles when they contain brain and meningoencephaloceles when they contain both. If the herniated brain contents include a portion of the ventricle, it will be referred to as a ventriculocele. Cephalocele are also classified according to their location [4, 9], occipital (70–75%) and frontal (25–30%). The overall incidence of cephalocele is about 0.8–3.0 per 10,000 live births with encephaloceles being the most common form [3, 8].

Frontal encephaloceles are most common in Asians [5, 9] though they have been described in Africans as well [5, 9]. Those lesions that extend from the area of the orbit, nose or forehead are called sincipital encephaloceles (Table 1). Transphenoidal and basal encephaloceles are rather rare. The pathogenesis is not well known; however current theories tend to favor the fact that it is a primary disturbance in the separation of neural and surface ectoderm during the final part of neural tube formation [4].

## RATIONALE

*Clinical features.* Usually, the diagnosis is easily made at birth and consists of a fluctuant, round, translucent or opaque mass that protrudes from the skull. The mass may be covered completely by normal skin and may also pulsate. Prenatal diagnosis is made around 16 weeks of gestational age particularly for large lesion [7, 8].

Neurologic examination is most of the time normal at birth except in cases of severe developmental abnormalities of the brain. Particular attention should be paid to visual function in cases of huge occipital encephaloceles.

Special mention must be made for the frontoethmoidal or sincipital encephaloceles which present as a facial mass and they are characterized by a defect between the ethmoidal and frontal bones, at the foramen cecum, with the crista galli at the posterior aspect of the defect [2, 5, 9]. They are divided into:

1. Nasofrontal when they protrude at the root of the nose above the level of the nasal bones. The medial orbital walls are displaced laterally, and the ethmoidal bone is displaced posteroinferiorly.

---

*Keywords:* encephaloceles, pediatric neurosurgery, cranial malformations

**Table 1.** Classification of encephaloceles based on the location of the skull defect [9]

---

- I. Occipital encephalocele
  - II. Encephalocele of the cranial vault
    - A. Interfrontal
    - B. Anterior fontanelle
    - C. Interparietal
    - D. Posterior fontanelle
    - E. Temporal
  - III. Frontoethmoidal encephalocele
    - A. Nasofrontal
    - B. Nasoethmoidal
    - C. Naso-orbital
  - IV. Basal encephalocele
    - A. Transethmoidal
    - B. Sphenoethmoidal
    - C. Transsphenoidal
    - D. Frontosphenoidal/Spheno-orbital
- 

- 2. Nasoethmoidal when they protrude below the nasal bones uni- or bilaterally and in front of the nasal septum and cartilage at their attachment to the ethmoid nasal mucosa. The later forms the medial surface and the medial wall of the orbit forms the lateral surface. The nasal bone is displaced superiorly, and the nasal cartilage inferiorly along with the most anterior portion of the ethmoid at the foramen cecum.
- 3. Naso-orbital when they cause proptosis and displacement of the eye. Most of the time the protrusion occurs from the medial aspect of the orbit, through the lachrymal and ethmoidal plates, displacing the globe laterally, the swelling may be noticed beneath the nasal bone. Sometime, the lesion may protrude through a dysplastic orbital roof, displacing the eye inferiorly and expanding beneath the superior palpebral fissure.

Other lesions such as basal and transsphenoidal encephaloceles are not clinically visible. The first may cause upper-airway obstruction and the second may cause dysfunction of herniated optic pathways or endocrine malfunctions. These lesions need to be distinguished from nasal glioma, nasal polyp and dermoid cyst [4].

Other congenital abnormalities may be associated with encephaloceles and these are dextrocardia, pulmonary hypoplasia and laryngomalacia, renal agenesis, and myelomeningocele. Anterior encephaloceles are sometimes associated with arhinencephaly and anophthalmia [4, 8].



## DECISION-MAKING

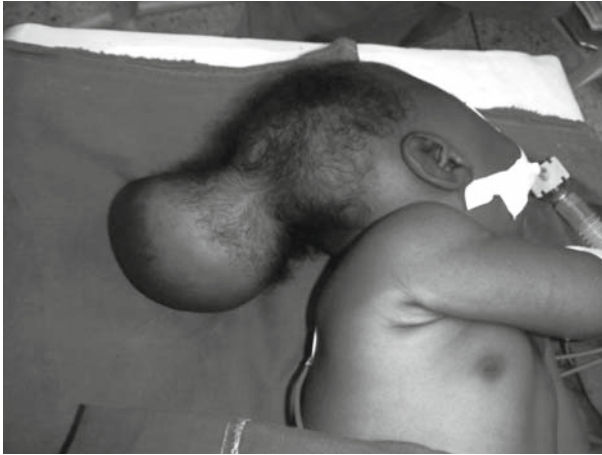- Neurologic examination is of primary importance for diagnosis.
- Magnetic Resonance Imaging (MRI) is the investigation of choice if it is available though ultrasound scan may be useful for occipital encephaloceles. The aim is to visualize the amount of brain structures contained in the sac [4]. In case of fronto-ethmoidal encephaloceles, further bone study with a CTscan may be required to show better the bony defects [5–7]. Cerebral angiography is at times necessary to exclude major blood vessels which may supply the brain contained into the sac.
- The basic principles are the same for both types of encephaloceles: removal of unnecessary herniated contents into the sac, watertight closure of the dura, repair of bone defect, closure of skin in order to achieve good cover and acceptable cosmetic result. This is necessary to avoid damage to the sac with possible infection and to prevent further herniation of the intracranial contents [2–5, 10].

## SURGERY

Most of our children are operated a week or two after birth to allow stabilization of child.

*Closure of occipital encephalocele* is done with the child in prone or lateral position. We perform a transverse elliptical skin incision which will provide adequate skin closure. The pericranium is identified and dissected from the herniated structures. The sac is opened from the top to empty the fluid content and to allow inspection of the content. Amputation of the sac is carried out together with the encephalocele. In case of huge bone defect, this can be repaired with a piece of adjacent bone. During the skin closure, redundant skin is removed being careful to leave enough skin to avoid any tension on the incision. No drain is put in place and antibiotics are given for 48h. Particular attention must be paid to the blood loss from the skin, from major sinuses around the torcula, to vital brain structures like brain stem and air embolism. Usually, most of the herniated brain tissue is not functional [4, 5]. However, the viability of the herniated brain tissue may be examined preoperatively with neurophysiological studies such as visual evoked potentials [1]. Post operative monitoring is of paramount importance as 60 to 70% of children develop hydrocephalus. In some babies in whom ventricles were already large, hydrocephalus was treated first before excision of encephaloceles or both operations were performed in the same sitting. We prefer the later approach (Figs. 1, 2).

*Frontoethmoidal encephaloceles* can be operated electively and in the presence of hydrocephalus, the later will be treated in the same sitting [2–5, 10]. Basic principles apply here too with more emphasis on reconstruction of the external bony deformities leading to hyperthelormism. The contents into the dural sac consist of glial tissue and can be resected [2–7].

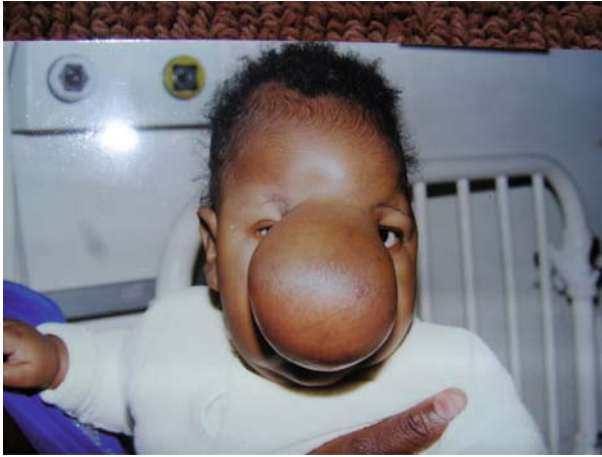

**Fig. 1.** Newborn with occipital encephalocele

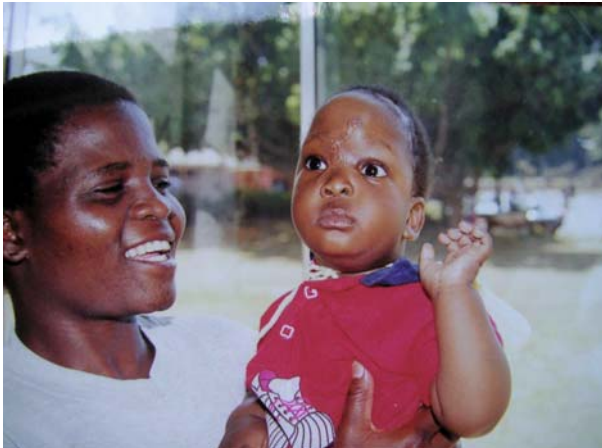

**Fig. 2.** Child a month after the operation

Patient is placed in a supine position with the head in a neutral position but elevated by 30°. The skin is infiltrated with 0.5% lidocaine with 1/200,000 parts epinephrine. A bicoronal skin incision is performed and the flap is reflected anteriorly. A standard bifrontal craniotomy for exposure of the floor of the frontal fossa is carried out. Repair of the frontal encephalocele is done intradurally and this part of the operation ends with closure of the dural defect. The defect in the frontal floor, often in the region of the cribriform plate is closed with a bone harvested from the bone flap [2–7]. In the presence of hypertelorism [6, 7], the external mass is excised followed by a craniofacial reconstruction (Figs. 3, 4).



**Fig. 3.** Frontoethmoidal encephalocele in a three months old child



**Fig. 4.** Child seen few months after the operation

The bone flap is replaced and the skin is closed in a routine manner. Antibiotherapy is prescribed for a minimum of 48 h.

## CONCLUSIONS

Children with anterior defects and encephaloceles have a much better prognosis [5, 8] because of minimal amount of herniated brain. The majority of these patients will have a normal life if no other congenital defects are present.

Posterior encephaloceles have a much poorer outcome. Only 20–30% of children will have a normal intellect, while a 50% of them will also have hydrocephalus and associated complications [4, 5, 8].

## References

- [1] Engel R, Buchan GC (1974) Occipital encephaloceles with and without visual evoked potentials. *Arch Neurol* 30: 314-318
- [2] Eppley BL, Hathaway RR, Kalsbeck JE, Rosenthal M (1999) Craniofacial correction of giant frontoethmoidal encephalomeningocele. *J Craniofac Surg* 10(2): 111-116
- [3] Holm C, Thu M, Hans A, Martina M, Silvia GS, Moritz S, Wolfgang M (2008) Extracranial correction of frontoethmoidal meningoencephaloceles: feasibility and outcome in 52 consecutive cases. *Plast Reconstruc Surg* 121(6): 386e-395e
- [4] Hoving EW (2000) Nasal encephaloceles. *Childs Nerv Syst* 16(10-11): 702-706
- [5] Kalangu K, Levy LF, Makarawo S, Nkrumah FK (1990) Anterior encephalocele – our experience in Harare, Zimbabwe, after the introduction of CAT Scanning. *Centr Afr J Med* 36(9): 213-218
- [6] Lello GE, Sparrow OC, Gopal R (1999) Management of fronto ethmoidal (sincipital) encephalocele. *J Craniofac Surg* 10(2): 135-139
- [7] Lello GE, Sparrow OC, Gopal R (1989) The surgical correction of fronto-ethmoidal meningo encephaloceles. *J Cranio Maxillofac Surg* 17(7): 293-298
- [8] Lo BW, Kulkarni AV, Rutka JT, Jea A, Drake JM, et al. (2008) Clinical predictors of developmental outcome in patients with cephaloceles. *J Neurosurg Pediatrics* 2(4): 254-257
- [9] Suwanwela C (1972) Geographical distribution of frontoethmoidal encephalomeningocele. *Br J Prev Soc Med* 26: 193-198
- [10] Wolf B, Kalangu K (1993) Early repair of frontoethmoidal meningoencephalocele in Bulawayo, Zimbabwe. *Trop Geogr Med* 45(4): 182-183



### **Kazadi K. N. Kalangu**

Kazadi K. N. Kalangu is Professor of Neurosurgery and the Head of the Department at the University of Zimbabwe – College of Health Sciences.

He was born in Lubumbashi, Democratic Republic of Congo and completed his medical education in the academic year 1978 at Padua University in Italy.

After his internship, he joined the Department of General Surgery in October 1979 for 1 year (Free University of Brussels, Belgium) under Professor Bremer, then the Department of Neurology (University of Liège, Belgium) under Professor Franck. These are the prerequisites for training in Neurosurgery.

His neurosurgical training was at the University of Liège under Professor Joël Bonnal until 1985. He then worked as a voluntary assistant in the same University before coming to Harare, Zimbabwe in 1987.

He introduced formal academic course-structured training program in Neurosurgery and has had the privilege to host also trainees from USA, Canada, Europe and other African countries.

He was until 2008 the general secretary of PAANS (Pan African Association of Neurological Sciences) and he is currently the president of the newly created Association of Neurosurgical Societies of Africa (ANSA). He has also served in various committee and

faculty of the WFNS. His dream is to be able to provide neurosurgeons for all African countries.

Professor Kalangu is married and has two daughters and a son.

His hobbies include music, soccer, golf, meditation, reading, travelling, anthropology and motivational psychology.

**Contact:** Kazadi K. N. Kalangu, Department of Neurosurgery, University of Zimbabwe, College of Health Sciences, P.O. Box 178A, Harare, Zimbabwe  
E-mail: kazkal2003@hotmail.com; kalangu@mweb.co.zw

---

# EPILEPSY SURGERY IN CHILDREN

O. DELALANDE

## INTRODUCTION

Epilepsy surgery is a functional surgery; the boundaries of the epileptogenic zone and the volume of resection are essentially determined in children by the extra- and intracranial electroencephalographic findings. The operative results are strongly correlated with a rigorous patient selection.

## RATIONALE

The particularity of epilepsy surgery in children lies in the pivotal role of cerebral maturation. There clearly exist interferences between cognitive functions and the child's apprenticeship on one side and epilepsy, which manifests itself as repetitive clinical seizures or as an electrical status, on the other side. It has been now well established that an epilepsy which includes the cerebral regions representing language function will lead either to retardation or absence of language development in an early onset of the epilepsy, to a deterioration of language when the epilepsy occurs later in childhood, i.e. in the Landau-Kleffner syndrome or to a language development in the contralateral symmetrical cerebral region (plasticity or equipotentiality) [4, 8]. One may suppose that similar interferences exist as well for other cognitive functions which have yet to be studied. The preliminary results on the outcome of a population of 70 children following hemispherotomy demonstrate that the capacity of socialisation and the development of superior cerebral functions are inversely correlated with the child's age at the time of surgery [2]. Time and the child's age are the principal determinants for a surgical decision-making.

## DECISION-MAKING

The prerequisite for any surgical consideration is a medical approach in order to localize the single or multiple epileptic foci and to identify the cause of the seizure disorder.

---

*Keywords:* epilepsy, childhood, epilepsy surgery

## 1. LOCALIZING THE EPILEPTIC FOCUS

The epileptic focus (epileptogenic zone) is defined by the cortical volume involved in the initial seizure discharge (generation) and the zone of immediate propagation [6]. Its identification relies essentially on the long-term scalp video-EEG evaluation (between 2 and 10 days) which enables electro-clinical/topographical correlations in the course of the spatio-temporal propagation of the seizures.

In order to obtain precise localizing value from a surgical point of view, the scalp electrodes have to be placed according to the international 10/20 system [5]. The recording should cover at least a 24-hour period because sleep is an activator of seizures in childhood. The presence of at least one of the parents during the recording is indispensable because their experience facilitates to signalize the onset of the habitual seizures.

In the case of a polymorph epilepsy, the child has to be recorded for the time period necessary to identify all the types of seizures. The use of seizure detection software is desirable in order to identify seizures and subclinical discharges which take place unnoticed, particularly during night sleep. In the cases of questionable seizures, it is mandatory to visually analyze them in the presence of the parents.

In certain forms of temporal lobe seizures, the use of an intracranial electrode, placed through the foramen ovale in the hippocampal formation [9], permits to verify the implication of the middle part of the hippocampus at the onset or in the course of the seizures.

## 2. IN SEARCH OF AN ETIOLOGY

The etiologic assessment relies on the medical history taking, the neurological and the dermatological examinations, the CT scan and particularly the cerebral MRI of the child [1]. In order to obtain high quality imaging, general anesthesia is indispensable in the very young and uncooperative child. The abnormal neuroimaging findings can be clearly visible as in the case of a hemimegalencephaly, or more discrete, indicating a thickened gyrus or an abnormal cortical white matter organization. The CT scan is useful in order to identify abnormal calcifications as particularly in Sturge-Weber disease and tuberous sclerosis. The different etiologies will be described in more detail according to the age.

## SURGERY

It is useful to distinguish curative from palliative epilepsy surgery.

Two different types of surgery have been proposed, depending on the localization and the extent of the epileptogenic zone: anatomical resection and disconnection which may involve up to a complete hemisphere (hemispherotomy).



## 1. CEREBRAL RESECTION

Cerebral resection is limited to the epileptogenic focus, i.e., the initial starting point of the seizures and the regions of immediate propagation.

*Simple resections* can be performed if the semiology of the seizures, the EEG and the neuroimaging findings are anatomically corresponding, if the focus is situated outside of functionally eloquent regions and if the lesion has anatomically well-defined boundaries. This is the case with seizures of a temporo-mesial and anterior temporal origin, as well as in more extended temporal seizures of the non-dominant hemisphere. This is likewise the case in children with a lobar or infra-hemispheric STURGE-WEBER angiomatosis, in which the anatomical limits of the lesion and the epileptogenic zone are superimposable.

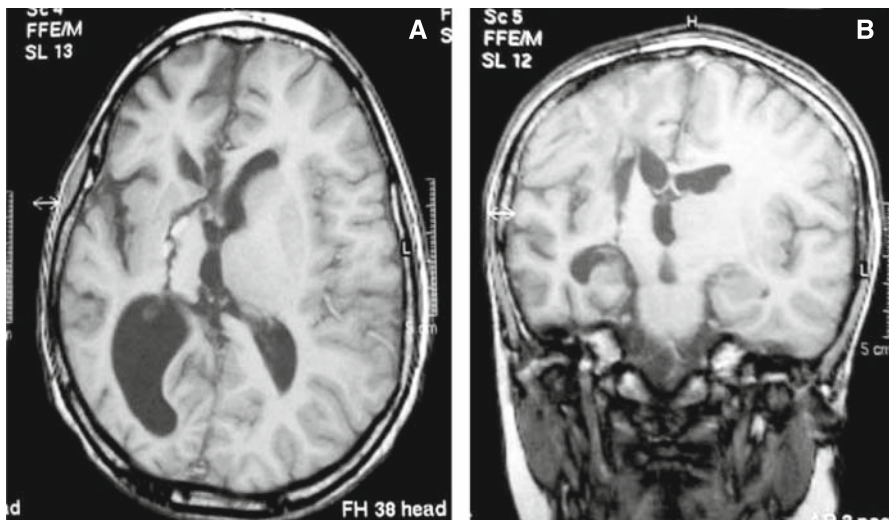
*Resections associated with an intracranial exploration* are indispensable when there exists an anatomical discordance between the different preoperative examinations and/or if the focus is located in or nearby functionally eloquent regions, thus implicating a potential postoperative deficit. This situation concerns most of the patients in infancy and childhood because of the frequency of extra-temporal lesional epilepsies and of cryptogenic epilepsies as compared to adult population. The key investigation is the recording of the seizures with depth electrodes, with two objectives: first, to determine precisely the epileptogenic zone, and secondly, to create a functional mapping which allows identification of the sensorimotor and language regions in order to protect them during surgery. Two methods for electrode placement are possible: the use of depth electrodes by stereotactic means or subdurally implanted grids combined with depth electrodes through a craniotomy.

The choice of either one or the other method is a matter of “school” but depends as well on the patient’s age and the location of the focus.

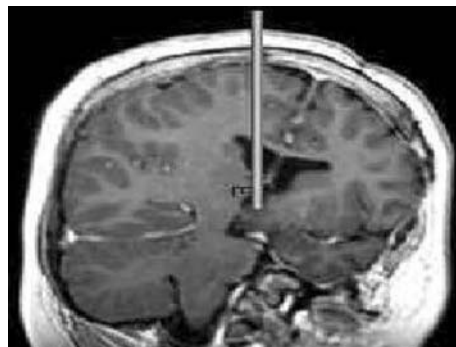The intracranial recording of the seizures and the mapping of the functionally eloquent regions allow a precise delineation of the epileptogenic zone of which depends surgical feasibility and avoidance of postoperative deficits.

## 2. DISCONNECTIVE SURGERY

In functional hemispherectomy and hemispherotomy [8] a whole cerebral hemisphere is being deafferented, whereas its vascular supply is being preserved. These techniques tend to replace the classical hemispheric resection (hemispherectomy), which has the disadvantage of leaving a large dead space, therefore giving rise to long-term complications. This type of surgery is indicated when the epilepsy involves a whole cerebral hemisphere which is not any longer functional. The preexisting deficit (hemiplegia, hemianopia) is only slightly or not at all modified by this procedure and a preexisting ability to walk is preserved. The difficulty lies in being sure about the strictly unilateral character of the seizures and in the functional integrity of the contralat-



**Fig. 1.** Hemispherotomy, post-operative MRI scan (A, axial view; B, coronal view) in a case of Rasmussen encephalitis



**Fig. 2.** Hypothalamic hamartoma, trajectory of the endoscope for disconnection

eral hemisphere. A more localized disconnection is possible in order either to prevent a central functional region or to preserve a cerebral region not implicated by the epilepsy, which however remains extensive.

### 3. SURGERY OF HYPOTHALAMIC HAMARTOMAS

Hypothalamic hamartomas are congenital neuronal malformations localized in the diencephalic region (hypothalamus and mammillary bodies). They are responsible for a pharmaco-resistant epilepsy with polymorph seizures, including a gelastic component, with a variable degree of mental retardation

and behavioral disorders. They are frequently associated with precocious puberty. The surgical treatment of these lesions which are located in a region of considerable risk, at proximity to the brainstem, has become possible only recently, due to an improvement in surgical techniques. The method we have proposed consists in disconnecting the hamartoma either by conventional microsurgical techniques or by endoscopy-assisted surgery [9].

#### 4. THE SO-CALLED PALLIATIVE SURGERY

The objective of this type of surgery is to limit the propagation of the seizure discharges by disrupting certain pathways.

*Callosotomy* consists of sectioning the anterior two-thirds or the entire callosal body in its longitudinal axis, thereby interrupting the principal pathways of the inter-hemispheric propagation. Presently the indications are multifocal or generalized epilepsies, as in the Lennox-Gastaut syndrome or intractable infantile spasms, and the goal is the prevention of generalized seizures leading to falls and injuries. The procedure leads neither to a neuropsychological nor to a language deterioration when performed before the age of 10 years.

*Subpial transection* consists of a series of parallel transections of the short cortico-cortical fibers, considered to be a support of the epileptogenicity, whereas the pial vascularization and the long vertical cortical-subcortical fibers are being preserved. This technique, only occasionally applied, is indicated in epilepsies involving highly functional regions (sensorimotor, language) and results in a suppression of the epileptogenicity while preserving their functional integrity. Encouraging results have been reported in the Landau-Kleffner syndrome. The subpial transection may be performed isolated or in combination with a cerebral resection. It is, however, not indicated in cases with cortical dysplasia.

#### HOW TO AVOID COMPLICATIONS

It is difficult to systematize the contraindications. Evolving diseases are principally to be excluded, with the exception of Rasmussen encephalitis, which represents a clear indication for hemispherotomy, when one hemisphere is involved. It is advisable to be more reluctant in cryptogenic epilepsies, since the surgical failure rate is higher when compared with lesional epilepsies. Multifocal epilepsy is generally incompatible with resective surgical techniques, but in certain circumstances (tuberous sclerosis), resection of the most active focus may lead to an improvement.

#### CONCLUSIONS

Epilepsy surgery for children needs to be performed within the frame of a multidisciplinary (pediatric) team.

## References

- [1] Adamsbaum C, Robain O, Cohen PA, Delalande O, Fohlen M, Kalifa G (1998) Focal cortical dysplasia and hemimegalencephaly: histological and neuro-imaging correlations. *Pediatr Radiol* 28: 583-590
- [2] Bulteau C, Delalande O, Fohlen M, Jalin C, Pinard J-M, Castelli N, Delatollas G (2002) Comportement et cognition chez l'enfant traité par hémisphérotomie. *ANAE Approach Neuropsychol Apprentiss Enfant* 68: 204-206
- [3] Delalande O, Bulteau C, Dellatolas G, Fohlen M, Jalin C, Buret V, Viguier D, Dorfmueller G, Jambaqué I (2007) Vertical parasagittal hemispherotomy: surgical procedures and clinical long-term outcomes in a population of 83 children. *Neurosurgery* 60(2 Suppl 1): 19-32
- [4] Hertz-Pannier L, Chiron C, Jambaque I, Renaux-Kieffer V, Van de Moortele PF, Delalande O, Fohlen M, Brunelle F, Le Bihan D (2002) Late plasticity for language in a child's non-dominant hemisphere: a pre- and post-surgery fMRI study. *Brain* 125: 361-372
- [5] Jasper HH (1958) Report of the Committee on methods of clinical examination in electroencephalography. *Electroencephalogr Clin Neurophysiol* 10: 370
- [6] Penfield W, Jasper H (1954) *Epilepsy and the functional anatomy of the human brain*. Little, Brown & Co, Boston
- [7] Procaccini E, Dorfmueller G, Fohlen M, Bulteau C, Delalande O (2006) Surgical management of hypothalamic hamartomas with epilepsy: the stereoscopic approach. *Neurosurgery* 59(4 Suppl 2): 336-344
- [8] Vicari S, Albertoni A, Chilosi AM, Cipriani P, Cioni G, Bates E (2000) Plasticity and reorganization during development in children with early brain injury. *Cortex* 36: 31-46
- [9] Wieser HG, Siegel AM (1991) Analysis of foramen ovale electrode-recorded seizures and correlation with outcome following amygdalohippocampectomy. *Epilepsia* 32: 838-850



**Olivier Delalande**

Olivier Delalande is head of the Paediatric Neurosurgery Unit in Foundation Rothschild in Paris. Born in 1949, Olivier Delalande came to neurosurgery in 1977. He was trained by Prof. Gerard Guiot and Prof. Jacques Rougerie in Hospital Foch in Suresnes and Jean Talairach in hospital Sainte-Anne in Paris. He started paediatric neurosurgery in 1983 and epilepsy surgery in children in 1987. In 1995 he was called to create the paediatric neurosurgery unit in Fondation Rothschild in Paris. He developed there the main centre in France devoted to infants and children epilepsy surgery, with all the possibilities of intracranial recording and disconnective surgery as hemispherotomy (which he created in 1989) and endoscopic surgery of hypothalamic hamartoma. Occasionally playing trumpet, he is also president and founder of a non profit association which promotes and helps the raising of paediatric neurosurgery in developing countries.

**Contact:** Olivier Delalande, Paediatric Neurosurgery Unit, Fondation Rothschild,  
25 rue Manin, 75019 Paris, France  
E-mail: [odelalande@fo-rothschild.fr](mailto:odelalande@fo-rothschild.fr)

**SPINE**

---

# MANAGEMENT OF SPINE TRAUMAS AND SPINAL CORD INJURY

R. ROBERT

## INTRODUCTION

The treatment of spinal cord injuries remains a controversial issue. It is designed to avoid any displacement that could induce or accentuate spinal cord and nerve root lesions. Persistent dogmas divide the supporters of a “no touch” (no surgery) approach and an “all surgery” approach without the use of orthopaedic or functional methods. Common sense should allow a more rational approach taking into account the instability of the lesions and their risk of progression, and neurological lesions encouraging early nerve decompression to ensure optimal conditions for recovery.

Without going as far back as Hippocrates, who described extremely brutal techniques to treat spinal cord injuries, orthopaedic and surgical techniques were developed during the 20th century. In the first half of the 20th century, Böhler [4] described the treatment of spinal cord injury patients with the available methods, giving birth to the concept of rational and specific management: early reduction of lesions essentially by orthopaedic procedures, plaster immobilization of the reduction obtained, and early functional rehabilitation. Little has changed since then apart from improvement of techniques and the possibility of more audacious surgery in parallel with progress in anaesthesia and intensive care.

Spinal fusion techniques were then developed. Wilson was the first to propose transverse screw fixation of spinal processes. This was a simple but unreliable method because of the fragility of the anchor sites and was abandoned in favour of more appropriate techniques. Harrington and then Lucke used rods initially for distraction and then for compression. The rigid nature of these rods, not allowing adaptation to spinal curvatures gave rise to new concepts. In the 1960s, Roy Camille [14] and his teacher Judet, then Saillant developed the ingenious approach of transpedicular screw fixation of the vertebrae based on anatomical and biomechanical studies emphasizing the solidity of this spinal sector. Screws are maintained by plates, but this technique has certain limitations: thoracic pedicles are fragile and narrow, difficulty of transpedicular screw fixation in the axis of the structure due to convergence of the pedicles. However, its advantage is that it is also adapted to the cervical spine: bipedicular screw fixation can be performed at C2, while articular

---

*Keywords:* spine traumas, spinal cord injury, spinal cord

screws are used for the lower cervical vertebrae. In parallel, Cotrel and Dubousset [5] developed a new concept of clamp fixation (interlaminar, pediculotransverse) adapted to all spinal levels, with implants attached to rods that can be perfectly adapted to the physiological curvatures of the spine. Other approaches included the Hartshill rectangle developed by Dove which requires perilaminar wiring, consequently involving dangerous intrusions into the spinal canal, especially in the thoracic spine.

The main advances have subsequently concerned the need for recalibration, hence the strategic choices of anterior or posterior surgical approaches guided by various classifications. The timing of surgery in spinal cord injury patients is also a highly controversial subject, in which the supporters of early surgery justify their approach on research similar to that performed in head injury patients. Finally, so-called minimally invasive techniques are designed to replace conventional techniques.

## **RATIONALE**

### **1. BIOMECHANICS**

Apart from the first two cervical vertebrae, the discovertebral complex is composed of the following two components: the intervertebral disk and the adjacent vertebral endplates. This complex is mobile in all directions. Movement guides are required to ensure certain axes of displacement, corresponding to the joints that are specifically oriented according to the spinal level:

- in a frontal plane but about 30° oblique to the sagittal plane in the cervical spine, they allow very ample flexion, extension, lateral inclination and rotation movements, and most of these movements are combined;
- in a strictly frontal plane in the thoracic spine, they allow only very limited movements designed to optimize thoracic volume;
- in a roughly sagittal plane in the lumbar spine, they allow large flexion-extension movements and are subjected to severe constraints on rotation.

Brakes to movement are also required: the discovertebral complex and ligaments that are barely visible by radiological techniques.

The behaviour of vertebrae in response to trauma differs according to the level: the highly mobile and slender nature of the cervical spine is achieved at the expense of its stability which is essentially ligamentous; the thoracic spine is fixed and consequently subject to simple compression fractures (imposed by kyphosis) in a context of minor trauma or dislocations with marked displacement in a context of severe trauma. Instability of the thoracic spine is



essentially related to bone structures. The lumbar spine supports the weight of the body; it is strong due to its bone structure and mobile as a result of its ligamentous component; it presents a mixed, osseous and ligamentous instability.

## 2. CLASSIFICATIONS

Assessment of the severity of vertebral lesions is based on identification of potential instability. Clinical examination is not contributive and this assessment is essentially based on radiology. Many classifications have been proposed for each spinal segment. Only the most widely accepted classifications will be presented and discussed.

### 2.1 Cervical spine

The cervical spine is classically divided into the upper cervical spine (occiput-C1–C2) and lower cervical spine from C3 to C7. Cervical vertebrae are small and very mobile. Bone lesions only draw attention to the presence of a fracture, but the stability of the lesions depends on the ligaments that are not visible on X-rays.

#### *Upper cervical spine*

- *Craniovertebral junction*: it comprises atlanto-occipital dislocations and occipital condyle fractures. Several classifications have been proposed [3, 18]. The essential points are as follows: nondisplaced occipital condyle fractures are considered to be stable. Other fractures are unstable and can be considered to be atlanto-occipital dislocations. Assessment of the displacement of atlanto-occipital dislocations (Wholey 1958) is based on the distance between the basion and the apex of the odontoid process, which must not exceed 12 mm. A more precise assessment is based on the distance between the vertical line through the posterior surface of the odontoid and the basion, which must be between 4 and 12 mm. When this distance is less than 4 mm, it indicates anterior displacement, and when it is more than 12 mm, it indicates posterior displacement.
- *Atlas fractures*: they were well described by Jefferson [8]. Instability is assessed by two criteria: correct positioning of the lateral masses of C1 over the C2 facets, and integrity of the transverse ligament assessed by the distance between the posterior margin of the anterior arch of the atlas and the odontoid process, which must not exceed 3 mm in adults (5 mm in children). 50% overhang of one or both lateral masses indicates instability.
- *Rotary atlantoaxial dislocation*: this injury usually occurs in children and is accompanied by persistent torticollis. X-rays are difficult to interpret and this lesion is very often overdiagnosed.

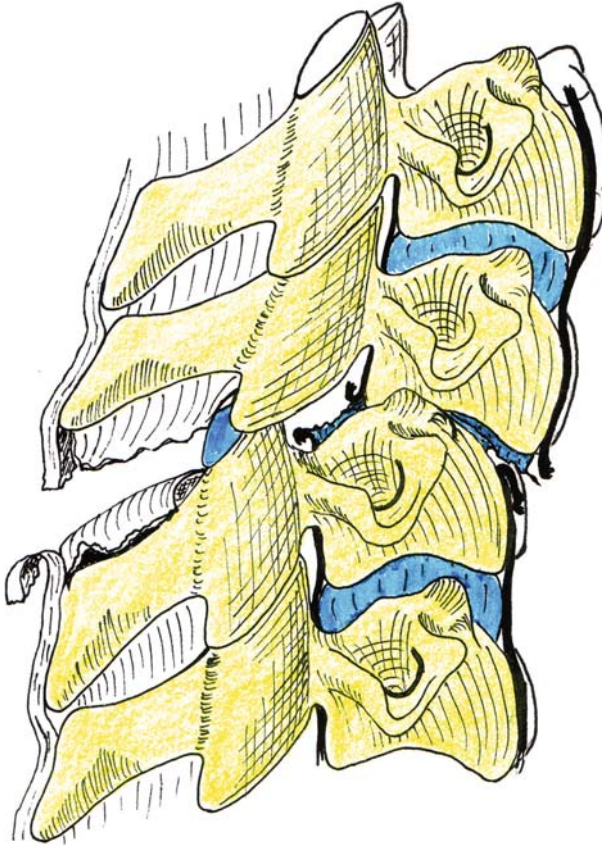
- *Odontoid fractures*: The classical classification proposed by Anderson and D'Alonzo [2] distinguishes type 1: fracture of the tip of the dens, type 2: fracture of the body of the dens, and type 3: fracture of the base of the dens. This classification is similar to that formerly proposed by De Mourgues and Fischer and is considered to have a prognostic value, as type 2 fractures (fractures of the body of the dens) are characterized by a high risk of non-union. Roy Camille [15] proposed a much more realistic classification assessing the direction of the fracture line: anterior oblique, posterior oblique and horizontal, which is particularly unstable. It has been demonstrated that the level of the fracture line is not predictive of the degree of instability or the risk of non-union, the vascular factor is not involved, as all segments of the odontoid process have a good blood supply. Two situations are observed in clinical practice:
  - displacement and the fracture is unstable,
  - no displacement and very cautious dynamic lateral views by fluoroscopy will determine the presence of pathological mobility of a nondisplaced fracture.
- *Bilateral fractures of C2 (Hangman's fractures)*: One of the most widely used classifications is that proposed by Francis, Fielding and Hawkins [7]. It takes into account the direction of the fracture line and displacement. According to this classification, instability at this level depends on the presence or absence of C2–C3 intervertebral disc herniation. Dynamic views are also very valuable to assess nondisplaced fractures.

#### *Lower cervical spine*

Allen [1] proposed a classification of lower cervical spine fractures with the frequencies of the various types of fractures observed:

- A: compression injuries (33% of cases): type I: anterior compression, type II: comminuted fracture, type III: teardrop fracture, the most frequent (Fig. 1).
- B: flexion-extension-distraction injuries (28%): type I: moderate sprain, type II: severe sprain (14%) defined by Saillant by the triad: disc kyphosis, exposure of facet joints and fanning of interspinous distance, type III: bilateral fracture-dislocations with a high risk neurological damage (Fig. 2).
- C: rotation injuries (39%): type I: unifacet fracture, type II: fracture-separation of the articular pillar, type III: unilateral dislocation, wrongly called “sub-dislocation” by Roy Camille, as they are true unilateral dislocations representing a major risk for nerve roots.

This classification takes the mechanism into account, but the mechanism of a lesion is very difficult to determine when so many pathogenic movements are involved.



**Fig. 1.** Ligamentous instability of the caudal cervical spine

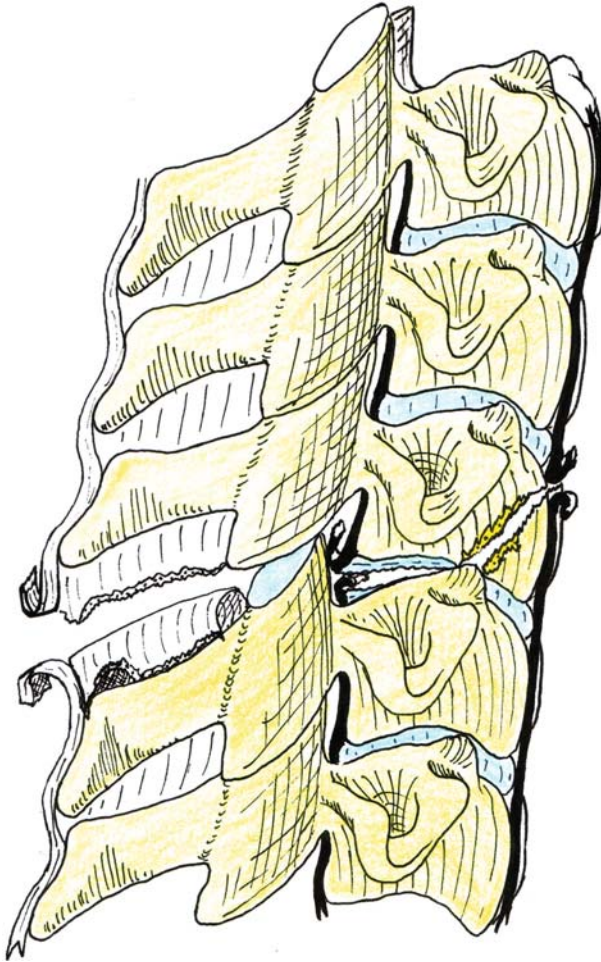
## 2.2 Thoracolumbar spine

The thoracolumbar Injury Classification and Severity Score established by the Spine Trauma Study Groups adds the neurological status and the appreciation of lesions concerning the posterior ligamentous complex. The Load Sharing Classification is based on mechanical experiences in fresh bovines and is near from the AO classification that we will describe [19, 20]. Two main classifications can be used:

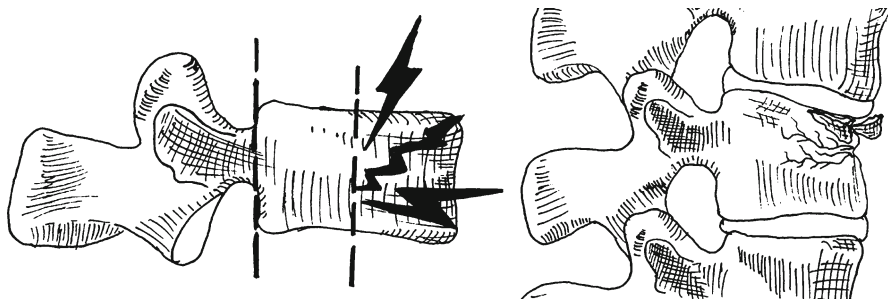
- *The Denis classification* is based on the classical three-column concept defined as [6]:
  - anterior column formed by the anterior half of the vertebral bodies and intervertebral discs including the anterior longitudinal ligament

- middle column comprising the posterior half of the vertebral bodies and intervertebral discs and the posterior longitudinal ligament and the vertebral insertions of the pedicles
- posterior column comprising all other structures as far as the spinous processes.

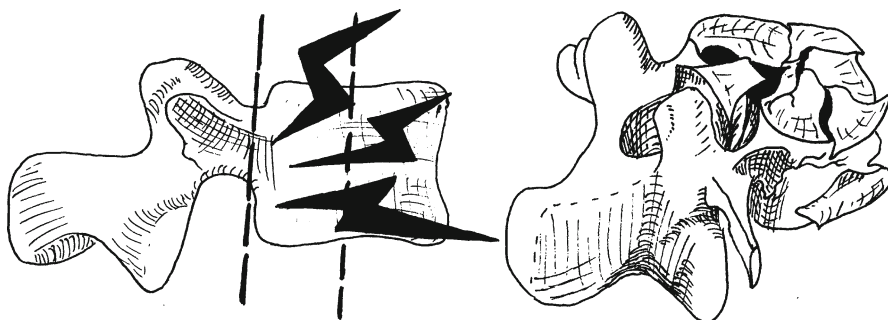
Note that the middle column comprises Rieuneau's vertebral wall or Roy Camille's posterior wall including the posterior longitudinal ligament and constituting the anterior limit of the spinal canal.



**Fig. 2.** Teardrop fracture in caudal cervical spine. Note the ligamentous destruction which leads to instability



**Fig. 3.** Compression fracture in the thoraco-lumbar spine: the ventral column is fractured (Denis classification)

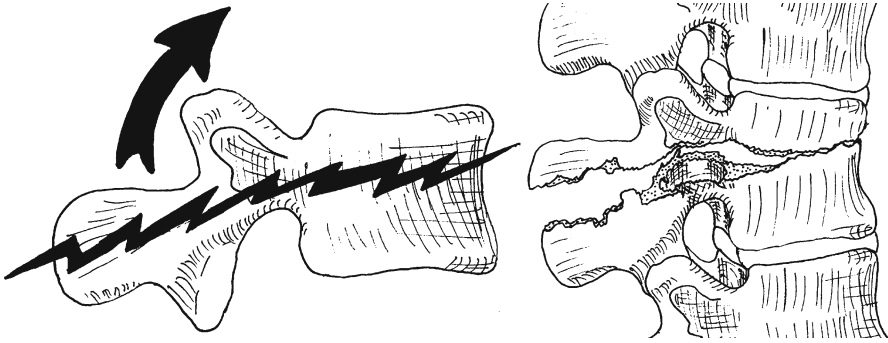


**Fig. 4.** Burst fracture: Both ventral and middle columns are fractured (Denis classification)

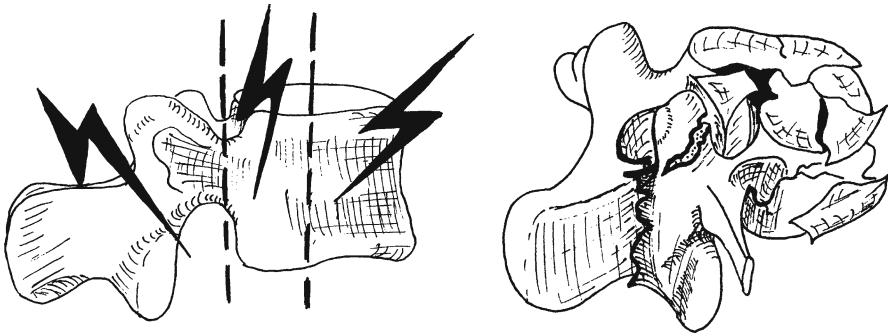
Four types of fractures are described:

- Isolated lesion of the anterior column = compression (wedge) fracture (Fig. 3)
- Simultaneous lesion of anterior and middle columns = burst fracture (Fig. 4)
- Simultaneous lesion of middle and posterior columns = seat belt fracture (Fig. 5)
- Simultaneous lesion of all three columns = dislocation (Fig. 6).

These main lesions have been further subdivided into complex subgroups. As for all classifications, these subgroups are useful for case reviews and for detailed analysis of the lesions, but, in practice, a good classification must be simple and sufficient to assess the potential instability of a lesion. The Denis classification, that we have used since its creation, combines these qualities. Compression fractures are stable and do not induce neurological lesions. Burst fractures are potentially unstable and must be considered to be unstable in the presence of neurological signs related to interpedicular migration of the vertebral body. Seat belt fractures are sometimes unstable depending on the



**Fig. 5.** Seat belt fracture: Both middle and dorsal columns are fractured (Denis classification)



**Fig. 6.** Dislocation fracture: The three columns are fractured (Denis classification)

displacement of the posterior arch, but in practice they only exceptionally cause neurological lesions. Dislocations are fracture-dislocations which, by definition, are always unstable and almost always associated with neurological lesions.

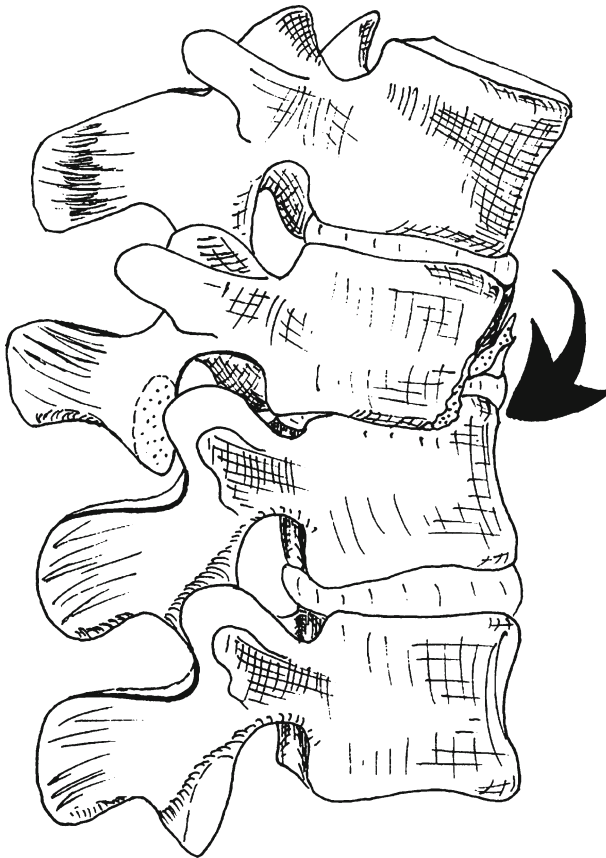
• *The AO classification* (Arbeitsgemeinschaft für Osteosynthesefragen) reported by Magerl [10] is similar to the previous classification and is increasingly used throughout the world. Briefly, it defines 3 types of fractures (A, B, C), each comprising three groups (1, 2, 3) each further subdivided into three subgroups (1, 2 or 3). Each type corresponds to a main mechanism of injury and each group and subgroup corresponds to an anatomical and morphological lesion with an increasing degree of severity.

- Type A: vertebral body compression, comprising A1 (impaction), A2 (split) and A3 (burst) fractures.
- Type B: anterior and posterior element injury with distraction, especially disc and ligamentous lesions. Type B1: Posterior disruption

predominantly ligamentous, B2: Posterior disruption predominantly osseous, B3: Anterior disruption through the disc.

- Type C: Anterior and posterior element injury with rotation, with dislocation of the three columns in the most severe forms (Fig. 7).

• These classifications are *complementary*. The AO classification is more complete but also more complex. In particular, it describes the diversity of seat belt (Chance) fractures predominantly ligamentous or osseous, more clearly defines the problem of split fractures, in which the fracture line passes between the anterior and middle columns with central impaction of the vertebral body.



**Fig. 7.** Rotation fracture which can lead to dislocation (Magerl, AO classification)

### **3. SPINAL CORD INJURY**

The physiological behaviour of the spinal cord must be taken into account: animal studies have shown that the initial spinal cord injury at the time of the accident leads to biochemical changes inducing impairment of the initial neurological state. Emergency spinal cord decompression is therefore essential to avoid mechanical and ischaemic compression [17]. Research is underway to reduce neuronal toxicity.

## **DECISION-MAKING**

All unstable lesions must be stabilized and all displaced lesions must be reduced and stabilized. The degree of emergency depends on the associated neurological lesions. Surgery must comprise procedures on the spinal canal in the case of associated neurological lesions for the thoracolumbar spine (laminectomy, impaction of a migrated fragment, etc.).

### **1. UPPER CERVICAL SPINE**

#### **1.1 Lesions of the craniovertebral junction**

In the light of the above, the treatment modality may be functional, orthopaedic or surgical, bearing in mind that craniovertebral fusion has major functional consequences. It is very tempting to prefer the orthopaedic method (halo vest) and reserve surgery for failures of this immobilization system.

#### **1.2 Atlas fractures**

Only displaced fractures raise problems. Nondisplaced atlas fractures should be treated orthopaedically by cervical collar or halo vest depending on local practices.

Patients with fracture-dislocation of a lateral mass or rotary atlantoaxial dislocation must be treated by traction. Reduction of these fractures is followed by immobilization by external fixation.

#### **1.3 Rotary atlantoaxial dislocation**

As this fracture is usually observed in children, reduction and immobilization is the preferred approach. In adults, reduction of the fracture is followed by C1–C2 screw fixation.

#### **1.4 Odontoid fractures**

The indication for odontoid fractures is simple: all displaced fractures are unstable due to associated ligamentous lesions and a nondisplaced fracture can may mask instability. More than the various classifications, only dynamic views



can determine the choice of treatment. Dynamic views must be passive with the surgeon holding the patient's head and applying flexion-extension movements under fluoroscopic control. A mobile fracture indicates instability.

### 1.5 Hangman's fractures

Hangman's fractures require surgical stabilization after reduction.

Odontoid and Hangman's fractures that are considered to be stable require functional treatment, as stability depends on intact ligaments which must be preserved.

## 2. LOWER CERVICAL SPINE

It is essential to determine whether the fracture is stable or unstable. In the presence of displacement, regardless of the bone lesion, the fracture is unstable. If no displacement is observed, fluoroscopic dynamic views performed after several hours of muscle relaxants can provide a better idea of the degree of stability. The presence of neurological signs is usually correlated with frank instability. When this is not the case, dynamic views must be obtained. Absence of instability, often encountered in Schneider's syndrome (tetraparesis with predominant brachial diplegia) may question the value of decompression on an osteophytic spine. In the same aim and at any level, a neurological deterioration without vertebral instability must lead to MRI researching a discal herniation.

The child's spine represents a particular situation, as it can sometimes be radiologically intact, but accompanied by quadriplegia with true spinal cord avulsion (the classical "Spinal Cord Injury Without Radiologic Abnormality" (SCIWORA)).

N.B.: dynamic views are contraindicated in the presence of a displaced, by definition unstable lesion.

## 3. THORACOLUMBAR SPINE

Can the two proposed classifications be used to guide treatment?

### 3.1 The Denis classification

This is the classification used in our center because it is simple and allows rational management of the lesions:

- Compression fractures are treated by functional methods. When the compression fracture is considered to be excessive, orthopaedic treatment (brace) or kyphoplasty may be proposed.
- Burst fractures are usually treated surgically. Note that a divergent appearance of the fractured vertebra on an AP film (increased inter-

pedicular distance compared to the adjacent vertebrae) indicates a severe osseous and ligamentous lesion and requires surgery.

- Seat belt fractures are usually treated orthopaedically by lordotic brace. Lordosis surgery may be indicated in the case of particularly marked angulation.
- Dislocations are unstable and must therefore be treated surgically.

### 3.2 The AO classification (Magerl)

The therapeutic approach used by supporters of this classification (which we consider to be especially useful to analyse results) can be summarized as follows:

The indications according to lesions of the columns defined by Louis (i.e. a large anterior column consisting of the discs and vertebral bodies and posterior columns consisting of the partes interarticulares and facet joints), which differ from the columns defined by Denis, are as follows:

- A lesion is stable if it alters the osseous part of only one column.
- Lesions of the osseous parts of two or three columns (types A2, A3, B2 and C) constitute transient osseous instability requiring reduction followed by immobilization.
- Lesions of the discoligamentous parts of several columns (types B2, B3 and some type C) must be treated surgically. The same applies to lesions with loss of substance of one column (types A1, A3.3, A2).

However, a treatment option must be chosen and sometimes as an emergency, which is why the Denis classification is used in our department with complete satisfaction. However, Magerl's classification is certainly more rigorous for case reviews and is generally accepted by most countries. Correspondences between these two classifications can be easily established, for example, Magerl type A3 are burst fractures, A1 are compression fractures, B1 are seat belt fractures, and C3 are dislocations.

Note that a neurological deficit is an indication for surgery with a few rare exceptions and implies urgent treatment according to the above indications.

## TREATMENT

### 1. PURELY FUNCTIONAL METHOD

The Magnus method consists of immediate weightbearing in a context of adapted physiotherapy and a radiological assessment on first standing, the following day, one week later, one month later, then three months later. The risk is that patients may not return for follow-up with a risk of secondary

displacement of the lesions which may cause neurological lesions, making deferred management more difficult.

## 2. ORTHOPAEDIC METHODS (PRIOR TO SURGERY)

### 2.1 Reduction

#### *Cervical spine*

Displaced fractures must be reduced, possibly progressively by means of skull traction using tongs. This is an important procedure: the position of the tongs must be precisely determined, the patient must be reassured about the safety of the procedure and must be encouraged to remain strictly prone during the hours or days that it takes to achieve reduction, with the use of medical sedation if necessary. The patient's active or passive cooperation is essential. Traction must take into account the axis of reduction and the traction pulley must be placed below the level of the spine to achieve extension reduction or above the spine to achieve flexion reduction. An average mass of 2–3 kg is sufficient for the upper cervical spine with an additional kilogram for each vertebra in the lower cervical spine. Traction must never be applied to a nondisplaced spine.

The effects of traction must be immediately verified radiologically, as excessive traction can be dangerous. Consequently, no traction is performed before radiological assessment.

Manual reduction is indicated in pure bilateral dislocations complicated by neurological signs on an anaesthetized, muscle-relaxed patient, in the axis of the spine under fluoroscopic control, on the operating table and by an experienced surgeon. We have never observed the slightest neurological deterioration.

#### *Thoracolumbar spine*

The use of bands to ensure lordosis for several weeks in a prone patient is a thing of the past. Simply placing the patient in lordosis on the operating table is sufficient to reduce most lesions. Orthopaedic reduction is performed on a table or frame under fluoroscopic control in a sedated patient.

### 2.2 Immobilization

Immobilization can be simple: a cervical collar for the cervical spine (including at least a thoracic brace), a brace for the thoracolumbar spine although it is of little use below L3, which may make surgical treatment preferable for low lumbar lesions.

The halo vest is used for cervical lesions. Although it may appear aggressive, it represents a very effective method of immobilization. Turnbuckles allow progressive modification of the curvature but are only used in very specific cases, for example to obtain reduction of fractures on a pathological spine (spondylitis).

### 3. SURGICAL METHODS

Surgical techniques obviously vary according to the level of the injury. Certain rules must be observed: from the site of the accident until arrival in the department or the operating room, the injured patient must be mobilized according to well defined rules, avoiding any movements that could displace the lesions and induce or worsen neurological deficits.

#### 3.1 Upper cervical spine

##### *Atlanto-occipital and atlas fractures*

Traction has been demonstrated to be potentially harmful at this level. Occipitocervical fusion induces ankylosis, decreasing the patient's mobility by at least 50% especially in rotation. These consequences must be taken into account in the indications for this technique. However, this is a vital zone and no instability can be tolerated. Bone grafts are recommended but may have limited efficacy, as re-operations usually reveal bony masses that may or may not have a stabilizing role.

We prefer the inverted hook occipital clamp technique described by Faure.

##### *Rotary atlantoaxial dislocation*

These dislocations are reduced by progressive transcranial traction. After reduction, C1–C2 screw fixation is performed by means of a simple technique but which can be dangerous due to the variable proximity of the vertebral artery. Fluoroscopic navigation is very useful in this setting. The key to the technique is to penetrate the caudal part of the C2 articular processes and direct the screw towards the anterior arch of the atlas.

##### *C2 fractures*

- *Odontoid fractures*: Displaced fractures are reduced by progressive traction (tongs). Anatomical reduction is essential prior to anterior screw fixation.

The classifications are very useful to select the most appropriate technique: posterior displacement (posterior oblique fracture) requires fixation by anterior screw fixation according to a standardized technique: the entry point of the screw, visualized by image intensifier (fluoroscopy) on AP and lateral views, is situated at the anterior aspect of the inferior endplate of C2. Advancement of the K wire and guide tube used to insert the perforated system (drill then screws) is monitored. Correct screw length reaches the apex of the dens. Self-tapping screws that are only threaded in their distal part are used to apply compression on the fracture site. The subject's morphology may make this technique difficult or even impossible in the case of barrel chest, preventing screw fixation of the axis.

Anterior oblique fractures require a posterior approach with C1–C2 fusion between the posterior arch of the atlas and the laminae of C2. Regardless

of the instrumentation used (wiring deserves its bad reputation), fixation must ensure compression and a bone graft is usually performed between the posterior arch of C1 and the cranial aspect of the previously roughened laminae of C2. This also avoids overcorrection in lordosis.

Horizontal fractures are preferably treated by anterior screw fixation.

- *Hangman's fractures:* The lesion of the C2–C3 disc determines the instability of this fracture, which must be reduced by tongs. An anterior or posterior approach is used depending on the site of the fracture line. The anterior approach consists of C2–C3 intervertebral arthrodesis with a screw plate. The posterior approach consists of bipedicular screw fixation, which is a simple technique when the screw is inserted into the superomedial quadrant of the articular process of C2 and when the C1–C2 interspace is widened by removing an equivalent amount of ligamentum flavum. Initial progression of the screw in the pedicle is monitored under direct vision.

### 3.2 Lower cervical spine

The techniques used depend on the type of fracture and whether one or several segments are involved. Two situations are commonly observed, others are rarer:

#### *The lesion involving one or only a few segments is reduced preoperatively*

An anterior approach should be used, as this easy technique is better supported by a supine patient. For lesions involving one segment (bilateral dislocation of the facet joints for example), the anterior sternocleidomastoid approach is easy and anatomical, as it only sections one omohyoid muscle or one superior thyroid artery and only very occasionally. This is a noninvasive approach. The blood vessels are situated laterally, the viscera are medial and, after dissection of the midline fascia of the neck, the finger is in contact with the spine. Discectomy is systematically performed. Abrasion of the endplates must not destroy them. The autologous bone graft or bone substitute, which is very useful in this situation, is inserted and maintained by a 4-screw plate. The length of the screws must not exceed 16 mm and bicortical screw fixation is unnecessary and can be dangerous. A teardrop fracture does not require reduction, which is only rarely obtained and which is dangerous in view of the associated ligament damage, with a risk of overcorrection with traction of the spinal cord. This lesion resembles a burst fracture of the lumbar vertebrae but comprises very severe ligamentous lesions. Corpectomy is generally required, and is filled by a tricortical graft maintained by a screwed plate.

#### *The lesion is not reduced*

This is often the case in unilateral dislocations. A posterior approach is required allowing fusion by articular screw fixation and plates or rods or by interlaminar clamps with rods.

*Lesions at multiple levels*

They should be treated via a posterior approach.

*Dual approach*

A dual approach is only indicated for lesions with vertebral defects or routinely in ankylosing spondylitis regardless of the level.

### 3.3 Thoracolumbar spine

We prefer a posterior approach which is the approach most often used in France. This single approach is simple and the failures leading to malunions following this technique are rare [11]. Reduction of the lesions, apart from dislocations which require difficult reduction manoeuvres especially in the thoracic spine, is generally achieved by placing the patient on the operating table. The length of the plate, classically estimated at two levels on either side of the fractured vertebra, depends on the severity of the lesions. Short plates have the advantage of a shorter incision and a more limited future restriction of movement, but should be reserved to cases in which screw fixation in the fractured vertebra is possible (depending on the state of the pedicles). Techniques are otherwise simple and essentially involve the pedicle.

*Pedicle screw fixation*

*Thoracic spine:* Pedicle screw fixation is performed below the interspace, at the level of the transverse process which is the main landmark of the pedicle. The angle of the screw is guided by CT views of the direction of the pedicles. Screws must not be larger than 5 mm in diameter and are connected by plates or rods adapted to the patient's kyphosis.

*Lumbar and lower thoracic spine:* the diameter of the pedicles allows the use of screws 6.5 mm in diameter, but barely longer than 45 mm due to the vascular risks. Pedicle screw fixation is performed at the junction of the articular process and the transverse process and is convergent, as lumbar pedicles are also often convergent.

*Pediculotransverse clamp fixation*

We prefer to use pediculotransverse clamps in the thoracic spine, as kyphotic stresses can lead to screw pullout and the pedicular diameter is sometimes too small to allow the use of 5 mm screws. Pediculotransverse clamps constitute an ideal solid anti-pullout system. Pediculolaminar clamps are used in the upper thoracic spine (T1 and T2), as the transverse processes are too far from the midline. Interlaminar clamps are dangerous in the thoracic spine as all of the spinal canal is filled by spinal cord at this level. Rods must always be shaped to the patient's morphology and the curvatures of the spine.

*Anterior approaches*

We only use anterior fusion as a second-line procedure when there is a large anterior defect or in the case of non-union which is rare (about 2% of our patients). The surgical approach is simple: short right thoracotomy, flank incision. Thoracolaparotomy is gradually being replaced by minimally invasive techniques. Anterior fusion consists of corpectomy or discectomies filled by autologous bone grafts and maintained by fixation of the vertebral bodies.

*Bone grafts*

Bone grafts are used systematically in all anterior fusion procedures. Synthetic grafts are used for lesions involving a single vertebra and autologous bone grafts are used after corpectomy. Posterolateral bone grafts are used in posterior approaches to the thoracolumbar spine only in the rare case of pure ligamentous lesions.

**3. EVALUATION, PROGRESS IN TECHNIQUES, SPECIAL CASES****3.1 Evaluation**

These fixation procedures give good long-term results. Loss of reduction after removal of instrumentation (which is performed only after one year) is minimal and is negligible, apart from active pseudarthroses. Instrumentation is only removed when the patient complains of disabling stiffness or pain. Spinal fusion no longer needs to be defended and is mandatory in all cases of instability with a risk of neurological deficits. Complications are rare and can be avoided by a rigorous technique. Spine surgery cannot be improvised, but “practice makes perfect”.

**3.2 Recalibration**

Recalibration is one of the objectives of spinal surgery and consists of laminectomy which we only perform in the case of associated neurological signs. Even severe stenosis with no neurological signs does not require any reduction and follow-up over several years shows excellent remodelling of the spinal canal [16]. Interpedicular impaction of a fragment of vertebral body is a difficult procedure which requires dissection of the vertebral body by lamino-arthro-pediculectomy. Dural opening with augmentation duroplasty has never been validated.

**3.3 Minimally invasive techniques**

Minimally invasive techniques only refer to a shorter incision. Complications are neither rare nor minor, regardless of the type of surgery performed. Kyphoplasty [9], a complementary procedure performed at the same time as a posterior approach or used alone for thoracolumbar vertebral body compression lesions certainly has a future, but the outcome of the cement used

has yet to be determined, especially in young subjects. Percutaneous fusions, which are only technical improvements of the basic techniques described above and which require a learning curve for all spinal surgeons, are under development and are only indicated for short fusions [12, 13].

### 3.4 Timing

Timing is the key to optimal axonal preservation. The six-hour rule must be used as a guide [17].

### 3.5 Trauma in children

Different traumatic lesions are observed in children. Apart from SCIWORA, described above, fixation must be performed very cautiously as it corresponds to arthrodesis at this age. The resulting growth disorders very often have a pejorative functional course. Orthopaedic techniques should be preferred in children and surgery should be reserved for the fortunately rare cases of extreme instability.

## HOW TO AVOID COMPLICATIONS

The best way to avoid complications of surgery is a rigorous surgical technique. There is now a sufficient number of workshops to acquire these techniques on cadavres. To prevent neurological impairment, handling of patients prior to surgery must be clearly understood and rigorously applied by all teams involved from the site of the accident to the operating room. Bladder catheterization is performed as an emergency to preserve future bladder contractions. Skin capital must be preserved by protecting exposed areas and preventing pressure ulcers. Ventilatory assistance with careful intubation must be used in the early stages, especially for tetraplegic patients, followed by tracheotomy, when necessary, to prevent dramatic atelectasis. The patient's positions in bed must be defined and observed daily to avoid abnormal positions of paralysed joints, especially the ankles. Spasticity must be rapidly treated by drugs. Overactive bladder must be treated early to prevent damage to the upper urinary tract. Good realignment of the spine constitutes the best prevention of the very high rate of posttraumatic syringomyelia (about 28% of paraplegic and quadriplegic patients). However, the essential guideline is that all spinal cord injury patients, until radiological proof to the contrary, must be considered to be unstable, from the time of the accident until installation on the operating table.

## CONCLUSIONS

Spinal injuries must be assessed in terms of their potential instability. Various classifications have been proposed, leading to different approaches that can



be functional, orthopaedic or surgical. Surgical techniques and approaches are guided by the anatomical profiles of each segment of the spine and by the mechanisms of the lesions. Spinal cord injuries require immediate decompression and stabilization within 6 hours after trauma. Every effort must be made to avoid other complications such as bladder distension, pressure ulcers, lung infections or atelectasis, abnormal positions of the joints, spasticity; overactive bladder and posttraumatic syringomyelia. A multidisciplinary approach in collaboration with rehabilitation physicians can avoid the initial negligence that can sometimes have very serious repercussions.

## References

- [1] Allen BL Jr, Ferguson RL, Lehman RT, O'Brien RP (1982) A mechanistic classification of closed, indirect fractures and dislocations of the lower cervical spine. *Spine* 7: 1-27
- [2] Anderson LD, D'Alonzo RT (1974) Fractures of the odontoid process of the axis. *J Bone Joint Surg American* Volume 56: 1663-1674
- [3] Anderson PA, Montesano PX (1988) Morphology and treatment of occipital condyle fractures. *Spine* 13(7): 731-736
- [4] Boehler L (1944) *Technique de traitement des fractures*. Tome 1 Masson, Paris
- [5] Cotrel Y, Dubousset J (1984) Nouvelle technique d'ostéosynthèse rachidienne segmentaire par voie postérieure. *Rev Chir Orthop* 70: 489-494
- [6] Denis F (1983) The three column spine and its significance in the classification of acute thoracolumbar spinal injuries. *Spine* 8: 817-831
- [7] Francis WR, Fielding JW, Hawkins RJ (1981) Traumatic spondylolisthesis of the axis. *JBJS* 63-B(3): 313-318
- [8] Jefferson G (1920) Fracture of the atlas vertebra: report of four cases, and a review of those previously recorded. *Br J Surg* 7: 407-422
- [9] Korovessis P, Repantis T, Petsinis G, Iliopoulos P, Hadjipaviou A (2008) Direct reduction of thoracolumbar burst fractures by means of balloon kyphoplasty with calcium phosphate and stabilization with pedicle-screw instrumentation and fusion. *Spine* 33(4): 100-108
- [10] Magerl F, Aebi M, Gertzbein SD, Harms J, Nazarian S (1994) A comprehensive classification of thoracic and lumbar injuries. *Eur Spine J* 3: 184-201
- [11] Oertel J, Niendorf WR, Darwish N, Schroeder HWS, Gaab MR (2004) Limitations of dorsal transpedicular stabilization in unstable fractures of the lower thoracic and lumbar spine: an analysis of 133 patients. *Acta Neurochir (Wien)* 146(8): 771-777

- [12] Payer M, Sottas C (2008) Mini-open anterior approach for corpectomy in the thoracolumbar spine. *Surg Neurol* 69(1): 25-31
- [13] Ringel F, Stoffel M, Stürer C, Totzek S, Meyer B (2008) Endoscopy-assisted approaches for anterior column reconstruction after pedicle screw fixation of acute traumatic thoracic and lumbar fractures. *Neurosurgery* 62(5 Suppl 2): 445-452
- [14] Roy Camille R, Demeulenaere C (1970) Ostéosynthèse du rachis dorsal, lombaire et lombosacré par plaques métalliques vissées dans les pédicules et les apophyses articulaires. *Presse Med* 78: 1447-1448
- [15] Roy Camille R, Saillant G, Lapresle P, Léonard P (1983) Fractures récentes de l'odontoïde facteurs de pronostic. *Presse Med* 12(36): 2233-2236
- [16] Scapinelli R, Candiotti S (1995) Spontaneous remodeling of the spinal canal after burst fractures of the low thoracic and lumbar region. *J Spin Disorders* 8: 486-493
- [17] Tator CH (1999) An evidence-based review of decompressive surgery in acute spinal cord injury: rationale, indications, and timing based on experimental and clinical studies. *J Neurosurg* 91: 1-11
- [18] Tuli S, Tator CH, Fehlings MG, Mackay M (1997) Occipital condyle fractures. *Neurosurgery* 41(2): 368-376
- [19] Vaccaro AR, Lehman RA, Hulbert RJ (2005) A new classification of thoracolumbar injuries: the importance of injury morphology, the integrity of the posterior ligamentous complex, and neurologic status. *Spine* 30: 2325-2333
- [20] Wang XY, Dai LY, Xu HZ, Chi YL (2007) The load-sharing classification of thoracolumbar fractures: an in vitro biomechanical validation. *Spine* 32(11): 1214-1219



### **Roger Robert**

Roger Robert is an Anatomist and Head of the Neurosciences Department at Nantes University Hospital. He has been interested for a long time in the management of spinal cord injury patients and trained with Raymond Roy Camille and Gérard Saillant at La Pitié Hospital in Paris in 1978. With Prof. Jean François Mathé, he formed the first multidisciplinary team for spinal cord injury and founded the neurotrauma centre in Nantes in 1984. He has developed surgical techniques in collaboration with GICD (Cotrel-Dubousset international group), giving courses and workshops all around the world. He has conducted research into spinal cord injuries with Prof. Marc Tadié (Bicêtre Hospital in Paris) with grafting of L2, L3 and L4 motor roots into the ventral grey matter of the cord above the lesion. He is now working with Prof. Pierre Rabishong (Montpellier) in the field of neurostimulation of peripheral nerves of the lower limbs guided by a computer-assisted programme in paraplegic patients to enable walking. In another field, he is well known for his work concerning perineal pain and described the surgical technique of transgluteal release of pudendal nerve entrapment. He is also a member of the research team into firearm head injuries and protection of civilians and military personnel.

Beside his medical work, Roger Robert is pianist and played several years in a professional group of pop music as singer and organ player. He is also a fan of bullfighting and belongs to the French Society of so called “taurin surgeons”.

**Contact:** Roger Robert, Service de Neurotraumatologie Hôtel-Dieu, CHU de Nantes  
Place Alexis Ricordeau 44093 Nantes Cedex 1, France  
E-mail: roger-robert@chu-nantes.fr

---

# APPROACHES TO CERVICAL SPINE

G. MATGÉ

## INTRODUCTION

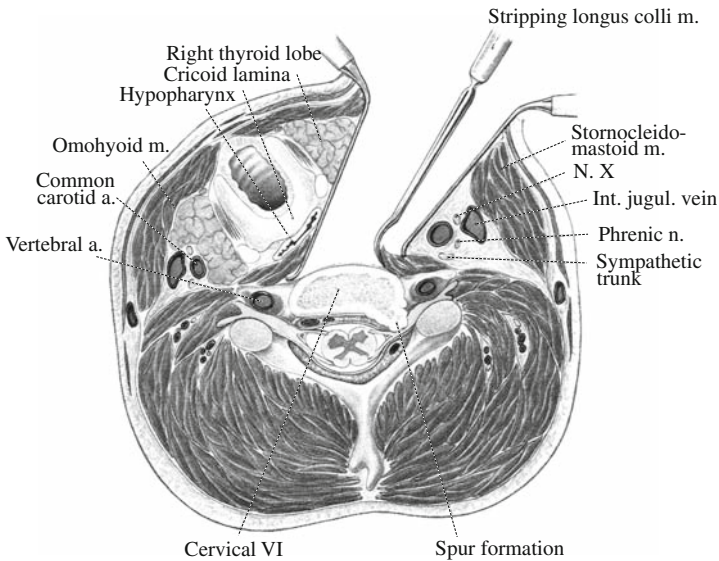
The evolution of spinal surgery has revolved around three basic surgical principles: decompression, stabilisation and deformity correction. From a historical point of view, laminectomy was the only procedure for trauma, tumor and infection of the spine. Anterior cervical spine approaches were developing in the 1950s with Robinson and Smith, Dereymaker and Moulrier, and Cloward [3]. Thereafter, Caspar's instrumentation clearly influenced the dominant use of anterior cervical approach (discectomy with fusion) long before the cage, dynamic plating and arthroplasty area. Anterolateral approaches initiated 1968 by Verbiest saw further development with George and miniaturisation with Hakuba and Jho [4]. Meantime, and mainly because of instability recognition, there was new development in posterior approaches in 1970s with laminoplasty (Hirabayashi), posterior instrumentation (Roy-Camille), foraminotomy (Kempe) and endoscopic decompression (Theron) in 1990s [2, 9]. The complex area of upper cervical spine and craniovertebral junction was even more dependent on surgical technology, imaging and monitoring improvements to find the best approach [1, 5]: transoral or transcervical with dens resection (Menezes), direct anterior odontoid peg fixation (Apfelbaum) or occipito-cervical stabilisation (Grob). Benzel's recent book about spine surgery is an excellent reference for history, biomechanics, indications, techniques and management according to approaches [2].

## RATIONALE

The aim of choosing a given approach to cervical spine is depending on dominant pathology (75% are anterior lesions in degenerative cervical spine), number of involved levels (myelopathy with multi-level stenosis), patient's health condition limiting invasive procedures (metastasis, odontoid fracture in elderly), and lastly surgeon's training and experience (complex instrumentation). The goal of any surgical approach is finding the offending lesion through the less aggressive method assuming decompression of involved neural structures, not destabilising or deforming the spinal canal otherwise needing adapted reconstruction. Spinal surgery is moving

---

*Keywords:* spine, spine traumas, cervical spine approaches, degenerative spine



**Fig. 1.** Anatomical section through C6. During anterior approach, neurovascular structures are retracted laterally and visceral structures medially. Note elevation of longus colli muscles. Disc herniation may be reached by an anterior (as depicted) or a posterior (arrow) midline subperiosteal approach (from Kempe [7])

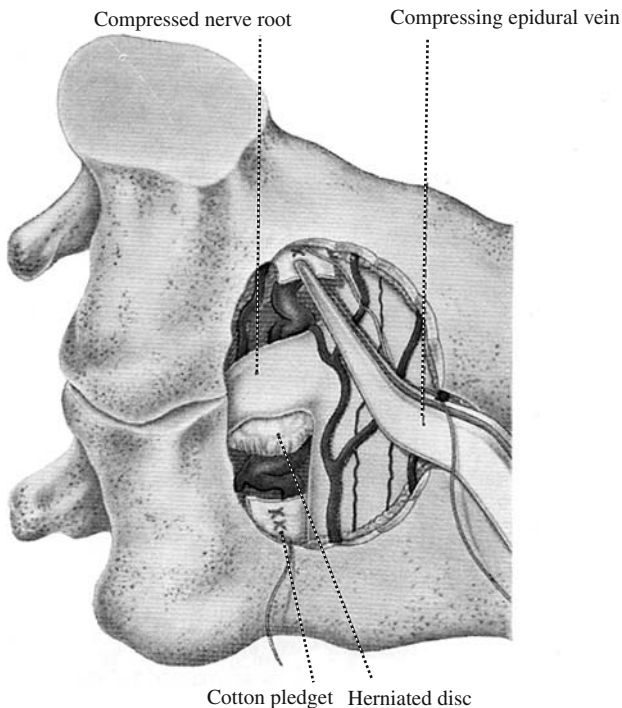
away from simplistic decompression alone, involving more and more bio-mechanics to restore primary function of the spine that means motion in stability without pain. The complexity of this phenomenon is a serious challenge for the surgeon who has a real interest in subspecialisation: an extensive lesion or some severe instability with or without deformity may require combined approaches. Today's spinal surgeon should be trained in all of them.

Surgical anatomy of anterior cervical spine approach is nicely outlined in Kempe's book on operative neurosurgery [7] and reproduced in Fig. 1. Frontal inspection of a subaxial spine C3–T1 (from a surgical point of view, T1 may be considered the 8th cervical vertebra) demonstrates a direct exposure most suitable for discectomy or corpectomy. The anterior approach is a non traumatic way to the intervertebral disc by dissecting only soft tissues (skin, muscles and fascia, anterior longitudinal ligament) without offending bone structures to reach the intervertebral space. Up to 3 segments are easily exposed through an aesthetic transverse skin incision. Total discectomy can only be achieved by an anterior approach which allows decompression of spinal cord (posterior longitudinal ligament and osteophyte removal) and exiting nerve roots (drilling internal part of uncus and foramen) in radiculomyelopathy. Next step is reconstruction and stabilisation of intervertebral space with bone graft, cage or prosthesis. The microscope adds light, precision, and security in the operative field. In corpectomy cases (severe

myelopathy from stenosis, trauma, tumors), the anterior approach allows large radicodural decompression and easy reconstruction with bone, spacers and plates for immediate stability.

The upper cervical spine (C0C1C2) anatomy is more complex with large articular surfaces and strong ligaments without intervening disc favouring rotation instead of flexion-extension dominant in subaxial spine. Main anterior surgical approaches concern odontoid lesions in relation to the anterior arch of C1 and lower end of clivus (trauma, tumors, malformation, and inflammatory diseases).

Surgical anatomy of the posterior spine is also visible in Fig. 1. The posterior approach needs a muscle and ligament separation technique (more painful) from bony structures (spinous process, lamina, facet joint). The next step is a certain degree of bone resection to enter the spinal canal and to visualise the epidural space (veins) with dura and nerve root, needing some neural retraction and medial facetectomy to see the lateral border of the disc (Fig. 2): laminotomy/arthrotomy approach preferentially under



**Fig. 2.** Posterior foraminotomy approach with key-hole lamino-arthrotomy exposing lateral dura and compressed nerve root by underlying disc herniation. Note dilated epidural veins compressed by micro-cottons (from Kempe [7])

microscope. The approach is clearly hindered by spinal cord which should not be mobilised. This posterior microforaminotomy allows radicular decompression by removal of a free disc fragment and some lateral osteophyte. In myelopathy, laminectomy (multilevel), flavectomy and medial facet resection risk some destabilisation which may be corrected with adapted instrumentation.

The cranio-cervical junction complex C0C1C2 is of major surgical interest in trauma, tumor and malformation because of problems related to frequent instability requiring thorough reconstructive techniques, hindered by a deep operative field endangered laterally by vertebral arteries, lower cranial nerves and medially underlying bulbo-medullary transition.

## **DECISION-MAKING**

### **1. DIAGNOSTIC CRITERIA**

*Clinical arguments* intervene in selecting the approach together with surgeon's experience in similar lesions:

- neck pain dominant
- mono or multilevel radiculopathy
- myelopathy
- acute or chronic presentation
- age and general health of patient

A larger clinical check-up is required according to patient's history and presentation (trauma, tumors, infection). Neurophysiological tests may further contribute to rule out differential diagnosis: lateral amyotrophic sclerosis, multiple sclerosis, mono- or polyradiculitis, brachial plexus lesions...

*Radiological evaluation* targets at precisising lesion, stability and compression of nervous structures (dynamic XR, contrast CT and/or MRI):

- side and level(s) of compression for vertical extend of lesion
- dominance of anterior or posterior compression for horizontal extend
- frontal and sagittal alignment (scoliosis or kyphosis)
- diameter of cervical spinal canal (stenosis)
- instability in dynamic views (degenerative or traumatic)
- quality of bone (trauma, osteoporosis, infections, tumors, vascular lesions)
- typical aspects on MRI: disc herniation and radiculitis, stenotic myelopathy, spondylodiscitis and epidural abcess, meningioma/neurinoma, Chiari and syringomyelia



- compression: deformation or invasion of nerve roots (neurofibroma) and/or spinal cord (ependymoma)
- contrast-enhanced studies: benign or malignant processes (vascular lesion, metastasis)

A more general and neuroradiological evaluation is indicated in any suspect lesion and according to clinical check-up, mostly general health and previous patient history.

## 2. INDICATIONS

Clear-cut exclusive indications are sometimes difficult to define because of trends and habits in surgery, and experience related results of operators.

### 2.1 Anterior approach

In practice, an anterior lesion – that means situated in front of spinal cord or nerve root – is best approached and cured by an anterior route, avoiding manipulation of nervous structures and allowing reconstruction of the spinal canal with arthrodesis or dynamic technologies (fusion versus mobility preservation). This is the case for most degenerative pathologies (disc herniation and stenosis) in the cervical spine [8]. Traumatic, infectious and tumor diseases involving the vertebral body are nearly absolute indications owing to imperative reconstruction of the destabilised anterior spinal column. Modern spinal neurosurgeons are most used to the anterior route with the advantage of a straight and medial approach to the spinal column [12]. Postoperative airway obstruction and hoarseness are feared complications.

Concerning upper cervical spine, the transcervical route is mostly used for direct odontoid fractures fixation and the transoral approach for dens resection together with a posterior cervico-occipital stabilisation (for transoral approach see special chapter in this book). Indications for direct dens screwing are unstable type II fractures, with intact alar ligaments, reducible by positioning on table or by traction [1].

### 2.2 Anterolateral approach

Only a few specialised surgeons retain an anterolateral route in (micro) foraminotomy for radiculomyelopathy if pathology is dominant on one side, arguing that they may avoid disc space destabilisation and reconstruction, even in multi-level patients [4]. Recent biomechanical testing does not confirm this view [11]. There is a complementary vascular (VA) and neural risk (Horner). On the other hand, a more lateral approach with control of vertebral artery in tumors with foraminal extension (dumbbell schwannomas, some bone tumors) is really indicated and useful [4].

The anterolateral high cervical approach for dens resection is rarely used since technical progress in transoral route and not detailed in this chapter.

### 2.3 Posterior approach

The posterior route is most familiar to neurosurgeons owing to their experience in lumbar spine. A soft disc herniation (DH) is an excellent indication, and certainly at C7–T1 where the herniation is very lateral (foraminal) due to the fact there is no more uncus. With a short neck, the lesion may be difficult to be reached by an anterior approach [12]. There is new interest of posterior approach since improvements in endoscopic techniques through small tubes (no personal experience). Multi-level stenosis in elderly patients with rigid spine needing only decompression is another excellent indication. Most extra- and intramedullary tumors, epidural abscess and posterior arch traumatic lesions are best approached from behind. Postoperative muscle pain is a common complain.

Instrumentation in posterior approach is constantly improving (trans-articular and transpedicular screwing, sublaminar hooks, occipital screw fixation), and mainly for occipito-cervical stabilisation in trauma, degeneration/malformation and tumors allowing large decompressions with immediate mobilisation of patients. Cervico-occipital fusion is also indicated in dens fractures not suitable for direct anterior screwing (Fig. 6). A major concern is preoperative studying course of VA to avoid vascular lesion [5].

## SURGERY

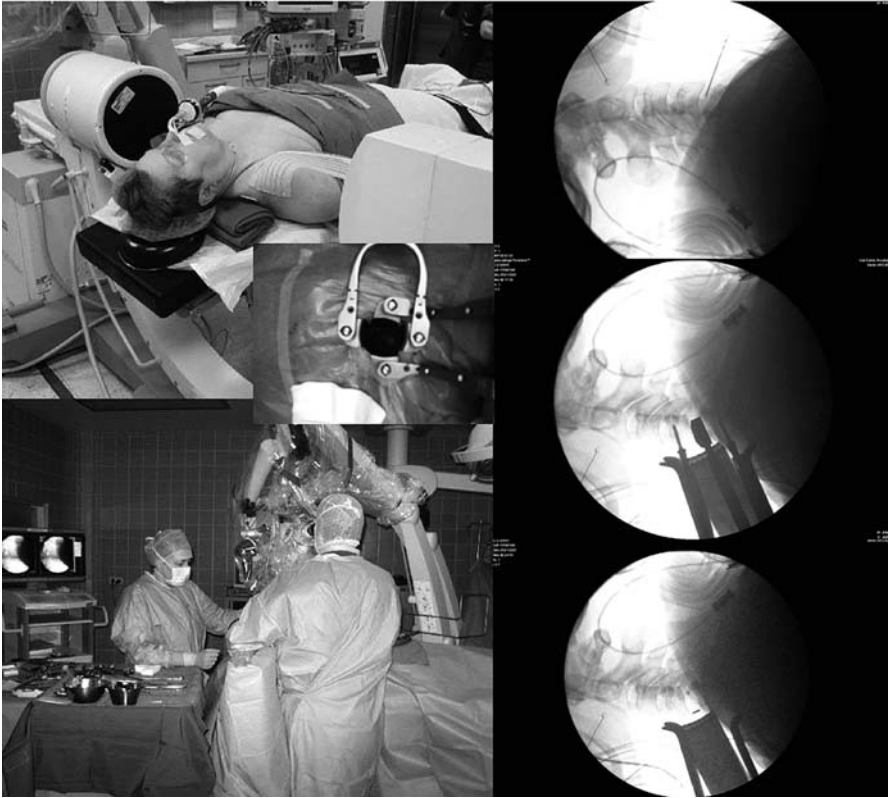
### 1. OPERATIVE TECHNIQUE FOR ANTERIOR APPROACH

#### 1.1 The surgical technique

The surgical technique is detailed step-by-step, for *degenerative disc pathology in subaxial spine* (Fig. 3) as a basic example for the general approach with complication avoidance at each step [2, 3, 8, 12].

#### *Anaesthesia*

- Standard intubation for the standard case: tube protection (spiral) avoids kinking
- High volume, low pressure cuffs: reduce trauma to tracheal mucosa and innervation
- Alternative: naso-tracheal intubation with extension tube fixed to forehead
- Endoscopic intubation: cervical instability, severe stenosis with myelopathy, any foreseen difficult intubation (anatomical factors)



**Fig. 3.** Anterior cervical approach for microscopic C5C6 discectomy and cage fusion. Note installation, Caspar retractors, microscopic procedure under fluoroscopic control

### *Positioning*

- Flat on the back, neck slightly extended for a horizontal approach
- No head fixation except in instability (Mayfield)
- Lateral fluoroscopy (antero-posterior only for disc prosthesis or dens screwing)
- Shoulders caudally fixed in case of short neck, or C6 to T1 approach, elbows protected
- Check-up of tracheal tubing to respirator
- Neuromonitoring if requested by pathology (severe myelopathy)

### *Side of approach*

- Right side for right handed surgeon
- Left side from C6-T1 reduces recurrent laryngeal nerve irritation or lesion

- Some difficult reoperations may be easier handled from the other side (or by a posterior approach)
- Globally, view is better to the opposite foramen and especially in anterolateral approach

#### *Skin incision*

- Transverse centered on disc space is cosmetically best, 3–6 cm for 1–3 levels, reaching or crossing midline 1 cm (prosthesis)
- Transverse cutting of platysma, upper and lower mobilisation to transform wound to a more vertical approach by small Gelpi retractor
- Dissection of superficial fascia followed by atraumatic finger dissection along anterior border of sternocleidomastoid muscle, feeling common carotid artery pulsations

#### *Prevertebral space*

- Using smooth retractors, the visceral content is mobilised medially and the vascular package laterally down to deep fascia, opened near midline to expose prevertebral space (thyroid vessels mostly preserved)
- Attention: recurrent laryngeal nerve!
- Lateral fluoroscopy to localise disc space with a needle
- Dissect and elevate longus colli insertions (difficult with large osteophytes) avoiding venous bleeding (only bipolar coagulation)
- Attention: vertebral artery (VA) if dissection too lateral!

#### *Retraction*

- Only centered incision and correct dissection allow atraumatic retraction
- Teethed Caspar retractor blades are inserted under longus colli muscle to avoid vascular or visceral lesion, with reasonable opening pressure to visualise the whole anterior disc space
- Retainer pins midline insertion near the center of vertebral body facilitates orientation during decompression, essential in case of prosthesis or further plating

#### *Discectomy*

- Microscope gives light, precision, security
- Annulus incision, clearing of disc space with curettes, small rongeurs and disc punches avoiding cartilage penetration
- Only large anterior osteophytes should be removed to avoid anterior vertebral rim weakening promoting cage or prosthesis subsidence
- Complete discectomy down to posterior longitudinal ligament (PLL) and medial to remaining lateral annulus (PLL is preserved only if soft DH and no subligamentous extrusion)

*Decompression*

- Really begins in posterior 1/3 of disc space under magnification, aided by progressive intervertebral distraction
- Removal of osteophytes and uncal with microdrill, 1-2 mm Kerrison rongeurs, internal foraminotomy to visualise emerging nerve root
- Microincision in PLL, elevate with micro nerve hook and resect completely with posterior rim attachment, from midline to foramina
- Attention: venous plexus, VA
- Careful haemostasis with bipolar, gelfoam, bone wax (fibrin glue if heavy bleeding)

*Implantation*

- Nothing: avoid too much anterior and lateral decompression favouring kyphosis
- Iliac bone graft: observe tricortical graft with anterior rim contact limiting subsidence
- Cage: same, avoid endplate weakening
- Prosthesis: exactly centered midline on spinous process line in anteroposterior view (malfunction)
- Plate: flatten anterior rim and medialise screws for improved stability

*Wound closure*

- Last fluoro-check for implants
- Review haemostasis: epidural, bony, muscular
- Usually no wound drainage required
- Only platysma and intradermal suture (small dressing)
- No collar unless severe traumatic instability
- Awake on table with neurological examination

*Postoperative care*

- Analgesics, non steroid antiinflammatory drug, 24 h ATB, low molecular heparin next day
- Corticosteroids only in deficit or abnormal tracheal swelling requiring laryngoscopic screening
- CT or MRI immediately in case of any new deficit to rule out bleeding, compression versus contusion
- EMG for peripheral nerve lesion (plexus, ulnar)
- Get-up next day with X-ray control for implants
- Stay 3–6 days with rehabilitation as needed
- Next visit 1 month (and 3 m, 1 y for implants)

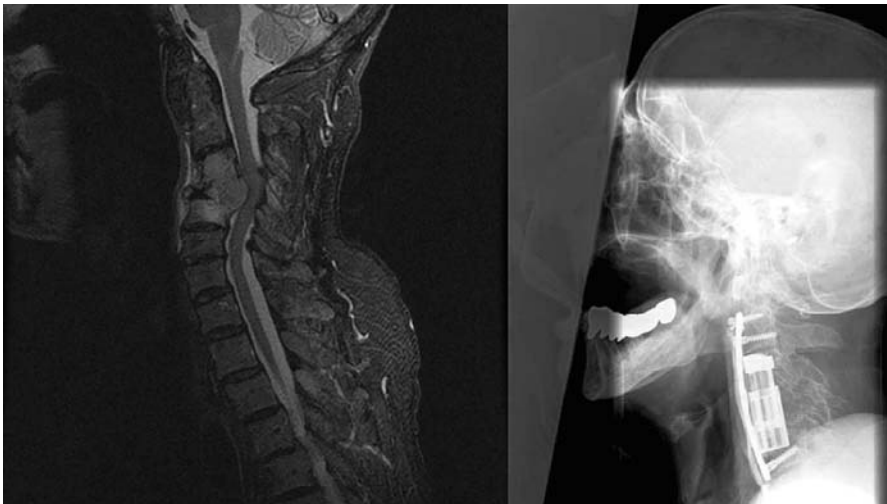### 1.2 Corpectomy (Fig. 4)

Indication: degeneration, trauma, tumor with *severe myelopathy*

- More radical, also retrocorporeal dural decompression by vertebral body resection (1–3 levels) in extended stenosis, including disc above and below
- Impacted graft or better adapted spacer with bone filling for improved stability until fusion
- Common risk is graft dismantling typically at the inferior border with recurrent myelopathy
- Plating mandatory to avoid fracture and pseudarthrosis of long grafts
- Intermediate fixation technique (Benzel) increases stability with 3-point fixation
- Dynamic plating adapts natural graft settling and avoids screw displacement (kyphosis)
- Drain the wound as haematoma, air way obstruction more frequent

### 1.3 Anterolateral approach

- *Unilateral corporo-transverse approach for oblique decompression* (Verbiest, George)
- *Anterior microforaminotomy* (Hakuba, Jho)



**Fig. 4.** Corpectomy C3C5 for metastatic cancer with spacer and plate fixation for lordotic stabilisation. Note osteolytic tumor compressing spinal cord with marked kyphosis on preoperative MRI

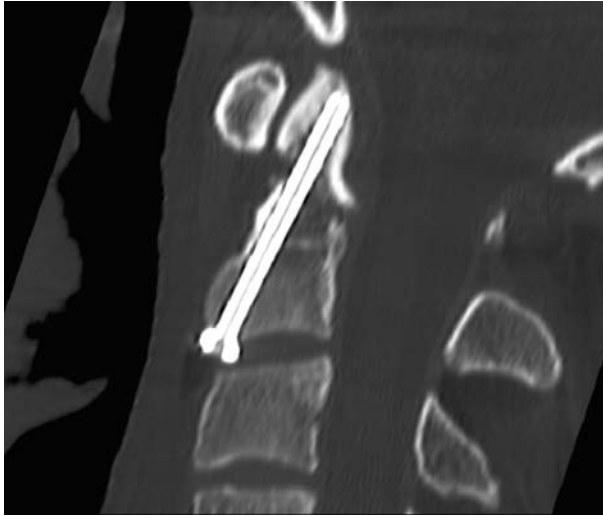
For technical details the reader should refer to the original publications. A cadaver training is highly recommended before using these approaches because of more difficult vascular handling [2, 4, 11]:

- Surgical principle is freeing and protecting vertebral artery (VA) for a more lateral approach to the anterior offending lesion in radiculopathy, with bilateral anterior decompression from the most pathological side in myelopathy
- Total or subtotal uncus resection respecting as much as possible the intervertebral disc to avoid instability, no instrumentation required claimed by pioneers
- Risk:
  - Vertebral artery (VA) (bleeding, AV fistula, vertebro-basilar stroke) and sympathetic chain (Horner)
  - Spinal accessory nerve above C3, lymphatic chain below C6
- Technically demanding more in myelopathy than in radiculopathy (for specialists)
- Most useful when control of VA required: foraminal tumors or vascular lesions

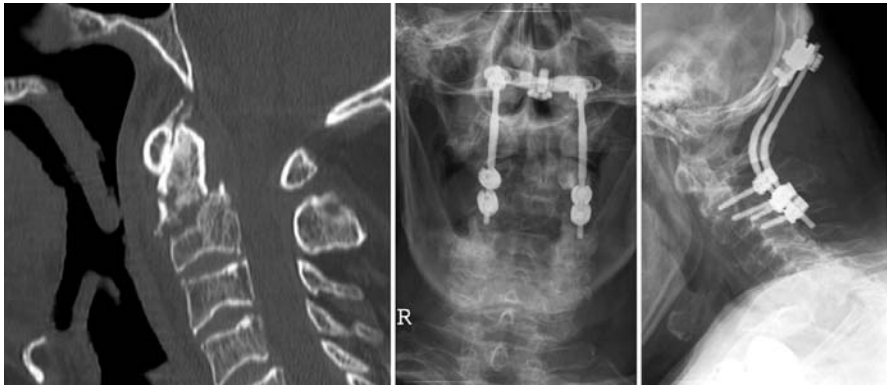#### 1.4 Direct anterior dens screwing (Fig. 5)

Indication: *odontoid type II fracture* [1]

- Double fluoroscopy: lateral L + anteroposterior AP: visualise dens in open mouth view (cotton roll packed between teeth)
- Maximum neck extension under fluoro-control in Mayfield clamp or in slight submandibular traction: fracture reducible suitable for anterior approach otherwise posterior fixation
- Simulate ideal screw trajectory (L view) by metal bar along neck from odontoid tip to thoracic wall: limited neck extension and thoracic kyphosis are contraindications
- Transverse skin incision at C5 with upward transmuscular finger dissection to palpate and mark C2C3 disc at midline with a pointer under AP+L view (entry point)
- Resect some bone around entry point on midline C3 anterior rim (logging also further screw head) to improve instrument inclination for virtual screw axis created by pointer a few mm behind anterior rim of C2 and a few mm in the endplate
- Introduce an adapted guide wire in the hole with fluoro-control, then the tubular guide for instrument passing and protection of soft tissues for next steps avoiding vascular and visceral lesions
- Drill guide wire (easier to correct trajectory) under AP+L view through middle of fracture line up to the cortex of odontoid tip followed by canulated drill and tap on same wire



**Fig. 5.** Direct anterior screw fixation for displaced reducible odontoid type II fracture. Note entry point, direction and tip of cannulated lag screw



**Fig. 6.** Cervico-occipital stabilisation for unstable odontoid type III fracture. Note anterior subluxation in preoperative CT, reduced in postoperative flexion X-ray

- Evaluate screw length on scale and position cannulated lag screw under compression of distal fragment (screw passing fracture line in L view) in/ or better slightly through odontoid tip cortex for improved stability
- Retract tubular guide, palpate and inspect screw head logging in bone cavity
- Last fluoro-check for screw position in AP + L



- Review haemostasis and close wound in 2 layers usually without drainage
- Immediate mobilisation without collar, very useful in elderly patients
- Technical failures: instability, pain and rarely neurological deficit, non union or pseudarthrosis in evolution indicating reoperation by anterior or posterior approach:
  - Insufficient fracture reduction by positioning or fracture distraction by a too short screw
  - AP or L screw deviation mostly by incorrect C2 approach, prominent thorax, poor dens visualisation in osteoporosis

## 2. OPERATIVE TECHNIQUE FOR POSTERIOR APPROACH

- Prone position of patient with careful padding on table, arms fixed along the body
- Head fixation in a Mayfield clamp avoids ocular and throat compression
- Slight flexed neck to enhance exposure by opening space between posterior arches
- Slight reverse Trendelburg position to empty cervical draining veins avoiding head about heart: risk of air embolism (main reason against sitting position)
- Operative level is checked on fluoroscopy and marked with a drop of methyl blue at the facet junction of corresponding disc (more precise than spinous process in limited approach)
- In case of any foreseen instrumentation, fluoroscopy is draped in the operative field
- Actually the author does not use navigation proposed by some investigators for C1C2 transarticular screwing because of cumbersome handling and lack of mm precision in a moving procedure

### 2.1 Microforaminotomy

Ideal case: *Lateralised DH (soft)* mainly at cervico-thoracic junction (Fig. 2).

- Small midline incision sufficient for subperiosteal unilateral muscle stripping over the corresponding facets allowing introduction of a tubular retractor centered on lamino-articular junction
- Introduction of microscope for light, precision and security
- Key-hole lamino-arthrotomy with microdrill and/or small 2 mm Kerrison: medial facet resection is mandatory to avoid dural retraction
- Following careful flavum resection, the epidural veins are compressed by small cotton at upper and lower corner (the only permanent retractors)
- Micro-hook palpates disc fragment or protrusion under the displaced nerve root near axilla

- Gentle elevation of nerve root allows disc fragment removal and limited curettage
- Careful hemostasis with bone wax and micro-bipolar is required to avoid an epidural or wound haematoma (always drain in dubious case)
- No need for a collar in absence of instability except for initial muscle pain

## 2.2 Laminectomy

Classical *posterior decompression for stenosis* is mostly sufficient in elderly patients with rigid spine. Additional instrumentation for instability is required according to preoperative sagittal imbalance and degree of facet undermining during operation.

- Laminectomy should be sufficiently high and large
- Pay attention: facets, C2 spinous process muscle insertions (rotatory muscles)
- Careful lamina resection with small instruments: risk of dural laceration or cord contusion in severe stenosis, easier handling on microscope
- Sufficient foraminal nerve decompression: foraminotomy
- Limited attempt at disc exploration (only laterally allowed): risk of neurological deficit
- Meticulous epidural, bone and muscle haemostasis with drainage: risk of haematoma
- In case of dural tear or defect (trauma, tumor): primary closure with microsuture/graft if accessible otherwise sandwich packing with fat/muscle reinforced with fibrin glue, more meticulous closure of muscle (eventually flap rotation according to plastic surgery techniques), fascial, subcutaneous plan with separate stitches on skin
- Common risk: kyphosis, instability with axial neck and shoulder pain, C5 paresis (spinal cord posterior migration following decompression) mostly regressive
- Contraindication: loss of lordosis indicating posterolateral fusion and collar
- Or more stable: transarticular arthrodesis according to Roy-Camille (short screw straight ahead avoiding neuroforamen) or to Magerl (longer screw superolaterally orientated avoiding VA)
- Alternative: translaminar screw fixation at cervico- thoracic junction

*Instrumented* laminectomy (or/and double approach) are mandatory in case of osteoporotic, traumatic and tumor involvement of anterior column.

## 2.3 Laminoplasty

Multiple techniques mainly developed in Japan (where OPLL is frequent), but increasing interest outside because impressive enlargement of spinal canal

at multilevel stenosis much like laminectomy with less destabilisation (unless using long posterior fixation) avoiding also extended anterior approaches with graft related problems (now better controlled with intervertebral spacers and dynamic plating):

- *Z-laminoplasty (Hattori)*
- *Open-door technique (Hirabayashi)*
- *En bloc laminoplasty (Kurokawa)*
- *Instrumented laminoplasty*

The surgical principle is to open the canal on one side (open-door) for bilateral decompression much as in laminectomy and to maintain enlargement by fixation of lamina (wire, screw, spacer) in a higher position. Sagittal imbalance and preoperative instabilities are also relative contraindications. Complications are about the same as for laminectomy (neck/shoulder pain, C5 paresis). Laminoplasty is probably underused in degenerative pathology, but also in *spinal cord tumors* mainly in children to replace posterior arches avoiding long term deformity.

### 3. LONG-TERM RESULTS/COMPLICATIONS

The scope of this chapter is not to analyse the results and percentages from publications of the numerous approaches to cervical spine, but the most relevant ideas for surgical use in practise avoiding specific complications [2].

According to literature and author's experience, anterior cervical discectomy with cage fusion has more favourable long-term outcome compared to simple anterior or posterior discectomy concerning neck and arm pain [3, 8, 12]. The posterior microforaminotomy stays a good alternative for C7/T1 DH. Prosthetic solutions seem to protect from adjacent accelerated degeneration following anterior fusion [10], much less seen in posterior approach respecting cervical motion. That is also a personal but limited experience with a dynamic cervical implant (not yet published personal data) on 15 cases since 2004. Dysphagia and dysphonia mostly transient are specific complications of anterior approach [6], and neck/shoulder pain is more seen in posterior route. Shoulder weakness (C5 paresis) generally regressive is specific for large posterior decompressions [9].

The results of anterior approach seem dominant again in most myelopathies owing to the fact that about 75% of stenotic lesions are anteriorly located in cervical spine [8]. Beyond direct approach not hindered by nervous tissue, the spinal column may be more efficiently reconstructed in balance (less non-union/neck pain) with newer technologies (instrumented multi-level discectomy or corpectomy compared to laminectomy). But mod-

ern instrumented laminectomy and laminoplasty techniques improve results of extensive posterior decompression mainly, although there stays a concern in follow-up for neck pain and reduced motion [9].

Anterolateral approaches have good results in pioneer's hands but expose to major vascular risks [4] in less experienced operators, with a concern for instability [11].

In odontoid fractures, direct anterior screwing is superior to occipito-cervical fusion because of motion preservation in a less morbid operation (more patient satisfaction). The fact that a patient may die from a VA lesion (about 4% VA lesion in 1300 reported cases) in transarticular C1C2 screwing is of concern for the posterior approach mainly in elderly patients [1, 5].

The morbidity of posterior cervical approach for tumor cases is very low except in children because of risk of deformity of growing spine, inviting to use laminoplasty techniques [9].

## **HOW TO AVOID COMPLICATIONS**

Most complications are foreseen because typical for each approach and detailed step-by-step in the section Surgery (Complications).

### **1. PAIN/INSTABILITY**

Postoperative neck pain is a negative point for the posterior approach in general, even after simple discectomy, and more specific for extensive laminectomy with arthrotomy without fusion or laminoplasty technique.

Persistent cervicgia indicates a check-up for kyphosis or instability in dynamic views following anterior or posterior approaches. Radicular or myelopathic pain may or may not be associated. If conservative treatment fails, surgical stabilisation is required.

Persistent brachial pain indicates insufficient decompression or wrong level surgery confirmed by imaging, requiring reoperation. Good peroperative fluoroscopy is mandatory for checking involved levels, difficult at cervico-thoracic junction sometimes only visible on oblique views because of shoulder projection.

### **2. NEUROLOGICAL DEFICIT**

Nerve root or spinal cord lesion is rare with strict micro-techniques and to some point avoidable with neuro-monitoring in exposed cases with severe compression (traumatic luxation, OPLL, some tumors and any extensive operations). Any postoperative deficit requires an immediate imaging to

rule out bleeding (epidural haematoma), contusion, CSF leak, bone graft or material displacement with instability. Urgent reoperation is the treatment of choice in most cases with best chances for recovery, eventually after additional decompression and further stabilisation.

C5 palsy in extensive laminectomy or laminoplasty is believed to result from stretching these shorter nerve sleeves where posterior migration of spinal cord is maximum following decompression. Additional preventive or curative foraminotomy at C4C5 is indicated.

Peripheral nerve compression (EMG) concerns brachial plexus, ulnar and peroneal nerve from traction or insufficient protection during installation of patients (responsibility of anaesthesiologist and surgeon).

### **3. DYSPNEA, DYSPHAGIA, DYSPHONIA**

Airway obstruction and postoperative dysphagia is of concern in extensive anterior approach (instrumentation) and mostly related to malposition of retractors or forceful spreading without temporary release improving local perfusion of trachea and oesophagus. Some bradycardia and hypertension from carotid glomus and X nerve are also related to spreading. Postoperative wound bleeding should always be ruled out.

Recurrent laryngeal nerve palsy is a feared complication with much higher than thought incidence [6]. Recommendations for avoidance are: preoperative ENT checking, left side approach in lower cervical spine, careful dissection of longus colli muscles avoiding transverse section but rather lifting up to securely place teathed Caspar's blades under the muscles. Again forceful spreading could lesion the nerve. Recovery is generally satisfying, but persistent cases need laryngoscopic check-up with sometimes Teflon injection by ENT surgeon.

These complications may be avoided by a posterior approach if indicated.

### **4. VASCULAR LESION**

This is the main concern against anterolateral approach as a vertebral artery avulsion by drilling or punch may be catastrophic for the patient. Prevention is training on cadavers, preoperative checking of VA course in transverse foramen on contrast injected views seeking for abnormalities also important in a standard approach during lateral dissection of anterior vertebral body [4]. Treatment is first stay cool: compression and obstruction of the arterial leak with Surgicel, muscle fragment with glue held in place with cotton by sucker, and later replaced by bone wax. Primary repair of arterial wall defect is mostly not feasible because of lack of exposure. Ligation in general is not recommended except in inadvertent arterial transection during anterolateral approach where exposure is sufficient. Operation proceeds from the other side to complete neurological decom-

pression as required without turning back to the weak foramen. Postoperative imaging visualises the vascular lesion with eventually indication for endovascular treatment: balloon occlusion if vertebrobasilar compliance sufficient or stent to maintain the vessel if possible. Stroke may result from ischemia or secondary embolism on clot, indicating anticoagulation after the procedure.

The same reasoning is true for transarticular C1C2 screwing concerning VA lesion and handling [5].

## CONCLUSIONS

Many cervical approaches may reach the target, the simplest way with less complications being the best is a logical conclusion, but several points are to be considered, and first general health of patients. Anatomical location of suspected lesion on clinical and imaging examinations intervene in selecting rather an anterior, a posterior or even a double approach. Pre-, per- and post-operative biomechanical reasoning should always guide the surgical route mainly in expected reconstructions. Finally surgeon's training and experience may be a determinant factor in difficult cases.

## References

- [1] Apfelbaum RI, Lonser RR, Veres R, et al. (2000) Direct anterior screw fixation for recent or remote odontoid fractures. *Neurosurg Focus* 8(6): Article 2
- [2] Benzel CE (2005) *Spine Surgery: techniques, complication avoidance and management*, 2nd edn. Vols. 1 and 2, Elsevier, Philadelphia
- [3] Cloward R (1958) The anterior approach for removal of ruptured cervical disks. *J Neurosurg* 15: 602-617
- [4] George B, Gauthier N, Lot G (1999) Multisegmental cervical spondylotic myelopathy and radiculopathy treated by multilevel oblique corpectomies without fusion. *Neurosurgery* 44: 81-90
- [5] Gluf WM, Schmidt MH, Apfelbaum RI (2005) Atlantoaxial transarticular screw fixation: review of surgical indications, fusion rate, complications and lessons learned in 191 patients. *J Neurosurg Spine* 2: 155-163
- [6] Jung A, Schramm J, Lehnherdt K, et al. (2005) Recurrent laryngeal nerve palsy during anterior cervical spine surgery: a prospective study. *J Neurosurg Spine* 2: 123-127
- [7] Kempe LG (1968) Cervical radiculoneuropathy. Herniated nucleus pulposus and spondylosis. *Operative neurosurgery*, vol. 2. Springer-Verlag, Berlin Heidelberg New York, pp 251-265

- [8] Matgé G (2002) Cervical cage fusion with 5 different implants: 250 cases. *Acta Neurochir* 144: 539-550
- [9] Ratliff JK, Cooper PR (2003) Cervical laminoplasty: a critical review. *J Neurosurg Spine* 98: 230-238
- [10] Robertson JT, Papadopoulos SM, Traynelis VC (2005) Assessment of adjacent-segment disease in patients treated with cervical fusion or arthroplasty: a prospective 2-year study. *J Neurosurg Spine* 3: 417-423
- [11] Schmieder K, Kettner A, Brenke C, et al. (2007) In vitro flexibility of the cervical spine after ventral uncoforaminotomy. *J Neurosurg Spine* 7: 537-541
- [12] Sonntag VKH, Han PP, Vishteh AG (2001) Anterior cervical discectomy. Operative nuances. *Neurosurgery* 49: 909-912



**Guy Matgé**

Guy Matgé is neurosurgeon at the Centre Hospitalier in Luxembourg. He subspecialised through the years in spinal surgery with a large experience in cage fusion and dynamic instrumentation (published data). Dr. Matgé is actually practising about 70% of spinal and 30% of cranial surgery. He has a major interest in cervical and lumbar reconstructive surgery for degenerative, traumatic and tumor cases. He was developing a dynamic cervical implant called DCI, actually used in a multi-center study to evaluate adjacent-level protection. Through EANS, UEMS and JRAAC (harmonisation of neurosurgical training in Europe) he is involved in education, examination and site visiting of departments. He was a Vice-President of EANS from 2003–2007 (organising Meeting 2006) and President of the Francophone Society of Spinal Surgery from 2005–2008 (organising Meeting 2003).

**Contact:** Guy Matgé, National Neurosurgical Department, Centre Hospitalier de Luxembourg, 4 Rue Barblé, 1210 Luxembourg, Luxembourg  
E-mail: [matge.guy@chl.lu](mailto:matge.guy@chl.lu)



---

# MANAGEMENT OF DEGENERATIVE DISEASE OF THE CERVICAL SPINE

J. BRUNON

## INTRODUCTION

Cervical degenerative disease is a very frequent problem. In younger patients it is related with the circumstances of life responsible for cervical traumas, unique or repetitive, which give disc lesions. In the older patients it is in relation with progression of a spondylotic or arthritic process, which concern all the spine structures, particularly the discs but also articular processes and ligaments, etc.

Today no treatment can stop the evolution of the lesions; in future, perhaps molecular biology could repair the degenerative damages related with aging.

The neurological consequences of spondylosis – radiculopathies or myelopathies – are disabling; they can be improved by surgical treatment. For radiculopathy, the direct approach is indicated after medical treatment proved ineffective. For myelopathy, the surgical treatment may improve, in about 50% of cases, the situation for some years.

Several techniques are described, each indicated in relation with the clinical symptoms and the neuroradiological data.

## RATIONALE

The surgical treatment is suitable in two major clinical circumstances: radiculopathy resistant to medical treatment and myelopathy. Radiculopathy and myelopathy are often associated in a myeloradiculopathy syndrome.

The initial physiopathology of the neurological symptoms is the mechanical compression and microtraumatic insults of the neural structures by the spinal lesions, which give secondary microvascular disturbances, inflammatory reactions, and neural degeneration.

The spinal lesions responsible for the neural insults are multiple and must be carefully explored before surgical decision. A nonexhaustive list of observed lesions includes disc herniation (soft compression), calcified degenerative discopathy and/or osteophytes (hard compression), interapophyseal arthritis, segmental stenosis (congenital or acquired), calcifications of posterior longitudinal ligament, inflammatory arthritis (rheumatoid), and sublux-

---

*Keywords:* cervical myelopathy, cervical radiculopathy, cervical anterior approach, cervical laminectomy, cervical arthroplasty

ations (acquired spondylolisthesis). It is indispensable to determine the exact site (anterior or posterior) of the compression, its extension, and the stability or instability of the lesions.

The choice of the better surgical management is based on both the clinical and radiological informations, a rigorous anatomical-clinical correlation study and if necessary on neurophysiological explorations.

The goal of the surgical treatment is to decompress the neural structures by direct approach (anterior or posterior), if possible to restore the normal anatomy and if necessary to stabilize the spine.

## **DECISION-MAKING**

Patient's selection for surgical treatment is based on clinical evaluation, radiological findings, and neurophysiological explorations. Except for certain cases with neurological deficit, a medical treatment is mandatory in all cases before surgical decision.

### **1. CLINICAL PRESENTATION AND EXAMINATION**

#### **1.1 Cervico-brachial neuralgia (radiculopathy) due to cervical nerve root compression**

Acute radicular pain can occur in young patients spontaneously or after a mild trauma; it usually corresponds to a tear in the annulus and a prolapse of the nucleus pulposus. Subacute or chronic radicular pain appears in older patients with chronic spondylosis (degenerative discopathy) or after an acute phase resistant to medical management.

The pain is important, its description is different from one patient to another. Pain is mechanical, intensified by effort, coughing, sneezing, Valsalva maneuvers, and certain cervical movements like flexion or rotation (Spurling sign).

The topography of the pain is determined by the level of the root compression and is located in the corresponding dermatome, more frequently at C6, C7, or C8 levels, but the anatomical-clinical correlation is not always perfect in relation with anastomosis between the cervical roots.

In the (rare) pure painful forms, the neurological examination is normal, without any motor or sensory deficit, and with all reflexes present. But in the majority of cases, mild neurological signs are present; a sensory deficit, permanent paresthesias are noted, the reflex which would travel through the compressed root is absent, mild motor deficit and amyotrophies are observed.

The initial management is medical and includes pharmacological and rehabilitation treatment. Analgesics (opioid if necessary), nonsteroidal anti-inflammatory drugs, and myorelaxants are the mainly used drugs. Anticonvulsants and antidepressants are useful if the pain has a neurogenic component. In some cases, oral corticosteroids are necessary. Local radio-

guided injections of a corticosteroid in the epidural space or in the intervertebral foramen can be performed.

The majority of cases respond to the medical treatment, and surgery is indicated only if that treatment is ineffective after 8–10 weeks or when a neurological deficit appears.

## 1.2 Cervical myelopathy (spinal cord compression)

Spondylotic changes of the spine are the major etiology of cervical myelopathy, but inflammatory or degenerative diseases, such as rheumatoid arthritis and posttraumatic spine deformations, can lead to the same syndrome.

Spondylotic compression is the most frequent cause of spinal dysfunction in the elderly. The pathophysiology is not clear, the initial mechanism is the spondylosis, but many factors interfere, such as microcirculation disturbances and microtraumatism due to instability.

The natural history is controversial. First reports in the literature described two periods: an initial period with neurological deterioration and a second with stabilization or improvement. More recent papers describe a progressive neurological deterioration. It is generally admitted that the patients improve after neurosurgical treatment, but the published studies are in the low-evidence category. The results are better after early interventions with mild deficit. Furthermore, patients with severe spondylosis have a significant risk of spinal cord injury after a minor cervical trauma.

The first symptoms are generally a gait disturbance and leg weakness in relation with proprioceptive and pyramidal deficits. In a second period, the patient presents a loss of dexterity of the hands to execute complex and precise movements such as writing. The evolution is progressive during many months or years, sphincter disturbances appear along the disease progression. In few cases, patients can present an acute evolution after a traumatic cervical hyperextension or hyperflexion, related to a central cord syndrome. Pain is often present in the neck, arms, and legs.

In typical cases, clinical findings associate pyramidal, proprioceptive, and spino-thalamic signs in the legs and peripheral signs in the arms due to compression of the roots or ischemic lesions of the gray matter (anterior horn). Flexion of the neck produces electrical shocks along the spine and the limbs (Lhermitte's sign, initially described for multiple sclerosis).

Many scales have been developed to evaluate the disease progression and the effect of the treatments (medical or surgical). The most popular and reliable ones are the Nurik and the modified Japanese Orthopedic Association (JOA) functional scores.

The clinical signs are not specific for the cervical spondylotic myelopathy; all diseases of the cervical spinal cord can give the same symptoms, for example, amyotrophic lateral sclerosis (never sensory abnormalities), primary spinal atrophy, multiple sclerosis, tumors, syringomyelia. Electrophysiological studies may help to differentiate these different pathologies.

### 1.3 Neck pain

The pathophysiology of neck pain results from multiple associated factors: muscular, ligamentous, discal and articular degenerative lesions, together with harmful psychosocial events. There is no correlation between the intensity of the pain and its functional consequences and the neuroradiological data. When neck pain persists after more than six months of conservative treatment, and if the lesions are limited to one or two levels, surgical treatment can be discussed in selected cases. Many papers found no significant difference in outcome between surgical and nonsurgical management, but a few papers report on benefit of posterior or anterior arthrodesis. No significant results are available for prosthesis.

## 2. RADIOLOGICAL FINDINGS

### 2.1 Plain films, incidences and dynamics

Still today, plain films are useful and remain an excellent tool to basically screen patients with neck symptoms, radiculopathy, and/or myelopathy. They are not expensive and the dynamic flexion-extension views help to diagnose an instability.

In case of radiculopathy, the films can be normal, but often changes can be observed at one or multiple intervertebral levels as pinching disc or degenerative disc disease with osteophytes.

In case of spondylotic myelopathy, the abnormalities may be the same in symptomatic and asymptomatic elderly patients. However, if the films do not show important lesions, the diagnosis is unlikely.

### 2.2 Computed tomography

Computed tomography (CT) with axial slices and sagittal reconstruction is the best radiological investigation to study the bony structures and the foraminal regions. Its accuracy is more than 75%, and it is possible to distinguish the soft or bony structures responsible of the neural (root or spinal cord) compression. It is superior to MRI to visualize osteophytes and other bony changes. In many cases, the surgical decision can be made with this single technique.

Myelography coupled with CT (computerized myelography) provides a greater specificity in more than 95% of cases. It is the only technique when MRI is not possible (because of aneurysm clips or pace maker, etc.).

### 2.3 MRI

Today MRI is the most common method used to explore the spine, the roots, the subarachnoid space, and the spinal cord. It allows to predict the lesions in more than 85% of cases. Because disc herniations are

detected in more than 15% of asymptomatic patients, and degenerative diseases are observed in more than 25% patients younger than 40 years and in more than 60% of older patients, it is very important to correlate these findings with the clinical symptoms and the neurological examination.

MRI shows the site of the neural compression – anterior (disc, osteophytes, and posterior longitudinal ligament, etc.) or posterior (ligamentum flavum hypertrophy, and articular arthritis, etc.) – and provides major information for the surgical strategy. It is possible to determine the “compression ratio” measured by dividing the smallest sagittal by the transverse diameter at the same level and the “transverse area”. A compression ratio of less than 0.4 and a transverse area of less than 40 mm<sup>2</sup>, especially after surgery, entails a bad prognosis.

In cases with myelopathy, it is common to observe intramedullary signal changes in T1- and T2-weighted sequences. A nonspecific T2 hyperintense signal of the spinal cord is observed in about 80% of patients who have a long duration of the disease and a poor preoperative JOA score. The prognostic significance of this abnormality is controversial, the postoperative result seems better without T2 hyperintensity, but there is no statistically significant difference.

#### 2.4 Cervical discography

Cervical discography can be used in cases with pure neck pain, when surgical treatment is considered. The injection can produce and mimic the patient’s usual pain. Discography allows to evaluate the morphological changes of the intervertebral space. However, one should recall that the correlation with the clinical symptoms and the postoperative result is not always good. In addition, the psychosocial profile affects the interpretation of results.

### 3. NEUROPHYSIOLOGICAL EXPLORATIONS

Neurophysiological investigations are not always necessary but can give important information when the diagnosis remains uncertain and when the radiological findings are not well correlated with the clinical data.

Electroneuromyography (ENMG) can distinguish cervical radiculopathy from other neurological disturbances by studying the muscles of the same myotome. The measurement of nerve conduction allows to exclude peripheral nerve pathologies. In cases with pure sensitive radiculopathy or mild forms, ENMG can be normal or little informative. ENMG is important to eliminate amyotrophic lateral sclerosis.

Study of somatosensory evoked potentials explores the lemniscal tract and therefore assesses a spinal cord dysfunction at the cervical level.

## **SURGERY**

### **1. ANTERO-LATERAL APPROACH**

The anterior approach described during the 19th century for the treatment of retropharyngeal tuberculous abscess has been definitively standardized by Smith and Robinson, Dereymaker and Mulier, Cloward and Verbiest in the fifties. It is amazing how these authors were initially criticized, this approach being considered as very dangerous for the vessels, esophagus, trachea, and spinal cord. Today this technique is popular and frequently performed.

A specific instrumentation is necessary: a self-retaining retractor for soft tissues, esophagus, trachea, and thyroid gland medially and carotid artery, jugular vein, and vagus nerve laterally. This retractor has detachable blades of several lengths and designs: blunt blades for soft tissues and sharp blades for the retraction of the longus colli muscles. A vertebral interbody distractor is also necessary; the type described by Cloward is a very strong instrument, but it can injure the vertebral end plate; the type described by Caspar with pins screwed in the vertebral body is easier to maintain in place for performing an intervertebral grafting, but its handling is more difficult.

The cervical spine can be approached from both sides: the right side is more convenient for right-handed surgeons, but the recurrent nerve is more exposed for the inferior discs: C6/C7 on C7/Th1. Approaching from the side opposite to the symptoms, for example, right approach for left symptoms, allows a better access to the uncus. Current practice of the surgeon is the most important criterion of choice.

A small horizontal incision (4 cm) along Langer's line is more cosmetic and permits the access to two intervertebral spaces. Before the incision, the level is identified by fluoroscopy. For three or more spaces, a longitudinal incision (along the medial border of the sternocleidomastoid muscle) should be performed. Such an incision permits the approach of all the cervical spine from C2/C3 to C7/Th1, but it is less cosmetic and can be retractile and painful.

The medial border of the sternocleidomastoid muscle is easily identified and the superficial cervical fascia is divided. The cleavage plane between the carotid artery and the esophago-tracheal axis is identified and dissected with the finger; this is not elegant but is safer to avoid damaging these structures. The omohyoid muscle identified by its diagonal fibers can be sectioned, but it is not always necessary; it can be retracted up- or downward. Its section can modify the voice in the high frequencies. The recurrent nerve can be injured if the retraction of the oesophago-tracheal axis is too strong.

The level is verified by fluoroscopic control after insertion of a needle into the disc. The avascular prevertebral fascia (anterior longitudinal ligament) is medially sectioned and the medial border of both longus colli muscles is identified and scrapped from the vertebral body as far lateral as possible.

A self-retaining tooth retractor is placed under each longus colli muscle and retracts the carotid artery laterally and the esophagus and trachea medially.

### 1.1 Discectomy and osteophyte resection

The longitudinal ligament and the anterior wall of the disc are incised with a sharp scalpel about 1 cm deep as far lateral as possible. The uncovertebral joints limit laterally the disc incision.

The incised disc is partially removed with curettes and rongeurs before the insertion of the vertebral spreader. It is very important to remove more than two-thirds of the disc before the insertion of the Cloward type distractor. If this condition is not met, the distraction can injure the vertebral end plate. The same is not required for the Caspar vertebral distractor, but this instrument is less strong than the Cloward one.

In our practice, we use both types of distractors: the Cloward type inserted in the intervertebral space for discectomy and the Caspar type screwed in the adjacent vertebral bodies for graft insertion.

The whole disc and the osteophytes may be removed with small straight and curved curettes, osteotomes, and rongeurs and with high-speed burrs. Optic magnification is preferable but not mandatory. Fluoroscopic control is possible during resection of osteophytes.

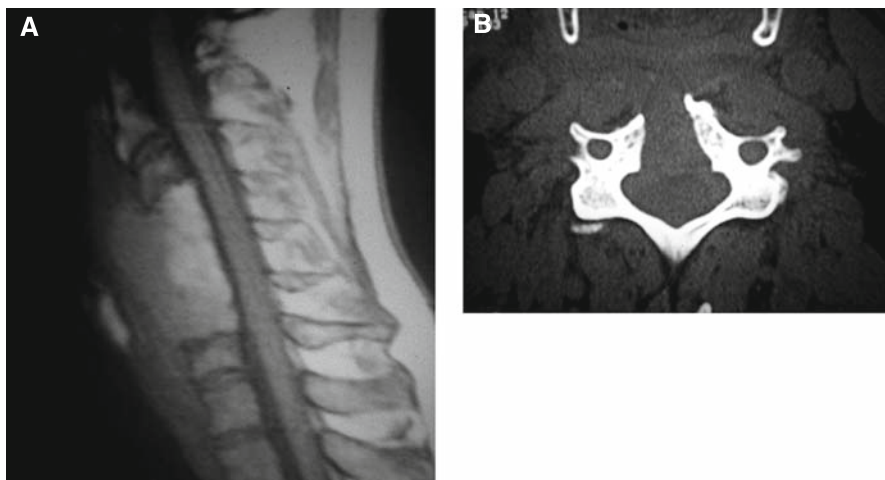
It is not a consensus to remove the posterior longitudinal ligament. Its resection provides a better decompression of the dura but risks injury to the epidural veins and consequently significant bleeding. When the ligament is preserved, some disc fragment or an aggressive osteophyte may be missed.

### 1.2 Median somatotomy

Discectomy with or without reconstruction is the technique used when the compression is limited to one, two, most rarely three levels without extended stenosis of the cervical channel. In cases of myelopathy with extended anterior lesions, it is possible to decompress the anterior spinal cord by a median somatotomy (Fig. 1).

The approach is the same, a longitudinal skin incision is necessary for more than two levels. The superior and inferior limits of the somatotomy are verified by a fluoroscopic control. The anterior longitudinal ligament is incised on the midline. The bone resection is performed with mechanical burrs to the posterior longitudinal ligament. In an axial plane the resection may be trapezoidal, about 10 mm in the front and 12–14 mm at the posterior part of the vertebra. Laterally the resection may spare the uncovertebral joint to avoid late spinal instability. The posterior longitudinal ligament, which is often partially calcified, is resected or transected for an optimal decompression of the dura and the initial part of the roots.

Many authors complete the decompression by an iliac crest tricortical or peroneal graft and anterior osteosynthesis. In our experience, particularly in elderly patients who suffer of myelopathy with extensive spondylosis, graft-

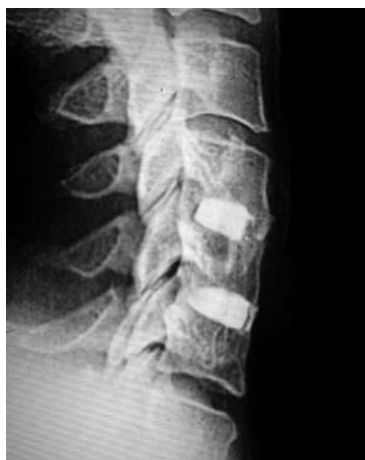

**Fig. 1.** Anatomical result after median somatotomy without graft. **A** MRI: the T1 hypersignal from C3 to C7 corresponds to the fibrous scar. **B** CT: aspect of the bone trapezoidal resection

ing or plating is not necessary, late secondary kyphosis is not more frequent than after osteosynthesis.

### 1.3 Disc and bone defect reconstruction

Disc reconstruction (Fig. 2) is a controversial issue. Initial clinical results are the same with or without interbody spacing, the size of the intervertebral



**Fig. 2.** Late result after a double discectomy and intercorporeal graft with a bone substitute. No degeneration of the adjacent levels



foramen is larger with interbody spacing but not correlated with the clinical results. Spine deformations as kyphosis are more frequent without interbody grafting. Long-term results are not well known. Grafting and/or plating show specific complications or morbidity.

In 2000 we have studied the practice of a panel of European French-speaking neurosurgeons: one third did not use grafts, one quarter used a graft without osteosynthesis, and the others used various devices: plates, cages, and cage-plates, etc. When a graft was performed, an autologous bone was used in 60% and a substitute in the other cases.

The best graft is the autologous tricortical iliac crest, which gives a rapid fusion, but in 10–15% of cases, complications occur at the donor site: infection, hematoma, or late disabling pain. For these reasons, many surgeons use allograft or bone substitute such as tricalcium phosphate or hydroxyapatite. The mechanical properties and delay of incorporation of these grafts are not as good as those of iliac crest, the graft can be placed in a metallic, synthetic, or bioresorbable cage which provides the initial stabilization. It is also possible to use anterior screwed plates or a special implant associating cage and plate.

Each of these complementary techniques is responsible for specific complications as loosening of the internal fixation and is relatively expensive.

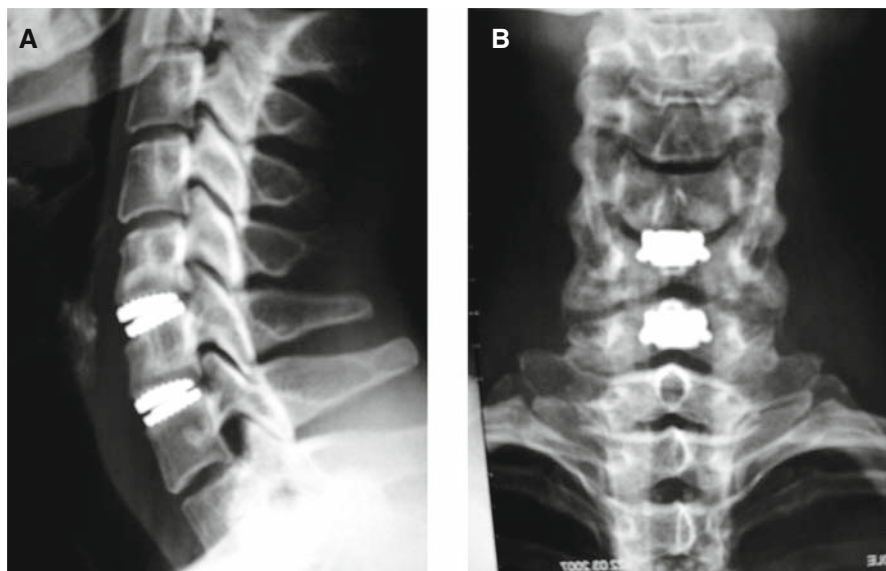
#### 1.4 Cervical arthroplasty (disc prosthesis)

It was postulated that cervical fusion induces an increase of biomechanical stress at the adjacent levels, early spondylotic changes, and need for new operations. But it has not yet been established whether these manifestations follow the natural course of the degenerative disease or are direct consequences of the fusion.

Cervical arthroplasty (Fig. 3) is a new surgical technique to replace the disc, maintain and/or restore the mobility with the objective to prevent degeneration of the adjacent disc. Since a few years, some prostheses are available with different technologies and designs of the joint. The Bryan metal–polyurethane cervical disc is the more popular but its implantation is complex. Other designs have metal–metal, polyethylene–metal, or metal–ceramic contacts.

The implantation of the prosthesis is easy for a surgeon trained for the anterior approach of the cervical spine.

The clinical results may be as good or better as classical techniques, and the frequency of second operation may be little. In 2007, a multicenter prospective randomized study reported by Mummaneni et al. included 541 patients [5]. The results were better in the group with prosthesis: motion was preserved in the majority of cases, but the spine curvature was often worsened without clinical incidence as in case of fusion, heterotopic ossifications were relatively frequent, more than 20% of prostheses had a significant limi-



**Fig. 3.** Double arthroplasty at C5/C6 and C6/C7 (result after 18 months with a good clinical improvement)

tation of motion. To be noticed, the study was sponsored by the manufacturer of the Prestige ST cervical disc system.

Cervical prosthesis is a logical concept; the surgical technique is simple. But this new technique must still be evaluated in the long term, prospective randomized studies must be continued. Complications are more frequent than for anterior cervical discectomy with fusion. The device is more expensive than other anterior techniques, particularly when no graft is used.

## 2. POSTERIOR APPROACH

The posterior approach was developed since the middle 19th century and was the most popular until 1950 when it was supplanted by the anterior approach. The posterior approach combines many advantages: the exposure is easy, no stabilization is required in the majority of the cases, there is no risk to the cervical vessels, esophagus and recurrent nerve, the neural structures are under direct visualization. But it presents some disadvantages such as post-operative pain, risk of dural tear and nerve injury, risk of instability with kyphosis related to injury of paraspinal muscles or arthroectomy, and above all, it leaves any anterior agents of the neural compression (osteophytes and ossification of the posterior longitudinal ligament, etc.) in place.

Under general anesthesia with oral intubation, the patient is placed in prone position or rarely in sitting position, which entails the risk of air embo-

lism. The head is fixed in a Mayfield clamp with a slight flexion. The vertical skin incision is performed on the midline. The aponeurosis is sectioned on the midline and the paraspinal muscles are retracted on one side or the two sides according to the type of decompression. A lateral fluoroscopic control may be necessary for interspace localization in case of radiculopathy.

### 2.1 Treatment of radiculopathy: laminoforaminotomy and disc fragment resection

The early surgical procedures were aggressive, often with dura opening, section of the dentate ligament, transdural excision of the disc fragments, and resection of osteophytes. These techniques have a high morbidity rate. Today the approach is minimally invasive (keyhole), strictly extradural to avoid neurological complications. A mini open endoscopic foraminotomy can be performed.

After a unilateral approach at the level of the nerve root compression, the dissection exposes the lamina and the medial part of the facet joint.

A limited bony resection is performed by hemilaminectomy, foraminotomy, and partial medial arthroectomy to open the dorsal part of the intervertebral foramen. The root is identified at its dural emergence. In case of radiculopathy by spondylosis and stenosis of the intervertebral foramen, this decompression, which concerns the half medial part of the articular process, is often sufficient. In case of disc herniation, the free fragments of disc are removed, the disc itself is not resected. With a very little drill, gently handled, it is sometimes possible to resect the osteophytes developed from the uncovertebral joint but there is a risk of injuring the root and the vertebral artery.

### 2.2 Treatment of myelopathy: laminectomy and alternatives

Cervical laminectomy is the most classical treatment of myelopathy caused by multilevel spondylosis and ossification of the posterior longitudinal ligament. Its extent is determined by the neuroradiological data, especially MRI, and must reach below and above the lesions, often from C2 to C7 or Th 1. It must be atraumatic. In our experience, after resection of the spinous process, the laminectomy is performed with a little high-speed drill and a little Kerisson rongeur at the junction of the lamina and the articular process.

However, this technique can induce cervical instability with kyphotic deformity (especially when a resection of facet joints is performed) and formation of a post-laminectomy membrane and does not treat physiopathologic dynamic factors of the spinal cord dysfunction. Many alternatives have been proposed such as the following three.

One possibility is to preserve the nuchal, supraspinous, and interspinous ligaments. After a midline incision, a unilateral approach is made and paraspinal muscles are retracted only on this side. Spinous processes are cut on their insertion on the lamina, with an oscillating saw or another adapted instru-

ment, one level above and below the site of the spinal decompression (for example, from C2 to Th 1 for a decompression C3 to C7). The complex realized by the spinous process and ligaments is retracted on the other side of the approach by a self-retaining retractor. Then, laminectomy is conducted as classical. At the end, the complex is repositioned in the midline, and the closure is performed as usual.

Another possibility is to prevent late instability and treat the dynamic factors of the pathophysiology, as has been proposed by many authors, by systematically performing an osteosynthesis with plates screwed in the articular process as described by Roy Camille associated with a graft or BMP (bone morphogenic protein).

Since 1970, Japanese authors have developed many techniques of laminoplasties. All these techniques aim to reconstruct the posterior arch after the expansion of the cervical canal. The most common is the “open-door” technique with or without plating and grafting with autologous bone or osseous substitute. It is also possible to split the spinous process in the midline and interpose a graft as a spacer.

### 3. RESULTS

It seems logical to directly attack the pathogenic factor of the neurological dysfunction. It is suitable to perform an anterior approach when the compression is anterior, and a posterior approach when the compression is posterior or extended.

Numerous studies compared the results of these different techniques, but only a few of them were prospective and randomized. It has been clearly demonstrated that clinical results of the surgical treatment are not correlated with the technique when the anatomical result of the decompression is sufficient. The prognosis depends essentially on preoperative clinical conditions, duration of symptoms, and concomitant diseases. The conclusions of these publications can be summarized as follows.

For radiculopathy without neurological deficit the clinical results are independent of the technique. The anterior approach with or without graft and the posterior approach yield good results in more than 90% of cases at short- and medium-term follow-up [8]. Late results are not well known and the frequency of a second intervention is misevaluated, from 3 to 15% or more. The recurrence is at the same level after the posterior approach and at other levels after fusion.

For myelopathy, the surgical treatment results in early improvement for 55% and in stabilization for 35% of the patients, while in about 10% the disease continues to progress. After 5 years, only 50% of the patients are improved, the late functional status is related to the myelopathy, but also to other pathologies as hip arthritis or degenerative stenosis of the lumbar spine.

The clinical results are independent of the anatomical results.

After a laminectomy, the posterior fusion prevents late instability but limits cervical motion.

Laminoplasties do not yield better clinical results than laminectomies and limit cervical motion as does a posterior fusion.

The spinal alignment is similar after laminectomy or laminoplasty.

## HOW TO AVOID COMPLICATIONS

The anterior or posterior surgery of the cervical spine for degenerative disease is a safe technique, but as for all surgical procedures, complications can be observed.

General complications, such as death, postoperative infection, phlebitis and pulmonary embolism, and anesthetic accident, are very rare and correlated with the age and the general status of the patient, with the pathology (myelopathy more than radiculopathy), and with the approach (posterior more than anterior). Neurological worsening is also very rare for both approaches; other complications, such as vascular, digestive, or tracheal complications after the anterior approach, are rarely observed.

After the anterior approach, a more frequent complication is transient or definitive dysphonia by compression of the recurrent nerve between the self-retaining retractor and the balloon of the tracheal tube. The inflation pressure of the balloon should be as low as possible and controlled with a manometer, the retraction of the aerodigestive tract may be limited by the uncus plane.

A C5 and/or C6 radiculopathy after anterior or posterior approach can be observed, for which there is no clear explanation. Possibly it results from the traction on the shoulder to make the fluoroscopic control easier.

A morbidity on the donor site graft is observed in 10–18% of the patients: hematoma, infection, and/or residual pain; this is the most important reason to prefer substitute to autologous bone.

With all techniques, mechanical complications may be observed at the spine as instability or kyphosis. The laminectomy increases the range motion of the cervical spine and can give an instability with late kyphosis, the preservation of the nuchal ligament restrains cervical spine flexion. Hypermobility and instability are more frequent when a facetectomy is performed. In the adult, when facet joints are spared, the incidence of postoperative instability is not well known: from none to more than 20% of cases, but without clinical correlation. It was postulated that the formation of a post-laminectomy membrane can induce a late deterioration; however, experimental studies with dogs and clinical studies have not confirmed this hypothesis.

After the anterior approach, a pseudarthrosis is observed in 2–20% of cases, more frequently with allograft or bone substitute. In worsened patients, postoperative instability or pseudarthrosis are frequently observed. The

fusion can induce an early degenerative disease of the adjacent (upper) segment and 3 to 20% of the patients have to be reoperated within the next years [4, 9]. It is very difficult to determine the respective role of the fusion itself and the natural course of the degenerative disease in such evolution. A kyphosis is frequently observed at the fused segment and at the whole cervical spine without clinical consequence in the majority of cases. An anterior plating limits the rate of pseudarthrosis and kyphosis but induces specific complications.

## CONCLUSIONS

It is difficult to give a clear answer with regard to the choice of the better technique. In our experience we have adopted the following guidelines according to the clinical presentation and anatomical data evaluated with CT scan or MRI.

Radiculopathies or myelopathies related with one or two anterior compressions by discopathy are treated with discectomy and osteophyte resection. In the majority of the cases, an interbody fusion with bioresorbable cage and osseous substitute is performed. The reason for the graft is to prevent kyphosis and restore the size of the intervertebral foramen. Since two years, in case of radiculopathy in young patients (less than 55 years), we perform disc prostheses.

For radiculopathy, we rarely perform a posterior approach.

Myelopathies related with more than two anterior compressions by discopathies are treated with median somatotomy. Graft with or without plating is indicated only for young people, no significant instability with late neurological deterioration is observed in patients older than 65 years.

Myelopathies related to a congenital stenosis, posterior compression by facet joint hypertrophy are treated by the posterior approach. In the majority of the cases, a classical laminectomy with partial facetectomy (less than 25%) is performed. We have no experience of laminoplasty in this clinical context.

Myelopathies related to preoperative spinal instability (role of dynamic physiopathological factors) are treated by decompression with fusion. If the instability concerns one or two levels, an anterior approach is performed; when the instability is "global" (very rare in our experience), a laminectomy with posterior fusion is performed.

## References

- [1] Brunon J, Fuentes JM, Azan F, Benezech J, Duthel R, Fotso MJ, George B, Lapras C, Lesoin F, Robert G (1996) Chirurgie antérieure et antero-latérale du rachis cervical, vingt cinq ans après H. Verbiest. *Neurochirurgie* 42: 105-122 and 229-248

- [2] Brunon J, Nuti C, Duthel R, Fotso MJ, Dumas B (2005) Myélopathies cervicales. *Traité Encyclop Médico-Chir Neurol* 17-660-A-10
- [3] Edwards CC 2nd, Heller JG, Murakami H (2002) Corpectomy versus laminoplasty for multilevel cervical myelopathy: an independent matched-cohort study. *Spine* 27: 1168-1175
- [4] Hilibrand AS, Carlson GD, Palumbo MA, Jones PK, Bohlman HH (1999) Radiculopathy and myelopathy at segment adjacent to the site of a previous anterior cervical arthrodesis. *J Bone Joint Surg Am* 81: 519-528
- [5] Mummaneni PV, Burkus JK, Haid RW, Traynelis V, Zdeblick TA (2007) Clinical and radiographic analysis of cervical disc arthroplasty compared with allograft fusion: a randomized controlled clinical trial. *J Neurosurg Spine* 6: 198-209
- [6] Ratliff JK, Cooper PR (2003) Cervical laminoplasty: a critical review. *J Neurosurg* 98(3 Suppl): 230-238
- [7] Wang MC, Chan L, Maiman DJ, Kreuter W, Deyo RA (2007) Complications and mortality associated with cervical spine surgery for degenerative disease in the United State. *Spine* 32: 342-347
- [8] Wirth FP, Dowd GC, Sanders HF, Wirth C (2000) Cervical discectomy: a prospective analysis of three operative techniques. *Surg Neurol* 53: 340-348
- [9] Yue WM, Brodner W, Highland TR (2005) Long-term results after anterior cervical discectomy and fusion with allograft and plating: a 5- to 11-year radiological and clinical follow-up study. *Spine* 30: 2138-2344



**Jacques Brunon**

Jacques Brunon is a neurosurgeon since 1973, first in Lyon and then in Saint-Etienne, where he established the neurosurgical department in 1979, which today employs eight neurosurgeons. He has a large experience in spinal surgery. After a stage with Raymond Roy-Camille in Paris, he was the first French neurosurgeon to perform a posterior transpedicular osteosynthesis. He was chairman of the French Society of Neurosurgery and of the Francophone Society of Spinal Surgery and is now a member of the Scientific Directory Committee of the French-Speaking Neurosurgical Society. Spinal surgery represents 50% of his activity, particularly in degenerative diseases, but also traumas and tumors. He has developed bioresorbable implants for anterior cervical surgery and is one of the two national responsables for the evaluation of cervical and lumbar disc prostheses. He has organized in Saint-Etienne two international meetings on neurosurgery in 1982 and 2002.

**Contact:** Jacques Brunon, Neurosurgeon, Emeritus Professor, Chairman of the Neurosurgical Department of Bellevue Hospital, University Jacques Lisfranc, 42055 Saint Etienne Cedex 2, France; Personal address: 31 chemin de la Colache, 42800 Rive de Gier, France  
E-mail: [jbrunon@club-internet.fr](mailto:jbrunon@club-internet.fr)



---

# MANAGEMENT OF LUMBAR DISC HERNIATIONS AND DEGENERATIVE DISEASES OF LUMBAR SPINE

A. K. MSADDI

## INTRODUCTION

Between the degenerative spine diseases, disc herniation is the most common pathology encountered and managed by general neurosurgeons, orthopedists and spinal surgeons.

Mixter WS and Barr IS in 1934 are the first to correlate the lower back and sciatic pain to the herniated disc materials and describe surgical treatment for disc herniation.

Surgery for lumbar disc became more practiced with the introduction of myelography around 1930 and discography which was mentioned by Lindblom in 1948.

Laminectomy and hemilaminectomy represented the standard approach for decades [7]. As these techniques were associated with frequent complications and high percentage of failed back surgeries introduction of less traumatizing surgical approach was necessary.

Since Yaşargil, and Caspar introduction to microsurgery [2–12], microsurgical discectomy progressively became popular and represent the gold standard in the treatment of lumbar disc herniation.

Great improvement and refinement of the microsurgical technique was done by renowned surgeons like John A. McCulloch and H. M. Mayer [6, 8].

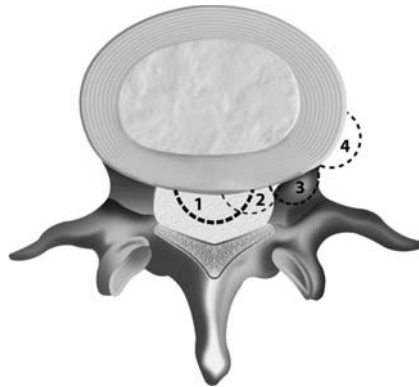
Furthermore, motion preservation with total disc replacement (TDR) in the treatment of discogenic low back pain is an ingenious concept, which is gaining much popularity but so far still there is lack of long term follow-up with comparison to the microsurgical discectomy or fusion.

## RATIONALE

Spinal degeneration is synonymous of spondylosis, the process of degeneration takes long years and involves the intervertebral disc first followed by the facet joints, ligaments and endplates with spurs and osteophytes formation. With aging the disc suffers changes in shape, volume and structure represented mainly by progressive decrease of proteoglycans, increase of collagen content

---

*Keywords:* spine, lumbar disc herniation, degenerative disease, lumbar spine



**Fig. 1.** Illustration of the location of the lumbar disc herniation, 1: central, 2: paracentral, 3: foraminal, 4: extra foraminal

and loss of water content determining a loss of hydrostatic pressure with reduction to compressive forces and overload on the inner layers of the annulus with subsequent appearance of annular fissures. There will be loss of clear transition nucleus-annulus leading to what is called black disc, loss of disc height follows. Under increased fatigue and mechanical forces the degenerated nucleus disc fragments herniate through the pre-existing annular fissures [9].

Some studies suggested that genetic factors may play a significant role in the process of disc degeneration [5].

Classification of the type and location of the disc herniation helps the surgical planning and the prediction of the outcome. Disc herniation is classified by the location as follows: central, paracentral, foraminal and farlateral or extraforaminal. The paracentral form is the most frequently encountered (Fig. 1).

## DECISION-MAKING

### 1. DIAGNOSTIC CRITERIA

Description of pain and paresthesias helps to localize the level of the herniated disc, it is essential to correlate the clinical findings to the imaging findings, that is why we need to have a clear definition of different types of herniations; paracentral herniation causes compression on the traversing nerve root, e.g. L3–L4 disc herniation causes compression on L4 nerve root and L4–L5 disc herniation causes compression on L5 traversing nerve root. Foraminal herniation causes compression on the exiting nerve root and in some cases with lateroforaminal extension, it may cause compression on both the traversing and the exiting nerve roots, while the far lateral extraforaminal causes compression on the nerve root in its paraspinal course. The upward herniated fragment may cause compression on the supraadjacent exiting root.

## 2. HISTORY AND CLINICAL EXAMINATION

Most of the patients with degenerative disc herniation start their symptoms with some low back pain followed by leg pain, however, this may not apply to younger patients who may complain only of leg pain.

The type of pain is classical, provoked and increased with loading and weight bearing, improved with unloading, long sitting and standing and physical strains worsen the pain while walking and lying down relieves the pain, the leg pain has a dermatomal distribution with or without numbness. The majority of the patients with degenerative disc herniation have no neurological deficit, pain with limited range of spine motion are the main findings, positive straight leg raising sign and possible reflex changes. Plantar or dorsal flexion weakness of the foot associated with hypoesthesia are not rare findings in neglected cases or with severe root compression. Cauda equina syndrome is seen with very large herniation causing severe compression on the thecal sac and it is manifested by multiple root involvement with sphincteric problems. In the case of extraforaminal disc herniation, the straight leg raising sign is negative and the nerve root involved is the supra-adjacent exiting one and not the traversing root at the disc level.

## 3. IMAGING STUDIES

It is important to balance the requirements not to miss treatable organic pathology with the need to avoid unnecessary and costly investigation.

### 3.1 Plain X-ray

AP and lateral help to identify the presence of transitional vertebrae, sacralization or lumbalization, loss of height of the disc, pars-interarticularis defect and spina bifida defect. Dynamic lateral X-rays in flexion-extension are indicated if there is possible instability which could be aggravated by the discectomy and may influence the outcome of the surgery.

### 3.2 MRI

The gold standard investigation for the diagnosis of degenerative disc disease and disc herniation. It provides information upon neural structures, disc status (dehydration, internal disc disruption, herniation, migrating fragments, extraforaminal herniation, loss of height), facet joints and ligamentum flavum folding and hypertrophy.

In acute disc herniation, more attention must be paid when studying T2 images as the disc fragment is very bright on T2WI which may cause misdiagnosis thus it is recommended to look more carefully to T1 images. The possibility of adding contrast can differentiate between recurrent disc herniation and epidural scar, sequestered disc and intraspinal tumor.

### 3.3 CT scan

CT scan is done when MRI is contraindicated or when more bony details are required e.g. calcified disc herniation, the sensitivity and specificity is increased when combined with myelography.

### 3.4 Myelography

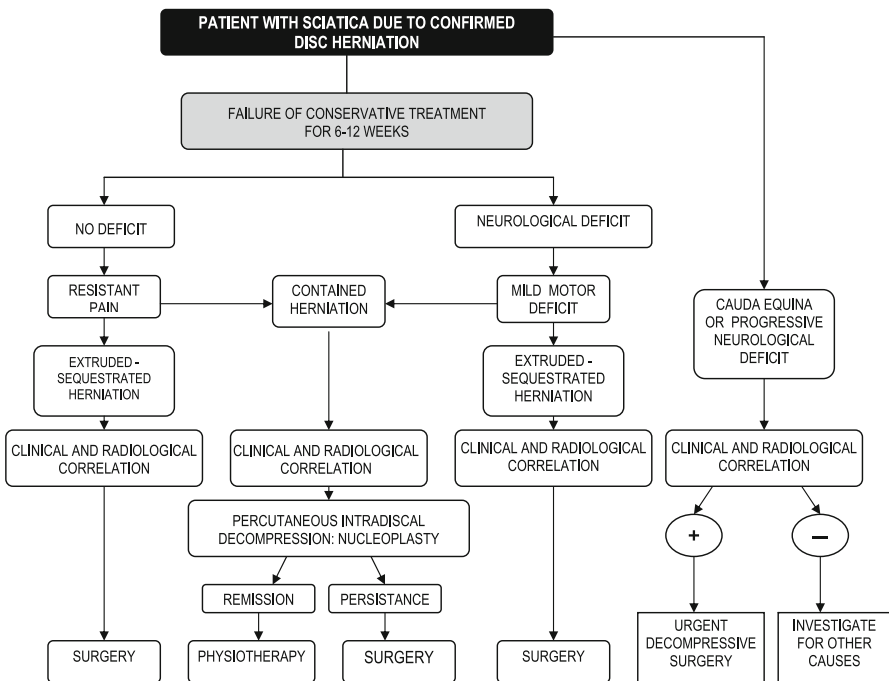
This is helpful in the presence of metal implant affecting the quality of the images, and when dynamic information is required, it has some limitation in diagnosing the extra-foraminal disc herniation, better when combined to the CT scan.

### 3.5 Medial branches and facet blocks

Help confirming the presence of facet pain and how significant it is in the patient pain syndrome.

## 4. EMG/NCS

Provide complimentary evidence to the MRI diagnosis.



**Fig. 2.** Indications for surgery after failure of conservative treatment

## 5. INDICATIONS

Poor patient selection is the main cause of bad results of surgery for herniated disc or degenerative lumbar spine diseases.

Early or urgent intervention can be indicated if the patient is presenting cauda equina syndrome with bowel and bladder symptoms, rapidly progressive motor weakness, severe intractable pain not responding to medical treatment.

Elective surgery is in general the rule for lumbar disc herniation and symptomatic degenerative spine diseases:

Surgery is indicated when failure of well conducted conservative treatment for 6–12 weeks including epidural infiltration.

The surgical indication should be based on positive correlation between radiological studies, mainly MRI, history and physical examination findings and occasionally on electrophysiological data (Fig. 2).

## SURGERY

### 1. HOW TO DO IT

#### 1.1 Percutaneous nucleoplasty

I believe that a small category of patients with contained lumbar disc herniation without upward or downward subligament extension may benefit of a percutaneous intradiscal decompression procedure such as nucleoplasty [4]. (PercDLE SpineWand; Arthrocare) which was introduced in July 2000.

The indications are leg pain or combined back and leg pain due to contained disc herniation, failure of well conducted conservative treatment for 6–12 weeks. The disc height must not be less than 70% and the disc must not be very degenerated.

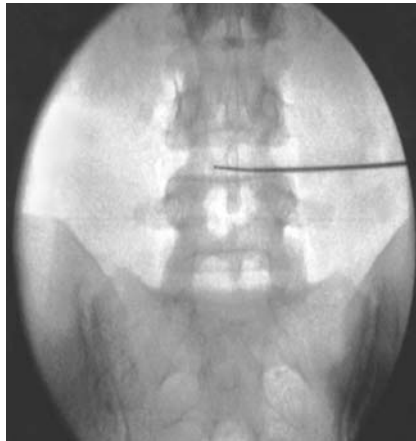
The procedure is done under local anesthesia, the approach is posterolateral, with fluoroscopy guidance, the patient stays 4–6 h in the hospital and he is allowed to walk after one hour.

With this technique I have experienced good results based on VAS with 75% out of 80 patients with contained centro-lateral or lateral intracanalicular disc herniation. The results in 13 patients with foraminal far lateral disc herniation were not good with a failure rate exceeding 50% (Fig. 3).

#### 1.2 Microdiscectomy

The gold standard surgery for lumbar disc herniation.

Pre-operative preparation consists of a complete clinical examination, anesthesia assessment and as required, medical clearance with internal medicine



**Fig. 3.** Percutaneous nucleoplasty for intradiscal decompression, fluoroscopic A.P. view showing the SpineWand device inside the disc

or cardiology consultation, aspirin, Plavix must be stopped 5 to 7 days before surgery, appropriate blood work should be completed, informed consent should be signed explaining success and failure, risks and possible complications of the procedure.

Clinical examination should be repeated the day of admission for surgery, any new signs or deficit must be documented, MRI study must be checked again and needs to be repeated if it is relatively old or if new presenting complaints or neurological deficit appear.

## 2. OPERATIVE TECHNIQUE

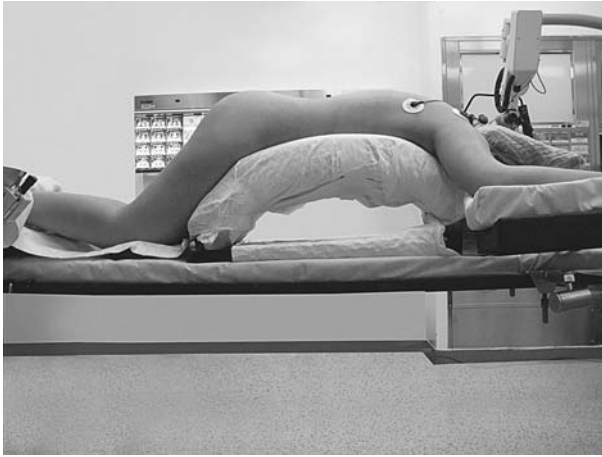
### 2.1 Surgical technique in a non-operated back

#### *Positioning*

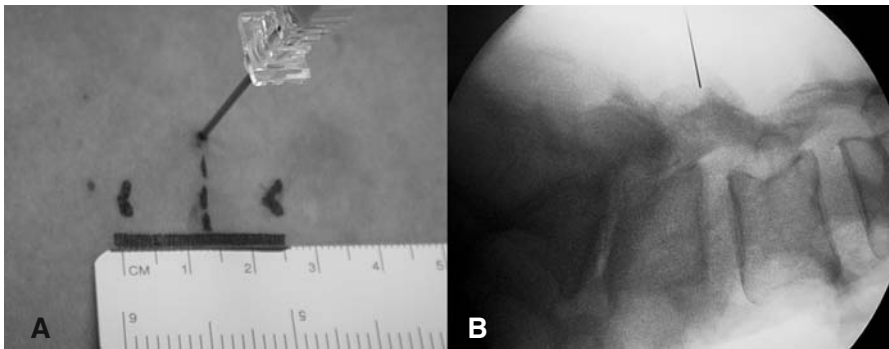
After anesthesia induction and intubation, intravenous prophylactic antibiotics is given, we do use Rocephin (cephalosporin) 2g as a single bolus.

I do prefer to operate my patients on a Wilson frame (OSI, USA) as this easily decreases the lumbar lordosis, spreads apart the lamina and open the posterior part of the disc space making the intradiscal approach easier, while keeping the abdomen free of any pressure which reduces the epidural bleed (Fig. 4).

We occasionally use the knees-chest position which is giving nearly similar results. All the pressure points should be carefully padded, the arms of the patients should not be abducted more than 90°. It is also important to avoid excessive neck extension during any prone operation especially in elderly with spondylosis.



**Fig. 4.** Positioning of the patient on the Wilson frame over OSI table



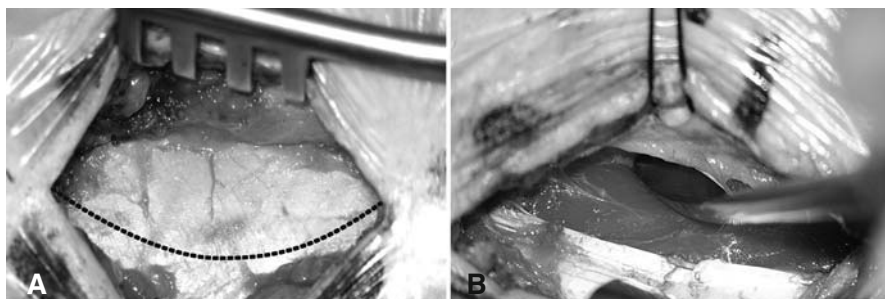
**Fig. 5. A** Skin incision 5 mm paramedian centering the disc space (dotted line) with the needle inserted in the non operated side for confirmation of level. **B** Fluoroscopic lateral view showing the needle confirming the disc level

#### *Localization and skin incision*

The disc to be approached is localized and the laterality is confirmed with a needle inserted on the contra-lateral side under fluoroscopy (Fig. 5A, B).

The skin incision is placed about 5 mm off the midline on the side to be operated, it should contain the disc space in its middle third and it should be fashioned according to the extension of the herniated disc keeping in mind that the interlaminar space is slightly below the level of the disc.

In most of the cases the skin incision can be limited to 2–3 centimeters, but the surgeon must keep in mind that this technique requires suitable instruments and the size of the skin incision must not cause excessive traction with resulting bad scar.



**Fig. 6.** **A** Dotted line showing the curvilinear incision of dorsolumbar fascia. **B** The facial flap is retracted medially and maintained with stitches and the Cobb elevator dissecting the muscles from the interspinous ligament down to the interlaminar space

#### *Interlaminar space exposure*

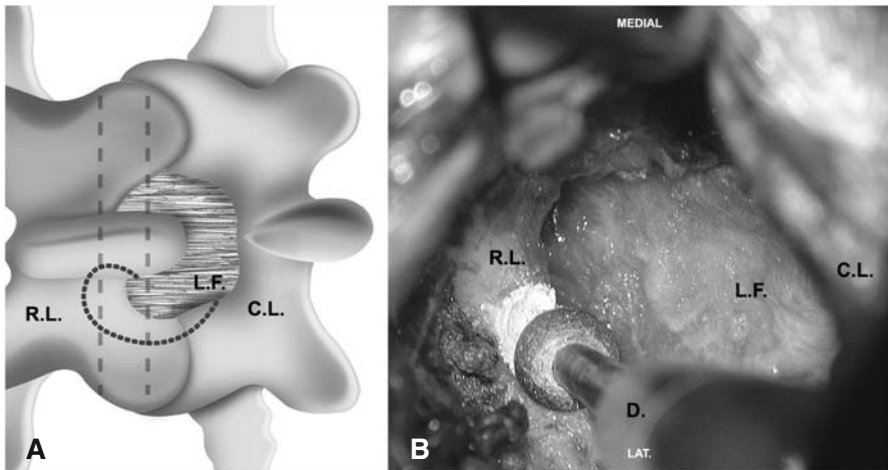
After skin incision, blunt dissection through the subcutaneous tissue is performed, the thoracolumbar fascia is exposed and the two layers are sectioned in an arcuate fashion (Fig. 6A, B).

The fascial flap is secured with stitch and retracted towards the midline. The opening should center the interlaminar space as well as the disc level. At this point the underlying paravertebral muscles are separated from the interspinous ligament, spinous processes and laminae with a large sharp Cobb elevator down to the interlaminar space exposing partially the laminae to the medial part of the facet joint. At this point, self retaining retractor (FEHLING NDM Germany) is inserted into the wound with the blade side placed lateral to the facet retracting the muscles. The blade width is 1 centimeter allowing more exposure, the hook side is placed medially on the interspinous ligament. Face to face surgical microscope is taken at this step and the remaining surgery is continued under microscope. The interlaminar space is cleaned off the soft tissue exposing the ligamentum flavum and the laminae. I usually reconfirm the level before entering the spinal canal with another fluoroscopic shot to avoid any possibility of wrong level surgery.

#### *Opening of the spinal canal and exposure of the nerve root*

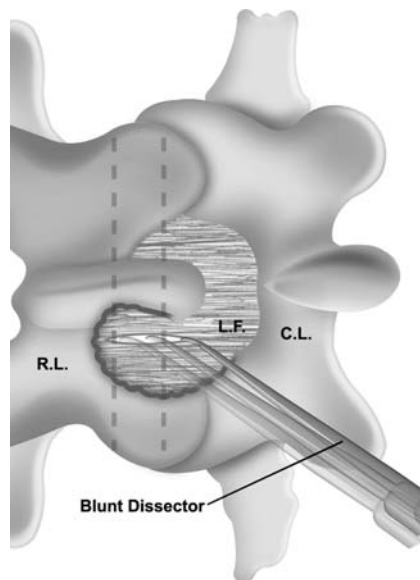
Once the interlaminar space is cleaned and exposed, and before the opening of the ligamentum flavum which protects the content of the canal, partial resection of the lower part from the rostral lamina to the medial part of the facet joint is performed using the high speed drill or Kerrison (Fig. 7A, B). This bony removal eases the removal of the superficial layer of the ligamentum flavum from its attachment and helps to expose the disc level which is higher than the interlaminar space except for L5-S1 where there is no need in general for bone removal to approach the disc. Obviously, if the pre-operative radiological studies show a downward migrated disc fragment, partial removal of



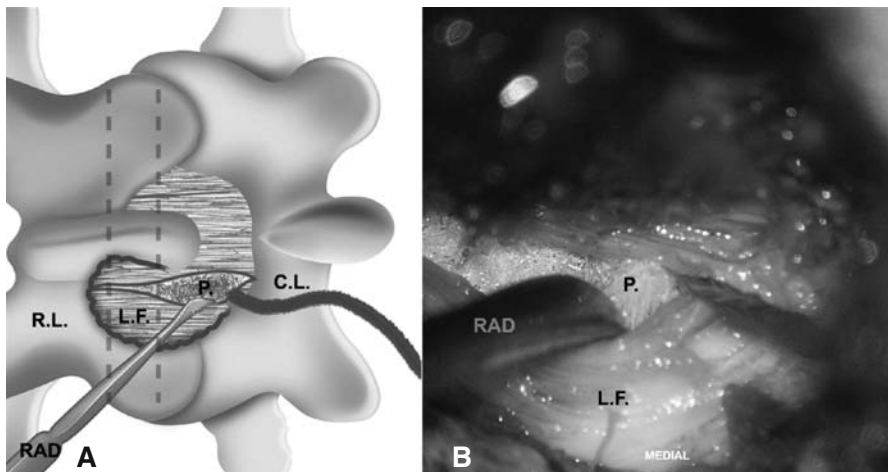


**Fig. 7. A** Dotted line showing the part of the bone to be removed (either by drill or by Kerrison) from the rostral lamina (R.L.) and if needed from the medial aspect of the facet joint, C.L. (caudal lamina), L.F. (Ligamentum Flavum). **B** Drilling the lower part of the rostral lamina to the medial aspect of the facet joint

the upper part of the caudal lamina is necessary. The superficial layer of the ligament is removed and entered with a sharp dissector then it is removed from the upper insertion under the superior lamina with a Kerrison.



**Fig. 8.** Opening of the ligamentum flavum in cranio-caudal direction movements using a blunt dissector

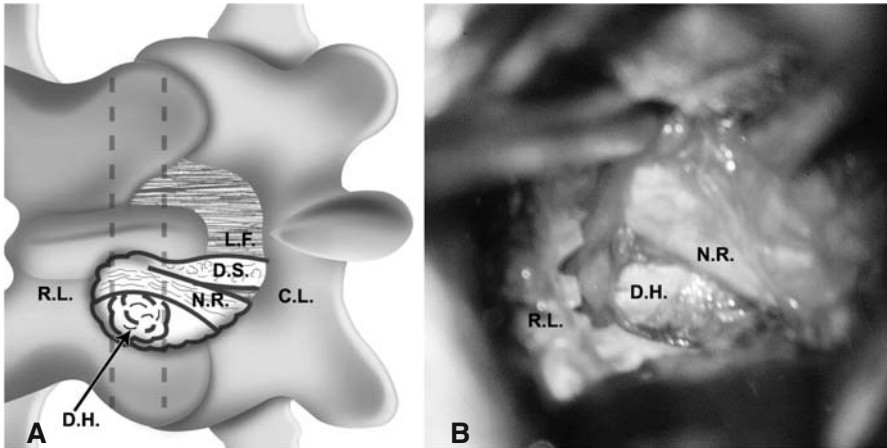


**Fig. 9. A** Illustration showing the opening of the ligamentum flavum with patty protecting the dural sac and nerve root before starting the removal of the ligament. **B** Surgical view from microscope, P, patty, L.F. Ligamentum Flavum, RAD: Right Angle blunt Dissector freeing the ligament from any possible adhesions before removing it with the Kerrison

Thereafter, residual thin ligament is safely perforated with a blunt dissector medially in cranio caudal movements, except for L5-S1 where the ligamentum flavum fibers are nearly horizontally directed and the opening is done in a medio-lateral movement (Fig. 8). Once the ligament is penetrated I pass a right angle blunt dissector under the ligament and free the ligament from any possible adhesions. Thereafter, a small patty is inserted into the canal protecting the dural sac and the nerve root and the ligament removal is completed using oblique forward Kerrison (Fig. 9A, B). Removal of a minimal part of the medial aspect of the inferior articular process and less frequently a small part of the superior articular process may be necessary to decompress and expose the lateral aspect of the nerve root. This procedure is performed routinely when a lateral recessus stenosis or articular hypertrophy is present. Drilling is done in oblique way with the microscope tilted to have clear direct vision on the medial aspect of the facet and lateral recessus which help to avoid thinning of the isthmus. The nerve root is identified and approached at its lateral border, it is dissected from the eventual adhesions and mobilized medially, then it is followed proximally to the disc level, which is usually less than 10 mm above the pedicle, and distally, until its entrance into the foramen.

#### *Exposure of the herniation and microdiscectomy*

After this exposure, the nerve root is slightly retracted medially and the space lateral to it is cleaned from the soft tissue. At this point epidural vessels are usually encountered and if can not be protected, they are divided after being



**Fig. 10.** **A** Illustration showing the exposure of the lateral aspect of the nerve root and the herniated disc. R.L. Rostral lamina, N.R. Nerve root, D.S. Dural sac, C.L. Caudal lamina, D.H. Disc herniation. **B** Surgical view

coagulated by fine bipolar forceps on low current intensity with irrigation to avoid overheating the nerve root. Now the size and extent of the disc herniation can be exposed and identified (Fig. 10A, B). If during these steps a free sequestered disc fragment is found, it is gently mobilized and teased free using a blunt dissector and a disc rongeur. The use of the suction tip in an alternating retract-relax fashion to retract the nerve root and expose the disc will avoid the need for excessive retraction which may cause injury to the nerve root with possible post-operative deficit. At this point the herniation and annulus are exposed, I perform an oblique opening in the annulus fibrosus which offer better healing. Through this slit the herniated part is freed and removed, and the disc decompression is achieved with various straight and angulated disc rongeurs. Thereafter, the subligamentous space is explored with the aid of a long hook and or right angle fine dissector and the migrated material removed. In the case of extruded or sequestered disc, I do prefer to explore the disc space and take out the loose parts easily removable with the rongeurs, I don't use the curettes in microsurgical discectomy. At the end of discectomy I rinse the disc space two to three times with normal saline mixed to antibiotics (gentamycin). However, it should be mentioned that there is no consensus yet regarding the amount of disc that should be removed in order to decrease the rate of recurrence. The nerve root and the thecal sac are covered using the epidural fat or free fat graft with care not to cause any compression.

In case of central herniation, after performing the discectomy and creating an empty space inside the disc, I use a long right angle blunt dissector to push the remaining protruded disc from under the annulus to the empty disc space from where it is easily removed with disc rongeur. This movement will avoid

excessive retraction on the nerve root and thecal sac. At the end of the procedure the annulus may be closed with one resorbable suture and if the annulus mass is bulky I shrink it with the bipolar coagulation. I found this less aggressive approach very rewarding in terms of recurrent disc herniation.

### *Closure*

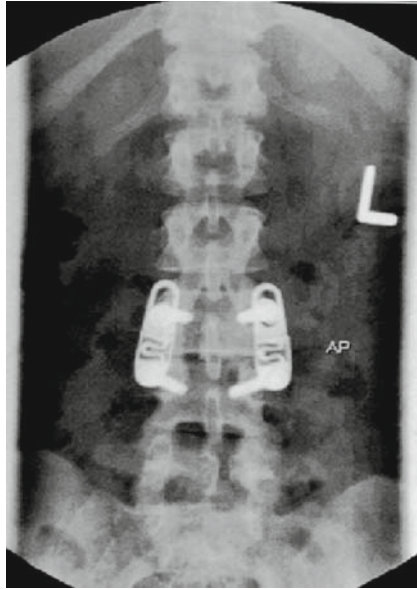
Is done in anatomical layers after careful hemostasis. Placing a drain is rarely needed in microdiscectomy.

## 2.2 Surgical technique in recurrent disc herniation

Re-operation for scar alone or arachnoiditis is unlikely to be helpful to the patient. Despite following similar surgical principles, few differences are significant enough to be mentioned. MRI with Gadolinium is the main examination needed, CT-myelography is used when there is contraindication or artifacts for the MRI. This allows proper evaluation of the scar localization and extension as well as the amount of recurrent disc. Plain X-rays with AP and lateral views are very important for the bony landmarks and to assess a possible instability.

The patient is positioned on a Wilson frame as previously described, the skin incision is marked according to the side and location of the recurrent disc. After the skin incision, the fascia is opened near the midline. Using the monopolar and sharp Cobb the muscles are stripped off the spinous processes and laminae starting from the normal bone landmarks in a subperiosteal plane which minimize the bleeding. Once the exposure of intact bone is completed, a scar tissue filling the interlaminar space and covering the edges of the lamina is identified, then the scar thinning is started layer by layer against the laminae first, the laminotomy is then extended superiorly and inferiorly till healthy dural sac is encountered. The dissection is started from the healthy dura medial to lateral by enlargement of the lateral recess and dissection of the scar against the bony structures until exposure of the pathology. However, it should be reminded that the scar over the dorsal aspect of the dural sac is not symptomatic and aggressive dissection has no benefit rather than increase risk of CSF leak. After thinning of the scar is achieved the dissection is followed in the direction cranio-caudal and mediolateral until the nerve root is clearly identified and freed. With the lateral recess enlarged and the nerve root free in the foramen, it becomes possible to remove the recurrent disc fragments. If the annular opening is wide, it is our policy to remove the residual loose disc material from the disc space.

Sometimes the adhesions are so dense that it is wiser to leave a thin layer of scar tissue rather than trying to obtain a total removal with the risk of dural tear or nerve root injury. If bone removal and massive discectomy is needed, I perform spinal stabilization of this segment using pedicle screws and semi rigid plate, which helps avoiding the instability syndrome and adjacent segment disease (Fig. 11). The closure is done in classical way. At the end of



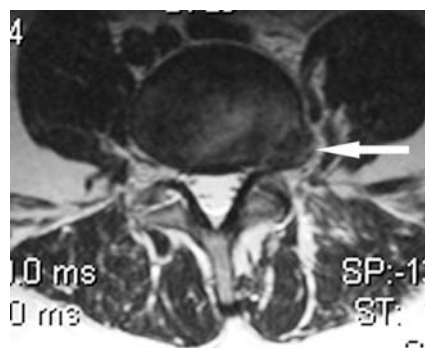
**Fig. 11.** Dynamic semirigid fixation using ALADYN Plate (Scient'x –France) after massive discectomy for recurrent disc herniation

the surgery, I cover the dura and nerve root with a thin layer of free fat graft.

### 2.3 Surgical technique for extraforaminal disc herniation

Extraforaminal disc herniation is relatively rare, and encountered in elderly more than younger patients being more frequent in higher lumbar levels L3–L4, L2–L3 more than L5–S1 (Fig. 12). The herniation is mostly sequestered and it is migrating up in the foramen and extra foraminal. We do practice 2 techniques, the classical interlaminar for contained extraforaminal herniations and for L5–S1 level. In this case we start by classical microdiscectomy then with long right angle blunt dissector we push inside the empty disc space the foraminal extraforaminal annulus and try to separate the herniated part off the inner annulus with the same dissector, then it is removed with upward 45° disc rongeur. The other one is the paramedian – intertransverse approach which avoids the need for wide facetectomy and offer clear exposure of the extraforaminal compartment. Here is a short description of the technique.

Under general anesthesia the patient is positioned on a Wilson frame that opens the intertransverse and the disc space and maintains the abdomen free. The level is localized with one needle inserted lateral to the spinous processes aiming towards the superior border of the involved disc. A lateral fluoroscopic



**Fig. 12.** MRI in T2 WI axial cut, showing extra foraminal disc herniation (white arrow)

view is taken. A 4 cm skin incision is performed about 3 cm off to the midline with the needle mark in the center of the incision aiming wider exposure of the foramen as most of these herniations tend to migrate up. The thoracolumbar fascia is opened and blunt dissection with the finger in the plane between the multifidus and longissimus muscles is carried down till the medial part of upper transverse process, the upper and lower facet joints and the pars in between are palpated. Then we insert anterior cervical discectomy retractor with the adequate blade length. At this point the remaining steps of the surgery is continued under operative microscope. The intertransverse membrane as well as the pars, upper facet and medial part of the transverse process are cleaned off and exposed. An intra-operative lateral radiographic control is performed to reconfirm the level.

The fascia is opened, a small amount of bone from the superolateral aspect of the facet is drilled off. Thereafter the intertransverse membrane is detached by blunt dissector from the superior aspect of the caudal transverse process as well as the lateral edge of the pars and retracted laterally. After this maneuver, the fat surrounding the nerve should appear. Using a blunt dissector the nerve root is identified. If the nerve root is difficult to find, the upper pedicle is palpated, inferior to it the nerve root can be exposed and followed down to the disc level. Care should be taken to minimize the manipulation of the nerve root and the use of bipolar as injury to the dorsal ganglion may cause post-operative neuropathic pain. In most of the cases the nerve is pushed cranially and laterally by a free disc fragment. Removal of the fragment is usually enough, however if a significant opening in the annulus is identified I go inside the disc with disc rongeur and excise the loose, easily removable fragments. Care must be taken here as the approach is oblique to the disc space, the surgeon must stay attentive and put his disc rongeur always oblique forward inside the disc. Injury to the retroperitoneal vessels and ureter is easier and possible if the rongeur goes straight downward in the paraspinous space.

The wound is closed in anatomical layers. Placing a drain is optional. Post-operatively the patient is mobilized 4–5 h after the procedure and discharged

on the second day. Before discharge the patient is instructed by the physiotherapist. Active physiotherapy is started 4 weeks postoperative.

### **3. LONG-TERM RESULTS AND COMPLICATIONS**

Success rates in microdiscectomy ranges from 75 to 95% or higher in various series. However, it has been suggested by other studies that a success rate of 75–80% is a more accurate and realistic outcome expectation [1].

Lumbar microdiscectomy has very low complication rate range in a good hand, between 3 and 7%, these complications are:

Position related, wound infection and discitis, hematoma, dural tear, nerve root injury, symptomatic epidural scar, recurrent herniation, instability.

## **HOW TO AVOID COMPLICATIONS**

### **1. RELATED TO THE POSITION**

Ulnar nerve (the most common) can be avoided by placing protection pads. Peroneal nerve injury by avoiding hyperflexion and compression of the popliteal fossa mostly with knee–chest position.

Brachial plexus lesions: Avoid  $>90^\circ$  abduction.

Cervical spinal cord injury: avoid excessive neck extension in elderly mainly.

### **2. OPERATING THE WRONG LEVEL OR THE WRONG SIDE**

Perform fluoroscopy before skin incision. I frequently repeat the fluoroscopy before opening the ligamentum flavum and entering the canal.

### **3. EPIDURAL HEMATOMA**

Check the patient for subtle coagulation problems and secure good hemostasis.

### **4. DURAL TEAR AND CSF LEAK**

Work under magnification, use blunt dissector, and dissect the dura from under the ligament and lamina before using the Kerrison or curettes, use patties to protect the dura.

### **5. NERVE ROOT INJURY**

Avoid excessive root and dural sac retraction.

Use bilateral approach when very large central disc herniation, observe pre-operative X-rays to rule out spina bifida occulta. Avoid excessive coagu-

lation. Use irrigation while coagulating close to the nerve, enter the disc rongeurs in closed position while discectomy.

## **6. IATROGENIC INSTABILITY**

Avoid thinning the pars and aggressive facetectomy, stabilize if necessary.

## **7. INFECTION**

Surgery must be delayed if there is any infection.

Consider prophylactic antibiotherapy especially in diabetic patients.

## **8. FAILED BACK SURGERY SYNDROME (FBSS)**

All previously mentioned complications are factors of failed back surgery syndrome. Patient selection is more important rather than technical problems in FBSS.

## **CONCLUSIONS**

Management of degenerative spinal diseases still represents a challenge to neurosurgeons with the wide range of clinical and radiological presentation. Different procedures, minimally-invasive and classical surgical techniques are being in use for the treatment of degenerative spinal diseases. In view of its high rate of success and low incidence of complications, microdiscectomy has imposed as the gold standard in the treatment of degenerative lumbar disc herniation. However, once again it should be stressed that good results can be obtained only by the combination of careful selection of the patient in association to microsurgical expertise.

## **References**

- [1] Asch HL, Lewis PJ, Moreland DB, et al. (2002) Prospective multiple outcomes study of outpatient lumbar microdiscectomy; should 75% to 80% success rates be the norm? *J Neurosurg* 96(Spine 1): 34-44
- [2] Caspar W (1977) A new surgical procedure for lumbar disc herniation causing less tissue damage through a microsurgical approach. *Adv Neurosurg* 4: 74-80
- [3] De Devitit R, Spazinate R, Stella L, et al. (1984) Surgery of the lumbar intervertebral disc; results of a personal minimal technique. *Neurochirurgie* 27: 16-19



- 
- [4] Gertszten, PC, Welch WC, et al. (2006) Quality of life assessment in patients undergoing nucleoplasty based percutaneous discectomy. *J Neurosurg Spine* 4: 36-42
- [5] Heikkila JK, Koskenvuo M, Heliovaara M, et al. (1989) Genetic and environmental factors in sciatica. Evidence from a nationwide panel of 9365 adult twin pairs. *Ann Med* 21(5): 393-398
- [6] Mayer HM (2000) Minimally invasive spine surgery, principles of microsurgical discectomy in lumbar disc herniations. Springer-Verlag, Berlin Heidelberg New York, pp 73-77
- [7] Love JG, Walsh MN (1938) Protruded intervertebral discs: report of 100 cases in which operation was performed. *JAMA* 111: 396-400
- [8] McCulloch JA, Young PH (eds) (1998) Essentials of spinal microsurgery. Lippincott-Raven, Philadelphia
- [9] Moore RJ, Vernon-Roberts B, Fraser RD, et al. (1996) The origin and fate of herniated lumbar intervertebral disc tissue. *Spine* 21(18): 2149-2155
- [10] Oppen F, Schramm J, Schirmer M (1977) Results and complicated courses after surgery for lumbar disc herniations. In: Wullenweber R, Brock M, Hamer J, et al. (eds) *Advances in neurosurgery*, vol. 4. Springer, New York, pp 36-51
- [11] Weber H (1983) Lumbar disc herniation. A controlled prospective study with ten years of observation, *Spine* 8: 131-140
- [12] Yaşargil MG (1977) Microsurgical operation of herniated lumbar disc. *Adv Neurosurg* 8: 422-427



**Abdul Karim Msaddi**

Abdul Karim Msaddi is Professor in Surgery, Head of Neurosurgical and Spinal Department, Medical Director, Neuro Spinal Hospital, Dubai, UAE. Past President of the Emirates Neuroscience Society, UAE. Chairman of Scientific Committee, Emirates Neuroscience Society of UAE. President of Dubai Spine Conferences – over the last five years. Member of many international and regional neurosurgical and spinal societies. Main interest is spinal surgery, pain and spasticity.

**Contact:** Abdul Karim Msaddi, Neuro Spinal Hospital, P.O. Box 71444, Dubai, United Arab Emirates  
E-mail: [nsshmeet@yahoo.com](mailto:nsshmeet@yahoo.com)

---

# MANAGEMENT OF LUMBAR SPONDYLOLISTHESIS

R. G. FESSLER

## INTRODUCTION

Spondylolisthesis is defined as anterior or posterior displacement of one vertebral body over another. In the adult, this occurs as the result of abnormalities of bony architecture, degeneration of the spinal elements or trauma. Degenerative spondylolisthesis, probably the most frequently seen type of spondylolisthesis, was first described by Junghanns [3]. MacNab further defined the clinical and pathologic features of this condition [6].

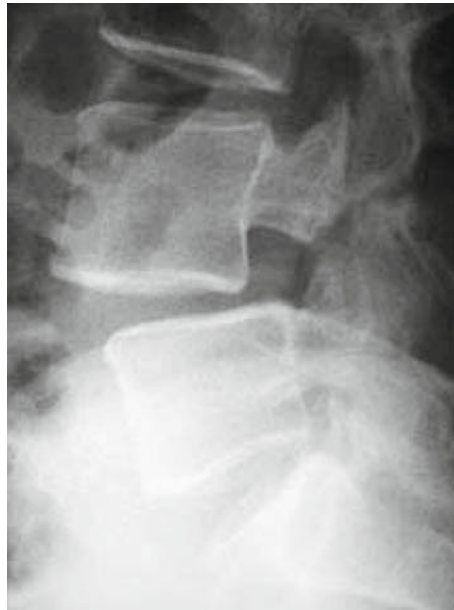Although several classification schemes have been proposed, one very useful one is based upon the etiology of the disease process, and distinguishes between pathologic processes that cause spondylolisthesis [5]. Within this classification scheme, two broad categories of spondylolisthesis have been defined: developmental and acquired. Among the most frequent types of spondylolisthesis seen clinically, degenerative spondylolisthesis is a subtype of acquired spondylolisthesis, and can be further subdivided into primary and secondary spondylolisthesis. Primary degenerative spondylolisthesis is that commonly seen in those individuals presenting in middle age with symptoms of spinal stenosis. Secondary degenerative spondylolisthesis occurs as a result of some predisposing factor, such as adjacent level degeneration above a previous fusion.

The other most frequently encountered form of spondylolisthesis is Isthmic spondylolisthesis, involving abnormalities of the pars interarticularis, and can be either developmental or acquired (Fig 1). Wiltse et al. [11] has divided isthmic spondylolisthesis into 3 subcategories. Subtype A occurs as a result of fatigue failure of the pars and is evident by a complete defect of separation of the adjacent bone. Subtype B occurs as a result of repeated microfractures and healing of the pars with gradual slippage occurring, and is evident as an elongated pars. Finally, subtype C is an acute pars fracture.

The clinical presentation of spondylolisthesis, regardless of the subtype, is similar. Patients may be asymptomatic or present with back pain, leg pain, or a combination of both. Back pain is commonly aggravated by extension or rising to standing position from a bent posture. Leg pain may be either radicular or present as neurogenic claudication (lower extremity pain, paresthesias, or weakness associated with standing or walking). Pain is the most frequent symptom, being present in 94% of patients, with numbness (63%)

---

*Keywords:* Spondylolisthesis, spinal surgery, degenerative disc disease, lumbar fusion



**Fig. 1.** Type A congenital spondylolisthesis

and weakness (43%) reported less frequently [4]. Symptoms of claudication are typically bilateral, whereas radicular symptoms are usually dermatomal in distribution and frequently unilateral.

## **RATIONALE**

Several factors have been identified which may contribute to the likelihood of developing spondylolisthesis. Degenerative disc disease predisposes to instability through collapse of the disc space height and annular/ligamentous laxity. This compromises the ability of the disc to resist ventral shear forces as the spine is loaded. Relative sagittal facet orientation may also predispose to slip by transferring resistance from the bony structures to the facet capsules and annulus. Furthermore, as forward slippage progresses, focal kyphosis occurs, which increases the shear moment and tendency toward progressive translation.

The variable anatomy of the pars between spinal segments may also contribute to the probability of developing stress fractures at those levels. Although the pars is quite large in diameter at the higher lumbar levels, it is relatively thin at L 5 [10]. Upright posture, and activities such as gymnastics, contact sports, and weight lifting increases the force concentrated across the pars. Thus, the probability of fracture is highest at those levels with the narrowest pars diameter.

As with many, if not most, spinal conditions, the natural history of spondylolisthesis, once diagnosed, is not well characterized. Thus, surgical decision making can be quite difficult. Matsunaga et al. [8] followed 40 patients with degenerative spondylolisthesis between 5 and 14 years (mean = 8.25 years). Progressive slip was noted in 12 patients (30%), but none of these patients reported clinical deterioration. Four patients (10%) did experience clinical deterioration, but none of these patients were in the group reporting progressive slip. Thus, these authors found no correlation between slip and symptom progression. Further review of the literature on natural history of degenerative spondylolisthesis, however, seems to suggest that only about 1/3 of untreated patients achieve satisfactory outcomes [2, 9]. Cinotti et al. [1] suggested that intervertebral disc narrowing, spur formation, subcartilaginous sclerosis and ligamentous ossification may function as spinal re-stabilizers and decrease the likelihood of slip progression.

## DECISION-MAKING

Ultimately, decision making for the treatment of spondylolisthesis comes down to the answers to a series of questions. First, is the patient symptomatic? Asymptomatic or minimally symptomatic spondylolisthesis does not require treatment. Surgical correction of cosmetic deformity secondary to spondylolisthesis may be elected, but is not otherwise mandatory. Second, is the patient neurologically impaired? If so, surgical intervention should be considered to maximize the probability of recovery of function. Third, if the patient is sufficiently symptomatic to warrant treatment but is neurologically intact, has an adequate trial of non-surgical therapy been attempted. Non-surgical therapy should initially consist of physical therapy and non-steroidal anti-inflammatory analgesics for pain management. Exercises should be directed toward strengthening of the core and paraspinal musculature, and stretching of these muscles as well as of the lower extremities (paying particular attention to the hamstrings, which become very tight in spondylolisthesis). Weight loss and aerobic conditioning should be added as necessary, and bracing can be used as an adjunct to physical therapy. Epidural and/or facet capsule steroid injections can also decrease pain in the acute phase, but just as with narcotic medication, are not recommended for chronic treatment secondary to potential cumulative side effects. With this regimen, most patients will experience symptom relief within 3 to 6 months. If patients do recover with non-surgical therapy, a daily exercise routine should be incorporated into their schedule to maintain their strength and flexibility. If they do not recover, surgical treatment can be considered.

Finally, if surgery is being considered, the next question to answer is what operation would be best suited for the specific patient? Surgical options include: (1) direct repair of the pars interarticularis, (2) decompression of the neural elements alone, (3) decompression and in-situ posterolateral fusion,


(4) decompression, posterolateral fusion and pedicle screw instrumentation, and (5) decompression, instrumentation, and interbody fusion. For each option, of course, multiple minor variations of specific technique also exist. Although the literature on this question is enormous, consensus regarding the best treatment does not exist. Most studies suggest that patients undergoing decompression with fusion achieve superior outcome than patients undergoing decompression alone. It is less clear, however, that the addition of instrumentation significantly enhances the outcome. Clearly, there are cases where the addition of instrumentation would seem the best medical decision. For example, in the young, active person, who has clear evidence of instability on flexion/extension X-rays, the immediate stability provided by instrumentation and the secondary benefits derived from this (such as elimination of the need for external bracing, more rapid initiation of physical therapy, and more rapid return to normal activities) would seem to justify the additional time, cost, and risk of placing the instrumentation. On the other hand, in less clear cut individuals (such as in elderly individuals who appear stable on flexion/extension films), instrumentation may not provide significant added benefit. After noting the association between the use of instrumentation and higher fusion rates, a position statement by the Scoliosis Research Society published in *Spine* recommended the use of spinal instrumentation for spinal stenosis with degenerative spondylolisthesis [7].

This manuscript will describe the technique I use for fusion of grade I to 2 lumbar spondylolisthesis, and report the results obtained. It is a minimally invasive technique which technically not difficult and achieves results equivalent or superior to traditional open technique.

## **SURGERY**

### **1. EQUIPMENT**

The minimally invasive transforaminal lumbar interbody fusion (TLIF) requires the following equipment: C-arm fluoroscopy, a tubular retraction system, a laminectomy tray with modified instruments for working through a tubular retractor, a high-speed drill, tools for endplate preparation, an interbody graft, and a percutaneous pedicle screw system. Currently, I place all instrumentation using fluoroscopy. I use an expandable tubular retractor (Fig. 2A [*X-Tube*®, Medtronic Sofamor Danek, Memphis, TN, USA]), which has a diameter of 26mm proximally (skin entry) but can be expanded in situ to a final working diameter of 44 mm distally. This feature is particularly helpful for two level fusions. I perform the procedure using loupe magnification with a headlight. The decompression is performed with standard laminectomy instruments that are lengthened and bayoneted for working through a tubular retractor. The tools for preparing the disc space



**Fig. 2.** Sextant instrumentation system. **A** Expandable tubular retractors. **B** Screw extenders. **C** Rod holder and guide

for graft placement consist of distractors (7–14 mm), rotating cutters, and endplate scrapers. Many options exist for interbody graft material. We have had good results when using either allograft bone or cages. Currently my practice is to use a PEEK cage with autograft collected during facetectomy and rhBMP-2 (*Infuse*<sup>®</sup>, Medtronic Sofamor Danek, Memphis, TN, USA). Placement of percutaneous screws requires an 11-gauge bone biopsy needle (*Jamshidi*<sup>®</sup>, Cardinal Health), a Kocher clamp, K-wires, a drill, fluoroscopy, and a percutaneous pedicle screw system. I use the *Sextant*<sup>®</sup> system (Fig. 2B, C [Medtronic Sofamor Danek, Memphis, TN, USA]).

## 2. OPERATING ROOM SET-UP AND POSITIONING

The operating table is placed in the center of the room, with anesthesia at the patient's head and fluoroscopy monitor at the patient's feet. The C-arm base is placed on the opposite side of where the TLIF is to be performed. The technician and equipment tables are kept behind the surgeon on the operative side and a Mayo stand is situated over the feet to pass instruments in active use.

Following induction and intubation, a Foley catheter is placed and neurophysiological monitoring with free running EMG capabilities is set up. After intubation, the anesthetist should avoid the use of relaxants and nitrous oxide, which may interfere with EMG recordings. A single dose of appropriate antibiotic is administered. Sequential compression devices are placed on the legs and the patient is positioned on the operating table. The patient is positioned prone on a Wilson frame and Jackson table. All arm joints are bent to  $<90^\circ$  and placed along side the patient's head. The knees, axilla, elbows and wrists are carefully padded. The legs are elevated with pillows to reduce stretch on the sciatic nerve. The face is placed in a padded mask that has a mirrored surface (*Prone View*<sup>®</sup>, Dupaco, Oceanside, CA, USA) to ensure visualization of the eyes and the endotracheal tube throughout the procedure. An occlusive barrier is placed at the top of the gluteal cleft, and the skin is prepped and draped in standard fashion. The C-arm is brought in for a lateral view of the affected level and draped into the field.

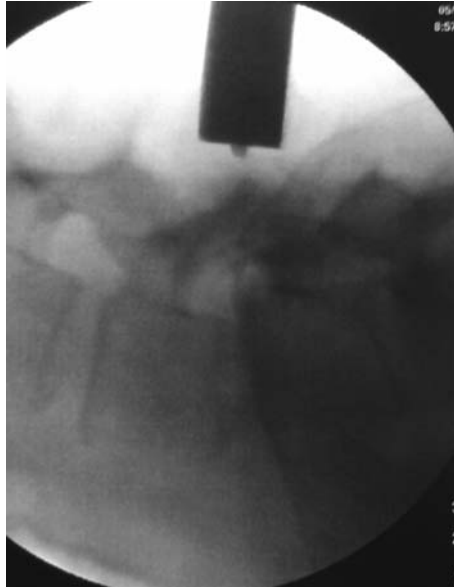
## 3. LOCALIZATION AND EXPOSURE

Localization of the appropriate level is made with fluoroscopy and a K-wire. Once marked and infiltrated with local anesthetic, a stab incision is made 3 cm from midline, and the K-wire is inserted until it rests on bone. Ideally, the point should be on the facet complex of the affected level, orthogonal to the disc space. If localization is satisfactory, the skin incision is extended to a final length of 2.5–3 cm with the K-wire bisecting the incision. Sequential dilators from the tubular access system are passed to expand the soft tissue in a step-wise fashion. Fluoroscopy is used to confirm positioning. After insertion of the final dilator, a depth measurement is made and a working channel of appropriate length is introduced. The ideal final position of the working channel is over the facet, perpendicular to the disc space, and spanning the pedicles to be instrumented (Fig. 3). Inevitably some residual muscle and soft tissue remains after dilation and this is cleared from the lamina and facet with monopolar cautery in preparation for the decompression.

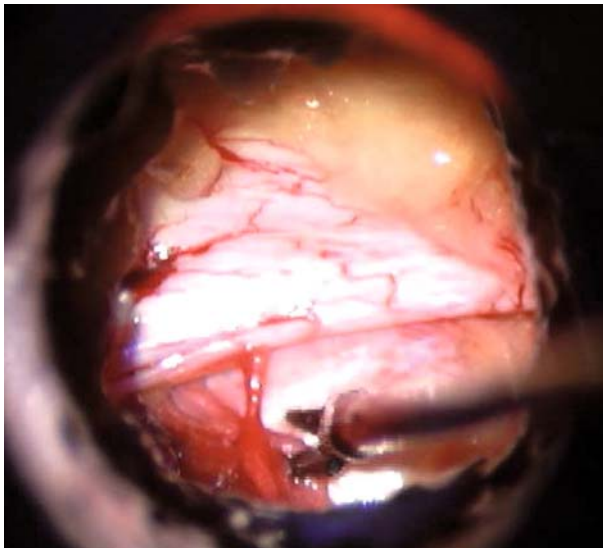
## 4. LAMINOTOMY/FACETECTOMY

A straight curette is used to define the interlaminar space, a plane developed between the ligamentum flavum and bone with an angled curette, and the





**Fig. 3.** Appropriate position of expandable retractor over facet complex as seen in lateral fluoroscopic image



**Fig. 4.** Visualization of lateral edge of dura, exiting nerve root, and disc space as seen through tubular dilator

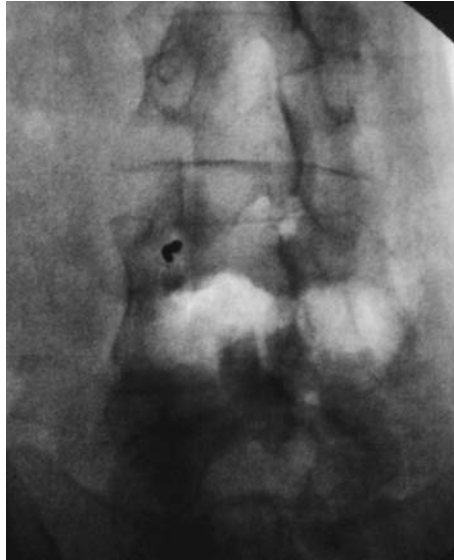level is confirmed with fluoroscopy. A laminotomy is performed with Kerrison rongeurs, revealing the ligamentum flavum and defining the lateral extent of the spinal canal. The inferior articular process of the rostral level is removed with osteotomes guided by fluoroscopy, exposing the superior articular process of the caudal level. All bone is saved for later use in the interbody fusion. The decompression should extend from pedicle to pedicle in a rostral-caudal direction. Fluoroscopy can be used as needed to assess position and evaluate the extent of decompression. Laterally, a near-total or total facetectomy is done to provide adequate space for graft placement; however, the portion of facet directly over the pedicle distal to the disc space should be preserved to provide an adequate platform for pedicle screw starting points. The ligamentum flavum is removed. If necessary the working channel can be angled medially for a contralateral decompression. Epidural veins are coagulated with bipolar cautery and divided if necessary. The lateral edge of the dura, the nerve root and the disc space should be clearly visualized (Fig. 4).

## **5. INTERBODY FUSION**

A 15-blade scalpel is used to cut the annulus, and the initial discectomy proceeds using curettes and pituitary rongeurs. A down-angled curette is helpful to ensure that subligamentous disc fragments and the contralateral disc are properly removed. Next, the rotating cutter is introduced parallel with the disc space and twisted to prepare the vertebral body endplates. The endplates are scraped, and debris is removed with a pituitary rongeur. A chisel or Kerrison can be used to expand the annulotomy or to remove osteophytes. Templates are then inserted to expand and to measure the interbody space for the appropriately sized graft. Before placing the PEEK cage, we first lay a rhBMP-2 soaked sponge along the anterior annulus followed by a generous amount of autograft. Another rhBMP-2 sponge and more autograft is placed in the cage and inserted obliquely such that it is centered in the disc space. Fluoroscopy is used to confirm graft position. Hemostasis is achieved using standard techniques, and the working channel is withdrawn slowly in order to permit periodic cauterization.

## **6. PEDICLE SCREW FIXATION**

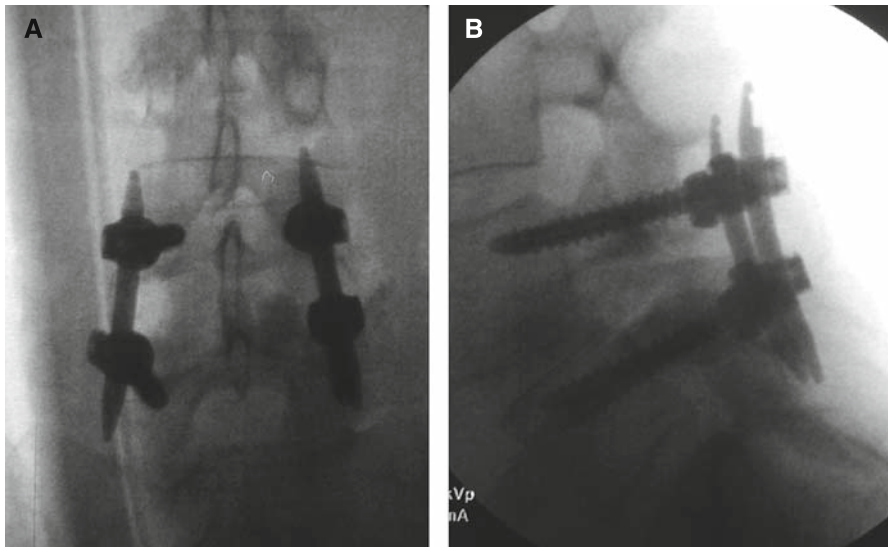
Minimally invasive TLIF relies on AP and lateral fluoroscopy for pedicle screw placement. After rotation of the C-arm for a true AP view in parallel to the disc space, starting points for screws are marked over the center of the pedicle. A bone biopsy needle is passed through the soft tissue and docked onto the entry point. We try to orient the needle directly in line with the pedicle, such that the needle will appear as a single spot (“bull’s eye”) in this orientation (Fig. 5). For ipsilateral screw placement this may require an extension of the previous incision by a few millimeters. On the contralateral



**Fig. 5.** “Bulls eye” fluoroscopic image of K-wire in appropriate position following insertion through Jamshidi needle

side two separate incisions of approximately 1.5 cm are required. The needle is tapped into the pedicle with a mallet and position is confirmed by fluoroscopy. Then, with the needle held firmly in the correct orientation, the stylet is removed and a K-wire is drilled approximately 1 cm into the pedicle. The bone needle is removed and fluoroscopy is used to confirm that the K-wire is in the center of the pedicle. Once all the wires are placed, the C-arm is brought to the lateral position and the K-wires are advanced about two-thirds the length of the vertebral body parallel with the end plate.

The remainder of the procedure can be completed in less than 30 minutes. Soft tissue over the K-wires is serially dilated with the tubes included in the Sextant kit and the pedicles are tapped. Cannulated screws are passed over the K-wires and inserted using fluoroscopy guidance. Once the screws are placed, the rod size is calculated using a template. The Sextant device is attached to the screw extenders and the rod is pushed through separate distal stab incisions and the paraspinal soft tissue. A depth tester is then used to confirm that the rod is correctly through each screw head. The screws are then compressed, tightened and broken off with a torque wrench. The Sextant is disconnected from the rod and removed. The process is repeated on the opposite side. Final construct position is assessed (Fig. 6A and B). Wounds are irrigated with antibiotic saline and closed in layers with absorbable suture. The wound is dressed with 2-octyl cyanoacrylate (*Dermabond*<sup>®</sup>, Ethicon, Somerville, NJ, USA).



**Fig. 6.** Appropriately place percutaneous screws and rods as seen in the (A) A/P and (B) lateral views

## 7. RESULTS

In a recent review of our data, 108 patients had sufficient pre- and postoperative data for the outcomes analysis. The median follow-up period was 14.8 months (range 8.3–25.3 months) after surgery. All measured outcomes (3 VAS pain scores, ODI, and 8 subscales of SF-36) were significantly improved, except SF-36 general health subscale.

The results of a longitudinal analysis of changes in pain score and quality of life for the 3 VAS pain scores, revealed significant improvement in the first 3 months with effects maintained to 2 years. Oswestry disability index significantly improved in the first 3 months, further improved at lower rate between month 3 and 7, and did not change after month 7. For five SF-36 subscales (Physical function, Role-physical, Vitality, Social function, and Role-emotional), there were significant improvements in the first 7 months and the effects maintained after month 7. SF-36 body pain subscale significantly improved in the first 3 months, further improved at lower rate between month 3 and 7, and did not change after month 7. There was a small increase in SF-36 general health subscale in the first 3 months. SF-36 mental health subscale also increased in the first 3 months.

The average operative time was 4.1 hours (SD=1.2, range 1.1–8.5). The operative time was significantly longer for patients undergoing multilevel surgery than those undergoing single level surgery (t test,  $p < 0.0001$ ). Other

factors including age, height, weight, BMI, side of surgery and pre-operative pain score, ODI, and SF-36 scores were not correlated with operative time. The median estimated blood loss was 150 ml (range 10–1000). The average length of hospital stay was 84 hours (SD = 36, range 20–182).

## HOW TO AVOID COMPLICATIONS

A number of complications are possible with this technique, however, with experience, care and anticipation, most can be avoided. During the initial dilation, it is possible for the K wire or the dilators to slip into the interlaminar space and cause dural perforation or nerve injury. This can be avoided by removing the K wire after passage of the first dilator and assuring the dilators are docked on bone with passage of successive dilators. Dural tears and nerve root injury that can occur with removal of bone and ligament can be avoided with the generous use of angled curettes to define and develop a subperiosteal plane. This is particularly important in the presence of scar tissue. The use of intraoperative EMG monitoring provides immediate feedback of nerve root irritation throughout the procedure, and can alert the surgeon to overly aggressive nerve root traction especially during graft placement. The frequent use of fluoroscopy is also helpful to guide decompression and for confirmation of accurate screw placement.

## CONCLUSIONS

Most studies suggest that patients undergoing decompression with fusion achieve superior outcome than patients undergoing decompression alone. There are cases where the addition of instrumentation seem the best decision, for example in the young patients, who have clear evidence of instability on flexion/extension X-rays.

## References

- [1] Cinotti G, Postacchini F, Fassari F, et al. (1997) Predisposing factors in degenerative spondylolisthesis: a radiographic and CT study. *Int Orthop* 21: 337-342
- [2] Feffer H, Weisel S, et al. (1985) Degenerative spondylolisthesis: to fuse or not to fuse. *Spine* 10: 286-289
- [3] Junghanns H (1930) Spondylolisthesen ohne Spalt in Zwischengelenkstueck. *Arch Orthop Unfallchir* 29: 118-127
- [4] Katz JN, Dalgas M, Stucki G, et al. (1995) *Arthritis Rheum* 38: 1236-1241

- [5] Marchetti PG, Bartolozzi P (1997) Spondylolisthesis: classification of spondylolisthesis as a guideline for treatment. In: Bridwell R (ed) *The Textbook of Spinal Surgery*, 2nd edn. Lippincott, Williams and Wilkins, Philadelphia, pp 1211-1254
- [6] MacNab I (1950) Spondylolisthesis with an intact neural arch: the so-called pseudo-spondylolisthesis. *J Bone Joint Surg Br* 32: 325-333
- [7] Mardjetko S, Albert T, Andersson G, et al. (1995) Spinal stenosis with spondylolisthesis: a meta-analysis of literature, 1970–1993. *Spine* 30(6 Suppl)
- [8] Matsunaga S, Sakou T, Morizono Y, et al. (1990) Natural history of degenerative spondylolisthesis: pathogenesis and natural course of slippage. *Spine* 15: 1204-1210
- [9] Saal JA, Saal JA, Parthasarathy R (1995) The natural history of spinal stenosis. The results of non-operative treatment. Presented at the 10th annual meeting of the North American Spine Society. Washington, DC
- [10] Wiltse LL, Widell EH, Jackson DW (1975) Fatigue fracture: the basic lesion in isthmic spondylolisthesis. *J Bone Joint Surg Am* 57: 17-22
- [11] Wiltse LL, Newman PH, McNab I (1976) Classification of spondylolysis and spondylolisthesis. *Clin Orthop* 117: 23-29



**Richard G. Fessler**

Richard G. Fessler serves as Professor of Neurosurgery at the Feinberg School of Medicine of Northwestern University, Chicago. Prior to assuming this position he was the John Harper Seeley Professor and Chief of Neurosurgery at the University of Chicago Hospitals and Clinics. He previously founded and directed the Institute for Spine Care at the Chicago Institute of Neurosurgery and Neuroresearch (CINN) and was Professor of Neurological Surgery at Rush Medical College in Chicago, after serving as Director of Clinical Services and Education at the University of Florida Brain Institute. Additionally, at the University of Florida, he held the Dunsbaugh-Dalton Chair of Brain and Spinal Surgery and served as Professor in the Department of Neurological Surgery.

Dr. Fessler completed his Medical Doctorate with honors, and Surgical and Neurosurgical residencies at the University of Chicago. In addition to surgical training, Dr. Fessler completed a Doctorate of Philosophy in Pharmacology and Physiology, and a Masters of Science in Psychology. Continuing education after earning doctoral degrees, Dr. Fessler held research Fellowships at the University of Chicago Medical Center in Neurological Surgery and Psychiatry. The Chicago Surgical Society honored Dr. Fessler with the Excellence in Surgical Research award.

Dr. Fessler is internationally known for his contributions to endoscopic and microendoscopic surgical developments. He has developed many of the current minimally invasive

surgical techniques, including “minimally invasive decompression of lumbar stenosis”, “minimally invasive microendoscopic posterior cervical discectomy”, “minimally invasive decompression of cervical stenosis”, “unilateral transforaminal lumbar interbody fusion, and has contributed to the development of many more. The Kambin Foundation awarded Dr. Fessler their annual research award for his research in the field of minimal invasive spinal surgery. He was also asked to deliver the inaugural “Rhoton lecture” of the American Association of Neurological Surgeons on these revolutionary surgical techniques.

Dr. Fessler is also well known for his pioneering research into human embryonic spinal cord transplantation for the treatment of spinal cord injury. He was co-principal investigator on the first human transplant study to evaluate the safety and efficacy of human embryonic spinal cord transplantation for the treatment of syringomyelia, and is the only physician in the United States to have performed these procedures.

Routinely listed in “Best Doctors of America”, Dr. Fessler is also listed in the Consumer Research Council of America “Guide to America’s Top Surgeons”, and “Who’s Who” Dr. Fessler is a member of the American Medical Association, Congress of Neurological Surgeons, American Association of Neurological Surgeons, Neurosurgical Society of America, Joint Section on Disorders of the Spine and Peripheral Nerves, North American Skull Base Society, Joint Section on Pain, Joint Section on Trauma and Critical Care, American College of Surgeons, Society of Neurological Surgeons, Southern Neurosurgical Society, and the North American Spine Society. He has held leadership positions for several of these professional organizations, and has been a course director or faculty member for several hundred courses sponsored by these groups. For the Federal Government, Dr. Fessler is currently on Advisory Committees for the Food and Drug Administration. In addition to the FDA, Dr. Fessler served on the government committees of the Department of Health and Human Services and the National Head Injury Foundation. At the state-level as well, Dr. Fessler has served on several advisory councils for the state of Florida.

A prolific author, Dr. Fessler has written sixteen books and contributed over 100 book chapters to medical texts. He has published 110 articles in peer-reviewed journals, and presented numerous papers at peer-reviewed symposiums. Dr. Fessler lends his expertise to the Editorial Boards of Neurosurgery, The Spine Journal, Journal of Spinal Disorders, Spine Surgery, and Neuro-Orthopaedics, and he is an editorial reviewer for several other professional journals. He is frequently invited for speaking engagements and visiting professorships worldwide.

In addition to all of the above accomplishments, Dr. Fessler is a Medical Specialist and Flight Surgeon for NASA/Space Shuttle.

**Contact:** Richard G. Fessler, MD, PhD, Professor, Department of Neurosurgery, Northwestern University, Feinberg School of Medicine, 676 N. St. Clair St., Chicago, IL 60611, USA  
E-mail: rfessler@nmff.org



---

# NON-TRAUMATIC EXTRA-MEDULLARY SPINAL CORD COMPRESSION

F. LAPIERRE

## INTRODUCTION

The suffering and injuries of the spinal cord are known since 2500 BC, with the first references in the Edwin Smith Surgical Papyrus. Very few documents exist until the rise of the Greek civilisation. Hippocrates is credited of the first clinical descriptions of para- and tetraplegias, with some treatment descriptions. Celsus (30 BC) established the role of the spinal cord in post-traumatic palsies. Galen (150 BC) experimentally reproduced spinal lesions and described their consequences in the animals, and studied them in the gladiators. However, the concept of decompressive surgery was first advocated by Paulus of Aegina (625–690).

Gui de Chauliac (1300–1368) brought the modern concepts of the possibility to cure the paralysis of spinal cord injury. All the literature during these periods, and the Renaissance concerned the post-traumatic compressions. The first reference to spinal cord decompression even in the absence of vertebral fracture comes from the writings of Desault in 1796, following the experience concerning the first decompressions performed by Geraud 1753, and then Louis 1752 (Removal of bullets with functional improvement of the patients). Analysis of spinal cord dysfunction without traumatism had to wait for the discovery of the radiology during the 20th century, and the use of intradural contrast injection. Now CT scanner and MRI give complete and satisfactory imaging of the spine and its content.

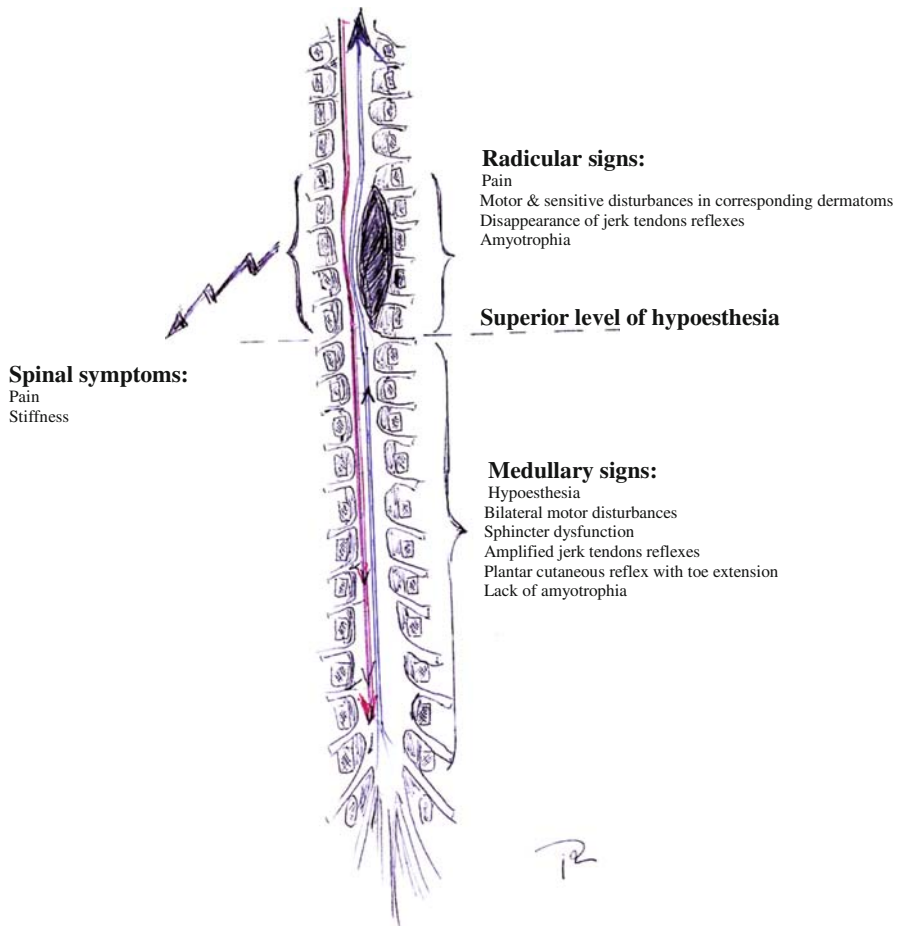
## RATIONALE

The main background concerning this pathology is:

- Any structure surrounding the spinal cord may generate its compression in pathological conditions (Fig. 1).
- An extradural compression, arising in vertebral bodies or epidural tissues occurs in 55% of cases.
- An intradural extramedullary, arising in leptomeninges or roots in 40%, primarily meningiomas and neurinomas (together about 55% of intradural-extramedullary tumors).

---

*Keywords:* spine, spinal cord, tumor, extramedullary compression



**Fig. 1.** Spinal cord compression symptoms

- Metastatic lesions comprise the majority of extradural tumors.
- The questioning of the patient and his history leads in most cases to suspect the diagnosis.
- The post-therapeutic functional status of the patient depends on that status at time of the treatment (decompression) whatever the cause: The greater the neurologic deficit when treatment is initiated, the worse the chances for recovery of lost function.
- The emergency of the decompression is linked to the acuteness of the evolution.
- Stabilization of the spine must be discussed in each case of bone tumor case.

## 1. SURGICAL ANATOMY AND PHYSIOLOGY

Merging from the brainstem the spinal cord runs embedded in the spine from C1 to L2.

The symptoms of spinal cord compression come from:

- The spine itself resulting in the spinal syndrome.
- The presence in the spinal cord of descending motor tracts, the sensory ascending tracts causing the central nervous suffering signs.
- The sprouting of nerve roots at each level corresponding to the segmental distribution, giving a group of peripheral signs (Fig. 1).

According to the level of the compression, the various symptoms can be associated. Below L2, cauda equina compression will include only peripheral signs. The vascularisation of the spinal cord comes from the vertebral arteries at the cervical level and the Adamkiewicz artery (often named “lumbar enlargement artery”) at the low thoracic and lumbar levels 5 (Fig. 2). The midthoracic territory constitutes an intermediate territory “watershed zone”, more susceptible to vascular insults.

## DECISION-MAKING

### 1. CLINICAL FEATURES AND PRESENTATION

Past medical history of the patient: previous pathologies, especially cancers, infections...

History of the disease is pivotal to the diagnosis: onset is often insidious, but abruptness may occur.

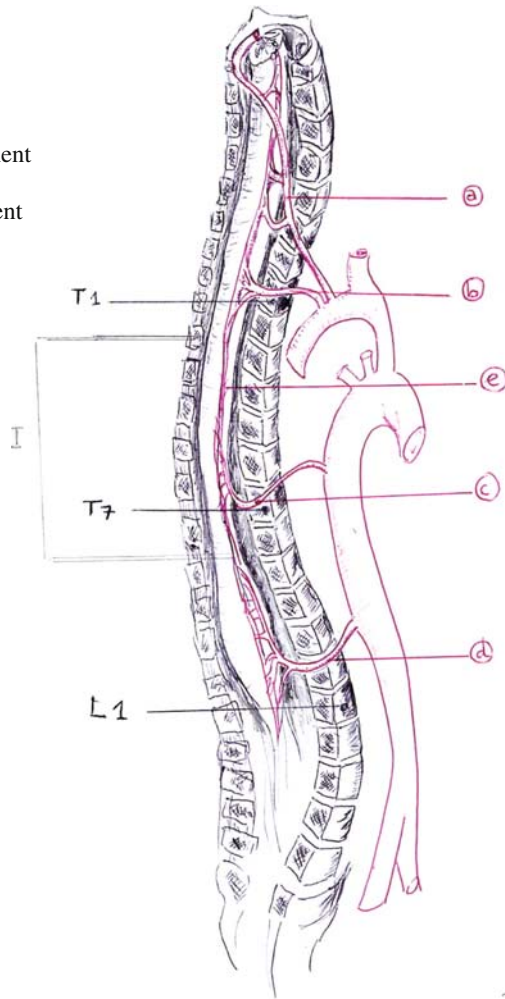
Common findings include:

- Persistent pain at one precise site of the spine, even in recumbency, radicular component pain (commonly bilateral in thoracic region, worse in cervical and lumbar lesions), exacerbated by movements, coughing, sneezing or straining.
- Motor weakness of the lower limbs, with progressive shortening of walking performance.
- Sensory disturbances with lowered perception of stimuli.
- Autonomic disturbances such as urinary urgency or hesitancy, constipation.

### 2. EXAMINATION

- Will check the general status of the patient, and the different courses of treatment.

- a) Vertebral artery
- b) Artery of the cervical enlargement
- c) Dorsal radicular artery
- d) Artery of the lumbar enlargement
- e) Anterior spinal artery
- I) Watershed zone



**Fig. 2.** Vascularization of the spinal cord

- Will examine all other organs: lungs, liver, testis, breast...
- Spine examination.
- Will include total skin examination looking for “café-au-lait” spots and any sign evocating a NF1, any melanic spot.
- Will check the functional status:
  - Ambulation.
  - Radicular suffering and pain intensity.
  - Autonomic dysfunction.

This examination should conclude:

- To a categorization of the patient based on the rapidity and seriousness of the neurologic findings: able to walk, able to move legs but not antigravity, slight residual motor and sensory function, complete failure below the lesion.
- To its ability to undergo surgery.
- To the risk of rapid deterioration and necessity of immediate assessment.

### 3. RADIOLOGIC EVALUATION

Plain X-rays of entire spine may show pedicle erosion (defect in “owl’s eyes” on antero-posterior view, pathological compression fracture, osteoblastic changes (may occur with prostate cancer, Hodgkin’s disease, occasionally breast cancer and rarely with myeloma), vertebral osteomyelitis, spondylodiscitis, primary bone tumor.

MRI, without and with contrast, T1, T2, Flair, T2\* is the most contributive, showing the spine and its content. It must be done in at least 2 different planes (axial and sagittal in all cases).

Myelo-scanner is indicated only if MRI is contraindicated.

Bone scintigraphy: this will be an emergency evaluation if acute evolution of the neurologic deterioration.

### 4. GENERAL EVALUATION

- Blood cell count, coagulation, ionogram.
- Plain chest X-rays.
- Myelogram if myelocytoma suspected.

### 5. CHECKING OF SURGICAL CONTRAINDICATIONS

Especially when the compression is the consequence of a spinal or epidural metastasis conditions with an important impact on perioperative morbidity and mortality have to be crucially considered: the patient should have a potential survival of at least 6 months, a relatively stable systemic disease, a potential to regain deambulation and respiratory autonomy.

### 6. FINAL DECISION

- Depends on the type and site of compression  
The urgency of treatment which is correlated with the abruptness of the symptoms: The shortest the delay of the onset with rapid deterioration, the greatest the emergency for treatment to give the patient a chance to recover function.

- Patients can be categorized into three groups:  
 Group I: signs/symptoms of new or progressive (hours to days) cord compression (ascending numbness, motor dysfunction, urinary emergency): These patients carry a high risk of rapid deterioration and require immediate evaluation and treatment.  
 Group II: mild and stable signs/symptoms of cord compression – less emergent situation but require evaluation and treatment within few days.  
 Group III: Back pain with very slight neuro symptoms – can be evaluated as outpatient over several days.

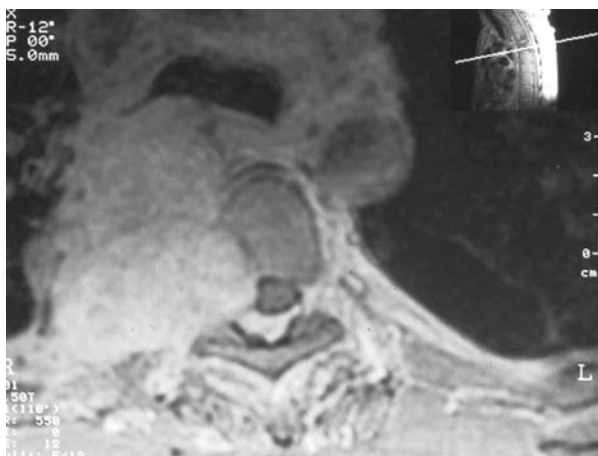
## MANAGEMENT AND SURGERY

Whatever the timing, the modality of the procedure must be adapted to the suspected pathology, and the patient status which is the best way to avoid complications:

### 1. METASTASES, SPINE TUMORS

Are the most frequent cause of cord compression in adults. Occur in 10% of all cancer patients, 5–10% of malignancies present initially with cord compression.

The usual route of spread is hematogenous dissemination to vertebral body, with erosion back through the pedicles, and extension to the epidural space. Direct invasion from an adjacent tumor can also occur (Fig. 3). The primary site is in 80% of cases lung, breast, prostate, seminomas.



**Fig. 3.** Direct spine invasion by a lung cancer: axial plan MRI T1 sequence with gadolinium

The most common site is thoracic (50–60%).

Sometimes collapse of the pathologic vertebra occurs, with abrupt neurological deterioration.

If bony pathology is demonstrated, goal of treatment is pain control, preservation of spinal stability, preservation of ability to ambulate and of sphincter control. In most cases, an epidural extension is present.

If patient is Group III, the discussion must involve oncologists and radiotherapists. If the cancer is already diagnosed, according to the cancer, chemo- and/or radiotherapy will be considered.

Surgery is indicated if stabilisation of the spine is necessary. If the bony pathology is the initial presentation of the cancer, CT scan of chest and abdomen must search the least invasive site for biopsy. If no tumor is detected, a bony needle biopsy of the vertebra has to be performed under CT scan control, or a surgical one. A surgical decompression is indicated if the epidural extension is threatening the cord.

If patient is group I or II, surgery is nearly always indicated.

Particular procedures:

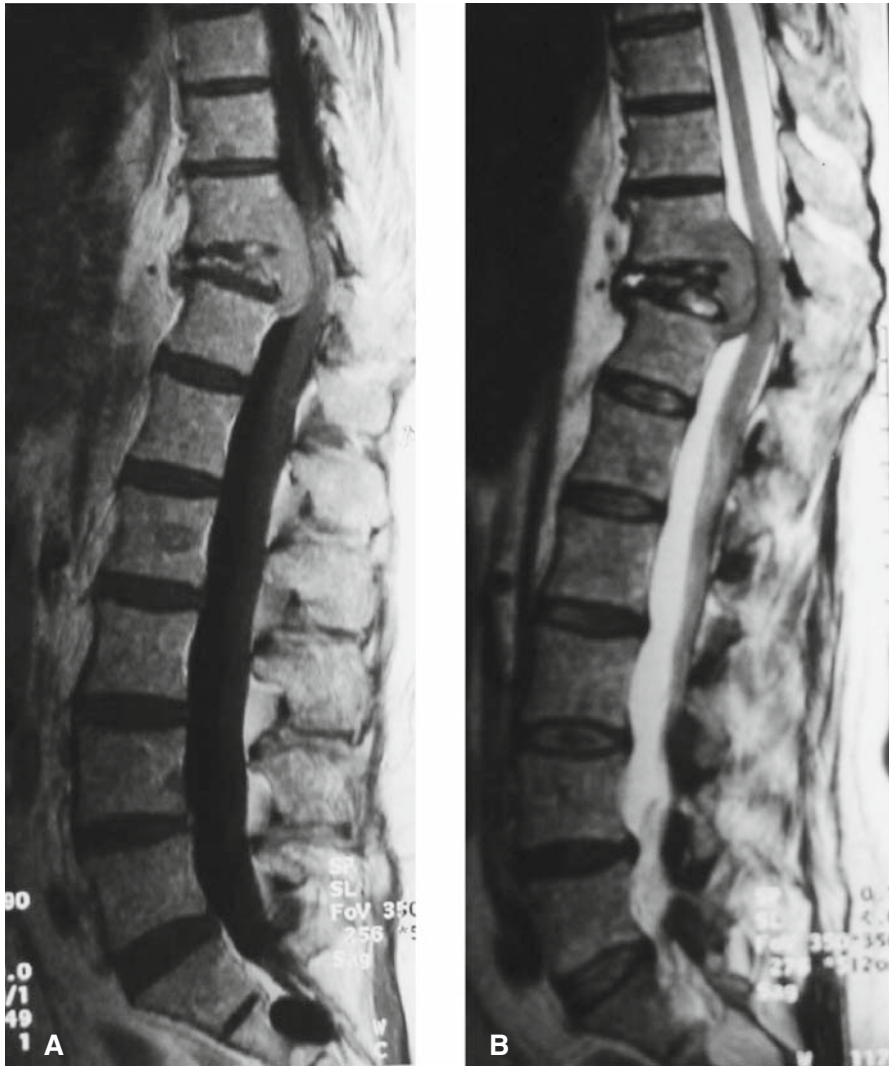- Metastases to the upper cervical spine (0.5% of spinal metastases)
 

They result in suboccipital and posterior cervical pain, and 15% of patients develop spinal cord compression, thanks to the wideness of the spinal canal. Their complication is quadriplegia due to atlantoaxial subluxation (6% of cases).

Posterior fusion is achieved, followed by radiation. An anterior approach must be avoided due to difficulty and high morbidity.
- Metastases at the other cervical levels: an anterior approach with corpectomy, inter corporeal graft and osteosynthesis is indicated before radiation.
- Metastases to the thoracic and lumbar levels:
 

The posterior route is commonly preferred for spinal cord decompression, and posterior osteosynthesis. If the vertebral body is severely involved, an associated kyphoplasty or an anterior approach must be discussed and achieved, posterior stabilisation alone being not effective.
- At the cervicothoracic junction, the anterior approach when stability is compromised can require extension through a median sternotomy, manubrial resection, and combined cervical approach and thoracotomy.
- Pure epidural metastatic compression requires laminectomy and can be related to lymphomas, leukaemia and all mentioned primary lesions (Fig. 4).
- Predictors of ambulatory function:
 

Preoperative non ambulatory patients require a more extensive surgery and have more surgical site complications.



**Fig. 4.** A Thoracic myeloma: sagittal T1 weighted MRI, demonstrating vertebral collapse and gadolinium enhancement and with sagittal T2-weighted image (B)

Bad functional outcome are inability to walk at time of surgery, pathological vertebral compression fracture, and preoperative radiotherapy.

The likelihood of regaining ambulatory ability is increased if symptoms are present for less 48 h, and if a postoperative radiotherapy is possible.



## 2. DISC HERNIATIONS

Though uncommon can cause progressive neurologic deficits, and must be treated with gratifying results. Their most common level is cervical (C5–C6 and C6–C7), associated or not to myelopathy, and lumbar. Thoracic herniations are the most difficult to treat. Acute onset do occur, specially in the low lumbar sites. The cervical or thoracic level will present with various association of radiculopathy, quadriplegia or paraplegia. If dealt with expeditiously, within the first day, patients have the potential to recover.

- Cervical herniations will be treated through an anterior approach: Removal of herniation and disk, followed by intersomatic graft and/or fixation.
- Approaches to thoracic disk herniations can be posterior (laminectomy), posterolateral (costotransversectomy), anterolateral (transthoracic or thoracoscopic), or anterior (transsternal), depending on the level of herniation, side involved, surgeon's experience, number of involved vertebral levels.

Laminectomy is the worst way to treat this pathology, with a high rate of post-operative neurological deterioration.

Costo-transversectomy and trans-pedicular approaches used for levels from T4 to T12 in lateral disk herniations.

Anterior approaches have become established as the standard for the appropriate treatment of disk lesions primarily anterior to the spinal cord. Thoracotomy remains the standard open procedure providing optimal ventral exposure, which must be applied in these most often midline calcified lesions.

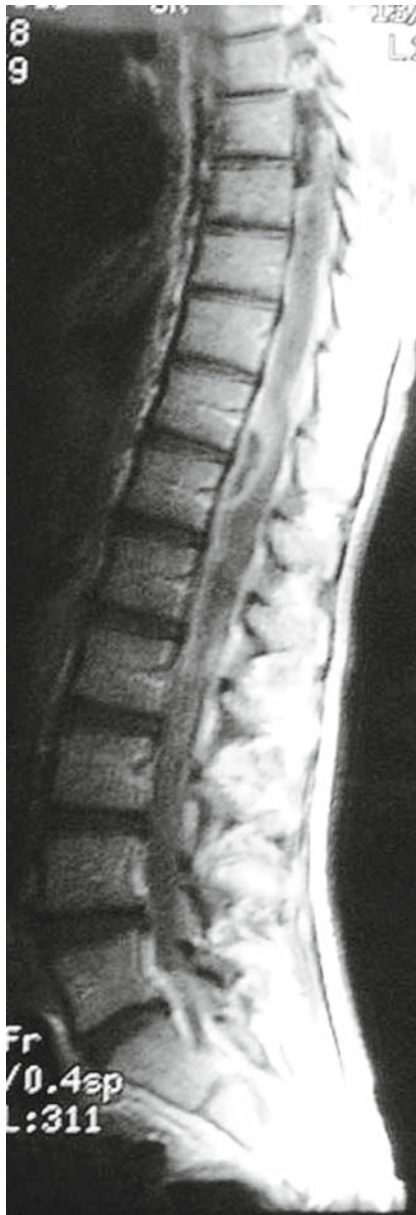Nowadays thoracoscopic techniques become the gold standard. However, many neurosurgeons prefer a trans-thoracic approach through a small thoracotomy of the 5 left intercostal space.

- A postero-lateral approach is to be used at lumbar levels.

## 3. INFECTIOUS PROCESSES

Can be caused by bacteria, fungi, and parasite organisms. Usually affect the lumbar and thoracic spine (Fig. 5). Cervical localization is uncommon but often involves an epidural abscess, carrying a high risk of morbidity and death.

- Pyogenic osteomyelitis is the most common encountered in adults, patients usually suffering from an underlying disease such as diabetes mellitus, rheumatoid arthritis, cancer, drug use, hemodialysis patients, or patients treated for several weeks in an intensive care unit and even elderly patients with no other identifiable risk.



**Fig. 5.** Polymicrobial thoracic epidural abscess. Sagittal T1-weighted MRI image with Gadolinium enhancement

Sources of infection are the urinary tract, dental flora, respiratory tract, soft tissues, and sites of previous surgery, the most common causative organism is *Staphylococcus aureus*, but numerous organisms have been reported.

Tuberculosis is uncommon in developed countries, common in third world.

The most common presentation is back pain. Average delay from onset is a few weeks. Fever may not exist.

Plain X-rays can be contributive but after a delay and CT-Scan and MRI constitute the standard for diagnostic.

When early discovered, medical therapy is the treatment of choice, especially if the causative organism can be cultured from a closed needle biopsy or blood cultures, even if the patient is afebrile.

When neurologic deficit or instability is present, surgery is indicated. Surgery is also indicated when all other attempts to identify a pathogen have failed.

- *Epidural abscess*: is a rare but threatening affection of the peridural space: Is responsible of mechanical compression of the cord the effect of which is enhanced by hypoxia due to inflammation and vascular compromise of feeding arteries or draining veins resulting in thrombosis, thrombophlebitis, or ischemic myelitis.

MRI is the gold standard for diagnosis.

Immediate surgical evacuation of the abscess must be performed, most often with a post-operative drainage, followed by long-term administration of intravenous antibiotics. Laminectomy or laminotomy are the preferred approaches.

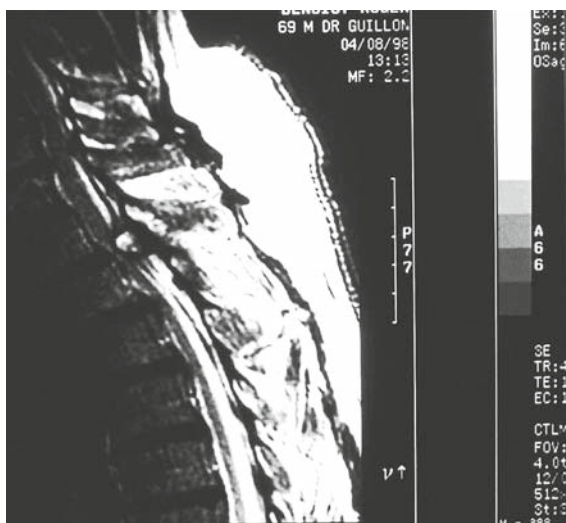
- *Discitis*: spontaneous discitis occurs in:
  - Adults: susceptible patients
  - Juvenile ones under 20 years, due to the presence of primordial feeding arteries irrigating the nucleus pulposus, and disappear after age 20–30.

Spinal cord compression seldom occurs, mainly after long-time delayed diagnosis. Surgery is indicated in these cases, to remove compression and treat associated instability.

#### 4. JUXTAFACET CYSTS

Are located beside the facet joint, exhibit a communication with the facet joint, and closely related with its degeneration, include synovial and ganglion cysts.

Their most common localisation is lumbar often associated to spondylosis, but they can develop anywhere in spine.



**Fig. 6.** Synovial cyst: sagittal T2-weighted MRI image

Occur in adults (average 60 years old, range 33–88), with a slight female predominance.

They can be responsible of radiculopathy, associated with paraparesis, or quadriparesis. Symptoms may be more intermittent than with firm compressive lesions and their sudden exacerbation may be due to hemorrhage within the cyst.

On MRI (Fig. 6), they can mimic neurofibromas, disk herniation ...

May be isointense to the ligamentum flavum, hypo- or hyperintense on T2-weighted sequences. On T2-weighted sequences they can be iso- or hypointense to the CSF. Most show a peripheral enhancement after contrast administration.

They often are associated to a more or less severe degree of central canal stenosis.

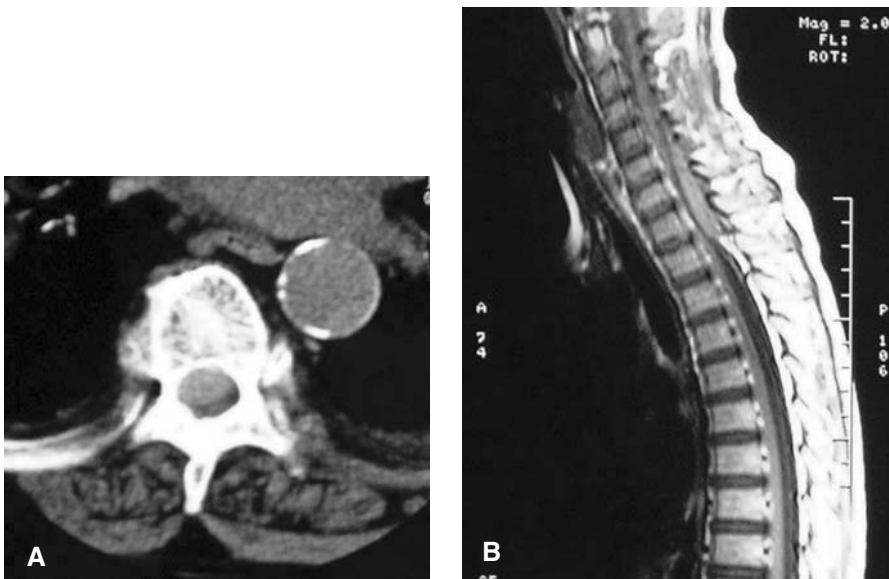
On CT, calcifications and gas within the cyst are common findings.

Surgery is indicated through a medial facetectomy: en bloc resection of the cyst, usually adherent to the dura mater with the adjacent ligamentum flavum gives gratifying results, depending as usual on the preoperative functional status of the patient.

## 5. SPINAL EPIDURAL HEMATOMA

Spontaneous spinal epidural hematomas seldom occur. These hematomas include hemorrhage from vertebral hemangiomas.

Most often they occur in patients with anticoagulation therapy, thrombocytopeny, or having bleeding diathesis.



**Fig. 7. A** Thoracic epidural hematoma: axial CT-scanner. **B** Cervico-thoracic epidural hematoma: sagittal T1-weighted MRI

No cause can be found in at least one third of cases.

Any spinal level may be involved, however thoracic is most common but may extend to entire spine. Most often they are located posterior to spinal cord.

The clinical presentation usually starts with severe back pain with radicular component, rapidly quickly followed by a progressing neurological deficit.

In bedridden patients, the motor weakness can remain unnoticed, or rather late after the onset. Neurological deterioration may be more progressive.

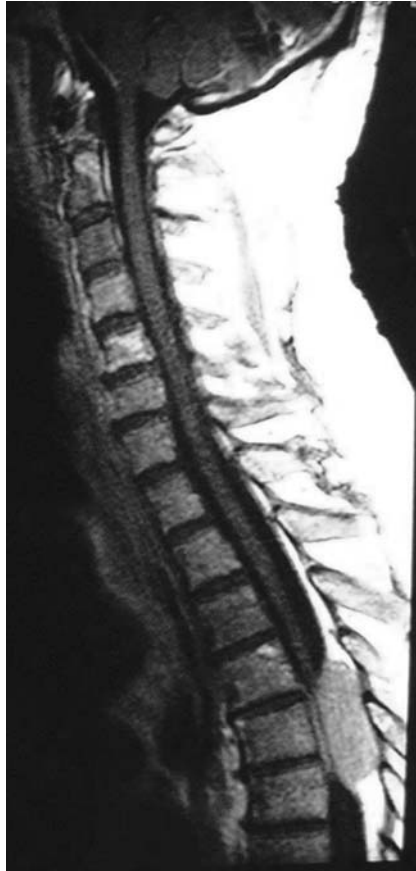CT scan showing blood in the epidural space is very contributive as well as MRI (Fig. 7) with T2\* sequences.

Emergency treatment: decompression is the treatment of this condition, after reversion of anticoagulants. Patients whose anticoagulation is prescribed during the acute phase of myocardial infarction or any other severe condition have a very poor prognosis.

## 6. EPIDURAL TUMORS

Spinal epidural metastasis are the most frequent cause of spinal cord compression.

Of epidural malignancies, lymphoma is the most important though representing only 2% of extra-nodal non hodgkinian lymphomas. Males about 55 years old will present with compression of the thoracic cord. Presentation may have a rapid evolution. MRI will show the epidural mass (Fig. 8). Prompt



**Fig. 8.** Thoracic epidural lymphoma: Sagittal T1-weighted image with gadolinium enhancement

laminectomy will confirm the suspected diagnosis, followed by radiation and chemotherapy. The lymphoma carry a better prognosis than other metastases.

Some other tumors can arise in the epidural space:

- Meningiomas: 15% arise in vertebral bodies or epidural tissues. Complete removal is able to cure them.
- Lipomas: can occur spontaneously, but have also been induced by long-term steroid treatments
- Angiolipomas: associating mature angiomatous and lipomatous components are benign tumors causing progressive spinal compression sometimes partially regressing and mimicking multiple sclerosis. They occur in adults (average 47 years). They arise mostly at thoracic level.

There removal is easy and is followed by a rapid recovery.

## 7. INTRADURAL EXTRA-MEDULLARY TUMORS

### 7.1 Meningiomas

Meningiomas represent 15–20% of spinal compressions. The average of patients is 60 years, with female sex predominance.

The intradural tumor can occur at any location around the circumference of the spinal canal, but tend to be lateral to the spinal cord, with ventrolateral being the most common site. They are most frequent in the thoracic region.

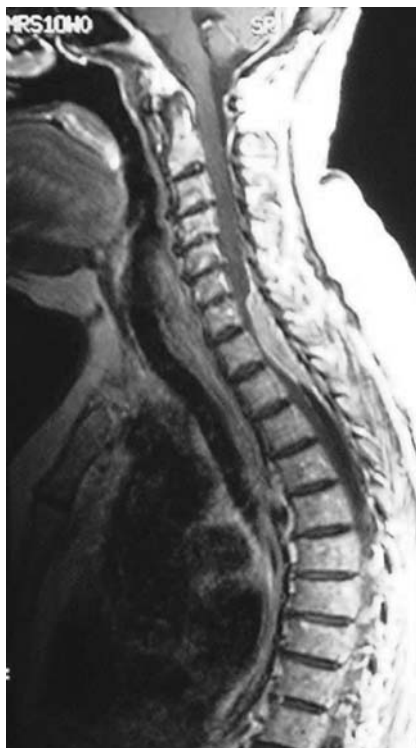Plain X-rays may show calcifications of the tumor, inside the spinal canal.

MRI (Fig. 9) will provide all needed information to plan the surgical procedure.

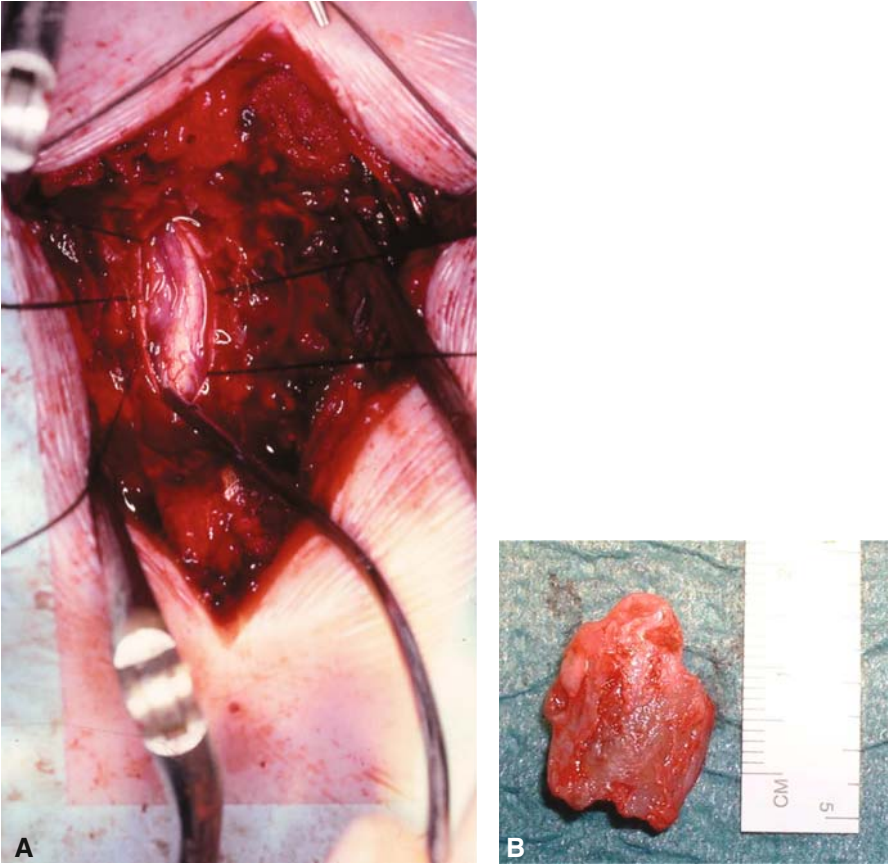
Advanced age is never a contraindication for surgery, neither a severe neurological disability, all series reporting significant neurological improvement.

Adequate exposure must be tailored according to the attachment of the meningioma. Posterolateral or posterior approach permit in nearly all cases the tumor removal and coagulation or resection of the dura mater (Fig. 10).

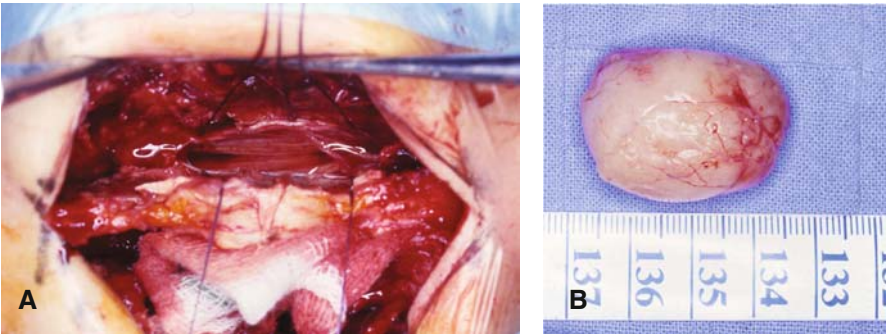
Long-term results are very good, with rare recurrences.



**Fig. 9.** Cervical meningioma: sagittal T1-weighted MRI image with gadolinium enhancement

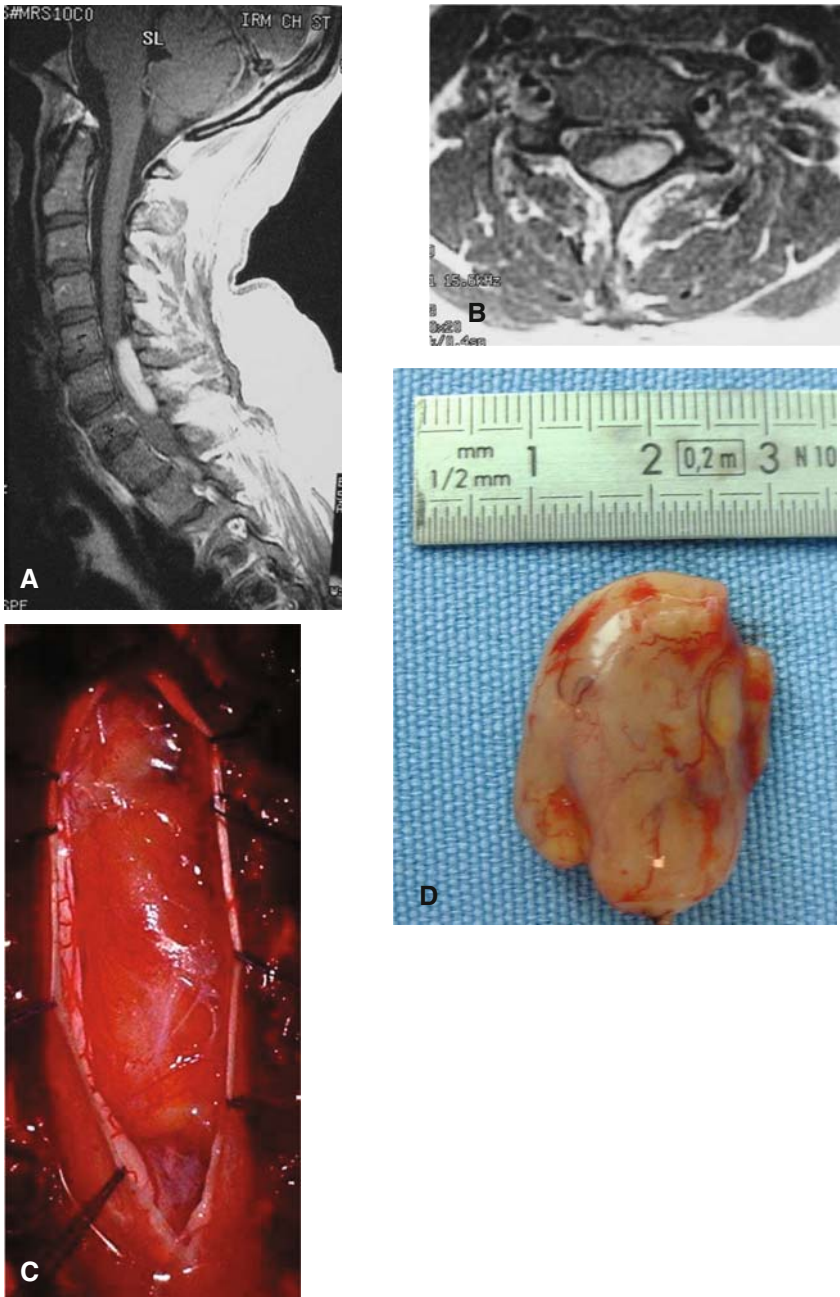


**Fig. 10.** **A** Thoracic meningioma: operative view. **B** The removed meningioma



**Fig. 11.** **A** Schwannoma: operative view. **B** The removed neurinoma





**Fig. 12.** **A** Neurolipoma: sagittal T1-weighted MRI. **B** Axial T1-weighted MRI image. **C** Operative view. **D** After removal

## 7.2 Schwannomas

Comprise approximatively 25% of all spinal tumors. They share with the intracranial tumors a predominant tendency to involve the sensory roots. Most growth are intradural, but some include both intra- and extradural component.

They are most commonly seen in the low cervical region, but can be found in thoracic and lumbar ones with an increasing cranio-caudal frequency.

Age is far lower than in meningiomas, the average being 30, with male sex predominance.

They can be discovered when searching the cause of pain or neurologic disturbance, or during the follow-up of neurofibromatosis patient. In young patients, this disease must always be eliminated.

Particular presentation feature: The pain is often exacerbated in the night.

Plain X-rays and CT scan show enlargement of the intervertebral foramen. CT scan and MRI both without and with contrast show the tumor, with enhancement. On T1 sequences the tumor is isointense in relation to the spinal cord, and of a mixed intensity on T2-weighted images. It may erode the vertebra, extend through the foramen, and give an extraspinal portion (dumbbell tumors).

Radical excision of the tumor (Fig. 11) carry a very good prognosis, including patients preoperative disability.

Patients without neurofibromatosis have nearly no recurrence.

## 7.3 Spinal acute subdural hematoma

Occurs rarely. May result from coagulation abnormalities and iatrogenic causes such as spinal puncture.

Early surgical treatment is always indicated when the patient's neurological status deteriorates, and with good results mainly in patients who do not experience associated subarachnoid hemorrhage.

## 7.4 Subdural arachnoid cysts

May cause spinal cord compression, myelopathy, syringomyelia, or become symptomatic when hemorrhage occurs inside the cyst after a traumatism.

Surgical excision or drainage may be necessary when the patient's condition deteriorates, but recurrence of the cyst can compromise long-term results.

## 7.5 Neurolipomas (Fig. 12)

Most often can be completely resected. If they cannot be divided from the spinal roots some remnants may be left in situ to avoid post-operative deficit.

## POST-OPERATIVE MANAGEMENT

- Prevention of bed-rest complications (bed sores, thrombo-embolic), must be prescribed and has to be controlled at any time by a well trained staff.
- Any site or general complication must be detected in immediately treated.
- As well as the management of sphincterian disturbances and bowel evacuation, sometimes increased by morphinic prescription.
- Post-operative radiology is performed after osteosynthesis.
- If necessary, a brace must be done as soon as possible.
- Rehabilitation is begun as soon as the general status and pain allow it, with programming of staying in a readaptation center.
- Further exploration of extension of the malignant affection has to be done if a metastasis was the first symptom, with programming of radiotherapy.
- The follow-up with the different concerned physician has also to be planned.

## CONCLUSIONS

Spinal cord compression is a pathologic presentation the physician has to face daily.

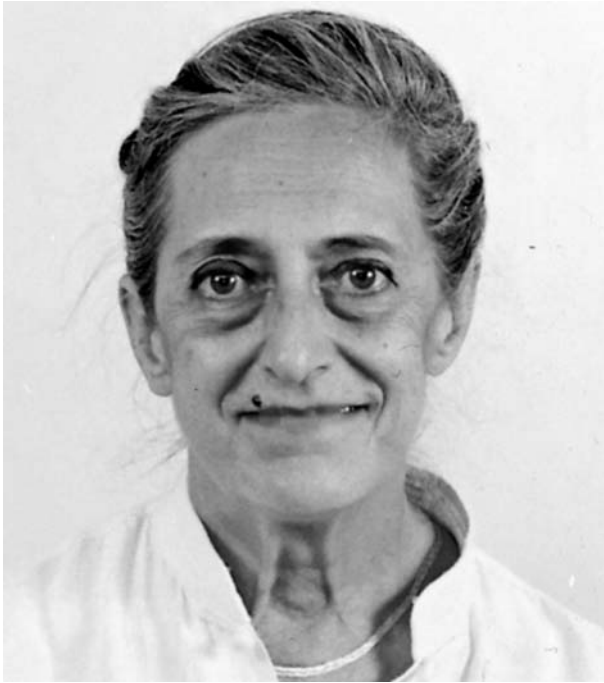The optimum management is complicated by emergency of decompression – which is the only chance for the patient to recover function-intricated in a great number of cases with severe underlying pathologies, each patient requiring a personal judicious evaluation.

Good decision making, adapted technics and treatment will bring gratifying results in many cases both for the patient and the surgical team, helped by readaptation structures often postoperatively needed by the patients.

## References

- [1] Akhaddar A, Gazzaz M, Derraz S, Rifi L, Aghazi A, El Ouahabi A, El Khamlichi A (2000) Les angioliipomes rachidiens épидурaux: une cause rare de compression médullaire. *Neurochirurgie* 46(6): 523-533
- [2] American Association of Neurological surgeons (2004) A brief history of therapy for traumatic spinal cord injury. *Neurosurg Focus* 16(1)
- [3] Arnold PM, Beak PN, Bernardi RJ, Luck EA, Larson SJ (1996) Surgical management of non tuberculous thoracic and lumbar osteomyelitis: report of 33 cases. *Surg Neurol* 47: 551-561

- [4] Boockvar JA, Philips MF, Telfeian AE, O'Rourke DM, Marcotte PJ (2001) Results and risk factors for anterior cervicothoracic junction surgery. *J Neurosurg (Spine)* 94: 12-17
- [5] Chaichana KI, Woodworth GF, Sciubba DM, Mc Girt MJ, Witham TJ, Bydon A, Wolinsky JP, Gokaslan Z (2008) Predictors of ambulatory function after decompressive surgery for metastatic epidural spinal cord compression. *Neurosurgery* 62: 683-692
- [6] Cohen JE, Ginsberg HJ, Emery D, Schwartz ML (1998) Fatal spontaneous spinal epidural hematoma following thrombolysis for myocardial infarction. *Surg Neurol* 49: 520-523
- [7] Cohen-Gadol AA, White JB, Lynch JJ, Miller GM, Krauss WE (2004) Synovial cysts of the thoracic spine. *Neurosurg (Spine)* 1: 52-57
- [8] Cruz J (1998) *Neurologic and neurosurgical emergencies*. W.B. Saunders, Philadelphia
- [9] Curry WT, Hoh BL, Amin-Hanjani S, Eskandar EN (2005) Spinal epidural abscess: clinical presentation, management and outcome. *Surg Neurol* 63: 364-371
- [10] Dinh DH, Tompkins J, Clark SB (2001) Transcostovertebral approach for thoracic disk herniations. *J Neurosurg (Spine)* 94: 38-44
- [11] Domenicucci M, Ramieri A, Ciappetta P, Delfini R (1999) Non traumatic acute spinal subdural hematoma. *J Neurosurg (spine)* 91: 65-73
- [12] Greenberg MS (2007) *Handbook of neurosurgery*. Thieme, New York
- [13] Klekamp J, Samii M (1999) Surgical results for spinal meningiomas. *Surg Neurol* 52: 552-562
- [14] Liu Z, Qingfang J, Xu Jianguo, Wang X, Li Sanzhong, Chao You (2008) Spontaneous spinal epidural hematoma: analysis of 23 cases. *Surg Neurol* 69: 253-260
- [15] Oskouian RJ, Johnson JP, Reagan JJ (2002) Thoracoscopic microdiscectomy. *Neurosurgery* 50: 103-109
- [16] Wang MY, Levi ADO, Green BA (2003) Intradural spinal arachnoid cysts. *Surg Neurol* 60: 49-56



**Françoise Lapierre**

Françoise Lapierre is chief neurosurgeon of the neurosurgical department in Poitiers University Hospital. She has been involved in peripheral nerve surgery for 30 years. She performed personal research concerning the maturation of the peripheral nerve from birth to death, and its patterns of regeneration after different type of traumatism, in correlation with the age.

More recently she directed a research dealing with morphologic and physiological changes and behaviours of the peripheral nerve after permanent impairments of the central nervous system (brain, spinal cord), in rats and the humans. She was especially involved in the treatment and follow-up of patients with phacomatosis, and the teaching of these diseases.

**Contact:** Françoise Lapierre, Neurosurgery Department, CHU La Milétrie, 86021 Poitiers Cedex, France  
E-mail: [f.lapierre@chu-poitiers.fr](mailto:f.lapierre@chu-poitiers.fr)

---

# INTRAMEDULLARY TUMORS

J. BROTCCHI

## INTRODUCTION

The surgical treatment of intramedullary tumors was pioneered by Elsberg [6]. Thereafter, several neurosurgeons greatly contributed to the surgical approach, mainly Cooper [5], Epstein and Epstein [7], Guidetti et al. [9], McCormick et al. [10], Malis [11], Stein [12].

The revolutionary changes that have been brought about by new neuroradiological diagnostic tools such as magnetic resonance imaging (MRI) and new neurosurgical techniques, including microsurgical techniques, bipolar coagulation, ultrasonic aspiration and recently per-operative neurophysiology, have made the majority of these tumors curable rather than hopeless. However, these lesions are rare and with few exceptions, the experience of most neurosurgeons is limited to a few numbers of cases. Unfortunately, that has led to suboptimal results: incomplete removal of potentially resectable tumors, unsatisfactory neurological outcome due to intraoperative misjudgments, or surgical timidity and failure to provide the neuropathologists with sufficient material to arrive at a correct diagnosis. Furthermore, it should be clear that the gold standard treatment of these lesions is complete removal with some exceptions in malignant tumors and infiltrative gliomas for preservation of quality of life. Therefore, surgical technique should be very precise and based on a very well known anatomy of spinal cord.

## RATIONALE

The goal is complete removal but the way to approach differs according to tumoral nature and location. When writing this chapter, our experience is based on 410 intramedullary tumors. We confirm what we have previously said when publishing our results in the past and in 2006 [1–3, 8]. Our strategy differs from gliomas to vascular tumors. For gliomas (ependymomas, astrocytomas), we favor a midline approach with gentle separation of posterior columns. Vascular tumors (hemangioblastomas, cavernomas), which are mostly subpial lesions, are directly approached where they are seen under the microscope. A midline approach means finding the midline under the microscope, which is not always easy. On the other hand, going directly on a subpial lateralized lesion needs a complete preoperative MRI study with axial, sagittal and coronal views to avoid searching for the lesion.

---

*Keywords:* spinal cord, intramedullary tumors, neuro-oncology, microsurgery

In deep-seated lesions, the first difficulty the surgeon has to face is to secure the midline. It is not always easy, especially with asymmetrically developed astrocytomas. Identification of the midline may sometimes be difficult with the need to search it above or below the tumor where the spinal cord is normal. High-powered microscopic magnification will allow localization of the dorsal median sulcus, which appears as a distinct median “raphé”, over which the very tortuous posterior spinal vein runs. Sometimes, this sulcus is identified only by the convergence of vessels toward the midline. Those vessels of varying size running vertically over the dorsal columns are dissected and mobilized laterally to expose the posterior sulcus, trying to spare all the thinnest arterial or venous vessels in the sulco-commissural region. Another way is to appreciate the midline between both posterior collateral sulci.

## **DECISION-MAKING**

### **1. DIAGNOSTIC CRITERIA**

Spinal cord tumors have no typical clinical presentation. The initial presentation may consist of sensory disorders, torticollis, motor disorders, urinary dysfunction, scoliosis, myoclonus, rarely papilledema, subarachnoid hemorrhage or hydrocephalus mainly in children. Most commonly, adult patients complain of back or radicular pain, or paresthesias. Children present with scoliosis or neurological complaints. The clinical course may be insidious (during several years), abrupt in onset, or may progress episodically. One should not forget the value of clinical history since MRI alone does not guarantee an accurate diagnosis in every case. That is the reason why we recommend taking care of anamnesis and neurological exam to avoid making unnecessary surgery on multiple sclerosis lesion or vascular myelitis. In any doubt, a complementary brain MRI should be performed for searching demyelinated plaques. CSF analysis and, if any hesitation, clinical and MRI follow-up may be more secure and wiser than unnecessary surgery.

### **2. INDICATIONS**

It is now generally agreed that only symptomatic lesions should be treated surgically. In incidental discovery, it is wise to follow the patient clinically and with an MRI every 6 months. We do not recommend operating a stable lesion in an asymptomatic patient. But, as soon as the first clinical signs appear, or if the lesion grows on subsequent MRIs, a decision for surgery should be made without waiting for deep neurological deficits since it has been well demonstrated that quality of life is directly related to the preoperative status [4, 5]. Risks of surgery are greater in handicapped patients than in those with light neurological deficit.

## SURGERY

### 1. GENERAL CONSIDERATIONS

The patient is positioned prone on bolsters, freeing the abdomen and the thorax from any pressure. We do not use the sitting position for intramedullary tumors, even for those in the cervico-medullary junction. General anesthesia is performed using intravenous opioids and a continuous administration of propofol. Dosage adjustments are necessary to keep the patient's invasively monitored blood pressure close to the one measured supine and awake. Halogenated volatile anesthetics should be avoided since they modify sensory evoked potentials. Short-acting muscle relaxants are used only to facilitate the intubations but are not re-administered, allowing the use of motor evoked potentials during the entire procedure.

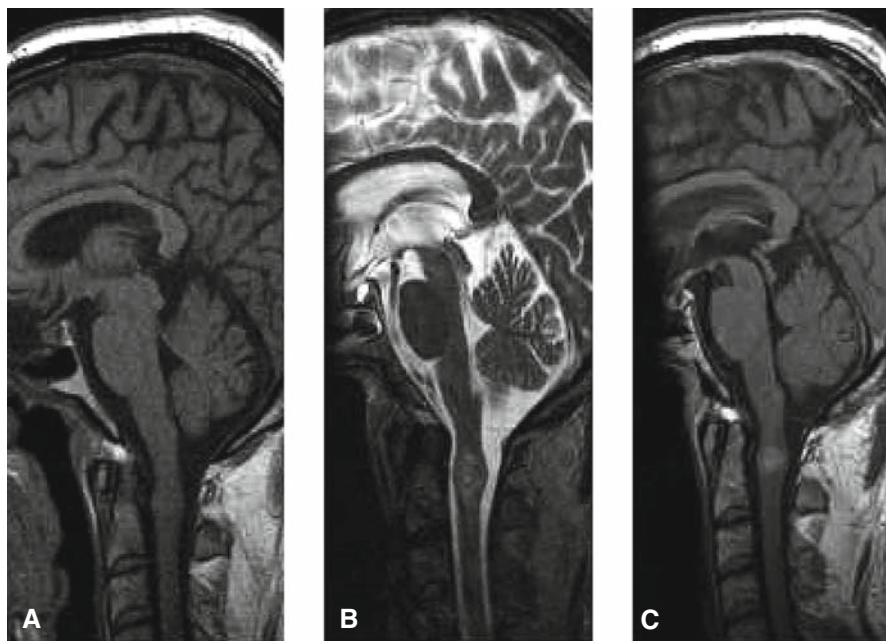
To prevent inadvertent cervical flexion and pressure on the face, we use a three-point head fixation. Before starting surgery, sensory (SEP) and motor evoked potentials (MEP) are monitored. When the location of the tumor is cervical, we take care of sensory evoked potentials record to avoid any cord compression due to head position. At the beginning of the procedure, we like giving the patient a large dose of methylprednisolone (30 mg/kg bolus followed by 5.4 mg/kg/h during 23 hours).

A midline skin incision is made, centered at the level of the lesion extending above and below it, cutting across the "raphé" and allowing symmetrical retraction of muscular masses. Laminectomy, laminotomy or laminoplasty are performed gently and patiently, avoiding any damage to the adjacent spinal cord and preserving the lateral masses, to diminish the risk of post-operative kyphosis. Bone opening is limited one level above and one level under the solid part of the tumor.

In pediatric patients, we always do a laminotomy. In infants, one can perform a unilateral incision of the soft tissues, and unilateral laminotomy is possible. However, when an extensive laminectomy or laminotomy has to be performed in children or in adults, we recommend the preservation of one posterior arch every five to six vertebrae. Hemostasis in the epidural space requires as much care as that in the soft tissues. A very clean field without any bleeding must be obtained before opening the dura.

We like opening the dura under the microscope, keeping the arachnoid intact whenever possible. Dural suspension by simple traction sutures may often be sufficient, but sutures to adjacent muscles allow better surgical room. The arachnoid is then opened separately with microscissors, and delicately freed from the posterior or lateral spinal cord, keeping it intact for closure at the end of surgery. Careful inspection of the spinal cord under magnification may show a subpial color modification by the tumor. In any doubt, we use intraoperative ultrasonography, which is helpful in locating solid and cystic parts of the tumor according to MRI data, but most of the times, we do not





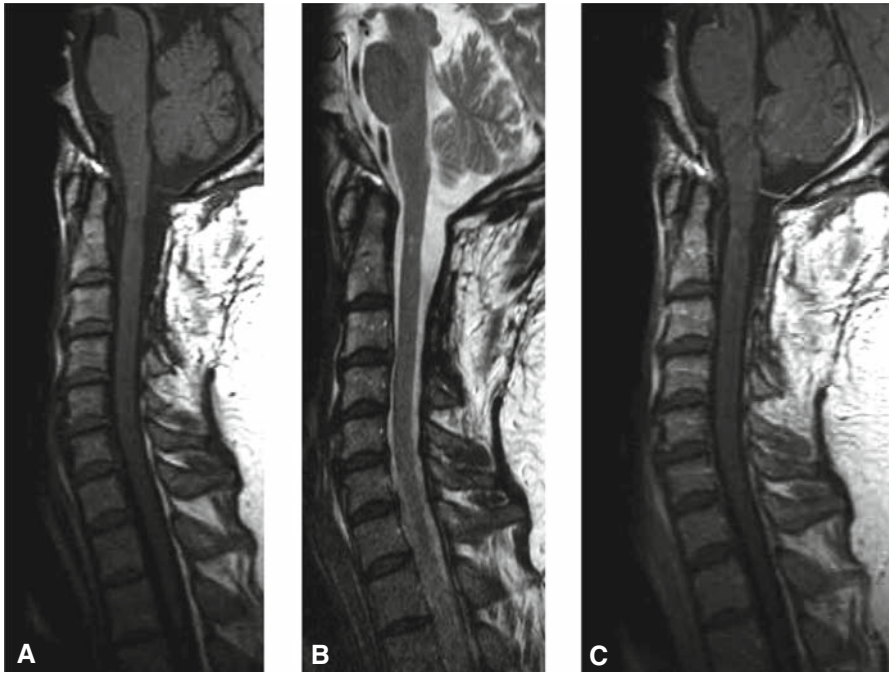
**Fig. 1.** C2 ependymoma pre-operative MRI. **A** T1Wi, **B** T2Wi, **C** Gadolinium T1Wi

need it. Now, it has to be decided if the approach will be posterior through the midline or lateral. In our view, the midline surgical approach is an absolute rule, with one exception: when the lesion is located in one dorsal column and is apparent on the surface without any cortical “mantle”. Ependymomas are centrally located tumors (Figs. 1 and 2). They will benefit of surgery through the posterior midline. Astrocytomas are eccentric tumors. Sometimes they are exophytic and may be followed from outside to inside the spinal cord, but in most of the cases, the approach will be similar to the one advocated for ependymomas, all the more so because it is difficult to know the nature of the tumoral process before getting a biopsy. Some rare deep located hemangioblastomas may also be approached through the midline, but most of them are superficial, subpial, so are cavernomas. There is no need to enter the spinal cord through the midline in such a situation. It is safer to go where the tumor has already prepared the way.

## 2. SURGERY ACCORDING TO PATHOLOGIES

### 2.1 Ependymomas and astrocytomas

As said above, the first difficulty the surgeon has to face is to secure the midline. It is not always easy, especially with asymmetrically developed astrocytomas. Identification of the midline may sometimes be difficult with the

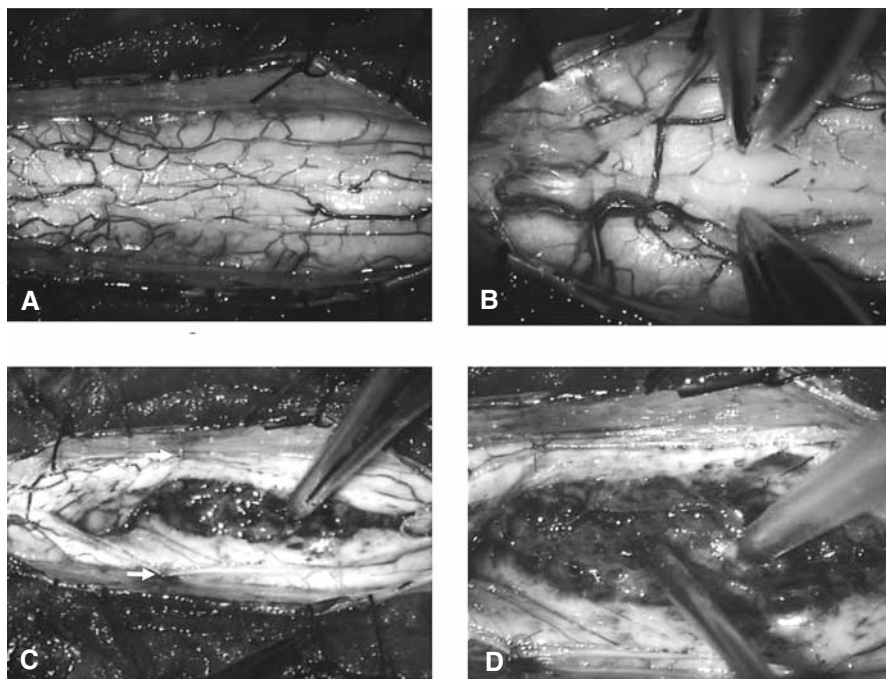


**Fig. 2.** C2 endymoma. Post operative MRI 6 years after complete removal. **A** T1Wi, **B** T2Wi: only a small residual cavity is seen. **C** Gadolinium T1Wi: no more contrast enhancement

need to search it above or below the tumor where the spinal cord is normal (Fig. 3). The dorsal columns are carefully retracted and opened progressively with microforceps and scissors, not with laser, over the entire length of the solid portion of the tumor, as if they were pages of a book. This manoeuvre is continued to expose the rostral and caudal cysts, if present.

Pial traction suturing improves the surgical exposure and reduces the severity of repeated trauma due to dissection. This can be accomplished using a 6-0 suture without tension to hold the median pia mater and the dura mater close together, instead of using suspension with sutures and weights at the ends of the sutures. We are aware of SEP recording during that handling to be sure keeping good function of posterior columns. Sometimes, the pressure of the tumor itself helps keeping the posterior columns separate and no pial traction is needed.

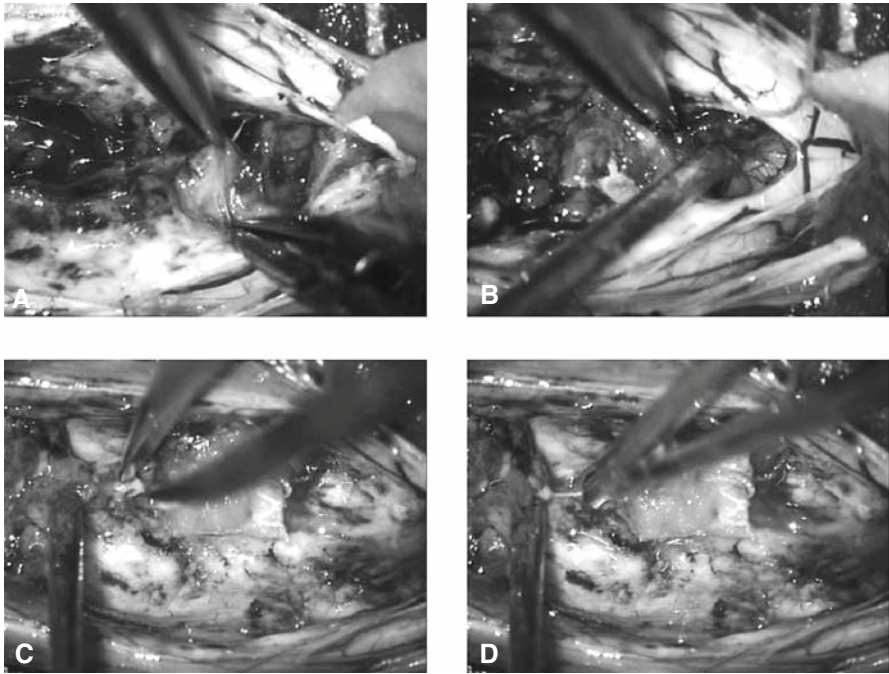
Intraoperative monitoring of the functional integrity of the spinal cord during intramedullary procedures has been recognized as a promising adjunct that may help in intraoperative decision-making and prediction of neurological outcome. The preservation of the SEPs must encourage us to proceed an aggressive intervention, but loss of SEPs is of little value for motor deficit. On the other hand, MEPs correlate more closely with the postop-



**Fig. 3.** C2 ependymoma. Surgical sequences. **A** Localization of the midline. **B** Separation of both posterior columns with forceps. **C** Pial sutures to dura to keep open the surgical room. **D** Debulking with ultrasonic aspirator

erative motor function. A decline of 50% or more in amplitude of MEPs is a warning sign to the surgeon almost when the tumor is infiltrative. Nevertheless, when there is a good plane of separation, after waiting a few minutes, we go ahead, even if MEP are bad.

We start by exposing a sufficient portion of the tumor to perform a biopsy with forceps and scissors, without coagulation. This is followed by immediate histological examination, while careful hemostasis is carried out before proceeding with surgery. Any information suggesting an infiltrating or malignant tumor, or a non-tumoral process such as sarcoidosis, can be crucial in deciding whether tumor removal should be continued or not, especially when the infiltrative character of the lesion is obvious. Otherwise, we adopt the same policy with ependymomas and astrocytomas: we do a debulking of the tumor, before searching for a cleavage plane. That is essential to avoid any traction or pressure on the spinal cord. Reducing the volume of the tumor is made by using ultrasonic aspiration after setting the suction at the lowest possible level and using vibratory force to a suitably low degree, because of the fragility of the location. Intratumoral resection is performed from inside to outside and this is sometimes facilitated by the presence of a cyst or an intra-



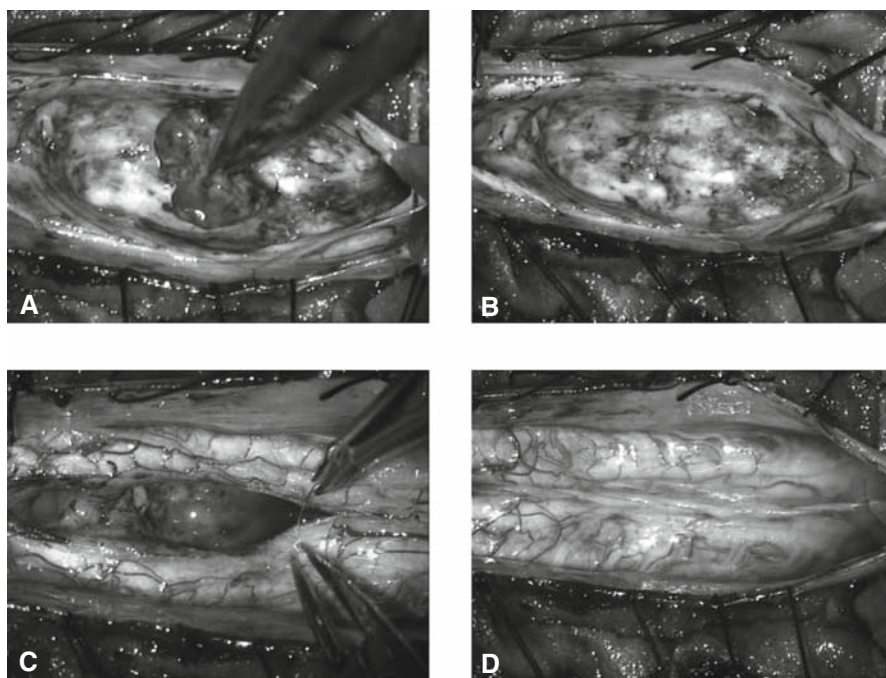
**Fig. 4.** C2 ependymoma. Surgical sequences. **A** Gentle separation of the tumor from spinal cord. **B** Normal anterior spinal cord is found. **C** Coagulation of the last arterial feeder coming from anterior spinal artery. **D** Division after coagulation of the last arterial feeder

tumoral hematoma. One must also remember that no ultrasonic aspirator differentiates between tumor and spinal cord. Only the surgeon does. We are not in favor of laser surgery, which chars the tissues in a procedure in which the best landmark between tumor and normal cord is the color. We prefer to keep that landmark clean under our eyes. Thereafter, it is essential to look for a cleavage plane, which exists in most ependymomas and in 30 to 40% of astrocytomas. Finding the cleavage plane makes the tumor removal possible, the objective being total removal. The best dissection is made with two microforceps, likewise we do when separating an acoustic schwannoma from the brain stem. It is safer than using microdissectors that may hurt the spinal cord (Fig. 4). We also like using cottonoid moistened with saline at 37 °C or a protection at the tip of the sucker. It is essential to keep the field clean from blood in order not to lose the plane. If there is a capsule, or if the tumor is not too friable, it can be grasped, allowing visualization of the correct cleavage plane, which must be respected. We have frequently observed that the difficulties are often different on each side or on each pole of the tumor. That is the reason why, instead of persisting in a particularly difficult area, or when SEP or MEP give us warning signs, we recommend moving the microscope

either from one side to the other, or from one pole of the tumor to the other, and coming back later after further reduction of the tumor bulk has been carried out with the ultrasonic aspiration.

If the plane is not easy to find, particularly if the intraoperative appearance is suggestive of an infiltrating tumor, we exercise caution and we do not continue tumor removal at any cost since this may be both dangerous and unnecessary for the patient. At that stage, MEPs are of great help to safely go as far as possible, keeping always in mind the quality of life. If no plane of separation is found, as often in many astrocytomas, no aggressive surgery should be done.

The last difficulty lies in the vascular pedicle or pedicles that supply the tumor and are connected to the anterior spinal artery, which must not be injured. Careful coagulation and division of the small arterial feeders makes hemostasis easy. In fact, when removal is macroscopically complete, there is no more bleeding (Fig. 5). In view of the small size of the cord vessels, which stop bleeding spontaneously, it is unusual to have to coagulate an area outside the tumor. When normal spinal cord tissue can be seen through a transparent cyst wall, surgery can be terminated, as the cyst wall is similar to that seen in syringomyelic cavities.



**Fig. 5.** C2 endpendymoma. Surgical sequences. **A** Removal of the last piece of tumor. **B** Complete removal with a clean surgical room. **C** Pial suture to reapproximate both posterior columns. **D** The arachnoid layer has been sutured over the surgical field

After tumor removal, the dorsal columns are released from pial traction and brought together again with caution. Whenever possible, we approximate the cord with non-absorbable silk 6-0 pial sutures, putting gently together both posterior columns at the condition the tumor has been totally removed. The arachnoid may also be partially reconstituted with the same suture, if it has been preserved on opening. Indeed, after tumor removal, there often is enough arachnoid since the cord volume is smaller than when surgery started. In partial or subtotal removal, we only close the arachnoid.

## 2.2 Hemangioblastomas and cavernomas

Those lesions are mostly superficial, lying over and in the spinal cord. When they are purely intra, surgery is done through the midline, as described above but no debulking is made, otherwise massive bleeding may compromise the surgery. When the tumors are seen after opening of the dura on the posterior or postero-lateral surface of the spinal cord, they are directly approached. In some small lateral hemangioblastomas associated with a huge and tense syringomyelic cyst, it is useful to gently aspirate the fluid through a 22-G needle to flatten the spinal cord and get an easy access to the solid tumoral nodule. In huge hemangioblastomas, one should pay attention not to coagulate the draining vein at the beginning of the procedure. Under magnification, we start by searching for the limit of the tumor at an area with few vessels. This is the starting point of our dissection. Cautious coagulation on the tumor surface enables to obtain slight retraction that helps detach the lesion from the cord and its vascular connections that are step by step coagulated and divided, ending by the draining vein. Both hemangioblastomas and cavernomas should be removed "en bloc". The fundamental principle is to avoid debulking and to injure the lesion during dissection. This is mandatory for hemangioblastomas, for which we advise against the use of the ultrasonic aspiration. The cleavage plane is distinct as long as bleeding does not interfere with the dissection. We like closing the arachnoid layer over the surgical field to avoid spinal cord tethering to dura. In huge cystic cavities associated to hemangioblastomas, removal of the tumor nodule with opening of the cyst is sufficient to solve the problem. No shunting of the associated syringomyelia is necessary. We never had to do it, even in a second stage. In Von Hippel-Lindau disease, only symptomatic lesions should be treated. Multifocal forms, which may or may not be associated with other neuraxial or visceral lesions in Von Hippel-Lindau disease, raise the question of operative indications in the absence of clinical manifestations. It is now generally agreed that only symptomatic lesions should be treated surgically.

With cavernomas, an approach similar to that for hemangioblastomas is advocated. Many cavernomas are antero-laterally located. They may be safely approached after division of one or two dentate ligament attachments, allowing to gently rotate the spinal cord with the help of 6-0 silk sutures holding

the ligament. That gives a nice room giving access to the antero-lateral spinal cord from which one may see the cavernoma through a transparent pia mater. We approach the lesion directly, with a small but sufficient opening of the pia through which we often put 8-0 silk sutures to keep the way open. Then, with gentle coagulation on the lesion, we shrink it, which gives place to dissect and separate it from the cord. In some huge cavernomas, it may be necessary to make a strategy combining different approaches (posterior and antero-lateral) in the same surgical procedure.

Many cavernomas are incidentally discovered. In our opinion, only symptomatic lesions should be operated. We will operate on cavernomas that have bled and those producing symptoms, even mild like radicular pain, but we have been quite conservative in recommending surgical removal of incidental cavernomas.

In hemangioblastomas and cavernomas, we do not try to close spinal cord opening. It is not possible in most cases. However, we cover the surgical field with the arachnoid, which that may be approximated and sutured as done in ependymomas and astrocytomas.

In all the procedures, the dura is closed in watertight fashion and without tension, with a 5-0 non-absorbable silk. When a biopsy alone has been made, it is better to make a duraplasty. If laminotomy has been performed, the bone is returned to its place with internal fixation, taking care to avoid any compression of the spinal cord. If needed, spacer may be placed to gain a larger spinal canal volume. Paraspinal muscles are reapproximated and sutured, so is fascia over the raphe. The skin is closed in two layers, with a postoperative orthosis in place for 6 months for children with laminotomy. When the tumor is cervical, the patient is progressively awakened and extubated in the intensive care unit, where he stays monitored one night. When the lesion is in the thoracic cord, the patient is awakened and extubated in the operating room, then placed for a few hours in the recovery room before going back in the normal care unit.

All the patients have an MRI on the next day. They are aware of temporary aggravation of sensory and sometimes motor deficit below the level of the lesion. They also receive analgesics and anti-inflammatory drugs to alleviate often distressing but temporary pain in the limbs and the spine. Early postoperative mobilization is advocated to achieve a better functional result.

### **3. RESULTS**

#### **3.1 Functional results**

When they awake from surgery, in the recovery room, many patients frequently complain of discomfort and are quite anxious, often more so than patients who have undergone surgery for other conditions. They feel pain everywhere and have diffuse hyperesthesia and paresthesias. They

cannot, or dare not, move. Position sense in the extremities is poorly perceived. Muscle and spinal pain complete this picture of discomfort, which lasts for several days and is quite unresponsive to the usual analgesic drugs. The severity of the postoperative picture depends on the extent of the surgery.

Prior to the patient's discharge from the hospital, a basic functional evaluation is made by the four-grade system proposed by McCormick et al. [10] to document motor and sensory function. Immediately after surgery, an increase in post-operative deficit, of varying severity, is often seen in nearly all patients. Although this early evaluation provides important information, it does not allow any prognosis to be made, even for the medium term, since most of those signs may be transitory.

At three months, the neurological situation is more or less definitive. We have observed on 410 patients improvement in tumors with satellite cysts only. If we go deeper in the results according McCormick's grades, we see the following:

- In preoperative grade I patients, 5% worsened and 95% were unchanged.
- In preoperative grade II patients, 7% worsened, 86% were unchanged and 7% improved.
- In preoperative grade III patients, 18% worsened, 52% were unchanged and 30% improved.
- In preoperative grade IV patients, none except one (a child) improved. Most remained unchanged.

That means that intraspinal cord tumors should be operated in grade I or II for the best results. A yearly MRI is recommended for the follow-up. When tumor removal has been complete, confirmed by MRI, subsequent MRIs are still necessary to make certain that there has been no recurrence. The appearance or reappearance of contrast enhancement suggests tumor recurrence or resumed progression of tumor growth.

Early MRI examination is of particular value when trying to demonstrate the presence of residual tumoral tissue too. Diagnosis of residual tumor is easy when the lesion was found to enhance after contrast injection prior to surgery. If there was no enhancement preoperatively, the diagnosis is more difficult and is mainly based on the presence of residual increased signal on T2-weighted images. This examination will evaluate the residual tumor and serves as a baseline for assessing subsequent progression of the lesion.

### 3.2 Complications

In our personal series based on 410 patients, the operative mortality is 1.7% with none in the last 197 cases.



Surgical complications (4%) had no effect on the mortality rate and included the following: hematoma at the operative site or epidural hematoma, arachnoiditis, sepsis, meningocele, cerebrospinal fluid fistula, pulmonary embolism, perforated gastric ulcer and cervical kyphosis post laminectomy.

The risk of postlaminectomy spinal deformity is well known, especially for children. Risk factors often responsible for postoperative deformities are young age, the presence of preoperative spinal deformity, cervical laminectomy including C2, laminectomy involving at least six vertebrae, malignant neoplasm and adjunctive radiotherapy. Awareness of the risk factors can enable the surgeon to prevent such deformities by avoiding injury to intervertebral joints, by using osteoplastic laminotomy in children followed by at least six-month immobilization of the spine, by orthopedic and radiological monitoring until the end of the child's growth period, and by not giving radiotherapy to patients with low-grade glial and nonglial tumors.

We are convinced that there is no indication for radiotherapy in benign spinal cord tumors even after incomplete removal or recurrence or progression. Our personal opinion is based on a follow-up longer than 5 years in 182 patients operated either for a low-grade ependymoma (116 cases) or a low-grade astrocytoma (66 cases), without adjunctive radiotherapy. We observed 5 recurrences only (2 ependymomas after 18 and 9 years and 3 astrocytomas after 5, 6 and 7 years). Even low-grade astrocytomas removed may have a very indolent evolution. Seventeen remained stable in spite of partial removal; few showed a slow MRI evolution without any clinical impairment. Furthermore, we found very difficult to reoperate several patients who had previously received radiotherapy after biopsy or partial removal. All have been worsened after our surgery opposite to those who did not receive radiotherapy.

In malignant gliomas, the treatment is only palliative as it is in brain. If in low-grade astrocytomas, irrespective of their histological type, we never prescribe adjunctive radiotherapy, we do it for malignant gliomas; but whatever treatment was used for malignant astrocytomas, whether repeat surgery, radiotherapy, or chemotherapy, the disease was always fatal within nine months to three years.

## HOW TO AVOID COMPLICATIONS

1. Do a correct preoperative diagnosis, discuss with the neuroradiologist, avoid to operate infarct or demyelinating disease.
2. Do laminotomy or laminoplasty in children. Never laminectomy.
3. Keep great care of C2 and of all articular joints.
4. Learn anatomy of spinal cord.
5. Operate in a clean field. Do meticulous haemostasis. Keep in mind that the best landmark between a tumor and spinal cord is the difference of color.

6. No retractor should be used in the spinal cord. Keep surgical field open with gentle sutures between pia and dura.
7. Debulk gliomas, which makes dissection easier. Never debulk haemangioblastomas or cavernomas.
8. Be aware to stop if no clear plane of delineation.
9. Close the arachnoid and sometimes the pia. Do not let the dura tether to an open spinal cord.
10. Always do a watertight dura closure, with fat and glue in addition if needed.

## CONCLUSIONS

Surgery is the gold standard in the treatment of spinal cord tumors. Complete removal is the first goal. Post-operative results are dependent on surgeon's experience but also on the pre-operative neurological status. Indeed, in our series, no paraplegic patients recovered except one child. In ambulatory patients, risks of permanent post-operative deficits were 5%. But in already handicapped patients, surgical risks of permanent worsening jumped to 18%. That is the reason why we say that for hoping to get a good quality of life after surgery, patients with an intramedullary tumor should be operated before harboring heavy neurological deficit.

## References

- [1] Brotchi J (2002) Intrinsic spinal cord tumor resection. *Neurosurgery* 50: 1059-1063
- [2] Brotchi J, Bruneau M, Lefranc F, Balériaux D (2006) Surgery of intraspinal cord tumors. *Clin Neurosurg* 53: 209-216
- [3] Brotchi J, De Witte O, Levivier M, Balériaux D, Vandesteene A, Raftopoulos C, Flament-Durant J, Noterman J (1991) A survey of 65 tumors within the spinal cord: surgical results and the importance of preoperative magnetic resonance imaging. *Neurosurgery* 29: 652-657
- [4] Constantini S, Miller DC, Allen JC, Rorke LB, Freed D, Epstein FJ (2000) Radical excision of intramedullary spinal cord tumors: surgical morbidity and long-term follow-up evaluation in 164 children and young adults. *J Neurosurg (Spine 2)* 93: 183-193
- [5] Cooper PR (1989) Outcome after operative treatment of intramedullary spinal cord tumors in adults: intermediate and long-term results in 51 patients. *Neurosurgery* 25: 855-859
- [6] Elsberg CA (1925) Tumors of the spinal cord and the symptoms of irritation and compression of the spinal cord and nerve roots: pathology, symptomatology, diagnosis and treatment. Hoeber, New York

- [7] Epstein F, Epstein N (1982) Surgical treatment of spinal cord astrocytomas of childhood. A series of 19 patients. *J Neurosurg* 57: 685-689
- [8] Fischer G, Brotchi J (1996) *Intramedullary spinal cord tumors*. Thieme, Stuttgart
- [9] Guidetti B, Mercuri S, Vagnozzi R (1981) Long-term results of the surgical treatment of 129 intramedullary spinal gliomas. *J Neurosurg* 54: 323-330
- [10] McCormick PC, Torres R, Post KD, Stein BM (1990) Intramedullary ependymoma of the spinal cord. *J Neurosurg* 72: 523-532
- [11] Malis LI (1978) *Intramedullary spinal cord tumors*. *Clin Neurosurg* 25: 512-539
- [12] Stein BM (1979) Surgery of intramedullary spinal cord tumors. *Clin Neurosurg* 26: 529-542



**Jacques Brotchi**

Jacques Brotchi is Emeritus Professor at Free University of Brussels and Honorary Chairman of the Department of Neurosurgery, Erasme Hospital, Brussels, Belgium. In 1981, he founded the Department of Neurosurgery in Erasme Academic hospital of the Free University of Brussels. Full Professor and Chairman until September 2007, President of the World Federation of Neurosurgical Societies (WFNS) 2005–2009. Member (Honorary, active or associate) of over 15 foreign national and international neurosurgical societies. Over 350 scientific publications in international journals and medico/surgical textbooks. Advisory Board member of 14 scientific international neurosurgical reviews. Knighted by His Majesty, King Baudouin of Belgium in 1988 and Baron by King Albert in 2007.

**Contact:** Jacques Brotchi, M.D., PhD., President of WFNS, Emeritus Professor and Chairman, Neurosurgery Department, Erasme Hospital-ULB Brussels, 808 Route de Lennik, 1070 Brussels, Belgium  
E-mail: [jb.wfns@erasme.ulb.ac.be](mailto:jb.wfns@erasme.ulb.ac.be)

---

# CHIARI MALFORMATION

J. A. GROTENHUIS

## INTRODUCTION

The entire concept of these malformations emerged toward the end of the 19th century. Chiari's initial work, on what would become known as Chiari malformation (CM), was published in the *Deutsche Medizinische Wochenschrift* in 1891 and entitled "Concerning alterations in the cerebellum resulting from cerebral hydrocephalus". As the title suggests, his goal was to describe "the consecutive changes established in the region of the cerebellum by cerebral hydrocephalus" [4].

The interest in these conditions surged in 1935 after Russell and Donald introduced the notion of Chiari malformations into the English-language literature. They described 10 consecutive infants with Chiari II malformation, typically associated with congenital neural tube defects.

Adult cases of Chiari I malformation were not described until 1938, when McConnell and Parker reported five cases, all with hydrocephalus and neurological symptoms, in whom surgical exploration was performed; an autopsy procedure was performed in three. They used the term "tonsils" to describe the prolapsed cerebellar tissue. The same year, Aring reported a 20-year-old man with an adult Chiari malformation but no hydrocephalus. This was the first reported case of adult Chiari malformation (aCM) in a patient in whom hydrocephalus was not also present. The condition was diagnosed by cerebellar exploration, and the patient died 18 hours later. The cerebellar tonsils reached down to the axis.

Adams et al. [2] delineated the clinical syndrome and classified the symptoms into five groups: increased intracranial pressure, involvement of several of the cranial nerves, compression of the brainstem, compression of the spinal cord, and cerebellar signs, and they described the myelographic appearance of the protruding cerebellar tonsils. Other reports followed, which were mostly isolated case reports and some small series.

However, it was during the 1970s that the term adult Chiari malformation gained popularity and large series were published. This trend increased considerably over the following two decades, especially with the introduction of magnetic resonance (MR) imaging with its ease of visualization of the craniocervical junction. But this also has led to confusion in the literature regarding the concept of Chiari I malformation or adult Chiari malformation because there has been an increase in the number of patients with

---

*Keywords:* Chiari malformation, CSF, cerebellum, craniocervical function

radiological evidence of tonsillar herniation, some of whom are asymptomatic, raising questions as to its true clinical relevance and making it difficult to define the line between a truly pathological situation and an innocent anatomical variant [1, 3, 7, 8, 10, 12].

The classification of Chiari malformations has changed over the years, but right now I use the following classification:

*Type 0:* Symptoms of Chiari without cerebellar tonsillar ectopia and without syringomyelia but somewhat more crowded posterior fossa and lower obex.

*Type 0.5:* Symptoms of Chiari without cerebellar tonsillar ectopia but with syringomyelia and with or without crowded posterior fossa or lower obex.

*Type 1:* Complete or partial herniation of cerebellar tonsils at least 3–5 mm below the foramen magnum, frequently but not always associated with syringomyelia.

*Type 1.5:* In addition to type I also exhibit caudal descent of the brainstem and increased grades of odontoid retroversion but without spinal dysraphism.

*Type 2:* Herniation of elongated tonsils, vermis and pons down into cervical canal, associated with spinal dysraphism and hydrocephalus and on MRI many other posterior fossa abnormalities like beaked tectum, elongated tubelike fourth ventricle, low-lying torcular Herophili, cerebellar hemispheres wrapping around the brainstem anteriorly, concave clivus, medullary spur and medullary kink.

*Type 3:* (occipito) cervical hernia containing cerebellar tissue.

*Type 4:* Aplasia or hypoplasia of cerebellum (sometimes associated with encephalocele).

## **RATIONALE**

Tonsillar herniation should be viewed as a cranioccephalic disproportion or disproportion between the container (skull) and the contents (brain). This is confirmed by examples of acquired tonsillar descent. Acquired tonsillar ectopia is seen in various conditions; in some cases the volume of the cranial cavity is reduced, and in others the volume of the intracranial contents is increased. Disorders associated with the former condition include severe craniosynostosis and lesions that cause calvarial thickening such as Paget disease, rickets, and erythroid hyperplasia. Disorders that cause an increase in the volume of the intracranial contents and induce tonsillar descent are associated with supratentorial tumors and infratentorial mass lesions.

Nishikawa et al. [9] found a higher volume ratio of the posterior fossa brain compared with that of the posterior fossa cranium in Chiari I malformation.

Milhorat et al. [8] have also reported similar findings, and they concluded that Chiari I malformation is a disorder of the mesoderm leading to a volumetrically small posterior fossa that predisposes patients to hindbrain overcrowding. Experimentally-induced small posterior fossa was also found to lead to tonsillar herniation.

All these findings point to the fact that CM 0–1 is a developmental disorder of the skeleton (i.e. the posterior fossa), so it should be considered as being mesodermal in origin, not (neuro-)ectodermal.

The typical finding of an *ascending course and elongation of the upper cervical nerve roots* in CM reflects the abnormal, caudo-cranially proceeding growth of the cervical spine! This *cervical growth reversal* is a compensatory event related to an *impairment in the distal spinal growth* (in case of myelomeningocele) or to *dysproportionate growth between caudal and cranial part* later in life.

So we should consider CM 0–1 as a representative of a wide variety of “*osteo-neural growth pathologies*” encompassing some dysplastic disorders of the axial skeleton such as basilar impression, platyspondyly, idiopathic scoliosis, Scheuermann’s kyphosis and achondroplasia. They all can be associated with CSF disturbances.

Based on the review of all these papers the following remarks can be made.

1. Radiologically significant tonsillar ectopia may be completely asymptomatic.
2. There are patients in whom the tonsillar herniation extends less than 5 mm from the foramen magnum, whose clinical behavior is similar to the remainder of the Chiari population, including even those with radiological evidence of syringohydromyelia.

The disease is most common in women, with a female-to-male ratio of 3:1. The age of onset is about 25 years ( $\pm 15$  years). The aCM syndrome continues to be under- or misdiagnosed, with an average delay in diagnosis of 5 years after onset of symptoms, and more than half of patients with aCM labeled psychogenic.

Between 30 and 50% of CM type 0.5–1 and 45–90% of CM type 2 have an associated syrinx, and up to 70% of all syringomyelias are related to a hind-brain disorder. There have been many hypotheses and theories about the pathophysiology of Chiari-induced syringomyelia, starting with Gardner’s theory and until present days another 15 possible explanations have been given. Although a detailed description of this subject, however interesting, is beyond the scope of this book, the pathological CSF flow pattern and its restoration after decompressive surgery has been described extensively in the modern literature [6, 11, 13].

With the increased understanding of the pathophysiological basis for the development of syringomyelia in Chiari I malformation and with the common experience accumulated in numerous series, there is little controversy

today that the common denominator of all treatment strategies is posterior craniovertebral decompression. However, details of the procedure, its extent and invasiveness, the technique of dural closure, and whether a drainage system should be placed in the syrinx cavity, are subject to considerable dispute.

## DECISION-MAKING

### 1. DIAGNOSTIC CRITERIA

A carefully taken history and physical examination should be the start of the evaluation of every patient with aCM. Neurologic examination should specifically focus on presence or absence of papilledema, function of lower cranial nerves, pain during or limitation of neck motion, scoliosis, discrepancy in leg-length, any sensory deficit over the trunk and asymmetry of abdominal reflexes.

The clinical syndrome of aCM consist of:

- Headaches
- Pseudotumor (IIH)-like episodes
- Menière's disease-like symptoms
- Lower cranial nerve signs
- Spinal cord disturbances (even in the absence of syringomyelia!)

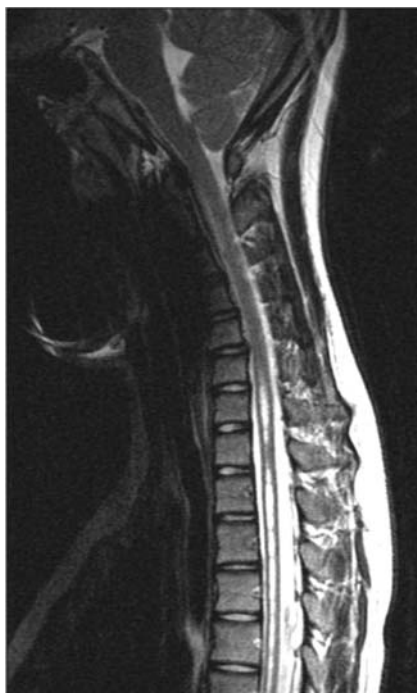Every patient with aCM will undergo MR imaging of the craniocervical region. The typical MRI findings in aCM (type 0–0.5–1) are:

- Obliteration of retrocerebellar fluid spaces with small posterior fossa
- Any degree of (but also absence of) tonsillar herniation
- Pegshaped tonsils
- Increased slope of the tentorium
- Reduced length of the clivus (which is often slightly concave!)
- Reduced height of the supraocciput
- Medullary kinking
- Varying degrees of cranial base dysplasia

However, it should be routine to do a complete neuraxis MR investigation, including the whole brain and the thoracic and lumbar spine too. Be aware of the fact that the syrinx in a patient with aCM can skip the whole cervical region and appear only in the thoracic region (Fig. 1). If hydrocephalus is present, this should be addressed first before considering any intervention in the posterior fossa.

The MRI should be carefully checked for any ventral compression (by the dens itself or tissue around it), since this can be an important contributing





**Fig. 1.** Tonsillar herniation less than 5 mm with thoracic syringomyelia

factor in the formation of the hindbrain herniation. If substantial ventral compression is present, this should be addressed first! Modern MR imaging techniques even allow MRI in flexion and extension to evaluate this, but this is not yet routine.

For the planning of a posterior fossa decompression, the extent of the tonsillar herniation should be assessed together with the presence or absence of any brainstem displacement, the position of the torcular Herophili and presence or absence of any obstruction membranes around the lower brainstem and the fourth ventricle outlets.

Although a lot has been published about the use of cine-MRI for evaluation of the CSF flow, we are still lacking critical data from this modality that can really help in the decision-making.

## 2. INDICATIONS FOR SURGICAL TREATMENT

As mentioned before, treatment of ACM is surgical. However, not every tonsillar ectopia, Chiari-related syringomyelia, or symptomatic ACM needs to be treated.

The following factors are taken into consideration when addressing the risk/benefit ratio:

- The severity and nature of the symptoms;
- The alteration in the patient's quality of life secondary to these symptoms;
- The likelihood that these symptoms are related to the tonsillar ectopia, taking into consideration the clinical presentation, associated medical conditions, and the radiological findings;
- Associated psychological factors;
- The surgical complication rate; and
- The long-term results for surgical treatment of the particular symptom that is being addressed, with most series reporting a long-term success rate between 50 and 85%.

The surgical decision is highly individualized, especially because most symptoms are subjective. The expected improvement in quality of life should outweigh the potential uncertainty regarding the causal relationship between the tonsillar ectopia and the particular symptoms, the risk of the surgery, and the long-term failure rate. Surgery should be reserved for patients with disabling or unbearable symptoms that are likely to be related to the ACM. Some patients with minor symptoms need only reassurance that their symptoms are caused by a real disease, and that they are not dangerous or life-threatening.

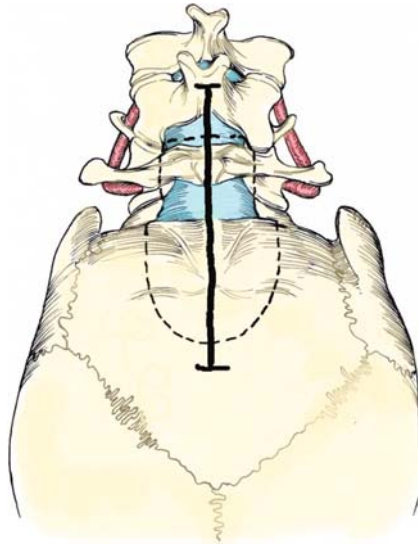
## **SURGERY**

### **1. OPERATIVE TECHNIQUE**

A successful neurosurgical procedure starts with the proper positioning of the patient. I always perform this surgery in the prone position with the head flexed and then fixed in a skull clamp (Mayfield or Zeppelin-Grotenhuis headholder). The flexion is not extreme, there should be space for at least two fingers between chest and chin! Then the operating table is put into an anti-Trendelenburg position until the subocciput is horizontal with the floor.

The hair is clipped (but not shaved) for one centimeter in the midline. A straight skin incision is made from just below theinion to the upper cervical region. The muscles and periosteum are stripped laterally. Take care to leave the muscular and ligamentous attachments to C2 intact, this will minimize postoperative discomfort and, even more important, will prevent instability.

A small suboccipital craniectomy and a C-1 laminectomy are performed (Fig. 2). The craniectomy usually extends from the foramen magnum 2.5–3 cm upward, reaching the inferior nuchal line of the occipital bone, but not



**Fig. 2.** Patient in prone position. Skin incision and bone removal depicted

resecting the insertion area of the rectus capitis posterior minor muscle, and the medial insertion area of the rectus capitis posterior major muscle!

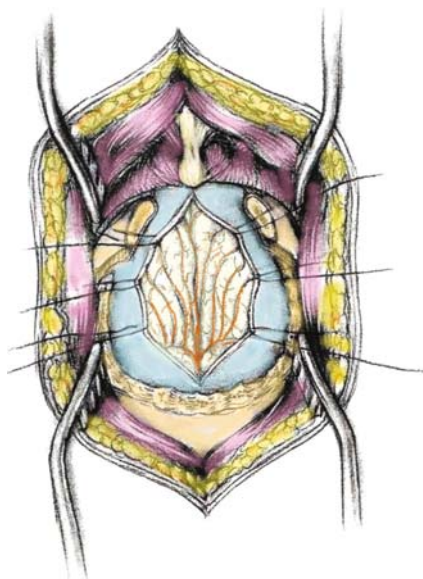
The tonsils are visualized using intraoperative ultrasonography. If the tip of the tonsils cannot be sufficiently exposed, a C-2 laminectomy is additionally performed but this is rarely the case in Chiari 0 and 1. The dura is opened in a Y-shaped fashion, starting at the spinal part and trying not to open the arachnoid initially. It is a common finding to see the arachnoid bulging out strongly into the dural opening since the CSF cannot enter the intracranial compartment. After further opening of the dura overlying the tonsils and the cerebellum, often the arachnoid starts to pulsate already and the bulging becomes less, pointing to the fact that CSF circulation at this level is improved just by opening the dura.

In the majority of cases the low-lying cerebellar tonsils are the only part of the cerebellum that will be seen in the opening (Fig. 3).

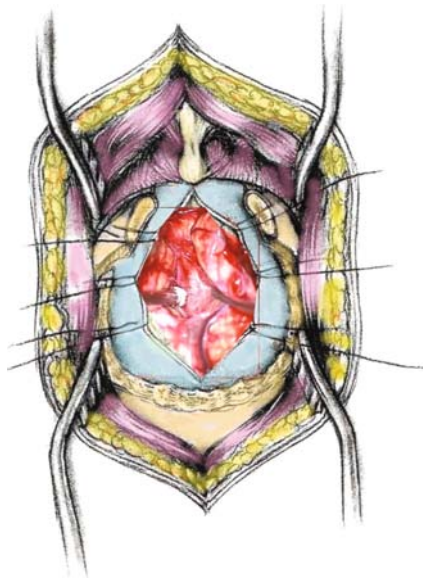
Only in cases of extensively large tonsils, subpial resection of one tonsil is performed. Look for the more blanched, gliotic tonsil that usually has lost its fine reticular vascular pattern. Normalization of the position of the tonsils, visualization of the obex between the tonsils, and decompression of the brainstem and cranial nerves are the goals of this maneuver.

The foramen of Magendie is also exposed by careful separation of the tonsils to ensure that there is no obstruction (Fig. 4). Arachnoid membranes in this area are widely opened to ensure CSF outflow of the 4th ventricle.

As soon as the white, avascular floor of the fourth ventricle is visualized, dissection is sufficient. I never perform plugging of the obex or placement of any kind of stent during a primary posterior fossa decompression.



**Fig. 3.** After removal of the arch of C1 and dural opening, the low-lying tonsils are visible



**Fig. 4.** Intraoperative photograph inserted into the drawing. Separation of the tonsils reveal arachnoid membranes, obstructing the foramen of Magendie

The dura is closed with periosteum and if this cannot be harvested a dural graft (either Dura Matrix, TissuDura or Neuropatch) is used ensuring the reconstruction of an open CSF space at the craniocervical junction. I use a synthetic sealant (DuraSeal) for a watertight closure and prevention of CSF leakage.

The patients are generally extubated in the operating room and the patient will stay overnight in a medium care unit. Patients are discharged from the hospital around the 4th postoperative day.

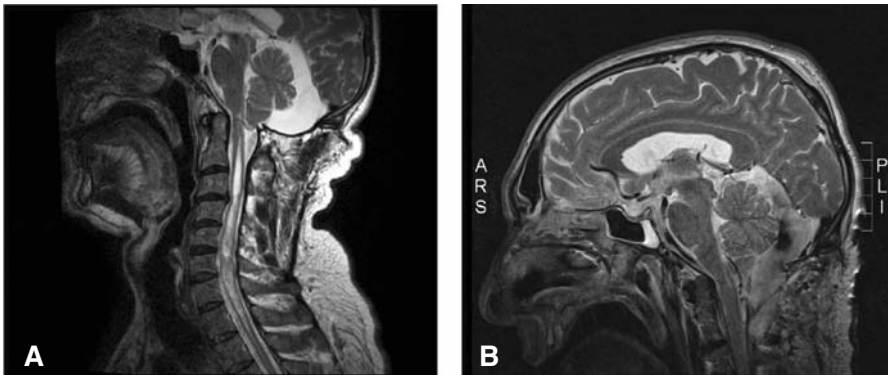
Patients are monitored clinically and postoperative MR imaging is done only on indication, except those patients with a syringomyelia. These patients have a postoperative MRI after 3 months to assess the effect of the decompression.

## 2. HOW TO DEAL WITH CHIARI INDUCED SYRINGOMYELIA

Concerning the syringomyelia, most surgeons agree that the flow of CSF around the herniated tonsils must be restored in order to see the syrinx resolve, or collapse. The best surgery for syringomyelia will aim to fix the cause of the syrinx and not to operate on the syrinx directly. But the bottom-line is that every patient is different. Some have as little as one or two millimeters of tonsillar herniation, others have more than twenty! Some have scar tissue, some don't. In this you can see how successful treatment will really depend on whether the surgeon can figure out what exactly is causing the blockage of CSF (Fig. 5A and B)!

But even when collapse of the syrinx occur, the syrinx cavity can have done permanent nerve damage, which is why early treatment is essential. If a patient has numbness associated with a syrinx, there is a good chance it will go away if the operation is successful.

If the patient has burning pain, this is most likely permanent and can be reduced but not resolved completely. Finally, if patients have weakness in their extremities associated with the syrinx, this is also most likely to be permanent.



**Fig. 5.** **A** Wide retrocerebellar CSF space after posterior fossa decompression with continuous bony compression and syringomyelia. **B** Scan on 2nd postoperative day with already disappearance of the syringomyelia and good CSF flow

The nature of syringomyelia is progressive, and so treatment to fix the cause of the syrinx is absolutely vital as soon as possible. Otherwise, the patient will continue to get worse as the damage becomes more and more permanent.

At present, the difficulty is to visualize the exact area of disturbed CSF flow in any case of syringomyelia, whether or not associated with Chiari malformation, because the major goal of surgery is to restore normal flow of the CSF.

### **3. COMPLICATIONS**

Operative complications from posterior fossa decompression should be exceedingly few but it is good to know all possible problems that can occur. The following present some of the typical complications of suboccipital decompression for ACM.

#### **3.1 Cerebrospinal fluid leak**

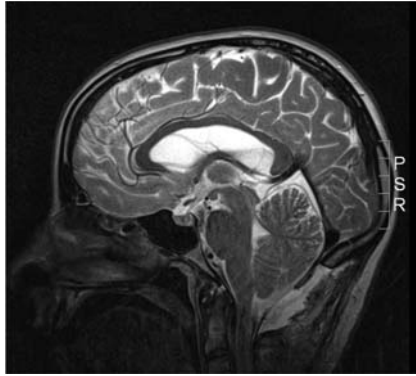
Cerebrospinal fluid leakage can be fatal if it leads to meningitis. This complication is prevented by watertight dural closure and tight fascial and skin closure. If it occurs, it is treated by over-sawing the incision and lumbar drainage if the leak persists. But be aware of the fact that lumbar drainage can lead to recurrence of the Chiari symptoms. Although it is very uncomfortable for the patients, I prefer to have them in bed in a Trendelenburg position. Furthermore, the possibility of an intracranial space-occupying mass should be excluded before the drain is placed by either CT or MRI-scan, the latter being the preferred method for postoperative imaging.

#### **3.2 Pseudomeningocele**

Some failures result from compressive pseudomeningocele. Prevention is by watertight dural closure, and initial treatment is by lumbar drainage. If the latter fails, reexploration may be indicated. But be aware of the fact that some epidural CSF collection is a rather usual finding on postoperative MRI and as long as it is not compressive and cause any symptoms this should be accepted (Fig. 6).

#### **3.3 Brainstem infarction**

Brainstem infarction may occur secondary to injury to the vertebral artery or posteroinferior cerebellar artery (PICA). The vertebral artery may be injured during dissection of the posterior arch of C1 when this is done too far laterally. The PICA can have an extradural origin, making it subject to injury during extradural exposure. It also may be injured during intradural dissection. So, avoiding unnecessarily wide or aggressive dissection over the arch of C1 is advocated as a preventive measure. I always avoid aggressive intra-arachnoid



**Fig. 6.** Postoperative image after posterior fossa decompression with resolution of all symptoms. The submuscular CSF collection is not compressive and causes no symptoms

dissection to reduce the risk of vascular injury to the PICA so be aware of it, especially when starting to work on the tonsils. Although I have, fortunately, never experienced any vascular injury, when such an event occurs, arterial repair should be attempted if feasible.

### 3.4 Cerebellar sag

Cerebellar sag has been reported to occur following too generous suboccipital decompression. It leads to intractable headaches and recurrent syringomyelia. Treatment is by suboccipital cranioplasty or ventriculoperitoneal shunting [5].

## CONCLUSIONS

Perhaps it is the opening statement written by Ball and Crone in their article that seems appropriate as a concluding remark: “Ever since the initial post-mortem description by Chiari in 1891 of the group of malformations that bears his name, it seems there have always been more questions on this subject than answers”. The definition of the adult Chiari malformation has varied with the evolution of neurodiagnostic capabilities and knowledge of pathophysiology.

There is no single test that allows a clear-cut distinction between clinically significant tonsillar ectopia and incidental tonsillar descent. With the fluidity of the definition of the adult Chiari malformation, as well as the increasing number of asymptomatic patients with significant radiological tonsillar herniation, it is the clinical judgment of the physicians evaluating this disorder that is of the utmost importance to avoid the therapeutic extremes of pursuing unnecessary surgery or withholding necessary treatment from patients.

## References

- [1] Aboulezz AO, Sartor K, Geyer CA, Gado MH (1985) Position of cerebellar tonsils in the normal population and in patients with Chiari malformation: a quantitative approach to MR imaging. *J Comput Assist Tomogr* 9: 1033
- [2] Adams RD, Schatzki R, Scoville WB (1941) The Arnold-Chiari malformation. *N Engl J Med* 225: 125
- [3] Badie B, Mendoza D, Batzdorf U (1995) Posterior fossa volume and response to suboccipital decompression in patients with Chiari I malformation. *Neurosurgery* 37: 214
- [4] Ball WS Jr, Crone KR (1995) Chiari I malformation: from Dr. Chiari to MR imaging. *Radiology* 195: 602-604
- [5] Holly LT, Batzdorf U (2001) Management of cerebellar ptosis following craniocervical decompression for Chiari I malformation. *J Neurosurg* 94: 21
- [6] Iskandar BJ, Hedlund GL, Grabb PA, et al. (1998) The resolution of syringomyelia without hindbrain herniation after posterior fossa decompression. *J Neurosurg* 89: 212-216
- [7] Mikulis DJ, Diaz O, Eggin TK, Sanchez R (1992) Variance of the position of the cerebellar tonsils with age: preliminary report. *Radiology* 183: 725
- [8] Milhorat TH, Chou MW, Trinidad EM, et al. (1999) Chiari I malformation redefined: clinical and radiographic findings for 364 symptomatic patients. *Neurosurgery* 44: 1005
- [9] Nishikawa M, Sakamoto H, Hakuba A, et al. (1997) Pathogenesis of Chiari malformation: a morphometric study of the posterior cranial fossa. *J Neurosurg* 86: 40-47
- [10] Nyland H, Krogness KG (1978) Size of posterior fossa in Chiari type I malformation in adults. *Acta Neurochir* 40: 233-242
- [11] Oldfield EH, Muraszko K, Shawker TH, Patronas NJ (1994) Pathophysiology of syringomyelia associated with Chiari I malformation of the cerebellar tonsils. *J Neurosurg* 80: 3
- [12] Stovner LJ, Bergan U, Nilsen G, et al. (1993) Posterior cranial fossa dimensions in the Chiari I malformation: relation to pathogenesis and clinical presentation. *Neuroradiology* 35: 113-118
- [13] Tominaga T, Kosu K, Ogawa A, et al. (1991) Transoral decompression evaluated by cine-mode magnetic resonance imaging: a case of basilar impression accompanied by Chiari malformation. *Neurosurgery* 28: 883-885





### **J. André Grotenhuis**

J. André Grotenhuis is Professor of Neurosurgery, Radboud University Nijmegen, The Netherlands and Chairman, Department of Neurosurgery, Radboud University Nijmegen Medical Center.

Became Doctor of Medicine in October 1979. Training in neurosurgery from March 1981–March 1987. Board examination and certification in Germany in April 1987 and board certification in The Netherlands in July 1987. 1987–1995 staff member at assistant professor level; 1995 associate professor. Since 1999 chairman. Since 2001 full clinical professor.

Author of 77 peer-reviewed articles, 23 book chapters and 2 (single-authored) books on endoscopic neurosurgery. More than 250 international lectures (more than 100 as invited lecture).

Active in national and international neurosurgical organization (e.g. Chairman of the national legal expertise committee, member of the accreditation committee, chairman of the EANS Postgraduate Education Committee, member of the EANS Training Committee, second national delegate to the WFNS).

Special interest: minimally invasive techniques (especially endoscopic neurosurgery) and instrument invention, pituitary surgery, vascular neurosurgery, microvascular decompression; CSF dynamics, hydrocephalus, Chiari malformations and syringomyelia.

**Contact:** J. André Grotenhuis, Department of Neurosurgery, Radboud University Medical Center, Reinier Postlaan 4, 6525 GC Nijmegen, The Netherlands  
E-mail: [j.grotenhuis@nch.umcn.nl](mailto:j.grotenhuis@nch.umcn.nl)

---

# SYRINGOMYELIA

J. KLEKAMP

## INTRODUCTION

The term syringomyelia was introduced by Ollivier D'Angers in 1827 [12] for cystic cavitations of the spinal cord. However, not every cystic formation of the spinal cord should be addressed as a syrinx. Syringomyelia describes a progressive accumulation of fluid inside the spinal cord. This fluid may be localized inside the parenchyma or the central canal. The term hydromyelia may be used to describe a syrinx confined to the central canal. Syringomyelia has to be differentiated from dilatations of the central canal, cystic neoplasms of the spinal cord, gliopendymal cysts and myelomalacia. The first surgeons to operate on a syrinx were Abbe and Coley in 1892 [11]. They punctured the spinal cord using a hemilaminectomy but did not produce a benefit for the patient. Next came surgeons like Charles Elsberg [2] and Ludvik Puusepp [13] who advised cyst punctures and myelotomies with only a few patients treated until the late 1920s. In the 1930s reports appeared recommending shunts for syringomyelia. Almost any type of material was used for this purpose. This type of treatment remained the state of the art until the advent of modern imaging techniques in the 1970s and 1980s. At that time, it became more and more clear, that a syrinx is always associated with other pathologies in the spinal canal or craniocervical junction. Actually, almost any pathology in the spinal canal or craniocervical junction may be related to a syrinx. Surgeons observed that if they neglected the syrinx and just treated the associated disorder, the syrinx often regressed. Pioneers in the area of the craniocervical junction were James Gardner [3] and Bernard Williams [15] who popularized the decompression of the foramen magnum for syringomyelia associated with Chiari type I malformation in the 70s and 80s. But also for spinal pathologies such as posttraumatic syringomyelia or syringomyelia associated with arachnoiditis surgeons like Bernard Williams [16] and Ulrich Batzdorf [1] started to treat the spinal disorder since the 1990s.

Up to this day no pathophysiological concept for the development of syringomyelia can be considered as generally accepted. However, by the 21st century it is generally agreed that syringomyelia is always related to another pathology that either causes a disturbance of cerebrospinal fluid (CSF) flow, spinal cord tethering or to an intramedullary tumor [4, 5]. If this associated pathology can be treated successfully, no further measures for the syrinx are needed. This chap-

---

*Keywords:* syringomyelia, chiari malformation, craniocervical instability, basilar invagination, hydrocephalus; spinal arachnoid scarring, spinal arachnoid cyst, tethered cord syndrome; spinal dysraphism

ter will outline the diagnostic measures required to identify the cause of a particular syrinx and the surgical treatment that I use for the commonest entities.

## RATIONALE

The pathophysiology of syringomyelia is not fully understood. The current understanding is based on observations, that syringomyelia is related to obstructions of cerebrospinal fluid (CSF) flow. Currently, I consider a syrinx as an intramedullary cyst caused by accumulated extracellular fluid of the spinal cord [4, 5].

Basically, any disorder of the spinal canal may alter CSF flow and, thus, be responsible for a syrinx (Table 1). This chapter can only mention the commonest disorders. At the craniocervical junction, the Chiari type I malformation has to be looked for as the commonest pathology related to syringomyelia. Spinal pathologies causing a syrinx are characterized by areas of arachnoid scarring. Such scarring may be related to trauma, infection, hemor-

**Table 1.** Syringomyelia and its associated disorders

### Craniocervical junction

Chiari I malformation	492
▪ with syringomyelia	374
▪ no syringomyelia	118
▪ Basilar invagination	35
Chiari II malformation	25
▪ with syringomyelia	13
▪ no syringomyelia	12
Foramen magnum arachnoiditis	28

### Spinal canal

Arachnoid scarring	331
▪ Posttraumatic scarring	115
▪ Postinflammatory scarring	216
Intramedullary tumors	216
▪ with syringomyelia	103
▪ no syringomyelia	113
Extramedullary tumors	488
▪ with syringomyelia	29
▪ no syringomyelia	459
Spinal dysraphism + tethered cord	99
▪ with syringomyelia	30
▪ no syringomyelia	69
Degenerative disc disease	57

rhage, irritation by old contrast agents such as metrizamide, or surgery, to mention a few. As a general rule, arachnoid scarring in the cervical area will generally cause a syrinx below the spinal level of arachnoid scarring, whereas thoracic arachnoid scars lead to an upward expansion of a syrinx.

A syrinx always starts to develop in a spinal segment close to the underlying pathology and expands from there with time. This has a number of implications:

1. The underlying pathology comes first and with it the first clinical symptoms. In other words, a careful clinical history can provide clues to the underlying pathology. The first clinical symptoms tend to be related to the disorder causing the CSF flow obstruction rather than to the syrinx!
2. Repeating MRI scans may disclose the direction in which a syrinx expands. The underlying cause will then be found at the opposite end of the syrinx!

It is always puzzling that patients may harbour a huge syrinx and yet have just minor symptoms with exactly the opposite observation for some smaller syrinx cavities associated with major neurological deficits. My explanation for this paradox is, that a great deal of the clinical problems are related to the underlying disease process causing the syrinx rather than to the syrinx itself [8].

The classical symptoms of syringomyelia are a dissociated sensory loss with loss of sensation for temperature and pain but preserved sensation for light touch. Pain related to syringomyelia is either permanent or aggravated by maneuvers such as coughing and sneezing and perceived in dermatomes corresponding to the syrinx. Motor deficits may develop subsequently, correspond to damage of anterior horn cells and lead to atrophy of affected muscle groups favouring small muscles at first. Late features are trophic changes leading to skin and joint damages, particularly in the shoulder and elbow.

## DECISION-MAKING

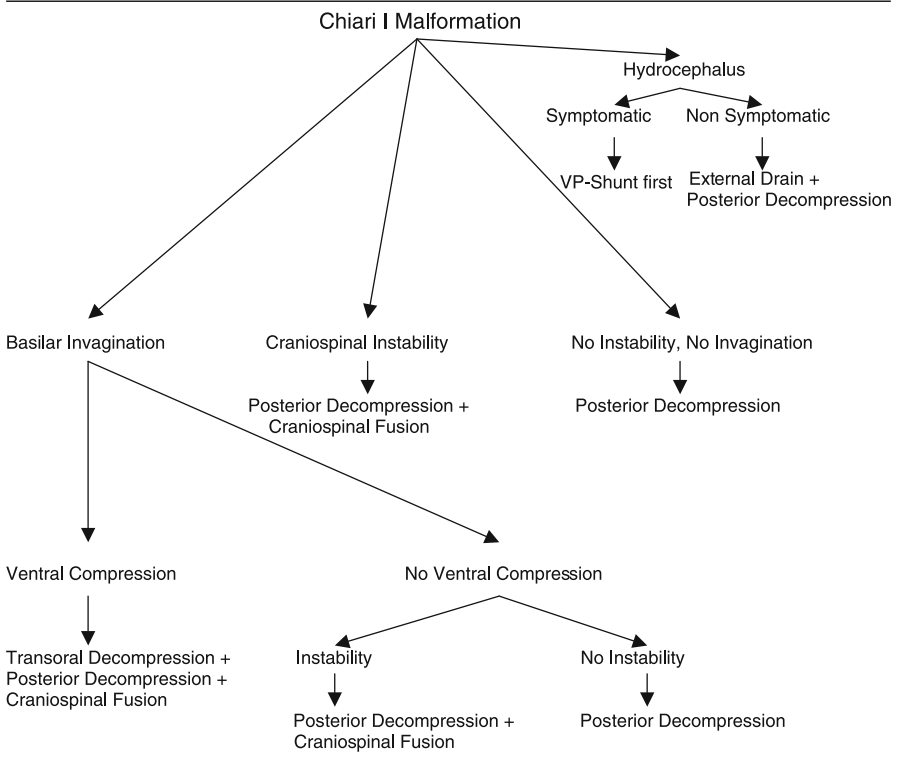
The observation, that each syrinx is the result of another disorder is a fundamental one for the correct management of these patients, that cannot be over-emphasized. First of all, each patient with a syrinx has to be analysed for the presence of an intramedullary tumor or for dysraphic malformations that cause a tethered cord. These two pathologies are not featured in this chapter [7]. Once these have been ruled out, diagnostic work has to look for areas of CSF flow obstruction. These can be divided into those at the craniocervical junction and those in the remainder of the spinal canal. The commonest underlying diseases are:

1. Chiari type I malformation
2. Spinal arachnoid scarring

### 1. CHIARI I MALFORMATION

This malformation is characterized by herniation of cerebellar tonsils into the spinal canal. This may be related to an undersized posterior cranial fossa that forces parts of the cerebellum to grow down into the spinal canal during the cerebellum’s main growth period in the first 2 years of life. This leads to a high cervical cord compression and CSF flow obstruction at the foramen magnum. This congenital form may be associated with other bony abnormalities such as assimilation of the atlas to the occiput, incompetent craniocervical joints causing instability, congenital fusion of cervical vertebrae, or basilar invagination, to mention the most important ones. Hydrocephalus is a rare feature of this malformation. Alternatively, a Chiari I malformation can be acquired due to arachnoid scarring at the foramen magnum, which may be related to birth trauma, intracranial tumors or lumboperitoneal shunts, again mentioning the commonest forms. About 75% of patients with a Chiari I malformation will develop a syrinx. An important distinction is the differential diagnosis between Chiari I and Chiari II malformation. In Chiari II, the foramen magnum is grossly enlarged and parts of the entire cerebellum, brainstem, and 4th ven-

**Table 2.** Treatment strategy for patients with Chiari I malformation



tricle are displaced into the spinal canal. The area of cord and brain stem compression is not at the foramen magnum but at the upper cervical canal. Almost all these patients have a spina bifida aperta and a congenital hydrocephalus. Syringomyelia is not as common in Chiari II malformation as in Chiari I.

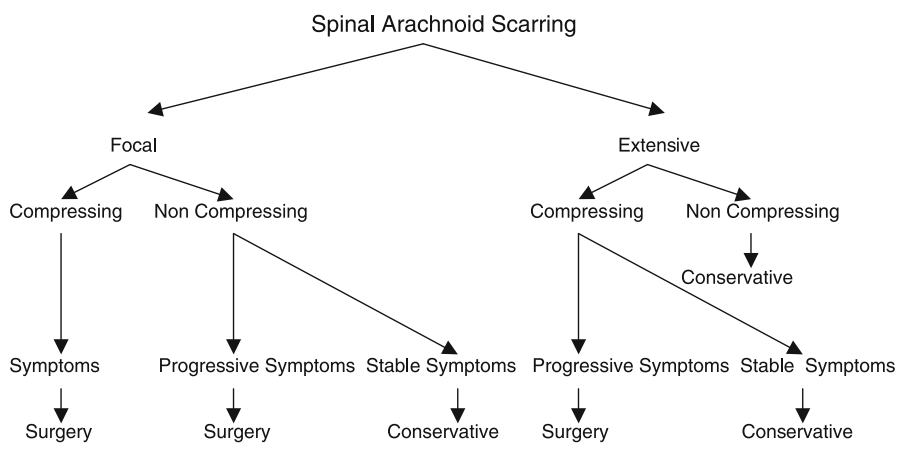
In general, surgery should be recommended to symptomatic patients only (Table 2). The commonest symptoms in adults are occipital headaches, nystagmus, and signs of upper spinal cord compression such as gait ataxia, sensory changes and motor deficits. The latter affect mainly the upper extremities. Rarer symptoms may be affections of caudal cranial nerves or sleep apnea. In small children, symptoms tend to be more dramatic with respiratory problems such as apnoea spells and cyanosis. The diagnostic workup has to rule out hydrocephalus and additional bony anomalies as well as demonstrate the entire extent of a syrinx if present [8].

## 2. SPINAL ARACHNOID SCARRING

Spinal arachnoid scarring causes alterations of CSF flow and may also lead to tethering of the spinal cord. Quite commonly, arachnoid scars even develop into pouches or cysts compressing the cord. As a general rule, many years go by before arachnoid scarring can produce a symptomatic syrinx. In my series, a posttraumatic syrinx became symptomatic on average about 10–11 years after trauma, for instance. Depending on the spinal segments affected by syringomyelia, the scarring will be located at the upper or lower pole of the syrinx. Arachnoid scars are often difficult to demonstrate on standard MRIs unless they cause displacement, compression or other signs of alterations of the spinal cord contour. I recommend cardiac gated cine-MRI as the most sensitive method of detection. But the interpretation requires some experience and it may be misleading or even useless in patients with significant spinal deformities such as scoliosis. Sometimes significant flow signals can be detected in the syrinx itself. In such cases, the highest flow velocities in the syrinx can be expected adjacent to the arachnoid scarring. Myelography and postmyelographic computer tomography (CT) are alternative methods to demonstrate arachnoid pathologies but have a lower sensitivity. In patients with posttraumatic arachnoid scarring and syringomyelia, the diagnostic workup will also have to include X-rays and CT for the area of trauma to address kyphotic angles, instabilities or a spinal stenosis during surgery if necessary [8].

Depending on its severity and extent arachnoid scarring may produce clinical signs by itself in terms of a progressing myelopathy. Usually these clinical signs will be apparent before symptoms related to a syrinx develop. I distinguish compressing and non-compressing types of arachnoid scars or arachnopathies according to MRI. With compressing types, I will generally recommend surgery for symptomatic patients. With non-compressing types, I reserve surgery for patients with progressive neurological symptoms (Table 3).

Pain and dysesthesias, particularly of burning character, may be major problems for patients with syringomyelia. Even though these do get better in

**Table 3.** Treatment strategy for patients with spinal arachnoid scarring

some patients after successful surgery, this is certainly not the rule. Therefore, I try to make decisions for or against surgery disregarding pain and dysesthesias as criteria. In general, I will recommend surgery for patients with arachnoid scarring, provided the scarring is limited to about 2–3 spinal segments. For patients after meningitis, multiple intradural surgeries or spinal subarachnoid hemorrhage, for example, surgery cannot provide a normal CSF passage anymore [8]. For such cases, programmable the coperitoneal shunts may be employed which are placed above the level of CSF obstruction. Pressure settings need to be set as low as possible avoiding signs of overdrainage and low intracranial pressure. For patients with a complete cord lesion, corpectomy at the level of the lesion is a very efficient alternative to treat a syrinx.

## SURGERY

The golden standard for treatment of syringomyelia is the treatment of the disease that caused it:

- In patients with intramedullary tumors, the tumor should be removed [7].
- In patients with a Chiari I malformation, a decompression of the foramen magnum is required (Table 2).
- In patients with arachnoid scarring related to trauma, subarachnoid hemorrhages, infections or other causes, the arachnoid scar should be resected and CSF flow established (Table 3).
- In patients with spinal stenosis, the spinal canal has to be decompressed.
- In patients with a tethered cord, the tethering has to be released [7].

Whenever the underlying cause of syringomyelia can be treated successfully, no further measures are required. The syrinx will decrease in size and/or syrinx pressures will decrease, so that no further spinal cord damage will occur [8].

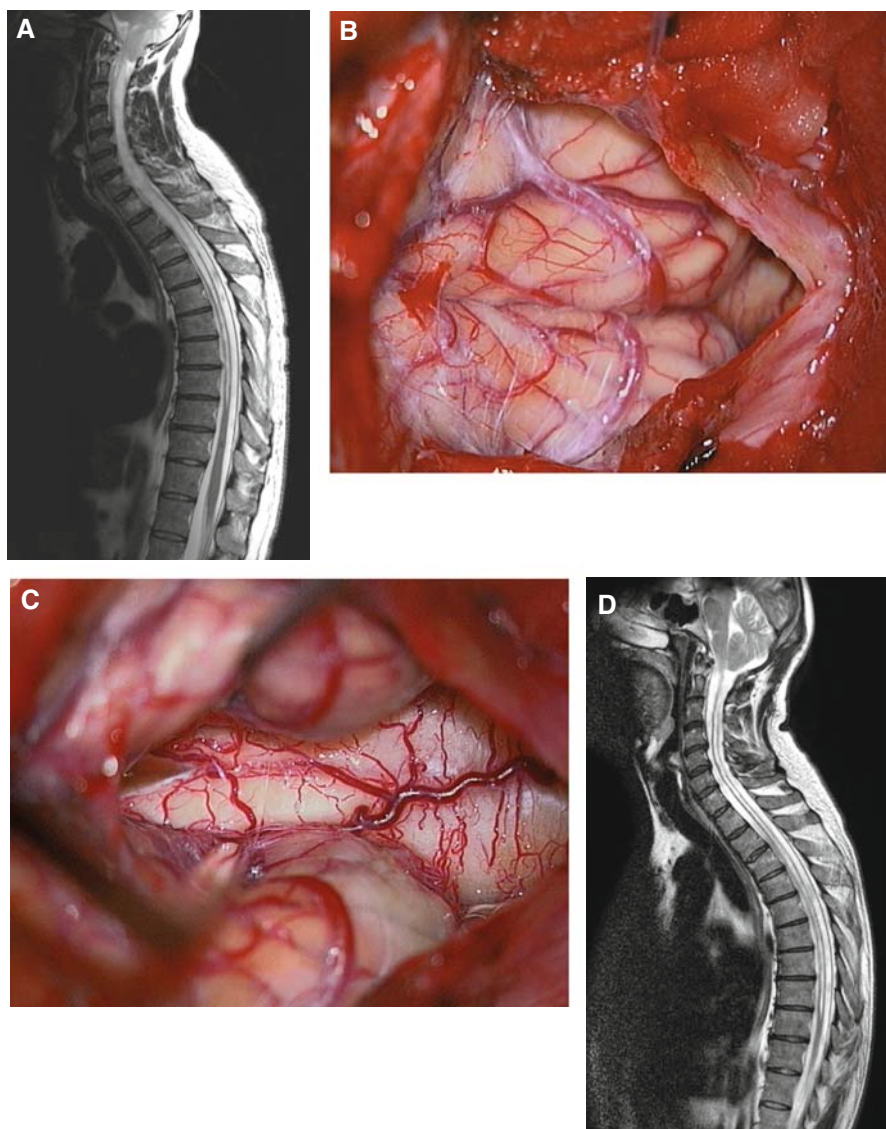
## 1. CHIARI I MALFORMATION

In patients with a combination of Chiari I malformation and hydrocephalus a ventriculoperitoneal shunt should be placed, whenever clinical signs of an elevated intracranial pressure are present before a foramen magnum decompression is performed. Without clinical signs of hydrocephalus, I would recommend to combine an external ventricular drain with the foramen magnum decompression, so that the situation can be monitored postoperatively. Most of these patients will not require a ventriculoperitoneal shunt after foramen magnum decompression. Without hydrocephalus decompression of the foramen magnum is the procedure of choice for patients with a Chiari I malformation (Fig. 1). Patients should be operated in prone position. During positioning I recommend monitoring of evoked sensory potentials (SEP) to prevent any undue compression of the brainstem. Flexion of the neck in particular may cause significant compression at the foramen magnum. After a midline incision and detachment of the neck muscles from the occipital bone and the arches of C1 and – depending on the extent of tonsillar herniation – further cervical laminae, a small laminectomy of the exposed arches and a craniectomy is performed, which includes the foramen magnum. The width of the craniectomy is adjusted to the width of the upper cervical dural sac and should not exceed 3 cm. Likewise, the upper extension of the craniectomy is tailored to create a cisterna magna and to visualize the Foramen of Magendie. Therefore, it is not necessary to expose the transverse sinus and the longitudinal extent of the craniectomy can be limited to about 3 cm as well. The occipital bone can be quite thickened. In the midline in particular, the crista occipitalis interna can be so enlarged that the entire space of the cisterna magna is completely taken up by bone.

Once the bone removal is complete, pulsations of the dura are usually not observed. A thickened part of the atlantooccipital membrane may constrict the dura at the level of the foramen magnum and usually contains a vein. This constricting dural band needs to be transected and should be mobilized off the dura to both sides for a few millimeters to facilitate dura closure at the end of the procedure.

Surgery is continued under the microscope and the dura is incised in a Y-shape. Care should be taken to leave the arachnoid intact during dura opening. Upon opening of the dura venous sinuses may be encountered. A suboccipital sinus may persist in the midline in the dura of the posterior fossa. An oblique occipital sinus may be located at the foramen magnum encircling the spinal cord at this level. Even the entire dura of the posterior fossa may contain one big sinus. If present these have to be closed by a running suture.





**Fig. 1.** **A** This sagittal T2-weighted MRI shows a syrinx from C2 to Th9 in a 45-year old man with a Chiari I malformation and a 6-year history of sensory loss in his left arm and a slight gait ataxia. **B** This intraoperative view after dura and arachnoid opening demonstrates the cerebellar tonsils reaching into the spinal canal. **C** After bipolar coagulation at the tonsillar tips, the Foramen of Magendie is inspected and patent. No further manipulations were required and the dura was closed with a spacious graft. **D** This postoperative MRI after 9 months shows a free CSF passage at the foramen magnum and a decrease of the syrinx. Symptoms remained unchanged

Upon opening the dura one has to watch out for bridging veins from the cervical cord, brainstem, or cerebellum which may enter these sinuses to avoid their rupture.

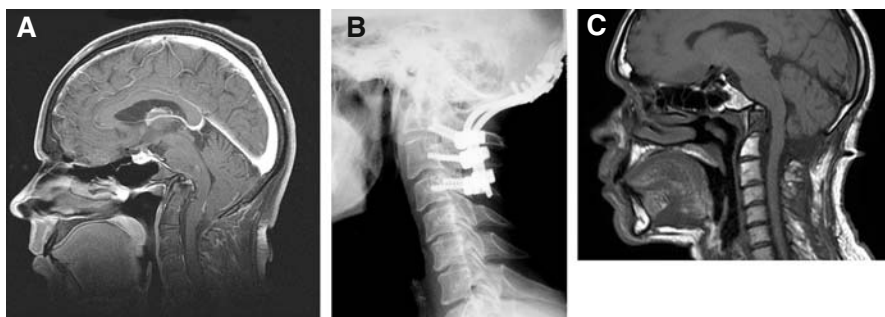
After dura opening the arachnoid should be inspected carefully for evidence of scarring and underlying bridging veins or perforating arteries which may be attached to it. Unlike other authors who recommend to leave the arachnoid intact, I always incise it to check for an adequate outflow from the foramen of Magendie. For this purpose, the arachnoid is dissected in the midline. I strongly recommend to avoid blunt dissection of the arachnoid as this may injure such vessels and emphasize to use sharp dissection instead. The cerebellar tonsils are gently spread apart with two microdissectors. Neuropathological studies have shown that herniated tonsils consist of atrophic, ischemic and non-functioning tissue. Therefore, coagulation and shrinkage of this tissue during surgery does not carry a risk in terms of postoperative neurological deficits. Coagulation of the tonsils at their tips and medial surfaces may provide a tremendous amount of space for the cisterna magna and easy access to the foramen of Magendie. If this is obstructed by arachnoid membranes, the foramen is opened. Once a free outflow from the 4th ventricle is present, arachnoid adhesions may be transected towards cerebellopontine cisterns or spinal canal. However, dissection always remains close to the midline. Arachnoid dissection should concentrate exclusively on these points. Dissection lateral of the brainstem is not advised to avoid injury to perforating arteries or cranial nerves.

Finally, I recommend to use a spacious artificial dura graft to create a large cisterna magna. The graft should be inserted with a tight running suture to avoid fistulas or pseudomeningoceles. For the same reason, I emphasize to close the soft tissues meticulously. A good closure of the muscular layer in particular is the best safeguard against CSF fistulas [8].

In the literature, the necessity of arachnoid dissection during this procedure is discussed with much controversy. To outline all pros and cons is beyond the scope of this chapter [14]. I always open the arachnoid to make sure, that CSF flow is established at the end of the procedure. Not all obstructions can be ruled out without opening of the arachnoid according to my experience.

In some instances, arachnoid scarring can be so severe, that a free passage of CSF cannot be created without undue risks. A history of meningitis, previous surgery at the foramen magnum, or birth complications may indicate that arachnoiditis at the foramen magnum might be present. Radiologically, hydrocephalus or arachnoid cysts in the posterior fossa are indicators of extensive arachnoid pathology [6, 8]. For the individual patient, however, it is not possible to predict precisely what will be encountered intraoperatively in terms of arachnoid pathology.

For patients with basilar invagination and Chiari I Malformation, management is more complicated. First of all, one has to decide whether a posterior decompression alone – with or without fusion – may be sufficient or



**Fig. 2.** **A** This sagittal T1-weighted MRI demonstrates a combination of basilar invagination and Chiari I malformation in a 43-year old man with a 3-year history of occipital pain, gait ataxia and swallowing problems. Due to the significant anterior compression in this patient, a combined surgical approach with transoral resection of the odontoid followed by foramen magnum decompression and craniospinal fusion C0 to C4 was chosen. **B** The postoperative lateral X-ray shows the instrumentation with lateral mass fixation with a good sagittal profile of the cervical spine. **C** The postoperative MRI after 6 months shows a good ventral decompression and a free CSF passage at the foramen magnum. The patient reported improvements of swallowing and occipital pain. The slight gait ataxia has persisted

whether a transoral resection of the dens followed by posterior decompression and fusion is required. Whenever the dens leads to profound kinking or compression of the brain stem, I would suggest a transoral decompression. This procedure is always followed by a postoperative decompression and craniospinal fusion in a second operation a few days later (Fig. 2) [9]. Between surgeries I immobilize the patients with a stiff neck collar.

Whenever the anterior element appears to be insignificant, a posterior decompression may be sufficient. The question then arises, whether decompression alone can be performed or additional fusion is required. Obviously, a fusion is done in patients with evidence of instability. However, these are exceptions. Most patients are able to compensate instabilities so well, that they are difficult to demonstrate on functional studies. Whenever a decompression alone is performed, the patient should be informed, that craniospinal instability may develop as a result of this surgery later, so that a fusion may be necessary subsequently. In patients with additional signs of bony malformations such as assimilation of the atlas to the occiput or congenital fusion of upper cervical segments I would recommend to combine the posterior decompression with fusion straight away, as these patients carry a high risk of postoperative instability after foramen magnum decompression in my experience.

Postoperatively, all patients with a Chiari I Malformation are monitored on intensive care for at least one day.

Immediate postoperative results are usually characterized by cessation of occipital headaches and improvements of gait ataxia and caudal cranial nerve deficits. Sensory changes, dysesthesias, and motor deficits usually stay as they

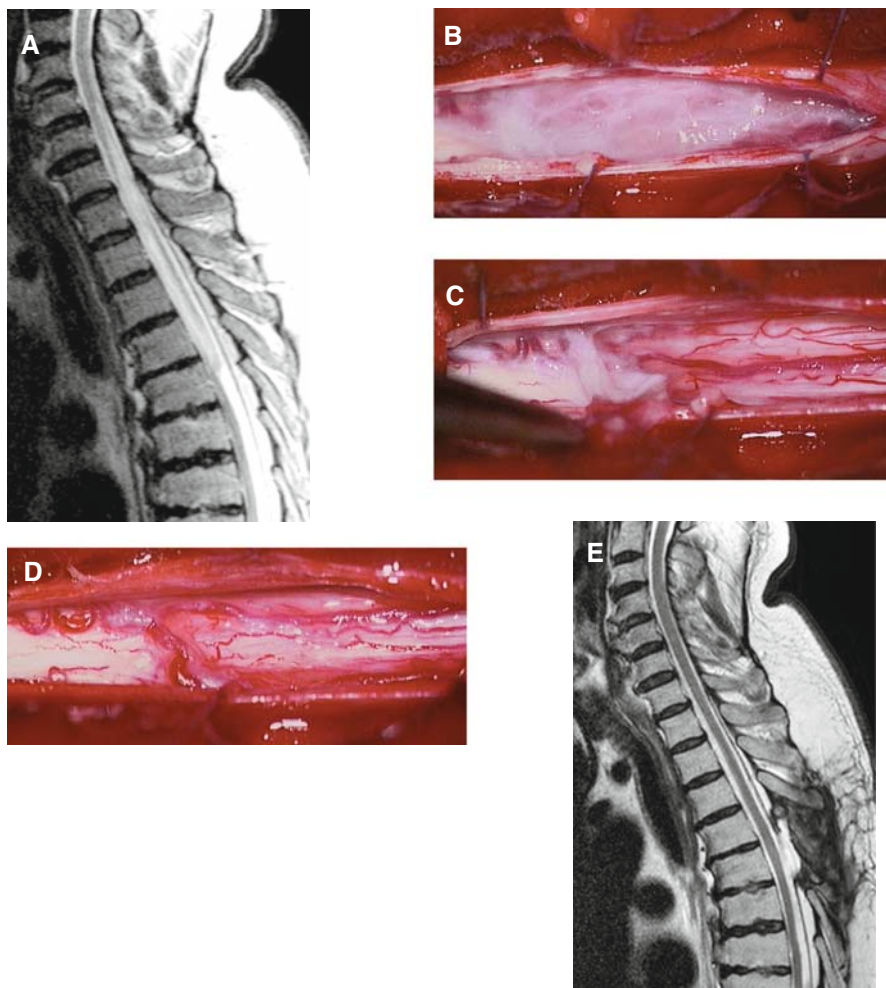
were before surgery. About 78% of patients report at least some postoperative improvements. A postoperative decrease of the syrinx was observed for 82%, with 14% demonstrating no change and the remaining 4% showing an increase at some stage after surgery.

For analysis of long term results, clinical recurrence rates were calculated according to the Kaplan–Meier method. Overall, recurrence rates of 16% after 5 and 10 years were observed. This analysis also demonstrates a correlation of recurrence rates with the extent of arachnoid pathology encountered during surgery: with no arachnoid pathology at all, the 5 year recurrence rate was 14%, with slight arachnoid adhesions without obstruction of the foramen of Magendie it rose to 21% and for severe changes with obstruction of the 4th ventricle the rate was 39%.

## 2. SPINAL ARACHNOID SCARRING

The operation is performed in prone position except for cervical cases which are operated in the semisitting position (Fig. 3). The head is fixed in the Mayfield clamp in neutral position. Medianus- and tibialis-SEP are employed for neurophysiological monitoring. After a midline incision vertebral laminae are exposed according to the extent of arachnoid pathology. The fascia is incised on either side of the spinous process and muscles are detached with subperiosteal dissection. The laminotomy is restricted to a width of 15 mm to avoid damage of intervertebral joints. The yellow ligament is resected and the dura mater becomes visible. As contamination of the CSF with blood may cause inflammatory reactions of the arachnoid, great care is taken to achieve good hemostasis. For this purpose, the entire surgical field is covered by moist cottonoids, which keep soft tissues moist and soak up any minor bleeding.

With ultrasound the intradural situation can now be examined: The syrinx can be visualized. Pulsations of syrinx fluid and CSF may become visible. Sometimes, arachnoid septations can be seen. Most importantly, the safest spot for opening of the dura can be chosen with this technique. Arachnoid scarring may cause adherence of the cord to the overlying dura. With ultrasound such an area can be avoided for the start of the dura incision. Once the outer and inner layer of the dura have been incised in the midline under the microscope, the dura is held under gentle tension on either side by retracting sutures. The arachnoid should always be left intact during dura opening. In this way, any injury to nervous tissue or small vessels can be easily avoided. Once the dura has been opened, the arachnoid pathology becomes visible. In most instances, areas of arachnoid scarring can easily be depicted as thickened arachnoid obscures the view to the underlying cord tissue. If the exposure is adequate, the rostral and caudal end of the dura opening should reveal a normal, translucent arachnoid layer. If this is not the case, the dura opening has to be extended. In order to obtain a sufficient CSF passage, the operation has to extend into the unaffected subarachnoid space on either side of the exposure.



**Fig. 3.** **A** This sagittal T2-weighted MRI demonstrates a syrinx between C5 and Th4 in a 57-year old man with a 3-months history of painful dysesthesias in his left arm and upper trunk. At the lower pole of the syrinx the spinal cord appears pushed anteriorly and compressed indicating the area of the arachnopathy. **B** This intraoperative view shows the arachnopathy after dura opening. Above and below the pathology the arachnoid appears translucent again indicating an adequate exposure. Starting at the caudal end the arachnopathy is resected with micr scissors putting the arachnoid under slight tension. **C** This view shows the upper part of the arachnopathy attached to veins on the posterior cord surface. **D** At the end of intradural dissection, this view shows a free CSF passage across the area of surgery. Note the small remnants of thickened arachnoid left on the spinal cord to preserve the large posterior veins. The dura is closed with a spacious graft. **E** The postoperative MRI after 10 months shows a perfect result with decompression of the cord at Th4, a free CSF passage and a complete resolution of the syrinx. Three months after surgery the dysesthesias had vanished and have not recurred since

Obviously, any surgeon should be familiar with the normal anatomy of the spinal subarachnoid space [10]. The posterior subarachnoid space is divided in two halves by a posterior longitudinal arachnoid septum. This septum extends between the outer arachnoid layer and an intermediate layer on the cord surface. The insertion on the cord surface is related to the midline dorsal vein. Further strands of arachnoid may be encountered in the posterior and – to a lesser degree – anterior subarachnoid space. Another landmark are the dentate ligaments, which originate from the spinal cord pia mater, run between posterior and anterior nerve roots, and insert close to the dural nerve root sleeve.

With a microdissector, arachnoid and dura can be separated from each other without any problem in areas without arachnoid scarring, i.e. at either end of the exposure. In the area of scarring, sharp dissection with microsissors may be required to achieve this. Starting at the rostral and caudal end of the exposure, the arachnoid is then incised in the midline and opened towards the area of scarring. Sometimes, just one side of the posterior subarachnoid space may be affected by the arachnoid pathology. At that level, the arachnoid may become densely adherent to the cord surface. With opening of the rostral and caudal subarachnoid space, CSF flushes into the surgical field and often the cord, which was distended by the syrinx, starts to pulsate and the syrinx may collapse at this point. The arachnoid scar is now resected further layer by layer leaving a last sheath of arachnoid on the cord surface to avoid injury to the cord or surface vessels. This last layer resembles the intermediate arachnoidal layer mentioned above. At that stage, the intradural dissection is completed and need not be extended further.

I again emphasize to use sharp dissection exclusively for this purpose. Blunt dissection carries the risk of rupturing small perforating vessels. No arachnoid dissection is performed laterally or anteriorly. The risk of injury or tearing spinal cord arteries is extremely high if the surgeon does not restrict his activities to the posterior aspect of the spinal canal. Depending on the extent of scarring laterally and anteriorly, this technique may not only achieve a free posterior CSF pathway but also an untethering of the cord – provided the scar does not extend too far laterally or anteriorly.

Any surgical intervention aiming at reducing scar tissue carries the risk of causing new scar formation which may even turn out to be worse than the situation that prompted the surgery in the first place. Considerable experience is needed to be successful with this surgical technique. The more focussed the surgery, the less scarring may result. If unnecessary steps are taken, such as a too extensive dura opening, or the surgical field is contaminated with considerable amount of blood, postoperative scarring may counterbalance completely the effect of surgery. On the other hand, if the dura opening is not extensive enough to gain access to the normal subarachnoid space above and below the level of scarring, the procedure is insufficient. As always, it is the right measure that counts and determines whether an operation will be successful or not.

To limit the risk of postoperative scar formation and tethering an extensive duraplasty is inserted. For this purpose, a number of different materials have been used in the past: lyophilized dura, fascia lata, and Gore-Tex. Autologous material carries a considerable risk of scarring as severe adhesions may form with the cord surface due to vascularization of the fascia by pial vessels. For these reasons, I prefer Gore-Tex for the duraplasty. A few technical points should be followed to minimize the risk of CSF fistulas with the use of this material. Gore-Tex has a rather stiff texture. In order to avoid wrinkling of the duraplasty, the size of the graft should be exactly fitted to the dura opening leaving the retention sutures in place during fitting and suturing. In this way, the size of the graft can be adjusted adequately and there is no risk to injure the cord during suturing. After a tight running suture has been applied, I perform “tenting sutures” to lift the dura graft off the cord surface. These sutures are anchored at intervertebral joint capsules or in epidural scar tissue. Finally, the wound is closed layer by layer. Special attention is paid to a good, tight closure of the muscle layer to prevent any CSF from entering the epifascial space. In patients who have been operated at that level before, as in patients with posttraumatic syringomyelia who underwent spinal instrumentation for instance, I place a lumbar drain prophylactically if the soft tissue is scarred and sparsely vascularized [8].

Postoperative clinical results are commonly characterized by unchanged neurological symptoms. The analysis was performed separately for patients with small, circumscribed arachnoid pathology, i.e. focal arachnoid scarring, and for patients with extensive arachnoid scarring. With focal scarring, 51% experienced some neurological improvements, 41% reported no change and 9% worsening. With extensive scarring, the corresponding figures were 40%, 40% and 20% for improvement, no change and worsening, respectively. In my experience, postoperative improvements are more common for compressing types of arachnopathies rather than for arachnoid scars which just cause CSF flow obstruction and some tethering. As far as pain is concerned, only pain attacks provoked by coughing and sneezing should be expected to improve after surgery. Constant pain or dysesthetic pain of burning type is not altered by surgery, even in patients with a postoperative decrease of syrinx size. Such a decrease of the syrinx was observed in 49% of patients with focal arachnoid scarring and 55% with extensive arachnoid pathologies. Whereas the size remained unchanged in 42% of patients with focal scarring and increased in 8%, the corresponding figures for extensive arachnoid scarring were 21% and 24% for unchanged and increasing sizes, respectively.

Analysing long-term results with the Kaplan–Meier method revealed profound differences between patients with focal and extensive arachnoid scarring: with focal arachnoid scarring, a recurrence rate of 32% for 5 years was determined, as compared to 65% with extensive arachnoid scarring.

These results underline why surgery should be reserved for patients with progressive clinical symptoms. Even though these results are far from perfect,

they are considerably better than those which can be obtained with syrinx shunting, because syrinx shunting never addresses the underlying cause of syringomyelia and the clinical symptoms related to it.

## HOW TO AVOID COMPLICATIONS

Surgery for Chiari I malformation was followed by complications in 21%. The commonest was a CSF fistula in 6%, which can be avoided by a tight running suture of dura and meticulous closure of the muscle layer. If a fistula develops nevertheless, a CT should be performed to rule out a postoperative hydrocephalus, which I observed in 3% requiring a ventriculoperitoneal shunt. Postoperative infections were seen in 4% and hemorrhages in 1%. As a hemorrhage may have grave consequences postoperative surveillance on intensive care for at least 24 hours is an absolute must. The remaining complications were not directly related to the surgery consisting of urinary tract infections, pneumonias etc.

After surgery for arachnoid scarring, complications were seen for 16% of patients. Fistulas, infections and hemorrhages made up for 3% each with the remainder again related to non-surgical problems.

Major postoperative complications may arise from inadequate pre-operative planning: neglecting craniospinal instability in patients with a Chiari I malformation or ventral compression in patients with additional basilar invagination creates severe problems that often lead to a worse long-term result as if the whole pathology had been addressed correctly first time. Likewise, the management of posttraumatic syringomyelia may have to deal with such issues as kyphotic angles, spinal stenosis or inadequate instrumentation during the initial management to avoid disappointing results.

## CONCLUSIONS

The diagnosis of syringomyelia should be reserved for patients with a space occupying intramedullary cyst of progressive character and differentiated from such entities as a harmless dilatation of the central canal or myelomalacia. Syringomyelia is not a disease in its own right but a manifestation of a disorder of the spinal canal or craniocervical junction, that has either resulted in an obstruction of CSF flow or spinal cord tethering or is associated with an intramedullary tumor. Management of patients with syringomyelia requires the correct diagnosis of the underlying disorder and the successful treatment of it. As this can be done in the overwhelming majority of patients, no further surgical measures for the syrinx are required. Shunting the syrinx in particular can and should be avoided as the first line of treatment. The long-term prognosis depends on the treatability of the underlying disorder.



## References

- [1] Batzdorf U (2000) Primary spinal syringomyelia: a personal perspective. *Neurosurg Focus* 8: E7
- [2] Elsberg CA (1916) *Diagnosis and treatment of surgical diseases of the spinal cord and its membranes*. Saunders, Philadelphia
- [3] Gardner WJ (1965) Hydrodynamic mechanism of syringomyelia: its relationship to myelocoele. *J Neurol Neurosurg Psychiatry* 28: 247-259
- [4] Greitz D (2006) Unraveling the riddle of syringomyelia. *Neurosurg Rev* 29: 251-263; discussion 264
- [5] Klekamp J (2002) The pathophysiology of syringomyelia – historical overview and current concept. *Acta Neurochir (Wien)* 144: 649-664
- [6] Klekamp J, Iaconetta G, Batzdorf U, Samii M (2002) Syringomyelia associated with foramen magnum arachnoiditis. *J Neurosurg Spine* 97: 317-322
- [7] Klekamp J, Samii M (2007) *Surgery of spinal tumors*. Springer, Berlin Heidelberg New York
- [8] Klekamp J, Samii M (2001) *Syringomyelia – diagnosis and treatment*. Springer, Berlin Heidelberg New York
- [9] Menezes AH, VanGilder JC, Graf CJ, McDonnell DE (1980) Craniocervical abnormalities. A comprehensive surgical approach. *J Neurosurg* 53: 444-455
- [10] Nicholas DS, Weller RO (1988) The fine anatomy of the human spinal meninges. A light and scanning electron microscopy study. *J Neurosurg* 69: 276-282
- [11] Nicolaidis KH, Campbell S, Gabbe SG, Guidetti R (1986) Ultrasound screening for spina bifida: cranial and cerebellar signs. *Lancet* 2: 72-74
- [12] Ollivier D'Angers CP (1827) *De le moelle épinière et de maladies*. Chez Crevot, Paris
- [13] Puusepp L (1926) Traitement opératoire dans deux cas de syringomyélie avec amélioration notable. *Rev Neurol (Paris)* 43: 1171-1179
- [14] Schijman E, Steinbok P (2004) International survey on the management of Chiari I malformation and syringomyelia. *Childs Nerv Syst* 20: 341-348
- [15] Williams B (1978) A critical appraisal of posterior fossa surgery for communicating syringomyelia. *Brain* 101: 223-250
- [16] Williams B (1990) Post-traumatic syringomyelia, an update. *Paraplegia* 28: 296-313



**Jörg Klekamp**

Jörg Klekamp is neurosurgeon at the Christliches Krankenhaus in Quakenbrück, Germany. Born on May 31st, 1958 in Osnabrück, Germany. Graduation from High School in 1977 with excellence. Medical Study at the Medical School of Hannover 1977 to 1984. Doctoral thesis on brain anatomy at the Dept. of Neuroanatomy of the Medical School of Hannover in 1984. Postdoctoral grant of the Deutsche Forschungsgemeinschaft for a scientific project on the anatomical development of the human brain 1986 to 1988 at the Department of Neuropathology of the University of Sydney, Australia, under supervision of Prof. Clive Harper. Neurosurgical training under supervision of Prof. Dr. med. Madjid Samii at the Nordstadt Hospital Hannover, Germany, from 1989 to 2003. Certified neurosurgeon since 1994. Scientific and clinical work on syringomyelia, malformations and tumors of the spinal canal and craniocervical junction since 1991. Experimental and clinical work on syringomyelia under supervision of Prof. Ulrich Batzdorf at UCLA, Los Angeles from 1993 to 1995. Wilhelm Tönnis Prize of the German Society of Neurosurgery in 1995 for work on syringomyelia. Habilitation in 1999 at the Medical School of Hannover on the pathophysiology and treatment of syringomyelia. Publication of a monograph (Syringomyelia – Diagnosis and Treatment) on Syringomyelia in 2001 and of a textbook on surgery of spinal tumors in 2007.

**Contact:** Jörg Klekamp, Christliches Krankenhaus, Danziger Strasse 2, 49610 Quakenbrück, Germany  
E-mail: [j.klekamp@christliches-krankenhaus-ev.de](mailto:j.klekamp@christliches-krankenhaus-ev.de)

---

# INFECTIONS IN SPINE

A. EL KHAMLI

D. J. Lrhezzioui is co-author of this chapter.

## INTRODUCTION

Evidences of spinal infections have been discovered in the remains of prehistoric man from 700 BC [15]. Hippocrates first described the infection of the vertebral column. Later on, Galen related this infectious process to spinal deformity. Servino and Potts characterized and described the pathology of tuberculous infection of the spine. In 1879, Lannelongue described bacterial osteomyelitis as we recognize it today. The initial procedure introduced for the surgical treatment of spinal infections was laminectomy [17]. While Hodgson and Stock performed fusions by the anterior approach, Hibbs and Albee independently presented techniques for posterior spinal fusion in the treatment of spinal tuberculosis (TB) [17].

Early studies of spinal infections reported an incidence of only one case per 10000 hospital admissions [8]. Recent reports clearly demonstrated that this incidence is increasing 10- to 15-fold [8]. Spinal TB (Pott disease) is the most frequent location of extrapulmonary TB with a frequency of 38 to 53% [1]. Spinal parasitic infections are rare. Thus, spinal location of hydatid disease occurs in about 1% of all cases of hydatidosis; however, it presents 50% of skeleton locations of the disease [7].

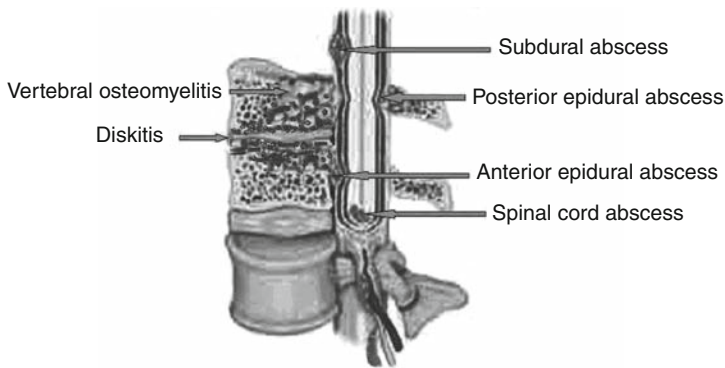
Spinal infections can be thought of as a wide spectrum of pathologic entities comprising intervertebral disk space infection or diskitis, vertebral osteomyelitis (VO), spinal epidural abscess (SEA), spinal subdural empyema or abscess (SSA), and intramedullary spinal cord abscess (SCA) (Fig. 1). Many of these may occur in combination, especially diskitis, VO, and SEA. SSA and SCA are very rare. Contemporary neuroimaging techniques are very helpful to approach spinal infections diagnosis and to make therapeutic strategies with the current role of surgery in light of the recent trend toward nonoperative management.

## RATIONALE

Spinal infection is a devastating disease with a high rate of patients left with neurological deficits [3], especially with SEA, for which this rate is almost 90% if motor deficit is present at the time of diagnosis. Thus, the goal of this

---

*Keywords:* infectious diseases, spine, diskitis, neurosurgery, antibiotics



**Fig. 1.** Spectrum of spinal infections

chapter is to emphasize the importance of early diagnosis and adequate treatment to reduce mortality and prevent permanent disability. Unfortunately, early identification of this infection is difficult given its frequency and the nonspecific nature of symptoms.

Spinal infections are divided into two groups: pyogenic and nonpyogenic infections. In the first group the most common pathogens are bacteria like *Staphylococcus aureus*, streptococci, and gram-negative bacilli or mycobacteria (Pott disease). In the second group, the agents may be parasites (echinococcus and toxoplasma, etc.) or fungi (*Aspergillus*, *Candida*, and *Coccidioides*, etc.). The predisposing factors [8, 5, 16] include diabetes mellitus, extraspinal infectious focus especially of the urinary tract, the skin, and the lungs, chronic renal failure, alcoholism, malignancy, intravenous drug abuse, long-term steroids use, AIDS infection, chemotherapy, and past operative spine procedures.

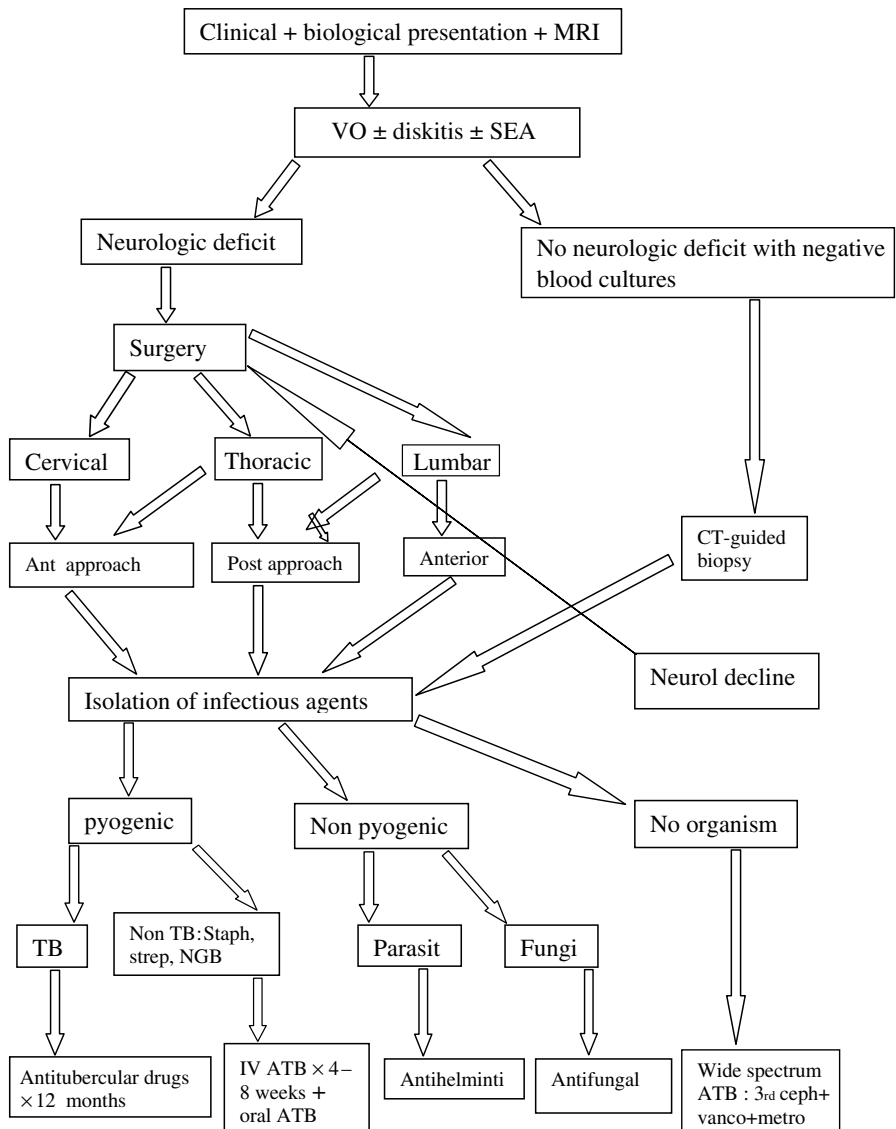
Organisms arrive in the spine by two different ways, either hematogenous or nonhematogenous seeding. By the first way, infection is seeded from a remote source (endocarditis, pulmonary abscess or tuberculosis, and urinary infection, etc.) either through direct arterial seeding by way of nutrient arteries derived from the posterior spinal, intercostal and lumbar arteries or through retrograde venous seeding through Baston's epidural venous plexus, which shares numerous connections with the pelvic veins in pelvic infections. Sources of nonhaematogenous seeding can be surgical procedures, penetrating trauma, or contiguous infection.

## DECISION-MAKING

Spinal infection diagnosis is based on association of clinical, biological, and radiological data (Fig. 2).

The past medical history is checked for the above mentioned predisposing factors.

Clinical data are not specific and associate spinal back pain, radicular pain, local spine stiffness, fever, and neurologic deficits in different combinations (Table 1).



**Fig. 2.** Decision-making for the choice of therapeutic options for VO and diskitis. *Ant appr* anterior approach, *Post appr* posterior approach, *staph* staphylococci, *strep* streptococci, *NGB* gram-negative bacilli, *IV* intravenous, *3rd ceph* third-generation cephalosporin, *vanco* vancomycin, *metro* metronidazole

Routine laboratory investigations are generally not specific but are somewhat helpful in establishing spinal infection diagnosis. The increased erythrocyte sedimentation rate (ESR) is more valuable in monitoring the therapy

**Table 1.** Rate of different clinical symptoms revealing spinal infections

Clinical symptom	% Cases presenting symptom with:						
	Spinal TB (our series, 360 cases)	Other pyogenic VO and diskitis		Spine parasitic infection, hydatid disease (our series, 35 cases)	SEA [3, 8, 12]	SSA [14]	SCA
		Our series (23 cases)	Other series [6, 8]				
Spinal back pain	79.7	91	>90	60	85	back pain fever, and	only a few cases
Radicular pain	34.2	48	33	25	62–90	neurologic deficits	reported with back pain,
Stiffness	62	48	>90	2.85	52	highly suggestive	fever, and neurologic deficits
Fever	7.2	30.5	48–78	0	32–75		
Neurologic deficit	66.4	21	50	91.42	41–71		

effect than in establishing a diagnosis, because of false positive and false negative results. The peripheral white blood cell count is usually normal or slightly elevated. Cerebrospinal fluid analysis often shows evidence of parameningeal process with pleocytosis, elevated protein, and normal glucose except in case of associated meningitis. However, lumbar puncture is discouraged in patients with VO or SEA especially in thoracolumbar location to avoid introduction of bacteria in the subarachnoid space and to prevent possible neurological deterioration. Blood cultures are usually positive in patients with spinal infections [11]. Cultures from any other potential source of infection should be obtained. Immunodiagnosis has gained importance recently, especially in TB and hydatid disease (PCR and ELISA, etc.).

Radiological features (Table 2) detected by imaging studies of the spine represent the cornerstone of diagnosis of spinal infections. Plain radiographs should be performed in all patients and are helpful in localizing the level and extent of the lesion. Unfortunately, early in the course of spinal infections, they may be entirely normal. In VO, new bone formation and fusion occur late as the infection resolves and healing takes place. CT provides excellent details of bone anatomy and the paravertebral soft tissue but is not particularly sensitive for demonstrating SEA, SSA, and SCA. It is most valuable in performing image-guided percutaneous biopsies of the vertebral body, disk, and paravertebral tissue to obtain culture material. MRI is the most important imaging modality in detecting spinal infections because of direct visualization of the spinal cord and paraspinal soft tissues with multiplanar images and because of its noninvasive nature. Its sensitivity, specificity, and accuracy are respectively 96, 94, and 92% [15].

Considering clinical data, most of the time not specific, biological inflammatory syndrome, and very suggestive radiological findings, the diagnosis of

**Table 2.** Imaging findings in spinal infections

Spine infection	% Cases with infection location		X-rays	CT scan	MRI		
	Cervical	Thoracic Lumbar			T1WI	T1 + gado T2WI	
Spinal TB (our series, 360 cases)	10.3	56.7	33	lytic bone-destructive changes of vertebral body, disk hypodensity, paravertebral soft tissue abscess, lytic changes of posterior arc, rib lysis	hyposignal vertebral body; loss of delineation of the end plates from the disk	enhancement of affected vertebral body and disk	hypersignal of affected disk and end plates
Other pyogenic VO (our series, 23 cases)	26.4	30.4	43.2	lytic bone-destructive changes, disk hypodensity, paravertebral soft tissue abscess	hyposignal vertebral body; loss of delineation of the end plates from the disk	enhancement of affected vertebral body and disk	hypersignal of affected disk and end plates
Spinal parasitic infections (our series of hydatid diseases, 35 cases)	17	54	29	vertebral body collapse, lytic pedicle lesions, lytic changes of posterior arc, rib lysis, lytic bone-destructive changes of vertebral body	vertebral hypodense multivesicular lesions with paravertebral soft tissue extension without enhancement after IV contrast	hypointense multivesicular lesions involving vertebral body, pedicles, posterior arc, epidural space, rarely subdural space	the same T1 lesions but in hypersignal

(Continued)

**Table 2** (Continued)

Spine infection	% Cases with infection location		X-rays	CT scan	MRI		
	Cervical	Thoracic Lumbar			T1W1	T1 + gado T2W1	
SEA [6, 9]	32	34.6	normal or spine deformity	myelo CT: complete or partial extradural type stop	convex epidural collection with iso- or hyposignal	little or no enhancement of the abscess cavity; enhancement of chronic granulations	slight hyper- or hyposignal
SSA			normal or spine deformity	myelo CT: intradural extramedullary lesion	intradural extramedullary slightly hyper- or hypointense mass	capsular enhancement	hypersignal
SCA			normal or spine deformity	enlarged spinal cord	hyperintense intramedullary lesion	rim enhancement	iso- or hypersignal



**Table 3.** Main anti-TB drugs used in spinal TB spondylitis treatment

Drug	Dosage	Side effects	Contraindications
Rifampicin	oral 10 mg/kg/day	liver toxicity, gastrointestinal symptoms	jaundice, pregnancy
Isoniazid	oral 10 mg/kg/day or 5 mg/kg/day if associated to rifampicin	peripheral neuritis, psychosis, rarely convulsions and Lupus syndrome	liver diseases, maniaco-depressive psychosis
Pyrazinamid	oral 20–30 mg/kg/day	hepatitis, hyperuricemia	liver damage
Streptomycin	intramuscular 1 g/day (20–25 mg/kg/day)	ototoxicity, renal disturbances	pregnancy, renal failure
Ethambutol	oral 15 mg/kg/day	retro-bulbar optic neuritis, peripheral neuritis	optic neuritis

spinal infection can be summarized in the following three situations (Fig. 2), differing by the presence or absence of an extraspinal focus of infection, of neurological deficit, and of spine instability.

In the first situation, clinical and radiological findings are suggestive of spinal infection with already diagnosed extraspinal infectious focus, patient has neither neurological deficit nor spine instability. In this situation, the patient underwent nonoperative treatment with adapted antibiotherapy or anti-TB or antiparasitic drugs, in addition to external immobilization using soft or rigid lumbar, thoracic, or cervical collar or halo. In patients with spinal TB, the treatment associates a combination of three anti-TB drugs (rifampicin, isoniazid, and pyrazinamide) with streptomycin or ethambutol for 2 months followed by rifampicin and isoniazid for another 10–13 months (Table 3). For patients with other non-TB pyogenic spinal infections, intravenous antibiotics are prescribed for 4 to 8 weeks with regard to the responsible bacteria if isolated. When cultures remain negative, a combination of third-generation cephalosporin, vancomycin, and metronidazol against the most frequent responsible bacteria (staphylococci, streptococci, gram-negative bacilli) is recommended. Patients with spinal hydatid disease receive albendazole at a dosage of 10 mg/kg/day, usually 400 mg twice a day. Because of albendazole's liver toxicity, it is administered in three 4-week cycles with intervals of 14 days. The treatment monitoring of liver enzymes is necessary during treatment. It has been proven in our series of hydatid disease that continuous treatment achieves better efficacy with no increased adverse effects.

In the second situation, clinical and radiological findings are suggestive of spinal infection but without extraspinal infectious focus, patient has no neurological deficit or spine instability. CT-guided biopsy is made with pathological and microbiological studies to identify the responsible organism and

antibiogram; the patient undergoes nonoperative management as in the previous situation

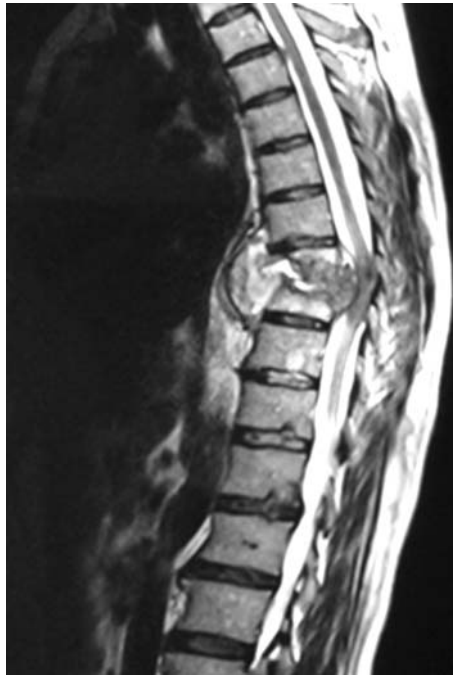In the third situation, clinical and radiological findings are suggestive of spinal infection and patient has already neurological deficit and/or spine instability. The patient undergoes surgery with pathological study and microbiology, followed by adapted antibiotherapy.

## **SURGICAL MANAGEMENT**

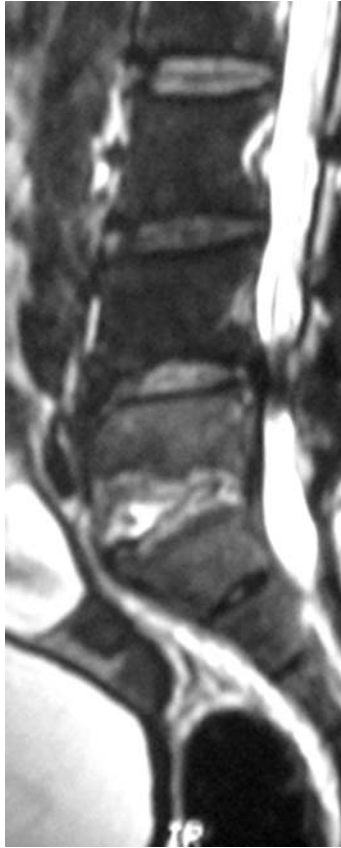
### **1. TREATMENTS**

#### **1.1 Patients with spinal tuberculosis (STB)**

In patients with spinal TB, bony involvement usually includes the vertebral body and intervertebral disk with kyphosis as complication (Fig. 3), while the posterior arc involvement is unusual (12 of 360 cases, 3.33% in our series). So the anterior approach is the best technique to restore the integrity of anterior column and allows a better exposure of the lesions and their debridement.

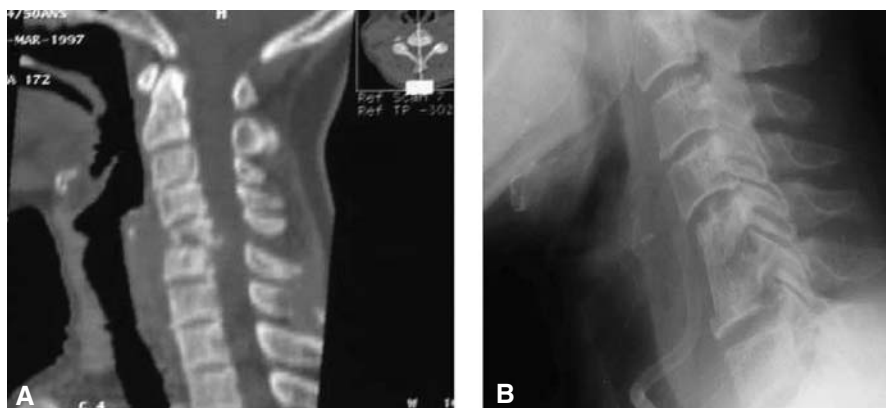

**Fig. 3.** Th9 tuberculous vertebral osteomyelitis with ventral SEA and kyphosis. T2-weighted sagittal MRI

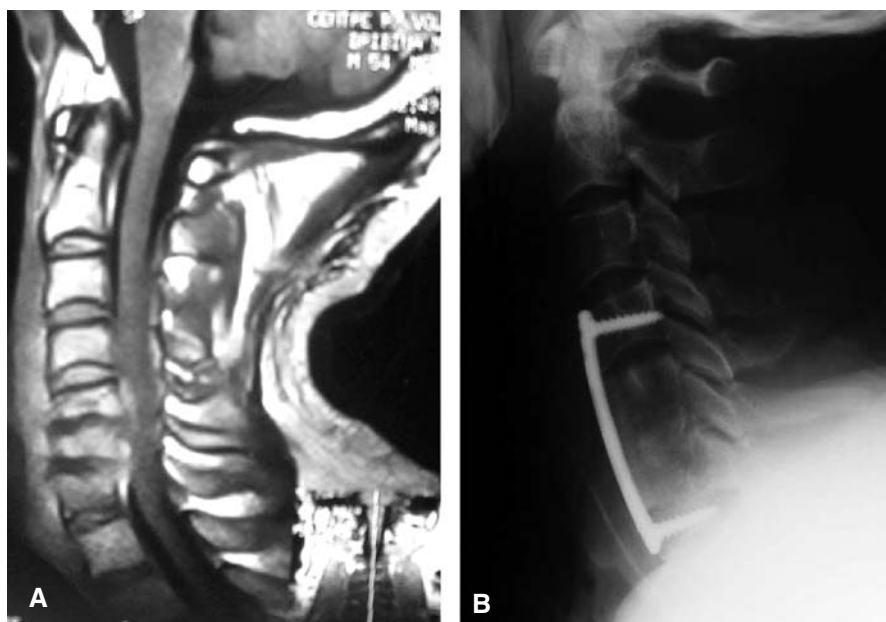

**Fig. 4.** TB involving one disk, L5-S1, and partially two vertebrae, L5 and S1. T2-weighted sagittal MRI

Spinal TB or VO involves at least one disk and two vertebrae in most of the cases (Fig. 4). So, in the majority of the cases, anterior decompression requires one-level discectomy with one partial or total vertebrectomy (Fig. 5A, B) or three-level vertebral corpectomy and two-level discectomy (Fig. 6A, B). The patient undergoes surgery under general anesthesia with endotracheal intubation in supine position for cervical spine and lateral position for thoracic segment. The goal is to decompress the spinal cord by removing the affected disk and infected bone and to stabilize the spine with a bone graft. Of our 360-patient series, 79% were treated surgically by the anterior approach: transpleural thoracotomies or thoracophrenotomies in thoracic or thoracolumbar location, 58 cases (Fig. 7A, B); retroperitoneal lumbotomies in lumbar location, 55 cases; and anterolateral cervicotomies in cervical location, 21 cases (Fig. 6A, B). Twelve patients with posterior arc TB

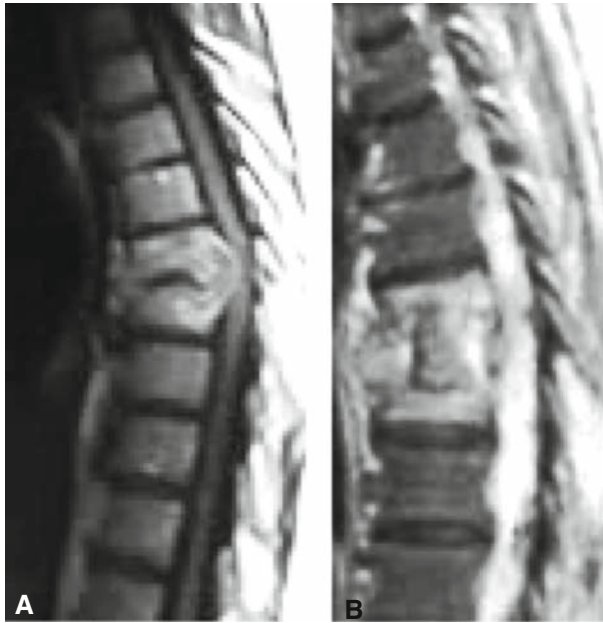

**Fig. 5.** **A** Cervical CT scan with sagittal reconstruction. C5 TB vertebral osteomyelitis with one-level diskitis C5-C6. **B** X-ray after surgery (one year). C5-C6 discectomy and partial C5 and C6 corpectomies with bone graft and external immobilization for 3 months

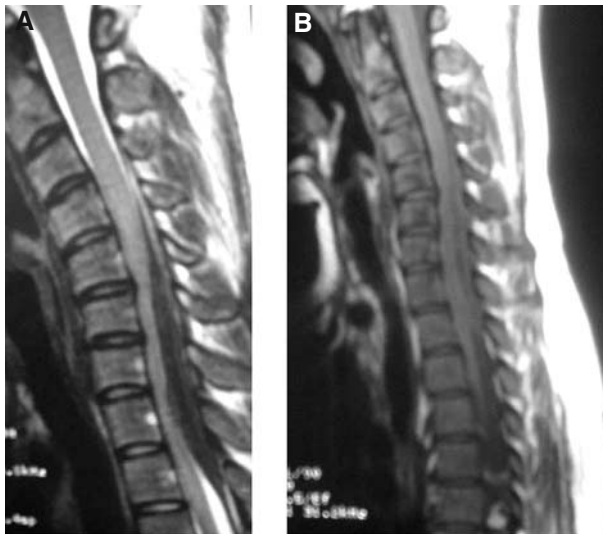


**Fig. 6.** **A** T1-weighted sagittal MRI. Cervical spine TB involving two disks (C4-C5 and C5-C6) and three vertebral bodies (C5, C6, and C7). **B** Postoperative cervical spine X-ray showing C5, C6, and C7 partial corpectomy with iliac bone graft and anterior osteosynthesis with plate

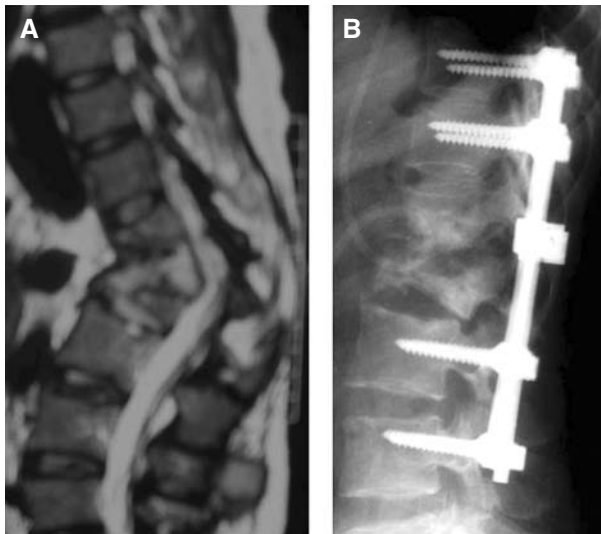
or with extended intraspinal TB mass were treated by laminectomy to decompress the spinal cord (Fig. 8A, B). Laminectomy without instrumentation is also indicated in elderly patients and emergency situations, for neural



**Fig. 7.** **A** Thoracic MRI. Spine TB with Th 8 and Th 9 vertebral osteomyelitis and Th 8–Th 9 diskitis compressing the cord anteriorly. **B** Postoperative control after anterior approach (transpleural thoracotomy) showing Th 8, Th 9 corpectomy and Th 8–Th 9 corpectomies and bone graft



**Fig. 8.** **A** T2-weighted sagittal MRI. Biconvex cervical epidural hypointense TB abscess. **B** T1-weighted sagittal MRI with gadolinium. The same lesion in iso signal without enhancement. The patient underwent surgery with C5–T2 laminectomy and excision of the intrarachidian TB mass

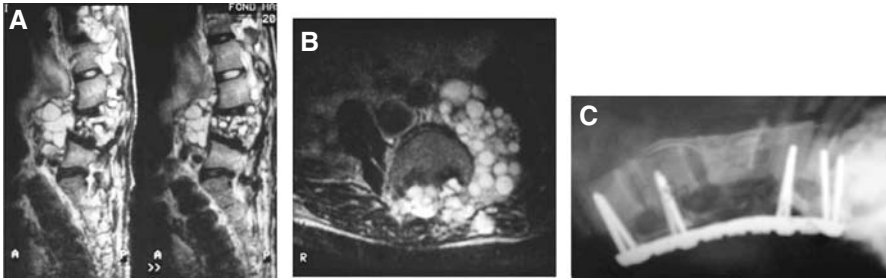


**Fig. 9.** **A** T2-weighted sagittal MRI. Thoracolumbar Pott disease (Th12-L1-L2) with spinal cord compression due to vertebral body collapse with an important kyphosis (Cobb angle of 152°). **B** Postoperative thoracolumbar X-ray. Th12-L1-L2 lamino-arthrectomy with posterior laminectomy and posterior fixation (osteosynthesis with screws). Note kyphosis improvement (25°)

compression with minimal bone involvement. Laminectomy with posterior instrumentation (Fig. 9A, B) could be an alternative to the anterior approach if the surgeon is not familiar with the anterior approach in the thoracic spine location. In all cases, independently of the surgical choice, the specific anti-biotherapy is administered as described above.

### 1.2 Patients with spine hydatid disease (SHD)

In patients with SHD, both anterior and posterior arcs are involved, with multilevel involvement and large epidural invasion (Fig. 10A, B), so the posterior approach is the best way to ensure adequate radiculomedullary decompression. After laminectomy and removal of epidural multiple cysts, the operative field should be irrigated repeatedly with hypertonic saline solution to avoid dissemination. Stabilization with plates and pedicle screws is necessary to avoid instability (Fig. 10C). In some rare cases, bony involvement concerns vertebral body with kyphosis and additional anterior approach becomes necessary. Of our 35 patients with SHD, 33 were operated by the posterior approach and only 2 patients by additional anterior approach. An antiparasitic drug (albendazole) was administered to 21 patients, who were diagnosed after 1993, with good outcome (only 3 recurrences, successfully treated), whereas in cases treated with surgery alone (before 1993), recurrences were noted in 71% of the cases.



**Fig. 10.** **A, B** T2-weighted sagittal and axial MRI. Lumbosacral spine hydatid disease. **C** Postoperative X-ray one year after surgery (L3 laminectomy with posterior osteosynthesis); albendazole therapy

Other parasitic diseases like onchocerciasis, toxoplasmosis, and toxocaridias can also be seen in spine. In our experience, in addition to hydatid disease, we have seen a case of spine schistosomiasis [4] revealed clinically by radiculomyelitis with tetraparesis. Schistosoma eggs were found in the urine and blood and schistosomiasis serologies of the cerebrospinal fluid were positive. The patient was treated with niridazole in three 10-days cycles with intervals of 1 month associated to corticosteroids (30 mg/day) for 3 month and vitamin B therapy with good recovery.

For isolated SEA without VO, a laminectomy over the involved levels will be sufficient for adequate decompression, followed by antibiotic treatment taking into consideration the causative agent. Occasionally, SEA extends over many segments. Schulz et al. [13] reported two cases with involvement of the entire spine and suggested as surgical approach one- or two-segment laminectomy at the rostral and caudal level of the abscess. A Fogarty nr. 5 catheter can then be advanced into the epidural space until the balloon is seen at the other laminectomy site. The balloon is inflated with 1 to 1.5 ml of air and then slowly and gently withdrawn until it reaches the insertion site, allowing purulent material to be “milked” from the epidural space. This procedure is repeated until purulent material has been adequately removed.

## 2. LONG-TERM RESULTS

For spinal TB, the global mortality rate in our 360-patient series was less than 1%. We notice complete recovery in 60% and partial neurologic impairment in 20% of 284 operated patients. Of 75 patients managed conservatively (medical treatment with external immobilization), 37 were secondarily operated because of neurological worsening. If we compare the radiological results versus surgical approaches we notice better improvement of scoliosis by the anterior approach. On the other hand, worsening of kyphosis was detected in patients treated conservatively or surgically by only decompressive laminectomy.

For patients with SHD, the outcome is closely related to the number of cysts: in case of a unique cyst and removal without rupture (3 cases intradural extramedullary and 1 case with epidural cyst in our series of 35 cases) the outcome is good without recurrence. The recurrence rate for SHD with bone involvement is significantly higher (71%) in the subgroup treated by surgery alone (7 of 10 patients treated before 1993) than in the subgroup undergoing surgery with antihelminthic drugs (22.2%). Indeed, recurrence was seen in 3 of 21 patients treated after 1993 who discontinued albendazole on their own after hospital discharge.

The mortality rate in patients with SEA is approximately 15% [10], which remains unacceptably high. Approximately 45% of patients who survive will be left with some degree of neurologic impairment [8]. Sixteen percent (meta-analysis of 915 patients with SEA) have significant motor deficit or even complete paralysis, which means an important long-term disability [10]. It has been pointed out that patients admitted with severe neurologic deficit and those with rapid or acute clinical decline have a much poorer prognosis than do patients without deficit or with more chronic clinical course [2, 8].

## HOW TO AVOID COMPLICATIONS

Early diagnosis and treatment are the best way to decrease morbidity and mortality.

To prevent graft displacement after anterior approach, we advise to apply anterior plates to stabilize the graft. In our experience, infections do not contraindicate the use of instrumentation.

To prevent kyphosis, using the anterior approach is preferable. If for the reasons already mentioned, the posterior approach is used, an additional stabilization with plates and pedicle screws is mandatory in all cases with spinal instability.

To make early diagnosis of secondary spinal instability, it is wise to perform clinical and radiological control every 3 months during the first year, every 6 months during the second year, and every year during the following 3 years.

To prevent recurrence and secondary neurological deterioration, the treatment should be based on precise infection diagnosis and specific drugs targeted to the isolated causative agent should be administered.

## CONCLUSIONS

Infections in spine are not unusual. VO and diskitis are the most common aspect. Mycobacterium tuberculosis and *Staphylococcus aureus* are the most



frequent pathogens. Despite the support provided by clinical and radiological studies, pathological examination and cultures are often necessary to confirm diagnosis. Surgery, combined with adequate specific antibiotics, keeps a great place in the management of spinal TB and non-TB infections for neural decompression and extended bone lesions with spinal deformity. The anterior approach is the best operative option which allows a better exposure, large debridement, spinal reconstruction, and rapid reversal of neurological deficits. Despite all our efforts, spinal TB still has a severe functional prognosis. The best way to prevent spinal TB and TB in general is the generalized and controlled immunization with improvement of health care and life conditions of the population.

SEA is less common but noisy and acute requiring urgent surgical drainage except in rare cases which could be managed conservatively.

Surgical management of SHD combined with antihelminthic medications is the best way to reduce recurrence rate. Prevention of this disease by eradication of the parasite remains the mainstay to avoid such debilitating illness.

## References

- [1] Ahmadi J, Bajaj A, Destian S, Segall HD, Zee CS (1993) Spinal tuberculosis: atypical observations at MR imaging. *Radiology* 189: 489-493
- [2] Bagley CA, Dudukovich KJ, Wolinsky JP, Gokaslan ZL (2005) Surgical management of cervical spinal epidural abscesses. *Oper Tech Neurosurg* 7: 193-198
- [3] Davis DP, Wold RM, Patel RJ, Tran AJ, Tokhi RN, Chan TC, Vilke GM (2004) The clinical presentation and impact of diagnostic delays on emergency department patients with spinal epidural abscess. *J Emerg Med* 26: 285-291
- [4] El Amrani A (1988) Localisation radiculo-médullaire de la Bilharziose. A propos d'un cas. Thèse doctorat en médecine no 70, Faculté Medecine et Pharmacie de Rabat, Rabat, Morocco
- [5] Lee MC, Mislow J, Fessler RG (2006) Primary reconstruction for spinal infections. In: Schmidek HH, Roberts DW (eds) Schmidek and Sweet's operative neurosurgical techniques: indications, methods, and results, vol. 2, 5th edn. Elsevier Saunders, Philadelphia, pp 1703-1714
- [6] McHenry M, Easley K, Locker G (2002) Vertebral osteomyelitis: long-term outcome for 253 patients from 7 Cleveland-area hospitals. *Clin Infect Dis* 34: 1342-1350
- [7] McManus DP, Zhang W, Li J, Bartley PB (2003) Echinococcosis. *Lancet* 362: 1295-1304
- [8] Osenbach RK, Little K (2006) Spinal infections: vertebral osteomyelitis and spinal epidural abscess. In: Schmidek HH, Roberts DW (eds) Schmidek and

- Sweet's operative neurosurgical techniques: indications, methods, and results, vol. 2, 5th edn. Elsevier Saunders, pp 1687-1701
- [9] Payer M, Walser H (2008) Evacuation of a 14-vertebral-level cervico-thoracic epidural abscess and review of surgical options for extensive spinal epidural abscesses. *J Clin Neurosci* 15: 483-486
- [10] Reihaus E, Waldbaur H, Seeling W (2000) Spinal epidural abscess: a meta-analysis of 915 patients. *Neurosurg Rev* 232: 175-204
- [11] Rezai A, Woo H, Errico T, Cooper T (1999) Contemporary management of spinal osteomyelitis. *Neurosurgery* 44: 1018-1025
- [12] Rigamonti D, Liem L, Sampath P, Knoller N, Namaguchi Y, Schreiber DL, Sloan MA, Wolf A, Zeidman S (1999) Spinal epidural abscess: contemporary trends in etiology, evaluation, and management. *Surg Neurol* 52: 189-197
- [13] Schulz C, Comey C, Haid R (2001) Pyogenic spinal epidural abscess: a minimally invasive technique for multisegmental decompression. *J Spinal Disord* 14: 546-549
- [14] Sorar M, Er U, Seçkin H, Ozturk MH, Bavbek M (2008) Spinal subdural abscess: a rare cause of low back pain. *J Clin Neurosci* 15: 292-294
- [15] Tali ET (2004) Spinal infections. *Eur J Radiol* 50: 120-133
- [16] Vajramani GV, Nagmoti MB, Patil CS (2005) Neurobrucellosis presenting as an intra-medullary spinal cord abscess. *Ann Clin Microbiol Antimicrob* 4: 14
- [17] Vinas FC, Rhodes JR (2003) Spinal infections. eMedicine from WebMD, eMedicine Specialities, Orthopedic Surgery, Spine, <http://www.emedicine.com/orthoped/TOPIC558.HTM>



### **Abdeslam El Khamlichi**

Abdeslam El Khamlichi is professor and head of the Department of Neurosurgery at the Hôpital des Spécialités at the University Hospital Center of Rabat. He is the director of the Rabat Reference Center for Training of Young African Neurosurgeons of the World Federation of Neurosurgical Societies and coordinator of WFNS Committee Activities. His fields of interest are sellar region tumors, vascular surgery, central nervous system infections, intracranial meningiomas, and neurosurgery in developing countries.

**Contact:** Abdeslam El Khamlichi, Department of Neurosurgery, Mohamed V University, Hôpital des spécialités, Rabat, Morocco  
E-mail: fh2nch@menara.ma

# **FUNCTIONAL NEUROSURGERY**

---

# STEREOTACTIC TECHNIQUES

D. A. BOSCH

## INTRODUCTION

Stereotaxis means a spatial (i.e. three-dimensional) arrangement, that is: localizing any point in space by the application of mathematical principles.

Stereotactic neurosurgery started in 1908, when Horsley and Clarke published work on a new method of brain research using a Cartesian tri-coordinate system [2]. Horsley investigated the functions of tracts and nuclei positioned deep in the brain of animals, by making electrolytic lesions with targeted electrodes, but he was aware of the need to place such lesions deep inside the brain very precisely. This brought Clarke to the idea to use the cranium as a platform for localizing and also calculating the positions of intracranial targets with the use of a mechanical instrument that should be firmly fixed to the skull. This so-called stereotactic instrument consisted of a frame of brass which by its construction represents the three orthogonal planes needed for accurate localization and calculation of the target. With this coordinate system any point of interest inside the brain could be defined by its coordinates  $x$ ,  $y$  and  $z$  (Fig. 1).

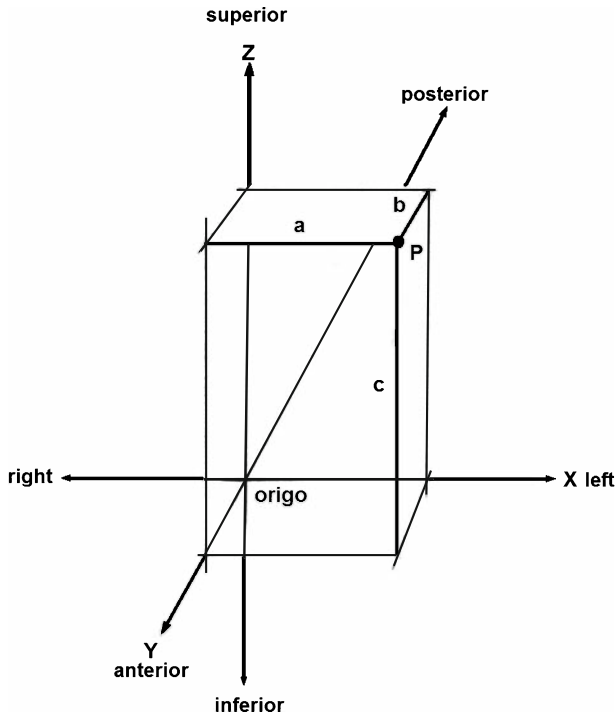
The first stereotactic instrument was a cubic frame which had to be applied to the head of the animal by means of rods attached to plugs inserted into the external auditory meatuses and adjustable bars resting on the nose and orbital margins. It was fixed to the skull by pins which were screwed in laterally. The electrode was supported by another bar that could be moved in three planes at right angles to each other: the horizontal, coronal and sagittal planes. Based on this instrument stereotactic maps (so-called atlases) of horizontal, coronal and sagittal sections of the brain of cat and monkey were published. Between 1908 and 1947 this new technique was only applied in experimental brain research.

Clarke already realized that there is no constant relationship between the skull and the intracerebral structures and that the only way to find out where to place a needle tip in a given brain target was to construct a map on which every target could be related to an intracerebral tricoordinate system.

In 1947 Spiegel et al. [6] reported the first human stereotactic operation with the use of their own instrument, especially constructed for use in humans.

---

*Keywords:* stereotaxis, frames, techniques



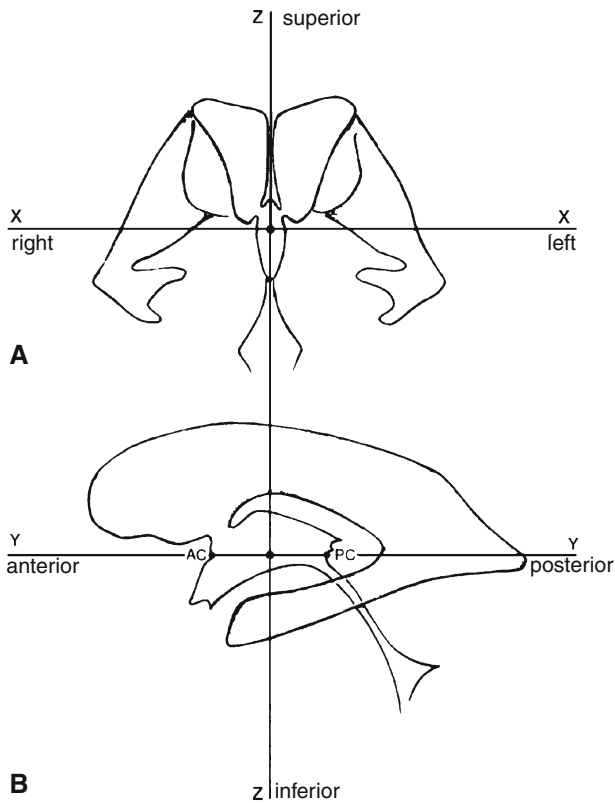
**Fig. 1.** Cartesian tricoordinate system for spatial orientation. The origo is the zero-point. P is given by:  $x = a$  mm lateral to zero (to the left),  $y = b$  mm anterior to zero,  $z = c$  mm superior to zero. XY-plane is horizontal or axial plane, XZ-plane is frontal or coronal plane, YZ-plane is sagittal plane

## RATIONALE

### 1. THEORETICAL CONSIDERATIONS

For the internal reference system, according to Spiegel and Wycis the most reliable structure for the geometrical localization of intracerebral targets is the third ventricle. Later on, their reference to the contours of the third ventricle has proven to be very reliable indeed.

In particular, the line interconnecting the anterior and posterior commissure (the AC-PC line) has become the standard line for the introduction of the intracerebral reference system. A three-dimensional Cartesian coordinate system, consisting of the AC-PC plane as the horizontal plane with the coronal and sagittal planes running through the midpoint of the AC-PC line, forms the internal reference system (Fig. 2). This reference system is the basis for the stereotactic brain atlas by Schaltenbrand and Wahren [5]. Because of



**Fig. 2.** Intracerebral reference points according to Schaltenbrand and Wahren: AC and PC with a perpendicular erected in the midpoint of the intercommissural line. Middle point is zero point of system of axes. **A** anteroposterior view, **B** lateral view

the fact, that the distance AC–PC is in all human brains approximately  $25\text{ mm} \pm 3\text{ mm}$ , a very precise calculation can be made of the position of any target, giving its relation to the midpoint of this standard line.

The stereotactic brain atlas gives photographs of microscopical sections of the normal human brain in three orthogonal planes: the horizontal, coronal and sagittal planes running through the midpoint of the AC–PC line. Overlying the magnified photographs of the sections are transparent grids of  $10\text{ mm}^2$ , which indicate exactly the position of the midpoint of the AC–PC line in relation to any plate.

The functional stereotactic surgeon can therefore easily look up in the atlas what the coordinates are of any target of interest in relation to this central point (x, y, z).

The coronal plane is giving the lateral coordinate x, the horizontal plane the y and the sagittal plane the z.

Targets of interest in functional stereotactics have been called “invisible targets” because they were only visible with the help of a stereotactic brain atlas [1]. With present-day MRI scanning techniques, however, these targets sometimes may be visible in the individual patient. Originally, the term “visible targets” has been coined for pathological lesions, which are visible by themselves when using scanning techniques or cerebral angiography (such as tumors or vascular pathology).

It should be stressed, however, that distinguishing between visible and invisible targets is very useful for a good understanding of the stereotactic principles. With visible targets the surgeon only needs the stereotactic reference system incorporated in the stereotactic headframe (external reference system), whereas the functional surgeon with invisible targets needs both the internal and the external reference systems: with the internal reference system the invisible target is defined in relation to the central midcommissural point and can be made visible in the stereotactic MRI data set of the individual patient by feeding the stereotactic software with the three coordinates  $x$ ,  $y$  and  $z$ . In a way, this manoeuvre makes the target visible in the three appropriate planes. The next step is the definition of the position of the target in the stereotactic space as is given by the frame and its external reference system.

Nowadays this is automatically retrieved from the software that is compatible with the stereotactic frame. In the old days, with stereotactic X-ray pictures in lateral and antero-posterior direction, visualization of the third ventricle was done with ventriculography, the AC–PC line was drawn on the lateral picture and the coordinates derived from the brain atlas were marked on both pictures in relation to the individual patient’s midcommissural point. The positions indicated on both the lateral and antero-posterior X-ray pictures then could be used as visible targets for the final step: the calculation of the instrument coordinates  $x$ ,  $y$  and  $z$  with the external reference system of the frame.

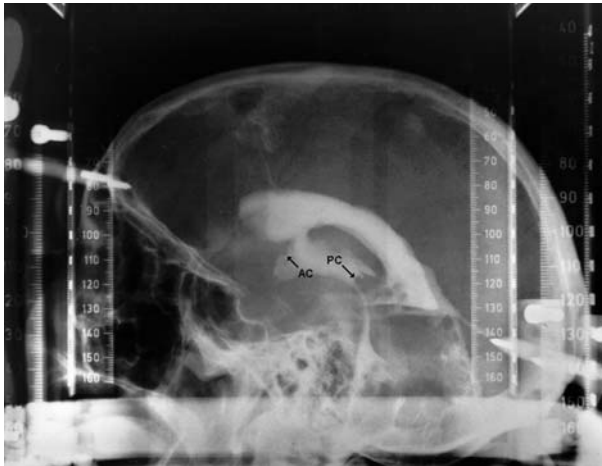
## 2. VISUALIZATION TECHNIQUES

From the theoretical considerations follows that all invisible targets are defined in space by their coordinates in relation to the midpoint of the AC–PC line, which is the center point of the grids overlying the brain sections in the stereotactic atlas.

Visualization of the target is thus based upon the visualization of the third ventricle and with it of the AC–PC line [3].

Originally this has been realized with pneumo-encephalography/ventriculography and stereotactic X-ray pictures perpendicular to the frame in lateral and frontal projections, which give the AC–PC line and the midcommissural point (Fig. 3). These pictures originally were made by teleradiography (>6 m), which gives no magnification of the third ventricle. Later on, X-rays were taken with a shorter, but standardized distance giving a standard



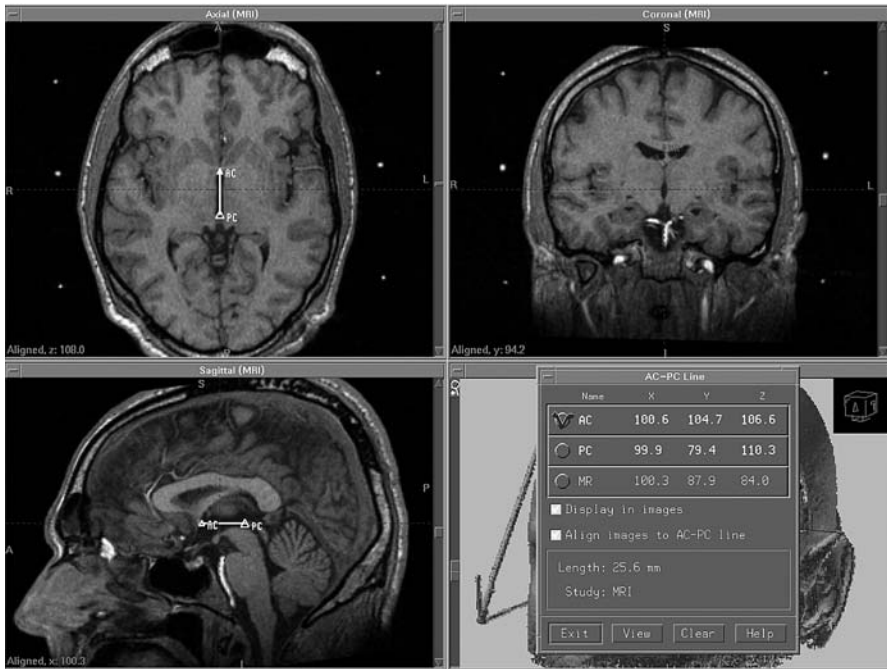


**Fig. 3.** Stereotactic ventriculography with positive contrast. Stereotactic instrument of Leksell. Lateral view with AC and PC indicated

magnification for which a correction is needed to obtain true distances and positions of target points.

With MRI (and also spiral CT) scanning techniques under stereotactic conditions a midsagittal plane is produced that clearly visualizes the AC and PC and thus the distance between them and the midcommissural point. Originally, CT scanning could only produce axial pictures, which often do not run through the AC-PC plane and therefore were not usable for transfer of atlas-based coordinates which are derived essentially from the horizontal AC-PC plane. Therefore, up to ten years ago, the gold standard for visualization of the AC-PC line has been stereotactic X-rays with ventriculography. However, in the last decade, MRI scanning in combination with an instrument-based dedicated software program for stereotactic imaging of the three Cartesian planes has become available. This enables the stereotactic surgeon to load the stereotactic MRI images of the patient in the computer program, which then automatically reformats the pictures in alignment with the true AC-PC plane, and thus the other two planes as well. The surgeon only has to point out the AC and PC in the midsagittal picture and the program thereafter gives the position of the midcommissural point plus the three orthogonal planes through this central point.

As a second step in the procedure, the three coordinates of the target point are fed into the program, which then automatically visualizes the target point in the three appropriate planes with the position coordinates  $x$ ,  $y$  and  $z$ . Finally, the surgeon may check the indicated position with the real images of the target area, which allows some fine-tuning of the atlas-based coordinates with the patient's anatomy.



**Fig. 4.** Surgiplan (Elekta Instrument) software, showing stereotactic MRI data in three orthogonal planes after alignment of the AC-PC plane in the horizontal position. The coordinates x, y and z of any point can be shown in the display on the screen. In this figure the coordinates of AC and PC are given

After the final decision regarding its position, the last step is to ask for the external (instrument-based) coordinates of the target point (Fig. 4). The patient is then transferred to the operating suite for surgery.

### 3. STEREOTACTIC TECHNIQUE VERSUS NEURONAVIGATION

The main difference between surgery using the stereotactic approach and surgery with neuronavigation is that with neuronavigation there is no need for the use of a stereotactic headframe. With neuronavigation about five fiducials are fixed to the scalp, after which a special MRI program is carried out that visualizes the brain including the scalp fiducials. These pictures are fed into a dedicated software program and transferred to the neuronavigation computer in the operating room.

The patient is prepared for surgery with the scalp fixed in a Mayfield clamp, whereafter the fiducials are used as indicators for defining the position of the brain in the surgical space with the help of an infrared camera system linked to the OR computer. The position of the operating microscope and/or

surgical instruments is then known and both the track towards the target area and the target itself may be seen on the MRI display. For further details the reader is referred to the chapter on brain navigation.

However, functional neurosurgery has to do with the very precise calculation of the point of interest in space. Frequently used target points are the subthalamic nucleus, the ventrolateral nucleus of the thalamus, the internal pallidum and the nucleus accumbens. All these targets need a surgical precision of 1–2 mm, which is only reached with frame-based stereotactic techniques.

Although there is a trend to rely on neuronavigation also in functional procedures, this is only acceptable in the surgical handling of target areas, such as the motor cortex for stimulation, but not for target points in the opinion of the author.

Especially with the introduction of deep brain electrodes in the awake patient, often bilaterally, frame-based surgery is much more convenient, because no continuous navigational control of the position in space is needed.

## **DECISION-MAKING**

### **1. INDICATIONS**

Absolute indications regarding the disease are interventions which can only be carried out by stereotactic frame-based techniques. This holds for all procedures in which the placement of a stereotactic coagulation or a stimulating deep brain electrode is considered.

Absolute indications regarding the patient are frame-based interventions which form the only possible treatment left. Examples are bilateral deep brain stimulation of the pallidum internum in patients with torticollis in whom other treatments have failed and deep brain stimulation in patients with obsessive-compulsive disorders who do not respond enough to behavioural and medical therapies.

Relative indications are interventions that can also be performed without a frame: neuronavigation for brain tumor biopsies or conventional microsurgery for colloid cysts of the third ventricle.

Generally established indications for frame-based stereotactic procedures can be subdivided in functional and diagnostic interventions.

Functional interventions [4] are made form movement disorders such as essential tremor, cerebellar tremor, (hemi-)dystonia, torticollis spasmodica and Parkinson's disease; pain syndromes due to lesions in the central nervous system; otherwise intractable epilepsy; psychiatric diseases such as obsessive-compulsive disorders or severe depression.

For further information the reader is referred to the appropriate chapters.

Diagnostic interventions [1] are made especially for deep seated lesions, multiple lesions and lesions which are probably not due to tumor, which may be handled easier and more safe with frame-based biopsies as compared with neuronavigation. Easier because local anesthesia may be applied, and more safe due to the use of the frame as a rigid platform for introducing biopsy instruments. Also intra-operative tissue diagnosis may be awaited with the forceps at the target site, as another biopsy may be needed.

## 2. CONTRAINDICATIONS

Frame-based stereotactic surgery is not possible in the very young patient and in others with fragile skull bones. The headframe needs at least three fixation points for the application of the pins that are screwed into the bone. Moreover, skull defects may prohibit placement of the frame in the appropriate position.

Thoracic dorsal kyphosis may be severe enough to make it impossible to have a stereotactic CT or MRI scan, because the frame should be locked in the head coil or frameholder to obtain accurate stereotactic scan data.

In general, however, the only contraindications are disturbed blood clotting or pathological vascularity of the target area. To rule out these possibilities, pre-operative tests and MRI with contrast are needed. In the old days, cerebral angiography was performed to rule out vascular pathology of the target area.

In diagnostic procedures there is a relative contraindication to perform a tissue biopsy near the arachnoid space because the biopsy instrument may hook itself into this layer and tear apart small vessels, which leads to bleeding with considerable morbidity and sometimes even peroperative death. This hooking may be felt by the surgeon, however, and in such a situation he should refrain from taking a biopsy.

This is the reason that tissue samples should not be taken superficially or near the cerebral sulci. Open surgery is mandatory in such a situation, as for example in taking a cortical biopsy for neuropathological investigation in the search for a diagnosis in neurological diseases.

Overall mortality in frame-based stereotactic surgery is less than 1% in both functional and diagnostic procedures and is – according to most authors [1] – caused by bleeding at the target site.

## SURGERY

Anesthesia is almost always local for application of the pins of the headframe and for performing burr holes for the introduction of stereotactic electrodes or needles.

In particular with functional procedures for movement disorders, an essential part of the intervention is the test-phase, in which the patient is tested

for positive and negative effects of the stimulation applied. With Parkinson's disease positive effects are a decrease in rigidity, tremor or dysdiadochokinesis with more fluent moving of extremities, whereas negative (side-)effects are speech disturbances or motor weakness. Careful examination on how the patient performs during stimulation with various stimulation settings and at different electrode positions is mandatory to obtain good surgical results.

Sometimes general anesthesia is needed with a "wake-up phase" during the period of test stimulation, as for example in general dystonia. With stereotactic biopsies also general anesthesia may be applied.

The patient is prepared for surgery as is usual with minimally invasive procedures.

Before surgery the patient is started on antibiotics in case of placement of permanent electrodes. When the electrodes are to be externalized for some days of postoperative testing, the antibiotics should not be stopped until 12 h after the final surgery with internalization/connection to the stimulator. Thrombosis prophylaxis is administered as with other surgical procedures.

After fixation of the stereotactic frame the patient is sent for MRI scanning. The scan data are transferred to the dedicated computer for determination of the AC-PC line and alignment of the axial AC-PC plane in a horizontal position for the accurate visualization of the three orthogonal planes. The coordinates of the target point as known from the stereotactic atlas are fed into the software, after which the screen shows the target in the three planes and gives the true frame coordinates.

Multiple target points may be calculated this way; often bilateral targets are needed for implantation of electrodes at both sides. Then the patient is brought to the operating room, placed on the table with the frame fixed in the frame-holder and prepared for the operation. The hair is shaved only in the surgical field, which is cleaned aseptically, after which local anesthesia is applied at the site(s) of the burr hole(s). The area is draped and the sidebars and arc of the instrument are fixed to the frame in the positions that are given by the frame coordinates  $x$ ,  $y$  and  $z$ .

Burr holes are made, the dura is opened and after coagulation of the entry point in the cortex the stereotactic electrode or needle is placed in the arc's aiming device and slowly introduced into the brain. At different depths along the path the surgeon may want to explore the tissue surrounding the tip. In functional surgery often micro-recording with multiple parallel electrodes is carried out to get information about target-specific firing patterns of neurons. Test stimulation is done to look for positive and negative effects on clinical symptoms. Finally the electrode is left in place at the best position found and is anchored to the edge of the burr hole. It is crucial to check the final position and depth with X-rays before closing the wound. See appropriate chapters for further reading on deep brain stimulation. In general, it is recommended to make a stereotactic CT scan before removing the frame, for fusion with the

preoperative MRI and checking of the final position of the electrode with the calculated target point.

In diagnostic procedures the surgeon may take biopsies at different depths through the mass lesion and await histological proof before closing the wound.

## **HOW TO AVOID COMPLICATIONS**

Surgery with stereotactic techniques is relatively safe because the gadget which is introduced into the brain has a blunt tip and is not carried free-hand. With the frame as platform the introduction is mechanically and through a rigid aiming device. This minimizes the risk for tissue damage and bleeding at the target site.

From the literature one can estimate the risk for bleeding at the spot as being 1% for functional and 2% for diagnostic interventions. However, it is clear that deep inside the brain surgically induced bleeding has serious effects with considerable morbidity or even mortality as result. To avoid a bleeding, one should introduce the gadget very gently, not by pushing but by slowly twisting it into the brain. Only with biopsies and very seldom a resistance is felt, and, if so, it is better to change the coordinates of the target point for some millimeters and to introduce the needle again. With stereotactic biopsies the more dangerous brain areas comprise the major vessel trajectories such as the sylvian fissure, the epithalamic roof with deep cerebral veins, the parasellar and uncal areas and the superficial brainstem.

If by accident a bleeding occurs at the target site, it is extremely important to keep the biopsy instrument at the spot, to note the depth by reading it off on the scale of the instrument carrier and to wait some minutes whilst removing and replacing the inner needle through the outer shaft. This allows for spontaneous drainage and may lead to spontaneous clotting in the case of venous bleeding. With arterial bleeding (only happening with pathological vascularity) there was no good indication for performing a biopsy and an emergency craniotomy should follow to stop it.

Local infections may be seen in up to 2% of procedures in which the permanent placement of electrodes, extension wires and stimulators is done, especially, when some days of clinical testing are needed with the use of temporarily externalized leads. CSF leakage may be avoided by sealing off the open dura in the burr holes with tissucol.


## **CONCLUSIONS**

With functional neurosurgical procedures the use of a stereotactic frame and the appropriate instrumentation is strongly recommended. Nowadays each type of instrument available comes with dedicated hardware and software.

After MRI scanning under stereotactic conditions a target of interest is defined by its three coordinates and during actual surgery there is no need any longer for navigation, positioning in a head clamp or general anesthesia.

### References

- [1] Bosch DA (1986) Stereotactic techniques in clinical neurosurgery. Springer, Wien New York, 278 pp
- [2] Horsley V, Clarke RH (1908) The structure and functions of the cerebellum examined by a new method. *Brain* 31: 45-124
- [3] Leksell L (1971) Stereotaxis and radiosurgery. An operative system. Charles C Thomas, Springfield, Ill., 69 pp
- [4] Sakas DE, Simpson BA (2007) Operative neuromodulation, vol. 2. Neural networks surgery. Springer, Wien New York, 590 pp
- [5] Schaltenbrand G, Wahren W (1977) Atlas for stereotaxy of the human brain, 2nd edn. G. Thieme, Stuttgart
- [6] Spiegel EA, Wycis HT, Marks M, Lee A (1947) Stereotaxic apparatus for operations on the human brain. *Science* 106: 349-350



**Dirk Andries Bosch**

Dirk Andries Bosch is professor of neurosurgery at the University of Amsterdam and chairman of the department at the Academisch Medisch Centrum. He was born in 1942, studied medicine at the University of Groningen, the Netherlands, followed a Ph.D. program in experimental neuro-oncology and obtained the Doctorate in Medicine in 1973. During his specialization in neurosurgery he spent one year at the Karolinska Hospital in Stockholm, Sweden, to study stereotactic and functional neurosurgery under Prof. Lars Leksell (1976–1977). He got his qualification as neurosurgeon in 1978. In 1986 he published the textbook “Stereotactic Techniques in Clinical Neurosurgery”. He has been president of the European Society for Functional and Stereotactic Neurosurgery from 2002 to 2006.

**Contact:** Dirk Andries Bosch, Department of Neurosurgery, Academisch Medisch Centrum, Meibergdreef 9, 1105 AZ Amsterdam, The Netherlands  
E-mail: [d.a.bosch@amc.uva.nl](mailto:d.a.bosch@amc.uva.nl)



---

# SELECTIVE THALAMOTOMY

C. OHYE

## INTRODUCTION

Looking back the development of the stereotactic functional neurosurgery, there were several important landmarks together with the progress of neuroscience of that time. In the very beginning of the stereotactic surgery for Parkinson's disease pallidotomy was first tried by Narabayashi in 1952 and by Spiegel and Wycis. The early pallidotomy was different from present time pallidotomy in which more postero ventral part of internal segment of globus pallidus (GPi) is focused. Then in the late 1950th, a German group proposed thalamotomy because pallidotomy was not effective for tremor although rigidity was well ameliorated. By a relatively large thalamic lesion, parkinsonian tremor and rigidity were improved and ventrolateral (VL) thalamotomy was widely accepted in the world as the main route for the surgical treatment of Parkinson's disease.

Since early 1970 up to date, we have operated about 150 cases (Table 1) by microrecording aided selective thalamotomy for movement disorders mainly of Parkinson's disease, although deep brain stimulation (DBS) developed quickly, The different aspects of our selective thalamotomy were already presented in several other occasions [7, 12, 15, 16].

Anyway, to achieve the best clinical effect, understanding of the human brain is inevitable, especially of the stereotactic target area and its neural network, in other words, its structure and function. Without such knowledge and use of modern technique, further progress cannot be achieved.

So, in this paper, its essential and more practical procedures will be described.

## RATIONALE

Stereotactic functional neurosurgery nowadays is performed by DBS by implanted electrodes [2]. This is certainly an effective way to treat several symptoms of Parkinson's disease and that is why it is widely used as an "a la mode". But certainly it is not almighty, several hazardous accidents may happen.

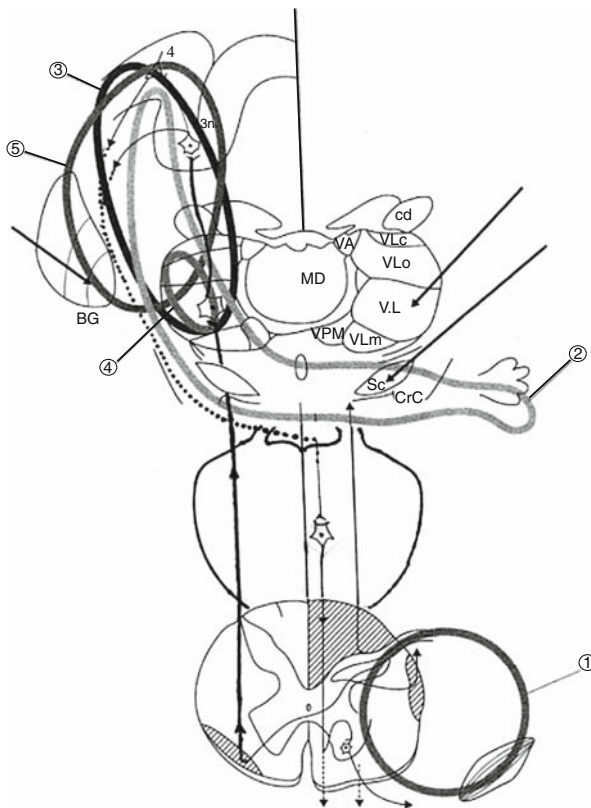
As mentioned above, surgical treatment of Parkinson's disease initiated some 60 years ago by pallidotomy and then shifted to thalamotomy. Up to

---

*Keywords:* thalamotomy, microrecordings, thalamic Vim neurons, tremor stereotaxy, kinesthetic response, functional neurosurgery

**Table 1.** Patient list

Diagnosis	Number
Parkinson's disease	78
Juvenile Parkinson's disease	7
Essential Tremor	29
Others	21
Central Pain	3
	138



**Fig. 1.** Simplified schema showing the tremor mediating circuit with its accessory loops. From up to down cerebral cortex, basal ganglia, thalamus, part of brain stem, pons and spinal cord are drawn with the main route of tremor and several accessory loops. Main loop consists of from trembling muscle, crossing at spinal cord taking spinothalamic route, coming up to thalamic Vim nucleus (in this map VI), to cortical 3a, and together with area 4 elements, cross again to pontine reticular Formation, descending path of reticulothalamic tract, finally back to the original muscle. Accessory loops are: 1 spinal reflex arch, 2 cerebello-thalamo-cortico cerebellar loop, 3 cortico thalamo cortical loop, 4 thalamic reticular nucleus-thalamic loop, 5 cortico-basal ganglia-thalamo-cortical loop. Three oblique arrows are directed to the actual target of stereotactic surgery

present time probably more than million cases with Parkinson's disease were treated surgically, in early times by thalamotomy and recently DBS to the thalamus, pallidum and subthalamic nucleus. By careful analytical observation of this tendency, it is certain that there is still place to practice thalamic surgery with refined techniques of microrecording [1] and at the same time advanced understanding of the thalamus in the light of modern neuroscience [5, 10, 13, 14, 17].

In this sense, we are continuing to do thalamotomy always reflecting up on the neuronal mechanism of Parkinson's symptoms such as tremor, rigidity and akinesia, etc. So as for the tremor and rigidity we can treat them successfully, although complete understanding is still not clear. On the other hand, we have studied on experimental tremor in monkeys, which led us to conclude a hypothetical long loop neuronal circuit, passing through Vim nucleus [20]. Therefore, clinical and experimental studies together support our hypothesis of tremor maintaining system, as shown in Fig. 1.

Mechanism of rigidity is not yet clear but it is reflected to pallido (GP)-thalamic(Vo) circuit, and we can treat either by pallidotomy or Vo thalamotomy.

## DECISION-MAKING

### 1. DIAGNOSTIC CRITERIA

For the definition of tremor, we follow that of French neurology claiming that "rhythmic oscillation around one joint, in one plane". Clinically there are several classifications of the tremor [4] but in relation to the condition of involved muscles, resting, postural, intentional are simple and reasonable concept (physiological tremor is not indicated). All of these tremors are treated by stereotactic surgery, whatever the cause of tremor; Parkinsonian, post cerebral vascular disorders, post traumatic, etc. On clinical observation of the patients with tremor, it is often the case that other involuntary movements such as dyskinesia, dystonia, chorea, ballism, etc. are combined or mixed. But in our sense, if the element of the tremor is found in it, the stereotactic treatment is possible if not complete arrest is achieved. In such case, by the thalamic surgery, Vim plus Vo thalamotomy would be considered as described below.

### 2. INDICATIONS

In this paper, treatment of the patient with Parkinson's disease is described. But the idea and technique will be applied further to other patients with movement disorders. For Parkinson's disease (PD), the standard indication is as follows:

1. Tremor and/or rigidity.  
Therefore, gait disturbance and disturbance of equilibrium are not well treated.

2. Up to 70–75 years old.  
The limit is not absolute, depending on the patient's general condition. In our experience, the maximum age was 83 years old.
3. Unilateral symptoms are preferable.  
Thalamic coagulation is generally thought to be performed only in one side at one time, mainly because the bilateral invasion may result in speech disturbance. This could be true if microrecording technique is not used. This point will be described in the following section.
4. Drug incompatibility.  
If the patient cannot accept enough anti-Parkinsonian drugs, surgical therapy is considered.
5. No major complications such as hypertension, thalamic dorsomedial nucleus, and a psychiatric problem or damage.

Maybe, as a direct extension of this indication, the patients with other kinds of tremors, essential tremor, post traumatic tremor, post stroke tremor, could be treated as well.

So called dyskinesia, dystonia and cerebral palsy are also indicated in some cases. For these cases, clinical examination aided by neurological examination, EMG, video, MRI and etc. are useful. Even if the complete amelioration is not expected, some positive and better condition is offered for the disabled patients.

### 3. HOSPITALIZATION

In our clinic, the patient is hospitalized for two weeks, will come to the hospital on Monday, have a general physical examination (blood analysis, cranio and chest – XP, EEG, EMG, CT) during two days, the third day (Wednesday) for operation.

Preoperative estimation of the patient's clinical state and morphological examination of the thalamic configuration (for thalamotomy) are very important to make preoperative planning of the thalamic surgery.

Patient's clinical state is obtained from neurological examination, what kind of abnormal movement (tremor, rigidity, dyskinesia, and etc.) exists, where it is manifested (upper limb, lower limb, body trunk, head and neck) are precisely observed. Quantitative estimation by EMG, UPDRS are convenient ways to compare quantitatively the pre and post operative states. To know exactly where the abnormal movement is manifested most severely it is very important to make final and effective operative lesion, considering how large and where in the thalamus should be invaded are approximately estimated before the operation.

On CT image taken on the day before operation, careful observation is inevitable to estimate general state of the patient's brain as a whole (atrophy, general configuration abnormal shadow, if any). Especially, in and around the thalamus, we should pay special attention to infarction and vascular anomaly.

In the evening of the second day, all results of the examination are shown to the patient and his or her family to get full agreement for operation.

The patient is observed after the operation until the end of the next week.

During this period, post operative examinations are made to estimate the results of operation (post operative CT, MRI, EEG and EMG, etc.). After about two weeks' hospitalization, the patient is discharged if remarkable abnormal finding is not found.

Usually, the patient was referred to our clinic from distant area, so the patient returned home and continued consultation of his home neurologist. No regular follow up examination is obligated, so that the patient comes again to our clinic rather irregularly for post operative examination.

The patient will discharge around the end of the next week, if nothing particular. That means hospitalization is for 12 days. Therefore, the visit for follow up study may be at random. We send a letter informing of the operation and its results and necessary advice for the follow up care. If the patient needs another operation for symptom of the contra lateral surgery, 6–24 months interval is recommended.

## **SURGERY**

### **1. OPERATIVE TECHNIQUE**

#### **1.1 Preparation**

In the morning of the operation, Leksell's stereotactic frame is fixed on the skull of the patient, under local anesthesia (Xylocaine 100 mg/10 ml).

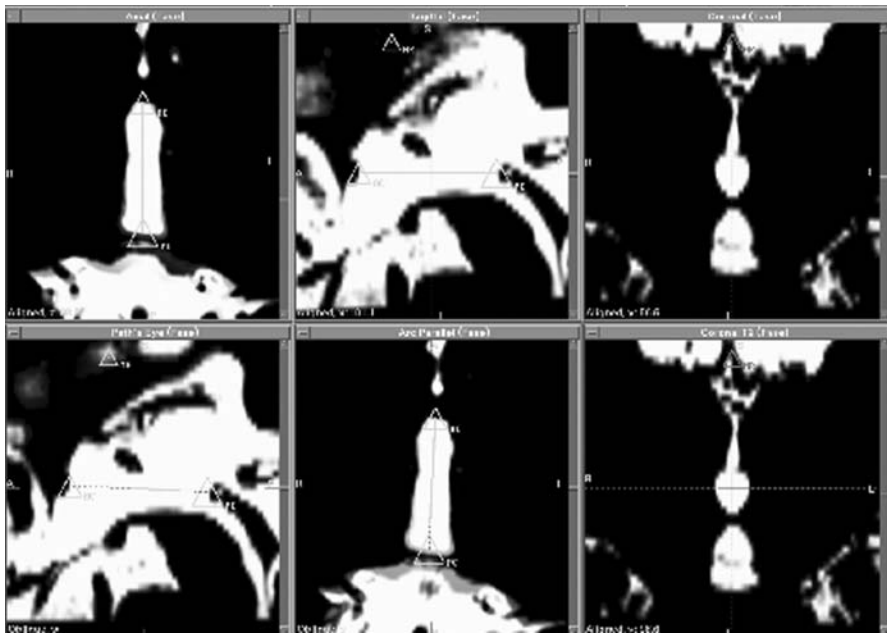
By four fixation pins, the frame is solidly fixed. At this moment, care is taken to the angle of the frame in relation to the patient's chin, to avoid compression of the respiratory tract when later fixed by the head rest of MR machine and of operation table. In this sense, it is not necessary to fix the frame parallel to the internal capsule (IC) line, alignment is guaranteed by using Leksell's surgiplan. Certainly, oblique fixation to the mid sagittal plane is avoided also severe left-right rotation is not accepted.

#### **1.2 MRI, CT**

With the fixed frame, MRI and CT are taken and sent to the supporting system of surgiplan. For MRI, heavy T2 and proton image are recommended (Fig. 2). The former is used for anterior commissure (AC), posterior commissure (PC) decision and hence IC-line, the latter is for tentative target planning by surgiplan (Fig. 3).

One of the most important processes in the operative planning is target decision.

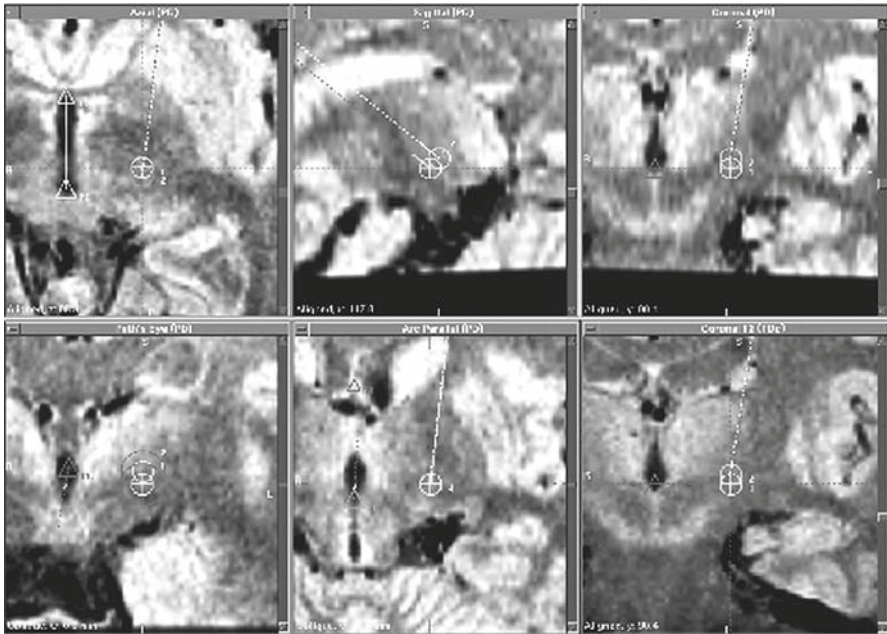
In the functional stereotactic surgery, exact target (zero) point is not visible in MR or CT images. Thus, after decision of IC-line, a temporary target



**Fig. 2.** Determination of intercommissural line by surgiplan. FASE image (heavy T2) is used to determine AC and PC and consequently the IC line is drawn. Upper three MR images were used. *Left:* Axial plane, *center:* Sagittal plane, *right:* Coronal plane. All images change together with the same 3D coordinate

is marked by taking  $x$  (laterality) = 2 mm medial to the lateral border of the thalamus,  $y$  = 5 mm anterior to PC, and  $z$  = 0 on the plane of IC line.

These 3D coordinate values are deduced from our own experience of selective thalamotomy guided by microrecording, to get the best result for tremor surgery. But notice that this zero point is just for orientation of the center electrode (and coagulation needle), and the final coagulation center is usually placed 3–4 mm above this point according to the result of the microrecording. This relation will be explained in detail later. Also it should be mentioned that around this point, tremor related neurons and kinesthetic neurons are most densely distributed as shown later. In the very early period of our thalamotomy, the target decision was dependent on the measurement from the point of PC as shown above. But later, more reliable correction method was used. That is an anatomical notion that each thalamic nucleus is represented by the proportion of the thalamic length [3]. In this sense, it is true that for example, our target of the Vim nucleus located about 45% from anterior limit of the whole thalamic length. In contrast, usual reference point PC is represented by this method 53–66% [18], being much variable. Any way, it is better to refer to several different kind of standard 3D Atlas of the human thalamus [6, 9, 11, 21, 23, 24].



**Fig. 3.** Determination of zero point by surgiplan. Proton image is used. Upper images, *left*: axial section, *center*: sagittal section, *right*: coronal section. Lower images, *left*: image of surgeon's eye, *center*: image along trajectory, *right*: coronal, but reconstructed image. All images change together with the same 3D coordinate

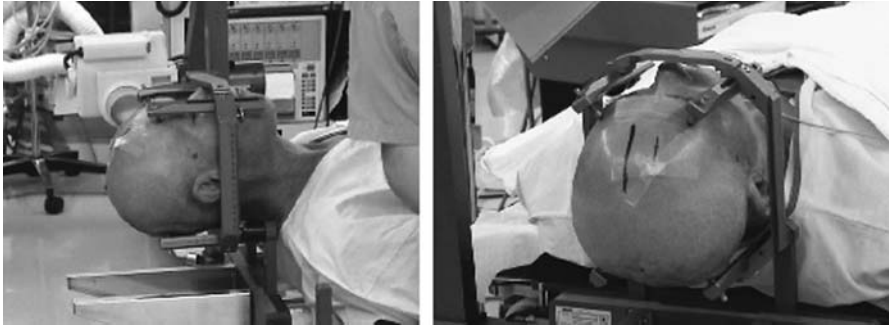Another point related to target determination is the possible displacement of MR image due to unstable gamma ray field. To correct this kind of displacement, CT image taken on the same day after frame fixation is used by image fusion with MRI. In our case, sometimes, 1–2mm difference in the sense of left-right direction. In such case, this difference is taken into consideration when lateral coordinate value is determined.

### 1.3 Operative procedure

#### *Burr hole opening*

After fixation of the head as shown in Fig. 4, and the comfortable whole body posture is assured, the head is covered by sterile cloth except burr hole area. A burr hole is opened over the prefrontal area, at the point toward previously planned zero point.

A small incision of dura matter and arachnoid membrane under the burr hole is made for electrode passage. At this moment the cortical veins should be carefully avoided, not to be damaged by the later passage of electrode. If unexpected large veins may disturb the trajectory, slight change of the electrode angle is possible. Rarely, burr hole edge is slightly longer away. Be

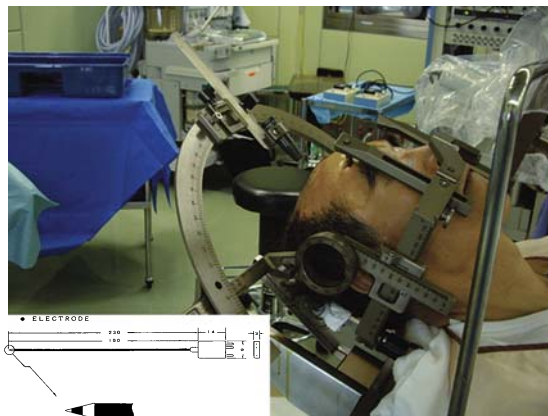


**Fig. 4.** Photographs of patient's head taken from two different view points in supine position on the operation table with Leksell's stereotactic frame

cautious enough, the cut edge of dura and arachnoid is coagulated to avoid CSF leakage.

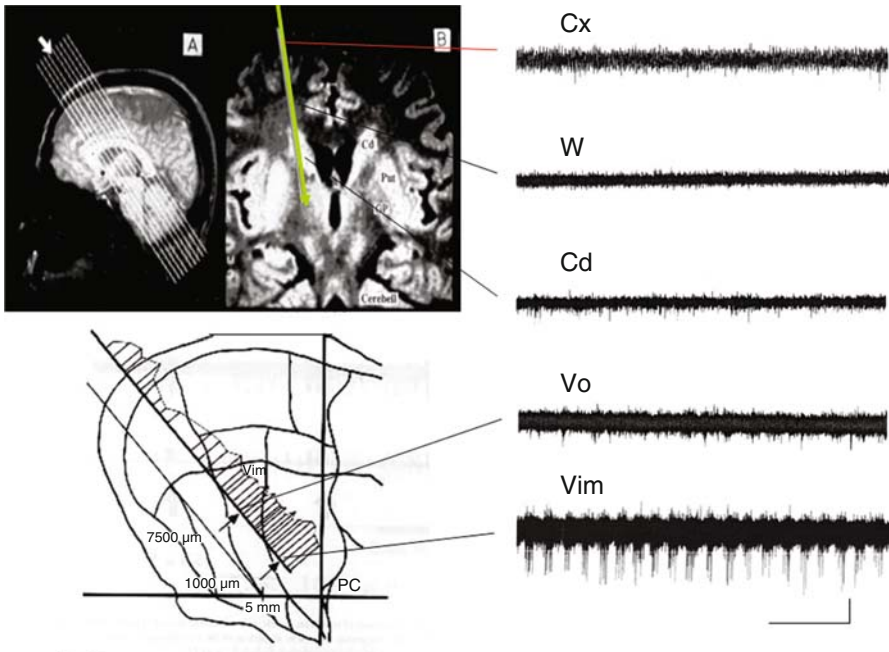
#### *Microrecording*

Highlight of the selective thalamotomy is microrecording of the deep brain structures to identify and ascertain the position of the electrode tip and finally to make a selective lesion (coagulation). The recording electrode is concentric bipolar needle type with electrical resistance less than  $100\text{ k}\Omega$  (Fig. 5). Its detail was described already. The advantage of this type of electrode is low noise and easy usage in usual operating room without particular cage to avoid high frequency parasite. Moreover, with the aide of micromanipulator (motor driven, with three different speeds, distance from zero point automatically shown by  $10\text{ }\mu\text{m}$  steps on photo electric tube), global background activity around the



**Fig. 5.** Patient's head fixed on the operation table. Leksell's frame with arch and electrode (or needle) holder is set. Left lower corner is shown a bipolar concentric type microelectrode with its tip enlarged





**Fig. 6.** Typical electrical activities along the trajectory shown on the left side. *Left upper corner:* MR images, of sagittal (with cut angle for images) and coronal view. Invading electrode track is also shown. *Left lower corner:* Simplified drawing of thalamic sagittal plane including Vim and its surroundings. In this atlas, a pair of oblique lines denote recording electrode (or coagulation needle) trajectory, with a line graph of level of background activity along the track. Approximate points of depth electrical activities shown on the right side are correlated schematically with the left side atlas. *Cx* cortex, *W* white matter, *Cd* caudate nucleus, *Vo* thalamic ventralis oralis, *Vim* thalamic ventralis intermedius

electrode tip and even extra cellular single spike discharge are recorded. For this, one important technical point is to set the ground line at one pole.

Recording electrode is set 3 mm posterior to the center tracking (for zero) parallel to the mid sagittal plane. In early time, a pair of recording electrodes has been used, one in the center position and the other one in either anterior or posterior position. But after several experiences, we noticed that the posterior tracking can record more rhythmic discharge and/or kinesthetic response and is hence more useful for operative purpose. The posterior tracking serves also as the posterior wall when coagulations are made without touching the sensory nucleus of ventralis caudalis (*Vc*). Using surgiplan, simulation of the center track and posterior track is possible from the cortical surface to the zero point. Thus the distance from zero to the landmark points, for example, position of the caudate nucleus, thalamic entrance, and dorsal thalamus and Vim zone is calculated. These useful landmark points in mind, the electrode is introduced toward zero by micromanipulation. Our standard angle of the

electrode is 45° referring to the IC line and about 10° or less to the mid sagittal plane.

In fact, as already described, from the entrance point of cortical surface to zero point (it is about 6–7 cm), different or characteristic electrical activities are recorded, which tell us the position of the electrode tip. For the economy of time, we start recording from about 3 cm above zero, almost at the entrance point of caudate nucleus.

Characteristic electrical activity of different structure toward the thalamus:

Cerebral cortex: 20–30 Hz slow wave and spike.

White matter: positive small spikes.

Caudate nucleus: about 20 Hz slow wave and spikes of wide duration.

Dorsal thalamus (Vo): relatively small negative spikes.

Ventral thalamus (Vim): large spikes that may respond to passive limb movement and/or rhythmic burst discharge time locked with tremor.

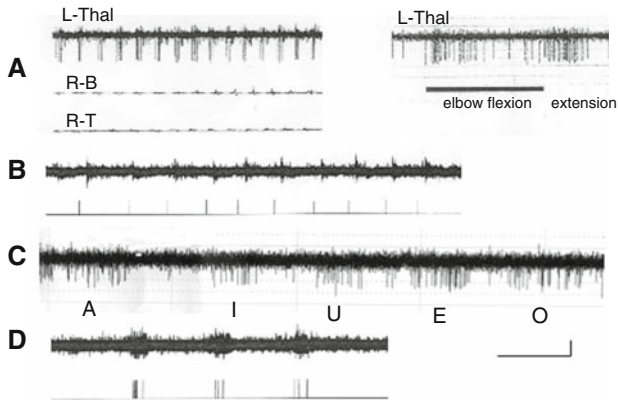
Ventral thalamus (Vc): large spikes respond to light touch on the skin surface.

So, when the electrode comes in the Vim zone, large spontaneous discharge is recorded. With the micromanipulator, single or distinguishable couples of spikes are separated to examine whether it (or they) responds to passive movement of the contralateral limb. If the patient has spontaneous tremor, it is not difficult to find the grouped rhythmic discharge related to EMG rhythm. So the peripheral receptive field is identified usually.

It is important to decide the origin of peripheral receptive field, what is the related muscle, what kind of movement (flexion, extension, pronation, supination, etc.). This serves later for matching with clinical symptom.

If the electrode is still in the dorsal thalamus, probably in the Vo nucleus, the spontaneous activity is not very active and only small spikes are recorded to the passive movement of the limbs, but may be activated during voluntary action. In this sense, Vo neurons are considered to be classified as active motor function, contrasting to the Vim neurons that are activated during passive movement. Therefore, the behavior of individual neurons and global background activity in Vo and Vim are quite different and not difficult to distinguish them during the operation.

Further advancing the electrode passing through Vim zone into the Vc nucleus, there are another electrophysiological features. The background activity is similar as that of Vim nucleus but the Vc neurons respond to light touch to the contralateral skin surface. There is strict contra lateral representation of the respective field, as known in the animal experiment. Roughly, the dorso-lateral to the ventro medial part of the Vc nucleus, lower limb, upper limb and face area are arranged in this order, rostro caudal laminal sense. It is interest-



**Fig. 7.** Examples of characteristic neuronal response in and around the Vim nucleus. **A** Typical thalamic Vim responses. Rhythmic grouped discharge (left upper trace) time locked with contralateral tremor shown by EMG (a pair of traces recorded simultaneously with the thalamic discharge). Right: The same tremor neuron now responds to passive movement of elbow flexion and extension. **B** Response to the tapping of the contralateral III and IV finger tip. **C** Response to the vocalization of Japanese vowels. **D** Response to the light touch on the surface of the finger tip

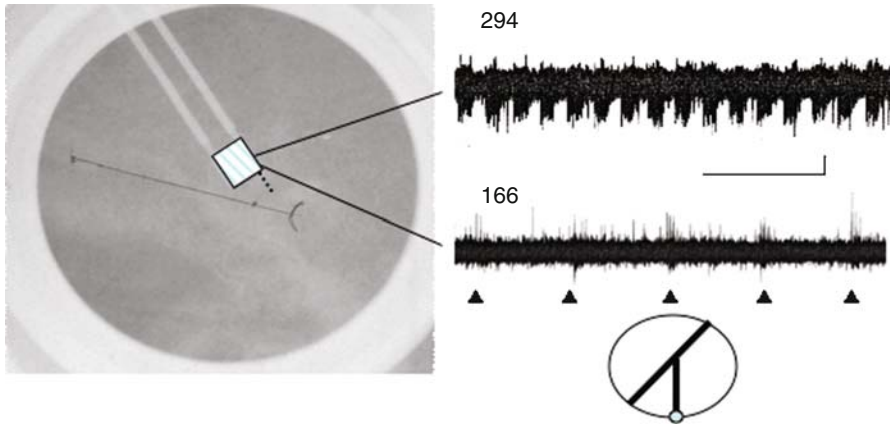
ing to note that in the Vim nucleus, kinesthetic neurons are organized almost the same fashion: rostrocaudal laminar organization.

Recently, we found between Vim kinesthetic zone and Vc zone, there is a group of “Tap responsive neurons” which shows a particular response of large positive wave superimposed by several spikes. Until this tap response zone, coagulation is possible without paresthesia. Examples of these different responses are shown in Fig. 7.

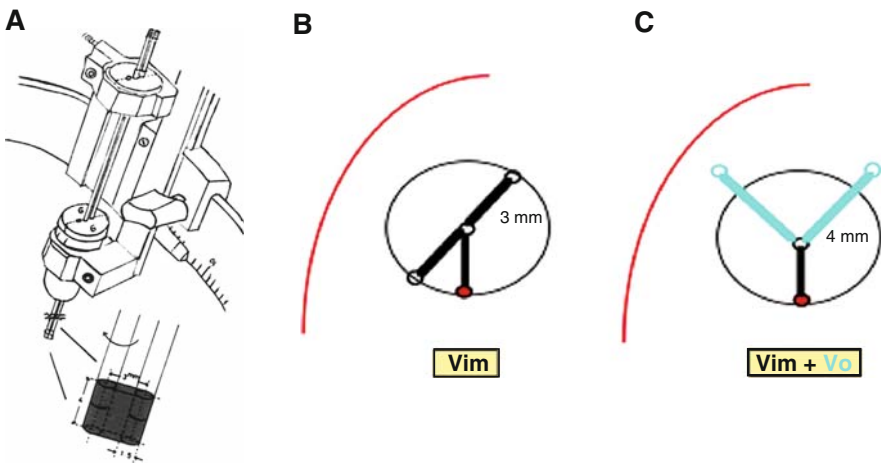
One should remind of the structure and functional organization of the Vim and its surroundings. In fact, microrecording is not only essential for the thalamic surgery by technical reason but also it provides us with the opportunity to investigate the human thalamus [8, 13, 14, 18].

*c) Selective coagulation.* Taking all results of the physiological examination as mentioned above into consideration, the therapeutic coagulation is planned. The lesion should include the points of kinesthetic and tremor rhythmic neurons (Fig. 8), high spontaneous activity zone as far as possible. But also important exclusion of (1) Vc nucleus of light touch neurons, (2) internal capsule consisted of mainly positive small spikes. With these criteria, matching of distribution of clinical symptoms and actual thalamic point where the recording electrode located is considered. For example, in the patient with tremor in upper limb receptive field, the first coagulation is made including this recording point.

As Leksell stereotactic system uses a pair of coagulation needles (effective coagulation tip is 4 mm and the interval of the pair of needles are set 3 mm apart), there is free space for directional selection, 360° around the center needle. That is, within this cylinder of 3 mm radius and 4 mm height, lamellar coagulation is achieved, also with dorsoventral depth control (Fig. 9).



**Fig. 8.** Precise technique to make a selective thalamic lesion. After thalamic recording, the electrode is replaced by coagulation needle, and then the position of the needle is checked by X-ray film, a part of which is presented on the left. Tip of the pair of needle is seen with imaginary coagulation area (hatched area and its overview shown in the right lower). Two examples of Vim response, one being rhythmic grouped discharge of the tremor and the other being response to tap on the middle finger. For coagulation, see illustration in Fig. 9



**Fig. 9.** Method of radiofrequency coagulation between the pair of coagulation needle is illustrated. **A** A sketch of coagulation device of Leksell stereotactic instrument. Tip of the needle is enlarged to show direction selective method around center needle. **B, C** Overview of the selective coagulation along the border of the thalamus (curved line) by three directions (**B**), and using longer interval of 4 mm

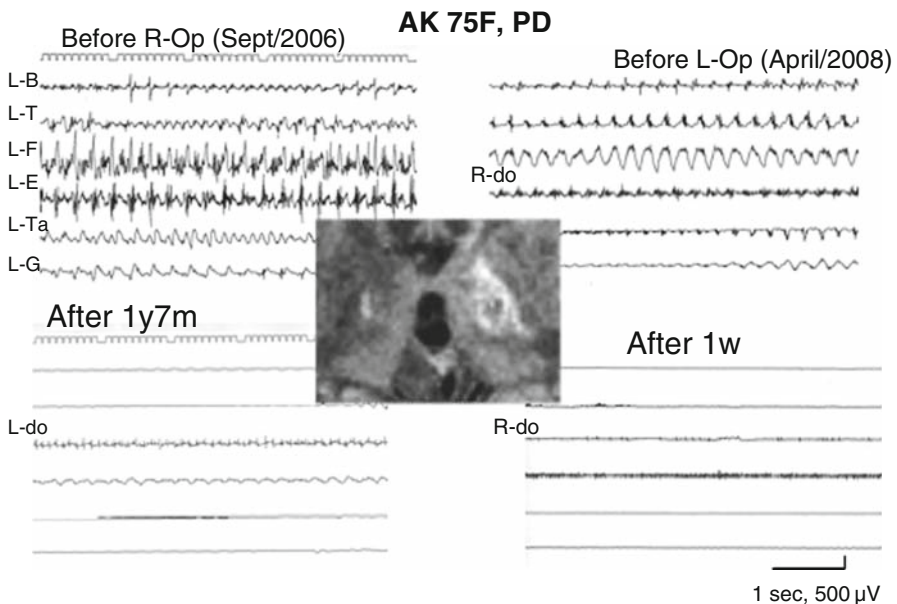
Therefore, usually the second lesion is made about 2 mm dorsal part by displacing coagulation set. Then as the third coagulation, posterior needle is in anterior hole taking the position of anteromedial position along the thala-

mo-capsular curve, considering a lamellar structure. It is usually the case that the tremor disappears by the first coagulation. If the tremor stops only by introduction of the coagulation needles into the target point, it will be certain that the good effect continues for considerable long period (5–10 years). Even if the tremor stops at the first coagulation, it is necessary to add 2nd or 3rd coagulation, turning the posterior needle to certain necessary position to add coagulation. In average, we made 3–4 coagulations.

For the case with rigid type PD, we use electrode guider of 4 mm interval in order to invade into more anterior zone of the Vo nucleus.

## 2. LONG-TERM RESULTS

As far as Parkinsonian tremor is concerned, it is certain that in all cases the tremor stopped on the operation table. Once it disappeared, the effect continues for long time base of 5–10 years [12, 22]. An example is shown in Fig. 10. Other kinds of tremor, essential tremor, post CVD tremor post traumatic tremor etc. are also improved, if not completely arrested. It was usually



**Fig. 10.** Effect of selective Vim thalamotomy. In this particular case, R-thalamotomy and then L-thalamotomy were carried out with the interval of 1y7m and the respective clinical results were demonstrated with the thalamic lesion (*center image*). Each thalamotomy resulted in complete arrest of the tremor. Left side tremor disappeared for 1y7m (*left column*) after operation and right side tremor after 1W (*right column*). Note that the previous lesion in the right shrunk to small one, while the new lesion in the left is relatively large, which will get smaller within a couple of months

the case that tremor of high amplitude, low frequency (<3 Hz) was sometimes difficult to control, and larger coagulation was necessary.

As mentioned above, if the recurrent tremor is troublesome for the patient's life quality, re-operation is considered. Overall results of selective thalamotomy for tremor guided by micro recording are more than 90%.

### **3. COMPLICATIONS**

By our method of physiologically controlled selective thalamotomy, untoward effect is minimal. If something may happen (in one among 10 operations), temporary dysesthesia of the contra lateral thumb (and index finger) and/or of lip corner, or feeling of some weakness (not motor paresis) are noticed. These abnormal sensations or weaknesses gradually subside within a couple of weeks.

Severe complication such as massive cerebral hemorrhage was rare, one in 150–200 operations. In such case, emergency craniotomy and evacuations of hematoma would be necessary.

## **HOW TO AVOID COMPLICATIONS**

### **1. MOTOR PARESIS**

If motor paresis occurs, it is certainly due to hazardous damage into the part of internal capsule. As we always ascertain the position of the electrode tip physiologically, we do not make a direct coagulation in IC. No case showed true sense of paresis but only temporal weakness due to secondary (vascular damage) invasion of the IC. In this regard, such weakness occurs more often in the leg because leg area in the thalamus is located just medial to the IC. So we should be careful to treat clinical symptom in the leg.

### **2. PARESTHESIA**

As in the case of motor weakness mentioned above, paresthesia may occur by the secondary invasion of the more posterior part of the Vim, namely sensory thalamus of the Vc. We do not destroy Vc area directly, carefully pay attention to the tactile response when the electrode comes into the deeper area. But in some cases, the sensory neuron allocates very close to the Vim of kinesthetic neurons, and consequently inevitable damage may occur. In that case, the paresthesia persists for several months or even a year, although gradually reducing. Therefore whenever starting coagulation, we ask the patient to be careful of some strange feeling emerge in the body part, tell us as quickly as possible, so as we can switch off the coagulator. In such case, paresthesia disappears within a couple of days. It is noteworthy that the paresthesia occur often in the finger tip (often 1st finger) and corner of the lip together. This type of

paresthesia is mentioned as so called cheiro-oral syndrome, indicating that in the thalamic Vc nucleus, finger and lip area are situated next to each other.

### 3. CSF LEAKAGE

Usually, supine position is used during operation. But sometimes slightly head up posture or half sitting posture is taken. For aged patients with cortical atrophy, the head up position is preferred to prevent leakage of the CSF from burr hole. If too much leakage occurs, the brain might sink a couple of mm, which brings about miscalculation of the electrode position.

In some 5% of the operated cases, recurrence of the tremor was noticed. In such cases, there were two reasons: one is very early or quick recovery of the coagulation lesion and the other displacement of the brain due to excess loss of CSF during operation.

For the former, it may happen in young patients. So we assume that there is some particular neural mechanism of recovery in the younger patients.

The latter case, displacement of the brain during operation can be avoided by careful prevention of CSF leakage as mentioned above, patient's head position, coagulation of arachnoid under the burr hole area. In such condition of brain sinking, a couple of mm gap between the physiological recorded point and the center of coagulation will make significant mismatch and as a consequence, an excellent clinical effect may not be achieved. One of the most troublesome complications is motor paresis caused by direct coagulation of internal capsule by a more dorsally deviated needle. Therefore in the case with cortical atrophy, a special attention is necessary.

### 4. SPEECH DISTURBANCE

Long since, speech disturbance is noted after bilateral thalamotomy. But again, as far as microrecording control is done and carefully making a lesion without touching the oral or pharyngeal response area, there is no problem. In the early epoch, we had an experience of severe dysarthria after right side thalamotomy, during which pharyngeal response compression of throat was recorded. See also the response to vocalization presented in Fig. 7C. We thought at that time, destruction of deep pharyngeal representation area was responsible for this damage. Since this experience, when pharyngeal or vocal response was found, this area was avoided during the therapeutic lesion. This area should be untouchable.

### 5. REOPERATION

The immediate effect of selective thalamotomy guided by microrecording is almost 100% as far as tremor is concerned. Recent operation results in complete arrest of tremor of whatever causes on the operation table. However,

slight recurrence in some part of the body may be noticed. But this type of partial recurrence is not serious and no risk for further progress, the patient can tolerate without major disability.

In the care where recurrence of the symptom shows almost the same level as before operation and brain image reveal deviation of the coagulated lesion, re-operation is the best solution if the patient agrees.

In our series, we had 7 such cases (5%), in whom the microrecording in adjacent area of the previous coagulation again exhibited active spontaneous activity and kinesthetic or rhythmic discharges. The coagulation of this area results in the arrest of the tremor and/or decrease of the rigidity.

## CONCLUSIONS

Details of microrecording guided selective thalamotomy were described. Tremors of what ever cause can be treated by this surgical procedure. The effective and safety target is the lateral part of thalamic Vim nuclear where kinesthetic neurons and/or tremor time locked rhythmic discharging neurons among the high spontaneous active zone are clustered. To find exactly this critical point, it is inevitable to use microrecording. The characteristic features of this area are: (1) high spontaneous activity with large amplitude spikes, (2) some of the spikes respond to passive movement of the contralateral limbs, (3) tremor time locked rhythmic discharge if the patient has tremor.

When making a coagulation lesion in this particular area, the use of dual coagulation needle and matching of clinically involved area and thalamic receptive field are essential. Estimated minimal effective volume is, as already shown, about 60 mm<sup>3</sup>. Radio frequency coagulation 3–4 different angles and heights, by 3 × 4 mm needle tip, induces a temporary larger thalamic reaction but it diminishes in a couple of months to become a small sphere or slit like permanent lesion, that results in 90% success without noticeable complications.

## References

- [1] Albe-Fessard D, Arfel G, Guiot G (1963) Activités électriques caractéristiques de quelques structures cérébrales chez l'homme. *Ann Chir* 17: 1185-1214
- [2] Benabid A, Pollak P, Gao G, Hoffman D, Limousin P, Gay E, Payen I, Benazzouz A (1996) Chronic electrical stimulation of the ventralis intermedius nucleus of the thalamus as a treatment of movement disorders. *J Neurosurg* 84: 203-214
- [3] Brierley JB, Beck E (1959) The significance in human stereotactic brain surgery of individual variations in the diencephalons and globus pallidus. *J Neurol Neurosurg Psychiatr* 22: 287-298
- [4] Deuschl G, Bain P, Brin M (1998) Consensus statement of movement disorder society on tremor. Adhoc scientific committee. *Mov Disord* 13(Suppl 13): 2-23



- [5] Hamani C, Dostrovsky JO, Lozano AM (2006) The motor thalamus in neurosurgery. *Neurosurgery* 58: 146-158
- [6] Hassler R (1982) Architectonic organization of the thalamic nuclei. In: Schaltenbrand G, Wahren W (eds) *Stereotaxy of the human brain*, 2nd edn. G. Thieme, Stuttgart, pp 140-180
- [7] Hirai T, Miyazaki M, Nakajima H, Shibazaki T, Ohye C (1983) The correlation between tremor characteristics and predicted volume of effective lesions in stereotaxic Vim thalamotomy. *Brain* 106: 1001-1018
- [8] Hirai T, Ohye C, Nagaseki Y, Matumura M (1989) Cytometric analysis of the thalamic ventralis intermedius nucleus in humans. *J Neurophysiol* 61: 478-487
- [9] Hirai T, Jones EG (1989) A new parcellation of the human thalamus on the basis of histochemical staining. *Brain Res Rev* 14: 1-34
- [10] Jones EG (2002) Thalamic organization and function after Cajal. *Prog Brain Res* 136: 333-357
- [11] Morel A, Margnin M, Jeanmonod D (1997) Multiarchitectonic and stereotactic atlas of the human thalamus. *J Comp Neurol* 387: 588-630
- [12] Nagaseki Y, Shibazaki T, Hirai T, Kawashima Y, Hirato M, Wada H, Miyazaki M, Ohye C (1986) Long term follow-up after selective thalamotomy. *J Neurosurg* 65: 296-302
- [13] Ohye C, Shibazaki T, Hirai T, Wada H, Hirato M, Kawashima Y (1989) Further physiological observations on the ventralis intermedius neurons in the human thalamus. *J Neurophysiol* 1: 488-500
- [14] Ohye C (1997) Functional organization of the human thalamus. In: M Steriade, EG Jones, DA McCormick (eds) *Thalamus*. Elsevier, Amsterdam, pp 517-542
- [15] Ohye C (1998) Thalamotomy for Parkinson's disease and other types of tremor. Part 1. Historical background and technique. In: Gildenberg PL, Tasker RR (eds) *Textbook of stereotactic and functional neurosurgery*. McGraw Hill, New York, pp 1167-1178
- [16] Ohye C (1998) Neural noise recording in functional neurosurgery. In: Gildenberg PL, Tasker RR (eds) *Textbook of stereotactic and functional neurosurgery*. McGraw Hill, New York, pp 941-947
- [17] Ohye C (2002) Thalamus and thalamic damage. In: Ramachandran VS (ed) *Encyclopedia of human brain*, vol. 4. Academic Press, Amsterdam, pp 575-587
- [18] Ohye C, Shibazaki T (2002) Location of the thalamic Vim nucleus. Its relation to the whole thalamic length. *Func Neurosurg* 41(2): 52-53 (Jpn)

- [19] Ohye C, Shibasaki T, Sato S, Cai XT (2003) Distribution of kinesthetic neurons in the thalamic ventralis intermedius nucleus. Its relation to gamma thalamotomy. *Func Neurosurg* 42: (2)108-109
- [20] Ohye C (2005) Production and physiological study of Holmes tremor in monkeys. In: LeDoux M (ed) *Animal models of movement disorders*. Elsevier, Amsterdam, pp 377-391
- [21] Schaltenbrand G, Wahren W (1977) *Atlas for stereotaxy of the human brain*. G. Thieme, Stuttgart
- [22] Tasker RR (1998) Thalamotomy for Parkinson's disease and other type of tremor. Part II. The outcome of thalamotomy for tremor. In: Gildenberg PL, Tasker RR (eds) *Textbook of stereotactic and functional neurosurgery*. McGraw-Hill, New York, pp 1179-1198
- [23] Talairach J, Tournoux P (1989) *Co-planar stereotaxic atlas of the human brain*. Stuttgart, G. Thieme Verlag, New York
- [24] Van Buren JM, Borke RC (1972) *Variations and connection of the human thalamus*. Springer-Verlag, Berlin-Heidelberg, New York



### **Chihiro Ohye**

Chihiro Ohye is neurosurgeon at the Functional Gamma Knife Surgery Center at Hidaka Hospital, Gunma, Japan. Graduated at the Faculty of Medicine (MD), Tokyo University in 1960, and Post Graduate Course (DMSc) in Brain Research Institute (Prof. Tokizane) 1965. Since this period, he started stereotactic surgery, cooperating with Prof. Narabayashi at his Neurological Clinic, until his death in 2001. During this time, studied neurosurgery under Prof. Sano, microrecording (Prof. Albe-Fessard, Prof. Guiot) in Institute Marey and Hopital Foch in Paris. Basic study continued in Quebec, Canada (Prof. Poirier). Hobby: Classic Music, Opera.

**Contact:** Chihiro Ohye, Hidaka Hospital, Functional Gamma Knife Surgery Center, 886 Nakao-machi, Takasaki, Gunma, Japan  
E-mail: [stereohye@dan.wind.ne.jp](mailto:stereohye@dan.wind.ne.jp)

---

# TARGETS FOR ELECTRICAL STIMULATION IN FUNCTIONAL NEUROSURGERY

F. VELASCO-CAMPOS

## HISTORICAL NOTES

In 1964, Sheally applied for the first time chronic electrical stimulation of the spinal cord in patients with neuropathic pain. The idea was to activate fibers traveling in the dorsal columns, that would interfere with nociceptive impulses at the level of the spinal cord entrance zone of dorsal roots. He used an internalized battery powered pulse generator similar to the cardiac pacemakers, connected to an epidural electrode. In 1973, Cooper presented before neuroscience meeting audience, cases of children with cerebral palsy that were treated with electrical stimulation of paravermian cerebellar cortex and improved in both: seizure control and spasticity. In 1989, Benabid et al. reported parkinsonian tremor control by chronic electrical stimulation of Vim thalamic nucleus, based in intraoperative experience that high frequency stimulation prior electro coagulation of that target, arrested contralateral tremor [1]. In 1999, Nuttin et al. presented cases of obsessive compulsive disorder (OCD), successfully treated by electrical stimulation (ES) of the anterior branch of the internal capsule [13]. These pioneer observations opened the field of ES of nervous structures in the treatment of chronic neurological disorders that is nowadays one of the most rapidly developing fields in medicine. Indications and targets have rapidly multiplied and most of them represent hypothesis based on animal experiments, extrapolated to clinical cases. Indications for ES include bladder and diaphragm control, vascular peripheral insufficiency and vascular headache among others. Therefore, the field has attracted specialists in neurosurgery, neurology, algology, psychiatrists, urologists, general surgeons, vascular surgeons and pneumologists.

On the other hand, study of mechanisms of action and improvement in technology have attracted the interest of an every day larger number of neurophysiologists, biomedical engineers, neurochemists, imaging doctors and technicians. Since ES may excite or inhibit neurons and fibers, depending on the stimulated place and stimulation parameters, we now refer to the treatment as neuromodulation, because “stimulation” may be taken as equivalent to “excitation”.

---

*Keywords:* stereotactic neurosurgery, targets in functional neurosurgery, brain lesioning, deep brain stimulation

## ELECTRICAL STIMULATION FOR NEUROPATHIC PAIN

Targets to treat pain have extended from the peripheral nerve to the cerebral cortex. Figure 1 summarizes the currently used targets and Table 1 the indications, contraindications, ES parameters and consensus on the expected improvement in pain for each target. Although both, nociceptive and neuropathic pain are likely to improve with neuromodulation, this treatment has been indicated mainly in cases with chronic neuropathic pain syndromes, i.e. pain induced by lesions of peripheral or central neural structures.

The rationale to use electrical stimulation for pain control is different for different targets:

**1. Peripheral nerve stimulation (PNS).** High frequency stimulation interferes with neuronal fiber conduction.

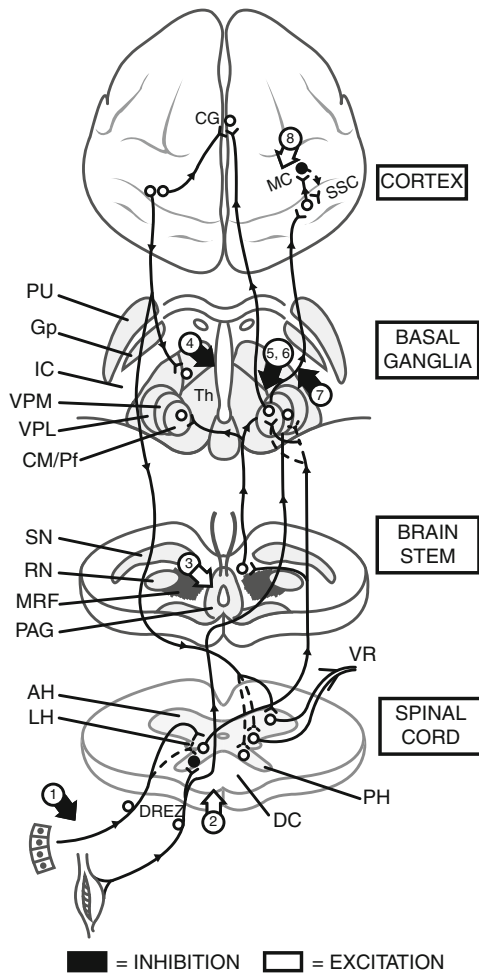
**2. Spinal cord stimulation (SCS).** Proprioceptive and nociceptive information compete at the dorsal root entry zone. Excitation of proprioceptive fibers inhibits nociceptive neurons at the level of the dorsal spinal cord horn,

**Fig. 1.** Rationale for targets used in the treatment of pain. Diagrammatic representation of sensory pathways from the peripheral nerve to the cerebral cortex. They are also descendant pathways modulating incoming sensory information. The places where anatomic physiologic mechanisms of pain perception have been interfered by electrical stimulation are indicated by arrows. 1 High frequency stimulation (>130Hz) in predominant peripheral sensory nerves interfere with pain perception in the corresponding territory. 2 Nociceptive and Proprioceptive information compete at the level of dorsal root entry zone (DREZ), by inhibition or excitation of the Rolando's gelatinous substance. Enhancement of excitation of this marginal zone of the posterior horn of the spinal cord (PH), which is inhibitory of nociceptive neurons, is accomplished by low frequency stimulation of the dorsal columns (DC). Other abbreviations at this level: anterior horn (AH), lateral horn (LH), Ventral root (VR). 3 At the mesencephalic level, the Periaqueductal gray (PAG) contains high concentration of endorphin receptors. Relatively low frequency (<30Hz) stimulation in this area has resulted in pain control. Other abbreviations: mesencephalic reticular formation (MRF), red nucleus (RN), substantia nigra (SN). 4 The postero-medial hypothalamus is related to sympathetic control as well as behavioral rage reactions. Stimulation in this area (130Hz) has been used to control cluster headache accompanied by sympathetic changes, as well as impulsive aggressive behavior. 5, 6 Sensory thalamus is composed by VPM-VPL nucleus which receives Proprioceptive and cutaneous information other than pain. However, Spinothalamic tract sends inhibitory collaterals to those nuclei. On the other hand, pain information reaches CM-Pf nuclei inducing excitation, while Proprioceptive fibers probably induce inhibition. Therefore, the hypothesis of a second gate mechanism modulating sensory information at the thalamic level has been advanced. Stimulation of VPM-VPL and CM-Pf nuclei intends to modulate this mechanism. 7 The same applies for stimulation of efferent fibers from VPM-VPL to somatic-sensory cortex (SSC) that travel in the internal capsule (IC). Other abbreviations: Thalamus (Th), globus pallidum (Gp), Putamen (Pu). 8 Motor cortex (MC) receives facilitator impulses from SSC and sends back inhibitory impulses to SSC, according to a hypothesis proposed by Tsubokawa. Besides, MC modulates sensory input at the level of the thalamus and facilitates cingulate gyrus (CG) control of emotions (Peyron et al. 1999). Finally there is evidence that sensory input is modulated by MC at the level of the spinal cord. Low frequency MCS controls pain through all these mechanisms. In the diagram, continuous lines and clear circles represent facilitatory pathways, while discontinuous lines and dark circles inhibitory pathways, arrows on these pathways represent the direction of impulses. Larger white arrows point to targets stimulated using low frequency to excite fiber or neuronal activities and dark arrows point to those stimulated using high frequency to inhibit local activity

according to the gate control theory, proposed by Wall and Melzack. Low frequency stimulation (LFS) (<40 Hz), delivered through epidural electrodes on the dorsal surface of the spinal cord intend to activate proprioceptive fibers. It has been demonstrated that SCS extends beyond the dorsal spinal columns, and activate selective neurotransmitter mechanisms.

**3. Periaqueductal gray area stimulation (PAGS).** Endorphin receptors, sensitive also to exogenous morphine, concentrate along the wall of the 3rd ventricle and PAG. ES <30 Hz intends to activate receptor uptake in PAG endorphin receptors.

**4. Posteriormedial hypothalamic stimulation (PMHS).** fMRI has shown intense hyperactivity of PMH during bouts of cluster headaches (Horton's



**Table 1.** Neuromodulation for the treatment of pain: most commonly used targets, indications, contraindications, stimulation parameters and stimulation mode reported as effective and safe. Data on pain control represents the consensus in the literature

Target	Indications	Contraindications	Stimulation parameters	Expected improvement rate
PN	Pain in territories of predominant sensory nerves (trigeminal, major occipital, supraorbital)	Pain involving multiple nerve territories of mixed motor and sensory nerves	<ul style="list-style-type: none"> <li>• HFS (&gt;60 Hz)</li> <li>• Continuous or cycling mode</li> </ul>	40–60%
SC	<ul style="list-style-type: none"> <li>• Localized uni or bilateral pain territories (from 1 to 6 atoms dermatomes)</li> <li>• Failed spine surgery</li> <li>• Reflex sympathetic dystrophy</li> <li>• Intermittent claudication</li> <li>• Post-traumatic root injury</li> </ul>	<ul style="list-style-type: none"> <li>• Cephalic pain</li> <li>• Pain involving four extremities</li> <li>• Complete spinal cord transection</li> <li>• Spinal blockage</li> </ul>	<ul style="list-style-type: none"> <li>• LFS (10–40 Hz)</li> <li>• Cycling mode</li> <li>• Adjusted by the patient</li> </ul>	30–70% better in sympathetic dystrophy
PAG	<ul style="list-style-type: none"> <li>• Painful territory involving the 4 extremities (neuropathies, quadriplegics)</li> </ul>	<ul style="list-style-type: none"> <li>• Localized pain territory</li> </ul>	<ul style="list-style-type: none"> <li>• &gt;30 Hz</li> <li>• Cycling mode</li> </ul>	40–60%
VPM-VPLCM Pf and IC	<ul style="list-style-type: none"> <li>• Unilateral post-stroke pain</li> <li>• Neuropathies (post-herpetic)</li> <li>• Nociceptive pain in cancer patients</li> </ul>	<ul style="list-style-type: none"> <li>• Pain localized territories</li> </ul>	<ul style="list-style-type: none"> <li>• 50 Hz</li> <li>• Cycling or continuous</li> </ul>	±60%
PMH	<ul style="list-style-type: none"> <li>• Cluster headache with sympathetic component</li> <li>• Facial pain secondary to central lesions</li> </ul>	<ul style="list-style-type: none"> <li>• not reported</li> </ul>	<ul style="list-style-type: none"> <li>• HFS (150 Hz)</li> <li>• Continuous or cycling mode</li> </ul>	50–100%
MC	<ul style="list-style-type: none"> <li>• Cephalic pain</li> <li>• Pain secondary to thalamic and supratthalamic lesions</li> <li>• Phantom limb</li> <li>• Sympathetic dystrophy</li> </ul>	<ul style="list-style-type: none"> <li>• complete motor and sensory deafferentation</li> <li>• restricted cortical representation of painful territory</li> </ul>	<ul style="list-style-type: none"> <li>• LFS &lt;40-Hz</li> <li>• Cycling mode</li> <li>• 90–120 μs</li> <li>• &lt;5.0 V</li> </ul>	40–80% Failures often reported

Targets: *PN* Peripheral nerve; *SC* spinal cord, *PAG* periaqueductal gray; *VPM-VPL*, *CM-Pf* and *IC* sensory thalamic nuclei and fibers, *PMH* posteromedial hypothalamus, *MC* motor cortex

headache). ES at 130 Hz in the PMH ipsilateral to the migraine has been successful to control pain and sympathetic changes.

**5, 6 and 7. Stimulation of thalamic sensory nuclei:** ventralis posteromedial and lateral (VPM-VPL) and centromedian parafascicularis (CM-Pf), and

thalamic-cortical sensory fibers in the internal capsule. Spinothalamic tract branches in both VPM-VPL and CM-Pf nuclei, in turn VPM-VPL project to the primary sensory cortex through fibers traveling in the posterior third of the posterior branch of internal capsule (IC). Since VPM-VPL also receive other cutaneous and proprioceptive sensory information, another gate control mechanism for sensory information has been proposed at the level of the thalamus. ES of 50–60 Hz have been used for neuromodulation in the sensory thalamic nuclei and their cortical projections. Combinations of electrodes in VPM-VPL and CM-Pf or PAG intend to optimize pain control.

**8. Motor cortex stimulation (MCS).** Low frequency (20–50 Hz) ES of the motor cortex induces analgesia through a still unknown mechanism. Since MCS is accompanied by increase of neuronal activity of the thalamus and cingulate gyrus, as revealed by hyper metabolism of these areas in PET studies, control of nociceptive information at the thalamic sensory relay nucleus and increased cingulate related emotional control have been proposed to induce analgesia by MCS. There is also evidence that MCS controls nociceptive input at the level of the spinal cord.

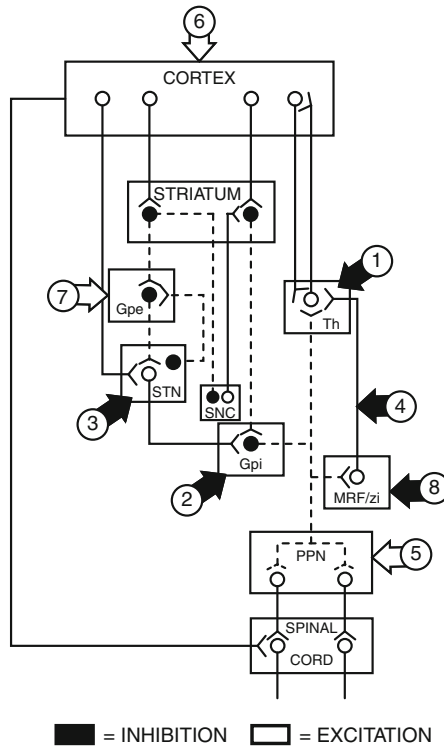
Pain control resulting from the use of the above listed methods is highly variable according to different reports. The percentage improvement expected for each method is presented in the table as the result of revision of the literature.

## ELECTRICAL STIMULATION FOR MOVEMENT DISORDERS

**High frequency stimulation (130–185 Hz)** of ventralis intermedius thalamic nucleus (Vim) was proposed to treat Parkinson's disease (PD) in patients that had been previously treated, lesioning Vim in the contralateral side. This was an attempt to avoid side effects induced by bilateral lesions in Vim, mainly on speech. Subsequently, ES of other targets was reported effective in controlling symptoms, such as globus pallidum internus (Gpi) and prelemniscal radiations (Raprl). **Targets based in Alexander and De Long proposal for the physiology of motor control** have been successfully used to treat PD and other involuntary movements. Examples of that are ES of the sub thalamic nucleus (STN) and the globus pallidum externus (Gpe). Stimulation of other sub thalamic nuclei such as zona incerta, above (Zir) and behind (Zic) STN, has been reported highly effective in controlling PD symptoms in the extremities. Pedunculopontine nucleus (PPN) ES in the brain stem has been stimulated to treat mainly axial symptoms (gait and posture) in PD. Finally, MCS is being evaluated in the treatment of involuntary movements such as PD and intention tremor. Up to the present, PPN is indicated when STN and Gpi failed in controlling axial symptom in PD, while Gpe has been used in Gilles de la Tourette syndrome. STN, Gpi and Raprl are being used in PD. Gpi and STN are also used in focal and generalized dystonias and Raprl in tremors of different etiologies.



TARGETS FOR MOVEMENT DISORDERS



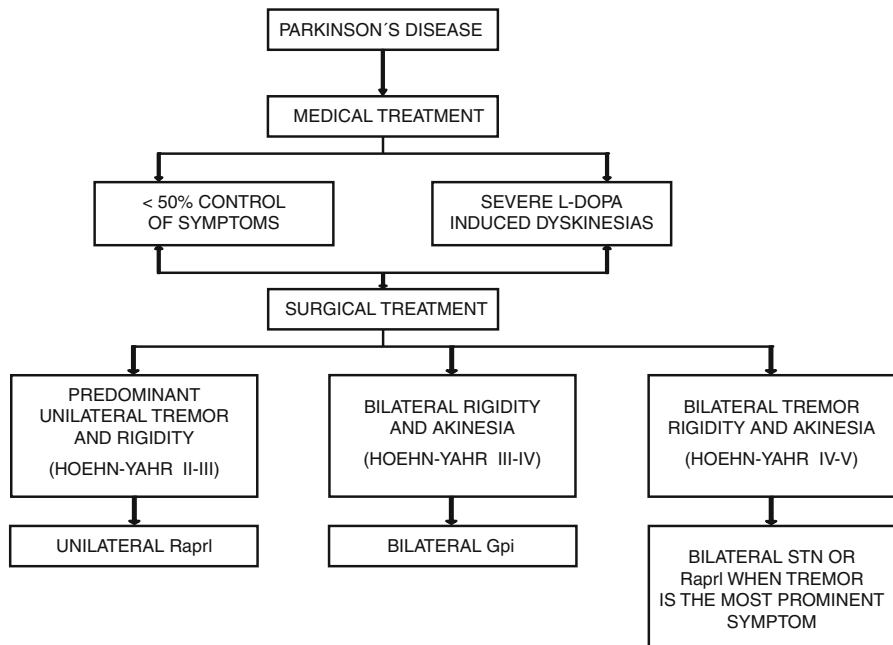
**Fig. 2.** Diagram proposed by Alexander and De Long to illustrate the physiology of movement control, which has been modified to incorporate other important anatomical structures, not considered in the original proposal. Clear circles and continuous lines indicate facilitator, glutamate mediated pathways. Dark circles and discontinuous lines indicate GABA mediated inhibitory pathways. Motor cortex facilitates striatum activity, which in turn modulates globus pallidum internus (Gpi) and substantia nigra pars reticularis (SNr). Gpi inhibit ventral lateral thalamic neurons (Th) that are facilitator of cortical activity. Striatum control on Gpi uses direct and indirect pathways. Indirect pathway goes through globus pallidus externus (Gpe) and sub thalamic nucleus (STN). The striatum is modulated by the substantia nigra pars compacta (SNc) which maintains an excitatory inhibitory balance. Thalamic activity is also modulated by ascending sub thalamic fibers or prelemniscal radiations (Raprl), probably originated in the mesencephalic reticular formation (MRF), zona incerta (Zi) and pedunculopontine nucleus (PPN). PPN has descending bilateral projections that facilitate spinal cord activity and is known as the brain stem motor center. This descending fiber system represents an alternative pathway to the pyramidal and extrapyramidal fibers in motor control. Gpi has bilateral descending inhibitory pathways to PPN, which explains bilateral improvements of symptoms in the extremities, and improvement in axial symptoms of PD with unilateral Gpi lesion or stimulation. The arrows indicate the targets used to treat movement disorders using neuromodulation and are numbered in chronological order: 1 Vim, 2 Gpi, 3 STN, 4 Raprl, 5 PPN, 6 Motor Cortex, 7 Gpe, 8 Zona incerta pars caudata (Zic). Dark arrows are those targets in which high frequency stimulation is applied to inhibit local neurons or fibers. Clear arrows indicate those targets in which low frequency stimulation is used to excite local neurons. Numbers 5 to 8 have been reported in the past 3 years

In general, high frequency ES is used to mimic the effects of lesions of different targets, low frequency is used to induce neuronal excitation in PPN, Gpe and motor cortex.

**Table 2.** Degree of improvement obtained for different PD symptoms from reports that used the same scale (UPDRS part III motor) and follow up period (one year) to evaluate the results and reported as % improvement

Target	T	R	A	P	G	Author	Year
STN	80	90	60	58	56	Benabid	2000
Raprl	92	94	65	35	50	Carrillo-Ruiz	2008
Zic	93	76	65	NA	NA	Plaha	2007
Gpi	78	68	68	67	59	Jimenez	2006
Vim	80	NA	NA	NA	NA	Benabid	1996
PPN	NA	NA	NA	70	80	Mazzone	2005

T Tremor, R rigidity, A akinesia, P posture, G gait. Authors and year of the report are quoted (see references). Targets: STN Subthalamic nucleus; Raprl prelemniscal radiations; Zic zona incerta caudalis; Gpi globus pallidum internus; Vim ventralis intermedius thalami; PPN peduncle pontine nucleus. NA Non available data



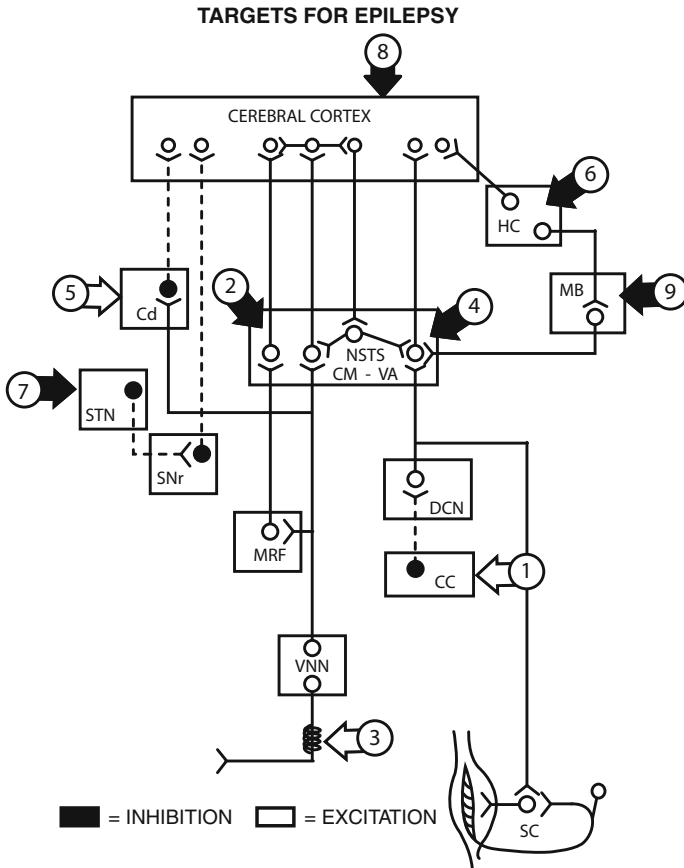
**Fig. 3.** Paradigm of treatment used in PD. Candidates for neuromodulation are patients in whom medical treatment has lost its efficacy, improving less than 50% the severity of symptoms and/or the period of time of improvement around the clock (ON-OFF periods). Other indication is the presence of severe L-DOPA induced dyskinesias. Target is chosen according the predominant symptom and the stage of the disease. PPN is restricted for those patients having mainly axial posture and gait abnormalities

Figure 2 presents Alexander and De Long proposal for motor control that has been modified to include other anatomical structures that participate in this process. In the legend for this figure, the rationale to use different targets is explained.

On the other hand, all targets but Vim improve other PD symptoms besides tremor (Table 2). Degree of improvement reported for different symptoms varies for different targets. Therefore, at the present one may choose the target that better controls the predominant symptom in each particular case. Figure 3 presents the paradigm we are currently following in the General Hospital in Mexico.

### ELECTRICAL STIMULATION FOR EPILEPSY

Figure 4 summarizes the neurobiological background behind the use of different targets for seizure control.





**Fig. 4.** Rationale for targets used in the treatment of epilepsy. Continuous lines ending in axonal terminal with clear circles indicate facilitatory pathways for cortical neuronal excitation. Discontinued lines and dark circles indicate inhibitory pathways. Dark arrows indicate targets stimulated with high frequency (HFS) to inhibit local neuronal to axonal fibers, clear arrows point to structures stimulated with low frequency (LFS) to excite anatomical structures. Targets are numbered in chronological order as they were proposed.

1. Cerebellar cortex (CC) inhibits deep cerebellar nuclei (DCN), which in normal conditions induce cerebral cortex and monosynaptic spinal cord reflex excitation. LFS of cerebellar cortex (CS) decreases both clinical and experimental seizures and spasticity. HFS of DCN is used to induce inhibition of neuronal activity of those nuclei and has the same antiepileptic effect.
2. Non specific thalamic system (NSTS) is a relay of cerebellar, mesencephalic, reticular formation (MRF), other brain stem nuclei like vagal nerve, basal ganglia and cortical areas. Cortical synchronization and desynchronization are mediated or regulated by NSTS. Thalamic-cortical reverberating activity seems responsible for generation of spike-wave complexes and secondary synchronous discharges seen in various forms of epilepsy and participates in propagation of cortically initiated seizures. Centromedian (CM) and anterior thalamic (AN or VA in animals) nuclei are part of NSTS. CM-HFS interferes with cortical synchronization like spike wave complexes and propagation of cortical epileptic activity.
3. Vagal nerve nucleus (VNN) and in particular nucleus of the solitary tract, have extensive connections with other brain stem, basal ganglia and mesial temporal lobe structures (not shown in the figure). Antidromic activation by 20–50 Hz currents applied in the vagal nerve at the neck (VNS), result in antiepileptic effect by a still undetermined mechanism.
4. AN-HFS has the same effect on seizures than CM, but in addition it may interfere with propagation of complex partial seizures originated in the hippocampus (HC) through fornix, mammillary body (MB) and mammillo-thalamic tract.
5. Ventral caudate nucleus (Cd) is inhibitory of cortical activity. LFS of this part of Cd results in cortical inhibition and antiepileptic effect. In contrast HFS increases seizures end EEG paroxysmal discharges.
6. Low amplitude DC currents, applied to the temporal lobe amygdale, using the same electrode to induce seizures in a paradigm stimulation for kindling in rats, disrupts epileptogenesis and increases the threshold for after discharges. Subacute HFS of hippocampal epileptogenic foci or Para hippocampal cortex decreases or abolishes seizures and ictal and interictal paroxysmal discharges in humans. The effect is mediated through GABA receptors. Chronic cycling HCS has successfully controlled seizures initiated in the mesial temporal lobe unilaterally or bilaterally.
7. Substantia nigra pars reticulata (SNr) is a potent inhibitor of cortical excitability, through a GABA mediated mechanism. STN maintains tonic inhibition on SNr. Therefore, HFS of STN intends to inhibit local neuronal activity which releases SNr to inhibit the cortex.
8. As for hippocampus and Para hippocampus, HFS of extra temporal epileptic foci may reduce epileptogenesis by the same GABA mechanism. Stimulation parameters are settled to deliver low current density charge. Therapeutic low amplitude stimulation of foci in eloquent areas does not induce neurological deficits.
9. HFS of mammillary bodies and mammillo-thalamic tract reduce partial complex seizures and gelastic seizures secondary to hypothalamic hamartomas. Surprisingly stimulation of these areas does not induce side effects.

Many experimental observations made in animal models of epilepsy have been extrapolated to humans to treat difficult to control seizures. The degree of improvement varies for different procedures and seizure type. High frequency stimulation has been used to inhibit local neuronal activity in the target, while low frequency activity is used to increase neuronal activity (Table 3 and Fig. 4).

**Table 3.** Seizure control induced by ES in different targets on various seizure types

Target	Parameters and mode	Seizure type						
		GTC	AA	CxP	FM	ADV	GEL	MYOC
VN	20–50Hz, 0.5 mA, 130–500 $\mu$ s cycling+ reinforcement	+	+	+	+	+	-	NA
CC	10Hz, 2.0 $\mu$ C/cm <sup>2</sup> /phase cycling (4 min on, 4 min off) mono polar	+++	++	+	+	++	-	-
CM	130Hz, 3.0–4.0V, 450 $\mu$ s, bipolar cycling (alternating right-left 1 min on, 4 min off)	+++	+++	+	+++	++	-	-
AN	90–130Hz, 3.0–4.0V, 60–110 $\mu$ s bipolar, cycling similar to CM	++	++	+++	+	++	-	NA
HC	130Hz, 3.5–4.5V, 450 $\mu$ s bipolar, cycling similar to CM	+++*	++	+++	NA	NA	NA	NA
ELA	130Hz, 2.5–3.5V, 210 $\mu$ s bipolar, cycling similar to CM	+++*	NA	NA	+++	++	NA	NA
STN	130–185Hz, 2.0–3.0V, 60 $\mu$ s monopolar continuous	++	NA	+	++	+++	NA	++
MB and MTT	130Hz, 2.0–3.0V, 90 $\mu$ s, bipolar, continuous	NA	NA	NA	NA	NA	+++	NA

Targets: VN Vagal nerve; CC cerebellar cortex; CM centromedian nucleus; AN anterior thalamic nucleus; HC hippocampus; ELA eloquent extratemporal cortices; STN subthalamic nucleus; MB mammillary body; MTT mammillo-thalamic tract. The parameters and stimulation mode recommended is quoted. Seizure types: GTC generalized tonic clonic; \* focally initiated GTC; AA atypical absences; CxP complex partial; FM focal motor; ADV adversive tonic; GEL gelastic; myoc myoclonic. Seizure improvement: (-) = <30%; (+) = 30–50%; (++) = 50–80%; (+++) = >80% NA Non available data. Improvement takes as reference baseline seizure occurrence before starting electrical stimulation

1. **Cerebellar stimulation** was used in the 70s and 80s and open label studies described an overall improvement of 50%. However, two double blind studies casted doubts on the efficacy of CS, as it was not significant difference in the number of seizures during the periods ON and OFF stimulation. Recently, a double blind study in which the maneuver started at the onset of stimulation, showed significant differences in the number of seizures in ON and OFF conditions. Improvement of generalized tonic (GT) and tonic-clonic (GTC) seizures was 80% at two years follow up.

2. Similar to CS, in **centro median thalamic stimulation (CMS)** there was no significant differences in the number of seizures in ON and OFF stimulation periods in two double blind protocols. In both studies, the double blind maneuver initiated after a period of several months ON stimulation, when seizures had decreased over 80% the baseline level and improvement was maintained during the 3 months OFF stimulation. This probably represents a residual anticonvulsive effect of chronic stimulation. Therefore, double blind maneuvers to evaluate the efficacy of ES in epilepsy must be scheduled at the beginning of the study and avoid cross over protocols. The best effect of CMS has been on GTC and atypical absences (AA) of the Lennox Gastaut syndrome, with an overall improvement of 83% and 15.4% of the patients becoming seizure free.

3. **Vagus nerve stimulation (VNS)** has been in use for over 15 years as coadjutor therapy in difficult to control seizures that are not candidates for ablative procedures. It is the only neuromodulation therapy for epilepsy that has been approved by FDA up to date, in spite of its relative modest effect on seizures. Side effects include dysphonia, headache and increase peptic ulcer and insulin dependant diabetes mellitus conditions.

4. **Anterior thalamic nucleus stimulation (ANS)** is being evaluated in a multicentric study that includes over 100 cases. Pilot studies reveal seizure reductions of various types with an improvement of 62–68% in the total number of seizures, particularly GTC and complex partial (CxP).

5 and 8. **Hippocampal stimulation.** Cases with bilateral temporal independent foci confirmed by depth recordings, and patients with memory deficits in neuropsychological testing are considered poor candidates for ablative procedures. Patients with high surgical risk often derived from toxic effects of anticonvulsant drugs, such as hepatic damage are also rejected for temporal lobectomy.

In those cases, unilateral or bilateral hippocampal stimulation (HCS), particularly in cases without mesial temporal sclerosis (normal MRI), has been found highly effective for seizure control, with 80% seizure reduction and 33% of patients becoming seizure free. In contrast, patients with hippocampal sclerosis have a delayed response and a seizure decrease from 50–80%. Electrical stimulation of eloquent (ELAS) areas (motor and sensory) induce also significant decrease of simple partial seizures and secondary generalization in all cases treated so far. Most important is that neither HCS nor ELAS

have induced deterioration in neuropsychological performance, and HCS may be accompanied by an improvement in memory testing.

**6 and 7. Caudate nucleus stimulation.** Some studies have explored the anticonvulsive role of basal ganglia and reported that low frequency stimulation of **caudate nucleus (Cd)** decreases electrocortical epileptic activity (Chkhenkeli, 1997). The best anticonvulsive effect has resulted from stimulation of the ventral part of Cd and has been sustained for 1.2 years.

**7. Subthalamic nucleus stimulation.** More recently, the STN has been stimulated with HFS for seizure control. A relatively small number of cases with various epileptic conditions have been treated in strict double blind controlled protocols. Improvement varies from 30 to 82% in different reports and seems to be better for seizures initiated in the frontal lobe and myoclonic seizures [5].

**9. Hypothalamic stimulation.** Cases of complex partial seizures have been recently treated by electrical stimulation of mammillary bodies at the hypothalamus, with reduction in seizure occurrence and surprisingly no side effects. Also, some cases with gelastic seizures originated in hypothalamic hamartomas have been treated by electrical stimulation of the mammillo-thalamic tract.

**10. Epileptic zone stimulation (ES)** of temporal lobe and extra temporal foci have been coupled with detectors of EEG activity that may anticipate seizure onset, as well as a stimulation system that delivers electric current through an electrode placed on the epileptic zone. The initial reports are promising, although seizure anticipation may depend of EEG activities that are not specific. Besides, in all trials of neuromodulation for seizure control, best anticonvulsive effect takes time to be reached. For HCS it takes weeks, for CMS it takes months, and for VNS and CS it takes years.

## **ELECTRIC STIMULATION FOR THE TREATMENT OF PSYCHIATRIC DISORDERS**

### **1. HISTORICAL BACKGROUND**

Although early attempts to treat psychiatric disorders using neurosurgical procedures were performed in 19th century, it was until 1936 that the so called “frontal leucotomy” was introduced by Egas Moniz as an alternative for the treatment of psychiatric patients. Frontal leucotomy was based on the pioneer work by Fulton and Jacobsen on chimpanzees, which were turned docile by ablations of the frontal lobe. Leucotomies rapidly evolved to restricted lesions in the frontal lobe, such as orbitofrontal undercutting, sub caudate tractotomy, anterior capsulotomy and cingulotomies. Introduction of stereotactic techniques allowed performing precise lesions in subcortical structures, like posterior medial hypothalamic lesions, temporal lobe amygdalectomy and lesions of the posterior medial orbitofrontal cortex (area 13).

In the late 60s and early 70s psychiatric neurosurgery was practically abandoned. Reasons to reject neurosurgical procedures to treat psychiatric conditions were multiple; however, the most important were the development of new drugs more specific and effective to control symptoms, the abuse of psychosurgery procedures and the social fear that such procedures might be used for political control on dissident people.

In 1974 US Senate ordered a revision of psychosurgical procedures applications and results. The Commission performing this evaluation concluded that "certain surgical procedures had been helpful to very sick patients without destroying their intelligence or rob them of their feelings". For the next 30 years neurosurgical procedures to treat psychiatric disorders were confined to a selected group of institutions and restricted to few indications. Scientific and ethical considerations of the protocols of study became strictly supervised by institutional and international committees.

Simultaneously, rapid development of technology in neuroimaging, stereotaxis, electrophysiology and neurochemistry provided important information on the anatomy and physiopathology of mental illness. Such information allows reconsidering neurosurgical procedures in psychiatric conditions in a more scientific and safe perspective. Finally, neuromodulation seems an ideal method to deal with psychiatric conditions, as one may reverse any adverse reaction by turning OFF or simply adjusting stimulation parameters. This solves the ethical problem of changing the personality or mind in a way not desired by the patient.

## 2. RATIONALE FOR TARGETS USED IN PSYCHIATRIC DISORDERS

Neuromodulation has concentrated so far in the treatment of obsessive compulsive disorder (OCD), major depression disorder (MDD), impulsive aggressive behavior (IAB) and alimentary disorders (anorexia or obesity).

HFS has been directed to interfere with fiber conduction of the same structures that had been destroyed to treat OCD. HFS of anterior branch of the internal capsule has controlled both obsessions and compulsions in the majority of cases. When stimulators are turned OFF or battery charge depletes, OCD symptoms rapidly return, indicating that electrical current was responsible for the improvement. Stimulated area in the anterior branch of internal capsule includes several tract fibers connecting basal ganglia with frontal cortex, so it is difficult to decide which one is responsible for the clinical effect. Recently, stimulation has been concentrated in the most medial and inferior end of the internal capsule, nearby the genu. Still, current charge density necessary to obtain adequate clinical results is high, depleting battery charge of the internalized pulse generators rapidly, with the consequent increase in the cost for the treatment.

Seeking for more specific targets to treat OCD that might require less current charge to be effective, a structure immediately below the genu of



internal capsule has been stimulated. The nucleus accumbens represents a medial extension of the temporal lobe amygdale and is profusely interconnected with the basal ganglia and frontal and temporal lobes. Electrical stimulation of the periphery or “shell” of this structure has been claimed effective to control OCD symptoms. Unfortunately, the reports do not use the conventional Yale-Brown scale for obsessive compulsive disorders to evaluate the improvement, so it is difficult to compare with stimulation of other targets.

Inferior thalamic peduncle (ITP) that represents the link of orbitofrontal cortex with non specific thalamic nuclei has been reported effective to control MDD and OCD. This tiny structure may have the advantage of been more punctual and require less current charge to get inactivated. However, so far HFS 130 Hz, 4.0–5.0 V and 210–450 ms are necessary to maintain the effect on OCD over time.

Vagal nerve stimulation (VNS) has been used to treat difficult to control seizures. Some of the epileptic patients suffering severe depression were improved in both the number of seizures and depressive condition. Effect on depression may be explained by the extensive connections of the solitary tract nucleus with areas participating in the physiology of mood and behavior, such as locus coeruleus, posteromedial hypothalamus, caudate nucleus and mesial temporal structures. The initial trials of VNS for depression reported significant decrease in scores of specific scales for depression.

PET scans in OCD and MDD show conspicuous hyperintensity of orbital frontal cortex, including subgenual cingulate cortex (area 25), as well as temporal lobe amygdale and midline thalamic nuclei. Such hyper intensity disappears when OCD and MDD are successfully treated with medication, to become hyperintense again during relapses. In contrast, frontal cortex in the convexity is hypointense in OCD and MDD and metabolic activity increases in this region when symptoms are controlled by medication.

These observations oriented stimulation of subgenual cortex in the treatment of MDD. Initial results are very promising and subgenual cortex stimulation is being evaluated in a multicentric study.

Finally, the posterior medial or sympathetic hypothalamus is known to be involved in rage and aggressive behaviors in animals. In the 60s lesions in these areas were used to treat IAB. Recently, the area has been stimulated with HFS in that type of patients. The target corresponds to the same area used to treat Horton’s headache and its accompanying sympathetic symptoms, with the difference that to treat IAB bilateral stimulation is needed.

#### Glossary of abbreviations

ES	Electrical Stimulation
HFS	High Frequency Stimulation

LFS	Low Frequency Stimulation
MRI	Magnetic Resonance Imaging
fMRI	Functional MRI
PET	Position Emission Tomography
S	Stimulation

*Pain Section*

AH	Anterior Spinal Cord Horn
CG	Cingulate gyrus
CM	Centro Median Thalamic Nucleus
DC	Dorsal Spinal Cord Column
DREZ	Dorsal Root Entry Zone
Gp	Globus pallidum
IC	Internal Capsule
LH	Lateral Spinal Cord Horn
MC	Motor Cortex
PAG	Peri Aqueductal Gray
Pf	nucleus parafascicularis
PH	Posterior Spinal Cord Horn
PMH	Posterior Medial Hypothalamus
PN	Peripheral Nerve
SCS	Spinal Cord Stimulation
SSC	Somato Sensory Cortex
Th	Thalamus
VPL	Ventralis postero lateralis nucleus
VPM	Ventralis postero medialis nucleus
VR	Ventralis root of spinal cord

*Movements Disorder Section*

A	Akinesia
G	Gait
Gpe	Globus pallidus externus
Gpi	Globus pallidus internus
MRF	Mesencephalic reticular formation
P	Posture
PD	Parkinson's disease
PPN	Pedunculo pontine nucleus
R	Rigidity
Raprl	Prelemniscal radiation
SNC	Substantia nigra pars compacta
STN	Subthalamic nucleus
T	Tremor
Vim	Nucleus Ventralis intermedius
Zic	Zona incerta caudalis
Zir	Zona incerta rostralis

*Epilepsy Section*

AA	Atypical Absences
ADV	Adversive seizures
AN	Anterior Thalamic Nucleus
CC	Cerebellar Cortex
Cd	Caudale nucleus
CS	Cerebellar Stimulation
CMS	Centro Median Thalamic Stimulation
Cxp	Complex Partial Seizures
DCN	Deep Cerebellar Nucleus
FM	Focal Motor Seizures
GABA	Gamma Aminobutyric Acid
GEL	Gelastic seizures
GT	Generalized Tonic Seizures
GTC	Generalized Tonic Clonic Seizures
HC	Hippocampus
HCS	Hippocampus stimulation
MB	Mammillary body
MTT	Mammillo Thalamic Tract
Myoc	Myoclonic Seizures
NSTS	Non Specific Thalamic System
SC	Spinal Cord
SNr	Substantia Nigra pars reticulata
VA	Ventralis Anterior or Anterior Thalamic nucleus
VNN	Vagal Nerve Stimulation

*Psychiatric Disorder Section*

IAB	Impulsive Aggressive Behavior
ITP	inferior Thalamic Peduncle
MDD	Major Depression Disorder
OCD	Obsessive Compulsive Disorder

**References**

- [1] Benabid AL, Pollack P, Gao D, Hoffman D, Limousin P, Gay E, Payen I, Benazzouz A (1996) Chronic electrical stimulation of the ventralis intermedius nucleus of the thalamus as treatment of movement disorders. *J Neurosurg* 84: 203-214
- [2] Broggi GV (2008) Pain and psycho affective disorders. *Neurosurgery* 62(Suppl): 901-920
- [3] Cameron T (2005) Safety and efficacy of spinal cord stimulation for the treatment of chronic pain: a 20 year literature review. *J Neurosurg* 100(Suppl Spine): 254-267

- [4] Carrillo-Ruiz JD, Velasco F, Jimenez F, Castro G, Velasco AL, Hernandez JA, Ceballos J, Velasco M (2008) Bilateral electrical stimulation of prelemniscal radiations in the treatment of advanced Parkinson's disease. *Neurosurgery* 62: 347-359
- [5] Chabardes S, Minotti L, Chassagnon S, Piallat B, Torres N, Seigneuret E, Vercueil L, Carron R, Hirsch E, Kahane P, Benabid AL (2008) Basal ganglia deep brain stimulation for treatment of drug resistant epilepsy: review and current data (French). *Neurochirurgie* 54: 436-440
- [6] Davis R, Emmonds SE (1992) Cerebellar stimulation for seizure control: 17 year study. *Stereotact Funct Neurosurg* 58(1-4): 200-208
- [7] Heller AC, Amar AP, Liu CY, Apuzzo MLJ (2008) Surgery of the mind and mood: a mosaic of issues in time and evolution. *Neurosurgery* 62: 921-940
- [8] Jimenez F, Velasco F, Carrillo Ruiz JD, Garcia L, Madrigal A, Velasco AL, Marquez I (2006) Comparative evaluation of the effects of unilateral lesion versus electrical stimulation of the globus pallidus internus in advanced Parkinson's disease. *Stereotact Funct Neurosurg* 84(2-3): 64-71
- [9] Limousin P, Martin-Torres I (2008) Deep brain stimulation for Parkinson's disease. *Neurotherapeutics* 5(2): 309-319
- [10] Lipsman HO, Neimat JS, Lozano AM (2007) Deep brain stimulation for treatment refractory obsessive compulsive disorder. The search for a valid target. *Neurosurgery* 61: 1-13
- [11] Lüders HO (ed) (2004) Deep brain stimulation and epilepsy. Martin Dunitz, London, pp 3-361
- [12] Mazzone P, Lozano AM, Stanzione P, Galati S, Scarnati E, Peppe A, Stefani A (2005) Implantation of pedunculopontine nucleus: a safe and clinical relevant target in Parkinson's disease. *Neuroreport* 28(16-17): 1877-1881
- [13] Nuttin BJ, Gabriels AL, Cosyns PR, Meyerson BA, Andreewitch S, Sunaert SG, Maes AF, Dupont PJ, Gybels JM, Gielen F (2008) Long-term electrical capsular stimulation in patients with obsessive-compulsive disorder. *Neurosurgery* 62(Suppl): 966-985
- [14] Plaha P, Ben-Shlomo Y, Patel NK, Gill SS (2006) Stimulation of the caudal zona incerta is superior to stimulation of the sub thalamic nucleus in improving contralateral parkinsonism. *Brain* 129(Pt 7): 1732-1747
- [15] Rezaei AR, Kopell BH, Gross RE, Vitek JL, Sharan AD, Limousin P, Benabid AL (2006) Deep brain stimulation for Parkinson's disease: surgical issues. *Mov Disord* 21(Suppl 14): S197-S218

- [16] Velasco F, Velasco AL, Velasco M, Carrillo-Ruiz JD, Castro G, Trejo D, Rocha L, Cuellar-Herrera M, Nuñez JM (2008) Central nervous system neuromodulation for the treatment of epilepsy. Part I. Efficiency and safety of the method. Part II. Mechanisms of action and perspectives (French). *Neurochirurgie* 54: 418-435
- [17] Velasco M, Lozano AM (eds) (2000) Neuromodulation of intractable neurological symptoms. *Arch Med Res* 31(Suppl): 231-328



### **Francisco Velasco-Campos**

Francisco Velasco-Campos is head of the Unit for Stereotactic and Functional Neurosurgery at the Hospital General de Mexico. He was born in Mexico City, May 2nd 1939. He graduated from the University of Mexico in 1961. Post-Graduate training included: residence in Internal Medicine from 1961–1964, General Surgery 1964–1965 and Neurosurgery from 1965–1969 at Johns Hopkins Hospital in Baltimore MD. Stereotactic neurosurgery at Notre Dame Hospital in Montreal, PQ 1969–1970. Academic positions include: Chairman of Neurosurgery at the National Institute of Medical Sciences (1970–2000) and Mexico General Hospital (1998–2008). Senior Investigator in the National Medical Center (1970–2001), and National Research System (1985–) in Mexico. He is presently acting as Director of the Research Division in Mexico General Hospital. He has proposed targets for the treatment of epilepsy, such as centromedian thalamic nucleus, hippocampal and para hippocampal cortex and therapeutic stimulation of cortical epileptic foci. He has studied the posterior subthalamic target for the treatment of Parkinson's disease symptoms and other involuntary movements, he recently proposed the electrical stimulation of inferior thalamic peduncle in the treatment of major depression disorder and obsessive compulsive disorder. Those targets have been the result of neurophysiological observations in experimental animals and humans made along 40 years. He founded the Neurosurgical Service in the Institute of Medical Sciences (1970), the Unit for Stere-

otactic, Functional Neurosurgery and Radiosurgery in Mexico General Hospital (1980) and the Latin American Society for Stereotactic and Functional Neurosurgery (1998). He has been the representative for Latinamerica in the World Society for Stereotactic and Functional Neurosurgery and the Neurosurgical Society for French Speaking Neurosurgeons.

**Contact:** Francisco Velasco-Campos, M.D., Unit for Stereotactic and Functional Neurosurgery, Hospital General de México, Creston 116, Jardines del Pedregal, México D.F. 01900, México  
E-mail: slanfe@prodigy.net.mx

---

# FUNCTIONAL NEUROSURGERY FOR PARKINSON'S DISEASE

A. L. BENABID

## INTRODUCTION

Functional neurosurgery for movement disorders started in the early 1940s. It was mainly based on lesion (ablative surgery) using various methods of destruction aimed at various targets on the basis of either theoretical anatomo-functional considerations or anecdotal observations, the most famous being the introduction of thalamotomy and pallidotomy following Irving Cooper's observations of an accidental ligature of the anterior choroidal artery. Later, trial and error based methods, associated to electrophysiology, led to the definition of an ideal target defined as the magnocellular part of the ventral intermedius (Vim) nucleus of the thalamus. This became the standard target and electrocoagulation the standard surgical technique to treat tremor, both in Parkinson's disease (PD) and in essential tremor (ET). The most frequently improved symptom was tremor, with good and long lasting results, with two main drawbacks. (i) The effects did not last and needed reoperation when the lesion was well placed but too small. (ii) Side effects could be observed when the lesion was too large, involving peri-target structures, particularly the internal capsule which led to motor deficits, not always reversible. Moreover, bilateral surgery, often required by the clinical status of the patient, was too often associated with neurocognitive deficits.

Surgery was the only efficient treatment of PD until the introduction in the 60s of the substitutive treatment with levodopa (L-dopa) by Cotzias, based on the pioneering work of Arvid Carlsson. PD was known to be related to a deficit in dopamine in the basal ganglia (BG) since Hornykiewicz. The drawbacks of ablative surgery, together with the striking beneficial effects of levodopa, were responsible of the almost disappearance of ablative lesions, until the recognition of the long-term side effects of dopatherapy, mainly motor fluctuations and dyskinesias, triggered a renewed interest in surgical methods, with no or little tolerance for complications. This need for less invasive techniques triggered a series of basic research-based approaches. This was the main motivation for neural transplantation, still not considered as a routine treatment. In this context of a quest for a new procedure, the unexpected observation during intraoperative exploratory

---

*Keywords:* stereotaxy, deep brain stimulation, functional neurosurgery, movement disorders, subthalamic nucleus



electrophysiology [2] of the effects of high-frequency stimulation (HFS) able to mimic in a reversible and adjustable manner the effects of local destruction of functional targets triggered, in a serendipitous approach, the development of HFS of functional targets as a specific therapeutic tool. Initially applied to movement disorders, this has been more recently applied to an increasingly larger field of indications such as psychosurgery.

Vim HFS is very efficient on tremor, the most spectacular but not the most disabling symptom of PD. However, there is no effect on bradykinesia and rigidity. The disability of advanced PD patients is essentially related to akinesia and rigidity. The publication in 1990 by the groups of Mahlon DeLong [4] and of Crossman [1] of the prominent role of the subthalamic nucleus (STN) in the control of motor function and of its capacity, when destroyed, to improve bradykinesia and rigidity in 1-methyl-4-phenyl-1,2,3,6-tetrahydropyridine (MPTP)-exposed monkeys has opened new horizons for deep brain stimulation (DBS) in movement disorders. Although the STN can be the source of hemiballism when destroyed by haemorrhages, the experience acquired during HFS of the thalamus suggested that the STN could be a target for neuroinhibition-like methods as provided by HFS. This was supported by experiments using HFS instead of lesioning in MPTP-exposed monkeys. The ultimate confirmation of the interests of this target was given when the first patients with advanced PD were implanted, showing that tremor, rigidity, and bradykinesia were very significantly improved by this method [11], allowing to decrease the drug dosage by 60% in average [12], and therefore alleviating the levodopa-induced motor fluctuations and dyskinesias [9]. Since that time, this has been used all over the world and several thousands of patients have been operated and improved, making this method the reference surgical procedure for advanced PD. In this chapter, we will not consider any other techniques but DBS, neither any other targets but the STN.

## **RATIONALE**

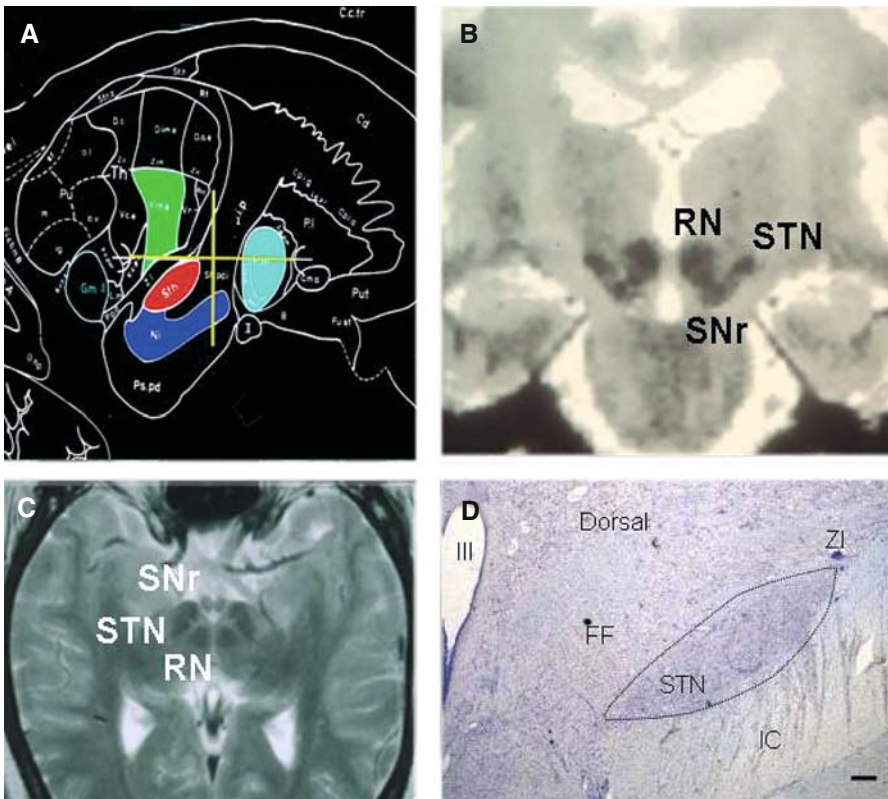
### **1. ROLE OF STN IN THE CONTROL OF MOTRICITY**

The basal ganglia (BG) are closely involved in the control of movements, and subsequently in the genesis of movement disorders, when a component of this network is altered by a pathological process, such as the nigrostriatal degeneration which is at the basis of PD. This results in a dysregulation of the function of these networks which interconnect the various nodes of the networks, most often resulting in an abnormal firing pattern made of a combination of hyperactivity and bursting, creating an irregular activity, the most demonstrative being associated with tremor and observable in several nuclei of the network, such as the thalamus, the STN, and the internal pallidum. A simplistic approach towards therapeutic application is to consider that symptom alleviation could be obtained from alteration of these abnormal activities, either by suppression

(obtained by ablative surgery) or by functional inhibition, such as delivering a sort of blank noise, achieved by high-frequency stimulation (HFS) which would jam or mask or disrupt the abnormal bursty hyperactivity.

## 2. ANATOMY OF STN

There is a consensus to consider the STN as a major driving force of BG activity and hence a key influence on movement control, together with cognitive and limbic-type functions. In particular, the cortex is thought to drive BG circuitry, not only through the striatum but also through the STN. It is not surprising that dysfunction of this nucleus generates clinical symptoms



**Fig. 1.** Subthalamic nucleus. **A** The STN nucleus (red) is above the SNr (substantia nigra pars reticulata, dark blue), behind and medial to GPI (pallidum internus, pale blue), anterior, inferior and more medial to the Vim (ventral intermedius of the thalamus, green). **B** Coronal and **C** axial T2 weighted image showing the hyposignal of the Red Nucleus, the STN and the SNr. **D** Nissl stained coronal section of a Rhesus monkey brain showing the densely homogeneous cluster of subthalamic nucleus (STN) neurons surrounded by fibers in the ZI zona incerta, IC internal capsule, FF fields of Forel. Scale bar = 100  $\mu$ m. III: third ventricle

and that it has become a therapeutic target. The STN is generally oval-shaped and lies on the inner surface of the peduncular portion of the white matter of the internal capsule (Fig. 1). More caudally, the medial part of the nucleus overlies the rostral portions of the substantia nigra complex. The STN has a high density of darkly Nissl-stained cells; its boundaries can be distinguished clearly from surrounding diencephalic structures. Each gives rise to several spiny dendritic processes, parallel with the rostrocaudal axis, and remaining within the boundaries of the STN. The dominant neurotransmitter associated with the STN cells is glutamate, which exerts extremely powerful excitatory effects on its target structures and could be a major driving force of the BG circuitry. The STN can be divided into distinct functional sectors: (i) a large sensorimotor dorsolateral, where cells have high spontaneous tonic activity with irregular bursts [8] and respond by increased firing to passive movement of the contralateral limbs; (ii) a small associative ventromedial, where cells are activated during visual oculomotor tasks; (iii) a limbic sector, occupying the medial tip of the nucleus, receiving inputs from limbic cortex and ventral regions of the globus pallidus. The STN has major connections with primary motor cortex, the external segment of the globus pallidus (GPe), substantia nigra pars reticulata (SNr) and the pedunculopontine tegmental nucleus (PPN); minor connections are with the striatum, intralaminar nuclei of the thalamus and various brainstem nuclei. STN has no projections to the cortex, which in turn provides a major input from layer V to the STN, mainly from primary motor cortex, and to a lesser extent, from prefrontal cortex. The STN cells project to either the internal segment of the globus pallidus (GPi) or the GPe, not to both. STN cells lying caudal and medial in the nucleus project to the GPi, while cells lying centrally in the nucleus project to the GPe. The STN sends excitatory inputs to both GPi and GPe but receives the heaviest inhibitory gabaergic inputs from the GPe only. The STN also projects to the other BG output nucleus, the SNr. There is also a direct but sparse STN projection to the SNc, which could still generate glutamate excitotoxicity in the parkinsonian condition. Since the STN projects to both the globus pallidus and SNr, which constitute the output systems of BG, prior to arrival of striatal signals, it might influence the whole output of the BG. In view of recent experimental evidence, the PPN has become included by most authors in the BG scheme and might be a contributing factor in generating the overactivity of the STN in PD cases. Reciprocal connections between PPN and STN have been documented. STN cells project directly to the PPN (pars compacta portion) and not elsewhere and receive in turn an excitatory cholinergic (and glutamatergic) projection.

### 3. PHYSIOLOGY OF STN

Dysfunction of the STN leads to motor disorders. The lesion of the STN in humans induces hemiballism. Conversely, STN overactivity (oscillatory

bursts and synchronicity) induces PD symptoms (akinesia, rigidity and tremor) [9]. Further, in PD patients and MPTP-treated monkeys, both lesion and HFS of the STN alleviate the PD symptoms, presumably by reducing the BG output. For these reasons, the STN is viewed as a centrepiece of pathophysiology in PD and has become a popular surgical target for relief of motor symptoms.

## **DECISION-MAKING**

The best indication for HFS, particularly for STN HFS, is the idiopathic PD, defined as the association of at least one of the triad symptoms and levodopa responsiveness.

### **1. CLINICAL INDICATIONS AND GOOD PROGNOSIS FACTORS**

The best indication is for idiopathic PD patients in whom the main symptoms of the triad (bradykinesia, rigidity, and tremor) will be significantly improved [5, 9–11]. The percentage of improvement with the best optimal antiparkinsonian medication or suprathreshold dose of levodopa is highly predictive of a similar improvement after optimal placement of the electrodes into the STN [5]. Severe levodopa-related motor complications are also significantly improved, which plays a major role in the improvement of the quality of life [6]. This is explained by the mechanism of dyskinesia induction, related to the pulsatile administration of levodopa.

### **2. CONTRAINDICATIONS**

Dementia, as well as cognitive deficits, are not improved by STN HFS. Moreover, they may be elements of an atypical parkinsonian syndrome, or the entrance of the patient in a stage of additional system degeneration, in particular, cholinergic, or their entrance in a stage of the disease where their quality of life will be mostly impaired by the cognitive disorder. All surgical contraindications (anticoagulants, terminal cancer, infectious disease and immunodeficiency, etc.) apply to the selection of the patient for DBS in general. Additional contraindications are related to the generation of high-frequency electrical side effects which may interfere with sensing devices such as in cardiac pacemakers and defibrillators.

### **3. BAD PROGNOSIS FACTORS**

Age, as in all surgical therapies is more or less negatively related to the general outcome, but this varies for each patient.

Gait disturbance has to be taken into account in the decision-making process. When freezing (usually responding to levodopa when it is due to

bradykinesia) persists in the on-medication period, it is usually not improved by STN HFS (and might be improved by the low-frequency stimulation of the new PPN target [13]).

Speech is improved, but much less than the other motor symptoms [7]. Hypophonia present before surgery might be worsened after, particularly when the medication doses are significantly decreased.

Atypical Parkinsonisms (multiple systemic atrophy, progressive supranuclear palsy) are usually not improved, at least not significantly. This should be carefully balanced, the improvement of the motor symptoms being sometimes of a real value for the patients even for a relatively short period of time.

#### **4. FREQUENTLY ASKED QUESTIONS**

Previous ablative surgery (thalamotomy, pallidotomy, etc.) is not a contraindication for DBS in general, and of STN in particular, provided that the ablative procedure has not destroyed the target itself.

When a previous DBS (STN, other targets) has failed, while all selection criteria were fulfilled to predict a beneficial effect, it is always possible to reimplant at other targets. Moreover, it is not even necessary to remove the inefficient electrode, situated by definition elsewhere than in the right target. We have reoperated several patients in whom the electrode was not satisfactory or leading to side effects, and the new electrode was in all cases more efficient and beneficial.

### **SURGERY**

#### **1. PREPARATION OF THE PATIENT AND LIST OF NECESSARY EQUIPMENT**

The head is shaved, although some teams do not do so. Head, neck and superior part of the torso are scrubbed. The surgery is stereotactic, using a frame (Radionics, Leksell, Talairach, etc.), although some teams favour frameless stereotaxy, the advantages of which still are to be established. Intraoperative X-ray setup is used, but not by all teams. The use of stereotactic robots is still limited to high-tech centers. Intraoperative electrophysiology requires specific equipment (microelectrodes, data acquisition stages, data processing softwares) which are increasingly commercially available and user friendly; and skilled electrophysiologists. DBS hardware is mandatory and currently available on the market from an increasing number of companies.

#### **2. OPERATIVE TECHNIQUES**

The procedure described in this chapter is the one followed in Grenoble and is applied to all targets (STN, GPi, Vim, PPN, subgenual cortex CG25). This does

not pretend to be the ultimate procedure to be followed, but just describes the state of the art of the method in our team. There are obviously other ways to perform it, as reported by other teams, as well as, depending on the future technical improvements, the method might evolve in our own team.

### 2.1 Preoperative imaging and planning

Stereotactic ventriculography is performed under general anesthesia, on a modified Talairach frame, using four transcranial hollow screws (Dixi, Besançon, France), allowing reproducible replacements, a biorthogonal tele X-ray setup, and flat digital detectors. Four pins held by verniers of the four posts of the frame are inserted into the holes of the screws. The millimetric values recorded on the verniers will be reused for subsequent repositioning of the patient in an exactly similar position. A Cushing cannula is inserted in the right frontal horn at 6.5 cm from the skin surface, using a twist drill (9 cm from nasion, 2.5 cm from midline). Two milliliter of air are injected to check its correct placement. X-ray images are acquired in a 12 s sequence, during the injection of 6.5 ml of contrast medium (Iopamiron, Schering). This is immediately followed by X-rays taken in the anterior-posterior direction, usually without any new injection of contrast medium.

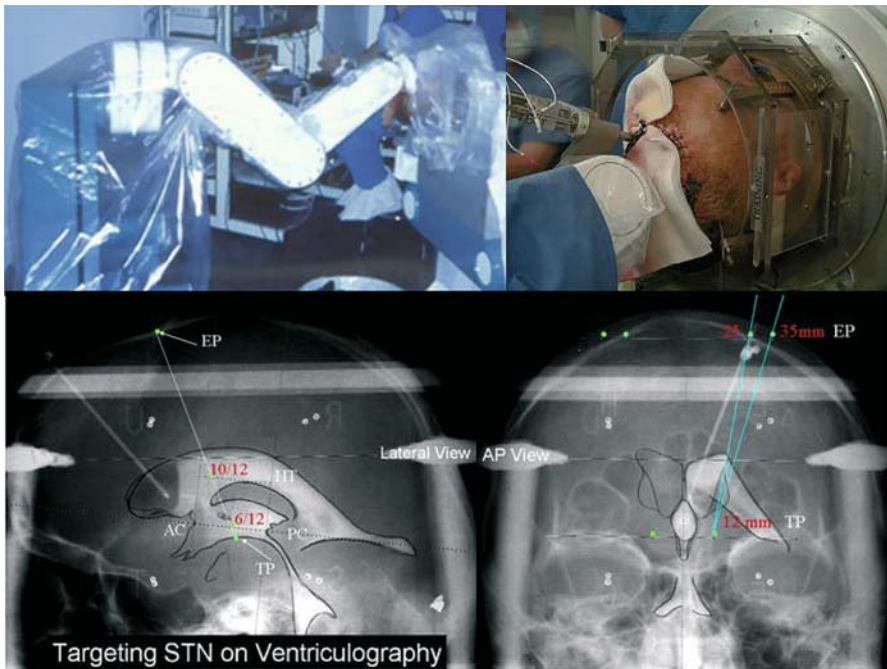
Stereotactic MRI is performed within 24 hours, using a stereotactic MRI localizer made of plates containing an N-figure tube filled with copper sulfate, the dimensions of which are coherent with the stereotactic frame used for ventriculography and with the angiolocalizer features.

Planning is made by merging ventriculographic and MRI images and constructing the stereotactic target by graphic tools and subroutines of the neuronavigation software.

The STN target construction is based on ventriculographic landmarks: anterior commissure (AC), posterior commissure (PC), height of the thalamus (floor of the lateral ventricle), and 3rd ventricle midline (Fig. 2, Table 1). This X-ray target is fused with the MRI images (3D axial T1 and coronal T2 weighted, with contrast injection) imported into the Voxim software of the robotized arm (Neuromate), through the hospital image network.

Coherence of X-ray and MRI data is checked by matching two anatomical structures, AC and PC, clearly visible on both modalities. They usually match, but there is often a discrepancy, up to 2 to 3 mm between AC images for instance, stressing the still unsolved problem of MRI based localization.

If this is satisfactory, one checks the matching between the ventriculography based theoretical STN target, and the T2 weighted MRI actual image of STN. If there is a significant mismatch, the laterality is corrected. If the MRI-ventriculography coherence is not satisfactory, the theoretical target is used alone. The MRI planning of the entry point must avoid the cortical vessels, the deep vessels in the sulci, if possible the ventricle, and the caudate nucleus, possibly related to postoperative confusion. The planning data are then exported to the Neuromate controller.



**Fig. 2.** Robotized stereotactic procedure. The procedure is based on a robotized stereotactic arm (*upper left*), physically linked to the stereotactic frame (*upper right*) holding the head of the patient. The tool holder of the robot holds the microdrive insuring the intracranial progression of the microelectrodes. Stereotactic ventriculography performed in a biorthogonal teleradiological setup produces lateral (*lower left*) and antero-posterior (*lower right*) images with a low (1.05) magnification coefficient allowing a precise indirect targeting, based on the statistical values of the coordinates of the successfully implanted electrodes, the precise location being confirmed by the electrophysiological investigation

**Table 1.** Coordinates of the STN target

	Antero-post 1/12° AC-PC	Verticality 1/8° HT	Antero-post (mm)	Verticality (mm)	Laterality (mm)	AC-PC (mm)	HT (mm)
Mean	5.19	-1.25	10.91	-2.70	11.57	24.04	10.49
SD	0.70	0.70	1.47	1.51	1.76	2.68	1.55

## 2.2 Electrode implantation

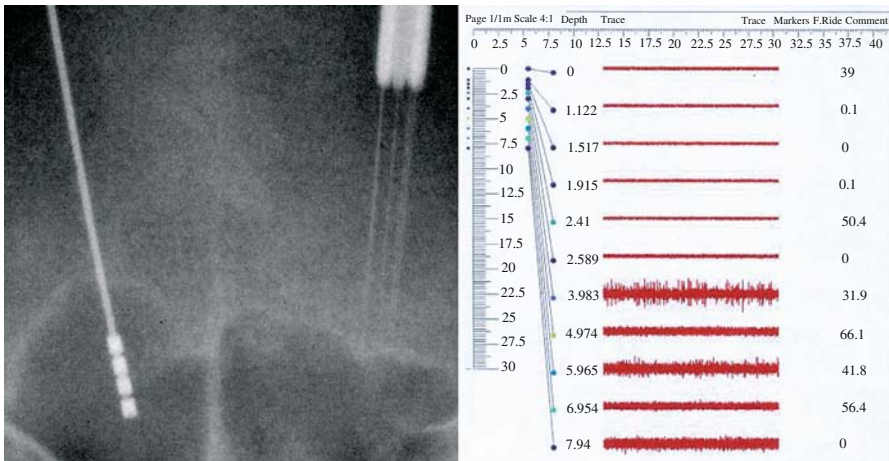
### *Implantation track*

It is performed under local anesthesia three days later. The patient is reinstalled on the frame, the pins reinserted into the hollow screws using the previous

vernier readings. The correct replacement is checked by X-rays. The Neuromate is launched and reaches the preplanned position on the first side to be operated (contralateral to the worst clinical side). An arciform skin incision (postero-medial concavity) is cut, centered on the entry point designated by the Neuromate. The scalp is elevated from the skull, a 6 or 9 mm burr hole is performed, through the Neuromate tool holder. The electrode guide tool (Ben Gun with five parallel channels, distance of 2 mm from axis to axis) is introduced down to the dura, which is not opened. The microelectrode guide tubes are introduced by perforation of the dura mater with sharp styletes and then lowered into the brain with blunt styletes, which are replaced by microelectrodes (tip diameter, 1  $\mu\text{m}$ ; impedance, 1–10 M $\Omega$ , FHC, Bowdoinham, ME) in their own guide tubes, inserted at 15 mm above the target point, which is controlled by X-ray. They are connected to the electronic stages of the data acquisition and processing system (AlphaOmega Neurotrack) and moved towards the target by a micromanipulator.

#### *Microrecording of neuronal activities*

The electrophysiological pattern of the STN units, as reported in literature [8], is made of asymmetrical spikes at rather high frequency, exhibiting bursting patterns in PD. They respond to passive contralateral limb movements and proprioceptive inputs, and exhibit tremor synchronous activity. The length of recording in STN varies from 5 to 6 mm, between two silent zones



**Fig. 3.** Microrecording and stimulating electrodes. During a one stage procedure, microrecording of the neural activity is obtained during the progression of a set of five microelectrodes (right side of the X-ray image), at different depths along the track. The STN target is recognized when the electrode records a high-frequency and high-amplitude spike activity (line 7 of the right image) after the neural silence typical of the Internal capsule (6 first lines). The activity of the SNr is found deeper (line 9) and corresponds to the lower boundary of the functional target. The corresponding microelectrode is then replaced by a chronic tetrapolar stimulator electrode (left side of the X-ray image)



corresponding to white matter, the first one between zero and 2 to 3 mm below the AC-PC plane (subthalamic area and anterior zona incerta), the other one between 9 and 11 mm corresponding to the white matter just above the substantia nigra reticulata (SNR). SNR neurons fire in regular, symmetrical, large amplitude spikes, generally unresponsive to external stimuli (Fig. 3).

Microstimulation is performed with the microelectrode used for recording, with current intensities up to 10 mA for short (10–30 s). This essential step allows the observation of beneficial effects (improvement of PD symptoms) inside the target and of side effects (limiting factors for efficient stimulation) outside of it. The rigidity of the wrist, not requiring patient participation, is the most convenient test to be semi-quantitatively scored by neurologists in the OR. Speech and akinesia are difficult to test consistently over the whole duration of the surgery. Tremor is an excellent index but is often absent in advanced stages of PD. The side effects depend on the surrounding fiber tracks. Laterally to the STN, muscular contraction (face and upper limb mostly) are induced by the excitation of cortico-spinal fibers, and cortico-nuclear fibers induce conjugated binocular deviation towards the contralateral side. More posterior, lemniscus medialis fibers induce paresthesias. Medially to the STN, and deeper, the oculomotor nerve induces monocular deviation, towards the midline, or either upward or downward. These side effects must be taken into account to avoid placing the chronic electrode in these places where postoperative side effects would limit the possibilities of efficient stimulation.

When the best track (best beneficial effects, least side effects, largest security margin between thresholds for improvement and for side effects) has been identified, the corresponding microelectrode is removed and replaced by a chronic lead (DBS 3389, 1.5 mm contact length, 0.5 mm spacing, 1.27 mm diameter), sutured to the rim of the burr hole (using a small oblique twist drill), and (after removing the other microelectrodes) embedded in dental cement, preventing CSF leakage as well as backward infection. The external part of the electrode is folded under the periosteum and the skin sutured.

The Neuromate is then aimed at the other side, for a similarly preplanned procedure.

#### *Postoperative imaging and IPG implantation*

Three days later, postoperative MRI is performed as in the preoperative stage: the patient is replaced into the MRI localizer as after ventriculography, by resetting the readings of the four pins at the previously recorded data. Axial T1 and coronal T2 weighted sequences, performed without contrast, are imported into the software for control and comparison of electrode positions. It is important to check the absence of any postoperative bleeding (subdural or intraparenchymal) and it provides a legal document. This systematic postoperative control has never induced any side effect or complications. This observation is important, as currently, the recommended threshold values of the SAR (surface absorption rate) are lowered for safety reasons, making it more

difficult to perform and jeopardizing the quality control of the surgical procedures. After the MRI examination, the screws are removed and the skin incisions are sutured with non-resorbent material.

Five days after electrode implantation, electrodes are connected under general anesthesia to low profile extensions, tunneled (sufficiently deep to prevent adhesion to the subdermal area of the skin of the neck) down to the subclavicular area (or, for cosmetic reasons, under the breast, using a subaxillary incision) and connected to the implantable pulse generator (IPG; Kinetra, Medtronic, Minneapolis, MN) inserted in a subcutaneous pouch. After haemostasis and local Rifampycine irrigation, the skin incisions are sutured. Incisions must not cross or overlay implanted material.

### 3. POSTOPERATIVE CARE

#### *Programming*

Programming is started by the neurologists during the week following IPG implantation.

There are not 64 combinations, but only 4: frequency at 130Hz, pulse width at 60 $\mu$ s, case positive, DBS contact negative. The voltage is set at 0V and progressively increased while observing clinical benefits and side effects, subsequently investigating the four contacts. The typical setting is 2 to 3.5 V.

At the end, one, or sometimes two, contacts appear to be the best (highest threshold for side effects, lowest threshold for clinical improvement). Using this strategy, one cannot miss a good setting. Conversely, all possible combinations of contacts and parameters cannot transform a failed surgery into success. Properly setting the balance of stimulation parameters and drug doses is the responsibility of the neurologist, whose task strongly depends on the accuracy of implantation.

When the best contact has been selected, it is convenient to increase the voltage progressively over several days to avoid the dyskinesias. They tend to amend and particularly their threshold increases along time. At the same time, the medication, already significantly reduced before the operation, is further decreased in accordance with the clinical improvement, and set as a compromise value, low enough to prevent the appearance of dyskinesias, and high enough to prevent apathy and hypophonia.

#### *Surgical postoperative care*

Usually, patients are returned to their room in the ward and closely followed-up by the nurses and the resident. As surgery was done under local anesthesia, patients are awake and if their level of alertness permits, they may even have a light food and liquid intake. There is normally no need for analgesic medication, and depending on the off clinical level, medication can be re-prescribed by the neurologist. The wounds are checked regularly and the sutures removed on day 10.

There might be confusion in 20% of the patients, spontaneously regressing within 3 days to 3 weeks.

When the patient is alert immediately postoperatively, quite often the clinical status is improved, due to a postoperative microlesioning effect which tends to heal within 2 or 3 weeks, and allowing during this time a decreased drug regimen.

#### 4. LONG-TERM RESULTS

##### 4.1 Clinical improvement at six months [6]

In an unblinded randomized-pairs trial on 156 patients under 75 years of age with advanced PD and severe motor symptoms, neurostimulation of the STN plus medication was compared to medical management [5]. The primary end points were the changes from baseline to six months in the quality of life (Parkinson's Disease Questionnaire, PDQ-39), and the severity of symptoms without medication (Unified Parkinson's Disease Rating Scale, part III, UPDRS-III).

Pairwise comparisons from baseline to six months showed that neurostimulation, as compared with medication alone, caused greater improvements in the PDQ-39 (50 of 78 pairs,  $P=0.02$ ) and the UPDRS-III (55 of 78,  $P<0.001$ ), with mean improvements of 9.5 and 19.6 points, respectively. Neurostimulation resulted in improvements of 24 to 38% in the PDQ-39 subscales for mobility, activities of daily living, emotional well-being, stigma, and bodily discomfort and 22% improvement in the physical summary score of the SF-36, a generic quality-of-life scale.

The mean UPDRS-III score improved by 41% in the off medication state (from  $48.0 \pm 12.3$  at baseline to  $28.3 \pm 14.7$  at six months) and by 23% in the on medication state (from  $18.9 \pm 9.3$  at baseline to  $14.6 \pm 8.5$  at six months). UPDRS-II markedly improved (by 39%). The mean PDQ-39 summary index score improvement was 23.9% ( $41.8 \pm 13.9$  at baseline and  $31.8 \pm 16.3$  at six months), the dyskinesia scale obtained while the patient was not taking medication improved from  $6.7 \pm 5.3$  to  $3.1 \pm 3.5$  (54%).

The dopaminergic equivalents were reduced by 50%. The amplitude of stimulation was  $2.9 \pm 0.6$  V; the frequency,  $139 \pm 18$  Hz; and the pulse duration,  $63 \pm 7.7$   $\mu$ s.

##### 4.2 Clinical improvements at five years [10]

###### *Off medication evaluation in the off medication state*

STN stimulation improved the total score of UPDRS-III, as compared to the baseline value ( $55.7 \pm 11.9$ ), by 66% at one year, 59% at three years and 54% at five years. At five years, the improvement compared to baseline was 75% for tremor, 71% for rigidity, and 49% for akinesia. Postural stability and gait also improved, but speech improved only during the first year and then pro-

gressively returned to the baseline at five years. The total score of UPDRS-II, as compared to baseline value ( $30.4 \pm 6.6\%$ ), improved by 66% at one year, 51% at three years, and 49% at five years, the worsening between one and five years was significant ( $P < 0.001$ ).

The improvement was dramatic, postoperatively in the off medication condition, at five years. Most patients were independent in the activities of daily living in the off medication condition (mean score on Schwab and England's scale, 73%), whereas before surgery most had been fully dependent on a caregiver (Schwab and England's scale, 33%). Before surgery, off medication painful dystonia was observed in 71% of the patients, while it was present in only 19% at one year and 33% at five years.

#### *On medication evaluation*

Motor function and activities of daily living in the on medication state did not improve after the stimulation of the STN, there were no significant changes for tremor and rigidity but scores for akinesia, speech, postural stability, and freezing of gait worsened ( $P < 0.001$ ), which resulted in the worsening of the total score of UPDRS-III and -II. Schwab and England's score was unchanged, and compared to the baseline, the disability related to dyskinesia decreased by 58% and its duration by 71%. Twenty-nine of 42 patients (69%) had levodopa-induced dyskinesias before surgery, and only four at three months and two at five years.

#### *Neuropsychological evaluation*

There were no significant changes on the Beck Depression Inventory, the Mattis Dementia Rating Scale was worse at five years reflecting progressive dementia in three patients, but the changes were not significant ( $131 \pm 18$  versus  $136 \pm 10$  at baseline,  $P = 0.07$ ). The average score for frontal lobe function was slightly worse at five years. ( $37.3 \pm 11.2$  versus  $40.4 \pm 9.2$ ,  $P = 0.03$ ).

#### *Medications and stimulation settings*

The levodopa equivalent daily dose decreased from  $1409 \pm 605$  mg at baseline to  $584 \pm 366$  mg at one year,  $526 \pm 328$  mg at three years, and  $518 \pm 333$  mg at five years ( $P < 0.001$ ). At five years, 11 or 42 patients (26%) were no longer taking levodopa and three were not taking any dopaminergic drugs. The stimulation settings after one year ( $2.8 \pm 1.6$  V,  $143 \pm 19$  Hz,  $61 \pm 6$   $\mu$ s) were not significantly different at five years ( $3.1 \pm 0.4$  V,  $145 \pm 19$  Hz,  $64 \pm 12$   $\mu$ s). Monopolar stimulation was used in 90% of patients at one and five years, only one patient required replacement of the stimulators within the five first years.

## **5. COMPLICATIONS**

Three-hundred and twenty-five consecutive bilateral STN cases operated since 1993 (97.5% bilaterally operated patients, 641 implanted sides) have been reviewed. All adverse (complications and side effects) effects (AE)

have been considered, regardless of their severity, in an attempt to be exhaustive. AE have been classified as follows:

- Benign: asymptomatic (e.g. only MRI visible), no need for a prolonged stay, no need for reoperation
- Significant: symptomatic, need for prolonged stay or reoperation, but no permanent deficit
- Severe: symptomatic, needing reoperation or specific treatment, permanent deficit.

The number of patients without any complication is an important parameter.

57.5% of the STN patients had no AE, 42.5% had (at least one) AE: 19.8% severe, 32.5% significant, 47.7% benign. 7.4% are related to ventriculography and frame setting, 20.9% to electrode implantation, 13.5% to IPG and hardware, and 31.1% to stimulation. Infections (4.4% of cases: 1.1% severe, 1.3% significant, 1.9% mild or benign) are mostly superficial, hardware related.

Haemorrhages (8.4% of cases: 3.4% asymptomatic only MRI visible, 4.4% transient, 0.6% permanent) are mostly at the entry point or subcortical, rarely in the target.

Neuropsychological and behavioral complications occurred were multifactorial, partly related to treatment changes and to societal issues. Transient hypomania developed in 8%, and transient apathy in 5%, responding to medication. Apathy did not respond to dopaminergic treatment in 12% and dementia appeared in three patients (7%) between the third and the fifth year. 24% exhibited transient postoperative confusion, 17% postoperative depression, there were 1.3% of suicide attempts, and only one (0.2%) suicide. 31% of patients had eye lid opening apraxia at three months, 19% at five years. Stimulation-induced dyskinesias was reversible by decreasing the voltage. Most of the patients gained weight (mean, 3 kg; maximum, 5 kg). Three patients died (1 three years after a postoperative intracerebral hemorrhage, 1 myocardial infarction eleven months after surgery, and 1 suicide six months after surgery).

## HOW TO AVOID COMPLICATIONS

The higher morbidity of STN surgery (compared to GPi or Vim) does not seem to be related to the duration of surgery (STN and GPi procedures are equivalently long), to the number of passes (both STN and GPi targets are targeted by the same procedure). The difference might be due more to the entry point, target, age and disease. There are biases such as the evolution of the methods, the careful record of adverse effect along time, and the multiplicity of operators.

Implantation-related complications could be avoided using a very careful planning on MRI, to avoid the vessels, the sulci (which contain a high density

of vessels), the caudate nucleus (where preliminary data suggest that its bilateral traumatism by the exploring tracks during the microrecording might cause postoperative confusion), and finally the ventricle (where some vessels, such as the thalamo-caudate vein, may be hit). Also, the re-entry of the cannula and electrodes into the parenchyma at the level of ependyma might be a cause of deviation of electrodes. Targeting on MRI, to be reliable, assumes that the brain is in the same situation than it was at the time of the acquisition of the images. This is definitely not the case when the dura is opened, which might cause a loss of CSF, which is sometimes significant. This is why the dura is not opened but just punctured by the guide tubes, preventing CSF leakage. Opening the dura is usually performed to observe cortical vessels, sparing them or allowing coagulation. This is actually a false security, as the vessels situated in deeper layers, and in the sulci, are not visible.

Hardware-related complications must be prevented by the improvement of the hardware design. This must be required from the companies under the advices of the surgeons: for instance, the shape and size of the transcranial screws used in our procedure have been modified, and the extra-skull part is better long than short in order to avoid that the scalp covers them and creates inflammation with an opportunity for external to internal infection. Low-profile extensions are currently provided, and we may expect new perspectives in nanotechnologies, leading to miniaturized systems. The hardware must not be crossed or overlaid by the incisions, it must be placed under the periosteum or the aponeuroses in order to prevent their migration towards the surface. The leads and extensions must be tunnelled sufficiently deep to prevent adhesion to the subdermal area of the skin of the neck.

Duration of surgery, microelectrode recording, number of passes, are poorly related to the clinical outcome and to the complication rate, although several publications have addressed this issue [8].

The neurocognitive complications are multifactorial. A careful inventory of the preoperative neuropsychiatric episodes (depression, delusion, suicide attempts or ideas, etc.) may help eliminating patients who could be predicted to impair along the various surgical steps. Postoperative societal changes may be responsible, at least partly, for depression and even suicide. The patients cannot cope with the important life, social, familial, professional, changes to which they have not been prepared. Serious pre- and postoperative psychological preparations should help them to readapt in is why they are not so clearly reported after ablative surgery, where, in particular due to more often unilateral procedures, the results are not so visible. Depression and suicide are also observed in all surgeries significantly improving the patients, such as breast plastic surgery, as well as after recovery of freedom for long-term prisoners. These changes are more related to the magnitude of the improvement than to the target.

The stimulation related complications can be improved by optimal electrode placement of the avoiding diffusion to neighbouring structures responsible for adverse effects, which limit the stimulation voltage. Clear recognition of

the combined roles of stimulation and medication, can prevent some neurocognitive side effects: for instance, speech might be impaired by dysarthria induced by stimulation of the cortico-nuclear fibers in the internal capsule leading to the contraction of the laryngeal muscles, hypophonia might be related to the decrease of medication, not sufficiently compensated by the STN HFS induced improvement of speech [7]. Similarly HFS induced dyskinesias can be alleviated by decreasing either the drug dosage or the stimulation voltage.

Comparing the main targets, severe and significant adverse effects are more frequent in STN (22.2% of 325 patients) than in GPi (7.9% of 63 patients) and in Vim (8.6% of 138 patients). The reason might be that most STN patients have a long history of PD, are older, in a severe condition. Vim stimulation was performed in younger patients, mostly with tremor only and therefore in a better condition. GPi stimulation also involves young patients with dystonia, and the anatomical situation of GPi is less critical than for STN.

The number of complication-free patients clearly increased along the series of 300 bilateral STN cases, from 37.3% to 72.7% between the first and the last groups of 150 cases. The reason is unclear and could be due to a technical improvement (such as redesigned bone screws), to a more systematic use of MRI to determine the entry point in the last 150 patients, or to a less careful record of complications.

One must also consider, from the point of view of the intention to treat, the complications which happened during the selection or pre-implantation phases of patients who were finally not operated. This accounted for 2.6% of complication (haemorrhages, coagulation problems, cognitive breakdown) in 540 cases including all indications and all targets.

## CONCLUSIONS

The STN is currently the first-choice target for treatment of advanced PD cases, although a good double-blind controlled study to precisely establish the respective values of the internal pallidum and of STN is still lacking. This prominent position of STN as the most favored target is due to the following:

- Its strategic anatomo-functional situation, which makes it a central station, where several circuits and networks intercross and interact.
- Its MRI visibility.
- Its typical microelectrode recording pattern.
- Its relatively small size.

These advantages are also counteracted by drawbacks for the same reasons.

- Small size: the beneficial motor effects are associated to side effects due to the simultaneous involvement of other functions, such as mood in particular.

- Easy spreading of the current to internal capsule (motor side effect), lemniscus medialis (sensitive side effects), oculomotor nerve fibers (ocular deviation), hypothalamus (behavioral changes).

The clinical effects are depending upon careful patient selection, accuracy of placement of the electrodes, delicate balance between medical treatment and stimulation.

Complications seem more frequent than in the thalamus or in the pallidum, because again of its small size and situation, which would call for a better electrode design.

Despite the general agreement that STN is the best target and that STN stimulation is the most efficient surgical treatment for advanced PD cases, the best reported improvement ratios (about 70%) could be increased, the coverage of symptoms could be optimized and the side effects could be reduced. This calls for improvements at several technological levels, including progresses in MRI visualization, correction of the MRI distortion, improved electrophysiological methods to delineate the functional target (such as online more sophisticated data processing), new design of electrodes aiming at the three-dimensional steerable stimulated volume, new paradigms and waveforms pulses, multiple targets simultaneously implanted, optimized hardware design to decrease the extracerebral complications.

Keeping in mind that deep brain stimulation techniques are not aimed at becoming the unique treatment of neurodegenerative diseases, but are indicated in advanced cases, unless their neuroprotective effect would be demonstrated, which is not currently the case, one should resist the temptation of making these techniques too fast and expedite at the expense of the patients' benefit, which remains the only goal of these approaches.

### Acknowledgements


The author wants to thank his co-authors John Mitrofanis, Stephan Chabardes, Napoleon Torres, Valerie Fraix, Paul Krack, Pierre Pollak, Sylvie Grand, Jean François LeBas for their important contributions at different levels to this chapter.

### References

- [1] Aziz TZ, Peggs D, Sambrook MA, Crossman AR (1991) Lesion of the subthalamic nucleus for the alleviation of 1-methyl-4-phenyl-1,2,3,6-tetrahydropyridine (MPTP)-induced parkinsonism in the primate. *Mov Disord* 6: 288-292
- [2] Benabid AL, Pollak P, Louveau A, Henry S, de Rougemont J (1987) Combined (thalamotomy and stimulation) stereotactic surgery of the VIM thalamic nucleus for bilateral Parkinson disease. *Appl Neurophysiol* 50: 344-346



- [3] Benazzouz A, Gross C, Feger J, Boraud T, Bioulac B (1993) Reversal of rigidity and improvement in motor performance by subthalamic high-frequency stimulation in MPTP-treated monkeys. *Eur J Neurosci* 5: 382-389
- [4] Bergman H, Wichmann T, DeLong MR (1990) Reversal of experimental parkinsonism by lesions of the subthalamic nucleus. *Science* 249: 1436-1438
- [5] Charles PD, Van Blercom N, Krack P, Lee SL, Xie J, Besson G, Benabid AL, Pollak P (2002) Predictors of effective bilateral subthalamic nucleus stimulation for PD. *Neurology* 59: 932-934
- [6] Deuschl G, Schade-Brittinger C, Krack P, Volkmann J, Schäfer H, Bötzel K, Daniels C, Deuschländer A, Dillmann U, Eisner W, Gruber D, Hamel W, Herzog J, Hilker R, Klebe S, Kloss M, Koy J, Krause M, Kupsch A, Lorenz D, Lorenzl S, Mehdorn HM, Moringlane JR, Oertel W, Pinsker MO, Reichmann H, Reuss A, Schneider GH, Schnitzler A, Steude U, Sturm V, Timmermann L, Tronnier V, Trottenberg T, Wojtecki L, Wolf E, Poewe W, Voges J (2006) German Parkinson Study Group, Neurostimulation Section. A randomized trial of deep-brain stimulation for Parkinson's disease. *N Engl J Med* 355: 896-908. Erratum in: *N Engl J Med* 355: 1289
- [7] Gentil M, Chauvin P, Pinto S, Pollak P, Benabid AL (2001) Effect of bilateral stimulation of the subthalamic nucleus on parkinsonian voice. *Brain Lang* 78: 233-240
- [8] Hamel W, Schrader B, Weinert D, Herzog J, Müller D, Deuschl G, Volkmann J, Mehdorn HM (2002) Technical complication in deep brain stimulation. *Zentralbl Neurochir* 63: 124-127
- [9] Hutchison WD, Allan RJ, Opitz H, Levy R, Dostrovsky JO, Lang AE, Lozano AM (1998) Neurophysiological identification of the subthalamic nucleus in surgery for Parkinson's disease. *Ann Neurol* 44: 622-628
- [10] Krack P, Batir A, Van Blercom N, Chabardes S, Fraix V, Ardouin C, Koudsie A, Dowsey-Limousin P, Benazzouz A, Le Bas JF, Benabid AL, Pollak P (2003) Five-year follow-up of bilateral stimulation of the subthalamic nucleus in advanced Parkinson's disease. *N Engl J Med* 349: 1925-1934
- [11] Limousin P, Pollak P, Benazzouz A, Hoffmann D, Le Bas JF, Broussole E, Perret JE, Benabid AL (1995) Effect of parkinsonian signs and symptoms of bilateral subthalamic nucleus stimulation. *Lancet* 345: 91-95
- [12] Limousin P, Krack P, Pollak P, Benazzouz A, Ardouin C, Hoffmann D, Benabid AL (1998) Electrical stimulation of the subthalamic nucleus in advanced Parkinson's disease. *N Engl J Med* 339: 1105-1111
- [13] Stefani A, Lozano AM, Peppe A, Stanzione P, Galati S, Tropepi D, Pierantozzi M, Brusa L, Scarnati E, Mazzone P (2007) Bilateral deep brain stimulation of the pedunculopontine and subthalamic nuclei in severe Parkinson's disease. *Brain* 130: 1596-1607



### **Alim Louis Benabid**

Alim Louis Benabid is Scientific Advisor at the Atomic Energy Commission and is in charge of developing the Clinatec Institute for application of nanotechnologies to Neurosciences. He was born on May 2nd 1942, obtained his M.D. in 1970 and his Ph.D. in Physics in 1978. After a postdoctoral fellowship (1979–1980) with Floyd Bloom (Salk Institute, La Jolla), he has been appointed Professor at Grenoble University, in Experimental Medicine until 1983, then in Biophysics until 2007. He was the Director of the INSERM U318 “Preclinical Neurosciences Laboratory” (1988–2007), and from 1989 to 2007, Head of Neurosurgery at the Grenoble University Hospital. He is Coordinator of the Claudio Munari Center for Surgery of Epilepsy and Movement Disorders, at Hospital Ni Guardia in Milan since 1998. His activities belong to neurosurgical robotics, experimental neuro-oncology, functional neurosurgery. He is a member of the Institut Universitaire de France, the Academy of Sciences, the Academy of Medicine and the Royal Academy of Medicine of Belgium, and he received a Doctorate Honoris Causa from the Universities of Galway, Ireland, of London, Ontario, and from McGill University, Montreal. He is Honorary Visiting Professor at Imperial College, London.

**Contact:** Alim Louis Benabid, CEA Minatec LETI, Clinatec building 4022, 17 Avenue des Martyrs, 38054 Grenoble, France  
E-mail: [alimlouis@aol.com](mailto:alimlouis@aol.com)

---

# FUNCTIONAL NEUROSURGERY FOR DYSTONIAS

M. I. HARIZ

## INTRODUCTION

Dystonia is a term first used by Oppenheim in 1911 to describe a peculiar movement and posture disorder in children. Dystonias consist of involuntary movements with spasmodic, often painful, muscle contractions and twisting repetitive movements and/or abnormal postures. Dystonias are classified according to several criteria [5]: Primary (previously called idiopathic torsion dystonia or dystonia musculorum deformans), that can be hereditary (most often due to DYT1 mutation on chromosome 9) or non-hereditary, or secondary dystonias due to trauma, infection, stroke, metabolic abnormality, neuroleptic-induced, etc. Dystonia is also classified according to age of onset (early or late onset) or according to involved body parts (generalized, focal, multi-focal, segmental, hemi-dystonia). The most common dystonia is cervical dystonia, even called spasmodic torticollis for which surgery has been performed since the early 20th century, with myotomies as well as intradural procedures such as sectioning of accessory nerve roots and anterior rhizotomy of C1–C2 (McKenzie and Dandy-Foerster procedures), and later on microvascular decompression of the accessory nerve roots (Jannetta procedure). These methods have yielded inconsistent results, which, together with the high risks of complications, especially concerning swallowing, have prompted a shift towards use of other more lenient techniques [2]. Cerebellar, and epidural cervical stimulation have been tried but abandoned. With the advent of stereotactic techniques, safe and precise surgery on basal ganglia and thalamus became possible and surgical treatment was attempted not only for cervical but also for generalized dystonia. Cooper reported one of the first attempts at treating this disorder with chemopallidectomy in 1956. Eventually, Hassler and Cooper advocated thalamotomies in ventral oral nuclei for both cervical and other focal and generalized dystonias, although here too the results were inconsistent, and the side effects in bilateral thalamotomies were frequent [3]. Nevertheless, unilateral thalamotomy has been widely used for some time, including in children in the seventies and eighties. Today ventral oral thalamotomy is rare but still used by Taira in Japan for focal hand dystonia. Deep brain stimulation (DBS) in thalamus and subthalamic area, including in pallido-fugal fibers has been tried in the 70s by Mundinger in Germany and also

---

*Keywords:* dystonia, peripheral denervation, Bertrand procedure, deep brain stimulation, pallidum, stereotactic surgery, movement disorders

by Cooper but was abandoned because of the cumbersomness of the technique and because of problems with the hardware [11]. Owing to still sub-optimal and inconsistent results of stereotactic procedures, especially for torticollis, Claude Bertrand from Montreal proposed in 1978 the combination of thalamotomy and selective peripheral muscle denervation, and in 1984, he abandoned completely thalamotomy in favor of solely selective peripheral denervation, that came to be later called “the Bertrand procedure” [1, 2].

Following the good results of “Leksell’s posteroventral pallidotomy”, resurrected by Laitinen in 1992, on parkinsonian dyskinesias, pallidotomy was tried on few patients with generalized dystonia by Iacono and Lozano in the mid-90ies. However, since DBS in the pallidum, then in the subthalamic nucleus (STN), overtook pallidotomy as main surgical treatment for Parkinson’s, DBS was tried in same posteroventral pallidal target of Laitinen first by Coubes in 1996 on a child for severe generalized dystonia, then by Krauss in 1999 on patients with cervical dystonias. Especially the dramatic effects obtained by Coubes on generalized dystonia [4] prompted the worldwide spread of this technique in surgical treatment of several types of dystonias. Thus, today the two main surgical methods used are, in order of importance and spread, globus pallidus internus (GPi) DBS for virtually all types of dystonia—albeit with variable results depending on the nature of the dystonia—, and Bertrand’s selective peripheral denervation for some types of cervical dystonia. These two methods will be described in this chapter.

## **RATIONALE**

There is no medical or surgical cure for dystonias and any treatment is therefore only symptomatic. The goal of surgery is to alleviate the painful muscular spasms and involuntary contractions, to facilitate re-establishing of normal movements and normal postures of affected body areas, and thereby to improve the disability of the patient. Depending on the distribution of dystonia, one can perform a peripheral denervation (reserved for certain types of spasmodic torticollis) or a stereotactic procedure targeting the GPi or, more rarely, the motor thalamus.

While the rationale for selective denervation of the main muscles involved in cervical dystonia is obvious, the rationale for pallidal surgery is still not fully elucidated. It has been long known that dystonia results from pallidal dysinhibition of the thalamo-cortical circuitry, and stereotactic surgery has been directed towards interruption of the pathways from pallidum to thalamus at various levels with lesions targeting GPi, pallido-fugal fibres of ansa and fasciculus lenticularis, Forell’s field, ventral oral nuclei of thalamus, and centre median [11].

Recent studies of dystonia patients have demonstrated abnormally reduced excitability of inhibitory connections within the brain and spinal cord, and reduced intracortical inhibition in patients with DYT1 dystonia, which may

disturb normal movement by failing to suppress unwanted movements [6]. PET studies have shown overactivity of prefrontal areas and reduced activity of primary sensorimotor cortex during voluntary movement in patients with primary generalized dystonia. It is believed that this abnormal cortical activity is the result of a decreased thalamocortical inhibition due to a pathologically decreased inhibitory activity of the GPi, which is one main output structure of the basal ganglia projecting to the thalamus. This pathological basal ganglia function has been confirmed by microelectrode recording (MER) studies of pallidal activity in dystonia patients undergoing stereotactic surgery. MER showed reduced firing rates and irregular firing patterns compared to findings of MER in patients with Parkinson's disease. Furthermore, it has been shown that neuronal firing in the GPi correlates with EMG activity from dystonic extremities [6], and local field potential recordings from GPi have shown low frequency oscillatory activity that correlates with dystonic contractions on EMG. Hence, abnormal neuronal firing patterns and excessive low frequency oscillations in GPi, affecting negatively cortical motor function may be a pathophysiological hallmark of dystonia and may provide the rationale for surgery directed at silencing the pathological outflow of the GPi.

## **DECISION-MAKING**

### **1. DIAGNOSTIC CRITERIA**

The diagnosis of dystonia is mainly clinical and is sometimes obvious but often not. The mere fact that in the title of this Chapter, Dystonias, is in the plural form bears witness to the heterogeneity of this condition. The diagnosis of this illness – as well as the indications for surgery – should be discussed together with an experienced movement disorder neurologist, and it is beyond the scope of this Chapter to provide detailed diagnosis of all the forms of dystonias. For this, appropriate literature should be studied [5].

From neurosurgical point of view, it is primordial to establish first if the disorder is indeed a dystonia, and if the symptoms are purely “extrapyramidal” or if they also reflect affection of cortico-spinal pyramidal tract (paresis, spasticity, atrophy), which is not uncommon especially in secondary dystonias. Of equal importance is to establish that the disorder is not psychogenic, which also is not too rare in dystonia-like disorders. In case of torticollis or other focal dystonias, a history of previous or current treatment and its effect is important in the diagnosis, especially the response of the symptoms to botulinum toxin injections. Once the dystonic symptoms and signs have been documented including their onset, evolution, distribution in various parts of the body-focal, multi-focal, segmental, generalized- etc., it is very important from diagnostic and surgical prognostic points of views to establish whether this is a primary or secondary dystonia. Appropriate genetic tests should be taken as there are at least 15 different subtypes of dystonias that can be distin-

guished genetically (viz, DYT 1 mutation in primary generalized dystonia, DYT 11 mutation in myoclonic dystonia, DYT 3 mutation in the rare form of Lubags dystonia, etc.). In suspected cases of non-primary dystonia, the etiology should be sought through careful history of previous diseases and events since birth, including history of previous anoxia, encephalitis, trauma, treatment with neuroleptic, etc., together with laboratory tests for the various metabolic, mitochondrial, enzymatic and other disorders that may provoke dystonia. A MRI of the brain is mandatory to rule out or confirm structural damage anywhere, especially in basal ganglia and thalamus, which if found, will by definition confirm that the dystonia is secondary, and if not found may indicate, but not confirm, that the dystonia is primary.

## 2. INDICATIONS

The “best” indications are in patients with pure primary dystonia of the mobile type, i.e., in hyperkinetic dystonias. The “worst” indications are in secondary dystonias with severe affection also of corticospinal pathways or with fixed postures and orthopedic deformities. In cervical dystonia, the indications for which surgery, DBS or peripheral selective denervation, depend among other issues on pattern of torticollis and on which muscles of the neck that are affected.

The preoperative assessment should include a detailed history of the illness and a comprehensive neurological and general examination of the patient, not forgetting palpation of the affected muscles (especially important in patients with cervical dystonia), and evaluating possible muscular contractures and skeletal deformities of limbs and spine. During examination, one should attempt to distract the patient to evaluate any psychogenic component of the symptom, and also attempt to mentally stress the patient to verify exacerbation of symptoms. Tasks such as walking, undressing, removing shoes and socks, pouring liquid from a cup, drinking, writing, talking and other fine motor movements should be investigated in the examination room, to assess the impact of dystonia on these daily activities. A minimal state examination should be carried out as well as a short evaluation of mood and behavior. A scoring of the symptoms and of the functional disability using validated scales including a standardized video of the patient are very important. The Burk-Fahn-Marsden dystonia rating scale [13, 14] is a commonly used one for generalized dystonia while for cervical dystonia, other scales such as Tsui rating scale [12], or Toronto western spasmodic torticollis rating scale (TWSTRS) [9, 11] can be used. A MRI of the brain (and in relevant cases of the spine too) is mandatory.

Primary generalized dystonias, with or without the DYT1 mutation, are good indications for pallidal DBS, which will sometimes have a striking effect especially on the mobile components of the dystonia. The same applies for myoclonic dystonia. Among the secondary dystonias, neuroleptic-induced

tardive dyskinesia is also a good indication for pallidal DBS, as well as dystonia due pantothenate kinase associated neurodegeneration (PKAN, former Hallervorden-Spatz syndrom), even if the latter can exhibit associated non-dystonic symptoms and intellectual impairment. Secondary dystonias that develop following encephalitis or post-anoxic may also benefit from pallidal DBS but to a much lesser degree due to the severity of the symptoms and the multifactorial impairment of the patient.

Cervical dystonia may also be a good indication for pallidal DBS. However, some types of cervical dystonia such as laterocollis, retrocollis, latero-retrocollis, may be amenable to treatment by selective peripheral denervation. A simultaneous 4 channels EMG of left and right neck muscles should be obtained, especially EMG of sterno-cleido-mastoid (SCM) muscles, splenius, semi-spinalis and upper trapezius. A selective peripheral denervation should not be considered if the dystonia affects other parts of the body than the neck, and if concomittant dystonic tremor of limbs is present, nor if there is an anterocollis with affection of anterior muscles of the neck and scalenic muscles. Sometimes a selective nerve block with lidocaine of affected muscles may help in diagnosis and in predicting the effect of subsequent selective denervation.

A detailed and comprehensive discussion of the pros and cons of surgery, including type of surgery, time in hospital, effects and possible side effects and complications, requirements for after-care, etc. should be carried out with the patient and the relatives. Emphasis should be put on the expectations from surgery. A realistic description should be provided concerning what may be ameliorated by surgery and at what risks, and what cannot be. It should be made obvious that in case of fixed postures with orthopedic deformities, one should not expect an improvement in that particular area. It should also be made clear that surgery will not “cure” the dystonia.

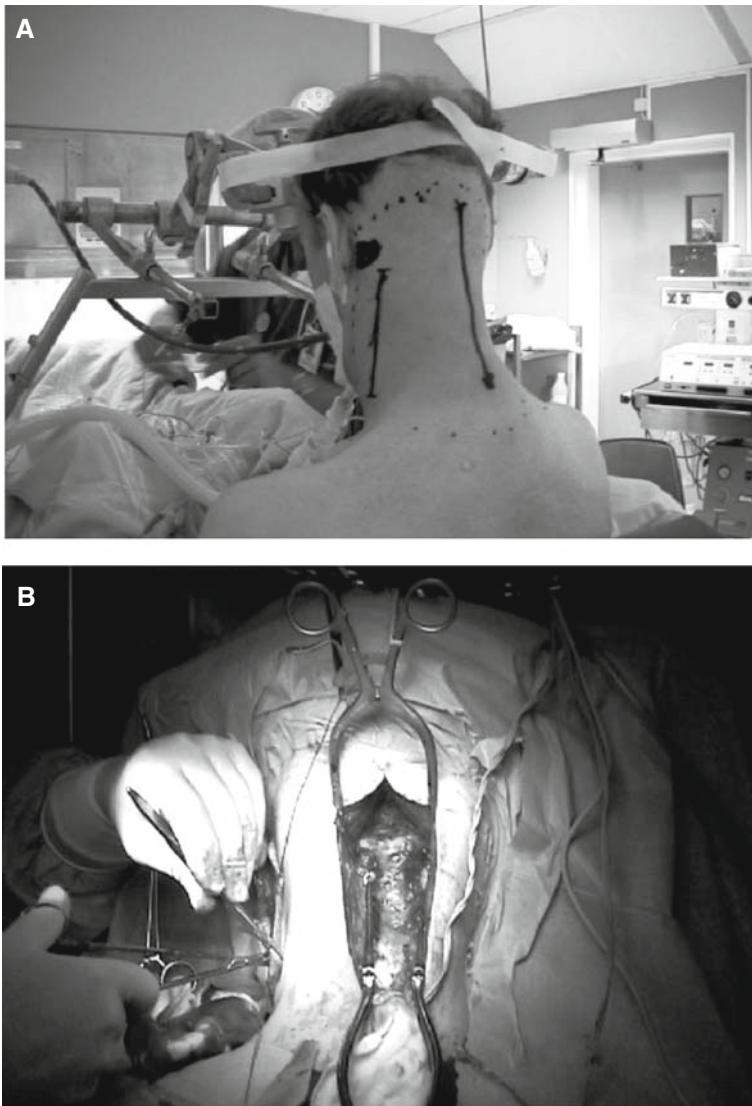
In cervical dystonia, a cervical pathology with disc herniation, subluxation should be excluded. If a peripheral denervation in the sitting position is planned, because of the risk for air embolism in the sitting position, a screening for persistent foramen ovale should be made and appropriate intraoperative monitoring for dealing with air embolism including central venous catheter and oesophagus ultrasound probe should always be available.

## **SURGERY**

### **1. PROCEDURES**

#### **1.1 Bertrand's procedure**

In case of patients with torticollis, laterocollis, or retro-torticollis presenting a clinically and EMG verified affection of a unilateral sterno-cleido-mastoideus



**Fig. 1.** **A** Patient on general anesthesia in a sitting position, in view of a Bertrand's procedure: a linear midline incision from occiput to C6 is planned as well as an incision along the posterior border of the left sterno-cleido-mastoid muscle. **B** Same patient as in (**A**), with two neurosurgeons operating in parallel (Dr. Bergenheim and Dr. Hariz), one denervating the left sterno-cleido-mastoid muscle and the other preparing for dorsal ramisectomy C1-C6

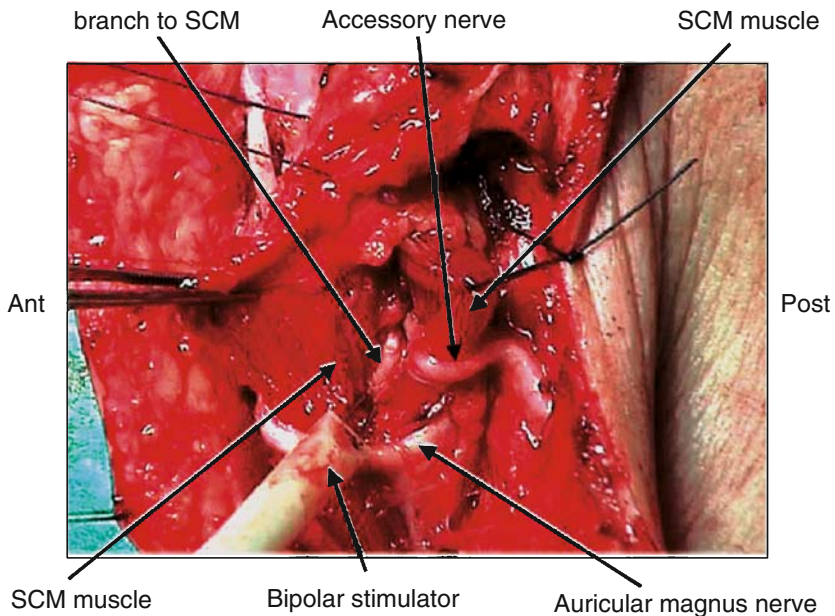
(SCM) (rare) or more commonly, concomittant affection of one SCM and a contralateral – or bilateral – semispinal and splenius muscles, the Bertrand procedure can be tried. This involves a selective denervation of the SCM on



one side and a unilateral or bilateral dorsal ramisectomy from C1 through C6. This procedure, such as performed by the author together with Professor Tommy Bergenheim at the University Hospital of Northern Sweden in Umea, is described:

Under general endotracheal anesthesia, the patient receives a central venous catheter and an intra-oesophageal ultrasound probe, after which the patient is placed sitting with appropriate cushions and with head slightly flexed and held firmly in a Mayfield 3-pin head holder. After scrubbing and draping, a linear midline incision from occiput to C6 is planned as well as an incision along the posterior border of the affected SCM muscle, from the mastoid down to just above the clavicle (Fig. 1A). It is important to use anesthesia without muscle relaxant in order to permit intraoperative electrical stimulation of the nerves. It is also an advantage, time wise and otherwise, for patient and operative staff, that two neurosurgeons operate in parallel, one denervating the SCM and the other performing the dorsal ramisectomy, as shown in Fig. 1B.

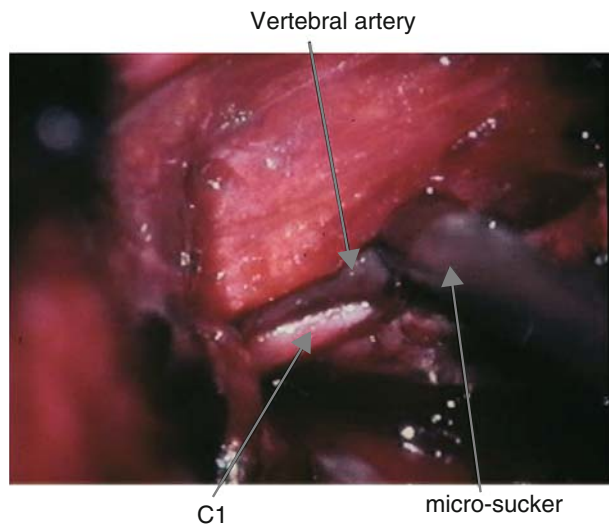
For the SCM, it is very useful to identify first the sensory auricularis major nerve, which runs at the superficial aspect of the SCM crossing it from posterior to anterior, because this is a landmark to finding at that level, but in deeper layer, the accessory nerve (Fig. 2). The accessory nerve is verified by



**Fig. 2.** Dissection of the branches of the left accessory nerve that innervate the left sternocleido-mastoid (SCM) muscle. Bipolar stimulation is applied on one of these branches, prior to sectioning it, to ascertain that it innervates selectively the SCM. *Ant* anterior, *Post* posterior

bipolar electrical stimulation with 3–5 Hz that will provoke violent jerks of the shoulder. This nerve must be spared in order not to affect the patient's ability to abduct and elevate the arm. The accessory nerve is then dissected caudally and cranially and its branches innervating the SCM are identified visually (Fig. 2) and by electrical stimulation that will provoke jerks limited to the SCM. When such a branch is verified, it is bipolarly cauterized and sectioned, and its distal end that looses itself into the body of the SCM is avulsed. After all visible branches have been identified, cut and avulsed from the muscle, the SCM is sectioned in two parts that are flipped one upward and one downward, revealing the deeper medial aspects. There too dissection and stimulation of eventual visible branches are undertaken to find additional selective innervation to the SCM. At the end of the procedure, the two sectioned parts of the SCM are adapted to each other with continuous Vicryl or Dexon.

*The posterior ramisectomy* is performed in parallel (if two surgeons are operating). Following incision from occiput to C7 level, the muscles are separated sub-periostally from the laminae as for a laminectomy. However, the separation of the muscles should extend very laterally as to reach beyond the intervertebral joints, without too much strain and pulling on the muscles, and hence on the rami posterior, in order not to affect their ability to react to nerve stimulation. It is an advantage to start with dissection of the rami posterior of C1, using the microscope. The posterior branch of C1 is identified on the lateral posterior aspect of the dorsal surface of the C1 lamina, just infero-posterior to the vertebral artery (Fig. 3), the integrity of which must be



**Fig. 3.** Microscope view of the left ramus posterior of C1, running just infero-posterior to the vertebral artery

absolutely spared. Here some venous plexa may be bothersome, but with a combination of micro-dissection, gentle bipolar coagulation and use of small pieces of oxycel cotton to obliterate venous plexa, the dorsal C1 ramus can be identified at the lateralmost aspect of the C1 lamina. The ramus is followed laterally and stimulated whereby contraction of adjacent posterior muscle should be obtained. Care should be taken to verify that it is really the posterior ramus by asking the anesthesiologist to verify that there are no contractions of the throat upon stimulation of that branch. Also care should be taken not to stretch too much the posterior branch because it will pull also on the anterior branch provoking a postoperative swallowing difficulty. Once the posterior branch of C1 has been identified, it is bipolarly cauterized then sectioned as lateral as possible, and its distal part entering the muscle is avulsed. The posterior ramus of C2 is much thicker, in fact it is the thickest of all the rami from C1 to C6. It is easy to visually identify medial to the intervertebral joint, running right above the arch of the axis, and sometimes it is itself split in two branches. Again, after dissection and isolation, bipolar stimulation is applied to verify jerks in adjacent muscles before it is sectioned and its distal end avulsed and sent for histopathology, along with all other avulsed rami. The posterior rami of C3–C6 run immediately lateral to the facet joints. The same procedure of dissection, stimulation, section and avulsion is performed in same manner until the rami posterior of C6 are identified and peripherally avulsed.

The procedure of dorsal ramisectomy is performed bilaterally if indicated, such as in cases of retrocollis. It is worth remembering that dorsal rami of C2–C6 innervate the splenius muscles, and C1 to C6 innervate the semispinal muscles. Other muscles as well are innervated by some of the dorsal rami in question such as the rectus capiti, oblicus capiti, and longitissimus capiti. When one can no longer find dorsal rami that respond to stimulation, surgery is terminated by generous irrigation, bipolar cauthery of small bleedings and if needed use of small patches of oxycel cotton, before closure in layers of muscles and skin. No drainage is needed.

The sitting position has the advantage of easy access and comfort for the surgeon, and provides a clear view since eventual small bleedings and oozings will not disturb the vision. The disadvantage is the risk for air embolus, and in parallel with that, the inability for the surgeon to identify bleeding from paravertebral venous plexus, especially around the rami of C1, that should be attended to before closure of the wound. Therefore, the anesthesiologist should be asked now and then during the procedure to exert some pressure on both sides of the neck to increase the venous pressure and thereby reveal to the surgeon eventual small bleeding from venous areas that need to be attended to before closure of the wound.

Postoperatively, the patient should be observed in a high dependency unit, with monitoring of vital signs as well as of speech, swallowing and checking for sub-cutaneous haematoma especially in the region of the SCM incision.

## 1.2 Pallidal DBS

The present author uses a strictly MRI-guided surgery in general anesthesia based on detailed visualization of the pallidal area, individual direct targeting, impedance monitoring during surgery and immediate postoperative stereotactic MRI. The 3389 narrow space electrode is used, as well as the dual channel Kinetra neurostimulator (Medtronic, Minneapolis, USA).

Following endotracheal general anesthesia, the head may be shaved (optional) and Leksell's stereotactic frame (Elekta, Stockholm, Sweden) is attached to the head parallel to a line joining the tragus to the infero-lateral orbital rim.

Scanning is performed with 2 mm-thick axial and coronal contiguous scans using a proton density sequence [8] that permits exquisite visualization of all the subdivisions of the globus pallidus (Globus pallidus pars interna, GPi, laminae medullaris interna and externa, Globus pallidus pars externa, GPe) and their surrounding structures (putamen, internal capsule, optic tract). Then a volumetric T1 scanning is made of the whole head in order to use for trajectory planning. The scanning time using these parameters last for less than half an hour, following which the patient is taken to the surgical theatre. Enlarged hard copies of relevant MRI slices are obtained as well as a CD-ROM containing digital MR images. For stereotactic target coordinate calculation, two methods are used. The manual method is based on calculations and measurements on the hard copies and is corroborated by calculations on digital images on the Framelink Medtronic software or any other dedicated software.

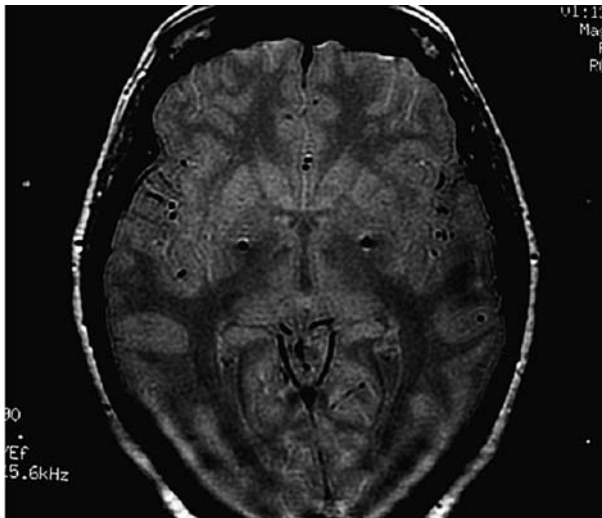
The target point is indicated on the axial scans in the ventralmost part of the visible GPi just above and lateral to the one showing the optic tract, and close to the lamina medullaris interna, that is, into the posteroventrolateral part of the GPi. Since the target itself is readily visualized, there is no need to refer to the landmarks of the third ventricle and to an atlas to obtain the location of the target in the individual patient. Nonetheless, the target point can still be compared with the atlas-defined one that usually lies 0–2 mm anterior to the midcommissural point, 4–6 mm below the bi-commissural line and at a laterality of 19–23 mm from the midline of the third ventricle. The target point is transferred to the relevant coronal scan (that usually lies at the level of the mammillary bodies) and its laterality and especially depth in relation to optic tract and supra-amygdala are verified. On the coronal scan, the trajectory from cortex to target is simulated and the entry point on the skull should be at the level of the coronal suture, 2–2.5 mm from the midline, to enable an orthogonal parasagittal trajectory of the electrode toward the target. Thereby, all 4 contacts of the DBS electrode can be ideally made to lie within the GPi. Trajectory planning and entry-point definition can be refined on the Framelink software to try to avoid passage through sulci or ventricles.

At surgery, small skin incisions are made on each side of the head or a single curved coronal skin flap. Burr holes, 14 mm in diameter, are performed

and a Medtronic Stimloc device is attached with bone screws around the burr hole. Dura, Pia and cortex are coagulated and an Elekta radiofrequency (RF) electrode with a non-insulated tip of  $2 \times 1.5$  mm is introduced towards the target under impedance monitoring. With a trajectory from the frontal coronal burr hole, 2–2.5 cm from the midline, the probe traverses the white matter of the rostral internal capsule into the grey matter of the anterodorsal putamen or anterodorsal pallidum. The high white matter impedance (700–1000 Ohm) falls suddenly over a distance of 1 mm between white matter tracts and the grey matter of the rostral pallidum or putamen and shows 400–600 Ohm. One can sometimes notice a slight brief rise in impedance if the electrode traverses the various medullary laminae, then again if it reaches beyond the base of the pallidum. In case of a medial deviation in the planned trajectory, the pitch of the auditory signal of the impedance will rise to that typical of white matter indicating transgression of the electrode into the internal capsule.

After withdrawal of the RF electrode, the DBS electrode is introduced in the same trajectory and to the same depth, and secured to the burr hole with the Stimlock device. Same procedure is performed on the second pallidum and the excess DBS electrodes are buried under the skin. The incisions are temporarily sutured.

The patient is then returned to MRI for an immediate postoperative stereotactic scanning performed with same proton density sequence as the preoperative one but with fewer slices, the axial ones centered around the distal



**Fig. 4.** Postoperative stereotactic axial MRI scan at the anterior commissure-posterior commissure level, showing DBS electrode artifacts in the posteroventral GPI (arrows)

8–10 mm of the electrode and the coronal ones from burr hole area to target, that is, covering the electrode path. The accuracy of electrode placement in relation to target point is verified (Fig. 4) and the patient is returned to theatre, where the frame is removed and the patient re-scrubbed. A pocket is made usually below the left collar bone, more rarely below the arcus. The right electrode had been passed previously to the area of the left frontal incision so there is no need to re-open the right sided wound on the head. From the infra-clavicular pocket to the left burr hole area, two Medtronic extension cables are tunneled, with help of an extra incision behind the mastoid. The cables are connected to each electrode and the connections are placed lateral to the left burr hole and in some patients with severe jerky dystonia, the connections are sutured to the galea as to not pull on the electrode in case of continuous jerks of the neck, and strain on the cables. By convention left electrode cable is connected to channel 1 of the Kinetra and right cable to channel two. The Kinetra is then put into the pocket that was not made too big and after careful hemostasis and generous irrigation all wounds are closed in layers. Antibiotic with 1.5 mg Cefuroxim is given IV from the start of surgery then every eight hours until 24 hours after surgery. Postoperatively, the patient is observed for six hours in the high dependency unit before returning to the ward.

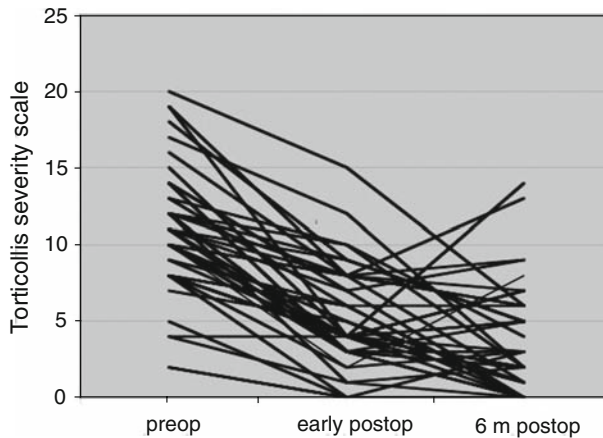
## 2. RESULTS

The results of surgery for dystonias depend above all on the type of dystonia, as well as on the type of surgical procedure. Reports on long-term results are rare and standardization of results according to validated scales is relatively new. The most used scales in contemporary literature have been for cervical dystonia the Tsui's torticollis severity scale [12] and/or the Toronto western spasmodic torticollis rating scale (TWSTRS) [9], and for generalized dystonia the Burke-Fahn-Marsden dystonia rating scale (BFMDRS) [13, 14].

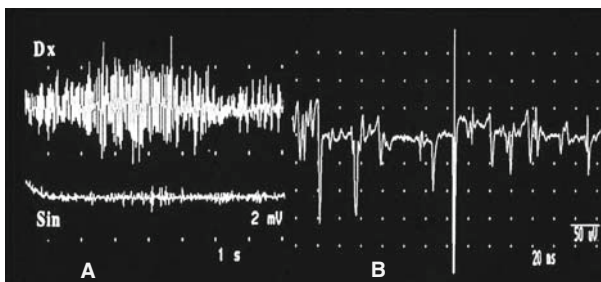
### 2.1 Bertrand's procedure

For cervical dystonia operated on using selective peripheral denervation, Bertrand himself in 1993 reported 260 patients with "marked improvement" in 88% [1]. Other more recent studies reported improvement around 36–46% on the TWSTRS [10]. Taira reported an improvement of more than 80% of his 44 patients operated on with his modified denervation technique [12]. In general, complications of selective denervation were few and affected mainly swallowing, most often transiently, but the risk of recurrence of symptoms is not negligible.

In the series of 36 patients of Bergenheim and Hariz from Umea, Sweden, Tsui's torticollis severity scale showed around 60% improvement at 6 months (Fig. 5). A repeat EMG showed so-called denervation potentials confirming



**Fig. 5.** Scores of Tsui's Torticollis Severity Scale, preoperatively, at 1–2 weeks, and at 6 months postoperatively, in 36 patients from Umeå, Sweden (Photo courtesy of Professor Tommy Bergenheim, University Hospital of Northern Sweden)



**Fig. 6.** EMG of right hyperactive sternocleidomastoid muscle before surgery (A) and six months after (B), showing denervation potentials (Photo courtesy of Professors Rolf Libelius, neurophysiologist and Tommy Bergenheim, neurosurgeon, University Hospital of Northern Sweden)

the denervation of the intended muscle(s) (Fig. 6). Almost all patients experienced sensory deficit in the C2 area, which sometimes may bother the patient. Three patients suffered transient dysphagia, with also transient dysphonia in one. Two patients had postoperative hematomas in the SCM area that necessitated surgical treatment without further sequelae.

Clinical and EMG verified re-innervation occurred in four patients necessitating re-operation with a new denervation procedures. In several patients, however, there were later on new cervical dystonia symptoms involving other muscles than those denervated, and three of these patients so far have undergone subsequently GPi DBS, with substantial improvement in two of them.

## 2.2 DBS of GPi

The results of pallidal DBS for cervical dystonia are emerging and look promising with more than 50% improvement of motor symptoms as well as of pain and disability at a mean of 2.5 years [9]. For primary dystonia, a wealth of information is available today to support its efficiency in the medium long term [13, 14]. Improvement on the BFMDRS ranges between 46% and 89% for both motor and ADL parts of the scale. Improvement is progressive over few weeks to few months, generally reaching a plateau by six months after surgery. Phasic symptoms improve more than tonic, and younger patients more than older. The stimulation parameters are however higher than for patients with Parkinson's disease and stimulator replacement is therefore needed at a mean of about 3–4 years after surgery. Side-effects were rare and included speech deterioration, gait difficulties and infection or breakage of hardware.

In the author's published series of 15 patients at 6 months, improvement was of 69.5% [13]. In the author's total series of over 50 consecutive patients who had DBS for dystonia over the last five years, there were no bleedings, paresis or infections, and no spontaneous displacement or breakage of the DBS electrodes. Other hardware related adverse events occurred in three patients: One patient had an accident provoking a breakage of the cables at their entrance into the neurostimulator that had been implanted in the abdominal wall, necessitating change of both stimulator and extension cables. In one patient there was intermittent stimulation due to loosening of the screws securing the cables to the stimulator, which was attended to by changing stimulator and tightening screws. Finally one patient had a dysfunction of the battery due to a fabrication fault and necessitated emergency replacement due to acute and severe recurrence of dystonia.

Concerning myoclononic dystonia, as well as Meige's syndrom, there are few case reports in the literature, as well as experience of the author in few cases, suggesting that pallidal DBS may improve substantially the symptoms. Concerning secondary dystonias, it seems that neuroleptic-induced dystonia and dystonia due to PKAN (Hallervorden-Spatz disease) are good indications for pallidal DBS with a significant improvement of symptoms.

## HOW TO AVOID COMPLICATIONS

Concerning the *Bertrand procedure*, to avoid the dysesthesia in the C2 area, and to avoid complications related to the bleedings from venous plexa and injury of vertebral artery at C1 level, Taira devised a modification of the Bertrand procedure by which he performs dorsal ramisectomy of C3–C6 but not C1 and C2. Instead he performs unilateral intradural anterior rhizotomy of C1 and C2 [12]. Otherwise, provided one respects the safety measures outlined above concerning the risks of surgery in the sitting position, and pro-



vided a careful dissection of the nerves, and meticulous stimulation prior to sectioning, the complications of this procedure are few in experienced hands. If the cervical dystonia involves other muscles than those that can be denervated safely, and especially if it is in a non-stable and progressive phase, then the Bertrand procedure should be avoided. This is because dystonic symptoms will show up in other muscles of the neck some time after the operation and this recurrence will be detrimental to the patient. One should remember that dystonia, including cervical dystonia is a basal ganglia disorder, and when the basal ganglia loose contact with a given denervated muscle, they may “seek contact” with other adjacent muscles, prompting thereby propagation of the symptoms to those other muscles resulting is recurrence of torticollis often with another phenotype than the previous one. Hence, today, more surgeons are turning to GPi DBS instead of peripheral denervation to attack the disorder centrally rather than peripherally.

Concerning *pallidal DBS*, complications can be grouped in those due to surgery, those due to the hardware and those due to the chronic stimulation itself [7]. To avoid surgical complications (mainly bleeding in the brain) blood coagulation parameters and blood pressure should be normal; excessive CSF leak should be avoided by quick surgery and use of tisseel to seal the dura opening; One should use as few as possible passages of the electrodes in the brain (by adequate visualization of target and calculation of its coordinates), and avoid the use of multiple tracks microelectrode recording (MER); if MER is to be used it will necessitate a gadolinium-enhanced MRI and careful planning of trajectories as to avoid blood vessels and sulci. Strict aseptic technique and quick surgery, together with short prophylactic course of antibiotics will decrease the risks of infection of the hardware. Pulling or break of DBS electrodes through strain of movements on cables is avoided by securing electrode with dedicated device instead of with a metal plate, and avoiding placement of connectors in the neck area as well as by suturing the connection between electrode and cable to the subcutaneous tissue. Seroma and infection of the pulse generator can be avoided by having a tight subcutaneous pocket and meticulous hemostasis, and it is a surgical advantage, although maybe not a cosmetic one, to place the stimulator right on the pectoralis fascia below the clavicle rather than in the more moving and further away abdominal wall. As for the complications of stimulation, these are minimized by a proper accurate placement of the electrode in the ventroposterolateral pallidum and inclusion of as many contacts as possible within the GPi avoiding the internal capsule and of course the optic tract. Also, stimulation-related complications necessitate experience with programming and close cooperation with an experienced DBS neurologist and specialist nurse, unless the neurosurgeon has the skills and time to monitor and adjust the stimulation parameters as needed. Finally, one should be aware that a sudden failure of stimulation, either due to battery depletion or any other reason may become a surgical emergency because some patients who had been relieved of dystonia for some time may

suffer from acute dystonic crisis or status dystonicus when the stimulation is abruptly stopped. To avoid that, the author recommends preemptive change of stimulator when the battery shows values towards its end of life.

## CONCLUSIONS

Dystonias are heterogenous conditions and several types of medically or botulinum toxin-resistant dystonia are amenable to surgical treatment. In cervical dystonia, selective peripheral denervation ad modum Bertrand is rather rarely performed, and is indicated only if the cervical dystonia is stable and involves SCM alone or SCM with contralateral or bilateral splenius and semi-spinal muscles, which must be verified clinically and with 4 channel EMG. The results are generally good on the movement disorder and on the associated pain, but with risk of recurrence. Pallidal DBS has emerged as a method of choice mainly in primary generalized dystonia but also in cervical dystonia, as well as in myoclonic dystonias, and less so in secondary dystonias.

Pallidal DBS, to be efficient, must target the ventroposterolateral GPi. It is a safe procedure. Mobile phasic dystonia responds better than tonic fixed one, and early surgery has better results than surgery late in the disease progression. Some patients on GPi DBS may need emergency replacement of stimulator when battery is empty. A prophylactic change of stimulator before end of battery life to avoid rebound of symptoms and dystonic crisis is recommended. The very long-term results of GPi DBS are unknown as yet, and there is a need for a long follow up, especially for primary dystonias, since people affected are generally younger with an otherwise long life expectancy.

## Acknowledgements

The author wishes to thank the following colleagues: Professor Antonio DeSalles, UCLA, for having been instrumental in introducing Bertrand's procedure in Umeå, Sweden; Professor Tommy Bergenheim who has been, and continues to be, very involved in all the selective denervation procedures performed at the University Hospital of Northern Sweden, and who kindly provided updates of patients with torticollis operated on with the Bertrand procedure; Doctor Steve Tisch, Sydney, Australia, formerly at Queen Square, London, who has defended a Ph.D. thesis on DBS for dystonia in August 2007, and who has been the neurologist in charge of selection and follow up of the patients with DBS of the GPi. Dr. Laura Cif, Montpellier, France, for sharing her large experience in the various dystonias treated by pallidal DBS.

## References

- [1] Bertrand CM (1993) Selective peripheral denervation for spasmodic torticollis: surgical technique, results, and observations in 260 cases. *Surg Neurol* 40: 96-103

- [2] Bertrand CM (2004) Surgery of involuntary movements, particularly stereotactic surgery: reminiscences. *Neurosurgery* 55: 698-703
- [3] Cooper IS (1976) 20-year follow up study of the neurosurgical treatment of dystonia musculorum deformans. *Adv Neurol* 14: 423-452
- [4] Coubes P, Cif L, El Fertit H, Hemm S, Vayssiere N, Serrat S, Picot MC, Tuffery S, Claustres M, Echenne B, Frerebeau P (2004) Electrical stimulation of the globus pallidus internus in patients with primary generalized dystonia: long-term results. *J Neurosurg* 101: 189-194
- [5] Geyer HL, Bressman SB (2006) The diagnosis of dystonia. *Lancet Neurol* 5: 780-790
- [6] Hallett M (2004) Dystonia: abnormal movements result from loss of inhibition. *Adv Neurol* 94: 1-9
- [7] Hariz MI (2000) Complications of movement disorder surgery and how to avoid them. In: Lozano A (ed) *Progress in neurological surgery*, vol. 15. Movement disorder surgery. Karger, Basel, pp 246-265
- [8] Hirabayashi H, Tengvar M, Hariz MI (2002) Stereotactic imaging of the pallidal target. *Mov Disord* 17(Suppl 3): S130-S134
- [9] Hung SW, Hamani C, Lozano AM, MD, Poon Y-YW, Piboolnurak P, Miyasaki JM, Lang AE, Dostrovsky JO, Hutchison WD, Moro E (2007) Long-term outcome of bilateral pallidal deep brain stimulation for primary cervical dystonia. *Neurology* 68: 457-459
- [10] Jankovic J (2006) Treatment of dystonia. *Lancet Neurol* 5: 864-872
- [11] Krauss JK, Yianni J, Lohr TJ, Aziz TZ (2004) Deep brain stimulation for dystonia. *J Clin Neurophysiol* 21: 18-30
- [12] Taira T, Hori T (2003) A novel denervation procedure for idiopathic cervical dystonia. *Stereotact Funct Neurosurg* 80: 92-95
- [13] Tisch S, Zrinzo L, Limousin P, Bhatia KP, Quinn N, Ashkan K, Hariz M (2007) Effect of electrode contact location on clinical efficacy of pallidal deep brain stimulation in primary generalised dystonia. *J Neurol Neurosurg Psychiatry* 78: 1314-1319
- [14] Vidailhet M, Vercueil L, Houeto JL, Krystkowiak P, Lagrange C, Yelnik J, Bardinet E, Benabid AL, Navarro S, Dormont D, Grand S, Blond S, Ardouin C, Pillon B, Dujardin K, Hahn-Barma V, Agid Y, Destée A, Pollak P; French SPIDY Study Group (2007) Bilateral, pallidal, deep-brain stimulation in primary generalised dystonia: a prospective 3 year follow-up study. *Lancet Neurol* 6: 223-229



**Marwan I. Hariz**

Marwan I. Hariz is professor to the United Kingdom's first Chair of Functional Neurosurgery at the National Hospital for Neurology and Neurosurgery, and Institute of Neurology, Queen Square, London, where he established a multidisciplinary clinical and academic Unit of Functional Neurosurgery. Marwan I. Hariz received the Baccalauréat in Beirut, Lebanon at the Lycée Franco-Libanais, then studied medicine in Reims, France and in Umeå, Sweden. He trained in Neurosurgery in Umeå, with Lauri Laitinen as main mentor. He received a Ph.D. in 1990 in stereotactic neurosurgery. His main interests are in surgery for movement disorders and psychiatric illness, and in critical appraisal of published literature in these areas. He has published over 100 scientific papers and book chapters.

**Contact:** Marwan I. Hariz, National Hospital for Neurology and Neurosurgery, Unit of Functional Neurosurgery, Institute of Neurology, Box 146, Queen Square, London WC1N 3BG, UK  
E-mail: [m.hariz@ion.ucl.ac.uk](mailto:m.hariz@ion.ucl.ac.uk)

---

# NEUROSURGICAL MANAGEMENT OF CANCER PAIN

Y. KANPOLAT

## INTRODUCTION

Because of environmental factors and humanity's advanced age, the incidence of cancer is gradually increasing, and its treatment is emerging as a social problem worldwide [48]. Cancer is the second most common cause of death in developed countries. Cancer pain is seen in 20–50% of patients when the disease is diagnosed, and can affect up to 75% of patients in advanced cancer stages. Pain is moderate or severe in 40–50% of patients and very severe or excruciating in 25–30% [2, 3]. This chapter has been allocated for the presentation of destructive methods that remain efficient in treating intractable pain problems in cancer patients and which are based on destruction of the pain conducting pathways. A historical background of the later – with corresponding references – is also the matter of this chapter.

The pain conducting pathways were described by Edinger at the end of the 19th century (1899) based upon degeneration experiments in amphibians and newborn cats [42]. Further investigations by Edinger, Ramon y Cajal, Wallenberg, Petren, Spiller and Foerster have completed our knowledge of the secondary pathways of pain and temperature of the spinal cord [42]. These observations guide neurosurgeons in destruction of the lateral spinothalamic tractus, termed “cordotomy”, for controlling unilateral pain located in one half of the body [28, 34].

An understanding of facial and cranial pain conduction was based on observations of Wallenberg, who described a special syndrome in 1895. Lesioning of the pain conducting pathways of the Vth nerve was referred to as trigeminal tractotomy by Sjöqvist [42, 44].

Conduction of the visceral pain pathways is not as clear. It was shown in some animal studies that visceral pain pathways were in the midline of the posterior column [1, 9]. Pain procedures based on lesioning of the central cord are known as stereotactic cervical myelotomy [11], stereotactic extralemniscal myelotomy [35], and punctate midline myelotomy [4].

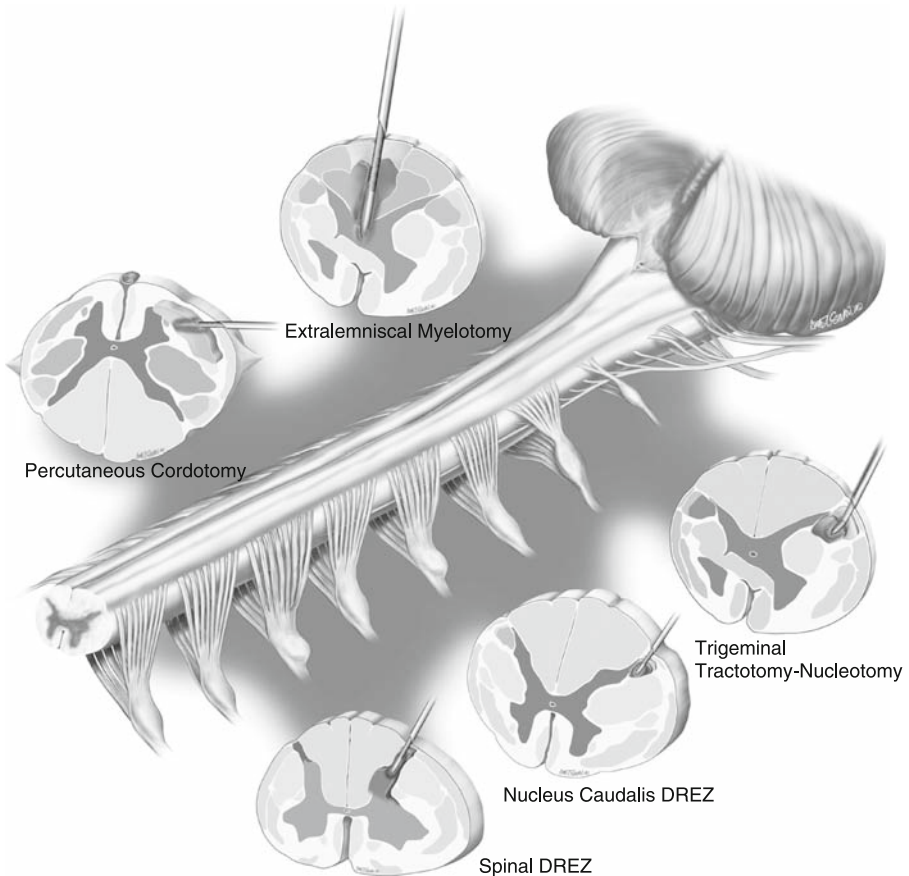
One of the very important unique targets in pain surgery is known as the dorsal root entry zone, or DREZ, meaning especially not only a target for

---

*Keywords:* cancer pain, cordotomy, trigeminal tractotomy-nucleotomy, extralemniscal myelotomy, DREZ-lesioning, CT-scan guidance

nociceptive pain surgery but also for the surgery of neuropathic pain and spasticity. This area was first described by Vic-D'Azyr [45]. In 1824, Luigi Rolando described a gelatinous layer in part of the H-shaped structure [35]. The first procedure in this area was performed by Sindou in 1974 [37]. Nashold described the method as a DREZ operation and later used the same procedure for substantia gelatinosa of the nucleus caudalis, which he termed as the Nucleus Caudalis DREZ operation [6, 29].

The main principals of the destructive procedures in these targets for intractable cancer pain are illustrated in Fig. 1.



**Fig. 1.** Schematic drawings of spinal cord destructive procedures (spinal DREZ; percutaneous cordotomy, trigeminal tractotomy-nucleotomy, extralemniscal myelotomy, nucleus caudalis DREZ)

## RATIONALE

A variety of alternatives in the treatment of chronic intractable pain are used in practice today. Stimulation is usually used for neuropathic pain; implantable pump catheter systems for morphine infusion are more commonly used for intractable pain in cancer with short-life expectancy. For a large number of colleagues, the methods mentioned here are referred to as “ablative” instead of “destructive”. Definition of the term “ablation” according to Webster’s Third New International Dictionary as “removal of an organ or part by surgery” does not reflect reality [46]. The procedures performed on the pain conducting pathways should be named “destructive”.

The first method is known as antero-lateral *cordotomy* and is based on lesioning of the lateral spinothalamic tract. The method was initially performed by open method [43]. The procedure was then applied percutaneously by Mullan et al. [28] and used with radiofrequency energy by Rosomoff et al. [34]. Cordotomy has been routinely used by us with computerized tomography (CT) guidance since 1986 [12–14]. The rationale of the procedure is based on the denervation of nociceptive pain on the side of the body opposite to the site of the procedure, primarily.

The second procedure, *trigeminal tractotomy (TR)*, is based on lesioning of the descending trigeminal tract. The procedure was performed by open method by Sjöqvist [42]. In 1969, Sweet observed hypoalgesia in the regions innervated by the VIIth, IXth and Xth cranial nerves after tractotomy [47]. This procedure is indicated for the treatment of cancer pain located in the area of these nerves, usually in the craniofacial or oral region [30, 36]. In 1965 Kunc used high cervical approach for cutting the tract to denervate the glossopharyngeal nerves [25]. Then Crue and Hitchcock, independently, developed the technique percutaneously and stereotactically [7, 10]. We adapted CT guidance to the system and have used it safely and effectively since 1989 [15–17].

The third procedure is *extralemniscal myelotomy (EM)*. It involves lesioning of the ascending nonspecific polysynaptic pathways, which are located in the midline around the central canal [11]. The procedure was employed by Hitchcock empirically but was later ascribed different names in nearly the same anatomical region as midline myelotomy, punctate myelotomy, or other variations [4, 35, 21, 22]. There has not been a significant accumulation of knowledge in this field and it remains an unknown area. My personal experience is only 19 cases; most were cancer patients suffering from abdominal visceral pain.

The final procedure is the *DREZ-lesioning operation*. This operation is used in cancer-originating neuropathic pain forms. It is effective not only in neuropathic pain forms but also in the nociceptive pain forms like Pancoast tumors [37]. We have used nucleus caudalis DREZ in the intractable form of craniofacial and oral pain [18].

## DECISION-MAKING

### 1. DIAGNOSTIC CRITERIA

*Diagnosis of intractable pain should be evaluated according to:*

- a) location (side)
- b) severity
- c) duration
- d) patient activity

The effectiveness and risks of the considered procedure should be explained to the patients. There is a general tendency in cancer patients to believe that the pain procedure will solve not only the pain problem but also the general cancer. The neurosurgeon should not be solely a technician; s/he should provide leadership/emotional support as well, and must encourage the patient to return to normal activities of daily life if the pain resolves and the cancer remains stable. This is the most important advantage of the destructive pain procedures. With morphine pump infusions the patient remains dependent on hospitals, drugs and physicians, etc., while destructive pain procedures provide an opportunity for the patient to become independent in this regard.

### 2. INDICATIONS

The best candidates for CT-guided percutaneous cordotomy are those with unilateral localized pain, as seen in mesothelioma of the chest wall or carcinoma of the lower extremities [18–20]. Bilateral CT-guided cordotomy is selected for the patient with intractable pain localized in the lower part of the body [14, 19, 21]. There is a generally accepted opinion that cordotomy is chosen just after morphine therapy [8, 31, 32]. However, we recommend cordotomy just prior to initiation of narcotic agents, especially if the patient's survival is expected to be more than six months. The rationale of this strategy is based on the effectiveness and safety of the procedure observed over the course of our 20 years of clinical experience. Patients with severe pulmonary dysfunction and in whom partial oxygen saturation is lower than 80% are not suitable candidates for cordotomy [21].

*CT-guided trigeminal tractotomy-nucleotomy (TR-NC)* is for patients with pain in the area of the Vth, VIIth, IXth and Xth nerves. Patients with head, face and neck malignancies, which cause both nociceptive and neuropathic pain, are the best candidates. If the procedure does not sufficiently control the pain problems, nucleus caudalis DREZ operation is chosen [18, 21, 22].

The *CT-guided EM* indication is controversial. We usually accept patients with cancer in the pelvic or abdominal region, or those with malignancies causing pain in the lower trunk or lower extremities [21, 22].



*DREZ-operation* is necessary if there is an indication that nociceptive pain will progress to neuropathic pain. This can be seen in the prolongation of Pancoast tumors because of the infiltration of the brachial plexus. In this group, spinal DREZ-operation is the best choice if the patient's general condition permits [41]. Nucleus caudalis DREZ-operation can also be indicated for cancer pain located in the area of the Vth, VIIth, IXth, Xth nerves and C<sub>2</sub> level [18].

## **SURGERY**

### **1. OPERATIVE TECHNIQUE**

#### **1.1 CT-guided percutaneous cordotomy**

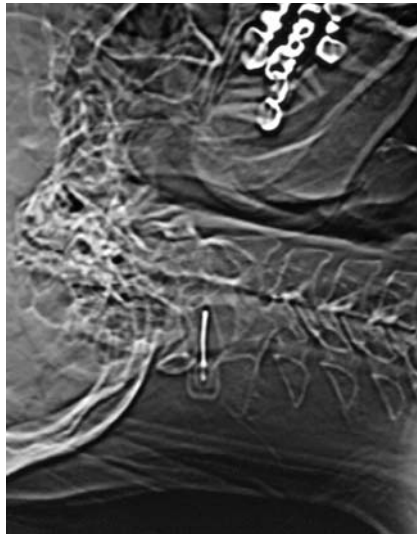
The procedure is routinely performed with CT guidance. The patient should be fasted for five hours before the operation. If required, neuroleptic analgesia should be given at a dose that will not affect patient cooperation during the procedure. A cranial CT scan must be taken to rule out a mass lesion due to metastasis, as this would be a contraindication to performing cordotomy. Kanpolat cannula and electrode system are recommended for this procedure (Kanpolat Electrodes KCTE, Cosman Company, Burlington, MA, USA) [23].

Contrast material should be administered into the subarachnoid space of the spinal cord. Iohexol (7–8 mL) is given 20–30 min before the operation by lumbar puncture. After injection of contrast medium, the table is repositioned to Trendelenburg position for 15 min to observe the contrast in the cervical region. If the general condition of the patient does not permit lumbar puncture, contrast material is injected during the procedure at the C<sub>1</sub>–C<sub>2</sub> level [21, 22]. The target is the anterolateral section of the spinal cord where the lateral spinothalamic tractus is located.

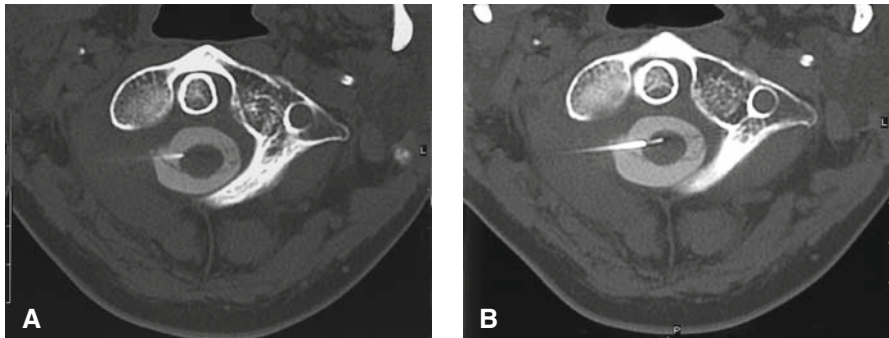
The patient is placed on the CT table in supine position, with the head flexed and fixed. After injection of the local anesthetic, a 20-gauge plastic hub needle is inserted inferior to the tip of the mastoid process in a vertical plane perpendicular to the axis of the spinal cord.

Placement of the cannula at the C<sub>1</sub>–C<sub>2</sub> level can be visualized in the lateral scanogram (Fig. 2), and direction of the needle is manipulated toward the anterior aspect of the spinal cord using axial CT sections (Fig. 3A). Ideal placement is 1 mm anterior to the dentate ligament for lumbosacral fibers and 2–3 mm anterior for thoracic and cervical fibers. When the needle is ideally positioned, the straight or curved active electrode is inserted (Fig. 3B).

At this stage, impedance measurements are taken to identify whether the active electrode tip is in the cerebrospinal fluid (around 100Ω), in contact with the spinal cord (around 300 or 400Ω) or inside the spinal cord (more than 700Ω). The target electrode relationship is easily demonstrated by direct visualization of the needle-electrode system under CT guidance [21, 22].



**Fig. 2.** Localization of the cannula between C<sub>1</sub> and C<sub>2</sub> level in lateral CT scanogram in percutaneous cordotomy



**Fig. 3.** **A** Final position of the cannula in axial CT slices (right side) in percutaneous cordotomy. **B** Final position of the electrode, anteromedial section of the target, in axial CT slices in percutaneous cordotomy

Final neurophysiological confirmation of the target can be achieved by stimulation. With 5-Hz stimulation, motor contraction in the ipsilateral occipital muscles indicates that the electrode is near the upper cervical anterior gray matter. If the electrode locates in the target, the patient describes a warm or cool sensation and tingling in the sensory dermatomes of the electrode localization with 50–100 Hz high-frequency stimulation. 0.2–3 V is recommended. Voltage of stimulation usually indicates the electrode in or near the target. If sensorial response is taken with lower voltage, it

indicates that the electrode is in the target. Positioning of the electrode helps selective destruction, indicating CT-guided selective cordotomy.

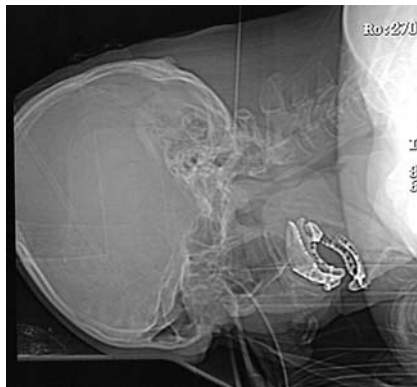If the electrode is properly located anatomically and neurophysiologically, the procedure is finalized with lesioning. The first lesion is usually accepted as a test lesion, and temperature must be more than 43°C; we usually prefer 50–60°C. If the patient describes analgesia level, 2 or 3 lesions at more than 70°C are made. Motor and sensorial testing is repeated during and after lesioning. In bilateral cordotomy, we prefer to minimize the number of the lesions.

### 1.2 CT-guided trigeminal tractotomy-nucleotomy (TR-NC)

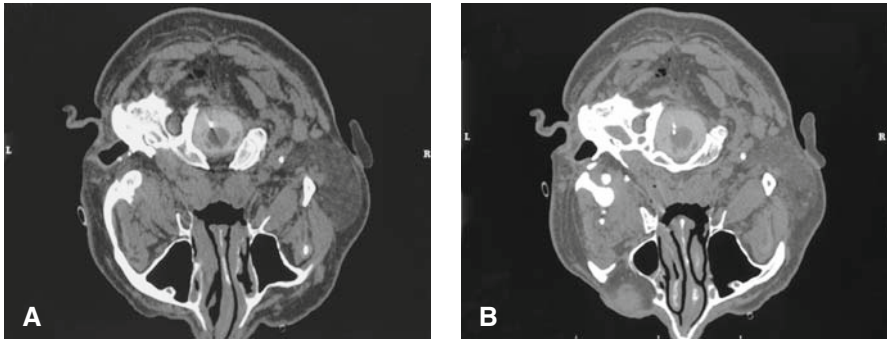
The procedure is routinely performed with CT guidance. The patient should be fasted for five hours before the operation. General principals of the cordotomy are also used in this procedure. Kanpolat cannula and electrode system are recommended for this procedure (Kanpolat Electrodes KCTE, Cosman Company, Burlington, MA, USA) [23].

Contrast material should be administered into the subarachnoidal space of the spinal cord. Iohexol (7–8 mL) is given 20–30 min before the operation by lumbar puncture. After injection of the contrast medium, the table is repositioned to Trendelenburg position for 15 min to observe the contrast in the cervical region. If the general condition of the patient does not permit lumbar puncture, contrast material is injected during the procedure at the C<sub>1</sub>-occiput level [21, 22]. The target is the posterolateral section of the spinal cord where the descending trigeminal tractus and nucleus caudalis are located.

The patient is placed on the CT table in prone position, with the head flexed and fixed. The chest is elevated and supported with soft pads. A nasal catheter is placed to provide oxygen during the procedure [21]. After injection of the local anesthetic, a 20-gauge plastic hub needle is inserted.



**Fig. 4.** Position of the cannula at occiput C<sub>1</sub> level in lateral scanogram in TR-NC



**Fig. 5. A** Final position of the cannula in axial CT slices (left side) in TR-NC. **B** Final position of the electrode, posterolateral section of the spinal cord, in axial CT slices in TR-NC

Immediately after the local anesthetic injection, the cannula is placed at the C<sub>1</sub>-occiput level, 7–8 mm lateral from the midline on the pain side. Lateral scanogram is taken (Fig. 4); diametral measurements of the spinal cord are taken with axial CT slices. Distance between dura and skin is measured [24]. The cannula is localized in the posterolateral section of the spinal cord with CT guidance (Fig. 5A). The active electrode is inserted (Fig. 5B) and morphological demonstration of the needle-electrode system is visualized. It should be remembered that insertion of the active electrode to the tractus or nucleus is painful. The patient must be appropriately warned, and neuroleptic drugs can be given intravenously if necessary.

At this stage, impedance measurements are taken to identify whether the active electrode tip is in the cerebrospinal fluid (around 100  $\Omega$ ), in contact with the spinal cord (around 300 or 400  $\Omega$ ) or inside the spinal cord (more than 700  $\Omega$ ). The target electrode relationship is easily demonstrated by direct visualization of the needle-electrode system under CT guidance [21].

Stimulation provides very impressive information. With 50 to 100 Hz stimulation, the patient describes a paresthesia type of sensation on the ipsilateral half of the face. It must be remembered that voltage of high-frequency stimulation should be started with the lowest value (0.1 V). Stimulation disturbs the patient, for this reason, we recommend the lowest voltage values (0.1–0.5 V). If the electrode is properly located anatomically and neurophysiologically, the procedure is finalized with lesioning. The first lesion is usually accepted as a test lesion, and the temperature must be more than 43°C; we usually prefer 50°C. A second or third lesion is gradually increased to 60–65°C. Motor and sensorial testing is repeated during and after lesioning. As previously mentioned, lesioning of the trigeminal tractus or nucleus caudalis is painful, and the patient should be warned appropriately.

### 1.3 CT-guided percutaneous extralemniscal myelotomy (EM)

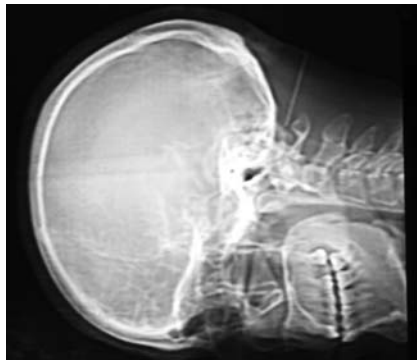The procedure is routinely performed with CT guidance. The patient should be fasted for five hours before the operation. General principals of the cordotomy are also used in this procedure. The Kanpolat cannula and electrode system are recommended for this procedure (Kanpolat Electrodes KCTE, Cosman Company, Burlington, MA, USA) [23].

Contrast material should be administered into the subarachnoidal space of the spinal cord. Iohexol (7–8 mL) is given 20–30 min before the operation by lumbar puncture. After injection of contrast medium, the table is repositioned to the Trendelenburg position for 15 min to observe the contrast in the cervical region. If the general condition of the patient does not permit lumbar puncture, contrast material is injected during the procedure at the C<sub>1</sub>-occiput level [21, 22]. The target is the central cord, which contains the ascending multi-synaptic pathways at the occipitocervical junction in the midline.

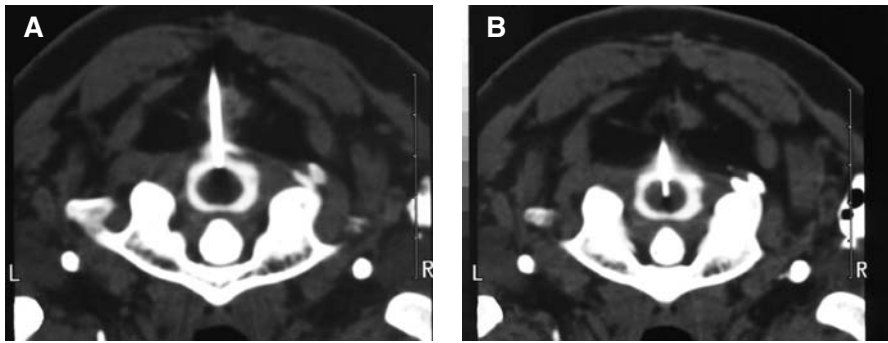
The patient is placed on the CT table in prone position, with the head flexed and fixed. The chest is elevated and supported with soft pads. A nasal catheter is placed to provide oxygen during the procedure [21]. After the injection of local anesthetic, a 20-gauge plastic hub needle is inserted at the C<sub>1</sub>-occiput level in the midline.

Lateral scanogram is taken (Fig. 6); diametral measurements of the spinal cord are taken with axial CT slices. Distance between dura and skin is measured [24]. The cannula is localized in the posterolateral section of the spinal cord in the midline with CT guidance (Fig. 7A). Active electrode is inserted and morphological demonstration of the needle-electrode system is visualized (Fig. 7B).

At this stage, impedance measurements are taken to identify whether the active electrode tip is in the cerebrospinal fluid (around 100 $\Omega$ ), in contact with the spinal cord (around 300 or 400 $\Omega$ ) or inside the spinal cord (more than 700 $\Omega$ ). The target electrode relationship is easily demonstrated by direct visualization of the needle-electrode system under CT guidance [21, 22].



**Fig. 6.** Position of the cannula at occiput C<sub>1</sub> level in lateral scanogram in EM



**Fig. 7.** **A** Final position of the cannula in axial CT slices in EM. **B** Final position of the electrode in axial CT slices, occiput-C<sub>1</sub> level, in EM

Stimulation provides very impressive information. With 50 to 100 Hz, 0.5–2 V stimulation, the patient describes paresthesia of the bilateral lower extremities, indicating that the electrode is in the proper target. If the electrode is properly located anatomically and neurophysiologically, the procedure is finalized with lesioning. The first lesion is usually accepted as a test lesion, and the temperature must be more than 43°C; we usually prefer 50°C. A second or third lesion is gradually increased to 60–70°C. Motor and sensorial testing is repeated during and after lesioning [21].

#### 1.4 DREZ

Spinal-DREZ is located in the rootlets of the painful dermatomes. This approach requires open technique with laminectomy. If the patient is a child, we recommend replacement of laminae (laminotomy). For spinal-DREZ we usually prefer the prone position.

In nucleus caudalis-DREZ, the target is the substantia gelatinosa of the nucleus caudalis, located at the intermediolateral sulcus between the obex and C<sub>2</sub> rootlets. The lesions are performed 1 mm in width and 2 mm in depth. This width and depth should be arranged according to the diametral measurements of the spinal cord [18]. Also for this operation, prone position is preferred.

In spinal DREZ, the target is DREZ of the painful dermatomes, which locates at the intermediolateral sulcus. According to Sindou's description, each of the C<sub>2</sub>–C<sub>4</sub> roots divides into approximately 4 rootlets, which are distinct, well-marked and with cylindrical penetration. C<sub>5</sub>–C<sub>8</sub> roots divide into approximately 6 rootlets, with a diameter of 1.5 mm, making them the thickest together with lumbosacral rootlets. They run together and also have a cylindrical penetration. Thoracal roots divide into approximately 5 rootlets, which are wide and well-marked. They are very small, with a diameter of 0.25 mm, and have a filiform penetration. L<sub>1</sub>–L<sub>3</sub> roots divide into approximately 10 rootlets, and these rootlets have a secondary division and a filiform

penetration. L<sub>4</sub>, L<sub>5</sub> and S<sub>1</sub>-S<sub>3</sub> divide into approximately 7 rootlets and also have a cylindrical penetration. Independent from their level, each rootlet has an approximately 1 mm subpial course within the intermediolateral sulcus [37-40].

## 2. RESULTS

Visual analogue scale (VAS) and Karnofsky scale were used pre- and postoperatively as measures of change in patient pain and performance, respectively. All patients were evaluated in four groups postoperatively as: grade I: no pain, grade II: partial satisfactory pain relief, grade III: partial non-satisfactory pain relief, and grade IV: no change in pain. Grades I and II were accepted as successful outcome and grades III and IV as unsuccessful.

### 2.1 Percutaneous CT-guided cordotomy

Between 1986 and 2008, we performed 246 CT-guided percutaneous cordotomies in 222 patients. Most (207) suffered from intractable pain related to malignancy. In 12 cancer-related cases, CT-guided cordotomy was performed bilaterally and selectively, while in 210 cases, the procedure was performed unilaterally. In the malignancy group, the majority of cases (48.3%) were due to pulmonary malignancies (n: 61), mesothelioma (n: 24) and Pancoast tumor (n: 15). Twenty-six patients had gastrointestinal carcinoma and 21 had metastatic carcinoma; 60 patients presented with other malignancy types. The procedure was applied to 15 cases with benign pain due to various causes.

Following cordotomy, 92% of the patients reported initial pain relief (grades I-II). Minimum and maximum preoperative Karnofsky scores were 20 and 70, respectively (mean  $45.54 \pm 14.31$ ), versus postoperative Karnofsky scores of 20 and 100, respectively (mean  $64.50 \pm 15.56$ ), and the difference was determined to be highly significant ( $p < 0.001$ ).

Mean preoperative VAS score was  $7.62 \pm 0.68$  (minimum: 3, maximum: 10), versus postoperative scores of 0 and 8, respectively (mean  $1.18 \pm 1.89$ ), and the difference was determined to be highly significant ( $p < 0.001$ ).

There was no mortality and very limited morbidity related to percutaneous cordotomy [temporary motor paralysis (n: 5) and ataxia (n: 5) (2.2%) which resolved within three weeks]. In bilateral cordotomy, temporary hypotension and temporary urinary retention occurred in three and two cases, respectively. The only permanent complication was dysesthesia in four cases (1.8%). Lorenz [27] and Sindou [41] first collected a large series from the literature. In their reports, percutaneous cordotomy was described as a risky procedure for the treatment of intractable pain; but these reports were published in 1976 and 1990. The new modality of cordotomy is giving the chance of lesioning just in the target area. In the report of Lahuerta, complications usually occurred when the lesion of the cordotomy was more than 20% of the spinal cord [26].

## 2.2 Percutaneous CT-guided trigeminal tractotomy-nucleotomy (TR-NC)

Between 1988 and 2008, we performed 88 CT-guided percutaneous TR-NC in 75 patients. Sixteen of them suffered from intractable pain related to malignancy. In four cases, TR-NC was performed twice.

Following TR-NC, 56.2% of the patients reported initial pain relief (grades I–II). Minimum and maximum preoperative Karnofsky scores were 40 and 80, respectively, versus postoperative Karnofsky scores of 40 and 90, respectively. Preoperative VAS score was minimum 5, maximum 8, versus postoperative scores of 0 and 6. There was no mortality or morbidity in this group.

## 2.3 Percutaneous CT-guided extralemniscal myelotomy (EM)

Between 1987 and 2008, we performed 21 CT-guided percutaneous EM in 19 patients. Eighteen of them suffered from intractable pain related to malignancy.

Following EM, 63.1% of the patients reported initial pain relief (grades I–II). Minimum and maximum preoperative Karnofsky scores were 30 and 60, respectively, versus postoperative Karnofsky scores of 30 and 90, respectively. Preoperative VAS score was minimum 7, maximum 9, versus postoperative scores of 0 and 8. There was no mortality or morbidity in this group.

## 2.4 DREZ

Between 1986 and 2008, we performed 62 (49 spinal, 13 nucleus caudalis) DREZ procedures in 58 patients. Spinal DREZ in seven cases and nucleus caudalis DREZ in five cases were performed for intractable pain related to malignancy.

Sixty percent of the patients reported initial pain relief (grades I–II) following spinal DREZ while 80% of the patients reported initial pain relief (grades I–II) following nucleus caudalis DREZ. Minimum and maximum preoperative Karnofsky scores were 30 and 60, respectively, versus postoperative Karnofsky scores of 30 and 100, respectively. Preoperative VAS score was minimum 7, maximum 9, versus postoperative scores of 0 and 9. There was no mortality or morbidity in the cancer group.

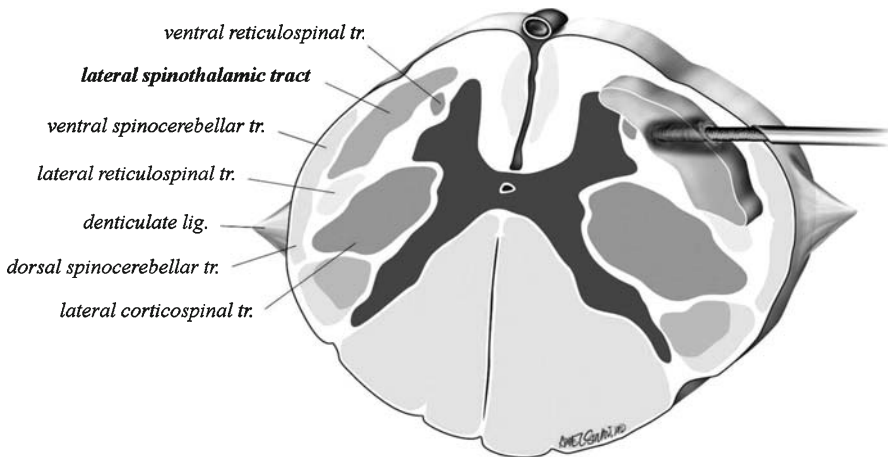
## HOW TO AVOID COMPLICATIONS

Prior to surgery, the rationale for performing the procedure and the risk of complications must be carefully explained to the patients and their relatives. The most important complications in destructive pain-relieving procedures are discussed hereunder.

### 1. CT-GUIDED PERCUTANEOUS CORDOTOMY

The target for percutaneous cordotomy is located in the anterolateral quadrant of the spinal cord in the upper cervical region, in which the tract



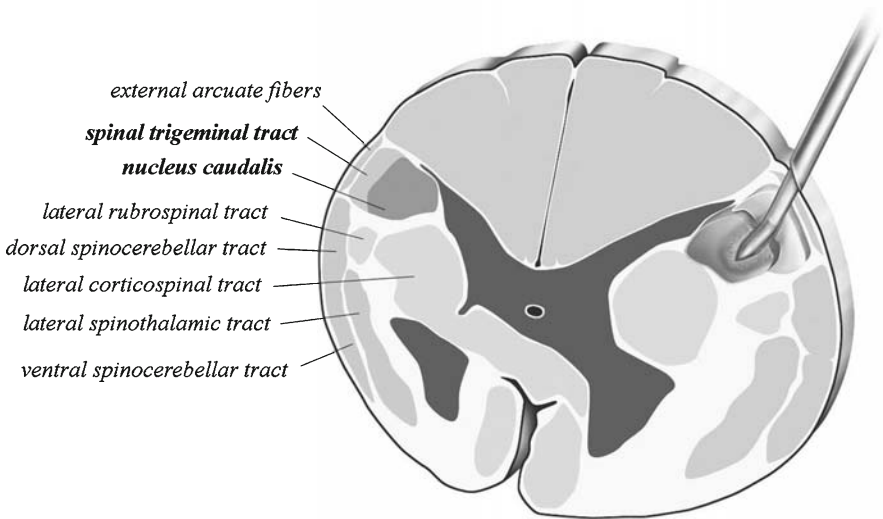


**Fig. 8.** Schematic drawing of percutaneous cordotomy and target-electrode relation with main anatomical structures

is surrounded by some important structures. The pyramidal tract is located just posteriorly (Fig. 8). Impairment would result in hemiparesis on the ipsilateral side. The ventral spinocerebellar tract is located between the posterior lateral surface of the spinal cord and the lateral spinothalamic tract. Lesion would cause ipsilateral ataxia. Multiple puncturing to the spinal cord at this location should be avoided. The ventral reticulospinal tract is located on the median side of the lateral spinothalamic tract. Bilateral lesioning of this tract would cause sleep-induced apnea (Ondine's syndrome) [5, 21, 27]. All of these potential complications can be prevented with CT-guidance since proper demonstration of the cannula-electrode-target relations can be visualized.

## 2. CT-GUIDED PERCUTANEOUS TRIGEMINAL TRACTOTOMY-NUCLEOTOMY (TR-NC)

The target for percutaneous TR-NC is located in the posterolateral quadrant of the upper spinal cord in the occipito-cervical region, in which the tract is surrounded by some important structures. The lateral corticospinal tract is located anteriorly (Fig. 9). Impairment would result in hemiparesis on the ipsilateral side. External arcuate fibers are located between the posterior lateral surface of the spinal cord and descending trigeminal tract. Lesion would cause ipsilateral ataxia. Same complication could be seen following lesioning of the dorsal spinocerebellar tract located in the lateral part of the upper spinal cord. Medial localization of the electrode would cause ataxia because of lesioning of the fasciculus cuneatus.



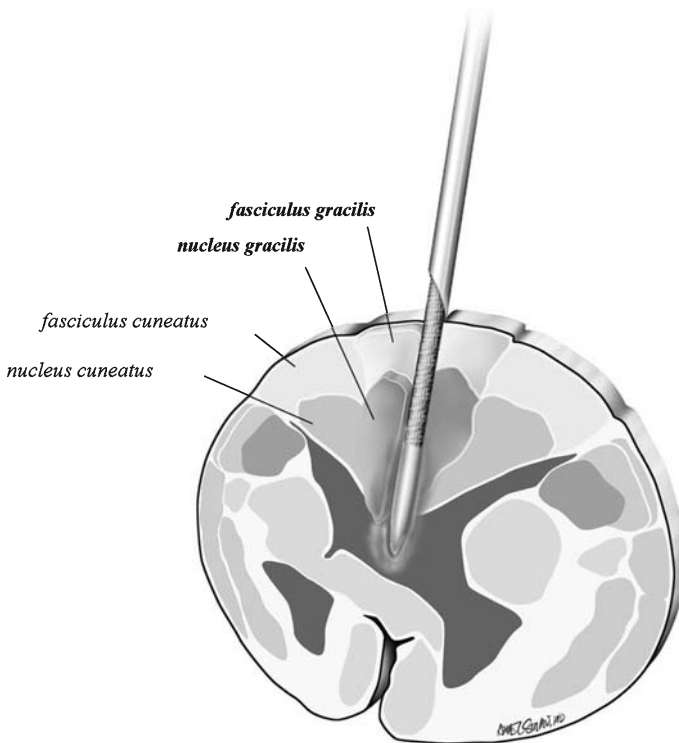
**Fig. 9.** Schematic drawing of percutaneous TR-NC and target-electrode relation with main anatomical structures

### 3. CT-GUIDED PERCUTANEOUS EXTRALEMNISCAL MYELOTOMY (EM)

The target for CT-guided percutaneous EM is located in the medial central cord in the occipito-cervical region, located between both the fasciculus gracilis and central part of the spinal cord (Fig. 10). There is scarce published data regarding the procedure in this region and its related complications. No complications were observed in our experience.

### 4. DREZ

The target for the DREZ procedure is located in the lateral part of the dorsal root entry zone and substantia gelatinosa [33–45]. These procedures are performed under general anesthesia. The most important criterion preventing the risks of anesthesia and of the procedure is the general status of the patient. Younger patients can usually tolerate these operations very well. The most important complications are related first with the lesioning of the dorsal rootlets, which causes sensory denervation of the fibers. If the destruction is performed on the medial side of the DREZ region, the risk of ataxia is higher because of damage to the posterior funiculus. To prevent these complications, we prefer to lesion the lateral part of the DREZ. Other complications related to improper destruction of the spinal cord are prevented by evoked potential monitoring [44].



**Fig. 10.** Schematic drawing of percutaneous EM and target-electrode relation with main anatomical structures

## CONCLUSIONS

Some cancer patients have intractable pain that destroys their motivation and prevents the conduct of their daily life. Furthermore, some cancer patients remain dependent on hospitals, doctors and some special medical agents or devices. The rationale for treating intractable cancer pain is to solve this dependency. I have been interested in the surgical treatment of cancer pain for nearly forty years and can offer the following observations:

1. Some cancer pains can be treated with particular destructive neurosurgical pain procedures. These procedures must be performed by expert neurosurgeons.
2. Percutaneous cordotomy is the best method for denervating unilateral cancer pain. In bilateral lower body pain, the procedure is performed bilaterally with a one-week interval. Central cord lesioning is an effective procedure, but more evidence regarding the efficiency

and mechanisms of these procedures are needed. Some forms of intractable craniofacial cancer pain can be treated surgically with tractotomy-nucleotomy or with the more invasive form of tractotomy-nucleotomy, the nucleus caudalis DREZ lesions. The DREZ operation is a weighty operation and must be performed with open technique by laminectomy. This technique can be used not only for nociceptive cancer pain but also for neuropathic cancer pain.

3. In current practice, many cancer patients are being insufficiently treated by some pain centers and physicians. I recommend that physicians address this issue and attempt to resolve, or at a minimum to prevent new complications, in the cancer patients suffering from intractable pain.

### Acknowledgement

This work was partly supported by the Turkish Academy of Sciences. I express my gratitude to Drs Atilla H. Elhan and Mevci Özdemir for statistical evaluation of my series, Mrs. Mukaddes Kurum Yücel for her assistance in writing the manuscript, Mrs. Corinne Logue Can for her language editing, and Dr. Ahmet Sinav for his creative illustrations.

### References

- [1] Al-Chaer ED, Lawand NB, Weslund KN, Willis WD (1996) Pelvic visceral input into the nucleus gracilis is largely mediated by the postsynaptic dorsal column pathway. *J Neurophysiol* 76: 2675-2690
- [2] American Cancer Society (2008) *Cancer Facts & Figures*, 70 pp
- [3] Arbit E, Pannullo S (2003) Neurosurgical modalities in the management of cancer-related pain. In: Sykes N, Fallon MT, Patt RB (eds) *Cancer pain*. Arnold Publishers, London, pp 259-267
- [4] Becker R, Sure U, Bertalanffy H (1999) Punctate midline myelotomy – a new approach in the management of visceral pain. *Acta Neurochir (Wien)* 141: 881-888
- [5] Bekar A, Kocaeli H, Abaş F, Bozkurt M (2007) Bilateral high-level percutaneous cervical cordotomy in cancer pain due to lung cancer: a case report. *Surg Neurol* 67: 504-507
- [6] Bernard EJ Jr, Nashold BS Jr, Caputi F, Moosy JJ (1987) Nucleus caudalis DREZ lesions for facial pain. *Br J Neurosurg* 1(1): 81-91
- [7] Crue BL, Carregal JA, Felsoory A (1972) Percutaneous stereotactic radiofrequency. Trigeminal tractotomy with neurophysiological recordings. *Confin Neurol* 34: 389-397

- [8] Gybels JM (1995) Indications for the use of neurosurgical techniques in pain control. In: Bond MR, Charlton JE, Wolf J (eds) *Proceedings of the Sixth World Congress on Pain*. Elsevier, Amsterdam, p 475
- [9] Hirshberg RM, Al-Chaer ED, Lawand NB, Weslund KN, Willis WD (1996) Is there a pathway in the posterior funiculus that signals visceral pain? *Pain* 67: 291-305
- [10] Hitchcock ER (1970) Stereotactic trigeminal tractotomy. *Ann Clin Res* 19: 131-135
- [11] Hitchcock E (1970) Stereotactic cervical myelotomy. *J Neurol Neurosurg Psychiatry* 33: 224
- [12] Kanpolat Y, Deda H, Akyar S, Bilgic S (1989) CT-guided percutaneous cordotomy. *Acta Neurochir Suppl (Wien)* 46: 67-68
- [13] Kanpolat Y, Akyar S, Caglar S, Unlu A, Bilgic S (1993) CT-guided percutaneous selective cordotomy. *Acta Neurochir (Wien)* 123: 92-97
- [14] Kanpolat Y, Savas A, Caglar S, Temiz C, Akyar S (1997) Computerized tomography-guided percutaneous bilateral selective cordotomy. *Neurosurg Focus* 2: Article 4
- [15] Kanpolat Y, Deda H, Akyar S, Caglar S, Bilgic S (1989) CT-guided trigeminal tractotomy. *Acta Neurochir (Wien)* 100: 112-114
- [16] Kanpolat Y, Savas A, Batay F, Sinav A (1998) Computed tomography-guided trigeminal tractotomy-nucleotomy in the management of vagoglossopharyngeal and geniculate neuralgia. *Neurosurgery* 43: 484-490
- [17] Kanpolat Y, Savas A, Caglar S, Aydin V, Tascioglu AB, Akyar S (1999) Computed tomography-guided percutaneous trigeminal tractotomy-nucleotomy. In: *Techniques in Neurosurgery*, vol. 5, no 3. Lippincott Williams & Wilkins Inc., Philadelphia, pp 244-251
- [18] Kanpolat Y, Tuna H, Bozkurt M, Elhan AH (2008) The spinal and nucleus caudalis DREZ operations for chronic pain – technical report. *Oper Neurosurg* 62(Suppl 1): ONS235-ONS244
- [19] Kanpolat Y, Caglar S, Akyar S, Temiz C (1995) CT-guided pain procedures for intractable pain in malignancy. *Acta Neurochir Suppl* 64: 88-91
- [20] Kanpolat Y (2003) Cordotomy for pain. In: Schulder M (ed) *Handbook of stereotactic and functional neurosurgery*. Marcel & Dekker, New York, Basel, pp 459-472
- [21] Kanpolat Y (2007) Percutaneous destructive pain procedures on the upper spinal cord and brain stem in cancer pain: CT-guided techniques, indications and results. *Adv Tech Stand Neurosurg* 32: 147-173

- [22] Kanpolat Y (2002) Percutaneous stereotactic pain procedures: percutaneous cordotomy, extralemniscal myelotomy, trigeminal tractotomy-nucleotomy. In: Burchiel K (ed) Surgical management of pain. Thieme, Stuttgart, New York, pp 745-762
- [23] Kanpolat Y, Cosman E (1996) Special RF electrode system for CT-guided pain procedures. *Neurosurgery* 38: 600-603
- [24] Kanpolat Y, Akyar S, Caglar S (1995) Diametral measurements of upper spinal cord for stereotactic pain procedures (Experimental and clinical study). *Surg Neurol* 43: 478-483
- [25] Kunc Z (1965) Treatment of essential neuralgia of the 9th nerve by selective tractotomy. *J Neurosurg* 23: 494-500
- [26] Lahuerta J, Lipton S, Wells JC (1985) Percutaneous cervical cordotomy: results and complications in a recent series of 100 patients. *Ann R Coll Surg Engl* 67: 41-44
- [27] Lorenz R (1976) Methods of percutaneous spinothalamic tract section. *Adv Tech Stand Neurosurg* 3: 123-154
- [28] Mullan S, Harper PV, Hekmatpanach J, Torres H, Dobbin G (1963) Percutaneous interruption of spinal pain tracts by means of a strontium 90 needle. *J Neurosurg* 20: 931-939
- [29] Nashold BS Jr, Urban B, Zorub DS (1976) Phantom pain relief by focal destruction of the substantia gelatinosa of Rolando. In: Bonica JJ, Albe-Fessard D (eds) *Advances in pain research and therapy*, vol. 1. Raven Press, New York, pp 959-963
- [30] Osenbach RK (2004) Nontrigeminal craniofacial pain syndromes. In: Follett KA (ed) *Neurosurgical pain management*. Elsevier Inc., Philadelphia, pp 84-98
- [31] Osenbach RK, Burchiel KJ (2000) Percutaneous cordotomy. In: Kaye A, Black P (eds). *Operative neurosurgery*, Chapter 128. Churchill-Livingstone, Philadelphia, pp 1569-1579
- [32] Raslan AM (2008) Percutaneous computed tomography-guided radiofrequency ablation of upper spinal cord pain pathways for cancer-related pain. *Oper Neurosurg* 62: ONS226-ONS234
- [33] Rolando L (1824) *Ricerche Anatomiche sulla Strucura del Midollo Spinale* (in Italian). Dizionario Periodico di Medicina. Staperia Reale, Torino, Italy
- [34] Rosomoff HL, Brown CJ, Sheptak P (1965) Percutaneous radiofrequency cervical cordotomy: technique. *J Neurosurg* 23: 639-644
- [35] Schvarcz JR (1976) Stereotactic extralemniscal myelotomy. *J Neurol Neurosurg Psychiatry* 39: 53-57
- [36] Schvarcz JR (1975) Stereotactic trigeminal tractotomy. *Confinia Neurol* 37: 73-77

- [37] Sindou M, Fischer G (1974) La radicellotomie posterieure selective. Premiers resultats dans le chirurgie de la douleur (in French). *Neurochirurgie* 20: 397-408
- [38] Sindou M (1998) Spinal entry zone interruption for persistent pain. In: Gildenberg PL, Tasker RR (eds) *Textbook of stereotactic and functional neurosurgery*. McGraw-Hill, Houston, pp 1565-1572
- [39] Sindou M (2002) Dorsal root entry zone lesions. In: Burchiel KH (ed) *Surgical management of pain*, Chapter 56. Thieme Medical Publishers, New York, pp 701-713
- [40] Sindou M (2006) Microsurgical DREZotomy. In: Schmidek HJ, Roberts DW (eds) *Operative neurosurgical techniques: indications, methods and results*, 5th edn. Elsevier-Saunders, Philadelphia, pp 1573-1588
- [41] Sindou M, Jeanmonod D, Mertens P (1990) Ablative neurosurgical procedures for the treatment of chronic pain. *Neurophysiol Clin* 20: 399-423
- [42] Sjöqvist O (1938) Studies on pain conduction in the trigeminal nerve. *Acta Psychiatrica et Neurologica [suppl]* XVII: 139 pp
- [43] Spiller WG, Martin E (1912) The treatment of persistent pain of organic origin in the lower part of body by division of the anterolateral column of the spinal cord. *JAMA* 58: 1489-1490
- [44] Teixeira MJ (1998) Various functional procedures for pain. In: Gildenberg PL, Tasker RR (eds) *Textbook of stereotactic and functional neurosurgery*, Part II, Facial pain. The McGraw-Hill Companies Inc., New York, pp 1389-1402
- [45] Vic-D'Azyr F (1786-89) *Traité d'Anatomie et de Physiologie*, vol. 1, Anatomie et Physiologie du Cerveau, vol. 2, Planches Anatomiques, Paris, Didot
- [46] Webster's Third New International Dictionary (1993) Merriam-Webster, 4th edn. Springfield, Massachusetts
- [47] White JC, Sweet WH (1969) Pain and the neurosurgeon. In: *Pain and the neurosurgeon*. Charles C. Thomas Publisher, Springfield, IL, pp 232-243
- [48] World Health Organization (1996) *Cancer pain relief and palliative care*, 2nd edn. WHO, Geneva



**Yücel Kanpolat**

Yücel Kanpolat has been chairman of the Department of Neurosurgery at Ankara University

Graduated from Ankara University, School of Medicine

1969–1974: Neurosurgical Training, University of Ankara, School of Medicine, Department of Neurosurgery

1978: Associate Professor in Neurosurgery

1989: Full Professor in Neurosurgery

2000: Chairman of the Department of Neurosurgery

1995: Associate Member of the Turkish Academy of Sciences

1996: Active Member of the Turkish Academy of Sciences

2008: President of the Turkish Academy of Sciences

Main interests: Functional Neurosurgery, Pain Surgery, CT-Guided Destructive Pain Procedures

Contact: Yücel Kanpolat, Inkilap Sokak 24/2, 06640 Kizilay-Ankara, Turkey

E-mail: kanpolat@ada.net.tr



---

# NEUROSURGERY FOR NEUROPATHIC PAIN

M. SINDOU

## INTRODUCTION

According to the definition of the International Association for the Study of Pain (IASP) – given by the Kyoto protocol of IASP, Basic Pain Terminology in Pain 2008, 137: 473–477 – neuropathic pain is that arising as a direct consequence of a lesion or disease affecting the somatosensory system, peripheral or central.

Treatment of neuropathic pain is very arduous, a majority of affected patients having disabling neurological disorders together with severe neuropsychological handicaps. Medications, physical therapy and psychotherapies are often insufficient to reduce the pain to a bearable level. In some well-defined circumstances functional neurosurgery may provide a solution.

Two types of neurosurgical methods have been developed for managing neuropathic pain. The first ones are modulative techniques; they aim at enhancing the physiological control of the pain system; these techniques include electrostimulation and drug delivery systems. The second ones are neurodestructive techniques; they consist of performing selective therapeutic lesions in well-defined targets sustaining pain generators.

Before surgery is indicated and the most appropriate procedure chosen for a particular patient, the anatomical and physiological mechanisms at the origin of the pain must be analyzed accurately, which needs solid basic and clinical knowledge.

## RATIONALE

### 1. PATHOLOGICAL MECHANISMS IN PRIMARY AFFERENT NEURONS

After injury, primary afferent nociceptors can be sensitized and acquire ongoing spontaneous discharges, a lowered activation threshold and an increased response to suprathreshold stimuli. In addition the C-fiber nociceptors that survive a partial nerve injury may develop noradrenergic sensitivity and therefore contribute to causalgic phenomena, manifested as a Complex Regional Pain Syndrome (CRPS).

In damaged primary afferent axons the regenerating sprouts acquire abnormalities that produce ectopic discharges. Their generation at the site of

---

*Keywords:* neuropathic pain, functional neurosurgery, neuromodulation, DREZ-lesioning

stump neuromas after amputation or complete nerve transection has been well documented by microneurographic recordings. Abnormal primary afferent sproutings are also present in many nontraumatic conditions, for instance after herpes zoster invasion; when regenerating sprouts attempt to reinnervate, they are likely to be trapped in intraneural scars. Such neuromas in-contiguity can also be present after subtotal nerve trauma especially after crush or stretch injuries.

Where fibers have been demyelinated, abnormal electrical connections between adjacent axons may be responsible for so-called ephaptic (“cross-talk”) phenomena, which are triggered by the discharge of other afferents. Also, locally demyelinated axons can give rise to “reflected” impulses, which propagate both ortho- and anti-dromically. This is likely able to produce dysesthetic “buzzing” sensations.

The abnormalities detected in sprouts of axotomized primary afferent neurons can also be expressed at the level of their cell bodies in the Dorsal Root Ganglion (DRG). It is now clear that continued – or even *de novo* – ectopic discharges from the DRG may explain pain not eliminated by excision of the neuroma, without the need of postulating any central mechanism.

## **2. CHANGES IN THE CENTRAL NERVOUS SYSTEM AFTER PERIPHERAL NERVE INJURIES**

Lesions in the peripheral nervous system can be at the origin of secondary changes inside the Central Nervous System (CNS) especially the dorsal horn, where primary afferents terminate. It has been demonstrated that the intraspinal terminal arbors of axotomized primary afferents sprout and invade new territories within the dorsal horn. Axotomized afferents cease making their normal neuropeptides (e.g., substance P, calcitonin gene-related peptide, ...) and begin making different ones (e.g., neuropeptide Y, galanin, vasoactive intestinal polypeptide, ...). There is a dramatic upregulation of early immediate gene regulation (e.g., C-fos) in intrinsic spinal neurons that suggests an important and prolonged response of second-order neurons to changes in their input. These changes that follow peripheral nerve injury may have central consequences that are of potential pathophysiological importance.

C-nociceptor discharge produces a central state of hyperexcitability whereby wide dynamic range neurons show increased discharges when their receptive fields (RFs) are stimulated. In addition the size of cell RFs is enlarged. These electrophysiological changes are associated with exaggerated nocifensive withdrawal reflexes, which are indicative of perpetual hyperalgesia. This hyperexcitability involves activity at glutaminergic synapses of the N-methyl-D-aspartate (NMDA) type. High levels of activity in these synapses produce excitotoxic insults in dorsal horn neurons. The phenomenon can be detected anatomically by the appearance of transsynaptic degenerative changes in dorsal horn neurons. Once initiated, central hyperexcitability may

be maintained by sources of ongoing discharges, for example – in sympathetically-maintained pain – by activity in sympathetic afferents, whereas – in sympathetically-independent pain – by spontaneous ectopic discharges from nociceptor sprouts in a neuroma or by essentially normal nociceptor input from poorly healed tissue damage.

Interruption of the dorsal roots produces deafferentation of spinal cord neurons. This is usually the result of traumatic avulsion or vertebral fracture. Deafferented spinal neurons acquire abnormal spontaneous patterns of discharge. This discharge is of high frequency and appears in one of patterns: long trains of fairly regular discharges or paroxysmal burst discharges. Spontaneous discharges are found in cells in both the superficial and the deep laminae of spinal gray. Hyperactivity has been recorded during surgical procedures in the dorsal horn of patients with deafferented spinal cord [4]. There is also the possibility that the pathological change in the spinal cord generates hyperactivity in the thalamus, and change in the thalamus in turn generates hyperactivity in the cortex. It is also possible that the thalamocortical abnormal activity becomes secondarily independent from the spinal cord. This might be a cause of failure of pain surgery at the deafferented spinal cord segments if surgery is performed too late.

### 3. ABNORMALITIES AFTER CNS INJURY

Spontaneous and evoked pain, as well as dysesthesias, may appear after injury to the spinal cord, brainstem, thalamus, and although more rarely cortex. Central pain was classically considered due to a loss of control of the “extralemniscal” structures by the “lemniscal” pathways. Actually careful sensory testing and imaging techniques have led to the conclusion that there is a common feature to most patients with “central” pain, namely, damage to some part of the spinoreticulothalamic system. In patients with central pain, neurons with receptive fields (RFs) lying around the border of the anesthetic area have RFs larger than normal. Many of the thalamic neurons have spontaneous high-frequency burst discharges, a rare finding in the normal patient and very different from the spontaneous regular discharge of 10 Hz of the normal thalamus. Microstimulation in the vicinity of neurons without RFs frequently produces painful sensations, often similar to the patient’s clinical pain, which are believed to arise from the anesthetic area, contrarily to normal patients in whom there is no pain but only paresthesias.

## DECISION-MAKING

When dealing with patients suffering from so-called neuropathic pain, the *first step* is to verify that all pathological causes that might be at the origin have

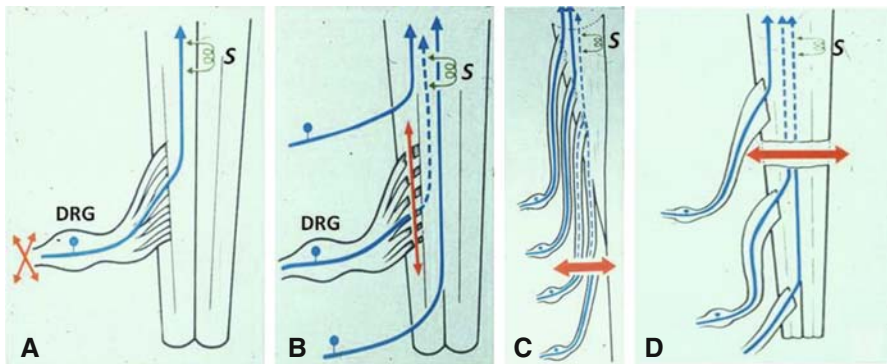
been well-corrected. Such eventualities are far from to be exceptional; as a matter of fact numbers of patients are directly referred to a pain center instead of having passed through the filter of appropriate specialists. This holds particularly true for atypical tunnel syndromes or spondylotic radiculopathies, ...

The *second step* is to analyze the anatomical–physiological mechanisms of each particular type of pain.

The *third step* is to be certain that all pharmacological varieties of medications have been seriously tried, especially for neuropathic pain: anticonvulsants and tricyclic antidepressants. We do not indicate surgery before having tried to control pain by high dosages of imipramine, administered IV, with progressively increased doses up to 150 mg/day on average, for a minimum of ten days.

The *fourth step* is to consider, among the multiple neurosurgical procedures available, the one(s) which should be logically effective according to the hypothesized mechanisms of the pain. If more than one procedure can be proposed, the conservative one is preferred as the first choice.

Over a 30-year experience we have learned that consideration of the topographical level of the causal lesion, as well as of its impact on the sensory structures, is of prime importance for choosing the appropriate target (Fig. 1).



**Fig. 1.** Impact of lesion on the Dorsal Column fibers. When the lesion is at the peripheral nerve level or the radicular level distally to the Dorsal Root Ganglion (DRG), axons going up to the brainstem sensory relay nuclei, through dorsal column, are intact (A). When the lesion interrupts the fibers centrally to the DRG, as for instance in brachial plexus avulsion (B), dorsal column fibers are degenerated up to the brainstem. When a lesion damages the root centrally to the DRG at the lumbo-sacral level, as does a lumbar disc herniation not removed early enough, fibers are centrally degenerated (C). Consideration of site of the causal lesion, together with the degree of completeness of interruption of fibers, is of prime importance to predict effectiveness of stimulation methods, especially SCS (S). Same applies for spinal cord lesions (D). If dorsal column fibers are totally interrupted, SCS cannot be effective. Usefulness of SSEPs measurements (Central Conduction Time) before considering surgery is indicated [modified from Sindou MP, Mertens P, Garcia-Larrea L., Surgical Procedures for neuropathic pain, Neurosurgery Quarterly, 2001, 45-65]

## 1. DECISION-MAKING FOR PAIN CAUSED BY PERIPHERAL NERVE LESIONS

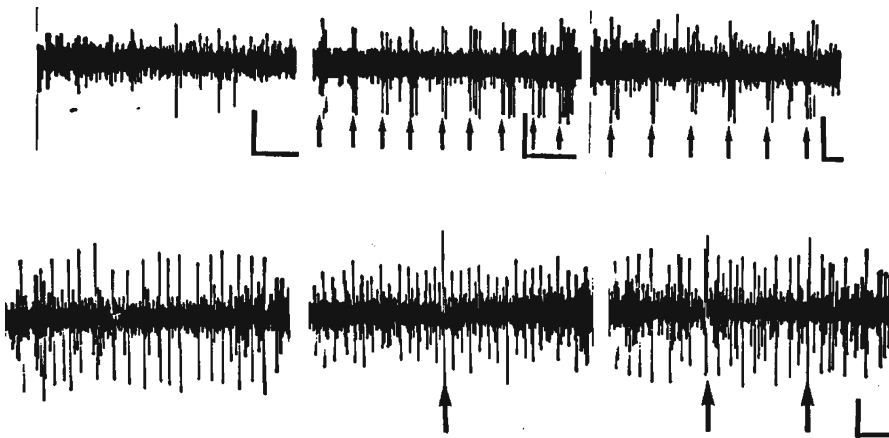
When the causal lesion concerns a single sensory nerve (especially if located in the distal part of the nerve) and when there is reasonable evidence that the pain is related to scar tissue adhesions and/or formation of a true neuroma, a direct surgical approach at the lesion site can be justified for anatomical treatment. The nerve is freed; if there is a neuroma it is resected and the proximal stump ligated and protected. When the lesion involves a mixed nerve trunk, a similar strategy can be adopted, but even more prudently because of the greater functional importance of such nerves.

When there is no argument for anatomical treatment, peripheral nerve stimulation with external transcutaneous nerve electrical stimulation (TNES) or direct peripheral nerve stimulation (PNS) if the nerve is deeply situated, or the more commonly used spinal cord stimulation (SCS) methods can be indicated. When several nerves are involved, SCS at the corresponding spinal cord segments is the first choice. If SCS fails, lesioning-surgery in the Dorsal Root Entry Zone (DREZ) may be considered, but – according to our experience – only if the main components of pain are of the paroxysmal and/or the allodynic types. A type II Complex Regional Pain Syndrome (CPRS) may accompany peripheral nerve lesions. The presence of type II CPRS does not modify the above guidelines. CPRS are particularly responsive to SCS.

After limb amputation two main types of pain, that may coexist, may be encountered: pain in the phantom limb and pain in the stump. SCS is the first option. If it fails, DREZsurgery may be considered. DREZ-lesioning generally relieves phantom limb pain when rootlets are avulsed, but pain in the stump is less constantly influenced; however, good results are obtained when the pain is of the paroxysmal and/or the allodynic types. The newly developed Precentral (motor) Cortex Stimulation (PCS) seems to be promising for pain after amputation; location of the electrodes on the cortex must be determined after f. MRI study has found out the representation site of the motor function corresponding to the amputated limb.

## 2. DECISION-MAKING FOR PAIN CAUSED BY PLEXUS OR ROOT LESIONS

When the pain is related to plexus or root lesions, it is of prime importance to determine the exact situation of the lesion – whether it is distal or central to the Dorsal Root Ganglion (DRG) – as well as the completeness or not of the anatomical-functional interruption of the radicular fibers. This can be assessed by studying the Nerve Conduction Velocity (NCV) and the Somato-Sensory Evoked Potentials (SSEP). If interruption is central to the DRG and total, SCS cannot be effective because of degeneration of the DRG axons in the corresponding dorsal columns, from lesion up to the brainstem relay nuclei. Target for stimulation should consequently be the contralateral tha-



**Fig. 2.** *Dorsal horn microelectrode recordings in humans.* The electrode was a floating Tungsten-glass microelectrode, implanted intraoperatively by free-hand under the operative microscope approximately 5 mm in depth (i.e., in laminae IV–VI). *Upper trace, normal activity.* Recordings in a non-deafferented dorsal horn at the lumbo-sacral level (spastic patient). *Left:* Almost no spontaneous activity (three spikes at random). *Middle:* spike burst discharges (arrows) evoked by regular light tactile stimulation of the corresponding dermatome. *Right:* Spike burst discharges evoked by electrical stimulation of the corresponding peripheral nerve. *Lower trace, deafferentation hyperactivity.* Recordings in the L5 cord segment of a patient with pain due to a traumatic section of the hemicauda equina from root L4 to S4. *Left:* Spontaneous activity of the recorded unit: continuous, regular, high frequency discharge. *Middle:* The unit during light tactile stimulation of the L4 to S1 dermatomas (arrow). *Right:* During electrical stimulation of the tibial nerve (the arrows are two consecutive stimuli). Note the continuous regular discharge that remains unaltered. The vertical bars are 50  $\mu$ V; the horizontal bars are 100 ms [from Jeanmonod D, Sindou MP, Magnin M, Baudet M. Intra-operative unit recordings in the human dorsal horn with a simplified floating microelectrode. *Electroencephalogr Clin Neurophysiol* 1989; 72: 450-454]

lamic somatosensory nucleus, namely, the ventroposterolateral nucleus), or the precentral (motor) cortex.

DREZ-lesioning is particularly effective in true deafferentation pain syndromes, known to be accompanied by hyperactivity of the dorsal horn cells, such as those occurring after brachial plexus avulsion (or less frequently lumbo-sacral avulsion) or after cauda equina injury (Fig. 2) [7, 19].

In pain due to herpes zoster, which corresponds to lesions of both the dorsal ganglion cells (with their related axons running through the spinal cord) and the dorsal horn cells themselves, SCS can be tried if enough dorsal column fibers corresponding to the painful area are still functional. Their functionality can be checked by studying the Central Conduction Time on SSEPs. Surgery in the DREZ can be indicated if the main components of the post-herpetic pain are of the paroxysmal and/or allodynic types, the permanent superficial burning or deep aching components being generally poorly relieved.

### 3. DECISION-MAKING FOR PAIN CAUSED BY SPINAL CORD LESIONS

Chronic pain after spinal cord or cauda equina injuries may of course be related to mechanical factors such as bony instability; it also may correspond to neuropathic pain in the affected spinal cord segments and/or in the territory caudal to the lesional level. Neuropathic pain after spine injuries may be classified as radicular, segmental (corresponding the level of the injured cord segments), infrasegmental (i.e., below the lesion) or visceral. Pain that resides in the dermatomes corresponding to the injury may be merely radicular, resulting from nerve root contusion, entrapment or scarring at the level of injury, or may be related to segmental central pain caused by the deafferentation of, or the direct damage to, the corresponding central neurons. Deafferented dorsal horn neurons acquire abnormal spontaneous patterns of discharge that can be recorded with microelectrodes during surgical procedures, as shown in Fig. 2.

The first step in managing pain after spinal injury is to verify the absence of persisting compressive factors in relation with bony instability, deformity or bone fragments in the canal; if present, they should be treated surgically.

In patients whose pain has a “radiculo-metameric” distribution, that is, the pain corresponding with the level and extent of the spinal cord lesions (we name this pain: “segmental”), surgery in the DREZ gives satisfactory effects [7, 22]. In contrast pain in the territory below the lesion, especially in the perineosacral area, is not influenced even if DREZ-surgery is performed at the (lower) corresponding medullary segments. This is particularly true when the pain consists of a permanent burning sensation and is located in an infralésional, totally-anesthetic, area. Therefore DREZ-surgery must be reserved for pain syndromes related to the injured medullary segments and the adjacent ones if modified by consecutive pathological process (e.g. cavitation, gliosis, arachnoiditis). In patients with incomplete paraplegia, it is of paramount importance that DREZ-lesioning be performed not too deeply and extensively, to avoid additional neurologic deficits. On the contrary, in patients with complete motor and sensory deficits, DREZ-surgery can be done extensively on the selected segments. The best indications for DREZ-surgery are the traumatic lesions of the thoraco-lumbar vertebral junction with complete functional interruption of the conus medullaris, especially when the pain is located in the legs rather than in the perineum. Pain caused by lesions in cauda equina can also be favourably influenced by DREZ-surgery performed at the corresponding spinal cord segments.

When pain corresponds to the territory below the lesion, SCS could be effective only if the corresponding dorsal columns retain sufficient functional value. If the territory below the lesion is totally anesthetic, that is the sensory tracts totally interrupted, SCS would not work due to degeneration of the dorsal column fibers. Indeed, electrodes – even implanted above the lesion – could

not stimulate contained fibers which have degenerated up to their brainstem relay nuclei. When clinical assessment and imaging cannot ascertain integrity of the dorsal column fibers, study of the Central Conduction Time (CCT) is of considerable help. When CCT is altered the patient should not be implanted.

DBS thalamic stimulation has not been enough explored in those indications to know whether infralesional pain can be alleviated or not by this method. Perhaps in the future, Precentral (motor) Cortex Stimulation shall reveal effectiveness. A few cases treated with PCS have been reported at meetings on pain surgery, with pain favourably influenced.

#### **4. DECISION-MAKING FOR PAIN CAUSED BY BRAIN LESIONS OR LESIONS WITH ANESTHESIA DOLOROSA IN THE CEPHALIC TERRITORY**

Central pain after stroke, of ischemic or hemorrhagic origin, was classically not accessible to neurosurgical treatments. However the recently-introduced Precentral Cortex Stimulation (PCS) method revealed effective in two-thirds of the patients operated on. Main indication is the so-called Dejerine-Roussy thalamic syndrome, indications can be extended to all similar painful post-stroke syndromes; not only the one due to strictly thalamic lesion, but also the ones supra-thalamic (cortico-subcortical areas) or infrathalamic (brainstem, Wallenberg syndrome) [14, 26].

Neuropathic pain in the trigeminal territory, especially the one characterized by anesthesia dolorosa can be an indication of PCS [14, 26] or of Nucleus-Caudalis Lesioning [7].

#### **5. PAIN DUE TO MALIGNANCIES**

In cancer pain, which is ordinarily thought to be caused by nociceptive mechanisms (e.g., inflammation, nerve compression,...), true neuropathic mechanisms may supervene, either by infiltration of nerve fibers or after radiotherapy by loss of fibers.

Good candidates for pain surgery are patients with long life expectancy and topographically-limited pain caused by well-localized lesions. Pancoast-Tobias syndrome at the thoracic apex is typically a good indication for DREZ-surgery performed from C6-C7 to T1-T2. Other indications are pain due to involvement of the lumbo-sacral/plexus. Because extensive DREZ-operations at the lumbar and/or the sacral segments would inevitably result in leg hypotonia and/or sphincter disturbances, for pain below the waist in patients who are able to walk the procedure should be indicated only if it has to be limited.

#### **6. PAIN ASSOCIATED TO HYPERSPASTIC STATES**

A particular but not unfrequent situation is pain associated to severe spasticity in paraplegic patients. When the pain is related to the spastic state, it can



be dramatically improved, together with the spasticity, by Intrathecal Infusion of Baclofen delivered through an implanted pump or by DREZ-surgery performed from L2 down to the sacral roots [18, 20].

Another frequent situation is pain on the paralyzed side in an hemiplegic patient, especially in the upper limb. If there is sufficient evidence that the pain be related to an excess of the spasticity, DREZ-surgery can be performed at the cervical spinal cord segments from C5 to T1 [18, 23].

The antispastic effects of MDT are explained by the interruption of the afferent components of the myotatic (monosynaptic) and of the nociceptive (polysynaptic) arc reflexes, which so deprives the somatosensory relays of the dorsal horn from most of their excitatory inputs (see Fig. 5) [17, 24].

## **SURGERY**

### **1. PERIPHERAL NERVE STIMULATION (PNS) AND TRANSCUTANEOUS ELECTRO-NEURO-STIMULATION (TENS)**

On the basis of the Gate Control theory [12], in 1967 Wall and Sweet [27] were the first to implant electrodes on the median and ulnar nerves in a patient suffering from neuropathic pain. PNS is justified only if one nerve of a region is involved. Because of the proximity of motor and sensory fibres in peripheral nerves, the range of electrostimulation is much smaller than is the case for Spinal Cord Stimulation (SCS). Therefore PNS is now rarely used other than for the treatment of occipital neuralgia.

TENS is not strictly part of the surgical armamentarium; however it should be tried before use of more invasive techniques. Electrodes may be placed on the skin over the corresponding peripheral nerve. The relief of pain is the more effective as (1) the pain is of peripheral origin, (2) the stimulated nerve lays superficially under the skin so it is accessible to electrical current delivered by external electrodes and (3) the electrodes are applied proximally to the causative lesion. Of major importance is that TENS be able to elicit evoked paresthesias in the whole painful territory.

### **2. SPINAL CORD STIMULATION (SCS)**

SCS is a modulative reversible neurosurgical method which aims at enhancing the inhibitory control of the large primary afferent fibres of the dorsal columns on pain message processing. Experimental studies show a modification in the neurotransmitters of the dorsal horn following SCS: inhibition of excitatory amino-acid through GABAergic neurotransmission. The fact that patients experience electrostimulation paresthesias raises the question whether a superimposed placebo-effect contributes to the neurophysiologic effects.

Evidence of objective modifications of spinal responses to noxious stimuli – namely the RIII flexion reflexes in the hamstring muscle in response to painful stimuli applied to the sensory sural nerve – after SCS has been well-documented in patients. Study shows depression of the RIII reflex during SCS, as well as during TENS, when these methods are clinically effective. In addition, experimental data shows an inhibition of long-term potentiation of the wide dynamic range neurons of the dorsal horn following SCS in rats.

*Careful patient selection* is crucial. The clinical examination and the imaging investigations have to determine if the dorsal column fibers are intact between the Dorsal Root Ganglion (DRG) and the cuneate-gracilis relay nuclei of the brainstem. SomatoSensory Evoked Potentials (SSEP) recordings are a valuable tool to assess the functional status of the dorsal columns and the lemniscal system [21]. When Central Conduction Time (CCT) – i.e., the time course between the dorsal horn potential and the cortical potential – is significantly altered, the patient should not undergo SCS. When CCT is normal, electrode implantation can be performed without a preliminary percutaneous surgical trial. When clinical, imaging and electrophysiological assessment cannot be certain of the integrity of the fibers to be stimulated, a percutaneous stimulation test has to be performed for a few hours or for a longer period but with a subsequent higher rate of infection.

The selected patients are then *operated* on either through an open interlaminar approach or percutaneously. The best location of the electrode is at the upper level of the spinal cord segments corresponding to the painful territory. Electrodes must be placed ipsilateral to the pain. For high thoracic and cervical positioning of the electrode, an open surgical implantation through an unilateral interlaminar approach is preferred. In addition, movement of a percutaneously implanted electrode is more likely in the cervical region. For lower thoracic positioning of the electrode the percutaneous technique is preferred, with entry point to the epidural space being distal to conus medullaris to lessen the neurological risk. The percutaneous technique has the advantage of positioning the electrode appropriately under local anaesthesia. The most effective position is that which induces stimulation-evoked paresthesias in the whole painful territory. In case of open surgery (under general anaesthesia) absence of post-operative induced paresthesias or partial covering of the pain territory necessitate electrode repositioning.

*Neuropathic pain syndromes for which SCS may be helpful* include: pain due to radiculopathy after Failed Back Surgery Syndrome (FBSS), pain after peripheral nerve lesion, post-amputation pain, Complex Regional Pain Syndrome (CRPS) and Peripheral Vascular Disease (PVD). In FBSS, results are better when pain is anatomically limited rather than diffuse and when unilateral rather than bilateral. For FBSS, pain relief greater than 50% is obtained in 60–75% of the patients. North et al. found 52% of good results at 7 years of follow-up. SCS can also be indicated in diabetic neuropathy refractory to

medical treatment, except when autonomic neuropathy is present. In contrast, post-herpetic pain and intercostal neuralgia syndromes seem to respond less favourably. Low back pain in FBSS was considered in early series as a poor prognostic factor for SCS. The high positioning of the electrode between the 7th and 10th thoracic vertebrae seems to give good results in at least 50% of the patients so implanted.

*Complications of SCS* mainly include infection, in the order of 5% in the large series, and the need for revision of the system in 13%, on average. Complications and technical problems in early systems are nowadays less common thanks to evolving technology. Migration of electrode is observed in 7% of cases with recent multi-channel electrodes and mainly observed in association with the percutaneous technique; Bipolar electrostimulation has greater clinical reliability and fewer side-effects than unipolar systems in terms of uncomfortable, sometimes unbearable, paresthesias and motor twitches by diffusion of current to the neighbouring sensory and motor rootlets, respectively.

### **3. DEEP BRAIN STIMULATION (DBS)**

DBS has been used since 1954 for treatment of intractable neuropathic pain. Among the several stereotactic targets described, the most commonly chosen were the Ventro-Postero-Lateral and Ventro-Postero-Medial thalamic nuclei [11], and the PeriAqueductal/Periventricular Grey matter [16].

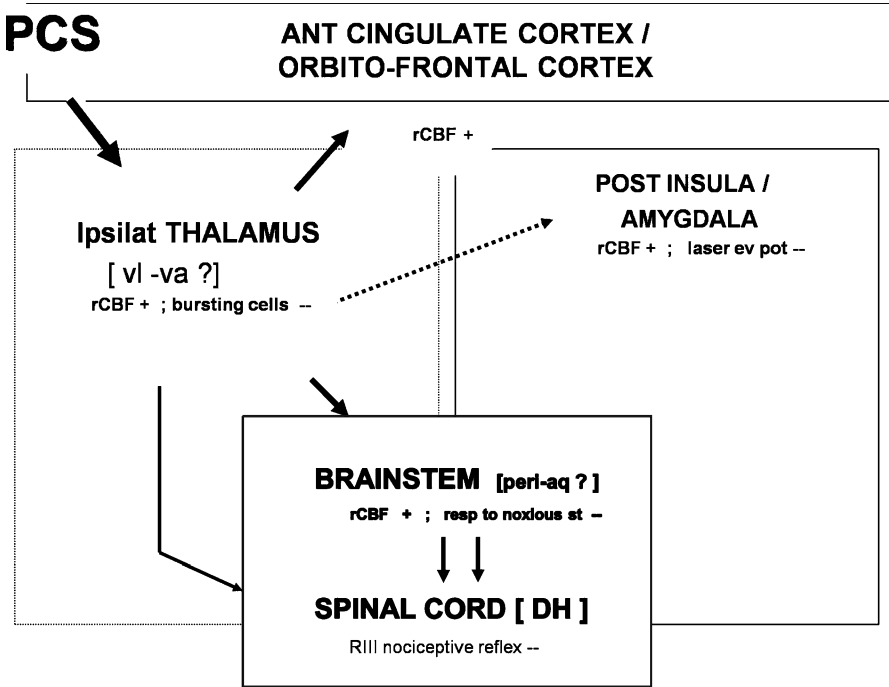
Mechanisms of action are not all well understood. Thalamic DBS would induce inhibition of dorsal horn activity through descending pathways. PAG/PVG stimulation would induce release of endorphins.

DBS can be considered when SCS has failed, or is not indicated because of loss of large primary afferent neurons, or for central pain with supraspinal lesions when thalamus is intact. Targets are thalamic ventro-postero-lateral thalamic nucleus for extremities pain and ventro-postero-medial thalamic nucleus for facial pain. Periaqueductal and periventricular grey matter stimulation have been mainly indicated to treat cancer pain.

### **4. PRECENTRAL (MOTOR) CORTEX STIMULATION (PCS)**

Stimulation of the motor cortex was first described by Tsubokawa et al. for post-stroke pain in 1991, on the basis that hyperactivity in thalamic relay neurons following spinothalamic tractomy in cats was inhibited by motor cortex stimulation [26].

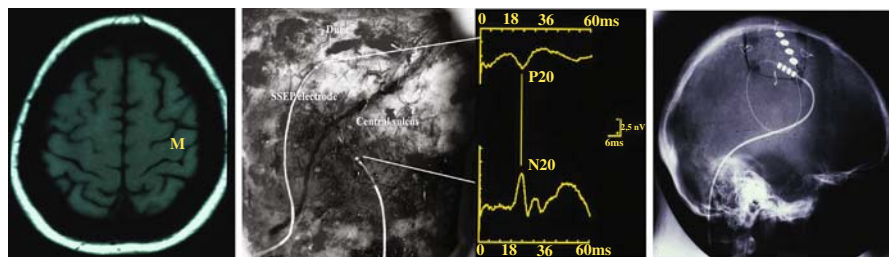
Precentral Cortical Stimulation (PCS) would be a more appropriate naming because implication of the pyramidal cells themselves in the analgesic effect of the method is far from to be proven, and it might be that many other neural structures be involved.



**Fig. 3.** Mechanisms of action of Precentral (motor) Cortex Stimulation (PCS)

According to recent studies, the thalamus is strongly implicated. Using position emission tomography, Peyron et al. [15] and Garcia-Larrea et al. [3] found an increase of cerebral blood flow in the ventro-lateral and also the medial thalamus, ipsilaterally to PCS, as well as in the orbito-frontal and the anterior cingulate gyri, the insula and the upper brainstem (Fig. 3). Pet studies using diprenorphine have shown implication of brain opioid structures, which would explain the delayed as well as the long-lasting effects of PCS [10].

*Surgical technique* is extradural. A small craniotomy is performed in front of the motor cortex corresponding to the contralateral painful territory. The location of the central sulcus has to be identified precisely using: (a) *Somato-Sensory Evoked Potential monitoring*; location of the central sulcus is confirmed by phase reversal of the N20 wave recorded from the electrode applied extradurally. When the recording electrode is moved from the post-central to the precentral area, the N20 becomes positive P20 (Fig. 4); (b) *MRI neuro-navigation*; it can be very helpful for determining the central sulcus using anatomical landmarks, the more so as this can be difficult in patients having had stroke. (c) *Electrostimulation of the cortex and clinical observation or EMG recordings of the muscular contractions following stimulation of motor area*;



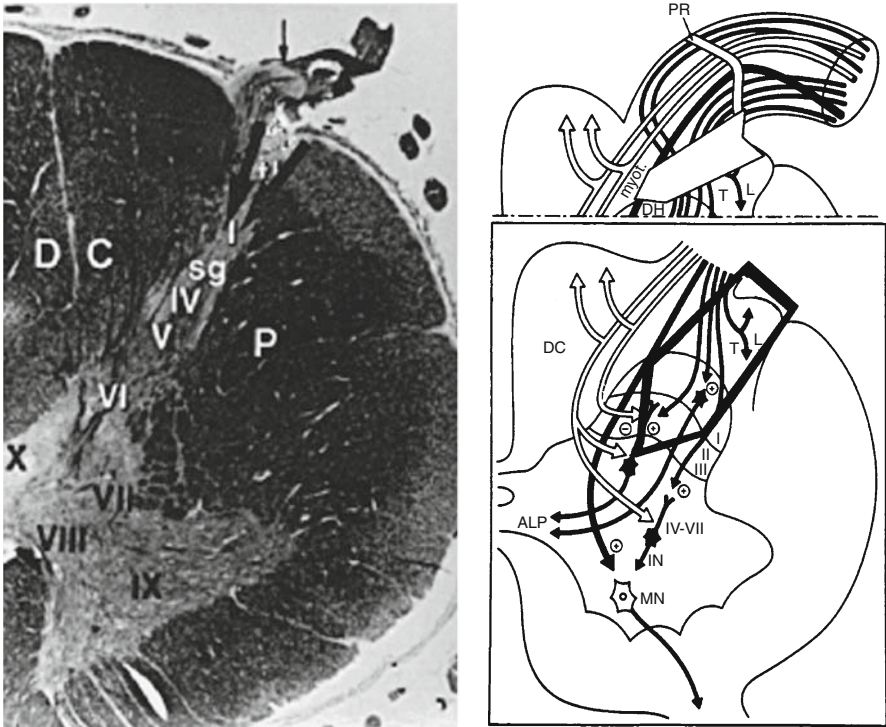
**Fig. 4.** Precentral (Motor) Cortex Stimulation. *Left:* Precentral (Motor [M]) Cortex on MRI. *Center:* operative view of extradural space in the central region after 5 × 5 cm craniotomy: Central sulcus landmark (black line) was drawn on dura at the sites of the reversal N20 (post-central) and P20 (precentral) potentials of intra-operative SSEP, recorded with platine ball electrode. *Right:* Postoperative lateral X-ray radiography of the electrode implanted extradurally, on the right precentral cortex, in a patient with hyperpathic thalamic syndrome in the left side of the body. Pain developed one year after a stroke in the right subcortical posterior parietal area. In this case, PCS gave total and long lasting relief of pain (follow-up 5 years)

the optimal location of the electrode is where the bipolar stimulation produces twitches in the painful area with the lowest threshold.

Afterwards, the electrode is tightly sutured on the dural surface and the stimulation system is internalized. Unlike spinal cord stimulation system, the patient does not have induced paresthesias. The intensity of stimulation has to be restricted to a level lower than the threshold of muscle twitches and paresthesias.

Validated *indications* for PCS include post-stroke pain and trigeminal neuropathic pain; according to literature review and personal results respectively 52% and 72% of patients are improved of more than 50% of their pain. In those patients, satisfaction – i.e., patients declaring favourable to re-intervention if the same beneficial outcome could be guaranteed – was observed in 70% of the cases. Other indications are under evaluation: other central pain syndromes, pain after spinal cord injury, brachial plexus avulsion or peripheral nerve injury, phantom limb pain, ... Since efficacy of PCS is not observed in all patients with neuropathic pain, *predictive factors* for success are under study. A recent report [14] indicates that neither pre-operative motor status, pain characteristics, type or localisation of lesions, quantitative sensory testing, SSEPs, nor the interval between pain and surgery, are predictive factors of the efficacy of PCS. Only the level of pain relief evaluated in the first month following implantation is a strong predictor of long-term relief ( $p < 0.0001$ ). Transient pain relief after repetitive transcranial magnetic stimulation (TMS) of the motor cortex seems to be correlated with a positive PCS effects [8]; TMS might be a useful tool for selecting patients for surgery.

Post-operative *complications* are very rare; they include infection (2%) and extradural haematoma (2%). Side-effects include rare epileptic seizures during stimulation (0.7%), speech disorders (0.7%), headaches (1%), dysesthesias and paresthesias (2%), pain on the side of the implanted electrode (0.7%) and supernumerary phantom arm (0.3%).



**Fig. 5.** *Microsurgical DREZotomy.* *left:* Rexed's lamination (I–IX). Transverse hemisection of the spinal cord (at the lower cervical level) with myelin stained by luxol-fuschine, showing the myelinated rootlet afferents that reach the dorsal column. (DC Dorsal column; P pyramidal tract; SG substantia gelatinosa; TL tract of Lissauer) The small arrow designates the pial ring of the dorsal rootlet (diameter, 1 mm). The large arrow shows MDT target. *right:* Schematic representation of the Dorsal Root Entry Zone (DREZ) area and the target of micro-DREZotomy (MDT). *Upper part:* Each rootlet can be divided (owing to the transition of its glial support) into a peripheral and a central segment. The transition between the two segments is at the pial ring (PR), which is located approximately 1 mm outside the penetration of the rootlet into the dorsolateral sulcus. Peripherally, the fibers are mixed together. As they approach the PR, the fine fibers (considered nociceptive) run toward the rootlet surfaces. In the central segment, they group in the ventrolateral portion of the DREZ and enter the dorsal horn (DH) through the tract of Lissauer (TL). The large myotatic fibers (myot) are situated in the middle of the DREZ, whereas the large lemniscal fibers are located dorsomedially. *Lower part:* Schematic data on DH circuitry. Note the monosynaptic excitatory arc reflex, the lemniscal-influence on a DH cell and an interneuron (IN), the fine excitatory input onto DH cells, and the IN, the origins in layer I and Layers IV to VII of the anterolateral pathways (ALP) and the projection of the IN onto the motor neuron (MN). (DC, dorsal column). Rexed laminae are marked from I to VI. The MDT (arrowhead) cuts most of the fine and myotic fibers and enters the medial (excitatory) portion of the LT as well as the apex of the dorsal horn. It should preserve most lemniscal presynaptic fibers, the lateral (inhibitory) portion of TL, and most of the DH

## 5. SURGERY IN THE DORSAL ROOT ENTRY ZONE (DREZ)

In the sixties, the Gate Control Theory [12] drew neurosurgeons' attention to the dorsal horn as the first and an important level of pain modulation. This area was then considered a possible target for pain surgery through different ways: spinal cord stimulation and destructive surgery in the Dorsal Root Entry Zone (DREZ). It is in 1972 that we introduced the concept of surgery in the DREZ through our medical thesis [17] (Fig. 5). Our method, named Microsurgical DREZotomy (MDT), is a destructive procedure directed to the Dorsal Root Entry Zone (DREZ) which aims at interrupting the nociceptive circuitry and eliminating the pain generators located in the dorsal horn [24]. The DREZ-area was defined as an entity including the central portion of the dorsal rootlets, the most medial part of the Lissauer's tract, and the dorsal most layers (I-V) of the dorsal horn where the afferent fibers synapse with the cells of the spino-reticulo-thalamic ascending pathways [17, 24]. Same year microsurgical lesioning of DREZ was attempted for human pathologies. After encouraging results in malignancy pain, namely in the thoracic apex Pancoast-Tobias syndrome, the procedure was attempted in patients with neuropathic pain syndromes secondary to paraplegia, amputation and brachial plexus avulsion in 1974. Soon after, alternatives to MDT for DREZ-lesions were developed by other neurosurgical teams, especially for brachial plexus avulsion with: the Radio-Frequency thermocoagulation by Nashold [13], the Laser-beam by Levy [9] and Ultrasound probe by Kandel [6] and Dreval [2].

The rationale for DREZ-lesioning is illustrated in Fig. 5 (in patients with conserved dorsal roots and remaining sensory functions). MDT aims preferentially to interrupt the small (nociceptive) fibers grouped in the lateral bundle of the dorsal rootlets, as well as the (excitatory) medial part of the TL. The upper layers (I-V) of the dorsal horn are additionally destroyed if microbipolar coagulations are made inside the dorsal horn, which suppresses the neurons that became hyperactive after deafferentation.

*Surgical technique depends on pathologies and topographical levels.*

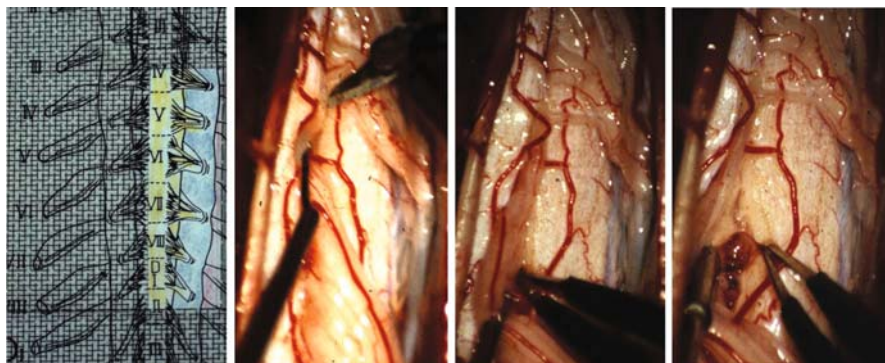
Instruments for microsurgical DREZotomy (MDT) are the following: (1) curved and buttoned microhook for manipulating and holding the spinal roots, (2) malleable microprobe (of the Jacobson type) for gentle dissection and sustained retraction of the rootlets, (3) buttoned microsucker (of an original design) that can be used not only as a sucker but also as a probe and/or the rootlets [ref 12-04220 from Microsurgical DREZ-tomy Kit], (4) curved sharp microscissors to divide the fine arachnoidal filaments, the pia mater, and the tiny pial vessels [ref 12-30108 from Microsurgical DREZ-tomy Kit], (5) curved razor blade holder whose jaws are striated to allow better stability of the piece of razor blade [An ophthalmic microKnife can be used instead of razor blade], and (6) bipolar bayonet-shaped forceps insulated except over 5mm at the tip, sharp and graduated every millimeter as shown in the magnified view [Ref 12-30179 from microsurgical DREZ-tomy Kit]. "Sindou

Instrument-Kit for Microsurgical DREZ-tomy”, Ref: 12-29000. Howmedica Leibinger, FL Fischer GmbH. Bötzingen Strasse 41, D-7911 Freiburg, Germany and 14540 Beltwood Parkway East, Dallas, Texas 75244.

### 5.1 Operative procedure at the cervical level when roots are intact (Fig. 6)

The prone position with the head and neck flexed in the “*Concorde*” position has the advantage of avoiding brain collapse caused by cerebrospinal fluid depletion. The head is fixed with a three-pin head holder. The level of laminectomy is determined after identification of the prominent spinous process of C2 by palpation. For unilateral DREZ-surgery a hemilaminectomy, generally from C4 to C7 with preservation of the spinous processes, allows sufficient exposure to the posterolateral aspect of the cervical segments that correspond to the upper limb innervation, that is, the rootlets of C5 to T1.

Dura and arachnoid are opened longitudinally. Then the exposed roots are dissected free by separating the tiny arachnoid filaments that bind them to each other to the arachnoid sheath and to the cord pia mater. The radicular vessels are preserved. Each ventral and dorsal root from C4 to T1 is electrically stimulated at the level of its corresponding foramen to identify precisely its muscular innervation and its motor functional value. Stimulated ventral roots have a motor threshold at least 3 times lower than the dorsal roots. Responses are in the diaphragm for C4 (the response is palpable below the lower ribs), in the



**Fig. 6.** MDT technique at the cervical level. (1) Schematic representation of right *hemilaminectomy* allowing exposure of the dorso-lateral aspect of the cervical spinal cord. (2) *Microsurgical views*: *Left*: Exposure of the right dorso-lateral aspect of the cervical cord at C6. The rootlets of the selected dorsal root(s) are displaced dorsally and medially with a hook or a microsucker to obtain access to the ventro-lateral aspect of the DREZ in the dorso-lateral sulcus. *Center*: Then an incision –2 mm in depth, at 35° ventrally and medially – is made with a microknife in the lateral border of the dorso-lateral sulcus. *Right*: Microcoagulations are then performed, down to the apex of the dorsal horn, in a dotted manner, using a sharp graduated bipolar microforceps



shoulder abductors for C5, in the elbow flexors for C6, in the elbow and wrist extensors for C7, and in the intrinsic muscles of the hand for C8 and T1.

Microsurgical lesioning is performed at the selected levels, that is, those that correspond to the pain territory. The technique is summarized and illustrated in figure. The incision is made with a microknife (razor blade in a blade-holder or an ophthalmologic micro-scalpel). Then microcoagulations are made in a “chain” (i.e., dotted every millimeter) manner. Each microcoagulation is performed – under direct magnified vision – by short-duration (a few [one to three] seconds), low intensity, bipolar electrocoagulation, with a specially designed sharp bipolar forceps incremented in millimeters. The depth and extent of the lesion depend on the desired therapeutic effect and the preoperative status of the limb.

If the laxity of the root is sufficient, the incision is performed – continuously – in the dorsolateral sulcus, ventrolaterally along all of the rootlets of the targeted root, thus accomplishing a sulco-myelotomy.

## 5.2 Operative procedure in brachial plexus avulsion

As an example, for a total plexus avulsion (that is C5-T1) hemilaminectomy is performed from C3 to C7. Dura mater and arachnoid opening is often difficult because of strong fibrotic adhesions to the cord. Pseudomeningoceles with fragile membranes, instead of dural sheaths, are frequently found at the level of the avulsed segment(s).

The anatomical aspect (normal, grayish and atrophic, and partially or totally avulsed) of roots – either ventral or dorsal – is carefully noted. The functional status of remaining ventral roots is checked by observing muscular responses to direct electrical stimulation at 1mA (NIMBUS Stimulator, Newmedic/Hemodia, Toulouse, France). The cord is sometimes dramatically atrophic and/or distorted with an abnormal rotation. Identification of the dorso-lateral sulcus is often difficult, due to necrotic or gliotic changes in the cord at the level of the avulsed roots. To solve this problem the sulcus is isolated at the intact remaining rootlets, above and below the avulsed segment(s). The presence of tiny radicular vessels entering the cord helps to determine the site of the sulcus. Yellow areas corresponding to old haemorrhages on the cord surface, microcavities in the depth of the sulcus and gliotic tissue within the dorsal horn provide guidance for tracing the dorso-lateral sulcotomy. Intra-operative monitoring of the dorsal column SSEPs evoked by stimulation of the homolateral tibial nerve may be helpful, especially when the sulcus is difficult to find.

The extent, in length, of the surgical lesioning is established on the basis of pain topography, which generally corresponds with the avulsed segments as well as the altered adjacent rootlets.

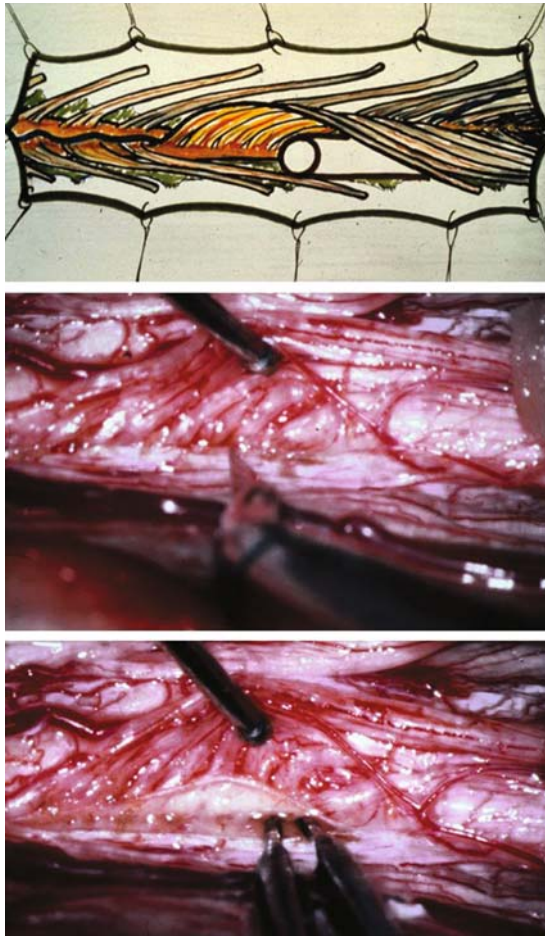
An incision, 2 mm in depth and oriented 35° medially and ventrally, is made in the dorsolateral sulcus by using a microknife in the axis of the cervical DH. With a sharp graduated bipolar forceps, dotted micro-coagulations

are performed inside the DH (3 mm in depth from the surface of the cord). Each coagulation is performed with the aid of direct vision for 2 seconds at low intensity on the bipolar generator. Special care is taken to locate these microcoagulations inside the limits of the dorsal horn, in between the cuneate fasciculus of the dorsal column, medially, and the cortico-spinal tract, laterally, to avoid impairing the sensory and motor pathways, respectively.

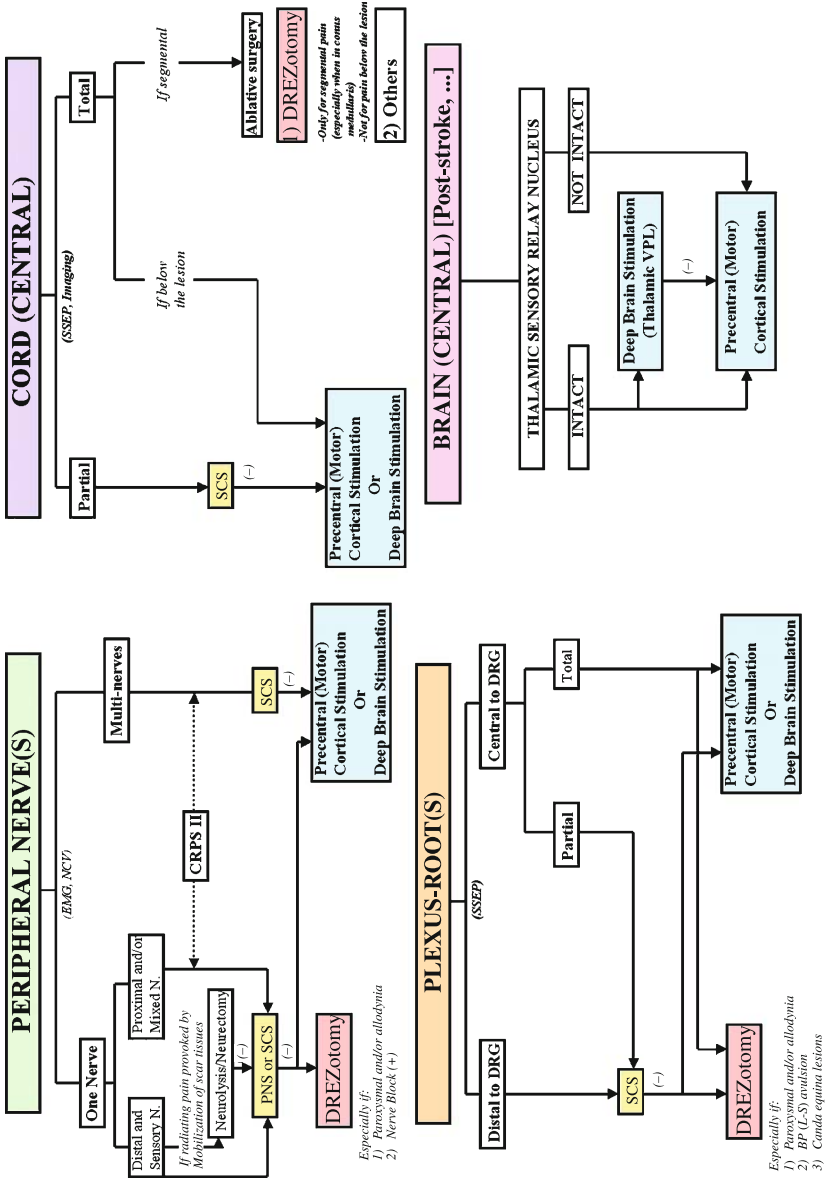
### 5.3 Operative procedure at the lumbo-sacral level (when spinal cord and roots are intact) (Fig. 7)

The patient is positioned prone on thoracic and iliac supports and the head placed 20 cm lower than the level of the surgical wound to minimize the loss of cerebrospinal fluid. The desired vertebral level is identified by palpation of the spinous processes or, if this is difficult, by lateral X-ray study that includes the S1 vertebra. Interspinous levels identified by a needle can then be marked with a droplet of a nontoxic dye (methylene blue). A laminectomy, either bilateral or unilateral, according to pain topography, is performed from T11 to L1 (or L2). The dura and arachnoid are opened longitudinally, and the filum terminale is isolated. Identification of roots is performed by electrical stimulation. The L1 and L2 roots are easily identified at their penetration into their respective dural sheaths. Electrical stimulation of L2 produces a response of the iliopsoas and adductor muscles. Identification of L3 to L5 is difficult for many reasons: (1) exit through their respective dural sheaths is caudal to the exposure, (2) the dorsal rootlets enter the sulcus along an uninterrupted line, (3) the ventral roots are hidden in front of the dentate ligament, and (4) the motor responses in the leg to stimulation of the roots are difficult to observe because of the patient's prone position. Stimulation of L3 produces a preferential response in the adductors and quadriceps, of L4 in quadriceps, and of L5 in the anterior tibialis. Stimulation of the S1 dorsal root produces a motor response of the gastrocnemius-soleus group that can be confirmed later, by repeatedly checking the Achilles ankle reflex before, during, and after MDT. Stimulation of the S2 to S4 dorsal roots (or better, directly, the corresponding spinal cord segments at the DREZ) can be assessed by recording of the motor vesical or anal response by use of cystomanometry, rectomanometry or electromyography of the anal sphincter (or simply with a gloved finger into the rectum). Because neurophysiologic investigations are time-consuming to perform in the operative room, we have found that measurements at the conus medullaris can be sufficient in the patients who already have severe preoperative impairment of their vesicoanal functions. These measurements, based on human postmortem anatomic studies, have shown that the landmark between the S1 and S2 segments is situated around 30 mm above the exit from the conus of the tiny coccygeal root.

MDT at the lumbosacral levels has the same principles as the ones at the cervical level; but at the lumbosacral level, MDT is difficult and possibly dan-



**Fig. 7.** MDT technique at the lumbosacral level. *Top Drawing:* Exposure of the conus medullaris through a Th11 to L1 laminectomy. Approach of the dorso-lateral sulcus, (on the left side in this example). For doing so, the dorsal rootlets are displaced dorsally and medially to obtain proper access to the ventrolateral aspect of the DREZ. *Upper operative view:* The rootlets of the selected dorsal roots (on left side) are retracted dorso-medially and held with a (specially designed) ball-tip micro-sucker, used as a small hook, to gain access to the ventrolateral part of the DREZ. After division of the fine arachnoidal filaments sticking the rootlets together with the pia-mater with curved sharp micro-scissors (not shown), the main arteries running along the dorso-lateral sulcus are dissected and preserved, whilst the smaller ones are coagulated with a sharp bipolar micro-forceps (not shown). Then, a continuous incision is performed using a microknife, made with a small piece of razor blade inserted within the striated jaws of a curved razor-blade-holder. The cut is – on average – at a 45° angle and to a depth of 2 mm. *Lower operative view:* The surgical lesion is completed by doing micro-coagulations under direct magnified vision, at a low intensity, inside the postero-lateral sulcomyelotomy down to the apex of the dorsal horn. These microcoagulations are made all along the segments of the cord selected to be operated on by means of the special sharp bipolar forceps, insulated except at the tip over 5 mm and graduated every millimeter



**Fig. 8. Algorithms:** Decision-making according to the topography of the causal lesion. NCV: Nerve conduction velocity; EMG Electromyogram; SSEP Somato-Sensory Evoked Potentials; DRG Dorsal Root Ganglia; BP Brachial plexus; L lumbar; S Sacral

gerous because of the rich vasculature of the conus. The dorsolateral spinal artery courses along the dorsolateral sulcus; its diameter is 0.1–0.5 mm, and it is fed by the posterior radicular arteries and joins caudally with the descending anterior branch of the Adamkiewicz artery through the conus medullaris anastomotic loop of Lazorthes. This artery has to be preserved by being freed from the sulcus.

#### 5.4 Operative procedure in injured spinal cord

In most patients, the microsurgical procedure is preceded by a long dissection of the dura from the surrounding epidural fibrosis and a delicate dissection of the cord and the roots from adherent arachnoiditis. In patients with spinal fractures not previously completely operated, one must start with liberation of the neural structures from residual bone fragments occupying the intrarachidian space and even sometimes the intradural space. This preparatory approach may be long and bloody; in that eventuality, it is better to perform the first stage of the operation in a separate setting, followed by MDT two weeks later. Then MDT is then performed at the cord segments corresponding to the pain territory.

#### 5.5 Operative procedure in hyperspastic states

The cord levels related to the undesirable spasticity are identified by studying the muscle responses to bipolar electrical stimulation of the ventral and dorsal roots. The motor threshold for stimulation of ventral roots is one-third that of the threshold for dorsal roots. Technical procedure is as follows. The ventro-lateral aspect of the DREZ is exposed so that the microsurgical lesions can be performed in the dorso-lateral sulcus, 2–3 mm deep and at 35° angle (for cervical) or 45° angle (for lumbo-sacral) levels, all along the selected segments of the spinal cord. See detailed description in Reference [18]. Intraoperative neurophysiological monitoring is used to help in identifying cord levels, as well as quantifying the extent of MDT.

*Main complications* of MDT would be: lesioning of the ipsi-lateral pyramidal tract and dorsal column, injury or coagulation of the spinal cord vasculature. Performing this type of surgery requires “good knowledge on pain anatomy and physiology and, as well as a good training in microsurgery”.

## CONCLUSIONS

The most important prerequisites for choosing the appropriate neurosurgical procedure in neuropathic pain are the underlying mechanism(s) of the pain and the topographic level of the lesion. TENS can be effective especially when the peripheral nerve to be stimulated is close to the skin with a lesion distally situated. SCS effectiveness requires integrity of the dorsal column fibers up to the brainstem nuclei, verified by CCT on SSEPs recordings. DBS and more

recently PCS are indicated when SCS fails or is not indicated, and when the causal lesion is above spinal cord. Destructive techniques, especially DREZ surgery, can be useful for root avulsion pain, segmental pain after spinal cord lesions and peripheral nerve lesions when paroxysmal and/or allodynic pain components are predominant. Whatever pain syndromes are confronted, indications for surgery (Fig. 8) must be considered within the framework of the whole armamentarium of pain surgery [1, 5, 25, 28] and through a multi-disciplinary team.

## References

- [1] Burchiel KJ (2002) Surgical management of pain. Thieme, New York
- [2] Dreval ON (1993) Ultrasonic DREZ-operations for treatment of pain due to brachial plexus avulsion. *Acta Neurochir* 122: 76-81
- [3] Garcia-Larrea L, Peyron R, Mertens P, Gregoire MC, Lavenne F, Le Bars D, Convers P, Mauguière F, Sindou M, Laurent B (1999) Electrical stimulation of motor cortex for pain control: a combined PET-scan and electrophysiological study. *Pain* 83: 259-273
- [4] Guenot M, Bullier J, Rospars J, Lansky P, Mertens P, Sindou MP (2003) Single unit analysis of the spinal dorsal horn in patients with neuropathic pain. *J Clin Neurophysiol* 20: 142-150
- [5] Gybels JM, Sweet WH (1989) Neurosurgical treatment of persistent pain. In: Gildenberg PL (ed) *Pain and headache*, vol. 2. Karger, Basel, pp 293-302
- [6] Kandel EL, Ogleznev KIA, Dreval ON (1987) Destruction of posterior root entry zone as a method for treating chronic pain in traumatic injury to the brachial plexus. *Vopr Neurochirur* 6: 20-27
- [7] Kanpolat Y, Tuna H, Bozkurt M, Elhan AH (2008) Spinal and Nucleus Caudalis Dorsal Root Entry Zone operations for chronic pain. *Neurosurgery* 62: 235-244
- [8] Lefaucheur JP, Drouot X, Keravel Y, Nguyen JP (2001) Pain relief induced by repetitive transcranial magnetic stimulation of precentral cortex. *Neuroreport* 12: 2963-2965
- [9] Levy WJ, Nutkiewicz A, Ditmore M, Watts C (1983) Laser-induced dorsal root entry zone lesions for pain control. Report of three cases. *J Neurosurg* 59: 884-886
- [10] Maarrawi J, Peyron R, Mertens P, Costes N, Magnin M, Sindou M, Laurent B, Garcia-Larrea L (2007) Motor cortex stimulation for pain control induces changes in the endogenous opioid system. *Neurology* 69: 827-834
- [11] Mazars G (1975) Intermittent stimulation of nucleus ventralis postero-lateralis for intractable pain. *Surg Neurol* 4: 93-95

- [12] Melzack R, Wall PD (1965) Pain mechanism. A new theory. *Science* 155: 971-979
- [13] Nashold BS, Ostidalh PH (1979) Dorsal Root Entry Zone lesions for pain relief. *J Neurosurg* 51: 59-69
- [14] Nuti C, Peyron R, Garcia-Larrea L, Brunon J, Laurent B, Sindou M (2005) Mertens – Motor cortex stimulation for refractory neuropathic pain: four year outcome and predictors of efficacy. *Pain* 118: 43-52
- [15] Peyron R, Garcia-Larrea L, Deiber MP, Cinotti L, Convers P, Sindou M, Manguière F, Laurent B (1995) Electrical stimulation of precentral cortical area in the treatment of central pain: electrophysiological and PET Study. *Pain* 62: 275-286
- [16] Richardson DE, Akil H (1977) Pain reduction by electrical brain stimulation in man. II: Chronic self – administration in the periventricular gray matter. *J Neurosurg* 47: 184-194
- [17] Sindou M (1972) Study of the Dorsal Root Entry Zone. Implications for pain surgery. M.D. Thesis, University of Lyon Press, Lyon
- [18] Sindou M (2004) Neurosurgical management of disabling spasticity. In: Spetzler RF (ed) *Operative techniques in neurosurgery*, vol. 7. Elsevier, Philadelphia, pp 95-174
- [19] Sindou M, Blondet E, Emery E, Mertens P (2005) Microsurgical lesioning in the dorsal root entry zone for pain due to brachial plexus avulsion: a prospective series of 55 patients. *J Neurosurg* 102: 1018-1028
- [20] Sindou M, Jeanmonod D (1989) Microsurgical DREZotomy for the treatment of spasticity and pain in the lower limbs. *Neurosurgery* 24: 655-670
- [21] Sindou M, Mertens P, Bendavid U, Garcia-Larrea L, Manguiere F (2003) Predictive value of somatosensory evoked potentials for long-lasting pain relief after spinal cord stimulation: practical use for patient selection. *Neurosurgery* 52: 1374-1383
- [22] Sindou M, Mertens P, Wael M (2001) Microsurgical DREZotomy for pain due to spinal cord and/or cauda equina injuries. Long-term results in a series of 44 patients. *Pain* 92: 159-171
- [23] Sindou M, Mifsud JJ, Boisson D (1986) Selective posterior rhizotomy in the dorsal root entry zone for treatment of hyperspasticity and pain in the hemiplegic upper limb. *Neurosurgery* 18: 587-595
- [24] Sindou M, Quoex C, Baleyrier C (1974) Fiber organization at the posterior spinal cord-rootlet junction in man. *J Comp Neurol* 153: 15-26
- [25] Tasker RR (1984) Deafferentation. In: Wall P, Melzack R (eds) *Textbook of pain*. Churchill-Livingstone, Edinburgh, pp 119-132

- [26] Tsubokawa T, Katayama Y, Yamamoto T, Hirayama T, Koyama S (1991) Chronic motor cortex stimulation for the treatment of central pain. *Acta Neurochir (suppl)* 52: 137-139
- [27] Wall PD, Sweet WH (1967) Temporary abolition of pain in man. *Science* 155: 108-109
- [28] White JC, Sweet WH (1969) Pain and the neurosurgeon. A forty-year experience. C.C. Thomas, Springfield

Contact: Marc Sindou, Hôpital Neurologique P. Wertheimer, University of Lyon,  
59 Bd Pinel, 69003 Lyon, France  
E-mail: marc.sindou@chu-lyon.fr



---

# MICROVASCULAR DECOMPRESSION FOR HEMIFACIAL SPASM

M. SINDOU

## INTRODUCTION

Hemifacial Spasm (HFS) is a benign, chronic, involuntary movement of one side of the face, and characterized by twitching, tonic spasm, and synkinesis of the muscles innervated by the facial nerve. Primary HFS fulfills the three following criteria: (1) not a sequela of ipsilateral facial palsy, (2) chronic in evolution and self-limiting, (3) with normal investigations, except for the presence of a vascular compression of the seventh nerve, generally in the Root Exit Zone (REZ) at imaging.

There is now considerable evidence that primary HFS is related to functional changes in the facial motor nucleus, caused by vascular compression of the facial nerve at REZ. Its logical curative treatment – the Micro-Vascular Decompression (MVD) procedure – was pioneered by Gardner [3] and Jannetta [6]. Over the last three decades an abundant literature has been produced on findings, techniques and results, the quotations of which can be found in the following references [1, 8, 15, 17].

## RATIONALE

MVD is based on the hypothesis of a Neuro-Vascular Conflict (NVC) at the origin of the disease. According to literature, in 98% of the patients an arterial loop is found, which makes a cross-compression, and in accentuated cases an indentation, at the facial nerve exit from the brainstem (see quotations in the following references [17, 18]). Of importance, several vessels may participate in the facial compression, in as many as 40% of the cases in our series [8].

Theory is that the chronic compression by the offending vessel(s) would generate spasms through a chain of different but complementary mechanisms. (1) The systolic mechanical pulsations at the REZ would produce excitatory stimuli triggering discharges of muscle twitches, the more so as REZ harbours the transitional zone between central and peripheral myelin, of higher excitability. (2) In addition the uninterrupted pulsations would

---

*Keywords:* hemifacial spasm, functional neurosurgery, microvascular decompression

alter the fiber sheaths of the facial nerve, which fibers would contract neosynapses (so-called “ephapses”) and sustain “cross-talk” phenomena [3, 7]. These cross-talk phenomena would be at the origin of synkineses and lateral spread motor responses [10]. (3) These ectopic electrophysiological phenomena would fire – antidromically – the facial nucleus, and consequently generate intrinsic hyperactivity of this nucleus [9]. The “central” hyperactivity of the nucleus would facilitate the appearance of motor discharges that may be provoked by a variety of peripheral stimuli, as well as by emotional events relayed by the brainstem reticular formation.

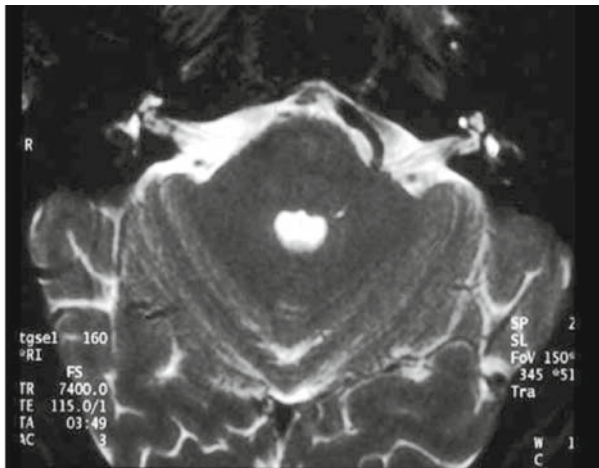
These putative mechanisms are consistent with the clinical and electrophysiological features of the spasms, namely the “Lateral Spread Motor Responses” which can be recorded at EMG [10], as well as the frequently-observed long delay before complete relief is obtained by decompression of the nerve [5].

## DECISION-MAKING

Only primary typical HFS are an indication for MVD. In typical primary HFS spasms usually begin as slight intermittent unilateral twitching of the orbicularis oculi muscle; lower facial muscles are involved only secondarily.

EMG recordings confirm the diagnosis by showing a typical electrophysiological signature: clonic facial muscle contractions, hyperactivity, synkinesis, lateral spread evoked responses.

Time for surgery is when the disease is felt as disabling. Progressively over years, HFS becomes more severe and persistent, and spreads over all the



**Fig. 1.** MRI (axial section) showing on left side neurovascular compression at facial root exit zone from brainstem, by vertebral artery and PICA junction, in a patient with left-sided hemifacial spasm

muscles of the face. Pharmacological treatments including Carbamazepine, Clonazepam, Baclofen, Gabapentin have little efficacy. When the patient considers spasms harmful, he generally asks for an effective treatment even if invasive. Choice is between (1) Repeated local injections of Botulinum toxin, and if not effective, MVD surgery or (2) directly MVD as the first option.

Imaging can be useful for confirming that HFS is primary in nature and due to a neurovascular compression (Fig. 1). In most cases (in the order of 95% of the patients) the compressive vessel, generally an artery, is seen on MRI combined with MR-Angio (MRA). MRA offers both projectional angiography and native thin sections that can be reformatted; 3D-TOF-Angio gives hyperintense signal of vessels. High resolution T2-sequence (CISS for GE, DRIVE for Philips, ...), are to be used to get good delineation of the facial nerve. 3D-Angio and high resolution T2 sequences are to be used conjointly, because they are complementary. Important to note, there might be a few false-negative and a number of false-positive as vascular contacts with cranial nerves are common in asymptomatic patients. However in patients with HFS, the compressive artery(ies) are at brainstem in the REZ, in a ventro-caudal location.

## **SURGERY**

### **1. SURGICAL PROCEDURE**

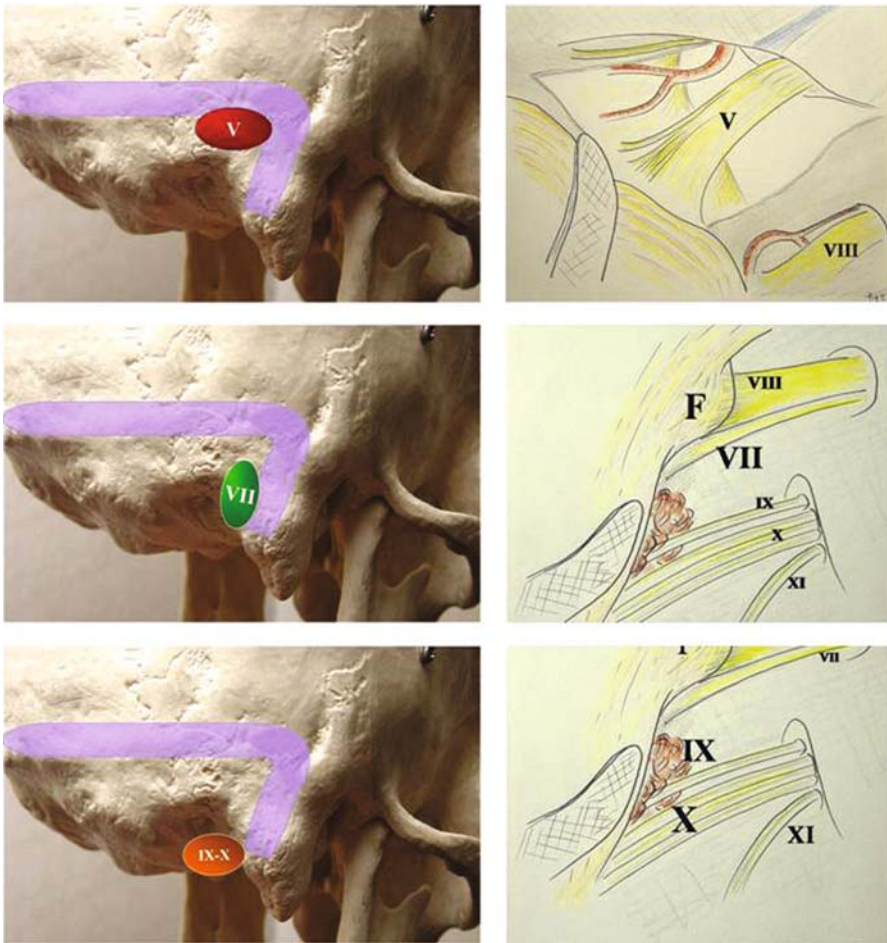
The method consists of freeing the nerve from the compressive vessel(s), namely the postero-inferior cerebellar artery (PICA), the anterior-inferior cerebellar artery (AICA) and/or the vertebro-basilar artery (VB). In our series of 147 patients PICA, AICA and/or VB were respectively found as the responsible vessel(s) in 61%, 56% and 27% of the cases. Importantly, there can be several, that is two or even three compressing vessels, in the same patient. Such an eventuality occurred in as many as 40% of the patients. Ignoring this could be the source of surgical failure.

There is a consensus to consider that the optimal technique would be the following. The patient is in the lateral decubitus position. Surgical approach is a “keyhole” retromastoid craniotomy, in the order of 2 cm in diameter, just posterior to the tip of the mastoid process so that the facial nerve can be reached from below, passing infero-laterally to the cerebellar hemisphere (Fig. 2). Reaching the facial nerve from below along an infra-floccular route is important for two reasons. (1) NVCs are usually located ventro-caudally at the REZ. (2) A lateral – to – medial retraction of the cerebellar hemisphere would exert stretching of the VIIIth nerve and lead to hearing loss, as demonstrated by intraoperative BEAP recordings [4, 12, 14, 16].

After identification of the Xth and IXth nerves before they enter the pars nervosa of the Jugular Foramen, arachnoid is opened, first dorsally to the Xth and IXth nerves, then in front of the choroid plexus emerging from the Foramen of Luschka, and finally at the level of the flocculus where it covers the

vestibulo-cochlear nerve. Offending loops are usually found just ventral to the choroid plexus, which must be slightly retracted. Mobilization of the compressive artery(ies) must be gentle for vessel(s) and cleavage from the VIIth and VIIIth nerves atraumatic. Care has to be taken to respect the tiny perforating collaterals of VB, PICA or AICA, and manipulation of the labyrinthine artery should be avoided so as not to generate vasospasm and consequently cochlear ischemia (Fig. 3).

A good knowledge on the various neuro-vascular compressive patterns should help to facilitate surgery [13]. The conflicting loop(s) are maintained apart by interposing a small rectangular plate of Teflon (approximately 15 mm × 4 mm in size) between REZ/brainstem on a side and the offending



vessel(s) on the other. The piece of Teflon must not exert any “neo-compressive” effect on the facial nerve, and the vestibulo-cochlear nerve as well, and not kink artery(ies). Any excessive vascular manipulation might provoke mechanical vasospasm, and generate ischemia in corresponding territories; regular irrigation of vessels with a few droplets of papaverine in solution is wise precaution. Not too much of Papaverine should be used because of its very acid pH. Then dura is closed in a as tight way as possible. If mastoid cells have been open, closure is completed by affixing a piece of fascia lata on dura and fat tissue on cells. Bony powder is put back only if mastoid cells have not been opened.

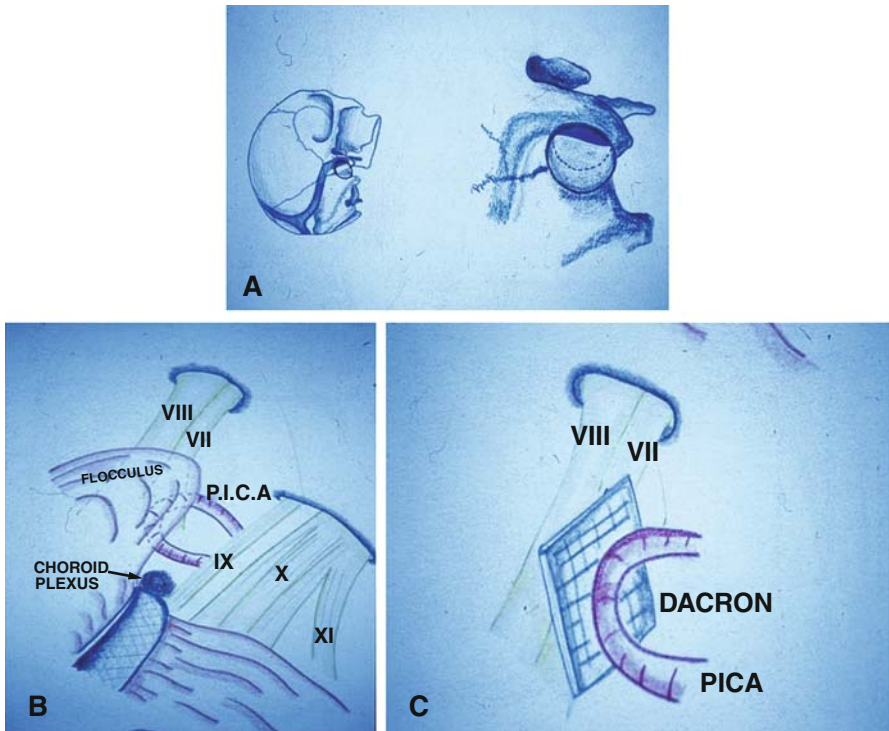
## 2. INTRA-OPERATIVE BRAINSTEM AUDITORY EVOKED POTENTIALS (BAEP) MONITORING FOR HEARING PRESERVATION

VIIIth nerve is at risk during MVD for HFS. The use of intraoperative monitoring of BAEPs has been acknowledged to reduce the risk of hearing impairment [4, 12, 16]. In series without monitoring, hearing loss after surgery ranged from 7.7% to 20% [18]. Thanks to the use of BAEP monitoring, the rate is below 5% in main series, 2.3% in our own series [14].

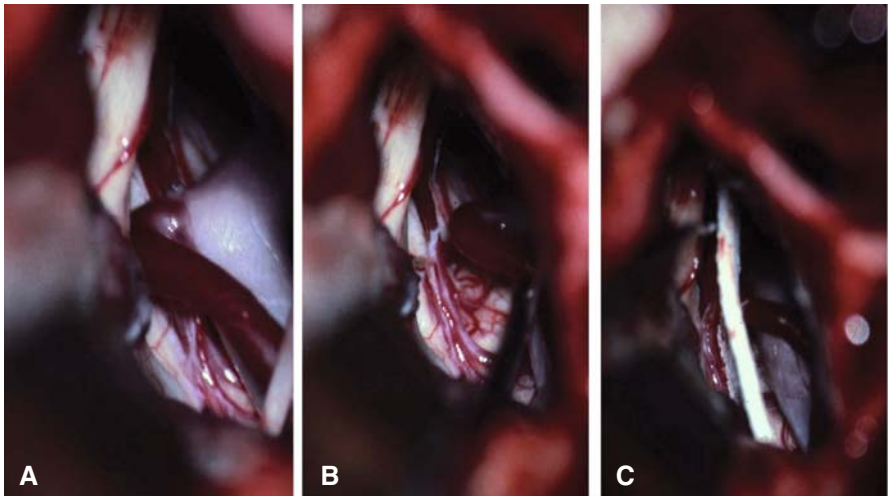
The recorded waves corresponding to the auditory tract from cochlea to brainstem are Waves I to V. Although the generators of these specific waves have no unequivocal correlation to a single anatomical structure, for reasons of clinical simplification it can be estimated that Waves I and II are generated in the distal and proximal parts of the cochlear nerve, respectively, and Waves III to V along the brainstem auditory pathways from the cochlear nucleus up to the inferior colliculus.

←  
**Fig. 2.** For performing MVD of cranial nerves, most surgeons agree to consider important the following technical points:

- Patient is placed on the table in the contralateral lying position, the head moderately elevated, rotated 15° toward the contralateral side and laterally flexed at 25° for TN, but less elevated and more laterally flexed for HFS.
- A retromastoid craniectomy of the key-hole type (2 cm diameter) is performed: (1) posterior to the base of the mastoid process and below the transverse sinus, to expose the dura at the angle formed by the transverse and the sigmoid sinuses, for TN (*upper-left*); (2) posterior to the tip of mastoid and adjacent to the sigmoid sinus, to expose the infero-lateral aspect of the cerebellum and corresponding cisterns for VIIth or VIIIth nerve decompression (*center left*); (3) evenmore inferiorly, at the retrocondylar fossa, to enter the cerebello-pontine – angle infero-laterally to the tonsil for lower cranial nerve decompression (*lower-left*).
- To avoid stretching the VIIth–VIIIth nerve complex,
  - the trigeminal nerve is accessed via infratentorial-supracerebellar route along the superior petrosal sinus (*upper right*), and not by retracting from lateral-to-medial the cerebellum, that would consequently stretch the VIIth–VIIIth nerve complex as well as the labyrinthine artery;
  - the VIIth–VIIIth nerves complexe (*center right*), is accessed through an infrafloccular trajectory and reached at the caudal aspect of REZ;
  - the lower cranial nerves are approached infero-laterally to the tonsil, to reach their ventral entry/exit zones on lateral aspect of the medulla (*lower right*)



**Fig. 3.** Operative techniques: Schematic drawings of facial nerve approach for MVD

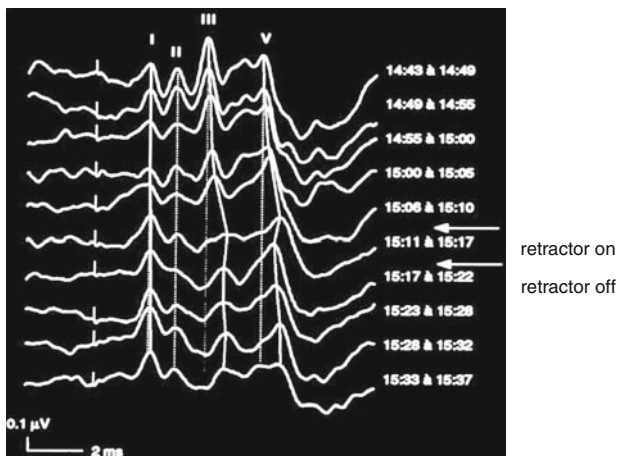


**Fig. 3.** Operative views. An elongated loop of the posterior-inferior cerebellar artery (PICA) is compressing the facial nerve at its exit zone at brainstem (A). After pushing away the offending artery (B), a small plate of Teflon is interposed between the facial nerve and the compressive vessel (C)

**Peak V warnings.** Damage to the VIIIth nerve results in a delay in latency and reduction in amplitude of Wave V. When this delay becomes significant, the neurophysiologist must inform the surgeon so that the procedure be stopped, cause identified and dangerous maneuvers corrected (Fig. 4).

Main critical situations are: stretching of the VIIIth nerve when retracting cerebellum, manipulation of the labyrinthine artery or the antero-inferior cerebellar artery, direct trauma by instruments or a nearby coagulation, and at end of surgery neocompression of the cochlear nerve by the prosthesis [16]. According to our experience, two levels of warning signals of practical importance to provide information on hearing function during surgery were determined [14].

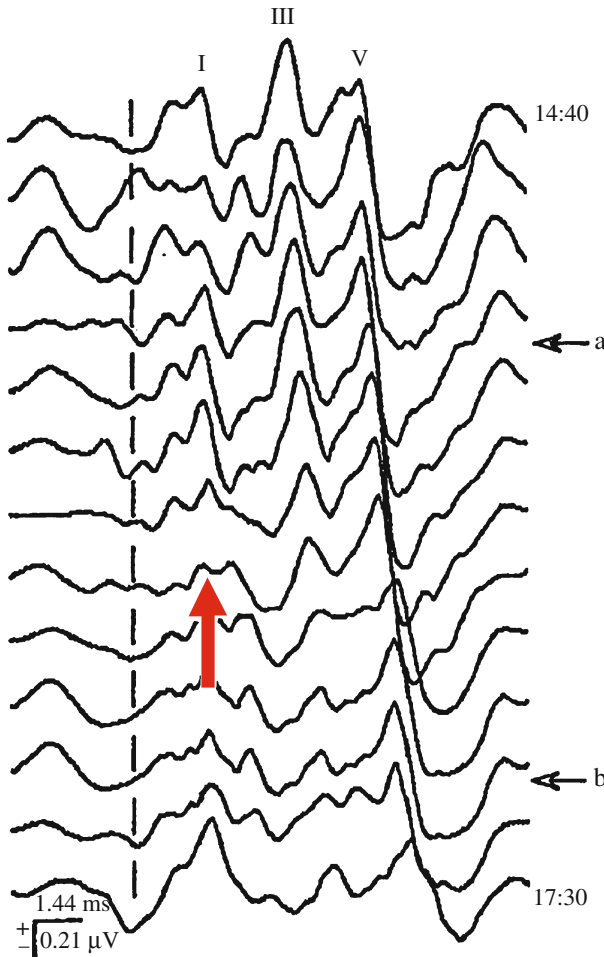
- Delay in latency of Peak V of 0.6 ms. In our series, below this value, no patient had post-operative hearing loss. So below 0.6 ms, the surgeon can consider that his or her surgery is within safety limits. Above this value, he or she has to be watchful. This signal may be called the “warning of a real risk”.
- Delay in latency of Peak V of 1 ms. Above this value, in our series, patients had at least some transient hearing loss. Therefore as soon as the delay reaches 1 ms, the surgeon has to be advised and to stop the procedure, withdraw the retractor, identify the cause(s) of the VIIIth nerve damage, and urgently make appropriate corrections before resuming surgery. We consider a 1-ms delay as the ultimate “critical warning before irreversibility”.



**Fig. 4.** Intraoperative Brainstem Auditory Evoked Potentials (BAEPs) monitoring during Micro-Vascular Decompression (MVD). Note decrease in amplitude and increase in latency of peak V (and also peak III) during manipulations (retractor on), and the return to normal signals when retraction stops (retractor off)

Stability of amplitude and latency of peak V is the warranty of an absence of operative injury, stretching and/or neo-compression of the cochlear nerve.

**Peak I warnings.** Preservation of a normal amplitude of peak I is the guaranty of integrity of the cochlea; ischemia resulting from vasospasm in the labyrinthine artery or the AICA parent artery would result in a progressive or sudden decrease in amplitude of peak I (Fig. 5).

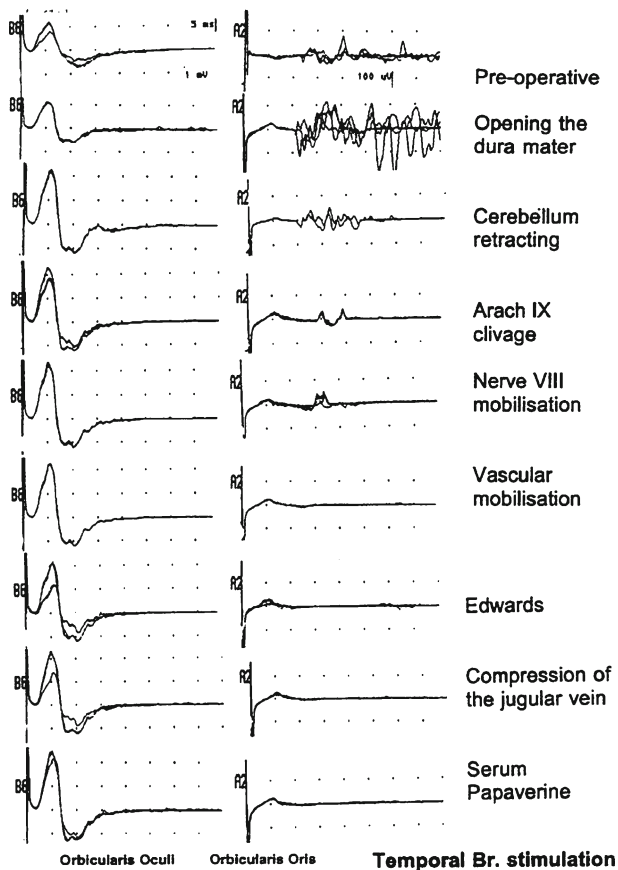


**Fig. 5.** Tracings showing BAEP changes during MVD for HFS. Start (a) and end (b) of surgery. Note that in the mid-course there was a significant but transient decrease in wave I amplitude. This decrease was considered a warning-signal of cochlear dysfunction



Conversely, an exaggerated amplitude of peak I would signify impairment in the inhibitory descending pathways to cochlea through the vestibular nerve, that is injury or stretching or neocompression of the vestibular nerve.

**Importantly**, the warning signals have to be interpreted by the neurosurgeon and the neurophysiologist working together in the operating theatre during the time when hearing is at risk. Therefore the neurophysiologist needs to fol-



**PER-OPERATIVE RECORDING**

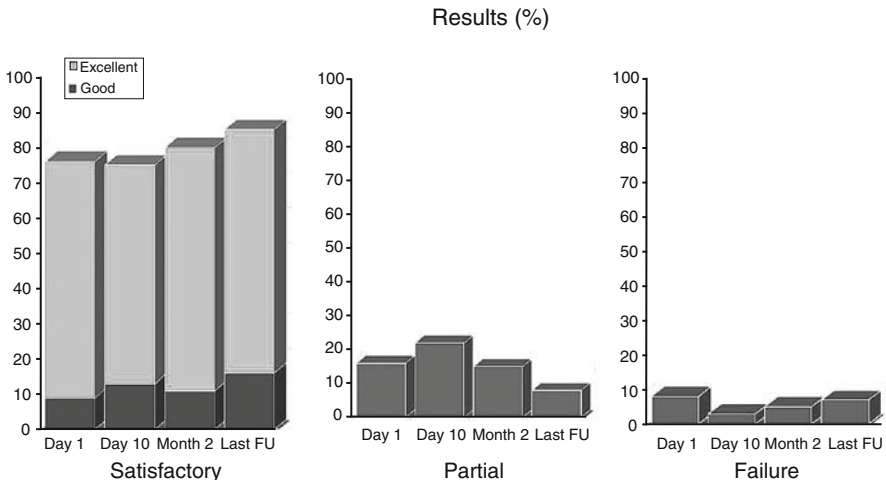
**Fig. 6.** Lateral Spread Responses (LSR) recorded intraoperatively, using facial EMG monitoring. In this patient, the stimulation was applied to the zygomatic branch (i.e., upper branch) of the facial nerve, and EMG recordings were made in the orbicularis oculi and the orbicularis oris muscles. On these tracings a normal direct response is seen in orbicularis oculi (left vertical column). A (abnormal) LSR is observed in orbicularis oris (right vertical column). From top to bottom, one can see the progressive disappearance of LSR during decompression of the nerve. Edwards: Insection of Teflon plate in between nerves and artery

low the microsurgical steps on the microscope videoscreen so that electrophysiological events may be discussed extemporaneously between the two colleagues according to the anatomic/surgical events.

### 3. INTRA-OPERATIVE MONITORING OF THE FACIAL EMG RESPONSES

In 1959, Magun and Esslen found evidence that stimulation of the facial nerve on the affected side gave rise to repetitive EMG response from the facial muscles in patients with HFS [7]. This was presumed to be due to cross-transmission of the antidromic activity at the lesion site. Later, Lateral Spread Responses (LSR) could be recorded from one muscle innervated by the superior branch of the facial nerve when the inferior branch was stimulated or inversely [11]. These phenomena were presumed to be related to ephaptic transmission at the lesion site, alone or in combination with motor nucleus hyperactivity [9].

In 1987, Moller and Jannetta advocated routine intraoperative EMG recordings of Lateral Spread Responses (LSR) during MVD to ensure that adequate decompression was achieved [11]. With others, they concluded that spasms were likely to persist if LSR was still observed at the end of the procedure. For them, the absence of LSR would indicate that spasms are likely to



**Fig. 7.** Long-term results (1 to 20 years; 7 years on average) in a personal series of 147 patients who underwent MVD for HFS. Result was considered excellent when there was no residual spasm and no EMG abnormal activity, good when the patient considered himself no longer disturbed by his disease, that is with a decrease in spasms of more than 80%. Excellent and good results are regrouped under the vocable "satisfactory". Result was considered a failure when spasms were decreased by less than 20%. When spasm was alleviated of in between 20% and 80%, result was considered partial. Note the high number of delayed effects

disappear. Reliability of LSR monitoring as an indicator of good or bad outcome is not our personal experience; even the patients in whom abnormal LSR persisted upon closure were cured, some of them after a delay as long as one year after surgery [5].

#### 4. RESULTS ON HFS: CURE WITH A FREQUENTLY DELAYED EFFECT

##### 4.1 Overall results

For evaluating efficacy of surgery, in our series we considered the percentage of spasm relief, given not only by the patient and his (her) relatives, but also by the neurologist who performed the pre- and post-surgical electrophysiological investigations. The result was considered “*excellent*” when no residual spasms and also no abnormal activities on EMG were noted and “*good*” when the patient felt cured but with some residual twitching under emotional conditions (in the order of 20% or less) or when there was still some synkinetic activity on EMG. The result was considered “*insufficient*” when decrease in spasms was only between 80% and 20%. The result was considered a *failure* when decrease was none or below 20%.

In our 147 patient series results were satisfactory (i.e., excellent or good) in 75% at discharge, in 80% at the first outpatient visit (usually on third month) and in 87% at latest follow-up that ranged from 1 to 20 years (7 years on average). In brief, a satisfactory result was immediate in two-thirds and delayed in one-third of the patients. The delay of cure was within the 6 first months in 51%, between the 6th month and one year in 38%, and after more than 1 year in 11% (up to 3 years and 6 months in 2 patients!) “Unsatisfactory” results at latest follow-up were at 13%; they included true recurrences in 9% and failure + only partial relief of less than 80% in 4%.

In the most important study in terms of length of follow-up and number of cases (612 patients surveyed), the one by Barker et al. on Jannetta’s series [1], the rate of excellent outcome was 88%.

##### 4.2 Results along time

The recurrence rate according to literature review amounts at 1% only in patients spasm-free after two years from surgery.

Conversely, a large percentage of patients, in the order of one-third, benefits from a progressive cure, with delays reaching more than one year is as many as 10%. Therefore there is now an agreement to consider that final assessment should not be done before one year from surgery at least.

##### 4.3 Prognostic factors

Statistical analysis on our one-hundred first patients had not shown any significant influence on outcome, of gender, age, side and nature of the neuro-

vascular conflict. Surprisingly, duration of symptoms and/or use of Botulinum toxin before surgery (which was given in half of our patients) had not played any significantly detrimental role [8].

## 5. COMPLICATIONS

A detailed review of the complications reported in the literature was published in a didactic article by Sauvain et al. [15]. In the two most numerous reported series (Barker et al.: 648 patients [1] and Chun et al.: 310 patients [2]), hearing loss amounted at 3.3% and 2.2% and permanent facial weakness was 3.4% and 4.8%, respectively. Among other complications, CSF leakage affected 2.7% and 2% of the patients. There was one surgical death in the first series and none in the second.

In our 147 surveyed patients there was neither death nor ischemic complications. A CSF-leakage (through mastoid cells, middle ear, Eustachian tube) with rhinorrhea occurred in 10 patients and required either repeated depletive lumbar punctures or transient lumbar external drainage to be cured. Since we came to use patching dura with fascia-lata and obliterating mastoid cells with fat tissue harvested from the thigh at the end of the surgery, there was no further CSF rhinorrhea.

In our series, the following cranial nerve complications were noted: (1) permanent hearing loss in 7 cases on the operated side, of whom 5 were completely deaf. Three of these 5 patients had been operated on at a time when intraoperative BAEP monitoring was not currently used; the two others were patients who had already an important degree of auditory deficit preoperatively; (2) reversible IXth–Xth deficit with severe swallowing disturbances in one patient who had arachnoiditis associated to the NVC; (3) permanent facial palsy in 2 cases; (4) to be noted, in 7 patients a delayed (of around one week), temporary (of around one month), facial palsy occurred; mechanism was unclear although it resembled “a frigore” facial palsy.

## HOW TO AVOID COMPLICATIONS

### 1. COMPLICATIONS LINKED TO THE CRANIAL APPROACH

Skin and musculo-aponeurotic incisions have to be located so that the great occipital nerve be avoided; muscular incision must not go too deeply in the direction of the vertebral artery which may have a procident loop at the atlo-occipital space.

When performing the retromastoid craniectomy, care should be taken not to endanger the sigmoid sinus, its external wall being generally reduced to a thin endothelial layer adhesive to the bone.

To avoid CSF leakage, the dural closure may be reinforced by affixing a small piece of fascia lata and the mastoid cells, when opened, packed with fat tissue also harvested from the thigh.

## 2. HEARING LOSS

Because the main cause of hearing loss is stretching of the VIIIth nerve, an infero-lateral cerebellar route along the tenth-ninth nerves, then the choroid plexus emerging from the Foramen of Luschka caudally to the flocculus (= infrafloccular), is advocated. This is the safer way to reach the facial exit zone caudally at brainstem, which is the most frequent site of the vascular compressions. PICA and AICA are equally responsible, with the frequent association of a big megadolicho-Vertebro-Basilar (VB) artery invaginated in the neighbouring brainstem surface.

The danger of stretching VIIIth nerve during facial approach at REZ, and also of producing mechanical vasospasm in the labyrinthine artery or the parent AICA artery, makes intraoperative BAEP monitoring useful – if not mandatory – at least during the so-called learning period of the surgical team.

## 3. FACIAL PALSY

To minimize this complication, stretching of the VIIth–VIIIth nerve complex, coagulations nearby the nerve especially at the REZ or a prosthesis touching the facial nerve should be avoided.

The eventuality of occurrence of a facial palsy – as well as of an hearing loss – has to be specifically mentioned prior operation in the written informed patient's consent. The possibility of a delayed – although almost always reversible – facial palsy should be also mentioned.

## CONCLUSIONS

In nearly all cases, primary HFS is in relation with an arterial compression of the facial nerve in the root exit zone at brainstem. The offending arterial loops originate from PICA, AICA and/or VB. In as many as 40% of the patients, NVC are multiple. The cross-compression at the brainstem is almost always seen on MRI combined with MRA. Botulinum toxin can be useful by alleviating the symptoms; but the effects are inconstant and only transient. The definitive conservative treatment is MVD, which cures the disease in 85% to 90% of the patients. In experts' hands, the MVD procedure can be done with relatively low morbidity. Because cure of spasms is frequently delayed – of several months to even a few years – we do not recommend early re-operation in patients with failure or until one year of follow-up at least. Delayed cure could well be explained by the slow reversal of the plastic changes in the nucleus that may have caused the symptoms [9].

## References

- [1] Barker FG II, Jannetta PJ, Bissonette DJ, Shields PT, Larkins MV, Jho HD (1995) Microvascular decompression for hemifacial spasm. *J Neurosurg* 82: 201-210
- [2] Chun IH, JH-Hsing L, Liang-Shong L (1992) Microvascular decompression for hemifacial spasm: analyses of operative findings and results in 310 patients. *Neurosurgery* 30: 53-57
- [3] Gardner WS, Sava GA (1962) Hemifacial spasm – a reversible pathophysiologic state. *J Neurosurg* 19: 240-247
- [4] Grundy BL, Jannetta PJ, Procopio PT, Lina A, Boston JR, Doyle E (1982) Intraoperative monitoring of brainstem auditory evoked potentials. *J Neurosurg* 57: 674-681
- [5] Hatem J, Sindou M, Vial C (2001) Intraoperative monitoring of facial EMG responses during microvascular decompression for hemifacial spasm. Prognostic value for long-term outcome: a study in a 33 patient series. *Br J Neurosurg* 15: 496-499
- [6] Jannetta PJ (1970) Microsurgical exploration and decompression of the facial nerve in hemifacial spasm. *Curr Top Surg Res* 2: 217-220
- [7] Magun R, Esslen E (1959) Electromyographic study of reinnervated muscle and hemifacial spasm. *Am J Phys Med* 38: 78-86
- [8] Marneffe V, Polo G, Fischer C, Sindou M (2003) Décompression Vasculaire Micro Chirurgicale pour Spasme Hemifacial; Résultats cliniques à plus d'un an et facteurs pronostiques. Etude d'une série de 100 cas. *Neurochirurgie* 495: 527-535
- [9] Moller AR (1999) Vascular compression of cranial nerves II. Pathophysiology of hemifacial spasm. *Neurol Res* 21: 439-443
- [10] Moller AR, Jannetta PJ (1984) On the origin of synkinesis in hemifacial spasm: results of intracranial recordings. *J Neurosurg* 61: 569-576
- [11] Moller AR, Jannetta PJ (1987) Monitoring facial EMG responses during microvascular decompression operations for hemifacial spasm. *J Neurosurg* 66: 681-685
- [12] Moller AR, Moller M (1989) Does intraoperative monitoring of auditory evoked potentials reduce incidence of hearing loss as a complication of microvascular decompression of cranial nerves? *Neurosurgery* 24: 257-263
- [13] Park JS, Kong DS, Lee JA, Park K (2008) Hemifacial spasm: neurovascular compressive patterns and surgical significance. *Acta Neurochir* 150: 235-241
- [14] Polo G, Fischer C, Sindou M, Marneffe V (2004) Brainstem auditory evoked potential monitoring during microvascular decompression for hemifacial spasm: intraoperative brainstem auditory evoked potential changes and warning values

to prevent hearing loss. Prospective study in a consecutive series of 84 patients. *Neurosurgery* 54: 97-106

- [15] Sauvain MO, Magistris MR, de Tribolet N (2001) Microvascular decompression of the facial nerve. In: Spetzler R (ed) *Operative techniques in neurosurgery*, vol. 4. Saunders, Philadelphia, pp 127-136
- [16] Sindou M, Fobe JL, Ciriano D, Fischer C (1992) Hearing prognosis and intra-operative guidance of brainstem auditory evoked potentials in microvascular decompression. *Laryngoscope* 102: 678-682
- [17] Sindou M, Keravel Y, Moller A (1997) *Hemifacial spasm. A multidisciplinary approach*. Springer-Verlag, Wien
- [18] Wilkins RH (1991) Hemifacial spasm: a review. *Surg Neurol* 36: 251-277

**Contact:** Marc Sindou, Hôpital Neurologique P. Wertheimer, University of Lyon,  
59 Bd Pinel, 69003 Lyon, France  
E-mail: marc.sindou@chu-lyon.fr

---

# MICROVASCULAR DECOMPRESSION FOR TRIGEMINAL NEURALGIA

M. SINDOU

## INTRODUCTION

The surgical treatment of primary [= idiopathic = essential = classical] Trigeminal Neuralgia (TN) was one of the first successful treatments introduced in the history of neurosurgery. It was as early as 1901 that retro-gasserian trigeminal neurotomy appeared in the therapeutic armamentarium, long before the use of phenytoin in 1942 and carbamazepine in 1963. Besides the open and percutaneous lesioning techniques, the conservative micro-vascular decompression (MVD) procedure was developed step by step since the first observation in 1934 by DANDY of the occurrence of trigeminal root compression by a neighbouring elongated artery, at the time of performing juxtapontine selective rhizotomies [2]. The first decompression of the root from its offending vessel was performed in 1959 by Gardner [4], but the method was really promoted in 1967 by Jannetta, who codified the operation using the microsurgical techniques [5].

## RATIONALE

1. The goal of MVD is to decompress the trigeminal root from its offending vessel(s). Which are these compressive vessels? In our 579 patients studied [9], no neuro-vascular conflict (NVC) was found in only 3.3%, whilst in 96.7% one (or several) compressive vessel(s) could be identified. The compressive loop originated from an elongated, superior cerebellar artery (SCA) in 74.3%, anterior-inferior cerebellar artery (AICA) in 6.1%, SCA and AICA in association in 16.3%. A vein embedded in the nerve was found as the sole NVC in 3.3%, whilst a vein adherent to the nerve and associated with an arterial compression was found in 24% of the cases. Locations of the NVC along the root are as indicated in Fig. 1. The degree of severity of the compression was a simple contact (grade I) in 17.6%, a distortion of the nerve (grade II) in 49.2% and a marked indentation (grade III) in 33.2%. Alterations of the whole trigeminal root (in addition to the vascular compression) were frequently observed, namely, a significant degree of global atrophy in 42% and a local thickening of

---

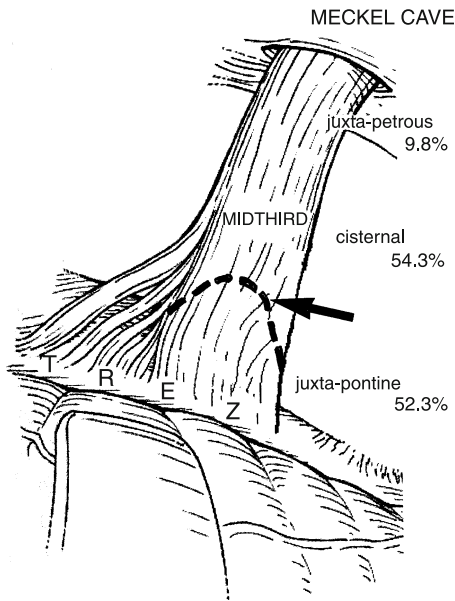
*Keywords:* trigeminal neuralgia, functional neurosurgery, microvascular decompression



the arachnoid adhesive to the root in 18.2%. In 12.6% of the cases in the whole series the root had a marked angulation on crossing over the petrous ridge; in 3.9% the nerve was squeezed between the pons and the petrous bone due to the small size of the posterior fossa.

- Classically the Root Entry Zone (REZ) is considered the site of the pathology. The transitional zone between the central and the peripheral myelin, i.e., the Obersteiner–Redlich (O–R) transitional zone, is located on average 5 mm outside the entry of the root into the pons (Fig. 1). Both the central portion and the O–R zones are vulnerable parts of the nerve.

The most generally admitted pathophysiology is vascular compression, most often at the central portion of the root. Through chronic pressure and pulsations, vascular compression causes focal demyelination, with groups of axons juxtaposed without interstitial glia. These focal alterations would be at the origin of neosynapses (= ephapses), with direct cross-talk between fibres. Ectopic spontaneous firing, chronically sustained, would generate hyperactivity in the trigeminal system nuclei. These mechanisms are consistent with the epileptiform characteristics of TN together with its specific responsive-



**Fig. 1.** Schematic drawing of the (*right*) Trigeminal Root (through posterior approach) from exit of Meckel's Cave to Trigeminal Root Entry Zone (TREZ) at brainstem. The root is constituted of a peripheral portion and a central portion with the Transitional Zone (*arrow*) situated at 5 mm from brainstem (pons). From personal observations, neuro-vascular conflicts (NVC) were located at TREZ (juxtapontine) in 52.3%, mid-third of the root (cisternal) in 54.3% and exit from Meckel's Cave porous (juxta-petrous) in 9.8%. Importantly, 17% of the patients had more than one, definite NVC [9]

ness to anticonvulsants, and would explain how pure MVD can restore a normal function of the nerve in a large majority of patients [13].

## DECISION-MAKING

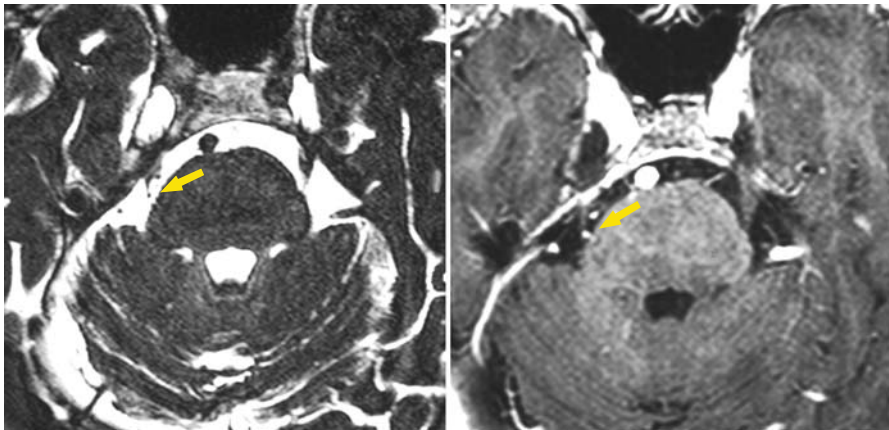
### 1. DIAGNOSTIC CRITERIA

Diagnosis of typical primary TN is a clinical one; the criteria in the presentation are:

- location on one side of the face
- no extension outside the trigeminal territory
- paroxysmal pain of the “electric shock” type and no pain between the attacks (i.e. refractory periods), at least at the beginning of the disease
- pain paroxysms that may occur spontaneously but more are triggered by stimuli
- no sensory deficit, no decrease in corneal reflex and no symptoms in other cranial nerve territories
- effectiveness of anticonvulsants, at least initially.

Over time the pain becomes more frequent, pain free intervals shorten and an aching/burning background pain appears, sometimes with vasomotor phenomena, giving the neuralgia an atypical presentation.

TN can be diagnosed as “primary” only after all specific causes have been eliminated by appropriate investigations. High resolution T2



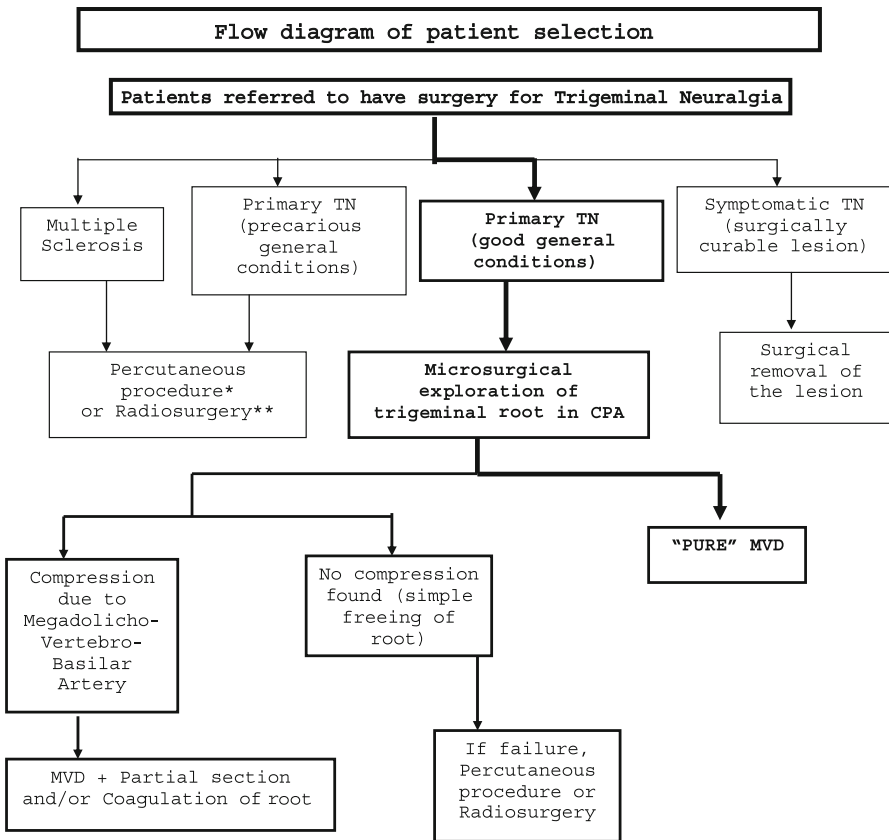
**Fig. 2.** Right TN due to NVC from elongated SCA. MRI with CISS sequence (*left view*), 3D Angio MR (*right view*) and corresponding axial sections from same patient. Note loop compressing REZ at pons in medial location and distortion of the root (*arrows*)

(CISS= Constructive Interference in Steady State) together with 3D Angio MR are the best MRI sequences to demonstrate a NVC (Fig. 2). Important, there might be false-positive and false-negative results.

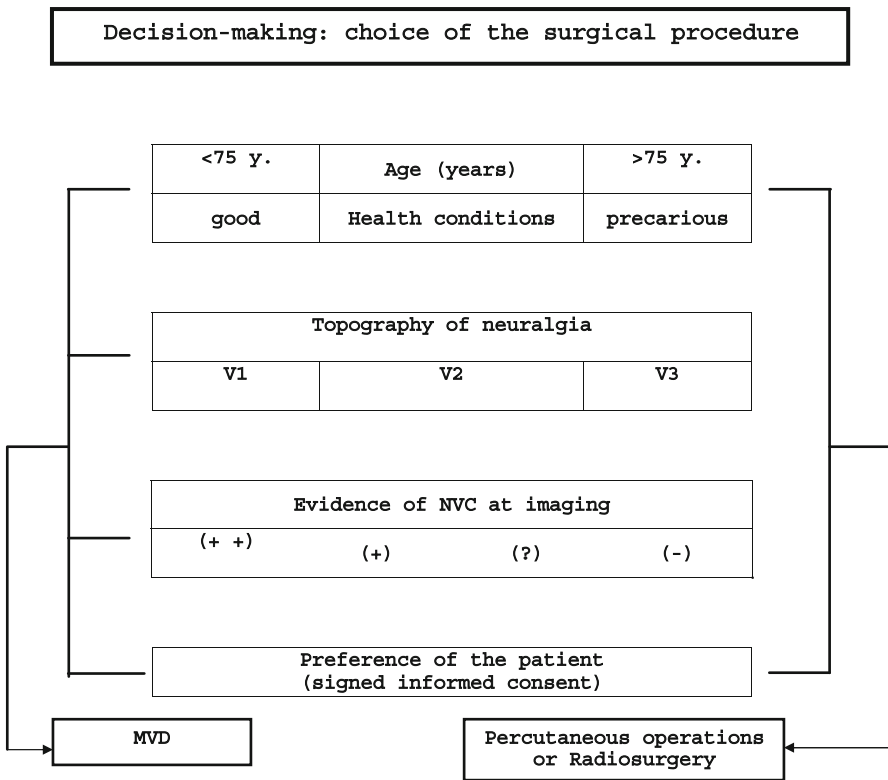
**2. INDICATIONS**

Which patients should be candidates for MVD surgery? The flow diagram of Fig. 3 indicates our selection process.

As an illustration, in our series of (more than 3000) patients with TN referred for surgery, 1.5% had symptomatic TN due to a surgically removable lesion, 3.2% had multiple sclerosis and underwent percutaneous thermorhizotomy



**Fig. 3.** Flow diagram of patient selection [from our 3000 patient series referred to undergo surgery for trigeminal neuralgia (1980–2005)]. \*Percutaneous procedure: thermorhizotomy in retrogasserian location at the level of the triangular plexus (Sweet), Balloon compression of the Gasserian ganglion in Meckel’s cave (Mullan), Glycerol neurolysis by injection in the trigeminal cistern in Meckel’s cave (Hakanson). \*\*Radiosurgery: Gamma Knife, LINAC



**Fig. 4.** Decision-making after failed medical treatment

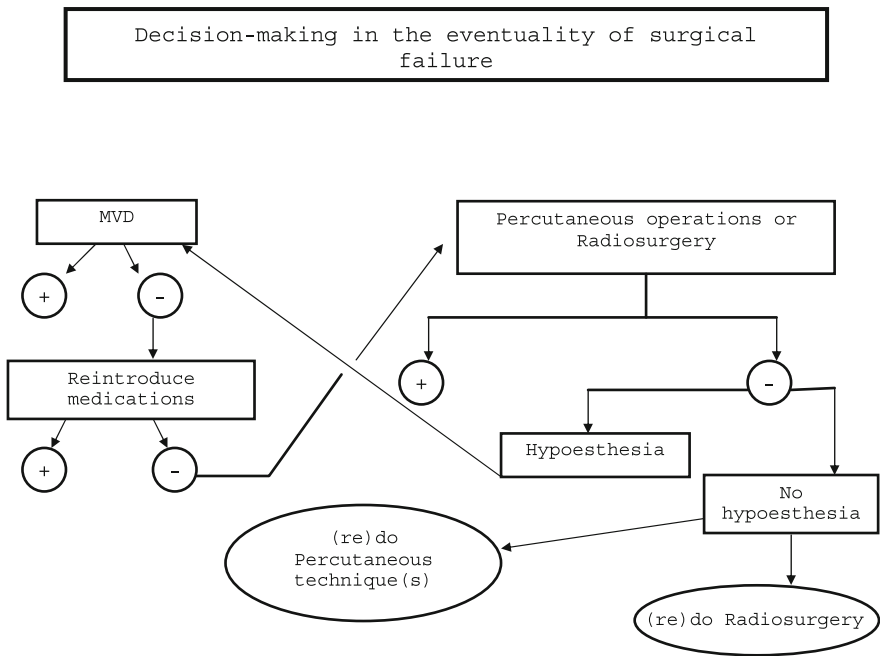
(th-rhiz), 64.2% had primary TN that was also treated with th-rhiz because of age, precarious health condition or patient's preference, and 31.1% had primary TN that led to posterior fossa exploration. Of the latter group, 3.3% had a compressive megalolicho-basilar artery and underwent MVD + partial rhizotomy, 93.1% had NVC and pure MVD without any additional cutting or coagulation of the adjacent rootlets; in only 3.6% no vascular compression was found.

The guidelines for the choice of the surgical procedure after medical treatment failed and the decision-making process in the eventuality of a surgical failure are indicated in Figs. 4 and 5, respectively.

## SURGERY

### 1. OPERATIVE TECHNIQUE (Figs. 6 and 7)

- Under general endotracheal anaesthesia the patient is placed in the contralateral decubitus position with the head moderately elevated, slightly



**Fig. 5.** Decision-making after failure of previous surgery

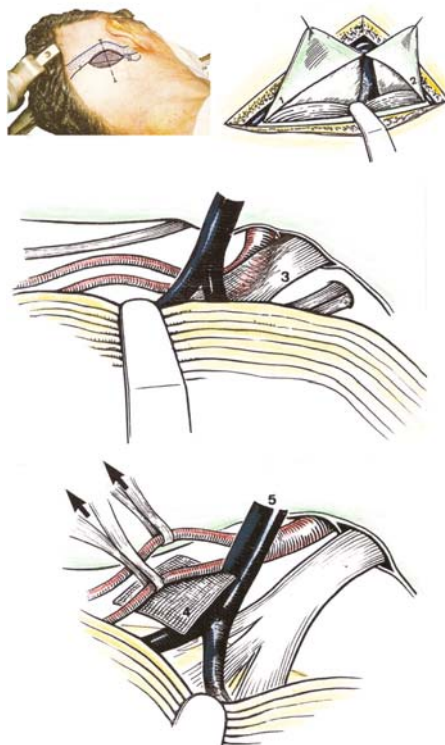
flexed and rotated 15° toward the contralateral side and secured with a three-pin holder. The ipsilateral shoulder is taped and pulled caudally and posteriorly. Hair is shaved in the retro-mastoid region. The mastoid process and superior nuchal line which are the landmarks for the retro-mastoid craniectomy are identified by palpation with the index finger. A skin incision 5 cm in length is made obliquely, 1 cm medial to the bisector of the angle formed by the nuchal line and the posterior aspect of the mastoid process. The underlying subcutaneous tissue and muscles are divided using electrocautery. If the occipital artery is encountered, it is divided between two silk ligatures. The posterior aspect of the mastoid process is cleared of soft tissue. The mastoid emissary vein within the bone is obliterated first with Surgicel and then with wax.

- A retro-mastoid craniotomy is performed, first by a burr hole just posterior to the base of the mastoid process just below the nuchal line, then by enlarging the hole with a rongeur, so that first, the inferior border of the transverse sinus and secondly the posterior border of the sigmoid sinus are exposed. The burr hole must not be made too laterally toward the mastoid process as this would endanger the sigmoid sinus, the external wall of which is often reduced to a thin endothelial layer adhesive to the bone. If bleeding occurs suturing would not be possible owing to its friable texture and packing to achieve haemosta-

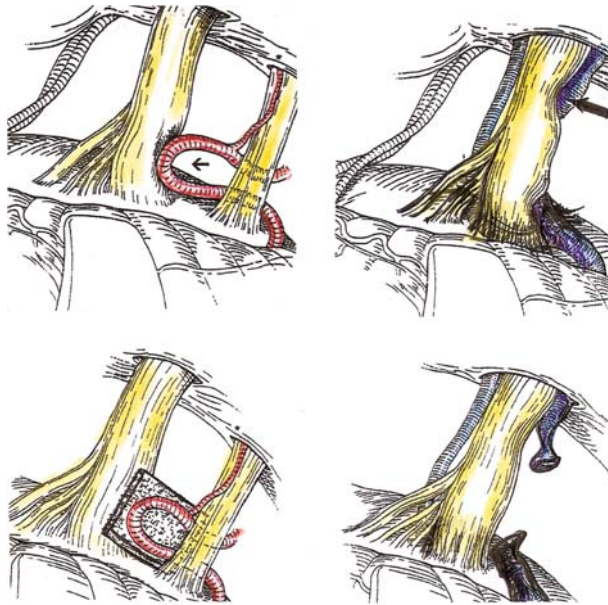
sis could lead to lateral sinus occlusion. Importantly, the craniectomy should expose the transverse sinus first and the sigmoid sinus thereafter, because the external wall of the transverse portion of the sinus being stronger and less adhesive to the bone than the sigmoid one.

- The craniectomy used is elliptic in shape, 2 cm × 1.5 cm in size. If mastoid cells are opened as is common, they are occluded by affixing a piece of subcutaneous tissue (e.g. fat plus aponeurosis). The dura is opened by making two small flaps, a superior one retracted along the transverse sinus and a lateral one along the sigmoid sinus. A self-retaining retractor – of the Yasargil type – mounted with a very thin blade (Sugita-Fukushima type) is placed on the superior cerebellar surface, no more anteriorly than the level of the superior petrosal veins, so as to reach the trigeminal root via an infratentorial-supracerebellar approach.
- The microscope is then placed posteriorly and inferiorly to the head and positioned with its visual axis parallel to the superior petrosal sinus. The arachnoid covering the dorso-lateral aspect of the cerebral peduncle is opened from the superior petrosal venous trunk in a medial direction, parallel to the tentorial incisura and 1–2 mm below the trochlear nerve. This is done with a micro-sucker in one hand to attract and immobilize the arachnoid and sharp micro-scissors in the other. Care must be taken not to injure the thin and fragile trochlear nerve, especially with excessive suction.
- The superior petrosal trunk and its three main tributaries: the (dorsal) mesencephalic, the (superior) cerebellar, and the (lateral) pontine veins, are then dissected free from the surrounding arachnoid. This is very important to allow downward retraction of the cerebellum without stretching the superior venous trunk. Its avulsion from the superior petrosal sinus would lead to profuse bleeding and venous sacrifices. Preserving the petrosal veins not only avoids venous infarction, but also prevents excessive retraction and thereby stretching of the VIIth and VIIIth nerves. The arachnoid is then opened laterally and inferiorly toward the VIIth and VIIIth nerves; limited dissection of the arachnoid around these nerves will reduce the likelihood of hearing complications. The retractor tip is then placed so that the entire root can be examined through the various triangles defined by the petrosal veins, from Meckel's cave to the REZ at the pons, and all possible NVCs identified. The root is dissected free by dividing the pia-arachnoid filaments (= chordae). Not infrequently the arachnoid is thickened and strongly adhesive to the trigeminal rootlets but its dissection needs to be meticulous and as atraumatic as possible.
- Superior Cerebellar Artery (SCA) is the most commonly conflicting vessel (Fig. 6). Its normal anatomical situation corresponds to a course from anterior and lateral to posterior and medial around the pons,

with a bifurcation at a certain distance superiorly to the REZ, before distributing to the medial and lateral superior cerebellar surfaces and the dorsolateral aspect of the peduncle. When responsible, SCA is elongated and has one of two types of relationship to the root: either anterior to the REZ or superiorly positioned lying on the rootlets in their cisternal portion.



**Fig. 6.** Surgical technique of MVD; right TN due to NVC from SCA. Keyhole retro-mastoid approach on right side. *Upper left view:* Position of head, landmarks of skin incision and craniectomy. *Upper right view:* The dura is opened by turning two small flaps, one being retracted along the transverse sinus [1] and the other along the sigmoid sinus [2]. The self-retaining retractor is placed on the cerebellar hemisphere surface to achieve a supracerebellar-infratentorial approach to the trigeminal nerve. The superior petrosal veins, which drain towards the superior petrosal sinus are respected. *Middle view:* The arachnoid of the dorso-lateral middle part of the peripeduncular cistern is incised along and below the trochlear nerve. The SCA and its two division branches are compressing (grade II) the trigeminal root [3] from above. *Lower view:* The arteries are detached from the nerve and transposed upward just beneath the tentorium. Teflon tapes, 3 cm in length and 2 mm in width are passed around the arteries to pull (arrows) and detach then without touching the nerve. Transposition is maintained by wedging the tapes in between the superior aspect of the cerebellum and the inferior surface of the tentorium. Then, to avoid any secondary mal-repositioning of the arteries, a square piece (1 × 1 cm) of semi-rigid prosthesis (made of Dacron or Teflon) [4] is placed on the superior petrosal vein [5], as a console, to hold the arteries



**Fig. 7.** Surgical technique of MVD; right TN due to NVC from AICA (*left views*) and embedded vein (*right views*). Keyhole retro-mastoid approach on right side. *Left views (AICA)*: AICA compressing the trigeminal root entry zone (arrow) inferiorly (*upper view*). Decompression and interposition of a prosthesis (1 cm<sup>2</sup>), because the AICA could not be transposed away owing to the labyrinthine artery (*lower view*). *Right views (VEIN)*: Compression of the trigeminal nerve (arrow) by the inferior transverse pontine vein (*upper view*). Decompression by coagulation and division of the compressing vein (*lower view*)

When Anterior Inferior Cerebellar Artery (AICA) is the offending vessel (Fig. 7), compression is exerted by an upward loop on the inferior aspect of the pars major at its brainstem entry.

With veins, it is often difficult to be certain of their responsibility in causing NVC except when they markedly groove the root (Fig. 7).

In the eventuality of a compressing artery, the vessel is detached from the nerve and pons by dividing with microscissors the chordae which keep the artery adherent to the adjacent neural structures so that the artery can be transposed away from the root. Throughout the vascular manipulations gentle irrigation with saline and from time to time application of a few drops of papaverine solution (1 ml in 10 ml saline) are important measures to avoid mechanical vasospastic reactions in the arteries.

When SCA is the conflicting vessel (Fig. 6), it is transposed upwards under the tentorium. Since collaterals of the SCA are generally long, transposition of this vessel is relatively easy. The artery is kept apart from the root by means of sling/s usually one around each of the two divisions, 3–4 cm in length and



2–3 mm in width, made of shredded fibres of Teflon Felt. They are passed around the artery(ies) to exert a pulling effect and are held by simple insertion and wedging between the superior aspect of the cerebellum and the inferior surface of the tentorium. To prevent subsequent displacement, a square piece of semirigid prosthesis (made of Dacron or Teflon Felt) is placed on the superior petrosal vein as a console to hold the artery in place which also prevents the prosthesis touching the root (Fig. 6).

*When AICA is the vessel causing compression*, transposition is usually difficult (Fig. 7), because it frequently has short perforators to the brainstem and also gives origin to the labyrinthine artery. In most cases the loop cannot simply be pulled away and a small piece of semirigid prosthesis and/or a small balled cushion of Teflon has to be interposed between the REZ and the loop.

*When a vein is found grooving the root* (Fig. 7), most often laterally or inferiorly [often the inferior transverse pontine vein at the exit of the root from Meckel cave], it is preferable to coagulate and to divide the vessel. When a vein is coursing parallel to the nerve, it is difficult to be certain of its pathological role. If there is no other obviously responsible vessel the vein may be pushed away and maintained apart.

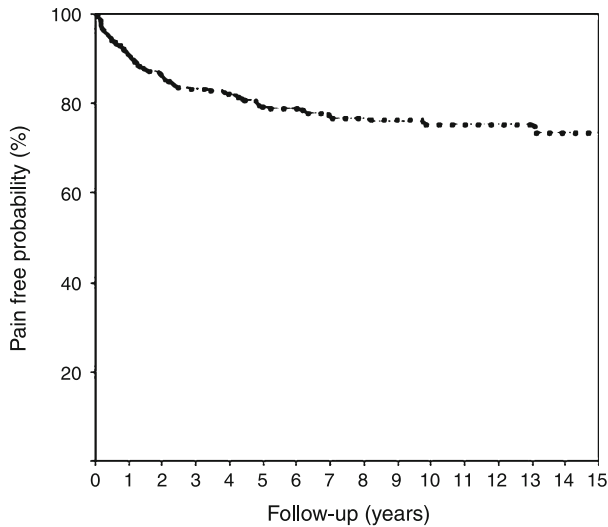
- After the decompression has been completed, venous haemostasis is confirmed by requesting the anaesthesiologist to perform sustained digital compression at the neck of both jugular veins or, if this is not possible, by carrying out a Valsalva manoeuvre with the ventilation machine. Arterial haemostasis is ensured by irrigating the vessels with droplets of papaverine in saline to reverse all possible spasm due to surgical manipulation.

The dura is closed with single stitches. In order to achieve watertight closure a piece of subcutaneous fascia or of fascia lata is affixed externally to the dura. Additional fatty tissue is packed into the mastoid cells, which are exposed during the opening. Bone chips are packed over the craniectomy defect only if mastoid cells were not opened. Finally, the muscular, subcutaneous and cutaneous layers are closed with interrupted sutures and a compressive dressing is applied to avoid meningocele and decrease the risk of CSF fistula or of rhinorrhoea through the Eustachian tube if mastoid cells were opened.

## 2. LONG-TERM RESULTS

According to the publications with a follow-up of more than 5 years and a Kaplan-Meier study (see references in 12), the rates of long-term success (i.e. pain free and no medication) are 63.5%–84% (69.6% at 10 years in Jannetta's series [1]) and 73.4% at 15 years (Fig. 8) in our own series [12].

The following is a summary of a recent personal study on the factors which affect prognosis [10].



**Fig. 8.** Long term cure (no pain, no medication). Kaplan-Meier curve at 15 years of patients free of pain in our series [12]

1. Factors related to the patient: gender, age at surgery and past history of systemic hypertension, as well as – although surprisingly – the duration of the neuralgia prior to surgery including previous failed trigeminal operation did not play a role in prognosis.
2. Factors related to the neuralgia: side, topography and extent did not exert an adverse influence; neuralgia with atypical manifestations had the same satisfactory outcome as typical neuralgia [12].
3. Factors related to anatomical findings: neither the type of the compressive vessel nor its location along or around the root were significant; in contrast, the severity of the compression did play a significant role with more severe compression being associated with a better the outcome [ $p = 0.002$ ]. The presence of a clear-cut and marked compression at surgery (and possibly – although not yet quite reliably – on preoperative MRI) is the guarantee of a higher than 90% success rate [10]. The presence of focal arachnoiditis had a significant (although mild) adverse influence [ $p = 0.002$ ].

### 3. COMPLICATIONS

Mortality reported in the literature [see references in 3 and 6] ranged between 0.2% and 1.2% (0.3% in our series). It was mainly related to cerebellar/brainstem infarction. CSF leakage (transient) was observed from 2% to 17% according to published series; this complication was decreased in our series

from 17% to 3% since affixing a piece of fat tissue harvested from the thigh to enhance watertight dural closure. Permanent trochlear and facial nerve palsy occurred, due to stretching in 0.5% and 0.4%, respectively, in our series. An incidence of persistent hearing loss of 0.8% to 4.5% was reported in the literature (1.5% in our series). Trigeminal sensory disturbances are uncommon with pure MVD; dysesthesiae were reported in 2% to 5% in the literature (4%, and mild, in our series).

## **HOW TO AVOID COMPLICATIONS**

### **1. HEARING LOSS**

The best approach to avoid hearing loss is to use the infratentorial-supracerebellar approach. As a matter of fact it has been clearly demonstrated with intra-operative BAEP recordings that lateral to medial retraction of the cerebellar hemisphere entails a high risk of excessive traction on the VIIth–VIIIth nerve complex, as well as of the labyrinthine artery [8]. A limited approach through a keyhole craniectomy, not only prevents from excessive CSF depletion, but also from avulsion of the bridging petrosal veins. Preservation of the superior petrosal veins offers a firm guarantee of limiting traction on the fragile eighth nerve and the labyrinthine artery.

### **2. TROCHLEAR NERVE PALSY**

The infratentorial-supracerebellar approach has the disadvantage of exposing the thin trochlear nerve to direct surgical injury. For this reason, we recommend to open the peripeduncular arachnoid to expose the SCA and its branches, not at the level of the trochlear nerve itself but as far below as possible, in the pedunculo-cerebellar fissure. By doing so, a “curtain” of arachnoid, posterior to the nerve, will assure its protection from trauma by the instruments and from surgical suction.

### **3. VASCULAR COMPLICATIONS**

Since arteries may be endangered by stretching or kinking, especially during transposition, they must be constantly checked under direct vision. Avulsion of tiny perforators might occur if care is taken to avoid excessive traction on the main trunk or branches. Manipulation of vessels often generates “mechanical” vasospastic reactions with potentially severe ischemic consequences. We regret that two patients in our series developed cerebellar hemorrhagic infarction probably related to such a mechanism and recommend that arteries are regularly irrigated with warm saline and droplets of papaverine in saline. Avulsion of the petrosal veins might lead to profuse haemorrhage soiling the cisternal spaces. In the eventuality of bleeding, pres-

ervation of vein patency must be attempted by affixing small pieces of Surgicel to the tear. Compact packing that would compress and occlude the vein(s) must be avoided; this could be dangerous by creating oedema or hemorrhagic infarction of cerebellum and brainstem.

#### 4. CSF LEAK

Keyhole approaches render hermetic closure of the dura (under tension) difficult. To achieve this we affix a piece of subcutaneous fat or fascia harvested from the operative wound or if necessary from the fascia lata at thigh. Bone chips are replaced only if the mastoid cells were not opened; if they were breached the craniectomy is packed only with fatty tissue. We do not recommend the use of fibrin glue because it is rapidly resorbed, which leads to delayed CSF leak. We advise not packing wax into the opened cells, as it may migrate into the middle ear, where it may cause chronic serous otitis with otalgia or granulomas and secondary infection. A compressive dressing helps to decrease the risk of meningocele, fistula and/or rhinorrhoea through the Eustachian tube.

#### 5. AVOIDANCE OF NEO-COMPRESSION BY THE IMPLANT

Simple decompression without any material inserted would be idealistic. However, it would be unwise not to keep the conflicting vessel(s) apart with implantation of a piece of synthetic prosthesis. A recent study [11] strongly supports performing the procedure without the implant in contact with the root ( $p=0.05$ ). This is easier with the superior cerebellar artery, because of its laxity and small number of perforating branches, than with the anteroinferior cerebellar artery, which has perforators to the brainstem and labyrinthine artery arising from its cisternal portion.

Interesting, the significantly better long-term cure rate when the implant is not in contact with the roof favors the “pure” decompressive effect of the MVD procedure, rather than a conduction block mechanism [11].

## CONCLUSIONS

MVD is able to cure (i.e., no pain, no medication) primary TN due to vascular compression in 75% of the patients, 90% when the compression is marked on preoperative MRI. This can be achieved without side-effects in almost all the cases. Recourse to the new fine MR images may demonstrate, although not always reliably, the compressive vessel(s) and root distortions. A keyhole retro-mastoid and infratentorial-supracerebellar approach obviates the need for BAEP monitoring for preserving hearing as soon as the learning curve has become “good”.

Surgery should be considered only after anticonvulsant medications have failed or if medical treatment is not well-tolerated, including asthenia and drowsiness. MVD may be the first option when patients are in good health, whereas percutaneous lesioning operations or radiosurgery are preferable in those with adverse co-morbidity.

## References

- [1] Barker FG, Jannetta PJ, Bissonnette DJ, Larkins MV, Jho HD (1996) The long-term outcome of micro-vascular decompression for trigeminal neuralgia. *New Engl J Med* 334: 17: 1077-1083
- [2] Dandy WE (1934) Concerning the cause of trigeminal neuralgia. *Am J Surg* 24: 447-455
- [3] Elias WJ, Burchiel KJ (2004) Trigeminal neuralgia – Micro-vascular decompression. In: Fisher WS Burchiel KJ (eds) *Pain management for the neurosurgeon: Part 2. Seminars in neurosurgery*, vol. 15, numbers 2/3. Thieme, New York, pp 143-150
- [4] Gardner WJ, Miklos MV (1959) Response of trigeminal neuralgia to decompression of sensory root. Discussion of cause of trigeminal neuralgia. *JAMA* 170: 1773-1776
- [5] Jannetta PJ (1967) Arterial compression of the trigeminal nerve at the pons in patients with trigeminal neuralgia. *J Neurosurg* 26: 159-162
- [6] Rovit RL, Murali R, Jannetta PJ (1990) *Trigeminal neuralgia*. Williams & Williams, Baltimore, 288 pp
- [7] Sindou M (2000) Micro-vascular decompression for trigeminal neuralgia. In: Kaye AH, Black PM (eds) *Operative neurosurgery*, vol. 2. Churchill-Livingstone, London, pp 1595-1614
- [8] Sindou M, Ciriano D, Fischer C (1991) Lessons from brainstem auditory evoked potential monitoring during micro-vascular decompression for trigeminal neuralgia and hemi-facial spasm. In: Schramm J, Moller AR (eds) *Intra-operative neurophysiologic monitoring in neurosurgery*. Springer-Verlag, Berlin, pp 293-300
- [9] Sindou M, Howeidy T, Acevedo G (2002) Anatomical observations during micro-vascular decompression for idiopathic trigeminal neuralgia (with correlations between topography of pain and site of the neurovascular conflict). Prospective study in a series of 579 patients. *Acta Neurochir* 144: 1-13
- [10] Sindou M, Leston J, Decullier E, Chapuis F (2007) Microvascular decompression for primary trigeminal neuralgia: long-term effectiveness and prognostic factors in a series of 362 consecutive patients with clearcut neurovascular conflicts who underwent pure decompression. *J Neurosurg* 107: 1144-1153

- [11] Sindou M, Leston J, Decullier E, Chapuis F (2008) Microvascular decompression for trigeminal neuralgia: the importance of a non-compressive technique – Kaplan-Meier analysis in a consecutive series of 330 patients. *Neurosurgery* 63: ONS 341-ONS 351
- [12] Sindou M, Leston J, Howeidy T, Decullier E, Chapuis F (2006) Micro-vascular decompression for primary trigeminal neuralgia (typical or atypical). Long-term effectiveness on pain; prospective study with survival analysis in a consecutive series of 362 patients. *Acta Neurochir* 148: 1235-1245
- [13] Sindou M, Mertens P, Amrani F (1991) Does microsurgical vascular decompression for trigeminal neuralgia work through a neocompressive mechanism? Anatomical-surgical evidence for a decompressive effect. *Acta Neurochir [suppl]* 52: 124-127

**Contact:** Marc Sindou, Hôpital Neurologique P. Wertheimer, University of Lyon,  
59 Bd Pinel, 69003 Lyon, France  
E-mail: marc.sindou@chu-lyon.fr

---

# NEUROSURGERY FOR TRIGEMINAL NEURALGIA

K. J. BURCHIEL

## INTRODUCTION

As early as 1730, the first treatments for trigeminal neuralgia (TN) involved direct section of peripheral branches of the trigeminal nerve and later injection of caustic liquids. The main limitation of these simple peripheral destructive procedures was the short duration of pain relief [21]. Section of more central branches of the trigeminal nerve was first attempted by Victor Horsley in 1891, who, using a subtemporal intradural approach, cut the trigeminal root between the brainstem and the gasserian ganglia [11]. This approach was later popularized by Spiller and Frazier, who used a selective resection sparing the motor and first division fibers [7]. In 1925, Walter Dandy proposed a posterior fossa approach to partial sectioning of the sensory root at the pons and reported 500 cases in 1932 with excellent results [5]. Percutaneous approaches to the trigeminal ganglion commenced with direct injections of alcohol by Harris in 1912 [9]; however, although effective, alcohol leakage outside the cistern and production of other cranial neuropathies limited its applicability. In 1914, Hartel subsequently detailed a percutaneous technique for needle insertion outside the oral cavity using external landmarks which are still used today [10]. Percutaneous electrocoagulation of the ganglion was described by Kirschner in 1932 using a head frame and a diathermy apparatus [14]. In 1965, William Sweet introduced a less painful and safer technique which included intermittent sedation, physiological localization and controlled lesion production using radiofrequency [26]. Tew and Taha described further refinements in 1996 [27]. Percutaneous balloon compression of the trigeminal ganglion was developed by Mullan and Lichtor in 1983 [20], although the practice of compression of the ganglion during craniotomy had been practiced by neurosurgeons since the 1950s. In 1981, Hakanson serendipitously discovered that percutaneous glycerol rhizotomy was an effective treatment for TN and this has become the agent of choice for cisternal injection ever since [8].

Radiosurgery, originally using an orthovoltage X-ray tube coupled to a first-generation intracranial stereotactic frame, was developed by Lars Leksell in 1951 and originally used on two patients with TN as a minimally

---

*Keywords:* radiosurgery, trigeminal neuralgia, vascular decompression, percutaneous techniques

invasive destructive procedure [15]. With subsequent development and refinement in the last two decades, gamma knife radiosurgery to the proximal trigeminal root has now become one of the fastest growing indications for this technology.

In spite of the efficacy, albeit short term, of the above destructive procedures, the etiology of TN remained a mystery until the reported association of TN and neurovascular conflict at the nerve root entry zone in 1966 by Jannetta [12]. Although reported originally by Dandy and then by Gardner, Jannetta deserves credit for advancing the neurovascular compression hypothesis; refining the surgical technique and demonstrating good long-term follow-up with a nondestructive surgical technique.

## **RATIONALE**

The goal of surgical treatment of TN is to produce pain relief with minimal, if any, morbidity or mortality and minimal, if any, new neurological deficit.

### **1. MICROVASCULAR DECOMPRESSION (MVD)**

In most cases of TN, but not all, vascular compression of the trigeminal nerve root from its pontine origin to the entry into Meckel's cave may be observed. Offending vessels include the superior cerebellar artery, anterior inferior cerebellar artery, vertebrobasilar trunk or veins [25]. Recently, preoperative high-resolution MR imaging with 3-D reconstruction has been useful in demonstrating both the type of vessel and its anatomical relationship to the trigeminal root [18, 19]. Histologically, demyelination of the trigeminal root, particularly at the transitional zone between central and peripheral myelin or the Obersteiner-Redlich transitional zone has been observed in patients with TN undergoing MVD [6]. These changes are proposed secondary to constant arterial pressure pulsation and are hypothesized to cause spontaneous ectopic firing triggering aberrant hyperactivity within the trigeminal system resulting in TN. The theoretical rationale for early operative intervention is therefore to prevent the development of irreversible damage to the nerve.

### **2. DESTRUCTIVE APPROACHES**

Destructive surgery includes radiofrequency lesioning, balloon compression, glycerol injection, peripheral nerve section and radiosurgery. The goal of all of these techniques is to cause hypalgesia in the affected primary trigeminal division by causing injury preferentially to A-delta and C fibers (nociceptive fibers). Although the exact mechanism of nerve injury differs between these modalities, it appears from outcome studies that the duration



of pain relief and risk of deafferentation complications is related to the extent of injury [13].

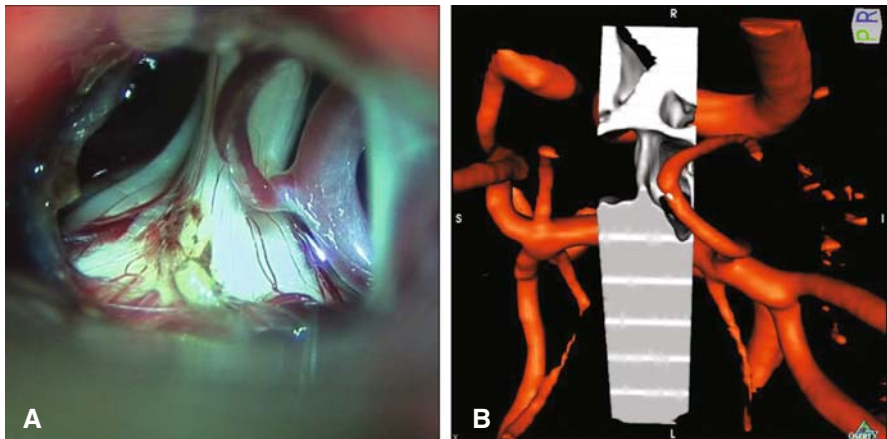
## DECISION-MAKING

### 1. CLINICAL DIAGNOSIS

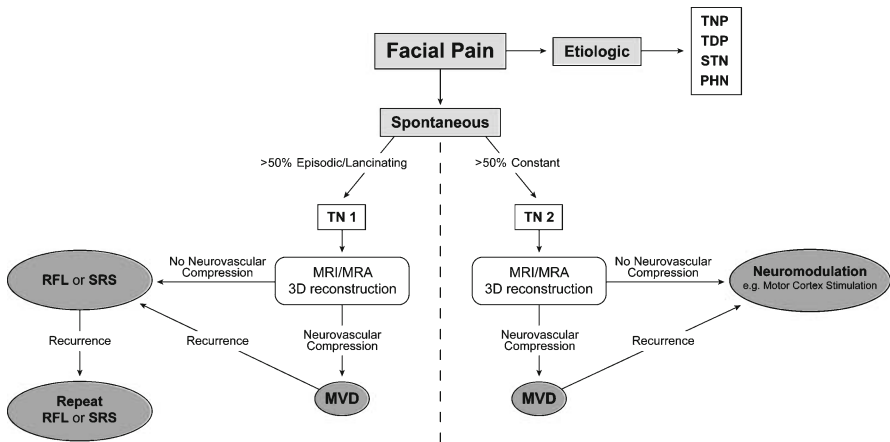
Trigeminal neuralgia is a clinical diagnosis characterized by facial pain within the distribution of the trigeminal nerve, is predominantly unilateral, triggerable, paroxysmal, severe, electric shock or lancinating in nature. Clinical examination typically shows no trigeminal sensory disturbance and a normal neurological examination. We have found the use of a facial pain questionnaire helpful in the prediction of a diagnosis [16]. The distinction between patients with predominantly intermittent facial pain (TN type 1) and those with predominantly constant facial pain (TN type 2) is helpful in predicting pain outcome following MVD regardless of the intraoperative findings (Fig. 1A). Excluding mass lesions and demyelination, MR imaging, especially with MR angiography and 3-D reconstruction [18] may prove useful for excluding neurovascular compression in patients in whom the diagnosis of TN is difficult (Fig. 1B).

### 2. INDICATIONS

Surgical treatment for TN is recommended for patients with TN that is medically refractory, who are intolerant of medication or who prefer surgery as their primary treatment of this condition.



**Fig. 1. A** Intradural exposure of the trigeminal root and compressing vessel at craniotomy. **B** MR imaging with 3-D reconstruction demonstrating neurovascular compression of the trigeminal nerve by looping the branch of the superior cerebellar artery



**Fig. 2.** A surgical treatment algorithm for TN

*Microvascular decompression* is offered to patients less than 70 years of age with evidence of arterial or venous compression demonstrated on MR images because this option gives the best chance of long-term pain relief and of cure. For both TN type 1 and TN type 2 patients with imaging suggestive of compression, MVD is still a reasonable first option, although for TN type 2 pain, outcomes are not as beneficial and improvement in the TN type 2 component is less predictable.

*Radiofrequency (RF) gangliolysis* is offered to patients with recurrent TN type 1 pain following MVD, patients with TN type 1 pain but no evidence of neurovascular compression on high-resolution imaging, older patients with TN type 1 pain who cannot tolerate MVD, and those patients who request a less invasive procedure. We prefer radiofrequency lesioning over other ablative options because intraoperative stimulation can confirm needle localization, lesioning can be titrated, the effects of lesioning are immediately testable and it is repeatable.

*Radiosurgical lesioning* may be considered as a third line option in patients intolerant to RF lesioning.

Patients who have constant or burning facial pain, with or without sensory loss suggestive of trigeminal neuropathic pain (TNP) are not surgical candidates and their pain may be worsened by nerve-destructive procedures. Neuromodulation therapies including motor cortex stimulation may be options. See Fig. 2 for a TN surgical management algorithm.

### 3. PREOPERATIVE ASSESSMENT

Routine preoperative assessment includes cessation of anticoagulant medications, routine biochemical, hematology and coagulation profile and anesthesia review. Cardiac and respiratory consultation may be sought as necessary. In-

formed consent is obtained from the patient and the risks of incomplete relief of pain, worsening of pain with facial anesthesia, recurrent facial pain, infection, cerebrospinal fluid (CSF) leak, neurological deficit and death are explained.

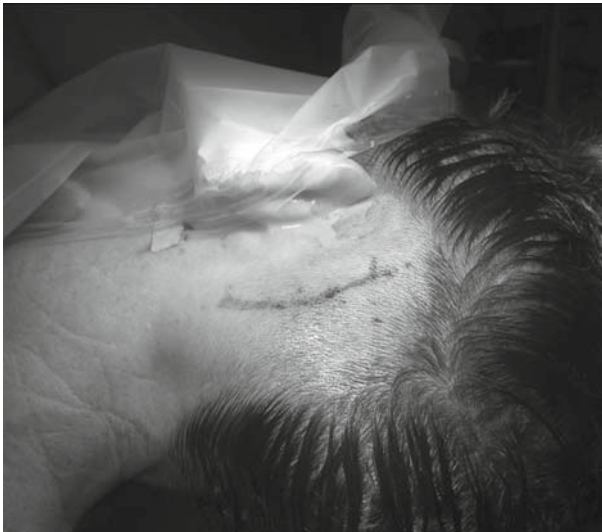We have used high-resolution (3 T) MR imaging with 3-D reconstruction for all patients preoperatively to confirm the presence and accurately localize the site of neurovascular conflict. This can be helpful in counseling patients preoperatively particularly for those patients who do not have classic symptoms.

## **SURGERY**

### **1. MICROVASCULAR DECOMPRESSION**

An operating microscope with video recording capability and standard microneurosurgical instruments are used. Brainstem auditory evoked potentials (BAEP) are recorded and facial nerve EMG is performed for all cases.

Following general anesthesia and endotracheal intubation intravenous antibiotics are given, a urinary catheter is inserted and calf compression devices are fitted. Electrodes for brain stem auditory evoked potentials and facial nerve monitoring are placed as standard. The patient is positioned supine with a large sandbag under the ipsilateral shoulder. The head is rotated 90° to the contralateral side with the vertex parallel to the floor and fixed in the Mayfield 3-pin holder. The ipsilateral shoulder may be taped down as necessary to improve the working angle between the shoulder and retromastoid area. The landmarks of the mastoid process,inion and likely position of the



**Fig. 3.** Patient positioning and planned incision for MVD

venous sinuses are marked out and retromastoid area is shaved, prepared, draped and infiltrated.

An 8–10 cm curved incision is made approximately 2 fingerbreadths posterior to the pinna, commencing at a level of the top of the pinna and directed toward the digastric groove (Fig. 3). Dissection is performed down to the occipital bone using the monopolar cautery and a self-retaining retractor is placed to maintain the exposure. The occipital artery may be encountered and ligated and also the mastoid emissary vein, which is waxed. The asterion is identified. A 3 cm diameter craniectomy is performed with the high-speed drill and completed with punches to remove bone overlying the junction of the sigmoid and transverse sinuses, the edges of which must be clearly seen. If opened, mastoid air cells are waxed. Epidural hemostasis is obtained with fibrillar collagen prior to dural opening. The dura is opened with two limbs paralleling the sigmoid and transverse sinuses and meeting at the junction of the two. The free edges are hitched with suture to the adjacent tissues to aid hemostasis and maximize intradural visualization. A wet cottonoid is then placed on the cerebellar surface to allow CSF to drain but not allow the cerebellum to herniate. The Greenberg retraction system is set up and a tapered retractor is introduced over the cottonoid. The retractor is aimed toward the top of the pinna, approximating the location of the trigeminal nerve at the petrotentorial junction and advanced progressively with cottonoids underneath to allow slow egress of CSF and cerebellar relaxation. The operating microscope is then brought into the operating field and the surgeon is seated. Once adequate brain relaxation has occurred, the superior petrosal vein is identified and is coagulated proximally, distally and then sharply divided. The trigeminal cistern and the trigeminal nerve are next identified. Sharp arachnoid dissection around the trigeminal root is necessary for thorough exposure to look for a compressing vessel (Fig. 1A). The entire length of the root should be examined. Review of the preoperative 3-D reconstruction MR images (Fig. 1B) is helpful here to direct attention to the likely site of compression. Once any relevant arterial loop is adequately mobilized, Teflon is positioned between the arterial loop and the nerve. It is important to ensure no kinking of the mobilized vessel occurs and that adequate packing occurs so that the Teflon will not move. Using a leaf of intact arachnoid to buttress the Teflon is helpful. If no arterial compression is seen after thorough exploration, veins causing compression may be coagulated. If no convincing vessel is seen, the trigeminal rootlets may be combed. Once intradural hemostasis is obtained, a watertight dural closure is achieved with interrupted nonabsorbable suture with muscle plug reinforcement as required. Mastoid air cells are waxed. Cranioplasty is performed using Norian cement and titanium mesh. The scalp wound is closed in layers with interrupted absorbable suture and a continuous absorbable skin suture.

The patient is observed in a neurosurgical intensive care unit overnight and has a postoperative brain CT immediately following surgery. Patients are usually transferred to the neurosurgical ward the following day and dis-

charged home in 2–3 days when their wound pain is controlled and they are ambulating safely.

Most series report short-term pain relief around 90% at 2 years [4], long-term pain relief ranging from 60% to 85% at 10 years [1, 24]. Important variables that determine pain relief are the pattern of neuralgia, nature of vascular compression (better outcome with arterial compression) and the length of time since operation. There is a small but consistent recurrence rate of pain following MVD of 2%.

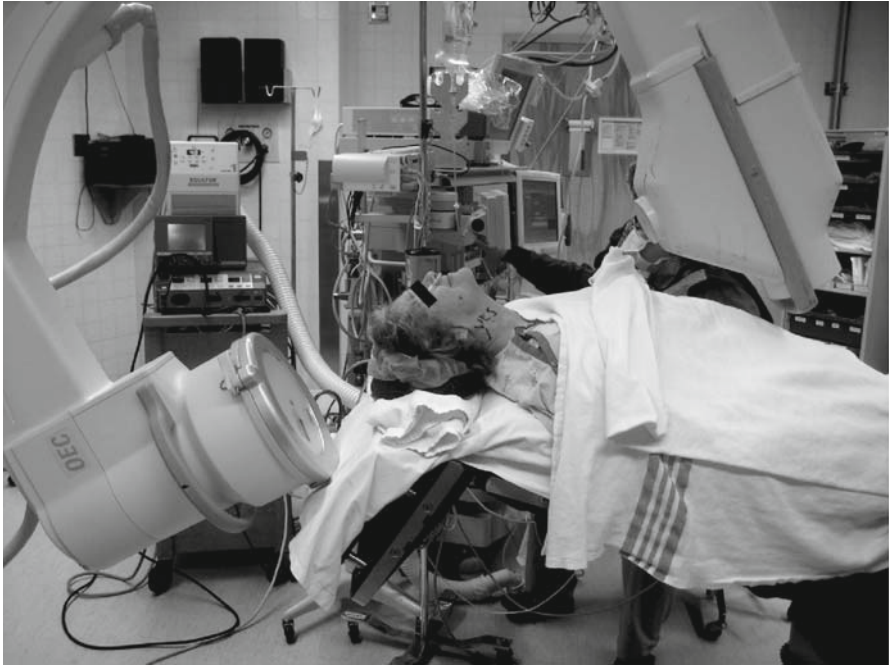The most serious complications include death, cerebrovascular injury or cerebellar injury and are fortunately rare. The more common complications include CSF leak, infection, hearing loss and postoperative wound pain. Hearing loss has been substantially reduced since the use of BAEP (brainstem auditory evoked potentials) and postoperative wound pain has been less since the routine adoption of cranioplasty in wound closure.

## 2. RADIOFREQUENCY GANGLIOLYSIS

A Tew radiofrequency cannula with stylet and electrode, Radionics radiofrequency generator and C arm fluoroscopy unit are used.

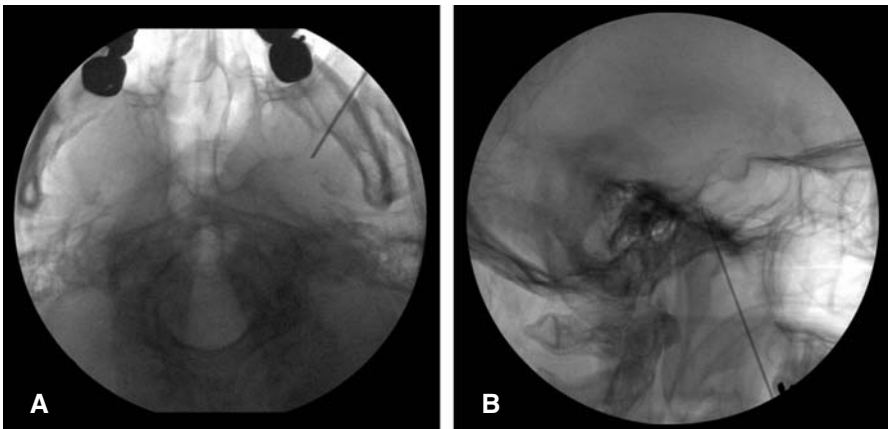
The patient's side and distribution of pain are checked and facial sensation to pin is tested prior to the procedure. The patient is positioned whilst awake on the operating table with the trunk flexed at the hips, the knees flexed, the arms wrapped by a sheet to the side of the patient and the head extended. The surgeon stands on the side of the patient to be treated. The fluoroscopy unit is brought in from the opposite side of the surgeon and the gantry positioned to take a submento vertical X-ray to demonstrate the ipsilateral foramen ovale. The ipsilateral cheek is then prepared with antiseptic solution and draped (Fig. 4).

Intravenous sedation is administered (we prefer Propofol) until the patient is unresponsive to stimulation. A nasopharyngeal airway may be inserted. A poke incision is made 2.5 cm lateral and 1 cm inferior to the ipsilateral oral commissure. With a gloved finger in the mouth the Tew needle with stylet is introduced and guided to a point of intersection on the anterior skull base approximately 3 cm anterior to the external auditory meatus and the medial pupil using Hartel's technique. Fluoroscopy is helpful in guiding the needle tip toward the foramen. Entry into the foramen, usually at a depth of 6–8 cm is signaled by a jaw jerk and often the flow of CSF. The C arm unit is then positioned laterally to check the depth of the needle aiming toward the junction of the clivus and petrous temporal bone at a point 5 mm below the floor of the sella. To reach the more medial ophthalmic fibers a more lateral entry to the foramen may be better. Electrode position is guided by the X-ray, the division to be treated and the results of test stimulation. Using fluoroscopy initially the needle is placed proximal to the clival line for V3 pain, at the clival line for V2 and beyond the clival line for V1. The curved tip is useful for picking up the ophthalmic branches medially. Once this initial



**Fig. 4.** Patient positioning for radiofrequency gangliolysis

radiographic position is obtained the patient is woken for test stimulation (Fig. 5). A square waved current of 50 Hz at 1 msec and 0.1 V is used to evoke parathesiae. The patient is asked where the stimulation is felt. Once stimulation satisfactorily localizes the affected branch, the patient is resedated and



**Fig. 5.** Fluoroscopic image of needle in foramen ovale (submental) and lateral

radiofrequency lesions are made. For a first-time patient without evidence of nerve injury a solitary lesion at 70 °C for 90 sec may suffice, whereas two or even three lesions may be necessary. Facial flushing will usually be observed in the distribution being treated. Following lesioning the patient can be woken again and sensory testing performed to confirm the presence of hypesthesia to pin in the affected distribution and the loss of triggerability of pain. If further lesioning is necessary this can be further performed and testing repeated. Once completed, the cannula is removed and a band aid applied to the poke incision. The patient is discharged later from the recovery room following sensation retesting and seen in clinic follow-up at 2 weeks.

Pain relief is immediate in 99% of patients and 35% of patients have been reported pain free at 5 years [4]. The median length of pain relief is 3–4 years but is dependent upon the extent of the lesion performed and the degree of prior nerve injury.

Serious complications may rarely occur from incorrect initial positioning of the cannula including injury to the carotid artery, superior orbital fissure contents, jugular foramen, cavernous sinus and abducens nerve. Although the aim is to produce sensory hypesthesia in the affected trigeminal division, patients may report complications related to sensory disturbance including intolerable numbness, difficulty chewing, loss of taste, drooling, dysesthesias characterized by sensations of intermittent crawling, burning or itching and most rarely anesthesia dolorosa. Masseter weakness and reduced hearing have also been reported.

### 3. GLYCEROL RHIZOTOMY

A 20 G spinal cannula with stylet, 99.9% anhydrous glycerol, radio-opaque contrast and C arm fluoroscopy unit are used.

Preparation of the patient and positioning was described above.

As described above, the foramen ovale is cannulated with a 20 G spinal needle and needle position is confirmed on X-ray as above. CSF flow from the needle is desirable in confirming needle position in Meckel's cave. However, CSF flow is also encountered if the needle is subtemporal and no CSF may flow in patients who are undergoing revision surgery or have a narrow foramen. The patient is positioned sitting upright and radio-opaque contrast (iohexol) is then injected under live fluoroscopy to visualize the trigeminal cistern and rootlets and estimate volume. Anhydrous glycerol is then injected (average dose of 0.25 ml). The patient is kept in a semi-sitting position for 2 hours to prevent escape of glycerol into the posterior fossa.

Immediate or early pain relief has been reported in 80–90% of patients and may take up to 2 weeks. Long-term pain relief has been variably reported to range from 17–99% depending upon the definition of failure [8, 3].

Complications are similar to those from radiofrequency lesioning, although sensory complications have been reported to be less.

#### 4. PERCUTANEOUS BALLOON COMPRESSION

A No. 4 Fogarty balloon catheter with cannula and obturator, radio-opaque contrast and C arm fluoroscopy unit are used.

The patient is given a general anesthetic and intubated in the supine position.

As described above, the foramen ovale is cannulated and the balloon catheter is inserted with radiological confirmation. The balloon is then inflated to the desired pressure and shape and dye is injected to confirm position. Bradycardia and hypertension often occur and inflation is maintained for 1 minute before removal of the balloon.

Initial pain relief (93%) and recurrence (26%) at 3 years has been reported [2].

Complications are similar to other percutaneous procedures.

#### 5. GAMMA-KNIFE RADIOSURGERY

Leksell Gamma Knife (Elekta Instruments, Atlanta, GA, USA), Leksell model G stereotactic frame and MR imaging capabilities are used.

The patient is given short-acting intravenous sedation (midazolam) and atropine and positioned sitting in the bed.

The Leksell (model G) stereotactic frame is applied using local anesthesia. The patient then undergoes stereotactic MR imaging (1.5 T) with contrast enhancement. T1, T2 and T2 inversion recovery sequences to visualize the trigeminal root from the brainstem to Meckel's cave are acquired and are transferred to the workstation for reconstruction and planning in the axial, sagittal and coronal planes. A 4 mm isocenter is placed in the distal cisternal trigeminal root, 2–4 mm anterior to the junction of the trigeminal root and pons and 60 to 90 Gy prescribed using GammaPlan software.

Depending upon the dose given (60–90 Gy), 50–75% of patients remain pain free at 3 years; however, long-term follow-up data remains to be determined [17, 23, 22].

Some degree of facial sensory loss has been reported in up to 10–40% of treated patients depending on the dose. The most serious complications, although rare, have arisen from targeting errors as a result of inadequate identification of the trigeminal root.

### HOW TO AVOID COMPLICATIONS

#### 1. MICROVASCULAR DECOMPRESSION

1. *Hearing loss and cerebellar injury.* These appear to be related to the extent of lateral to medial retraction of the cerebellar hemisphere and consequent traction on the seven eight complex. Adequate ex-



- posure of the transverse sigmoid junction, the judicious release of CSF with time, dissection focused toward the petrotentorial junction and adequate arachnoid dissection should minimize cerebellar retraction.
2. *Vascular complications.* These may occur secondary to venous injury causing hemorrhage or occlusion and arterial kinking or stretching causing ischemia. Continuous visualization of all vascular structures during exposure, manipulation, following placement of Teflon and release of the cerebellar retractors is the best means of preventing these complications.
  3. *CSF leak.* An excellent dural closure performed with interrupted neuralon suture is the most critical step. If this cannot primarily be achieved, muscle patch reinforcement with artificial dural substitute (Duragen) and dural sealant (Duraseal) followed by cranioplasty using a titanium mesh and methylmethacrylate (Norian) is effective. Waxing of the mastoid air cells is also important to prevent escape of CSF into the middle ear.

## 2. RADIOFREQUENCY GANGLIOLYSIS

1. *Incorrect needle placement.* Careful attention to patient positioning, fluoroscopic visualization of the foramen ovale before sedation is given, the use of Hartel's landmarks and continuous fluoroscopic guidance will minimize the risk of injury to the carotid or other foraminae. A jaw jerk is helpful clinically to indicate penetration of the foramen and if present CSF flow. The lateral X-ray ensures safety of the depth of the cannula. Use of a medially curved tip is useful in picking up more medial and superior ophthalmic rootlets.
2. *Dysesthesias and anesthesia dolorosa.* Titration of the amount of thermal injury to the nerve during the procedure to produce analgesia and pin hypesthesia as a safe endpoint minimizes the risks of dysesthesia and anesthesia. We start with 70°C for 90 sec, increasing the temperature as necessary for patients with prior nerve injury.
3. *Glycerol rhizotomy.* As for radiofrequency gangliolysis.
4. *Percutaneous balloon compression.* As for radiofrequency gangliolysis.
5.  *radiosurgery.* Careful anatomical identification of the trigeminal root is critical.

## CONCLUSIONS

We recommend MVD as the first-line therapy for younger patients with TN type 1 pain as this gives the best chance of long-term pain relief and cure. Outcome for patients with mixed pattern or predominantly TN type 2 pain

is less beneficial. If, however, imaging suggests vascular compression, MVD is a reasonable first option. For patients with recurrent pain following MVD, older patients who cannot tolerate MVD, and those patients who request a less invasive procedure we recommend radiofrequency gangliolysis as the ablative procedure of choice, because the affected trigeminal division can be most accurately targeted, sensory loss titrated and the procedure can be repeated. Balloon compression, glycerol injection and radiosurgery are alternative options which have more variable onset of pain relief and higher recurrence rates because of limited ability to localize the affected division and titrate the degree of nerve injury, but may be considered in patients with first division pain with a high risk of sensory loss or out of patient preference.

### Acknowledgments

Andrew C. Zacest has to be acknowledged for his participation in this chapter as a co-author. We thank Shirley McCartney, PhD for professional manuscript preparation and Andy Rekito, MS for figure preparation.

### References

- [1] Barker FG 2nd, Jannetta PJ, Bissonette DJ, Larkins MV, Jho HD (1996) The long-term outcome of microvascular decompression for trigeminal neuralgia. *N Engl J Med* 334: 1077-1083
- [2] Brown JA, McDaniel MD, Weaver MT (1993) Percutaneous trigeminal nerve compression for treatment of trigeminal neuralgia: results in 50 patients. *Neurosurgery* 32: 570-573.
- [3] Burchiel KJ (1988) Percutaneous retrogasserian glycerol rhizolysis in the management of trigeminal neuralgia. *J Neurosurg* 69: 361-366
- [4] Burchiel KJ, Steege TD, Howe JF, Loeser JD (1981) Comparison of percutaneous radiofrequency gangliolysis and microvascular decompression for the surgical management of tic douloureux. *Neurosurgery* 9: 111-119
- [5] Dandy W (1925) Section of the sensory root of the trigeminal nerve at the pons. *Bull Johns Hopkins Hosp* 36: 105-106
- [6] Devor M, Govrin-Lippmann R, Rappaport ZH (2002) Mechanism of trigeminal neuralgia: an ultrastructural analysis of trigeminal root specimens obtained during microvascular decompression surgery. *J Neurosurg* 96: 532-543
- [7] Frazier C (1925) Subtotal resection of sensory root for relief of trigeminal neuralgia. *AMA Arch Neurol Psychiatry* 13: 378-384
- [8] Hakanson S (1981) Trigeminal neuralgia treated by the injection of glycerol into the trigeminal cistern. *Neurosurgery* 9: 638-646

- [9] Harris W (1912) Alcohol injection of the gasserian ganglion for trigeminal neuralgia. *Lancet* 218-221
- [10] Hartel F (1914) Ueber die intracranielle Injectionsbehandlung der Trigemineuralgie. *Med Klin* 10: 582-584
- [11] Horsley V, Taylor J, Colman W (1891) Remarks on the various surgical procedures devised for the relief or cure of trigeminal neuralgia (tic douloureux). *Br Med J* 2: 1249-1252
- [12] Jannetta PJ (1967) Arterial compression of the trigeminal nerve at the pons in patients with trigeminal neuralgia. *J Neurosurg* 26: Suppl 159-162
- [13] Kanpolat Y, Ugur HC (2005) Systematic review of ablative neurosurgical techniques for the treatment of trigeminal neuralgia. *Neurosurgery* 57: E601
- [14] Kirschner M (1931) Zur Elektrochirurgie. *Arch Klin Chir* 167: 761-768
- [15] Leksell L (1971) Stereotaxic radiosurgery in trigeminal neuralgia. *Acta Chir Scand* 37: 311-314
- [16] Limonadi FM, McCartney S, Burchiel KJ (2006) Design of an artificial neural network for diagnosis of facial pain syndromes. *Stereotact Funct Neurosurg* 84: 212-220
- [17] Maesawa S, Salame C, Flickinger JC, Pirris S, Kondziolka D, Lunsford LD (2001) Clinical outcomes after stereotactic radiosurgery for idiopathic trigeminal neuralgia. *J Neurosurg* 94: 14-20
- [18] Miller J, Acar F, Hamilton B, Burchiel K (2008) Preoperative visualization of neurovascular anatomy in trigeminal neuralgia. *J Neurosurg* 108: 477-482
- [19] Miller J, Acar F, Hamilton B, Burchiel K (2009) Radiographic evaluation of trigeminal neurovascular compression in patients with and without trigeminal neuralgia. *J Neurosurg* (in press)
- [20] Mullan S, Lichtor T (1983) Percutaneous microcompression of the trigeminal ganglion for trigeminal neuralgia. *J Neurosurg* 59: 1007-1012
- [21] Osenbach R (2002) Trigeminal neurectomy. In: Burchiel KJ (ed) *Surgical management of pain*, vol 1. Thieme, New York, pp 828-840
- [22] Petit JH, Herman JM, Nagda S, DiBiase SJ, Chin LS (2003) Radiosurgical treatment of trigeminal neuralgia: evaluating quality of life and treatment outcomes. *Int J Radiat Oncol Biol Phys* 56: 1147-1153
- [23] Pollock BE, Phuong LK, Gorman DA, Foote RL, Stafford SL (2002) Stereotactic radiosurgery for idiopathic trigeminal neuralgia. *J Neurosurg* 97: 347-353
- [24] Sindou M, Leston J, Howeidy T, Decullier E, Chapuis F (2006) Micro-vascular decompression for primary trigeminal neuralgia (typical or atypical). Long-term

- effectiveness on pain; prospective study with survival analysis in a consecutive series of 362 patients. *Acta Neurochir (Wien)* 148: 1235-1245; discussion 1245
- [25] Sindou MP, Chiha M, Mertens P (1994) Anatomical findings observed during microsurgical approaches of the cerebellopontine angle for vascular decompression in trigeminal neuralgia (350 cases). *Stereotact Funct Neurosurg* 63: 203-207
- [26] Sweet WH (1976) Controlled thermocoagulation of trigeminal ganglion and rootlets for differential destruction of pain fibers: facial pain other than trigeminal neuralgia. *Clin Neurosurg* 23: 96-102
- [27] Taha J, Tew J (1996) Comparison of the surgical treatment of trigeminal neuralgia: reevaluation of radiofrequency rhizotomy. *Neurosurgery* 38: 865-871



**Kim J. Burchiel**

Kim J. Burchiel is the John Raaf Professor and Chairman of the Department of Neurological Surgery at Oregon Health & Science University, Portland, Oregon. His interests include functional and stereotactic neurosurgery, pain surgery, and epilepsy surgery. Dr. Burchiel's research interests are concerned with the physiology of nociception and neuropathic pains, including trigeminal neuralgia, the neurosurgical treatment of movement disorders, and image-guided neurosurgery. He is a past director of the American Board of Neurological Surgery, and is a past-president of the Western Neurosurgical Society, the Society of University Neurosurgeons, and the American Board of Pain Medicine. He currently serves on the editorial board of the *Journal of Neurosurgery*, and is Secretary of the Society of Neurological Surgeons.

**Contact:** Kim J. Burchiel, Neurological Surgery, Oregon Health & Science University, 3303 SW Bond Ave., Portland, OR 97239, USA  
E-mail: [burchiek@ohsu.edu](mailto:burchiek@ohsu.edu)

---

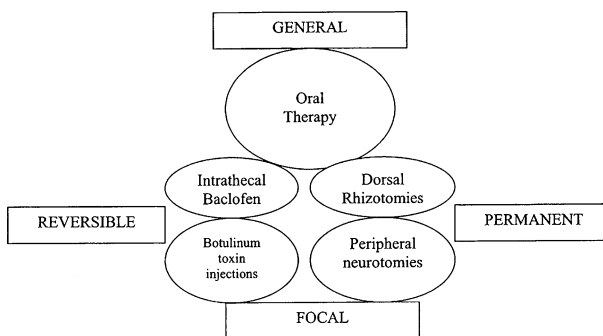
# NEUROSURGERY FOR SPASTICITY

P. MERTENS

## INTRODUCTION

Spasticity corresponds to muscular hypertonia in relation to hyperexcitability of the stretch-reflex. This hyperactivity of spinal reflex is related to the loss of inhibitory influences from descending supraspinal structures. Spasticity is a component of the upper motor neuron syndrome especially in addition to weakness and loss of selective motor control. Spasticity should not be treated just because stiffness is present. Most of the time spasticity is useful to assure safe balance and for compensating loss of motor strength. With these considerations in mind, spasticity should only be treated when excess muscular tone leads to further functional losses, impairs locomotion, or induces deformities, or chronic pain. As for most procedures in functional neurosurgery, surgery for spasticity should be considered as a second line treatment after failure of medical therapies (i.e. physical, pharmacological and Botulinum toxin injections).

The different surgical methods are classified according to whether their impacts are large or focal and whether the effects are temporary or permanent. They include IntraThecal Baclofen therapy (ITB) and hyperselective lesions in the peripheral nerves, dorsal roots, dorsal root entry zone in the spinal cord and the spinal cord itself (Fig. 1).



**Fig. 1.** Methods to manage spasticity based on effects of techniques whether focal or general and whether permanent or temporary

---

*Keywords:* spasticity, movement disorders, functional neurosurgery

## DECISION-MAKING

Because features of disabling spasticity and their consequences differ from one patient to another, the general rule is to tailor an appropriate neurosurgical program to each patient. The first step is to define the objective(s) of the treatment: improvement in function, prevention of deformities, or alleviation of discomfort and pain in very disabled patients. In other words, to define what can be gained and what will not be obtained with neurosurgery. These issues must be explained to the patient, relatives, and care-givers managing the patient. The neurosurgical program must be conceived, discussed and applied within the scope of a multidisciplinary medico-surgical team taking into account the global medico-psycho-social status of the patient.

There is no unique fashion to take care of patients suffering from hyper-spasticity, as their clinical status (mono-, hemi-, para- or quadriplegics) and the mechanisms leading to spasticity (post traumatic, post stroke, neurodegenerative...) are quite different. Our experience with neurosurgical treatment of spasticity over the last 20 years has led us to believe that teams treating spasticity should be acquainted with all the technical modalities actually available in order to be able to devise the best therapeutical strategy for every individual patient [1].

Whatever the procedure may be, it must be performed in a way that excess of tone is reduced without suppressing useful muscular tone or impairing any residual motor/sensory functions. In patients retaining some masked voluntary motility, the goal is to re-equilibrate the articular balance between paretic agonist muscles and spastic antagonist muscles, resulting in the improvement (or reappearance) of voluntary motility. In patients with poor residual or no motor function preoperatively, the aim is to stop the progressive orthopaedic deformities and improve comfort.

It is necessary to provide neurosurgical treatment together with intensive physical therapy for several weeks. To take the maximal benefit out of surgery, patients have to be sent back to the rehabilitation center postoperatively to optimise their new neurological status by a rigorous and intensive program of physical therapy. The result of surgery and its impact on the daily life of patients can be appreciated only after a follow-up of not less than 6 months.

Complementary orthopaedic operations may be required in patients with irreducible contractures, tendon retractions and/or joint deformities when persistent after prior neurosurgical treatment. Indeed, when managing spastic patients, it seems logical to first aim at controlling the origin of the disabilities, i.e. the spasticity itself, and then only secondarily try to correct its neuro-orthopaedic consequences after spasticity has been reduced.

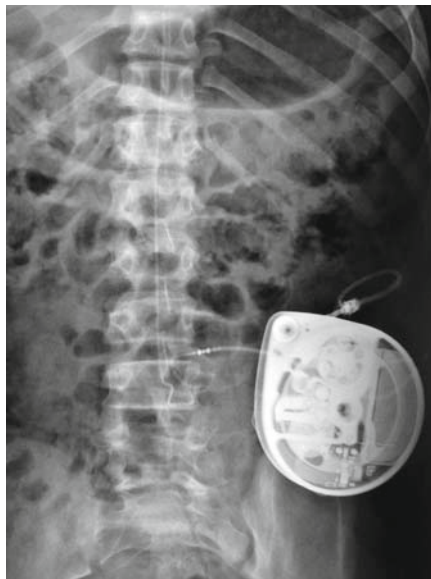
## INTRATHECAL BACLOFEN THERAPY (ITB)

### RATIONALE

ITB was developed and reported by Richard Penn and Jeffrey Kroin in 1985 [10]. The method consists of delivering Baclofen (a GABA-B agonist) in the CSF close to an area of high concentrations of gamma aminobutyric acid-B binding sites: the spinal dorsal horn. This GABAergic molecule is able to decrease the transmission of sensory input pre- and postsynaptically and thus decrease reflex hyperactivity. Pharmacokinetics of baclofen, infused intrathecally, reduces significantly its side-effects as compared to the oral route (namely weakness, drowsiness, nausea, confusion, seizures...). This way of delivering baclofen allows for a dramatic decrease of the dosage from an average of 10–90 mg per day orally to an average of 20–800 µg per day intrathecally.

### SURGERY

ITB is delivered by a metal device implanted subcutaneously (under the abdominal skin), including a reservoir containing the drug that is refilled percutaneously every 3–6 months on average and a programmable pump that



**Fig. 2.** X-ray of a patient showing a programmable pump under the abdominal skin connected to an intrathecal catheter to treat a diffuse spasticity of both lower limbs



provides the desired flow through a catheter directed to the intrathecal space (Fig. 2). The tip of the catheter is generally placed through a lumbar puncture at the level of the conus medullaris (T12–L1 vertebral levels) for paraplegic patients to modulate the muscular tone in both inferior limbs. Only one model of programmable pump is available (Synchromed II® from Medtronic company, US).

A trial of ITB is required before performing the surgical implantation of the pump to check on the efficacy and absence of side-effects of the method. This test allows the surgeon to define whether there is an appropriate dosage of intrathecal baclofen suppressing the excess of spasticity without impairing the useful muscular tone necessary to stand and for ambulatory patients to walk. For the latter patients, the therapeutical interval for an optimal dosage between an excessive and an insufficient antispastic effect is often very narrow. These tests can be performed via bolus injections of baclofen through lumbar punctures when just an “on-off” effect is checked. In the absence of a positive response, indicated by a two-point reduction in Ashworth score 4 to 8 hours following drug administration, the bolus dose is increased by 25 µg increments up to a maximum bolus of 100–150 µg. Once a positive response is observed without unacceptable loss of function, the patient is considered to be a candidate for pump implantation. The “bolus-method” is entailed by “false-negative responses” in the sense that the bolus can produce a brutal or exaggerated loss of motor power and muscle tone, which might be interpreted by the patient as a decrease in functional status. Since this could lead to an absence of indication of pump implantation, especially in patients with abilities to walk, the bolus-test should be replaced by a continuous infusion test, using an external automatic injection pump connected to a temporary intrathecal catheter. The test should last from a few days to an entire week so that functional capabilities can be reliably evaluated.

The initial post-implantation infusion dose depends, in part, on the effective screening dose. Typically, the initial starting dose is double the effective screening bolus dose. The dose is then increased daily by 10–30% until the desired effect is achieved. The most useful criteria for dose adjustment are the effective suppression of the reflexes, i.e. tendon jerk, clonus, spasms, cramps, and the decrease of muscle tone. Once the effective dose has been ascertained and stabilized, the administration of the drug can be fine-tuned. A programmable pump allowing cyclical dose adjustments makes it possible to provide levels that correlate with the daily variability of spastic symptoms.

## **INDICATIONS – RESULTS**

Best indication for ITB is spasticity in relation to spinal lesion, mainly spasticity due to vertebral trauma or advanced multiple sclerosis. A multicenter study has been carried out to determine doses at 12 months, safety and efficacy of ITB in spasticity from spinal origin (205 patients studied). Doses were

between 167 and 462  $\mu\text{g}/\text{day}$  [average: 298  $\mu\text{g}$ ]. Ashworth score decreased from 3–4 to 0.5–1.8 according to the series [5].

ITB can also be proposed for hyperspastic states due to brain stem or brain lesion and also for severely affected cerebral palsy patients [2]. ITB, even through simple lumbar punctures, has been proposed to minimize severe paroxysmal sympathetic activity that could happen during the early stage of post traumatic cerebral coma. Due to the size of available pumps, ITB cannot be performed in children weighting less than 25 kg. Patients with associated choreo-athetosis, hypotonia of neck and trunk, obesity, poor motivation and/or severe multiple deformities, are poor candidates for ITB.

## HOW TO AVOID COMPLICATIONS

A serious risk of ITB is overdose, which might be irreversible because of the lack of true baclofen antagonists. ITB withdrawal syndrome is a very rare but potentially life-threatening complication caused by an acute cessation of intrathecal baclofen [5]. Therefore this technique requires great care, regular check-up of the pump, education of patients and their care-givers with regard to these syndromes. Other complications include mechanical catheter migration or occlusion and infection requiring revision or removal of the system, respectively. Advantage of the technique is the reversibility of its effects and its capacity of being modulated; but high costs, the necessity of periodically refilling and reprogramming the pump, and also the geographic dependence of the patient on the specialized ITB center, have to be taken into account when this conservative method is considered.

## SELECTIVE PERIPHERAL NEUROTOMIES (SPN)

### RATIONALE

Peripheral Neurotomies were introduced for the treatment of localized spastic deformities in the foot by Stoffel. More recently Gros and associates, Sindou and the present author [8, 12] have made PN more selective by using microsurgery for fine dissection of fascicles and by mapping with intraoperative electrical stimulation to better identify the function of the individual nerve fascicles.

Selective PN consists in partial sectioning of one or several motor branches of the nerve(s) innervating targeted muscle(s) in which spasticity is considered to be excessive. It interrupts segmental reflex arc by acting on both afferent and efferent pathways. Neurotomy eliminates the afferent pathway corresponding to the myotatic arc of the concerned muscle and partially reduces muscle strength by section of the efferent pathway. Neurotomy must never involve the

fascicles of a nerve trunk composed of mixed motor and sensory nerve fibers, as even partial sectioning of the latter could be responsible for deafferentation pain. There is no scientific basis for defining the extent of the section. However, all surgeons agree that partial neurotomy to be effective must include sectioning of 50–80% (usually 75%) of all branches to a targeted muscle.

## **SURGERY**

### **1. TECHNICAL PRINCIPLES**

#### **1.1 Pre-operative. Motor blocks**

Before considering SPN, a test using motor blocks innervating the targeted muscle(s) is of prime importance. These blocks, using local anaesthetics such as long-lasting bupivacaine, enable the surgeon to evaluate the motor strength of antagonist muscles and determine if limitations in articular motion result from spasticity or from musculotendinous contractures/articular ankyloses.

Botulinum toxin injections can be used as a “prolonged” test for several weeks or months before pursuing neurosurgical treatment, as their effects mimic the outcome of selective neurotomies on the injected muscles.

This strategy of using pre-operative injection tests allows the patient to appreciate the benefit that can follow a selective neurotomy. Objectives of surgery may be cosmetic (for instance to allow the patient to put his or her hand in a pocket), related to nursing (for instance to allow a caregiver to wash the palm of the patient’s hand), or functional (to improve walking performance by reducing an equinus foot).

#### **1.2 Anesthesia**

Neurotomy is generally performed under general anaesthesia. Patient positioning is not always easy because of contractures and limited passive mobility. It may be useful to test the efficacy of the neurotomy procedure intraoperatively by examining the stretch reflex which implies that reflex pathways are not depressed by the anaesthetic drugs. Changes in reflexes can be evaluated by intraoperative recording of the H reflex to guide surgery. Therefore, muscle relaxant drugs must be avoided as much as possible, and nitrogen monoxide and propofol are contraindicated because they modify reflex excitability. Also, general anaesthesia has to be performed without long-lasting curarization so that the motor responses elicited by bipolar electrical stimulation of motor branches can be detected to identify the nerve.

#### **1.3 Mapping**

Mapping signifies the anatomical identification of motor branches. Frequent variation in the emergence of nerve branches and limited surgical access can

nevertheless make this a difficult step. It requires the use of the operating microscope. Nerve identification is based on the descriptive anatomy but needs to be checked by study of the muscular responses to electrical stimulation. Parameters of stimulation are: 2 Hz frequency, low intensity – usually at 1 mA – to avoid electrical diffusion and incorrect interpretation. Bipolar (or even a triple stimulation hook that limits current diffusion, composed of an anode between two cathodes), is used to grasp the nerve branch to be stimulated. Finally, the muscular responses to stimulation are appreciated clinically by the surgeon himself or by EMG recordings.

#### 1.4 Sectioning

Once all motor branches have been identified by electrical stimulation, those considered responsible for harmful spasticity are marked separately with coloured tapes. According to the preoperative evaluation and subsequent program, variable proportions (50–80% depending on the degree of preoperative spasticity) of the isolated motor branches (or fascicles) are resected under the operating microscope near the muscle to ensure that only the muscular branches (or fascicles) are cut. The resection is 5 mm long from the proximal stump, which is coagulated with fine bipolar forceps to prevent regrowth of fibres. When there are several nerve branches for one muscle, one or more branches can easily be sectioned completely until the global amount needed for the muscle in question is attained.

The effect of each nerve resection on spasticity is then evaluated by comparing muscle responses to electrical stimulation, first proximally then distally to the resected portion of the nerve. If the response after proximal stimulation is still intense, further resection can be performed. Aim is to decrease muscle innervation enough to avoid further recurrence of spasticity by “take-over” (reinnervation or “adoption” of muscular fibres denervated as a result of neurotomy, by the surrounding motor fibres).

#### 1.5 Postoperative care

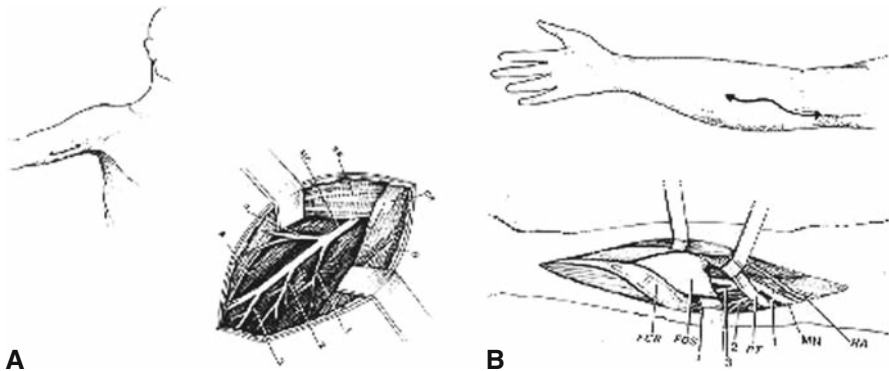
Immobilisation and casts are not systematic after SPN. Patients are encouraged to mobilize the operated limb as soon as possible. As early as cicatrization is obtained, a tailored program of rehabilitation begins for several months to stretch progressively previously spastic muscles and in the best of cases to take profit of new functional capacities.

## 2. SURGICAL TECHNIQUE

### 2.1 For the upper limb (Fig. 3) [4, 7]

*Pectoralis major muscle neurotomy for spastic shoulder in adduction [4]*

Neurotomy of collateral branches of the brachial plexus innervating the pectoralis major is indicated for spasticity of the shoulder with internal rotation



**Fig. 3.** Selective peripheral neurotomies for upper limb. **A** Skin incision line for right *musculocutaneous neurotomy*, along the medial aspect of the biceps brachii, under the inferior edge of the pectoralis major muscle. Dissection of the right musculocutaneous nerve (MC) in the space between the biceps brachii (BB) laterally, the coraco brachialis (CB) medially, and the brachialis (B) posteriorly. Branches to brachialis [1, 2] and to biceps brachii [3, 4] are recognized by stimulation giving elbow flexion. Humeral artery (H) with median nerve are situated medially and are not dissected. **B** Skin incision line on the right forearm for *median neurotomy* from the medial aspect of the biceps brachii at the level of the elbow longitudinally along the bicipital crest. Dissection of the median nerve, the pronators teres (PT) is retracted upward and laterally, the flexor carpi radialis (FCR) medially. Branches from the median nerve (MN), before it passes under the fibrous arch of the flexor digitorum superficialis (FDS), are dissected: to the pronators teres [1], and the nerve trunks to the flexor carpi radialis, palmaris longus and flexor digitorum superficialis [2, 3]. The fibrous arch of the FDS can be sectioned to allow a more distal dissection of the median nerve and its branches to flexor pollicis longus, flexor digitorum profundus and interosseous nerve and its proper branches that can be targeted for neurotomies in case of spastic flexion of fingers

and adduction. The skin incision is made at the innermost part of the deltopectoral sulcus and curves along the clavicular axis. First, the claviopectoral fascia is opened. Then the upper border of the pectoralis major muscle is reflected downward. Close to the thoraco-acromial artery, the ansa of the pectoralis muscle is identified with the aid of a nerve stimulator.

#### *Teres major muscle neurotomy for spastic shoulder [4]*

Neurotomy of collateral branches of the brachial plexus innervating the teres major is also indicated for spasticity of the shoulder with internal rotation and adduction. The skin incision follows the inner border of teres major, from the lower border of the deltoid muscle's posterior head to the lower extremity of the scapula. The lower border of the long portion of brachii triceps constitutes the upper limit of the approach. The dissection continues deeply between teres minor and major muscles. In the vicinity of the subscapularis artery, the nerve ending on teres major is identified. The nerve is surrounded by thick fat when approaching the anterior facet of the muscle body.

*Musculo-cutaneous neurotomy for spastic elbow in flexion [7]*

Neurotomy of the musculo-cutaneous nerve is indicated for spasticity of the elbow with flexion, depending on the biceps brachii and the brachialis muscles. The skin incision is performed longitudinally. It extends from the inferior edge of pectoralis major, medial to the biceps brachii, down to 5 cm. The superficial fascia is opened between the biceps laterally and the brachialis medially. The brachial artery and median nerve exit medially. The dissection proceeds in this space, where the musculocutaneous nerve lies anterior to the brachialis muscle. Opening of the epineurium allows the fascicles of the nerve to be dissected under high magnification of the operating microscope. The motor fascicles are distinguished from the sensitive ones by using the nerve stimulator.

*Median neurotomy for spastic wrist and fingers [7]*

Neurotomy of the median nerve is indicated for spasticity of the forearm with pronation depending on the pronator teres and quadratus muscle and spasticity of the wrist with flexion depending on the flexor carpi radialis and palmaris longus muscles. For the hand, median neurotomy is indicated for spasticity of the fingers with flexion depending on the flexor digitorum superficialis (flexion of proximal interphalangeal joint and metacarpophalangeal joint) and on the flexor digitorum profundus muscle (flexion of distal interphalangeal, proximal interphalangeal, and metacarpophalangeal joint), partly innervated by the median nerve. Swan neck deformation of the fingers depending on the lumbrical and interosseous muscles can be limited by neurotomy; these muscles being innervated by the median and ulnar nerves. Concerning the thumb, neurotomy of the median nerve is indicated for spasticity with flexion and adduction/flexion (thumb-in-palm deformity) depending on the flexor pollicis longus. The skin incision begins 2–3 cm above the flexion line of the elbow, medial to the biceps brachii tendon, passes through the elbow, and curves toward the junction of the upper and middle thirds of the anterior forearm. Thereafter, the median nerve is searched medially to the brachial artery and recognized at the elbow, deeply under the lacertus fibrosus, which is cut. Sharp dissection is used to separate all the muscular branches of the median nerve. The belly of pronator teres with its two heads is retracted medially and distally so that its muscular branches can be inspected. This muscle is retracted up and laterally while the flexor carpi radialis is pulled down and medially. The muscular branches to the flexor carpi radialis and to the flexor digitorum superficialis then can be seen. Finally, the latter is retracted medially uncovering the branches to the flexor digitorum profundus, the flexor pollicis longus, and the pronator quadratus. These latter muscular branches may be individualized as separate branches or remain together in the distal trunk of the anterior interosseous nerve. Sometimes, it may be useful to divide the fibrous arch of the flexor digitorum superficialis muscle to make dissection easier. This wide approach with a large dissection along the anterior compartment of the forearm is necessary as there is no alternative allowing a safe control of all the muscular branches of the median nerve. An attempt to dissect the motor fascicles proximally in the trunk of

the median nerve includes the risk of sensory complications, especially of developing a complex regional pain syndrome as motor, sensitive and vegetative fibres are mixed in the fascicles composing the median nerve at this level.

#### *Ulnar neurotomy for wrist and fingers [7]*

Neurotomy of the ulnar nerve is also indicated for spastic wrist in flexion and ulnar deviation, both depending on the flexor carpi ulnaris. In the hand, ulnar neurotomy is indicated for spasticity of the fingers with flexion depending on the flexor digitorum profundus muscle (flexion of distal interphalangeal, proximal interphalangeal, and metacarpophalangeal joint), partly innervated by the ulnar nerve. A separate, arched skin incision is performed to expose the ulnar nerve at the medial part of the elbow. After subcutaneous dissection, the ulnar nerve is identified medially to the medial epicondyle, it then enters distally between the two heads of the flexor carpi ulnaris. There, the motor branches to this latter muscle are identified. More distally, the branches to the medial half of the flexor digitorum profundus are found.

Ulnar neurotomy is also indicated for spasticity with a “thumb in palm” deformity (adducted and flexed thumb). For this indication, it is preferable to control the ulnar nerve at the level of the wrist by a short skin incision just lateral to the insertion of the ulnar carpi flexor muscle on the pisiform bone. After section of the expansion of the flexor retinaculum, the division of the nerve between a superficial sensory branch and a deep motor branch is identified. Under magnification and stimulation, the motor fascicles for the adductor pollicis muscle and the deep part of the flexor pollicis brevis are identified and partially sectioned.

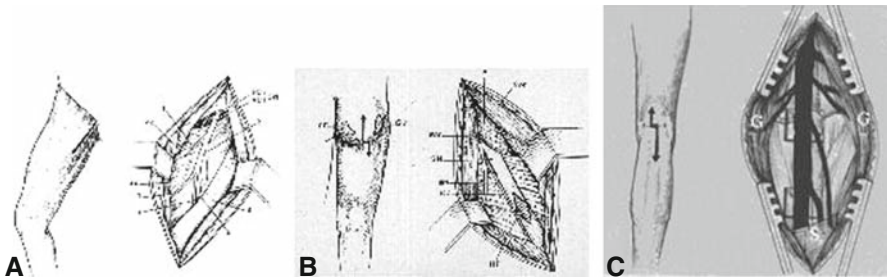
## 2.2 For the lower limb (Fig. 4) [5, 8]

### *Obturator neurotomy for the spastic hip*

Obturator nerve SPN reduces spasticity in adductor muscles. It is often proposed for diplegic children with cerebral palsy when their walking is hampered by scissoring posture of the lower limbs. It can also be proposed to facilitate perineal toilet and self-catheterization. To isolate the anterior branch of the obturator nerve, a transverse skin incision is performed in the hip flexion fold, centered on the prominence of the adductor longus tendon. This incision facilitates adductor longus tenotomy when considered in the same surgical procedure. The dissection is conducted laterally to the adductor longus muscle body just below the subpubic canal. The posterior branch is situated more deeply and should be spared to preserve the muscles useful for the stabilization of the hip.

### *Hamstring muscles neurotomy for the spastic knee in flexion*

Hamstring neurotomy counters flexion deformity of the knees. The transverse incision is performed in the gluteal fold, centered on the groove between the ischium and the trochanter major. After retraction of the fibers of the gluteus maximus, the sciatic nerve is identified in the depth of the incision.



**Fig. 4.** Selective peripheral neurotomies for lower limb. **A** Skin incision for (right) *obturator neurotomy*, on relief of adductor longus muscle [1] or in the hip flexion fold centered on the prominence of the adductor longus tendon [2] which gives a cosmetic advantage. Dissection of the anterior branch (AB) of the right obturator nerve (ON). The adductor longus (AL) is retracted laterally and the gracilis (G) medially. The nerve is anterior to the adductor brevis (AB). Adductor brevis nerve [1, 2], adductor longus nerve [3], gracilis nerve [4, 5]. The posterior branch (PB) of the obturator nerve lies under the adductor brevis (AB) and should be spared. **B** Skin incision for *hamstring neurotomies* (on the right side) is located on the midline between the ischial tuberosity (IT) and the greater trochanter (GT) [1]. A transverse incision can also be performed in the gluteal fold [2] centered on the groove between the ischial tuberosity and the greater trochanter, for better aesthetic results. Dissection of the right sciatic nerve (SN), under the piriformis muscle (P), after passing through the fibers of the gluteus maximus muscle (GM). The epineurium of the nerve is opened and fascicles for hamstring muscles (HF) are localized in the medial part of the nerve trunk. Inferior gluteal nerve (IGN), inferior gluteal artery (IGA). **C** Skin incision for *tibial nerve*, neurotomy in the right popliteal fossa. Dissection of the tibial nerve, dorsal view of the right popliteal region

- The sensory sural nerve lies superficially just beneath the subcutaneous aponeurosis between the two gastrocnemius muscles
- The medial and lateral gastrocnemius nerves may arise either separately from both sides of the tibial trunk or posteriorly from a common origin, sometimes including the sensory sural nerve. Each gastrocnemius nerve usually divides into two distal branches when approaching the muscle.
- The one or two soleus nerves may arise from a common origin or quite separately from the tibial nerve.
- The posterior tibialis nerve, like the soleus nerve, originates from the ventro-lateral aspect of the tibial nerve, but more distally at the level of the soleus arch. Sometimes it may originate from a common trunk with the inferior branch of the soleus nerve.
- The distal trunk of the tibial nerve contains 12–15 groups of fascicles averaging 1 mm in diameter each; two thirds of them are motor fascicles, one third are sensory ones

The branches to the hamstring muscles are isolated at the lateral border of the nerve and identified by the responses of the semitendinosus and semimembranosus muscles.

#### *Tibial neurotomy for the spastic foot [12]*

Tibial neurotomy is indicated for the treatment of equino-varus spastic foot with or without claw toes. All motor branches of the tibial nerve at the popliteal fossa (i.e. the nerves to gastrocnemius and soleus, tibialis posterioris, popliteus, flexor hallucis longus, and flexor digitorum longus) are identified and isolated. The skin incision can be vertical on either side of the popliteal fossa. Over recent years, a transverse incision in the popliteal fossa, which gives a



much better long-term aesthetic result, has been adopted. The first nerve to be identified is the sensory medial cutaneous nerve of the leg. Situated immediately anterior to the saphenous vein, it must be spared. More deeply, the tibial nerve trunk from which the nerves to the lateral and medial gastrocnemius come into view is easily identified. The superior soleus nerve is situated in the midline, just posterior to the tibial nerve (often via a common branch with the lateral gastrocnemius). The effect of a soleus neurotomy is assessed by the immediate intraoperative disappearance of ankle clonus. By retracting the tibial nerve trunk medially, the other branches can be identified by electrical stimulation as they emerge from the lateral edge of the tibial nerve trunk. The most lateral branch is often the popliteal nerve, followed by the tibialis posterior nerve, and finally by the inferior soleus nerve. To avoid a large dissection of the posterior compartment of the leg to control all the branches for flexor muscles of the toes, it is possible to open the tibial nerve trunk in the distal part of the popliteal fossa. After dissection of the epineurium, the motor fascicles for flexor digitorum and hallux longus muscles can be identified by tripolar stimulation in the anterior and lateral compartments of the nerve trunk. Care has to be taken to avoid any sensory fascicle lesion and to reserve sectioning to fascicles with clear muscular responses at the lowest intensity of stimulation. Some fascicles, often larger, can give a toe flexion response via intrinsic toe flexors. However, neurotomy of these fascicles is not recommended if they cannot be clearly individualized at this level as they may be mixed with sensory fibers.

#### *Anterior tibial neurotomy for extensor hallucis*

This neurotomy (rarely performed) is indicated to treat permanent extension of the hallux (permanent Babinski reflex) making it difficult to wear shoes, and after botulinum toxin injections have failed. In practice, this neurotomy may be indicated after unjustified section of the flexor hallucis tendon, responsible for a disequilibrium that favours the extensor. A vertical incision is centered on the junction between the tibialis anterior and the extensor hallucis, at the middle third of the anterior side of the leg. The tibial nerve is situated deeply between these two muscle heads and the neurotomy is performed on the motor branch to the extensor hallucis.

#### *Femoral neurotomy for spastic quadriceps*

Femoral neurotomy is indicated to treat excessive spasticity of the quadriceps muscle. This muscle is very often spastic and can interfere with gait by limiting knee flexion during the swing phase. Given its “strategic” importance in maintaining upright posture, a motor block is an essential part of preoperative evaluation. The neurotomy mainly concerns the motor branch to the rectus femoris and vastus intermedius muscles. The incision is horizontal in the hip flexion fold. The dissection passes medial to the sartorius muscle body and exposes the branches of the femoral nerve. First the nerve to the rectus femoris and then, more deeply, the nerve to the vastus intermedius are identified by electrical stimulations taking care to save the large number of sensory branches of this nerve.

## HOW TO AVOID COMPLICATIONS

Local complications include postoperative hematoma and infection. They are rather rare if preventive measures are respected. Sensory disturbances, such as paresthesias and dysesthesias, followed by transient neuropathic pain, could be observed if sectioning accidentally included sensory fascicles. No need to stress the importance of a rigorous identification of motor fascicles by precise stimulation. Patients rarely complain of decreased muscle strength after selective neurotomy. Muscle function is redundant, and no single muscle ensures the movement of a body segment without the possibility of substitution by another muscle.

Specifically in surgery of the upper limb, complications include (rare) transient hypesthesia of the anterior part of the forearm because of the surgical approach with lesion of subcutaneous sensitive branches rather than of neurotomies themselves (concerning only muscular nerves). Paresis of flexors of the elbow, wrist, fingers, or both (because of excessive nerve sectioning) is rare, generally transient, and responds to physical therapy.

Recurrence of spasticity can be observed when the mean amount of sectioning is insufficient; in this case reintervention can be performed after new motor block testing.

## SURGERY ON DORSAL SPINAL ROOTS

### RATIONALE

In 1898, using the animal model of mesencephalic trans-sectioning, Sherrington described that decerebration rigidity could be abolished by sectioning dorsal roots. From these experimental data, Foerster in 1908 performed the first dorsal rhizotomies from L1 to S2 (not L4, root of quadriceps) for the treatment of lower limb spasticity in cerebral palsy. The results of his series of 159 patients were published in 1913. To reduce the sensory harmful effects of Foerster's original technique, Gros and collaborators [6] introduced a slight modification which consisted of preserving one rootlet out of five (on average) for each root, from L1 to S1. The number of preserved rootlets was sufficient to maintain normal sensations in the patients' lower limbs in 70% of cases. In addition to the effects in the lower limbs, the authors have observed indirect effects such as a decrease in the spasticity of the upper limbs and an improvement in speech and swallowing. To further reduce the incidence of secondary effects on the postural tone of patients that were capable of walking, Gros and pupils introduced the topographical selection of rootlets to preserve the innervation of muscles responsible for the useful tone (especially quadriceps, abdominal and gluteal muscles). This technique called "sectorial

posterior rhizotomy” is based on the mapping of the dorsal roots by electrical stimulation.

In 1977, Fraioli and Guidetti developed a slight variation of dorsal rhizotomy: the “partial dorsal rhizotomy”, which consisted of sectioning the dorsal part of each rootlet of roots a few millimeters before their entry into the dorsolateral sulcus.

In 1976, Fasano and collaborators introduced the “functional dorsal rhizotomy”. This technique was based on the intra-operative bipolar stimulation of dorsal rootlets in association with observations of clinical responses and electromyographic monitoring of the muscles of the lower limbs. The authors believe that responses characterized by an exaggeration in duration or extent of motor responses are dependent on the roots involved in the abnormal circuits that cause spasticity. These roots have to be surgically sectioned.

In contrast, in cases with lower limb spasticity, very few dorsal rhizotomies have been attempted at the cervical level for upper limb hypertonia.

In 1945, Munro suggested sectioning of ventral roots from the last thoracic roots to the first sacral root to treat irreducible spasticities with severe spasms. This type of procedure was recommended in cases of spasticity associated with spontaneous hyperactivity of motor neurones, as observed following anoxia. In such cases, clinical and experimental data show that attempts to section dorsal roots are ineffective, whereas ventral root sectioning abolishes spasms. More recently, Albright and Tyler-Kabara [3] proposed an association of ventral and dorsal rhizotomies to treat children suffering from spasticity associated with secondary dystonia who have axial hypotonia and are not candidate for ITB.

In parallel with open surgical techniques, intrathecal chemical rhizotomies, originally introduced for the treatment of pain associated with cancerous lesions, were also used for the treatment of severe spasticity. The frequent appearance of undesirable effects on motoricity and sphincter functions, and the fact that results did not always persist at long-term follow-up led to abandoning this technique. Percutaneous thermorhizotomy was also applied to treat focal spasticity, especially in cases with neurogenic detrusor hyperreflexia of the bladder that are treated by sacral rhizotomy through the sacral foramina. Percutaneous thermocoagulation was also described on lumbar roots, in particular L2–L3 for the treatment of flexion-adduction of the spastic hip [14].

## **SURGERY**

Dorsal rhizotomies are most frequently used for children with cerebral palsy. The techniques will therefore be developed in a corresponding chapter by R. Abbott.

Surgical approaches for dorsal rhizotomies may significantly differ from one team to another. The most classical technique – described by Peacock and

Arens and Abbott et al. [1] is as follows. The L1 through S1 laminae are removed using a power saw, which allows replacement of the lamina at the end of the procedure. Bipolar stimulation of the sensory roots (or rootlets), usually of L2 through S1 bilaterally, is carried out using a multichannel EMG recorder to allow electrical monitoring outside the myotome of the root being stimulated. In addition, it is important to palpate the leg muscles for evidence of contraction. Roots which – when stimulated – cause either muscle activity outside of its myotome or activity lasting after cessation of the stimulus current are deemed abnormal, and they are separated into their rootlets. The rootlets are in turn stimulated and the same criteria are used to judge their normality. Abnormally responsive rootlets are best candidates to be cut.

To further reduce the invasiveness of the approach, Sindou in 2001 designed the “staged interlaminar (IL) approach” [5, 11]. The level(s) depends on the roots to be targeted according to the preoperative chart (=i.e. the program elaborated with the rehabilitation team). The lumbo-sacral spine is approached posteriorly on the midline, so that the preselected interlamina spaces can be reached. For L2 dorsal root, the interlaminar approach should be L1–L2, for L3: L2–L3, for L4: L3–L4 for L5: L4–L5, for S1 and/or S2: L5–S1. After resecting the flavum ligament, the interlaminar space has to be enlarged by resecting (in the order of) the lower half of the susjacent and the upper half of the subjacent laminae. Then the dural sheath is opened on the midline over two centimeters. L2 and L3 roots can be reached through L1–L2 opening, L4 and L5 roots through L3–L4 IL opening, S1–S2 roots through L5–S1 IL opening. Generally, the dorsal rootlets (five on average) are easily identified, as they are grouped posteriorly to the ventral root, separated from the latter by an arachnoid fold. Evoked motor responses to stimulation (with a bipolar electrical stimulator) are tested for ventral and then dorsal root (rootlets). Threshold for obtaining motor responses by stimulating dorsal root (rootlets) is at least three times the one of the corresponding ventral root (rootlets). After identification of the dorsal rootlets, the appropriate number of them is divided, between one-third and two-thirds of the overall dorsal rootlets, according to the preoperative chart. Then, the dural incision is sutured in a tight fashion and the dural suture line covered with fat tissue harvested from the subcutaneous layer. Whatever the modality of dorsal rhizotomy may be, surgery is tailored according to the preoperative status [11].

## INDICATIONS – RESULTS

The results of posterior rhizotomies in children with cerebral palsy have recently been reported in several publications. In brief, these publications show that about 75% of the patients had nearly normal muscle tone at one year or more after surgery and which no longer limited the residual voluntary movements of the limbs. After physical therapy and rehabilitation programs, most children demonstrated improved stability in sitting and/or increased efficien-

cy in walking. However, installed deformities were not retrocessive and might require complementary orthopaedic surgery.

## **HOW TO AVOID COMPLICATIONS**

Special care must be taken to avoid instability of spine by excessive laminectomy.

Bilateral partial section of S3 rootlets induce micturation disturbances. To avoid such undesirable lesions of S3, some authors advocate for the use of intraoperative cystometry (i.e., monitoring of bladder pressure that is increased by S3 root stimulation) via a transurethral catheter.

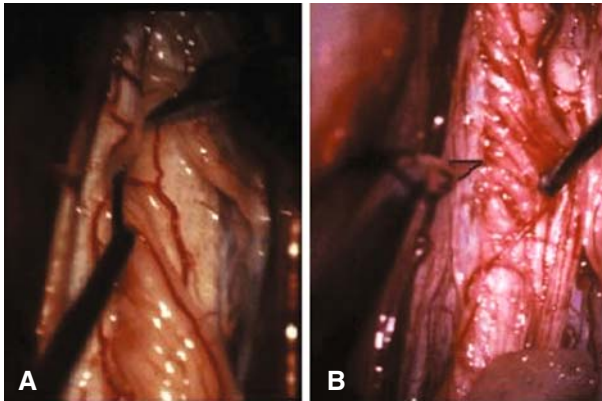
## **SURGERY IN THE SPINAL DORSAL ROOT ENTRY ZONE (DREZ)**

### **RATIONALE**

Surgery in the Dorsal Root Entry Zone (DREZ) of the spinal cord was introduced in 1972 by M. Sindou for the treatment of chronic pain. This technique also induced important hypotonia and was therefore used by the author in cases of severe focalized spasticity [13], not only for lower limb but also for upper limb hyperspasticity [11]. The purpose of the microsurgical DREZotomy technique is to preferentially interrupt both small (nociceptive) and large (myotatic) caliber, tonigenic fibers of the dorsal roots, either situated laterally and in the middle of the entry zone. This surgical lesion is partially, if not totally, able to spare the medial large caliber fibres that project into the dorsal column of the cord.

### **SURGERY (Fig. 5)**

The microsurgical technique is presented in more details in a separate chapter of this book devoted to neurosurgery for neuropathic pain. In brief, for patients with spastic paraplegia, the L2–S1 spinal metameric levels are approached through a T11–L2 laminectomy, whereas for a spastic upper limb, a C4–C7 hemilaminectomy with conservation of the spinous processes is sufficient to reach the C5–T1 segments. Identification of the cord levels related to the undesirable spastic mechanisms is achieved by studying the muscle responses to bipolar electrical stimulation of the anterior and/or posterior roots. The motor threshold for stimulation of anterior roots is one-third that of the threshold for posterior roots. Then, the lateral aspect of the DREZ is exposed so that the microsurgical lesions can be performed



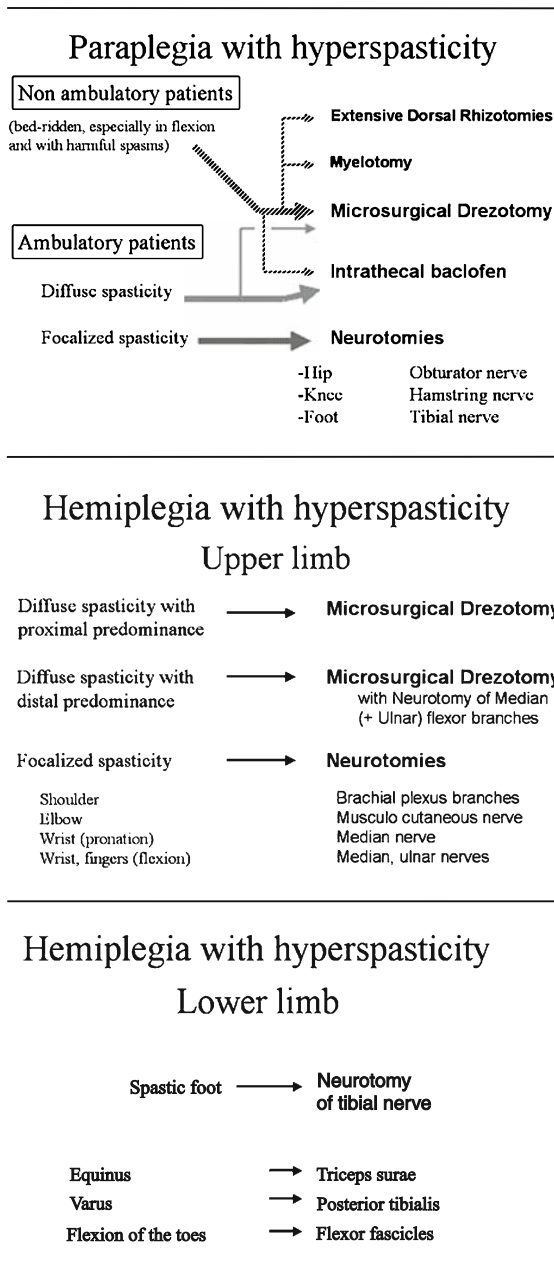
**Fig. 5.** Operative view of DREZotomy. **A** At the cervical level for upper limb spasticity. Incision with a microknife in the dorsolateral sulcus at the level of the right C6 root which is retracted medially. Incision is a 35° angle descending to a depth of 2–3 mm. **B** At the lumbosacral level for lower limb spasticity. Exposure of the dorsolateral aspect of the conus medullaris on the left side. The rootlets of the selected dorsal roots are retracted dorso-medially and held with a (specially designed) ball-tip microsucker, which is used as a small hook to gain access to the ventrolateral part of the DREZ. Incision with a microknife in the dorsolateral sulcus. At each level, the surgical lesion is completed by performing microcoagulations under direct magnified vision (at a low intensity) inside the incision by means of a special sharp bipolar forceps, which is insulated except at the tip over 5 mm and graduated every millimeter

3 mm in depth and angles of 35–45° in the ventro-lateral aspect of the sulcus. Bipolar coagulation is performed ventrolaterally at the entrance of the dorsal rootlets into the dorsolateral sulcus, along all the spinal cord segments selected for surgery and corresponding to the metameric levels of innervation of the targeted disabled spastic muscles. Any coagulation is performed under direct vision for 1–3 seconds at low intensity with the bipolar generator [14].

## INDICATIONS – RESULTS

Microsurgical DREZotomy (MDT) is indicated in paraplegic patients, especially when they are bedridden as a result of disabling flexion spasms and in hemiplegic patients with irreducible and/or painful hyperspasticity in the upper limb. MDT can also be applied at levels S2–S3 to treat neurogenic bladder with uninhibited detrusor contractions resulting in the voiding around a vesical catheter.

In our series [11], a significant decrease in spasticity (at least a 2-point reduction in Ashworth score) allowing the withdrawal of antispasmodic medications was obtained in 78% of patients with spastic upper limb. A similarly useful effect was obtained in 75% of patients with spasticity in the



**Fig. 6.** Guidelines for treating disabling hyperspasticity, paraplegic (top), and hemiplegic (middle and bottom) patients

lower limbs. Improvement in abnormal postures and articular limitations was achieved in about 90% of patients. For the hemiplegic upper limb, the increase in articular amplitude was most remarkable for the elbow and shoulder (when not “frozen”), but much more limited for the wrist and fingers, especially if there was retraction of the flexor muscles and no residual voluntary motor activity in the extensors. For the lower limb(s) with abnormal postures in flexion, the increase in articular amplitude was very much dependent on the degree of preoperative retractions. When the post-MDT gains were deemed insufficient due to persistent joint limitations, complementary orthopaedic surgery was indicated. Bladder capacity was significantly improved in 85% of patients with hyperactive neurogenic bladder with urine leakage around the catheter. Pain, when present, was in general favourably influenced. MDT constantly produced a marked decrease in thermo-algic sensations, so that the patient has to be informed preoperatively.

## HOW TO AVOID COMPLICATIONS

With the microsurgical DREZotomy technique, permanent neurological complications due to long tract impairments were reported in 3.5% of the patients. Ataxia with tactile and arthrokinesthetic hypoesthesia in the ipsilateral lower limb was observed when the DREZ lesion was performed too medially and impaired the dorsal column tract. Motor disturbances in the ipsilateral lower limb happened in case of pyramidal tract lesion if lesions were placed too lateral. 1.3% of patients complained about genito-urinary disturbances, presumably due to excessively deep lesioning into the central cord. CSF leak occurred in 1.5% of the cases.

## SURGERY OF THE SPINAL CORD

In 1951, Bischof described the longitudinal myelotomy technique for the treatment of spasticity. His aim was to interrupt the spinal reflex arc between the ventral and dorsal horns by vertical coronal incision, performed laterally from one side of the spinal cord to the other from L1 to S1 metameric levels for cases with total paraplegia. Pourpre modified Bischof's myelotomy technique to avoid complete interruption of cortico-spinal fibres. Through a T9 to L1 laminectomy, the procedure was performed via posterior longitudinal sagittal incision of the spinal cord prior to performing a cruciform myelotomy by transversal incision on either side using a stylet with right-angled extremity. The purpose of this surgical lesion was to interrupt the spinal reflex arc between the ventral and dorsal horns without sectioning the fibers con-



necting the pyramidal tract to the motoneurons of the ventral horn. Later on, this technique was popularized by Laitinen and Singounas, who created a special surgical knife to perform less damaging myelotomies. Longitudinal myelotomy is indicated (only) for spastic paraplegias with flexion spasms when the patient has no residual useful motor function and no bladder or sexual controls [14].

## CONCLUSIONS

A neurosurgical program for the treatment of disabling spasticity resistant to physical and medical therapy has to be tailored to the individual problems of each patient. Intrathecal Baclofen infusion is indicated for para- or tetraplegic patients with severe and diffuse spasticity in the lower limbs. Owing to its reversibility, this method has to be considered prior to selecting an ablative procedure. Neuro-ablative techniques are indicated for severe focalized spasticity in the limbs of paraplegic, tetraplegic or hemiplegic patients. Neurotomies are indicated when spasticity is localized in a group of muscles innervated by a small number of peripheral nerves. When spasticity affects an entire limb, DREZotomy is preferred. Several types of neuroablative procedures can be combined for the treatment of one patient. Whatever the situation and the aetiology may be, orthopaedic surgery is to be considered only after spasticity has first been reduced by physical and pharmacological treatments and, if necessary, by neurosurgical procedures.

When managing these patients, the neurosurgeon must be aware of the risks connected with each of the available procedures. To minimize these risks, the surgeon needs rigorous methods to assess and quantify the disorders and the ability to work within the scope of a multidisciplinary team.

## References

- [1] Abbott R, Forem SL, Johann M (1989) Selective posterior rhizotomy for the treatment of spasticity. *Child's Nerv Syst* 5: 337-346
- [2] Albricht AL, Cervi A, Singletary J (1991) Intrathecal baclofen for spasticity in cerebral palsy. *JAMA* 265: 1418-1422
- [3] Albright AL, Tyler-Kabara EC (2007) Combined ventral and dorsal rhizotomies for dystonic and spastic extremities. Report of six cases. *J Neurosurg* 107(4 suppl): 324-327
- [4] Decq Ph, Filipetti P, Fevet A, Djindjian M, Saraoui A, Keravel Y (1997) Peripheral selective neurotomy of the brachial plexus collateral branches for the treatment of the spastic shoulder: anatomical study and clinical results on five patients. *J Neurosurg* 86: 648-653

- 
- [5] Decq P, Mertens P (2003) *Neurosurgery for spasticity*. Masson, Paris, 419 pp (in French)
- [6] Gros C (1979) Spasticity – clinical classification and surgical treatment. *Adv Tech Stand Neurosurg* 6: 55-97
- [7] Maarrawi J, Mertens P, Luaute J, Vial C, Chardonnet N, Cosson M, Sindou M (2006) Long-term functional results of selective peripheral neurotomy for the treatment of spastic upper limb: prospective study in 31 patients. *J Neurosurg* 104(2): 215-225
- [8] Mertens P, Sindou M (1991) Selective peripheral neurotomies for the treatment of spasticity. In: Sindou M, Abbott R, Keravel Y (eds) *Neurosurgery for spasticity: a multidisciplinary approach*. Springer, Wien New York, pp 119-132
- [9] Mertens P, Sindou M (2008) Surgical management of spasticity. In: Barnes MP, Johnson GR (eds) *Clinical management of spasticity*. Cambridge University Press, Cambridge, pp 239-265
- [10] Penn RD, Kroin JS (1985) Continuous intrathecal baclofen for severe spasticity. *Lancet* 20: 125-127
- [11] Sindou M (2004) Neurosurgical management of disabling spasticity. In: Spetzler RF (ed) *Operative techniques in neurosurgery*, vol. 7. Elsevier, Philadelphia, pp 95-174
- [12] Sindou M, Mertens P (1988) Selective neurotomy of the tibial nerve for treatment of the spastic foot. *Neurosurgery* 23: 738-744
- [13] Sindou M, Jeanmonod D (1989) Microchirurgical-DREZ-otomy for the treatment of spasticity and pain in the lower limbs. *Neurosurgery* 2: 655-670
- [14] Sindou M, Abbott R, Keravel Y (1991) *Neurosurgery for spasticity: a multidisciplinary approach*. Springer, Wien New York, 320 pp



**Patrick Mertens**

Patrick Mertens is Director of the Pain Center of University Hospital Lyon  
Boarded in Neurosurgery 1989

Associate Professor 1991

PhD in Neurosciences 1999

Professor of Anatomy at the University of Lyon 2002

Chairman of the Department of Anatomy 2005

Fields of interest:

- Functional neurosurgery for chronic pain, movement disorders, spasticity and dysfunction of cranial nerves
- Research works in neuroanatomy and pain system

**Contact:** Patrick Mertens, Department of Neurosurgery, Hôpital Neurologique et Neurochirurgical, Université de Lyon, 59 Boulevard Pinel, 69003 Lyon, France

E-mail: [patrick.mertens@chu-lyon.fr](mailto:patrick.mertens@chu-lyon.fr)

---

# SELECTIVE DORSAL RHIZOTOMY FOR THE TREATMENT OF CHILDHOOD SPASTICITY

R. ABBOTT

## INTRODUCTION

The most common disorder of the nervous system affecting young children is cerebral palsy. Cerebral palsy is a non-progressive disorder of the nervous system affecting muscle tone, posture and movement. It is due to an injury to the nervous system sustained either in utero or at birth. Some would expand the definition to include non-progressive nervous system disorders due to injuries not only during the perinatal period but also during the first several years of life.

Cerebral palsy can affect the legs (diplegia), the arms and legs (quadriplegia), one side of the body symmetrically (hemiplegia) or both sides of the body with one side being affected more than the other (double hemiplegia). Generally, the tone aberration can be spastic in nature, dystonic or mixed (both spasticity and dystonia) (Table 1). As the child with cerebral palsy ages secondary complications such as muscle contracture and joint subluxations can occur complicating the management and care of the child. For that reason a multitude of treatments have been advanced to avoid these complications. One such treatment is the selective dorsal rhizotomy or the cutting of sensory nerve roots coming from the legs of a child with spasticity.

## RATIONALE

The reason a child undergoes a selective dorsal rhizotomy (SDR) is either to make a physical therapist's efforts more successful by normalizing the muscle tone in an extremity or to ease the burden of care takers by eliminating spasticity that complicates dressing, bathing, toileting and positioning. The more involved the child's limbs are with spasticity the more important is the discussion with the child and parents as to what their goals are for the SDR. It is not unusual for families to have secreted goals such as wanting a normal child or a child who will run and engage in normal activities. It is best to discover these secreted goals prior to surgery so that they can be addressed realistically. One effective way to address this issue is to discuss with the treating therapist what sort of goals will be set once tone is normalized. This is

---

*Keywords:* rhizotomy, selective posterior rhizotomy, sensory rhizotomy, functional rhizotomy, childhood spasticity, cerebral palsy

**Table 1.** Types of childhood hypertonia

Type	Characteristics
Spasticity	Hypertonia builds with movement.
Dystonia	Involuntary, sustained muscle contractions which result in a stereotypic pattern of movement ending in a fixed posture.
Athetosis	Worm-like movement seen typically in fingers.
Tension "Athetosis"	Extensor pattern of generalized hypertonia which can be shaken out of child by rapidly shaking body.
Chorea	Abrupt spontaneous, irregular movements which have a smooth, non-repetitive nature.
Rigidity	Initial resistance to movement which does not build with repetitive movements and commonly diminishes with movement.
Mixed	One or more of above. Typically athetoid movements will be seen in the hands and rigidity in the legs. Spasticity not uncommonly present.

particularly effective when the therapist is experienced in working with children after SDR. The surgeon and therapist can then discuss these goals with the family. Also important is an understanding of what type and amount of therapy will be available for the child after the SDR. Again, this surgery only decreases muscle tone. It does *nothing* to the functioning of the targeted limb. In fact, it is not uncommon for a limb to transiently deteriorate in its function after a SDR. It is therefore extremely important that the child have therapy after a SDR. The surgery should not be done if therapy will not be available for the child after the SDR.

## DECISION-MAKING

Selective dorsal rhizotomy (SDR) only treats spasticity. If employed on a child with either dystonic cerebral palsy or mixed cerebral palsy, there will be a treatment failure within several years of the surgery. Consequently for these types of cerebral palsy (CP) intrathecal baclofen is favored over SDR. Key to successfully using SDR on children with cerebral palsy is knowledge on how to perform a good tone examination. First, a good history is taken. Spastic children typically have a history of being born around 30 weeks gestation. If the child was born at term, the overwhelming probability is that the child does not have spasticity or has mixed cerebral palsy and will not be a good candidate for an SDR. During the history taking, time is spent observing the child sitting in its parent's arms relaxed. If choreoathetoid or writhing finger movements are noted the child has either dystonic CP or mixed CP and is not a good candidate for SDR. Similarly, if the child cannot maintain an erect posture, i.e., has the so called floppy trunk, then the child is not purely spastic and is not a good candidate for SDR.

Next the arms and legs are tested for spasticity. Spasticity is defined as “a motor disorder characterized by a velocity dependent increase in tonic stretch reflexes (muscle tone) with exaggerated tendon jerks, resulting from hyperexcitability of the stretch reflex” [5]. So to examine a child for spasticity one first slowly moves an extremity to evaluate the passive range of motion available for the joints of the limb. Once this is accomplished and the passive range of motion is noted the limb is rapidly and repetitively moved while assessing whether or not the available range of motion of the limb’s joints is less during rapid stretch than was present during slow movement. Also, any increase in muscle tone (increased resistance to movement) is noted. Either of these findings indicates that spasticity is present in the limb.

Sometimes there is little spasticity noted on passive exam. For that reason observational gait analysis is very important if the child is ambulatory. This part of the exam can precede the formal tone examination if there is concern about upsetting the child. Typical features of a spastic gait pattern is persisting flexion at the hips with an associated hyperlordosis, inward rotation of the hip joints and scissoring of the legs (hyper-adduction of the hips with a resulting crossing of the advancing limb in front of the limb in stance phase). The latter abnormality can be of such a severity that repetitive limb advancement is blocked. At the knees there is difficulty with extension due to hamstring spasticity. This results in a crouched gait with shortened stride length. At the ankles there is an equinovalgus deformity (heel is elevated off the ground and rotated outwards at foot strike and during stance phase). When these deformities are present and there is good tone in the trunk and no writhing in the fingers, then it can be assumed that pure spasticity is present.

Finally, it should be determined whether or not the child derives a benefit from its spasticity. In other words, is the child using the spasticity in his or her legs to assist in weight bearing and will they lose this function if the spasticity is eliminated. This is an important question. It is important to understand that it is impossible to control which muscles are affected by a SDR. There have been rhizotomy techniques advanced in the past that patterned the planned lesioning on the preoperative muscle tone exam and the planned rhizotomies intentionally left out nerves whose myotome included the quadriceps muscles with the thought that such a plan would minimize any effect on the hypertonicity present in these muscles. The result was disappointing with a large number of children experiencing loss of tone in their quadriceps and some of these children losing function due to an inability to stand. To guard against such an unanticipated loss of tone and function the child’s quadriceps strength should be examined if that child is weight bearing or assisting in transfers from bed to chair. This is best done by determining the child’s ability to rise from a squatting to standing position. The child should not be allowed to use its arms in this maneuver. The examiner can assist the child by squatting behind the child and holding its legs at the knees so as to maintain their alignment as they rise. If the child

**Table 2.** Preoperative locomotive abilities and expected outcomes following SPR\*

Group	Preop function	Postop goals
I	walks w/out assistive devices	improve appearance and efficiency of walking
II	walks w/assistive devices	improve quality of walking and decrease amount of assistance (use of canes, crutches, walkers) required for ambulation
III	quadruped crawlers limited ability to stand and reciprocally move legs	improve ability to reciprocally move the legs in the standing position w/assistive devices
IV	commando or belly crawlers	improve ease of care taking; facilitate function in sitting position
V	no locomotive abilities fully dependent	improve ease of care taking; facilitate positioning in adaptive equipment

\* Based on the New York University classification system [1]

can do this maneuver 7 times rising to a full stand and then going back to squatting without using its hypertonicity, then it has adequate strength to withstand the complete elimination of spasticity in its legs. After completing the tone and strength exam the child can be categorized and goals for the surgery can be set (Table 2). This is best done in coordination with the child's treating therapists.

Children born with cerebral palsy typically have a perinatal period marked by complications. These should be searched for as many are predictive of surgical complications. Many children born prematurely spend time on a ventilator or have other features in their history suggestive of bronchopulmonary dysplasia. It is important to discern this as children with a history of bronchopulmonary dysplasia have a high incidence of reactive airways that can complicate an anesthesia. Any history of use of a bronchodilator should also warn the surgeon that there could be reactive airway problems during an anesthesia. Children with these histories can have life threatening bronchospasm during an anesthesia. When we are confronted with this problem we have the children use a bronchodilator prophylactically for several days prior to their surgeries and with extreme cases will also prescribe steroids. Another potential complication children can experience when they undergo SDR is a transient or permanent neurogenic bladder. Neurogenic bladders are not uncommon in children with cerebral palsy. McNeal found 36% of children interviewed at a cerebral palsy center had signs of a neurogenic bladder (enuresis, stress incontinence or dribbling). An early group of our patients experienced a 14% incidence of urinary retention after their SDR with one being left permanently catheter dependent. Therefore part of the history taking should focus on symptoms of urinary dysfunction (recurrent urinary tract infections [UTI] in females or a single UTI in a male, stress incontinence or dribbling).

## **SURGERY**

### **1. THE PROCEDURE**

The SDR surgery is relatively straightforward and certainly not as complicated as candidate selection. As mentioned above thought should be given to anesthetic risks prior to the surgery. The main concern should be identification of a child at risk for intraoperative bronchospasm and protective measures should be taken for these children. Next the case should be discussed with the personnel who will support the surgeon with physiologic monitoring and mapping during the case. If the S2 roots are to be included in the SDR evaluation and cutting, then some form of physiologic mapping or monitoring should be employed to prevent postoperative bladder dysfunction. When we started to include the S2 sensory roots in our SDR lesioning, the incidence of postoperative neurogenic bladder climbed from 5% to 24%. One obvious response to this risk is to avoid lesioning the S2 roots but we showed that when S2 is not included in the testing and potential lesioning, the risk of residual spasticity in the plantar flexors is 80% with nearly half of such affected children having residual, functionally disabling spasticity. Because of all this our response has been to use the pudendal neurogram. Once the cauda equina is exposed and prior to performing the SDR we stimulate either the shaft of the penis or the surface of the clitoris and record which sensory roots (S1, S2 and/or S3) carry the evoked potential rostrally into the cord. With its use we have seen a roughly 6% incidence of transient need for intermittent catheterization and in most cases this has been due to urethral irritation causing pain on urination.

After protective measures for the maintenance of bladder function have been taken the SDR is performed. I prefer to do a laminotomy. The lamina are cut well medially to the facet joints and the ligament cut between S1 and L5. This allows one to simply flip the freed lamina rostrally out of the surgical field. I prefer to expose the L2 through S2 levels so I rongeur off the S1 and a portion of the S2 lamina. The dura is opened at midline and then it is confirmed that the L2 through S3 nerve roots can be seen as they exit the dural sleeve. There is variation in the technique employed to perform an SDR but most first determine the threshold of stimulation required to evoke muscle contraction in the limb. This is done with a single square-wave pulse using a constant voltage stimulator starting at 0.1 mV and increasing the voltage until muscle contraction is appreciated. Either an individual can palpate the legs to feel the evoked contraction or evoked EMG activity in the legs can be monitored. I have favored doing both. Once the stimulation threshold is determined for a muscle, a stimulus train is delivered with a frequency of 60 Hz and with intensity equal to threshold value.

The definition of an abnormal response to stimulation is controversial and not settled. There has been a tendency for centers performing SDRs to modify and introduce subtle variations to the technique. Fasano in first describing



the SDR outlined criteria for defining an abnormal response to nerve root stimulation [4]. There was an abnormal pattern of contractions of muscles outside of the nerve root's myotome, any sustained muscle contraction or fluctuating muscle contraction during the stimulus train. He stated in his manuscript that a normal response should be momentary and should not last for the duration of the stimulus train owing to the normal exhaustion of the involved synapses that occurs with repeated action potentials hitting the synapse. What surgeons learned during the 1990s was that sustained muscle contraction for the duration of the stimulus train was the norm and could not be used as a descriptor for an abnormal root. Most now use the spread of muscle activity outside of the nerve root's myotome as a sign of an abnormal root but even this has been shown to occur when stimulating seemingly normal nerve roots. Distant spread to the contralateral leg or to the arms is felt to be more abnormal than spread to muscles innervated by nerve roots immediately neighboring the nerve root being stimulated. Park has even developed a grading scheme for evoked muscle contracture based on the degree of spread with 1 being sustained contraction in muscles in the stimulated nerve root's myotome, 2 contraction of muscles of myotomes immediately neighboring the stimulated nerve root, 3 contraction of muscles of myotomes at a distance from the stimulated nerve and 4 contraction of muscles in limbs not innervated by the stimulated nerve [9]. He advocated cutting only those nerves who when stimulated cause group 3 or 4 type contractions.

As stated above my surgery begins with establishing the threshold stimulus voltage that will evoke muscle contraction. An anesthetic technique of continuous propofol and narcotic infusion is used so as to maintain a maximally reactive nervous system. After establishing a nerve root's threshold for activation I then deliver a stimulus train prior to moving on to the next nerve. The muscles that contract when the stimulus train is delivered are noted but no nerves are cut on this first pass. Once the S2 through L2 nerves have been stimulated on both the right and left side the patterns of evoked muscle contraction are studied for each nerve as is the pudendal nerve stimulation mapping of the S1 through S3 nerve roots bilaterally. I then perform a second round of stimulation of the nerves using a stimulus train of 60Hz lasting 1 second with the stimulus intensity again being at the nerve's threshold. Any nerve stimulated in this manner that causes muscle contraction outside the nerve's myotome is deemed to be abnormal. Such nerves will be divided into their component "rootlets" and these in turn will be stimulated. These rootlets are typically very evident and easily separated; however, in some children they are not and in these cases an arachnoidal knife can be inserted into the root and then run rostrally and caudally for a short distance to divide the nerve into several rootlets. Typically there are 3–5 rootlets for each root and they tend to be of similar sizes. The same descriptor for an abnormal response to stimulation is used for the rootlets as is used for the roots. Abnormal rootlets are cut unless they contain significant afferent pudendal nerve activity.

I find that roughly 20 to 40% of nerves respond abnormally and that abnormally responding nerves usually have at least 50% of their rootlets responding abnormally. In rare situations less than 20% of the nerves tested respond abnormally. In these cases I first check that the anesthesia is appropriate and that there is no problem with the stimulator. If these check out, then I review the pattern of responses on the first go-around and repeat the stimulation of nerves that responded abnormally the first time but not the second. If I still cannot elicit an abnormal response from these nerves, then I will partially lesion them in a random manner.

## **2. OUTCOME**

Using this protocol our patients have experienced a reliable reduction in their spasticity. We have reported that there was a significant reduction in muscle tone in all of our patients for every muscle tested [3]. This reduction persisted up to 5 years. When there was a return of hypertonicity noted we usually found that the child was experiencing something noxious such as of an acute otitis or a hip dislocation. When these were treated the tone lessened to the level previously seen. As mentioned above we have seen persisting, problematic hypertonia after SDR when the S2 nerve roots were not included in the lesioning [6].

With regard to functional benefit, papers are becoming available that document the impact of SDR on function. Using the gross motor function measure several groups have shown that children undergoing rhizotomy experience a significant improvement in their motor skills. One group showed that the major improvements seen in their children occurred in scored tasks involving the lower extremities and that these scores improved by 10% one year after surgery, 20% after three years and 34% after five years [7, 8].

## **HOW TO AVOID COMPLICATIONS**

Complications can occur during the surgery, immediately after the surgery and at a time distant from the surgery. It is best to be aware of their potential and measures that can be taken to minimize their impact. As mentioned earlier, children with cerebral palsy have an increased incidence of reactive airway disease. They or their parent should be questioned about previous episodes of reactive airway disease and/or the use of bronchodilators as such children are at risk for bronchospasm during their anesthesia. If such a history is present, then their airways should be prepared for an anesthesia. Children with cerebral palsy can have an incompetent fundus with a resultant history of reflux. Such children typically have slowed gastric motility and are at risk for having retained gastric contents at surgery. Aspiration pneumonia can occur in such a setting, so the history of gastric reflux and/or aspiration pneumonia should

be searched for. If present, then protective measures should be taken to both buffer the stomach contents and increase gastric motility prior to the anticipated surgery.

There can be several problems that arise after a child has undergone a rhizotomy. First, the family should be warned that the first few days will be marked by the child being in severe pain. This is due to the fact that these children have hyperactive muscle reflex circuits that are responsive to pain. The pain will cause their back's musculature to tighten in spasm and this is typically of such a degree as to render nearly all analgesics inadequate. In such situations the judicious use of muscle relaxants can break this pain-spasm cycle, rendering the analgesics more effective. There is an increased incidence of urinary tract dysfunction in children with cerebral palsy. For this reason they or their parents should be questioned about this prior to surgery. If there is such a history, then thought should be given as to when to remove the Foley. I typically leave it in until the child is released from bed rest. About 2–4% of patients will experience a subdermatomal sensory loss. While not functionally debilitating this does raise the risk of skin injury if the child is wearing a brace that encompasses an area of sensory loss. Parents should be warned of this before surgery. The risk for this occurring can be lessened by not lesioning two adjacent sensory roots completely. Also, about 40% of children undergoing an SDR will experience dysesthesia in their lower legs for a week or two. This does not interfere with their recovery but can be discomforting. Usually it can be treated by simply having the child wear socks. I have rarely had to revert to the use of medications for this as it typically resolves within days. CSF leakage and wound healing problems while theoretically possible are extremely unlikely.

Children who have undergone a selective dorsal rhizotomy need to be followed after their surgery. There is a risk for their developing scoliosis and spondylolisthesis. Peter reported that 9 out of 55 children developed scoliosis, 5 spondylolysis and 2 spondylolisthesis. Children post SDR can also be bothered by low back pain. Peter reported a 4% incidence and Steinbok a 14% incidence of this [10, 11]. The risk for these back problems occurring can be lessened by taking care to keep the laminotomy/laminectomy well medial to the facet joints. Children who have had their spasticity treated by an SDR are still at risk for the development of functionally debilitating muscle contracture. We have reported on an incidence of 8% in our patients [3]. As a result we counsel all of our patients on the need for a post-operative stretching program to maintain their range of motion. Finally, hip subluxation can occur after a SDR. This typically occurs in a child with weak hip musculature and a history of nonambulation prior to an SDR. When the child starts to bear weight and walk the hip weakness results in hip adduction during the stance phase of walking. We reported on 6 such children and now recommend that our patients use long-leg bracing when we are concerned about the strength of their hip musculature [2].

## CONCLUSIONS

SDR is a valuable technique for the management of spasticity in children with cerebral palsy. Its use should be done in a thoughtful manner as when correctly employed it can result in great benefit to such children.

## References

- [1] Abbott I, Johann-Murphy M, Forem S (1991) Childhood spasticity, its etiology and assessment. In: Sindou M, Abbott I, Keravel Y (eds) *Neurosurgery for spasticity: a multidisciplinary approach*. Springer, Wien New York, pp 51-58
- [2] Abbott R (1992) Complications with selective posterior rhizotomy. *Pediatr Neurosurg* 18: 43-47
- [3] Abbott R (1996) Sensory rhizotomy for the treatment of childhood spasticity. *J Child Neurol* 11: S36-S42
- [4] Fasano VA, Barolat-Romana G, Zeme S, et al. (1979) Electrophysiological assessment of spinal circuits in spasticity by direct dorsal root stimulation. *Neurosurgery* 4: 146-151
- [5] Lance JW (1980) Symposium synopsis. In: Feldman RG, Young RR, Koella WP (eds) *Spasticity: disordered motor control*. Symposia Specialists, Miami, Fla, pp 485-500
- [6] Lang FF, Deletis V, Cohen HW, et al. (1994) Inclusion of the S2 dorsal rootlets in functional posterior rhizotomy for spasticity in children with cerebral palsy. *Neurosurgery* 34: 847-853; discussion 853
- [7] Mittal S, Farmer JP, Al-Atassi B, et al. (2002) Long-term functional outcome after selective posterior rhizotomy. *J Neurosurg* 97: 315-325
- [8] Mittal S, Farmer JP, Al-Atassi B, et al. (2002) Functional performance following selective posterior rhizotomy: long-term results determined using a validated evaluative measure. *J Neurosurg* 97: 510-518
- [9] Park TS, Gaffney PE, Kaufman BA, et al. (1993) Selective lumbosacral dorsal rhizotomy immediately caudal to the conus medullaris for cerebral palsy spasticity. *Neurosurgery* 33: 929-933; discussion 933-924
- [10] Peter JC, Hoffman EB, Arens LJ (1993) Spondylolysis and spondylolisthesis after five-level lumbosacral laminectomy for selective posterior rhizotomy in cerebral palsy. *Childs Nerv Syst* 9: 285-287; discussion 287-288
- [11] Steinbok P, Schrag C (1998) Complications after selective posterior rhizotomy for spasticity in children with cerebral palsy. *Pediatr Neurosurg* 28: 300-313



**Rick Abbott**

Rick Abbott is Clinical Professor of Neurosurgery at the Children's Hospital at Montefiore, Bronx, NY, USA.

He was born on August 31, 1950 in Schenectady, New York. He received his B.A. in Biology from Colorado College in 1972. After completing a four-year tour of duty with the Air Force he attended Baylor College of Medicine graduating there in 1980. He then did a one-year rotating internship at Baylor Affiliated Hospitals in Houston, TX followed by a 5-year residency in Neurosurgery finishing his chief residency in June of 1986. He traveled to New York City in 1986 to serve as clinical fellow in pediatric neurosurgery under Dr. Fred J. Epstein at New York University Medical Center. He was then appointed to the faculty of New York University rising to the rank of Associate Professor prior to leaving that institution in 1996 to help in the establishment of the Institute for Neurology and Neurosurgery at Beth Israel Hospital in Manhattan. While there he served as the fellowship director for pediatric neurosurgery participating in the education of 10 fellows and he was acting director of Pediatric Neurosurgery from 2001 to 2004. He left there to join the faculty at Montefiore Medical Center in 2004.

Dr. Abbott has held numerous posts in the national and international pediatric neurosurgery organizations. He has served as the Treasurer, Secretary, Chairperson-Elect and Chairperson of the AANS/CNS Joint Section for Pediatric Neurosurgery; Treas-

urer and Secretary for the American Society of Pediatric Neurosurgeons; Scientific Program Chair, Treasurer, President-elect and President of the International Society for Pediatric Neurosurgery; and Chairman of the Credentials Committee of the American board of Pediatric Neurological Surgery. He is a Geographical Editor for Child's Nervous System. He has given numerous invited lectures including the Bruce Hendricks Lecture at Sick Children's Hospital in Toronto and the Visiting Professor Lecture at the University of British Columbia. He has authored 57 peer reviewed manuscripts and 20 book chapters in addition to editing two books.

**Contact:** Rick Abbott, Department of Neurosurgery, The Children's Hospital at Montefiore, Montefiore Medical Center, 111 E. 210th Street, Bronx, NY 10467, USA  
E-mail: rabbott@montefiore.org

---

# STATE-OF-THE-ART OF SURGICAL THERAPIES FOR PSYCHIATRIC DISORDERS: DEPRESSION

A. M. LOZANO

## INTRODUCTION

The introduction and widespread use of deep brain stimulation (DBS) has been a major advance in neurosurgery. With the extensive experience in the use of DBS in Parkinson's disease, the possibility of using DBS to treat other disorders including psychiatric disease has been made possible. To date, several psychiatric disorders including Tourette's syndrome, Obsessive Compulsive Disorder and Depression are being studied. Multiple brain targets are being used for these disorders including the anterior limb of the internal capsule, the nucleus accumbens, the globus pallidus and various thalamic nuclei and outflow tracts. Of importance, they appear to be disorders of circuitry and indeed it may be possible to ameliorate these psychiatric symptoms at various points along the circuits that control limbic and cognitive functions.

While there is a long history of ablative procedures to treat psychiatric illness including cingulotomy, subcaudate tractotomy, anterior capsulotomy and limbic leucotomy, the application of DBS in these disorders is relatively recent and considered as an emerging rather than an established therapy. I will limit the discussion to DBS of the subcallosal cingulate gyrus (SCG) for treatment of refractory depression.

Depression is a common disorder with a lifetime incidence of 17%. The one-time prevalence is in the order of 5–6%. Women are affected more commonly than men, and depression is one of the world's leading cause of disability.

Advances in the understanding of the neurobiology of depression have identified some of the neural circuits which mediate depressive symptoms. These circuits are potential targets for intervention with neuromodulation.

The diagnosis of depression is made by established criteria (Table 1). It is clear that depression is a multi-symptom disorder with cognitive, affective, behavioral and somatic/vegetative components. Any intervention which is to be successful must address some of these multiple facets. While many patients with depression are well managed with medications, psychiatric therapy and in severe cases electroconvulsive therapy, there remain many patients, esti-

---

*Keywords:* psychiatric disorders, psychosurgery, deep brain stimulation, stereotaxy, depression

**Table 1.** Diagnostic criteria for major depressive episode

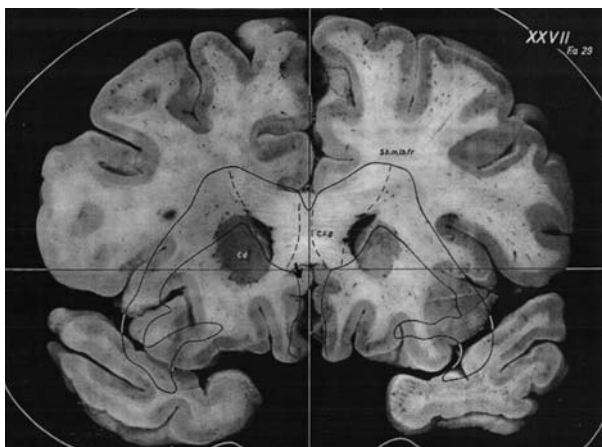
Five or more of the following symptoms (present for at least two weeks):

1. Depressive mood most of the day, nearly every day
2. Markedly diminished interest or pleasure in all, or almost all activities most of the day, nearly every day
3. Significant weight loss or weight gain
4. Insomnia or hypersomnia nearly every day
5. Psychomotor retardation or agitation nearly every day
6. Fatigue or loss of energy nearly every day
7. Feelings of worthlessness or excessive or inappropriate guilt nearly every day
8. Diminished ability to think or concentrate or indecisiveness nearly every day
9. Recurrent thoughts of death, recurrent suicidal ideation without a specific plan, or a suicide attempt, or specific plan for committing suicide

mated at 10–20% of the depression population that are resistant and disabled despite all these therapies. Novel approaches are required for these treatment resistant patients.

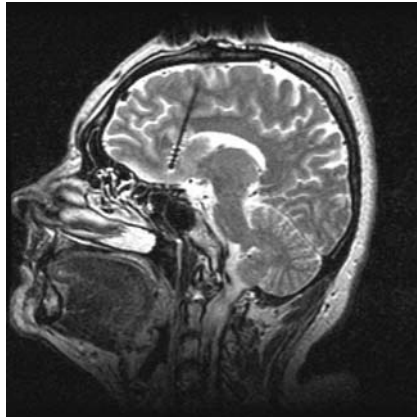
## RATIONALE

The subgenual cingulate gyrus (SCG) is connected to neural structures which mediate many of the signs and symptoms of depression. This area is connected to the hypothalamus where it is in a position to regulate sleep, appetite and cortical regulation. It is connected to the amygdala where it may be



**Fig. 1.** Location of the subgenual cingulate gyrus. The figure shows a Schaltenbrand and Wahren Stereotaxic Atlas section showing the position of the subgenual gyrus marked with an arrow (Modified from Schaltenbrand G, Wahren W (1977) Atlas of Stereotaxy of Human Brain. Thieme, Stuttgart)





**Fig. 2.** MRI of a patient with electrodes implanted in the subgenual cingulate gyrus. The figure shows the position of the DBS electrode in the sagittal plane

important in involving stress responses and emotional reactivity and projects to the brain stem periaqueductal areas where it may modulate sleep and pain, and projects to the shell of the nucleus accumbens where it could modulate motivational drive and anhedonia.

Imaging studies have shown that Area 25 within the SCG is involved in mood regulation. The induction of acute sadness in normal volunteers is associated with a rise in the blood flow and metabolic activity of Area 25. Further, the improvement of depression that occurs with drugs is associated with a decrease in the metabolic activity of this area. With the great need for novel treatments of depression with a strong anatomic rationale and with the imaging studies which indicate that Area 25 plays a crucial role, our group embarked on a study of SCG in the treatment of refractory depression. The objective of this work was to determine whether modulation of the activity of the subgenual cingulate area in patients with severe treatment resistant depression could improve their illness.

## DECISION-MAKING

This work must be performed in the context of a multidisciplinary team of psychiatrists and neurosurgeons. We recruited men and women ages 20–70 with a diagnosis of Major Depressive disorder with occurring episodes duration of at least 12 months. All patients showed response failure to multiple treatment regimens and resistance or intolerance to a minimum of at least four different drug treatments from different categories of sufficient dose and time. All patients either failed or refused electroconvulsive therapy. All patients scored greater than 20 on the Hamilton Depression Rating Scale-17 (HDRS-17) and had a global assessment function score less than 50. All

patients were able to give informed consent. Exclusion criteria included no other major psychiatric Axis I or Axis II diagnoses and no current suicidal ideation, plan or intent, or recent attempt in the last three years. The approach is multidisciplinary involving psychiatrists, neuroimaging, neuropsychologists and neurosurgeons.

## **SURGERY**

### **1. THE PROCEDURE**

The procedure involves placement of stereotactic frame and obtaining stereotactic coordinates of the target area. In targeting the SCG, we use T1-weighted coronal MRI images and choose a coronal section just in front of the head of the caudate. The target lies 5–10 mm from the midline and the 10 mm span of DBS electrode contacts covers the entire vertical extent of the SCG. The procedure is performed using local anaesthesia. Bilateral burr holes are placed 1 cm in front of the coronal suture and 2 cm from the midline. The dura is opened and the pia is coagulated. The DBS electrodes are implanted under fluoroscopic guidance to ensure that they reach target and do not move during the procedure or fixation. Acute stimulation through the implanted electrodes (incrementally from 1 to 8 V, 130 Hz and 6–90 ms pulse width) is used to look for positive as well as negative effects. Acute stimulation can produce a variety of effects including a sudden sense of intense calm, peacefulness, improvement in psychomotor speed, change in intensity of perception of colors, obvious changes in interest, motivation, curiosity, apathy, initiation, change in anhedonia, clearing of “sense of void”, clearing of black cloud and relief of the sensation of pressure on chest. The effects are contact and stimulation parameter specific.

Once in place, the electrodes are then connected to the pulse generator implanted under general anaesthesia. Programming usually involves settings at 3–4 V and 90 ms with rates of 130. We use right and left homologous electrode pairs (deepest, midpoint or superior) systematically in each patient. Changes in stimulation parameters are made no more frequently than every two weeks due to the delay in clinical effects with stimulation.

### **2. RESULTS**

We have found both acute and long-term effects in these patients. We have demonstrated that compared to healthy controls, patients with severe treatment resistant depression have elevated metabolic activity in the SCG. Further, the application of DBS to this area reverses this abnormality returning it to a more normal level. This is accompanied with striking improvements in mood and motivation in these patients. We have shown that we are able

to modulate the activity of the limbic circuits with DBS both locally and remotely. We have been able to show a reversal of the hypermetabolic activity in the SGC area and a reactivation of the hypometabolic frontal lobes in depression patients with SGC DBS. The procedure appears to be effective but these are, of course, open label studies and a definitive double blind trial is required. The location of stimulation parameters is important as there are optimal electrode locations.

We have found both acute and long-term effect stimulation in these patients. In approximately 70% of the patients they report an acute change in their response to stimulation. This can include a sudden sense of calmness, a sudden sense of karma, a sense of lifting of a heavy burden, or a sense of clearing of a cloud that seems to be over their head. This can be followed 10–15 s later by increase engagement, increase attention, and increase interactions with the environment and with people around them. These acute findings are not necessarily indicative of the long-term outcome.

We now have experience of approximately 30 patients having undergone DBS of the subgenual cingulate gyrus. Our results indicate that some 60% of patients are responders, i.e. have a >50% improvement in the Hamilton Depression Scales at 6 months or 1 year. These improvements are seen across all dimensions of depression including somatic, sleep and mood aspects.

### **3. ADVERSE EFFECTS**

The incidence of serious adverse effects in stereotactic DBS surgery is less than 1% of patients. The most serious is the production of an intracranial hemorrhage related to the procedure. In addition, electrodes can migrate, the hardware can fail, the skin over the hardware can erode and there can be infections. In the depression population there is, in addition, the natural history of psychiatric disease to contend with and the high incidence, estimated at approximately 15%, of suicide in the treatment resistant depression population.

## **CONCLUSIONS**

It is still early in the evolution of DBS for psychiatric disease. The procedures appear safe and offer the advantage over the previously used ablative procedures of reversibility and adaptability. These features may increase the acceptability of this approach in patients disabled by their illness by patients, their families and the medical community at large. Particular attention must be placed on the ethical issues to consider in this vulnerable population.

One of the most puzzling features of DBS for depression is that some patients respond and others do not. The features that distinguish the responders from no responders are yet to be elucidated. We feel that these procedures may represent a novel therapy in the treatment of patients who otherwise do not respond to medical therapies.

## Acknowledgement

The author thanks Drs. Mayberg, Kennedy and Giacobbe for their ongoing collaboration and Dr. Clement Hamani for his critical review and assistance in the manuscript.

## References

- [1] Agid Y, Buzsaki G, Diamond DM, Frackowiak R, Giedd J, Girault JA, et al. (2007) How can drug discovery for psychiatric disorders be improved? *Nat Rev Drug Discov* 6: 189-201
- [2] Johansen-Berg H, Gutman DA, Behrens TE, Matthews PM, Rushworth MF, Katz E, Lozano AM, Mayberg HS (2008) Anatomical connectivity of the subgenual cingulate region targeted with deep brain stimulation for treatment-resistant depression. *Cereb Cortex* 18(6): 1374-1383
- [3] Lozano AM, Mayberg H, Giacobbe P, Hamani C, Craddock C, Kennedy SH (2008) Subcallosal cingulate gyrus deep brain stimulation for treatment-resistant depression. *Biol Psychiatry*
- [4] Mayberg HS, Liotti M, Brannan SK, McGinnis S, Mahurin RK, Jerabek PA, et al. (1999) Reciprocal limbic-cortical function and negative mood: converging PET findings in depression and normal sadness. *Am J Psychiatry* 156: 675-682
- [5] Mayberg HS (2003) Modulating dysfunctional limbic-cortical circuits in depression: towards development of brain-based algorithms for diagnosis and optimised treatment. *Br Med Bull* 65: 193-207
- [6] Mayberg HS, Lozano AM, Voon V, McNeely HE, Seminowicz D, Hamani C, et al. (2005) Deep brain stimulation for treatment-resistant depression. *Neuron* 45: 651-660
- [7] McNeely HE, Mayberg HS, Lozano AM, Kennedy SH (2008) Neuropsychological impact of Cg25 deep brain stimulation for treatment-resistant depression: preliminary results over 12 months. *J Nerv Ment Dis* 196(5): 405-410
- [8] Neimat JS, Hamani C, Giacobbe P, Kennedy SH, Mayberg HS, Lozano AM (2008) Neural stimulation successfully treats depression in patient with prior ablative cingulotomy. *Am J Psychiatry* 165(6): 687-693
- [9] Ressler KJ, Mayberg HS (2007) Targeting abnormal neural circuits in mood and anxiety disorders: from the laboratory to the clinic. *Nat Neurosci* 10: 1116-1124
- [10] Seminowicz DA, Mayberg HS, McIntosh AR, Goldapple K, Kennedy S, Segal Z, et al. (2004) Limbic-frontal circuitry in major depression: a path modeling metanalysis. *Neuroimage* 22: 409-418



**Andres M. Lozano**

Andres M. Lozano is currently Professor and RR Tasker Chair in Functional Neurosurgery and holds the Canada Research Chair in Neuroscience at the University of Toronto. He obtained his MD degree from the University of Ottawa and his PhD in Neurobiology from McGill University. He was appointed to the neurosurgical faculty at the University of Toronto in 1991 and became full Professor in 1999. Dr. Lozano's research is focused on understanding the cellular pathogenesis and developing novel treatments for neurological and psychiatric disorders. His work has appeared in over 300 publications and he has been invited lecturer or visiting professor throughout the world. He serves on the board and executive of several international organizations and editorial boards and is currently President of the World Society for Stereotactic and Functional Neurosurgery, and Chairman of the Stereotactic and Functional Neurosurgery Section of the World Federation of Neurosurgical Societies. His team in Toronto has trained many of the future leaders in Functional Neurosurgery.

**Contact:** Andres M. Lozano, Department of Surgery, Faculty of Medicine, University of Toronto, 399 Bathurst Street WW 4-447, Toronto, OT M5T 2S8 Canada  
E-mail: lozano@uhnres.utoronto.ca

---

# NEUROSURGERY FOR PSYCHIATRIC DISORDERS: OBSESSIVE-COMPULSIVE DISORDER

V. STURM

## INTRODUCTION

In 1949 E. Moniz received the Nobel Award for the development of frontal leucotomy. Surgical interruption of a major part of fronto-thalamic connections had a clear and often beneficial sedating effect in patients suffering from severe psychosis but irreversible side-effects, namely emotional blunting, had been frequent. Growing public criticism for misuse in improperly selected patients as well as the development of neuroleptics made this treatment obsolete in the late 50s. In the 60s stereotactic techniques became more and more refined, enabling precise lesioning of small volumes of brain tissue. Stereotactic cingulotomy, fronto-basal-tractotomy and anterior capsulotomy had become the most frequently used stereotactic procedures to treat anxiety-disorders and obsessive-compulsive disorders. Although amenable results could be achieved in these often devastating conditions, there remained the fact, that thermo-, like cryo-ablations, are irreversible procedures which may lead to persistent side-effects. This and the historically bad connotation of psychosurgery in general, had been the reasons why stereotactic psychosurgical procedures had been used but exceptionally and in very limited numbers.

This situation changed after the introduction of deep brain stimulation (DBS) for motor disorders by Alim Benabid in the early 90s [1]. Excellent results in advanced Parkinson's disease and the benignity and full reversibility of DBS changed the attitude of conservative neurologists and later also of biological psychiatrists, who realized the clear advantages of DBS compared to pharmaco-therapy which is much less specific. It is fair to state that the findings in DBS for Parkinson's disease stand at the beginning of a change in pathophysiological paradigms applying not only to motor disorders but, in the definitive opinion of the author, also to pathological circuitry underlying major psychiatric disorders: a morphological or functional deficit in relatively small, circumscribed brain areas (e.g. the substantia nigra pars compacta in Parkinson's disease) has a dramatic effect on oscillations in 'downstream' circuits which finally cause neurologic or psychiatric symptoms. As shown in

---

*Keywords:* psychiatric disorders, psychosurgery, obsessive-compulsive disorder, deep brain stimulation, stereotaxy

Parkinson's disease, DBS in circumscribed, relevant parts of these pathologically communicating circuits can replace pathogenic oscillations with the stimulation volleys of DBS and thus 'liberate' and normalize the functionality of dependent circuitry.

Nuttin and Cosyns [7] had been the first to replace anterior capsulotomy with DBS in the latter structure in carefully selected patients with therapy-refractory obsessive-compulsive disorder with remarkably good therapeutic effects. Although effective, DBS in the anterior capsule had to be performed at unusually high stimulation-amplitudes, yielding side-effects and early battery-consumption. Based on anatomical and physiological considerations, the author of this article introduced the nucleus accumbens as primary target for DBS in OCD (in 2000 and later) as well as for Major Depression and alcohol dependency [4, 9, 10].

## **RATIONALE**

Obsessive-compulsive disorder (OCD) is a chronic and disabling condition, characterized by recurrent obsessive thoughts, yielding intense discomfort, tension, as well as anxiety and fear reactions which can partly be coped with by often uncontrollable compulsive reactions (e.g. repetitive behavioural or mental acts).

The fact, that the syndrome comprises affective, cognitive and motor symptoms points to the involvement of limbic and paralimbic cortical prefrontal structures as well as the basal ganglia which have in fact been shown to exhibit a changed activation pattern in this disorder.

The following anatomical and physiological considerations support the author's notion of the pathophysiology of OCD and prompted to introduce the caudo-ventro-medial accumbens as primary target for DBS in this disorder, and slightly changed also in major depression and addiction (alcohol-dependency).

The nucleus accumbens is located in the basal forebrain immediately underneath the anterior limb of the internal capsule. In the 3 D-space it is oriented rather oblique-horizontally covering the area rostral to the anterior commissure. Medially adjacent is the vertical part of Broca's diagonal band. The lateral border is formed by the claustrum and piriform cortex. Dorsally, neighbouring structures are the anterior limb of the internal capsule and rostral extensions of the globus pallidus. Dorso-laterally, the nucleus accumbens extends into the ventral putamen and dorso-medially into the ventral caudate without a sharp demarcation.

Traditionally, the nucleus accumbens is divided into a peripheral shell and a central core, the former being anatomically and functionally closely linked to the extended amygdala, an important part of the limbic system, the latter to the extrapyramidal motor system. The shell region contains higher

concentrations of D1- and D3-receptors as well as of certain neuropeptide-receptors like VIP, CCK, enkephalines, substance P, neurotensin and cocaine-amphetamine regulated transcript (CART) receptors than the core region.

In the primate, it is confined to the medial part of the nucleus. Inside the nucleus accumbens, input flow is from shell to core. There is strong cortical input from the anterior cingulate. Major subcortical afferents are from the dopaminergic midbrain areas (VTA, dorsal tier of the substantia nigra) and from both baso-lateral and centro-medial amygdala [6]. Main projections reach the ventral pallidum which projects back to the dopaminergic midbrain areas, the ventro-medial subthalamic nucleus, as well as to the midline and dorso-medial thalamic nuclei. The latter nuclei project back to the anterior cingulate and from Brodmann area 24 to the ventral striatum with the accumbens as its major part, thus closing this limbic-paralimbic circuit.

The central position of the nucleus accumbens between the limbic and the extrapyramidal motor system, as well as in the mesolimbic dopaminergic reward-system along with its modulating dopaminergic activity justified its selection as target for DBS in OCD. Main features in the pathophysiology of OCD are fear and tension including obsessive thoughts and the resulting compulsive behavioral acts, often with motor components. Moreover, OCD is frequently comorbid with anxiety disorders which might be attributed to pathological activity of the amygdala as well as with depression, presumably caused by disturbed activity in the mesolimbic dopaminergic system. As mentioned above, the nucleus accumbens plays a modulating role in these limbic-extrapyramidal and mesolimbic dopaminergic circuits.

The strongest empirical reason for choosing the accumbens as target for DBS in OCD has been the observation, that the most efficient lesional treatments for OCD are subcaudate tractotomy, ventral anterior capsulotomy, anterior cingulotomy and dorso-medial thalamotomy. All these interventions partially include the nucleus accumbens (subcaudate tractotomy, anterior capsulotomy), or closely linked thalamic or cingulate areas.

## **DECISION-MAKING**

Although favorable results have been obtained by various groups using DBS in the anterior-capsule-nucleus accumbens-area for treatment of severe, therapy-resistant obsessive-compulsive disorder, the procedure has not yet been approved by regulatory authorities in Europe and the USA and is still experimental.

This means, that it should only be applied in clinical studies approved by ethical committees, and according to German law in exceptional 'individual attempts to cure patients'.



The treatments have to be performed by a team of specialized psychiatrists and stereotactic neurosurgeons. For patients-selection, inclusion in studies, as well as for postoperative care the psychiatric team-members are primarily responsible. The indication for surgery must be established by both psychiatrists and neurosurgeons.

*Main psychiatric criteria for inclusion in a study are:*

1. Patients must suffer from long standing, severe OCD refractory to best medical and psychotherapeutic treatment. To ensure this, the following criteria have to be met:
  - 1.1. OCD must be the primary diagnosis assessed in the Structured Clinical Interview for DSM-IV.  
The Yale-Brown Obsessive Compulsive Scale (YBOCS) [3] should be used to determine the severity of the OCD. Minimum score should be 25.
  - 1.2. Treatment resistance
    - 1.2.1. No substantial improvement with best medical therapy. At least 3 serotonin reuptake inhibitors (SSRIs) including Clomipramine must have been tried with doses recommended by the FDA for more than 3 months each, as well as augmentation of an SSRI with a neuroleptic and with benzodiazepine.
    - 1.2.2. A minimum of 20 sessions of behavior therapy (exposure and response prevention) is required.
  2. The OCD must be chronic, i.e. at least 10 years in duration.
  3. *Exclusion criteria:*
    - 3.1. Neurosurgical:  
Clinically significant neurological disorders or medical illness, leading to increased surgical risks.  
Significant brain abnormalities, including internal and external brain atrophy.
    - 3.2. Psychiatric:  
History of current or past psychiatric disorders (except comorbidity with OCD)  
Manic episode within the preceding 3 years  
Current or remitting substance abuse or dependency  
Severe personality disorder  
Imminent suicidal risk
  4. *Preoperative assessment:*  
Detailed neurological, medical and anesthesiological investigation, as used in other elective neurosurgical procedures  
Recent MRI  
Informed consent of patient and thorough information of close relatives  
In case of studies: Approval by the local ethical committee

## SURGERY

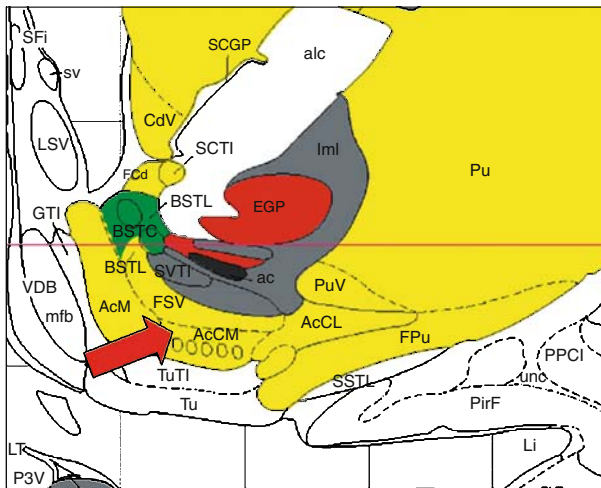
### 1. ANESTHESIA

Electrode implantation is performed preferably under local anesthesia.

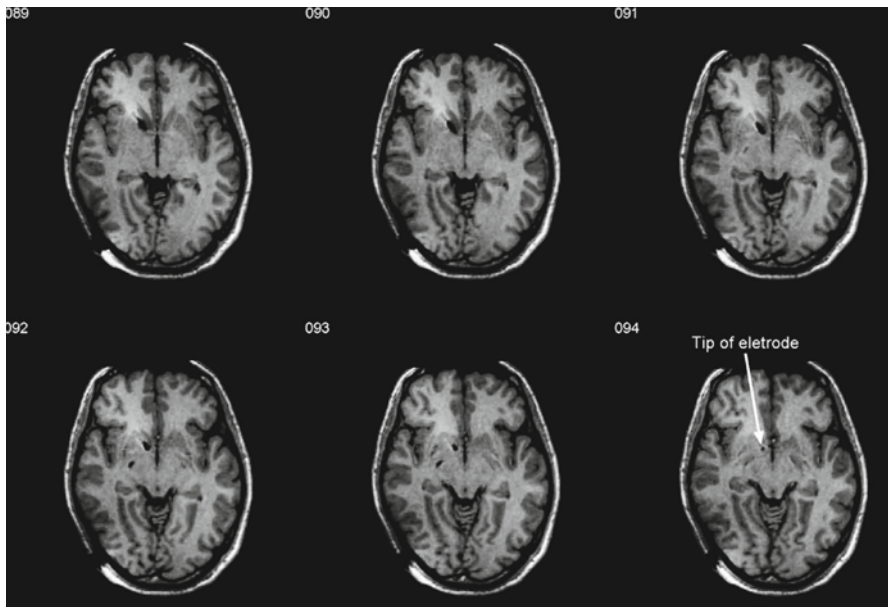
The patients are cared for by an anesthesiological team throughout the whole operation. For fixation of the stereotactic frame, during intraoperative imaging, the period of trajectory-planning, making the burr-holes, etc. the patients are sedated with adequate doses of i.v. Propofol which is withdrawn for intraoperative test-stimulation, primarily used to reveal possible side-effects of accumbens-stimulation. Since there are no reliable electrophysiological and clinical data, enabling to validate the electrode-position so far, in special cases electrode-implantation can be performed on general anesthesia.

### 2. ELECTRODES AND IMPULSE-GENERATORS

We have used the quadripolar DBS-electrode model 3387 (length of the poles 1.5 mm, distance between poles 1.5 mm) and a dual channel impulse-generator (IPG) which can serve both electrodes (Kinetra, Medtronic Inc., Minneapolis). Usually, we would implant the IPG immediately after the electrode-implantation, but on general anesthesia. The IPG is implanted



**Fig. 1.** Frontal section of the human brain at the level of the target point in the ventro-medio-caudal part of the nucleus accumbens. Arrow head indicates the target point. Coordinates 2.5 mm rostral anterior border of AC, 6.5 mm lateral of midline, 4.5 mm ventral AC (Atlas of Mai et al. [5])



**Fig. 2.** Post-operative T1-weighted MRI depicts exact electrode placement in the desired area. Note the dark artefact surrounding the electrode, which is due to disturbance of the local magnetic field by the electrode and not caused by tissue damage

subcutaneously over the right breast muscle, the extension wires are placed subcutaneously and connected to the DBS-electrodes in a right parietal site.

In a prospective randomised study including 16 patients as well as in a preceding pilot series we have implanted unilaterally in the right accumbens. Results have been favorable, but not as constant as with bilateral implantation which is now our routine-procedure.

### 3. TARGET LOCALIZATION AND TRAJECTORY-PLANNING

These topics are of highest relevance for achieving favorable results and avoiding operation- and stimulation-induced side-effects. As outlined above, the shell-region of the accumbens receives strong afferents from both basal and centro-medial amygdala and is anatomically and physiologically closely linked to the ‘extended amygdala’. Moreover, the density of D1- and D3-receptors is highest in this part of the nucleus, making it the preferred target for modulating dopaminergic input from the mesolimbic dopaminergic midbrain-areas. Thus, I have defined the caudo-ventro-medial accumbens as target for DBS.

The target is derived from the Brain-Atlas by Mai et al. [5]; Standard-coordinates refer to the line between the posterior border of the anterior and the anterior border of the posterior commissure (AC–PC-line):

- x: 7.5 mm lateral of the midline of the third ventricle
- y: 2 mm rostral to the anterior border of the AC at the level of the midline of the 3rd ventricle
- z: 4 mm ventral to the AC–PC-line.

Since location and extension of the nucleus accumbens are highly variable between individuals, the coordinates must be adapted according to individual landmarks:

- y: The length of the standard – AC–PC-line is 25 mm. The length of the AC–PC-line in the very patient is divided by 25 and multiplied by 2, giving the individual distance of the target point from the anterior border of the AC.
- x: The standard width of the hemisphere (maximal width in the parietal region), measured in coronal sections of CT or MRI, is 63.5 mm. The individual width of the hemisphere is divided by this measure and multiplied by 7.5.

The z-coordinate (4 mm below the AC–PC-line) is highly variable and individually chosen according to the planning-MRI. It is relatively close to the horizontal section of the anterior cerebral artery and has to be placed at least 2 mm dorsal to this vessel.

The x-coordinate (laterality of the target-point) seems to be most critical for the therapeutic outcome. Important anatomical landmarks are the vertical limb of Broca's diagonal band, which borders the ventro-medial accumbens medially. This structure belongs to the cholinergic activating system and should not be included in the stimulation-field. It can be visualized in axial and frontal high-resolution MRI-scans in the T1-series. We place the target-point 2.5 mm lateral to this structure. The target point should project to the level of the caudo-ventro-medial edge of the anterior limb of the internal capsule, 4 mm ventral to the anterior-commissure.

#### 4. TRAJECTORY

In the Medtronic-DBS-electrode Model 3387 the distance from the distal edge of contact 0 to the proximal edge of contact 3 is 10.5 mm.

We use a deep fronto-lateral approach, placing the 2 distal poles within the caudo-medial accumbens (contact 1 reaching the most ventral fibers of the internal capsule) and the 2 proximal contacts within the capsule.

Since this requires an unusually far lateral approach, the avoidance of branches of the middle cerebral artery can necessitate a more medial place-

ment of the two proximal contacts in the medial part of the capsule or at the border to the caudate.

For both target- and trajectory-planning we use preoperative 3 T-MRI, intraoperative 1.5 T-MRI and CT-imaging, the two latter procedures being performed with localizers mounted to the stereotactic frame. Preoperative 3 T-imaging is fused with the intraoperative 1.5 T-MRI, CT- and X-ray-imaging using landmark fusion which in our experience is more accurate than the use of automatic fusion-programs. The latter procedure bears the risk of location-errors due to geometrical image distortion especially in the T1-series.

Postoperative electrode placement is verified by final stereotactic X-ray-exposures or postoperative CT.

Since routinely both electrode-implantation and implantation of the IPG (the latter being performed in general anaesthesia), are performed in one session, we observe the patient in the intensive care unit through the following night. He is kept in the Stereotactic ward until the first wound dressing 2 days post op. and then transferred to the psychiatric ward, where the IPG is activated. Neither steroid nor antibiotic treatment is given except intraoperative antibiotic prophylaxis.

For accumbens-stimulation we start with unipolar stimulation of the distal poles of both electrodes (0 and 4, respectively), 0 and 4 negative versus case positive using rectangular impulses of 90  $\mu$ s impulse duration, 130 Hz and -1.5 V. Every two days the voltage is increased by 0.5–1 V to levels of 4–6 V. Usually therapeutic effects do not occur immediately, nor do stimulation induced side-effects. Patients are released from the psychiatric ward after 2–3 weeks but are seen at regular intervals of 4–12 weeks, when stimulation parameters are adjusted and more proximal poles are additionally (or sometimes alternatively) activated.

## 5. LONG-TERM RESULTS (SUMMARY)

In 2000, we introduced accumbens stimulation in a patient with therapy refractory anxiety disorder. The implantation had been performed bilaterally, but it turned out, that stimulation of the right accumbens was crucial for the beneficial effects (complete, enduring remission of symptoms) which had been gained. This was confirmed in patients in a pilot series on OCD [10] and prompted us to use only unilateral stimulation of the right caudo-ventro-medial accumbens in a prospective randomized double blind study, where 16 patients with severe OCD (YBOCS > 30) had been included and observed for 2 years. 3 of 10 patients, who reached the endpoint so far, are full responders, 3 patients responded partially and 4 patients are non-responders, although each patient in the latter group showed minor benefits (OCD-symptoms and global assessment of function).

A first series of bilateral DBS in the more rostral part of the anterior limb of the internal capsule, improved OCD symptoms but needed extremely high stimulation amplitudes, which resulted in early battery consumption and yielded side effects [2, 7, 8]. Later on these authors, and most other groups located their targets to posterior sites very similar to ours. Results improved dramatically.

It turned out that bilateral stimulation in the accumbens yielded better results and clearer improvements than unilateral stimulation as used in our study. So we decided to implant all following patients bilaterally with clear further improvement of our results.

## HOW TO AVOID COMPLICATIONS

Surgical complications (bleeding, infections) are rare. In 45 patients implanted in the accumbens so far by our group for OCD, depression and Tourette-syndrome neither bleeding nor infection occurred. Stimulation induced hypomania in one patient. This could be reversed by reducing the stimulation amplitude. In one patient, a displacement of the electrode caused a stimulation induced feeling of heat and sweating due to stimulation of the anterior hypothalamus. No cognitive or affective impairments had been observed. There was a tendency to mood elevation but with the above mentioned exception no manic or hypomanic symptoms occurred which are sometimes seen in patients with Parkinson's disease, treated with DBS in the subthalamic nucleus.

To avoid hemorrhage, CT and MRI-based trajectory-planning is essential. Not only visible blood vessels have to be avoided, but also sulci in which small vessels, undetectable in MRI and CT, can be hidden.

We pay special attention to minimize CSF-leakage during surgery by carefully plugging the burrhole with fibrin-sponges, cotton pads, etc. in order to avoid brain shifts, which might shift vessels into the pre-planned electrode-trajectory.

## CONCLUSIONS

According to the available limited data, chronic high frequency stimulation in the caudo-ventro-medial nucleus accumbens and its transition area to the anterior limb of the internal capsule seems to be a safe and effective treatment modality for severe and otherwise untreatable OCD.

The results gained so far need still to be confirmed in larger controlled prospective studies. Although most groups using DBS in OCD are now targeting areas similar to the accumbens-target introduced by the author, the optimal fine-localization has yet to be determined.

## References

- [1] Benabid AL, Pollak P, Gervason C, Hoffmann D, Gao DM, Hommel M, Perret JE, de Rougemont J (1991) Longterm suppression of tremor by chronic stimulation of ventral intermediate thalamic nucleus. *Lancet* 337: 402-406
- [2] Greenberg BD, Malone DA, Friehs GM, Rezai AR, Kubu CS, Malloy PF, Salloway SP, Okun MS, Goodman WK, Rasmussen SA (2006) Three-year outcomes in deep brain stimulation for highly resistant obsessive-compulsive disorder. *Neuropsychopharmacology* 31: 2384-2393
- [3] Goodman WK, Price LH, Rasmussen SA, Mazure C, Delgado P, Henninger GR, et al. (1989) The Yale-Brown obsessive compulsive scale. II. Validity. *Arch Gen Psychiatry* 46: 1012-1016
- [4] Kuhn J, Lenartz D, Huff W, Lee S, Koulousakis A, Klosterkötter J, Sturm V (2007) Remission of alcohol dependency following deep brain stimulation of the nucleus accumbens: valuable therapeutic implications? *J Neurol Neurosurg Psychiatry* 78(10): 1152-1153
- [5] Mai JK, Assheuer J, Paxinos G (1997) Atlas of the human brain. Academic Press, San Diego
- [6] Mulder AB, Hodenprijl MG, Lopes da Silva FH (1998) Electrophysiology of the hippocampal and amygdaloid projections to the nucleus accumbens of the rat: convergence, segregation, and interaction of inputs. *J Neurosci* 18(13): 5059-5102
- [7] Nuttin B, Cosyns P (1999) Electrical stimulation in anterior limbs of internal capsules in patients with obsessive-compulsive disorder. *Lancet* 354: 1526
- [8] Nuttin B, Gabriels LA, Cosyns PR, Meyerson BA, Andriewitch S, Sunaert SG, et al. (2003) Long-term electrical capsular stimulation in patients with obsessive-compulsive disorder. *Neurosurgery* 52: 1263-1272; discussion 1272-1274
- [9] Schlaepfer TE, Cohen MX, Frick C, Kosel M, Brodesser D, Axmacher N, Joe AY, Kreft M, Lenartz D, Sturm V (2008) Deep brain stimulation to reward circuitry alleviates anhedonia in refractory major depression. *Neuropsychopharmacology* 33(2): 368-377
- [10] Sturm V, Lenartz D, Koulousakis A, Treuer H, Herzholz K, Klein JC, Klosterkötter J (2003) The nucleus accumbens: a target for deep brain stimulation in obsessive-compulsive and anxiety disorders. *J Chem Neuroanat* 26: 293-299



### **Volker Sturm**

Volker Sturm is Director and Chairman of the Department of Stereotactic and Functional Neurosurgery, University of Cologne, Germany.

Born December 6, 1943 in Heidelberg. Studies of Medicine in Heidelberg. Residency in the Departments of Neurosurgery at the Heidelberg University (Chairman: Prof. Dr. Helmut Penzholz) and Department of Stereotactic Neurosurgery, University Homburg/Saar (Prof. Dr. Gerd Dieckmann, Prof. Dr. Rolf Hassler). Basic training in Stereotactic Surgery in Homburg, the Karolinska Institute Stockholm (Prof. Dr. E.O. Backlund), and the Hopital St. Anne, Paris (Prof. Dr. G. Szikla).

1981 establishment of a unit for Stereotactic Neurosurgery, in close cooperation with the Department of Medical Physics (Prof. Dr. Wolfgang Schlegel) at the German Cancer Research Center Heidelberg. Development of the first image-based treatment-planning programs for interstitial irradiation of gliomas and Linear-accelerator Radiosurgery, introduction of radiosurgical treatment of brain metastases.

Since 2003 Director of the unit for Stereotactic Neurosurgery at the International Neuroscience Institute (INI) Hannover (President: Prof. Dr. Madjid Samii), 2005 acceptance of the Leibniz-Chair, Institute of Neurobiology, Magdeburg.



Main scientific interest is defining of DBS-targets and introduction of new stimulation algorithms in neuromodulation developed by Prof. Dr. Dr. Peter Tass, Research Center Jülich.

In 2000 introduction of the Nucleus Accumbens as target for DBS in anxiety disorders as well as obsessive-compulsive disorders (OCD) and later on for Tourette's-syndrom, Major Depression and Alcohol-Dependency.

Awards: Meyenburg-Preis für hervorragende Leistungen in der Krebsforschung, Claudius-Galenus-Award, Erwin-Schrödinger-Award of the Stiftungsverband der Deutschen Wissenschaft/Helmholtz-Gemeinschaft.

**Contact:** Volker Sturm, Department of Stereotactic and Functional Neurosurgery, University of Cologne, Kerpener Str. 62, 50937 Köln, Germany  
E-mail: volker.sturm@uk-koeln.de

---

# NEUROSURGICAL MANAGEMENT OF EPILEPSY IN ADULTS

B. C. DEVAUX

## INTRODUCTION

Epilepsy is a chronic disorder affecting 0.5–1% of the population. Despite the use of many antiepileptic medications, including the most recently available, 30–40% of patients continue to have seizures and about 20% will be considered as drug-resistant [5, 7]. Among those, 50–60% have a partial epilepsy, 25% of whom could be surgical candidates.

The goal of surgical treatment is first to relieve patients from their disabling seizures, but also to improve neurological, neuropsychological and social aspects of their disease, without additional deficit related to the surgical procedure.

Surgical treatment includes numerous resective and non-resective procedures, curative or palliative, and has proven to be superior to medical treatment in refractory temporal lobe epilepsy [25].

Postoperative seizure relief depends essentially on a careful selection of patients and an appropriate preoperative workup and surgical technique that warrants a dedicated multidisciplinary team.

Historical landmarks are being summarized as follows. Surgical approach to treat epilepsy started almost two centuries ago, in North America and Europe. In 1828, Benjamin J. Dudley reported in Lexington five patients with post-traumatic epilepsy who underwent trephination, three of those becoming seizure-free. In 1852, a Canadian survey conducted by Steven Smith reported 27 operated cases. A few years later, in London, Europe, Sir Victor Horsley, considered as the father of epilepsy surgery, reported in 1886 three patients with severe epilepsy successfully operated, while in Germany Fedor Krause (Berlin, 1893) and Otfried Foerster (Breslau, 1920) also started surgery for chronic epilepsy. In 1928 at Montreal, Wilder Penfield, who trained with Foerster, developed a methodology using electrical stimulation to evoke patient's auras and to map functional areas of the brain exposed during surgery. Later, in 1934, Herbert Jasper in Montreal and Frederic and Erna Gibbs in Chicago developed the scalp EEG, which changed the understanding of epilepsy. Later, Jasper and Penfield at the Montreal Neurological Institute

---

*Keywords:* epilepsy surgery, temporal lobe epilepsy, extratemporal epilepsy, stereo-electro-encephalography, depth electrodes recordings, image-guided neurosurgery

developed direct intraoperative electrocorticography that enhanced surgeon's ability to remove completely the epileptogenic cortex.

Hippocampal sclerosis has been described as a marker of chronic epilepsy of temporal origin as early as 1825 by Bouchet and Cazauvieilh and by Sommer in 1880. Falconer et al. described an en bloc resection of temporal lobe in 1964 and were the first to propose the term "mesial temporal sclerosis" associated with temporal lobe epilepsy.

In Europe, epilepsy surgery was pioneered in the late 1950s by Jean Bancaud and Jean Talairach in Paris. They developed a method based on clinical, neurophysiological and anatomical correlations, using intracranial depth electrode exploration (stereo-electroencephalography, SEEG) and tailored epileptogenic cortex resection (cortectomy).

The dramatic advances in cerebral imaging profoundly changed the selection of surgical candidates. New surgical techniques, such as callosotomy (Van Wagenen and Herren, 1940), hemispherectomy (McKenzie, 1938; Krynauw, 1950), cerebellar stimulation (Cooper, 1973), and later selective amygdalohippocampectomy (Niemeyer and later Wieser and Yaşargil, 1982), various intracranial targets for neuromodulation (Velasco, 1987), multiple subpial transections (Morrell, 1969) and more recently radiosurgery (Regis, 1993), have widened the surgical offer to better fit with epilepsy characteristics of each patient.

Since the historical HM case who in 1953 underwent bilateral temporal lobe resection for epilepsy ensuing with a severe and persisting global amnesia, neuropsychological consequences of surgical damage to mesial temporal structures have been largely documented following the pioneering work of Brenda Milner at the Montreal Neurological Institute starting in 1958 and still represent a challenge for mesial temporal resections. Furthermore, because of a higher rate of abnormal hemispheric dominance among epileptic patients, its identification is a part of the preoperative evaluation. Intracarotid sodium amyltal test, introduced by Juhn Wada in 1956, is still performed in cases of non-conclusive functional MRI.

Large international meetings such as those organized in 1986 and 1992 by Jerome Engel allowed the report of large multicenter cohorts of patients and a comprehensive update in all issues of surgical epilepsy. Today, surgery for epilepsy is a well established domain of functional neurosurgery.

## **RATIONALE**

Surgical treatment can be offered to patients suffering from a chronic drug-resistant focal epilepsy, with seizures originating from a cerebral abnormal region – the epileptogenic zone – and abnormally functioning circuits leading to repeated seizures. The gold standard is a complete resection of the lesional or anatomical substrate of the epileptogenic zone, when unique and surgically accessible – i.e. the epileptogenic zone does not contain important functional cortex [10, 20].

Surgical procedures are divided in curative and palliative techniques and include three orders of procedures: resection, disconnection and modulation. Curative procedures tend to remove the epileptogenic zone and/or to disconnect the seizure spread pathways; they include lobar, multilobar or tailored epileptogenic cortex resections (cortectomies), selective stereotactic destructions, lobar or hemispheric disconnective procedures. Palliative procedures tend to reduce the frequency and severity of seizures when ablation of the epileptogenic zone is not possible; they include corpus callosotomy, multiple subpial transections, various techniques of deep brain neuromodulation and vagus nerve stimulation.

Surgically remediable epilepsy syndromes have been identified [6]. They include mesial temporal lobe epilepsy (MTLE), epilepsy associated with indolent tumors or malformations of cortical development, scars secondary to traumatism, infection, or hematoma, and some hemispheric syndromes associated with infantile hemiplegia. Identification of patients presenting with one of these syndromes, the most frequent of them is temporal lobe epilepsy (TLE) – accounting for 70–80% of surgical series –, should be followed by successful surgery on seizure outcome.

An epilepsy surgery program requires a multidisciplinary team including neurologists, neurophysiologists, neurosurgeons, neuroradiologists, neuropathologists, psychiatrists, neuropsychologists and EEG laboratory technicians. In addition, healthcare networks with referring centers and physicians, social workers, and rehabilitation centers should complete the epilepsy surgery program [10].

## DECISION-MAKING

The success of any surgical procedure for epilepsy first depends on a careful selection of the surgical candidates.

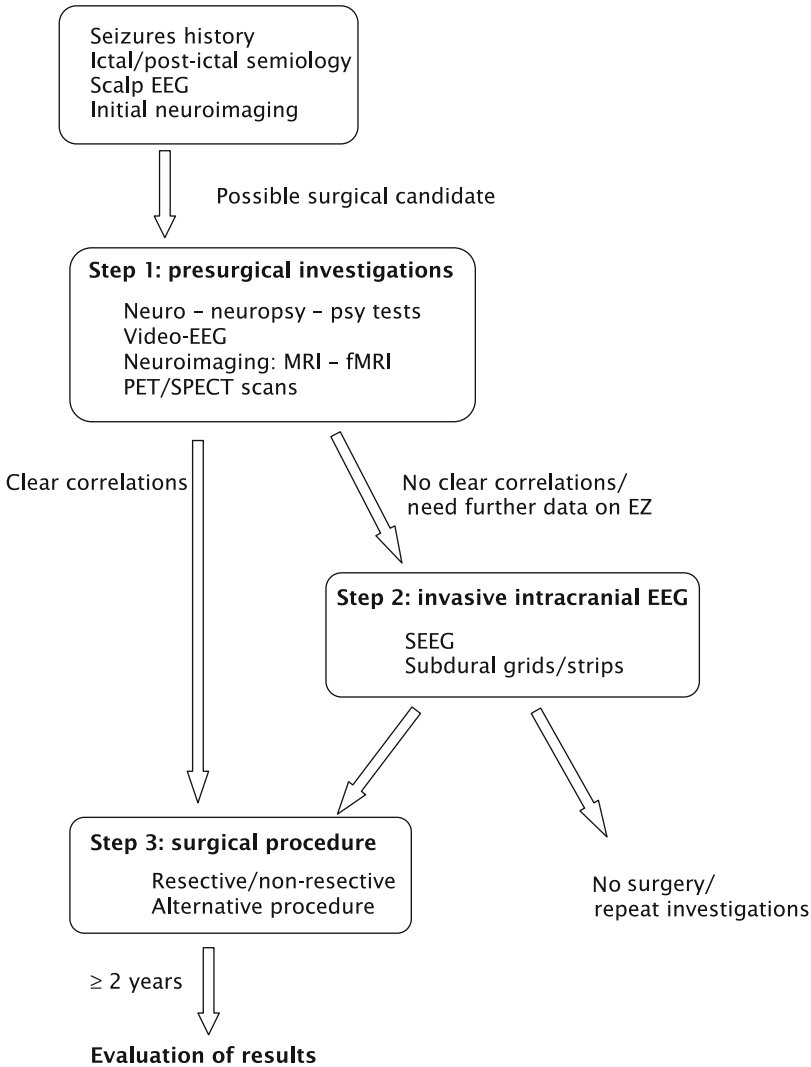
Figure 1 illustrates the general strategy leading to surgery as well as a more detailed surgical strategy depending on location and etiology of epilepsy.

Initial evaluation, that first selects patients who are felt to be surgical candidates includes a careful clinical evaluation with patient's and relatives' medical history, seizure semiology description (and when possible, seizure observation), scalp EEG, and initial imaging including CT and MRI scans. Based on this evaluation, most patients would be classified into one epileptic syndrome potentially curable by surgery. If so, selected patients will enter into a surgical program made of three steps.

*Step one* is the presurgical non-invasive investigations. They include a correlative analysis of collected clinical data, spontaneous-seizure monitoring using video-EEG, high-resolution neuroimaging including additional MRI sequences (T2, Flair, DTI, 3-D T1 with special attention to cortical abnormalities), functional MRI (for language dominance and other functions when necessary), functional imaging ( $[^{18}\text{F}]$ fluorodeoxyglucose [FDG] PET scan,

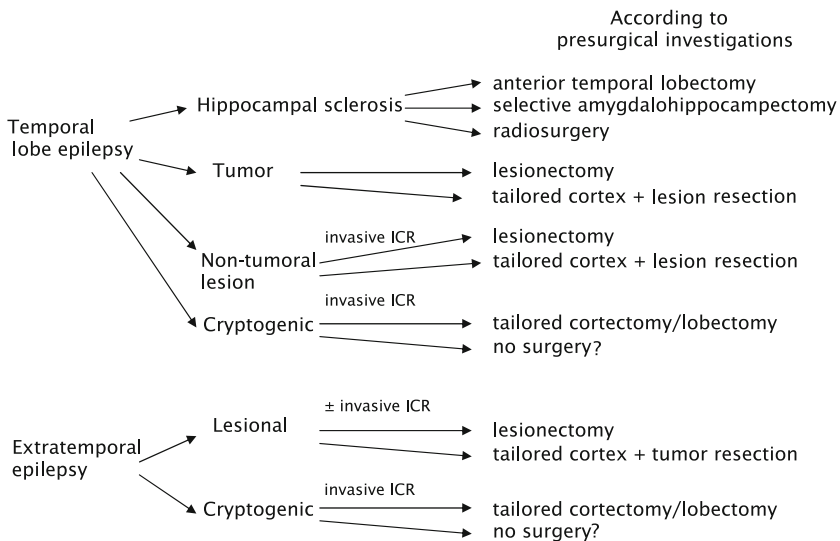
SPECT, co-registered with MRI), neuropsychological tests and psychiatric evaluation. When all data are concordant – in most patients with mesial temporal lobe epilepsy associated with hippocampal sclerosis, for example –, surgical decision is easy and the appropriate procedure corresponding to presurgical investigations data (*step three*) will be offered to the patient. Con-

**a) General strategy in patients presenting with partial intractable epilepsy**



**Fig. 1.** Decision making in adult partial chronic epilepsy. *EZ* Epileptogenic zone, *ICR* intracranial recordings

**b) Detailed resection strategy according to etiology, location, and data from the preoperative investigations.**



**Fig. 1.** (Continued)

versely, if not all data are concordant, or when additional information about the epileptogenic zone and intracranial seizure patterns are necessary for the surgical strategy, invasive intracranial recordings are indicated [5, 20].

*Step two* is invasive intracranial recordings and comprise different methods of intracranial electrodes placement and EEG abnormalities recordings. They include semi-invasive (sphenoidal and epidural electrodes) with a limited yield of informations, and invasive procedures with surgical implantation of subdural grids or strips of flat electrodes covering the cortical surface, and depth semi-rigid intracerebral electrodes. We favour the latter technique – the SEEG – that allows a real three-dimensional analysis of interictal and ictal events patterns. Depth electrodes are able to record abnormalities directly from deep cortex (i.e. mesial cortex, depth of sulci, insular cortex, etc.) through a well-tolerated procedure.

Currently, in reference centers for epilepsy surgery, about one third of patients still necessitate invasive intracranial recordings, a rate due to referral biases with difficult cases and complex seizure patterns, or failures from previous surgery [5].

*Step three* is the choice of the most appropriate procedure in a particular patient, according to the characteristics of his or her epilepsy.

Patients with TLE associated with hippocampal sclerosis will be offered anterior temporal lobectomy (variations in resection extent may depend on individual epilepsy patterns), selective amygdalohippocampectomy, or in

selected cases radiosurgery. TLE associated with a tumor will lead to a resection limited to the image-defined tumor volume (lesionectomy) or a larger resection; TLE associated with non-tumoral lesions may also lead to lesion resection or lobar resection, depending on preoperative evaluation that may include invasive intracranial recordings. Cryptogenic TLE should lead to invasive recordings that would guide a tailored temporal lobectomy or reject surgery if widespread or bitemporal abnormalities.

Patients with extratemporal epilepsy will also be offered lesionectomy, extended lesion resection, tailored cortectomy, or lobar or multilobar resection depending on lesional or cryptogenic epilepsy and the findings of pre-surgical investigations.

According to all reported results following surgery for chronic epilepsy, the best candidates – in whom the highest rate of seizure freedom is anticipated – are MTLE associated with hippocampal sclerosis and temporal or extratemporal lesion-related epilepsy. However, it should be considered that lesion-related means the presence of an epileptogenic lesion that will be removed and histologically confirmed but not necessarily identified on imaging. Focal cortical dysplasia (FCD) may not appear on MRI scans and be misdiagnosed as cryptogenic epilepsy, ensuing with inadequate surgical strategy. Negative MRI should, in patients with extratemporal epilepsy and clinical presentation and video-EEG suggestive of a FCD, lead to further investigations, with FDG PET scan (searching a focal hypometabolism) and SEEG (that will show specific patterns if an electrode is implanted within the dysplasia) [3].

## **SURGICAL PROCEDURES AND OPERATIVE TECHNIQUES**

### **1. GENERAL CONSIDERATIONS**

Surgical techniques are divided into resective techniques – the most widely used, including standardized and customized resections – and non-resective ones, including disconnective techniques – hemispherotomy, corpus callosotomy, multiple subpial transections –, radiosurgery and neuromodulation techniques – deep brain stimulation of various intracerebral targets and vagus nerve stimulation. In addition, recently developed techniques such as lobar or selective disconnections, endoscopic resection/disconnection of hypothalamic hamartomas and multiple focal thermocoagulation techniques are still under evaluation.

Surgical environment is the one of conventional neurosurgery. Helpful tools include operative microscopic magnification, neuronavigation guidance and cortical/subcortical stimulation techniques for resections in eloquent areas. The additional value of intraoperative MRI in resection extent determination awaits further evaluation. Awake craniotomy and resection can be used for lesion resection in language areas. Intraoperative electrocorticogra-

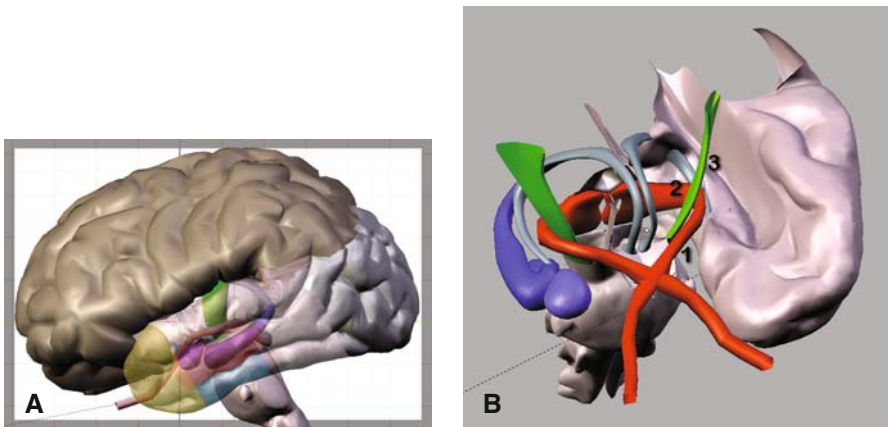
phy is still performed in some centers as a guide to resection, although obtained abnormalities are local, limited in time, and modified by operative conditions. The benefit of its use remains debated [14]. Intraoperative neuropathological examination of resected specimen may be helpful in patients with a lesion poorly limited macroscopically, as are focal malformations of cortical development; however, histological intraoperative techniques are not sufficient for identification of structural and architectural abnormalities.

## 2. TECHNIQUES FOR TEMPORAL LOBE RESECTIONS

*Anterior temporal lobectomy (ATL).* ATL may be standardized or tailored according to individual epilepsy patterns obtained from preoperative investigations.

Figure 2A illustrates the temporal lobe regions that are usually resected in anteromesial TLE.

Under general anesthesia, patients are in supine position with ipsilateral elevated shoulder and 70°–80° rotation of the head with minor downward bending using a Mayfield-Kees headclamp. Hair shaving may be limited to the incision line, starting from the zygomatic arcade to the lateral frontal area with no or minimal incision frontally to the hairline. Osteoplastic or pediculated temporal flap allows for exposing the anterior two-thirds of the temporal lobe.



**Fig. 2.** Three-dimensional brain surface rendering, illustrating the basic scheme of a temporal lobectomy for anteromesial temporal lobe epilepsy. **A** Lateral view. Through temporal lobe transparency, the amygdala, hippocampus (dark blue) and pyramidal tract (green) are visible. Large variations are observed in resection extent, from a limited mesial structure – entorhinal cortex, amygdala, hippocampus and parahippocampal gyrus – to a large standardized lobectomy, but in most cases the temporal pole (yellow), basal cortex (light blue), mesial structures (red) are removed. **B** Antero-inferior view. Neurovascular structures located close to the mesial aspect of the temporal lobe and potential sources of postoperative complications when injured: posterior cerebral artery, anterior choroidal artery, optic tract (1), lateral geniculate body (2), pyramidal tract in the mesencephalon (3)



Microsurgical resection includes successively the lateral neocortex, the temporal pole and basal cortex – making easier the hippocampal resection – and then mesial structures: uncus, amygdala, hippocampus and parahippocampal gyrus. Once the pole has been resected down to the rhinal sulcus, the anterior part of uncus and the amygdala (identified by its color and presence of numerous capillaries) is resected. The anterior part of the temporal horn of the ventricle is then opened and widened posteriorly to get access to the hippocampus. The anterior two-thirds of the hippocampus are resected en bloc, the posterior limit corresponding to a frontal plane passing through the quadrigeminal plate. The hippocampus is separated from the parahippocampal gyrus (subiculum) by incision of the arachnoid of the hippocampal sulcus. The parahippocampal gyrus is then resected along with the posterior aspect of the uncus, with a posterior limit also corresponding to the quadrigeminal plate. The resection of uncus and parahippocampal gyrus can be performed using the CUSA, taking care to preserve as completely as possible the arachnoid membrane covering the major neurovascular structures lying underneath, from front to back and below to upper: intracranial portion of the carotid artery, posterior communicating artery and second segment of the posterior cerebral artery, oculomotor nerve running below the tentorial edge, and anterior communicating artery, basilar vein and optic tract joining posteriorly the lateral geniculate body, visible immediately above the choroidal fissure at the posterior level of hippocampal resection. Similarly, the lateral aspect of the optic tract represents the upper limit of uncus resection. A particular care should be taken to avoid any mechanical or ischemic (using bipolar coagulation) lesion of all these structures (Fig. 2B). When preoperative investigations suggest a rapid seizure spread to frontal lobe or to insula or perisylvian areas, the cortex corresponding to the lower bank of area tempesta (at the contact of lower border of middle cerebral artery), preserving the perforating branches of the MCA, and of the 15–20 mm anterior of the lower insular cortex should be resected.

*Other techniques of anterior temporal lobectomy* are also described. Standard en bloc or staged temporal lobectomy classically includes the resection described above associated with lateral and basal cortex with a posterior limit that depends on the side of surgery according to the hemispheric dominance: 4–6 cm from the temporal pole on average on the non-dominant and 3–5 cm on the dominant, in order to avoid language areas [1, 18].

*Selective amygdalohippocampectomy* is a selective technique developed first by Niemeyer in Brazil and then by Yaşargil in Zurich for the surgical treatment of pure mesial TLE. Resection is limited to mesial structures (amygdala, hippocampus and parahippocampal gyrus) in order to completely preserve temporal neocortex in a functional perspective. The surgical route is transsylvian – with dissection of the sylvian fissure and a 10–15 mm incision of the inferior insular cortex, temporal stem and opening the roof of the temporal horn of the ventricle, before en bloc resection of mesial structures [26].

Other approaches, in particular lateral transcortical – with a 2 cm incision through the middle temporal gyrus directed towards the ventricle – have also been described, with minimal neocortical injury and reduced risks of vascular injury associated with transsylvian route [5].

### 3. TECHNIQUES FOR EXTRATEMPORAL RESECTIONS

They depend mostly on the presence of an imaging-defined epileptogenic lesion. The question – that remains unsolved – is to determine whether the resection should be limited to the image-defined lesion volume or be performed on a larger area or whether an electrophysiological intraoperative monitoring would increase the probability of favorable seizure outcome.

*Lesionectomy.* An epileptogenic lesion, such as indolent tumor, identified FCD, vascular malformation, and scar, should be resected as completely as possible to obtain the highest chance of seizure freedom; incomplete resection is usually reported as a factor associated with poor seizure outcome in statistical analyses [1].

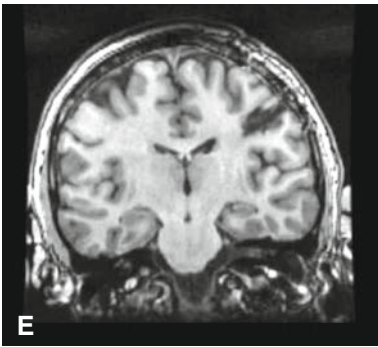
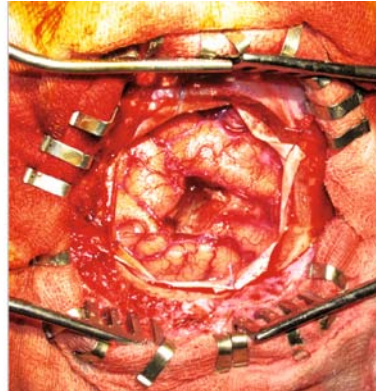
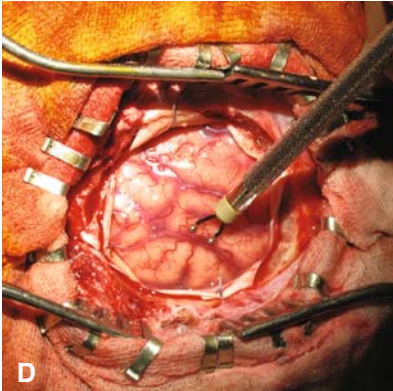
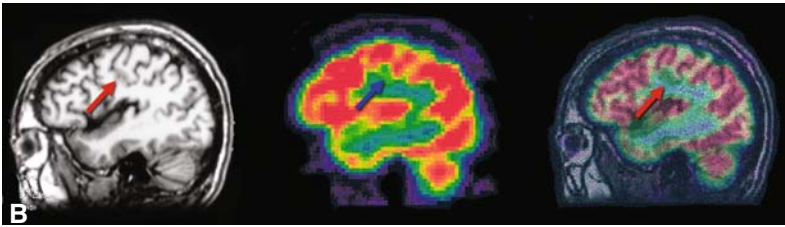
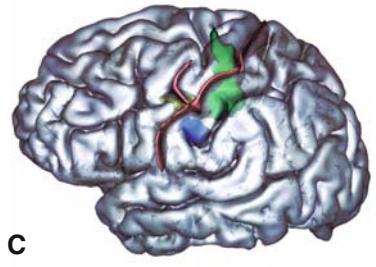
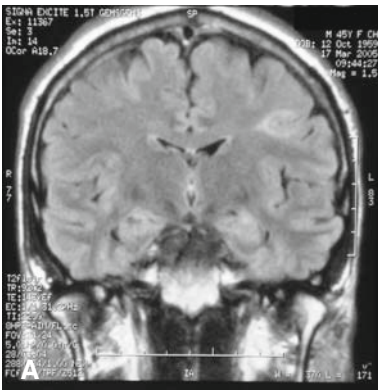
Lesionectomy requires a standard microsurgical technique, but caution should be made to minimize tissue fragmentation for adequate tissue neuropathological examination. In eloquent areas, indolent tumors, such as dysembryoplastic neuro-epithelial tumors [4] and gangliogliomas and also FCD can be safely removed, since no functional tissue has been, in our experience, found within the lesion, either on preoperative fMRI or intraoperative cortical and subcortical stimulation mapping [5]. Figure 3 illustrates a lesionectomy for a Taylor type focal cortical dysplasia (TTFCD) of the sensorimotor cortex.

*Non-lesional resections: tailored cortectomies.* Cryptogenic epilepsy is much more difficult to cure than lesion-related epilepsy. Complete seizure relief is possible in patients in whom the epileptogenic cortex remains focal. In these patients, the surgical strategy is closely dependent on a thorough correlative study of clinical and video-EEG data, abnormalities on functional imaging, and findings of SEEG or any other intracranial recordings [11].

*Extended lobar and multilobar resections.* These large tailored resections are rarely followed by seizure-free outcome, although a significant seizure reduction can be obtained. Like with tailored cortectomies, such resections are based on detailed preoperative investigations including intracranial recordings.

### 4. RADIOSURGERY

Radiosurgical procedures have been initially developed to treat MTLE as a less invasive resective-like procedure. A single dose of high energy photons, from cobalt-60 sources (Gamma knife) or a linear accelerator, is delivered to a specific intracerebral target with a specific volume and shape, using a stereotactic frame for target localization.



Currently, radiosurgery has demonstrated an efficacy for treatment of MTLE and hypothalamic hamartomas causing partial epilepsy with gelastic seizures [15]. The MTLE targets are the mesial structures. Delivered peripheral doses are 18 Gy for MTLE and 17 Gy for hypothalamic hamartomas. Reported results are comparable to those obtained after surgical resection, although an increase of auras is often reported by patients between the 8th and the 18th month following radiosurgery [16].

## 5. OTHER NON-RESECTIVE PROCEDURES

They include several techniques of cerebral disconnection. Their indications are currently limited to specific cases. They include hemispheric disconnections – procedures commonly performed in children –, multiple subpial transections that can be performed alone or in combination with a resection or lobar disconnections.

*Hemispherotomy* has replaced hemispherectomy, a procedure performed to treat epilepsy in the 50s. Hemispherotomy is indicated for the treatment of hemispheric epileptic syndromes, such as hemimegalencephaly, extensive hemispheric cortical dysplasias, Rasmussen's encephalitis, infantile hemiplegia caused by perinatal brain injury, Sturge-Weber syndrome. Several approaches have been described (vertical parasagittal, periinsular, transsylvian), all of them consist of a complete disconnection of all lobes from basal ganglia and internal capsule, including a complete callosotomy, through white matter incisions and minimal parenchyma resection [24].

*Corpus callosotomy* is also an old technique for treatment of epilepsy. Indications include tonic and atonic seizures, tonic-clonic seizures, atypical absences, in patients not fulfilling criteria for resective surgery. The technique consists of a complete vertical section, through a frontal parasagittal route, of anterior two-thirds of the corpus callosum. Neuronavigation is helpful to control the posterior limit of the section. This procedure is rarely performed alone (most often in combination with a frontal resection or as a part of a hemispherotomy), since vagus nerve stimulation, a much less invasive technique, has been offered in patients with similar seizure patterns.

**Fig. 3.** Focal resection in central region for Taylor type focal cortical dysplasia (TTFCD) in a 46-year-old patient with a 39-year history of right hemifacial and upper extremity motor seizures. **A** Coronal FLAIR MRI shows left central signal abnormalities. **B** <sup>18</sup>F-DG PET scan co-registered with MRI shows an area of focal PET hypometabolism corresponding to an area of thickened cortex frontal to the central sulcus, typical for a TTFCD. **C** Surface rendering obtained from 3-D T1 sequences co-registered with functional MRI, showing the central sulcus extraction (red), location of the area of TTFCD (yellow), face (blue) and upper extremity (green) motor activation maps. **D** Intraoperative views: a circular craniotomy allows for a limited exposure of the central region; cortical stimulation of the anterior bank of the central sulcus (*left*) and after the focal resection (*right*). **E** Postoperative MRI shows a focal resection limited to the dysplastic tissue. The patient has been completely seizure-free for 3 years without any neurological sequelae except for a slight facial hypesthesia

*Multiple subpial transections* is an intracortical disconnective technique that consists of multiple linear parallel incisions of the cortex in order to interrupt horizontal intracortical connecting fibers responsible for discharge spread to adjacent cortical areas and synchronization leading to seizure generation, while preserving ascending and descending fibers that bear major cortical functions. They are indicated in patients with epilepsy originating from non-lesional cortex in a functional area, such as language, motor, sensory or visual areas, when a resection would lead to unacceptable deficit. Other indications are epileptic syndromes such as Landau-Kleffner syndrome. The technique consists in performing parallel incisions at 5 mm intervals along the gyri exhibiting electrocorticographically recorded epileptiform activity, sparing the pial surface and cortical blood supply. Incisions are performed using a surgical hook after a puncture of the arachnoid and pia of each gyrus, the tip being oriented underneath the pial surface. Multiple subpial transections can be performed either as a single procedure or as a complement of a surgical resection in patients with large epileptogenic zone partially involving functional areas [8].

*Lobar temporal disconnections* are an alternative to temporal lobectomy, using the same principles as hemispherotomy but limited to the temporal lobe, with indications and results similar to those for temporal lobectomy. *Intralobar disconnections*, such as hippocampal transections, are still under evaluation.

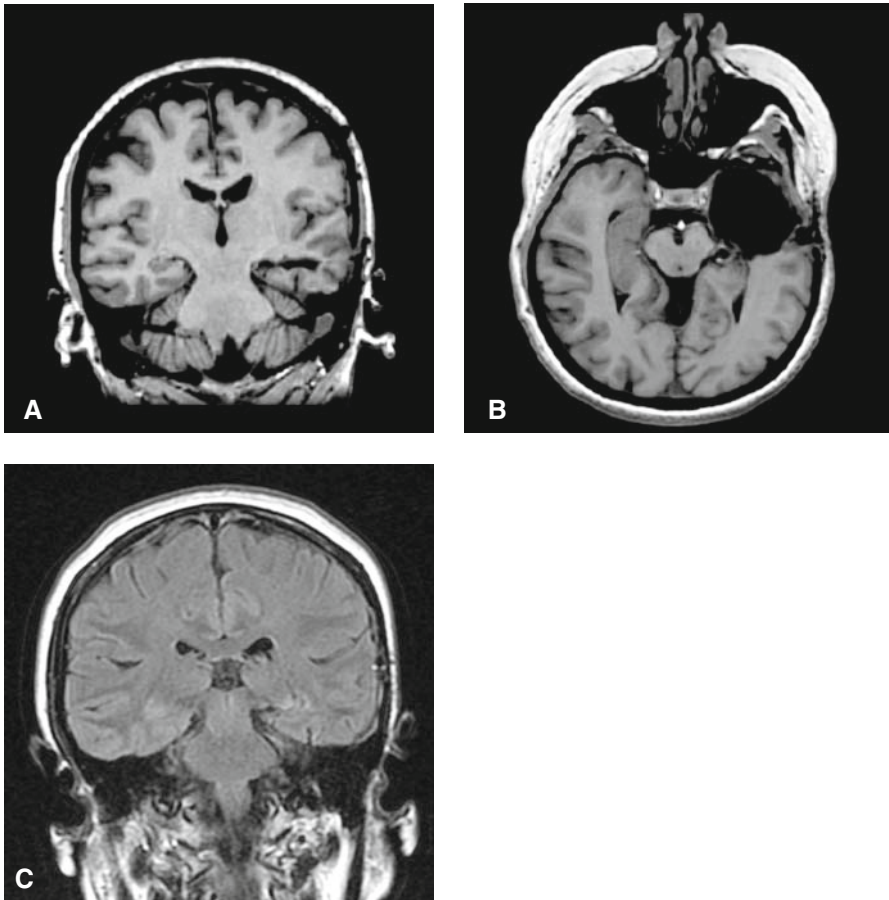
## 6. NEUROMODULATION TECHNIQUES

Some specialized centers have developed neuromodulation techniques; few are standardized and validated in a large population. These are palliative procedures, the seizure control depending on a functional implantable deep brain stimulation (DBS) device. Neuromodulation is based on experimental observations of a subcortical control of cortical excitability or of inhibitory effect on a brain structure by high-frequency stimulation or of an activation effect by a low-frequency stimulation or of an interruption of cortical epileptic activity by inhibition of subcortical structures.

Multiple intracranial targets for chronic DBS have been experienced, since the original work of Irvin Cooper on cerebellar stimulation reported in 1973: paravermian cortex of the cerebellum, centrum medianum – parafascicular nucleus of the thalamus, subthalamic nucleus, anterior ventral nucleus of the thalamus, hippocampus and recently direct cortical stimulation of epileptogenic cortex located in functional areas. High frequency (130 Hz) is used for most targets, low frequency (10–40 Hz) is used for cerebellar stimulation. Chronic DBS electrodes are bilaterally stereotactically implanted and connected to a subcutaneous subclavicular pulse generator. Indications include patients with partial epilepsy from various origin and not candidates for resective procedures because of multiple, extensive or poorly defined epileptogenic zone [22, 23].

## 7. VAGUS NERVE STIMULATION

Vagus nerve stimulation is a palliative procedure that will not be described in details in this chapter. Indications include partial epilepsies with or without secondary generalization, in patients not candidates for resective surgery



**Fig. 4.** Six months postoperative MRI scan following left side temporal lobectomy in a 35-year woman presenting with a left MTLE associated with hippocampal sclerosis. Anterior, basal and mesial temporal structures were removed. **A** 3-D SPGR sequence in the coronal plane, showing posterior mesial structures resection and preserved basal cortex. **B** 3-D SPGR sequence in the hippocampal axial plane, revealing the extent of hippocampal resection. **C** FLAIR sequence in the coronal plane, passing immediately posterior to the resection cavity and showing minimal injury to surrounding brain. **D** Preoperative (*left*) and postoperative (*right*) 3-D surface rendering of the left hemisphere showing the resection of the anterior third of the superior temporal gyrus and larger resection of the middle and inferior temporal gyrus and mesial structures

because of excessive risk of functional deficit, widespread or multifocal epileptogenic zone, or bilateral seizure onset. Operative technique consists of left cervical incision, left vagus nerve dissection at the posterior aspect of the vascular stem, and placement of a spiral electrode around the nerve, followed by a subcutaneous placement of an extension connected to a pulse generator which is usually placed below the clavicle or better in the axillary through a hidden incision behind the pectoralis major muscle. Usual stimulation parameters are cyclic stimulation (30 s on, 5 min off), 0.75 to 2 mA, 30 Hz, 250–500  $\mu$ s pulses [17].

## 8. POSTOPERATIVE CARE

Postoperative care includes a one-day intensive care follow-up in most temporal lobe operated patients, immediate administration of usual antiepileptic drug (AED) treatment associated with intravenous clonazepam (2–3 mg/day) to avoid early postoperative seizures. Control CT or MRI scan is performed within one week after surgery. Postoperative controls are made at 2, 6 and 12 months postoperatively, then every year. Postoperative evaluation at 6 months include MRI scan, scalp EEG, and repeated neuropsychological tests (Fig. 4). AED discontinuation is usually initiated after 2 years of seizure freedom, with progressive suppression of a first AED followed by others, over a time range depending on patient age, preoperative duration on epilepsy, severity and frequency of seizures, and postoperative EEG patterns.

## RESULTS

Temporal lobe resections are the most performed procedures and account for 77–87% of all resective procedures, while extratemporal resections account for 13–19% [5].

Results after surgery consider first the seizure outcome, expressed according to the widely used Engel's scale [6]. The functional outcome with respect to neurological, neuropsychological and psychiatric status is an important part of the social and personal benefit following surgery. In addition, the management of AEDs should be considered in the seizure outcome. Complete evaluation of the outcome after surgery for epilepsy should include all these parameters.

Results should of course be expressed according to the length of the follow-up. After an initial period of seizure freedom, recurrent seizures may occur, usually within the first postoperative year, although late recurrences can also be observed.

Table 1 summarizes the global results after temporal lobe and extratemporal resections, according to recent large institutional series, multicenter surveys and meta-analyses.

**Table 1.** Results of epilepsy surgery among recent single institution large series, multi-center study and literature reviews

Disorder, author, year	No. of patients	Study type	% Patients with seizure outcome:	
			Class I	Class IA
<b>Temporal lobe epilepsy</b>				
Engel et al., 1993	3579	MCS	67.9	–
Bien et al., 2001	148	ICS C	–	44.6
Clusman et al., 2002	279	ICS	70.7	–
Jutila et al., 2002	140	ICS	56	46
Salanova et al., 2002	215	ICS	69	–
Engel et al., 2003	1952	MA	67	–
Wieser et al., 2003	453	ICS	67	57
Tellez-Zenteno et al., 2005	3895	MA	66	–
Spencer S. et al., 2005	297	MCS	68	56
Dupont et al., 2006	183	ICS	71	48
Sindou et al., 2006	100	ICS	85	74
Devaux et al., 2008	1221	MCS	80.6	56.7
<b>Extratemporal epilepsy</b>				
Engel et al., 1993	805	MCS	45.1	–
Zentner et al., 1996	60	ICS	54	–
Engel et al., 2003	298	MA	50	–
Tellez-Zenteno, 2005	169	MA	34	–
Spencer et al., 2005	42	MCS	50	–
Devaux, 2008	267	MCS	66	44

ICS Institutional case series; MA meta-analysis; MCS multicenter survey; C controlled

For TLE, recent meta-analyses report a 66% long-term seizure freedom, although higher percentages (over 80% of patients) are reported from single centers or in multicenter-based studies. In extratemporal epilepsy, results are more variable due to smaller number of patients and various etiologies and techniques, and generally less favorable seizure-free rates (around 50%) are expected postoperatively [7, 19, 21].

However, those global results do not reflect the large variability of seizure outcome in subgroups of patients depending on seizure patterns, etiology, extent of epileptogenic zone that are identified on preoperative investigations. As an example, extreme outcomes with respect to seizures are observed in cryptogenic extratemporal epilepsy (less than 40% Class I), while a complete resection of extratemporal TTFCD may be followed by a 90–95% seizure-free rate [5].

Despite current excellent seizure outcome following most resective techniques and extensive and up-to-date investigations, there is still 15–30% of patients with TLE, and even more on a long-term observational period, and



40–60% of patients with extratemporal epilepsy who are not rendered seizure-free after surgery.

Early seizure recurrence is usually due to inadequate resection or procedure, misinterpretation of preoperative data leading to a wrong identification of localization and/or extent of the epileptogenic zone, and a misdiagnosed multifocal epilepsy or widespread epileptogenic zone [1].

Predictive factors of late recurrence include longer preoperative duration of epilepsy, absence of image-defined lesion and specific lesion on pathological examination of resected specimen, and occurrence of early postoperative seizures [13]. More specifically, a higher likelihood of seizure recurrence after temporal lobectomy includes history of head injury or encephalitis, late seizure onset, several types of seizures. After extratemporal resection, normal neuroimaging and absence of pathology is associated with higher risk of seizure recurrence [27]. The risk of late recurrence in seizure-free patients may warrant continuation of AEDs in patients with higher risk, although there is no evidence in the literature for such recommendation.

Reoperation is a valid option for those patients in whom a clearly inappropriate resection has been performed. Additional structural lesion or mesial temporal or neocortical structures resection, following repeated and careful preoperative investigations, may lead to a seizure-free outcome, reportedly in half of the reoperated patients [1, 12].

Surprisingly, shorter experience in epilepsy surgery is not associated with significantly higher rate of failures, when using an appropriate selection of candidates. Longer experience is also associated with referral of more complex cases, of more risky procedures such as those in functional areas or of more indications for palliative methods.

## HOW TO AVOID COMPLICATIONS

1. *General complications* include postoperative hematomas that do not differ in severity and causes from those observed in general neurosurgery, hydrocephalus especially in older patients, infections in 2% of patients, and thromboembolic complications more frequently in patients older than 50 years. Aseptic meningitis is not uncommon after temporal lobectomy, it does not require antibiotics and resolves spontaneously within a few days [9]. We found a 5% rate of general complications in our 2008 multicenter survey totaling more than 2600 patients [5].

2. *Functional complications* include those from invasive intracranial recordings and from surgical resections.

*Complications from invasive intracranial recordings.* Complications from the use of depth electrodes include hemorrhage (1–3% requiring surgical evacuation or causing neurological deficit) and infection (1–5%).

With grid or strip electrodes, subdural bleeding is rare, but infection occurs more frequently (1–7%) [2, 5]. Careful implantation planning of intracranial electrodes avoiding surface and sulcal vessels – especially veins – for depth electrodes and bridging cortico-dural veins for subdural grids would limit the occurrence of hemorrhagic complications, while a rather short duration of recordings would limit the occurrence of infection. In our experience, invasive recordings in a patient should better not exceed five days.

*Neurological side effects and complications* from surgical resections may be transient or permanent.

*Expected side effects of temporal lobe resections* include visual field defects, language disturbances and verbal memory deficits when performed on the dominant side, non-verbal memory deficits on the non-dominant side.

Visual field defects are usually contralateral superior quadrantanopsia that resolves partially in a few months; it is due to the opening of the temporal horn which interrupts Meyer's loop optical fibers. Quadrantanopsia is not disabling; car driving can be permitted, while complete contralateral hemianopsia is a severe complication. Hemianopsia is caused by two major mechanisms: (1) surgical trauma of the optic tract or of the lateral geniculate body during the resection of the mesial aspect of the hippocampus (lateral geniculate body lies just underneath the fimbria in the surgical position) or (2) anterior choroidal artery occlusion (most often by inadvertent coagulation). Careful dissection of these structures may be difficult in patients with severe hippocampal and mesial structure scleroses that are firm and adherent to the arachnoid membrane protecting the basal vessels and nerves. Avoidance of coagulation of any vessels except small pial branches can prevent such complications.

Importantly, a limited anterior opening of the ventricle does not produce any visual field defect.

Aphasia is likely to occur if the temporal neocortical resection extends posteriorly beyond the anterior third of the superior temporal gyrus. In patients with limited resection of this gyrus a mild transient aphasia may occur, resolving within a few days. Awake craniotomy may help to prevent this complication; however, no permanent aphasia is expected if the neocortical resection of the superior temporal gyrus is limited.

Verbal memory deficits are observed in 10–60% of patients operated on the temporal lobe, due to limbic structures resection.

*Hemiparesis or hemiplegia* is not expected after temporal lobectomy. They may be caused by mechanical injury of the mesencephalon during resection of mesial structures, or by anterior choroidal artery occlusion, which leads to severe long-standing hemiplegia and permanent hemianopsia [1].

*Expected side effects following extratemporal resections* depend on their location. When performed in eloquent areas, a hopefully transient deficit, complete or incomplete, is anticipated, due to brain tissue dis-

section, retraction, dessication, resolving usually within days or weeks. Supplementary motor area deficits may last 2–3 weeks and then resolve rapidly. Inferior precentral cortex resection is associated with a transient facial paresis that also resolves in a few weeks. Superior precentral cortex resection is associated with a permanent motor (and sometimes sensory) deficit and should be avoided. When an epileptogenic lesion should be removed in those regions, careful microsurgical dissection under cortical/subcortical stimulations helps to avoid such permanent unacceptable deficits.

*Psychiatric side effects or complications* from epilepsy surgery occur in 2–40% of the patients; they include acute psychosis, anxiety or depression. The risk of suicide is increased postoperatively. Preoperative personality disturbances are predictive of postoperative psychiatric complications. Other psychiatric disorders such as schizophrenia and obsessive compulsive disorder are less frequent.

In our survey, we found a 4.3% complication rate for invasive recordings and a 8% global rate of surgical complications among 14 centers and more than 2600 patients: 3.7% were minor disabling, 1.6% were major but without disabling sequelae and 2.7% were major with permanent disabling sequelae.

## CONCLUSIONS

MTLE associated with hippocampal sclerosis and lesion-related temporal and extratemporal epilepsy – especially if associated with a congenital tumor and a focal cortical dysplasia – represent the most favorable indications for resective surgery with 80–95% chances of postoperative seizure relief.

Epilepsy surgery requires a dedicated multidisciplinary team. Besides technical skills, epilepsy surgery requires, as any functional neurosurgery, additional particular care beyond medical and surgical treatment. Healthcare networks and psychosocial rehabilitation are necessary and contribute to a global outcome in those incapacitated patients.

The future of epilepsy surgery belongs to curative minimally resective procedures, better sparing functional brain. Alternative procedures, such as radiosurgery, stereotactically guided thermocoagulations or MRI-guided focal lesioning, will be offered to patients.

Because most partial chronic epilepsies have their onset during childhood, and better results on both seizures and developmental, social and personal outcomes are expected after early surgery, epilepsy surgery should be more extensively promoted in children and young adulthood although excellent results may also be observed in adults after a long-standing focal epilepsy.

## References

- [1] Awad I (1992) Anatomic considerations in temporal lobe surgery. In: Luders HO (ed) *Epilepsy surgery*. Raven, New York, pp 547-558
- [2] Behrens E, Schramm J, Zentner J, König R (1997) Surgical and neurological complications in a series of 708 epilepsy surgery procedures. *Neurosurgery* 41: 1-10
- [3] Chassoux F, Devaux B, Landre E, Turak B, Nataf F, Varlet P, Chodkiewicz JP, Daumas-Duport C (2000) Stereoelectroencephalography in focal cortical dysplasia: a 3D approach to delineating the dysplastic cortex. *Brain* 123: 1733-1751
- [4] Daumas-Duport C, Scheithauer BW, Chodkiewicz JP, Laws E Jr, Vedrenne C (1998) Dysembryoplastic neuroepithelial tumor: a surgically curable tumor of young patients with intractable partial seizures. Report of thirty-nine cases. *Neurosurgery* 23: 545-556
- [5] Devaux B, Chassoux F (eds) (2008) *Les traitements chirurgicaux de l'épilepsie (Surgical treatments of epilepsy)*. *Neurochirurgie* 54(3)
- [6] Engel J Jr, Wiebe S, French J, Sperling M, Williamson P, Spencer D, Gumnit R, Zahn C, Westbrook E, Enos B (2003) Practice parameter: temporal lobe and localized neocortical resections for epilepsy: report of the Quality Standards Subcommittee of the American Academy of Neurology, in association with the American Epilepsy Society and the American Association of Neurological Surgeons. *Neurology* 60: 538-547
- [7] Engel J Jr, Van Ness P, Rasmussen T, Ojemann L (1993) Outcome with respect to epileptic seizures. In: Engel J Jr (ed) *Surgical treatment of the epilepsies*, 2nd edn. Raven, New York, pp 609-621
- [8] Fisher R, Uthman B, Ramsay RE, Penry JK, Morrell F, Velasco F, Velasco M, Wilder BJ, Whistler W, Krauss G, Davis R (1993) Alternative surgical techniques for epilepsy. In: Engel J Jr (ed) *Surgical treatment of the epilepsies*, 2nd edn. Raven, New York, pp 549-564
- [9] Girvin J (1992) Complications of epilepsy surgery. In: Luders HO (ed) *Epilepsy surgery*. Raven, New York, pp 653-660
- [10] Luders HO (ed) (1992) *Epilepsy surgery*. Raven, New York
- [11] Olivier A, Awad I (1993) Extratemporal resections. In: Engel J Jr (ed) *Surgical treatment of the epilepsies*, 2nd edn. Raven, New York, pp 489-500
- [12] Polkey C, Awad I, Tanaka T, Wyler A (1993) The place of reoperation. In: Engel J Jr (ed) *Surgical treatment of the epilepsies*, 2nd edn. Raven, New York, pp 663-667
- [13] Primrose D, Ojeman G (1992) Outcome of resective surgery for temporal lobe epilepsy. In: Luders HO (ed) *Epilepsy surgery*. Raven, New York, pp 601-611

- [14] Rasmussen T (1983) Surgical treatment of complex partial seizures: results, lessons and problems. *Epilepsia* 24(Suppl 1): S65-S76
- [15] Regis J, Bartolomei F, Rey M, Hayashi M, Chauvel P, Peragut JC (2000) Gamma Knife surgery for mesial temporal lobe epilepsy. *J Neurosurg* 93(Suppl 3): 141-146
- [16] Regis J, Arkha Y, Yomo S, Bartolomei F, Peragut JC, Chauvel P (2008) Rôle de la radiochirurgie Gamma Knife dans le traitement des épilepsies pharmacorésistantes: situation actuelle, résultats et perspectives (Radiosurgery for drug-resistant epilepsies: state of the art, results and perspectives). *Neurochirurgie* 54: 320-331
- [17] Roux FX, Turak B, Landré E (2008) Stimulation chronique du nerf vague dans le traitement de l'épilepsie pharmacorésistante (Vagus nerve stimulation for the treatment of refractory epilepsy). *Neurochirurgie* 54: 332-339
- [18] Spencer D, Ojemann G (1993) Overview of therapeutic procedures. In: Engel J Jr (ed) *Surgical treatment of the epilepsies*, 2nd edn. Raven, New York, pp 455-471
- [19] Spencer SS, Berg AT, Vickrey BG, Bazil CW, Shinnar S, Langfitt JT, Walczak TS, Pacia SV (2005) Predicting long-term seizure outcome after resective epilepsy surgery. The Multicenter Study. *Neurology* 65: 912-918
- [20] Talairach J, Bancaud J (1974) Stereotaxic exploration and therapy in epilepsy. In: Vinken PJ, Bruyn GW (eds) *The epilepsies. Handbook of clinical neurology*, vol 15. North-Holland, Amsterdam, pp 758-782
- [21] Tellez-Zenteno JF, Dhar R, Wiebe S (2005) Long-term seizure outcomes following epilepsy surgery: a systematic review and meta-analysis. *Brain* 128: 1188-1198
- [22] Velasco F, Velasco M, Jimenez F, Velasco AL, Brito F, Rise M, Carrillo-Ruiz JD (2000) Predictors in treatment of difficult to control seizures by electrical stimulation of the centromedian thalamic nucleus. *Neurosurgery* 47: 295-304
- [23] Velasco F, Velasco AL, Velasco M, Jiménez F, Carrillo-Ruiz JD, Castro G, Trejo D, Núñez JM (2008) Neuromodulation du système nerveux central dans le traitement des épilepsies I: efficacité et sécurité de la méthode (Central nervous system neuromodulation for the treatment of epilepsy. I. Efficiency and safety of the method). *Neurochirurgie* 54: 418-427
- [24] Villemure JG (1992) Hemispherectomy techniques. In: Luders HO (ed) *Epilepsy surgery*. Raven, New York, pp 569-578
- [25] Wiebe S, Blume WT, Girvin JP, Eliasziw M (2001) A randomised, controlled trial of surgery for temporal-lobe epilepsy. *N Engl J Med* 354: 311-318
- [26] Wieser HG (1986) Selective amygdalohippocampectomy: indications, investigative technique and results. *Adv Tech Stand Neurosurg* 13: 39-133
- [27] Williamson P (1993) Lessons from failures. In: Engel J Jr (ed) *Surgical treatment of the epilepsies*, 2nd edn. Raven, New York, pp 587-591



**Bertrand C. Devaux**

Bertrand C. Devaux is full-time neurosurgeon at Sainte-Anne Hospital in Paris, which is a well-known center for Stereotaxis and Functional neurosurgery, especially in the field of epilepsy surgery. In this center, Talairach and Bancaud developed an original methodology based on clinical, neurophysiological and anatomical correlations, using intracranial depth electrode exploration, the so-called stereoelectroencephalography. Following this institutional experience, Dr. Devaux's particular interests include stereotactic methodology and its various applications: besides epilepsy surgery, tumor biopsies in critical locations, treatment of movement disorders, pain, psychiatric diseases. Major interest is surgical treatment of drug-resistant partial epilepsy, mostly in adults.

**Contact:** Bertrand C. Devaux, PUPH, Service de Neurochirurgie, Centre Hospitalier Sainte-Anne, 1, rue Cabanis, 75674 Paris Cedex 14, France  
E-mail: [b.devoux@ch-sainte-anne.fr](mailto:b.devoux@ch-sainte-anne.fr)

---

# NEUROPHYSIOLOGY APPLIED TO NEUROSURGERY

F. MAUGUIÈRE

## INTRODUCTION

For more than five decades progress in functional neurosurgery has been boosted at every time surgeons and physiologists have accepted the idea that the best way to restore a function, or to control a functional disorder, through a surgical operation, was to share their knowledge and to elaborate together new concepts as well as innovative procedures to the benefit of patients. The two most famous examples of such an efficient collaboration are without doubt the couples formed by Herbert Jasper and Wilder Penfield in Montreal and by Jean Talairach and Jean Bancaud in Paris, who both contributed to settle the principles of epilepsy surgery, but through distinct and complementary approaches that are still a matter of debate nowadays. The same type of collaboration has also permitted significant breakthroughs in neurosurgical treatment of pain and movement disorders.

The neurosurgeon may need also some help from the neurophysiologist when preservation of function is at stake during operation; this is why electrophysiological neuromonitoring during surgery using both recording and stimulation procedures has known a considerable development for the past twenty years. Lastly electrophysiological recordings contribute to the prognosis of coma in intensive care units. In this chapter, we will review only the contributions of clinical neurophysiology to epilepsy and pain surgery and to neuro-monitoring during surgery, because these fields are those where neurophysiology has a direct impact for optimal achievement of neurosurgery.

## ELECTROENCEPHALOGRAPHY (EEG), MAGNETOENCEPHALOGRAPHY, AND INTRACRANIAL EEG IN EPILEPSY

### 1. WHAT DOES ROUTINE SCALP EEG BRING TO THE NEUROSURGEON?

Despite the progress of modern imaging techniques, in particular that of magnetic resonance imaging (MRI), the recording of scalp EEG is still carried out,

---

*Keywords:* clinical neurophysiology, monitoring, mapping, epilepsy, functional neurosurgery

as part of the diagnostic evaluation of patients suffering from epileptic seizures. The idea that EEG might contribute to the diagnosis of the lesion causing epileptic fits has been abandoned since the early seventies, when computerized X-ray tomography (CT) became available in most epilepsy departments. There is however a consensus among epileptologists that the recording of interictal paroxysms known as spikes or spike waves is essential, in combination with the clinical presentation of seizures, to the classification of epileptic syndromes and, particularly, to make the distinction between generalized and partial epilepsies. Because only the latter may be symptomatic of a focal lesion, the presence of focal EEG paroxysms on a routine scalp EEG remains a reliable indicator that a focal lesion must be actively searched for, with the exception of some childhood epileptic syndromes for which the association of focal seizures with focal interictal spiking is the manifestation of a developmental non-lesional benign epileptic syndrome. Focal interictal EEG slow waves also suggest the presence of a causal lesion in this context. More pertinent for the neurosurgeon is the question whether transient interictal EEG paroxysms provide some information regarding the location of neuronal population that produces the seizures, usually referred to as the epileptogenic zone (EZ) in epilepsy surgery literature. In other terms, are focal spikes usable for surgical treatment of the epilepsy itself? Routine scalp EEG is unable to tackle this question without the help of source modeling of interictal spikes.

## **2. SOURCE IMAGING OF EEG AND MEG INTERICTAL PAROXYSMS**

The basic assumption supporting the use of spikes sources imaging for localizing the epileptogenic zone is that the so-called irritative zone, which produces interictal spikes, might be coextensive with that producing the ictal discharges. This assumption is far from being validated by depth recordings of ictal and interictal signals, which rather suggest that in the majority of cases the irritative zone is larger than the EZ.

### **2.1 MEG versus EEG**

Before looking briefly at the technical requirements of source modeling, a few comments are necessary concerning the respective advantages and disadvantages of magnetoencephalography (MEG) versus EEG for modeling sources of interictal spikes [9]. MEG consists of recording of magnetic fields produced by the neuronal electric activity. Electric and magnetic fields produced by a single dipolar source in the brain volume are oriented in orthogonal planes according to Maxwell's law and reflect the same ionic flux through the neuronal membrane, and thus the same physiological phenomena. In other words, MEG does not provide information in addition to that of EEG. Furthermore, MEG-based localization of sources raises the same fundamental mathematical problems as EEG-based source modeling. One advantage of MEG over EEG is that magnetic signals are immune to field distortion caused



by volume conductor effects due to crossing of tissues with different conductivities from brain to surface (brain, meninges, cerebrospinal fluid, skull bone, and scalp), while EEG signals are sensitive to these distortions. This contributes to an enhanced accuracy of source modeling by MEG. The number of sensors which are contained in a helmet without direct contact with the head is over 200 in last-generation MEG devices, a number difficult to achieve with EEG electrodes pasted onto the scalp surface. This high spatial sampling also contributes to the source model accuracy, even though high-density EEG now permits to apply more than 100 electrodes on the scalp surface. Lastly, other differences between EEG and MEG cannot be viewed as a clear advantage of one technique over the other. For instance, MEG can pick up only magnetic fields perpendicular to the scalp surface produced by superficial cortical sources tangent to scalp surface located in the banks of cortical fissures, while EEG is sensitive to sources located both in fissures banks and gyral crests as well as to deeply located sources. The spatial filtering of MEG can be viewed as an advantage because the signal is not contaminated by deep sources, but also as a major drawback since MEG is blind to signals from gyral surface, which accounts for one third of the total cortical surface. If one adds that MEG is much more expensive than EEG, there are not so many arguments suggesting that EEG will be marginalized by MEG. Therefore, we will make no distinction between EEG- and MEG-based source modeling in what follows.

## 2.2 General principles and limitations of source modeling

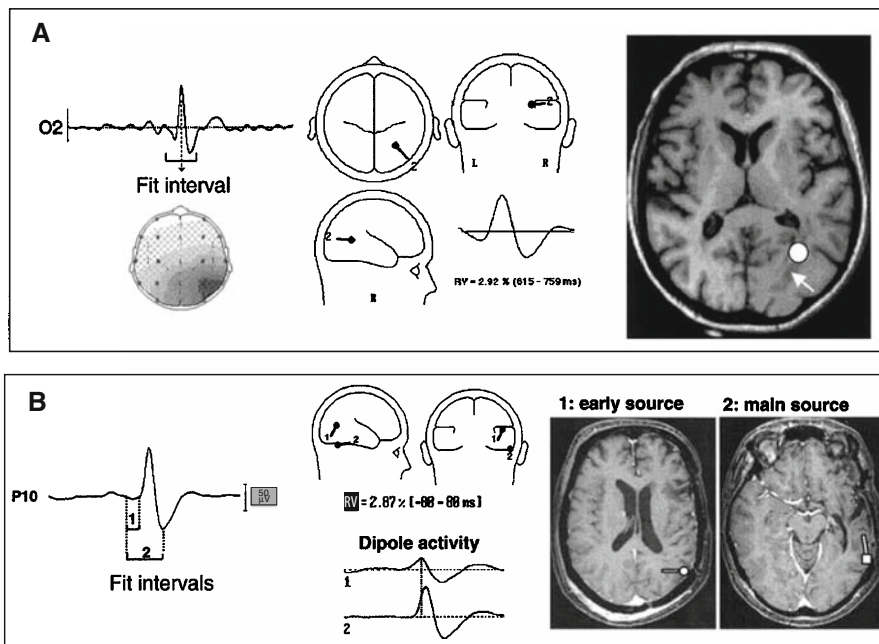
Source modeling is based on an iterative statistical estimation of the locations, orientations, and amplitudes of the intracerebral generators from surface signals and this requires models for both generators and conductive media [8]. If, at a given time, the source distributions and configurations within the brain as well as the conductive properties of the tissues are known, the resulting potentials at the scalp surface can be calculated on the basis of physical principles. This is generally referred to as the forward problem and has a unique solution. Inversely, dipole modeling methods search for the location of intracerebral generators whose activity might explain scalp potentials and this is referred to as the inverse problem. Thus, source modeling consists of a three-dimensional extension of conventional two-dimensional EEG (or MEG) analysis.

As signals are recorded at only a finite number of sites on the scalp, it is theoretically possible to obtain an infinite number of intracerebral source configurations for a given surface distribution. In practice, however, knowledge of the underlying pathology and physiology allows for the definition of some constraints which considerably help to reduce the number of solutions (for example, sources cannot be located in ventricles, white matter, and eyes, etc.). Solutions are calculated using an iterative process by which the dipole location, orientation, and amplitudes are changed step by step to obtain the best fit between the real and the computed scalp potential distributions. The

quality of the solution is evaluated by goodness of fit or residual variance parameters reflecting the percentage of data variance explained or left unexplained by the model, respectively.

The easiest way to represent a current source is with a current dipole, which is produced when an ion flow through the neuronal membrane occurs at the synaptic cleft during postsynaptic excitation or inhibition of pyramidal cells dendrites. This flow is counterbalanced by a current stream along the postsynaptic membrane, resulting in a group of negative and a group of positive charges, separated by a small distance along the axis of the pyramidal cell (i.e., a dipole). If a sufficient number of focal neurons are synchronously active, as is during an epileptic spike, currents may be obtained with sufficient amplitude to produce a measurable potential difference at the surface because pyramidal cells are organized in columns orientated perpendicular to the cortical surface. The geometry of neuronal aggregates is of particular importance since closed-field configurations, i.e., groups of neurons with radial or random orientations of their dendritic trees (as in amygdala or thalamus for example), will theoretically give rise to very small or nil equivalent dipoles with no recordable electrical potential outside. Conversely, if neurons are orientated in a parallel way (open field), as is for cortical pyramidal cells, their activity can be modelled by an equivalent dipole, representing the vectorial sum of each of the unitary dipoles. The possibility to detect spikes thus heavily depends on the configuration of the generators, but also on their spatial extent and depth. For instance, the question whether spikes originating from mesial temporal structures are detectable on the scalp surface, which is crucial for pre-surgical evaluation of temporal lobe epilepsy (TLE), has been much debated in literature. A few studies suggested that mesial temporal spikes are detectable on the scalp, but without direct validation by intracranial recordings. Combined depth EEG and surface recordings showed that intracranial spikes involving solely the deepest mesial contacts in TLE are hardly visible on surface.

The main limitation of the equivalent dipole model is that the neuronal sources of spikes are modelled with a few dipoles that do not provide information on the spatial extent and configuration of the generators. To overcome this intrinsic limitation, volumetric methods have been developed of which the most basic one consists of distributing regional dipoles over a predetermined volumetric grid which usually consists of sources lying on the cortical surface [2]. Following segmentation of the MR volume, dipolar sources are regularly placed along the surface of the cortical mantle. A realistic representation contains on the order of ten to one hundred thousand dipole "pixels". Resolution of the inverse problem thus requires the use of either explicit or implicit constraints on the allowed current source distributions (see above). Despite their attractiveness, those alternatives to classical dipole modeling approaches, which provide a more realistic picture of the spike sources, have not yet been formally compared to older methods. Projection of sources onto three-dimensional MRI represents the final op-



**Fig. 1. A, B** Source imaging of interictal spikes. **A** Sequence of source modeling showing the spike and the topographic distribution of the potential fields at the peak of the spike (left), the computed location and time activity of the source (middle), and the projection of the source location on each patient's brain MRI (right). For this patient with right parieto-occipital epilepsy, voltage maps at different peaks of the averaged interictal spike showed identical scalp distributions. This type of spike can be explained by a single source and adding others does not improve the residual variance (2.92%). This source was matched with the MRI, which showed grey matter heterotopia in the right occipital white matter (arrow). **B** Two distinct sources were necessary to explain the spikes with an acceptable residual variance (2.87%) for this patient with extensive frontotemporal atrophy of the right hemisphere. These two sources are activated sequentially and suggest early involvement of the temporoparieto-occipital junction followed by that of the posterior temporal neocortex (From Ref. [2] with permission)

eration of source modeling. Coregistration of dipole modeling and anatomical data implies that both are in the same frame; most available software packages now allow for automatic registration of dipole modeling results onto individual or averaged MRI data. The term "source imaging" has been proposed to qualify the final presentation of data in which sources are fused with the MRI (Fig. 1).

### 2.3 Is source imaging of interictal spikes useful for localizing the epileptogenic zone?

A few studies have tackled the question whether source imaging could contribute to the localization of the EZ. The only means to address this question is to

refer to the even definition of the EZ, which is based on a seizure-free outcome after surgery, even though this leaves open the question whether a more limited resection could have been as efficient. This issue has been reviewed recently by Plummer and collaborators [9]. Most studies have compared the location of spike sources with resection margins in good outcome patients (Engel class 1 and 2). Comparing source models of interictal MEG spikes, MRI, interictal video-EEG and intracerebral recordings, some authors found dipole modeling to be the second most sensitive method, after ictal intracerebral recordings, for predicting the EZ in TLE. In extratemporal cases the sensitivity is less. A recent study using single source dipolar-distributed modeling of 128 channel EEG data reported that in 18 of 24 patients, all but 2 with lesional focal epilepsy, who underwent epilepsy surgery (17 temporal, 7 extratemporal) the source maximum fell within the border of the resection area; 16 of these patients having an Engel class 1 outcome. However, the investigators were not blinded to MRI data during the source fitting procedure. The concordance between the resection volume and the extent of the distributed source solution proved satisfying (>50% overlap) and was also observed in 90% of children with focal epilepsy, most of them being seizure free after surgery.

The only study that has addressed directly the question whether the spatial extent of the spiking network (as defined by spike modeling) may help in delineating the EZ and planning resection is the MEG study by Fischer et al. [4]. Using a single dipole model for a series of 33 patients who underwent epilepsy surgery, these authors showed that both the concentration of spike sources in a restricted area and a high coverage of this area by the resection volume correlate with a good outcome. However, these promising results have some limitations: (a) a single spike may reflect the activation of several sources and this does not imply that all sources need be removed to control seizures; (b) a number of TLE patients who are seizure free after mesial temporal surgery may actually show interictal spike sources in the lateral neocortex prior to surgery; (c) seizure spread may include areas uninvolved in interictal spiking.

#### 2.4 Is source imaging helpful to guide surgical resection of epileptogenic lesions?

Most studies exploring the relationships between MRI abnormalities and the generators of interictal paroxysms reached a fairly good spatial agreement. Most have used single dipole source modeling. These results come from series of various sizes (1–16 patients) including epilepsies of different types and may therefore be contradictory. However, global analysis shows dipole sources to be located within lesions or close to them (within 10 mm) in about 80% of cases, regardless of the technique used to record the spikes (EEG or MEG). Thus, both techniques seem to provide a similar degree of accuracy. As far as the type of lesion is concerned, the best spatial congruence between spike sources and lesion locations are found in focal dys-

plasia or heterotopia (86%), followed by hippocampal atrophy (79%), whereas sources are close to tumors in only 50%. In cavernous angiomas, interictal MEG spike sources were located less than 20 mm from the lesion itself or from the surgical scar after unsuccessful lesion resection. Thus, source modeling could be useful to identify the epileptogenic lesion in patients with multiple cavernous angiomas. These data suggest that the spatial relationships between lesions and sources of interictal spikes can vary and seem to depend on the lesion type. In the majority of cases, an overlap exists between the lesional zone and the network involved during interictal spikes. Whether a good spatial congruence between lesion and spike sources is predictive of a seizure-free outcome after lesion removal remains to be validated in large groups of patients, conversely a clear spatial mismatch may prompt the recording of spontaneous seizures before surgery, eventually using invasive intracranial recordings, in order to better delineate the spatial relation between lesional and epileptogenic zones. For invasive recordings the placement of electrodes can be guided by source imaging of interictal spikes.

### 3. ICTAL SCALP AND INTRACRANIAL EEG RECORDINGS

Scalp video-EEG recording of spontaneous seizures is considered as a prerequisite to epilepsy surgery. Combined with MRI, and eventually with other noninvasive investigations (source imaging of interictal spikes [see above]), ictal single-photon emission computerized tomography [SPECT], and positron emission tomography [PET] using fluorodeoxyglucose [FDG] or radioligands of neuronal receptors, scalp video-EEG recording can provide enough information for the planning of the surgical resection of the EZ, without need for invasive intracranial EEG recording of seizures. However when data from noninvasive explorations are not congruent enough to delineate precisely the EZ, intracranial ictal recordings may be necessary; in what follows we review briefly the state of the art and indications of these invasive procedures.

#### 3.1 Aims and limitations of ictal intracranial EEG recordings

The main advantage of intracranial recordings over noninvasive methods is to assess directly the abnormal paroxysmal neuronal discharge that characterizes the epileptic seizures with either subdural grids of electrodes applied on the cortical surface or depth intracerebral electrodes implanted through MRI guided stereotaxy (stereo-electroencephalography, SEEG). Intracranial electrodes also offer the possibility of stimulating the cortex either to reproduce seizures or to perform a functional mapping of eloquent areas (see below). Their main disadvantage is that the exploration is restricted to a limited area which is chosen according to preimplantation hypothesis based on data from scalp video-EEG ictal recordings and neuroimaging data. Thus, this approach

suffers from a spatial sampling bias and some degree of circularity in the implantation strategy. Furthermore, while intracerebral recordings through depth electrodes provide with a three-dimensional exploration of the cerebral volume, subdural recordings using electrode grids do not explore the depth of cortical sulci and deep cortical areas, such as the insula, that represent more than 50% of the cortical surface. The need for such invasive procedures stems from the fact that data from video-EEG recordings and neuroimaging can be either poorly informative (for instance, in cases of cryptogenic epilepsy with normal MRI) or discordant. As an example, in a series of 100 consecutive patients with temporal lobe epilepsy, of whom 69 showed hippocampal atrophy on MRI, excluding patients with cavernous angiomas, low-grade astrocytomas, and oligodendrogliomas, who have been operated between 1994 and 2003 in the Lyon Functional Neurosurgery Department [12], 48 underwent depth electrode recordings (SEEG) before surgery. Invasive recordings were considered necessary after a noninvasive assessment that included scalp video-EEG recording of seizures, MRI, and FDG PET. This percentage is high compared to those reported from other epilepsy centers because a number of cases were referred from centers with no facility to perform SEEG recordings, but where patients with typical mesial TLE were operated after a noninvasive presurgical assessment. In spite of this sampling bias, this percentage shows that in many cases invasive recordings are needed to plan a tailored cortical resection and contribute to ameliorate the surgical outcome. Indeed, 85 of our 100 patients are seizure free after surgery (Engel class 1); a figure that compares favorably with most of the published series.

### 3.2 Indications of intracranial EEG recordings in epilepsy surgery

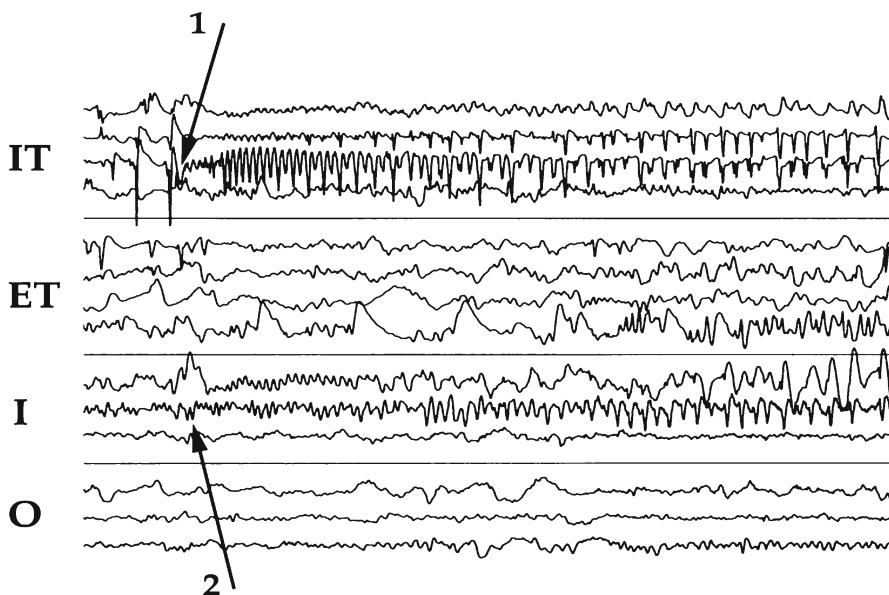
On the basis of the reliability and specificity of the information brought by imaging and invasive EEG recordings, four strategies can be proposed according to the clinical context of the surgical decision.

Imaging studies other than MRI and invasive ictal EEG recording are not needed in at least three frequent instances where clinical history, MRI, and scalp video-EEG ictal recordings are sufficient to make a surgical decision. The first one is that of newly diagnosed epileptic seizures revealing a single focal lesion the location of which explains the seizure symptoms. In that situation, lesion resection is the right decision. Similarly, in patients with focal cortical dysplasia suffering from long lasting drug-refractory partial seizures, lesion resection can be performed without sophisticated imaging investigations or invasive ictal EEG recordings, on the condition that there is no discordance between lesion location, ictal symptoms, and scalp EEG data as assessed by video-EEG recording of seizures. Thirdly in drug-refractory TLE, anterior temporal lobectomy can be proposed on the condition that all of the diagnosis criteria of mesial TLE are met, including: (a) history of febrile convulsions in early childhood; (b) epilepsy onset in late childhood or adolescence; (c) drug-resistant partial seizures with epigastric aura, oro-alimentary

automatisms, loss of contact, postictal confusion state; (d) rare secondary generalized seizures; (e) unilateral temporal interictal EEG spikes; (f) temporal ictal theta EEG discharge occurring after seizure clinical onset and; (g) unilateral hippocampal atrophy on the side of EEG abnormalities. When available, interictal glucose hypometabolism on FDG PET in the epileptogenic temporal lobe can be useful because it is predictive of a favorable surgical outcome.

EEG-MEG source imaging, SPECT, and/or PET can make useless invasive recordings in symptomatic partial epilepsies when the questions at stake are either to demonstrate that the spiking and lesional areas are coextensive or to identify the epileptogenic lesion in patients with multiple lesions such as cavernous angiomas or tubers.

Either subdural or depth SEEG ictal recordings are needed in all cases of cryptogenic epilepsies in order to delineate the EZ. There is no evidence that one approach is superior to the other. Subdural recordings can cover a cortical area larger than that explored with a limited number of depth electrodes, but the latter are better adapted to the exploration of deep cortical gray mat-



**Fig. 2.** Focal epileptic mesial temporal and insular discharge recorded by SEEG. The spike discharge is detected at the hippocampal (*IT*, arrow 1) and insular (*I*, arrow 2) recording sites, while its onset is unseen at recording sites located in temporal operculum (*O*) and lateral temporal neocortex (*ET*). These SEEG traces illustrate the limitations of surface cortical recordings by subdural electrode grids by showing that, when the seizure onset zone is situated in mesial temporal structures and/or perisylvian cortex, cortical surface recordings are blind to the seizure discharge

ter. Similarly, in large lesions both approaches can be used to decide whether a partial lesion resection is possible.

Depth EEG recordings (SEEG) are recommended in TLE patients when some of the criteria of mesial temporal lobe epilepsy are missing, in particular unilateral hippocampal atrophy (see above), and also when ictal symptoms suggest an insular or perisylvian origin of seizures [7]. In that indication, depth recordings are superior to subdural recordings because they offer the possibility of exploring the whole volume of the temporal lobe and perisylvian cortex including the insula (Fig. 2). Furthermore in all types of extratemporal epilepsies, depth SEEG recordings provide direct access to both outer and inner aspects of the hemisphere and also to the gray matter buried in cortical sulci. This represents a great advantage over subdural electrode grid recordings, which are limited to a two-dimensional surface exploration.

## **NEUROPHYSIOLOGY APPLIED TO SURGICAL TREATMENT OF PAIN**

### **1. IS CLINICAL NEUROPHYSIOLOGY USEFUL TO EXPLORE THE PAIN PATHWAYS?**

The first method proposed to explore the pain system consists of recording the spinal flexion reflex (SFR) triggered by noxious stimuli, the threshold of which closely correlates with the subjective pain threshold. This technique explores the segmental spinal reflex to pain, but not directly the responses of spinal and supraspinal neurons involved in pain transmission. Somatosensory and pain evoked responses offer this possibility [1]. The standard somatosensory evoked potentials (SEPs) to electric stimulation of peripheral nerves only assess function of the dorsal column-medial lemniscus system. Therefore, whereas abnormal SEPs provide good evidence for an impairment of the somatosensory system, normal SEPs cannot exclude a selective impairment of the spinothalamic system. Only laser-evoked potentials (LEPs) explore the spinothalamic pathways up to their cortical targets. Laser stimulators deliver brief heat pulses (1–100 ms) that ensure synchronous activation of peripheral A delta and C pain fibers. It is possible to activate preferentially subsets of these fibers by changing the stimulus characteristics (energy, duration, area of the irradiated spot). LEPs can detect conduction abnormalities at any point in the pain-temperature pathways, from periphery to cortex. However only cortical responses are recordable after laser stimulation so that, contrary to standard SEPs, which can detect segmental spinal, cervicomedullary, and cortical responses, LEPs give no indication regarding the site of the dysfunction along the spinothalamic pathways. In spite of their limitations, electrophysiological techniques proved useful to better understand the mechanisms of both pain and current surgical procedures that are proposed for its control.



## 2. IS CLINICAL NEUROPHYSIOLOGY USEFUL FOR THE SURGICAL TREATMENT OF PAIN?

Since the pioneer work of Wall and Melzack suggesting that pain is caused by an unbalance between activities of the dorsal column and the spinothalamic pathways, neurosurgical treatment of pain has aimed either at filtering pain input transmission by spinal cord or motor cortex electric stimulation or at reducing the activity of spinothalamic system mostly at the spinal level, either by selective posterior rhizotomy or dorsal root entry zone (DREZ) coagulation. Electrophysiology proved useful for choosing the most appropriate procedure in each patient and to better understand the mechanisms by which some surgical procedures are efficient for chronic pain treatment [5].

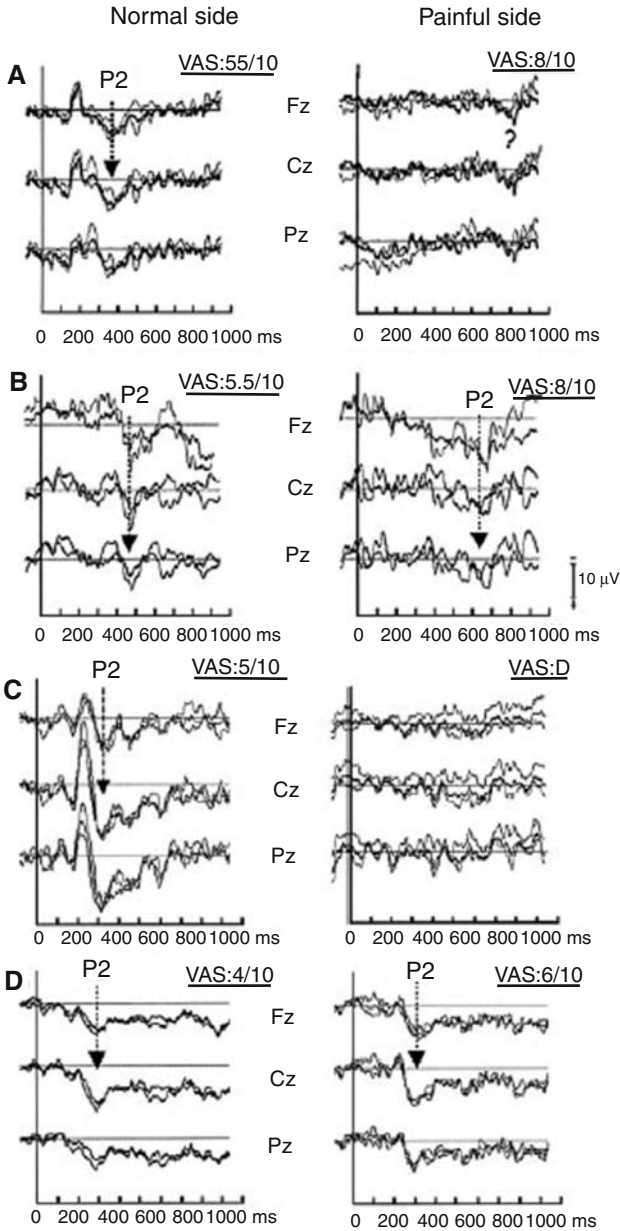
The recording of SFR and LEPs can be useful to assess the psychogenic participation to chronic pain syndromes. SFR permits to measure an “objective” pain threshold. Unfortunately, application of this technique is restricted to pain located in the territory of the upper sacral roots because normal SFR thresholds for the upper limb are not available. The contribution of LEPs mostly concerns patients with neuropathic pain resulting from a direct injury to the nervous system. In this context, LEP attenuation after stimulation of the painful territory reflects the degree of spinothalamic deafferentation (Fig. 3). Conversely, LEPs are not attenuated, and can even be enhanced, in patients with nonorganic pain syndromes [6].

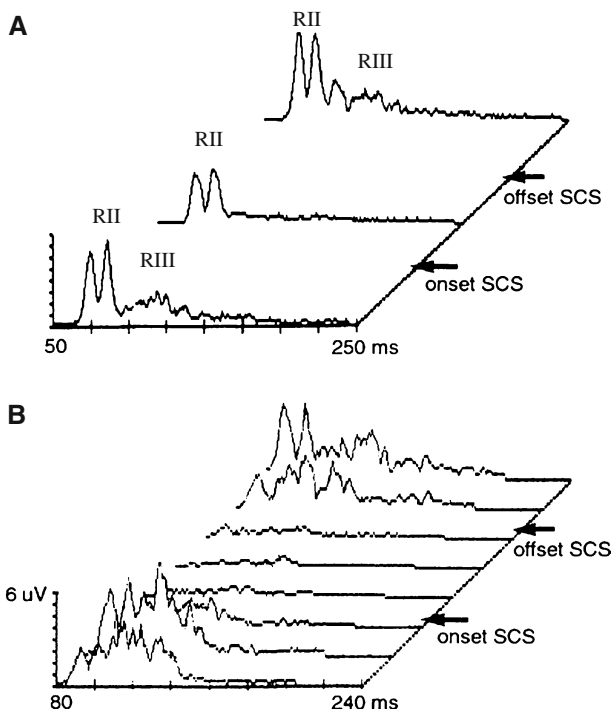
SEPs are useful to assess the degree of peripheral deafferentation in patients with pains caused by root avulsion, in particular those with brachial plexus injuries. After stimulation of median or ulnar nerves, preservation of peripheral responses with absent central responses, in particular the spinal segmental response, indicates a root avulsion proximal to the dorsal ganglion and predicts a favorable analgesic effect of DREZ coagulation.

SEPs contribute to predict the analgesic effect of spinal cord stimulation (SCS), which is based on the assumption that the dorsal column fibers, supposed to be the main target of the electric stimulation, should retain some degree of functional integrity to exert an inhibitory effect on the pain transmission system. Although both SCS and SEPs have been developed 40 years ago, it was only quite recently that Sindou et al. [11] have evaluated the predictive value of SEP recordings on SCS outcome by reviewing a large series of 95 patients treated by SCS, who had benefited from preoperative SEP recording with measurement of the central conduction time in the spinal somatosensory pathways. The main conclusion of this study was that SCS failed in alleviating pain in all patients showing prolonged central conduction time or absent SEP central components. Therefore, preoperative SEP recordings are recommendable before undertaking SCS in chronic pain patients.

The main conclusions issued from electrophysiology regarding the effects of neurosurgical procedures upon pain transmission are the following [1, 5].

The SFR is depressed by SCS, pointing to the spinal segmental target of this procedure (Fig. 4). Spinal dorsal horn neurons are hyperactive after peripheral deafferentation and an optimal pain relief is obtained when the segmental





**Fig. 4. A, B** Occlusion of the SFR by SCS. The SFR obtained in the biceps femoris muscle in response to sural nerve stimulation is clearly visible (RIII) before and after, but not during SCS. Conversely, the nonnociceptive earlier reflex responses remain unaffected by the SCS procedure. **A** Voltages of all spinal reflexes. **B** Voltages of the RIII SFR only (rectified EMG) (From Ref. [8] with permission)

spinal SEPs are reduced by more than 60% after DREZ coagulation. Lastly, pain relief obtained by motor cortex stimulation can be reproduced by repetitive transcranial magnetic stimulation of the motor cortex, but only when

←

**Fig. 3.** LEPs in four patients with spinal ependymoma (**A–C**) and nonorganic (**D**) pain syndrome. **A** Patient, 51 years old, with spinal ependymoma, central pain, thermal hypesthesia, hyperalgesia to laser. **B** Patient, 74 years old, with thalamocortical hemorrhage, hemihypesthesia, mechanical and thermal allodynia, and allodynia to laser. **C** Patient, 45 years old, with spinal cord angioma, central pain (L2), thermal hypesthesia, and no provoked pain. **D** Patient, 43 years old, with no organic lesion, left C6 and T7 pain, no sensory deficit, and hyperalgesia to laser. LEPs to stimulation of the nonpainful side (left traces) were within normal limits. After stimulation of the painful side (right traces) only delayed and desynchronized LEPs were obtained for patients A and B, and no LEPs were visible in patient C. Conversely, LEPs were normal in patient D after stimulation of the painful area. LEP abnormalities reflect the dysfunction of the spinothalamic pathways and can be observed in association with hyperalgesic (**A**) or allodynic (**B**) reaction to the laser stimulus (From Ref. [9] with permission)

delivered at a high excitatory frequency, suggesting that the effect of motor cortex stimulation is caused by activation, rather than by inhibition, of the stimulated area.

## **INTRAOPERATIVE NEUROMONITORING DURING SURGERY**

Because any neurosurgical operation entails the risk of postoperative permanent deficits with medico-legal consequences, intraoperative monitoring based on electrophysiological recordings has known a huge expansion during the past two decades [1]. This field covers many aspects including (a) EEG using scalp or cortical surface electrodes (electrocorticography or ECoG) for monitoring the effects of anesthesia, controlled hypotension, cerebral hypoperfusion during carotid surgery; (b) EMG in particular for facial nerve monitoring during posterior fossa surgery; (c) somatosensory, motor, and auditory evoked potentials during spinal cord and posterior fossa surgery; and (d) cortical stimulation during surgery of brain lesions, particularly tumors. In what follows we will develop only the monitoring based on evoked potentials in spinal cord and cerebello-pontine angle (CPA) surgery and on cortical stimulation in mass lesions and epileptic foci surgery.

### **1. SPINAL CORD MONITORING**

Paraplegia is the most feared postoperative complication of scoliosis surgery but also represents a major risk in the surgery of spinal cord compression and intramedullary lesions. Therefore the monitoring of motor evoked potentials (MEPs), which directly measures pyramidal tract function, has supplanted that of SEPs in this indication, even though both recordings can be performed in the same patients in the operation theater. MEPs can be obtained noninvasively by electric or magnetic transcranial stimulation of the motor cortex and recording of the muscle evoked response at the periphery. Similarly, scalp SEPs can be obtained by stimulating a peripheral nerve. These noninvasive techniques present the advantage of not interfering with the surgical procedure, in contrast to the invasive stimulation and recording methods that have been implemented for both MEP and SEP recordings. The objective is clearly to provide the surgeon with an alarm at each time a significant change is observed. The difficulty is to define what is a "significant" change and to avoid false alarms. An amplitude reduction of more than 50% as well as a latency increase over 5% are commonly used for alarm, on the condition that such changes cannot be attributed to anesthesia, local or general hypothermia, or deterioration of hemodynamic condition. As a rule, signals recorded directly on the spinal surface, such as the D-waves elicited by transcranial stimulation of the

motor cortex or dorsal column responses elicited by peripheral nerve stimulation, are less sensible to factors not directly related to an injury of the motor or sensory pathways than are muscle responses or cortical SEPs. Thus, invasive recordings are considered more reliable than noninvasive techniques and have improved the long-term motor outcome of intramedullary spinal cord tumors surgery. Furthermore, the reversibility of the changes with a return to normal before the end of operation is frequently not associated to a postoperative deficit.

## **2. BRAINSTEM AUDITORY EVOKED POTENTIALS IN CEREBELLO-PONTINE ANGLE SURGERY**

Hearing loss is a potential complication of surgery involving the CPA. It can occur owing to drilling, cerebellar retraction, cauterization, compression, or vascular compromise of the acoustic nerve. Its occurrence is particularly feared in surgery of trigeminal neuralgia and hemifacial spasm. Firstly developed in the early eighties in Erlangen by J. Schramm, in Pittsburgh by A. R. Moller and P. J. Jannetta, and in Lyon by C. and G. Fischer and M. Sindou, monitoring of brainstem auditory evoked potentials (BAEPs) is now applied worldwide to prevent hearing loss during microsurgical decompression of trigeminal and facial nerves and surgery of CPA tumors including acoustic neuromas. BAEPs are responses to repetitive auditory stimulations by clicks generated by the acoustic nerve and auditory pathways and relays up to the upper brainstem within the 10 ms after stimulus onset. The advantage of this technique over direct recordings on the surface of the acoustic nerve is that the signal is recorded on the scalp so that its acquisition does not interfere with the surgical procedure. BAEPs are composed of five waves (I to V), of which two are of particular interest for monitoring: wave I, which reflects the activity of the acoustic nerve itself, and wave V, which is produced at the lateral lemniscus and inferior colliculus levels. Amplitude decrease and latency increase of Wave V and prolongation of the I–V interval are widely considered as the most reliable alarm signals. As for spinal cord monitoring the question at stake is to determine the degree of changes that entails a high risk of postoperative hearing loss. In a recent study of BAEP monitoring during microvascular decompression for hemifacial spasm, the Lyon team [10] reported that a wave V latency increase of less than 0.4 ms during surgery was never associated to postoperative hearing loss, while in the group of patients with postoperative hearing loss the mean prolongation of wave V latency was 1 ms. The authors proposed to deliver to the surgeon a “watching” signal when wave V latency increase reaches 0.4 ms and a first “warning” signal at 0.6 ms. When the increase reaches 1 ms (critical warning signal), interruption of the procedure, withdrawal of the retractor, as well as identification and correction of the cause of the acoustic nerve dysfunction are recom-

mended. The permanent loss of wave V also indicates a high risk of hearing loss. These warning thresholds have been discussed controversially but the impact of BAEP monitoring for patient's safety is not questioned any more.

### **3. CORTICAL STIMULATION IN MASS LESIONS AND EPILEPTIC FOCI SURGERY**

Functional mapping of so-called eloquent cortical areas involved in motor, sensory, language, and memory functions has become a major issue in resection of hemispheric mass lesions, in particular low-grade gliomas, and in epilepsy surgery. Before operation, functional neuroimaging, principally functional MRI (fMRI), provides reliable information regarding the lateralization and location of language areas and is likely to supplant the amobarbital intracarotid injection (Wada test) in this indication; similarly, the sensorimotor cortex is correctly mapped by functional MRI. However, rearrangement of functional areas at the periphery of slowly evolving tumors and epileptogenic lesions and uncertainty regarding the neuronal correlates of changes in blood oxygen level-dependent signal in pathologic tissue make fMRI functional mapping less reliable in patients than in healthy subjects. Furthermore, fMRI is not really able to distinguish between areas essential for a function, which should be surgically preserved, and those that can be resected without postoperative deficit. Lastly, lateralization of memory areas by fMRI is not yet fully validated and the Wada test remains the reference for assessing separately the implication of each mesial temporal lobe in memory before temporal lobectomy or selective amygdalo-hippocampectomy. This explains why cortical stimulation, performed either before epilepsy surgery with subdural electrode grids or depth intracerebral electrodes or during lesion resection, is still widely used for functional mapping. Intraoperative electrical stimulation (IES) has seen a true revival in the past ten years mostly because it has enabled optimization of low-grade gliomas resection [3]. The IES technique was first proposed by Wilder Penfield more than half a century ago and has not experienced any fundamental evolution in its principles since then. The stimulating electrode delivers biphasic current pulses either as single shocks or as trains at 50–60 Hz frequencies under general or local anesthesia. Sensory and cognitive functions can be tested under local anesthesia only and most of the IES advances stem from the progressive refinement of the tasks that are tested under stimulation in the awake subject during surgery. The principle is to detect transient disturbances in task performances induced by IES. Depending on the supposed function of the operated area, language (spontaneous speech, naming, comprehension, and writing, etc.), memory, calculation, and complex visuospatial tasks can thus be tested. The basic assumption is that when IES produces a transient modification of task performance the stimulated area is essential to the function and should be preserved. Thus IES has opened the field of “neuro-

psychology applied to neurosurgery”, the results of which look very promising. It has permitted to extend the limits of lesion resection in cortical areas such as the supplementary motor area, the insula, close to the so-called Broca area, and in the supramarginalis gyrus of the hemisphere dominant for language.

## CONCLUSIONS


In all neurosurgical teams having contributed to the progress of epilepsy and pain surgery and to the development of intraoperative monitoring, the neurophysiologist is a full member of the surgical staff playing an active role before and during surgery. The neurophysiologist needs to be aware of the technical difficulties of surgery and, reciprocally, the neurosurgeon must be confident upon the information provided by electrophysiology both in planning the operation and during the surgical procedure itself. Every time this fusion has been achieved, innovative surgical procedures and new concepts have been developed to the benefit of patients.

## References

- [1] Binnie C, Cooper R, Mauguière F, Osselton J, Prior P, Tedman B (eds) (2004) Clinical neurophysiology, vol. 1: EMG nerve conduction and evoked potentials. Elsevier, Amsterdam, pp 403-604
- [2] Dale AM, Liu AK, Fischl BR, Buckner RL, Beliveau JW, Lewine JD, Halgre E (2000) Dynamic statistical parametric mapping: combining fMRI and MEG for high-resolution imaging of cortical activity. *Neuron* 26: 55-67
- [3] Duffau H (2007) Contribution of cortical and subcortical electrostimulation in brain glioma surgery: methodological and functional considerations. *Neurophysiol Clin* 37: 373-382
- [4] Fischer MJ, Scheler G, Stefan H (2005) Utilization of magnetoencephalography results to obtain favourable outcomes in epilepsy surgery. *Brain* 128: 153-157
- [5] Garcia-Larrea L, Peyron R, Mertens P, Laurent B, Mauguière F, Sindou M (2000) Functional imaging and neurophysiological assessment of spinal and brain therapeutic modulation in man. *Arch Med Res* 31: 248-257
- [6] Garcia-Larrea L, Convers P, Magnin M, André-Obadia N, Peyron R, Laurent B, Mauguière F, Sindou M (2002) Laser-evoked potential abnormalities in central pain patients: The influence of spontaneous and provoked pain. *Brain* 125: 2766-2781
- [7] Isnard J, Guénot M, Sindou M, Mauguière F (2004) Clinical manifestations of insular lobe epileptic discharges: a stereo-electroencephalographic study. *Epilepsia* 45: 1079-1090

- [8] Merlet I, Mauguière F (2004) Dipole source modeling. In: Shorvon S, Perucca E, Fish D, Dodson E (eds) *The treatment of epilepsy*. Blackwell, Oxford, pp 665-679
- [9] Plummer C, Harvey AS, Cook M (2008) EEG source localization in focal epilepsy: where are we now? *Epilepsia* 49: 201-218
- [10] Polo G, Fischer C, Sindou M, Marneffe V (2004) Brainstem auditory evoked potential monitoring during microvascular decompression for hemifacial spasm: intraoperative brainstem auditory evoked potential changes and warning values to prevent hearing loss: a prospective study in a consecutive series of 84 patients. *Neurosurgery* 54: 97-104
- [11] Sindou M, Mertens P, Bendavid U, Garcia-Larrea L, Mauguière F (2003) Predictive value of somatosensory evoked potentials for long-lasting pain relief after spinal cord stimulation: practical use for patient selection. *Neurosurgery* 52: 1374-1384
- [12] Sindou M, Guénot M, Isnard J, Ryvlin P, Fischer C, Mauguière (2006) Temporomesial epilepsy surgery: outcome and complications in 100 consecutive adult patients. *Acta Neurochir (Wien)* 148: 39-45





**François Mauguère**

François Mauguère is Professor of Neurology and Head of the Functional Neurology Department in the Lyon University Hospital. He is presently Past-President of the International Federation of Clinical Neurophysiology (IFCN). He has contributed to the development of evoked potentials and EEG applied to functional neurosurgery of pain and epilepsy, in collaboration with Prof. Marc Sindou.

**Contact:** François Mauguère, Department of Functional Neurology and Epileptology, Lyon University and Lyon Federative Institute of Neuroscience, Neurological Hospital, 59 Boulevard Pinel, 69003 Lyon, France  
E-mail: [mauguere@univ-lyon1.fr](mailto:mauguere@univ-lyon1.fr)

---

# NEURONAL TRANSPLANTATION: A REVIEW

J. P. NGUYEN

## INTRODUCTION

Numerous experimental studies have shown that embryonic dopaminergic neurons transplanted into the striatum of animal models of *Parkinson's disease* are able to grow and induce clinical improvement. The first studies in man confirmed these results, but showed that the clinical result can vary considerably from one patient to another, suggesting that a number of improvements, especially technical, had yet to be made prior to clinical application of this experimental procedure. Relatively recent clinical studies, reporting a considerable number of cases of postoperative dyskinesia, considered to be a specific complication of neuronal transplantation, have questioned the very principle of this procedure in the treatment of Parkinson's disease.

The second field of application of neuronal transplantation is the treatment of *Huntington's disease*. In this setting, embryonic striatal neurons are transplanted into the striatum of patients with Huntington's disease in order to prevent cortical atrophy that is thought to be secondary to the death of striatal GABAergic neurons. The first studies in man were also encouraging in this disease, but the preliminary results of a controlled trial show a marked variability of the results.

This review will discuss the various aspects of the neuronal transplantation procedure and will try to predict the place of this treatment modality in the future.

## FUNDAMENTAL ASPECTS

The first attempts at cerebral transplantation date back to 1890 and consisted of transplantation of a part of the cortex of an adult animal into the brain of an adult animal of another species. Successive failures of this procedure led several authors to transplant portions of embryonic cortex that were thought to have a better potential for survival and development in the host brain. The results reported by Legros-Clark [6] confirmed that embryonic neurons had a much better chance of survival than adult neurons. These same studies showed that the blood supply of the transplant was an essential element to survival, and that the conditions of blood supply were better for smaller transplants. Consequently, since these studies, most experimental work

---

*Keywords:* neural transplantation, functional neurosurgery, stereotaxy

has focused on the transplantation of small fragments of embryonic brain and have demonstrated the possibility of survival and development of these transplants in an adult host brain.

Over the following years, studies were devoted to clinical applications of these techniques. Very rapidly, research scientists became interested in the treatment of Parkinson's disease, as, in this disease, neuronal loss concerns a particular group of neurons, dopaminergic neurons, situated in a limited part of the brain, the locus niger. Bjorklund [3] was the first to show clinical effects in an animal model of Parkinson's disease after transplantation of embryonic dopaminergic neurons in the striatum. In parallel, several studies showed that a similar approach could also induce clinical recovery in monkey models of Huntington's disease [12].

## **TECHNICAL ASPECTS**

### **1. WHAT IS THE IDEAL SITE OF TRANSPLANTATION?**

Embryonic neurons are initially undifferentiated and then subsequently migrate within a dedicated structure and differentiate to play a programmed functional role. In a subsequent step, these neurons send processes towards their target neurons to establish functional circuits.

The dedicated structure for dopaminergic neurons is the locus niger and the target neurons are striatal GABAergic neurons. Transplantation of embryonic dopaminergic neurons into the locus niger was associated with a risk that they may not be able to send processes to the striatum, or only after a very long time. For this reason, most authors preferred to implant the transplant directly in the striatum, as close as possible to the target neurons. As the objective was to improve the motor disorders of Parkinsonian patients, the site of transplantation was selected in the sensorimotor part of the striatum, i.e. mainly the dorsolateral and post-commissural part (posterior to the anterior commissure of the third ventricle) of the putamen, as the other zones of the putamen are devoted to associative and cognitive functions. No study has been able to demonstrate the potential harmful effects when the transplant overlaps onto these zones. The dorsolateral portion of the putamen is clearly visualized on MRI and is easy to reach by almost vertical trajectories descending from the coronal region. The inferior part of the putamen can also be clearly visualized and must be avoided not only because of the potential risks of cognitive disorders but also because this zone has a particularly rich blood supply (perforating arteries) [13].

In Huntington's disease, the objective is to palliate the loss of GABAergic neurons in the striatum. Embryonic neurons can be easily transplanted directly into the striatum. As the objective is to prevent cortical atrophy and the resulting dementia, the transplant must include the sites involved in cognitive functions, especially the head of the caudate nucleus.

## **2. WHAT IS THE OPTIMAL STAGE TO HARVEST EMBRYONIC NEURONS?**

In order to be sure to harvest dopaminergic neurons, it is important to wait until embryonic neurons have migrated to the locus niger. In man, this stage corresponds to 6 weeks (post-conception) of embryonic development. The technique mainly consists of identifying and harvesting the ventral mesencephalic region of the embryo. As this region is identified by means of anatomical landmarks, the embryo must not have been submitted to excessive deformation during extraction. To avoid trauma to embryonic neurons during harvesting, neurons must be harvested before they have developed their processes due to the risk of retrograde degeneration. In man, this means that embryonic neuron harvesting must be performed before the tenth week. For clinical applications in Parkinson's disease, most authors have defined the optimal period for embryonic neuron harvesting between the 7th and 9th weeks post-conception [7]. These dates are the same for applications to the treatment of Huntington's disease, but the site of embryonic neuron harvesting is different in this application, as neurons are harvested from the lateral ganglionic eminence.

## **3. WHAT IS THE RISK OF IMMUNE REACTION LEADING TO TRANSPLANT REJECTION?**

The brain is an immunologically protected site. Any tissue, derived from the same species or a different species, can develop in the brain without inducing a rejection reaction, provided the blood-brain barrier remains intact. In practice, even when using very fine instruments, rupture of the blood-brain barrier always occurs during introduction of neurons into the host brain. Furthermore, the use of very small calibre cannulae may cause transplant compression and necrosis. Experimental studies have suggested that the best compromise in man is to use cannulae with an inner diameter of about 0.5 mm [7]. Other experimental studies have shown that the endothelium of vessels situated in tissues surrounding neurons is one of the structures responsible for immune reactions leading to rejection. The Lund group consequently proposed to reduce the transplant to a neuronal suspension in order to eliminate the tissues surrounding embryonic neurons, especially blood vessels. This preparation requires the use of DNase and trypsin. Even despite these measures, there is still a risk of immune reaction and it has been recommended to systematically use immunosuppressive therapy similar to that used for organ transplantation [7].

## **4. WHAT IS THE OPTIMAL QUANTITY OF EMBRYONIC NEURONS TO BE TRANSPLANTED?**

Animal experimentations are of limited value to predict the optimal quantity of neurons to be transplanted in order to achieve a functional effect in man. This fundamental approach was therefore based on clinical studies. The

New York group [11] has reported 2 cases of bilaterally transplanted patients with marked clinical improvement, who died several months after transplantation from causes unrelated to the transplantation procedure. Post-mortem examination of these 2 patients revealed that between 80,000 and 135,000 dopaminergic neurons had survived on each side. These neurons had established connections with neurons of the host putamen, ensuring re-innervation of 24–78% of the putamen. Based on the estimation of the percentage of neurons surviving after transplantation (10–20%) and the proportion of dopaminergic neurons contained in the transplant, the number of embryos necessary for transplantation of a striatum has been estimated to be 3 for each side [7].

Estimation of the number of surviving neurons must take into account various factors such as the interval between tissue harvesting and transplantation and the mode of storage of embryonic tissues, although experimental studies have not demonstrated any significant difference according to the mode of storage.

## 5. HOW SHOULD TRANSPLANTS BE IMPLANTED?

Experimental studies have shown that the best survival rate of transplanted neurons is obtained by injection of small quantities of embryonic neurons (neuronal suspension) regularly distributed throughout the structure to be transplanted. In practice, it is recommended not to exceed a volume of 5  $\mu$ l in each injection site, and each site must be separated from the adjacent site by an interval of at least 1 mm. For re-innervation of the sensorimotor striatum (Parkinson's disease and Huntington's disease), distribution of the transplant over 24 sites (8 sites along 3 trajectories) appears to be sufficient (total of 120  $\mu$ l). Preparation of the neuronal suspension comprises mechanical fragmentation, reducing the tissue sample into very small fragments. Neurons are then dissociated by means of DNase and trypsin. Ideally, the suspension should be injected within 6 hours, which requires good coordination between the various teams (neurobiologists and neurosurgeons). The neuronal suspension transplantation technique has the theoretical advantage of minimizing immune reactions by excluding from the transplant blood vessels present in the supporting tissues, as some studies have suggested that vascular endothelium could play an important role in rejection reactions [7].

Other teams, on the contrary, have recommended the injection of small fragments of tissue rather than a cellular suspension. This technique has the advantage of being technically simpler. Studies by the New York group [11] have suggested that this technique allows the development and integration of a sufficient quantity of dopaminergic neurons to induce functional improvement. As this technique is likely to induce a higher rate of immune reactions than the neuronal suspension technique, immunosuppressive therapy would

theoretically need to be continued indefinitely. The Denver group [4] injects the transplant, composed of small fragments of tissue, along horizontal trajectories, without intervals between injection sites. The potential risk of this technique is that the transplant may induce a local mass effect, predisposing to necrosis of the transplant. Another risk is that of accidentally implanting the transplant into the inferior part of the putamen.

## CLINICAL ASPECTS

### 1. PARKINSON'S DISEASE

#### 1.1 Early studies

Backlund [2], in 1985, was the first to attempt cerebral transplantation in a patient with Parkinson's disease. For ethical reasons, this author did not use embryonic neurons and preferred to transplant chromaffin cells of the adrenal medulla that are able to secrete dopamine precursors in the striatum (caudate nucleus). Although the feasibility of stereotactic tissue transplantation was demonstrated, the functional benefit was only minimal and transient.

Based on the same principle, Madrazo [9] transplanted several patients by open surgery (intraventricular approach) without any lasting success, and at the price of major local and systemic complications.

The Lund group [7], by grafting embryonic dopaminergic neurons into the striatum, was the first to demonstrate definite clinical effects, at least in one patient who maintained a spectacular long-term improvement. This group had previously optimized the transplantation technique in the course of several experimental studies: injection of a neuronal suspension through a 0.5 mm diameter cannula, along stereotactic trajectories and in sites separated by 1 mm intervals. This technique was subsequently used by the Créteil [14] and Halifax [10] groups.

#### 1.2 Recent studies

Experience of the Lund and Créteil groups. In 1998 [8], the pioneer group in Lund published the results of 6 patients operated between 1989 and 1994 (follow-up ranging from 10 to 72 months). Patients were operated only on one side (injection of a neuronal suspension in the post-commissural putamen). A marked improvement was observed in 4 patients. A bilateral improvement of rigidity and hypokinesia was observed, predominantly on the side opposite to the transplant. Transplantation did not modify the severity of dyskinesia. FluoroDopa uptake on PET scan increased by average of 68% and was observed only on the transplanted side. Immunosuppressive therapy was stopped at an average of 29 months after transplantation, without inducing any clinical deterioration of the UPDRS score. In contrast, most patients

subsequently developed a relatively moderate recrudescence of dyskinesia, especially in OFF periods. The Créteil group started to develop the same approach in 1990 [14], but patients were systematically operated on both sides (15 cases). The results confirmed those reported by the Lund team, especially in terms of dyskinesia which was not improved in the long-term. Similarly, the Créteil group revealed a marked variability of the clinical results, even when patients had received an identical quantity of embryonic neurons.

Experience of the Denver group [4]. Transplantation was performed from 4 embryos for each side in the form of tissue fragments deposited in the putamen along 4 horizontal trajectories. Embryonic tissues were cultured after harvesting and implantation was always delayed, sometimes 1 month after harvesting. No patient received immunosuppressive therapy. Patients were randomized to 2 groups: (1) bilateral transplantation, (2) medical treatment only (identical operation without transplantation). Clinical assessment was performed under double-blind conditions. A significant improvement of motor symptoms was observed in patients under the age of 60 (transplantation versus no transplantation), while older patients were only slightly improved, and not statistically significantly. No difference was observed in the non-transplanted group. In 15% of patients improved by neuronal transplantation, severe dyskinesia occurred or was worsened despite reduction of dopatherapy (dyskinesia in OFF period).

Experience of the New York group [11]. In a preliminary study, this group performed bilateral transplantation in 6 patients. Transplantation was performed using small fragments of tissue and immunosuppression was maintained for 6 months. Transplants were deposited along vertical trajectories targeting the post-commissural putamen and each injection site was separated by an interval of about 5 mm. Implantation was performed 1–2 days after harvesting. All patients were markedly improved, but medical treatment could not be decreased. Dyskinesia was improved in this first series of patients. This group has reported 2 autopsy cases which demonstrated that transplanted neurons survived and established connections with target neurons of the putamen. However, the presence of several macrophage infiltrates around the transplant suggested the possibility of very progressive rejection. A second study was performed by this group according to a protocol similar to that used by the Denver group. One to 4 embryos were used for each side and transplantation was performed bilaterally according to the procedure used during the first study. Patients receiving transplants from 4 embryos on each side were improved compared to non-transplanted patients (or transplanted from only one embryo on each side), but the difference has not statistically significant. In 56% of transplanted patients (whether or not they were improved clinically), severe, persistent dyskinesia appeared during OFF periods. The absence of any significant clinical improvement and the presence of complications considered to be transplant-related led the authors to conclude that this procedure could not be recommended for the treatment of Parkinson's disease.

Experience of the Halifax group [10]. This group has recently reported the results of an autopsy study performed in 2 patients in whom transplantation induced a marked clinical improvement. Like the transplantations performed in Lund and Créteil, this team performed intrastriatal injection of a neuronal suspension associated with immunosuppression. The authors observed much better integration of the transplanted neurons compared to the autopsy results reported by the Denver team. These neurons developed processes extending much further into the host striatum than in the Denver study. In the Halifax study, there were also virtually no areas of gliosis, suggesting a minimal immune reaction likely to lead to transplant rejection. This is an important finding, as it contradicts the negative results reported by the Denver team which could be related to an inappropriate transplantation procedure, leading to partial rejection after stopping immunosuppression.

## 2. HUNTINGTON'S DISEASE

The Créteil group has conducted a first pilot study on 5 patients using an embryonic neuronal transplant taken from the median eminence and implanted into the head of the caudate nucleus and the putamen [1]. The major difference compared to neuronal transplantation in Parkinson's disease is that patients with Huntington's disease present atrophy of the striatum, limiting the number of trajectories and the quantity of neurons that can be transplanted. Transplants were performed using small fragments of tissue. The assessment at 2 years showed that 3 patients obtained cognitive and motor improvement and that this improvement was correlated with increased metabolic activity in the transplanted striatum. However, another assessment at 6 years showed that the clinical condition of these patients had deteriorated with no alteration of the metabolic activity in the transplanted striatum. These results are similar to those recently published by Keene [5], who reported the findings of an autopsy study in 2 patients transplanted 74 and 79 months previously, in whom no apparent clinical improvement was demonstrated. The autopsy study revealed a significant quantity of surviving neurons, but relatively few connections with surrounding host neurons, suggesting that the transplant was not really integrated. In this report, transplants had also been performed with small tissue fragments.

## CONCLUSIONS

Overall, clinical and autopsy data suggest that the transplantation technique is an important element in the success of the procedure. Transplantation using small fragments of tissue can be followed by survival of a large number of neurons within the transplanted structure, but the transplant does not become truly integrated. Transplanted neurons develop processes, but they are relatively short and do not appear to connect physically and functionally with



host neurons. The presence of areas of gliosis around the transplant also suggests the existence of immune reactions which could lead to progressive transplant rejection. Rejection phenomena appear to be much less severe when transplantation consists of a neuronal suspension and groups using this technique report better and more lasting clinical results than those using small tissue fragments.


Regardless of the transplantation technique used, prolonged immunosuppression appears to be essential, which adds the specific problems related to this treatment. A large number of donors also appears to be necessary to ensure the survival of a sufficient number of neurons, especially in the context of Parkinson's disease. In Huntington's disease, the limiting factor is atrophy of the target structure.

These main findings indicate that neuronal transplantation raises too many problems to be used as a treatment for Parkinson's disease or Huntington's disease, except in the context of research. The use of stem cells in the near future will probably modify this cell therapy approach.

## References

- [1] Bachoud-Levi AC, Remy P, Nguyen JP, et al. (2000) Motor and cognitive improvements in patients with Huntington's disease after neural transplantation. *Lancet* 356: 1975-1979
- [2] Backlund EO, Grandberg PO, Hamberger B, et al. (1985) Transplantation of adrenal medullary tissue to striatum in parkinsonism. *J Neurosurg* 62: 169-173
- [3] Björklund A, Stevani U (1979) Reconstruction of the nigrostriatal dopamine pathway in the adult rat by intracerebral nigral transplants. *Brain Res* 177: 555-560
- [4] Freed CR, Greene PE, Breeze RE, et al. (2001) Transplantation of embryonic dopamine neurons for severe Parkinson's disease. *N Engl J Med* 344: 710-718
- [5] Keene CD, Sonnen JA, Swanson PD, et al. (2007) Neural transplantation in Huntington disease: long-term grafts in two patients. *Neurology* 68: 2093-2098
- [6] Legros-Clark WE (1940) Neuronal differentiation in implanted foetal cortical tissue. *J Neurol Psychiatry* 3: 263-284
- [7] Lindvall O, Rehnström S, Brundin P, et al. (1989) Human fetal dopamine neurons grafted into the striatum in two patients with severe Parkinson's disease. A detailed account of methodology and a 6-month follow-up. *Arch Neurol* 46: 615-631
- [8] Lindvall O (1998) Update on fetal transplantation: the Swedish experience. *Mov Disord* 13: 83-87
- [9] Madrazo I, Drucker-Colin R, Diaz V, et al. (1987) Open microsurgical autograft of adrenal medulla to the right caudate nucleus in two patients with intractable Parkinson's disease. *N Engl J Med* 316: 831-834

- [10] Mendez I, Sanchez-Pernaute R, Cooper O, et al. (2005) Cell type analysis of functional fetal dopamine cell suspension transplants in the striatum and substantia nigra of patients with Parkinson's disease. *Brain* 128: 1498-1510
- [11] Olanov CW, Goetz CG, Kordower JH, et al. (2003) A double-blind controlled trial of bilateral fetal nigral transplantation in Parkinson's disease. *Ann Neurol* 54: 404-414
- [12] Palfi S, Condé F, Riche D, et al. (1998) Fetal striatal allografts reverse cognitive deficits in a primate model of Huntington's disease. *Nat Med* 4: 963-966
- [13] Palfi S, Nguyen JP, Brugières P, et al. (1998) MRI-stereotactical approach for neural grafting in basal ganglia disorders. *Exp Neurol* 150: 272-281
- [14] Peschanski M, Defer G, Nguyen JP, et al. (1994) Bilateral motor improvement and alteration of L-dopa effect in two patients with Parkinson's disease following intrastriatal transplantation of foetal ventral mesencephalon. *Brain* 117: 487-499



### **Jean Paul Nguyen**

Jean Paul Nguyen is Professor of Neurosurgery at the Laennec University Hospital in Nantes.

Born on 26 March 1949, 3 children

- Education

1978: Graduate in Neuroanatomy

1980: Doctor in medicine

1982: Neurosurgeon

1990: Full Professor in Neurosurgery

- Professional Affiliations

1990: Professor in Neurosurgery, Henri Mondor Hospital, Créteil

2006: Professor in Neurosurgery, Laennec Hospital, Nantes

2004: Vice President of the French Neurosurgical Society

2006–2009: Secretary of the French Neuromodulation Society

President of the French Neurosurgical Society

- Academic Interests

General Neurosurgery

Neuromodulation procedures (deep brain, cortical, occipital, spinal cord)

Functional Neurosurgery (movement disorders, pain)  
Neuronal graft for the treatment of Parkinson's and Huntington's diseases

**Contact:** Jean Paul Nguyen, Service de Neurochirurgie, Hôpital Laennec, 44000  
Nantes, France  
E-mail: [jean-paul.nguyen@chu-nantes.fr](mailto:jean-paul.nguyen@chu-nantes.fr)

# **PERIPHERAL NERVES**

---

# **MANAGEMENT OF NERVE INJURIES (WITH EMPHASIS ON NERVE ACTION POTENTIAL (NAP) RECORDINGS\*)**

D. G. KLINE

## **INTRODUCTION**

There are three relatively large categories of peripheral neuropathies that may be helped by the neurosurgeon with operative experience with nerves. These are nerve injuries, entrapments, and tumors. A number of good texts address these entities. Of course, there are also less frequent occasions where the neurosurgeon is involved in working up and managing a medical neuropathy [6, 7, 45]. This is usually done by nerve and/or muscle biopsy and under exceptional circumstances, operative exploration for suspected but not proven neural pathology.

This chapter will concentrate on severe nerve injuries and especially the most frequent and difficult to manage, the lesion in continuity. Extra emphasis will be given to operative recordings of nerve action potentials (NAPs).

## **RATIONALE**

The majority of serious injuries affecting nerve leave it in continuity. Some lesions recover enough function in the early months after injury to make operative intervention unnecessary; some do not, and then the operative decision whether to resect the lesion or not can be difficult. Inspection and palpation can be misleading. Simple stimulation may provide contraction in muscles with relatively early innervation distal to the lesion.

However, with serious injuries involving major nerves, stimulation cannot be expected to do so for many, many months. Furthermore, an occasional lesion with an injury site that has primarily poor regenerative potential will permit a few hundred axons to reach distal muscle site and thus muscle will have some response to stimulation. By comparison, an adequately regenerating nerve will have thousands of axons extending through the injury site and into the distal stump by 2 to 3 months post injury, and yet will not have enough distal muscular input to reverse denervational changes as seen by

---

*Keywords:* peripheral nerves, peripheral nerve traumas, transections, neuromas, nerve action potentials (NAPs)

\* From LSUHSC Neurosurgery 2020 Gravier Street, N.O. La. 70112

EMG or for the nerve to respond to simple stimulation. Where injury involves an element of stretch even finding fascicular continuity by internal neurolysis can be misleading because intrafascicular injury can be neurotmetic rather than axonotmetic.

Thus, nerve action potential or NAP recording becomes important in the timely and relatively early evaluation of lesions in continuity. The need to differentiate NAPs from muscle action potentials (MUAPs) and pre from post ganglionic responses in plexus lesions as well as proper electrode positioning has been stressed in this chapter as well as the practical neurophysiology involved.

## **DECISION-MAKING**

### **1. NERVE INJURIES AND TRANSECTIONS**

There are two major categories of mechanical nerve injury. The smallest category and yet the one most often presumed by many physicians caring for nerve lesions to be the cause of loss is transection or partial laceration of the nerve or plexus element. Such injuries represent only approximately 30% of all serious nerve injuries but nonetheless are an important category to consider. There are two categories of lacerations and transections – sharp and dull or blunt and thus contusive. This is far from just a mechanistic stratification because these two categories have a different management algorithm.

#### **1.1 Sharp transection or laceration**

This is usually due to knife, glass, or from a sharp metal edge. The forces necessary to divide nerve are minimal and thus, damage to the stumps is minimal. As a result, these are excellent cases for relatively acute nerve repair i.e. within the first 72 hours post injury [15, 23]. This approach offers many advantages because the nerve can be repaired with the expectation of a reasonable result and can be done at the same time as repair of associated injuries to adjacent structures such as vessels and tendons [1, 20]. Such early repair when possible has the best outcomes even for the brachial plexus (see Table 1). If not done relatively acute, the stumps retract and the need for grafts to bridge the gap increase and outcomes with them although possible are not as good as with end-to-end repair.

#### **1.2 Blunt transection**

This type of injury is due to fan and propeller blades, auto metal, and other blunt objects. The blunt injury is best managed secondarily after a delay of several weeks [34, 43]. This is because the forces of transection are large and blunt, and there is a degree of proximal and distal stump injury which is unpredictable acutely. After the elapse of several weeks, the extent of damage

**Table 1.** Surgical outcome in brachial plexus lacerations<sup>a</sup>

	Elements in continuity	Sharp transection	Blunt transection	Totals
Plexus cases	20	28	23	71
Plexus elements	57	83	61	201
Neurolysis (+NAPs)	24/26	0/0	0/0	24/26 (92%)
Primary suture	0/0	25/31	0/0	25/31 (81%)
Secondary suture	7/9	8/12	3/5	18/26 (70%)
Secondary graft	17/22	21/40	25/56	63/118 (58%)
Total elements	48/57	54/83	28/61	130/201 (65%)

Results are given as number of elements recovering to grade 3 or better (LSUHSC system)  
 Primary = repair within 72 hours of injury; secondary=delayed repair, usually after several weeks

<sup>a</sup>N=71

a=Number of patients

can be operatively both palpated and visualized permitting resection back to healthy tissue and thus the chance of coapting good to good rather than bad to bad. If blunt transection is encountered acutely it is best to tack the stumps down with non-resorbable suture to adjacent fascial planes. This step maintains length so that later end-to-end repair after resection to healthy tissue rather than graft repair can be done.

Despite a penetrating mechanism, nerves can be displaced, contused, stretched or sometimes partially divided leading to neuromas or lesions in continuity (Table 1). These are best operated upon and evaluated if surgery is necessary at 2 to 3 months when operative nerve action potential (NAP) recordings can be used to guide decisions about resection and repair, partial resection and split repair, or simple neurolysis where the nerve is cleared 360° around over a length and freed up from surrounding scar or other injured tissues.

## 2. OTHER INDICATIONS FOR ACUTE OPERATION

There are some other relatively urgent indications for operating on nerve(s) acutely. The most easily understood is a blood clot, where acute compression of the nerve unless ameliorated can lead to either long standing or non-reversible neuropathy [1, 23]. For example, not all pelvic clots associated with anticoagulants let alone those associated with trauma resolve enough spontaneously to permit recovery of femoral nerve function. Even less certain without surgical intervention are subpectoral, axillary, popliteal and subgluteal clots where acute surgical intervention is often necessary.

Another relatively acute indication for surgery is a pseudoaneurysm or A-V fistula usually due to a penetrating wound and affecting axillary or popliteal artery [1, 20, 32, 41]. The pseudoaneurysm or fistula needs resection and a neurolysis of the affected plexus cord and plexal elements or tibial nerve done.



Sometimes nerve in an extremity is badly swollen by trauma and needs exposure and neurolysis acutely especially if it is near a potential area of tightness or entrapment such as ulnar nerve at elbow, median at wrist, and peroneal behind the surgical neck of the fibula [29]. Of course, in many of these cases fasciotomies will be necessary but under some circumstances neurolysis of the nerves will also be needed [40, 42]. A good example of this is Volkman's ischemic contracture due usually to distal humeral fracture and oftentimes elbow dislocation and brachial artery compromise [48]. Here in addition to volar and dorsal forearm fasciotomies it may also be advisable to expose the median, radial, and sometimes even the ulnar nerve.

### 3. LESIONS OR NEUROMAS IN CONTINUITY

This, the largest and most difficult to manage category of injury, requires special attention. Mechanisms are usually blunt and associated with contusion and stretch involving nerve or plexus elements [48, 55]. Classic but by no means exclusive settings include fractures and gunshot wounds involving limb, neck, shoulder, or pelvis [20, 30, 31, 38]. A very large category which can be associated with or without fracture(s) is stretch-contusion to the plexus with or without avulsion of nerve roots [19, 35]. As seen under the transection-laceration category, occasionally, these mechanisms can also lead to either partial or complete division of the elements, More often than not though, lesions in continuity of the plexus result from stretch/contusion either at a supraclavicular or infraclavicular level.

A careful clinical examination with grading of all muscles and then sensation especially that of the hand or foot is an important first step [24, 28, 33]. Radiologic studies especially MRI scans and myelography may be very important in some workups [8]. An early EMG study may be indicated if the clinician suspects prior injury, entrapment or disease [18, 47]. Early conduction studies centered on some sites more commonly involved by a potential neurapraxic injury may also be useful [18, 44]. Usually with more serious injuries, the initial EMG study is done at 3 weeks or so post injury because the Wallerian degenerative process takes time to occur [47]. For most suspected lesions in continuity, a 3 month or so period of repetitive clinical and EMG studies before surgery is needed since some patients will have evidence in this period of early clinical or electrical recovery and thus be spared operation [2, 12]. When such does not occur, then operative exploration, external neurolysis of the involved elements, operative stimulation as well as NAP recordings, and based on that information, resection or not of the lesion in continuity is indicated [16, 38].

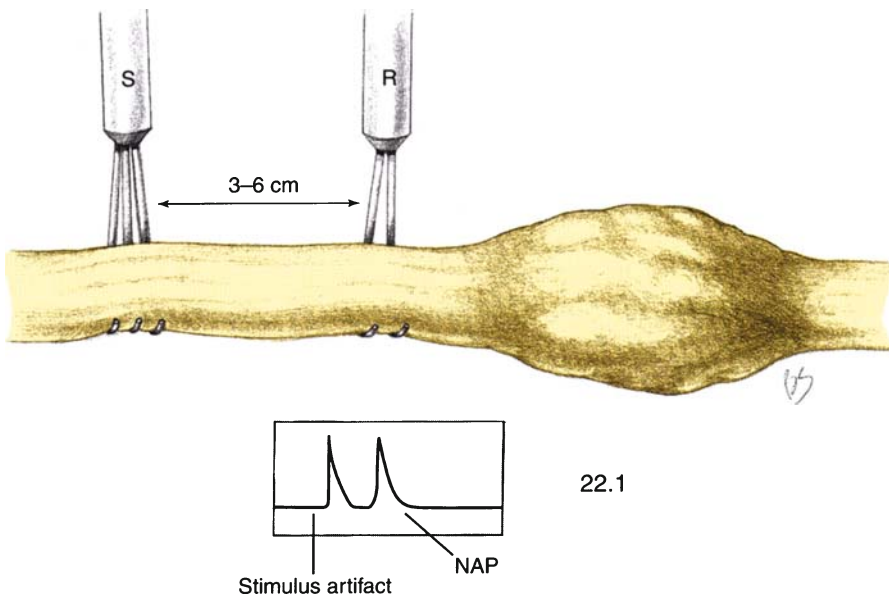
The presence of a compound nerve action potential or NAP indicates viable axons. At the recording site in primates, a NAP seems to require at least 4,000 moderate or larger-sized fibers with some degree of myelination [22, 26]. When this requirement is met in vivo, direct recording does not require

excessive amplification or summation. Recording an NAP distal to an injury site correlates with a satisfactory clinical outcome due to spontaneous regeneration [27]. Resection and repair of such a lesion would usually give a less satisfactory outcome. By comparison though, resection of a non-conducting lesion is necessary since spontaneous and useful recovery will be poor or non-existent without repair [14, 25].

## TECHNIQUES

### 1. ELECTRODES USED FOR NAP STIMULATION AND RECORDING

Electrodes are made of either a noble metal such as platinum or medical grade stainless steel in order to minimize electrolysis associated with metal in contact with the nerve during stimulation [13]. Eighteen-gauge wire is bent like a shepherd's crook on one end so that nerve can be suspended in the crook and gently lifted away from other tissues (Fig. 1). The other ends of the wires are placed through the center of a drilled out Delrin or Teflon rod and soldered to leads for attachment to instrumentation used for stimulating and recording [14]. The drilled out center of the rod is then sealed with a surgical epoxy



**Fig. 1.** Artists' depiction of NAP recording from segment of nerve proximal to lesion in continuity. A three pronged stimulating(s) electrode is to the left and a 2 pronged recording electrode to the right. From [20]

cement. When materials are carefully selected, the electrodes can withstand autoclaving, gas sterilization and water absorption.

The ends of the two active electrodes used for stimulation are separated by at least 3 mm. Electrode tips are separated by a long distance of 5 to 7 mm for stimulation of big nerves such as sciatic or some brachial plexus elements since a larger volume of tissue is involved. If electrode tips are spaced too closely, not all fibers will be stimulated. Stimulation of a nerve both in continuity and in situ differs from the classic physiologic recording in vitro with one or both nerve ends killed. As a result, some small but important alterations in electrode configuration are necessary.

If two stimulating electrode tips are used, there is not only a current generated in the gap between the two but also flowing away from the electrodes through nerve as well as through other body tissues and back again to nerve [11, 13]. This shock is almost instantaneous but still tends to give a large stimulus artifact. When stimulating and recording montages are relatively close, as they have to be in some clinical situations, the "after-slope" of this stimulus artifact can obscure the evoked NAP. One way to minimize this is to use three tips for the stimulating electrode [13, 49]. The outermost two tips are a common anode and are connected one to the other while the middle tip is the cathode. Application of a potential difference between the outermost and innermost active electrodes still produces two currents but neither involves the whole nerve, and thus the stimulus artifact is reduced. The tripolar stimulation electrode also limits the spread of the stimulation current along a longitudinal course in the nerve, making for a more precise and somewhat isolated site of stimulation. Generally, the fidelity of recordings from larger nerves will be optimal if larger caliber electrodes are used and better for smaller if finer caliber electrodes are used [14].

Recording electrode configuration is also important. The electrodes are bipolar and each wire or tip records from an active and the other from a relatively inactive portion of the nerve. The bipolar electrodes recording tips should be separated by as much as a centimeter for relatively large nerves such as the sciatic, femoral or proximal median. If these two recordings tips are too close together on the nerve, amplitude of the evoked NAP can be reduced, or the NAP can be eliminated altogether. When the distance between stimulating and recording electrode montages is larger, there is also a need to separate the two recordings electrode tips by a greater distance than when recordings are made over a short distance. There is a larger length of active nerve due to greater temporal dispersion in conduction when recordings are made over a longer distance [5]. The time of arrival of responses at the recording site is thus quite variable. This temporal dispersion is due to differences in conduction velocities amongst different-sized myelinated axons.

Distance between stimulating and recording electrode sets is also important. If they are too close, the stimulus artifact will still be extensive despite use of a tripolar stimulating electrode.

**Table 2.** Initial steps for NAP recording

- 
- Check electrodes and recording equipment preoperatively.
  - Adequate 360° exposure of the lesion and distal nerve and if possible proximal segment.
  - Unplug potential sources of 60 cycle interference such as warming blanket, IV fluid warmer, bovie, fluorescent light box for X-rays. Sometimes a ground wire is led from the bovie pad to the recording machine.
  - Irrigate the wound with warm saline.
  - Separate stimulating and recording electrodes by 3 to 4 cm.
  - Separate as much as possible the lead out wires to the recording machine.
  - Record a proximal strip NAP. An adjacent, less involved element or nerve can be tested to check equipment when a proximal nerve segment is not available.
- 

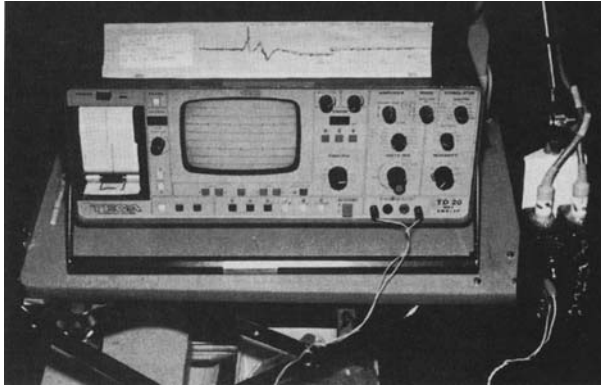
Fine EEG needles can also be placed in nerve to both stimulate and record NAPs [16]. When done carefully, this is not damaging even to intact nerve. Needle recordings are especially useful when the surgical exposure of nerve is limited or at a deep level. Usually, two needles are placed in the nerve or element to be evaluated several mm apart for stimulation proximally, and then two needles are separated by several mm more distally.

Lead-in and out wires from the stimulating and recording electrodes should be separated by several inches if possible, otherwise capacitance between the wires can further increase stimulus artifact and also produce other electrical noise [51] (Table 2). Shielding is usually used for lead-in and lead-out wires since isolation needs to be maximized. Electrode-to-wire connections and integrity of the wire can be readily checked by use of an amp meter [52].

Grounding can be provided by attaching the lead-out from a bovie pad affixed to the patient's skin to the grounding portion of the recording machine. The electrosurgical unit is turned off to provide safe grounding and to reduce unwanted electrical noise. Operating room equipment which is either battery-operated or motor-driven, such as body and fluid warmers, TCD machines and fluorescent lights should be turned off. Or better yet, equipment should be disconnected by having their plugs removed from nearby wall sockets. This reduces the possibility of 60 cycle interference. A single wave isolated from a 60 cycle recording may be misinterpreted as a positive NAP by an inexperienced observer.

## 2. STIMULATING AND RECORDING EQUIPMENT

Most electromyographic (EMG) machines manufactured within the last 20 years or so will have the necessary built-in stimulating and recording parameters for satisfactory NAP recording [13, 14]. In recent years we have found it convenient to use the TECA, model TD 20 which is self-contained and provides some degree of flexibility [27] (Fig. 2). We also have access to a larger



**Fig. 2.** EMG machine in this case a TECA TD 20 used for stimulation and recording. Stimulating electrodes are led out of the stimulating portion of the instrument (*bottom right*) and recording electrodes to differential amplifier plug ins to the far right. Tracing, propped, on top of the instrument is of a nerve action potential recorded just distal to the site of a stretch injury involving an axillary nerve. From [20]

Nicolet Spirit Machine which can be programmed for a variety of operative electrophysiological studies. My colleague, Robert L. Tiel uses a very compact machine, a XLTEK Neuromax C1004 for his NAP recordings [49]. One can also construct a system using a Grass model stimulator (S-44) with a stimulus isolation unit (SIU-6) to provide stimulation [28]. Recordings can be done using an oscilloscope with a differential amplifier as is available for the Tektronix 7000 series. A trigger wire can be led from the stimulator to the oscilloscope so that a trace will be prompted with each stimulus delivered to the stimulating electrode(s).

Whether a compact EMG machine such as the TECA TD20 or a larger system is used, attention must be paid to both the high and low-frequency filters. The low-frequency filter setting is usually placed in the 5 to 10 Hz range or lower and the high-frequency setting at 2500 Hz or higher. These settings tend to decrease stimulus artifact and noise without filtering out the evoked NAP response. If over filtered, the stimulus artifact will be greater and the amplitude as well as the integral of the NAP less. If a 60 Hz notch filter is built into the recording instrument, it is usually better not to use it for NAP recording. The filter device itself can generate a wave resembling a NAP [14].

### 3. TECHNIQUE FOR STIMULATING AND RECORDING NAPS

Short-duration stimuli are used to both decrease stimulus artifact and to decrease stimulation of fine fibers which may or may not mature with further time and lead to useful function (Table 3). Typical settings range between 0.05 to 0.1 ms in duration. This requires increased voltage for adequate stimulation.

**Table 3.** Recording the NAP

- Turn on the trace and turn on the stimulus and make sure the stimulus artifact is seen at the beginning of the trace. Stimulus site plug-in can be interchanged to provide an upright stimulus artifact.
- Keeping the stimulus duration short 0.05 to 0.1 ms, gradually increase the voltage intensity until a NAP is evoked. Can interchange the recording plug-ins to make the NAP upright.
- Gradually increase amplification. Try different low and high frequency filters to optimize the evoked NAP
- Once a proximal segment NAP is recorded, move the more distal recording electrodes onto the injury site and then to distal nerve to see if a NAP is maintained. See how far distally the response is recorded.
- Amplification settings may have to be increased further and/or filters further adjusted.
- Observe muscles distal to the stimulation site(s) for contraction.
- For supraclavicular plexus stretch injuries, stimulation as well as recording has to sometimes be done distal to the lesion site.

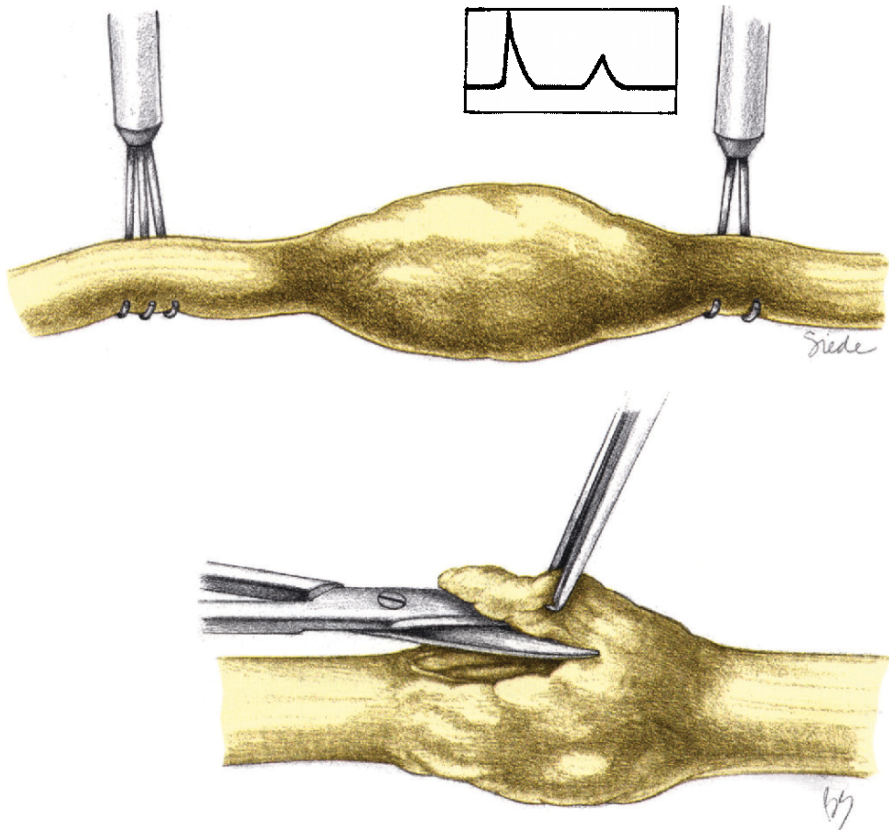
While healthy nerves may require voltages between 3 and 15 V, regenerating nerve may need 100 V or more. Frequency of stimulation should be kept at 3 per second or less to prevent damage to nerve with these short duration, high voltage stimuli. NAPs are recorded with the oscilloscope set between 50  $\mu$ V and 5 mV per division on the oscilloscope face (Table 4). The time base is set at 0.5 to 2 m per division. We usually begin by recording the NAP by stimulating and recording the NAP proximal to the injury site. If electrodes as well as stimulating and recording equipment are working and 3 to 4 or more centimeters of nerve can be exposed proximal to the lesion in continuity, a NAP response should be recorded [22] (see Fig. 1). Alternatively, NAPs are recorded from an adjacent, healthy nerve or plexus element [4]. These steps ensure that the entire system is functioning properly. If the recordings are suboptimal, all equipment is checked in a systematic way before any attempt is made to record from the injured nerve. Recording electrodes are then moved onto the lesion site and beyond to see if a NAP can be recorded and, if so, how far distal to the

**Table 4.** Usual instrument settings

Stimulus	Settings
Duration	0.05 to 0.1 msec
Intensity	10 to 200 V
Frequency	2 to 3 per second
Recording	Settings
Amplification	50 $\mu$ V to 5 mV per division
Time frame	0.5 to 2.0 m per division
Frequency filters	1 to 3 Hz

For high frequency a filter of 2500 Hz or higher

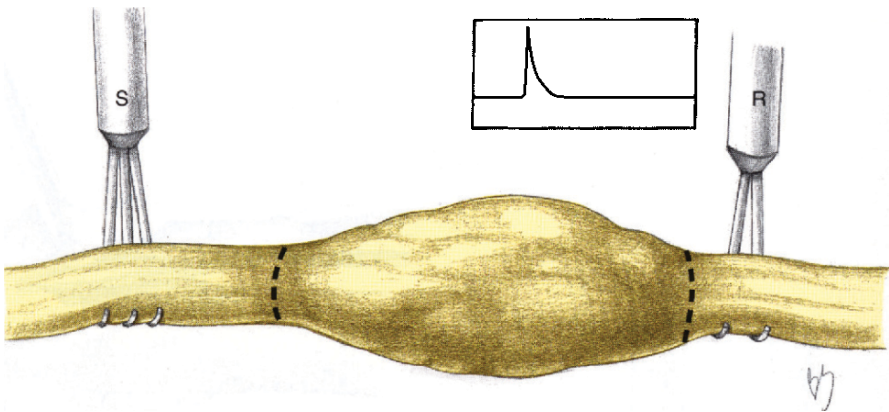
For low frequency a filter of 5 to 10 Hz or lower



**Fig. 3.** A NAP was transmitted through a lesion and recorded just distal to the neuroma leading to a neurolysis. Lower Figure shows section of epineurial scar (From [21])

injury site (Fig. 3). If a proximal segment of the injured nerve is not available for a baseline recording, then an adjacent uninvolved nerve may be used to check the electrodes and the stimulation and recording settings. These settings can then be used as a starting point to stimulate and record from the injured nerve. Intensity of stimulation and, if need be, duration can be increased as well as amplification used for recording. There are cases, particularly when severe plexus stretch injuries are studied intraoperatively where one cannot stimulate from nerve proximal to injury site or even from other uninvolved or less involved nerves [19, 25]. One must then be content with stimulating at the lesion site or even distal to it and recording below or distally.

Response of distal muscle to stimulation of nerve proximal to a lesion is also noted since contraction usually indicates good regeneration not only through the lesion but to that muscle [3, 38]. Since the limb must therefore be available for inspection and palpation throughout the operation, appropriate



**Fig. 4.** A NAP did not transmit through this neuroma so it was resected (see dotted lines) (From [21])

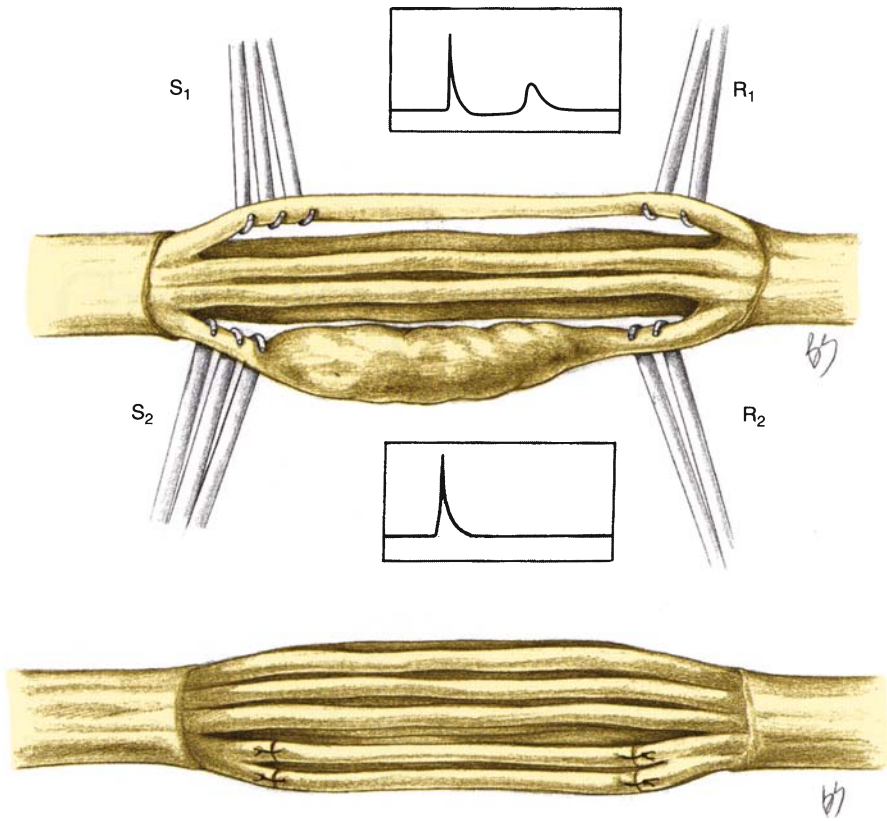
draping at the start of the operation is essential. In general, however in the early months post injury, such obvious evidence of sparing or recovery will usually not be present unless the lesion was partial to begin with.

The objective in operative recording is to measure an NAP distal to the lesion. In the initial 9 months after injury, the NAP's amplitude and conduction velocity are not as important as the simple presence or absence of a response [25, 34, 46]. Presence of an NAP indicates axons of sufficient number, caliber, and maturation to presage useful recovery of function for at least a portion of the injured cross section of nerve. Absence of an NAP indicates that recovery will not occur without resection and repair (Fig. 4). An NAP recorded a year or more after injury across a lesion in continuity with severe clinical loss should have moderately good amplitude and conduction greater than 30 m/s.

In some cases, an NAP is present but visual inspection of the conducting segment suggests that one portion of the lesion's cross section is more severely involved than another (Fig. 5). Then, the lesion can be split into groups of fascicles, and these fascicles conduct and others do not [50, 52, 54]. This leads to a split repair, in which a portion of the nerve is repaired by direct suture or graft and a portion by neurolysis alone.

As stimulation and recording begin, the stimulus intensity (voltage) is gradually increased, and the amplification for recording is also increased until an NAP is seen (Table 3). Different filter settings can also be tried. The stimulating electrodes are usually placed proximally since that stimulation site ensures activation of a maximal number of fibers [24, 27, 33]. If a stimulus site proximal to an injured but regenerating nerve is accessible, more normal fibers can be stimulated proximally than distally. This decreases the need for a high-intensity stimulus and, as a result, decreases the stimulus artifact record-





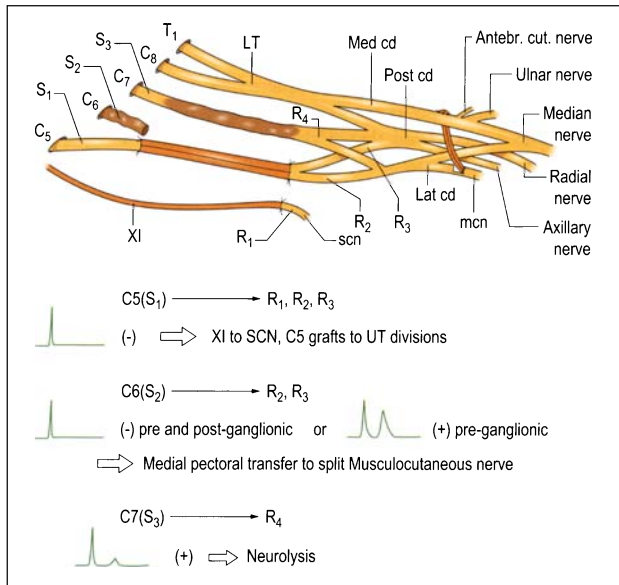
**Fig. 5.** A portion of this lesion in continuity (*top figure*) conducted (*top tracing*) and a portion did not (*bottom tracing*). As a result a split graft repair was done after an internal neurolysis (*bottom figure*) (From [21])

ed distally. Stimulating and recording electrode tips are used to lift and hold the nerve away from other tissue.

More distal evoked muscle action potentials (MAPs or MUAPs) can be picked up by the recording electrodes placed on nerve. These responses however, are quite delayed compared to NAPs. Their calculated velocities are slow, usually less than 20 m/s. They are also larger in amplitude than NAPs and more likely to be polyphasic and to have a broader base than a NAP.

#### 4. THE PARTICULAR CIRCUMSTANCES OF PREGANGLIONIC PLEXUS LESIONS

With a plexus lesion, where spinal nerves or roots are injured at a preganglionic level but are intact postganglionically, rapidly conducting (60–80 m/s)



**Fig. 6.** In this model of a C5, C6, C7 stretch injury to supraclavicular plexus C6 had no usable outflow due to very proximal injury whereas C5 did. Grafts were led from C5 spinal nerve to upper trunk divisions and accessory nerve was transferred to suprascapular nerve while at an infraclavicular level medial pectoral branches were sewn to a split musculocutaneous nerve (From [20])

and relatively large amplitude NAPs can be recorded [25]. This is due to the fact that the large and well-myelinated sensory fibers have been spared Wallerian degeneration and, when stimulated, conduct a rapid and large response. These responses differ from slower, lower amplitude regenerative NAPs and may even be faster and larger than those seen when recording from an intact plexus element [25]. If there is doubt, the proximal part of the spinal nerve can be stimulated and attempt made to record somatosensory evoked potentials via cutaneous electrodes placed previously over the upper and posterior cervical spine area. With preganglionic injury, these evoked responses will be absent. If there is both pre and post ganglionic lesions, the NAP trace will be flat much as with a non-regenerating lesion present lateral to the dorsal root ganglion (Fig. 6).

## 5. OTHER PRECAUTIONS

If any extremity is operated on under tourniquet and the latter is inflated for 60 min or longer, the tourniquet should be left down for 20 or more minutes before NAP recording is tried. Ischemia as well as low wound temperature can block successful recordings [46] (Table 5). In several earlier

**Table 5.** Trouble shooting

---

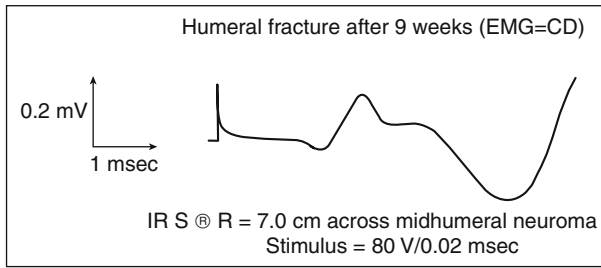
- Make sure electrodes have good contact with nerve and away from other tissues.
  - When nerve elevated on the "Crook's" of the electrodes make sure tension is minimal or else conduction will be blocked.
  - Make sure there is an adequate distance between the two prongs of the recording electrodes. The distance will need to be greater, the larger the nerve. Some separation of the stimulating prongs is also advisable.
  - Irrigate with warm saline before recording.
  - If tourniquet used on the limb let it down for 20 min before recording.
  - Use of local anesthetic in the area of the nerve can block conduction.
  - Muscle action potential will have broader base, high amplitude and more likely to be multiphasic than NAP.
- 

cases done under tourniquet, NAP traces were flat and yet regeneration as shown by either histologic study of the resected segment or subsequent clinical course was adequate [23]. One also has to be careful of local anesthetic use that may also temporarily block conduction. Since the block can persist for many hours, absence of a NAP may not under these circumstances indicate resection. On the other hand, muscle paralysis by curare-like drugs does not interfere with NAP recording. Even so, discussion with the anesthetist preoperatively will result in an anesthetic technique in which neuromuscular blockage used on induction will have worn off by the time the surgeon has dissected the area of injury. The surgeon is thus able to stimulate normal and/or injured nerve, observe the effect of appropriate muscle contraction, and then elicit NAPs from nerves which give no response to direct stimulation. Once the NAP recording phase of the operation is concluded, the anesthetist can use whatever anesthetic technique he/she prefers.

Noninvasive recording of NAPs is possible for some peripheral nerve lesions, but has a definite incidence of false negative traces as subsequently shown by intraoperative NAP studies. Such recordings are more readily achieved with nerves distal in the extremity and close to skin such as median or ulnar close to the wrist. Occasionally, stimulation of a nerve close by but uninvolved by the injury will produce a falsely positive study so patients have to be carefully selected for such a noninvasive approach.

## RESULTS

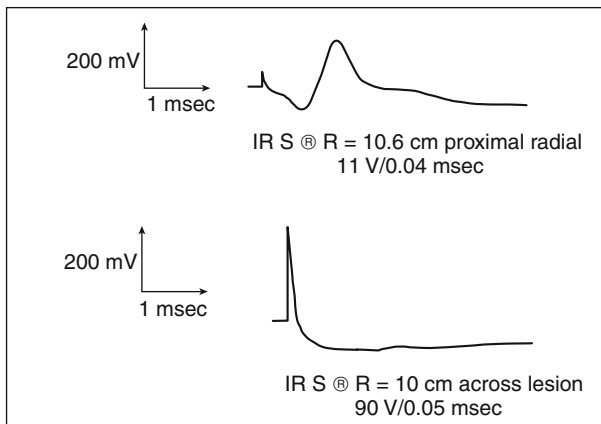
Outcomes from this approach for individual nerve can be found in a succession of publications in both the *Journal of Neurosurgery* and *Neurosurgery*. A recent summation of NAP recording is in the proceedings of the 13th World Congress of Neurological Surgery held in Marrekesh [27] (Table 1).



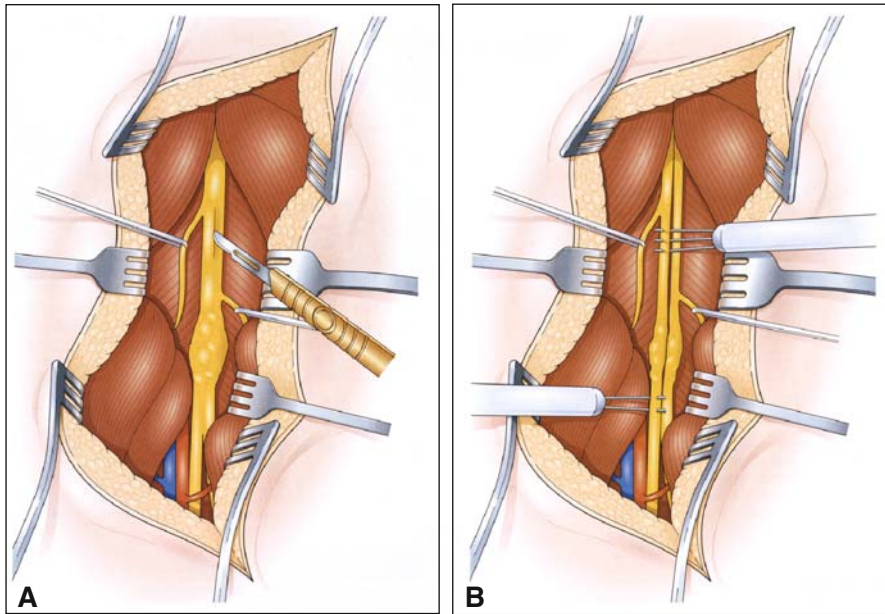
**Fig. 7.** Recording made distal to a neuroma involving midhumeral level radial nerve and secondary to a fracture 9 weeks previously. Loss was complete clinically and by EMG. A neurolysis was done and overall radial recovery was 4/5 by the LSUHSC grading system by 3 years postoperatively. *IR* Invasive recording, *S* stimulus, *R* recording (From [20])

Recovery to a LSUHSC grade 3 or better level occurred in 1255 of 1422 (94.7%) injured nerves elements having (+) NAPs (Fig. 7). If there was no conduction across the lesion and thus the trace was flat just distal to the lesion the lesion was resected and repaired by epineurial and end to end suture or by interfascicular grafts (Fig. 8). Histologic study of the resected specimens showed neurotmetic lesions.

Outcomes to an LSUHSC grade level of 3 for whole nerve or plexus averaged 56% for suture and graft repairs. This figure included elements or nerves favorable for repair as well as unfavorable ones such as lower plexus trunk, medial cord, ulnar nerve, and peroneal nerve or division of the sciatic as well as more favorable ones. In a nerve such as the sciatic each of its divisions



**Fig. 8.** Operative NAP recording proximal to another radial lesion (*top trace*) and across the lesion (*bottom trace*). Only a tiny NAP is seen in the *lower trace*. Lesion was resected and was Sunderland Grade IV histologically. *IR* invasive recording, *S* stimulus, *R* recording (From [20])



**Fig. 9.** (A) High level sciatic nerve is shown in this drawing being sharply split into its two division after transmitting a NAP across the lesion. (B) NAP recording electrodes are shown in place on the tibial division. Tibial division transmitted but peroneal did not so a repair of the latter was done (From [21])

needed evaluation by recordings and sometimes different operative management based on those results (Fig. 9).

Recordings in 950 entrapped nerves usually but not always confirmed preoperative electrodiagnostic studies. Operative recordings in 364 ulnar entrapments validated the diagnosis in 62 cases where less invasive preoperative conductive studies were normal and documented the olecranon notch as the site of maximal nerve involvement in 95% of the cases [20]. Operative recordings at the supraclavicular level in a series of 160 suspected thoracic outlet (TOS) cases showed amplitude and velocity abnormalities at the level of spinal nerves T1 and C8 close to the spinal column and not more laterally between 1st rib and clavicle [19, 20]. These abnormalities were compared to recordings from less involved elements such as C5 and C6 to the upper trunk level where velocities and amplitudes were significantly greater.

Finally, operative NAP recordings have been used to identify nonfunctional fascicles entering and leaving neural sheath tumors, – schwannomas and neurofibromas as well as documenting less involved fascicles [20].

The validity of NAP recordings has been validated by numerous publications from other centers [1, 4, 9, 10, 16, 17, 28, 32, 36, 37, 39, 41, 42, 45, 46, 50, 52–54, 57].

## CONCLUSIONS

If a NAP was present in this series, the lesion usually had an external neurolysis, if unassociated with pain, or an internal neurolysis if severe and neuritic pain was a problem. Some lesions in continuity having a NAP had more obvious severe injury to one portion of the nerve than to another. In these cases, the nerve was split into groups of fascicles and differentially evaluated by NAP recordings. A split repair was then usually done. Those lesions in continuity not transmitting a NAP two or more months post injury were resected and proven to be neurotmetic or Sunderland Grade IV histologically.

NAP recording was also used as an investigative tool for entrapments such as those involving ulnar, posterior interosseus or peroneal nerves or plexus elements in presumed thoracic outlet cases as well as in tumors arising from or involving nerve(s).

## References

- [1] Birch R, Bonney G, Wynn Parry C (1998) Surgical disorders of the peripheral nerve. Churchill Livingstone, Edinburgh
- [2] Carter G, Robinson L, Chang V, Kraft G (2000) Electrodiagnostic evaluation of traumatic nerve injuries. *Hand Clin* 16(1): 1-12
- [3] Collins W, O'Leary J, Hunt W, Schwartz H (1955) An electrophysiological study of nerve regeneration in the cat. *J Neurosurg* 12: 39-46
- [4] Crum B, Strommen J (2007) Peripheral nerve stimulation on monitoring during operative procedures. *Muscle Nerve* 35: 15-170
- [5] Dorfman L, et al. (1981) Conduction velocity disturbances: a population approach to electrophysiology of nerve. W.R. Liss, New York
- [6] Dyck P, Thomas PK (1993) Peripheral neuropathy, 3rd edn. W.B. Saunders Co., Philadelphia
- [7] England J, Sumner A (1987) Neuralgic amyotrophy: an increasing diverse entity. *Muscle Nerve* 10: 60-68
- [8] Filler A, Kliot M, Hune F (1996) Application of magnetic resonances neurography in the evaluation of patients with peripheral nerve pathology. *J Neurosurg* 85: 229-309
- [9] Friedman W (1992) The electrophysiology of peripheral nerve injuries. *N.S. Clinics NA* 21: 43-56
- [10] Gabriel E, Villavicencio, A, Friedman A (2001) Evaluation and surgical repair of brachial plexus injuries. *Semin Neurosurg* 12(1): 29-48

- [11] Galbrath J, Meyers R (1991) Impulse conduction. In: Gelberman RH (ed) *Operative nerve repair and reconstruction*. J.B. Lippincott Co., Philadelphia, pp 19-45
- [12] Gilliat R (1981) Physical injury to peripheral nerves: physiologic and electrodiagnostic aspects. *Mayo Clin Proc* 56: 361-370
- [13] Happel L, Kline D (1991) Nerve lesions in continuity. In: Gelberman R (ed) *Operative nerve repair and reconstruction*. J.B. Lippincott Co., Philadelphia
- [14] Happel L, Kline D (2002) Intraoperative neurophysiology of the peripheral nervous system. In: Deletis V, Shils J (eds) *Neurophysiology in neurosurgery*. Academic Press, Amsterdam London, pp 269-294
- [15] Hudson A, Hunter D (1977) Timing of peripheral nerve repair: important local neuropathologic factors. *Clin Neurosurg* 24: 392-405
- [16] Hudson AR, Trammer B (1985) Brachial plexus injuries. In: Wilkins R, Rengachary S (eds) *Neurosurgery*. McGraw Hill, New York
- [17] Kaplan B, Friedman W, Gravenstein D (1984) Intraoperative electrophysiology in treatment of peripheral nerve injuries. *J Fla Med Assoc* 71: 400-403
- [18] Kimura J (1983) *Electrodiagnosis in diseases of nerve and muscle: principles and practice*. F.A. Davis, Philadelphia
- [19] Kim D, Cho Y, Tiel R, Kline D (2003) Outcomes of surgery in 1019 brachial plexus lesions treated at LSUHSC. *J Neurosurg* 98: 1005-1016
- [20] Kim D, Midha R, Murovic JA, Spinner Teil J (2008) *Kline and Hudson's nerve injuries: operative results for major nerve injuries, entrapments and tumors*, 2nd edn. Elsevier, Philadelphia
- [21] Kline D, Hudson A, Kim D (2001) *Atlas of peripheral nerve surgery*. W.B. Saunders, Philadelphia
- [22] Kline DG, DeJonge BR (1968) Evoked potentials to evaluate peripheral nerve injuries. *Surg Gynecol Obstet* 127: 1239-1250
- [23] Kline DG, Hackett ER (1975) Reappraisal of timing for exploration of civilian peripheral nerve injuries. *Surgery* 78: 54-65
- [24] Kline DG, Hackett ER (1985) The neuroma-in-continuity: a management problem. In: Wilkins RH, Rengachary S (eds) *Neurosurgery*. McGraw-Hill, New York
- [25] Kline DG, Hackett ER, Happel L (1985) Review of surgical lesions of the brachial plexus. *Arch Neurol* 43: 170-181
- [26] Kline DG, Hackett ER, May PR (1969) Evaluation of nerve injuries by evoked potentials and electromyography. *J Neurosurg* 31: 128-136

- [27] Kline DG, Happel L (2004) Nerve action potential recording for nerve lesions. From laboratory to operating room: a 35 year experience. Proceedings 13th World Congress of Neurological Surgery, Medimond s.r.l. Bologna, Italy, pp 981-984
- [28] Kline DG, Nulsen FE (1972) The neuroma-incontinuity: its preoperative and operative management. *Surg Clin North Am* 52: 1189-1209
- [29] Lundborg G (1988) Nerve injury and repair. Churchill Livingstone, Edinburgh
- [30] Lyons W, Woodhall B (1949) Atlas of peripheral nerve injuries. W.B. Saunders Co., Philadelphia
- [31] MacKinnon S, Dillon A (1988) Surgery of peripheral nerve. Thieme, New York
- [32] McGillicuddy J (1992) Clinical decision-making in brachial plexus injuries. *N.S. Clinics NA* 2(1): 137-150
- [33] Midha R, Kline D (1998) Evaluation of neuroma in continuity. In: Omer G, Spinner M, Van Beek A (eds) Management of peripheral nerve problems. W.B. Saunders, Philadelphia
- [34] Midha R, MacKay M (2001) Principles of nerve regeneration and surgical repair Sem. In: Naff N (ed) Neurosurgery, vol. 12(1). pp 81-92
- [35] Millesi H (1988) Brachial plexus injuries. Nerve grafting. *Clin Orthop* 237: 36-42
- [36] Nath N (2001) Preface to seminars in neurosurgery. 12(1): 3
- [37] Nelson KR (1988) Use of peripheral nerve action potentials for intraoperative monitoring. *Neurol Clin* 6: 917-933
- [38] Nulsen FE, Lewey FH (1947) Intra-neural bipolar stimulation: a new aid in the assessment of nerve injuries. *Science* 106: 301
- [39] Oberle J, Antoniadis G, Ruth S, Richter H (1997) Value of nerve action potentials in surgical management of traumatic nerve lesions. *Neurosurgery* 41(6): 1337-1344
- [40] Omer G, Spinner M, VanBeek A (1998) Management of peripheral nerve problems. W.B. Saunders, Philadelphia
- [41] Roganovic Z, Misovic S, Kronja G, Savic M (2007) Peripheral nerve lesions associated with missile-induced pseudoaneurysms. *J Neurosurg* 107: 765-775
- [42] Secar HI, Daneyemez M, Sonul, E, Fzci Y (2007) Surgical repair of ulnar nerve lesions caused by gunshot and shrapnel: results in 407 lesions. *J Neurosurg* 107: 776-782
- [43] Seddon HJ (1972) Surgical disorders of the peripheral nerves. Williams & Wilkins, Baltimore
- [44] Smith S (1996) The role of neurophysiological investigation in traumatic brachial plexus injuries in adults and children. *J Hand Surg* 21B: 145-148



- [45] Spinner M (1998) Peripheral nerve problems—past, present, and future In: Management of peripheral nerve problems, 2nd edn. W.B. Saunders Co., Philadelphia
- [46] Spinner R (2004) Complication avoidance. *Neurosurg Clin N Am* 15: 193-202
- [47] Sumner A (1980) The physiology of peripheral nerve disease. W.B. Saunders Co., Philadelphia
- [48] Sunderland S (1978) Nerves and nerve injuries, 2nd edn. Churchill-Livingstone, Edinburgh
- [49] Tiel R, Happel L, Kline D (1996) Nerve action potential recording method and equipment. *Neurosurgery* 39(1): 103-109
- [50] Terzis J, Dykes R (1976) Electrophysiological recordings in peripheral nerve surgery: a review. *J Hand Surg* 1: 52-66
- [51] Van Beek A (1998) Intraoperative nerve stimulation and recording techniques. In: Management of peripheral nerve problems, 2nd edn. W.B. Saunders Co., Philadelphia
- [52] Van Beek A, Hubble B, Kinkead L (1983) Clinical use of nerve stimulation and recording. *Plast Reconstr Surg* 71: 225-232
- [53] Vanderark G, Meyer G, Kline D, Kempe L (1970) Peripheral nerve injuries studied by evoked potential recordings. *Mil Med* 135(2): 90-94
- [54] Williams HB, Terzis JK (1976) Single fascicular recordings: an intraoperative diagnostic tool for the management of peripheral nerve lesions. *Plast Reconstr Surg* 57: 562-569
- [55] Woodhall B, Nulsen F, White J, Davis L (1957) Neurosurgical implications. In: Peripheral nerve regeneration. V.A. Monograph, US Government Printing Office, Washington, D.C.
- [56] Zachary R, Roaf R (1954) Lesions in continuity. In: Seddon H (ed) Peripheral nerve injuries. Her Majesty's Stationary Office, Med Res Council Spec Report, Series No. 282
- [57] Zalis A, Rodriguez A, Oester Y, Maius D (1972) Evaluation of regeneration by means of evoked potentials. *J Bone Jt Surg* 54A: 1246-1253



**David Gellinger Kline**

David Gellinger Kline is chairman of the Department of Neurosurgery at the Louisiana State University in Lenoir, NC.

He was born in Philadelphia on October 13, 1934. In Michigan he completed his training in neurosurgery under Edgar Kahn and Richard Schneider and worked in Elizabeth Crosby's laboratory, where he further developed an intraoperative method of evaluating neuromas and lesions in continuity by nerve action potential recording.

He was recruited in 1967 to come to Louisiana State University School of Medicine.

Dr. Kline became head of the Division of Neurosurgery in 1971, Professor of Surgery in 1975 and Chairman of the Department of Neurosurgery in 1976. In 1995, the University named him a Boyd Professor, one of eight such in the LSU Medical Center.

In addition, he served as scientific and meeting chairman for the Executive Committees of the Congress of Neurological Surgery and the American Association of Neurological Surgeons. In 2006, Dr. Kline received the Cushing Medal, the highest recognition given by the North Americans' spokesman society the AANS.

His research and clinical interests remain focused on nerve injuries and especially the neurophysiology of regeneration and peripheral nerve tumors. Early clinical experience included work with Dr. Frank E. Nulsen of Cleveland; and in the last 30 years

he worked in both the clinical and the laboratory arena with Dr. Alan R. Hudson of Toronto and in recent years with Drs. Daniel Kim, Leo Happel and Robert Tiel. Seventy-five fellows from this and other countries and from other disciplines, as well as neurosurgery, have spent time at LSU working in the area of nerve.

Dr. Kline is the author of 275 articles and chapters and two books, with Dr. Hudson as co-author. He is presently serving on the editorial boards of a number of journals. He is married to the former Helen Colt Levey of New Orleans and has three children by a former marriage, Susan, Robert and Nancy, and two stepchildren, Mary and Mike, as well as 7 delightful grandchildren.

**Contact:** David Gellinger Kline, Boyd Professor, Louisiana State University Health Sciences Center, 7041 Globe Road, Lenoir, NC 28645, USA  
E-mail: [dkline@lsuhsc.edu](mailto:dkline@lsuhsc.edu)

---

# TUNNEL COMPRESSION SYNDROMES OF MEDIAN AND ULNAR NERVES

J. HAASE

## INTRODUCTION

Entrapment means, “to be caught in a trap”. Nerve compression syndromes that are caused by entrapment may thus be treated by surgical decompression increasing the free space surrounding the nerve. In e.g. the carpal tunnel syndrome (CTS) it is believed that the median nerve is compressed in the carpal tunnel due to an increased pressure within the tunnel. Surgical decompression lowers this compression and thereby the entrapment of the median nerve. It is suggested in textbooks that almost any peripheral nerve can be compressed [1]. It is not the aim of this chapter to discuss all of these – often hypothetical – entrapments and their surgical treatment.

I shall concentrate on the most common entrapments of the median- and ulnar nerves.

**History.** The most common entrapment syndrome is the CTS [1, 2, 6]. Paget first described CTS based on an old radius fracture in 1865. Hunt suggested an occupational neuritis in 1909. Few years later Marie and Foix suggested that the transverse carpal ligament (TCL) could be the compressive agent resulting in proximal neuromas of the median nerve. For a number of years cutting the TCL was used to prevent motorpalsy/thenar atrophy. Immediately after World War 2, great interest was raised for peripheral nerve surgery. Zachary described thenar palsy due to CTS in 1945 and in 1946; Cannon and Love published results of nine CTS operated patients. In 1947 Brain discussed the pathophysiology of CTS and Phalen introduced the concept of neuropathy in 1950. The second most common entrapment syndrome is that of the ulnar nerve at the elbow [1]. Henry Earle described in 1816 the first surgical case in a 14-year-old girl [4]. Further differential diagnostics on ulnar nerve tunnel syndromes were later introduced and the cubital tunnel syndrome described [10].

Sunderland’s monumental work on peripheral nerves leads to a better understanding of peripheral nerve anatomy [13]. This resulted in further surgical refinement including introduction of magnification and operative microscopes, micro sutures, fibrin glue, nerve grafting and use of intra- and preoperative neurophysiology [5]. Late in the 80s endoscope surgical treatment was introduced and recently a combination of open surgery and endoscope surgery [8].

---

*Keywords:* tunnel syndromes, ulnar nerve, median nerve, surgical technique, microsurgery

## PART 1: MEDIAN NERVE – ENTRAPMENT (CTS)

### RATIONALE

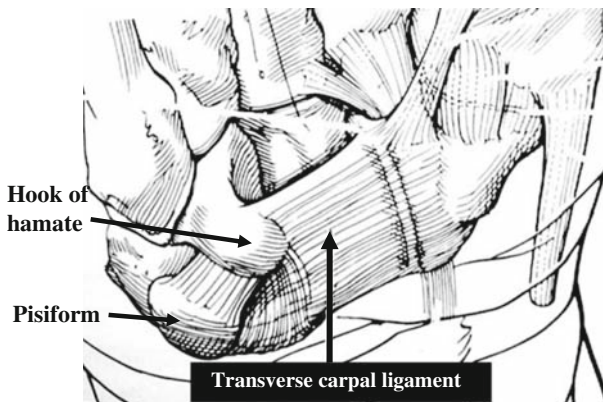
Carpal tunnel anatomy. The carpal tunnel is situated distal to the transverse crease at the hand wrist. It has a length of approximately 4 cm (2–5 cm) with a roof created by the 0.5 cm thick transverse carpal ligament (TCL). The carpal tunnel is 2–3 cm wide and has floor and walls defined by the Navicular-, Trapezius-, Scaphoid-, Hamate- and Pisiform wrist bones (Fig. 1).

Entrance to the carpal tunnel is proximal and distal defined by the rim of the TCL. The abductor brevis muscle to the thumb inserts from the radial side upon the TCL (Fig. 2).

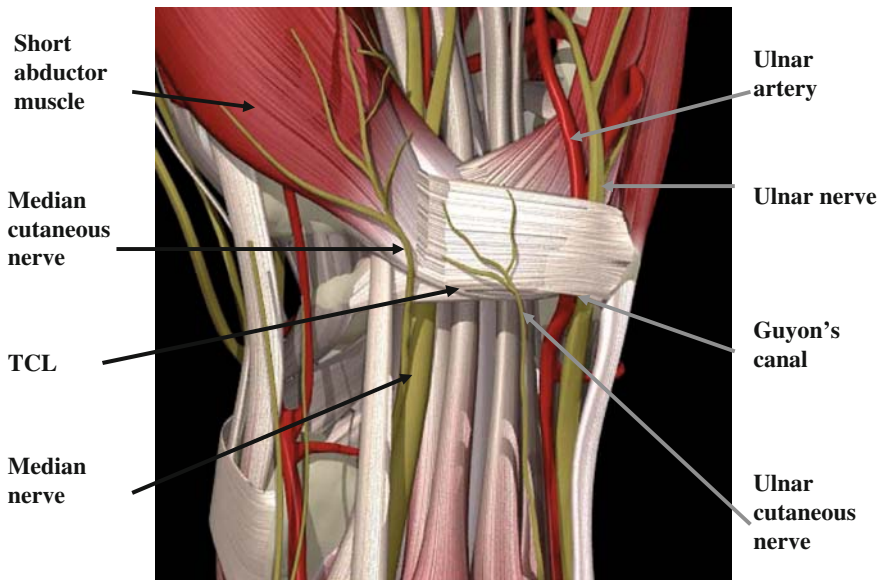
In the palm and superficial to the TCL lies the palmar aponeurosis. It contains superficial longitudinal fibres that proximal is in continuity with the tendon of the long palmar muscle. Deeper transverse fibres of the palmar aponeurosis continue into the antebrachial fascia of the forearm (Fig. 2).

Carpal tunnel size. There is a great difference between measuring anatomical structures on cadavers and in the living. With the introduction of Magnetic Resonance Imaging (MRI) we have received better information regarding the carpal tunnel among the living (Fig. 3).

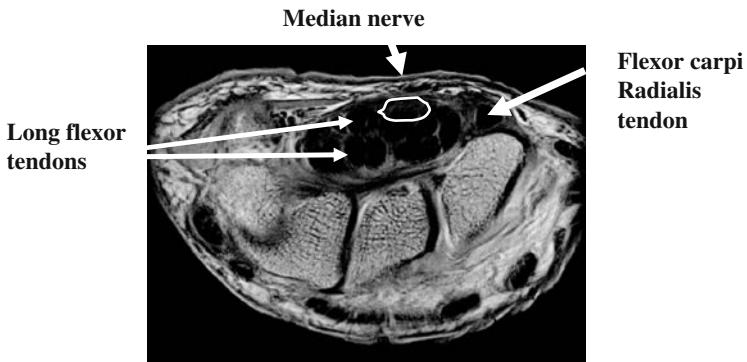
The cross-sectional area of the carpal canal is smallest distal. MRI measurements proximal and distal to the wrist flexion crease demonstrates a gradual increase in the cross section area moving proximal, starting approximately 23 mm from the distal point. The volume of the carpal tunnel depends on the wrist position and decreases with wrist extension. The volume of a 40 mm long TCL is 114.280 mm<sup>3</sup>.



**Fig. 1.** Anatomical demonstration of hand bones and transverse carpal ligament



**Fig. 2.** Anatomical demonstration of the carpal tunnel region. Tendons, vessels, nerves and muscles



**Fig. 3.** Magnetic Resonance Imaging (MRI). Cross section of the carpal tunnel contents. Median nerve relation to tendons and hand bones

Carpal tunnel contents. The carpal tunnel harbours the median nerve and nine long flexor tendons (Figs. 2 and 3).

The *median nerve* consists of sensory and motor fibres to the radial part of the hand [13]. The median nerve enters the carpal tunnel under the radial edge of the long palmar muscle tendon after having given off a cutaneous palmar branch that lies radial to the tendon of the long palmar muscle start-

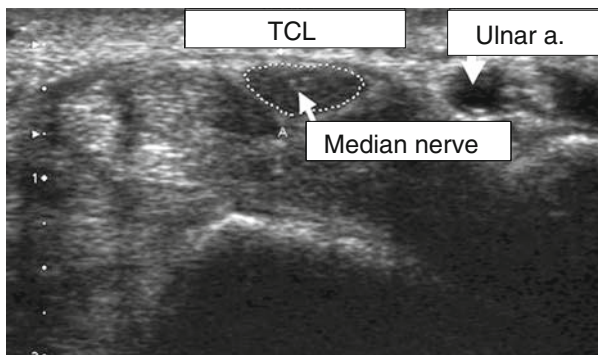
ing 3–11 cm proximal to the wrist. Short palmar branches originate proximal to the wrist crease penetrating the fanning fibres of the long palmar muscle tendon and terminate in the TCL. The palm derives its cutaneous sensation from branches of both the median- and ulnar nerves. The cutaneous branch from the ulnar nerve is found up to 16 cm proximal to the wrist crease and innervates skin at the thenar eminence in approximately 50% of patients (Fig. 2).

The median nerve passes through the carpal tunnel located volar close to the TCL and radial to the superficial flexor tendons lying between those to the middle finger and the radial flexor carpi tendon (Figs. 2 and 4).

Among half of patients the median nerve gives distal to the TCL rim a recurrent motor branch to the abductor brevis muscle of the thumb. This branch is usually given off free inside the carpal tunnel but may be subligamentous or intraligamentous placed. This branch may also innervate the first interdigital and lumbrical muscles. Distally to the TCL the median nerve divides in branches to the 1st, 2nd, 3rd web spaces and the radial side of the thumb. A communicating branch (Berettini branch) between the ulnar- and median nerves is found in soft fat 2–26 mm distal to the TCL together with the superficial vessel arcade between radial- and ulnar arteries (Fig. 2).

The median nerve changes size and format according to the position of the wrist joint and with movements and elongation of the TCL. It is oval at the proximal pisiform bone level becoming more elliptical at the level of the Hamate bone. With the wrist extended it is found more deep to the TCL whereas it in flexion is pressed towards the TCL. It may move up to 2 cm during flexion/extension.

The *eight superficial flexor- and the deep flexor tendons* are in the same synovial sheet, whereas the *long flexor tendon to the thumb* has its own sheet radially placed in the TCL (Fig. 3).



**Fig. 4.** Ultrasonographic imaging. Cross section of the carpal tunnel contents. Median nerve size shown

The TCL serves as a trolley for these long flexor tendons that move up to 5 cm in normal situations.

The many variations in the anatomy of the median nerve at the wrist are of importance to the surgeon preparing to divide the TCL.

## DECISION-MAKING

*Diagnosis* of CTS is unfortunately commonly based on patients symptoms (subjective) alone: numbness and/or tingling with or without pain in the median nerve distribution in the hands – symptoms which we as physicians often states: “*are caused by compression neuropathy of the median nerve at the wrist.*” e.g. – a typical ring conclusion. The variability lead to the development of the hand diagram by Szabo [5]. Here the patients fill out a questionnaire to be given to the MD. However the results are closely linked to the epidemiology of the patients. If we give hand diagrams to a group of patients in a hand-surgical outpatient clinic its value is low [5]. If we screen a normal population it is high. Szabo showed that the combinations of a patient with completed hand diagram, presence of nightly pain, abnormal sensibility using monofilament testing and a positive Durkan’s test had both a high sensitivity and specificity. If all 4 parameters were abnormal the diagnosis of CTS was correct in 86% [5]. Most important is the fact that for scientific comparison of patient groups we cannot accept to define CTS caused by compression from patient information symptomatology alone and then compare these cases with cases of documented nerve abnormalities.

Verification of peripheral nerve lesions can be made by *electrophysiology and imaging and electrophysiology.*

We therefore often supplement our investigations with electrophysiological validation. The problems of diagnostic specificity still exist despite this 30% of patients with “typical clinical symptoms of CTS” have normal neurophysiologic examinations, 32% with “uncertain” clinical symptoms have positive electrophysiological studies and 18% of persons without any symptomatology have positive electrophysiological studies [3].

This emphasizes how we often include many types of and degrees of “CTS” in our so-called syndrome.

## 1. ELECTROPHYSIOLOGY

Focus on muscles, alpha motor nerve fibers and large myelinated sensory nerve fibers whereas autonomic functions and sensory functions mediated by the thin myelinated fibers or unmyelinated C-fibers are not systematically investigated. Precisely these fibers are presumably those first involved



in the CTS. Technical factors such as amplifier gain, filter settings, electrode size, form and material, distance between electrodes and hand/arm temperature plays an important role. Surface electrodes are the predominantly used. Prolonged distal motor latency (DML) and blocked sensory nerve conduction velocity (SNCV) at the TCL are the most used electrophysiologic parameters used for diagnosing CTS. Electrophysiology is also important for diagnosing polyneuropathy and to exclude patients with other diseases.

## 2. IMAGING (MRI)

MRI is used to demonstrate edema and ischemia inside the median nerve (Fig. 2).

Most important is that these abnormalities are found by using T2 weighted fast spin-echo fat suppressed technique (chemical shift selection or inversion recovery). T1 weighted imaging with planes parallel and transversely along the nerve using phased-array coils gives similar excellent anatomical data. How these data are correlated with carpal tunnel pressure increase and electrophysiology is not yet completely solved.

## 3. IMAGING (ULTRASONOGRAPHY)

Ultrasonography is also used to document nerve size and other abnormalities within the carpal tunnel. An increased size of the median nerve seems to be the most constant factor (Fig. 4).

For validation of the symptomatology of a CTS neuropathy in different stadiums, clinical symptoms/hand diagrams are combined with electrophysiological data.

The clinical symptoms and the electrophysiological changes make it possible to divide suspected CTS patients in four groups/stadiums:

*Stadium 1.* Intermittent ischemia of sensory neurons, but with no significant SNCV disturbances. Clinically these patients harbor acroparaesthesia, but no sensory disturbances to be found by clinical investigation.

Remember that Stadium 1 is not a stadium where validation of pressure changes is evident using electrophysiology. This is the most common stadium! Many of these patients claim that symptoms started when they were using wrist loading work e.g. potato peeling, cloth twisting or knitting.

*Stadium 2.* Chronic ischemia of sensory axons with focal reduction of SNCV due to paranodal demyelization. Clinically presenting with minor degrees of subjective hypoesthesia, clumsiness, and pain by wrist provoking movements and nightly painful paraesthesia. These patients will often present with clinical sensory disturbances of the median nerve territory.

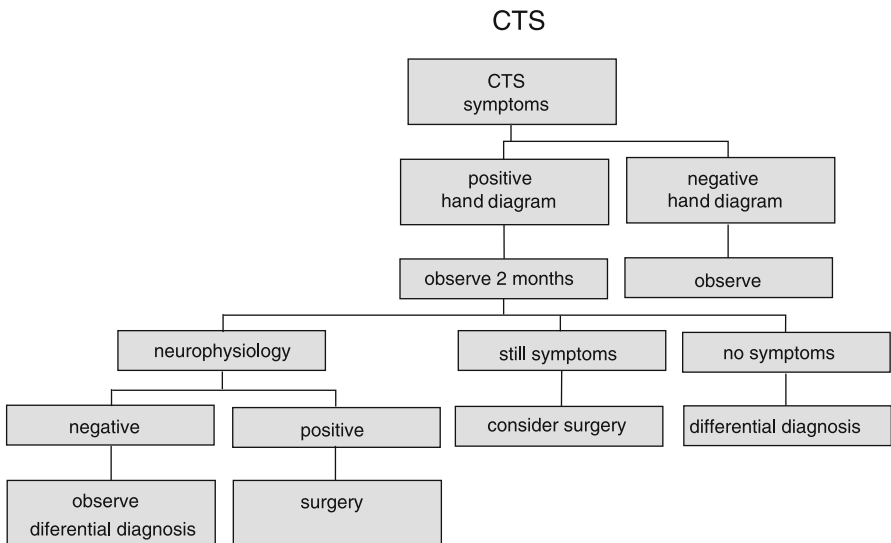
*Stadium 3.* Axonal degeneration with reduced SNCV, decreased amplitude of sensory nerve potentials and denervation potentials in abductor pollicis brevis muscle. Clinically they are still clumsy and beginning atrophy and palsy of the abductor pollicis brevis muscle is found. They may have moderate nightly painful paraesthesia and clinical sensory disturbances.

*Stadium 4.* Loss of many axons and subsequent significant reduced SNCV, which in the end-stadium may show no functioning fibers at all. Persistent hypoaesthesia/anaesthesia is found and the median nerve territory. Subjective symptoms are now changed and nightly paraesthesia is uncommon. Many patients are first diagnosed at this stage because they are investigated for other diseases as their symptoms does not infer with normal daily life. They have been accustomed to the loss of sensibility and are not bothered by pain.

**4. CONCLUSIONS**

Due to this, one must conclude that in order to document functional disturbances in the median nerve, clinical electrophysiologic investigations play a role in describing and defining the types of CTS that needs surgical decompression. Similar we need a precise classification if we want to compare patients and patient treatments.

**5. CHECKLIST – FLOW DIAGRAM**



**Fig. 5.** Flow chart. Diagnostics and treatment of carpal tunnel syndromes

## SURGERY

The patient is preoperatively carefully informed about how the operation is carried out. It is described how local anesthesia is used and that he/she can feel “something” happening during the operation, but will have no pain during the operation. Additional anesthetics can be applied if necessary. No tourniquet is used.

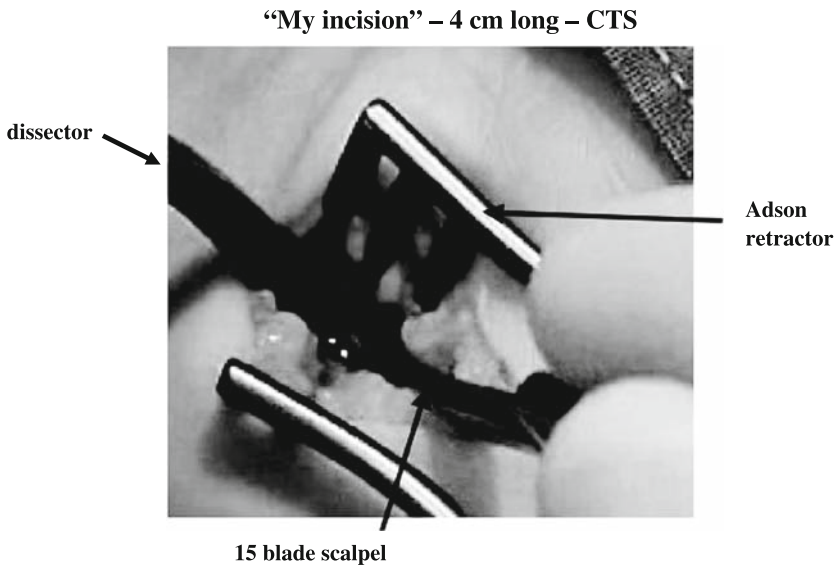
Instruments needed are surgical knife with a 15 blade, an Adson retractor is used and preferable an operative microscope or loupes for better viewing.

The patient is told not to eat after midnight. He arrives in the outpatient clinic and relaxes with a newspaper. He is then brought into the operating room in his normal clothes. The hand/arm is carefully prepped with iodine or similar disinfection material. The hand is then placed on a well bolstered separate arm table. If it is the right hand, the right-handed surgeon places himself at the ulnar side of the hand to be operated upon. Vice versa if the surgeon is left handed. The reason being that the surgeon then will cut and dissect from proximal towards distal whereby the risk of injuring nerve branches is reduced.

The operative microscope is brought to its place. The oculars and interpupillary distance are set correctly by the surgeon and the microscope may be draped. The operative field is with this type of surgery rather stationary so draping can be excluded!

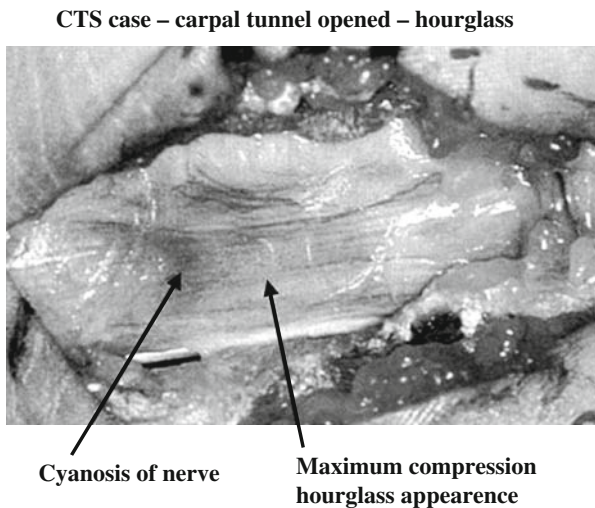
With a thin needle 4–5 cc lidocain 1% is infiltrating the skin over the carpal tunnel. Then after 4–5 minutes I test the quality of sensation with small pin pricks at the anesthetic area and outside this to make the patient comfortable by sensing the difference between normal painful areas and analgesic areas.

I use two pair of gloves at the introduction. A 3–4 cm long incision is made with a 15 blade from the distal crease of the hand towards the interdigital space 3/4. A small self-retaining retractor is used to pull the skin edges apart (Fig. 6). Haemostasis is carefully applied with bipolar coagulation if necessary. I removed the first pair of gloves that are contaminated with skin bacterial flora. With aid of the microscope the palmar aponeurosis is now visualized and cut longitudinally with a fresh 15 blade. Eventual cutaneous nerve structures or vessels are avoided. The TCL is now visualized with its white transverse fibers. It is cut open in the middle, slightly ulnar to the midline. When the carpal tunnel contents are encountered, the incision is carried further distally to the rim of the TCL and until the normal fat is visualized. Then the proximal part of the ligament is cut and eventually part of the antebrachial fascia again keeping ulnar. The palmar cutaneous nerve branch is usually never seen with this approach. The median nerve is visualized and hourglass shape and eventual cyanosis described (Fig. 7). Movements of the tendons by pulling the fingers secure that the contents in the canal is free. The ligament edges are coagulated with low current bipolar coagulation and the skin closed in one layer with single 5–0 nylon sutures. The wound is covered with a band-aid and the hand bolstered leaving the fingers free for active movements immedi-

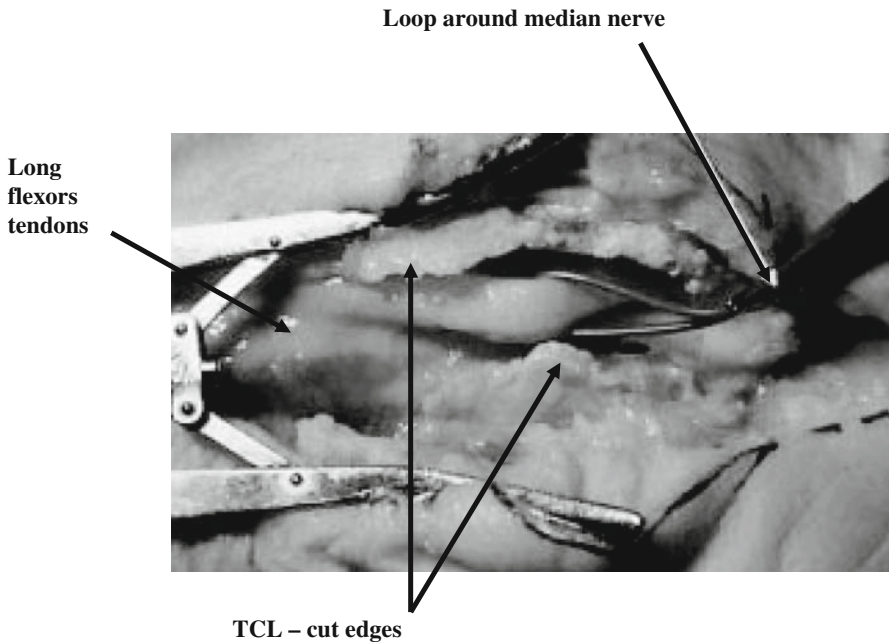


**Fig. 6.** Carpal tunnel opening using “my incision” – straight, 4 cm long

ately after surgery. The hand is kept high the first day and skin sutures removed after 10–14 days. Decreased wrist movements are common after the two weeks immobilization and should be treated by active movements after



**Fig. 7.** Carpal tunnel opened showing hourglass appearance of a compressed median nerve



**Fig. 8.** Cadaveric specimen of carpal tunnel. Vascular loop placed around median nerve

the skin sutures have been removed. A cadaveric image of the carpal tunnel contents is seen in Fig. 8.

Complications from larger series in modern time ranges from 0 to 24% among open surgically treated CTS demonstrating the influence of the surgical learning curve and/or surgical competence. In our own series at Aalborg Hospital (approx. 100 cases/year) we found in one year 13% complications where residents performed the operations. This was in contrast to 0% the year after, where all these operations were carried out by two experienced neurosurgeons.

The most common complication to open surgery is:

- Inadequate cutting of the distal part of the transverse ligament. These patients will not experience a relief of the painful paraesthesia after the operations, which is normal for all others within a few days. If the patient still complains after 2–3 days consider this complication.

The other complications are:

- Erroneous decompression of the ulnar nerve in Guyon's canal instead of median nerve (no magnification used?).
- Direct surgical lesion of the median nerve.

- Direct surgical lesion of the motor branch of median nerve.
- Lesion of the palmar cutaneous branch of median nerve which often leads to reflex sympathetic dystrophy (RDS).
- Hypertrophy scar is only seen if the skin incision has been carried proximal to the wrist crease.
- Hypersensitive scar and slight pillar pain are common in the first weeks after surgery.
- Injury to superficial vascular arch and wound infection is rarely encountered. Decreased grip strength is common for the first 2–3 months, but will normally disappear.

## HOW TO AVOID COMPLICATIONS

To see is the first and most important factor. With my described technique the nerve is clearly seen because magnification is used with the operative microscope. Furthermore the microscope includes excellent light in the operative field. It is possible to preserve the whole operation on a DVD or as slides in a PowerPoint presentation.

Second important issue is that I never use tourniquet. Thereby all degrees of nerve compressions including their colour changes and vessels stasis are clearly shown. Performing the skin incision the larger cutaneous nerves may be seen and protected. The white transverse fibres of the TCL are also easily visualized with the microscope. The motor branch of the median nerve is never found during this dissection and thus never sectioned because you see all details of the operation – nothing is blinded. Similar I never use a pair of scissors to cut the TCL for the same reason. I never use a protecting instrument placed into the carpal tunnel so that you may cut directly on this. If you do so you merely resemble the standard endoscope treatment and its possible mistakes [5].

Cutting the TCL proximal and its continuation into the antebrachial fascia can also be seen and the free median nerve felt in the arm.

## CONCLUSIONS

In stages 1 and 2, total relief of pain and nightly paraesthesia is obtained in close to 96% of all cases within 24–48 hours. In stadia 3 and 4 full return of sensation and muscle power cannot be anticipated, as regeneration of the axonal injured nerve fibers will take up till several years. One of the main causes for surgical mistakes is improperly placed incisions [6]. Hands are different and incisions must take aim of visualization of the ligament and then the contents of the carpal tunnel. Lack of magnification and light both disturbs the possibilities of viewing the carpal ligament sufficiently. Most series published are “personal” and thus not suited for generalizing – which

is still done. The surgical learning curve is important and because one great endoscope surgeon or microneurosurgeon can carry out CTS without complications this does not invariably indicate that the rest of surgeons will do the same. From a variety of series the complications varies from 0 to 23% demonstrating the value of experience [5]. The serious complications must be regarded as the result of: – “careless or inexperienced surgery and the established principle of surgery under direct vision has provided reliable protection against disaster” (J Hand Surg 1994: 19B; 3–4).

It is often quoted that following endoscope decompression the time of return to work is shorter than with the open techniques despite that no controlled randomized series exist to prove this statement.

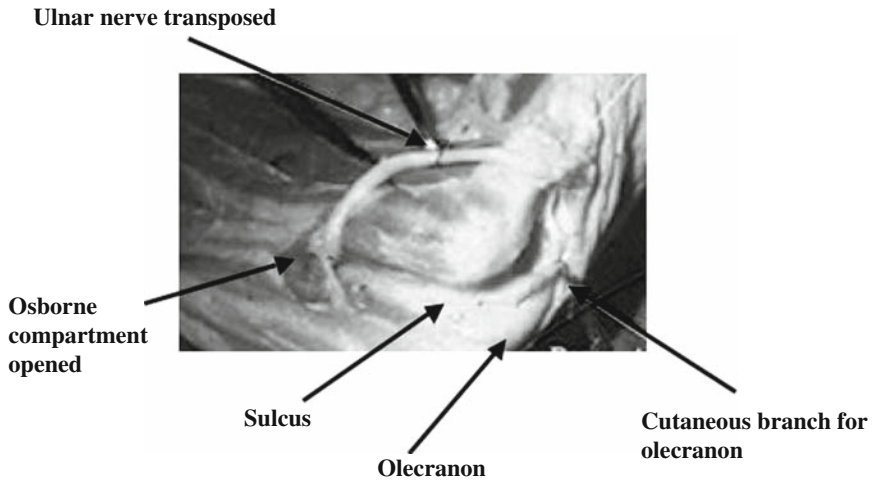
## **PART 2: ULNAR NERVE ENTRAPMENT**

### **RATIONALE**

The ulnar nerve follows the medial head of the triceps muscle to the groove between the Olecranon process and the medial epicondyle. The ulnar nerve enters the retrocondylar groove with only 2–4 fascicles and is here heavily protected in a fibro-osseous tunnel. After crossing the elbow it gives off branches to the elbow joint, skin at the olecranon and motor branches to the ulnar carpal flexor- and the medial half of the deep flexor muscles. Upon leaving the groove it enters the cubital tunnel (Osborne compartment) under the arcuate aponeurosis (Osborne ligament) constructed by the two heads of the ulnar carpal flexor muscle inserting on the medial epicondyle and the olecranon [10]. The nerve digs down under these two heads into the Osborne compartment and continues into the forearm lying between the ulnar carpal flexor muscle and the deep long flexor muscle closely joined with the ulnar artery. Here it gives motor branches to the long flexor muscles. Where it digs into under the Osborne ligament it gives off articular branches to the elbow joint (Fig. 9).

Distal at the wrist it enters Guyon’s canal where it to the volar ulnar part of the hand and 4th and 5th fingers. I has superficial and deep motor branches to the small hand muscles, the interossei – thumb adductor, thumb flexor, opponence and two ulnar lumbrical muscles (Fig. 2).

The motor fibres for hand muscles are located superficially in the ulnar nerve at the elbow level [13]. Anastomosis between the ulnar- and median nerves in the forearm and distally in the palm exists in many patients. Similar many variations in the ulnar nerve anatomy exist. A gliding movement of up to 4.7 cm of the only 2–4 fascicles of the ulnar nerve is taking place during flexion/extension of the elbow in normal persons [13]. During flexion of the elbow the sulcus size decreases and similarly it increases during extension. In contrast the cubital tunnel space decreases with elbow



**Fig. 9.** Cadaveric specimen of elbow region showing ulnar nerve transposed from sulcus

extension. The strain at elbow flexion is maximal directly behind the medial epicondyle with pressures that increases up to 3 times by elbow flexion.

The ulnar nerve may very rarely be compressed proximal to the sulcus. More common it is compressed at the level of medial epicondyle due to recent elbow fractures. If the fibro-osseous tunnel is reduced in size the ulnar nerve may easily be entrapped here. In the cubital compartment an elbow flexion causes stretching of the ligament and the compartment flattens leading to pressure on the ulnar nerve. When the ulnar nerve leaves this “Osborne compartment” it perforates the fascia layer (arcuate ligament) between the superficial and deep long flexor muscles, which may lead to a possible entrapment [9, 10, 12].

## DECISION-MAKING

Diagnosis is made from careful history taking noting the time of symptom debut and by objective clinical evaluation. Is there a history of trauma towards elbow – even an old one in childhood? It must be described how symptoms are transient or continuous, related to work, opening jars or turning doorknobs, bending the elbow using hand-held phones or driving a car? With repetitive hand work the patient may note weakness of hand developing together with hand coordination problem such as typing and playing an instrument. A decreased handgrip and pinch strength is therefore a sign of an ulnar nerve irritation. Pain along inside of shoulder blade and paraesthesia may



also wake them from sleep. Many patients have severe pain at the elbow flexor muscles radiating down towards the 5th finger or centrally towards the shoulder and neck.

Wasting of muscles is often seen – classically in the first hand space and the hypothenar. Froment's sign is then positive. The ulnar carpal muscle and the ulnar part of the deep flexor muscles will also often be paretic. Sensibility disturbances are present on the 4th and 5th finger including the dorsal part of the hypothenar. Patients with compression in Guyon's canal will have same motor dysfunction but preserved sensibility on the dorsal side of the hypothenar. Vibrating tools or direct trauma are the most common causes of symptoms. Ganglia have been reported in the canal but not in the sulcus.

Patients with polyneuropathy (diabetes mellitus) seem more vulnerable to repeated trauma and to ischemic changes in the nerve. Differential diagnosis includes evaluation of the cervical spine for a cervical disc herniation. Are the shoulder movements normal? Is there any suggesting of a thoracic outlet syndrome or a Pancoast tumor of the lung apex? Palpation for peripheral nerve tumors at the supraclavicular space or along the medial aspect of the upper arm. Does the patient have a neglected elbow fracture or luxation? Did he have a supracondylar fracture as a child? Are there signs of severe arthrosis or rheumatic arthritis? Is the nerve subluxating over the epicondyle during maximal elbow flexion? The ischemia leads to progressing interstitial connective tissue proliferation and reduced gliding properties of the fascicles and thereby symptomatology [9].

Patients are for practical reasons often grouped based on degree of symptomatology:

1. *Mild symptomatic patients* with intermittent paraesthesia and hypoesthesia.
2. *Moderate symptomatic patients* with persistent symptoms and varying degrees of motor weakness and muscle atrophy.
3. *Worst symptomatic patients* with marked intrinsic muscle atrophy, weakness and deformity.

Group 1 should primarily be treated in a non-operative way. The stadia 2 and 3 may need surgery depending on the degree of internal nerve fibrosis and axonal degeneration.

Preoperative assessment. *Laboratory tests* include ruling out anaemia, diabetes mellitus and hypothyroidisms. If rheumatoid arthritis is suspected the relevant blood tests should be performed.

*Neurophysiology.* Controversies exist but most prominent feature is a reduced nerve conduction velocity over the elbow being >10msec reduced compared to the velocity measured in the nerve in the distal part of the arm. However, when and if axonotmesis occurs, in later phases, correlation with the other side is more valuable. The recommendations from the American

Association of Electrodiagnostic Medicine (Haase) include as a standard that the ulnar sensory and motor NCV be performed with surface stimulation and recording. If NCV is found abnormal, further studies must be carried out to exclude a diffuse process in the nerve. For standardization, the elbow is positioned in a 70–90° flexion and across – elbow distances should be around 10 cm.

*Imaging* includes radiographs of the chest for Pancoast tumor and cervical rib. Radiograph of the elbow is obtained if valgus deformity or shallow groove is found.

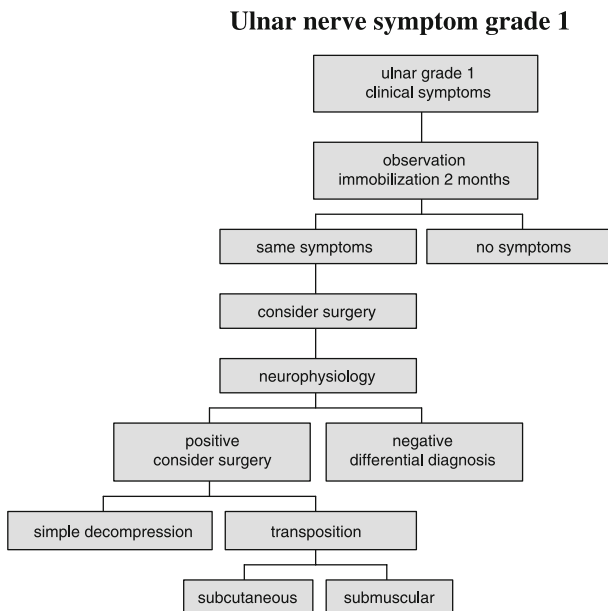
*Ultrasonography* demonstrates the groove with the ulnar nerve and the Osborne space and arcuate ligament.

*MRI* is used in a few cases, but the value of all these tests are still developing.

For *entrapment in Guyon’s canal* MRI of the wrist bones may be needed. Guyon’s canal EMG shows a prolonged distal motor latency to the dorsal interossoeus muscle of 1st interstitium and reduced sensory nerve conduction velocity in the hand.

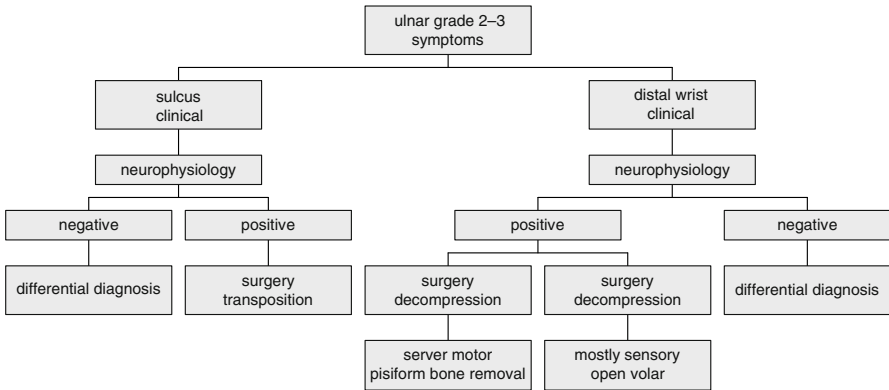
Ultrasonography has so far no scientific documented place as an imaging tool.

Flow charts for treatment of these different grades are found in Figs. 10 and 11.



**Fig. 10.** Flow chart. Diagnostics and treatment of ulnar nerve compression. Grade 1

### Ulnar nerve symptom grade 2–3



**Fig. 11.** Flow chart. Diagnostics and treatment of ulnar nerve compression. Grades 2–3

## SURGERY

The patient is preoperatively carefully informed about the operation. With the simple decompression it is described to the patient how local anesthesia is used and that he/she can feel “something” happening during the operation, but will have no pain. Additional anesthetics can be applied if necessary. No tourniquet is used. With transposition procedures general anaesthesia is preferred [1, 12]. The minimal invasive technique by endo/microsurgery may have an advantage but needs long-term validation [8].

### 1. SIMPLE DECOMPRESSION TECHNIQUES

#### 1.1 Osborne operation

The muscle aponeurosis over the cubital tunnel is opened using local anesthesia but the retrocondylar groove is kept untouched. The skin distal to the olecranon is infiltrated with 5 cc of local anaesthetics. The skin is then opened from the middle of the line between the olecranon and the epicondyle distal to the groove. The muscle aponeurosis is cut and the Osborne compartment opened. The ulnar nerve is located and the nerve dissected beneath the two heads of the ulnar carpal flexor muscle. I always use magnification at this stage (operative microscope). When the fascia has been opened I move the arm to see how the nerve is sliding. I do not open the retrocondylar groove unless compression here is suspected. If I open it, it is only the distal half of the fibro osseous tunnel. Other authors do it routinely, releasing the nerve from its groove and let it lie freely only covered

by connective tissue. To me the patient needs to have a deep condylar groove to do this. The risk of a new chronic nerve irritation is obvious with the nerve sliding over the epicondyle. With elbow flexion. I then close the skin in two layers. The patient is urged to move the elbow freely immediately after surgery. At night an elbow bandage made by a towel is used to prevent maximum elbow flexion for the next 2–3 weeks. Skin sutures are removed after 2 weeks [10].

Open surgery is the standard; the cubital tunnel release with endoscope assistance has been advocated with a new micro/endo version in 2006 [8].

## 1.2 Epicondylectomy

Medial epicondylectomy is another hypothetical way to release pressure on the ulnar nerve at the elbow. This operation needs general anaesthesia. Excision of the proper amount of bone is critical to the success of this procedure. If too much bone is excised, damage to the medial collateral ligament of the elbow deep in the groove may lead to a valgus instability and pain. Osteomyelitis is a severe complication to this operation. Other complications are injury to the anterior fibres of the medial collateral ligament giving painful instability of the medial elbow, heterotopy ossification as the result of osteotomy and continuous minor trauma as the nerve now is unprotected [7, 12].

The author has never carried out this operation.

## 2. ULNAR NERVE DECOMPRESSION WITH TRANSPOSITIONS OF THE NERVE

Surgical decompression of the ulnar nerve with subsequent anterior transposition to the medial epicondyle is often used. Hereby the position of the ulnar nerve should be shorter and tension of the nerve thus be relieved. Interfascicular gliding should also be improved. The ulnar nerve may be positioned subcutaneously above the muscle fascia or submuscular either under or inside the pronator teres muscle [1, 7, 9]. Lesions of cutaneous branches to the olecranon/elbow joint may result from transposition techniques and long dissection of muscular and cutaneous branches may be needed.

### 2.1 The subcutaneous technique

An incision starts some 8 cm proximal to the medial epicondyle and continues in front of this to some 6 cm distal over the flexor carpi ulnaris muscle. Branches of the medial antebrachial cutaneous nerve are carefully protected to prevent neuroma development. The ulnar nerve is found proximally and then dissected distally. It is freed from all septa, Osborne ligament and flexor carpi ulnaris fascia. The distal medial intermuscular septum should also be cut protecting major vessels here. The ulnar nerve is mobilized in front of the

medial epicondyle preserving the motor branches to the flexor muscles. If necessary, the articular branch to elbow joint should be preserved too. The nerve now lies on the fascia and the subcutaneous fat is sutured to the tip of the medial epicondyle. Thereby a subcutaneous tunnel is created. It is secured that the nerve lies freely and moves (Fig. 9). Then the skin is sutured in two layers. Postoperatively, immobilize the elbow in a cast or splint at 45° of flexion for 2 weeks. Active mobilizations started after two weeks. It is the simplest technique but must be carried out meticulously to prevent later kinking proximal and distal [1, 9].

## 2.2 Submuscular techniques

In submuscular transposition the initial dissection is as with the subcutaneous technique. The idea is to position the ulnar nerve deeper inside the muscle tissue. Therefore the origin of the flexor-pronator muscle group is released and the nerve positioned under these on the brachialis muscle. Then the flexor-pronator muscle is reattached securely. Variations of this technique exist.

Postoperatively, the elbow is immobilized in 45° of flexion in a post mold or cast for 3–4 weeks [1, 7].

## 3. GUYON'S CANAL – WRIST – DECOMPRESSION

A surgical decompression is carried out most often from the volar side of the wrist with a straight incision and a Z at the wrist creases. Another approach is from the ulnar side of the hand via a Z-shaped incision lateral along the hypothenar. Hereafter the pisiform bone is removed whereby the deep motor branch is decompressed. Little postoperative problems are the result of this.

*Results of surgical treatment of ulnar nerve compression.* Many different clinical situations exist and one simple treatment of all these cannot be given. The ulnar neuropathy is manifested by multiple pathogenesis factors. The acute Ulnar nerve neuritis is a completely different entity than that of an ulnar nerve neuropathy or a median nerve neuritis. We have no controlled and validated information with regard to proper treatment. We must accept this and be cautious in our suggestions of what type of treatment the patients should achieve. Prevention seems better than any surgical cure in the first stadium of the disease.

*Conservative treatment* is based primarily on prevention of compression. Keep the elbow as straight as possible, use headsets instead of mobile telephone, adjust workspace if necessary and use elbow protectors. This will in most cases lead to reduced symptoms. Only if these treatments fail, surgery can be considered.

Basically the operative treatments consist of the “simple” decompression with a minimum of complications. Simple decompression should in the majority of cases be the first choice of surgery. The technically more complicated

transposition of the ulnar nerve leads to many complications [1, 9, 10]. Transposition is carried out in cases where medial dislocation of the nerve is a prominent feature and the choice of subcutaneous and submuscular transposition is not clear – I personally favor the simplest choice.

## HOW TO AVOID COMPLICATIONS

A kinking of the ulnar nerve can easily occur against the medial intermuscular septum and under the aponeurosis arch between the two heads of the ulnar flexor carpi muscle. This happens if sufficient decompression is not carried out. Most common complications to operative treatment are injury to the nerve while decompressing it or transposing it and neuromata of the medial antebrachial cutaneous nerve [12].

Endoscope decompression has been described but only lately with the combined endo-micro technique [8] and it seems to be a tool to be taken seriously.

## References

- [1] Al-Mefty O, Origitano TC, Harkey HL (eds) (1996) *Controversies in neurosurgery*. Thieme Medical Publishers, New York, chapter 35, pp 340-349
- [2] Assmus H, Antoniadis G, Bischoff C, Haussmann P, Maartini AK, Mascharka Z, Scheglmann K, Schwerdfeger K, Selbmann HK, Towfigh H, Vogt T, Wessels KD, Wüstner-Hofmann M (2007) Diagnosis and therapy of carpal tunnel syndrome. *Handchir Mikrochir Plast Chir* 39: 276-288
- [3] Atroshi I (1999) *Carpal tunnel syndrome: prevalence, electrodiagnosis and outcome instruments*. Thesis, Lund University, Sweden
- [4] Bartels RHMA (2001) History of the surgical treatment of ulnar compression at the elbow. *Neurosurgery* 49: 391-400
- [5] Haase J (2007) Carpal tunnel syndrome – a comprehensive review. *Adv Tech Stand Neurosurg* 32: 178-249
- [6] Hudson AR, Wissinger JP, Salazar JL, Kline DG, Yarzagary L, Danoff D, Fernandez E, Field EM, Gainsburg DB, Fabri RA, Mackinnon SE (1997) Carpal tunnel syndrome. *Surg Neurol* 47: 105-114
- [7] Kline D, Hudson A (eds) (1995) *Nerve injuries*. WB Saunders, Philadelphia
- [8] Krishnan KG, Pinzer T, Schackert G (2006) A novel endoscopic technique in treating single nerve entrapment syndromes with special attention to ulnar nerve transposition and tarsal tunnel release: clinical application. *Neurosurgery* 59(1 Suppl 1): ONS89-ONS100

- [9] Lundborg G (2000) A 25-year perspective of peripheral nerve surgery: evolving neuroscientific concepts and clinical significance. *J Hand Surg* 25A: 391-414
- [10] Osborne GF (1970) Compression neuritis of the ulnar nerve at the elbow. *Hand* 2: 10-13
- [11] Pecina MM et al. (eds) (2001) *Tunnel syndromes*, 3rd edn. CRC Press, Boca Raton
- [12] Posner MA (1998) Compressive ulnar neuropathies at the elbow: I. Etiology and diagnosis. *J Am Acad Orthop Surg* 6(5): 282-288
- [13] Sunderland S (1978) *Nerve and nerve injuries*. Churchill Livingstone, New York



### **Jens Haase**

Jens Haase is Professor Emeritus (active) at HST/SMI, AAU. He was previously Head of the neurosurgical departments at Odense University Hospital and Aalborg Hospital/Aarhus University from 1976 to 2001. He was a founding member of the Danish Microsurgical Society in 1984 and served as its chairman 1994–1997. President of the Scandinavian Neurosurgical Society from 1989 to 1992. Are at present teaching microsurgical techniques within the European Association of Neurological Societies (EANS) and was member of the training committee of EANS 1986–2000. Co-founding member of the EANS Examination Committee in 1992 and chairman of the same from 1995 to 2003. He has also served as president of the ESPN (European Society for Paediatric Neurosurgery) and is an Associated Editor of Surgical Neurology. He was founder of the Virtual Brain Project at Aalborg University in 1996 and became professor in 2000. Is surgical advisor for Functional Electric Stimulation of walking in company Neurodan/Otto Bock. He has presented several publications and lectures on this topic locally and abroad in the US and Europe.

**Contact:** Jens Haase, Department of Health Science and Technology, Aalborg University, Fredrik Bajejis Vej, 9220 Aalborg, Denmark  
E-mail: [jph@hst.auc.dk](mailto:jph@hst.auc.dk)



---

# TUMORS OF THE PERIPHERAL NERVES

F. LAPIERRE

## INTRODUCTION

Most reports of nerve tumors were done in the 17th century.

Cheselden in 1741 (*Anatomy of the human body*) described a tumor occupying the center of the ulnar nerve, and Woods dissecting it established that the tumor could be divided from the majority of the fascicles, which probably have been the first description of a schwannoma. The distinction between neuroma and nerve tumors was not clearly established yet. This tumor was rediscovered in 1800 by Home, with enucleation of the tumor, but the patient died of an unknown cause. As late as 1855, patients with neuromas or nerve tumors were most often treated by amputation. Virchow in 1864 divided tumors between true and false. Nelaton and Krause advocated the simple excision of the well encapsulated tumors, and the amputation was seldom performed after.

In 1882 Friedrich von Recklinghausen published his monograph describing the NF1 type neurofibromatosis, and the nerve tumors. The NF2 type was distinguished by Vincent Riccardi in 1981, and the other types of peripheral nerve tumors were described by the modern anatomopathologists: Rubinstein...

## RATIONALE

Most tumors of the peripheral nerves develop in the nerve sheaths and are of benign type.

### 1. CLASSIFICATION OF TUMORS

#### 1.1 Nerve sheath tumors

- *Benign tumors:*  
Schwannomas (also called neurinomas or neurilemmomas)  
Neurofibromas
- *Malignant tumors:*  
Malignant schwannomas  
Fibrosarcomas

---

*Keywords:* peripheral nerves, tumor, microsurgery

### 1.2 Primary neuronal tumors: coming from the autonomic nerve ganglion cells

- Neuroblastomas
- Ganglioneuromas
- Pheochromocytomas
- Paragangliomas (also called chemodectomas)

### 1.3 Metastatic tumors

From melanomas, lung carcinomas, lymphomas... .

### 1.4 Tumors of non-neuronal origin

- Lipomas and lipofibromatosis of the median nerve and seldom others
- Ganglion cysts arising from synovial remnants, mostly in the hand
- Vascular lesions such as vascular malformations, hemangiomas
- Miscellaneous: Endometriosis...

### 1.5 Exceptional tumors

Neurothecomas, perineuromas, melanotic neurinoma, hamartomas, myxomatous cysts... .

### 1.6 Non-neoplastic lesions

Traumatic and non-traumatic nervomas: Can mimic tumors when becoming rather big but are not true tumors.

## 2. NEUROFIBROMATOSIS

Neurocutaneous disorders formerly called phacomatosis are a group of conditions of which neurofibromatosis are the most common with an involvement of every tissues.

Neurofibromatosis Type 1 (NF1) and Type 2 (NF2) are autosomal-dominant disease.

### 2.1 NF1

NF1 occurs in 1 out of 3500 individuals and is the most frequent of the phacomatoses, is clinically heterogenous, and characterized by neural-crest derived tumors. Neurofibromas, complex tumors arising from peripheral nerves sheaths are the key feature of NF1.

This disease has been linked to a genetic defect on chromosome 17q 11,2. This gene products the neurofibromin protein.

The penetrance of the NF1 mutation is virtually 100% by the age of 10 years. Half of the patients represent new mutations, and 80% of new mutations are paternal origin.

The diagnosis requires at least 3 criterias of the seven of the disease:

- At least 6 Café-au-lait spots, each of 5 mm minimum in pre-pubertal individuals, or 15 mm in post-pubertal patients
- 2 or more neurofibromas of any type or one plexiform neurofibroma
- Optic glioma
- Hyperpigmentation in the axillary or inguinal areas
- 2 or more Lisch nodules (pigmented iris hamartomas appearing as translucent yellow or brown elevations)
- Osseous abnormalities: Sphenoid dysplasia or thinning of long bone cortex, with or without pseudarthrosis
- A first degree relative with NF1 by above criteria.

A lot of associated conditions may be found:

- Schwann-cell tumors of any nerve
- Spinal or peripheral nerve neurofibromas
- Macrocephaly
- Intra-cranial tumors: hemispheric astrocytomas, solitary or multicentric meningiomas, ependymomas, brain stem gliomas...
- Unilateral defect in superior orbit with pulsatile exophthalmos
- Neurologic or cognitive impairment
- Kyphoscoliosis (2–10%)
- Syringomyelia
- Visceral manifestations: tumors of autonomic nerves or ganglia within the organs
- Malignant tumors: Neuroblastoma, sarcoma, leukemia, Wilm's tumor, ganglioglioma...
- Pheochromocytomas, in adults (unusual)

## 2.2 NF2

The prevalence of NF2 is estimated to be one case per 35,000 persons a year, with each sex equally affected.

This disease has been linked to a defect on chromosome 22q12, where a tumor suppressor gene called merlin or schwannomin is located.

The diagnostic criterias are:

- Bilateral eight nerve tumor on imaging  
or
- A first degree relative with NF2 and either:  
or

- 2 of the following:
  - Neurofibroma
  - Meningioma
  - Gliomas including astrocytoma, ependymoma
  - Schwannoma including spinal root ones
  - Juvenile posterior subcapsular posterior cataract or opacity.

Associated conditions:

- Seizures or focal deficits
- Skin nodules, café-au lait spots, dermal neurofibromas, less common than in NF1
- Multiple intra-spinal tumors: schwannomas, ependymomas,
- Antigenic nerve growth factor is increased (not in NF1)
- Long-term survival rate is unfavourable.

## **DECISION-MAKING**

*Depends on the background:*

- Diagnosis of a solitary tumor in a normal patient
- Or diagnosis of one or several tumors in a patient harbouring a neurofibromatosis.

### **1. DIAGNOSIS OF PERIPHERAL NERVE TUMORS**

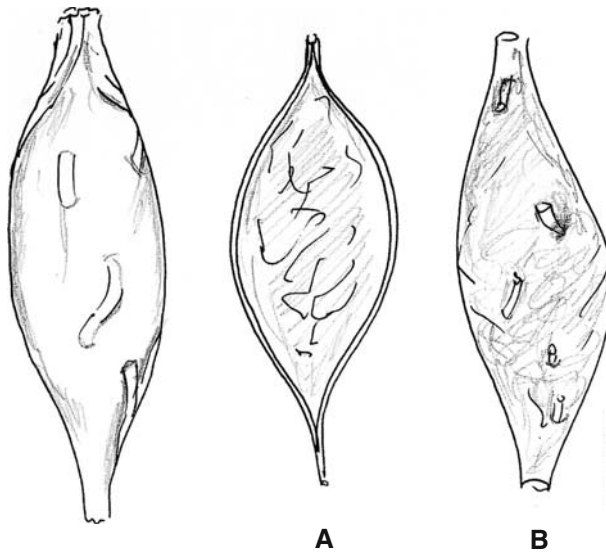
The most common feature is pain which can be either in day and more typically in night (25% of patients), sometimes as an electric discharge sensation, caused by contact, some specific movements or small traumatism. It is present in 98% of the cases. Its location depends on the involved nerve and it can mimic a sciatica, a cervico-brachial neurology, a tunnel entrapment syndrome... which explains that the delay for the diagnosis is between 2 weeks and 18 years!

The patient can discover the tumor by himself, or following a traumatism, and complains from a mild motor dysfunction in 20% of the cases, and a sensory impairment in 15%.

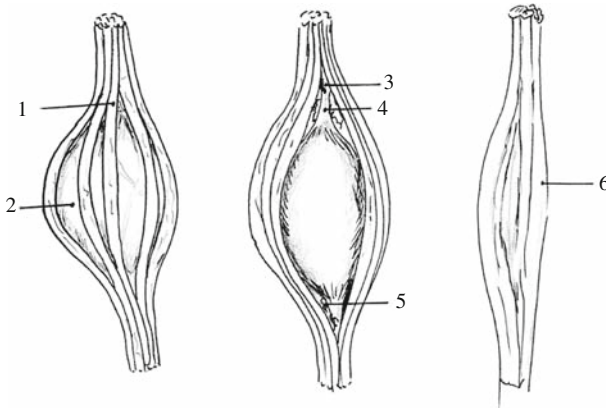
In most cases the tumor is found through palpation, horizontally mobile, and when tapped can produce paresthesias.

A motor deficit is present in 50% of the patients, a sensory one in 20%. The search of neurofibromatosis signs must always be performed in young patients.

The general status of the patient must be checked: a recent alteration is an argument for malignancy.



**Fig. 1.** Various types of tumors. **A** Schwannoma (encapsulated). **B** Neurofibroma (non encapsulated, with anarchic disposition of the fascicles)



- 1 – Normal fascicles stretched on the tumor
- 2 – Schwannoma
- 3 – Satellite tumor
- 4 – The pathologic fascicle
- 5 – Vessels
- 6 – The nerve after enucleation of the tumor

**Fig. 2.** Removal of a Schwannoma

## 2. INVESTIGATIONS

Electro-neuro-myography can be performed, may be useful if the tumor is not palpable.

It shows the functional disturbances due to the tumor, an increase of distal latencies and a diminution of the conduction velocity. But it also may be normal.

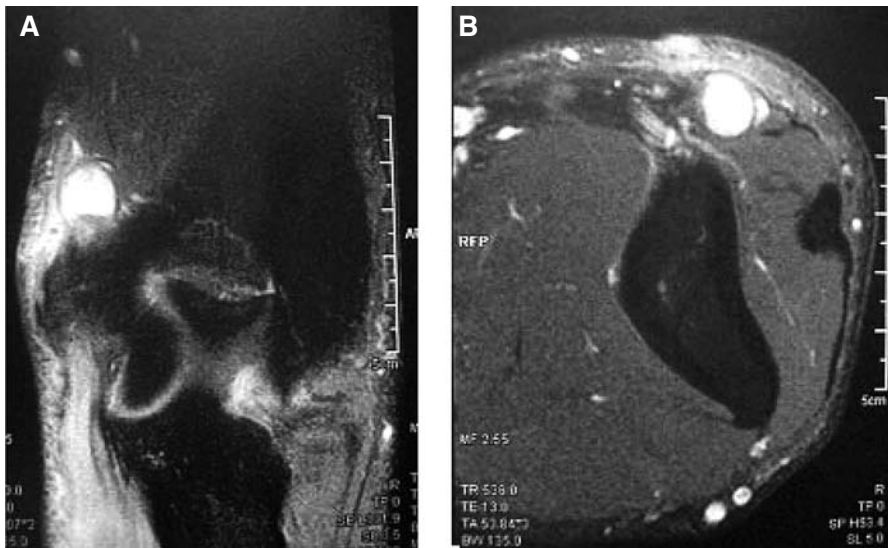
Intraoperative motor- and sensory-monitoring techniques during tumor resection may help to spare functioning fibers.

Post-operatively it helps to predict the functional restauration.

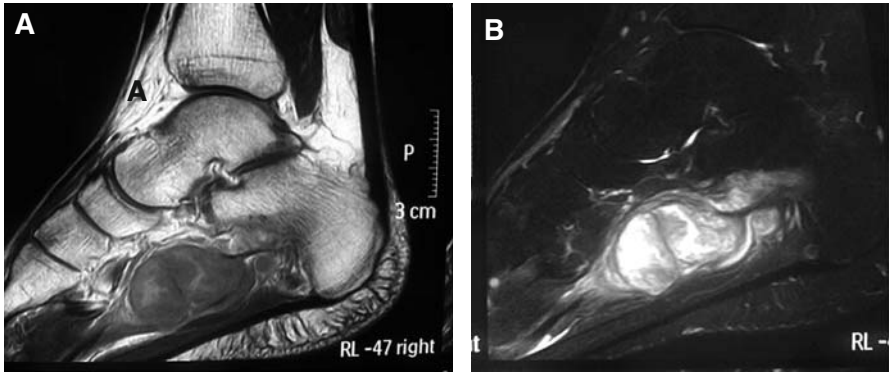
*Echography can help to localize the tumor. The gold standard exam is MRI, without and with gadolinium injection. In most cases, post-contrast fat-saturated image show the enhancing tumor. Its characteristics are correlated to the anatomo-pathology, but may be modified by an intra-tumoral bleeding or necrosis. The relations with the surrounding structures must be properly appreciated (Figs. 3–5).*

## 3. PRE-OPERATIVE ASSESSMENT

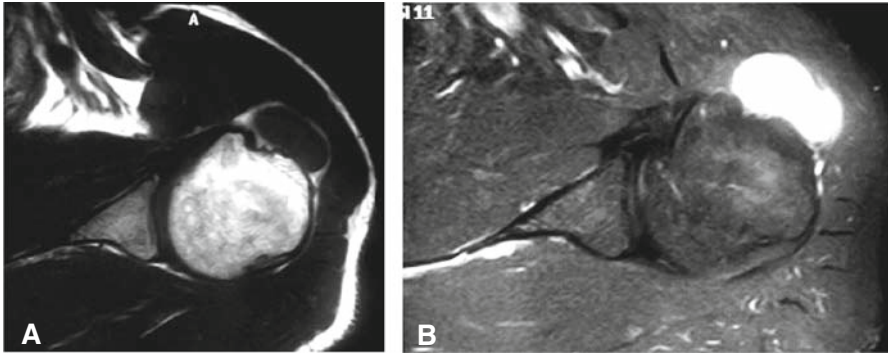
- *In case of fibromatosis* an exhaustive check-up of the disease must be performed, with a multi-disciplinary approach (genetic, dermatologic...).



**Fig. 3.** Schwannoma of the ulnar nerve. **A** T1 weighted MRI images with gadolinium showing homogenous enhancement. **B** Axial T1 MRI image with gadolinium enhancement



**Fig. 4.** Schwannoma associated to neurofibroma in the right foot of a NF1 patient. Sagittal T1-weighted MRI image without (A) and with (B)



**Fig. 5.** Schwannoma of the left shoulder (sensory nerve): T1 weighted MRI without (A) and with (B) gadolinium enhancement

- *In case of an isolated tumor*, the usual pre-operative assessment is appropriate.
- *In both cases*, one must consider.
  1. The discomfort of the patient
  2. The suspicion of malignancy: impaired general status, a speedy expansion of the tumor which also can be the witness of an intratumoral bleeding not synonymous of malignancy, a neurofibromatosis.
  3. The risk to generate any neurological impairment, and deterioration, correlated to the involved nerve (sensitive, motor or both).
  4. The suspected histology: Schwannoma or neurofibroma, the second one being the cardinal feature of neurofibromatosis, arising from large and small nerves, occurring anywhere in the body. It can progress to malignancy, and when removed lead to remove the bearing nerve.

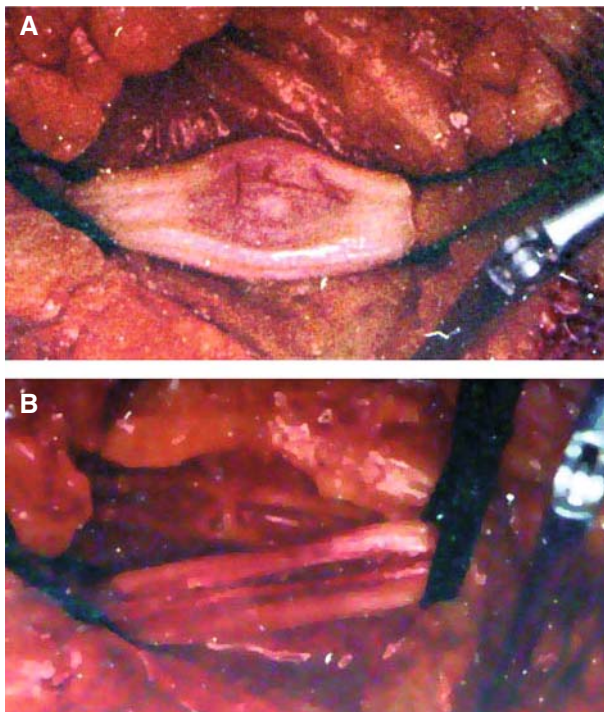
## SURGERY

### 1. TECHNIQUES

Surgery must be performed by a well-trained physician, and requires the surgical microscope.

- Is performed through the most direct approach and the least invasive.
- Must be conservative for the intact part of the nerve.
- Is performed under general anaesthesia, excepted for the very distal localisations.
- The first stage of surgery is to identify the tumor and confirm the pre-operative suspicion.
- Dissection of the tumor and the concerned nerve has to be performed.

A *schwannoma* (90% of cases) expands from one fascicule which has to be identified proximally and distally, under optic magnification. Then the well encapsulated tumor will be cautiously divided from the healthy fascicules.



**Fig. 6.** Schwannoma of the sciatic nerve: before (A) and after (B) removal



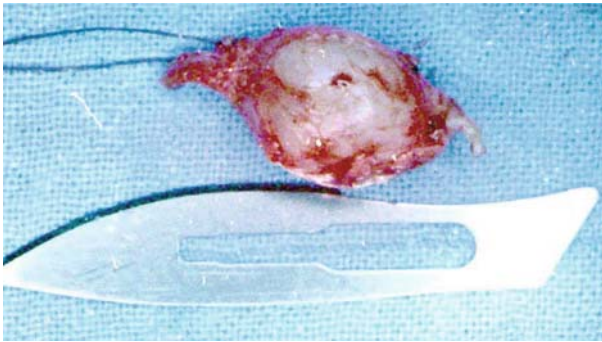
The bearing fascicule is then resected at least one centimeter above and below the tumor: This last point is important due to the fact that some small satellite schwannomas can occur on the same fascicule above and below the main tumor. If left in situ, they former give a recurrence (Figs. 1 and 2).

In nearly all cases, 98% of the nerve will be preserved, with no functional deficit (Figs. 6–8).

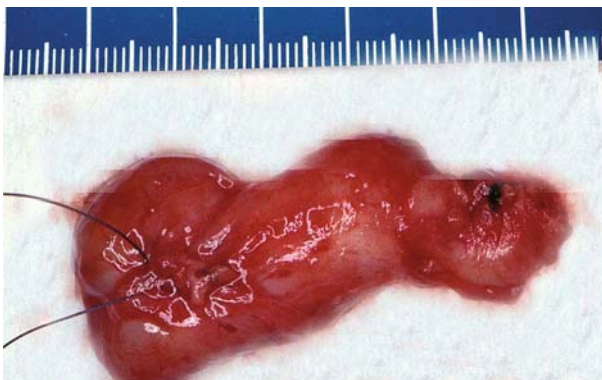A *Neurofibroma* (Fig. 1) involves the whole nerve trunk and fascicules. Its removal needs to remove the bearing nerve. In many cases it develops on a sensitive branch which has become non functional pre-operatively, and can be removed “en-bloc” (Figs. 8–10).

If a major trunk is involved, such as the sciatic or the median nerves, a biopsy will be the best option in the majority of the cases. Resection and reconstruction will be performed later if malignancy is proved.

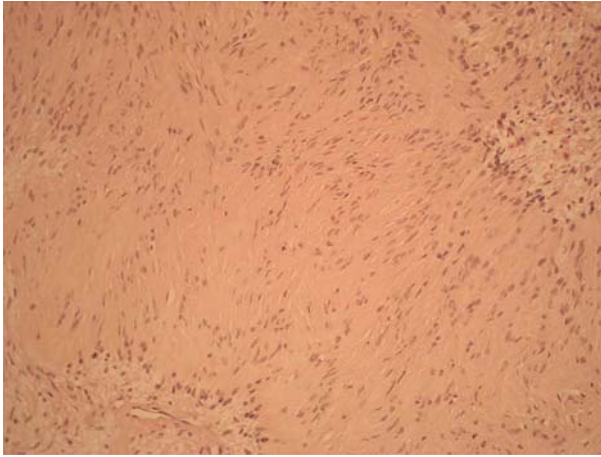
*In case of malignant tumors* (schwannomas or neurofibromas), there is no consensus about extension of surgery: Some recommend to remove widely the



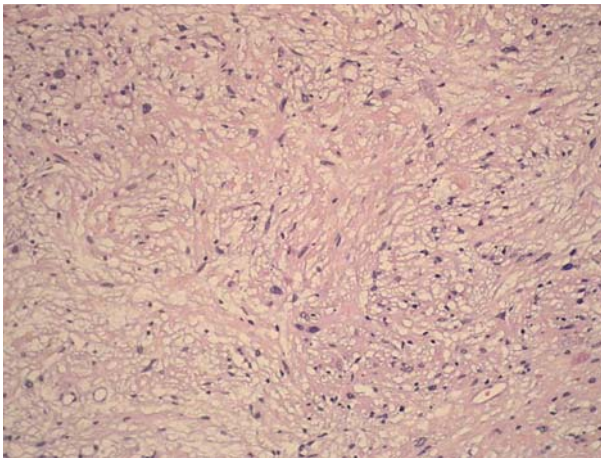
**Fig. 7.** Schwannoma (enucleated)



**Fig. 8.** Neurofibroma



**Fig. 9.** Schwannoma (Photo: Levillain, Poitiers)



**Fig. 10.** Neurofibroma (Photo: Levillain, Poitiers)

nerve, including the peripheral tissues, others to perform amputation when ever possible. An extensive appraisal for secondary location is mandatory (lung metastasis is the most frequent site).

Post-operative radiotherapy and chemotherapy have showed no efficacy and the prognosis is dreadful.

After surgery histologic diagnosis must be obtained.

Lipomas must be reduced but their complete removal is most often impossible: if located in an anatomic tunnel, a isolated decompression is indicated.

*Nerve ganglion cysts* most often involve the peroneal nerve, about 50% of cases and any other. Motor deficit, pain, and sensory changes are present in 83%, 78% and 48% of cases respectively. A history of acute trauma is noted in 22%. The complete removal is the treatment of choice, but recurrences are described, and some of these cysts may have an aggressive behaviour with recurrence after a mean range of 16 months. Repeated surgery will cause functional sequelae.

*Pseudo-tumoral neuromas* are resected, and the proximal end of the nerve is deeply buried in the surrounding tissues (even bone) to avoid solicitation by small superficial traumatism and skin adherence.

Rare tumors most often need biopsy, and the treatment will be later adapted accordingly.

## 2. RESULTS

After the schwannoma removal, pain dramatically improves in 92% of cases.

Patients are discharged one or two days following surgery, depending on the tumor site.

A well-removed schwannoma is cured by surgical resection.

A 2 years MRI follow-up guarantees the complete cure.

A post-operative deficit may occur: The principal causes are due either to a traumatic dissection either to vascular occlusion of vessels irrigating the nerve and the tumor, with extensive coagulation for haemostasis. Sensitive deficits have a worse outcome than motor ones. A delay of one year minimum is required to define the definitive functional status.

As previously mentioned, malignant tumors survival is poor.

The pertinent pre-operative assessment is the best way to avoid complications, thanks to an appropriate surgical procedure.

## CONCLUSIONS

Diagnosis and treatment of peripheral nerve tumors requires a good clinical appreciation, wide knowledge of phacomatosis, and anatomy, and a good surgical training.

If so, most benign tumors will be cured, with no post-operative disagreement.

## References

- [1] Artico M, Cervoni L, Wierzbicki V, Nucci F (1997) Benign neural sheath tumors: Characteristics in 119 cases of major nerves. *Acta Neurochirurgica (Wien)* 139: 1108-1116
- [2] Benzel EC (1992) Practical approaches to peripheral nerve surgery. AANS Publications Neurological Topics ISBN 1 9624246-6-8

- [3] Bianchi S, Montet X, Martinoli C (2007) Echographie des nerfs des membres inférieurs. *Revue du rhumatisme* 74(4): 415-423
- [4] Celli P (2002) Treatment of relevant nerve roots involved in nerve sheath tumors: removal or preservation. *Neurosurgery* 51: 684-692
- [5] Donner THR, Voories RM, Kline DG (1994) Neural sheath tumors of major nerves. *J Neurosurg* 81: 362-373
- [6] Ducatman BS, Scheitauer BW, Piepgras DG, Reiman HM, Ilstrup DS (1986) Malignant peripheral nerve sheath tumors. *Cancer* 57: 2006-2021
- [7] Gherardi R, Gray F, Poirier J (1985) Neurinomes et neurofibromes: Eléments histologiques distincts. *Arch Anat Cytol Pathol* 33(5-6): 297-301
- [8] Gottfried NO, Viskochil DH, Fuets DW, Couldwell TW (2006) Molecular, genetic, and cellular pathogenesis of neurofibromas and surgical implications. *Neurosurgery* 58: 1-16
- [9] Harbaugh KS, Tiel RL, Kline DG (1997) Ganglion cyst involvement of peripheral nerves. *J Neurosurg* 87(3): 403-408
- [10] Kim DH, Murovic JA, Tiel RL, Kline DG (2004) Management and outcome of 353 surgically treated sciatic nerve lesions. *J Neurosurg* 101: 8-17
- [11] Kim DH, Murovic JA, Tiel RL, Moes G, Kline DG (2005) A series of 397 peripheral nerve sheath tumors: 30 years experience at Louisiana State University Health Science Center. *J Neurosurg* 102: 246-255
- [12] Klekamp J, Samii M (1998) Surgery of spinal nerve sheath tumors with special reference to neurofibromatosis. *Neurosurgery* 42: 279-290
- [13] Otsuka G, Saito K, Nagatani T, Yoshida J (2003) Age at symptom onset and long-term survival in patients with neurofibromatosis Type 2. *J Neurosurg* 99: 480-483
- [14] Pivalaki M, Chourmouzi A, Kirizidou A, Skordalaki A, Tarampoukas T, Drevenlegas A (2004) Imaging of peripheral nerve sheath tumors with pathologic correlation. *Eur J Pathol* 52(3): 229-239
- [15] Tongstad JH (2006) Clinical manifestations and management of neurofibromatosis type I. *Semin Pediatr Neurol* 13(1): 2-7
- [16] Zadeh G, Buckle C, Shannon P, Massicotte EM, Wong S, Guha A (2007) Radiation induced peripheral nerve tumors: case series and review of the literature. *J Neurooncol* 83(2): 205-212

Contact: Françoise Lapierre, Neurosurgery Department, CHU La Milétrie, 86021 Poitiers Cedex, France  
E-mail: f.lapierre@chu-poitiers.fr

## **EDUCATION**

---

# **MESSAGE FROM THE CHAIRMAN OF THE EDUCATION AND TRAINING COMMITTEE OF THE WFNS**

A. A. DE SOUSA

## **AS WIDELY KNOWN, ONE OF THE MOST IMPORTANT AIMS OF THE WORLD FEDERATION OF NEUROSURGICAL SOCIETIES/WFNS IS TO PROVIDE HELP IN THE EDUCATION AND TRAINING OF NEUROSURGEONS ALL OVER THE WORLD**

For this purpose, it has an Education and Training Committee: to be in charge of the Federation's education and training programs by organizing courses, workshops and seminars in many different countries, always giving privilege to locations or regions where neurosurgeons should have difficulties in traveling to international meetings.

It is important to mention that the WFNS Education and Training Committee was capable of achieving its present relevance and renowned status due to the contribution of some professionals who deserve our deepest respect and thankfulness. It all began back in 1991, when the Committee made a historical change in its philosophy as Professor Armando Basso organized, in Buenos Aires, a memorable event that became a reference for all the future courses. After that, Professor James Ausman became the Chairman of the WFNS Education and Training Committee and then started to organize courses in many cities around the world, following the standards set by the one earlier held by Basso and opening ways for an education and training activity of real worldwide reach.

Later on, Professor Jacques Brotchi was elected the new Chairman, followed by Maurice Choux and, then, myself. The previous work was continued as it had proved to be the right way to accomplish the goals of the Committee. Therefore, in the past few years the WFNS Education and Training Committee has organized from four to eight courses each year, in every continent and several different locations, always finding eager interest and active participation of large audiences, which proves that such initiatives are undoubtedly profitable in the sense education and training are meant to be.

The Faculty of the Committee, responsible for most of the lectures in the courses, is composed by about fifty neurosurgeons, experts in all fields of neurosurgery and from a varied number of countries. With the kind collabo-

---

*Keywords:* education, training, neurosurgery

ration of these professionals and the effort of the always devoted local organizers, besides the participation of some local lecturers, the Education and Training Committee does its best in order to try to achieve one of the most valuable ideals of the WFNS and to spread it over the world. For sure the Committee could never carry on such a task without the great help of all the people involved with the local organization of the courses and mainly of the Faculty, who always kindly and promptly give not only their time and dedication but who also afford for their travelling expenses so as to participate in the courses. I take this chance, my dear colleagues and friends, to once more express my most sincere thanks on behalf of the WFNS.

Looking at all that the WFNS Education and Training Committee has done and at the list below, of the courses it has organized in the past years and the ones planned for 2009, it is almost needless to say: being its Chairman for four years has been a unique experience in my life. I believe that everyone who has had the chance to be a part of the events we organize knows how rewarding and enriching they are, and how pleasant it is for us to be able to contribute to the education and the training of professionals in our area who otherwise would probably never participate in international meetings. Moreover, the exchange of experiences is an immeasurable gain for ourselves, and something we shall never forget.

## **COURSES HELD BY THE WFNS EDUCATION AND TRAINING COMMITTEE IN THE PAST YEARS AND PLANNED FOR 2009**

### **2005**

- ✓ Chişinău, Moldavia, April 29 and 30;
- ✓ Beijing, China, May 14 to 17;
- ✓ Saint Petersburg, Russia, September 2 to 4;
- ✓ Campos do Jordão, Brazil, October 31, November 1 and 2.

### **2006**

- ✓ Mumbai, India, January 27;
- ✓ Seoul, South Korea, April 11 and 12;
- ✓ Antigua, Guatemala, May 8 and 9;
- ✓ Xi An, China, June 7 and 8;
- ✓ Urunqi, China, June 9;
- ✓ Bali, Indonesia, November 21 and 22;
- ✓ Ho Chi Minh City, Vietnam, December 5 and 6.

### **2007**

- ✓ Dhaka, Bangladesh, February 20 and 21;
- ✓ Lahore, Pakistan, February 23 to 26;

- ✓ Buenos Aires, Argentina, April 30, May 1 and 2;
- ✓ Hong Kong, China, May 27;
- ✓ Macau, China, May 28;
- ✓ Guangzhou, China, May 29;
- ✓ Moscow, Russia, May 30, 31 and June 1;
- ✓ João Pessoa, Brazil, August 1 and 2;
- ✓ Yaoundé, Cameroon, October 2 and 3;
- ✓ Sharm-el-Sheik, Egypt, October 24 to 26.

## 2008

- ✓ Montevideo, Uruguay, April 3 and 4;
- ✓ Dakar, Senegal, June 14 and 15;
- ✓ Goa, India, May 10 and 11;
- ✓ Baikal Lake, Siberia, September 3 to 5;
- ✓ Kunming, China, October 11 and 12;
- ✓ Bratislava, Slovakia, November 21 and 22;
- ✓ Taiwan, China, November 29 and 30;
- ✓ Kuala Lumpur, Malaysia, December 2 and 3.

## 2009

- ✓ Jordan, January 7 to 9;
- ✓ El Kharton, Sudan, January 11 to 13;
- ✓ Isla Roatan, Honduras, March 20 and 21;
- ✓ Salta, Argentina, March 25 and 26;
- ✓ Kathmandu, Nepal, probably in April;
- ✓ Fortaleza, Brazil, August 5 and 6;
- ✓ Libreville, Gabon, November 6 to 8;
- ✓ Yemen, date uncertain;
- ✓ Pakistan, date uncertain.

As the Chairman of the Education and Training Committee of the WFNS, it is an honor and a pleasure to have this message printed in the *Practical Handbook of Neurosurgery*, a publication which, I have no doubt, is of major importance for practicing neurosurgeons and a helpful tool in the education and the training of neurosurgeons all over the world.

In the certainty the *Practical Handbook of Neurosurgery* will be a great success, I leave here my best wishes.





**Atos Alves de Sousa**

Atos Alves de Sousa is Professor of Neurosurgery at Ciências Médicas Faculty in Minas Gerais State, Belo Horizonte, Brazil. He graduated in medicine at the Federal University of Minas Gerais/UFMG, Minas Gerais/Brazil in 1972, went through specialization courses in neurosurgery in Brazil, France, Switzerland, and the United States in the 70s and 80s, and got his doctorate title in neurosurgery from the Federal University of São Paulo/UNIFESP, São Paulo/Brazil, in 1999.

Besides being the chairman of the WFNS Educational and Training Committee, he is presently: Professor of Neurosurgery at Ciências Médicas Faculty, in Minas Gerais State/Brazil; head of the neurosurgery department at Life Center Hospital, Belo Horizonte, Minas Gerais/Brazil; effective assistant neurosurgeon at Santa Casa de Misericórdia Hospital at Belo Horizonte, Minas Gerais/Brazil; member of the Brazilian Society of Neurosurgery; member of the Congress of Neurosurgical Surgeons; member of the Société de Neurochirurgie de Langue Française; corresponding member of Sociedad Peruana de Neurocirugía; corresponding member of Sociedad Chilena de Neurocirugía; honorary member of Sociedad Argentina de Neurociencias; honorary member of Asociación Guatemalteca de Cirugía Neurológica; honorary member of the Cameroun Neurosurgery Society; consulting editor for Surgical Neurology (being the editor of its Brazilian Supplement in 2007); member of the editorial board of

Operative Techniques in Neurosurgery; member of the advisory board of the official journal of the Romanian Society of Neurosurgery; member of the international advisory board of the African Journal of Neurosurgical Sciences; and member of the international liaison and advisory board of the Official Journal of the Congress of Neurological Surgeons.

Professor de Sousa has published 65 articles in specialized periodicals and nearly 480 papers in event annals, in addition to being the author of 11 chapters in books and co-author of nearly 50 works. He has participated in about 380 international and national events, all of them specialized in neurosurgery. His scientific production and professional activities are focused on vascular neurosurgery.

**Contact:** Atos Alves de Sousa, Faculdade de Ciências Médicas de Minas Gerais, Santa Casa and Life Center Hospital, Rua Ceará, 600, conj. 2, 30150-310 Belo Horizonte – Minas Gerais, Brazil  
E-mail: sousatos@hotmail.com

---

# WHAT DO YOUNG NEUROSURGEONS REALLY NEED

Y. KRAVEL

- *Teaching neurosurgeons in training* has always been essential to maintain the quality of the specialty within the various health care systems throughout the world. The value of the university training, the importance given to the apprenticeship by more experienced members of the team and the level of the scientific research in neurosciences represent strong indicators of the level of training of the young doctors in our specialty.

There is obviously a marked disparity between so-called emerging countries and countries in which universities and hospitals can provide high quality training both in terms of basic knowledge and surgical expertise.

Several options are available to young neurosurgeons to improve this situation. The first possibility is to complete neurosurgical training in his/her own country, in a university equipped with greater resources than the one of hometown; but the institution's limited training capacities may be rapidly overwhelmed. The second possibility is to undertake training in a foreign country, either during residency or at end of. However, this foreign training often presents a number of drawbacks. In a renown unit, access to practical experience can be limited because of the large number of individuals in training, and the student may be confined to research work for the majority of his or her stay. On returning home, it may be difficult for the young surgeon to be integrated in the local training programme, especially when he or she has been away for a long time.

- In this difficult context, *courses organized by neurosurgical societies* all over the world play an essential role. The marked growth in the attendance of these courses over the years clearly illustrates their value, despite the parallel development of databases set up by national and international neurosurgical societies.

These training courses can consist of several forms:  
teaching sessions in the frame of national congresses, which is extremely frequent;  
whole day sessions devoted to a given theme, as satellite congresses;  
national training congresses devoted exclusively to the country's young neurosurgeons;  
courses lasting several days organized by international societies, for example the European Association of Neurosurgical Societies (EANS), the French-speaking Neurosurgical Society (SNCLF) or the World Federation of Neurosurgical Societies (WFNS).

---

*Keywords:* education, training, neurosurgery

These training courses are becoming increasingly popular all over the world and the number of young neurosurgeons participating in these events increases each year to the point of sometimes raising local logistic problems. Several options are available to organize these courses; either an annual or biennial course is organized in a country member of the international society such as for the courses organized by the EANS, or a course is organized locally at the request of a national society by the WFNS with the help of lecturers renowned in their respective fields.

- *Several financial difficulties may be encountered when organizing these courses.* The funding of travel and accommodation costs can raise problems for young neurosurgeons when not covered by their hospital or national society. Travel and accommodation costs of lecturers are generally not completely funded. In the context of courses organized by EANS, SNCLF or WFNS, for example, the lecturer's accommodation costs are funded by the hosting national society, but travel expenses are paid by the lecturer. It may be therefore sometimes difficult to recruit a sufficient number of lecturers to conduct a given training course.
- Over recent years, there has been a marked increase in the number of national societies wishing to organize this type of 2- to 3-day course. The *geographical distribution of these courses* must be taken into account to ensure an equitable distribution between the various continents without favouring a particular country in order to avoid any diplomatic problems. These courses are generally organized by an education committee whose composition and functioning varies from one society to another.
- The many technical problems related to *organization of these training courses*, which were almost insurmountable about ten years ago, are now in the process of being resolved especially in terms of data processing, although problems of incompatibility of video systems sometimes persist.

Invited experts must understand that a lecture presented in the context of a training course is completely different from a scientific presentation at a congress, as the lecturer invited because of his or her experience in a particular field is required to provide guidelines concerning indications, technical problems, complications and errors to be avoided, without focussing on personal results. Young neurosurgeons are very often frustrated because the lecturer presents "before and after surgical cases", without providing guidelines and without proposing a decisional flow-chart. Similarly, the slides presented at this type of course must comprise a small number of items to avoid slides overloaded with graphs and/or videos which confuse the final message of the presentation.

Various types of presentations must be organized: lectures by an expert on a specific topic, review of surgical techniques concerning a particular type of operation, presentation of clinical cases by foreign experts or local organizers, whenever possible, organization of a practical training day before the course (skull base, endoscopy, etc.).

Courses should combine:

- presentations on topics concerning the everyday experience of the participants, for example: head injury, treatment of hydrocephalus, spinal disease or intracranial tumor;
- and conferences on subjects which introduce young neurosurgeons to techniques which are currently not available due to financial constraints or limited research structures in their country (intracranial cerebral stimulation for the treatment of movement disorders, gene therapy, endovascular treatment of aneurysms, etc.)

Discussion between speakers and participants must be encouraged, as this aspect is often neglected in classical conferences. However, exchanges can be made difficult when the local host society does not have the necessary resources to ensure simultaneous translation. When the translation is performed by a local neurosurgeon, the visiting lecturer must try to simplify and concentrate his message, which is not always positively perceived by the lecturers themselves.

- The interest in training of young neurosurgeons by courses and the growing attendance of these courses emphasize their important role. It must be stressed that *national and international neurosurgical societies play an essential role.*
- The *reciprocal enrichment* between participants and lecturers is obvious and the warm welcome by local organizers often leaves lasting memories for the lecturers, especially when they discover a country situated away from the usual tourist destinations.



### **Yves Keravel**

Yves Keravel is Chief of the Neurosurgical Department of Henri Mondor Hospital (Paris-Creteil). He was born in 1944 in Paris, is married and has two boys.

M.D. was obtained at the Medical School of Paris in 1973 on “The Empty Sella syndrome”. He was appointed Professor in Neurosurgery in 1982 and then he was elected Vice-Dean of the School of Medicine of Paris (1990–1998).

Among main distinctions: Founding Member of the International Association for the Study of Pain (1975), Président of the French Neurosurgical Society (1989–1991), Member of the Director Committee of the International Neuromodulation Society since 1996, Member of the Executive Committee of the Congress of Neurological Surgeons (2000–2001), President of the French Speaking Neurosurgical Society (2000–2003).

He is member of the editorial boards of Neurosurgery, Neurosurgical Research, Critical Reviews of Neurosurgery, Neuromodulation.

He participated in around 200 publications of which one-third in English and has been editor of three books in English: Keravel Y, Sindou M (1988) Giant intracranial aneurysms: therapeutic approaches. Springer, Berlin-Heidelberg, Sindou M, Abbott R, Keravel Y (eds) (1991) Neurosurgery for spasticity. A multidisciplinary approach.

Springer, Wien-New York, Sindou M, Keravel Y, Moller AR (1997) Hemifacial spasm: a multidisciplinary approach. Springer, Wien-New York, 1997 and of six books in French: La névralgie du trijumeau (140 pp), 2 editions. Y. Keravel, B. Laurent, M. Sindou; Neuro-anatomie fonctionnelle de la cellule aux comportements. Vol. 1: le neurone (272 pp), P. Cesaro, Y. Keravel, H. Ollat, M. Peschanski, M. Sindou; Neuro-anatomie fonctionnelle de la cellule aux comportements. Vol. 2: le cerveau et la moëlle épinière (403 pp), P. Cesaro, Y. Keravel, H. Ollat, M. Peschanski, M. Sindou; Neuro-anatomie fonctionnelle de la cellule aux comportements. Vol. 5: les systèmes sensoriels (290 pp), P. Cesaro, Y. Keravel, H. Ollat, M. Peschanski, M. Sindou; Neuro-anatomie fonctionnelle de la cellule aux comportements. Vol. 6: les systèmes moteurs (372 pp), P. Cesaro, Y. Keravel, H. Ollat, M. Peschanski, M. Sindou; Neurochirurgie. Ph. Decq and Y. Keravel Universités Francophones. Ellipses Aupelf-Uref 1996. 704 pp. (Spanish edition edited in Mexico).

Main fields of neurosurgical interests are: Vascular neurosurgery (Giant aneurysms and intracranial fistulas); neurosurgical treatment of chronic pain; stimulation for movement disorders; functional surgery for trigeminal pain and hemifacial spasm; neurosurgical treatments for spasticity.

**Contact:** Y. Keravel, Department of Neurosurgery, Hôpital Henri Mondor, 51 Avenue Maréchal de Lattre de Tassigny, 94010 Creteil Cedex, France  
E-mail: ykeravel@yahoo.fr

---

# **THE ROLE OF THE WORLD FEDERATION OF NEUROSURGICAL SOCIETIES IN THE DEVELOPMENT OF WORLD NEUROSURGERY**

G. L. ROSSEAU

## **ORIGINS OF THE WORLD FEDERATION OF NEUROSURGICAL SOCIETIES**

The World Federation of Neurosurgical Societies (WFNS) was founded in Brussels, Belgium in 1955. The founding of this international federation by the 18 representatives of 13 national neurosurgical societies was a natural evolution of the international cooperation among member neurosurgeons since the first days of the specialty in the modern era.

Since its early days, the WFNS has grown from a few forward-thinking and internationally-minded neurosurgeons into a professional organization with a vision of providing worldwide neurosurgical education and improve the care of neurosurgical patients. Represented at the World Health Organization and, by its member societies, at surgical societies around the globe, the WFNS operates as the official spokesorganization for neurosurgery and neurosurgical patients.

## **THE MISSION OF THE WORLD FEDERATION OF NEUROSURGICAL SOCIETIES (WFNS)**

- To facilitate the personal association of neurological surgeons throughout the world (Fig. 1).
- To aid in the exchange and dissemination of knowledge and ideas in the field of neurological surgery.
- To encourage research in neurological surgery and allied sciences.
- To address issues of neurosurgical demography.
- To address issues of Public Health.
- To implement, improve and promote the standards of neurosurgical care and training throughout the world.

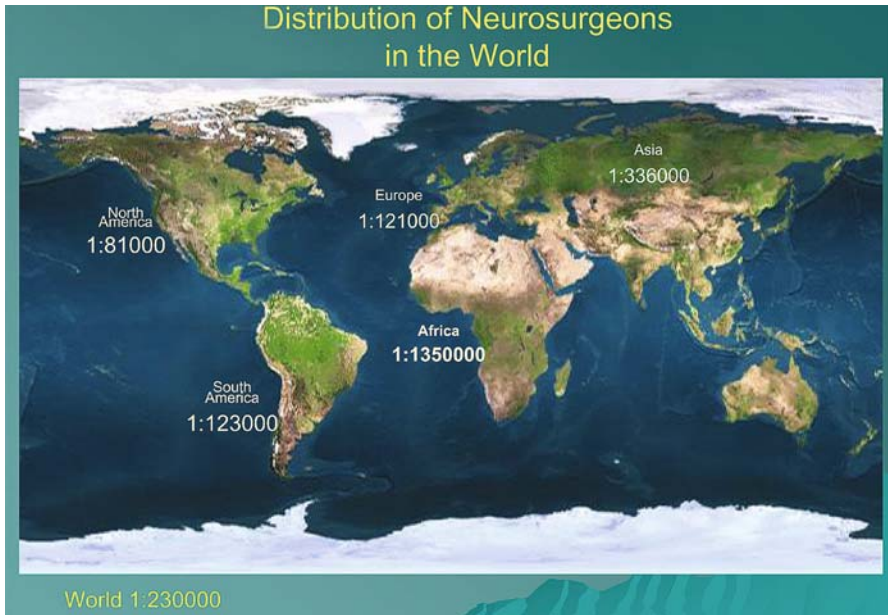
## **ORGANIZATIONAL STRUCTURE**

- At present, the WFNS is composed of 101 national, 5 regional and 6 affiliate neurosurgical societies, for a total of 112 member organiza-

---

*Keywords:* World Federation of Neurosurgical Societies, education, training





**Fig. 1**

**Table 1.** WFNS International Congresses of Neurological Surgery

Year	Presidents of WFNS	Site of Congress
1957	Geoffrey Jefferson (UK)	Brussels (Europe)
1961	Paul Bucy (USA)	Washington, D.C. (North America)
1965	Edward Busch (Denmark)	Copenhagen (Europe)
1969	Earl Walker (USA)	New York (North America)
1973	Keiji Sano (Japan)	Tokyo (Asia)
1977	Gosta Norlen (Sweden)	Sao Paulo (South America)
1981	Charles Drake (Canada)	Munich (Europe)
1985	Willem Luyendijk (The Netherlands)	Toronto (North America)
1989	Kemp Clark (USA)	New Delhi (Asia)
1993	Lindsay Symon (UK)	Acapulco (Latin & North America)
1997	Armando Basso (Argentina)	Amsterdam (Europe)
2001	Madjid Samii (Germany)	Sydney (Asia)
2005	Edward Laws (USA)	Marrakech (PAANS)
2009	Jacques Brotchi (Belgium)	Boston (North America)
2013	Peter Black (USA)	Seoul (South Korea)

tions. This represents approximately 30,000 neurosurgeons throughout the world. The membership meets every 4 years for a World Congress (Table 1).

- The WFNS is governed by an Executive Committee consisting of two delegates of each member society and an Administrative Council com-

posed of officers of the Federation, who serve 4-year terms. The goals of the WFNS are pursued by the Scientific, Standing, and Ad Hoc committees of the organization.

## WFNS ACTIVITIES

The WFNS achieves its mission through its educational, philanthropic and communication activities.

- One of the most important activities of the WFNS is the organization of **Educational courses**. Offered 6–10 times per year, these courses bring updates in standards and techniques to neurosurgeons of member societies throughout the world. Practical, hands-on courses and “How I Do It” sessions offer the opportunity for neurosurgeons to practice and update their technical skills, while didactic courses present the latest scientific information available in the applied neurosciences. WFNS courses may be requested in writing from any member society and are arranged based on need and geographic considerations. Recognizing the huge disparity in neurosurgical manpower between different regions around the world, the WFNS locates the vast majority of these courses in areas that are under-served geographically. WFNS volunteer faculty pay their own transportation costs to the course locations.
- Through its philanthropic arm, the WFNS Foundation, the organization provides training and material aid to neurosurgeons in developing nations. Through training centers in Rabat, Morocco; Recife, Brazil; and, recently, Dakar, Senegal, the WFNS Foundation provides additional training to senior residents from the developing world in the use of techniques and equipment which may not be currently available in their own training center. The Foundation also offers a number of fellowships each year to residents and recent graduates who wish to pursue subspecialty training abroad in areas such as trauma, radiosurgery, cerebrovascular surgery, and cranial base surgery.

In addition, the WFNS Foundation provides high quality equipment, including operating microscopes, bipolar cautery and basic surgical instrument sets at low costs to applicant neurosurgeons operating at public and university hospitals in the developing world.

- The **official website** of the World Federation of Neurosurgical Societies, [www.wfns.org](http://www.wfns.org) is the main instrument of communication with and between national and continental neurosurgical societies. This interactive and intuitive website has been a major force in linking the

neurosurgeons of developed and developing nations. The site includes details on the WFNS mission and activities, announcements, book reviews, a World Calendar of educational courses, history of the society, as well as the free on-line journal, World Neurosurgery. Applications for fellowships and equipment donations, as well as submissions to the journal and book reviews and calendar events may all be found on the website.

## **CONCLUSIONS**

The World Federation of Neurosurgical Societies is the official organ of neurosurgery throughout the world. Composed of member societies, rather than individuals, it represents the educational and philanthropic goals of over 30,000 neurosurgeons throughout the world. It has a rich and successful 50-year history of international neurosurgical cooperation for the improvement of public health throughout the world.



**Gail L. Rosseau**

Gail L. Rosseau, M.D., is Chief of Surgery at the Neurologic and Orthopedic Institute of Chicago (NOIC) and Director of skull base surgery services at the Chicago Institute of Neurosurgery and Neuroresearch (CINN) in Chicago, Illinois. She is a Member of the Department of Neurosurgery at Rush Medical College, Rush University Medical Center, Chicago, Illinois. She is board certified and has been an examiner for the American Board of Neurological Surgery.

Her practice includes a wide range of neurosurgery, with special expertise in caring for patients with cranial base disorders. This includes extensive experience with pituitary tumors, meningiomas, acoustic neuromas, and head and neck malignancies. She is the author of dozens of papers, numerous invited lectures and courses in these topics.

Dr. Rosseau did her neurosurgical residency training at George Washington University in Washington, DC. after graduating from medical school at that institution. She completed a fellowship in cranial base and microvascular surgery at the University of Pittsburgh. She writes and speaks often both in the U.S. and abroad on neurosurgical topics. Her most frequent subjects include innovative treatments for patients for pituitary tumors, trigeminal neuralgia, meningiomas and normal pressure hydrocephalus. She was a pioneer in the use of minimally invasive endoscopic surgery for treatment

of pituitary tumors. Her current research funding is for clinical trials in breast cancer metastasis and idiopathic normal pressure hydrocephalus.

Dr. Rosseau is the recipient of many honors and awards, including Chicago Woman Mentor of the Year and the American Association of Neurological Surgeons/American College of Surgeons Health Policy Fellowship. She has been listed in Best Doctors in America, Who's Who in America and the Consumer Research Council's Guide to Top Surgeons. She has served on the FDA Advisory Council for Neurological Devices. She has served in a number of leadership positions in organized neurosurgery both nationally and internationally. Dr. Rosseau is frequently quoted in news articles relating to neurological sciences and health. She has appeared recently on the public broadcasting network medical program, *Second Opinion* and *60 Minutes II*. She has appeared on national and local network television and radio programs, as well as print media.

She devotes considerable time to philanthropic endeavors. She is the volunteer coordinator of the Foundation for International Education in Neurosurgery, which sends volunteer neurosurgeons to the developing world. She is on the Board of Directors of the World Federation of Neurosurgical Societies Foundation, which raises funds and donations-in-kind to provide equipment for neurosurgical services in the developing world. She has launched a program in Religious Pluralism in Chicago to improve inter-faith relations.

With her children, Natalie, age 13 and Brendan, age 11, she has launched a head and spine injury prevention initiative for children in French-speaking Africa. She provides ongoing leadership to a number of people interested in the neurosciences as a career. She and her husband, Rick, an orthopedic surgeon, enjoy history, French language and culture, and marathon running.

**Contact:** Gail L. Rosseau, CINN at the Neurologic & Orthopedic Hospital of Chicago, 4501 N. Winchester Ave., 2nd floor, Chicago, IL 60640, USA  
E-mail: [grosseau@neurosource.com](mailto:grosseau@neurosource.com)

---

## EPILOGUE

*A bottle to the sea, ...*

*Dear friends, we have travelled together through major fields of Neurosurgery.*

*We hope the reading of these ninety-nine chapters, written by well-recognized experts and at same time leading neurosurgeons, has been of interest and will benefit to your patients. Authors have to be acknowledged for having brought the best of their experience; they have stressed on “How to do the surgery” and “How to avoid complications”.*

*We wish the book will serve the Neurosurgical Community, and will be recommended by Educational Committees.*

*Knowledge is regularly improving; techniques are constantly evolving. The new generation who builds at present modern neurosurgery, has to prepare settling the next of this endeavour.*

Dr. Marc Sindou, M.D., D.Sc.  
University of Lyon  
Editor

---

## LIST OF CONTRIBUTORS

### **Rick Abbott**

Department of Neurosurgery  
The Children's Hospital at Montefiore  
Montefiore Medical Center  
111 E. 210th Street  
Bronx, NY 10467, USA  
E-mail: rabbott@montefiore.org

### **Benaissa Abdennebi**

Department of Neurosurgery  
Salim Zemirli Hospital  
University of Algiers  
Route de Baraki  
Algiers, Algeria  
E-mail: babdennebi@yahoo.fr

### **Nejat Akalan**

Department of Neurosurgery  
Hacettepe University School of  
Medicine  
Ankara 06100, Turkey  
E-mail: nakalan@hacettepe.edu.tr

### **Ossama Al-Mefty**

Department of Neurosurgery  
University of Arkansas for  
Medical Sciences  
4301 W. Markham, #507  
Little Rock, AR 72205, USA  
E-mail: keelandamye@uams.edu

### **Armando J. Basso**

President of the WFNS Foundation  
Director of Neurosciences Institute  
Buenos Aires University  
Ayacucho 1342  
Buenos Aires 1111, Argentina  
E-mail: armandobasso@aol.com

### **Alim Louis Benabid**

CEA Minatec LETI  
Clnatec Building 4022  
17 Avenue des Martyrs  
38054 Grenoble, France  
E-mail: alimlouis@aol.com

### **Vladimír Benes**

Department of Neurosurgery  
1st Faculty of Medicine  
Central Military Hospital  
Charles University  
Unemocnice 1200  
16902 Prague 6, Czech Republic  
E-mail: vladimir.benes@uvm.cz

### **Helmut Bertalanffy**

Department of Neurosurgery  
University Hospital of Zurich  
Frauenklinikstrasse 10  
8091 Zurich, Switzerland  
E-mail: helmut.bertalanffy@usz.ch

### **Peter M. Black**

Department of Neurosurgery  
Brigham & Women's Hospital  
75 Francis Street  
Boston, MA 02115, USA  
E-mail: pblack@partners.org

### **Dirk Andries Bosch**

Department of Neurosurgery  
Academisch Medisch Centrum  
Meibergdrees 9  
1105 AZ Amsterdam  
The Netherlands  
E-mail: d.a.bosch@amc.uva.nl

**Albino Bricolo**

Department of Neurosurgery  
University Hospital  
Piazzale Stefani 1  
Verona 37126, Italy  
E-mail: albino.bricolo@univr.it

**Jacques Brotchi**

President of WFNS  
Department of Neurosurgery  
Erasme Hospital-ULB Brussels  
808 Route de Lennik  
1070 Brussels, Belgium  
E-mail: jb.wfns@erasme.ulb.ac.be

**Jacques Brunon**

Chairman of the Neurosurgical  
Department of Bellevue Hospital  
University Jacques Lisfranc  
42055 Saint Etienne Cedex 2, France  
E-mail: jbrunon@club-internet.fr

**Kim J. Burchiel**

Neurological Surgery  
Oregon Health & Science University  
3303 SW Bond Ave.  
Portland, OR 97239, USA  
E-mail: burchiek@ohsu.edu

**Jean Chazal**

Service de Neurochirurgie A  
Centre Hospitalier et Universitaire  
de Clermont-Ferrand  
Université d'Auvergne, B.P. 69  
63003 Clermont-Ferrand Cedex 1  
France  
E-mail: jchazal@chu-clermontferrand.fr

**Maurice Choux**

14 Avenue Solvert  
13009 Marseille, France  
E-mail: mchoux4842@numericable.fr

**Alexandru Vlad Ciurea**

Clinical Hospital Bagdasar-Arseni  
First Department of Neurosurgery  
10-12 Bercent Street  
Bucharest, Romania  
E-mail: rsneurosurgery@gmail.com

**Alan Crockard**

Victor Horsley Department of  
Neurosurgery  
The National Hospital for  
Neurology and Neurosurgery  
Queen Square  
London WC1N 3BG, UK  
E-mail: alan.crockard@uclh.nhs.uk

**Philippe Decq**

Université Paris XII  
Department of Neurosurgery  
Assistance Publique –  
Hôpitaux de Paris  
Henri Mondor Hospital  
94010 Creteil Cedex, France  
E-mail: philippe.decq@hmn.aphp.fr

**Enrico de Divitiis**

Dept. of Neurological Sciences  
Division of Neurosurgery  
Università degli Studi di Napoli  
Federico II  
Via Sergio Pansini 5  
80131 Napoli, Italy  
E-mail: dediviti@unina.it

**Olivier Delalande**

Paediatric Neurosurgery Unit  
Foundation Rothschild  
25 rue Manin, 75019 Paris, France  
E-mail: odelalande@fo-rothschild.fr



**Vedran Deletis**

Albert Einstein College of Medicine  
St Luke's-Roosevelt Hospital, 11C-08  
1000 Tenth Avenue  
New York, NY 10019, USA  
E-mail: vdeletis@chpnet.org

**Roberto Delfini**

Department of Neurological  
Sciences and Neurosurgery  
University of Rome "Sapienza"  
Policlinico Umberto I  
Via del Policlinico 155  
00161 Rome, Italy  
E-mail: delfiniroberto@gmail.com

**Jean D'Haens**

Neurochirurgie  
UZ Brussel  
Laarbeeklaan 101  
1090 Brussels, Belgium  
E-mail: jean.dhaens@uzbrussel.be

**Atos Alves de Sousa**

Faculdade de Ciências Médicas de  
Minas Gerais  
Santa Casa and Life Center Hospital  
Rua Ceará, 600, conj. 2  
30150-310 Belo Horizonte – Minas  
Gerais, Brazil  
E-mail: sousatos@hotmail.com

**Nicolas de Tribolet**

Division of Neurosurgery  
Geneva University Hospitals and  
University of Geneva  
24 rue Micheli-du-Crest  
1211 Geneva, Switzerland  
E-mail: nicolas.detribolet@  
unige.ch

**Bertrand C. Devaux**

PUPH, Service de Neurochirurgie  
Centre Hospitalier Sainte-Anne  
1 rue Cabanis  
75674 Paris Cedex 14, France  
E-mail: b.devaux@ch-sainte-anne.fr

**Pedro Pablo Diaz Vasquez**

Fundacion Hospital Frances de  
Santo Domingo  
Calle Duarte 359, Zona Colonial,  
Santo Domingo  
E-mail: ppdiazvasquez@hotmail.com

**Concezio Di Rocco**

Pediatric Neurosurgeon  
Policlinico Gemelli  
Catholic Univ. Medical School  
Largo Gemelli 8  
00168 Rome, Italy  
E-mail: cdirocco@rm.unicatt.it

**Tamás P. Dóczi**

Department of Neurosurgery  
Medical School of University of Pécs  
2. Rét St.  
7623 Pécs, Hungary  
E-mail: tamas.doczi@aok.pte.hu

**Richard G. Fessler**

Department of Neurosurgery  
Northwestern University  
Feinberg School of Medicine  
676 N. St. Clair Street  
Chicago, IL 60611, USA  
E-mail: rfessler@nmff.org

**Takanori Fukushima**

Carolina Neuroscience Institute PC  
4030 Wake Forest Rd, Ste 115  
Raleigh, NC 27609, USA  
E-mail: fukushima@  
carolinaneuroscience.com

**Bernard George**

Neurochirurgie  
Hôpital Lariboisière  
2, rue Ambroise Paré  
75010 Paris, France  
E-mail: bernard.george@lrb.aphp.fr

**Roberto C. Heros**

Department of Neurosurgery  
University of Miami School  
of Medicine  
1095 NW 14th Terrace  
Miami, FL 33136, USA  
E-mail: rheros@med.miami.edu

**J. André Grotenhuis**

Department of Neurosurgery  
Radboud University Medical Center  
Reinier Postlaan 4  
6525 GC Nijmegen  
The Netherlands  
E-mail: j.grotenhuis@nch.umcn.nl

**Tomokatsu Hori**

Department of Neurosurgery  
Tokyo Women's Medical University  
8-1 Kawadacho, Shinjyuku  
Tokyo 162-8666, Japan  
E-mail: thori@nij.twmu.ac.jp

**Jens Haase**

Department of Health Science and  
Technology  
Aalborg University  
Fredrik Bajers Vej  
9220 Aalborg, Denmark  
E-mail: jph@hst.auc.dk

**Peter J. A. Hutchinson**

Department of Clinical  
Neurosciences  
Neurosurgery Unit  
University of Cambridge  
Cambridge CB2 3EB, UK  
E-mail: pjah2@cam.ac.uk

**Marwan I. Hariz**

National Hospital for Neurology  
and Neurosurgery  
Unit of Functional Neurosurgery  
Institute of Neurology  
Box 146, Queen Square  
London WC1N 3BG, UK  
E-mail: m.hariz@ion.ucl.ac.uk

**Kazadi K. N. Kalangu**

Department of Neurosurgery  
University of Zimbabwe  
College of Health Sciences  
P.O. Box 178A, Harare, Zimbabwe  
E-mail: kazkal2003@hotmail.com;  
kalangu@mweb.co.zw

**Juha Hernesniemi**

Department of Neurosurgery  
Helsinki University Central Hospital  
Topeliuksenkatu 5  
00260 Helsinki, Finland  
E-mail: juha.hernesniemi@hus.fi

**Yücel Kanpolat**

Inkılâp Sokak No. 24/2  
06640-Kızılây-Ankara, Turkey  
E-mail: kanpolat@ada.net.tr

**Amin Bardai Kassam**

Department of Neurological Surgery  
 University of Pittsburgh  
 School of Medicine  
 Director Minimally Invasive  
 endoNeurosurgery Center  
 Univ. of Pittsburgh Medical Center  
 200 Lothrop Street, Suite PUH B-400  
 Pittsburgh, PA 15213, USA  
 E-mail: kassamab@upmc.edu

**Takeshi Kawase**

Department of Neurosurgery  
 School of Medicine  
 Keio University  
 35 Shinanomachi, Shinjuku-ku  
 Tokyo 160-8582, Japan  
 E-mail: kawase@sc.itc.keio.ac.jp

**Andrew H. Kaye**

Department of Neurosurgery  
 University of Melbourne  
 The Royal Melbourne Hospital  
 Parkville, Victoria 3050, Australia  
 E-mail: a.kaye@unimelb.edu.au

**Yves Keravel**

Department of Neurosurgery  
 Hôpital Henri Mondor  
 51 Ave. Maréchal de Lattre de Tassigny  
 94010 Creteil Cedex, France  
 E-mail: ykeravel@yahoo.fr

**Abdeslam El Khamlichi**

Department of Neurosurgery  
 Mohamed V University  
 Hôpital des spécialités  
 Rabat, Morocco  
 E-mail: fh2nch@menara.ma

**Jörg Klekamp**

Christliches Krankenhaus  
 Danziger Strasse 2  
 49610 Quakenbrück, Germany  
 E-mail: j.klekamp@christliches-  
 krankenhaus-ev.de

**David Gellinger Kline**

Louisiana State University Health  
 Sciences Center  
 7041 Globe Road  
 Lenoir, NC 28645, USA  
 E-mail: dkline@lsuhsc.edu

**Engelbert Knosp**

Department of Neurosurgery  
 Vienna Medical University  
 Währinger Gürtel 18-20  
 1090 Vienna, Austria  
 E-mail: engelbert.knosp@  
 meduniwien.ac.at

**Shigeaki Kobayashi**

Medical Research and Education  
 Center, Aizawa Hospital  
 Honjo 2-5-1  
 Matsumoto 390-8510, Japan  
 E-mail: skb0305@wa2.so-net.ne.jp

**Françoise Lapierre**

Neurosurgery Department  
 CHU La Milétrie  
 86021 Poitiers Cedex, France  
 E-mail: f.lapierre@chu-poitiers.fr

**Edward R. Laws**

Department of Neurosurgery  
 Brigham and Women's Hospital  
 PBB3, Harvard University  
 15 Francis Street  
 Boston, MA 02115, USA  
 E-mail: elaws@partners.org

**Ken Lindsay**

Department of Neurosurgery  
Southern General Hospital  
1345 Govan Road  
Glasgow G51 4TF, UK  
E-mail: ken.lindsay@ggc.scot.nhs.uk

**Ramiro D. Lobato**

Service of Neurosurgery  
Hospital "12 de Octubre"  
Avda. Cordoba Km 6  
28041 Madrid, Spain  
E-mail: rdiez.hdoc@salud.madrid.org

**João Lobo Antunes**

Hospital Univ. de Santa Maria  
Av. Egas Moniz  
1649-035 Lisbon, Portugal  
E-mail: jlobo.antunes@mail.telepac.pt

**Hugues Loiseau**

Department of Neurosurgery  
University of Bordeaux 2  
Hôpital Pellegrin Tripode  
Place Amélie Raba Léon  
33076 Bordeaux, France  
E-mail: hugues.loiseau@chu-bordeaux.fr

**Andres M. Lozano**

Department of Surgery  
Faculty of Medicine  
University of Toronto  
399 Bathurst Street WW 4-447  
Toronto, OT M5T 2S8, Canada  
E-mail: lozano@uhnres.utoronto.ca

**L. Dade Lunsford**

University of Pittsburgh  
Medical Center  
Presbyterian B400  
200 Lothrop Street  
Pittsburgh, PA 15213, USA  
E-mail: lunsfordld@upmc.edu

**Jean Claude Marchal**

Chirurgie Pédiatrique (Pôle Neuro.  
Tête et Cou)  
Bâtiment des Neurosciences  
Hôpital Central  
54035 Nancy Cedex, France  
E-mail: jc.marchal@chu-nancy.fr

**Guy Matgé**

National Neurosurgical Department  
Centre Hospitalier de Luxembourg  
4 Rue Barblé  
1210 Luxembourg, Luxembourg  
E-mail: matge.guy@chl.lu

**François Mauguière**

Department of Functional  
Neurology and Epileptology  
Lyon University and Lyon  
Federative Institute of Neuroscience  
Neurological Hospital  
59 Boulevard Pinel  
69003 Lyon, France  
E-mail: mauguiere@univ-lyon1.fr

**Patrick Mertens**

Department of Neurosurgery  
Hôpital Neurologique et  
Neurochirurgical  
Université de Lyon  
59 Boulevard Pinel  
69003 Lyon, France  
E-mail: patrick.mertens@chu-lyon.fr

**Basant Kumar Misra**

Consultant Neurosurgeon  
Head, Dept. of Neurosurgery  
P. D. Hinduja National Hospital &  
MRC, V. S. Marg, Mahim,  
Mumbai – 400 016, India  
E-mail: basantkmisra@gmail.com

**Jan Jakob A. Mooij**  
 Department of Neurosurgery  
 University Hospital UMCG  
 Groningen, Hanzplein 1  
 9713 GZ Groningen  
 The Netherlands  
 E-mail: j.j.a.mooij@nchir.umcg.nl

**Abdul Karim Msaddi**  
 Neuro Spinal Hospital  
 P. O. Box 71444  
 Dubai, United Arab Emirates  
 E-mail: nsshmeet@yahoo.com

**Jean Paul Nguyen**  
 Service de Neurochirurgie  
 Hôpital Laennec  
 44000 Nantes, France  
 E-mail: jean-paul.nguyen@chu-nantes.fr

**Chihiro Ohye**  
 Hidaka Hospital  
 Functional Gamma Knife  
 Surgery Center  
 886 Nakao-machi  
 Takasaki, Gunma, Japan  
 E-mail: stereohye@dan.wind.ne.jp

**M. Necmettin Pamir**  
 Department of Neurosurgery  
 School of Medicine  
 Acibadem University  
 Inonu cad., Okur sok. 20  
 Kozyatagi  
 34742 Istanbul, Turkey  
 E-mail: pamirmn@yahoo.com

**John D. Pickard**  
 Academic Neurosurgery Division  
 Box 167, Level A4  
 Addenbrooke's Hospital  
 Cambridge CB2 0QQ, UK  
 E-mail: prof.jdp@medschl.cam.ac.uk

**Alain Pierre-Kahn**  
 Hôpital Necker-Enfants Malades,  
 149 rue de Sèvres  
 75743 Paris Cedex 15, France  
 E-mail: alain.kahn@nck.aphp.fr;  
 apk1@wanadoo.fr

**Christian Raftopoulos**  
 Neurosurgical Department  
 Clinique Universitaire Saint Luc  
 Université Catholique de Louvain  
 Av. Hippocrate 10  
 1200 Brussels, Belgium  
 E-mail: christian.raftopoulos@uclourain.be

**Jean Régis**  
 Neurochirurgien des Hôpitaux  
 U751-INSERM  
 Service de NeuroChirurgie  
 Fonctionnelle et Stereotaxique  
 Hôpital d'adulte de la Timone  
 264 bvd Saint Pierre  
 13385 Marseille Cedex 05, France  
 E-mail: jregis@ap-hm.fr

**Roger Robert**  
 Service de Neurotraumatologie  
 Hôtel-Dieu, CHU de Nantes Place  
 Alexis Ricordeau  
 44093 Nantes Cedex 1, France  
 E-mail: roger-robert@chu-nantes.fr

**Gail L. Rosseau**  
 CINN at the Neurologic and  
 Orthopedic Hospital of Chicago  
 4501 N. Winchester Ave.  
 Chicago, IL 60640, USA  
 E-mail: grosseau@neurosource.com

**François-Xavier Roux**  
 Hôpital Sainte-Anne  
 1 rue Cabanis  
 75014 Paris, France  
 E-mail: fx.roux@ch-sainte-anne.fr

**Elie Samaha**

Hôtel-Dieu de France Hospital  
P.O. Box 16  
6830 Beyrouth, Liban  
E-mail: elie.samaha@hdf.usj.edu.lb

**Madjid Samii**

Int. Neuroscience Institute  
Rudolf Pilchmayr Str. 4  
30625 Hannover, Germany  
E-mail: samii@ini-hannover.de

**Henry W. S. Schroeder**

Department of Neurosurgery  
University of Greifswald  
Ferdinand-Sauerbruch-Strasse  
17475 Greifswald, Germany  
E-mail: henry.schroeder@uni-greifswald.de

**Laligam N. Sekhar**

Department of Neurosurgery  
University of Washington  
Harborview Medical Center  
325 Ninth Avenue, Box 359924  
Seattle, WA 98104-2499, USA  
E-mail: lsekhar@u.washington.edu

**Marc Sindou**

Hôpital Neurologique  
P. Wertheimer  
University of Lyon  
59 Bd Pinel  
69003 Lyon, France  
E-mail: marc.sindou@chu-lyon.fr

**Juraj Šteňo**

Department of Neurosurgery  
Comenius University School  
of Medicine  
Derer's Hospital  
Limbova 5  
83305 Bratislava, Slovakia  
E-mail: juraj.steno@fmed.uniba.sk

**Volker Sturm**

Department of Stereotactic  
and Functional Neurosurgery  
University of Cologne  
Kerpener Str. 62  
50937 Köln, Germany  
E-mail: volker.sturm@uk-koeln.de

**Graham M. Teasdale**

The Royal College of Physicians  
and Surgeons Glasgow  
232-242 St. Vincent Street  
Glasgow G25RJ, UK  
E-mail: graham.teasdale@hotmail.co.uk

**David G. T. Thomas**

The National Hospital for  
Neurology and Neurosurgery  
Private Consulting Rooms  
Box 147, Queen Square  
London WC1N 3BG, UK  
E-mail: marcel.yazbeck@uclh.nhs.uk

**Joerg-Christian Tonn**

Ludwig-Maximilians-University  
Klinikum Grosshadern  
Marchioninistr. 15  
81377 Munich, Germany  
E-mail: joerg.christian.tonn@med.uni-muenchen.de

**Tomasz Trojanowski**

Department of Neurosurgery and  
Paediatric Neurosurgery  
Medical University in Lublin  
Jaczewskiego 8  
20950 Lublin, Poland  
E-mail: t.trojanowski@am.lublin.pl

**Felix Umansky**

Department of Neurosurgery  
Hadassah–Hebrew University  
Medical Center  
P. O. Box 12000  
91120 Jerusalem, Israel  
E-mail: umansky@hadassah.org.il

**Geirmund Unsgård**

Department of Neurosurgery  
St. Olav University Hospital  
The Norwegian University of  
Science and Technology (NTNU)  
Olav Kyrres gate 17  
7005 Trondheim, Norway  
E-mail: geirmund.unsgard@  
ntnu.no

**Francisco Velasco-Campos**

Unit for Stereotactic and Functional  
Neurosurgery  
Hospital General de México  
Creston 116, Jardines del Pedregal  
México D.F. 01900, México  
E-mail: slanfe@prodigy.net.mx

**Manfred Westphal**

Department of Neurosurgery  
University Medical Center  
Hamburg-Eppendorf  
Martinistr. 52  
20246 Hamburg, Germany  
E-mail: westphal@uke.uni-  
hamburg.de

**M. Gazi Yaşargil**

Department of Neurosurgery  
University of Arkansas for  
Medical Sciences  
4301 W. Markham Street, #507  
Little Rock, AR 72205, USA  
E-mail: williamsronaldae@uams.edu

**Yasuhiro Yonekawa**

University of Zurich  
Haldenbachstrasse 18  
8091 Zurich, Switzerland  
E-mail: yasuhiko.yonekawa@usz.ch

---

## AUTHOR INDEX

- Abbott R III/387  
Abdennebi B I/469  
Akalan N II/543  
Al-Mefty O I/99
- Basso AJ I/183  
Benabid AL III/235  
Beneš V I/337  
Bertalanffy H I/325  
Black PM I/63  
Bosch DA III/183  
Bricolo A II/349  
Brotchi J III/115  
Brunon J III/45  
Burchiel KJ III/349
- Chazal J II/525  
Choux M II/485  
Ciurea AV II/497  
Crockard A I/203
- D'Haens J II/217  
de Divitiis E I/31  
de Sousa AA III/533  
de Tribolet N II/287  
Decq P II/275  
Delalande O II/609  
Deletis V II/461  
Delfini R II/99  
Devaux BC III/419  
Di Rocco C II/561  
Diaz Vasquez PP I/485  
Dóczi TP II/301
- Fessler RG III/79  
Fukushima T II/129
- George B II/373  
Grotenhuis JA III/131
- Haase J III/497  
Hariz MI III/255  
Hernesniemi J I/245  
Heros RC I/303  
Hori T II/427  
Hutchinson PJA I/411
- Kalangu KKN II/601  
Kanpolat Y III/273  
Kassam AB II/201  
Kawase T I/233  
Kaye AH II/181  
Keravel Y III/539  
El Khamlichi A III/163  
Klekamp J III/145  
Kline DG III/475  
Knosp E II/79  
Kobayashi S I/287
- Lapierre F III/93, III/519  
Laws ER II/49  
Lindsay KW I/271  
Lobato RD I/455  
Lobo Antunes J II/255  
Loiseau H II/59  
Lozano AM III/399  
Lunsford LD I/49
- Marchal JC I/167  
Matgé G III/25  
Mauguière F III/441  
Mertens P III/365  
Misra BK II/115  
Mooij JJA I/213  
Msaddi AK III/61
- Nguyen JP III/461
- Ohye C III/195



Pamir MN II/319  
Pickard JD I/383  
Pierre-Kahn A II/585

Raftopoulos C I/257  
Régis J II/385  
Robert R III/3  
Rosseau GL III/545  
Roux FX I/85

Samaha E II/155  
Samii M II/333  
Schroeder HWS I/441  
Sekhar LN I/135

Sindou M I/71, II/169, III/293,  
III/317, III/333  
Šteňo J II/235  
Sturm V III/407

Teasdale GM I/395  
Thomas DGT II/29  
Tonn J-C II/449  
Trojanowski T I/429

Umansky F I/115  
Unsgård G II/407

Velasco-Campos F III/215

Westphal M II/3

Yaşargil MG I/3  
Yonekawa Y I/155, I/355

---

## CONTENTS

### **Volume 1: Cranial Approaches, Vascular, Traumas, Cerebrospinal Fluid, Infections**

<b>Cranial Approaches</b>		<b>1</b>
M. G. YAŞARGIL	Microneurosurgery: principles, applications, and training	3
E. DE DIVITIIS	Endoscopy: principles and techniques	31
L. D. LUNSFORD	Image-guided radiosurgery using the Gamma knife	49
P. M. BLACK	How to perform surgery for intracranial (convexity) meningiomas	63
M. SINDOU	The “dangerous” intracranial veins	71
F. X. ROUX	How to perform subfronto-orbito-nasal approach for anterior cranial base surgery	85
O. AL-MEFTY	How to perform cranio-orbital zygomatic approaches	99
F. UMANSKY	How to perform middle fossa/sphenoid wing approaches	115
L. N. SEKHAR	How to perform central skull base approaches	135
Y. YONEKAWA	How to perform selective extradural anterior clinoidectomy	155
J. C. MARCHAL	How to perform approaches of the orbit	167
A. J. BASSO	How to perform transsphenoidal approaches	183
A. CROCKARD	How to perform transoral approaches	203
J. J. A. MOOIJ	How to perform posterior fossa approaches	213
T. KAWASE	How to perform transpetrosal approaches	233

<b>Vascular Lesions</b>		<b>243</b>
J. HERNESNIEMI	Principles of microneurosurgery for safe and fast surgery	245
C. RAFTOPOULOS	Surgical management of intracranial aneurysms of the anterior circulation	257
K. LINDSAY	Intracranial aneurysms in the posterior circulation	271
S. KOBAYASHI	Giant aneurysms	287
R. C. HEROS	Arteriovenous malformations of the brain	303
H. BERTALANFFY	Intracranial cavernomas	325
V. BENEŠ	Carotid endarterectomy	337
Y. YONEKAWA	Brain revascularization by extracranial-intracranial arterial bypasses	355
J. D. PICKARD	Management of intracranial venous pathologies – potential role of venous stenting	383
<b>Traumas, Cerebrospinal Fluid, Infections</b>		<b>393</b>
G. M. TEASDALE	The Glasgow Coma and Outcome Scales: practical questions and answers	395
P. J. A. HUTCHINSON	Cranial trauma in adults	411
T. TROJANOWSKI	Hydrocephalus in adults (including normal pressure hydrocephalus syndrome)	429
H. W. S. SCHROEDER	Arachnoid cysts	441
R. D. LOBATO	Brain infections	455
B. ABDENNEBI	Parasitoses of the central nervous system: hydatidosis	469
P. P. DIAZ-VASQUEZ	Parasitoses of the central nervous system: cysticercosis	485

## **Volume 2: Intracranial Tumors, Intraoperative Explorations, Pediatrics**

<b>Intracranial Tumors</b>		<b>1</b>
M. WESTPHAL	Classification of brain tumors and corresponding treatments	3
D. G. T. THOMAS	Stereotactic biopsies for tumors: indications, limits, diagnosis with histopathology and other laboratory techniques	29

E. R. LAWS	Management of (malignant) intracranial gliomas	49
H. LOISEAU	Management of lymphomas	59
E. KNOSP	Management of anterior fossa lesions	79
R. DELFINI	Management of tumors of middle fossa	99
B. K. MISRA	Management of central skull base tumors	115
T. FUKUSHIMA	Management of cavernous sinus lesions	129
E. SAMAHA	Management of convexity meningiomas	155
M. SINDOU	Meningiomas involving the major dural sinuses: management of the sinus invasion	169
A. H. KAYE	Posterior fossa meningiomas	181
A. B. KASSAM	Endoscopic surgery for skull base meningiomas	201
J. D'HAENS	Management of pituitary adenomas	217
J. ŠTEŇO	Craniopharyngiomas	235
J. LOBO ANTUNES	Management of tumors of the anterior third and lateral ventricles	255
P. DECQ	Endoscopic management of colloid cysts	275
N. DE TRIBOLET	Management of pineal region tumors	287
T. P. DÓCZI	Epidermoid/dermoid cysts	301
M. N. PAMIR	Tumors of the fourth ventricle and cerebellum in adults	319
M. SAMII	Vestibular schwannomas	333
A. BRICOLO	Brainstem tumors	349
B. GEORGE	Management of Foramen Magnum tumors	373
J. RÉGIS	Radiosurgery for intracranial tumors	385
<b>Intraoperative Explorations</b>		<b>405</b>
G. UNSGÅRD	Ultrasound-guided neurosurgery	407
T. HORI	Brain neuronavigation for deep-seated targets	427
J.-C. TONN	Brain mapping	449
V. DELETIS	Intraoperative neurophysiology in neurosurgery	461
<b>Pediatrics</b>		<b>483</b>
M. CHOUX	Specificities of, and changes in, pediatric neurosurgery	485
A. V. CIUREA	Cranial traumas in children	497
J. CHAZAL	Management of hydrocephalus in childhood	525
N. AKALAN	Intracranial tumors in childhood	543

C. DI ROCCO	Nonsyndromic craniosynostoses	561
A. PIERRE-KAHN	Management of lumbosacral lipomas	585
K. K. N. KALANGU	Management of encephaloceles	601
O. DELALANDE	Epilepsy surgery in children	609

### **Volume 3: Spine, Functional, Peripheral Nerves, Education**

<b>Spine</b>		<b>1</b>
R. ROBERT	Management of spine traumas and spinal cord injury	3
G. MATGÉ	Approaches to cervical spine	25
J. BRUNON	Management of degenerative disease of the cervical spine	45
A. K. MSADDI	Management of lumbar disc herniations and degenerative diseases of lumbar spine	61
R. G. FESSLER	Management of lumbar spondylolisthesis	79
F. LAPIERRE	Non-traumatic extra-medullary spinal cord compression	93
J. BROTCHE	Intramedullary tumors	115
J. A. GROTENHUIS	Chiari malformation	131
J. KLEKAMP	Syringomyelia	145
A. EL KHAMLICHI	Infections in spine	163
<b>Functional Neurosurgery</b>		<b>181</b>
D. A. BOSCH	Stereotactic techniques	183
C. OHYE	Selective thalamotomy	195
F. VELASCO-CAMPOS	Targets for electrical stimulation in functional neurosurgery	215
A. L. BENABID	Functional neurosurgery for Parkinson's disease	235
M. I. HARIZ	Functional neurosurgery for dystonias	255
Y. KANPOLAT	Neurosurgical management of cancer pain	273
M. SINDOU	Neurosurgery for neuropathic pain	293
M. SINDOU	Microvascular decompression for hemifacial spasm	317
M. SINDOU	Microvascular decompression for trigeminal neuralgia	333

---

K. J. BURCHIEL	Neurosurgery for trigeminal neuralgia	349
P. MERTENS	Neurosurgery for spasticity	365
R. ABBOTT	Selective dorsal rhizotomy for the treatment of childhood spasticity	387
A. M. LOZANO	State-of-the-art of surgical therapies for psychiatric disorders: depression	399
V. STURM	Neurosurgery for psychiatric disorders: obsessive-compulsive disorder	407
B. C. DEVAUX	Neurosurgical management of epilepsy in adults	419
F. MAUGUIÈRE	Neurophysiology applied to neurosurgery	441
J. P. NGUYEN	Neuronal transplantation: a review	461
<b>Peripheral Nerves</b>		<b>473</b>
D. G. KLINE	Management of nerve injuries (with emphasis on nerve action potential (NAP) recordings)	475
J. HAASE	Tunnel compression syndromes of median and ulnar nerves	497
F. LAPIERRE	Tumors of the peripheral nerves	519
<b>Education</b>		<b>531</b>
A. A. DE SOUSA	Message from the chairman of the education and training committee of the WFNS	533
Y. KERAVEL	What do young neurosurgeons really need	539
G. L. ROSSEAU	The role of the World Federation of Neurosurgical Societies in the development of world neurosurgery	545
M. SINDOU	Epilogue	551
List of Contributors		553
Author Index		563