



G. Schütze

# Epiduroscopy

Spinal Endoscopy



Springer

G. Schütze

**Epiduroscopy – Spinal Endoscopy**

G. Schütze

# **Epiduroscopy – Spinal Endoscopy**

With 178 figures and 10 tables

**Dr. med. G. Schütze**

Klinikdirektor

Märkische Kliniken GmbH

Klinik für Anästhesiologie, Intensivmedizin und Spezielle Schmerztherapie

Marienhospital Letmathe

Hagener Str. 121

58642 Iserlohn

Germany

[www.pain.de](http://www.pain.de)

E-Mail: [schuetze@pain.de](mailto:schuetze@pain.de)



The Pain Clinic Iserlohn has initiated and adopted a quality system for the scope of application diagnosis and treatment of pain syndromes with a focus on spinal endoscopy – epiduroscopy – and neuromodulation which meets the following international standard: ISO 9001:2000 (identical with DIN EN ISO 9001:2000 and EN ISO 9001:2000). The demonstration was provided by a certification audit, Report No. 6008804. The condition for maintaining the certification is the implementation of annual surveillance audits.

Translated by :

Dr. phil. Karen Leube

Maria-Sibylla-Merian Str. 71

55122 Mainz

Germany

E-mail: [LeubeTranslation@aol.com](mailto:LeubeTranslation@aol.com)

ISBN 978-3-540-87544-4 Springer Medizin Verlag Heidelberg

Bibliografische Information der Deutschen Nationalbibliothek

The Deutsche Bibliothek lists this publication in Deutsche Nationalbibliographie; detailed bibliographic data is available in the internet at <http://dnb.ddb.de>.

This work is subject to copyright. All rights are reserved, whether the whole or part of the material is concerned, specifically the rights of translation, reprinting, reuse of illustrations, recitation, broadcasting, reproduction on microfilms or in any other way, and storage in data banks. Duplication of this publication or parts thereof is permitted only under the provisions of the German Copyright Law of September 9, 1965, in its current version, and permission for use must always be obtained from Springer-Verlag. Violations are liable to prosecution under the German Copyright Law.

**Springer Medizin Verlag**

[springer.com](http://springer.com)

© Springer Medizin Verlag Heidelberg 2008

The use of general descriptive names, registered names, trademarks, etc. in this publications does not imply, even in the absence of a specific statement, that such names are exempt from the relevant protective laws and regulations and therefore free for general use.

Product liability: The publishers cannot guarantee the accuracy of any information about dosage and application contained in this book. In every individual case the user must check such information by consulting the relevant literature.

Planning: Hanna Hensler-Fritton, Heidelberg

Project management: Diana Kraplow, Heidelberg

Copy-editing: Hilger Verlagsservice, Heidelberg

Design: deblik Berlin

Typesetting: TypoStudio Tobias Schaedla, Heidelberg

SPIN 12270293

Printed on acid free paper

18/5135/DK – 5 4 3 2 1 0

To achieve the possible, you must keep  
attempting the impossible.

Hermann Hesse

# Foreword

---

We are on the threshold of a new era in disease and symptom management. Vision gained from pioneering work in spinal canal endoscopy hints at gains to come.

Everything we do in success or failure in pain medicine is ultimately expressed at the cellular level and represents changes in electrical patterns, neurotransmitters and metabolism. We up- and down-regulate cells, alter neurotransmitters, change electrical patterns through medication, physical therapy, surgery, chemotherapy, radiation, acupuncture, cognitive behavioral therapies, etc. For any therapy to be successful there has to be a return of homeostasis, a return to the normal regulated state. Spinal canal endoscopy provides a window into the inner workings of the body and allows for direct observation of anatomy such as movement of nerves back and forth through neural foramina, but the spinal canal endoscope's future is pinned on its unique ability to study physiology from a number of different vantage points. (This distinguishes endoscopy from standard imaging techniques.) By reaching out and physically touching and potentially sampling areas of interest, a better understanding will develop of mechanisms of disease (inflammation) and allow for creation of cures, return to homeostasis when heretofore symptom management was all that was dreamed of for spinal related pain syndromes.

Spinal canal endoscopy is the visualization of the spinal canal using a flexible fiber optic light source and endoscope. When intrathecal (subarachnoid), the term is myeloscopy, when epidural, epiduraloscopy or epiduroscopy. A convergence of technologies has given birth to spinal canal endoscopy: principally miniaturization of flexible fiber optics, non-heat emitting light sources and digital photography/videography. Currently, spinal endoscopy is primarily utilized as epiduroscopy. Direct observations are made of the dorsal and ventral epidural space, allowing for visualization of blood vessels, ligaments, connective tissue, fat, inflammation and the products of inflammation, scar tissue. These images are direct images of the spinal canal as opposed to computer reconstructions via tomography or magnetic resonance. There is visualization of color, allowing localization of inflammation and blood flow and dynamic observations, viewing what happens to the dura mater, nerve roots, blood vessels, etc when contents are tugged via various maneuvers such as a straight leg raise. It is through these observations that better understanding is achieved of gross anatomy affecting function of the spinal canal contents and through these observations the dichotomy of spinal canal disease anatomically/physiologically appreciated. For example, adherent scar tissue identified by pulling and tugging on nerve roots and obstruction of venous return secondary to ligament hypertrophy (tourniquet effect) with formation of venous channels compressing nerve are both anatomic observations not appreciated via other forms of imaging. These are both gross anatomic observations and in themselves contribute to the possibility of how to manage a disease state. Presumably by releasing scar or cutting back ligament, nerve pulled or compressed will be freed. Today such procedures can possibly be done with difficulty depending on nature, location, available technology if anatomic cause of the pain complaint is found. Our ability to make disease-altering observations is limited because the vastness of the spinal canal, the tremendous number of structures involved, the endless array of connective tissues, scar, fat, blood vessels, etc that are anatomically present, some a part of the normal aging process and not a part of the pain complaint, make effective targeting difficult.

Spinal canal endoscopy as it is practiced today attempts to lyse scar tissue in an effort to mobilize tissue planes, but for the reasons cited above, as well as the fact that the underlying physiology after lysis is the same as before lysis, regeneration of scar (inflammation) is prob-

able; long-term benefits simply from lysis unlikely. If scarring/inflammation is responsible for loss of tissue plane mobility or for obstructive effect on blood flow, it would seem managing growth/regeneration of scar (inflammation) should be the goal of evolving epiduroscopic care. Further research needs to be directed into this area. We know that as part of an inflammatory cascade, cellular elements are called in from the immune system, via cytokine messaging, and activated to deposit collagen. The reasons for deposition are unclear, but may be reflective of a protective mechanism, shielding irritants (contents of a nucleus pulposus) from the immune system (umbrella effect.) Interfering with the process, release of irritants, activation and response of the immune system would alter the inflammatory reaction and the consequences; pain, inflammation, scarring, etc. This constitutes physiological high ground and should be the focus of active research.

Our current mode of management has some impact on the inflammatory process, presumably from irrigating the area with saline to remove inflammatory mediators, cytokines, often followed by steroid, designed to membrane stabilize and slow an inflammatory response. This technique has the potential to work well if the mediators are adequately removed and re-accumulation of mediators prevented. Unfortunately, the underlying anatomic derangements that led to a leaky disc or synovial joint are usually still present after epiduroscopy. Thus if there was some canal stenosis and irritation complicating the canal stenosis, endoscopic irrigation and injection of steroid might help. However, to get long-term response, it would be necessary to achieve reduced functional irritation from the stenosis. This is unfortunately nearly impossible via non-surgical means, although altering posture through use of a shoe orthotic is potentially helpful. It would be far better to be able to interfere with the inflammatory process at the target with specific chemotherapy that inhibits recurrence of inflammatory state, despite persistence of pathology.

It is medically probable that an endoscopic device will be able to sample the tissue bed involved in the inflammatory process and via a bedside test kit the nature of the inflammatory response determined. In so doing this, specific chemotherapies could be placed to inhibit the reaction, inflammation, and scarring and improve long-term outcome. Thus the endoscopic platform has a very rich future. The textbook *Epiduroscopy – Spinal Endoscopy* written by Dr. Schütze is a gateway to the future and reveals opportunities and an entirely new subspecialty: spinal canal endoscopy. With the knowledge imparted from this text, it is our hope that future endoscopists will be inspired to fulfill the vast potential of these new devices.

*Lloyd R. Saberski, M.D.*

*New Haven, Connecticut, USA*

# Introduction

---

The publication of the English edition of my German book *Epiduroscopy – A practice-oriented guide to epiduroscopic diagnosis and treatment of spinal pain syndromes* provided an opportunity to thoroughly revise and complete the book. The new edition reflects the latest developments in this area of medicine and expands the textbook.

Diagnosing and treating spinal pain syndromes is often difficult and is generally of limited success. It continues to pose a challenge in clinical practice. The effectiveness of the drugs used for pain management and the patients' tolerance of these drugs, as well as surgical procedures and their costs play a role.

Manchikanti (2000) reported that in the United States, back pain is a widespread problem affecting between 8% and 56% of the population. An estimated 28% of the population will suffer from back pain at least once during their lifetime. Fourteen percent of the U.S. population experience pain episodes that persist at least 2 weeks. Each year, 8% of the entire workforce misses work due to back pain.

The lifetime prevalence for low back pain has been reported as between 65% and 80%. The symptoms of back pain often last for only brief periods and in 80% to 90% of cases, disappear after six weeks regardless of treatment. On the other hand, several studies describe recurrent, chronic back pain evaluated at 3 months, 6 months and 12 months and which occurred in 35% to 79% of chronic pain patients. The risk factors for chronic back pain reported by Manchikanti are affected by numerous factors, which may be physical, emotional or sociodemographic in nature.

Effective pain management is one of the physician's major responsibilities. However, studies by Breivik et al. show that one-third of all patients with chronic pain are not treated, and only 2% of all patients are treated by pain therapists. In Europe, the symptoms of 90% of all pain patients are not explained through medical tests. Over 60% of all pain patients report that their treatment is suboptimal and associated with intolerable side effects.

In Germany, too, the results of traditional treatment measures offered by a wide spectrum of medical specialties for chronic low back pain is often disappointing for the patients in question.

In response to the fact that up to 30% of all disc operations produce unsatisfactory results, a number of minimally invasive treatment methods have been developed in the past decades.

The early 1990s saw a vision emerge that involved the use of an endoscope to examine the epidural space, which can contain key information for diagnosis and treatment, and possibly develop an examining technique for clinical application. It was the rapid development of flexible, small-caliber endoscopes with corresponding image transmission systems that provided the technical capabilities needed to perform spinal endoscopy.

This textbook is based on my years of clinical experience in pain management. It intends to serve as a guide and a strategy for epiduroscopic diagnosis and therapy in patients with spinal pain syndromes.

As a percutaneous minimally invasive endoscopic examination, epiduroscopy (EDS) permits spatial, real color visualization of spinal anatomical structures such as the spinal dura mater, blood vessels, ligamentum flavum, longitudinal ligament and nerve and fatty tissue. In addition, epiduroscopy allows pathological and anatomical anomalies to be distinguished, such as epidural fibrosis after invasive procedures, adhesions, fibrotic lesions, nerve root compression, scar and granulation tissue and spinal stenosis, which often cannot be visualized with other imaging methods.



The indication for invasive diagnostics and pain therapy is frequently persistent unresolved pain experienced by a patient who has been subjected to any number of ineffective treatment attempts.

In day-to-day practice, an exact diagnosis is often elusive, because precisely locating the anatomical pain generator is not possible in the patient with chronic pain.

In many cases, the pain symptoms have been improperly treated, resulting in chronicity of the pain.

Incorporating invasive epiduroscopic diagnosis and treatment at an early stage in a sensible multidisciplinary pain management concept is thus extremely important.

Choosing the proper time for performing epiduroscopy is an important criterion for averting potential pain chronicity. Simply continuing conservative treatment without questioning its effect carries with it the risk that pain chronicity will set in.

For clinical pain management, epiduroscopy permits treatment such as targeted drug delivery, placement of catheter systems, as well as epidural surgery including biopsy, laser adhesiolysis, microsurgical lysis of fibrosis and removal of foreign bodies, even if the anatomical circumstances are problematic.

Based on our clinical experience and results with EDS management in over 1600 chronic pain patients, all of which has been positive, and the high level of patient satisfaction, epiduroscopy can be considered an extremely efficient procedure, and if performed by a well-trained therapist, is a safe means of endoscopic diagnosis and therapy for spinal pain syndromes.

However, in order to ensure that epiduroscopy is effective, the pain therapist must have a well-founded theoretical background, experience with the method and a high level of manual dexterity.

This guide has been written for doctors working in all specialties in both clinical and private practice settings. It offers a hands-on introduction to the world of epiduroscopy and its use in the specific area of pain medicine.

The book provides the reader with a brief overview of the latest options for endoscopic diagnostics and treatment of spinal pain syndromes. The primary focus is on the basic features of the procedure. Many details are mentioned only in passing. The major medical and technical foundations and special methods in this discipline have been presented in a detailed and easy to understand manner. The tips and advice presented here can be put into practice directly.

This textbook aims to provide helpful and supportive impulses for both novices and experienced users of epiduroscopy. In addition, it intends to offer advanced users help with problems they may experience or issues they may encounter in their everyday work with EDS. This revised edition, now in English, should serve to provide a practical overview of epiduroscopic diagnostics and therapy of spinal pain syndromes. The images in this textbook present examples of visualized findings. Supplementary material is available as a DVD (G. Schütze: *Epiduroscopy*. Multilingual DVD-ROM, ISBN 3-89756-757-1). In addition to a detailed presentation of epiduroscopy (topographic and endoscopic anatomy, endoscopic pathology, clinical applications of epiduroscopy, endoscopic equipment, preoperative measures, preparation, approach technique, additional diagnostic procedures, epidural irrigation, examination, epiduroscopic procedures, complications, golden rules, prognosis), the DVD also presents epiduroscopic findings as an image atlas and video album. This DVD may be ordered free of charge from Karl Storz GmbH & Co. KG, Mittelstraße 8, 78532 Tuttlingen, Germany, [www.karlstorz.com](http://www.karlstorz.com).

The theoretical overview is supported by the results from our clinical experience with epiduroscopy. They underscore the merit of incorporating this new, intelligent form of diagnosing and treating spinal pain syndromes into a multimodal strategy for modern, future-oriented and intelligent pain management to benefit the chronic pain patient.

# Table of Contents

<b>1</b>	<b>Evolution of Epiduroscopy</b> .....	<b>1</b>	<b>5</b>	<b>Epiduroscopic Equipment and Surgical Setting</b> .....	<b>47</b>
1.1	Definition .....	4	5.1	Technical aspects .....	48
1.2	Indications .....	5	5.1.1	Structure and function of endoscopes .....	48
1.3	Contraindications .....	5	5.1.2	Epiduroscopes .....	51
1.4	Our own results .....	6	5.1.3	Reprocessing epiduroscopic equipment .....	54
<b>2</b>	<b>Epiduroscopic Diagnostics</b> .....	<b>9</b>	5.2	Camera and video technology/DVD/CD-ROM .....	58
2.1	Clinical relevant anatomy .....	10	5.3	Documentation .....	59
2.1.1	Epidural space .....	11	5.4	Work station .....	60
2.1.2	Spinal dura mater .....	12	5.4.1	Technical assistance in the operating room .....	60
2.1.3	Ligamentum flavum .....	13	5.4.2	Instrumentarium .....	61
2.1.4	Blood vessels and lymphatics .....	13	5.5	Preoperative management .....	63
2.1.5	Neural structures .....	14	5.5.1	Preoperative history, clinical examination and anesthesiological evaluation .....	63
2.1.6	Posterior longitudinal ligament .....	15	5.5.2	Electrophysiological tests .....	64
2.1.7	Fatty tissue .....	16	5.5.3	Other tests .....	64
2.2	Endoscopic anatomy .....	16	5.5.4	Standards for hygiene .....	65
2.2.1	Spinal dura mater .....	16	5.5.5	Positioning .....	65
2.2.2	Fatty tissue .....	16	5.6	Anesthesia management .....	66
2.2.3	Neural structures .....	18	<b>6</b>	<b>Performing Epiduroscopy</b> .....	<b>67</b>
2.2.4	Ligamentum flavum .....	19	6.1	Accessing the epidural space .....	68
2.2.5	Posterior longitudinal ligament .....	19	6.1.1	Puncture technique .....	69
2.2.6	Blood vessels .....	20	6.1.2	Our own experience with epiduroscopy .....	69
2.3	Endoscopic pathology .....	21	6.2	Epidurography .....	73
2.3.1	Pathological endoscopic findings .....	21	6.2.1	Definition .....	73
2.3.2	Our own results .....	28	6.2.2	Indication .....	73
2.4	Histopathology .....	29	6.2.3	Contraindications .....	73
2.4.1	Histological findings .....	30	6.2.4	Epidurography management .....	74
2.4.2	Microbiological diagnostics .....	31	6.3	Epidural irrigation .....	76
<b>3</b>	<b>Additional Imaging Diagnostics</b> .....	<b>37</b>	6.3.1	Saline infusion .....	76
3.1	Computed tomography (CT) .....	38	6.3.2	Epidural pressure .....	76
3.2	Magnetic resonance imaging (MRI) .....	38	6.4	Segmented epidural examination .....	77
3.3	Myelography .....	39	6.4.1	Examining sacral segments .....	77
3.4	Discography .....	39	6.4.2	Examining lumbar segments .....	78
3.5	Our own clinical results .....	39	6.4.3	Thoracic examination .....	78
<b>4</b>	<b>Functional Epiduroscopic Diagnostics</b> .....	<b>43</b>	6.4.4	Cervical examination .....	79
4.1	Diagnostic blocks and laser-evoked potentials .....	44	6.5	Concluding epiduroscopy .....	80
4.2	Epidural pain provocation test (EPPT) .....	44	6.6	Follow-up epiduroscopy .....	80
4.2.1	Our own results .....	45	6.7	Ultrasound-assisted epiduroscopy (SONO-EDS) .....	83

6.7.1	Ultrasonography in anesthesia and pain medicine .....	83
6.7.2	Epidural sonography .....	84
6.7.3	Our own results .....	85
6.8	Myeloscopy .....	87
<b>7</b>	<b>Treatment Strategies .....</b>	<b>89</b>
7.1	Context .....	90
7.2	Spinal pain syndromes .....	91
7.2.1	Treating spinal pain syndromes .....	91
7.3	Epiduroscopic interventions .....	94
7.3.1	Epiduroscopic catheter management .....	96
7.3.2	Indications .....	96
7.3.3	Technique .....	98
7.3.4	Complications .....	98
7.3.5	Our own experience .....	99
7.4	Endoscopically assisted epidural analgesic therapy (EAT) – spinal endoscopic adhesiolysis .....	101
7.4.1	Indications .....	102
7.4.2	Drugs used in epidural analgesic therapy .....	102
7.4.3	Pharmacologic options .....	104
7.4.4	Performing epidural analgesic therapy (EAT) .....	106
7.4.5	Results .....	107
7.5	Epidural laser adhesiolysis .....	108
7.6	Epiduroscopically assisted electrode implantation .....	110
7.7	Epiduroscopic (pulsed) radio frequency therapy .....	113
7.8	Neurolysis .....	114
<b>8</b>	<b>Complications .....</b>	<b>117</b>
<b>9</b>	<b>Costs and Benefits of Epiduroscopy ...</b>	<b>123</b>
<b>10</b>	<b>Training Program for Epiduroscopy .....</b>	<b>127</b>
<b>11</b>	<b>Recommendations for Epiduroscopy ...</b>	<b>131</b>
<b>12</b>	<b>The Future of Epiduroscopy .....</b>	<b>133</b>
	<b>Literature .....</b>	<b>137</b>
	<b>Subject Index .....</b>	<b>147</b>

# Evolution of Epiduroscopy

- 1.1 Definition – 4
- 1.2 Indications – 5
- 1.3 Contraindications – 5
- 1.4 Our own results – 6

The development of endoscopy from the invention of the first real endoscope by Adolf Kussmaul in 1868 to the presentation of the first flexible fiber-glass endoscope by Hirschowitz at the 1958 World Congress for Gastroenterology in Washington, D.C. is a medical milestone.

Its history was launched by Frankfurt physician Phillip Bozzini, who constructed the first rigid medical endoscope in 1806. In 1855, French physician Antonin J. Desormeaux replaced the candle Bozzini had used as a light source with a kerosene lamp, thus refining the »Bozzini« endoscope. In 1879, German physician Maximilian Nitze presented the »cystoscope,« which he had produced with the help of the Austrian craftsman Josef Leiter, marking the beginning of the application of endoscopy in clinical practice with a rigid endoscope. B.I. Hirschowitz then developed the first flexible endoscope in 1958, a milestone in medicine, which gave rise to meteoric advances in diagnostics and therapy, evolving from a combination of intuition and meticulous observation on the part of committed researchers, as well as sheer coincidence, egregious errors, false assessments and misinformation.

Endoscopic examination of the epidural space is still a relative fledgling technique with regard to clinical application. However, experiments for visualizing the spinal canal have already been carried out for over 60 years.

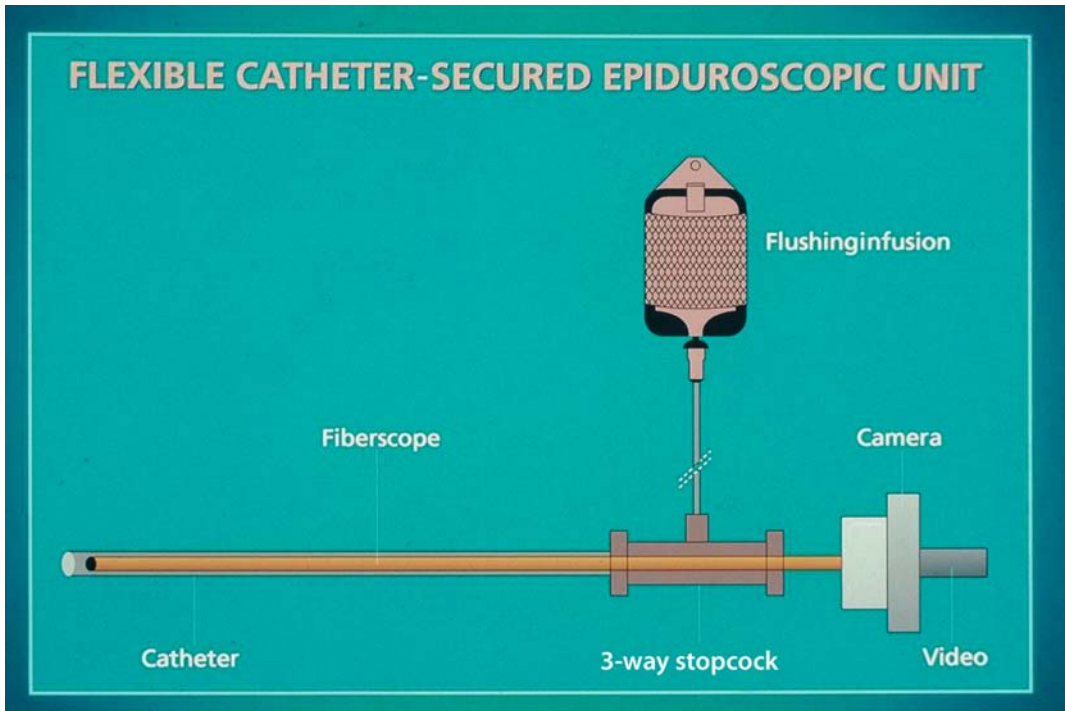
Pioneer work was performed by Burman, who used arthroscopic instruments to inspect cadaver vertebral columns. The first myeloscope used on patients was developed by Stern (1936). Pool reported on the first clinical application of myeloscopia in 1937 and by 1942, had examined 400 patients using this technique. In a large number of cases conditions such as neuritis, herniated disc, neoplasms, adhesions and venous congestion could be diagnosed. Despite these encouraging results, there were no further reports on myeloscopia in the literature until the late 1960s. This is especially surprising considering the lack of competing methods in this pre-CT era and the relative ease with which myeloscopia can be performed. Saberski attributed this to the introduction and widespread application of myelography and the fact that findings could not be photographically

documented. Starting in 1967, the Japanese researcher Ooi restored the focus on myeloscopia. Between 1967 and 1977, he examined 208 patients with an instrument that combined a flexible light source with rigid optics. In the years that followed, Blomberg, Olsson, Holström and Möllmann et al. the epidural space of both human cadavers and live patients.

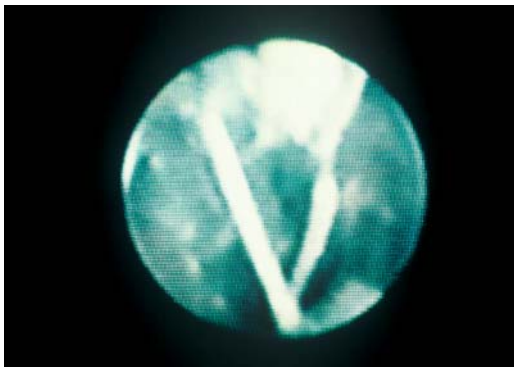
The key breakthrough for clinical application of spinal endoscopy – epiduroscopy (EDS) – was the development of small-caliber, flexible optics and light sources.

In 1991, Heavner et al. reported on endoscopic examinations of the epidural and spinal space of rabbits, dogs and human cadavers using a flexible endoscope. Epiduroscopic technology with flexible optics has been used in clinical application on patients since the early 1990s. In 1993, Leu reported on peridural and intraductal endoscopies in patients in whom the sacral approach technique was used. In addition to diagnostics, endoscopy can also be used for therapeutic intervention. Kizelshteyn et al. reported on the adhesiolysis of epidural adhesions with an epidural balloon catheter system in animal experiments. The use of an epidural catheter to lyse epidural adhesions under radiological control has been reported as well.

In 1994, Schütze and Kurtze published results of the first video-optic examinations of the epidural space in chronic patients with a »flexible catheter-secured epiduroscopic unit.« Between February and August 1992, the lumbar epidural spaces of 12 patients with various pain syndromes were examined endoscopically before placing an epidural catheter. A flexible catheter-secured epiduroscopic unit was developed for visual examination of the epidural space (■ Fig. 1.1). This examination unit consisted of an ultralow bore 0.8-mm fiberscope with an aperture angle to a Karl Storz Endovision 9050, a camera control unit (CCU), and a VHS videorecorder and monitor. The irrigation system consisted of a catheter (1.1×1.7 mm, 350 mm long) with a 3-way stopcock. An infusion pump system was used for epidural irrigation with sterile 0.9% saline solution. The epidural space was punctured with a 14-gauge Hustead needle. The flexible catheter-secured epiduroscopic unit was



■ Fig. 1.1. Flexible epiduroscope, used for epidural diagnostics in chronic pain patients for the first time in 1992



■ Fig. 1.2. First picture of the epidural space with pathological structures (tissue filaments) from the flexible catheter-secured epiduroscopic unit (1992)

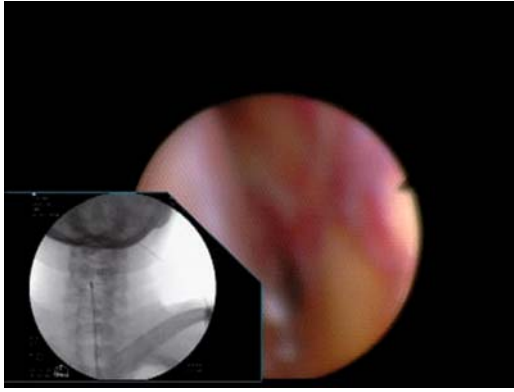then introduced into the epidural space through this needle. During the examination, the epiduroscope was advanced a total of 5 to 8 cm in a cephalad direction (■ Fig. 1.2).

In 1996, the U.S. Food and Drug Administration (FDA) approved epiduroscopy for visualization of the epidural space.

In 1997, Schütze published the first report on epiduroscopically assisted SCS electrode implantation. Ruetten et al. reported on clinical application of epiduroscopically assisted laser therapy for post-nucleotomy syndrome.

Michel and Metzger reported in 1997 that EDS is advantageous because it can be used to assess the epidural pathology. In 1999, Winston C.V. Parris of the University of South Florida in Tampa stated that epiduroscopy is a technique that may dominate in the new millennium. In 2000, Ovassapian wrote that the role of epiduroscopy for chronic back pain is explored

In the same year, Schütze reported on the method and described the results of a retrospective examination of 165 epiduroscopies. In 2001, the same author reported on ultrasonography-assisted epiduroscopic examinations.



■ Fig. 1.3. The first cervical epiduroscopy performed with a brand new 90-cm epiduroscope (KARL STORZ, Germany), February 16, 2006, Pain Clinic Iserlohn, (Picture-in-Picture technique)

In June 2000, Igarashi et al. reported on epiduroscopic examinations in 52 pregnant women.

In 2004, Schütze described over 500 epiduroscopies in chronic pain patients. This publication described endoscopically assisted epidural analgesic therapy as well as the treatment of painful epidural fibrosis and adhesions with laser technology. Lorinson et al. (2006) described percutaneous epiduroscopy in dogs. Graziotti (2007) reported that he had performed nearly 300 epiduroscopic interventions. The launch of the flexible epiduroscope with FLEX-X<sup>2</sup> technology in 2005 made it possible to effectively carry out diagnostics and treatment in the entire epidural space, from the sacral to the cervical segments (■ Fig. 1.3).

2006 saw the publication of the first book on epiduroscopy, G. Schütze's *Epiduroscopy – A practice-oriented guide to epiduroscopic diagnostics and therapy of spinal pain syndromes*. Pabst Verlag, ISBN 389967-252-6 (in German) and the DVD *Epiduroscopy* ISBN 3-89756-757-1 (English and German).

## 1.1 Definition

According to Schütze, EDS is a percutaneous minimally invasive endoscopic examination of the epidural space that permits spatial and color imaging

of spinal anatomical structures such as the spinal dura mater, blood vessels, connective tissue, nerves and fatty tissue. Pathological structures and changes such as adhesions, sequestrers, inflammatory processes, fibrosis and stenosing processes can also be described via endoscopy.

The following definition of epiduroscopy was approved in 2002 in line with the international recommendations of September 17, 1998 in Iserlohn, Germany, the conference of experts of October 3, 1998 in Bad Dürkheim, Germany, the consensus conference in Innsbruck, Austria, in 2001:

»Epiduroscopy is a percutaneous minimally invasive endoscopic examination of the epidural space that can also be used for therapeutic inventions.«

The consensus committee [D. Beltrutti (Italy), G.J. Groen (The Netherlands), L. Saberski (United States), A. Sander-Kiesling (Austria), G. Schütze (Germany), G. Weber (Austria)] of the Consensus Conference held in Graz, Austria, on March 3 and 4, 2006 and organized by the World Initiative on Spinal Endoscopy (WISE), agreed on the following definition:

Epiduroscopy (EDS) or spinal (canal) endoscopy is defined as a percutaneous minimally invasive endoscopic investigation of the epidural space with the assistance of a flexible endoscope introduced through the sacral hiatus. It allows visualization of normal anatomical structures, such as the dura mater, blood vessels, connective tissue, nerves and fatty tissue, as well as of pathological structures, such as adhesions, sequestrers, inflammatory processes, fibrosis and stenotic changes. It permits potential targeted treatment, such as delivery of epidural steroids, epidural catheter placement, SCS electrode implant and application of cytokine-targeting drugs. In addition to epiduroscopy, other analyses, such as biopsy or aspiration are possible.

I understand epiduroscopy to be an integral component of invasive pain management. It can serve as an important diagnostic procedure and supportive treatment option in a multimodal, multidisciplinary pain management strategy if indicated and if risks and possible side-effects are taken into account.

## 1.2 Indications

A major task for the pain therapist involves treating unexplained pain symptoms.

Spinal pain syndromes do not disappear by simply ignoring them. On the other hand, they are resistant to a number of treatments. Zenz emphasized the importance of spotting the yellow and red flags and of carrying out in-depth and comprehensive pain diagnostics.

It can be extremely difficult to classify and treat chronic spinal pain syndromes when there is no explanation for the pain. Epiduroscopy offers a technique for diagnosing and treating spinal pain syndromes. It makes sense to distinguish between diagnostic and therapeutic indications for epiduroscopy:

### Diagnostic indications

The main indication for epiduroscopy is for diagnosis of spinal pain syndromes. This may involve distinguishing pathological and anatomical structures and circumstances, such as epidural fibrosis following invasive procedures and radiculopathies, performing biopsies and smears, removing irrigation fluid, as well as performing an epidural pain provocation test (EPPT).

### Therapeutic indications

Therapeutic indications for epiduroscopy include procedures such as direct application of pharmacologic therapy, lysis of scar tissue, catheter placement (epidural, intrathecal) and implantation of stimulation electrodes (radio frequency therapy, spinal cord stimulation) under direct vision, in the case of problematic passage through the epidural space or if placement is not possible or too risky for the patient during radiological procedures. Support during minimally invasive surgical procedures is another therapeutic indication for epiduroscopy.

In 2006, the consensus committee of the World Initiative on Spinal Endoscopy (WISE) defined the following indications:

Indications for spinal endoscopy (WISE):

To improve diagnosis:

- Diagnosis of clinically relevant epidural pathology, if pain can be attributed to epidural space (spinal canal) structures based on current history, physical examination and supportive present day laboratory investigations
- Biopsy for histopathological and/or histochemical analysis
- Provocative stimulatory tests (e.g. electrical, light, mechanical)

To provide (potential) treatment:

- Irrigation
- Direct application of therapeutic agent
- Direct lysis of adhesions/scar tissue with physical or chemical agents (e.g. mechanical, pharmacological, laser, radio frequency)

As a supportive tool:

- Placing catheter systems (epidural, spinal)
- Implanting stimulation electrodes (spinal cord stimulation)
- As an adjunct in minimally invasive surgery
- Retrieval of foreign bodies
- (Potentially) for postoperative assessment

At our clinic, epiduroscopy has become an integral component for the diagnosis and treatment of spinal pain syndromes. We believe that it should be used as a »first-line« treatment.

In the case of equivocal, contradictory clinical and/or radiological findings, epiduroscopy should be used as early as possible to counteract pain chronicity in patients with spinal pain syndromes.

## 1.3 Contraindications

The contraindications for epiduroscopy correspond to those for epidural regional anesthesia techniques. In addition, the particular anatomical circumstances of the patient must be taken into account.

The major contraindications for epiduroscopy are listed below:

- Bleeding tendency
- Therapy with anticoagulants



- Infections in the area of the puncture site
- Special neurological disorders
- High risk of cardiovascular disease
- Patient's refusal to undergo the procedure

The recommendations of the German Association for Anesthesiology and Intensive Care Medicine for epidural regional anesthesia and thrombolytics/anticoagulation and the required time interval between administration of anticoagulants and peridural/spinal puncture and removal of a peridural catheter should also be observed.

In 2006, the consensus committee of the World Initiative on Spinal Endoscopy (WISE) defined the following contraindications:

**Absolute contraindications.** Psychiatric diseases that potentially interfere with informed consent and/or perception of pain, retinal disease, presence of or increase in intracranial pressure, pregnancy, manifest bowel and bladder dysfunction and sensory disturbances in the S2-S4 area, congenital anomalies that do not permit safe endoscopy, cerebrovascular disease, renal or liver insufficiency, inflammatory or dystrophic skin lesions in the area of the sacral canal (anal fistula, sacral osteomyelitis, etc.), meningeal cysts, meningoceles, meninomyeloceles, severe respiratory insufficiency (COPD), known allergies to the drugs required to implement epiduroscopy, unstable angina pectoris, malignant tumors.

**Relative contraindications.** Coagulopathy, psychiatric diseases that potentially interfere with informed consent and/or perception of pain, inability

to lie in a prone position for more than 60 minutes, severe respiratory insufficiency (COPD), drug or alcohol abuse, etc.

## 1.4 Our own results

In our patient population, which to date numbers more than 1600 epiduroscopies, the primary indications for epiduroscopy are epidural diagnostics and targeted epidural analgesic therapy for chronic spinal pain syndromes.

Over 64% of the 1130 epiduroscopies evaluated in 2005 involved patients who had undergone spinal surgery. In the majority of these patients, symptoms were classified as failed back surgery syndrome (FBSS, ICD-10 M96.1). Thirty-five percent of the patients undergoing epiduroscopy suffered just as frequently from chronic back pain and other chronic pain requiring epidural catheter placement for pain management (EAT).

Another frequent therapeutic indication for epiduroscopy was primary epidural surgical pain management, such as biopsy, adhesiolysis or the resection of scar tissue.

In 22% of the patients with clinically and radiologically equivocal spinal pain syndromes undergoing epiduroscopy, the diagnosis was confirmed by the epiduroscopy or the histological examination of a tissue specimen from the epidural space. In this special group of patients, the diagnosis of radiculopathies is another important indication for epiduroscopy.

Since the introduction of our laser pain provocation test (LPPT) in 2004, this test has been

■ **Table 1.1.** Primary diagnoses of 230 patients undergoing EDS at the Iserlohn Pain Clinic in 2006

Number of patients	ICD-10 classification	Diagnosis
134	M 96.1	Postlaminectomy syndrome, not elsewhere classified
66	M 51.2	Other specified intervertebral disc displacement
55	M 48.0	Spinal stenosis
6	M 50.1	Cervical disc disorder with radiculopathy
7	M 50.2	Other cervical disc displacement
13	M 54.5	Lumbar pain

performed in 70% of the epiduroscopic examinations in order to confirm or rule out the pain relevance of pathological structures in the epidural space.

In a further study carried out in 2006 on 230 patients undergoing EDS, the youngest patient was 16 years old and the oldest patient was 86 years old. The ratio of men to women was 45% to 55%. Over 58.2% of the 230 epiduroscopies evaluated in 2006 involved patients with postlaminectomy syndrome (M96.1). ■ Table 1.1 presents a list of the diagnoses of the 230 patients undergoing epiduroscopy at the Iserlohn Pain Clinic in 2006. In 78% of the patients, epiduroscopy was used to examine the lumbar region, in 12% the thoracic region and in 10% the cervical region. In several cases, more than one diagnosis was made. During this period, microbiological laboratory tests were also carried out during all 230 EDS.

# Epiduroscopic Diagnostics

## 2.1 Clinical relevant anatomy – 10

- 2.1.1 Epidural space – 11
- 2.1.2 Spinal dura mater – 12
- 2.1.3 Ligamentum flavum – 13
- 2.1.4 Blood vessels and lymphatics – 13
- 2.1.5 Neural structures – 14
- 2.1.6 Posterior longitudinal ligament – 15
- 2.1.7 Fatty tissue – 16

## 2.2 Endoscopic anatomy – 16

- 2.2.1 Spinal dura mater – 16
- 2.2.2 Fatty tissue – 16
- 2.2.3 Neural structures – 18
- 2.2.4 Ligamentum flavum – 19
- 2.2.5 Posterior longitudinal ligament – 19
- 2.2.6 Blood vessels – 20

## 2.3 Endoscopic pathology – 21

- 2.3.1 Pathological endoscopic findings – 21
- 2.3.2 Our own results – 28

## 2.4 Histopathology – 29

- 2.4.1 Histological findings – 30
- 2.4.2 Microbiological diagnostics – 31

## 2.1 Clinical relevant anatomy

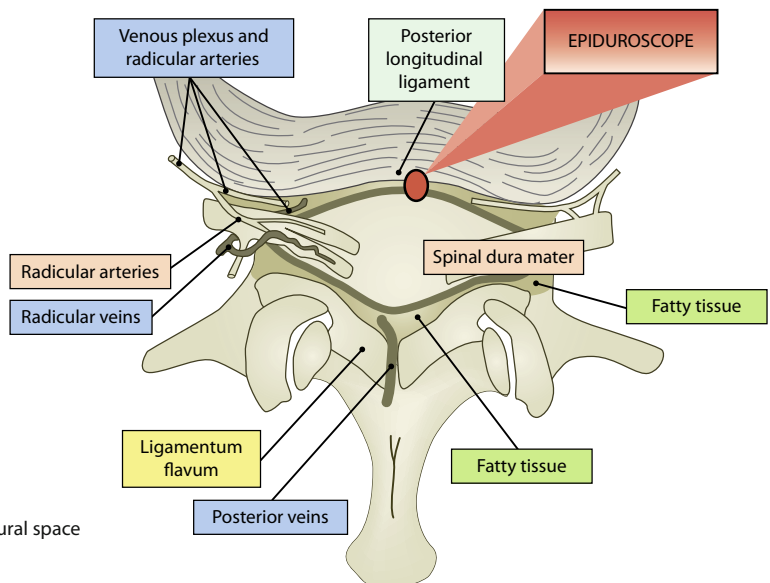
The familiar shape of the spinal canal is characterized by various bends in the spinal column. In the areas with the greatest flexibility, such as the cervical and lumbar region, the spinal canal is triangular. In the thoracic region, where there is a low degree of flexibility, the spinal canal is round. The spinal canal is delimited ventrally by the individual vertebrae and the intervertebral discs. The spinal canal is delimited dorsally by laminae, the ligamentum flavum and the vertebral arches. Lateral delimitation is rendered by the pedicles and the laminae. In the area of the spine, several bands that span vertebrae can be distinguished, such as the supraspinous ligament, the anterior longitudinal ligament and the posterior longitudinal ligament. The supraspinous ligament runs over the tips of the spinal processes from C7 to the sacrum. The interspinal ligaments, which are attached to the spinous processes, the ligamentum flavum, which is attached to the vertebral arches, and the posterior longitudinal ligament, which runs within the spinal canal along the dorsal surface of the vertebrae, and the anterior longitudinal ligament, which runs ventrally along the vertebrae, are the most important intervertebral ligaments. The spinal canal contains the epidural, subdural and subarachnoid space.

Of primary interest for endoscopy is the actual epidural space (■ Fig.2.1), also referred to as

the peridural space, cavum epidurale or spatium epidurale. The space is formed at the great occipital foramen and ends in segment S2-S3 in the sacral hiatus in combination with the sacrococcygeal ligament.

In addition to familiarity with the anatomy of the epidural space, an important precondition for proper implementation of epiduroscopy is a secure technique for accessing the sacral canal. Safely accessing the epidural space for surgery and examinations requires skill and experience on the part of the physician. The technique cannot be learned by simply reading books. In addition to dexterity and experience, basic knowledge of the topographic anatomy of the region is a basic precondition for performing the procedure. The sacrum is a fusion of the five vertebrae S1–S5. The sacral hiatus, which is important for the puncture, is located in segment S5, whereby the apex can often reach up to S4 and farther toward cranial. Important marking points for locating the sacral hiatus also include the sacral horns, which vary widely in size and often cannot be used as a marking aid. The sacral hiatus is covered by the sacrococcygeal ligament.

The wide range of anatomical variation in the lumbar region may considerably complicate sacral access to the epidural space. This problem can only be solved by gathering extensive experience in puncture and access technique and in epiduroscopic navigation.



■ Fig. 2.1. Topography of the epidural space

### 2.1.1 Epidural space

#### Epidural space

In addition to the spinal cord, the vertebral canal contains the spinal dura mater, the arachnoid mater and the pia mater. The three sheaths form the subdural space, the subarachnoid space and the epidural space.

Morphological findings regarding the epidural space (spatium epidurale, cavum epidurale) derived from anatomical specimens, X-ray examinations, MRI, CT epidurography and our own results of epiduroscopy are contradictory.

The literature shows that the anatomy of the epidural space is hotly debated.

Newer literature divides the epidural space into a posterior, lateral and anterior epidural space. Bogduk and Twomey divided the lumbar epidural space into a dorsal and a ventral compartment. Luyendijk et al. published findings that describe a membrane (plica mediana dorsalis) extending between the dorsal circumference of the spinal dura mater and the ligamentum flavum. Savolaine et al. also used computer tomography to distinguish various differences in intensity of very delicate triangular connective tissue structures with minimal fat deposits and discontinuities. They also found additional dorsolateral fiber tracts. Together with the median fiber system, they emerge at the periosteum of the vertebra and then take an anterolateral course. This forms a dorsomedian and a dorsolateral epidural compartment. The overwhelming majority of incidents of failed contrast spread in the epidural space could be explained by the existence of such connective tissue structures and characteristics of the posterior epidural fat body. According to findings from anatomical dissection by Hogan et al., however, these are more likely to be imaging artifacts, thus casting doubt on the existence of these membranes dividing the space. We too have the impression that the anatomical findings published by Luyendijk et al. are more likely to have been brought about by the anomalies in dissection and share the doubt that such dividing membranes exist.

The epidural space is delimited by the spinal dura mater to the spinal cord and by the ligamentum flavum toward the spinous process. Fibrous

tracts that extend from the posterior longitudinal ligament to the inner epidural leaflet form a barrier in the anterior epidural space between the right and left areas. In the posterior epidural space the inner epidural leaflet is loosely attached to the vertebral arches by fibers. The anterior and posterior connective tissue tracts have gaps that can be linked by delicate membranes, which allows a functional closure of the epidural space to form. According to an examination by Hamid et al. in 2002, the anatomy of the epidural space differs from that of the examined fetal stage in several ways. In the fetus, the structures of the epidural space are fully developed after 13 weeks; however, incremental changes occur in the structures within the connective tissue.

The size of the epidural space is also affected by pregnancy. In epiduroscopic examinations of pregnant women, Igarashi et al. observed that the epidural space in pregnant women is smaller than in women who are not pregnant. In pregnant women in their final trimester, the proportion of fibers and connective tissue was significantly higher than in women who were not pregnant. However, no differences in the amount of epidural fatty tissue could be observed. In the epidural space there is a slightly negative pressure. The negative intrathoracic pressure is first transferred to the intervertebral space and from there into the intervertebral foramina. Igarashi et al. reported that under epiduroscopic conditions, the epidural space expands when the patient breathes deeply. The size of the epidural space reported in the literature ranges from 2.0 to 12.0 mm. In the area of the cervical spine and the upper thoracic spine, the epidural space is between 2.0 and 3.0 mm. In the literature, a diameter of 3.0 to 6.0 mm is reported for the mid-thoracic region and 4.0 to 6.0 mm for the lower cervical spine and lumbar spine.

#### Subarachnoid space

The content of the subarachnoid space (cavum subarachnoidale) consists of the spinal cord and its offshoots, which are covered by the pia mater, as well as the cerebrospinal fluid, which is enclosed by the arachnoid mater and the blood vessels supplying the spinal cord. The spinal dura mater and

the arachnoid mater constitute a double layer that forms the dural sac and encloses the cerebrospinal fluid. Cranially, the spinal dura mater is attached at the circumference of the foramen magnum and at the dorsal surfaces of the C2 and C3 vertebrae. In 43% of adults the dural sac terminates at the transition from S1 to S2, in 32 percent in the middle of S2 and in 23% at the transition from S2 to S3. In some cases, the dural sac can even extend to the transition from S3 to S4.

### Subdural space

The tiny subdural space is formed by the spinal dura mater and the arachnoid mater, which are closely apposed. The subdural space is moistened by a minimal amount of fluid. Shah and Heavner reported that the subdural space is not an actual space, but rather one that can be formed. Mechanical force can tear neurothelial cells in the dura-arachnoid interface and form a subdural space.

#### 2.1.2 Spinal dura mater

The spinal dura mater consists of dense connective tissue, although it also contains elastic fibers between which a mucopolysaccharide-rich basic substance and fibroblasts are located. The dura, with its external sheet of the lamina externa, lines the spinal canal. The epidural space is located between the inner layer of the spinal dura mater (lamina interna) and the lamina externa of the dura mater. The actual dural sac formed by the dura mater generally extends from the foramen magnum down to the level of the second sacral vertebra. The dural sac is fused together with the filum terminale internum and as the filum of spinal dura mater, radiates down to the periosteum of the sacrum. The spinal dura mater encloses both the two roots of the spinal nerves and the spinal ganglion.

Together with the arachnoid mater and the pia mater, the spinal dura mater forms a coherent uniform organ. Reina et al. took samples from the dural sac of the spine from human cadavers between 65 and 72 years old. They examined the samples with a scanning electron microscope,

which showed that the dural sac consists of the arachnoid mater and dura mater with a thickness of 100 to 150  $\mu\text{m}$ .

The inner layer of the epidural space is composed of the spinal dura mater. Together with the spinal arachnoid mater and the spinal pia mater, the spinal dura mater encloses the spinal cord and the anterior and posterior nerve roots. Upon entering the anterior and posterior nerve roots through the epidural space, the dural sheath becomes the epineurium of the spinal nerve roots. The external layer of the dura mater consists primarily of collagen fibers that run alone or in groups in all three directions, longitudinal, horizontal and transverse.

Dittmann et al. used scanning electron microscopy to visualize the spinal dura mater. Their findings contradict the classic findings that present the course of the fibers in the spinal dura mater as parallel and longitudinal in the tangential. The group of Dittmann, Reina, López García observed that in the outer (epidural) layer of the spinal dura mater, the collagen fibers are bundled together in bands that run in all directions. Elastic fibers 2 mm thick are woven into this three-dimensional network of collagen systems. On the inside (the arachnoid side) thin collagen fibers are fused into layers such that the innermost layer resting on the arachnoid mater has a smooth, shiny appearance comparable to that of a serosa. It is attached to the actual dura with a band of connective tissue. Remnants of the subdural neurothelium contribute to the smooth appearance of the surface aspect.

The thickness of the spinal dura mater is reported to be 1.0 to 1.5 mm in the regional of the cervical spine, 1.0 mm in the mid-thoracic spine and 0.3 to 0.7 mm in the region of the lower thoracic spine and lumbar spine.

One of the most important functions of the spinal dura mater is providing mechanical, thermal and immunological protection. The mechanical protective function of the spinal dura mater consists in anchoring the spinal cord in the spinal canal and in forming an adaptable fluid casing.

### Arachnoid mater

The arachnoid mater is a very delicate, vessel-poor, connective tissue-like set of threads consisting of

the arachnoid trabeculae and membrane covered by endothelium on both sides. The arachnoid mater is separated from the pia mater, which lies directly below it, by the cerebrospinal fluid.

After leaving the intervertebral foramen, the arachnoid mater forms the perineurium of the spinal nerves along with the spinal dura mater and the pia mater. The arachnoid mater is closely apposed to the dura mater; however, it may become quite distended as a subdural space in the case of bleeding and other events.

Clinical practice often reports cases in which epidural catheters accidentally reach the subdural space when they are placed using conventional techniques.

### Pia mater

The pia mater is closely apposed to the spinal cord and the spinal nerves and is attached to the spinal nerves at the side. Together with the spinal dura mater and the arachnoid dura mater, the pia mater forms the connective tissue ensheathes the spinal nerves. The pia mater is separated from the arachnoid mater by the cerebrospinal-fluid filled subarachnoid space.

### 2.1.3 Ligamentum flavum

The yellowish elastic ligamentum flavum stretches between each of two posterior parts of the vertebral arches dorsally into the articular processes and covers the interlaminar foramen.

In the lumbar region, the interlaminar foramen is nearly round. It becomes increasingly flatter in the thoracic, cervical and sacral regions.

The ligamentum flavum plays a special role in the practice of regional anesthesia. This is because in the technique used to perform epidural anesthesia, the ligamentum flavum needs to be punctured with the correct technique (loss of resistance technique), for instance, from the lumbar to the cervical spine region, in order to reach the epidural space.

According to studies by Bromage, the greatest distance between the ligamentum flavum and the spinal dura mater is 5.0 to 6.0 mm in the L2 region. Near C7, the distance is between 1.5 and

2.0 mm. In the cervical region, the ligamentum flavum is relatively thin and becomes thicker toward the caudal aspect.

The ligamentum flavum consists of genuinely elastic connective tissue similar to that in the ligamentum nuchae and the vocal ligament, as well as that of the ligamentum suspensorium of the penis. The elastic fibers, arranged like a lattice, give the ligamentum flavum its yellowish color. Pathological changes in the area of the ligamentum flavum, such as thickening or cysts can lead to stenoses in the spinal canal or root compression.

### 2.1.4 Blood vessels and lymphatics

**Arterial blood vessels.** The arterial vessels in the epidural space are branches of the spinal rami from the intercostal arteries. The spinal ramus divides into three branches after passing through the intervertebral foramen, the anterior and posterior vertebral canal arteries for the spine and the contents of the epidural space, and the neuromedullary artery for the spinal cord and its sheaths. The posterior spinal canal artery supplies the vertebral arch and the ligamentum flavum. The anterior spinal canal artery bifurcates into the ascending and descending rami, which anastomose with the arteries of the opposing side and the neighboring segments. After giving off smaller branches to the posterior longitudinal ligament, they then penetrate the posterior surface of the vertebrae as posterior central rami.

**Venous blood vessels.** In addition, there are heavily branched, valveless internal vertebral venous plexuses arranged in a ring-like manner. At each vertebral level, each of these venous plexuses receives a venous influx from the spinal veins, vertebral veins and veins of the vertebral arch. The epidural venous plexus forms a vertically arranged network. The venous plexus is reinforced by the anastomized intervertebral veins. The venous system is finally drained into the superior vena cava via the azygos veins and the hemiazygos veins. This anastomosing venous network provides connections to the deep veins of the neck and head cranially as well caudally via venous connections

to the veins of the pelvis. The epidural venous plexus provides a flexible cushion for the dural sac, which balances its fluctuations in volume.

**Lymphatics.** The lymphatics in the epidural space are located in the nerve root. Lymph drainage takes place through the intervertebral foramina into the deep cervical, intercostal, lumbar and presacral lymph nodes.

The epidural vascular network, along with a dense vascular supply of the spinal dura mater to the extravertebral venous plexuses, provide favorable anatomical conditions for reasonable thermoregulation of the spinal cord through the venous blood and the liquid sheath provided by the cerebrospinal fluid.

### 2.1.5 Neural structures

In the epidural space, spinal nerves give off a thin sinuvertebral meningeal ramus. With their fine branches, the meningeal rami supply the periosteum of the vertebral canal, the spinal dura mater, epidural vessels and the posterior longitudinal ligament. The epidural space is innervated by a heavily branched multisegmental neural plexus. Its origin is in the sympathetic trunk, the communicating rami of the spinal nerves and perivascular nerves. The sensory innervation of the dorsal epidural space takes place via the lateral and medial rami of the dorsal ramus of the spinal nerves and the communicating rami.

The fact that the nerves of the cauda equina at the end of the internal layer of the dura enter the epidural space at the S1-S2 level is significant for epiduroscopy not just from the point of view of topography and anatomy, but from a clinical perspective. In the child, the spinal cord extends to L3 and the dural sac to L4, farther than in the adult (L2).

### Spinal cord

The axial part of the central nervous system is composed of the spinal cord, whose average length ranges from 42 to 54 cm. It runs from the cranial surface of the atlas to the upper border of the second

lumbar vertebra. The spinal cord consists of 30 spinal segments (8 cervical, 12 thoracic, 5 lumbar and 5 sacral). With their meningeal processes, all spinal segments, with the exception of the sacral segments, branch off through the epidural space from the subarachnoid space. The distal end of the spinal cord transitions into the filum terminale, extending to the end of the dural sac in the spinal canal.

The cauda equina is formed by the nerve roots that, along with the filum terminale, extend down to their exit sites.

The dural sac (theca), which sheathes the spinal cord, is the continuation of the dura mater of the intracranial space. It ends in the middle of the sacrum. In addition to the spinal cord, the filum terminale and the cauda equina, the dural sac also encloses the stub-shaped lateral protrusions of the two roots of the spinal nerves and the spinal ganglion. The blood supply of the spinal cord is provided by the anterior spinal artery and the paired posterior spinal artery. The afferent vessels from the vertebral artery and the intercostal arteries run through the intervertebral foramina as ventral and dorsal radicular arteries and have varying calibers. Many of them are even obliterated. Numerous anastomoses exist between the dorsal and the ventral vascular area of the spinal cord.

**Cerebrospinal fluid.** The cerebrospinal fluid produced in the choroid plexus of the fourth ventricle reaches the subarachnoid space via the median aperture and the lateral apertures. The clear and colorless cerebrospinal fluid fills the internal cavities of the CNS and the subarachnoid space from the brain and spinal cord, offering mechanical protection and serving to balance fluctuations in temperature and hydrostatic pressure.

Cerebrospinal fluid is a watery solution whose individual components have a composition comparable to that of the interstitial space. The total volume of fluid is approximately 150 mL. The individual volume of fluid is variable and is dependent on changes in intraabdominal pressure and changes in the filling status of the epidural veins, as well as other factors. Carpenter et al. reported considerable variation in the individual lumbosacral fluid volume of 42 mL to 8 mL based on magnetic resonance imaging.



Higuchi et al. reported a volume of lumbosacral fluid in 40 patients that ranged from 20.5 mL to 61.6 mL. Cerebrospinal fluid is not static. It is subject to a balance from production and reabsorption. At the level of the spinal cord it also moves in a flow. The fluid column oscillates in direct dependence on the arterial pulsation. The amplitude of the fluid movement decreases from cranial to caudal and measures approx. 0.4 mL/systole at the level of the thoracic transition.

### Spinal nerves

The cervical, thoracic, lumbar, sacral and coccygeal nerves arise from the spinal cord. Each spinal nerve is created by the unification of two nerves, the anterior spinal nerve or radix ventralis and the posterior spinal nerve or radix dorsalis.

Within the intervertebral canal, the short trunk of the spinal nerves divides into four branches:

- ramus meningeus, a branch that innervates the dura mater
- ramus dorsalis, which innervates the erector spinae
- ramus ventralis, the branch of the spinal nerves located closest to the front
- ramus communicans albus, a branch of the spinal nerves that provides the connection to the sympathetic trunk.

### Root

The two lateral longitudinal sulci of each side of the spinal cord are caused by the anterior and posterior roots of spinal nerves. Each spinal nerve connects with the spinal cord with two roots, an anterior root, the radix ventralis and a posterior root, the radix dorsalis.

While the spinal nerves contain both afferent (sensory) and efferent (motor) fibers, the two types of fibers connect with the spinal cord separately through the two roots of the spinal nerves, so that the anterior root contains the motor fibers and the posterior root contains the sensory fibers. Just before the union of the two roots to form the trunk of the spinal nerves, the posterior root develops into the spinal ganglion. Each root of a spinal nerve consists of 5-10 bundles of nerve

fibers, the root fascicles, which run together to the particular intervertebral foramen in a fan-like manner. The ventral roots are formed by numerous fine bundles lying next to each other in two to three vertical rows, while the dorsal roots are formed by several stronger bundles lying in a row.

### 2.1.6 Posterior longitudinal ligament

The posterior longitudinal ligament, which is tightly attached to the posterior wall of the vertebrae, bridges the back part of the vertebrae along the body axis. In the cranial region, the posterior longitudinal ligament is broader than in the caudal region. In the lumbar region, it narrows to a thin strip. Connective tissue trabeculae connect the spinal dura mater with the wall of the spinal canal, especially with the anterior longitudinal ligament.

According to studies performed by Bertram et al., the longitudinal ligament consists of two layers. A deep layer is segmental, diamond-shaped in the region of the motor segments and inserts at the intervertebral discs, the margins of the neighboring vertebral bodies and the posterior surface of the vertebral bodies.

Many of these epidural connective tissue tracts contain nerve fibers that arise from the neural plexus of the anterior longitudinal ligament and merge into the dense nerve fiber network of the spinal dura mater. Innervation takes place via the sinuvertebral nerves, which are recurrent branches of the ventral rami. The sinuvertebral nerves (rami meningei) spread out in the area of the posterior longitudinal ligaments and anterior polysegmental ligaments. Faustmann used experimental immunohistochemical and molecular biological examinations of spinal muscles during an operation for failed back surgery syndrome to determine that myelinated nerve fibers and positive neuronal markers for pain-leading fibers were also positive in the dorsal region of the anulus and the posterior longitudinal ligament. Interestingly, nerve sprouting into the nucleus pulposus of the degenerated disc was found. Innervation takes place via the sinuvertebral nerves, which

are recurrent branches of the ventral rami. They spread out, plexus-like, in the area of the posterior longitudinal ligaments and anterior polysegmental ligaments.

### 2.1.7 Fatty tissue

In addition to the internal vertebral venous plexus, the main component of the epidural space is epidural fatty tissue. The fatty tissue forms an ideal pressure cushion for the spinal structures. The epidural fatty tissue offers an excellent depot for drugs that are administered in the epidural space. During implantation of electrodes and catheters, the epidural fat protects the dura mater from perforations caused by the implanted tip of the electrode or catheter (■ Fig. 7.1a–d).

The distribution of fat in the epidural space varies widely and does not correlate with the overall fat distribution in the rest of the body.

## 2.2 Endoscopic anatomy

With epiduroscopy, an invasive and interventional endoscopic epidural examining technique, it is possible to optically display the corresponding morphological structures. As a direct three-dimensional imaging procedure, epiduroscopy allows spatial and color pictures of epidural anatomical structures of the spinal dura mater, ligamentum flavum, posterior longitudinal ligament, blood vessels, connective tissue, nerves and fatty tissue to be reproduced in high video-optic quality, depending on the epiduroscopic equipment used.

In addition to the dynamics of the epidural space, epiduroscopy provides visual understanding of this topographic region.

However, very few reports and limited reliable visual material depicting the endoscopic anatomy or pathological changes are available. The images sporadically published in the literature do not provide a uniform picture. The DVD *Epiduroscopy* by G. Schütze (multilingual, DVD-ROM, ISBN 3-89756-757-1) attempts to present a uniform nomenclature and a visual epiduroscopic atlas.

### 2.2.1 Spinal dura mater

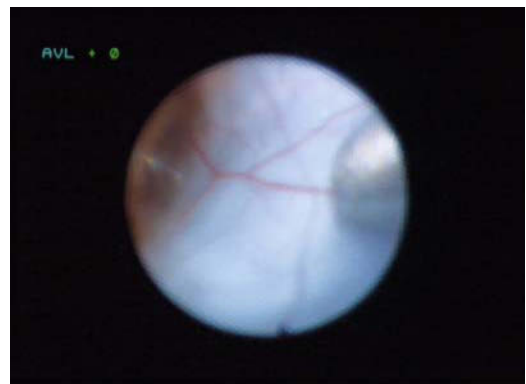
In the endoscopic picture, the spinal dura mater appears as a blue-gray or gray-white connective tissue structure (■ Fig. 2.2, 2.3a,b) with small blood vessels on the surface. The thickness of the spinal dura mater varies depending on the particular segment under examination. The thickness of the dural wall ranges from a maximum of 1.5 mm, as we observed, to near transparency in the intrathecal space. The elasticity of the spinal dura mater is very easy to determine by triggering the »tenting« phenomenon. A catheter tip, biopsy forceps or the epiduroscope tip itself can be used to »tap« the dura mater and determine the dural resistance or elasticity. When relatively sharp instruments are used (laser fiber, biopsy forceps, etc.), the likelihood of perforating the dura is high.

We like to use the spinal dura mater as an optical guide rail when navigating in the epidural space.

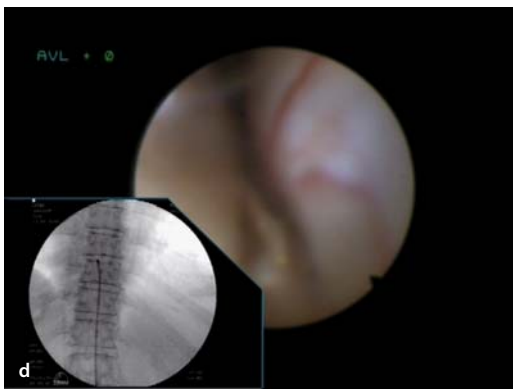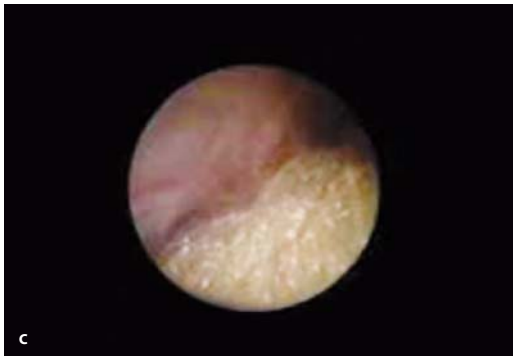
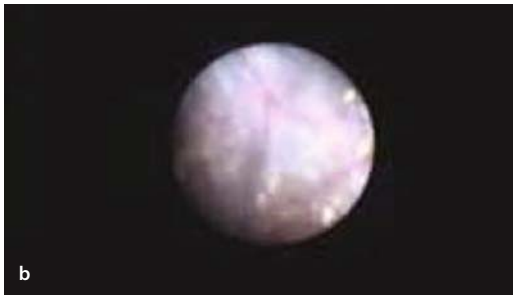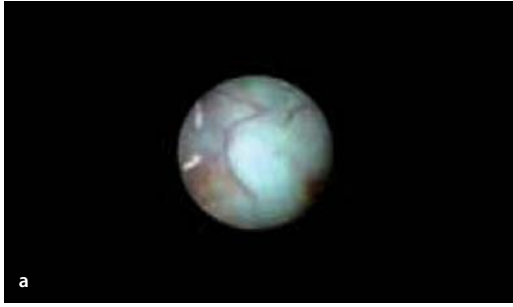
### 2.2.2 Fatty tissue

In the endoscopic picture, the epidural fatty tissue appears as a glistening white to yellow color (■ Fig. 2.4a,b). The fatty tissue is often traversed by small blood vessels. The epidural fatty tissue varies in the different epidural regions and serves as a lipophilic store.

Igarashi demonstrated that the epidural fatty tissue is important as the connective tissue layer



■ Fig. 2.2. Dura mater spinalis with tip of catheter



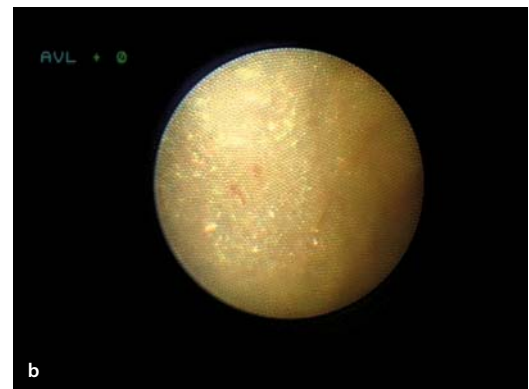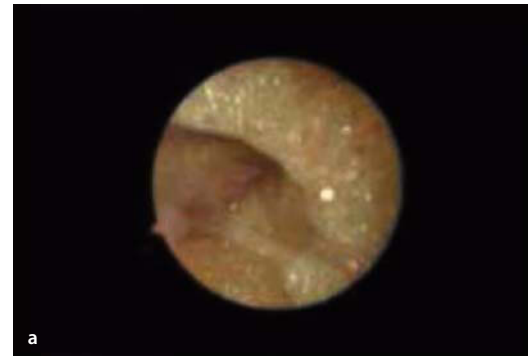■ Fig. 2.3. a,b Spinal dura mater. c Spinal dura mater with fatty tissue. d Spinal dura mater and posterior longitudinal ligament

for the nerves and that it is used up after chronic inflammatory processes. This can lead to involvement of the neural structures in the scar tissue being formed.

Reina et al. observed a large proportion of fat cells both between and below the layers of the dura mater.

They reported that like the fat in the peripheral nerves, fat is present within and below the dural sheath. The fat found in the dural sheath is in close contact with the axons of the nerve roots. This differs from the fat contained in the epidural space. The lipophilic substances released in the fat of the dural sheath may have a greater effect on the nerve roots as a result of the small distance separating the fat from the axons and due to the low vascular clearance.

Our epidural investigations show that the proportion of fatty tissue in the epidural space varies greatly. Results of our investigations show that the



■ Fig. 2.4. a Dorsolateral epidural fatty tissue. b Epidural fatty tissue

majority of the epidural fatty tissue is found in the dorsal epidural space.

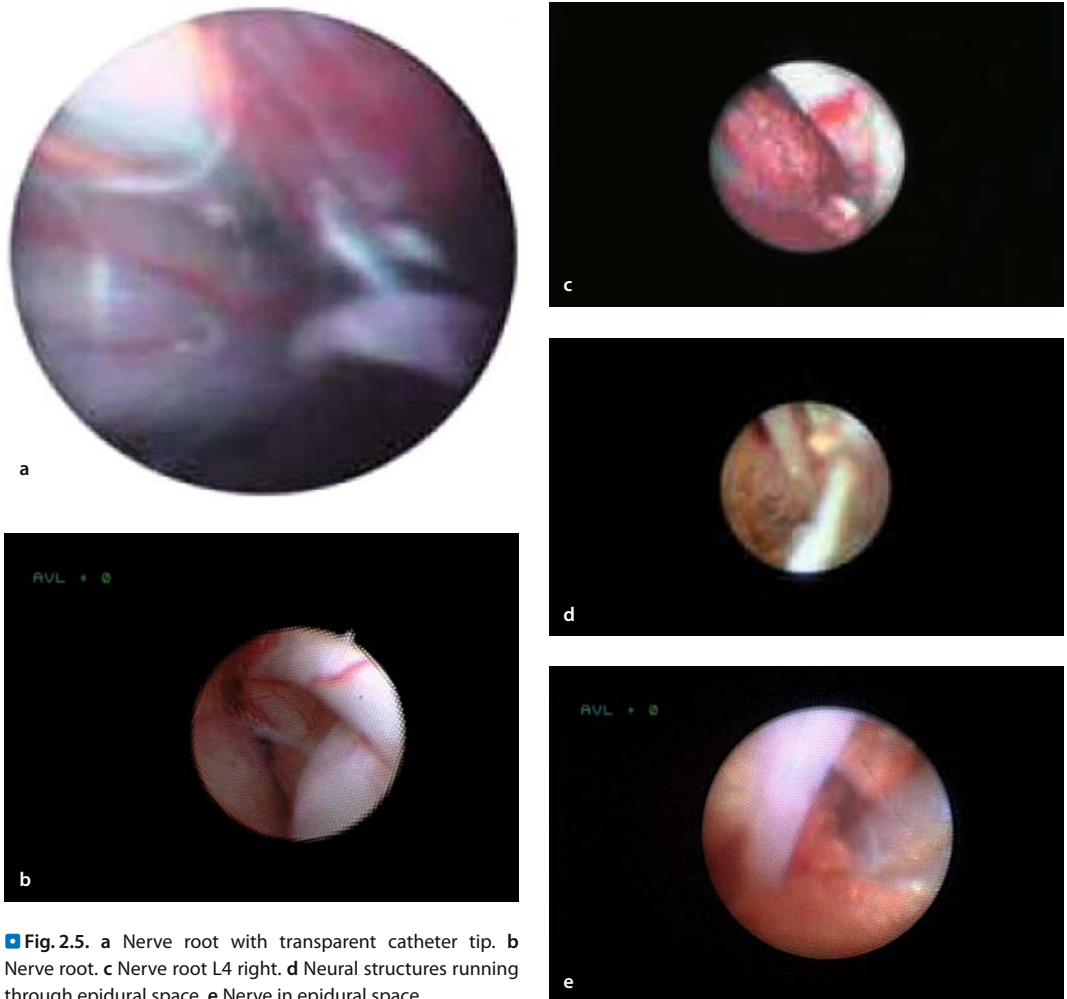In addition, our findings show that especially in the ventral epidural space and postoperatively, only negligible amounts of fatty tissue exist.

### 2.2.3 Neural structures

Endoscopic inspection in the area of the nerve root is often difficult. However, it generally allows an assessment of the root. The proximity to the ascending and descending rami of the posterior and anterior vertebral arteries also allows assessment of the vas-

cular supply, pulsation, adhesion, edema and contact sensitivity of this topographic region. Nerve roots are generally depicted as being white to having a pink-yellow tinge with blood vessels that can extend across the surface of the nerve root. Nerve roots can also have a matte color structure that is generally caused by the presence of adhesions (■ Fig. 2.5a–e). It has repeatedly been observed that nerve roots are crossed by vessels running longitudinally.

The neural structures, which often extend through the epidural space completely unhindered, can be relatively easily identified due to their white color. However, they can also be easily mistaken for fibrotic tracts.



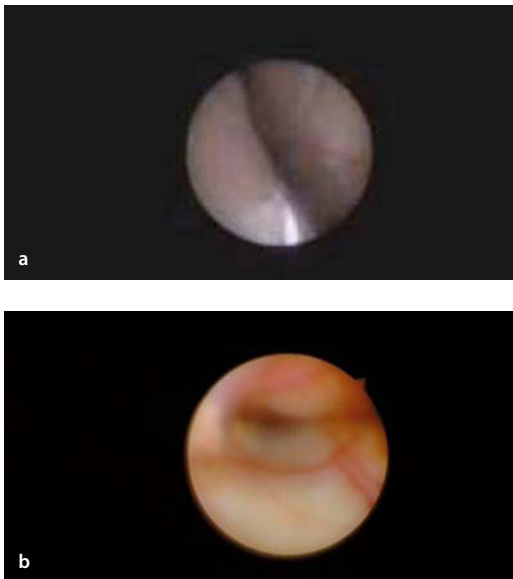
■ Fig. 2.5. a Nerve root with transparent catheter tip. b Nerve root. c Nerve root L4 right. d Neural structures running through epidural space. e Nerve in epidural space

### 2.2.4 Ligamentum flavum

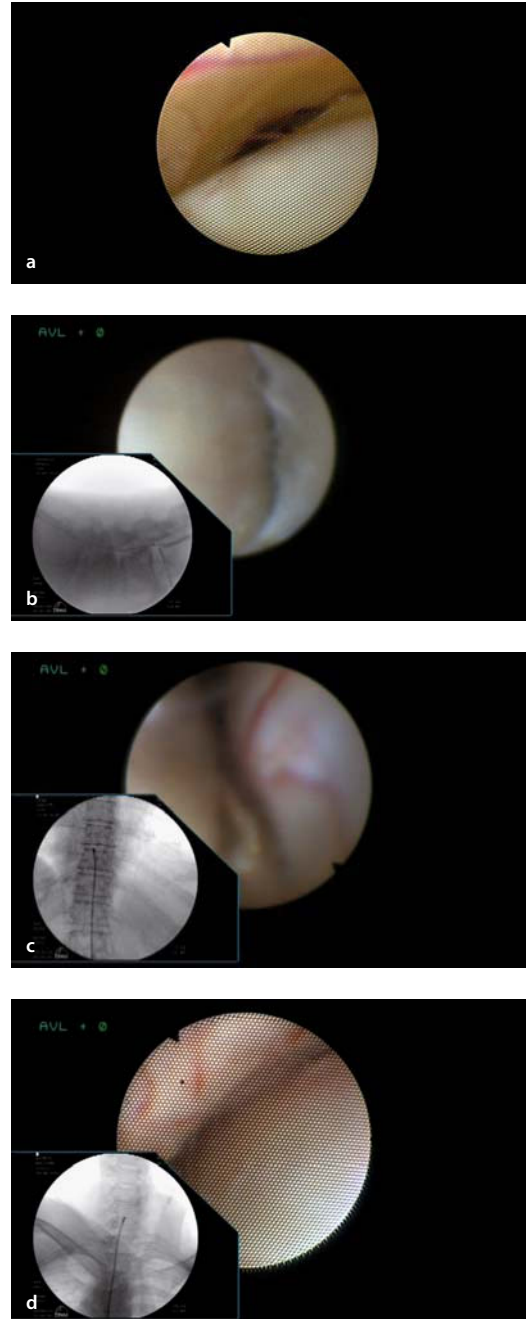
The yellowish color of the ligamentum flavum is caused by the elastic fibers arranged like a folding grille. The elastic connective tissue is a special form of dense connective tissue. It contains abundant thick elastic fibers with a parallel course. The ligamentum flavum can be identified in the endoscopic picture by its white to yellowish concave surface without visible vessels (■ Fig. 2.6a,b). Thickening of the ligamentum flavum can contribute to stenosis of the spinal canal.

### 2.2.5 Posterior longitudinal ligament

In the epiduroscopy of the ventral epidural space, in addition to the spinal dura mater, the posterior longitudinal ligament is easily visible. The relatively narrow ventral epidural space allows optimal visual imaging, especially in the thoracic and cervical segments of the spinal canal. Distinguishing the spinal dura mater and the posterior longitudinal ligament endoscopically is initially possible only on the basis of the differences in vascularization (■ Fig. 2.7a–d).



■ Fig. 2.6. a Ligamentum flavum (left side of the picture). b Ligamentum flavum

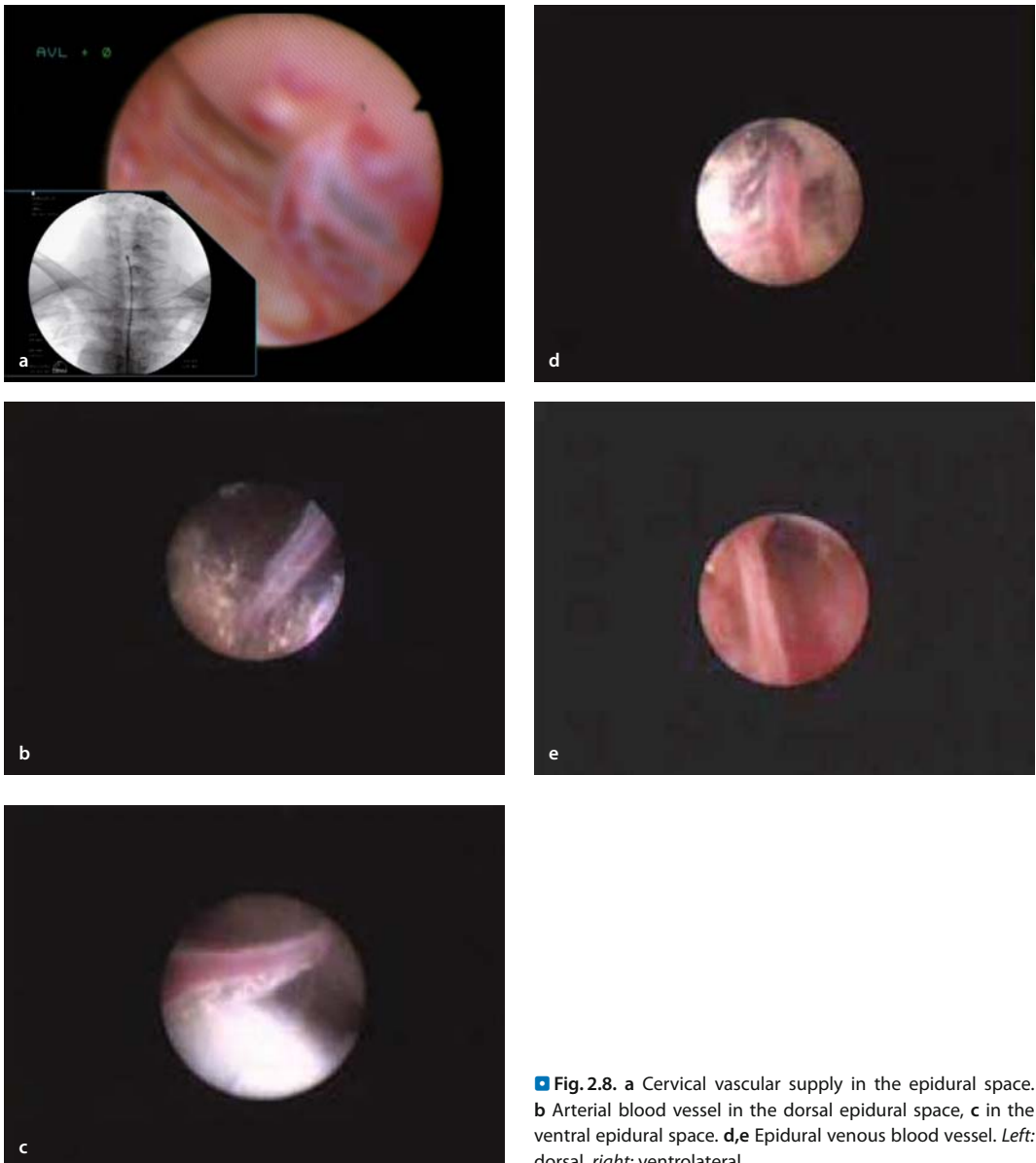


■ Fig. 2.7. a Longitudinal ligament (right side of the picture and fatty tissue, left side of the picture). b Posterior longitudinal ligament with bulging disc (Picture-in-Picture technique). c Spinal dura mater and posterior longitudinal ligament (Picture-in-Picture technique). d Longitudinal ligament (right side of the picture) and cervical spinal dura mater (left side of the picture, Picture-in-Picture technique)

In my experience, the primary distinguishing feature is »tenting,« the elastic tenting phenomenon, which is only positive for the spinal dura mater. In the endoscopic picture, the posterior longitudinal ligament appears white with a fibrous structure. The differences in the structure and color of the ventral epidural space can be used to assess which region of the epidural space the epiduroscopy is taking place.

## 2.2.6 Blood vessels

Both arterial and venous valveless epidural vessels pervade the epidural space (■ Fig. 2.8a–e). They can be easily distinguished from the pulsations that are easily visible. In the region of the left and right lateral ventral epidural space or in the right and left lateral dorsal epidural space small branches of the anterior or posterior spinal artery can be observed.



■ Fig. 2.8. a Cervical vascular supply in the epidural space. b Arterial blood vessel in the dorsal epidural space, c in the ventral epidural space. d, e Epidural venous blood vessel. Left: dorsal, right: ventrolateral

Obstructed epidural veins are primarily found in segments of the spinal canal that are growths and usually fibrotic. In epiduroscopic examinations of pregnant women in 2000, Igarashi observed that the epidural space in pregnant women had a denser vascular network than in women who are not pregnant. In Igarashi's study, the increase in vascular density in the epidural space occurred in the first trimester and could be observed until the last trimester.

## 2.3 Endoscopic pathology

### 2.3.1 Pathological endoscopic findings

A number of spinal pain syndromes are characterized by morphological changes in the epidural space, both in patients who have had surgery and those who have not.

Epidural pathological and anatomical changes in patients with spinal pain syndromes diagnosed via epiduroscopy include arachnoiditis, fibrosis, stenosis, ischemia, nerve root compression, perineural edema, obstructed veins or as chronic inflammatory processes, radiculopathy, sequesters, cysts or tumors.

Recent studies showed that degenerative changes and biomechanical processes, as well as biochemical processes are responsible for pain. In addition, Ohlmarker et al. used immunohistochemical examination techniques to determine that when autologous disc material comes into contact with nerve tissue, this causes immunological and inflammatory processes at the nerve root. These processes are considered to be immunocompetent cellular responses to exposed disc tissue. The detection of monoclonal antibodies against T-lymphocytes and macrophages appears to support this interpretation. Following the hypothesis that disc tissue is physiologically delimited from the immune system, it is assumed that exposing disc material can stimulate an autoimmune response in other tissues. In addition, clinical studies by Kuslich et al. showed that compressing or retracting a nerve root was only painful if nerve roots were irritated or inflamed. These results confirm the assumption that in the case of radicular

symptoms as well, not only purely mechanical changes of the nerve root contribute to pain.

No one mechanism is responsible for the onset and continuation of pain. Inflammatory and immunological processes exist with the activation of nociceptors in which mechanical impacts are involved to a greater or lesser extent. The nerve root can be compressed, deformed or stretched by the disc, facets joints or by the intervertebral foramina. These deformities of the nerve root or the dorsal spinal ganglion lead to changes in the local microcirculation of the blood flow. The tissue of the nucleus pulposus, which may protrude from a degenerated disc, causes a chemically induced radiculitis. These changes, combined with disturbed CSF circulation and insufficient fibrinolysis, lead to impaired nutrition of the nerve root, which ultimately results in changes of the nerve fibers and the cell body.

Epiduroscopy also allows clinical phenomena of epidural anesthesia with untypical spreading (missed segments) to be explained. The unfavorable result of the anesthesia may be caused by the pathological and anatomical anomalies following inflammatory processes, postoperative adhesions and/or fibroses. Korsten et al. found deposits in epidural areas even 36 days after epidural administration of 10% butyl-p-aminobenzoate (BAB). Richardson et al. performed endoscopy on patients with chronic severe low back pain and diagnosed epidural adhesions as the cause of pain in all the patients.

Epiduroscopy provides good conditions for diagnosing pathomorphological changes, which are often the source of pain, in the ventral or dorsal epidural space.

### Adhesions

Adhesions or adhesive areas are observed in our patient population relatively frequently (■ Fig. 2.9). Adhesions are easily visible epidural connective tissue structures that appear white and often bizarre. They range from delicate to robust. What is crucial is whether they are relevant for the patient's pain or not.

In an experimental investigation, it could be proven that epidural adhesions or fibroses can be induced after leakage of proteoglycans from the annulus fibrosus into the epidural space. This

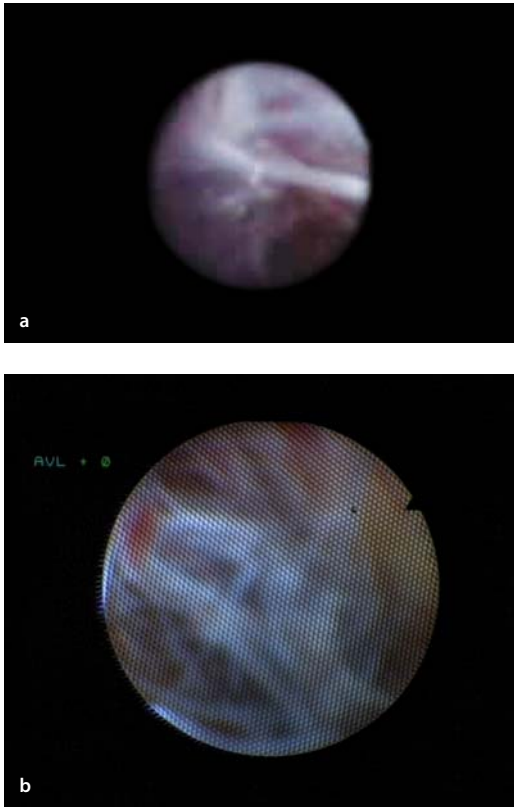


Fig. 2.9a,b. Epidural adhesions

explains that epidural adhesions can also occur even without prior surgery taking place. The ventral epidural leaflet is abundantly innervated with silent nociceptors with a high activation limit. These receptors do not become mechanosensitive until they have been sensitized by substances such as serotonin, histamine, bradykinin, prostaglandin and phospholipase A2. Afterward, inflammatory responses following protrusion of disc material through the ruptured annulus fibrosus may result in adhesions in the epidural space.

**Fibrosis**

Epidural fibrosis associated with stenoses, instabilities and herniated discs is a frequent diagnosis (Fig. 2.11, 2.12).

Through a regional inflammatory response with edema in the neurogenic structures, local circulatory impairment and fibrous adhesions the epidural fibrosis determines the symptoms. In addition, osteophyte growths as well as protrusions and herniated discs can stretch the posterior longitudinal ligament. Combined with inflammatory changes, this compression can also create changes in the permeability or in the transmural pressure of the endoneural capillaries at pressures as low as

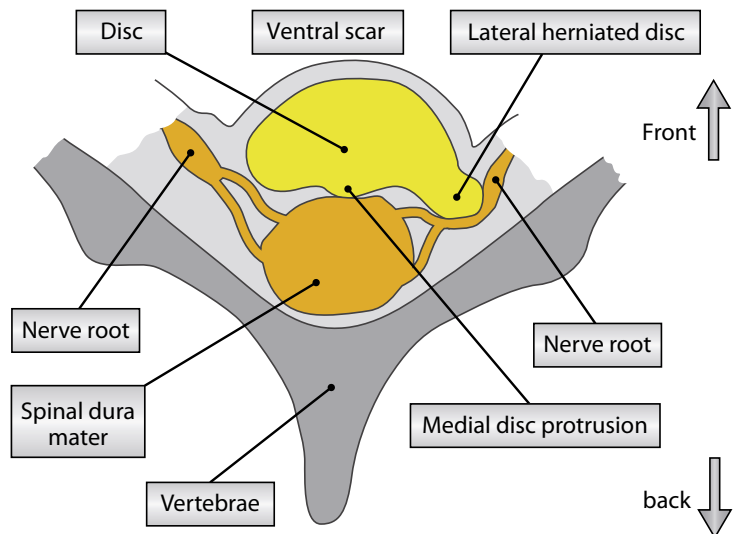
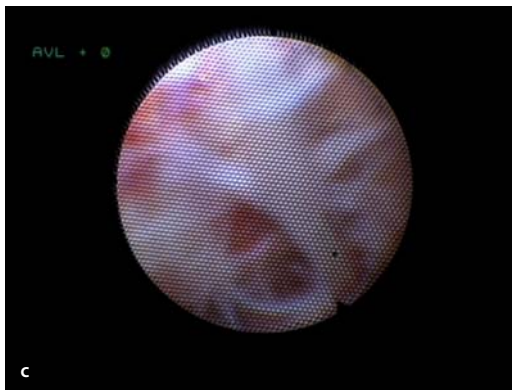
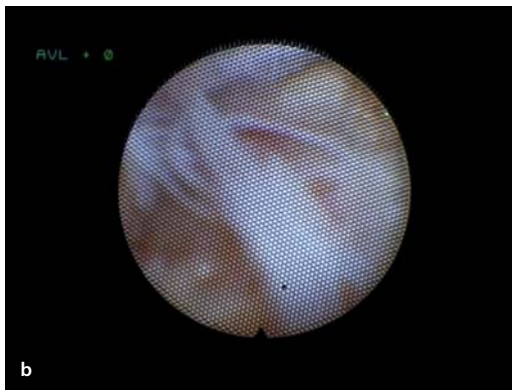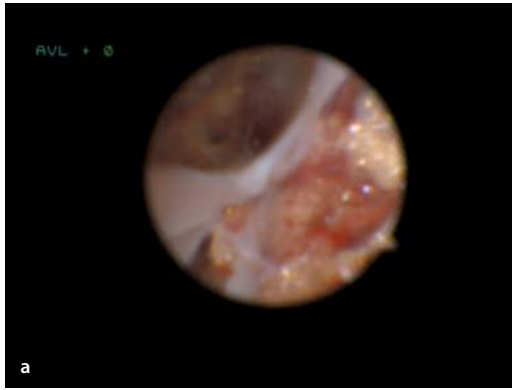


Fig. 2.10. Ventral scar

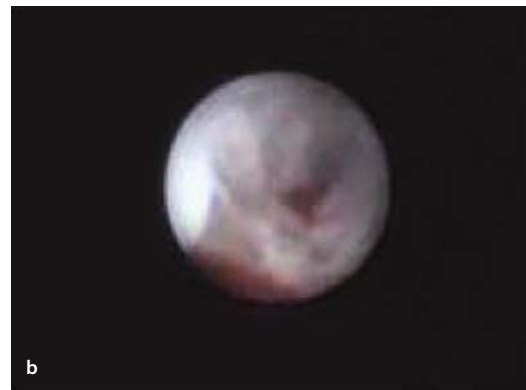
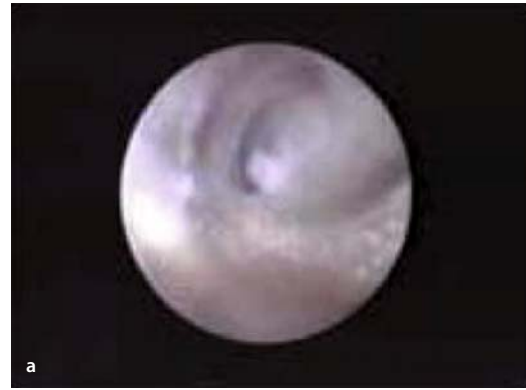


■ Fig. 2.11a–c. Epidural fibroses

50 mm Hg for 2 min, inducing edema. Ultimately, this process also triggers the strong edematous swelling that is visible during endoscopy, with elevated intraneural liquid pressure.

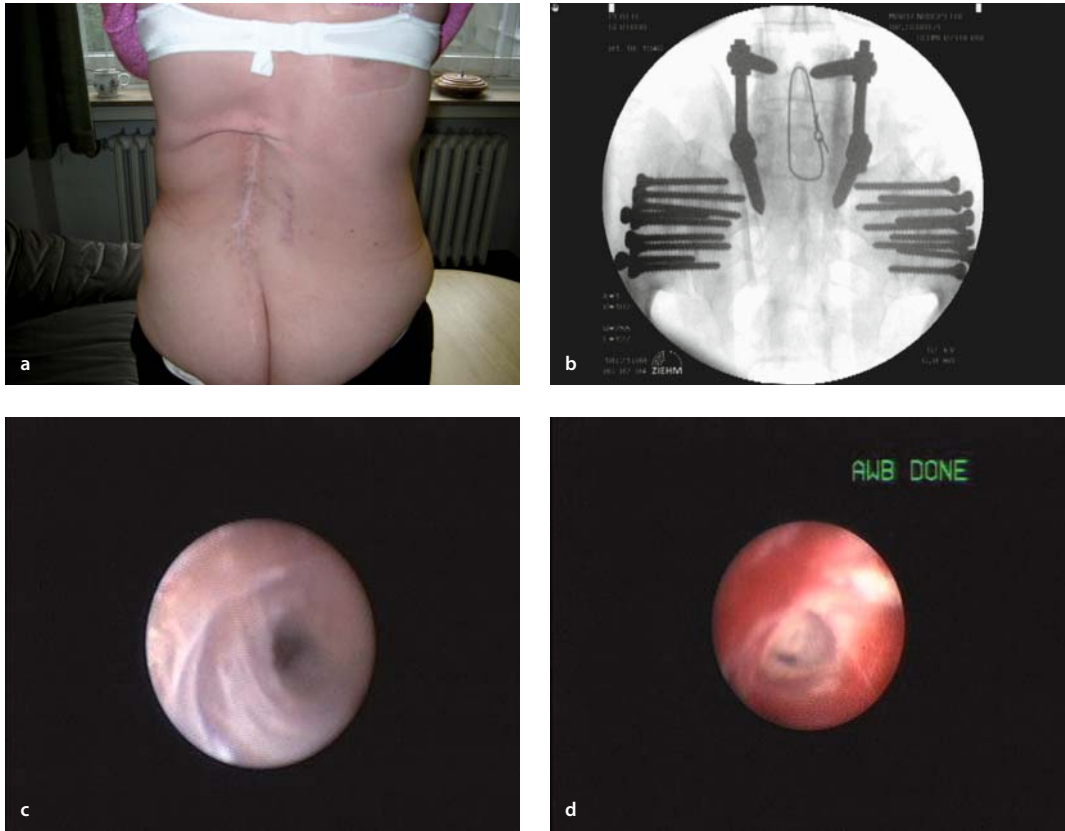
During endoscopy, pathologically changed nerve roots can appear to be avascular, most likely



■ Fig. 2.12a,b. Scars

due to the epidural adhesions surrounding them. The further process ultimately leads to an impairment of the epidural blood flow. According to studies by Brown, the venous blood flow in the affected segment can be disturbed at pressures as low as 5–10 mm Hg and the arterial supply can be reduced by 20 to 30%. The perfusion impairment also leads to a reduction in nutrition. Nutrition transport to the nerve root can be reduced by 20 to 30% at an applied pressure as low as 10 mm Hg. The inflammatory response promotes epidural fibrosis. By forming a sheath around the neurogenic structures and subsequent scarring, the scar tissue that has formed can lead to clinically remarkable signs of nerve root compression and localized back pain, as well as to reduced impulse conduction (■ Fig. 2.13).

The laser pain provocation test can be used to test the pain relevance of an endoscopically visible



■ Fig. 2.13a–d. (a) Forty-nine year-old woman after hemilaminectomy and spinal fusion and stabilizing surgery (FBSS) (b). Radiological documentation of implants in the L5/S1 region (c). The epiduroscopic images show fibrosis (d) and radiculitis (e).

scar. In the endoscopic picture, epidural fibroses, regardless of their severity, appear clear white and are generally avascular.

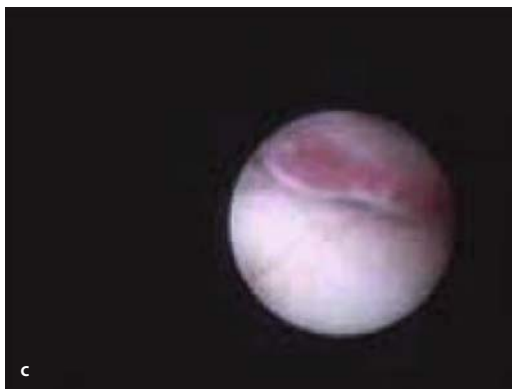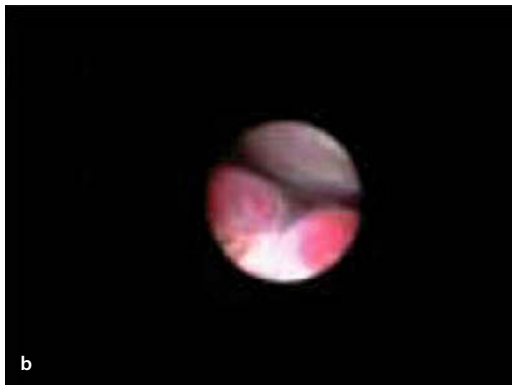
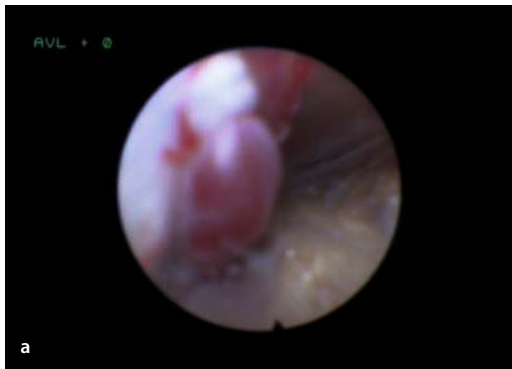### Vascular obstruction

Our epiduroscopic examinations of FBSS patients revealed veins and venous plexuses that were strangled by scar tissue and exhibited varicose changes. However, in our endoscopic investigations, these venous epidural obstructions (■ Fig. 2.14a–c) were not observed as frequently as had been assumed. In 120 patients we examined via epiduroscopy for FBSS in 2006, in the epidural segments from S1 to C4, only 12% showed a ventral scar with signs of obstructed epidural veins observed during endoscopy.

### Chronic inflammatory processes

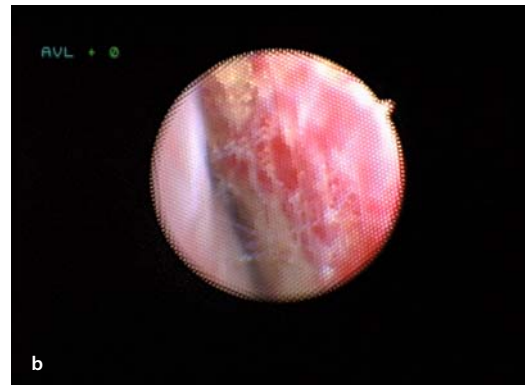
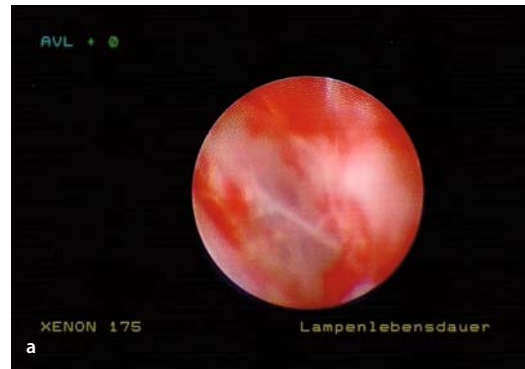
**Radiculitis.** Chronic inflammatory processes in the epidural space, such as epiduritis and radiculitis are depicted endoscopically as clearly edematously enlarged tissue structures. These inflammatory processes are the source of pain. The hyperemia renders the epidural structures bright red, similar to that of a localized radiculitis. It is important to mention the granulating and proliferative inflammatory form in this context. The granulating variety is characterized by the formation of a capillary-rich repair tissue and the proliferative form is characterized by sprouting of fibroblasts.

Studies involving the introduction of a Fogarty catheter in the spinal canal proved that inflating the balloon against the healthy dorsal nerve roots did not cause pain, but instead brought about hy-



■ Fig. 2.14a–c. a Venous epidural obstruction. b Obstructed vessels. c Compressed vein

pesthesis. However, if the balloon was inflated in the area of an inflamed nerve, the volunteer sensed radicular back pain. This experiment was repeated in various manners. Each time, the results showed that neural inflammation can cause pain, hyperalgesia and allodynia.



■ Fig. 2.15a,b. a Radiculitis. b Pronounced chronic inflammatory process (radiculitis) in the region of nerve root L3 right

In addition to the pathomorphological model of a mechanical spinal root irritation, a secondary inflammatory component at the spinal root is gaining in significance. It is a known fact that  $\text{TNF-}\alpha$  and Interleukin 1 (IL-1) are released as inflammatory mediators at the site of herniated disc tissue. An inflammatory response at the site of the involved nerve root is the result of the release of mediators. This phenomenon is easily visible via epiduroscopy (■ Fig. 2.15a,b) and plays a role in the choice of therapeutic approach.

**Epiduritis.** Epiduritis is a partial or full inflammatory process of epidural structures in the epidural space. In the endoscopic picture it is depicted with cardinal symptoms such as swelling, redness and a positive pain provocation test.

Young et al. (2001) reported on 24 patients who underwent epiduroscopy for chronic back

pain. All patients presented inflammation typical of epiduritis.

In contrast to these findings, relatively few of our patients undergoing epiduroscopy showed chronic inflammatory processes typical of epiduritis. Signs of inflammation such as elevated erythrocyte sedimentation rate, elevated C-reactive protein or elevated leukocytes were not regularly identified in patients with a diagnosis of epiduritis (■ Fig. 2.16a–c).

**Arachnoiditis.** The term arachnoiditis is widely used to describe both spinal and epidural adhesions. However, the term arachnoiditis actually refers to processes that take place subdurally on the caudal fibers and the nerve root sheaths. According to Day, arachnoiditis is a complex neuropathic pain event with a complex etiology (■ Fig. 2.17a,b).

As early as 1978, Burton broke down the course of arachnoiditis into three stages.

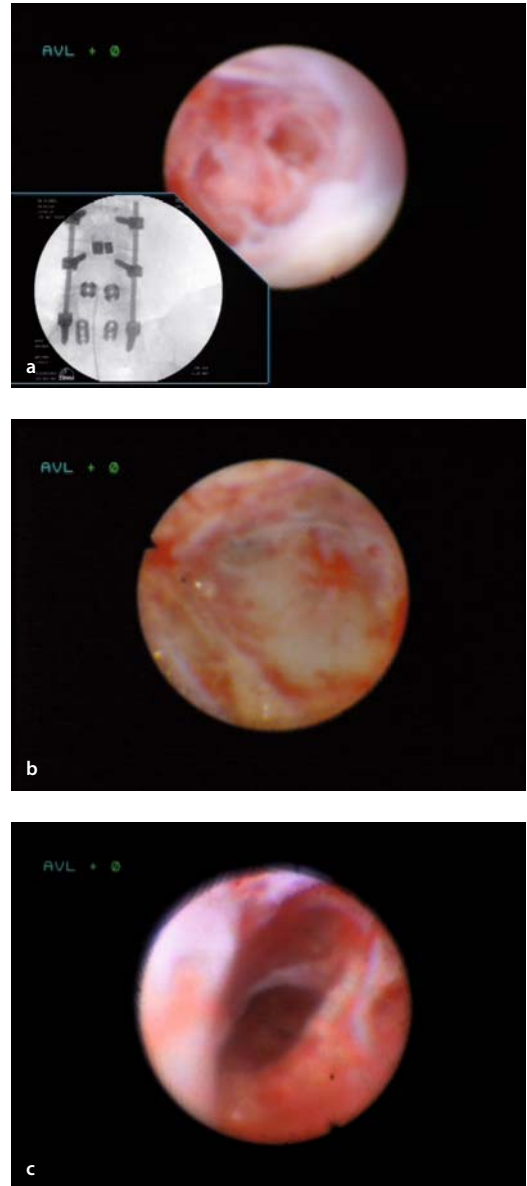
In the first stage, the pia mater is inflamed, accompanied by hyperemia and swelling of the caudal fibers and nerve roots (radiculitis).

Stage 2 is characterized by a proliferation of fibroblasts with deposition of collagen fibrils in the tissue. Tissue swelling is no longer present. The nerve roots become adherent to each other and the pia mater.

The third stage involves pronounced proliferation of the pia mater with a dense collagen structure. This leads to a constriction-like encapsulation of the atrophic and ischemic nerve roots.

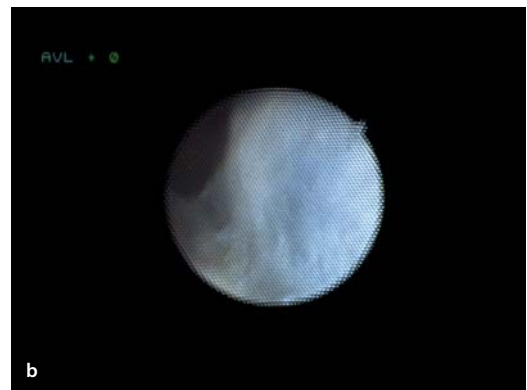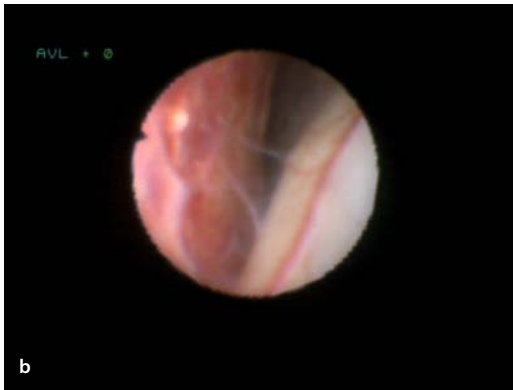
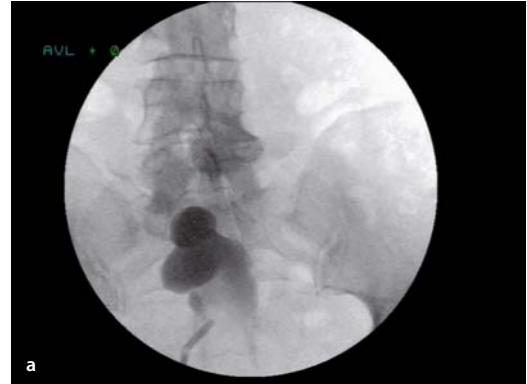
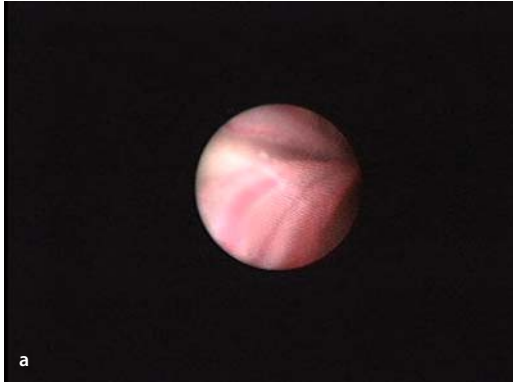
In the case of arachnoiditis and perineural nerve sheath fibrosis, the spinal dura mater appears thickened and the tissue appeared to have increased vascularization. In the case of disc protrusions, local veins can be subjected to compression, which renders the site an obstructed and dilated appearance. The ensuing reduced neural blood supply leads to a reduction of the nerve volume with the formation of perineural fibrosis. The occurrence of ischemic pain is explained by this situation.

The inflammatory responses in the epidural space occur in stages. The first stage involves an inflammatory response with hyperemia and swelling, for example of the nerve root, which arise from the collagen connections between the nerve root and the arachnoidea. In the next stage, a proliferation of fibroblasts causes adhesive arachnoidi-



■ Fig. 2.16a–c. Epiduritis

tis, whose course can include atrophy of the nerve root. Warnke and Mourgela claim that adhesive lumbar arachnoiditis is no longer a devastating diagnosis. A new endoscopic treatment of impaired CSF flow restores physiological response paths so that a long-term improvement in the clinical condition can be achieved.



■ Fig. 2.17a,b. a Arachnoiditis. b Arachnoiditis

■ Fig. 2.18a,b. a Patient L.E. with epidural sacral cysts S1/S2. A dural injury following laminectomy caused an arachnoidal cyst (radiological imaging). b Patient L.E. with epidural sacral cysts (endoscopic imaging)

### Other endoscopic findings

**Xanthosis.** Heavner et al. reported on the presence of yellow pigment (xanthosis) in the epidural space of a patient with chronic painful radiculopathy. The epiduroscopic findings reported by the authors in the area of nerve roots L5 and S1, associated with radiculopathy, included diffuse perivascular yellow pigments and increased vascularity and increased presence of sheets of fibrous tissue. Heavner et al. claim that this was a *novo* epiduroscopy finding.

We have observed similar findings in our own patient population; however, these have been incidental findings without pain relevance.

**Ligamentum flavum hypertrophy.** Sairyo et al. observed that fibrosis and scar tissue formation is responsible for hypertrophy of the ligamentum flavum. In addition, inflammation-related gene ex-

pression was discovered in the ligamentum flavum. Hypertrophy of the ligamentum flavum may possibly be prevented with anti-inflammatory drugs.

Delgado-López et al. reported that calcification of the ligamentum flavum (CLF) is a rare disease that mainly occurs in middle or advanced aged Japanese women. Various clinical and radiological features distinguish CLF from ossification of the ligamentum flavum.

**Cysts of the ligamentum flavum.** Cysts of the ligamentum flavum in the lumbar segments of the spinal canal are rarely observed. Bloch et al. reported on patients who underwent surgery for cysts in the area of the ligamentum flavum. These cysts can also be visualized in CT and MR imaging and can lead to root compression (■ Fig. 2.18a,b).

### 2.3.2 Our own results

In our endoscopic examination of dorsal and ventral sections of the vertebral segments from L5 to C3, 61.2% of our 1130 patients, most of whom had back pain, had pathological findings, including adhesions, fibrosis, stenosis, inflammatory processes, pronounced scar tissue and sequesters.

Our results coincide with the limited results in the literature: In our patient population, patients with FBSS had considerably lower or absent shares of fat and a clear reduction in vascularization in the affected part of the epidural space.

We studied a group of patients with FBSS between 1995 and 2000. During this period, we carried out 560 epiduroscopic examinations. In addition to considerably limited vascularization, we also observed a highly reduced proportion of fatty tissue. In the majority (70%) of our FBSS patients, a ventral epidural scar was identified as the morphological cause of pain. In 19% of the patients undergoing epiduroscopy, a scar as well as indications of chronic inflammatory processes were found in the dorsal epidural space.

In 2004, we carried out an evaluation of epidural diagnostics (S1-C3) in 120 pain patients with failed back surgery syndrome (M 96.1). There were no urgent indications for open intervention in any of the FBSS patients from neurological, functional or imaging points of view. In addition to the classical signs and symptoms of FBSS, all of the patients had been assigned to chronic pain Level III according to the Mainz Pain Staging System (MPSS), the highest level of pain chronification. In addition to primarily pronounced epidural fibrosis with stenosis, in the region from S1 to C3 adhesions and chronic inflammatory processes were also observed.

Summary of epiduroscopic findings of 120 patients with failed back surgery syndrome (Iserlohn Pain Clinic, 2004):

- 61% of the patients presented pronounced fibrosis with stenosis in the ventrolateral epidural space.
- 18% of the pain patients presented epidural fibrosis as well as a chronic inflammatory process typical of radiculitis.
- 15% of the pain patients presented adhesions and/or fibrosis in the dorsolateral epidural space.
- 13% of the patients examined presented a chronic inflammatory process (epiduritis).
- In 11% of the patients undergoing epiduroscopy, findings were unremarkable.

A recent study of 51 patients with exclusively lumbar spinal pain syndrome carried out in 2007 showed that 9.8% of the epiduroscopic examinations of segments S1-L3 showed signs of an inflammatory process.

Inflammatory changes could be confirmed through histological examination of excisional biopsies. In the context of this epiduroscopy study, fibrosis was discovered in 11 patients (21.6% of the patient population). The fibrosis was localized exclusively in the left and right dorsal part of the epidural space. Fibrosis in the left dorsal epidural space was most frequently observed in the area of L4/L5 and L5/S1, while the incidence of fibrosis in the right dorsal area was highest in the area of L4/L5 (■ Table 2.1). Signs of epidural vascular obstruction were detected in only one patient in the overall group during epiduroscopy. The vascular obstruction was located in the right dorsal section of the epidural space at the level of L4/L5.

In contrast to the unremarkable findings in patients who had undergone surgery (e.g. patients with FBSS), we observed reduced or absent shares of fat, considerably reduced vascularization, epidural adhesions and fibrosis. This corresponds to the rarely reported descriptions in the literature.

Epiduroscopic features for failed back surgery syndrome:

- Considerably reduced proportion of fat
- Reduced vascularization, in some cases vascular obstruction
- Adhesions
- Fibrosis
- Chronic inflammatory processes

After percutaneous epidural multiple punctures with a Tuohy needle, birefringent particles with characteristic multinuclear foreign body giant cells were detected in the histology (■ Fig. 2.21a–c) of the epidural tissue specimens in our patients undergoing epiduroscopy. This outcome underscores

the necessity of follow-up epiduroscopic studies regarding epidural multiple punctures and the behavior of epidurally injected fluids and continuous epidural long-term infusions.

However, experience with epiduroscopy is required in order to interpret the pathological findings precisely. Igarashi et al. (2004) performed epiduroscopy on 58 patients with degenerative lumbar spinal stenosis. The authors concluded that the epiduroscopic findings corresponded to the clinical symptoms. The 1130 epidural pathological changes diagnosed by us on the basis of epiduroscopy up to 2005 correlated with the clinical findings of the patients in 76.8% of the cases.

The clinical epiduroscopic results are not yet sufficient enough to provide a detailed response to the open anatomical issues, because we have not yet completed the comparative endoscopic studies on the anatomy of the epidural space on cadavers. However, preliminary results show that in a number of patients, partially occluding connective tissue structures and membranes have been discovered endoscopically at various levels of the epidural space whose origin cannot be clearly determined.

## 2.4 Histopathology

With regard to histopathological studies of the epidural space, we can only report on our own patient population. Our histological sections allow us to make statements that serve endoscopic diagnostics and quality control. Please consult the textbooks on histology and cytology for more detailed information on the foundations of histopathology.

### Histopathological features

The inflammatory response is a major factor in the generation of pain. It involves a complex response of the vascular connective tissue apparatus to tissue damage. The acute phase is marked by hyperemia with exudation as a serous inflammation (blood plasma), hemorrhagic inflammation (erythrocyte extravasation) and purulent inflammation (emigration of leukocytes). In contrast to the acute inflammatory response, the chronic stage of the inflammation is primarily characterized by the proliferation of

connective tissue cells, histiocytes and proliferation of capillaries, i.e. granulation tissue. The epidural inflammatory process varies widely in appearance and functional form. It generally involves connective tissue with a proliferation of fibroblasts as the formation of fibers, scar tissue, histiocytes and capillary sprouts. Lymphocytes and plasma cells or mast cells or polymorphonuclear leukocytes may also be assigned to this basic tissue. In accordance with histological nomenclature, the primary cell type is divided into a) cell-proliferating granulation tissue with abundant lymphocytes and histiocytes, b) granulation tissue in the narrower sense (capillary sprouts and fibroblasts) and c) infiltrating granulation tissue. As a consequence of the inflammation, healing of the defect (scarring) occurs.

### Histological studies

The rule that all surgically removed tissue should be histologically examined also applies to the field of invasive-interventional pain medicine. This serves to enhance quality control for epiduroscopic procedures and provides diagnostic certainty for the patient.

For this reason, we recommend that endoscopic pain diagnostics include targeted endoscopic biopsy under good visual conditions for histological examination.

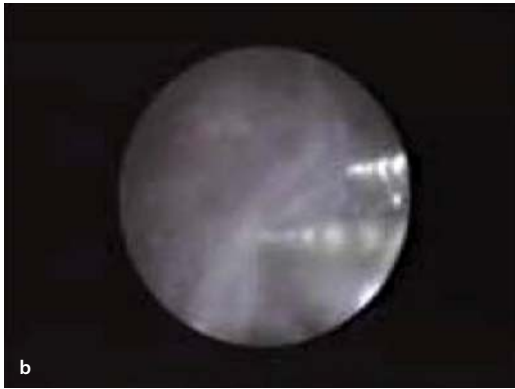### Biopsy

In order to take epidural tissue specimens, appropriate microsurgical instruments can be introduced and used via the epiduroscope's working channel. A number of biopsy forceps are available for extracting tissue samples under epiduroscopic visualization. Flexible biopsy forceps are available in various lengths and diameter depending on the epiduroscope and tissue (■ Fig. 2.19a,b and ■ Fig. 2.20a,b). The forceps are opened and closed via a control cable. To avoid injury to the biopsy canal through the barb of the forceps, for epiduroscopy, barbless forceps should be used.

For histological diagnostics, we take tissue samples from the epidural space with long, flexible graspers (for example, oval, flexible, working length between 60 and 160 cm with a diameter of 1.0 mm).



a

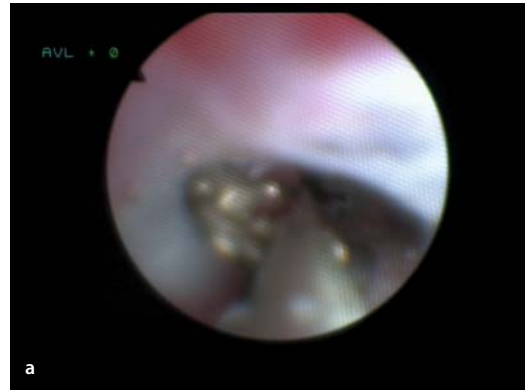

b

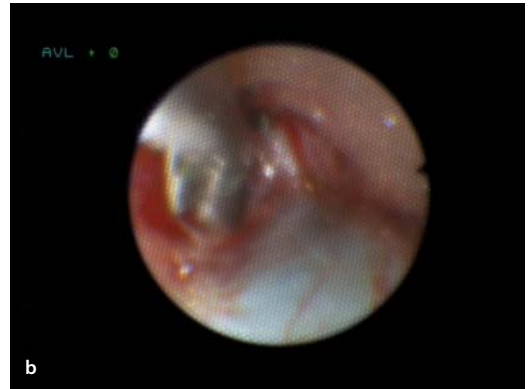
**Fig. 2.19a,b.** **a** Flexible biopsy forceps (KARL STORZ, Germany) in the working channel of the epiduroscope. **b** Flexible biopsy forceps (KARL STORZ, Germany) in the epidural space

Due to the vulnerability of the epidural structures, the utmost care must be taken to ensure that the biopsy is performed under good endoscopic vision and that no blood vessels or the spinal dura mater or other structures are injured. If vessels are damaged during a biopsy, they can be coagulated with laser fibers via the working channel. The biopsy procedure, especially in the thoracic and cervical part of the spinal canal, must be performed carefully and conscientiously. Particular care and attention are recommended in the case of inflammatory processes and in the area of the nerve root.

Tissue biopsy, especially in the vulnerable areas of the epidural space is often risky and problem-



a



b

**Fig. 2.20a,b.** **a** Flexible biopsy forceps in the epidural space. **b** Flexible biopsy forceps in the thoracic and ventral epidural space. Detaching adhesions between the spinal dura mater and the posterior longitudinal ligament

atic. Thus, in order to protect the patients, in our own work we do not perform high-risk biopsies, especially in the thoracic and cervical areas. This should be borne in mind when assessing the data we have provided on the histological situation during epiduroscopy.

#### 2.4.1 Histological findings

In the following box we present histological findings from biopsies taken from our patients via epiduroscopy. Courtesy of Prof. Böhm and Prof. Friemann of the Lüdenscheid Hospital's Department of Pathology.



- 398104: Fatty tissue from the epidural space left at the level of C5-C4 with discrete perivenous fibrosis and small non-calcified lamellar bone fragments outside the cluster.
- 776497: Complete, low-grade chronic inflammation with a regeneration phase. No specific inflammation. Nothing atypical. No indication of a malignant process.
- 891199: Accumulations of fibrin with bleeding and slight inflammatory infiltration suggestive of less pronounced acute epiduritis.
- 209599: Accumulations of fibrin and pronounced, primarily acute inflammation in the material submitted without any accompanying description. No indications of malignant cells.
- 316800: The histological picture of the two tiny tissue particles from the epidural space corresponds to a chronic recurrent inflammation. No indications of malignant growth. Does this histological picture correspond to the clinical findings?
- 826101: Groups of peripheral nerve fibers (biopsy taken from epidural space L3-L4). No specific inflammation.
- 853501: Apparently a localized, very loose connective tissue with isolated capillaries and tiny peripheral nerve fibers in the tissue submitted to us, taken from the epidural space at the level of L5.
- 1021702: Low-grade fibrosis in the submitted tissue taken from the dorsal epidural space. In addition, tiny birefringent particles with foreign body reaction can be seen. No indications of malignant growth.
- 759702: Low-grade, chronic, edematous, granulating inflammation. No specific inflammation. No indication of a malignant process (biopsy left epidural space at the level of S1).

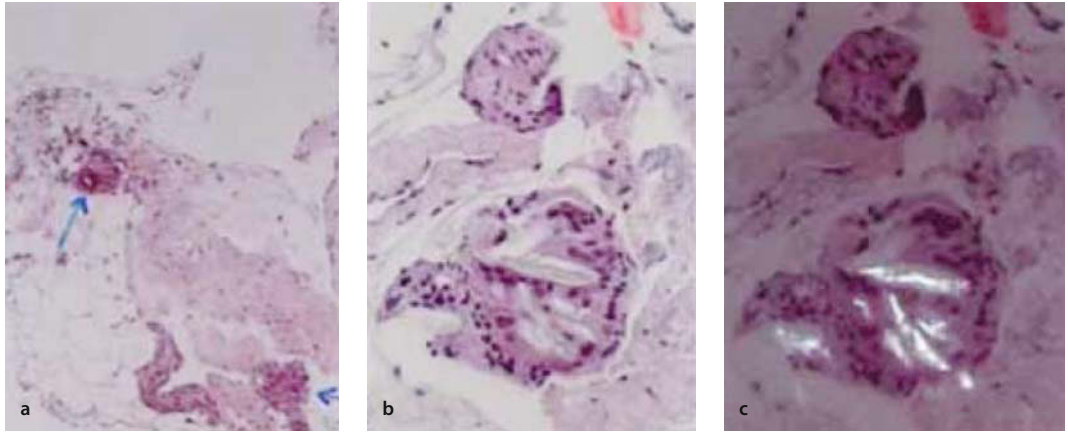
In 2004, 120 pain patients with failed back surgery syndrome underwent epiduroscopic diagnostics and epidural analgesic therapy (EAT) at our pain clinic. In each case, endoscopy was used to examine the dorsal and ventral part of the epidural space. To confirm diagnosis, 120 biopsies were taken from the epidural space. Seventy percent of the histological examinations revealed scarring of the connective tissue structures. Twenty percent of the biopsies showed lesions of the tissue structures indicative of chronic inflammation and 10% presented a normal histology.

In 2007, we assessed 46 histological examinations in 51 patients undergoing epiduroscopy as part of a comparative study. Only 4 of the 46 patients did not have pathological findings (8.7%). In 42 patients in whom a histological examination of the biopsied epidural tissue was carried out, fibrosis was identified in 28 patients (66.6%). In addition to vascular sprouting (28.2%), fatty tissue (26%), fibrous structures (21.7%) and collagen fibers (13.0%), in 4.3% of the biopsies, signs of inflammation could be detected in the histology.

In a number of biopsies (> 600) taken from the 1600 patients undergoing epiduroscopy at our pain clinic, in 22% of the cases changed tissue structures due to inflammation typical of epiduritis or radiculitis could be identified in the histological examination. The histological findings correspond to the epiduroscopic diagnosis.

### 2.4.2 Microbiological diagnostics

When using endoscopy to confirm diagnosis of conditions such as epiduritis, arachnoiditis, radiculitis or other inflammatory changes in the epidural space, a catheter is used to collect smears from the appropriate part of the epidural space through the working channel of the epiduroscope. Approx. 2–3 cm is cut off the contaminated tip of the catheter with a sterile scissors and placed in a sterile tube. Care must be taken to prevent the catheter tip from coming in contact with liquid transport media or blood culture bottles, which would render a semiquantitative assessment impossible.



■ **Fig. 2.21a–c.** Following several epidural punctures, the histological specimen shows birefringent particles with characteristic multinuclear foreign body giant cells. (Image courtesy of Prof. Böhm, Hospital Lüdenscheid, Department of Pathology)

Between January 1, 2005 and December 31, 2006, 288 bacteriological smears obtained at our pain clinic were submitted to the Institute for Laboratory Medicine headed by Dr. H.G. Wahl at Lüdenscheid Hospital as part of epiduroscopic examinations. The microbiological end findings of all the bacteriological examinations were negative.

**Table 2.1.** Examples of findings elicited simultaneously, including histological findings (Lüdenscheid Hospital, Department of Pathology, Prof. Friemann), MRI (Department of Radiology, Prof. Beyer, Hagen), EDS findings (Dr. Schütze, Pain Clinic Iserlohn) and neurological findings (Dr. Rother, ZIMT, Dortmund).

Patient Diagnosis	Histological findings	EDS findings	MRI findings	Neurological findings
401064645 Diagnosis: M 51.2 PSA 7 PSD 2 	Fatty tissue and scar tissue (epidural space at the level of L4 vertebra right) Findings suggest adhesion in the epidural space	Extensive epidural adhesions with partial fibrosis in right lateral segment L5-L4, inflammatory process in L4	Slightly pronounced medial disc protrusion in segment L5/S1.	No pathological findings
401064992 Diagnosis: M 51.2 PSA 6 PSD 3 	Vascularizing and higher-grade edematous loose adhesions in epidural space at the level of T11.	Epidural adhesions in segment T4, T11 and C6-C4.	Postural impairment in the region of the cervical spine, disc degeneration at C6-C7 with ventral disc protuberance, indicated protuberance of the disc at C6-C7 dorsal.	Remarkable unsteady gait with unsteady coordination tests.

Table 2.1. Fortsetzung

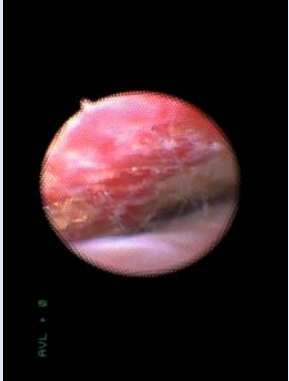


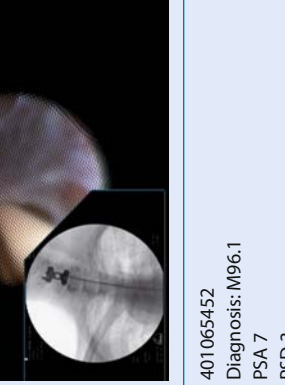
Patient Diagnosis	Histological findings	EDS findings	MRI findings	Neurological findings
<p>401065978 Diagnosis: M 96.1 PSA 8 PSD 4</p> 	<p>Vascularizing connective tissue and fatty tissue with chronic inflammatory response (epidural space at the level of lumbar vertebra 4).</p>	<p>Epidural adhesions and partial fibrosis in segments L5-L3, stenosis of the spinal canal at segment L5-S1, inflammatory changes in segment L4 left (radiculitis)</p>	<p>Scar formation after hemilaminectomy at L5-S1, encapsulation of the nerve root S1, protrusion at L4-L5.</p>	<p>Acute L5 root irritation left with radicular pain radiating into the left leg</p>
<p>401063049 Diagnosis: M48.06 PSA 7 PSD 1</p> 	<p>Medium-grade fibrosis in the epidural space left at the level of L5.</p>	<p>Epidural adhesions and stenotic fibrosis in segment S1-L5.</p>	<p>Lateral narrowing of the recess, broad-based protrusion with relative stenosis L4-L5-S1.</p>	<p>Spinal canal stenosis at L2-L4 with pseudoradicular pain radiation</p>

Table 2.1. Fortsetzung

Patient Diagnosis	Histological findings	EDS findings	MRI findings	Neurological findings
401064585 Diagnosis: M48.06 PSA 8 PSD 5 	Vascularizing adhesion from the epidural space at the level of lumbar vertebra 4 with discrete phlebosclerosis (from segment L4/L5)	Extensive epidural adhesions in segment L4/5, clearly adhering to the spinal dura mater, adhesions and fibrosis in segment S1-L5	Proper visualization of the discs	Proprioceptive reflexes equal & active bilaterally Straight leg raising sign negative bilaterally, sensory impairment detectable Knee jerk and ankle jerk not active, Mood: depressed
401057250 Diagnosis: M 51.2 M 54.5 PSA 7 PSD 2 	Adhesions with weak chronic inflammatory response at the level of lumbar vertebra 3 in the epidural space.	Epidural adhesions with extensive fibrosis in segment L4-L2 with chronic inflammatory process in segment L3 left laterally.	Lumbar disc degeneration with Modic I changes, lumbar protrusions L4/5 and L5/S1, stenosis of the lumbar spinal canal	Functional stenosis of the spinal canal with pseudoradicular radiating pain

Table 2.1. Fortsetzung

Patient Diagnosis	Histological findings	EDS findings	MRI findings	Neurological findings
401063485 Diagnosis: M 96.1 PSA 9 PSD 4	 <p>Hyalinized scar tissue without inflammatory infiltrates, corresponding to an adhesion (epidural space)</p>	<p>Epidural adhesions with partial fibrosis in segment C6-C4 left laterally Stenosis of the spinal canal in segment L5</p>	<p>Flat disc protrusion L4-L5 and L5-S1, with swelling of the ligamentum flava</p>	<p>Chronic pain syndrome with cervicocephalgia, History of surgery for herniated disc L5/S1 with stenosis of the spinal canal and spinal claudication. Possible damage in segment C7 right</p>
401065452 Diagnosis: M96.1 PSA 7 PSD 3	 <p>Dense connective tissue similar to that of the area of a ligament structure and vascularizing fatty tissue, possibly from an adhesion in the epidural space at the level of lumbar vertebra 5. Unspecific inflammatory infiltrates at the level of L5.</p>	<p>Extensive epidural adhesions with stenotic fibroses at L5, pronounced stenosis of the spinal canal in segment L5-S1.</p>	<p>Disc degeneration at L1-L5, circumscribed disc bulging at L4/L5 with impression of the dural sac right.</p>	<p>Peroneal nerve palsy right, radicular pain syndrome, gait impairment, unable to perform toe and heel raise on right</p>

Diagnostic key:

M 48.06 = Spinal stenosis; lumbar region; M 51.2 = Other specified intervertebral disc displacement; M 96.1 = Postlaminectomy syndrome, not elsewhere classified; PSA Pain score at admission (0-10 NRS); PSD Pain score at discharge (0-10 NRS)

## Additional Imaging Diagnostics

- 3.1 Computed tomography (CT) – 38
- 3.2 Magnetic resonance imaging (MRI) – 38
- 3.3 Myelography – 39
- 3.4 Discography – 39
- 3.5 Our own clinical results – 39

The increasing popularity and improved quality of sectional imaging techniques (CT, MRI) in radiology, conventional X-ray diagnostics have become considerably less significant. On the one hand, X-ray technology continues to be the diagnostic gold standard for ruling out fractures, quantifying a potential spondylolisthesis or identifying vertebral anomalies. However, its inability to provide clear images of soft tissue and the projection-related distortion or the superimposition of anatomical structures limit its use in some areas. On the one hand, modern radiological imaging techniques provide high-quality and detailed images. On the other hand, their diagnostic reliability for conditions such as radiculopathy is often unsatisfactory. Another disadvantage of radiological diagnostics is that it cannot distinguish the reasons for the pain or the deviation from the norm for trauma and age.

When diagnosing pathological changes in the vertebral canal, mainly sectional imaging techniques such as magnetic resonance imaging (MRI) and computed tomography (CT) are used. CT and MRI examinations produce nearly the same quality of images. However, they differ in the sagittal plane, which is provided by MRI. According to Bradley, MRI is the diagnostic procedure of choice for complicated lumbar pain, replacing myelography and computed tomography in recent years. Sectional imaging is indicated in suspected cauda equina syndrome, progressive segmental muscular dystrophy, infection, tumor and fracture.

However, if there are no warning signs, there is no urgent indication for imaging within four weeks. Evaluating diagnostic tests for spinal pain syndromes is complicated by the fact that the clinical picture is often defined on the basis of a combination of clinical symptoms and radiological findings.

### 3.1 Computed tomography (CT)

Computed tomography (CT) permits detailed differentiation of bony structures and disc tissue. When directly compared to MRI examination, the sectional imaging procedure computed tomography is better suited for analyzing bony structures. When planning surgical intervention, computed

tomography can also be used in combination with intrathecal application of contrast medium (post-myelographic computed tomography).

However, computed tomography has the disadvantage of a much higher exposure to radiation than regular radiographic procedures. This must be taken into account when indicating the procedure, whereby the good reliability of computed tomography justifies this procedure if the established indications are present.

In our computed tomography examinations, for example, well vascularized scar tissue shows better enhancement than dense layers of old fibrous scar tissue. For this reason, a postoperative computed tomographic image with the diagnosis of a recurrent herniated disc should be taken with a grain of salt, because most symptoms are not caused by a new herniated disc but by scars and adhesions. This was also the case for our surgical patients.

### 3.2 Magnetic resonance imaging (MRI)

Magnetic resonance imaging (MRI) can provide an in-depth picture of the sacral, lumbar, thoracic and cervical spine. According to the Agency for Healthcare Research and Quality (AHRQ Publication No. 01-E048, 2001), MR examination currently provides the best resolution of soft tissue structures in the sagittal and axial planes. When using STIR and T2-weighted fast spin echo sequences, clinically relevant findings can be reliably diagnosed with MRI. The advantages of MR examination include excellent imaging of the spinal cord, the dorsal or ventral roots of the spinal nerves and the paravertebral soft tissue.

Epidural scar tissue and disc material can be distinguished with a contrast-enhanced MRI. For this reason, in suspected recurrent disc herniation, carrying out a T1-weighted sequence with and without contrast agent is recommended.

MRI diagnostics are used especially often in patients with chronic back pain in order to diagnose or rule out radiculopathies, sciatica, cauda equina syndrome, herniated disc or spinal canal stenosis. During magnet resonance tomography, the signal-intensive cerebrospinal fluid creates a myelographic



### 3.5 · Our own clinical results

image of the dural sac. The spinal cord contrasts excellently against the cerebrospinal fluid and the dural sac stands out from the epidural space.

As with an acute radicular clinical finding with deficits, chronic epidural pain syndrome should be clarified with the use of an appropriate sectional imaging technique, such as MRI or computed tomography.

Richardson showed that epiduroscopy can be used to find pathologies that were not detected in an MRI and for which the epidurography that had been performed did not provide reliable results. The group led by Geurts reported on 20 patients in whom 19 showed adhesions via epiduroscopy. In 8 patients, 6 of whom had never undergone surgery, these were not detected with earlier magnetic resonance imaging.

Stand-up MRI promises to considerably improve MR imaging. The new MRI stand-up apparatus allows examination of the spine with the patient in a recumbent, slanted or upright position. In addition, scans of the cervical and lumbar spine can be carried out in hyperextension, hyperflexion and in scoliosis position.

Additional imaging procedures should be carried out based on the clinical course of the pain or the planned therapeutic treatments.

### 3.3 Myelography

Despite the fact that myelography offers the examiner information about the epidural structures, it has become less significant due to the widespread use and acceptance of magnetic resonance imaging or myelo-CT (computed tomography) on the one hand, and because of its invasive nature, on the other.

The quality of the examination also depends on the experience of the examiner and the compliance of the patient.

Its invasive nature makes myelography a procedure characterized by potential risks and adverse effects. Although the contrast agents used in the procedure are water soluble and can be completely resorbed, an intolerance to the agent can occur.

It is advised to follow up a CT or MRI examination with myelography only if there is a discrepan-

cy between the clinical signs and symptoms and the radiological findings. In combination with postmyelographic computed tomography, this diagnostic procedure is particularly valuable for the planning of a surgical procedure.

### 3.4 Discography

For suspected discogenic pain sources with supporting morphological evidence, contrast agent imaging of the interior cavity of the disc (discography) may be indicated. This is an invasive procedure with corresponding risks. In some cases a postdiscographic CT scan may be indicated.

Discography is often used to identify an intact annulus fibrosus prior to percutaneous interventions. Repeated discography may be indicated if the intervertebral disc that is responsible for the patient's symptoms cannot be unequivocally defined. Performing discography of the affected vertebral disc can also be helpful in the case of a positive test with pain-provoking injections in order to decide whether in the given case a segment-conserving or segment-fusing procedure is indicated.

### 3.5 Our own clinical results

Another difference between epiduroscopy and other imaging techniques is that epiduroscopic examination is carried out with the examiner responding to feedback by the patient. The major differences between epiduroscopy and MRI, particularly in the assessment of radiculopathy, are presented in [Table 3.1](#).

In a study comparing the diagnostic significance of epiduroscopy and that of magnetic resonance imaging, 51 patients were studied from 2004 to 2006 at our pain clinic. The patients underwent epiduroscopy and at the same time, MR examination, at our pain hospital for low back pain (51% lumbago, ICD-10 M54.5; 27.4% postlaminectomy syndrome, ICD-10 M96.1; 21.5% lumbago with sciatica, ICD-10 M54.4).

As part of the epiduroscopic diagnostics of the lumbar segments S1-L3 of this study, in 62.7% of the pain patients there were adhesions with partial

fibrosis, in 25.4%, adhesions with pronounced fibrosis, in 21.6%, only fibrosis, in 9.8%, radiculitis, in 4.2%, an inflammatory process, and in 2%, signs of epidural vascular obstruction. In 31.4% of the cases, epidural spinal canal stenosis was diagnosed during epiduroscopy.

In the MRI of the 51 pain patients in the study, in the same segments disc protrusions were identified in 68.8% of the cases, and fibrosis or scarring was found in 21.5% of the cases. In 9.8%, there were radiological signs of a herniated disc, in 3.9%, radiological signs of radiculitis, in 17.6%, there was a ligamental spinal canal stenosis, and in 29.4% of the cases, an osseus spinal canal stenosis was diagnosed. As additional findings, in 90.19% of the patients, degenerative lumbar spine changes such as osteochondrosis and facet arthropathy were identified in the MRI.

The still unpublished results of Roohani and Schütze on the significance of epiduroscopy compared to magnetic resonance imaging based on 51 pain patients with lumbar pain syndrome are presented in Table 3.1.

As part of differential diagnosis, in 2006 we carried out 68 discographies in 142 patients prior to planned pain-therapy interventions such as percutaneous laser disc decompression and nucleotomy (PLDN) and laser facet denervation (Fig. 3.1).

Our own clinical results indicate that the spatial and live color visualization and the evaluation of the spinal topography, including the testing of

pain relevance of the visible pathological and anatomical structures, greatly enhance the diagnostics of spinal pain syndromes (Table 3.2).

As part of differential diagnosis, in 2006 we carried out 68 discographies in 142 patients prior to planned pain-therapy interventions such as percutaneous laser disc decompression and nucleotomy (PLDN) and laser facet denervation.

**Table 3.2.** Comparison of EDS and MRI in the management of radiculopathy (mod. from Richardson)

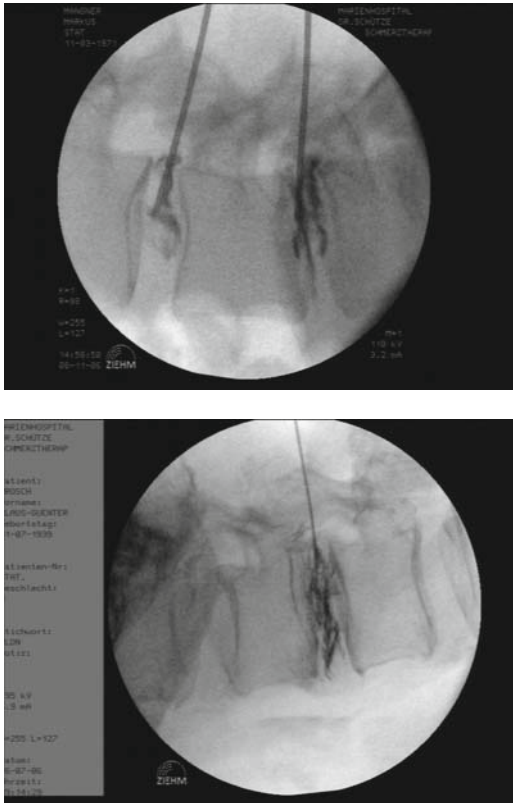
	EDS	MRI
Anatomy of the nerve root	+	++
Vascularization of the nerve root	++	-
Radiculitis	++	+/-
Nerve root sensitivity	++	-
Pain localization	++	-
Size of spinal canal	+/-	++
Identification of scar tissue	++	+
Identification of disc herniation	-	++
Ruling out various pathologies (biopsy)	++	++
Therapeutic aspects	++	(+)

++ very helpful, + helpful, - not helpful

**Table 3.1.** Significance of epiduroscopy compared to magnetic resonance imaging, based on 51 patients with chronic lumbar pain syndrome, Pain Clinic Iserlohn (2007)

Advantages of EDS	Advantages of MRI
Epiduroscopy is superior for observing, assessing and differentiating pathological and anatomical structures such as adhesions, fibrotic tissue and inflammatory processes.	For assessment of anatomic conditions of the nerve roots and size of the spinal canal, identification of disc herniation and protrusions, MRI is clearly superior to EDS.
In addition to endoscopic diagnostics, carrying out spinal function tests and options for spinal interventions are a considerable advantage of EDS compared to MRI.	
In comparing epiduroscopy and MRI in managing radicular back pain, epiduroscopy is superior for assessing vascularization, radiculitis, pain localization, ruling out pathologies (biopsies), identifying scar tissue, as well as for therapeutic aspects.	

## 3.5 · Our own clinical results



■ Fig. 3.1. Visualization of degenerated intervertebral discs (L3/L4, L4/L5) with a contrast medium. The fluoroscopic image shows the needle in position in the disc (L3/L4). Degenerated disc with an annular tear

# Functional Epiduroscopic Diagnostics

4.1 Diagnostic blocks and laser-evoked potentials – 44

4.2 Epidural pain provocation test (EPPT) – 44

4.2.1 Our own results – 45

## 4.1 Diagnostic blocks and laser-evoked potentials

Selective, endoscopically supported diagnostic epidural anesthesia and analgesia can be used to block both motor and sensory nerve functions and specific autonomic functions. In contrast to therapeutic blocks, diagnostic blocks do not primarily ease pain but are used to identify the reason for pain.

In addition to exact endoscopic localization, a differential block for diagnosing pain can also be carried out by titrating the concentration of the applied local anesthetic. This requires precise technical execution of the diagnostic block and carefully informing the patient about the planned procedure and anticipated results.

Established methods for objectively assessing whether the block has been successful or to prove a possible involvement of the sympathetic nerve system in the origin of pain include measuring the skin temperature at the extremities, as well as simple functional tests and duplex ultrasound.

Diagnostic injections at the facet joints, supported by imaging in the case of existing non-radicular or referred pain are established procedures, especially in the field of interventional pain therapy. The medial branch block with a local anesthetic for reasons such as differential diagnosis bring about a reliable disruption of the pain conduction, at least for the period the local anesthetic is in effect. Selective medial branch block is proof of the diagnosis facet joint pain. According to Stern, the diagnosis »facet arthropathy« can be made exclusively on the basis of two or three test medial branch blocks.

A prerequisite for a radio-frequency lesion or denervation of the medial branch via laser calls for a controlled, image-converter guided X-ray diagnostics to demask the neuronal structure of the pain transmission.

However, in pain medicine, we aim for standardized diagnostics and documentation. For example, one modern pain diagnostic tool is a suitable infrared laser stimulator that emits a clearly defined laser test stimulus.

This option for diagnosing pain can be beneficial for a number of examinations. Bromm (2007) reported that in patients with an acute nerve root irritation, diagnostics using laser-evoked potentials

can quantify root damage, even at an early stage of the disease. In such cases, surgical intervention is indicated at the earliest possible time. According to Bromm, laser-evoked potentials serve to estimate prognosis and early decisions to operate. The emitted laser stimulus not only evokes a defined pain, but also brain potentials that correlate to the strength of the perceived pain to a highly significant extent.

## 4.2 Epidural pain provocation test (EPPT)

One problem in pain therapy is unequivocal documentation of the strength of pain and reducing this pain through treatment. Nearly all investigative procedures are based on variables provided by the patients themselves.

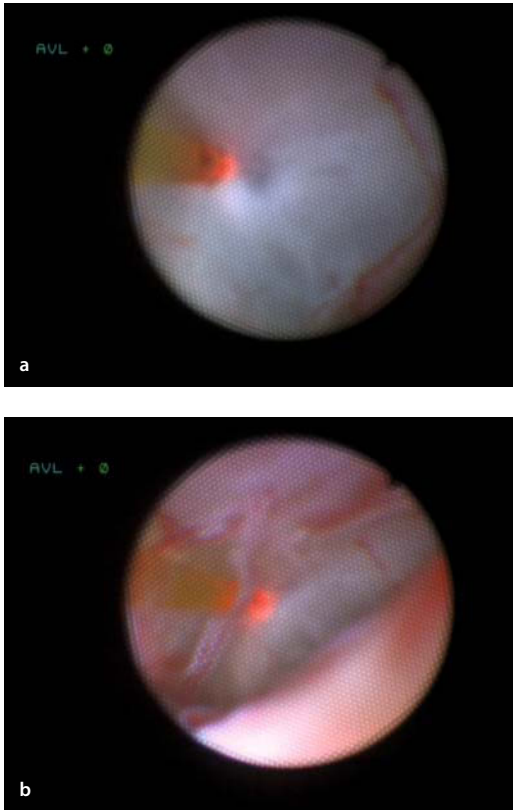
With the help of an epidural laser pain provocation test developed in our pain clinic, epiduroscopy is used in patients with spinal pain syndromes to examine the extent to which radiologically or endoscopically identified epidural pathological and anatomical structures such as epidural adhesions, fibrotic tissue and pronounced scar tissue or granulation tissue are actually relevant for the patients' pain.

With a defined laser beam (diode laser, DioLas) with a power of 1.0 watts and a laser action of 1 sec, reproducible pain can be stimulated in the epidural structures to be tested. The laser emits very short and steep heat impulses that are applied without touching, where they activate targeted afferences of the pain system. This stimulates a stabbing (A-delta fibers) and burning (C fibers) pain sensation (■ Fig. 4.1a,b).

As an alternative, the tip of the epiduroscope or catheter or a microsurgical instrument can also be used to provoke undefined pain.

During the epiduroscopic examination, depending on the cooperation of the patient, who may also be sedated, it is possible to carry out an epidural pain provocation test.

Under endoscopic vision it should be tested whether diagnostically significant pain – »memory pain« – can be provoked in the area being examined or not. During the procedure, the pain intensity can



■ Fig. 4.1. a Laser fiber with target beam in the epidural space. b Diode laser in action, pain provocation test

be assessed by the patient and/or examiner on the basis of the Numeric Rating Scale (0-10 NRS).

It is known that a compression or stimulus on a normally structured nerve root by the examiner will generally cause paresthesia and analgesia in the patient.

Ross et al. observed that epidural scars themselves are not painful. Epidural fibrotic tissue can induce mechanical problems and lead to scarred connections with neighboring nerve roots. Changes in length due to movement over the scarred tissue bridges cause pulling and mechanical irritation of the nerve roots that ultimately determine the symptoms of radiculopathy.

Compression of a traumatized nerve root can cause pain in the patient. This means that pain is only caused through compression on the nerve

root when the nerve root is damaged. In the case of non-inflamed nerve roots, memory pain cannot be triggered through such compression. An epidural pain provocation test can therefore cause memory pain under certain pathological conditions.

Interestingly, in 1994 Jensen et al. had already observed in a study that in 52% of asymptomatic volunteers the MRI of the lumbar spine showed significant abnormalities that were assessed as potential surgical pathologies.

However, in chronic inflammation, sensitivity to pain in response to pressure decreases. The overall pain symptoms remain and are not increased by external pressure. For the pain provocation test carried out through epiduroscopy, this means that a defined pain in the case of acute radiculitis can provoke massive pain, while in the case of radiculopathy no pain can be provoked.

#### 4.2.1 Our own results

In 2006 we assessed 120 pain patients at our pain clinic who had undergone EPPT as part of epiduroscopic diagnostics. Endoscopy was used to examine the dorsal and ventral part of the epidural space. The existence of dorsal and ventral epidural pain sources was examined through epiduroscopic visualization and a standardized epidural laser pain provocation test (EPPT) was carried out in all patients.

In order to verify diagnosis, in all patients tissue specimens were taken from the epidural space through the working channel of the epiduroscope; the specimens then underwent histological examination. In the epidural segments from S1 to C4 examined endoscopically, among the 120 patients pathological abnormalities such as adhesions, fibrotic tissue, stenoses, pronounced scarring, sequestrers and inflammatory processes were found; in some cases, however, epidural structures were normal.

With a defined laser beam (diode laser, DioLas) with a power of 1.0 watts and a stimulus duration of 1 sec, reproducible pain could be provoked in the epidural structures to be tested. Under endoscopic vision it was tested whether diagnostically significant pain could be brought about in the area

being examined or not. The pain intensity was assessed by the patient on a scale of 0–10 on the basis of the Numeric Rating Scale (NRS).

The question as to whether the radiologically or epiduroscopically diagnosed pathological processes of the pain patients with failed back surgery syndrome (FBSS) constitute the actual reason for pain was answered according to our results by the fact that of the 120 pain patients with FBSS, in 73.3% of the tested patients the pain provocation test was positive. This means that the endoscopically verified structures can actually be potential reasons for pain.

In 26.7% of the patients, the pain provocation test remained negative.

To confirm diagnosis, 120 biopsies were taken from the epidural space via endoscopy. Of the histological examinations, 70.4% revealed scarring of the connective tissue structures. In 20.8% of the biopsies there were lesions of the tissue structures indicative of chronic inflammation.

In 73.3% of the FBSS patients with a positive provocation test, 67% experienced memory pain in the upper or lower extremities and in 33% of these patients, memory pain could be stimulated in the back. Overall, an average pain score of 6.5 (0–10 NRS) was elicited.

In 2007, another study of the pain provocation test during epiduroscopy was carried out by Schütze and Roohani. In the study of 36 patients with lumbar spine syndrome, a standardized laser epidural pain provocation test was carried out during epiduroscopy. In 20 patients, the test was carried out on only one side (on only the right or only the left side) and in 16 patients, it was carried out on both sides. The intensity of the pain stimulated by the laser pain provocation test was assessed by the 36 patients during the procedure using the Numeric Rating Scale. Seven patients gave a score of 0 points on the Numeric Rating Scale, 13 patients reported 6 points, 8 patients 8 points and in 8 other patients, a pain score of 3.5 was reported.

In our experience with the epidural laser pain provocation test (ELPPT), the scarred areas identified via epiduroscopy are frequently, but not regularly, sensitive to pain.

It is conceivable that through the stimulated laser contact, for example with epidural fibroses, an

irritation of the meningeal branch is provoked because the above-mentioned pathological processes frequently adhered to the spinal dura mater, causing irritation of the meningeal branch. Afterward, the patients reported temporary severe acute pain in the pain region.

However, a precondition for performing ELPPT is the cooperation of the patient during the test. A level of analgesedation that is too high can have a profound impact on the result. In our pain clinic, CSM monitoring (cerebral state monitor, CSM, danameter) during epiduroscopy under analgesedation has proved advantageous.

With the epiduroscopic test described above, pain relevance of pathological structures can be identified or ruled out. The epidural pain provocation test also plays an important role in issues of pain appraisal.

Based on our clinical experience, results and assessments, the epidural laser pain provocation test has become an important and indispensable differential diagnostic instrument in our pain assessment work.

The establishment of a standardized endoscopic epidural laser pain provocation test has boosted the significance of this special method of diagnosing pain in spinal pain syndromes.

# Epiduroscopic Equipment and Surgical Setting

## 5.1 Technical aspects – 48

5.1.1 Structure and function of endoscopes – 48

5.1.2 Epiduroscopes – 51

5.1.3 Reprocessing epiduroscopic equipment – 54

## 5.2 Camera and video technology/DVD/CD-ROM – 58

## 5.3 Documentation – 59

## 5.4 Work station – 60

5.4.1 Technical assistance in the operating room – 60

5.4.2 Instrumentarium – 61

## 5.5 Preoperative management – 63

5.5.1 Preoperative history, clinical examination and anesthesiological evaluation – 63

5.5.2 Electrophysiological tests – 64

5.5.3 Other tests – 64

5.5.4 Standards for hygiene – 65

5.5.5 Positioning – 65

## 5.6 Anesthesia management – 66



With the introduction of spinal endoscopy in the field of pain medicine, compared to other imaging procedures the accuracy of the diagnostic findings can be further enhanced. In addition, interventions can be performed via the working channel of the epiduroscope.

To perform epiduroscopy efficiently and ensure patient safety, it is essential for the pain therapist performing the invasive procedure to have experience in the examination methodology and thorough theoretical knowledge, as well as a certain degree of manual dexterity.

In addition to exact endoscopic pain diagnostics and professional technical management, the success of epiduroscopy-assisted invasive pain therapy depends on the selection of suitable patients.

In general, when carrying out any invasive epiduroscopic procedure, a thorough clinical and functional examination and imaging diagnostics must be carried out. Regardless of the hospital structure, epiduroscopy should ideally be performed on a cooperative patient with adequate continuous monitoring of the vital functions in a suitable operating room.

## 5.1 Technical aspects

The history of endoscopy goes back to Bozzini, the inventor of the »light conductor«. He was the first person to successfully visualize the internal cavities of the human body.

Very old endoscopes consist of a rigid tube through which the needed light was reflected by a mirror. Longer endoscopes were also equipped with lenses in a tube on the front end, which finally allowed minor passive movement.

In order to follow and inspect the course of the natural body cavities without causing trauma, efforts were undertaken to develop endoscopes that were flexibly constructed. One further development involved positioning a remotely produced light with glass-coated fiber bundles on the tip of the tube and transmitting the imaging information via flexible, arranged fiberglass bundles (image conductors) to the eye of the examiner. This step was the key factor in making the endoscope flexible.

There are two kinds of endoscopes: flexible and rigid. Endoscopes can also be divided into glass fiber or video endoscopes, according to the type of image transmission they use.

In general, flexible endoscopes are used to examine organs and view structures such as mucosa, as well as for intervention. For this purpose, medical technology provides endoscopes with various outside diameters, lengths, working channels and functions (■ Figs. 5.1 and 5.2). For the most part, the individual components of different endoscope manufacturers cannot be easily combined.

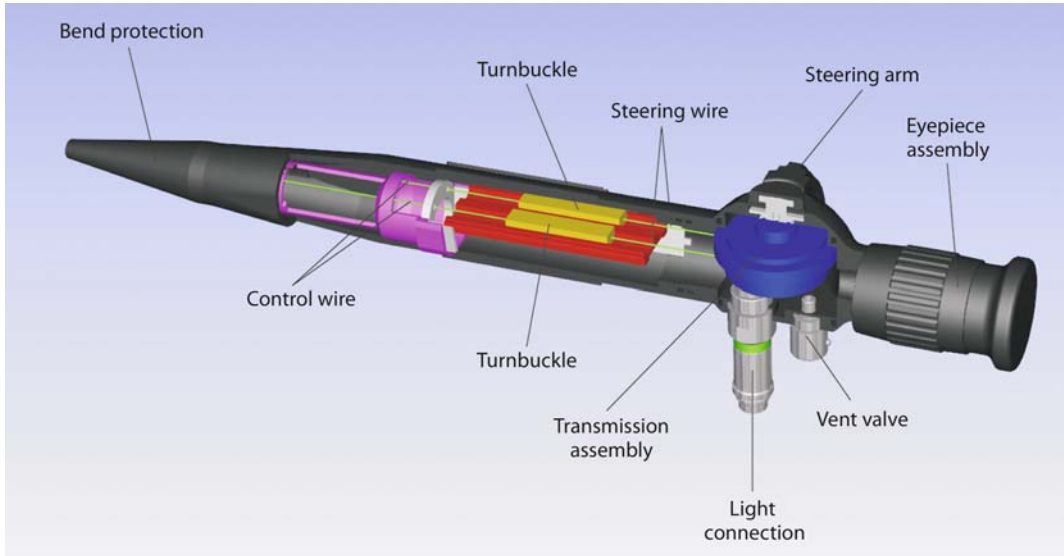
### 5.1.1 Structure and function of endoscopes

The inner structure of the insertion tube of an endoscope consists of metal bands or coils. The outside of the tube is enclosed by a special rubber material that serves to seal it. These materials are either bonded together or have been joined by a shrinking process. The bending section of the tube consists of guideable cardanic joints. The joints are guided by control cables and move the distal end in the desired direction. The joints are surrounded by a support system. The bending section rubber ensures that the tube is sealed.

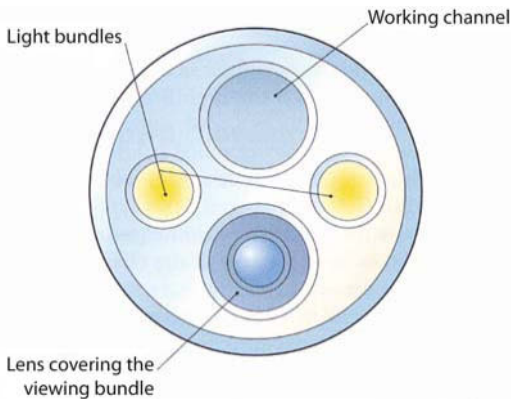
For the flexible endoscopes, lens systems provide for optical feedback and serve to close off the inner parts of the endoscope to the surroundings. The endoscope is guided by the guide wheels of the control body. The endoscope can be actively guided by means of Bowden cables.

The guide wheels shorten or lengthen the control cables, whereby the distal end can be deflected as needed. Irrigation and suctioning can be performed as needed via interior channels that are guided by valves on the control body.


Instruments can be inserted via the working channel near the control body. Video endoscopes have a video clip at the distal end of the endoscope. This video clip electrically transmits imaging information to the image processor. The signal is transmitted via very fine electrical wires with a diameter of approx. 0.1 mm, which are individually insulated.



■ Fig. 5.1. Assembly of an epiduroscope (KARL STORZ, Germany)



■ Fig. 5.2. Cross-section of the tip of an endoscope (KARL STORZ, Germany)



■ Fig. 5.3. Image transmission pixel by pixel. (KARL STORZ, Germany)

### Light and image conduction

In general, glass fibers are used for endoscopic light guides. With conventional flexible endoscopes, both the image and light are transmitted via glass fiber bundles. For glass fiber endoscopes, image transmission occurs via light-conducting fibers to the eyepiece. A glass fiber light guide with a fiber diameter of 7 to 10  $\mu\text{m}$  consists of up to 60,000 fibers, which means a resolution of 60,000.

Information on brightness and color is transmitted via the individual glass fibers. This corresponds to a resolution of approx.  $240 \times 180$  pixels. In the image guide, the glass fibers are located in a coherent bundle. This means that the position of each individual fiber is the same at the entry and exit side. The image is transmitted, pixel by pixel, via a bundle of sorted glass fibers (■ Fig. 5.3).

In contrast, with a light conductor, the individual fibers are not arranged in any particular order. The so-called Moiré effect must be borne in mind, as it decreases the quality of the image due to the superimposition of the fiber optic grid on the CCD grid. This gives the optical illusion of two nearly identical grids lying on top of each other. Depending on the position, individual color pixels are taken into account on the video chip to a greater or lesser extent. Electronic filters serve to eliminate the optical phe-

nomenon. For this reason, videoscopes are used that work electronically with a built-in CCD chip.

With video endoscopes, digital technology is used for image transmission and production. A CCD chip integrated on the lens of the endoscope produces a digital image of the object, which is transmitted to the relevant structural groups of the video endoscope via electric wires to the processor. The data received are processed by a processor or are saved to a hard drive, CD or DVD and the signals are sent to a monitor. Video endoscopy guarantees that the image or object can be processed, optimized or measured later on.

However, light guides now also exist that conduct the light by means of a gel as a transport medium. A light guide or endoscope manufactured by one company cannot necessarily be operated with a light source from a different manufacturer. However, leading manufacturers of endoscopes offer suitable adapters upon request.

### Angle of vision and effect

Due to optical laws there is a relationship between the angle of vision and the magnification factor. A large angle of vision means low magnification, similar to the wide angle in photography. With regard to the working diameter of the endoscope, the larger the diameter, the brighter and wider the image. A small angle of vision results in a strong magnification, similar to a telescopic lens in photography.

In the relationship between magnification and the distance between the lens and the object to be visualized with the endoscope, it must be taken into account that the magnification factor describes the size of the image or object relative to the actual size. In line with this, the magnification factor is inversely proportional to the distance. The number of degrees of the angle of vision determines whether it is an oblique or direct view, a fore oblique or front view, a right angle or lateral view or a retrograde or rear view.

Angle of vision:

- 0° oblique or direct view
- 40 to 80° fore oblique or front view
- 90° right angle or lateral
- 110 to 120° retrograde or rear

Flexible epiduroscopes must adapt to the constraints posed by the anatomical course of the spinal canal. The access to the epidural space is not arranged in a linear fashion. Thus the endoscopes must be flexible in order to follow the anatomical course. This is a major impact factor for the epiduroscope. In order for the epiduroscope to bend as needed without negative effects, a laser fiber cable is required with a diameter less than 300  $\mu\text{m}$ . Fiber cables with a diameter of 265  $\mu\text{m}$  are standard.

However, even normal use has a negative impact on the epiduroscope. The major problems involve physical factors resulting from mechanical impact and the effect of the chemicals used during reprocessing.

### Practical tips

Epiduroscopes are sensitive medical precision instruments that must be handled with care.

Due to the risk of damaging or slicing open the working channel, it is advisable not to insert the needed microsurgical instruments into an epiduroscope in a bent position or into a deformed shaft.


To prevent damage to the working channel and the forceps themselves, the forceps' double-action jaws should not be opened until the forceps are outside the working channel.

The laser fiber should always be inspected to ensure it is intact before it is inserted in the working channel in order to prevent burns in the working channel.


Damage to the endoscope shaft can lead to the lenses becoming loose or sliding around in the epiduroscope.

The shaft end of the epiduroscope with the integrated prism needs to be protected from temperatures that are too high. Every endoscope manufacturer has standard recommended values that range from 65 °C to 70 °C and up to 130 °C for exceptional applications.

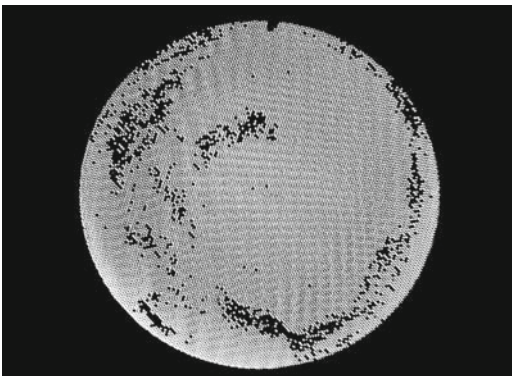
If the epiduroscope is bent too sharply or is heavily damaged, individual glass fibers can break in the glass fiber light guide, which are visible as black dots in the optic of the epiduroscope or on the monitor (■ Figs. 5.4 to 5.6).



■ Fig. 5.4. Undamaged fiber bundle. The image conductor is 100% intact



■ Fig. 5.5. Defective image conductor, still acceptable for EDS



■ Fig. 5.6. Condition of fiber bundle after several uses. Image conductor is defective

## 5.1.2 Epiduroscopes

Epiduroscopy is a supplementary diagnostic imaging procedure that can be used to reach otherwise inaccessible epidural areas via an artificial percutaneous opening and an epiduroscope.

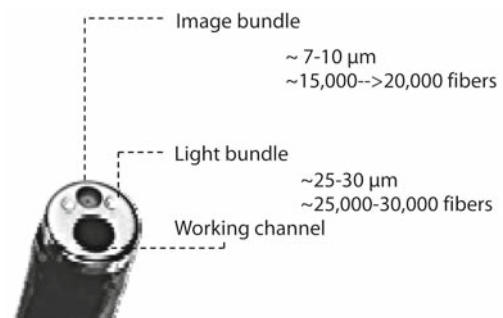
Epiduroscopes are flexible fiberscopes that have been specially developed for the needs of spinal endoscopy and have been adapted to meet the requirements of various certifications for clinical use.

The epiduroscopes favored by us are reusable, flexible epiduroscopes that have a certain degree of rigidity and are non-buckling. The epiduroscopes' especially smooth surface makes them particularly well suited for clinical interspinal application.

Epiduroscopes have various outside diameters ranging from 0.5 mm to 3.8 mm and are generally equipped with a working channel of 0.9 mm to 1.5 mm (■ Fig. 5.7). A distal opening angle of 90° and an optimized proximal image enlargement can provide excellent picture quality despite a distal lens size of far less than one millimeter.

The eyepiece is connected with a camera system. In clinical practice, a digital 3-chip camera system has also worked well, because the endoscopic image is transferred on three separate color chips. This allows color, contrast and resolution to be optimized directly on the camera head.

Various epiduroscopes and endoscopes for spinal endoscopy are available on the international market. The varying technical quality of the picture quality, outside diameter, working channel, flexibility, length of endoscope, reusability and tendency to require repairs make many of them inadequate or unsuitable for use.



■ Fig. 5.7. Image and light bundle (KARL STORZ, Germany)

In general, the market niche for single-use epiduroscopes in Europe is considered to be limited, not only for financial reasons. However, according to Bader et al., the use of single-use endoscopes to enhance patient safety from the point of view of hygiene is linked to worse optical image transmission, which in turn reduces the benefits of the improve-

ments with regard to high-resolution video technology. On the other hand, we have safe reprocessing methods for reusable epiduroscopes at our disposal. Standardized automated cleaning and disinfection procedures, combined with proper manual pre-cleaning, offers a high level of patient safety.

Most of the endoscopes available for use in epiduroscopy throughout the world can either be used to only a limited extent or not at all for microsurgical interventions.

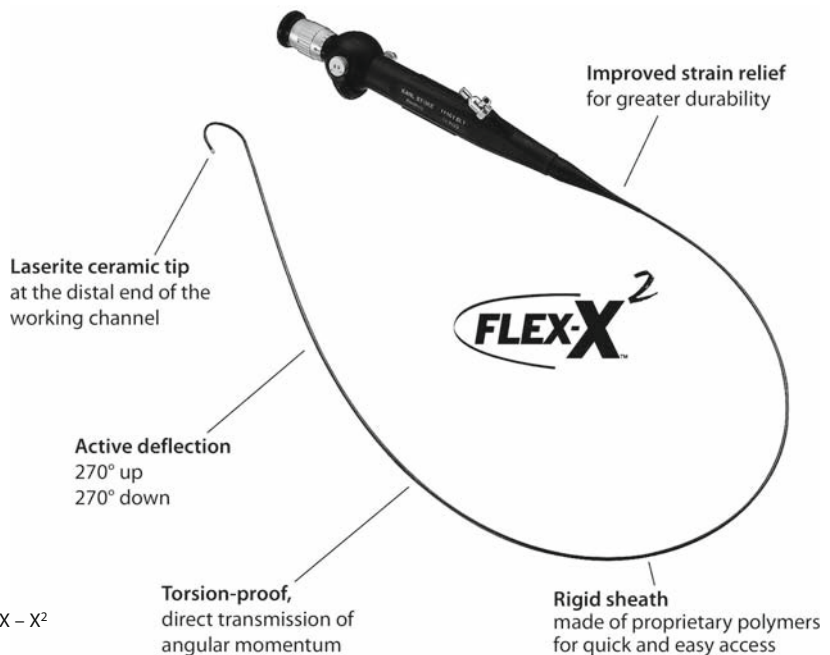
At our pain clinic, we primarily use the EDS systems from Karl Storz, Tuttlingen, Germany:

**Epiduroscope.** The flexible epiduroscope developed by G. Schütze (Karl Storz, Tuttlingen, Germany) is 40 to 70 cm long and has an outside diameter of 2.8 mm (■ Fig. 5.8). It has an integrated working channel with a diameter of 1.2 mm. The distal end can be deflected upward up to 120° and downward as far as 170°.

**Epiduroscope FLEX – X<sup>2</sup>** (Karl Storz, Germany). The flexible epiduroscope featuring FLEX-X<sup>2</sup> technology (■ Fig. 5.9) has a working length of 90 cm, an angle of vision of 0° and can be deflected from 270°/270° with a diameter of 3.1 mm. The



■ Fig. 5.8. Epiduroscope by G. Schütze (KARL STORZ, Germany)



■ Fig. 5.9. Epiduroscope FLEX – X<sup>2</sup> (KARL STORZ, Germany)

epiduroscope has an integrated instrument channel 1.2 mm in diameter. The use of special polymer materials for the endoscope shaft make the FLEX-X<sup>2</sup> epiduroscope stand out for its resilience and needed rigidity.


Special characteristics of the epiduroscope include an endoscopic image magnified by 50% and a markedly improved picture resolution. Special construction of the shaft allows the angular momentum to be directly transmitted with a 1:1 ratio. This makes it easier to steer the epiduroscope. At the distal end of the working channel there is a Laserite ceramic tip that guarantees protection from laser damage.

**Miniature epiduroscope Karl Storz.** For purely diagnostic purposes, a spinaloscopy or epiduroscopy with miniature endoscopes from Karl Storz, Tuttlingen, Germany, access is also possible via the

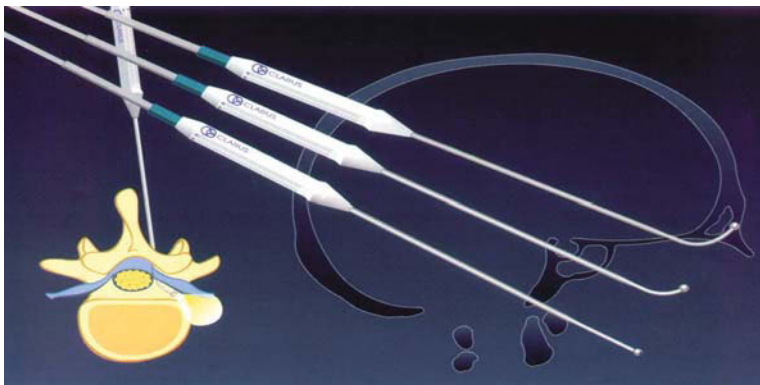
usual access points. The main feature of this endoscope is its especially small diameter of 0.5 mm, a very high flexibility with integrated fiber glass light guider, an angle of vision of 0° and an opening angle of 55° and a usage length of 150 cm (■ Fig. 5.10).

The following epiduroscopy systems are also used at our clinic:

**Clarus Spine Scope.** The semiflexible Spine Scope™ (Phoenix Spine Scope Clarus Medical System, Minneapolis, Minnesota), with an outside diameter of 2.3 mm, is designed for single use only. The working length of the endoscope measures 29.3 cm. The semiflexible Spine Scope is equipped with an integrated working channel with a diameter of 1.0 mm. The steerable endoscope tip has a flexibility of 45° and the field of vision is 70° (■ Fig. 5.11).



■ Fig. 5.10. Miniature epiduroscope (KARL STORZ, Germany)



■ Fig. 5.11. Clarus Spine Scope

**R. Wolf epiduroscope.** Richard Wolf GmbH, Knittlingen, Germany, manufactures a flexible epiduroscope with a length of 700 mm and an outside diameter of 2.5 mm (7.5 F), as well as 3.0 mm (9 F). The epiduroscopes each contain a working channel with a diameter of 1.2 mm (3.6 F) or 1.5 mm (4.5 F). The distal end can be deflected upward up to 130° and downward as far as 160° (■ Fig. 5.12).

**Flexible fiber optic endoscopes (Myelotec).** The short, flexible Myelotec epiduroscope is primarily used in the United States. The flexible fiber optic endoscope with a diameter of 0.9 mm can be placed with the help of a steerable, video-supported 2.7 mm or 3.0 mm catheter (■ Fig. 5.13). This catheter contains two working channels. The epiduroscopic equipment consists of an epidural endoscope, a video camera system and a video monitor. Kawanishi et al. (2006) reported that since 1996, they have used epidural endoscopes (Myelotec) with a diameter of 0.9 mm, inserting them from the sacral hiatus, in order to examine the lumbar epidural space. However, Kawanishi et al. also reported that several problems associated with epiduroscopy still need to be solved. They consider the dramatic pain relief brought about through epiduroscopy to be remarkable, however, and see it as a promising diagnostic tool.

### 5.1.3 Reprocessing epiduroscopic equipment

The cycle of reprocessing epiduroscopes includes preparation, manual cleaning, disinfection or machine cleaning and disinfection, inspection and maintenance, packaging, sterilization and storage and use (■ Fig. 5.14).


Flexible endoscopes are encapsulated systems that are closed to their environments, and this makes it difficult to inspect them visually. It is advisable to carry out a visual check of the epiduroscope for damage, especially of the insertion tube, the angulation system and the optical system.

The goal of inspection is to remove endoscopes before the reprocessing process. Before the endoscope is placed in the automated reprocessor, a leakage test must be carried out in line with instrument manufacturers' guidelines. To do this, slight excess pressure is forced into the inner part of the endoscope, which allows larger perforations to be localized. When the endoscope is then immersed in water air bubbles will escape at damaged areas.

Endoscopes, which are inserted into tissue or in sterile epidural areas must be absolutely sterile when used. After cleaning and disinfection, epi-



■ Fig. 5.12. Epiduroscope (Richard Wolf GmbH, Knittlingen, Germany)



■ Fig. 5.13. Myeloscope (Myelotec, Inc. Roswell, GA, USA)

durosopes must undergo a special sterilization procedure. Endoscopes or parts of endoscopes or accessories that can withstand high temperatures should be sterilized in an autoclave.


It is best for thermolabile epiduroscopes or parts of endoscopes to undergo plasma sterilization or gas sterilization with ethylene oxide.

Immersing the epiduroscope in solutions containing aldehyde with a sporicide effect is not an acceptable sterilization procedure!

In Europe, and in Germany in particular, disinfection and sterilization of medical products in health care facilities is regulated by the German Act on Medical Devices (MPG), Federal Law Gazette no. 657/1996 in its current version. According to this act, the cleaning, disinfection and sterilization with such devices or automated systems

and suitable validated procedures are to be carried out such that the success of the procedures can be guaranteed on a long-term basis and the safety and health of patients, users or third parties is not compromised. With regard to endoscopic equipment and current organization and implementation of reprocessing of epiduroscopes, the health to the fiber bundle, damage to the casing of the epiduroscope or blurriness.

The manufacturer (Karl Storz) issues a certificate of authenticity that certifies that the epiduroscope that has been returned and repaired is an original flexible Eclass fiberscope. The user is also guaranteed that the reprocessed epiduroscope has been manufactured and inspected according to the same high standards of quality, meeting the same demands as a new epiduroscope.



■ Fig. 5.14. Manual cleaning of epiduroscopes



## Repairs

Even when they are used carefully, epiduroscopes are subject to various changes and wear and tear. According to Hilger, clinical experience shows that in hospital operations in many cases the life expectancy of an endoscope is only about three years.

The flexible epiduroscope is a complex medical technical, sensitive precision instrument and is connected with a wide range of materials such as plastic, metal and glass in a watertight manner by gluing or bonding.

According to Bader et al., potential interactions through cleaning agents and disinfectants can cause plastic to be penetrated, dissolve glued areas and corrode metals, causing problems during the reprocessing of epiduroscopes. The interaction of alcohols and amino derivatives with plastics and adhesive connections can also lead to a penetration of these substances of disinfectants into the epiduroscope.

At our hospital, an average of 15 epiduroscopy procedures are carried out with each individual epiduroscope each year before they are sent to the manufacturer for repair due to leakage or damage to the fiber bundle, damage to the casing of the epiduroscope or blurriness.

The manufacturer (Karl Storz) issues a certificate of authenticity that certifies that the epiduroscope that has been returned and repaired is an original flexible Eclass fiberscope. The user is also guaranteed that the reprocessed epiduroscope has been manufactured and inspected according to the same high standards of quality, meeting the same demands as a new epiduroscope.

■ Table 5.1 presents a list of damage reports on defective Karl Storz epiduroscopes occurring among 263 epiduroscopic procedures performed in our pain clinic in 2006. During the overall period, the same epiduroscope was used an average of 16.4 times. After 30.48 EDS procedures, damage to an epiduroscope was observed.

## Cleaning and disinfection

Cleaning is an integral part of instrument reprocessing. Without reliable, and in particular, validated cleaning of epiduroscopes, successful sterilization is not possible.

Automated cleaning and disinfection is the preferred method because variables such as time, temperature, chemicals and mechanics can be better managed. Single and multi-chamber washers

■ **Table 5.1.** Damage reports on defective epiduroscopes in 2006 (at the Iserlohn Pain Clinic)

		Repairs
Epiduroscope 11301AB1	Steering defective, tube nozzle defective and leaky	2
	Signs of wear and tear, steering and tube nozzle defective	1
	Signs of wear and tear, tube nozzle defective	1
	Signs of wear and tear, tube nozzle defective and leaky, cloudy image conductor	1
	Signs of wear and tear, tube nozzle defective and leaky, defective image conductor	1
	Light fibers broken, steering broken	1
	Image conductor cloudy, insufficient angle, defective image conductor	1
	Image conductor cloudy, mechanical damage to shaft, tube nozzle defective and leaky, tube leaky	1
	Signs of wear and tear, tube nozzle defective and leaky, cloudy image conductor	1
Epiduroscope 11161 EL2	Signs of wear and tear, steering broken, tube nozzle defective and leaky	1

and disinfectant are used. At our clinic, we use the Endo Thermo Disinfector, Olympus ETD3 Basic GA (Olympus Winter & Ibe GmbH, Hamburg, Germany) for automated cleaning and disinfection of the flexible epiduroscopes.

For watertight endoscopes, automated cleaning and disinfection can be performed. For reprocessing, proper transportation of the endoscope must be ensured (■ Fig. 5.15), and the endoscopic equipment must be disassembled and in some cases manually pre-cleaned.

During the reprocessing of epiduroscopes, the following problems may occur:

- insufficient manual pre-cleaning prior to automated cleaning and disinfection
- incompatibility of the ingredients used in the agents (detergents with or without an antimicrobial effect) used for preparation with the active ingredients of agents used for final disinfection
- insufficient rinsing of detergents.



■ Fig. 5.15. Endo Thermo Disinfector (OLYMPUS WINTER & IBE GmbH, Hamburg, Germany)

## Sterilization

Ideally, when sterilizing an epiduroscope, all microorganisms and their spores are eliminated and viruses, plasmids and DNA fragments are destroyed. There is an important technical distinction between disinfection and sterilization. With sterilization, out of one million bacterial spores, no more than one may survive. Steam is not suitable for all kinds of sterile goods, especially not for modern instruments that are made of combinations of materials.

Currently, according to the Swiss NOSO CJD Task Force for Switzerland, the risk of transmitting prions during endoscopic procedures can neither be confirmed or quantified. Despite the fact that currently no procedure exists that is both compatible with the flexible, reusable epiduroscopes and is fully effective against prions, Balmelli reports that certain countries have published guidelines for this area.

The packaging material must also be coordinated with the particular sterilization procedure. The stringent regulations for sterile goods packaging must be observed. In addition, a number of European and U.S. standards are in place for sterilization that must be adhered to.

**Ethylene oxide sterilization.** Ethylene oxide can be used to sterilize medical devices and materials. However, this procedure should only be used if the classic thermal procedures with steam or hot air cannot be used because of the heat-sensitive nature of the goods to be sterilized.

Ethylene oxide is a reactive, flammable gas that forms an explosive mixture with air. For this reason, a mixture with inert gases is required. Ethylene oxide is irritating to the respiratory tract. It is a protoplasmic toxin and can cause cancer. It has good penetration properties and is absorbed by many materials, which requires airing times ranging from four hours to two weeks (up to  $\leq 1$  ppm residual content). The sterilization temperature is 50 to 60 °C. The gas ethylene oxide combines with all types of proteins, cells, viruses and cell components and inactivates them irreversibly. In addition, ethylene oxide on its own inactivates bacteria and viruses if the concentration is sufficiently high.

The long airing times required for gas sterilization limit its use in practice, however. The risks

associated with dealing with ethylene oxide and the long airing times are problematic for epiduroscopy sterilization. In Germany, guidelines for identifying and assessing the risks associated with ethylene oxide are laid down in Technical Rule 420 of the Technical Rules for Hazardous Substances (TRGS).

**Plasma sterilization.** Plasma sterilization can be used for most medical thermolabile instruments and devices. In our clinic, it has made great strides in the sterilization of highly-sensitive epiduroscopes and will ultimately replace ethylene oxide sterilization in the long run.

Plasma sterilization is based on the stimulation of hydrogen peroxide through high frequency at low pressure. This creates so-called peroxide plasma. This is a relatively new low-temperature sterilization procedure that was primarily developed for heat- and moisture-sensitive instruments and materials. The impact of hydrogen peroxide in combination with high frequency sterilizes the epiduroscopes. Plasma sterilization is not effective against prions. Compared to the conventional procedures, plasma sterilization has major advantages, because it works without radioactivity, high temperatures or toxic chemicals. Plasma sterilization does not leave behind any health-compromising residues. It is energy efficient and environmentally friendly.

Dry sterilization at 45 to 50°C without toxic residues and quick reprocessing cycle times for epiduroscopes are advantages offered by plasma sterilization.

Since the introduction of plasma sterilization at our clinic, we have used these advantages in the sterilization of our flexible, reusable epiduroscopes.

## 5.2 Camera and video technology/ DVD/CD-ROM

The constantly increasing complexity of epiduroscopic procedures calls for the opportunity for several parties to view the procedure simultaneously and for uninterrupted documentation. The best solution for meeting these needs is high-quality video technology, which is used during epiduroscopy.

In response to the important role epiduroscopy place in diagnosing spinal pain syndromes, the industry has pushed forward the development of endoscopic video technology.

We use the IMAGE 1® (■ Fig. 5.17), which is a digital video camera for the PAL and NTSC color systems. With the introduction of the new completely digital IMAGE 1® epiduroscopic 3-chip camera with the integrated IPM digital image processor, our expectations for an enhanced image quality for use in epiduroscopic diagnostics have been met. The use of the new IMAGE 1™ HD greatly improves the picture quality. The picture quality is presented in a 16:9 aspect ratio format and 1080 p-resolution for »FULL HD« technology with 2 million pixels. This is the highest possible resolution in medical technology.

With the TRICAM® 3D Endovision, Karl Storz introduced a three-dimensional endoscopic video system with three-chip technology for the PAL and NTSC color system to our pain clinic. The modular assembly allows us to integrate the central management, data processing and administration and telemedicine in the operating suite for pain surgery.

For some time now, Karl Storz has also offered autoclavable cameras. The new three- and single-chip digital cameras (■ Fig. 5.16), including the attachment cable, can be sterilized by autoclaving. Autoclave sterilization saves time and money by allowing rapid reprocessing and faster turnaround between cases. Today's digital cameras offer clearer and higher-resolution images than the previous analogue video cameras. IMAGE 1® is a video cam-



■ Fig. 5.16. The autoclavable IMAGE 1® camera (KARL STORZ, Germany)

era system with which the optical analogue images of the CCD sensing chip are converted to digital directly behind the chip while still in the camera head. This has the advantage that the image data are available continuously in digital form in the entire camera system at the highest possible quality. In addition to not being vulnerable to disruptions from external impacts, such as the use of HF surgery, it also provides advantages for digital image optimization. With Karl Storz video systems, this is integrated in the standard model through the digital IPM module. Since all camera heads manufactured by Karl Storz work with a single CCU, surgeons can use any IMAGE 1° camera head for any procedure, across every speciality. In addition, all new IMAGE 1° products are fully compatible with existing IMAGE 1° systems. With parfocal optical zoom capabilities and digital fiberscope filtration, IMAGE 1° autoclavable cameras automatically optimize the view for all endoscopes. Intuitive sterile filed access and control of all camera operations is enhanced at the press of a button.

In addition to all analogue signals, the IMAGE 1° (■ Fig. 5.16) video camera system has full Digital Video (DV) and Serial Digital Interface (SDI) compatibility for high-resolution, high-fidelity images.

For our operating suite, SDI is the preferred signal routing, image capture and display procedure. This technology allows the new ergonomic 19" TFT monitors to deliver more detailed, bril-

liant video sequences than the previous monitors with picture tubes.

Advantages of High Definition (HD) technology for EDS:

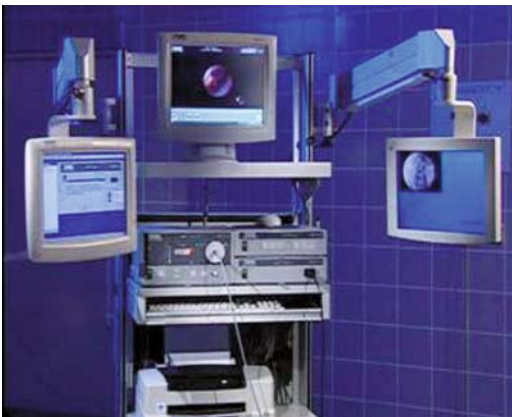- The up to 6-fold greater input resolution of the camera achieves greater detail and depth of field.
- The 16:9 format enlarges the viewing field during image generation.
- HD enhances ergonomic viewing.
- The images' brilliant colors optimize the evaluation of epiduroscopic findings.
- The lateral view is broadened by 32% when retracting the epiduroscope, while maintaining the same magnification as a standard system. Potential vertical information loss is restored and the lens stays clean.

### 5.3 Documentation

In order to record and transmit the EDS OR data, we use the KARL STORZ Advanced Image and Data Archiving System (AIDA) 2.0 modular system concept. With a push of a finger on the touch screen, via foot switch or via camera head key, still images, and video and audio sequences during the diagnostic or therapeutic procedure can be recorded and saved. The system replaces printers, VCRs and dictaphones with the AIDA computer-based archiving and documentation system.

The AIDA system consists of a database-supported application software and a corresponding hardware platform with a Windows operating system. The epiduroscopy data can be saved in an AIDA database on a patient-by-patient basis, can be saved to CD/DVD and/or transmitted to other systems (PACS, RIS and KIS) by CICOM3 and/or HL7 interface.

For our epiduroscopic procedures we also use the complete Image Management System, a digital patient image and document management system by Richard Wolf. From work stations for image capture, processing and archiving, it offers a range of server, network and telecommunications solutions for every conceivable form of image management and customized solutions for our particular needs.



■ Fig. 5.17. Imaging system (IMAGE/HDTV camera, AIDA documentation system, Twin Video, KARL STORZ, Germany)

With these systems, all data from the diagnostic or therapeutic procedure can be recorded directly from the sterile epiduroscopy area.

Comments on individual working steps can be recorded while the imaging material is being recorded.

The system control is tailored to the tasks and needs in the OR and offers exactly the functions that are currently needed, from recording patient data to defining data use, in a step-by-step manner.

The prepared text templates allow a surgical report on an invasive and interventional procedure to be generated in a very short time.

In 2006, the consensus committee of the World Initiative on Spinal Endoscopy (WISE) met in Graz and agreed that EDS data for documentation must include the following information:

- type of device
- quantity of injected fluids
- duration of the procedure
- adverse effects and complications
- type of EDS (diagnostic or therapeutic)
- associated procedures (laser, RF, mechanical adhesiolysis).

## 5.4 Work station

The modular assembly of the EDS examination unit allows us to integrate the central management, data processing and administration and telemedicine in the modern operating suite. With the introduction of the IMAGE 1° (■ Fig. 5.18b), the newest digital epiduroscopic 3-chip camera with

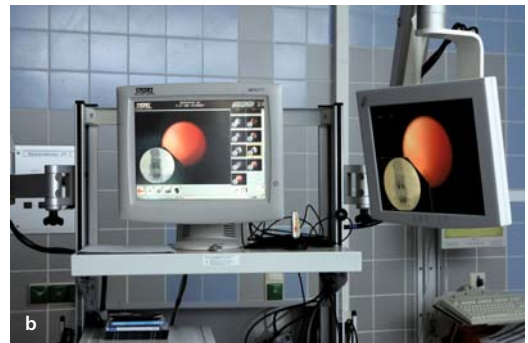the integrated IPM digital image processor, our expectations for enhanced epiduroscopic image quality were nearly completely met. Now, with the TRICAM® 3D, a three-dimensional endoscopic video system with a digital 3-chip camera for the PAL and NTSC color systems has been introduced in the clinic. In addition, we use the Richard Wolf MEDIMAGE system, a complete, digital patient image and documentation system (■ Fig. 5.18a).

### 5.4.1 Technical assistance in the operating room

At our pain clinic, an operating room technician does all preparations for epiduroscopy and prepares the necessary instruments and devices. The technician is also responsible for maintaining sterility and antiseptics.

After preparing for the surgical procedure itself, the technical assistance prior to epiduroscopy primarily involves connecting the sterile epiduroscope with the camera from the unsterile area. To solve the problem of the sterility of the camera, it is placed in a sterile long plastic sleeve along with the light cable and is connected with the sterile epiduroscope and the light cable. The use of a sterile epiduroscope holding system, consisting of an articulated stand with a clamping jaw, mounted on the operating table (■ Fig. 5.19) has proven to be very helpful.

Our saline solution irrigation system warmer set must be connected to the working channel of the epiduroscope. Other technical preparations for epiduroscopy include entering the necessary



■ Fig. 5.18a,b. a MEDIMAGE work station, b IMAGE 1° work station

patient-related and technical data into the AIDA system, checking parameters such as the intensity of light, the depth of focus, magnification, contrast and adjustment of the white balance.

Other assistants or the surgeon can manually or centrally control the devices integrated in the epiduroscopy system by pressing a touch screen, using an autoclavable remote control or speaker-independent voice control.

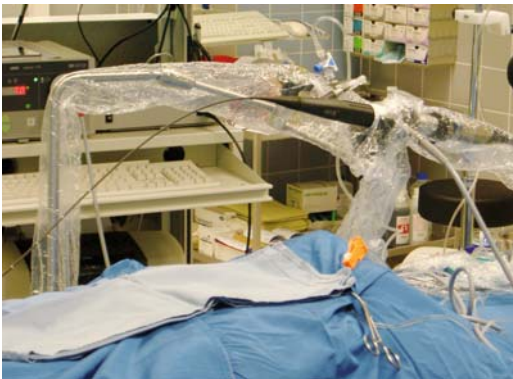After creating a suitable access to the epidural space, the operating room technician gives the examiner the desired instruments and devices and assists with epidural navigation.

Our operating room is equipped with a number of highly developed specialized devices for epiduroscopy. Controlling the various devices and computers can be complicated, and adds to the stress on the part of the surgeon and the operating room technicians. In addition to controlling the high-quality endoscopy equipment, the assistants

often have to operate the C-arm, saline irrigation system and laser and ultrasound technology simultaneously.

The newer digital technologies allow an improved concept for epiduroscopic diagnostics. With a simple, easy-to-use menu navigation system and control of the high-tech medical devices, new accents are being set in central operating room control. Cross-linking the high-quality endoscopy equipment allows OR personnel to manage the central system and devices via a central control panel. The menu navigation is easy to understand, simplifying use for the surgical assistants. The need to operate a complete digital patient image and document management system from a work station for image capture, processing and archiving, as well as server, network and telecommunications solutions, requires a high level of expertise by the assistants during epiduroscopy.

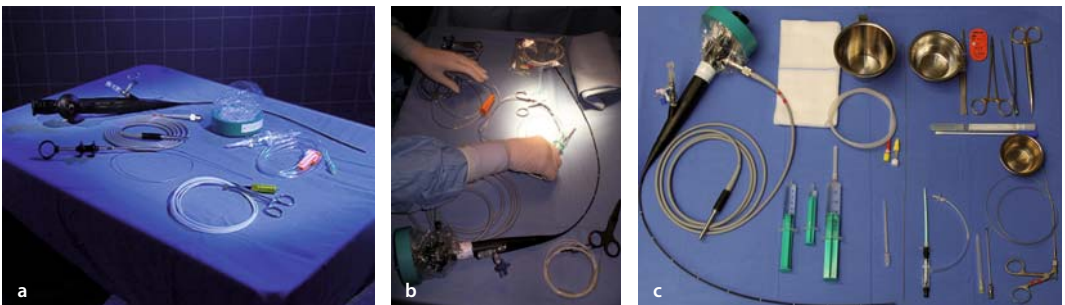
At our pain clinic, we go to great lengths to offer training and continuing education for especially apt and motivated nursing and technical staff. This in turn ensures us highly skilled staff providing technical assistance for invasive and interventional procedures, especially for epiduroscopy.



■ Fig. 5.19. Holding system for the epiduroscope

### 5.4.2 Instrumentarium

In addition to the digital endo-camera system, which consists of the epiduroscope, light guide and camera with a cable, carrying out epiduroscopy and endoscopic surgery requires that the proper sterile instruments are laid out on an instrument tray (■ Fig. 5.20a–c). For epiduroscopy,



■ Fig. 5.20a–c. Instruments required for EDS

**Table 5.2.** Instruments required for EDS

<b>Digital endo-camera system</b>	1 epiduroscope
	1 light conductor
	1 camera, including cable
<b>Basic instrument set for EDS</b>	1 sponge forceps
	6 towel clamps
	1 scalpel
	1 smooth forceps
	1 tissue forceps
	1 dissecting scissors
	1 needle holder
	1 cutaneous suturing material with needle
	Compresses
<b>Additionally required sterile disposables</b>	1 camera cover
	1 introducer set 9.5 F
	1 infusion line
	1 hemostasis valve
	1 Heidelberg extension
	1 3-way stopcock
	2 5-mL syringes (saline, contrast agent)
	1 10-mL syringe (contrast agent)

**Table 5.3.** Instruments required for EDS

<b>Prep A</b>	Gowns
	Gloves
	Patient drape sheets
	C-arm cover
	Cover for epiduroscope holder
<b>Prep B</b>	<b>Epiduroscope:</b> Camera cover 3-way stopcock Hemostasis valve Light cable
	<b>Saline attachment on solution warmer:</b> Infusion set with flow regulator 2 Heidelberg extensions
<b>Instrument tray</b>	Sponge forceps
	Towel clamps
	Tissue forceps
	Scissors
	Needle holder
	Scalpel
	Tuohy needle
	Introducer set
	Epidural catheter
	Biopsy forceps Laser fibers
	Dishes for saline, disinfection, local anesthetic
	20 mL syringe for local anesthesia with infection needles
	10 mL syringe for contrast agent (Solutrast 250M)
	5 mL syringe for saline
5 mL syringe for contrast agent (Solutrast 250M)	
Suturing material	

we have put together a special EDS set that consists of the sterile instruments presented in the tables above (Table 5.2 and 5.3):

Materials for epiduroscopy that need to be available in the OR include local anesthetics, contrast agents, surgical needles, saline and syringes, transport containers for tissue specimens and smears, catheters with stylets, electrodes, long, flexible foreign body forceps, laser fibers, introducer sets 9.5 F and 11.0 F, a fluid warmer for irrigation fluid and dressing materials. A great deal of time and money can be saved if the materials are sterilely packaged in ready-to-use coordinated sets.

## 5.5 Preoperative management

When performing elective invasive EDS procedures, certain standards for preoperative management must be observed. Because clinical pain symptoms and radiological findings are also used to explain spinal pain syndromes, assessing diagnostic examinations can be difficult. The diagnostic method is selected based on the patient's previous course of disease and the current clinical findings.

The multidisciplinary findings (e. g. radiological, neurological and psychiatric, orthopedic and neurosurgical findings, as well as the results of internal medicine and lab tests) and an informed consent discussion with the patient outlining the risks of the procedure are all integral parts of preoperative management for epiduroscopy.

### 5.5.1 Preoperative history, clinical examination and anesthesiological evaluation

By obtaining an in-depth history of the patient's pain and carrying out a thorough clinical examination, the surgeon can distinguish between nociceptive and neuropathic or mixed pain.

In addition to obtaining a detailed pain history, the surgeon also needs to carry out a clinical neurological examination. On a case-by-case basis, other diagnostic tests may include inspec-

tion, gait and posture examination, functional examination of the mobility of the spine, tests for tenderness and pain on percussion, as well as provocation tests. In addition, the straight leg raise test (Lasègue's sign), the femoral nerve stretch test, Bragard's sign, finger-floor distance and Schober's test should be carried out.

The examination must include an assessment of reflex status. In addition, motor strength should be assessed according to the British Medical Research Council Motor Grading Scale. A sensitivity test is also essential. A combination of root compression syndromes with myelopathy is also conceivable; thus symptoms of spinal cord injury, such as spasticity, ataxia, gait disorder and pathological reflexes should be observed. Krämer has compiled the cardinal signs of lumbar root syndromes (■ Table 5.4).

In general, as with an acute radicular clinical finding with deficits, a therapy-resistant pain syndrome should be clarified with the use of an appropriate sectional imaging technique, such as MRI or computed tomography. Imaging diagnostic findings that are of particular interest prior to epiduroscopy include results of MRI, CT, discography, myelography, and in some cases, plain radiography. They also provide the examiner with a basis for epiduroscopic navigation.

In order to prepare for the invasive procedure, both imaging and neurophysiological examinations are essential.

■ Table 5.4. Cardinal signs of lumbar nerve root syndromes (according to Krämer)

Segment	Peripheral pain and area of hypesthesia	Motor disorders (Key muscle)	Diminished reflex	Nerve root tension sign
L1/L2	Inguinal area	–	–	(Femoral nerve stretch pain)
L3	Anterior aspect of thigh	Quadriceps	Patellar reflex	(Femoral nerve stretch pain)
L4	Anterior aspect of thigh, medial aspect of calf and foot	Quadriceps	Patellar reflex	(Positive Lasègue's sign)
L5	Lateral aspect of calf, medial aspect of the dorsum of the foot, great toe	Long extensor muscle of great toe	–	Positive Lasègue's sign
S1	Posterior aspect of the calf, heel, lateral margin of the foot, third to fifth toes	Triceps surae, gluteal muscles	Achilles tendon reflex	Positive Lasègue's sign



The patient's experience of pain is colored by his or her subjective perception, as well as emotional and social factors. Pain assessment and documentation is also essential, both for preparation and for monitoring the course of treatment, checking the pain diagnosis and adapting treatment. The extent to which the patient is able to undergo the comprehensive battery of tests depends on the overall condition of the patient.

Prior to epiduroscopy, a consultation with the patient takes place in which he or she is informed about the planned epiduroscopic procedure, as well as follow-up treatment and the disclosure of possible complications. In addition, the patient is given written information about the procedure and is asked to sign a consent form.

For quality assurance reasons, it is essential to properly document the basic information on the patient consultation about the procedure as well as the patient's consent to undergo epidural diagnostic and pain treatment procedures.

### 5.5.2 Electrophysiological tests

Electrophysiological tests are used for special issues in the diagnosis of spinal pain syndromes. In order to objectify radicular symptoms in the case of pain that radiates into related areas for longer than 4 weeks, electromyography (EMG) is indicated. Identifying pathological electrophysiological potentials can be helpful when examining spinal canal stenoses or myelopathies.

Electrodiagnostic studies of the muscles and the associated nerves are necessary to determine the extent and acuity of a nerve root disorder and to localize it.

Assessing nerve conduction speed is a standard neurophysiological examination that shows how quickly an electrical impulse is transmitted along a nerve fiber or a nerve bundle. Electrophysiological diagnostics are well suited for diagnosing subclinical neurogenic lesions and for differential diagnosis of myopathies, as well as for the diagnosis of neuropathies, including exclusion of peripheral nerve root compression syndromes.

Somatosensory evoked potentials (SSEP) evaluation is an extension of sensory neurography.

This involves electrostimulation of somatosensory nerve fibers, which stimulates action potentials that are conducted afferently via the main nerve, plexus, posterior roots, posterior bundles of the spinal cord, brain stem and thalamus to the post-central cortex.

SSEP studies are helpful for diagnosing disorders in the area of the sensory neural pathways, from the posterior funiculi to the parietal cortex. Damage caused by inflammatory disorders, spinal cord compression or growths, as well as by cervical myelopathy, can be assessed. SSEPs can be used to identify interruptions to or deceleration of nerve conduction as a result of disc injuries or neural inflammation. Electrophysiological diagnostics are used for special clinical concerns prior to performing EDS.

### 5.5.3 Other tests

**Preoperative ECG.** In patients over 40 or patients with known cardiovascular disease or risk factors or who have cardiac illnesses including dyspnea on exertion or chest pain, administering cardiac or cardiotoxic drugs (cytostatics) and performing an ECG is recommended.

**Preoperative chest X-ray.** A chest X-ray is required for patients over 60, and for patients with a history of or current lung or intrathoracic disease, myocardial or valvular disorders, pathological vital signs or clinical examination results.

**Lab tests.** For preoperative work-ups or differential diagnosis, a basic lab test can rule out certain pathologies with a high degree of certainty or can point to other causes. Special immunological tests such as anti-Borrelia antibodies or liquor diagnosis are called for depending on the differential diagnostic aspects. CRP and ESR parameters may be used in the case of inflammatory spinal diseases, while glucose and HbA1c levels are checked in neuropathies caused by diabetes.

For patients under 60, it is recommended that lab tests for hemoglobin, glucose, sodium, potassium, creatinine, alanine aminotransferase, urea

and clotting (prothrombin time-PTT, platelet counts) be performed.

For patients over 60, lab tests for hemoglobin, glucose, potassium, creatinine, urea, alanine aminotransferase and bleeding time should be carried out. For patients assigned to categories ASA I and ASA II, blood clotting tests are only necessary if they have a history of clotting disorders or are taking anti-coagulants such as salicylic acid.

Case studies on epidural bleeding in epidural regional anesthesia lend credence to the assumption that there is a link between anticoagulation carried out perioperatively and thrombosis prophylaxis with low molecular weight heparins. In line with the recommendation by the consensus committee of the Second Consensus Conference on Neuraxial Anesthesia and Anticoagulation (see ASRA website: [www.asra.com/consensus-statements/2.html](http://www.asra.com/consensus-statements/2.html)) of the American Society of Regional Anesthesia and Pain Medicine (ASRA) and the German Society for Anesthesiology and Intensive Care Medicine (DGAI), risk to the patient should be reduced by maintaining certain time intervals between application of regional anesthesia (epiduroscopy) and/or catheter removal, on the one hand, and application of thrombolytics, on the other.

It is recommended that in patients with non-elective procedures for whom an epidural regional anesthesia procedure is planned, thromboprophylaxis should be started early after admission with 5,000 units of unfractionated heparin administered subcutaneously in order to gain as much time as possible before the procedure. Afterward, thromboprophylaxis can be adapted to the risks, for example, with a low molecular weight heparin approx. 7 to 9 hours after initial administration of unfractionated heparin, which generally results in a time interval of more than 4 hours after epidural regional anesthesia. The risk to the patient can be reduced by maintaining time intervals between epiduroscopy and/or catheter removal, on the one hand, and application of thromboprophylaxis, on the other.

Duration of thromboprophylaxis should be dependent on additional risk factors particular to the patient, to the surgical trauma and the degree of immobility.

To meet the needs and standards for patient safety, an independent anesthesiological stand-by should be used during the epiduroscopy.

#### 5.5.4 Standards for hygiene

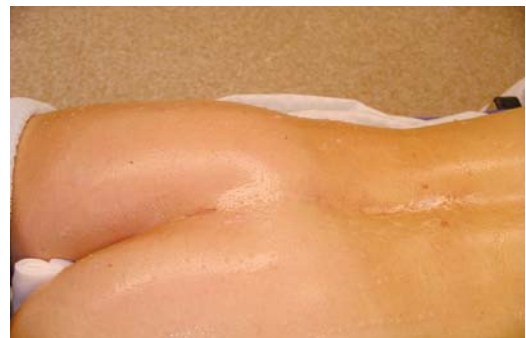When performing epiduroscopy, stringent safety standards for hygiene must be maintained. Absolute sterile techniques must be adhered to in the operating room when performing epiduroscopy.

In addition to surgical hand disinfection, the surgical staff must wear sterile gloves and gowns, masks and caps. Proper skin disinfection and sterile drapes, as well as the use of disposable materials (packaging of the light guide, laser, C-arm) are indispensable.

We recommend perioperative antibiotic prophylaxis. Administering a one-time dose of an antibiotic intravenously prior to the procedure is an effective method for preventing infections during the procedure. We generally use a one-time IV bolus of 1.5 g of cefuroxime immediately prior to carrying out epiduroscopy. We do not consider long-range antibiotic prophylaxis to be necessary.

#### 5.5.5 Positioning

Because of the sacral approach to the epidural space, the patient is positioned prone on the operating table. While epiduroscopy can also be performed in the lateral position, it is much easier and safer for both patient and surgeon when epiduro-



■ Fig. 5.21. Positioning the patient

scopy is performed with the patient in the prone position.

In order to simplify the technical procedure of puncturing the sacral canal, the operating table can be slightly bent near the patient's buttocks. In order for the sacrum to be exposed horizontally, a pillow may be placed under the patient's hips. To facilitate the puncture, the patient's heels may be turned outward and toes turned inward. To prevent disinfectants from spilling into the anal or genital area, a layer of gauze should be placed in the intergluteal cleft. In our experience, the procedure does not demand any special technical positioning requirements.

trends toward too deep or too shallow sedation can be detected. Cerebral state monitoring allows the quality of analgosedation to be improved, especially during performance of the epidural pain provocation test.

As with all types of epidural anesthesia, all equipment for treating complications must be in place. Before beginning epiduroscopy, preparations should be made. These include setting up an IV with infusion, blood pressure measurement, ECG and arterial O<sub>2</sub> saturation (SaO<sub>2</sub>).

## 5.6 Anesthesia management

---

The anesthesiologist is responsible for anesthesia management, including informing the patient, ordering lab tests, selecting and carrying out the analgesic procedure and postoperative care. According to studies by Buchner et al., patients with chronic back pain show a higher incidence of comorbidity. The authors considered the impairment due to comorbidity to be higher than for control persons.

Anesthesiological standards for preparing the operating room and carrying out the invasive procedure must be maintained at all times.

If required, the patient may be premedicated, for instance with midazolam 0.05 mg to 0.1 mg/kg administered intramuscularly or orally. In isolated cases, continuous analgosedation administered on an out-patient basis may also be beneficial for epiduroscopy, as this form of anesthesia management offers good control and entails an extremely short recovery phase after the operation.

To optimize patient safety, and quality of therapy and treatment, we are increasingly using an CSM (cerebral state monitor) monitoring system when analgosedation is required. CSM monitoring during analgosedation allows an adequate dosage of the hypnotic. Monitoring sufficient deep sedation is in turn a good method of ensuring that the patient's respiratory tract is free (risk posed by the prone position of the patient) or to prevent risk of pressure on the brain increasing, because

# Performing Epiduroscopy

## 6.1 Accessing the epidural space – 68

- 6.1.1 Puncture technique – 69
- 6.1.2 Our own experience with epiduroscopy – 69

## 6.2 Epidurography – 73

- 6.2.1 Definition – 73
- 6.2.2 Indication – 73
- 6.2.3 Contraindications – 73
- 6.2.4 Epidurography management – 74

## 6.3 Epidural irrigation – 76

- 6.3.1 Saline infusion – 76
- 6.3.2 Epidural pressure – 76

## 6.4 Segmented epidural examination – 77

- 6.4.1 Examining sacral segments – 77
- 6.4.2 Examining lumbar segments – 78
- 6.4.3 Thoracic examination – 78
- 6.4.4 Cervical examination – 79

## 6.5 Concluding epiduroscopy – 80

## 6.6 Follow-up epiduroscopy – 80

## 6.7 Ultrasound-assisted epiduroscopy (SONO-EDS) – 83

- 6.7.1 Ultrasonography in anesthesia and pain medicine – 83
- 6.7.2 Epidural sonography – 84
- 6.7.3 Our own results – 85

## 6.8 Myeloscopy – 87

## 6.1 Accessing the epidural space

The entry to the sacral canal is afforded by the sacral hiatus in the area of S5 (■ Fig. 6.3). The sacral approach was described by Sicard and Cathelin in 1901 and was used in 1909 by Stoeckel to administer analgesia during vaginal delivery.

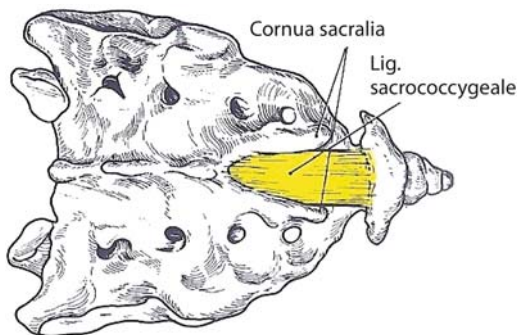
However, we consider the approach to the epidural space via the sacral hiatus, which we prefer for epiduroscopy, to not be free of complications, due to its constantly surprising and impressive anatomical variability. The anteroposterior diameter of the sacral canals studied by Trotter averaged 5.3 mm. However, in 5.5% of the cases they measured less than 2 mm. The lateral extension of the

sacral canal varies according to its volume between 12 and 65 mL. In their studies, Lanier et al. reported a mean distance of 47 mm from the spinal dura mater to the apex of the sacral hiatus with a range of 19 to 75 mm (■ Fig. 6.1). In 2004, Sekiguchi et al. carried out an anatomical study in which they examined 92 sacral hiatuses. In 42% of the cases, both the sacral hiatus and the sacral horns could be identified. The average diameter of the sacral canal was 6.0 mm. The most important finding of the study is the fact that 3% of the sacral hiatuses were closed.

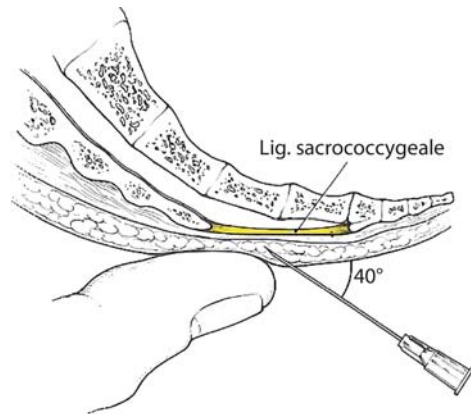
The sacral hiatus is closed by the sacrococcygeal ligament. In order to approach the epidural space, this membrane must be perforated by the introducer (■ Fig. 6.2).



■ Fig. 6.1. The sacrum is formed by the fusion of the five sacral vertebrae. The vertebral canal runs downward through the sacrum and terminates in the sacral hiatus. This gap is caused by the absence of the vertebral arch in the fifth sacral vertebra (Source: Buckhøj in: Scott, Techniques of Regional Anesthesia, 1996)



■ Fig. 6.2. Sacrococcygeal ligament (Source: Wildsmith, J.A.W., Armitage, E.N. 1991)



■ Fig. 6.3. Position of the introducer (Source: Wildsmith, J.A.W., Armitage, E.N. 1991)

A wide range of methods for identifying the epidural space have been described in the literature. The technique of choice is the loss of resistance method, or negative pressure in the epidural space. The loss of resistance technique is based on the fact that the position of the introducer tip causes marked resistance within the ligaments upon injection, which suddenly lets up after it passes through the ligamentum flavum.

It has been reported that when administering caudal injections for pain therapy, even among experienced doctors, when the C-arm technique is not used, the caudal epidural space is accessed in only 62% of cases. In a randomized study carried out by Price, in 200 patients the caudal (sacral canal hiatus) approach was compared to the lumbar approach with regard to accuracy of placement of epidural injections. Ninety-three percent of the lumbar and only 64% of caudal epidural injections were correctly placed. The majority of incorrectly placed caudal injections were subcutaneous. Six to nine percent of the caudal injections were intravenous.

White et al. also compared the caudal and lumbar approach to the epidural space in 334 patients. In their study, 25% of the caudal injections and 30% of the lumbar injections were incorrectly placed.

### 6.1.1 Puncture technique

Our sacral approach to the epidural space requires the patient to be positioned prone on the operating table. The skin is thoroughly disinfected and the patient is covered with sterile drapes. Local anesthesia with a local anesthetic such as 1% hydrochloride mepivacaine is injected around the sacral hiatus.

Once the local anesthetic has begun to take effect, and a stab incision has been made, the sacral hiatus is punctured with a puncture needle from the introducer set, approx. 4 cm from the intergluteal cleft at an angle of approx. 45°. Once the 18-gauge needle has perforated the sacrococcygeal ligament, the needle is aligned to the axis of the vertebral canal.

The distance between the end of the epidural cavity and the sacral hiatus, which is important in the sacral approach, varies greatly and can be anything up to 16 mm. For this reason, after a nega-

tive aspiration test at two levels with 180° needle rotation, the guide wire (double flex, 0.038 in, 45 cm, PVB, Smith Medical, Kirchseeon, Germany), can be introduced into the sacral hiatus, preferably over only a short distance (■ Fig. 6.4a).

A lateral control X-ray is very useful for identifying the guide wire in the sacral hiatus (■ Fig. 6.4b). The 9.5 or 11.0 F dilator with the shaft and its lateral tube connector from the introducer set can now be introduced percutaneously into the sacral canal over the wire, using the Seldinger technique (■ Fig. 6.4c). Epidurography may be performed.

After checking the exact position of the introducer, the dilator is now removed along with the guide wire. At this point the sterile epiduroscope can be carefully introduced into the epidural space over the plastic sleeve under constant control via the monitor.

### 6.1.2 Our own experience with epiduroscopy

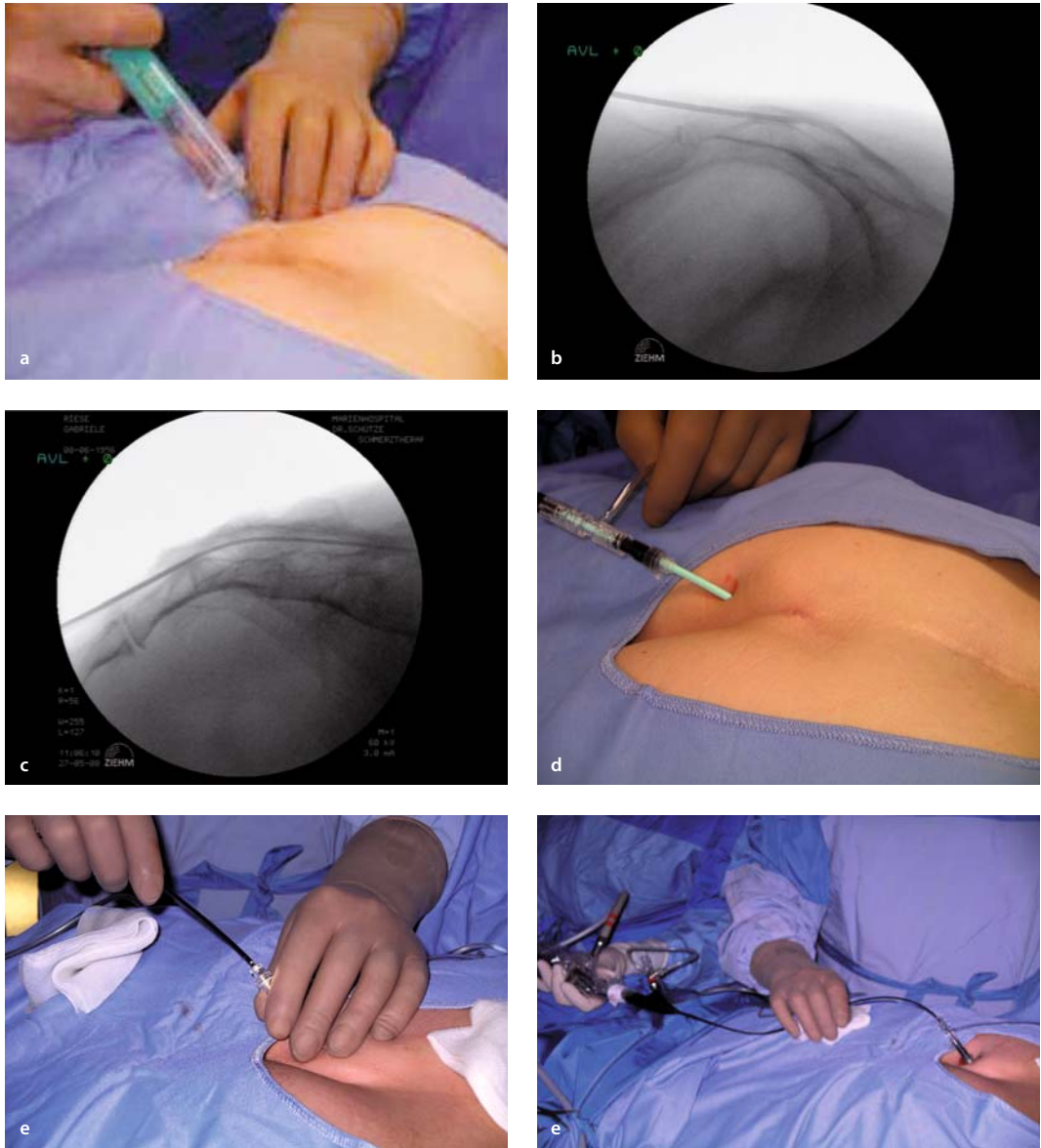
At our pain clinic, the sacral approach to the epidural space has proven to have numerous advantages and to be very feasible. We have used this method for years. We use a special introducer set (PVB, SMITH Medical, Kirchseeon, Germany) with 9.5 or 11.0 F dilators (■ Fig. 6.5).

The plastic sleeve from the introducer set inserted into sacral hiatus allows the epiduroscope to be introduced safely and atraumatically and to be advanced in the epidural space. It also provides essential anti-shearing protection (■ Fig. 6.4e,f).

Despite years of experience, from a clinical perspective the approach to the epidural space continues to be complicated in some cases due to the wide range of anatomic variation in this topographic area. Problems may already arise when placing the needle or the epiduroscopic introducer in the sacral hiatus.

Improper placement of the introducer may include the following:

The needle is located on the sacrum, underneath the periosteum of the sacral canal, ventral to the sacrum, or in the sacral foramen. The needle may end up between the sacrum and the coccyx or may even perforate the rectum. If bleeding oc-



**Fig. 6.4a–f.** a Puncture of the sacral canal. b Puncture cannula in the sacral canal. c Guide wire in the sacral canal. d 9.5 F introducer in the canalis sacralis. e,f Introducing the epiduroscope into the epidural space over the plastic sleeve

curs, the introducer can be withdrawn far enough for the blood flow to stop and then the lumen can be irrigated with saline solution. When the needle is placed correctly, dural injury is rare.

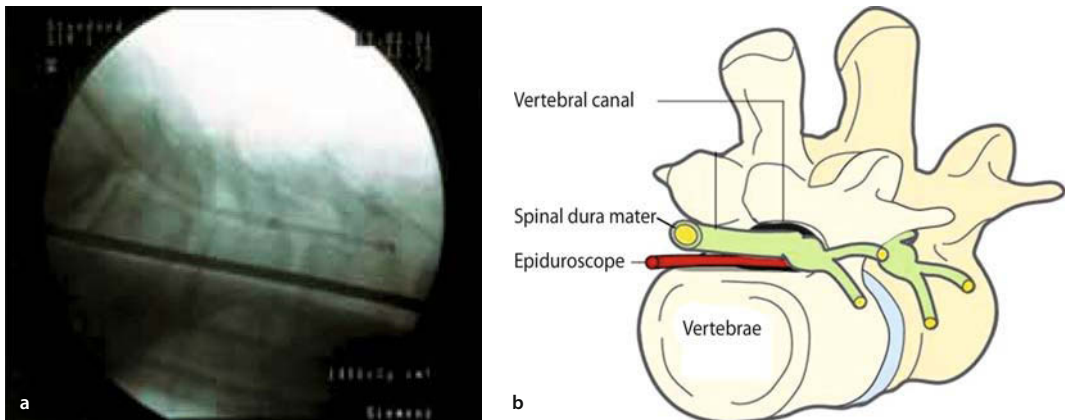
In many cases, needle placement succeeds only if the endoscope is navigated correctly. Occasion-

ally, needle placement is possible only if special guide wires and introducers or additional lateral C-arm fluoroscopy are used.

In 0.25% of our cases, severe stenosis of the sacral canal made it impossible to place the 9.5 F introducer, Witte et al. pointed out the need to use



■ Fig. 6.5. Special introducer (PVB, SMITH Medical, Kirchseeon, Germany)



■ Fig. 6.6a,b. **a** Epiduroscope in the ventral epidural space of a human cadaver. Epiduroscopy workshop held on February 17, 2001 at the University of Innsbruck's Department of Anatomy. **b** Topography of the spinal cord with the epiduroscope in the ventral space

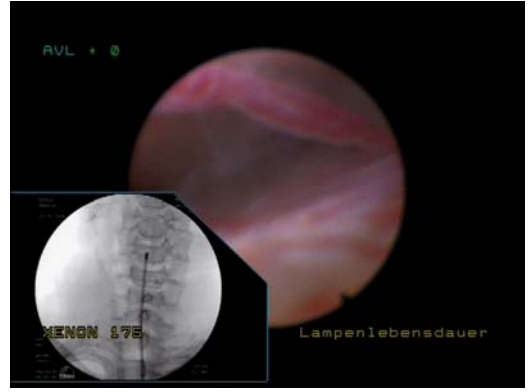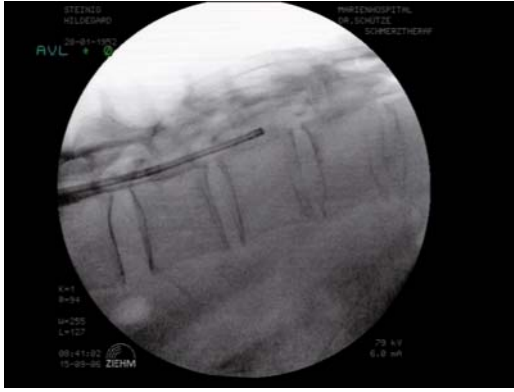flexible optics for epiduroscopy due to the problematic anatomy of the sacrum.

It is helpful to carry out epidurography via the placed introducers using contrast agents. Once the epidurogram has been assessed and the introducer has been repositioned if necessary, the sterile epiduroscope can be carefully inserted into the epidural space via the plastic sleeve either dorsally or ventrally as needed and under constant visual control on the monitor.

The notion that the anatomical situation allows only a dorsal approach for therapy is no longer valid. The same is true for the notion that spinal dura mater in the thoracic part of the vertebral canal is fused together with the posterior longitudinal ligament to such an extent that there is no ventral epidural space at this spot.

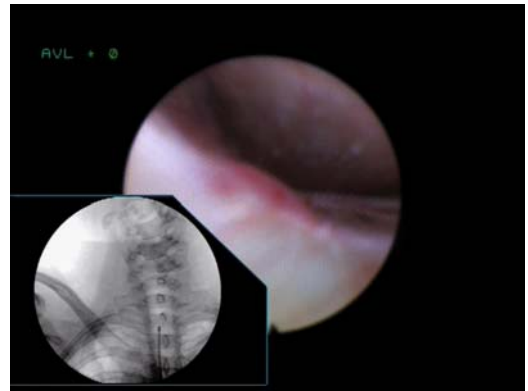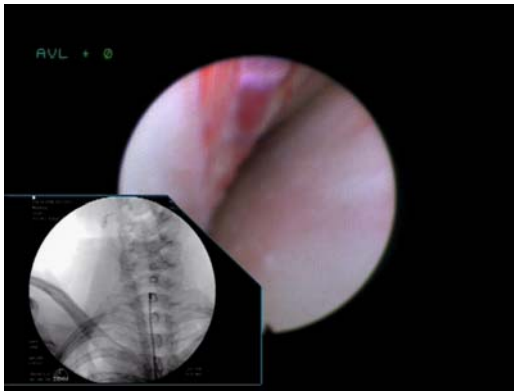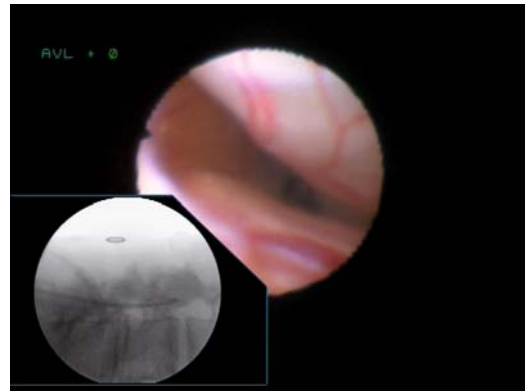
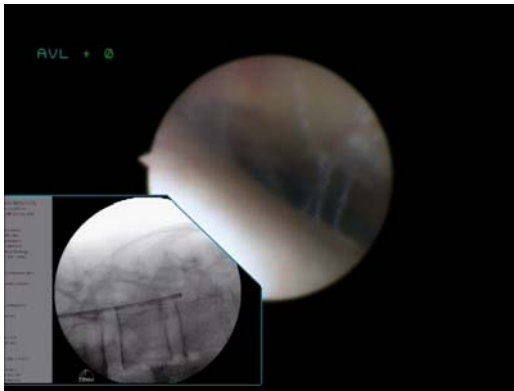
Epiduroscopy, on the one hand, and epidurography, on the other, have proven that a ventral approach for therapy is also possible (■ Fig. 6.6–6.9).





**Fig. 6.7.** Epiduroscope in the ventral epidural space of a pain patient

**Fig. 6.9.** Epiduroscope in cervical canal (Picture-in-Picture technique)



**Fig. 6.8a–d.** Epiduroscope in the ventral epidural space of a pain patient (Picture-in-Picture technique)

By using endoscopic diagnostics, we were able to identify the epidural space in cases in which it was possible to insert the introducer system in the sacral canal.

In 6% of our cases, once the sacral canal had been successfully punctured, inserting the 9.5 F introducer was very problematic due to the anatomical narrowness of the sacral canal of < 2.4 mm. Safe access to the epidural space could ultimately be achieved through a sophisticated dilatation technique with various introducers and various stylet sizes and an improved injection technique.

It is also possible to place a catheter or electrode as needed up to the cervical level without endoscopic support via the sacral introducer.

## 6.2 Epidurography

Providing diagnostic evidence for pain-related epidural pathological structures is often difficult with conventional procedures. In addition to conventional radiological diagnostic procedures, epidurography is particularly well suited for examining this special section of the epidural space.

### 6.2.1 Definition

Epidurography is a radiological procedure in which an X-ray contrast medium is applied to the epidural space and an X-ray video is made at the same time. The objective of epidurography is to distinguish between epidural tissues with similar X-ray densities. With the help of epidurography, additional and important radiological information about the current anatomical situation and functional processes of the patient's epidural space can be obtained.

### 6.2.2 Indication

Indications for epidurography include:

- diagnosing epidural pathological and anatomical structures
- checking catheter position

- identifying improper position of a catheter and if applicable, diagnosing an atypical local anesthetic block
- localizing level and distinguishing a ventral or dorsal position of the epiduroscope or a microsurgical instrument during EDS
- checking results of an epidural intervention.

Prior to every epiduroscopic procedure, we recommend performing epidurography with contrast agents, either via the needle introduced sacrally or the by way of the introducer. This gives the examiner an overview of the current anatomical and pathological conditions of the spinal canal.

Due to the wide range of variation in the anatomical structures of the sacral hiatus and the sacral canal, the current epidurogram is of vital importance for properly implementing epiduroscopy.

In addition, epidurography allows epidural septae, spinal canal stenoses, herniated discs and other growths, epidural fibrosis or adhesions or other abnormalities to be detected in advance.

For instance, clinical phenomena of epidural anesthesia with untypical spread of anesthesia can often be plausibly explained by epidurographic findings.

**Contrast agents.** For epidurography, we use the water-soluble contrast agent Solutrast® 250 M with iopamidol as the effective ingredient. One mL of contrast agent contains 510 mg iopamidol. The iodine atoms bound in the Solutrast® 250 M absorb X-rays, which constitutes the actual contrastive effect. After epidural application, the contrast agent moves into the bloodstream and is excreted by the kidneys in non-metabolic form. No more than 3.75 g iodine (15 mL Solutrast® 250 M) should be injected.

### 6.2.3 Contraindications

Contraindications for epidurography are the same as those for epidural regional anesthesia procedures.

Contraindications for the administration of iopamidol Solutrast® 250 M include severe renal disorders with coexisting severe excretion disorders of the liver, manifest hyperthyroidism and decompensated heart failure, pulmonary edema, neuromuscular hyperexcitability and manifest tetany.

## 6.2.4 Epidurography management

### C-arm technique

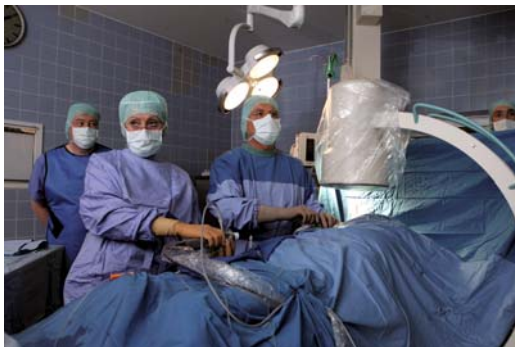For the sacral approach to the epidural space, navigating the spinal region and performing epidurography, C-arm technique is required (■ Fig. 6.10, 6.11).

During fluoroscopy, an image intensifier TV chain is used to present the radiation exiting the body – the radiation that has not been absorbed – as an image or video on a monitor. The diagnostic image quality primarily depends on the capacity of the C-arm equipment, the recording technique and the properties of the image intensifier TV system. Coordinating the overall image production system with the recording parameters and resolution capacity of the image intensifier TV system is essential for producing adequate image quality and an acceptable level of radiation exposure. Modern

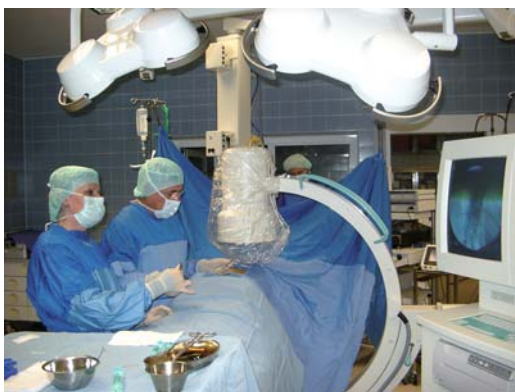digital image intensifiers allow the greatest possible reduction of radiation dosages by optimally intensifying the received X-rays. With the C-arm technique, the examiner can continuously observe functional processes in the spinal canal on the monitor. Various options for documentation are available for recording images. All patient-related data are also documented. A magneto-optical drive allows filmless archiving. The C-arm intensifier system is equipped with a video output and a CD drive with which the images can be exported in the computer-compatible TIF format.

### Performing the C-arm technique

With the C-arm technique, contrast agents for epidurography may be administered into the epidural space via a percutaneous injection technique, a sacral introducer, an in-dwelling epidural catheter or the epiduroscope itself. The contrast agent iopamidol (Solutrast® 200 M/250 M) contains 408.2 mg or 510.3 mg iodine/mL respectively. Volumes ranging from 1 mL to 15 mL of the contrast agent are injected as needed at the cervical, thoracic, lumbar or sacral level to be evaluated. During the injection of contrast agent, C-arm fluoroscopy can be used in the anteroposterior view and must be used in the lateral view for individual images or video recording to gain valuable information on pathological and anatomical changes in and around the epidural space.



■ Fig. 6.10. EDS workstation



■ Fig. 6.11. EDS workstation

### Complications

Although the available contrast agents are water soluble and are completely resorbed, adverse reactions such as headache, neck stiffness, fever, orthostatic dysregulation, spinal functional disorders, psycho-organic syndromes or »contrast agent allergy« may occur.

In such cases, the application of contrast agents should be dispensed with and the sole focus placed on the endoscopic diagnostics.

In special cases, pretreatment with cortisone and antihistamines can be carried out in order to prevent the severe allergic reaction.

Mizuno et al. (2007) described a case in which encephalopathy and rhabdomyolysis was induced by the administration of the contrast agent iotrolan

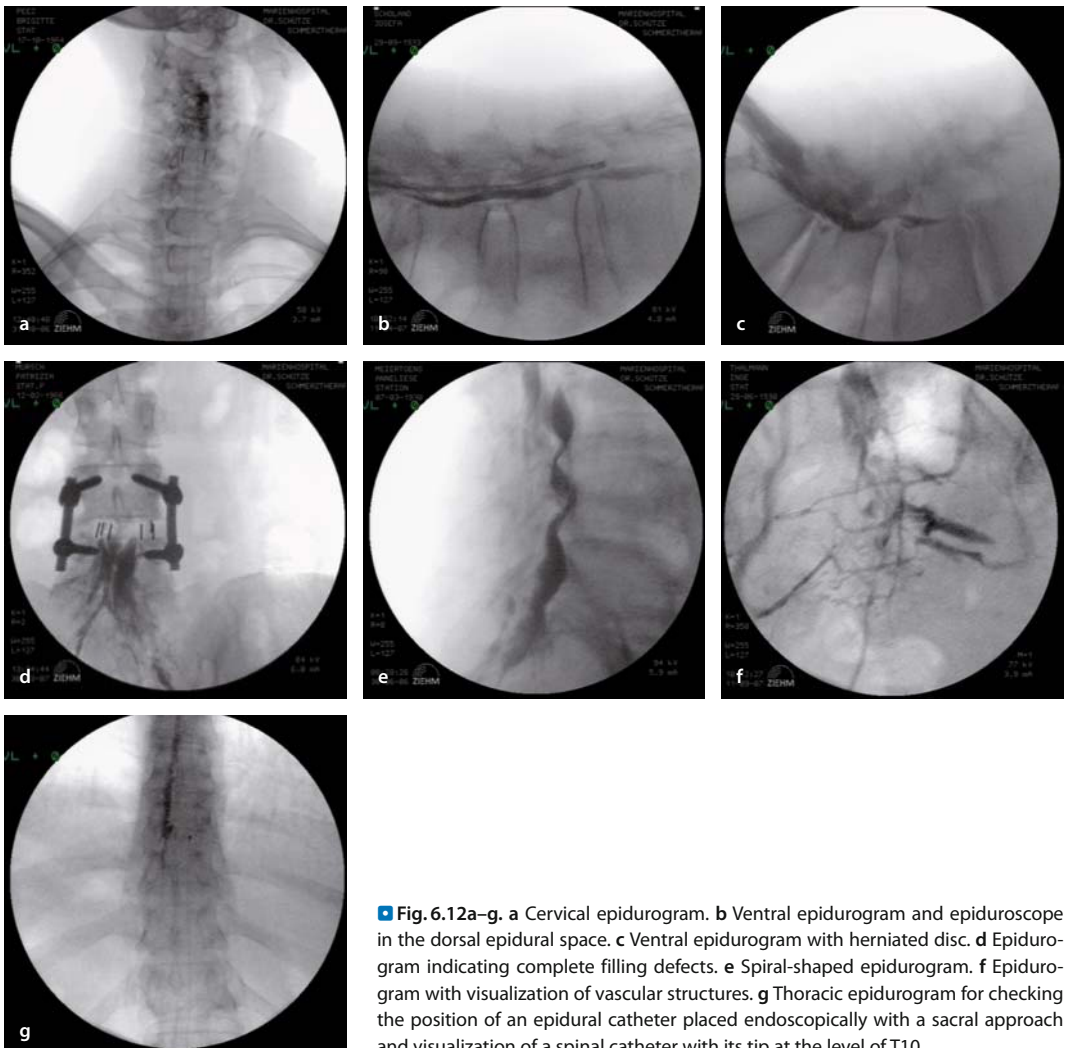
during epiduroscopy. A dural tear during epiduroscopy allowed the contrast agent to enter the subarachnoid space.

## Results

The widely held notion that the spinal dura mater and the posterior longitudinal ligament are fused together in the thoracic part of the vertebral canal such that there is no ventral epidural space in this area is not supported by our epidurographic (■ Fig. 6.12a–g) and epiduroscopic findings and must be rejected.

In my experience, with the sacral approach it is indeed possible to reach and examine lumbar, thoracic or cervical sections of the ventral epidural space. By checking the position of the epiduroscope in the spinal canal with the C-arm technique in the anteroposterior and lateral view this can be easily controlled.

Due to the individual morphology of the epidural space, the visualized epidurograms vary widely. The most frequently reported radiological irregularities reported among our patients were long and short gaps in contrast agent spread, narrow and wide bands of contrast agent, partial



■ Fig. 6.12a–g. a Cervical epidurogram. b Ventral epidurogram and epiduroscope in the dorsal epidural space. c Ventral epidurogram with herniated disc. d Epidurogram indicating complete filling defects. e Spiral-shaped epidurogram. f Epidurogram with visualization of vascular structures. g Thoracic epidurogram for checking the position of an epidural catheter placed endoscopically with a sacral approach and visualization of a spinal catheter with its tip at the level of T10

and complete filling defects. They included the frequently observed epidurographic image of a railroad track, which in the literature is generally interpreted to be a subdural catheter position or the expression of rhythmic segmental filling of the contrast medium in the lateral epidural space. For patients with failed back surgery syndrome, the injection of contrast agent in the epidural space frequently provided evidence of scarring in the epidurogram, generally unilateral in the lateral epidural space extending into the foramen. However, in fact the changes are due to pain-related pulling of dural structures that are often not captured by conventional radiological examination techniques.

Through epidurography, we have frequently observed that the medication delivered epidurally does not reach the site needed to be effective. Instead, due to epidural obstacles such as fibrosis, the medication quickly flows laterally, and in particular, caudally. A flow of the contrast medium via the vascular system is occasionally reported as well.

For quality assurance, the visualization of the contrast agent in the epidural space should always be documented in the anteroposterior and the lateral view.

In general, epidurography is an examining technique that is simple, safe and quick and provides a high level of information for the examiner with low risks to the patient.

## 6.3 Epidural irrigation

### 6.3.1 Saline infusion

When performing epiduroscopy, continuous epidural irrigation or adapted epidural infusion with physiological saline solution via the working channel of the epiduroscope is required. In our clinic, sterile saline irrigation solution is used for EDS. In order to prevent spinal irritation, a fluid warmer (Medi Temp III, Gaymar, Germany) is used to warm the saline irrigation solution to 37.5 °C. In our experience, initially only as much saline irrigation solution at body temperature should be used as is necessary to render a clear endoscopic field of view.

According to Saberski, the application of physiological saline solution can also be considered to be a therapeutic intervention, because it can flush out the abundant inflammatory mediators present in the epidural space. Identified substances include a number of pro-inflammatory cytokines, such as Interleukin-8 (IL-8) or phospholipase A2, as well as neurotrophic hormones such as nerve growth factor (NGF) or brain-derived neurotrophic factor (BDNF), which play an important role in the pathogenesis of chronic pain.

It has been suggested that epidural irrigation can remove chemical, immunological or inflammatory mediators and prevent the induction of local fibrosis.

If the drip rate of the saline solution is too fast, especially in the thoracic or cervical segment and stenosed areas of the spinal canal, this can cause pain in the patient.

Reducing the drip rate will bring about immediate relief.

Draining the irrigation fluid via a lateral external proximal tube connector of the lock located in the sacral hiatus is possible to only a limited extent.

For our epiduroscopies, we use an average of 85 mL sterile physiological saline solution per examination. This is well below the limit of 200 mL recommended by the international consensus (WISE) in 2006.

### 6.3.2 Epidural pressure

A fundamental problem associated with every epidural pressure measurement is whether the measurement site truly reflects the site of maximum pressure. Epidural probes are available for measuring pressure directly. When using an infusion pump, the mean infusion pressure should not increase above 60 mm Hg. It is also possible to install an epidural pressure monitoring system for continuous monitoring via an integrated transducer system. Depending on the volume of saline solution infused and the particular epidural pathological and anatomical structures, the epidural pressure measured in the 50 patients undergoing epiduroscopy in our clinic fluctuated between

22 mm Hg and 85 mm Hg. However, a careful epidural injection can already bring about a pressure of 50 mm Hg to 70 mm Hg, and a quick bolus application from a 10 mL syringe can create an epidural pressure up to 300 mm Hg.

In our experience, the impact of controlled 0.9% saline infusion appropriate to the situation on spinal pressure during epiduroscopy is negligible.

## 6.4 Segmented epidural examination

A standard examining strategy should be followed when performing endoscopic examination of the epidural space. Depending on the anatomical structure of the spinal canal and a professional examining technique, epiduroscopy can be performed via the sacral hiatus from a sacral approach up to the cervical segments of the spine.

The anatomical nomenclature for the position and direction of spinal structures allows for a standard description of the topography of spinal pathological and anatomical changes when performing and documenting epiduroscopy.

Judging by the literature on epiduroscopy, the majority of examinations of the epidural space focus on the sacrum or the lumbar segments of the spinal canal. One of the reasons for this is the fact that the majority of pathological processes take place in the lumbar segments. On the other hand, a number of the surgeons performing EDS use epiduroscopes whose technical construction permits examination only into the lumbar region.

Apart from our own examinations, there are no reports on thoracic or cervical epiduroscopies.

The anatomical architecture of the spinal canal and the vulnerability of the spinal structures to injury, especially in the cervical and thoracic segments, call for precise, standardized and professional performance of epiduroscopy (■ Fig. 6.13–6.15).

Generally, the dorsal section of the epidural space is reached first after the epiduroscope is inserted in the epidural space. Finding the ventral epidural space may pose problems initially. This requires substantial experience with epiduroscopy on the part of the examiner. Due to the anatomical structures of the spinal canal, the tip of the

epiduroscope has very little room to maneuver in the epidural space. Carefully rotating the epiduroscope externally, or changing the direction of the epiduroscope tip, which can be deflected upward up to 120° and downward as far as 170°, enables the surgeon to optimally change the epidural position of the epiduroscope tip.

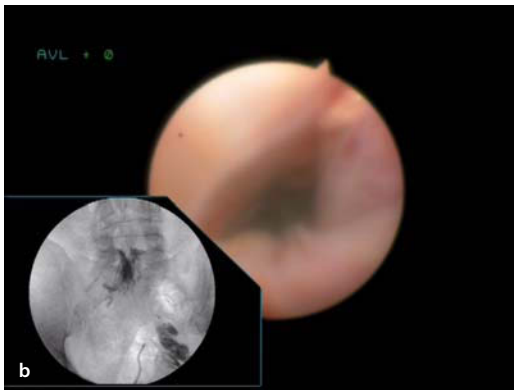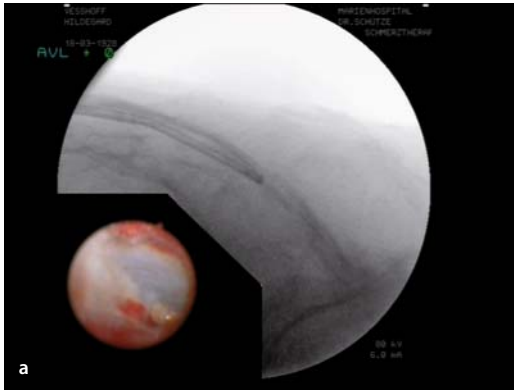
In my experience, adhesions or fibrotic tissue may be mobilized or removed using microsurgical instruments or a laser in order to provide access to the section to be examined. Adhesions that are not very pronounced can also be removed with saline injection or with the tip of the epiduroscope. Any manipulation and intervention with the flexible epiduroscope, including the use of microsurgical instruments, must always be carried out under endoscopic control in order to prevent injury and unnecessary pressure on the spinal structures.

To reach the epidural target position, the epiduroscope must not, under any circumstances, be advanced blindly or forcibly. Constant, optimal endoscope control prevents avoidable complications. With C-arm fluoroscopy or the picture-in-picture technique, locating the level of the epiduroscope in the spinal canal is easy. The Karl Storz epiduroscope now has markings at 5-cm intervals to facilitate location.

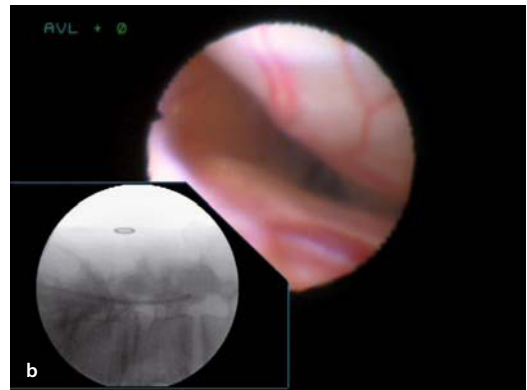
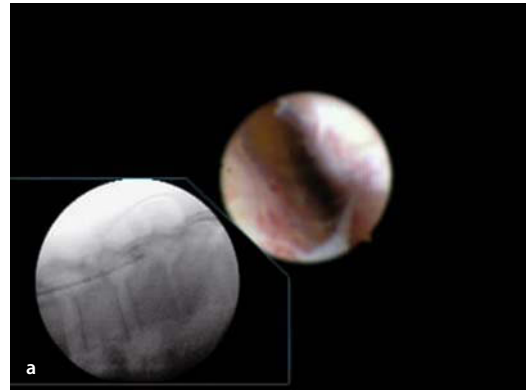
In order to reach the proper segments of the epidural space, I use the flexible epiduroscopes manufactured by Karl Storz, Germany, with working lengths of 40, 70 and 90 cm.

### 6.4.1 Examining sacral segments

After penetrating the sacrococcygeal ligament at the level of S2–S3, the epidural space becomes visible via the plastic sheath that has been introduced. Often, minimal bleeding caused by the guide wire can be observed; this bleeding is harmless. In the case of osseous stenoses, navigating the sacral region is particularly difficult. Simultaneous endoscopic and radiological navigation in the lateral view is very helpful in this situation and protects the epiduroscope from unnecessary damage. Once segment S1 has been reached, the proportion of epidural fat generally increases and the connective



■ Fig. 6.13a,b. a Epiduroscope in the sacral canal (Picture-in-Picture technique). b Epiduroscope in the sacral canal (Picture-in-Picture technique)



■ Fig. 6.14a,b. a Lumbar examination (Picture-in-Picture technique). b Lumbar examination (Picture-in-Picture technique)

tissue structures come together to form the ligamentum flavum. The spinal dura mater is generally visible in segment S1-L5 (■ Fig. 6.13).

#### 6.4.2 Examining lumbar segments

Epiduroscopic examinations are most frequently performed in the lumbar region because

- all cranially oriented examinations must be carried out via the lumbar segment,
- most epiduroscopic examinations and therapies are carried out in the patients' lumbar region due to the prevalence of low back pain, and
- epiduroscopes available on the market are primarily designed for examining the lumbar regions.

In segment S1-L5, the examiner can decide whether he or she wishes to use the ventral or dorsal approach to the epidural space.

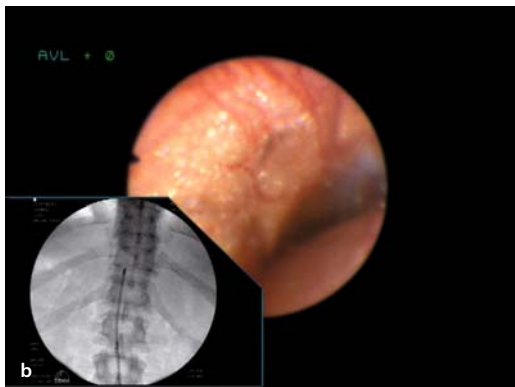
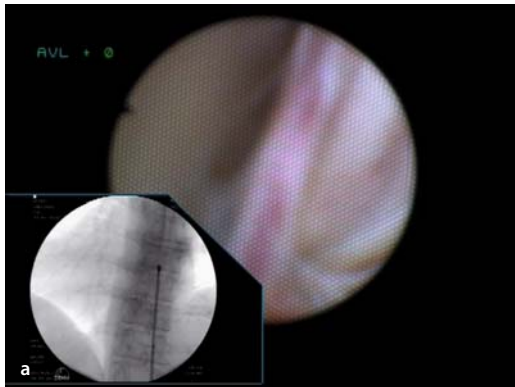
With skillful endoscopic and radiological navigation, it is possible to reach the less easily accessible ventral epidural space. In addition to endoscopic visualization of the posterior longitudinal ligament and the spinal dura mater, using the C-arm technique to control the position of the epiduroscope in the lateral view is highly recommended (■ Fig. 6.14).

#### 6.4.3 Thoracic examination

There is considerably less volume in the thoracic segments of the epidural space, making the qual-

ity of endoscopic images substantially better. In my experience, in the thoracic section the amount of saline irrigation fluid may often be considerably reduced as well. Our results with planned thoracic epiduroscopy show that it is preferable to perform the epiduroscopic procedure over several segments of the spine in order to rule out so-called incidental findings. Our examinations show that pain-causing pathological and anatomical structures are often found at great distances from the level originally planned for examination (■ Figs. 6.15a,b).

The simultaneous use of C-arm fluoroscopy and epiduroscopic imaging as a picture-in-picture technique and control of the volume of saline infusion offer excellent conditions for spinal navigation and a high level of patient safety.



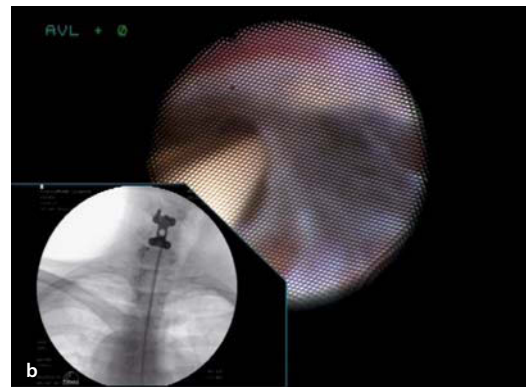
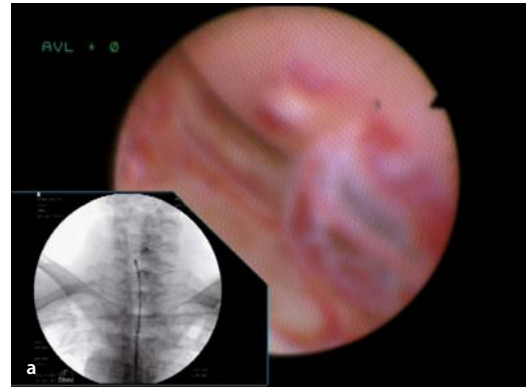
■ Fig. 6.15a,b. a Thoracic epiduroscopic examination (Picture-in-Picture technique). b Thoracic epiduroscopic examination (Picture-in-Picture technique)

A prerequisite for inspecting the thoracic segment is the use of a flexible epiduroscope with an adequate length (FLEX-X<sup>2</sup> epiduroscope, Karl Storz, Germany) with the necessary microsurgical accessories for interventions.

#### 6.4.4 Cervical examination

The new flexible epiduroscope with FLEX-X<sup>2</sup> technology and a working length of 90 cm also allows endoscopic inspection into the cervical region (■ Fig. 6.16).

To date over 80 epiduroscopies in the cervical section of the spine have been carried out successfully at the Iserlohn Pain Clinic without any complications.



■ Fig. 6.16a,b. a Cervical examination with vascular visualization (Picture-in-Picture technique). b Catheter in the cervical epidural space (Picture-in-Picture technique)



These are the first cervical epiduroscopies carried out in pain patients with the flexible Flex-X<sup>2</sup> epiduroscope, Karl Storz, Germany anywhere in the world.

Examining the cervical segments of the spinal canal calls for special attention and care. The anatomical circumstances and the excellent technical conditions allow ventral and dorsal live images with very good to brilliant quality, often without requiring irrigation fluid to be substituted. For this reason, epidural irrigation for enhancing optical conditions is generally unnecessary.

To perform procedures such as biopsy in the cervical segments of the spine, special instruments are required. The accessories of the FLEX-X<sup>2</sup> epiduroscope include flexible graspers or flexible biopsy forceps with a diameter of 1.0 mm and a working length of 160 mm. At our pain clinic, biopsies and laser adhesiolyses are initially performed only when absolutely indicated.

In my experience treating a large number of patients, cervical catheters can generally be placed via the epiduroscope without any problems. However, extra-long catheters are required. We use a 0.6×1.0×1800 mm epidural catheter from Vygon, Aachen, Germany, inserted via a stylet.

Due to the risk of injuring neural and other structures during epiduroscopy, this endoscopic examination may only be performed by operators with substantial experience.

## 6.5 Concluding epiduroscopy

During epiduroscopy, information including vital signs such as blood pressure, heart rate, SaO<sub>2</sub>, EEG and other monitoring, administration of drugs, entry and exit of fluid (epidural saline solution for irrigation, pressure measurement, infusion therapy), technology used (e.g. X-ray, laser, ultrasound, etc.), staff and time is recorded. »In clinical practice at our clinic the time for EDS should not exceed more than 30 minutes«. Current recommendations of the World Initiative on Spinal Endoscopy, WISE-Consensus, are not to exceed 60 minutes procedure time.

Prior to ending the epiduroscopic procedure, the area must be carefully checked to ensure all bleeding has stopped. The epiduroscope is then

carefully removed from the epidural space under constant control. Constant epidural irrigation and slow retraction of the epiduroscope generally also allow for the best video images to be recorded.

If the catheter is to remain in the epidural space, the epiduroscope should be carefully retracted via the in-dwelling catheter with its stylet under endoscopic vision.

The sacral puncture site can be closed with an interrupted suture or tissue adhesive (Ethyl-2 Cyanoacrylate, Meyer-Haake Medical Innovations, Germany). Once the wound has been dressed, the epiduroscopy is complete, with little to no pain experienced by the patient.

The results of the epiduroscopy must be recorded in a protocol. We recommend saving the endoscopic images on video film and/or a video printer or to a CD, memory stick or DVD.

The use of documentation management and archiving systems such as AIDA allows physicians, nursing staff and other clinical staff to modify typical workflows while processing information in the pain clinic.

Following epiduroscopy, the standard procedures for postoperative patient management for procedures performed under local anesthesia or analgesedation should be observed.

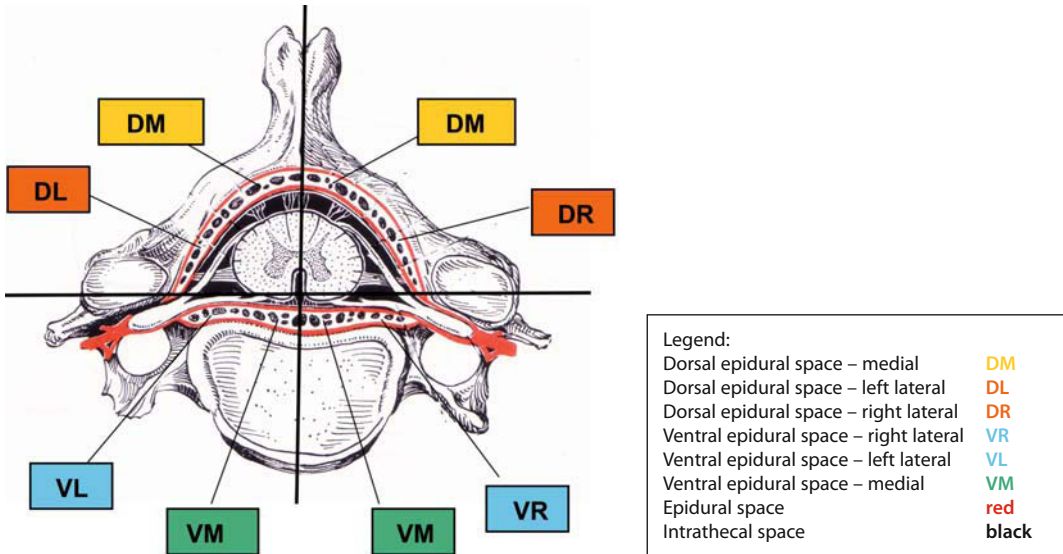
Following epiduroscopy, the patient should be observed by a physician or nursing staff until the analgesedation has worn off.

At our clinic, out-patients undergoing epiduroscopy remain in the recovery room for approx. 1 hour. Once they have met discharge criteria (stable vital signs, can tolerate food and drink, can empty their bladder and walk unassisted), they may leave the clinic if they are accompanied by a responsible adult.

It is particularly important that the patient have 24-hour access to a physician in case of questions or emergency. This also applies to patients undergoing outpatient examination. The patient returns to the clinic for out-patient follow-up the next day.

## 6.6 Follow-up epiduroscopy

During the course of epidural analgesic pain therapy, performing endoscopic monitoring is merited



■ Fig. 6.17. Guide to anatomical structures for EDS

in some cases. Using epiduroscopy for follow-up is also indicated in cases in which epidural-analgesic therapy or laser adhesiolysis or scar reduction have not led to clinical improvement.

The endoscopic follow-up can often show the free epidural passage and if needed, the correct placement of the catheter or the electrode.

If epiduroscopy or the use of the microsurgical instruments or laser fiber is not performed carefully, perforation of the dura or laser lesions are likely to occur. Epiduroscopic follow-up after surgical or accidental defects of the dura or epidural lesions can be helpful.

In individual cases, endoscopic control after administration of special drugs for adhesiolysis may be merited to check for effectiveness or for quality control.

In our experience, the outcomes of interventional treatment in patients undergoing endoscopic treatment after the second procedure, 5 to 7 days after the first intervention, could be considerably improved in a number of cases. In addition to repeating the therapeutic effect of epidural irrigation, the pain-related pathological processes, which often involve growths or stenoses, could be

further reduced or the catheter position for EAT could be optimized.

These repeated or expanded invasive pain-therapy interventions could relieve the patients' pain situation to the extent that their pain score during follow-up was reduced by up to 30%. Based on the Pain Disability Index, the quality of life of the chronic pain patients treated at our clinic showed overall improvement.

At our pain clinic, 25% of all epiduroscopies (263 EDS) performed from June 2006 to June 2007 were follow-up or control epiduroscopies (66 EDS).

In 22 patients, an epiduroscopic follow-up was performed within 5 to 7 days of the initial epiduroscopic procedure due to continued symptoms. Epiduroscopic examination or repeated EDS-assisted therapy (EAT or laser adhesiolysis) was successfully repeated in 13 patients after 6 months and in 31 patients after 12 or more months due to recurring pain.

Patients who were unable to benefit from the epiduroscopically assisted treatment received further treatment in line with multidisciplinary multimodal pain-therapy concepts, such as an algorithm for epidural pain therapy.

**Based on our clinical experience, the following indications are valid for follow-up or control epiduroscopy:**

- Continuing pain symptoms
- Epiduroscopy of a different spinal region
- Continued pronounced pain-related pathological findings that require additional microsurgical treatment
- Control and monitoring of
  - a) chronic inflammatory processes (radiculitis, epiduritis)
  - b) pharmacological local effects
  - c) catheter placement (optimizing placement of epidural catheter and probes)
- Control examinations following epidural interventions
- Interruption of the primary EDS due to:
  - a) Volume of infusion or time factor exceeded
  - b) Epidural bleeding
  - c) Dural perforation
  - d) Uneasiness on the part of the patient
  - e) Technical problems
  - f) Technical problems during primary EDS. Endoscope too short or defective (no other epiduroscope available)

For our group of patients, the most frequent reason for performing an additional epiduroscopic procedure within 5 to 7 days of initial epiduroscopy was for diagnostics and therapy of a different epidural region than for initial EDS.

In most cases, cervical epiduroscopy, including therapeutic measures, was performed after initially performing lumbar EDS.

Catheter techniques for EAT supported by epiduroscopy, in addition to epidural adhesiolysis, are further indications for a second epiduroscopy to be performed after 6 months to more than one year after the initial procedure.

The overall therapeutic results are very good. With the aid of epiduroscopic examination and treatment techniques, in the majority of cases open surgical intervention and revision can be avoided and long and drawn out and expensive treatment courses prevented.

It is also important to note that if endoscopic procedures do not lead to the desired result, there are no disadvantages for later conventional surgical interventions.

In a random sample of 100 patients who had undergone epiduroscopy, 12 months after EDS involving catheter placement for EAT and laser adhesiolysis patients were asked whether they would undergo the procedure a second time or not. All of the patients said they would undergo the procedure a second time. None of the patients reported complaints or adverse effects of EDS.

During the postoperative interval, the rate of pain relief is 50% for all epiduroscopic invasive procedures.

Endoscopic follow-up procedures also serve to provide objective information on the success of the operation and quality control. From the point of view of health economics, using epiduroscopy for diagnosing and treating spinal pain syndromes has the added benefit of being a low-cost procedure.

**Conclusion.** Epiduroscopy is a direct imaging technique which provides the examiner insight into the pathological and anatomical structures and the dynamics of the epidural space, as well as visual understanding of this important topographic region.

At our clinic, the sacral approach to the epidural space has proven to be a very practical method for performing epiduroscopy. The preferred injection method facilitates and guarantees safe access to the epidural space. However, due to the wide variation in anatomical structures of the sacrum, placing the special introducer for the epiduroscope in the sacral hiatus can be difficult.

Several very good reusable epiduroscopes with a working channel are now available for performing EDS.

With epiduroscopy, it is possible to unequivocally identify both the dorsal and ventral parts of the lumbar, thoracic and cervical epidural space.

According to the results of a special evaluation of EDS in 50 patients in our pain clinic who underwent an epiduroscopic procedure in 2007, epiduroscopy was described as easy to perform by the same experienced physician in 78.4% of the cases. In 19.6% of the epiduroscopies, the procedure was

described as difficult and in 2% as especially difficult to perform.

The anatomical architecture or pathological and anatomical structures of the vertebral canal and the possibility of damage to the spinal structures, especially in the cervical and thoracic segments, require the procedure to be carried out precisely and professionally, in a standardized manner.

In our opinion, epiduroscopy considerably increases diagnostic and therapeutic options, especially for the treatment of chronic pain, without a great deal of additional effort.

In addition to carrying out interventions under endoscopic vision, which in itself justifies epiduroscopy as a procedure, diagnostics can be enhanced and made more precise in a way that no other method allows. Reports in the literature are equally positive.

## 6.7 Ultrasound-assisted epiduroscopy (SONO-EDS)

Ultrasonography is an integral part of the medical diagnostic repertoire.

After a slow start, ultrasound diagnostics are now increasingly being applied in the areas of anesthesiology and intensive care and emergency medicine. Sonography is gaining in significance in the area of pain medicine as well.

### 6.7.1 Ultrasonography in anesthesia and pain medicine

To some extent, ultrasound-assisted epidural blocks are still in the clinical development phase. Grau examined the lumbar region of 20 healthy volunteers without relevant spinal disease both sitting and lying down using ultrasonography and MRI. With the patient in a sitting position, the results of the ultrasound using paramedian access were comparable or superior to the results of MRI. The correlation values and precision were especially good for depth determination of the individual structures, for example, of the ligamentum flavum and the dura mater. Lower correlation

values were achieved in determining the diameter of the spinal canal and the height of the vertebral bodies. The position-dependent variability of the structures in the area of the lumbar spine caused considerable differences in the measurements.

Leipold examined the possibility of visualizing the epidural space of the thoracic spine via ultrasound and compared the precision of the ultrasound measurement with that of MRI. The thoracic epidural space could be located in all volunteers with both procedures. The ligamentum flavum could be visualized equally well with both procedures and the spinal dura mater could be visualized well. The author reported a good correlation between the procedures. Leipold considered MRI and ultrasonography to be of equal value.

Ultrasonography prior to procedures such as thoracic epidural puncture can provide added safety to clinical routines. McLeod et al. studied 11 patients scheduled for corrective scoliosis surgery. The spine was examined ultrasonically using a portable ultrasound system with a 38-mm linear probe in two-dimensional B mode. Epidural catheterization was successful in 8 out of 11 patients at the identified level. In 2 other patients, the space above was used. The information was described as helpful in 7 patients. McLeod concluded that ultrasonography may have a potential role to facilitate insertion of epidural catheters in patients with scoliosis.

The advantages of using ultrasonography in anesthesiology and pain medicine are yielded by the special properties of the ultrasound. The latest generation of ultrasound equipment allows visualization of joint facet surfaces, muscles and even extremely delicate nerve fibers just millimeters in thickness. For example, it is now possible to use ultrasonography to visualize the course of local anesthesia applied in tissue. For pain medicine, ultrasonography has also proved helpful in performing stellate blocks.

In recent years, ultrasound-assisted peripheral nerve blocks have become increasingly significant.

Despite the difficult conditions for performing ultrasonography on the spine, concepts for the clinical use of ultrasound-assisted neuroaxial blocks are being tested. With ultrasonography, the spine can be visualized in the transverse and sagit-

tal planes. The spinous processes of the vertebral bodies can be visualized well in the sagittal (longitudinal) and median planes. With the so-called offline procedure, the epidural space is conventionally punctured with the loss of resistance method, however without ultrasound. Grau et al. carried out a randomized, prospective study of pregnant women. They showed that the use of ultrasonography for lumbar neuroaxial block reduces the number of puncture attempts as compared to the use of the loss of resistance method alone. The success of the block and patient satisfaction was higher in these patients. The same was true for anticipated difficult punctures.

In children between the ages of 6 and 8, ossification of the spine is not yet complete. As a result, acoustic shadows and acoustic attenuation are much less pronounced in children than in adults. According to Rapp, the insonation conditions of the lumbar region in children up to the age of 8 are very good in some cases due to the incomplete ossification of the spine. This allows needle placement, the placement of epidural catheters and injection of local anesthesia to be monitored with direct ultrasound visualization.

The primary advantages of ultrasonography include its low-risk, non-invasive and radiation-free and painless application, widespread availability and the quick nature of the procedure. The use of contrast media (echo-signal amplifiers) in ultrasonography has further enhanced ultrasound diagnostics. Ultrasonography with contrast media allows real-time continuous assessment of the dynamic contrast patterns.

In comparison to imaging procedures such as computed tomography or MRI and epiduroscopy, the costs for purchasing and operating ultrasound equipment is lower. Ultrasound diagnostics are now used in nearly all medical specialities. By sharing the equipment, costs can be cut. In addition, with ultrasonography, there is no need for radiation protection measures or instruction.

However, producing and interpreting ultrasonographic images requires skill and experience on the part of the examiner. Ultrasonography provides lower spatial resolution than EDS, CT and MRI, especially in deeper tissue. The quality of ultrasound images is dependent on factors such as the experi-

ence of the examiner with ultrasonography and anatomy, hand-eye coordination, position of the patient, handling and software settings.

### 6.7.2 Epidural sonography

While the steerable epiduroscopes currently available provide endoscopic guidance, they are of limited use for establishing the size or assessing the surface or epidural and neighboring structures, especially in severely pathological circumstances. In response to this problem and in order to optimize endoscopic examining techniques, in 2000 we integrated a microinvasive intraluminal ultrasound technique (intravascular ultrasound, IVUS) in the epiduroscopic technology.

To simplify interpretation of the ultrasound images, a modern spectral analysis procedure was incorporated into the epiduroscopic examining technique in the familiar IVUS technology.

IVUS technology provides the examiner detailed information on the patient's anatomical structures. The colorized virtual histology images show four types of components: fibrous, fibrofatty, dense calcium and necrotic core. The virtual histology images are created using Volcano's imaging console along with the Eagle Eye Gold IVUS (VOLCANO Corp. Rancho Cordova, CA, USA) imaging catheter. The ultrasound images are then displayed in real time in an EDS catheter lab, allowing the pain therapist who will be performing the procedure and his or her surgical team to evaluate the images easily while the patient is still on the operating table. This technology provides automated measurement tools to simplify image interpretation and employs a predetermined color key to display the composition of a specific point of the spinal dura mater or within the epidural space.

We used a Visions Five 64 catheter F/X TM IVUS imaging catheter. The 150-cm long intravascular ultrasound imaging catheter (outside diameter, 1.18 mm) is equipped with a transducer at the tip (tapered tip, outside diameter, 0.022"). The catheter size is 0.97 mm, with a maximum guide wire outside diameter of 0.356 mm. The minimum guide catheter inside diameter is 1.47 mm. The

distal shaft diameter is 0.037", midshaft diameter, 0.037" and proximal diameter, 0.035". The module is 1 mm in diameter and less than 3 mm long. It contains a multiple-element, cylindrical ultrasound transducer array. The incorporation of integrated circuits into the tip of the catheter enables the maximum degree of miniaturization in both the array and the microcable. There are no moving parts necessary to generate 360°, real-time images. This miniaturized transducer array contains circularly integrated chips (64 elements) that allow a picture format of 360° in a two-dimensional view. The ultrasound catheter was connected to the Cathscanner Imaging System of the Endosonic or Volcano ultrasound equipment, along with the epiduroscopic equipment.

### 6.7.3 Our own results

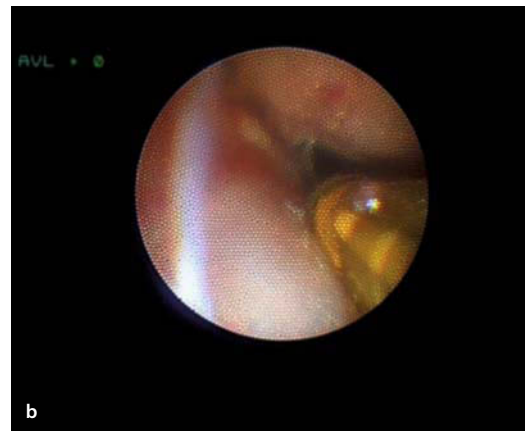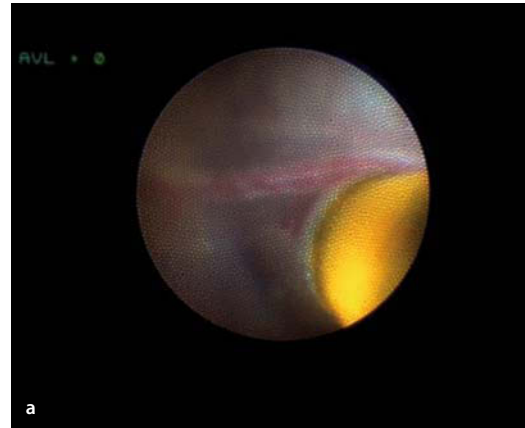
In 2000 we reported on ultrasound-assisted epiduroscopic examinations (SONO-EDS) and epidural catheter placement in patients with failed back surgery syndrome.

To date, there is no literature on invasive ultrasonographic examination of the epidural space. The ultrasound catheter is placed via the working channel of the epiduroscope. The ultrasound transducer array used parallel to the epiduroscopic optics at the same level created ultrasound images perpendicular to the axis of the ultrasound catheter with an angle of vision of 360 degrees. The behavior of the ultrasonic waves in the epidural space is responsible for the picture quality (■ Figs. 6.18a,b and 6.19).

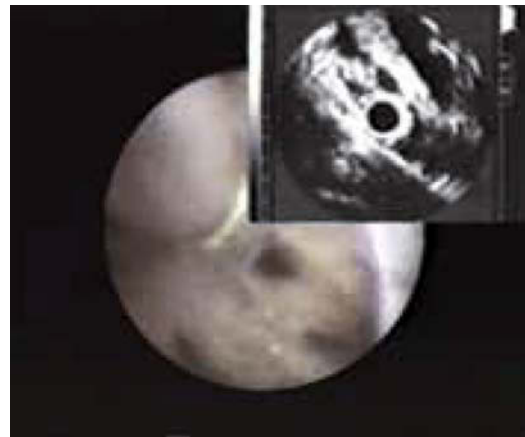Tissue density and water content of the epidural space, the beam angle, the shape of the incision of the anatomical structure in question or the pressure of the ultrasound probe on the tissue all have an effect on picture quality. However, the examiner has little control over these impacts on the ultrasound image.

During epiduroscopy we use the spinal dura mater as an optical guide.

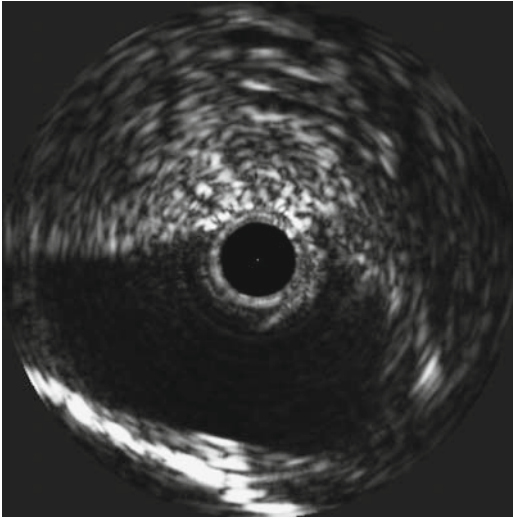
The ultrasound image of the spinal dura mater can be identified particularly well and serves as an excellent basis for navigation in the epidural space (■ Fig. 6.20). According intraoperative examina-



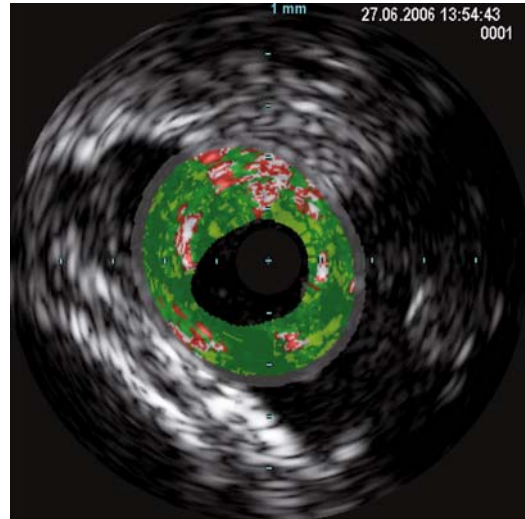
■ Fig. 6.18a,b. SONO-EDS, Ultrasound transducer (yellow) in the epidural space: a blood vessel, b nerve root



■ Fig. 6.19. SONO-EDS in Picture-in-Picture procedure



**Fig. 6.20.** Ultrasonography of the epidural space with the spinal dura mater



**Fig. 6.21.** Epidural ultrasound with virtual histology (blood vessels)

tions carried out by Lerch et al., even in patients with traumatic or tumor-related myelon compression, the highly echogenic spinal dura mater remains visible as a separating layer between bones or tumor tissue and myelon. According to Grau et al., ultrasound imaging of the spinal dura mater in the thoracic segments of the spinal canal is quite feasible.

The established ultrasound nomenclature can be used to analyze and describe the additional information simultaneously provided for the epiduroscopy. Automatic tracing with rapid calculation of the ultrasound findings provides reliable diagnostic information. The high contrast resolution permits reliable reproduction of the tissue histology in the ultrasound cross section. The Cathscanner technology allows realistic visualization of the spinal tissue localization at all times and reaches an ultrasound thickness resolution of one millimeter. Virtual histology is a special process for which the raw intravascular ultrasound data are used to classify plaques within the vascular walls in detail. The radio frequency data sets on which IVUS is based are subjected to spectral analysis and a computer comparison with existing data sets obtained through histological in-vitro validation assigns the individual plaque structures to histological classes.

However, due to the limited number of examinations carried out so far, we have been unable to obtain reliable information about the histological structure (Fig. 6.21).

Advantages of ultrasound-guided epiduroscopy (SONO-EDS):

- The SONO-EDS system prevents accidental dural injury.
- The ultrasound image can provide the examiner with the necessary additional morphological information (virtual histology). This is useful even in cases in which epiduroscopic vision is not restricted.
- Endoscopic imaging information can be optimized and anatomical structures outside the endoscopic live image may be taken into account.
- As a supplementary diagnostic imaging procedure, SONO-EDS enhances epidural imaging information and improves endoscopic navigation.

The SONO-EDS method can also be used to incorporate spinal structures that cannot be captured with the epiduroscope for technical reasons or due to the anatomical circumstances (e.g. CSF or spinal dura mater) into the overall epidural endoscopic image.

## 6.8 Myeloscopy

There are very few reports on the use of myeloscopy in the diagnosis and therapy of pain syndromes. Myeloscopy (spinaloscopy, thecaloscopy) involves endoscopic examination of the intrathecal space following targeted perforation of the spinal dura mater. The intrathecal space is the space between the pia mater and arachnoid mater and contains the spinal cord, spinal nerves and the blood vessels that supply them. Only isolated reports on myeloscopy are available in the international literature.

Hertz et al. (1985) reported on spinaloscopic examinations carried out on fresh cadavers. According to the authors, targeted examination of certain sections of the spinal canal both enhances assessment of the prognosis of trauma patients with paraplegic spinal injuries and supports diagnostics in tumors of the spinal canal, degenerative spinal cord disease and intraspinal angiodyplasia.

Jerosch et al. used an endoscopy system consisting of a spinaloscope 1.8 mm in diameter with portals for instruments and irrigation. The instrument portals can be used for surgical lasers, biopsy forceps or burs. They carried out their evaluations on fresh human spine specimens. In addition to the dura mater, ligamentum flavum, posterior longitudinal ligament and spinal nerves, the authors identified pieces of disc material and various fibrous bands.

In the 1970s, Ooi et al. reported on uneventful myeloscopic examinations in 86 patients between 13 and 78 years old with back pain. The authors concluded that treating special spinal diseases with a myeloscope would be possible in the future without requiring conventional open surgery. As with epiduroscopy, the instrument used for thecaloscopy is a flexible endoscope with an integrated working channel.

Uchiyama et al. (1998) reported that their endoscopes consisted of a fiberscope with an outside diameter of 0.5, 0.9 or 1.4 mm. Starting in 1987, they had performed myeloscopy on 18 patients between the ages of 7 and 69 who had pain or other neurological symptoms of unknown etiology. The spinal cord, roots, the arachnoid membrane and small vessels could be observed clearly. The en-

doscope could be advanced as far as the upper cervical spine. Cotton-candy-like proliferation of fibrous tissue was identified by myeloscopy in four paraparetic patients who had clinical and radiological features similar to those of a spinal cord herniation. The fibrous tissue beat on the spinal cord with the pulsation of the spinal fluid. Resection of the fibrous tissue with conventional surgery led to neurological improvement.

Blomberg (1995) reported on spinaloscopies of the lumbar and thoracic subarachnoid space with rigid endoscopes in 26 human cadavers. Fibrous adhesions were found between nerve roots and/or between nerve roots and the arachnoid membrane at least at one spinal level in 16 subjects. The appearance and density of the structures varied and caused restriction of nerve root mobility in 9 subjects. In 3 cases, the impeded mobility prevented the nerve root from yielding to the contact and pressure exerted by the tip of the endoscope or by a spinal needle. In another 3 cases, a distinct membranous structure was identified in the posterior midline of the subarachnoid space in the lower thoracic and upper lumbar regions. The findings explain the relationship of anatomical subarachnoid structures and the development of subarachnoid blocks.

An international thecaloscopy study group from Zwickau, Germany, reported that if adequate endoscopic equipment is used, thecaloscopy allows the examiner to inspect and maneuver about the intrathecal space. Minimally invasive surgical treatment of intrathecal pathologies is possible with endoscopic methods.

### Our own results

At our pain clinic our experience with elective myeloscopy has been extremely limited. The indication to perform intrathecal inspection should be limited to certain patients. However, an epiduroscopic procedure can easily turn into a myeloscopy if epiduroscopy is not adeptly performed and the dura is accidentally damaged (■ Fig. 6.22a–d). Accidental dural perforation is an avoidable complication of epiduroscopy.

In comparison to epiduroscopy, endoscopic inspection of the intrathecal space (myeloscopy) is somewhat easier. Because the dural sac is filled



with cerebrospinal fluid, saline irrigation is optional for myeloscopy.

It should be kept in mind that spinal headache syndrome can occur after myeloscopy. The reasons for postspinal headache syndrome are controversial.

Our results have shown that among 25 patients undergoing myeloscopy, 2 patients experienced postspinal headache syndrome. However, despite the relatively large dural injuries ( $\geq 2.5$  mm) the headache could be relieved with conventional treatment methods.

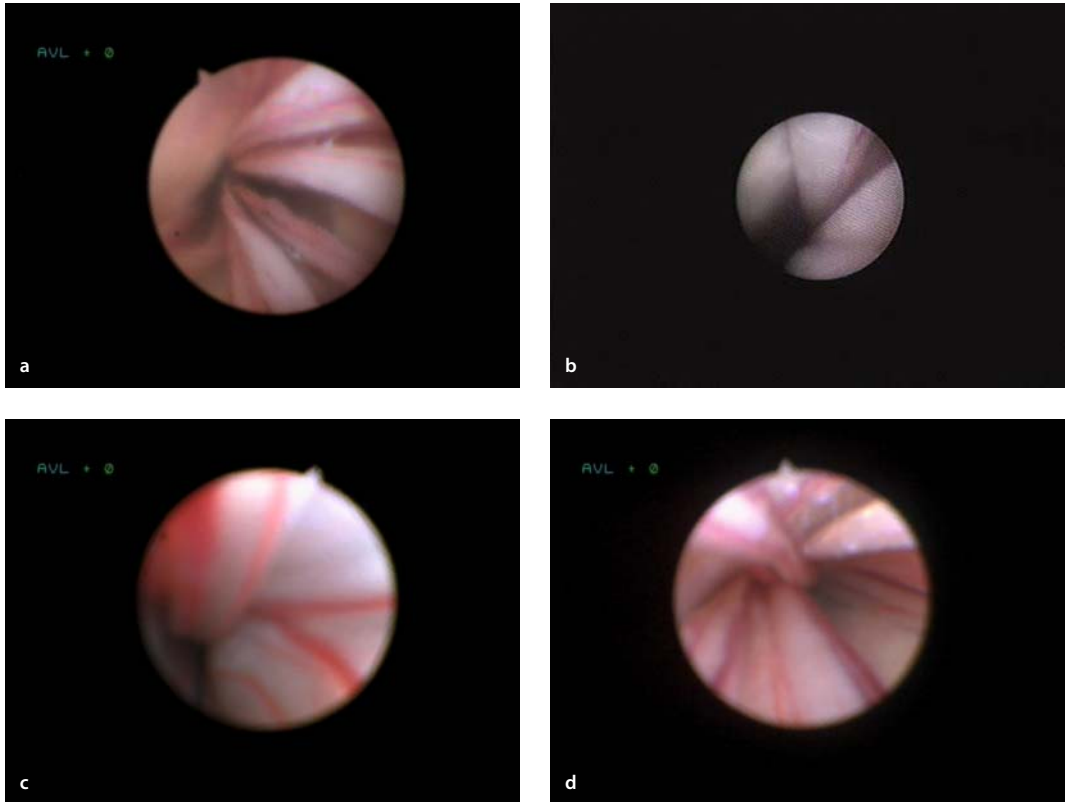


Fig. 6.22a–d. a Subarachnoid space. b Subarachnoid space. c Subarachnoid space. c Subarachnoid space

# Treatment Strategies

## 7.1 Context – 90

## 7.2 Spinal pain syndromes – 91

### 7.2.1 Treating spinal pain syndromes – 91

## 7.3 Epiduroscopic interventions – 94

### 7.3.1 Epiduroscopic catheter management – 96

### 7.3.2 Indications – 96

### 7.3.3 Technique – 98

### 7.3.4 Complications – 98

### 7.3.5 Our own experience – 99

## 7.4 Endoscopically assisted epidural analgesic therapy (EAT) – spinal endoscopic adhesiolysis – 101

### 7.4.1 Indications – 102

### 7.4.2 Drugs used in epidural analgesic therapy – 102

### 7.4.3 Pharmacologic options – 104

### 7.4.4 Performing epidural analgesic therapy (EAT) – 106

### 7.4.5 Results – 107

## 7.5 Epidural laser adhesiolysis – 108

## 7.6 Epiduroscopically assisted electrode implantation – 110

## 7.7 Epiduroscopic (pulsed) radio frequency therapy – 113

## 7.8 Neurolysis – 114

## 7.1 Context

In the United States, the most common reason for disability from work or for visiting a doctor is chronic back pain. In Germany too, spinal pain syndromes are the leading reason for sick days. According to Schöps and Hildebrandt, this pain is the main reason for hospital admission and accounts for 17% of all people going on disability and 40% of all patients undergoing in-patient rehabilitation.

According to other reports in the literature, approx. 80% of the population suffers from chronic back pain at some point in their life. In addition, a substantial number of orthopedic pain patients suffer from chronic back pain. One out of 10 cases of chronic back pain is diagnosed as radiculopathy. According to Junker, a survey of 500 patients in orthopedic and pain medicine practices conducted in 2004 showed that 38% of the patients who had undergone disc surgery complained of neuropathic pain.

In Germany, around 50,000 disc operations are performed every year. Despite increasingly sophisticated microsurgery techniques, 10% of the patients develop failed back surgery syndrome.

In the case of chronic spinal pain syndromes, patients are often dissatisfied with the results of traditional therapeutic efforts from a wide range of disciplines.

### Pathophysiological background

The pathophysiology of chronic pain makes a distinction between nociceptive and neuropathic pain. With nociceptive pain, the peripheral and central nociceptive neurons remain intact. During chronic stimulation of the nociceptive structures, functional and plastic reversible changes to the nerves occur. A precondition for the occurrence of neuropathic pain is damage to the peripheral and/or central structures of the nociceptive system. The injury to the nerve causes widespread structural and anatomical changes to the nociceptive system, some of which are irreversible and which can persist on a long-term basis. Characteristic clinical findings include permanent burning pain, paroxysmal attacks of pain and evoked pain as isolated phenomena or in combination.

While for teaching purposes, distinguishing between nociceptive and neuropathic pain makes sense, doing so does not do justice to the FBSS, because mixed, i.e. neuropathic and nociceptive pain already occurs in the early phase.

Due to the wide variety of pathophysiological mechanisms, in pain medicine the term »mixed-pain syndrome« has become established for describing a synthesis of nociceptive, inflammatory and neuropathic pain components. It is important to assign equal weight to all components in the initial pharmacologic treatment strategy in order to prevent further chronic pain.

### Red flags and chronicity

Indications of threatening chronic pain are provided by so-called red flags, such as age < 20 or > 55, cancer or HIV, infection (fever > 38 °C), recent severe trauma, weight loss, night pain, immunosuppression, steroid treatment, history of drug abuse, neurological symptoms, incontinence, saddle block anesthesia and pareses.

These red flags call for immediate and rapid diagnosis. The mechanisms that cause pain to become chronic have not been completely identified. It is known that risk factors, the so-called yellow flags, exist in a patient's history and environment that may allow these high-risk patients to be detected early on.

Yellow flags include inability to work for more than 4 months, low social status or low or non-existent job skills, low job satisfaction, previous disc surgery, emotional and social problems, depressive disorders, avoidance behavior or exaggerated endurance strategies, stressful childhood, absence of emotional relationships, lack of security, physical abuse, sexual abuse, frequent quarreling or divorce by parents.

Chronicity of pain occurs when neurons on the spinal cord level constantly receive pain stimuli from the periphery. This situation gives rise to a »wind up« phenomenon. This means that previously subliminal action potentials are suddenly transmitted without the corresponding nociceptors in the periphery signalling pain stimuli or existing peripheral pain stimulus becoming stronger.

Permanent pain situations not only lead to constant stimulation of the nerve cells in the posterior horn of the spinal cord but are also able to induce long-term functional and structural changes in the nervous system.

The glutamate receptors, especially the N-methyl D-aspartate (NMDA) receptors which are permeable for calcium ions, are involved in these spinal mechanisms. voltage-gated calcium channels and the ion channel of the NMDA receptor are opened to a greater extent in the excited state of the nerve cell, which increases intracellular calcium ion concentration. Calcium ions are a universal trigger for a number of signal transduction paths that are necessary for learning processes.

For this reason, according to Mense, chronic pain is nothing other than the result of an »involuntary« learning process.

The increased calcium ion concentration influences the cell metabolism. Calcium-dependent phosphorylating enzymes are activated, which changes the gene transcription. The nerve cells produce new proteins, as well as receptors, ion channels and membrane proteins, which means that the cell is now overexcitable and permanently restructured.

Due to the change in excitability the nerve cells respond to the same stimulus with a higher firing activity. Thus, weak pain stimuli trigger a permanently increased stimulus response and the cell fires high-frequency action potentials. These processes are the basis for pain chronicity and hyperalgesia.

The molecule BH4 is a crucial factor in the development of chronic pain. In a study, an international team led by Woolf reported that three genes showed an increase in expression in the case of nerve damage. These genes encode enzymes that are involved in the production and recycling of the molecule BH4, which is essential for the production of serotonin, dopamine and noradrenaline. These observations led the group to assume that human genes that are involved in the regulation of BH4 play a role in the intensity of the response to pain stimuli. In general, low BH4 levels were associated with less pain.

Molecular biological studies on the neuroplasticity of the nervous system carried out by Carr et al. have shown that changes that in principle lead to pain chronicity can occur in a matter of sec-

onds, minutes and hours, which means that time is not an adequate measure for the likelihood of a patient to develop chronic pain.

## 7.2 Spinal pain syndromes

---

Back pain is the most frequent form of pain in the population. A survey carried out in Germany in 2006 showed that an average of 69% of the population there suffers from occasional back pain. Fifteen percent of the respondents reported that they suffered from chronic back pain.

A study carried out in 2002–2003 broke down back-pain statistics by gender. According to the study, 65.8% of women were affected by occasional back pain, far more often than men (57.4%). The incidence of chronic back pain is also higher among women. 21.6% experience persistent pain. 15.5% of men suffer from chronic back pain. Back pain can be divided into specific and non-specific back pain. Specific back pain has an unequivocally identifiable somatic cause and includes herniated disc, spondylolisthesis, spinal canal stenosis, vertebral body fracture, tumors, infection or inflammatory disease.

In contrast, unspecific back pain cannot be explained by specific pathological physical changes. If unspecific back pain lasts for a long time or recurs frequently, there is a risk that the pain will become chronic. Recent research results show that 85% of all back pain is unspecific, which means that the reason for the pain remains unclear. For this type of back pain, treatment generally remains symptom-related. This means that treatment regimens are predominantly oriented toward reducing pain, improving mobility and strengthening muscles.

For patients with acute pain, the chances for quick pain relief are good. In 90% of cases, back pain improves within 6 weeks. The remaining 10% are problematic. These patients do not experience pain relief and their pain may become chronic.

### 7.2.1 Treating spinal pain syndromes

---

Although the focus of this book is on endoscopically assisted invasive therapy, conservative and

pharmacologic treatment strategies for treating acute and chronic spinal pain syndromes must be discussed due to their significance.

The guiding principle of modern therapeutic and multimodal concepts is based on the hypothesis that chronic back pain can lead to chronic impairment or disability as a result of the impact and interaction of biomechanical dysfunction, deterioration of physical condition and psychosocial stress factors. For therapeutic effectiveness, a distinction must be made between acute and chronic spinal pain syndromes.

Most of the regularly applied treatments used are of limited effectiveness for chronic back pain. The prognosis for acute back pain is relatively good, however. The term »chronic pain« takes the duration of pain into account, while the term »chronicity« considers the multidimensionality of the pain.

In order to break the vicious circle of pain – rest – decline in physical condition – pain, proper pharmacologic pain treatment is required. Only targeted pain therapy intervention can prevent pain memory. Psychotherapy can be extremely beneficial.

In the acute phase of illness, patients should also be encouraged to resume their daily activities as best they can. Patients need to be aware that they may move despite their pain. Bedrest for a period of several days is generally contraindicated.

A wide range of effective ingredients, including analgesics and anti-inflammatories are available for pharmacologic pain therapy. Due to the known adverse effects of non-steroidal anti-inflammatory drugs (NSAIDs), they should not be prescribed for long-term therapy.

For pharmacologic therapy, the WHO algorithm for pain therapy may be used as a guideline. It should be ensured that patients can transition quickly from one level to the next.

For pharmacologic pain therapy, adjuvant drug-based intervention for sedation and sleep promotion (tricyclic antidepressants, antiepileptics) should be integrated.

In many cases, surgical decompression is the only reasonable therapeutic intervention. As Deyo et al. concluded, patients with extensive motor deficits and patients with spinal trauma require surgery. Surgical procedures can reduce pain and

enhance function. If no larger neurological deficits exist, patients with herniated disc, degenerative spondylolisthesis or spinal canal stenosis generally do not require surgery. However, proper surgical treatment may bring about acceptable pain relief. Determining the indications and prudent decision-making is called for in this situation.

Pain associations currently recommend multimodal treatment of chronic back pain, which takes somatic, emotional and social aspects into account. The term »multimodal« does not mean that these individual components are simply collected and applied separately. According to studies by Pfingsten and Hildebrandt, multimodal programs for treating chronic back pain based on the principle of »functional restoration« are effective and can reduce treatment costs considerably. The concept was already presented by Mayer and Gatschel in the 1980s. It is characterized by its sports-medicine approach based on behavior-modification principles.

According to Roth-Brons, invasive pain therapy interventions are not methods of first choice. They should only be considered when conservative procedures that have been applied in a multimodal setting do not bring about sufficient pain relief.

This widely shared opinion is no longer up to date, and needs to be revised, not only due to technical advances in interventional pain therapy. The problem of pain chronicity should be addressed as well.

From the point of view of pain therapy, it is important to develop an integrative overall concept for a defined period of 6 to 8 weeks that takes all factors into account at the same time. In the case of resistance to therapy or an increase in symptoms, however, a proper differential diagnosis should be carried out after no later than 12 weeks. Chronic pain treatment must be carried out using an integrative approach and is time- and energy-consuming when undertaken in the conventional manner.

Outcomes are considerably better when therapy is started early on, making early intervention for at-risk patients a very good strategy.

The primary objective involves treating the origin of pain, generally by a specialist.

For non-threatening acute clinical symptoms, pragmatic symptom-oriented treatment is often the best strategy.

Using an invasive pain therapy procedure to meet the individual treatment objective can prevent patients from being prescribed long-term and high-cost WHO Level III opioids.

### Algorithm for spinal pain therapy

For patients with chronic pain syndromes, achieving full recovery in cases such as severe neuropathic pain is very difficult to nearly impossible. These pain syndromes generally constitute a domain of pharmacologic pain therapy using nerve blocks and neuromodulative procedures that are offered in out-patient or in-patient pain clinics.

With the exception of acute cauda equina syndrome, significant and progressive pareses and herniated disc with substantial neurological deficits, which require surgery, treating spinal pain syndromes is done in a multimodal, interdisciplinary conservative manner.

Pharmacologic pain therapy poses particular demands on the patient and the pain therapist, because the chances that any drug on its own will be 100% successful are very low. Therapy should begin with the administration of the drug with proper titration, replacing it with another drug if results are not satisfactory. In our experience, the use of one substance class is often not sufficient, and a combination of two or more effective ingredients is required from the very outset.

For pharmacologic therapy of neuropathic pain, we recommend a basic therapy independent of etiology. This drug-based therapy consists of tricyclic antidepressants/dual selective serotonin noradrenaline reuptake inhibitors (dual SNRIs, whose effective ingredients include mirtazapine, nefazodone and venlafaxine), anticonvulsants with an effect on neuronal calcium channels and anticonvulsants with membrane-stabilizing effect and slow-release opioids.

Keeping a pain diary and sharing reports on results at short intervals is recommended. A wide range of drugs, including gabapentin and pregabalin are available to treat neuropathic pain. For selected patients with particular pain conditions or special situations, it may be necessary to prescribe carbamazepine, amitriptyline, imipramine, doxepin and phenytoin.

The use of most other substances is generally prescribed when individualizing curative therapy.

For patients with a spinal pain syndrome, with the wide range of options for conservative treatment available, no gold standard for therapy has been defined.

Based on the internationally accepted recommendations of the Scottish Intercollegiate Guidelines Network (SIGN), the letters A to D are used to assess scientific evidence. Evidence-based guidelines for treating spinal pain syndromes exist.

- The letter D has been assigned to pain relief treatments. This means that there are no well-founded studies in this area. Statements on effectiveness are supported by case reports and expert opinions.
- For pharmacologic therapy, for example with analgesics and steroidal and non-steroidal anti-inflammatories, a body of evidence is available assigned the letter A. This means that the statement on effectiveness is supported by several adequate valid clinical studies or by at least one valid meta-analysis or systematic review.

The main principle is to bring about pain relief in order to subsequently achieve functional normalization. Advising bedrest for patients with low back pain or telling them to »take it easy« is not recommended, because there is no proven therapeutic effect for these measures.

Patients with radicular pain syndromes, too, are recommended to undergo physical therapy and resume activities no later than 4 days after the acute event. More than 4 days of bedrest is discouraged.

For conservative treatment, within a period of 6 to 8 weeks there should be a marked reduction of pain and an increased capacity on the part of the patient. If this is not the case, treatment modification or invasive diagnostics (epiduroscopy) or surgical intervention should be considered, because continuing conservative treatment may lead to pain chronicity.

Based on clinical results and the practical work of pain therapists who perform invasive procedures, the following algorithm was developed in cooperation with the task force for interventional pain therapy of the German Pain Association

(DGS). The algorithm needs to be adapted to the particular case in question.

- **Level I:** Series of epidural analgesias in the single-shot technique with 0.125% to 1.75% bupivacaine. Once it has taken effect, targeted physical therapy is started. If therapy is successful, no further invasive measures are needed.
- **Level II:** If the measures in Level I of the algorithm are only partially successful or not at all, an additional epidural application of a glucocorticoid is delivered. The course of combined invasive and physical therapy remains unchanged. For partial responders, epiduroscopy is indicated, specifically, targeted endoscopically assisted epidural-analgesic therapy.
- **Level III:** Epidural analgesias with local anesthesia and/or application of adequate dosage of opioid analgesics (WHO Level III) that lead to long-term pain reduction or freedom from pain in the case of peripheral or spinal source of pain. At this level of the algorithm, in the case of non-opioid-sensitive pain diagnoses that ruled out a spinal cause, indication for surgery, somatoform pain disorder or central pain sensitization need to be reviewed. If these reasons have been ruled out, after reviewing the stringent selection criteria, therapy with spinal cord stimulation (SCS) is indicated. If the test is positive, either the epidural therapy via epidural catheter is continued in the form of epidural analgesic therapy (EAT) over a limited period of 2 to 4 weeks or there is a direct transition to oral opioid therapy.
- **Level IV:** In the case of intolerable opioid-related adverse effects and/or insufficient analgesia, the transition is made to continuous spinal (intrathecal) opioid analgesia via spinal catheter and a drug pump. It must be kept in mind that the new algorithm approved by the Polyanalgesic Consensus Panel (PCP) on January 20, 2007 in Miami, Florida, now includes ziconotide as an alternative to first-line opioids, morphine and hydromorphone. Fentanyl was moved from a fourth-line treatment option to a second-line option and clonidine was recommended for neuropathic pain as a second-line single agent option. The 2007 PCP continues to recommend that ziconotide can be combined with other line

three treatment options (morphine, hydromorphone, bupivacaine and clonidine).

- **Level V:** Coordinated supportive therapy is indispensable for oral opioid long-term medication, as well as for spinal opioid analgesia or ziconotide therapy. Pain therapists have a wide range of epiduroscopically assisted invasive techniques at their disposal, including catheter management, epidural analgesic therapy, epidural laser adhesiolysis, SCS implantation, pulsed radio frequency therapy and surgical and neurolytic procedures, in order to meet the treatment objective or the individual treatment objective of the patient.

Setting a suitable early time for endoscopic diagnostics and therapy of spinal pain syndromes is crucial for counteracting potential pain chronicity.

### 7.3 Epiduroscopic interventions

For epidural diagnostics and therapy of pain syndromes, endoscopy of the epidural space – epiduroscopy (EDS) – is a new imaging procedure that supplements conventional procedures and can also be used to perform invasive procedures.

For epiduroscopically assisted interventions, such as biopsy, adhesiolysis, resection of scar tissue, removal of irrigation fluid or lipoma removal, cauterization, extirpation of foreign bodies and abscess drainage, flexible surgical instruments, surgical lasers and catheters are available for use via the working channel of the epiduroscope.

Invasive epidural pain therapy is usually indicated in patients with a clearly unresolved pain problem.

Spinal pain syndromes, including those with indications of radicular involvement, can be divided into those with nociceptive, neuropathic or mixed pain components. Microendoscopic discectomy (MED) as described by Perez-Cruet et al. is another neuroendoscopic intervention of the spine involving the posterior or posteromedial endoscopic approach via the interlaminar window for treating herniated disc and spinal canal stenosis. According to Hellwig et al., it is unclear whether neuroendoscopic surgical procedures have better

long-term results than microsurgical procedures in the spinal region.

For further diagnostics and therapy it is important to classify the different pain components as part of a thorough clinical neurological examination. For the therapy of patients with chronic pain, anesthesiological procedures such as nerve blocks, neurolysis and radio frequency therapy continue to be used.

Neurogenic pain can be maintained by the sympathetic nervous system, especially in the acute stage of the pain syndrome. This is referred to as sympathetically mediated pain (SMP). Sympathetic ganglion blocks with local anesthesia and/or with additional opioids generally have a long-term analgesic effect. However, if the sympathetic block does not have an analgesic effect, sympathetically independent pain (SIP) is involved. In this case, mixed nerve blocks are used, in some cases with a catheter procedure, to attempt to establish long-term analgesia.

As reported above, even without prior disc surgery, painful epidural adhesions can be induced after leakage of proteoglycans from the annulus fibrosus into the epidural space. It should be kept in mind that chronic processes can begin shortly after a painful irritation and within a matter of days can trigger morphological and functional changes. This may result in pain memory with plastic neural changes and considerable enlargement of the central receptive sensory fields. As the situation progresses, even unspecific stimuli can lead to subjectively specific pain perception in these patients. As the clinical results show, access to these processes through causal therapy is nearly impossible.

To date, ineffective pharmacologic pain therapy, intolerable adverse effects of drugs or the failure of non-invasive pain therapies, as well as surgical interventions that are unlikely to bring about pain relief have all been indications for therapeutic epidural interventions.

In my opinion, this widely held notion is neither effective nor up to date. A paradigm shift is needed. Based on our vast clinical experience with interventional pain management, an algorithm must be laid down for indications for performing EDS.

In my view, epiduroscopy must be integrated in the diagnostics and/or therapy of spinal pain syndromes early on in an intelligent, interdisciplinary overall pain therapy concept. In addition,

epiduroscopy should be classified as a first-line alternative for diagnostics and therapy in the area of pain management, alongside CT and MRI.

The methodology for epiduroscopic interventions offers the following advantages:

- Resection and reconstruction of healthy organs is minimized or avoided.
- The stress on the patient caused by surgery-related pain can be greatly reduced and the length of rehabilitation and hospital stays is substantially shortened.

The problems associated with epiduroscopic surgical procedures are:

- Assessing the area to be operated on by palpation is not possible.
- The surgical instruments cannot be used in the usual shape and manner.

Performing interventional procedures under epiduroscopic control requires intensive training. As with all new procedures, the surgical techniques are still in the developmental stage, they must be refined on many levels.

In a study carried out in 2000, Saberski compared two groups of patients, one with 22 patients treated with epiduroscopy and a second group with 13 patients who underwent laminectomy. After spinal canal endoscopy, 31.8% of Group 1 (epiduroscopy) patients were on opioid medication, whereas, 92.3% of Group 2 (laminectomy) patients were continued on opioid medication after laminectomy. The fact that 72% from the spinal canal endoscopy group and only 28% from the laminectomy group returned to work is striking. Based on 112 epidural endoscopies, Manchikanti et al. (2000) reported that epidural endoscopy with adhesiolysis is a relatively safe and cost-effective technique for the management of chronic back pain. According to the authors, epidural endoscopy management is less cost-intensive than conventional surgical treatment of chronic back pain. The U.S. expert group (authors: Boswell MV, Trescot AM, Datta S, Schultz DM, Hansen HC, Abdi S, Sehgal N, Shah RV, Singh V, Benyamin RM, Patel VB, Buenaventura RM, Colson JD, Cordner HJ, Epter RS, Jasper JF, Dunbar EE, Atluri SL, Bowman RC, Deer TR, Swicegood JR, Staats PS, Smith HS, Burton AW,



Kloth DS, Giordano J, Manchikanti L) published evidence-based practice guidelines in the management of chronic spinal pain.

For spinal endoscopic adhesiolysis, the evidence is strong (Level II) for short-term relief and moderate (Level III) for long-term relief.

These U.S. guidelines are not mandatory recommendations for treatment or a standard for examination and are not representative for the standard of care.

### 7.3.1 Epiduroscopic catheter management

In the context of anesthesiology and therapy of chronic pain syndromes, placement of epidural catheters for delivering local anesthetics, opioids or other drugs is an adequate, safe procedure.

Racz has developed epidural neuroplasty, as well as a special epidural catheter for pain therapy. Eligibility criteria for Racz epidural spinal catheter therapy include progressive sensory disorders, pain syndrome persisting longer than 4 weeks, disc protrusion/herniation with radicular pain symptoms without motor deficits and postoperative scarring.

Schneiderhan studied the effectiveness of the special Racz epidural catheter technique during the first postoperative year in 63 patients. The patients were surveyed after 4 weeks, 3 months and 1 year regarding their subjective satisfaction, use of pain relievers, postoperative pain development, continued pain and symptoms, new symptoms, ability to work, sports activities, relapse, surgical revisions and complications. 84.3% of the 63 patients surveyed by Schneiderhan reported good to very good results after 1 year, with 8.3% reporting satisfactory results and 4.4% unsatisfactory results. 4.7% of the patients reported a relapse. Complications were not reported.

Veihelmann et al. studied 128 patients with regard to the effectiveness of Racz epidural catheter therapy in a prospective, randomized study as compared to conservative therapy with physical rehabilitation. The authors concluded that if indications are equivocal, epidural catheter therapy is a worthwhile therapeutic option. They pointed out that after 3 months, Racz epidural catheter therapy is superior to conservative therapy with physical therapy.

Gerdesmeyer et al. (2003) studied the impact of Racz minimally invasive percutaneous neurolysis on low back pain syndrome in 25 patients with chronic lumbar back pain and radiculopathy in failed back surgery syndrome or lumbar disc protrusion/herniation. The authors concluded that the Racz procedure has fewer adverse effects and appears to be applicable for chronic low back pain syndrome.

Despite relatively widespread use of the Racz method, little comparative reliable scientific literature has been devoted to the procedure. Based on the internationally accepted recommendations of the Scottish Intercollegiate Guidelines Network (SIGN), the letters A to D are used to assess scientific evidence. There is evidence for treatment attempts with epidural local anesthetic infiltration and/or steroids delivered via a catheter over a period of several days, and these therapeutic measures for pain relief are assigned the letter D. This means that no reliable results of studies are available and that statements on effectiveness are supported by case studies and expert opinions.

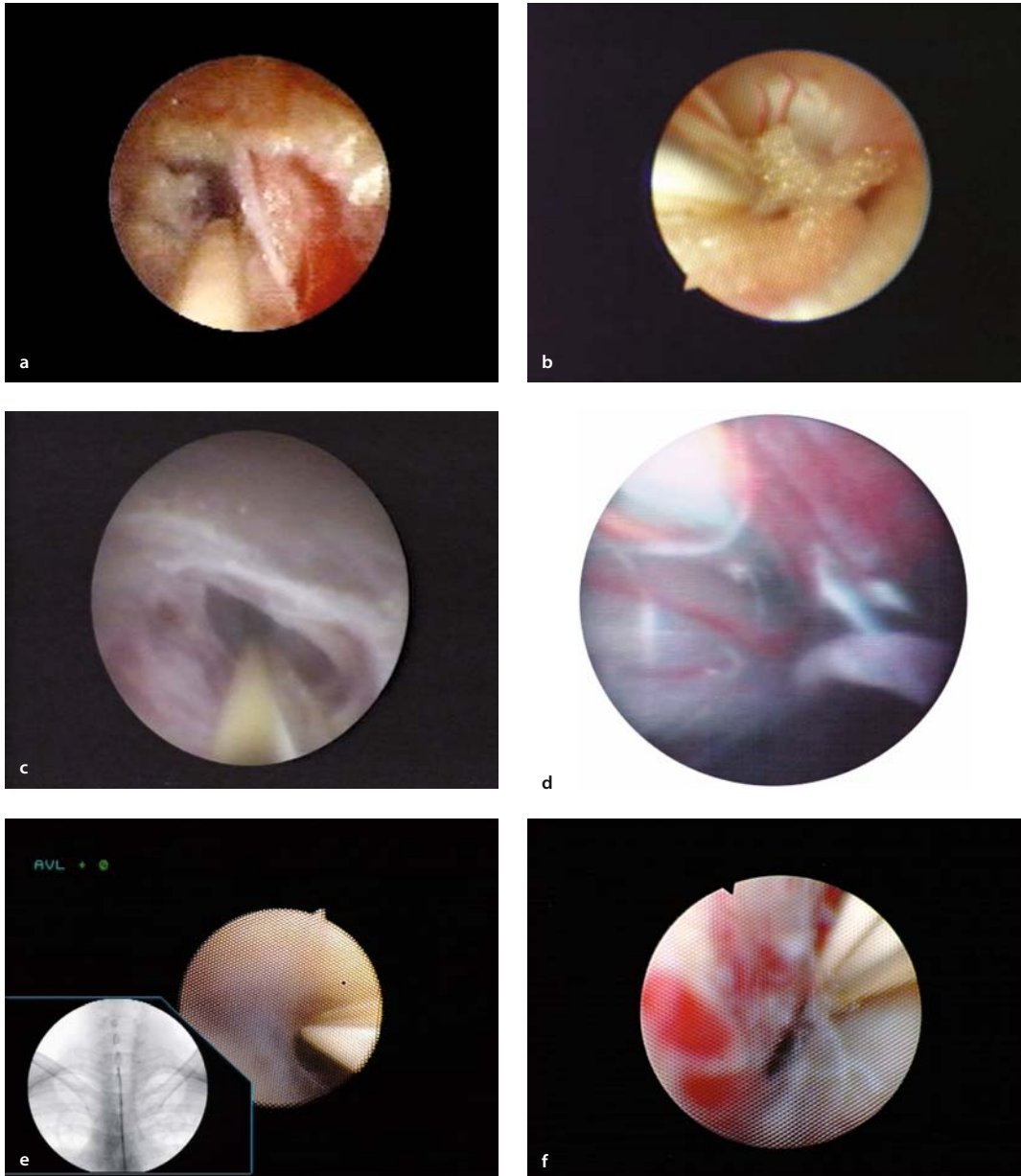
For surgeons with practice in this procedure, placing an epidural catheter is generally effortless and uncomplicated if anatomical circumstances are normal. However, in patients with skeletal and/or soft tissue changes of the supporting ligaments of the spine, this is much more difficult and often results in complications (■ Fig. 7.1a–f).

According to various publications, the rate at which the desired target position of the placed catheter is achieved is 12% for the lumbar region, 7% from the lumbar to the thoracic region and 18% for the thoracic target position.

### 7.3.2 Indications

Epidural catheter placement for procedures such as epidural analgesic therapy for chronic pain is frequently indicated when sufficient analgesia cannot be brought about despite the use of systemic analgesics or if adverse effects occur that are intolerable for the patient.

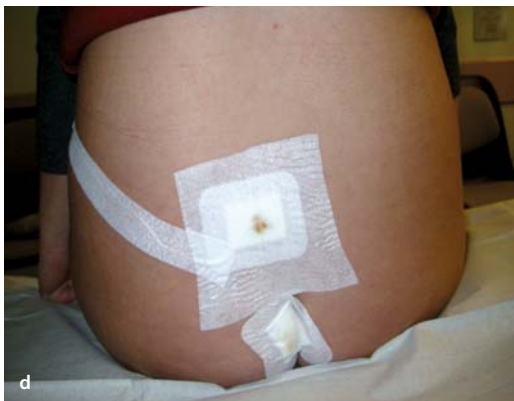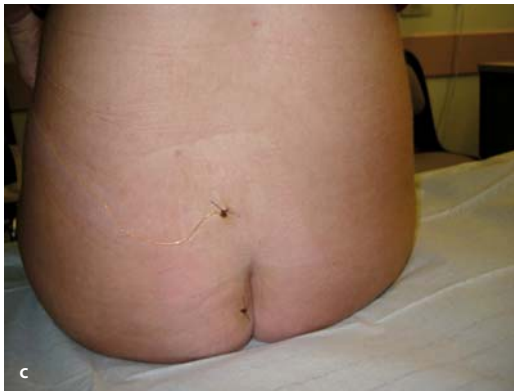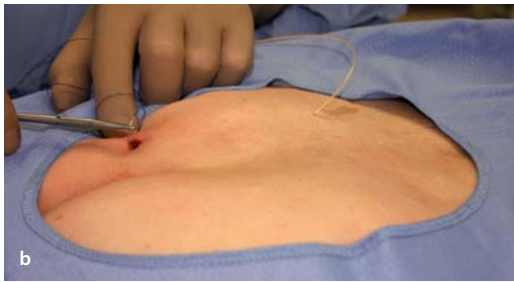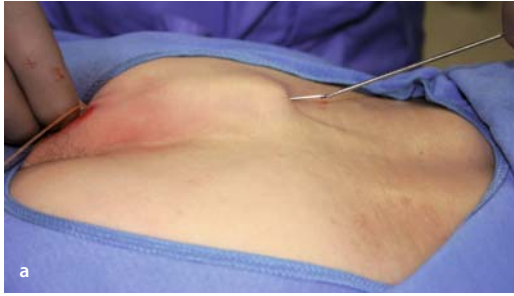It appears that catheter placement for epidural adhesiolysis has become the most frequent indication.



**Fig. 7.1.** **a** Catheter in epidural space with normal anatomical structures. **b** Epidural catheter between the spinal dura mater and fatty tissue. **c** Epidural catheter in the epidural space in the fibrotic tissue. **d** Catheter in the area of the nerve root. **e** Cervical catheter implantation (Picture-inPicture-technique). **f** Placement of a cervical epidural catheter

Therapeutic indications for epiduroscopy include catheter placement for problematic passage or if placement is not possible or the risk to the patient during radiological procedures is too great.

In the case of pathological alterations, it can be particularly difficult to unequivocally identify the epidural space, and this increases the risk of misplaced punctures, erroneous catheter placement



■ Fig. 7.2a–d. a,b Catheter tunneling technique. c Catheter exit site. d Dressing technique

and technical problems with catheters. Catheter placement under direct endoscopic vision, permitted by epiduroscopy, is generally well-suited for solving this dilemma.

Endoscopic catheter placement is the only method that permits treatments such as targeted therapy of the affected nerve roots or of the painful epidural region.

### 7.3.3 Technique

Epidural catheters can be placed safely and unequivocally under endoscopic vision via the working channel of the epiduroscope. Endoscopically assisted dorsal or ventral catheter positioning can be carried out in all regions, including the sacral, lumbar, thoracic and even cervical segments.

Conventional catheters, as well as catheters introduced with stylets, are available for endoscopic implantation of epidural catheters.

We use an epidural catheter with a stylet (Vygon, Aachen, Germany), 0.6×1.0×900 mm or 1800 mm, open distal end, catheter markings at the distal end at 1-cm increments from 5 cm to 15 cm, as well as at 20 cm.

Once the epidural catheter has been successfully placed, the epiduroscope can be removed from the epidural space via the catheter with the stylet under continuous observation. The stylet can then be removed.

For hygienic reasons, once local anesthesia has been ensured, we recommend creating an approx. 8-cm subcutaneous tract and then producing a craniolateral exit direction. The catheter can then be sutured at the percutaneous exit site (■ Figs. 7.2a–d).

### 7.3.4 Complications

Endoscopic catheter placement is sometimes associated with technical or neurological complications, which are dependent on a variety of factors. These include the experience of the surgeon, the anatomical circumstances of the patient, the type of material, the clarity of endoscopic vision, as well as the duration of catheter placement.

Neurological complications arising from epidural catheter procedures manifest as paresthesia or postspinal headache (intrathecal migration of the catheter) lasting several days. Neurological deficits may be caused by bleeding or infection. The symptoms can include irritation of individual nerve roots, cauda equina syndrome and even complete spinal cord injury. Neurological complications after epidural catheter placement are rare. Kindler et al. reported an interval of between 1 and 60 days from the placement of a catheter to the onset of neurological symptoms. In the literature, the incidence of life-threatening complications with perioperative therapy with epidural catheters is reported to range from 1:900 to 1:3000. For long-term catheter therapies, an increase in the incidence of complications can be assumed due to catheter-related infections, displacement of the catheter after initial correct placement and incorrect treatment/mistakes.

Even if the epidural catheter has initially been placed correctly, it is possible for the catheter tip to become displaced toward the subarachnoid space or penetrate a venous epidural blood vessel. This can lead to accidental intraspinal, subarachnoid or intravenous drug delivery. According to Scherer, neither careful aspiration prior to drug delivery, nor the application of a local anesthetic containing adrenaline as a test dose can provide absolute protection from incorrect injection. However, according to Wheatley and Schug, the incidence of such events is low, at 0.15% to 0.18%, for both intrathecal and intravenous displacement.

Gerdesmeyer et al. reported on complications following placement of a catheter for Racz epidural neurolysis. Twenty-one of the 61 patients developed slight transitory neurological deficits in the area of the lysed nerve root immediately following the procedure. According to the authors, the deficits were purely sensory in 14 cases. On the third postoperative day all patients experienced complete recovery. In two patients, during placement of an epidural catheter a perforation of the spinal dura mater occurred during treatment, which was discovered via epidurography prior to intended injection of the drugs. In two other patients, during placement of the epidural catheter and during further positioning attempts, partial

shearing of the catheter occurred. In one case, epidural infection occurred 7 days after catheter removal. It was detected on the basis of clinical symptoms, lab tests and MRI and treated successfully with antibiotics. Reihnsaus et al. undertook a meta-analysis of 915 patients with an epidural abscess described in the international literature and compiled initial symptoms that were highly indicative of epidural abscess (back pain, local hypersensitivity, signs of meningitis, parameters of acute inflammation). These symptoms necessitate emergency diagnostics (MRI) and therapy (laminectomy, antibiotics) to prevent permanent injury resulting from pronounced neurological deficits.

### 7.3.5 Our own experience

In our experience, when catheters are not placed with endoscopic assistance, injections may inadvertently end up near a nerve root, in a vein or in a ligament. Epidural injection of a non-isotonic, cold or neurotoxic solution or an injection technique that is too fast may cause the patient to experience pain during epidural injection. With catheter procedures, however, epidural injection pain may also occur in the further course of the pain therapy.

In our clinical experience, the pain that sometimes occurs after or during epidural injection does not occur after direct epiduroscopic catheter placement.

This gives credence to the notion that by endoscopically imbedding the catheter tip in a non-vulnerable epidural region, such as fatty tissue (■ Fig. 7.1a), pain from injection or contact can be prevented.

Compared to single-holed catheters, multi-holed catheters ensure more even distribution of the drug in the epidural space. Intravascular positions are also reported to be more reliably identified with multi-holed catheters. With some openings, a catheter placed without epiduroscopic assistance may be correctly located in the epidural space. However, with the same catheter, other openings may end up in a vessel or even in the intrathecal space.

We use the 19-G epidural catheter with a stylet (Vygon, Aachen, Germany). Its guide wire provides the required stability as needed by the polyurethane catheter. The bright color of the catheter and the markings facilitate handling during epiduroscopy.

EPIMED (EPIMED International, Inc., Gloversville, New York) has developed its Caud-A-Kath epidural catheter for percutaneous caudal catheter placement. Some models of epidural catheters are available that are equipped with a stylet, which is important for performing EDS. In our experience, special catheters such as a Racz catheter are not necessary.

In our patients, under endoscopic monitoring, in addition to normal catheter positioning, we could also observe the formation of loops and knots in the catheter, as well as bending of the catheter tip. By placing a catheter introduced by a stylet under epiduroscopic vision, it is nearly impossible for the catheter to roll up or for kinks or loops to form.

During endoscopic implantation of over 800 catheters, in 2% of the cases minor epidural bleeding occurred, the procedure was either interrupted until bleeding had stopped (with the endoscope in place) or was treated by laser coagulation.

In 12% of our patients, we had to microsurgically detach epidural adhesions or fibrotic tissue in order for the catheter to access the epidural target region. In 16% of our patients, we observed epidural stenoses that were too narrow for the catheter to pass and which restricted catheter placement in this region.

In 2007, Lang reported on the initial results of our German-Austrian cooperation with epiduroscopic and conventional positioning of epidural catheters for analgesia in pulmonary surgery. The author showed that the sacral approach under epiduroscopic vision is suitable for implanting epidural catheters prior to lung surgery, as well as for perioperative analgesia. The thoracic region was reached through epiduroscopy in all of the patients undergoing pulmonary surgery.

We are convinced that complications arising during catheter implantation can be avoided through preventive measures such as EDS. The use of epiduroscopy for catheter placement is a

preventive measure due to the fact that endoscopy prevents the complications that arise during the conventional procedure.

As with all invasive procedures, however, complications can arise. In this case, it is imperative to diagnose the problem immediately and begin treatment as soon as possible.

In summary, the sacral approach technique to the epidural space under epiduroscopic vision is an excellent means of placing catheters for pain therapy, preoperative measures and for analgesia. It is safe and prevents the shearing that occurs with conventional approaches.

We consider the endoscopic approach to the epidural space, including epiduroscopically assisted catheter placement to be superior to the conventional lumbar, thoracic and cervical catheter technique for epidural analgesia and anesthesia in the following aspects: handling, accuracy of placement, speed of placement, primary success of analgesia, secondary displacement, patient satisfaction, satisfaction of pain therapists, surgeons and users.

The endoscopic technique can be easily integrated into the perioperative clinical routine.

#### Clinical experience with epiduroscopic catheter placement:

- The sacral approach technique and the identification of the epidural space with epiduroscopy are generally uncomplicated.
- Epiduroscopic management is very well suited for positioning catheters (lumbar, thoracic, cervical) safely and unequivocally for anesthesia, postoperative analgesia or pain therapy (e.g. EAT).
- Epiduroscopic management is superior to conventional lumbar, thoracic and cervical catheter technique with regard to handling, accuracy of catheter placement, speed of placement, primary success of analgesia, secondary displacement, patient satisfaction and user satisfaction.
- Epidural management is easy to integrate in clinical routines.

## 7.4 Endoscopically assisted epidural analgesic therapy (EAT) – spinal endoscopic adhesiolysis

In our clinical experience, the use of epiduroscopy allows directed and targeted spinal dorsal and ventral epidural pharmacologic treatment and epidural analgesic therapy (EAT).

Exact endoscopic positioning of the catheter tip in the area of the pathological process is an important precondition for carrying out epidural analgesic therapy.

As part of epidural analgesic therapy, as we have referred to the special epidural pharmacologic therapy for years, substances such as local anesthetics, glucocorticoids and saline are delivered epidurally, individually or in various combinations.

Epidural drug delivery under endoscopic vision can prevent the use of unnecessarily high local concentrations and avoid intrathecal applications.

With the use of our epiduroscopy management, the epidural analgesic therapy can substantially contribute to optimizing the treatment strategy for problems such as failed back surgery syndromes, epidural fibroses and lumbar radiculopathy.

A group of experts (Boswell MV, Trescot AM, Datta S, Schultz DM, Hansen HC, Abdi S, Sehgal N, Shah RV, Singh V, Benyamin RM, Patel VB,

Buenaventura RM, Colson JD, Cordero HJ, Epter RS, Jasper JF, Dunbar EE, Atluri SL, Bowman RC, Deer TR, Swicegood JR, Staats PS, Smith HS, Burton AW, Kloth DS, Giordano J, Manchikanti L) confirmed that spinal endoscopic adhesiolysis definitely brought about short-term pain relief (Level II), while long-term relief had only moderate success (Level III) (Table 7.1). The methodological quality criteria for assessing pain relief included the criteria of the Agency for Healthcare research and Quality (AHRQ), the Quality Assessment of Diagnostic Accuracy Studies (QUADAS) and the Cochrane review. The individual stages for assessing pain relief were labeled as follows: Level I (conclusive relief), Level II (strong relief), Level III (moderate relief), Level IV (limited relief) and Level V (indeterminate relief).

Therapeutic epiduroscopically assisted interventions, combined with special exercise programs managed by a specialist, can have a positive effect on nerve root irritation syndromes or even counteract pain chronicity, among other problems.

Epidural analgesic therapy can be optimized through competent physical therapy. The relative protection of the local analgesic effect can help the patient to tolerate the therapy much better. This concept accelerates concrete progress in therapy and mobilization. Decoupling movement

Table 7.1. Designation of levels of evidence (Boswell et al. 2007)

<b>Level I</b> <b>Conclusive:</b>	Research-based evidence with multiple relevant and high-quality scientific studies or consistent reviews of metaanalyses.
<b>Level II</b> <b>Strong:</b>	Research-based evidence from at least 1 properly designed randomized, controlled trial; or research-based evidence from multiple properly designed studies of smaller size; or multiple low quality trials.
<b>Level III</b> <b>Moderate:</b>	<ul style="list-style-type: none"> <li>a) Evidence obtained from well-designed pseudorandomized controlled trials (alternate allocation or some other method);</li> <li>b) Evidence obtained from comparative studies with concurrent controls and allocation not randomized (cohort studies, case-controlled studies, or interrupted time series with a control group);</li> <li>c) Evidence obtained from comparative studies with historical control, two or more single-arm studies, or interrupted time series without a parallel control group.</li> </ul>
<b>Level IV</b> <b>Limited:</b>	Evidence from well-designed nonexperimental studies from more than 1 center or research group; or conflicting evidence with inconsistent findings in multiple trials.
<b>Level V</b> <b>Indeterminate:</b>	Opinions of respected authorities, based on clinical evidence descriptive studies, or reports of expert committees.

and pain in the patient's experience creates a high level of motivation for carrying out our treatment strategy.

To prevent and break pain chronicity, multimodal care strategies are needed. For instance, in addition to prompt epidural adhesiolysis and special pharmacologic therapy, such as EAT, providing in-depth information to the patient, having the patient avoid strain or incorrect posture, physical therapy, back school and behavior modification therapy should be included in the multimodal concept.

### 7.4.1 Indications

According to the task force for interventional pain therapy of the German Pain Association (DGS) the conference of experts held from February 10 to 12, 2000 in Innsbruck, Austria, confirmed that indications for epidural pharmacologic therapy are topical pain syndromes such as vertebrogenic, discogenic and radicular pain, as well as complex regional pain syndrome (CRPS).

The epidural pharmacologic therapy administered with the single-shot-technique or with a catheter is a safe and effective treatment for topical pain syndromes.

The effectiveness of epidural analgesic therapy is primarily controlled by the application of corticosteroids and local anesthetics in radicular pain syndromes.

The results of corticosteroids delivered epidurally and epidurally for radicular pain are hotly debated in controlled studies. The primary problem with these methods is accurate placement of the corticoid at the affected root.

Accurate delivery of the right drug for the particular symptom is the most important prerequisite for effective epidural analgesic therapy. Correct delivery via caudal injection is rarely possible under CT X-ray control, whereas lumbar epidural injection and periradicular injection work well under CT X-ray control.

Epiduroscopically assisted pharmacologic therapy is the only way to guarantee early epidural analgesic therapy for preventing pain from becoming chronic.

In 2005, the American Society of Interventional Pain Physicians published evidence-based treatment guidelines for the management of chronic spinal pain symptoms (epidural adhesiolysis, percutaneous adhesiolysis). The evidence was strong (Level II) for spinal endoscopy for managing chronic low back pain and lower extremity pain for short-term pain relief (up to 3 months) and moderate (Level III) for long-term pain relief (up to 6 months).

In the evidence-based guidelines for the United States, Abdi et al. (2007) pointed out that in the case of epidural scarring, percutaneous spinal endoscopic adhesiolysis was an important pain management instrument for the therapy of chronic refractory low back pain. They thus recommended assigning it Level II status.

It should be borne in mind that epidural pharmacologic therapy is not suitable for long-term therapy. In this case, intrathecal application is preferable.

### 7.4.2 Drugs used in epidural analgesic therapy

#### Glucocorticoids

Several reviews have reported on the effectiveness of epidural application of corticosteroids for pain syndromes due to spinal nerve compression and/or chronic inflammatory processes. The outcomes of these reviews are varied.

Due to new insights on the excretion of inflammatory mediators such as cytokines and prostaglandins from the disc tissue, this form of therapy is now once again in use. While it is a well-founded therapy from a pathophysiological point of view, more recent studies vary widely with regard to their injection technique, indications, choice of drugs, dosage and injection volumes. The main problem with these studies is their quality, particularly with regard to the technique of epidural applications, which is problematic in a number of areas.

While the effect of epidurally delivered corticosteroids appears to be relatively brief, it should be borne in mind that radicular pain tends to go away on its own anyway. In other publications, the authors concluded from the same studies that

epidural injections with corticoids are effective. The main problems associated with epidural injections with corticoids are indication and technical implementation.

The corticoid effect is more effective when the corticoid is applied as close as possible to the affected region. The effect is delayed by an interval of one day to up to one week. The actual injection target point of corticoid steroids for radicular pain syndromes, herniated disc or stenoses is often the ventral part of the epidural space, which is more difficult to access.

Epidurally delivered cortisone inhibits the formation of inflammatory cytokines such as Interleukin-1, Interleukin-6 and tumor necrosis factor (TNF), as well as that of interferon gamma, which activates macrophages formed by T-lymphocytes and the formation of leukotrienes and prostaglandins that are of relevance for the genesis of the painful inflammatory process.

The advantages compared to systemic application are derived from the fact that drug is deposited in the affected epidural segment, which with epiduroscopy is easy and can be verified unequivocally.

After an endoscopically targeted application of dexamethasone, a reduction in swelling that relieves pain and nerve decompression can be brought about through the anti-inflammatory effect of the cortisone.

According to Brune, the glucocorticoids are especially valuable for pain therapy for three reasons:

- Glucocorticoids reduce the expression (induction) of cyclo-oxygenase-2 in the inflamed tissue. This allows them to reduce the heightened sensitivity of the nociceptors due to prostaglandin.
- Glucocorticoids reduce the production of the proinflammatory cytokines (TNF- $\alpha$ , IL-1, IL-6).
- Glucocorticoids also reduce the expression of the cytokine-dependent cyclo-oxygenase-2 and the inflammatory responses mediated independent of prostaglandin production.

Glucocorticoids also elicit central nervous effects. They cause an optimistic, occasionally even euphoric, mood and can thus help the patient cope with pain. On the other hand, when high doses

of glucocorticoids are administered or when they are administered on a chronic basis, they can lead to massive adverse effects. When using corticoids, care should be taken to select suitable types, such as methylprednisolone, triamcinolone or dexamethasone. Due to its purely glucocorticoid effect, dexamethasone is the preferred corticoid. Hydrocortisone and prednisolone are unsuitable because of their higher mineralocorticoid effects.

In 2007, the renowned expert group led by Boswell published evidence-based practice guidelines for interventional techniques for managing chronic spinal pain. The following information is provided for classifying EAT:

- The evidence for caudal epidural steroid injections is strong for short-term relief (Level II) and moderate for long-term relief in managing chronic low back and radicular pain (Level III).
- The evidence was limited in managing pain of postlumbal laminectomy syndrome (Level IV).
- The evidence for interlaminar epidural steroid injections is strong for short-term relief (Level II) and limited for long-term relief (Level IV) in managing lumbar radiculopathy.
- The evidence is moderate for cervical nerve root pain (Level III).
- The evidence for transforaminal epidural steroid injections is strong (Level II) for short-term and moderate (Level III) for long-term improvement in managing lumbar nerve root pain, whereas, it is moderate (Level III) for cervical nerve root pain.
- The evidence for transforaminal injections is limited (Level IV) in managing pain secondary to lumbar post laminectomy syndrome and spinal stenosis.

### Local anesthetics

Local anesthetics block the influx of sodium ions into the nerve cell. The sodium channel block prevents depolarization and the threshold required to stimulate an action potential is no longer reached. The local anesthetic effect leads to targeted pain suppression and reduction of sensitivity to mechanical irritation in the case of nociceptors and nociceptive axons.



In the context of anesthesiology and pain therapy, the amino amide local anesthetic bupivacaine has been used for years for repetitive and continuous application. The S(-) isomer of the propyl analog of bupivacaine, ropivacaine, is also widely used in pain therapy. Ropivacaine is less lipophilic than bupivacaine and mediates a better differential block of sensory and motor fibers. In addition, ropivacaine appears to have only a slight vasoconstrictive effect, at least after epidural application. Ropivacaine's low cardio- and neurotoxicity are also advantageous. This allows the use of local anesthetic solutions at higher concentrations of 0.75% or 1.0%, leading to shorter onset times and better analgesic quality. Blockage of the individual pain-transmitting fibers occurs depending on the thickness of the myelinated A delta fibers (1-4  $\mu\text{m}$ ) and C fibers (0.4-1.2  $\mu\text{m}$ ).

In pain therapy, a basic distinction is made between diagnostic, prognostic, preventive and therapeutic blocks.

The therapeutic blocks in the form of EAT are used for causal and symptomatic therapy of the underlying condition.

We use local anesthetics for epidural analgesic therapy, always tailoring it to the individual endoscopic and clinical conditions. To do so, we administer anesthetics, for example, 5 to 15 mg bupivacaine, via the endoscopically placed catheter.

We generally use a perfusor system to infuse the bupivacaine. In the case of adverse effects, a distinction should be made between allergic reactions, technically-related incidents and local or systematic toxicity of the local anesthetics.

## Sodium chloride

In order to perform epidural analgesic therapy (EAT), we use a 0.9% physiological saline solution with or without corticoids or local anesthetics.

When we introduced percutaneous epiduroscopy with flexible endoscopes at our clinic back in 1990, we first used a lumbar approach with a »flexible catheter-secured epiduroscopic unit« (outside diameter 0.9 mm). We used 0.9% saline irrigation solution to achieve adequate endoscopic images.

After our first epiduroscopic examinations, which were only for diagnostic purposes, we

observed that after the procedure, our patients reported significantly less pain. Apparently the epidural flushing effect with 0.9% saline solution brought about pronounced, long-lasting pain reduction in the patients.

We then considered what the cause of analgesia could be. Were pain mediators such as cytokinins or substance P being flushed out during epidural irrigation? Later on, I followed the advice of James E. Heavner of Lubbock, Texas, to use 10.0% saline solution for epidural analgesic therapy or percutaneous neuroplasty. The 10.0% saline solution was purported to shrink the epidural scar tissue.

However, with our patients, we observed early on that results with the higher-percentage saline solution were no better than those achieved with physiological saline solution.

This coincides with the recent results of Abdi and Saberski and other users as well. These authors reported that corticosteroids, hyaluronidase and hypertonic saline solution were applied from a caudal approach for adhesiolysis and to treat inflammatory processes in their patients. They observed that this combined pharmacologic procedure had no major advantages over exclusively epidural application of corticoids.

The neurotoxic effects of the 10.0% saline can have severe consequences for the patient. In addition to very severe pain, reactions include muscle cramps, hypertension, arrhythmia, pulmonary edema, localized pareses lasting several hours, persistent paresthesia lasting several weeks, persistent loss of control over sphincter tone and sacral anesthesia.

For epidural procedures, we use only physiological saline solution, because we do not see any advantages to using hypertonic saline solution, which is associated with high risks.

## 7.4.3 Pharmacologic options

### Opioid analgesics

The consequence of epidural opioid application, such as morphine, fentanyl or sufentanil is an inhibition of excitatory transmission from the nociceptive afferent nerves to the next neurons. The diffusion of the epidurally administered opioid

analgesics from the epidural space to the intrathecal space is responsible for the opioid analgesic effect through binding, especially to opioid receptors, which are located in the posterior horn of the spinal cord at high concentrations. Depending on the lipophilia of the opioid analgesic, dosage-dependent supraspinal opioid effects are also brought about by the diffusion of the analgesic into the bloodstream. In addition, a certain percentage of the opioid analgesic is stored in the fatty tissue of the epidural space through diffusion, which brings about a long-term effect.

The higher the lipophilia of an opioid, the better its analgesic effectiveness. After epidural opioid application, the opioid analgesic morphine begins to take effect after 20 to 30 minutes and lasts 8 to 12 hours.

We primarily use morphine, the WHO reference opioid, for epidural analgesic therapy. In isolated cases, we also use sufentanil, a thio analog of fentanyl with 10-fold effectiveness, for epidural analgesic therapy. Rapid onset and good controllability are further advantages of the opioid analgesic sufentanil in epidural application.

### **Hyaluronidase**

The mechanism of the enzyme hyaluronidase involves the breakdown of the intercellular cement by hydrolyzing hyaluronic acid, mucoitin acid and chondroitin sulfuric acid and in turn, increasing the permeability of the connective tissue. This mechanism causes accelerated resorption after subcutaneous and intramuscular injections.

The resorption of local anesthetics is improved by hyaluronidase. In a study on dogs, as well as a study on humans, hyaluronidase achieved a significantly lower formation of epidural fibrosis after spinal cord surgery or epidural procedures.

The neuroplasty concept recommended by Racz calls for the use of corticoids, local anesthetics, hypertonic saline solution and the application of 1500 units of preservative-free hyaluronidase delivered via a special epidural catheter in the area of scarring. According to Racz et al., this mixture of substances brings about a local neurolytic and adhesiolytic decompression of the nerve root with an associated anti-inflammatory and anti-edema-

tous effect. The injection is repeated on the second and third day. The repeated doses have a prolonging effect. According to the authors, this procedure is worthwhile as long as the nerve root responsible for the pain is actually reached.

We do not routinely administer hyaluronidase epidurally, because in the past no local changes or better clinical outcomes could be achieved under epiduroscopic control.

### **Clonidine**

Alpha-2 adrenoreceptor agonists have numerous properties that are of interest for both anesthesia and for pain therapy and intensive care medicine, especially sympathicolysis, sedation, anxiolysis and analgesia. Clonidine is delivered in combination with opioid analgesics or local anesthetics.

Clonidine has an antinociceptive effect on the spinal level. This can prolong the effect of local anesthetics and enhance the effect of the opioids. Clonidine, a WHO reference substance, is the Alpha-2 adrenoreceptor agonist used most frequently intraoperatively and the one that has been best researched.

The theoretical basis for the epidural effect of clonidine in combination with opioids and local anesthetics is its interaction with Alpha-2 adrenoreceptors in the spinal cord. In the posterior horn of the spinal cord, stimulation of Alpha-2 adrenoreceptors modulates the central transmission of the nociceptive afferent nerves via A Delta and C fibers.

Alpha-2 adrenoreceptor agonists reduce the release of substance P while simultaneously strengthening the K<sup>+</sup> conductance, which increases the membrane polarization.

When clonidine is applied epidurally, it causes analgesia. The duration of analgesia depends on the dose. The substance takes effect after approx. 20 minutes and, depending on dosage, lasts from 1 to 5 hours. Because of the short duration of effect of clonidine, continuous epidural delivery is recommended.

Results with routine application of clonidine in the context of epiduroscopically assisted epidural analgesic therapy at our clinic are limited, since it has been used only in isolated cases to date.

## Ketamine

Ketamine blocks the N-methyl D-aspartate (NMDA) receptors in the central nervous system, which are involved in the origin of central sensitization. In addition to blocking the NMDA receptors, ketamine causes dissociative anesthesia.

The effects of epidural application of ketamine are hotly debated. Studies with the NMDA antagonist ketamine in patients with postzoster neuralgia and other neuropathic pain show substantial reduction of pain. Various authors also described successful outcomes when adding ketamine (preservative-free) to bupivacaine for spinal analgesia or caudal anesthesia.

The safety of epidural ketamine application was questioned in an animal experiment that pointed to potential neuronal damage. After repetitive intrathecal application of preservative-free S(+) ketamine, histopathological lesions can occur. For this reason, the scientific working group on pediatric anesthesia of the German Society for Anesthesiology and Intensive Care Medicine (DGAI) recommends that in children, S(+) ketamine should generally not be used as a supplement for caudal anesthesia.

To date, our own experience with epidural application of ketamine has been limited to very specific isolated cases.

## 7.4.4 Performing epidural analgesic therapy (EAT)

The basic prerequisite for performing neuroplasty or epidural analgesic therapy (EAT) involves precisely reaching the affected nerve root or other epidural regions in order to deliver the drug (local anesthetic, corticoid, saline solution) directly in the immediate proximity of the pathological process. In contrast to the catheter techniques described in the literature, the only way to carry out direct and accurate dorsal and ventral epidural pharmacologic therapy is with epiduroscopy management.

After targeted endoscopic placement of the epidural catheter, while still in the operating room or in the recovery room the patient receives an epidural injection or infusion that is tailored to his or her particular case via a perfusor, depending on the endoscopic diagnosis.

In line with the endoscopic findings, we infuse a 0.9% saline solution, corticosteroids (dexamethasone) or local anesthetics (bupivacaine) via the epidural catheter at a dosage that is appropriate for the situation.

The perfusor rate is adjusted according to the placement of the catheter (cervical, thoracic, lumbar or sacral), the epiduroscopic diagnosis and course of therapy.

■ **Table 7.2.** Catheter-assisted epidural analgesic therapy

Catheter position	Drugs		
Clinical application (Day 1 to Day 4)			
	Dexamethasone	Bupivacaine 0.5%	Saline 0.9%
Cervical	4 mg	2.5 mg = 0.5 mL	5 mL
Thoracic	4 mg	5 mg = 1 mL	7.5 mL
Lumbar	4 mg	7.5 mg = 1.5 mL	10 mL
Clinical application (after Day 4)			
	Dexamethasone	Bupivacaine 0.5%	Saline 0.9%
Cervical	∅	2.5 mg = 0.5 mL	5 mL
Thoracic	∅	5 mg = 1 mL	7.5 mL
Lumbar	∅	7.5 mg = 1.5 mL	10 mL

The drugs prescribed by us for continuous epidural analgesic therapy, for instance, 4 mg dexamethasone and 5–10 mL saline solution, are administered epidurally with a drug pump via the endoscopically placed catheter twice a day within 60 minutes (■ Table 7.2).

If pain symptoms are severe, the patient receives an additional 5 to 15 mg of bupivacaine epidurally, administered continuously or as a bolus.

We perform epidural analgesic therapy as a »walking epidural«, i.e., epidural analgesia with a low dose of local anesthetic that allows the patient to get up and walk around. These conditions allow the patient to participate in the accompanying exercise and mobility regimens. This procedure supports a multimodal therapy regimen for mobilizing the pain patient.

#### 7.4.5 Results

The above-described method of managing epidural analgesic therapy has been generalized. However, epidural analgesic therapy must be continuously clinically monitored and adapted. Taking the individual pathological and anatomical features into account can substantially enhance success of therapy in the individual patient.

The assessment of pain intensity is generally done with a numeric rating scale (NRS) or similar instrument. In studies of patients with chronic back pain, Farrar and Hägg described a reduction in pain intensity of 18/100 and 2/10, respectively, as clinically important. In contrast, Bodian et al. considered even minor changes in pain intensity to be significant for areas such as postoperative pain. According to Mesrian et al., a drop of 25/100 points on the visual analog scale is a clinically relevant improvement in pain.

In 2005, the American Society of Interventional Pain Physicians published evidence-based treatment guidelines and parameters for spinal endoscopy. They recommend that the procedures be limited to a maximum of two a year, provided that pain relief was over 50% for more than four months.

The study also provided convincing evidence for percutaneous epidural adhesiolysis. Spinal en-

doscopic adhesiolysis was assigned a Level II-recommendation for short-term relief and Level III for long-term relief.

Current guidelines for managing radicular back pain from a variety of disciplines point to the therapeutic effectiveness of epidural application, especially of corticosteroids.

In many cases, targeted epidural local anesthesiological therapy showed that the effect of the anesthetic lasted up to three months. In contrast, Dashfield et al. (2005) observed that targeted placement of epidural steroids on the inflamed nerve root did not significantly reduce the pain intensity, anxiety and depression as compared with untargeted caudal epidural steroid injection.

Koes et al. studied the effectiveness of epidural steroid injection for back pain and sciatica. They used four categories to assess 12 randomized clinical trials evaluating epidural steroid injections. The data were assessed for quality of the methods, using the following four categories: study population, interventions, effect management, and data presentation and analysis. The authors concluded that of the four best studies, two reported positive outcomes of epidural steroid injection and two reported negative results. In total, six studies indicated that the epidural steroid injection was more effective than the reference treatment. The other six studies showed that the injections were no better or worse than the reference treatment.

Geurts et al. (2002) reported that 19 of 20 patients examined through epiduroscopy showed adhesions. In eight patients, six of whom had never undergone surgery, the adhesions were not detected with earlier magnetic resonance imaging. Six patients showed concomitant signs of active root inflammation. Of 20 patients treated with a targeted epidural injection (120 mg methylprednisolone acetate, 600 IU hyaluronidase, 150 µg clonidine), 11 patients (55%) experienced significant pain relief at 3 months. This was maintained at 6, 9, and 12 months for 8 (40%) of the patients. Mean VAS at 3 months was significantly reduced ( $n = 20$ ;  $\Delta\text{VAS} = 3.55$ ;  $p < 0.0001$ ), and this persisted at 12 months ( $\Delta\text{VAS} = 1.99$ ,  $p = 0.0073$ ). According to the authors, epiduroscopy is of particular

value for the diagnosis of spinal root pathology. In sciatica, adhesions not detected by MRI could be identified. Targeted epidural medication results in prolonged pain relief

In 2004, Manchikanti et al. published a study on a one-day treatment of chronic back pain with lumbar epidural adhesiolysis and neurolysis with hypertonic saline solution. Seventy-two percent of patients in group III (catheter placement, adhesiolysis, local injection of local anesthetics, hypertonic saline solution and steroids) and 60% of patients in group II (catheter placement, adhesiolysis, injection of local anesthetics, physiological saline solution and steroids), compared to 0% in group I (control catheter placement without adhesiolysis, injection of local anesthetics, physiological saline solution and steroids) showed significant improvement after 12 months. Very few patients in group III, who had been given an injection with hypertonic saline solution, required repeat treatment as compared to the patients in group II.

Manchikanti concluded that percutaneous adhesiolysis with or without hypertonic saline neurolysis is a safe and effective treatment for chronic refractory back pain.

Manchikanti (2005) et al. also reported on 83 spinal endoscopic adhesiolyses with local anesthetics and steroids and concluded that a significant number (80% of the cases after 3 months, 56% after 6 months and 48% after 12 months) of his patients had experienced long-lasting significant pain reduction and improved function and psychological status.

Sakai et al. (2005) reported on 9 patients who had low back pain associated with spinal canal stenosis. To treat epidural adhesions detected via epiduroscopy, the patients received steroid and local anesthetics during epiduroscopy. In addition to pain relief, the function of the 9 patients improved as well.

The current perception threshold (CPT) values also improved. The current perception threshold is the only neurodiagnostic measurement that allows assessment of hypesthesia and measures nerve regeneration in all three subpopulations of nerve fibers. The CPT values in the ipsilateral legs 1 and 3 months after epiduroscopy were

significantly less than that before epiduroscopy at 2000 Hz ( $p < 0.05$ ), while CPT values at 250 or 5 Hz did not reveal any change throughout the study period.

In 2003 we reported on 50 patients with failed back surgery syndrome who underwent epidural analgesic therapy under standardized conditions at our pain clinic. Catheter placement was carried out in endoscopically selected epidural areas.

For epidural analgesic therapy, we applied 4 mg dexamethasone, 0.9% saline solution and 2.5–15 mg bupivacaine via an endoscopically placed catheter twice a day using a perfusor over a period of five days (■ Table 7.2). For the patients undergoing epiduroscopy, the epidural analgesic therapy was integrated in a pain management algorithm as part of a multidisciplinary concept. Immediately after the epidural analgesic therapy, our patients experienced a clinically measurable lower pain score (NRS), as well as a marked improvement in quality of life (Pain Disability Index). The continuing positive therapeutic effect (pain score reduction of 60%) was observed in 65% of the patients in the 6-month observation period. For 24% of the patients the pain score reduction of 45% lasted for over one year. The pain score (NRS) of the 50 patients in the study could be lowered by an average of 40% across the year.

In sum, the reports on targeted pharmacologic epidural therapy indicate that the procedure is effective. Controlled comparative clinical studies on which recommendations on the frequency and duration of epidural pharmacologic therapy can be based, are rare. Based on the existing data, it appears that this method offers clear clinically relevant advantages over other procedures. Our conviction and our clinical experience, as well as patient data allow us to conclude that the only way to enhance the efficacy of EAT is by using epiduroscopy.

## 7.5 Epidural laser adhesiolysis

The use of laser (LASER = light amplification by stimulated emission of radiation) technology expands the options for epiduroscopic surgery. The

bundled light has a number of medical applications, such as coagulation for bleeding, rechanneling stenoses caused by tumors and destroying plaques in vessel walls.

A sufficient number of medical pilot studies, prospective studies and prospective randomized studies have been carried out on the use of the 1064-nm Nd: YAG, 1320-nm Nd: YAG and 940-nm diode lasers.

Ruetten et al. (2002) reported on a study in which 47 patients in whom epidural adhesions had been detected by epiduroscopy were treated with a Holmium:YAG laser. The follow-up studies showed no deterioration in the symptoms of any of the patients. There was no occurrence of laser-related edema or adhesions. According to the authors, there are no negative effects associated with laser application with a (2100-nm) Holmium:YAG laser in the epidural space if the procedure is performed properly.

In addition to the Holmium:YAG laser, a 980-nm diode laser's physical properties in water also make it suitable for use in the region of the highly sensitive spinal structures. A diode laser is a modular device. Its laser beam can be applied directly for medical purposes. The diode laser can be used for all indications for which the Nd:YAG laser is used, primarily for coagulation and vaporization of tissue.

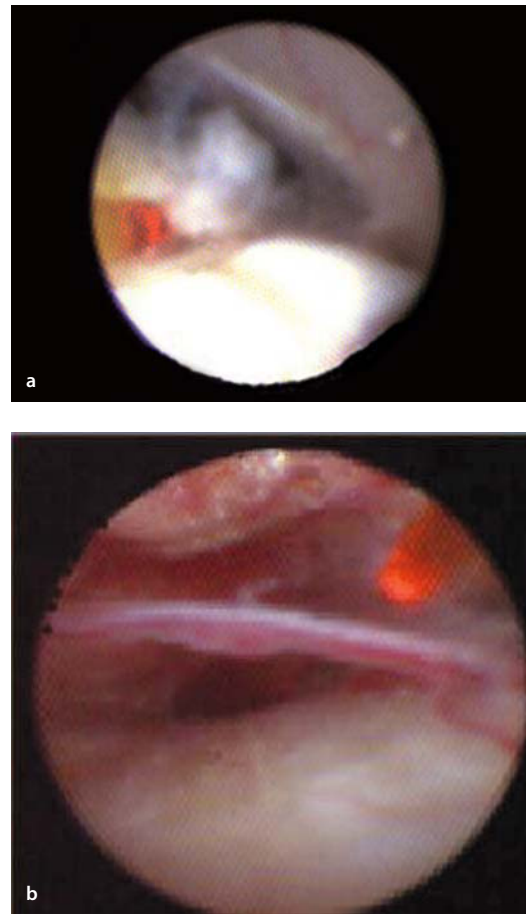
We have used a diode laser for epidural adhesiolysis, scar resection and coagulation since 2003. The light conductor, 320  $\mu\text{m}$  bare fiber, is introduced into the epidural space via the working channel of the epiduroscope under epiduroscopic vision. The wavelength of the diode laser is 980 nm. The power can be adjusted from 1 to 25 watts. The penetration depth of the laser in the tissue is dependent on the wavelength and is primarily dependent on the water content of the tissue in the infrared area. The diode laser beam penetrates the tissue and is not significantly absorbed by hemoglobin, melanin or water. The penetration depth of the diode laser is several millimeters.

The diode laser can be used only if there is excellent visual control. Fine navigation of the relatively rigid laser fiber is only possible via the flexible tip of the endoscope. The laser should not

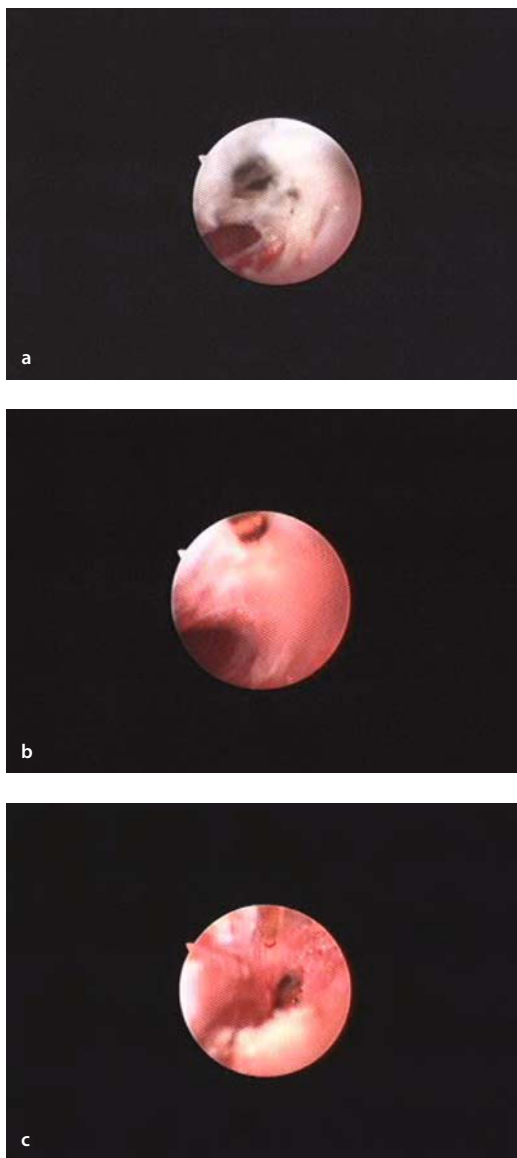
be activated until visual control is ensured and saline infusion has been started. With the help of the laser target beam, ablation can be pinpointed without bleeding.

In our experience, a laser power range of 5.0 to 8.0 watts is sufficient. Using a diode laser for purposes such as coagulation, and stenosis therapy is feasible.

Depending on the particular pathological and anatomical circumstances, there are limited possibilities for endoscopically assisted resection of epidural scar tissue. Endoscopic laser application permits adhesiolysis in both the dorsal and ventral part of the epidural space (■ Fig. 7.4a–c).



■ Fig. 7.3a,b. **a** Laser fiber with target beam in the epidural space. **b** Laser fiber with target beam on a blood vessel in the epidural space



■ Fig. 7.4a–c. **a** Slide depicting laser adhesiolysis, scar resection with a diode laser. **b** Laser fiber in the epidural space. **c** Laser fiber in the epidural space

It is important to note that we use the laser only to treat painful epidural structures or to stop bleeding in the endoscopic target area.

Adhesions near the nerve root should be avoided. If paresthesia occurs, the procedure must be stopped immediately. Painful adhesions in the

area of the nerve root that cannot be mobilized by moving the tip of the epiduroscope back and forth can be easily removed with the laser. Our experience with epiduroscopic laser therapy to date has been good, and this coincides with the positive results reported by Ruetten.

Complications arising during epidural laser therapy may include accidental injury of spinal structures, bleeding, restenosis caused by extensive fibrin plaques, instruments and endoscopes catching on fire, combustion of gases or toxic fumes. Major precautionary measures for preventing laser complications include maintaining excellent endoscopic vision and providing OR staff with comprehensive information and training. National accident prevention regulations and user guidelines must be observed.

## 7.6 Epiduroscopically assisted electrode implantation

Reports in the current literature and our own experience clearly show that neuromodulatory procedures are an adequate and effective treatment option for a selected patient population if indicated and if strict criteria for patient selection are observed.

Unfortunately, neuromodulation is not included in the pain management algorithm until after Level III of the World Health Organization algorithm has been implemented without success.

However, the invasive procedure should be integrated in the multidisciplinary and multimodal pain management strategy early on as a key module in order to counteract potential chronicity mechanisms.

For the major invasive pain management interventions, especially for neuromodulation, strict diagnostic and selection criteria are in place that allow the pain therapist to indicate a special pain therapy more precisely than is the case for pharmacologic therapy and other treatment options.

The neuromodulatory procedure epidural spinal cord stimulation (SCS) is not a destructive procedure, but rather reversibly influences the neuronal transmission of afferent and efferent fi-

bers of the central and peripheral nervous system. Through the electrical stimulation of the GABAergic interneurons, neurostimulation prevents a disproportionately high increase in the sensory information. Neurostimulation is possible at various levels of the nervous system. It is carried out in the area of peripheral nerves, the spinal cord, the thalamus, the trigeminal ganglion and the motor cortex.

Epidural spinal cord stimulation is one of the most frequently performed therapeutic interventions. The guidelines of the Working Group on Neuromodulation of the German Association for the Study of Pain (DGSS) for the standardization of invasive neuromodulatory procedures (AWMF (Association of Scientific Medical Societies) guideline no. 041/002) stipulate the following indications for the implantation of a spinal cord stimulation system for neuromodulation:

- Neuropathic pain: radiculopathy, incomplete plexus lesions, spinal cord lesions, phantom pain, stump pain, zoster and postzoster neuralgia, metabolic (poly)neuropathies, back-lower extremity pain syndrome (postoperative-post-traumatic)
- Sympathetically maintained pain: CRPS I (Sudeck's disease), CRPS II (causalgia)
- Ischemic pain: peripheral artery occlusive disease (Stage II b and III, Fontaine), refractory angina pectoris (CCS class III-IV).

The success rates for spinal cord stimulation reported in the literature vary. It should be kept in mind, however, that candidates for the procedure are difficult to treat with established, multimodal pain management methods.

Boswell et al. (2005) reported that the evidence for spinal cord stimulation for failed back surgery syndrome and complex regional pain syndrome was strong (Level II) for short-term relief and moderate (Level III) for long-term relief.

In a still unpublished four-country study which our clinic was represented, the cost-effectiveness of spinal cord stimulation for failed back surgery syndrome was assessed (Taylor R. S. et al.). The results of the study show that in both the short term and over the lifetime of the patient, spinal cord stimulation is a cost-effective option when

compared to conventional non-surgical medical therapy alone in selected failed back surgery syndrome patients.

The current SCS electrode implantation technique generally begins with the use of special (Tuohy) needles to locate the epidural space percutaneously with the loss of resistance method. With C-arm TV fluoroscopy, the SCS electrode is advanced through a special Tuohy needle into the epidural target area. Introducing the electrode epidurally in the spinal canal allows the surgeon to reach the area relevant for pain therapy. With conventional surgical electrode implantation, monitoring is only possible with C-arm diagnostics. The use of this »blind« technique can lead to a number of serious problems that complicate SCS electrode implantation or even render it impossible.

In patients in whom spinal structures and/or injuries cannot be easily located or in the case of pronounced epidural fibrosis, stenosis or scarring, implanting the SCS electrode can prove to be difficult and risky or may even fail.

In the literature, the danger of damaging spinal structures with the puncture needle or electrode is mentioned. Puncture injuries, accidental dural injuries, CSF cysts and fistulas, meningitis, epidural venous punctures, epidural bleeding, hematoma, spinal cord injury, nerve root injuries and other spinal cord lesions have been reported.

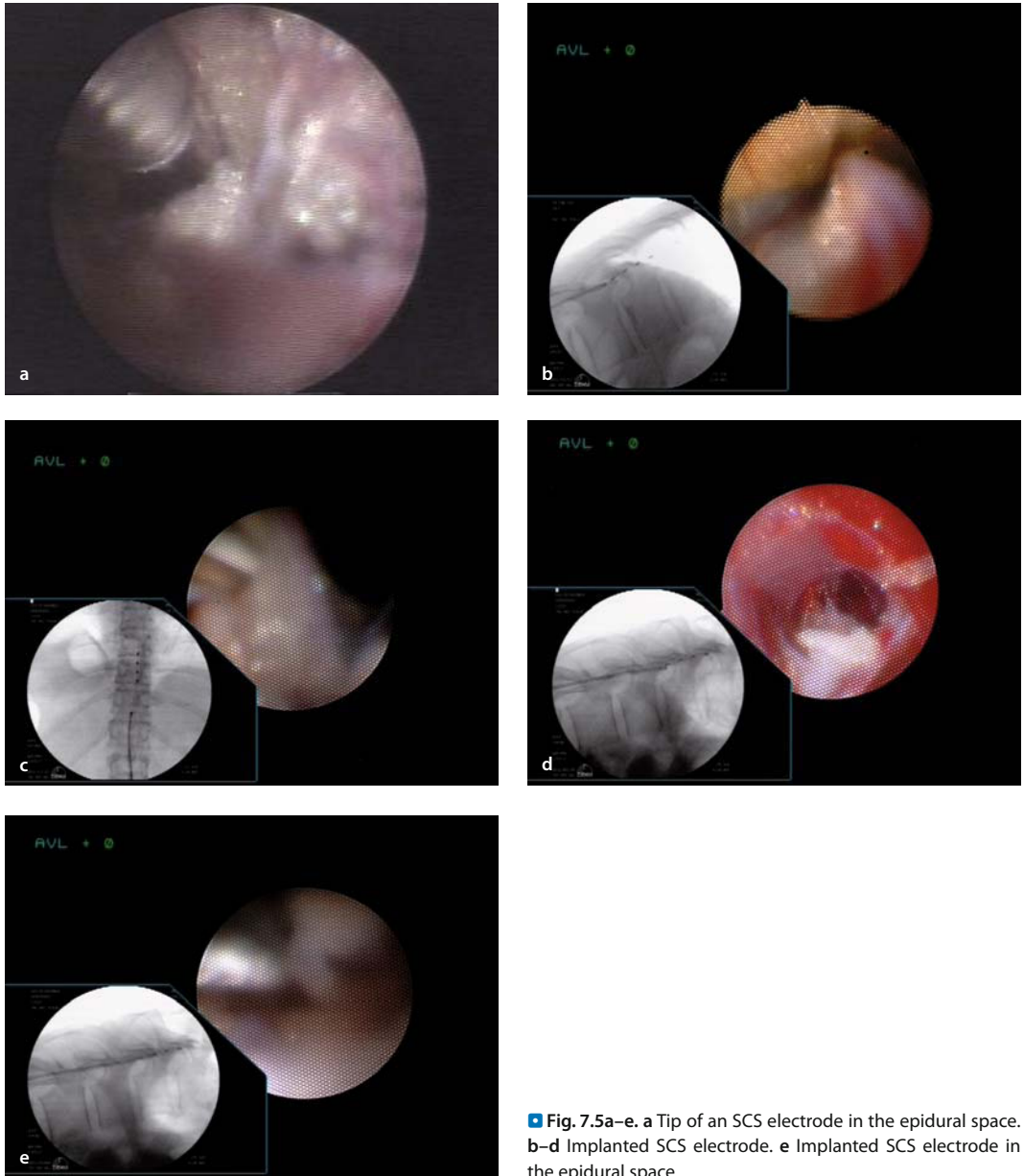
In 1997 we reported on patients who underwent epiduroscopically assisted SCS electrode implantation for neuromodulation for the first time to treat their failed back surgery syndrome.

After our extensive clinical experience with the neuromodulatory procedure, we can report that the indications for epiduroscopically assisted SCS electrode implantation are first and foremost: difficult pathological spinal circumstances, severe pathological lesions in the epidural region (pronounced epidural adhesions, fibrosis or severe scarring) as well as ensuring accurate placement of the electrode(s) in the epidural space.

Epiduroscopically assisted electrode implantation lowers the risk of injury to the spinal dura mater, epidural bleeding, spinal trauma and intraoperative pain.

In addition, unnecessary stimulation tests for displaced electrodes can be avoided and po-



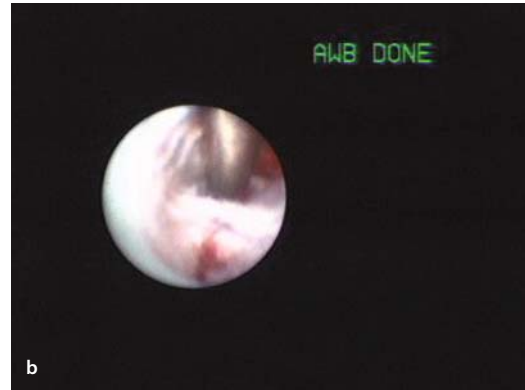
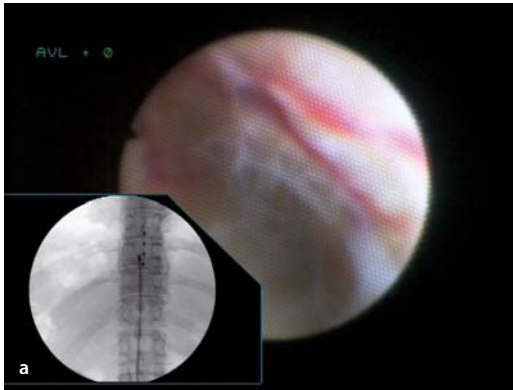


■ Fig. 7.5a–e. a Tip of an SCS electrode in the epidural space. b–d Implanted SCS electrode. e Implanted SCS electrode in the epidural space

tential high-risk situations recognized early on (■ Fig. 7.5a–e). This is essential for this very special patient population.

Increased scarring or fibrous growths that envelop the tip of an SCS electrode can cause the stimulation to become ineffective over time.

Epiduroscopy also allows this extraneous fibrous tissue or scarring near the implanted SCS electrode tip to be removed through microsurgery, in order to restore the efficacy of neuromodulation after long-term use without having to replace the electrode (■ Fig. 7.6a,b).



**Fig. 7.6a,b.** Implanted SCS electrode in the epidural space after 2 years in patient S.G., whose SCS stimulation was no longer effective due to epidural fibrosis near the tip of the

SCS electrode. Microsurgery with epiduroscopic assistance was used to lyse scar tissue that had surrounded the implanted SCS electrode, which improved the results of neuromodulation

In our experience with epiduroscopically assisted SCS electrode implantation and adhesiolysis of the electrode tip, we have the impression that using endoscopy substantially lowers the risks associated with SCS pain management.

The advantages of epiduroscopically assisted SCS electrode implantation and adhesiolysis can be summarized as follows:

- Safe epidural approach
- Exact placement of the electrode(s)
- Avoidance of pathological and anatomical obstacles
- Use of microsurgical adhesiolysis to eliminate the need to replace the electrode(s)
- Reduction of X-ray exposure.

The outcome of neuromodulatory therapy is significantly impacted by the quality of the diagnostics, strict patient selection criteria, a positive SCS result and as usual, the skill and experience of the surgeon carrying out pain management at the pain clinic.

## 7.7 Epiduroscopic (pulsed) radio frequency therapy

Radio frequency therapy (RFT) is a further invasive option for relieving chronic back pain. The original method of radio frequency thermolysis

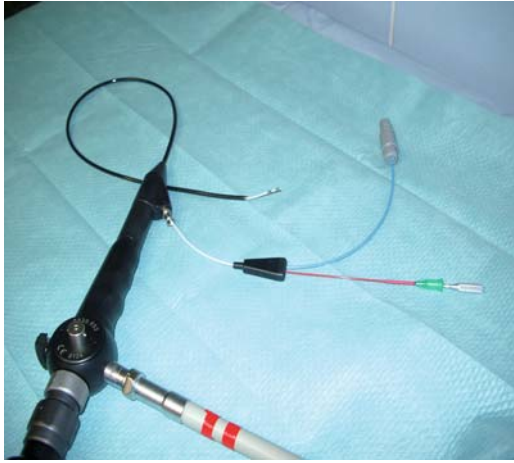heated up the surrounding tissue to high temperatures during the application of electrical current. While this brought about pain relief, it sometimes also resulted in permanent damage to the individual pain fibers.

To prevent additional inadvertent damage in the patient, in the late 1990s pulsed RFT was developed, which does not cause the tissue to heat up.

With pulsed radio frequency therapy, an electrical field acts upon the affected nerve with very short impulses and consequently causes permanent interruption of pain transmission.

The indications for pulsed frequency stimulation with a multifunction electrode include all kinds of spinal pain, regardless of cause, including radicular pain and neuropathic pain syndromes.

The recommended standard approach for pulsed RFT for lumbar and sacral pain, as well as pelvic and lower extremity pain, is paramedian access to the L3-L4 interspace from the contralateral side. Special (Tuohy) needles are used for epidural puncture. These needles are also used for introducing SCS electrodes. For dorsolateral epidural electrode placement, we recommend a flexible multifunction electrode (OMT, Rottweil-Neufra, Germany). With this electrode, nerve stimulation can be carried out at the desired frequency.



■ Fig. 7.7. Epiduroscope (R. Wolf, Germany) with multifunctional catheter in the working channel

In order to accurately target the right electrical field, we have placed the multifunction electrode precisely in the epidural space under endoscopic conditions.

The electrode was advanced to the epidural target point via the working channel of an R. Wolf epiduroscope (Germany) with an outside diameter of 3.5 mm (■ Fig. 7.7). For epidural pulsed radio frequency therapy, a short active 500,000-Hz electrical pulse of just 20 msec is applied under endoscopic vision, followed by a 480-msec pause. The maximum temperature allowed by the computer-controlled therapy device (Stryker Neuro-N 50, 0.1–0.7 watts) is 42 °C. Each nerve root is stimulated for approx. four minutes. Because the conductivity of electricity in the epidural fat body is 0.04 Ω/m-L compared to 1.4 Ω/m-L of the CSF, experts recommend injecting small amounts of isotonic saline solution epidurally, which is no problem with EDS. Sensory stimulation of the dorsal roots was carried out at 80 Hz under endoscopic vision and the position of the electrode tip was varied so that the patients could feel the stimulation at the lowest voltage. Voltages of under approx. 0.8 V could be registered by the patients.

Raffaelli und Righetti reported on 14 patients who underwent epiduroscopic fibrolysis using a radio-frequency device named »R-ResAblator Epiduroscopy.« RFT reduced pain by 90% in 8 pa-

tients, by 60% to 70% in 5, and by less than 30% in 1. The authors concluded that RF epiduroscopy offers greater therapeutic benefit than traditional epiduroscopy or other surgical techniques.

Our first results with 25 patients who underwent epiduroscopically assisted pulsed radio frequency generally coincide with the initial results reported by other users.

In my personal communication with various radio frequency centers, significant pain reduction has been achieved in up to 65% of patients. The first results of studies involving a small number of patients who have undergone pulsed radio frequency therapy for pain management are promising; however, they are not statistically reliable.

## 7.8 Neurolysis

The indication for epidural destructive neurolysis, particularly for spinal pain syndromes, is largely dependent on whether the pain is considered to be primarily organic or not.

For tumor-related pain, which used to be a classic application for neurodestructive procedures, the indications have dropped dramatically due to advances in oncological treatment and modern oral opioid therapy, as well as options for reversible neuromodulation. Considering the complexity of the peripheral and central nociceptive system and its plasticity, the use of many neurodestructive procedures is often questionable.

Indicating neurolysis, especially in the case of spinal pain syndromes, should be done prudently due to potential severe acute complications such as bladder and rectal disorders, paraparesis and late complications such as neuropathic pain. Neurodestructive procedures may only be performed by very experienced therapists.

Intrathecal neurolysis is possible for segmental thoracic pain between T3 and T12 and for perianal and peroneal pain.

Endoscopic application of neurolytics for the management of terminal pain is a recognized indication for neurolysis. Delivery of a neurolytic in the epidural space is rarely performed, however. A special form of the procedure involves epidural

neurolysis via the sacral approach and subdural neurolysis.

For subdural neurolysis, 0.5 to 2.5 mL of phenol-glycerol are administered between the spinal dura mater and the arachnoid mater in order to treat both tumor-related and non-tumor-related pain. After a positive test block with a local anesthetic, up to 1.2 mL 7.5% phenol solution is injected epidurally for definitive epidural neurolysis. This method is very effective for pain such as perianal tumor pain. The neurolysis, which can be repeated, generally lasts only approx. 2–3 weeks.

Our own experience with epiduroscopically assisted epidural application of neurolytics has been limited to very special isolated cases in the context of palliative medicine in the past.

## Complications

In addition to complications related to the procedure itself, complications may also include those arising from the drugs used in pharmacologic therapy or from other drugs the patient receives for other indications or associated diseases.

As with regional anesthesia procedures, complications associated with EDS may be divided into acute, medium-term and late complications.

Acute complications include toxic reactions or hypersensitivity to the delivered drugs.

Medium-term complications include motor paralysis and urinary retention. With regional anesthesia, late complications such as nerve damage are among the most feared complications. Potential nerve damage following epidural analgesia includes anterior spinal artery syndrome, adhesive arachnoiditis and space-occupying masses (hematoma or abscess).

Complications that may arise during epidural anesthesia procedures are generally caused by puncture trauma, accidental dural injury, puncture of an epidural blood vessel or epidural bleeding. The symptoms associated with these complications may include headache, general back complaints, vomiting, meningitis, radicular radiating pain, bladder and rectal disorders and even confusion.

Epidural injuries may be caused by the epiduroscope itself or by microsurgical instruments or a catheter, for instance, when optimal endoscopic vision is not ensured during surgical procedures. In order to achieve the epidural target position, the epiduroscope may not be advanced blindly or with brute force. Permanent optimal endoscopic vision prevents avoidable complications!

### Epidural pressure increase

A potential complication of EDS is increased pressure in the epidural space due to the epidural infusion.

With the exception of two instances of macular bleeding, no permanent injuries or complications arising from epiduroscopic procedures have been reported in the international literature.

In 2000 the journal *Archives of Ophthalmology* published a report on an acute incident of bilateral blindness associated with preretinal, retinal and subretinal hemorrhages following epiduroscopy.

The hemorrhages were attributed to an excessive infusion volume or pressurized epidural irrigation with saline solution. In order to obtain high-quality images from the epidural space, Raffaelli et al. reported volumes of saline solution of between 300 and 1200 mL!

Gill and Heavner reported that retinal hemorrhage following epidural injection during epiduroscopy was apparently related to cerebrospinal fluid pressure. A sudden increase in epidural pressure is transmitted to the optic nerve via the subarachnoidal space. This causes compression of the optic nerve and compression of the vessels that leads to a rupture and in turn to retinal hemorrhage.

In our experience, if saline irrigation fluid is infused too quickly, this can cause pain, especially in stenosed epidural areas and in the thoracic and cervical areas of the spinal canal under examination. The acute pain situation can be stopped by reducing or terminating the saline infusion.

At our pain clinic, we have used 0.9% saline infusion at body temperature at a limited pressure and volume. However, the examiner must have the speed and volume of the infusion under control at all times during EDS. During epiduroscopy performed at our clinic, we use an average of 85 mL of sterile physiological saline solution per examination. This amount is well below the maximum infusion volume of 200 mL per epiduroscopic examination recommended by the international consensus in Graz 2006 (WISE).

In our experience, the effects of using 0.9% saline infusion at body temperature adapted to the situation and controlled during the procedure on the pressure in the spine during epiduroscopy appear to be risk-free.

### Dural injuries

During regional anesthesia, headache may occur as a result of perforation of the spinal dura mater during spinal anesthesia or from accidental perforation of the dura when attempting to carry out epidural anesthesia. The dural perforation itself is not necessarily a complication. It does not become a complication unless the accidental dural perforation is not recognized and is not responded to, for instance, by applying local anesthetics (■ Fig. 8.1).

Post dural puncture headache (PDPH) is attributed to a rapid loss of cerebrospinal fluid, as well as the size of the dural leak. Pulling on pain-sensitive structures of the spinal dura mater is also considered to be responsible for post dural puncture headache, as is the possibility that the pressure gradient between the lumbar and intracerebral space causes reflectory vasodilatation and an increase in the intracerebral blood flow with a rise in intracranial pressure

It is astounding that in the case of accidental epiduroscopic dural perforations we have not observed adverse reactions such as PDPH, which are reported relatively frequently during spinal anesthesia, even with fine needles (29 G).

In 25 cases in which elective myelography was performed at our clinic, PDPH occurred in two patients. Conventional treatment methods provided quick relief despite the relatively large dural perforation  $\geq 2.5$  mm).

In my experience, depending on the particular case, an epiduroscopic procedure does not necessarily have to be terminated if there is a dural injury.

If the operator is able to skillfully change the position of the epiduroscope back into the epidural space, in our experience the epiduroscopic examination or surgical procedure can be continued without any risk to the patient. This may require high-level professional navigating skills.

We have also observed spontaneous closure of the perforated site under endoscopic vision.

However, if intense, persistent postspinal headache (PDPH) develops, we recommend applying an epidural blood patch under endoscopic vision in order to seal the dural puncture.

Epidural blood patches are a reliable way to treat dural perforation. Grau et al. reported on the visualization of dural perforations and blood patches with ultrasonography, which was used for the preparation or for monitoring of epidural punctures. In the clinical study, epidural blood patches were applied in four pregnant women who experienced PDPH after peridural anesthesia for childbirth. The authors reported that in three out of four cases during the preliminary examination, a continuity loss could be visualized in the dura mater at the leave of the previous puncture

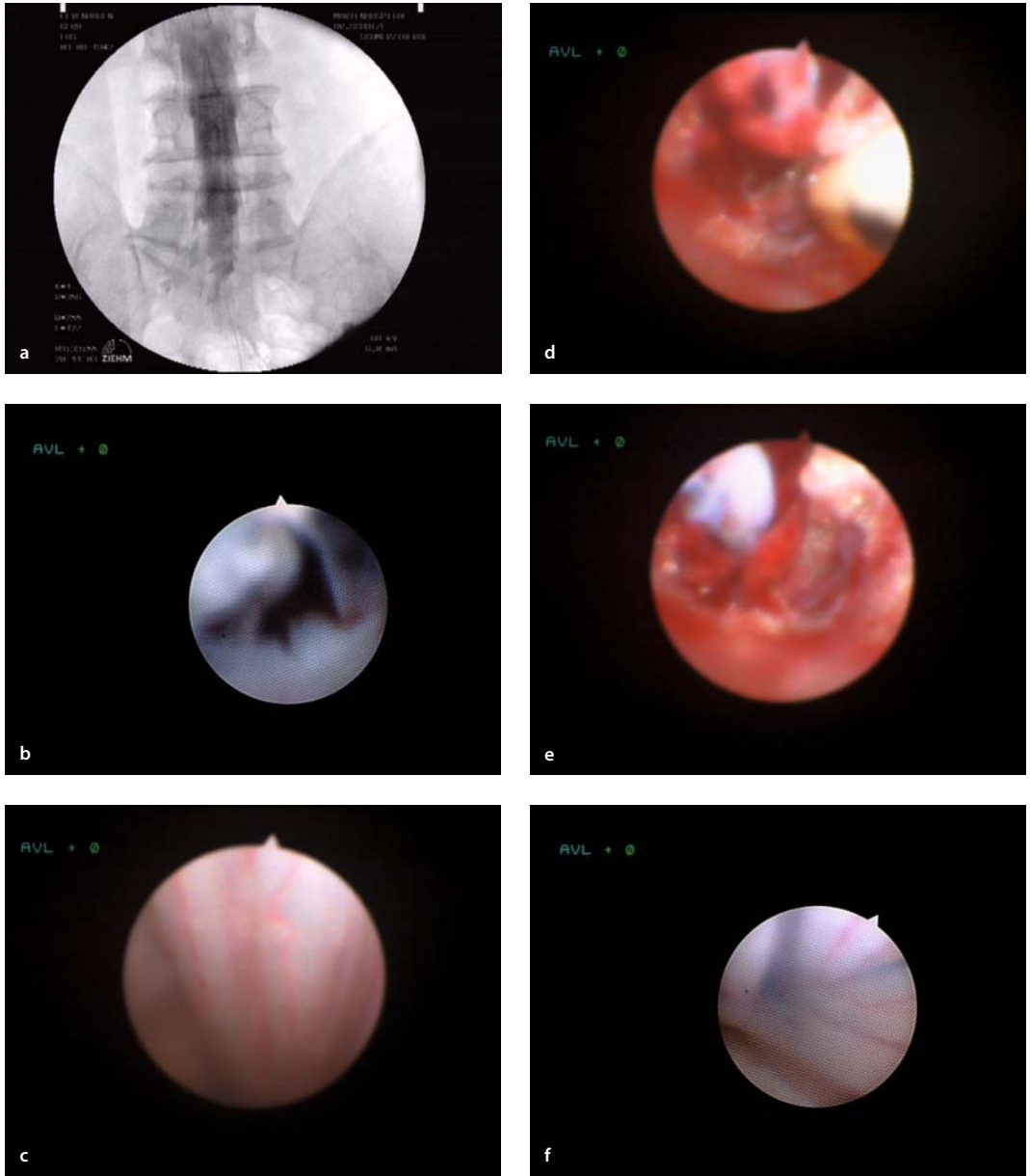
that was identical to the diameter of the Tuohy needle. In one patient, the defect in the membrane was considerably larger than in the preliminary investigations (2–3 mm). The ultrasonography of the epidural space was performed in the paramedian view. The blood patches were applied with the conventional loss of resistance technique and online ultrasound support. Approx. 20 mL of venous blood was withdrawn from the patients and an average of 17 mL injected in the epidural space. According to Grau et al., within 10 to 40 seconds after the injection a rearrangement of the dural fibers could be observed and the discontinuity of the dura doppel layer signal was no longer provable. Within a short time after the blood patch was applied, they could detect an increase in cerebrospinal fluid and the patients' headache was treated successfully.

Suggestions for treatment include bedrest, the administration of caffeine or  $3 \times 250$  mg oral theophylline, as well as epidural saline infusions and dextran. However, infusing fluid does not guarantee positive results.

In order to treat dural perforation during epiduroscopy we applied a blood patch in three of our patients (■ Fig. 8.1). Via the working channel of the epiduroscopic a catheter was placed in a targeted fashion at each puncture site under endoscopic vision. 10 mL of the patient's blood was carefully injected under endoscopic control via a catheter that had been placed at the transition area between the epidural and intrathecal space. The endoscope was left in place while coagulation took place. In this small number of cases at our clinic, the procedure could be completed successfully after the dural perforation was sealed through coagulation. In each case a full recovery could be achieved.

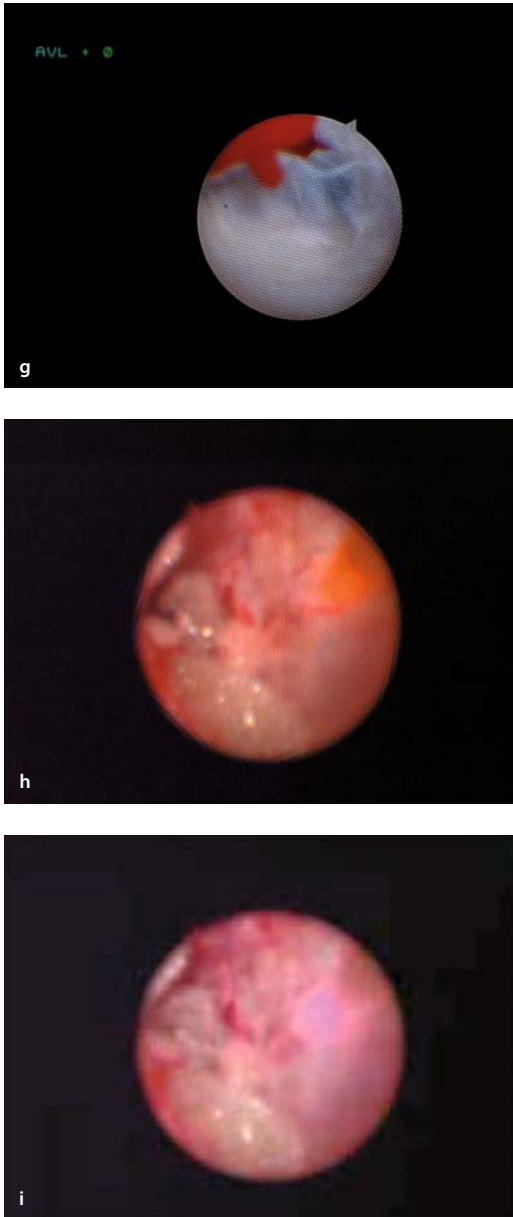
### Epidural bleeding

Epidural bleeding and epidural hematoma during or after epiduroscopy constitute extremely rare and extremely dangerous complications. This space-occupying bleeding may lead to direct myelonic compression and reduction of blood flow in the spinal cord and in the further course can lead to irreversible damage at the level of the spinal cord.



**Fig. 8.1a–f.** a Accidental myelogram. b Dural injury. c Dural perforation with a view of the intrathecal space. d Catheter in the area of the perforation. e Blood patch sealing the spinal dura mater. f View of the patient’s intrathecal space





■ Fig. 8.1g–i. g Sealing the puncture with a blood patch. h Epidural bleeding coagulation. i Bleeding stopped by laser

In our patient population, epidural bleeding occurred in very few cases and was minimal. The bleeding stopped spontaneously with the endoscope in place. Minor venous and arterial bleeding occurred during tissue biopsy, as well as during the removal of painful fibrotic material or implantation of epidural catheters. However, with laser coagulation, they could be treated quickly without complications (■ Fig. 8.1).

### Other complications

Mizuno et al. (2007) reported on encephalopathy and rhabdomyolysis due to iotrolan during epiduroscopy. Naseri et al. described Terson's syndrome caused by epidural saline irrigation.

In the more than 1600 epiduroscopies carried out at our clinic we did not observe a single case of sudden headache following epiduroscopy similar to that reported by the Korean group Oh et al.

The epiduroscopies performed at our clinic have either been completely painless or involved only minimal pain. No clinically relevant complications occurred during epiduroscopy. However, with every medical procedure in the spinal region, there is always a potential risk of inadvertent injury, even when it is performed properly and conscientiously. For this reason, it is imperative to keep these adverse events to a minimum.

In order to prevent adverse events and complications when performing epiduroscopy, safety standards need to be defined that must be adhered to by the individual pain clinics.

Using proper epiduroscopic equipment and ensuring optimal vision, as well as acquiring sufficient experience in using the epiduroscopic technique can prevent complications to a great extent.

## **Costs and Benefits of Epiduroscopy**

The European pain association EFIC reports that one in five Europeans suffers from chronic backache or headache, at an annual cost of € 34 billion to the economy. Some 500 million working days per year are lost due to chronic pain. According to EFIC, 75 million Europeans suffer from permanent pain. The study by Breivik et al. reports that nearly half of those affected are under 50.

According to epidemiological estimates by Pflingsten and Hildebrandt, approx. 85% of the population in the western industrialized countries will suffer from back pain at least once in their lifetime. The point prevalence is up to 40%. In some 10% of the cases, the pain is chronic and 5% are problem cases. Luehmann et al. reported that in some 5% of all patients with acute back pain, herniated disc was assumed to be the reason for the symptoms. In the course of conventional open disc operations, failed back surgery syndrome was observed in up to 30% of the patients after the initial procedures. In the case of microsurgery for herniated disc, considered to be the gold standard today, this share is only 12%.

The recent reluctance to indicate surgery is primarily due to the observation that the procedure does not lead to the desired result in all patients. Failed back surgery syndrome, in which the symptoms persist or are even exacerbated after the operation constitutes a worst case scenario. One of the major problems involves the high tendency for relapse with potential chronicity of the symptoms. The result is that 10% of the cases generate 80% of the costs and 5% of the cases 60% of the costs. The economic impact of back pain in the western industrialized nations is huge. Statistics for Germany compiled by Schwartz et al. indicated that sick days due to back pain generate far greater expenses than the treatment itself. In Germany, back pain is the second most frequent cause of sick days (75 million lost working days among 3.7 million cases of employment disability). The treatment costs in Germany amount to € 25 billion each year. Secondary measures, such as rehabilitation and sick days cost the economy another € 15 billion annually.

So far, diagnosing and treating spinal pain syndromes have been considered to be expensive. Epiduroscopy is less cost-intensive and invasive

than conventional surgical treatment, although it is still considered to be a costly form of treatment by healthcare providers and health insurance providers.

As early as 2000, Manchikanti et al., already showed the effectiveness of this new spinal endoscopic examination and treatment. Based on their clinical experience with 112 epidural endoscopies, they reported that epiduroscopy with adhesiolysis was a relatively safe and cost-effective technique for managing chronic back pain. The special advantage of epiduroscopy is the fact that it is both an excellent diagnostic method and at the same time, allows effective pain treatment to be carried out.

From the point of view of expenses, it is important to mention that the costs arising from the method should be weighed against the benefits to the patient, e.g. with regard to lowering the pain score and improving quality of life and reintegrating the patient into the work process.

In their retrospective study, Manchikanti et al. examined 85 patients who underwent 112 epiduroscopies between 1997 and 1998 as part of a pain management program. All the patients initially experienced significant pain relief, which decreased over a 12-month period. At 1 to 2 months, pain relief decreased to 94%, at 2 to 3 months to 77%, at 3 to 6 months to 52%, at 6 to 12 months to 21% and after the 12 months to 7%.

The costs per endoscopically assisted pain treatment procedure amounted to US\$ 2,961 and the significant pain relief for one week cost US\$ 156. Manchikanti et al. extrapolated these costs to one year in which improvement in quality of life was achieved and came up with a figure of US\$ 8,217. However, the cost effectiveness presented in the study did not include the patient's return to work or other benefits. Nor did Manchikanti et al.'s study take costs for drugs or other treatment methods into account in the analysis.

On the other hand, their study showed that on average, pain management assisted by spinal endoscopy could improve quality of life for one year and that costs amounted to US\$ 8,127. The costs for in-patient treatment can amount to US\$ 17,000 to US\$ 25,000, and out-patient treatment programs can cost between US\$ 7,000 and US\$ 10,000.

Boswell et al. studied the cost effectiveness of spinal endoscopy and adhesiolysis in two separate groups of patients. The overall costs for spinal endoscopy for intractable cases with conservative treatment, including percutaneous lysis with a spring-guided catheter, amounted to US\$ 7,020 to US\$ 8,127. Other studies show that an uncomplicated discectomy can lead to relief for a period of five months and costs US\$ 12,000 and life-time pain relief costs US\$ 29,200. In contrast, coronary artery bypass grafting for angina costs an average of US\$ 73,000 per year, pharmacologic treatment for hypertension costs an average of US\$ 38,000 and primary therapy to manage depression costs an average of between US\$ 11,766 and US\$ 24,403.

Manchikanti et al. proved the cost-effectiveness of adhesiolysis as an epiduroscopically assisted treatment option, especially in patients in whom other therapeutic procedures had failed. Weaknesses of the study include its retrospective approach, the absence of a second reviewer and the absence of parameters such as return to work, which is a major criterion for judging success. The analysis of the cost effectiveness presented in Manchikanti et al.'s study is considered to be up to date by other authors, because current cost factors for the patients were taken into account.

Another important result of the study is that epiduroscopy with adhesiolysis and targeted corticosteroid pharmacologic therapy is a relatively safe and cost-effective treatment measure for relieving chronic pain if it cannot be treated with other methods.

**Our own results.** In Germany the diagnosis-related group (DRG) system was expanded to a case group system in 2003. Since then it has been used to reimburse the individual hospital cases.

In the DRG system, patients are classified into case groups on the basis of their diagnoses and the treatment and are classified and evaluated according to the economic efforts required for treatment. The results are used to reimburse in-patient services.

The DRGs are used in various countries to finance hospital treatment. The sum of all various types of patients treated during a given period constitutes the case mix, and the average cost

weight per treatment case constitutes the case-mix index. In 2003 and 2004, each hospital was assigned an individual base rate. A hospital budget is calculated on the basis of the case-mix index, the base rate and the number of cases.

Taking the example of multimodal pain therapy, including epiduroscopy according to ICPM 1-698.1 and the primary diagnoses (ICD-10 M54.5, M48.06, M51.2, M50.1, M96.1), the costs for an average hospital stay of 11 days amount to an average of € 3,714 (US\$ 4,976.76, exchange rate of US\$ 1.34 to € 1) (DRG 153 Z, base rate: € 1,412, DRG 2007). The economic efficiency of an invasive pain management intervention including epiduroscopic diagnostics of spinal pain syndromes can only be assessed on the basis of a comprehensive, individual economic cost-benefit analysis that takes the hospital's own profile into account in addition to the expenses for operations, personnel, infrastructure and administration. According to our results, the major economic advantages of endoscopic diagnosis and treatment of spinal pain syndromes are constituted by the positive post-interventional results on a patient-by-patient basis. The major disadvantages involve the higher costs for surgery.

Currently, the DRG system allows for a reimbursement for material of 14% to 17%, which does not cover the actual costs of epiduroscopy. In the future, reimbursement in the DRG system should be broken down to reflect these costs.

# Training Program for Epiduroscopy

In recent years, considerable progress has been made in the area of endoscopic diagnosis and treatment of spinal pain syndromes. To publicize and encourage the use of spinal endoscopy, the World Initiative on Spinal Endoscopy (WISE), an international training institution for epiduroscopic diagnostics and therapy of spinal pain syndromes, was established in Iserlohn, Germany.

The initiative's objective is to teach interested physicians the skills required for epiduroscopy and allow them to practice and hone them. The courses and workshops offered by WISE have been specially developed for physicians already working in pain management with a focus on back pain who wish to learn about state-of-the-art techniques and procedures in this area. Our pain clinic offers a learning program and exclusive workshops for this purpose with a focus on hands-on learning of EDS.

Case studies are presented live in the OR or on video and are individually discussed in small groups and procedures are practiced (■ Fig. 10.1a). Our experience with a number of workshops presented in Dortmund, Cologne and Iserlohn, Germany, and Innsbruck, Graz and Vienna, Austria, has shown that procedures such as puncture of the sacral hiatus under radiological control is both an indispensable and ideal introduction to epiduroscopically assisted spinal diagnostics. Due to the extraordinarily wide range of variations in the anatomy of the sacral canal, each workshop for learning and practicing the sacral approach technique in the epidural space is suitable as an introduction to epiduroscopy (■ Fig. 10.1b–d).

The ability and skills required to perform the procedure also serve as a foundation, because they facilitate endoscopic work in the spinal canal and enhance the way the user understands the diagnosis and his or her picture of the anatomical structures.

After a practice phase in which learners are intimately acquainted with the anatomical architecture and learn to make diagnoses, they are ready to learn to perform the endoscopically controlled intervention. Simultaneous assessment of findings via epiduroscopy combined with radiologically controlled navigation is practiced. The

use of epiduroscopy to examine and treat the thoracic section of the spine, and especially the cervical section, must be taught and practiced separately.

In addition to making diagnoses via epiduroscopy, the courses focus on practicing correct handling of the epiduroscopic equipment.

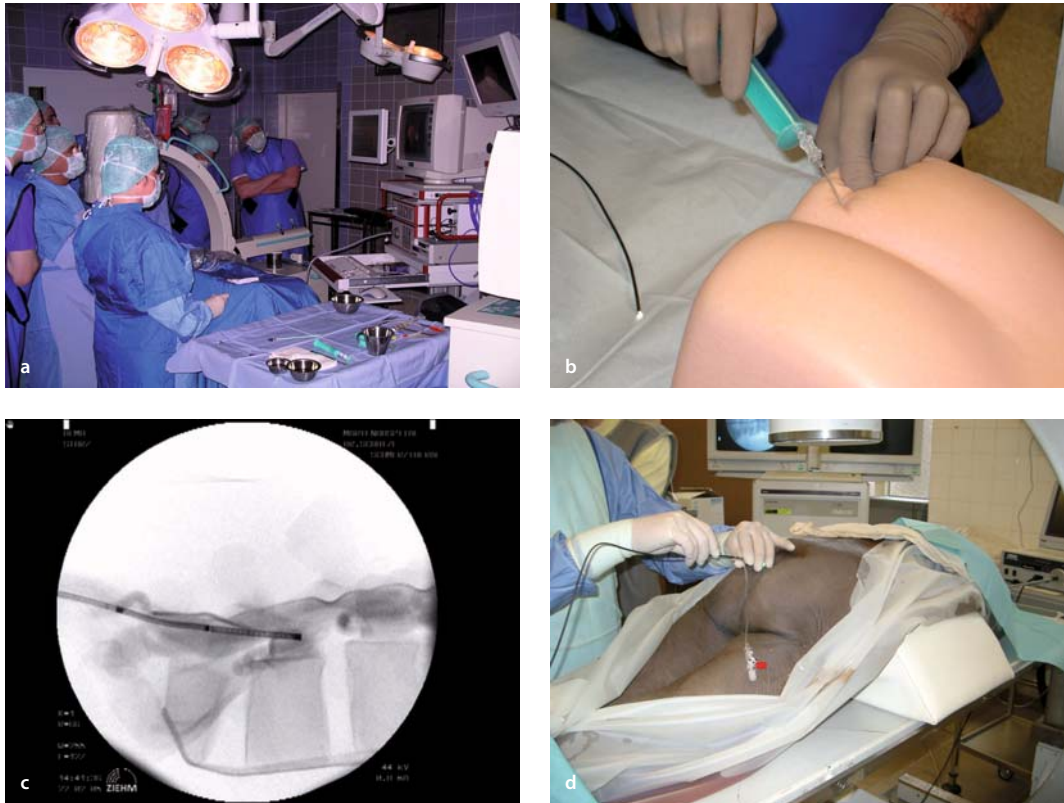
We recommend that once learners have had an in-depth introduction to the endoscopic technique and its special features, they practice the various epiduroscopically assisted applications several times under supervision.

The manual skills acquired through regular practice facilitate learning of the techniques that are the focus of the next part of the course, including correct diagnosis, epiduroscopically controlled epidural adhesiolysis, accurate use of the laser with epiduroscopic assistance, correct catheter placement, biopsies and targeted drug delivery. In addition to the theoretical foundations, which are essential for performing epiduroscopy and which can be learned fairly easily, hands-on learning and practicing of epiduroscopy should be taught in a very structured and graduated manner.

In cooperation with WISE, we established the online project Theoretical Basis Course on Spinal Endoscopy, which comprises 14 lectures. The goal of this training course is to teach students the indications, contraindications, adverse effects and complications of treatment with EDS. The participants learn about the basic concept of epiduroscopy, and this enables them to identify the anatomical structures of the spinal canal.

Once the participants have passed the first level »proficiency test on epiduroscopy« and pass a test on theory, they receive a certificate entitling them to take part in a practical cadaver course. If they meet the requirements posed by the supervising experts, they then receive the second level »proficiency certificate.«

In our experience, teaching is most effective if learners are in groups of no more than three or four participants and practical training at the pain clinic and operating room is individually tailored to the group. We consider this clinical component of advanced training to be an indispensable part of EDS training.



**Fig. 10.1.** **a** Live demonstration of epiduroscopy in the operating room. **b** Puncture of the dummy's sacral canal. **c** Epiduroscope in the spatium epidurale of a dummy with the C-arm technique. **d** Epiduroscopy in the cadaver workshop

In sum, a structured approach to acquiring EDS skills must include the following components:

- Teaching the theory of diagnosing and treating spinal pain syndromes
- Correct imaging and presentation of applications and diagnostic options provided by the epiduroscopic examination
- Epiduroscopic visualization of anatomical and pathological structures
- Coordinating and navigating epiduroscopic equipment
- Epiduroscopically controlled intervention (e.g. catheter implantation, adhesiolysis, biopsy)
- In addition to learning epiduroscopic management, practicing correct use of the epiduroscopic equipment should be the main focus of training.

## **Recommendations for Epiduroscopy**



The following recommendations are based on our years of clinical experience with epiduroscopy:

- To guarantee an efficient epiduroscopic procedure and ensure patient safety, the pain therapist performing the invasive intervention must be experienced in using the examination technique and have a well-founded theoretical background and a certain amount of manual dexterity.
- The procedure requires an epiduroscope or epiduroscopic equipment that meets the requirements for epiduroscopy.
- In addition to precise pain diagnostics and professional technical management, the success of an epiduroscopically assisted invasive pain management intervention depends on the selection of suitable patients.
- Basic prerequisites for performing the invasive epiduroscopic procedure are a thorough clinical and functional examination and imaging diagnostics.
- For quality assurance purposes, the basic information included in the informed consent discussion with the patient regarding epidural diagnostics and pain management must be documented.
- Regardless of the hospital structure, epiduroscopy should be performed only on cooperative patients with adequate continuous monitoring of vital signs (anesthesiological stand-by) in a suitable operating room.
- The anatomical architecture of the vertebral canal and the vulnerability of the spinal structures, especially in the cervical and thoracic segments, require epiduroscopy to be performed in a precise, standardized manner.
- We recommend that prior to each epiduroscopy, epidurography be performed with contrast media either via the needle introduced with a sacral approach or via the introducer.
- The use of a flexible, steerable epiduroscope requires a sacral approach to the epidural space.
- The sacral approach technique calls for the patient to be placed in a prone position on the operating table.
- Epiduroscopy should be performed under local anesthesia or analgesedation.
- Once the sacral hiatus has been punctured, an aspiration test should be performed. If it is negative, a guidewire should be introduced into the sacral hiatus via the puncture needle over a short distance using the Seldinger technique.
- Using a C-arm can be helpful for identifying the guidewire and locating the position and level of the epiduroscope in the vertebral canal.
- The dilatator and sheath are advanced a short distance in the sacral canal via the introduced guidewire.
- Continuous epidural irrigation with physiological saline solution at body temperature adapted as needed is absolutely mandatory for epiduroscopy. The aspects pressure-infusion volume limits, and if necessary, epidural pressure monitoring and drainage of the epidural irrigation fluid, must be taken into account.
- The epiduroscope may only be navigated if good vision (saline irrigation) is ensured. Interventions should be carried out only if endoscopic vision is good.
- For safety reasons, a laser should be on hand if coagulation is needed to stop bleeding.
- Prior to the procedure, instruments to be introduced into the working channel of the endoscope must be checked to ensure they are in good operating condition.
- The epiduroscopy must be recorded in a protocol. Endoscopic imaging should be documented on a video film, a memory stick, a CD-ROM or DVD.
- With suitable epiduroscopic equipment, ensuring optimal vision and by gaining experience with the epiduroscopic technique, complications can be kept to a minimum.
- Epiduroscopy is superior to imaging procedures, failed conservative treatment and open surgical techniques, especially with regard to the high rate of patient satisfaction and the remarkably low number of complications.

## The Future of Epiduroscopy

Since the invention of the first real endoscope by physician Adolf Kussmaul (1822–1902), now, at the beginning of the third millennium, endoscopy has become an integral part of modern medical diagnostics and treatment. Today, the spectrum of minimally invasive surgery includes frequently performed procedures such as inguinal and femoral hernia repair, endoscopically assisted joint surgery, laparoscopic appendectomy, laparoscopic gall bladder and colon surgery, staging laparoscopy, diagnostic laparoscopy, laparoscopic reflux surgery, minimally invasive surgery for benign diseases of the liver and transanal endoscopic microsurgery of the rectum.

These minimally invasive surgical techniques are also widely used in a number of other medical specialities, including gastroenterology, gynecology, orthopedics, neurosurgery, ophthalmology, ear, nose and throat medicine, urology, cardiology, oncology and vascular surgery.

The continuous refinement of special surgical techniques has made a major contribution to advances in pain medicine, especially for spinal endoscopy (epiduroscopy).

The development of epiduroscopy is connected to the international technological state of the art. In recent years, it has had an increasing influence on clinical and practical research and development work. This development is also reflected in the increasing significance of invasive intervention in pain medicine.

In order to enhance treatment and cut costs in the health care sector, in the future, endoscopically assisted invasive pain medicine interventions should take the following aspects into account:

- Interventional procedures should be developed that have the greatest possible therapeutic effect while causing the least possible traumatic impact on the patient.
- The pain therapist should be supported in planning and carrying out interventions with regard to safety, precision and quality.
- Workflows for patient care, intervention planning and performing interventional diagnostics and therapy should be streamlined.
- Effective and efficient follow-up and rehabilitation for pain patients should be organized and achieved.

Other future developments in the area of epidural endoscopy include the realization of new treatment options in which the advantages of diagnostic procedures (epiduroscopy, epidurography, ultrasonography) are used for pain management by sensibly combining instruments from the field of microsystems technology.

Considering the ongoing miniaturization of surgical instruments and the integration of different technologies in systems to comprise new functional modules with surgical components, the field of microsystems technology is a key factor in long-term development trends for EDS.

The constant improvement in visualization through the highest possible picture resolution of 1920 x 1080 pixels and the 16:9 aspect and high definition television (HDTV) platform mean that in the future working at the monitor for hours at a time will be practically effortless.

The advantages of HDTV, which in turn entails progress in visualization, involve the five-fold greater input resolution of the camera, which achieves greater detail and depth of field. The 16:9 format enlarges the viewing field and enhances ergonomic viewing. In the future, optimizing the color brilliance will also facilitate assessment of the epiduroscopic findings.

Future aspects of invasive pain management interventions will include robotic surgery and telemedicine. The constant refinement of surgical techniques has also had a considerable impact on advances in modern invasive treatment interventions in pain medicine, especially for epiduroscopy. For instance, telemedical units, endoscopic equipment and documentation facilities can be combined into a mobile system.

The major telemedical capabilities required for everyday clinical application of EDS are image transmission, videoconferencing and telephone capabilities. With plug and play technology, they can be used as needed throughout the clinic.

Further progress in the area of epiduroscopy was marked by the first in-depth introduction to epiduroscopy in G. Schütze's book *Epiduroscopy: A practice-oriented guide to epiduroscopic diagnostics and treatment of spinal pain syndromes*, written in German.

The growing international interest and increasing use of epiduroscopy at pain clinics throughout the world attest to the bright future of the procedure. This is also reflected by the increasing number of publications on EDS, the number of colleagues from outside Germany who come to our pain clinic and other venues to observe epiduroscopy in use, the growing number of participants in national and international workshops and the burgeoning number of visits to our website. In order to offer interested practitioners hands-on basic and advanced training and opportunities for medical clerkships, we will also be holding epiduroscopy workshops and other types of training in the future.

The establishment of the World Initiative on Spinal Endoscopy (WISE) in March 2006 is another sign of the trend toward international cooperation.

The market launch of the FLEX-X<sup>2</sup> epiduroscope by Karl Storz (Germany) marked a huge advance for epidural endoscopy. The convincing technical features of this innovation in epiduroscopy take endoscopy to a new dimension.

The FLEX-X<sup>2</sup> is the world's first epiduroscope to allow spinal endoscopy with the established sacral approach technique even up to the cervical segments of the spine. The FLEX-X<sup>2</sup> epiduroscope meets today's clinical requirements for epiduroscopy.

Our vast clinical experience, positive results and a high level of patient satisfaction all indicate that epidural endoscopic diagnostics and the associated possibilities for surgery constitute a safe, efficient, and especially future-oriented procedure for use in the management of pain.

Dealing with equivocal symptoms is part of the pain therapist's daily routine. Classifying chronic spinal pain is particularly difficult. Diagnostic procedures to date have not provided sufficient explanations for this type of pain. EDS expands possibilities for pain therapists to visualize pathological and anatomical changes and provides treatment options in the spinal canal. Endoscopic examination of the epidural space can also serve to bridge the gaps when discrepancies arise in results of various imaging procedures.

Future trends also include the epidural pain provocation test (EPPT) as an important professional instrument for differential diagnosis in pain

assessment, as well as for expert opinions. Based on our experience, EPPT should be used as a standardized procedure for more accurate pain assessment.

At our clinic, epiduroscopy has become an integral component for diagnosing and treating spinal pain syndromes. As I see it, pain clinics should use the procedure as a first line treatment. In order to counteract automatic chronicity of the pain process early on, choosing a suitable time to perform epiduroscopy or carry out an epidural intervention can be a major decision for the patient. Continuing conservative treatment measures without questioning their effectiveness has a great potential for pain becoming chronic.

For the treatment of spinal pain syndromes in particular, epiduroscopy opens up new treatment paths for the patient that are effective well before chronicity sets in. In the few publications on epiduroscopy, the advantages of the procedure are described in a similarly positive manner.

As with other new techniques, the epidural endoscopic examining technique must be used prudently and judiciously.

To date, international experience with epiduroscopy has been relatively limited. Further clinical studies involving larger patient populations are required that would shed more light on endoscopic anatomy and pathological morphology and allow better assessment of the value and effectiveness of invasive epiduroscopic interventions in the area of pain medicine.

A consistent dialogue between scientific research and clinical practice promises further progress in the area of epiduroscopy. In the future too, advances in epiduroscopy management can refine and expand diagnostic and therapeutic possibilities in the treatment of spinal pain syndromes without causing additional strain on the patient.

The aim of this book has been to present the background and method of spinal endoscopy and future developments for the procedure, as well our results with the method to date. Even more, however, it aims to advance the use of this new, intelligent form of diagnosing and treating spinal pain syndromes – epiduroscopy – as part of a multimodal strategy for modern, future-oriented and intelligent pain management to benefit the chronic pain patient.

# Literature

- Abdi S, Datta S, Trescot A.M, Schultz D.M, Adlaka R, Atluri, SL, Smith HS, Manchikanti L (2007) Epidural steroids in the management of chronic spinal pain: A systematic review. *Pain Physician* 10: 185–212
- Abdou SM, Hardy, RW (1999) Epidural fibrosis and the failed back surgery syndrome: History and physical findings. *Neuro Res* 21 [Suppl 1]: 5–8
- Abel R, Gerner, HJ, Mariss G (1998) *Wirbelsäule und Rückenmark*. Blackwell Wissenschafts-Verlag, Berlin, Vienna
- Akbarpour D, Seeliger A, Schütze G (2005) Invasive Therapieverfahren. In: Junker U, Nolte T (eds) *Grundlagen der speziellen Schmerztherapie Medizin und Wissen*. Urban & Vogel, Munich, pp 211–230
- American Society of Interventional Pain Physicians (2005) Evidence-Based Practice Guidelines, 2005, under Epidural Adhesiolysis; Percutaneous Adhesiolysis. In: *Interventional Techniques in the Management of Chronic Spinal Pain (Pain Physicians 8:1–47)*
- Amirikia A, Scott IU, Murray TG, Halperin LS (2000) Acute bilateral visual loss associated with retinal hemorrhages following epiduroscopy. *Arch Ophthalmol* 118: 287–289
- Arthur J, Racz GB, Heinrich R, Diede JH, McCann M, Wilson E, Heavner JC, Noe C (1993) Epidural space: Identification of filling defects and lysis of adhesions in the treatment of chronic painful conditions. In: *Abstracts 7th World Congress of Pain*, p 1485
- Askanazi J, Fulton-Peacock P, Nichols M, Gil KM (1996) Lysis of epidural adhesions in the treatment of chronic back pain. *Reg Anesth* 21 [Suppl 2S]: 91
- Babar S, Saifuddin A (2002) MRI of the post-discectomy lumbar spine. *Clin Radiol* 57: 969–981
- Bader L, Blumenstock G, Birkner B, Leib O, Heesemann J, Riemann J, Riemann JF, Selbmann H-K (2002) HYGEA (Hygiene in der Gastroenterologie-Endoskop-Aufbereitung): Studie zur Qualität der Aufbereitung von flexiblen Endoskopen in Klinik und Praxis. *Z Gastroenterol* 40: 157–170
- Balmelli C, Iffenecker A, Pittet D, Ruef C (2003) Risiko der Prionenübertragung in der Epiduroskopie: Aktueller Stand der Reinigung und Desinfektion von flexiblen Endoskopen in Europa und Empfehlungen der Swiss-NOSO-CJD-Task Force für die Schweiz. *Swiss-NOSO-CJD-Task Force*, Bd 10, Nr. 4
- Barsa JE, Charlton JE (1984) Diagnosis of epidural scarring and its possible contribution to chronic low back pain syndrome. *Pain* 18: 376
- Battaggia C, Salar G, Ori C (1987) Effects of hyaluronidase in patients with spinal arachnoiditis and peripheral entrapment neuropathies. *Pain* 24: 277
- Becke K (2007) Stellungnahme: S(+)-Ketamin als Supplement zur Kaudalanästhesie im Kindesalter. *Anästhesiol Intensivmed* 48: 299
- Bennett G, Al-Rashed S, Hoult JR, Brain SD (1998) Nerve growth factor induced hyperalgesia in the rat hind paw is dependent on circulating neutrophils. *Pain* 77: 315–322
- Benzon HT (1986) Epidural injections for low back pain and lumbosacral radiculopathy. *Pain* 24: 277–295
- Bloch HJ, Hawelski S, Benini A (1997) Kyste du ligament jaune lombaire: description de 6 cas. *Schweiz Med Wochenschr* 127: 728–732
- Blomberg R (1985) A method for spinal canal endoscopy and spinaloscopy: Presentation of preliminary results. *Acta Anaesthesiol Scand* 21: 113–116
- Blomberg R (1986) The dorsomedian connective tissue band in the lumbar epidural space of humans: An anatomical study using epiduroscopy in autopsy cases. *Anesth Analg* 65: 747–752
- Blomberg R (1987) The lumbar subdural extra-arachnoid space of humans: An anatomical study using spinaloscopy in autopsy cases. *Anesth Analg* 66: 177–180
- Blomberg R (1988) Technical advantages of the paramedian approach for lumbar epidural puncture and catheter introduction. A study using epiduroscopy in autopsy subjects. *Anesthesia* 43: 837–843
- Blomberg R (1991) The lumbar epidural space. Anatomical findings in epiduroscopy with reference to technical aspects of lumbar epidural anesthesia. Brochure published by Astra Pain Control: AB
- Blomberg R (1995) Fibrous structures in the subarachnoid space: A study with spinaloscopy in autopsy subjects. *Anesth Analg* 80: 875–879
- Blomberg R, Olsson SS (1989) The lumbar epidural space in patients examined with epiduroscopy. *Anesth Analg* 68: 157–160
- Boden SC, Wiesel SW (1992) The multiply operated low back patient. *Spine* 3: 1899–1906
- Boden SD, Davis DO, Dina TS (1990) Abnormal magnetic resonance scans of the lumbar spine in asymptomatic subjects. *J Bone Joint Surg* 72A: 403–408
- Bodian CA, Freedmann G, Hossian S (2001) The visual analog scale for pain: Clinical significance in postoperative patients. *Anesthesiology* 95: 1356–1361
- Bogduk N, Twomey LT (1996) *Clinical anatomy of the lumbar spine*, 2nd edn. Churchill Livingstone, New York: 107–110
- Boswell MV, Shah RV, Everett CR et al. (2005) Interventional techniques in the management of chronic spinal pain: Evidence-based practice guidelines. *Pain Physicians* 8: 1–47
- Boswell MV, Trescot AM, Datta S, et al. (2007) Interventional techniques: Evidence-based practice guidelines in the management of chronic spinal pain. *Pain Physician* 10: 7–111
- Bradley WG, Bydder G (1989) *Magnetic resonance imaging atlas of the brain*. Taylor & Francis, London
- Braun W, Demirel T (1982) *Einführung in die Schmerzchirurgie*. Hippokrates, Stuttgart
- Breivik H, Collet B, Venafriida V (2006) Survey of chronic pain in Europe: Prevalence, impact on daily life and treatment. *Eur J Pain* 10: 287–333
- Bronfort G, Goldsmith Ch, Nelson CF, Boline PD, Anderson AV (1996) Trunk exercise combined with spinal manipulative or NSAID therapy for chronic low back pain: A randomized, observer-blinded clinical trial. *J Manipulative Physiol Ther* 19: 570–82
- Brookoff D (2006) Neurophysiological underpinnings of electrophysiological analgesic neuromodulation for dummies. *Pain Med* 7: 103–120

- Bromm B (2007) Der Infrarot-Laser in der Schmerzdiagnostik. *MedReport* 13: 9
- Brown JH (1960) Pressure caudal anesthesia and back manipulation. *Northw Med* 59: 905–909
- Brune K, Beyer A, Schäfer M (eds) (2001) *Schmerz. Pathophysiologie – Pharmakologie – Therapie*. Springer, Berlin Heidelberg New York
- Buchner M, Neubauer E, Barie A, Schiltenswolf M (2007) Komorbidität bei Patienten mit chronischen Rückenschmerzen. *Schmerz* 21: 218–225
- Bues G (1990) *Endoskopie*. Deutscher Ärzte-Verlag, Cologne
- Burman MS (1931) Myelography or the direct visualization of spinal cord. *J Bone Joint Surg* 13: 695–696
- Burn JN, Guyer PB, Langdon L (1973) The spread of solutions injected into the epidural space. *Br J Anaesth* 45: 338–345
- Burton CV, Kirkaldy-Willis WH, Yong-Yong-Hing K, Heithoff KB (1981) Causes of failure of surgery on the lumbar spine. *Clin Orthop Rel Res* 157: 191–199
- Carpenter RL, Hogan QH, Liu SS, Crane B, Moore J (1998) Lumbosacral cerebrospinal fluid volume is the primary determinant of sensory block extent and duration during spinal anesthesia. *Anesthesiology* 89: 24–29
- Carr DB, Gaudas LC (1999) Acute pain. *Lancet* 353: 2051–2058
- Casper GD (1996) Results of a clinical trial of the holmium: yag laser in disc decompression utilizing a side-firing fiber: A two year follow-up. *Laser Surg Med* 19: 90–96
- Cathelin F. (1901) Une nouvelle voie d'injection rachidienne: methode des injections epidurales par le procede du canal sacre-applications a l'homme. *Compt Rend Soc De Biol*;53:452–3
- Cauchoux J, Ficat C, Girard B (1978) Repeat surgery after disc excision. *Spine* 3: 256–259
- Choi YK, Tan MH, Barbella JD, Grubb WR (2001) Epiduroscopic analysis of persistent back and leg pain and the efficacy of epiduroscopy in the treatment of failed back pain syndrome. *Reg Anesth Pain Med [Suppl]*: 26, 2: 90
- Collier BC (1998) *An Atlas of Epidurograms. Epidural Blocks Investigated*. Harwood Academic publisher, Amsterdam.
- Conradt M (1997) *Sternstunden der Medizin*. Einhorn, Reinbek
- Consensus Statement of the Second Consensus Conference on Neuraxial Anesthesia and Anticoagulation. Internet: [www.asra.com/consensus-steatments/2.html](http://www.asra.com/consensus-steatments/2.html). Accessed March 2007
- Coulter PD, Anne H (1994) Percutaneous Laser Disc Decompression (PLDD). *J Clin Laser Med Surg* 12: 181–182
- Cork RC, Kryc JJ, Vaughan RW (1980) Ultrasonic localization of the lumbar epidural space. *Anesthesiology* 52: 513–516
- Corvino BG, Scott DB (1988) *Epidurale Anästhesie und Analgesie*. VCH Verlagsgesellschaft, Weinheim
- Dashfield AK, Taylor MB, Cleaver JS, Farrow D (2005) Comparison of caudal steroid epidural with targeted steroid placement during spinal endoscopy for chronic sciatica: A prospective, randomized, double-blind trial. *Br J Anaesth* 94: 514–519
- Day P (2001) Arachnoiditis: A brief summary of the literature. *NZHTA Report*, <http://nzhta.chmeds.ac.nz>
- Davidson JT, Robin CC (1961) Epidural injections in the lumbosacral syndrome. *Br J Anaesth* 33: 595–598
- Delgado-López PD, Martín-Velasco V, Castilla-Díez JM, Velasco-Oses A (2007) Symptomatic cervical stenosis due to calcification of the ligamentum flavum after mild cervical trauma. *Neurocirugía* 18: 141–146
- Devulder J, Bogaert L, Moerman A, Rolly G (1995) Relevance of epidurography and epidural adhesiolysis in chronic failed back surgery patients. *Clin J Pain* 11: 80–90
- Deyo RA, Weinstein JN (2001) Low back pain. Primary care. *N Engl J Med* 344: 363–370
- Deyo RA (2007) Back Surgery – Who needs it? *N Engl J Med* 356: 2239–2243
- Diener HC, Maier C (2003) *Schmerztherapie*. Urban & Fischer, Munich Jena
- Dittmann M (1982) *Thorakale Epiduralanalgesie (TEA)*. Springer, Berlin Heidelberg New York
- Dittmann M, Reina MA, López García A (1998) Neue Ergebnisse bei der Darstellung der Dura mater spinalis mittels Rasterelektronenmikroskopie. *Der Anaesthesist* 47: 409–413
- Dvorak J, Grob D (2004) Epidurale Injektionen. *Orthopäde* 33: 591–593
- Dzelzitis J, Warnke JP, Morgela S, Aide H (2002) Thecaloscopy: operative technique, instrumentation and approach to lower back, cadaver studies. Internet: [http://www.dgnc.de/dgnc02/poster/Abstract\\_poster1504\\_091.pdf](http://www.dgnc.de/dgnc02/poster/Abstract_poster1504_091.pdf)
- El-Khoury GY, Ehara S, Weinstein JN, Montgomery WJ, Kathol MH (1988) Epidural steroid injection: A procedure ideally performed with fluoroscopic control. *Radiology* 168: 554–557
- Errando CL, Sifre C, Moliner S, Valía JC, Gimeno O, Mínguez A, Boils P (1999) Subarachnoid ketamine in swine – pathological findings after repeated doses: Acute toxicity study. *Reg Anesth Pain Med* 24: 146–152
- Evans VV (1930) Intracanal epidural injection in the treatment of sciatica. *Lancet* 2: 1225–1229
- Fager CA, Friedberg SR (1980) Analysis of failures and poor results of lumbar spine surgery. *Spine* 5: 87–94
- Farrar T, Young JP Jr, LaMoreaux L (2001) Clinical importance of changes in chronic pain intensity measured on an 11-point numerical pain rating scale. *Pain* 94: 149–158
- Figdor P (2002) Philipp Bozzini. Endo-Press, Tuttlingen
- Finnegan WJ, Fenlin JM, Marvel, Nardini RJ, Rothman RH (1979) Results of surgical intervention in the symptomatic multiply-operated back patient. *J Bone Joint Surg* 61 (A): 1077–1082
- Fredman B, Ben Nun B, Zohar E, Iraqi G, Shapiro M, Gepstein R (1999) Epidural steroids for treating »failed back surgery syndrome«: Is fluoroscopy really necessary? *Anesth Analg* 88: 3667–3672
- Freyenhagen R, Baron R, Koroschetz J, Rehm S, Ziegler D (2007) Die Pharmakotherapie neuropathischer Schmerzen. Individuell ausgerichtet, aber eingebettet in ein interdisziplinäres und multimodales Konzept. *Klinikerzt. Medizin im Krankenhaus* 5: 271–278
- Friedrich M, Gittler G, Arendasy M, Friedrich KM (2005) Long-term effect of a combined exercise and motivation pro-

- gram on the level of disability of patients with chronic low back pain. *Spine* 30: 995–1000
- Fudickar A, Maurer E, Lindstedt U, Dinkel M, Scholz J, Tonner PH (2007) Elektroencephalogramm und evozierte Potentiale in der Intensivmedizin. *Anästhesiologie* 48: 251–260
- Fujimoto T, Giles BP, Replogle RE, Fujimoto H, Miller SL, Purdy PD (2005) Visualization of sacral nerve roots via percutaneous intraspinal navigation (PIN). *Am J Neuroradiol* 26: 2420–2424
- Gerdesmeyer L, Wagner K, Rechl H, Ulmer M, Göbel M (2003) Einfluss der minimal-invasiven perkutanen Neurolyse nach Racz auf das Low-back-pain-Syndrom. *German Medical Science: Doc03dgu09-7*
- Gerdesmeyer L, Lampe R, Veihelmann A, Burgkart R, Göbel M, Gollwitzer H, Wagner K (2005) Chronische Radikulopathie. Einsatz der minimal-invasiven perkutanen epiduralen Neurolyse nach Racz. *Schmerz* 19: 285–295
- Geurts JW, Kallewaard JW, Richardson J, Groen GJ (2002) Targeted methylprednisolone acetate/hyaluronidase/clonidine injection after diagnostic epiduroscopy for chronic sciatica: a prospective, 1-year follow-up study. *Reg Anesth Pain Med* 27: 343–352
- Gill JB, Heavner JE (2005) Visual Impairment following Epidural Fluid Injections and Epiduroscopy: A Review. *Pain Medicine* 6 (5): 36–374
- Göbel H (2001) Epidemiologie und Kosten chronischer Schmerzen: Spezifische und unspezifische Rückenschmerzen. *Schmerz* 15: 92–98
- Gogarten W, Van Aken H, Büttner J (2003) Rückenmarksnahe Regionalanästhesien und Thromboembolieprophylaxe/antithrombotische Medikation. *Anästhesiologie* 44: 218–230
- Gourie-Devi M, Satish P (1980) Hyaluronidase as an adjuvant in the treatment of cranial arachnoiditis (hydrocephalus and optochiasmatic arachnoiditis) complicating tuberculous meningitis. *Acta Neurol Scand* 62: 368–381
- Gourie-Devi M, Satish P (1984) Intrathecal hyaluronidase treatment of chronic spinal arachnoiditis of noninfective etiology. *Surg Neurol* 22: 231–234
- Grau T (2005) Ultraschallgestützte Bildgebungsverfahren für neuroaxiale Blockaden Internet: <http://www.degum.de>
- Grau T, Leipold RW, Delorme S, Martin E, Motsch J (2002) Ultrasound imaging of the thoracic epidural space. *Reg Anesth Pain Med* 27: 200–206
- Grau T, Leipold RW, Conradi R, Martin E, Motsch J (2002) Die Darstellung von Duraperforationen und Bloodpatches mit Ultraschall. *Anästhesiologie* 48: 149–153
- Grau T, Fatehi S, Delorme S, Motsch J (2004) Präzisionsanalysen von Ultraschall und MRT in der Bildgebung des lumbalen Epiduralraumes. *Ultraschall Med* 25 (S1): WS 26–04
- Graziotti P (2007) DVD EPIDUROSCOPY. Spine-aligna Pty Ltd, 91 Circle Circle, Dalkeith, West Australia Internet: <http://www.ipmt.net>
- Grond S, Tamke B, Gaul C, Meyer O (2007) Tumorschmerztherapie – ein Update. *Anästhesiologie* 48: 261–278
- Gupta RC, Gupta SC, Dubey RK (1984) An experimental study of different contrast media in the epidural space. *Spine* 9: 778–781
- Haddad C, Blomstein A (1985) Diagnosis and treatment of epidural adhesions causing spinal pain. *Schmerz-Pain-Douleur* 4: 156–152
- Hamid M, Fallet-Bianco C, Delmas V, Plaisant O (2002) The human lumbar anterior epidural space: Morphological comparison in adult and fetal specimens. *Surg Radiol Anat* 24: 194–200
- Hankemeier U, Hildebrandt J (1998) Neurodestruktive Verfahren in der Schmerztherapie. Springer, Berlin Heidelberg New York
- Harrison GR, Parkin IG, Shah JL (1985) Resin injection studies of the lumbar extradural space. *Br J Anaesth* 57: 333–336
- Hatten HP Jr (1980) Lumbar epidurography with metrizamide. *Radiology* 137: 129–136
- Hägg G, Fritzell P, Oden A (2003) The clinical importance of changes in outcome scores after treatment for chronic low back pain. *Eur Spine J* 12: 12–20
- Heavner JE, Chokhavata S, Kizelshteyn G (1991) Percutaneous evaluation of the epidural and subarachnoid space with the flexible fiberscope. *Regional Anesthesia* 85: 1551
- Heavner JE, Racz G, Randolph P, Diederich J (1996) Prospective evaluation of lysis of epidural adhesions in the management of pain. Abstract, International Association for the Study of Pain, 8th World Congress on Pain
- Heavner JE, Bosscher H, Dunn D, Lehman T (2004) Xanthosis in the spinal epidural space – an epiduroscopy finding. *Pain Pract* 4: 39–41
- Hellinger J, Stern S, Hellinger S (2003) Nonendoscopic Nd:YAG 1064 nm PLDN in the treatment of thoracic discogenic pain syndromes. *J Clin Laser Med Surg* 21: 61–66
- Hellwig D, Tirakotai W, Riegel T, Heinze S, Bertalanffy H (2007) Endoskopische Verfahren in der Neurochirurgie. *Dtsch Arztebl* 104: A 185–191
- Hertz H, Schabus R, Wunderlich M (1985) Endoskopie des Spinalkanals – experimentelle Untersuchungen an Leichen. *Unfallchirurgie* 11 6: 275–277
- Higuchi H, Hirata J, Adachi Y, Kazama T (2004) Influence of lumbosacral cerebrospinal fluid density, velocity and volume on extent and duration of plain bupivacaine spinal anesthesia. *Anesthesiology* 100: 106–114
- Hildebrandt J (2005) Die Versorgung von Schmerzpatienten durch den Anästhesisten. *Klinikarzt* 34: 299–305
- Hilger C (2003) Flexible Endoskope – Belastungsmerkmale und Beanspruchungsparameter. *Medizintechnik* 123: 182–190
- Hitchcock E (1967) Hypothermic subarachnoid irrigation. *Lancet* 1: 1330
- Hitchcock E (1969) Osmolytic neurolysis for intractable facial pain. *Lancet* 1: 434–436
- Hodgson MC BJ, Sheehan HM (1994) Atlas of intravascular ultrasound. Raven Press, New York
- Hoffman RM, Wheeler KJ, Deyo RA (1993) Surgery for herniated lumbar discs: A literature synthesis. *J Gen Intern Med* 8: 487–496
- Hogan QH (1991) Lumbar epidural anatomy. A new look by cryomicrotome section. *Anesthesiology* 75: 767–775



- Holstrom B, Rawal N, Axewlson K, Larsson U, Amilon A, Dolk T, Nydahl PA (1991) Epiduroscopic study of risk of catheter migration following dural puncture by spinal and epidural needles: A video presentation. *Reg Anesth* 15: 86
- Holstrom B, Rawal N, Axelsson K, Larsson U, Amilon A, Dolk T, Nydahl PA (1995) Risk of catheter migration during combined spinal epidural block: Percutaneous epiduroscopy in autopsy cases. *Anesth Analg* 80: 747–753
- Horlocker TT, Wedel DJ, Benzon H, Brown DL, Enneking FK, Heit JA, Mulroy MF, Rosenquist RW, Rowlingson J, Tryba M, Yuan CS (2003) Regional anesthesia in the anticoagulated patient: Defining the risks (the second ASRA Consensus Conference on Neuraxial Anesthesia and Anticoagulation). *Reg Anesth Pain Med* 28: 172–197
- Hübler M, Koch T (2003) Thorakale epidurale Anästhesie und Analgesie. Arcis, Munich
- Husemeyer RP, White DC (1980) Topography of the lumbar epidural space. *Anaesthesia* 35: 7–11
- Igarashi T, Hirabayashi Y, Shimizu R, Saitoh K, Fukuda H, Mitsuhashi H (1997) The lumbar extradural structure changes with increasing age. *Br J Anaesth* 78: 149–152
- Igarashi T, Hirabayashi Y, Saitoh K, Fukuda H (1998) Thoracic and lumbar extradural structure examined by extraduroscope. *Br J Anaesth* 81: 121–125
- Igarashi T, Hirabayashi Y, Shimizu R, Saitoh K, Fukuda H (1999) The epidural structure changes during deep breathing. *Can J Anaesth* 46: 850–855
- Igarashi T, Hirabayashi Y, Shimizu R, Saitoh K, Fukuda H, Suzuki H (2000) The Fiberscopic Findings of the Epidural Space in Pregnant Women. *Clinical Investigations. Anesthesiology* 92: 1631–1636
- Igarashi T, Hirabayashi N, Seo K, Saitoh H, Fukuda H, Suzuki H (2004) Lysis of adhesions and epidural injection of steroid/local anaesthetic during epiduroscopy potentially alleviate low back and leg pain in elderly patients with lumbar spinal stenosis. *Br J Anaesth* 93: 181–187
- Ivanic GM, Pink TP, Homann NC, Scheitza W, Goyal S (2001) The post-discectomy syndrome. Etiology, diagnosis, treatment, prevention. *Arch Orthop Trauma Surg* 121: 494–500
- Jensen MC, Brant-Zawadzki MN, Obuchowski N, Modic MT, Malkasian D (1994) Magnetic resonance imaging of the lumbar spine in people without back pain. *NEJM* 331: 69–73
- Jewett DL, King JS (1971) Conduction block of monkey dorsal rootlets by water and hypertonic saline solutions. *Exp Neurol* 33: 22–237
- Jerosch J, Grönemeyer D, Gewargez A, Filler TJ, Peuker ET (1999) Möglichkeiten der Spinaloskopie im Rahmen der minimal invasiven Intervention – eine experimentelle Untersuchung. *Biomedizinische Technik* 44: 243–246
- Junker U (2004) Chronische Schmerzen: Das »mixed pain concept« als neue Rationale. *Dtsch Arztebl* 101: A-1393/B-1158/C-1115
- Katz J (ed) (1985) *Atlas of Regional Anesthesia*. Appleton-Century-Crofts, Norwalk, CT
- Kawanishi M, Kawase A, Kumagaya K (2006) Equipment for epiduroscopy and its clinical applications. *Masui* 55: 1112–1117
- Kawauchi Y, Yone K, Sakou T (1996) Myeloscopic observation of adhesive arachnoiditis in patients with lumbar spinal canal stenosis. *Spinal Cord* 34: 403–410
- Kefalianakis F (2006) *Leitfaden Sonografie für Anästhesisten*. Thieme, Stuttgart New York
- Kelsey JL, White A (1980) Epidemiology and impact of low back pain. *Spine* 5: 133–142
- Kepes ER, Duncalf D (1985) Treatment of backache with spinal injections of local anesthetics, spinal, and systemic steroids: A review. *Pain* 22: 33–47
- Kindler C, Seeberger MD, Staender SE (1998) Epidural abscess complicating epidural anesthesia and analgesia. An analysis of the literature. *Acta Anaesthesiol Scand* 42: 609–613
- King JS, Jewett DL, Sundberg HR (1972) Differential blockade of cat dorsal root C-fibers by various chloride solutions. *J Neurosurg* 36: 569–583
- Kitamura A, Sakamoto A, Aoki S, Ogura A, Kawahara T, Inoue T, Ogawa R (1996) Epiduroscopic changes in patients undergoing single and repeated epidural injections. *Anesth Analg* 82: 88–90
- Kizelshteyn G, Heavner JE, Levine S (1991) Epidural balloon catheter system lysing epidural adhesions. *Reg Anesth* 15: 87
- Klakow-Franck R, Rheinberger P (2003) Stellenwert der minimal-invasiven Wirbelsäulenkathetertechnik nach Racz. *Dtsch Arztebl* 100: A 1022–1023
- Koes BW, Scholten RJ, Mens JM, Bouter LM (1995) Efficacy of epidural steroid injections for low-back pain and sciatica: A systematic review of randomized clinical trials. *Pain* 63: 279–288
- Korsten HH, Ackerman EW, Grouls RJ, Van Zundert AA, Boon WF, Bal F, Crommelin MA, Ribot JG, Hoefsloot F, Sloof JL (1991) Long-lasting epidural sensory blockade by n-butyl-p-amino benzoate in the terminally ill intractable cancer pain patient. *Anesthesiology* 75: 950–960
- Krämer J (1994) *Bandscheibenbedingte Erkrankungen*. Thieme, Stuttgart New York
- Kukita F, Yamagishi KF (1979) Excitation of squid giant axons in hypotonic and hyper tonic solutions. *Jpn J Physiol* 20: 669–681
- Kuslich SD, Ulstrom CL, Michael CJ (1991) The tissue origin of low back pain and sciatica. *Orthop Clin North Am* 22: 181–187
- Lake DA, Barnes CD (1980) Effects of changes in osmolality on spinal cord activity. *Exp Neurol* 68: 555–567
- Lang T (personal communication) Epiduroscopy for longterm pain reduction in low back pain: A prospective randomized trial
- Leipold RW (2003) Die sonographische Darstellung des thorakalen Epiduralraums – Nichtinvasive bildgebende Diagnostik vor thorakaler Epiduralanästhesie. Heidelberg Internet: [www.ub.uni-heidelberg.de/archiv/4033](http://www.ub.uni-heidelberg.de/archiv/4033)
- Lerch K, Völk M, Neumann C, Nerlich M (2002) Intraoperative Sonographie des Myelons. *Spinalkanalstenose durch Fraktur oder Tumor. Ultraschall Med* 23: 113–118
- Lessl W-D (2004) Untersuchung zum Effekt der minimal invasiven Neruolyse mittels Epiduralkatheter in der Behand-

- lung lumbaler Wurzelreiz/kompressionssyndrome sowie einer speziellen Form des pseudoradikulären Schmerzsyndroms. Indikationen, Technik und Ergebnisse einer retrospektiven Patientenstudie. Dissertation, Technische Universität München
- Leu HJ (1993) Percutaneous techniques: Decompression and intradiscal laser in discoscopy, external pedicular fixation, percutaneous interbody fusion, peridural endoscopy with discoscopy. 12th course for percutaneous endoscopic spinal surgery. Balgrist, Zurich
- Levandowski EM (1997) The efficacy of solutions used in caudal neuroplasty. *Pain Digest* 7: 323–330
- Lipov E (2007) Stellate ganglion block may relieve hot flashes by interrupting the sympathetic nervous system. *Med Hypotheses* 69: 758–763
- Lorinson D, Kogler J, Größlinger K (2006) Perkutane Epiduroskopie beim Hund: Anatomische und technische Grundlagen. *Wien Tierärztl Mschr* 93: 278–282
- Lubenow T, Keh-Wong E, Kristof K, Ivankovich O, Ivankovich AD (1988) Inadvertent subdural injection: A complication of an epidural block. *Anesth Analg* 67: 175–179
- Luehmann D, Burkhardt-Hammer T, Borowski C, Raspe H (2005) Minimal-invasive Verfahren zur Behandlung des Bandscheibenvorfalles, HTA-Bericht 17. Deutsche Agentur für Health Technology Assessment des Deutschen Instituts für Medizinische Dokumentation und Information, Cologne
- Luyendijk W (1979) The plica mediana dorsalis of the dura mater and its relation to lumbar peridurography (canalography). *Neuroradiology* 11: 147–149
- Luyendijk W, Van Voorthuisen AE (1966) Contrast examination of the spinal epidural space. *Acta Radiol Diagn* 5: 1051–1066
- Macnab I (1972) The mechanism of spondylogenic pain. In: Hirsch C, Zotterman Y (eds) *Cervical pain*. Pergamon, Oxford, pp 89–94
- Malinovsky JM, Lepage JY, Cozian A, Mussini JM, Pinaud M, Souron R (1993) Is ketamine or its preservative responsible for neurotoxicity in the rabbit? *Anesthesiology* 78: 109–115
- Manchikanti L (2000) Epidemiology of low back pain. *Pain Physician* 3: 167–192
- Manchikanti L, Pampati V, Bakht CE, Pakanati RR (1999) Non-endoscopic and endoscopic adhesiolysis in post-lumbar laminectomy syndrome: A one-year outcome study and cost effectiveness analysis. *Pain Physician* 2: 52–58
- Manchikanti L, Pakanati RR, Pampati VS (2000) The value and safety epidural endoscopic adhesiolysis. *Am J Anesthesiol* 27: 275–279
- Manchikanti L, Singh V (2002) Epidural lysis of adhesions and myelography. *Curr Pain Headache Rep* 6: 427–435
- Manchikanti L, Rivera J, Pampati V, McManus CD, Brandon D, Wilson SL (2004) One day lumbar epidural adhesiolysis and hypertonic saline neurolysis in treatment of chronic low back pain: A randomized, double-blind trial. *Pain Physicians* 7: 177–186
- Manchikanti L, Boswell MV, Rivera J, Pampati V, Damron KS, McManus CD, Brandon DE, Wilson SR (2005) A randomized, controlled trial of spinal endoscopic adhesiolysis in chronic refractory low back and lower extremity pain. *BMC Anesthesiology* 5: 10
- Marhofer P, Koinig H, Kapral S (2003) Kaudalanästhesie: Die Wahl der Medikamente für die Kaudalanästhesie bei Kindern. *Anaesthesist* 52: 55–67
- Marshall LL, Trethewie CC (1987) Chemical radiculitis. A clinical, physiological and immunological study. *Clin Orthop* 129: 760–764
- Mayer TG, Gatchel RJ (1998) *Functional restoration for spinal disorders*. Lea & Febiger, Philadelphia
- McCarron RF, Wimpee MW, Hudkins PG, Laros GS (1987) The inflammatory effect of the nucleus pulposus: A possible element in the pathogenesis of low back pain. *Spine* 12: 760–764
- McLeod A, Roche A, Fennelly M (2005) Ultrasonography may assist epidural insertion in scoliosis patients. *Can J Anaesth* 52: 717–720
- Mense S (2007) Muskelverspannungen als Ursache von Rückenschmerzen. *MedReport* 31: 7–8
- Merrid U, Sogaard IB (1986) Sciatica caused by perifibrosis of the sciatic nerve. *J Bone Joint Surg* 68: 706
- Mesrian A, Neubauer E, Schiltewolf M (2007) Gutes Therapieergebnis nach Behandlung chronischer Rückenschmerzen. *Schmerz* 21: 212–217
- Meyers MA (1997) Visual Loss as a Complication of Spine Surgery – A review of 37 cases. *Spine* 22: 1325–1329
- Mizuno J, Gauss T, Suzuki M, Hayashida M, Arita H, Hanaoka K (2007) Encephalopathy und rhabdomyolysis provoquées l'iotrolan durant l'epiduroscopie. *J Anaesth* 54: 49–53
- Modic MT, Ross JS, Obuchowski NA, Browning KH, Cianflocco AJ, Mazanec DJ (1995) Contrast enhanced MR imaging in acute lumbar radiculopathy: A pilot study of the natural history. *Radiology* 195: 429–435
- Möllmann M, Holst D, Enk D, Filler T, Lübbsmeyer H, Deitmer T, Lawin P (1992) Spinaloskopie zur Darstellung von Problemen bei der Anwendung der kontinuierlichen Spinalanästhesie. *Anästhesist* 41: 544–547
- Möllmann M, Holst D, Lübbsmeyer H, Lawin P (1993) Continuous spinal anesthesia: Mechanical and technical problems of catheter placement. *Reg Anesth* 18: 469–472
- Moore DC (1951) The use of hyaluronidase in local and nerve block analgesia other than spinal block. 1520 cases. *Anesthesiology* 12: 611–626
- Myers RR, Katz J (1990) Neuropathology of neurolytic and semidestructive agents. In: Cousins MJ, Bridenbaugh PO (eds) *Neural blockade*. 2nd edn. Lippincott, Philadelphia, pp 567–568
- Naseri A, Blumenkranz MS, Horton JC (2001) Terson's syndrome following epidural saline injection. *Neurology* 57: 364
- North RB, Campbell JN, James CS, Conover-Walker MK, Wang H, Piantadosi S, Rybock JD, Long DM (1991) Failed back surgery syndrome: 5-year follow-up in 102 patients undergoing repeated operation. *Neurosurgery* 28: 685–690
- Obata K, Tsujino H, Yamanaka H, Yi D, Fukuoka T, Hashimoto N, Yonenobu K, Yoshikawa H, Noguchi K (2002) Expression of neurotrophic factors in the dorsal root ganglion in a rat model of lumbar disc herniation. *Pain* 99: 121–132
- Odendaal CL, Van Aswegen A (1993) Determining the spread of epidural medication in post laminectomy patients by

- radiculopathic admixture. Abstracts 7th World Congress of Pain, 487
- Ogon M, Maurer H, Wimmer C, Landauer F, Sterzinger W, Krismer M (1997) Minimally invasive approach and surgical procedures in the lumbar spine. *Orthopäde* 26: 553–561
- Oh WS, Lee SJ, Hong KH (2000) Fulminant Headache after Epiduroscopy. *Korean J Pain* 13: 130–133
- Olinger CP, Olhaber RL (1974) Eighteen Gauge Microscopic-Telescope Needle Endoscope with Electrode Channel: Potential Clinical and Research Application. *Surg Neurol* 2: 151–160
- Olmarker K, Rydevik B, Holm S (1989) Edema formation in spinal nerve roots induced by experimental, graded compression: An experimental study on the pig cauda equina with special reference to differences in effects between rapid and slow onset of compression. *Spine* 14: 569–573
- Olmarker K, Rydevik B (1998) Pathogenesis of sciatic pain: Role of herniated nucleus pulposus and deformation of spinal nerve root and dorsal root ganglion. *Pain* 78: 99–105
- Ooi Y (1981) Myeloscapy (in Japanese). *Orthop Traum Surg* 24: 659–669
- Ooi Y, Morisaki N (1969) Intrathecal lumbar endoscope (first report in Japanese). *Clin Orthop Surg* 4: 295–297
- Ooi Y, Satoh Y, Morisaki N (1972) Myeloscapy. *Igakuno Ayumi (Jpn)* 81: 209–212
- Ooi Y, Satoh Y, Morisaki N (1973) Myeloscapy. *Orthop Surg (Jpn)* 24: 181–186
- Ooi Y, Satoh Y, Hirose K, Mikanagri K, Morisaki N (1973) Myeloscapy, possibility of observing lumbar intrathecal space by use of an endoscope. *Endoscopy* 5: 90–96
- Ooi Y, Satoh, Sugawara S, Mikanagi K, Morisaki N (1977) Myeloscapy. *Int Orthopedics I*: 107–111
- Ooi Y, Satoh Y, Inoue K, Mikanagi K, Morisaki N (1978) Myeloscapy. *Acta Orthop (Belgium)* 44: 881–894
- Ooi Y, Mita F, Satoh Y (1990) Myeloscopic study on lumbar spinal canal stenosis with special reference to intermittent claudication. *Spine* 15: 544–549
- Parris WCV (1999) What is new and on the horizon in Pain Management. *American Society of Anesthesiologists* 63: 10
- Payne JN, Ruff NY (1951) The use of hyaluronidase in caudal block anesthesia. *Anesthesiology* 12: 162–172
- Peek RD, Thomas JC (1993) Diagnosis of lumbar arachnoiditis by myeloscapy. *Spine* 18: 2286–2289
- Perez-Cruet MJ, Foley KT, Isaacs RE, Rice-Wyllie L, Wellington R, Smith MM, Fessler RG (2005) Microendoscopic discectomy: technical note. *Neurosurgery* 51 (Suppl 2): 129–135
- Peul WC, Van Houwelingen HC, Van den Hout WB (2007) Surgery versus Prolonged Conservative Treatment for Sciatica. *N Engl J Med* 356: 2245–2256
- Pfingsten M, Hildebrandt J (2001) Die Behandlung chronischer Rückenschmerzen durch ein intensives Aktivierungskonzept (GRIP) – eine Bilanz von 10 Jahren. *Anästhesiol Intensivmed Notfallmed Schmerzther* 36: 580–589
- Pheasant HC (1975) Sources of failure in laminectomies; symposium on the lumbar spine. *Orthopedic Clinic of North America* 6: 319–329
- Pick CF, Bockhorn J (1980) Endoscopic examinations and computed tomography concerning cervical spine positioning intreatment of acute cervical spine injuries. *Archives of Orthopedic Trauma Surgery* 97: 43–49
- Polyanalgesic Consensus Panel (ed) (2007) Polyanalgesic Consensus Panel Issues New Guidelines for Pain Management via Intraspinal Infusion. *Business Wire*
- Pool JL (1938) Direct visualization of dorsal nerve roots of cauda equina by means of a myeloscope. *Arch Neurol Psychiatry* 39: 1308–1312
- Pool JL (1938) Myeloscapy: Diagnostic inspection of the cauda equina by means of an endoscope. *Bull Neurol Inst New York* 7: 178–189
- Pool JL (1942) Myeloscapy: Intraspinal endoscopy. *Surgery* 11: 169–182
- Price CM, Rogers PD, Prosser ASJ, Arden NK (2000) Comparison of the caudal and lumbar approaches to the epidural space. *Ann Rheum Dis* 59: 879–882
- Racz GB, Haynsworth RE, Lipton S (1986) Experiences with an improved epidural catheter. *Pain Clinic* 1: 21–27
- Racz GB, Heavner JE, Singleton W (1988) Hypertonic saline and corticosteroid injected epidurally for pain control. In: Racz GB (ed) *Techniques of Neurolysis*. Kluwer Academic, Boston, pp 73–86
- Racz GB, Kline WN (1988) New epidural adapter and epidural needle. In: Racz GB (ed) *Techniques of Neurolysis*. Kluwer Academic, Boston
- Racz GB, Holubec JT (1989) Lysis of adhesions in the epidural space. In: Racz GB (ed) *Techniques of Neurolysis*. Kluwer Academic, Boston, pp 57–72
- Racz GB (1995) Letter to the Editor. In response to article by Devulder et al. *Clin J Pain* 11: 151–158
- Racz G, Heavner JE, Diede J (1996) Lysis of Epidural Adhesions Utilizing the Epidural Approach. In: Waldmann SD, Winnie AP (eds) *Interventional pain management*, 1st ed. W.B. Saunders, Philadelphia, pp 339–359
- Racz GB, Heavner JE (1996) Aristocort and Depo-Medrol passage through a 0.2 $\mu$  filter. *Reg Anesth* 15: 25
- Racz GB, Heavner JE, Raj PP (1997) Epidural neuroplasty. *Semin Anesth* 16: 302–312
- Racz GB, Heavner JE, Raj PP (1998) Nonsurgical management of spinal radiculopathy by the use of lysis of adhesions (neuroplasty). Evaluation and treatment of chronic pain, 3rd ed. Williams & Wilkins, Philadelphia, pp 533–542
- Raffaelli W (1999) Periduroscopy: preliminary reports-technical notes. *Pain Clinic* 11: 209–212
- Raffaelli W, Righetti D (2005) Surgical radio-frequency epiduroscopy technique (R-ResAblator) and FBSS treatment: preliminary evaluations. *Acta Neurochir Suppl* 92: 121–125
- Raj PP, Lou L, Erdine S, Staats PS (2003) Radiographic imaging for regional anesthesia and pain management. Elsevier Science, Churchill Livingstone
- Rapp HJ, Grau T (2004) Ultrasound imaging in pediatric regional anesthesia. *Can J Anaesth* 51: 277–278
- Rapp HJ, Folger A, Grau T (2005) Ultrasound-guided epidural catheter insertion in children. *Anesth Analg* 101: 333–339

- Regan JF, McAfee PC (1995) Atlas of endoscopic spine surgery. Quality Medical Publishing, St. Louis
- Reihsaus E, Waldbaur H, Seeling W (2000) Spinal epidural abscess: a meta-analysis of 915 patients. *Neurosurv Rev* 23: 175–204
- Reina MA, Lopez Garcia A (1998) Novedades sobre la Arachnoides Humana. II. Jornadas de Anestesia Loco-Regional, Madrid
- Richardson J, McGurgan P, Cheema S, Prasad R, Gupta S (2001) Spinal endoscopy in chronic low back pain with radiculopathy. A prospective case series. *Anaesthesia* 56: 454–460
- Rizor RF (1994) Epiduroscopy: Technique for examination of the lumbar epidural space. Presented at the 19th meeting of the American Society of Regional Anesthesia, Chicago
- Roberson GH, Hatten HP jr, Hesselink JH (1979) Epidurography: Selective catheter technique and review of 53 cases. *AJR* 132: 787–793
- Rompe JD, Eysel P, Zöllner J, Heine J (1999) Intra- und postoperative Risikoanalyse nach lumbaler Bandscheibenoperation. *Z Orthop* 137: 201–205
- Roohani M (2007) Epiduroskopie – eine vergleichende Studie des diagnostischen Stellenwertes gegenüber der Magnetresonanztomographie. Inauguraldissertation (unpublished)
- Rosenberg PH (1996) Fiberoptic epiduroscopy: Current research [Abstract]. *Int Pain Clin* 7: 124
- Rosenberg AD (2006) Scientific and Educational Exhibits/Medically Challenging Cases. *ASA Newsletter* 70: 7
- Ross JS, Robertson JT, Fredrickson RCA, Petrie JL, Obuchowski N, Modic MT, Detribolet N (1996) Association between peridural scar and recurrent radicular pain after lumbar discectomy: magnetic resonance evaluation. *Neurosurgery* 38: 855–863
- Roth-Brons M, Roth C (2007) Handbuch Schmerz. Medizinische Medien Informations GmbH, Neu-Isenburg
- Ruetten S, Meyer O, Godolias G (2002) Application of holmium: YAG laser in epiduroscopy: Extended practicabilities in the treatment of chronic back pain syndrome. *J Clin Laser Med Surg* 20: 203–206
- Ruetten S, Meyer O, Godolias G (2002) Epiduroscopische Diagnostik und Therapie epiduraler Adhäsionen beim chronisch lumbalen Schmerzsyndrom des voroperierten Patienten: Erste Ergebnisse von 26 Interventionen. *Z Orthop* 140: 171–175
- Ruetten S, Meyer O, Godolias G (2003) Endoscopic surgery of the lumbar epidural space (epiduroscopy): results of therapeutic intervention in 93 patients. *Minim Invas Neurosurg* 46: 1–4
- Sabdi S, Datta S, Trescot AM, Schultz DM, Adlaka R, Atluri SL, Smith HS, Manchikanti L (2007) Epidural steroids in the management of chronic spinal pain: A systematic review. *Pain Physician* 10: 185–212
- Saberski LR (1996) Spinal endoscopy: Current concepts. In: Winnie & Waldman (eds) Evaluation of the patient in pain, Textbook. W. B. Saunders, Philadelphia
- Saberski LR (1996) Comment of epiduroscopic changes in patients undergoing single and repeated epidural injections. *Anesthesia, Letters to the Editor*
- Saberski LR (2000) A retrospective analysis of spinal canal endoscopy and laminectomy outcomes data. *Pain Physicians* 3: 193–196
- Saberski LR, Brull SJ (1995) Spinal and epidural endoscopy: A historical review. *Yale J Med* 68: 7–5
- Saberski LR, Brull SJ (1995) Epidural endoscopy-aided drug delivery: A case report. *Yale J Biol Med* 68: 17–18
- Saberski LR, Kitahata L (1995) Direct visualization of the lumbosacral epidural space through the sacral hiatus. *Anesth Analg* 80: 839–840
- Saberski LR, Kitahata L (1996) Persistent radiculopathy diagnosed and treated with epidural endoscopy. *J Anesthesia* 10: 292–295
- Sairyo K, Biyani A, Goel VK, Leaman DW, Booth R jr, Thomas J, Ebraheim NA, Cowgill IA, Mohan SE (2007) Lumbar ligamentum flavum hypertrophy is due to accumulation of inflammation-related scar tissue. *Epidemiology. Spine* 32: E340–E347
- Sakai T, Hojo M, Aoki H, Higashijima U, Sumikawa K (2005) Epiduroscopy improves the pain and the sensory nerve function in the patients with lumbar spinal stenosis. *Anesthesiology* 103: A 1003
- Samanta A, Beardsley J (1999) Sciatica: Which intervention? *BMJ* 319: 302–303
- Sandkühler J, Bromm B, Gebhart GF (2000) Nervous system plasticity and chronic pain. *Progress in brain research* 129, Elsevier, Amsterdam
- Sasaki N, Kikuchi S, Konno S, Sekiguchi M, Watanabe K (2007) Anti-TNF-[alpha] antibody reduces pain-behavioral changes induced by epidural application of nucleus pulposus in a rat model depending on the timing of administration. *Spine* 32: 413–4170
- Satoh Y, Hirose K, Ooi Y, Mikanagi K (1978) Myelography in the diagnosis of low back pain syndrome. Presented at the Third Congress of International Rehabilitation Medicine Association, Basel, Switzerland
- Satoh Y, Hirose K, Ooi Y, Mikanagi K (1981) Myelography, with special reference to blood flow changes in the cauda equina during Lasegue's test. *Int. Orthopedics* 4: 307–311
- Savolaine ER, Pandya JB, Greenblatt SH, Conover SR (1988) Anatomy of the human lumbar epidural space: New insights using C.T. epidurography. *Anesthesiology* 68: 217–220
- Scott BD (1996) Techniken der Regionalanästhesie. *Chapmann & Hall, Weinheim*
- Scherer R, Giebler R (2003) Thorakale Epiduralanästhesie. *Anästhesiologie Intensivmedizin Notfallmedizin Schmerzther* 38: 168–190
- Schneiderhahn R (2003) Racz-Katheter bei chronischen Schmerzen. *Schmerztherapeutisches Kolloquium* (19) 4: 21–24
- Schöps P, Hildebrandt J (2001) Schmerzen im Bereich der Wirbelsäule. In: Brune K, Beyer A, Schäfer M (eds) Schmerz: Pathophysiologie-Pharmakologie-Therapie. Springer Berlin Heidelberg New York, pp 79–89
- Schütze G (1996) Epiduroscopically guided percutaneous implantation of spinal cord stimulation electrodes. Management of pain a world perspective II. In: Raj P, Erdine S, Niv (eds) Management of pain. *Monduzzi Editore S.p.A, Bologna*, pp 301–304

- Schütze G (2000) Techniken und Technologien zur Therapie chronischer Schmerzen. Grünenthal GmbH, Wissenschaftliche Verlagsabteilung, Aachen
- Schütze G (2004) Epiduroskopie eröffnet neue Wege gegen Rückenschmerzen. *Schmerztherapie* 4: 12–13
- Schütze G (2004) Spinale Endoskopie, Rückenmarksnahe Therapie, DGS, ISBN 3-00-014548-6
- Schütze G (2006) EPIDUROSCOPY. Multilingual DVD-ROM, Karl Storz GmbH, Germany, ISBN 3-89756-757-1
- Schütze G (2006) Epiduroscopy for diagnosis and treatment of spinal pain syndromes. 12th International Pain Clinic World Society of Pain Clinicans. MEDIMOND, Turin (Italy), pp 215–221
- Schütze G (2007) Update 2007: Invasiv-Interventionelle Schmerztherapie (Teil 1). *ZNS & Schmerz* 3: 2–8
- Schütze G, Kurtze H (1985) Direct observation of the epidural space with a flexible catheter-secured epiduroscopic unit. *Reg Anesth* 19: 85–89
- Schütze G, Kurtze G, Groll O (1996) Endoscopic method for the diagnosis and treatment of spinal syndromes. *Anesthesiologie Reanimatol* 4: 62–64
- Schütze G, Kurtze H (1993) Percutaneous investigation of the epidural space using a flexible endoscope: A contribution to epiduroscopy. *Reg Anesth* 18: 24
- Schütze G, Kurtze H (1994) Perkutane endoskopische Untersuchung des Epiduralraums-Epiduroskopie. *Endoskopie heute* 4: 221–224
- Schütze G, Kurtze G, Groll O (1995) Epiduroskopie – Ein endoskopisches Verfahren für Diagnostik und Therapie rückenmarksnaher Schmerzsyndrome. *Medizin im Bild* 2: 7–13
- Schwartz FW, Bitzer EM, Dörning H (1999) Gesundheitsausgaben für chronische Krankheit in Deutschland. Pabst Science Publishers, Lengerich
- Sekiguchi M, Yabuki S, Satoh K, Kikuchi S. (2004) An anatomic study of the sacral hiatus: a basis for successful caudal epidural block. *Clin J Pain*; 20: 51–4
- Serpell MG, Coombs DW, Colburn RW, DeLeo JA, Twitchell BB (1993) Intrathecal pressure recordings due to saline instillation in the epidural space. Abstracts of the Seventh World Congress on Pain, Raven Press, Paris, Abstract 1535
- Serrano SC, Morales EM (1997) Una tecnica para visualizacion endoscopica del espacio epidural lumbo-sacro. 3rd Panamerican Symposium. Mexico Sociedad Mexicana de Anestesiologia, Cancun
- Shah RV, Heavner JE (2003) Recognition of the subarachnoid and subdural compartments during epiduroscopy: Two cases *Pain Practice* 3: 321–325
- Shimoji K, Fukuda S, Fujioka H, Fujiwara N, Kawashima M (1988) Development of fine fiberscopes for subarachnoid and epidural spaces (in Japanese). *J Japan Soc Clin Anesth* 8: 215–220
- Shimoji K, Fukuda S, Fujioka H, Onodera M, Hokari T, Hatori T, Fujiwara N (1991) Observation of spinal canal and cisternae with the newly developed small-diameter, flexible fiberscopes. *Anesthesiology* 75: 341–344
- Sicard A. (1901) Les injections medicamenteuses extra-durales par voie sacrococcygienne. *Compt Rend Soc De Biol*; 53:396–8
- Sommer C (ed) (2006) Therapie neuropathischer Schmerzsyndrome, 2. Aufl. UNI-MED, Bremen
- Squire AW, Calvillo O, Bromage PR (1974) Painless intrathecal hyper tonic saline. *Canad Anaesth Soc J* 21: 308–314
- Stark DD, Bradley WG (1998) Magnetic resonance imaging. Mosby, New York
- Stern EL (1936) The spinoscope: A new instrument for visualizing the spinal canal and its contents. *Medical Record (NY)* 143: 31–32
- Stern S (2005) Perkutane Neurotomie des Ramus medialis beim chronischen Lumbalen Facettengelenkschmerz durch Laser und deren Nachbehandlung mit der Tigges-Lumbalorthese. *MOT* 5: 84–87
- Stern S, Evermann H (1994) Experiences after lumbar laser nucleotomy in 280 patients with disc protrusion and disc prolapse since May 1993. Scientific conferences and practical workshops at the First Congress of IMLAS (Intern. Musculo-skeletal Laser Society). Neuchatel, Switzerland, pp 15–17
- Stern S, Evermann H (1997) Three years follow up non-endoscopic percutaneous laser disc decompression (PLDD). Abstracts of the 4<sup>th</sup> International Congress of the IMLAS, Nov. 1997, Kyoto, Japan
- Stevens WR (1997) Ophthalmic Complications after Spinal Surgery. *Spine* 22: 1319–1324
- Stewart HD, Quinell RC, Dann N (1987) Epidurography in the management of sciatica. *Br J Rheumatol* 26: 424–429
- Stith WJ, Judy MM, Hochschuler SH, Guyer RD (1991) Choice for Lasers for Minimally Invasive Spinal Surgery. *Orthopedic Review* 20 (2): 137–142
- Stoeckel W. (1909) Ueber sakrale Anästhesie. *Zentralbl Gynaekol*; 33:1
- Swerdlow M (1980) Complications of neurolytic neural blockade. In: Cousins MJ, Bridenbaugh PO (eds) *Neural Blockade*. J.B. Lippincott, Philadelphia, pp 543–553
- Tachihara H, Kikuchi S, Konno S, Sekiguchi M (2007) Does facet joint inflammation induce radiculopathy? An investigation using a rat model of lumbar facet joint inflammation. *Spine* 32: 406–412
- Taylor RS, Damm Hieu P, Fowo S et al. (2007) Cost effectiveness of spinal cord stimulation for failed back surgery syndrome: A four country survey. Poster, 4th World Congress, World Institute of Pain – WIP Budapest, Hungary
- Tegeder I, Costigan M, Griffin RS et al. (2006) GTP cyclohydrolase and tetrahydrobiopterin regulate pain sensitivity and persistence. *Nature Medicine*, Advance Online Publication, October 22, 10.1038/nm 1490
- Tilscher H, Thomalske G (1989) Rücken- und Kreuzschmerz. Edition medizin, CVH Verlagsgesellschaft mbH, Weinheim
- Trescot AM, Chopra P, Abdi S, Datta S, Schultz DM (2007) Systematic review of effectiveness and complications of adhesiolysis in the management of chronic spinal pain: an update. *Pain Physician* 10: 129–146
- Trotter, M. (1947) Variations of the sacral canal: Their significance in the administration of caudal analgesia. *Curr. Res. Anesth. Analgesia* 26:192–202
- Trotter M, Gleser GC (1952) Estimation of stature from long bones, *Amer J Phys Anthropol*, 10: 463–514

- Uchiyama S, Hasegawa K, Homma T, Takahashi H, Shimoji K (1998) Ultrafine flexible spinal endoscope (myeloscope) and discovery of an unreported subarachnoid lesion. *Spine* 23: 2358–2362
- Veihelmann A, Devens C, Birkenmaier C, Trouillier H, Refio HJ (2003) Signifikante Überlegenheit der Epiduralkathetertherapie nach Racz gegenüber Krankengymnastik – Eine prospektiv randomisierte Studie bei chronischem radikulärem Schmerzsyndrom. *German Medical Science: Doc03dgu09-8*
- Ventafridda V, Spreavice R (1974) Subarachnoid saline perfusion. *Adv Neurol* 4: 477–484
- Vranken JH, Troost D, DeHaan P, Pennings FA, Van der Vegt MH, Dijkgraaf MG, Hollmann MW (2006) Severe toxic damage to the rabbit spinal cord after intrathecal administration of preservative-free S(+)-ketamine. *Anesthesiology* 105: 813–818
- Vroomen PCAJ, De Krom MCT, Slofstra PD, Knottnerus JA (2000) Conservative treatment of sciatica: A systematic review. *J Spinal Disord* 13: 463–469
- Wagner KJ, Sprenger T, Pecho C, Kochs EF, Tölle A, Berthele L, Gerdesmeyer L (2006) Schwerwiegende Risiken und Komplikationen der epiduralen Neurolyse nach Racz. Eine Übersicht mit Fallbericht. *Anästhesiol Intensivmed Notfallmed Schmerzther* 41: 213–222
- Waldmann S (1998) *Atlas of Interventional Pain Management*. W. B. Saunders, Philadelphia
- Warnke JP, Mourgela S (2007) Lumbale adhesive Arachnoiditis. Endoskopische Subarachnoepidurostomie als neue Behandlungsmöglichkeit. *Adhesive lumbar arachnoiditis: Endoscopic subarachnoepidurostomy as a new treatment. Der Nervenarzt* 78(10): 1182–1187
- Watkins RG, Edward S (1995) *Spinal Endoscopy. Atlas of Endoscopic Spine Surgery*. Quality Medical Publishing, St. Louis
- Wheatley RG, Schug SA, Watson D (2001) Safety and efficacy of postoperative epidural analgesia. *Br J Anaesth* 87: 47–61
- White AH, Derby R, Wynne G (1980) Epidural injections for diagnosis and treatment of low-back pain. *Spine* 5: 78–86
- Winnie AP, Hartmann JT, Meyers HL Jr (1972) Pain clinic II: Intradural and extradural corticosteroids for sciatica. *Anesth Analg* 51: 990–999
- Witte H, Hellweg S, Witte B, Grifka J (1997) Epiduroscopy with access via the sacral canal. Some constructional equipment requirements from the anatomic and biochemical viewpoint. *Biomedizinische Technik* 42: 24–29
- Wittenberg RH, Greskötter KR, Steffen R, Schoenfeld BL (1990) Ist die epidurale Injektionsbehandlung mit hypertoner Kochsalzlösung beim Bandscheibenvorfall sinnvoll? (Die Wirkung von NaCl auf Bandscheibengewebe) *Z Orthop* 128: 223–226
- Woolf CJ, Allchorne A, Safieh-Garabedian B, Poole S (1997) Cytokines, nerve growth factor and inflammatory hyperalgesia: The contribution of tumour necrosis factor alpha. *Br J Pharmacol* 121: 417–424
- World Initiative on Spinal Endoscopy (WISE) (ed) (2007) *Epiduroscopy. Consensus Decision, March 2006*. Endo-Press™, Tuttlingen
- Zenz M (2007) Rückenschmerz. Viele Fragen und immer noch zu wenig Antworten. *Schmerz* 3: 199–201
- Ziegler K (1990) *Endosonographie*. Perimed Fachbuch-Verlagsgesellschaft, Erlangen
- Zoller WG, Gresseter U, Zöllner N (1994) *Einführung in die Ultraschalldiagnostik*. Karger, Basel

## Subject Index

### A

- Adhesiolysis 81, 82, 94–96, 101, 102, 104, 107–110, 113, 124, 125, 128, 129
  - cost effectiveness 125
- Adhesion 21
- Allodynia 25
- Alpha-2 adrenoceptor agonist 105
- Analgesia 44, 45, 68, 94–96, 100, 104–107, 118
- Analgesedation 66, 80
- Anesthetics
  - local 103, 62, 96, 101, 102, 104–106, 108, 118
- Anesthesia management 66
- Angle of vision 50
- Annulus fibrosus 21, 22, 39, 95
- Antibiotics 99
  - prophylaxis 65
- Antiepileptics 92
- Antihistamine 74
- Arachnoiditis 26, 31

- Arachnoid mater 12
- Arterial vessels 13
- Autoclave sterilization 58
- Autologous disk material 21

### B

- Back pain 87, 91, 107 ▶ also low back pain
  - annual cost 124
  - chronic 6, 90
- BH4 91
- Biopsy 29, 31, 40, 80
- Bleeding 5, 13, 31, 119
- Blood Patch 119–121
- Blood vessels 13, 20
- Bony structures 38
- Bowden cable 48
- Bozzini 2
- Bragard's sign 63
- Brain-derived neurotrophic factor (BDNF) 76
- Bupivacaine 94, 104

### C

- Calcification of the ligamentum flavum (CLF) 27
- Calcium ion concentration 91
- C-arm fluoroscopy 74, 77, 79
- C-arm technique 69, 74
- Catheter
  - epidural ▶ Endoscopy
  - multi-holed 99
  - techniques 82
  - tip 16
- Catheter-related infections 99
- Cathscanner Imaging System 85
- Cauda equina 14
- Cauda equina syndrome 93
- Caud-A-Kath epidural catheter 100
- Cavum epidurale ▶ epidural space 10, 11
- Cavum subarachnoidale
  - ▶ subarachnoid space
- Cerebrospinal fluid (CSF) 11–15, 38, 39, 88, 118, 119

Cervical  
 – epidurogram 75  
 – nerve root pain 103  
 – segments 80  
 – C2 to C7 10, 12, 13, 24, 28, 31, 33, 36, 45, 69  
 C fiber 44, 104, 105  
 Chest X-ray  
 – preoperative 64  
 Clarus Spine Scope 53  
 Clonidine 105  
 Complex regional pain syndrome (CRPS) 102  
 Complications 118  
 Computed tomography (CT)  
 – postmyelographic 38  
 Contrast agent allergy 74  
 Contrast agents 71  
 Cortisone 74, 103  
 Current perception threshold (CPT) 108  
 Cystoscope 2

## D

Degenerative spinal cord disease 87  
 Dexamethasone 103  
 Diagnosis-related group (DRG) system 125  
 Diagnostic blocks 44  
 Diagnostic tests 63  
 Digital endo-camera system 61  
 Digital fiberscope filtration 59  
 Digital video camera 58  
 Diode laser 45, 109  
 Discogenic pain 39  
 Discography 39  
 Disinfectant 57  
 Disc material, protrusion 22  
 Disc protrusions 40  
 Documentation 59  
 Dry sterilization 58  
 Dural perforation 118  
 Dural sac 12, 14  
 Dura mater 17

## E

Echo-signal amplifiers 84  
 Eclass fiberscope 56  
 Electrocardiogram (ECG) 64  
 Electroencephalogram (EEG) 80  
 Electrode  
 – implantation 3, 110, 112, 113  
 – multifunction 114  
 Electromyography (EMG) 64  
 Electrophysiological tests 64  
 Encephalopathy 74, 121  
 Endoscope 2, 48, 50, 51–57, 59, 70, 77, 82, 87, 100, 104, 109, 110, 119, 121, 132, 134  
 – fiber 49  
 – flexible 2, 4, 48, 49, 54, 87, 104  
 – miniature 53  
 – rigid 2, 48, 87  
 – structure and function 48  
 Endoscopic  
 – anatomy 16, 135  
 – follow-up 81, 82  
 – inspection 18, 79, 87  
 – pathology 21  
 Endoscopy 2, 4, 6, 10, 14, 21, 23, 31, 45, 46, 48, 50, 61, 87, 94, 100, 113, 134  
 – epidural 95, 135  
 – spinal canal 2, 4, 5, 48, 51, 60, 81, 95, 102, 107, 124, 125, 128, 134, 135  
 Epidural  
 – abscess 99  
 – adhesions 23, 33  
 – analgesia 94, 100, 107, 118  
 Epidural analgesic therapy (EAT) 4, 6, 31, 81, 94, 96, 101–108  
 Epidural anesthesia 13, 21, 44, 66, 73  
 Epidural bleeding 65, 82, 100, 112, 113, 118, 119, 121  
 Epidural block 83  
 Epidural blood flow 23  
 Epidural adhesiolysis  
 ▶ also Adhesiolysis  
 Epidural catheter 2, 4, 6, 13, 62, 74, 75, 80–84, 94, 96–100, 105, 106, 121  
 – placement 4, 6, 85, 96, 99  
 – catheterization 83  
 – technique 96, 98  
 – therapy 96  
 Epidural drug delivery 101  
 Epidural fatty tissue 16  
 Epidural fibrosis 4, 22, 23, 28, 73, 105, 111, 113  
 – hematoma 119  
 – injuries 118  
 – irrigation 2, 76, 77, 80, 81, 104, 118, 132  
 – laser adhesiolysis 94, 108  
 Epidural laser pain provocation test (ELPPT) 45, 46  
 Epidural neuroplasty 96  
 Epidural pain provocation test (EPPT) 5, 44–46, 66, 135  
 – pain therapy 81, 94, 95  
 – pressure 76, 77, 118, 132  
 – scar tissue 38, 104, 109  
 – segments 45, 24, 77  
 Epidural space 69, 100, 103, 105, 109–115  
 – approach 68, 113  
 – chronic inflammatory process 17, 21, 24–26, 28, 29, 35, 82, 102  
 – sacral approach 69  
 Epidural steroid injection 103, 107  
 Epidural target position 77, 118  
 Epiduritis 11, 24–26, 28, 31, 39  
 Epidurography 11, 39, 69, 71, 73, 74, 76, 99, 132, 134  
 Epiduroscope 29, 44, 50–62, 69, 71–80, 82, 84–86, 94, 98, 110, 118, 119, 129  
 – cleaning 52, 54–57  
 – disinfection 52, 54–57  
 – flexible 2, 4, 48, 49, 54, 87  
 – miniature 53  
 – single-use 51, 52, 53  
 – sterilization 54–58  
 – working channel 29, 30, 48



Epiduroscopic catheter placement  
4, 6, 85, 96, 99

Epiduroscopic surgical procedures  
5, 60, 95, 118, 119

Epiduroscopy (EDS) 2, 3, 4, 6, 7,  
33–36, 40, 51, 52, 56, 59, 60–64,  
73, 74, 76, 77, 80–86, 94, 95,  
100, 114, 118, 119, 128, 129,  
134, 135

- benefits 124, 125
- complications 60, 64, 77, 87,  
100, 118, 119, 120, 121, 128,  
132
- contraindications 5, 6, 128
- costs 124, 125, 134
- definition 4
- development 2, 58, 134, 135
- documentation 58, 60, 80,  
134
- indication 5, 6, 28, 73, 82, 96,  
97, 128
- instrumentarium 61, 62
- proficiency test 128
- technical preparations 60
- technology 2, 84
- training institution 128
- ultrasonography-assisted 3
- ultrasound-assisted  
(SONO-EDS) 83

Ethylene oxide 55, 57, 58

- sterilization 57

## F

Facet joint pain 44

- diagnostic injections 44

Failed back surgery syndrome 6,  
15, 24, 28, 31, 46, 76, 85, 90, 96,  
101, 108, 111, 112, 124

Fatty tissue 16, 97, 99, 105

FDA (Food and Drug Administra-  
tion), U.S. 3

Fiberglass bundles 48

Fiberscopes 2, 51

Fibroblast 12, 24, 26, 29

Fibrosis 4, 5, 22, 28, 33, 76

Fibrotic tissue 21–24, 40, 44, 45,  
77, 97

Finger-floor distance 63

Flexible catheter-secured  
epiduroscopic unit 2, 3

Flexible fiber optic endoscopes  
(Myelotec) 54

Fluoroscopy 70, 74, 77, 79,  
111

Fogarty catheter 24

## G

German Pain Association (DGS)  
94, 102, 111

Glass fibers 49, 50

Glucocorticoids 94, 101–103

- dexamethasone 103, 106–108

Guidewire 132

## H

Hemorrhages 118

Herniated disc 2, 22, 25, 36, 38,  
40, 73, 75, 91–94, 103, 124

High definition (HD) 59

High definition television (HDTV)  
134

Holmium:YAG laser 109

Hyaluronidase 104, 105, 107

Hydrocortisone 103

Hygiene 52, 65

Hyperalgesia 25, 91

Hyperemia 24, 26, 29

## I

Image conductors 48, 51, 56

Image transmission 48, 49, 52,  
134

Inflammation 25, 27, 29, 31, 45,  
46, 64, 99, 107

Infusion 62, 66, 76, 77, 79, 80, 82,  
106, 109, 118, 119, 132

Infusion pump 76

Infusion pump system 2

Injection technique 73, 74, 99,  
102

Interleukin

- 1 (IL-1) 25, 103
- 6 (IL-6) 103
- 8 (IL-8) 76

Intervertebral disc 6, 10, 15, 36,  
39, 41

Intraspinal angiodysplasia 87

Intrathecal application 38, 102,  
106

- neurolysis 115
- opioid analgesia 94
- space 16, 81, 87, 99, 105, 119,  
120

Intravascular ultrasound (IVUS)  
84, 86

Introducer 62, 68–71, 73, 74, 82,  
132

- set 62, 69

## K

Ketamine 106

## L

Lab test 63–66, 99

Laminectomy 2, 7, 34, 95, 99,  
103, 142

Lasègue's sign 63, 144

Laser

- adhesiolysis 80, 81
- evoked potentials 44
- fiber cable 16, 30, 45, 50, 6281,  
109, 110
- Nd:YAG 109
- pain provocation test 6, 23,  
44–46

Leakage test 54

Leukotrienes 103  
 Ligamentum flavum 11, 13, 19,  
 26, 69, 78, 83, 87  
 – cysts 27  
 – hypertrophy 27  
 Light conductor 48, 49, 62, 109  
 Loss of resistance technique 13,  
 69, 119  
 Low back pain 21, 39, 78, 93, 96,  
 102, 108  
 Lumbar epidural adhesiolysis 108  
 Lumbar  
 – segments 27, 39, 77, 78  
 – – L1 to L5, 13, 14, 18, 25, 27,  
 28, 31, 33–36, 39–41, 62, 63,  
 78, 114  
 Lymphatics 14  
 Lymphocytes 29  
 – T-lymphocytes 21, 103

## M

Magnetic resonance imaging (MRI)  
 14, 38–40, 107  
 Magneto-optical drive 74  
 Mainz Pain Staging System (MPSS)  
 28  
 Medial branch block 44  
 Memory pain 44, 46  
 Meningeal ramus 14  
 Methylprednisolone 103, 107  
 Microendoscopic discectomy  
 (MED) 94  
 Microsurgical instruments 29, 50,  
 77, 81, 118, 134  
 Mixed-pain syndrome 90  
 Moiré effect 49  
 Monoclonal antibodies 21  
 Morphine 94, 104, 105  
 Motor paralysis 118  
 Multifunction electrode 114  
 Myelography 2, 38, 39, 63  
 Myelogram 120  
 Myelon compression 86  
 Myeloscopy 2, 87, 88, 119  
 Myelopathy 63, 64

## N

Navigation 10, 61, 63  
 – epiduroscopic 63, 86  
 – epidural 85  
 – laser 109  
 – radiological 77, 78, 128  
 – spinal 79  
 – system 61  
 Nd:YAG laser 109  
 Needles 62, 111, 114, 119  
 – Tuohy 28, 62, 111, 119  
 Nerve blocks  
 – peripheral (ultrasound-assisted)  
 83  
 Nerve cells 91  
 Nerve growth factor (NGF) 76  
 Nerve roots 12, 14, 17, 18, 21, 23,  
 24, 26, 27, 40, 45, 87, 98, 99  
 – compression 21, 45, 23, 64  
 – irritation syndromes 44, 101  
 Nerve stimulation 114  
 Neural structures 14, 17, 18  
 Neuritis 2  
 Neuroaxial blocks  
 – ultrasound-assisted 83  
 Neurogenic pain 95  
 Neurolysis 96, 99, 108, 114  
 – subdural 115  
 Neuromodulation 111, 112, 115,  
 133  
 Neuroplasty 96, 104–106  
 Neurostimulation 111  
 N-methyl D-aspartate (NMDA)  
 receptor 91, 106  
 Non-steroidal anti-inflammatory  
 drugs (NSAIDs) 92, 93  
 Nucleus pulposus 15, 21  
 Numeric rating scale (NRS) 45, 46

## O

Opioids 93–96, 105  
 – analgesics 94, 104, 105  
 Osteophyte 22

## P

Pain  
 – assessment 44, 46, 64, 135  
 – economic efficiency 125  
 – ischemic pain 26, 111  
 – management 4, 6, 95, 102,  
 108, 111, 113, 114, 124, 128,  
 132, 134  
 – neuropathic 26, 90, 93, 94,  
 106, 111, 114, 115  
 – nociceptive 90  
 – pharmacologic 93  
 – therapy 92  
 Pain clinic 4, 6, 7, 28, 31–33, 39,  
 40, 44–46, 52, 56, 58, 60, 61, 69,  
 79–82, 87, 93, 108, 112, 118,  
 121, 128, 135  
 Pain diary 93  
 Pain Disability Index 81, 108  
 – intensity 107  
 Pain provocation test 45, 25,  
 46  
 Pain relief 54, 82, 91–93, 95, 96,  
 102, 107, 108, 113, 124, 125  
 Pain score 36, 46, 81, 124, 108  
 Pain syndrome 2, 87, 93–96, 102,  
 111  
 – chronic 93, 95, 96  
 – radicular 93, 102, 103  
 – topical 102  
 Patient safety 48, 52, 65, 66, 79,  
 132  
 Percutaneous injection technique  
 74  
 Percutaneous laser disc decom-  
 pression and nucleotomy  
 (PLDN) 40  
 Peridural space ► epidural space  
 Perineural nerve sheath fibrosis  
 26  
 Peroxide plasma 35, 58  
 Phlebosclerosis 35  
 Phospholipase A2 22, 76  
 Physical therapy 93, 94, 96, 100,  
 102  
 Pia mater 11–13, 26, 87

Picture-in-picture technique 4, 19, 72, 77, 78  
 Plasma sterilization 55, 58  
 Post Dural Puncture Headache (PDPH) 119  
 Posterior longitudinal ligament 10–17, 19, 20, 22, 30, 71, 57, 78, 87  
 Postlaminectomy syndrome 6, 7, 36, 39, 103  
 Postspinal headache 88, 99, 119  
 Prednisolone 103, 107  
 Preoperative management 63  
 Prostaglandins 102, 103  
 Puncture technique 69  
 – sacral 80

## R

Radiculitis 21, 24–26, 28, 30, 34, 40, 45, 82  
 Radiculopathy 6, 21, 27, 38–40, 45, 90, 96, 101, 103, 111  
 Radio frequency therapy (RFT) 113, 114  
 Red flags 5, 90  
 Reprocessing epiduroscopes 54  
 Rhabdomyolysis 74, 121  
 Robotic surgery 134  
 Ropivacaine 104

## S

Sacral approach 2, 65, 68, 69, 74, 75, 77, 82, 100, 115, 128, 132, 135  
 – canal 6, 10, 66, 68, 69, 70, 73  
 – hiatus 4, 10, 54, 68, 69, 73, 76, 77, 82, 128, 132  
 – technique 128  
 Sacral  
 – segments 14, 77  
 – S1 to S5 10, 12, 14, 24, 27, 28, 31, 33–36, 39, 45, 63, 68, 77, 78

Sacrococcygeal ligament 10, 68, 69, 77  
 Saline  
 – infusion 76, 77, 79, 109, 118, 119  
 – hypertonic solution 104, 105, 108  
 Scar tissue 5, 6, 17, 23, 24, 27–29, 33, 36, 38, 40, 44, 94, 104, 109, 113  
 Sciatica 38, 39, 107, 108  
 Scoliosis 39  
 – surgery 83  
 Seldinger technique 69, 132  
 Sensitivity test 63  
 Serial Digital Interface (SDI) 59  
 Skin disinfection 65  
 Sodium channel block 103  
 Sodium chloride 104  
 Somatosensory Evoked Potentials (SSEP) 64  
 Sonography 83  
 Spatium epidurale ► epidural space  
 Spinal canal 5, 10, 12–15, 19, 21, 24, 27, 30, 34–36, 50, 73–77, 80, 83, 86, 87, 95, 111, 118, 128, 135  
 Spinal canal stenosis 38, 40, 64, 73, 91, 94, 108  
 Spinal cord 5, 11–15, 38, 39, 63, 64, 70, 87, 90, 91, 119  
 Spinal cord stimulation (SCS) 94, 99, 111, 105  
 Spinal dura mater 4, 11–17, 19, 20, 22, 26, 30, 35, 46, 68, 70, 75, 78, 83–87, 97, 99, 113, 115, 118–120  
 Spinal endoscopic adhesiolysis 96, 108  
 Spinal endoscopy 2, 4–6, 48, 51, 60, 80, 102, 107, 124, 128, 134, 135  
 – cost effectiveness 125  
 Spinal headache syndrome 88  
 Spinal nerve 12–15, 38, 87  
 Spinaloscopy 53, 87  
 Spinal pain syndromes 21, 38, 40, 44, 46, 58, 63, 64, 82, 90–95, 114, 115, 124, 125, 128, 129, 134, 135

– chronic 6  
 – lumbar 28  
 Spinal root 25, 108  
 Sterilization 54–58  
 Steroids 108, 96  
 – corticosteroids 102  
 – epidural 4  
 – epidural injection 103, 107  
 Straight leg raise test 63  
 Subarachnoid space 10–14, 75, 87, 88  
 Subdural space 11–13  
 Sufentanil 104, 105  
 Sympathetically independent pain (SIP) 95  
 Sympathetically mediated pain (SMP) 95

## T

Technical assistance 60  
 Telemedicine 58, 60, 134  
 Terson's syndrome 121  
 Thecaloscopy 87  
 Theophylline 119  
 Thermoablation 113  
 Thoracic  
 – segments 77, 78, 83, 86, 132  
 – T1 to T4 33, 38, 75, 115  
 Three-dimensional endoscopic video system 58, 60  
 Thromboprophylaxis 65  
 Tissue biopsy 30, 121  
 TNF- $\alpha$  25, 103  
 Triamcinolone 103  
 Tricyclic antidepressants 92, 93  
 Tumor Necrosis Factor (TNF) 103

## U

Ultrasound catheter 85  
 Ultrasound diagnostics 44, 49, 83, 84

Ultrasound transducer array 40,  
85  
Urinary retention 118

## V

Vascular obstruction 24, 28  
Venous epidural obstructions 24  
Venous plexus 13  
Virtual histology 86  
Visual analog scale (VAS) 107  
Volcano ultrasound equipment  
85

## W

Wind up phenomenon 90  
Work Station 59–61  
World Initiative on Spinal  
Endoscopy (WISE) 4–6, 51, 61,  
77, 80, 118, 128, 135

## X

Xanthosis 27  
X-ray technology 38

## Y

Yellow flags 90  
Yellow pigments 27

## Z

Ziconotide 94